Get Full Access and More at ExpertConsult.com

Hinman's Atlas of UROLOGIC SURGERY

THIRD EDITION

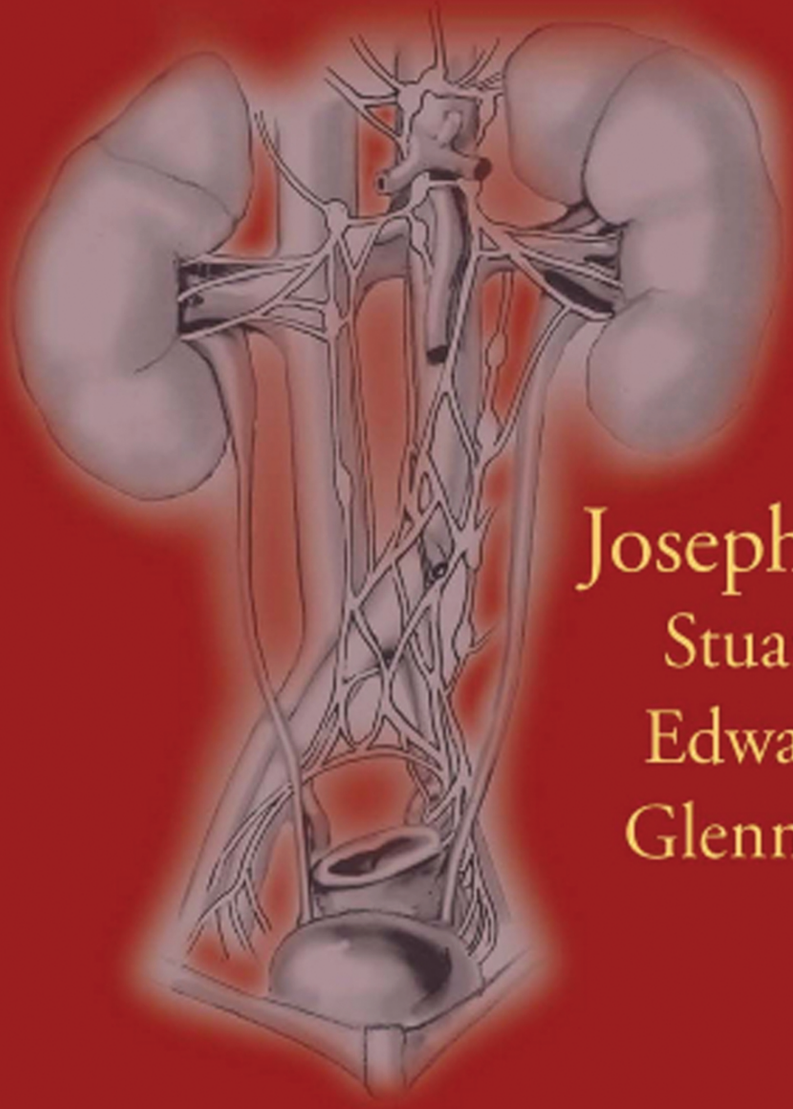

Joseph A. Smith, Jr.
Stuart S. Howards
Edward J. McGuire
Glenn M. Preminger

ELSEVIER
SAUNDERS

Hinman's Atlas of Urologic Surgery

This page intentionally left blank

Hinman's Atlas of Urologic Surgery

Third Edition

Joseph A. Smith, Jr., MD
William L. Bray Professor and Chairman
Department of Urologic Surgery
Vanderbilt University School of Medicine
Nashville, Tennessee

Stuart S. Howards, MD
Professor of Urology and Physiology
University of Virginia
Charlottesville, Virginia

Glenn M. Preminger, MD
James F. Glenn Professor and Chief
Urologic Surgery
Duke University Medical Center
Durham, North Carolina

Illustrated by William Winn, Atlanta, Georgia

ELSEVIER
SAUNDERS

ELSEVIER
SAUNDERS

1600 John F. Kennedy Blvd.
Ste 1800
Philadelphia, PA 19103-2899

HINMAN'S ATLAS OF UROLOGIC SURGERY, THIRD EDITION ISBN: 978-1-4160-4210-5

Copyright © 2012, by Saunders, an imprint of Elsevier Inc.
Copyright © 1998, 1992 by W.B. Saunders Company

All rights reserved. No part of this publication may be reproduced or transmitted in any form or by any means, electronic or mechanical, including photocopying, recording, or any information storage and retrieval system, without permission in writing from the publisher. Details on how to seek permission, further information about the Publisher's permissions policies and our arrangements with organizations such as the Copyright Clearance Center and the Copyright Licensing Agency, can be found at our website: www.elsevier.com/permissions.

This book and the individual contributions contained in it are protected under copyright by the Publisher (other than as may be noted herein).

Notices

Knowledge and best practice in this field are constantly changing. As new research and experience broaden our understanding, changes in research methods, professional practices, or medical treatment may become necessary.

Practitioners and researchers must always rely on their own experience and knowledge in evaluating and using any information, methods, compounds, or experiments described herein. In using such information or methods they should be mindful of their own safety and the safety of others, including parties for whom they have a professional responsibility.

With respect to any drug or pharmaceutical products identified, readers are advised to check the most current information provided (i) on procedures featured or (ii) by the manufacturer of each product to be administered, to verify the recommended dose or formula, the method and duration of administration, and contraindications. It is the responsibility of practitioners, relying on their own experience and knowledge of their patients, to make diagnoses, to determine dosages and the best treatment for each individual patient, and to take all appropriate safety precautions.

To the fullest extent of the law, neither the Publisher nor the authors, contributors, or editors, assume any liability for any injury and/or damage to persons or property as a matter of products liability, negligence or otherwise, or from any use or operation of any methods, products, instructions, or ideas contained in the material herein.

ISBN: 978-1-4160-4210-5

Senior Content Strategist: Stefanie Jewell-Thomas
Senior Content Development Specialist: Arlene Chappelle
Publishing Services Manager: Julie Eddy
Project Manager: Jan Waters
Design Direction: Steven Stave
Cover Designer: Steven Stave

Printed in China

Last digit is the print number: 9 8 7 6 5 4 3 2 1

Working together to grow
libraries in developing countries
www.elsevier.com | www.bookaid.org | www.sabre.org
ELSEVIER BOOK AID International Sabre Foundation

Dedication



The initial effort at producing a revised edition of *Hinman's Atlas of Urologic Surgery* was launched by Marty Resnick. It was only one of many contributions Marty made to urologic surgery, as he had an almost unparalleled impact on the specialty at many levels. His academic productivity and accomplishments significantly affected many aspects of patient care from management of stone disease to treatment of prostate cancer. He was an effective and visionary leader and served as President of the American Board of Urology and the American Urological Association. He functioned as editor of multiple publications including the Journal of Urology. Most important, though, Marty was a friend. The editors of the third edition of *Hinman's Atlas of Urologic Surgery* are pleased and honored to dedicate this text to the memory of Martin I. Resnick.

This page intentionally left blank

Contributors

Mark C. Adams, MD
Professor of Urology and Pediatrics
Vanderbilt University
Monroe Carell Jr. Children's Hospital at Vanderbilt
Nashville, TN
107: Colocystoplasty

David M. Albala, MD
Division of Urology
Duke University Medical Center
Durham, NC
135: Hand-Assisted Laparoscopic Surgery

Jennifer T. Anger, MD
Department of Urology
UCLA
Santa Monica, CA
113: Bladder Flap Repair (Boari)

Elizabeth Anoia, MD
Department of Urology
Duke University Medical Center
Durham, NC
110: Principles of Ureteral Reconstruction

Dean G. Assimos, MD
Professor of Surgical Sciences
Vice-Chair of Academic Affairs
Department of Urology
Wake Forest University School of Medicine
Winton-Salem, NC
158: Open Stone Surgery: Anatrophic Nephrolithotomy and Pyelolithotomy

Brian K. Auge, MD, FACS
Clinical Associate Professor of Surgery
Uniformed Services University School of Medicine
Bethesda, MA
Staff Urologist
Director of Endourology and Stone Disease
Naval Medical Center, San Diego
San Diego, CA
St. Luke's Hospital System
Mountain States Urology
Boise, ID
123: Ureteroscopic Endoureterotomy

Demetrius H. Bagley, MD, FACS
The Nathan Lewis Hatfield Professor of Urology
Professor of Radiology
Department of Urology
Thomas Jefferson University
Philadelphia, PA
125: Ureteroscopic Management of Transitional Cell Carcinoma

Linda A. Baker, MD
Professor of Urology
Director of Pediatric Research
University of Texas Southwestern Medical Center at Dallas
Pediatric Urologist
Children's Medical Center at Dallas
Dallas, TX
16: Flaps in Hypospadias Surgery

Daniel A. Barocas, MD
Department of Urology
NewYork Presbyterian Hospital/Weill Cornell Medical Center
New York, NY
96: Ileal Conduit

John M. Barry, MD
Division of Urology
Oregon Health & Science University
Portland, OR
143: Renal Transplant Recipient

Laurence S. Baskin, MD
Professor of Urology and Pediatrics
UCSF Children's Hospital
San Francisco, CA
12: Basic Instructions for Hypospadias Repair

Stephen Beck, MD
Department of Urology
Indiana Cancer Pavilion
Indianapolis, IN
60: Retroperitoneal Lymph Node Dissection

Anthony J. Bella, MD, FRCSC
Greta and John Hansen Chair in Men's Health Research
Assistant Professor of Urology
Department of Surgery
Associate Scientist, Neuroscience
University of Ottawa
Ottawa, Canada
28: Penile Arterial Revascularization;
29: Procedures for Peyronie's Disease

Jay T. Bishoff, MD, FACS
Associate Clinical Professor
Department of Surgery
University of Utah School of Medicine
Salt Lake City, UT
Director of Urology
Intermountain Urological Institute
Murray, UT
163: Laparoscopic Nephroureterectomy

Trinity J. Bivalacqua, MD, PhD
Assistant Professor of Urology and Oncology
Johns Hopkins Medical Institutions
Johns Hopkins University School of Medicine
Johns Hopkins Hospital
Baltimore, MD
30: Operations for Priapism

Jerry G. Blaivas, MD
Clinical Professor of Urology
Cornell University-Weill Medical College
New York, NY
Adjunct Professor
SUNY Downstate College of Medicine
Brooklyn, NY
36: Lateral Flap Urethral Reconstruction

Michael L. Blute, Sr., MD
Professor of Surgery
Director, Cancer Center of Excellence
UMass Memorial Medical Center University Campus
Worcester, MA
151: Anatomy and Principles of Renal Surgery;
152: Simple Nephrectomy;
153: Radical Nephrectomy;
154: Partial Nephrectomy;
155: Nephroureterectomy;
156: Extracorporeal Renal Surgery;
157: Vena Caval Thrombectomy

Stephen Anthony Boorjian, MD
Associate Professor
Mayo Clinic College of Medicine
Rochester, MN
104: Ureterosigmoidostomy

Joseph Borer, MD
Department of Urology
Children's Hospital Boston
Boston, MA
17: Two-Stage Repair of Hypospadias

James F. Borin, MD
Assistant Professor of Surgery
Director, Robotic Surgery
Greenebaum Cancer Center: Genitourinary Oncology
University of Maryland Medical Center
Baltimore, MD
160: Laparoscopic Transperitoneal Radical Nephrectomy

William O. Brant, MD
Assistant Professor
Department of Surgery
University of Utah Urology
Salt Lake City, UT
28: Penile Arterial Revascularization;
29: Procedures for Peyronie's Disease

John W. Brock III, MD
Professor of Urologic Surgery
Professor of Pediatrics
Vanderbilt University
Monroe Carell Jr. Professor
Surgeon-in-Chief
Monroe Carell Jr. Children's Hospital at Vanderbilt
Nashville, TN
106: Ileocystoplasty

Joshua A. Broghammer, MD, FACS
Assistant Professor
Department of Urology
University of Kansas School of Medicine
University of Kansas Medical Center
Kansas City, KS
31: Repair of Genital Injuries

Victor M. Brugh III, MD
Assistant Professor
Eastern Virginia Medical School
Norfolk, VA
50: Vasectomy

Jill C. Buckley, MD
Department of Urology
Lahey Clinic
Burlington, MA
141: Repair of Renal Injuries

Travis L. Bullock, MD
Urology
Missouri Baptist Medical Center
St. Louis, MO
94: Neuromodulation

Fiona C. Burkhard, MD
Assistant Professor
Department of Urology
University of Bern
Bern, Switzerland
105: Ileal Orthotopic Bladder Substitution

Arthur L. Burnett, MD, MBA
Patrick C. Walsh Distinguished Professor
Johns Hopkins Medical Institutions
Johns Hopkins University School of Medicine
Johns Hopkins Hospital
Baltimore, MD
30: Operations for Priapism

Jeffrey A. Cadeddu, MD
Professor of Urology and Radiology
UT Southwestern Medical School, Dallas
Dallas, TX
137: Renal Radiofrequency Ablation

Jeffrey B. Campbell, MD
Associate Professor
University of Colorado School of Medicine
Aurora, CO
161: Laparoscopic Heminephrectomy

David Canes, MD
Department of Urology
Lahey Clinic
Burlington, MA
126: Laparoscopic Ureterolithotomy

Patrick C. Cartwright, MD
Pediatric Urology Development
University of Utah School of Medicine
Salt Lake City, UT
109: Autoaugmentation by Seromyotomy

Erik P. Castle, MD, FACS
Associate Professor of Urology
College of Medicine
Mayo Clinic
Phoenix, AZ
Department of Urologic Oncology
Laparoscopic and Robotic Surgery
Mayo Clinic
Phoenix, AZ
84: Laparoscopic/Robotic Radical Cystectomy;
97: Laparoscopic/Robotic Ileal Conduit

Bradley Champagne, MD
Professor
Associate Professor
University Hospitals Case Medical Center
Cleveland, OH
10: Closure of Bowel Lacerations

Sam S. Chang, MD, FACS
Professor
Department of Urologic Surgery
Vanderbilt University Medical Center
Nashville, TN
78: Radical Cystectomy

Tony Y. Chen, MD
Minimally Invasive Urology Institute
Cedars-Sinai Medical Center
Torrance, CA
8: Methods of Nerve Block

Earl Y. Cheng, MD
Professor of Urology
Children's Memorial Hospital and The Feinberg School of Medicine at Northwestern University
Northwestern University
Chicago, IL
128: Endoscopic Incision of Ureterocele

Edward Cherullo, MD
Department of Urology
University Hospitals of Cleveland
Cleveland, OH
77: Partial Cystectomy

Alison M. Christie, MD
Assistant Professor of Clinical Urology
Department of Urology
Eastern Virginia Medical School
Norfolk, VA
Director of Robotic Surgery and Staff Urologic Surgeon
Naval Medical Center Portsmouth
Portsmouth, VA
76: Transurethral Resection of Bladder Tumors

Peter E. Clark, MD
Department of Urology
Vanderbilt University Medical Center
Nashville, TN
80: Pelvic Lymphadenectomy;
81: Pelvic Exenteration

Ralph V. Clayman, MD
Dean, School of Medicine
University of California, Irvine
Irvine, CA
Professor of Urology
University of California Irvine Medical Center
Orange, CA
160: Laparoscopic Transperitoneal Radical Nephrectomy

Michael S. Cookson, MD, MMHC
Professor of Urologic Surgery
Patricia and Rodes Hart Chair in Urologic Surgery
Vanderbilt University Medical Center
Nashville, TN
65: Anatomy and Principles of Excision of the Prostate;
66: Radical Retropubic Prostatectomy

Sean T. Corbett, MD
Department of Urology
Division of Pediatric Urology
University of Virginia Health System
Charlottesville, VA
55: Undescended Testis;
56: Reduction of Testicular Tension

Raymond A. Costabile, MD
Department of Urology
University of Virginia
Charlottesville, VA
51: Vasovasostomy and Vasoepididymostomy

Rodney Davis, MD
Professor
Department of Urology
Vanderbilt University
Nashville, TN
Adjutant Professor of Surgery
Meharry Medical College
Nashville, TN
84: Laparoscopic/Robotic Radical Cystectomy;
97: Laparoscopic/Robotic Ileal Conduit

Leslie A. Deane, MD
Assistant Professor
Director of Laparoscopy, Endourology and Robotic Urologic Surgery
Department of Urology
University of Illinois
College of Medicine
Chicago, IL
160: Laparoscopic Transperitoneal Radical Nephrectomy

Christopher B. Dechet, MD
Department of Urology
University of Utah School of Medicine
Salt Lake City, UT
79: Urethrectomy

John O. L. DeLancey, MD
Department of Obstetrics and Gynecology
University of Michigan at Ann Arbor
Ann Arbor, MI
38: Cystocele Repair, Enterocele Repair, and Rectocele Repair;
39: The Michigan Four-Wall Sacrospinous Suspension

Romano T. DeMarco, MD
Pediatric Urology
Vanderbilt University Medical Center
Nashville, TN
95: Vesicostomy

John D. Denstedt, MD, FRCS(C), FACS
Professor of Urology
Division of Urology
Department of Surgery
Schulich School of Medicine and Dentistry
Western University
London, Ontario, Canada
145: Percutaneous Endopyelotomy

Mahesh R. Desai, MS, FRCS
Department of Urology
Muljibhai Patel Urological Hospital
Gujarat India
146: Percutaneous Endopyeloplasty

Mihir M. Desai, MD
Glickman Urological Institute
Cleveland Clinic
Cleveland, OH
126: Laparoscopic Ureterolithotomy;
146: Percutaneous Endopyeloplasty

Rahul A. Desai, MD
Department of Urology
The Polyclinic
Seattle, WA
158: Open Stone Surgery: Anatrophic Nephrolithotomy and Pyelolithotomy

Grant Disick, MD
Endourology Fellow
Hackensack University Medical Center
Hackensack, NJ
150: Laparoscopic Live Donor Nephrectomy

Roger R. Dmochowski, MD, FACS
Professor of Urology
Director
Female Pelvic Medicine Reconstructive Fellowship
Vanderbilt University School of Medicine
Nashville, TN
32: Cecal Vagina;
86: Tension-Free Vaginal Tape/Suprapubic Midurethral Sling Pubovaginal;
87: Transobturator Midurethral Sling;
90: Transvaginal Repair of Vesicovaginal Fistula;
93: Female Vesical Neck Closure

Jack S. Elder, MD
Department of Urology
Case Western Reserve University
Rainbow Babies Children's Hospital
Cleveland, OH
52: Excision of Utricular Cyst

Sean P. Elliott, MD
Assistant Professor
Urologic Surgeon
Department of Urology
University of Minnesota
Minneapolis, MN
42: Reconstruction of Strictures of the Penile Urethra;
43: Reconstruction of Strictures of the Bulbar Urethra;
44: Reconstruction of Membranous Urethral Disruption Injuries

Donald A. Elmajian, MD, FACS
Professor of Urology
Louisiana State University Health Sciences Center—Shreveport
Director of Urologic Oncology
LSU Health
Shreveport, LA
59: Radical Orchiectomy

Amr Fergany, MD, PhD
Staff
Sections of Oncology, Laparoscopy and Robotics
Cleveland Clinic
Cleveland, OH
142: Surgery for Renal Vascular Disease

Brian J. Flynn, MD
Division of Urology
University of Colorado Health Science Center
Denver, CO
115: Repair of Ureterovaginal Fistula

Lindsay Fossett, MD
Attending Physician
North Shore Medical Center
Salem, MA
140: Surgery of the Horseshoe Kidney

Richard Foster, MD
Department of Urology
Indiana University
School of Medicine
Indianapolis, IN
60: Retroperitoneal Lymph Node Dissection

Arvind P. Ganpule, MD
Chief of Laparoscopy
Muljibhai Patel Urological Hospital
Nadiad, India
146: Percutaneous Endopyeloplasty

Patricio Gargollo, MD
Fellow
Department of Urology
Children's Hospital Boston
Boston, MA
17: Two-Stage Repair of Hypospadias

Inderbir S. Gill, MD, MCh
Glickman Urological Institute
Cleveland Clinic
Cleveland, OH
133: Retroperitoneal Laparoscopic Access

Carl K. Gjertson, MD
Assistant Professor of Surgery
Division of Urology
University of Connecticut School of Medicine
University of Connecticut Health Center
Farmington, CT
164: Laparoscopic Pyelolithotomy

David A. Goldfarb, MD
Professor of Surgery
Cleveland Clinic
Lerner College of Medicine
Director
Renal Transplantation
Glickman Urological and Kidney Institute
Cleveland Clinic
Cleveland, OH
144: Open Donor Nephrectomy/Cadaver Donor Nephrectomy

Marc Goldstein, BS, MD
Matthew P. Hardy Distinguished Professor of
Reproductive Medicine and Urology
Weill Cornell Medical College
Senior Scientist
The Population Council
Center for Biomedical Research
Surgeon-in-Chief
Male Reproductive Medicine and Surgery
New York Presbyterian Hospital
New York, NY
57: Simple Orchiectomy;
58: Testis-Sparing Surgery for Benign and Malignant Tumors

Mark L. Gonzalgo, MD, PhD
Assistant Professor of Urology and Oncology
Johns Hopkins University
Brady Urological Institute
Baltimore, MD
18: Partial Penectomy

E. Ann Gormley, MD
Professor of Surgery (Urology)
Dartmouth Medical School
Urologist
Dartmouth-Hitchcock Medical Center
Lebanon, NH
85: Autologous Pubovaginal Sling

Michael Guralnick, MD
Associate Professor of Urology
Medical College of Wisconsin
Milwaukee, WI
117: Ileal Ureteral Replacement

Georges-Pascal Haber, MD
Department of Urology
Cleveland Clinic
Cleveland, OH
133: Retroperitoneal Laparoscopic Access

George E. Haleblian, MD
Assistant Professor of Surgery
Co-Director
Section of Minimally Invasive Urologic Surgery and
Endourology Fellowship
Brown University Alpert School of Medicine
Providence, RI
120: Ureteroscopic Instrumentation
135: Hand-Assisted Laparoscopic Surgery

David Hartke, MD
Tidewater Physicians Multispecialty Group
Newport News, VA
67: Radical Perineal Prostatectomy

Wayne J. G. Hellstrom, MD, FACS
Professor of Urology
Chief
Section of Andrology
Tulane University School of Medicine
New Orleans, LA
54: Epididymectomy

S. Duke Herrell, MD, FACS
Associate Professor
Department of Urologic Surgery
Vanderbilt University Medical Center
Nashville, TN
68: Pelvic Lymph Node Dissection

†Frank Hinman, Jr.
Clinical Professor of Urology
Department of Urology
University of California School of Medicine
San Francisco, CA
32: Cecal Vagina;
90: Transvaginal Repair of Vesicovaginal Fistula

† Deceased

Jeffrey M. Holzbeierlein, MD, FACS
Associate Professor of Urology
Director of the Division of Urologic Oncology
University of Kansas Hospital
Kansas City, KS
19: Total Penectomy

Andrew I. Horowitz, MD
Resident
Case Medical Center
Case Western Reserve School of Medicine
University Heights, OH
7: Mobilization of the Omentum

William C. Hulbert, MD
Associate Professor of Urology and Pediatrics
University of Rochester School of Medicine and Dentistry
Attending Physician
Strong Memorial Hospital
Rochester General Hospital
University of Rochester School of Medicine and Dentistry
Rochester, NY
13: Postoperative Management

Hiroyuki Ihara, MD
Department of Urology
Institute of Minimally Invasive Surgery
Shintoshi Clinic
Iwata, Japan
170: Laparoscopic Approaches to the Adrenal Gland

Brant Inman, MD
Department of Urologic Surgery
Duke University Medical Center
Durham, NC
151: Anatomy and Principles of Renal Surgery;
152: Simple Nephrectomy;
153: Radical Nephrectomy;
154: Partial Nephrectomy;
155: Nephroureterectomy;
156: Extracorporeal Renal Surgery;
157: Vena Caval Thrombectomy

Thomas W. Jarrett, MD
The James Buchanan Brady Urological Institute
Johns Hopkins Hospital
Baltimore, MD
163: Laparoscopic Nephroureterectomy;
167: Percutaneous Resection of Upper Tract Urothelial Carcinoma

Gerald H. Jordan, MD, FACS, FAAP
Professor
Department of Urology
Eastern Virginia Medical School
Norfolk, VA
41: Reconstruction of the Fossa Navicularis

Steven A. Kaplan, MD
Department of Urology
Cornell University Medical Center
New York, NY
75: Retropubic Prostatectomy

Melissa R. Kaufman, MD, PhD
Assistant Professor of Urologic Surgery
Vanderbilt University Medical Center
Nashville, TN
1: Surgical Basics;
46: Direct Vision Internal Urethrotomy;
89: Technique for Insertion of Artificial Urinary Sphincter

Louis R. Kavoussi, MD, MBA
Waldbaum Gardner Professor of Urology
Hofstra North Shore—LIJ School of Medicine
Uniondale, NY
Chairman of Urology
Smith Institute for Urology
North Shore—LIJ Health System
New York, NY
61: Laparoscopic Retroperitoneal Lymph Node Dissection

Stuart Kesler, MD
Department of Urology
Hartford Hospital
Hartford, CT
150: Laparoscopic Live Donor Nephrectomy

Phillip S. Kick, MD
Department of Urology
Cooley Dickinson Hospital
Northhampton, MA
118: Open Ureterolithotomy

Andrew J. Kirsch, MD, FAAP, FACS
Georgia Pediatric Urology
Atlanta, GA
127: Endoscopic Management of VUR

Frederick A. Klein, MD
Department of Urology
University of Tennessee Medical Center
Knoxville, TN
98: Sigmoid and Transverse Colon Conduits

Kathleen C. Kobashi, MD
Continence Center at Virginia Mason Medical Center
Seattle, WA
33: Urethrovaginal Fistula Repair

Philippe Koenig, MD
Department of Urology
Cleveland Clinic
Cleveland, OH
133: Retroperitoneal Laparoscopic Access

Chester J. Koh, MD
Department of Urology
Children's Hospital of Los Angeles
Los Angeles, CA
25: Hidden Penis

Paul Kokorowski, MD
Department of Urology
Children's Hospital of Los Angeles
Los Angeles, CA
25: Hidden Penis

Venkatesh Krishnamurthi, MD
Director
Kidney/Pancreas Transplant Program
Cleveland Clinic Foundation
Cleveland, OH
144: Open Donor Nephrectomy/Cadaver Donor Nephrectomy

Bradley P. Kropp, MD, FAAP, FACS
Professor of Urology
University of Oklahoma
Chief, Pediatric Urology
Children's Hospital of Oklahoma
Oklahoma City, OK
161: Laparoscopic Heminephrectomy

Ramsay L. Kuo, MD
Director
St. Peter's Hospital Kidney Stone Center
St. Peter's Hospital
Albany, NY
132: Percutaneous Nephrolithotomy

Jaime Landman, MD
Division of Urologic Surgery
Washington University School of Medicine
St. Louis, MO
159: Laparoscopic Simple Nephrectomy

Kindra Larson, BS, MD
Assistant Professor
Eastern Virginia Medical School
Norfolk, VA
38: Cystocele Repair, Enterocele Repair, and Rectocele Repair

Jerilyn M. Latini, MD
Associate Professor of Urology
University of Michigan
Ann Arbor, MI
100: Principles of Continent Reconstruction

Gary E. Leach, MD
Director
Tower Urology Institute for Continence
Los Angeles, CA
35: Female Urethral Diverticulectomy

David I. Lee, MD
Assistant Professor of Urology/Surgery
Perelman School of Medicine
University of Pennsylvania
Chief of Urology
Penn Presbyterian Medical Center
Philadelphia, PA
147: Laparoscopic Renal Biopsy

Wendy W. Leng, MD, MS
Associate Professor of Urology
University of Pittsburgh School of Medicine
University of Pittsburgh Medical Center
Pittsburgh, PA
91: Transvesical Repair of Vesicovaginal Fistula

James O. L'Esperance, MD
Department of Urology
Naval Hospital in San Diego
San Diego, CA
135: Hand-Assisted Laparoscopic Surgery

Raymond J. Leveillee, MD
Department of Urology
University of Miami School of Medicine
Miami, FL
149: Robot-Assisted Laparoscopic Pyeloplasty

David A. Levy, MD
Assistant Professor of Surgery/Urology
Cleveland Clinic Lerner College of Medicine
Faculty Department of Regional Urology
Glickman Urological and Kidney Institute
Cleveland Clinic Foundation
Cleveland, OH
62: Midline Lower Abdominal Peritoneal Incision;
63: Transverse Lower Abdominal Incision;
64: Gibson Incision

James E. Lingeman, MD
Methodist Urology
Indianapolis, IN
131: Percutaneous Renal Access

Tom F. Lue, MD
Department of Urology
University of California School of Medicine
San Francisco, CA
28: Penile Arterial Revascularization;
29: Procedures for Peyronie's Disease

John H. Makari, MD
Department of Pediatric Urology
Hartford Hospital
Hartford, CT
111: Ureteroneocystostomy

Eric L. Marderstein, MD, MPH
Assistant Professor
Division of Colorectal Surgery
Department of Surgery
Case Western Reserve School of Medicine
University Hospitals Case Medical Center
Cleveland, OH
6: Bowel Stapling Techniques

Charles G. Marguet, MD
Division of Urology
Duke University Medical Center
Durham, NC
122: Ureteroscopic Management of Renal Calculi

Frances M. Martin, MS, MD
Urologic Oncologist
Lakeland Regional Cancer Center
Lakeland, FL
102: Ileocecal Reservoir

Jack W. McAninch, MD
Professor and Vice Chair
Urology
Chief of Urology
San Francisco General Hospital
San Francisco, CA
42: Reconstruction of Strictures of the Penile Urethra;
43: Reconstruction of Strictures of the Bulbar Urethra;
44: Reconstruction of Membranous Urethral Disruption Injuries;
141: Repair of Renal Injuries

R. Dale McClure, MD
Clinical Professor of Urology
University of Washington School of Medicine
Attending Urologist
Virginia Mason Medical Center
Seattle, WA
47: Testis Biopsy

Edward J. McGuire, MD
Professor
Department of Urology
University of Michigan Health System
Ann Arbor, Michigan
37: Urethral Prolapse-Caruncle;
88: Bulking Agents for Incontinence and Reflux

Kevin T. McVary, MD
Department of Urology
Northwestern University Feinberg School of Medicine
Chicago, IL
74: Suprapubic Prostatectomy

Robert A. Mevorach, MD
Associate Professor of Urology and Pediatrics
University of Rochester School of Medicine
Golisano Children's Hospital
University of Rochester
Rochester, NY
13: Postoperative Management

Richard G. Middleton, MD
Department of Urology
University of Utah School of Medicine
Salt Lake City, UT
45: York-Mason Repair of Recto-Urinary Fistula

Douglas F. Milam, MD
Associate Professor of Urologic Surgery
Vanderbilt University
Attending Urologist
Vanderbilt University Medical Center
Nashville, TN
20: Ilioinguinal Lymphadenectomy;
21: Laser Treatment of the Penis;
46: Direct Vision Internal Urethrotomy;
71: Transurethral Resection of the Prostate;
72: Transurethral Incision of the Prostate;
73: Laser Treatment of Benign Prostatic Disease

Elizabeth A. Miller, MD
Department of Urology
University of Washington Medical Center
Seattle, WA
116: Ureteroureterostomy and Transureteroureterostomy

Nicole Miller, MD
Department of Urologic Surgery
Vanderbilt University School of Medicine
Nashville, TN
73: Laser Treatment of Benign Prostatic Disease;
131: Percutaneous Renal Access

Joshua K. Modder, MD
Wisconsin Institute of Urology
Appleton, WI
74: Suprapubic Prostatectomy

Ali Moinzadeh, MD
Assistant Professor of Urology
Tufts University School of Medicine
Director of Robotic Surgery
Lahey Clinic
Burlington, MA
11: Basic Robotic Surgery

Manoj Monga, MD, FACS
Professor of Urology and Biomedical Engineering
Cleveland Clinic Lerner College of Medicine
Case Western Reserve University
Director
Stevan Streem Center for Endourology and Stone Disease
Cleveland Clinic
Cleveland, OH
119: Ureteral Access

Drogo K. Montague, MD
Glickman Urological Institute
Cleveland Clinic
Cleveland, OH
27: Inflatable Penile Prosthesis Implantation

James Montie, MD
Professor of Urology
University of Michigan
Ann Arbor, MI
100: Principles of Continent Reconstruction

Charles R. Moore, MD
Department of Urology
Forrest General Hospital
Hattiesburg, MS
149: Robot-Assisted Laparoscopic Pyeloplasty

Allen F. Morey, MD
Urology Center
Brooke Army Medical Center
San Antonio, TX
40: Urethral Reconstruction: General Concepts

Daniel M. Morgan, MD
Department of Obstetrics and Gynecology
University of Michigan at Ann Arbor
Ann Arbor, MI
38: Cystocele Repair, Enterocele Repair, and Rectocele Repair

Shelby N. Morrisroe, MD
Urology Specialists of Southern California
Torrance, CA
91: Transvesical Repair of Vesicovaginal Fistula

Patrick W. Mufarrij, MD
Assistant Instructor
Department of Urology
Wake Forest School of Medicine
Winston-Salem, NC
165: Laparoscopic Caliceal Diverticulectomy

Ravi Munver, MD, FACS
Associate Professor
The University of Medicine and Dentistry of New Jersey
New Jersey Medical School
Newark, NJ
Chief, Minimally Invasive & Robotic Urologic Surgery
Hackensack University Medical Center
Hackensack, NJ
150: Laparoscopic Live Donor Nephrectomy

Christopher S. Ng, MD
Chief
Division of Urology
Cedars-Sinai Medical Center
Los Angeles, CA
8: Methods of Nerve Block
9: Repair of Vascular Injuries

Alan A. Nisbet, MD
Corpus Christi Urology Group
Corpus Christi, TX
19: Total Penectomy

[†]Andrew C. Novick, MD
Glickman Urological Institute
The Cleveland Clinic
Cleveland, OH
142: Surgery for Renal Vascular Disease

R. Corey O'Connor, MD
Associate Professor of Urology
Associate Residency Program Director
Medical College of Wisconsin
Milwaukee, WI
117: Ileal Ureteral Replacement

Zeph Okeke, MD
Assistant Professor
Hofstra University North Shore Long Island Jewish School of Medicine
Hofstra University
Hempstead, NY
Attending Physician
Arthur Smith Institute for Urology
North Shore Long Island Jewish Health System
New Hyde Park, NY
140: Surgery of the Horseshoe Kidney

Raymond W. Pak, MD, PharmD
Medical Director of Robotic Surgery
Piedmont Hospital
Atlanta, GA
125: Ureteroscopic Management of Transitional Cell Carcinoma

Dipen J. Parekh, MD, MCh
Director of Robotic Surgery
Department of Urology
University of Texas Health Sciences Center
San Antonio, TX
18: Partial Penectomy;
104: Ureterosigmoidostomy

Margaret S. Pearle, MD, PhD
Professor of Urology and Internal Medicine
University of Texas Southwestern Medical Center
Dallas, TX
124: Ureteroscopic Endopyelotomy

Elise Perer, MD
Urology Specialists of Southern California
Torrance, CA
35: Female Urethral Diverticulectomy

Andrew C. Peterson, MD, FACS
Associate Professor of Urologic Surgery
Duke University
Durham, NC
114: Ureteral Stricture Repair and Ureterolysis

Courtney K. Phillips, MD
Assistant Professor
Department of Urology
The Mount Sinai Hospital
New York, NY
159: Laparoscopic Simple Nephrectomy

Ketsia Pierre, MD
Urology Specialists of Southern California
Torrance, CA
99: Fecal Diversion

Thomas J. Polascik, MD, FACS
Professor of Surgery
Director
Society of Urologic Oncology Program
Duke University Medical Center
Durham, NC
136: Renal Cryosurgery

[†] Deceased

Lee Ponsky, MD, FACS
Associate Professor
Department of Urology
Case Western Reserve University School of Medicine
Director
Center for Urologic Oncology and Minimally Invasive Therapies
Leo and Charlotte Goldberg Chair in Advanced Surgical Therapies
Urology Institute
University Hospitals Case Medical Center
Cleveland, OH
2: Basic Surgical Techniques;
3: Basic Laparoscopy;
4: Suture Techniques

John Pope, MD
Department of Pediatric Urology
Vanderbilt Children's Hospital
Nashville, TN
108: Ureterocystoplasty;
111: Ureteroneocystostomy

Glenn M. Preminger, MD
James F. Glenn Professor and Chief
Urologic Surgery
Duke University Medical Center
Durham, NC
121: Ureteroscopic Management of Ureteral Calculi;
122: Ureteroscopic Management of Renal Calculi

Juan C. Prieto, MD
Pediatric Urology Fellow
University of Texas Southwestern Medical Center
Dallas, TX
Pediatric Urologist
Driscoll Children's Hospital
Assistant Professor
Texas A&M University
Corpus Christi, TX
16: Flaps in Hypospadias Surgery

Ronald Rabinowitz, MD
Professor of Urology and Pediatrics
Associate Chair
Department of Urology
University of Rochester School of Medicine and Dentistry
Chief of Pediatric Urology
Strong Memorial Hospital
Rochester General Hospital
Rochester, NY
13: Postoperative Management

David E. Rapp, MD
Clinical Fellow
Urology and Renal Transplantation
Virginia Mason Medical Center
Seattle, WA
33: Urethrovaginal Fistula Repair

Shlomo Raz, MD
Reconstructive Surgery and Urodynamics
The Geffen School of Medicine at UCLA
Los Angeles, CA
34: Bulbocavernosus Muscle and Fat Pad Supplement

John F. Redman, MD
Professor of Urology and Pediatrics
Department of Urology
University of Arkansas College of Medicine
Little Rock, AR
138: Anatomy and Principles of Open Reconstructive Renal Surgery

Lee Richstone, MD
The Smith Institute for Urology
Long Island, NY
61: Laparoscopic Retroperitoneal Lymph Node Dissection

William W. Roberts, MD
Associate Professor
Department of Urology
University of Michigan Health System
Ann Arbor, MI
134: Transperitoneal Laparoscopic Access

Michael J. Rosen, MD
Assistant Professor of Surgery
Chief, Division of General and Gastrointestinal Surgery
Case Medical Center
Case Western Reserve University School of Medicine
Cleveland, OH
7: Mobilization of the Omentum

Gregory S. Rosenblatt, MD
Minimally Invasive Urology Institute
Cedars-Sinai Medical Center
Torrance, CA
9: Repair of Vascular Injuries

Randall G. Rowland, MD, PhD
Professor of Surgery/Urology
University of Kentucky
Lexington, KY
102: Ileocecal Reservoir

Rajiv Saini, MD
Attending Urologist
Brookdale University Hospital and Medical Center
Brooklyn, NY
75: Retropubic Prostatectomy

Francisco J. B. Sampaio, MD, PhD
Rua Siqueira Campos
Rio de Janeiro, Brazil
130: Anatomical Basis for Renal Endoscopy

Harriette M. Scarpero, MD
Department of Urology
Vanderbilt University Medical Center
Nashville, TN
82: Excision of Vesical Diverticulum;
83: Cystolithotomy

Douglas S. Scherr, MD
Associate Professor of Urology
The Ronald Stanton Clinical Scholar in Urology
Weill Medical College of Cornell University
Attending Physician
New York Presbyterian Hospital
New York, NY
96: Ileal Conduit

Peter N. Schlegel, MD
Department of Urology
New York Presbyterian Hospital
New York, NY
48: Sperm Retrieval;
53: Spermatocelectomy

Neil D. Sherman, MD
Division of Urology
University of Medicine and Dentistry of New Jersey
New Jersey Medical School
Newark, NJ
112: Psoas Hitch

John Shields, MD
Miami, FL
149: Robot-Assisted Laparoscopic Pyeloplasty

Katsuto Shinohara, MD
Professor
Department of Urology
University of California, San Francisco
Attending Physician
Helen Diller Family Comprehensive Cancer Center
University of California, San Francisco
San Francisco, CA
70: Cryotherapy

Steven W. Siegel, MD
Center for Continence Care
Metropolitan Urologic Specialists
St. Paul, MN
94: Neuromodulation

Eila Skinner, MD
Department of Urology
Keck School of Medicine of the university of Southern California
Los Angeles, CA
129: Surgical Approaches for Open Renal Surgery

Steven J. Skoog, MD, FAAP, FACS
Professor of Surgery and Pediatrics
Director of Pediatric Urology
Doernbecher Children's Hospital
Oregon Health and Science University
Portland, OR
24: Penile Curvature in the Pediatric Patient

Arthur D. Smith, MD
Professor of Urology
Hofstra University North Shore Long Island Jewish School of Medicine
Hofstra University
Hempstead, NY
Chairman Emeritus
Attending Physician
Arthur Smith Institute for Urology
North Shore Long Island Jewish Health System
New Hyde Park, NY
140: Surgery of the Horseshoe Kidney

Joseph A. Smith, Jr., MD
William L. Bray Professor and Chairman
Department of Urologic Surgery
Vanderbilt University School of Medicine
Nashville, TN
1: Surgical Basics;
69: Robotic-Assisted Laparoscopic Prostatectomy

Warren T. Snodgrass, MD
Professor of Urology
University of Texas Southwestern Medical Center at Dallas
Chief of Pediatric Urology
Children's Medical Center
Dallas, TX
15: Decision-Making in Hypospadias Surgery

Hooman Soltanian, MD, FACS
Assistant Professor of Plastic Surgery
Case Western Reserve School of Medicine
Chief
Division of Breast Plastic Surgery
Case Medical Center
Cleveland, OH
5: Plastic Surgical Techniques

Rene Sotelo, MD
Director
Robotic and Minimally Invasive Surgery
Department of Urology
Instituto Médico la Floresta
Caracas, Venezuela
126: Laparoscopic Ureterolithotomy

J. Patrick Spirnak, MD
Department of Urology
Metro Health Medical Center
Cleveland, OH
118: Open Ureterolithotomy

William D. Steers, MD
Department of Urology
University of Virginia School of Medicine
Paul Mellon Professor and Chair
University of Virginia Hospital
Charlottesville, VA
26: Insertion of Flexible Prosthesis;
29: Procedures for Peyronie's Disease

† John P. Stein, MD
The USC Norris Comprehensive Cancer Center
Los Angeles, CA
101: Ileal Reservoir (T-Pouch)

Michael D. Stifelman, MD
Department of Urology
NYU School of Medicine
New York, NY
165: Laparoscopic Caliceal Diverticulectomy

Urs E. Studer, MD
Professor of Urology
Expert Consultant
Department of Urology
University Hospital of Bern
Bern, Switzerland
105: Ileal Orthotopic Bladder Substitution

Chandru P. Sundaram, MD
Department of Urology
Indiana University School of Medicine
Indianapolis, IN
164: Laparoscopic Pyelolithotomy

Roger L. Sur, MD
Associate Professor of Surgery
University of California, San Diego School of Medicine
Director
University of California, San Diego Comprehensive Kidney Stone Center
University of California, San Diego Health System
San Diego, CA
121: Ureteroscopic Management of Ureteral Calculi

Richard W. Sutherland, MD
Department of Surgery
University of Northern California–Chapel Hill
Chapel Hill, NC
148: Laparoscopic Pyeloplasty

Kazuo Suzuki, MD
Department of Urology
Institute of Minimally Invasive Surgery
Shintoshi Clinic
Iwata, Japan
170: Laparoscopic Approaches to the Adrenal Gland

Yeh Hong Tan, MBBS, M.Med, FRCSEd, FAMS
Director of Endourology
Director of Laparoscopy and Robotic Surgery
Department of Urology
Singapore General Hospital
Singapore
166: Laparoscopic Renal Cyst Ablation

Cigdem Tanrikut, MD
Assistant Professor of Surgery (Urology)
Harvard Medical School
Director
Male Reproductive Medicine
Massachusetts General Hospital Fertility Center
Assistant in Urology
Massachusetts General Hospital
Boston, MA
48: Sperm Retrieval;
53: Spermatocelectomy;
57: Simple Orchiectomy;
58: Testis-Sparing Surgery for Benign and Malignant Tumors

David D. Thiel, MD
Department of Urology
Mayo Clinic
Jacksonville, FL
162: Laparoscopic Partial Nephrectomy

John C. Thomas, MD, FAAP
Assistant Professor of Urologic Surgery
Division of Pediatric Urology
Monroe Carell Jr. Children's Hospital
Vanderbilt University
Nashville, TN
103: Appendicovesicostomy

Raju Thomas, MD
Department of Urology
Tulane University Health Science Center
New Orleans, LA
84: Laparoscopic/Robotic Radical Cystectomy;
97: Laparascopic/Robotic Ileal Conduit

Veronica Triaca, MD
Department of Urology
Concord Hospital
Concord, NH
34: Bulbocavernosus Muscle and Fat Pad Supplement

Joseph A. Trunzo, MD
Resident
University Hospitals Case Medical Center
Cleveland, OH
6: Bowel Stapling Techniques

Nobuo Tsuru, MD
Department of Urology
Hamamatsu University School of Medicine
Hamamatsu City, Japan
170: Laparoscopic Approaches to the Adrenal Gland

Paul J. Turek, MD
Department of Urology
University of California, San Francisco
San Francisco, CA
49: Varicocele Ligation

† Deceased

Christian O. Twiss, MD
Director, Female Urology, Pelvic Medicine, and Pelvic Reconstructive Surgery
Assistant Professor of Surgery
Department of Surgery
University of Arizona
Tucson, AZ
34: Bulbocavernosus Muscle and Fat Pad Supplement

Brian A. Vanderbrink, MD
Department of Urology
Nationwide Children's Hospital
Columbus, OH
61: Laparoscopic Retroperitoneal Lymph Node Dissection

Sandip P. Vasavada, MD
Associate Professor of Surgery (Urology)
Cleveland Clinic Lerner College of Medicine
Urologic Director
Center for Female Urology and Reconstructive Pelvic Surgery
Cleveland Clinic Glickman Urological and Kidney Institute
Cleveland, OH
92: Transperitoneal Vesicovaginal Fistula Repair

E. Darracott Vaughan, Jr., MD
Professor Emeritus
Department of Urology
Weill Cornell Medical College
New York Presbyterian Hospital
New York, NY
168: Adrenal Anatomy and Preparation for Adrenal Surgery;
169: Open Approaches to the Adrenal Gland

Dennis D. Venable, MD, FACS
Professor and Chairman of Urology
Louisiana State University Health Sciences Center—Shreveport
Chief of Urology Service
LSU Health—Shreveport
Shreveport, LA
59: Radical Orchiectomy

Srinivas Vourganti, MD
Clinical Fellow
National Cancer Institute
Bethesda, MD
2: Basic Surgical Techniques;
3: Basic Laparoscopy;
4 : Suture Techniques

Kristofer R. Wagner, MD
Director, Robotic Surgery
Department of Urology
Temple Clinic
Temple, TX
167: Percutaneous Resection of Upper Tract Urothelial Carcinoma

Dena L. Walsh, MD
Evans Army Community Hospital
Colorado Springs, CO
82: Excision of Vesical Diverticulum;
83: Cystolithotomy

Thomas J. Walsh, MD
Assistant Professor
Department of Urology
School of Medicine
University of Washington
Seattle, WA
49: Varicocele Ligation

Julian Wan, BS, MD
Clinical Associate Professor of Urology
Department of Urology
University of Michigan
Attending Pediatric Urologist
CS Mott Children's Hospital and Von Voigtlander Women's Hospital
Ann Arbor, MI
22: Circumcision;
23: Dorsal Slit

W. Bedford Waters, MD
Division of Urology
The University of Tennessee Medical Center
Knoxville, TN
98: Sigmoid and Transverse Colon Conduits

George D. Webster, MB, FRCS
Professor of Urology
Duke University Medical Center
Durham, NC
110: Principles of Ureteral Reconstruction

Hunter Wessells, MD
Professor and Chair
Department of Urology
University of Washington School of Medicine
Harborview Medical Center
Seattle, WA
31: Repair of Genital Injuries

Wesley M. White, MD
Division of Urology
The University of Tennessee Medical Center
Knoxville, TN
98: Sigmoid and Transverse Colon Conduits

John S. Wiener, MD
Associate Professor of Surgery (Urology) and Pediatrics
Head
Section of Pediatric Urology
Duke University School of Medicine
Durham, NC
14: Pediatric Meatotomy;
139: Open Pyeloplasty

Geoffrey R. Wignall, MD
Division of Urology
Department of Surgery
Schulich School of Medicine and Dentistry
University of Western Ontario
London, Ontario, Canada
145: Percutaneous Endopyelotomy

Howard N. Winfield, MD
West Alabama Urology Associates
Tuscaloosa, AL
162: Laparoscopic Partial Nephrectomy

Paul E. Wise, MD
Associate Professor of Surgery Director, Vanderbilt Hereditary Colorectal Cancer Registry
Vanderbilt University Medical Center
Nashville, TN
99: Fecal Diversion

J. Stuart Wolf, Jr., MD
The David A. Bloom Professor of Urology
Head
Division of Endourology
Associate Department Chair for Clinical Affairs
Department of Urology
University of Michigan
Ann Arbor, MI
134: Transperitoneal Laparoscopic Access

Christopher E. Wolter, MD
Department of Urology
Mayo Clinic
Scottsdale, AZ
86: Tension-Free Vaginal Tape/Suprapubic Midurethral Sling Pubovaginal;
87: Transobturator Midurethral Sling;
93: Female Vesical Neck Closure

Michael E. Woods, MD
Assistant Professor
Department of Urology
Loyola University Health System
Maywood, IL
84: Laparoscopic/Robotic Radical Cystectomy;
97: Laparascopic/Robotic Ileal Conduit

Ilia S. Zeltser, MD
The Bryn Mawr Urology Group
Rosemont, PA
124: Ureteroscopic Endopyelotomy;
137: Renal Radiofrequency Ablation

Foreword

In order that the reader should fully understand a surgical procedure, a clear description of the surgery in which the author explains each step in detail is necessary. The addition of line drawings and photographs not only helps our understanding of the written word but also increases the reader's understanding of how complex an operation is and makes it a more interesting endeavor toward making one more adept. There is no question that the combination of illustrations and clear text is of great interest to those who want to learn a surgical procedure and to those who may, perhaps, need a reminder about a particular anatomical or surgical detail.

It is common practice today for residents to look up a particular method of performing a procedure before surgery in order to be of greater help during the operation. The value of having a series of illustrations that can be accessed preoperatively is incalculable, especially if they explain the surgical anatomy in the clearest way. I can think of so many videos of new techniques that have been prepared by experts and that have been looked at intensely by residents and experienced surgeons alike. The fact that many of these are now available online is an added bonus.

Hinman's Atlas of Urologic Surgery is an example of such an invaluable work, and the fact that it is now in its third edition is testament to its popularity. The editors are to be congratulated on creating a textbook that is inclusive of all the techniques in contemporary urology, including both the tried and tested methods that have been used for many years as well as the newest techniques, such as those involving laparoscopic and robotic technology. In this way, a textbook has been produced that should be of interest and of value to everyone. The clarity of the illustrations will add to this interest and additionally make a particular technique more accessible to the reader. It is, in my opinion, unusual to have a reference book that addresses all areas of interest in urology.

I first met Frank Hinman, Jr. toward the end of his urologic career and early on in my own. He was a charming person who always had time to speak to even the least important and to listen to what they had to say. When I gave my first presentation to the American Association of Genitourinary Surgeons it was a wonderful experience to have him discuss the paper and to give his critique, but I wish to stress that this was with a smile on his face, by adding his insight and experience in a most helpful way.

Frank Hinman was not only a delightful person but also a very serious innovator. His understanding of many aspects of urology across a very wide spectrum led to multiple, widely read publications. In addition, his innovation produced a considerable number of academic textbooks, which live on after him. Besides his *Atlas of Urologic Surgery,* there have been many books in more specific areas of urology, not least of which is *Hinman's Atlas of Pediatric Urologic Surgery.*

This book is a testament to a great man, who excelled in a great specialty. This, however, is a very changed textbook. The layout and the table of contents have a distinctly modern ring to them, which is due to the diligence of the Editor Jay Smith and the Associate Editors Glenn Preminger and Stuart Howards. They have created an exhaustive list of the leading contributors in their fields. They are to be congratulated for having produced a superlative textbook. I am delighted and honored to write this foreword and to warmly recommend it to those who enjoy urologic surgery.

John M. Fitzpatrick
March 2012
Dublin, Ireland

This page intentionally left blank

Preface

For almost three decades, *Hinman's Atlas of Urologic Surgery* has been an essential text for both novice and experienced surgeons performing procedures involving the genitourinary system. Even when the first edition was written, urologic surgery was becoming increasingly varied and complex but urologists were generally expected to be adept at all procedures within the domain of the specialty. Nonetheless, it is remarkable to realize that one person, Dr. Frank Hinman, Jr., could be capable of overseeing and, indeed, writing a comprehensive atlas of urologic surgical procedures while working with only a single illustrator.

The second edition was published in 1998 and included updates of procedures described in the original text, introduction of newer operative approaches and techniques, and expert commentary. Topics in the second edition did not include endoscopic or percutaneous surgery. Laparoscopic approaches received relatively little attention and robotic surgery had not yet been developed. The book was comprehensive and contemporary, though, and remained the standard and the best step-by-step surgical atlas for urologic procedures.

Medicine in general and urology in particular are changing at an almost unimaginable pace. The 14 years between publication of the second edition of *Hinman's Atlas of Urologic Surgery* and his third edition have seen the emergence of new surgical approaches, refinements in operative technique, and the availability of instruments previously unimagined. The increasing depth and breadth of urology have made it almost impossible for one individual to be a master of all domains. Increasingly, urologic surgeons are developing focused expertise and practice in subdisciplines within urology. This has elevated the need for a comprehensive atlas to serve as an expert but practical guide for both novice and experienced surgeons.

The editors of this third edition of the classic text carefully reviewed the table of contents of the prior editions. Some topics or procedures simply were outdated and no longer used and were deleted. Others were updated. There was an obvious need for the inclusion of new subjects, such as robotic surgery, and expansion of laparoscopic topics. Importantly, a decision was also made to include endoscopic and percutaneous surgery. Time-honored and important open surgical approaches remain, but the reality is that the majority of urologic surgery is now performed through laparoscopic or endoscopic access.

Expansion of the scope of the text also required a fundamental difference in the approach to authorship. Rather than a single-author text with commentary from experts, each chapter was assigned to a recognized authority who was expected to provide a practical surgical guide as well as tips and suggestions based on personal experience. Many new illustrations were needed for new or updated procedures. Importantly, color illustrations and operative photographs are now included.

Regardless of the many changes that have occurred with this third edition, the fundamental basis of the text is unaltered. The same surgical principles apply regardless of approach and despite new innovations. Step-by-step discussion of operative technique is presented with outstanding quality illustrations and photographs. In fact, some of the procedures and figures from the initial publication of *Hinman's Atlas of Urologic Surgery* are included in this revised edition with little or no modifications.

The increasing complexity of urologic surgery makes a comprehensive, high-quality surgical atlas even more valuable. Novice surgeons can use the information in this text to supplement other training and to help develop their surgical technique and skills. Almost no surgeon can have extensive experience with all aspects of urologic surgery now, so even highly skilled surgeons will find the operative descriptions and illustrations of benefit for procedures they may perform less frequently.

A book of this complexity and comprehension requires the contributions of many individuals. Stuart Howards and Glenn Preminger have been invaluable in their role as associate editors. Both are highly skilled surgeons and respected leaders in urology. They have provided the advice, oversight, and review necessary to ensure the outstanding quality expected of this text. All of the editors are particularly indebted to the many contributing authors. It is their willingness to share lessons learned from their own experiences that contribute not only to the excellence of the book but, more meaningfully, to the care of patients.

Urologic surgery is more diverse and complex than it was 30 years ago and so, necessarily, is the third edition of *Hinman's Atlas of Urologic Surgery*. Surgeons bear great responsibility to patients who entrust their lives to them to be as prepared as possible to perform operations with the skill, knowledge, and the judgment to provide optimal outcomes. It is hoped that this surgical atlas will facilitate that goal. For that reason, I am honored to serve as editor of a classic and essential text, *Hinman's Atlas of Urologic Surgery*.

Joseph A. Smith, Jr., MD

This page intentionally left blank

Contents

I
SURGICAL BASICS 1

1. Surgical Basics (Melissa R. Kaufman & Joseph A. Smith, Jr.) 3

II
THE UROLOGIST AT WORK 13

2. Basic Surgical Techniques (Lee Ponsky & Srinivas Vourganti) 15
3. Basic Laparoscopy (Lee Ponsky & Srinivas Vourganti) 17
4. Suture Techniques (Lee Ponsky & Srinivas Vourganti) 29
5. Plastic Surgical Techniques (Hooman Soltanian) 39
6. Bowel Stapling Techniques (Joseph A. Trunzo & Eric L. Marderstein) ... 53
7. Mobilization of the Omentum (Andrew I. Horowitz & Michael J. Rosen) 61
8. Methods of Nerve Block (Christopher S. Ng & Tony Y. Chen) 65
9. Repair of Vascular Injuries (Christopher S. Ng & Gregory S. Rosenblatt) 71
10. Closure of Bowel Lacerations (Bradley Champagne) 77
11. Basic Robotic Surgery (Ali Moinzadeh) 81

III
PENIS: PLASTIC OPERATIONS 85

12. Basic Instructions for Hypospadias Repair (Laurence S. Baskin) 87
13. Postoperative Management (Ronald Rabinowitz, William C. Hulbert, & Robert A. Mevorach) 93
14. Pediatric Meatotomy (John S. Wiener) 95
15. Decision-Making in Hypospadias Surgery (Warren T. Snodgrass) 97
16. Flaps in Hypospadias Surgery (Juan C. Prieto & Linda A. Baker) 103
17. Two-Stage Repair of Hypospadias (Patricio Gargollo & Joseph Borer) 109

IV
PENIS: MALIGNANCY 113

18. Partial Penectomy (Mark L. Gonzalgo & Dipen J. Parekh) 115
19. Total Penectomy (Alan A. Nisbet & Jeffrey M. Holzbeierlein) 119
20. Ilioinguinal Lymphadenectomy (Douglas F. Milam) 123
21. Laser Treatment of the Penis (Douglas F. Milam) 131

V
PENIS: CORRECTION 137

22. Circumcision (Julian Wan) 139
23. Dorsal Slit (Julian Wan) 145
24. Penile Curvature in the Pediatric Patient (Steven J. Skoog) 147
25. Hidden Penis (Paul Kokorowski & Chester J. Koh) 151

VI
PENIS: RECONSTRUCTION 159

26. Insertion of Flexible Prosthesis (William D. Steers) 161
27. Inflatable Penile Prosthesis Implantation (Drogo K. Montague) 169
28. Penile Arterial Revascularization (Anthony J. Bella, William O. Brant, & Tom F. Lue) 173
29. Procedures for Peyronie's Disease (William D. Steers, William O. Brant, Anthony J. Bella, & Tom F. Lue) 177
30. Operations for Priapism (Trinity J. Bivalacqua & Arthur L. Burnett) 183
31. Repair of Genital Injuries (Joshua A. Broghammer & Hunter Wessells) 187

VII
FEMALE GENITAL RECONSTRUCTION ... 191

32. Cecal Vagina (Frank Hinman, Jr. & Roger R. Dmochowski) 193
33. Urethrovaginal Fistula Repair (Kathleen C. Kobashi & David E. Rapp) 197

34. Bulbocavernosus Muscle and Fat Pad Supplement (Shlomo Raz, Christian O. Twiss, & Veronica Triaca) 201
35. Female Urethral Diverticulectomy (Gary E. Leach & Elise Perer) 205
36. Lateral Flap Urethral Reconstruction (Jerry G. Blaivas) 215
37. Urethral Prolapse-Caruncle (Edward J. McGuire) 217
38. Cystocele Repair, Enterocele Repair, and Rectocele Repair (Kindra Larson, Daniel M. Morgan, & John O. L. DeLancey) 221
39. The Michigan Four-Wall Sacrospinous Suspension (John O. L. DeLancey) 227

VIII
URETHRAL: RECONSTRUCTION 235

40. Urethral Reconstruction: General Concepts (Allen F. Morey) 237
41. Reconstruction of the Fossa Navicularis (Gerald H. Jordan) 241
42. Reconstruction of Strictures of the Penile Urethra (Sean P. Elliott & Jack W. McAninch) 247
43. Reconstruction of Strictures of the Bulbar Urethra (Sean P. Elliott & Jack W. McAninch) 265
44. Reconstruction of Membranous Urethral Disruption Injuries (Sean P. Elliott & Jack W. McAninch) 275
45. York-Mason Closure of Recto-Urinary Fistula (Richard G. Middleton) 287
46. Direct Vision Internal Urethrotomy (Melissa R. Kaufman & Douglas F. Milam) 289

IX
TESTIS: REPAIR AND RECONSTRUCTION 293

47. Testis Biopsy (R. Dale McClure) 295
48. Sperm Retrieval (Cigdem Tanrikut & Peter N. Schlegel) 299
49. Varicocele Ligation (Paul J. Turek & Thomas J. Walsh) 303
50. Vasectomy (Victor M. Brugh III) 311
51. Vasovasostomy and Vasoepididymostomy (Raymond A. Costabile) 315
52. Excision of Utricular Cyst (Jack S. Elder) 321
53. Spermatocelectomy (Cigdem Tanrikut & Peter N. Schlegel) 323
54. Epididymectomy (Wayne J. G. Hellstrom) 325
55. Undescended Testis (Sean T. Corbett) 327
56. Reduction of Testicular Tension (Sean T. Corbett) 345

X
TESTIS: MALIGNANCY 347

57. Simple Orchiectomy (Cigdem Tanrikut & Marc Goldstein) 349
58. Testis-Sparing Surgery for Benign and Malignant Tumors (Cigdem Tanrikut & Marc Goldstein) 351
59. Radical Orchiectomy (Donald A. Elmajian & Dennis D. Venable) 353
60. Retroperitoneal Lymph Node Dissection (Stephen Beck & Richard Foster) 357
61. Laparoscopic Retroperitoneal Lymph Node Dissection (Lee Richstone, Brian A. Vanderbrink, & Louis R. Kavoussi) 367

XI
SURGICAL APPROACHES TO THE PELVIS 379

62. Midline Lower Abdominal Peritoneal Incision (David A. Levy) 381
63. Transverse Lower Abdominal Incision (David A. Levy) 385
64. Gibson Incision (David A. Levy) 391

XII
PROSTATE: MALIGNANCY 393

65. Anatomy and Principles of Excision of the Prostate (Michael S. Cookson) 395
66. Radical Retropubic Prostatectomy (Michael S. Cookson) 403
67. Radical Perineal Prostatectomy (David Hartke) 415
68. Pelvic Lymph Node Dissection (S. Duke Herrell) 427
69. Robotic-Assisted Laparoscopic Prostatectomy (Joseph A. Smith, Jr.) 435
70. Cryotherapy (Katsuto Shinohara) 445

XIII
PROSTATE: BENIGN DISEASE 449

71. Transurethral Resection of the Prostate (Douglas F. Milam) 451
72. Transurethral Incision of the Prostate (Douglas F. Milam) 459
73. Laser Treatment of Benign Prostatic Disease (Nicole Miller & Douglas F. Milam) 463
74. Suprapubic Prostatectomy (Joshua K. Modder & Kevin T. McVary) 473
75. Retropubic Prostatectomy (Rajiv Saini & Steven A. Kaplan) 483

XIV
BLADDER: EXCISION 491

76. Transurethral Resection of Bladder Tumors (Alison M. Christie) 493
77. Partial Cystectomy (Edward Cherullo) 495
78. Radical Cystectomy (Sam S. Chang) 501
79. Urethrectomy (Christopher B. Dechet) 513
80. Pelvic Lymphadenectomy (Peter E. Clark) 517
81. Pelvic Exenteration (Peter E. Clark) 523
82. Excision of Vesical Diverticulum (Harriette M. Scarpero & Dena L. Walsh) 531
83. Cystolithotomy (Harriette M. Scarpero & Dena L. Walsh) 537
84. Laparoscopic/Robotic Radical Cystectomy (Erik P. Castle, Michael E. Woods, Raju Thomas, & Rodney Davis) 541

XV
BLADDER RECONSTRUCTION 549

Pubovaginal Sling for Stress Urinary Incontinence *549*
85. Autologous Pubovaginal Sling (E. Ann Gormley) 551
Synthetic *555*
86. Tension-Free Vaginal Tape/Suprapubic Midurethral Sling Pubovaginal(Roger R. Dmochowski & Christopher E. Wolter) 557
87. Transobturator Midurethral Sling (Roger R. Dmochowski & Christopher E. Wolter) 563
88. Bulking Agents for Incontinence and Reflux (Edward J. McGuire) 567
89. Technique for Insertion of Artificial Urinary Sphincter (Melissa R. Kaufman) 571
Vesicovaginal Fistulas *577*
90. Transvaginal Repair of Vesicovaginal Fistula (Frank Hinman, Jr. & Roger R. Dmochowski) 579
91. Transvesical Repair of Vesicovaginal Fistula (Wendy W. Leng & Shelby N. Morrisroe) 585
92. Transperitoneal Vesicovaginal Fistula Repair (Sandip P. Vasavada) 589
93. Female Vesical Neck Closure (Roger R. Dmochowski & Christopher E. Wolter) 593
94. Neuromodulation (Travis L. Bullock & Steven W. Siegel) 599

XVI
URINARY AND BOWEL DIVERSION 605

95. Vesicostomy (Romano T. DeMarco) 607
96. Ileal Conduit (Douglas S. Scherr & Daniel A. Barocas) 615
97. Laparoscopic/Robotic Ileal Conduit (Erik P. Castle, Michael E. Woods, Raju Thomas, & Rodney Davis) 629
98. Sigmoid and Transverse Colon Conduits (Wesley M. White, Frederick A. Klein, & W. Bedford Waters) 633
99. Fecal Diversion (Ketsia Pierre & Paul E. Wise) 637

XVII
CONTINENT RECONSTRUCTION 643

100. Principles of Continent Reconstruction (Jerilyn M. Latini & James Montie) 645
101. Ileal Reservoir (T-Pouch) (John P. Stein) 651
102. Ileocecal Reservoir (Randall G. Rowland & Frances M. Martin) 657
103. Appendicovesicostomy (John C. Thomas) 669
104. Ureterosigmoidostomy (Stephen Anthony Boorjian & Dipen J. Parekh) 673
105. Ileal Orthotopic Bladder Substitution (Urs E. Studer & Fiona C. Burkhard) 685

XVIII
BLADDER AUGMENTATION 691

106. Ileocystoplasty (John W. Brock III) 693
107. Colocystoplasty (Mark C. Adams) 697
108. Ureterocystoplasty (John Pope) 701
109. Autoaugmentation by Seromyotomy (Patrick C. Cartwright) 705

XIX
URETERAL RECONSTRUCTION AND EXCISION 707

110. Principles of Ureteral Reconstruction (George D. Webster & Elizabeth Anoia) 709
111. Ureteroneocystostomy (John Pope & John H. Makari) 711
112. Psoas Hitch (Neil D. Sherman) 727
113. Bladder Flap Repair (Boari) (Jennifer T. Anger) 731
114. Ureteral Stricture Repair and Ureterolysis (Andrew C. Peterson) 735
115. Repair of Ureterovaginal Fistula (Brian J. Flynn) 743

116. Ureteroureterostomy and Transureteroureterostomy (Elizabeth A. Miller) 747
117. Ileal Ureteral Replacement (Michael Guralnick & R. Corey O'Connor)....751
118. Open Ureterolithotomy (J. Patrick Spirnak & Phillip S. Kick)....755
Principles of Endoscopic Ureteral Surgery *757*
119. Ureteral Access (Manoj Monga)....759
120. Ureteroscopic Instrumentation (George E. Haleblian) 763
121. Ureteroscopic Management of Ureteral Calculi (Roger L. Sur & Glenn M. Preminger) 765
122. Ureteroscopic Management of Renal Calculi (Charles G. Marguet & Glenn M. Preminger) 769
123. Ureteroscopic Endoureterotomy (Brian K. Auge) 771
124. Ureteroscopic Endopyelotomy (Ilia S. Zeltser & Margaret S. Pearle) 775
125. Ureteroscopic Management of Transitional Cell Carcinoma (Raymond W. Pak & Demetrius H. Bagley) 781
126. Laparoscopic Ureterolithotomy (David Canes, Rene Sotelo, & Mihir M. Desai) 787
127. Endoscopic Management of VUR (Andrew J. Kirsch)....791
128. Endoscopic Incision of Ureterocele (Earl Y. Cheng)....795

XX SURGICAL APPROACHES TO THE KIDNEY 797

Open Renal Surgery.... *797*
129. Surgical Approaches for Open Renal Surgery (Eila Skinner) 799
Endoscopic Renal Surgery.... *833*
130. Anatomical Basis for Renal Endoscopy (Francisco J. B. Sampaio)....835
131. Percutaneous Renal Access (Nicole Miller & James E. Lingeman) 845
132. Percutaneous Nephrolithotomy (Ramsay L. Kuo) 855
133. Retroperitoneal Laparoscopic Access (Philippe Koenig, Georges-Pascal Haber, & Inderbir S. Gill) 857
134. Transperitoneal Laparoscopic Access (J. Stuart Wolf, Jr. & William W. Roberts) ...861
135. Hand-Assisted Laparoscopic Surgery (George E. Haleblian, James O. L'Esperance, & David M. Albala) 867
136. Renal Cryosurgery (Thomas J. Polascik) 871
137. Renal Radiofrequency Ablation (Ilia S. Zeltser & Jeffrey A. Cadeddu) 879

XXI KIDNEY: RECONSTRUCTION 883

138. Anatomy and Principles of Open Reconstructive Renal Surgery (John F. Redman)....885
139. Open Pyeloplasty (John S. Wiener) 887
140. Surgery of the Horseshoe Kidney (Zeph Okeke, Lindsay Fossett, & Arthur D. Smith)....897
141. Repair of Renal Injuries (Jack W. McAninch & Jill C. Buckley)....905
142. Surgery for Renal Vascular Disease (Amr Fergany & Andrew C. Novick) 911
143. Renal Transplant Recipient (John M. Barry) 919
144. Open Donor Nephrectomy/Cadaver Donor Nephrectomy (David A. Goldfarb & Venkatesh Krishnamurthi)....933
145. Percutaneous Endopyelotomy (Geoffrey R. Wignall & John D. Denstedt) 939
146. Percutaneous Endopyeloplasty (Mahesh R. Desai, Mihir M. Desai, & Arvind P. Ganpule) 943
147. Laparoscopic Renal Biopsy (David I. Lee) 949
148. Laparoscopic Pyeloplasty (Richard W. Sutherland) 951
149. Robot-Assisted Laparoscopic Pyeloplasty (Charles R. Moore, Raymond J. Leveillee, & John Shields) 955
150. Laparoscopic Live Donor Nephrectomy (Grant Disick, Stuart Kesler, & Ravi Munver) 959

XXII KIDNEY: EXCISION 965

151. Anatomy and Principles of Renal Surgery (Michael L. Blute, Sr. & Brant Inman) 967
152. Simple Nephrectomy (Michael L. Blute, Sr. & Brant Inman) 975
153. Radical Nephrectomy (Michael L. Blute, Sr. & Brant Inman) 989
154. Partial Nephrectomy (Michael L. Blute, Sr. & Brant Inman) 1001
155. Nephroureterectomy (Michael L. Blute, Sr. & Brant Inman) 1009
156. Extracorporeal Renal Surgery (Michael L. Blute, Sr. & Brant Inman) 1021
157. Vena Caval Thrombectomy (Michael L. Blute, Sr. & Brant Inman) 1025

158. Open Stone Surgery: Anatrophic Nephrolithotomy and Pyelolithotomy (Rahul A. Desai & Dean G. Assimos) 1043
159. Laparoscopic Simple Nephrectomy (Courtney K. Phillips & Jaime Landman) 1047
160. Laparoscopic Transperitoneal Radical Nephrectomy (Leslie A. Deane, James F. Borin, & Ralph V. Clayman) 1053
161. Laparoscopic Heminephrectomy (Jeffrey B. Campbell & Bradley P. Kropp) 1063
162. Laparoscopic Partial Nephrectomy (David D. Thiel & Howard N. Winfield) 1067
163. Laparoscopic Nephroureterectomy (Jay T. Bishoff & Thomas W. Jarrett) 1071
164. Laparoscopic Pyelolithotomy (Carl K. Gjertson & Chandru P. Sundaram) 1081
165. Laparoscopic Caliceal Diverticulectomy (Patrick W. Mufarrij & Michael D. Stifelman) 1085
166. Laparoscopic Renal Cyst Ablation (Yeh Hong Tan) 1087
167. Percutaneous Resection of Upper Tract Urothelial Carcinoma (Kristofer R. Wagner & Thomas W. Jarrett) 1091

XXIII
ADRENAL EXCISION 1095

168. Adrenal Anatomy and Preparation for Adrenal Surgery (E. Darracott Vaughan, Jr.) 1097
169. Open Approaches to the Adrenal Gland (E. Darracott Vaughan, Jr.) 1103
170. Laparoscopic Approaches to the Adrenal Gland (Kazuo Suzuki, Nobuo Tsuru, & Hiroyuki Ihara) 1111

Index 1123

This page intentionally left blank

Section I

SURGICAL BASICS

This page intentionally left blank

Chapter 1

Surgical Basics

MELISSA R. KAUFMAN AND JOSEPH A. SMITH, JR.

STRATEGY AND TACTICS

Perhaps at no time since the advent of transurethral prostatectomy by Dr. Hugh Hampton Young over a century ago has the repertoire of urologic techniques advanced as rapidly as during the last decade. Today's urologist has access to a vast array of ever-expanding technologies, with seemingly novel iterations presented every week. Minimally invasive approaches are replacing some time honored fundamental urologic procedures. The manual and mental skills required to not only perform these advanced procedures, but also to simply evaluate which method to use have generated a substantial increase in expectations for urologists and their patients. For the contemporary urologist, choosing a correct operative strategy now incorporates not only appreciation of historical methods but also a critical evaluation of current evidence.

This atlas is designed primarily to assist the urologic surgeon in developing an appropriate strategy to approach the myriad technical issues involved with urologic operative procedures. However, it is apparent that there are limitations to this type of didactic lesson, and surgical skill is gained primarily through experience at the operative table. Several axioms heard, usually rather stridently, during surgical training are worth repeating because they represent fundamental principles of superior technique that should become second nature to the experienced surgeon. These elemental strategies were eloquently and enthusiastically described by Dr. Hinman in the prior edition of this atlas and are paraphrased and expanded below.

Foremost, having a strategy involves knowledge of your patients and their pathology. Although unexpected findings are frequent during surgery, attention to detail and preoperative knowledge of the patient and the disease process can minimize surprises, which could affect patient outcome. Be compulsive about detail. Dr. Hinman counseled us to ensure adequate exposure, fend off difficult planes and vascular traps, use delicate technique, irrigate debris, obtain good hemostasis, close dead spaces, and provide adequate drainage. We are directed to have a plan, promote a team effort, and be gentle but not indecisive. Dr. Hinman reminds us to tie sutures just to approximate the tissue, dissect and follow the natural tissue planes, work from known to unknown, keep tissues moist and covered, and, above all, keep calm and conduct ourselves like leaders. Even with the technical advances that have almost revolutionized urologic surgery, these fundamental principles of technique still apply.

With these mentoring concepts, the continued mission of this atlas is to share the knowledge—and admonitions—of experts with pronounced and specialized surgical experience. By reviewing these chapters before embarking on a particular procedure, the urologist will have access to a critical resource in step-by-step technique as well as a warning regarding the pitfalls to avoid. Surgery is an apprenticeship learned literally at the shoulder of those who have chosen to impart their skills. And, like the motive of the professor instructing the intern, the ultimate goal of this atlas is to serve and benefit our patients.

PREOPERATIVE EVALUATION

Except in dire circumstances, the complete evaluation of the patient before undertaking any operative procedure merits substantial consideration. Preoperative knowledge can dramatically impact the operative outcome and allow more efficient communication with colleagues from other medical and surgical disciplines.

Evaluation of Risks

The American Society of Anesthesiology's (ASA) Physical Status Scale describes preoperative physical condition and groups patients at risk for experiencing an adverse event related to general anesthesia (Table 1-1). ASA Physical Status 1 represents a normal healthy individual; physical status 2, a patient with mild systemic disease; physical status 3, a patient with severe systemic disease that is not incapacitating; physical status 4, a patient with an incapacitating systemic disease that is a constant threat to life; physical status 5, a moribund patient who is not expected to survive for 24 hours with or without an operation, and ASA physical status 6 defines a declared brain-dead

TABLE 1-1

AMERICAN SOCIETY OF ANESTHESIOLOGY PHYSICAL STATUS

Class	Definition
Physical Status 1	A normal healthy patient
Physical Status 2	A patient with mild systemic disease
Physical Status 3	A patient with severe systemic disease
Physical Status 4	A patient with severe systemic disease that is a constant threat to life
Physical Status 5	A moribund patient who is not expected to survive without the operation
Physical Status 6	A declared brain-dead patient whose organs are being removed for donor purposes

From (1963). New classification of physical status. American Society of Anesthesiologists. Anesthesiology 1963;24:111; http://www.asahq.org/clinical/physicalstatus.htm.

patient whose organs are being removed for donor purposes.

Although cardiac status has long been appreciated as a significant risk factor for perioperative mortality, the past decade has witnessed remarkable changes in evaluation and management of the cardiac patient. Important considerations regarding the widespread utilization of coronary revascularization, anticoagulation, and beta-blocker administration are of particular concern for the contemporary surgeon.

Of particular importance in the context of considering surgical interventions in an elderly population, is the management of antithrombolytic medications. The American College of Chest Physicians has created evidence-based clinical practice guidelines to address specifically the perioperative management of patients who are receiving vitamin K antagonists, such as warfarin, or antiplatelet drugs, such as aspirin or clopidogrel. These guidelines are a continually evolving process and undergo frequent modification as new clinical data are evaluated. Thus the surgeon should be familiar with the primary guidelines publication. Consultation with the cardiologist or practitioner managing the anticoagulation can help develop a multidisciplinary comprehensive treatment plan for the patient.

Contradictory evidence has recently been published regarding use of β-blocker therapy and perioperative mortality following noncardiac surgery. Current recommendations from the American College of Cardiology and American Heart Association principally suggest continuation of β-blocker therapy for patients already managed with such agents, but the routine administration of β-blockers preoperatively is not advisable. Initiating β-blocker therapy on naive patients should require the expertise of a cardiologist or anesthesiologist more suited to evaluate the risk parameters involved.

Issues with pulmonary function and postoperative recovery from intubation are most frequently a consequence of preexisting conditions that place the patient at particular pulmonary risk. In patients with obstructive lung disease or severe asthma, it is best to consult with the pulmonologist or anesthesiologist about the safest route to provide the surgical intervention. Intubation may be avoidable, but even so, appropriate counseling requires recognition of the hazards. Patients who smoke should be counseled not only on their risks for multiple malignancies but also on the jeopardy of prolonged respiratory failure and poor wound healing.

Nutrition

Special emphasis should be given to assessment of the patient's preoperative nutritional status because many urology patients, particularly those with malignancy or renal dysfunction, may have recent weight loss or nutritional deficits related to chronic illness. Nutritional deficiency can predispose the patient to issues with poor wound healing as well as hematologic and immunologic compromise. In severe cases, hyperalimentation may be required to overcome the nutritional barrier that prevents safe operative management.

Venous Thromboembolism Prophylaxis

Of increasing concern in the perioperative period is the incidence of thromboembolic complications and the associated repercussions, including pulmonary embolism (PE). With recognition of the heightened risk in the surgical patient, the American College of Chest Physicians created extensive guidelines detailing pharmacologic and mechanical strategies for prevention of deep vein thrombosis (DVT). American Urological Association (AUA) guidelines panel has published the AUA best practice policy statement "Prevention of Deep Vein Thrombosis in Patients Undergoing Urologic Surgery" (Table 1-2). These guidelines integrate available evidence from the urologic and surgical literature into treatment strategies for pharmacologic and mechanical prophylaxis for each category of urologic surgery and include patient risk stratification. Every urologist should review these best practice recommendations and incorporate them into their perioperative approach to diminish the risk for DVT and PE.

Evaluation by the Anesthesiologist

The issues involving anesthesia evaluation are becoming more difficult as the acuity of the patient and the complexity of procedures, many of which are managed on an outpatient

TABLE 1-2 VENOUS THROMBOEMBOLISM PROPHYLAXIS

Patient Risk Stratification	Description	Prophylactic treatments
Low risk	Minor surgery in patient <40 years with no additional risk factors	No prophylaxis other than early ambulation
Moderate risk	Minor surgery in patients with additional risk factors Surgery in patients aged 40-60 years with no additional risk factors	Heparin 5000 units every 12 hours subcutaneous OR Enoxaparin 40 mg subcutaneous daily OR Pneumatic compression device if risk of bleeding is high
High risk	Surgery in patients >60 years Surgery in patients aged 40-60 years with additional risk factors	Heparin 5000 units every 12 hours subcutaneous OR Enoxaparin 40 mg subcutaneous daily OR Pneumatic compression device if risk of bleeding is high
Highest risk	Surgery in patients with multiple risk factors (*ex* age >40 years, cancer, prior VTE)	Enoxaparin 40 mg subcutaneous daily AND adjuvant pneumatic compression device OR Heparin 5000 units every 8 hours subcutaneous AND adjuvant pneumatic compression device

Adapted from Forrest JB, Clemens JQ, Finamore P, et al. (2009). AUA Best Practice Statement for the prevention of deep vein thrombosis in patients undergoing urologic surgery. J Urol 181:1170-1177.

basis, continually amplify. Appropriate attention is necessary to control preoperative hypertension and electrolyte abnormalities because these may become more pronounced during general anesthesia. The preoperative anesthesia evaluation is designed to assess basic cardiac, pulmonary, and systemic risk factors, which may influence tolerance and recovery from both anesthesia and the surgical procedure. Although frequently there are mechanisms in place to notify the surgeon of any abnormalities uncovered by these tests, it remains the responsibility of the operative surgeon to review all available data before the procedure and to assess the fitness of the patient to proceed with the planned surgical procedure.

PREPARATION FOR SURGERY

Outpatient Surgery

Many contemporary urologic surgeries are amenable to performance on an outpatient basis. Indeed, even for major procedures such as radical prostatectomy, length of hospital stay may not exceed 24 hours. Therefore special consideration must be given to patient preparation and counseling in advance of the date of surgery. Thoroughly informing the patient and family on the general pragmatic concerns and recovery expectations can noticeably decrease patient anxiety and ease work flow on the day of surgery.

Although overall most patients amenable to outpatient surgery have fewer risk factors than patients slated for hospital admission, preoperative evaluation by the anesthesia service in advance of the day of surgery is recommended. Outpatient surgeries are particularly suited for children, because such surgeries are generally well tolerated and children can recover in their home environment.

Preparation of the Operative Site

The preoperative checklist in Table 1-3 details the majority of items that surgeons should consider before proceeding to the operating room. Current concepts in surgical safety advocate use of a "time out" prior to initiation of the procedure. In collaboration with the operating room staff and anesthesia team, patient identification, surgical site, consent, procedure, instruments, imaging, antibiotics, and post-operative plans are all reviewed and confirmed prior to the initiation of the surgery. Adherence to such checklists promises a reduction in perioperative morbidity as potential issues are readily reviewed and opened for discussion in a structured manner.

Marking

Today most hospitals require marking of the surgical site before proceeding to the operating room. This safety measure is particularly important in urology, where intervention on one of dual organs is performed routinely. The critical nature of this reassurance to the surgeon and the patient cannot be underestimated. For cases involving midline structures, such as penile or vaginal surgeries, site marking may not be required.

PREOPERATIVE CHECKLIST FOR SURGEONS

TABLE 1-3

Assess Operative Risk
Nutrition (serum albumin)
Immune competence
Medications (anticoagulants, corticosteroids, antibiotics)
Pulmonary dysfunction
Wound healing (anemia, irradiation, vitamin deficiency)
Obesity
Patient Preparation
Informed consent
Blood banking
Site marking
Skin preparation
Bowel preparation
Preanesthetic medication
Blood transfusion
Hydration
Medications
Antibiotics

Shaving and Epilation

Shaving increases bacterial colonization and should be done as near to the time of operation as feasible. Electric clippers with replaceable cartridge blades are often preferred to safety razors and are frequently required by hospital committees, because they provide less opportunity for skin damage and subsequent bacterial colonization. In select cases, epilation of skin that will be incorporated into the urethra may be necessary and can be accomplished by needle or laser ablation.

Skin Preparation

Once the patient is appropriately positioned and shaved, a mechanical wash should be performed to exfoliate skin and expose bacteria so they can be reached by topical antiseptic agents. An iodophor, such as povidone-iodine (Betadine), in which iodine is complexed with a surfactant compound, releases iodine slowly to act on contaminants. Scrub the area for at least 5 minutes (10 minutes for implants such as penile prostheses or artificial urinary sphincters), then paint the site with concentrated iodophor. When prepping the delicate skin of the genitalia, use of less caustic detergent reagents, such as hexachlorophene (Hibiclens), is preferable.

Draping

Adhesive drapes are barriers to bacteria and also form a thermal barrier. Particularly in children who are more susceptible to hypothermia, decrease the time between the skin prep and draping. Cover the areas adjacent to the site of the incision with sterile dry towels and keep them in place with towel clips. Keep these towels dry to reduce irritation and heat wicking due to moisture adjacent to skin. Nonabsorbent, plastic stick-on drapes may reduce contamination but foster bacterial proliferation under them, particularly if moisture is trapped, unless they are porous to vapor. If the drapes do not have self-contained pockets, fold the covering drape upon itself to form a lateral pocket for instruments and drainage. Creation of a drape pocket is particularly important for vaginal and perineal surgery where the patient is in lithotomy position and the surgeon is seated.

Contamination

Bacteria colonize the shedding superficial cells of the skin and hair follicles. Contamination from the surgeon and staff comes less from the hands than from hairs falling into the wound. Appropriate coverings for the head and neck reduce contamination of the operative field. Although several novel alcohol-based agents now exist for preoperative hand decontamination, it is recommended that at least the primary wash of the day be a traditional mechanical scrub with soap, scrub brush, and nail cleaning.

Bowel Preparation

Even for patients undergoing procedures involving bowel reconstruction, current recommendations by the general surgical community leave the decision to perform a mechanical bowel preparation to the surgeon's discretion. No evidence based guidelines exist specifically for urologic surgery and many surgeons continue to provide a cleansing agent such as magnesium citrate or a more vigorous mechanical prep with a polyethylene glycol electrolyte lavage solution such as GoLYTELY® for complex cases.

Vascular Access

The preoperative holding room nursing staff or anesthetist can comfortably obtain vascular access by percutaneous methods in the vast majority of cases with the use of topical anesthetic. If central venous access is required, subclavian or internal jugular vein cannulation is typically preferred. Central venous lines are usually placed following the induction of general anesthesia. For surgery on critically ill patients, or when substantial blood loss is anticipated, the anesthesia team will often place an arterial line for accurate monitoring of blood pressure and blood gases.

PERIOPERATIVE ANTIBIOTICS

Recently the AUA published best practice guidelines (auanet.org) specifically addressing antibiotic prophylaxis in urologic surgery (Table 1-4). This evidence-based approach to perioperative antibiotic utilization incorporates the contemporary recommendations of the National Surgical Infection Prevention Project and provides a practical outline for antibiotic

ANTIBIOTIC PROPHYLAXIS

TABLE 1-4

Procedure	Prophylaxis indicated	Antimicrobial(s) of choice	Duration of therapy
Lower Tract Instrumentation			
Catheter removal	If risk factors	Fluoroquinolone Trimethoprim-sulfamethoxazole	≤ 24 hours
Simple cystourethroscopy, cystography	If risk factors	Fluoroquinolone Trimethoprim-sulfamethoxazole	≤ 24 hours
Urodynamics	If risk factors	Fluoroquinolone Trimethoprim-sulfamethoxazole	≤ 24 hours
Cystourethroscopy with manipulation	All	Fluoroquinolone Trimethoprim-sulfamethoxazole	≤ 24 hours
Prostate brachytherapy or cryotherapy	Uncertain	1st generation cephalosporin	≤ 24 hours
Transrectal prostate biopsy	All	Fluoroquinolone 2nd/3rd generation cephalosporin	≤ 24 hours
Upper Tract Instrumentation			
Shock-wave lithotripsy	All	Fluoroquinolone Trimethoprim-sulfamethoxazole	≤ 24 hours
Percutaneous renal surgery	All	1st/2nd generation cephalosporin Aminoglycoside + Metronidazole or Clindamycin	≤ 24 hours
Ureteroscopy	All	Fluoroquinolone Trimethoprim-sulfamethoxazole	≤ 24 hours
Open or Laparoscopic Surgery			
Vaginal surgery	All	1st/2nd generation cephalosporin Aminoglycoside + Metronidazole or Clindamycin	≤ 24 hours
Without entering urinary tract	If risk factors	1st generation cephalosporin	Single dose
Involving entry into urinary tract	All	1st/2nd generation cephalosporin Aminoglycoside + Metronidazole or Clindamycin	≤ 24 hours
Involving intestine	All	2nd/3rd generation cephalosporin Aminoglycoside + Metronidazole or Clindamycin	≤ 24 hours
Involving implanted prosthesis	All	Aminoglycoside + 1st/2nd generation cephalosporin or Vancomycin	≤ 24 hours

Adapted from Wolf JS Jr, Bennett CJ, Dmochowski RR, Hollenbeck BK, Pearle MS, Schaeffer AJ. (2008). Best practice policy statement on urologic surgery antimicrobial prophylaxis. J Urol 179:1379.

therapy. Reference to this exhaustive review will enlighten many urologists, particularly those at institutions who may cling to outdated, costly, and potentially detrimental practices with regard to antibiotic use. The AUA guidelines also specifically address special situations such as antibiotic prophylaxis for mechanical cardiac valves, endourologic, and office-based procedures.

PROTECTION DURING SURGERY

Room temperature in the operating room must be a balance between surgeon comfort and maintenance of appropriate patient warmth. For children and infants, room temperature must be elevated substantially to reduce the insensible loss of body heat.

The appropriate position for the patient is shown in this atlas for each operation, but the details for protection of the patient vary. Be thorough in placing foam padding over all bony prominences to avoid damage to adjacent nerve trunks, especially the ulnar and peroneal nerves. When the patient is in the lateral position, place a pad in the axilla to protect the brachial plexus. The lithotomy position is especially likely to cause nerve injury. Avoid positions that put a strain on the muscles, ligaments, and joints. For minor procedures in children, use a restraining wrap (papoose board).

ANESTHESIA

Fluid and Electrolyte Replacement

Fluid losses increase during surgery because of myriad factors in addition to blood loss, including anesthesia, operating room lights, skin exposure, and visceral organ exposure. Inflammatory responses secondary to the insult of surgery provoke fluid accumulation in tissues outside of the vascular space. The anesthesia team should carefully provide sufficient fluid to replace these insensible losses and volume depletion due to third-spacing. By monitoring blood loss during the case and communicating this information, the surgeon can help the anesthesia team stay prepared for any possible physiologic derangements. The patient's hydration status can be monitored both by blood pressure and urinary output when appropriate, as well as visual inspection of the operative field by the surgeon. Monitoring of urinary output, serum electrolytes, blood glucose, and hematocrit are routine. For more complex cases, central venous pressure monitoring may be required.

Local Anesthesia

Several urologic procedures are comfortably performed with the use of local anesthesia. Injections of local agents at the conclusion of numerous cases performed under general anesthesia can assist significantly with postoperative pain management. Regional blocks are usually accomplished with bupivacaine (Marcaine) 0.5 to 1.0 mg/kg of a 0.25% solution. The addition of epinephrine 1:200,000 decreases local blood flow and rate of absorption of the agent, with resulting prolongation of anesthesia and reduction in area blood loss. However, epinephrine can produce systemic effect and may potentiate infection by diminishing local perfusion. It is not recommended that epinephrine be used on any tissue with end-organ perfusion such as the distal penis. Caution must also be used to prevent introducing bupivacaine into the vascular system as this agent can have devastating cardiac effects. For use of substantial quantities of agents such as bupivacaine, it is prudent to perform the procedures under monitored anesthesia care (MAC) where the patient may be appropriately monitored and briskly treated for adverse effects. In addition, sedoanalgesia with agents such as benzodiazepines may substantially improve patient comfort.

General Anesthesia

Common in the modern operating room are monitoring of body temperature, electrocardiogram, heart rate, blood pressure, and oxygen saturation via pulse oximetry. Major procedures may benefit from additional monitoring of central venous pressure as well as use of an arterial line for precise monitoring of blood pressure and blood gases.

Temperature is often assessed via a rectal or esophageal thermoprobe. Malignant hyperthermia is a rare but exceedingly serious complication of certain anesthetic agents in predisposed patients, and requires prompt and definitive treatment with hyperventilation, alkalinization, cooling with ice packs, and administration of dantrolene and diuretics. From the surgeon's perspective, dark blood in the wound may herald the onset of malignant hyperthermia or at least poor oxygenation and should be promptly reported to the anesthesia provider.

OPERATIVE MANAGEMENT

Assistance

The importance of an attentive and competent first assistant cannot be overstated. In an academic setting, frequently the house staff fills this role, which allows the resident to gradually incorporate an understanding of the steps of the procedure as well as the critical importance of excellent exposure. In many contemporary laparoscopic cases, skills of the first assistant can make an enormous difference in the ease of the procedure. Excellent spatial orientation, particularly in the pelvis and retroperitoneum, becomes critical. The first assistant is charged with the majority of exposure, use of suction and irrigation, and handling the transfer of sutures, clips, and specimens. All these tasks can be areas of great hindrance if the assistant is not facile with the procedure.

Protection of the Surgical Team from Viral Infection

Universal precautions are now considered standard for all surgical procedures. Preoperative testing for infectious diseases such as human immunodeficiency virus or hepatitis B and C is rarely performed. Thus the surgeon must assume that every patient would test positive, and it is the surgeon's

responsibility to not only provide service to the patient but also to protect the staff from inadvertent inoculation.

Surgeons, anesthetists, and scrub personnel should wear protective glasses during invasive procedures and should wear protective boots or impervious shoe coverings routinely. This is particularly important in many endourologic cases in which irrigation fluids may spill on the operating room floor. The risk to surgeons who operate with open skin lesions is unknown, but covering any small cuts or abrasions on the hands with sterile Tegaderm seals them in case of glove puncture.

When wearing gloves that have been contaminated, take care to not handle objects in the operating room that may not receive routine cleanings such as door handles or computer keyboards. One should remove all gowns, gloves, and shoe covers before leaving the operating room. Exposed skin surfaces should be washed with detergent immediately after contamination with blood or body fluids. Hands should be washed immediately after gloves are removed at the end of a procedure.

Extreme caution should be exercised with needles and sharp instruments. Meticulous technique is required both in the immediate operative field and in the entire operating room to minimize accidental exposure to infectious agents. Extreme care should also be taken to avoid needle-stick injuries with hollow-bore needles. Most needles are now equipped with safety devices to prevent the user from attempting to recap the needle and we caution not to remove these safety devices just because they are deemed cumbersome. After use, needles and disposable sharp instruments should be immediately placed in puncture-resistant containers for disposal.

Surgical Technique

Good surgical technique is essential to expedite complicated procedures. A good surgical technique is recognized by the absence of wasted motion and wasted time. Continually think ahead to the next step. Do not wait until another instrument or suture is needed; ask for it ahead of time so the scrub technician will have it ready. Often when a team has worked together for a time, the scrub technician can anticipate the surgeon's needs and a seamless transfer of items occurs with few words uttered. Accomplished surgeons keep moving yet watch every detail and are not afraid to stop during the procedure to consider alternatives.

Dissection

The tissue, the organ, and the technique determine how each instrument is applied. For a node dissection, a sweeping motion with a sucker or closed scissors may be useful. For a pyeloplasty, careful dissection is done by supporting the tissues with stay sutures, occasionally applying fine smooth forceps and sharply incising structures. Sometimes a little hand traction or finger dissection can be useful, but beware of blind finger dissection, which often leads to peril, and the lack of exposure makes control difficult. Do not cut what cannot be seen, because the interfering structures may be vascular, buried deep, and difficult to manage.

Handle the tissues gently and attempt to preserve as much vascular supply as possible to potentiate healing and reduce the risk of infection. Use stay sutures and skin hooks because even the most delicate of forceps can crush tissue. Be prudent with cautery or other tissue coagulation devices because all create some degree of devitalized tissue.

Visibility

The intensity of the light in the wound determines visual acuity. At least two light sources are usually required: overhead operating room lighting and a surgical headlamp worn by the surgeon or assistant. Focused beams should reach the bottom of the wound without interference. Headlights are particularly important in deep pelvic surgery where overhead lights rarely penetrate into the recesses the need visualizing. For vaginal surgery, a headlight or lighted suction device is especially useful.

Hemostasis and Contemporary Hemostatic Aids

Focused use of coagulation is quicker and can produce less tissue destruction than suture ligation. Try to specifically identify, isolate, and elevate vessels needing coagulation and prevent painting the surface of a structure, which can cause substantial damage and raise the risk of infection. Bipolar forceps produce minimal damage to adjacent tissues and are preferred in delicate environments.

In the contemporary operating room, a variety of nonsuturing techniques are used to provide hemostasis. Tissue sealants have gained increasing appreciation as important tools in the urologist's armamentarium for providing hemostasis in many formerly troublesome areas. These sealants and glues have shown particular utility when applied in nephron-sparing surgery and are frequently used for open prostatectomy, urethral reconstruction, and even percutaneous nephrolithotomy. Numerous products with differing mechanisms of action are available and outlined in Table 1-5. Novel vessel-sealing and tissue-cutting devices have also dramatically increased in use, particularly in laparoscopic surgery.

Blood Loss and Transfusion

Because 7% of body weight is blood, a man weighing 70 kg has a circulating blood volume of about 5000 mL. A loss during surgery of up to 15% of this volume rarely affects the patient's hemodynamic parameters. Unless other fluid losses occur, transcapillary refill and other compensatory mechanisms restore blood volume. A volume loss between 15% and 30%, representing 800 to 1500 mL of blood, results in tachycardia, tachypnea, and a decrease in pulse pressure. A loss of more than 30% (2000 mL) of blood volume may produce a measurable drop in systolic blood pressure.

Initially replace blood loss with an isotonic replacement fluid such as lactated Ringer's or Plasmalyte with a bolus of 1 to 2 L in adults or 20 mg/kg in children. If the signs are not reversed or only transiently improved and if urinary output remains low, proceed to transfusion with packed red blood cells. Some guidelines recommend transfusion if

TABLE 1-5 COMMON HEMOSTATIC AGENTS UTILIZED IN UROLOGIC SURGERY

Material	Commercial names	Mechanism of action	Requirements
Fibrin glue	Tisseel, Crosseal, Hemaseel CoStatis, Dynastat, Vivostat	Mixes fibrinogen, thrombin, and facotr XIII to generate clot	Must be warmed prior to use CoStatis requires dry surface
Thrombin	Thrombinar, Thrombin JMI	Interacts with fibrinogen in blood to form a fibrin clot	Circulating fibrinogen must be present in tissue
Collagen	Avetine, FloSeal, TachnoComb	Promotes platelet aggregation by providing physical matrix	Requires circulating fibrinogen
Absorbable gelatin	Surgifoam, SurgiFlo, Gelfoam	Initiation of clotting cascade through contact activation	Requires clotting factors
Cellulose	Surgicel	Cellulose fibers initiate clotting through contact activation	Functional clotting cascade

Pursifull NF, Morey AF. (2007). Tissue glues and nonsuturing techniques. Curr Opin Urol 17(6):396-401.

hemoglobin levels are below 7 to 8 or if a patient develops hemodynamic signs of blood loss.

Coagulopathy becomes a progressive issue after as few as 6 units of blood have been replaced, primarily due to hemodilution. If a screen for clotting factors finds significant deficiencies, transfusion with platelets or fresh frozen plasma may be necessary. Hypothermia exacerbates clotting abnormalities; therefore warm all fluids and gases, provide warm blankets, and irrigate the abdominal cavity with warm saline.

Fluid overload may occur even though the central venous pressure has not reached normal levels. In addition to monitoring the central venous pressure and other hemodynamic parameters, watch for return of adequate perfusion by observing urinary output, skin color, and return of pulse rate and blood pressure to within normal limits. Use diuretics prudently, recognizing their impact on accurate measurement of urine output as a guide and the risk for precipitating hypovolemia.

Drains

Drainage tubes may have several harmful effects to consider, but these are usually outweighed by their benefits in urologic surgeries. Drains may render the tissue more susceptible to bacterial invasion and provide a direct route for bacterial entry from the skin and external environment. However, drains also facilitate the exit of potentially contaminated urine, serum, and blood. The most common purpose for a drain is prophylaxis by preventing the accumulation of blood, serum, or urine that can potentially become infected. Currently, two types of drains are prominently used: passive drains such as the Penrose, and active-suction devices such as the closed drain Jackson-Pratt or open sump Hemovac. Passive drainage is sufficient for many urologic cases involving the scrotum or superficial tissues where fluid accumulation can be particularly problematic. Active drains are often more appropriate for intraabdominal and retroperitoneal surgeries and can usually be removed before hospital discharge.

Catheters and Urinary Drainage Tubes

Catheters are often inserted before the start of surgical procedures to measure urine output, to empty the bladder to avoid injury during entry, to fill the bladder for identification, to instill antibacterial or antineoplastic agents, or to allow identification of the urethra and vesical neck. For most occasions, a 16 French urethral catheter is sufficient, although if one anticipates significant clot formation, a larger bore catheter is preferable.

Always carefully secure the catheter in a flexible manner to the patient, usually to the leg, to help prevent the inadvertent trauma from unanticipated removal.

Suprapubic Drainage

Placement of a suprapubic (SP) tube may be considered after many operations involving the bladder or urethra. An SP tube has several advantages over a transurethral catheter. It allows for cystography and a trial of voiding prior to removal. This type of drainage is particularly useful for reconstructive urethral surgery and in patients anticipated to have difficulty with postoperative bladder emptying. Several types of catheters are commonly used for SP tube drainage, including the self-retaining Malecot catheter and the balloon catheter. An SP catheter may be placed during an open operation or indirectly positioned via the urethra.

Postoperative Nerve Block

Even for patients undergoing general anesthesia, a local block with an agent such as bupivacaine can markedly reduce postoperative pain. This is particularly useful in children and for outpatient surgery. Caudal blocks are routinely used in children and can provide many hours of comfort. For adult wounds often associated with significant postoperative pain, such as flank incisions, there are several iterations of subcutaneous infusion pumps that will release local agent into the wound over 3 to 5 days to diminish narcotic requirement and the associated systemic effects that may delay recovery.

POSTOPERATIVE MANAGEMENT

For complex cases, be particularly vigilant about instrument and sponge counts. For any discrepancy, obtain a radiograph in the operating room before the patient's emergence from anesthesia so any required intervention will be less traumatic.

Operative Report

The operative report is a key document for patient care, billing purposes, and medicolegal issues. The note should be sufficiently complete such that another surgeon could assume patient care with adequate knowledge of the key findings at surgery and the procedure performed. Variations in anatomy should be described, intraoperative findings outlined, and complications or difficulties documented.

Avoidance of Postoperative Complications

Many complications can be prevented with careful attention to detail. Prevention is the purpose of the Morbidity and Mortality conferences held at most institutions. There is much to learn from reviewing cases and considering what could have been done differently. In this atlas, many prevalent and important postoperative problems are described at the end of the surgical protocols. Review the possible complications before starting a procedure, and have a system in place to ensure steps have been taken to prevent the most common problems.

Postoperative bleeding may be from disruption of a suture line, an unrecognized and uncontrolled artery or vein, or diffuse oozing from a raw tissue surface area. Some vessels may not be actively bleeding at the time of surgery because of vasospasm. Medication that could precipitate bleeding should be excluded and coagulopathy must be considered. Serum hematocrit may not be a reliable indicator of acute blood loss in that an intravascular equilibrium must be established.

Fluid Requirements

Volume depletion is signaled by weakness, orthostatic hypotension, tachycardia, weak pulse, dry mucous membranes, and poor urine output. The blood urea nitrogen level is disproportionately high in relation to the serum creatinine level. Replacement of the fluid deficit should occur gradually depending on clinical signs. Use hypotonic solutions in patients with elevated sodium levels and isotonic saline solution for the others. Fluid overload may result in edema, often accompanied by dyspnea, tachycardia, venous engorgement, and pulmonary congestion.

Hypotonic hyponatremia occurs in surgical patients after third-space losses and results in low urine volumes associated with high osmolarity. Replace the losses with saline solutions. Hypovolemic hypernatremia results from unreplaced renal or gastrointestinal water losses, producing thirst, hypotension, and lethargy.

Pain Management

Nerve Blocks

Postoperative pain may be reduced by bupivacaine nerve blocks and wound infiltration to provide enough time for the patient to start oral pain medication. As mentioned previously, local blocks may also be helpful to decrease patient use of intravenous narcotic analgesia.

Continuous epidural anesthesia is advocated by many anesthesia providers and can be particularly versatile for both induction and maintenance of general anesthesia and as a method of postoperative pain relief. However, caution must be applied to this method in the urology population where early postoperative ambulation and voiding are often required because the epidural can induce a motor block as well as a sensory block.

Other side effects of epidural anesthesia include hypotension, pruritus, drowsiness, infection of the catheter, and the aforementioned weakness in the lower extremities. Respiratory depression is uncommon and usually resultant from overdose. The benefits include excellent pain control, decreased analgesic requirements, and decreased nausea.

Caudal block is especially useful in the pediatric population for circumcision, hypospadias repair, hernia repair, orchiopexy, and hydrocelectomy. The caudal block has an excellent safety record and may be used in several lower torso operations on adults.

Postoperative Analgesia

Providing adequate postoperative pain control to the patient is a primary responsibility of the surgeon. The need for analgesic medications varies widely depending on the surgical procedure and patient characteristics and needs. As a general rule, sufficient analgesic should be provided so that the patient's recovery is comfortable while recognizing that there are side effects of analgesic medications and methods.

Oral medicines are appropriate in some patients and acetaminophen with or without an oral codeine derivative is commonly used. Nonsteroidal antiinflammatory drugs provide good pain relief but may increase the risk of bleeding. Aspirin-containing drugs should be avoided in the postoperative period.

Agents such as morphine, meperidine, or hydromorphone are frequently used intravenous narcotic agents. These medications can be administered by nursing staff on an as-needed basis or self-administered via a patient-controlled anesthesia pump. To reduce narcotic use in select patients, adjunct use of ketorolac may be administered for several doses, although long-term use is discouraged. A loading dose of ketorolac of 30 mg in the recovery room followed by 15 mg every 6 hours for up to 4 additional doses can dramatically improve postsurgical pain control. When bowel function returns and a diet is started, transition the patient to oral medications. Efforts to limit narcotic use can facilitate resolution of postoperative ileus.

Postoperative Infections

Fevers occurring during the first or second postoperative day are likely to originate from the respiratory tract. Although substantiation for incentive spirometry (IS) use is limited, most surgeons routinely provide a device for performance of IS to provide feedback to the patient to promote deep breathing and pulmonary toilet following general anesthesia. After the first few postoperative days, urinary infections, abscesses, and extravasation of urine should be high on the differential diagnosis.

Wound infections are a problematic aspect of every urology practice and several prevalent risk factors such as uncontrolled diabetes and obesity put surgical patients at particularly high risk. For closure of wounds in the obese patient, skin staples provide a more flexible option than subcuticular stitching in case of wound infection, such that only a portion of the wound often needs to be opened to allow sufficient drainage. Antibiotic treatment is appropriate conservative management for superficial cellulitis, but for suspicion of any deeper infection the wound must be interrogated to prevent possible fascial breakdown and dehiscence.

Several problems can arise with the rampant use of antibiotics in the hospital environment including the development of resistance patterns and the more ominous opportunity for superinfections. For postoperative diarrhea, examine the stool for *Clostridium difficile* toxin and treat aggressively to prevent the substantial sequelae of *C. difficile* infection.

Wound Management

Most skin edges are closed primarily with either absorbable suture or surgical staples. Remove staples within 10 to 14 days to prevent tissue ingrowth, which makes removal painful and difficult. Superficial dehiscence may be managed with placement of adhesive strips or by secondary healing. Drainage of peritoneal fluid into a midline wound indicates fascial disruption, which may progress to wound dehiscence and even evisceration. In the absence of infection or severe compromise of the patient's immune or nutritional status, fascial dehiscence usually represents a technical issue that may be avoided by a careful running closure supplemented with internal retention, or in high-risk patients, external retention sutures. Early fascial disruption should be operatively managed by repeat primary closure, but repair of late incisional hernias may require application of synthetic mesh.

Section II

THE UROLOGIST AT WORK

This page intentionally left blank

Chapter 2

Basic Surgical Techniques

LEE PONSKY AND SRINIVAS VOURGANTI

Practicing urologists have need for skills and techniques common to all surgeons, including tissue approximation, large and small bowel anastomosis, and wound closure. These basic surgical techniques need to be a part of the armamentarium in which all urologists should be proficient and may be needed in performing any urologic operation. These include the elements of suturing and plastic repair, the techniques of laparoscopy and microsurgery, and the methods for the repair of vascular or intestinal injuries.

Not only must these basic techniques be a standard part of a urologist's training, but also the urologist must be prepared to occasionally perform procedures that are not strictly in the field of urology. The urologist must be prepared to manage diverse issues, whether addressing a splenic or vascular injury, forming a gastrostomy for feeding during recovery, or making a transverse colostomy for fecal diversion. Even when other surgical colleagues are consulted, urologists should be able to identify intraoperative issues that will require treatment and be prepared for any emergency by having an adequate repertoire of suitable procedures in general surgery. Thus all urologists should be able to perform key standard general surgical procedures without outside assistance. In this chapter these basic surgical techniques are described in detail so that they can be applied during any operation when required.

A surgeon is constantly faced with novel ideas and procedures. However, one must not forget the fundamental concepts established and proven by the pioneers of our art: aseptic technique, hemostasis, delicate tissue manipulation, and a deliberate exacting technique. These fundamentals stem from the teachings of William Stewart Halsted and should not be forgotten as we advance into new and exciting territories. Technology has allowed surgeons to distance themselves from the patient, completing surgery with minimal (or even no) physical contact. However, we must never allow this to interfere with our strict adherence to Halsted's fundamental teachings of gentleness and deliberation. History has demonstrated that to abandon these central tenets has led even the most sound techniques to fail.

This page intentionally left blank

Chapter 3

Basic Laparoscopy

LEE PONSKY AND SRINIVAS VOURGANTI

TRAINING FOR LAPAROSCOPY

Laparoscopic surgery requires a surgical skill set different from that for open or endoscopic surgery. Laparoscopic surgery in urology previously was in the domain of dedicated, often fellowship-trained surgeons. Laparoscopy is now a part of standard urologic practice and is routinely learned during residency training. The preferred approach for surgery depends on a number of factors, including disease characteristics and patient history, as well as surgeon skill and experience.

CONTRAINDICATIONS TO LAPAROSCOPY AND PATIENT SELECTION

Some of the advantages of the laparoscopic surgical approach are its potential for decreased pain and morbidity, with improved cosmesis and earlier return to normal activities. However, perioperative risks and potential complications remain. When deciding whether a patient is an appropriate candidate for a laparoscopic procedure, the contraindications of open surgery should be considered. In addition, there are issues specific to the laparoscopic approach.

Transperitoneal laparoscopy should be approached with caution in patients with abdominal wall infection, large abdominal hernias, extensive prior abdominal surgery, advanced intraabdominal malignancy, intestinal distention or obstruction, appreciable hemoperitoneum, or generalized peritonitis. Patients with severe cardiopulmonary disease who undergo laparoscopy may be at increased risk for complications because the pneumoperitoneum may reduce venous return to the heart. In addition, the hypercarbia resultant from carbon dioxide insufflation can exacerbate an underlying arrhythmia. Chronic obstructive pulmonary disease may be a contraindication because the pneumoperitoneum can interfere with already marginal pulmonary function. A thorough preoperative pulmonary evaluation is indicated in this setting. Patients who have large abdominal masses or aneurysms, who are extremely obese, or who have ascites present increased risk for bowel or vascular injury. In these situations, extra care should be exercised during port placement to prevent injury. Options to obtain pneumoperitoneum in this setting include open access (Hasson technique) or choosing alternative sites of initial access, remote from areas at risk for injury.

Extraperitoneal laparoscopy and minilaparotomy are alternatives under certain circumstances.

MONITORING EQUIPMENT

An electrocardiograph, pulse oximeter, blood pressure cuff, and precordial or esophageal stethoscope should be available for monitoring the patient. In addition, capnography should be available in order to follow CO_2 elimination. In longer cases, blood samples should be obtained to analyze blood gases.

INSTRUMENTATION

Instrumentation for laparoscopy has significantly evolved over the past several years and continues to improve with advancements in technology. Basic laparoscopic instrumentation includes an insufflator for the establishment of a consistent pneumoperitoneum, an imaging system with camera, and a video monitor.

Digital laparoscopes are now available, as are high-definition monitors. Laparoscopes are also now available with flexible tips with four-way movement. Veress needles and various sized trocars (3, 5, 10, and 12 mm), with or without sheaths (either reusable or disposable), are available. Many of these trocars are now noncutting; such trocars that employ radial dilation to accommodate the correct-sized trocar help eliminate vascular or bowel injury during access. Additionally, these trocars are intended to limit abdominal wall trocar site hernias. A large variety of laparoscopic instrumentation is now available, providing the laparoscopic surgeon with a number of tools with which to approach the laparoscopic procedure.

Grasping instruments include both traumatic and atraumatic, broad-based and pinpoint graspers, both with and

without the ability to lock the handles. A variety of scissors range from miniscissors with sharp tips to larger scissors with a more blunt and rounded tip. A number of different energy-based dissectors (e.g., hydrodissectors) allow the surgeon to cauterize or seal vessels before dividing or dissecting the tissue. Both monopolar and bipolar electrocautery instruments are available in a variety of different instrument shapes and applications. Several hemostatic ligating instruments, including metal, polymer, and absorbable ligating clips, can be applied for vessel control. Also, several different stapling devices allow for both vascular and tissue control. These staplers often offer rotation and reticulation to allow for precise placement. Several devices staple and divide the tissue between several rows of staples, while others just lay several rows of staples without dividing the tissue. For the extraperitoneal approach, balloon dilators develop a working space. The use of a rubber-gloved finger has also been used to dissect the extraperitoneal space. The use of the disposable suction irrigator is common. The reusable suction tip is often used for blunt dissection during laparoscopic procedures. For extirpative cases, several impermeable entrapment devices are available in various sizes for specimen removal.

A *standard laparotomy set* should always be in the room on standby, ready to use if necessary to convert from a laparoscopic to an open procedure.

PREPARATION

Patients need to be informed of all risks, benefits, and alternatives of the procedure. Risks specific to the laparoscopic approach include gas embolism, hypercarbia, and pneumothorax. The patient should always be informed of the possibility of converting to an open operation due to intraoperative bleeding, lack of progression, or the surgeon's judgment that the procedure will be safer from an open approach. Conversion to an open approach is not a complication; however, not recognizing the need to convert to an open approach could be.

For major cases or transabdominal procedures, a mechanical or antibiotic bowel preparation is recommended to reduce intestinal volume as well as to decrease the ill effects of inadvertent bowel injury. Type and screen (or cross-match for difficult cases) the patient's blood in case of hemorrhage. One dose of parenteral antibiotics is recommended for gram-positive coverage to reduce the risk of wound infection. If bowel work is anticipated, gram-negative coverage is also recommended. Compression stockings should be placed on the patient's extremities before inducing anesthesia to reduce the risk of developing deep vein thrombosis. Subcutaneous heparin may also be used perioperatively to reduce this risk, because increased pneumoperitoneum increases venous stasis.

Use of general endotracheal anesthesia is usually recommended for laparoscopic procedures because the pneumoperitoneum can limit the expansion of the diaphragm, respiration, and ultimately oxygenation. Adequate abdominal and diaphragmatic relaxation is mandatory. Muscle relaxants have been shown to decrease the incidence of sore throats and abdominal pain postoperatively. Immediate postoperative O_2 (2 L/min) prevents transient hypoxemia associated with laparoscopy. Other routine patient monitoring includes continuous eclectrocardiogram monitoring, intermittent noninvasive blood pressure monitoring, precordial or esophageal stethoscope monitoring, pulse oximetry, and end-tidal CO_2.

Insertion of a urinary catheter and a nasogastric tube to empty the bladder and stomach decompresses these hollow viscus organs and helps minimize their injury with Veress needle or trocar placement.

PATIENT POSITIONING

The specific position of the patient is decided based on the procedure being performed. For the standard supine position, the arms should be placed at the patient's sides to prevent brachial or ulnar nerve injury. The Trendelenburg position or other adjustments to the bed's position can be used to encourage the intestines to fall out of the field during the case. Thus it is imperative that the patient be completely secured to the table with appropriate straps and tape to prevent a fall. If the lateral position is required, the bottom leg should be flexed approximately 45 degrees with the ankle and knee padded. The top leg is straight. Several pillows or other similar padding should be placed between the lower and upper legs. An axial roll should be placed beneath the lower axilla to prevent a brachial plexus injury. In addition, all points of contact with the bed or positioning straps should be thoroughly padded. Careful attention to padding can avoid nerve or soft tissue injury. This is especially important during long procedures or in procedures on obese patients, wherein such complications, including the risk of rhabdomyolysis, are more likely. Prepare the skin from nipple to midthigh and from table top to table top; that is, have the abdomen prepared for an open operation if complications occur. Take special care to clean the umbilicus. Drape the patient to leave the scrotum or vagina exposed to allow manipulation of testes or uterus. Plan where an open incision will be made in case there is an emergent need to convert to an open operation.

PNEUMOPERITONEUM

If the operating room does not have a central supply of CO_2 directly from the wall, check the pressure in the operating room CO_2 tank and ensure that a spare tank is available.

The choice of method for initial transperitoneal access should be based on patient-specific factors. Open access methods, such as the Hasson technique, have the advantage of a more controlled entry into the peritoneum. This can potentially offer an advantage in settings where extensive adhesions are anticipated. It also may be useful in pediatric patients. Potential disadvantages to open access techniques include a larger incision, longer dissection time, and the possibility of gas leakage from around the trocar due to the larger size of the fascial defect. An alternative is a closed technique of access using a Veress needle.

Similarly, the exact site of initial access is based on patient factors as well as considerations specific to the procedure being performed. With the patient in the supine position, the most commonly chosen site of access is at the umbilicus. The advantage of this location is that here the abdominal wall is thin and surrounded by few vessels. In addition, a cosmetic advantage results from the midline location and proximity to the umbilicus, allowing for the scar to be easily hidden. One specific concern with initial access at the umbilicus is the potential for injury to major vessels, including the aorta, vena cava, or the left common iliac artery and vein. Another consideration when using the umbilicus for initial access is that, in the obese patient, there is inferior migration of this landmark due to presence of a pannus. More superior placement may be considered in this setting. Conversely, in a patient of normal weight, the umbilicus is considerably closer to the major vessels and greater care should be exercised to avoid injury during Veress needle access, that is, when directing the needle in a caudal direction.

With the patient in the lateral decubitus position, a commonly chosen site for initial Veress access is half the distance between the anterosuperior iliac spine and the umbilicus. This location is remote from the major vessels; however, the potential for injury to the bowel does exist at this site.

In patients with a history of abdominal surgery with anticipated adhesions, alternative sites of initial access may be chosen in order to minimize injury. One common choice is subcostal along either midclavicular line. The advantage of this site is that injury to the bowel is minimized. However, care should be taken to avoid injury to the viscera (especially the liver and spleen) when using such sites in the upper abdomen.

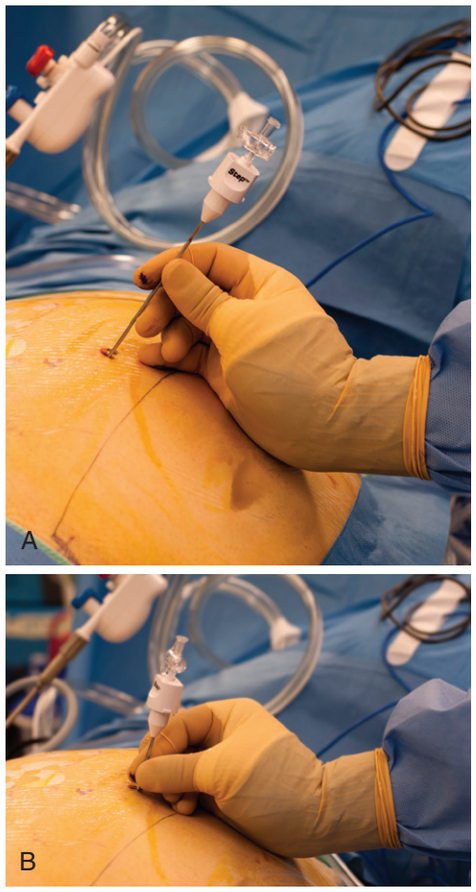

FIGURE 3-1.

Veress Needle Technique

The Veress needle has an internal diameter of 2 mm and an outer diameter of 3.6 mm. It is available in lengths from 70 to 150 mm. The outer sheath has a sharp cutting edge. The inner obturator is blunt and retracts within the sheath during passage through the body wall but extrudes within the abdominal cavity to protect the bowel.

The patient and table should be adjusted to allow gravity to help move the bowel content out of the way of the access site. Begin by infiltrating with local anesthetic and then making a very small incision at the site of initial access.

The Veress needle is held high on the needle in between the thumb and index finger of the surgeon's dominant hand (Fig. 3-1). The lateral aspect of the hand rests on the patient. This helps prevent the unintentional placement of the Veress needle too far into the abdomen, and allows for precise control of the depth of penetration of the needle. With finger dissection, the subcutaneous tissue can be bluntly dissected down to the fascia. The surgeon's nondominant index finger can be used to palpate the fascia as the needle is carefully advanced. Occasionally grasping and elevating the abdominal wall may be useful; however, caution should be taken because this can sometimes increase the preperitoneal space. As the Veress needle is advanced, two successive planes of resistance are felt as the needle passes first through the fascia and then through the peritoneum. Passage through the peritoneum is followed by an audible click as the obturator springs out to shield the sharp edge of the needle.

Confirm the position of the needle by aspiration. Place a 10-mL syringe containing 5 mL of saline on the stopcock, open it, and then simply aspirate. There should be no return: no blood, no bile, no intestinal contents, and no urine. Such a return indicates injury to peritoneal contents and possibly warrants open laparotomy, depending on the surgeon's experience (see "Intraoperative Problems"). Instill 5 mL of saline, which should enter freely. When aspirated, there should be no return. Disconnect the syringe and confirm that the meniscus of water seen in the hub of the Veress needle drops—"the drop test."

To perform the drop test, advance the needle 1 or 2 cm deeper; there should be no resistance if the needle is properly positioned. Connect the insufflator to the stopcock, and read the intraabdominal pressure. It should be less than 10 mm Hg and should fall when the abdominal wall is elevated. Start the flow of CO_2 at a low rate of 1 L/min, and check immediately to be sure that the pressure does not rise above 10 mm Hg. If the pressure rises above 10 mm Hg, do not hesitate to replace the needle, inserting it

several times if necessary until the proper parameters are achieved. Continue filling, now at an intermediate rate of 2 L/min (the maximum allowed by the caliber of the needle), until the pressure reaches 15 mm Hg in an adult (admitting between 5 and 7 L in about 5 minutes) or 6 mm Hg in a child younger than 6 months of age. Percuss the abdomen to ensure symmetric tympany, ensuring pneumoperitoneum. A higher pressure, up to 25 mm Hg, can be induced during initial trocar placement but should be reduced to less than 15 mm Hg for the procedure itself to minimize the risk for gas absorption and hypercarbia, as well as for reduced venous return secondary to compression of the vena cava and reduced renal function. Impaired ventilation results from excessive pressure on the diaphragm, requiring an increase in ventilatory pressure with risk for pneumothorax. Once pneumoperitoneum has been established, turn off the flow, and remove the needle.

Error

Be alert that the needle may have been placed in the preperitoneal space because it was inserted at too great an angle. In this abnormal position, the abdominal enlargement during inflation appears asymmetric. When the trocar and laparoscope are inserted, the error is recognized because only fat is seen. To correct the error, open the peritoneum with laparoscopic scissors and guide the trocar beneath it. An alternative is to aspirate the space with a needle and reattempt placement of the Veress needle or use the Hasson cut-down technique.

INSERTION OF PRIMARY PORT

A variety of reusable and disposable trocars are available. While historically only bladed (cutting) trocars were available, now noncutting, dilating trocars are available. Noncutting trocars spread rather than cut the abdominal tissue, allowing less opportunity for vessel and visceral injury, and decreasing the chance of a port site hernia. Alternatively, clear-tipped trocars allow endoscopic monitoring of the passage of the trocar for additional control.

The technique for placement varies depending on the type of trocar used. General techniques for trocar placement are reviewed here.

Hold the base of the trocar in the palm of the dominant hand while keeping the middle finger extended as a brace to prevent excessive penetration. At first, hold the instrument vertically while penetrating the subcutaneous tissue. The direction of insertion corresponds to the surgical site. For supine procedures in the midabdomen or upper abdomen, the trocar should be directed perpendicularly to the incision.

For supine procedures in the pelvis, the trocar should be directed at a 60- to 70-degree angle in a caudal direction. For lateral decubitus procedures (i.e., renal procedures), the trocar should be directed toward the site of interest. The trocar should be inserted with a twisting motion of the wrist so that it does not suddenly jump through the abdominal wall. Resistance to the passage is felt at the fascial and peritoneal levels.

As the trocar enters the peritoneal cavity, listen for the sound of gas escaping from the inflation valve. Remove the trocar from inside the sheath, and let the valve built into the sheath close the channel. Advance the trocar 1 to 2 cm. Connect the CO_2 tube, and set the flow control to maintain a pressure of 15 to 20 mm Hg.

Introduce the laparoscope into the sheath with an attached focused and oriented full-beam videocamera. Monitor the area on the video screen. First, check immediately below the trocar to be certain no abdominal structures have been injured during needle or trocar insertion. Next, watch for blood running down the sheath, indicating an injured vessel in the body wall (see "Intraoperative Problems"). Gas leakage around the trocar site should not occur with a closed system. If it does occur, placement of a pursestring suture may be required, or Vaseline gauze can be wrapped around the base of the trocar to maintain pneumoperitoneum.

Open (Hasson) Technique

Make a 2-cm incision (longer in obese patients) through skin to the level of the fascia while elevating the wall with towel clips (Fig. 3-2). Place two heavy nonabsorbable sutures in the tough periumbilical fascial fold, and incise it between them for 2 cm to reach the transversalis fascia and peritoneum. Pick up the peritoneum with forceps, and incise it under direct visualization to enter the peritoneal cavity. Insert a finger and sweep around the inside of the anterior abdominal wall to check for adherent bowel.

The Hasson cannula has a sleeve and a blunt-tipped obturator. Insert it through the opening in the peritoneum, and plug it firmly into the opening in the fascia. (An alternative is a screw-in port.) Wrap the fascial sutures around the wings to hold the occluding cone or sheath in place; they are used later to close the defect. Insufflate the peritoneal cavity at a rate of 6 to 8 L/min (insufflation can be faster than with the Veress needle). Insert the laparoscope with attached camera through the cannula.

Systematically inspect the peritoneal cavity as for diagnostic laparoscopy.

Male: Note that the bladder terminates in the median umbilical ligament (urachus), which reaches to the umbilicus. The medial umbilical ligaments (obliterated umbilical arteries) lie parallel and lateral to it. More laterally, the inferior epigastric vessels may be seen through the peritoneal covering. Next, the vas deferens can be traced after it passes over the iliac vessels to its entrance into the internal inguinal ring with the spermatic vessels. The ureter crosses those vessels at a higher level and terminates behind the bladder, passing beneath the vas deferens and medial umbilical ligament. The sigmoid colon is evident on the left and the cecum and appendix on the right.

Female: The median and medial umbilical ligaments are seen, as are the round ligament entering the internal inguinal ring and the iliac and epigastric vessels.

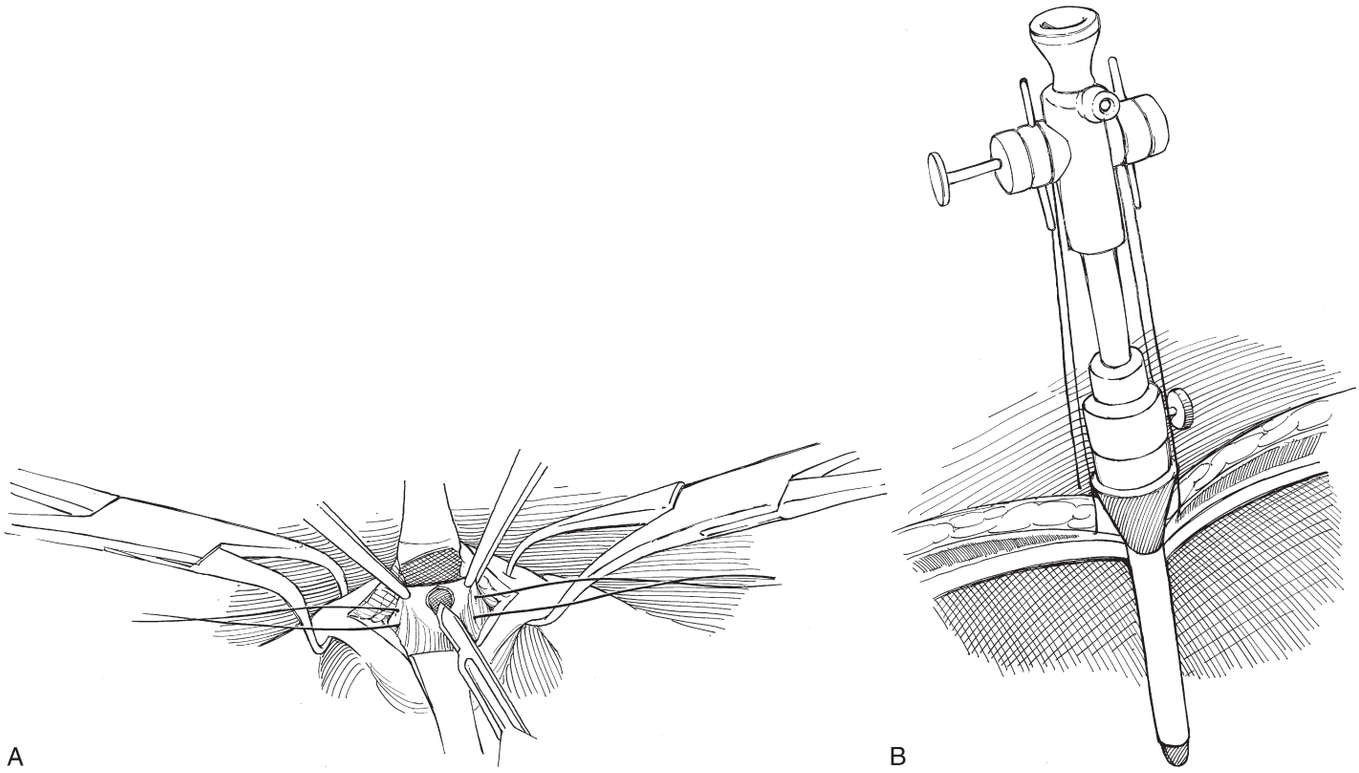

FIGURE 3-2.

Below the bladder are the uterus, ovary, tubes, and round ligament.

In the upper abdomen, inspect the omentum for injury. Note the position of the spleen, stomach, gallbladder, and liver.

INSERTION OF SECONDARY PORTS

After the initial port is established, select and mark appropriate sites for introduction of the additional ports, depending on the intended procedure. These trocars are 5 and 10 or 12 mm. The larger 10- or 12-mm ports are placed either singly or in multiples, depending on the instrumentation to be used during the procedure (e.g., clip applier or stapling devices). Placing a port too close to the operating site makes it difficult to manipulate such instruments as scissors and curved dissectors because of interference by the sheath. Placing it too far away creates a long fulcrum between the insertion site and the end of the instrument that, by exaggerating the movement of the tip, makes precise dissection difficult. Keep trocars away from bones and from each other. A few centimeters lateral to the border of the rectus muscle is usually a suitable site; beware of the inferior epigastric vessels.

Darken the room and transilluminate the anterior abdominal wall to visualize the inferior epigastric and other vessels. Ensure that the pneumoperitoneum is complete at a pressure of 20 to 25 mm Hg. Insert the trocars required for the operation. The trocars are placed under direct visualization in a standard triangulated position centered on the intended surgical site. The concept of triangulation replicates open surgery. The eyes in the center, with the surgeons hands coming in at 45-degree angles. The same triangulation is recommended for laparoscopic surgery, with the camera in the middle and the working instrument ports laterally. Press on the abdominal wall with a finger, and note that the site of indentation is clear of vessels by placing the tip of the laparoscope against the site to define crossing vessels. A finder needle used to inject local anesthesia can be used to identify the exact site of the trocar placement. Turn the laparoscope to bring the anterior abdominal wall into view. While illuminating the abdominal wall from within, insert the appropriate working ports, each with a twisting motion directed toward the area where the operation will be performed. Misdirected trocars are difficult to maneuver into proper alignment, and doing so may tear the peritoneum. Avoid traversing the inferior epigastric vessels, which can be seen by transillumination and by direct inspection.

The trocar sheath can be held by heavy sutures in the skin, hooked over wings on the sheath to prevent displacement. *Precautions* are necessary to avoid injury to abdominal structures. Visualize the position of all instruments and do not leave them unattended. As soon as another port is placed, insert a 5- or 10-mm laparoscope through the port to examine the entry point of the primary trocar, thereby ruling out inadvertent bowel or omental injury.

LYSIS OF ADHESIONS

With laparoscopic scissors, divide only those adhesions that limit access to the operative site. Because most adhesions are related to previous incisions, make traction against the abdominal wall that has been elevated by the pneumoperitoneum, or have an assistant provide downward countertraction. Problems arise from injury to the intestine by the cautery and bleeding that may not be noticed. This is an ideal place to use only mechanical cutting or bipolar current; if monopolar current is used, be especially careful of injuries.

RETRACTORS

Graspers can often function for retraction. A solid metal bar with a rounded tip is useful for restraining bowel or the edge of the liver. A locking instrument can be used to grasp the abdominal sidewall, retracting the lower edge of the liver superiorly, which is particularly helpful when operating on the right kidney or adrenal gland from a transperitoneal approach. A fan retractor has several flat blunt blades that open into a fan shape for holding back a wider area. Likewise, the 5- and 10-mm expanding mechanical or balloon retractors are effective, with the latter being atraumatic. Vein retractors can be used to retract vessels such as the external iliac vein.

IRRIGATION

With a combined aspiration/irrigation system, the aspiration channel is connected to the operating room vacuum system and the irrigation channel to a sterile saline or water container. High-pressure irrigation can be used for some soft tissue dissection.

SUTURING AND OTHER METHODS OF TISSUE APPROXIMATION

Tissue anastomosis can be one of the most challenging skills to gain in laparoscopy. Many laparoscopic techniques and tools have been developed to aid in accomplishing this task.

Automated Suturing Devices

The Endo Stitch (U.S. Surgical) allows laparoscopic tissue anastomosis while avoiding the need for intracorporeal manipulation of a free needle. The instrument may be passed through a 10-mm port, and its two jaws may be used to clamp onto tissue. A double-pointed needle may be passed between the jaws of the instrument and through the tissue by operating the needle lever on the instrument. A suture, which is secured to this needle, then follows the needle. The Endo Stitch has been shown to be a useful adjunct and has been demonstrated to decrease operative times, especially for beginning surgeons. However, as laparoscopists become increasingly experienced, most tend to favor the traditional laparoscopic needle holders for the additional control and precision that they offer.

Polydioxanone Clip Technique for Securing Suture

Clips (e.g., Lapra-Ty, Ethicon) may be used to avoid the need to perform intracorporeal knot tying. One technique is to make a preformed loop on the tail end of a suture. After passing the needle through the tissue, it may be passed through the loop. After applying tension, a clip may be secured next to the tissue to secure the suture. To secure a running suture, a clip may be placed at the tail end to anchor the starting and ending points of the suture.

Extracorporeal Suturing: Pushed Half Knot

Extracorporeally placed knots can be useful in that some surgeons may be more familiar with this type of classic knot versus one performed using intracorporeal techniques. The suture is introduced into the peritoneum while the tail is kept outside the body. The needle is advanced through the tissue and then retrieved through the same trocar. One end of the suture should be held under tension while the knots are thrown and replaced next to the tissue using a knot-pushing instrument. The first two knots should be thrown in the same direction, while the third should be thrown in the opposite direction in order to fix the knot.

LAPAROSCOPIC SUTURING

Insertion of the Needle

The needle should be introduced and removed from the peritoneum carefully. Unlike in open surgery, the needle should not be secured in the needle driver during insertion. This risks loss of the needle during trocar passage. Rather, the suture end should be secured in the needle grasper. One technique used to avoid problems is to use a reduction tube. After securing the suture approximately 3 cm proximal to the needle, the needle driver may be inserted into the reduction tube. The reduction tube is then inserted through the 10-mm trocar and the needle may then be passed safely into the patient. This should be done under visual guidance. The tube may be left in place throughout the procedure. When removing the needle from the abdomen, the needle holder and reduction tube should be removed simultaneously.

General Considerations

Choosing the appropriate length of suture is key to avoid problems. If the suture is too long, it will become difficult to find the end easily or it will become easily entangled. In addition, during suturing more than during any other activity, proper port placement helps avoid problems and surgeon frustration. Port sites should be chosen to allow an angle of 60 to 90 degrees in the field. In addition, the ports should be placed far enough apart to prevent interference between the two ports (generally at least 15 cm apart).

Intracorporeal Suturing

Two needle holders are used for suturing. Once the needle is in the abdomen, it should be loaded forehand into the dominant hand driver. It should then be passed through the tissue in a smooth motion, following the curve of the needle. Once the needle is through the tissue, the nondominant hand driver should grasp the needle while releasing the needle from the dominant needle driver.

The method of knot tying is by the "instrument tying" technique that is used in open surgery. The suture should be pulled though the tissue, leaving only a short tail. A C-loop should be formed with the nondominant needle grasper by grasping the needle end of the suture (not the free end) approximately 5 cm from the tissue and holding the suture with some laxity. The dominant needle driver should then be advanced into the concavity of the C-loop. The suture is then wrapped around the dominant needle grasper. The dominant needle grasper should then be used to grasp the short tail of the suture. The short tail is then pulled through the loop and the needle graspers are drawn apart to lay down the knot. This accomplishes the first half of the square knot (an overhand flat knot). The sequence is then repeated with the opposite hands in order to throw the second opposing flat knot, thus completing the square knot.

CLIPPING AND STAPLING

Clips are *occlusive* for securing blood vessels, *tacking* to approximate peritoneal surfaces (resurfacing), or *fastening* nonabsorbable mesh in place. Single-load appliers are cheaper in the long run, but multiple appliers save time, especially for operations involving numerous vessels or broad expanses of peritoneum, such as resurfacing the retroperitoneal space.

Staples (vascular or tissue load) are applied with a (disposable) stapler that inserts the staple and divides the tissue. They come in 3- and 6-cm lengths and usually place six rows of staples while simultaneously dividing the tissue between rows three and four. They are used, for example, to secure a cuff of bladder, to ligate large vessels (renal vein ligation), or to close the enterotomy following an anastomosis. Care should be taken not to fire staples over previously placed clips or staples to prevent malfunction.

HEMOSTASIS

Meticulous hemostasis is essential for laparoscopic surgery because any bleeding quickly obscures the field. When bleeding occurs, it is imperative that the surgeon remain calm and in control. The pressure of the pneumoperitoneum can be increased to 20 mm Hg or even 30 mm Hg temporarily. Follow the same principles of open surgery and apply pressure under direct visualization with a laparoscopic instruments. Traction of tissue may help identify and minimize the site of bleeding. Suction and irrigation may be needed to better identify the source of bleeding. If the patient is otherwise stable, take the time to dissect the area around the bleeding site and precisely identify the source. The use of packing material such as absorbable hemostatic material or 4 ×18 sponges can be passed easily through a 10/12-mm port. An additional port should be placed if necessary. If an artery has been injured, it can be seen spurting; if a vein has been injured, the increased intraabdominal pressure may provide tamponade (this is true even for the inferior vena cava). If the bleeding vessel is isolated, apply the electrocautery, or clip or suture it. The use of the argon beam coagulator is often very useful for bleeding from the liver and/or spleen. There is a need to vent gas while using the argon beam, because it releases several liters of gas per minute and can result in a tension pneumothorax if the intraabdominal pressures are not released. If the injury is to a large artery, or if the injury is thought to be difficult to control laparoscopically, convert to an open laparotomy, obtain vascular surgical consultation if necessary, and then do the repair. When bleeding is encountered, call for open instruments and retractors. Identify and plan for the preferred site of incision. While maintaining the pneumoperitoneal pressure, keep the laparoscope in the abdomen to visualize the incision into the abdomen, allowing for rapid and safe entry into the abdomen with direct visualization.

Multiple agents are now available to help control bleeding, including fibrin-based glues (Tisseel, Baxter; Crosseal, Johnson & Johnson), thrombin-soaked cellulose (FloSeal, Baxter), or activated cellulose microfibers (Avitene, Davol). All are helpful in situations of general oozing or even in more complicated situations such as renal parenchyma bleeding.

ORGAN ENTRAPMENT

Introduce an impervious sack of the appropriate size into the abdomen. Lead the whole organ into it and entrap it. Pull the drawstring to close the mouth of the sac, and deliver the string through a 10- or 12-mm port site. If morcellation is desired, the contents may be fragmented with ring forceps; remove the pieces to allow the sac to be withdrawn via a trocar incision. Many mechanical morcellators have been withdrawn from the market due to the rare but devastating complications of inadvertent abdominal organ or vascular injury with the morcellator. More commonly, the organ is removed intact with an enlarged port site incision or via a separate muscle splitting incision (a cosmetically preferable Pfannenstiel incision is often employed).

LEAVING THE ABDOMEN

Lower the intraabdominal pressure to 5 mm Hg. Inspect the operative site and each secondary trocar site. Consider evacuating the pneumoperitoneum completely for several minutes and then reinspect the abdomen for evidence of bleeding, in the absence of the intraabdominal pressure. Remove the larger 10-mm sheaths first while the assistant holds a finger in the defect to preserve the pneumoperitoneum. Place two large skin hooks to catch the fascia on either side, and allow the fascial edges to be grasped in Allis

clamps to maintain the pneumoperitoneum and to facilitate placement of the fascial suture. Several devices have been developed to aid in port site closure. They are especially helpful in obese patients in whom visualization of the fascial layer can be difficult. The Carter-Thomason needle can be used to introduce suture through one side of the fascial defect and then recover it through the fascia on the other side of the defect. This should be done under direct visualization with the laparoscope. Another option to accomplish this same task is the Endo Close suture carrier (U.S. Surgical).

The issue of closing trocar sites has been reconsidered following the popular use of noncutting, dilating trocars from traditional bladed trocars. Because the risk of bleeding and port site herniation is exceedingly low, some surgeons have advocated foregoing the need for fascial closoure in this setting. Check the completeness of the closure by transabdominal inspection.

Irrigate the wound, and close the skin with a 4-0 absorbable subcuticular suture. Visualize the primary 10-mm trocar through a 5-mm laparoscope in a 5-mm port if necessary; remove the larger trocar, and close the fascia as described. Remove the smaller trocar sheaths in succession under direct visualization while the assistant places a finger over each defect. Manually decompress the scrotum. Release the fingers from the 5-mm openings and allow the gas to escape.

Skin closure with 4-0 absorbable suture in a subcuticular fashion should be performed on all sites 10 mm or larger. Adhesive strips (Steri-Strips) or glue (DermaBond) may be used to approximate all other incisions.

POSTOPERATIVE CARE

Remove the nasogastric tube and balloon catheter. A broad-spectrum parenteral antibiotic should be continued for 24 hours. Oral intake should start in the evening. Occasionally pain requiring continued parenteral analgesics suggests an underlying abdominal complication, such as a "missed" or "late" bowel leak.

LAPAROSCOPIC SURGERY IN CHILDREN

Laparoscopic procedures are somewhat different in children because the distance between the anterior abdominal wall and the great vessels is smaller and the organs are closer to the surface. Having shorter instruments, which are under development, will help. In infants and small children, in whom the distance is extremely small, making a small paraumbilical incision first allows the insufflating needle to be passed by direct observation.

If the Veress needle is used, it requires less pressure because the child's fascia is less resistant; however, an open trocar insertion is safer. In the latter case, the peritoneotomy is sealed against the sheath with a pursestring suture. One new trocar has coarse threads and can be screwed into the abdomen through a small infraumbilical peritoneal incision. Less gas is needed to fill the small peritoneal cavity, and it can be added at a slower rate. Transillumination of the abdominal wall is easy in children, a fact that helps with placement of trocars so as to avoid vessels in the abdominal wall. Anatomic details are more clearly seen in children because they have only a small amount of preperitoneal fat, which also reduces the chance for preperitoneal insufflation during insertion. However, because the peritoneum is more loosely attached, it is more susceptible to emphysema. Also, the weak adherence to the abdominal wall makes the introduction of large cannulas difficult; an instrument introduced through a smaller port may be required to push upward on the abdominal wall to assist the entry of the larger sized port.

Because children swallow air, it is important to decompress the stomach with a nasogastric tube and to leave it in place for extensive procedures.

Caution the parents that even though the operation is done through three to five small incisions, it is still a major surgical procedure because hemorrhage and bowel injury can lead to serious complications. Moreover, warn the parents that it may not be possible to complete the procedure through the instruments; an open operation may become necessary.

If adhesions are anticipated, prepare the bowel by both mechanical and antibiotic means. Give a broad-spectrum antibiotic parenterally preoperatively and postoperatively. Whether blood should be matched depends on the type of procedure and the risk for vascular injury, but blood should always be screened. As noted, it is mandatory to have a standby table with instruments ready for laparotomy in case of complications.

Use general anesthesia in children; the irritation of the diaphragm by CO_2 is painful, and any motion by the child is hazardous. Moreover, muscle relaxation is important because of the small intraperitoneal space with a greater liability for injury to intraabdominal structures. Placement of a cuffed endotracheal tube is needed to ensure absence of voluntary respiratory movement and to allow mechanical assistance to respiration as the intraabdominal pressure rises. Be aware that hypercarbia from absorbed CO_2 may be a problem during long procedures.

Compared with landmarks in adults, the landmarks in children are readily palpated, including the aortic bifurcation and sacral promontory. The abdominal wall is thinner, and masses are easily felt. On the other hand, children have less space between abdominal wall and interior organs. They have an intraabdominally positioned urinary bladder. Both bladder and stomach need to be decompressed before trocars are introduced. It is probable that children are no more susceptible to hypercarbia than adults because they have good lungs. Lower insufflation pressure (6 to 10 mm Hg) helps limit CO_2-related problems and the development of subcutaneous emphysema. The volume of CO_2 required to fill the peritoneal cavity varies from 0.5 to 3 L, depending on the age of the child.

For initial positioning, place the child supine. Give a parenteral dose of antibiotic. Induce anesthesia, and insert a cuffed endotracheal tube. Provide for pulse oximetry and for monitoring of end-tidal CO_2. Empty the bladder with a catheter, and leave it indwelling. Have the anesthetist place a nasogastric tube because a full stomach depresses the omentum into the route of the trocars. Determine by

percussion that the stomach is empty. For orchiopexy and other pelvic procedures, insert a rolled towel under the lower back to create lordosis, and tip the table into a 10-degree head-down position to allow the intestines to drop out of the pelvis. Shift to a 30-degree head-down position for placement of the initial port. It can be helpful after the ports are inserted to tilt the table laterally 30 degrees to raise the involved side above the intestines. Prepare the entire abdomen in case laparotomy is required. Test all equipment before starting.

In infants younger than 1 year of age, an open (Hasson) insertion is safer. For closed insufflation, it may be preferable to insert the Veress needle above the umbilicus to avoid the yet undescended bladder. In addition, this avoids the obliterated umbilical arteries as well as the urachus. Begin insufflation with CO_2 at a rate of approximately 1 L/min until the pressure in a fully relaxed child reaches 15 to 20 mm Hg; then quickly withdraw the needle. Some anesthetists do not immediately achieve relaxation.

The *primary port* is placed above or below the umbilicus. A 5-mm port may be large enough for infants but limits the types of instruments that can be used. As soon as the primary port is in place, reduce the intraabdominal pressure to 10 to 15 mm Hg. *Secondary ports* are placed higher than in adults because a child has a smaller pelvis with generally shorter working distances. Therefore place secondary ports at the umbilical level in infants and small children. The *physiologic effects* of laparoscopy in children include increased end-tidal CO_2, increased airway pressures, hyperthermia, oliguria, and mild renal tubular injury.

DIRECT EXTRAPERITONEAL ACCESS (GAUER)

Simple insufflation of the extraperitoneal space provides inadequate exposure because dissection is not uniform. By inflating a balloon just outside the peritoneum, the fibrous connections between it and the transversalis fascia can be separated, as is done with open extraperitoneal techniques of mobilization.

A balloon dissector is required. One can be made from materials available in the operating room: a finger of size 7 surgical glove (washed) or latex balloon is tied over an 8-French red rubber catheter that is attached by a T to the pump of a sphygmomanometer and to a manometer to allow inflation and simultaneous observation of pressure. Alternatively, obtain a balloon dissector commercially.

For renal procedures, after the usual preparation and under general anesthesia, place the patient in the lateral position. Make a 2-cm incision through all layers just off the tip of the 12th rib. Using small retractors expose the lumbodorsal fascia and incise with electrocautery. Using blunt finger dissection, develop the retroperitoneal space between Gerota's fascia and the lateral side wall. Balloon-dilate the retroperitoneal space, inflating until a bulge on the abdomen can be seen. The balloon pressure varies from the 110 mm Hg needed to separate the transversalis fascia from the properitoneal fat to 40 or 50 mm Hg as the space is developed. Leave the balloon inflated for a few minutes for hemostasis, then deflate and remove it. Insert a 10-mm Hasson-type laparoscopic sheath through the opening into the retroperitoneal space, and close the opening in the fascia and skin around it with a mattress suture. Balloon trocars can cinch all tissue layers of the skin and abdominal wall between the internal and external balloons of the device. Insufflate in the usual way, maintaining the pressure between 15 and 20 mm Hg during the procedure. Insert a second 10-mm sheath posteriorly. A third may be placed in line with the anterosuperior iliac spine and in line with the trocars placed previously. If needed, place a fourth port above the iliac crest in the inferior lumbar triangle.

Proceed with laparoscopic dissection of the lower pole of the kidney, the ureter, the paraaortic lymph nodes, and the spermatic vessels, which lie directly under the anterior lamina of Gerota's fascia.

For extraperitoneal exposure of the pelvis for pelvic node dissection, radical prostatectomy, place the balloon just inferior to the umbilicus. For bladder neck suspension, place it midway between the symphysis pubis and umbilicus. Amplify the exposure by blunt dissection.

INTRAOPERATIVE PROBLEMS

Most complications occur during initial trocar insertion or during insufflation.

Preperitoneal emphysema from improper placement of the insufflation needle is heralded by scrotal emphysema early in the case, making identification of landmarks difficult. Alternatives include stopping the procedure, switching to the Hasson technique, or evacuating the insufflation and starting over. Emphysema of the omentum obstructs the view. Leakage around a trocar sheath can cause emphysema, which usually resolves spontaneously. Emphysema may be an indication of malfunction of the insufflator, with resulting abnormally high pressures. *Pneumothorax* may result from defects in the diaphragm or from barotrauma from excessive positive-pressure ventilation. It can usually be treated expectantly, but needle aspiration followed by tube thoracotomy, placing a 12-French chest tube through the fourth intercostal space just behind the anterior axillary fold, may be needed.

Pneumomediastinum/pneumopericardium may be heralded by subcutaneous emphysema or pneumothorax. Consider stopping the procedure and allowing spontaneous absorption. Pericardial tamponade requires pericardiocentesis of the gas.

Barotrauma results from extended excessive intraperitoneal pressure, greater than 15 to 20 mm Hg in adults and greater than 10 to 15 mm Hg in children. The effect is a decrease in venous return and in myocardial filling pressure that fosters hypotension. In addition, pneumothorax may result from alveolar rupture caused by increased ventilation pressures secondary to pressure on the diaphragm. High insufflation pressures suggest improper placement of the needle or a faulty CO_2 pump. Gas from the CO_2 cooled laser tip and the argon beam coagulator may also cause increased intraabdominal pressure, requiring venting through one of the ports.

Extraperitoneal leakage of CO_2 from high filling pressures or from inadvertent external abdominal pressure usually clears spontaneously, although it can be evacuated with a

needle by pressing the skin against the fascia. *Pneumomediastinum* is more serious and can cause dyspnea or even cardiorespiratory failure. The symptomatic presentation of pneumomediastinum requires immediate termination of the procedure.

Gas embolization has been reported with resultant cardiovascular collapse and pulmonary edema. A "mill-wheel" murmur may be heard over the heart, and the electrocardiographic tracing can become abnormal. Deflate the pneumoperitoneum at once, and turn the patient on the left side and head down. Supply 100% oxygen and hyperventilate the patient. If possible, insert a central venous catheter and aspirate the gas. In severe cases, perform cardiopulmonary resuscitation. *Cardiac arrhythmia* is a common occurrence from the effects of hypercarbia (sinus tachycardia, premature ventricular contractions, and depression of the myocardium). The treatment is to reduce insufflation pressure, supply 100% oxygen and hyperventilate, and give appropriate cardiac medication.

Hypotension/cardiovascular collapse can result from hemorrhage, pneumomediastinum or pneumothorax, tension pneumoperitoneum, rupture of the diaphragm, vasovagal reflex, or gas embolus.

Injury of the *anterior abdominal wall vessels* leads to bleeding and formation of hematomas. It is more common with the Hasson technique but also is more readily managed because the wound is open. *Injury to the inferior epigastric vessels* by the sheath is recognized by blood dripping into the pelvis. Cauterize the route that the vessels pass through with the aid of the laparoscope, or enlarge the incision and transfix the vessels with a suture above and below the puncture site. Alternatively, insert a balloon trocar, draw the internal balloon up against the vessel, and cinch the external balloon down compressing the bleeding vessel. If controlled, the case can proceed and this should be inspected at the end of the procedure when the balloon trocar is released. Another technique is to pass a nonabsorbable suture on a Stamey needle through the abdominal wall near the port responsible for the injury, remove the suture from the eye intraabdominally, reinsert the empty needle nearer to the port to straddle the vessel, thread the suture in the eye, withdraw the needle, and tie the suture. Another alternative is to pass an angiocatheter through the subcutaneous tissue alongside the port. Loop a monofilament suture, and crimp the loop so that it will pass through the catheter. Remove the catheter, insert it on the other side, and introduce a single suture. Transabdominally pass a grasper through the loop of the first suture, and grasp the end of this second suture. Pull the looped suture to carry the first suture to the surface, where it is tied.

Vascular injury, including needle puncture of the abdominal aorta or other major vessel, is followed by a spurt of blood. Make a decision whether to withdraw the needle and reinsert it or to proceed directly to laparotomy. Usually the puncture site is small if the needle has not been moved, so intervention is not necessary. Minor injury to small vessels can be controlled with electrocautery. Application of clips, laparoscopic suturing, or Endoloops may be considered, but if accumulation of blood is marked and suction is inadequate, then open repair is necessary. Likewise, major bleeding uniformly occurs from trocar or Veress needle injury. Here, leave the Veress needle or trocar sheath in place for tamponade and as a guide to the site of injury, and proceed with emergency laparotomy. Maintaining the pneumoperitoneum facilitates the subsequent exposure. Keep pressure on the vessel until the patient's blood pressure is stable.

Thermal injuries from the electrocautery occur when the unit is activated when the entire noninsulated portion of the tip is not in view or when a disruption occurs in the insulation on the shaft of the instrument. The injuries are more severe than they appear at first and often require open operation.

Puncture of a viscus with the Veress needle is usually not harmful, as long as the needle is not connected to the active CO_2 supply. Bowel penetration may be indicated when intestinal gas or cloudy fluid is aspirated or when the patient passes flatus or stool. Withdraw the needle, and insert a new needle in a better place. Inspect the site subsequently and, if necessary, repair it either laparoscopically or by open operation. Reinspect the site at the end of the procedure. *Trocar injury* to the bowel is more serious but in some cases may be managed laparoscopically by closure in two layers using sutures or staples. Leave the trocar in place while the abdomen is opened to limit bleeding and localize the site of injury. Resection of a bowel segment or fecal diversion is seldom needed. The bowel may also be injured by the unipolar electrocautery, especially when it is inadvertently activated out of the field of view. If only a white area is seen, the injury usually heals spontaneously, especially in the large bowel. If the muscularis or submucosa is exposed, either laparoscopic repair or formal laparotomy is required. Cutting instruments may lacerate the bowel if they are allowed to stray outside the field or are passed into the field blindly. Bipolar electrocautery produces a more limited injury, but one that still may require repair. *Bladder laceration* is rare if the bladder remains deflated. It is managed either by continuing urethral drainage or by suture repair either laparoscopically or through a small suprapubic incision. *Ureteral injury* requires stenting and possibly sutured closure.

Injuries to joints and nerves result from improper padding and, more often, from inadequate fixation of the patient during the movements (head-down and lateral rotation) required for the procedure. Guard against brachial nerve injury by limiting arm abduction and rotation. The ulnar and peroneal nerves must be padded. *Obturator nerve palsy* can occur during pelvic node dissection. *Soft tissue injury, including rhabdomyolysis leading to the compartment syndrome* may be seen in on the contralateral side (dependant side) when patients are positioned on their side. Ensure that the padding is adequate and the operative time is minimized, especially in large or obese patients.

Deep venous thrombosis arises from poor venous return due to increased intraabdominal pressure. Sequential pneumatic compression stockings and the usual early ambulation reduce the incidence. For long cases, subcutaneous heparin may be advisable.

Overhydration is not uncommon because of the oliguria associated with the pneumoperitoneum and because the anesthetist automatically includes the insensible loss expected from the open abdomen. In older patients, this may lead to congestive heart failure. Central venous pressure is

not accurate because of the pneumoperitoneum and the position of the patient. If this information is needed, place a Swan-Ganz catheter into the pulmonary artery.

POSTOPERATIVE COMPLICATIONS

Bleeding is rarely seen if the operative and trocar sites have been closely inspected at low pressure (i.e., 5 mm Hg at the end of the procedure). *Dehiscence* through a large port or the development of an incisional hernia occurs if the fascia is not closed.

Bowel injury must be suspected if nausea, vomiting, and ileus occur. Institute nasogastric suction; diagnostic computed tomography (CT) scanning or operative exploration is required if improvement does not follow. *Ureteral injury*, especially from using electrocoagulation, may not be recognized at laparoscopy. It is suggested by flank pain from renal obstruction or development of a urinoma. Stenting may be tried; otherwise open repair and drainage are required. Because less manipulation is involved than in open procedures, *abdominal adhesions* are less often found and are related to the extent of the dissection.

Severe pain should not persist for more than a few hours postoperatively. If it does, look for a rectus sheath hematoma producing an abdominal bulge, and confirm its presence with CT. The exception is shoulder pain secondary to irritation of the diaphragm by CO_2. This usually resolves in a day or two. If severe abdominal pain persists, rule out a bowel leak by CT scan. Similarly, pain increasing postoperatively indicates a bowel leak or hernia, with the latter being localized to a specific port site. Pain out of proportion to expected postoperative pain should lead the surgeon to consider rhabdomyolysis.

Peritonitis occurring in the first 2 days is usually from mechanical injury of the bowel. The effect of electrosurgical injury appears later. Urgent abdominal exploration must be done.

This page intentionally left blank

Chapter 4

Suture Techniques

LEE PONSKY AND SRINIVAS VOURGANTI

The aim of suturing is to hold tissues together with the least interference with their blood supply. Apply the technique most suitable for the tissue, but use the smallest size and, for economy, the fewest types of sutures.

KNOT-TYING TECHNIQUES

There are three basic knots: square, surgeon's, and double throw (Fig. 4-1).

- *Square knot* (see Fig. 4-1A). The simple square knot holds in polyglactin and polyglycolic acid sutures if they are uncoated (Dexon). If coated sutures (Vicryl and Dexon S) are used, an additional throw is needed (see Fig. 4-1B). Care must be taken to lay each throw square to the last.
- The *surgeon's knot* (see Fig. 4-1C) allows the suture to hold the tissue without slipping after placement of the first throw but is no more secure than the square knot, requiring, except with Dexon, additional throws.
- The *double-throw knot* (see Fig. 4-1D), essentially a double surgeon's knot, has the greatest knot-holding ability for all suture materials. Only polydioxanone (PDS) and nylon (Ethilon, Dermalon) require an extra throw. Polyglyconate (Maxon) was found to be the best for knot-holding capacity and breaking force. To be absolutely safe, tie synthetic absorbable sutures (SAS) with three knots. Monofilament nonabsorbable sutures (NAS) may require six or even seven extra throws, all placed flat.

Tie a suture while holding it near its free end; the suture may thus be used twice, saving suture material and time. Instrument ties are somewhat slower to make but use appreciably less suture material.

SUTURES

Selection

Individual surgeons have their own preferences for sutures, but two important variables must be considered: the persistence of strength and the degree of tissue reactivity. The initial strength is proportional to size, but the rate of loss of strength is a function of the suture material. The rate of absorption also depends on the suture material, but it is not directly related to the rate of loss of strength. In general, the strength of the suture is lost much more rapidly before it has been absorbed. A suture must maintain sufficient strength to ensure adequate apposition of tissue until the wound can withstand stress without mechanical support. Decrease in the strength of a suture during healing should be no more than proportional to the gain in wound strength. Relative absorption of suture material in the subcutaneous tissues: catgut—1 month; polyglactin (Vicryl)—2 to 3 months; polyglycolic acid (Dexon plus)—4 months; PDS—6 months; polyglyconate (Maxon)—7 months. Bladder regains 70% of tensile strength in 2 weeks, fascia 50% in 2 months, and skin 30% in 3 weeks.

Reactivity of the tissue to the foreign body depends on the size and type of suture material and the type of reaction it invokes. The larger the size, the greater the reaction:

Most Reactive	→	Catgut Cotton Silk	→	Synthetic absorbable Multifilament nonabsorbable	→	Nylon Steel Polyethylene Polypropylene	→	Least Reactive

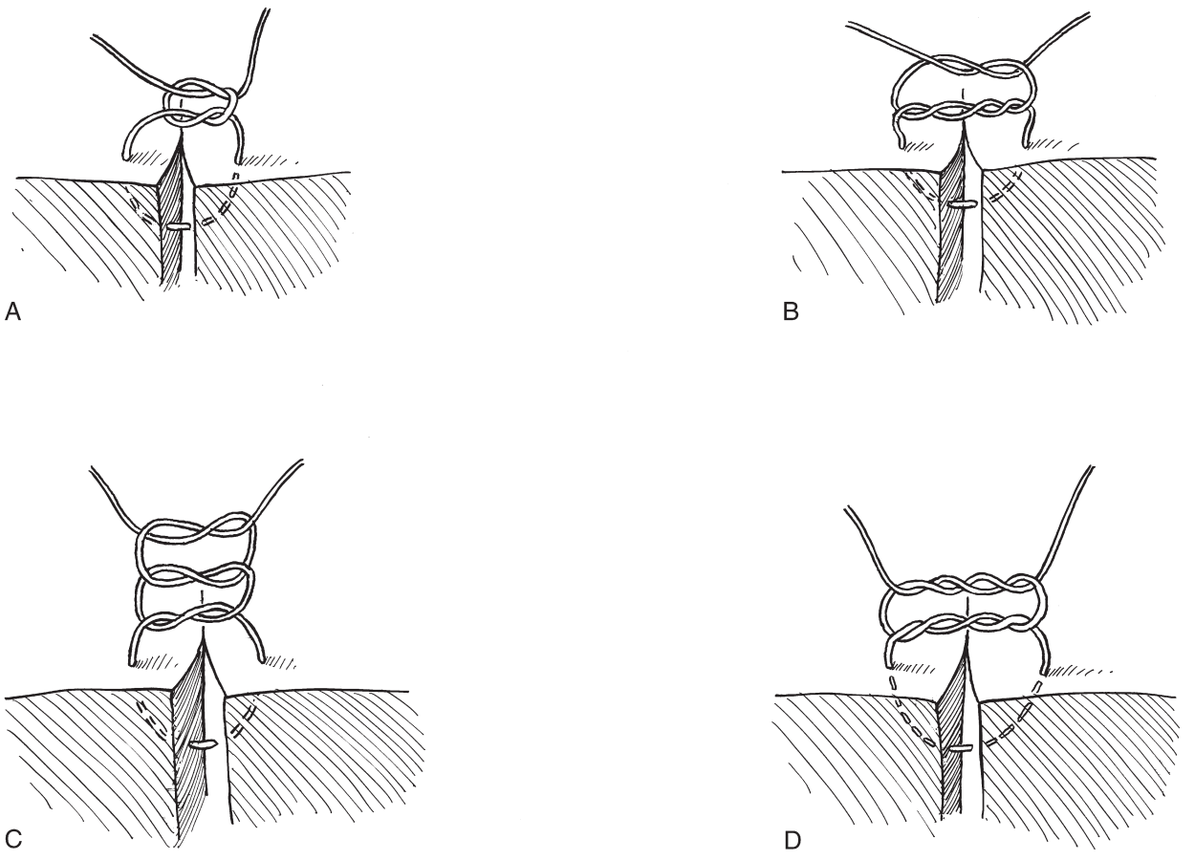

FIGURE 4-1.

Absorbable and nonabsorbable sutures have different effects. Plain catgut (PCG) and chromic catgut (CCG) sutures, being absorbed by proteolytic enzymes, have quite a variable absorption time and incite the most reaction in the tissue. In addition, they vary in tensile strength, which is generally lower than that of synthetic sutures. SAS, in contrast, are removed by hydrolysis and have moderate tissue reactivity and predictable absorption times. Those made from polyglycolic acid (Dexon, Vicryl) retain 20% of their strength at 14 days, and those made from PDS retain 50% of their strength at 4 weeks, but neither is absorbed for several months. In infected urine, catgut sutures retain the most strength. NAS as monofilaments stimulate the least reaction in the tissues and have the least attraction for bacteria; when braided, they handle better and tie more securely. They are unsuitable in the presence of bacteria or urine. Silk and cotton rapidly lose their strength after the second month but probably are useful in the outer layer of an intestinal anastomosis and in the mesentery. Nylon is a polyamide, Dacron is a polyester, and polyethylene and polypropylene are polyolefins; of these, nylon loses its strength first.

Table 4-1 summarizes the characteristics of several sutures. In general, polyglycolic acid sutures are preferable to PCG or CCG for urologic surgery, except in cases of infected urine and for the skin. Because of expense, use as few different sizes and kinds of sutures as possible in a given case. Even though suture selection is a matter for the individual surgeon, certain practical guidelines can be considered.

Fascia

Regardless of what suture is used, the immediate strength of the wound is only 40% to 70% of the intact structure. With NAS, reduced strength persists at least for the 2 months or so that it takes for the wound to heal completely. For an absorbable suture, the initial strength is the same as that of a nonabsorbable one if an equivalent size is used, but in 1 or 2 weeks the strength declines appreciably. However, by that time, the wound itself has gained enough strength that it balances the diminished strength of the sutures. Thus the wound is most vulnerable to separation during the second week. For this reason, NAS are often used for closure of wounds subjected to stress, such as those of abdominal and flank incisions.

For contaminated wounds, the process of absorbing the sutures stimulates macrophage activity with resultant low tissue oxygen tension. This activity also reduces endothelial migration and capillary formation, thus providing a suitable environment for anaerobic bacterial growth. Polyglycolic acid sutures foster the least inflammatory response of absorbable sutures, and the degradation products themselves may be antibacterial. Conversely, NAS, especially monofilaments, produce the least reaction, but once infected they may stay infected because they remain in the wound. Polypropylene is the best choice in contaminated wounds, much better than silk or cotton. For a debilitated patient, in whom poor healing is expected, use either an NAS or an absorbable

SUTURE TYPES

TABLE 4-1

		TRADE NAME	
		Ethicon	**Davis & Geck**
Absorbable			
Synthetic Braided			
Polyglactin	Coated	Vicryl	
	Uncoated		Dexon S
Polyglycolic acid	Coated		Dexon plus
Synthetic Monofilament			
Polyglyconate			Maxon
Polydioxanone		PDS	
Gut			
Plain gut		Plain gut	Plain gut
Chromic gut		Chromic gut	Chromic gut
Nonabsorbable			
Synthetic Braided			
Polyester	Uncoated	Mersilene	Dacron
Nylon	Coated		Surgilon
Synthetic Monofilament			
Nylon	Uncoated	Ethilon	Dermalon
Polypropylene		Proline	Surgilene

Adapted from Edlich RF, Rodeheaver GT, Thacker JG. (1987). Considerations in the choice of sutures for wound closure of the genitourinary tract. J Urol 137(3):373.

suture that retains its strength the longest (i.e., PDS). Retention sutures of heavy nonabsorbable material (polypropylene or wire) may be needed in a debilitated patient, especially if the wound is contaminated. Bolsters cut from a red rubber catheter reduce damage to the skin.

Subcutaneous Tissue

The subcutaneous tissue layer is the site of most wound infections because of the weak defense mechanisms in the fatty areolar tissue. Do not use sutures here unless necessary, and then use the finest minimally reactive absorbable suture of polyglycolic acid. Avoid PCG or CCG.

Skin

Waterproof tape is best if it is not subjected to too much tension. Staples, if not too tight, are the next best choice because they do not penetrate the wound, but they cost more and require subsequent removal. A subcuticular stitch of monofilament nonabsorbable material leaves a better wound but must be removed. Polyglycolic acid sutures subcuticularly can remain until resorbed, at the same time producing little reaction. This material is not suitable when placed through the skin as interrupted sutures because absorption depends on hydrolysis, and so it persists on the dry surface.

Urinary Tract

Urothelium covers the suture line within 5 days. Ureteral and vesical wounds gain strength more rapidly than those in the body wall; normal strength is reached in 21 days. The type of suture material is not as critical here, but absorbable sutures cause less reaction than nonabsorbable ones in the long term. Although more subject to encrustation, absorbable sutures are usually gone before stones can form. Polyglycolic acid sutures are less reactive than CCG sutures, and they have a more predictable rate of absorption. Although polyglycolic acid sutures are not completely absorbed before 28 days, they are usually the better choice, with one exception. In the presence of *Proteus* infection, resorption is much too rapid and catgut should be used.

Intestine

Use interrupted NAS, reaching through the muscularis well into the submucosa. If a hemostatic layer is desired, place a running absorbable suture in the mucosa-submucosa. CCG is suitable for sutures penetrating the lumen; otherwise,

use SAS. Controlled-release needles speed the process of suturing. In general, place continuous sutures if the tissue is of good quality and interrupted sutures if tissue quality is poor.

Vascular

Monofilament synthetic NAS are strongest and least reactive.

Size and Type

The size and type of suture and the appropriate needle for various structures are listed in Table 4-2.

SKIN SUTURE TECHNIQUES

Alternative skin suture techniques include a subcuticular suture, interrupted sutures, staples, and tapes.

Subcuticular closure (Fig. 4-2): Use a 4-0 SAS or a monofilament pull-out NAS.

Start the stitch from a buried knot at one end (see Fig. 4-2A). Pull the subcutaneous tissue forward with a fine skin hook, and drive the needle point well into the dermis in a plane parallel to the surface, entering exactly opposite the exit site of the last bite.

To bury the last knot, place a deep stitch and, after tying it, bring the end out through the skin 1 cm from the wound (see Fig. 4-2B). Cut the excess suture, and let the end retract. *Alternatively*, lock the suture at the start by passing back and forth at one end of the wound, having the needle enter exactly at the site of exit of the suture (Giddins). Do the same lock after the subcuticular suture line is completed. Another alternative is to apply inverted absorbable interrupted subcuticular sutures, thus burying each knot.

Vertical mattress suture (Fig. 4-3): This suture is a double stitch that forms a loop around the tissue on both sides to produce eversion of the skin. Use monofilament NAS, and catch only the very edge of the skin in the second bite. Throw four or five knots.

TABLE 4-2 SUGGESTED TYPE AND SIZE OF SUTURE FOR VARIOUS TISSUES

	ADULT		PEDIATRIC	
Tissue	***Type***	***Size***	***Type***	***Size***
Skin				
Cosmetic closure	Absorbable	4-0	Absorbable	5-0
Noncosmetic closure	Staples		Nonabsorbable	5-0
	Nonabsorbable	4-0		4-0
		3-0		
Fascia	PDS	Zero	PDS	3-0
	Maxon silk	1-0	Maxon silk	2-0
Muscle	Absorbable	1-0	Absorbable	3-0
		2-0		3-0
Bladder	Absorbable	3-0	Absorbable	4-0
		2-0		3-0
Ureter-pelvis	Absorbable	5-0	Absorbable	5-0
		4-0		6-0
Urethra (vascular)	Absorbable	4-0	Absorbable	5-0
	(Maxon, PDS)	5-0		6-0
Bowel	Staples		Staples	
	Absorbable (inner layer)	3-0	Absorbable (inner layer)	5-0
		4-0		4-0
	Nonabsorbable (outer layer)	3-0	Nonabsorbable (outer layer)	4-0
Vascular	Nonabsorbable	4-0	Nonabsorbable	4-0
		5-0		5-0

Adapted from Foster LS, McAninch JW: Suture material and wound healing: An overview. AUA Update 11:86, 1992.

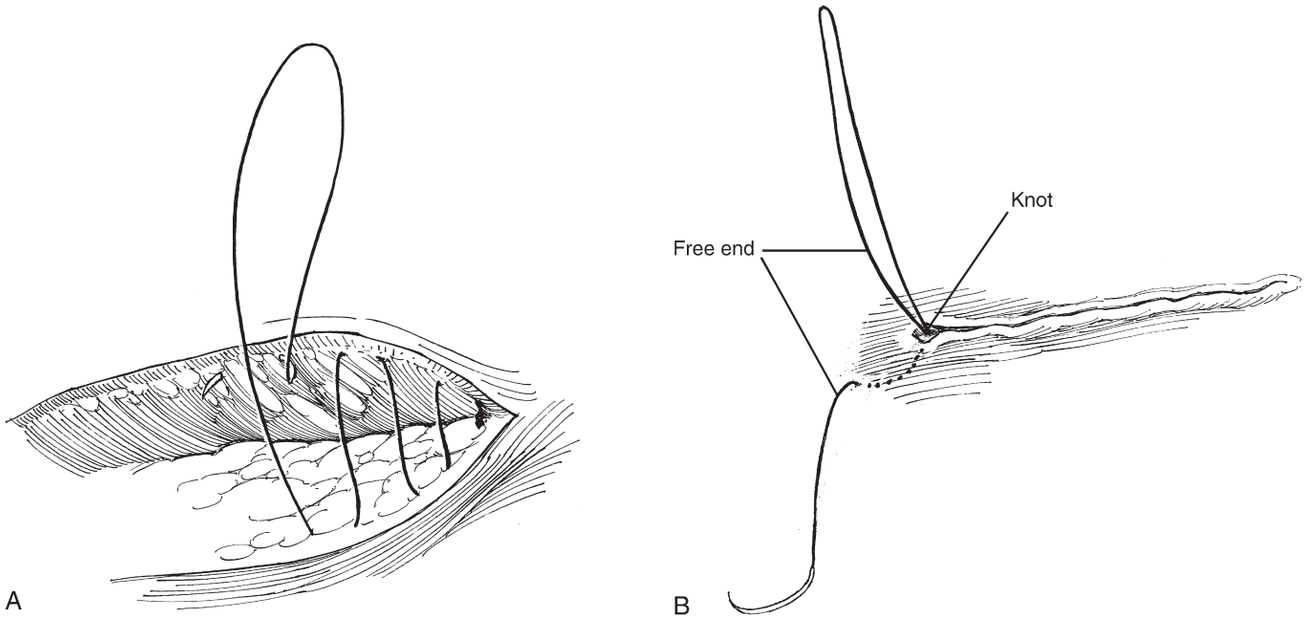

FIGURE 4-2.

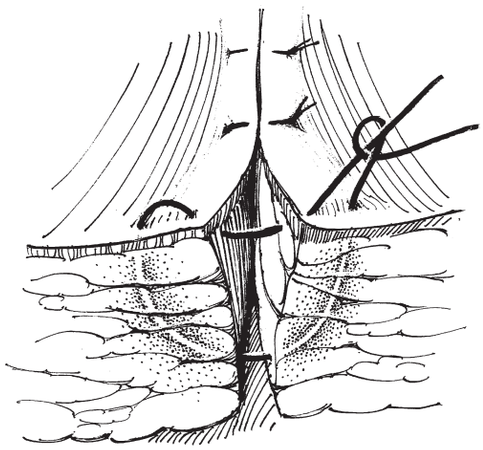

FIGURE 4-3.

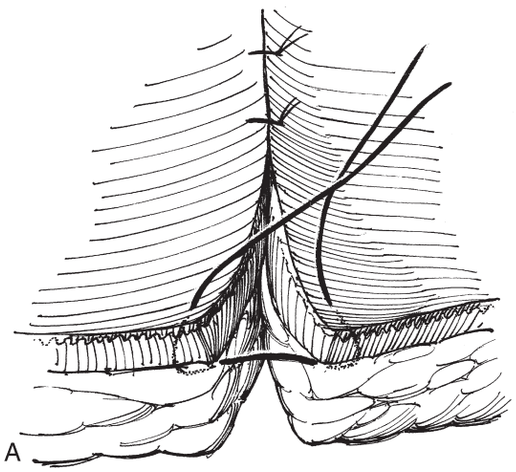

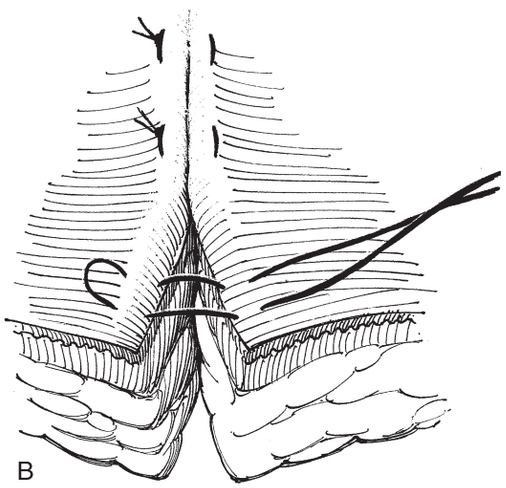

FIGURE 4-4.

Everting interrupted suture (Fig. 4-4A): For plastic procedures, penetrate the skin close to the edge of the incision, then encircle a larger amount of tissue beneath.

Halsted mattress suture (see Fig. 4-4B): This suture inverts the edge. Pass the suture into the skin, and have it pass out again near the skin edge.

FASCIAL SUTURES

Interrupted Sutures

Place 2-0 synthetic absorbable or monofilament sutures 1 cm deep and 1 cm apart (the "one-by-one" rule) (Fig. 4-5A).

Tie suture only tight enough to bring the edges in contact. Throw at least three square knots (see Fig. 4-5B). Monofilament sutures consist of only one strand, so they "can be

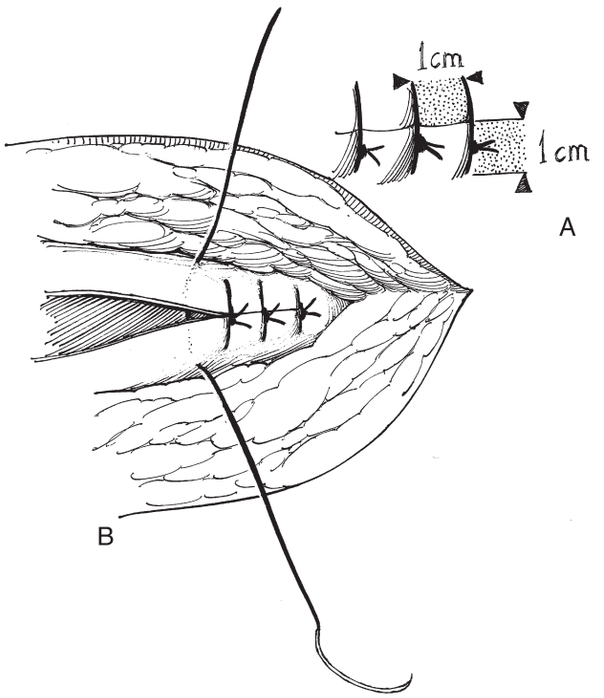

FIGURE 4-5.

inadvertently and easily damaged by any instrument, needle or sharp-edged material that cuts or scratches its surface" (The Wound Closure Manual, Ethicon, Inc.). This risk is greater with running sutures that depend on a single knot at either end. If the terminal knot is tied with the so-called loop-to-strand knot, it may pull out. In thin patients and in children, bury the knots to prevent wound discomfort.

Far-and-Near Sutures

Place 2-0 SAS at 1-cm intervals, first deep on one side and shallow on the other, then shallow on one side and deep on the other (Fig. 4-6).

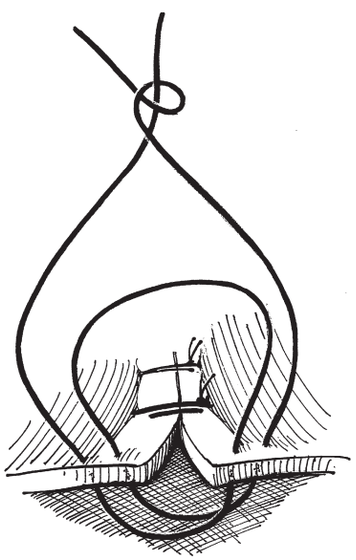

FIGURE 4-6.

Skin Clips

Skin clips in an automatic dispenser are a rapid but relatively expensive way of closing the skin. Partially squeeze the handle to advance the staple into position. Hold the end of the stapler loosely against the skin with the arrow in line with the incision. Fire the staple. Clips require subsequent removal.

Other Types of Fascial Sutures

Near-and-far suture for mass closure of the abdomen (Fig. 4-7A): Use 2-0 NAS. Place the deep sutures first, then catch the edges with the shallower bites.

Smead-Jones fascial closure technique (see Fig. 4-7B): Place 2-0 NAS 2 cm apart as figure-eight stitches, taking bites near and far.

Vertical mattress suture (sometimes called a Gambee stitch) incorporates both fascial layers (see Fig. 4-7C): On the first

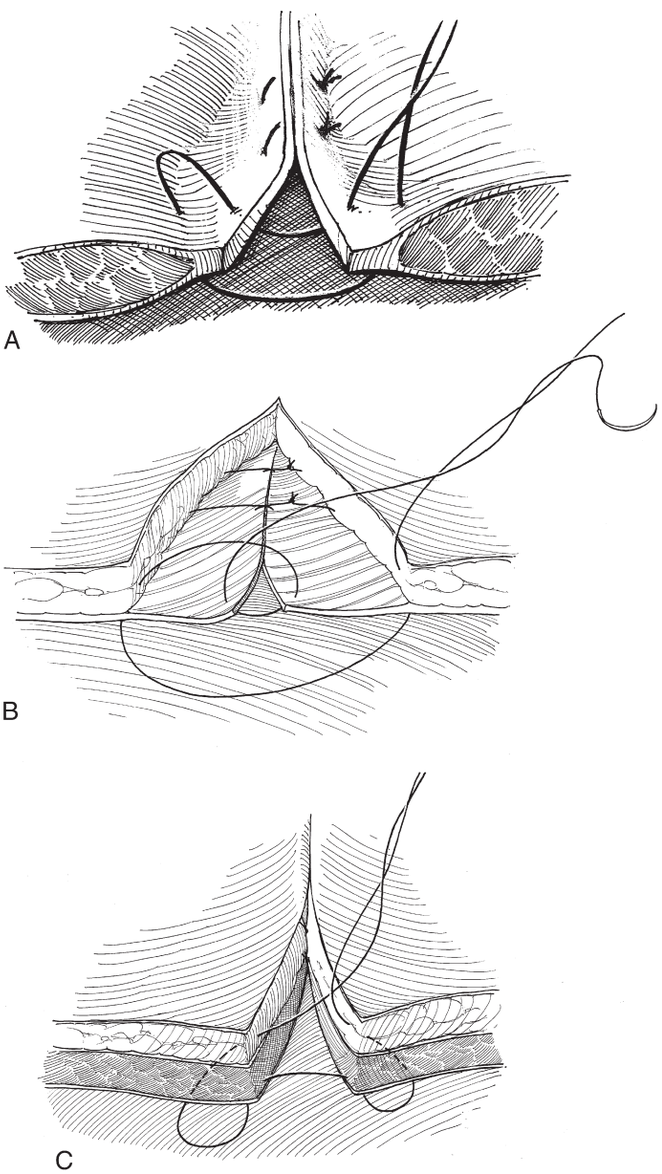

FIGURE 4-7.

side, pass the suture through the superficial and deep fascia and the peritoneum, then back through the peritoneum to exit from the muscle. Cross to the other side of the wound, enter the muscle layer, pass out through the peritoneum and deep fascia and then back through the peritoneum and both layers of fascia; tie the knot subcutaneously.

The stitch was originally designed as a bowel stitch to prevent herniation of the mucosa (see Fig. 4-12). For application as a bowel suture, pass it through all layers on one side, then through the mucosa and submucosa on the opposite side, next through the submucosa to exit from the mucosa on the first side, and finally through all layers on the opposite side.

BOWEL SUTURES

Connell Suture

The Connell suture is a continuous suture that inverts the inner wall of the intestine.

Insert the stitch so that it enters and exits the bowel on each side successively (Fig. 4-8A). It may include only the mucosa and submucosa. Use 3-0 SAS.

When passed from the inside to the outside, it is an especially useful technique for closing the angles of a bowel anastomosis see (see Fig. 4-8B).

Lembert Suture

An inverting suture that produces serosal apposition, the Lembert suture includes the muscular layer and some of the submucosal layer. (No satisfactory form of intestinal anastomosis was available before the introduction of the Lembert suture.)

Place the suture as an interrupted suture. Insert each bite to reach into but not through the tough submucosal layer (Fig. 4-9A).

The suture may be placed as a continuous stitch (see Fig. 4-9B). This stitch is useful for closing the end of the bowel or for anastomosis of two ends. Use 4-0 braided NAS. Be sure to catch the submucosa.

To close the end of the bowel, use interrupted Lembert sutures over a clamp (see Fig. 4-9C). Start by placing a traction suture at each end. Lay all the sutures. Hold the sutures on each side, and remove the clamp carefully. Tie each suture successively as the mucosa is inverted.

For a one-layer bowel anastomosis, place interrupted Lembert sutures on both sides, then have an assistant gently withdraw the clamps (see Fig. 4-9D). Tie each suture successively, taking care that the ends are inverted.

Pursestring Suture

Place a continuous suture around a defect for inversion (appendix) or closure (hernia sac) (Fig. 4-10).

Lock-Stitch

The lock-stitch is a continuous suture used for mucosal edges (Fig. 4-11). Pass every third or fourth stitch under the previous one. Select this stitch when puckering is to be avoided.

Figure-Eight Bowel Suture

Figure-eight bowel suture is an interrupted suture that approximates the mucosa independently from the muscularis and serosa (Fig. 4-12). Pass the suture through all layers on one side, then through the mucosa and submucosa on both sides. Finally, bring it through all layers on the other side.

Laparoscopic Suturing

In laparoscopic suturing, two needle holders are used. Once the needle is in the abdomen, it should be loaded forehand into the dominant hand driver. It should then be

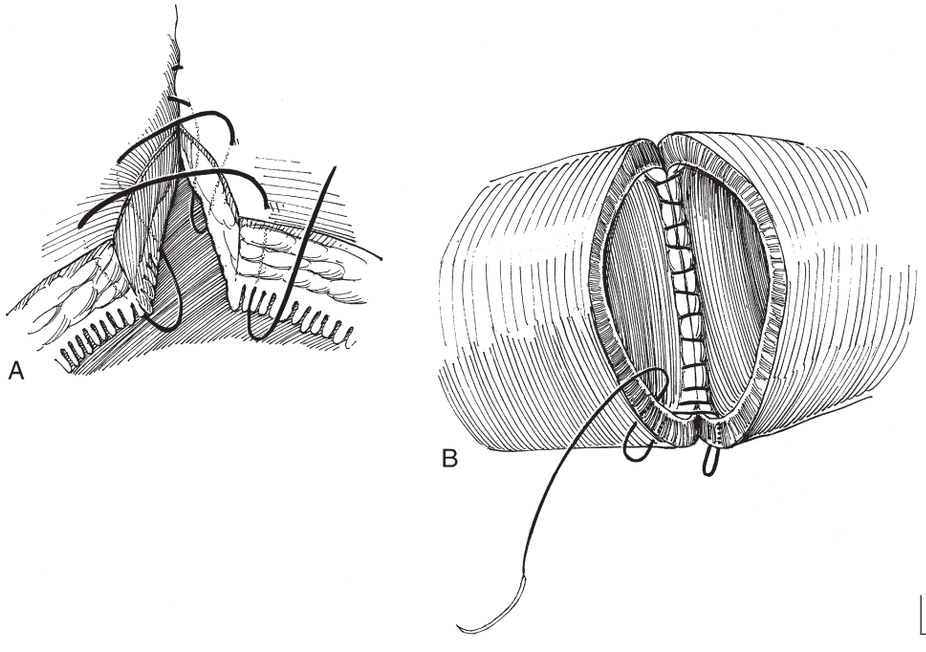

FIGURE 4-8.

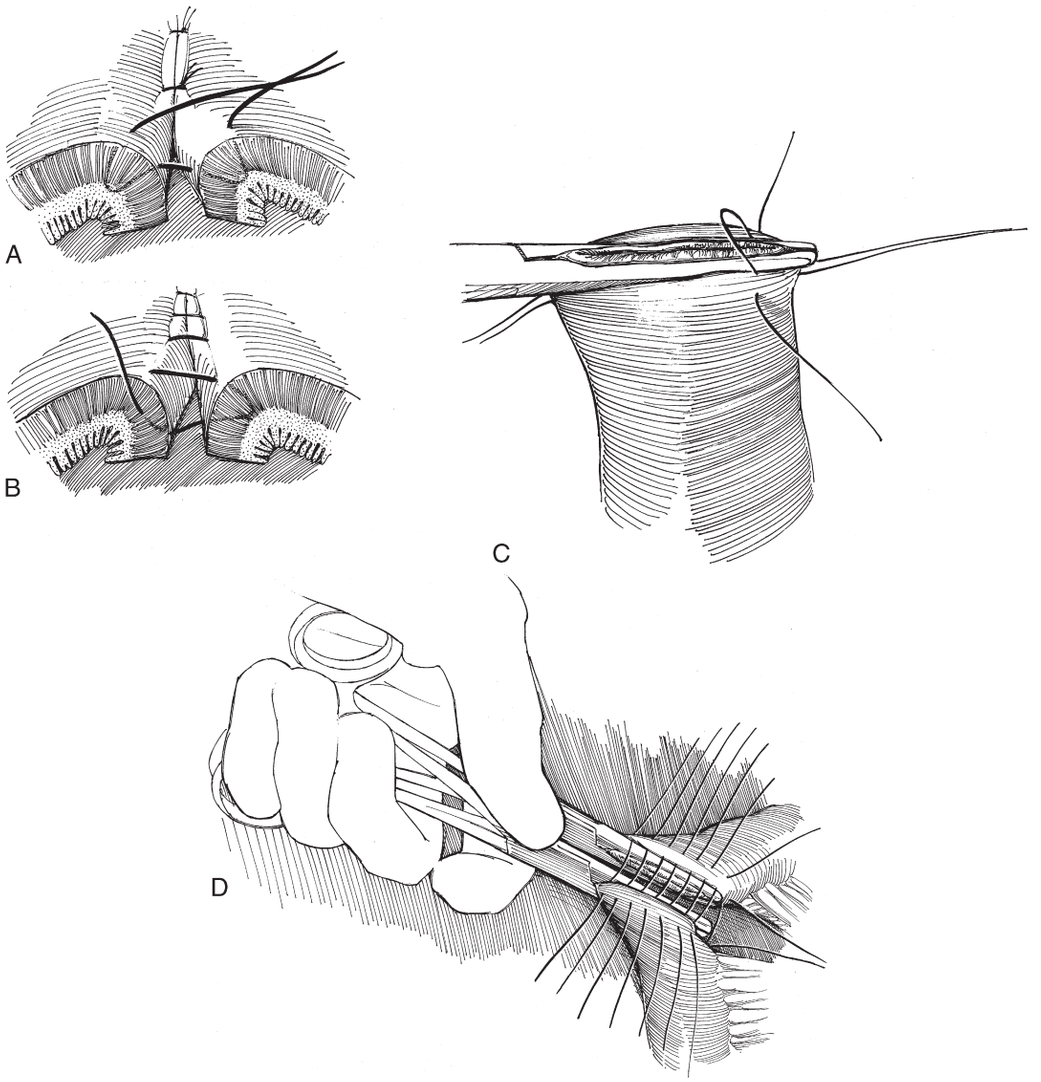

FIGURE 4-9.

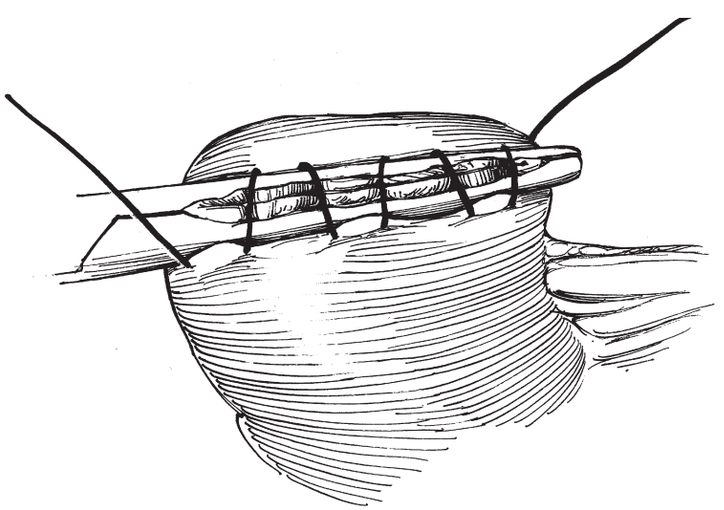

FIGURE 4-10.

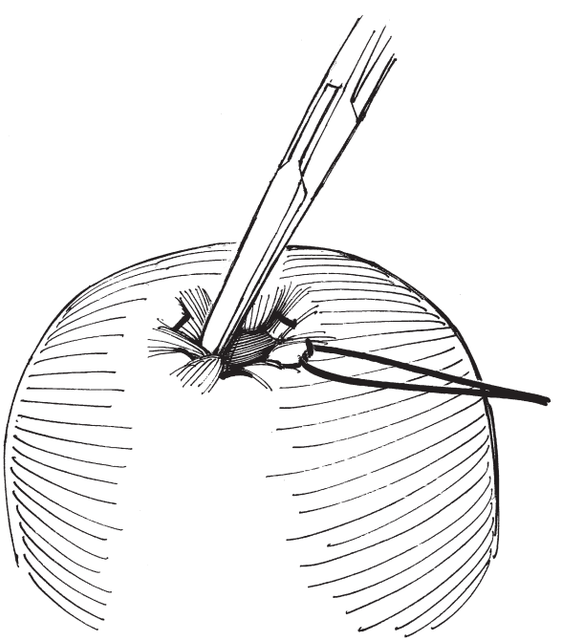

FIGURE 4-11.

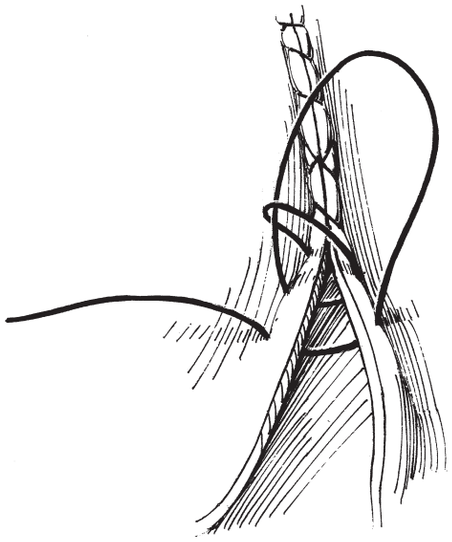

FIGURE 4-12.

passed through the tissue in a smooth motion, following the curve of the needle. Once the needle is through the tissue, the nondominant hand driver should grasp the needle while releasing the needle from the dominant needle driver.

The method of knot tying is by the "instrument tying" technique that is used in open surgery. The suture should be pulled though the tissue, leaving only a short tail. A C-loop should be formed with the nondominant needle grasper by grasping the needle end of the suture (not the free end) approximately 5 cm from the tissue and holding the suture with some laxity. The dominant needle driver should then be advanced into the concavity of the C-loop. The suture is then wrapped around the dominant needle grasper. The dominant needle grasper should then be used to grasp the short tail of the suture. The short tail is then pulled through the loop and the needle graspers are drawn apart to lay down the knot. This accomplishes the first half of the square knot (an overhand flat knot). The sequence is then repeated with the opposite hands in order to throw the second opposing flat knot, thus completing the square knot.

For fascial sutures, interrupted sutures in the young healthy male who is muscular or the patient who may be cachectic from cancer or malnutrition are preferable. In other patients, a running absorbable monofilament (size 0) suture is acceptable. It must be emphasized that the fascia should be approximated, not strangulated. Fascial sutures that use near-far figure-eight-type stitches tend to strangulate one of the loops. The Connell suture is a particularly nice technique to use on each end of the inner layer of a bowel anastomosis. This stitch tends to avoid pursestringing the lumen. Its disadvantage is that it is not a hemostatic stitch.

This page intentionally left blank

Chapter 5

Plastic Surgical Techniques

HOOMAN SOLTANIAN

Grafts, as free segments of tissue, depend on support from the vascular bed onto which they are transferred. Flaps carry their blood supply with them or it is surgically reestablished once the graft is transferred.

BLOOD SUPPLY TO THE SKIN

Blood is supplied either through a longitudinal artery arising dorsally that lies deep to the muscle or fascia, supplying perforators to the subdermal and intradermal plexus in the overlying skin, or through longitudinal vessels arising ventrally that lie superficial to the fascia, connecting directly to the plexuses in the skin (Fig. 5-1). These systems are interconnected by a complex network of vessels of varying sizes. They are very delicate and cannot withstand compression in forceps, twisting, or undue stretching. Skin hooks and stay sutures are essential tools to preserve them.

GRAFTS

Grafts, bereft of central connections, must acquire nutrients from the bed for the first 24 to 48 hours (imbibition), then during the next 2 days must establish local vascular connections (inosculation). This requires that the graft remain immobilized and closely applied to the bed, which in turn must be well vascularized. Seromas and hematomas block these steps, as do infection and scar tissue.

Thickness of Skin Grafts

Grafts may be full thickness to include the entire dermis to the adipose layer, or they may be split thickness (Fig. 5-2).

Full-Thickness Skin Grafts

Full-thickness grafts, made up of all skin layers, contract only 5% to 25%, provide a very durable skin covering, and are less likely than split-thickness grafts to become hyperpigmented, but they also carry the skin adnexal structures, making hair growth a potential problem. They are more demanding than split-thickness grafts in regard to the vascularity and quality of the recipient bed, not only because they are thicker (bulkier) and thus require a greater supply of blood, but also because they depend almost totally on new vascular connections to the disrupted subdermal plexus, which characteristically has relatively fewer vessels available for the process of inosculation. The requirements for a "take" are an extremely well-vascularized bed and absolute immobilization. For urethral construction, if genital skin is not available, full-thickness grafts of bladder epithelium or buccal mucosa may be used.

Full-thickness grafts must be cleared of underlying fatty areolar tissue to allow the vessels of the subdermal plexus direct contact with the new bed (Fig. 5-3).

A good compromise for grafts from the lower abdomen may be a thick split-thickness graft (>0.19 inch) because it has most of the favorable qualities of the full-thickness graft and little of the tendency to contract as a thinner split-thickness graft would. Full-thickness grafts from the prepuce, the bladder, or the mouth, on the other hand, are thin and pliable, and inherently have little subcutaneous fat. They too must have their deep surface meticulously prepared to expose the deep laminar plexus optimally.

Split-Thickness Skin Grafts

Split-thickness skin grafts may be thin (to include a minimal amount of dermis, from 0.010 to 0.015 inch), intermediate (approximately half the thickness of the dermis, from 0.016 to 0.19 inch), or thick (three fourths or more of the dermis, more than 0.19 inch). Composed of only part of the dermis along with the epidermis, split-thickness skin grafts take better than full-thickness grafts but provide a more fragile covering. Split-thickness skin grafts can contract about 50%, or even more in unsupported areas.

Dermal Grafts

Dermal grafts, cleared of both epidermis and fat, can be more elastic than full-thickness grafts and become vascularized on both sides. They are useful for replacement of deep structural layers such as penile tunica albuginea and fascia.

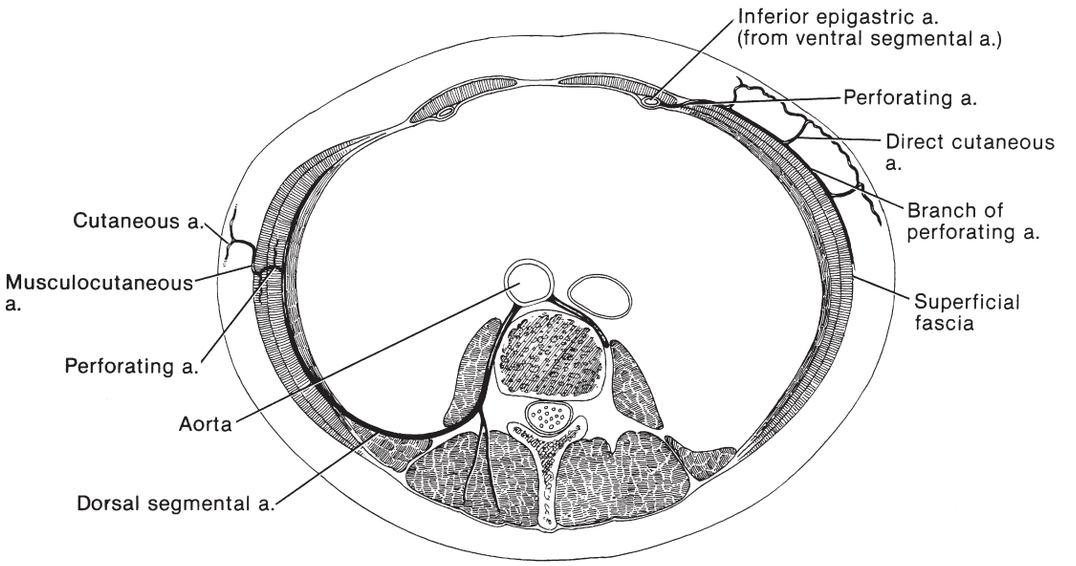

FIGURE 5-1.

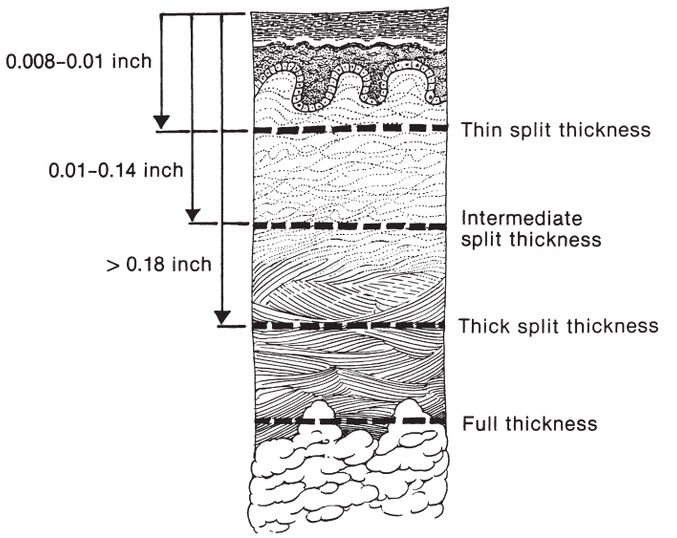

FIGURE 5-2.

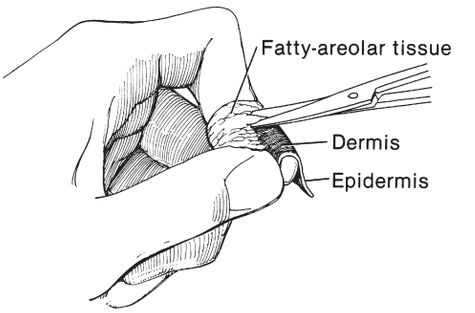

FIGURE 5-3.

Acellular dermal matrix harvested from cadaveric donors may be an alternative to autologous dermal grafts.

Application of Split-Thickness and Meshed Grafts

Meshing the skin graft in a mesher allows for expansion and provides greater coverage if necessary but, more importantly for the genitourinary surgeon, allows escape of serum and blood. However, such a graft may contract more because the openings in the mesh heal by secondary intent. A meshed graft conforms more easily to curved and irregular recipient surfaces. The graft must be placed with good hemostasis, be relatively free of contamination, and also be immobilized. Mesh grafts are placed with the slits parallel to the existing skin lines. They can be expected to contract 30% to 60%, except on the back of the hand and on genital tissue.

Apply a nonmeshed split-thickness graft to a functioning penis because a meshed graft offers no advantages and can be expected to contract from 30% to 60%, creating a cosmetically unsightly appearance to the reconstructed penis. For reconstruction of the scrotum, however, a meshed graft allows for better contact with the underlying complex contours, avoids collections in the contour interfaces, and creates a cosmetically pleasing appearance, because the mesh scars are similar in appearance to the rugae seen in normal scrotal skin (Fig. 5-4).

FLAPS

The deep surface of a cutaneous flap is composed of fat; a fasciocutaneous flap is composed of fascia; a musculocutaneous flap is composed of muscle. Flaps may be used to cover (skin flaps), to provide structure and function and contribute to revascularization (muscle flaps), to provide sensation (sensible fasciocutaneous flaps), or for a combination of these purposes.

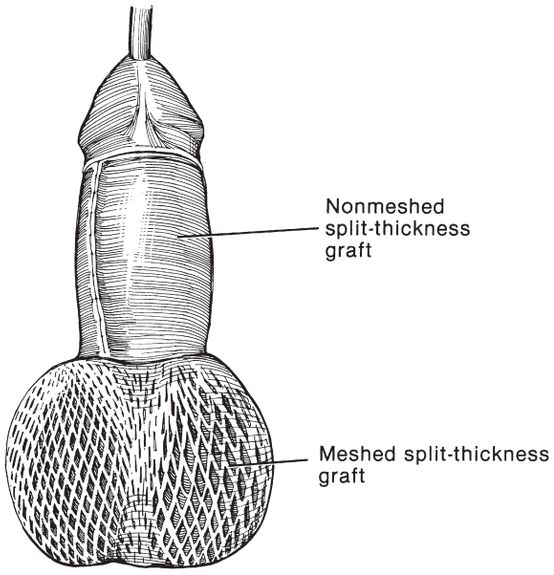

FIGURE 5-4.

In contrast to grafts, flaps bring their own blood supply with them. Flaps can also be reattached directly to a new supply by microvascular techniques. Flaps may be random pattern flaps for transposition, rotation and tube flaps, or axial pattern flaps. For a flap to be classified as either random or axial depends on the inherent pattern of vascularity of the flap itself. Random flaps have no defined cuticular vascularity, which varies from individual to individual and is somewhat undependable. In contrast, axial flaps have an organized, self-contained blood supply and defined cuticular vascular territories that vary little from one individual to another and thus are predictable and dependable.

Another approach to classifying flaps is to divide them into peninsular, island, and microvascular free transfer (MVFT) flaps. These classifications address the design and shape of the flap itself. *Peninsula flaps*, as the name implies, are shaped like a peninsula, and thus both the cuticular and vascular portions of the flap remain attached to the "mainland" (body). A *random peninsula flap* (all random flaps are peninsula flaps by definition) is thus mobilized so that the skin survives on the random distribution of the skin plexuses. In the past, surgeons attempted to make random flaps more dependable by defining length/width ratios for the flap (i.e., if the flap was 3 cm long, its base needed to be 3 cm wide, for a 1:1 ratio). However, ratios are more limiting than useful, because certain areas in the body with a 1:2 ratio or even a 1:3 ratio allow reliable survival. In other areas and in certain individuals, a 1:1 ratio approaches the limit.

If in a peninsula flap the skin remains attached to the mainland, then in an island flap it does not. The term *island flap* implies that the cuticular continuity is interrupted but the vessels remain attached (the flap dangles on its vessels). If the vessels are detached, then the flap becomes an *MVFT flap* or free flap.

The *musculocutaneous* or *fasciocutaneous flap* has come to be viewed as an island flap, but it is only truly an island flap if the muscle and/or fascia is totally detached, both origin and insertion, with the flap unit moved on the vessels supplying it. For most clinical uses, the muscle is left attached at the origin and transposed to the adjacent defect. To be accurate in both theory and semantics, the surgeon must view the muscle or fascia as the flap and the attached skin unit as a passenger on the flap. The proper term then is *skin island or paddle*. To use the gracilis as an example, the flap is properly thought of and termed "a gracilis flap with a skin island/paddle." Fascial flaps, almost by definition, cannot be elevated as islands. To use an example of a flap that has become almost common urologic terminology, the preputial/penile skin island flap should correctly be designated a dartos fascial flap with a preputial/penile skin island/paddle.

The *musculocutaneous flap*, useful in reconstructive urology, is formed by elevating skin and muscle, together with their independent cutaneous vascular territory, on a single pedicle on the superficial inferior epigastric, superior epigastric, or superficial circumflex iliac artery.

Preparation of a Flap

Choose a flap with a size and ability to arc into place, with adequate vasculature, accessibility, proper composition, and an acceptable donor site remaining. Outline the defect to be grafted with a marking pen, then quickly press a piece of glove-wrapper paper against it to obtain a pattern for the graft. Skin grafts and flaps are viscoelastic, so stretch the graft in place to overcome the elastic fibers, in the skin. A pull for 10 or 15 minutes enlarges a flap, owing to stress relaxation and creep. However, undue tension may compromise vascularity.

Secondary contraction between the skin graft and its bed occurs with maturation of the scar tissue, beginning after the 10th day and continuing for 6 months. Thin grafts, flexible beds, and complete take all reduce the chances for contraction. Sensation begins to return to a graft in 3 weeks if dense scarring does not intervene. Skin grafts and flaps grow as the patient grows, stimulated by tension from the surrounding skin.

Avoid *marks in the skin* that result from tension on the sutures. Tie the suture just tight enough to approximate the edges and no tighter. Subcutaneous sutures reduce the tension, as does placing the incision parallel to the skin lines. The length of time that the sutures remain is also a factor: 6 or 7 days are usually adequate, but allow 10 to 14 days for heavy skin on the back. Small bites of tissue close to the edge are associated with less apparent skin marks: infection is accompanied by more prominent ones. Of course, a patient prone to keloid formation is at greatest risk.

Slight *eversion of the skin edges* results in a flat scar; inverted edges leave a depressed scar. In some areas, a vertical mattress suture is necessary to stabilize the skin edges. If skin clips are used, they should grasp the skin with equal bites and should be angled so that they slightly evert the skin. Microporous skin tape, used in conjunction with buried sutures, may be placed initially as primary skin closure or applied at the time of suture or clip removal. It helps adherence to wipe the skin with alcohol or acetone

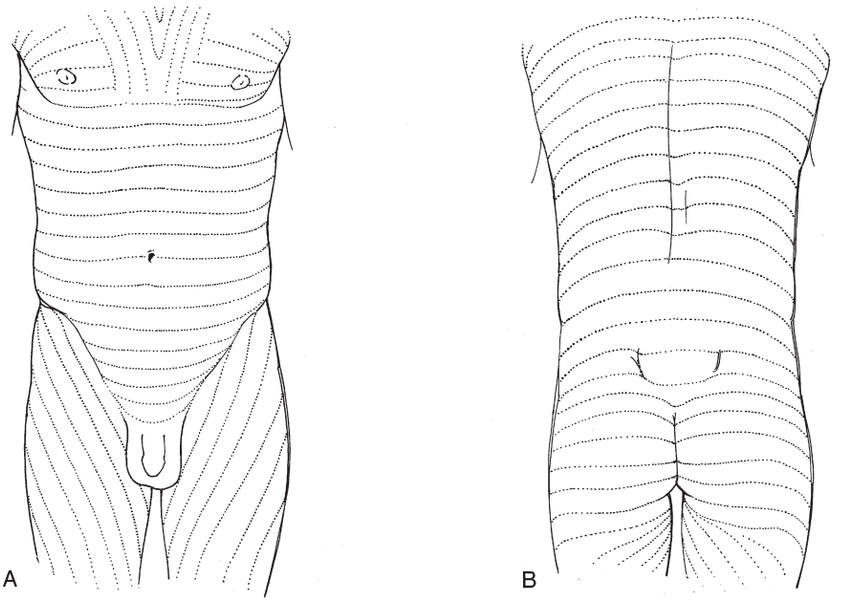

FIGURE 5-5.

before application. Skin tapes have the advantages of quick application and avoidance of suture marks, and they do provide added tensile strength. Their disadvantages are that they do not evert the skin edges and they may come off prematurely.

Local Anesthesia

Use 1% lidocaine with 1:200,000 epinephrine; for a child, use 0.5% lidocaine with 1:400,000 epinephrine. Hyaluronidase may aid in diffusion of the agents. Inject it slowly while explaining the procedure to the patient. Stop for a minute if the injection is causing pain. Regional block is often better than local infiltration.

Use of Langer's Lines

Make incisions parallel to Langer's lines (Fig. 5-5). These are oriented at right angles to the line of maximal tissue extensibility. By orienting excisions or incisions with the lines, the wound tension (not to be confused with innate skin tension) is properly aligned.

Island Flap

The island flap maintains all of the favorable vascular qualities of the peninsular flap but has the advantage of a maneuverable narrow vascular pedicle that contains the essential axial artery and vein. By completely severing attachments to the skin, the little blood supply lost from the random cutaneous vascular plexuses is made up by gain in greater mobility (Fig. 5-6).

Choose a flap for size, ability to arc into place, and presence of adequate vessels. Although the island flap can be transposed much more easily than the peninsular flap, the supplying vessels are fragile and easily injured. Flaps that can be transposed with much more freedom are the muscle flaps or fascial flaps and their respective skin island paddles.

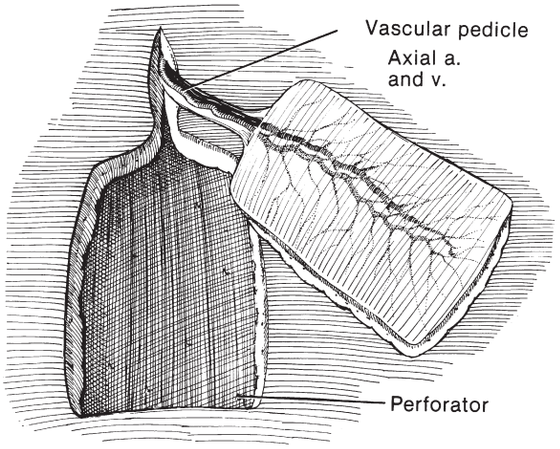

FIGURE 5-6.

Correction of Dog Ear

1. Retract the center of the longer edge that remains beyond the last stitch (Fig. 5-7A).
2. Incise the skin in the line of the incision for a short distance on the opposite side (see Fig. 5-7B).
3. Incise the skin on the redundant side, also in the line of the incision, to excise the flap of excess skin (see Fig. 5-7C).
4. Close the remainder of the wound (see Fig. 5-7D).

MUSCULOCUTANEOUS FLAPS

Elevation of muscle and the overlying skin on a single pedicle produces a musculocutaneous flap. These flaps are useful in the repair of urogenital defects, especially when based on the gracilis and inferior rectus abdominis muscles.

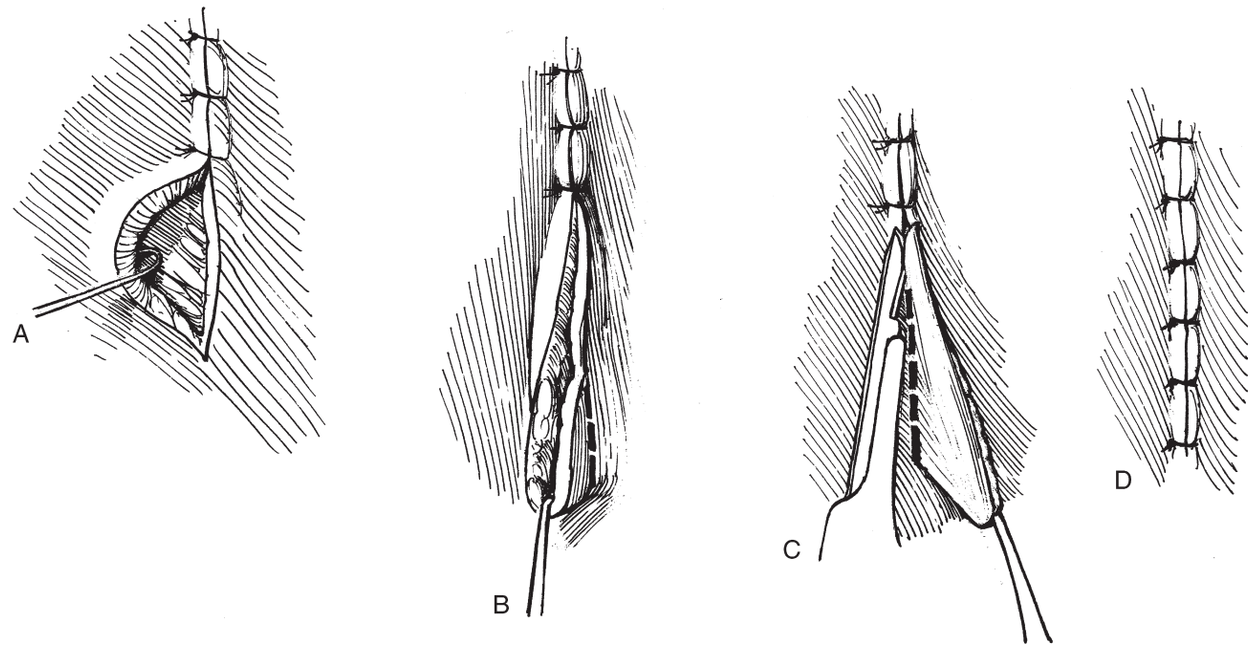

FIGURE 5-7.

Examples (Fig. 5-8): Muscles with perforators that supply the overlying cutaneous vascular territories suitable for formation of musculocutaneous flaps are shown. On the left are the deep inferior epigastric vessels supplying the *rectus abdominis muscle.* On the right is the medial circumflex femoral artery to the *gracilis muscle.*

Gracilis Myocutaneous Flap

The gracilis flap is well suited for reconstruction of the perineum and genitalia, pelvic fistulas, and vaginal and phallic reconstruction.

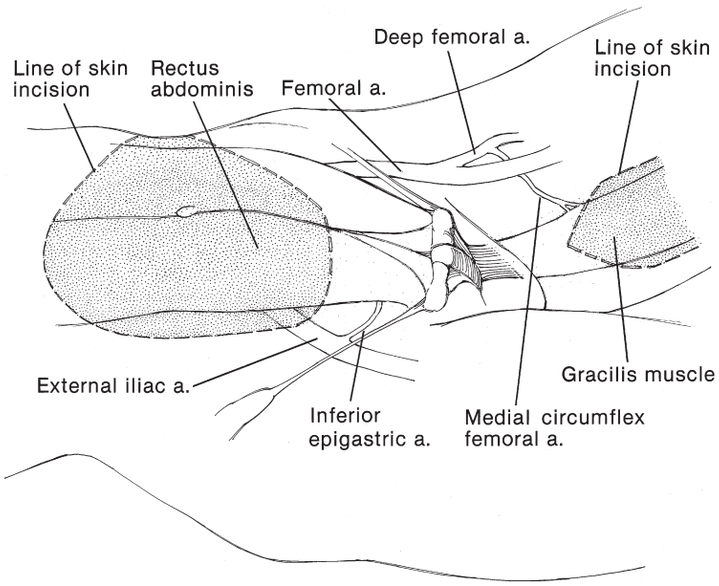

FIGURE 5-8.

The gracilis originates from the outer surface of the inferior pubic ramus and the ischial ramus, and inserts on the medial shaft of the tibia below the medial condyle (Fig. 5-9). These bony sites can be palpated reliably. When the leg is abducted, the gracilis is the most medial of the superficial muscles of the leg, lying medial to and slightly posterior to the adductor longus, a relationship that is helpful in identifying the muscle. The skin element of the flap lies behind a line drawn from the pubic tubercle to the medial tibial condyle.

The major vascular supply to the gracilis is the median circumflex femoral artery, a branch of the deep femoral artery. It enters the muscle about one third of the way (8 to 10 cm) from the proximal end, allowing the muscle to be transposed into the perineum, the pubic or ipsilateral inguinal area, or the ischial fossa.

Position: Place the patient in the low dorsal lithotomy position, and establish the normal anatomic relationships before abducting the leg. Mark the pubic tubercle and the medial condyle at the knee (Fig. 5-10). It is often useful for orientation to mark the line between the pubic tubercle and medial condyle while the patient's leg is flat and mildly abducted *(dashed line)* because the flap consists of the island of skin and the muscle posterior to the line between these two structures. Prepare the left (or right) leg from the lower abdomen to the midcalf. Also prepare and drape the vulva and vaginal area in female patients.

Incision: The adductor longus tendon, inserting on the tubercle, is on tension as the leg is abducted, providing the key to locating the gracilis muscle that lies medial and posterior to it. Proximally, palpate the soft area below the pubic tubercle where the gracilis muscle originates.

Mark a 6- or 7-cm wide ellipse (12 cm if needed for construction of a neovagina), beginning 10 cm below the tubercle and ending cephalad to the medial epicondyle about 18 cm distally. When marking the ellipse, take care to keep the skin of the thigh in its anatomic position because if it is redundant,

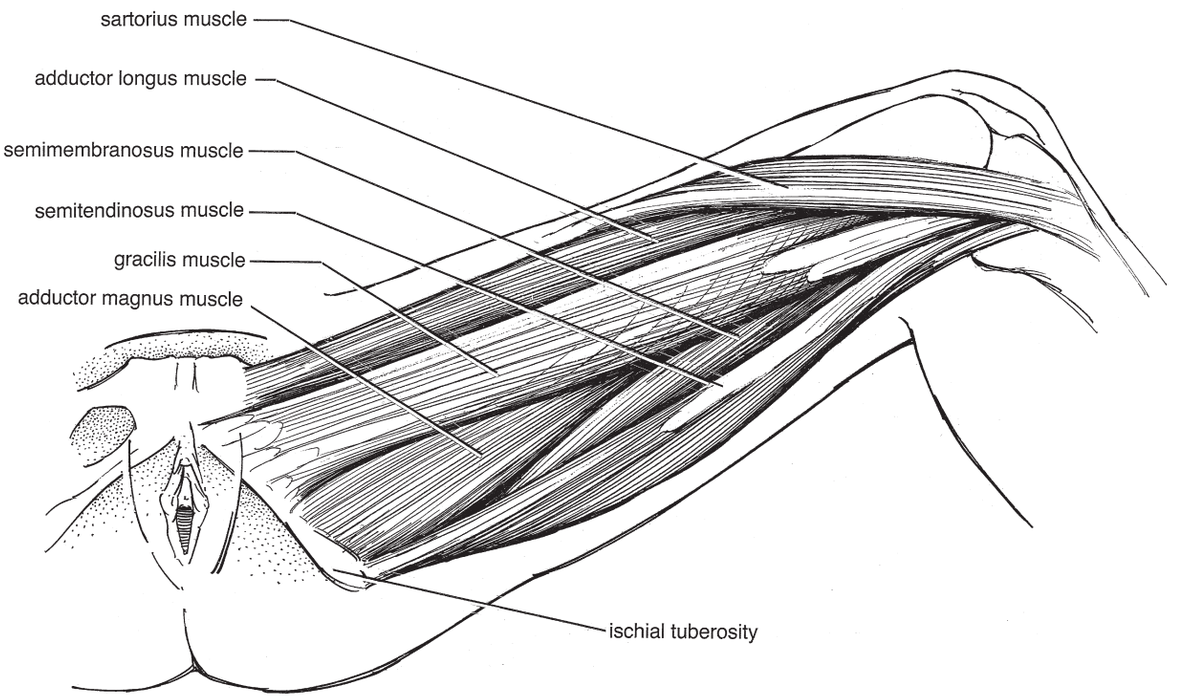

FIGURE 5-9.

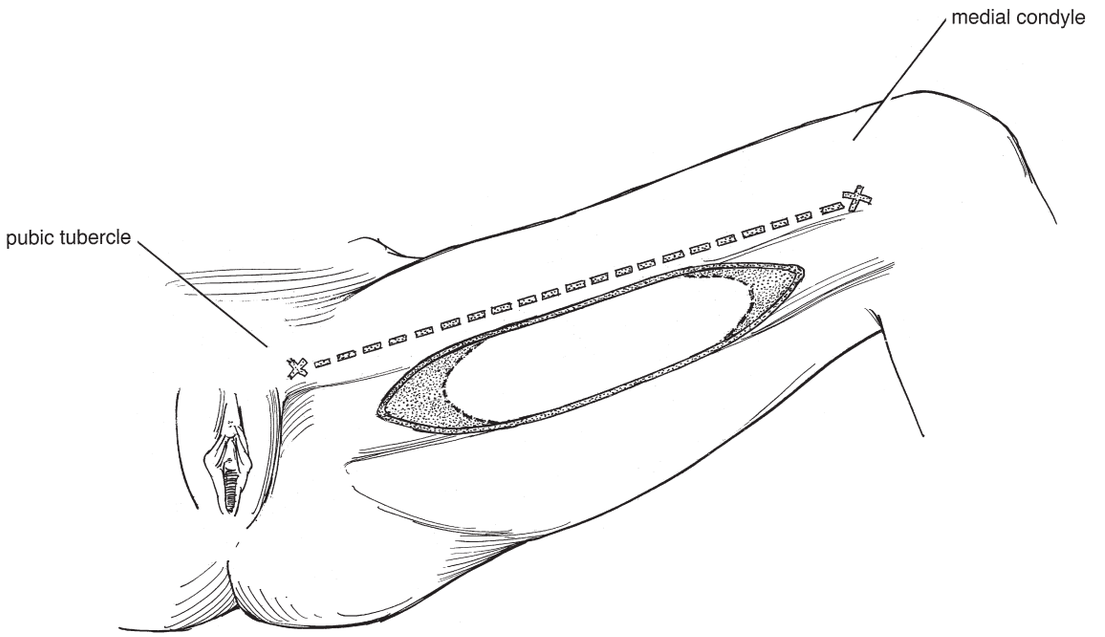

FIGURE 5-10.

it can sag posteriorly where it will no longer be supplied by perforators from the gracilis. This ellipse is made longer than required for the flap itself to allow for a tapering closure of the defect; the ends are trimmed later.

The circulation to the skin island overlying the proximal two thirds of the muscle belly is very reliable. Distally, it may not be consistently so. Therefore, if the distal portion of the island is needed for the repair, check the circulation in that portion of the flap with fluorescein after elevation.

First opening (Fig. 5-11): Make an incision at the medial condyle, and bluntly dissect the subcutaneous tissue until the tendinous insertion of the gracilis muscle is palpated where it lies under the sartorius and anterior to the insertion of the hamstring muscles (the semimembranosus and semitendinosus). Pass a right-angle clamp around the tendinous insertion of the gracilis, taking care to avoid the nearby popliteal artery. Pass a Penrose drain around the tendon, and hold it in a clamp.

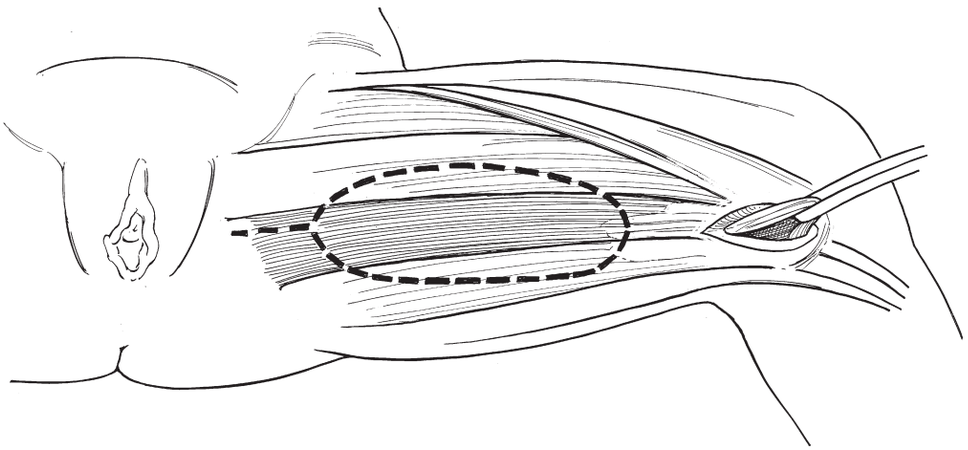

FIGURE 5-11.

Second opening: Tense the gracilis muscle by putting traction on the drain. Then palpate the origin of the muscle where it lies below the inferior pubic tubercle. Make an incision at this site. Dissect the subcutaneous tissue to locate the midpoint of the muscle belly.

Elevate the overlying skin if it is redundant and has slipped posteriorly; it should lie in an anatomic position over the muscle. A line connecting these two incisions identifies the midaxis of the muscle and its overlying skin paddle. Outline the paddle starting 4 to 6 cm from the origin to about 10 cm from its insertion. Usually a width of 7 to 8 cm is satisfactory.

Possible errors: The first is to elevate the sartorius instead of the gracilis. Avoid this mistake by recognizing that the insertion of the gracilis muscle is truly tendinous in consistency, whereas the sartorius is muscular. The other is mistaking the adductor longus for the gracilis. Although the adductor longus also has a tendinous insertion, it lies under the distal end of the sartorius, whereas the gracilis is generally posterior to the main belly of the sartorius. Thus, if the sartorius muscle belly must be retracted to dissect the distal end of the muscle, suspect that the muscle being elevated is the adductor, not the gracilis. You will not confuse the gracilis with the semimembranosus and semitendinosus muscles that lie behind because they are entirely tendinous.

Divide the gracilis tendon with the electrocautery. Insert a silk traction suture, and lift the tendon from beneath the sartorius. Incise further along the sides of the skin paddle, at the same time tacking the island to the muscle as the incision progresses (Fig. 5-12). Anteriorly, dissect the gracilis from the adductor. Preserve the two or three nondominant distal pedicles until the major pedicle has been identified. Place a bulldog clamp on each set of vessels, and check the vascularity of the distal limits of the flap with the Doppler probe. Continue to incise the lateral margins of the paddle. Adjust the margins to fit the orientation of the gracilis as it is dissected from the adductor longus anteriorly and the adductor magnus posteriorly and proximally. The saphenous vein is encountered. The branches from the saphenous vein to the gracilis can be divided. Divide the vein, keeping it anterior.

Continue dissecting on the medial side of the adductor longus, progressively exposing the belly of the gracilis muscle until the vascular pedicle of the gracilis muscle is approached. Locate the major pedicle that perforates from beneath the belly of the adductor longus muscle. If extra pedicle length is needed, the pedicle can be dissected back as far as the deep femoral artery.

Complete the elliptical incision over the belly of the gracilis, keeping the skin island attached to the muscle with

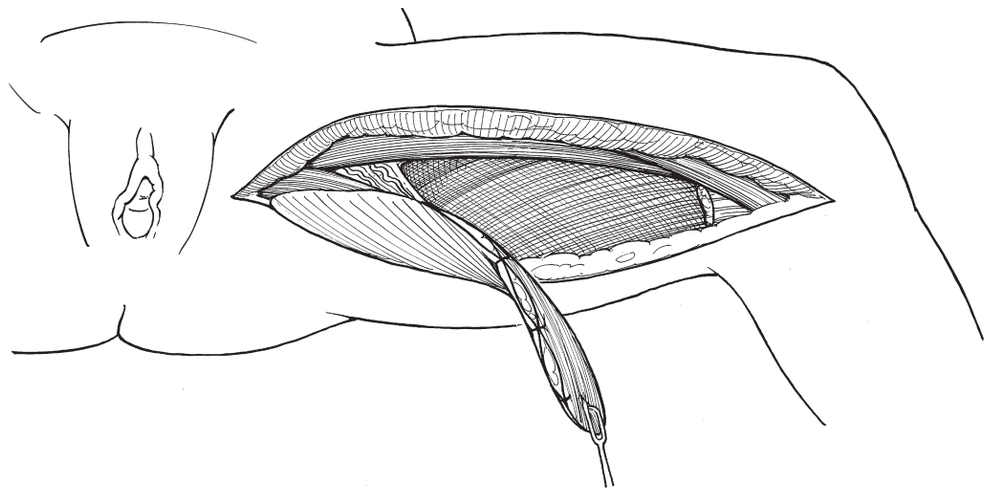

FIGURE 5-12.

sutures. Continue the dissection to the origin of the muscle, which usually does not need to be detached. Before removing the flap from its bed, place marking sutures at regular intervals along the muscle edges to prevent uneven tension when the flap is sutured in place.

The flap is now ready for rotation into a position as cover of a perineal defect or for vesicovaginal reconstruction.

Tunnel under (or divide) the bridge of skin and subcutaneous tissue in the groin to provide a generous passageway (Fig. 5-13A). Transpose the flap clockwise (counterclockwise for the right gracilis). If there is any question about the size of the tunnel, divide the bridge and reapproximate it after the flap has been set in place.

Suture the muscle in position over the defect with 3-0 chromic catgut sutures. Approximate the skin edges of the donor site over a drain (see Fig. 5-13B).

Gracilis Muscle Flap

For a muscle flap to fill a pelvic defect, raise the gracilis muscle as a flap as previously described but without including the overlying skin (Fig. 5-14). Adduct the leg, pass the flap through a tunnel, and suture the flap in place. Fix the base of the flap to the adductor magnus. Detach the origin of the muscle to allow for more vigorous transfer. However, if this is done, take care to avoid tension on the vessels. In cases of aggressive transfer, obtain further freedom of the flap by dividing the profunda distal to the circumflex femoral vessel. Before doing this, be certain that the superficial femoral circulation is intact distally.

Inferior Rectus Abdominis Flap

Use the inferior rectus abdominis flap for lower abdominal, perineal, and groin defects, for phallic and vaginal reconstruction, for vascular interposition in the deep pelvis, and for coverage of perineal defects.

The rectus abdominis is supplied inferiorly by the deep inferior epigastric artery and vena comitans, which are medial branches of the external iliac artery and vein. The supply from the superior epigastric artery is not necessary to maintain the caudal part of the muscle or the skin; that vessel can be sacrificed. However, the major perforators are periumbilical, requiring that skin islands include the periumbilical area to be reliably vascularized. Below the arcuate line, the muscle lies directly on the transversalis fascia and peritoneum; above that line, the muscle lies on the posterior rectus sheath. The inferior epigastric artery provides a very flexible pedicle in most cases for placement of a musculocutaneous flap in defects around the genitalia. The vessels lie on the deep surface of the muscle almost to the level of the umbilicus in most individuals. Because the fulcrum of transposition is deep in the pelvis, in most cases the flap can be easily transposed. By dividing the attachment of the rectus to the symphysis, the muscle can be moved freely into place and can be used for coverage of the contralateral groin.

The donor site is readily closed. Either rectus muscle may be used, depending on the quality of the common femoral artery. The fulcrum of transposition of the flap allows placement into the perineum for reconstruction of the vagina and for repair of defects of the base of the bladder.

Prepare the recipient site first. If there is any question regarding the integrity of the common femoral artery on

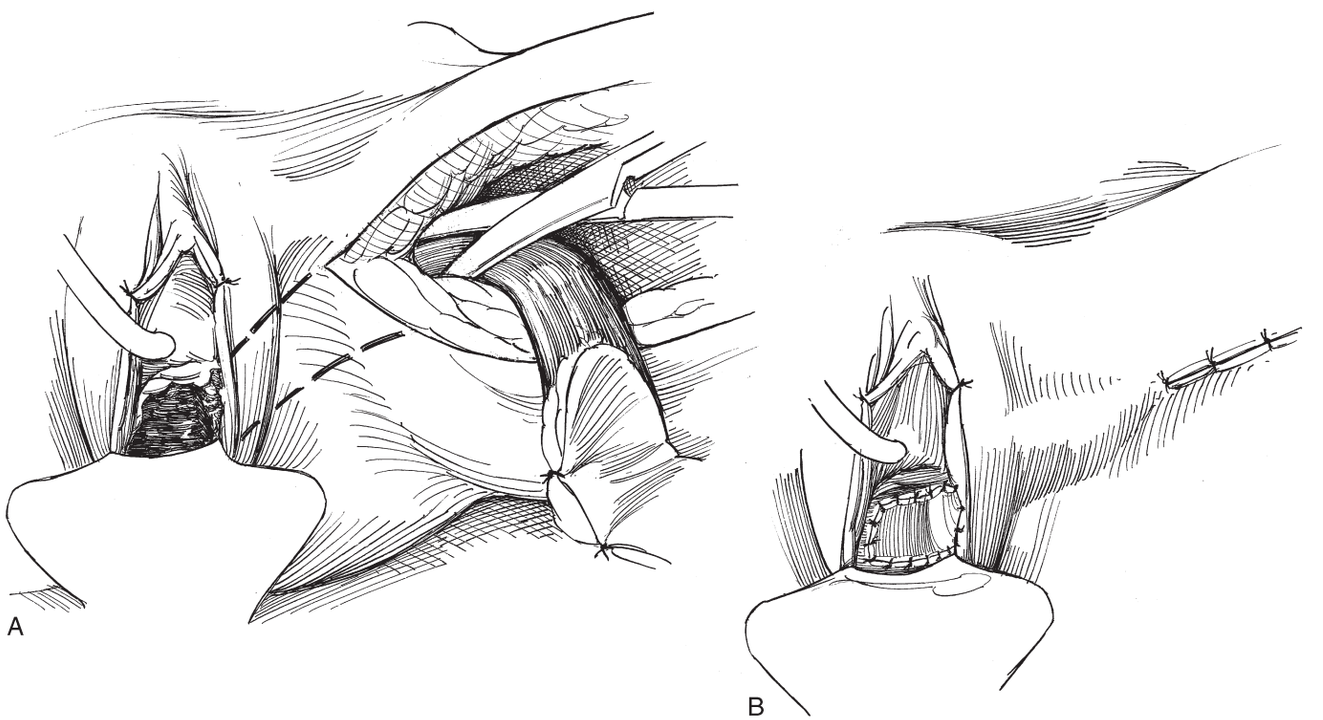

FIGURE 5-13.

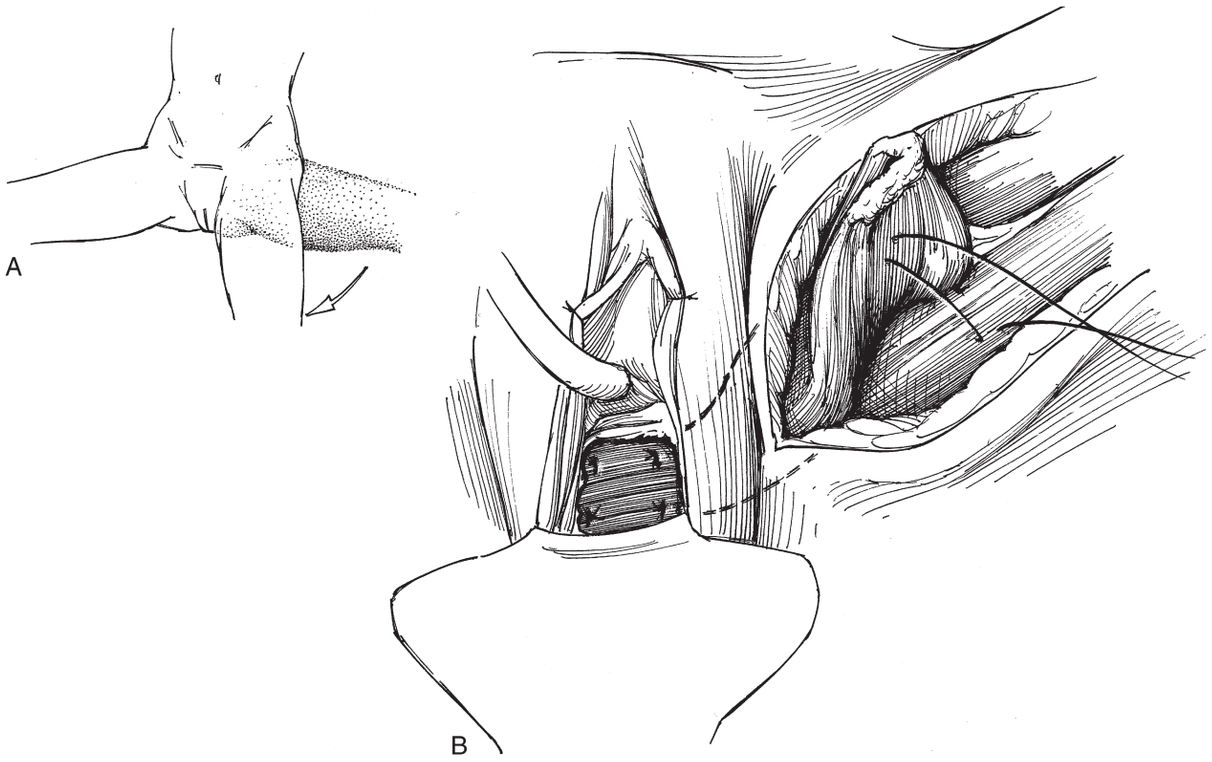

FIGURE 5-14.

one side, use the contralateral rectus muscle. If there is any question about the size or patency of the deep inferior epigastric artery, examine it by duplex ultrasonography. The relationship of the vessel to the muscle may be determined by the same modality.

Outline an asymmetric flap extending well below the umbilicus in order to include the perforating vessels that enter there (Fig. 5-15A). The width depends in part on the size needed for coverage of the defect and in part on the laxity of the abdominal wall for closure. The skin island can be oriented vertically, entirely transversely, or transversely with a vertical component. Incise the skin and subcutaneous tissue down to the rectus sheath. Circumscribe the umbilicus so that it may remain behind, adherent to a part of the rectus sheath.

Alternatively, incise beside the umbilicus for a better cosmetic appearance (see Fig. 5-15B).

Elevate the skin edges (see Fig. 5-15C). Preserve perforating vessels.

Divide the fascia beneath the skin edges, beginning along the lateral border of the rectus (see Fig. 5-15D). Leave 1 to 1.5 cm of the anterior sheath laterally for closure.

Dissect the rectus muscle from its sheath, again starting laterally, freeing its upper half to the midline posteriorly (Fig. 5-16). The vessels usually enter the belly of the muscle at the level of the umbilicus and usually bifurcate there.

First dissect the anterior and then the posterior sheaths from the muscle (Fig. 5-17). Inferiorly, below the arcuate line, the dissection is made directly on the peritoneum. Leave the major perforating vessels joining fascia to skin. Place silk tacking sutures to hold the skin edges to the muscle. During this dissection be cautious not to injure the muscle or small vessels; fortunately, the separation of muscle from sheath is usually not difficult except at the tendinous inscriptions.

Divide the rectus muscle, even as far as its attachment at the xiphoid, and secure the superior epigastric artery (Fig. 5-18). Insert a traction suture of 2-0 silk in the end. Continue freeing the muscle posteriorly, while dividing and clipping the segmental motor branches.

Approach the inferior end with care (Fig. 5-19). The inferior epigastric vessels that make up the vascular pedicle arise somewhat laterally to enter into the lower fifth of the rectus muscle. Dissect these vessels, and encircle them with a vessel loop. The inferior end of the rectus muscle may be divided to allow the flap to rotate more freely and to reduce concern that it will be compressed when placed in a tunnel. Alternatively, leave that end intact to provide a margin of safety against harmful traction during placement. If divided, insert a stay suture in that end to aid in positioning.

Tunnel the flap into position in the perineum or groin, making sure that the pedicle is not kinked or constricted, and fix it in place with two layers of sutures after inserting a suction drain beneath it (Fig. 5-20). Close the rectus sheath with a running (possibly doubled) 0 nylon suture. Because the posterior wall is weak in the distal third where the posterior sheath is absent, a sheet of synthetic material (Gore-Tex) may be cut to size and sutured in place with heavy monofilament synthetic sutures tied with eight or nine knots. Insert a suction drain within the rectus sheath because it often communicates with the

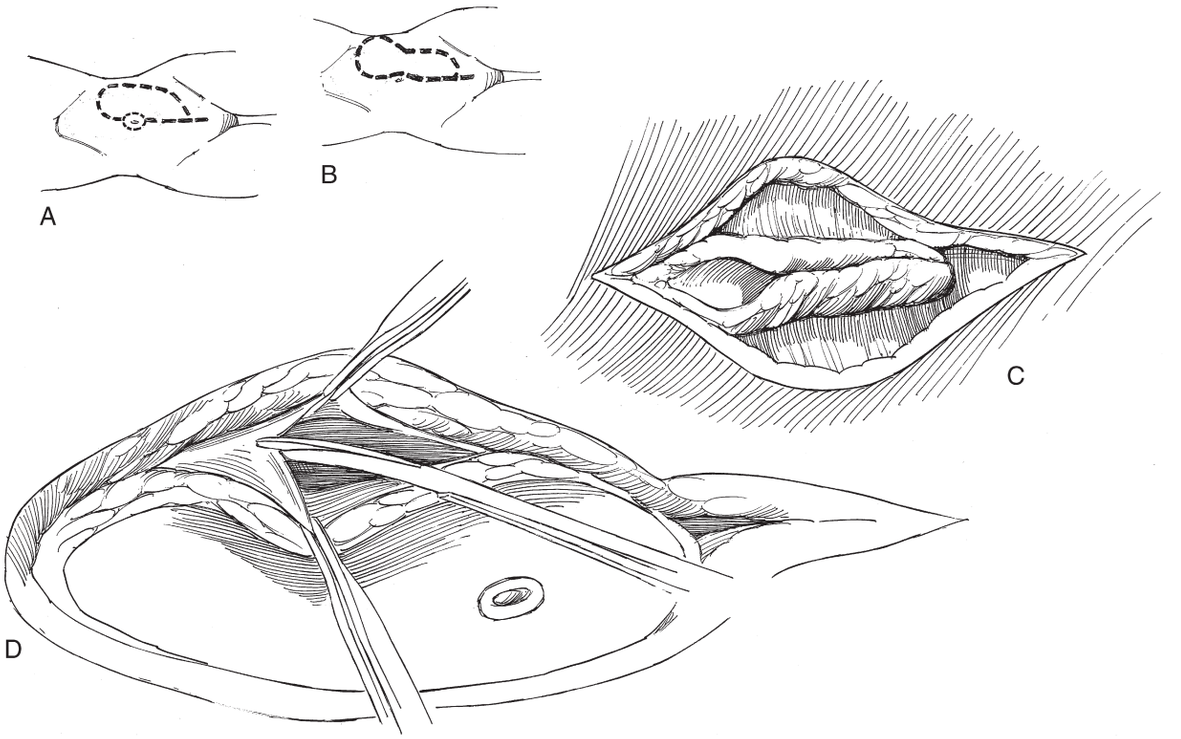

FIGURE 5-15.

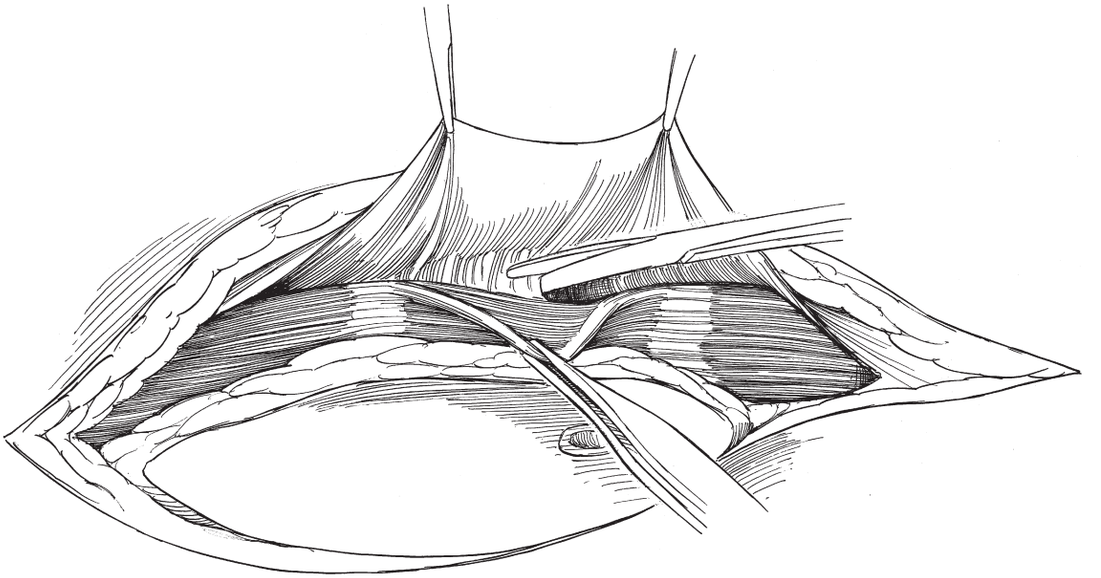

FIGURE 5-16.

perineal or groin defect, which may drain lymph. Close the subcutaneous layer with a running suture of 2-0 synthetic absorbable sutures (SAS) and the skin intracuticularly with a 4-0 SAS on a PC-3 needle. Postoperatively, give two spaced doses of methylprednisolone (Solu-Medrol) to reduce the inflammatory reaction. The patient finds it difficult to walk at first but should not be allowed to sit for more than a few minutes and must either stand or lie down, perhaps on an air-cushioned bed.

Dressings for Grafts and Flaps

Fixation of the graft to the recipient site is essential to optimize graft apposition to the host bed. It depends on the quality of the dressing and the activity of the patient. Adhesive tape dressings, including sterile strips, adhere better if gum mastic (Mastisol) rather than tincture of benzoin is applied to the skin first. In the case of externally placed grafts, bolster dressings can help with this function. A misconception exists that bolsters

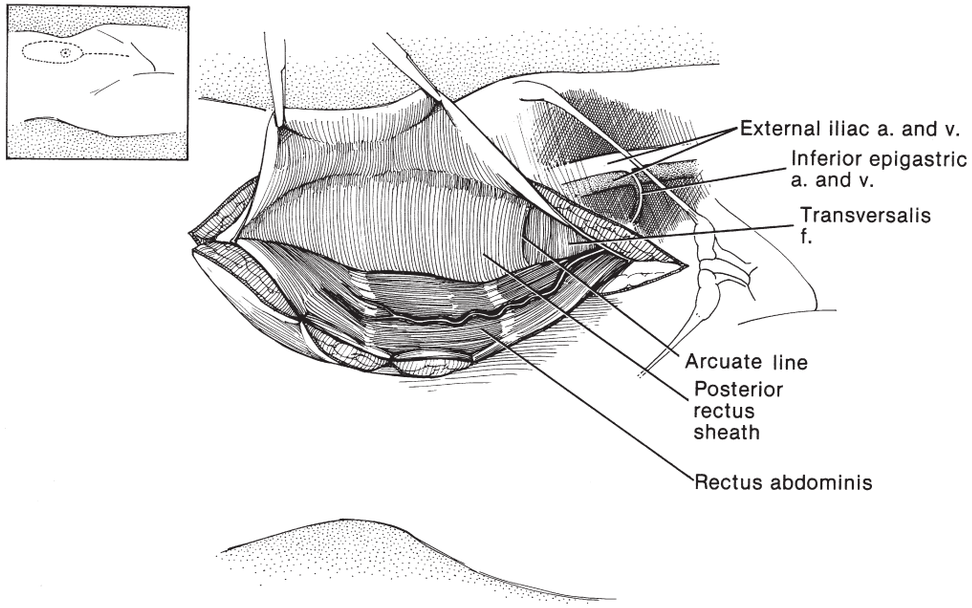

FIGURE 5-17.

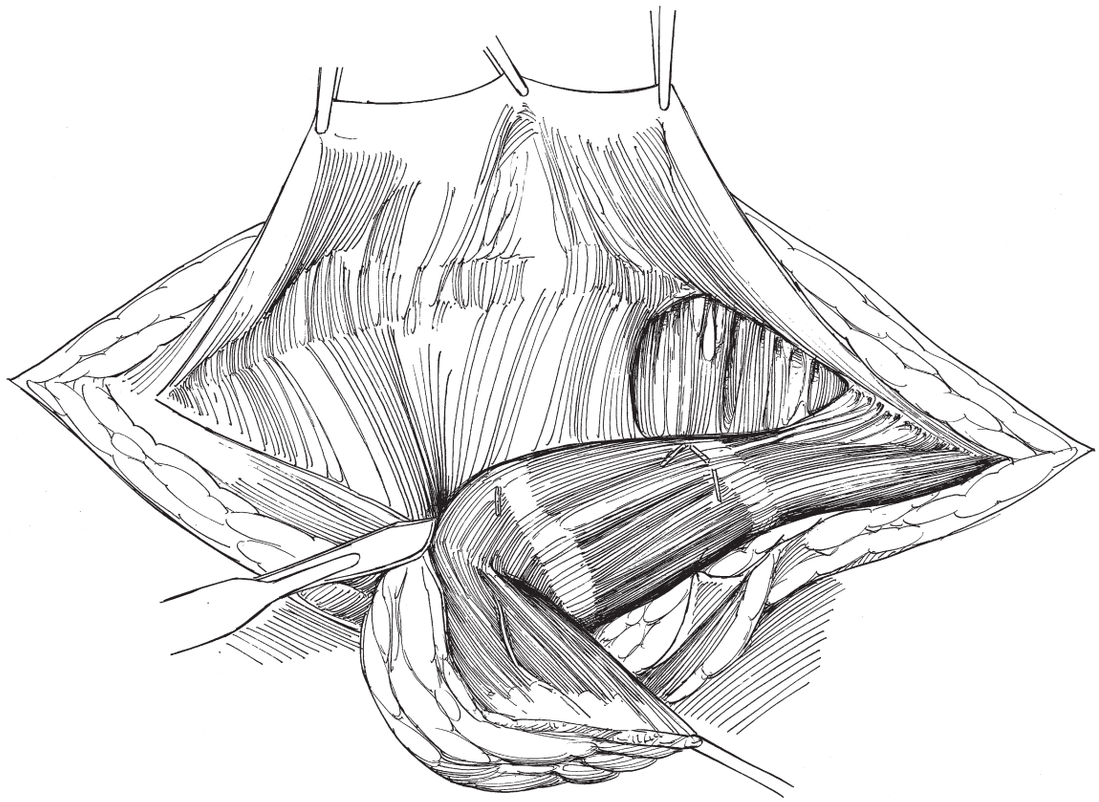

FIGURE 5-18.

prevent the accumulation of hematomas or seromas beneath the graft, but laboratory studies have shown that bolsters applied tight enough to prevent accumulations beneath the graft are also tight enough to interfere with the process of graft take. For grafts, the bolster serves as the graft dressing. Graft donor sites can be dressed with transparent adhesive dressings. Dressings are not usually needed for flaps. Antibiotic ointment can be placed on the suture line and sterile strips placed across it, but an occlusive dressing is usually not applied.

PROBLEMS AFTER GRAFT PLACEMENT OR FLAP TRANSFER

Loss of a skin graft results from factors that interfere with optimal graft take. Graft loss results from poor adherence, most often caused by hematoma, but incomplete immobilization of the graft is next in importance. Thus perfect hemostasis and proper fixation are the keys to success. *Hematomas* and *seromas* separate the graft from the underlying

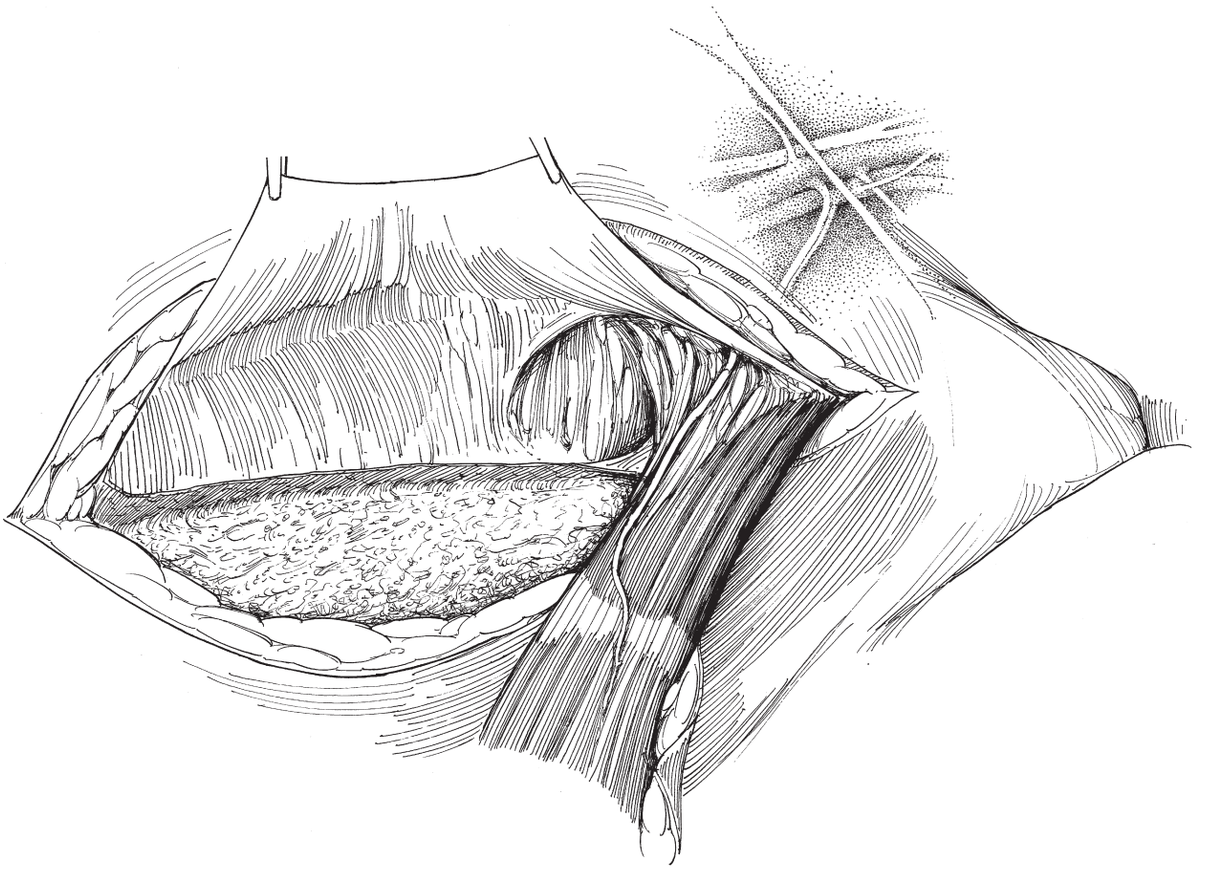

FIGURE 5-19.

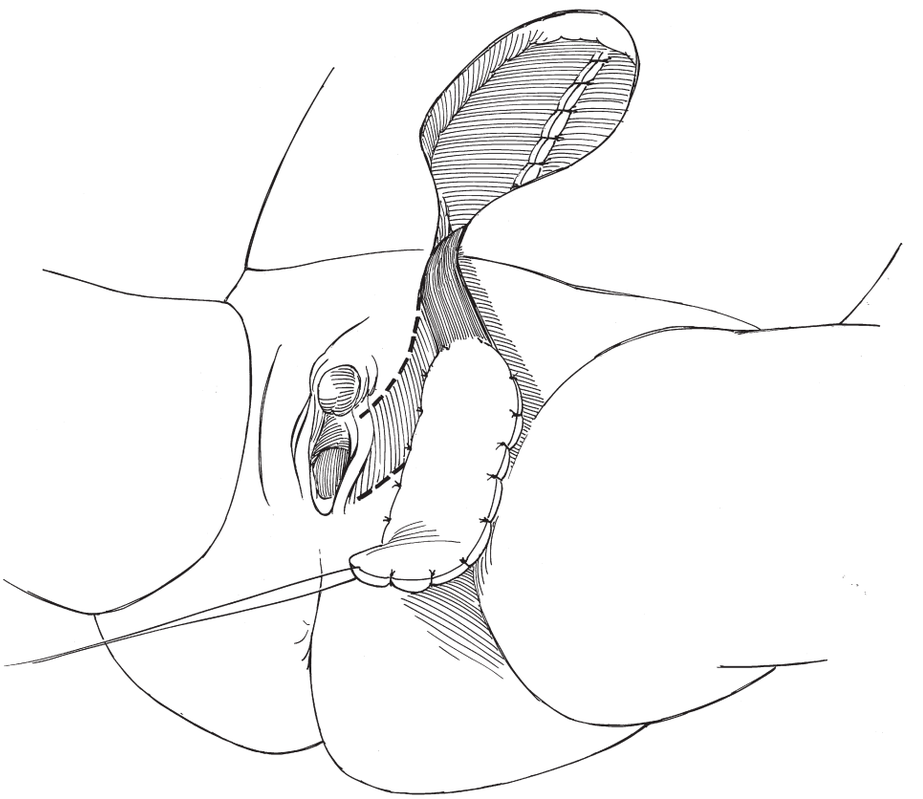

FIGURE 5-20.

recipient vessels. Hematomas can likewise interfere with the survival of flaps. They secrete substances that are vasospastic and can adversely affect a flap that has been aggressively transposed. Promptly drain a hematoma or seroma seen accumulating early in the area of the graft; it may be possible to salvage the graft. *Infection* beneath flaps and grafts can arise because of direct bacterial contamination during the transfer process or can represent seromas or hematomas that become infected. Not only do such *purulent collections* separate the graft vessels from the underlying recipient vessels, but the purulent reaction produces a direct toxic effect that interferes with endothelial migration.

A flap that is *too small* is usually the result of either improper selection of a flap or improper design of a skin island. Failure should never be the result of putting the graft on upside down.

Ischemia results in necrosis of the flap. This is in contrast to loss of grafts, which is the result of interference with the processes of graft take. It can come from surgical damage to the blood supply or from overstretching the vessels in the skin through failure to use a back cut or a long enough pedicle. *Tension* is especially harmful when the blood supply is marginal. Release a few of the sutures at once. It may be necessary, however, to redesign the closure or even put the flap back into its original position, to be remobilized at a later time. Inadequate blood supply is the principal cause of ischemia, usually from deficient arterial inflow, although venous congestion with stasis may be the initial event. As venous tension increases in the flap, flap perfusion suffers. Appropriate techniques during the procedure preserve the blood supply but do not completely eliminate the risk of ischemia. *Compromise of the vascular pedicle* can occur from passage through a tunnel that is too small, from stretching of the pedicle, or from blood and serum accumulation around the pedicle. In some cases, when the blood supply to the flap is tenuous, it may be necessary to open one aspect of the flap or the tunnel. These defects can be closed secondarily or grafted later. In the case of venous congestion, if the above measures are not successful, one may contemplate the use of medical leeches to salvage a flap.

Anticoagulation is seldom indicated, but aspirin in low doses may be helpful in improving survival of a flap. A number of drugs adversely affect the general circulation; nicotine from cigarette smoking is probably the substance most commonly encountered, and patients who smoke need to be so advised. Cocaine and cocaine-containing medications are also potent vasospastics and should not be used or administered following tissue transfer.

This page intentionally left blank

Chapter 6

Bowel Stapling Techniques

JOSEPH A. TRUNZO AND ERIC L. MARDERSTEIN

Surgical stapling instruments are a widely accepted means for division and anastomosis of gastrointestinal tissues. The first development of a surgical stapler for bowel surgery was created by a Hungarian surgeon, Hümér Hültl, and a surgical instrument designer, Victor Fischer, initially in 1908. This model took 2 hours to assemble and weighed approximately 5 kg. Their design was later refined in 1920 by another Hungarian surgeon, Alàdar Petz, whose modifications made it lighter and it could be assembled in minutes. It was then further modified to the more modern stapling devices in the 1950s by a Russian development program known as the Scientific Research Institute for Experimental Apparatus and Instruments in Moscow. Here the first iteration of the circular anastomotic stapling device was constructed.

Much of the early experiences with stapling devices described in the United States are attributed to the published work by surgeons Mark M. Ravitch and Felicien M. Steichen. Their work described multiple techniques for usage of the stapler on gastrointestinal surgery from esophageal to colonic surgery including one of the earliest publications discussing the modern end-to-end anastomosis (EEA) stapling instrument and its use.

The surgical stapler revolutionized intestinal surgery by decreasing the risk for bowel contamination and lowering postoperative complication rates. The stapled anastomosis is still used because of the significant decrease in operative time required to create the closure as well as its consistent results. This, however, has not resulted in a notable difference in postoperative complications when using a standard sutured anastomosis. For example, some evidence suggests that a hand-sewn anastomosis may be superior when creating an anastomosis following an abdominal injury in the trauma patient, emphasizing the point that, for the stapling device to function properly, the bowel must be normal and the mechanical specifications of the stapler cannot be exceeded. Most problems with stapling devices arise when they are used for tasks for which they were not designed.

The three main stapling instruments are the gastrointestinal anastomosis instrument (GIA), the thoracoabdominal (TA) instrument, and the EEA instrument.

GASTROINTESTINAL ANASTOMOSIS INSTRUMENT

The GIA instrument is made of two separate linear components that are interlocked together when ready to staple. Each component represents half of the handle and a protruding limb that directly oppose each other as jaws. One limb is loaded with a replaceable cartridge that holds two double rows of staples, and its opposing limb forms the staples into a B-shape when the instrument is fired. Once the instrument is assembled, the jaws are closed on the tissue by squeezing the handle. It is fired by sliding a driver trigger along the length of the limbs. This trigger deploys the staples and slides a knife between the double rows of staples to divide the tissue. The staple line extends past the cut line. The driver is then pulled back, the handle is opened, and the jaws release. The bowel is now divided with staple lines on each stump.

The GIA comes in varying lengths with three standard sized staple loads. The three types refer to the staple's leg length and are identified by color: 2.5 mm (white), 3.8 mm (blue), and 4.8 mm (green). Generally a 3.8-mm blue load is used for bowel surgery. White loads are reserved for vascular applications, and green is used for thicker tissues such as the stomach.

A laparoscopic GIA functions in the same manner as the standard GIA, but is a single device with a hand trigger. The device can be rotated 360 degrees and, depending on the model, can angle or reticulate at the distal end. Several designs are available with minor differences between them.

THORACOABDOMINAL INSTRUMENT

The TA instrument is a single component device that delivers a linear staggered double row of staples of 30, 55, and 90 mm in length depending on size chosen. At the end of the handle is a C-shaped jaw. The proximal portion or upper jaw houses the staple cartridge. The distal portion or lower jaw forms the staples. Once the tissue is between the jaws, a narrow pin is either screwed or pushed into place from the proximal to the distal portion, enclosing the C. Its purpose

is to prevent tissue from being squeezed outside the jaw and to maintain the alignment for precise staple closure. The tissues are then approximated by screwing the shaft down to the appropriate degree, indicated by a form of detector on the shaft. The staples are deployed by squeezing the handle. The end of the tissue is then manually cut with a knife after the staples are formed.

END-TO-END ANASTOMOSIS INSTRUMENT

The EEA instrument is a two-component device that is made up of an anvil and the main staple deployment arm. Two rows of staples are arranged in a circular pattern at the end of the arm with a circular knife within its end. The diameter of the cartridge is variable: 25, 27, 29, or 31 mm. The stapler arm engages with an anvil that is placed within the opposing tissue for anastomosis. The two components are engaged and the instrument is screwed down to the appropriate approximation as shown in an indicator window on the device. The handle is then compressed, deploying the staples and engaging the circular knife. The handle is unscrewed one 360-degree turn and the instrument is removed. Two complete doughnut-shaped rings should be delivered within the device's end, representing the two tissues cut from the opposing anastomosis. A circular row of staples is left behind as the anastomosis.

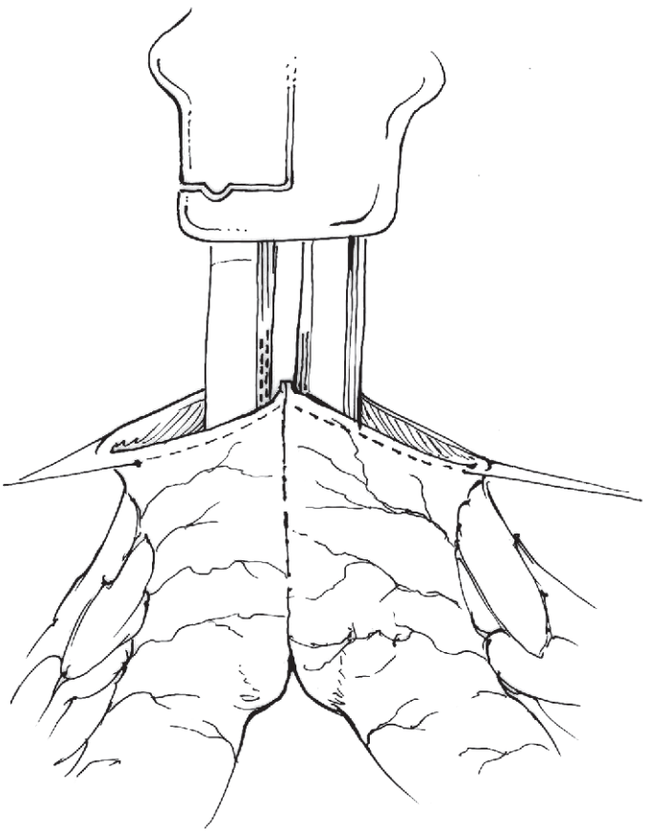

(series modified from Baker)

FIGURE 6-1. *(Redrawn from Stapling Techniques: General Surgery, 3rd ed. U.S. Surgical Corporation, 1988.)*

COMMON BOWEL APPLICATIONS FOR A STAPLING INSTRUMENT

Side-to-Side Anastomosis

The two open ends of bowel are held up with Allis clamps or stay sutures and the opposing limbs of a GIA are placed within the lumens. Take care to place the limbs along the antimesenteric border and lock them in place (Fig. 6-1). A seromuscular suture can be placed through the end and approximately 4 to 5 cm down from the opposing segments of bowel, along the antimesenteric border, to maintain the bowel position before firing. At this point, squeeze the handle to secure the jaws on the tissue. Before firing, ensure that none of the mesentery will be incorporated in the staple line. This is done by direct inspection and aided by placing the surgeon's hand underneath the stapler and spreading the two bowel limbs apart. When safety is assured, push the driver to the end of the limbs and back to deploy the staples and cut. With the lumens still open, it is beneficial to observe the staple line from within to evaluate for bleeding. Oversew any bleeding areas as needed. We recommend placing a crotch stitch at the apex of the GIA staple line to act as tension relief on this high-stress area to reduce the chance of a leak in that location.

To complete the closure, the open ends of bowel are approximated with Allis clamps or stay sutures. A TA is placed beneath the clamps along the edge of the open bowel line (Fig. 6-2). It is critical to ensure that the TA staples are placed below any exposed mucosa; if they are not, the anastomosis will leak. We also recommend that the opposite sides of the GIA staple line be offset from each other and not directly across. This may increase the strength of areas of the anastomosis where two staple lines intersect. The TA instrument is engaged and fired. A knife is used to remove the excess tissue as close to the TA instrument as possible, using the groove in the top of the device as a guide. The TA instrument is removed, and the anastomosis is complete. Interrupted Lembert sutures can be placed along the staple lines for reinforcement if desired. Any bleeding from the staple line can be controlled with figure-eight sutures. Patency of the anastomosis can be checked by inspection or direct palpation. The mesentery is closed per surgeon's preference.

Most times, as in urologic surgery scenarios in which a segment of bowel is being isolated for reconstruction of the urinary tract, the two ends of bowel are stapled off. In this situation, two seromuscular stay sutures can be placed as described to maintain opposition of the bowel. The corner segments on the antimesenteric border are then excised on both sides using heavy scissors (Fig. 6-3). The cut is generally through the end of the staple line and must accommodate a single limb of the GIA stapler on each side. Once both limbs are inserted, lock the handle together and fire the device (Fig. 6-4). The ends of the two loops of bowel are then restapled below the defects created along with the former staple line with a TA instrument as discussed earlier. The remnant is then recut above the TA with a knife.

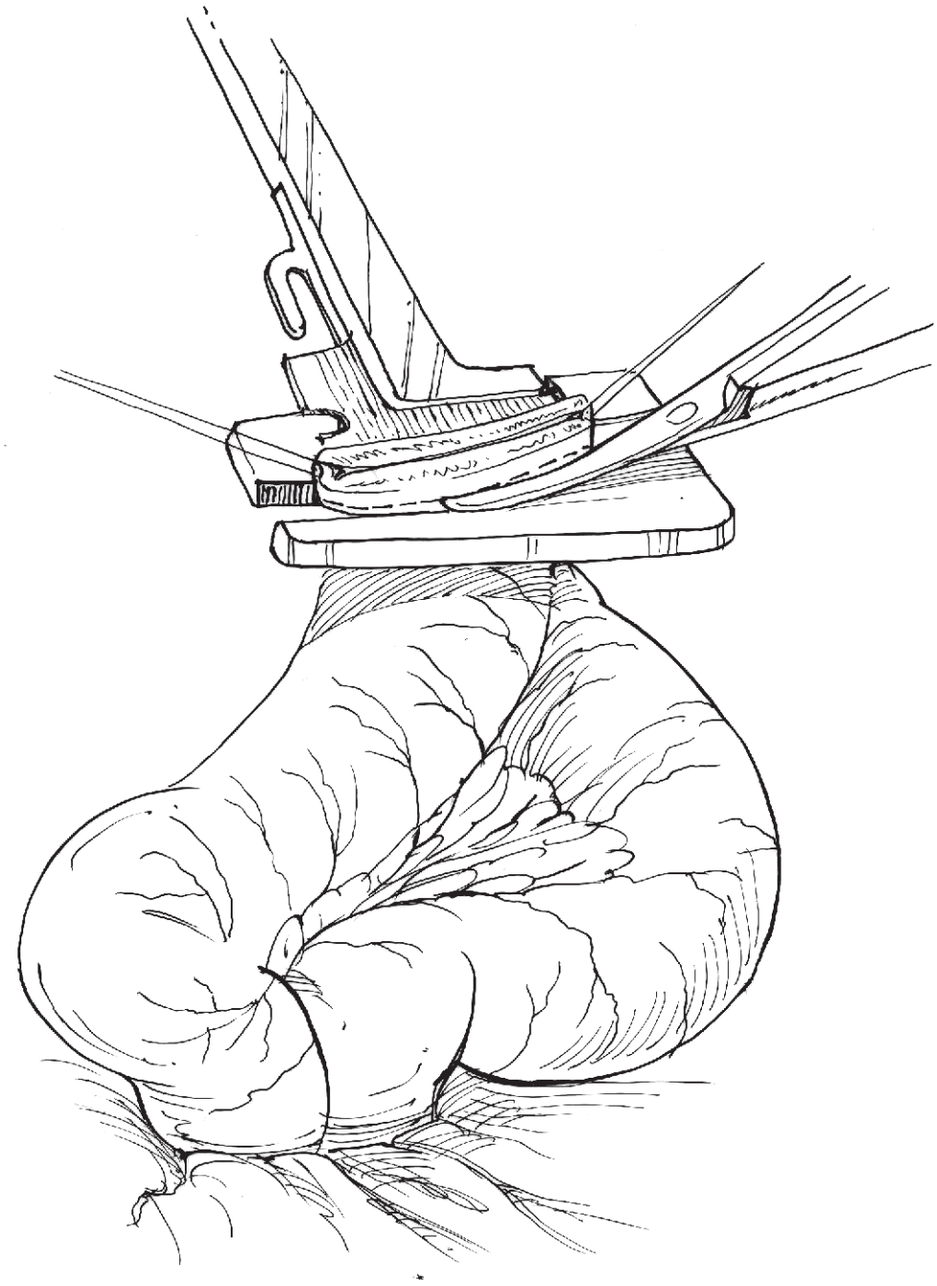

FIGURE 6-2. *(Redrawn from Stapling Techniques: General Surgery, 3rd ed. U.S. Surgical Corporation, 1988.)*

End-to-End Anastomosis

The EEA device has revolutionized the ability to perform intestinal anastomosis in difficult to expose areas of the gastrointestinal tract, such as the gastroesophageal junction and deep in the pelvis. Begin by releasing and separating the anvil from the spindle at the distal end of the device. The most common usage of the EEA instrument involves what is described as the "double-staple" technique. Most commonly, the distal bowel is stapled with a TA device and the proximal bowel is open. By contrast, in the "single technique," both proximal and distal bowel are open, receive pursestring sutures, and are tied down before anastomosis. The double-staple technique is favored by most because it is less technically challenging to staple the distal bowel than to make a well-placed pursestring suture deep in the pelvis or at the gastroesophageal junction.

For a double-staple anastomosis, a pursestring suture is created in the proximal bowel. Ensure that the full thickness of the bowel wall is incorporated in the pursestring suture. Furthermore, very little mucosa should be incorporated and the bites should not be too close together or else the knot will not cinch down tightly against the anvil. Automatic pursestring devices are available for this purpose, but

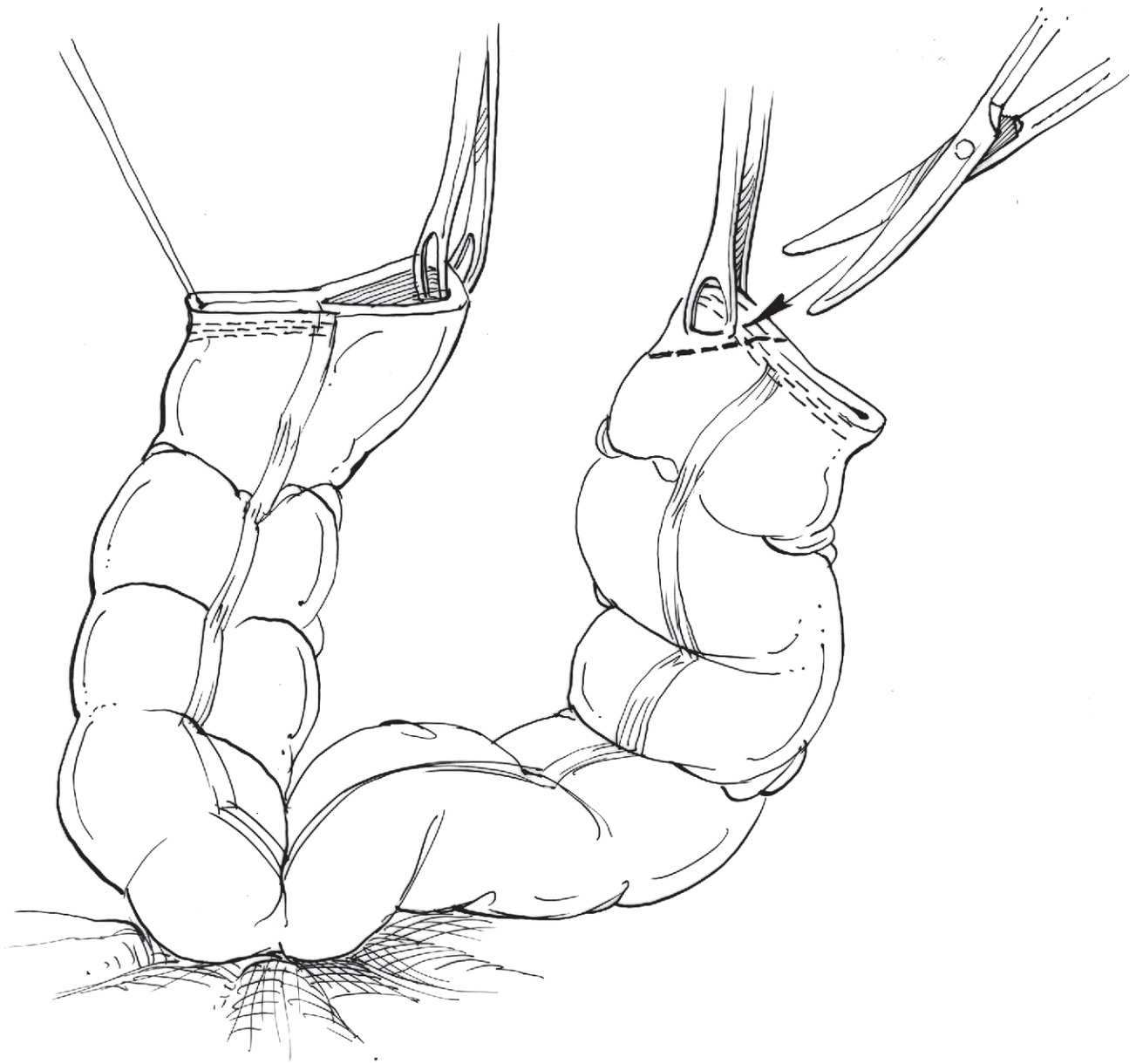

FIGURE 6-3. *(Redrawn from Stapling Techniques: General Surgery, 3rd ed. U.S. Surgical Corporation, 1988.)*

our preference is to perform this key step with manual suturing to accommodate variations in bowel configuration with each pass of the needle. Once the pursestring is placed, the lubricated anvil is placed in the proximal bowel and tied down tightly (Fig. 6-5).

Choosing an EEA stapler that is too large will result in wasting the device and potentially traumatizing the bowel in the process. In general, the proximal bowel is used to select the device size because in most cases it is the smaller piece of bowel. Reusable sizers are available to assist the surgeon in choosing the appropriate device size. A 29-mm EEA will work well for most adult applications.

The main EEA shaft is placed into the closed bowel either through the anus, if a low anastomosis, or via a linear transverse enterotomy/colotomy away from the closed stump. When placing the EEA transanally in the case of a low stapled rectal stump it should be done with great care so that it does not cause dehiscence of the TA staple line. This is a very challenging and time-consuming problem to fix. If necessary, the anus can be effaced with Allis clamps during insertion. Once inserted, advance the EEA through the stump where the planned anastomosis site is and apply it firmly against the tissue. Place the EEA device adjacent to the staple line, not over it, if a staple line is present. Rotate the engagement knob on the handle to advance the spindle through the stump, and then connect the anvil to it (Fig. 6-6). Some operators aim to have the spindle protrude posterior to the staple line whereas others prefer having it protrude anterior to the staple line. No data are available to support one method over the other, but we prefer to have the spindle

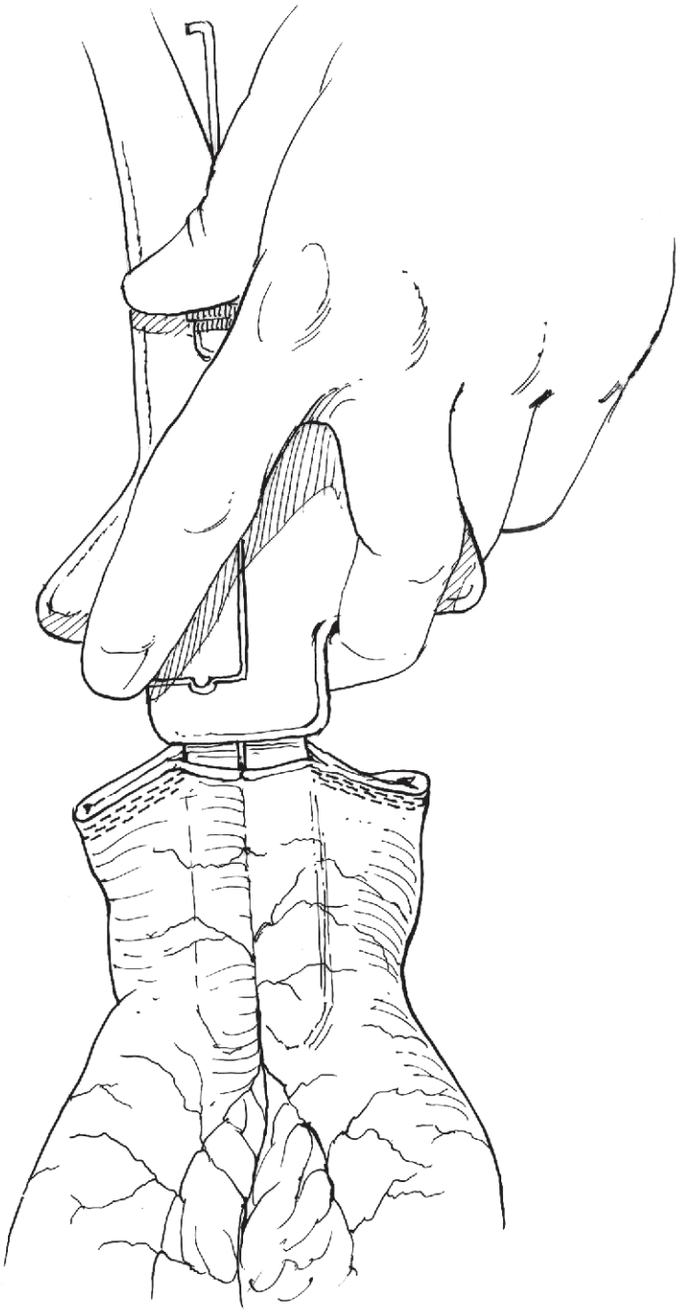

FIGURE 6-4. *(Redrawn from Stapling Techniques: General Surgery, 3rd ed. U.S. Surgical Corporation, 1988.)*

protrude posteriorly to minimize the chance of inadvertent incorporation of anterior tissues, such as those of the vagina or prostate.

Approximate the tissue using the engagement knob until the indicator is shown on the handle demonstrating the appropriate depth. Remove the safety latch on the device and squeeze the handle to engage the staples and cut the tissue (Fig. 6-7). A circular row of staples is applied and the center is cut out. At this point, the anastomosis is complete. Untwist the knob 360 degrees and gently remove the EEA device from the bowel with a twisting motion. Inspect the cut tissue remnants on the device, which should form two complete doughnut shapes around the anchoring shaft. Their presence suggests a good staple line and a complete cut. Finally, close the enterotomy/colotomy with a TA stapler or by hand-sewing in a transverse manner to avoid bowel stricture. If it is a low rectal anastomosis, it can be tested for leak by filling the pelvis with saline and insufflating the rectum with air. Our practice is liberal use of proximal diversion with loop ileostomy for patients having a low colorectal anastomosis who have had previous radiation or poor general health, or if the anastomosis is technically unsatisfactory or with a small leak. The remedy of a leaking anastomosis is not diversion, but rather a redone anastomosis that is satisfactory when possible.

CONCLUSION

When dividing and anastomosing bowel, a good understanding of the current stapling instruments is a key component to success. These tools can provide consistent results and are generally safe for use with normal healthy bowel. Most current literature does not show any difference in postoperative complication or leak rate when compared with hand-suturing, but they do consistently show a significantly shorter operative time. However, these instruments can fail and occasionally must be corrected using standard hand-sewn anastomosis to complete the procedure. Having a good background in manual hand-sewing techniques is essential for the safe practice of gastrointestinal surgery.

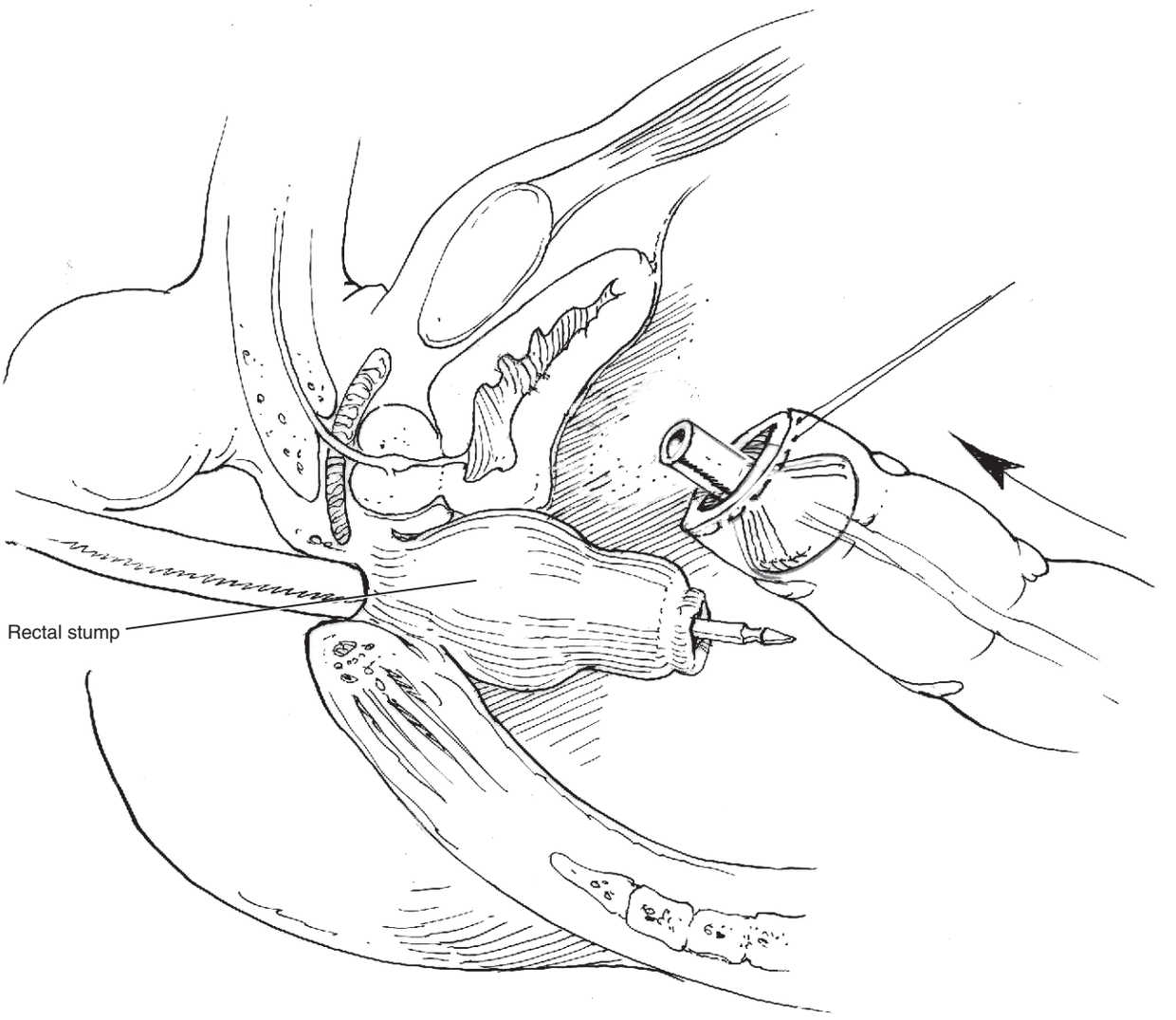

FIGURE 6-5. *(Redrawn from Stapling Techniques: General Surgery, 3rd ed. U.S. Surgical Corporation, 1988.)*

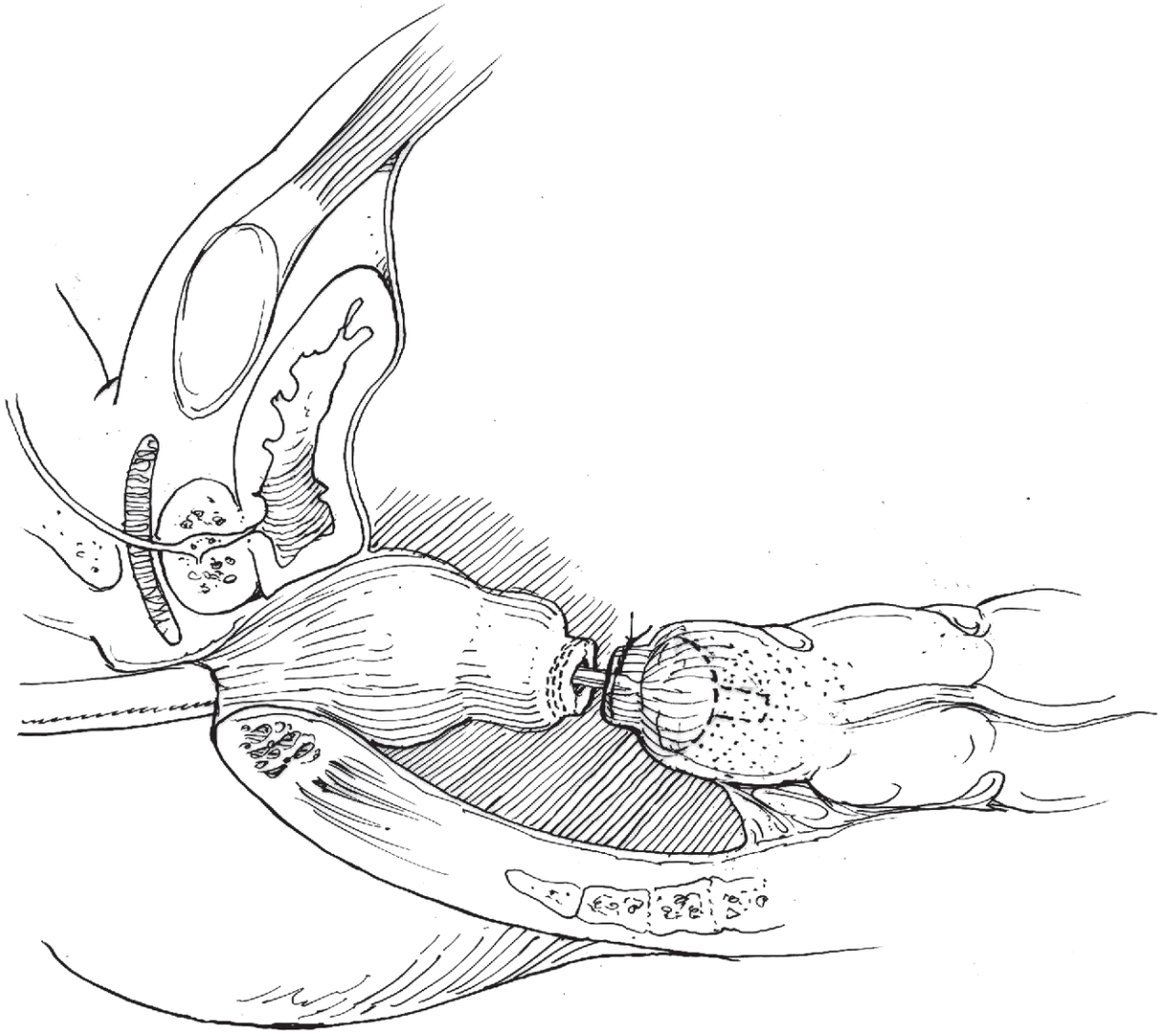

FIGURE 6-6. *(Redrawn from Stapling Techniques: General Surgery, 3rd ed. U.S. Surgical Corporation, 1988.)*

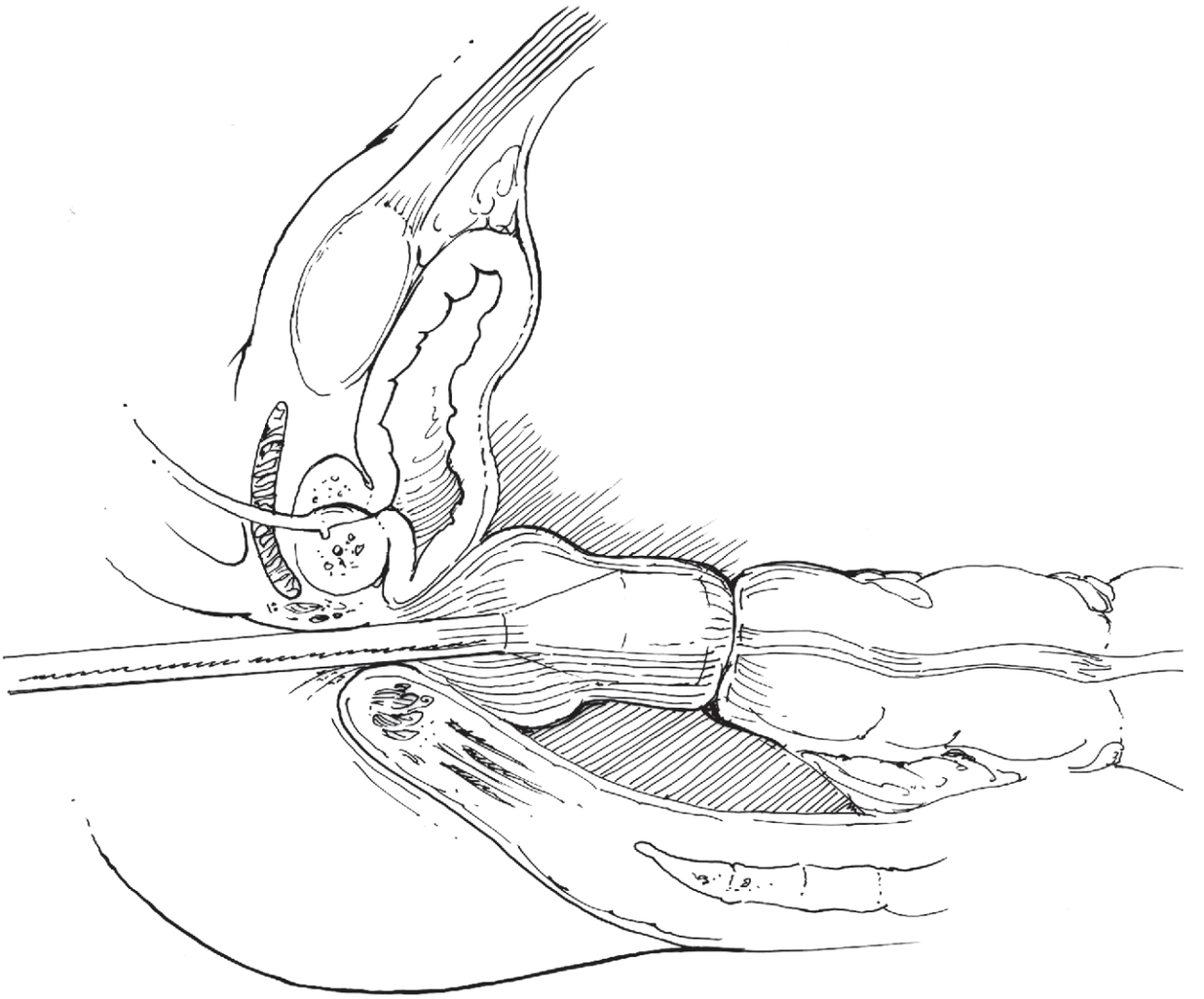

FIGURE 6-7. *(Redrawn from Stapling Techniques: General Surgery, 3rd ed. U.S. Surgical Corporation, 1988.)*

Chapter 7

Mobilization of the Omentum

ANDREW I. HOROWITZ AND MICHAEL J. ROSEN

Reconstruction of intraabdominal defects can occasionally be successfully managed only with the omentum because of its vascularity and immunologic properties. The traditional intraperitoneal use has been expanded to include retroperitoneal applications by lengthening its vascular pedicle or microvascular anastomosis. Laparoscopic mobilization of the omentum also provides the inherent benefits of the omentum through a minimally invasive technique, reducing the potential morbidity associated with a laparotomy.

PHYSIOLOGY

The omentum is an excellent tissue for use in reconstructive surgery due to its absorption qualities, reduced adhesion formation, early neovascularization, accelerated healing of dead space, and relative resistance to radiation damage. The trabecular connective tissue framework of the omentum houses arteries, veins, lymphatics, fat pads, and transparent mesothelial membranes. The mesothelial membrane, the stroma, contains scattered fibroblasts, fibrocytes, pericytes, fat cells, and lymphoreticular bodies (milky spots). The omentum provides hemostasis via certain innate properties:

- Reduced hemorrhage via activation of prothrombin, by increasing a hemostatic tissue factor that rapidly changes fibrinogen to fibrin
- Polypeptide growth factors with angiogenic growth factors for neovascularization
- Omental lipid fraction that shows vasodilation and neovascularization enhancing skin flaps
- Immunization by lymphoreticular bodies

ANATOMY

The surface area of the omentum varies between patients from 300 to 500 cm^2, length varies between 14 and 36 cm, and width varies between 20 and 46 cm. The blood supply of the omentum is directly from the right and left gastroepiploic arteries, which are branches from the gastroduodenal artery and splenic artery respectively. The celiac trunk branches to both the splenic artery and the common hepatic artery, which feeds to the gastroduodenal artery and then also anastomose with blood from the superior mesenteric artery via the pancreaticoduodenal arcade (Fig. 7-1). The arcades of fine omental blood vessels descend mostly at right angles to the greater curvature of t he stomach and anastomose via small branches with adjacent epiploic vessels. This region is called *Barkow's arcade* (arcus epiploicus magnus of Barkow) and is formed by the anastomosis of the left and right epiploic arteries within the posterior layers of the greater omentum below the transverse colon, which runs parallel to the gastroepiploic arcade.

OPEN SURGICAL TECHNIQUE

Mobilization of the omentum proceeds in a systematic fashion based on preservation of the blood supply. First, the omentum is dissected from the transverse colon and anterior surface of the pancreas (Fig. 7-2). This avascular plane allows for blunt or sharp dissection. Next, the gastroepiplolc arch is exposed and dissected to the left (Fig. 7-3). The plane between the epiploic appendices or diverticula can at times be difficult to ascertain and should be performed sharply. Excessive bleeding indicates that dissection plane is incorrect, often injuring the highly vascular epiploics of the colon. If extra length is required, divide and ligate the left gastroepiploic artery from its splenic origin (Fig. 7-4). For transposition at a vascular pedicle, the flap is formed by dissecting the omentum from the stomach (see Fig. 7-4) by dividing and ligating the gastroepiploic arteries and veins, starting from the first short gastric branch of the left gastroepiploic artery (Figs. 7-5 and 7-6) and continuing to divide the arteries close to the stomach until the gastroduodenal origin is reached (Fig. 7-7). To prevent omental stretch from gas filling the bowel, pass the omentum behind the mesentry at the paracolic gutter by mobilizing the hepatic flexure and a section of the ascending colon (Fig. 7-8). This technique is applied to female patients of child-bearing age to prevent the omentum from interfering with ovum transport from the ovary to the fallopian tube.

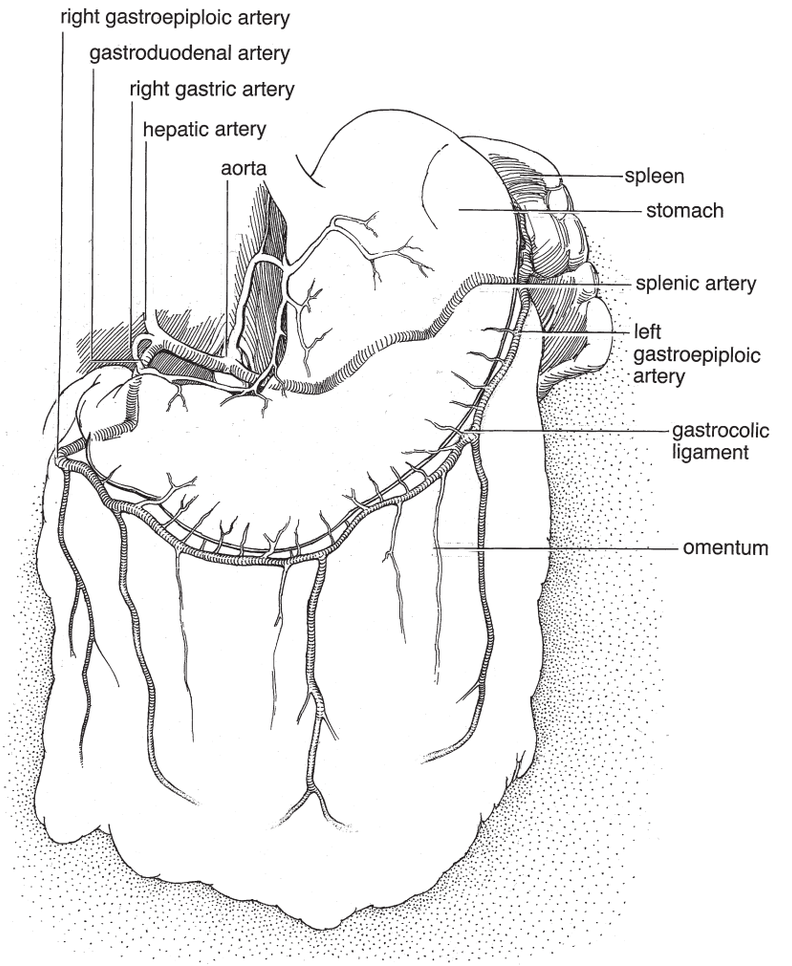

FIGURE 7-1.

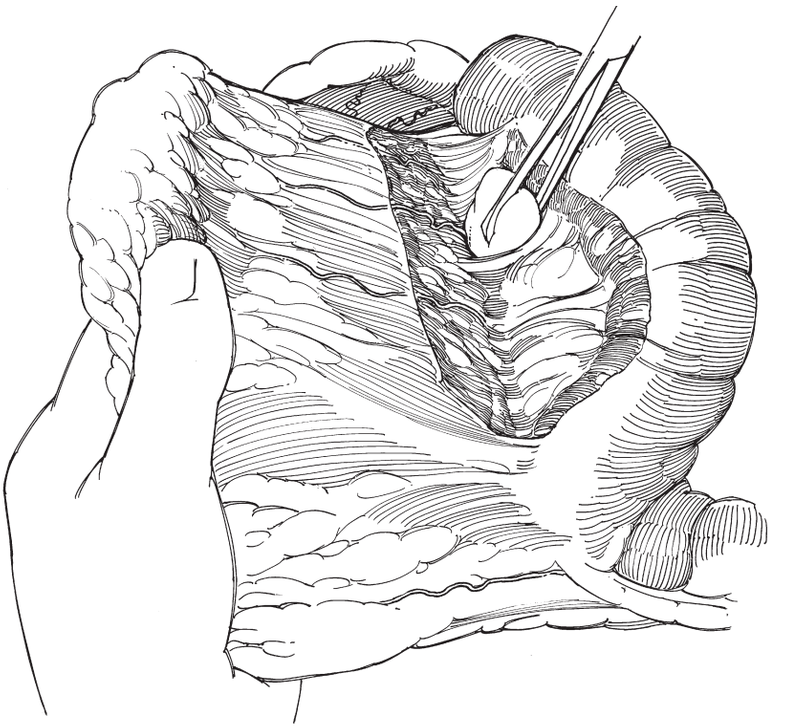

FIGURE 7-2.

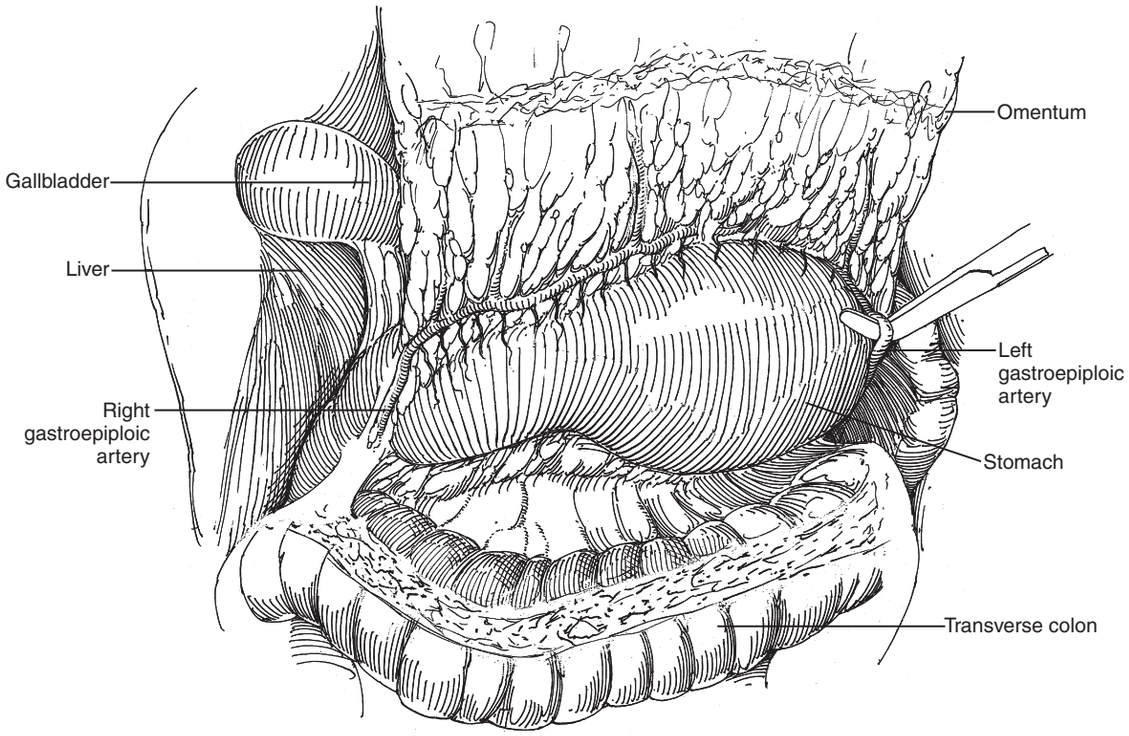

FIGURE 7-3.

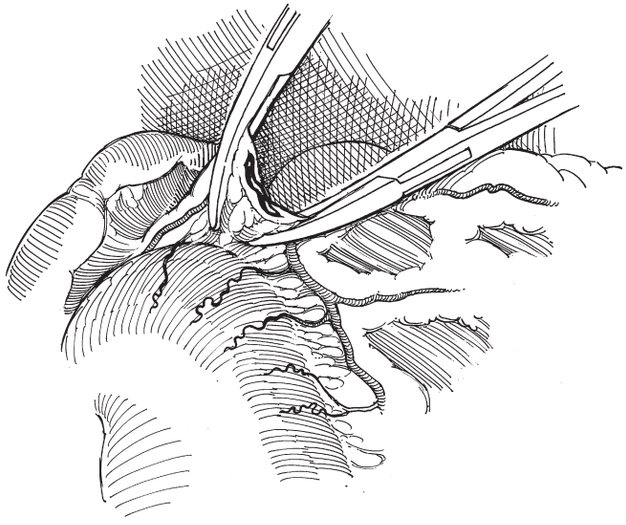

FIGURE 7-4.

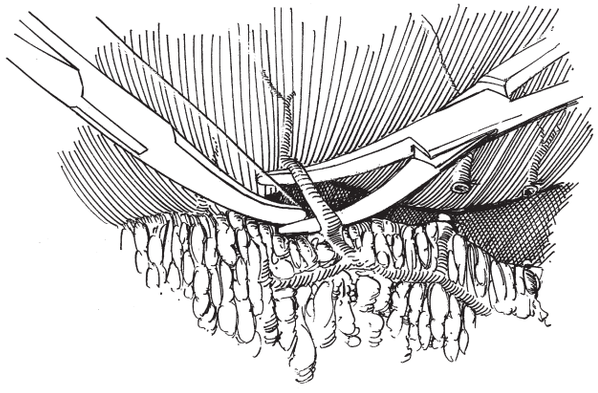

FIGURE 7-5.

Ileus and gastric distention can compromise blood supply to the transposed omentum from compression, which encourages prophylactic nasogastric suction or potentially a temporary gastrostomy tube. The right gastroepiploic artery is usually more substantial and is preferred as the primary vascular pedicle in that it provides two thirds to three fourths of the blood supply to the omentum. Delicate omental vessels are vulnerable to compression and tension, thus care should be taken to avoid strangulating or kinking the vascular pedicle. Once the appropriate location of the omental pedicle is ascertained, fine and loose interrupted sutures or tissue glue are used to secure the omentum.

LAPAROSCOPIC TECHNIQUE

With the increased use of laparoscopic surgery in the urologic field, recent reports have described techniques for laparoscopic mobilization of the omentum. Key aspects

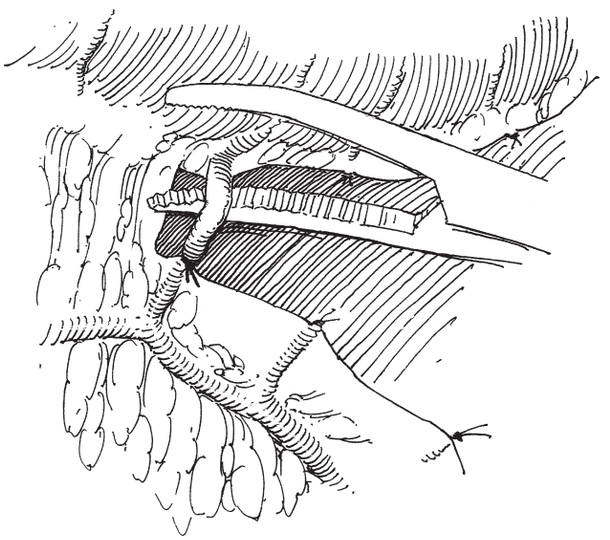

FIGURE 7-6.

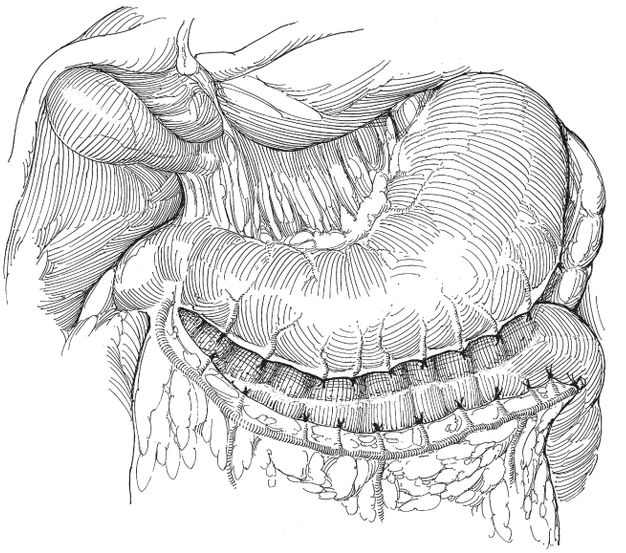

FIGURE 7-7.

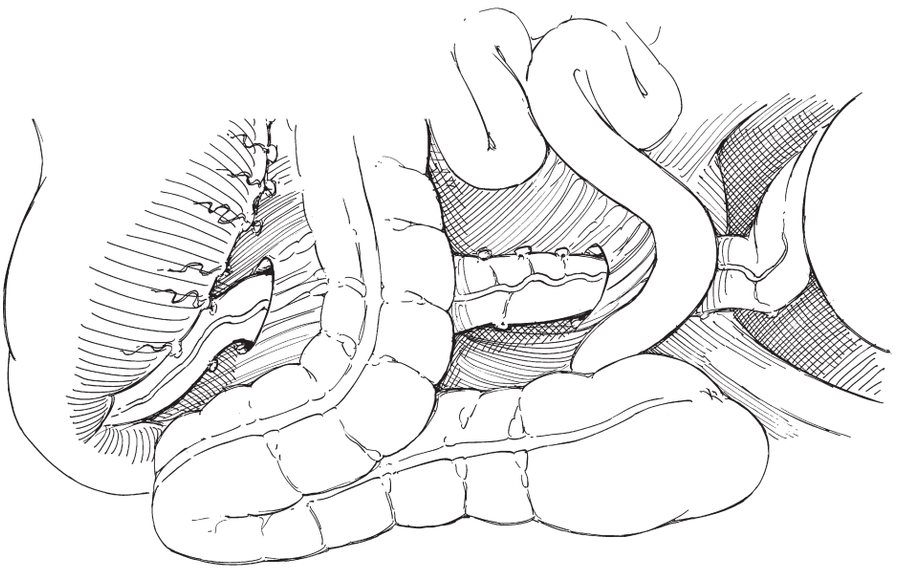

FIGURE 7-8.

of laparoscopic technique for the harvest of omental flap include (1) division and ligation at the coloepiploic attachment, (2) division and ligation of the anastomotic arterial branches between Barkow's arcade and the gastroepiploic arcade, (3) mobilization of the greater omentum pedicle on the right gastroepiploic artery (preferred), and (4) transposition of omental flap to extraabdominal sites, which requires care to avoid twisting the gastric greater curvature and flap itself. These steps can typically be achieved using a three-port technique. Often it is useful to use some form of ultrasonic dissection to maintain hemostasis.

CONCLUSION

Due to the omentum's multiple surgical attributes, it has recently become a popular tissue for urologists to use for hemostasis, neovascularization, wound care, immunology, and organ augmentation. Laparoscopic and open omental pedicle flap mobilization each requires the surgeon to have a thorough understanding of the omental blood supply. Advantages of laparoscopic omental mobilization include (1) small incisions, (2) less postoperation pain, (3) versatile application for intraabdominal and extraabdominal sites, (4) shorter hospital stay, (5) decreased risk for infection, and (5) cosmesis.

Chapter 8

Methods of Nerve Block

CHRISTOPHER S. NG AND TONY Y. CHEN

PHARMACOLOGY

The commonly used local anesthetics, such as lidocaine and bupivacaine, are amides. Ester class anesthetics, such as procaine, cocaine, tetracaine and benzocaine have limited clinical use due to allergic reactions and toxicity. Lidocaine is metabolized by the liver and excreted by the kidney, and therefore needs to be adjusted in patients with impaired hepatic or renal function. It is given at a dose of 3 to 5 mg/kg, not to exceed a total dose of 300 mg; or 7 mg/kg when combined with epinephrine, not to exceed a total dose of 500 mg. Onset is 2 to 5 minutes, and action lasts 30 minutes to 2 hours. Bupivacaine is contraindicated in pregnant women or in patients with compromised respiration. The dosage of bupivacaine alone is 1 to 2 mg/kg, and up to 3 mg/kg with epinephrine, not to exceed a total dose of 400 mg. Its action lasts from 2 to 4 hours. The addition of epinephrine allows for a greater amount of anesthetics to be delivered locally. However this should not be used in areas supplied by end arteries.

Injection of local anesthesia for nerve blocks commonly causes discomfort at the site of injection. Techniques to decrease the discomfort include the use of a small needle, slow injection rate, warming the anesthetics to body temperature, buffering the medication in alkaline solution, and using topical anesthetics or skin infiltration with local anesthetics before nerve block. Serious toxicity such as respiratory failure or cardiac arrest can occur with allergic reaction or excessive injection, especially if given intravascularly. To prevent serious complications, infiltrative local anesthetics should be administered slowly in a monitored environment, with frequent but gentle aspiration to prevent intravascular injection. A "crash cart" for cardiopulmonary resuscitation must be readily available.

INTERCOSTAL NERVE BLOCK

Anatomic Relationships

The intercostal nerves, branches of dorsal spinal nerves, run segmentally under the respective ribs external to the endothoracic fascia. After passing the angle of the rib, the nerve continues below the artery and vein in the costal groove between the internal and external intercostal muscles.

Procedure

Place the patient in a lateral position with the ipsilateral arm extended over the head. The midaxillary line is the safest approach to the intercostal space. Palpate the lower margin of the rib just beyond the angle. Insert a fine needle vertically until it touches the lower half of the rib (Fig. 8-1). With the free hand, pull the skin with the embedded needle caudally until the needle point slips off the rib. Push it 3 mm deeper until a click is felt. Then angle the needle upward and advance it 2 to 3 cm under the lower edge of the rib. Aspirate for air or blood. Inject 5 mL of anesthetic agent, preferably bupivacaine 0.5%, with epinephrine. Close monitoring is needed because pneumothorax can occur in a delayed fashion.

PENILE BLOCK

Anatomic Relationships

The two dorsal nerves of the penis arise from the pudendal nerve, pass under the symphysis, and penetrate the suspensory ligament of the penis to run under the deep (Buck's) fascia. The ventral aspect of the penis is partially innervated by perineal nerves.

Procedure

Palpate the symphysis pubis. Insert a short 22-gauge needle to one side of the midline at the 10-o'clock position to reach the caudal border of the symphysis (Fig. 8-2). Withdraw it slightly and move it so that it just misses the bone. Pop it through Buck's fascia. Aspirate and inject 10 mL of 1% lidocaine or 5 mL of 0.5% bupivacaine, both without epinephrine. Repeat the procedure at the 2-o'clock position. Alternatively, a subcutaneous ring block at the base of the penis can be performed with 0.5% bupivacaine. For

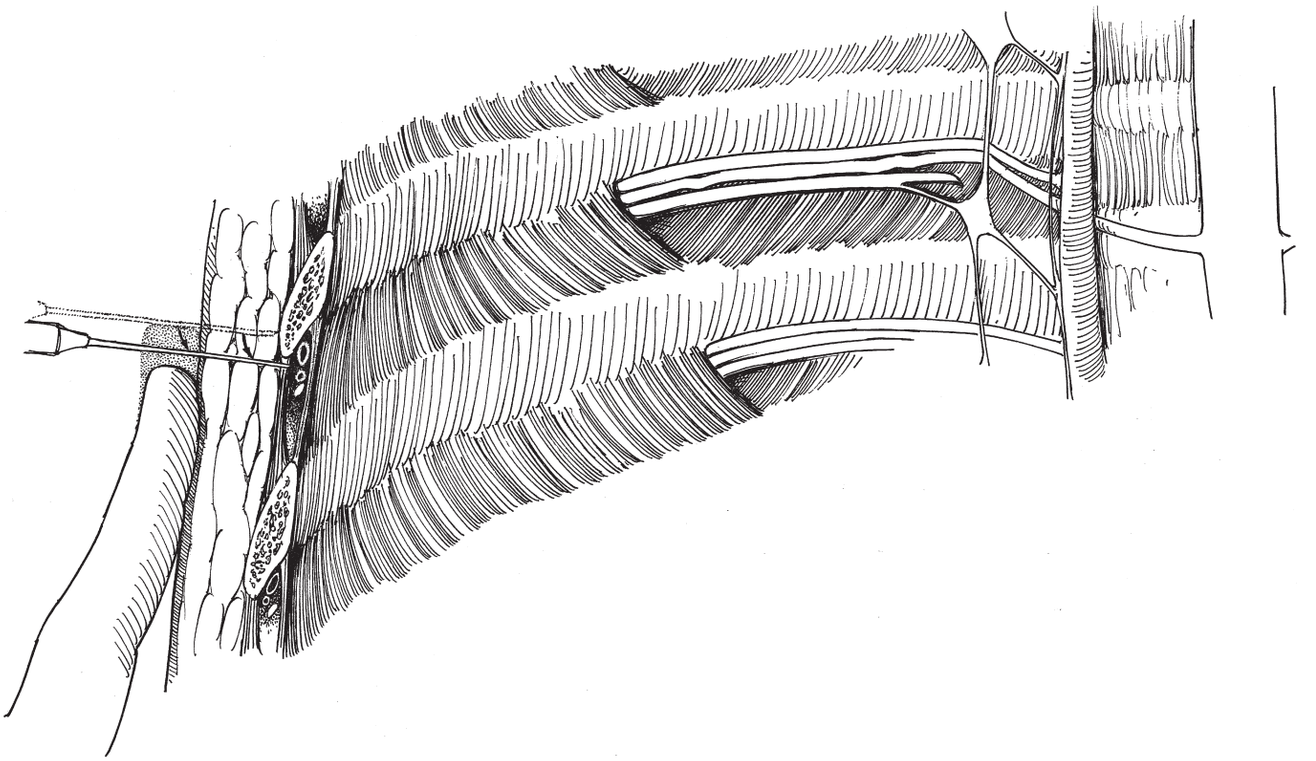

FIGURE 8-1.

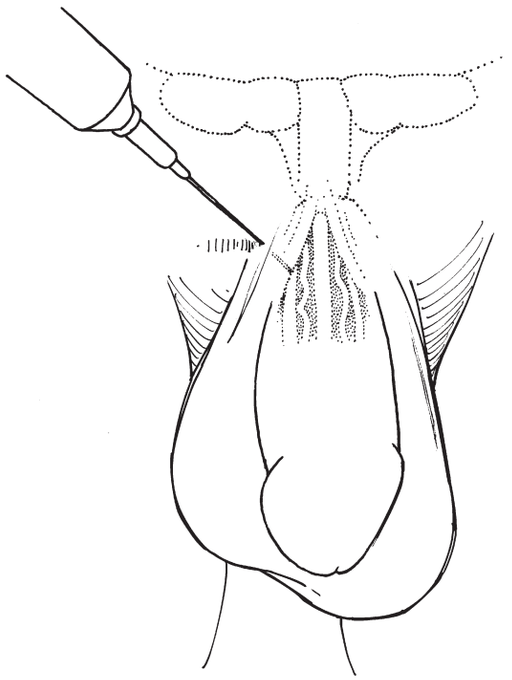

FIGURE 8-2.

intracorporeal block, apply a tourniquet to the base of the penis, and inject 20 to 25 mL of 1% lidocaine into a corpus through a butterfly scalp vein needle. Release the tourniquet after waiting 1 minute. This should be done in a monitored setting, because systemic lidocaine absorption is proarrhythmic.

ILIOINGUINAL, ILIOHYPOGASTRIC, AND GENITOFEMORAL NERVE BLOCKS

Anatomic Relationships

The ilioinguinal and the iliohypogastric nerves originate from the lumbar plexus (Fig. 8-3). Near the iliac crest, the ilioinguinal nerve and the medial branch of the iliohypogastric nerve crosses the muscles to lie in the plane at the inner surface of the external oblique fascia. The genital branch of the genitofemoral nerve lies in the same fascial plane.

Procedure

The site of puncture is located at the point one-fourth lateral and three-fourths medial on the line joining the umbilicus and anterior superior iliac spine. Insert a 22-gauge 3.5-inch spinal needle at a 45- to 60-degree angle and aim toward the midpoint of the inguinal ligament until a pop is felt as the external oblique fascia is pierced. Then inject 10 to 15 mL of 0.5% bupivacaine with epinephrine in a fan-shaped manner, half above and half below the fascia. This allows for anesthesia for all three nerves in the same fascial plane. Alternatively a two-injection point technique can be used to block these three nerves. To block the iliohypogastric and ilioinguinal nerves for operations, palpate the anterior superior iliac spine, and mark a point 2.5 to 3 cm medial and 2 to 3 cm caudal to it. Insert a 4-cm 22-gauge needle to touch the inner surface of the iliac bone, and inject 5 to 7 mL of 1% bupivacaine (or a mixture of equal parts of 1% lidocaine and 0.5% bupivacaine) (Fig. 8-4). Inject as the needle is withdrawn. Repeat the procedure more medially,

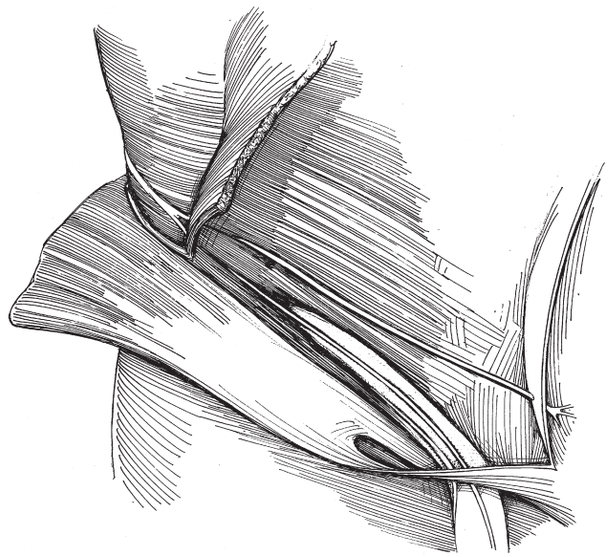

FIGURE 8-3.

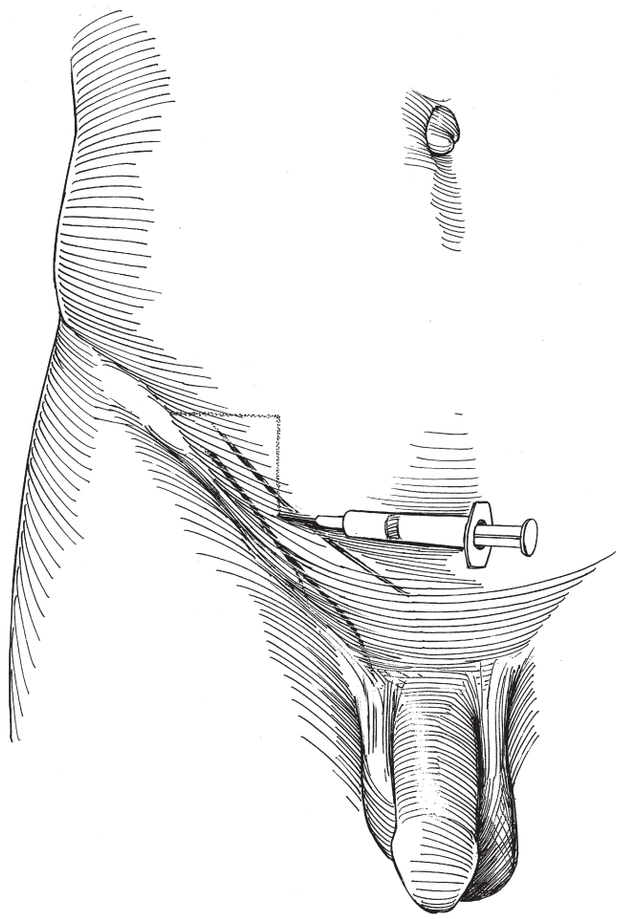

FIGURE 8-4.

injecting 5 to 7 mL of solution just beneath the fascia of the three muscle layers. To block the genitofemoral nerve, palpate the pubic tubercle and inject 5 to 7 mL of the anesthetic solution in the muscle layers laterally, cranially, and medially. Supplement the nerve block with subcutaneous injections fanned out to the inguinal fold laterally and the midline medially to reach the skin supplied by the pudendal nerve and perineal branches of the posterior cutaneous nerve of the thigh.

TESTIS NERVE BLOCK

Anatomy

The testis is innervated by nerves from two sources: aortic/renal plexus and pelvic plexus. These nerves travel with the gonadal vessels and with the vas deferens, respectively. Sensation over the tunica vaginalis and scrotum is supplied by the genital branch of the genitofemoral nerve.

Procedure

Stand on the right side of the patient, and pull the testis down to relax the cremaster. Grasp the cord with the left hand, placing the thumb in front and the index finger behind the cord at the top of the scrotum. With the needle approaching the index finger, infiltrate the cord with 1% lidocaine solution without epinephrine through a 2.5-inch 25-gauge needle. Alternatively, infiltrate the cord over the symphysis after it exits from the external inguinal ring. Frequent and gentle aspiration is required to prevent inadvertent intravascular injection.

PUDENDAL NERVE BLOCK

Anatomic Relationship

The pudendal nerve arises from S2, S3, and S4; runs laterally and dorsally to the ischial spine and sacrospinous ligament; and divides into the perineal nerve and the inferior rectal nerve (Fig. 8-5). Aim to block the nerve as it passes the ischial spine. The pudendal artery, a terminal artery, is close to the nerve. Thus epinephrine should be avoided.

Procedure

With the patient in the lithotomy or frog-leg position, insert an index finger in the rectum and palpate the ischial spine (Fig. 8-6). Make a skin wheal 2 to 3 cm posteromedially to the ischial tuberosity. Insert a 12- to 15-cm 20-gauge needle on a 10-mL syringe in a posterior and lateral direction to pop the needle through the sacrospinous ligament. Use the index finger as a guide to determine that the needle comes in contact with the bony prominence of the ischial tuberosity. Aspirate and inject 5 to 10 mL of local anesthetic laterally and under the tuberosity to anesthetize the inferior pudendal nerve. Move the needle to the medial side of the tuberosity, and inject another 10 mL after aspiration. Then advance the needle 2 to 3 cm into the ischiorectal fossa and inject 10 mL. Finally, guide the needle dorsolaterally to the ischial spine, and pop the needle through the sacrospinous ligament there. Aspirate for blood and inject 5 or 10 mL of the agent. Repeat the procedure on the other side.

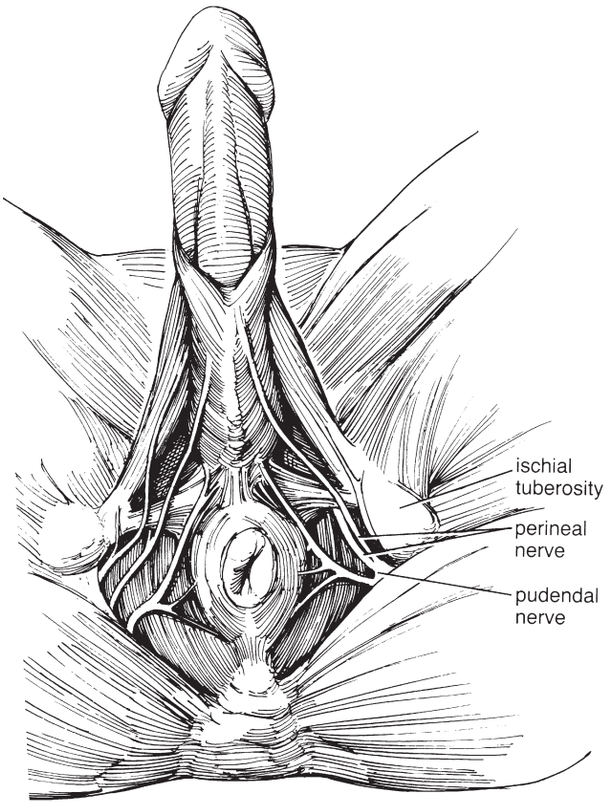

FIGURE 8-5.

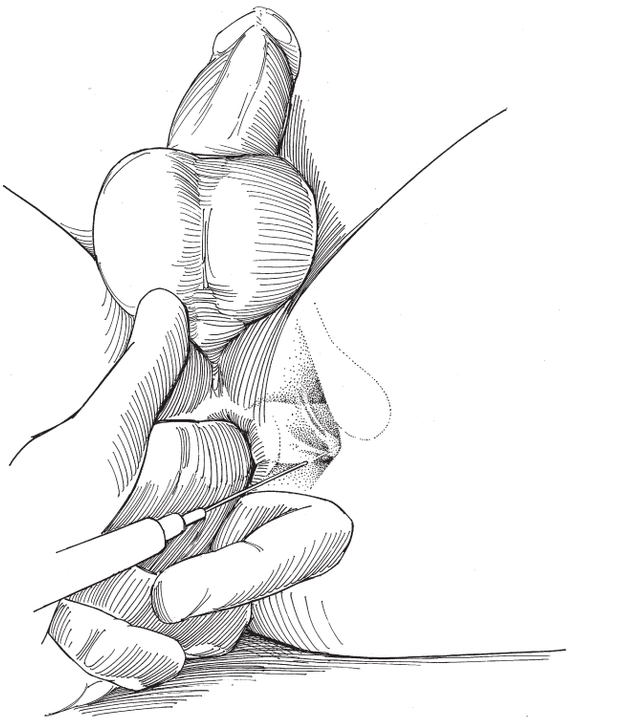

FIGURE 8-6.

TRANSSACRAL BLOCK

Anatomic Relationship

A layer of highly vascular fatty tissue lies between the two layers of the sacrum. This continuation of the lumbar epidural space contains the posterior primary divisions of the sacral nerve, which exit through the posterior foramina to supply the buttocks, and the anterior primary divisions, which exit through the ventral foramina to innervate the perineum and part of the leg (Fig. 8-7). The S3 foramina are usually located 11 cm from the anal verge or 9 cm cephalad to the tip of the coccyx. Alternatively, the location can be approximated by the line joining the superior portions of the sciatic notches bilaterally. The foramen is located 1 to 2 cm lateral to the midline on either side of the sacrum. The S2 and S4 foramina are located 1 fingerbreadth above and below, respectively.

Procedure

Place the patient prone with a pillow under the hips. Palpate and mark the bony sacrum and estimated location for foramina. Inject the agent subcutaneously to raise wheals (Fig. 8-8). Insert a 12-cm 22-gauge spinal needle containing a stilet perpendicular to the surface to contact the rim of the selected foramen. Move the rubber marker on the needle to a point 1.5 cm from the skin surface. Withdraw the needle slightly, and angle it 45 degrees caudally and 45 degrees medially to insert it into the foramen up to the marker, a depth of 1.5 cm. Inject 1.5 to 2 mL of anesthetic agent. For total caudal anesthesia, inject 15 to 25 mL. Hazards include producing a subarachnoid block and injecting the agent intravascularly in the large venous plexus.

Mark a point 1.5 cm medial and 1.5 cm cephalad to the posterior superior iliac spine to locate the first sacral foramen. Draw a line from this point to the lateral surface of the sacral cornua. Mark points 2 cm apart below the first foramen for the other three foramina.

PROSTATIC NERVE BLOCK UNDER ULTRASOUND GUIDANCE

Anatomic Relationship

The neurovascular bundle reaches the prostate at its base posteriorly at the 5- and 7-o'clock positions (Fig. 8-9).

Procedure

Place the patient in the left lateral decubitus position. Load a 5-mL syringe with a 50:50 mixture of 1% lidocaine and 0.5% bupivacaine. Inject through a 7-inch 22-gauge spinal needle. Under the guidance of a biplanar variable-frequency transrectal ultrasound probe, insert the needle and inject the solution into the region of the neurovascular bundle at the base of the prostate, just lateral to the junction of the prostate and the seminal vesicle on each side. Alternatively, inject 10 mL of the solution along the lateral aspect from the prostate, from the apex to the base.

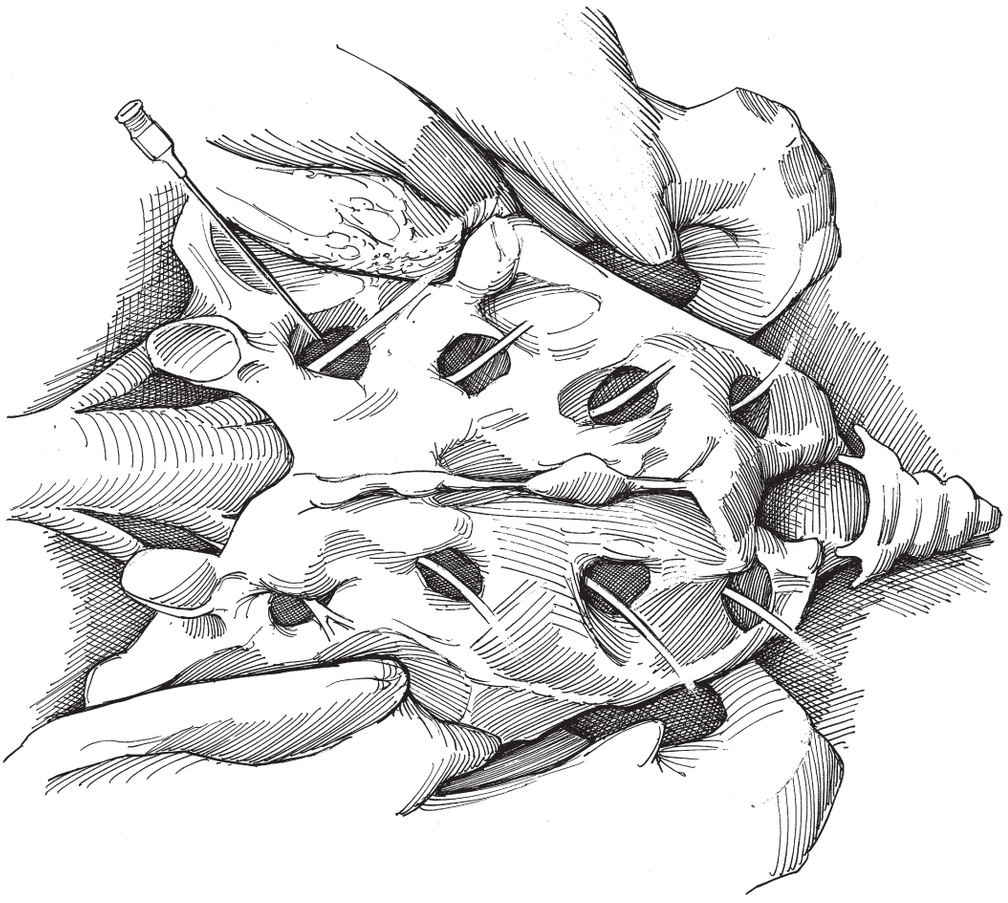

FIGURE 8-7.

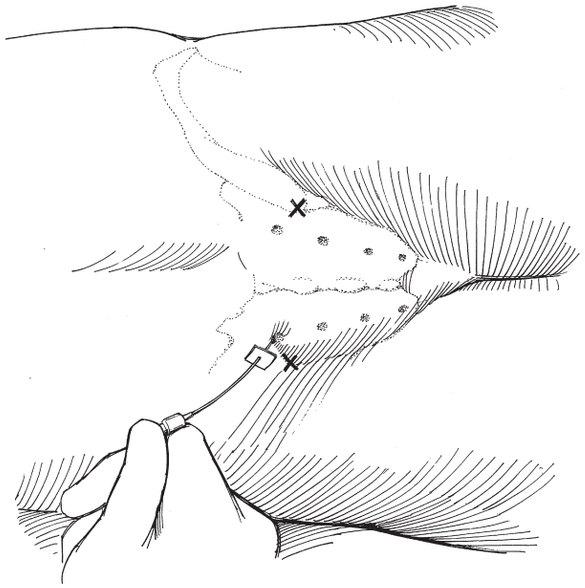

FIGURE 8-8.

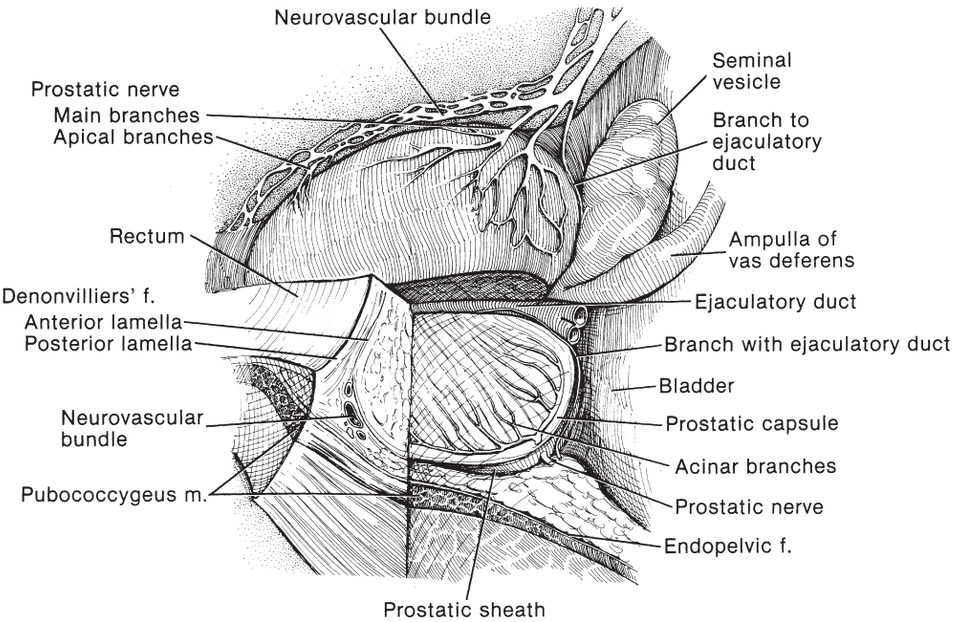
Neurovascular bundle
Seminal vesicle
Prostatic nerve
Main branches
Apical branches
Branch to ejaculatory duct
Rectum
Ampulla of vas deferens
Denonvilliers' f.
Ejaculatory duct
Anterior lamella
Posterior lamella
Branch with ejaculatory duct
Bladder
Neurovascular bundle
Prostatic capsule
Acinar branches
Pubococcygeus m.
Prostatic nerve
Endopelvic f.
Prostatic sheath

FIGURE 8-9.

Chapter 9

Repair of Vascular Injuries

CHRISTOPHER S. NG AND GREGORY S. ROSENBLATT

For vascular injuries during laparoscopy, see Chapter 3. For vascular injuries during open surgery or after conversion from laparoscopy to open surgery, control the bleeding with digital pressure. Dissect to increase the exposure, obtain blood, establish appropriate intravenous access, set up a second suction, obtain appropriate instruments and sutures, and get assistance.

VENOUS INJURIES

Laceration of the Vena Cava

For laceration of the vena cava, have your assistant compress the vessel digitally at the site of injury. Inform the anesthesiologist, and have the operating room circulator open a vascular tray.

Free the vena cava from the surrounding tissues above and below the laceration, taking care to avoid further injury to small tributaries and lumbar veins. Have your assistant block the flow above and below using sponge stick compression (Fig. 9-1). Small lacerations may be closed either with figure-eight sutures or with a continuous suture. Alternatively, apply a Satinsky clamp and oversew the laceration with a continuous 4-0 monofilament vascular suture. Larger tears require formal repair, which involves further mobilization of the vena cava. Sponge sticks should be used until exposure is adequate. Further iatrogenic injury is likely if adequate mobilization of the vena cava is not performed.

Use Allis clamps to approximate the edges of the laceration (Fig. 9-2). This helps control bleeding and allows for further dissection if better exposure is required. Run a 4-0 monofilament vascular suture along the laceration, inserting the needle and drawing the suture up as the clamps are successively removed. Although not required for adequate repair, the surgeon may opt to run the same suture in the opposite direction, back to the start point, before tying the suture to itself.

For large defects, dissect to mobilize the vena cava and cross-clamp it. Continued bleeding may require clamping or ligation of the entering lumbar vein. If the injury involves both the anterior wall and the posterior wall, the defect in the posterior wall should be repaired first, working through the anterior wall defect. It may be necessary to extend the anterior wound to facilitate access to the posterior wall. Most inferior vena cava injuries can be repaired primarily, but an interposition graft can be used if necessary. A saphenous vein patch graft, cut to size, should be sutured into place using 4-0 or 5-0 vascular suture material. When a saphenous vein patch graft is not available, a synthetic graft of polytetrafluoroethylene (PTFE) or Gore-Tex, both of which are nonporous materials that do not require preclotting, can be cut to fit and sutured into place using a running 4-0 or 5-0 monofilament vascular suture.

Pelvic Venous Plexus Injury

For a pelvic venous plexus injury, immediately pack the area with moist sponges. Do not clamp blindly. Orient yourself to the anatomic distribution of the pelvic veins before attempting repair. Slowly remove the pack and identify the bleeding vein. In most instances, it is acceptable to clamp and/or ligate the bleeding vein. If repair is to be attempted, use a stick sponge to compress the injured vein distal to the tear, and proceed with repair using 4-0 or 5-0 monofilament suture. Blind suture ligation can result in an arteriovenous fistula and should be avoided. If exposure is inadequate, expose the ipsilateral internal iliac artery and place a temporary vascular clamp at its origin from the common iliac artery. Continued inability to identify the injury may also require temporary clamping of the contralateral internal iliac artery. Slowly remove the pack and suture the vessel. For persistent bleeding, pack the pelvis with laparotomy pads and construct a temporary abdominal wall closure. Second-look laparotomy should be performed 36 to 72 hours later. Use of a rubber dam reduces traction on the vessels as the packs are removed, decreasing the chance for rebleeding.

Injury of the Common and External Iliac Veins

For injury of the common and external iliac veins, maintain direct pressure over the site. These veins are located in a more superficial location, compared with the hypogastric

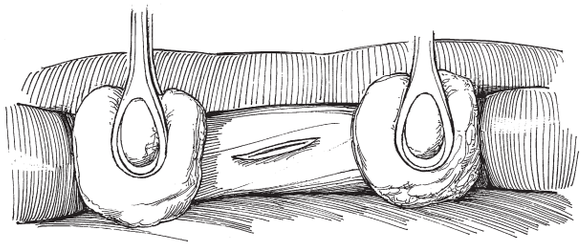

FIGURE 9-1.

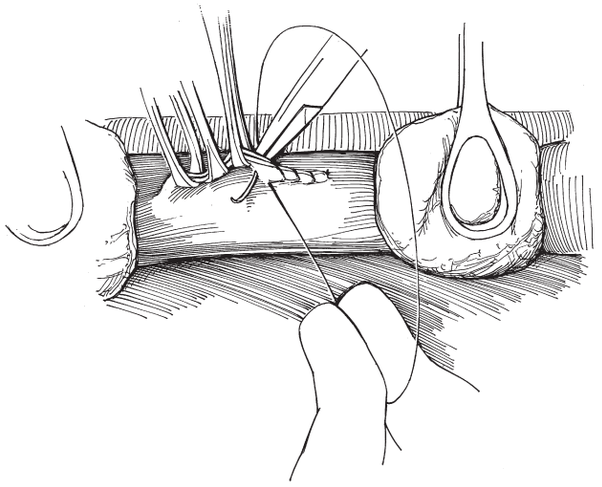

FIGURE 9-2.

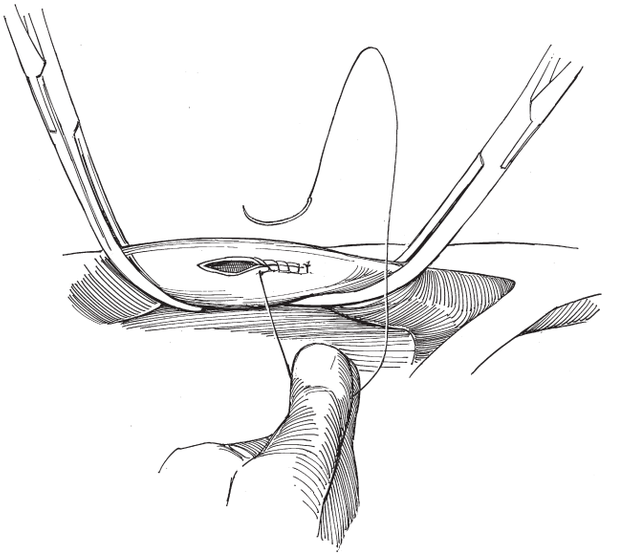

FIGURE 9-3.

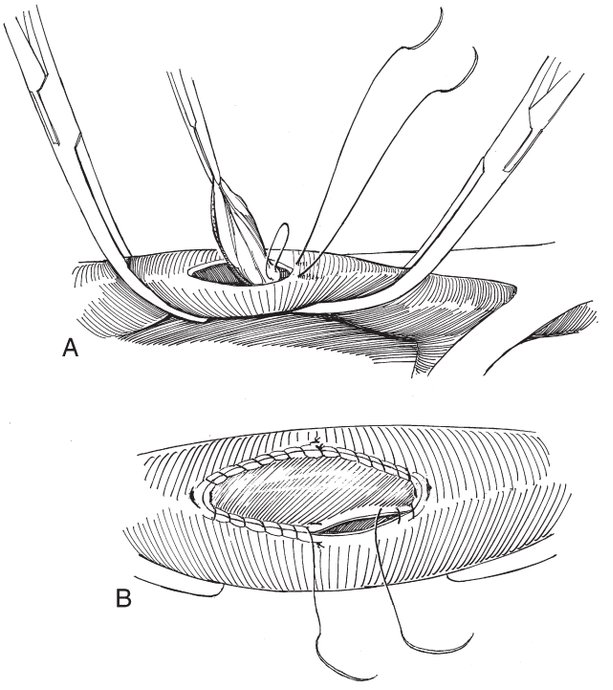

FIGURE 9-4.

and pelvic veins, which usually obviates the need for Trendelenburg tilt and/or proximal occlusion of the common iliac artery. Obtain proximal and distal control of the vessel with stick sponge compression or with vascular tape/clamps.

Longitudinal laceration, transverse laceration, or complete division can be repaired primarily when tension and venous constriction are avoided. The edges of the defect should be approximated with a running 4-0 or 5-0 monofilament vascular suture. Suture bites should be 1 to 2 mm deep and 1 mm apart, and care should be taken to approximate intimal tissue to intimal tissue (Fig. 9-3). Inspect the vein for constriction.

When the caliber of the vein would be significantly reduced by simple closure (>50% loss of diameter), employ a venous patch graft (either saphenous vein graft or synthetic graft) (Fig. 9-4A). For saphenous vein grafting, expose the saphenous vein in the opposite leg. Resect a suitable length of vein, open it longitudinally, and excise the valves. Trim one end to fit the defect. Manipulate the patch by the edges that will be trimmed to avoid intimal trauma and later platelet deposition and thrombosis. Suture the trimmed end to an end of the defect with a double-armed 4-0 or 5-0 monofilament mattress suture.

Fasten the midportions of the patch to the corresponding part of the laceration with monofilament sutures. Trim the distal end, and coapt it with a second double-armed mattress suture. Complete the anastomosis by running the two mattress sutures, starting at each end and tying them to each other in the middle on each side (see Fig. 9-4B). Release the vascular clamps one at a time starting with the outflow clamp.

For repair after transection of a vein, trim the ragged edges obliquely (Fig. 9-5A). Do not spatulate the cut ends. Mobilize the vein proximally and distally to allow the ends to come together without tension. If tension is inevitable, one should employ an interposition graft of saphenous vein or synthetic material.

Place two double-armed 5-0 monofilament sutures (see Fig. 9-5B).

Run one down each side (see Fig. 9-5C).

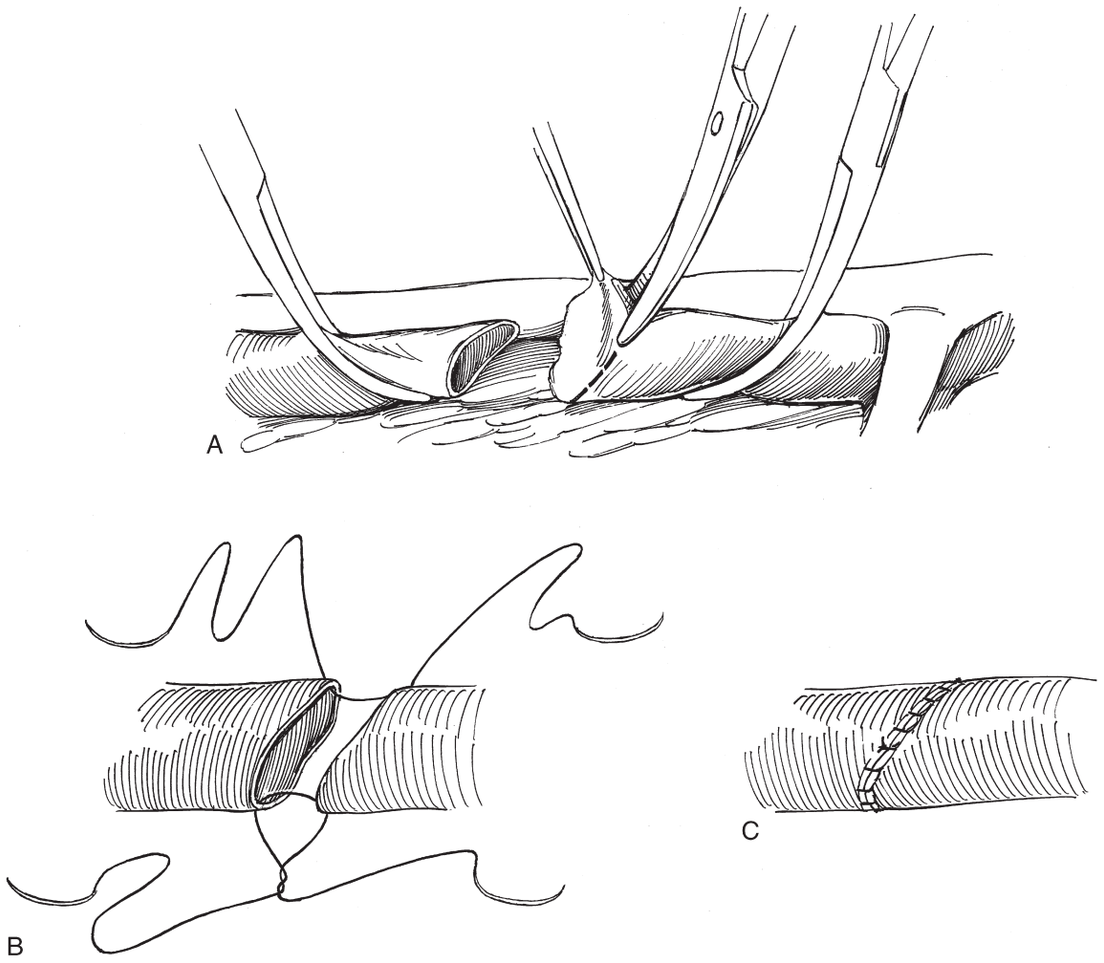

FIGURE 9-5.

In order to enhance venous flow to maintain patency of a synthetic graft, a small arteriovenous fistula can be constructed in the groin, usually between the superficial femoral artery and the common femoral vein. In some patients, ligation of the vein may be necessary in conjunction with postoperative heparin and transition to warfarin for a 3- to 6-month treatment course. Compression hosiery should be used until sufficient venous collaterals have developed to prevent chronic venous insufficiency and venous stasis in the lower extremities.

If near-total occlusion of the iliac vein is present and pelvic collaterals have been disrupted, the patient may be at risk for ischemic loss of the ipsilateral lower extremity. In this situation, a saphenous tube graft or placement of a ring-enforced ePTFE graft may be attempted, keeping in mind the high risk of thrombosis, especially with use of circumferential synthetic graft. Obtain a vein graft 6 or 7 cm long from the opposite saphenous vein. Mark the proximal end with a suture to indicate the direction of the valves. Trim the saphenous vein to a length twice that of the defect. Open the vein longitudinally with Potts scissors, and cut it in half transversely (Fig. 9-6A).

Suture one side of each half together with a running 5-0 monofilament suture (see Fig. 9-6B).

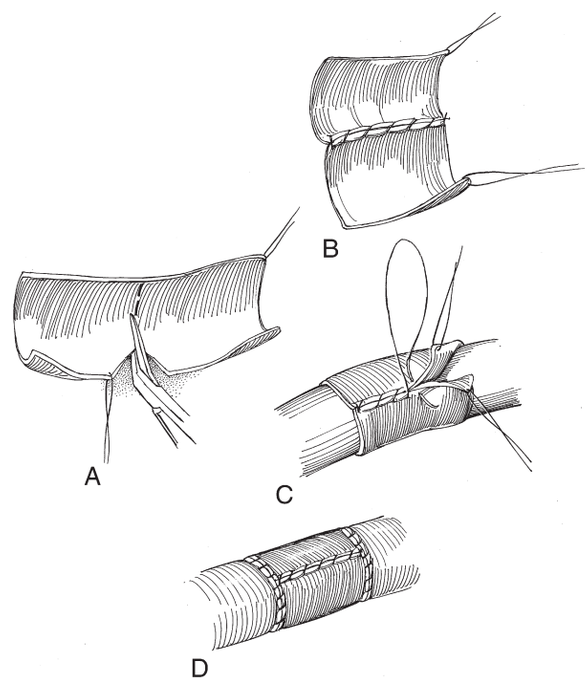

FIGURE 9-6.

Place the combined segments over a catheter of the same size as the iliac vein to be replaced, maintaining the correct orientation. Trim the other side, and suture the graft around the catheter (see Fig. 9-6C). Cut the catheter next to the graft, and gently slide the graft free.

Suture the graft in place as for an end-to-end anastomosis (see Figs. 9-5 and 9-6D).

As an alternative, use an appropriately sized synthetic graft as described earlier, providing a small distal arteriovenous fistula to enhance flow.

Note: Collaterals are numerous and can dilate in a few days after acute occlusion of a major vein.

Injury of a Lumbar Vein

For injury of a lumbar vein, while slowly removing the pack, gently grasp each end of the lumbar vein with an Allis clamp and occlude it (Fig. 9-7). Suture-ligate the ends using 5-0 or 6-0 monofilament suture. If the cut end retracts into the intervertebral space, pack the site. Once bleeding has ceased, expose the area and oversew the end of the vein. If the vein cannot be oversewn, bone wax may be placed to occlude the foramen.

ARTERIAL INJURIES

Aortic Laceration

For an aortic laceration, gain proximal control with an occlusive vascular clamp or, if possible, direct manual or sponge stick compression. Control backbleeding with digital pressure and suture the laceration with a 4-0 or 5-0 mattress suture (Fig. 9-8). Teflon pledgets can be used on both sides of the mattress suture to avoid further tears in the aorta as the suture is tied.

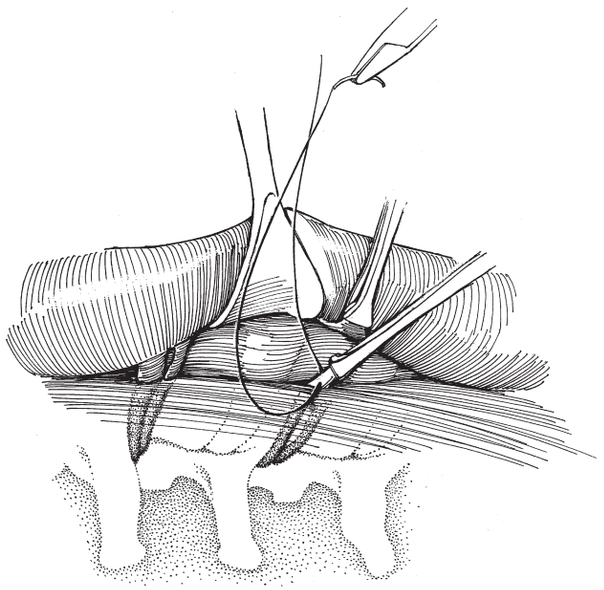

FIGURE 9-7.

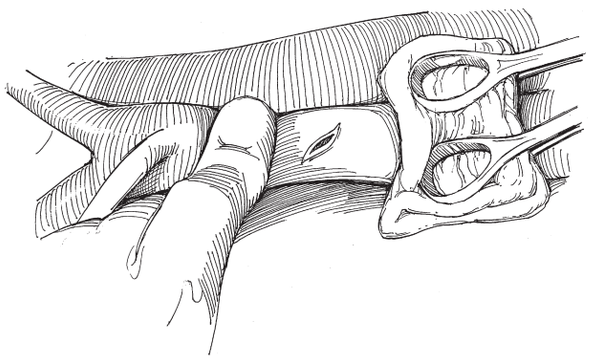

FIGURE 9-8.

Laceration of the Branches of the Internal Iliac Artery

For laceration of the branches of the internal iliac artery, temporarily occlude the abdominal aorta just above its bifurcation with one hand to reduce the bleeding. Clamp and ligate the cut artery (Fig. 9-9). This can be done without risk of ischemia. Alternatively, maintain pressure on the bleeding point with a stick sponge while you free up the artery proximally and distally for several centimeters. Apply an arterial clamp proximally only tight enough to stop blood flow; be wary of dislodging a friable arterial plaque. Divide and ligate the vessel. When diffuse pelvic bleeding is present, consider ligation of the internal iliac artery on one side of the pelvis as a hemostatic measure.

External Iliac Artery Laceration

For laceration of the external iliac artery, maintain compression over the defect with a stick sponge or fingers. Free the vessel proximally and distally. Apply vascular clamps, minimally closed, and approximate the defect by running 5-0 monofilament suture (Fig. 9-10A).

If the laceration is tangential or irregular, divide, trim, and reanastomose the artery (see Fig. 9-10B). Typically, up to 1 cm can be lost without consequent tension. Check the anastomosis for a strong pulse and absence of a thrill. If a thrill is palpable, redo the anastomosis. An arterial graft

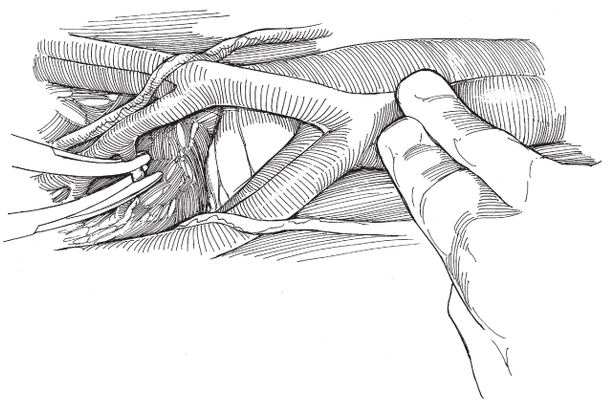

FIGURE 9-9.

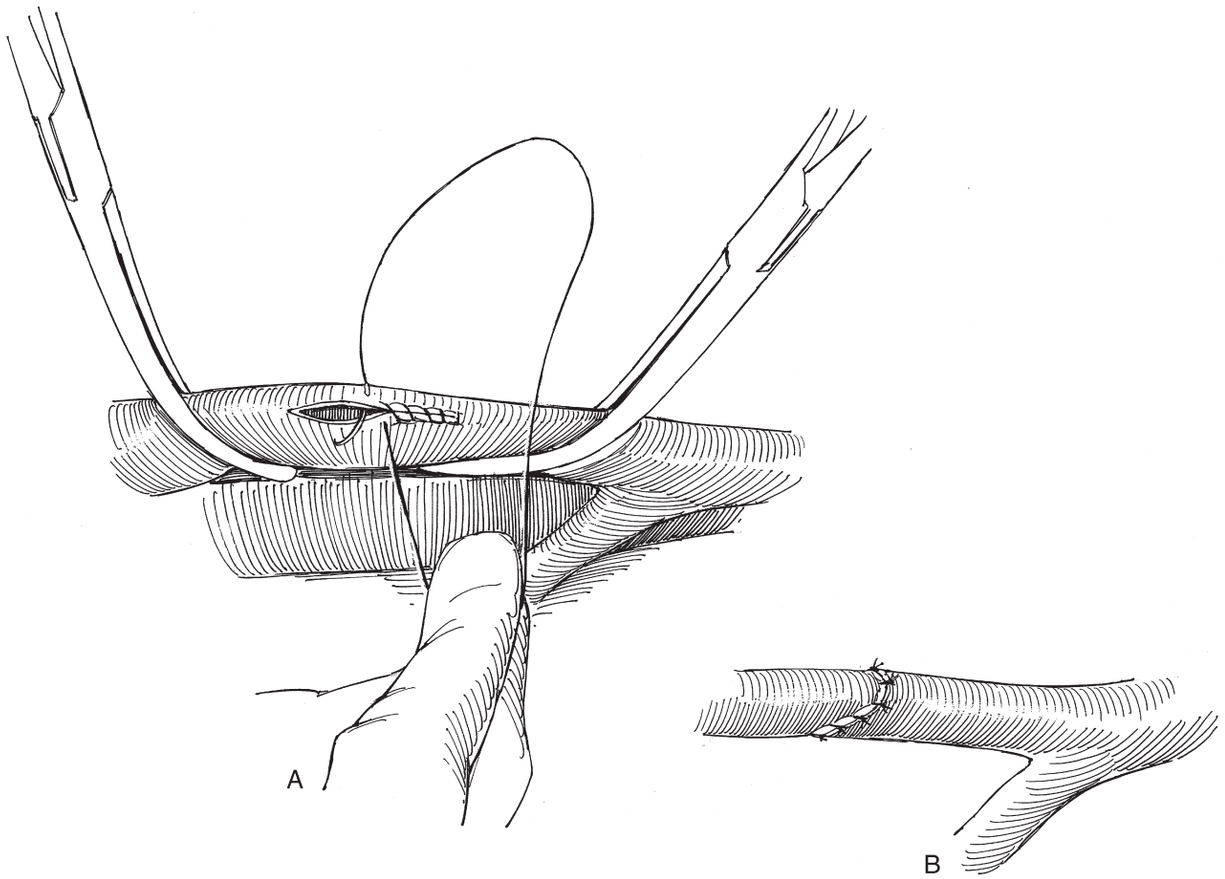

FIGURE 9-10.

may be inserted, however this is seldom necessary in the external iliac arteries.

When a major artery is clamped, the clamp should be briefly released to allow injection of saline with heparin into both ends of the artery to prevent local thrombosis.

Loss of Control of a Renal Artery

With loss of control of the left renal artery during flank nephrectomy, especially during donor nephrectomy when a long segment of artery is removed, compress the area of the pedicle. Expose the aorta just below the diaphragm and compress it. Identify, clamp, and suture-ligate the stump of the artery (Fig. 9-11A).

Control the stump with stick sponge or digital pressure while freeing the aorta over the vena cava. Clamp and suture-ligate the stump (see Fig. 9-11B). During a difficult nephrectomy, before placing a clamp on the *right* renal artery, it may be advisable to dissect the vena cava away from the aorta above and below so that, in an emergency, the aorta itself may be clamped.

Necessary Arterial Resection

When arterial resection is necessary, remove the segment of a major vessel involved in the disease process after controlling blood flow proximally and distally. A vascular surgeon should then be called for assistance.

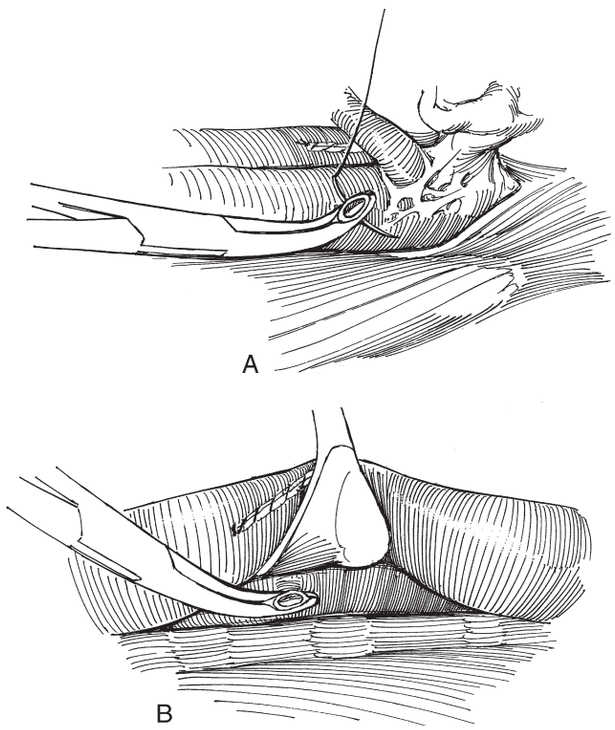

FIGURE 9-11.

If the wound is not infected, select a knitted Dacron graft of a size similar to that of the artery, place it in a sample of the patient's blood, and allow clotting. Aspirate the intraluminal clot before use. Anastomose it to the less accessible end first with a 4-0 or 5-0 monofilament continuous suture (Fig. 9-12A). Stretch the graft to flatten the crimps, and trim it to length. Alternatively, PTFE graft may be used.

Begin the second anastomosis on the back side, and run it up both lateral walls with a double-armed suture. Before the last sutures are placed and tied, release the proximal clamp to flush the graft with heparinized saline (see Fig. 9-12B). Complete the anastomosis and release the distal clamp, followed by release of the proximal one.

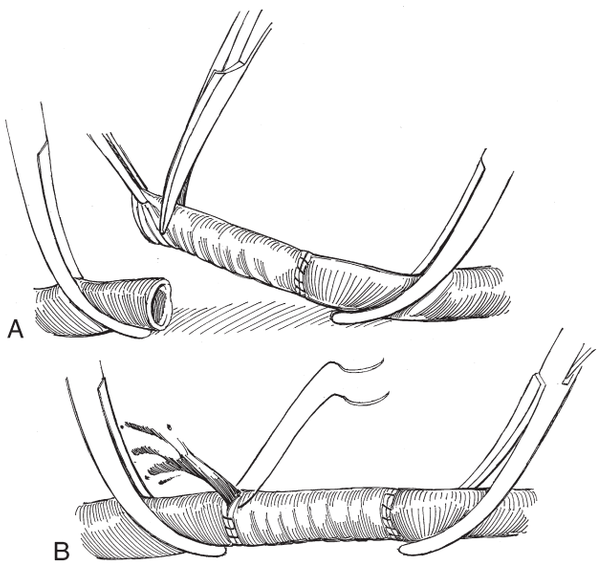

FIGURE 9-12.

Chapter 10

Closure of Bowel Lacerations

BRADLEY CHAMPAGNE

SMALL BOWEL REPAIR

Transverse or Small Puncture Laceration

For a clean transverse laceration, place a Lembert suture (see Fig. 4-9) of 3-0 silk at the mesenteric and antimesenteric ends of the laceration (Fig. 10-1A).

Place the sutures on traction (see Fig. 10-1B).

Invert the opening with interrupted Lembert sutures (see Fig. 10-1C).

Longitudinal Lacerations

For longitudinal lacerations, place Lembert 3-0 silk sutures on either side to convert a short linear laceration (<3 cm long) into a transverse one to avoid narrowing the lumen (Fig. 10-2). Tag the sutures and have your assistant put gentle traction on them.

Midway between those already placed, divide each remaining gap in half with bites of 3 to 4 mm of 3-0 Vicryl that successively pass through serosa, muscularis, submucosa, and serosa on each side. The sutures should penetrate the tough submucosa but not enter the intestinal lumen. Next, place Lembert sutures of 4-0 silk 4 mm apart as a second layer (Fig. 10-3).

Have your assistant depress the edges of the bowel under the sutures with a mosquito clamp as you tie them successively (Fig. 10-4). For lacerations longer than 3 cm, close them longitudinally, but if the lumen appears narrowed, resect the segment and perform end-to-end anastomosis (see Chapter 96).

LARGE BOWEL REPAIR

Suction usually manages the leakage of fecal contents; if such leakage interferes with repair, occlude the bowel above and below the lesion with intestinal clamps passed through small windows in the mesentery, as shown in Figure 10-5 (not with tapes, which could harm the vessels). Trim the edges of the defect. Place a row of 3-0 Vicryl full-thickness interrupted sutures 3 to 4 mm apart.

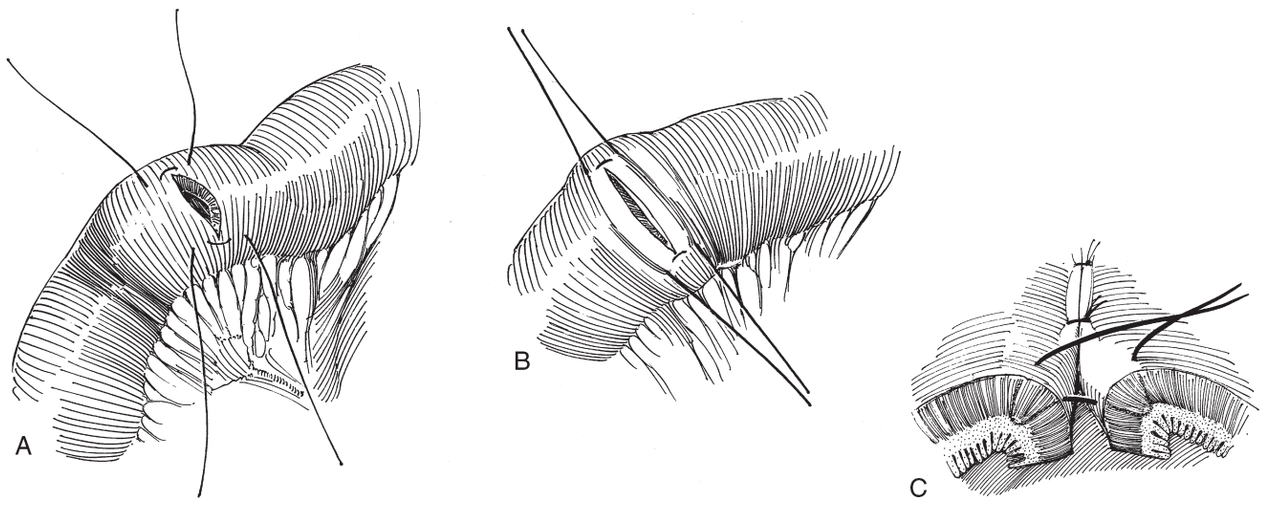

FIGURE 10-1.

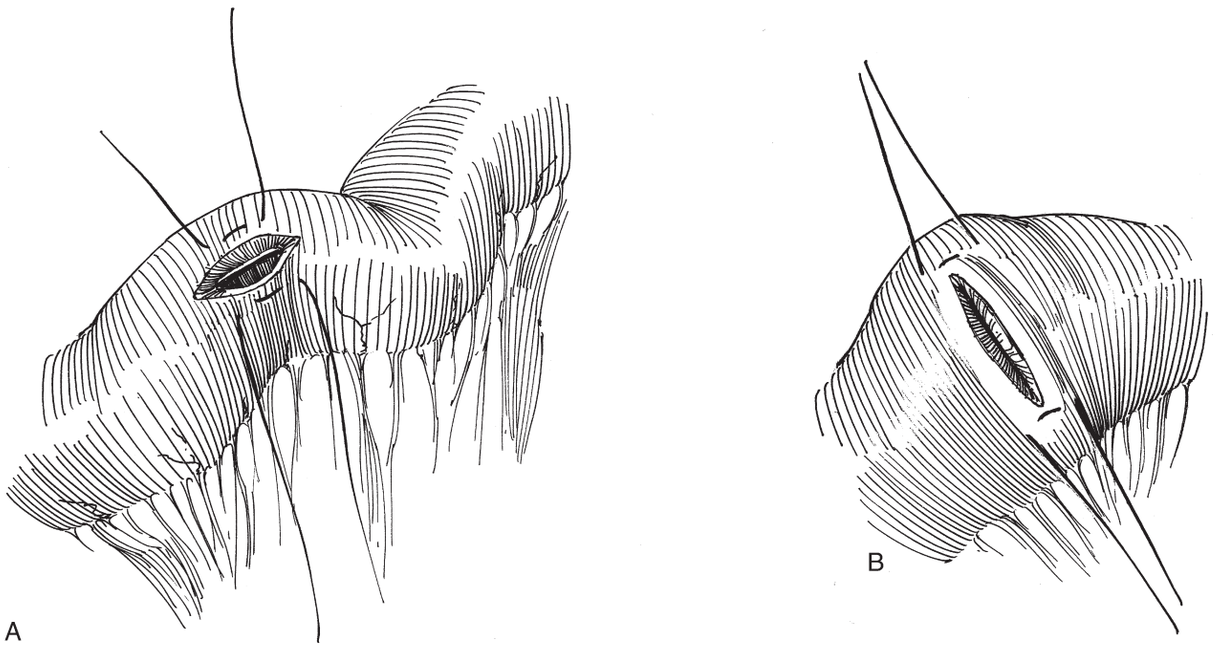

FIGURE 10-2.

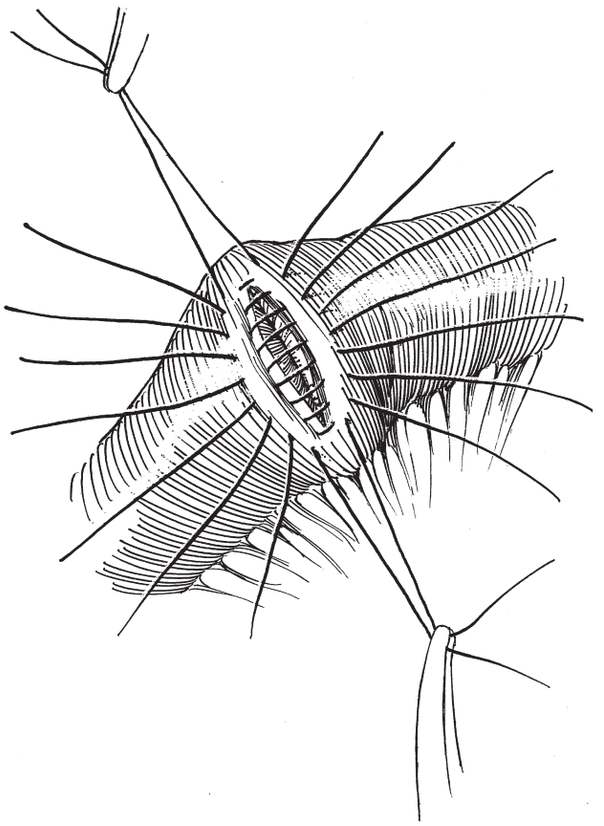

FIGURE 10-3.

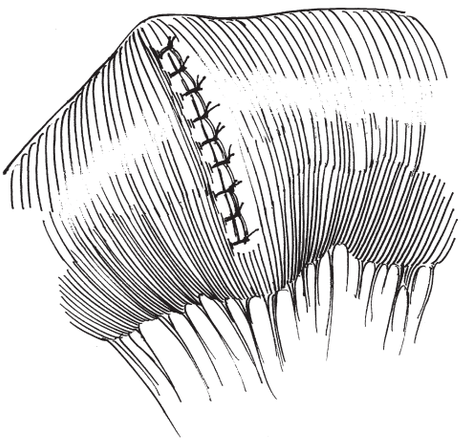

FIGURE 10-4.

Add a second row of 3-0 silk interrupted sutures; place these as Lembert sutures to invert the bowel over the first row (Fig. 10-6).

RECTAL INJURY

For a small injury occurring during retropubic prostatectomy, complete the operation before repair. Trim devitalized edges. Close the rectal defect transversely with interrupted 3-0 SAS. Apply a second layer of 3-0 silk Lembert sutures. Tack any adjacent fat over the layer. Thoroughly irrigate the wound. Mobilize the omentum (see Chapter 7) and cover the defect. Insufflate the rectum with air after filling the pelvis with saline and occluding the lumen proximally to test for a leak.

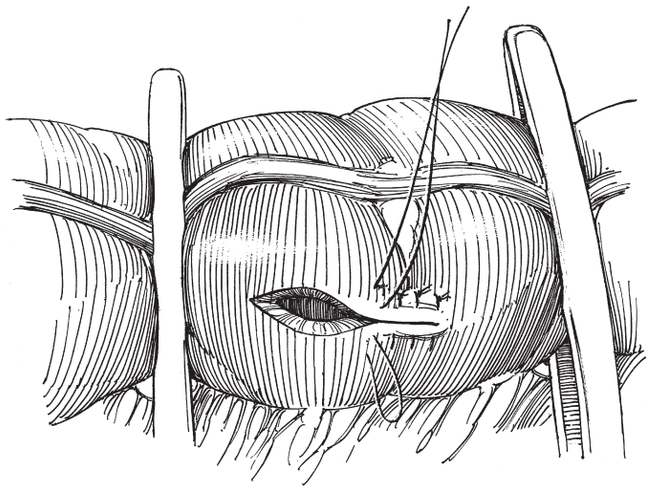

FIGURE 10-5.

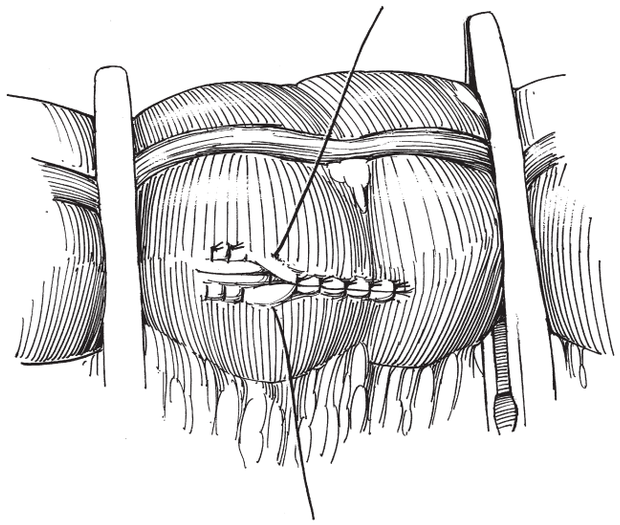

FIGURE 10-6.

Overdilate the anal sphincters digitally. Irrigate the pelvis copiously, and place drains in the pelvis. Consider a diverting ileostomy if the repair is tenuous (typically with a larger or tangental defect), the injury is related to prior irradiation, there is a leak on insufflation, the patient is malnourished, there is significant contamination, or the patient's condition is unstable.

If the rectum is injured during laparoscopic prostatectomy, the outcome is dependent on the ability of the surgeon to accurately perform an identical two-layer closure that would be performed in the open setting. If this cannot be accomplished laparoscopically, then the procedure should be converted to an open surgery through a lower midline incision. Alternatively the defect can be closed through the anus with the appropriate operating anoscopes but this can be cumbersome with the patient in the lithotomy position and may be done with the assistance of a colorectal surgeon.

Repair of rectal injury occurring during perineal surgery is described in Chapter 45.

This page intentionally left blank

Chapter 11

Basic Robotic Surgery

ALI MOINZADEH

TRAINING FOR ROBOTIC SURGERY

There is currently only one commercially available computer-assisted laparoscopic system, the da Vinci surgical system (Intuitive Surgical, Sunnyvale, Calif.). Training on the system occurs either during residency/fellowship or with postgraduate training. Postgraduate hands-on training may be obtained at one of several centers throughout the country. Hospital credentialing requirements typically mandate a predefined number of mentored cases in the presence of an expert. In order to provide a high level of surgical care for patients, the surgeon should candidly estimate their case volume so as to anticipate a level of proficiency.

Robotic Environment and Controls

A minimally invasive operative room large enough to accommodate the robotic equipment is ideal. Flat panel monitors in multiple locations in the room aid the assisting surgical technician and bedside assistant (Fig. 11-1). An integral part of success with robotic surgery is the early identification of a "robotic team." An efficient robotic team ensures proper component setup, takedown, and troubleshooting. A technically skilled robotic bedside assistant minimizes the need for repetitive teaching.

A detailed explanation of all facets and setup of the surgical system is beyond the scope of this chapter. Critical components are highlighted herein. The robotic system may be divided into three components:

1. *Patient cart*—manipulates surgical instruments within the patient at the bedside
2. *Vision cart*—houses the light source and camera unit
3. *Surgeon console*—allows surgeon to manipulate instruments with use of hand and foot controls

Knowledge of basic surgeon console controls is critical for the operating surgeon. Hand-controlled buttons may be divided into the left and right side pod (Fig. 11-2).

On the lateral aspect of the left pod, "UP/DOWN" buttons adjust the console's viewer hood height. The "SCALING" button allows the surgeon to choose from three distinct scaling ratios. The "Fine" scaling is the default setting and generally the appropriate scaling for the beginning surgeon. The "SCOPE ANGLE" button allows for toggling between three scope directions. The 30° up or down setting is useful for renal procedures. The scope angle setting should correspond to the angle and direction of lens introduced at the bedside. Rarely, the "SILENCE ALARMS" and subsequently "FAULT OVERRIDE" button on the left pod may need to be pressed in the event of an error. Insertion of the surgeon's forehead at the console's forehead site activates the robot and allows for active manipulation of the instruments. On older daVinci units, the right pod's "READY" green button may need to be pressed if the robot is in the standby mode (yellow "STANDBY" button is lit).

The master grips accommodate two fingers, typically the thumb and index finger. The surgeon's forearms should rest comfortably on the armrest of the robotic console to place the operating surgeon in the best ergonometric position (Fig. 11-3). The foot clutch switch may be used to reposition the masters.



FIGURE 11-1. Robotic minimally invasive suite.



FIGURE 11-2. Left and right pods on the daVinci S surgical system console.



FIGURE 11-3. Master grips at the surgical console.

The foot switch panel consists of five controls (Fig. 11-4), from left to right:

1. CLUTCH: Press and hold to reposition the hand masters without moving the instruments inside the patient. A quick press and release switches between a predesignated instrument robotic arm and the third instrument robotic arm when available.
2. CAMERA: Press and hold to change the position of the camera arm while simultaneously moving the masters.
3. +/− pedal: Focuses the camera. A digital zoom system is available on the newer Da Vinci S-HD model and can be activated by simultaneously pressing and holding the "CAMERA" foot pedal while moving both master grips out (zoom out) or in (zoom in).



FIGURE 11-4. Foot controls at the surgical console.

4. AUX or nonlabeled pedal: May be connected to a bipolar device.
5. COAG: Press the foot pedal to activate monopolar coagulation.

A Da Vinci Si model uses a more facile docking system and transfers some of the surgeon instrument control from the foot pedals to the hand controls. In addition, a second console can be used. This may be useful for teaching purposes but also permits a second surgeon to assist at the secondary console.

Robotic Instrumentation

At our institution, we routinely perform the following variety of urologic procedures: robotic-assisted radical prostatectomy, radical cystectomy with extended lymph node dissection, partial nephrectomy, pyeloplasty, vaginal vault suspension, bladder augmentation, and distal ureteral reconstructive procedures (Boari flap/psoas hitch). An assortment of robotic instruments allow for this ever increasing role of robotic-assisted urologic procedures. Nearly all instruments rotate and articulate. Some of the more frequently used instruments are shown in Figure 11-5. Robotic instruments should be advanced initially under direct vision to avoid injury.

Abdominal Access and Port Placement

Refer to the basic laparoscopic surgery chapter in this textbook for details regarding abdominal, extraperitoneal, and retroperitoneal access. Aspects specific to robotic-assisted laparoscopic access and port placement are noted herein.

During port placement, we employ a standard laparoscopic video camera and 10-mm lens at the outset of all robotic-assisted cases. The 10-mm lens is valuable in cases in which balloon dissectors are used to gain pelvic extraperitoneal access or renal retroperitoneal access. The 10-mm dissecting balloon trocars typically do not accept the 12-mm robotic lens. In addition, manual manipulation of robotic lens/camera systems during port placement may be cumbersome given their relative large size and weight.

At the time of trocar insertion, robotic trocars should be placed perpendicular to the skin rather than in the direction of the target organ. This is of paramount importance in obese patients in whom nonperpendicular port placement may lead to close proximity of the instruments inside the abdomen. To minimize limitation of instrument movement, given potential collision of robotic arms outside the patient, ports should be placed at least 8 cm apart at the skin level. A thick black line on the cannula is considered the trocar's "center." This thick black

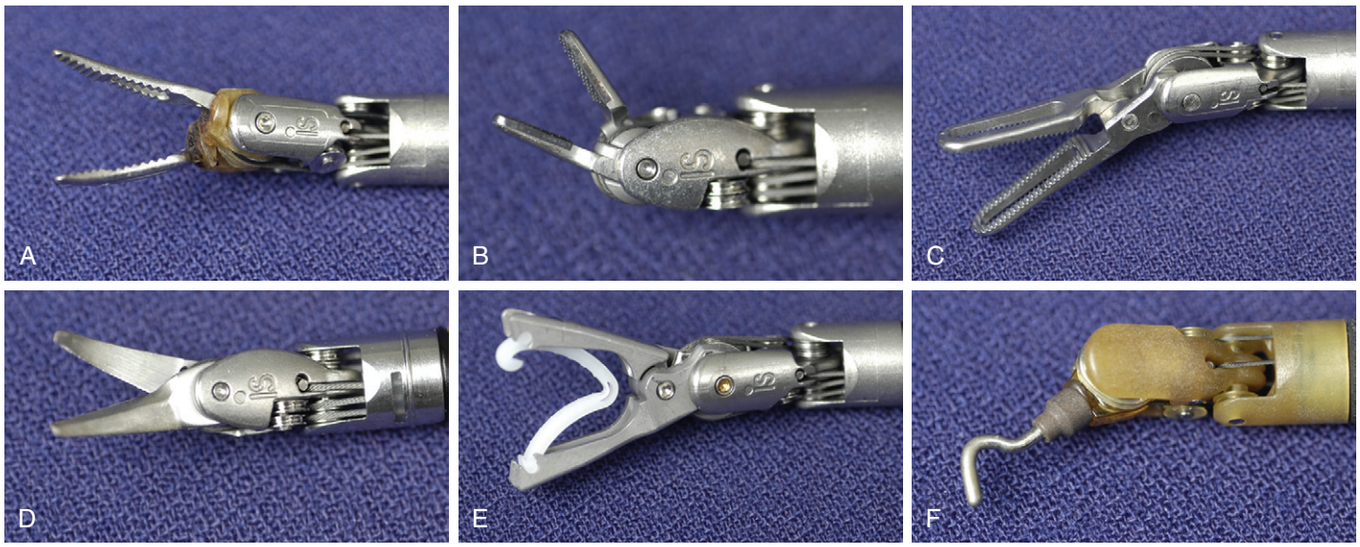

FIGURE 11-5. A sample of available robotic instruments. Only 8-mm instruments are demonstrated. **A,** Maryland bipolar: used as the primary instrument in surgeons non dominant hand. **B,** Needle drivers: smaller pediatric needle drivers are available. **C,** Prograsper: as the name implies, best instrument for grasping. Used during dissection of seminal vesicles, vas deferens dissection. Aids in retraction of bowel during radial cystectomy and partial nephrectomy. **D,** Monopolar scissors: workhorse instrument used in all procedures in the surgeon's dominant hand. Allows for cutting and coagulation. **E,** Clip applier: excellent for precise placement of Weck Hem-o-lok Clips (Teflex, Research Triangle Park, N. C.) during nerve-sparing prostatectomy or during renal surgery. **F,** Monopolar hook: Author's instrument of choice for dissection near vessels during pelvic lymph node dissection or renal hilum.

line should be placed within the patient's body wall so as to minimize the friction and trauma to patient tissue. Trocars may need to be advanced beyond this point when the instrument length is too short. This may occasionally be necessary for urethrovesical anastomosis during radical prostatectomy.

The Robotic Assistant

The robotic assistant's main roles include docking of robot, robotic instrument change, retraction, suction, and insertion and removal of sutures. Communication between the operating console surgeon and bedside assistant is ameliorated by the use of a speaker/microphone system. Verbal communication is also paramount when sutures are removed. For example, at our institution the assisting surgeon verbally states "needle in" or "needle out" during insertion or removal of suture needles to assist with correct counts at the end of the case. The assistant also benefits from his or her own sterile table. This allows for self-sufficient instrument exchange without the need for scrub nurse intervention. Long suction irrigation increases the working distance between the assistant's hands and robotic arms.

The importance of excellent visualization of the procedure for the assistant and operating surgeon cannot be understated. Fluid warming trays safely house the robotic lenses and decrease incidence of lens fogging that is common with "cold lens" during the procedure (Fig. 11-6). A flat panel monitor with adjustable height gives the assistant the choice of sitting or standing during the procedure. The operating surgeon has the advantage of 3D visualization given a dual lens system afforded at the operating console. Although we have not found it necessary, 3D visualization may be afforded to the assistant by the use of special 3D lenses and 3D wall-mounted projection. If the assistant's image becomes obscured by debris on one lens tip, the circulating nurse may easily switch to contralateral lens image.



FIGURE 11-6. Fluid warmer safely housing robotic lens.

Robotic Suturing and Knot Tying

Suturing with the robotic needle drivers is no different than instrument tying. The surgeon should clutch the masters and keep the forearm and elbows resting comfortably on the console bar. Both the surgeon's knot and slip knot techniques may be employed. Manipulation of the suture material should occur at the instrument tips and not at the more proximal articulating surface so as to minimize suture fraying or unintentional suture breaking. Because haptic feedback is minimal, visual cues gleaned with experience ensure proper cinching of knots. Lapra-Ty Clips (Ethicon Endosurgery, Cincinnati, Ohio), used to cinch sutures, reduces the need for intracorporeal suturing (Fig. 11-7).



FIGURE 11-7. Suture with Lapra-Ty clip on end *(white arrow)*. Clips placed at the end of suture lines eliminate the need for knot tying.

Section III

PENIS: PLASTIC OPERATIONS

This page intentionally left blank

Chapter 12

Basic Instructions for Hypospadias Repair

LAURENCE S. BASKIN

GOALS

Hypospadias is defined by the three major anatomic defects: (1) the abnormal location of the urethral meatus, (2) penile curvature, and (3) abnormalities of the foreskin.

The objective in treating patients with hypospadias is to reconstruct a straight penis for normal coitus and place the new urethral meatus on the terminal aspect of the glans to allow a forward directed stream. There are five basic steps for a successful hypospadias outcome: (1) orthoplasty (straightening), (2) urethroplasty, (3) meatoplasty and glanuloplasty, (4) scrotoplasty, and (5) skin coverage. These various elements of surgical technique can be applied either sequentially or in various combinations to achieve a surgical success.

MEATAL ABNORMALITIES

Hypospadias is characterized by an abnormality in location and configuration of the urethral meatus. The urethral meatus may be ventrally placed just below a blind dimple at the normal meatal opening on the glans or so far back in the perineum that it appears as a "vaginal" hypospadias. The meatus is encountered in a variety of configurations in form, diameter, elasticity, and rigidity. In the case of the megameatus intact prepuce, the distal urethra is enlarged, tapering to a normal caliber in the penile shaft. Often, there is an orifice of a periurethral duct located distal to the meatus that courses dorsal to the urethral channel for a short distance. It is blind ending and does not communicate in any way with the urinary stream. Unless these ducts are inadvertently closed, leading to a blind-ending epithelial pouch, they are of no clinical consequence.

SKIN AND SCROTAL ABNORMALITIES

The skin of the penis is radically changed as a result of the disturbance in the formation of the urethra. Distal to the meatus, there is often a paucity of ventral skin, which may contribute to penile curvature. The frenulum is always absent in hypospadias.

The skin proximal to the urethral meatus may be extremely thin, so much so that a catheter or probe passed proximally is readily apparent through a tissue paper thickness of skin. When it is present, it abrogates the use of perimeatal skin flaps in repairs.

The urethral plate extending from the hypospadiac meatus to the glanular groove may be well developed. Even with a meatus quite proximal on the shaft, this normal urethral plate is quite elastic and typically nontethering. A normal urethral plate may be incorporated into the surgical repair. However, if the urethral plate is underdeveloped, it will act as a tethering fibrous band that bends the penis ventrally during artificial erection. Often, when this fibrous chordee tissue is divided, the penis straightens.

Normally, the genital tubercle should develop in a cranial position above the two genital swellings. The penis may be caught between the two scrotal halves and become engulfed with fusion of the penoscrotal area.

PENILE CURVATURE

The curvature of the penis is caused by deficiency of the normal structures most commonly on the ventral side of the penis. Penile curvature can be from skin deficiency, a dartos fascial deficiency, a true fibrous chordee with tethering of the ventral shaft, or deficiency of the corpora cavernosa on the concave side of the penis.

Other penile anomalies occasionally seen include congenital urethral fistula and curvature of the penis without hypospadias or so-called chordee without hypospadias.

HYPOSPADIAS SURGEONS

Success is directly related to the experience of the surgeon. For a successful result in hypospadias repair, the penile tissues must be handled with great care. Experience in mobilizing and rotating skin flaps is needed, as are the minutia involved in plastic surgical techniques. Knowledge of a few methods is

*Reprinted from Hinman & Baskin: Hinman's Atlas of Pediatric Urologic Surgery, 2nd edition. Elsevier, 2009.

not enough, because the one used must be the best for the individual situation of the child.

PREOPERATIVE EVALUATION

Because hypospadias is an isolated anomaly, the entire genitourinary tract does not require evaluation. The absence of one gonad, perineal hypospadias, severe chordee, or a bifid scrotum suggests a disorder of sex development and requires genotypic evaluation. If both gonads are not palpable, consider the possibility of congenital adrenal hyperplasia in a phenotypic female.

AGE FOR OPERATION

Select a time between 6 and 9 months for surgery. At this age the infants do not seem to remember the surgery as teenagers and adults. Parenteral testosterone may be administered to increase the size of the penis and especially the size and vascularity of the prepuce in case it is needed for proximal and perineal hypospadias repair. Give 25 to 50 mg intramuscularly, repeated once or twice at 3-week intervals before operation.

OUTPATIENT REPAIR

An uncomplicated hypospadias operation can be done without hospital admission.

PROPHYLACTIC ANTIBIOTICS

Prophylactic antibiotics are not essential except for salvage repairs, although administration intraoperatively of a systemic antibiotic may be wise.

MAGNIFICATION

As a pediatric urologist, you should have your own 2.5- or 3.5-power loupes or commercial magnifying visor. An operative microscope with a stand placed at the end of the table and covered from the field can be helpful. Use microsurgical instruments and sutures.

NERVE BLOCK

Caudal nerve block is a good alternative to or a supplement for local anesthesia. Performed by an anesthesiologist at the start of the operation, it has become the standard of care.

Local nerve block is an alternative. At the beginning of the operation, place a penile nerve block with 3 to 4 mL of 0.5% long-lasting bupivacaine mixed with 1% quick-acting lidocaine. Inject it at the base of each crus just below the notch of the symphysis, or vertically in the midline deep to the notch of the symphysis, with a 1½-inch 22-gauge needle. When placed at the beginning of an operation, the nerve block will reduce the amount of general anesthesia required and will provide anesthesia that will last well into the postoperative period.

SURGICAL HINTS

Hemostasis

For hemostasis, use 1% lidocaine 1:100,000 epinephrine and inject it through a 27-gauge needle within the glans and the area of abortive spongiosum. Wait 7 minutes for it to act. This vasoconstrictor will reduce the bleeding during the dissection but if the operation is prolonged beyond 90 minutes, rebound vasodilation can be expected. Halothane anesthesia sensitizes the heart to catecholamines, thus promoting arrhythmias. Avoid electrocoagulation. Moreover, once the skin flaps are applied, bleeding seems to stop, and a pressure dressing usually achieves hemostasis. A tourniquet can be used to facilitate hemostasis.

Artificial Erection

Place a broad rubber band or small red rubber catheter around the base of the penis and snug it with a hemostat. Introduce a 25-gauge butterfly needle through the glans into a corpus cavernosum or directly into the corpus cavernosum. Gently distend the penis with injectable normal saline solution. Maintain the erection during evaluation of the chordee. After the chordee has been corrected, create a second erection to check penile alignment.

Suturing

Absorbable sutures are best for the skin and subcutaneous tissues because anesthesia is not required for their removal. Alternatively, use fine sutures of 6-0 PDS (polydioxanone), although Vicryl or Dexon-S may occasionally be suitable. Polyglycolic acid sutures are not as good as polyglactic sutures; they last too long and thus may promote fistulas. Place sutures subcuticularly to avoid sinuses caused by epithelium growing in along the suture track (more frequently with braided sutures).

LOCAL URINARY DIVERSION IN CHILDREN

Diversion of urine away from the suture lines has always been a problem in children because any indwelling tube, particularly one terminating in a balloon, induces bladder spasms that force urine around it into the repair. This disrupts the suture line and leads to formation of fistulas.

Many techniques have been tried to minimize these problems with diversion. The simplest method for infants, one that combines stenting with drainage, is to insert a fine silicone tube, such as 6-French peritoneal shunt

tubing or neurosurgical tubing with its wandlike end, into the bladder through the urethra and fasten the end to the glans in one or two places with nonabsorbable sutures.

Alternatively, place a 6-French Kendall catheter of soft Silastic with a Luer-loc at the end to prevent internal migration and allow irrigation (Fig. 12-1). Collect the urine in a double diaper. For older boys, use a urethral balloon catheter; tape it to the abdomen so that it cannot disturb the ventral glans repair. Drainage should be continued for 4 to 7 days for distal and penile shaft repairs and for 7 to 10 days more for severe hypospadias repairs.

DRESSINGS

Apply a dressing to immobilize the area, to reduce edema, and to prevent the formation of a hematoma. Use transparent and permeable absorbent plastic film (Tegaderm or Op-Site) applied over Telfa or tincture of benzoin. Let the catheter drain into an outer diaper. The dressing may be removed in 2 to 3 days after a few warm baths at home. Once the dressing has been removed, use petroleum jelly on the diaper to keep the repaired penis from sticking, typically 4 to 5 days.

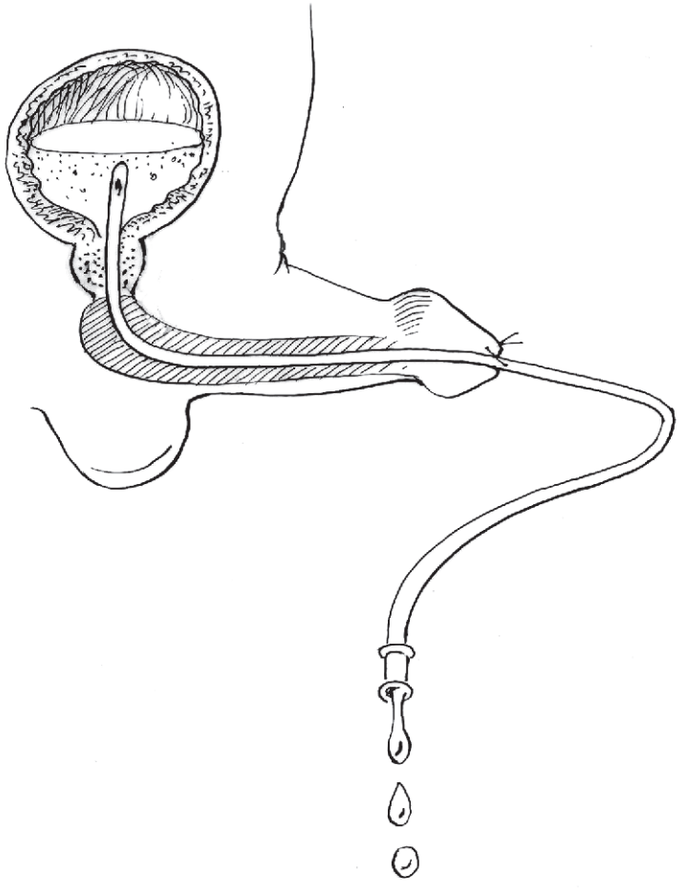

FIGURE 12-1.

SET UP FOR OPERATION

Instruments

Select instruments designed for delicate handling of tissues. A reasonable list includes:

- Loupe magnification
- Genitourinary fine and microsurgery sets
- Microsurgical knife
- Toothed and nontoothed forceps
- Fine Allis clamps
- Fine clamps
- Two pairs of Bishop-Harmon forceps or 0.5 platform forceps
- Jeweler's forceps
- Sharp small tenotomy scissors
- Iris scissors
- Microtip Castroviejo scissors
- Microtip Castroviejo needle holders
- Four small two-pronged skin hooks
- Two small one-prong skin hooks
- Plastic scissors and plastic needle holders
- Peanut dissector
- Ring retractor (Scott) and hooks

Also have available the following: bougies á boule, 5- and 8-French infant feeding tubes, rubber bands, a marking pen, a 25-gauge butterfly needle and syringe, and a handheld Bovie or an ophthalmic electrocautery.

Have fine sutures of appropriate sizes and types at hand but unopened: synthetic absorbable suture, nonabsorbable suture (e.g., Prolene on a C-1 tapered needle for glans traction, 7-0 PDS for urethral anastomosis, and 6-0 or 7-0 chromic catgut for the skin.

SELECTION OF THE OPERATIVE TECHNIQUE

Several procedures are available for the repair of hypospadias depending on quality of the preputial flap or in the case when local skin is not available the use of free graft such as bladder, buccal, or preputial skin grafts. Mild and moderate penile curvature can be corrected by dorsal midline (Fig. 12-2) or lateral placement of sutures in the tunica albuginea. For severe curvature requiring resection of the urethral plate and not responsive to dorsal plication, dermal grafting is warranted.

The shape of the glans helps determine the appropriate operative technique. With a flattened glans, the urethral plate usually is normal and may be preserved for subsequent tubularization or application of an onlay flap with the glans supporting the repair. In contrast, a cone-shaped glans usually is accompanied by a fibrous urethral plate that requires division, followed by two-stage repair. Skin coverage depends on leaving the dorsal skin intact and recreating the incision from a circumcision along with a ventral midline seam.

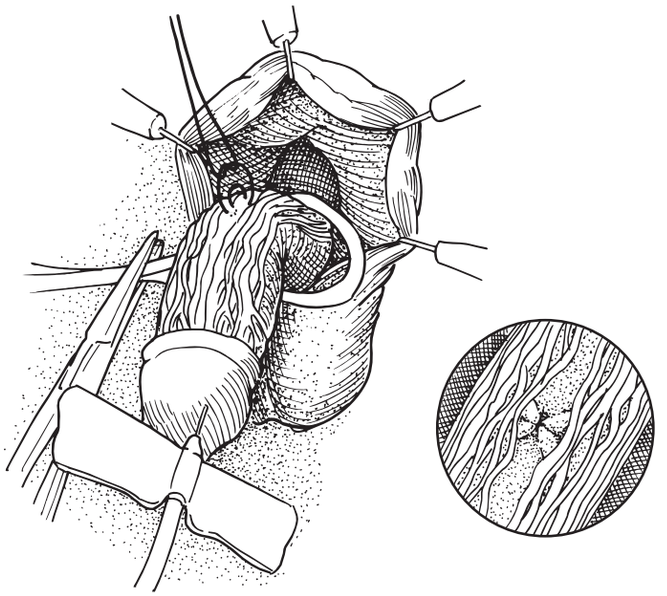

FIGURE 12-2.

SPECIFIC OPERATIONS

Figure 12-3 presents an algorithm for the reconstruction of hypospadias. A tried and true approach is to start each repair by preserving the urethral plate, dissecting the skin to the penile scrotal junction and assessing for the presence of penile curvature. If curvature is not present or is mild to moderate and amenable to dorsal plications, then a one-stage approach is typically successful. The specific repair becomes dependent on the meatal configuration and the surgeon's preference.

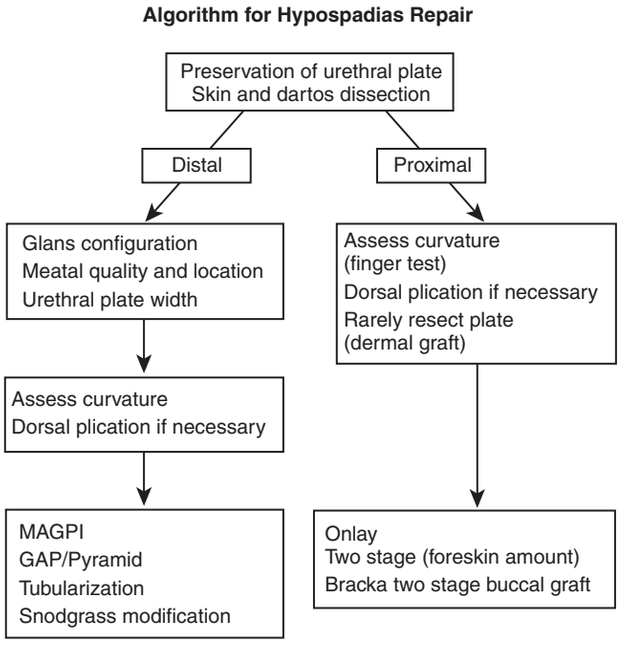

FIGURE 12-3.

Patients with a coronal mobile meatus and a web of tissue within the glans can be treated with the Meatal Advancement Glansplasty Incorporated (MAGPI) procedure. Patients with a fishmouth meatus and glanular or distal meatus can be treated with the Glans Approximation (GAP) procedure. The hypospadiac variant of megameatus intact prepuce is amenable to the pyramid procedure. Because of their abundant dorsal vasculature, island flaps that are laid on as patches have become increasingly popular because poorer vascularization associated with the Mathieu flip-flap procedures has been recognized. Urethral advancement with the ability to place the new urethral meatus in a normal position within the remodeled glans favors the balanitic groove technique.

For penile shaft and more severe hypospadias, the onlay island flap has been tested over time. In patients with a healthy urethral plate, primary tubularization alone or in combination with incision of the urethral plate (Snodgrass modification) is gaining widespread popularity.

In patients with severe hypospadias requiring resection of the urethral plate, one-stage procedures, such as the transverse tubularized island flap or the specialized onlay urethroplasty parameatal foreskin flap, are described. Free tube grafts also have their use in more severe cases. For severe hypospadias, a planned two-stage approach for primary repairs is an acceptable alternative to a one-stage repair with a high complication rate. Repair of penoscrotal transposition is typically done in a second stage. The special circumstance of foreskin preservation is requested by more and more families. This technique can be performed safely in patients with minimal penile curvature.

POSTOPERATIVE PROBLEMS

To decrease bladder spasms, give analgesics and antispasmodics. Give stool softeners and a suitable diet because the antispasmodic regimen may result in constipation and lead to straining and urine leakage.

Bleeding is an infrequent problem. A compressive sandwich dressing resolves the problem in all but the rare patient.

If postoperative erections in older boys become a problem, use amyl nitrate ampules or diazepam sedation to reduce them.

Continue bathing the child twice a day for 7 to 10 days two days after the surgical repair to reduce swelling and facilitate healing. See the patient 6 weeks and 1 year after the repair. Reevaluate after toilet training and at puberty to confirm patient satisfaction and the absence of fistula, stenosis, diverticulum, recurrent chordee, and cosmetic issues.

COMPLICATIONS

Complications occur after 10% to 30% of hypospadias operations. These include meatal retraction, urethrocutaneous fistula formation, meatal stenosis, urethral stricture, development of a diverticulum (sometimes with hair, followed by stones), and persistent chordee. Of these, strictures, fistulas, and urethral diverticula account for most of the late problems. Manage these complications at least 6 months from the time of the initial surgery.

PRACTICAL CONCLUSIONS

1. Hypospadias should be repaired within the first year of life.
2. Pain control and catheters seem better tolerated and the baby's lack of mobility simplifies postoperative care.
3. A terminal slitlike meatus should be the goal, with or without preservation of the foreskin, depending on parental preference.
4. Preservation of the urethral plate creates the best possible chance to recreate normal urethral anatomy by incorporating the abortive spongiosum into the repair.
5. Midline dorsal plication is safe and effective for the correction of penile curvature in most patients. (Placing more than two rows of sutures is a sign that another technique such as dermal grafting is indicated.)
6. In the small percentage of patients who require resection of the urethral plate, a two-stage approach is generally warranted.
7. Vascularized pedicle onlay flaps are successful in primary and redo hypospadias surgery.
8. Deepithelized vascular flaps should be used as a second layer for all urethroplasties.
9. Patients with a paucity of skin are best managed with the Bracka two-stage buccal repair.
10. Coronal fistulas require a redo glansplasty.

Commentary by DAVID A. BLOOM

These basic instructions will serve anyone well when approaching hypospadias repair. Baskin updates the tenets of hypospadiology, espoused by his mentor John Duckett. The surgeon must have a full range of techniques to triage for each unique individual on the operating table. Lacking good data to inform every choice, each surgeon inevitably will have individual preferences for methods and materials.

The ideal glanular position is not exactly terminal, but a bit ventral and in some extreme cases, such as a small glans, we may settle for a coronal location if stream and orthoplasty are adequate.

In terms of orthoplasty, we are still governed by local history here in Ann Arbor with a preference for a Nesbit-like plication.

The timing of repair has ideally gravitated to a 6- to 9-month period in most centers, but this should depend upon the pediatric anesthesia level of skill and comfort.

As for the use of preoperative testosterone, we have been equally satisfied with preoperative ointment; even though it seems less precise, it spares the infant boys a shot. However, with good optical magnification, we have been utilizing testosterone far less often and only in the most severe instances.

Regarding prophylactic antibiotics, we use them with the belief that they will suppress inevitable colonization if an indwelling catheter is employed.

Like Baskin, we are absolute fans of magnification (3.5 power loupes), regional blocks, and careful epinephrine hemostasis. I rarely use a tourniquet or cauterization. Baskin utilizes an important adjective when he describes artificial erection. He suggests that you "gently" inject saline (be certain it is never the epinephrine solution!) into the corpus spongiosum. Excessive pressure will damage the delicate spongy tissue. Since the erectile mechanism will be expected to perform well over a half century of service, why threaten it with a hyper-physiologic pressure challenge in infancy?

The question of urinary diversion is unresolved by international consensus, and certainly catheters bring their own problems. However, we generally favor a short interval of catheterization for most significant repairs.

Choice of operation is in part a matter of experience and the art of medicine. In severe cases with scant skin, we utilize buccal mucosa to provide a more physiologic moist urethra and save "skin for skin."

This page intentionally left blank

Chapter 13

Postoperative Management

RONALD RABINOWITZ, WILLIAM C. HULBERT AND ROBERT A. MEVORACH

Consistent postoperative management after penile surgery is essential to ensure an excellent functional and cosmetic result. Many penile reconstructions are performed in the first year of life, and there is significant parental anxiety concerning the postoperative management, in that almost all such reconstructions are carried out in an ambulatory surgical setting. Thus the family has a significant responsibility for the postoperative management. Straightforward postoperative care is easier for both the surgeon and the family.

Unless there is some overlying risk factor, we do not give antibacterials for penile reconstructions.

For the vast majority of boys undergoing penile reconstruction, Motrin and/or acetaminophen is sufficient. In some boys who need additional analgesia, Tylenol with codeine is appropriate.

Because penile reconstructions may have significant postoperative swelling, a compression dressing is used. Our goal in this aspect of management is to have a dressing that is easily available, simple to place, easy to manage, and easy to remove if it does not fall off spontaneously. Our dressing is a small Tegaderm (3M) with the edges attached dorsally and with the distal portion trimmed to expose the urethral meatus if a catheter is not used postoperatively.

If catheter drainage is used, we prefer using a small silicone catheter with the eyes near the base of the bladder. A 6-French Kendall (Tyco) catheter, which has a caliber smaller than the neourethra, is sutured to the glans with looped 4-0 Prolene to allow for some sliding of the drip catheter and to accommodate glans edema. For most infants, this is at the 15-cm mark. If a drip catheter is used, the distal portion of the Tegaderm dressing can be attached to the catheter.

To further assist in decreasing postoperative swelling, we request parents to aim the penis toward the chest for 2 weeks so that the penis does not hang downward in a dependent position. Thus when the infant or child is sitting, standing, walking, or being carried, the surgical site is elevated against gravity. When a catheter is used, the double diaper technique further helps to keep urine away from the repair. A small hole is placed approximately 3 cm from the top of the front of the inner diaper, and the drip catheter is passed through this opening to drain into the outer diaper (Figs. 13-1 and 13-2). This technique also ensures elevation of the penis toward the chest. The parents are instructed to have this inner diaper prepared before changing both inner and outer diapers to avoid struggling with an infant while trying to simultaneously punch a hole in the diaper. Using double diapers, the inner diaper need only be changed after a bowel movement.

If the Tegaderm dressing rolls back toward the base of the penis, thereby possibly causing increased distal swelling from constriction, the parents are instructed to stretch the



FIGURE 13-1.



FIGURE 13-2.

dorsal portion of the dressing until it separates and is no longer circumferential.

Following penile reconstruction, bathing is avoided for 2 to 4 days, depending on the extent of the surgery. After circumcision, 5-minute daily tub baths can begin on the second postoperative day. Following repair of chordee, we generally wait 2 or 3 days depending on the extent of the dissection. After hypospadias repair, when a drip catheter is used, we prefer that bathing be avoided until the fourth postoperative day.

When the Tegaderm dressing comes off, the family is instructed to apply A & D ointment to the inner aspect of the diaper with each diaper change to prevent any sutures or areas of reepithelization from sticking to the diaper. Once reepithelization is complete and drip catheter (if one is used) removed, A & D ointment is applied to the operative site and suture lines for skin softening and to prevent any skin sutures from becoming hard and needlelike. If thickening of the area of reconstruction is observed, topical steroids for a few months are often helpful in softening the tissue.

Commentary by DAVID A. BLOOM

The Rabinowitz-Hulbert-Mevorach plan is a clear road to successful postoperative hypospadias management. Tegaderm is one of a number of satisfactory dressing types. The main difference between what I do and the procedure presented here is that I avoid using a glanular stitch. The suture is certainly the safest approach to retaining the catheter successfully; however, suture removal is one small unpleasantry avoided by using either a 6-French balloon catheter or a 6- or 8-French stent secured by tape for a few days.

Chapter 14

Pediatric Meatotomy

JOHN S. WIENER

INDICATIONS

Meatal stenosis can be congenital or acquired. Acquired stenosis can result indirectly after neonatal circumcision or directly after distal urethral surgery, particularly following hypospadias repair. Congenital stenosis often is seen with a prominence of glanular tissue on the ventral edge of the meatus, and this obstructing tissue presents with marked upward deflection of the urinary stream that makes toilet training difficult. Acquired stenosis can result in a pinpoint meatus that can lead to symptoms of a narrowed, deflected stream or obstructive voiding symptoms.

TECHNIQUE

Meatotomy can be performed either as an office procedure with topical anesthesia or in the operating room under general anesthesia. Application of lidocaine 2.5%/prilocaine 2.5% cream (EMLA) to the glans with a bio-occlusive dressing for 60 minutes allows most meatotomies to be conducted in the office without sedation in cooperative boys. Cases with a pinpoint meatus or significant postoperative scarring may be best performed under general anesthesia in the operating room.

Steps

The glans is grasped between two fingers to stabilize the meatus.

Most cases are amenable to a ventral meatotomy, particularly congenital cases with excess ventral tissue. A fine straight or curved hemostat is used to crush the tissue ventral to the meatus (Fig. 14-1). This allows subsequent cutting of the meatus without bleeding. Because the meatotomy often partially heals and makes the eventual size of meatus too small, it is advisable to crush farther than the point of the desired meatal edge. If necessary, a dorsal meatotomy can be performed in a similar fashion.

The crushed tissue is cut with fine sharp straight scissors (Fig. 14-2).

The newly enlarged meatus is spread. In the office, this maneuver is demonstrated to the parents so that they can perform this maneuver at home twice daily for several weeks to prevent healing and secondary stenosis. Steroid cream (betamethasone dipropronate 0.05%) can be applied to prevent restenosis, or ophthalmic antibiotic ointment can be used, inserting the tip of the tube to gently dilate the meatus.

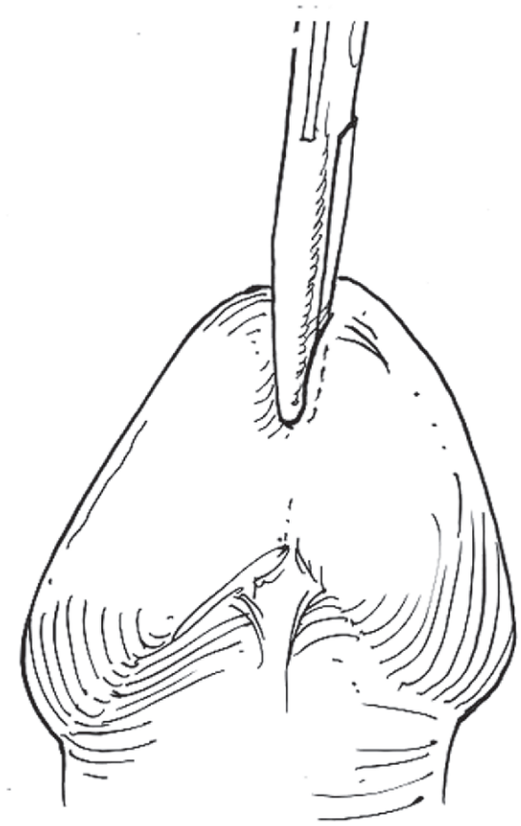

FIGURE 14-1. Straight portion of fine hemostat is used to crush glans in midline ventral to meatus. The length of the crushed line should exceed the eventual desired length of the meatus to allow for partial postoperative healing.

When a problematic case of stenosis is taken to the operating room, it is preferable to place sutures to fix the meatus open. Two sutures of 6-0 or 7-0 synthetic absorbable sutures are placed on each side in glans lateral to the meatus before grasping the urethral mucosa, creating eversion of the mucosa to prevent restenosis. In refractory cases, a formal meatoplasty may be necessary.

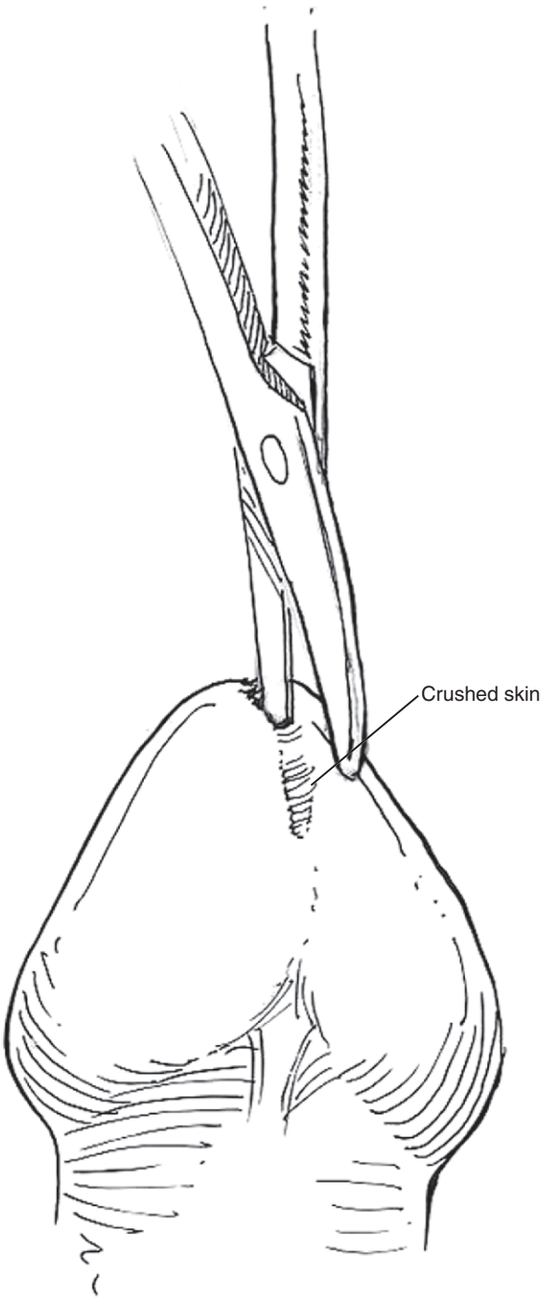

FIGURE 14-2. Fine sharp straight scissors are used to cut the entire length of crushed glans.

Commentary by DAVID A. BLOOM

Congenital meatal stenosis that we see periodically is actually less of a narrowing than it is a weblike bit of ventral epithelium that may cause a distressing dorsal deflection of the stream. Interestingly, we saw this in two boys whose father (a pediatrician) said he had the same problem himself as a child. Acquired meatal stenosis, the more typical form, may well be a consequence of the condition once called "ammoniacal meatitis" resulting from diaper abrasion of the delicate meatus after circumcision. This may be avoided by generous use of petroleum jelly ointment on the meatus with each diaper change. Wiener's approach works with either form and is very similar to ours, except that we make a deal with the family. We tell them that we can open the meatus, but Nature will try to close it again during the healing phase. So we give them an 8-French feeding tube for intermittent obturation of the meatus: twice a day for 1 month and then once a day for 2 months, which should practically guarantee no recurrence. If the child has had no distress at the initial intervention, he will generally have little trouble with intermittent passage of the catheter (or other device) and may indeed take to intermittent self-obturation.

Chapter 15

Decision-Making in Hypospadias Surgery

WARREN T. SNODGRASS

Hypospadias surgery radically changed when the urethral plate was identified as a distinct structure. Three important concepts emerged:

1. The urethral plate represents tissues that should have formed the urethra.
2. Penile curvature indicates relative shortening of ventral structures, rather than fibrous scar that needs to be excised.
3. Midline incision widens the plate for tubularization without flaps and heals by reepithelialization without stricture.

Primary hypospadias repair begins with the assumption that the urethral plate will be used for urethroplasty. The main exception to this principle is ventral curvature leading to transection of the plate to facilitate penile straightening, a situation encountered in a minority of proximal hypospadias cases. As a result, decision making is greatly simplified as shown in the algorithm of options for primary operations (Fig. 15-1). Complication rates have diminished with increasing use of the urethral plate and an emphasis on fewer surgical techniques to be mastered. Cosmetic outcomes have significantly improved so that the expectation is that repair will create a penile that looks normal, or nearly so.

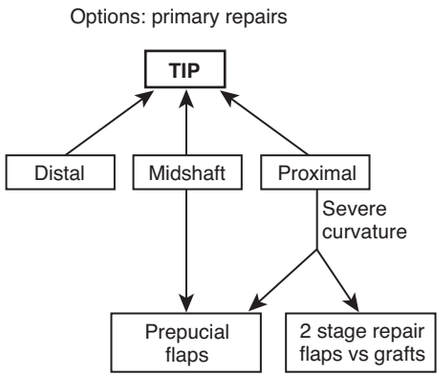

FIGURE 15-1. Algorithm for primary hypospadias repair

PREOPERATIVE CONSIDERATIONS

Preoperative Investigations

When hypospadias occurs with cryptorchidism, a karyotype is obtained to exclude disordered sexual development.

STRAIGHTENING PENILE CURVATURE

Etiology

Ventral curvature is normal during formation of the penis, and so may persist when arrested development results in hypospadias. Curvature occurs in approximately 15% of distal and in more than 50% of proximal cases. The extent of bending typically is less than 30 degrees in distal forms, while in exceptional proximal cases it can exceed 90 degrees. When arrested development leaves ventral curvature, all tissues including skin, dartos, corpus spongiosum, urethral plate, and corpora cavernosa, potentially are shortened.

Correction

Release of ventral skin and underlying dartos often resolves apparent ventral bending. The urethral plate can be preserved in all cases during initial dissection until the extent and cause of curvature can be determined. Artificial erection is obtained by saline injection using a butterfly needle inserted into the corpora cavernosa either along the shaft or through the glans. Options for straightening bending that persists after the penis is degloved include the following:

Dorsal Plication (Fig. 15-2)

Midline incision through dartos and Buck's fascia directly opposite the point of greatest curvature exposes the tunica albuginea of the dorsal corpora cavernosa. Sensory nerves and blood vessels typically lie to either side of the midline

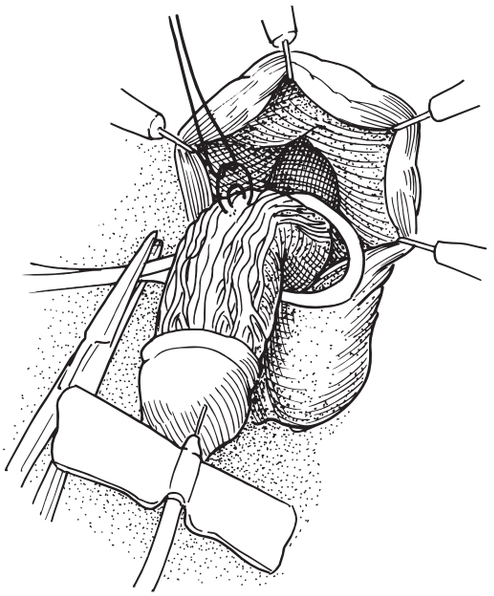

FIGURE 15-2. Correcting curvature with dorsal placation. *(From Hinman F, Baskin LS. [2009]. Hinman's atlas of pediatric urologic surgery, 2nd ed. Philadelphia: Elsevier.)*

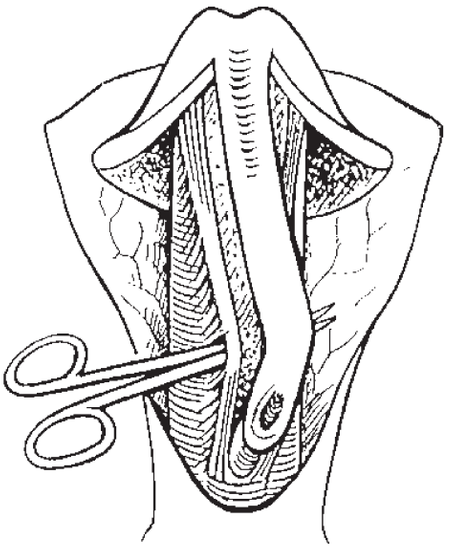

FIGURE 15-3. Correcting curvature with urethral plate elevation.

and are not damaged. There is no need to incise the tunica albuginea in prepubertal boys, as a single stitch of 6-0 or 5-0 polypropylene traversing a distance of approximately 5 mm and tied burying the knot will achieve straightening when bending is less than 30 degrees.

The major concerns with dorsal plication are shortening of the penis and recurrent curvature at puberty. A single plication will not appreciably decrease penile length, but multiple stitches are not advised.

Urethral Plate Elevation (Fig. 15-3)

Shortened ventral tissues in proximal hypospadias may include the corpus spongiosum and urethral plate. Most often there is also disproportion in length between the ventral and dorsal surfaces of the corpora cavernosa. Releasing the corpus spongiosum splayed to either side of the urethral plate, and sometimes extending dissection completely under the plate, may resolve or lessen curvature for straightening without plate transection. Blood supply to the urethral plate is preserved by proximal connection to the native urethra and distal attachment to the glans.

Dissection is facilitated by use of a proximal tourniquet. With traction on one of the lateral extensions of the splayed spongiosum, the plane between the spongiosum and the tunica albuginea of the corpus cavernosum is identified and entered using scissors. This plane is further developed proximally to the point the spongiosum envelopes the native urethra, and carried distally to the fusion of the splayed spongiosum with the ipsilateral glans wing. This connection to the glans is severed transversely, which also releases ventral glans tilting. The same dissection then is repeated on the other side.

If curvature persists, the plane of dissection is extended under the entire urethral plate until it is elevated from the native urethra into the proximal glans. Persistent bending less than 30 degrees is corrected by dorsal plication. Greater degrees of curvature have led to transection of the urethral plate and ventral corpora grafting (see later), although mobilization of the native urethra can be continued proximally to near the membranous portion maintaining continuity with the urethral plate to increase options for straightening while preserving the plate. This maneuver is combined with ventral grafting versus 3 transverse corporotomies (Fig. 15-4) and/or dorsal plication, relying on elasticity of the urethra and urethral plate to allow straightening of corpora cavernosa disproportion without creating "bowstring" tension. After correction of bending, the preserved urethral plate

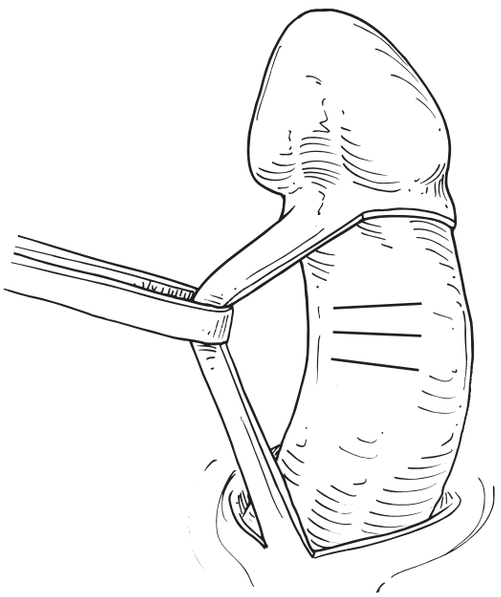

FIGURE 15-4. Correcting curvature using 3 corporotomies from 4° - 8° through the region of greatest bending.

can either be incised and tubularized or combined with an onlay flap to create the neourethra.

Ventral Corporal Lengthening (Fig. 15-5)

When curvature exceeds 30 degrees, grafting is commonly used to increase ventral length. The urethral plate is transected and then the tunica albuginea of the corpora is incised from 3 to 9 o'clock at the point of greatest bending down to spongy tissues, exposing the corporal septum. The resultant defect is repaired using a dermal graft. This oval graft is harvested from the inguinal region by incising through epithelium along the desired perimeter, removing the epithelium, and then separating the dermis from underlying fatty connective tissues. The dermis is sewn with a running absorbable suture along the margins of the corporal incision. Reported alternatives to dermal grafts include tunica vaginalis grafts or flaps, and small intestinal submucosa (SIS).

Ventral lengthening is also achieved by 3 transverse corporotomies into the tunica albuginea, which are more superficial than described earlier and do not expose spongy erectile tissue. The first incision is placed at the point of greatest bending, and then additional parallel cuts are made a few millimeters above and below. The combination of these three incisions allows expansion of the ventral corpora but does not require grafting.

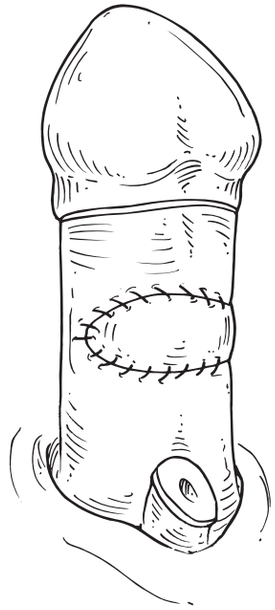

FIGURE 15-5. Correcting curvature with ventral grafting.

DISTAL TIP REPAIR (Fig. 15-6)

Initial skin incision depends upon the family's preference for circumcision versus foreskin reconstruction. In either case the corners of the dorsal preputial hood are identified. When circumcision is planned, the dorsal incision begins approximately 1 cm below the coronal margin from the 2- to the 10-o'clock position but then angles sharply downward to the corners of the foreskin, preserving inner prepuce to later create the ventral "mucosal collar." Ventrally the incision extends from the preputial corners transversely 1 to 2 mm below the meatus. The penis is next degloved to the penoscrotal junction in the plane between dartos and Buck's fascia dorsally, but immediately under the skin ventrally to later create a ventral dartos barrier flap.

For preputial reconstruction, the initial skin incision is V-shaped from the corners of the foreskin ventrally to beneath the meatus, with no incision dorsally. Then only the ventral shaft is dissected until normal dartos tissues are encountered.

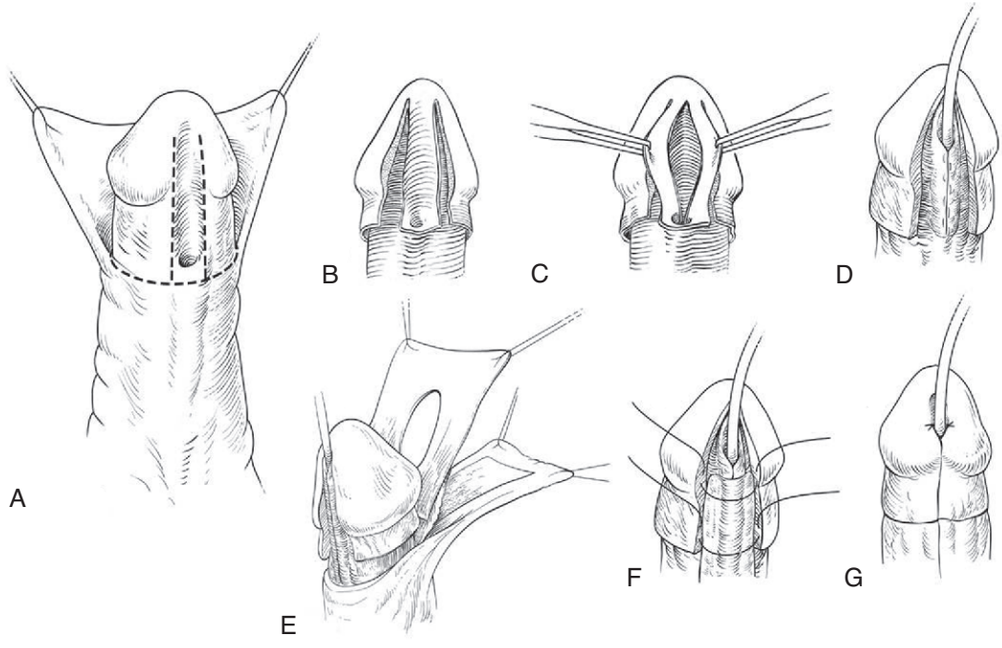

FIGURE 15-6. Distal TIP repair. *(From Snodgrass WT, Nguyen MT: Current technique of tabularized incised plate hypospadias repair. Urology 60(1): 157-162, 2002.)*

Artificial erection is performed and curvature less than 30 degrees corrected by dorsal plication. Bending greater than 30 degrees is rarely encountered in distal hypospadias unless a transparently thin distal urethra between splayed corpus spongiosum masks a truly proximal defect.

Separation of the glans wings from the urethral plate is facilitated by injection with 1:100,000 epinephrine and/or a tourniquet. Proposed lines for incision are marked beginning distally at the point of the future meatus, continuing proximally along the junction of the glans wing to urethral plate, and finally ending a few millimeters to either side of the meatus. A superficial incision is made with a sharp scalpel, and then the glans wings are further mobilized laterally with tenotomy scissors to enable subsequent tension-free approximation over the neourethra. Care is taken to preserve sufficient wing thickness for suturing, while avoiding perforation into the sides of the urethral plate.

Urethral plate incision begins in its mid portion with surgeon and assistant holding symmetric countertraction. Using tenotomy scissors, the incision continues proximally and distally, maintaining even countertraction. The proximal extent of incision reaches just inside the meatus, while distally dissection ends at the tip of the urethral plate without extending into glans. The dorsal limit of midline plate incision is the tunica albuginea of the underlying corpora cavernosa.

A 6-French stent is passed into the bladder and secured to the glans traction suture. Urethral plate tubularization begins distally about 3 mm below the end of the plate, which corresponds to approximately the midpoint of the glans wings. This creates an oval meatus. The initial stitch is placed through all layers and tied, and then a running subepithelial closure continues proximally using 7-0 polyglactin on an ophthalmic needle. The knot is tied, and a second layer is sewn proximally to distally. All epithelium of the urethral plate should be turned into the lumen of the neourethra.

Dartos flaps interposed between the neourethra and overlying glans and skin closures are thought to reduce likelihood for fistulas. A dartos flap is raised from under the dorsal prepuce and shaft skin, dissecting in the same subepithelial plane used to mobilize preputial flaps. Once dissection reaches the penopubic region, there should be sufficient mobility to transpose the flap ventrally without tension. The distal end is button-holed and the flap is brought over the glans and placed covering the neourethra; 7-0 polyglactin stitches tack the corners of the flap deep inside the glans wings on either side of the neomeatus. Alternatively, ventral dartos preserved during degloving can be used as a flap over the neourethra.

When foreskin reconstruction is done, dorsal dartos is not readily accessible for a barrier layer. However, sufficient dartos can be raised ventrally and/or laterally to provide a flap over the neourethra.

Glansplasty begins distally, approximating the wings at the point where the ventral lip of the neomeatus should lie. Typically this is the highest point along the contour of the glans wing, and it is important to emphasize that no attempt is made to align the glans closure to the underlying tubularized urethra. Interrupted subepithelial 6-0 polyglactin stitches complete closure of the glans wings proximally to the corona. Usually 3 stitches are used.

Remnants of shaft skin originally adjacent to the hypospadiac meatus are excised from the subcoronal midline, and then the mucosal collar of inner prepuce is sutured together. The first stitch is placed proximally and then used to provide gentle traction to straighten the collar. Interrupted subepithelial 7-0 polyglactin stitches approximate the edges up to the corona. One or two 9-0 polyglactin stitches can be placed through the epithelium at the corona to finish closure.

When circumcision is desired, the dorsal prepuce and shaft skin are split down the middle to the coronal margin. Then a subepithelial stitch of 7-0 polyglactin anchors the dorsal shaft skin to the inner preputial collar at the 12-o'clock position. Next, ventral shaft skin is approximated proximally to distally with subepithelial stitches to recapitulate a median raphe, which is secured to the mucosal collar at 6 o'clock. Excess shaft skin to either side is excised and closure finished with interrupted subepithelial 7-0 polyglactin stitches.

After the mucosal collar is sewn in patients for foreskin reconstruction, the prepuce is reduced over the glans and a second layer of stitches placed for reinforcement. Finally the remaining outer prepuce and shaft skin are closed with a running subepithelial 7-0 polyglactin suture.

A sheet of Tegaderm encloses the penis; then a small gauze is placed and a second, larger sheet of Tegaderm secures the penis to the abdominal wall. This dressing falls off spontaneously within a few days and the dripping stent is removed between 5 and 7 days.

MIDSHAFT AND PROXIMAL TIP (Fig. 15-7)

The initial skin incision extends ventrally alongside the urethral plate taking care not to include hair follicles from adjacent skin in the tissues that will form the neourethra.

Skin incisions are outlined as for less severe cases described above, with the ventral lines running alongside the urethral plate ventrally to 1 to 2 mm beyond the meatus proximally. Midline incision then continues through the mid scrotum to later harvest tunica vaginalis. All these ventral lines are first injected with 1:100,000 epinephrine before incision. This is especially useful in proximal cases since often the ventral dartos is deficient and shaft skin is closely adherent to corpus spongiosum, increasing risk for significant bleeding if spongy tissues are inadvertently injured while degloving the skin.

After releasing skin and dartos, the corpus spongiosum alongside the urethral plate is elevated from the corpora and transected from the glans wings for later spongioplasty over the neourethra. At this point artificial erection is performed to assess bending. Bending less than 30 degrees can be straightened by dorsal plication, but greater curvature next leads to dissection completely under the urethral plate, freeing it off the corpora from the hypospadias meatus to the coronal margin. This mobilization can additionally be continued along the native urethra proximally all the way to the bulb. Persistent curvature greater than 30 degrees is corrected using 3 transverse corporotomies attempting to preserve

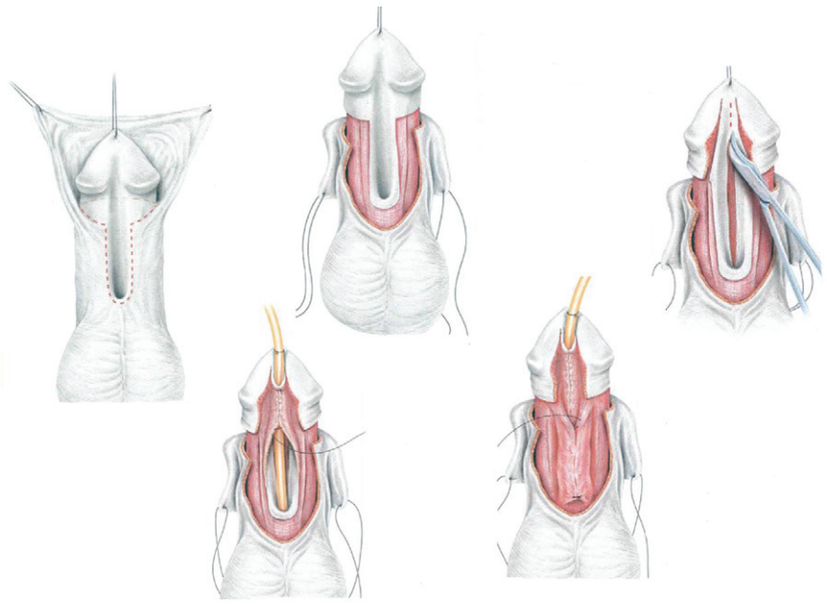

FIGURE 15-7. Proximal TIP repair. *(From Snodgrass WT: Snodgrass technique for hypospadias repair. BJU Intl 95:683-693, 2005.)*

the plate, or with transection of the plate as needed for straightening.

Incision of the plate follows, and a 6-French stent is placed into the bladder. Occasionally an enlarged utricle hinders catheter placement, in which case a wire can be passed directly or inserted through a cystoscope, over which the stent is positioned.

Tubularization of a long urethral plate differs from the technique in distal repairs. The first layer uses 7-0 polyglactin interrupted subepithelial stitches to turn epithelium into the lumen and securely tubularize the neourethra. A second running layer of 7-0 polydioxanone suture reinforces this suture line. Then spongioplasty is completed, approximating the corpus spongiosum over the neourethra with interrupted 7-0 polyglactin.

Dartos does not provide a satisfactory covering to the neourethra to prevent fistulas in proximal surgery. Consequently, a testicle is delivered from the scrotum and the tunica vaginalis opened transversely (Fig. 15-8). A 5-0 polypropylene stitch is placed into the tunica albuginea as a traction suture, and stay stitches are also used to secure the 2 corners of the tunica vaginalis flap. Then dissection continues proximally freeing the spermatic cord from the tunica vaginalis to the external ring. The testicle is replaced and its compartment sutured closed, while the tunica vaginalis flap is laid over the entire neourethra and secured with a few 7-0 polydioxanone stitches along its perimeter.

Glansplasty follows as described for distal operations. Penoscrotal transposition should also be corrected at this time. Often incisions can be made at the visible junction of scrotum to ventral shaft skin extending to the 3- and 9-o'clock locations, and subsequently bringing the 3- and 9-o'clock points together ventrally, additionally anchoring the shaft skin to the corpora on either side of the neourethra using 5-0 polydioxanone. This smooths the penopubic junction dorsally and may obviate need for more extensive scrotoplasty. However, when scrotal wings extend well above the penis, inverted U-incisions along their margins are made and

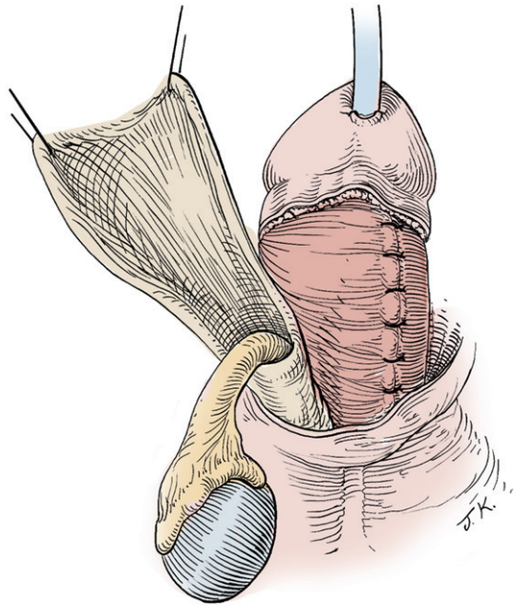

FIGURE 15-8. Tunica vaginalis flap. *(From Wein AJ [ed]. [2007]. Campbell-Walsh urology, 9th ed. Philadelphia: Elsevier.)*

the resultant flaps are swung down and to the midline under the ventral shaft of the penis. Shiny skin and scrotal clefts in the midline are excised and the scrotum closed in layers to prevent dead space and recreate a median raphe.

Tegaderm bandages are applied as described earlier. The stent remains for 14 days.

POSTOPERATIVE MANAGEMENT

Anticholinergics are provided to children 3 years of age and older to reduce bladder irritability while the stent is in place. In our experience, younger boys do not require this therapy.

Commentary by DAVID A. BLOOM

In the past 150 years the condition of hypospadias has stimulated dozens of ingenious surgical corrections that, by Darwinian progression, have led to better and better solutions. At the worst, hypospadias and chordee result in a life of daily voiding awkwardness, social embarrassment, sexual dysfunction, and infertility. Surgical correction should normalize everything. Many surgical innovations were building blocks that, as intermediate forms, have been discarded as they have no value in today's armamentarium. Now, in 2011, the Snodgrass repair is an essential, indeed dominant, procedure in the armamentarium for most common variations of hypospadias. If you don't like eponyms, consider that repair the "tabularized incised urethral plate," or TIP. We have little to add to Snodgrass's superb approach, but list them just to offer a few small regional variations.

1. For serious chordee, we favor a careful bilateral corporal plication, under short gaps of mobilized neural bundles, agreeing that a single line is usually sufficient. The midline single stitch is useful for moderate to minor bending, although very minor ventral deflection can be left alone. An erection test that overdistends the corpora may "overstate" the chordee. Usually, when doing the erection test we ask the participants in the operating room—"Does this look straight enough?" If not we would follow the Snodgrass protocol.
2. Small technical details. We find the #11 knife blade ideal for most skin incisions in hypospadias, facilitating the great precision necessary. We utilize 7-0 Vicryl sutures, preferring the less rigid knots left behind. Often we can raise a good flap to cover the neourethra from the penile shaft tissues rather than the prepuce as Snodgrass does when he is trying to preserve prepuce. Our routine dressing employs an inner wrap of Owens gauze, an outer wrap of Kling-type gauze, and four quadrants of foam tape applied to a Mastisol base. The tube is either a 6-French Foley with small balloon or a simple stent secured by the diaper. The tape secures a catheter/stent—which we remove in 2 to 7 days, depending on the repair. Double diapers are preferred, although older boys would get a traditional catheter and leg bag.

Chapter 16

Flaps in Hypospadias Surgery

JUAN C. PRIETO AND LINDA A. BAKER

Vascularized pedicle skin flap urethroplasties are described by their location of flap origin (perimeatal, parameatal, or preputial) and by their final configuration (flip-flap, onlay, or tube). In general, skin flap repairs are less commonly employed for primary hypospadias urethroplasty due to higher complication rates and diminished cosmesis when compared with the tubularized incised plate urethroplasty. The wise hypospadiologist will understand these techniques to use them when needed.

PERIMEATAL-BASED FLAP REPAIR

Mathieu, 1932

Although less popular today, the Mathieu, or flip-flap, procedure is suitable for primary repair of distal shaft, coronal, or subcoronal hypospadias associated with minimal or no penile curvature. This procedure requires a healthy underlying wide-grooved urethral plate and a thick, well-vascularized perimeatal midline shaft skin proximal to the hypospadiac meatus for the flip-flap. The maximum length of this flap is three times the base; thus, as a rule, this technique cannot be used to cover more than 1.5 cm. Keeping the dartos attached to the skin flap improves vascularity. Thin, transparent skin just proximal to the hypospadiac meatus associated with significant corpus spongiosal thinning and splaying will not support a Mathieu procedure, which, if done, would lead to meatal stenosis. The split prepuce can be reconstructed if circumcision is not desired. Glanular tilt and mild distal curvature may be corrected easily by dorsal plications.

Additional classic variations of the Mathieu procedure include the Mustardé and Horton-Devine repairs. In the Mustardé repair, the meatal based flap is tubularized and anastomosed to a triangular glanular flap through a tunnel created in the glans. The Horton-Devine technique differs from Mathieu procedure in that the creation of the triangular flap of the glans reduces the risk of meatal stenosis.

Place a 5-0 polypropylene nonabsorbable suture (NAS) into the glans for traction (Fig. 16-1) and to secure the urethral catheter at the end of the procedure. Mark lines for the glans wings on either side of the glanular urethral groove, 6 to 8 mm apart and extending from the planned neomeatus to the hypospadiac meatus. Measure the distance between the hypospadiac meatus and the planned neomeatus. Mark the incisions for the parameatal based urethral flap, matching the previous length measurement and ensuring a width that is 6 to 7 mm wider than the glanular groove width. Infiltrate the subcutaneous tissue with 1:100,000 epinephrine in 1% lidocaine (optional), and incise along the marks. Incise the prepuce circumferentially 10 to 12 mm proximal to the coronal sulcus and deglove the penis. This maneuver may remove curvatures caused by shortened ventral skin and dartos tissue. To assess for intrinsic corporal curvature, induce an artificial erection via rapid intracorporeal injection of normal saline (~10 to 15 mL) via a 20-gauge butterfly needle. If needed, perform corporal plication.

Dissect the glans wings, leaving Buck's fascia intact while generating thick, well-mobilized wings for further tension-free closure (Fig. 16-2). Raise the parameatal based flap from the shaft, preserving the attached vascularized subcutaneous tissue. The vascular supply is most tenuous at the hinge of the flap. Avoid the base during dissection to preserve the adventitial blood flow. Fold the flap over the glandular urethral plate, and anastomose the lateral sides of the flap to the lateral urethral plate with 7-0 subcuticular running absorbable sutures over a 6- or 8-French Silastic catheter. Invert the mucosa to minimize fistula formation (Fig. 16-3). Check for watertightness and reinforce areas of leaks. Tack the subcutaneous dartos tissue of the flap to the deep tissue of the glans.

Draw the shaft skin around to the ventrum by incising the foreskin in the dorsal midline as Byars' flaps (Fig. 16-4). A portion of one of these flaps may be deepithelialized and tacked over the urethroplasty to provide a barrier layer to minimize fistula formation.

Approximate the glans wings with subepithelial 6-0 or 7-0 interrupted absorbable sutures (undermine the flaps to avoid tension).

Trim excess foreskin if circumcision is desired and close the ventral and circumferential defect. Secure the catheter with the glans traction suture for 1 week.

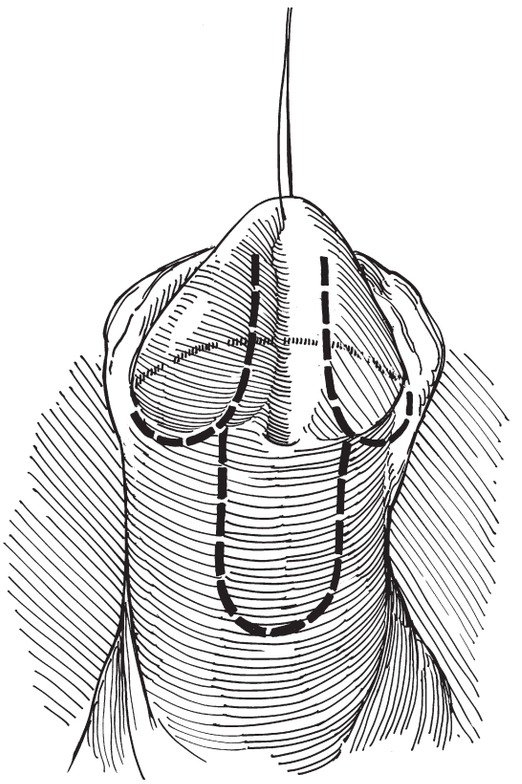

FIGURE 16-1.

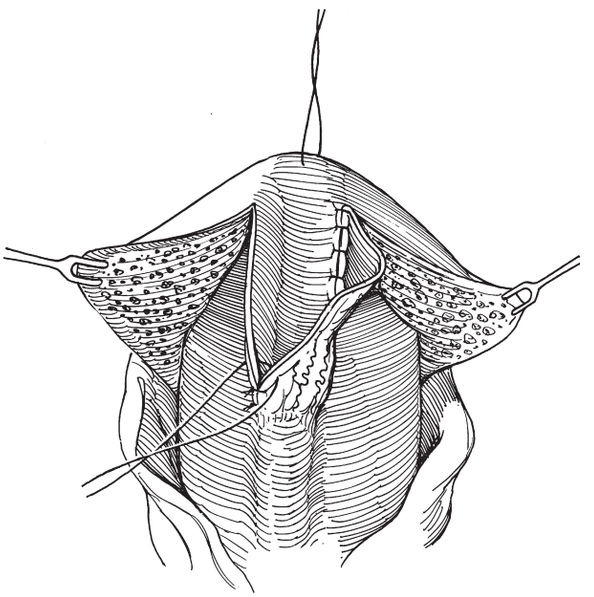

FIGURE 16-2.

ONLAY PREPUTIAL TRANSVERSE ISLAND FLAP

Duckett, 1980

Duckett popularized this onlay approach, which was initially described by Asopa in 1971, with the introduction of the transverse preputial island flap.

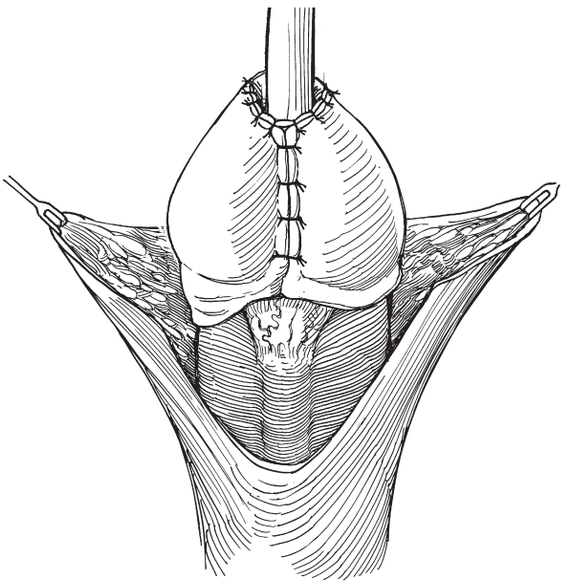

FIGURE 16-3.

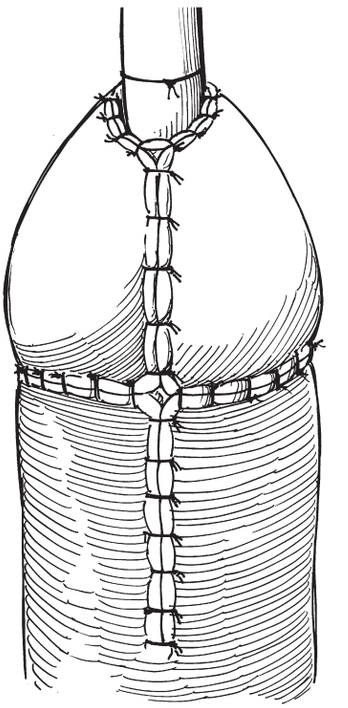

FIGURE 16-4.

Place a 5-0 stay suture on a tapered needle in the glans. Assess the tissue quality proximal to the hypospadiac meatus with a urethral sound and cut back the meatus into good spongiosal tissue if thin. Infiltrate the ventral meatal area and glans with 1:100.000 epinephrine-lidocaine solution. Mark and incise the coronal sulcus 6 to 8 mm proximal to the glans circumferentially except at the urethral plate. Extend an 8- to 10-mm-wide U-shaped incision around the urethral plate and proximal to the hypospadiac meatus. Deglove the penis to the deep base. If artificial erection shows curvature, perform dorsal tunica albuginea plication (TAP) tucks and/or urethral plate mobilization distally into

the glans, and off the corpora cavernosae to straighten. If still curved, an onlay preputial transverse island flap is not applicable because the urethral plate will require transection.

Once the penis is completely straightened with an intact urethral plate, develop glans wings by extending the urethral plate incisions along the glans urethral groove to the planned neomeatus (Fig. 16-5). Mobilize the glans wings by dissecting in the plane between the glans and the tips of the corpora cavernosae. Measure the distance from the hypospadiac meatus to the planned neomeatus.

In a rectangular fashion, place four traction sutures (5-0 polypropylene) in the dorsal inner preputial skin. Mark the inner preputial onlay flap to be 8 to 10 mm wide and at least as long as the length of the measured dissected urethral plate. Incise along the marks. Dissect a vascular pedicle for the preputial flap from the overlying dorsal shaft skin down to the base of the penis. Take great care not to devascularize the flap.

Rotate the flap ventrally from the side (Fig. 16-6). Suture the flap to the native meatus first along the lateral edge of the urethral plate nearest the pedicle, starting at the meatus and using subcuticular 7-0 synthetic absorbable suture. Redundant skin should be trimmed to accommodate the 8- or 10-French urethral stent (age dependent), preventing future kinking or diverticular formation. At the neomeatus, sutures should be interrupted to permit flap length adjustments and meatal size adjustments. The pedicle is then tacked to the tunica albuginea on each side to flatten the pedicle and to cover the neourethral anastomotic lines. Cut the remaining foreskin dorsally as Byars' flaps and rotate ventrally. If skin is available, some may be deepithelialized and also tacked over the urethroplasty to provide another barrier layer to minimize fistula formation. Alternatively, a tunica vaginalis flap may be used for this purpose.

Bring the glans flaps together in the midline over the onlay using subcuticular interrupted 6-0 or 7-0 synthetic absorbable sutures. Excise excess foreskin for circumcision. Reapproximate the skin to cover the shaft with interrupted subcuticular suturing. Apply the dressing and secure the urethral stent with the glans stay suture in place for 7 days.

TUBULARIZED TRANSVERSE PREPUTIAL ISLAND FLAP

Duckett, 1995

Currently less popular, this tube technique has been used in patients with proximal hypospadias with severe curvature that needed correction by division/resection of the urethral plate. The missing segment of urethra is bridged with a preputial skin tube raised as an island flap. While long tubes can be generated from a horseshoe-shaped zone of the prepuce, the resulting circular anastomoses is subject to fistula, stricture, and diverticular formation. Rotational torsion has also been noted from the vascularized flap. Thus, even on a proximal hypospadias case, if penis can be straightened by TAPs and aggressive radical proximal urethral mobilization, then leave the urethral plate intact and perform a single-stage, long, proximal tubularized incised plate urethroplasty.

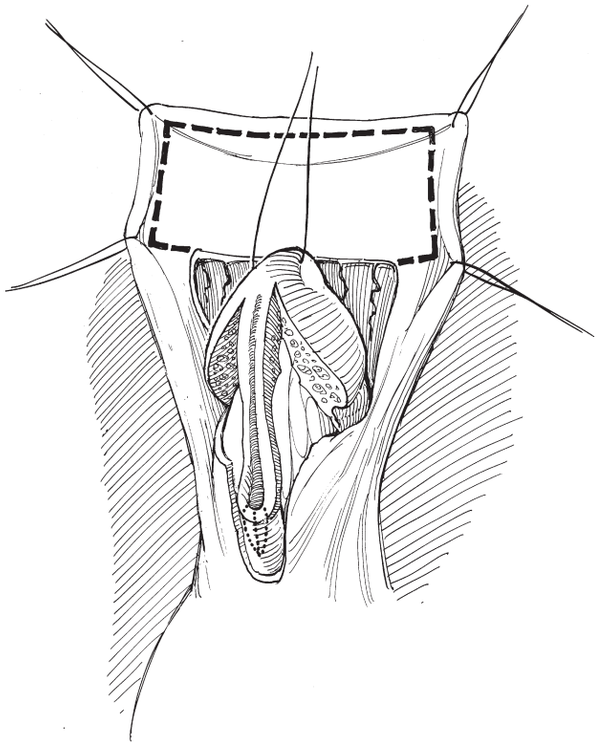

FIGURE 16-5.

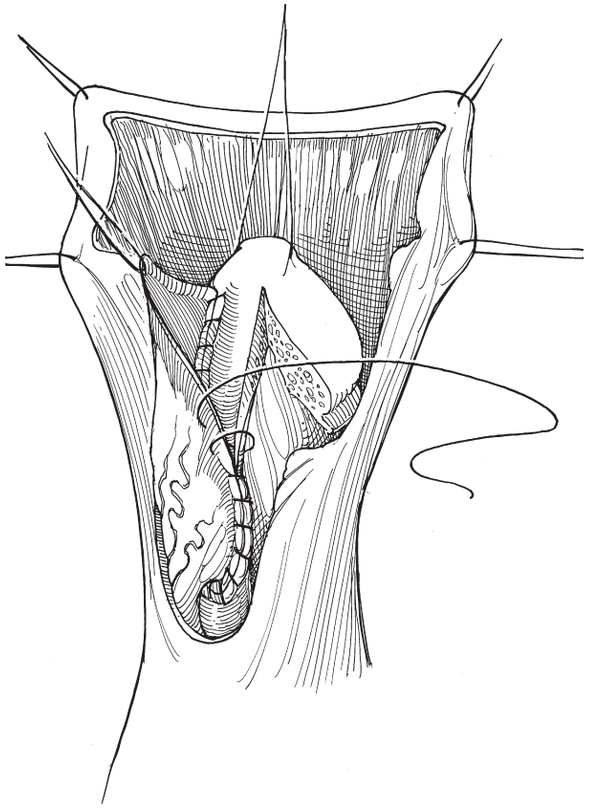

FIGURE 16-6.

Place a 5-0 stay suture in the glans. Assess the tissue quality proximal to the hypospadiac meatus with a urethral sound and cut back the meatus into good spongiosal tissue if thin. Mark and incise the coronal sulcus 6 to 8 mm proximal to the glans circumferentially except at the urethral plate (Fig. 16-7). Extend an 8- to 10-mm-wide U-shaped incision around the urethral plate and proximal to the hypospadiac meatus. Deglove the penis to the deep base. Perform an artificial erection. If curvature persists despite TAP and distal and proximal urethral plate mobilization, dissect the urethral plate off of the corporal bodies.

Place four fine traction sutures in the inner prepuce to fan out the ventral surface of the prepuce. Mark the skin for the neourethra to provide a width of 12 to 15 mm and enough length to bridge the gap. Incise along the marks just into the subcutaneous tissue.

Develop a plane deep to the superficial vascular supply well down to the base of the penis between the flap and the outer prepuce to form a substantial pedicle (Fig. 16-8). The vasculature of the pedicle usually is obvious, but take great care not to devascularize the flap.

Roll the preputial flap over an 8- to 12-French catheter (age dependent) and invert the edges with a running subepithelial 7-0 synthetic absorbable suture but place interrupted sutures at each end to permit trimming (Fig. 16-9). Examine the ends of the flap for ischemia and resect appropriately. Tubularization can also be performed, leaving initially the inner prepuce in situ against the foreskin. Approximate the subcutaneous tissue as a second layer over the suture line with a continuous 7-0 synthetic absorbable suture.

Rotate the tubularized flap around its base so that the right side of the flap is proximal. Avoid torsion by freeing the base of the pedicle adequately (the inner preputial flap can also be transferred ventrally through a mesenteric window and then the tube can be fashioned after anchoring one margin of the flap to the native meatus). Trim and spatulate the urethra, and suture the flap to it with 7-0 interrupted subepithelial synthetic absorbable suture. Orient the hypospadic urethral meatus so that the long suture line of the tubularized flap lies dorsally against the corpora. Tack the anastomotic area and neourethra to the corpora.

With sharp scissors, develop a plane ventrally between the cap of the glans and the corpora, and snip a path to the tip of the glans for the neourethral tube. Make a V-shaped incision at the tip. Remove a large plug of glans (2 × 15 mm), and reach inside the meatus to excise excess glanular tissue for a wide channel, at least 16 French in size. Check the caliber with bougies à boule. If the tunnel is not adequate, split the glans and form glans flaps. Pull the tubed flap through the glans channel, keeping the suture line against

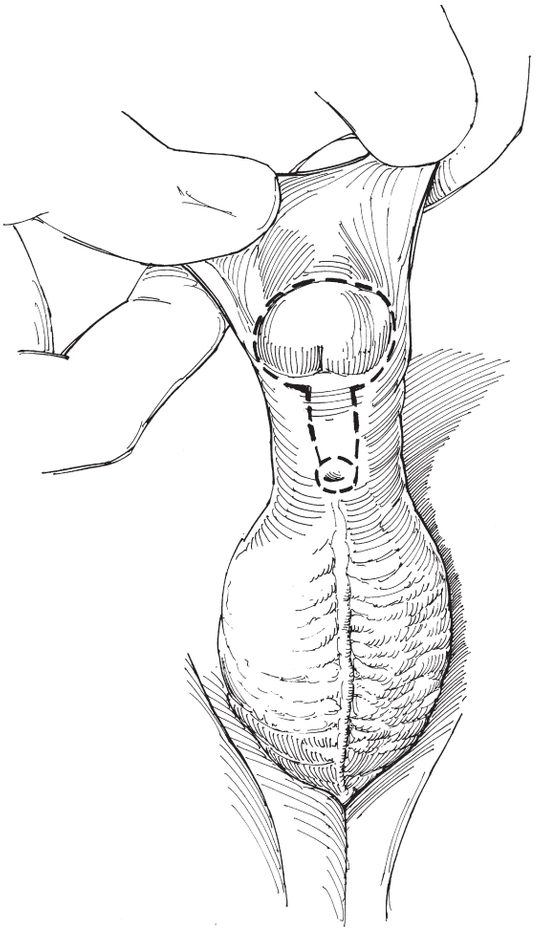

FIGURE 16-7.

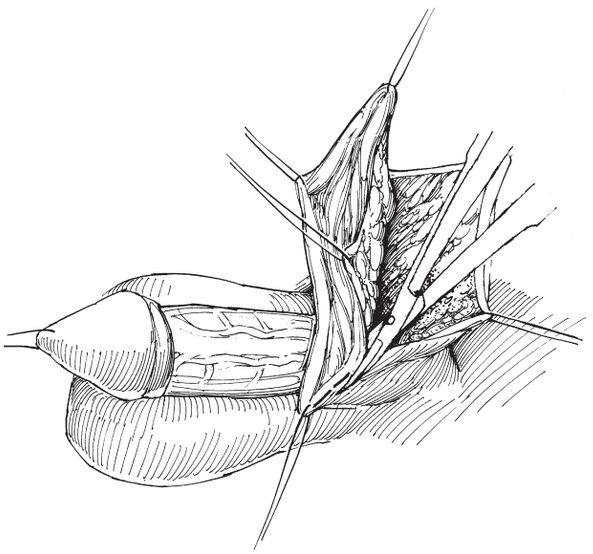

FIGURE 16-8.

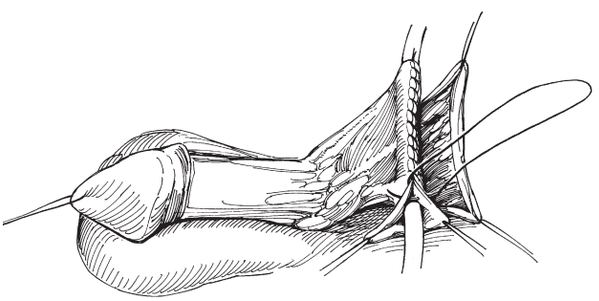

FIGURE 16-9.

the corporal bodies. Eliminate redundancy and excise excess tube. Suture the tubed flap to the new meatus carefully with interrupted 7-0 synthetic absorbable suture. Tack the tube to the corpora along the shaft with suture to prevent kinking of the anastomosis. Insert an 8-French silicone stent into the bladder and secure it to the glans. Cover the anastomotic lines with subcutaneous pedicle tissue, tacking it in place to cover the whole repair without compromising its vascular supply. Remember that if the flap appears to have been devascularized, it can be defatted and converted into a free graft.

Divide the dorsal prepuce in the midline, rotate the flaps ventrally, and trim them appropriately for skin coverage. Apply dressings. Remove the silicone tube in 1 week.

This page intentionally left blank

Chapter 17

Two-Stage Repair of Hypospadias

PATRICIO GARGOLLO AND JOSEPH BORER

The majority of hypospadias can be repaired with a one-stage procedure. In the setting of scrotal or perineal hypospadias, severe curvature, and a small penis, we prefer to perform a two-stage repair as described by Retik and colleagues. (See Chapter 15 for algorithm.)

PREOPERATIVE CONSIDERATIONS

Preoperative Testosterone Administration

Androgen stimulation or androgen supplementation may be undertaken preoperatively in patients with a small phallus, although controversies exist regarding their use. The two main routes of administration are intramuscular (IM) and transdermal. The following dosage schedules are recommended:

- Intramuscular (IM) human chorionic gonadotropin
  - Begin to 6 to 8 weeks preoperatively
  - 250 IU twice weekly in boys younger than 1 year
  - 500 IU twice weekly in boys aged 1 to 5 years
- IM testosterone enanthate
  - Administer at 5 and 2 weeks preoperatively
  - Alternatively administer weekly for 3 weeks
  - Dose: 2 mg/kg or 25 mg per dose
- Topical dihydrotestosterone cream
  - Administer daily for 4 weeks preoperatively
  - Administer 5% cream twice daily for 3 weeks preoperatively

OPERATIVE TECHNIQUE

The basic principle of a two-stage repair is to create a "new" urethral plate with a graft of alternative tissue during the first stage and then tubularize this tissue to create a neourethra during a second stage. The choice of tissue for the initial graft depends on several factors including surgeon experience, availability of preputial skin, and history of previous surgeries. The following are main categories of grafts for the initial (first stage) repair:

- Byars' flaps—pedicled skin flaps of the dorsal hood foreskin, which are repositioned ventrally
- Bracka graft—free, partial thickness skin graft onlay
- Mesh free skin graft onlay
- Buccal mucosa free graft onlay

First Stage

At the first stage, an orthoplasty is performed and a graft is placed on the ventral penis, which serves as the tissue for tubularization and neourethra creation during the second stage. Traction on the penis is maintained by placing a 5-0 Prolene suture in the glans. Incisions are made along the lines shown in Figure 17-1. The penis is completely degloved, any ventral tethering tissue is resected and the urethral plate is divided. An artificial erection is established to determine the severity of penile curvature intraoperatively (described in Chapter 23). If significant curvature persists after performing these maneuvers to straighten the penis, then an orthoplasty may be undertaken at this time.

Orthoplasty Techniques

Orthoplasty may be performed with one of several techniques. We prefer to use an interposition dermal graft inlay after transverse incision of the corpora cavernosa directly at the apex of maximal concave curvature (Fig. 17-2A). A full thickness skin graft is taken from the inguinal region and the subcutaneous fat and epithelium are completely removed. This is then inlayed into the cavernosal defect (see Fig. 17-2B). An alternative to ventral dermal grafting for persistent chordee is the use of a tunica vaginalis graft.

Once the penis is straight, the glans is deeply incised in the ventral midline distally to the point of the eventual neomeatus (Fig. 17-3). For those with a deep glanular groove, longitudinal incisions may be placed lateral to the groove, bilaterally (see Fig. 17-3 inset). Another option is to leave the glans intact, cover the ventral shaft with the appropriate tissue (e.g., skin, buccal graft), and reapproximate the distal end of graft to the subcoronal circumcising incision. A tubularized incised plate (TIP) urethroplasty can then be performed for the distal aspect of the neourethra at the second stage of the repair.

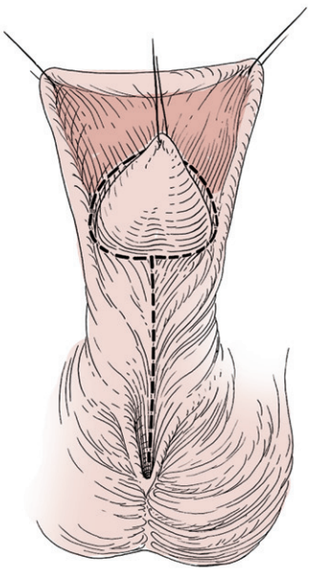

FIGURE 17-1. *(From Wein AJ [ed]. [2007]. Campbell-Walsh urology, vol 4, 9th ed. Philadelphia: Elsevier, p 3736.)*

Pedicled Dorsal Foreskin Flaps (Byars' Flaps)

A midline longitudinal incision is made in the preputial and dorsal distal penile shaft skin. The apex of the split dorsal flap is fixed to the dorsal coronal sulcus with 4-0 or 5-0 interrupted absorbable sutures. The resulting flaps are brought around their respective sides on the lateral aspect of the penis and anastomosed with fine, interrupted absorbable sutures to the penile ventrum beginning at the distal apex of the glans incision (Fig. 17-4). Sutures are placed with a simple interrupted full-thickness technique to approximate the transferred skin in the ventral midline. Simple interrupted sutures approximate transferred skin and native meatus proximally. In some cases, it may take all of the preputial skin to cover the ventral aspect of the liberated and straightened shaft. These steps provide well-vascularized tissue to be used for neourethra formation (tubularization) at the second stage.

Extragenital Grafts

In certain cases there may not be enough penile shaft skin to create a pedicled genital skin flap for ventral penile coverage during the first stage. In these cases, it becomes necessary to use free onlay grafts from extragenital sources. The concept of free onlay grafts is independent of the type of tissue used. Namely, coverage is provided for the ventral penis to provide enough tissue for future tubularization and neourethra creation/formation during the second stage. Regardless of the graft tissue chosen, the initial steps remain the same and are described earlier (First Stage).

Free, Partial Thickness Skin Graft (Bracka Graft)

The source of this type of graft should bear as little hair as possible to prevent future complications relating to hair growth in the neourethra. Possible skin donor sites include the inner forearm, the buttocks, inguinal region, and preputial skin. If there is insufficient skin for coverage, the graft may be meshed. Once this graft is harvested, it is fashioned and trimmed to cover the ventral penis and the deep incision made in the glans. Similar to the Byars' flap technique described earlier, the edges of the graft are reapproximated to the skin edges of the penile shaft skin on both sides laterally and to the edges of the glans incisions distally using fine, interrupted absorbable sutures. Several small holes should be made on the graft sharply to prevent seroma/hematoma formation between the graft and the ventral penis, which could inhibit graft take.

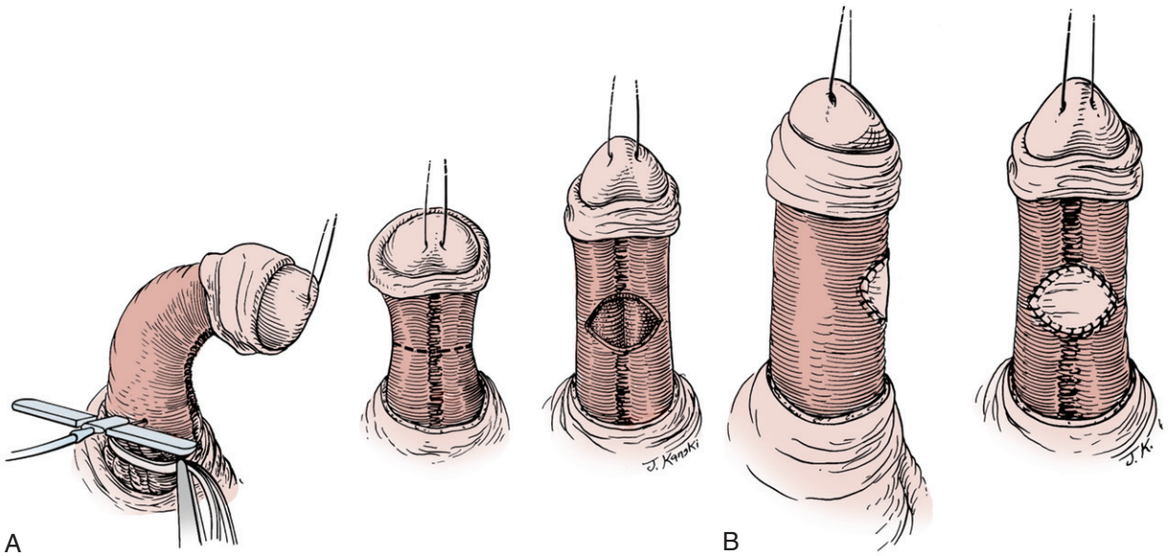

FIGURE 17-2. *(From Wein AJ [ed]. [2007]. Campbell-Walsh urology, vol 4, 9th ed. Philadelphia: Elsevier, p 3736.)*

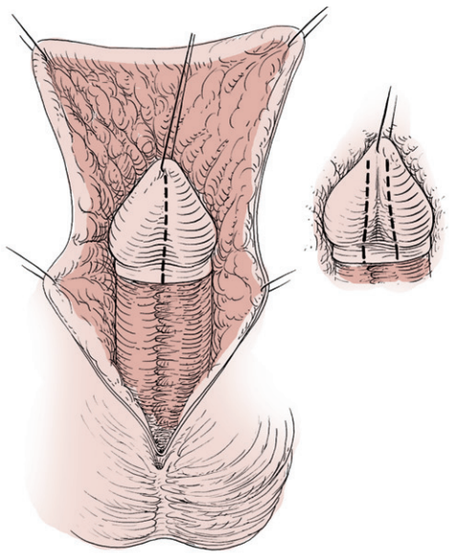

FIGURE 17-3. *(From Wein AJ [ed]. [2007]. Campbell-Walsh urology, vol 4, 9th ed. Philadelphia: Elsevier, p 3736.)*

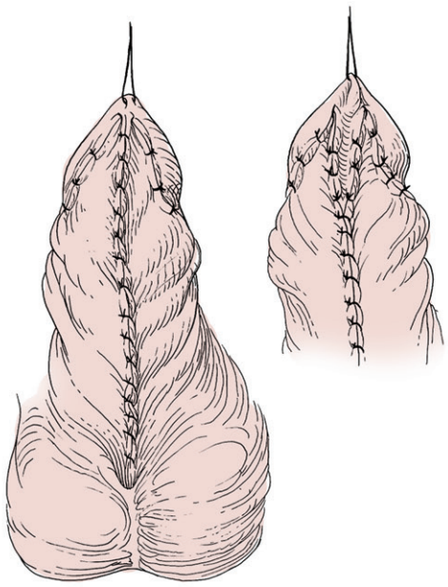

FIGURE 17-4. *(From Wein AJ [ed]. [2007]. Campbell-Walsh urology, vol 4, 9th ed. Philadelphia: Elsevier, p 3736.)*

Dressing and bolsters for free onlay grafts are discussed later.

General Postoperative Care After First Stage

The bladder is drained with a catheter in the urethra. Alternatively, a suprapubic tube may be placed. Free grafts are bolstered with a compressive occlusive dressing—a dental roll. Byars' flaps are wrapped with a sterile gauze. If a buccal graft is used, then patients, if old enough, should rinse their mouth three times per day with a warm salt solution or a 50% peroxide mixture.

Second Stage

The second stage is performed 6 months or more after completion of the first stage. The primary goal of the second stage of the procedure is to create a neourethra that bridges the defect between the hypospadiac meatus and the tip of the penis. The adequacy of any orthoplasty performed during the first stage should also be assessed with an artificial erection. Tissue to be used for neourethra construction is marked on the ventral aspect of the penis at a width of approximately 15 mm, centered on the midline (Fig. 17-5). Once incised, the lateral edges of this tissue are dissected only minimally toward the midline so as to preserve the vascular supply to the neourethra. Tubularization of local skin proceeds in Thiersch-Duplay fashion using a running, inverting, full-thickness subcuticular suture of fine Vicryl. Reapproximation of the glans over the newly constructed urethra should be done loosely in two layers. To accomplish this, the glans should be incised deeply laterally and reapproximated with 6-0 Vicryl over a sound inserted between the glans and the urethra to avoid making the glans too tight. Second-layer neourethra coverage is either with local subcutaneous tissues or a tunica vaginalis flap. Subcutaneous tissues and penile skin are approximated in the ventral midline with interrupted simple 4-0 absorbable sutures (chromic). We prefer urinary diversion with a urethral and a suprapubic catheter for 7 and 14 days, respectively. The penis is dressed in an occlusive dressing and the patient is immobilized as much as possible for 2 to 3 days. The meatus should be dilated daily by the parent or the patient for 6 months.

A well-vascularized second layer of tissue coverage placed over the neourethra suture line is perhaps the

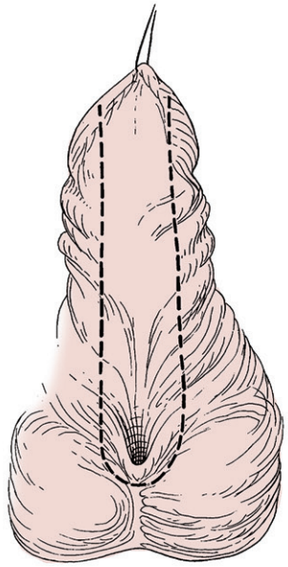

FIGURE 17-5. *(From Wein AJ [ed]. [2007]. Campbell-Walsh urology, vol 4, 9th ed. Philadelphia: Elsevier, p 3736.)*

single most important step in decreasing the risk of urethrocutaneous fistula. In general, unless immediate reexploration is indicated for bleeding, infection, or debridement, reoperation for complications should not be performed sooner than 6 months after previous repair.

When reoperation is indicated, complications such as meatal stenosis, urethrocutaneous fistula, and urethral stricture can be repaired expeditiously. However, more serious complications involving either partial or complete breakdown of the hypospadias repair may require a major reconstructive effort.

DAVID A. BLOOM

Commentary by

Even in the most optimistic days of single-stage hypospadiology, we argued strongly along with Retik that a staged approach would always be a wise choice in some boys with severe hypospadias. Furthermore, we have seen some infants with concomitant severe chordee who can be rendered straight as an arrow at initial orthoplasty, but over a year or so interval they may develop some recurrence, although never to the degree of the original chordee. The point is that modest recurrence can be easily adjusted in a second stage. An underappreciated condition with severe chordee is penoscrotal transposition. This can be easily fixed at a preliminary procedure by V-Y scrotal rotation flaps, which result in more normal-appearing genitalia. We believe in identifying and solving these preliminary conditions before committing to the neourethra construction and glansplasty.

You will usually notice that penile skin and subdermal tissue coverage are at a premium in these little boys, thus we have been firm believers in the buccal graft since first seeing it demonstrated in Varese by Gerard Monfort in 1993. We have used buccal grafts in three ways: as onlays over a narrow ventral strip of cutaneous skin, as true tubes, and as "tadpole grafts" that are widely onlayed proximally to obviate a stricture, but tubularized distally to the meatus. We do rinse, trim, and secure the grafts in ice saline baths and slushes, figuring that warm ischemia and hot operating room lights are not good for these little autotransplants. Gargalo and Borer rightly state that a well-vascularized second layer of coverage is critical. This is made more likely when penile skin is not sacrificed to be used as a neourethra.

Section IV

PENIS: MALIGNANCY

This page intentionally left blank

Chapter 18

Partial Penectomy

MARK L. GONZALGO AND DIPEN J. PAREKH

Partial penectomy is the surgical standard of care for invasive tumors of the mid to distal penis. A distance of 2 cm from the surgical margin of resection has been historically recommended as a primary goal to achieve optimal cancer control. Recent data suggest that acceptable local recurrence rates can be obtained with a surgical margin of 1 cm. Microscopic invasion of penile carcinoma has been shown to be influenced by tumor grade and should be considered when determining the final extent and margin of surgical resection.

The primary goal of partial penectomy is cancer control. A secondary goal includes preservation of the ability to void in the standing position. The length of penile shaft remaining after partial penectomy can be variable and approximately 3 cm has been suggested as an acceptable length to maximize functional outcomes. Voiding from a penile stump that is too short to control a urinary stream may be less desirable than voiding through a perineal urethrostomy. Total penectomy with reconstruction of a perineal urethrostomy should be considered when negative surgical margins cannot be achieved with partial penectomy or in cases when the remaining penile stump is too short to effectively direct the urinary stream.

Position: supine. After the area is prepped and draped in the standard fashion, the lesion is excluded from the surgical field with a surgical glove or towel. A tourniquet is applied to the base of the penis using a Penrose drain, a red rubber catheter, or plastic tubing. A Foley catheter can be inserted at the beginning of the procedure to facilitate mobilization of the urethra during surgery.

Incision: a circumferential incision is made along the penile shaft skin 1.5 to 2 cm proximal to the lesion (Fig. 18-1A). The incision is carried down from the skin to the level of Buck's fascia (see Fig. 18-1B). The superficial and deep dorsal veins are ligated and divided. Buck's fascia is incised to the level of the tunica albuginea of the corpora cavernosa.

The corpora cavernosa are divided, leaving the corpus spongiosum intact (Fig. 18-2). The tourniquet can be temporarily released to identify bleeding vessels, which can be oversewn with absorbable suture. Tissue can be obtained from the penile stump for frozen section analysis.

The urethra is dissected from the corpus spongiosum distally for a distance of approximately 1 to 1.5 cm and transected (Fig. 18-3). The urethra is spatulated on its dorsal surface to facilitate reconstruction and prevent stenosis of the neourethra.

The ends of both corpora are closed transversely with interrupted absorbable 2-0 sutures that incorporate the septum (Fig. 18-4). Two sutures are placed in the corpus spongiosum around the urethra. The tourniquet can be released to identify any additional bleeding vessels that require suturing.

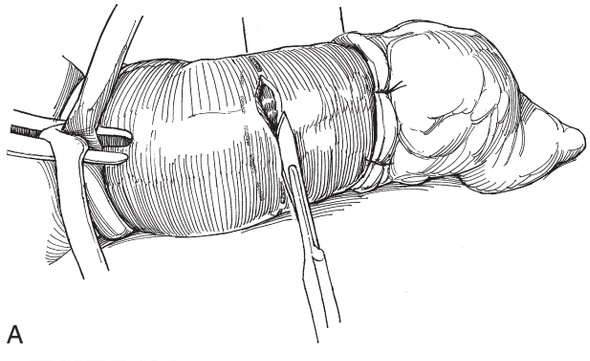

A



B

FIGURE 18-1.

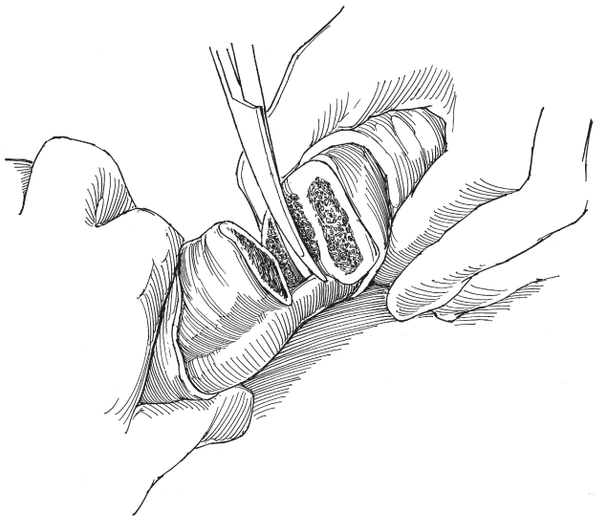

FIGURE 18-2.

The penile skin is closed on the ventral surface in the midline with interrupted 3-0 or 4-0 absorbable suture material (Fig. 18-5A). The spatulated urethra is approximated to the penile skin to create an oblique meatus with its open side at the 12-o'clock position. The remaining penile skin can be sutured dorsally with interrupted 3-0 or 4-0 absorbable sutures (see Fig. 18-5B). A sterile dressing can be applied and an 18-French Foley catheter is left indwelling for 3 to 5 days (see Fig. 18-5C).

POSTOPERATIVE PROBLEMS

Early complications following partial penectomy include infection, bleeding, and meatal stenosis. *Infection* and *tumor spillage* can be decreased by use of perioperative antibiotics and by excluding the tumor with a surgical glove before incision. *Stenosis* of the urethral meatus can be reduced by creating a long elliptical suture line.

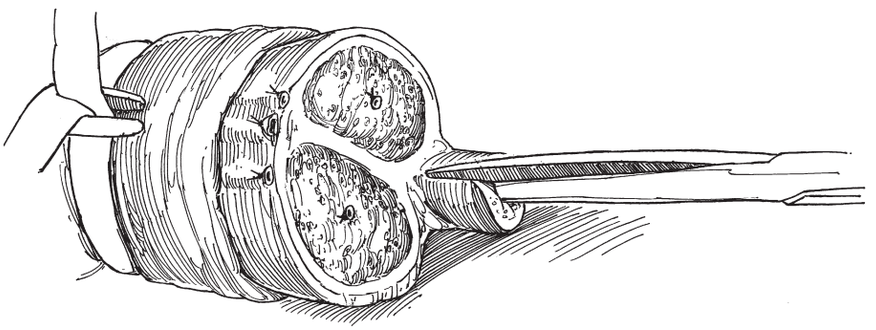

FIGURE 18-3.

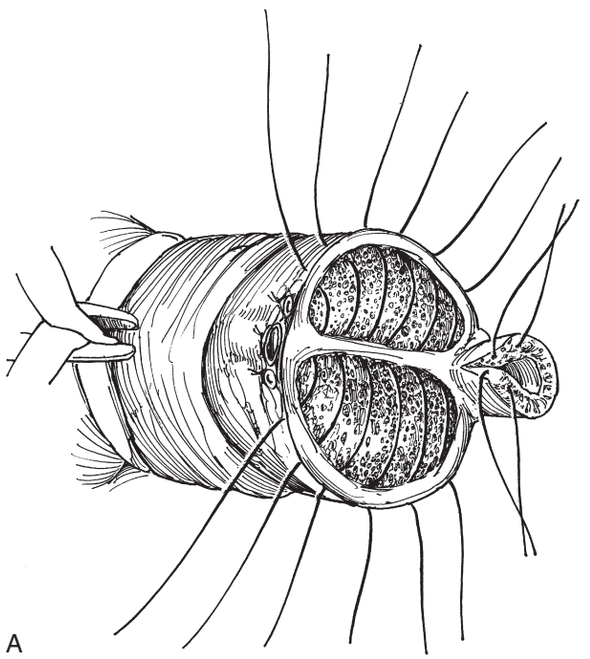

A

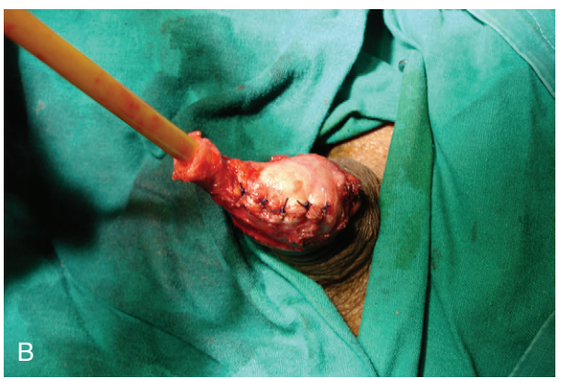

B

FIGURE 18-4.

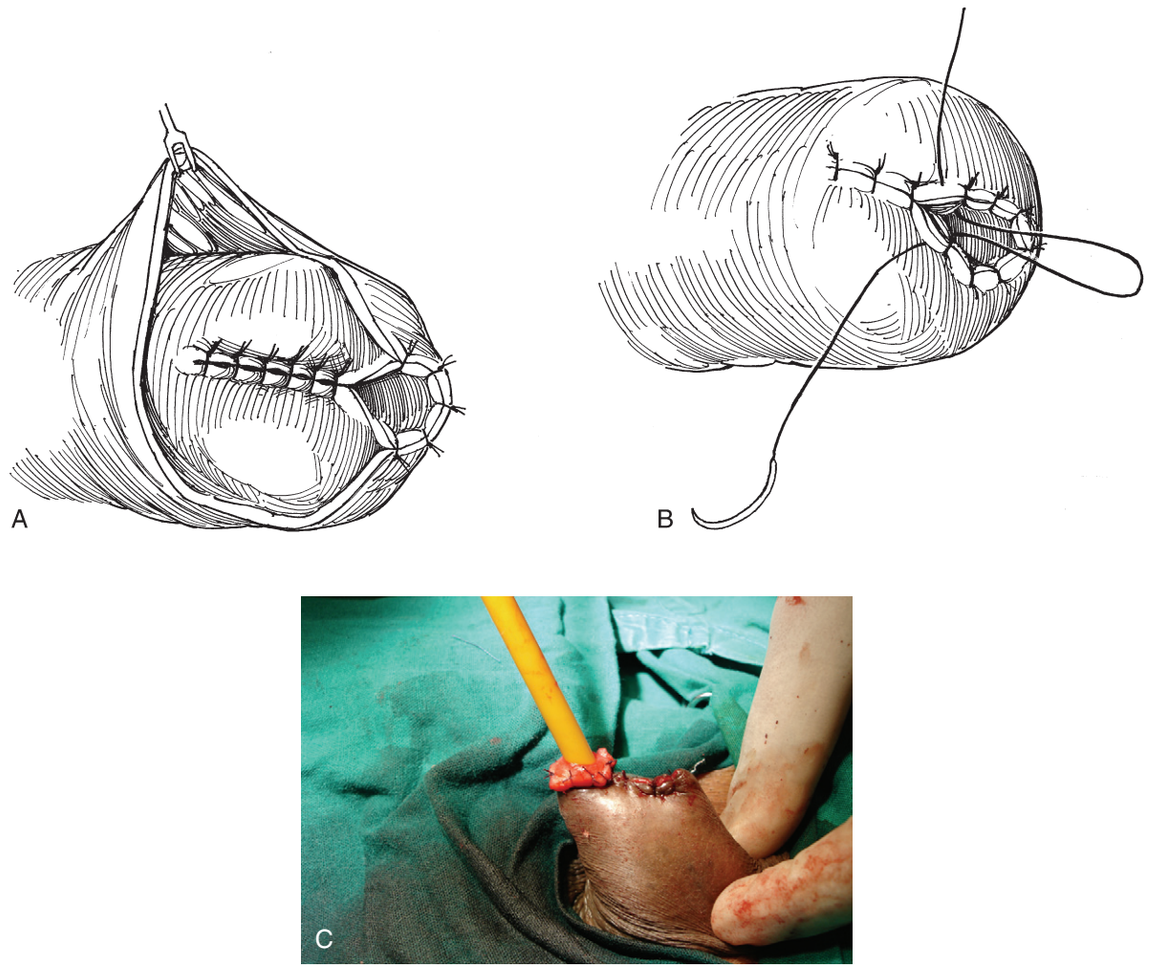

FIGURE 18-5.

This page intentionally left blank

Chapter 19

Total Penectomy

ALAN A. NISBET AND JEFFREY M. HOLZBEIERLEIN

Most penile cancers are fairly obvious (Fig. 19-1); however, before total penectomy is undertaken, the diagnosis should be confirmed histologically by either punch biopsy or touch prep. Excisional biopsy may be obtained at the time of surgery from the lesion for frozen section before penectomy.

Secondary infection of the involved penis is common; therefore antibiotic coverage should be started 3 to 5 days preoperatively when feasible.

A thorough staging workup, including careful palpation of the inguinal nodes, a computed tomography scan of the chest, abdomen, and pelvis, and bone scan should be performed before surgery. In addition, laboratory evaluation should be performed with careful attention to calcium values, which may need correction before surgery in patients with advanced penile cancer.

TECHNIQUE

Step I

Place the patient in an exaggerated dorsolithotomy position (similar to that for a perineal prostatectomy). Isolate the lesion by sewing a surgical glove in place over the lesion with 3-0 silk or by placing a condom over the penis (Fig. 19-2). Make an elliptical incision around the penis (Fig. 19-3) and dissect through the subcutaneous tissue dorsally with the electrocautery.

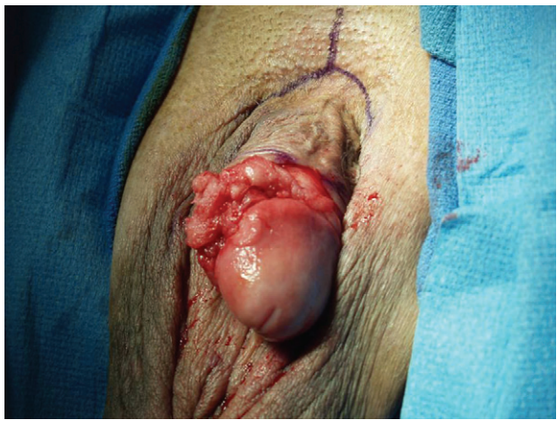

FIGURE 19-1.

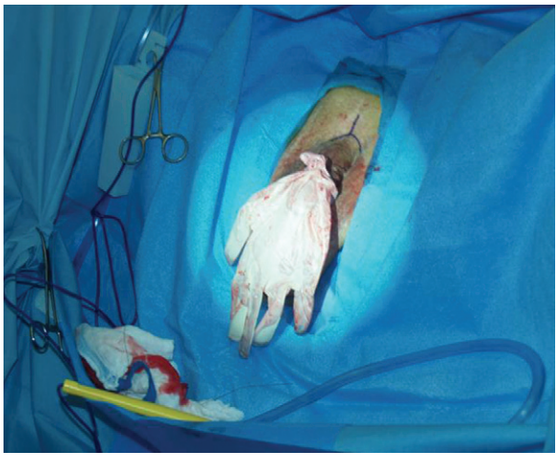

FIGURE 19-2.



FIGURE 19-3.

Step 2

Divide the suspensory ligaments to the penis with electrocautery and ligate the superficial dorsal vasculature of the penis with a 2-0 silk tie.

Step 3

Open Buck's fascia on the ventral aspect of the penis to identify the urethra. Dissect the urethra and isolate it from the corporal bodies, leaving plenty of length to reach the perineum. Divide the urethra sharply and tag the distal end at the 12-o'clock position with a 3-0 silk suture. Continue the dissection of the urethra off of the corporal bodies back to the pubic ramus (Fig. 19-4).

Step 4

Using both sharp and electrocautery dissection, dissect the corporal bodies back to their insertion on the pubic rami. Divide the corporal bodies with the electrocautery and then oversew the stumps individually with a running 2-0 polygalactin suture. A 2-cm incision has been classically recommended, although more recent reports suggest lesser margins are adequate.

Step 5

Make a 1- to 2-cm elliptical incision in the perineum with a #15 scalpel blade and carry this through the dermis and subcutaneous fat. Pass a tonsil clamp through this incision into the defect created from the penectomy. Grasp the 3-0 silk suture on the end of the urethra and gently bring the urethra through the perineal opening. Careful attention should be made not to angulate the urethra.

Step 6

Sharply excise any excess urethra and then spatulate the urethra at the 12-o'clock position. "Mature" the urethra by placing interrupted 4-0 monofilament poliglecaprone sutures in a circumferential fashion around the urethra starting at the crotch beginning of the spatulation on the urethra (Fig. 19-5). The sutures should include small bites of the urethra and then a bite of the subcutaneous tissue and skin on the perineum. Place a Foley catheter through the urethra into the bladder. Make sure that it passes easily with a smooth course. Then wrap the catheter at the perineal opening with Vaseline gauze.

Step 7

Close the scrotal skin to the suprapubic skin with interrupted 2-0 nylon sutures in a vertical mattress fashion. Before closing, place a Penrose drain deep in the defect and bring out through one side of the incision (Fig. 19-6). Suture the drain to the skin and place a safety pin through the end to prevent loss of the drain.

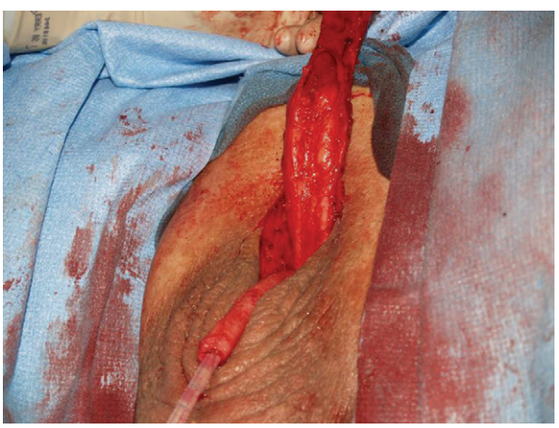

FIGURE 19-4.



FIGURE 19-5.

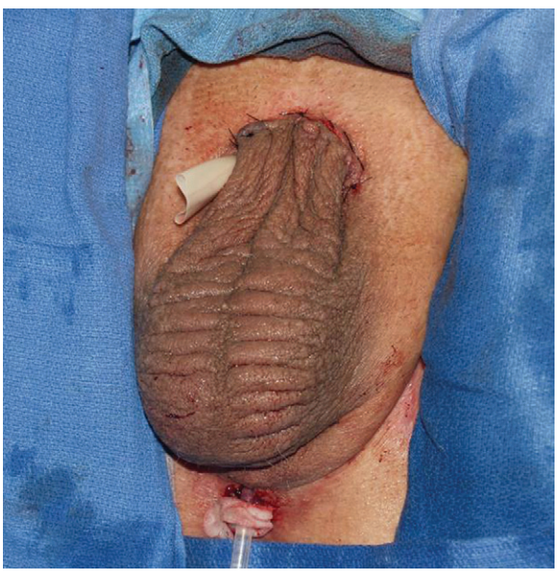

FIGURE 19-6.

Step 8

Dress the wound with Kerlix Fluffs and place either an elastic undergarment or an athletic supporter on to hold the dressing in place.

POSTOPERATIVE PROBLEMS

Meatal stenosis of the urethral opening is the most common complication of the procedure. Dilation with VanBuren sounds is usually successful in keeping the opening open and should be started as soon as the patient notices any decrease in stream.

Bleeding is not excessively common but may occur if the patient develops an erection in the immediate postoperative period, although this is relatively rare. The Penrose drain should allow assessment of this and prevent hematoma formation. For severe bleeding, opening of the wound and oversewing any bleeding tissue may be necessary. *Wound infection* is not uncommon, particularly in obese and diabetic patients. Superficial skin infections should be treated with antibiotics while deeper wound infections may require incision and drainage. Wounds should be packed and debrided, and allowed to heal by secondary intent. *Urethral necrosis* may occur in patients in whom infection develops postoperatively or in diabetic patients. Careful debridement of the wound and any nonviable urethra should be performed. Skin darts can then be dropped back to the urethral edge at a later date to prevent stenosis.

This page intentionally left blank

Chapter 20

Ilioinguinal Lymphadenectomy

DOUGLAS F. MILAM

The extent of surgical dissection during ilioinguinal lymphadenectomy remains controversial. Historically, in many centers all patients with invasive penile cancer were treated with radical ilioinguinal lymphadenectomy. Surgical treatment remains today the most effective staging method, has therapeutic benefit for those with minimal nodal disease, and provides effective local control for high-volume nodal disease. Many investigators have questioned the need for radical ilioinguinal lymphadenectomy in patients with clinically normal examinations. Less aggressive modified lymphadenectomy designed to minimize postoperative morbidity in patients without evidence of grossly positive nodes is now widely practiced (Catalona WJ. Modified Inguinal Lymphadenectomy for Cancer of the Penis with Preservation of Saphenous Veins: Technique and Preliminary Results, J Urol 1988; 140: 306-310). Modified lymphadenectomy provides better staging information and better cancer control than sentinel node biopsy.

Partial or total penectomy is performed at a separate setting to determine the depth and extent of tumor invasion. Palpable inguinal lymph nodes may be due either to the spread of tumor or inflammation due to chronic infection at the primary tumor site. Treatment with oral antibiotics may minimize postoperative complications and are helpful in reducing the size of inflammatory nodes. For palpable nodes, treat with antibiotic agents for 4 to 6 weeks before performing inguinal lymphadenectomy. Patients with palpably gross tumor should be treated with radical inguinal lymphadenectomy. Other patients with a high-risk primary tumor, but clinically negative nodes may be treated with modified inguinal lymphadenectomy.

On the day of lymphadenectomy, give appropriate intravenous antibiotics perioperatively and postoperatively. After resecting gross inguinal metastasis using radical inguinal lymphadenectomy, consider a myocutaneous flap to repair the defect. Select unilateral dissection if ipsilateral nodes are detected late after penectomy; perform bilateral dissection for most patients due to bilaterality of nodal metastasis.

Instruments. Include a marking pen, skin hooks, loop retractors, vascular clips, closed suction, and a standard surgical tray.

UNILATERAL DISSECTION

Note distribution of lymph nodes and extent of exposure through an inguinal incision (Fig. 20-1). The black node is the sentinel node. This node, usually the first to be involved with penile carcinoma, lies no more than 1 cm away from the superficial epigastric vein. In some cases, more than one lymph node is found in this group. In this situation, all nodes should be removed, but the sentinel node is always the larger and more medially situated.

Sentinel Node Biopsy

The usefulness of sentinel node biopsy is debated. Modified superficial saphenous vein–sparing lymph node dissection for patients with a clinically normal inguinal exam can be strongly advocated. Sentinel node biopsy is discussed here for completeness. Proceeding directly to node dissection, even without evidence of nodal involvement, is advocated with increasing frequency because 20% of patients with metastasis have no external evidence of nodal involvement.

To biopsy the sentinel node, make a 5-cm incision 2 fingerbreadths lateral and 2 fingerbreadths inferior to the pubic tubercle, positioning it over the junction of the saphenous vein with the femoral vein. Insert the index finger under the flap in the direction of the pubic tubercle to palpate the sentinel node group. Retraction of the small flap allows dissection of the local nodal group while preserving all surrounding structures.

It is usually better to perform biopsy and frozen section examination as a step in the lymphadenectomy rather than as a separate procedure. If the frozen section biopsy results are positive from the sentinel node, proceed with lymphadenectomy. During modified lymphadenectomy, consider performing a biopsy of the sentinel node first; if it is negative and no nodes are palpable, then a more superficial saphenous vein sparing procedure may be considered. The presence of positive nodes may necessitate radical lymph node dissection.

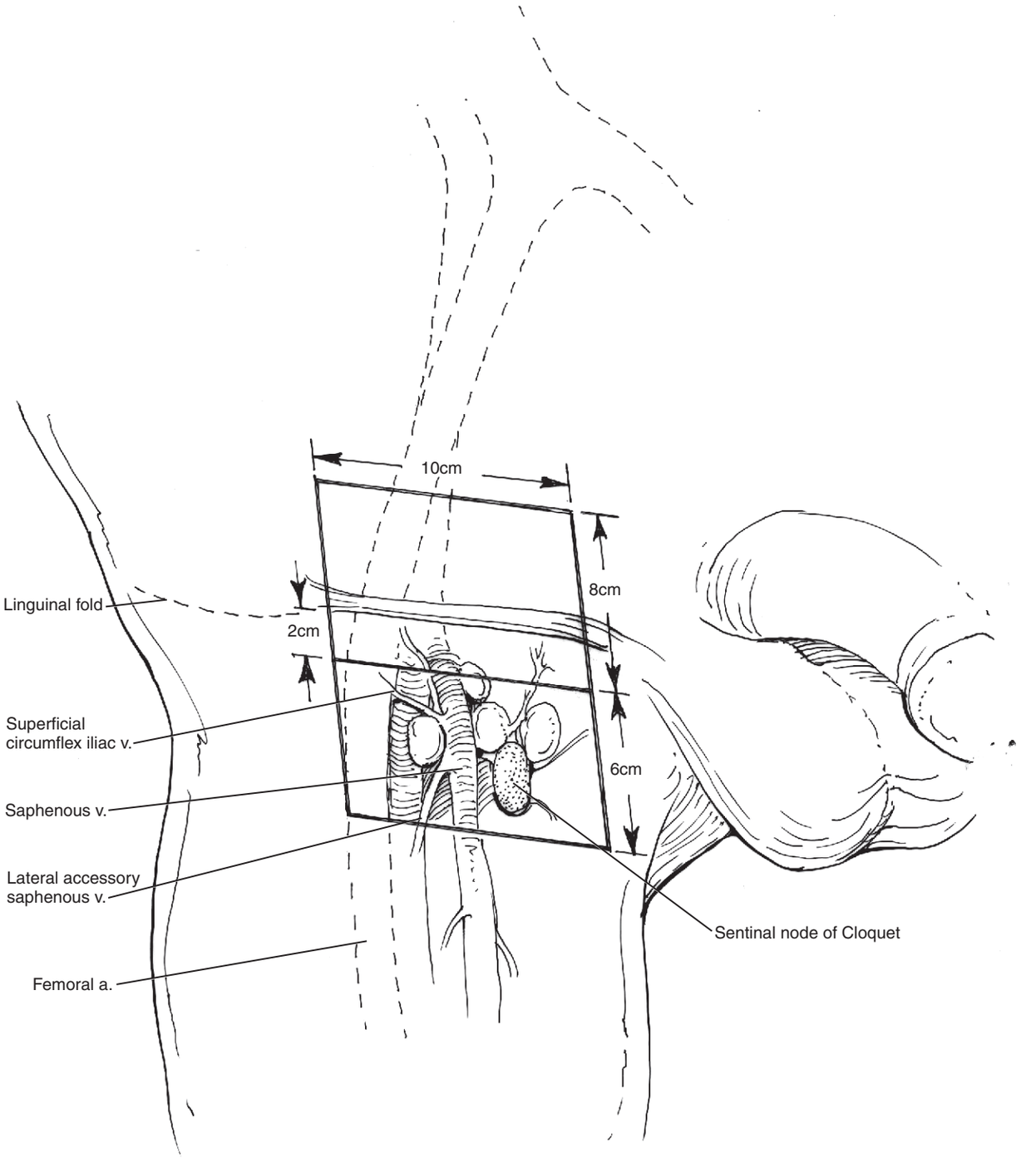

FIGURE 20-1.

If a percutaneous biopsy has been previously performed, incise the tissue widely around the site and include the skin in the specimen.

Modified Inguinal Lymphadenectomy for Squamous Cell Carcinoma of the Penis

The modified lymphadenectomy described here has a lower complication rate than the traditional radical operation. Modified lymphadenectomy preserves the saphenous vein to minimize lower extremity lymphedema, uses a shorter 10-cm incision, avoids dissection lateral to the femoral artery, and eliminates the need for sartorius muscle transposition.

Position. Abduct and externally rotate the thigh, and place a small pillow under the knee. Anchor the foot to the opposite leg (Fig. 20-2). Put the elastic stocking on to the level of the knee; after the operation, extend it to the thigh. Venous compression stockings are helpful to minimize the chance of deep venous thrombosis. Drape to expose the

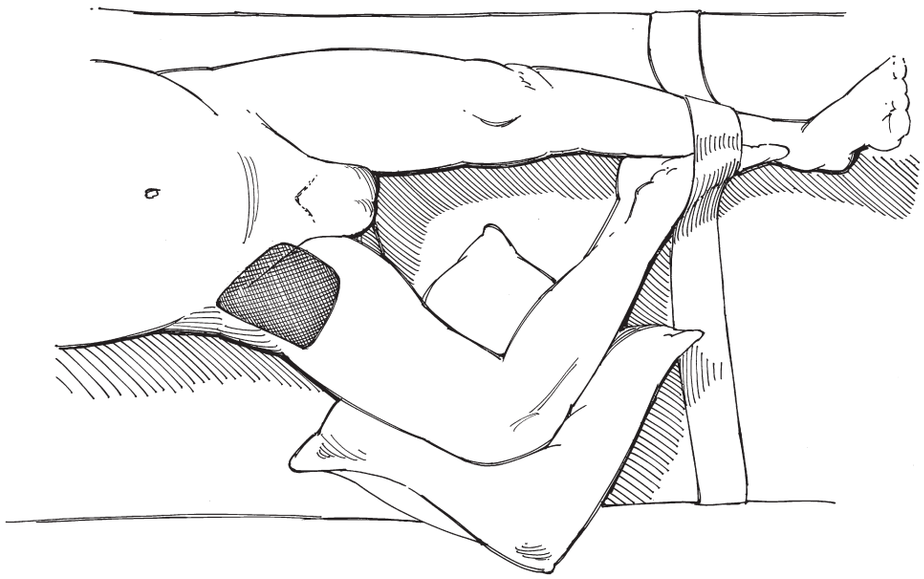

FIGURE 20-2.

umbilicus, pubic tubercle, anterior superior iliac spine, and anterior thigh. It may be advisable to insert an 18-French urethral catheter through the penile stump. Exposure may be improved by suturing the scrotum to the opposite thigh. Mark a 10-cm skin incision 2 cm below the inguinal fold. The extent of the tissue to be excised can also be marked with a pen on the skin. Flaps are developed about 8 cm superiorly and 6 cm inferiorly.

Incision. Incise the skin obliquely from the anterosuperior iliac spine to the pubic tubercle, running it about 2 cm below and parallel to the groin crease. If a biopsy specimen was obtained, excise a strip of skin to include that site; if not and if the nodes are not palpable, excise one of them for biopsy and obtain a frozen-section diagnosis. If the biopsy results are positive, proceed to the next step.

Important. To prevent lymphoceles, control all subcutaneous lymphatics at the periphery of the dissection and leave at least two Jackson-Pratt suction drains under the tissue flaps.

Fashion skin flaps above and below by sharp dissection, extending to the marked margins and to the depth of the fascia lata (Fig. 20-3). The skin should be supported adequately by developing the plane immediately superficial to Scarpa's fascia with its attached subcutaneous fat. Use skin

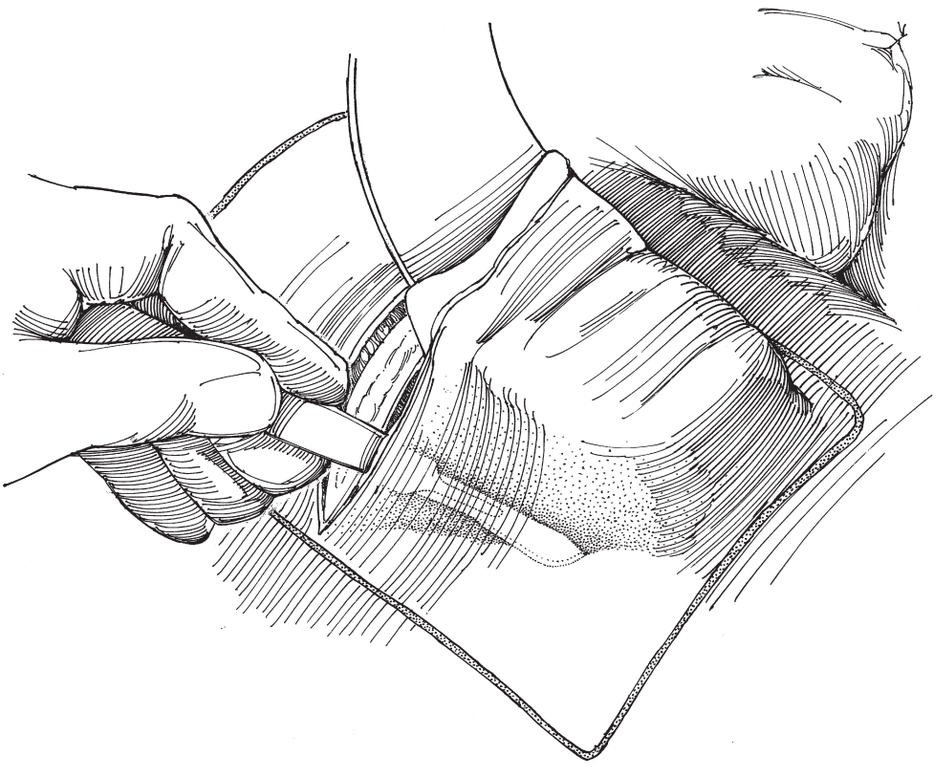

FIGURE 20-3.

hooks, stay sutures, and retractors. Handle the flap edges gently, and keep them covered with saline-moistened sponges. Avoid grasping flap edges with forceps, which would crush the tissue. Mobilize to the premarked margins but not beyond. If skin is involved with tumor, excise it; consider muscle flap coverage with subsequent skin graft placement or the use of a myocutaneous flap.

Begin at the upper margin of the incision to expose the external oblique fascia, and clear the superficial fascia and areolar tissue downward over the inguinal ligament to the fascia lata of the thigh (Fig. 20-4).

Start incising the fascia lata just below the inguinal ligament along its lateral margin over the sartorius muscle, dividing the tissue between clamps and ligating it with fine synthetic absorbable sutures (Fig. 20-5). Avoid lymphatic leakage by clipping or tying all identifiable vessels.

Free the deep lateral and medial margins by dissection and ligation. When the greater saphenous vein is reached inferomedially, dissect around it but preserve it to reduce edema of the leg postoperatively (Fig. 20-6). With bulky disease, the vein may require sacrifice. Avoid dissection inferolaterally to the fossa ovalis.

Mobilize the mass by blunt and sharp dissection from the lateral to medial side, over the branches of the femoral nerve and then over the femoral sheath (Fig. 20-7). Preserve the motor nerves but sacrifice the cutaneous nerves, and divide those branches of the femoral vascular system supplying the overlying subcutaneous tissue.

Mobilize the deep fascia medially from the adductors to the femoral sheath and excise the fascia (Fig. 20-8).

Skeletonize the femoral vasculature medially and anteriorly in the femoral triangle (Fig. 20-9). Avoid dissection lateral to the femoral artery below the fossa ovalis, but ligate

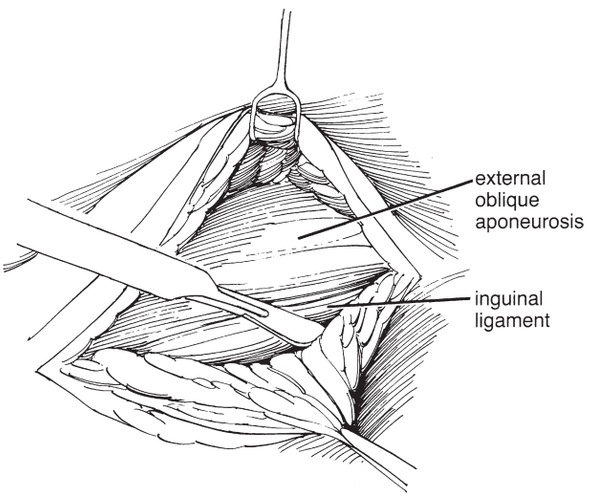

FIGURE 20-4.

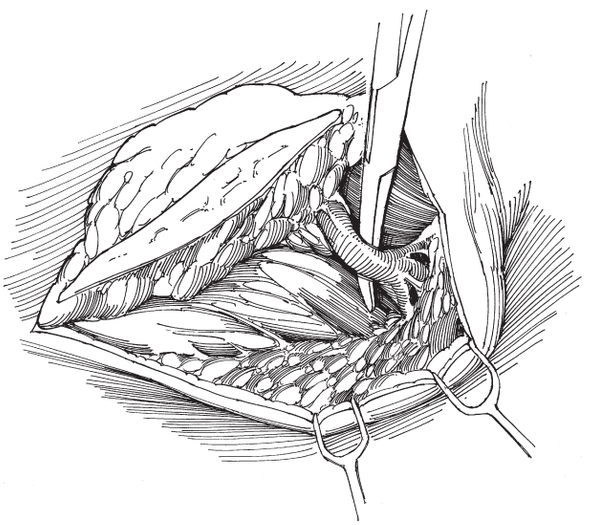

FIGURE 20-6.

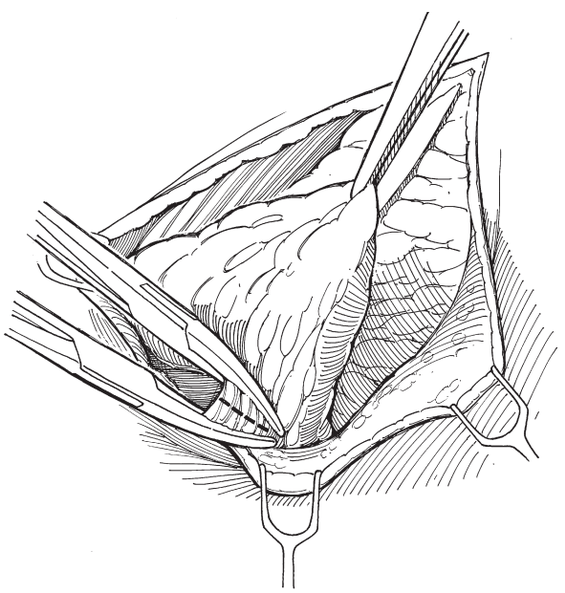

FIGURE 20-5.

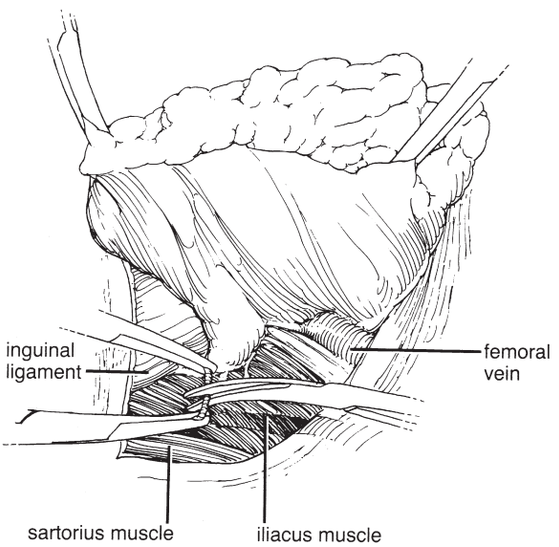

FIGURE 20-7.

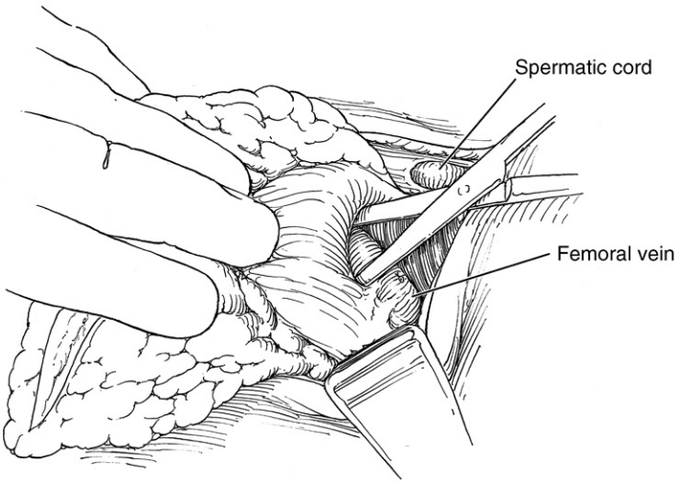

FIGURE 20-8.

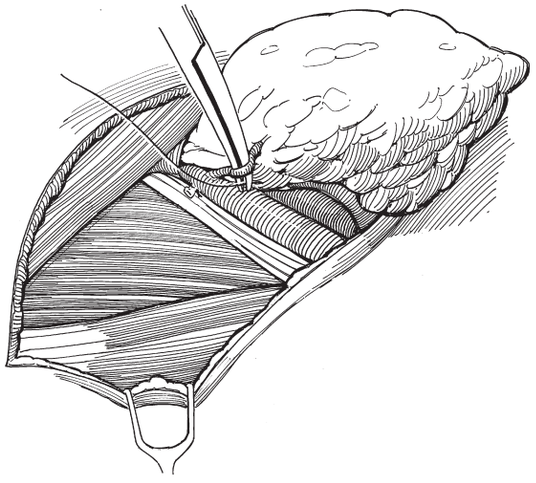

FIGURE 20-9.

all the branches, thus freeing the deep inguinal nodal mass. The presence of grossly positive disease may necessitate resection of nodal tissue lateral to the femoral artery and nerve as part of a radical inguinal lymphadenectomy.

Preserve the greater saphenous vein. Dissect it free, leaving an empty fossa with the nodal mass attached only at the femoral canal (Fig. 20-10). Send suspicious nodes for frozen-section diagnosis. Grossly positive disease may necessitate saphenous vein resection.

Pelvic Lymphadenectomy for Squamous Cell Carcinoma of the Penis

The value of pelvic lymphadenectomy in patients with squamous cell carcinoma of the penis is widely debated. The lack of effective chemotherapy causes some urologists to advocate resection of gross disease seen on computed tomography imaging. While the value of pelvic lymphadenectomy is debated, the influence on postoperative morbidity from lymphedema is not. Patients who undergo inguinal lymph node dissection usually have little or a tolerable amount of dependent lymphedema. Adding pelvic lymph node dissection markedly increases the number of patients who develop severe lymphedema. If needed, pelvic lymphadenectomy is usually performed at a separate setting after the inguinal node dissection has adequately healed. If done in that way, the pelvic lymphadenectomy can be approached through a lower midline incision similar to that routinely performed before radical retropubic prostatectomy. En bloc pelvic node dissection done in continuity with inguinal node dissection is described here.

Closure of Radical Inguinal Lymphadenectomy or When Skin Flap Viability Is Questionable

Aggressive lymphadenectomy for large-volume inguinal tumor will necessitate skeletonizing the femoral vessels. Additionally, tissue coverage of the vessels may be compromised by involvement of tumor into the superficial tissues, necessitating substantial thinning of skin flaps. In these cases, reliable coverage of the femoral vessels may be performed by rotation of a muscle flap.

Coverage with Sartorius

Divide the sartorius muscle where it joins the anterior iliac spine. Place it over the femoral nerve and vessels. Suture it to the reflection of the inguinal ligament, tacking it laterally as well (Fig. 20-11). Check the skin margins, especially the lower margin, and excise any nonviable edges. If necessary, do not bring the flap edges together and apply a split-thickness skin graft. This strategy is preferable to having substantial flap tissue loss later.

Coverage with Rectus Abdominis Myocutaneous Flap

An *inferior rectus abdominis myocutaneous flap* may be applied in patients who have extensive unilateral inguinal node metastasis with disruption of the overlying skin or who required extensive dissection for inguinal metastasis with consequent postoperative skin breakdown and wound infection. Raise a flap from the contralateral rectus muscle (see Fig. 20-12). Include an ellipse of skin unless the flap is to be covered with a split-thickness graft. Move the flap anterior to the ipsilateral rectus muscle, and pass it through a subcutaneous tunnel into the groin defect (Fig. 20-12). Place a suction drain in the abdominal defect before closure, and place one in the groin area.

Insert suction drains through nondissected areas, placing the tubes on both sides of the sartorius muscle (Fig. 20-13). Close the skin with absorbable subcuticular sutures. Do not apply a compression dressing. Raise the elastic stocking to the thigh level. Continue antibiotics for 1 week or longer if drains remain present. Position the patient in bed with the foot of the bed slightly elevated for a long enough postoperative period to ensure flap viability. Remove the drains when output remains low after ambulation. Warn the patient about sitting with the thighs flexed and about the need for wearing the stockings. With this regimen, delayed skin grafting is seldom necessary.

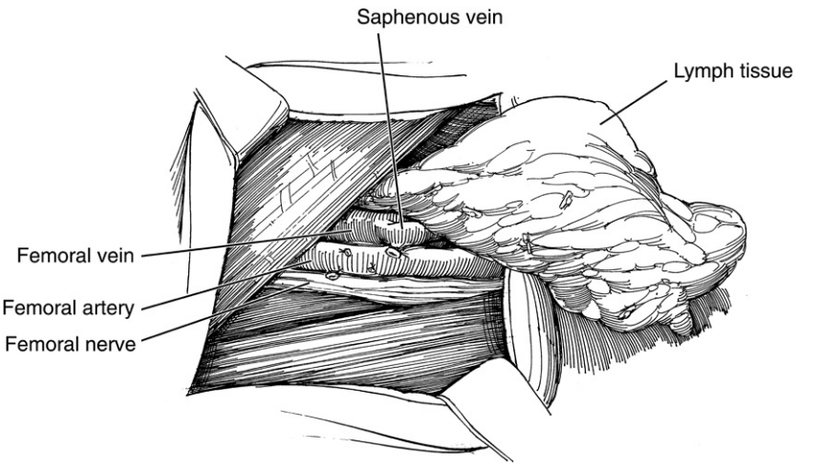

FIGURE 20-10.

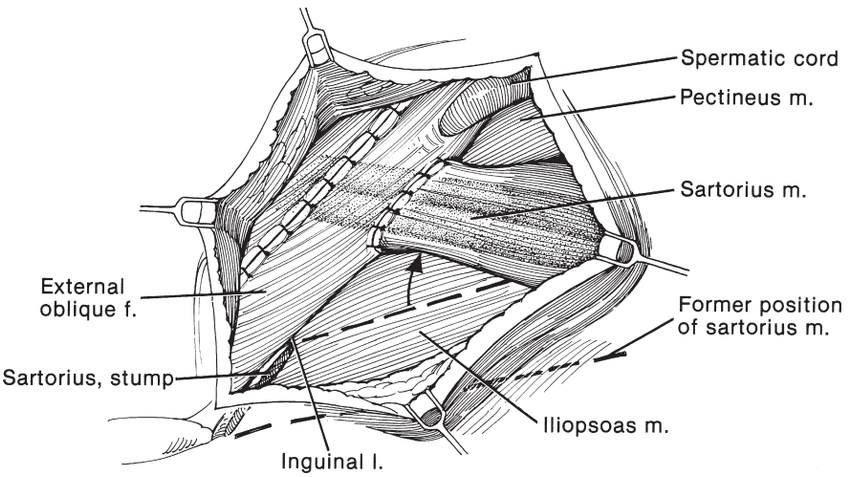

FIGURE 20-11.

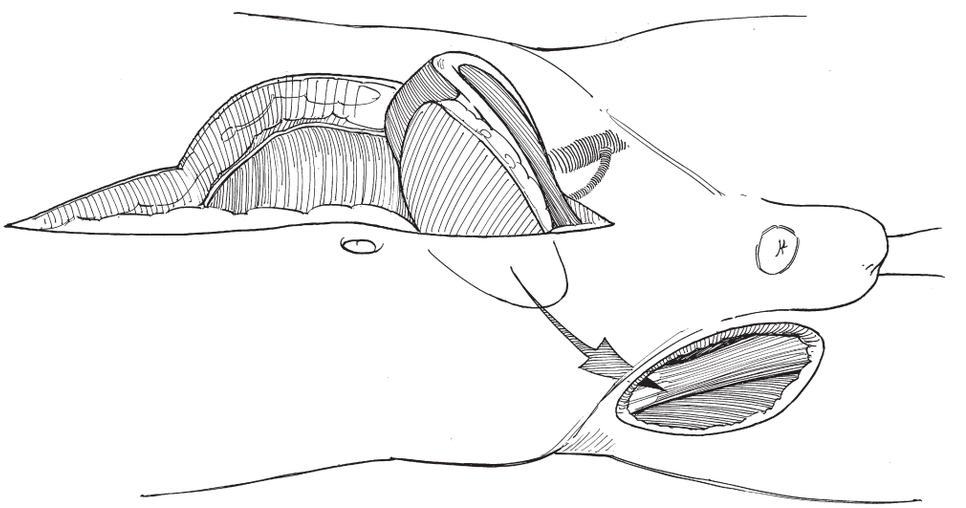

FIGURE 20-12.

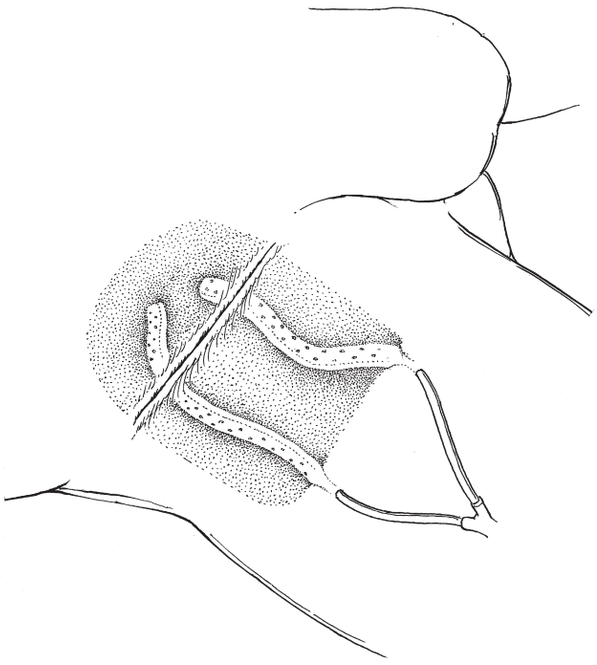

FIGURE 20-13.

INTRAOPERATIVE PRECAUTIONS

Careful dissection prevents *venous bleeding*. Do not clamp blindly. Do not place clamps on the thin-walled pelvic veins; rather, isolate and pass ligatures or use medium-size surgical clips. If a vein is torn, control bleeding with sponge sticks placed above and below the rent to allow suturing with swaged 5-0 arterial polypropylene suture as the rent is progressively exposed. For veins that are avulsed flush with apertures in the pelvic wall, apply sponge pressure. Because these veins cannot be clamped, use a 3-0 suture swaged on an intestinal needle to oversew the site.

POSTOPERATIVE PROBLEMS

Necrosis of the edges of the skin flaps is not uncommon. Lymphadenectomy often interrupts the blood supply coursing from deep subcutaneous tissue. Small defects may be debrided and allowed to heal by second intention. Later application of split-thickness skin grafts may be necessary for defects that will not readily close by granulation. *Wound infection* begins in areas of devascularization and in dead spaces; it is difficult to really cleanse the bacteria from the skin in this area. *Seromas* are not rare and are minimized by the use of surgical drains. *Lymphoceles* can form but are inhibited by ligating all lymphatics and by tacking the skin flaps down to the muscle, providing adequate suction drainage, and placing proper dressings. Treat them with intermittent aspiration or by continuous closed percutaneous aspiration. *Lymphorrhea*, however, is rare. Early cautious mobilization of the patient can reduce the chance of deep vein thrombosis (DVT) without jeopardizing healing of the wound. Preoperative and postoperative low molecular weight heparin and venous compression stockings can reduce the incidence of DVT and pulmonary embolus. Prolonged lymphatic drainage may be exacerbated by heparin, however. *Lymphedema* of the leg is to be expected, and waist-high elastic stockings should be fitted before the patient begins ambulation. Have him keep the leg elevated when sitting and when in bed. Diuretics may help. Paresthesia medial to the operative site can also be expected but is not disabling.

This page intentionally left blank

Chapter 21

Laser Treatment of the Penis

DOUGLAS F. MILAM

Laser phototherapy is often the most effective and time efficient form of treatment for benign or malignant penile lesions. Laser therapy is most commonly performed in the operating room. The techniques, however, can be used in the office setting when appropriate laser safeguards are established. Benign penile lesions such as condylomata acuminata are commonly treated with laser therapy. Unlike topical treatment, benign penile lesions often respond to a single session of laser therapy. Several different types of lasers may be used for penile surgery. Choice of laser is determined by the disease process and the required depth of coagulation (Fig. 21-1).

CHOICE OF LASER

The most common laser used in penile surgery is the carbon dioxide (CO_2) laser. This is a continuous wave laser delivering an invisible beam of 10,600 nm energy from a handpiece. The CO_2 infrared wavelength is strongly absorbed by most types of glass so a traditional glass optical fiber is not used. The CO_2 laser incorporates an articulating arm and handpiece. The beam may be tightly focused to produce a cutting effect, or it may be defocused to produce superficial coagulation over a wider field. CO_2 laser energy is very strongly absorbed by water in tissue. Because of this, the CO_2 laser produces a very superficial lesion (<1 mm), which is ideal for diseases such as condyloma acuminata and erythroplasia of Queyrat. Any protective laser eyewear with either glass or plastic lenses are sufficient for protection from CO_2 laser light.

The neodymium:YAG (Nd:YAG) laser was formerly the most commonly encountered urologic laser. Only the holmium:YAG laser is now used more often. The Nd:YAG laser operates in continuous wave mode, producing an invisible 1064-nm beam and resulting in a deep zone of coagulation reaching 8 to 10 mm. Of all commonly available urologic lasers, the Nd:YAG produces the deepest treatment zone. Like the potassium-titanyl-phosphate (KTP) laser, the Nd:YAG laser produces too great a tissue defect to be useful for superficial benign disease. The Nd:YAG laser is useful when a penile cancer is treated using a phallus-sparing technique. The added depth of the Nd:YAG laser coagulation produces a safety zone of coagulation whereby minimally invasive lesions may be safely managed. Use of the Nd:YAG laser requires wavelength-specific protective eyewear. Clear lenses are available, but must be specific for Nd:YAG laser use.

KTP lasers are actually Nd:YAG lasers that pass the coherent laser beam through a potassium-titanyl-phosphate frequency-doubling crystal. The invisible 1064-nm Nd:YAG energy is frequency-doubled to the brilliant green 532-nm light associated with the KTP laser. The KTP laser produces a mid-depth of coagulation. KTP lasers do use an optical fiber that can be mounted inside a handpiece or passed through an endoscope. Use of the KTP laser produces about 4 mm depth of tissue coagulation. This is often too deep for condyloma acuminata and erythroplasia of Queyrat, but is very useful for extremely superficial squamous cell carcinomas or other more concerning lesions. KTP laser light requires wavelength-specific eyewear.

The holmium laser, though the most commonly used laser for endoscopic treatment in urology, is not particularly suited for skin lesions of the penis. Holmium laser is a 2070-nm pulsed laser with a very prominent high-energy pulse. Holmium energy is very rapidly absorbed in tissue and does not lend itself to a painting motion. The same characteristics that make this laser useful for urologic stone surgery limit its usefulness when treating penile surface lesions. In most cases, lesions that could be treated with the holmium laser, could be better treated with a CO_2 laser.

DIAGNOSTIC INDICATIONS

Penile Condylomata

Penile condylomata is optimally treated using the CO_2 laser. Because CO_2 energy is strongly absorbed, it is concentrated in a very thin section of tissue. One should begin treatment with a low energy setting. For treatment of penile condylomata, 4 W is a safe initial setting. Depending on the tissue effect, wattage can be increased as

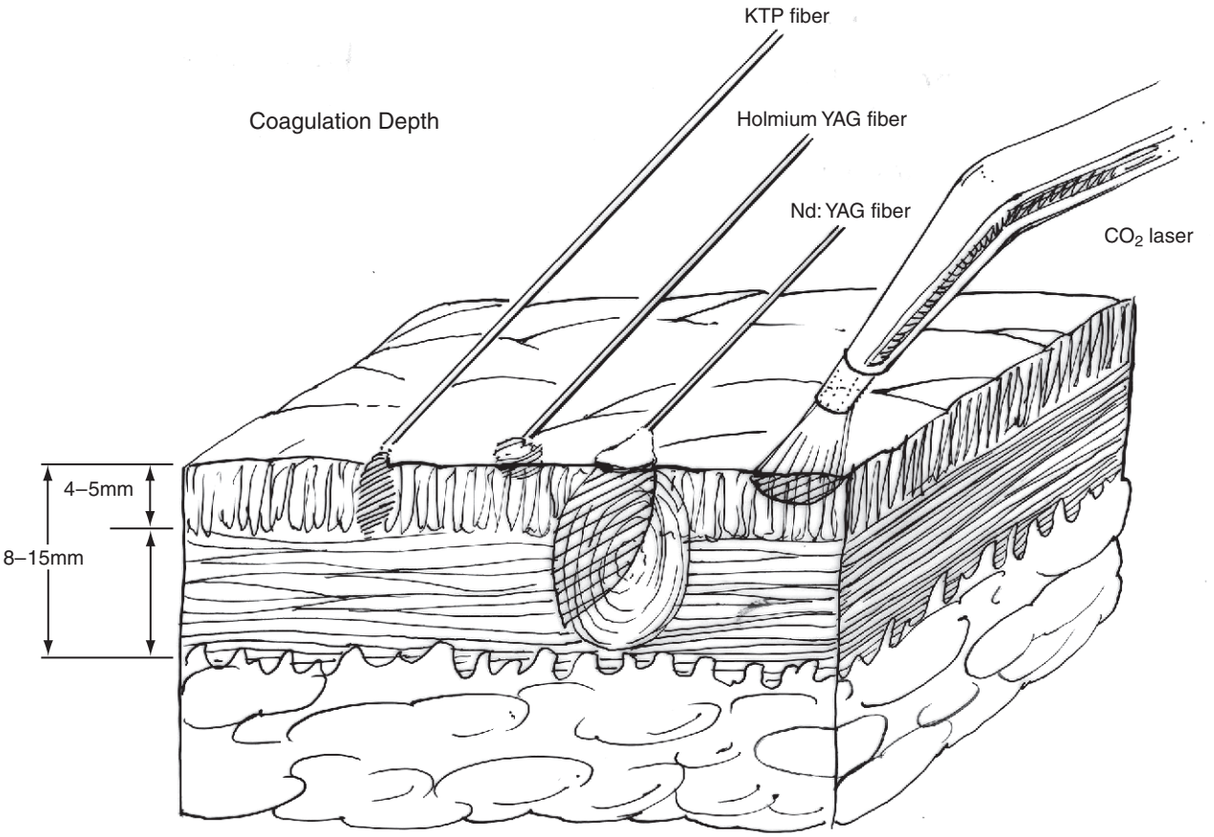

FIGURE 21-1.

needed. Rarely is more than 10 W required. The CO_2 laser energy is directed by a laser handpiece and the beam is slightly defocused by withdrawing the handpiece 1 to 2 cm such that the beam is a circle instead of a pinpoint. A painting motion is performed, leading to coagulation of the condylomata. Slight overlapping of the edges of the lesion ensures complete coverage. Once the lesion appears to be thoroughly coagulated, it can be "wiped off" using a dampened 4 × 8 sponge. Because of the superficial depth of coagulation, the lesion shears off the deeper tissue, leaving structurally intact dermis. Care should be taken to leave viable skin bridges between areas of treatment. Treatment should be limited to areas less than 1 cm at the base of the lesion, which markedly increases the rate of healing and should eliminate the possibility of large areas of necrotic skin that could require skin grafting. If the lesions are particularly large, skin bridges should be left untreated and elective return to the operating room should be planned once the originally treated areas have epithelialized.

Condylomata such as these are optimally treated with a CO_2 laser (Fig. 21-2). Careful control of the laser beam avoids injury to the urethral meatus.

The penile skin is placed on mild stretch to eliminate skin folds. The defocused aiming beam is placed on the side of the lesion. Care is taken to treat the lesion base; however, 1 mm or less overlap into normal skin is necessary.

Painting motion is performed thoroughly covering an individual lesion (Fig. 21-3). The beam motion is rapid enough to avoid char formation on tissue.

After treatment, the lesion may be "wiped off" with a gauze sponge, leaving intact living dermis.

Erythroplasia of Queyrat

Erythroplasia of Queyrat is particularly amenable to treatment with the CO_2 or KTP laser. Considerable experience exists with use of the CO_2 laser. The entire lesion is methodically painted with the defocused beam of the CO_2 laser

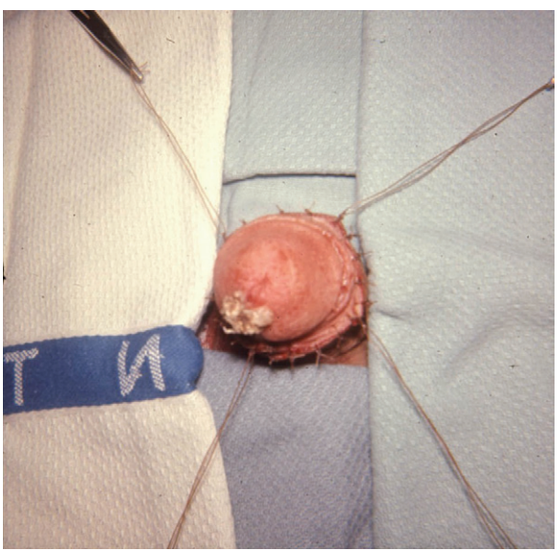

FIGURE 21-2.

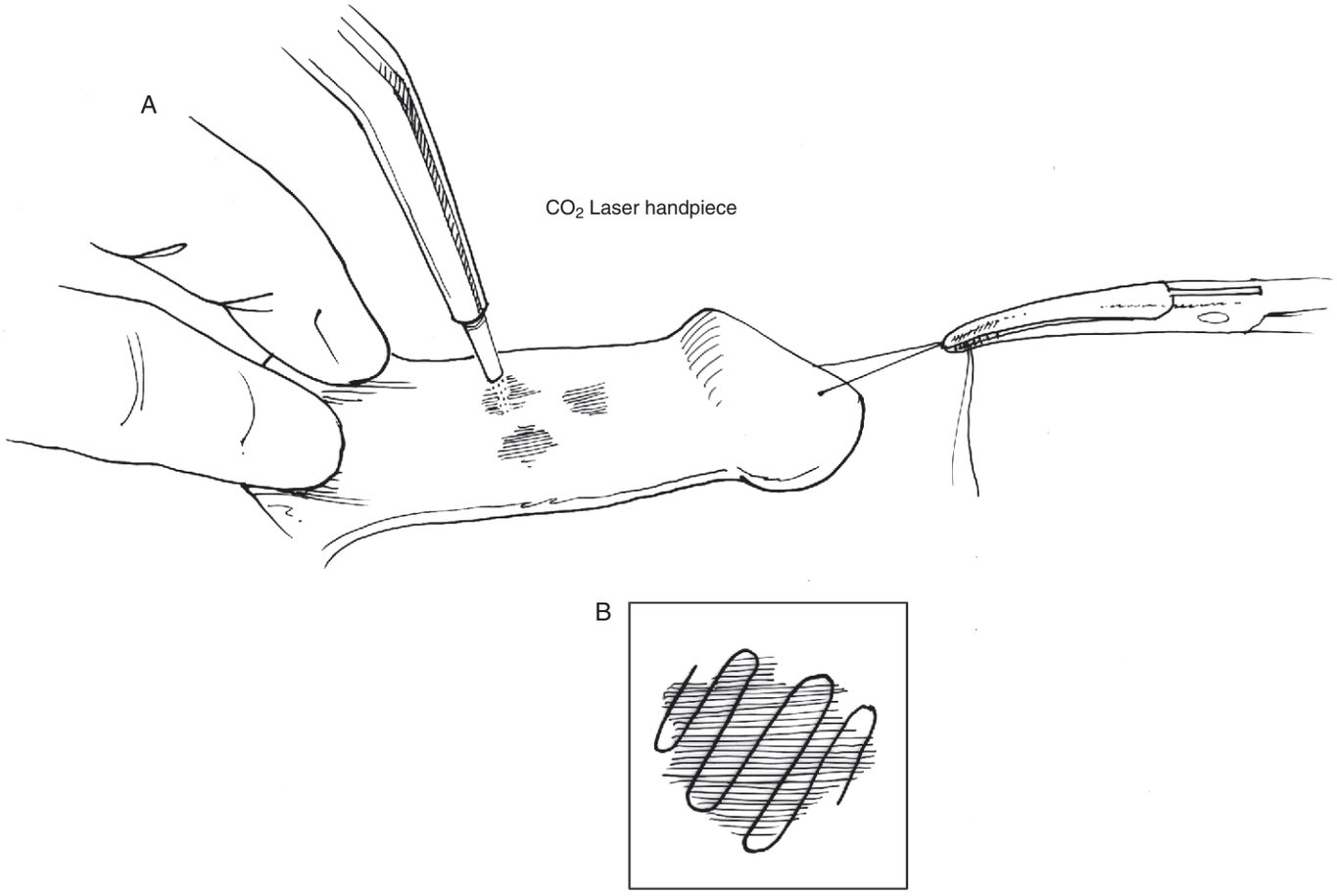

FIGURE 21-3.

energy. Overlap of 1 mm into normal tissue is advised. Unlike treatment of condyloma acuminata, one typically does not "wipe off" the superficial tissue when treating erythroplasia of Queyrat. Nevertheless, there should be uniform coagulation through of all diseased tissue. The lesion is often treated completely in a single treatment. When the area is large, however, multiple treatment sessions should be planned. This is especially true when using the KTP laser because it has greater depth of coagulation than the CO_2 laser.

This small lesion of erythroplasia of Queyrat (Fig. 21-4) may be treated with a thorough painting motion with either the CO_2 or KTP laser. Treated tissue is left in situ and is replaced with normal, though less pigmented, epithelium.

Squamous Cell Carcinoma

Squamous cell carcinoma can be treated using laser therapy. This should be considered a phallus-sparing technique in which the patient understands that there is some risk that the treatment of the primary tumor may not be adequate. Most urologists consider primary excision with a substantial margin to be the routine treatment of choice for invasive squamous cell carcinoma of the penis. Nevertheless, for small tumors or for individuals who are, for one reason or another, not good candidates for more substantial therapy, Nd:YAG coagulation of squamous cell carcinoma of the penis is a viable option. The tissue is moistened slightly to

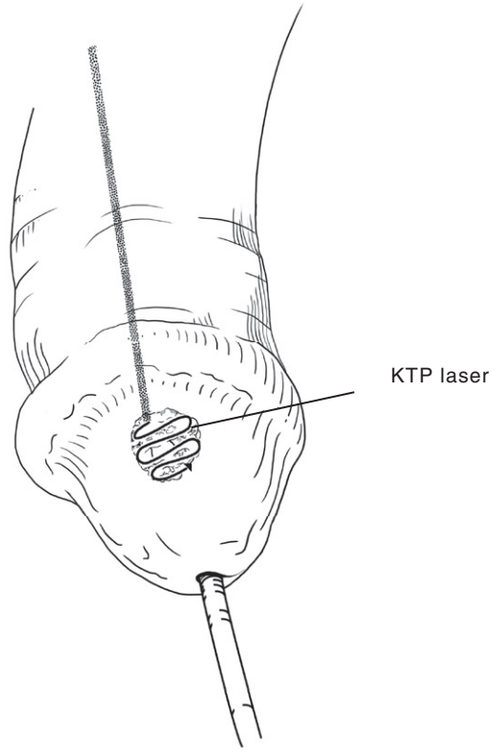

FIGURE 21-4.

prevent rapid char formation. Carbonization substantially increases superficial tissue absorption and decreases the depth of the coagulated zone. Using a free beam of Nd:YAG laser energy on continuous wave with an initial setting of 10 W, the surgeon slowly and very methodically paints the lesion and a surrounding border of normal tissue. Once the lesion appears thoroughly coagulated, it is often worthwhile to paint the lesion with strokes going the other direction to ensure thorough coverage. It is, however, counterproductive to treat the lesion until a light char formation occurs. Treatment with the Nd:YAG laser produces a deep third-degree burn. If the lesion is large and a substantial area requires treatment, one should consider primary excision and skin closure. Complete healing requires several weeks.

Discrete penile cancers of the glans (Fig. 21-5) can be treated with the Nd:YAG laser. The surface is cooled with water to prevent surface char.

The lesion is thoroughly painted using the aiming beam as a guide (Fig. 21-6). Treatment should overlap at least 2 mm into normal adjacent tissue.

Two weeks after treatment a burn eschar is well developed (Fig. 21-7).

After healing is complete, only a small tissue defect remains (Fig. 21-8).

POSTPROCEDURE MANAGEMENT

The length of the healing process is directly related to the depth of tissue injury. Lesions from the CO_2 laser, therefore, heal more rapidly than lesions produced by the Nd:YAG laser. No special measures are necessary in the postoperative period. The patient should understand that there should be some weeping of serum from the treated areas until reepithelialization occurs. Normally, reepithelialization from CO_2 laser therapy is well underway after 1 week and is nearly complete in 2 to 3 weeks. Reepithelialized areas typically do not contain skin pigment since the melanocytes are usually killed. Patients need to understand that this may leave white spots on the penis where condyloma formerly grew. Usually, however, the surface of the reepithelialized areas has the same contour of the normal phallus. The same is true for lesions where erythroplasia of Queyrat is treated with the

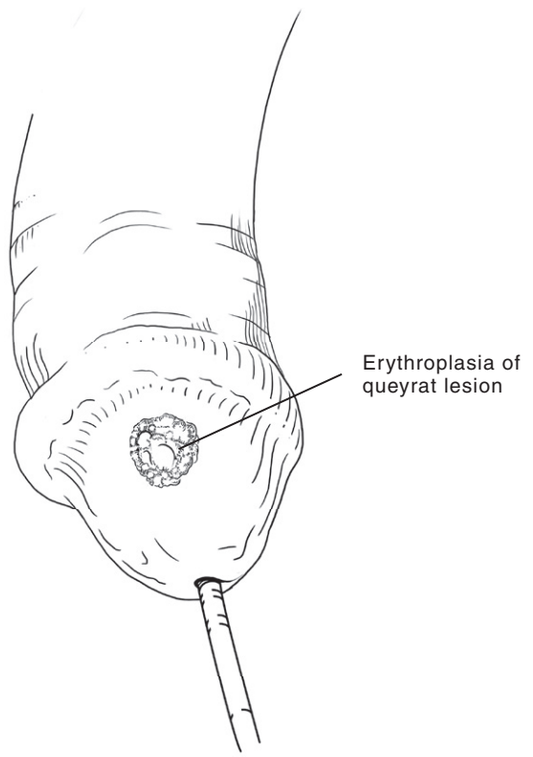

FIGURE 21-5.

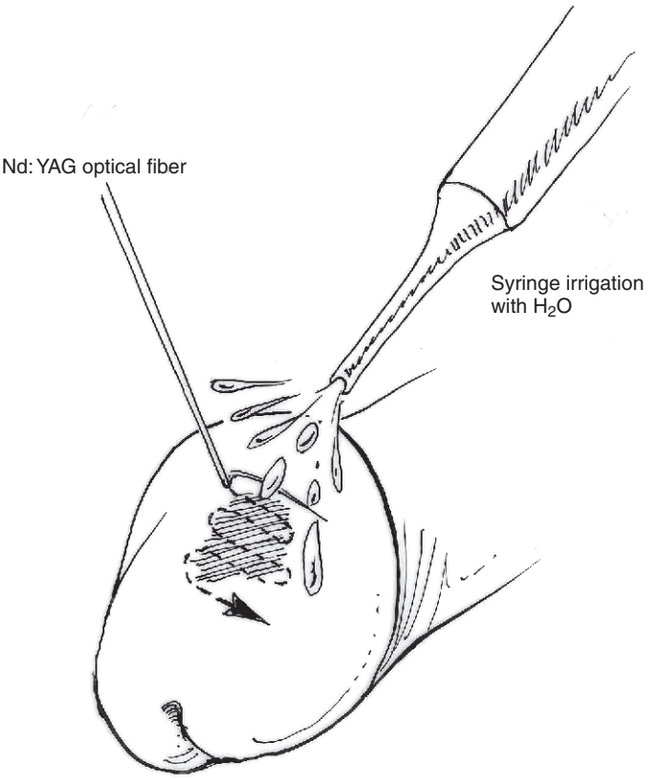

FIGURE 21-6.



FIGURE 21-7.



FIGURE 21-8.

CO_2 laser. Other than changes in pigmentation, the original location of the lesion is unidentifiable.

Treatment of lesions with the Nd:YAG laser produces a substantially greater depth of coagulation than seen with the CO_2 laser. Consequently, the postoperative healing process is much more prolonged and often results in mild disfigurement. Complete healing often requires 6 weeks, even for 1- to 1½-cm diameter lesions. Both the skin tissue and deeper tissue will become necrotic and slough off. Typical skin contracture as one usually sees with a burn decreases the diameter of the scar over several months. Nevertheless, in addition to eventual replacement with a thinned epithelial surface, a mild tissue defect (or divot) will result. Most patients gladly accept this compromise when the alternative is more aggressive resection.

This page intentionally left blank

Section V

PENIS: CORRECTION

This page intentionally left blank

Chapter 22

Circumcision

JULIAN WAN

Circumcision is among the most commonly performed urologic surgeries. It is also historically one of the oldest and at times controversial surgeries. Indications include religious rite, social habit, and medical treatment and prophylaxis. The latter category includes phimosis, paraphimosis, hygiene, and reducing the relative risk for urinary tract infections and sexually transmitted diseases.

Removal of the prepuce exposes the tip of the penis and results in a change in the microenvironment of the glans. The glanular epithelium changes from a moist glabrous transitional tissue, which is translucent to a dry tough squamous layer. Changing the surface of the penis has been suggested to reduce the risk for urinary tract infection by eliminating an otherwise favorable harbor for urinary tract pathogens. The tougher keratinized surface has recently been shown in a series of randomized controlled studies to help increase the relative resistance to infection with human immunodeficiency virus in adult men.

When planning circumcision in babies a careful physical examination is necessary to ensure that there are no congenital conditions that preclude circumcision, notably hypospadias. An intact foreskin, a straight shaft with equal ventral and dorsal penile shaft skin length, and a defined penile scrotal junction should all be present. Any irregularities should cause one to reconsider performing the procedure. A careful history should be obtained, with particular attention given to bleeding problems. Informed consent should be obtained and the possibility of finding a megameatus should be discussed so that there are no surprises.

The genitals are prepped with an iodine-based solution. Anesthetic is administrated. In infants, a penile block using 1 mL of 1% to 2% lidocaine without epinephrine or 0.25% bupivacaine hydrochloride can be administered using a tuberculin syringe and a fine 26-gauge needle. Topical lidocaine/prilocaine cream (EMLA) has also been used in infants, but requires application for 15 to 30 minutes for full effect and the tip of the glans and the inner prepuce may not be as fully anesthetized. In older boys and adolescents, general anesthesia is usually preferable. For adult men, local, spinal, and general anesthesia have been successfully used. Tourniquets may be used in adult patients to assist in hemostasis, but they usually are not necessary.

SLEEVE INCISION (DOUBLE-INCISION) TECHNIQUE

The sleeve incision technique is used in adults and children older than infants.

Retract the foreskin. If the foreskin is phimotic and does not retract easily, make a dorsal slit. Next take down any adhesions and clean out any accumulated smegma deposits. A blunt-tipped curved hemostat and a gauze soaked with iodine prep solution frees up most adhesions without tearing the surface of the glans. Carefully examine the glans and note the location of the meatus. At this point, anomalies (e.g., megameatus, true hypospadias with a complete foreskin) can be detected before any incision is made on the shaft or near the glans. This is an important step functionally and from a medicolegal standpoint. Completely free and re-prep the glans down to the preputial sulcus with iodine prep solution. Be especially careful when taking down the frenulum while coming across the ventral glans. Replace the foreskin. Using a fine-tipped marking pen, draw out the path of the outer incision. It should be at the level of the coronal sulcus.

Retract the prepuce and mark the second inner incision 0.5 to 1 cm from the edge of the glans. Follow the curve of the glans when marking. It is a common error to drift too close to the glans when marking.

Incise along the marked lines using a #15 blade. It does not matter whether the inner incision or the outer one is made first. Use a fresh blade and stretch the skin taut with dry gauze (Fig. 22-1). Check for hemostasis and control any significant "bleeders."

A collar of skin should now be isolated between the two incisions. Divide the skin to convert the collar into a long strip of skin (Fig. 22-2). This can be done sharply with a knife or scissors. Electrocautery if used carefully can be effective in splitting the skin while minimizing blood loss.

Pick up the edges of the skin and free it from the underlying dartos layer. Sharp dissection using scissors or electrocautery can be used to take down these connections. Again establish good hemostasis with judicious use of electrocautery or suture ligatures of 5-0 or 6-0 absorbable suture.

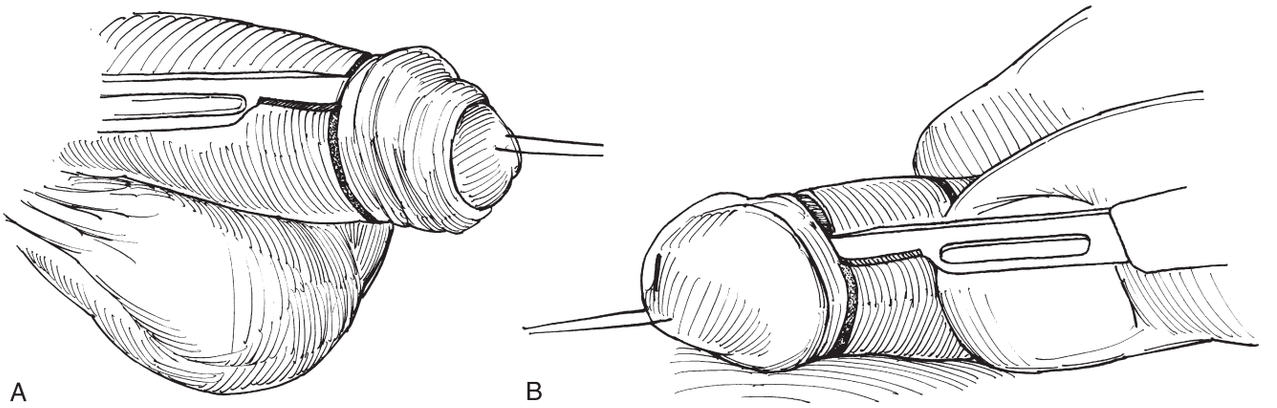

FIGURE 22-1.

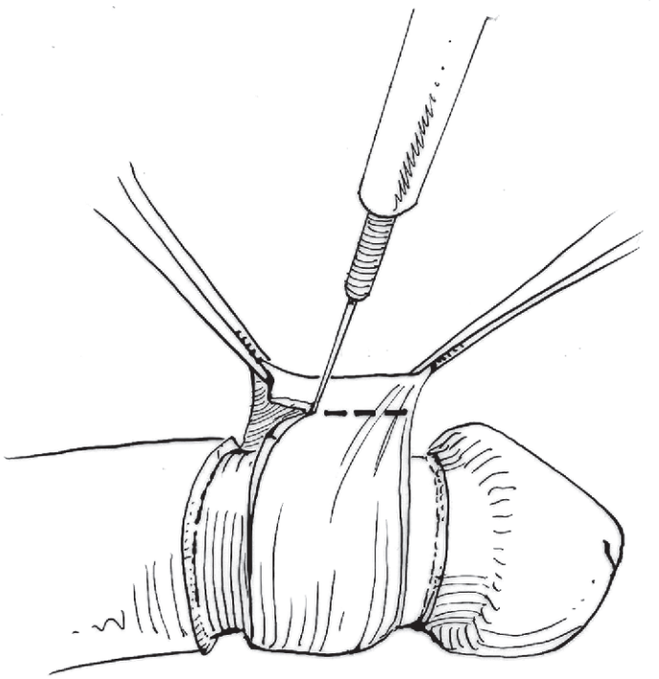

FIGURE 22-2.

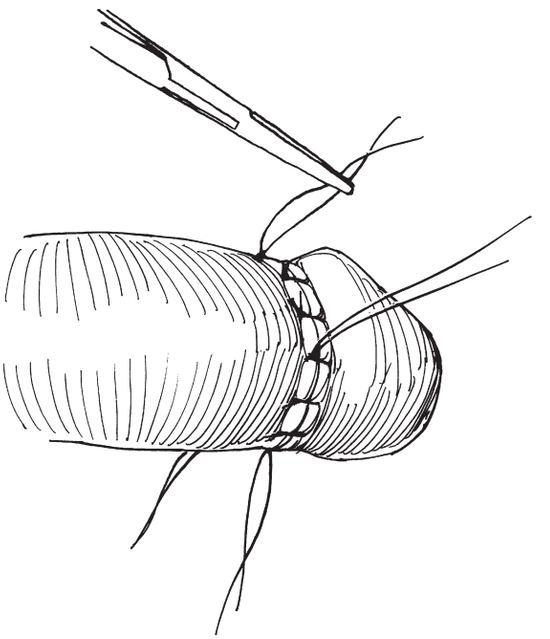

FIGURE 22-3.

Sew the edges of the shaft skin to the new preputial collar using fine absorbable sutures (Fig. 22-3). For infants and children, use 6-0 suture. For older children and adults consider 5-0 suture. To prevent twisting, place the first suture dorsally at the 12-o'clock position and the second suture at the 6 o'clock position. Leave the tails long and apply mosquito clamps to help position the penis. In older children, a second set of stay sutures at the 3-o'clock and 9-o'clock positions can be used but two stay sutures are usually sufficient. Pay careful attention to suture placement and incorporate some of the underlying subcutaneous tissue to help evert the skin edges and to minimize the possibility of suture tracks.

A variety of dressings can be applied. Some practitioners apply only Bacitracin ointment to the tip of the penis. Others apply Telfa, Tegaderm, and/or gauze.

ALTERNATIVE TECHNIQUE

An alternative technique may be used in small children and in those whose prepuce cannot be easily retracted.

After anesthesia has been induced and the penis has been prepped, mark the shaft to the level of the coronal sulcus with the prepuce in place. Pick up the prepuce and make a dorsal slit down to the level of the mark (Fig. 22-4). Re-prep the glans with iodine prep solution and clear away any smegma and adhesions. Take care not to cut too close to the inner preputial collar.

Divide both layers of the prepuce circumferentially following the marked line using sharp scissors. Take care to keep equal tension when holding the prepuce to avoid spiraling the cut.

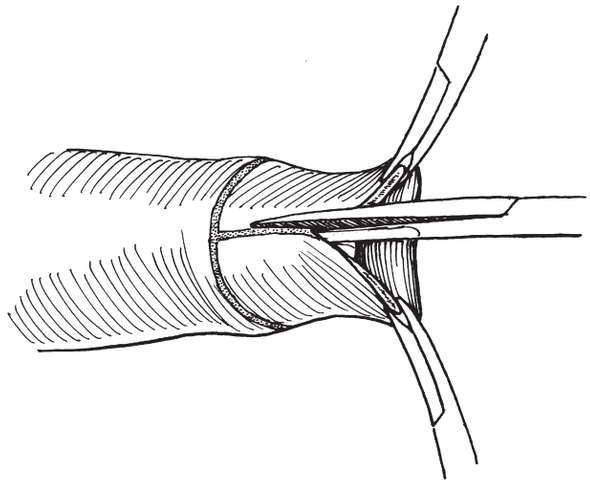

FIGURE 22-4.

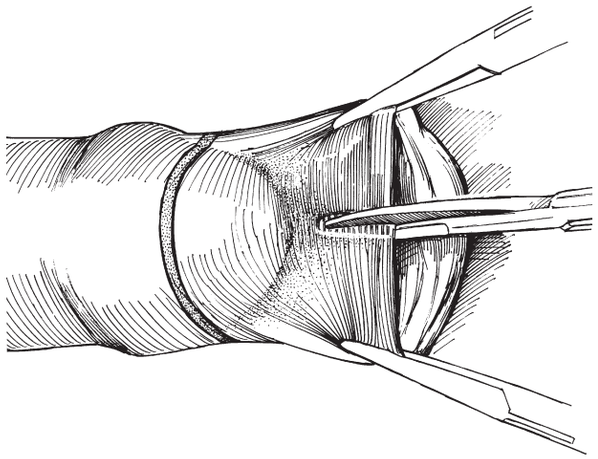

FIGURE 22-5.

Work around from the dorsum to the ventrum, taking care at the frenulum to achieve good hemostasis. Reapproximate the edges as described previously.

PLASTIBELL TECHNIQUE

The Plastibell method is used exclusively for infants. Obtain informed consent from the guardians. Before beginning the procedure, check that all of the instruments and supplies are available and ready. Carefully place the baby in a papoose restraint. Prepare the penis with iodine prep solution and drape in a sterile fashion. Be fastidious about maintaining asepsis. Place a local anesthetic block using 1 mL of 1% to 2% lidocaine without epinephrine. Use a 26-gauge needle to infiltrate a ring block around the base of the penis. Always check by aspirating before injecting to avoid accidental intravascular injection.

Mark the level of the coronal sulcus on the shaft of the skin. Dilate the prepuce with a hemostat and check that the urethral meatus is normal. Using a straight hemostat, clamp the prepuce in the dorsal midline about halfway down toward the corona (Fig. 22-5). Leave the clamp on for 10 seconds. Divide the crushed groove with fine sharp scissors. This should allow the prepuce to be retracted. Free up any adhesions and clean away any smegma collections using a fine-tipped blunt curved hemostat or a flexible probe.

Select the correct size of Plastibell from the available models. Choose one whose bottom edge of the bell covers completely the corona. Note the location of the groove that will hold the hemostatic ligature (Fig. 22-6A). Draw the prepuce back over the bell and glans. Apply tension using forceps so that the skin mark is at the level of the groove on the bell (see Fig. 22-6B).

Tie an absorbable suture (5-0 plain gut) tightly in the groove of the bell. Use a surgeon's knot to achieve a tight square knot. Cut the prepuce isolated distally with scissors or scalpel just past the outer groove. Do not use electrocautery. Break off the handle. The remaining ring should naturally fall off in a few days. Otherwise the parents must contact the physicians for urgent removal. In this situation, divide the

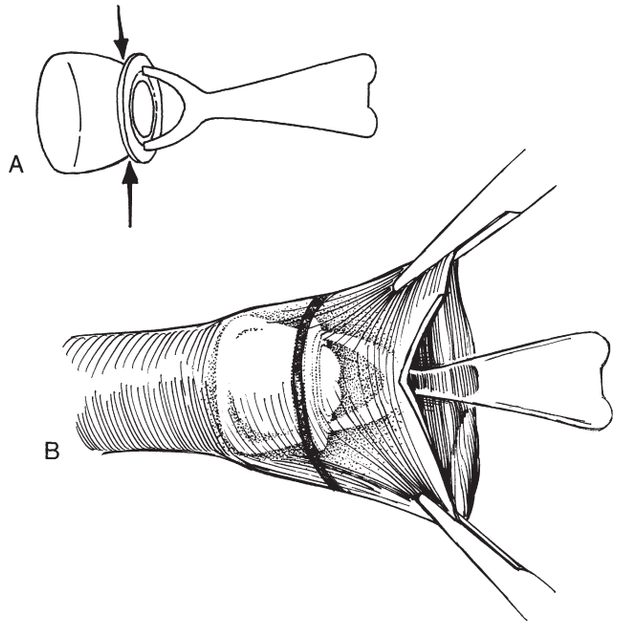

FIGURE 22-6.

ring using a bone-cutting forceps. Have the guardians apply Bacitracin ointment to the tip for 2 weeks. The infant should not ride or straddle toys for 2 weeks. When using car seats and high chairs, be sure the baby is not leaning his body weight on the groin safety strap.

GOMCO CLAMP TECHNIQUE

The Gomco device is one of the oldest and most commonly used circumcision devices for neonates. Before starting, be sure that all of the necessary equipment is available and in good operating condition. Carefully disassemble the Gomco clamp. Check that the base plate, nut, and bell are in good condition with no sharp edges.

After securing the baby in a papoose restraint, place a local anesthetic block as described in the section on the

Plastibell technique. Examine the penis carefully. Most infants will need a 1.1- or 1.3-cm diameter Gomco bell. Create a dorsal slit, retract the prepuce, and clear away any smegma collections.

Select the bell large enough to fit over the glans but no larger (Fig. 22-7A).

After the bell has been positioned, replace the foreskin over the bell. Be sure that the penile shaft skin is symmetric and even (see Fig. 22-7B).

Apply the base plate, drawing the foreskin up evenly through the hole. Be sure that the skin is symmetric and that there are no twists or folds. Apply the clamp and tighten the nut down on the screw. Brace the base plate when applying the nut so that the penile skin does not twist (see Fig 22-7C).

Leave the clamp on for 5 minutes to achieve good hemostasis. Do not hurry this step. This time limit is mentioned in the original paper of the device but is often ignored by some practitioners to their regret. Use a fresh scalpel blade and cut the foreskin against the bell at the point where it emerges from the base plate. Use a firm steady stroke and avoid "sawing."

Disassemble the device. Use a curved blunt-tipped hemostat to gently push the crushed hemostatic skin edge from the bell. Control any bleeding and apply a dressing of copious Bacitracin ointment. Never use electrocautery with a Gomco clamp.

REVISION CIRCUMCISION

Residual foreskin. Take down any adhesions and scar bands. Using a pen, carefully mark out the redundant skin and excise in the manner described for the sleeve incision technique.

Concealed or buried penis. Consider approaching this situation in the same way as approaching a hidden penis (see Chapter 25). Usually the penis is covered by dense cicatrix. After exposing the glans, deglove the penis and allow the penis to straighten out. Redistribute the skin to cover the ventral and dorsal shaft. Try to align the suture lines to maintain symmetry and allow the scar to resemble the natural raphe and skin creases. These cases must be managed individually depending on availability of skin.

Shaft and prepuce disparity. Sometimes the original circumcision was uneven and there is marked disparity of the shaft skin and glans. When this occurs, try degloving the penis and redistributing the skin. Place the first few sutures dorsally and ventrally, and work the excess tissue laterally where it can be trimmed away and closed. When the ventral side is shortchanged, perform a vertical cut on the dorsal shaft skin to allow enough skin to rotate forward. Another method is to make a careful transverse incision at the penoscrotal junction. Deepen and fully mobilize the skin edges, then close it in a vertical fashion. This Heineke-Mikulicz approach can free up another 1 to 2 cm of ventral length and will redefine the penoscrotal junction.

Phimosis postcircumcision. A dorsal slit is the simplest and most expedient procedure but it is often simpler to remove the constricting skin and just revise the circumcision. Be suspicious however of patients with unusual scarring after surgery. They may have an unappreciated skin disorder such as balanitis xerotica obliterans.

POSTOPERATIVE PROBLEMS FROM CIRCUMCISION

The most important complication is *failure to recognize hypospadias.* Repair of hypospadias after the foreskin has been removed is more difficult and is an avoidable problem. *Necrosis of shaft skin and glans* may occur if epinephrine is

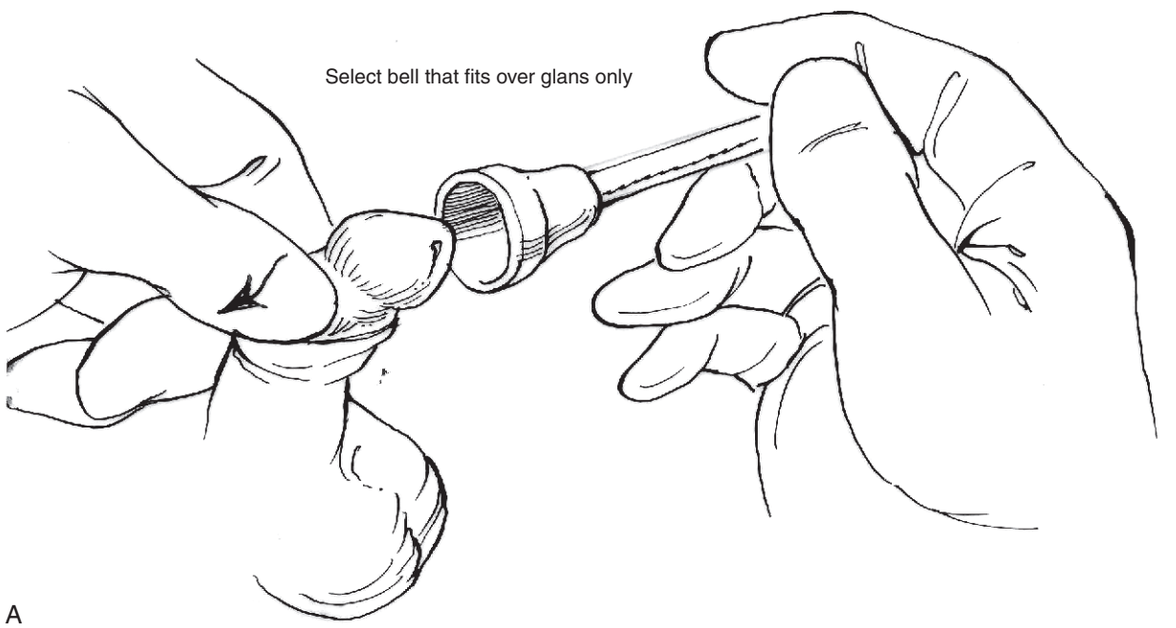

A

FIGURE 22-7.

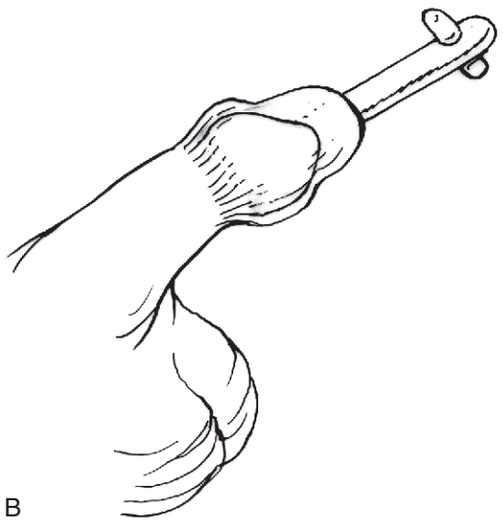

B

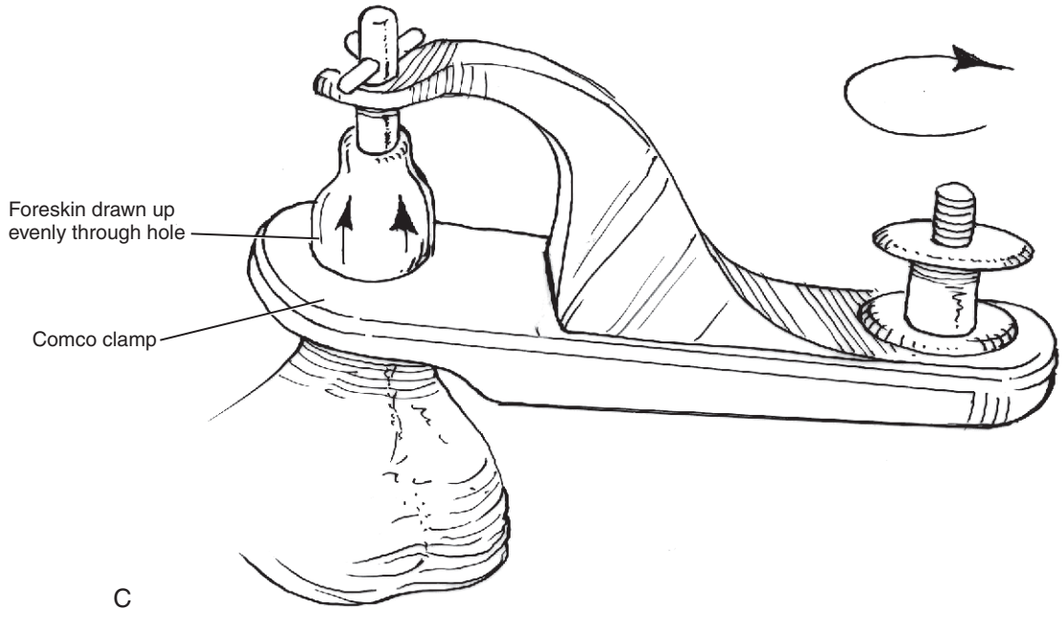

C

FIGURE 22-7, cont'd.

used when infiltrating a local block or if electrocautery is used injudiciously. Never use electrocautery when performing neonatal circumcision involving the Plastibell or Gomco devices. When the Plastibell is used, guardians must return with the baby within 1 week to be sure the ring has fallen off; if left on too long, the ring can deform the glans. *Laceration of the glans or amputation of the tip of the glans* can occur if one of the older blind circumcision techniques is used. It is also seen as a complication of circumcision device such as the Mogen clamp. Immediate reanastomosis of the glans is usually successful. *Bleeding* can occur along the edge of the incised skin, from penetrating vessels on the shaft or from the frenulum. Direct pressure, suture ligature, and very careful use of fine needle point electrocautery control nearly all cases. Be suspicious of bleeding disorders when infants and young children have intraoperative or postoperative bleeding problems. When using the Plastibell or Gomco devices, be sure that the device is applied correctly.

The Gomco clamp should be applied for at least 5 minutes for its full hemostatic effect. *Infections* are rare. Localized infections can be treated with topical and oral antibiotics and drainage. Systemic infections, including Fournier's gangrene, have been reported, but are exceptionally rare. Aggressive therapy with parenteral antibiotics and debridement of necrotic tissue are needed. *Separation of the circumcision seam* can occur but usually resolves well. When it occurs within the first week of life, it usually heals spontaneously with excellent cosmesis. The treatment is usually copious amounts of antibiotic ointment on the tip and careful observation. Skin grafting and surgery are not advised. *Redundant residual foreskin* can occur when an insufficient or uneven amount of foreskin had been resected. Treatment is usually a revision circumcision. *Adhesions* usually result from residual foreskin clinging to the lower edge of the glans. These can be either peeled back or resected as part of a revision circumcision. *Skin bridges or bands* can occur when a narrow web of skin grows from the circumcision seam onto the glans. These create pockets of dead space into which smegma and other debris can accumulate. Treatment involves sharply taking down these bands flush against the glans and penile shaft. *Penile torsion and chordee* can occur if there is an unevenness or twist in the shaft skin. The usual treatment is to take down the penile shaft skin and to correct the imbalance. *Glanular division* can occur during the vertical slitting of the foreskin. Taking down preputial adhesions before cutting and awareness of this complication are key to prevention. Treatment is primary repair and closure over a catheter when the urethra is involved. *Inclusion cysts* can occur when portions of the skin become entrapped during closure. This results in a buried space, which over time fills with smegma and debris. Treatment is excision of the cyst and its lining. *Urethral injuries and urethrocutaneous fistula* can occur when sutures used to control bleeding inadvertently catch the urethra. Treatment is primary closure. When the fistula is close to the glans tip, it is preferable to split the glans down to the fistula and recreate the distal urethra using a hypospadias technique. *Urinary retention* can occur due to secondary phimosis or overly tight dressing. *Suture tracks* occur when the paths of the dissolving sutures do not collapse but become keratinized tunnels. The tracks fill with lint and other debris, giving the appearance of small dark spots and streaks. Treatment is unroofing these tracks sharply. To prevent the development of these tracks, inverted buried closure has been advocated. *Meatal stenosis* has been identified as a long-term possible complication of neonatal circumcision. Up to 7% of circumcised neonates later developed meatal stenosis.

UNCIRCUMCISION

Lynch and Pryor

Make a circumferential incision along the base of the penis. Place four stay sutures symmetrically on the mid-to-upper penile shaft skin (Fig. 22-8A). Mobilize under the penile shaft skin. Deglove the penis in reverse; head toward the glans rather than the usual base. Make four small evenly spaced circumferential incisions and tag with marking sutures. These will define the new preputial opening. Using the stay sutures, pull the shaft skin upward, thereby creating the neoprepuce (see Fig. 22-8B). Close the four small incisions vertically to help narrow the caliber of the opening. Elevate a midline full-thickness skin flap from the scrotum approximately the size of the defect on the lower shaft. Raise the flap, keeping the dartos pedicle intact and wrap it around the base of the shaft. Place a urinary catheter for 1 week.

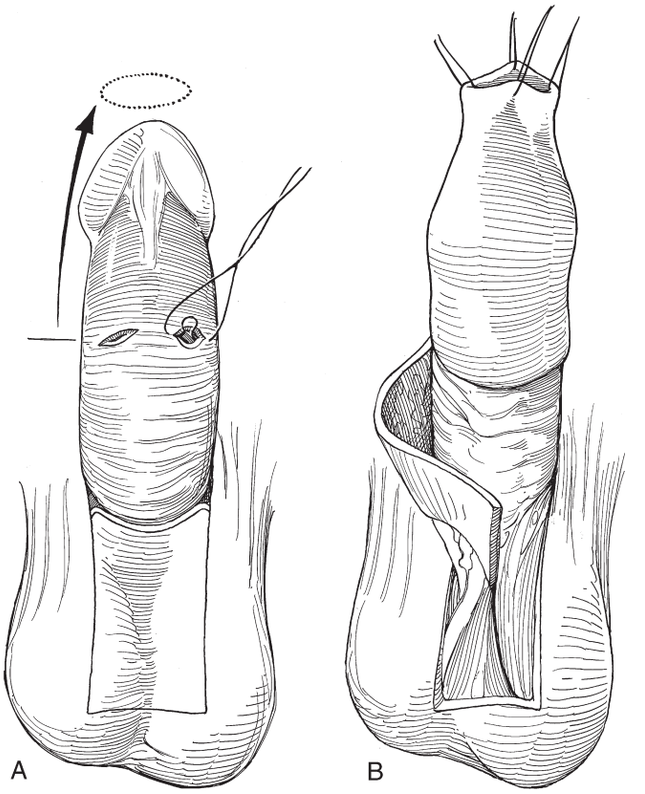

FIGURE 22-8.

Chapter 23

Dorsal Slit

JULIAN WAN

The dorsal slit procedure is useful as a standalone operation for phimosis and paraphimosis or as an adjunct to other operations that require preliminary exposure of the glans. For families and patients who need to resolve phimosis but who do not wish to appear circumcised, the dorsal slit is a useful alternative.

DORSAL SLIT FOR PHIMOSIS

1. Carefully dilate the opening and take down any adhesions.
2. Mark out a vertical incision that extends about halfway down to the coronal sulcus (Fig. 23-1).
3. Pick up the prepuce and clamp along the marked line using a straight hemostat. Leave the clamp applied for 10 seconds.
4. Using sharp scissors or fine needle point electrocautery, carefully cut along the mark. Protect and guard the underlying glans from inadvertent injury.
5. Check for hemostasis and then close the edges with 6-0 or 5-0 fine absorbable sutures in an interrupted fashion (Fig. 23-2).
6. Apply copious amounts of Bacitracin ointment on the suture lines three to four times each day until the sutures have fully dissolved. Have the family gently move the foreskin periodically two to three times a day to avoid sticking and adhesion formation.

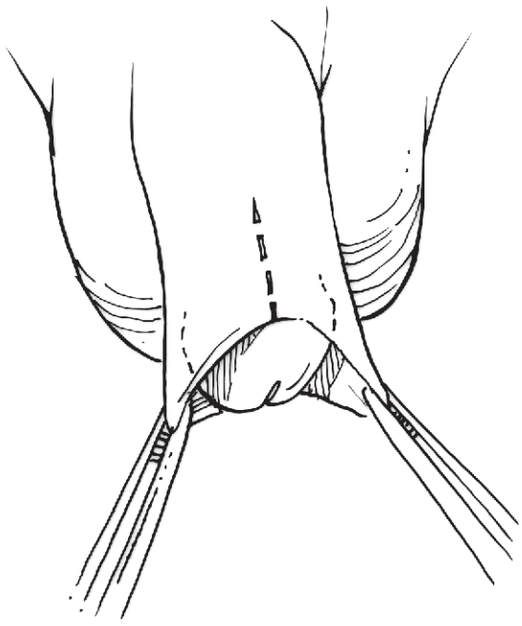

FIGURE 23-1.

DORSAL SLIT FOR PARAPHIMOSIS

This procedure is used when it is not possible to reduce the paraphimosis manually.

1. Find the dorsal midline. Identify the junction point where the prepuce had been rolled back. There is usually

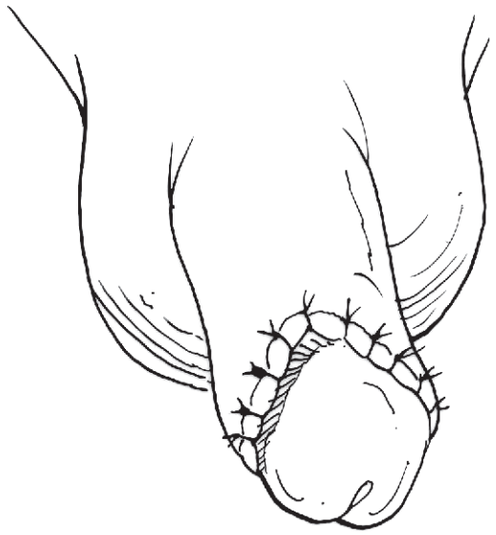

FIGURE 23-2.

a difference between the inner shinier smooth skin and the outer duller skin. Make a vertical incision at this point. If placed correctly, the cut should release the constriction (Fig. 23-3A). The prepuce should now be freed up. Mobilize the prepuce and check that it can slide freely over the top of the glans and back down. If necessary, extend the incision further until this mobilization is achieved, but stop before reaching the corona sulcus.

2. Close the incision transversely with fine 6-0 or 5-0 absorbable sutures.
3. Put the prepuce back to its natural position and apply copious amounts of Bacitracin ointment (see Fig. 23-3B).

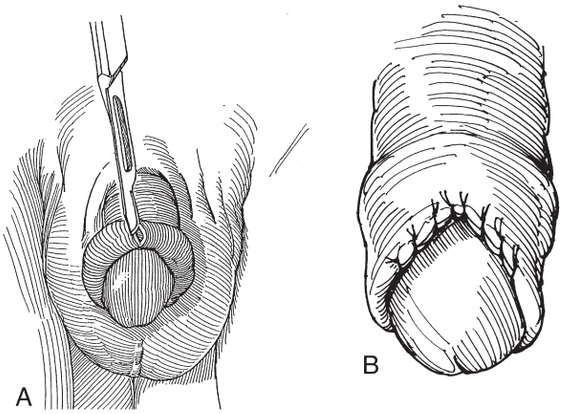

FIGURE 23-3.

Chapter 24

Penile Curvature in the Pediatric Patient

STEVEN J. SKOOG

PENILE TORSION

Penile torsion is defined as rotation along the long axis of the penis. It occurs in approximately 1 in 80 patients. The rotation almost always occurs in a counterclockwise direction. It appears to be secondary to dysgenetic dartos bands with rotation of the median raphe. The orientation of the corporal bodies and the corpus spongiosum are normal. It may occur secondarily following prior hypospadias repair, repair of chordee, or circumcision. The torsion seen in the uncircumcised penis is due to abnormal skin and dartos fascia investiture of the penile shaft. The location of the median raphe offers the best clue that underlying torsion is present.

Surgical Repair

Surgical repair is indicated when greater than 60 degrees of counterclockwise rotation of the penis is present and the family desires a circumcision. The procedure is begun by making a circumferential incision proximal to the coronal margin. The skin is dissected completely off the shaft of the penis to the base of the penis, transecting dysgenetic dartos bands. It may be necessary to transect the dorsal suspensory ligament (Fig. 24-1A). After the penis is degloved, if the urethral meatus is not rotated to the left, simply realigning the median raphe back to the midline after removing excess skin is sufficient to correct penile torsion in mild cases.

With moderate cases of torsion, a broad-based dartos flap is mobilized from the undersurface of the dorsal penile skin (see Fig. 24-1A). Liberal use of stay sutures on the penile shaft skin and separate sutures in the dorsal dartos tissue will assist in dissecting the dartos flap from the undersurface of the dorsal penile skin. The dartos flap can then be rotated around the right side of the penile shaft and sutured with interrupted 5-0 Vicryl suture ventrally (see Fig 24-1B). The sutures should not be placed directly over the urethra. The amount of flap rotation is determined by the degree of penile torsion that needs to be corrected. This maneuver rotates the penis in a clockwise direction, thereby correcting the counterclockwise torsion.

In more severe cases of penile torsion, dysgenetic dartos bands must be severed at the base of the penis and the base of the right corporal body is sutured, affixing it to the pubic symphysis. This assists in clockwise rotation, counteracting the counterclockwise rotation of the dysgenetic bands.

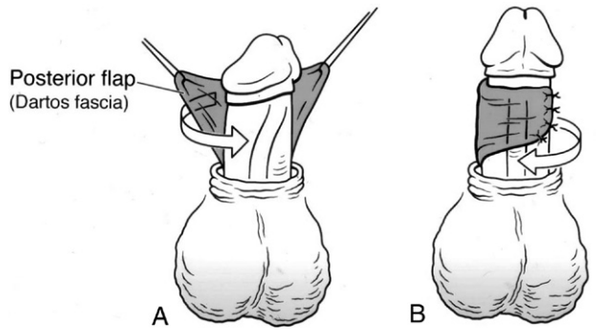

FIGURE 24-1. *(From Fisher C, Park M. [2004]. Penile torsion repair using dorsal dartos flap rotation. J Urol 171:1903-1904.)*

The procedure is completed by realigning the shaft skin circumferentially around the phallus after excess skin has been removed in performance of the circumcision. In the infant this is usually accomplished with 5-0 or 6-0 chromic suture. The penis is then dressed with a Tegaderm or bio-occlusive dressing, which is positioned circumferentially around the shaft of the penis tight enough to prevent oozing, but not so tight as to prevent voiding.

LATERAL PENILE CURVATURE AND CHORDEE WITHOUT HYPOSPADIAS

Lateral penile curvature in the infant and young child is almost always due to corporal body disproportion. In this circumstance, the urethral spongiosum and urethral length are normal, not causing bending of the phallus. With erection, the longer corporal body will push laterally toward the shorter corporal body, creating lateral curvature.

In children with chordee not due to urethral abnormality, the defect represents an arrest in normal development. This chapter discusses curvature secondary to corporal body disproportion and fibrotic Buck's or dartos fascia. Curvature secondary to a short fibrotic urethra is discussed elsewhere.

An understanding of the sensory distribution of the dorsal penile nerves is helpful in surgical correction of penile curvature. The most important neuroanatomic finding related to the anatomy of the dorsal nerve is that it has multiple branches running along the surface of the tunica albuginea from the classic dorsal 11-o'cock and 1-o'clock positions to the 5-o'clock and 7-o'clock positions at the junction of the corporal bodies with the urethral spongiosum. The 12-o'clock midline position does not have any neural structures.

Surgical correction of penile curvature can be accomplished by a number of different procedures depending on the severity of the curvature. The most accepted method for the correction of penile curvature was described by Nesbit. Nesbit's procedure is the same whether there is lateral curvature or chordee without hypospadias.

With lateral penile curvature as well as with ventral chordee, the first step is to make a circumcising incision. The skin is then degloved from the shaft of the penis down to its base. An artificial erection is induced. The corporal bodies are measured on their lateral aspect. The neurovascular bundle is mobilized from the dorsum of the penis by incising Buck's fascia laterally at the 4-o'clock and 8-o'clock positions. Buck's fascia with the neurovascular bundle is then carefully dissected from the dorsal tunica albuginea (Fig. 24-2A). A vessel loop or ¼-inch Penrose drain can then be passed under the neurovascular bundle to assist in elevation and dissection of the neurovascular bundle. The tunica albuginea can be grasped with an Allis clamp as illustrated in Figure 24-2B or outlined with a marking pen. The tunica is then excised sharply. We have found in infants and children that the use of a Weck knife is valuable in performing this maneuver. Once the ellipse is removed, it is closed with interrupted 5-0 polydioxanone suture (PDS) or Maxon suture. The knots are buried. These ellipses are excised in a more lateral eccentric location with corporal body disproportion causing lateral curvature. They are excised in a corresponding location on the right and left corporal bodies when dealing with ventral chordee. Following completion of the excision of the first ellipse, a repeat artificial erection is created to assess the results and determine the need for further excisions. This is particularly important in the child. I never remove more than a 0.5 cm width to the ellipse.

Alternative #1: tunica albuginea plication (TAP) (Fig. 24-3A). The TAP procedure is a modification of the Nesbit operation

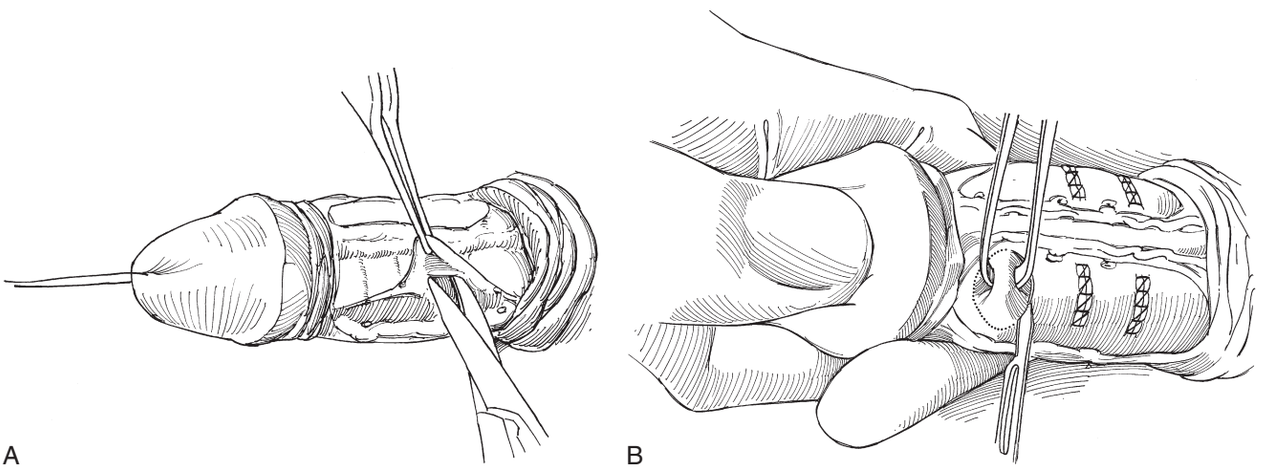

FIGURE 24-2.

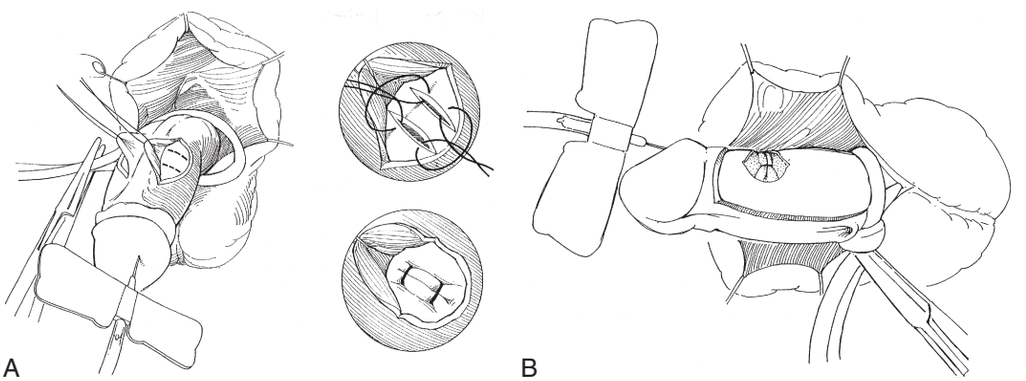

FIGURE 24-3. *(From Mingin G, Baskin LS. [2002]. Management of chordee in children and young adults. Urol Clin N Am 29(2):277-284.)*

and can be used to correct penile curvature secondary to corporal disproportion. Buck's fascia is elevated from the shaft of the penis at the 4-o'clock and 8-o'clock positions with mobilization of the neurovascular bundle. Rather than excise the corporal tissue, two parallel incisions approximately 4 to 6 mm apart and 8 mm long are made through the tunica albuginea at the point of maximum curvature. Without excision of the intervening tunica, the outer edges of the incisions are approximated with interrupted nonabsorbable suture (5-0 Prolene in infants and children) (see Fig. 24-3B). This shortens the corporal body and reverses the curvature. More than one plication may be necessary in severe cases. An artificial erection is created to assess the result and need for further plication.

Alternative #2: dorsal midline plication (Fig. 24-4). Dorsal midline plication is most applicable in patients with mild ventral chordee and a normal urethra that is not corrected by degloving. This technique is based on anatomic studies that show the position of the dorsal nerves and the absence of neurologic structures at the 12-o'clock position. The 12-o'clock position of the tunica albuginea is the thickest and strongest portion of the tunica albuginea. With dorsal plication, it is not necessary to mobilize the neurovascular bundle. An artificial erection is created to determine the point of maximum curvature. This area is marked with a marking pen. An incision is made at the 12-o'clock position with a #15 blade and is carried down through Buck's fascia and partially into the tunica albuginea (see Fig. 24-4). In infants and children, the length of this incision should not be longer than 0.75 cm. Again, a 4 or 5-0 PDS or Maxon suture on an atraumatic needle is positioned at the proximal and distal end of this longitudinal incision. The knot is buried and the suture is tied in the midline (see Fig. 24-4). An artificial erection is again induced to assess the results of the plication. If two parallel dorsal midline plication sutures do not straighten the penis, additional rows of midline plication sutures can be placed along the area of maximum curvature. This technique is effective in straightening a penis with mild to moderate chordee.

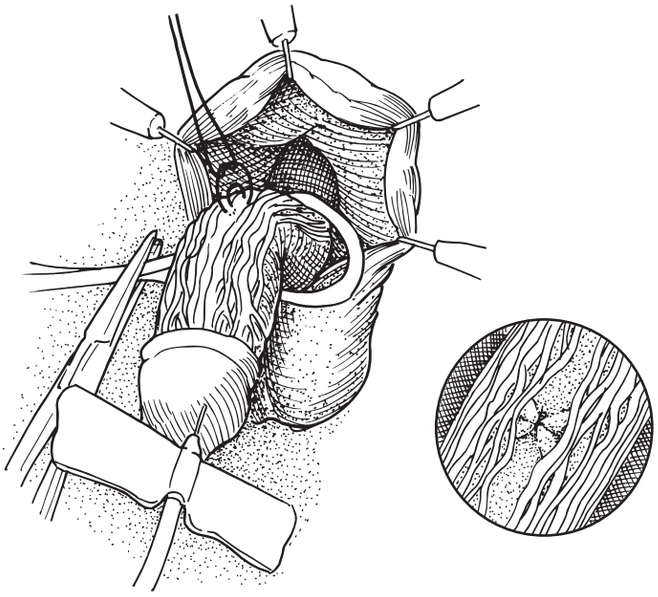

FIGURE 24-4. *(Hinman F, Baskin LS. [2009]. Hinman's atlas of pediatric urologic surgery, 2nd ed. Philadelphia: Elsevier, p 673.)*

Alternative #3: Yachia plication. This plication technique involves the same steps of circumcising incision, degloving the penis, and inducing an artificial erection. While the artificial erection is being induced, an Allis clamp is applied to the most convex part of the corpora to assess correction of the curvature. Longitudinal incisions are made between the marks made by the clamp. The longitudinal incisions are closed transversely with 4-0 or 5-0 Maxon or PDS sutures. These sutures are buried. By performing longitudinal incisions and closing them horizontally by the Heineke-Mikulicz principle, the longer side of the tunica albuginea is shortened. It is helpful when closing the incision to use small nerve hooks to hold the edges of the incisions from the middle and pull laterally. These are then closed with 5-0 PDS or Maxon suture in children and a larger diameter suture in adolescents. If the edge of the suture line bulges, it can be smoothed out by a superficial simple plicating suture.

The closure is the same in all the described procedures. Buck's fascia is reapproximated with an absorbable monofilament suture in a running locking fashion. The skin is approximated after performance of a circumcision with interrupted 5-0 chromic suture. A circumferential Tegaderm dressing is applied to the shaft of the penis.

This page intentionally left blank

Chapter 25

Hidden Penis

PAUL KOKOROWSKI AND CHESTER J. KOH

The inability to clearly see the phallus causes much distress for the parents of young boys. The condition is often recognized by parents who seek the advice of pediatricians. While much has been written on the topic, variable terminology has been used to describe the varied appearances with a number of different descriptive terms being used without standardized diagnostic definitions (Table 25-1).

Maizels is commonly credited with the first comprehensive classification system, which included the subtypes of concealed (before circumcision), buried (adolescent), webbed, trapped (postsurgical), and micropenis. Casale and colleagues recognized that this condition often was the result of several etiologic factors and thus should be considered along a continuum. Their patients were stratified into three groups based on etiology: poor fixation of skin at the base of the penis, cicatricial scarring after penile surgery, and excessive obesity. We believe that the terms *hidden, inconspicuous, concealed, trapped,* and *buried* penis can be used virtually interchangeably. However, *trapped penis* most often refers specifically to a hidden penis secondary to scarring from prior surgery, such as neonatal circumcision. It is essential to recognize the underlying processes that contribute to a particular appearance such that a directed surgical approach can be undertaken.

Distinct from this group of abnormalities is the webbed or tethered penis and the micropenis. Webbing or tethering of the penis refers to the distal attachment of scrotal skin to the ventral aspect of the phallus. Whereas Maizels considered this to be part of the same continuum of abnormalities, we consider it separately here. Anatomic repair is simply performed with a transverse untethering incision with longitudinal (vertical) skin closure. Alternatively a circumferential incision can be made and Byars' flaps created to cover the ventral skin defect, with or without anchoring sutures between scrotal skin and penile base. Micropenis, on the other hand, refers specifically to unusually small corporal and glans structures associated with an endocrinopathy. Because the normal stretched length for full-term male neonate is 3.5 ± 0.7 cm, micropenis refers to a normally formed penis that is at least 2.5 standard deviations (SD) below the mean in size. The finding of a micropenis should immediately prompt hormonal investigation. Hidden penis by definition has normal sized phallic structures; however, Redman and colleagues noted a significantly smaller stretched length in these boys, even though the average length did not necessarily meet the criterion for micropenis.

Management of this condition consists of observation or surgical correction. Even though a watchful waiting

TABLE 25-1 TERMS FOR HIDDEN PENIS

Name	Description
Primary (hidden, concealed, inconspicuous, buried)	Congenital abnormal attachment, deficiency of phallic skin, obesity
Secondary (hidden, concealed, inconspicuous, buried, trapped penis)	After circumcision, hypospadias repair, or other penile surgery
Webbed or tethered penis	Abnormal ventral attachment of scrotal skin distally
Micropenis	Small phallic structures > 2.5 standard deviations below normal

approach can be successful, correction is often necessary to alleviate repeated bouts of balanitis, difficulties with hygiene, social embarrassment, or difficulties with grasping the phallus to direct the urine stream during voiding. Surgical correction has been shown to effectively improve hygiene, penile accessibility, and subjective patient/parent concerns.

Current opinion suggests three major pathologic mechanisms: congenital penile skin to fascial attachment abnormalities, postsurgical (cicatricial) related scarring with tethering, and obesity-related mechanisms. Some authors have suggested that the primary abnormality is the deficiency of penile shaft skin rather than any abnormal attachments, although the etiology is likely multifactorial.

Congenital versions of the hidden penis are characterized by an abnormal attachment between the dartos layer of the scrotum, Scarpa's fascia of the abdominal wall, and the distal shaft that is often associated with a deficiency of ventral penile shaft skin. Attachment of Scarpa's/dartos layers to the distal shaft skin prevents penile protuberance while promoting expansion of inner preputial skin, leading to penile concealment. With continued growth, the preputial skin inverts, which can lead to an overabundance of inner preputial skin.

Secondary or "trapped" forms of hidden penis are related to prior penile surgery, most often circumcision. A tight phimotic ring at the site of prior circumcision leads to a trapping of the glans penis and corporal structures beneath. With growth of the phallus, the surrounding skin is stretched for accommodation; however, the penis remains hidden. This version may have a nearly identical appearance to that of the congenital buried penis.

Obesity was once thought to be the primary cause of all cases of hidden penis before updated anatomic descriptions were reported. Expectant management strategies emerged from the observation that many of these boys developed a normal appearance with weight loss and with the expected phallic enlargement associated with puberty. Certainly the presence of obesity can accentuate the appearance of hidden penis. However, the discovery of anatomic abnormalities that contribute to the formation of hidden penis and the recognition of adolescent and adult forms suggest that obesity is an uncommon solitary etiologic factor. Furthermore, early intervention may prevent consequences such as recurrent infection, difficulty directing stream, and social embarrassment.

Many surgical techniques have been described to correct this group of abnormalities, each with their own strengths and weaknesses. Virtually all are designed to address specific surgical principles required for successful cosmetic and functional outcomes.

First, it is important to incise or excise the tight phimotic ring that is commonly encountered. Failure to do so will make delivery of the glans difficult and cause constriction of the penile shaft.

Second, incision of all abnormal attachments found congenitally between the layers of the penis or as a result of scarring should be performed. This is best accomplished by thorough degloving of the penis superficial to Buck's fascia. Degloving also allows adequate exposure for fixation of penile skin to the base of the phallus at the penopubic and penoscrotal junction. These maneuvers should be performed with care to avoid injury to the neurovascular bundles originating on the dorsal surface of the phallus just beneath Buck's fascia coursing distally with branches extending laterally along the shaft.

Finally, penile skin coverage with local flaps or grafts is often required with the abundance of "inner preputial" skin serving as an excellent source for covering materials in some cases. Removal of excess fat is advocated by others for improved cosmetic result; however, this is usually unnecessary, unless the fat pad thickness exceeds the length of the flaccid penis.

The following represents our preferred method of surgical repair with emphasis on correction of congenital buried penis and trapped penis.

Preoperative Appearance

The gross appearance of a typical buried or trapped penis is characterized by the mound-shaped outer preputial skin (Fig. 25-1). Little or no penile shaft skin is evident. Depression of the surrounding skin results in exposure of glans only, with little or no shaft visible. The prepuce appears to arise from pubic and scrotal skin.

Incision of Phimotic Ring

A phimotic ring is most often present, either representing the scar from a prior circumcision or secondary to repeated episodes of balanitis (Fig. 25-2A). A dorsal slit, although not uniformly necessary, allows release of the phimotic portion and allows access to the glans and inner preputial skin. Clamping of the skin before incising the skin aids with hemostasis (see Fig. 25-2B). A 5-0 Prolene stitch should be placed in the glans at this point for traction to allow for a circumferential incision (see Fig. 25-2C).

Degloving the Phallus

Begin with circumferential incision roughly 5 mm proximal to the coronal margin. Complete penile degloving is essential for disrupting any abnormal attachments between the dartos or Scarpa's layers and the penile fascia. Dissection can be performed with Metzenbaum scissors between the penile dartos layer and Buck's fascia (Fig. 25-3). Staying in this surgical plane avoids injury to the neurovascular bundles while allowing mobility to the superficial layers of the skin. Freeing the penile skin to the base is essential for releasing all attachments and allows placement of anchoring sutures.

Placement of Anchoring Stitches

The number and location of anchoring sutures varies with surgeon. The goal is fixation of shaft skin with 5-0 polydioxanone sutures from the dermal layer to Buck's fascia at the base of the phallus. We prefer to place fixation at the 2- and 10-o'clock positions dorsally and the 5- and 7-o'clock positions ventrally (Fig. 25-4), taking care to avoid injury to the neurovascular bundles and urethra. Care should be taken at this step to preserve as much skin as possible for penile coverage.

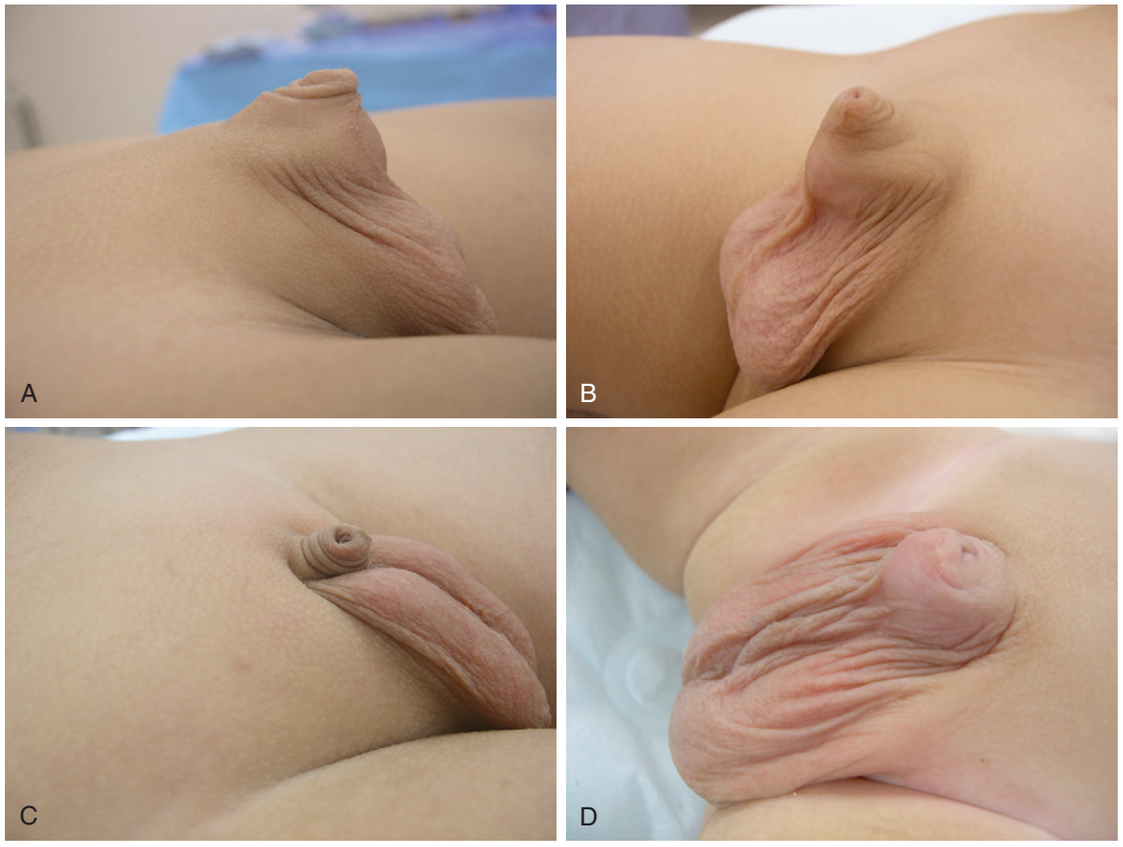

FIGURE 25-1.

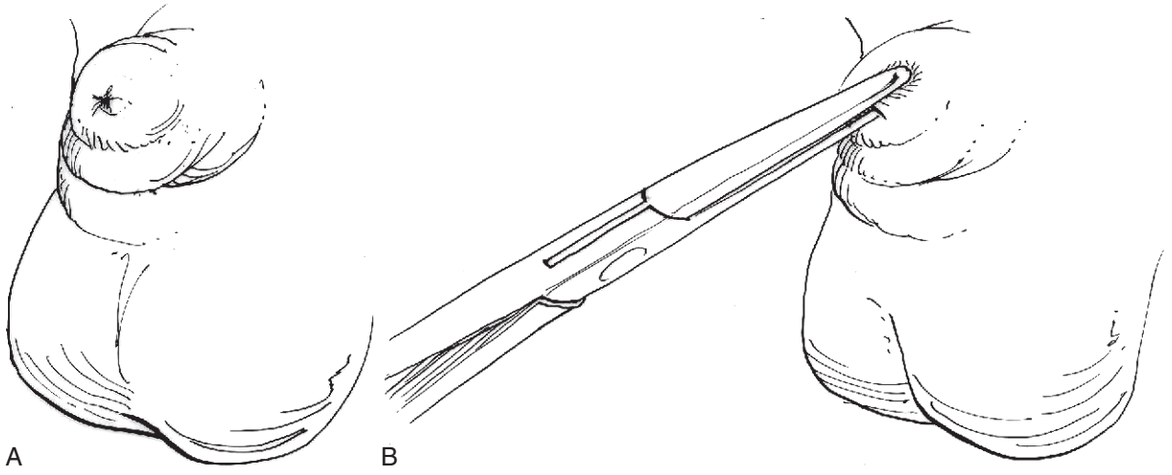

FIGURE 25-2.

Continued

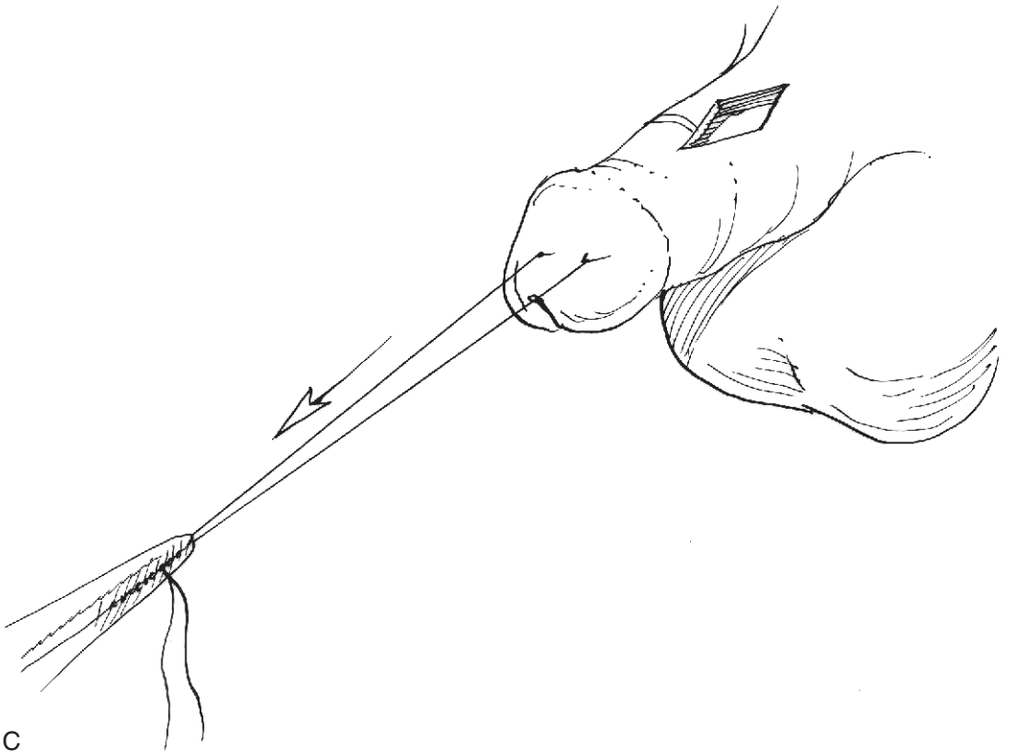

C

FIGURE 25-2, cont'd.

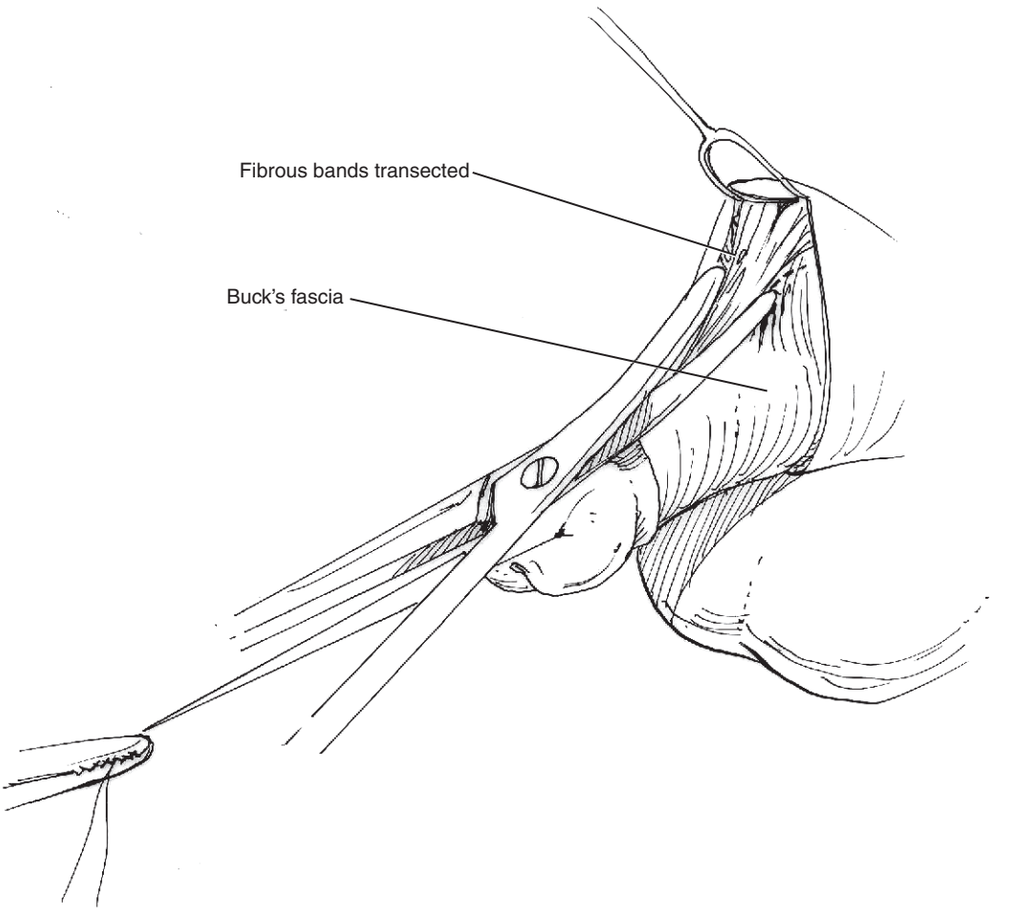

FIGURE 25-3.

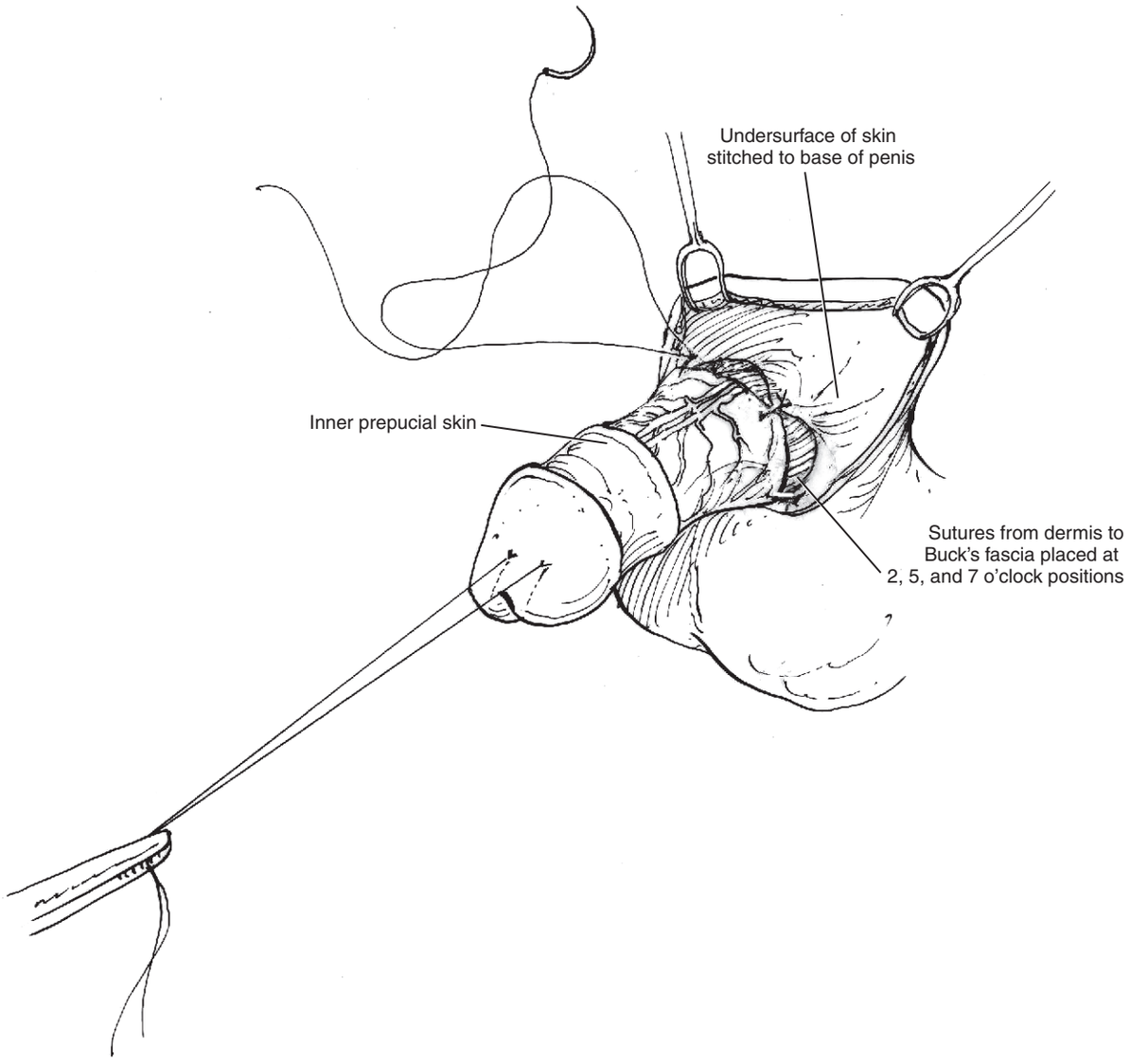

FIGURE 25-4.

Flap Closure of Penile Skin

Removal of excess skin is performed and skin edges are reapproximated with interrupted chromic sutures (Fig. 25-5). Our preference is to use as little inner preputial skin as possible for better tissue handling and improved cosmetic appearance, even though various experts have reported excellent results when using this skin. If there is deficient penile skin ventrally, a dorsal slit can be performed with rotation of the skin flaps to the ventral aspect (Byars' flaps).

Postoperative Considerations and Complications

The procedure is easily performed in the outpatient setting. A penile dressing can be placed that consists of a nonstick gauze dressing (Telfa) over the suture lines followed by Tegaderm covering the shaft and affixed to the scrotum and abdominal wall. After removal of the dressing in 1 week, parents are instructed to apply an antibiotic ointment to the suture lines. Gentle retraction of the edematous foreskin is often required during the first 3 to 4 weeks to prevent adhesions and cicatricial trapping of the phallus. We generally recommend sitz baths twice daily for optimal hygiene.

Bleeding is the most common serious complication of the procedure. The risk is increased in part due to the chronic inflammation often present under the inner preputial skin, which leads to increased friability. Infection is an uncommon complication and the use of postoperative antibiotics are not usually necessary.

Satisfaction with surgical treatment is high, with reported improvements in penile hygiene, penile accessibility, and general cosmesis. In patients who reported less than complete satisfaction with persistent or partial concealment, obesity or adolescent age were common features. Late complications, such as penile adhesion formation or secondary trapping of the penis requiring repeat procedures, occur rarely (0%-5%) in most reports.

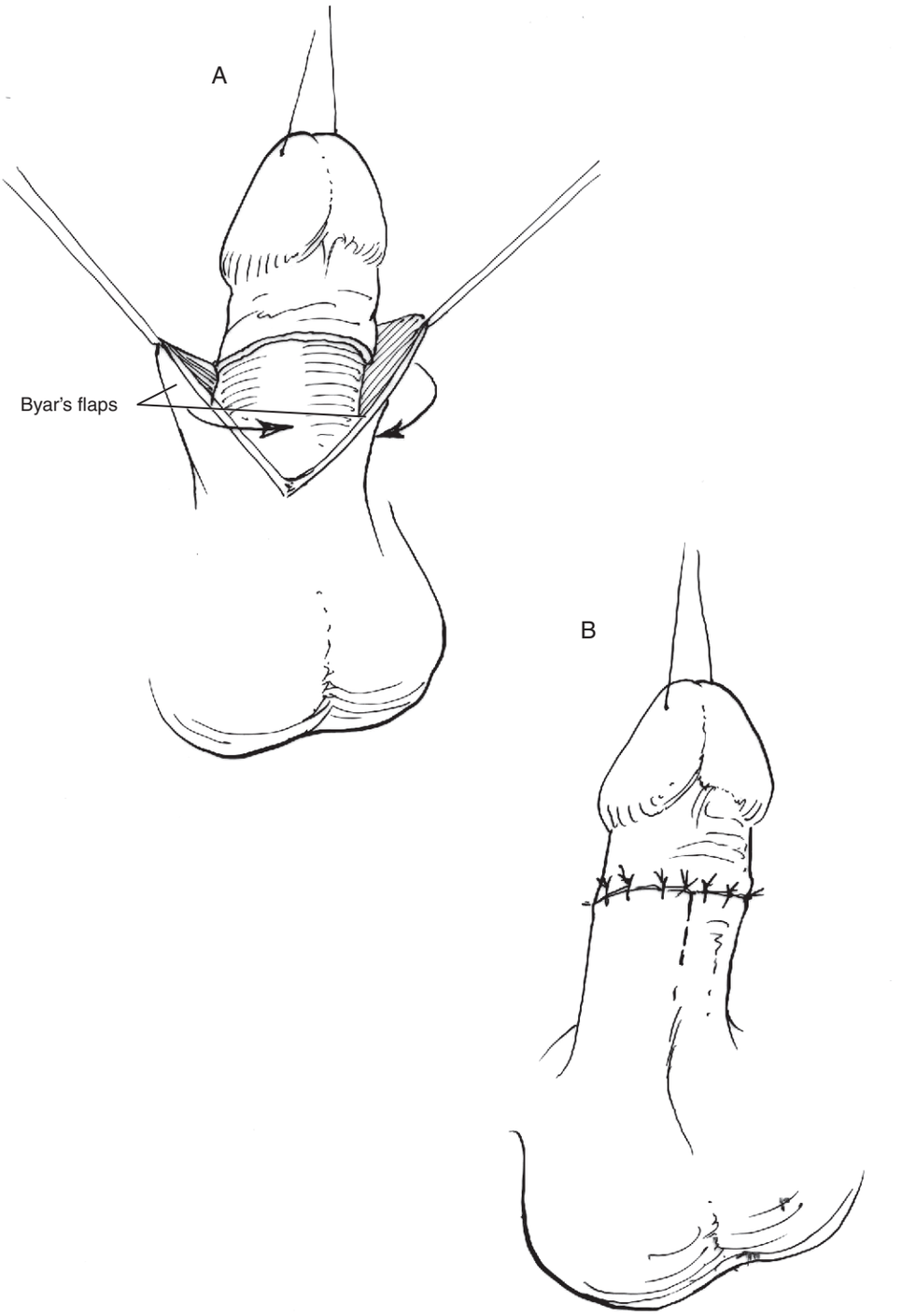

FIGURE 25-5.

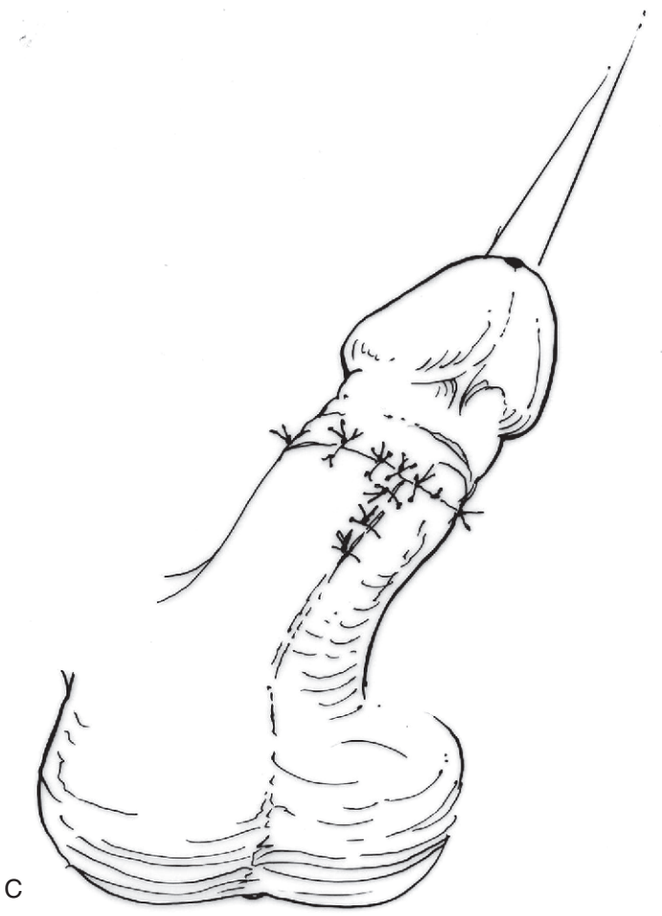

FIGURE 25-5, cont'd.

This page intentionally left blank

Section VI

PENIS: RECONSTRUCTION

This page intentionally left blank

Chapter 26

Insertion of Flexible Prosthesis

WILLIAM D. STEERS

Flexible prostheses are implanted far less commonly than multicomponent devices because of patient preference for more physiologic results with devices that inflate and deflate. Nevertheless flexible devices may be preferred for complex reconstruction or when patients have significant issues with manual dexterity. Three single-component flexible prostheses are available in the United States (Table 26-1). Have proper sizers and sizes available and sterile, either in a sealed package or soaking in an erythromycin solution (500 mg in 500 mL of saline). Make sure sizing instructions are available in the operating room and that a full complement of devices and a backup device are present.

Approaches for insertion. Although the subcoronal, penoscrotal, and infrapubic approaches are most commonly used, the penoscrotal incision is used by most surgeons. Implantation by the perineal approach takes longer and increases the risk of infection because of proximity to the anus. The dorsal penile incision may be followed by penile edema from obstruction of the dorsal lymphatics. Partial sensory loss into the glans can occur after making a distal penile incision, even though the midline dorsal nerve is avoided. A circumcision probably is not necessary, and it increases the risk of infection. If simultaneous insertion of an artificial urinary sphincter or male sling device is contemplated, separation of wounds (e.g., perineal and dorsal approaches) may reduce risk of simultaneous infections of prostheses in case one device becomes infected.

Preparation. Start parenteral broad-spectrum antibiotics the day before an incision. Oral antibiotics for 7 to 14 days are given postoperatively. In patients at high risk for infections,

TABLE 26-1 NONINFLATABLE PENILE PROSTHESES

Name	Type	Company/Contact	Country
Promedon tube	Malleable	cesaroriz@promedon.com.ar	Argentina
HR Penile Prosthesis	Malleable		Brazil
Silimed Malleable	Malleable	www.silimed.com.br	Brazil
Jonas (ESKA)	Malleable	www.Eska-medica.com	Germany
Shah Implant	Nonmalleable		India
Virilis I and II	Nonmalleable	Giant Medical (www.giant-medical.com)	Italy
Apollo Implant	Tissue expander	Giant Medical (www.giant-medical.com)	Italy
Genesis Malleable	Malleable	Coloplast	USA
AMS Malleable 650/600M	Malleable	American Medical Systems	USA
AMS Dura II	Positionable	American Medical Systems	USA

From Simmons M, Montague DK. (2008). Penile prosthesis implantation: past, present and future. Int J Impot Res 20:437-444,2008.

parenteral antibiotics for 12 hours following surgery before initiation of oral antibiotics can be considered. Gram-positive bacteria are the main pathogens for prosthetic infections. Have the patient scrub his genitalia in the shower for 10 minutes with povidone-iodine or chlorhexidine solution the night before and the morning of surgery. Patients with active infections such as a urinary tract infection, decubitus ulcer or osteomyelitis should have the infection source treated before any implant is considered. Shave or depilate the genital area in the operating room and scrub for 10 minutes with povidone-iodine or newer alcohol based preparations. A sterile urethral catheter is inserted and removed as soon as the patient can voluntarily void. Antibiotics are administered intravenously at the start of the procedure.

A positive pressure operating room should be used. Irrigate the wound frequently with antibacterial solution, and consider instilling gentamicin into the corpora after corporotomy and dilation. If this is a removal of a previous device, extra irrigation with antibiotics is needed since the pseudocapsule usually contains a biofilm with gram-positive cocci. If the device is infected, in the absence of gross pus, an attempt at salvage using a seven-component irrigating solution and mechanical irrigator can be made as outlined by Muchahy.

Instruments: Provide a basic set; Hegar dilators; small Army-Navy, Weitlander, and phrenic retractors or Brantley Scott ring retractor; an 18-French 5-mL silicone balloon catheter with 12-mL syringe; plug and lubricating jelly and bacitracin-neomycin irrigant.

If an inflatable penile prosthesis is to be replaced with a flexible one, infiltrate the base of the penis with lidocaine. Sever the tubing and remove the old prosthesis through incisions in the corpora at the penoscrotal junction. Make an incision in the scrotum after infiltrating it with local anesthesia and remove the pump. Most surgeon now remove the reservoir as well to avoid late infections.

VENTRAL PENILE APPROACH

Anesthesia: Local anesthesia is effective. Make a cutaneous penile block with lidocaine.

Incision: Make a 4- to 5-cm incision in the midline raphe in the penile shaft distal to the penoscrotal junction (Fig. 26-1A). Some surgeons use a transverse incision (see Fig. 26-1B), mostly for multicomponent devices to facilitate reservoir placement via the internal inguinal ring. Draw the incision distally to expose the dartos and Buck's fascia in midshaft. Grasp the subcutaneous tissue with small clamps to act as retractors or place a Weitlaner retractor; spread fascia and develop planes with vein or phrenic retractors, or place a Scott ring retractor. Dissection through each fascia layer using electrocautery and a tonsil clamp to develop and lift each layer from the tunica albuginea makes dissection nearly bloodless. Expose the urethra and corpus spongiosum and select an insertion site to one side. Fulgurate any superficial vessels. If the corpus spongiosum is nicked, close it with a figure-eight 4-0 synthetic absorbable suture (SAS).

Place two stay sutures in the tunica albuginea and make a 3-cm incision between them into the corpus, beginning

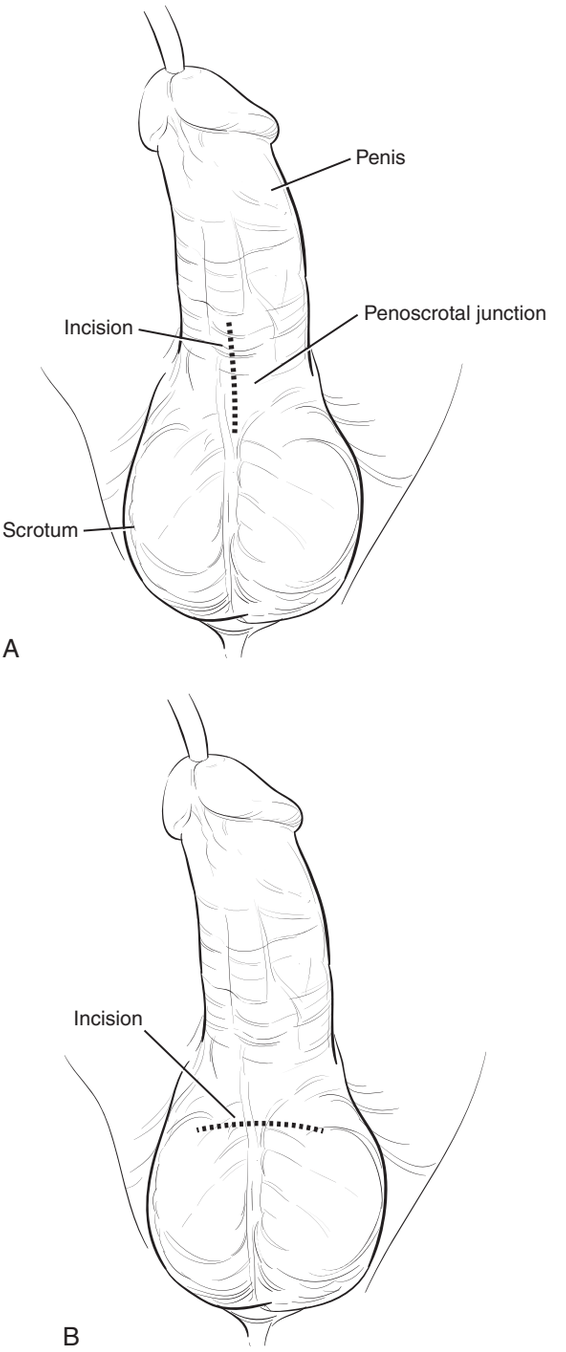

FIGURE 26-1.

0.5 cm from the distal end (Fig. 26-2). Electrocautery can be used to make this incision.

Use scissors to develop the initial subtunica plane proximally to the tip of the crura and proximally to the glans penis, taking care to avoid perforation (Fig. 26-3A). If corpora cavernosa are obliterated due to priapism, infection, or previous scarring, a urethrotome or cavertome can be used to develop a potential space for the implant. Stretch the corporal incision and insert a 10-mm Hegar dilator (or an AMS Dilamezinsert instrument, if available) until it fits well beneath the glans (see Fig. 26-3B). Progress through larger dilators, pointing the curve laterally, to 12 or even 14 mm, depending on the type of prosthesis. Sponge forceps may

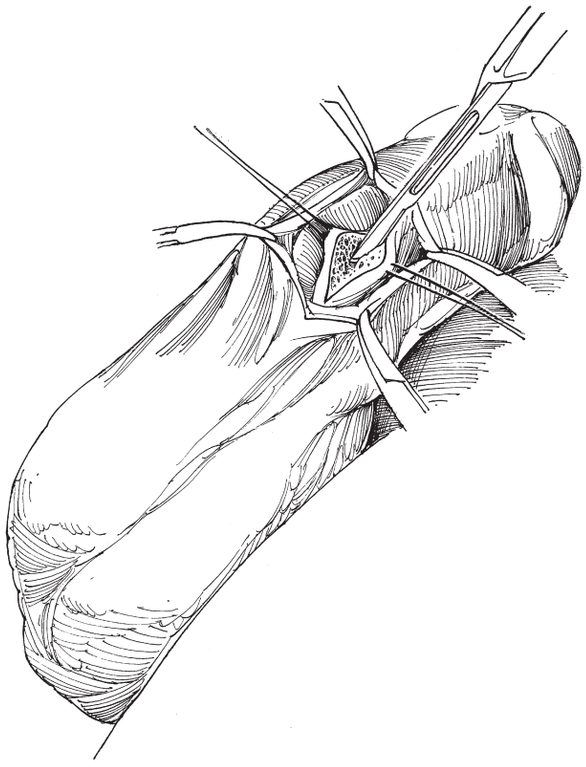

FIGURE 26-2.

help the dilation under the glans (see Fig. 26-3C). Insert an 8- or 10-mm dilator proximally (see Fig. 26-3D), again taking care not to perforate the crus. Stop when the dilator is held up at the ischial tuberosity. It is unnecessary to use larger dilators there because the prosthesis is tapered proximally.

Difficulty with dilation, such as after trauma, priapism, or Peyronie's disease, may require use of long scissors to cut through the fibrotic cavernous tissue, followed by the dilators. A urethrotome may be used if the blade is kept away from the inferior quadrant of the corpus cavernosum, thus avoiding the urethra. A cavertome is probably easier to use and avoids potential incision into the urethra. If that fails, peel back the penile skin, fillet the corpora, and cover the defect with a Marlex or Dacron mesh patch. Terminate the procedure if the urethra is accidentally perforated. Distally place a balloon catheter to remain for 10 days, and wait for 6 weeks to reoperate. If the septum is breached with the dilator, it is felt beneath the opposite side of the glans. Go to the second side and dilate the corporal body, insert the prosthesis on that side first, then return to the first side to redilate and implant. If the crus is perforated, continue dilating but be careful not to make the hole larger. If the crus does not support the prosthesis, fold, stitch, and trim an 8- × 3-cm piece of absorbable synthetic mesh or a length of size 12 or 14 vascular graft to fit over the proximal end as a buttress. If necessary, the mesh or graft may be sutured to the pubic rami. Irrigate liberally with antibiotic solution. Irrigate the corpora in both directions with the antibiotic solution. If a patient has had a male sling or artificial urinary sphincter, review the old operative notes to ensure that a transcorporeal technique has not been used. If scarring precludes placing two cylinders, then one may be left in place. While adequate for some patients, others complain of this result.

Change gloves before handling the prosthesis. Measure the length needed for the prosthesis. Follow manufacturer's guide for prosthesis sizing especially with the Duraphase device, because proximal extenders need to be sized correctly to allow bending at the mid to distal shaft.

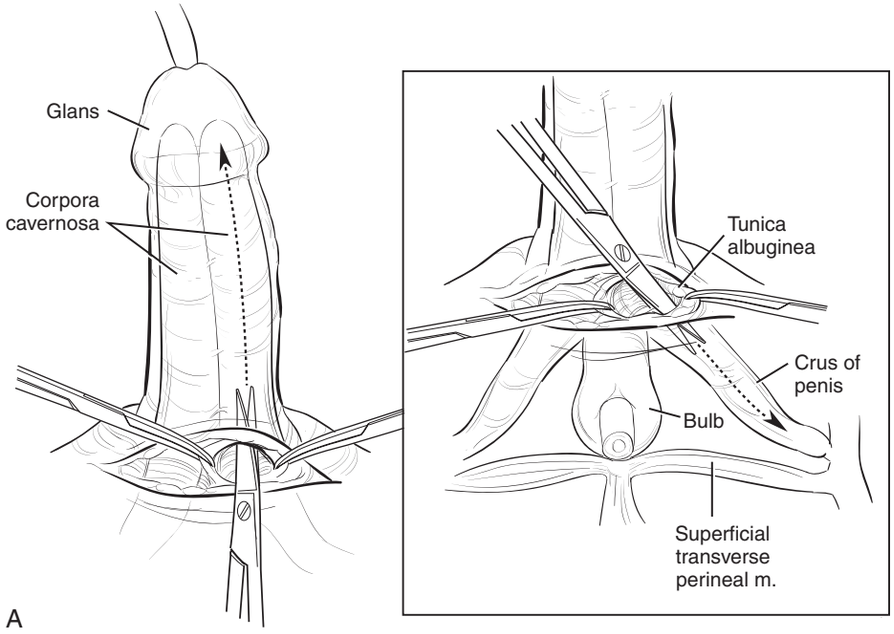

FIGURE 26-3.

Continued

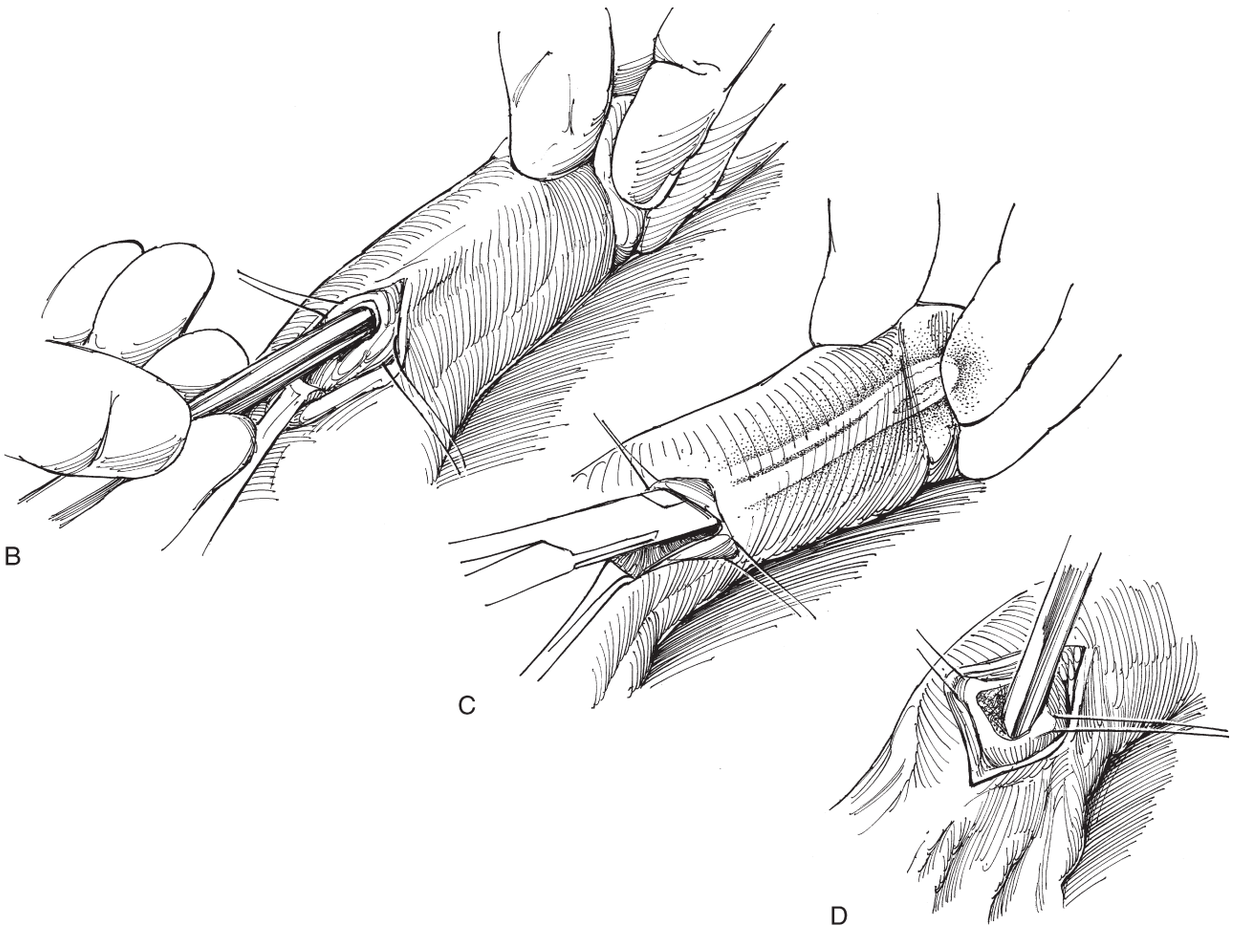

FIGURE 26-3, cont'd.

Insert the proximal end of the prosthesis first (Fig. 26-4).

Bend the distal end into a loop or circle (Fig. 26-5). Enlist the aid of your assistant to slip it into the corpus. It may be necessary to open the tunic a little more to get it in. A vein retractor can be inserted like a shoehorn to lift the distal end of the corporotomy over the end of the prosthesis. Check for length. If the prosthesis bows the corpus, remove it and trim off 1 cm more. If it is too short and the glans droops downward, add appropriate rear tip extenders. Irrigate the wound with bacitracin-neomycin solution. Perform the same procedure on the other side. Too short a prosthesis runs the risk of a glanular tilt (SST deformity). Too long a prosthesis risks glanular erosion and chronic pain.

Close the tunica albuginea with a running 3-0 SAS (Fig. 26-6). Check the position of the paired prosthesis and irrigate the wound again. Close the subcutaneous tissues with 4-0 SAS, and approximate the skin with 4-0 SAS placed subcuticularly.

Continue antibiotic coverage, and caution the patient to obtain coverage at future manipulations or operations.

PERINEAL APPROACH

If the possibility exists that the patient may need a subsequent incontinence procedure, this approach should be avoided to allow virginal planes for future surgery.

Anesthesia: General.

Position: Lithotomy. Exclude the anus from the operative field by a sterile plastic drape securely cemented and sutured to the skin (not shown).

Incision: Make a midline or inverted U-shaped incision. Expose the bulb of the urethra in the midline, and free its lateral attachments so it may be swung to one side and the other (Fig. 26-7). Expose the crus of each corpus cavernosum by bluntly separating the ischiocavernosus muscles in the direction of their fibers. Laterally, each crus is fused to the ischial tuberosity, providing a useful landmark. Incise each crus with a #10 blade for a distance of 2 to 3 cm, entering the cavernous tissue. Place a 2-0 silk suture through each edge for traction and localization. Proceed as for the penoscrotal approach.

SUBCORONAL APPROACH

This approach is suitable for the all three flexible prostheses. However, this approach can at times cause a partial sensory loss into the glans.

Position: Supine. For local anesthesia, infiltrate 10 mL of 0.25 percent lidocaine subcutaneously around the base of the penis under the dartos layer and 5 mL subcoronally. Compress the base of the penis against the symphysis and inject another 5 mL into a corpus cavernosum.

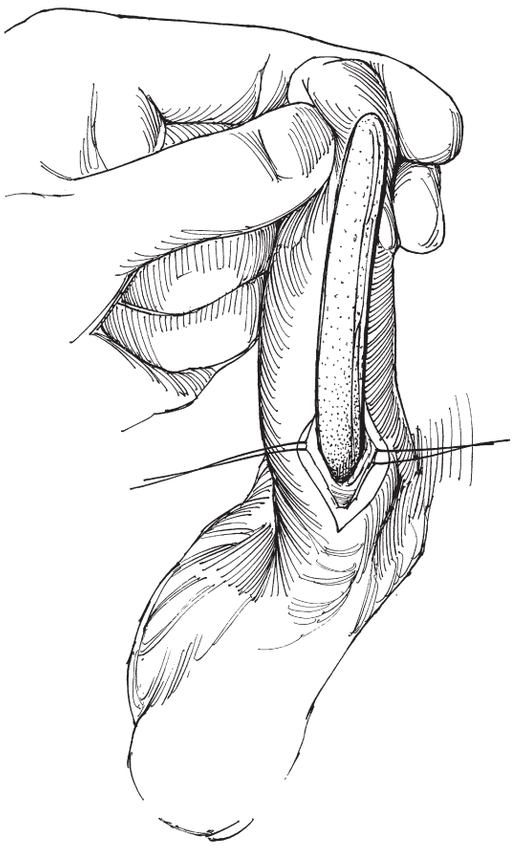

FIGURE 26-4.

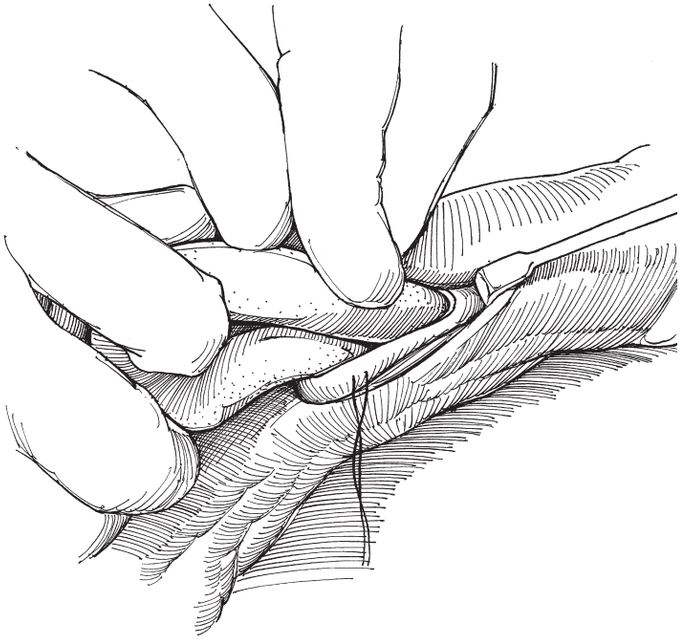

FIGURE 26-5.

Incision: Make a dorsal transverse skin incision 1 cm proximal to the coronal sulcus. Alternatively, through a circumcising incision, retract the penile skin to midshaft. Expose the corpora. Mobilize the dorsal neurovascular bundle medially. Stay sutures may help exposure. Incise each corpus transversely, making a 1-cm cut (Fig. 26-8).

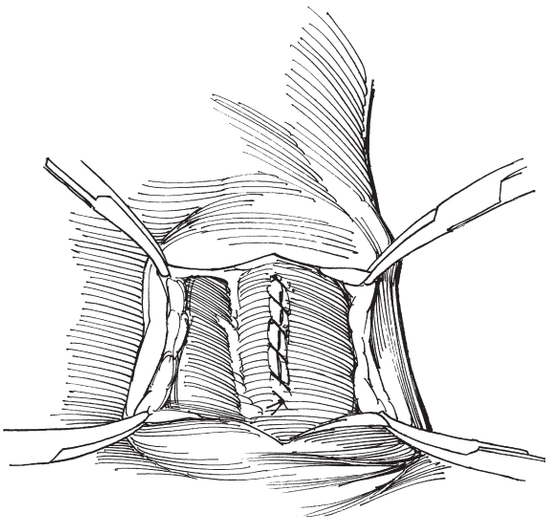

FIGURE 26-6.

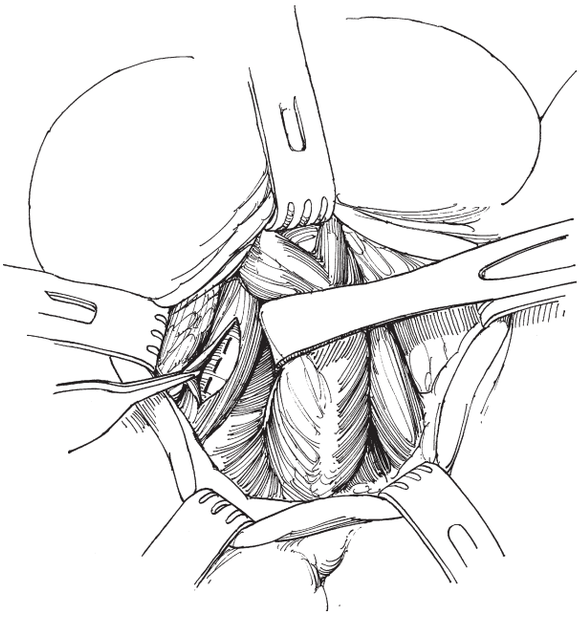

FIGURE 26-7.

Alternative: Make the cuts longitudinally (*dotted line*) to avoid the neurovascular bundle. Place stay sutures on both sides of each incision. Dilate and measure appropriately, as described in step 3. Insert the prosthesis proximally first, then bend the distal end to insert it (steps 4 and 5). Instead of bending the prosthesis, use a vein retractor to lift the distal end of the corporotomy over the end of the prosthesis. Conclude the operation (step 6). When local anesthesia is used, the patient may be treated in the same-day surgery unit.

DORSAL PENILE SHAFT APPROACH

This approach is usually not desirable because it may result in penile edema because of obstruction of the dorsal lymphatics.

Position: Supine.

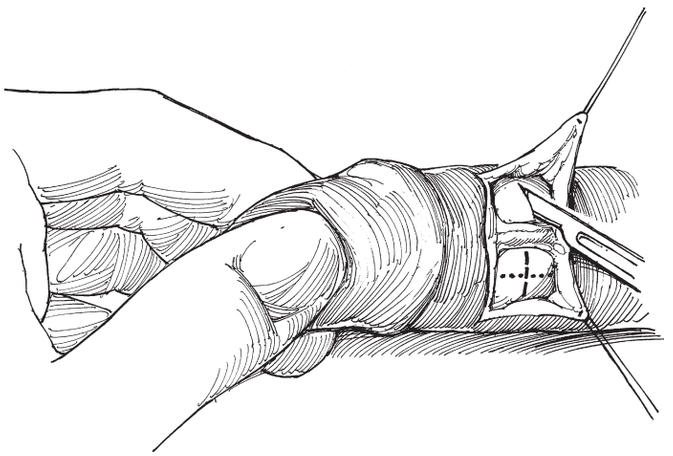

FIGURE 26-8.

Incision: Make a single incision on the dorsum near the proximal end of the penis. Dissect down to the tunica albuginea, avoiding the neurovascular bundle. Retract the skin, and place a pair of stay sutures in the tunica albuginea on each side of the proposed incision (Fig. 26-9).

Incise the tunics individually. Measure and insert the prosthesis proximal end first (Fig. 26-10). Complete the operation as described previously.

VENTRAL APPROACH

Block the penile nerves with 1 percent lidocaine.

Make a 4- to 5-cm midline ventral incision over the proximal shaft. Open the dartos and Buck's fascia over the corpus spongiosum. Expose the tunica albuginea of the corpora on either side. Draw the penile skin distally with a vein retractor, place stay sutures, and incise the tunic for a distance of 2 to 3 cm beginning 0.1 cm from the distal end. Proceed as in steps depicted in Figures 26-3 through 26-7, using a vein retractor to "shoehorn" the distal end into the cavernous space.

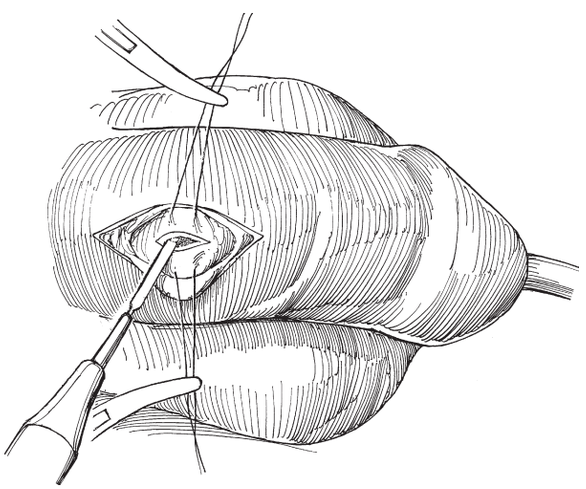

FIGURE 26-9.

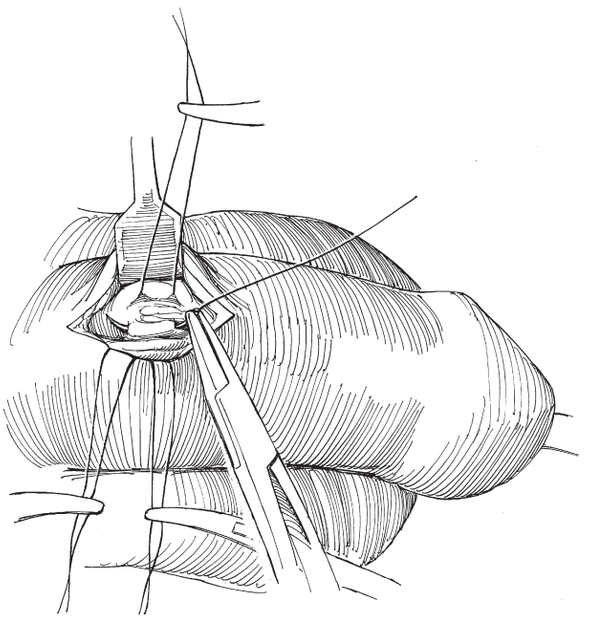

FIGURE 26-10.

PUBIC APPROACH

Position: Supine.

Incision: Make a transverse incision just above the inferior border of the symphysis pubis. Expose the dorsal surfaces of the corpora cavernosa under Buck's fascia and the associated connective tissue over each corpus, uncovering the shiny, tough tunica albuginea (Fig. 26-11). Avoid the midline neurovascular bundle. A rake retractor helps expose the bases of the corpora. Complete the operation as previously described.

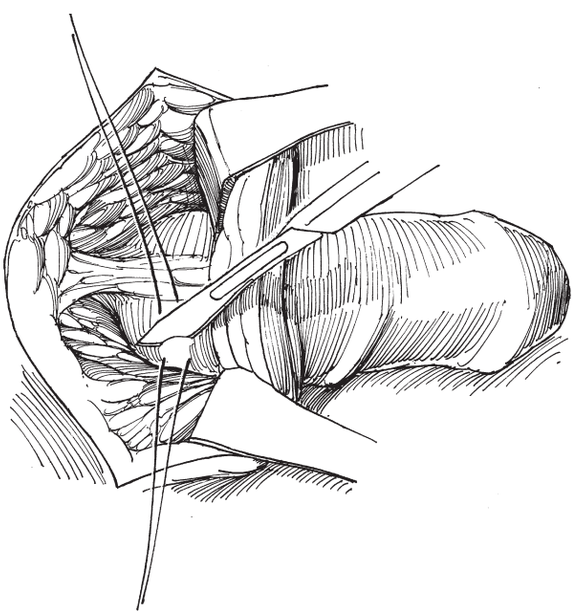

FIGURE 26-11.

POSTOPERATIVE PROBLEMS

Ventral sagging of the glans (SST deformity) results from inadequate dilation under the glans and placement of a short prosthesis. It requires redilation and placement of a longer cylinder or insertion of a dorsal tuck.

Erosion may result from overdilation or too long a prosthesis. Premature intercourse may cause erosion. Tell the patient to wait 6 weeks before starting sexual activity. Prolonged pain or bowing of the penis is caused by an implant that is too long.

If endoscopy becomes necessary, use a flexible cystoscope. If endoscopic resection is necessary, insert a resectoscope through a perineal urethrostomy to avoid the problem of penile rigidity.

Infection is the most serious problem, usually appearing in the first few weeks and requiring removal of the prosthesis. Try incision and drainage and give antibiotics both orally and as wound irrigants, but do not persist too long before removing the prosthesis. Remove infected components one at a time through separate noncontaminated incisions (pump via scrotal incisions, reservoir via inguinal incision, and cylinders through the incisions used in their placement). In the absence of gross pus or immunosuppression, a trial of sequential antibiotics and cytotoxic agents with mechanical irrigation has been used with successful salvage in up to 80% of devices.

Alternatively, flush the spaces with antibiotic solution through drains (Jackson-Pratt or Hemovac) to irrigate the wounds each 8-hour shift. A new component could be placed after 3 days of irrigation or, for more severe infections, after 1 year. At the time of reimplantation, allow cultures to incubate for 48 hours to be certain that bacteria are sensitive to the antibacterials used in the irrigant. Infection may appear after a long interval, the bacteria borne by a hematogenous route from infection elsewhere in the body. Previous recommendations of antibiotic prophylaxis during dental repair or other sources of bacteremia is probably unnecessary.

Paraphimosis may be seen in a patient with a short foreskin that cannot be kept over the glans; it may require an in situ dorsal slit. Although some surgeons recommend routine circumcision with all penile implants it probably is unnecessary until extensive surgery is completed with interruption of lymphatics or if previous penile surgery has been performed. Pain with or without intercourse occurs occasionally. If persistent this is a harbinger of an infected device. Warn patients that the glans may feel cool in cold environments or cold weather.

Preexisting scarring secondary to priapism or scleroderma may make proper insertion of dilating sounds impossible. In such a case, insert a flexible prosthesis between Buck's fascia and the tunica albuginea. Alternatively, perform cavernosal reconstruction: Incise the scar tissue, lay the prosthesis in the resulting trough, and rebuild the outer wall of the corpus cavernosum using a synthetic material such as Gore-Tex or Dacron.

This page intentionally left blank

Chapter 27

Inflatable Penile Prosthesis Implantation

DROGO K. MONTAGUE

TYPES OF PENILE PROSTHESES

The devices that provide best prosthetic erections need to transfer a large volume of fluid into expandable penile cylinders for erection. For flaccidity, this fluid needs to return to a reservoir. Only three-piece devices (paired cylinders, scrotal pump, and abdominal fluid reservoir) approach this ideal. The Coloplast Titan prosthesis and the American Medical Systems AMS 700 MS series prosthesis are the current three-piece inflatable prostheses manufactured in the United States.

The Titan prosthesis provides girth expansion only. The AMS 700 MS series prosthesis has three cylinder types. CX and CXR cylinders produce girth expansion only. The CX cylinders are useful when penile curvature is present because they have better straightening properties. The small diameter CXR cylinders are useful in revision cases when corporal dilation is limited because of fibrosis or small penis size. In men with good penile elasticity and straight penises, LGX cylinders are useful because they expand not only in girth but also in length.

PREOPERATIVE PREPARATION

The patient's partner should also be included in preoperative counseling if possible. The various types of implants and their advantages and disadvantages need to be discussed.

Most patients will need oral narcotic analgesia for up to 1 week postoperatively. When a three-piece device is implanted, we recommend no straining or heavy lifting for 4 weeks to avoid reservoir displacement. Patient instruction on inflating and deflating the device takes place at 4 to 6 weeks when healing is complete. The patient may then use the device for coitus.

Infection in the space around an implant rarely causes significant illness; however, it is the most significant complication of prosthetic surgery in that complete removal of the device is almost always required for this type of infection. If a prosthetic device is removed because of infection, scarring within the corpora cavernosa may decrease penile size and make prosthesis reimplantation more difficult. Erosion of a prosthesis through the skin or into the urethral will also require surgical revision or device removal.

If mechanical failure of the device occurs and the patient wishes to remain sexually active, replacement or revision of the device is necessary. If the man can have an orgasm and/or ejaculate before prosthesis implantation; he should be able to do so afterward.

When prosthesis implantation is successful and the patient is unhappy, the most common reason is loss of length with the prosthetic erection. We demonstrate the patient's stretched flaccid penile length preoperatively and tell him this will be the approximate length of the prosthetic erection. For most men, this is somewhat shorter than their natural erection. If the patient is a candidate for LGX cylinder implantation, there may still be loss of length be but less so.

The implant recipient should be free of systemic and urinary tract infection and there should be no open or infected skin lesions in the operative area. Broad spectrum antibiotics are given 1 hour before the incision until patient discharge from the ambulatory surgical center the morning after surgery.

Shaving is done just before the procedure.

SURGICAL APPROACHES

Three-piece inflatable penile prosthesis implantation is done either by the infrapubic or the penoscrotal approach. We prefer the penoscrotal approach because it provides better corporal exposure, permits anchoring of the pump, and avoids possible damage to the dorsal nerves of the penis with subsequent sensory loss. The penoscrotal approach requires blind reservoir placement. Figures 27-1 through 27-8 show the steps of implantation of the AMS 700 LGX prosthesis into a 52-year old man with organic erectile dysfunction due to diabetes mellitus.

Implantation of AMS 700 LGX Inflatable Penile Prosthesis

The patient is supine and a traction suture of 0 silk is placed through the glans. A 4-cm transverse upper scrotal incision 2 cm below the penoscrotal junction is outlined.

The incision is carried down transversely through dartos fascia, and the inferior fascial flap is dissected off the urethra and both proximal corpora bodies. Exposure is maintained with a ring retractor.

Two-centimeter corporotomies are made and two horizontal mattress sutures of 2-0 polydioxanone (PDS) are placed on each side of the corporotomy.

The distal corpora are dilated from 8 to 14 mm with Hegar dilators. A measurement is made from the distal end of the corporotomy; in this case, it is 9 cm (Fig. 27-1).

The proximal corpora are dilated from 8 to 16 mm with Hegar dilators. A measurement is made from the proximal end of the corporotomy; in this case it is 10 cm (Fig. 27-2). The 2-cm corporotomy is not included in this measurement of corporal length because surface measurement with a sizing instrument usually results in a measurement that is 2 cm too long. In this case, the total length is 9 + 10 or 19 cm. An 18-cm cylinder with 1 cm of rear tip extender will be used.

The prosthesis is filled with normal saline. LGX cylinders expand both in girth and in length.

The cylinders are inserted distally using a Furlow cylinder inserter (Fig. 27-3).

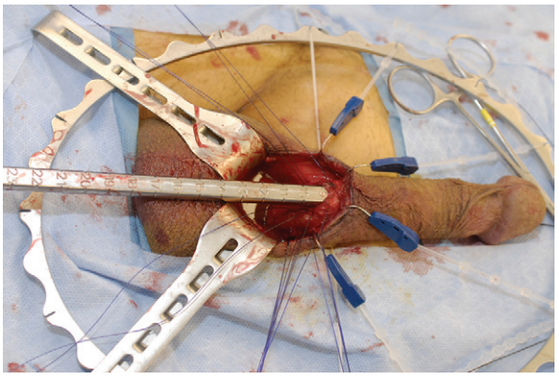

FIGURE 27-1.

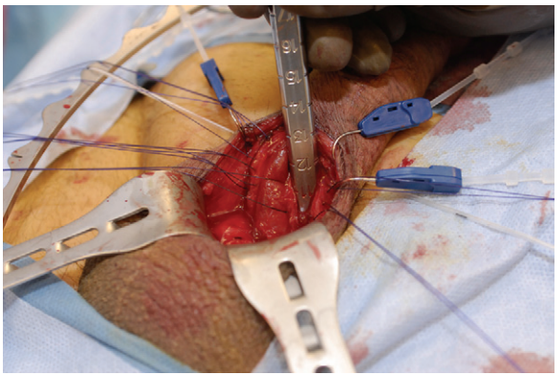

FIGURE 27-2.

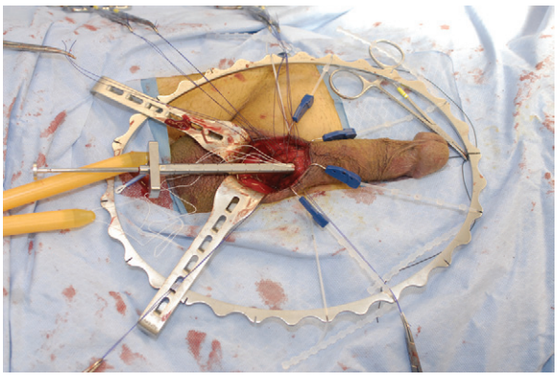

FIGURE 27-3.

A 1-cm rear tip extender is applied to the 18-cm cylinder, and the cylinder is inserted proximally.

The cylinder should lie absolutely flat, suggesting that it is exactly sized.

To confirm the sizing, release the penis from the retractor and palpate the cylinder tips (Fig. 27-4).

The corporotomies are closed by tying opposing proximal 2-0 PDS sutures, pulling down the knot, and then tying opposing distal sutures.

A second incision is made through dartos fascia over the midline of the scrotum. A subdartos pouch is developed for the pump using ring forceps (Fig. 27-5).



FIGURE 27-4.

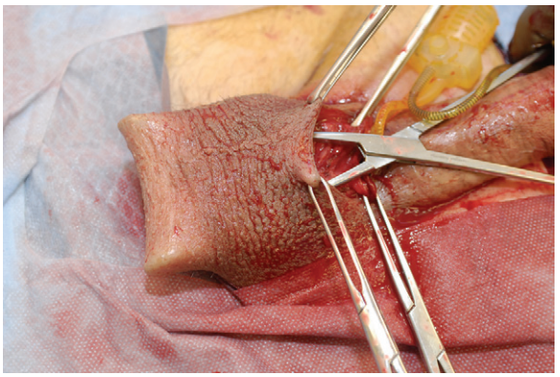

FIGURE 27-5.

A right angle clamp is passed deep in the scrotum through the back wall of the pouch (Fig. 27-6). This clamp is replaced by the blades of a nasal speculum inserted from the opposite side.

The nasal speculum spreads the fascial opening and the pump is passed through it into the septal pouch.

The top of the septal pouch is closed with running 3-0 Dexon suture. A 50-mL syringe filled with normal saline is attached to the reservoir tubing. The syringe serves as a temporary reservoir.

With inflation, the length of the penis increases from 13 to 15 cm (Fig. 27-7). The device is then deflated.

An 18-French catheter attached to closed sterile drainage is inserted and the bladder is completely emptied. Through the incision the left external inguinal ring is palpated. The fascia in the floor is perforated with scissors or a clamp. Correct entry into the retropubic space is confirmed by palpating the back of the symphysis pubis. The scissors are replaced by inserting a long blade nasal speculum. If the external ring cannot be located by palpation, a point for the fascial perforation just above the pubic tubercle is chosen.

The nasal speculum maintains the spread fascial opening and the empty reservoir is inserted into the retropubic space using the surgeon's index finger (Fig. 27-8). The reservoir is filled with the requisite volume of saline, in this case 100 mL. The correct positioning of the reservoir beneath the fascia is confirmed by palpation. The tubing hub should be positioned so that it is protruding through the fascial defect.

A connection is made between the reservoir and the pump. A 7-mm Blake drain is inserted through a stab incision in left inguinal area and brought down to the penoscrotal incision. The penoscrotal incision is closed in layers; all prosthesis tubing and the drain are below the dartos fascial closure.

POSTOPERATIVE CARE

The catheter and drain are removed on the morning after surgery. The patient is instructed to maintain the penis up on the lower abdomen using a scrotal supporter or briefs. If the penis is long and worn down during healing, ventral penile curvature may result. The patient is also instructed to gently pull the pump toward the bottom of the scrotum three times a day.

The first visit is in 1 month. The patient is advised to inflate and deflate the prosthesis twice daily for a month. During this time, the capsule that has formed around the cylinders stretches and inflation becomes easier. The patient may have coitus when he is pain-free following device inflation. The use of a water-soluble lubricant is encouraged to avoid partner pain, which might result from vaginal dryness.

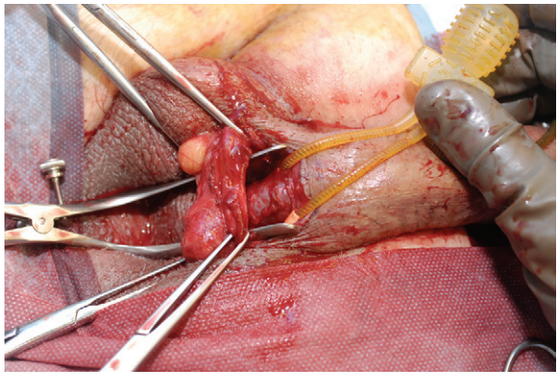

FIGURE 27-6.



FIGURE 27-7.

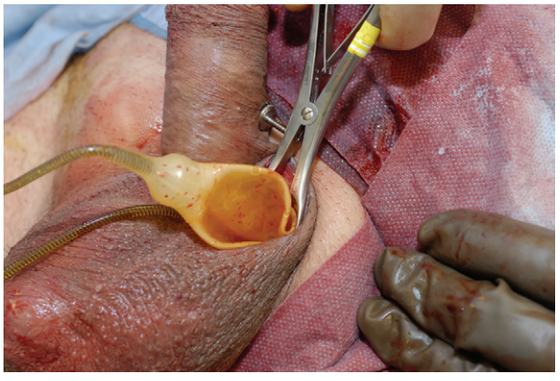

FIGURE 27-8.

Commentary by

CULLEY C. CARSON III

The implantation of inflatable penile prostheses has evolved since their inception in the 1970s. While there are many intraoperative options to facilitate this procedure, the basic principles of the penoscrotal placement are well described. Our practice is to eliminate the corporal dilation for initial implants. Instead, the corpora are measured with a Furlow insertion tool and the cylinders placed without dilation. Positioning is as accurate as with dilation but the trauma to the penis is less and 10 minutes are saved.

The use of drains after implantation is controversial. Many implanting surgeons use these drains in all cases while others rarely use drains. Studies have not demonstrated an advantage or disadvantage to the use of drains, and they are used by surgeon preference and judgment.

Chapter 28

Penile Arterial Revascularization

ANTHONY J. BELLA, WILLIAM O. BRANT, AND TOM F. LUE

Revascularization can be done by several techniques, all of which have limitations. The operations that have been most successful connect the inferior epigastric artery to the dorsal artery (revascularization) or deep dorsal vein (arterialization).

In patients younger than age 45 years, make the diagnosis of reduced arterial inflow by the intracavernous injection and stimulation test and by duplex ultrasonography. Use color Doppler imaging to detect communications between the dorsal and cavernous arteries and the direction of blood flow. Locate the site of the block by phalloarteriography combined with intracavernosal papaverine injection. This serves three purposes: (1) to locate the site of blockage, (2) to confirm the presence of communications between the dorsal and cavernous arteries, and (3) to ensure that both the donor (the inferior epigastric) and recipient (dorsal) arteries are healthy. It is important to assess the inferior epigastric arteries on angiogram and assess which has the larger caliber with fewest branches, because this will likely be the best one for harvest.

Instruments: Provide the following: basic, GU plastic, and GU micro sets; an Andrews suction tip, a bipolar hand electrode, a microscope and drape, a bulb syringe, Weck spears, microwipes, visibility background, vascular loops, vessel clips, vascular sutures, heparinized saline in a syringe with a 20-gauge angiocatheter sheath, 9-0 Dermalon sutures with an LE-100 needle, and 10-0 Dermalon sutures with a TE-100 needle.

Position: Place the patient supine, and place a Foley catheter.

SECURING THE EPIGASTRIC ARTERY

Make a vertical lower abdominal incision two fingerbreadths from the midline. Alternatively, make an oblique incision in Langer's lines. Incise the anterior rectus sheath over the center of the muscle, open the sheath with scissors, and retract it laterally with Kocher clamps. Alternatively, a midline abdominal incision will allow access to both arteries in case the first is not suitable for the surgery.

Expose and dissect the inferior epigastric artery, including its two accompanying veins, from the connective tissue underlying the muscle and hold it in a vascular tape (Fig. 28-1A).

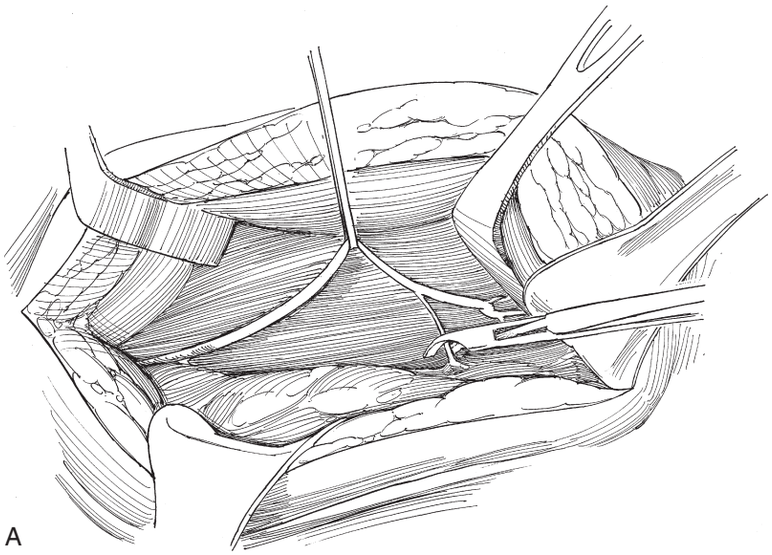

A



B

FIGURE 28-1.

Continue dissecting cephalad to the level of the umbilicus to free the artery. Divide and ligate other, more proximal vascular branches. Apply papaverine hydrochloride topically to reduce arterial spasm.

Another option is to harvest the epigastric artery laparoscopically. A balloon-tipped Hassan cannula is placed in the midline just below the umbilicus using a 1-cm transverse incision in the anterior rectus sheath. The balloon is inflated and the initial dissection is carried out bluntly. Two additional radially dilating (Step) trocars are placed laterally in a triangular fashion (see Fig. 28-1B). The inferior epigastric bundle is identified below the arcuate line and bluntly dissected off the abdominal wall with sparing use of electrocautery. Placement of a vessel loop facilitates dissection in a cephalad direction. Branches of the vessel bundle are gently dissected free, clipped, and divided. The dissection of the vessel bundle is carried cephalad near the umbilicus and caudally to its origin from the external iliac artery. The vessel bundle is clipped and divided with the harmonic scalpel at the most cephalad extent of the dissection. A 10-mm port is placed ipsilaterally through Hesselbach's triangle via a small skin incision near the base of the penis. The artery is gently delivered through the port up to the base of the penis. A bulldog clamp is placed on the end of the artery for microvascular anastomosis.

EXPOSURE OF THE PENILE VASCULATURE

Make a short midline incision at the base of the penis, beginning at the pubic tubercle to Buck's fascia at the depth of the neurovascular bundle (Fig. 28-2). Expose the base of the penis. Although some surgeons pass the epigastric artery through the inferior end of the rectus sheath, we generally pass it through the ipsilateral inguinal ring to avoid the possibility of kinking at the fascial level. Watch out for twisting and tension. Apply a microvascular clamp to the free end and remove the one placed at the proximal end after placing a vessel loop to allow reapplication if needed later. If a laparoscopic approach is used, the epigastric artery is brought to the external inguinal ring via the 10-mm port.

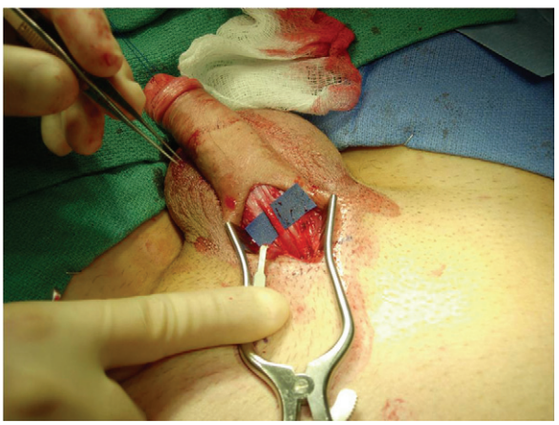

FIGURE 28-2.

The fundiform and suspensory ligament of the penis may or may not be taken down, depending on surgeon preference and the anastomotic site, although the penis should be resuspended to the pubic periosteum if the ligament is divided. Adventitia is removed only at the sites of anastomosis of the two vessels. The anastomosis is accomplished microscopically using 8-0 to 10-0 monofilament vascular suture. The vessels are clamped with low-tension vascular bulldog clamps and the inferior epigastric artery is usually flushed with a dilute heparin and/or papaverine solution just before the anastomosis.

The surgeon has several choices for utilization of the epigastric artery, depending on the findings of arterial occlusion. The best solution usually is to connect the epigastric artery to the divided dorsal artery with an anastomosis of a branch both distally and proximally. The alternative is to anastomose the end of the epigastric artery to the side of the dorsal artery or to a segment of the deep dorsal vein, with or without an additional anastomosis to the dorsal artery. In our opinion, an adequate pressure gradient between the epigastric and dorsal arteries is critical to the success of the anastomosis. Therefore, before performing the anastomosis, assess the pressure gradient to help decide whether revascularization or arterialization is indicated. Request the anesthesiologist to set up an arterial line. Puncture the dorsal artery with a 25-gauge angiocatheter to measure the arterial pressure and insert the plastic sheath of the angiocatheter directly into the lumen of the transected epigastric artery. A pressure gradient of more than 15 mm Hg should exist to allow adequate flow through the anastomosis. If the gradient is less than 10 mm Hg, anastomosis to the dorsal vein is performed instead.

In the postoperative period, start miniheparin (5000 units subcutaneously every 12 hours for 2 days) after the anastomosis is completed, followed by daily baby aspirin or dipyridamole (Persantine) for 3 months.

EPIGASTRIC ARTERY-DORSAL ARTERY ANASTOMOSIS

Arterial anatomy: The internal pudendal artery, becoming the penile artery, passes through the urogenital diaphragm and along the medial margin of the inferior ramus of the pubis. As it passes the bulb, it divides into three terminal branches—the bulbourethral, the dorsal, and the cavernous arteries. The bulbourethral artery enters the bulb of the urethra. The dorsal artery of the penis runs along the dorsum of the penis between the deep dorsal vein lying medially and the dorsal nerve lying laterally to it. It divides into a number of circumflex branches that supply the corpus. The cavernous artery enters the corpus cavernosum at the base of the penis and runs to the tip, giving off the multiple helicine arteries in the cavernous spaces. Crural arteries, small branches of the main penile artery, supply the crura on both sides (Fig. 28-3).

Position the microscope over the field. Expose one dorsal penile artery, a vessel that communicates with the cavernous artery. Free 3 cm of the artery proximally, avoiding the

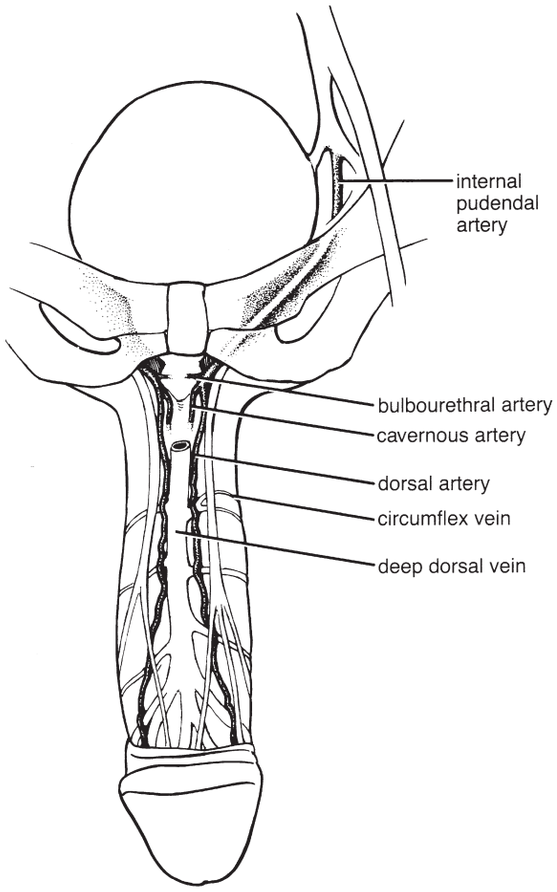

FIGURE 28-3.

adjacent nerve fibers. Divide it and prepare the lumen of each end. Be very careful to avoid injury to the endothelium. Irrigate with papaverine solution. Clear the adventitia for a distance of 0.5 cm. Use bipolar coagulation for bleeding. Remove the microvascular clamp to check the flow in the epigastric artery. Place two small microvascular clamps on the dorsal penile artery, and transect it between them. Clear the adventitia and anastomose the distal end to one branch of the inferior epigastric artery by a microvascular technique using two running sutures. If the vessels are different sizes, tailor them before anastomosis. Placement of a stent may prevent backwalling; take the stent out before inserting the last four sutures. Although some do an end-to-end anastomosis using one branch of the epigastric artery, others anastomose the second branch to the proximal end of the dorsal penile artery. Alternatively, insert the inferior epigastric artery into one of the dorsal arteries by an end-to-side technique (Fig. 28-4).

Close the abdominal wound. Bring Buck's fascia over the artery and close the infrapubic skin defect.

Discharge the patient the following day. Instruct the patient to avoid all sexual activity for 4 to 6 weeks.

Other Procedures

The second branch of the epigastric artery may be inserted into the opposite dorsal artery. Or the donor artery may be anastomosed end-to-side to one dorsal artery, then the artery

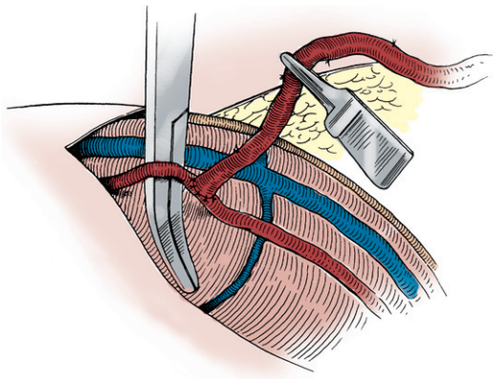

FIGURE 28-4. *(Reproduced with permission of the Mayo Clinic Foundation.)*

swung across and connected end-to-end to the other dorsal artery. A length of greater saphenous vein may be used as a connection between the femoral artery and the cavernous artery. For younger men who have suffered injuries, the inferior epigastric artery may be inserted end-to-side in one dorsal artery. In addition, the epigastric artery may be anastomosed to the dorsal vein.

EPIGASTRIC ARTERY—DORSAL VEIN ANASTOMOSIS

If there is less than 15 mm Hg pressure gradient between the dorsal artery and the systemic blood pressure, perform an epigastric artery to deep dorsal vein anastomosis.

Harvest the epigastric artery as previously described. Expose the neurovascular bundle and deep dorsal vein. Divide and ligate the deep dorsal vein beneath the symphysis between the suspensory ligament and the urogenital diaphragm. The multiple branches of the deep dorsal vein near the glans are ligated with an absorbable suture, as well as large trunks of the deep dorsal vein that anastomose to the spongiosum laterally along the shaft of the penis. Valves in the deep dorsal vein may be removed with a 2-mm LeMaitre valvulotome or a similarly sized Fogarty balloon catheter, although we do not routinely do this. Still others have reported a variation of this technique using antegrade dorsal vein arterialization which does not require rupture of the venous valves. We prefer an end-to-side arteriovenous anastomosis at the base of the penis and ligation of the deep dorsal vein both proximally and distally.

Harvest the inferior epigastric artery with its vena comitans, and deliver it to the base of the penis through the external inguinal ring. Control the vein with vessel loops distally and proximally. Remove the adventitia for a distance of 2 to 4 cm. Make a dorsal venotomy, and anastomose the vessels with 7-0 or 8-0 nylon sutures (Fig. 28-5). Release the vessel loops and observe blood filling the epigastric artery. Remove the clamp on the artery and observe venous pulsations.

Some surgeons additionally anastomose the second branch of the epigastric artery to the dorsal artery.

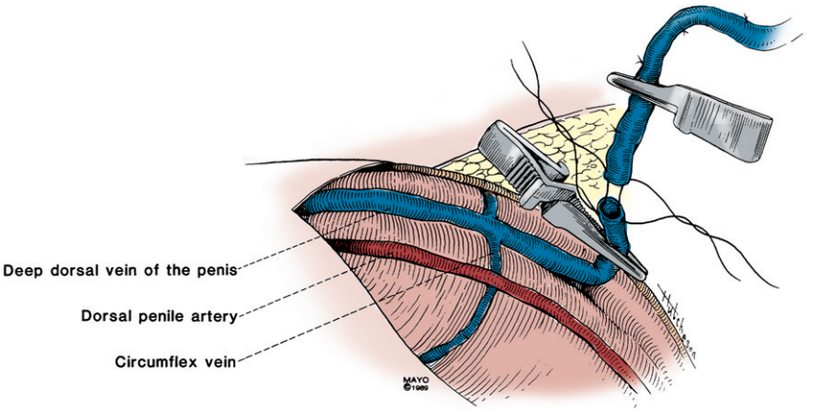

FIGURE 28-5. *(Reproduced with permission of the Mayo Clinic Foundation.)*

POSTOPERATIVE PROBLEMS

The most dreadful complications are priapism (after epigastric artery-corpus cavernosum anastomosis) and (IS) glans hyperemia (after epigastric artery-dorsal vein anastomosis). The former surgery is no longer performed. To prevent glans hyperemia, all the venous channels distal to the epigastric artery-dorsal vein anastomosis should be ligated to prevent overperfusion of the glans. Visualization of these channels can be facilitated by injecting saline with methylene blue into the dorsal vein before anastomosis is performed.

Commentary by

CULLEY C. CARSON III

Penile arterial revascularization has long been performed at select centers throughout the world. The procedures performed have changed markedly since their introduction in the 1970s. The concept is an important one but the outcomes are variable. Indeed, despite the long history of this operation, there is little long-term outcome data to evaluate the operation to be performed or the best candidates for revascularization.

Chapter 29

Procedures for Peyronie's Disease

WILLIAM D. STEERS, WILLIAM O. BRANT, ANTHONY J. BELLA, AND TOM F. LUE

Wait until the patient has experienced no increased pain for at least 6 months and he reports that the curvature has stabilized, but he still has difficulty with intercourse because of the curvature. The three most important preoperative criteria are (1) patient erectile function, (2) ability to penetrate (i.e., the extent of the deformity, including hinging and curvature), and (3) patient expectations. Three general procedures are available for correction:

1. For a very short penis or one with a deformity (e.g., hourglass or severe indentation) with good erectile function, apply a biologic graft (either autograft or xenograft).
2. For a penis of adequate length and adequate erectile function, perform a straightening procedure, either nonincisional (16-dot) or incisional (Nesbitt, Yachia).
3. For curvature associated with severe erectile dysfunction, place an inflatable prosthesis and perform associated procedures if the prosthesis alone does not provide adequate straightening.

Be sure that the patient has a realistic expectation of the outcome. Photographs should be obtained; this may be done by the patient at home or in the office after pharmacologically induced erection. The photographs should capture the extent of disease and should be taken from several angles. Stretched penile length should be obtained, measuring from the pubis (with pressure to account for the pubic fat pad) to the tip of the glans.

GRAFT TECHNIQUES

Incision and Vein Graft Technique (Lue)

The patient may be supine unless performing a saphenous vein graft, in which case the nondominant leg should be abducted in a frog-leg position and appropriately padded. Prepare the genital area. Do not induce a pharmacologic erection, which would increase intraoperative bleeding and impair visualization.

Incision: Make a circumcision incision, especially if the patient wishes to be circumcised. If he is already circumcised, cut through the easily visualized scar; it may be nearly at midshaft. Deglove the penis by dissecting in the layer between the deep dartos and Buck's fascia.

Elevate Buck's fascia beginning just lateral to the corpus spongiosum. Dissect with scissors against the tunica albuginea on either side of the corpus spongiosum. For cases of ventral curvature, dissect and tie off the deep dorsal vein, then carefully elevate the dorsal nerves and vessels and displace them first to one side and then to the other. This latter step may be difficult, as the tissue overlying the plaque may be affected by the underlying inflammatory disorder. When the dissection becomes easy, that often marks the extent of the underlying plaque.

Mark the extent of the plaque with a marking pen. Create an artificial erection to judge the effect of the plaque on the curvature. Place a 21-gauge scalp needle into one corpus, preferably in an area that will be incised or excised. One hand is used to compress the proximal corpora as proximally as possible, squeezing between the thumb and second finger, while injectable saline is infused through the scalp needle. It is difficult to place a tourniquet proximally enough, and the extent of the curvature may be underestimated. In addition, placing a tourniquet directly over the dorsal nerve may cause numbness of the penis.

Make an H-shaped relaxing incision through the plaque. Do not attempt to excise it. Different H shapes may be necessary to accommodated varying degrees of curvaature and indentation (Fig. 29-1). Measure the extent of vein that will be needed. A general guideline is that a normal segment of saphenous vein will be 1 cm wide when opened. There is minimal postoperative contracture of vein, so plan to harvest 2 cm more vein than is measured. The impulse of the femoral artery is palpated in the inguinal region and an incision is made to expose the greater saphenous vein. Care should be taken to control more superficial vessels and lymphatics. To avoid a long incision, we typically make several smaller incisions and tunnel the vein out. Ligate tributaries with absorbable ligatures. Hemostasis must be excellent. The wounds are then irrigated and packed with moistened

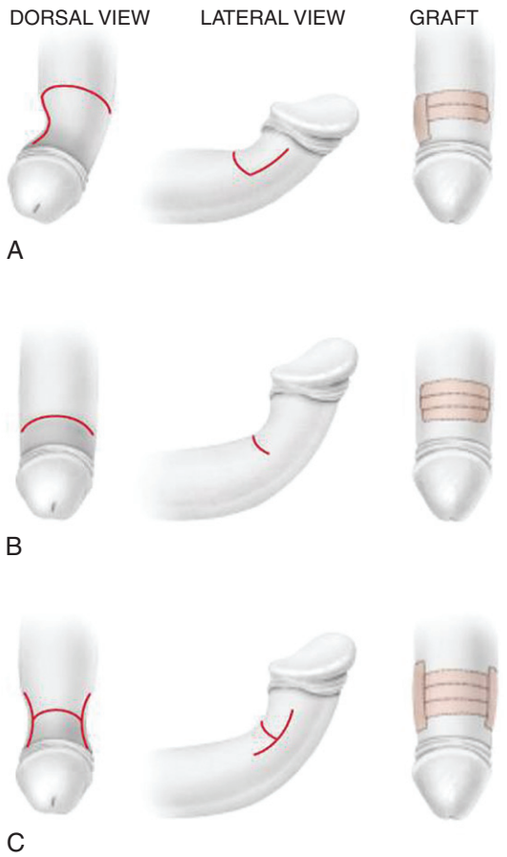

FIGURE 29-1. Different incisions for different types of curves. *(From Brant WO, Bella AJ, Garcia MM, et al. [2006]. Surgical atlas. Correction of Peyronie's disease: plaque incision and grafting. BJUI 97[6]:1353-1360.)*

pads while the graft is prepared. The wounds are closed in 2 layers using absorbable sutures for Scarpa's fascia and a subcuticular layer. Open a segment of vein (Fig. 29-2). To determine vein length: if the H incision measures 5cm wide by 3cm high, choose a vein length of approximately 17 cm to yield 5- × 3-m segments with a small surplus of material.



FIGURE 29-2. An H-shaped incision has been made and the edges stretched to expose the recipient site. Notice the incision made to harvest a 15-cm length of saphenous vein.

Vein has the least contraction of any of the biologic graft materials; it is easier to tailor other graft choices to size (see later).

Vein preparation: Using a silastic block, the vein's adventitia is removed and the vein is divided into segments. Tributary sites are opened during division to minimize postoperative leakage. Using short 25-gauge needles is helpful in fixing the vein to the block while working; 5-0 Maxon is used to anchor segments together and the sides are joined using 1.4-mm VCS titanium vascular staples. The graft is kept moist until it is used (Fig. 29-3). The corners are sewn into place first, using 4-0 Maxon. The remainder of the graft is sewn into place in a running, locking fashion. Leaks tend to occur at the corners where the running suture goes around the previously placed corner knots. This may be avoided by not locking the stitch at these sites and by advancing the stitch very little in these areas. If multiple individual relaxing incisions were made, suture an open segment of vein into each of the defects (Moriel). Cover the graft as much as possible with Buck's fascia. Test with saline inflation for elimination of the curvature. If the curvature is overcorrected or if lateral curvature persists, place plication sutures in the ventral aspect of the penis without excision of an ellipse of the tunica albuginea. Return the neurovascular bundles to their normal position, close the wound with 4-0 chromic catgut sutures, and wrap the penis in a lightly compressive dressing, checking the glans after an hour to be sure the dressing is not too tight. Change the dressing in

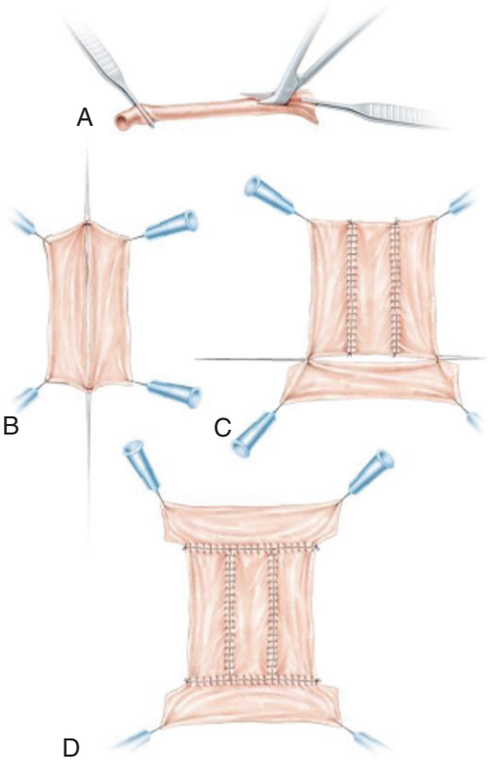

FIGURE 29-3. Preparation of vein. *(From Brant WO, Bella AJ, Garcia MM, et al. [2006]. Surgical atlas. Correction of Peyronie's disease: plaque incision and grafting. BJUI 97[6]:1353-1360.)*

24 hours, and instruct the patient in daily changes for 10 days. Intercourse is permitted in 6 weeks.

DERMAL GRAFT TECHNIQUE (DEVINE)

Mark an ellipse of skin on the lower flank over the iliac crest lateral to the hairline, and remove the epidermis either freehand or with a dermatome set at approximately 0.012 inch (Fig. 29-4A). Then excise the dermis and close the donor site in two layers. Remove the subcutaneous tissue from the graft. Tack the graft to the inner edge and ends of the defect with four fine absorbable monofilament sutures; then run a suture along the entire inner edge, locking every third stitch (see Fig. 29-4B). Fold the graft back and run a suture down the center of the graft, fixing it to the septal fibers in the midline. Place two more tacking sutures, and run a suture down the outer edge. Make sure the suture line is watertight by repeating the artificial erection, a maneuver that also proves that the deformity has been corrected. If it has not, further excision of the plaque is required. This technique may also be used with xenografts, such as porcine dermis or bovine pericardium. It is important to allow for postoperative graft contracture, approximately 20% to 25%. The sutures down the center of the graft are optional. With the additional material, there is often a "humpback" deformity with artificial erection. A pair of longitudinal braided nonabsorbable sutures (NAS) may be placed to act as a bolster to prevent too much bulging and to prevent overcorrection.

A graft may contract during the first 3 months. At 2 weeks, ask the patient and his sex partner to massage and gently straighten the erect penis to counter this tendency. By 6 to 8 weeks, intercourse should be safe and beneficial to healing. By 3 months, the dermal graft starts to soften, and erection should become straighter again. If potency does not return, this procedure does not interfere with insertion of a penile prosthesis at a later date. Before proceeding with prosthetic insertion, be certain that the impotence has an organic cause.

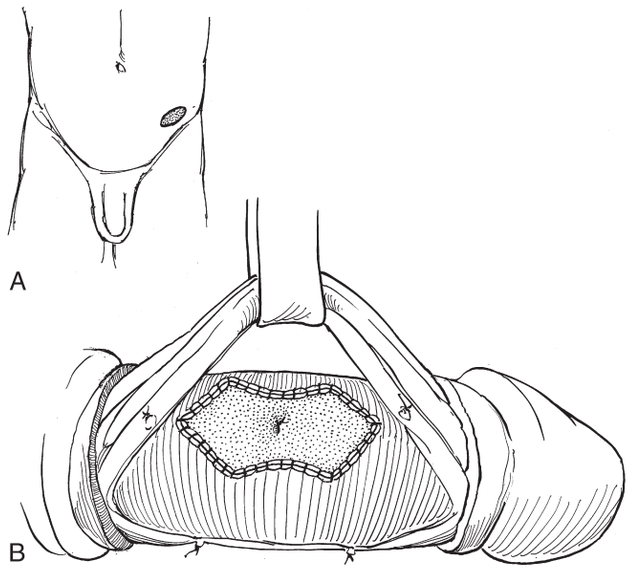

FIGURE 29-4. A, Site for dermal graft harvest. **B,** Placement of dermal graft.

PLICATION TECHNIQUES

Nonincisional

16-Dot (Lue)

Under light intravenous sedation, 60 mg of papaverine is injected into the corpus cavernosum using a 25-gauge needle. While the surgeons are scrubbing, the genital area is prepped and painted with the antiseptic of choice. A full erection should result. For dorsal curvature of the penis, either a circumcising or a ventral longitudinal incision can be used, depending on patient preference. If preservation of uncircumcised foreskin is desired, a longitudinal incision should be used. A circumcising incision often requires more extensive degloving dissection. More edema and pain can be expected postoperatively after such degloving. If a ventral penile scar is acceptable to the patient, the longitudinal incision is better tolerated. Bupivacaine at a 0.25% concentration is given along the planned longitudinal incision or around the base of the penis for a circumcising incision. Buck's fascia is then incised longitudinally adjacent to the corpus spongiosum. Extending just lateral to the corpus spongiosum, the ventral tunica albuginea is exposed along the length of the curvature (Fig. 29-5).

The center of the curvature is then marked. The entry and exit points of the sutures are marked, measuring approximately 0.5 to 1 cm apart. The points are placed 2 to 3 mm lateral to the corpus spongiosum. Every four dots correspond to one suture; most curvatures require two or three sutures on each side of the corpus spongiosum to straighten the deformity (total 16 or 24 dots) (Fig. 29-6). In rare cases with severe angle of deformity or an extremely long phallus, four pairs of sutures (32 dots) are used. A 2-0 braided polyester NAS is placed through the full thickness of the tunica albuginea. With the erection still relatively full, the sutures are tied with a single throw of a square knot, and a rubber-shod clamp is placed just above each half-knot (Fig. 29-7). With manual



FIGURE 29-5. Longitudinal ventral incision. The tunica albuginea is cleared.



FIGURE 29-6. The 16 dots have been placed; four sutures have been put in (each is in-out-in-out).



FIGURE 29-8. The curve is assessed after the first throw of knots.

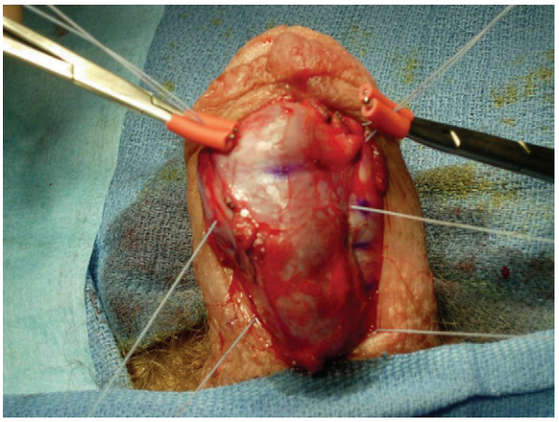

FIGURE 29-7. A half-throw has been made. A shod is used to hold these in place to assess the curvature before tying down the rest of the knots.

compression of the base of the penis, a rigid erection is created, and the straightness of the penis can be properly assessed (Fig. 29-8). Any correction can be made by loosening or tightening the sutures; then reevaluation is performed.

For ventral curvature, the sutures are placed between the deep dorsal vein and the paired dorsal arteries. For lateral curvature, the sutures are placed on the lateral aspect of the convex side of the penis under the neurovascular bundles.

Incisional

Ventral Tuck Technique (Nesbit, Pryor-Fitzpatrick)

Create an artificial erection by rapid infusion of normal saline through a scalp needle with a pump or by applying a tourniquet and filling the corpora with a syringe, recognizing that a tourniquet distorts the configuration.

Incise the penile skin and dartos fascia circumferentially 1 cm from the coronal sulcus, and deglove it back to the base. Replace the tourniquet. Dissect the corpus spongiosum from the corpora cavernosa and retract it with a Penrose drain. Excise ellipses from Buck's fascia and the tunica albuginea at a point exactly opposite the site of greatest concavity. Alternatively, the corpus spongiosum can be left in place, with the tucks taken on both sides of it. For a deformity of 45 degrees, make the ellipses about 0.5 cm wide, encompassing one third of the circumference of the corpora cavernosa. For 90 degrees of curvature, increase the maximum width to 0.8 cm. Close the defects with interrupted 3-0 NAS with the knots buried. Alternatively, merely take multiple bites with each NAS without excising ellipses. Remove the tourniquet and reinstitute the erection, looking for leaks and persistent curvature.

For leakage, add sutures; for curvature, insert another tuck with or without excision of an ellipse. Tack the bulbospongiosus and urethra back in place with fine sutures; they may be somewhat redundant. Replace the penile skin and suture it as in a circumcision. If a catheter was used, attach it to drainage and remove it as soon as the dressing is taken off.

Heineke-Mikulicz incision and closure technique: Make 1-cm longitudinal incisions in both sides of the tunica albuginea, and close them transversely with interrupted 3-0 SAS.

PROSTHESIS IMPLANTATION

For impotent patients requiring penile straightening for Peyronie's disease, several options are available: penile modeling, simple plication (e.g., 16-dot), or plaque incision/excision and grafting.

Modeling: Place an inflatable prosthesis and forcibly straighten the curvature.

After implantation of the prosthesis, partially inflate it to the point where curvature is noted, then forcibly straighten the penis until a cracking sound is heard. Repeat this maneuver until the prosthesis is fully inflated and the penis is as straight as it can be made. Check that the corporotomies for cylinder insertion remain sutured. If curvature persists, expose the plaque and make transverse incisions through it, taking care not to injure the cylinders. The defect in the corpus does not need to be covered if an AMS 700CX cylinder is used.

Plication: The key is to not injure the cylinder. Fully deflate the prosthetic after marking the curvature and planned suture sites (see earlier section on 16-dot). The prosthetic should still have the guidance suture attached to its distal tips and thus can be backed out of the corpora to allow suture placement without risk of injury. Once the sutures are placed, the cylinder is replaced, inflated, and the sutures are tied down as described earlier.

Grafting: This technique is best for deformities that involve more than just curve (e.g., severe hourglass or indentation). A xenograft is almost always adequate. Incision or excision of the plaque is performed and the graft is placed as described earlier, again with the cylinder temporarily removed to prevent risk of injury.

POSTOPERATIVE PROBLEMS

We do not prevent erections postoperatively because they may improve the straightening and assist with penile perfusion. Sexual play and intercourse, however, is discouraged for 6 weeks. After plication procedures, intercourse is less risky than after grafting. Hematomas occur if hemostasis was inadequate or the dressing was displaced; they may also occur in the setting of a strong erection postoperatively, especially in the time period 6 to 8 weeks after surgery. They may require evacuation, which may be performed under ultrasound guidance. Infection can result in loss of the graft and need for a repeat procedure. Alternatively, a chronic sinus may result, requiring removal of the graft and its sutures. Pain is not generally a problem after the period of healing, although a small percentage of postplication patients complain of pain at the knot sites. This may be treated with local injections of anesthetic and steroid mixture, and may be performed every few weeks, sometimes up to six sessions. Edema is reduced by ice packs applied to the dressing during the first 48 hours. Anesthesia of the glans may occur after extensive mobilization of the neurovascular bundle. Skin loss can result from too tight a dressing. For impotence not diagnosed before operation, the patient should be worked up in the standard way; some may require a prosthesis at a second operation. Return of curvature after grafting may be seen a month or so later as a result of contraction of the graft, but after 3 to 6 months this secondary deformity usually resolves. The disease may recur on the opposite side.

Commentary by

CULLY C. CARSON III

The surgical treatment of Peyronie's disease is an especially challenging process. Patients must understand the expectations and must realize that postoperative rehabilitation may be necessary. Graft choice is less important than surgical procedures performed. Plaque should not be excised unless there is significant calcification precluding good suture placement, then the calcified portion may be removed. Use of a tissue sealant beneath the graft appears to reduce the "humpback" deformity described.

After surgery, dressings should not be compression type and it is helpful to have a small drain beneath the skin for the first day. Rehabilitation using a penile extender and daily PDE 5 inhibitor medication are useful in returning penile length and function and are best begun 4 to 6 weeks after surgery.

This page intentionally left blank

Chapter 30

Operations for Priapism

TRINITY J. BIVALACQUA, AND ARTHUR L. BURNETT

DIAGNOSIS OF PRIAPISM (ISCHEMIC VS. NONISCHEMIC)

Priapism is defined as an erectile disorder, in which erection persists uncontrollably without sexual purpose. The pain associated with priapism is perceived to be a consequence of tissue ischemia and increased pressure generated within the corporal bodies. This condition frequently results in erectile dysfunction (ED), and therefore prompt management is indicated. Ischemic (low-flow) priapism is more prevalent than nonischemic (high-flow) priapism. Low-flow priapism due to pharmacologic, hematologic (sickle cell anemia), or neurogenic causes is a condition whereby there is a persistent, painful erection characterized clinically by absent cavernous blood flow. Failure to recognize this as an emergency and to instigate immediate treatment may lead to corporal tissue ischemia/anoxia, fibrosis, and long-term ED. High-flow priapism commonly follows an episode of trauma to the perineum or genitalia, resulting in increased flow through cavernosal arteries and leading to the formation of arteriocavernous shunts with increased arterial flow into the cavernous tissue.

The diagnosis and classification of priapism is based on history and physical examination (penis/perineum) in combination with corporal blood gas evaluation via aspirated blood directly from the corpora cavernosa. Acidotic ($pH < 7.25$, $po_2 < 30$, $pco_2 > 60$) penile blood gas indicates ischemic priapism, while normal blood gases ($pH > 7.4$, $po_2 > 50$, $pco_2 < 50$) is suggestive of nonischemic priapism. To further determine the type of priapism, color duplex Doppler ultrasound may be performed to evaluate cavernosal arterial inflow. No cavernosal artery flow is pathognomonic for ischemic priapism, while a ruptured cavernosal artery with unregulated arterial flow and blood pooling may be seen in the nonischemic form of priapism. In ischemic priapism, definitive first line treatment consists of evacuation of blood and irrigation of the corpora cavernosa along with intracavernous injection of an α-adrenergic sympathomimetic agent before initiating any surgical treatment. If the diagnosis of nonischemic priapism is confirmed by ultrasound imaging, then embolization of the ruptured cavernous artery angiographically constitutes first line therapy.

ISCHEMIC PRIAPISM

Nonsurgical Management

Ischemic priapism of greater than 4 hours warrants decompression of the corpora cavernosa. A dorsal nerve block or local penile shaft block with lidocaine is usually performed. Then, a scalp vein needle (19 or 21 gauge) is inserted directly in the penile shaft for therapeutic aspiration of old blood and injection of α-adrenergic agonists (sympathomimetics). Hemodynamic monitoring is recommended to monitor potential side effects, such as hypertension, headache, reflex bradycardia, tachycardia, and cardiac arrhythmia, which may result from medication entry into the systemic circulation. The α-1 selective agonist phenylephrine is preferred for this application because it minimizes the risk of cardiovascular side effects. Phenylephrine in a dose of 100 to 200 μg is injected via the same needle into the corpora cavernosa and observed for 5 minutes. If the penis is still rigid, then aspiration of blood and injection of phenylephrine (100 to 200 μg) is performed until detumescence occurs. If the penis remains tumescent after a reasonable duration and dose escalation of phenylephrine (1 mg of diluted phenylephrine over 1 hour), then another Doppler ultrasound may be performed to evaluate the status of cavernosal arterial flow in the penis. Reevaluation may be warranted at this time because the penis may simply be edematous with restored corporal arterial flow and not a persistent ischemic state. Ischemic priapism of extended durations (i.e., more than 24 hours) is unlikely to resolve with intracavernous injection/irrigation therapy; therefore surgical shunting should be performed in a timely manner.

For priapism related to sickle cell disease, medical therapies such as intravenous hydration, oxygenation, alkalinization, and exchange transfusion may be performed. However, these interventions should not lead to delays in intracavernous therapies directed at the end organ.

Surgical Management

Before proceeding to distal corporoglanular surgical shunt procedures, the placement of needles into the corpora cavernosa distally and proximally at the penile crura with

the patient in lithotomy position offers an approach for maximally irrigating the corporal bodies.

Corporoglanular (Winter) Shunt

A penile-glans block is performed to ensure adequate local anesthesia. The tips of the rigid corpora cavernosa are palpated and a large biopsy needle is inserted through the glans into the corpus cavernosum several times (Fig. 30-1). This results in multiple core biopsy windows or fistulas between the glans and each corporal body. Several biopsy core fistulas are necessary in order to create enough communicating channels to cause detumescence. Close the puncture site with a figure-eight 3-0 chromic suture. Have the patient squeeze the penis every few minutes to lessen blood pooling in the penis for the next 12 hours. If partial (>50%) erection persists, repeat the procedure or resort to an alternative shunt.

Corporoglanular (Ebbehoj and T-) Shunt

If a Winter shunt is unsuccessful, then proceed to an Ebbehoj shunt. The Ebbehoj shunt procedure involves the use of a #11 blade scalpel passed percutaneously several times through the glans into the corpus cavernosum (Fig. 30-2). This results in several larger fistulas between the glans and each tip of the corpus cavernosum. The scalpel blade is inserted into the corpora away from the urethral meatus and pulled back to create an opening in the tunica albuginea between the glans and corporal bodies. A modification of the Ebbehoj shunt procedure is the T-shunt procedure. A size 10 blade scalpel is placed vertically through the glans penis into the corpus cavernosum. The scalpel is then turned 90 degrees away from the urethra and pulled out (Fig. 30-3). This maneuver creates a T-shaped opening in the tunica albuginea. Both of these shunt procedures can be performed unilaterally or bilaterally if necessary. In theory, this T-shunt should provide a large enough fistula between the corpora cavernosa and spongiosal tissue of the glans for detumescence. Closure of the defects in the glans is performed using 3-0 chromic sutures, especially for the T-shunt.

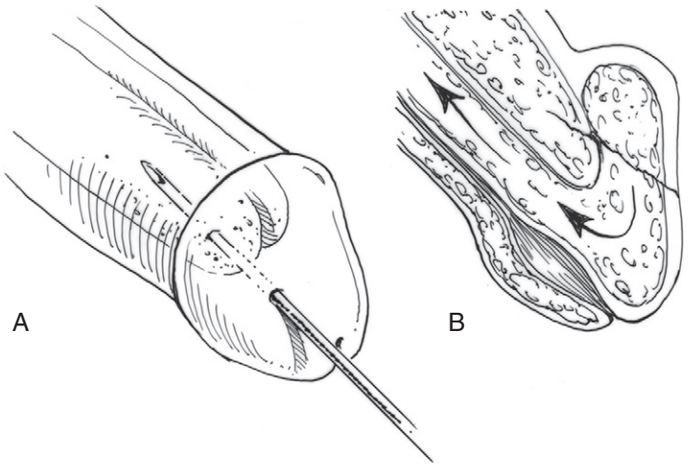

FIGURE 30-1. Corporoglanular (Winter) shunt.

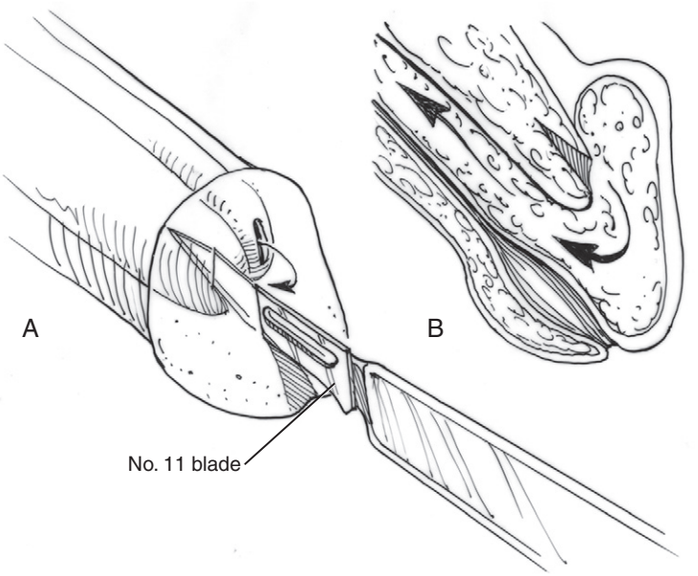

FIGURE 30-2. Corporoglanular (Ebbehoj) shunt

Corporoglanular (Al-Ghorab) Shunt

If the previously described percutaneous distal shunts are unsuccessful, then an Al-Ghorab shunt procedure is performed (Fig. 30-4). Typically, distal shunts fail because there is not a large enough window between the priapic corpora cavernosa and the corpus spongiosum. This shunt is usually done under general anesthesia in combination with a penile-glans block. A tourniquet is placed around the penis. A 2-cm transverse incision is made on the dorsum of the glans 1 cm distal to the coronal sulcus. A transverse incision is not recommended in the distal penile shaft proximal to the corona because this incision may cut sensory nerves to the dorsal aspect of the glans and possibly cause distal atrophy. Then, separate the tips of the corpora cavernosa from the glans, transfix them with 2-0 sutures or grasp with a Kocher clamp so that they will not withdraw during detumescence, and sharply excise a circular cone segment of approximately 5 × 5 mm of tunica albuginea from each corporal body. Dark blood will drain from the corporal bodies. The use of urethral sounds (Lue) and Hagaar dilators (Burnett) can be used to dilate and evacuate old ischemic blood from the corpora cavernosa. Once detumescence occurs, then reapproximation of the skin with 3-0 chromic sutures is performed. Care is taken not to obliterate the spongy vascular space of the glans penis.

Corporospongiosal Shunt

A proximal corporospongiosal shunt procedure is performed in rare circumstances. When distal shunts are unsuccessful or technically unachievable, then a proximal shunt is required to reestablish blood drainage and thus produce penile detumescence. Under general anesthesia, the patient is placed in lithotomy position and an 18-French

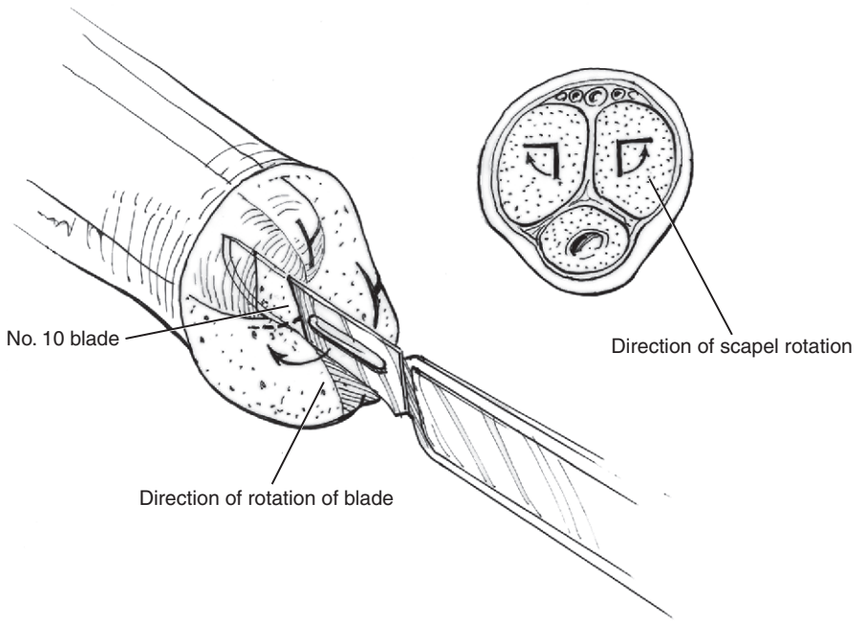

FIGURE 30-3. Corporoglanular (T-shunt) shunt

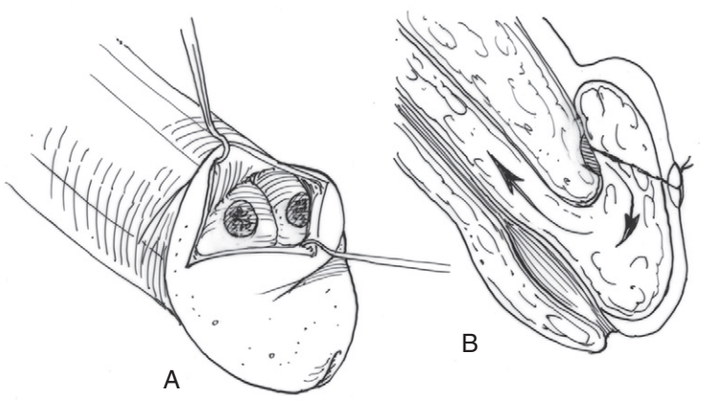

FIGURE 30-4. Corporoglanular (El-Ghorab) shunt

5-mL balloon catheter is placed in the bladder. In the perineum, the bulbocavernous muscle is dissected off the corpus spongiosum (Fig. 30-5). A longitudinal incision or excision of 1 cm long ellipses of tissue is made in the spongiosal and corporal bodies (see Fig. 30-5). Care is taken to avoid incising the urethra, which results in a fistula. The incision/excision is made in close proximity to each other in order to suture the defects together. Once the corporal bodies are open, old stagnant blood should be irrigated until bright red blood drains. The walls of the two openings in the spongiosum and corpora are sewn together in a running fashion using 5-0 polydioxanone suture. It may be necessary to perform bilateral shunting procedures if detumescence is not satisfactory, which is usually performed by staggering positions of the proximal shunts on the spongiosal and corporal bodies (see Fig. 30-5). The skin is closed with 3-0 chromic sutures.

SURGICAL PEARLS OF WISDOM FOR ISCHEMIC PRIAPISM

It is important to avoid pressure dressings that may compromise the shunt. Color duplex Doppler imaging may be performed to document penile vascular arterial blood flow status if desired after corporoglanular and proximal shunts. Additionally, intracavernosal pressure monitoring may help evaluate the effectiveness of the shunt procedures.

NONISCHEMIC PRIAPISM

The initial management of nonischemic priapism is observation. Spontaneous resolution of untreated nonischemic priapism occurs in greater than 50% of patients. Therefore the patient is advised about chances for spontaneous resolution, complication risks after treatment (ED, abscess, neurologic sequelae), and lack of significant adverse consequences resulting from delayed therapy for many months. Early presentation of nonischemic priapism can be managed with ice or pressure packing to cause vasospasm and thrombosis of the ruptured artery to efficiently close the fistula. If the fistula does not close, selective angiographic arterial embolization may be needed. The approximate resolution rate is 75%. Of note, because use of nonpermanent materials are associated with lower ED rates postprocedure (5% vs. 39% with permanent substances), these biomaterials are preferred. If angiographic embolization fails, then penile exploration and direct surgical ligation of sinusoidal fistulas or pseudoaneurysms may be performed with the assistance of intraoperative color duplex ultrasonography.

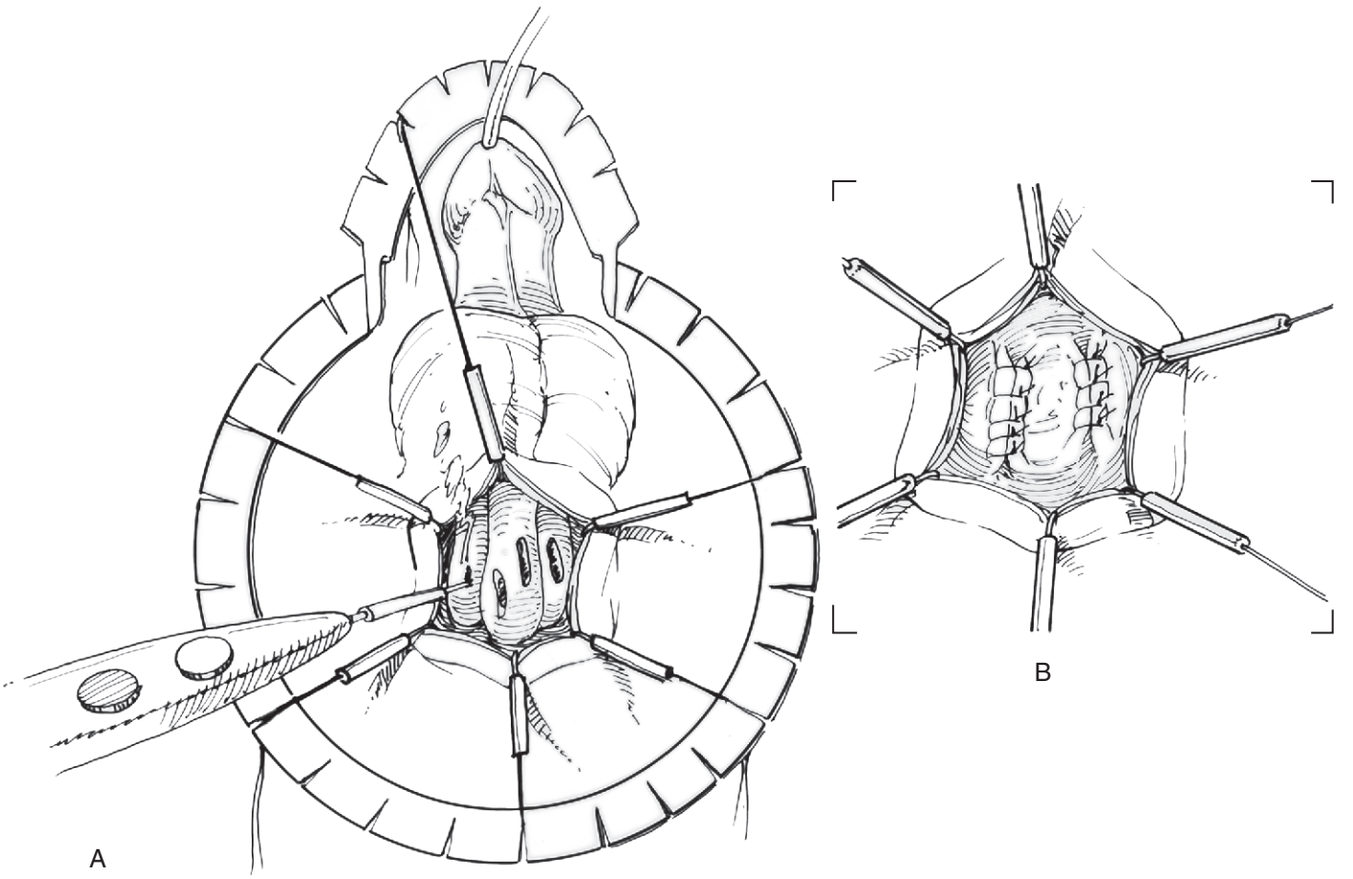

FIGURE 30-5. Corporospongiosal (Quackels/Sacher) shunt

Commentary by

CULLEY C. CARSON, III

Surgery for priapism is often unsuccessful with continued accumulation of blood and penile induration. Newer techniques that combine distal shunts with corpus cavernosum dilation and tuneling techniques as described by Burnett and Lue at the time of shunting have improved the outcomes in many patient, especially those with long standing priapism.

Chapter 31

Repair of Genital Injuries

JOSHUA A. BROGHAMMER AND HUNTER WESSELLS

The goal of surgical repair of genital injuries should be to minimize further injury, prevent erectile dysfunction, preserve reproductive function, allow micturition, and provide adequate cosmesis. Operative repair requires wound irrigation, debridement of devitalized tissue, and wound closure in multiple layers. Wound contamination and time to surgical repair can also have an impact on surgical modalities.

GENITAL SKIN LOSS

Most genital skin wounds should be treated with limited initial debridement of devitalized tissue. Copious irrigation with normal saline and removal of foreign material is imperative to reduce the risk of wound infection. Wet-to-dry dressings help complete debridement of full thickness skin loss and prepare the wound bed for skin grafting.

It has been our practice to place cadaveric skin or allograft over full thickness skin loss in order to prepare the wound bed for split thickness skin grafting. These biologic dressings stimulate growth factor production for wound healing, reduce wound infections, and perform the barrier function of normal skin. The timing of initial application depends on wound bed characteristics, including contamination and ischemia. The allograft is removed 1 week after placement during the time of autograft harvest.

Avulsion Injuries

Injured areas to the scrotum and penis should be debrided and irrigated with normal saline. Because there is a rich vascular supply to the genitals, even large lacerations, if uncontaminated, can be closed primarily within 6 to 12 hours. Scrotal skin loss of up to 50% can be closed primarily owing to the inherent elastic properties of the remaining skin. Complete circumferential full thickness injuries to the penile shaft skin can result in lymphatic disruption and subsequent edema of distal shaft skin. Shaft skin distal to the injury site should be removed preemptively in anticipation of future skin grafting.

Burn Injuries

Thermal burns can be treated with a 1% silver sulfadiazine cream. Await separation of eschar from healthy tissue before attempting repair. Flush chemical burns with normal saline. Water should be avoided in lye burns. Treat alkaline burns with a mild acetic acid solution and acidic burns with a mild sodium bicarbonate solution. The extent of electrical burns is difficult to determine due to dissemination of current into the surrounding tissues. Debridement should not be undertaken until the demarcation between viable and nonviable tissue has been delineated.

Bite Injuries

Wounds from animal bites should be treated with tetanus toxoid and appropriate broad spectrum antibiotics such as cephalexin or doxycycline. If *Pasteurella* resistance is suspected, administer penicillin V. Avoid primary closure in human bites, because they are more prone to infectious complications. Despite different bacterial flora in human bites, they can be treated with similar antibiotic regimens.

Meshed Unexpanded Split Thickness Skin Grafting of the Penis

Anchor the scrotal and pubic skin to the penile shaft with buried 4-0 synthetic absorbable sutures (SAS) to prevent future penile retraction, graft loss, and buried penis. The residual coronal skin is removed.

Obtain a split thickness skin with a wide (12.5 cm) pneumatic dermatome. Donor sites include the inner or outer thigh and lower abdominal wall. The posterolateral thigh is the ideal donor site with thicker skin allowing for more rapid reepithelialization. Shave the leg and cover in a sterile stocking for intraoperative manipulation. Place the patient in the frog-leg position. Harvest a split thickness skin graft 0.015 inches thick, 12.5 cm wide, and 15 cm long. Mesh the graft in a 1:1 ratio.

Place the meshed split thickness skin graft over the penile shaft (Fig. 31-1). When applying the graft, orient the

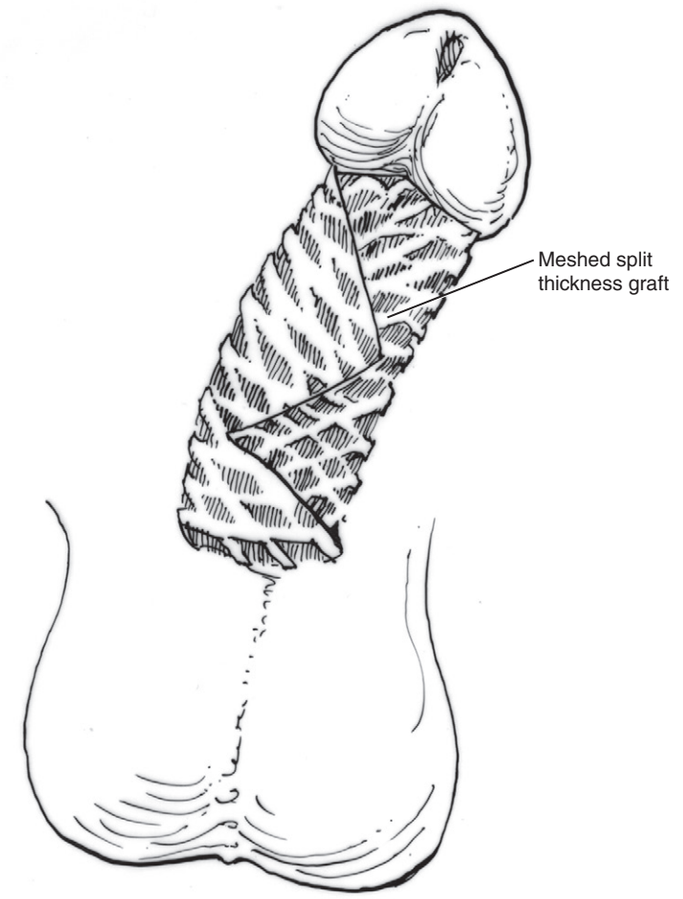

FIGURE 31-1.

meshing transversely. The width of the graft will cover the length of the penis. Wrap the longitudinal portion of the graft around the penis circumferentially. Apply the meshing without stretch, leaving the graft unexpanded. Overlap the graft on the ventral aspect of the penis. Trim the excess graft in a zigzag fashion to prevent chordee development associated with a linear suture line. Secure the suture line and graft edges to the proximal and distal penile skin using 5-0 plain catgut (PCG) suture.

Multilayer compressive dressings are used to fix the graft to its bed (Fig. 31-2). A layer of fine mesh gauze is covered with Kling, followed by Kerlix, and a second layer of Kling. Secure the dressing to the suprapubic skin with a single nonabsorbable suture (NAS). Moisten all layers of the dressing with Sulfamylon every 4 hours. Treat the donor site with epinephrine-soaked Telfa, followed by application of Acticoat. Place the patient on strict bed rest for 3 to 5 days before the first dressing change. Apply nonadherent petroleum gauze over the graft after the initial dressings are taken down.

Alternative techniques: Many advocate the use of unmeshed sheet grafts for the penile shaft to prevent contraction. Unmeshed grafts have the disadvantage of fluid accumulation beneath the graft (blebbing), higher rates of graft infection, and reduced graft take. Contraction is more associated with higher messing ratios, that is, 1.5:1. We have not had

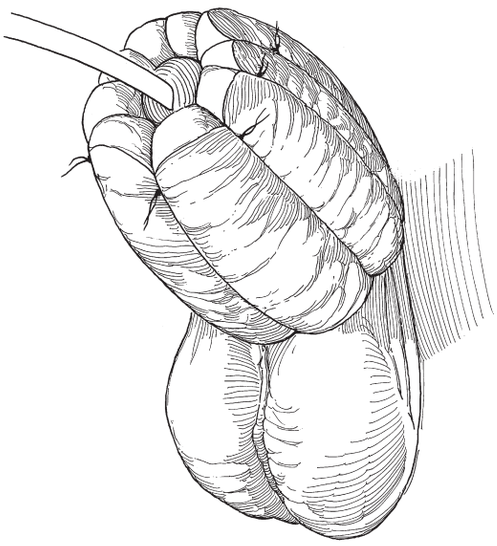

FIGURE 31-2.

these results using a meshing ratio of 1:1 and unexpanded (unstretched) graft placement.

Meshed Split Thickness Skin Grafting of the Scrotum

All attempts should be made to achieve primary closure with native scrotal skin. As much as 50% of the scrotal skin can be lost and still primarily closed. Perform a deep closure layer with interrupted 4-0 SAS. Skin closure is variable but should be interrupted to reduce ischemia. If native skin is unavailable, alternative methods can be performed.

After thorough debridement and preparation of the testes for grafting, secure the testes and spermatic cord anteriorly and posteriorly in the midline with 4-0 SAS.

Perform a split thickness skin graft with a graft thickness of 0.015 inches in a similar fashion as described previously. The dimensions should be extended to 12.5 × 25 cm if complete scrotal coverage is required. Mesh the graft in a 1:1 ratio. Orient the meshed graft in a longitudinal fashion by placing over the posterior surface of the testes. Wrap the graft around the inferior portion of the testes to create the anterior neoscrotum. Secure in place with interrupted 5-0 PCG. Cover with fine meshed gauze soaked with Sulfamylon.

PENILE FRACTURE

Operative management should be performed for penile fracture as soon as possible, even if the patient does not present immediately. Conservative treatment of penile fracture results in worse outcomes than surgical repair. Perform a retrograde urethrogram if blood is found at the meatus or a coexisting urethral injury is suspected.

Incision: Make a circumferential incision 1 cm proximal to the corona. Deglove the penis to reveal the underlying hematoma. Alternatively, make a longitudinal incision over

the median raphe if the injury is suspected to be ventral. Bucks fascia is often ruptured at the site of injury and can be entered via a longitudinal incision. Take care to avoid the neurovascular bundle on the dorsum of the penis. Evacuate the clot and define the injury. Freshen the edges of the tunica albuginea with Metzenbaum scissors and close with interrupted 3-0 SAS.

Closure: Replace the skin shaft and suture it to the coronal margin using interrupted 3-0 CCG. Leave a catheter overnight and administer prophylactic antibiotics.

Complex injuries: Complex penile fractures may extend across the midline, involving both corpora cavernosa and the urethra. For proper repair, mobilize the corpus spongiosum off the corpora cavernosa with sharp dissection. Close the urethral laceration with interrupted 5-0 PDS suture over an 18-French silicone catheter. Leave the catheter in place for 2 weeks and perform a pericatheter retrograde urethrogram before removal.

PENILE REIMPLANTATION

Prepare the amputated portion by wrapping the penis in sterile saline-soaked gauze and place into a plastic bag. Then place the first bag into a second bag containing ice slush. This minimizes ischemic injury and may allow reattachment up to 24 hours after amputation. When ready for reattachment, clean the distal stump and copiously irrigate with antibiotic solution.

Under loupe or microscopic magnification, mobilize the penile skin edges 1 cm (Fig. 31-3). This allows proper identification of the dorsal neurovascular structures. Bleeding from the penile stump is controlled with application of a tourniquet. Perform very minimal debridement. Identify the largest dorsal vein and ligate all other accessory veins.

Place an 18-French silicone catheter to stabilize the distal segment. Anastomose the urethral mucosa with interrupted 5-0 PDS suture (Fig. 31-4). Place a second layer of interrupted sutures through the tunica of the corpus spongiosum.

When urethral repair is completed, close the tunica albuginea of the corpora cavernosa with interrupted 3-0 PDS (Fig. 31-5). Reanastomosis of the cavernosal arteries is not required but is advocated by some in very proximal amputation injuries where dorsal arterial blood supply alone may not ensure distal segment viability. With the aid of microscopic magnification, spatulate the proximal vein on its dorsal aspect and the distal vein on the ventral aspect. With a double-armed 9-0 nylon NAS, repair the vein with a continuous everting suture. Tie the free ends in a tension-free closure.

Alternatively, a single stitch may be used by tying a knot on one side, running the remaining ventral aspect, and back around the dorsum of the repair.

Under magnification, approximate the epineurium of the dorsal nerves with 9-0 NAS (Fig. 31-6). Anastomose the dorsal arteries with 10-0 NAS.

Reapproximate Buck's and Colles' fascia with interrupted 3-0 SAS. Complete the skin closure with interrupted 4-0 PCG sutures. If there is overlap of excess penile skin, trim the distal penile skin and pull the proximal penile shaft skin over the wound to offset the suture lines.

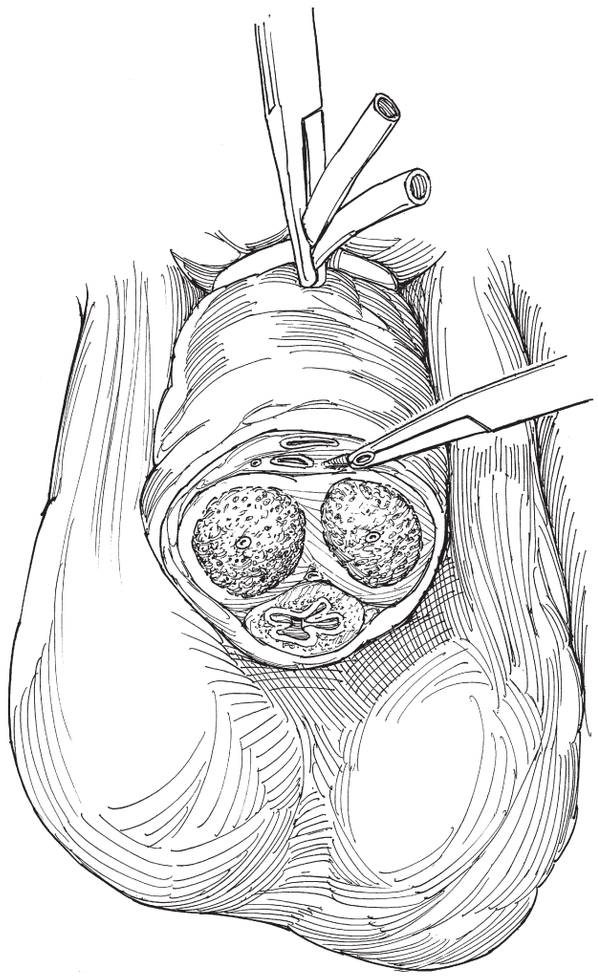

FIGURE 31-3.

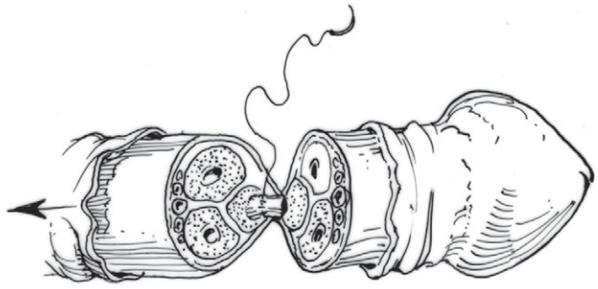

FIGURE 31-4.

Postoperatively the patient should remain on broad spectrum antibiotics. Venous congestion in the distal stump can be aspirated or treated with medical leeches. Perform a pericatheter retrograde urethrogram after 2 to 3 weeks, prior to catheter removal. Distal skin necrosis is treated with split thickness skin grafting as necessary.

Partial penile amputation injuries when the distal penis is not recovered can be closed in a similar fashion to partial penectomy procedures for penile cancer (see Chapter 18).

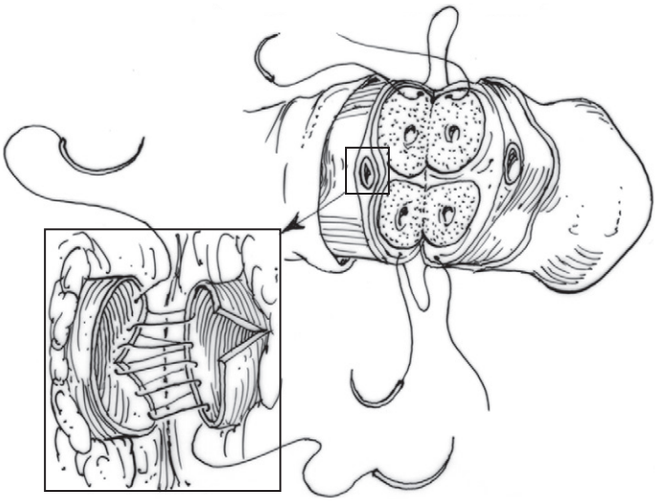

FIGURE 31-5.

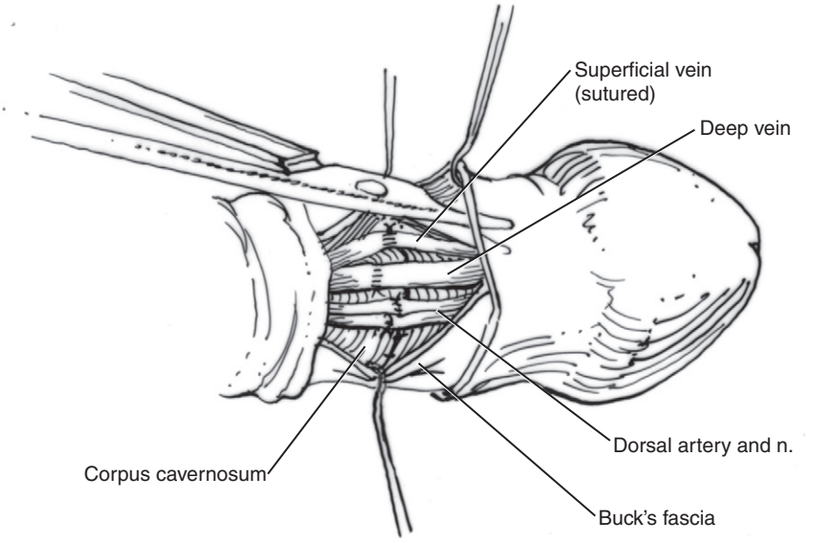

FIGURE 31-6.

TESTICULAR RUPTURE

Make a transverse incision over the affected hemiscrotum. Enter the traumatic hematocele and evacuate the residual blood clot. Examine the testis and ligate any bleeding vessels. Perform conservative debridement of the seminiferous tubules. Close the tunica albuginea over the extruded tubules with a running 3-0 SAS. Consider exploration of the contralateral testes, especially in penetrating mechanisms, unless ultrasonography has definitively ruled out injury.

Cover the defect with the tunica vaginalis. Make a small stab incision at the dependent portion of the scrotum and place a Penrose drain. Close the dartos fascia with continuous 4-0 SAS. Close the skin with interrupted 4-0 CCG or monofilament NAS. Continue postoperative antibiotics. Remove the Penrose when drainage decreases.

Section VII

FEMALE GENITAL RECONSTRUCTION

This page intentionally left blank

Chapter 32

Cecal Vagina

FRANK HINMAN JR. AND ROGER R. DMOCHOWSKI

Although placement of a cecal vagina may be used as a primary procedure, usually one resorts to intestinal segments to substitute for a vagina when previous procedures have failed and have left the area scarred or involved in fistulas. The procedure is useful in infants and children because it does not require postoperative dilation.

Provide preoperative bowel preparation and prophylactic antibiotics. Insert a nasogastric tube.

Position: Supine, with the legs slightly flexed and widely abducted and the head tilted down. Prepare and drape a single abdominoperineal field. Insert a urethral catheter.

Make a vertical lower abdominal incision (Fig. 32-1A). Mobilize the posterior wall of the bladder and urethra. Incise the peritoneum along the white line to free the cecum and ascending colon, and continue the release around the hepatic flexure to allow the subsequent anastomosis of ileum to colon (see Fig. 32-1B). Locate the ileocolic artery by transillumination to determine that the segment will be adequately vascularized and that the ileocolic vascular pedicle will allow the colon to reach the perineum.

Divide the colon and the terminal ileum, spatulate the ileum, and perform an ileocolic anastomosis. Close the mesentery. Irrigate the segment with saline through a balloon catheter. *Optional:* Perform an appendectomy. Rotate the cecum 180 degrees counterclockwise (*arrows*) (Fig. 32-2).

If the lower part of the new vagina is short or sacculated, incise the antimesenteric border for a distance of several centimeters and close the mesenteric border for a similar distance (Fig. 32-3). A transverse incision in the peritoneum of the mesentery may allow additional length. If high insertion of the ileocolic artery prevents inversion and descent, open the cecum and close the colonic end. If the cecum still does not reach, create a cuff from a U-shaped piece of ileum to attach to the colon distally.

Make an H-shaped or Y-shaped incision (Fig. 32-4A). Additionally if the patient has some vaginal capacity left and is undergoing the procedure due to surgical injury to the vagina, the vaginal apex should be widely opened with similar types of incision with the vaginal walls mobilized

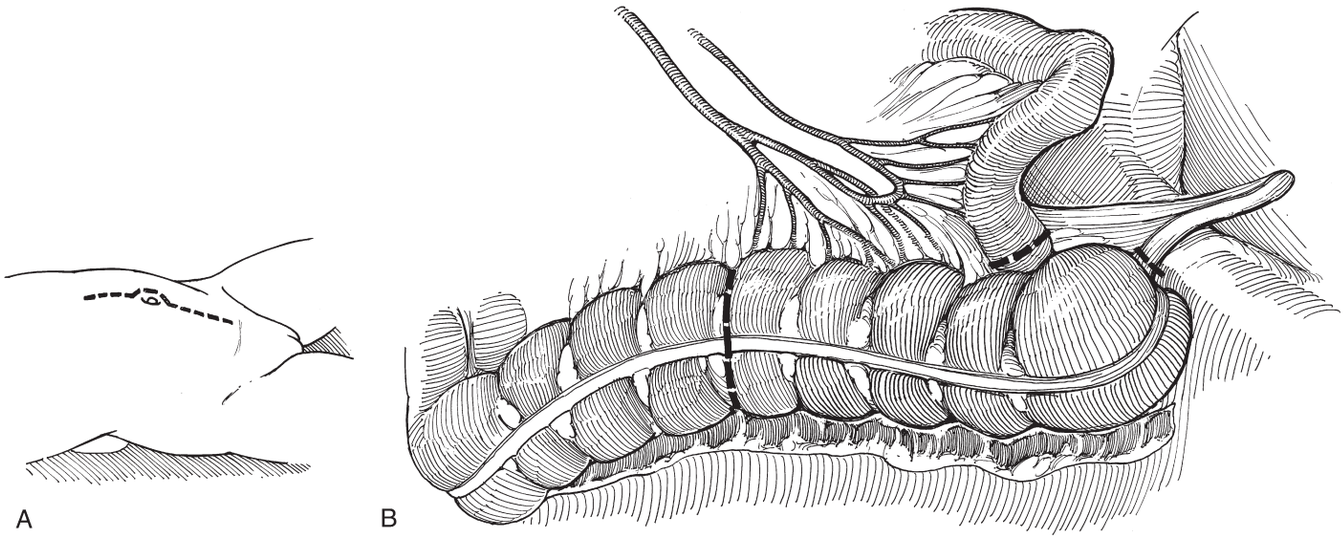

FIGURE 32-1.

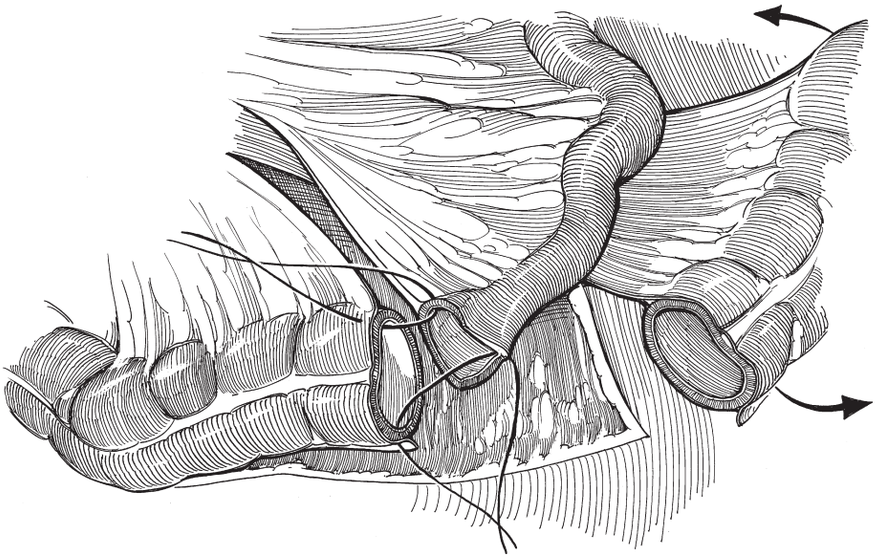

FIGURE 32-2.

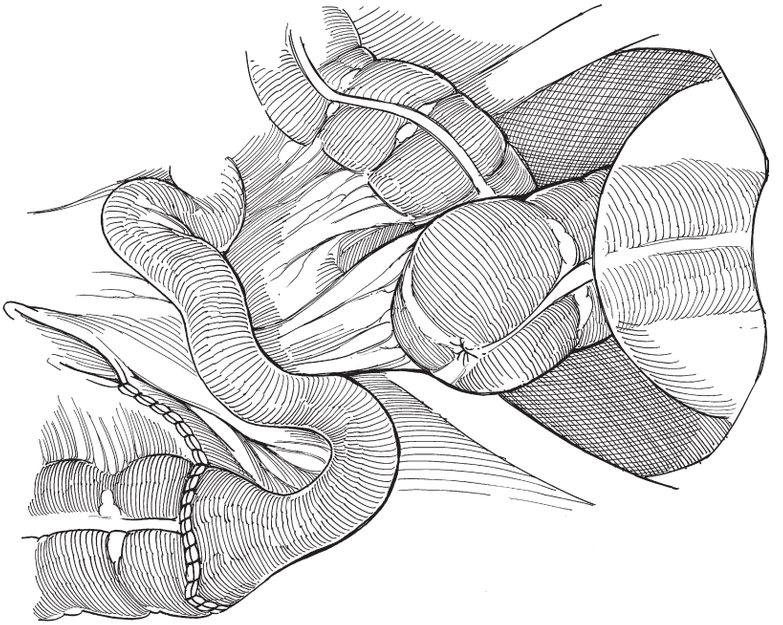

FIGURE 32-3.

for purposes of tension-free anastomosis to the intestinal segments. In some male pseudohermaphrodites raised as females, the perineum is flat without an introital appearance, so that larger flaps are required. With blunt and sharp dissection, create a canal to the level of the vesicorectal pouch (see Fig. 32-4B). The new canal should accommodate three fingers in the adult. Pull the bowel through the perineal tunnel. Anchor the neovagina to the sacrum and insert a vaginal drain, and close the abdominal wound.

Suture the margin of the colon to the vulva or remnant vagina with 3-0 SAS. Attach the posterior flap of perineal skin first, tying the sutures with the knots inside. Connect the anterior flap by placing all the sutures and tying them after placement (Fig. 32-5). Place a vaginal pack or form coated with petroleum jelly in the new introitus. After 1 week, examine the perineum under sedation to separate accumulated synechiae. At 3 weeks, have the patient start daily dilation for 5 or 10 minutes twice a day, continually increasing the size of the dilator. Dilations must not be stopped until coitus is begun.

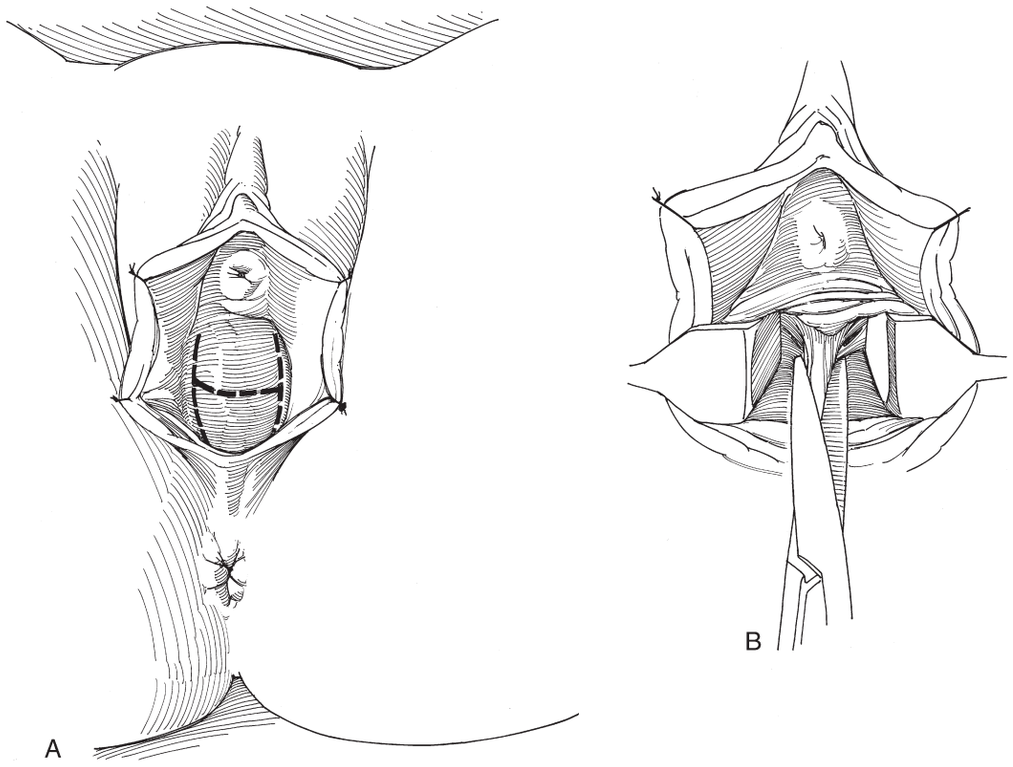

FIGURE 32-4.

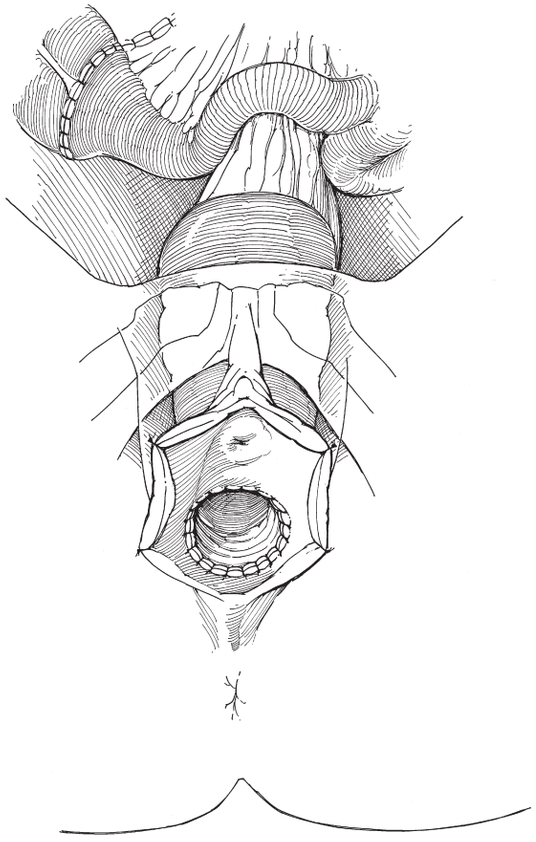

FIGURE 32-5.

This page intentionally left blank

Chapter 33

Urethrovaginal Fistula Repair

KATHLEEN C. KOBASHI AND DAVID E. RAPP

Preparation: Diagnosis of urethrovaginal fistula is based on history, full physical examination, and thorough evaluation. Associated examination including speculum exam and tampon test, or described variations, are useful. Cystourethroscopy can be useful to identify fistula location in most cases. Voiding cystourethrography and intravenous pyelography are necessary adjuncts to rule out associated vesicovaginal or ureterovaginal fistulas.

Principles of fistula repair include adequate tissue mobilization and fistula visualization, the use of sharp dissection, absence of infection, and removal of foreign bodies if present. Furthermore, successful fistula closure is maximized by the use of healthy tissue flaps, two-layer and tension-free closure, and adequate postoperative urinary drainage. Excision of the fistula tract remains controversial. The initial attempt to perform fistula repair provides the best opportunity for success. Simple fistulas may be amenable to simple excision and closure. Tissue interposition techniques may be advantageous in the setting of complex fistulas. Involvement of the bladder neck represents a further challenge, and may require bladder neck reconstruction or subsequent antiincontinence procedures.

Instruments: Basic set, GU fine set, Lone Star retractor (Cooper Surgical, Stafford, TX), weighted speculum, punch cystostomy set, 16-French 10-mL silicone balloon catheter, 12-French 5-mL silicone balloon catheter, standard cystourethroscopy set, 0.038-inch glide wire, 10-mL syringe of injectable saline.

Position/exposure: Lithotomy. Prepare the lower abdomen, perineum, and vagina. A vaginal Betadine douche is preferred. Insert a 12-French suprapubic punch tube (SPT) via cystostomy under direct visualization and plug it. Perform cystourethroscopy to identify the fistula location. When possible, cannulate the fistula tract in a through-and-through fashion with a glide wire. Insert a 16-French urethral catheter. Obtain exposure through positioning of a Lone Star retractor and weighted speculum. Skin hooks are used to facilitate further vaginal exposure (Fig. 33-1). In the rare instance of compromised exposure resulting from a narrow introitus, a posterolateral vaginal relaxing incision can be used to enhance visualization (Fig. 33-2).

Incision: An inverted U-shaped incision is made in the anterior vaginal wall, extending in its distal-most aspect to the proximal fistula border. The fistula opening is incised in a circumferential fashion. Holding sutures may be placed in proximity to the fistula tract to facilitate dissection (Fig. 33-3).

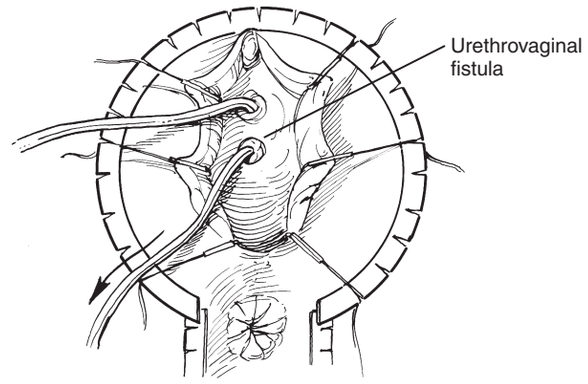

FIGURE 33-1.

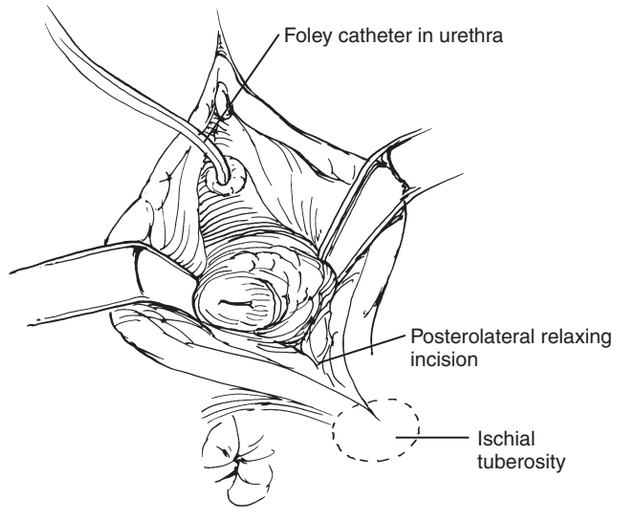

FIGURE 33-2.

Using Metzenbaum scissors, undermine the vaginal epithelium in its lateral, distal, and proximal extents until

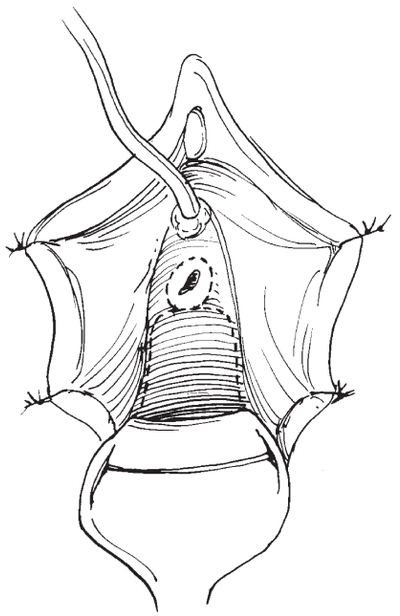

FIGURE 33-3.

mobilization of the vaginal flap is achieved (Fig. 33-4). Excise the margins of the fistula back to normal urethral tissue. Alternatively, some authors advocate avoiding fistula excision such that a ring of vaginal epithelium surrounds the fistula and may be used in the closure of the urethra. This may be appropriate if a large urethral defect is anticipated in order to facilitate a tension-free closure.

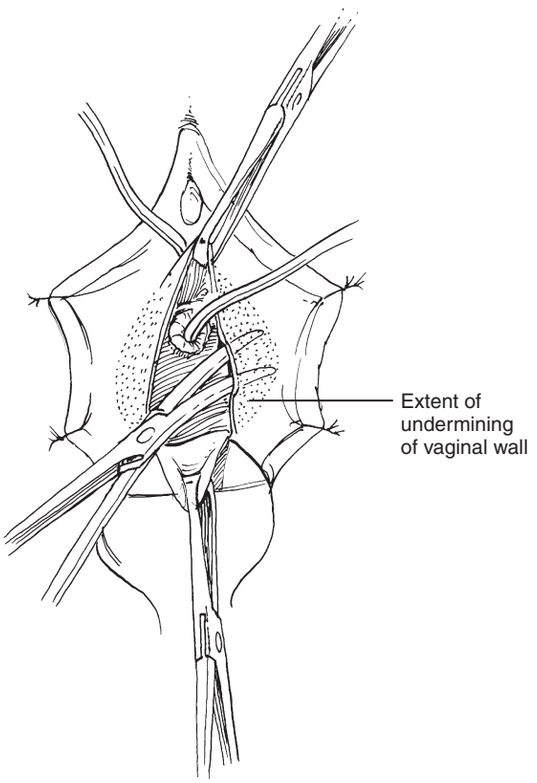

FIGURE 33-4.

Close the urethral defect in a transverse, tension-free fashion using a running 4-0 absorbable suture (Vicryl or Monocryl preferred) (Fig. 33-5A). A second reinforcing layer is performed by approximating the periurethral tissue in a vertical fashion using interrupted Lembert stitches of 4-0 absorbable suture (see Fig. 33-5B).

The vaginal U-flap is then closed over the double-layered repair using a running 2-0 Vicryl suture (Fig. 33-6). Accordingly, closure is completed in a tension-free fashion with avoidance of overlapping suture lines.

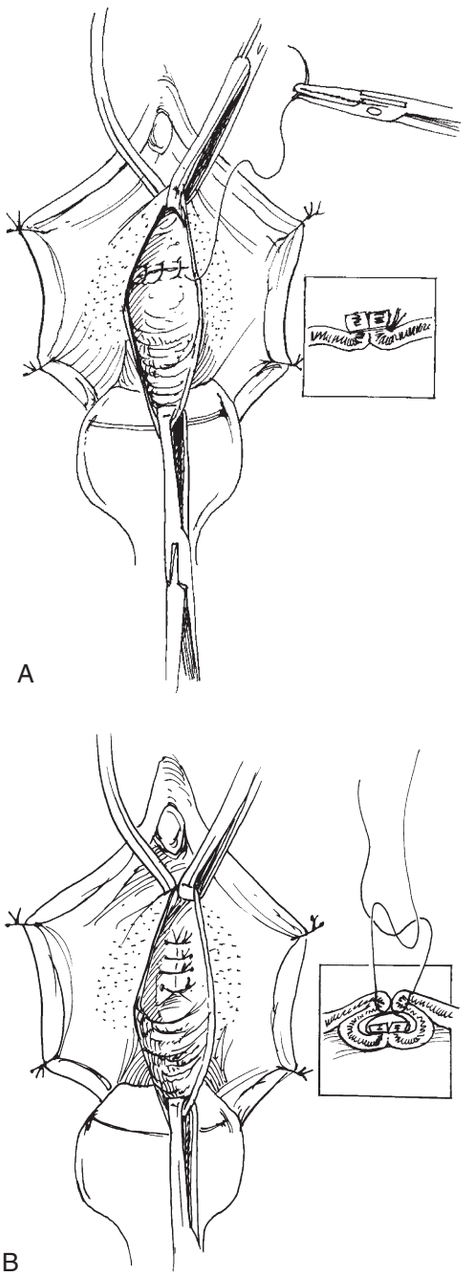

FIGURE 33-5.

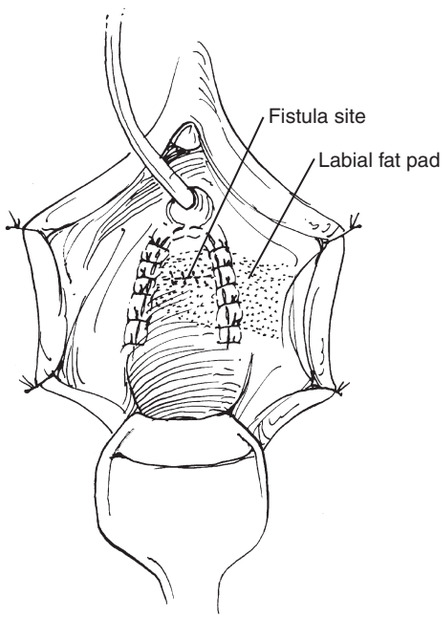

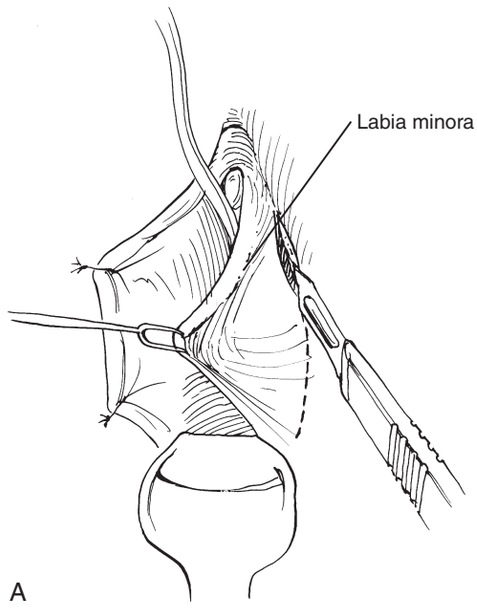

FIGURE 33-6.

BULBOCAVERNOSUS MUSCLE INTERPOSITION WITH FAT PAD SUPPLEMENT (Martius Flap)

Interposition flaps may be placed for additional reinforcement of complex fistulas. The female bulbocavernosus muscle has an origin at the dorsum of the clitoris at the perineal membrane with an insertion into the central tendon of the perineum. When necessary, interposition may include a flap of surrounding labial adipose tissue. Finally, modified interposition techniques incorporating full thickness labial cutaneous flaps are described for large defects.

Tissue interposition is performed before closure of the vaginal flap. A vertical incision is made sharply lateral to the groove between the labium majus and minus. A holding suture may be placed in the labium minus to facilitate dissection. Skin hooks are used to further facilitate vaginal exposure (Fig. 33-7A). Mobilization of the graft is performed with care taken to preserve the vascular supply of the deep perineal branch of the external pudendal artery, which enters posteriorly (see Fig. 33-7B). The flap is divided at its anterior aspect.

A tunnel is fashioned between the harvest site and the lateral vaginal wall extending beneath the labium minus. The flap is passed through the tunnel, to provide coverage of the fistula site is obtained. The flap is anchored to the periurethral tissue using interrupted 2-0 Vicryl suture to finalize defect coverage (Fig. 33-8A). As described earlier, the vaginal U-flap is then closed over the completed repair using a running 2-0 Vicryl suture (see Fig. 33-8B).

Before closure of the flap harvest site, hemostasis is ensured. A ¼-inch Penrose drain is placed in the flap fossa, tunneled through a separate skin incision lateral to the labium majus, and secured to the skin using 3-0 nylon suture. The flap incision is closed in two layers using absorbable 3-0 and 4-0 suture for the subcutaneous and cutaneous tissues, respectively.

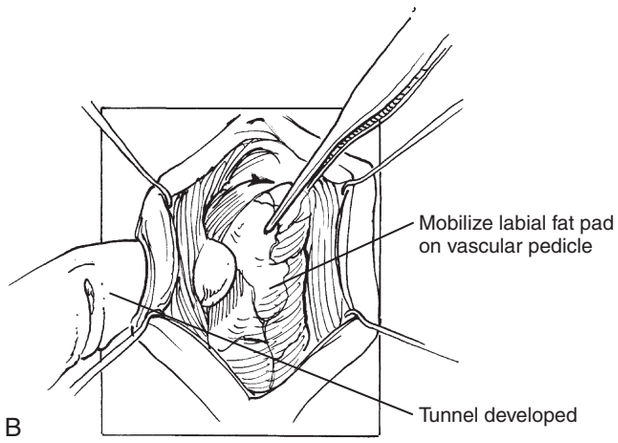

FIGURE 33-7.

Postoperative technique: A 16-French 10-mL urethral catheter is maintained to gravity drainage for bladder decompression. The suprapubic cystostomy is plugged. A vaginal pack is placed perioperatively and removed several hours after surgery. Voiding cystourethrogram (VCUG) is performed 10 to 14 days postoperatively to determine the presence or absence of extravasation that would suggest persistent fistula. The urethral catheter is removed for VCUG performance and is not replaced even in the face of extravasation, in which case the SPT is opened to gravity drainage. The VCUG is repeated approximately 2 weeks later.

Once lack of extravasation is confirmed, the SPT is plugged and the patient is instructed to check postvoid residual volumes. The SPT is removed when residual volumes are consistently low (<100cc).

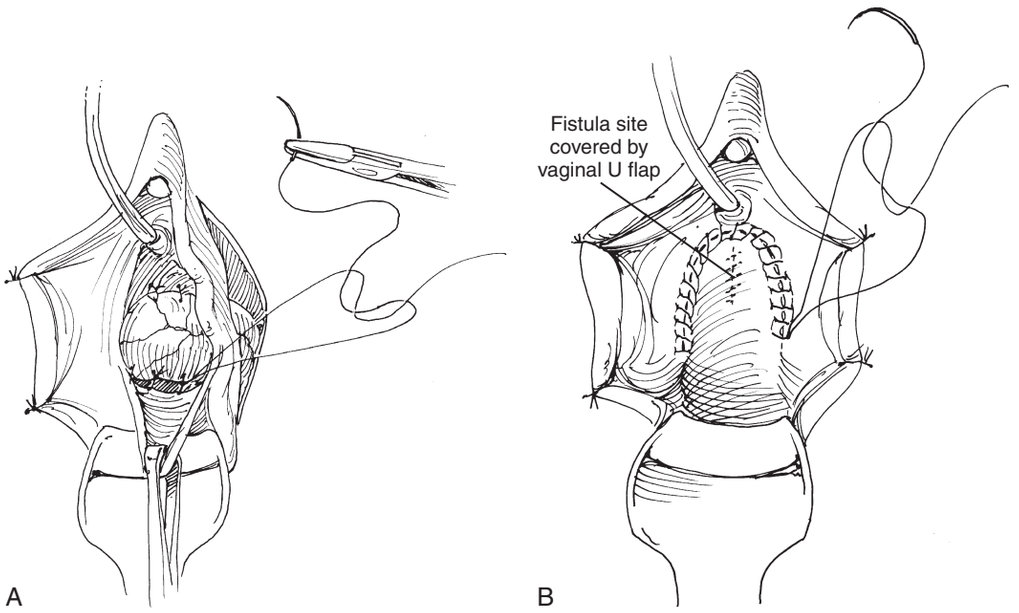

FIGURE 33-8.

Commentary by ROGER DMOCHOWSKI

Critical to successful urethrovaginal fistula closure is the realization that the fistulous tract should be mobilized well. The fistula itself should not actually be excised on the urethral aspect, but rather oversewn. This maneuver avoids increasing the overall surface area of the fistula. As the authors point out, a layered closure is critical and my personal preference is Vicryl for this purpose. The surgeon should be aware that alternative materials for secondary sling placement in these patients are few given the risks of erosion. Recent guidelines have advised against the use of synthetic materials in this situation and most authors recommend autologous fascia for purposes of sling interposition in the indicated patient. When the urethrovaginal fistula is large and involving the bladder neck, preoperative documentation of stress incontinence may be difficult. However, given the location of fistula and its proximity to bladder neck it is reasonable to assume they will have intrinsic urethral dysfunction and a sling is justified in these individuals as a component of the surgical correction.

This chapter describes the use of the bulbocavernosus muscle interposition, otherwise known as the Martius flap. The flap can be modified for purposes of location and may be based either on a posterior or anterior blood supply (pudendal or epigastric) and function quite well with either of these blood supplies. It is rare that the actual cavernosus muscle is necessary and the overlying fibrofatty tissues almost always will provide enough bulk and interposition material. Interestingly enough, the usual occurrence is that after harvest and mobilization, the graft is actually too thick and requires tailoring for purposes of placement in the vagina. A large bulk effect from the graft complicates vaginal mucosal closure and may cause postoperative symptoms.

Chapter 34

Bulbocavernosus Muscle and Fat Pad Supplement

SHLOMO RAZ, CHRISTIAN O. TWISS, AND VERONICA TRIACA

CLASSIC MARTIUS

Locate the bulbocavernosus muscle and its associated fat pad by palpating it between the index finger placed just inside the hymenal ring and the thumb on the labium majus.

After repairing the fistula but before closing the vaginal mucosa, make a vertical incision in the groove between the labium majus and labium minus (Fig. 34-1).

Expose the fat pad and underlying bulbocavernosus muscle. Dissect the muscle free with the fat pad surrounding the muscle (Fig. 34-2). Take care not to disturb the blood supply, which comes from the deep perineal branch of the external pudendal artery and enters the muscle posteriorly close to its origin. Ligate the tip of the muscle and divide it anteriorly.

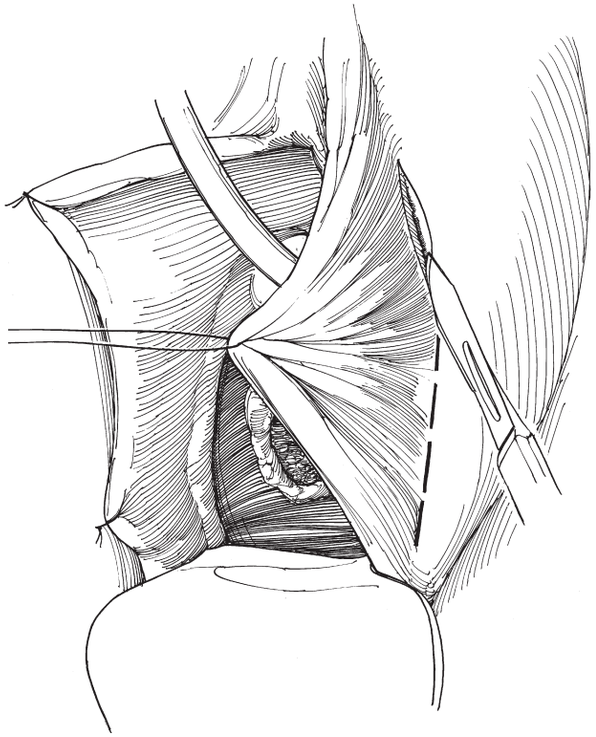

FIGURE 34-1.

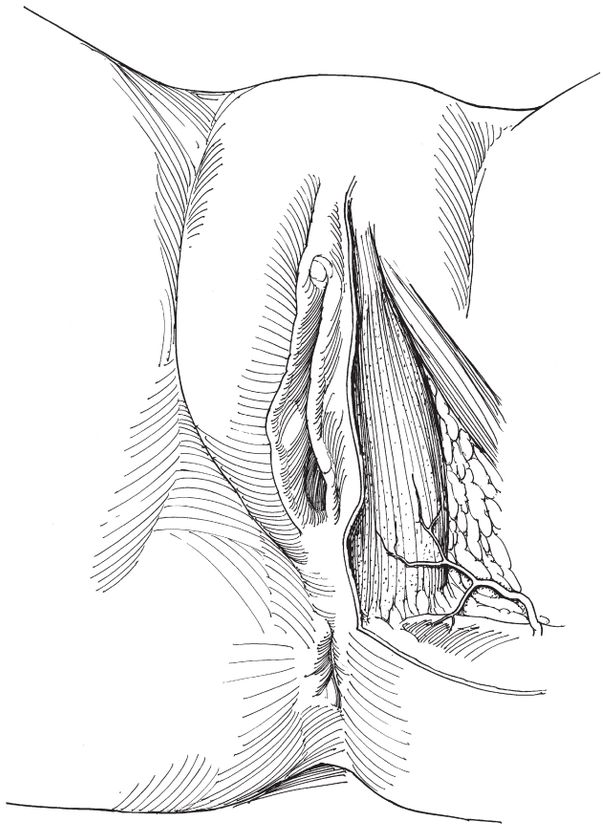

FIGURE 34-2.

With a Mayo clamp, develop a tunnel starting near the repair, extending laterally under the labium minus, and ending near the dissected muscle. Enlarge it with the left index finger positioned against the tip of the clamp as it is withdrawn (Fig. 34-3).

Grasp the tip of the muscle and pull it through the tunnel. Suture it over (around) the defect with interrupted 3-0 SAS (Fig. 34-4).

Approximate the vaginal mucosa after trimming it asymmetrically, and close the lateral labial defect with a subcuticular 4-0 SAS (Fig. 34-5).

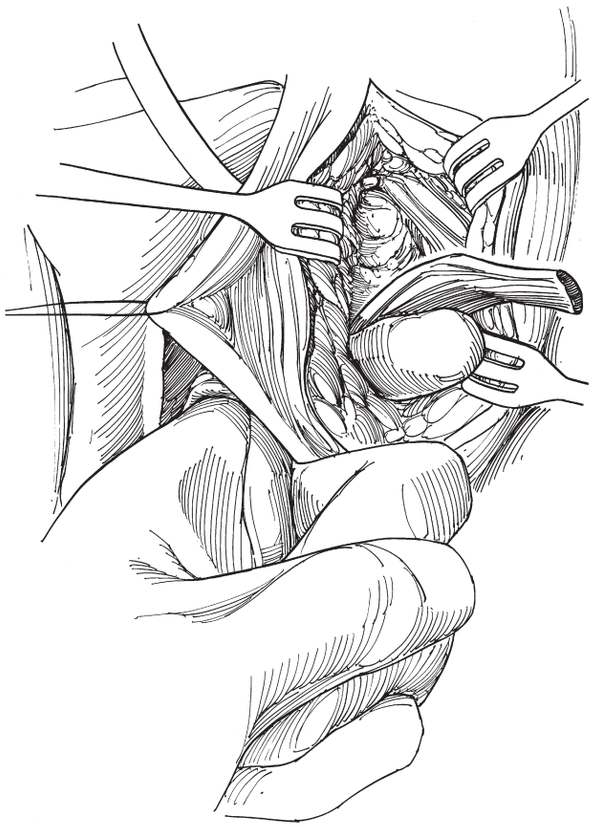

FIGURE 34-3.

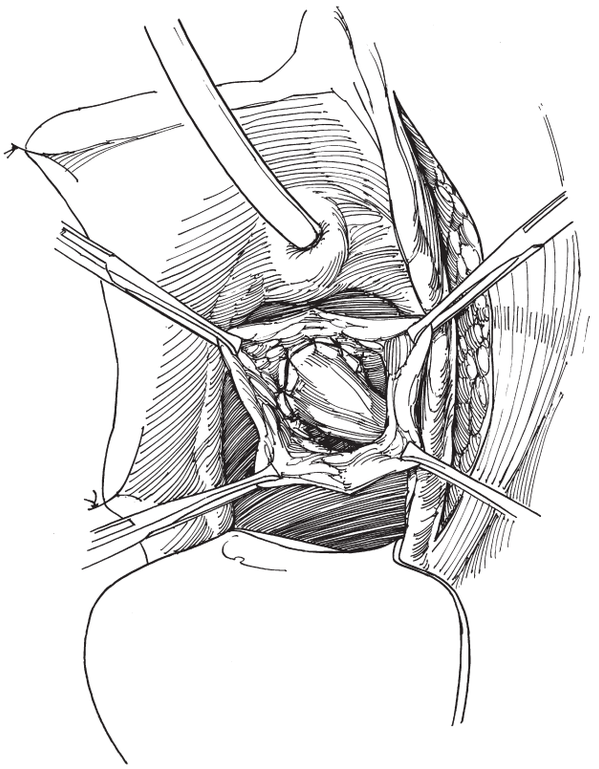

FIGURE 34-4.

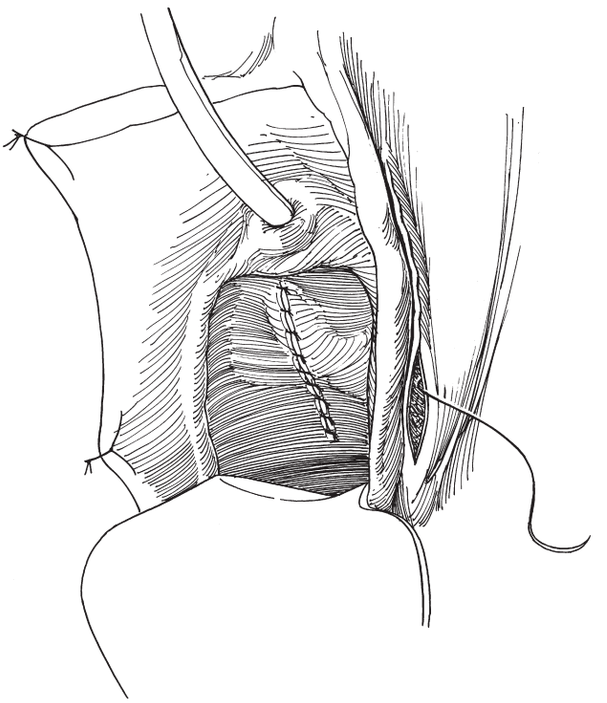

FIGURE 34-5.

Alternative: If less tissue supplementation is needed, instead of mobilizing the bulbospongiosus muscle itself, dissect through the subcutaneous fat to reach the labial fat pad that overlies the muscle. Preserve the blood supply that enters the pad posteriorly. Create a tunnel under the lateral vaginal wall. Rotate the fat pad under the skin bridge and fasten it over the repair with interrupted 4-0 SAS. Close both incisions.

IN SITU MARTIUS FLAP

The vaginal incision through which the surgical repair has been performed is extended to the labia (Fig. 34-6). A tunnel is developed subcutaneously toward the adductor muscles laterally. This initial dissection saves the later step of having to create an access tunnel for the flap to reach the prevaginal space.

A generous flap is then dissected by extension superiorly to the anterior symphysis of the pubic bone, while leaving a wide base of pedicle inferiorly (Fig. 34-7A). The upper segment is transected and tied with suture ligature (see Fig. 34-7B). The flap is transferred to the prevaginal space and sutured in place over the repair (see Fig. 34-7C). The vaginal incision is reapproximated. There is no additional labial incision and no drain is left. By avoiding a labial incision, there is no transection of the superficial branches of the pudendal nerve, and the risk of injury to the posterior labial branches of the internal pudendal artery is minimized.

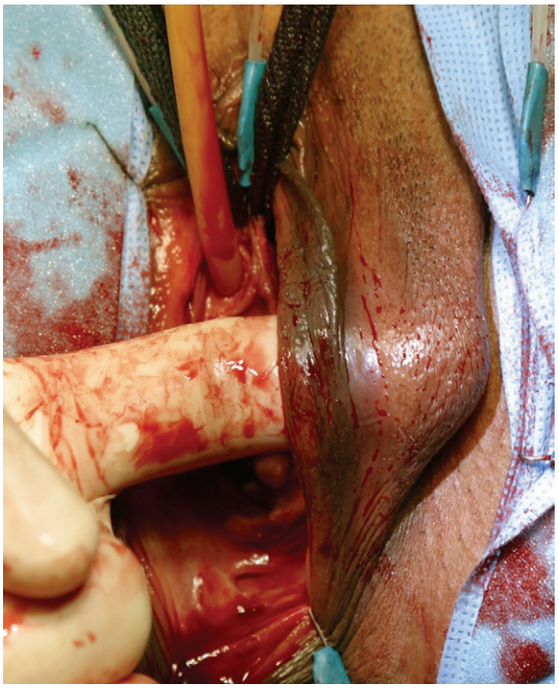

FIGURE 34-6.

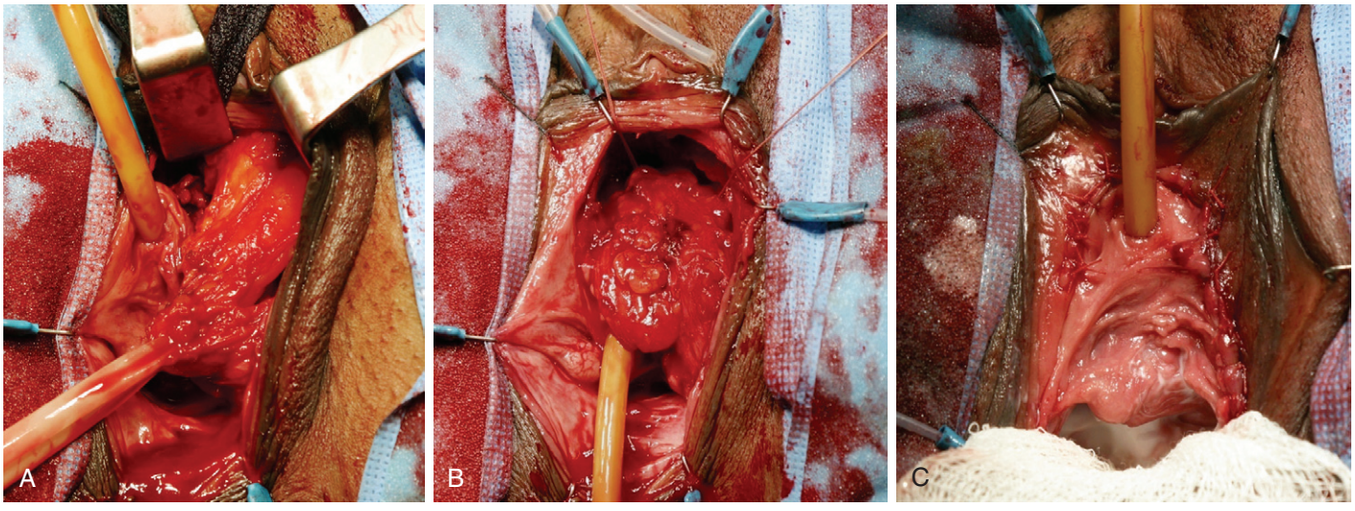

FIGURE 34-7.

LABIAL FLAP

An alternative labial flap can be employed to repair distal urethrovaginal fistulas that are not amenable to Martius flap use, or those that have failed previous Martius flap repair.

The lateral vagina is incised. The incision is extended from the fistula to the introitus and toward the anterior surface of the labia majora (Fig. 34-8).

The fistulous tract is closed and the labial flap is mobilized to cover the repaired fistula. The skin is then closed (Fig. 34-9).

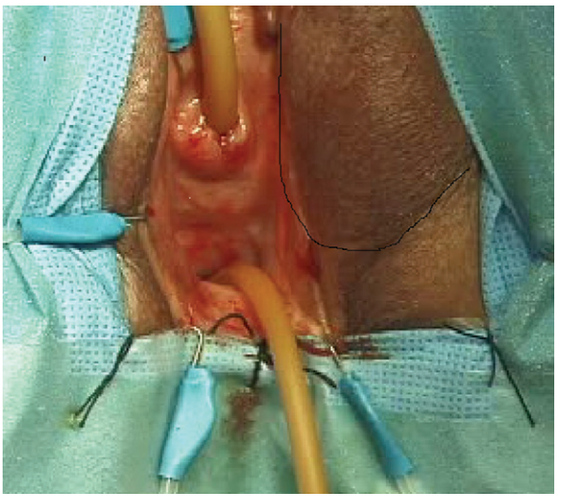

FIGURE 34-8.

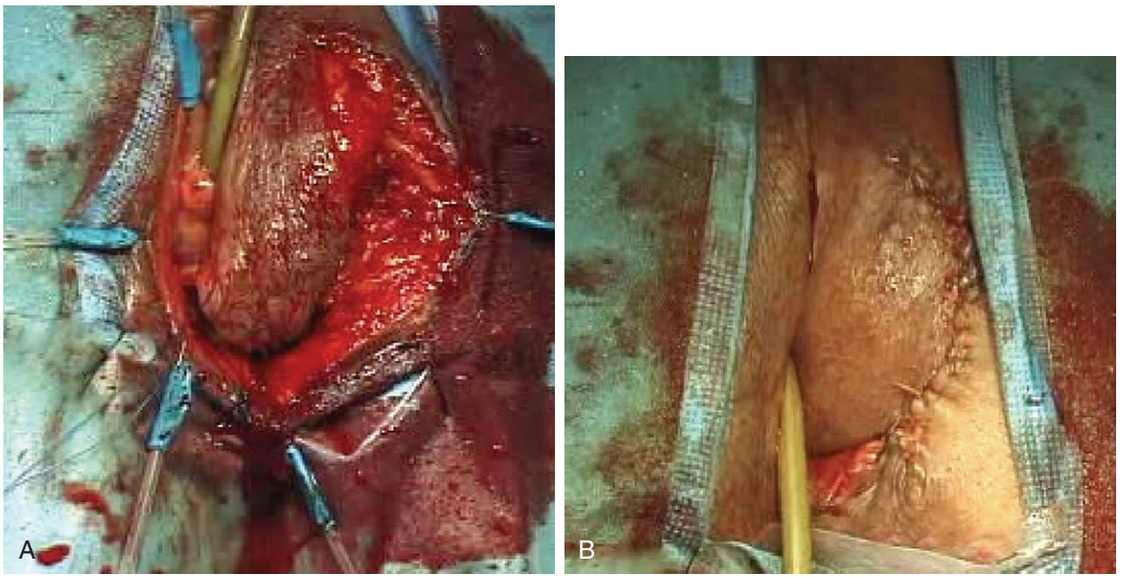

FIGURE 34-9.

Commentary by ROGER DMOCHOWSKI

The labial fat pad graft can be used in all areas of the vagina; however, very proximal apical lesions may be difficult to reach with this particular graft, given the extent of tunneling that would be necessary under the vaginal fornices. One of the concerns regarding labial fat pad interposition is the bulk of the tissue being inlaid and the potential that this bulk may complicate vaginal wall closure. Therefore, it is critical that the implanting surgeon limit the overall width of the graft. The graft can be based on either the anterior or posterior circulation (pudendal or epigastric) depending upon the location of the lesion to be covered.

Postoperative drainage of the graft bed in the labia is critical and a ¼-inch Penrose used for the evening of surgery is usually sufficient to prevent hematoma collection.

Women should be counseled that the donor labial site will appear to be somewhat deformed after harvest but that within 6 months new adipose tissue will correct any cosmetic abnormality.

Chromic suture is best for skin closure to avoid prolonged vaginal discharge.

Chapter 35

Female Urethral Diverticulectomy

GARY E. LEACH AND ELISE PERER

The classic presentation of a urethral diverticulum has been described as the *three Ds* (dysuria, dyspareunia, and postvoid dribbling). Physical examination may reveal a tender anterior vaginal wall mass from which pus, blood, or urine extrudes from the urethral meatus on anterior vaginal wall pressure. Pelvic magnetic resonance imaging is now considered the gold standard for diagnosis. Detection of the communication site between the diverticulum and urethra before repair is recommended to ensure complete excision at the time of the procedure. Identification can be accomplished by using a blunt-tipped female urethroscopy with a 30- or 0-degree lens to examine the urethra while putting pressure on the anterior vaginal wall, which may cause the contents of the diverticulum to be extruded into view, facilitating identification of the diverticular neck. A classification system (L/N/S/C3: L, location; N, number; S, size; C3, configuration, communication, continence) is useful in planning surgical repair. Urodynamic studies should also be considered in patients with incontinence. When genuine stress incontinence is present, we recommend an antiincontinence procedure after the diverticulectomy repair is well healed.

MARSUPIALIZATION TECHNIQUE (SPENCE-DUCKETT)

This technique is appropriate for diverticula that open below the continence mechanism. The result is a shortened urethra, which can be a factor in urinary incontinence following childbirth. It leaves a patulous intravaginal urethral meatus, which can cause spraying of the urinary stream and vaginal voiding with postmicturition incontinence, as well as difficulty with catheterization.

Retract the labia majora with traction sutures and insert a weighted speculum. Insert traction sutures on both sides of the meatus.

Identify the orifice of the diverticulum with the panendoscope. Insert Mayo scissors into the meatus and cut the urethra, urethrovaginal septum, and anterior vaginal wall from the meatus to the diverticular orifice, including the wall of the diverticulum itself, to saucerise the sac (Fig. 35-1).

TRANSVAGINAL EXCISION

Delineate the diverticulum preoperatively as described above. Attempt to sterilize the urine preoperatively and provide prophylactic antibiotics. Perform a preoperative vaginal preparation. Place the patient in lithotomy position and drape the rectum from the field.

Place a suprapubic tube, as previously described, and a urethral catheter. A ring retractor with hooks is placed to obtain vaginal exposure. Make an inverted U-shaped incision on the anterior vaginal wall, with the apex of the inverted U incision at the distal one third of the urethra. Dissect the anterior vaginal wall flap off the urethra to the bladder neck without entering the periurethral fascia (Fig. 35-2).

After the anterior vaginal wall flap is reflected to the level of the bladder neck, identify and open the periurethral fascia by making a horizontal incision (Fig. 35-3A). Dissect the periurethral fascia off of the underlying diverticulum. The anterior and posterior components of the periurethral fascia will open like leaves of a book to expose the underlying diverticulum (see Fig. 35-3B). Once the diverticulum is exposed, the entire diverticulum is dissected out down to the diverticular neck.

Excise the entire diverticulum and its communication site with the urethra (Fig. 35-4). A urethrotomy is made and the 14-French urethral catheter is exposed.

Close the urethral wall with a running, locking Vicryl suture (Fig. 35-5).

The periurethral fascia is closed transversely with a running 3-0 Vicryl suture (Fig. 35-6).

When a watertight closure cannot be obtained or if the periurethral tissue is deficient, a Martius labial fat pad graft can be placed over the periurethral fascia to bolster the repair and prevent urethrovaginal fistula (Fig. 35-7).

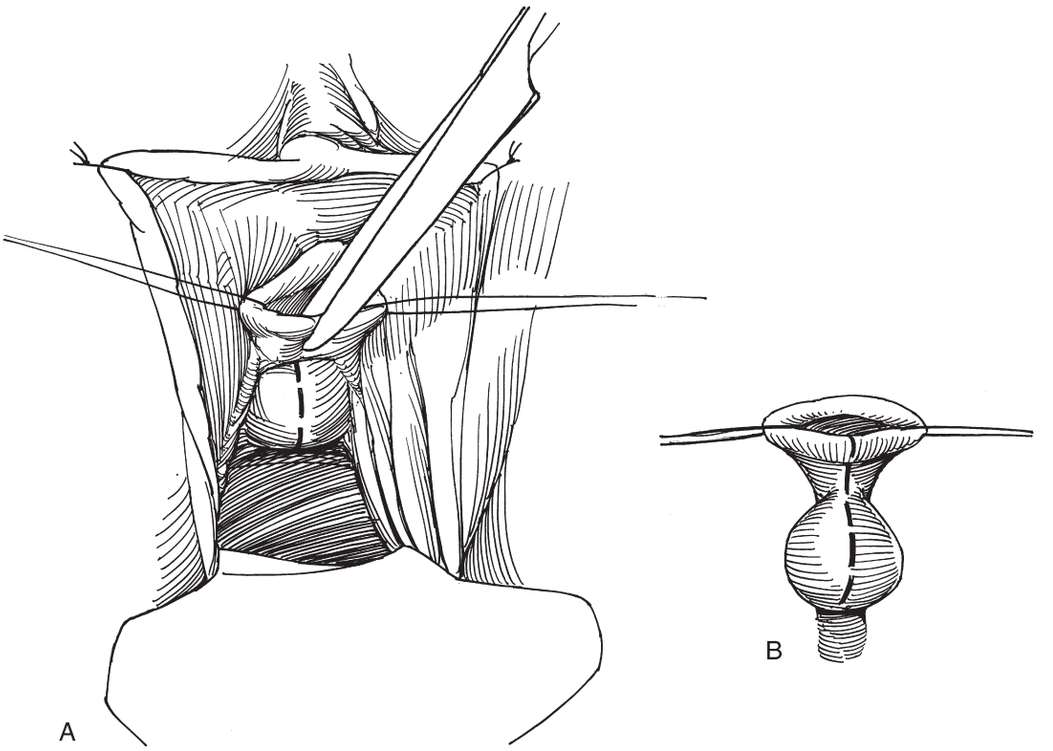

FIGURE 35-1.

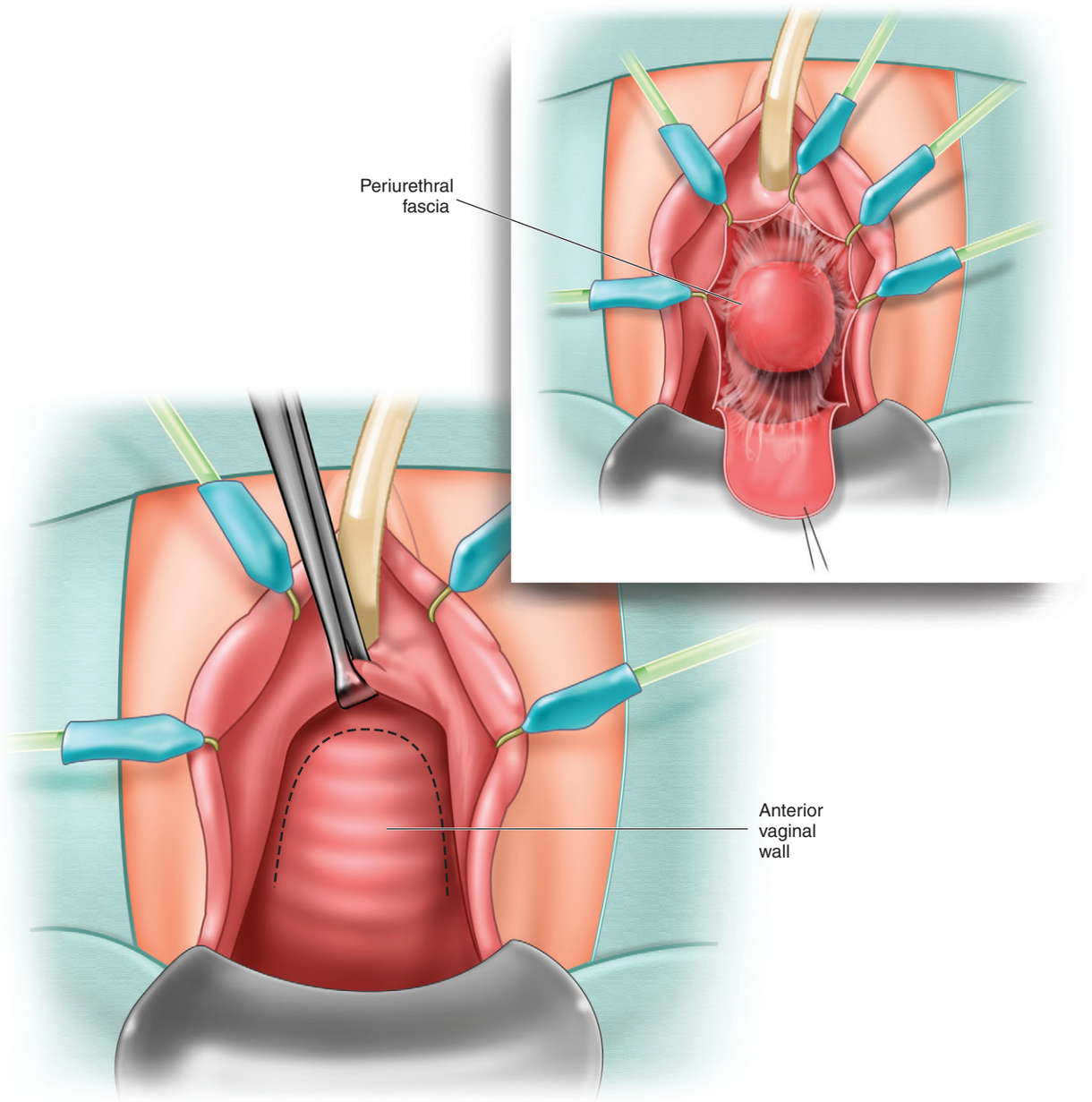

FIGURE 35-2. *(Modified from Nitti V, ed. [2012]. Vaginal surgery for the urologist. Philadelphia: Elsevier-Saunders.)*

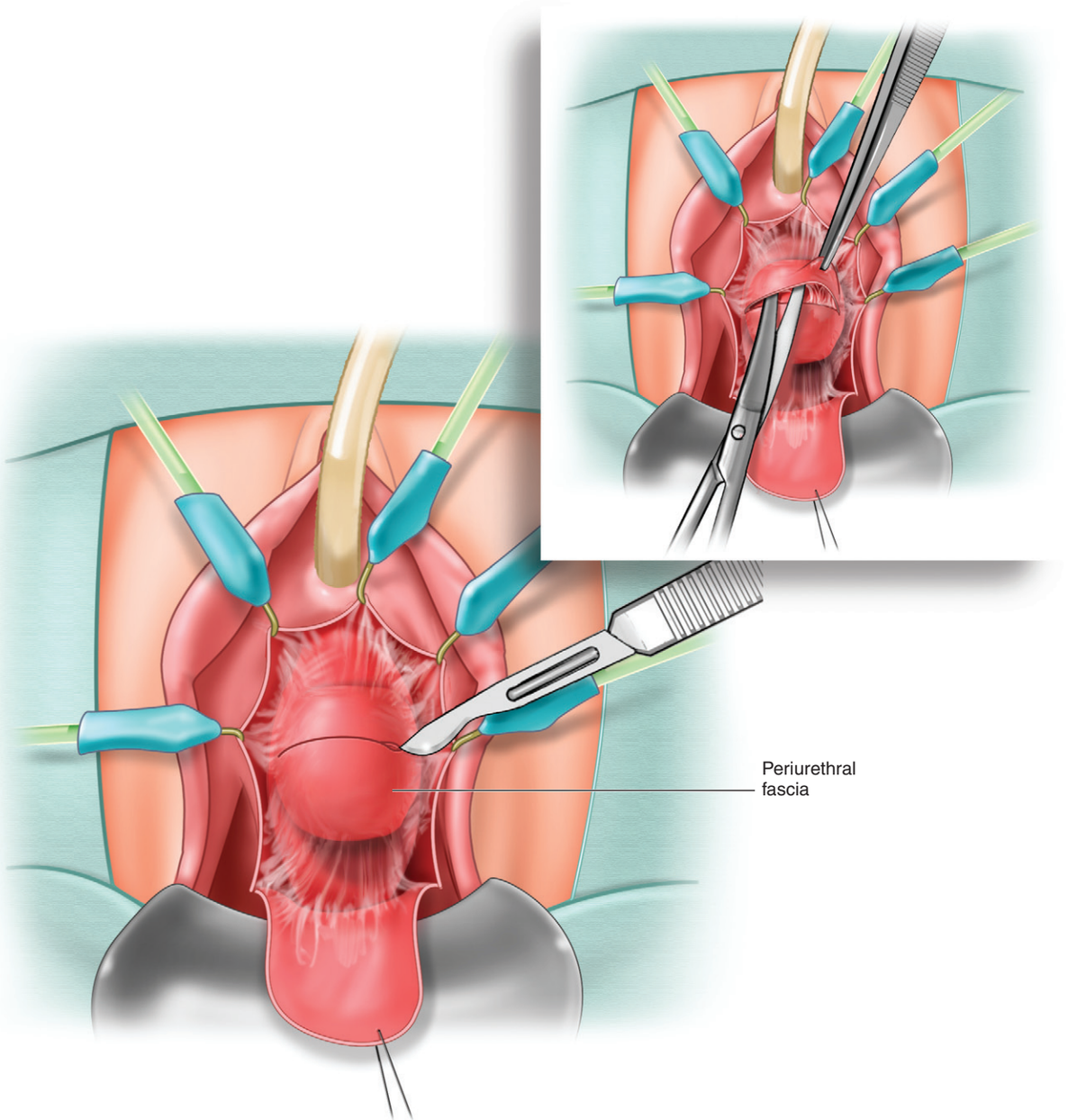

FIGURE 35-3. *(Modified from Nitti V, ed. [2012]. Vaginal surgery for the urologist. Philadelphia: Elsevier-Saunders.)*

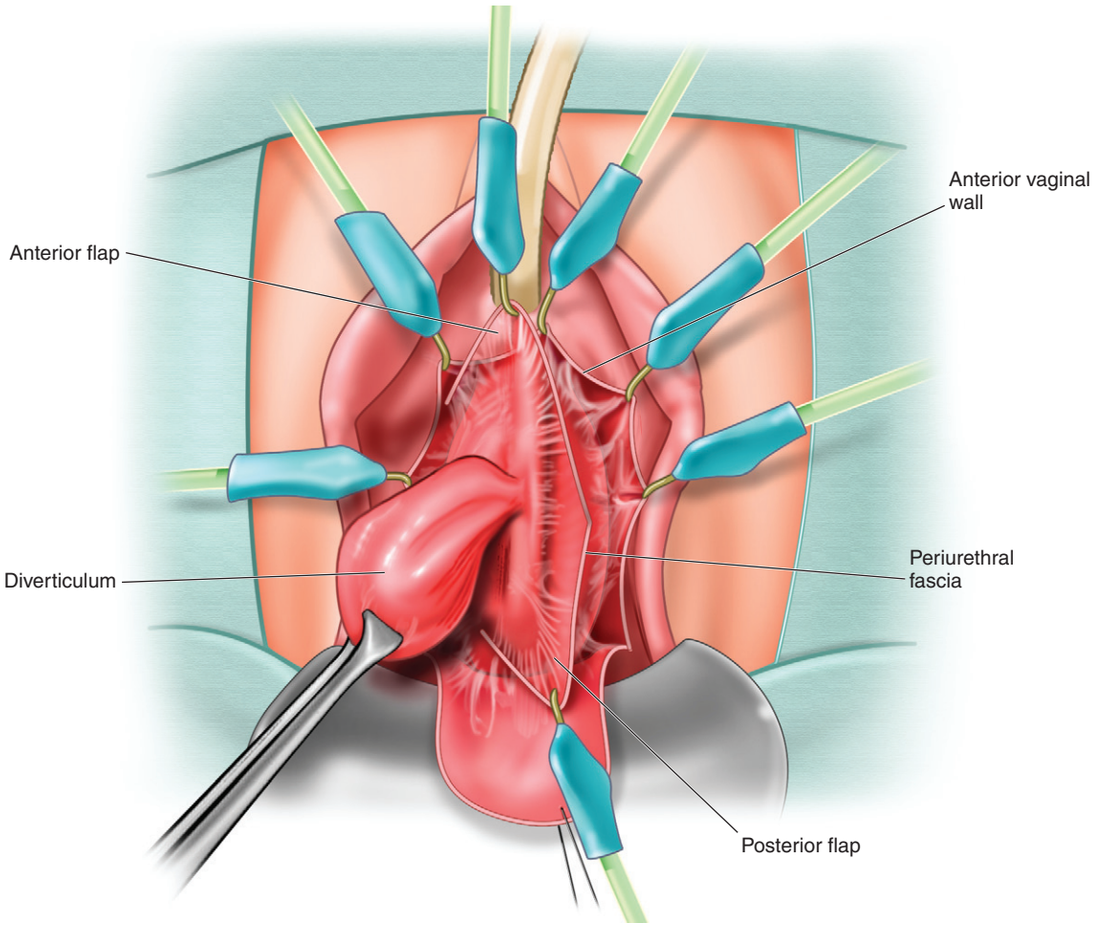

FIGURE 35-3, cont'd.

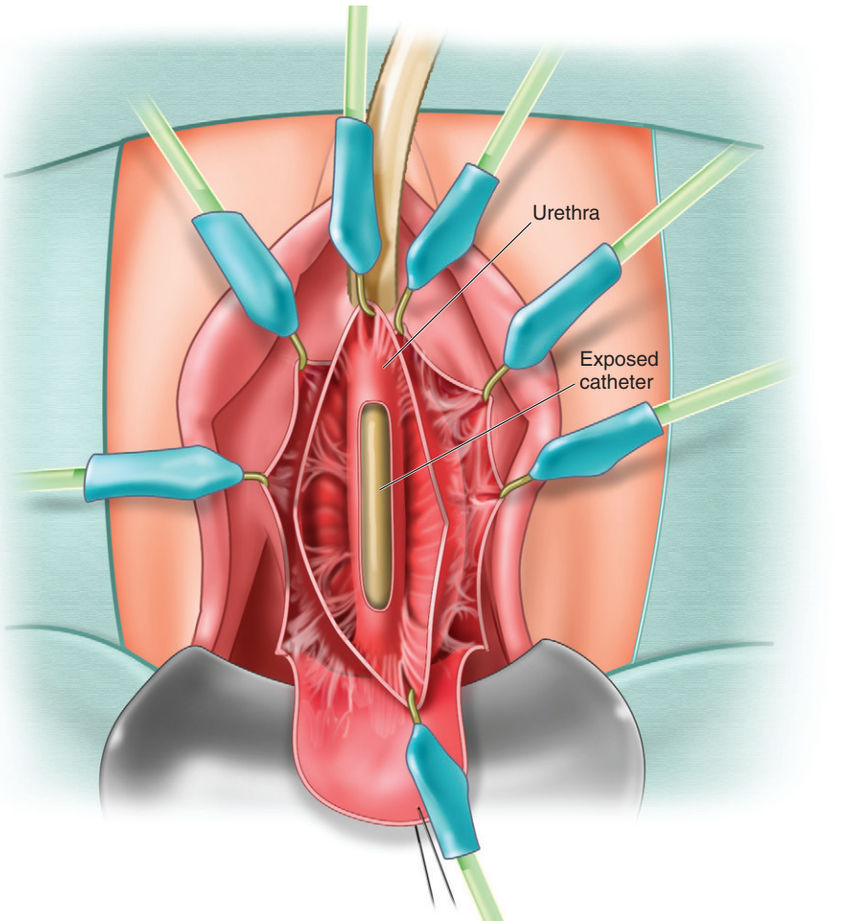

FIGURE 35-4. *(Modified from Nitti V, ed. [2012]. Vaginal surgery for the urologist. Philadelphia: Elsevier-Saunders.)*

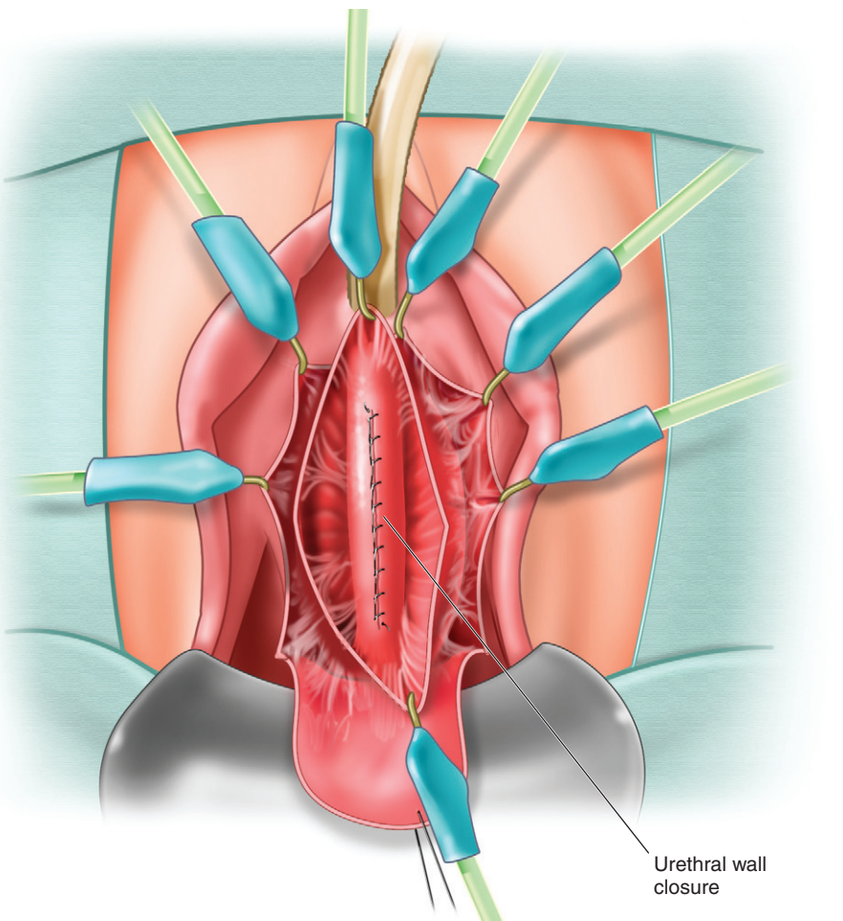

FIGURE 35-5. *(Modified from Nitti V, ed. [2012]. Vaginal surgery for the urologist. Philadelphia: Elsevier-Saunders.)*

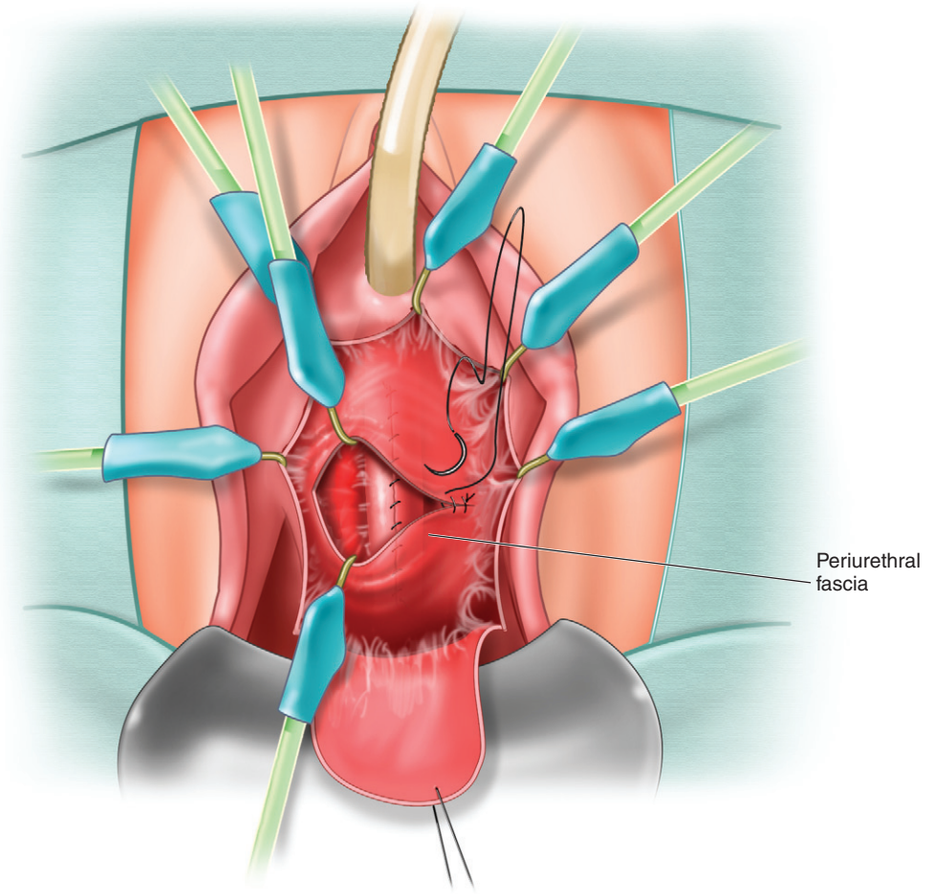

FIGURE 35-6. *(Modified from Nitti V, ed. [2012]. Vaginal surgery for the urologist. Philadelphia: Elsevier-Saunders.)*

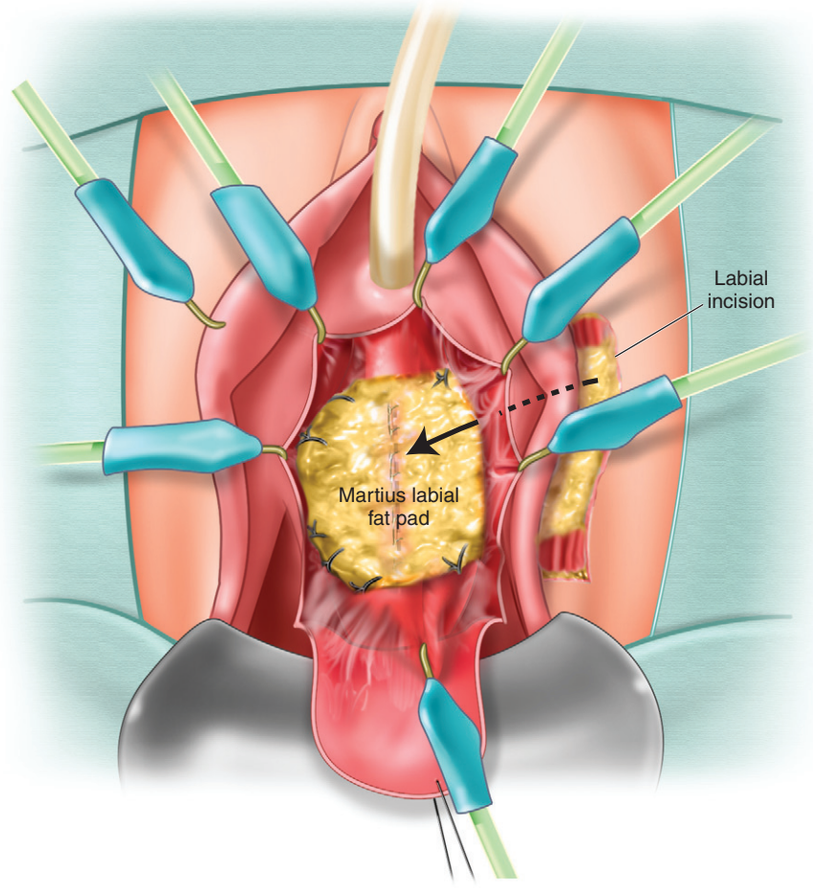

FIGURE 35-7. *(Modified from Nitti V, ed. [2012]. Vaginal surgery for the urologist. Philadelphia: Elsevier-Saunders.)*

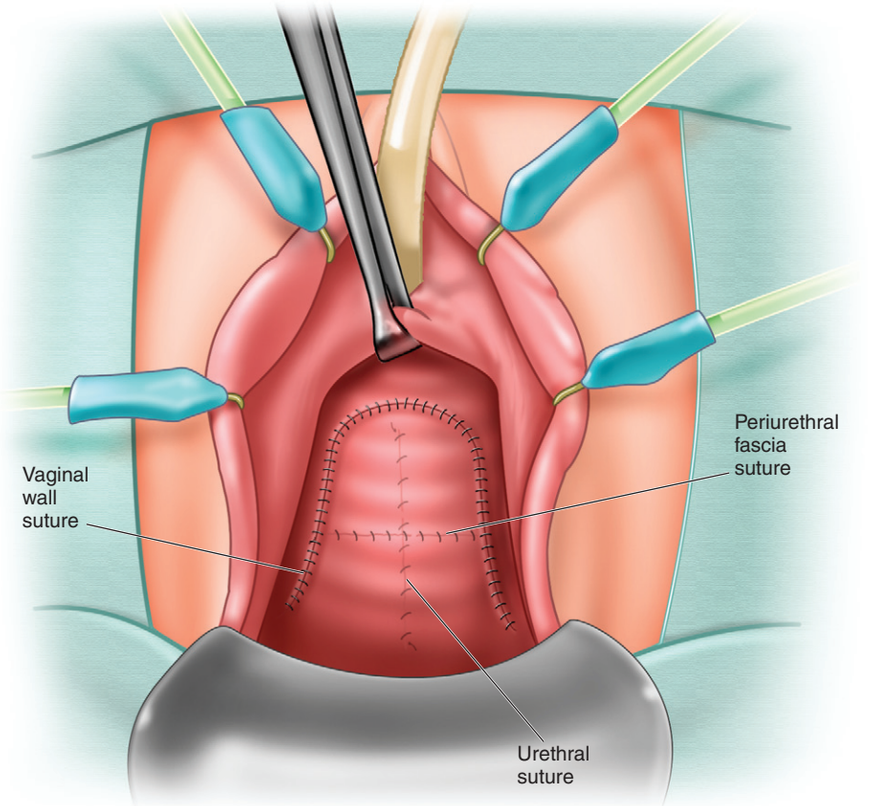

FIGURE 35-8. *(Modified from Nitti V, ed. [2012]. Vaginal surgery for the urologist. Philadelphia: Elsevier-Saunders.)*

The U-shaped incision in the vaginal wall is closed with a 2-0 Vicryl (Fig. 35-8). This method allows for a multilayer closure with avoidance of overlapping suture lines.

POSTOPERATIVE CARE

Postoperative care consists of placing a vaginal pack overnight. The suprapubic and urethral catheters are placed to sterile gravity drainage. Oral anticholinergic medication is given while the catheters are in place. After 10 to 14 days, the urethral catheter is removed and a voiding cystourethrogram (VCUG) is performed by filling the bladder by gravity through the suprapubic tube. Anticholinergic medication is stopped 24 hours before performing the VCUG. When there is no evidence of extravasation on voiding views and the bladder empties to completion, the suprapubic tube is removed. When there is any extravasation noted at the urethral reconstruction site, the suprapubic tube is placed to gravity drainage and repeat VCUG is performed in 7 to 10 days. Reinsertion of the urethral catheter through the repaired urethral is not recommended.

Commentary by

ROGER DMOCHOWSKI

The successful excision of the female urethral diverticulum is one of the most problematic cases in urology and only recently has the full impact of functional outcomes after surgical correction been considered and reported. It is critical in the informed consent discussion that this patient be reminded that she may have continued dribbling of urination due to the urethral closure. She may also have some voiding dysfunction, either persistent stress or de novo urgency, and she may also have persistent urethral pain or dyspareunia that was attributed to the diverticulum but actually may be related to the generalized inflammation of the vaginal wall with now superimposed postoperative fibrosis.

Large diverticula can be approached with a urethral transection type procedure as described by some authors. In this author's experience, the need for that approach is unusual. The most critical aspects during diverticulectomy are identification and amputation of the ostia with adequate closure of these apertures. In some cases, the diverticulum may extend proximally into the retroperitoneum and at some point the decision may be made to amputate the diverticulum, cease dissection, and leave remnant cavity behind. This maneuver is not associated with the recurrence of the lesion. This remnant tissue, however, should be electrofulgurated or laser fulgurated to sclerose the lining of the cavity.

Resection of the diverticulum occasionally may also include a section of the contiguous urethral wall, which may then require urethral mural reconstruction. This should be anticipated when approaching large diverticula, given the fact that a primary closure may cause a urethral stenosis or stricture, which would require subsequent recurrent treatments. Urethral reconstruction may be accomplished with a vaginal mucosal flap or a free flap of buccal mucosa.

One important aspect of diverticular correction is the recognition of concomitant incontinence and the requirement for simultaneous autologous pubovaginal sling at the time of diverticulum closure. Recent guidelines have suggested that the optimal material for slings in this indication is autologous fascia.

Suggested Readings

Aspera AM, Rackley RR, Vasavada SP. (2002). Contemporary evaluation and management of the female urethral diverticulum. Urol Clin North Am 29(3):617-624.

Leach GE, Sirls LT, Ganabathi K, et al. (1993). LNSC3: A proposed classification system for female urethral diverticulum. Neurourol Urodyn 12:523-531.

Ljungquist L, Peeker R, Fall M. (2007). Female urethral diverticulum: 26 year followup of a large series. J Urol 177(1):219-224.

This page intentionally left blank

Chapter 36

Lateral Flap Urethral Reconstruction

JERRY G. BLAIVAS

Position: Lithotomy. Prepare the vagina and perineum. Suture the labia laterally. Insert a 24-French Foley catheter into the bladder, and place a posterior retractor in the vagina.

Incision: Make a U-shaped incision in the distal vagina proximal to the remaining urethral meatus (Fig. 36-1). Undermine the vaginal flaps as little as is necessary, being careful to preserve the blood supply, to allow the edges to meet in the midline without tension over the catheter. Approximate the flaps in the midline with 3-0 chromic catgut (CCG) over the catheter and make an inverted U-shaped incision just proximal to the neourethra (Fig. 36-2). Undermine the inverted U and advance the flap to cover the neourethra and suture it in place with 3:0 CCG (Fig. 36-3). Alternatively, for creation of the neourethra, only half of a U-shaped incision can be used and the flap rotated to become the posterior wall of the urethra and sutured to the opposite lateral edge of the urethral wall.

For added security when blood supply is marginal, or when synchronous pubovaginal sling is necessary, cover the suture line with a Martius flap. When a synchronous sling is done, place the Martius flap between the neourethra and the sling.

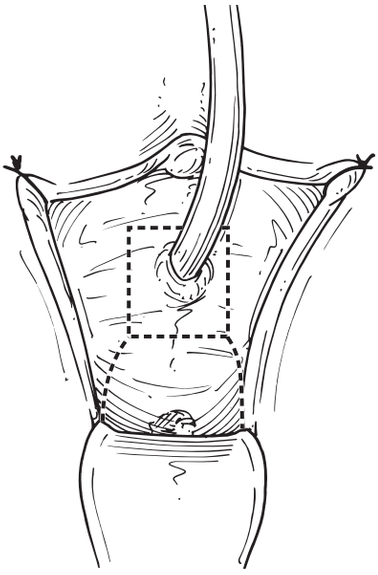

FIGURE 36-1.

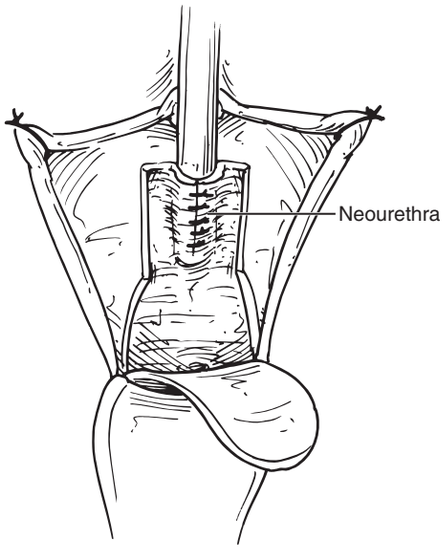

FIGURE 36-2.

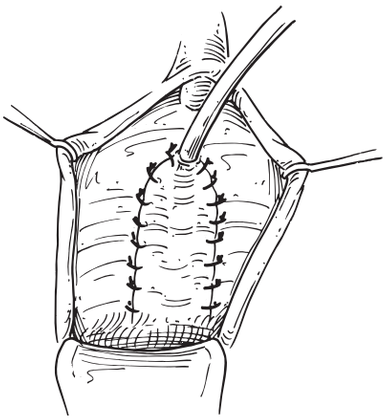

FIGURE 36-3.

Commentary by EDWARD J. McGUIRE

Jerry Blaivas has perfected these procedures by necessity. He sees a lot of them. These are terrible injuries, produced by catheters, long-term catheters, and surgery on or around the urethra. It is possible to reconstruct a urethra from lateral flaps and, depending on how much urethra is lost, the reconstituted urethra may function. If the patient is incontinent, however, and the destruction is total right up to the bladder neck, then a sling should be done at the time of the reconstruction in conjunction with a labial fat pad procedure as Dr. Blaivas has described. In these cases, autologous fascia is clearly the only material one can safely use to compress a reconstructed urethra.

Chapter 37

Urethral Prolapse-Caruncle

EDWARD J. McGUIRE

These conditions result when the urethral mucosa partially prolapses, forming a *caruncle,* or completely circumferentially forms a *prolapse.* Caruncles are bright red, but a full prolapse is bluish, mottled, and very dusky. The surgical objective is resection of the prolapsed redundant mucosa and reconstitution of the normal urethral mucosal-vaginal relationship.

Place a small catheter to aid the dissection. The meatus is hidden to the side of a caruncle and in the middle of a prolapse. If a full prolapse is very edematous, the lumen may not be obvious, but it is there. Grasp the prolapsed mucosa and gently pull it toward you (Fig. 37-1). Sharply incise the prolapsed mucosa circumferentially (Fig. 37-2), and remove it so the normal nonedematous urethral mucosa is visible just inside the external urethral orifice (Fig. 37-3). Using fine absorbable sutures, reconstitute the mucocutaneous junction of the orifice (Fig. 37-4). Take the catheter out. In older women, vaginal estrogen cream aids healing if used for a few days.

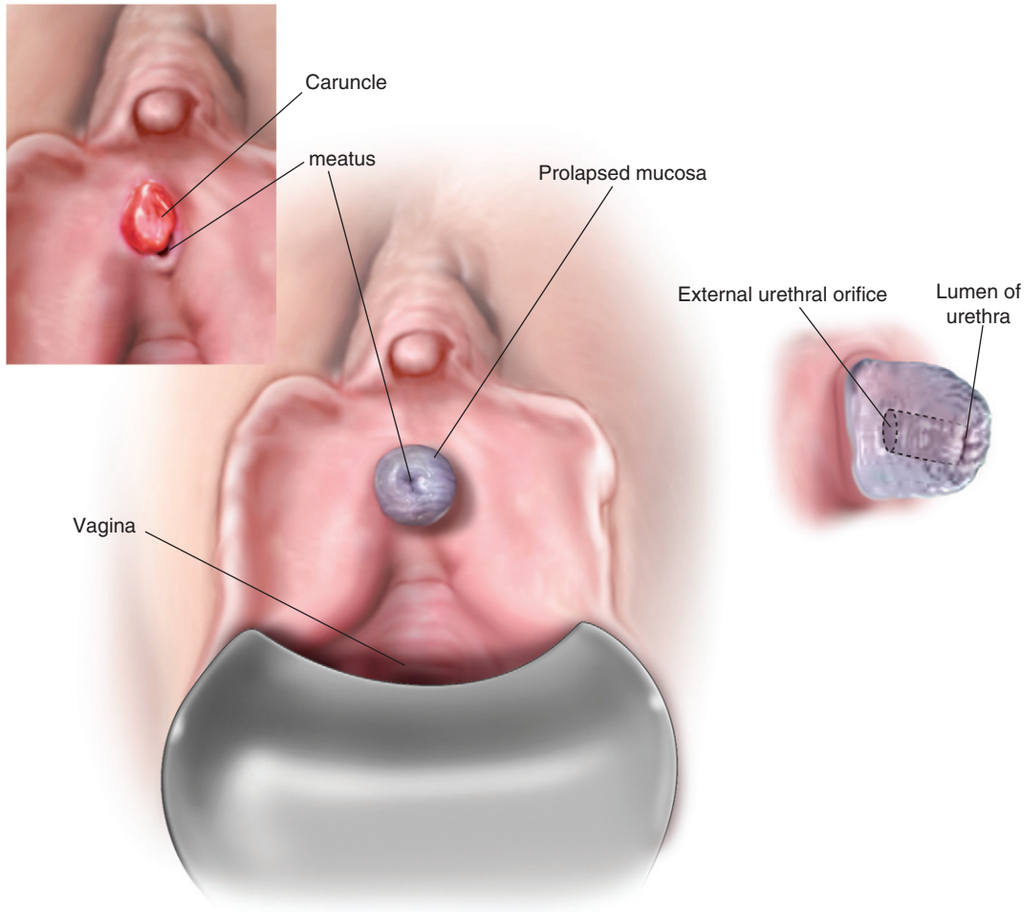

FIGURE 37-1.

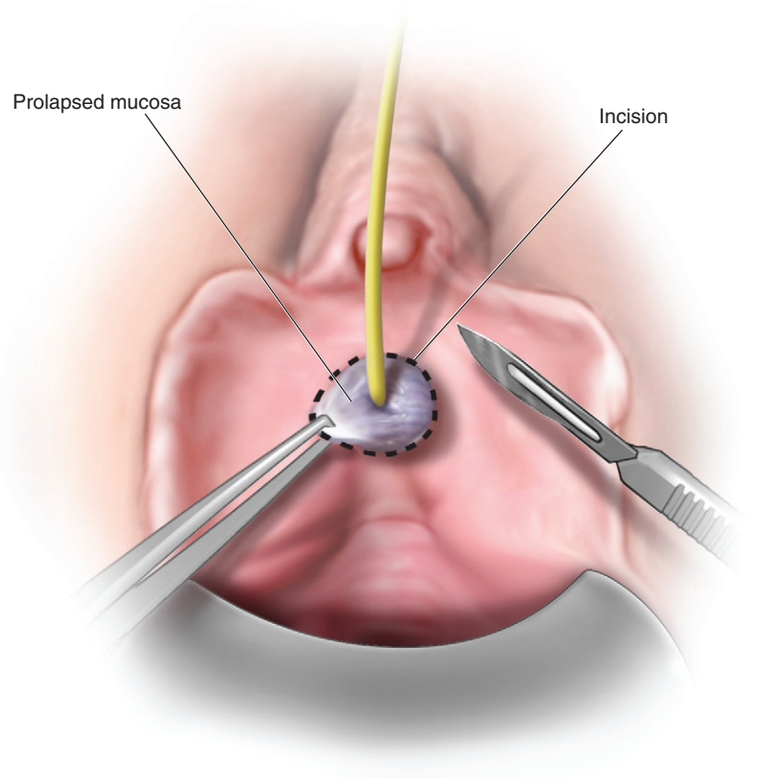

FIGURE 37-2.

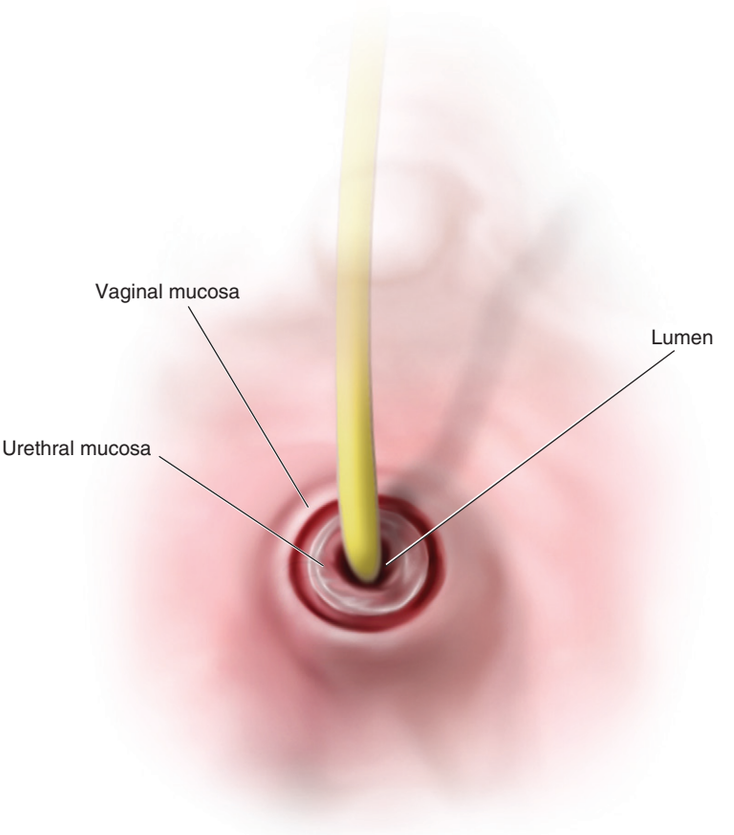

FIGURE 37-3.

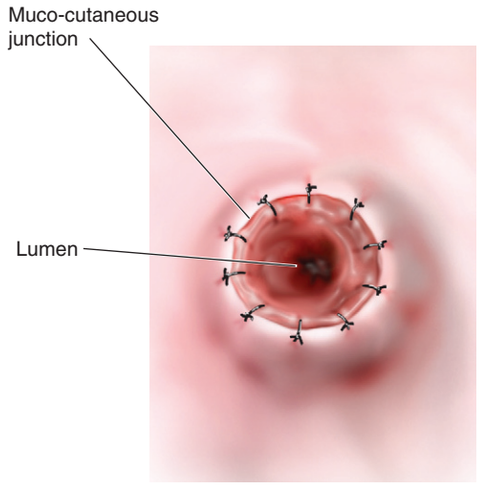

FIGURE 37-4.

This page intentionally left blank

Chapter 38

Cystocele Repair, Enterocele Repair, and Rectocele Repair

KINDRA LARSON, DANIEL M. MORGAN, AND JOHN O. L. DeLANCEY

ANTERIOR COLPORRHAPHY

Cystocele repair is often done concurrently with surgical procedures for stress urinary incontinence to both alleviate symptoms of pelvic organ prolapse and to avoid bladder neck obstruction. This repair is typically performed with the patient in the dorsolithotomy position using candy-cane, yellow-fin, or Allen stirrups. It is crucial to determine whether there is an apical failure that is contributing to the cystocele, because simple anterior repair without resuspension of the vaginal apex in these individuals will increase the patient's chances of recurrent prolapse.

1. Ensure adequate exposure. After performing an exam under anesthesia and before the sterile surgical prep, use an electric razor to shave labial hair that may obscure your field for the anterior repair. After completion of the surgical prep, Foley catheter is placed under sterile conditions. Visualize urine in the Foley tubing to ensure that the bladder is indeed draining. Suture the labia back to the vulva/groin or use a self-retaining vaginal retractor (e.g., the Lone Star or Scott ring) for exposure. A posterior, weighted speculum can also be used to provide exposure of the anterior vaginal wall.
2. Grasp the vaginal wall with two Allis clamps, just off the midline at the proximal portion of cystocele (this can be as high as the cervicovaginal junction in a woman who retains her uterus). This will become the apex of the cystocele repair, which will extend distally to within 1 cm of the urethral meatus (Fig. 38-1).
3. If desired, inject approximately 10 mL of dilute vasopressin (20 units in 50-mL sterile normal saline) subcutaneously in the midline of the anterior vaginal wall where you anticipate your incision location to hydrodissect as well as improve hemostasis. This step is optional and driven by surgeon preference. Other agents used include lidocaine with epinephrine.

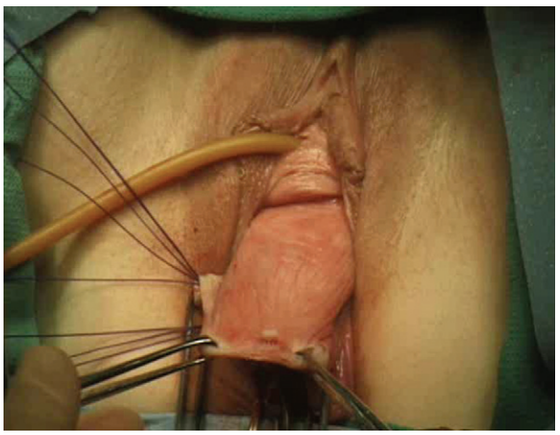

FIGURE 38-1.

4. Make a transverse vaginal incision between the two Allis clamps using a #15 blade scalpel.
5. Using curved Mayo scissors, incise the vaginal epithelium in the midline at the level of the two Allis clamps. Traction with a third Allis clamp in the midline several centimeters distal to the incision can make the subsequent dissection easier.
6. Undermine the vaginal epithelium in the midline distally to the level of the midline Allis by opening and closing the Mayo scissors with tips pointed toward the vaginal epithelium, away from the bladder. This creates a plane between the vaginal epithelium and underlying fibromuscular tissue, including both vaginal muscularis and fascial tissue referred to by several different names—pubovesical, pubocervical, or endopelvic fascia (Fig. 38-2).
7. Incise the vaginal epithelium in the midline in this undermined area to the level of the midline Allis. Place two additional Allis clamps, one to either side of the incised tissue, and move the midline Allis several centimeters distally to provide traction for the next segment.

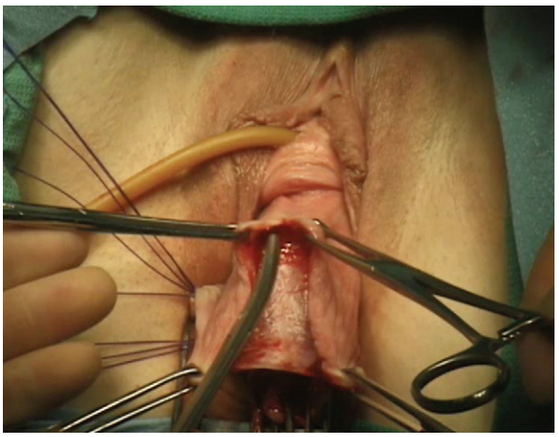

FIGURE 38-2.

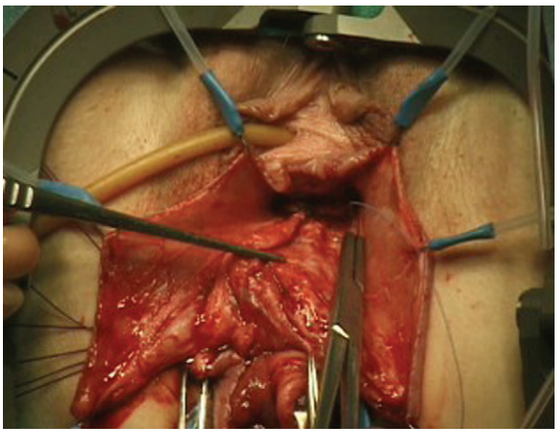

FIGURE 38-4.

8. Repeat the above process until the anterior vaginal wall midline incision extends from the apex (defined by your initial two Allis clamps) to within 1 cm of the urethral meatus (Fig. 38-3).
9. Place your nondominant finger on one side of the vaginal epithelium and simultaneously with the same hand provide traction on the ipsilateral, distal Allis. You can then reflect the excised vaginal epithelium over this finger, and using Metzenbaum or Church scissors sharply separate the vaginal epithelium from underlying fibromuscular tissue. It often helps to have your assistant provide countertraction medially on the bladder and fibromuscular tissue during this step (Fig. 38-4). Once the dissection is initiated sharply, blunt dissection with a four-by-four sponge can be used if the plane pushes easily; otherwise, one can continue with sharp dissection. This dissection is continued laterally until equal to the level of the hymen. This dissection is continued distally to within 1 cm of the urethral meatus.
10. This process is repeated on the other side.
11. Using 3-0 polydioxanone or 2-0 polyglactin (or other surgeon preference for absorbable or delayed-absorbable suture), drive your needle through the fibromuscular tissue, just medial to the lateral groove developed between the vaginal epithelium and fibromuscular tissue. Bring the suture across the midline and repeat the process in the opposite direction on the contralateral side, creating a modified mattress stitch that will plicate the fibromuscular tissues (Fig. 38-5). This will be tied in the midline without tension on the Allis clamps. A modification of this step is to include shallow portion of the fibromuscular tissue in your stitch as you bring it across the midline. It is important to stay shallow to avoid incorporating the bladder using this technique.
12. Continue placing interrupted plicating stitches along the length of the cystocele repair. Ensure that each subsequent stitch abuts the prior stitch so that no gaps in support are present.
13. Incorporate the vaginal epithelium in the apical plicating stitch, and hold this stitch with a surgical snap or hemostat to provide traction.
14. Replace the Allis clamps along the edges of the vaginal epithelium to allow fanning of the epithelium with equal tension, usually requiring 3-4 Allis clamps

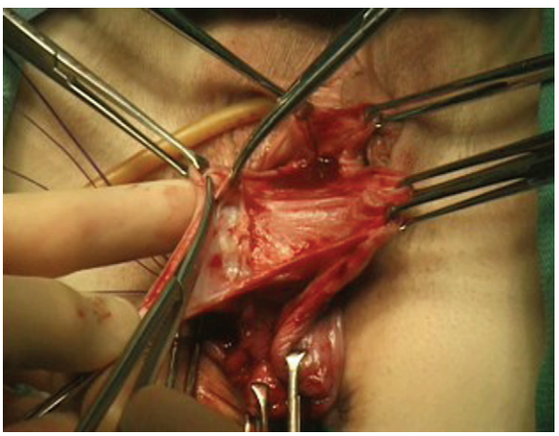

FIGURE 38-3.

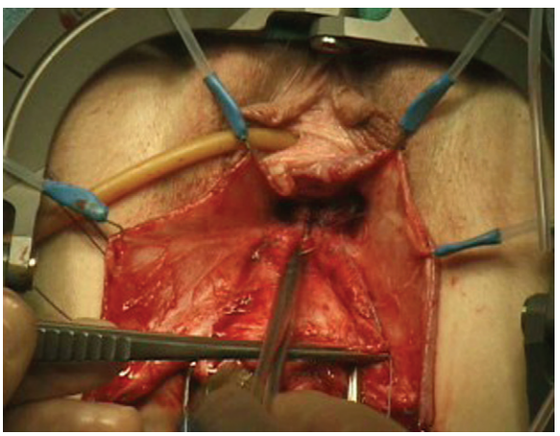

FIGURE 38-5.

distributed evenly along the length of the cystocele repair.

15. Trim both edges of the vaginal epithelium with curved Mayo scissors, starting at the apical Allis clamp and moving toward the distal Allis near the urethral meatus. The trimmed portion of the tissue should get more narrow as you move distally (Fig. 38-6).
16. With countertraction on both ends of the cystocele incision, close the vaginal epithelium with 2-0 or 3-0 polyglactin (or other absorbable suture). You can use a running stitch or interrupted stitches (Fig. 38-7). Interrupted sutures decrease the amount of vaginal shortening that occurs with the closure.
17. A modification of the procedure described above, involves the incorporation of graft material into the repair instead of plicating the fibromuscular tissue. This technique is used when there is not significant fibromuscular tissue, but must be weighed against the known complications of dyspareunia and mesh/graft erosion. The graft material is anchored at the apex and distal end of the repair and is sutured to the lateral margins of the dissection. Vaginal epithelium is then closed over this as described earlier for the traditional repair.

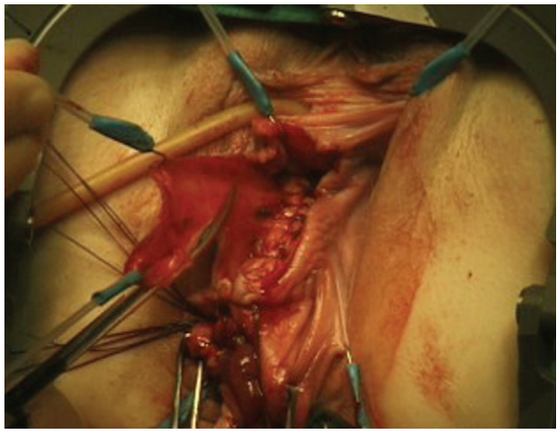

FIGURE 38-6.

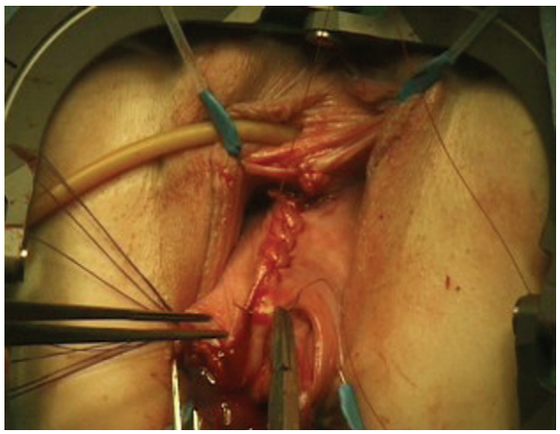

FIGURE 38-7.

18. Perform cystoscopy after completion of the anterior colporrhaphy to ensure that no stitches are in the bladder mucosa and that the ureters are still patent. Intravenous indigo carmine can help visualize the ureteral jets.

CONCURRENT ENTEROCELE REPAIR

Enterocele repairs are typically performed in conjunction with other types of repairs (i.e., commonly with apical suspensions) and may be performed vaginally or abdominally. This section outlines the steps to the vaginal type of repair—a high enterocele sac ligation and reincorporation of uterosacral/cardinal ligament complex into the apex.

1. Once an enterocele sac is encountered in conjunction with the dissection for an anterior or more commonly posterior repair, grasp the edges of the sac using 2 Tonsil clamps.
2. Demonstrate transparency of the layers and palpate the sac to ensure no bowel is present.
3. Incise the enterocele sac.
4. Explore the sac to determine that intraperitoneal access has been obtained, and to assess for adhesions.
5. If the bowel protrudes into the sac, moisten a laparotomy sponge and pack the bowel out of the field. Tag the laparotomy sponge with a surgical snap.
6. Place a Wilson retractor gently into the enterocele sac and expose the posterior portion of the sac. Countertraction on the peritoneum with an Allis or Tonsil can be helpful for visualization (Fig. 38-8).
7. Use nonabsorbable suture to perform a pursestring stitch around the base of the enterocele sac (Fig. 38-9). This should extend up into the peritoneal cavity to ensure that you are ligating the entire hernia sac; however, care must be taken to avoid bowel or ureteral injury. Moving the Wilson to the position opposite of where you are attempting to place the pursestring stitch can provide better visualization. If the uterosacral

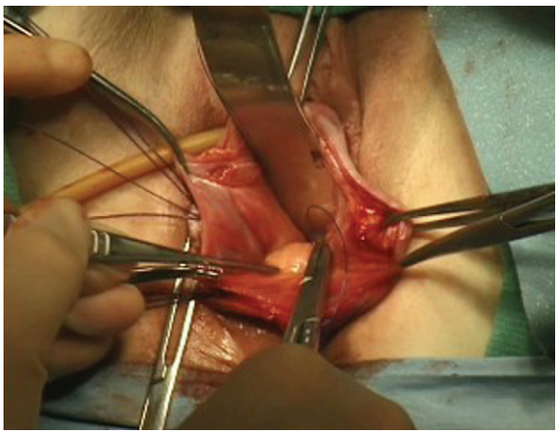

FIGURE 38-8.

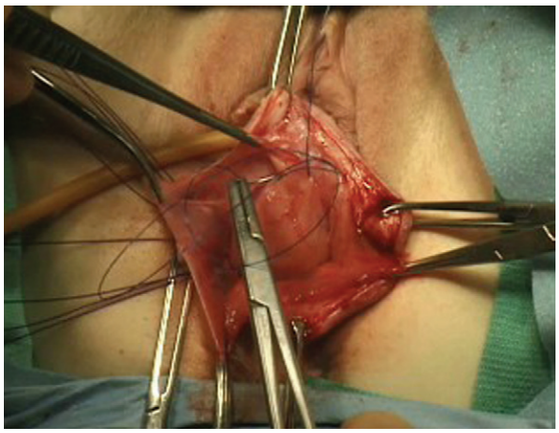

FIGURE 38-9.

ligaments (best visualized on upward tension) are visualized at this step in the procedure, you can incorporate them into the pursestring.

8. Before tying the suture in step 7, a second permanent pursestring can be placed.
9. Place a finger into the enterocele sac; with the finger in place, remove the bowel pack (if placed).
10. Tie the proximal pursestring suture, removing the intraperitoneal finger as the knot is clinched down to ensure that no bowel is incorporated into the closure (Fig. 38-10).
11. Tie the distal pursestring suture.
12. Continue with concurrently planned procedure (anteroposterior colporrhaphy/apical suspension) resulting in closure of the vaginal epithelium over the closed enterocele sac. At this stage, we typically incorporate the uterosacral/cardinal ligament complex into the apical closure to re-establish apical support. For example, if concurrent hysterectomy is performed, we perform a Richardson angle stitch.
13. Cystoscopy should be performed at the end of the procedure to ensure ureteral patency because uterosacral involvement can result in "kinking."

POSTERIOR COLPORRHAPHY

Rectocele repair is often done concurrently with other surgical procedures for pelvic organ prolapse. This repair is typically performed with the patient in the dorsolithotomy position using candy-cane, yellow-fin, or Allen stirrups. When determining the appropriate method for repair of a rectocele, it is crucial to determine if there is an apical failure that is contributing to its size. Simple rectocele repair without resuspension of the vaginal apex in these individuals will increase the patient's chances of recurrent prolapse. The steps that follow outline a midline plication of the fibromuscular tissue in the posterior wall and do not address "site-specific" repairs.

1. Ensure adequate exposure. After performing an exam under anesthesia and before the sterile surgical prep, use an electric razor to shave labial hair that may obscure your surgical field. After completion of the surgical prep, Foley catheter is placed under sterile conditions. Visualize urine in the Foley tubing to ensure that the bladder is indeed draining. Suture the labia back to the vulva/groin or use a self-retaining vaginal retractor (e.g., the Lone Star or Scott ring) for exposure. If additional exposure of the posterior wall is needed, a Wilson or Deaver retractor can be placed along the anterior wall.
2. Place two Allis clamps at the level of the hymen along the posterior wall to identify the lateral margins of the placation (Fig. 38-11).
3. Test the degree of vaginal narrowing by bringing the Allis clamps together in one hand and placing 2 fingerbreadths in vagina. If the vagina is tight against your fingers or if the vagina is too loose around your fingers, adjust the Allis clamps appropriately and retest.
4. Grasp the proximal end of the rectocele in the midline using an Allis clamp.
5. Using a #15 blade scalpel, incise a triangle in the posterior vaginal wall epithelium using your three Allis clamps as your triangle corners (Fig. 38-12). If concurrent perineorrhaphy is indicated, instead of making a transverse incision along the posterior fourchette between the distal Allis clamps to form the base of the

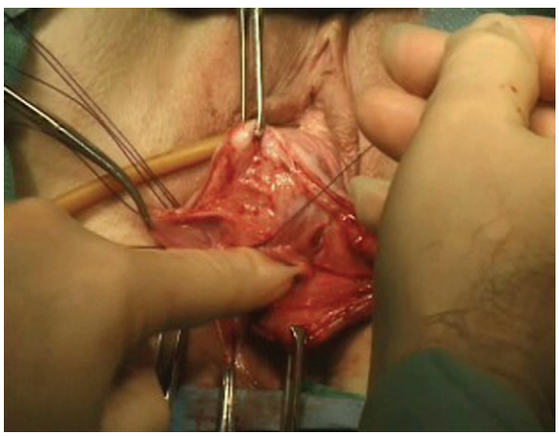

FIGURE 38-10.

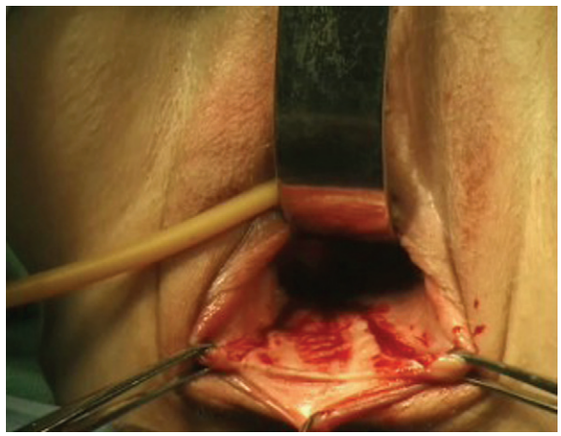

FIGURE 38-11.

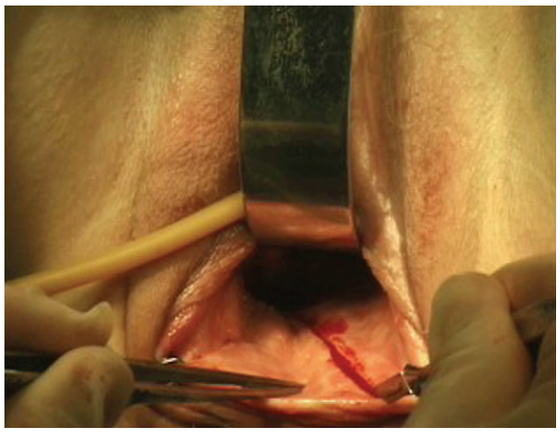

FIGURE 38-12.

triangle, create a triangle incision in the skin overlying the perineal body.

6. Grasp the distal portion of the incision (either the transverse incision forming the base of the triangle or interior point of the perineal incision) with an Allis clamp and elevate the epithelium. Using a #15 blade scalpel, dissect the epithelium off of the perineal body muscles (if perineorrhaphy included) and the fibromuscular tissue—also called the perirectal, rectovaginal, endopelvic, or Denonvilliers fascia. This excises the vaginal epithelium within the triangle on the posterior vaginal wall. Upward traction on the epithelium is critical during this portion of the dissection (Fig. 38-13). Some surgeons also prefer to perform this and subsequent steps 7 through 10 with one finger in the rectum to better identify the proximity to the rectal wall.
7. The suture (2-0 polyglactin or other surgeon preference for absorbable suture) is anchored through the vaginal epithelium at the proximal portion of the rectocele repair. This needle is then protected and put aside for closure of the vaginal epithelium at a later time.
8. Place downward traction on the exposed rectocele using a finger on the nondominant hand. This not only moves the rectum away from the suture plane, but also helps identify the lateral attachments of the fibromuscular tissue.
9. Starting at the apex of the rectocele repair, drive the 2-0 polydioxanone suture (or other surgeon preference for delayed absorbable suture) through the lateral fibromuscular tissue in a plane horizontal to the posterior vaginal wall, bring it across the midline, and perform the same stitch on the opposite side (Fig. 38-14). Continue placing these sutures, plicating fibromuscular tissue in the midline as you move distally on the rectocele, until you reach the posterior fourchette. As you move more distally on the rectocele, each suture incorporates more tissue in order to reconstruct the normal caliber of the vagina without creating a shelf in the posterior wall. Avoid plicating the levators in the midline of a sexually active woman to decrease the likelihood of postoperative dyspareunia.
10. If perineorrhaphy is indicated, reapproximate the superficial and deep transverse perineal muscles as well as the bulbocavernosus muscles with interrupted 2-0 polydioxanone sutures. We prefer to bury our knots on the portion of this repair to minimize postoperative discomfort associated with suture ends protruding through the perineal skin.
11. Close the vaginal epithelium by running the 2-0 polyglactin suture that was anchored to the apex in step 7 (Fig. 38-15). Ensure closure of dead space by including

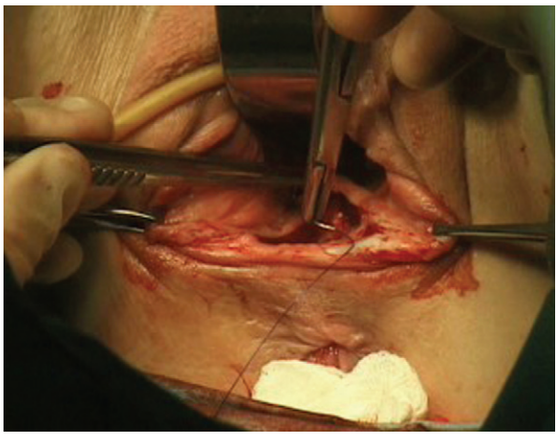

FIGURE 38-14.

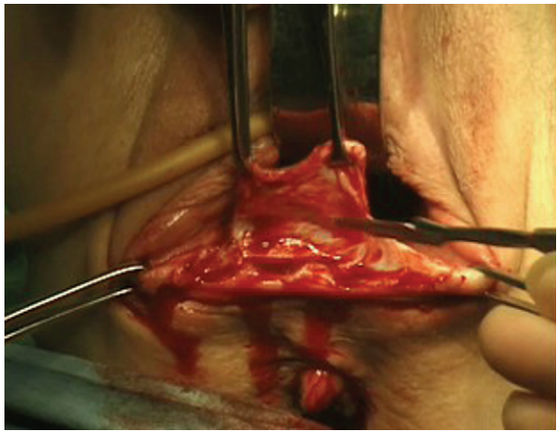

FIGURE 38-13.

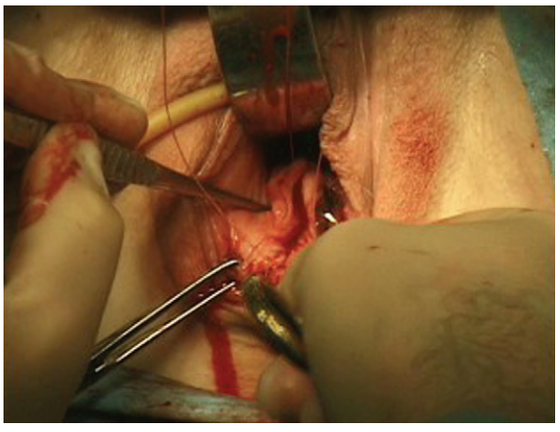

FIGURE 38-15.

the fibromuscular plication in the running epithelium closure. After reapproximating the vaginal wall to the level of the hymen, if perineorrhaphy was performed, subcutaneous closure of the skin over the perineum is then completed using this same suture.

12. Perform careful rectal examination with attention to presence of suture in the rectal mucosa along the length of the repair.
13. A modification of this procedure includes the use of graft material to augment the repair. Data from a randomized controlled trial comparing standard repair, site-specific repair and augmentation with porcine craft illustrated worse anatomic outcomes in the graft augmentation group.
14. Counsel the patient regarding the importance of avoiding excessive straining with defecation. Stool softeners, mineral oil, and fiber supplementation can be tried to find a regimen allowing for regular soft bowel movements.

Suggested Reading

Paraiso MFR, Barber MD, Muir T, Walters M. (2006). Rectocele repair: a randomized trial of three surgical techniques including graft augmentation. Am J Obstet Gynecol 195:1762-1771.

Chapter 39

The Michigan Four-Wall Sacrospinous Suspension

JOHN O. L. DeLANCEY

Vaginal vault eversion following hysterectomy is a serious condition that leads to significant patient distress. Because of its challenging nature, it is frequently seen in referral centers. Over the last 50 years, several techniques have emerged as effective treatment for this condition. The most popular of these techniques include sacrospinous ligament suspension, abdominal colposacropexy, uterosacral ligament suspension, and colpocleisis.

In 1973, Dr. George W. Morley, MD, first performed a unique modification of the classic sacrospinous suspension that has come to be known as the Michigan four-wall suspension. Over the intervening 35+ years it has been used at our institution on more than 1000 cases with excellent surgical results in more than 90% of patients.

HOW DOES MICHIGAN FOUR-WALL SACROSPINOUS LIGAMENT SUSPENSION DIFFER FROM TRADITIONAL SACROSPINOUS TECHNIQUES?

The Michigan four-wall technique is a completely different operation than the traditional sacrospinous suspension except that the sacrospinous ligament is used as a suspension point. The three key differences are listed in Table 39-1. This approach begins with the initial incision at the vaginal apex as opposed to a posterior colporrhaphy incision. In the Michigan four-wall technique, the anterior, posterior, left, and right walls of the vagina are attached to the ligament so that all four are equally suspended. (In conventional methods, typically only the posterior wall is suspended.) Thus the technique prevents the formation of an anterior enterocele and prevents sagging of the contralateral vaginal apex—two common problems of traditional approaches to sacrospinous suspension.

As mentioned previously, the initial incision is made at the vaginal apex, where, if necessary, excess vaginal tissue is excised. This normalizes the length of the vagina so that all four walls reach the ligament. It also eliminates the sagging that can occur when the vagina is longer than the distance between the introitus and ligament. Making this incision creates a vaginal cuff similar to that seen at the time of vaginal hysterectomy. In addition, because it resuspends the anterior and posterior vaginal walls, anterior enterocele, which occurs with the traditional technique, is prevented.

Figure 39-1 demonstrates these points. The key is to ensure that the length of each vaginal wall (anterior, posterior, and lateral) is the same as the distance to the point on the ligament where the suspension sutures will be placed.

TABLE 39-1 KEY DIFFERENCES BETWEEN THE MICHIGAN FOUR-WALL AND TRADITIONAL TECHNIQUES

Michigan 4-Wall Modification	Traditional Technique
Begins at vaginal apex and excises redundant length	Begins through posterior colporrhaphy incision
Attaches the full width of the anterior, posterior, left and right vaginal wall	Attaches the left posterior vaginal wall to the ligament
Sews the cut edge of the vaginal cuff to the ligament, where it heals directly to the ligament	Depends on a permanent suture to hold the posterior vaginal wall in place

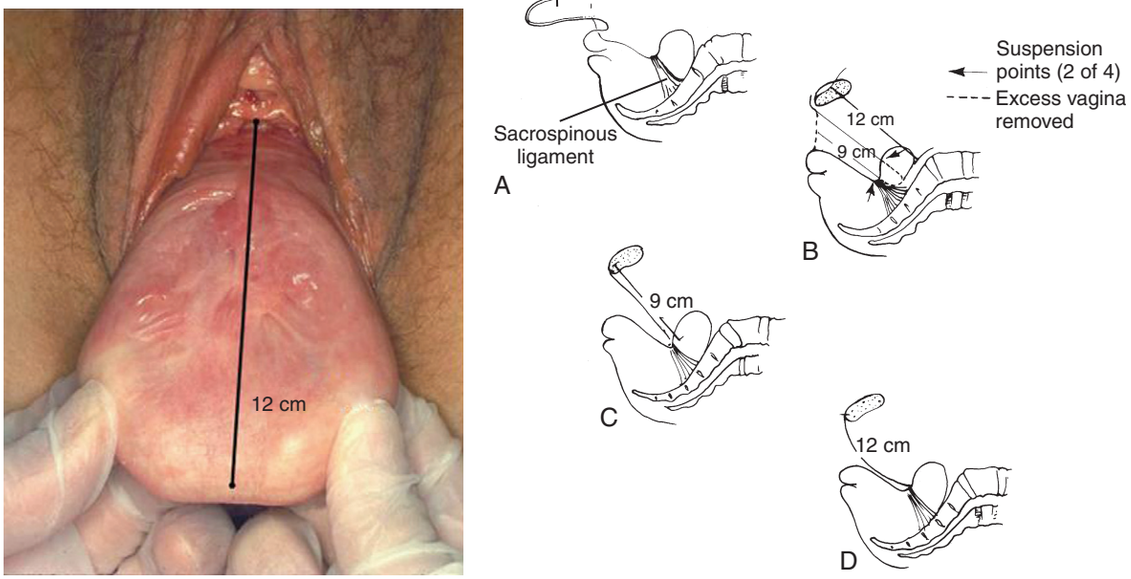

FIGURE 39-1. Vaginal vault eversion demonstrating elongation from chronic distention where the vagina is 12 cm long (left panel) while the distance to the sacrospinous ligament is 9 cm. The need to excise is demonstrated in the panels to the right. The everted vagina is shown in **(A).** When replaced, the vagina is longer than the distance to the sacrospinous ligament **(B).** Anterior and posterior suspension points are selected *(arrows)* and excess vagina excised *(gray)* to result in proper suspension **(C).** If vagina is not removed **(D),** sagging of the anterior vaginal wall (for example) occurs.

ADVANTAGES OF MICHIGAN FOUR-WALL TECHNIQUE

There are several key concepts underlying this technique (Table 39-2). The attachment of the anterior wall to the ligament avoids the anterior enterocele that occurs after the traditional sacrospinous due to the fact that the vaginal wall anterior to the suspension point could prolapse as it was not suspended. In addition it avoids prolapse of the contralateral wall that has led to bilateral sacrospinous techniques. This cuts in half the number of bleeding problems and lessens postoperative pain that can arise at the suspension sites when the surgeon to perform the ligament dissection and suture placement on both the left and right sides. The cut edge of the open apex is directly attached to the sacrospinous ligament, allowing the apex to heal to the ligament. By using absorbable suture, suture-related pain resolves with resorbtion, avoiding the occasional need to return to the operating room to remove a painful suture.

This open cuff is sewn directly to the sacrospinous ligament so that the cut surface can heal to the ligament, eliminating the need for a nonabsorable suture and allowing a firm and permanent union to form between the full width of the vaginal apex and the ligament. Suture-related postoperative pain resolves when the suture dissolves.

TABLE 39-2

PRINCIPLES UNDERLYING THE MICHIGAN FOUR-WALL APPROACH

Principle	Explantion
All 4 vaginal walls are suspended	Prevents an anterior enterocele and sagging of the contralateral side
Customizable apex location and vaginal length adjustment	Optimally suspends all 4 walls with equal support and tension
A new vaginal cuff is sewn to the ligament	Provides a broad area where the vaginal apex heals to the ligament, yielding a durable result, and avoids the need for permanent sutures

OPERATIVE TECHNIQUE

The first and most critical step is to decide where the apex should be centered and how much excess vaginal length should be removed (see Fig. 39-1). Estimate the distance between the introitus and the sacrospinous ligament (typically between 8 and 10 cm) and place an Allis clamp on the vaginal wall at this distance from the introitus—one clamp on each wall. These clamps mark the estimated new lengths of the anterior, posterior, left, and right vaginal walls and define the portion of the vagina that will be excised (Fig. 39-2). This first placement is a rough approximation and should be adjusted before making the initial incision.

To determine whether refinements in clamp placement are necessary, test each clamp against the ligament. If a clamp will not reach the ligament, it should be moved so that less vagina is removed. Simply regrasp the vagina further from the introitus until the clamp can be brought to the ligament without undue tension. Conversely, if elevating the clamp to the ligament does not adequately reduce vaginal sagging, the clamp should be moved closer to the introitus. Repeat this process with each clamp until all four reach the ligament and support the vagina (see Fig. 39-2B, C). This usually results in an asymmetrically placed apex, because only one of the two sacrospinous ligaments is used to suspend the vagina in this technique (usually the right). Therefore the right vaginal wall will be slightly shorter than the left.

The placement of the clamps—and with them the new vaginal apex—vary with each patient, in that a wide variety of vaginal-vault prolapse exists. In some, the cystocele predominates, with the anterior vaginal wall becoming greatly elongated. In others, the enterocele is dominant, with less anterior wall defect. Nonetheless, in all women, each of the four vaginal walls must be suspended with just the right amount of elevation. For example, in a woman with a large enterocele and a previous anterior colporrhaphy that has shortened the anterior vaginal wall, the point of the vagina that would best approximate the ligament lies posterior to the hysterectomy scar. In such a case, the new apex would lie entirely on the posterior wall of the vagina.

The relation between the new apex and the hysterectomy scar is unimportant, regardless of the type of vaginal-vault prolapse present. What is crucial is ensuring that all four vaginal walls are supported with equal tension and that sagging is resolved.

Once the new vaginal apex is appropriately placed, excise the intervening vaginal wall through its full thickness, including both the mucosa and the fascia (Fig. 39-3). Care should be taken not to dissect the fascia off of the remaining vaginal mucosa because both the fascia and the mucosa need to be suspended to the sacrospinous ligament at the end of the operation.

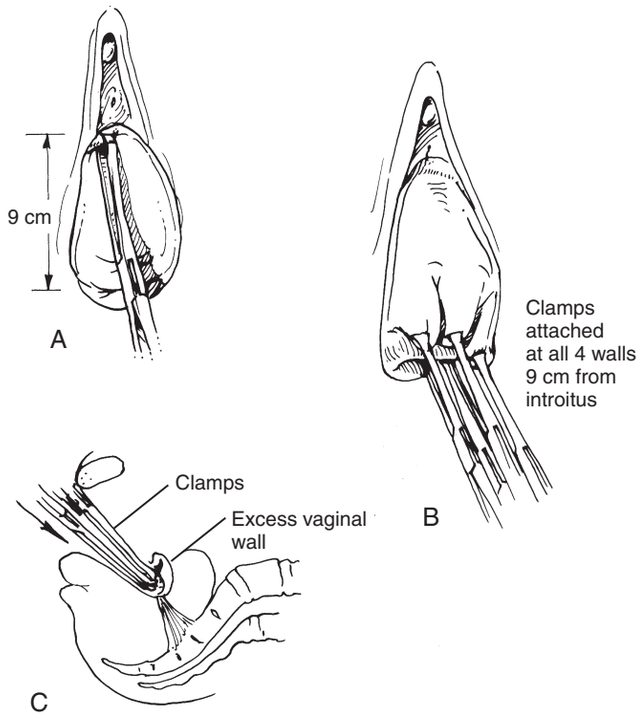

FIGURE 39-2. An Allis clamp is placed at a point on the vaginal wall 9 cm from the introitus **(A).** The similar placements are made for the other four clamps. The intent of this step is to have each clamp placed at a point on the vaginal wall so that when it is suspended to the ligament there is no sagging and that it will reach the ligament without undue tension. To ensure correct clamp placement before the intervening vagina is excised, the clamps are clustered together **(B)** and then tested against the ligament **(C).** If one or more of the clamps do not reach the ligament, then it is replaced further from the introitus. If the vaginal wall still is slack when the clamp is held against the ligament, then it is placed on the vagina at a distance that eliminates the slack.

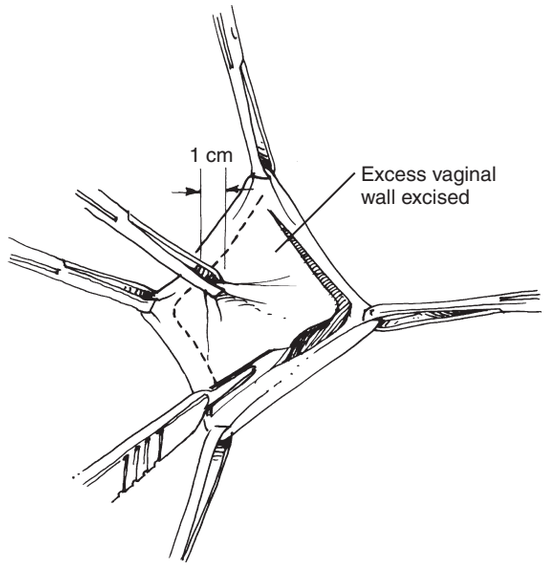

FIGURE 39-3. The intervening vaginal wall is then excised. The incision is placed approximately 1 cm inside the clamps. This provides a width of vaginal wall into which the sutures can be placed during resuspension.

The next step is to identify and enter the enterocele sac, which typically is found posterior to the hysterectomy scar. It is easily located in cases where a large pulsion enterocele is present. After the enterocele sac has been opened, perform blunt dissection between it and the vaginal wall all the way down to the sacrospinous ligament (Fig. 39-4). This retroperitoneal plane should dissect easily, even in women who have undergone prior surgery. When a large cystocele is present, the peritoneum may not be distended. In these instances, the peritoneum need not be entered and the retroperitoneal plane can be dissected adjacent to the vaginal wall. If the apical incision is considered a clock fact, the proper plane is typically located at the 7:30 position. It is immediately adjacent to the peritoneum and is located dorsal to the remnants of the cardinal and uterosacral ligaments, which can be identified by placing an Allis clamp on the "dimple" in the vaginal wall making downward traction and palpating the ligaments that have been put on tension by this maneuver.

Enlarge the opening made during this dissection with two narrow malleable or Briesky retractors. Once the tissue overlying the coccygeus muscle and its contained sacrospinous ligament is reached, pierce this "rectal pillar" with a long sharp-tipped instrument such as a Crawford clamp and directly expose the coccygeus muscle that lies on the inner surface of the sacrospinous ligament. It is best to start below the ligament and push the tip upward to reach the target. If the tip is placed over the ligament, it may pass too far cephalad before gaining entry to the proper space.

Branches of the internal iliac vessels and the sacral plexus of nerves lie immediately above the upper margin of the ligament. For this reason it is wise to avoid dissecting too far cephalad. The inferior gluteal vein is close to the ligament and overly vigorous retraction or dissection can cause substantial hemorrhage in this area.

All loose connective tissue should be cleared off the muscle so that direct healing between the vaginal apex and the ligament can occur (Fig. 39-5). The muscle need not be stripped off of the ligament. When the proper space has been entered, the fascia over the coccygeus muscle has the slippery feel of a wet surgical glove. Care should be taken during this step to avoid injuring the rectum. An examining finger may be placed in the rectum to outline its lateral margin before this step if necessary.

We have found that a Deschamps ligature carrier works well for this part of the procedure, because it makes it possible to obtain a deep bite of muscle so that the suture can be embedded in the ligament. Pass the tip of the ligature carrier through the ligament so that it emerges 1 fingerbreadth from the ischial spine. If only the superficial coccygeal muscle is grasped, the ligature carrier moves relative to the patient when it is pushed inward or pulled outward. This superficial tissue and the overlying fascia may at first seem strong, but such suture placement should not be accepted if a high success rate is desired. Instead, make a bite deep enough to include the lower half of the wood-hard ligament. Doing so is one of the keys to success; therefore it must be accomplished even if it necessitates removing the ligature carrier and inserting it again.

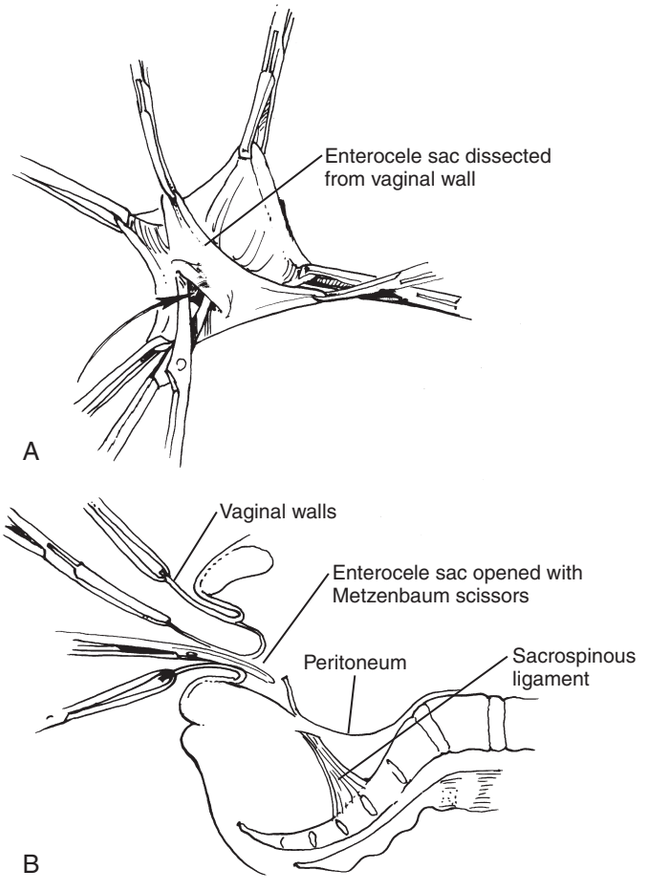

FIGURE 39-4. Two hemostats are pulling the edges of the opened enterocele sac away from the vaginal wall and Metzenbaum scissors are used to spread into the retroperitoneal plane **(A).** Finger dissection is used to open and enlarge this retroperitoneal space. Countertraction with a narrow malleable retractor can be used to help place the tissues on effective tension.

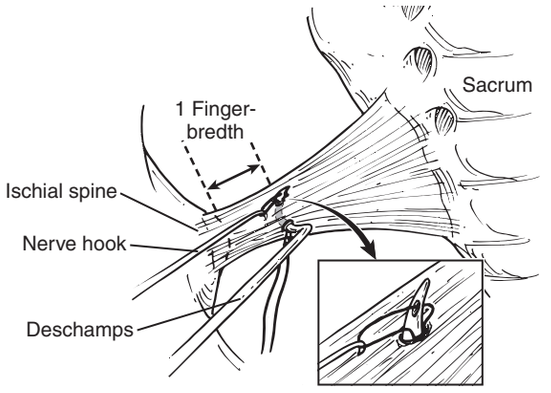

FIGURE 39-5. The loose areolar tissue that overlies the coccygeus muscle and sacrospinous ligament are opened with a Crawford clamp. Once this opening has been made, a Deschamps ligature carrier is passed through the muscle and its underlying ligament **(B).** A nerve hook is then used to retrieve the suture as demonstrated. When this retrieved loop is cut, two strands of suture pass through the same point on the ligament.

With the ligature carrier inserted in the ligament, retrieve the suture loop and hold it in place while removing the instrument. Cut the loop to obtain two strands of suture that pass through one point in the ligament. Repeat this process with a second pass of the ligature carrier a few centimeters either medial or lateral to the first depending on where the ligament is the most favorable and again retrieve and divide the suture loop. This results in four sutures being placed in the lower half of the sacrospinous ligament (Fig. 39-6). Mark the two ends of each hemostatic clamp. For example, the first pair can be marked with a standard hemostat (Crile); the next can be marked with a pair of tonsil forceps; the third can be marked with a pair of Heaney clamps and the fourth, with a pair of Kelly clamps. Attach these clamps to the adjacent drape to hold the sutures until they are needed. (These suture strands eventually will be placed through the edges of the vaginal cuff, with one end of each strand placed through the anterior cuff and one through the posterior cuff. However, this should not be done until the enterocele is closed with a pursestring suture of 2-0 polypropylene and the anterior colporrhaphy is completed.)

If an anterior colporrhaphy is needed, it should be performed as it would be during a vaginal hysterectomy before tying the apex up to the ligament. This can be done in the same way that an anterior repair is started at the time of vaginal hysterectomy, by beginning at the anterior portion of the vaginal incision. If the entire apical incision is on the posterior vaginal wall, the dissection still starts at the 12-o'clock position of the cuff and extends toward the urethra, recognizing that the initial part of this dissection occurs on the vaginal wall that is posterior to the hysterectomy scar.

We use a Bonney stitch (often referred to as a Kelly plication) to grasp the tissue that is attached to the pubic bones. This supports the urethra. In approximating the remainder of the vaginal fascia, we prefer interrupted sutures because a running suture may shorten the anterior vaginal wall and make it difficult for the anterior cuff to reach the sacrospinous ligament. Using this strategy our stress incontinence rate after surgery has been approximately 5%. If a midurethral tape is needed, the surgeon can insert it in the same way as if proceeding with repair of a cystocele and placing a tape.

After completing the anterior colporrhaphy, use a threadable needle to place the sacrospinous sutures through the open vaginal cuff (Fig. 39-7). Insert the suture strands nearest the ischial spine into the right side of the cuff and place the strands nearest the sacrum in the left side. Space the intervening sutures evenly between. If the cuff is thought of as a clock face, with the anterior colporrhaphy at the 12-o'clock position, the spine suture is placed at the 8- and 10-o'clock positions, the next at the 7- and 11-o'clock positions, the next at the 1- and 5-o'clock positions, and the final one at the 2-o'clock and 4-o'clock positions. To facilitate, first stretch the cuff transversely between Allis clamps at the 3- and 9-o'clock positions. The dorsal end of each strand is placed through the posterior vaginal mucosa and fascia, while the ventral end is placed anteriorly.

As the sutures are tied (Fig. 39-8), the vaginal apex is brought into direct contact with the ligament. The sutures close the open apex in an anteroposterior direction and bring the fresh cut edge into direct contact with a broad area of the ligament (Fig. 39-9).

A posterior repair, when needed, can be performed. Most of the rectocele will have been corrected by the suspension of the posterior vaginal wall to the sacrospinous ligament, but the separated edges of the perineal structures must be reunited if they are not connected.

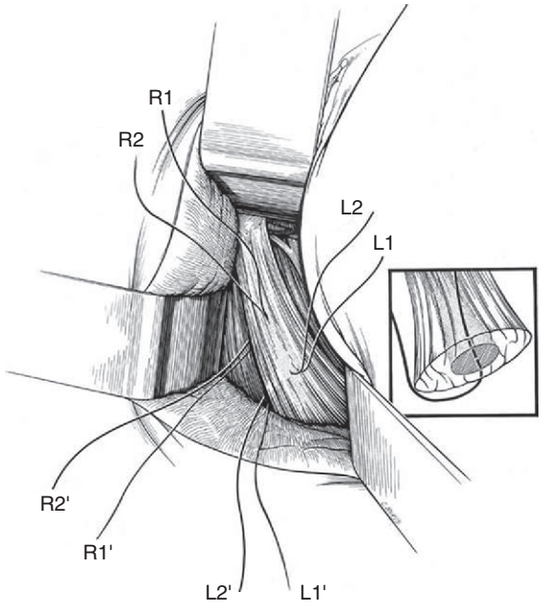

FIGURE 39-6. Two passes of the ligature carrier results in four strands that will be used to suspend the vagina. The right pair will go to the right side of the vagina and the left pair will go to the left side of the vagina.

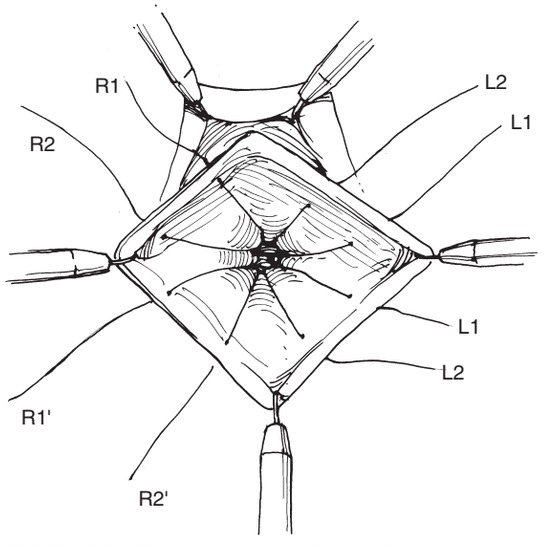

FIGURE 39-7. Each suture is placed through the vaginal wall at equally spaced locations. Note that the right pair of sutures goes to the right side of the vagina and the left pair goes to the left side.

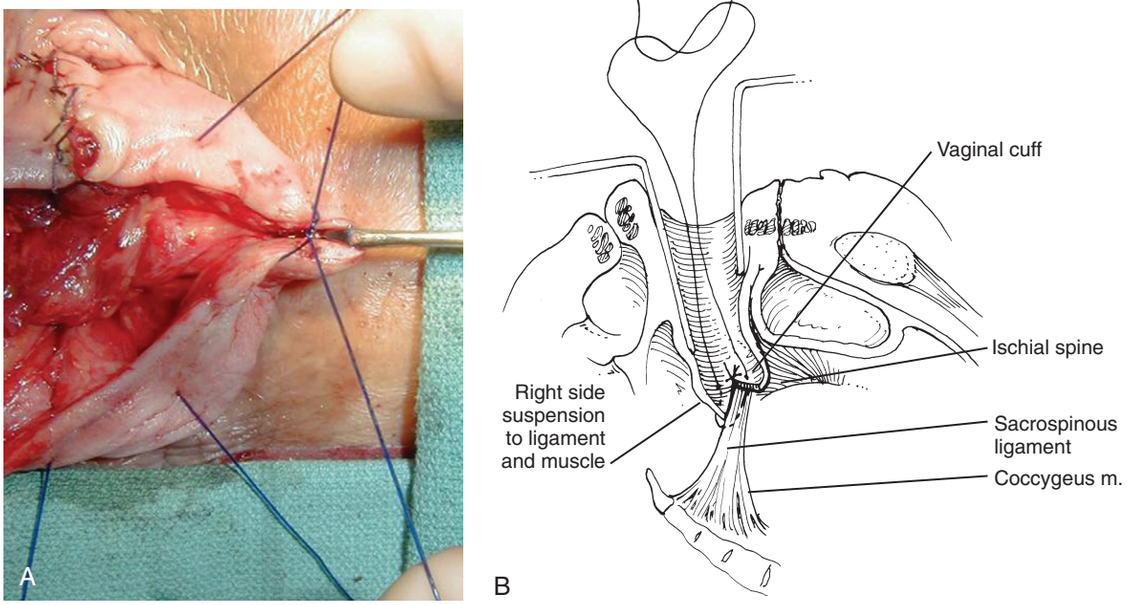

FIGURE 39-8. The first suture is tied, showing how it will close the vaginal wall. The left panel demonstrates what happens after the sutures are tied and how the anterior and posterior edges are approximated to the ligament (left suture pair not shown).

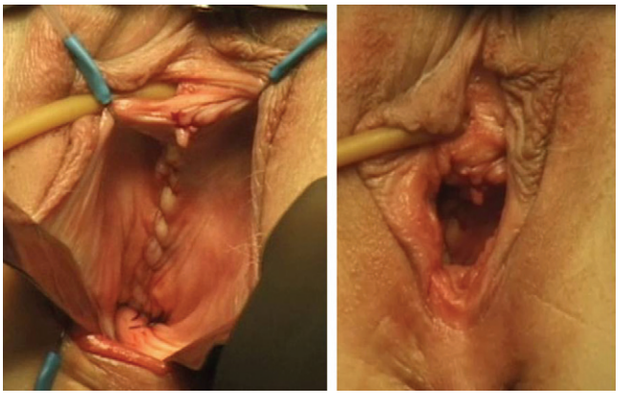

FIGURE 39-9. The apex of the vagina can be seen as it is attached to the ligament with the anterior repair extending from this point along the anterior vaginal wall. All four walls are elevated with equal degrees of tension to this suspension point. Once the retractors are withdrawn, normal support can be appreciated.

RESULTS

Using the Michigan four-wall technique in our first 100 patients, 90% had satisfactory outcomes at 1 year (Table 39-3). Six percent had symptomatic postoperative cystoceles and 4% developed recurrent apical prolapses. Since that report, we have continued to have excellent results. In recent years, after changing to monofilament long-acting delayed suture (polydioxane or polyglyconate), these apical failures virtually have been eliminated. Now, in treating more than 1000 women with large and complex vaginal-vault prolapses, we remain enthusiastic about the versatility and effectiveness of this technique.

TABLE 39-3

RESULTS OF MICHIGAN FOUR-WALL SACROSPINOUS LIGAMENT AT 1 YEAR IN 71 PATIENTS[1]

Results		
Satisfactory	90%	
Excellent		63%
Slight relaxation		14%
Other problems (4 Stress Incontinence, 4 vaginal stenosis)		13%
Symptomatic cystocele	6%	
Recurrent apical prolapse	4%*	

* With polydiaxanone now < 0.5%

KEY POINTS

- The Michigan four-wall technique provides stronger support than traditional methods because all four walls of the vagina are attached to the ligament to ensure equal suspension.
- The initial incision is at the vaginal apex, excising excess vagina, so all four walls are suspended with equal tension.
- The vaginal cuff that is formed during this procedure should be sewn directly to the sacrospinous ligament so that the cut surface can heal directly to the ligament, allowing a firm and permanent union.
- When securing the sutures in the ligament, the ligature carrier should bite deeply enough to ensure that both the coccygeal muscle and the lower half of the woody-hand sacrospinous ligament are pierced.

Commentary by ROGER DMOCHOWSKI

The sacrospinous suspension is a time-honored apical suspension technique. The enclosed surgical description delineates a more extended type of fixation technique using four instead of two paired sutures. One of the chronic issues with the sacrospinous repair has been de novo postoperative apical enterocele, and this technique attempts to avoid this eventuality.

It is critical when approaching the sacrospinous ligament to be aware of the neurovascular architecture behind the ligament. Suture placement should be accomplished as superficially as possible in the ligament and as laterally as possible to avoid vascular injury or neural entrapment, which may be problematic for the patient in the long term. Visualization with vaginal curve retractors is critical for purposes of adequate directional placement of the sutures involved with this technique.

The authors also describe placement of the suture in the vaginal wall. This ensures restoration of the vaginal wall to a more normal apical location. However, the vaginal wall represents the most significant structural component of this technique, that is, the dependence of the repair on the attenuated vaginal wall. Some authors have actually described interposition graft be placed using the sacrospinous sutures before the sutures being brought through the vaginal wall for purposes of optimal apical stabilization.

This page intentionally left blank

Section VIII

URETHRAL: RECONSTRUCTION

This page intentionally left blank

Chapter 40

Urethral Reconstruction: General Concepts

ALLEN F. MOREY

TECHNICAL CONSIDERATIONS

A period of urethral rest of several months' duration is desirable after recent trauma or instrumentation before urethroplasty so that the tissues have a chance to stabilize and delineate. Preoperative imaging should include both antegrade and retrograde studies to enable accurate planning and detect pockets and fistulas. A pouch drape connected to suction is helpful to collect bloody urinary drainage during perineal procedures. A plastic disposable Lone Star or the modified Jordan Bookwalter are each popular and effective retractor options.

High lithotomy positioning may result in lower extremity ischemic complications if prolonged, and thus should be reserved solely for perineal urethral exposure. Candy-cane or boot-type stirrups are equally effective for this purpose. Low lithotomy provides ample exposure for distal bulbar repair. I do not hesitate to sharply bivalve the scrotum (completely if necessary) to provide exposure for long strictures extending into the distal bulb.

Fine forceps, such as Cushing, Gerald, or DeBakey, are helpful for handling the delicate urethral mucosa. Optical magnification with 2.5× loupes and use of fine absorbable monofilament sutures (5-0 or 6-0) enable precise, atraumatic technique. A strong headlight is helpful for deep perineal urethral work. Catheters should be small (16 or 18 French) and removed after 3 to 4 weeks to prevent urethral ischemia or anastomotic trauma; nonreactive substances such as silicone are preferred. Suprapubic tubes are only necessary in cases of posterior urethral reconstruction and are otherwise removed at the time of anterior urethral reconstruction. Drains are unnecessary after urethroplasty and most cases may now be performed in an ambulatory or short-stay surgical setting. Perineal compression is nicely achieved by use of fluff dressings with fishnet shorts.

DISTAL RECONSTRUCTION

Distal urethral reconstruction is best performed via a flap or graft onlay procedure with the patient in the supine position. Tubularized grafts or flaps should be avoided. Penile skin flaps function well for distal urethral substitution even in circumcised men. The circular penile fasciocutaneous flap provides 12 to 15 cm of hairless tissue, and thus is the most versatile. Scrotal skin is a poor choice for urethral substitution.

For long strictures, I begin by passing an 8-French feeding tube in order to assess the caliber of the stricture, and thus the quality of the urethral plate. If the tube does not pass, a wider flap may be selected. When measuring flap width, use calipers and apply maximal stretch on the penis and foreskin to prevent redundancy, which may lead to urethral sacculation or postmicturition dribbling.

Penile flaps are best reserved for pendulous and distal stricture cases, because creation of a scrotal tunnel for flap transfer to the perineum is time-consuming and usually unnecessary. For longer strictures, it is prudent to couple flap repair with meatotomy (even to the subcoronal area if necessary) to prevent distal stenosis. Redundant dartos tissue from the harvested flap should be interposed over the suture lines to prevent fistula formation. Residual prepuce should be excised in order to provide the appearance of a complete circumcision because the remaining distal skin sleeve may otherwise be prone to ischemic complications if retained.

In general, grafts are not preferred for pendulous urethral reconstruction in most initial surgeries because the periurethral spongiosum is sparse in the distal penile shaft. Grafts are, however, appropriate for distal urethral reconstruction whenever local tissues are inadequate or unavailable (e.g., prior hypospadias surgery, short penile shaft length, severe fibrosis). Tunica vaginalis may be harvested through a scrotal counterincision and tunneled to the penile shaft as a graft bolster.

The extended meatotomy procedure (first stage Johansson) provides a simple, reliable option for older or debilitated men with distal strictures who may not desire advanced or lengthy reconstructive techniques. Extended meatotomy preserves the ability to void in the standing position and thus may be preferable to perineal urethrostomy when extensive tissue transfer maneuvers are not desired. Two-stage procedures are appropriate for strictures due to advanced lichen sclerosus when distal

penile skin is involved in conjunction with the urethral stricture.

Bulbar and Membranous Urethra

The bulb is the urethral segment most amenable to anastomotic urethroplasty because the surrounding spongiosum is thick and elastic (Fig. 40-1). Anastomotic urethroplasty should be performed whenever possible for short strictures (< 2.5 cm) because it is the most efficient, most successful form of reconstruction. The bulbar urethra begins at the penoscrotal junction and extends through the scrotum to the membranous area. In general, the closer the stricture is to the membranous area, the longer the stricture that can be excised in conjunction with direct primary anastomosis. Forceful cephalad retraction of the scrotum enables urethral mobilization, which ensures tension-free repair.

Buccal mucosa grafts are preferred for reconstruction of intermediate length bulbar strictures due to its robust texture, widespread availability, excellent performance characteristics, and concealed harvest scar. Cheek tissue is preferred over labial mucosa and donor site closure is optional. Although the tongue has recently been identified as an alternative donor site and is adequate, lingual mucosa is not as robust as cheek tissue.

Grafts may be applied ventrally, laterally, or dorsally according to surgeon preference with roughly equivalent long-term outcomes. Focally severe stricture segments may be excised in conjunction with graft onlay. Multiple grafts may be sewn together in tandem for long strictures or used synchronously for multiple strictures.

Pelvic fracture-related urethral disruption defects are distinctly different than anterior strictures because they involve complete luminal obliteration. No operation in urology is simpler conceptually nor more difficult practically than posterior urethroplasty. Most urethral avulsion injuries yield a defect of 3 cm or less, so stricture excision coupled with aggressive distal urethral mobilization in a delayed setting will suffice for successful repair in the vast majority of cases.

The keys to success in posterior urethral reconstruction are complete scar excision, up to 28 French in each direction, followed by a tension-free direct mucosal anastomosis using fine suture. I have found it is critical to excise enough periurethral scar tissue to enable adequate space for needle placement. I use 5-0 PDS on double-armed needles to facilitate optimal suture placement. Sometimes, in a deep hole, a lower profile suture needle such as a 6-0 PDS may be helpful. I aim for a 12-suture anastomosis and have found a direct correlation between the number of sutures and the overall outcome. If the

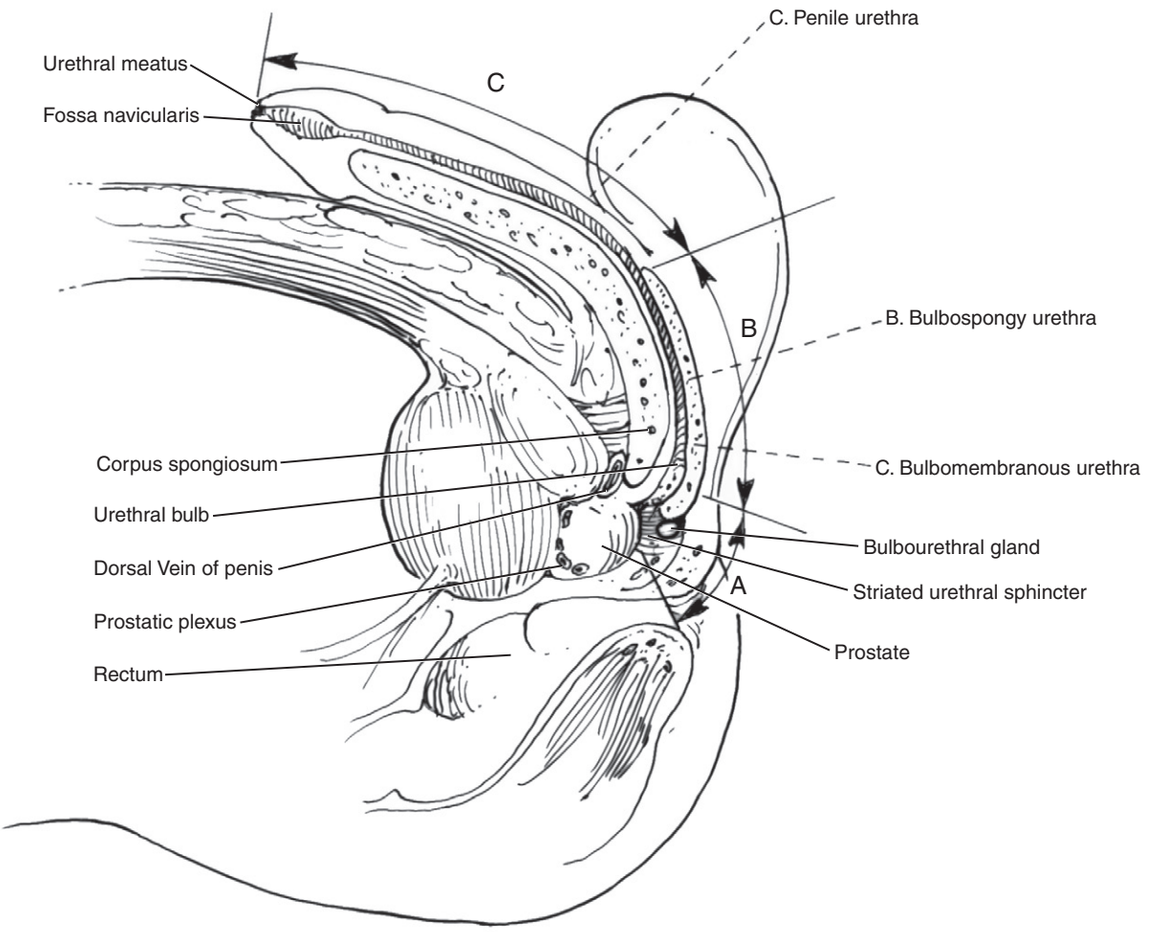

FIGURE 40-1.

proximal urethral access is limited, resulting in seven or fewer sutures, failure is likely.

I prefer a two-team abdominoperineal repair for salvage cases, incorporating retropubic dissection via a lower abdominal incision, which promotes complete exposure of the incarcerated proximal urethra, thus facilitating anastomosis. Complete or partial pubectomy is often helpful in challenging complex or reoperative cases. Ancillary maneuvers such as corporal splitting, inferior pubectomy, suprapubic urethral rerouting, and complete pubectomy should only be necessary for complex or reoperative cases because they are time consuming and invite additional complications.

Again, complete resection of fibrosis is mandatory for successful repair. Periurethral fibrosis should be excised using serrated "super-sharp" scissors and/or multiple fresh scalpel blades. I often go through as many as five or 10 blades to remove the obliteration. Longstanding suprapubic tubes tend to promote bladder stone formation, so intraoperative cystoscopy is prudent to enable stone removal and assess the quality and location of the proximal anastomotic site.

Commentary by

DOUGLAS F. MILAM

Eventual success of an onlay procedure depends on a quality posterior plate. The authors describe a nice technique to assess the quality of the posterior plate. An alternative technique to assess both urethral fibrosis and to guide the midline urethral incision through the stricture is flexible cystoscopy. Under direct cystoscopic vision, an assistant can pass a 1.25-inch 25-gauge needle in the midline immediately distal to the stricture. The urethra is opened under direct vision by incising along the side of the needle to ensure that one is in the ventral midline. Urethral incision continues both proximal and distal until normal tissue is encountered. Radiographic studies usually underestimate the length of urethral scarring.

The author's statement that complete scar excision is mandatory during end-to-end repair cannot be emphasized enough. This may create a long repair that the surgeon must be prepared to handle, however, leaving urethral scar tissue markedly increases stricture recurrence.

This page intentionally left blank

Chapter 41

Reconstruction of the Fossa Navicularis

GERALD H. JORDAN

Reconstruction of the fossa navicularis is one of the most significant challenges that a urethral surgeon faces. It is essential that the etiology of the meatal stenosis and fossa stricture be understood. Certainly the fossa stricture that follows urethral instrumentation, such as transurethral prostatectomy (TURP), is a much different entity than the fossa stricture associated with lichen sclerosus/balanitis xerotica obliterans. Meatal stenosis of childhood is in essence a fusion of the ventral aspect of the normal meatus secondary to ammoniacal balanitis. These stenoses respond very nicely to meatotomy. True meatal stenosis and stricture of the fossa navicularis do not respond well to dilation, or internal urethrotomy and thus require management with a home dilation protocol or, more likely, require reconstruction.

SKIN FLAP TECHNIQUE

(Cohney)

This technique is useful in strictures that are not associated with lichen sclerosus. The procedure does open the distal urethra well, but the patient is left with an unsightly appearance of the glans, meatus, and distal penile skin.

1. A traction suture is placed. The area of meatal stenosis and fossa stricture is opened. A random flap oriented transversely on the penile skin is elevated (Fig. 41-1).
2. The flap is spatulated into the meatotomy defect. Distally the edge of the glans is sutured to the edge of the opened stenotic fossa navicularis, and the flap donor site is closed per primum (Fig. 41-2). Urine is diverted with a Foley catheter for 24 to 48 hours.

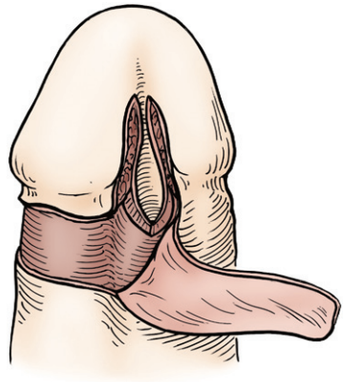

FIGURE 41-1. *(From Jordan GH, Schlossberg SM. [2007]. Surgery of the penis and urethra. In: Wein AJ [ed]. Campbell-Walsh urology, 9th ed. Philadelphia: Elsevier.)*

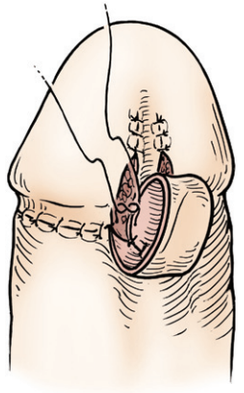

FIGURE 41-2. *(From Jordan GH, Schlossberg SM. [2007]. Surgery of the penis and urethra. In: Wein AJ [ed]. Campbell-Walsh urology, 9th ed. Philadelphia: Elsevier.)*

SKIN FLAP TECHNIQUE

(Blandy-Tresidder)

This technique is useful in strictures that are not associated with lichen sclerosus. The procedure does open the distal urethra well, but the patient is left with an unsightly appearance of the glans, meatus, and distal penile skin. The cosmetic appearance is improved over the flap procedure described by Cohney.

1. A traction suture is placed. The area of meatal stenosis and fossa stricture is opened. A V-shaped flap is dissected from the distal penile skin (Fig. 41-3). This flap is based on random vascularity.
2. The V-flap is then spatulated into the meatotomy. The glans edge is sutured to the edge of the stenotic portion of the distal urethra. The penile skin is then reapproximated to the edge of the glans (Fig. 41-4). The patient is diverted with a Foley catheter for 24 to 48 hours.

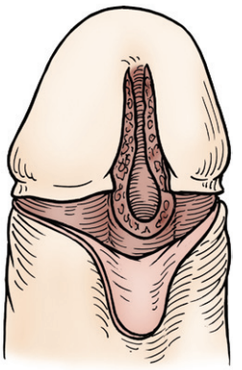

FIGURE 41-3. *(From Jordan GH, Schlossberg SM. [2007]. Surgery of the penis and urethra. In: Wein AJ [ed]. Campbell-Walsh urology, 9th ed. Philadelphia: Elsevier.)*

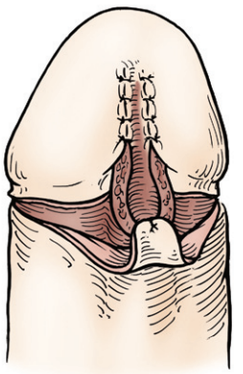

FIGURE 41-4. *(From Jordan GH, Schlossberg SM. [2007]. Surgery of the penis and urethra. In: Wein AJ [ed]. Campbell-Walsh urology, 9th ed. Philadelphia: Elsevier.)*

SKIN FLAP TECHNIQUE

(Brannen)

This method is aimed at trying to create a cosmetically better appearance of the glans and distal penile skin than that of the previously described procedures. This procedure is not useful for cases of lichen sclerosus/balanitis xerotica obliterans. The process of advancement is mechanically inefficient, and in most cases, the patient is left with a retrusive meatus. In fact, the penile skin that is advanced onto the ventral glans penis is in itself quite unsightly.

1. A glans traction stitch is placed. The stenotic meatus and fossa navicularis are opened and spatulated into the normal distal urethra. An accentuated V-flap is dissected from the distal penile skin and is advanced. The flap is spatulated into the meatotomy, but then sutured to the edge of the stricturotomy, out toward the tip of the glans penis (Fig. 41-5). This procedure requires significant advancement of the ventral penile skin.
2. The glans penis is then reapproximated to the edge of the advanced flap, and the penile skin is closed per primum to the coronal margin (Fig. 41-6).

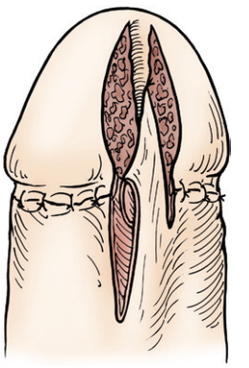

FIGURE 41-5. *(From Jordan GH, Schlossberg SM. [2007]. Surgery of the penis and urethra. In: Wein AJ [ed]. Campbell-Walsh urology, 9th ed. Philadelphia: Elsevier.)*

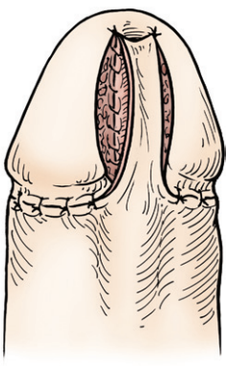

FIGURE 41-6. *(From Jordan GH, Schlossberg SM. [2007]. Surgery of the penis and urethra. In: Wein AJ [ed]. Campbell-Walsh urology, 9th ed. Philadelphia: Elsevier.)*

SKIN FLAP TECHNIQUE

(De Sy)

This technique is designed to create a cosmetically normal appearance of the glans penis and distal penile skin. The process of advancement is mechanically inefficient. In general, the vascularity is probably random. This technique is not useful in stenoses associated with lichen sclerosus/balanitis xerotica obliterans.

1. The glans traction stitch is placed and the stenotic meatus and fossa navicularis are opened to the level of the normal distal urethra. A V-flap is mobilized from the distal penile skin and advanced. The flap is spatulated into the normal urethra and then sutured to the edge of the opened fossa navicularis out to the meatus (Fig. 41-7).
2. The remaining flap is deepithelialized proximally, leaving the inner skin island carried on a narrow tongue of the dartos fascia (Fig. 41-8). The glans is then closed per primum, as is the penile skin closed to the coronal margin.

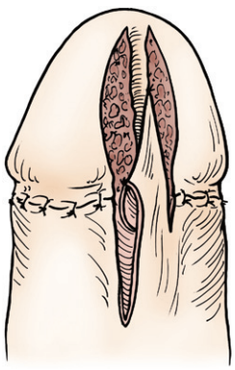

FIGURE 41-7. *(From Jordan GH, Schlossberg SM. [2007]. Surgery of the penis and urethra. In: Wein AJ [ed]. Campbell-Walsh urology, 9th ed. Philadelphia: Elsevier.)*

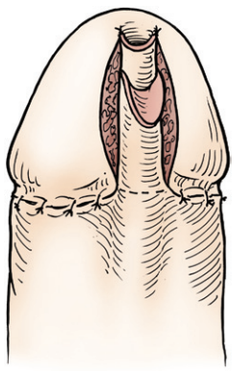

FIGURE 41-8. *(From Jordan GH, Schlossberg SM. [2007]. Surgery of the penis and urethra. In: Wein AJ [ed]. Campbell-Walsh urology, 9th ed. Philadelphia: Elsevier.)*

GRAFT TECHNIQUE

(Devine)

This technique was originally termed *resurfacing* of the fossa navicularis. As originally described, skin grafts were used. Certainly a buccal mucosal graft can be substituted for a skin graft. If one uses skin, the technique is not suitable for cases associated with lichen sclerosus/balanitis xerotica obliterans. Many would question the use of single-stage buccal mucosal graft in cases of lichen sclerosus/balanitis xerotica obliterans. The technique does create a cosmetically suitable appearance of the glans and the distal penile skin.

1. Glans traction stitch is placed, the stenotic fossa navicularis and meatus are excised, and the glans flaps are elevated off of the tips of the corpora cavernosa. The glans wings are widely mobilized to allow primary closure of the glans without recreating stenosis. If there is sufficient penile skin, it can be used for the graft (Fig. 41-9).
2. As originally described, the graft can be placed with the graft suture line ventrally. However, the graft suture line can be placed dorsally (Fig. 41-10). The advantage of

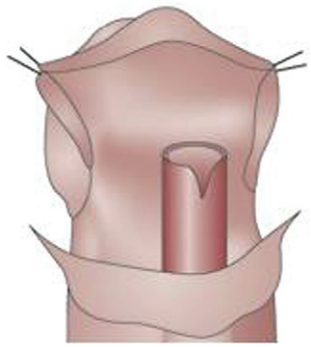

FIGURE 41-9. *(From Tonkin JB, Jordan GH. [2009]. Management of distal anterior urethral strictures. Nat Rev Urol 6:533-538.)*

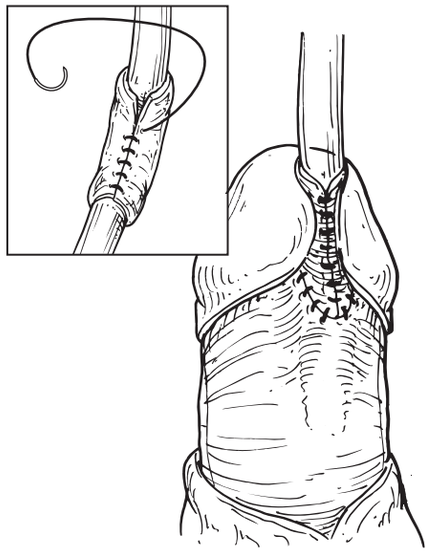

FIGURE 41-10.

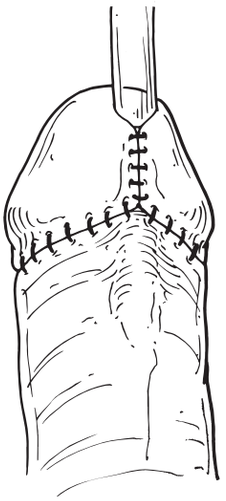

FIGURE 41-11.

placing the graft suture line dorsally is that it avoids overlying suture lines.
3. The glans is then closed per primum, as is the penile skin closed to the coronal margin (Fig. 41-11).

TRANSVERSE VENTRAL SKIN ISLAND TECHNIQUE

(Jordan Flap)

This technique uses a skin island oriented transversely on the ventral penile skin. The advantage of this technique is that the cosmetic appearance following reconstruction is virtually normal. Recent analysis would state that the failure rate of this procedure in cases of lichen sclerosus/balanitis xerotica obliterans is unacceptable. For other cases of meatal stenoses, strictures of the fossa navicularis, success rates are excellent.

1. A glans traction stitch is placed and a urethrotomy is created, extending from the meatus into the normal urethra. A transverse incision is created, leaving a small preputial cuff. That incision is carried approximately halfway around the circumference of the ventral penile shaft (Fig. 41-12).
2. The glans wings are aggressively dissected off of the tip of the corpora cavernosa, allowing for primary closure of the glans. The ventral dartos fascia is dissected deeply off of the Buck's fascia. In many cases, carrying the ventral Buck's fascia allows for an easier plane of dissection. The ventral skin is then dissected from the dartos fascia. This dissection is carried to the penoscrotal junction, allowing significant mobility of the fascial flap. The skin island is then inverted and transposed into the stricturotomy defect (Fig. 41-13, inset).
3. The skin island is sutured into the spatulation and onto the dorsal strip, which represents the opened stenotic fossa navicularis (Fig. 41-14).
4. The glans wings are closed per primum, the ventral skin island donor site is closed as the ventral penile skin allows. In some cases, a transverse closure is accomplished, and Burrow's triangles are used to excise the dog ears at the limits of the closure. In some cases, a longitudinal closure is accomplished (Fig. 41-15). The patient is diverted with a suprapubic tube and a urethral stent is placed. Voiding trial can be accomplished at approximately 10 days.

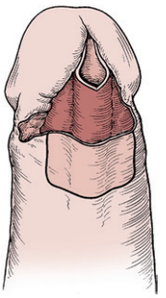

FIGURE 41-12. *(From Jordan GH, Schlossberg SM. [2007]. Surgery of the penis and urethra. In: Wein AJ [ed]. Campbell-Walsh urology, 9th ed. Philadelphia: Elsevier.)*

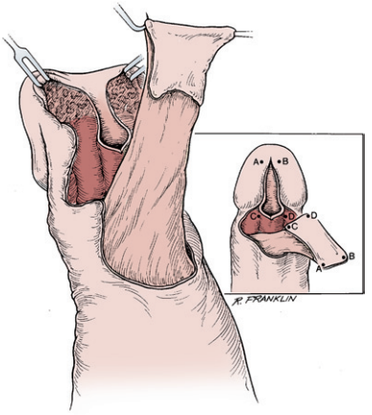

FIGURE 41-13. *(From Jordan GH, Schlossberg SM. [2007]. Surgery of the penis and urethra. In: Wein AJ [ed]. Campbell-Walsh urology, 9th ed. Philadelphia: Elsevier.)*

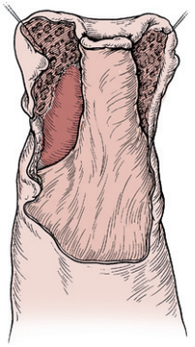

FIGURE 41-14. *(From Jordan GH, Schlossberg SM. [2007]. Surgery of the penis and urethra. In: Wein AJ [ed]. Campbell-Walsh urology, 9th ed. Philadelphia: Elsevier.)*

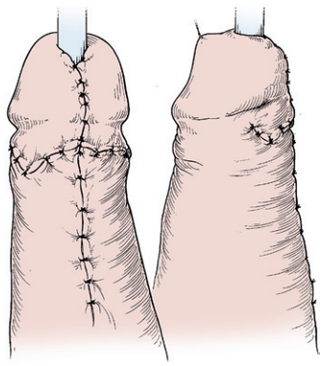

FIGURE 41-15. *(From Jordan GH, Schlossberg SM. [2007]. Surgery of the penis and urethra. In: Wein AJ [ed]. Campbell-Walsh urology, 9th ed. Philadelphia: Elsevier.)*

Commentary by

DOUGLAS F. MILAM

The staged buccal mucosa graft technique for fossa strictures from lichen sclerosus/balanitis xerotica obliterans has evolved into an "industry standard." This is due to the relatively higher stricture recurrence rate with the other procedures described herein. A staged buccal mucosa graft operation is not without cost, however. Many patients balk at the 6-month time frame during which the fossa navicularis is open while the graft matures. One-stage fossa reconstructions like the Jordan or McAninch repairs described herein remain reasonable treatment options for patients willing to accept a higher failure rate for the convenience of a one-stage repair.

This page intentionally left blank

Chapter 42

Reconstruction of Strictures of the Penile Urethra

SEAN P. ELLIOTT AND JACK W. McANINCH

The goal of penile urethral reconstruction should be unobstructed micturition from a glanular meatus with excellent cosmesis. Most repairs may be achieved in a single operation utilizing penile skin flaps or skin grafts. Anastomotic urethroplasty should be avoided in the penile urethra, even in short strictures, as tethering and chordee may result. In complex situations such as after previous failed repair, it may be necessary to stage the reconstruction.

Advanced patient age may make one more strongly consider periodic urethral dilation or a permanent first stage urethroplasty; whereas the younger patient may prefer complex urethral reconstruction. Other patient factors such as adverse wound characteristics (due to concomitant periurethral abscess or fistula) or poor wound healing (due to peripheral vascular disease, diabetes, or prior radiation therapy) should cause one to reconsider proceeding with a complex single-stage urethral reconstruction. Specifically, there has been much debate about the use of the penile skin flap for reconstruction of urethral stricture disease due to *lichen sclerosis et atrophicans*. In such cases, many prefer substitution with buccal mucosa graft in one or two stages.

ANATOMIC AND VASCULAR CONSIDERATIONS

The dermis of the penile and scrotal skin is composed of dartos muscle (Fig. 42-1). Deep to the dartos muscle is a subdermal vascular plexus. Beneath this is the dartos/Colles' fascia, which is continuous with Scarpa's fascia on the anterior abdominal wall. Deep to Colles' fascia is a loose subcutaneous areolar tissue containing the axial arteries of the penis. This layer is often termed the *tunica dartos*. Below this is Buck's fascia—a multilamellar fascia that surrounds the neurovascular bundle of the erectile bodies dorsally and splits ventrally to wrap around the corpus spongiosum.

A thorough understanding of the vascular supply of the penile skin is important in all urethral surgery and is particularly essential to successful construction of penile skin flaps. The penile skin derives its blood supply from the superior (superficial) and inferior (deep) external pudendal arteries, branches of the femoral artery. Venous drainage parallels the arterial supply (Fig. 42-2). All the various penile skin flaps are developed based on this blood supply. At the base of the penis the external pudendal arteries split into ventrolateral and dorsolateral axial penile arteries. These then give off delicate superficial branches to the subdermal plexus. It is incorrect to say that the vessels run in a particular fascia, because fascia is by definition avascular. In fact, the subdermal plexus runs superficial to the tunica dartos but deep to the dartos fascia, whereas the subcutaneous plexus runs deep to the tunica dartos but superficial to Buck's fascia.

DISTAL PENILE CIRCULAR FASCIOCUTANEOUS FLAP (McAninch)

This technique can be used in uncircumcised as well as circumcised men. It yields a hairless flap of up to 15 cm in length and can be used for strictures from the fossa navicularis to the bulbar urethra, making it extremely versatile. The penis is placed on stretch with a 2-0 holding stitch and the flap is marked out with calipers. The width of the flap varies between 2 and 2.5 cm depending on the caliber of the stricture. If the penis is uncircumcised, then the inner prepuce is chosen for the flap, whereas if the penis is circumcised, then the distal penile skin is used. The distal incision is carried down through the pedicle, leaving the pedicle with the proximal penile skin. Once a satisfactory plane is established, the dissection is continued proximally, degloving the entire penile shaft. The proximal/superficial incision is then made and the pedicle dissected off the proximal penile skin, circumferentially all the way to the base of the penis. This leaves a very mobile circular ring of penile skin supported by a circumferential pedicle (see Fig. 42-1).

The flap and pedicle are generally divided ventrally as we feel the dorsal branches of the pedicle are more robust (Fig. 42-3).

The flap is then rotated 90 degrees and brought around ventrally (Fig. 42-4).

The skin island is trimmed to meet the length of the stricturotomy and sutured to the urethral edge in a running fashion with fine absorbable suture over a 16-French catheter

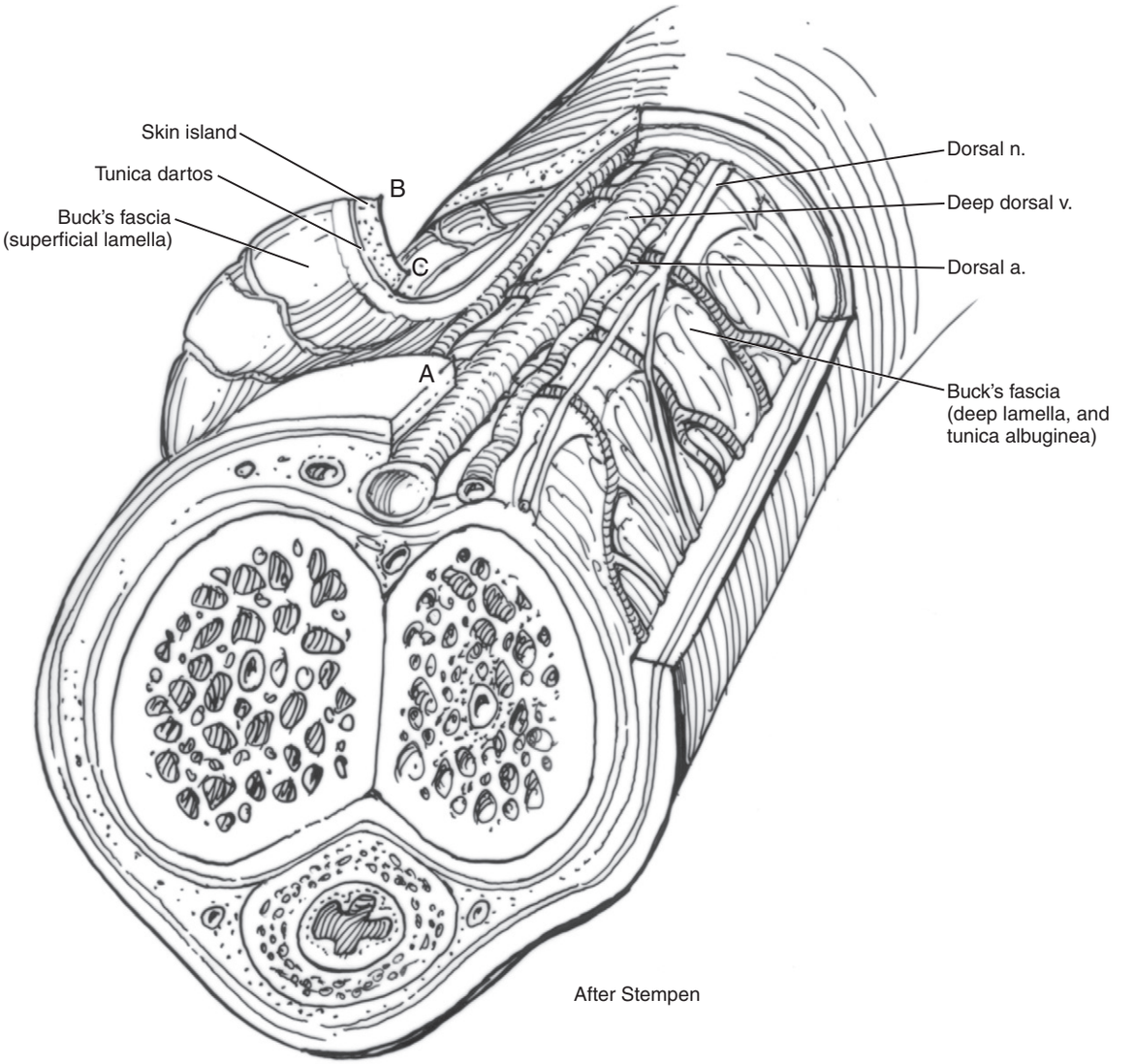
Skin island
Tunica dartos
Buck's fascia
(superficial lamella)
B
C
A
Dorsal n.
Deep dorsal v.
Dorsal a.
Buck's fascia
(deep lamella, and
tunica albuginea)
After Stempen

FIGURE 42-1.

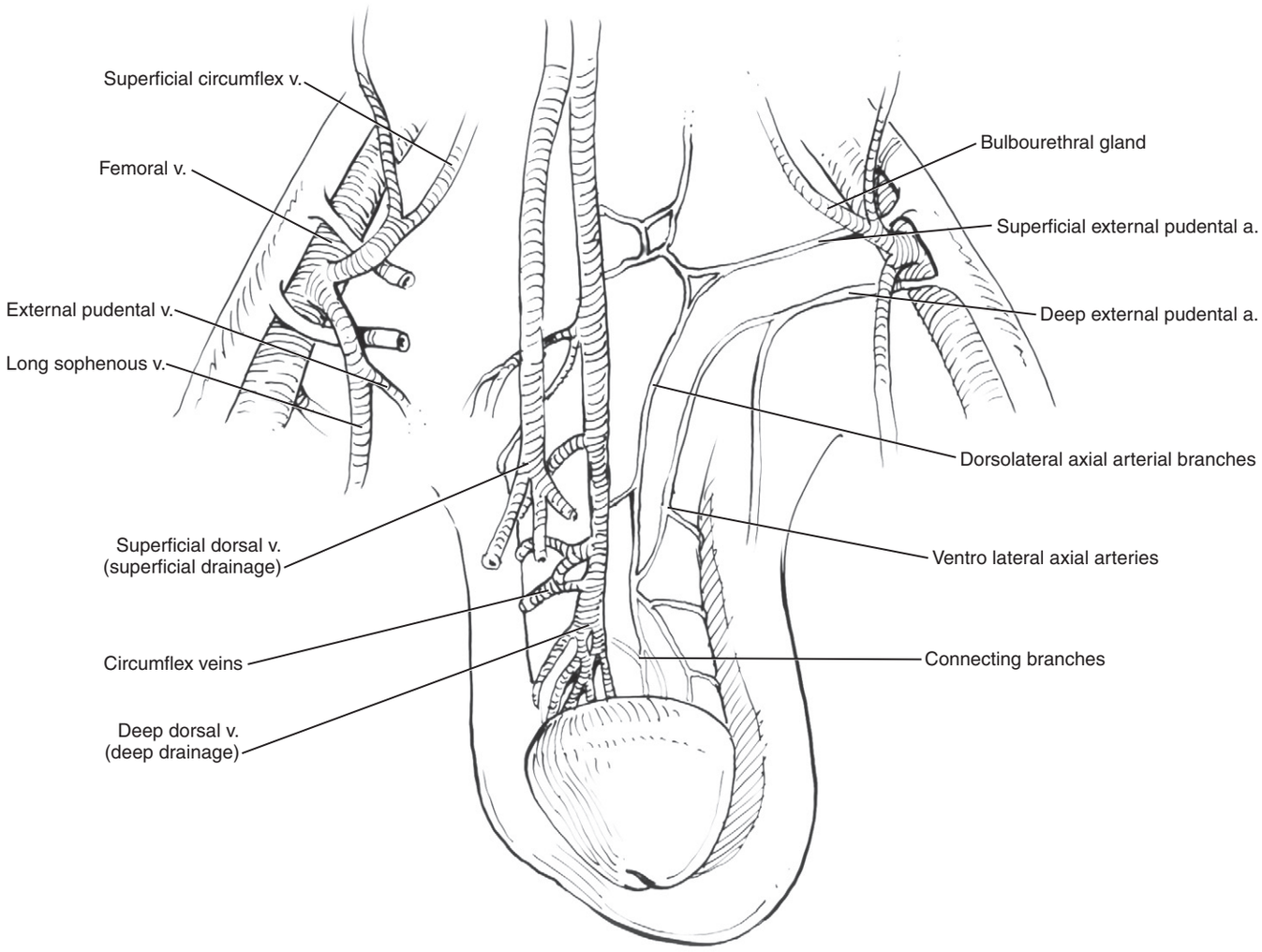

FIGURE 42-2.

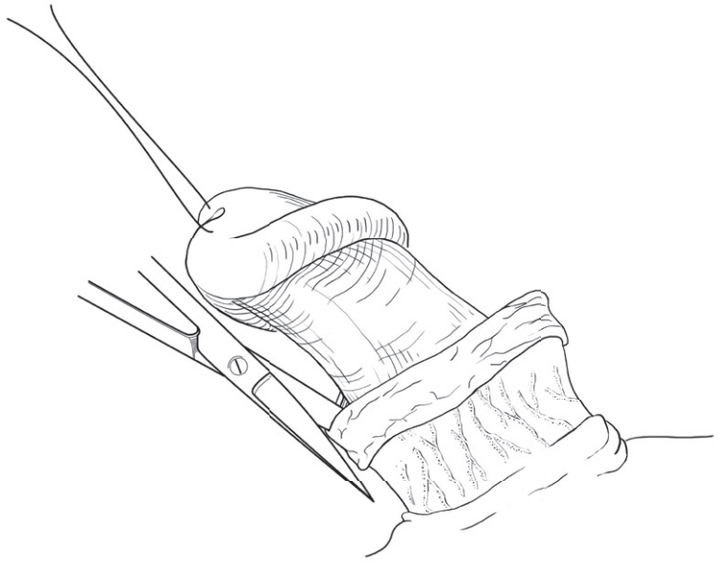

FIGURE 42-3.

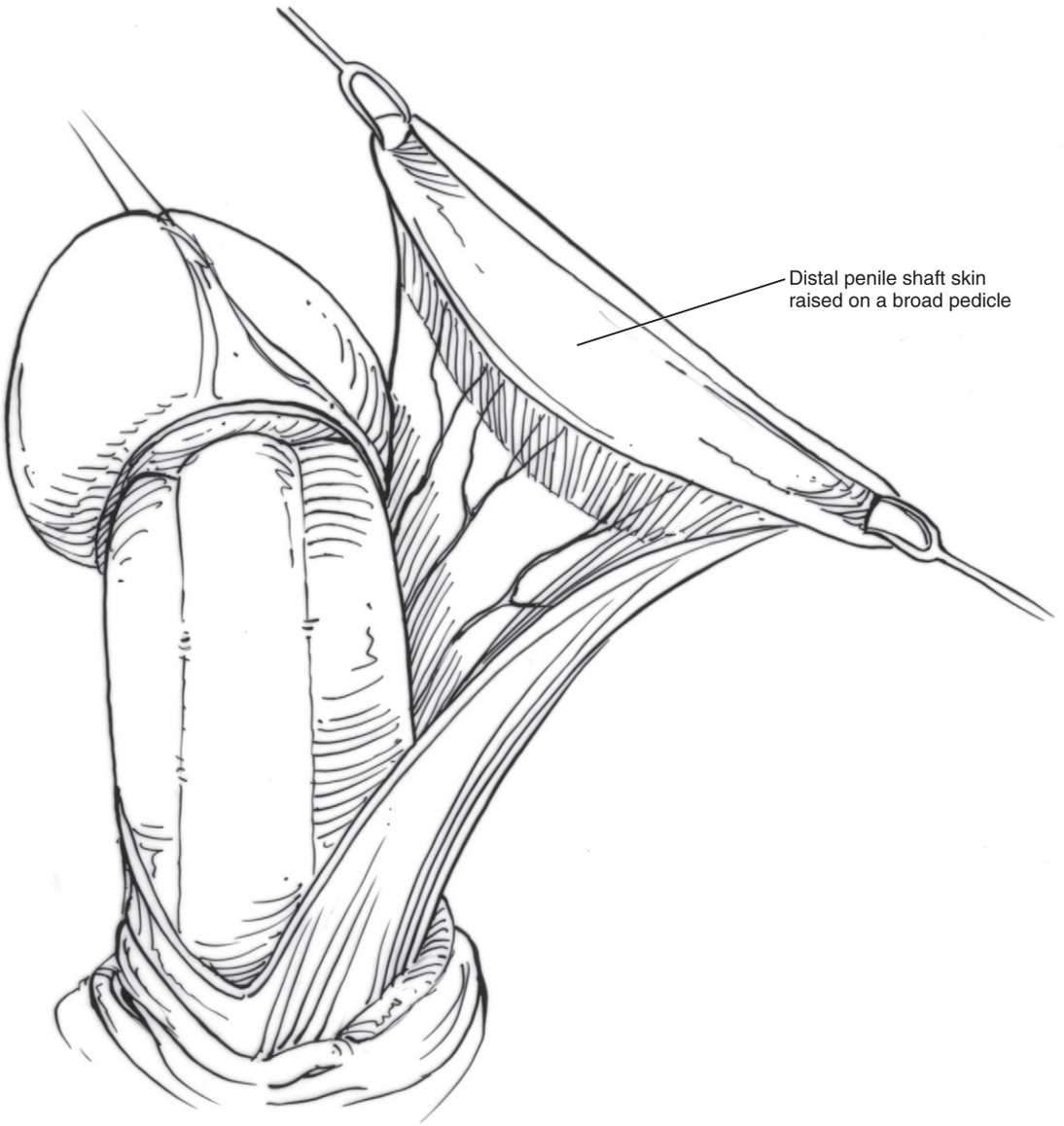

FIGURE 42-4.

(Fig. 42-5). The penile skin is replaced and the circumcising incision is closed.

LONGITUDINAL VENTRAL PENILE SKIN FLAP WITH A LATERAL PEDICLE (Orandi)

This technique is appropriate for strictures of the penile urethra only and has the disadvantage that with proximal extension of the flap one may incorporate hair-bearing skin.

With the penis on stretch, a ventral vertical penile shaft incision is made over the area of stricture just lateral to the urethra, approximating the length of the stricture. This incision is deepened to the lateral border of the corpus spongiosum. This serves as the deep incision (Fig. 42-6).

The plane is developed medially over the urethra. A lateral urethrotomy is made contralateral to the side of the initial skin incision and extended proximally and distally until normal urethra is encountered. The lateral urethrotomy helps minimize the amount of flap dissection necessary to obtain a tension-free anastomosis in this flap based on a lateral pedicle (Fig. 42-7).

The length and width urethral defect are then measured and the flap is marked out in an elongated hexagonal shape. The deep longitudinal incision serves as one of the two long segments of the hexagon with the second long hexagonal segment becoming the superficial incision (Fig. 42-8).

This superficial incision is carried down to but not through the pedicle and developed laterally until the flap can be rotated over onto the urethrotomy in a tension-free manner (Fig. 42-9).

Anastomosis of the inner wall (i.e., if the initial skin incision was on the right side and urethrotomy was on the left, then the right side of the flap is sewn to the left wall of the urethra) is accomplished with 5-0 monofilament suture in a simple running or subcuticular fashion (Fig. 42-10).



FIGURE 42-5.

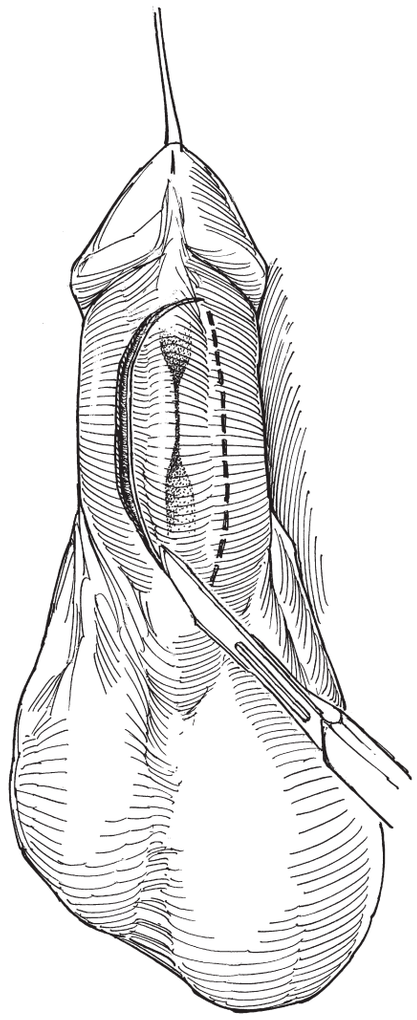

FIGURE 42-6.

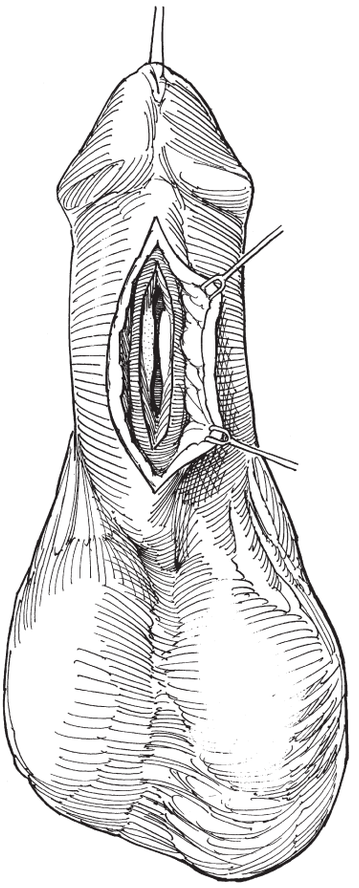

FIGURE 42-7.

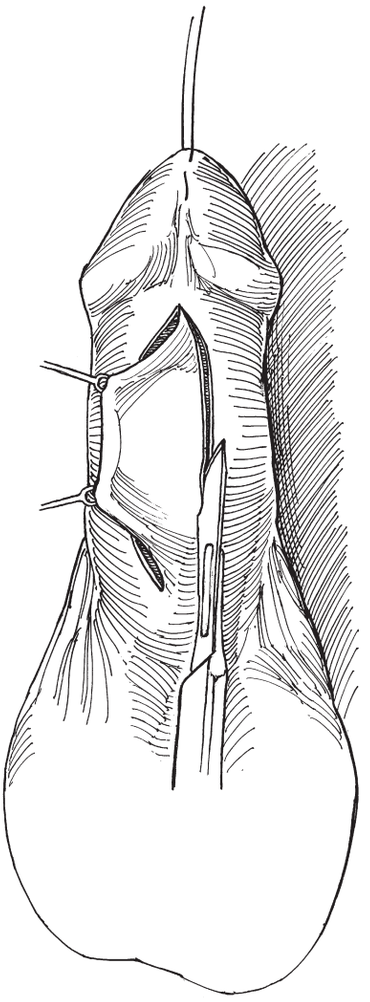

FIGURE 42-8.

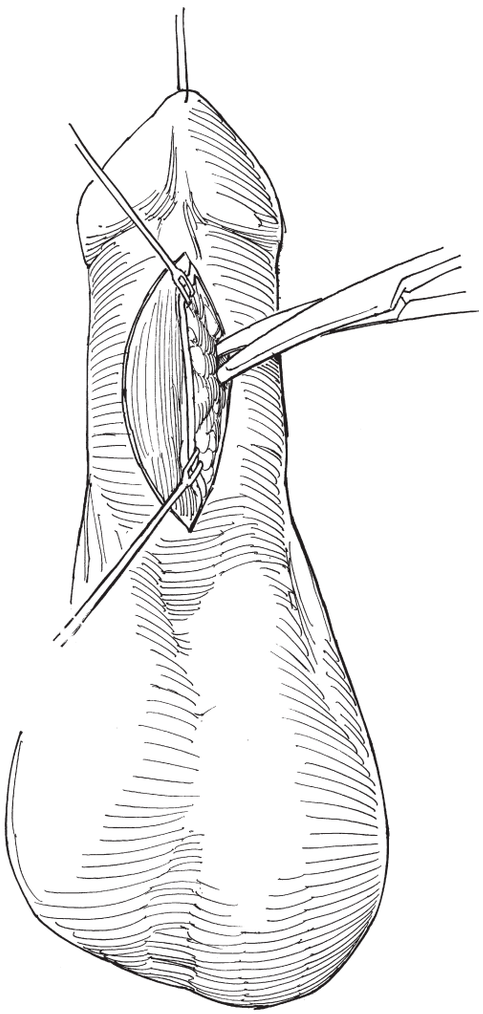

FIGURE 42-9.

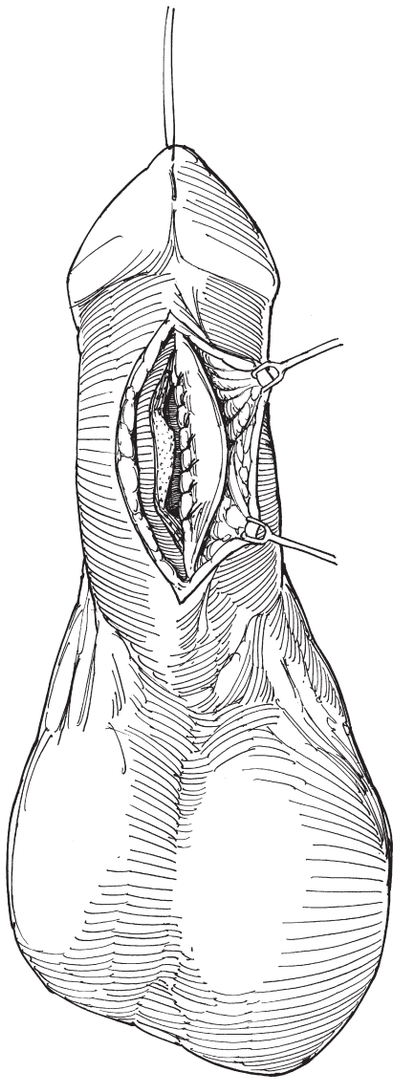

FIGURE 42-10.

The apices and outer wall are closed over a 16-French catheter and the penile skin incision is closed (Fig. 42-11).

LONGITUDINAL VENTRAL PENILE SKIN FLAP WITH A VENTRAL PEDICLE (Turner-Warwick)

Mr. Turner-Warwick described this flap as a *bilaterally* pedicled island penile skin flap (or BiPIPS), which differentiates it from the unilaterally pedicled island penile skin flap. Both flaps are based on a ventral pedicle. The broad bilateral pedicle (i.e., right and left ventrolateral branches of the external pudendal artery) ensures a more robust blood supply than the unilateral pedicle he described previously. Like the Orandi flap, this flap utilizes an elongated hexagonal patch of ventral penile skin and has the disadvantage of potentially incorporating hair-bearing skin at the proximal aspect of the flap. The skin island may be marked out preoperatively based on imaging of the stricture; if the flap is being used for bulbar urethral reconstruction, the skin island can be marked out after the bulbar urethra has been exposed via a separate perineal incision and the stricture measured.

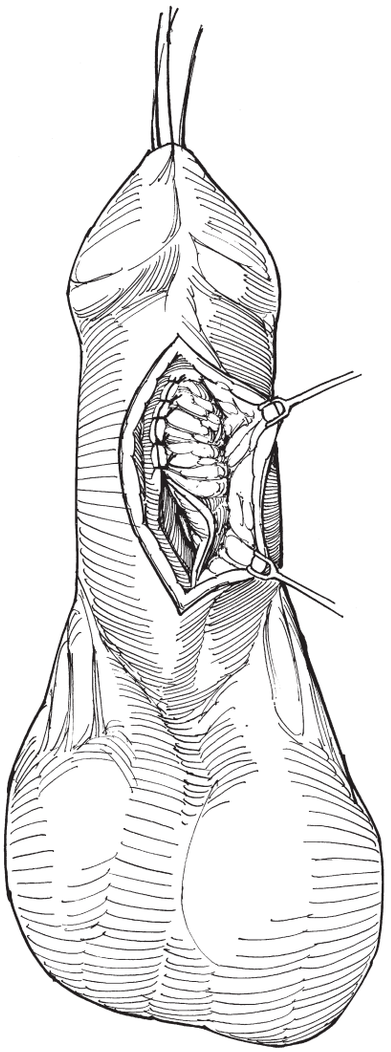

FIGURE 42-11.

A deep plane is developed over the urethra below the level of the pedicle around the distal apex of the island, and a superficial layer is developed around the proximal apex of the island. The island and its pedicle are thus elevated off the underlying penile urethra and overlying proximal penile shaft skin and scrotal skin. Development of the pedicle continues down into the scrotum (Fig. 42-12).

Due to the direction of development of the pedicle, Turner-Warwick described this flap to be most useful in *bulbar* urethral reconstruction, in which the flap is retrogradely inverted through a scrotal tunnel and brought out through a separate perineal incision and sewn to the bulbar urethrotomy. After trimming the skin island to match the urethral defect, the flap is sewn to the cut edges of the urethra as described earlier and the penile skin is closed (Fig. 42-13).

DORSALLY PLACED BUCCAL MUCOSA GRAFT (Barbagli)

Historically, excellent results were obtained with genital skin, postauricular skin, or bladder mucosa grafts, but in the modern era, buccal mucosa is the graft of choice for its excellent tissue characteristics and low morbidity of harvest. In the penile urethra, the corpus spongiosum is thin; hence ventral grafts are discouraged. Instead, a dorsal buccal mucosa onlay graft is used.

A 2-0 silk holding stitch is placed in the glans penis. A circumcising incision is made and carried down to Buck's fascia. The penis is degloved well beyond the area of stricture. A 20-French Bougie-à-boule is passed until it meets with obstruction, indicating the distal level of the stricture. The urethra is mobilized circumferentially off of the underlying corporal bodies along the length of the stricture. The urethra is rotated 180 degrees and a marking stitch or marking pen is used to indicate the 12-o'clock (dorsal) position along the length of the stricture (Fig. 42-14).

The stricture is opened over the Bougie-à-boule and the incision is continued along the dorsal aspect of the urethra until the urethra calibrates to 28 French; 5-0 monofilament absorbable sutures are pre-placed (outside-in) in the apices of the urethrotomy with the needles left on (Fig. 42-15).

The buccal mucosa graft is tailored appropriately. The apical sutures are passed through the apices of the graft, through the tunica albuginea of the corporal bodies, and tied (Fig. 42-16). A limited number of absorbable sutures are used to fix the graft laterally on the corporal bodies and to quilt it to the corporal bodies in the midline.

The urethral edge is then sewn to the lateral aspect of the graft and underlying corporal bodies along the length of the urethrotomy in a running fashion over a 16-French catheter. The penile skin is replaced and the circumcising incision is closed (Fig. 42-17).

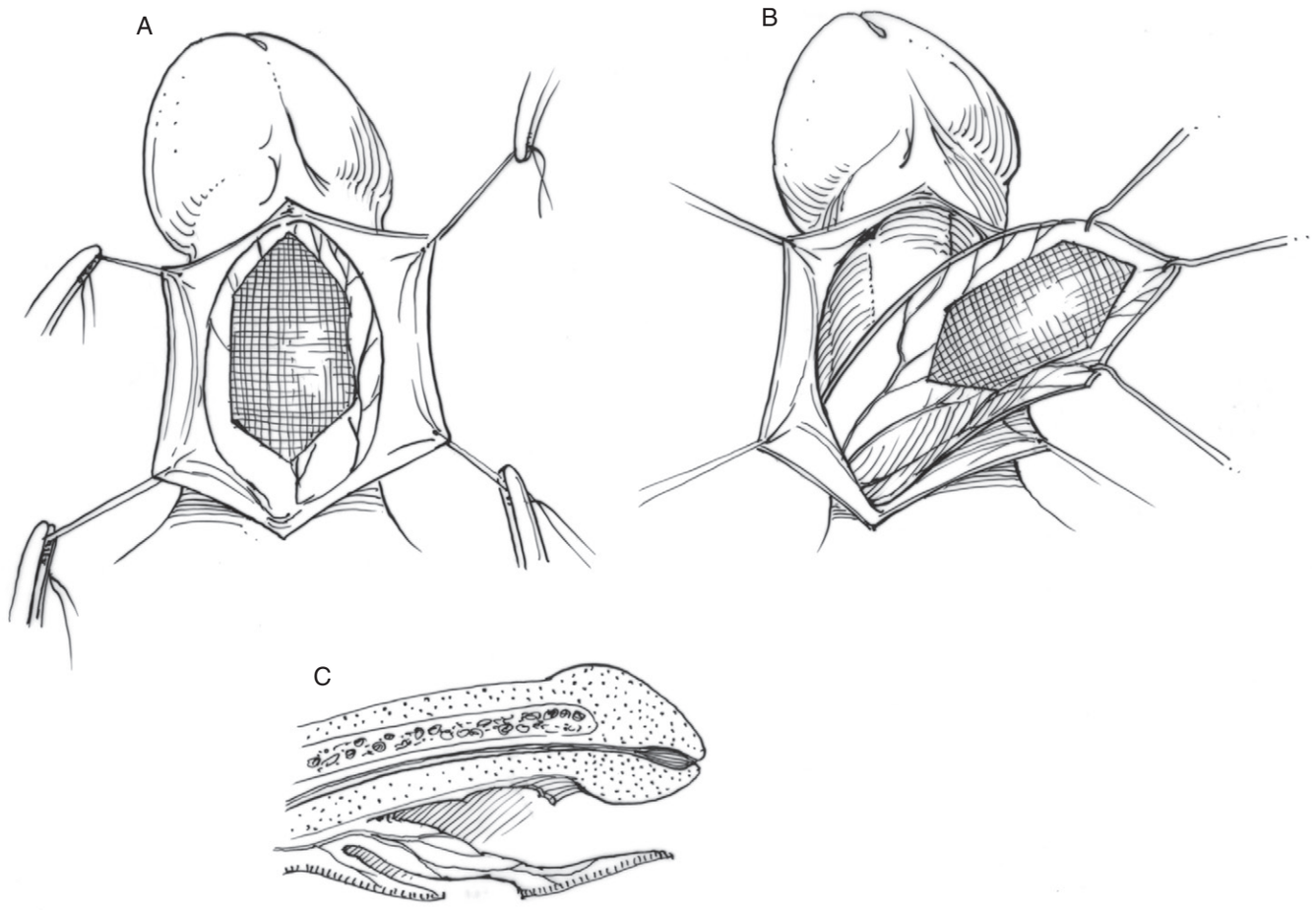

FIGURE 42-12.

TWO-STAGE URETHROPLASTY (Johannson)

First stage: The penis is placed on stretch and a 20-French Bougie-à-boule is passed until it meets with obstruction, indicating the distal extent of the stricture. A longitudinal penile skin incision is made over the stricture. A scalpel is used to incise over the Bougie-à-boule and the stricturotomy is carried proximally until the urethra calibrates to 28 French (Fig. 42-18).

The skin edges are sewn to the urethral edges with 4-0 Vicryl suture. A catheter is usually not necessary (Fig. 42-19).

When limited penile skin is available (i.e., due to multiple prior operations) or when it is unsuitable for use in the urethra (i.e., due to lichen sclerosis [LS]), skin grafts (buccal mucosa and/or split thickness skin graft) may be placed lateral to the urethra on either side or in place of the urethra if it has been completely excised. The graft is quilted to the underlying corporal bodies and sewn to the urethral plate medially (Fig. 42-20).

The lateral aspect of the graft and the nondiseased apices of the native urethra are sewn to the penile skin (Fig. 42-21). A neomeatus on the proximal shaft does not allow an adequate stream for micturition in the standing position; dribbling and soiling of the scrotum often results. In these cases, patients may be given a temporary perineal urethrostomy (follow same technique as that for penile first stage urethroplasty) at the time of first stage penile urethroplasty. This may be closed at the time of second stage urethroplasty.

Second stage: A 28-mm wide urethral plate is marked out with calipers and a pen. The plate is incised along the marking and closed in the midline. A dartos flap may be brought over the urethra to minimize fistula formation. The penile skin is closed in the midline (Fig. 42-22).

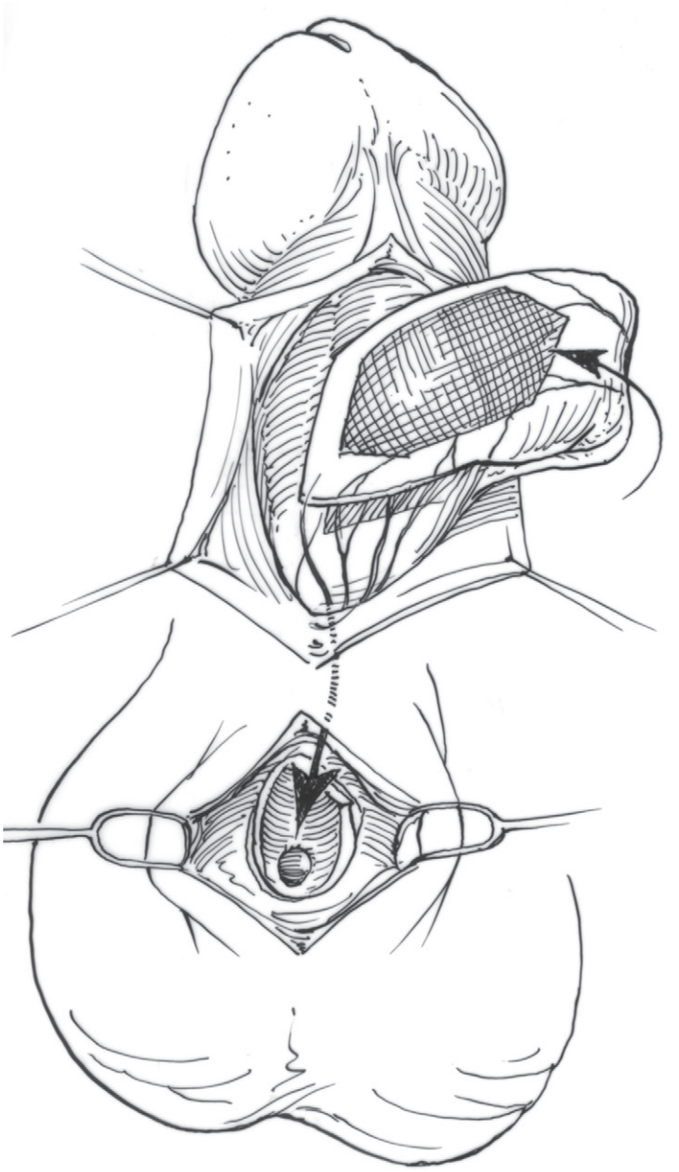

FIGURE 42-13.

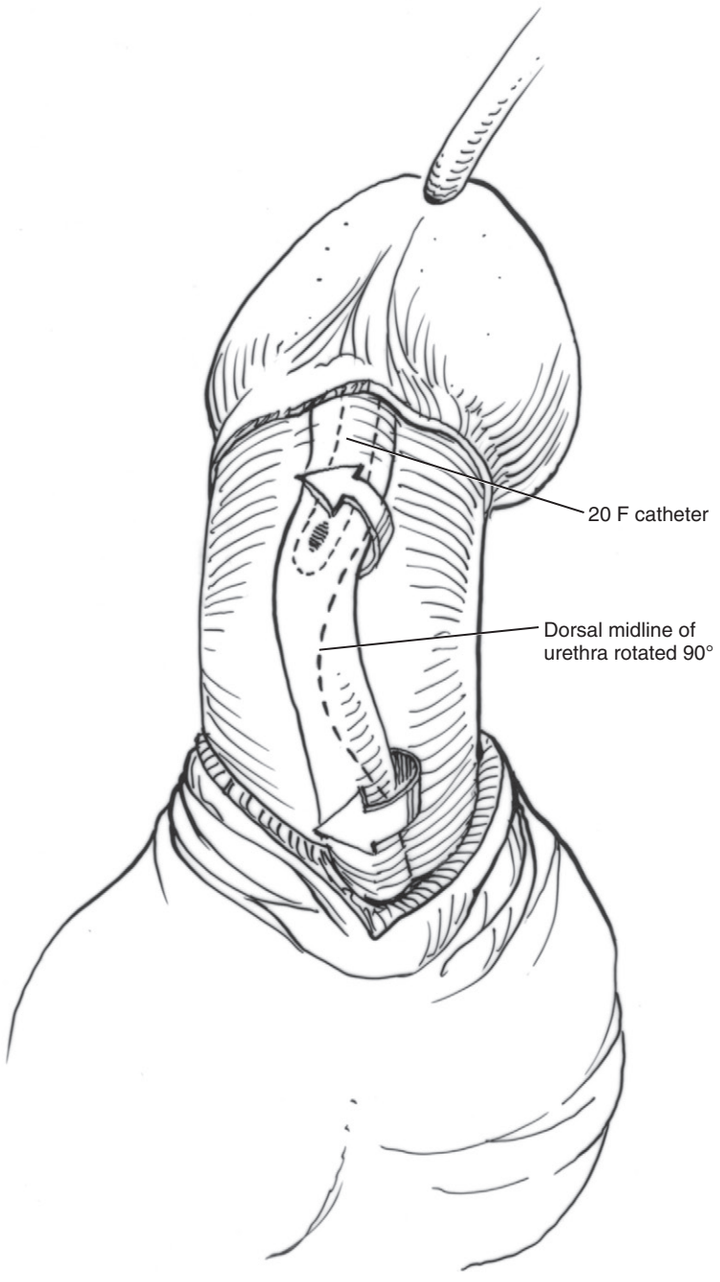

FIGURE 42-14.

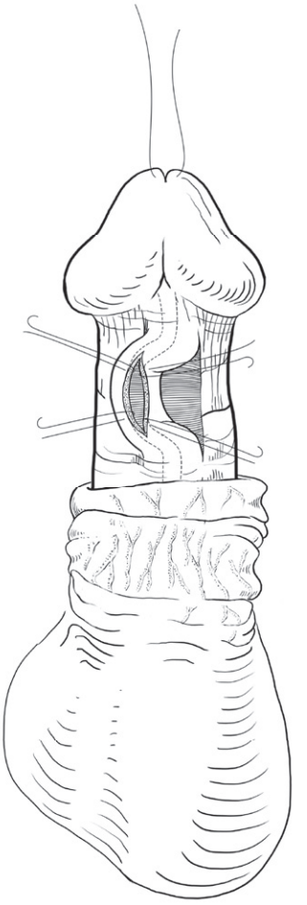

FIGURE 42-15.

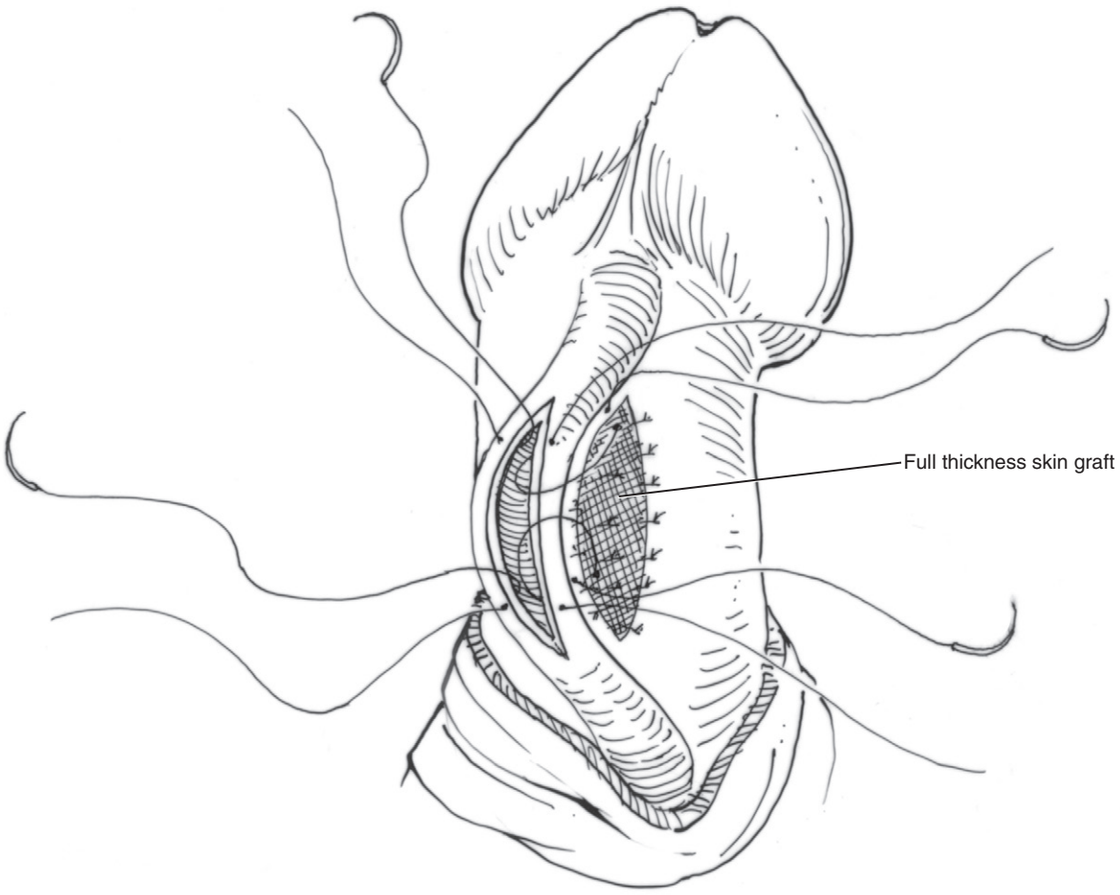

FIGURE 42-16.

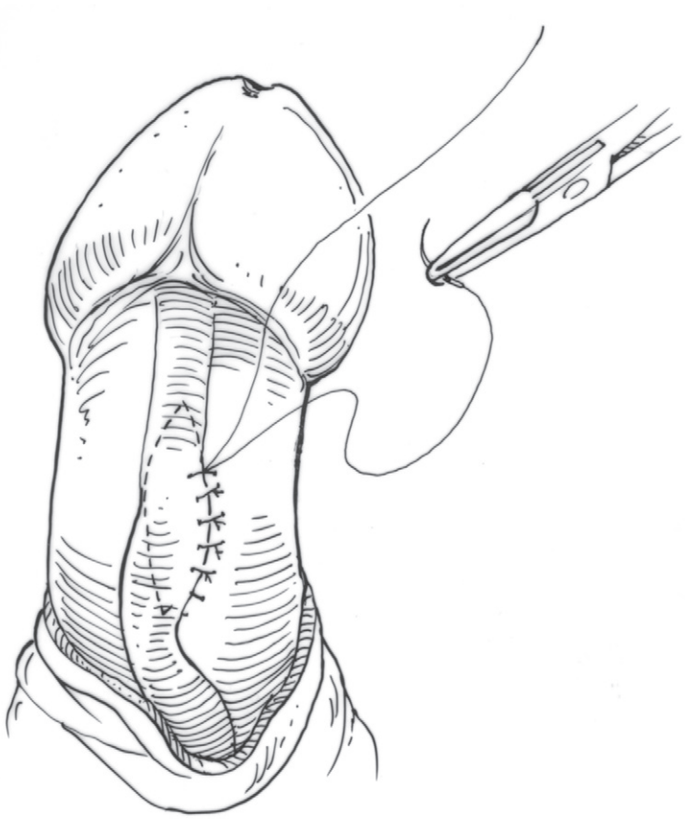

FIGURE 42-17.

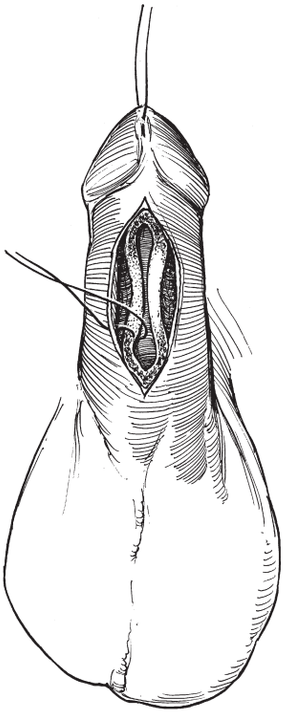

FIGURE 42-18.

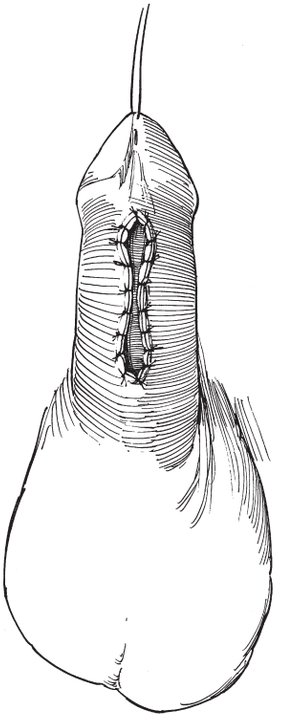

FIGURE 42-19.

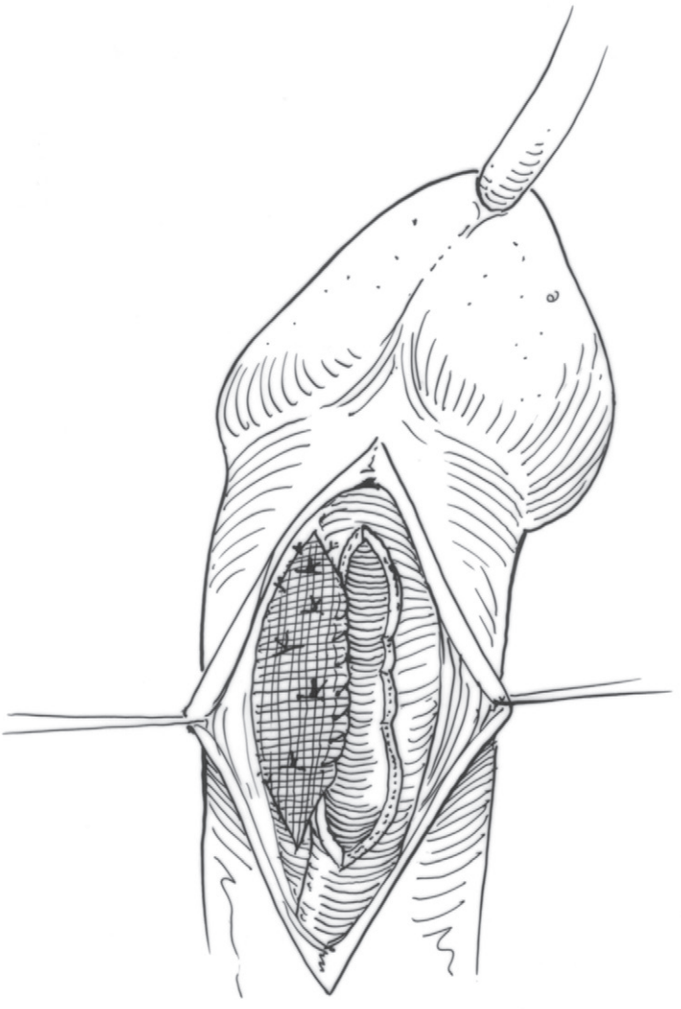

FIGURE 42-20.

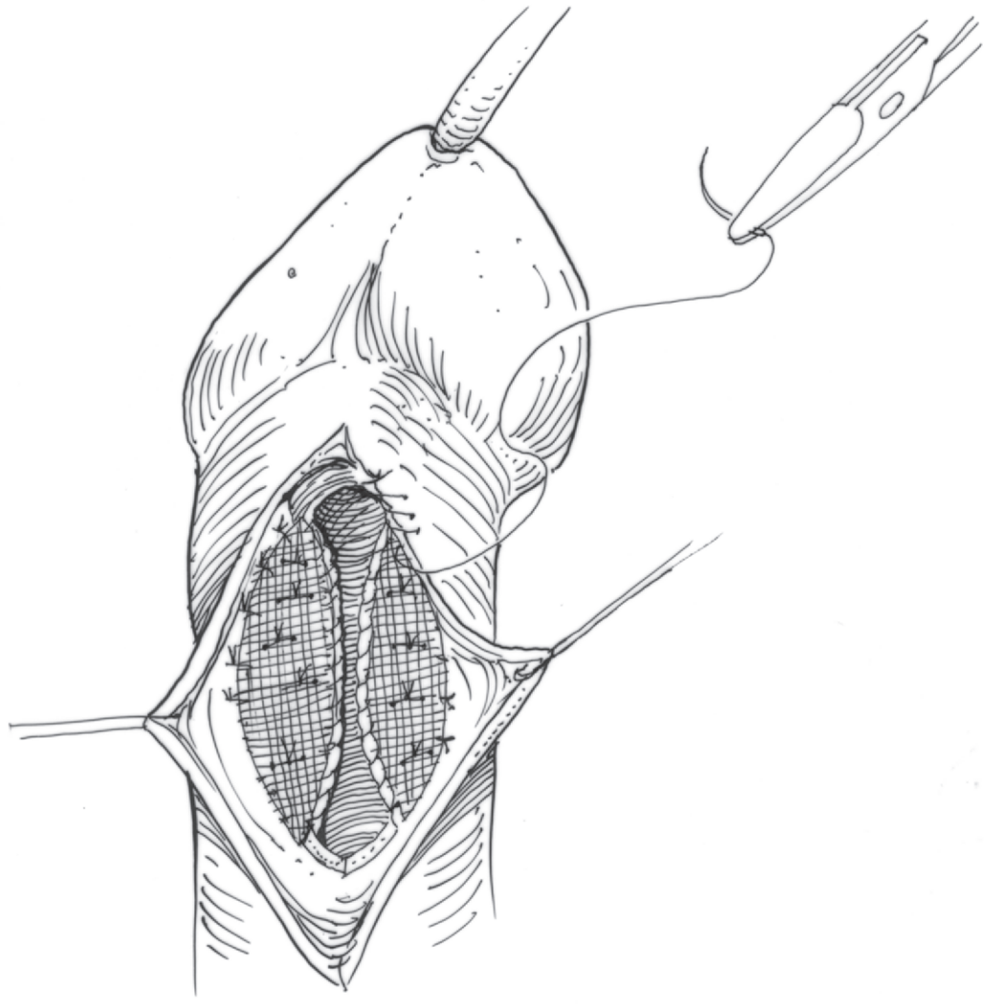

FIGURE 42-21.

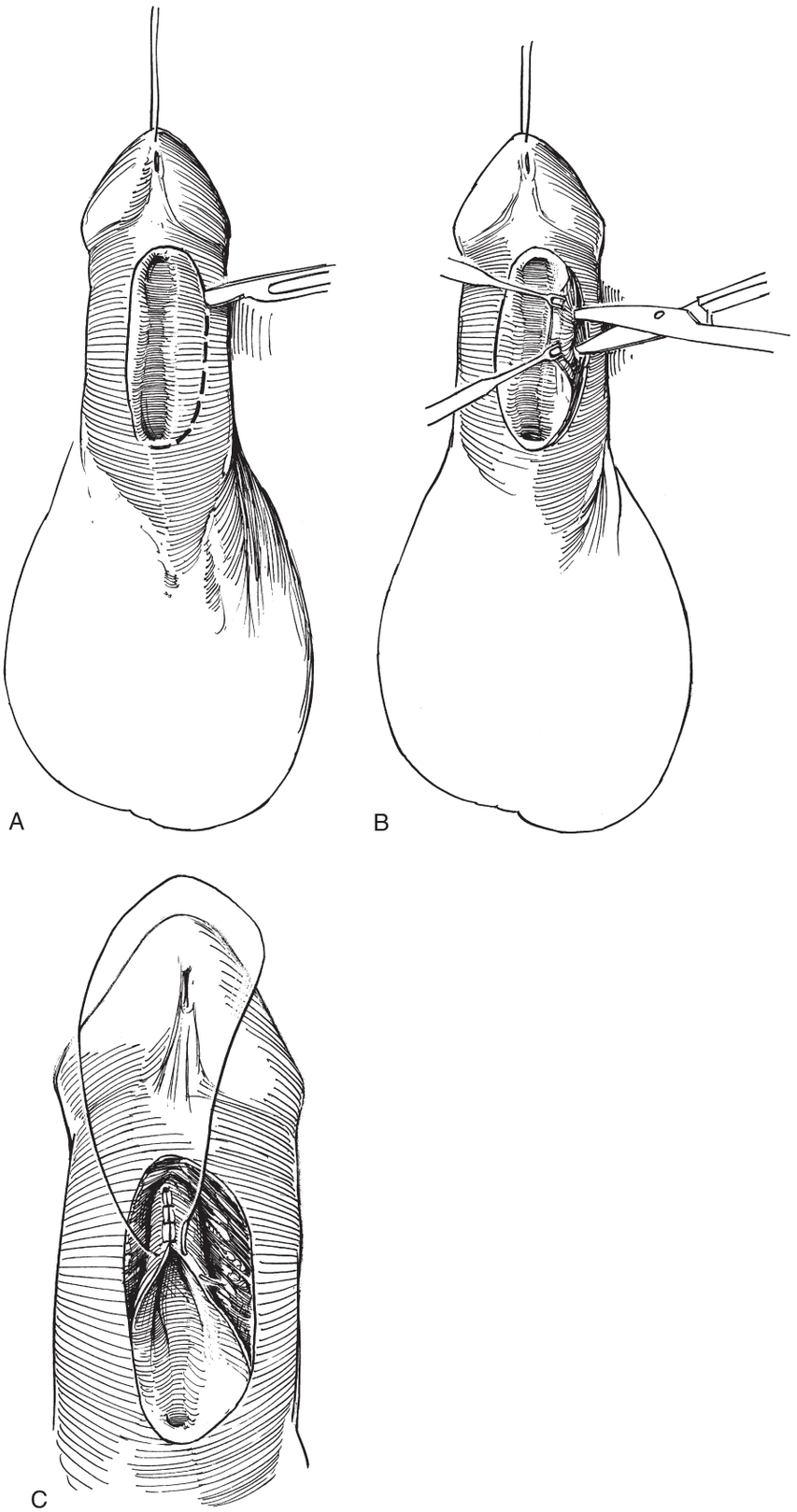

FIGURE 42-22.

Commentary by

DOUGLAS F. MILAM

The author states that anastomotic urethroplasty (stricture excision and end-to-end anastomosis) should be avoided in the penile urethra. This point deserves further emphasis. Often very helpful in the posterior urethra, anastomotic urethroplasty of the penile urethra results in functional shortening of the ventral penis, which can result in ventral penile curvature. Experience from surgery for Peyronie's disease teaches us that correction of each 10 degrees of curvature can be accomplished by 1.25 to 1.5 mm corporoplasty. Whereas the length of urethral tissue resected does not directly translate to decreased functional corporeal length, one can see that relatively modest ventral tethering can result in rather profound ventral curvature. Shortening of the ventral penis can be avoided by graft urethroplasty. Onlay grafts shown herein demonstrate better long-term patency than tubularized neourethral reconstructions.

This page intentionally left blank

Chapter 43

Reconstruction of Strictures of the Bulbar Urethra

SEAN P. ELLIOTT AND JACK W. McANINCH

Strictures of the bulbar urethra may be repaired with excellent success rates using anastomotic urethroplasty for strictures less than 2 cm and graft urethroplasty for longer strictures. While many of the previously described flaps (see Chapter 42) may be rotated into the perineum for bulbar urethroplasty, undesirable penile torsion may result and, hence, flaps have little role in modern bulbar urethral reconstruction. Staged repair, with or without grafting, does have a role in the repair of bulbar strictures. The technique is similar to that described for penile two-stage repairs (see Chapter 42) and is not described here.

SUPERFICIAL PERINEAL ANATOMY

Beneath the dermis lies Colles' fascia, an extension of the dartos fascia of the penis and continuous with Scarpa's fascia of the abdomen. In the midline of the perineum, deep to Colles' fascia, one encounters the midline raphe of the bulbospongiosus muscles as they cover the corpus spongiosum of the bulbar urethra. The bulbospongiosus muscle attenuates at the distal bulbar urethra. Lateral and slightly distal to the bulbospongiosus muscle is the ischiocavernosus muscle, covering the corpora cavernosa. The corpus spongiosum extends approximately 2 cm beyond the bulbomembranous urethral junction where the spongiosum is anchored to the perineal body. At the 5- and 7-o'clock positions of the proximal bulbar urethra, deep to the perineal body attachments, one encounters the bulbar arteries (Fig. 43-1).

ANASTOMOTIC URETHROPLASTY

The anastomotic urethroplasty technique is best reserved for strictures less than 2 cm in length, although good results have been reported in longer strictures if they are located in the very proximal bulbar urethra. Excision of longer strictures and subsequent extensive mobilization of the urethra off the corporal bodies may lead to chordee.

With the patient in exaggerated lithotomy position, a midline (or inverted-Y) perineal incision is made (see Fig. 44-1 for positioning). The bulbospongiosus muscles are split in the midline (Fig. 43-2A), mobilized off the underlying corpus spongiosum, and retracted laterally with hooks attached to a ring retractor (e.g., Scott retractor) or using a fixed Bookwalter retractor (see Fig. 43-2B). In mobilizing the muscles one should take note that the corpus spongiosum flares out to a wider caliber as it courses proximally. It is imperative that the plane of dissection is just outside the adventitia of the corpus spongiosum—if one errs further from the spongiosum, bulbospongiosus muscle is divided and the result is invariably a confusing and bloody field of dissection.

The urethra is dissected off the underlying corporal bodies circumferentially. A 20-French catheter aids in identifying the distal location of the stricture. Large Mayo scissors are used to transect the urethra at the tip of the catheter. Holding sutures passed through the lumen at the 3- and 9-o'clock positions aid in identification of the lumen and in manipulation of the free ends of the urethra. Additional resection is continued in both directions until the lumen calibrates to 28 French (Fig. 43-3).

The urethra is spatulated proximally and distally (Fig. 43-4).

A dorsal wall anastomosis is done in a single layer with interrupted 5-0 monofilament absorbable suture (Fig. 43-5).

The ventral wall anastomosis is done in two layers with 6-0 suture over a 16-French catheter. The wound is closed in layers (Fig. 43-6).

GRAFT URETHROPLASTY

For strictures larger than 2 cm, a graft urethroplasty offers excellent results without the penile shortening associated with anastomotic urethroplasty. The graft may be placed ventrally or dorsally.

Ventral Graft

The urethra is exposed as in the anastomotic urethroplasty; however, the urethra need not be dissected off the underlying corporal bodies. The distal location of the stricture is identified by passing a 20-French catheter. The urethra is incised in the ventral midline with a #15 blade scalpel

(Text continues on page 270)

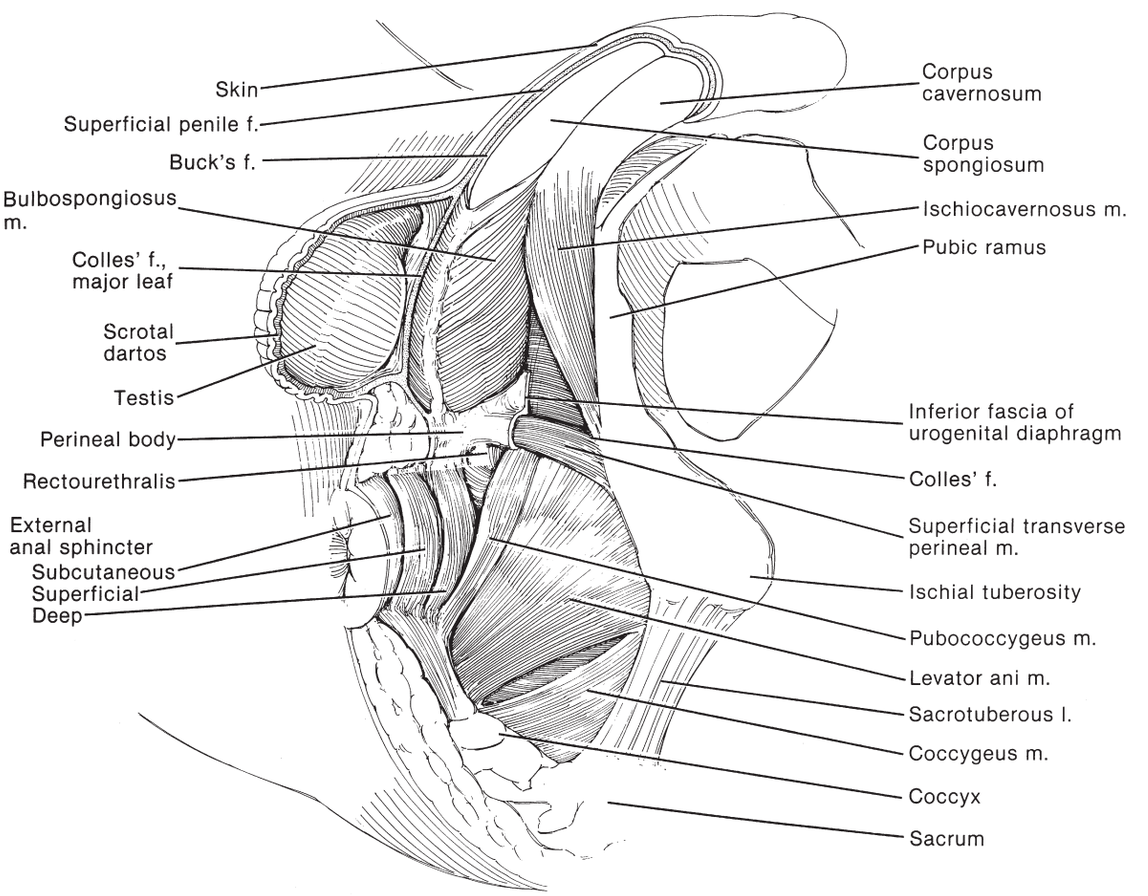
Skin
Superficial penile f.
Buck's f.
Bulbospongiosus m.
Colles' f., major leaf
Scrotal dartos
Testis
Perineal body
Rectourethralis
External anal sphincter
Subcutaneous
Superficial
Deep
Corpus cavernosum
Corpus spongiosum
Ischiocavernosus m.
Pubic ramus
Inferior fascia of urogenital diaphragm
Colles' f.
Superficial transverse perineal m.
Ischial tuberosity
Pubococcygeus m.
Levator ani m.
Sacrotuberous l.
Coccygeus m.
Coccyx
Sacrum

FIGURE 43-1.

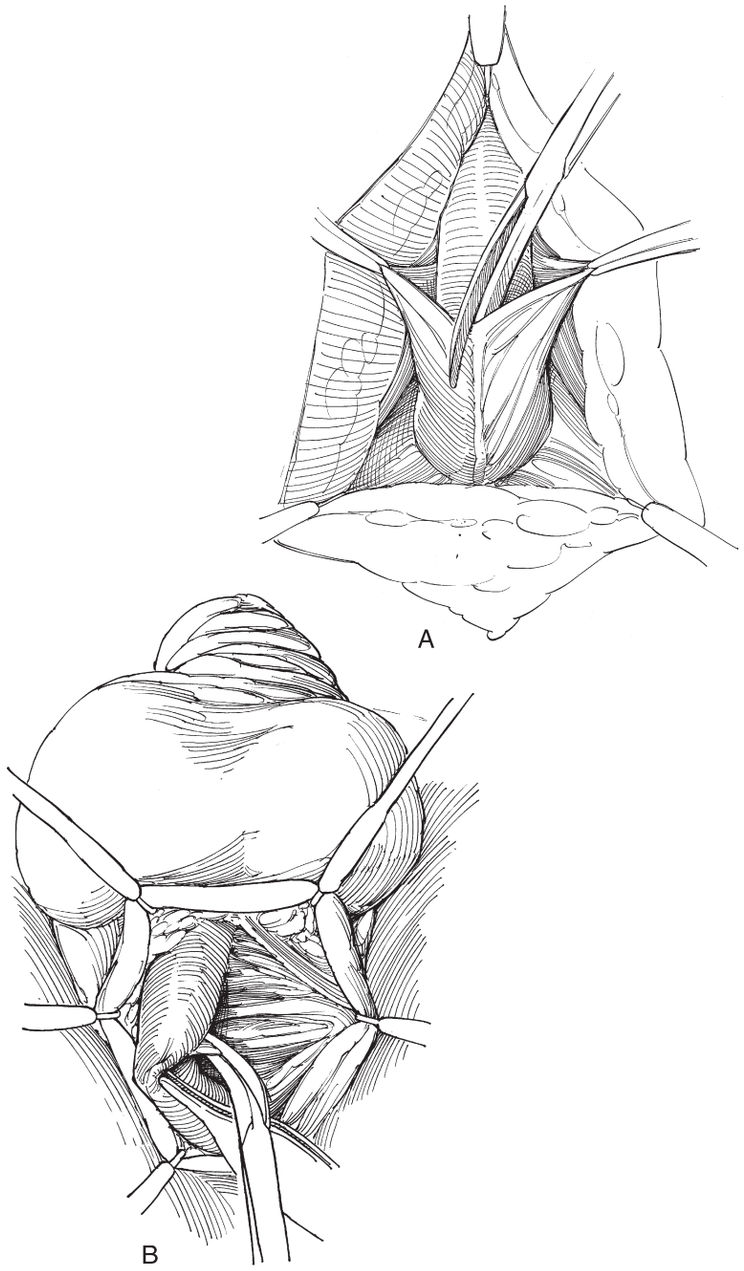

FIGURE 43-2.

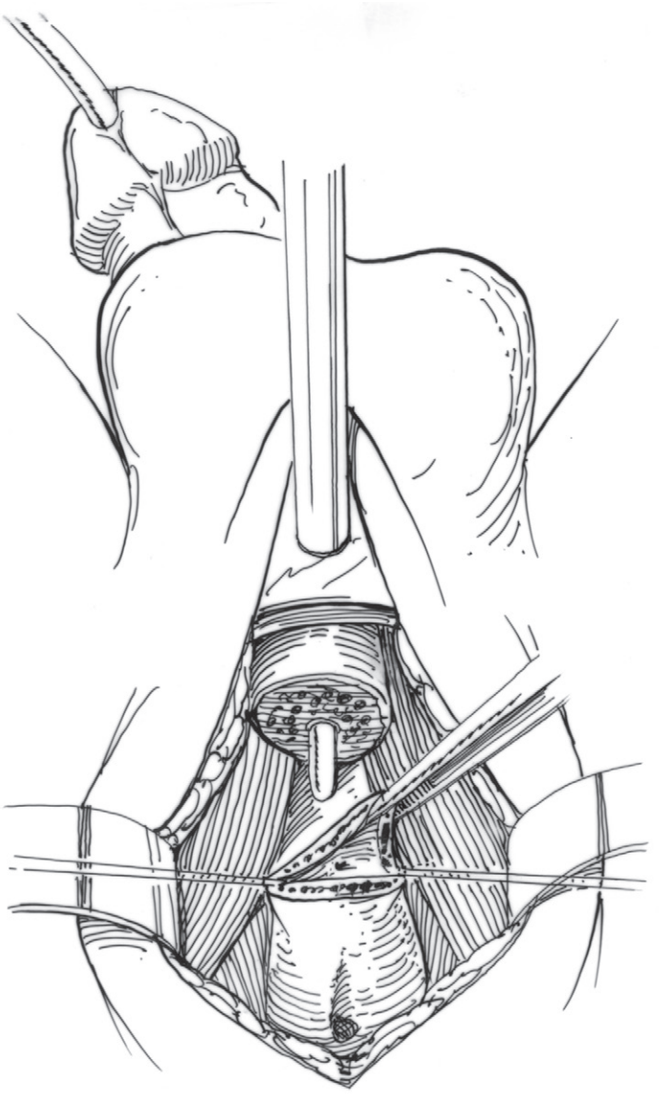

FIGURE 43-3.

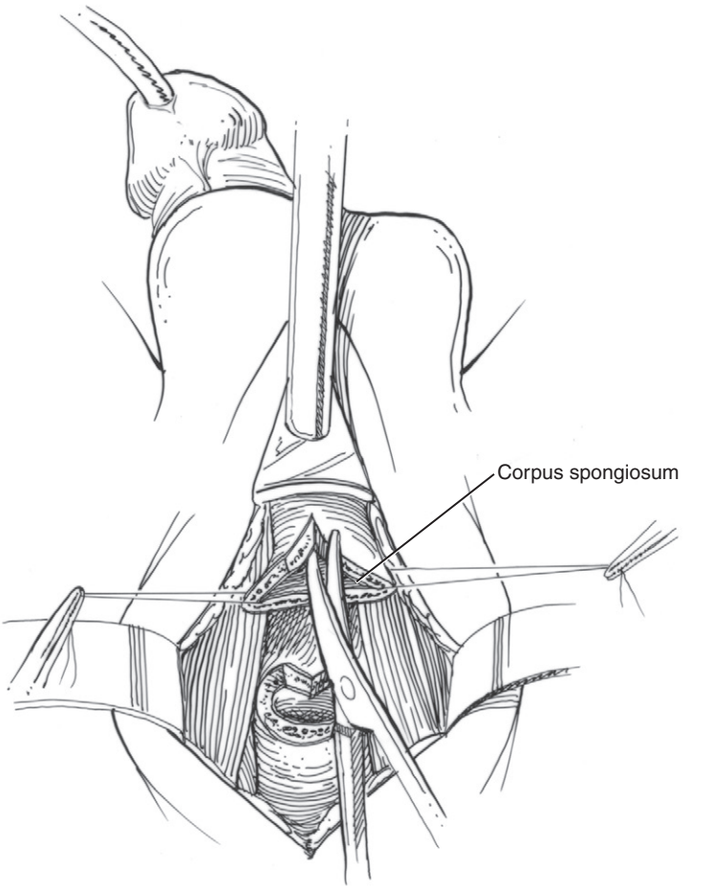

FIGURE 43-4.

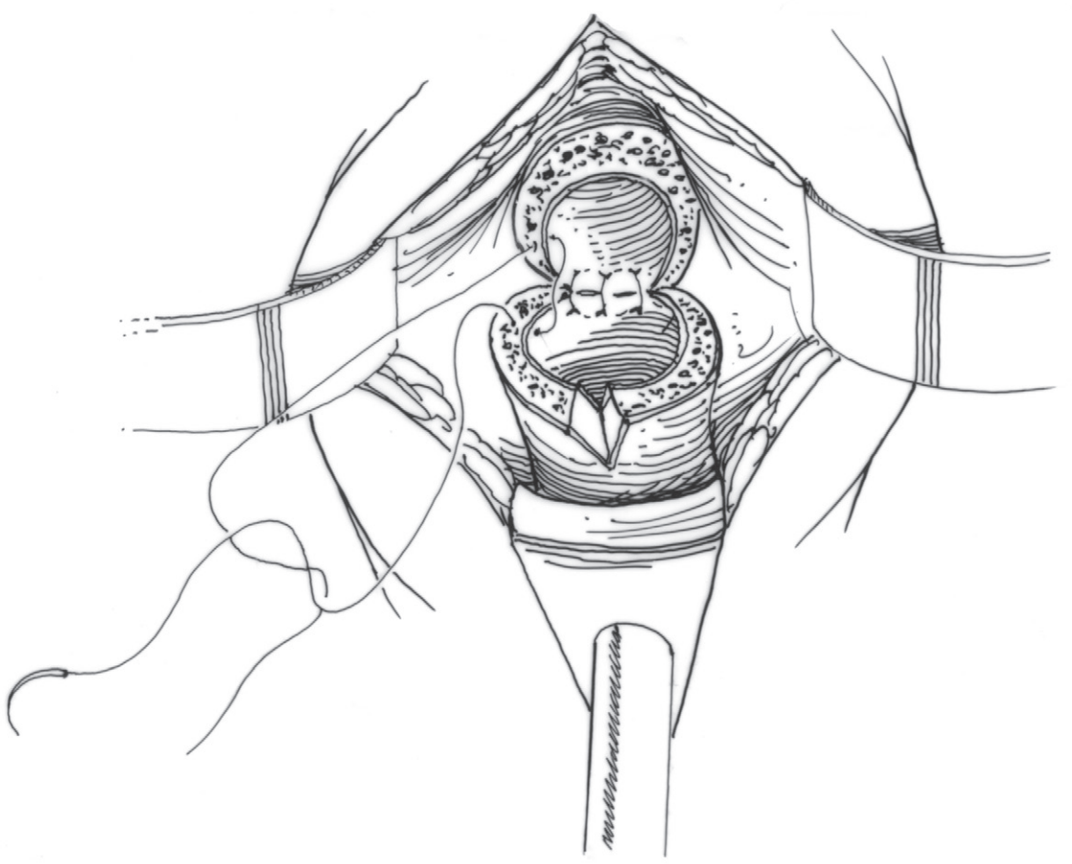

FIGURE 43-5.

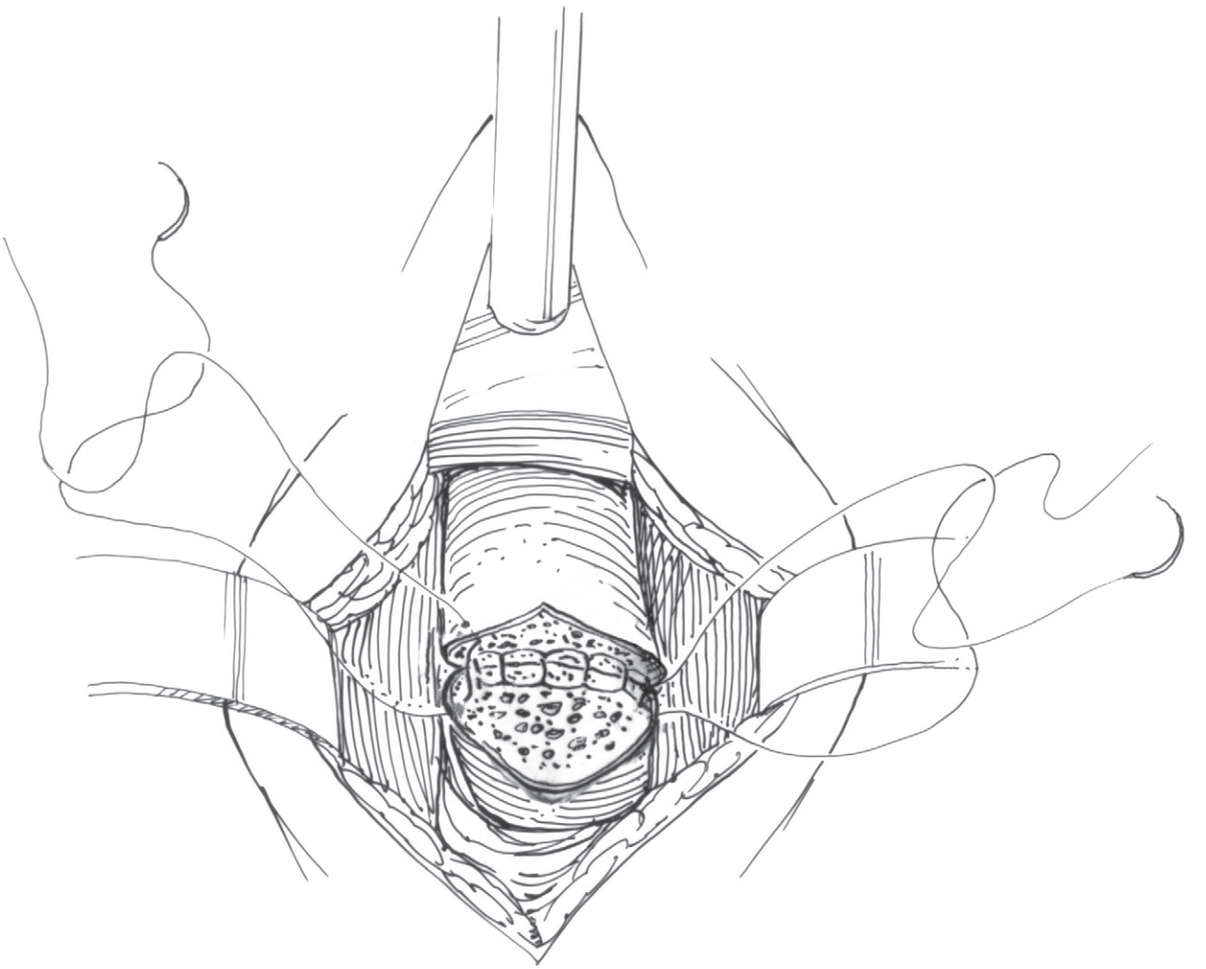

FIGURE 43-6.

over the catheter, and this incision is carried proximally and distally with fine scissors until the urethra calibrates to 28 French in both directions (Fig. 43-7).

Fine absorbable sutures are pre-placed in an outside-in fashion at both apices. The graft is tailored to the size of the defect, tapered at either end, and sewn in place (Fig. 43-8).

After tying down the apical sutures, a running suture may be used on either lateral side. A 16-French urethral catheter is placed after completing the first side of the closure (Fig. 43-9).

It is important to anastomose the graft to the urethral epithelium only. The spongioplasty is then accomplished by closing the adventitial layer over the graft. The perineum is closed in layers (Fig. 43-10).

Dorsal Graft

See description in Chapter 42. Contrary to the ventral graft, full-thickness bites of the urethra with corpus spongiosum should be used because no spongioplasty is done. The perineum is closed in layers.

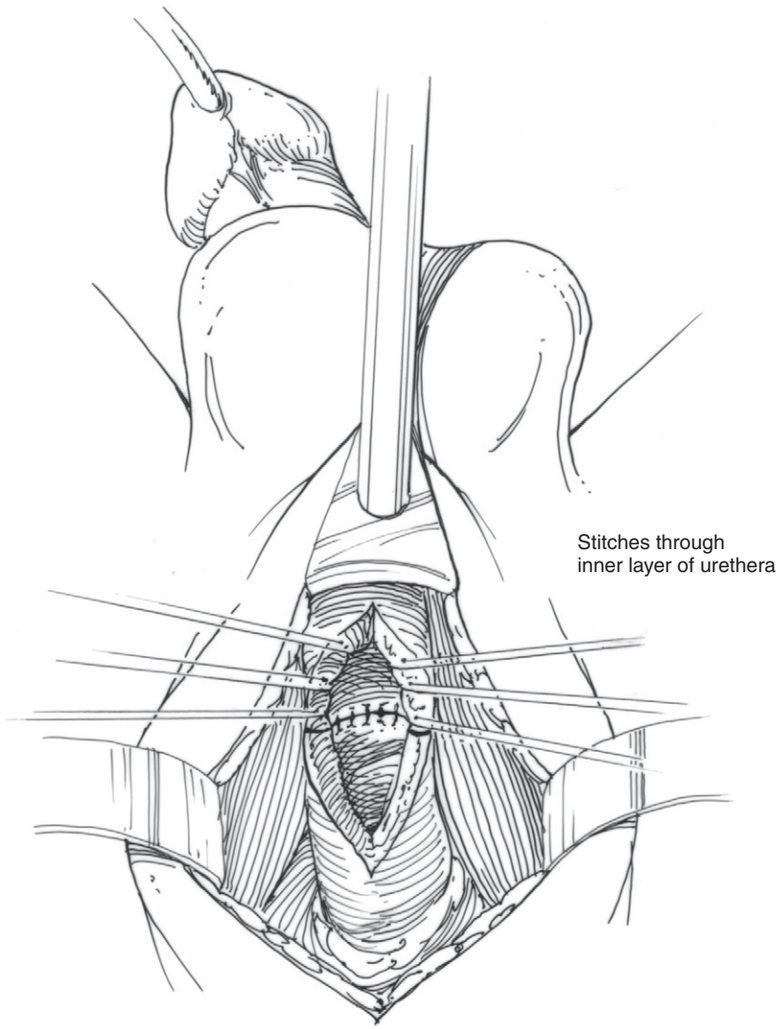

FIGURE 43-7.

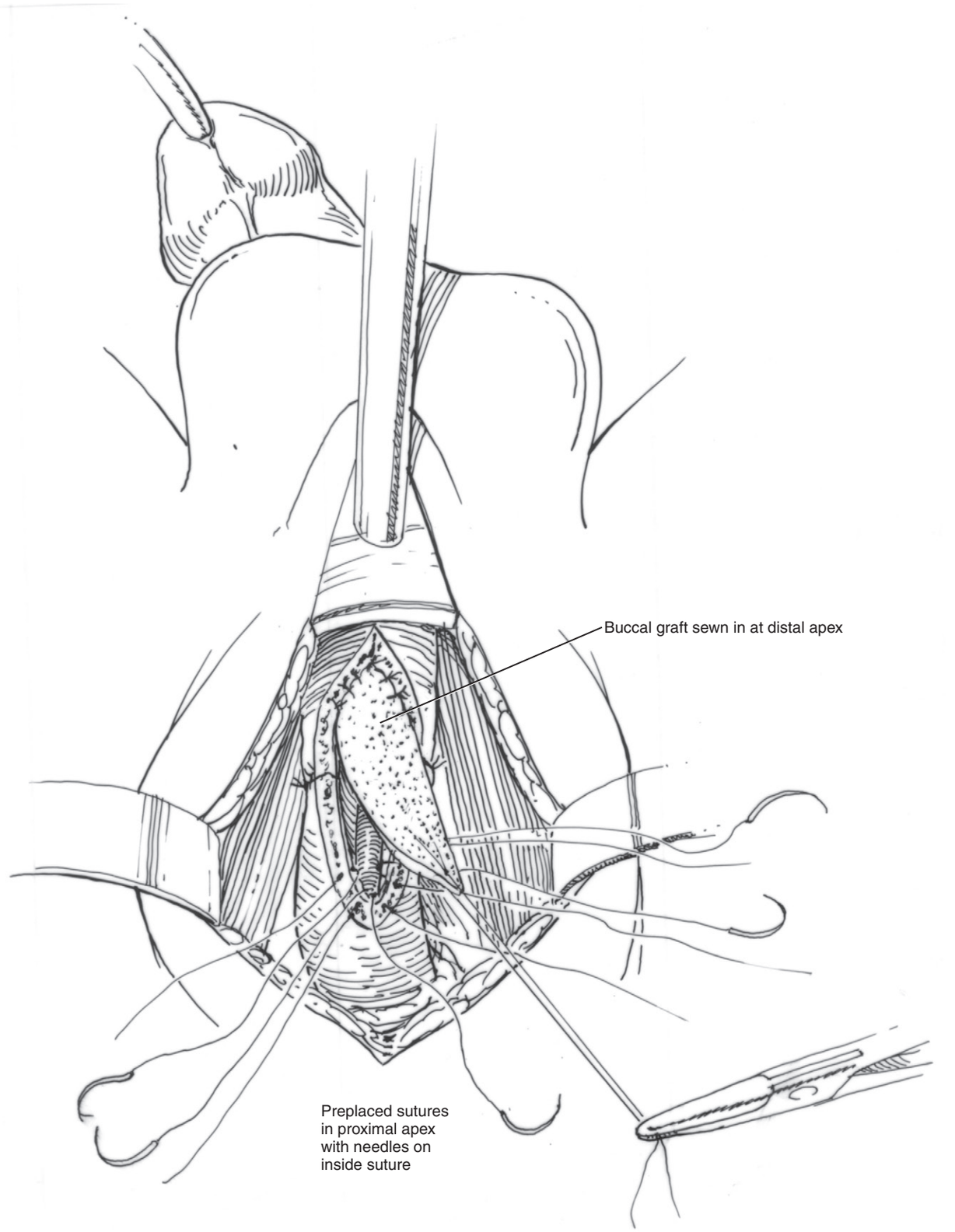
Buccal graft sewn in at distal apex
Preplaced sutures
in proximal apex
with needles on
inside suture

FIGURE 43-8.

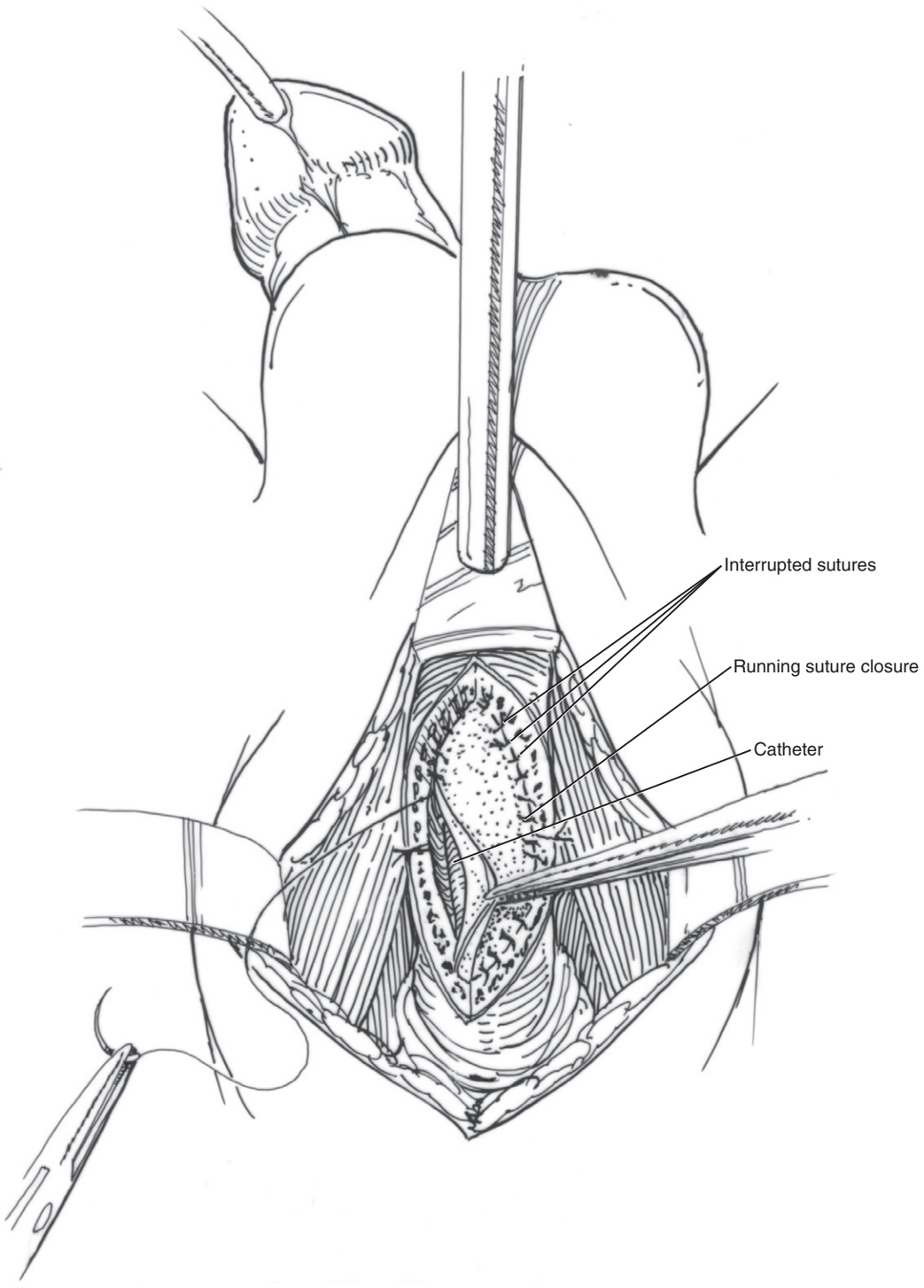

FIGURE 43-9.

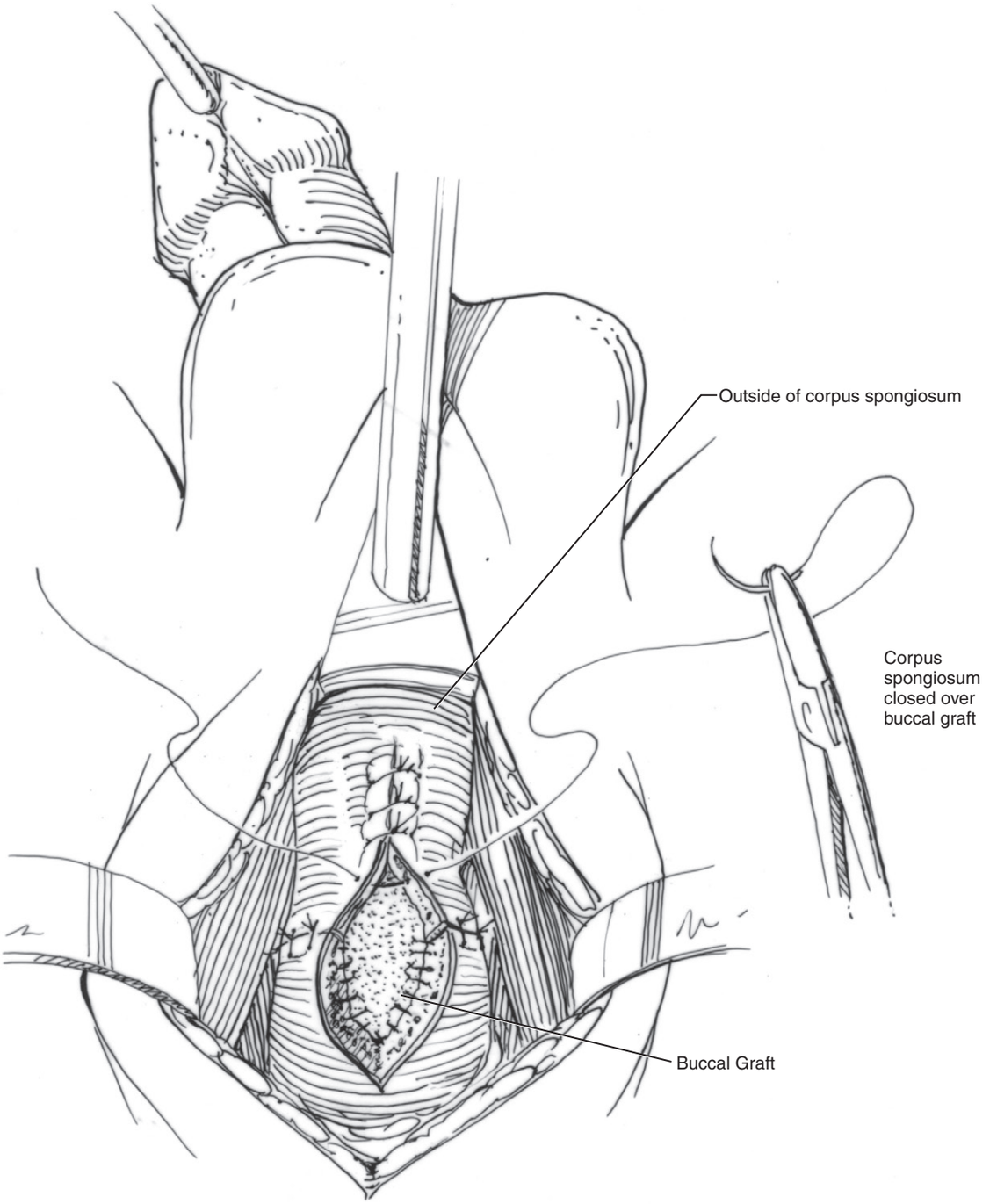

FIGURE 43-10.

Commentary by DOUGLAS F. MILAM

Experience has shown that both anastomotic and onlay urethroplasty are viable options for short (<2 cm) bulbar urethral strictures. Onlay urethroplasty begins to be favored in longer strictures because it avoids penile chordee and because the bulbar blood supply and bulbar arteries are almost never divided. The underlying injury that produced the stricture in the first place may have produced a relative devascularization of tissue, but a midline incision with very little circumferential dissection will not produce significant additional injury. The same cannot be said for long anastomotic urethroplasty procedures. Additionally, complete avoidance of the corpora cavernosa may prompt some to choose onlay over anastomotic urethroplasty in young sexually active men.

Chapter 44

Reconstruction of Membranous Urethral Disruption Injuries

SEAN P. ELLIOTT AND JACK W. McANINCH

Fractures of the bony pelvis frequently result in disruption of the membranous urethra, accompanied by superior displacement of the prostate due to pelvic hematoma. This is identified as extravasation of contrast on retrograde urethrography done for blood at the meatus or unsuccessful urethral catheter placement. Acute management of these patients should be directed at hemodynamic resuscitation, bony fixation, and obtaining bladder drainage via a large-bore suprapubic cystostomy catheter. The bladder should be explored at the time of cystostomy placement or a cystogram should be performed to rule out bladder or bladder neck injury. In select cases when the patient is hemodynamically stable, an attempt at endoscopic realignment is reasonable.

ENDOSCOPIC REALIGNMENT

Open urethral realignment or blind realignment with interlocking sounds or metallic sounds are inappropriate because of their low success rate and high complication rate. However, in a hemodynamically stable patient, endoscopic realignment has been shown to at least decrease the length of the rupture defect, making future open reconstruction easier and perhaps decreasing the likelihood of requiring open reconstruction. Realignment should be attempted only when appropriate support staff is available in the operating room to arrange for proper equipment and assist with fluoroscopy. For this reason, we discourage doing this as an "add-on" in the middle of the night.

PREOPERATIVE PLANNING FOR MEMBRANOUS URETHRAL RECONSTRUCTION

In contrast to the repair of anterior urethral strictures, a sine qua non of posterior urethral reconstruction is complete removal of all scar tissue. This is central to the pathophysiology of posterior urethral disruption injury in which the two ends of the urethra are separated by intervening scar tissue that results after consolidation of the traumatic pelvic hematoma. Thus, whereas in anterior urethral stricture disease there is often a urethral plate onto which to sew a graft or flap, there is no urethral plate in posterior urethral disruption injury. Therefore a successful reconstruction must incorporate complete excision of scar and anastomotic urethroplasty.

Complete preoperative staging of the defect is done with antegrade and retrograde cystourethrography through the suprapubic cystostomy and meatus, respectively. In many cases, the bladder neck may not open, making it impossible to measure the length of the defect by cystourethrogram because the prostatic urethra is not identified. In these cases, one may perform antegrade and retrograde cystourethroscopy under fluoroscopy or perform magnetic resonance imaging (MRI) of the pelvis. Best results are obtained with a special MRI protocol, necessitating good communication with the radiologist about the goals of the study. Advantages of an MRI include the ability to assess lateral and anteroposterior displacement of the prostate as well as avulsion of the corpora cavernosa off the inferior pubic rami. For urethral defects longer than 2.5 cm, one should be prepared to perform an inferior pubectomy combined with a perineal approach or a total pubectomy combined with an abdominoperineal (transpubic) approach.

PERINEAL ANASTOMOTIC URETHROPLASTY FOR MEMBRANOUS URETHRAL DISRUPTION INJURIES

A beanbag is rolled under the sacrum to elevate the buttocks and rotate the pelvis anteriorly. The legs are suspended from stirrups. With proper padding of the feet, especially laterally, pressure neuropathy is rare. With the patient in exaggerated lithotomy position, the perineum and lower abdomen are prepped and draped (Fig. 44-1).

A midline (or inverted-Y) perineal incision is made. The bulbospongiosus muscles are split in the midline



FIGURE 44-1.

and retracted laterally with hooks on a ring retractor (e.g., Scott retractor) or using a perineal Bookwalter retractor (see discussion in Chapter 43). The urethra is encircled and dissected off the underlying corporal bodies. The posterior attachments to the perineal body are divided (Fig. 44-2). The bulbar arteries are often obliterated by scar; however, if they are patent then they are suture-ligated at this point. A 20-French catheter is passed from the urethral meatus, and the urethra is transected at the level of distal obstruction.

Either a large (e.g., 16 to 20 French) Van Buren sound or flexible cystoscope is passed through the cystostomy tract down the prostatic urethra until meeting the proximal end of the obstruction (Fig. 44-3). Scar tissue is excised through the perineal incision until the sound or cystoscope is met. In some cases, it is helpful to lower the lights in the room and cut toward the cystoscope light.

Once the proximal lumen is entered, holding sutures are placed in the urethra at the 3- and 9-o'clock positions, and additional urethra is excised until the edges appear healthy and the lumen calibrates to 28 French (Fig. 44-4). This is often at the level of the prostatic apex. Retrograde cystoscopy is performed.

The distal urethra is further mobilized off the underlying corpora cavernosa toward the penoscrotal junction until the urethra can reach the proximal urethral stump without tension (Fig. 44-5).

If the urethral ends cannot reach without tension, then the corporal bodies may be split in the midline over the pubic symphysis using a scalpel to allow for a more direct course for the urethra (Fig. 44-6).

If tension persists, then an inferior pubectomy may be performed. The corporal bodies are mobilized off the underlying inferior pubic rami. The cavernosal nerves may be exposed at this point and care should be taken to avoid them. A mallet and osteotome are used to excise the inferior aspect of the pubic rami (Fig. 44-7). Bone wax may be applied to the cut edges of the bone if bleeding is problematic.

The urethral stumps are spatulated on opposite sides, and 12 absorbable 6-0 monofilament sutures are pre-placed in the proximal urethral stump, generally in a clockwise fashion starting at the 12 o'clock position. The needles should be left on the luminal (inside) end of the suture. For a right-handed surgeon, it is usually helpful to use double-armed sutures passed inside-out for the right side of the

(Text continues on page 282)

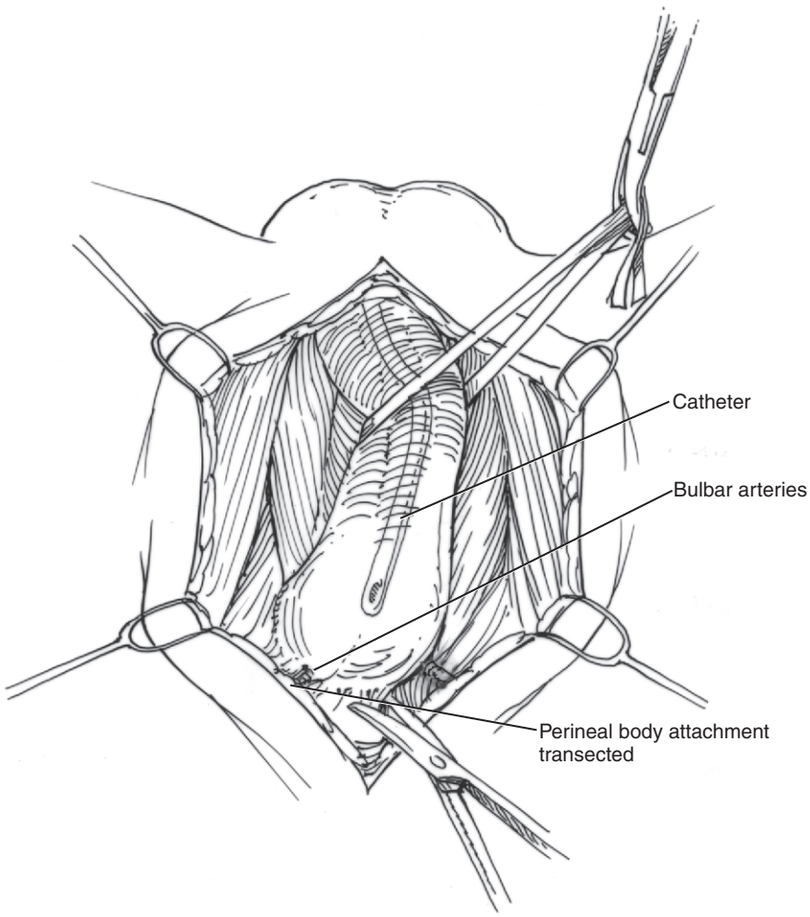

FIGURE 44-2.

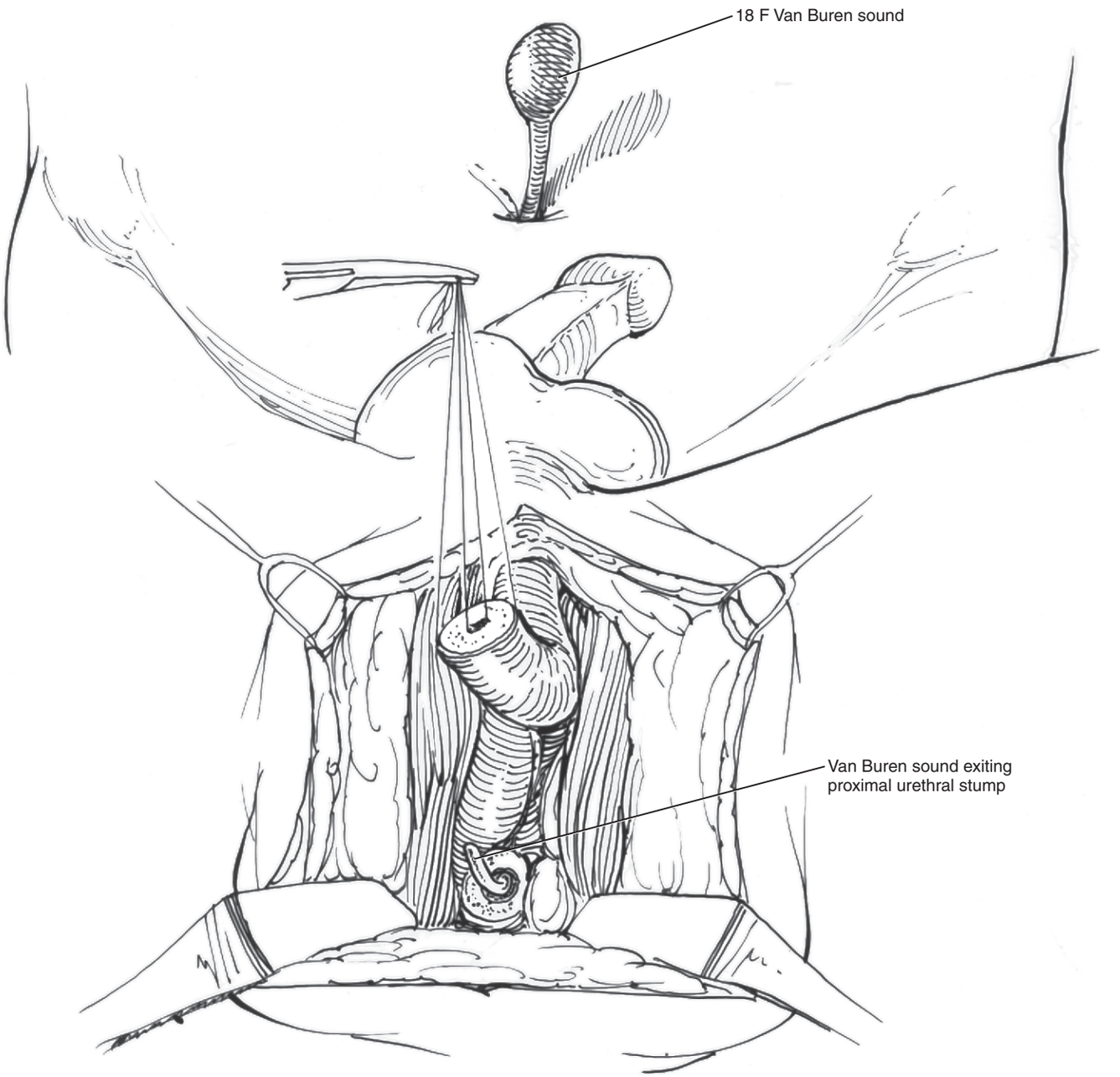
18 F Van Buren sound
Van Buren sound exiting
proximal urethral stump

FIGURE 44-3.

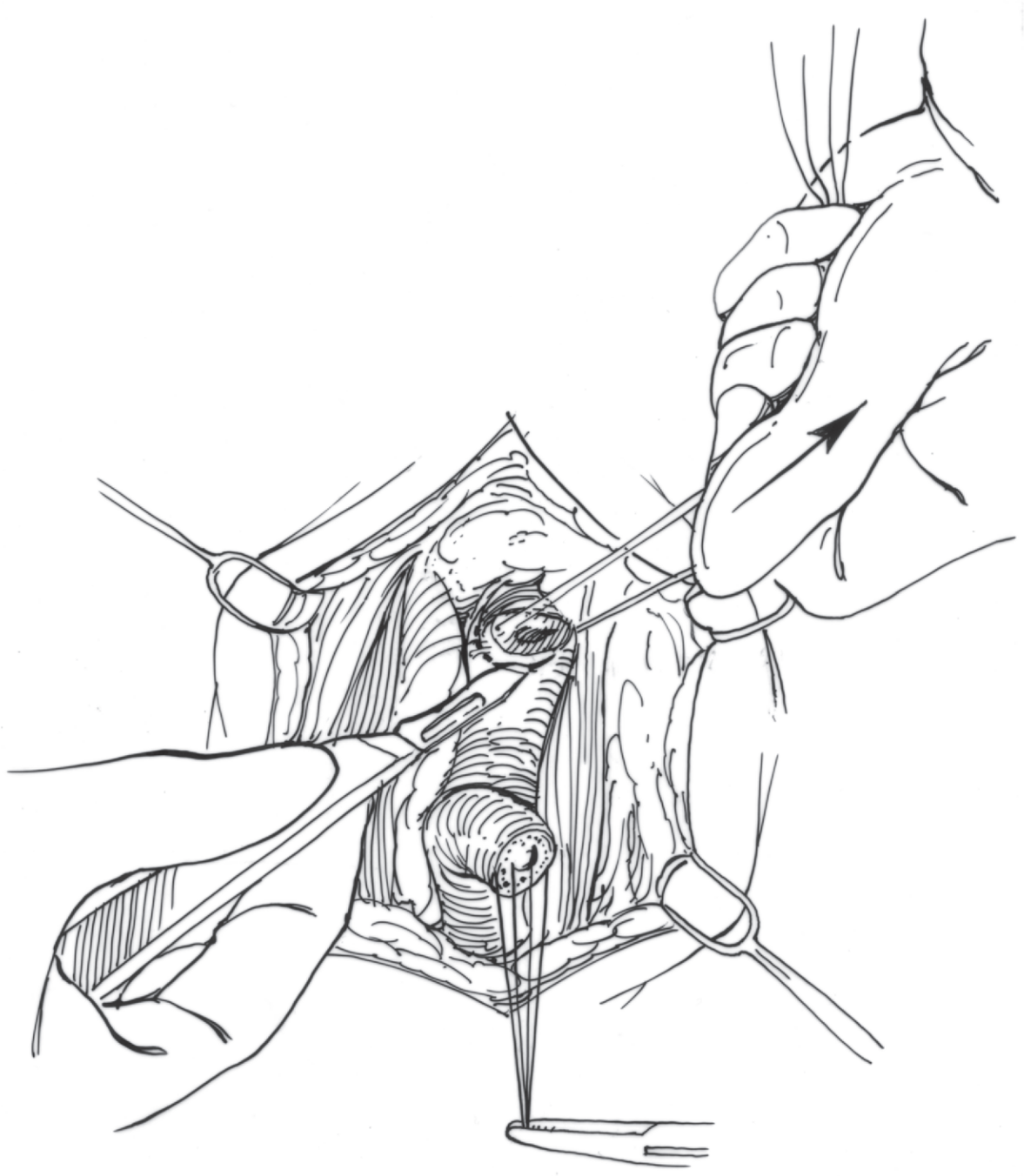

FIGURE 44-4.

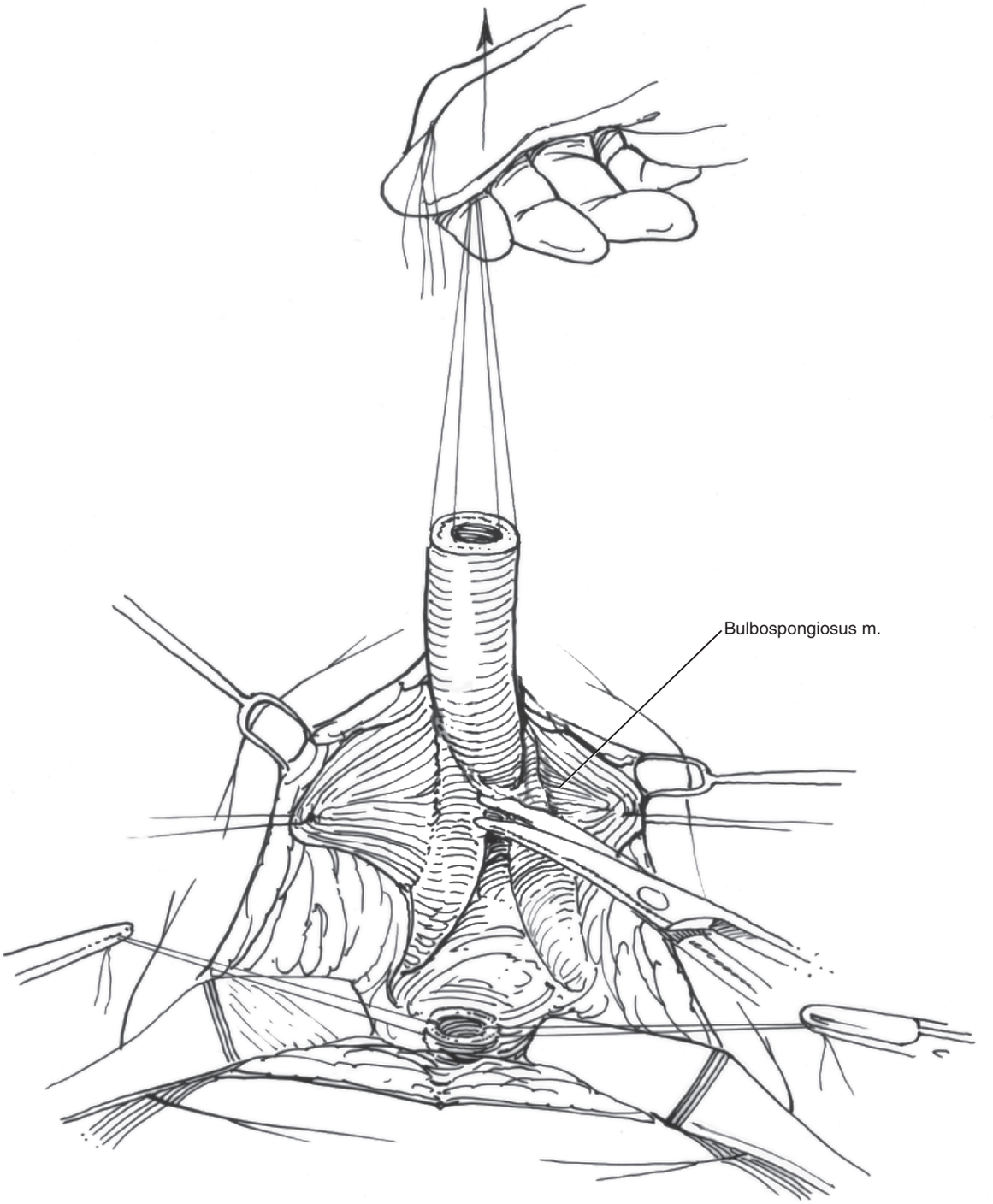

FIGURE 44-5.

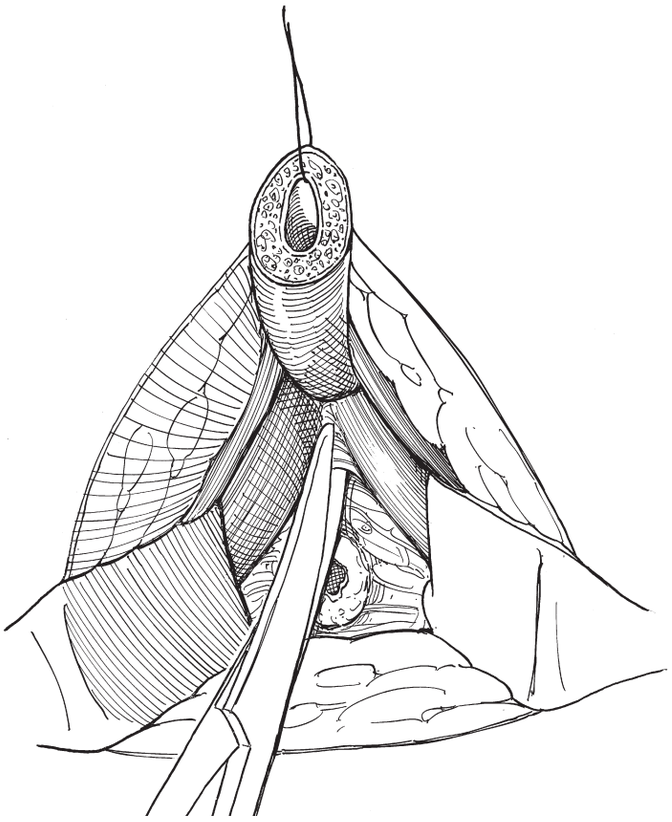

FIGURE 44-6.

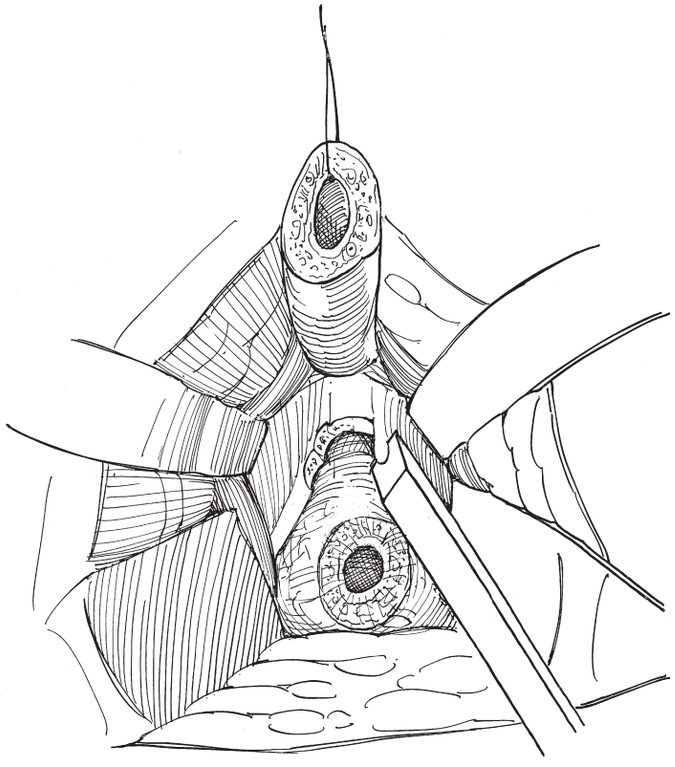

FIGURE 44-7.

urethra (i.e., 6- to 12-o'clock positions) and then cut off the outside needle. Sutures should be secured with numbered, rubber-shod fine clamps (Fig. 44-8).

Sutures are then passed inside-out through the distal urethral stump in single-layer, full-thickness fashion in the same clockwise order as before. Between the 5- and 7-o'clock positions, the abundant corpus spongiosum frequently precludes taking full-thickness bites. The urethral catheter should be passed after placing half the sutures in the distal stump (i.e., after the 6-o'clock stitch). Sutures are reclamped until all have been passed through the distal urethral stump (Fig. 44-9).

Sutures are then tied down circumferentially in a clockwise fashion starting at the 12-o'clock position, while the assistant uses DeBakey forceps to bring the distal urethra toward the proximal urethra, relieving any tension on the sutures (Fig. 44-10).

Keys to avoiding entanglement of sutures include (1) securing sutures with numbered clamps, (2) always passing/tying sutures in the same order (i.e., clockwise from the 12- to the 11-o'clock position), and (3) passing the urethral catheter after placing the 6-o'clock distal stump suture. After circumferential urethral closure, the wound is closed in layers. A new suprapubic cystostomy tube should be inserted and left in place until after the urethral catheter is removed because most patients have been dependent on a suprapubic catheter for many months leading up to surgery and are at risk for urinary retention in the early postoperative period, even with a patent urethra.

ABDOMINOPERINEAL (TRANSPUBIC) ANASTOMOTIC URETHROPLASTY FOR MEMBRANOUS URETHRAL DISRUPTION INJURIES

Indications for a transpubic approach include the following:

- To improve visualization in long distraction defects, because a pure perineal approach leads to a deep wound with poor visualization
- To allow a tension-free anastomosis in long distraction defects
- To allow excision of scar at the prostatic apex
- To aid in the excision of fistulous tracts and cavities

The patient is placed in lithotomy position using movable stirrups to enable switching from high to low lithotomy as necessary. The lower abdomen and perineum are prepped and draped. With the patient in high lithotomy position, the urethra is exposed and transected at the distal end of

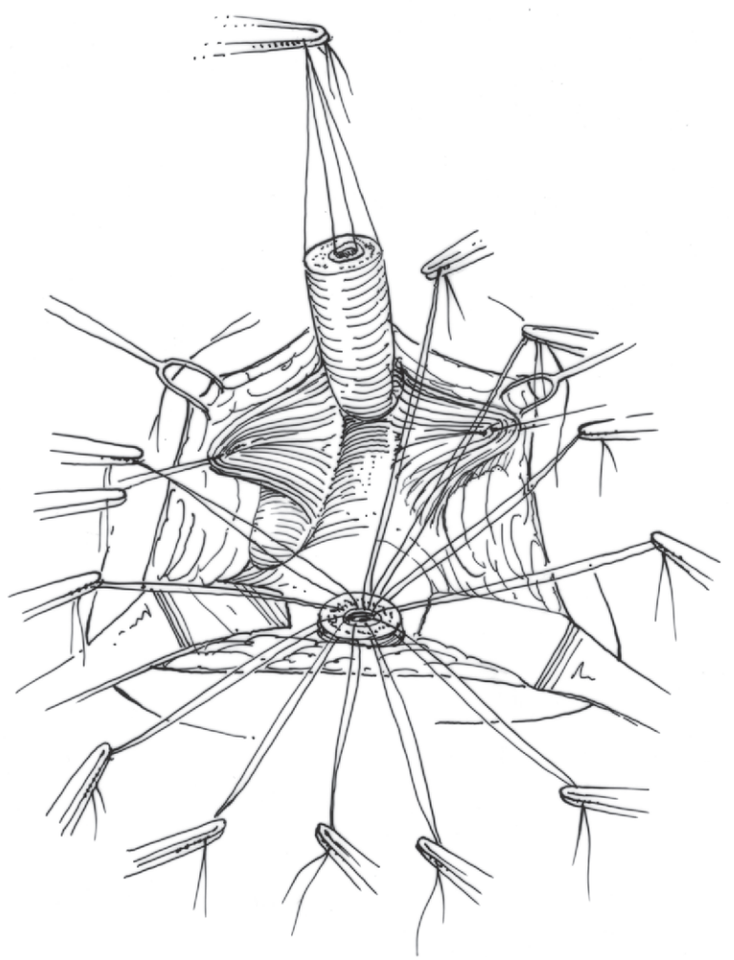

FIGURE 44-8.

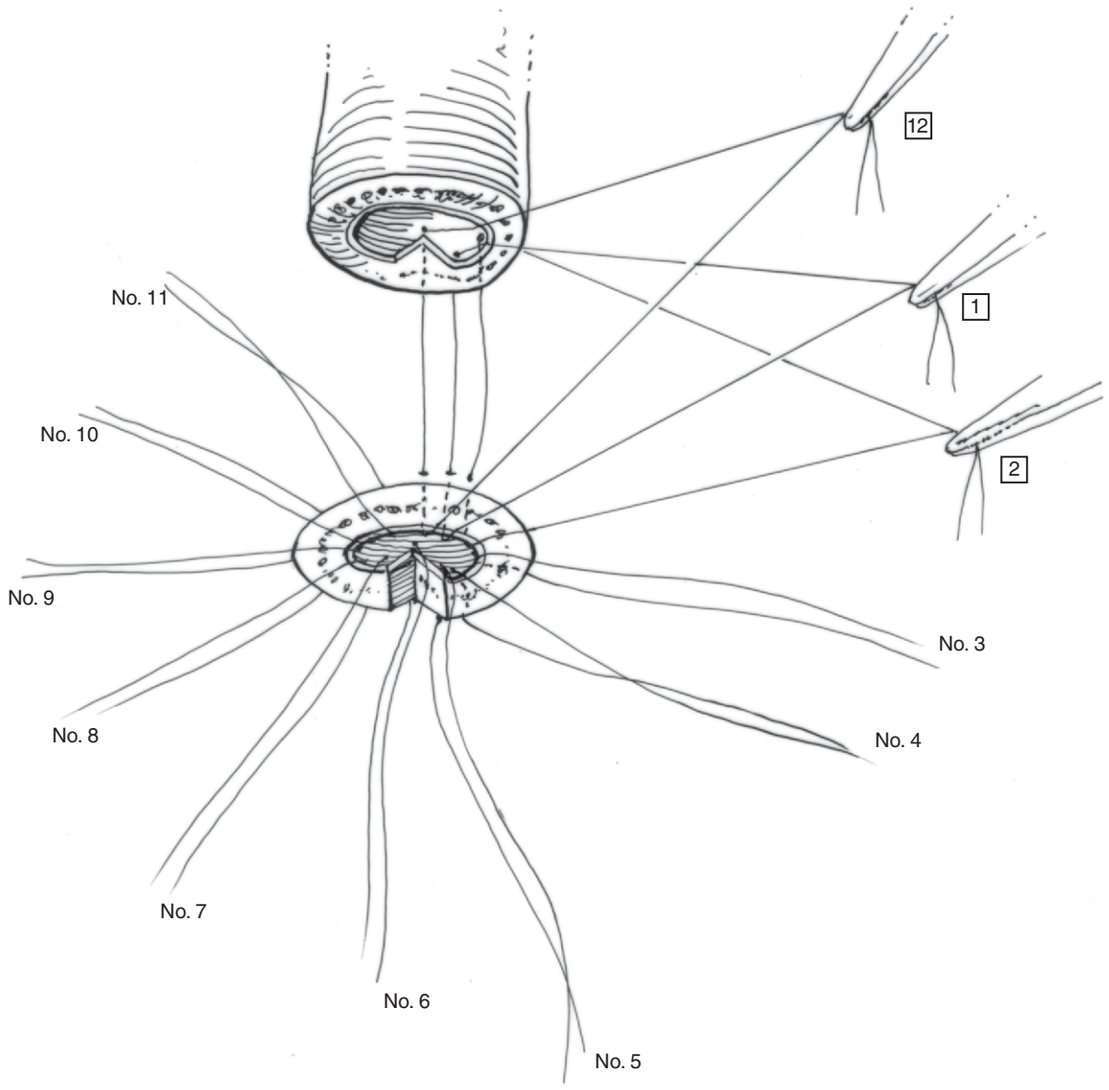

FIGURE 44-9.

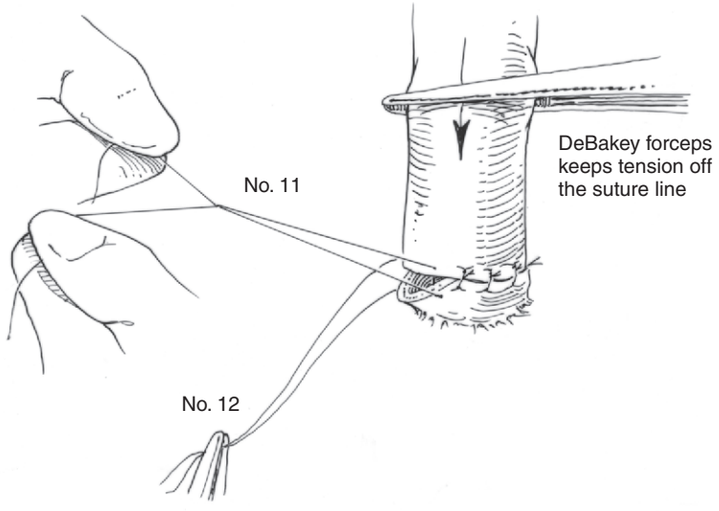

FIGURE 44-10.

the stricture (see Figs. 44-1 and 44-2). The legs are lowered and a midline suprapubic incision is made and carried over the pubic symphysis to the base of the penis (Fig. 44-11). The bladder is opened and the prostatic urethra is identified. The anterior symphysis is identified and exposed widely. The suspensory ligament of the penis is divided; care should be taken to avoid the cavernosal nerves.

Dissection is then carried to the posterior aspect of the pubic symphysis. There is a large amount of scar tissue in this area; thus to avoid troublesome bleeding, one should remain in a plane directly on the periosteum. At the inferior aspect of this dissection, one will encounter the anterior dissection (Fig. 44-12).

The pubic rami are encircled laterally and excised with an oscillating saw or Gigli saw (Fig. 44-13). Hemostasis is obtained; bone wax may be applied to the cut surfaces of bone.

With the improved exposure after pubectomy, the scar surrounding the prostatic apex can be resected until a urethral sound passed from above is visualized (Fig. 44-14). The prostatic urethra should calibrate to 30 French. This is spatulated on the anterior surface of the prostate. The distal urethra is mobilized off the corporal bodies until a tension-free anastomosis can be obtained. Anastomosis is accomplished as described in steps 8 to 10 of this chapter.

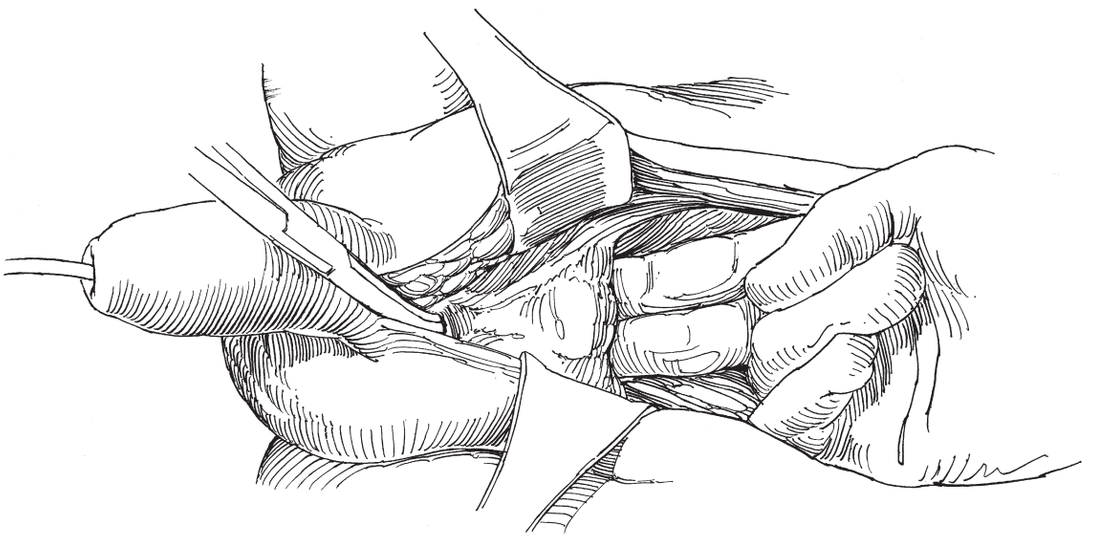

FIGURE 44-11.

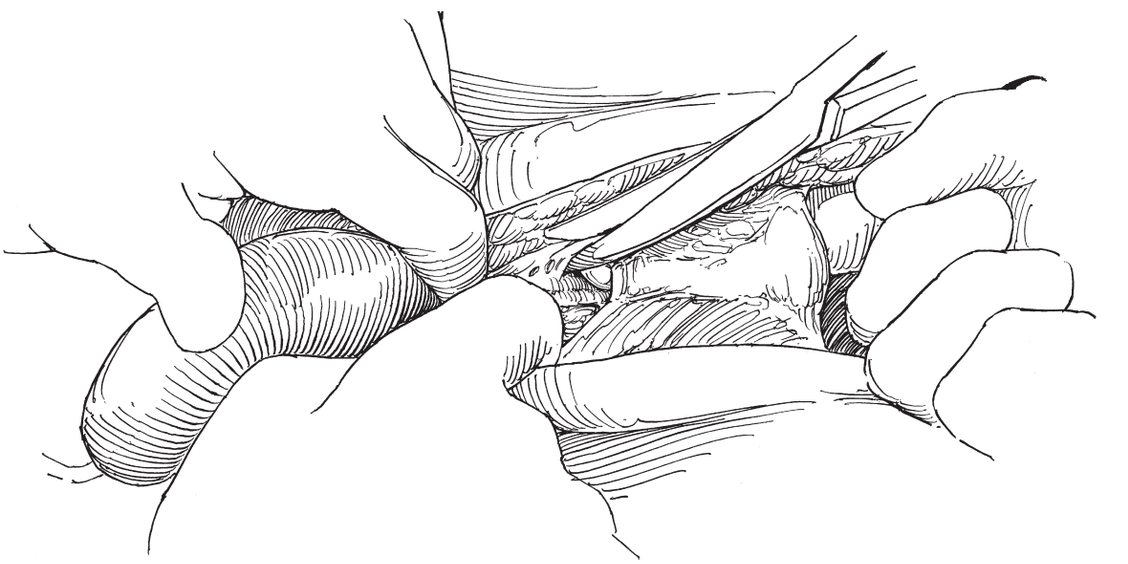

FIGURE 44-12.

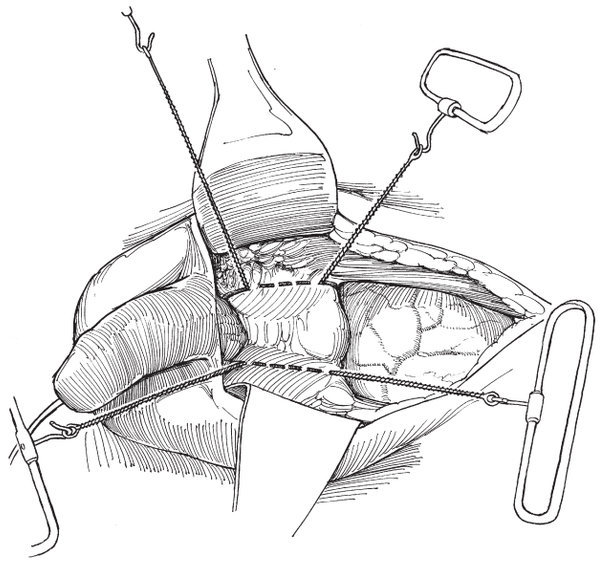

FIGURE 44-13.

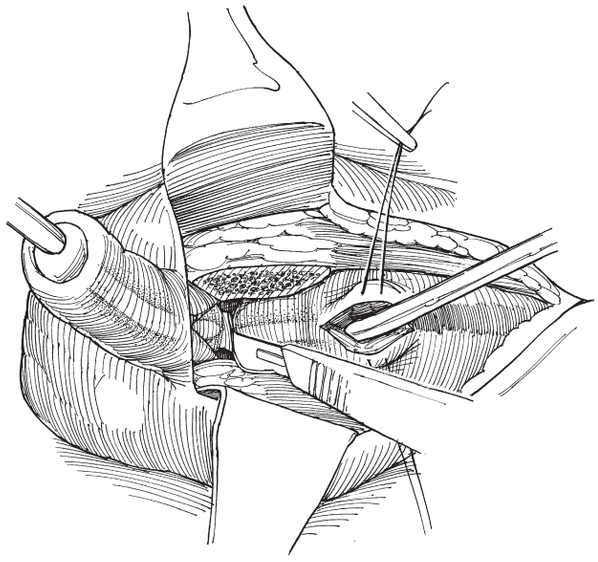

FIGURE 44-14.

Commentary by

DOUGLAS F. MILAM

The authors discuss the option of realignment of prostatomembranous urethral disruption in the initial postinjury period as opposed to placement of a suprapubic cystostomy. Whether or not to recommend endoscopic realignment within the first few days after an injury has been one of the most heated and longest running debates in reconstructive urology. Visual passage of a cystoscope and guidewire, or antegrade and retrograde passage of a soft catheter with a cystotomy and the space of Retzius exposed is a reasonable treatment option. Successful catheter passage across the urethral defect likely decreases the chance that further reconstructive surgery will be required.

This page intentionally left blank

Chapter 45

York-Mason Closure of Recto-Urinary Fistula

RICHARD G. MIDDLETON

Rectourinary fistulas may occur as a consequence of infection, malignancy, prior radiation, or operative injury. Sometimes, especially when associated with malignancy or an eroding infectious process, operative closure is not indicated and urinary diversion is performed. For fistulas that result from operative injury to the rectum, especially those that occur after radical prostatectomy, successful closure of the fistula should be a paramount goal. The York Mason approach is a relatively straightforward procedure with a high degree of success.

Rectourinary fistulas typically present with either fecaluria or urine drainage from the rectum. Pelvic abscess may be a presenting problem. Most often, bowel diversion with either a loop colostomy or ileostomy is the first step. Often, the fistula is palpable on rectal exam. Occasionally, spontaneous closure occurs, especially in a nonirradiated pelvis. Persistence of the fistula is an indication for operative repair.

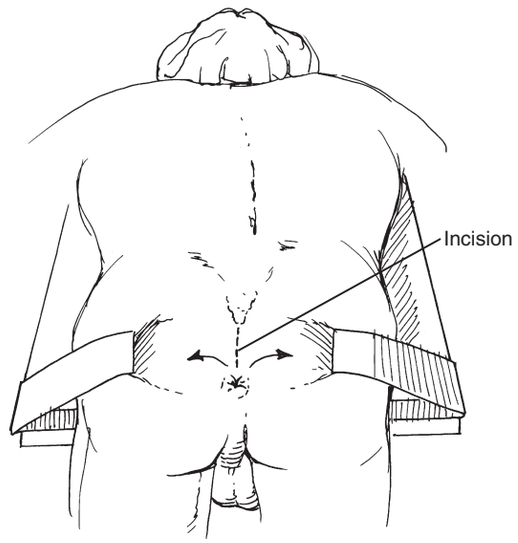

FIGURE 45-1.

OPERATIVE PROCEDURE

Position: The patient is placed on the operating table in a prone jackknife position. Adhesive tape can be used to separate the buttocks (Fig. 45-1). An incision is made in the midline from the tip of the coccyx to the anal verge. The anal sphincter is incised sharply. Tagging of the muscular layers of the sphincter with sutures can help identify the separate layers for closure. The posterior anus and rectum are opened along the full length of the incision (Fig. 45-2). Retractors are placed to separate the incision and allow vision of the anterior rectal wall. Usually, the fistula site is evident on gross inspection. With a small fistula, cystoscopic placement of a guidewire through the fistula and into the rectal lumen can be useful in identifying the fistula.

Some surgeons avoid excision of any tissue but our preference has been to excise the fistula tract itself to a point where the catheter placed preoperatively in the urethra is visible.

Ideally, three individual tissue layers are used for closure of the fistula. The wall of the urethra should be

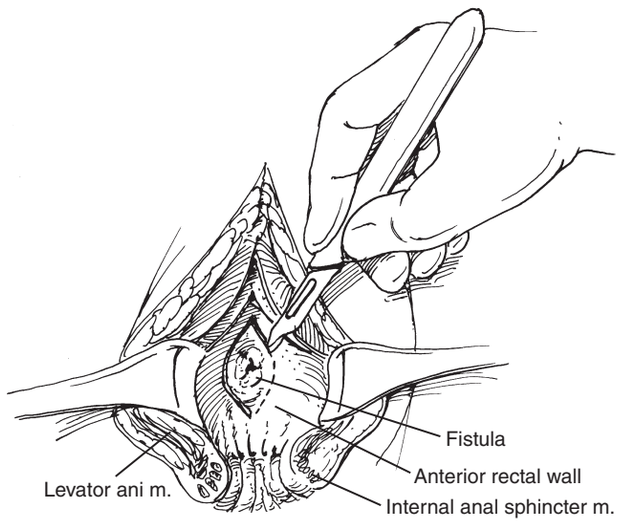

FIGURE 45-2.

separated from the overlying rectal wall for a distance to permit a secure closure with 2-0 absorbable sutures. The anterior rectal wall can then provide a sturdy layer for closure. The mucosa and submucosa of the rectal wall are undermined for a centimeter or 2 and then are closed as a third layer.

Wound closure is first accomplished by closing the posterior rectal wall with a running absorbable 2-0 suture. This is carried all the way to the anal verge. The anal sphincter is reconstructed by bringing together and reapproximating the muscular layers identified by the tagged sutures. A finger should be inserted in to the reconstructed rectum to make certain that the lumen is of good capacity. A Penrose drain is placed under the presacral fascia. The skin is closed with a subcuticular suture.

POSTOPERATIVE CARE

Resumption of a regular diet can occur immediately after surgery if the patient has bowel diversion. Postoperative pain is relatively mild and controllable with oral nonsteroidal anti-inflammatory drugs or oral narcotics if necessary. Urinary diversion with a Foley catheter should be maintained for 4 to 6 weeks to allow complete healing. Colostomy closure should be delayed for a couple of months to ensure that the fistula does not recur before closure. Cystoscopic verification of fistula healing as well as a careful digital rectal examination should be performed before colostomy closure. Despite complete incision through the anal sphincter mechanism, incontinence of stool is a very rare problem after surgery.

Commentary by DOUGLAS F. MILAM

The author has the longest running and largest published series describing the use of the York-Mason repair for rectourethral fistula. A few points are worth discussion and emphasis. Data from his papers coupled with colorectal surgical literature indicate that reconstructive procedures such as the York-Mason repair can be safely conducted in many patients without diverting colostomy. Mechanical and antibiotic bowel preparation is sufficient if the patient has normal immune status and the operative field has never been radiated.

Performing the repair shortly after fistula diagnosis is recommended by the author for patients who have not received local radiation or cryotherapy. Most of the patients in the published series had their fistula for a few months due to the time required for diagnosis, referral, and surgical scheduling. Allowing 3 months for local inflammation to subside before surgery is a reasonable option. Nevertheless, the excellent exposure and ample mobile local tissue provided by this technique allow for immediate repair. The author's recommendation to wait a longer period of time in radiation induced fistulas deserves emphasis. On many occasions I have seen small, newly diagnosed radiation fistulas progress to complete erosion of the urethra and anterior rectal wall. Severe, large radiation-induced fistulas are best handled by urinary diversion. Cystectomy, proctectomy, and diverting colostomy are often necessary for patients with these devastating fistulas.

Chapter 46

Direct Vision Internal Urethrotomy

MELISSA R. KAUFMAN AND DOUGLAS F. MILAM

Urethral stricture disease (USD) remains a significant and often recalcitrant urologic condition encountered by the majority of practicing urologists. Treatment algorithms for management often involve attempts at endoscopic management before progression to more definitive surgical interventions such as open urethroplasty. The range of pathologies that may manifest with urethral obstruction is protean, and vigilance must be maintained to ensure that morbid and ominous conditions such as urethral cancer have been adequately ruled out before undertaking to interventions for stricture disease.

In general, direct vision internal urethrotomy (DVIU) is a modality best used for initial formal opening of a short, defined bulbomembranous stricture (Fig. 46-1). DVIU presents a more controlled alternative to urethral dilation in many circumstances and may allow diminished circumferential fibrosis and decrease stricture recurrence. In very select instances, DVIU may also be used in the management of panurethral disease or to manage anastomotic strictures following urethroplasty procedures. Caution should be employed with regard to recurrent DVIU as repeat incisions portend lower probability of success as they tend to devascularize the tissue and precipitate deeper spongiofibrosis and progression of stricture disease. Several intrinsic factors are critical to consider as they influence success of DVIU, including stricture length, location, recurrence, and etiology. In general, strictures with dense fibrosis greater than 2 cm are poor candidates for endoscopic management with DVIU (Fig. 46-2).

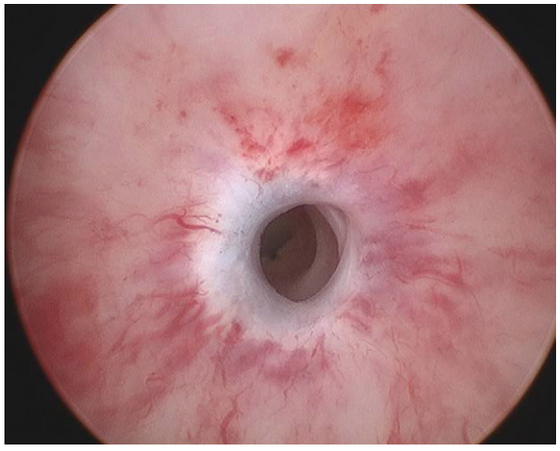

FIGURE 46-1. Short stricture with visualization of proximal normal urethra.

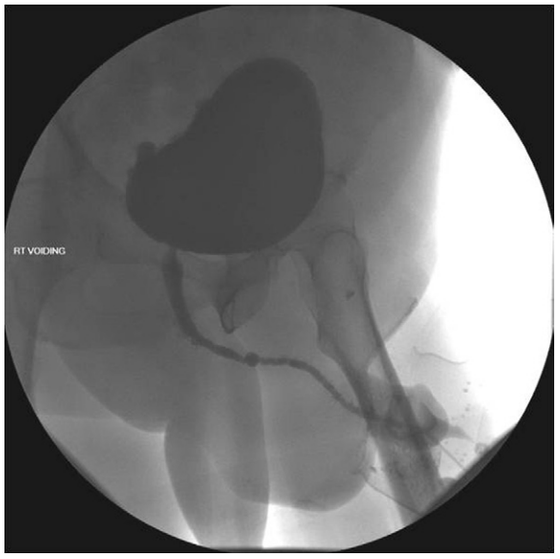

FIGURE 46-2. Dense, long stricture representing poor direct vision internal urethrotomy candidate.

Several modalities may be employed to perform DVIU; this chapter discusses classic cold knife techniques and newer modifications using holmium laser technology. We additionally discuss postoperative management of the DVIU patient and indications to progress to definitive urethroplasty.

PREOPERATIVE EVALUATION

Evaluation of the stricture anatomy is classically performed using retrograde urethrogram, if possible, in conjunction with voiding cystourethrogram, and is often augmented by

office cystoscopy. In addition to traditional preoperative anesthesia evaluation, urine culture before surgery can assist with antibiotic choice if the patient has a history of urinary tract colonization or infection. Immediately preoperatively patients should be administered antibiotics per the American Urological Association (AUA) guidelines. Appropriate agents suggested are fluoroquinolones or trimethoprim-sulfamethoxazole, and AUA guidelines recommend therapy for less than or equal to 24 hours for routine situations. These cases are often limited in time and purely endoscopic in nature, so deep vein thrombosis prophylaxis outside of early postoperative ambulation is not required for patients except those in the high-risk category. Patients should always be prepared preoperatively for possible need for placement of suprapubic drainage, in that occasionally the anatomy does not allow access in a retrograde fashion.



FIGURE 46-3. Passage of a guidewire.

1. Place the patient in dorsal lithotomy position with stirrups and appropriate padding to prevent neurapraxia. Following Betadine or chlorhexidine preparation and draping, a 22-French rigid cystoscope is used to directly visualize the stricture (see Fig. 46-1). It is critical at this juncture to not traverse the stricture with the scope as this produces dilation. Healing following dilation likely represents a different process than a controlled urethrotomy and may increase risk of recurrence. Via the cystoscope channel, a guidewire is then advanced into the bladder (Fig. 46-3). Guidewire passage is a critical component of this procedure and should not be omitted because the risk of bleeding obscuring the urethra or substantial damage precluding retrograde navigation to the bladder is ever present. Guidewire passage in exceptionally complex cases may need confirmation with fluorography. If primary urethrotomy is to be performed with a cold knife, the cystoscope is then removed and a urethrotome obtained. The urethrotome consists of a blind obturator for distal insertion with a 21-French irrigation sheath and a cold knife oriented to the 12-o'clock position. The urethrotome contains a trigger mechanism such that the knife is only deployed past the sheath when the rings are opened. The obturator and sheath are inserted distal to the level of the stricture, the obturator is extracted and the urethrotome inserted utilizing a 0-degree lens. It is critical for appropriate visualization of the knife and urethra that an angled lens not be employed with the urethrotome.
2. Extend the urethrotome knife, oriented toward the 12-o'clock position, through the stricture and with a single motion bring the knife back to the sheath and apply upward pressure to incise through the fibrous tissue (Fig. 46-4). The cut is repeated through the stricture, advancing the urethrotome as necessary, until the normal luminal diameter is produced. This is usually where spongiosum is encountered. It is important to obtain a full-thickness incision through scar to the spongiosal sinusoids to allow appropriate disruption of the circumferential stricture. The incision is created in the 12-o'clock position to avoid the arteries that course in the bulbar urethra at the 3- and 9-o'clock positions. Care must be taken to moderate the depth of the incisions because entry into the corpora cavernosa is possible. After adequate incision, the urethrotome with knife retracted can be advanced into the bladder for anatomic evaluation.
3. Strictures may additionally be incised with holmium:YAG (Ho:YAG) laser, which may be entirely performed via a rigid cystoscope. After guidewire passage, the cystoscope is removed and reinserted, and a 200- or 365-micron holmium laser fiber is passed via the working channel. Using

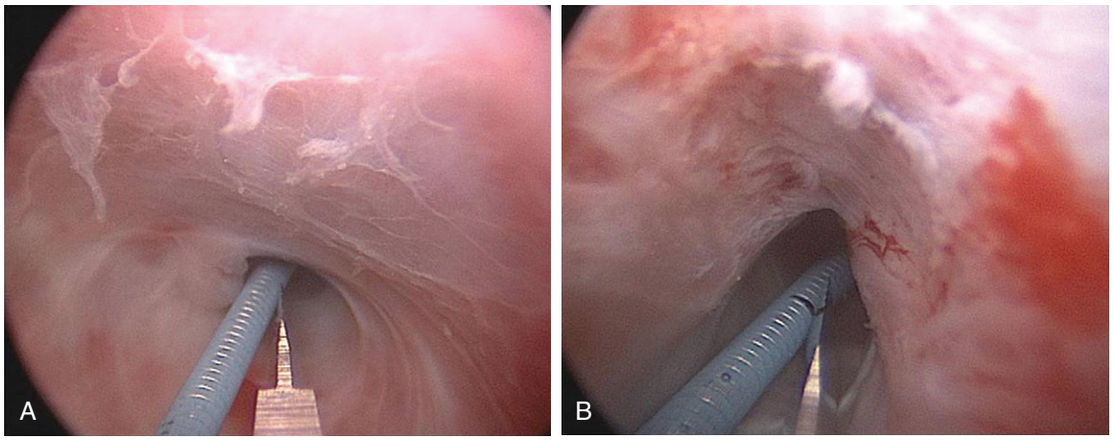

FIGURE 46-4. Initial incision with urethrotome.

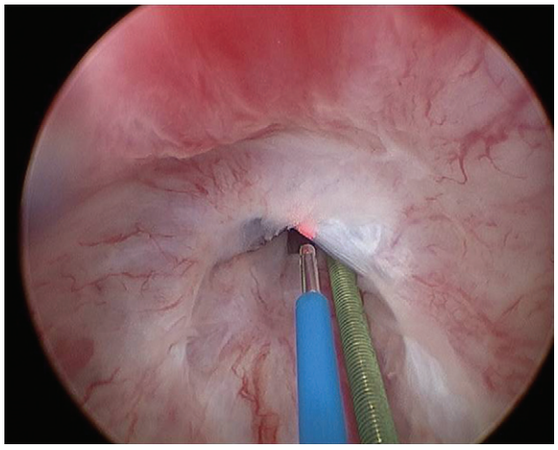

FIGURE 46-5. Initial incision with holmium laser.

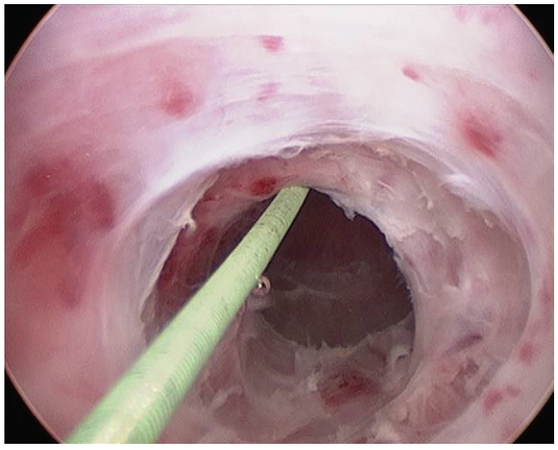

FIGURE 46-6. Completed direct vision internal urethrotomy.

low-power settings between 0.5 and 1 J with frequency of 5 to 10 Hz, the stricture is opened at the 12-o'clock position (Figs. 46-5 and 46-6). Because of the hemostatic properties of the Ho:YAG laser, this approach should theoretically reduce postoperative bleeding, a common complication with the cold knife urethrotome. Care should be taken to avoid interaction of the laser energy and wire because the Ho:YAG laser can disrupt the wire's coating and even completely sever the wire.

4. Following complete full-thickness opening of the stricture, the cystoscope or urethrotome is removed and a Council-tip catheter is fed over the guidewire to the bladder. Large-bore catheters, 20 to 22 French, are often preferred to allow circumferential compression to reduce postoperative bleeding as well as provide a wide stent during the early healing process. However, sparse data are available to support use of large catheters, and 16- or 18-French catheters may be equally effective. Irrigation of the catheter following passage is recommended to ensure proper placement.

POSTOPERATIVE CARE

In general, following uncomplicated DVIU, the patient is maintained with an indwelling catheter for 3 to 5 days. Longer catheterization is unnecessary and may provoke periurethral inflammation, although no standards currently exist to guide management decisions with regard to length of catheterization. Patients can be managed during this time with anticholinergic medications and, if preexisting issues with urinary infection are present, antibiotic therapy. Patients are instructed to perform intermittent self-catheterization (ISC) following catheter removal to maintain stricture patency. Again, no standard evidence-based protocol exists to guide postoperative ISC; however, once-daily passage of a 14-French rigid straight catheter may be recommended for several months, after which the patient may taper to weekly such catheterizations if stricture recurrence does not manifest. Uninstrumented uroflow is exceptionally useful in following this patient population and cystoscopy may be performed at a 3-month follow-up for anatomic evaluation or at any time that the patient manifests recurrent symptoms.

Commonly encountered complications of DVIU include hematuria and urinary tract infection. Less frequent but significantly distressing complications include fistula, development of false passages, urinary incontinence, and erectile dysfunction.

Progression to definitive open urethroplasty is recommended even for failure of a single stricture incision or for disease in locations not amenable to successful DVIU. Prognosis for successful urethroplasty is diminished by multiple repeated DVIU procedures. Therefore multiple endoscopic treatments are not recommended except in extreme circumstances.

Suggested Readings

Forrest JB, Clemens JQ, Finamore P, et al. (2009). AUA best practice statement for the prevention of deep vein thrombosis in patients undergoing urologic surgery. J Urol 181(3):1170-1177.

Voelzke, B. and H. Wessells. (2010). Role of direct vision internal urethrotomy in the management of urethral stricture. AUA Update Series 29(Lesson 20).

Wolf JS Jr, Bennett CJ, Dmochowski RR, et al. (2008). Best practice policy statement on urologic surgery antimicrobial prophylaxis. J Urol 179(4):1379-1390.

This page intentionally left blank

Section IX

TESTIS: REPAIR AND RECONSTRUCTION

This page intentionally left blank

Chapter 47

Testis Biopsy

R. DALE McCLURE

Testicular biopsy is used primarily in the diagnostic evaluation of the azoospermic male with normal gonadotropin levels (luteinizing hormone [LH] and follicle-stimulating hormone [FSH]) to differentiate between testicular failure and posttesticular (obstructive) causes of infertility. In an azoospermic individual with low semen volume, retrograde ejaculation should be eliminated by postejaculatory urinalysis. If no sperm are found in the urine and the patient has a palpable vas, ejaculatory duct obstruction should be ruled out by rectal ultrasonography. Although congenital bilateral absence of vas deferens is an uncommon cause of azoospermia, it results in a sample with a very low ejaculatory volume. Before performing biopsy, the urologist should carefully examine for the presence of bilateral vas deferens.

Biopsy is not indicated in an azoospermic individual with small testis (<15 cc) with a serum FSH level twice the upper limit of normal. These individuals have primary testicular failure. However, if one is contemplating extracting testicular sperm either by the microdissection or the random technique, the histologic pattern found at biopsy may be a useful prognostic indicator. Performing a biopsy in cases of severe oligospermia to look for partial ductal obstruction is still a very controversial indication. It may, however, be useful in providing information to the physician to guide future therapy.

Usually I do a unilateral biopsy, unless history or physical examination suggests asymmetric testicular pathology (e.g., unilateral testicular atrophy with contralateral ductal obstruction). In the era of intracytoplasmic sperm injection, by which testicular sperm are obtained from a testis specimen, planning the biopsy sites is important, because repeated procedures may be required.

In individuals who may require future microsurgical reconstructive surgery, the testicular biopsy should be undertaken using minimal dissection (i.e., "window" technique). Vasography is not carried out during this procedure because of its potential to cause scarring. The radiologic procedure could be carried out at the time of definitive microsurgical reconstruction.

A recent option is to perform percutaneous needle biopsy using one of a variety of needles, including the Vim-Silverman, Tru-Cut, or Biopty gun. These procedures may be performed in the physician's office under local anesthesia. In this technique, one must stabilize the testis and secure the epididymis posteriorly. The potential disadvantage of this technique is the inadvertent and unrecognized injury to a testicular blood vessel or injury to the epididymis. Other limitations include the small sample volume and distortion of seminiferous tubule histology.

Although bleeding is the most common complication of testicular biopsy, the most serious problem is the inadvertent biopsy of the epididymis. Finally, the use of improper fixatives or crushing of the tissue may create difficulties for the pathologists reading the histology.

Taking into account the intragonadal distribution of the arteries in the tunica vasculosa, the preferred biopsy site is either on the medial or lateral aspect of the superior pole where the vascularity is sparse (Fig. 47-1). However, incision on the anterior surface is still a reasonable option when obvious vessels are avoided.

The spermatic cord can be blocked by pulling the testis down to relax the cremasteric muscle and allow better spermatic cord infiltration. The cord should be grasped with the left hand, with the thumb in front and the index finger behind the cord (Fig. 47-2). The anterolateral and anteromedial sides of the cord as it emerges from the external ring near the pubic tubercle is anesthetized with a combination of 1% lidocaine hydrochloride and 0.5% bupivacaine hydrochloride (Marcaine) through a 2.5-inch 25-gauge needle. Initially, aspirate to prevent intravascular infiltration and avoid injecting near the vas to avoid injuring it.

The testis is grasped in the left hand and squeezed against the scrotal skin, making sure that the epididymis is held posteriorly out of the way. The anesthetic agents are then injected in the scrotal and dartos fascia along the line of incision. One should not inject the tunica albuginea and certainly not relax the grip on the testis.

Incise transversely through the skin, dartos, and tunica vaginalis, following the vasculature of the scrotum (Fig. 47-3). As one squeezes the scrotum, these layers retract.

One may place either a hemostat or an Allis clamp on either side of the tunica vaginalis for exposure or use a self-retaining iris clamp. Drop 2 to 3 mL of 1% lidocaine on the tunica albuginea and wait 30 seconds to help anesthetize the surface.

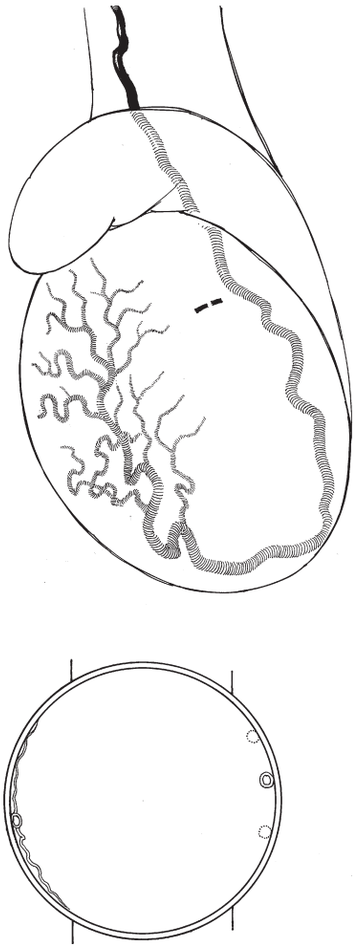

FIGURE 47-1.

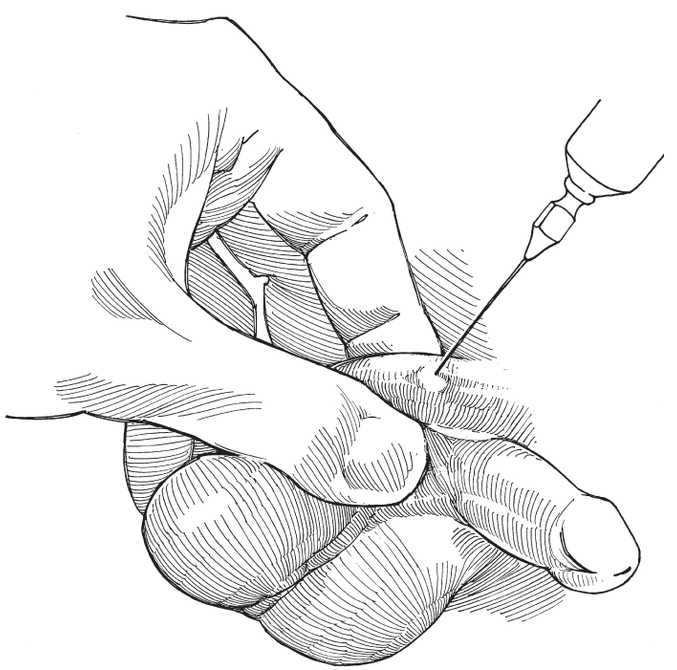

FIGURE 47-2.

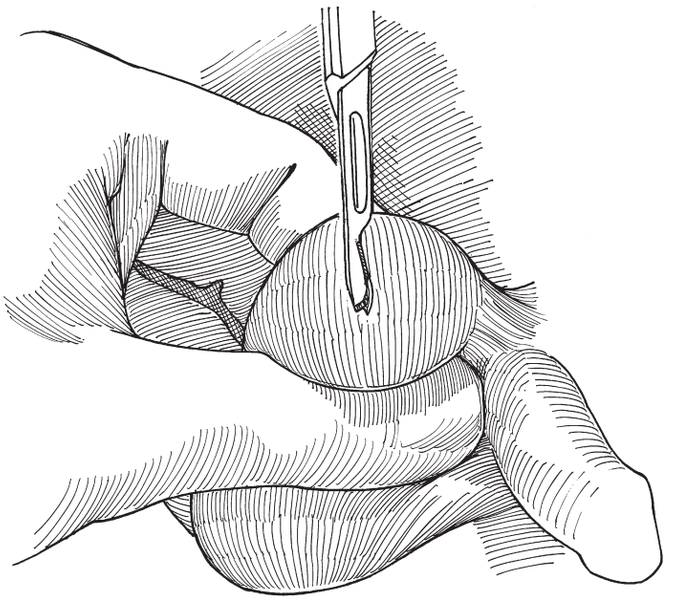

FIGURE 47-3.

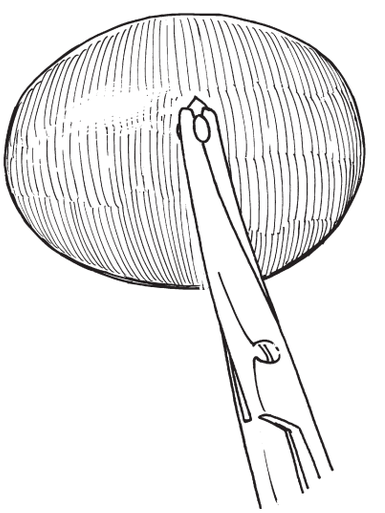

FIGURE 47-4.

Alternative: To prevent the incision site from inadvertently slipping away, one can place a stay suture of 5-0 chromic catgut on a tapered needle in the tunica albuginea to help stabilize the testis. The tunica albuginea should be incised with either a #11 blade or a microsharp ophthalmic blade (15°, 5mm) for a distance of 4 to 5 mm. Gentle testicle pressure applied for most extrusion of a piece of tissue measuring approximately 4 to 5 mm in size.

Extruded tubules should be excised with a moistened small curved iris scissors (Fig. 47-4). This specimen should be submerged immediately (no-touch technique) either in Bouin's, Zenker's, or buffered glutaraldehyde solution. Formalin distorts the histologic pattern adversely and should not be used. While in the operating room, one may touch the specimen directly on a sterile side and apply cytofixative to examine for spermatozoa.

While a grip is maintained on the testis within the scrotum, the tunica albuginea is closed with 2-3 sutures of

5-0 chromic on a tapered needle (Fig. 47-5). The tunica vaginalis is closed with a running lock suture of 5-0 chromic. Before a final closure of the tunica vaginalis, 0.5% solution of bupivacaine hydrochloride (Marcaine) is placed, creating a "Marcaine hydrocele" that reduces postoperative pain.

The dartos is closed with a running lock suture 4-0 chromic and the skin can be closed with vertical mattress sutures of 4-0 chromic (Fig. 47-6). A nonadherent dressing and a large padded scrotal suspensory can then be applied.

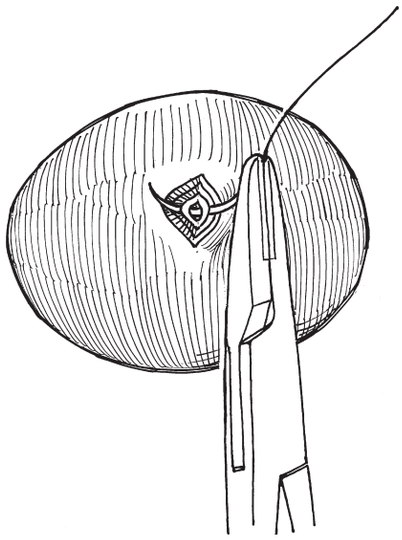

FIGURE 47-5.

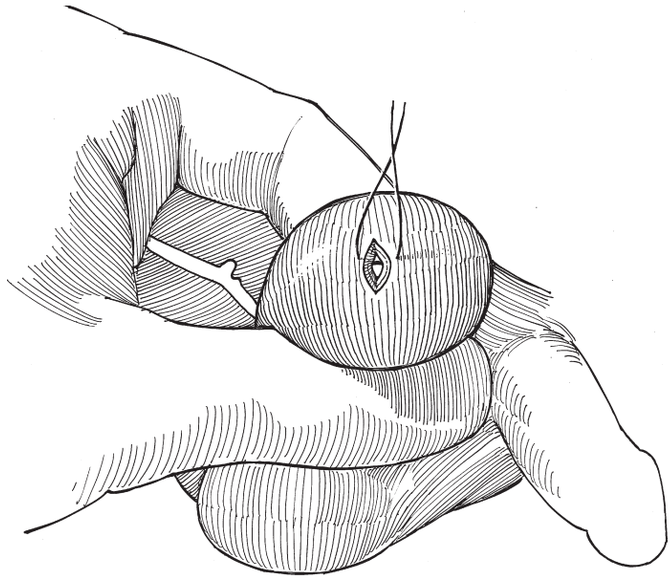

FIGURE 47-6.

GONADAL BIOPSY FOR INTERSEXES

True hermaphrodite: Expect any combination of ovary, testis, and ovotestis, with the last being most common. Look for ovotestes retroperitoneally, although half of them are found in the labioscrotal fold or the inguinal canal. Ovaries are usually in the normal retroperitoneal position.

Gonadal dysgenesis: Streak gonads of ovarian stroma lie in the normal position. With XX or Turner's type, malignancy is rare and excision is not needed. However, with the XY type, the chance of future malignancy is high (30%); immediate gonadectomy is required.

Perform laparoscopic exploration to locate the gonad. Expose it through a labioscrotal or an inguinal incision. In hermaphroditism, perform a deep biopsy of the organ because testicular tissue may exist only near the hilum, and obtain the sample longitudinally because the components are oriented end to end. For gonadal dysgenesis, excise the entire gonad.

Commentary by LARRY I. LIPSHULTZ, M.D.

The paradigm for when to perform a testis biopsy has changed considerably since the early 1990s. With the advent of intracytoplasmic sperm injection (ICSI), therapeutic biopsies have almost entirely replaced diagnostic biopsies. If one is trying to decide whether the patient has obstructive versus nonobstructive azoospermia, fine-needle aspiration of the testis should be considered.

The only time we have found a biopsy to be diagnostically important is when deciding whether or not to perform a bilateral varicocele repair in the azoospermic patient. Although admittedly a controversial procedure, investigation of the literature would suggest that only in cases of hypospermatogenesis or late maturation arrest is there even a reason to contemplate repair.[1] In these instances a frozen testis biopsy with an associated touch imprint has been helpful in considering whether or not to proceed.

[1]Weedin JW, Khera M, Lipshultz LI: Varicocele repair in patients with nonobstructive azoospermia: A meta-analysis. J Urol 183(6):2309–2315, Jun 2010.

This page intentionally left blank

Chapter 48

Sperm Retrieval

CIGDEM TANRIKUT AND PETER N. SCHLEGEL

PERCUTANEOUS EPIDIDYMAL SPERM ASPIRATION

Percutaneous epididymal sperm aspiration (PESA) may be performed with the patient under local anesthesia or locally with sedation. After sterile scrotal preparation, the testis is stabilized manually and the epididymis is grasped between the surgeon's thumb and forefinger. A 21-gauge butterfly needle is inserted into the caput epididymis and an attached 20-mL syringe is used to gently aspirate fluid. If no sperm are retrieved, as occurs in at least 20% of sperm retrieval attempts, then one must proceed with microsurgical epididymal sperm aspiration (MESA), testis biopsy, or testicular aspiration.

MICROSURGICAL EPIDIDYMAL SPERM ASPIRATION

MESA is most easily performed with the patient under general anesthesia in order to limit motion artifact while working under the operating microscope, although local procedures are possible as well. After shaving and sterile preparation of the scrotum, a median raphe incision is carried sharply down to the level of the tunica vaginalis and the testis is bluntly dissected within the tunica to deliver it through the wound. The tunica vaginalis is opened to expose the testis and epididymis, and the operating microscope is brought into the field. Use the left hand to hold the testicle.

Stabilize the epididymis between the left thumb and forefinger. Using the bipolar microforceps cautery along the longitudinal axis of the epididymis, create an avascular plane. Carefully incise along this plane using a 15-degree microknife without violating the epididymal tubules (Fig. 48-1).

Puncture an exposed epididymal tubule with a sharpened micropipet (Fig. 48-2). Gently draw the epididymal fluid into silicone tubing connected to the micropipet by aspiration of a glass syringe attached via a three-way stopcock. Flush the retrieved fluid into a 1.5-mL microtube for intraoperative microscopic evaluation to confirm presence of sperm. Repeat this procedure for multiple tubule locations. If micropipets are not available, incision of individual tubules with a microknife can be done with aspiration of the fluid that pours out of the dilated obstructed tubules.

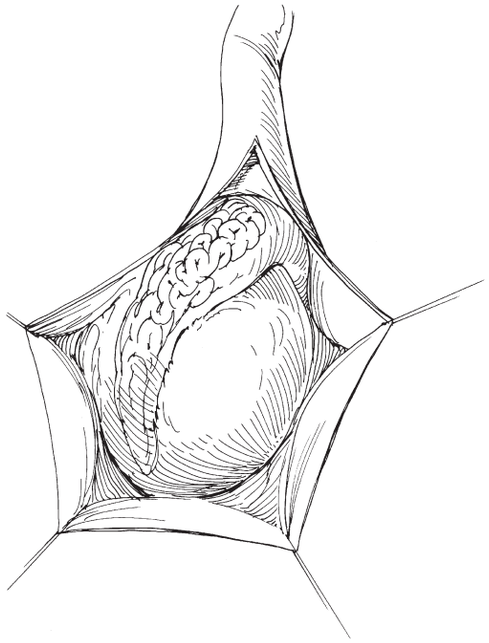

FIGURE 48-1. MESA: Epididymis under scope at low power. ~10×

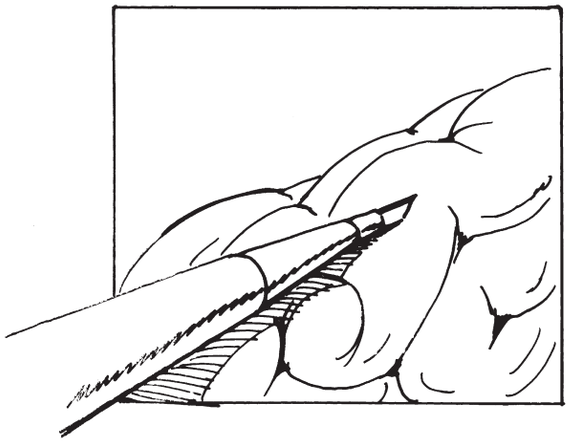

FIGURE 48-2. MESA: Micropipet in tubule. ~ 20×

Once adequate sperm are obtained, use the bipolar microforceps to seal the puncture holes and to attain hemostasis. Use a running 6-0 nonabsorbable monofilament to close the epididymal tunic.

Close the tunica vaginalis with running 4-0 absorbable monofilament suture. Inject 10 mL of bupivacaine beneath the closed tunica vaginalis for local anesthetic effect. Close the dartos muscle with 3-0 absorbable monofilament; before completing the closure, instill 10 mL of local anesthetic into the scrotal pouch. Inject the incision with bupivacaine and reapproximate the skin edges using 5-0 absorbable monofilament suture in a subcuticular fashion. Apply antibiotic ointment to the wound, dry fluffed gauze, and an athletic supporter.

TESTICULAR FINE NEEDLE ASPIRATION

Insert the needle along the long axis of the testicle, preferably off of longitudinal midline. The needle is passed in and out of the tissue and material is aspirated. Blind procedure – Seminiferous tubules are removed at end of needle in addition to aspirated fluid. This procedure, as with percutaneous testis biopsies, can be easily achieved after local anesthetic as a cord block and surrounding tissue infiltration.

PERCUTANEOUS BIOPSY

A 14-16 gauge automatic biopsy gun is used via a percutaneous approach to obtain one or more cores of testicular tissue for sperm extraction.

OPEN MULTI-INCISION TESTICULAR BIOPSY (TESE)

After exposure of testicle, make a small incision along the transverse axis of the testicle on its medial or lateral surface. Sharply excise extruded tubules using iris scissors. Multiple biopsies can be done in this fashion. Albuginea incisions are closed with 5-0 nonabsorbable monofilament after ensuring hemostasis is achieved.

MICRODISSECTION TESTICULAR SPERM EXTRACTION (MICROTESE)

Make a transverse equatorial incision with a 15-degree microknife in the avascular plane of the tunica albuginea, avoiding capsular vessels (Fig. 48-3).

Achieve hemostasis using bipolar, with copious irrigation for visibility. Place curved hemostats at edge of tunica albuginea and tubules to prevent separation of tubules from the tunica albuginea. Gently split the testicle (Fig. 48-4).

Using platform forceps, gently dissect sperm-containing tubules (Fig. 48-5).

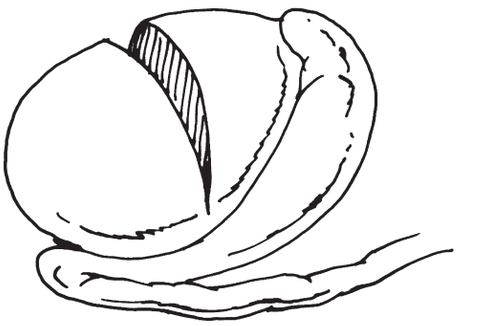

FIGURE 48-3. MicroTESE: Equatorial incision with subcapsular vessels apparent. ~10-15×

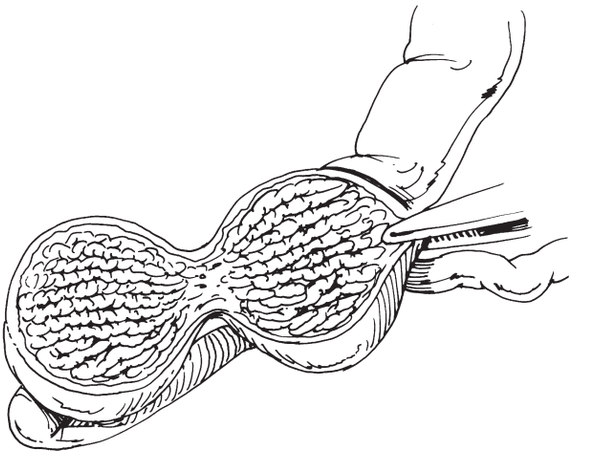

FIGURE 48-4. MicroTESE: Initial view of seminiferous tubules after splitting testicle, showing exposure with fingers and curved hemostats in place. 10-15×

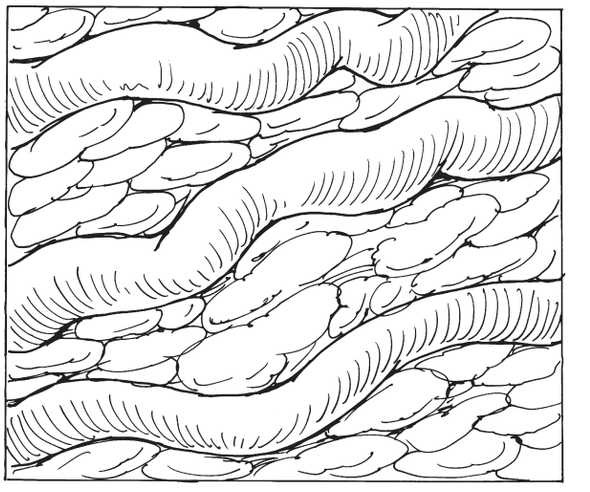

FIGURE 48-5. MicroTESE: Dissection of fuller, more opaque tubules in comparison to stringy, thin tubules. 20-40×

Place tubules in human tubal fluid medium, snip with iris scissors to break up the tubules, then flush through a 24-g Angiocath several times to release spermatozoa. Assess under phase contrast microscope for specimen adequacy.

Once adequate specimen is found, attain hemostasis with bipolar. Close tunica albuginea with running 5-0 non-absorbable monofilament. The remainder of closure is as described for MESA.

The advantages of microTESE over open biopsy are that sperm are found with microTESE even after failed multi-incision biopsy, there is less risk of vascular injury, and there are fewer postoperative changes in the testicle.

Commentary by LARRY I. LIPSHULTZ, M.D.

There are some interesting areas worthy of discussion in this chapter. If one is performing sperm retrieval on the day of *in vitro* fertilization (IVF), as is requested by some IVF centers, then one has to be cautious about percutaneous epididymal sperm aspiration (PESA). Assuming a failure rate of 20%, as is suggested by the authors, then one out of five times the patient will have to go to an open room for microscopic epididymal sperm aspiration (MESA). Given the complexity of current operating room scheduling, this is hardly worth the risk. Hence, I prefer MESA, when possible.

MESA, in my opinion, is one's best bet for obtaining copious healthy sperm. As suggested, a #25 Angiocath on a buffer-lubricated syringe works well. It is important to make sure that all aspirations are accumulated in the OR in an IVF-friendly (usually radiation sterilized) plastic tube. Since excess sperm will be cryopreserved, it is imperative that one follows FDA regulations for appropriate serum testing of the patient, assuring that most sperm banks will accept the specimen.

It should be emphasize that a well-trained IVF technician is essential to one's rapidly finding sperm during micro-testicular sperm extraction (TESE). While one cannot minimize the role of a skilled and experienced microsurgeon; it is the technician who will determine when adequate sperm are identified, indicating the end of the procedure and minimizing tissue removal.

This page intentionally left blank

Chapter 49

Varicocele Ligation

PAUL J. TUREK AND THOMAS J. WALSH

Palpate the spermatic cord while the patient is erect. Proceed with varicocele ligation in the setting of a palpable varicocele in a patient who is infertile, has testicular hypotrophy, or has pain without other cause.

The veins draining the testis, epididymis, and vas deferens connect with deep and superficial venous networks. The deep venous network has three components: the testicular vein and the pampiniform plexus, the funicular and deferential veins, and the cremasteric veins.

Four approaches are currently used: (1) subinguinal approach, (2) inguinal approach, in which the gonadal artery is spared, (3) retroperitoneal approach, in which the artery may be included in the ligation, and (4) laparoscopic approach, which offers variocele ligation at the same level as the retroperitoneal approach (Fig. 49-1).

SUBINGUINAL VARICOCELECTOMY

The microscopic subinguinal varicocelectomy offers high success with minimal morbidity. Microscopic visualization of lymphatic channels minimizes the occurrence of postoperative hydrocele, and identification of the gonadal artery is important for success.

Instruments: Microscopic set, fine vascular forceps, Jacobsen clamps, Kittner dissector, and a 3-mm Doppler ultrasound probe.

Position and incision: Position the patient supine and in slight reverse Trendelenburg to distend the pampiniform veins. Under intravenous sedation or with general anesthesia, identify the external inguinal ring digitally by invaginating the scrotum. If intravenous sedation is to be used, infiltrate

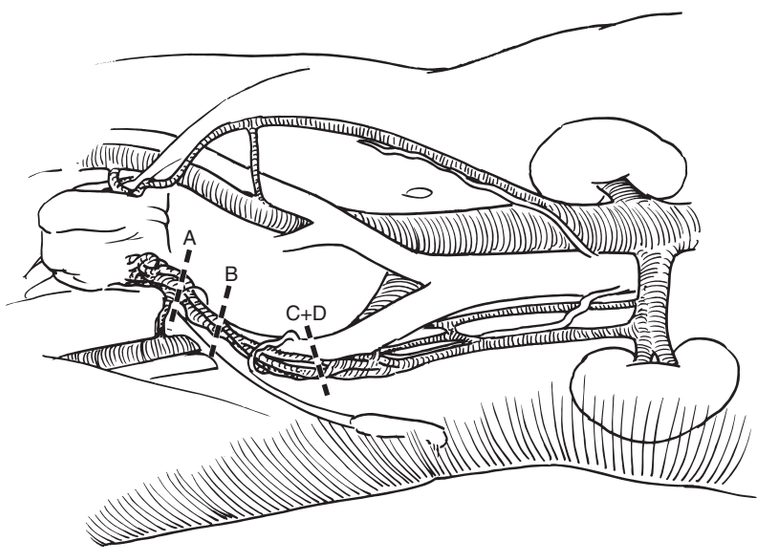

FIGURE 49-1.

the skin overlying the ring with 1% lidocaine mixed with an equal amount of 0.25% bupivacaine. Make a 2- to 3-cm transverse incision directly over the external ring, along the lines of Langerhans, and continue through the subcutaneous layer until Scarpa's fascia is reached. Using the index finger, gently dissect through Scarpa's fascia, and bluntly control the spermatic cord within the subinguinal region.

Lightly grasp the cord with a Babcock clamp, draw it slowly from the wound, and separate the cremasteric attachments with a Kittner dissector. Encircle the cord with a 1-inch Penrose drain. Clip or tie any dilated posterior cremasteric veins or external spermatic veins.

Insert a tongue depressor into the Penrose drain to provide a surgical platform, and with the aid of optical loupes or an operating microscope at 6× to 10× magnification, incise the external spermatic fascia (Fig. 49-2). Grasp the edges of the external spermatic fascia apart with mosquito clamps to expose the contents of the cord.

Inspect the cord contents, looking for pulsations that indicate the location of the gonadal artery and confirm the location of the vas deferens and vasal veins, because dissection of these structures should be avoided. Dilated veins may invest the artery to either side and these will require ligation (Fig. 49-3).

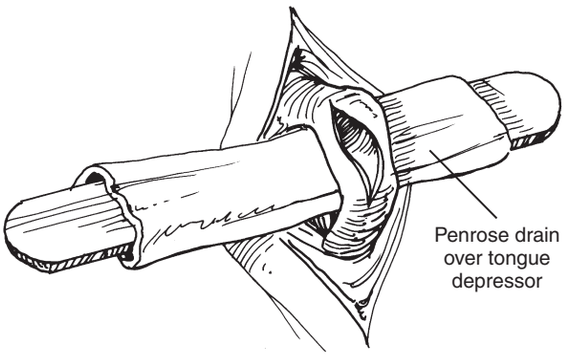

FIGURE 49-2.

Identify the internal spermatic veins within the pampiniform plexus and dissect them free with fine forceps or Jacobsen clamps. Ligate them with 4-0 or 2-0 silk ties or clips, beginning with the largest veins. Following ligation, division of the veins is optional.

Dissect around the vas deferens and gonadal artery, and ligate veins that accompany the latter. Preserve the lymphatics. A 3-mm Doppler probe helps identify and avoid the artery (Fig. 49-4). If the patient is awake, ask him to perform Valsalva maneuver to fill any missed veins. After all internal spermatic veins are ligated, infiltrate the proximal spermatic cord with 0.25% bupivacaine using a 25-gauge needle inserted beneath the external spermatic fascia, parallel to the cord. Close Scarpa's fascia with two to three sutures and the skin with a 4-0 running subcuticular suture.

An alternative technique described by Goldstein involves an additional step in which perforating scrotal veins are ligated for completeness. The spermatic cord is identified and encircled similar to as is done in the subinguinal approach. The testis and its investments are drawn out of the wound without disrupting the gubernaculum. Dilated external spermatic and gubernacular veins are identified and ligated. Return the testis to the scrotum, and proceed with dissection of the internal spermatic veins with the operative microscope as described for the subinguinal approach. This additional veins treated with this approach may help identify sources of recurrence after prior varicocelectomy.

INGUINAL APPROACH

This approach manages the internal spermatic veins at the level of the internal inguinal ring. It is easier than the retroperitoneal approach, especially in more obese patient, requires less assistance, and can be done under local anesthesia.

Instruments: Same as above.

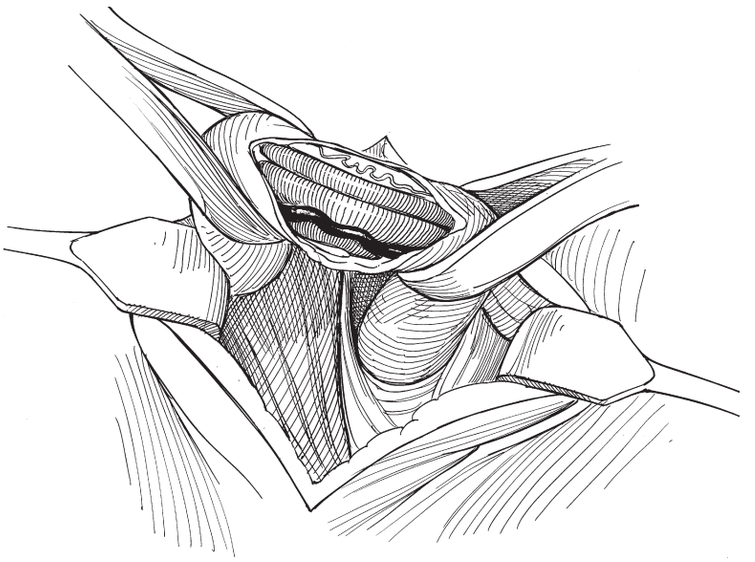

FIGURE 49-3.

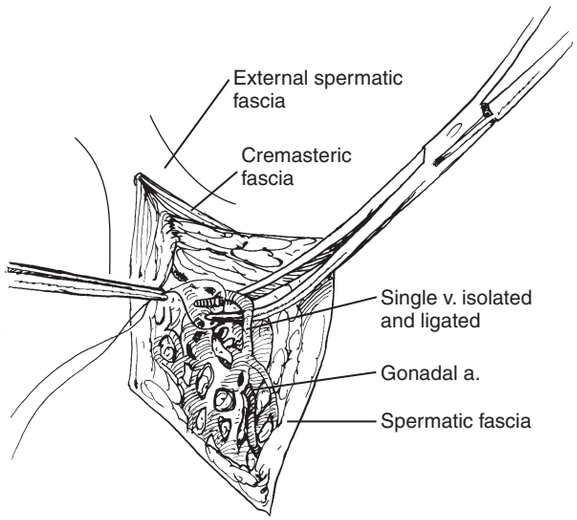

FIGURE 49-4.

Position and incision: Position the patient supine and make a 4-cm incision two fingerbreadths above the symphysis pubis in line with the lateral aspect of the scrotum (above the palpable external ring) and extending obliquely along the course of the inguinal canal.

Incise Scarpa's fascia, and gently clear the connective tissue overlying the external oblique aponeurosis and external ring (Fig. 49-5). Insert a self-retaining retractor and incise the aponeurosis along its fibers, beginning at the external ring and extending toward the internal ring. Avoid the ilioinguinal nerve beneath. Control the edges of the external oblique fascia with mosquito clamps, elevate the spermatic cord between the thumb and forefinger, and palpate the vas deferens and artery.

Pass a curved clamp or finger under the cord near the pubic tubercle and draw a Penrose drain under the cord. Stabilize the cord in the wound by fastening the ends of the drain to the drapes on each side.

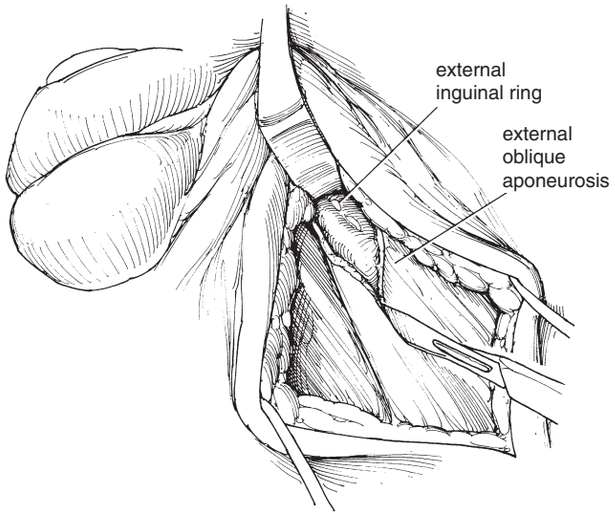

FIGURE 49-5.

Incise the internal spermatic fascia to expose the cord contents (Fig. 49-6). Sweep the underlying vas out of the field. With the aid of optical loupes or an operative microscope, use microvascular forceps to dissect the fine spermatic fascia from each of the (usually) three branches of the internal spermatic vein from each other and from the more tortuous artery and the lymphatics for 2 to 3 cm in both directions. Use a 3-mm Doppler ultrasound to localize the artery, especially if it has multiple branches. Identify and ligate the cremasteric vein that runs from the spermatic cord to the pudendal vein at the external ring.

Ligate each vein in succession with a 4-0 silk tie. Tip the patient into the reverse Trendelenburg position to distend remaining veins. Elevate the spermatic cord, and inspect the floor of the inguinal canal for collateral venous branches. Remove the Penrose drain to allow the cord to return to its bed.

Close the external oblique fascia with a running 4-0 synthetic absorbable sutures (SAS), starting laterosuperiorly and taking care not to entrap the ilioinguinal nerve or to injure the spermatic cord. Close Scarpa's fascia with interrupted sutures and the skin with a 4-0 running subcuticular sutures.

RETROPERITONEAL APPROACH

The entire spermatic vascular pedicle can be ligated within the retroperitoneum, ensuring minimal chance for failure. Because the ligation is high, adequate collateral arterial supply remains even though the artery is included in the ligature. This method is more easily performed on slender patients. Because some lymphatics are included in the ligation, hydroceles are more common postoperatively.

Instruments: Basic set, headlamp, 2.5× to 3.5× loupes, Sims, self-retaining, and narrow Deaver retractors; vascular forceps; tenotomy scissors; and Kittner dissectors.

Position: Supine, with the head elevated 10 degrees, more reverse Trendelenburg position if needed to fill the veins.

Incision: Make a short, transverse incision through the skin and subcutaneous tissue over the site of the internal inguinal ring, starting two fingerbreadths medial to the anterosuperior iliac spine. Expose the external oblique aponeurosis. Insert a self-retaining retractor to maintain exposure.

Incise the external oblique aponeurosis parallel to its fibers, taking care to avoid the adherent ilioinguinal nerve beneath it (Fig. 49-7).

Separate the internal oblique muscle bluntly by inserting a curved clamp. Retract the internal oblique muscle cranially. Incise the transversus abdominis muscle (Fig. 49-8).

Enter the retroperitoneal space 3 to 5 cm above and medial to the inguinal ligament.

Push the peritoneum medially with a Kittner dissector, exposing the vessels within the retroperitoneal fat as they join the vas deferens. Provide traction on the testis to aid in locating the cord structures. Insert narrow Deaver retractors to assist with exposure. Note that a retractor placed medially can obscure the spermatic veins adherent to the posterior peritoneum (Fig. 49-9).

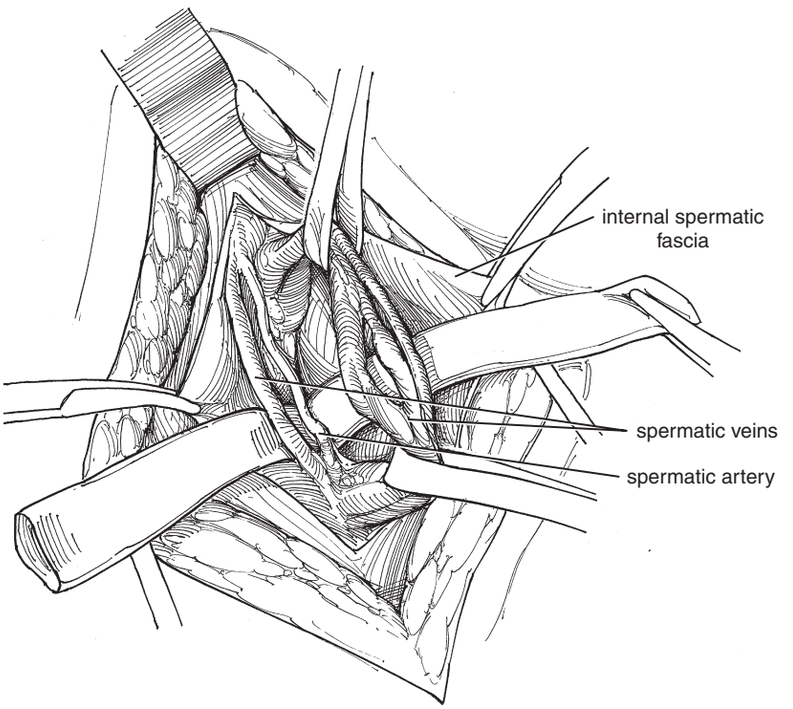

FIGURE 49-6.

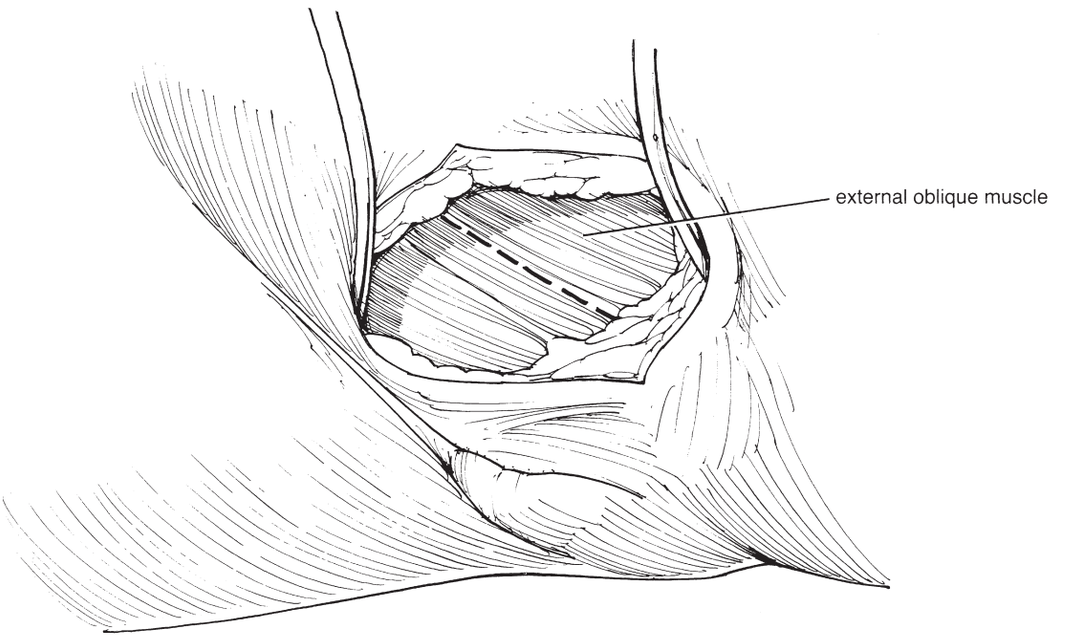

FIGURE 49-7.

Place a curved clamp or drain behind the vessels to elevate them into the wound. Use sharp and blunt dissection to isolate all (usually two) of the dilated veins from the adjacent artery and lymphatic vessels. If the artery is not apparent, skeletonize the cord by gently stripping the spermatic fascia. If necessary, drip papaverine solution onto the cord to cause the artery to dilate and become visibly pulsatile. Including the artery in the ligature is rarely harmful because adequate collateral circulation comes from vasal and cremasteric vessels. Placing the patient in the reverse Trendelenburg position may help fill and identify smaller veins.

Ligate each vein with two silk ties and divide between them. Irrigate the wound, and close each layer of the body wall. Infiltrate the subcutaneous tissue with 0.25% bupivacaine. Place a subcuticular 4-0 SAS to close the skin.

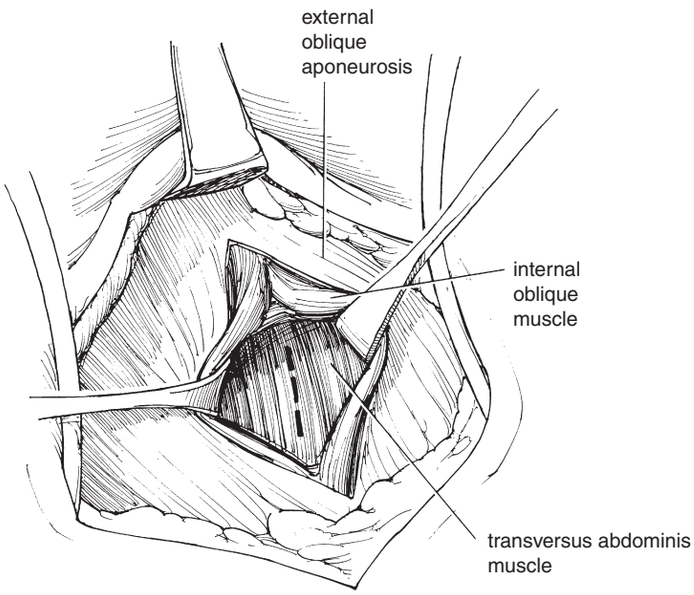

FIGURE 49-8.

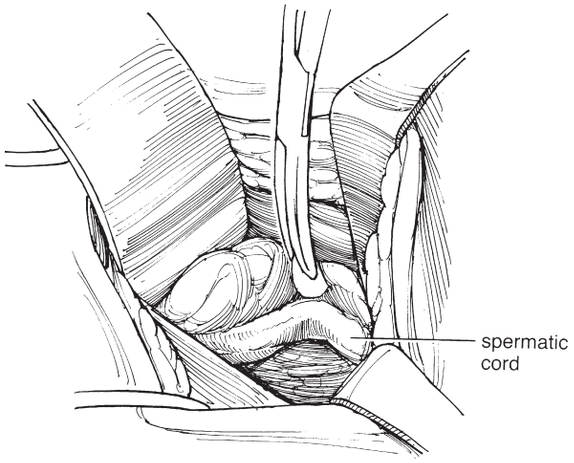

FIGURE 49-9.

LAPAROSCOPIC APPROACH

The indications for laparoscopic rather than open ligation of varicoceles have not been clearly delineated. General anesthesia is required, and the peritoneal cavity is entered with the accompanying risk of vascular or visceral injury. With this high retroperitoneal ligation, perforating external spermatic veins within the inguinal and subinguinal regions are not ligated and may be sources of varicocele recurrence. Postoperative pain is not significantly reduced and the time for convalescence is similar to that for lower, incisional ligations.

Position and incisions: Rotate the table to elevate the affected side, with 15- to 30-degree Trendelenburg position to distend the spermatic veins.

Place an 11-mm camera port within the lower curvature of the umbilicus, an 11-mm instrument port contralateral to the varicocele, 1 to 2 cm below the umbilical port and lateral to the rectus muscle, and a 5-mm port in a similar position on the opposite side. Stand on the side of the patient opposite the varicocele to be ligated. An assistant guides the laparoscope camera.

Identify the internal ring by following the vas deferens distally to its confluence with the spermatic cord. Retract the sigmoid colon medially. Compress the scrotum to observe the filling of the spermatic veins. Identify the gonadal artery early, before manipulation results in arterial spasm. Plan a T-incision lateral over the cord *(dashed lines)* (Fig. 49-10).

Elevate the peritoneum 4 to 5 cm proximal to the internal ring and slightly lateral to the spermatic vessels with grasping forceps. Use scissors to incise the peritoneum, first distally, then proximally, to expose the vessels. Elevate the medial edge of the peritoneum and incise a T extending to the edge of the iliac artery. Provide traction on the testis to identify veins adjacent to the spermatic pedicle that could cause recurrence. Gently dissect the vessels away from the retroperitoneal connective tissue and the psoas muscle (Fig. 49-11).

Using a pair of graspers, bluntly dissect the veins (usually three to eight) into multiple bundles while separating the spermatic artery. Occasional, intermittent traction on the testis helps identify the vessels. Elevate the venous bundles, and isolate them from the artery. Vasospasm may make identification of the artery difficult; it can be reduced by dripping papaverine or lidocaine through an aspirator-irrigator. A Doppler probe may also help to identify the spermatic artery. For the larger veins, place two titanium vaso-occlusive Endoclips proximally and two distally on each venous bundle. Cut the veins between the paired clips with scissors. Smaller veins may still be present around the artery. Tease them away and clip them, or fulgurate them with a fine bipolar electrosurgical device on low settings. Place the patient in a reverse Trendelenburg position. Look for dilated veins and for bleeding from the cut peritoneal edge and retroperitoneum; aspirate any blood or irrigant that may have collected.

Alternatively, the entire spermatic cord exclusive of the vas deferens and including the gonadal artery and veins can be doubly clipped in bulk after dissection off of the retroperitoneal wall. Finally, remove all ports under direct vision. Evacuate remaining CO_2 by compressing the abdomen. Close each 11-mm port site with a single 3-0 SAS and the skin with 4-0 subcuticular SAS.

POSTOPERATIVE PROBLEMS

Damage to the artery can occur with subsequent testicular atrophy. Atrophy is less likely with the high retroperitoneal or laparoscopic approaches. Injury to the vas deferens should be repaired immediately. *Persistent prominence* of the scrotal veins may be expected with large varicoceles. However, if examined by color Doppler ultrasonography, usually no reflux flow is observed in these ectatic veins. *Recurrence*

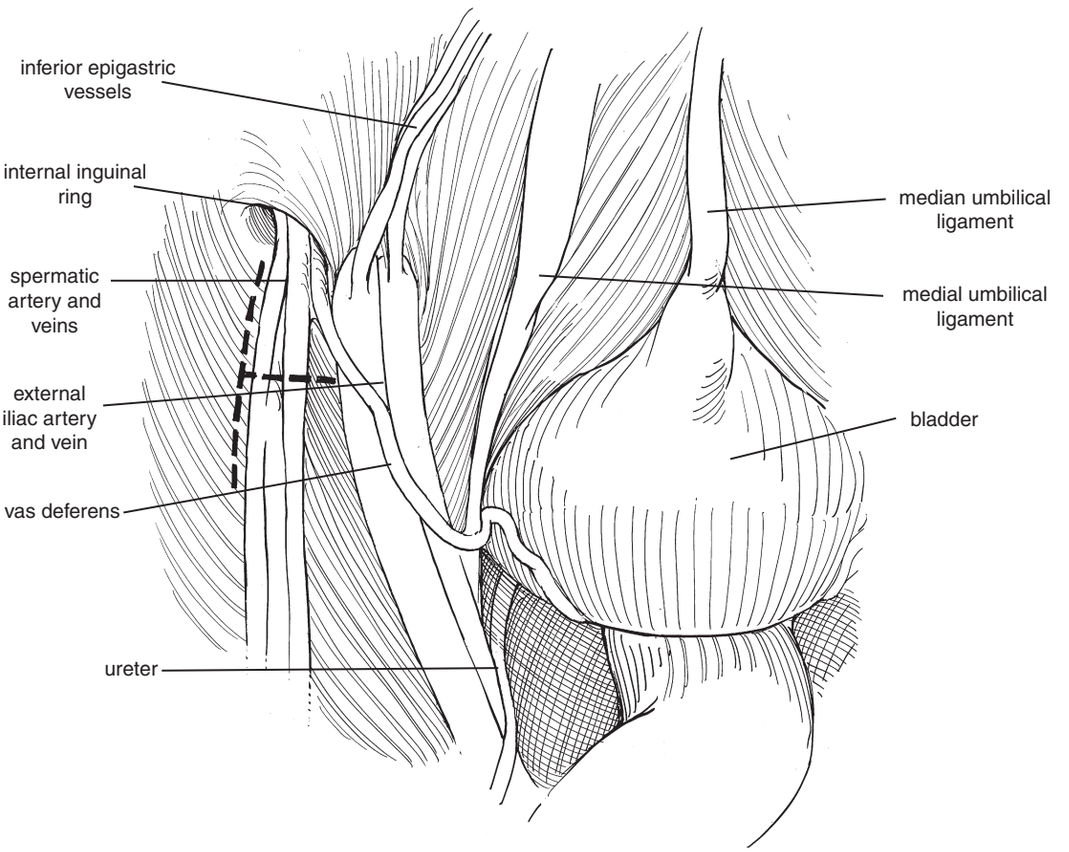

FIGURE 49-10.

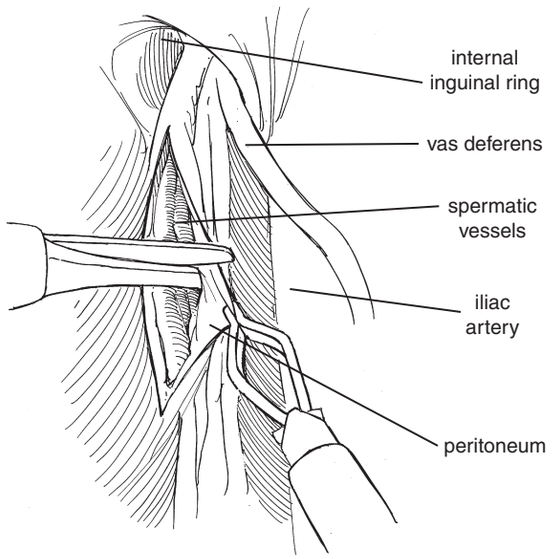

FIGURE 49-11.

or persistence of the varicocele is possible, however, either because a vein was missed or because of the existence of anomalous venous drainage.

Hydroceles develop because of lymphatic obstruction. Although infrequent, they occur more often with bulk ligature of the spermatic cord, as is performed with laparoscopic or retroperitoneal approaches. The occasional patient may note a *dull ache* in the testis on the operated side for several weeks after surgery, which is usually self-limited. It is most likely secondary to venous congestion within the testis from the ligation. As alternative venous drainage develops, the discomfort passes. If performed for infertility, check semen quality in 3 to 4 months after surgery.

Commentary by LARRY I. LIPSHULTZ, M.D.

While all four approaches to a varicocele repair are clearly described in this chapter, a retroperitoneal approach is becoming one of only historical importance. While it was often used by the pediatric urologist, I have seen a trend in recent years to increase use of the inguinal approach, even in this younger patient population.

I routinely perform the inguinal approach. Since the veins progressively branch as one moves caudally, there are fewer and larger veins in the inguinal canal than in the infrainguinal region. We have looked at postoperative pain in these two groups of patients and have found no difference, nor have we found a clinical advantage to delivering the testis in search of "gubernacular" vessels.

I tried using small hemoclips instead of silk for vessel occlusion but found the former all too often cut into the delicate venous walls, and I have since used only a 4-0 silk. I prefer isolating the spermatic cord with my thumb and forefinger, often finding a Babcock to have too small of a grasp, especially in the fat-infiltrated cord. I have also found the semen analysis to peak in quality at 8 to 10 months postoperatively, and I make sure that my infertility patients appreciate this and do not get prematurely disappointed with postsurgery semen reports obtained too early.

This page intentionally left blank

Chapter 50

Vasectomy

VICTOR M. BRUGH III

Vasectomy is a reliable procedure to attain permanent male sterilization. Interested men should be counseled on the nature of the procedure, the risks, what to expect before, during, and after the procedure, failure rates, the permanent intent of the procedure, and the need for continued contraception after vasectomy until azoospermia is confirmed. In many practices men are offered benzodiazepine 30 minutes to 1 hour before the procedure. Typically, vasectomies are most easily performed in a warm room to allow the scrotum to relax and the vas deferens to be easily identified. The procedure is started with a standard surgical prep.

The vas is first isolated from the adjacent cord structures and manipulated to the scrotal midline approximately one-third the distance from the penoscrotal junction to the bottom the scrotum. For a right-handed surgeon standing on the patient's right side, the vas is grasped between the thumb and middle finger of the surgeon's left hand with the middle finger on the posterior surface of the scrotum. The index finger is then placed cephalad to the surgeon's thumb on the anterior scrotum, pulling the scrotal skin tight between the thumb and index finger (Fig. 50-1). After the vas is isolated and secured using a three-finger technique, the scrotal skin, between the thumb and index finger, is anesthetized with 2% lidocaine. Initially a small subcutaneous wheal of lidocaine is injected. Through this wheal a vasal block is performed by advancing the needle alongside the course of the vas for approximately 1 to 1.5 cm toward the inguinal canal. Lidocaine is then injected as the needle is withdrawn. The perivasal tissues are anesthetized on both sides of the vas using this technique. With formation of the initial skin wheal, the patient typically experiences a "stick and burn" or "a beesting," and with anesthetizing the perivasal tissue typically a mild ache or pressure is sensed (Fig. 50-2).

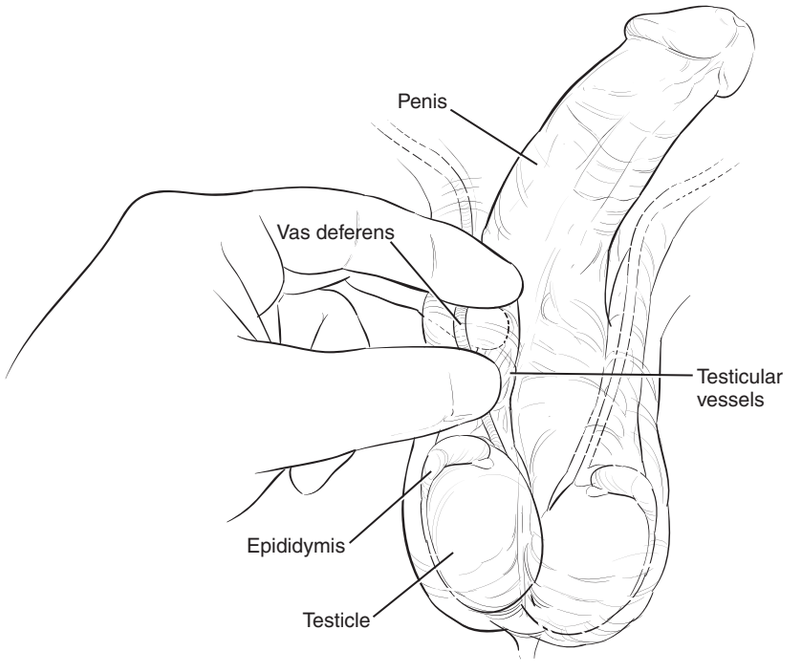

FIGURE 50-1. The vas is held using a three-finger technique. *(From Walsh PC (ed): Campbell's Urology, 8th edition. Philadelphia, Saunders, 2002.)*

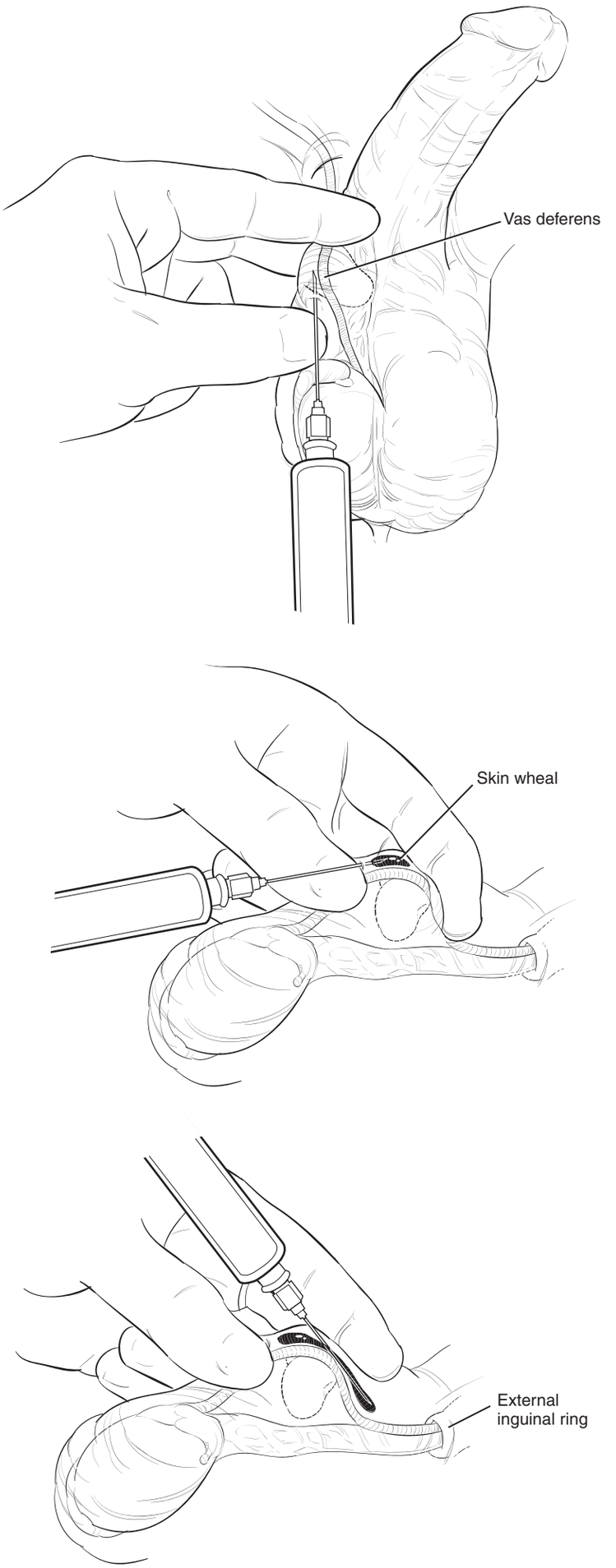

FIGURE 50-2. Anesthetizing the vas. *(From Graham SD (ed): Glenn's Urologic Surgery 5th edition. Philadelphia, Lippincott Williams and Wilkins, 1998.)*

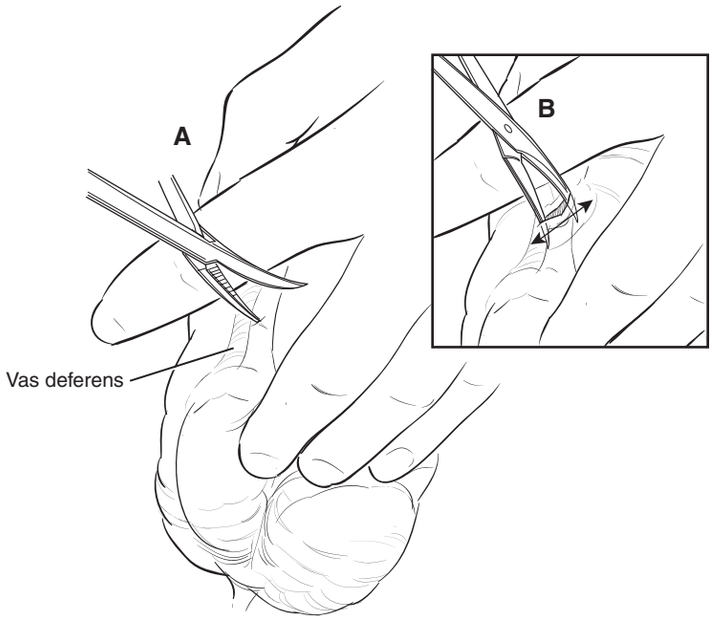

FIGURE 50-3. Incision.

The vas is approached through the anesthetized area by first puncturing the skin using a single arm of the no scalpel dissecting hemostat. Both arms are then inserted into the puncture wound and spread, separating the skin (Fig. 50-3). The vas is then grasped through the incision using the ringed hemostat and the dissection is continued through the dartos tunic and vasal sheath to expose the vas. The exposed vas is then delivered into the wound. Alternatively, the vas may be isolated through the scrotal skin with the ringed hemostat and then the incision is made just cephalad to the ringed hemostat. After the vas is delivered into the wound, it is cleared of its mesentery and the vasal vessels for a segment of 1.5 to 2 cm (Fig. 50-4). A 1.5- to 2-cm segment of cleared vas is excised and the vasal ends are occluded. Occlusion of the vasal ends may be achieved by several different techniques. The lumen may be ablated using cautery or the vas compressed using suture or hemoclips, or a combination of the two techniques may be used. The vasal sheath can be closed over the testicular or abdominal vasal remnant using a 4-0 absorbable suture to isolate the individual ends of the vas deferens from each other. Fascial interposition in this manner will further decrease the risk of recanalization.

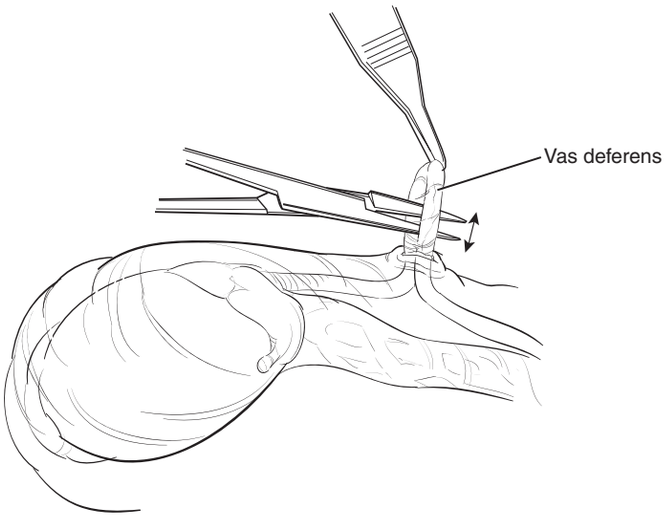

FIGURE 50-4. Freeing the vas. *(From Graham SD (ed): Glenn's Urologic Surgery 5th edition. Philadelphia, Lippincott Williams and Wilkins, 1998.)*

After confirming hemostasis of the vas and perivasal tissues, the vas is repositioned back into the scrotum. The identical procedure may then be performed on the left vas deferens through the same midline scrotal incision. Hemostasis of the skin is attained and the skin incision is closed either by compressing the skin edges together using the no scalpel dissecting hemostat or by placing one or two simple interrupted absorbable sutures. The incision is dressed with antibiotic ointment, sterile Telfa, fluffs, and a scrotal support.

In a similar manner, a vasectomy may be performed using a scalpel. As described, the vas is positioned and anesthetized in the midline scrotum. A transverse or longitudinal skin incision is made using a scalpel (Fig. 50-5). The vas is then secured using an Allis clamp or towel clip (Fig. 50-6). The dartos tunic and vasal sheath are divided using the scalpel to expose the vas (Fig. 50-7). The remainder of the vasectomy in regard to delivery, excision of a segment of vas, and vasal occlusion may be completed as described. The contralateral vasectomy may be performed through the same incision and after attaining hemostasis, the wound is closed with absorbable suture.

Patients are instructed to minimize their activity and intermittently apply cold compresses to the scrotal area during the day of the vasectomy and the following day. Postoperative discomfort may be managed using nonsteroidal antiinflammatories or oral narcotics. On postoperative day 2, patients may shower and resume usual daily activities, continuing to avoid heavy lifting, strenuous activity, and sexual activity for the next week. Once resuming sexual activity, the need for continued contraception until azoospermia is confirmed on two separate semen analyses is stressed to the patient.

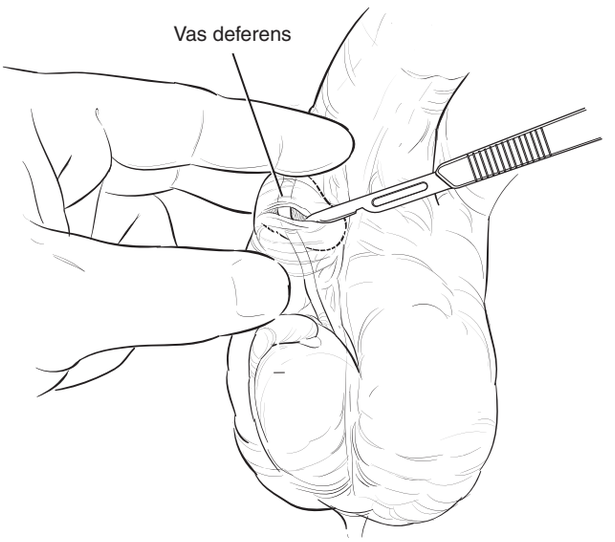

FIGURE 50-5. Conventional vasectomy: incision. *(From Graham SD (ed): Glenn's Urologic Surgery 5th edition. Philadelphia, Lippincott Williams and Wilkins, 1998.)*

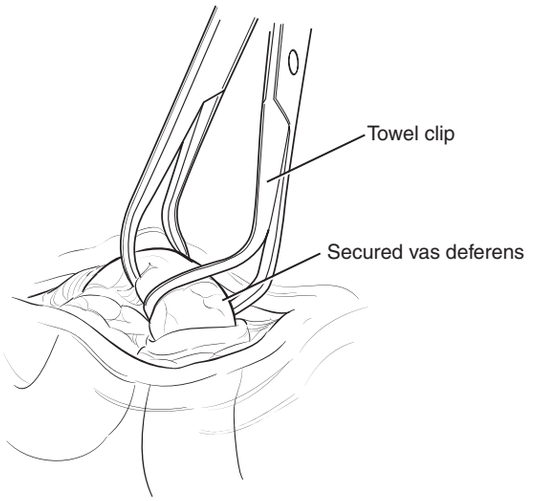

FIGURE 50-6. Conventional vasectomy: securing the vas.

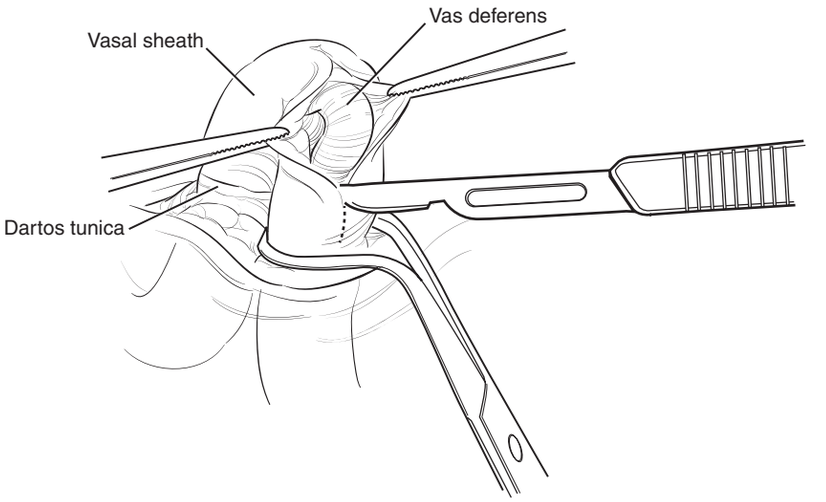

FIGURE 50-7. Convention vasectomy: delivery of the vas. *(From Graham SD (ed): Glenn's Urologic Surgery 5th edition. Philadelphia, Lippincott Williams and Wilkins, 1998.)*

Commentary by

LARRY I. LIPSHULTZ

The two common techniques for a vasectomy are clearly described and illustrated. I prefer a combination of the two: the use of a scalpel for the skin incision and a ringed hemostat for grasping the vas. Hemoclips for vasal occlusion have been used at Baylor for the past 40 years with a long history of success.

The real dilemma is when to consider a postvasectomy semen analysis "sterile." Is it a drop of neat semen demonstrating no sperm at all, the finding of only nonmotile sperm, or the absence of sperm from a centrifuged sample with microscopic examination of the resultant pellet? At this time there is no codified U.S. urologic standard.

Chapter 51

Vasovasostomy and Vasoepididymostomy

RAYMOND A. COSTABILE

Vasectomy reversal can be performed under local, regional, or general anesthesia. Patient preparation includes utilization of standard alcohol-based or povidone-iodine solutions on a shaved scrotum. If the patient has had prior inguinal surgery, both groins should be prepared for the possibility of performing an inguinal vasectomy reversal.

PATIENT POSITIONING

Correct patient positioning is essential to allow the microsurgeon to sit or stand to perform vasectomy reversal comfortably. The patient is positioned as far toward the foot of the operating table as possible using a table extension or stool. It is important that the surgeon and assistant support the ulnar portion of hands, wrists, and forearms to minimize tremor. The operating microscope should be positioned at the head or foot of the operating table with an overhanging suspensory bar. The microscope foot pedals should be accessible comfortably by the operating surgeon, as should the bipolar pedal for operative cautery.

INSTRUMENTS

Few specific instruments are needed for microscopic vasectomy reversal: (1) straight microforceps with typing platform, (2) curved nonlocking microneedle holders, (3) toothed tissue microforceps, (4) vas deferens clamp or holding apparatus, (5) curved tip microforceps, and (6) bipolar cautery forceps. Additional instruments include glass microscope slides and capillary tubes, microirrigator made from a 10-mL syringe and a 24-gauge angiocatheter, microknife, and surgical background.

INCISIONS

Several options are available for the initial incisions. Primary vasectomy reversal, where the vasectomy site is in the straight portion of the vas deferens can be performed through a small 1.5-cm midline raphe incision after grasping the vasectomy site or sperm granuloma with a penetrating towel clamp. It is preferable not to deliver the spermatic cord and testis for simple vasectomy reversal but reserve this approach for more difficult dissections or vasoepididymostomy. Alternate lateral incisions or an extended raphe incision can be made for more difficult dissections.

A healthy portion of the vas deferens is isolated for about 1 cm away from the vasectomy site without stripping the adventitia and eliminating blood supply to the anastomosis (Fig. 51-1). A metal ruler of flat clamp is placed under the vas deferens and a #10, #11 scalpel blade or microknife is used to transect the vas with a 90-degree perpendicular cut angle. A 6-0 nylon stay suture can be placed in the adventitia of the vas deferens to prevent migration.

Fluid is coaxed from the testicular portion of the vas deferens and examined for spermatozoa. The abdominal portion of the vas deferens is cannulated with a 24-gauge microirrigator and saline injected to ensure patency (Fig. 51-2). A free-flowing gentle injection of 3 to 5 mL of saline confirms patency.

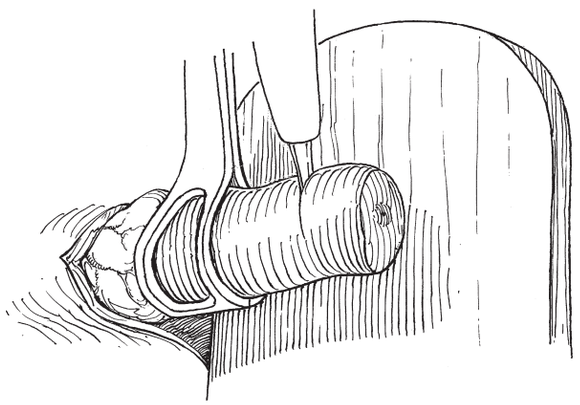

FIGURE 51-1.

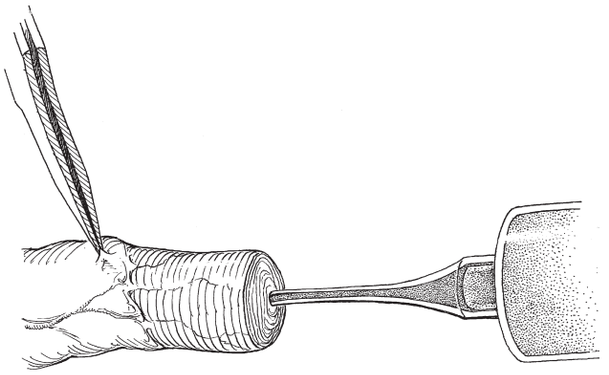

FIGURE 51-2.

MODIFIED ONE-LAYER CLOSURE

Six 9-0 nylon sutures (Ethicon vas 100-4 needle) are used for each layer of the anastomosis. Three initial sutures are placed through all layers (mucosa, muscularis, and adventitia) of the vas deferens on the back wall, incorporating the lumen, and then tied (Fig. 51-3).

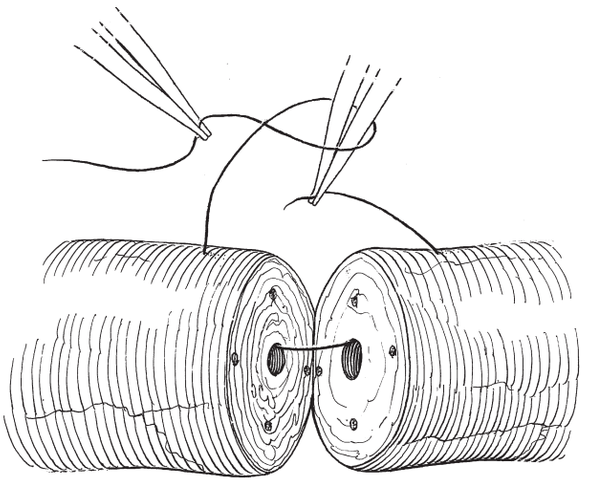

FIGURE 51-3.

Additional 9-0 nylon sutures are interposed between each full-thickness suture, incorporating only the seromuscular portion of the wall (Fig. 51-4).

The vas clamp is then rotated 180 degrees and three additional full-thickness sutures are placed without tying (Fig. 51-5). After all three are placed, they are tied and three seromuscular sutures are interposed between these full-thickness sutures to complete the anastomosis.

TWO-LAYER ANASTOMOSIS

A two-layer anastomosis can be performed for dissections where considerable discrepancy exists between the sizes of each cut lumen of vas deferens, particularly in the convoluted portion of the vas. Three luminal sutures are initially placed in the back wall, incorporating only the mucosa and a small portion of muscularis of the vas deferens (Fig. 51-6). Seromuscular sutures not incorporating the lumen are placed, the vas clamp is rotated 180 degrees, and the front wall completed in a similar fashion.

VASOEPIDIDYMOSTOMY

The vas deferens is transacted at the vasectomy site and patency of the abdominal portion confirmed with saline irrigation. A 6-0 nylon stay suture is placed in the adventitia of the abdominal portion of vas deferens.

End-to-Side Vasoepididymostomy

The epididymis is inspected and an area with opalescent tubules is identified in an attempt to locate mature, motile spermatozoa. Carefully dissect a single epididymal tubule after creating a window in the adventitia of the epididymis (Fig. 51-7). Using a microknife, microscissors or cutting needle, an opening is created in the side of the epididymal tubule similar in size to the lumen of the vas deferens. The epididymal fluid is collected and examined for spermatozoa (Fig. 51-8). Alternatively, the epididymal tubule can be completely transacted and an end-to-end anastomosis performed.

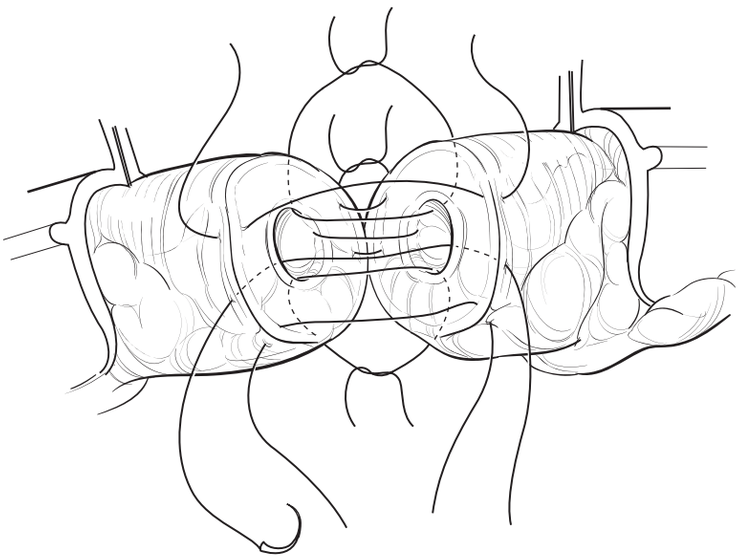

FIGURE 51-4.

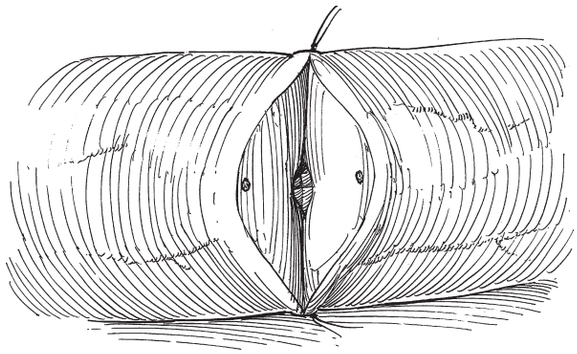

FIGURE 51-5.

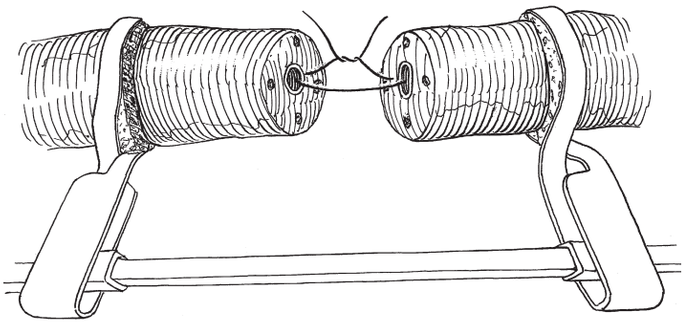

FIGURE 51-6.

The 6-0 stay suture placed in the adventitia of vas deferens is sutured to the adventitia of the epididymis to bring the lumens of the vas and epididymal tubule into proximity (Fig. 51-9). Every attempt should be made to ensure that the lumen of the vas deferens is adjacent to the lumen of the epididymal tubule and is not compromised by placement of the stay suture.

Sutures of 9-0 nylon are placed in the back wall of the adventitia of the vas deferens and anastomosed to the adventitia of the epididymis to more closely approximate each lumen (Fig. 51-10). Sutures of 9-0 or 10-0 nylon are used to perform a direct lumen-to-lumen anastomosis between the vas deferens and the epididymal lumen in the back wall, and are then tied. Continuous visualization of the epididymal lumen is essential. Front wall anastomotic sutures are placed before tying. After all luminal sutures are placed and tied, additional adventitial sutures are placed to cover the anastomosis (Fig. 51-11).

End-to-end Vasoepididymostomy

Alternatively, the direct lumen-to-lumen anastomosis can be performed in an end-to-end fashion using the completely transacted epididymal tubule (Fig. 51-12).

Intussusception Vasoepididymostomy

A simpler end-to-side anastomosis can be performed by triangulating sutures into the epididymal tubule before cutting the tubule. An incision is made in the tubule between the sutures and when tied the sutures intussuscept the epididymal tubule into the vas deferens (Fig. 51-13).

Postoperative Care

Patients are released on the day of surgery with orders to decrease physical activity for 2 weeks. Ice packs and a scrotal support will decrease narcotic use to 48 hours or less. Most patients can return to light work in 72 hours. Ejaculation should be delayed for 3 weeks following vasectomy reversal to decrease the risk of anastomotic sperm leak, granuloma formation, and stricture. A semen analysis is performed 6 to 8 weeks after surgery and every 3 months thereafter until the couple has achieved a pregnancy. Motile sperm should be found in the ejaculate less than 6 months after vasovasostomy. Delayed appearance of sperm in the ejaculate may occur up to 15 months following vasoepididymostomy.

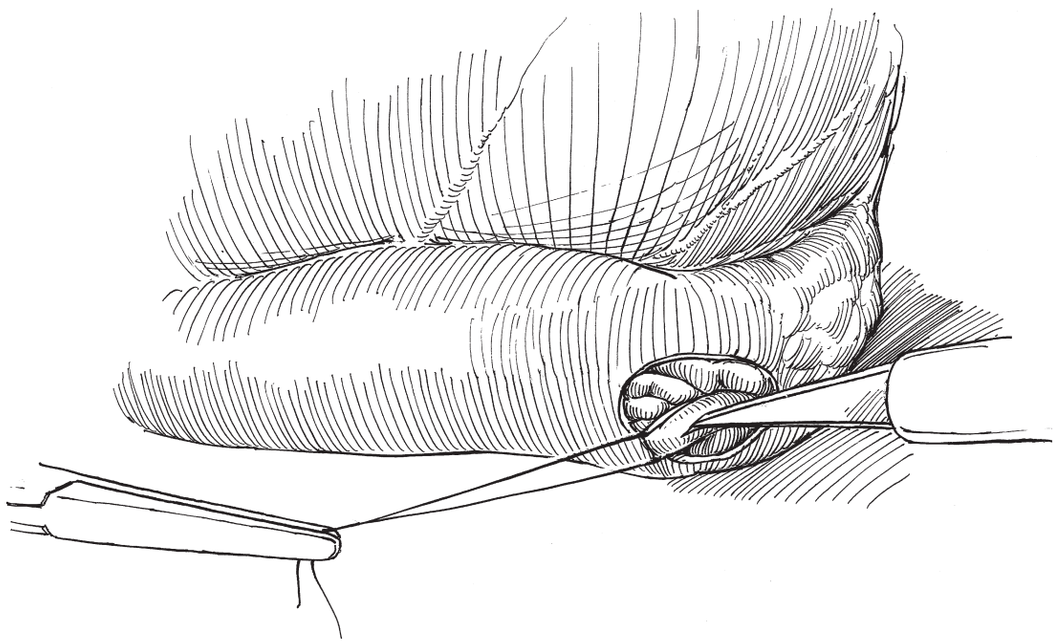

FIGURE 51-7.

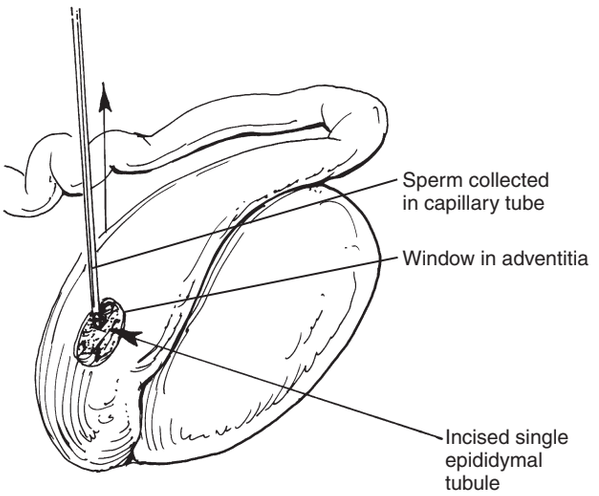

FIGURE 51-8.

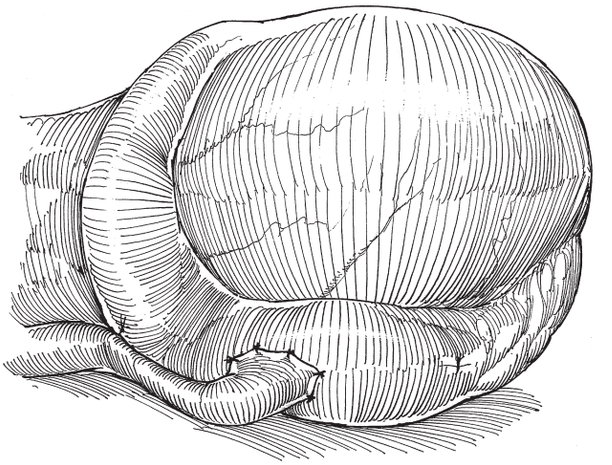

FIGURE 51-11.

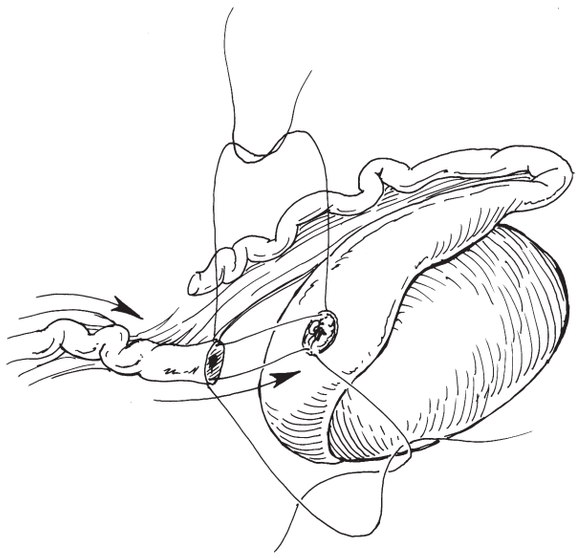

FIGURE 51-9.

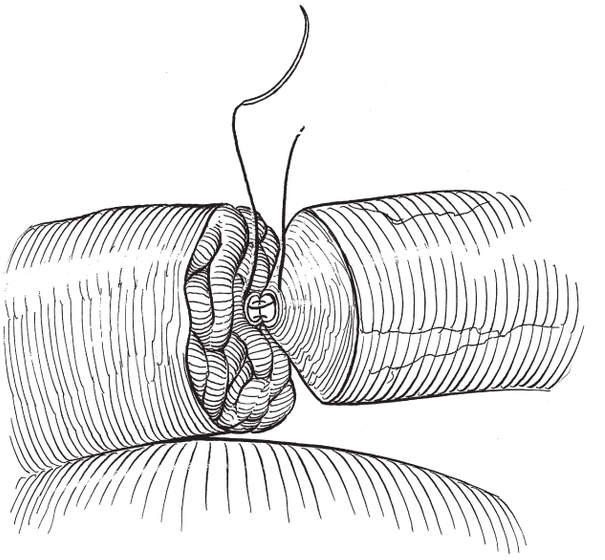

FIGURE 51-12.

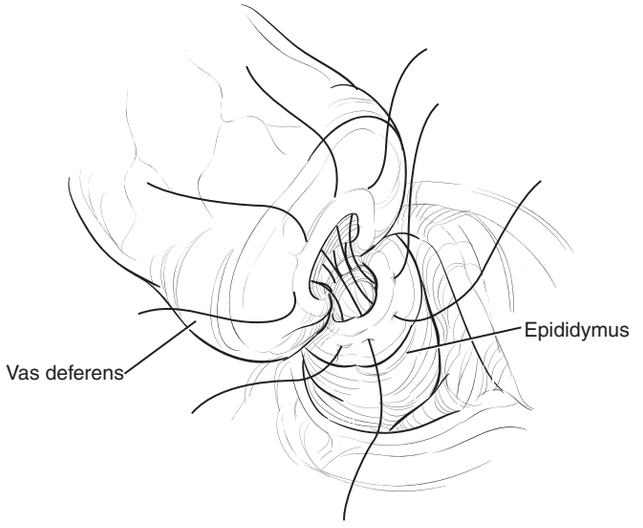

FIGURE 51-10.

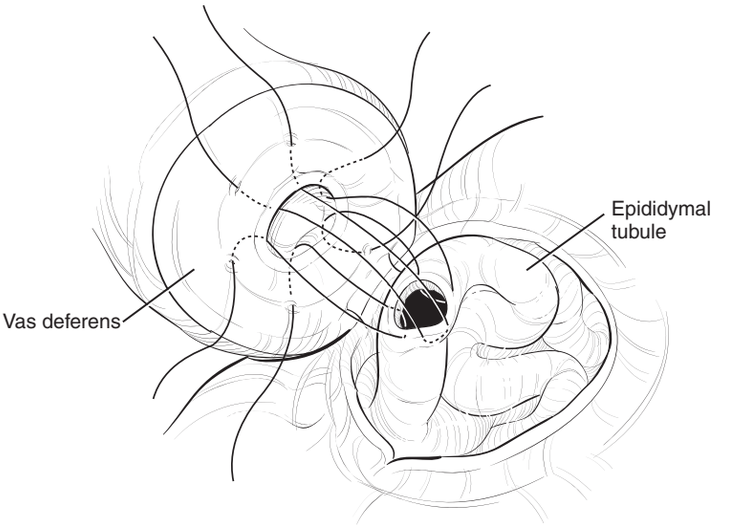

FIGURE 51-13.

Commentary by

LARRY I. LIPSHULTZ, M.D.

One of the mandates of a microsurgical procedure is that the surgeon remains comfortable. For that reason, I prefer sitting at a cantilevered table, allowing both my assistant's knees and my knees to fit comfortably beneath the table and for us to oppose each other with a 180-degree binocular microscope. I prefer a general anesthetic, since movement can occur with a regional anesthetic, and all movement is magnified 20 times under the microscope.

While the list of microscopic instruments described is essentially complete, I would add a 0.2 micro-tipped forceps for gently grasping the vas on its adventitial surface when necessary. It is also important to have a fine-tipped bipolar cautery set at a low setting to minimize tissue damage.

As stated, it is essential to keep the vas as healthy as possible, i.e., maintaining a thick adventitial layer with its rich supply of blood vessels so important to successful healing of the vas. Copious irrigation is an integral part of the procedure, making sure that the operative site is cleared of contaminating blood. For that reason, I use an irrigation bulb for starting the procedure and then go to Angiocath-tipped syringe for fine irrigation.

When I perform vasal microsurgery, I deliver the testis through small bilateral hemiscrotal incisions with the tunica vaginalis intact, identifying the proximal (testicular) and distal (abdominal) vasal ends with towel clips. This makes it quite easy to separate the vas from its surrounding tissue while maintaining gentle traction.

I think it is extremely important to cut the vas cleanly in a perpendicular fashion. For that reason, I used a #4 nerve holder and incise through its slotted groove with a Denis blade. I do not irrigate the abdominal vas unless the patient has had previous inguinal surgery. I am concerned about stripping the mucosa with the Angiocath and, therefore, no longer irrigate distally.

I have never used a microclamp but instead place a 5-0 PDS suture in the loose perivasal tissue on each end to approximate the proximal and distal segments. This maneuver allows for a totally tension-free anastomosis.

In my opinion an epididymovasostomy is many times more difficult than a vasovasostomy and has certainly been simplified by the use of the intussusception technique. However, it is not the microsurgical suture placement that makes an epididymovasostomy more difficult, but rather the intricate technique of bringing the vas to an identified epididymal tubule and allowing both to be accurately opposed. This requires careful sequential placement of an anchoring 5-PDS suture, an abutting 7-0 nylon suture and, finally, and epididymal tunic stitches of 9-0 nylon. I bring the distal vas through an incision in the tunica vaginalis, so that my entire anastomosis remains intravaginal. Again, I prefer the intussusception technique but have gone to two longitudinal 10-0 stitches rather than the originally described triangular technique.

This page intentionally left blank

Chapter 52

Excision of Utricular Cyst

JACK S. ELDER

TRANSTRIGONAL APPROACH (FIG. 52-1)

If possible, insert a small balloon catheter cystoscopically through the ostium of the cyst to aid in the dissection.

Open the bladder and place a Denis Browne retractor to expose the trigone. Insert pediatric feeding tubes into the ureteral orifices and secure them. Using cutting current with a needle point cautery tip, make a vertical incision through the trigone and posterior bladder wall that approaches the bladder neck. Place stay sutures through the bladder wall edges (not shown). The utricular cyst should be visible. Use a right-angle dissector to separate the cyst from the posterior bladder wall and use low cautery current with the needle point cautery to separate the attachments. Placement of a phrenic retractor under the bladder wall helps expose the cyst. Mobilize the cyst laterally and superiorly, and separate vasa deferentia off the cyst laterally. If the vas deferens enters the cyst, it needs to be transected. Ideally it will be implanted into the bladder with a short submucosal tunnel. The cyst should then be followed inferiorly to the bladder neck. At this point, the inferior retractor blade should be removed.

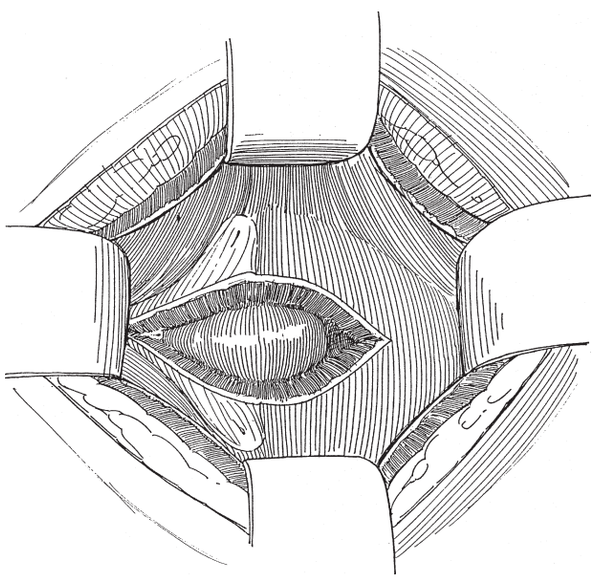

FIGURE 52-1.

Dissect the cyst to its junction with the posterior urethra as low as possible. Transect the urethra and oversew it.

Close the posterior bladder wall in one layer with a running imbricating suture. Place a suprapubic cystostomy tube, which should remain in place for 1 week. Close the bladder in two layers. A Penrose drain is unnecessary.

This approach to the retrovesical space also may be used to gain access to a residual stump of an ectopic ureter as an alternative to the extravesical approach. The transtrigonal dissection allows excision of the entire stump, which may be difficult with the extravesical approach.

LAPAROSCOPIC APPROACH (TRANSPERITONEAL)

The patient is placed in modified lithotomy position. Cystoscopy is performed and an attempt is made to identify the ostium of the cyst. If it is identified, 5 to 10 mL of a solution of indigo carmine may be injected to aid in identification of the cyst. The patient is placed in Trendelenburg position. An optical port is place in the inferior aspect of the umbilicus and two 5-mm operating instrument ports are inserted lateral to the rectus, either at the level of the umbilicus or in the left and right lower quadrants. A fourth 5-mm assistant port is placed on the right side of the abdomen. The bladder is filled partially. A 3-0 polyglycolic acid suture is passed through the anterior body wall, through the dome of the bladder, and out through the anterior body wall for traction. A Maryland forceps and hook are used for performing the dissection, and monopolar cautery is used. The peritoneal reflection is incised behind the bladder, between the vasa deferentia. The cyst is then exposed. The dissection is carried out anterior and posterior to the cyst, with care taken not to injure the vasa. Following complete mobilization, the neck of the cyst is ligated with an endoscopic loop or Hem-o-Lok clip and the cyst is removed through the 10-mm port. Alternatively, if the procedure is being performed with robotic assistance, the neck may be oversewn with polyglycolic acid suture. Drainage of the lower urinary tract is performed as described earlier.

POSTERIOR SAGITTAL APPROACH

The posterior sagittal transanorectal approach, described by Pena, utilizes the dissection often used for anorectal malformations, except that with normal rectal anatomy, the rectum is divided in the midline. This approach offers excellent visualization of müllerian duct cysts and allows straightforward removal. Urinary continence and erectile function are not affected, and a diverting colostomy is unnecessary. This approach is most useful in children in whom the transvesical approach or laparoscopic approach is unsuccessful, or in whom there is an associated anorectal malformation.

Chapter 53

Spermatocelectomy

CIGDEM TANRIKUT AND PETER N. SCHLEGEL

A spermatocele is a paratesticular, sperm-containing cystic structure attached to the superior aspect of the epididymis. Use of an operating microscope allows one to clearly identify structures adjacent to the spermatocele, aids in dissection of the spermatocele off of the epididymis (and away from the testicular blood supply), and allows isolation of the spermatocele neck for ligation and excision. The patient should be counseled regarding the following procedural risks: potential for epididymal obstruction and subsequent infertility, scrotal edema, scrotal hematoma, spermatocele recurrence, and infection.

Spermatocelectomy is most easily performed with the patient under general anesthesia in order to limit motion artifact while working under the operating microscope. We prefer a median raphe incision carried sharply down to the level of the tunica vaginalis, although a transverse scrotal incision is an acceptable alternative.

Bluntly dissect the tunica vaginalis to deliver the testis within the tunic through the skin incision. Achieve hemostasis of the dissected dartos fibers with electrocautery. Incise the tunica vaginalis to gain direct access to the testis, epididymis, and spermatocele (Fig. 53-1).

After bringing the operating microscope into the field, a combination of sharp and blunt dissection is used to isolate the spermatocele off of the testis and epididymis. Keeping the spermatocele intact allows for easier dissection and identification of tissue planes. Use bipolar microforceps cautery to ensure hemostasis during dissection. Once the fine neck of the spermatocele has been clearly identified and dissected free, ligate it on both the epididymal and specimen sides and divide (Fig. 53-2).

Close the tunica vaginalis with running 4-0 absorbable monofilament suture. Inject 10 mL of bupivacaine beneath the closed tunica vaginalis for local anesthetic effect. Close the dartos muscle with 3-0 or 4-0 absorbable monofilament; before completing closure, instill 10 mL of bupivacaine into the scrotal pouch. Inject the wound with local anesthetic, then reapproximate the edges using absorbable monofilament suture in a running subcuticular fashion. Apply antibiotic ointment to the wound, dry fluffed gauze, and an athletic supporter.

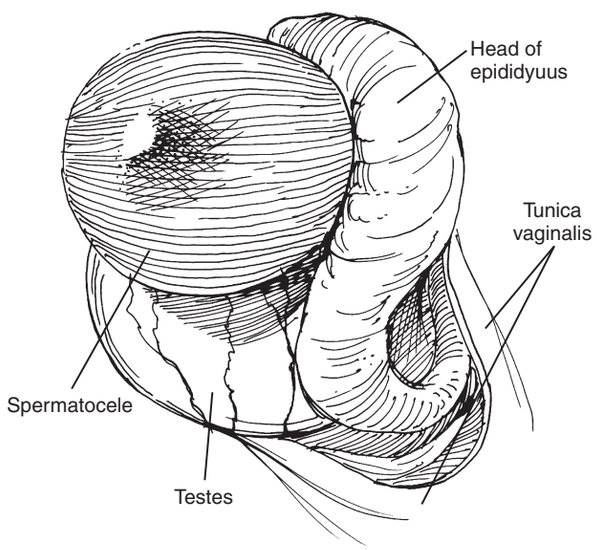

FIGURE 53-1. Gross figure of testis, epididymis, and spermatocele.

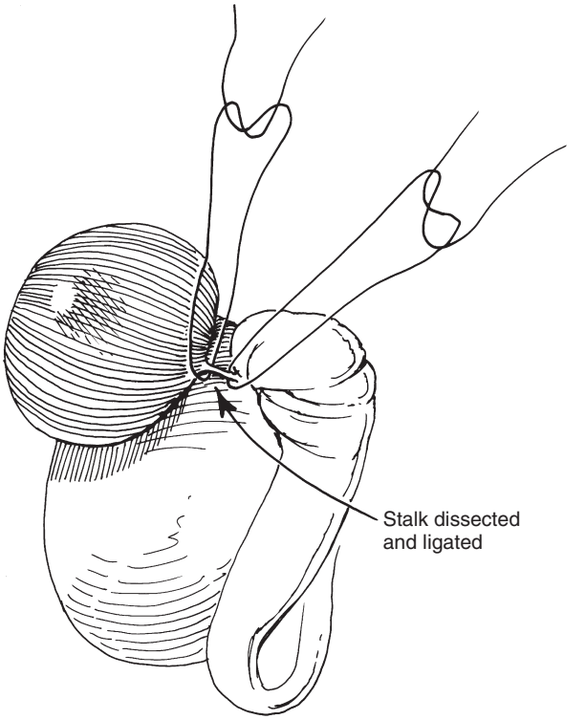

FIGURE 53-2. Thin neck of spermatocele coming off of epididymis, about to be ligated, ~10×.

Commentary by LARRY I. LIPSHULTZ, M.D.

While the authors have described the use of a microscope, and while it does offer high-powered magnification, I have found that 2.5-power loupes are quite adequate for spermatocele removal. I also used sharp-tip Jacobson's to develop a plane between the spermatocele and the epididymis. By spreading the Jacobson's, a plane can be exposed, and using a low coagulation current on a needle tip Bovie the tissue can be incised. The differential diagnosis of a spermatocele versus a paratesticular cyst can only be made by the identification of sperm in the cyst fluid; regardless, however, the excision technique remains the same.

Chapter 54

Epididymectomy

WAYNE J. G. HELLSTROM

ANATOMY AND PHYSIOLOGY OF THE EPIDIDYMIS

The epididymis is a long, tightly coiled single tubule located on the postero-lateral aspect of the testis. The epididymis has a rich blood supply from both testicular and deferential vessels. Because of extensive collaterals, either the deferential or testicular arterial branches to the epididymis can be ligated without affecting epididymal function. However, inadvertent damage to the testicular artery during epididymectomy may compromise testicular viability and function.

INDICATION FOR EPIDIDYMECTOMY

The indications for epididymectomy are chronic infections unresponsive to antibiotics, abscess formation with or without draining fistulas, tumors, chronic pain, trauma, and post-vasectomy syndrome (epididymitis/vasitis nodosa). When inflammatory cases progress and do not respond to medical therapy, then surgical intervention may be indicated.

Of note, pain may not be completely relieved by surgery in patients with chronic pain syndrome. Some surgeons may perform cord denervation as part of the epididymectomy for post vasectomy syndrome.

SURGICAL TECHNIQUE

While the surgical approach for epididymectomy is relatively straightforward, the presence of significant inflammation, fibrosis, or anatomic distortion may make this procedure difficult.

After the testis is delivered through an anterior scrotal incision, the tunica vaginalis is opened to provide access to the epididymis and vas deferens. The surgeon can approach epididymectomy from above or below.

From above, the straight portion of the vas deferens is ligated and the proximal vasal lumen fulgurated or ligated. The convoluted vas is then carefully dissected from the spermatic cord. The surgeons' thumb and forefinger carefully pinches the spermatic cord, keeping the epididymis anterior during dissection (Fig. 54-1). Lightly incising the adventitial junction between the epididymis and testis allows careful blunt and sharp dissection and lifting of the tail region. At the junction of the middle and upper third of the epididymis, the common origin of the testicular and epididymal arteries are encountered (see insert, Fig 54-1). Taking care to preserve the blood supply to the testis, only the epididymal artery is ligated.

Alternatively (or in combination), the lower approach places traction on the head of the epididymis (Fig. 54-2). Careful dissection lifts the head of the epididymis and allows either fulguration or ligation of the efferent ductules from the testicle. Further dissection close to the epididymis (and away from the vascular supply to the testicle) allows the remainder of the epididymis to be removed. Small bleeding points are meticulously cauterized and the remaining tunical edges closed over

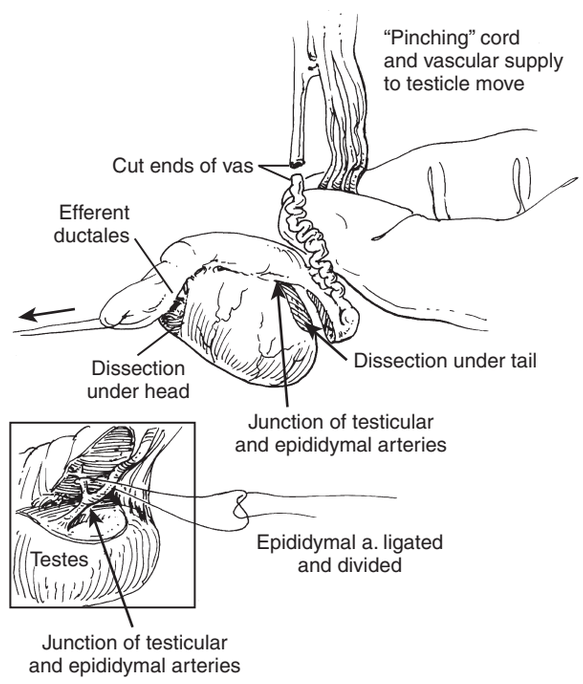

FIGURE 54-1.

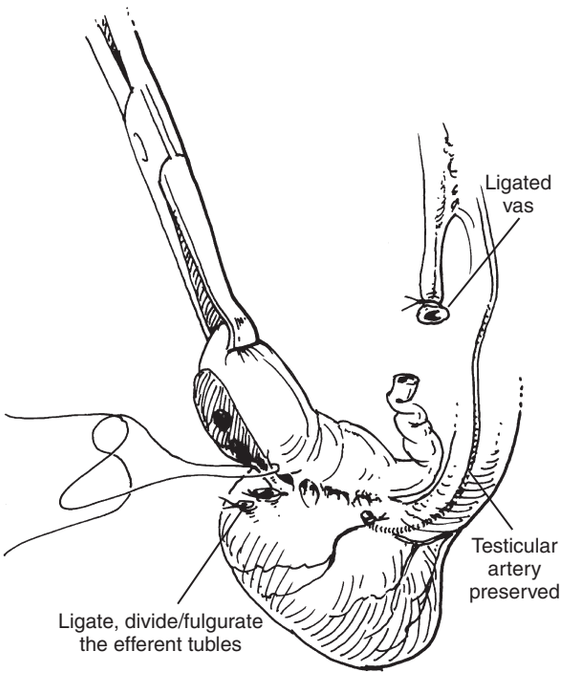

FIGURE 54-2.

the epididymal defect with absorbable 4-0 sutures (Fig. 54-3). The remaining scrotal incision is closed in layers with absorbable 3-0 sutures and a tight scrotal pressure dressing is applied.

If the epididymis involves abscess and cutaneous sinus tracts, this region may need to be debrided and excised. In these circumstances or when extensive bleeding has been encountered, a ¼-inch Penrose drain may need to be placed in a dependent position in the scrotum.

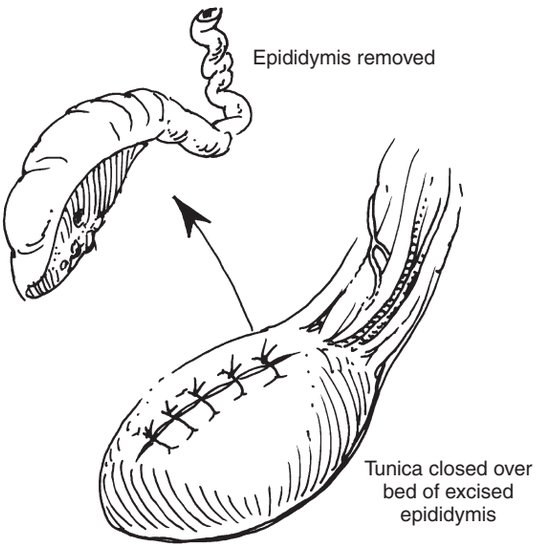

FIGURE 54-3.

POSTOPERATIVE CARE AND COMPLICATIONS

Most epididymectomy procedures can be performed on an outpatient basis with the patient discharged on antibiotics, analgesics, and pressure dressing.

The major complications from epididymectomy are infection and vascular compromise. Large hematomas may need drainage and ligation of bleeding vessels. Incidental injury to the testicular artery at the time of epididymal artery ligation may result in gradual testicular atrophy. If the contralateral testis does not provide sufficient androgen levels, serum testosterone measurement and replacement may be in order.

Commentary by

LARRY I. LIPSHULTZ, M.D.

It is important to note that the epididymis lies posterior lateral to the testis with its sulcus facing laterally. This is important to remember during the dissection so that all surgery is in the correct anatomic plane.

I like to ligate all vessels close to the epididymis, sparing the testicular branches of the testicular and deferential artery. To make sure that the artery is identified clearly and is intact, I use a 1mm tipped Doppler (VTI Instruments, Boston, MA).

I like to dissect progressively from the vasal end just distal to the convoluted tubules as well as from the epididymal head. After dissecting approximately 0.5cm of the caput epididymis, I like to cross-clamp this as well as the vasal stump. I can therefore put traction on both ends of the epididymis, lifting it away from the testis and making it easier to see the penetrating branches of the testicular artery. As stated, all ligations should be as close as possible to the epididymis, trying to preserve the testicular blood supply at all times.

Chapter 55

Undescended Testis

SEAN T. CORBETT

INGUINAL ORCHIOPEXY (OPEN TECHNIQUE)

Orchiopexy

Orchiopexy may be performed as early as 6 months of age. By that time, spontaneous testicular descent for palpable testes is unlikely and the boy is sufficiently developed to undergo anesthesia and operation.

Orchiopexy can usually be performed as an outpatient procedure, unless a cardiopulmonary condition is present. Allow solid food up to 8 hours, formula up to 4 hours, and clear liquids up to 2 hours before surgery. Operations on infants require magnification and special technique, particularly if the testis is in a high position.

The inguinal region in infants differs somewhat from that in adults in ways that are important for surgery at this age. The superficial fascia is much thicker, resembling the aponeurosis of the external oblique muscle, which in turn is relatively thin, with delicate medial and lateral crura. Before 2 years of age, the bladder extends well into the abdomen and can be injured during medial exposure of the spermatic cord.

A palpable, undescended testis is usually found in the superficial inguinal pouch or close to the internal ring. If the descended testis is enlarged, consider previous contralateral intrascrotal torsion with testicular atrophy; perform scrotal exploration to locate the remnant.

A nonpalpable testis may lie in the peritoneal cavity just within the internal ring. Several approaches are available: inguinal, laparoscopic, low ligation, staged Fowler-Stephens, or microvascular orchiopexy.

In a boy with bilateral nonpalpable testis, confirm that a disorder of sexual development does not exist such as congenital adrenal hyperplasia by karyotype. Figure 55-1 is an algorithm for determining an open approach to the nonpalpable testis.

Choose a laparoscopic or an open technique.

If cryptorchidism is detected postpubertally, consider an orchiectomy if there is a normal, descended contralateral testis. However, after 50 years of age, the risk from surgery becomes greater than the risk of cancer.

Open Inguinal Orchiopexy

In addition to initiating general anesthesia, have the anesthesiologist provide a caudal block at the beginning of the procedure to reduce anesthetic requirements and block pain during recovery. For the older child, a local nerve block is preferred.

Postoperative Problems

Inadequate testis position has an incidence as high as 10% as the result of incomplete retroperitoneal dissection; it can usually be corrected by a second operation. Late retraction of the testis occurs in a few cases.

Apparent atrophy is related to the degree of development of the testis, but the most serious complication is devascularization of the testis during dissection of the cord, which is avoided by the use of loupes, fine instruments, and sequential dissection. For an atrophic testis, orchiectomy may eventually be advisable because of the increased chance for cancer.

Accidental division of the vas can occur. Microvascular repair, either immediately or postpubertally, may correct the problem. This complication occurs more frequently in nonpalpable cases. Postoperative scrotal swelling is usually a sign of edema rather than infection or hematoma. Immediate progressive scrotal enlargement suggests uncontrolled bleeding and requires exploration. Avoid needle aspiration; it is seldom diagnostic and is harmful if the swelling should be due to herniation of bowel through the peritoneal defect.

Sharply incise the external oblique fascia from above. Use a knife or scissors to cut between the fibers that terminate at the external ring (Fig. 55-2). Identify and avoid the underlying ilioinguinal nerve with its medial and lateral branches. Free the fascia from the conjoined muscle and the cremasteric fibers beneath it. Look for the ilioinguinal nerve and gently free it from the fascia. Separate the internal oblique muscle with scissors or a fine clamp to expose the floor of the canal.

Identify the testis within the tunica vaginalis. Pick up the overlying cremasteric fibers on either side with a fine

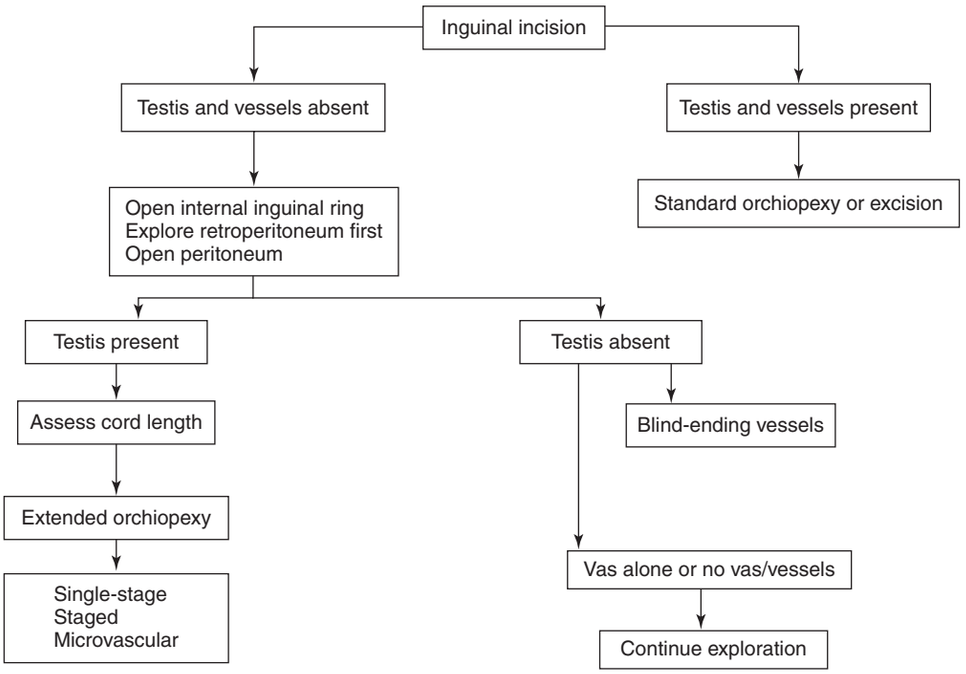

FIGURE 55-1. *(Adapted from Hinman F, Baskin LS. [2009] Hinman's atlas of pediatric urologic surgery. Philadelphia: Elsevier.)*

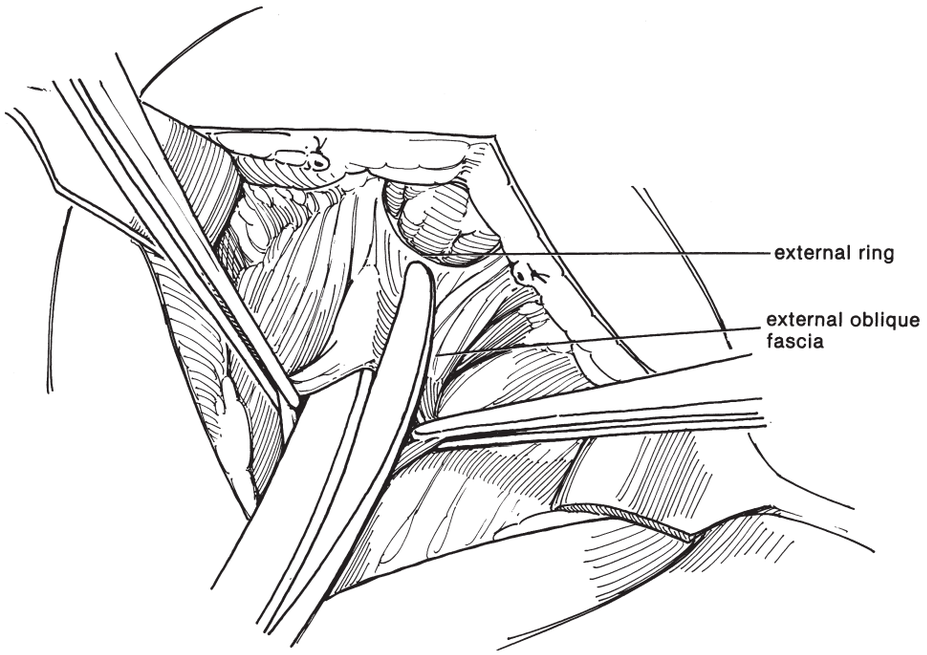

FIGURE 55-2. *(Adapted from Hinman F, Baskin LS. [2009] Hinman's atlas of pediatric urologic surgery. Philadelphia: Elsevier.)*

smooth forceps (Fig. 55-3). Sharply and bluntly peel them down and off the cord. Keep clear of the external spermatic artery and vein, branches of the inferior epigastric vessels. Let these vessels drop to the floor of the canal. Keep close to the tunica vaginalis to locate the communicating processus vaginalis. Excise the gubernacular attachments, freeing the testis so that its only attachment is the spermatic cord.

Open the tunica vaginalis hernia sac anteriorly and incise it proximally to the base of the cord (Fig. 55-4). Remove the appendix testis and appendix epididymis (if present).

Once it is apparent that the cord will become long enough when developed, grasp the edges of the tunica vaginalis near the internal ring with fine forceps, and insinuate fine scissors or a small straight hemostat between the peritoneal lining of the hernia canal and the vessels and vas. The tunica vaginalis may appear to surround the cord. It is easiest to separate it from the vessels and vas just below the internal ring. Dissect

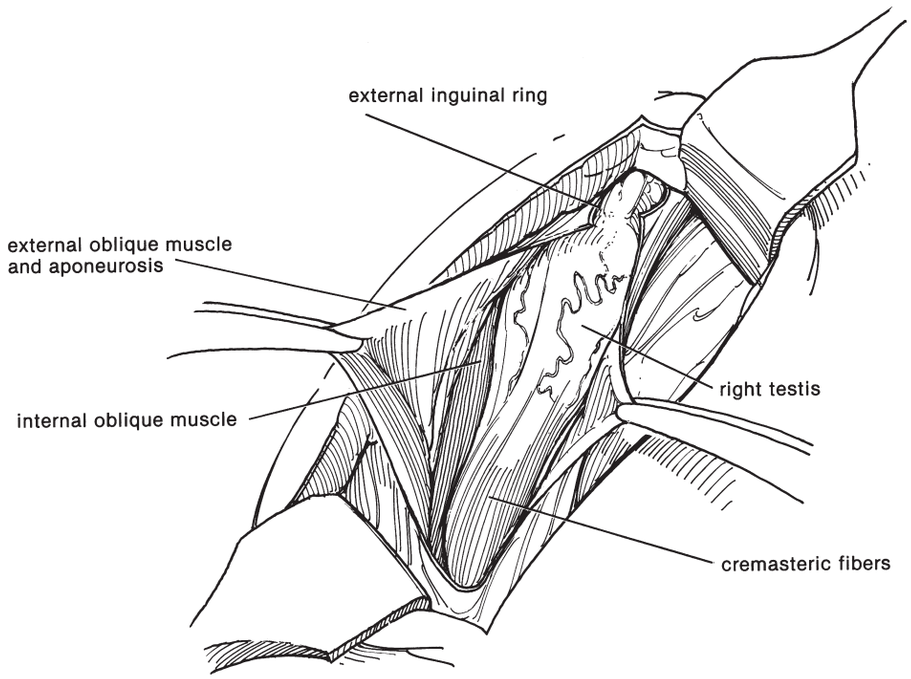

FIGURE 55-3. *(Adapted from Hinman F, Baskin LS. [2009] Hinman's atlas of pediatric urologic surgery. Philadelphia: Elsevier.)*

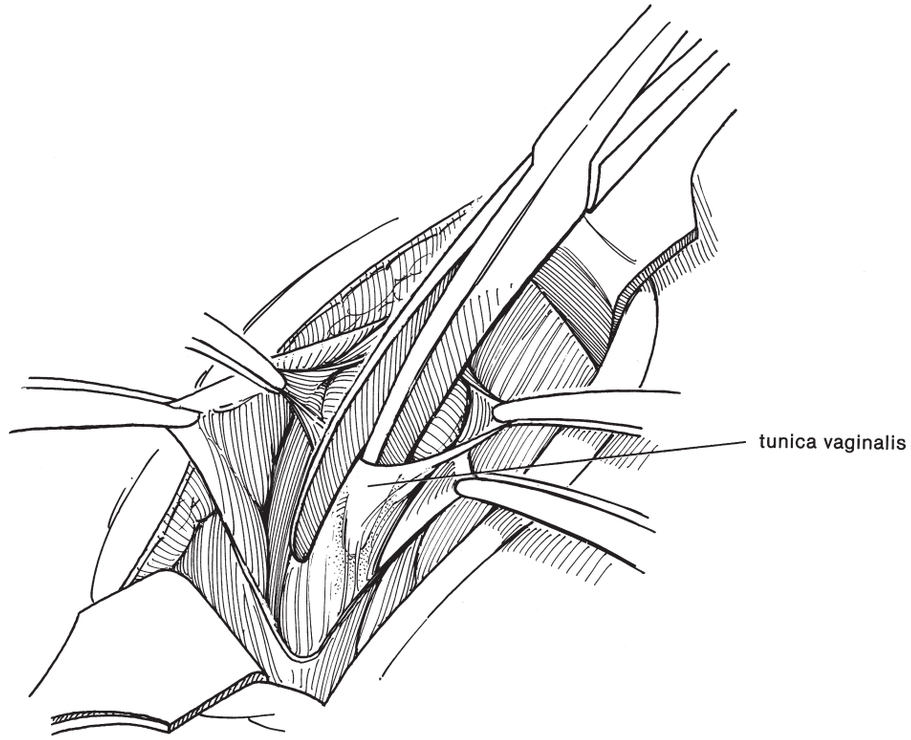

FIGURE 55-4. *(Adapted from Hinman F, Baskin LS. [2009] Hinman's atlas of pediatric urologic surgery. Philadelphia: Elsevier.)*

from both the medial and lateral sides. As the separation progresses, divide the free edges of the sac to obtain better exposure for the dissection, especially for the separation of the cord structures from the peritoneum. Finally, divide the posterior and lateral connections of the internal spermatic (transversalis) fascia to allow the cord to move medially.

If the cord remains too short, consider bringing the testis directly into the scrotum with the Prentiss maneuver, which bypasses the obliquity of the inguinal canal.

Place mosquito clamps on its edges, and complete the division of the sac. Close the peritoneal opening with a pursestring suture, or with the usually small hernia sac,

suture-ligation is enough (Fig. 55-5). It may be preferable to postpone this step and close the opening after upward mobilization has been completed, because, if closure is done too early, the subsequent retraction needed for the retroperitoneal dissection can tear out the repair. If the peritoneum does tear, oversew the opening into the peritoneal cavity with a fine continuous suture.

Inspect the testis for size and anomalies. Gauge the length of the cord by pulling the testis over the symphysis. If it is too short, meticulously free the remainder of the tunica vaginalis and the cremasteric fibers from it.

If necessary, open the internal ring by dividing the internal oblique muscles and more of the lateral spermatic fascia. Free the cord well retroperitoneally, and, with a peanut dissector, mobilize it medially, up toward the kidney as necessary. To avoid atrophy, dissect as little as possible about the vessels, vas, and cord structures, particularly in infants. Testes found in the superficial inguinal pouch need minimal dissection of the cord.

If the testis is found at or above the internal ring, first lengthen the inguinal incision: Elevate the skin at the upper end and open the lateral aspect of the internal ring by dividing the transversalis fascia. Place narrow Deaver retractors. With a Küttner dissector, bluntly develop the retroperitoneal space. Now incise the external oblique fascia in the line of the incision and split the internal oblique and transversalis fascias. Look for the vas or spermatic vessels adherent to the peritoneum under the subserosal fascia, and trace the vas to its proximal end (either to a testis or to a blind ending). If the cord, after thorough dissection and transposition, is still too short, consider an alternative procedure.

Dartos pouch technique for fixation of the testis in the scrotum. Pass the index finger into the scrotum along the usual course of testicular descent. Make a 2-cm incision with the scalpel through the scrotal skin (Fig. 55-6A). Develop a pocket for the testis from below by freeing the skin from the dartos fascia bluntly with a small clamp or scissors, for a distance of 1 to 2 cm (see Fig. 55-6B). Make a small opening in the dartos fascia while it is tensioned over the finger. Spread this incision with a clamp and grasp the fascial edges with small Allis clamps (see Fig. 55-6C).



FIGURE 55-5. *(Adapted from Hinman F, Baskin LS. [2009] Hinman's atlas of pediatric urologic surgery. Philadelphia: Elsevier.)*

Draw the testis out through the scrotal incision by passing a clamp from below against the index finger in the wound and grasping the edge of the tunica albuginea. Take care not to rotate the cord.

Close the dartos fascia behind the testis (Fig. 55-7). Seal it with skin adhesive.

Suture the internal oblique muscle to the shelving edge of the inguinal ligament over the cord with 3-0 or 4-0 synthetic absorbable sutures. Alternatively, simply approximate the internal oblique muscle with interrupted sutures.

Close the external oblique muscle with interrupted sutures from cephalad to caudad to create a new external ring (Fig. 55-8). Do not make the ring too tight. Reapproximate Scarpa's fascia, close the skin with a running 4-0 or 5-0 synthetic absorbable suture placed subcuticularly, and seal the skin with skin adhesive.

A hydrocele may form later from proliferation of remnants of the tunica vaginalis. If the hydrocele is small it can be ignored; if large, it requires transscrotal repair (see Chapter 123). Testicular extrusion secondary to ischemia of the overlying scrotal skin is uncommon. Bladder injury has been reported from gross ligation of the hernia sac.

SCROTAL ORCHIOPEXY

Make a skin incision in a cephalad scrotal skin crease (Fig. 55-9). Create a dartos pouch through this incision before testicular mobilization. Use blunt and sharp dissection of the subcutaneous tissues to approach the testicle. The loose skin and short distance from the external ring to the scrotum facilitate easy mobilization of the skin incision to the inguinal region for dissection without opening the inguinal canal. If the testis can be manipulated into the scrotum, a vertical or transverse scrotal incision can be used.

Release the gubernacular attachments to enable identification of the testicle within the cremasteric fibers, a patent processus vaginalis, and the cord structures. Create a dartos pouch by blunt dissection in caudal fashion just underneath the skin. During subsequent dissection, protect the ilioinguinal nerve when it is clearly present (it is not routinely identified) before proceeding further.

Carefully separate the cremasteric fibers and hernia sac from the cord structures. Under traction, divide the hernia sac between hemostats and suture-ligate it (Fig. 55-10). When additional cord length is required, dissect further through this incision by opening the external ring and canal as necessary. When further cord length is needed, make a standard inguinal incision to allow for retroperitoneal dissection. In patients with a trapped testis, the technique enables early identification of the testis and accompanying cord structures. Careful dissection cranially and en bloc fascia dissection may be required to obtain sufficient length.

Relocate the testis into the dartos pouch, or suture tunica albuginea to the scrotal septum, and narrow the pouch neck with simple interrupted absorbable suture to prevent ascent. Close the skin using a simple running subcuticular suture, confirming that the testicle is residing in the dependent scrotum. Apply skin adhesive as a dressing.

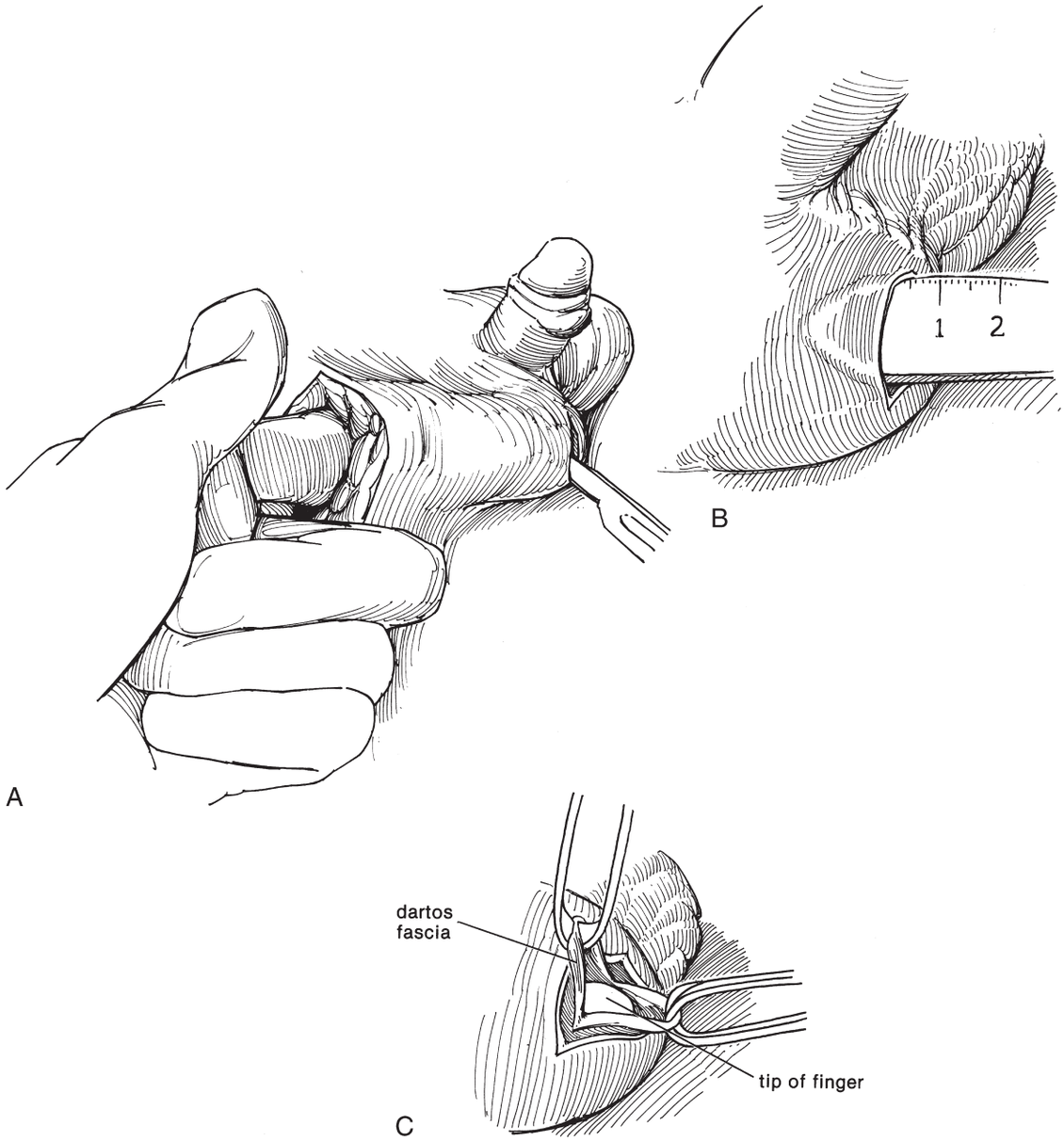

FIGURE 55-6. *(Adapted from Hinman F, Baskin LS. [2009] Hinman's atlas of pediatric urologic surgery. Philadelphia: Elsevier.)*

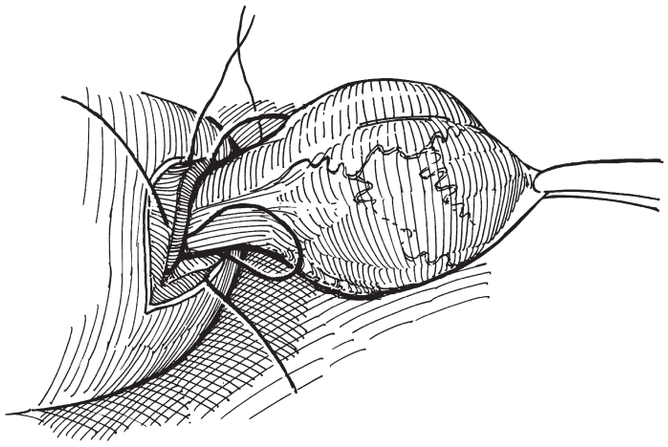

FIGURE 55-7. *(Adapted from Hinman F, Baskin LS. [2009] Hinman's atlas of pediatric urologic surgery. Philadelphia: Elsevier.)*

ORCHIOPEXY FOR ABDOMINAL TESTES

In practice, if laparoscopy has not been performed to locate the testis before the incision is made and a transperitoneal approach is used (see Fig. 55-11), proceed to open the peritoneum at the internal ring. If the testis is immediately identifiable and mobile, proceed with the orchiopexy. If the testis is identified high in the abdomen, the incision is closed and an extended inguinal incision is done.

If the testis has not been localized laparoscopically, an open approach can be used to identify the presence of a retained testis followed by orchiopexy. Three approaches can be used: (1) midline transperitoneal, (2) midline extraperitoneal, or (3) extended inguinal approach (LaRoque maneuver). The midline approaches are generally reserved for known, high intraabdominal testes as in prune-belly syndrome. In cases in which the external oblique muscle has

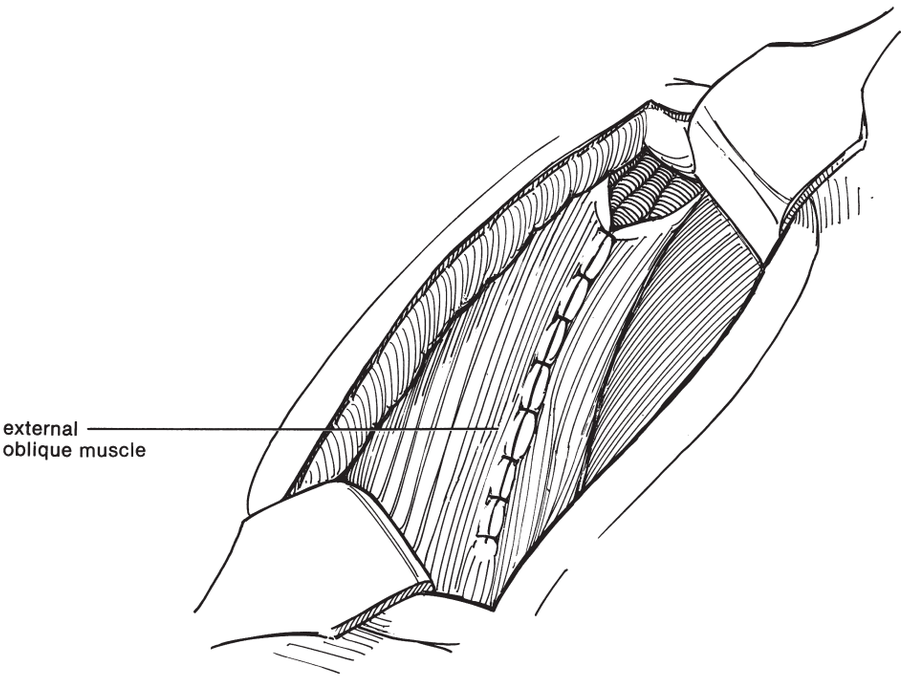

FIGURE 55-8. *(Adapted from Hinman F, Baskin LS. [2009] Hinman's atlas of pediatric urologic surgery. Philadelphia: Elsevier.)*

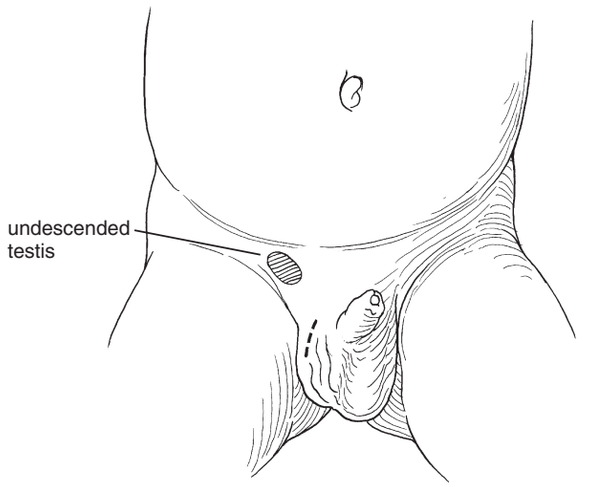

FIGURE 55-9. *(Adapted from Hinman F, Baskin LS. [2009] Hinman's atlas of pediatric urologic surgery. Philadelphia: Elsevier.)*

been opened in standard fashion from the external ring, superior and lateral toward the internal ring, and the peritoneum is opened at the internal ring without identification of either a mobile testis or testicular structures, the fascia may be closed. The same skin incision is lengthened and the fascia opened 3 cm superior for access directly into the peritoneum (LaRoque incision).

For bilateral cases, make bilateral skin crease lower-quadrant incisions and explore each groin. Usually, extensive retroperitoneal dissection through these incisions allows the testis to be placed in the scrotum. If the testes are not found, complete the middle of the incision and open the peritoneum, essential for adequate visualization of the internal spermatic vessels and those of the cord if a long-loop orchiopexy is planned.

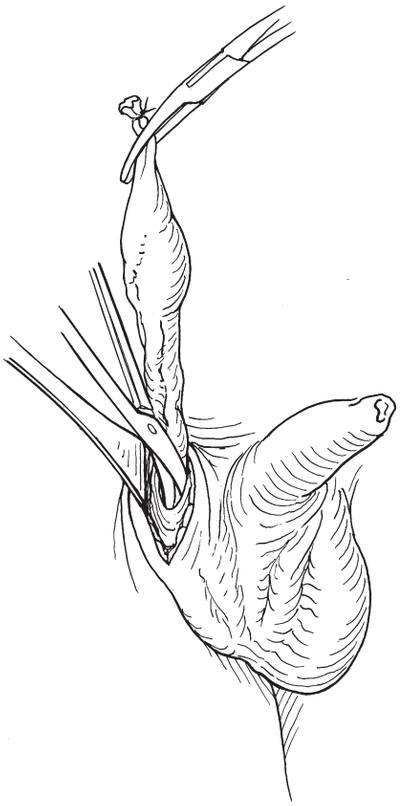

FIGURE 55-10. *(Adapted from Hinman F, Baskin LS. [2009] Hinman's atlas of pediatric urologic surgery. Philadelphia: Elsevier.)*

Transperitoneal Approach

Make a midline incision in the lower abdomen from pubis to umbilicus (Fig. 55-11A). Separate the rectus and underlying areolar tissue. Open the peritoneum and pack the intestines aside (see Fig. 55-11B). The testis is often found lying

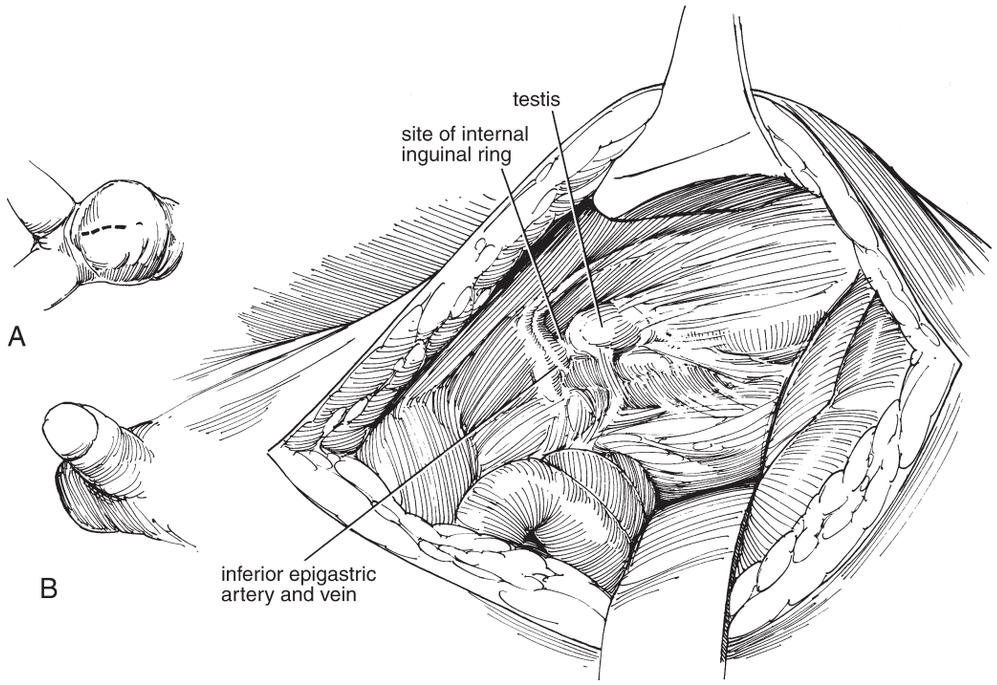

FIGURE 55-11. *(Adapted from Hinman F, Baskin LS. [2009] Hinman's atlas of pediatric urologic surgery. Philadelphia: Elsevier.)*

intraperitoneally, usually behind the bladder and often on a short mesentery.

Incise the peritoneum obliquely, and sharply free the vessels from the retroperitoneal tissue under direct vision.

Sharply free the vas behind the bladder, leaving 1 cm of peritoneum on either side (not shown in the figure), until sufficient length is achieved to place the testis in the scrotum (Fig. 55-12). Invert the scrotum through the external ring, and place a curved clamp against the fingertip from above. Push the clamp through the transversalis fascia and the conjoined tendon as the finger is withdrawn; then dilate the canal and scrotum with the clamp and finger as necessary to

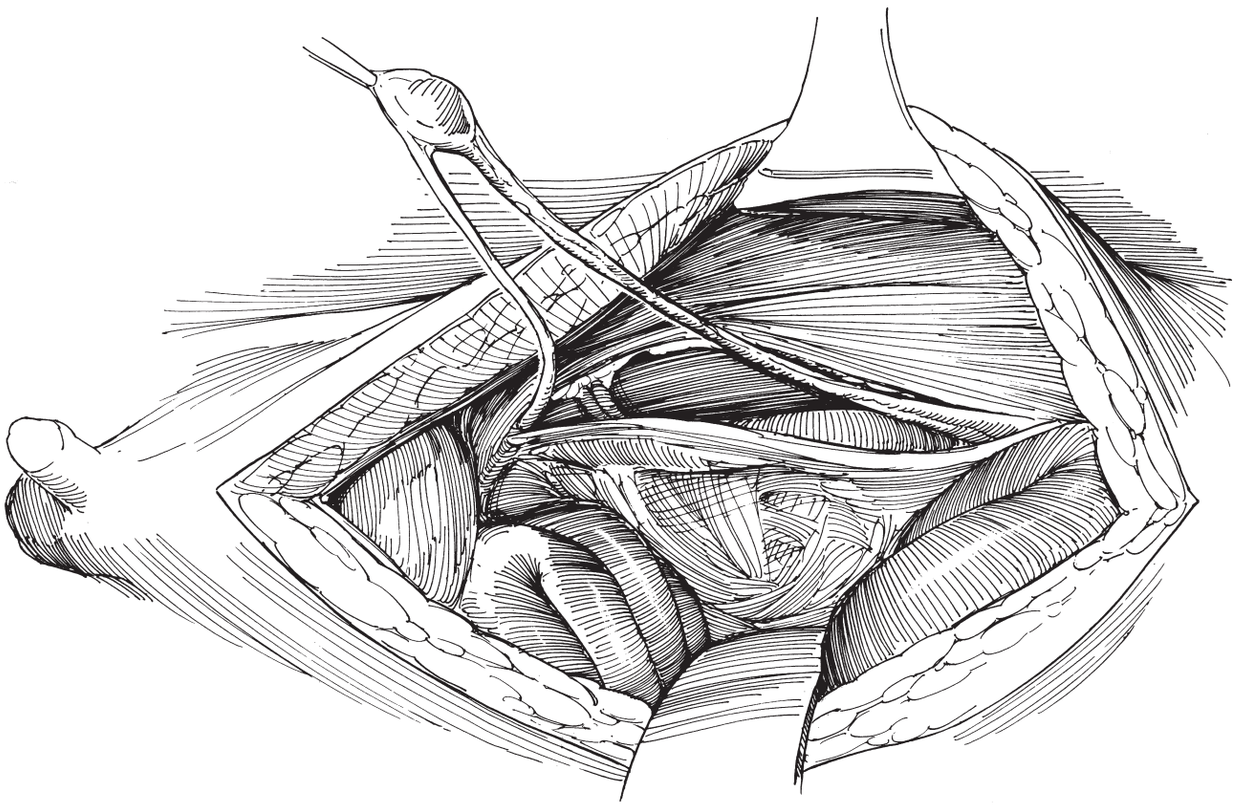

FIGURE 55-12. *(Adapted from Hinman F, Baskin LS. [2009] Hinman's atlas of pediatric urologic surgery. Philadelphia: Elsevier.)*

form a passage for the testis. Incise the scrotum over the finger. Place a suture in the tissue adjacent to the testis, and lead the testis through the canal to the bottom of the scrotum.

Fix the testis in a dartos pouch. Make a small nick in the dartos muscle, and introduce a curved clamp into the inguinal canal to grasp the suture and bring the testis into the scrotum with a little traction. Anchor the testis by closing the dartos muscle behind it with long-acting absorbable suture or by placing a single absorbable suture superficially through the tunica albuginea. The suture can then be passed through a dependent portion of the scrotal skin with a Keith needle. The suture is then secured over a skin bridge.

Extraperitoneal Approach

Make a lower abdominal midline incision from pubis to umbilicus. Separate the rectus muscles and bluntly reflect the peritoneal envelope medially (Fig. 55-13). Look first in the internal inguinal ring to pick up the cord structures. If found, bluntly free them along with the testis from the canal, bring them into the retroperitoneum, and divide the gubernaculum. The inferior epigastric vessels may prevent this maneuver; if they do, divide and ligate them. The internal inguinal ring may be too tight; divide it posteriorly and repair it later.

If the testis is not found near the internal ring, examine the posterior surface of the peritoneum, within which the testis is attached. Start by locating the vas deferens behind the bladder and follow it into the canal to the testis, which is concealed because it is intraperitoneal. The blind-ending vas and epididymis may be appreciably separated from the testis.

If the vas ends blindly or in a rudimentary epididymis, identify the spermatic vessels and follow them. If they too terminate blindly, the diagnosis is an absent (vanishing) testis.

If the testis is found retroperitoneally, incise the peritoneum around it and close the peritoneal defect. A pedicled flap of peritoneum, inferior to the testis, can be left attached to the testis and placed in the scrotum with it (not shown). This flap can supplement the blood supply and is necessary if a Fowler-Stephens orchiopexy is done. Encircle the testis with a small Penrose drain for traction, and bluntly and sharply free the vas down to the area of the prostate and the vascular bundle up to the level of the kidney.

Make an adequate opening through the transversalis fascia and the tendinous end of the rectus muscle immediately superior to the pubis above the ipsilateral side of the scrotum. Create a scrotal pouch bluntly and install the testis in the scrotum over the dartos muscle, taking care not to twist the cord. Close the abdominal wall without drainage.

Extended Inguinal Approach

If the nonpalpable testis was not localized by laparoscopy, start with a standard orchiopexy incision, with the expectation that the testis is located in a relatively low position, but do not extend the opening in the internal oblique muscle into the external ring. Expose the internal ring, and pull on the processus vaginalis at its point of exit to bring the intraabdominal testis into view. Open the anterior surface of the hernia sac and look for a long, looping vas deferens or an attenuated epididymis with a testis attached. A blind-ending vas and epididymis can be found in the inguinal canal, detached from the testes and outside the hernia sac.

If the testis is not discovered, open the external oblique muscle and retract the internal oblique muscle at the medial edge of the internal ring and open the peritoneum. Look for the vas behind the bladder near the obliterated hypogastric vessels, and trace it along with the spermatic vessels to their end, often in a nubbin that denotes anorchia. The vas should be resected for pathologic examination. If a testis is found, place a fine traction suture in the tunica albuginea at the lower pole and pull on it to assess vessel length. If it appears that enough length could be gained by high dissection of the vessels, proceed accordingly with a traditional orchiopexy. If traction shows that the vessels are too short, proceed with a two-stage Fowler-Stephens or one-stage low ligation orchiopexy.

Laroque Incision

Alternatively, lengthen the skin incision, close the external oblique muscle, and create a new incision in the fascia 3 cm superior for access into the peritoneum at a higher point.

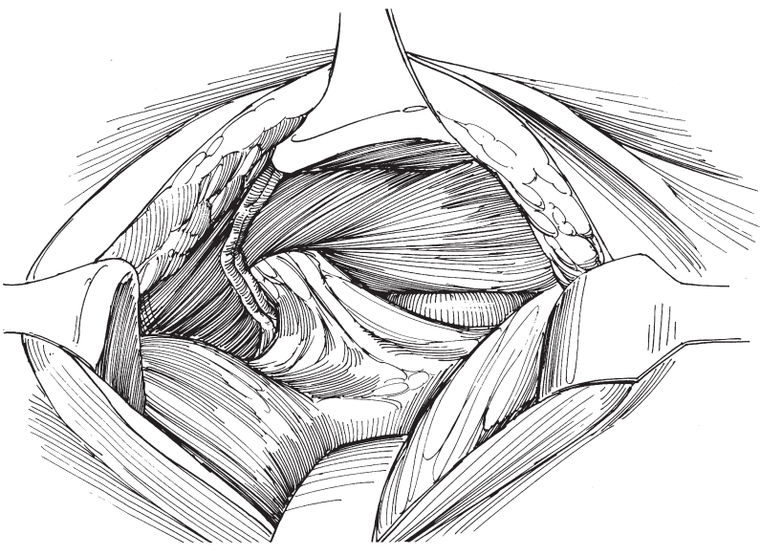

FIGURE 55-13. *(Adapted from Hinman F, Baskin LS. [2009] Hinman's atlas of pediatric urologic surgery. Philadelphia: Elsevier.)*

Under loop magnification, the peritoneum is incised lateral to the spermatic vessels, all the way to the lower pole of the kidney. Use Army-Navy or small Deaver retractors and a capable assistant to aid exposure. Proceed with primary intraabdominal orchiopexy, avoiding the need for the Fowler-Stephens procedure or low ligation orchiopexy.

HIGH LIGATION ORCHIOPEXY (FOWLER-STEPHENS)

This procedure was developed for a high-lying testis having so short a main vascular cord that it cannot be placed directly in the scrotum. Instead, it uses the secondary vascular loops that accompany the congenitally long vas.

On examination, the testis is impalpable or gliding within the inguinal canal. The loop of the vas lies on the pubic bone and may be palpable in thin boys. The testis may be expressed along the canal to become palpable in the external ring and a loop of vas on the pubis may also be palpable. Surgical exposure of the inguinal canal displays the testis, the patent processus vaginalis, and the loop of vas with rudimentary gubernaculum attached to the vas and tissues of the pubis, findings that make this operation especially indicated.

The long-loop vas with the undescended testis lies at the internal ring. The vasal artery (VA) runs in a long recurrent course with several anastomotic branches. The main trunk of the internal spermatic artery (ISA) branches into the testicular artery (TA) and the VA near the lower pole of the testis. The VA then runs a course that follows the looping vas and so provides several anastomotic arterial branches. In the technique described, the ISA and vein are divided, making the testis reliant on the connecting anastomotic branches that track across the loop.

This technique is not useful for testes situated higher in the abdomen with the usual short vas.

A separate first stage for vessel ligation is required only if the testis or the loop of vas deferens cannot be located by clinical examination. Such a stage may be done readily by a laparoscopic technique, which not only determines the presence and location of the testis, the course of the vas deferens, and the feasibility of the procedure, but also allows clipping or fulgurating of the appropriate spermatic vessels. Alternatively, an open approach can be used as a first stage, entering through a short abdominal incision to allow identification of the internal spermatic vessels and their ligation as high as possible.

Open Surgical Technique

Make an incision in the inguinal crease. Identify the special anatomic circumstances applicable for this technique. You must plan ahead for the Fowler-Stephens orchiopexy; do not mobilize the posterior wall of the hernia sac proximal to the testis and epididymis or disturb the floor of the inguinal canal or the epigastric vessels. Expose the processus vaginalis as for a standard orchiopexy. Dilate the internal inguinal ring or, if greater retroperitoneal exposure is needed, incise the internal oblique muscle.

Open the hernia sac, identify the epididymis, and note the course of the vas with its several vascular arcades looping down the posteromedial wall of the sac below the testis. Place a traction suture superficially in the testicular capsule; traction on the testis now will determine whether it has a long mesentery and can be brought into the scrotum by standard methods or it has a short one that will require division of some of the internal spermatic vessels. Dissect the sac well up inside the internal ring to the point where the vas turns medially. At the same time, keep the broad tongue of peritoneum, which lies more distally, attached medially and posteriorly to the vas. If necessary, inject saline under the peritoneum of the processus to aid dissection, then transect it, and close the peritoneum with a 4-0 nonabsorbable pursestring suture. Carefully separate the internal spermatic vessels from the vas and its accompanying vessels where they converge on the internal inguinal ring, and also from the loose collateral arcades on the posterior wall of the processus vaginalis.

If the spermatic artery has not been clipped at a first stage, conduct a bleeding test: Compress the ISA and veins with a bulldog clamp cranial to the testis. Make a 3-mm longitudinal incision in the testis between the faintly visible vessels in the tunica albuginea and expect brisk bleeding. If bleeding persists for 5 minutes, collateral circulation is adequate, and high ligation of the ISA is safe. Let the cut caudal end of the VA bleed for further confirmation: Place a bulldog clamp at point 1 of the arcade (Fig. 55-14). If bleeding continues, it is safe to divide this branch, thus further mobilizing the testis. If greater length is needed, repeat the procedure at point 2 (Fig. 55-14). Now ligate the ISA and close the incision in the tunica with a fine suture. Alternatively, if the bleeding stops almost immediately, consider anastomosis of the inferior epigastric vessels to the internal spermatic vessels to maintain viability after division of the spermatic artery.

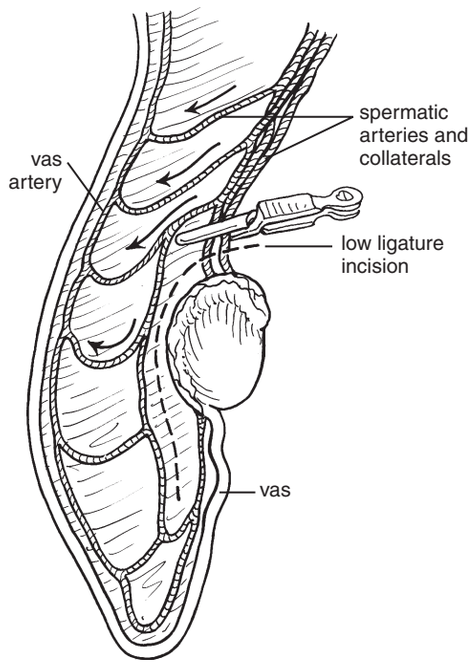

FIGURE 55-14. *(Adapted from Hinman F, Baskin LS. [2009] Hinman's atlas of pediatric urologic surgery. Philadelphia: Elsevier.)*

Transilluminate the cord structures to identify the vascular anastomotic arcades between the vas and the spermatic vessels alongside the testis and epididymis. This is best seen through the back wall of the hernia sac, a view enhanced by the accompanying venae comitantes. These anastomotic arcades are important to the blood supply, so divide only the arcade (or arcades) that are necessary to allow straightening of the loop of vas and placement of the testis in the scrotum without tension. Before dividing a major arcade, gently compress the vessel and note whether that impedes bleeding from the tunical opening: Continuous bleeding shows that it is safe to divide the arcade, whereas arrest indicates that the vessel is not expendable.

Close the tunica with a single fine suture, clamp and divide the pedicle above the bulldog clamp, and ligate it doubly (Fig. 55-15). Grasp the areolar tissue adjacent to the artery and temporarily release the bulldog clamp. Look for free bright bleeding from the distal cut end, indicating that the collateral circulation is adequate. Ligate this end of the artery. Divide only as many of these small arcades as needed to free the testis enough for rotation on the descending limb of the loop of the vas and its main vessels.

Turn the testis into the scrotum. For additional tension-free length, open the transversalis fascia up to the epigastric vessels. Develop a space under the vessels and pass the testis and its vessels through it (Fig. 55-16). Continue as for a standard orchiopexy.

Postoperative Problems

Testicular atrophy is the major complication. The cause may be loss of collaterals from failure to incorporate an adequate strip of peritoneum medial to and accompanying the vas, from injury to the VA, or from ligation of the spermatic vessels too close to the testis so that the arcades cannot function. The irregular pattern of local blood supply contributes to the problem. Injury to the vas or testis is also possible.

LOW LIGATION ORCHIOPEXY

The technique of orchiopexy using low spermatic vessel ligation is performed as an outpatient procedure via a standard inguinal skin crease incision.

Access the inguinal canal by incising the external oblique fascia to a level above the internal ring. Enlarge the internal inguinal ring by retraction or when necessary by superolateral incision of the internal oblique muscle, permitting visualization of the testis within the peritoneum or protruding through the ring within a hernial sac.

When the testis is not visible, place the patient in the Trendelenburg position and open the peritoneum. Identify the testis and place a stay suture in the medial aspect of the upper pole to avoid collateral vessels. With traction on the testis and the accompanying fold of peritoneum, identify the vasal collateral vessels.

A decision to transect the spermatic vessels must be made early in the procedure before any manipulation of the vas or vessels, or separation of the hernial sac (patent processus) from the spermatic cord. After identifying the vascular anatomy, mark the site of transection of the spermatic vessels as close to the testis as possible without compromising any collateral vessels (Fig. 55-16). Also mark the location of the extension of this incision, which will extend

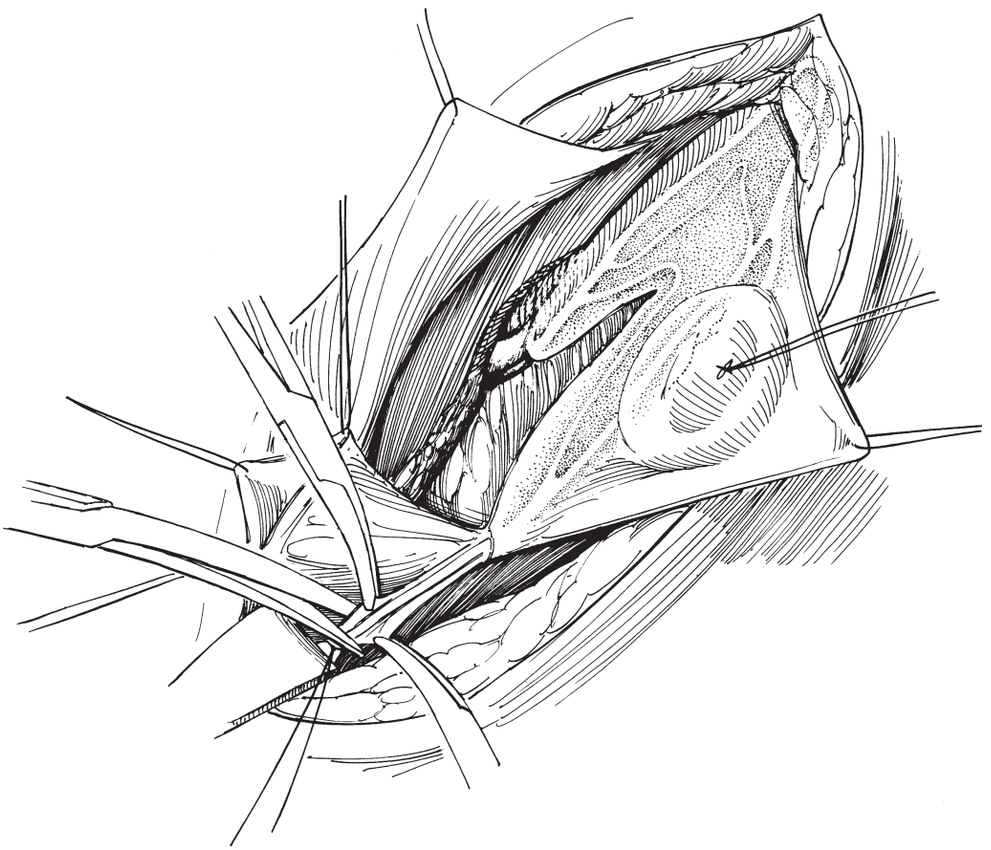

FIGURE 55-15. *(Adapted from Hinman F, Baskin LS. [2009] Hinman's atlas of pediatric urologic surgery. Philadelphia: Elsevier.)*



FIGURE 55-16. *(Adapted from Hinman F, Baskin LS. [2009] Hinman's atlas of pediatric urologic surgery. Philadelphia: Elsevier.)*

into a relatively avascular plane between the ascending and descending limbs of the long vas loop to allow their separation.

Before performing ligation and incision, both sides of the peritoneal fold covering these sites must be carefully incised. Ligate the spermatic vessels proximally to allow back-bleeding from the distal stump, which indicates continued collateral blood flow (Fig. 55-17). Incise between the two vas limbs, allowing the vas loop to be unfolded and the testis to be rotated down toward the scrotum. Divide any remaining lateral peritoneal or adventitial attachments, carefully ensuring that a continuous 1-cm-wide strip of peritoneum remains as an attached and undisturbed covering over the vas, accompanying vessels, and collaterals from their intraabdominal location to the testis. This covering helps preserve vascular integrity and blood flow. Separate any remaining tissue between the vasal limbs until the testis rotates down to and reaches the scrotum without tension.

Close the peritoneum, leaving a small aperture for the peritoneal strip covering the vas and vessels to emerge without angulation or compression. Continued back-bleeding confirms that closure is not causing vascular compromise.

Narrow the canal after placing the testis in the scrotum using a standard dartos pouch technique (Fig. 55-18).

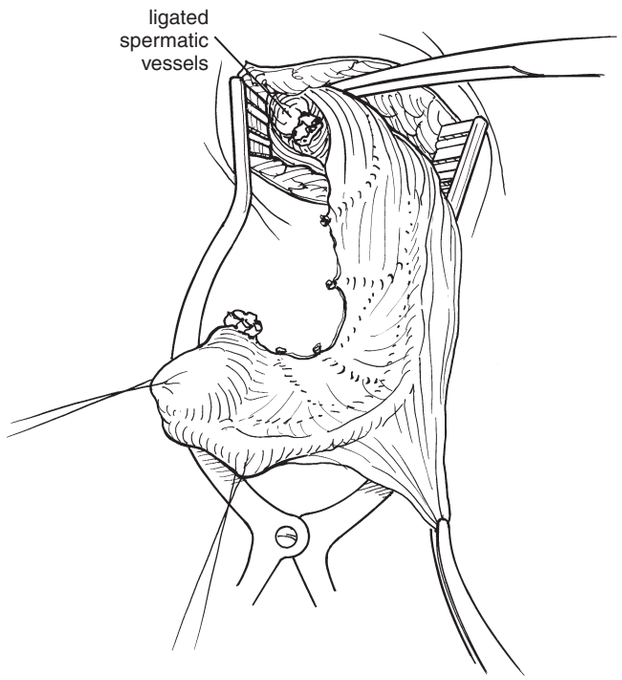

FIGURE 55-17. *(Adapted from Hinman F, Baskin LS. [2009] Hinman's atlas of pediatric urologic surgery. Philadelphia: Elsevier.)*

REDO ORCHIOPEXY

Review the previous operative report and caution the family about the possibility of orchiectomy and about the indications for and contraindications to a prosthesis.

Reenter the previous incision, extending it slightly at each end. The testis is probably found near the external inguinal ring and the pubic tubercle. Bluntly dissect the fatty subcutaneous tissue that lies over the cord structures to expose the lower pole of the testis. Place a suture in the scar tissue in the middle of the testis. With traction, dissect on

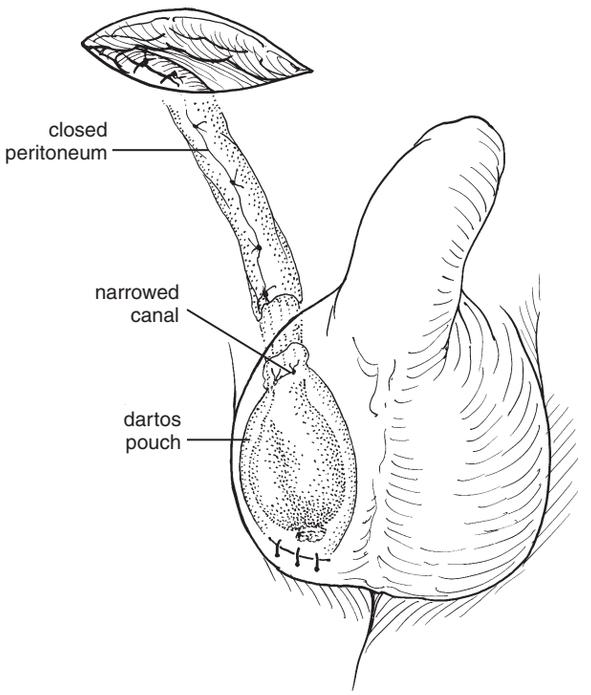

FIGURE 55-18. *(Adapted from Hinman F, Baskin LS. [2009] Hinman's atlas of pediatric urologic surgery. Philadelphia: Elsevier.)*

both sides behind the testis with a right-angle clamp and scissors (Fig. 55-19). Dissection along the floor on the transversalis fascia can be initiated bluntly; isolate and divide the medial and lateral attachments sharply. As the dissection of the cord reaches the level of the external ring, preserve a plate of external oblique fascia that adheres to the cord structures by incising the fascia on either side. Expose the fibers of the internal oblique muscle and safely transect the external oblique fascia by connecting these lateral incisions, leaving a protective strip of fascia 1 to 2 cm wide attached to the cord. At the level of the internal ring, open the internal oblique fibers and identify the vas deferens, the spermatic vessels, and the previously ligated sac. With traction on the testis, expose the anterior aspect of the peritoneum. Open it away from the vessels and dissect, usually in fresh tissue planes, under the posterior peritoneum behind the vas deferens and spermatic vessels, as is done for an initial orchiopexy. Gather the peritoneal edges in a clamp. With the aid of Deaver retractors, dissect retroperitoneally by dividing attachments to the endopelvic fascia until enough length is obtained. Division of the lateral spermatic fascia and the inferior epigastric vessels may also be needed. Suture the peritoneal opening closed at a high level. Place the testis in a dartos pouch, or hold it with a button on the skin if scarring is excessive. Place two or three sutures from the transversalis fascia to the inguinal ligament to reconstruct the floor of the canal, thus forming a new internal ring next to the pubic tubercle while at the same time protecting the vessels and the vas. Close the internal oblique musculature with mattress sutures, and suture the external oblique muscle together.

MICROVASCULAR ORCHIOPEXY

In children with genetic syndromes or known high intraabdominal testes, or in a child who has previously lost a high testis by a more traditional procedure, consider microvascular orchiopexy.

Provide a complete microvascular setup of instruments: an operating microscope with foot pedal controls, three-power loupes, and 10-0 or 11-0 nylon sutures on BV-6 or ST-7 needles.

Place the child on a heating blanket, using a table extension to provide space for the surgeon's knees. Make a generous inguinal incision in the skin crease. Extend it well laterally to permit abdominal access.

Open the external oblique muscle and identify the gubernaculum and the processus vaginalis. Displace the

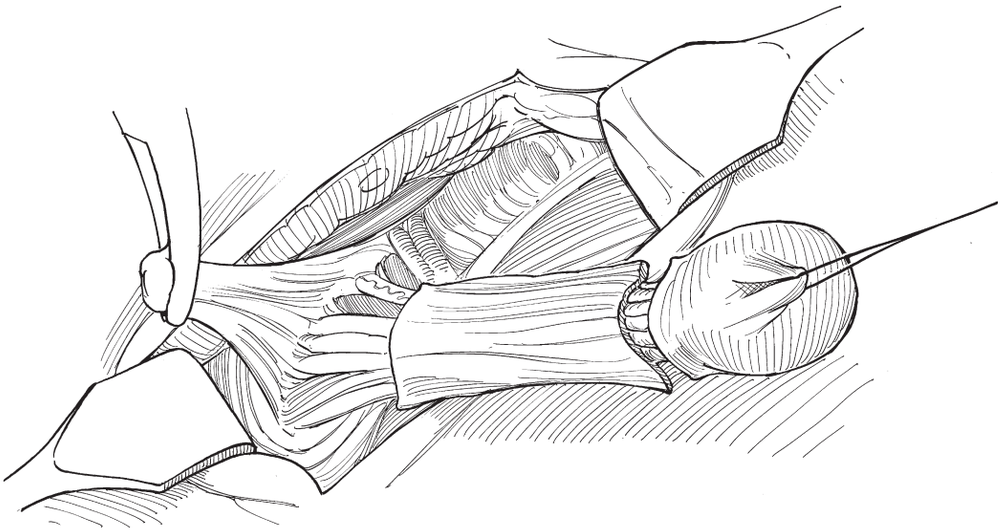

FIGURE 55-19. *(Adapted from Hinman F, Baskin LS. [2009] Hinman's atlas of pediatric urologic surgery. Philadelphia: Elsevier.)*

ilioinguinal nerve laterally and follow the processus vaginalis to the internal ring. Open the peritoneum at the internal ring. Locate the testis and place a traction suture in it. Expose the spermatic vessels. Move the testis out of the abdominal cavity into the retroperitoneal space and carefully dissect the peritoneum from its vascular pedicle. Close the peritoneum.

Bluntly dissect retroperitoneally, following the vessels to near their communication with the vena cava or renal vein and aorta. Tag them with untied sutures so that the artery and vein can be individually identified later. Ensure that the dissection of the vessels extends beyond the confluence of the pampiniform plexus, forming a single vein. Preserve the vasal vessels in a large patch of peritoneum as the vas is freed into the pelvis (Fig. 55-20). If the vas is too short, pass the testis under the lateral umbilical ligament.

Expose the inferior epigastric artery and its two venae comitantes by dissection through the internal oblique muscle aponeurosis and behind the transversus abdominis muscle. Divide all muscular branches. Hold them in a vessel loop. Assess them for size and flow. Ligate all of the side branches as far as possible from the main vessel because one of them may be of suitable size to be used for the anastomosis. Place a noncrushing microvascular clamp on the proximal ends and divide them high beneath the rectus muscle.

Under magnification, clear the adventitia from the artery and the larger vein, and cut them back to undamaged intima. (Preserve the other epigastric vein as a spare.) Regularly apply heparin-saline solution (10 U/mL) to the cut ends. Ligate or fulgurate their muscular branches with bipolar diathermy.

Prepare a dartos pouch. Ligate the spermatic vessels high and divide them distal to the ligature. Check for back-bleeding. Place the testis in the pouch. Close the peritoneal defect in the anterior part of the peritoneal cavity.

Bring the spermatic and the epigastric arteries into the microscopic field and place them in a microvascular clamp. Irrigate the ends of the vessels continuously with heparin-saline solution. Perform vascular anastomosis with 10-0 or 11-0 nylon sutures (Fig. 55-21). Make the arterial anastomosis first. Expect a considerable disparity in size between the arteries; an oblique or a spatulated anastomosis may compensate for the difference. Keep ischemia time to less than 1 hour. Repeat the anastomotic procedure for the veins. If that is not feasible, ligate them and depend on collateral circulation. On release of the clamps, administer heparin in half of the full dose for the child's size. Observe the anastomosis for 20 minutes to be sure occlusion will not occur. If thrombosis does result, resect and redo the anastomosis. Biopsy the testis and look for fresh bleeding from that incision. Fix the testis in the scrotum and close the inguinal wound carefully to avoid obstructing the vessels. Follow with intravenous dextran of low molecular weight, 500 mL/24 hr for 3 days.

LAPAROSCOPIC ORCHIOPEXY TECHNIQUES

Laparoscopic Technique in Children

A laparoscopic approach in children is different from that in adults because the distance between the anterior abdominal wall and the great vessels is shorter, and thus the organs lie closer to the surface.

If adhesions are anticipated, prepare the bowel both mechanically and with antibiotics. It is sensible to have a standby table of laparotomy instruments ready for complications.

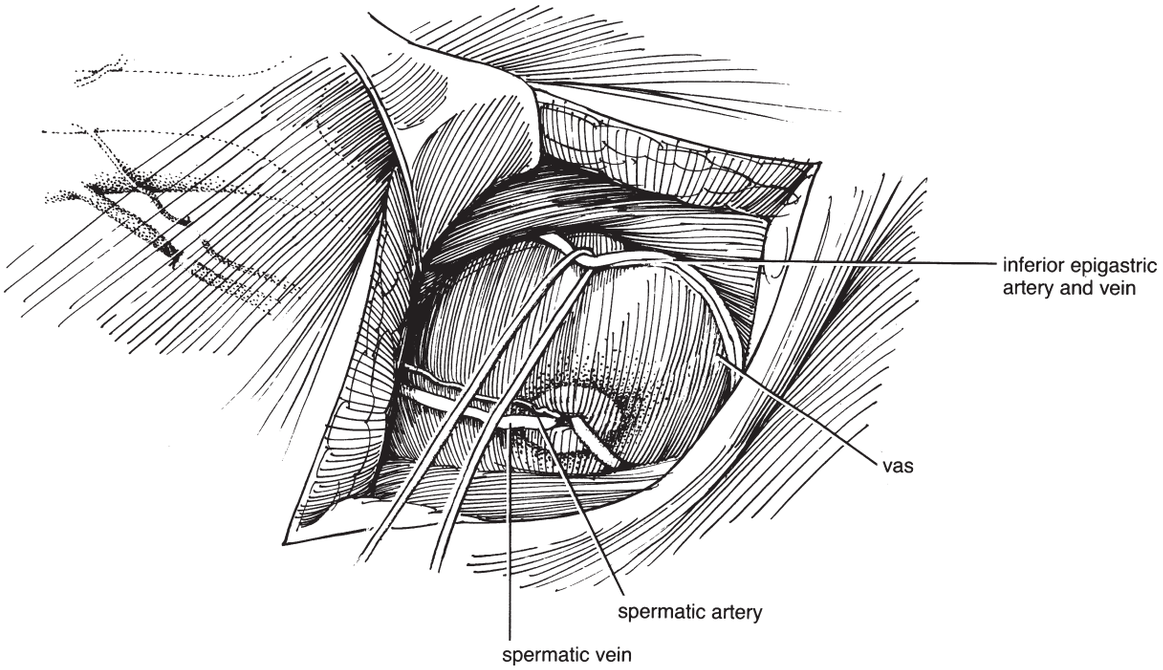

FIGURE 55-20. *(Adapted from Hinman F, Baskin LS. [2009] Hinman's atlas of pediatric urologic surgery. Philadelphia: Elsevier.)*

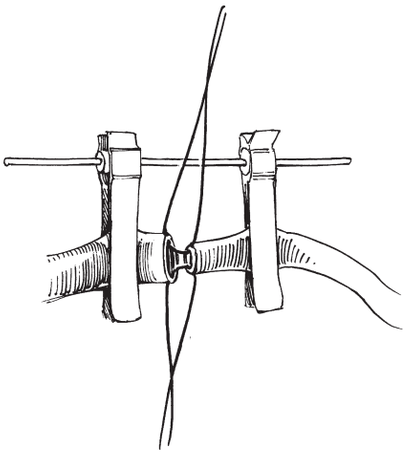

FIGURE 55-21. *(Adapted from Hinman F, Baskin LS. [2009] Hinman's atlas of pediatric urologic surgery. Philadelphia: Elsevier.)*

Use general anesthesia in children because carbon dioxide intraperitoneally causes pain, and any motion by the child is hazardous. Moreover, muscle relaxation is important because the chance for injury to intraabdominal structures is increased in the small intraperitoneal space.

After induction of anesthesia but before creation of a pneumoperitoneum, palpate the abdomen and inguinal area again seeking a gonadal organ that has been missed. If one is felt, it may be less expensive to explore the groin openly. This can be done rapidly, with minimal risk, and provides full information. It also may constitute the initial step of orchiopexy. Then, if no testis or nubbin is found, proceed with laparoscopy. Alternatively, make an umbilical puncture and explore with a small scope. If no testis is found, merely withdraw the instrument. But if an abdominal testis is seen, add another trocar and proceed with orchiopexy. Other uses for the laparoscope are the completion of a previously unsuccessful open orchiopexy; correction of bilateral cryptorchidism; and exploration when hypertrophy suggests maldevelopment of the contralateral testis.

Insertion of Trocars

Place the boy supine and induce anesthesia. Check again for a palpable testis: one in five may now be palpable. Insert a balloon catheter into the bladder and drain it. Consider placing a nasogastric tube; a distended stomach may depress the omentum into the route of the trocars. Once the child is relaxed, again examine for a testis in the distal canal, a position that would allow performance of a standard orchiopexy. If the testis is high but palpable, either proceed with laparoscopic orchiopexy or limit the laparoscopic procedure to the dissection of the intra-abdominal vessels and vas preparatory to an open operation.

Insert a rolled towel under the lower back to create lordosis. Tip the table into a 30-degree Trendelenburg position to move the intestines out of the pelvis. After introduction of the laparoscope, return to a 30-degree tilt for the operation. It can also be helpful to rotate the table 30 degrees laterally toward the surgeon to raise the involved testis above the intestine. Prep the genitalia and the entire abdomen in case laparotomy will be required (Fig. 55-22). Choose between a closed Veress and an open Hassan technique.

Veress technique: Right-handed surgeons should stand on the left side of the child. Palpate the sacral promontory and the aorta. Make a curved incision with a #15 blade in the lower edge of the umbilicus, one that penetrates the linea alba where the body wall is thinnest.

In infants younger than 1 year of age, because the umbilical fascia may be very thin, do not place the incision too close to the umbilicus proper, which could foster loss of the pneumoperitoneum. It may be better to insert the needle above the umbilicus to avoid the as yet undescended bladder. Remember that the distance from the anterior abdominal wall to the great vessels is very short; be careful not to pass instruments too deeply.

The Veress needle has two parts: a sharp beveled sheath to pass through the body wall and a blunt obturator that springs forward to fend off the intestine. Check the mechanism and patency. Start the flow of carbon dioxide and determine the passive resistance to flow. Infiltrate the site with a local anesthetic. Elevate the fascia with towel clips. Hold the Veress needle vertically and press it firmly through the incision at a 30-degree angle directed toward the hollow of the sacrum. Feel it pass first through the fascia and then through the peritoneum.

Check the position of the needle by aspiration with a syringe; there should be no return of blood or bowel contents. Apply the saline test: Inject 10 mL of saline irrigating solution; it should not be possible to aspirate it. Alternatively or additionally, place a drop of saline in the hub of the needle; normally it will disappear. Swing the needle through 360 degrees. Check intraperitoneal pressure to

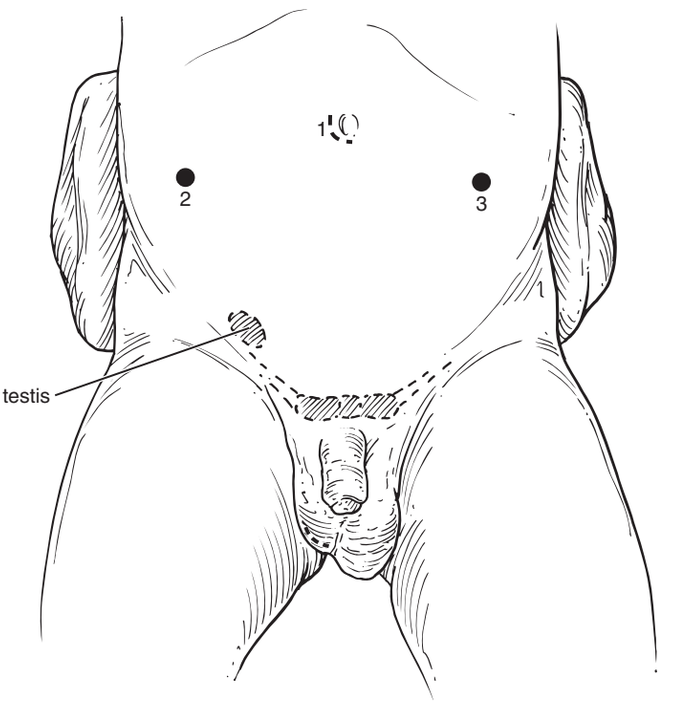

FIGURE 55-22. *(Adapted from Hinman F, Baskin LS. [2009] Hinman's atlas of pediatric urologic surgery. Philadelphia: Elsevier.)*

be sure it is less than 12 mm Hg and that it shifts with respiration.

Anatomic detail is seen more clearly in children because of the small amount of preperitoneal fat. Because the peritoneum is more loosely attached, this space is more susceptible to emphysema. Also, the weak adherence of the peritoneum to the abdominal wall makes the intraperitoneal introduction of large cannulas difficult. An instrument may have to be inserted through a smaller port to assist entry of the large port.

Hassan technique: Make an infraumbilical incision and insert two stay sutures on either side. Incise the peritoneum and palpate the underside of the abdominal wall with a finger to be sure it is clear of adherent bowel or omentum. Insert the obturator of the cannula. Move the outer conical sheath forward and push it tightly in the fascial opening; then secure it to the sheath. Draw the stay sutures up and fix them to the struts on the sheath of the cannula to produce a tight seal. Remove the obturator.

Begin insufflation with carbon dioxide at a rate of 1 L/min. If the flow remains low with high pressure, the needle tip lies preperitoneally; reposition it. Continue filling until the pressure in a typical relaxed child reaches 8 mm Hg, realizing that relaxation is achieved at different rates.

Insertion of sheath and trocar (site 1): Incise the fascia of the linea alba with a #11 blade. Identify the peritoneum, open it, and insert a 3 or 5-mm sheath (this is large enough for infants) with its contained, short pyramidal trocar. Point the trocar at the sacral promontory while pressing on the upper abdomen, and insert it into the abdominal cavity. Keep the index finger extended on the instrument to prevent the tip from going too deeply. When gas is heard escaping, quickly remove the trocar from the sheath to let the valve in the sheath close the channel. Connect the carbon dioxide supply and set the flow control on the insufflator to provide a pressure of 5 to 6 mm Hg above baseline. Inflate until the abdomen becomes tympanitic.

Insertion of the telescope: Insert a 3 or 5-mm laparoscope and attach a full-beam video camera to the eyepiece. Monitor the area on the screen placed at the foot of the table. First check to be certain no intraabdominal structures were injured during insertion. Then systematically inspect the pertinent organs in the peritoneal cavity.

Insertion of working ports: Rotate the lens to bring the anterior abdominal wall above the bladder into view. While the abdominal wall is transilluminated from within, insert two 3 or 5-mm working ports, one at each McBurney's point (sites 2 and 3) (Fig. 55-23). (Place them higher in infants to provide adequate working distance at the umbilical level.) Insert these ports by elevating the body wall with towel clips and then rotating the trocar to aid penetration. Avoid traversing the inferior epigastric vessels, which are visible by transillumination.

General precaution: To avoid injury to abdominal structures, keep the inner ends of all instruments in view; do not leave them unattended.

Normal Laparoscopic Landmarks

Inspect the peritoneal cavity, especially the underlying bowel. Visualize the inguinal ring contralateral to the affected testis, with its vessels and vas. Then visualize the ring on the cryptorchid side. Look for the vas where it crosses the medial umbilical ligament. Traction on the scrotum may make the vessels more obvious.

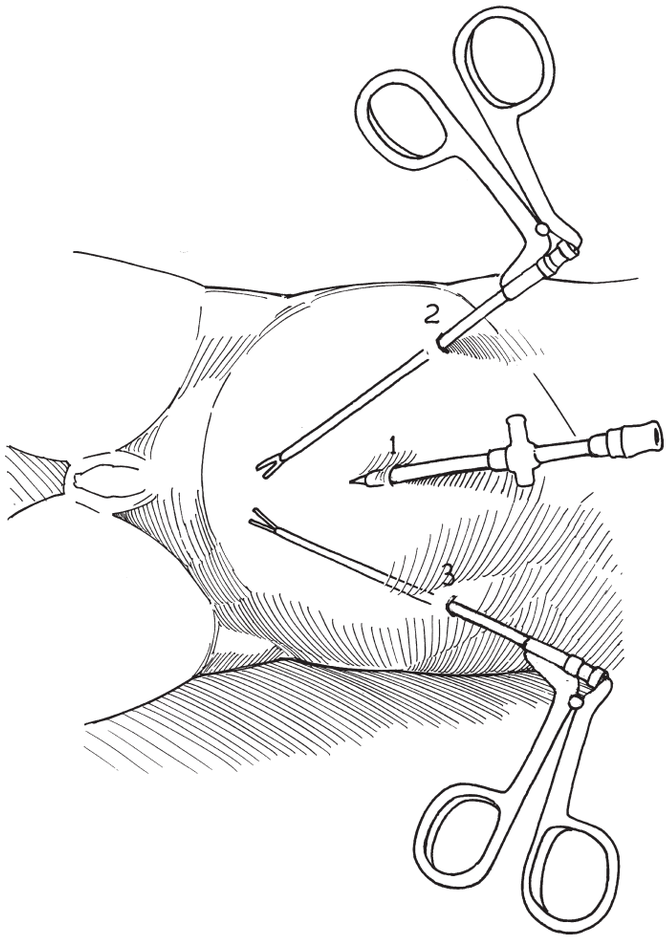

FIGURE 55-23. *(Adapted from Hinman F, Baskin LS. [2009] Hinman's atlas of pediatric urologic surgery. Philadelphia: Elsevier.)*

Landmarks (Fig. 55-24): The median umbilical ligament (the urachal remnant) runs from the bladder dome to the umbilicus. Lateral to it, find the medial umbilical ligament (the obliterated umbilical artery) extending from the hypogastric artery to the umbilicus. Identify the internal inguinal ring, the gubernaculum, the vas deferens (it may end blindly), and the gonadal vessels that normally run into the internal inguinal ring but may be atretic or absent. (If visualization and identification are problems, check the carbon dioxide insufflator for better insufflation.)

Exploration for the Unilateral Nonpalpable Testis

Look for one of seven possibilities:

1. The spermatic cord passes through the internal inguinal ring. This indicates the presence of a testis or remnant in the area of the groin. Press on the external ring to determine whether the testis can be pushed back into the abdomen. If it responds, perform either a standard or a laparoscopic orchiopexy. A standard orchiopexy can be

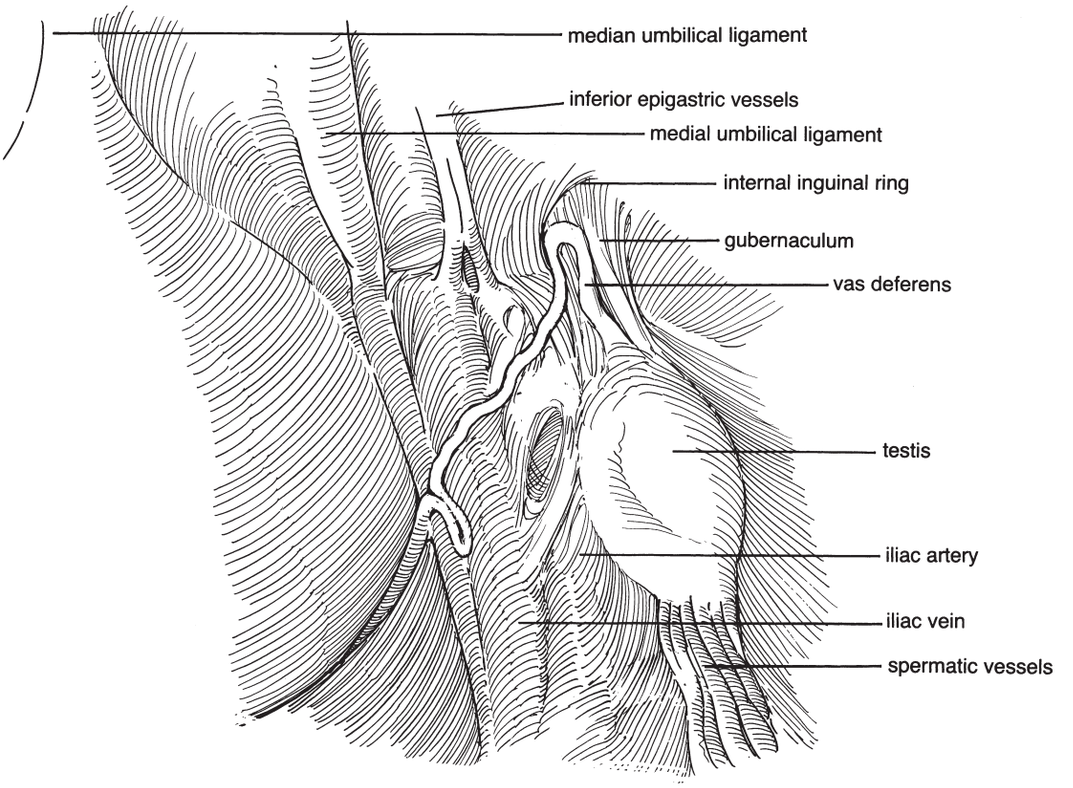

FIGURE 55-24. *(Adapted from Hinman F, Baskin LS. [2009] Hinman's atlas of pediatric urologic surgery. Philadelphia: Elsevier.)*

facilitated by laparoscopically mobilizing the spermatic vessels to the level of the kidney.

2. The testis is found just above the internal ring, but with a short processus vaginalis. Here, too, either type of orchiopexy is feasible.
3. No testis is found, but the cord structures disappear into the canal. Use a grasper to pull on these structures to expose a testicular remnant in the groin. If there is still a question, consider inguinal exploration through a small incision.
4. A testis with adnexa and a long looping vas is found lying well above the internal ring. This is best managed by a staged Fowler-Stephens orchiopexy (see the section, "Laparoscopic Two-Stage Orchiopexy [Fowler-Stephens]"). As the first stage, clip or fulgurate the spermatic vessels.
5. No testis is found. Look for blind-ending spermatic vessels as proof of testicular absence (the "vanishing testis").
6. An atrophic or dysmorphic testis is found. Remove it either laparoscopically or through a muscle-splitting incision in the lower quadrant.
7. Only a blind-ending vas is found at the internal ring but the vessels cannot be identified, indicating that a testis is present. Search the entire retroperitoneum to the lower pole of the kidney, even if this requires reflection of the colon.

Single-Stage Laparoscopic Orchiopexy

Stand on the side opposite that of the abnormal testis, with your assistant across from you. Inspect the pelvic peritoneal cavity with a 30-degree lens. Locate the medial umbilical ligament (urachal remnant) and the sigmoid colon. Move the colon medially for proximal access to the spermatic vessels.

Identify the intraabdominal testes. Grasp the gubernaculum and pull the testes over to reach the contralateral internal inguinal ring. If it reaches, it probably can be placed in the ipsilateral scrotum. If the vessels are too short, proceed with their division for a two-stage procedure.

Incise the peritoneum, starting around the internal ring distally up to the gubernaculum and bordering the testis laterally (Fig. 55-25, *long dashed line*).

To provide a large peritoneal covering that encompasses the vas deferens and the testicular blood supply, mobilize a flap of peritoneum that extends laterally 1 cm from the spermatic vessels toward the lower pole of the kidney and ventrally 1 cm from the vas deferens extending from the internal ring into the pelvis. Releasing the peritoneal attachments under the spermatic vessels allows mobilization of the testes. During the dissection, be cognizant of the location of the ureter, which runs over, then lies medial to, the iliac vessels.

For the site of the new inguinal canal, make a short incision in the peritoneum (see Fig. 55-25, *short dashed line*) between the bladder and the medial umbilical ligament, just lateral to the median umbilical ligament, to the site of the new canal.

Start dissection of the gubernaculum distally as far as possible to preserve all collateral vessels. Release the gubernacular attachment, typically from within the open internal ring. Check the mobility of the testes for placement into the

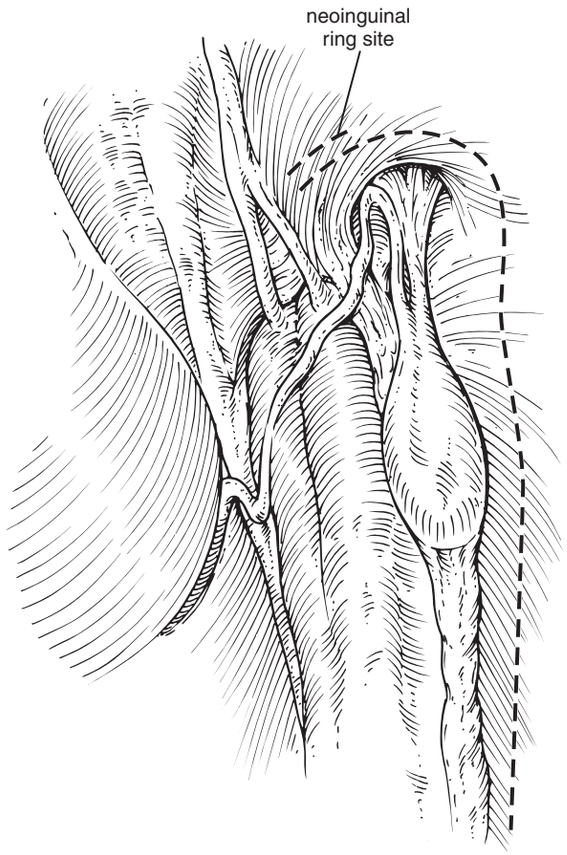

FIGURE 55-25. *(Adapted from Hinman F, Baskin LS. [2009] Hinman's atlas of pediatric urologic surgery. Philadelphia: Elsevier.)*

scrotum by again determining whether it will reach the contralateral ring. If more mobility is necessary, continue to raise the testis on the flap of peritoneum, leaving a broad isthmus of peritoneum on the vas.

Make a 2-cm external incision in the scrotum (Fig. 55-26). Form a new inguinal canal medial to the medial umbilical ligament by passing a clamp, an Amplatz dilator, or a radially dilating trocar from above through the peritoneal incision, then along the ventral surface of the symphysis, and out though the scrotal incision (the Prentiss maneuver). Lead a clamp or cannula back from below to pass out through the scrotal incision. Grasp the testis and draw it into the scrotum (this may be done through the cannula, if one is used). The assistant keeps pressure over the canal to conserve carbon dioxide, although the gas will be retained once the testis is in place. With traction on the testis, divide any remaining retroperitoneal attachments from above.

Fix the testis beneath the dartos muscle with fine synthetic absorbable sutures.

Close the scrotal wound with subcuticular synthetic absorbable sutures. Replace the parietal peritoneum over the area of the patent processus vaginalis. Inspect the vas and associated structures for torsion and the operative area for bleeding. Aspirate most of the carbon dioxide to reduce peritoneal irritation, and remove the instrument sheaths in order. Finally, before removing the visualizing port, inspect for bleeding at a pressure of 6 mm Hg. Close the skin with subcuticular sutures. Discharge the child on recovery from the anesthetic. Complications are rare.

Laparoscopic Two-Stage Orchiopexy (Fowler-Stephens)

If the testis is found associated with a long, looping vas deferens or lacks mobility within the abdomen, proceed with this first stage of a two-stage laparoscopic orchiopexy. Each stage may be done as an outpatient procedure.

First Stage: Laparoscopic Vessel Ligation

Position the patient as for one-stage laparoscopic orchiopexy and gain laparoscopic access.

Pull on the testis to determine whether the vessels are short and will require clipping, as a first stage, or whether to proceed at once with laparoscopic orchiopexy. If no testis is located, use graspers to move the abdominal organs and thus reach the lower pole of the kidney to search in that area. If a dysgenic testis is found, remove it.

Divide the vessels as high as possible. Several methods are available: The least secure is to insert an electrode, elevate and fulgurate the vessels with unipolar or bipolar current, and then divide them. Clipping is preferable, however. Separate the cord into bundles, and then pass a 5-mm clip applier and clip the vessels as high as possible. Apply a second set of clips so that the vessels may be divided between them at the second stage.

Remove the instrument sheath, evacuate the carbon dioxide to a level of 6 mm Hg, and inspect the area for venous bleeding. Remove the visualizing port. Close the 5-mm port opening with a 3-0 PDS suture to approximate both peritoneum and fascia. Close the skin with subcuticular sutures and sterile strips or skin adhesive.

Second Stage: Placement of the Testis

The second stage is performed 6 months after the first stage: Place the child supine. Insert a rolled towel under the lower back to create lordosis, and tip the table into a 10-degree head-down position to allow the intestine to drop out of the pelvis. After induction of anesthesia, shift the child to a 30-degree head-down position for placement of the initial port. After inserting both ports, tilt the table laterally 30 degrees to raise the involved testis above the intestines.

Incise the peritoneum, starting around the internal ring distally up to the gubernaculum and bordering the testis laterally. To provide a large peritoneal covering that encompasses the vas deferens and the collateral blood supply, take a generous triangular flap of peritoneum that extends laterally 1 cm from the spermatic vessels toward the kidney. Bring the incision medially at the site of the previous spermatic vessel ligation, preserving the collateral blood supply. Distally at the site of the internal ring the peritoneal incision should be ventrally 1 cm from the vas deferens, extending from the internal ring into the pelvis. Bluntly mobilize the spermatic vessels to the site of fulguration, and free the vas deferens.

Grasp the testis with forceps. Check for mobility and determine its attachment to the epididymis and vas deferens.

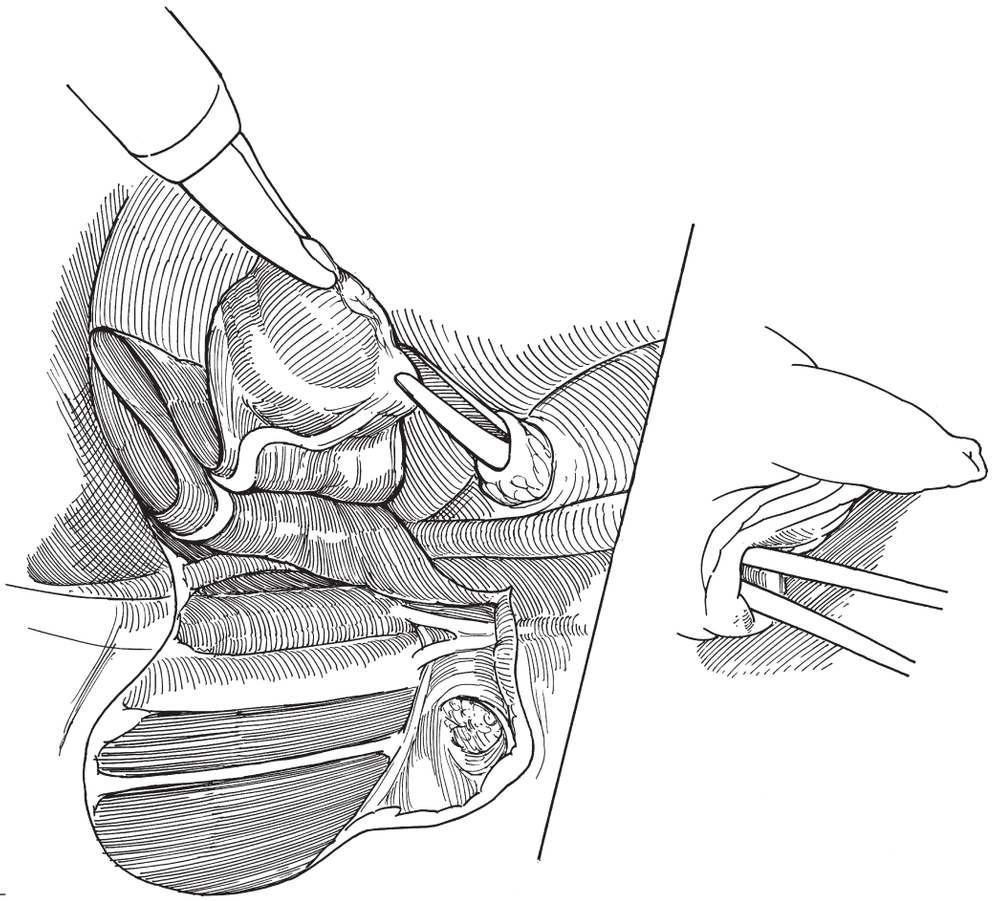

FIGURE 55-26. *(Adapted from Hinman F, Baskin LS. [2009] Hinman's atlas of pediatric urologic surgery. Philadelphia: Elsevier.)*

Start dissection of the gubernaculum distally as far as possible to preserve all collateral vessels. Raise the testis on the flap of peritoneum, leaving a broad isthmus of peritoneum on the vas.

Place the testes into the scrotum as described previously.

POSTOPERATIVE PROBLEMS

Problems During Any Laparoscopic Procedure

Most complications occur at the time of the initial insertion of the trocar or during insufflation.

Preperitoneal emphysema makes identification of landmarks difficult. Emphysema of the omentum causes it to obstruct the view. Too high an insufflation pressure causes tension pneumoperitoneum, a harmful event that can be missed in obese children. Puncture of the abdominal aorta or other major vessel is made obvious by a vigorous spurt of blood: Leave the sheath in place for tamponade and for a guide to the site of injury, and proceed with emergency laparotomy. Recognize injury to the inferior epigastric vessels by blood dripping into the pelvis. Cauterize the route of these vessels or enlarge the incision to transfix them with sutures above and below the puncture site. For injury to the bowel from the trocar or sheath repair can be performed laparoscopically if small and recognized, otherwise, open the abdomen and repair the bowel. It is seldom necessary to resect the bowel or divert the fecal stream. A puncture wound of the bladder can usually be sutured laparoscopically or closed by a suture passed through a small suprapubic incision. For ureteral injury, especially if caused by electrocoagulation, stent the ureter.

Problems from Laparoscopic Procedures of the Testis

Postoperative bleeding rarely occurs if the site of operation and the trocar sites have been closely inspected at low pressure at the end of the procedure. An incisional hernia, or dehiscence through a large port site, can occur if the fascia was not closed. Suspect bowel injury if nausea and vomiting and ileus appear. Institute nasogastric suction and, if improvement does not follow, explore the site.

Testicular retraction is the most common problem after orchiopexy. The cause is usually inadequate initial mobilization of the testis or failure to route the cord by a direct route. After the boy has fully recovered, reoperate through the groin. Dissect inferiorly, and then mobilize the spermatic cord en bloc, leaving the densely scarred tissue in place. Dissect into normal retroperitoneum where it may be possible to lengthen the cord. Testicular atrophy may result, either from actual division of the spermatic artery or, more often, by persistent vasospasm from excessive tension during fixation.

Adapted from Hinman F, Baskin LS: Hinman's Atlas of Pediatric Urologic Surgery, Elsevier, 2009.

Chapter 56

Reduction of Testicular Tension

SEAN T. CORBETT

Testicular torsion is one of the few true surgical emergencies in pediatric urology. Failure to treat in a timely fashion will result in testicular loss. First, differentiate extravaginal torsion from intravaginal torsion.

Extravaginal torsion: The neonate presents with a firm, nontransilluminating scrotal mass with a bluish cast. It is often painless. Doppler ultrasonography usually shows no signals of vascular return. Manual detorsion is not applicable. Because surgical salvage is usually unsuccessful, remove the testis. Contralateral orchiopexy can be performed at the time of orchiectomy; however, the evidence-based rationale remains controversial.

Intravaginal torsion most commonly occurs in adolescent boys between the ages of 12 and 18. The onset is acute, usually associated with scrotal pain that is moderate to severe. Treat it as an emergency. In equivocal cases, perform a clinical examination, with or without blocking the cord, and look for the displacement of the lower pole of the epididymis away from the lower pole of the testis (the anomaly that permits torsion). If in doubt, order a color Doppler ultrasound examination, which is highly sensitive for obstructed blood flow, but do not delay treatment if these studies are not immediately available.

MANUAL DETORSION OF INTRAVAGINAL TORSION

In adolescent boys, consider manual detorsion. Create a local cord block. Place local anesthetic in and around the cord, which is easily identified as it courses over the symphysis. Injection into the cord itself makes the cord balloon under the fingers. Always withdraw before injection. The block is successful when the scrotum can be grasped firmly without causing pain. Grasp the testis lightly and draw it distally. With torsion of 360 degrees or less, the testis may "snap" as it becomes detorsed. Otherwise, first attempt detorsion by outward rotation, because two of three cases torse inwardly. If there is resistance, try rotation in the opposite direction. Success is determined when a sudden release is felt and the testis snaps into place. Success is ensured when the testicle finally lies in the bottom of the relaxed scrotum, freely mobile without tension. If this is not achieved, proceed with surgical detorsion.

If detorsion is successful without question, proceed with the definitive surgical procedure of scrotal fixation, usually within the next 24 hours. The hope is that the testis has retained some blood supply.

SCROTAL FIXATION OF THE TESTIS

A caudal, ilioinguinal, or cord block will decrease postoperative pain. Prep the entire genital area. Incision: Grasp the scrotum with the thumb and index finger of the nondominant hand and press the testis forward against the skin. Make a short anterolateral incision through the skin and then through the dartos fascia, which may be edematous. Alternatively, make and incision in the median raphe of the scrotum. This will provide exposure to both testes through a single incision.

Extend the incision onto the tunica vaginalis, now possibly darkened from contained bloody serum (Fig. 56-1). Open the tunica vaginalis and evacuate accumulated hydrocele fluid. Extrude the testis, untwist the cord if any torsion persists, and then wrap the testis in warm saline sponges.

Nonviable testis: Check the color of the testis. If it remains dark and was associated with sanguineous hydrocele fluid, make a short incision in the tunica albuginea. Wait 10 minutes. If no active bleeding is seen, the testis is not viable. Palpate and inspect the contralateral testis. If that testis is normal, proceed with an orchiectomy on the affected side by dividing the cord structures between clamps and ligating with 2-0 chronic catgut sutures, including a transfixing stitch. If the quality of the contralateral testis is in doubt, leave the affected testis for its hormonal function.

Viable testis: If the testis is judged to be viable, trim excess tunica vaginalis and obtain hemostasis along the edge with careful fulguration. (When fulgurating, keep the testis grounded against the wound, not extended on the cord, or use bipolar electrocautery.)

Place two or three interrupted 3-0 synthetic absorbable sutures in the cut edges of the tunica vaginalis, approximating them behind the testis to eliminate the potential for formation of a hydrocele (Fig. 56-2).

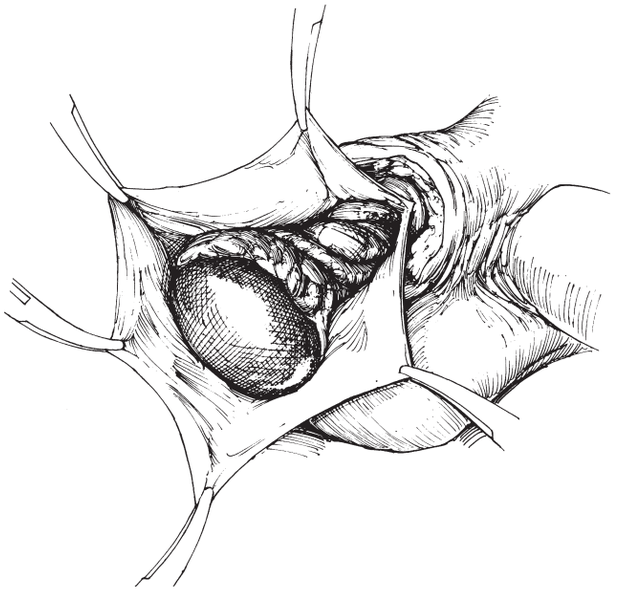

FIGURE 56-1. *(Adapted from Hinman F, Baskin LS. [2009] Hinman's atlas of pediatric urologic surgery. Philadelphia: Elsevier.)*

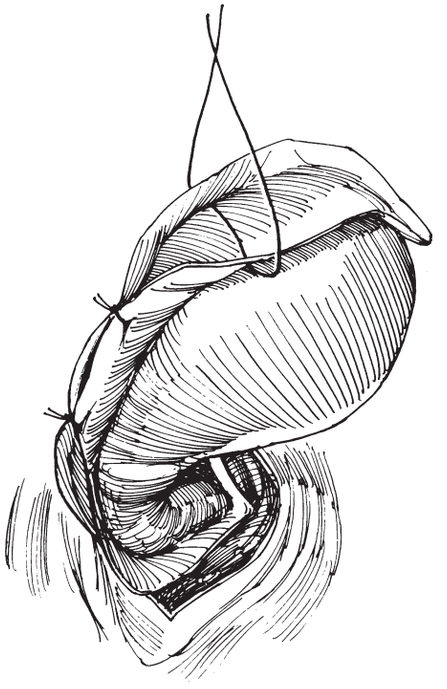

FIGURE 56-2. *(Adapted from Hinman F, Baskin LS. [2009] Hinman's atlas of pediatric urologic surgery. Philadelphia: Elsevier.)*

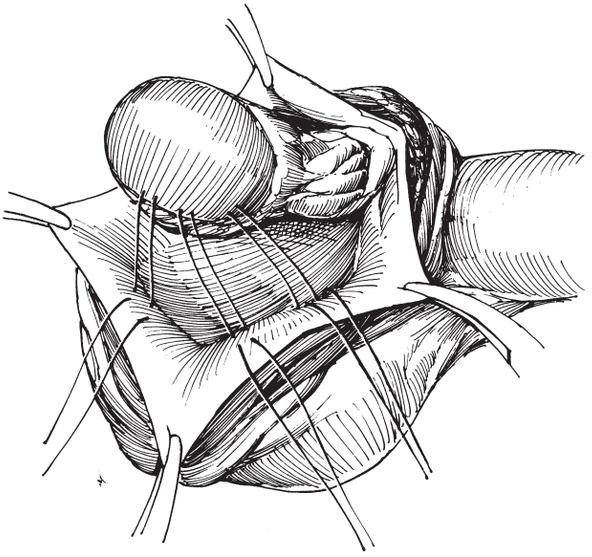

FIGURE 56-3. *(Adapted from Hinman F, Baskin LS. [2009] Hinman's atlas of pediatric urologic surgery. Philadelphia: Elsevier.)*

Dartos pouch: Place the testis in a dartos pouch or suture tunica albuginea to the scrotum with two or more sutures (Fig. 56-3). Make an incision on the cephalad aspect of the scrotum. Incise the parietal tunica vaginalis and extrude the testis until the cord is invested only by the visceral portion of the tunica. Close the divergence of the tunica vaginalis, fixing it to the internal spermatic fascia covering the cord. Create a scrotal pouch manually between the dartos muscle and the external spermatic fascia. Suture the cut edge of the external spermatic fascia to the tunica vaginalis covering the cord. Close the dartos fascia, incorporating that portion of the tunica vaginalis covering the cord. Alternatively, taking care not to penetrate the tunica albuginea, invert the scrotal septum with a finger, and fix the tunica albuginea to the dartos layer and septum in three places, two laterally and one inferiorly, with interrupted mattress 3-0 nonabsorbable sutures.

In all cases, open the contralateral scrotal sac and fix that testis also. Close the dartos layer with a figure-eight absorbable suture, and approximate the skin with a 4-0 or 5-0 absorbable subcuticular suture. Place a dry dressing with scrotal support. Inform the parents of the odds for salvage.

Adapted from Hinman F, Baskin LS: Hinman's Atlas of Pediatric Urologic Surgery, Elsevier, 2009.

Section X

TESTIS: MALIGNANCY

This page intentionally left blank

Chapter 57

Simple Orchiectomy

CIGDEM TANRIKUT AND MARC GOLDSTEIN

SIMPLE ORCHIECTOMY

Simple orchiectomy provides an effective means of achieving castrate levels of testosterone for patients with prostate cancer or for surgically castrating transgender male patients. Occasionally, simple orchiectomy may be employed for treatment of epididymoorchitis with abscess that is refractory to antibiotic treatment, particularly in older or immunocompromised patients. More rarely, simple orchiectomy is indicated for chronic orchialgia. Anesthetic options include regional anesthesia via spermatic cord block, sedation, spinal anesthesia, or general anesthesia.

After shaving and sterile preparation of the scrotum, a transverse hemiscrotal incision is made within the scrotal rugae, being cautious to avoid any prominent scrotal blood vessels (Fig. 57-1). Carry the incision down through the tunica vaginalis and deliver the testis into the wound. Provide gentle traction on the testis in order to expose the spermatic cord.

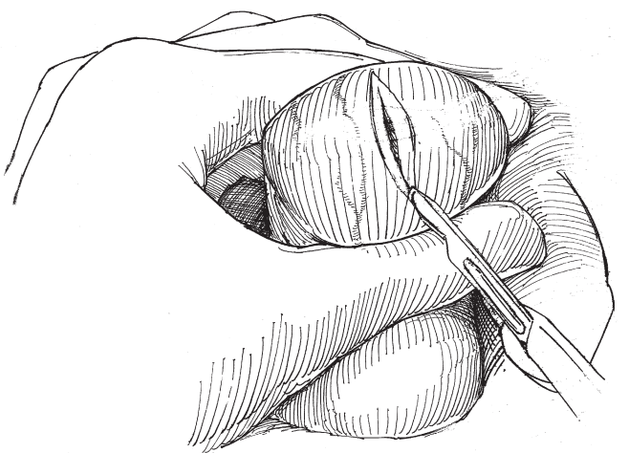

FIGURE 57-1. Transverse hemiscrotal incision.

Identify, ligate, and divide the vas deferens using a 2-0 silk ligature. Separate the cremasteric muscle from the internal spermatic vessels and ligate each separately using 2-0 silk sutures (Fig. 57-2). If a prosthesis is desired after simple orchiectomy, the gubernaculum and tunica vaginalis are left intact and the prosthesis is placed inside the tunica vaginalis. This allows a very natural position and appearance of the prosthesis.

Ensure meticulous hemostasis. The dartos muscle should be reapproximated in an interrupted fashion using 4-0 self-absorbing suture. Inject the wound with bupivacaine and then close the skin edges in a running subcuticular fashion with 5-0 absorbable suture, using two skin hooks at the apices to aid in closure (Fig. 57-3).

An identical operation is carried out on the contralateral side if indicated. At the completion of the procedure, the wound is dressed with antibiotic ointment, dry fluffed gauze, and an athletic supporter.

EPIDIDYMIS-SPARING ORCHIECTOMY

This procedure leaves a palpable mass within the scrotum; however, it is a bloodier operation than simple orchiectomy. Use of the operating microscope facilitates dissection.

After delivery of the testis as described for simple orchiectomy, bring the operating microscope into the field. Sharply dissect the epididymis off of the testis. Clamp and ligate the three major groups of epididymal vessels—superior, middle, and caudal—using 2-0 silk (Fig. 57-4).

Approximate the caput and cauda of the epididymis using 3-0 absorbable suture to create an ellipsoid structure (Fig. 57-5). Given the bloodier nature of this procedure, a drain should be placed through a dependent stab wound before closing. Return the epididymis to the tunica vaginalis and close the tunica vaginalis with 5-0 Vicryl. Completion of closure may be carried out as described for simple orchiectomy.

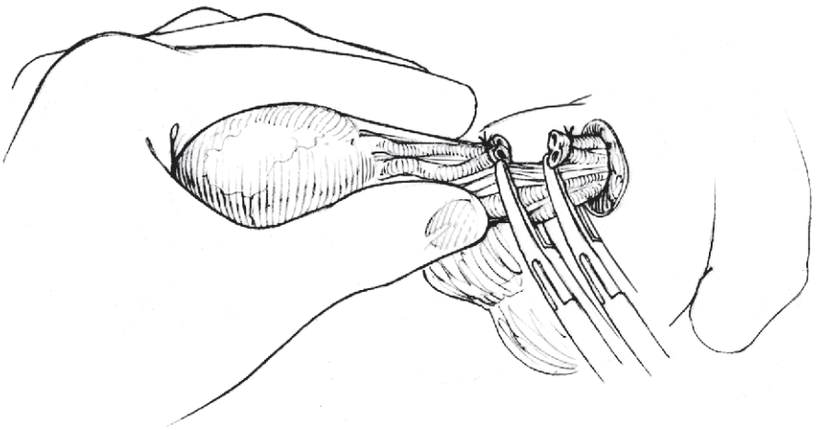

FIGURE 57-2. Magnified view of spermatic cord being separated out for ligation, ~10×.

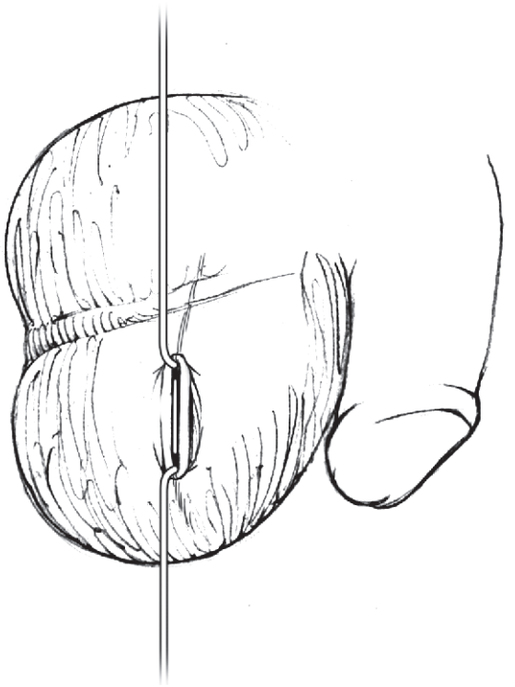

FIGURE 57-3. Skin hooks at apices of incision during subcuticular closure.

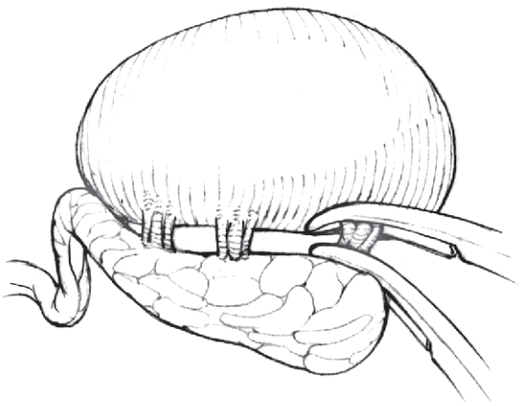

FIGURE 57-4. Dissection of epididymis off of testis under magnification with ligation of vessels.

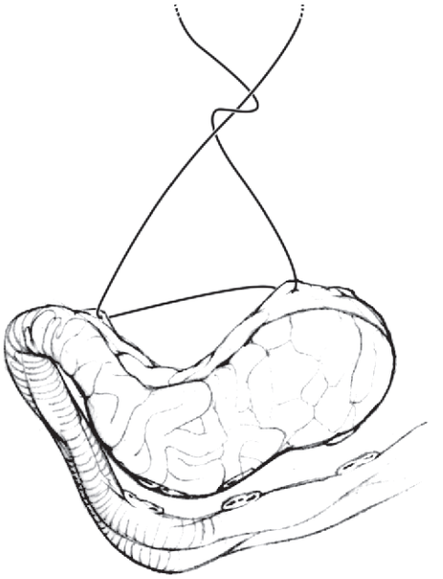

FIGURE 57-5. Approximation of epididymal ends.

Chapter 58

Testis-Sparing Surgery for Benign and Malignant Tumors

CIGDEM TANRIKUT AND MARC GOLDSTEIN

Indications for testis-sparing surgery in the setting of malignancy include solitary testis, abnormal contralateral testis, bilateral tumors, or infertility. Equipment needed for the procedure includes an operating microscope providing 6× to 25× magnification, ice slush, microsurgical instruments, an ultrasound machine for nonpalpable lesions, and a 30-gauge needle.

The initial preparation and approach is identical to that for radical orchiectomy (see Chapter 59). The testis is delivered through an inguinal incision and cooled with ice slush for 10 minutes to decrease warm ischemia. The gubernaculum is clamped and the spermatic cord occluded using two rubber-shod vascular clamps (Fig. 58-1).

If the tumor is not palpable, ultrasound-guided needle localization is performed before incision of the tunica albuginea. Once this is accomplished, the tunic is incised in an avascular region under 10× magnification using a 15-degree microknife (Fig. 58-2). Blunt dissection through the seminiferous tubules is carried out with a microneedle holder until the mass is visualized.

Bipolar electrocautery microforceps and blunt dissection are used to excise the lesion with a 2- to 5-mm margin of normal testicular parenchyma (Fig. 58-3). The excised mass is sent for frozen section analysis. If histopathologic diagnosis reveals a benign mass, the remainder of the testicular parenchyma can be preserved. If the mass is malignant

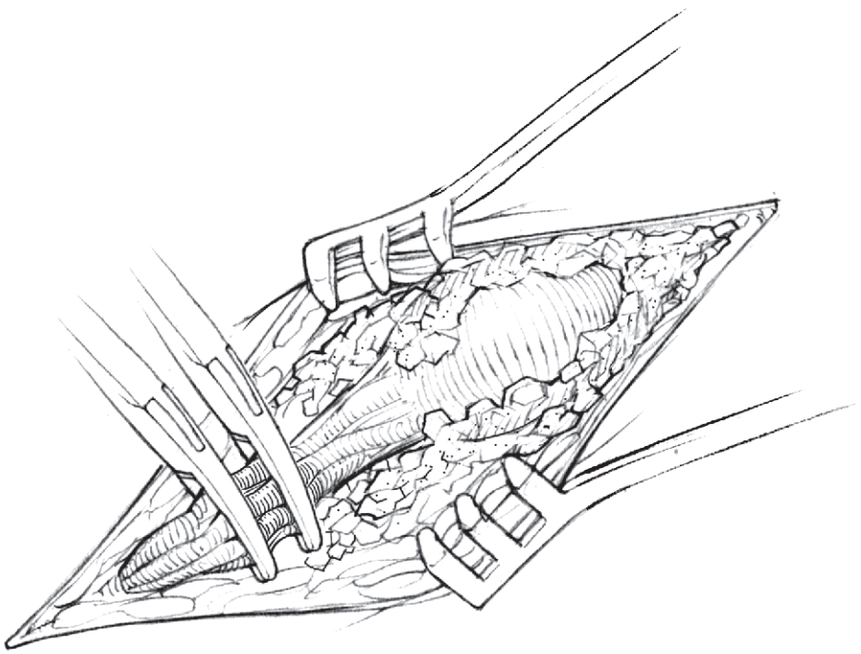

FIGURE 58-1. Cord and gubernaculum clamped; testis cooled.

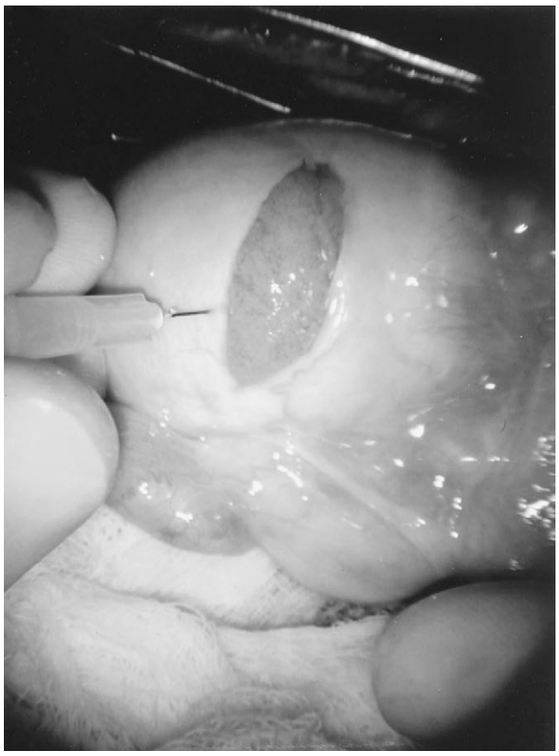

FIGURE 58-2. Mass identified by needle within testicular parenchyma.

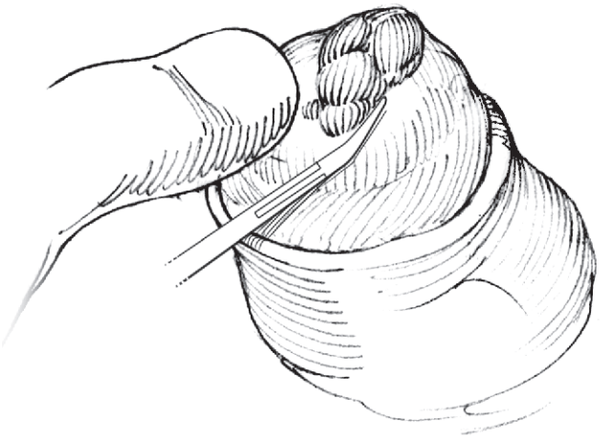

FIGURE 58-3. Dissection of mass using microneedle holder.

and the contralateral testis is normal, one should proceed with radical orchiectomy (see Chapter 59). However, if the patient has an indication for a testis-sparing procedure, then multiple random biopsy samples are obtained and the remaining testicular parenchyma may be preserved as long as negative margins are achieved. Additional testis tissue containing sperm can be cryopreserved. If radical orchiectomy is necessary in a solitary functioning testis, bench dissection of the orchiectomy specimen may allow cryopreservation of sperm for use with in vitro fertilization–intracytoplasmic sperm injection.

The gubernacular and spermatic cord clamps are released. After ensuring hemostasis using bipolar cautery, the tunica albuginea is closed with running 5-0 polyglycolic acid suture (Fig. 58-4). The testis is replaced into the tunica vaginalis, which is closed with a running 5-0 absorbable suture and then returned to the scrotum. The external oblique aponeurosis is reapproximated using running 3-0 absorbable suture. Scarpa's fascia is closed using interrupted 3-0 absorbable suture. Camper's fascia is reapproximated using interrupted 3-0 absorbable suture, burying the knots. The subcutaneous tissues are closed with horizontal mattress stitches of 4-0 absorbable suture. The wound edges are injected with bupivacaine and the skin is reapproximated with a running subcuticular stitch of 5-0 absorbable suture.

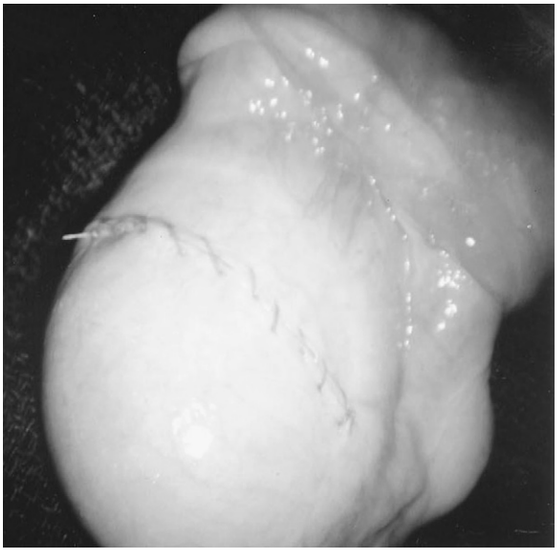

FIGURE 58-4. Closure of tunica albuginea.

Commentary by JOEL SHEINFELD

Appropriate patient selection is paramount when considering testis-sparing surgery. Favorable criteria include organ-confined disease with masses less than 2 cm, absence of intratubular germ cell neoplasia in the remaining testicular parenchyma, and negative surgical margins.

Frozen-section interpretation of testicular lesions can be quite challenging and the availability of pathology expertise is imperative. Testis-sparing surgery can be satisfactorily accomplished without 10× magnification for both benign and malignant lesions.

Chapter 59

Radical Orchiectomy

DONALD A. ELMAJIAN AND DENNIS D. VENABLE

Radical orchiectomy is typically the first step in any multidisciplinary approach to the management of men with testicular germ cell neoplasia. It yields histologic confirmation of the diagnosis, provides important staging information that guides additional management, accomplishes local tumor control, and may be curative in the patient with low stage disease who opts for an observation protocol.

Adjuncts to physical examination in the preoperative setting may include serum alpha-fetoprotein, serum beta human chorionic gonadotropin, urine pregnancy test, serum lactate dehydrogenase, testicular ultrasound, and computed tomography (CT) of the chest, abdomen, and pelvis. One may opt to forgo chest CT in lieu of chest x-ray study. We prefer CT preoperatively rather than postoperatively to obviate the possibility of postoperative retroperitoneal hematoma influencing the CT stage.

SURGICAL PROCEDURE

The anatomic landmarks readily visible with the patient in the supine position include the penis and scrotum, the pubic tubercle medially, the anterior superior iliac spine laterally and cephalad, and the inguinal ligament caudad, which may be palpable in thin men. A curvilinear incision is made beginning approximately 2 cm cephalad and lateral to the pubic tubercle, extending laterally along a Langer's line for 5 to 7 cm (Fig. 59-1). The incision can be oriented more obliquely and extend toward, or onto, the scrotum to facilitate delivery of a large testicular tumor.

The incision is carried through the subcutaneous tissue onto the external abdominal oblique aponeurosis with electrocautery. Camper's and Scarpa's fascia are often readily visible. Subcutaneous superficial inferior epigastric veins are frequently encountered laterally. One may opt to further dissect the subcutaneous tissue off of the external abdominal oblique aponeurosis to clearly identify the inguinal ligament and aid with closure. The external abdominal oblique aponeurosis is sharply opened over the inguinal canal extending medially to the external inguinal ring and laterally to a point overlying the level of the internal inguinal ring. The ilioinguinal nerve lying on top of the spermatic cord is identified

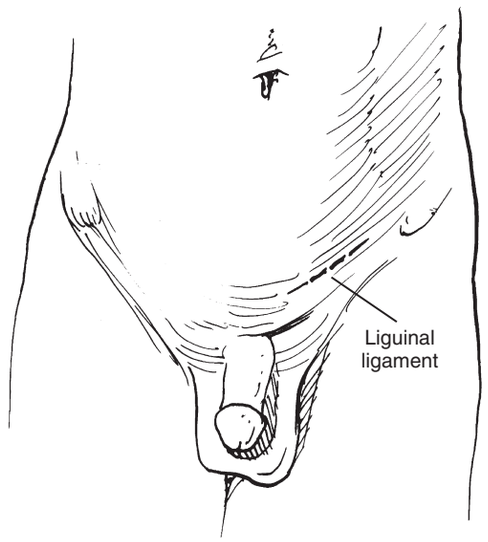

FIGURE 59-1.

and dissected free from its investing external spermatic fascia and cremasteric musculature, and retracted laterally out of harm's way (Fig. 59-2).

Gentle blunt dissection at the level of the pubic tubercle with the aim of circumscribing the spermatic cord and cremasteric musculature is next accomplished (Fig. 59-3). The surgeon's finger should subsequently easily pass posterior to the cord along the floor of the inguinal canal. Care should be taken to avoid dissection through the floor of the inguinal canal, avoiding the risk of the development of a postoperative direct inguinal hernia. The cord should be secured with a ¼-inch Penrose drain passed twice around and clamped with a hemostat, providing early vascular control before any tumor manipulation is done (Fig. 59-4).

The assistant surgeon should gently push the testicle from the base of the prepped hemiscrotum toward the incision to facilitate delivery of the intact testicle within the tunica vaginalis. The surgeon should apply gentle traction to the spermatic cord to aid this maneuver (Fig. 59-5). The surgeon may find that further blunt and/or electrocautery dissection is

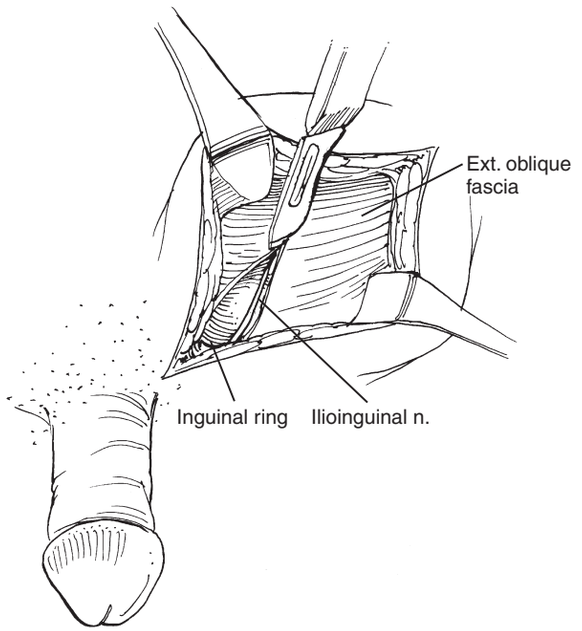

FIGURE 59-2.

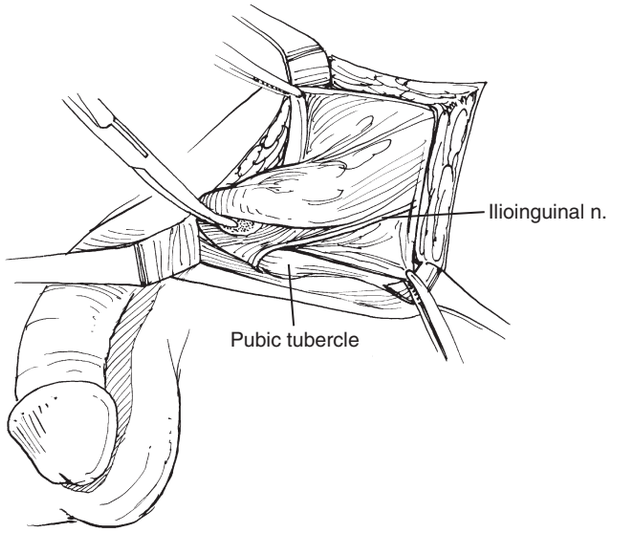

FIGURE 59-3.

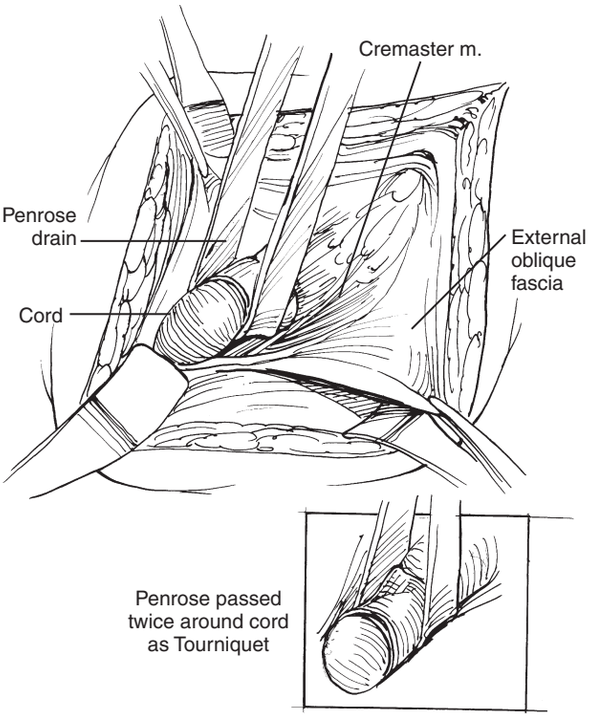

FIGURE 59-4.

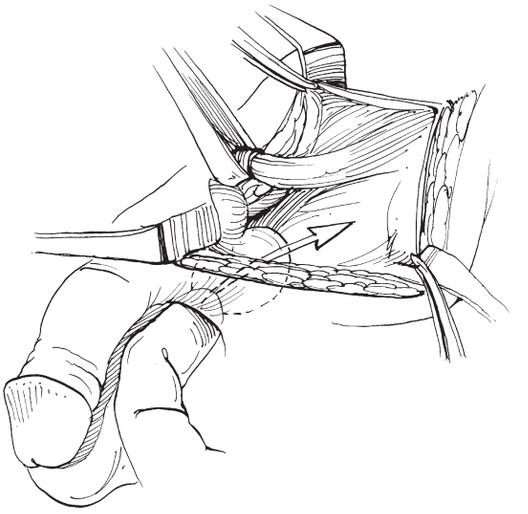

FIGURE 59-5.

necessary to free the tunica vaginalis from its investing fascial layers. Subsequent to delivery of the testicle, the hemiscrotum will be invaginated at the level of the incision by the gubernaculum, which should be incised by electrocautery. The delivered testicle within the tunica vaginalis is then free and attached only by the spermatic cord. In the rare instance that biopsy is indicated, it should be performed at this time.

To facilitate removal of the abdominal portion of the spermatic cord during retroperitoneal lymphadenectomy, we prefer high ligation of the spermatic cord. Accordingly, the cord is dissected proximal to the internal inguinal ring. Cremasteric muscle fibers are incised with electrocautery at this level, thus skeletonizing the cord and allowing clear visibility of the cord vasculature and vas deferens. A handheld retractor can be used to elevate the internal abdominal oblique musculature that forms the lateral edge of the internal ring, revealing retroperitoneal fat (Fig. 59-6). One can further dissect the cord proximally, visualizing the divergence of the vas deferens from the spermatic vessels and frequently see the reflection of the peritoneum overlying the cord anteromedially at this location.

We choose to ligate and divide the vas deferens separately from the cord at this level with 2-0 permanent suture.

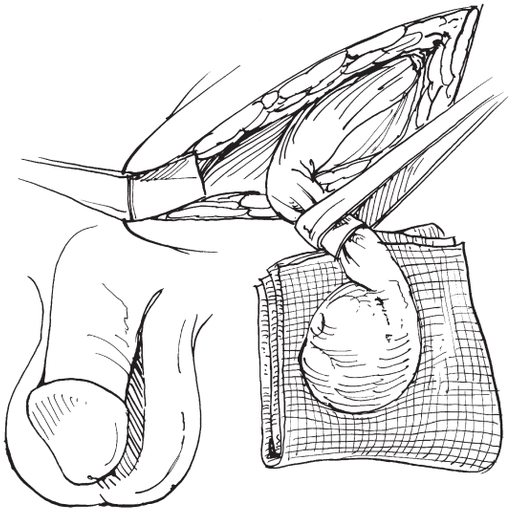

FIGURE 59-6.

The cord proper is doubly ligated and divided at this level with 0 permanent suture. Long tails of this permanent suture aid with identification of the cord stump during retroperitoneal lymphadenectomy. The surgical field is irrigated and meticulous hemostasis is obtained. The external abdominal oblique aponeurosis is approximated with running 2-0 absorbable suture, taking care to not include the ilioinguinal nerve. If desired, long-acting local anesthesia for assistance with postoperative pain control can be applied at this time. The subcutaneous fascial tissue layers are approximated with running 3-0 absorbable suture. The skin is closed in a routine fashion. We prefer a subcuticular closure with running 4-0 absorbable suture.

Commentary by JOEL SHEINFELD

Several points warrant emphasis. First, careful draping of the field is prudent before delivering the testicle and its investing tunica. Second, meticulous control of all gonadal vessels is critical, in that they may retract into the retroperitoneum, cause significant hemorrhage, and be potentially confused as metastatic disease on subsequent imaging. A testicular prosthesis, previously soaked in antibiotic solution, may be placed in the ipsilateral hemiscrotum, and the processus vaginalis closed with a pursestring absorbable suture.

This page intentionally left blank

Chapter 60

Retroperitoneal Lymph Node Dissection

STEPHEN BECK AND RICHARD FOSTER

STAGING

Proceed with staging after radical orchiectomy and pathologic confirmation of a nonseminomatous germ cell tumor.

1. Abdominal and pelvic computed tomography (CT) scan
2. Posteroanterior and lateral chest x-ray study (CXR) or chest CT
3. Repeat serum tumor markers

Proceed with chemotherapy when:

1. Disease is identified in the chest and abdomen
2. There is large-volume (>5 cm) retroperitoneal-only disease
3. Serum tumor markers remain elevated (even in patients with normal x-ray studies)

Patients with normal serum tumor markers and chest imaging are candidates for retroperitoneal lymph node dissection (RPLND) based on size of retroperitoneal tumor.

1. Normal abdominal/pelvic CT scan (clinical stage A). Treatment is surveillance, chemotherapy, or RPLND.
2. Retroperitoneal mass < 2 cm. Treatment is typically primary RPLND or chemotherapy.
3. Retroperitoneal mass between 2 and 5 cm. Treatment is either primary RPLND or chemotherapy.

For low-volume retroperitoneal disease, the decision to proceed with primary RPLND or chemotherapy is based on fertility issues, testicular histology, and potential morbidity of chemotherapy or surgery assessed for each patient.

Patients presenting with retroperitoneal tumor treated with induction chemotherapy are reimaged with abdominal/pelvic CT scans, CXR, and serum tumor markers. Patients with normal imaging (complete resolution of the retroperitoneal mass) and normal serum tumor markers are observed. Patients with normal serum tumor markers and residual retroperitoneal tumor undergo postchemotherapy RPLND. Patients with residual tumor and elevated serum tumor markers typically receive second line chemotherapy, although this treatment, as in all cases, must be individualized.

PREPARATION

Primary Retroperitoneal Lymph Node Dissection

In clinical stage A disease, if fertility is an issue, a left- or right-sided nerve-sparing procedure should be performed with preservation of antegrade emission approaching 99%. Vascular injury, need for nephrectomy, or development of chylous ascites is exceedingly rare. Preoperative preparation is minimal and no bowel preparation is necessary. At the time of operation, a type-and-screen is obtained, use of two large-bore peripheral venous access sites is routine (central venous access is not required), and an orogastric tube is anchored. Typical hospital stay is 3 days; use of a nasogastric tube is uncommon. Because RPLND is therapeutic, if the pathology reveals stage B1 disease, adjuvant chemotherapy is typically not recommended.

Postchemotherapy Retroperitoneal Lymph Node Dissection

Loss of antegrade emission should be discussed with the patient. Nerve-sparing technique can be performed in the postchemotherapy setting and is dependent on patient history, tumor location, and intraoperative judgment. The need for nephrectomy is usually less than 15% and again dependent on patient history, tumor location, and surgeon judgment. Vena caval resection and aortic replacement are uncommon (5% and 1%, respectively), although the surgeon should have experience in vascular reconstruction because the preoperative CT scan often underestimates the difficulty of the procedure. Patients should be counseled on the small risk for development of chylous ascites. A type-and-cross is obtained for 2 units of packed red blood cells, a central venous line is placed, and a nasogastric tube is anchored. Preoperative preparation is minimal; bowel preparation is usually not necessary. Due to potential pulmonary toxicity secondary to bleomycin, anesthesia should judiciously administer intravenous fluid while maintaining adequate urine output. Typical hospital stay is 4 to 5 days. Two courses of adjuvant chemotherapy are typically recommended if the pathology examination

reveals active cancer, whereas patients with residual teratoma or necrosis are observed.

APPROACHES

Exposure to the retroperitoneum can be obtained either via a midline or thoracoabdominal incision. With greater experience and understanding of retroperitoneal anatomy, more than 95% of cases can be safely completed using a midline incision. Physician preference is the most important factor in choosing surgical approach.

Bilateral Lymphadenectomy After Chemotherapy

Postchemotherapy RPLND is most commonly indicated for patients who have received cisplatin-based chemotherapy and who have normalized serum tumor markers but who have residual radiographic disease. A full bilateral RPLND involves dissection of the lymphatics from the crura of the diaphragm to the bifurcation of the common iliacs, from ureter to ureter (Fig. 60-1).

1. The patent is placed in a supine position with both arms extended. A nasogastric tube and Foley catheter are placed. A midline abdominal incision is made, the falciform ligament is divided, and a self-retaining retractor is used to retract the abdominal wall. The retroperitoneum is exposed by incising the posterior peritoneum. For smaller size tumors, adequate exposure can be obtained by incising from the cecum to the ligament of Treitz, dividing the inferior mesenteric vein (Fig. 60-2).
2. For larger tumors, it may be necessary to incise the posterior peritoneum from the foramen of Winslow to the cecum and to the ligament of Treitz.
3. The duodenum is retracted superolaterally, and the colon and small bowel placed either under the diaphragm or on the chest.
4. The split-and-roll maneuver is then performed over the left renal vein from its origin distally. This tissue is then rolled inferiorly from the renal vein, exposing the anterior aspect of the aorta (Fig. 60-3).
5. Next, the split maneuver is performed at the 12-o'clock position of the aorta just caudal to the left renal vein. The inferior mesenteric artery is identified and divided, allowing lateral retraction of the left mesocolon (Fig. 60-4).
6. The split maneuver is continued over the aorta, exposing the common iliac arteries and lumbar arteries (Fig. 60-5).
7. Continue the split maneuver over the aorta. With retraction of the aorta medially and the periaortic mass and/or lymphatic tissue laterally, the three lumbar arteries can be identified and divided between silk ties. The interaortocaval lumbar arteries are identified and divided (Fig. 60-6).
8. Splitting and rolling the tissue of the aorta as the first step allows for the prospective identification of any lower pole left or right renal arteries (Fig. 60-7).
9. The aorta, completely mobilized, can be retracted medially and laterally to aid in identifying the renal arteries and removal of the lymphatic tissue. The left gonadal vein is divided as it enters the renal vein, and the lumbar vein, if present, is divided to allow superior retraction of the left renal vein. This maneuver allows exposure of crura of the diaphragm, which represents the superior border of the dissection (Fig. 60-8).
10. The split maneuver is performed over the vena cava from the origin of both renal veins distally to the bifurcation of the common ilial veins. Tissue is rolled medially and laterally from the vena cava; in the course of this procedure the right gonadal vein is identified and divided between silk ties.
11. Retracting the vena cava superiorly, the lumbar veins can be divided.
12. The ureters are identified bilaterally and are dissected from the lymphatic tissue or tumor, delineating the lateral aspects of the dissection.
13. After complete mobilization of the vena cava and aorta (Fig. 60-9), the retroperitoneal lymph tissue, including the right paracaval, interaortocaval, precaval, and preaortic left periaortic packages, can be harvested, taking care to control lumbar arteries and veins as they penetrate the posterior body wall medial to the sympathetic chains.
14. The ipsilateral gonadal vein and associated lymphatics are dissected to the internal ring, at which point the vas

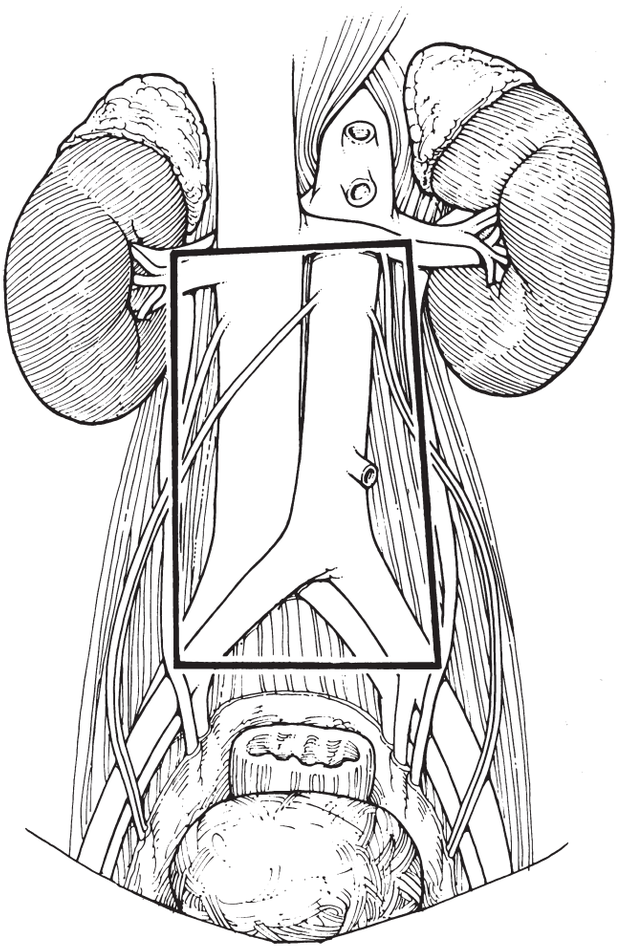

FIGURE 60-1.

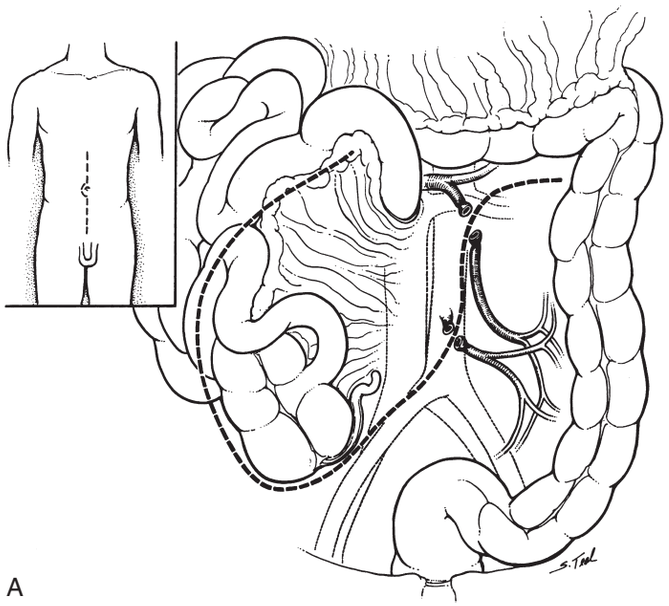

A

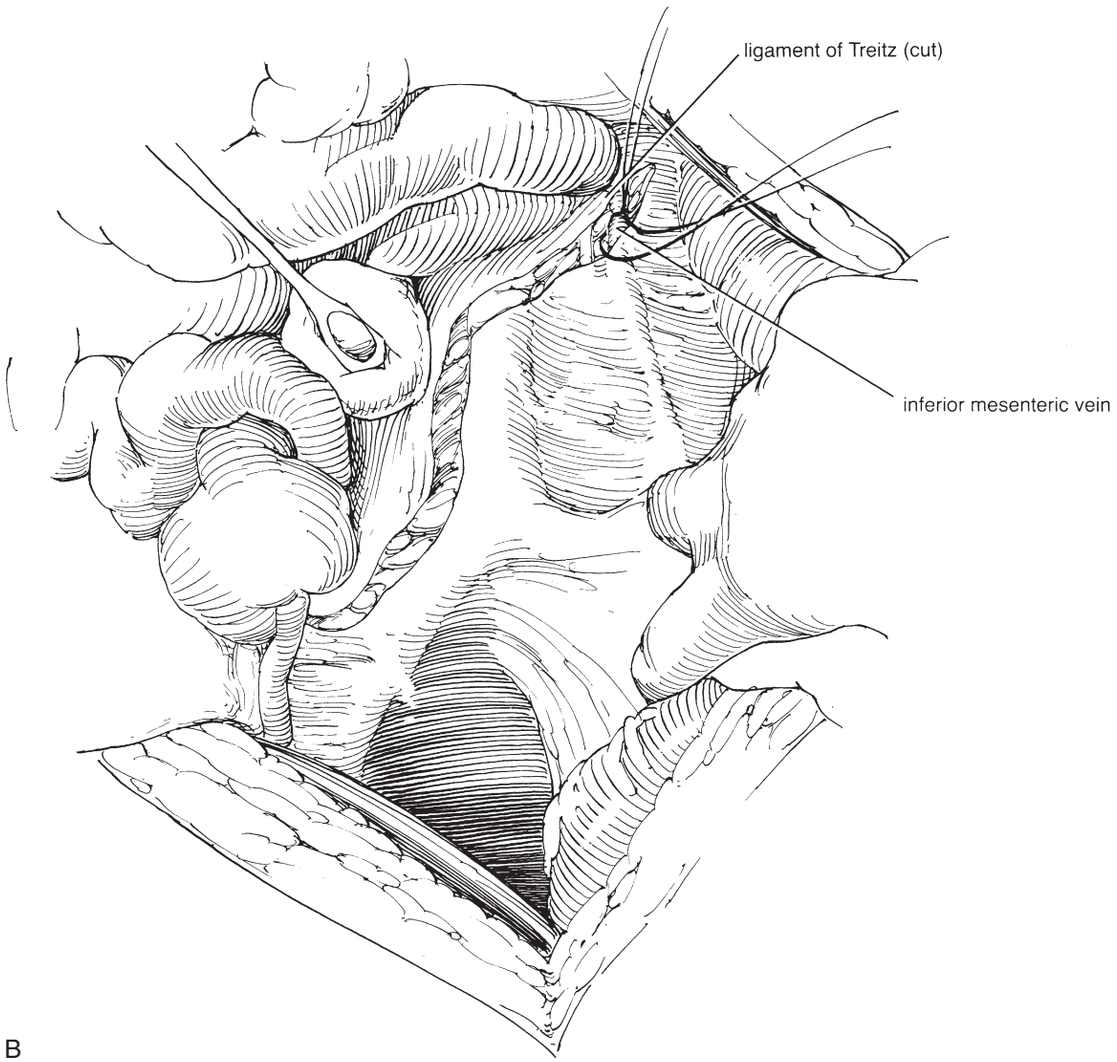

B

FIGURE 60-2.

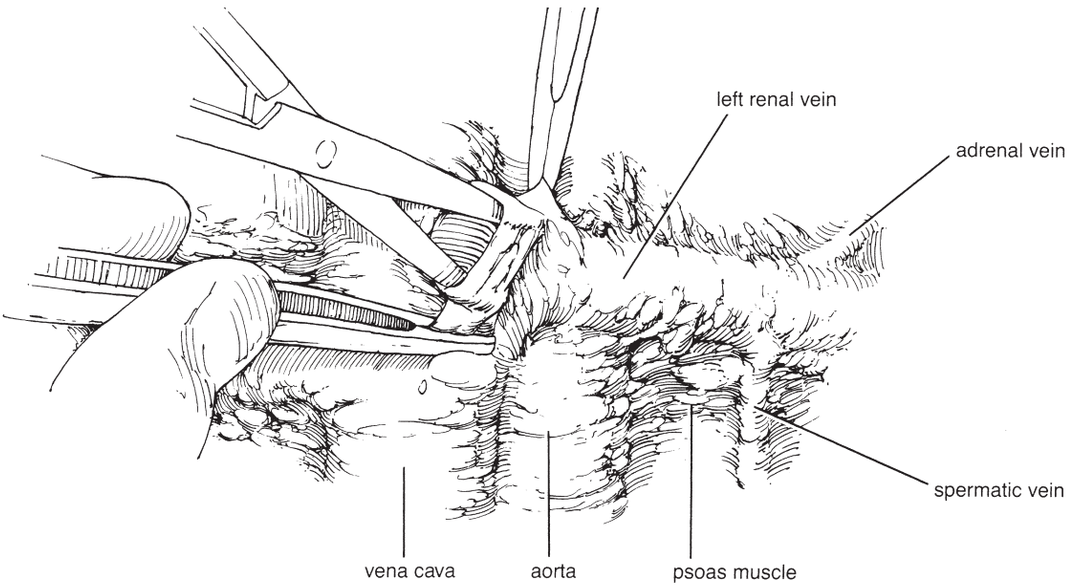

FIGURE 60-3.

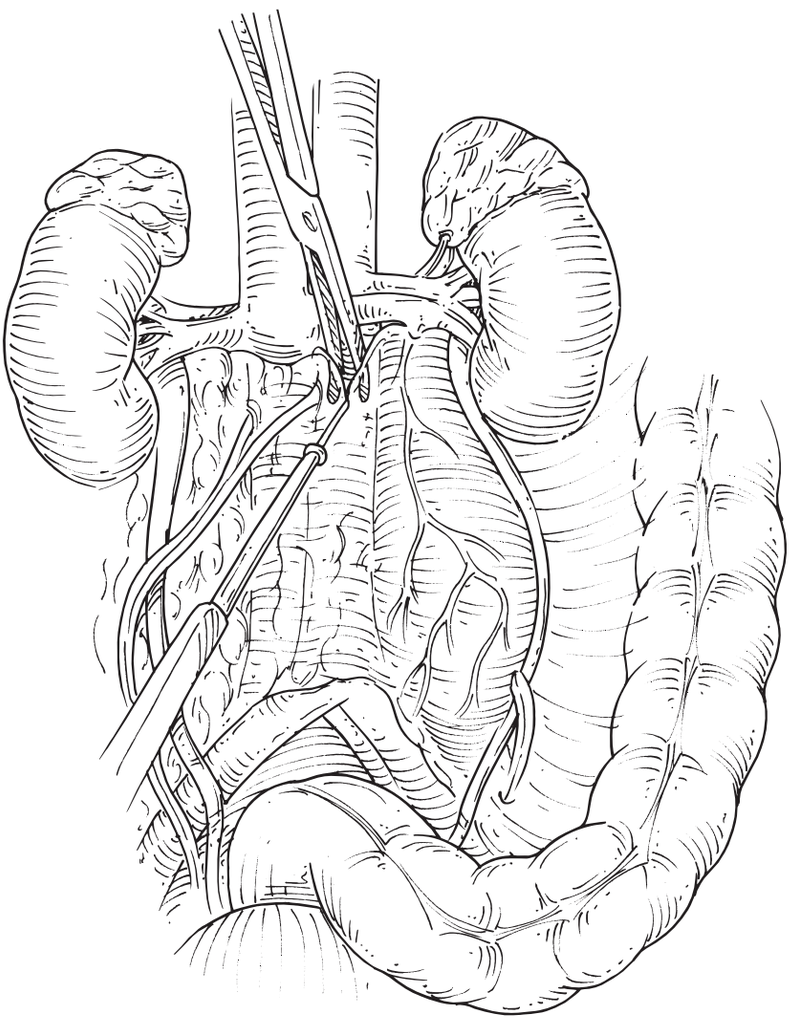

FIGURE 60-4.

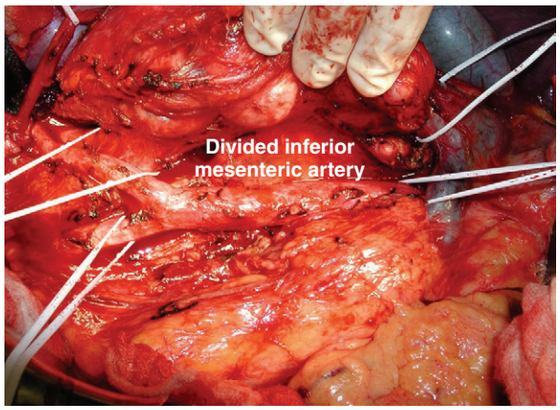

FIGURE 60-5.

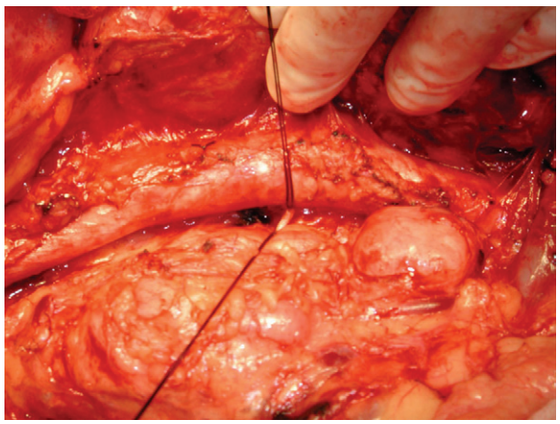

FIGURE 60-6.

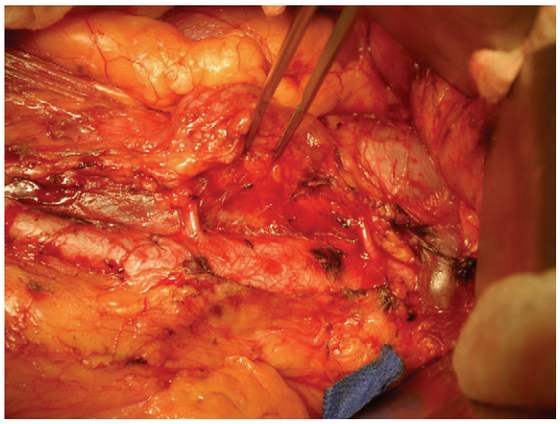

FIGURE 60-7.

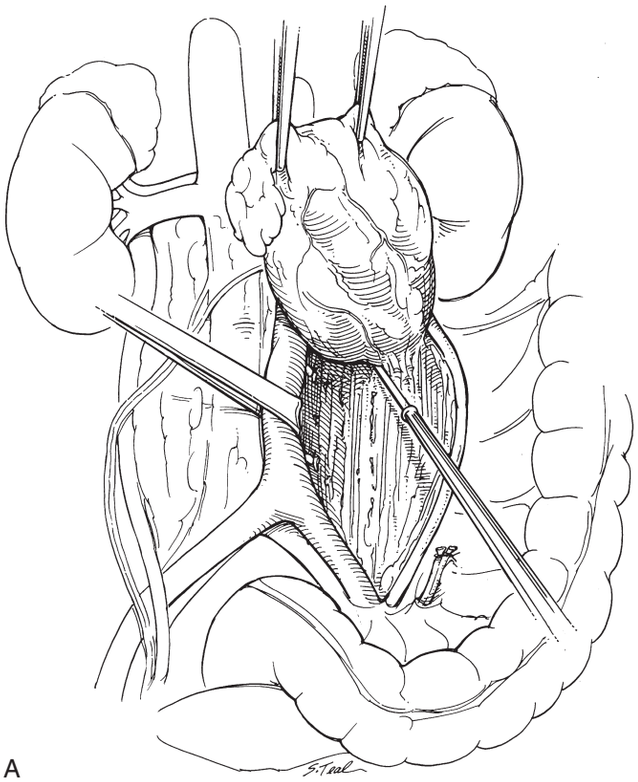

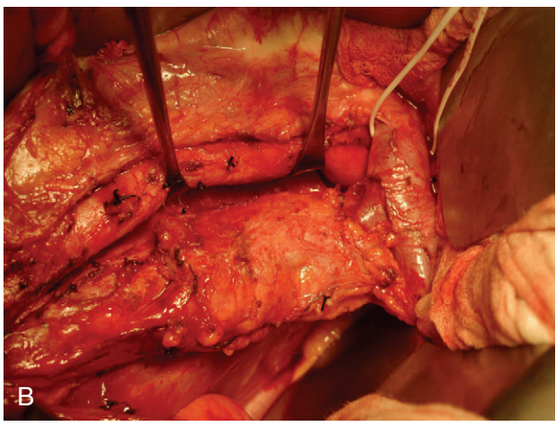

FIGURE 60-8.

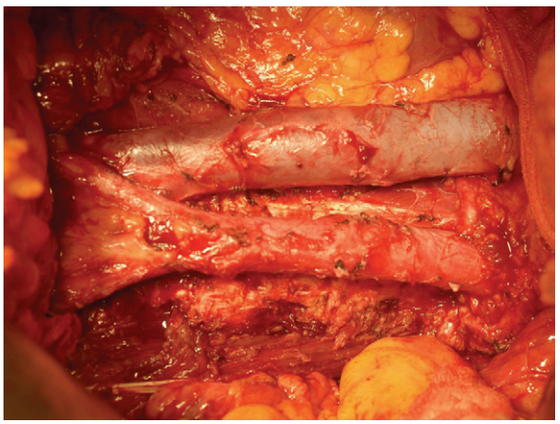

FIGURE 60-9.

deferens is identified and divided, and the stump of the spermatic cord is identified and dissected as specimen with the gonadal vein.

15. Irrigation is carried out, any bleeding is controlled, and the bowel is sewn back in anatomic position to the retroperitoneal structures.

ANATOMY AND TEMPLATES FOR NERVE-SPARING RETROPERITONEAL LYMPH NODE DISSECTION

The anatomy and course of the efferent sympathetic fibers in the retroperitoneum remains constant and can be prospectively dissected before removal of lymphatic tissue (Fig. 60-10).

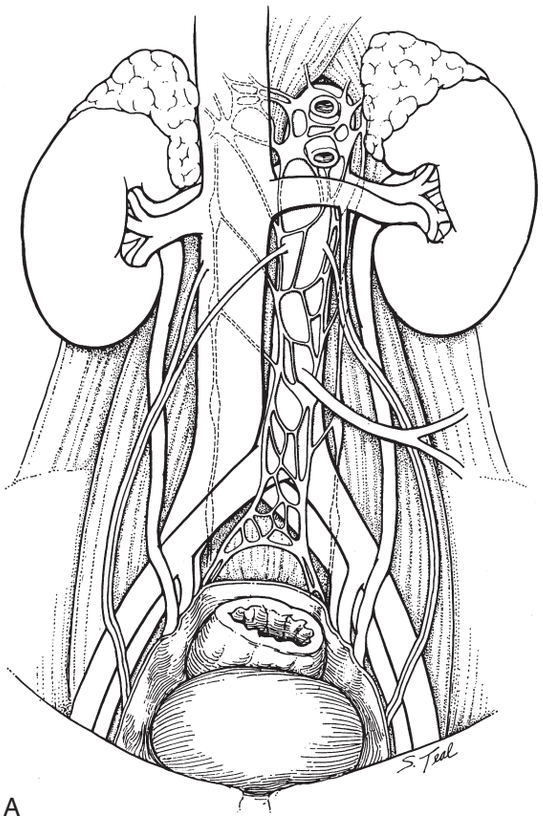

FIGURE 60-10.

On the right side, the postganglionic fibers and sympathetic chain is posterior to the vena cava, with nerve fibers (L1-L4) coursing medially to join the condensed sympathetic trunk in the ventral preaortic tissue (Fig. 60-11). The left sympathetic chain is dorsolateral to the aorta. The nerve fibers L1 to L4 can be recognized and preserved along the anterolateral aspect of the lower aorta (Fig. 60-12). The templates used for nerve-sparing modified RPLND are depicted in Figures 60-13 and 60-14. For a right-sided template, the nodal areas to be resected include the interaortocaval, precaval, right paracaval, and right iliac packages. For a left-sided template, areas of resection include the left periaortic and left iliac packages. For both right- and left-sided templates, a midline incision is made and a self-retaining retractor is placed. Palpation of the intraabdominal contents and retroperitoneum is performed to determine whether gross metastatic disease is apparent. If tumor at exploration is found to be high volume, the modified nerve-sparing retroperitoneal lymphadenectomy is abandoned, and a full bilateral dissection is performed. Whether or not nerve sparing is used during a full bilateral dissection is at the discretion of the surgeon.

Left-Sided Dissection

If the retroperitoneum is normal upon palpation, an incision is made lateral to the left colon and carried up through the lenocolic ligament; the left colon and its mesentery are reflected medially. Self-retaining retractors are placed to yield exposure of the left periaortic and upper interaortocaval zones. The ureter is reflected laterally, setting up the lateral margin of the resection.

The left sympathetic efferent fibers can be seen distally where they cross the left common iliac artery and can be traced proximally to their origin at the sympathetic chain (see Fig. 60-13). The split of lymphatic tissue over the anterior surface of the aorta is performed, and the tissue is rolled laterally off the aorta. Lumbar arteries are identified and divided between silk ties. The gonadal vein is divided at its origin from the left renal vein and, if present, the lumbar vein coursing from the posterior aspect of the left renal vein to the posterior body wall is divided. The renal artery is identified and dissected free. The lymphatic tissue is then dissected off the posterior body wall and passed of as specimen. The left gonadal vein and lymphatics are dissected to the internal ring, the vas deferens is identified and divided, and the stump of the spermatic cord is identified and dissected as specimen with the gonadal vein.

An alternative approach for a left-sided modified nerve-sparing dissection includes incising the posterior peritoneum from the cecum to the inferior mesenteric vein, which is divided. This allows exposure of the interaortocaval and upper periaortic zones, and mobilizing the sigmoid colon medially allows exposure off the lower periaortic region without division of the inferior mesenteric artery.

Right-Sided Dissection

After palpation of the retroperitoneum, an incision is made from the cecum along the root of the small bowel up to the ligament of Treitz. The duodenum and small bowel

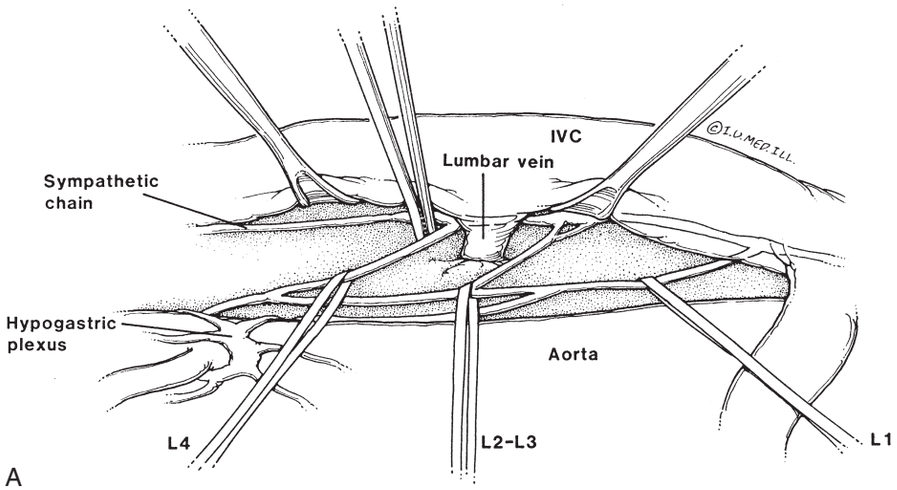

A

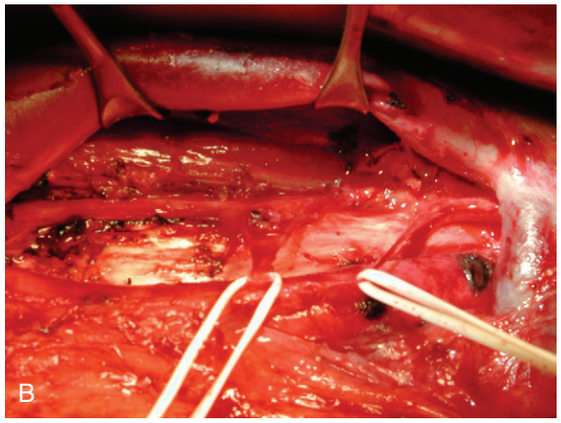

B

FIGURE 60-11.

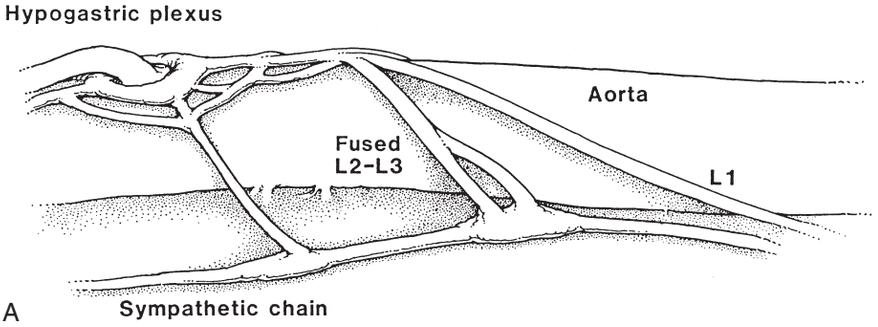

A

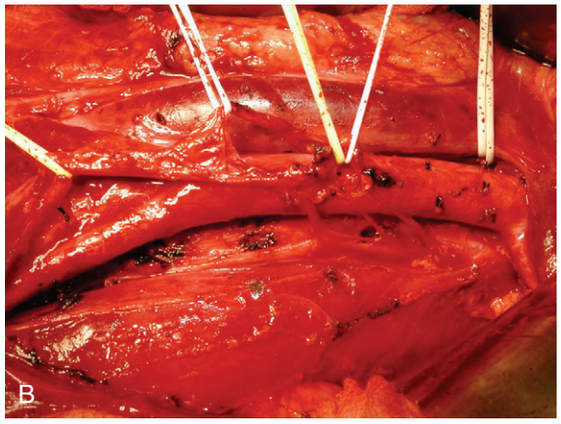

B

FIGURE 60-12.

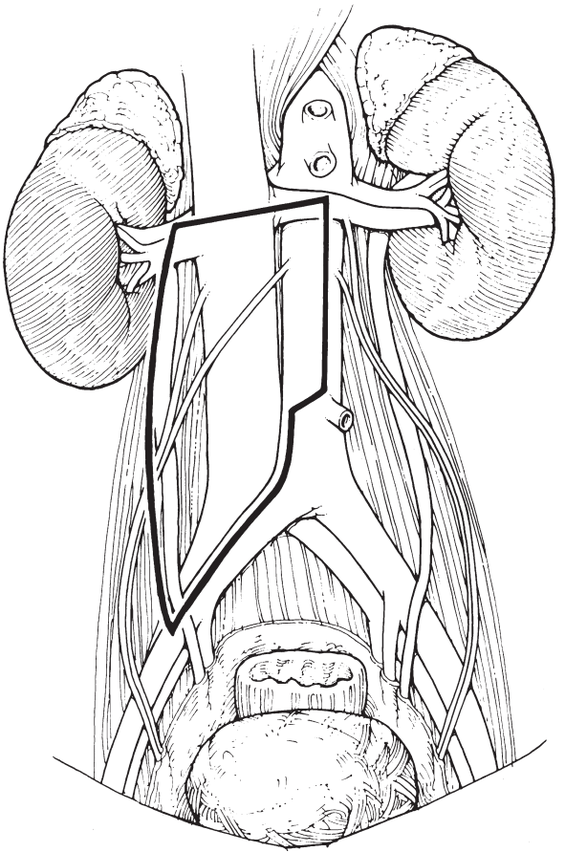

FIGURE 60-13.

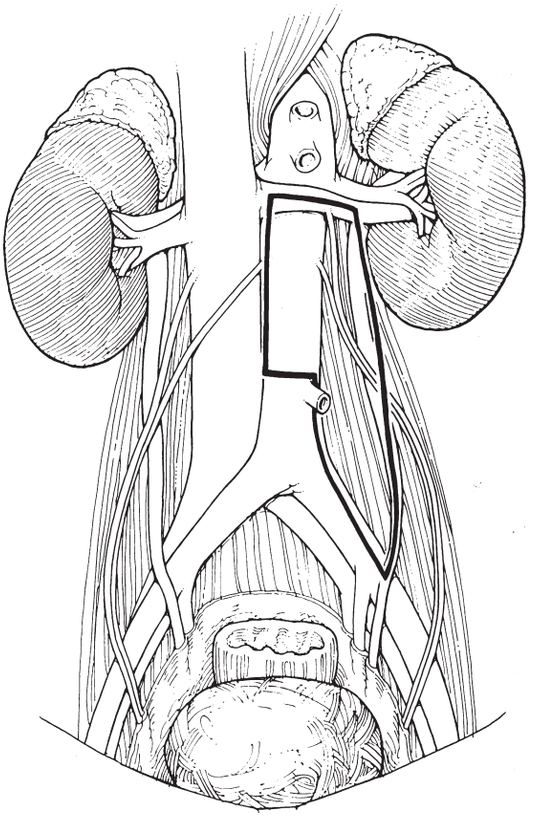

FIGURE 60-14.

mesentery are reflected off the retroperitoneum to expose the preaortic, interaortocaval, precaval, and right paracaval zones. Split-and-roll technique over the great vessels is employed. It is recommended to begin "splitting" over the anterior surface of the aorta rather than the vena cava, because precaval lower pole renal arteries sometimes are identified that can be divided inadvertently if the split maneuver is performed over the vena cava first.

Sympathetic efferent fibers can be identified as they course around the lumber veins and pass distally to the preaortic plexus. These fibers are dissected prospectively and placed in vessel loops (see Fig. 60-14). Lumber veins are usually divided immediately before the dissection of these sympathetic fibers. Right-sided lumbar arteries are divided between silk ties as they pass from the aorta to the posterior body wall. The right renal artery is identified at the superior aspect of the interaortocaval zone and dissected free of lymphatic tissue. The interaortocaval tissue is then removed by dissecting it off the anterior spinous ligament, taking care to clip lumbar arteries or veins as they penetrate the posterior body wall. The right paracaval zone is dissected after the tissue has been rolled laterally off the vena cava. In harvesting this tissue, care must be taken not to injure the sympathetic chain. Finally, the gonadal vein, which was divided from the vena cava during the split-and-roll maneuver, is dissected distally to the cord stump. Irrigation is then performed, and the posterior peritoneum is closed.

SPECIAL CONSIDERATIONS

In primary RPLND or uncomplicated post chemotherapy surgery, significant vascular injury, need for nephrectomy, or ureteral injury is rare. It is important to remain in the appropriate plane when dissecting the great vessels to avoid subadventitial dissection, which can weaken the vessel wall and make repair difficult. In complicated cases (desperation, late relapse), resection of the vena cava or replacement of the abdominal aorta may be required for complete tumor clearance.

Commentary by

JOEL SHEINFELD

The key to the safe performance of an RPLND are (1) thorough knowledge of retroperitoneal anatomy and common variations, (2) excellent exposure, and (3) meticulous split-and-roll technique to perform the actual lymphadenectomy.

Early identification of important structures will minimize and/or avoid injury: the superior mesenteric artery (SMA), inferior mesenteric artery (IMA), pancreas, renal vessels, and ureters. Approximately 20% to 25% of patients will have multiple renal arteries, usually accessory lower pole vessels. Intravenous mannitol as well as topical papaverine given before dissection of renal arteries can be helpful and protective of renal function. It is important to use minimal traction on the exteriorized duodenum and pancreas; careful division of their attachments to the anterior surface of the renal vein and inferior vena cava (IVC) are helpful. Periodic inspection of small bowel color or SMA pulsation is prudent. Meticulous ligation or clipping of numerous lymphatic vessels on the undersurface of the duodenum and pancreas is important to minimize lymphatic complications. Major lymphatic channels that also require control are located around the superior mesenteric artery, medial to the inferior mesenteric vein, posterior to the right renal artery, and in the area of the crus of the diaphragm.

RPLND is both a diagnostic and therapeutic procedure, but it should always be done with therapeutic intent. Surgical margins should never be compromised to preserve antegrade ejaculation. We agree that with suspected or documented disease, a bilateral dissection remains the standard. The data suggest that extratemplate disease increases with clinical and pathologic stage. Nerve-sparing techniques whereby the sympathetic chains, the postganglionic sympathetic fibers, and the hypogastric plexus are prospectively identified, dissected, and preserved should result in excellent antegrade ejaculation rates in primary RPLND patients and in approximately 80% of appropriately selected postchemotherapy patients.

Patients who receive bleomycin are at increased risk for pulmonary complications. Careful perioperative oxygen concentration and judicious fluid management with emphasis on colloid rather than crystalloid have reduced pulmonary toxicity.

This page intentionally left blank

Chapter 61

Laparoscopic Retroperitoneal Lymph Node Dissection

LEE RICHSTONE, BRIAN A. VANDERBRINK, AND LOUIS R. KAVOUSSI

Laparoscopic retroperitoneal lymph node dissection (RPLND) was initially described by Rukstalis and Chodak in 1992. Laparoscopic RPLND was initially employed for staging purposes, however, at select centers laparoscopic RPLND has evolved into an identical replication of the open technique. Laparoscopic RPLND can be performed with therapeutic intent, offering control of the retroperitoneum with the benefits of a laparoscopic approach.

Staging: Clinical staging of testis cancer is described elsewhere and is independent of the approach to retroperitoneal nodal dissection. Briefly, tumor markers (AFP, HCG, LDH) are drawn before radical orchiectomy and are followed until they are undetectable prior to consideration of RPLND. Patients with persistent tumor markers receive chemotherapy. Computed tomography (CT) imaging of the chest, abdomen, and pelvis is performed.

Indications: Candidates for LRPLND include patients with clinical stage I nonseminomatous germ cell tumors (NSGCT) as well as select patients with clinical stage IIa disease. The latter includes patients with small volume lymphadenopathy in the appropriate landing zone. LRPLND can also be performed for residual retroperitoneal mass following chemotherapy in presence of normal serum tumor markers. Postchemotherapy laparoscopic RPLND is technically more challenging than primary RPLND and should be performed by those with significant experience in laparoscopic procedures because rates of open conversion are higher. Additional indications for LRPLND include clinical stage I paratesticular rhabdomyosarcoma and clinical stage I Leydig cell tumor.

Patient preparation: Before LRPLND all patients should undergo mechanical bowel preparation and type and crossmatch. Patients who have received bleomycin are at risk of pulmonary complications; preoperative pulmonary function tests should be performed to identify patients at risk of pulmonary fibrosis and to aid in postoperative management. Preoperative sperm banking should be discussed.

Node dissection templates: Lymph node dissection templates are described elsewhere in this text. Briefly, right-sided template LRPLND includes all nodal tissue between the right ureter laterally, the renal vessels superiorly, the aorta (including the preaortic nodes), and the common iliac artery inferiorly. Inclusion of the paraaortic nodes as well as the performance of a nerve-sparing bilateral dissection can routinely be performed. Left template LRPLND is bordered by the ureter laterally, the vena cava (including precaval nodes), the common iliac artery, and the renal vessels. Similarly, extension to a full bilateral LRPLND may be performed. Our typical approach is to perform a template dissection as described earlier; if metastatic disease is suspected intraoperatively, a bilateral dissection is performed. In all cases the entire retrocaval and retroaortic nodal packets are excised, resulting in an exact replication of open RPLND.

POSITIONING AND TROCAR PLACEMENT

The operating room setup for LRPLND is shown in Figure 61-1. Both the operating and assistant surgeon stand on the same side of the patient. Two monitors are employed on either side of the patient. Standard laparoscopic instruments are used throughout the procedure, including a 10-mm 30-degree laparoscope, Veress needle, atraumatic grasping forceps, scissors, clip appliers, and irrigation/suction device. Specific equipment includes laparoscopic paddle retractor, radiolucent polypropylene clips (Hem-o-Lock, Weck Closure Systems, Triangle Park, NC), laparosopic needle driver loaded with 4-0 Prolene suture, oxidized cellulose (Surgicel, Ethicon, Piscataway, NJ), and laparoscopic bipolar coagulation.

General anesthesia is used, followed by placement of a Foley catheter and nasogastric tube. Sequential pneumatic compression devices are used throughout the procedure. The patient is secured to the operating room table in the supine position with both arms tucked to the side. Pneumoperitoneum is established via a Veress needle placed at the umbilicus. Four equally spaced 12-mm laparoscopic ports are placed in the midline beginning 2 to 4 cm below the xiphoid process (Fig. 61-2). An additional 5-mm port may be placed in the midaxillary line midway between the iliac crest and ribs for

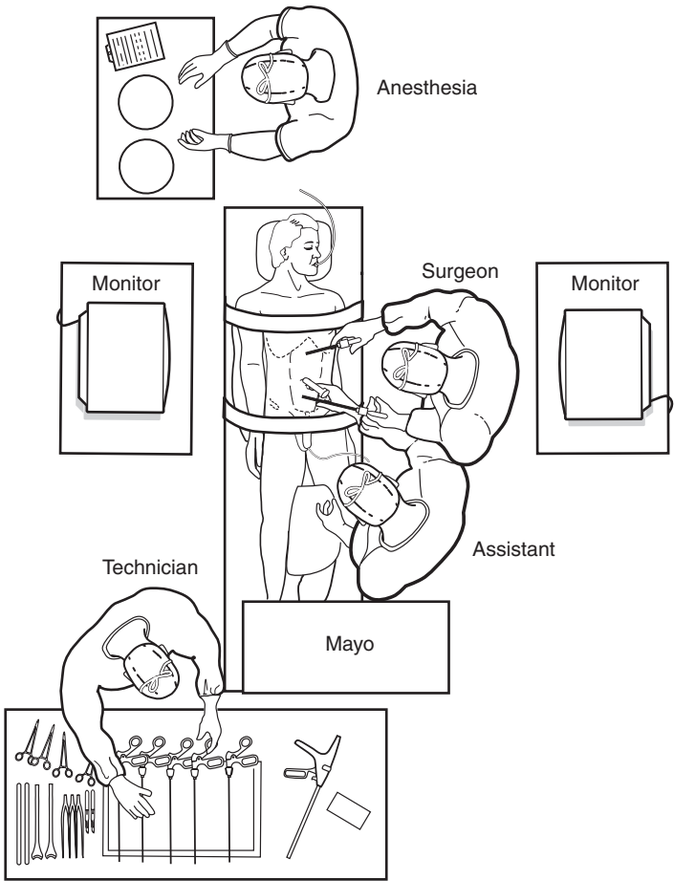

FIGURE 61-1. *(From Allaf ME: Laparoscopic retroperitoneal lymph node dissection. In Bishoff JT, Kavoussi LR (eds): Atlas of Laparoscopic Urologic Surgery. Philadelphia, Saunders, 2007, pp 238-249.)*

additional retraction, if needed. The bed is rotated to allow the bowel segments to fall away from the operative field.

RIGHT-SIDED LRPLND

Right sided dissection begins with complete mobilization of the ascending colon (Fig. 61-3). Incision of the white line of Toldt from the iliac vessels to the hepatic flexure is performed. A paddle retractor, introduced through the lower-most port, is used by the assistant to retract the bowel medially, whereas the primary surgeon uses the three most cephalad ports to begin the dissection. Care is taken to avoid injury of the mesenteric vessels. The duodenum is identified and a Kocher's maneuver is carried out using sharp dissection without cautery. This allows exposure of the anterior surfaces of the inferior vena cava (IVC), right renal vein, and contralateral renal hilum.

After colon mobilization, the primary surgeon then shifts trocars to use the three lower-most ports. The ipsilateral internal inguinal ring is identified and the peritoneum incised to mobilize the spermatic cord remnant (Fig. 61-4A). The suture securing the spermatic cord is identified. The gonadal vein and all associated lymphatics is then dissected in a cephalad direction to its insertion into the IVC.

Care should be taken to avoid injury to the inferior epigastric vessels and unnecessary hemorrhage (see Fig. 61-4B).

The gonadal vein is doubly clipped and divided at its insertion into the IVC, thus excising the entire gonadal vein and associated lymphatics (Fig. 61-5A).

Special care must be taken during right sided dissections to avoid avulsion of the gonadal vein off of the IVC. The spermatic artery is clipped and transected where it crosses over the vena cava (see Fig. 61-5B). The ureter is then identified as it crosses the iliac vessels.

All of the lymphatic tissue between the ureter and the great vessels is excised using the "split/roll" technique. All lymphatics are clipped before division to reduce risk of lymphocele development. The adventitia overlying the IVC is incised from cranial to caudal, superiorly to the renal vein and inferiorly to the common iliac vessels (Fig. 61-6).

The lateral nodal tissue comprising the precaval and paracaval lymph node packet is lifted, and blunt dissection is carried down to the lumbar vessels. The borders of this packet include the common iliac vessels inferiorly, the IVC medially, the ureter laterally, and the right renal vein superiorly (Fig. 61-7).

The irrigator/aspirator is an effective blunt dissection tool for this dissection. Lumbar vessels are identified, doubly clipped, and divided (Fig. 61-8). Lower pole renal arteries may be encountered and should not be confused with lumbar vessels.

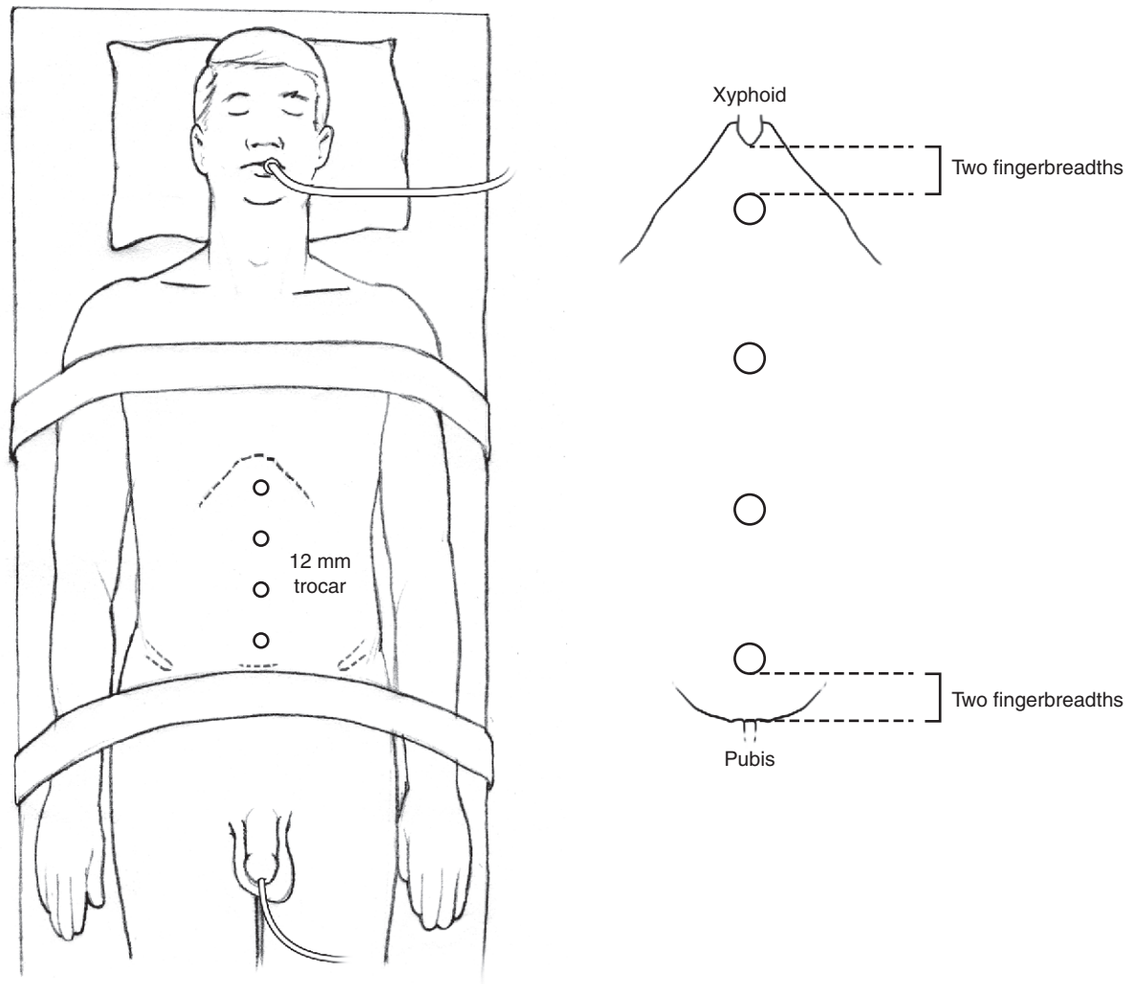

FIGURE 61-2. *(Modified from Allaf ME: Laparoscopic retroperitoneal lymph node dissection. In Bishoff JT, Kavoussi LR (eds): Atlas of Laparoscopic Urologic Surgery. Philadelphia, Saunders, 2007, pp 238-249.)*

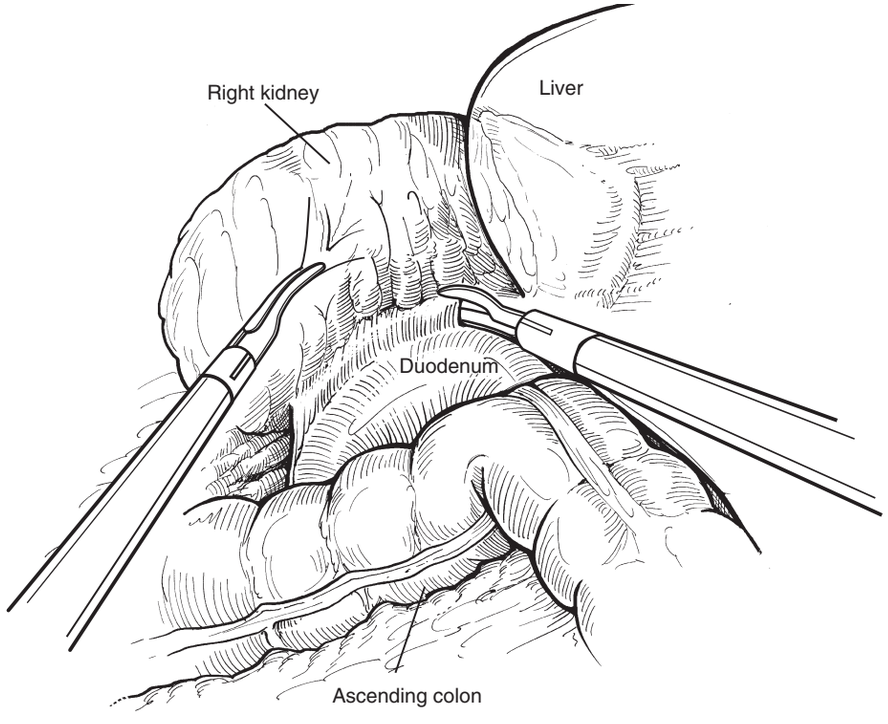

FIGURE 61-3. *(From Allaf ME: Laparoscopic retroperitoneal lymph node dissection. In Bishoff JT, Kavoussi LR (eds): Atlas of Laparoscopic Urologic Surgery. Philadelphia, Saunders, 2007, pp 238-249.)*

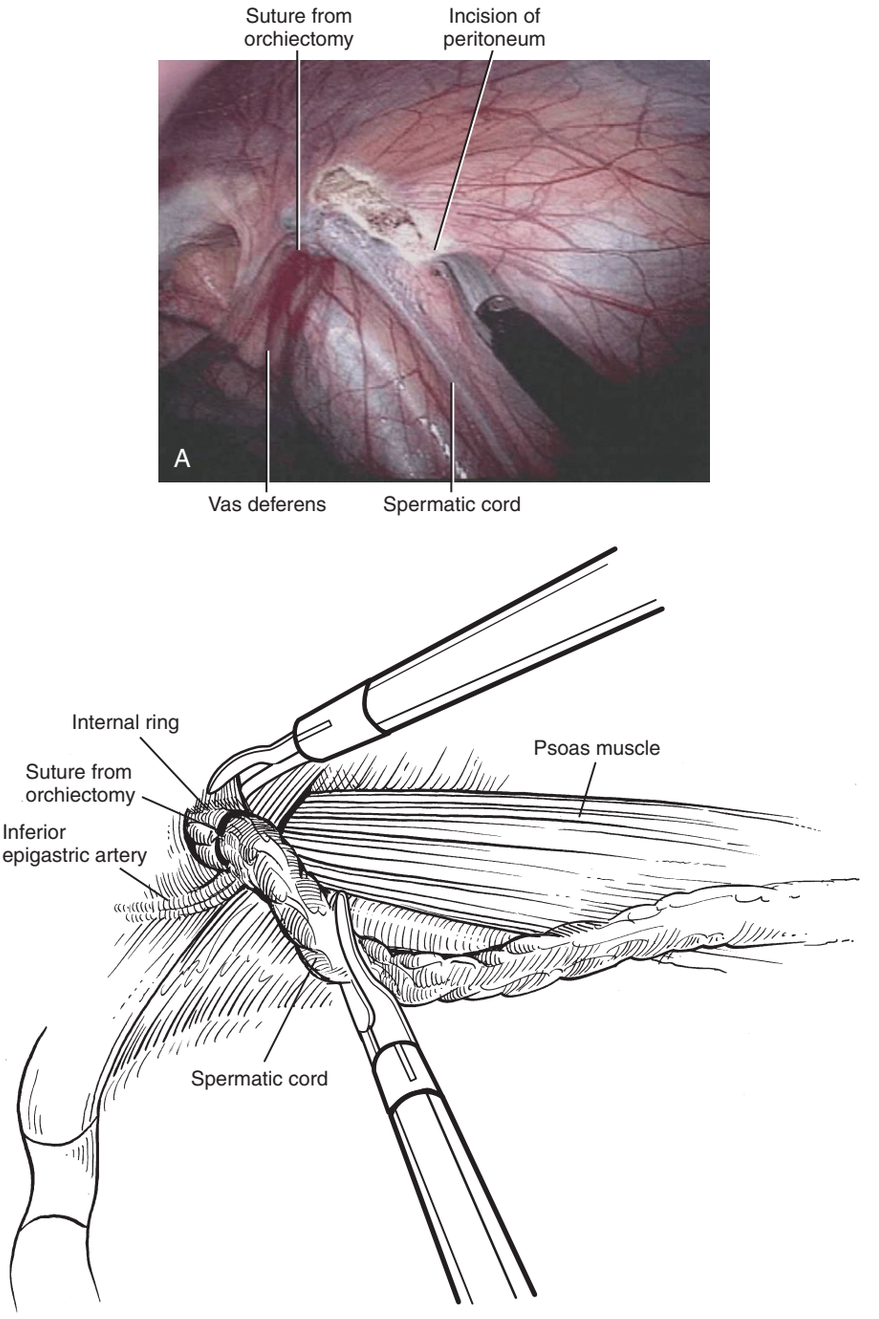

FIGURE 61-4. *(B, From Allaf ME: Laparoscopic retroperitoneal lymph node dissection. In Bishoff JT, Kavoussi LR (eds): Atlas of Laparoscopic Urologic Surgery. Philadelphia, Saunders, 2007, pp 238-249.)*

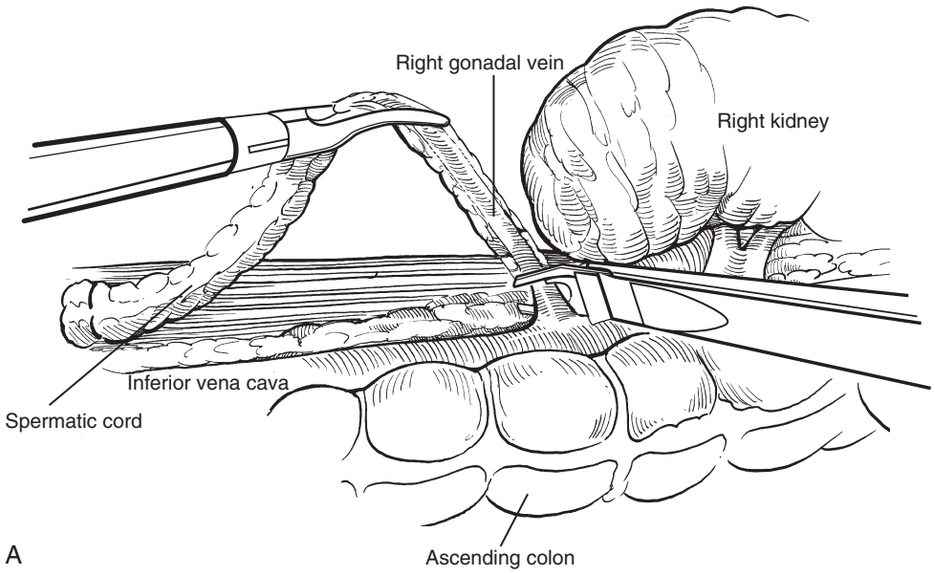

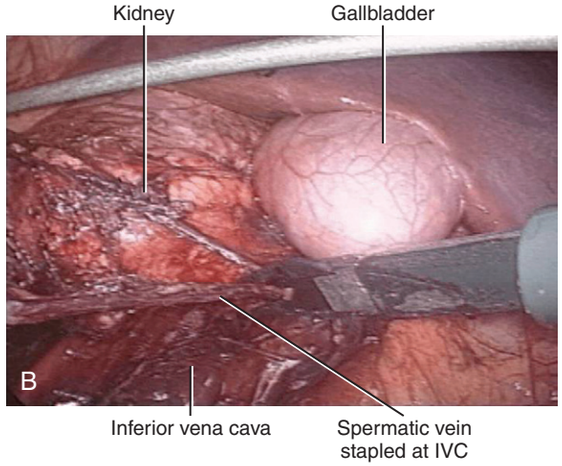

FIGURE 61-5. *(A, From Allaf ME: Laparoscopic retroperitoneal lymph node dissection. In Bishoff JT, Kavoussi LR (eds): Atlas of Laparoscopic Urologic Surgery. Philadelphia, Saunders, 2007, pp 238-249.)*

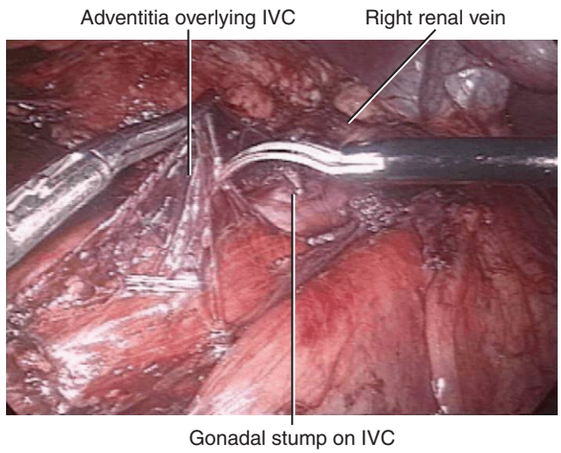

FIGURE 61-6.

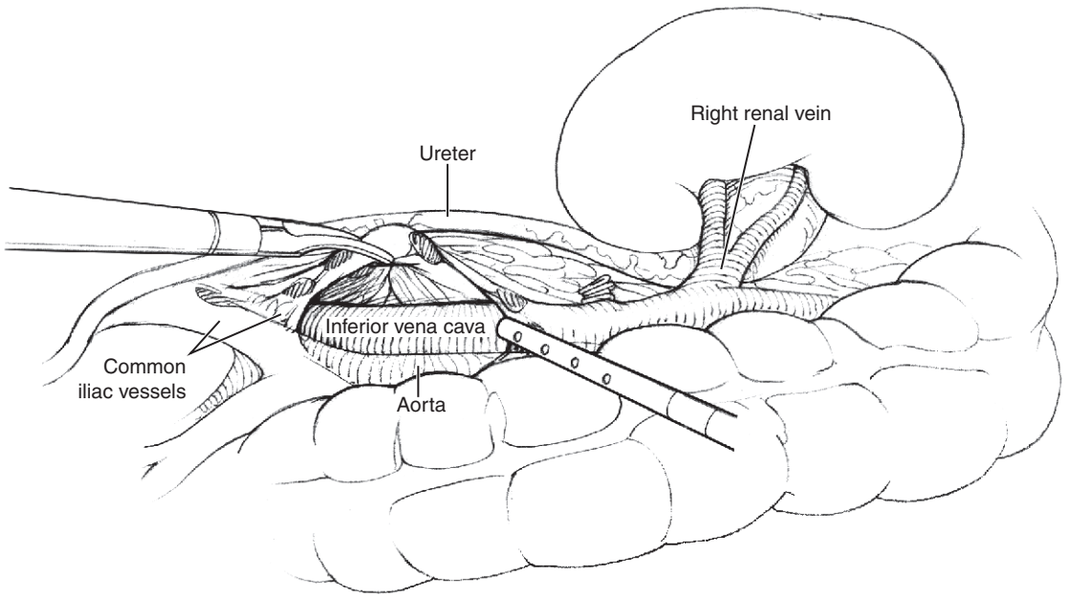

FIGURE 61-7. *(Modified from Allaf ME: Laparoscopic retroperitoneal lymph node dissection. In Bishoff JT, Kavoussi LR (eds): Atlas of Laparoscopic Urologic Surgery. Philadelphia, Saunders, 2007, pp 238-249.)*

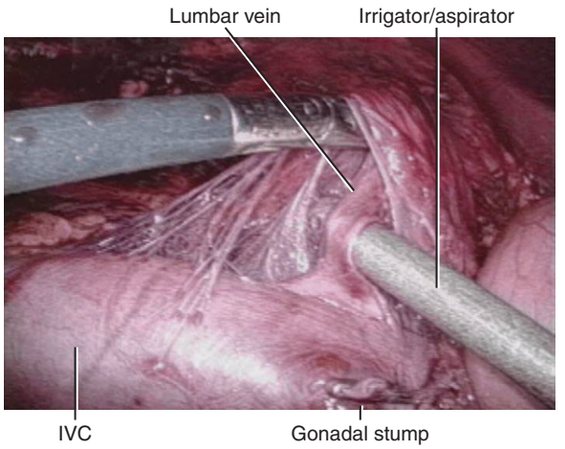

FIGURE 61-8.

The lymphatic tissue medial to the ureter is mobilized and excised. The underlying psoas fascia is preserved (Fig. 61-9A). The inferior limit of dissection is reached with clear visualization of the common iliac artery and vein (see Fig. 61-9B).

The interaortocaval (IAOC) dissection then proceeds cephalad to the interior mesenteric artery (Fig. 61-10A). Care is taken to identify all lumbar arteries and veins.

Lumbar veins and arteries encountered in the IAOC region are doubly clipped and divided. A laparoscopic atraumatic DeBakey forceps can be used to anteriorly retract the IVC, and the aspirator/irrigator is used for blunt dissection. The preaortic nodes are excised with the anterior surface of the aorta exposed (see Fig. 61-10B, C).

The retrocaval and retroaortic lymph node packets are excised completely (Fig. 61-11). Anterior retraction of

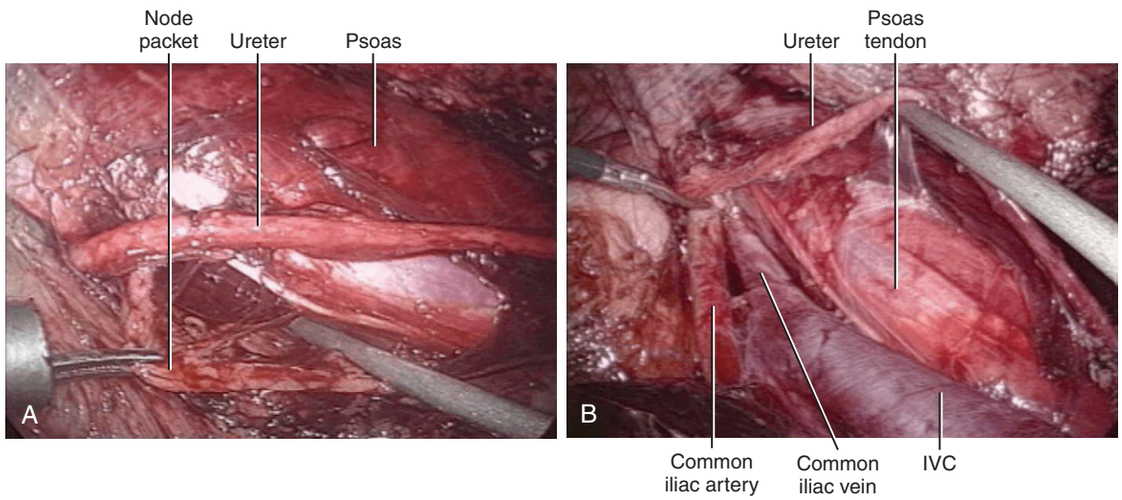

FIGURE 61-9.

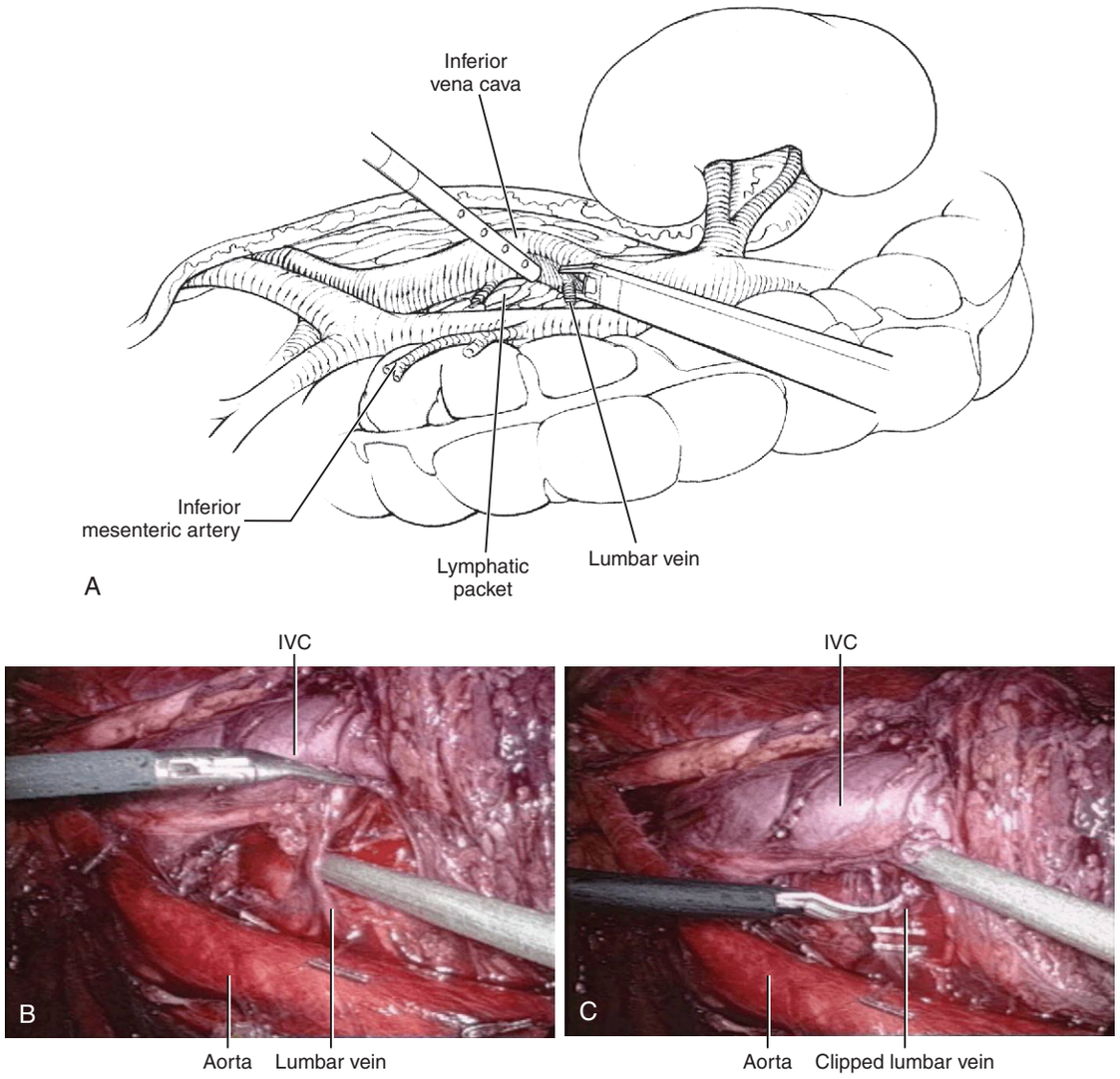

FIGURE 61-10. *(A, Modified from Allaf ME: Laparoscopic retroperitoneal lymph node dissection. In Bishoff JT, Kavoussi LR (eds): Atlas of Laparoscopic Urologic Surgery. Philadelphia, Saunders, 2007, pp 238-249.)*

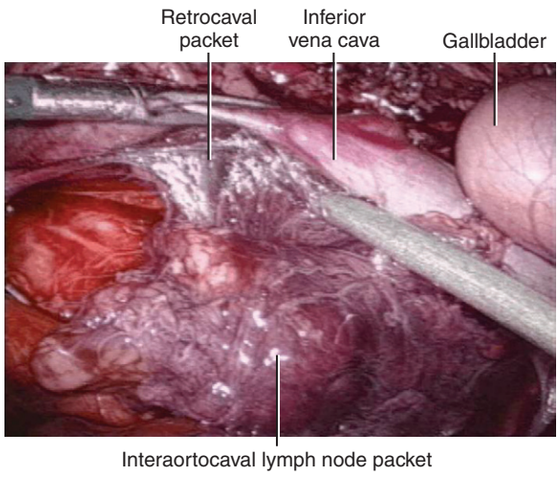

FIGURE 61-11.

the great vessels is possible, taking great care to avoid lumbar vessel avulsion. Constant attention to the location of the renal artery and vein, bilaterally, is imperative. It is essential to rule out the presence of a retroaortic or circumaortic left renal vein on preoperative imaging to avoid inadvertent injury to these vessels as well as the superior mesenteric artery (SMA).

The cephalad extent of the completed paracaval, precaval, and IAOC dissections is represented. The *right* renal artery and *left* renal vein represent the cephalad extent of the IAOC dissection (Fig. 61-12).

Complete IVC mobilization and anterior retraction highlights complete excision of the retrocaval nodes. The anterior spinous ligament is the posterior limit of the dissection (Fig. 61-13). During nerve-sparing LRPLND, the sympathetic chain and ganglia are preserved, as are the postganglionic sympathetic fibers show in Figure 61-13.

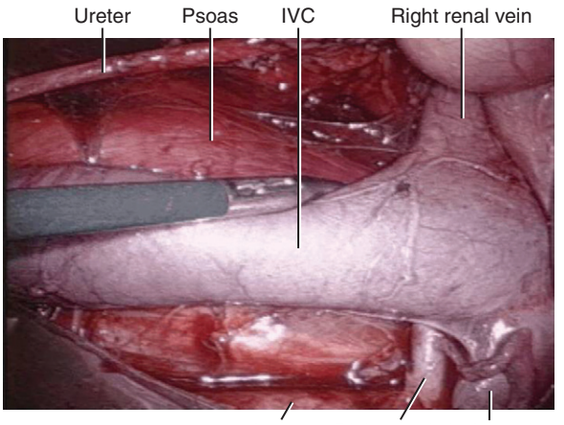

FIGURE 61-12.

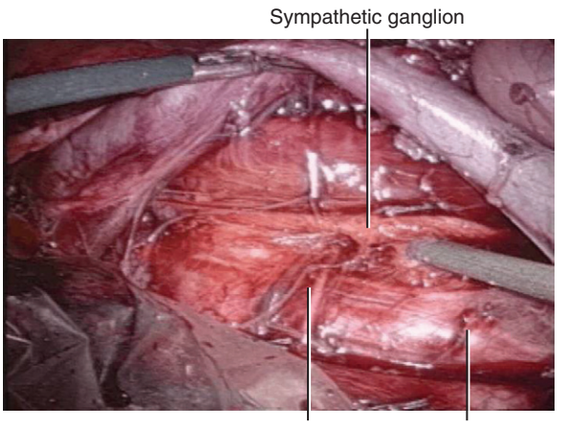

FIGURE 61-13.

LEFT-SIDED LRPLND

A left-sided template dissection begins with incision of the line of Toldt to mobilize the descending colon from splenic flexure to common iliac vessels. The lienorenal and splenocolic ligaments are divided to allow full exposure and splenic mobilization. The colorenal ligaments are divided. The anterior surface of the aorta and IVC are exposed. The spermatic cord remnant is identified and associated lymphatics mobilized.

The gonadal vein is dissected to the insertion at the left renal vein, doubly clipped and divided (Fig. 61-14). All associated lymphatics are excised en bloc. The ureter is identified and represents the lateral border of the dissection.

Mobilization of the preaortic and paraaortic lymph node packet follows. The spermatic artery as well as lumbar arteries are clipped and divided (Fig. 61-15). Retroaortic dissection is performed in an identical fashion to retrocaval dissection. However, attention must be paid to identify and preserve the sympathetic chain and postganglionic fibers during nerve-sparing dissection. IAOC dissection proceeds as outlined during right-sided dissection.

After completion of the dissection, all specimens are placed into Endocatch entrapment sacs (US Surgical, Norwalk, CT) and removed (Fig. 61-16). Intraabdominal pressure is lowered to 5 mm Hg to evaluate for bleeding. Drains

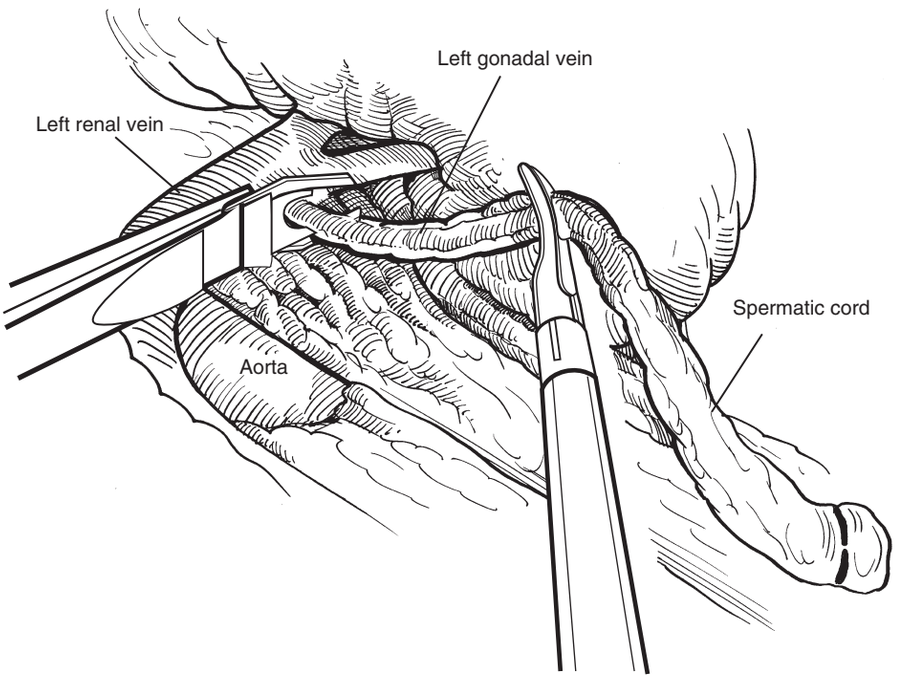

FIGURE 61-14. *(From Allaf ME: Laparoscopic retroperitoneal lymph node dissection. In Bishoff JT, Kavoussi LR (eds): Atlas of Laparoscopic Urologic Surgery. Philadelphia, Saunders, 2007, pp 238-249.)*

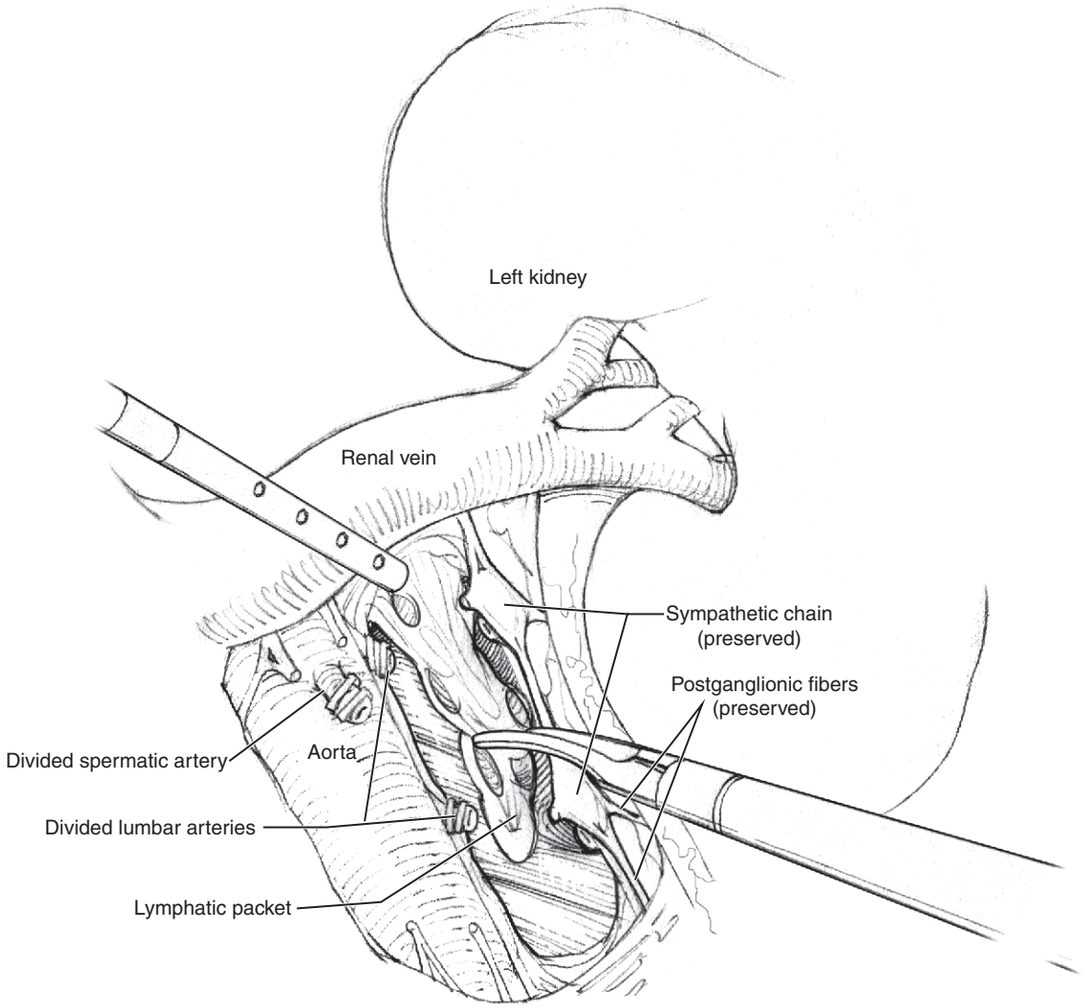

FIGURE 61-15. *(Modified from Allaf ME: Laparoscopic retroperitoneal lymph node dissection. In Bishoff JT, Kavoussi LR (eds): Atlas of Laparoscopic Urologic Surgery. Philadelphia, Saunders, 2007, pp 238-249.)*

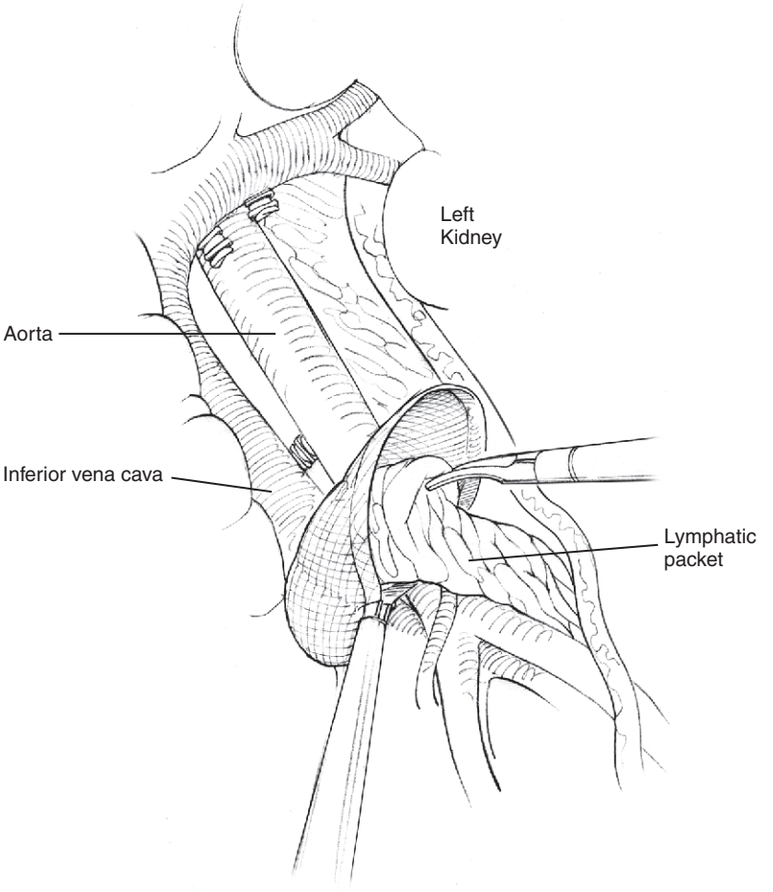

FIGURE 61-16. *(Modified from Allaf ME: Laparoscopic retroperitoneal lymph node dissection. In Bishoff JT, Kavoussi LR (eds): Atlas of Laparoscopic Urologic Surgery. Philadelphia, Saunders, 2007, pp 238-249.)*

are not routinely placed. All port sites are closed under direct vision to prevent herniation.

COMPLICATIONS

Hemorrhage is the most common major complication during LRPLND, and the most common cause for open conversion. Careful dissection around the great vessels is of paramount importance. Constant awareness of the location of critical major vascular structures including the renal vessels and SMA is imperative. Lacerations of the great vessels do not necessitate open conversion in experienced hands. Venous bleeding can often be controlled with direct pressure. Clips, bipolar cautery, and suturing are adjunctive measures. The use of 3-0 monofilament nonabsorbable sutures may be used to control arterial bleeding.

Additional complications during LRPLND include injury to surrounding visceral structures including bowel, pancreas, liver, spleen, and kidneys. Care must be taken to identify and protect accessory/supernumerary renal vessels. Special care must be taken to avoid the use of thermal energy when mobilizing the duodenum and head of pancreas on the right and tail of pancreas on the left.

In order to avoid troubling lymphocele formation, meticulous ligation of lymphatic channels with laparoscopic clip appliers is necessary throughout the procedure.

POSTOPERATIVE CARE

The nasogastric tube is removed before exiting the operating room. The Foley catheter is removed as soon as the patient is ambulatory. Postoperative pain can be managed with oral analgesics. Patients are placed immediately on clear liquid diet and advanced as tolerated. Low-fat, medium chain fatty acid diets are recommended to minimize the risk of chylous ascites. Patients are typically discharged home on postoperative day 2 and resume normal activity between 1 and 3 weeks.

Commentary by

JAMES McKIERNAN

Male germ cell tumor represents a unique entity in urologic oncology. First, it is a rare condition affecting approximately 6 in 100,000 people and the treatment algorithms associated with successful outcomes are often complex. It is the only urologic malignant disease state with an integrated role of medical, surgical, and radiation oncology disciplines necessary to afford universally high success rates for each individual patient. Due to the overall high cure rates in testes cancer, there has been a strong emphasis placed on reducing the burden of therapy over the past 15 years. Based on this principle, it is an ideal setting to pursue minimally invasive surgical techniques to limit the short-term morbidity of interventions. However, based on the overall high cure rates and long life expectancy of young healthy males, this reduction in short-term morbidity must be accomplished without impacting the long-term outcome in any patient.

The current review by Richstone and Kavoussi is an outstanding illustration of the necessary steps involved when undertaking the laparoscopic approach to RPLND. Using lateral template-based surgical exposure techniques, this highly experienced group of laparoscopic surgeons have clearly demonstrated an ability to recapitulate the principles of open RPLND while using a less morbid access technique.

The reader should be cautioned regarding the advanced laparoscopic skills necessary to achieve the anatomically precise surgical results that are illustrated in the current atlas description. In the modern era of urologic laparoscopy, the number of centers that will likely possess the necessary laparoscopic surgical experience to undertake this operation are limited.

Several additional caveats regarding the surgical decision-making aspects of this operation should be noted. The currently available literature regarding the role of unilateral template-based surgery during primary RPLND for right-sided germ cell tumors is fraught with controversy. It is therefore advised that universal inclusion of the paraaortic dissection space be included in all RPLNDs performed for right-sided primary tumors. As the undissected left paraaortic space has been frequently implicated in the dreaded reoperative RPLND for local recurrence and due to the known lymphatic crossover rate from right-sided primary tumors, routine exposure and dissection of the left paraaortic space is advocated in all RPLND surgeries. In addition, the surgeon approaching laparoscopic RPLND with limited oncologic experience should be aware that the therapeutic role of this operation for pathologic stage IIa disease should not be underestimated and complete bilateral dissection for patients with low-volume stage IIa disease should not necessitate postoperative chemotherapy. Additionally the detection of involved lymph nodes during RPLND should not lead to diminished scope of surgical intervention but rather a complete bilateral RPLND in all patients. These facts are based on the extensive literature suggesting that adjuvant chemotherapy cannot eradicate teratoma from an uncontrolled retroperitoneum. Finally the issue of conversion to open RPLND during primary or even more commonly during postchemotherapy RPLND is discussed in the review. In this setting it is imperative that open conversion RPLND be performed by a surgeon with extensive experience in this version of the operation because there are significant variations in outcome based on surgeon experience.

The emerging role of primary laparoscopic RPLND has a significant opportunity to decrease short-term morbidity and the current operative description will serve as a useful benchmark for trainees as well as experienced surgeons attempting to increase their understanding of this operation. The future role of robotic-assisted laparoscopic interventions and the identification of optimal patient and surgeon selection factors will likely lead to an increased role of minimally invasive surgery in male germ cell tumor in the future.

This page intentionally left blank

Section XI

SURGICAL APPROACHES TO THE PELVIS

This page intentionally left blank

Chapter 62

Midline Lower Abdominal Peritoneal Incision

DAVID A. LEVY

The midline lower abdominal peritoneal incision provides exposure for the lower ureter, pelvic lymph nodes, bladder, and prostate.

Position: The patient is supine with the lumbosacral junction over a break in the table which can be flexed to extend the lower back to aid in exposure. Antiembolism devices should be considered.

Incision: A midline skin incision is carried out from the umbilicus down to the pubic symphysis with a scalpel (Fig. 62-1). Cautery is used to incise the subcutaneous fat down to the fascia of the abdominal wall for the full length of the skin incision while applying lateral traction to the incised skin edges. Any small bleeders are controlled with smooth forceps and cautery. The crossing fibers of the linea alba are identified in the midline.

In the obese patient, if identification of the linea alba is difficult, one can dissect the subcutaneous fat laterally off of the abdominal wall fascia for a centimeter or more, thus exposing the crossing fibers.

The linea alba is incised with cautery and the transversalis fascia is identified and incised (Fig. 62-2). Two fingers are placed through the transversalis fascial incision to protect underlying structures and the incision is extended cephalad to the reflection of the peritoneum and caudally to the symphysis pubis.

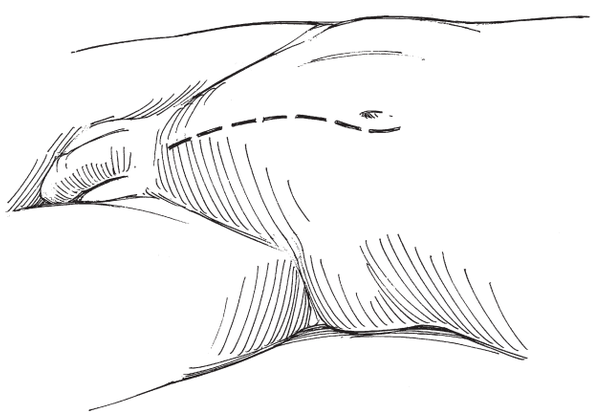

FIGURE 62-1.

Initial development of the space of Retzius is done with a manual maneuver using the index finger to develop a plane deep to the rectus muscle (Fig. 62-3). Once there is sufficient exposure, the dissection continues with the aid of Kintner dissectors and gentle manual countertraction using a moist laparotomy pad to fully develop the space of Retzius (Fig. 62-4). During this maneuver, it is helpful to have an assistant place a right-angle retractor on the incised edge of the abdominal wall to provide countertraction. Care should be taken to avoid placing traction on the inferior epigastric vessels or external iliac vein.

Once the space is developed, fixed tractor blades can be positioned at the inferior aspect of the incision, paying careful attention not to compress the external iliac vein. The Kintner dissector is used to sweep the perivesical fat and lymphatics laterally, toward the pelvic sidewall, thus gaining full exposure of the space of Retzius and the bladder. The endopelvic fascia can be identified and cleaned of any overlying fatty tissue and one can gain full exposure of the puboprostatic ligaments.

The origin of the inferior epigastric vessels can be identified where the external iliac artery passes under the inguinal ligament at which point it is renamed the femoral artery (Fig. 62-5). The external iliac vein and artery are also identifiable as is the obturator nerve lying deep to the external iliac vein. The lower portion of the ureter can be dissected below the level of the bifurcation of the iliac artery and followed to its intramural junction.

Closure: If the urinary system has been entered or a lymph node dissection done, place a Penrose or self-suction drain in the pelvis through a stab incision in the lower quadrant of the abdominal wall. If a self-suction drain is chosen, place it such that it is not in immediate contact with the suture closure of the urinary structure operated upon. The pelvis can be irrigated, the retractor removed, and the fascia closed with 0 synthetic absorbable sutures. The skin is closed based upon surgeon preference.

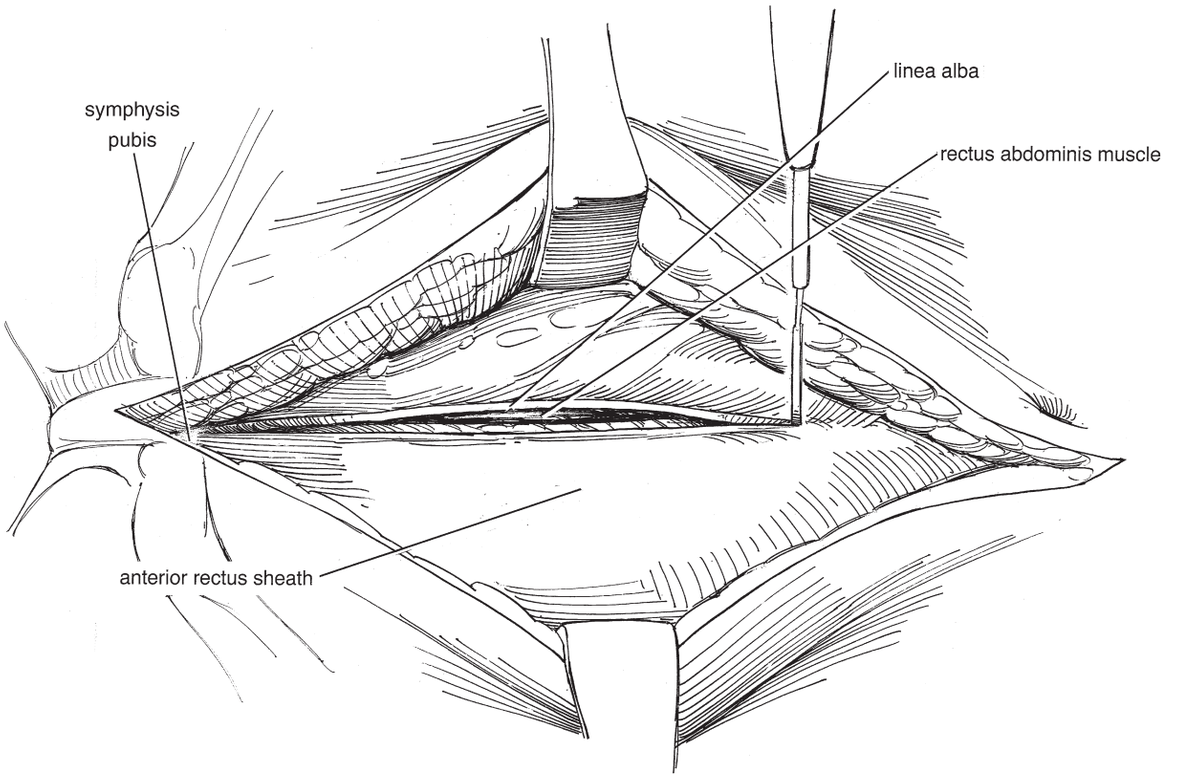

FIGURE 62-2.

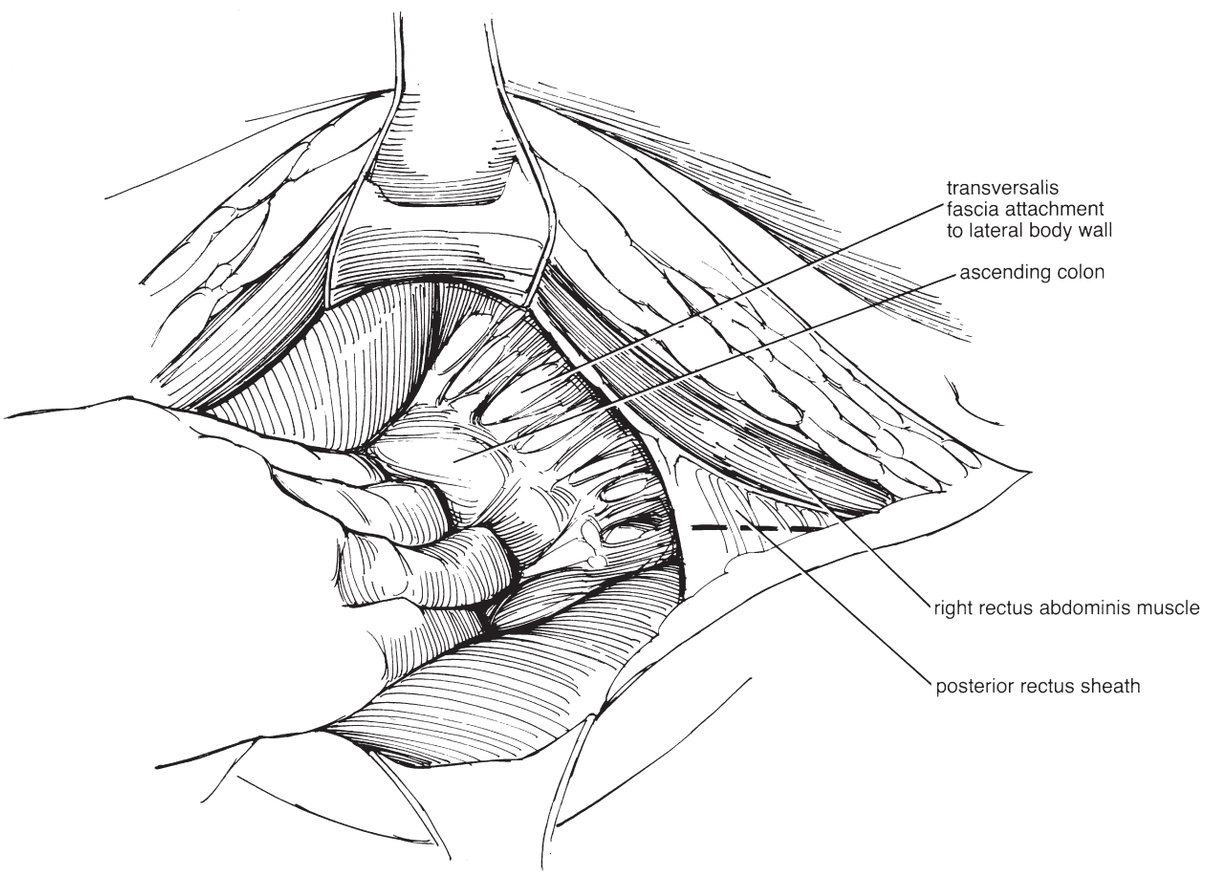

FIGURE 62-3.

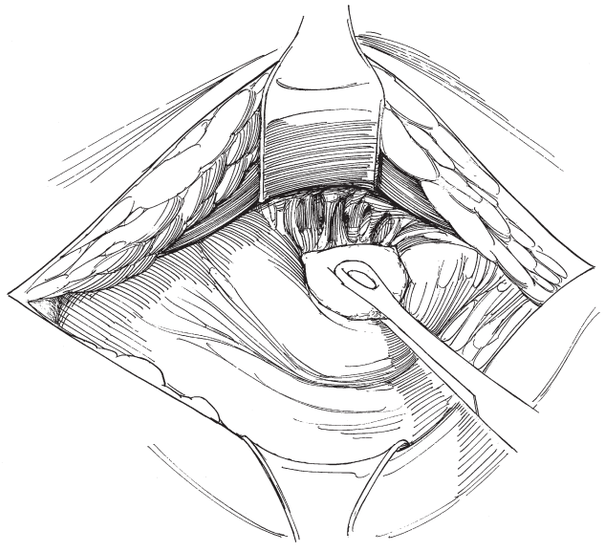

FIGURE 62-4.

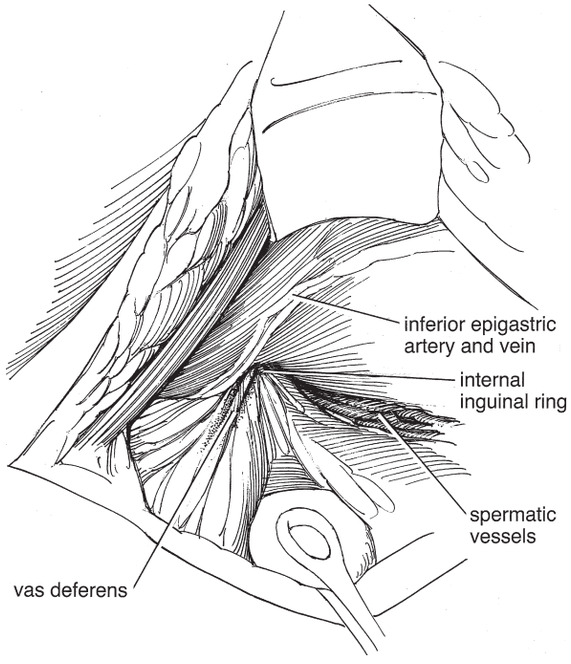

FIGURE 62-5.

This page intentionally left blank

Chapter 63

Transverse Lower Abdominal Incision

DAVID A. LEVY

A Pfannenstiel incision can provide excellent exposure of the pelvis for combined genitourinary/gynecologic procedures, as well as bladder, urethral, or ureteral surgery. An extraperitoneal as well as a transperitoneal approach can be made depending on the planned procedure.

The aponeuroses of the external and internal oblique muscles fuse to form the anterior rectus sheath (Fig. 63-1). The posterior covering of the rectus sheath below the level of the arcuate line is comprised of transversalis fascia. Vascular supply to the structures of the lower anterior abdominal wall is primarily from the external iliac vessels as they branch off of the external iliac vessels at the level of the inguinal ligament.

Position: The patient is supine with the lumbosacral junction over a brake in the operating room table. Alternatively, the buttocks are at the end of the table to allow for access to the perineum with the patient in dorsal lithotomy position. Positioning depends on the procedure. Regardless of the type of procedure, antiembolism devices on the lower extremities should be considered.

Incision: A Pfannenstiel incision is created with a scalpel, four finger breadths above the palpated pubic symphysis (Fig. 63-2). The lateral limits of the incision are generally the lateral borders of the rectus muscles. The incision is carried down to the fascia of the abdominal wall with electrocautery. Any small bleeders can be controlled with electrocautery at this time.

Extraperitoneal exposure of space of Retzius: The abdominal wall fascia is incised for the full width of the skin incision with a knife or electrocautery depending on surgeon preference. The underlying rectus muscle comes into view immediately (Fig. 63-3). If one seeks to gain access to the space of Retzius in an extraperitoneal manner without manipulation of the rectus muscle, one can incise the transversalis fascia with electrocautery where it attaches to the lateral borders of the rectus muscles. The inferior epigastric vessels immediately come into view and can be reflected laterally to avoid vascular injury. Blunt dissection medial to the inferior epigastric vessels will readily develop the space of Retzius in an avascular manner. This approach is particularly useful in pubovaginal sling procedures.

Alternatively, dissect the anterior rectus fascia off of the underlying rectus muscles, creating craniocaudad fascial flaps for full exposure of the infraumbilical portion of the rectus muscles (Fig. 63-4). The rectus muscles are separated in the midline with blunt dissection and the pyramidalis is divided with electrocautery (Fig. 63-5). The transversalis fascia is incised and a fixed ring retractor is placed for exposure. At this point, the peritoneum can be entered or retracted in a cephalad manner out of the pelvis with the aid of Kittner dissectors and sharp dissection at the level of the deep inguinal ring, thus exposing the spermatic cord structures, iliac vessels, lower ureters,

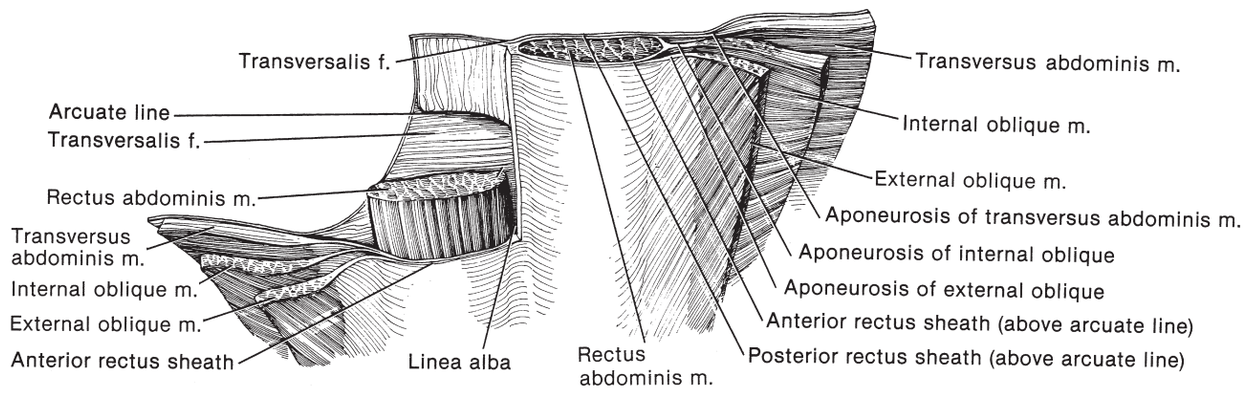

FIGURE 63-1.

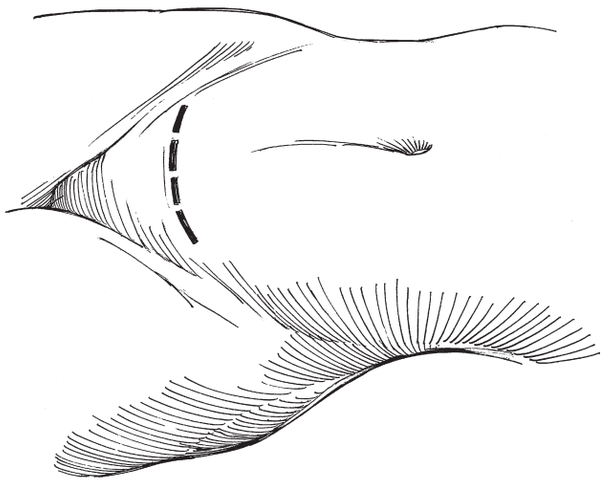

FIGURE 63-2.

pelvic lymph nodes and bladder. The procedure of choice can then commence.

Another approach is to dissect the rectus fascia off of the infraumbilical portion of the rectus muscle creating craniocaudad fascial flaps. Now divide the rectus muscles in a transverse manner with electrocautery (Fig. 63-6). Identify and control the inferior epigastric vessels coursing on the posterior aspect of the rectus muscles. Enter the transversalis fascia bluntly. If an intraperitoneal procedure is to be performed, elevate the peritoneum with smooth forceps and incise with Metzenbaum scissors. Retract the small bowel out of the pelvis and use a fixed ring retractor with well-padded retractor blades to gain constant exposure. Pay careful attention to avoid compressing the ureters or any vascular structures with the retractor blades. Expose the pelvic structures of interest and proceed. If an extraperitoneal procedure is to be done, then one can dissect and retract the peritoneum out of the pelvis in a cephalad manner, place well-padded fixed ring retractor blades, and proceed.

Closure: Close the peritoneum, if it was entered, with running 3-0 synthetic absorbable suture (SAS). Reapproximate the rectus muscle in the midline with interrupted figure-eight 2-0 SAS, or close the transverse rectus incision by incorporating the posterior sheath in the reapproximating suture closure. The anterior abdominal wall fascia is closed with a running nonbraded 0-SAS or 2-0 SAS suture. Scarpa's fascia is now reapproximated with interrupted SAS after copious irrigation of the subcutaneous tissues. The skin is closed with staples or subcuticular sutures, depending on surgeon preference.

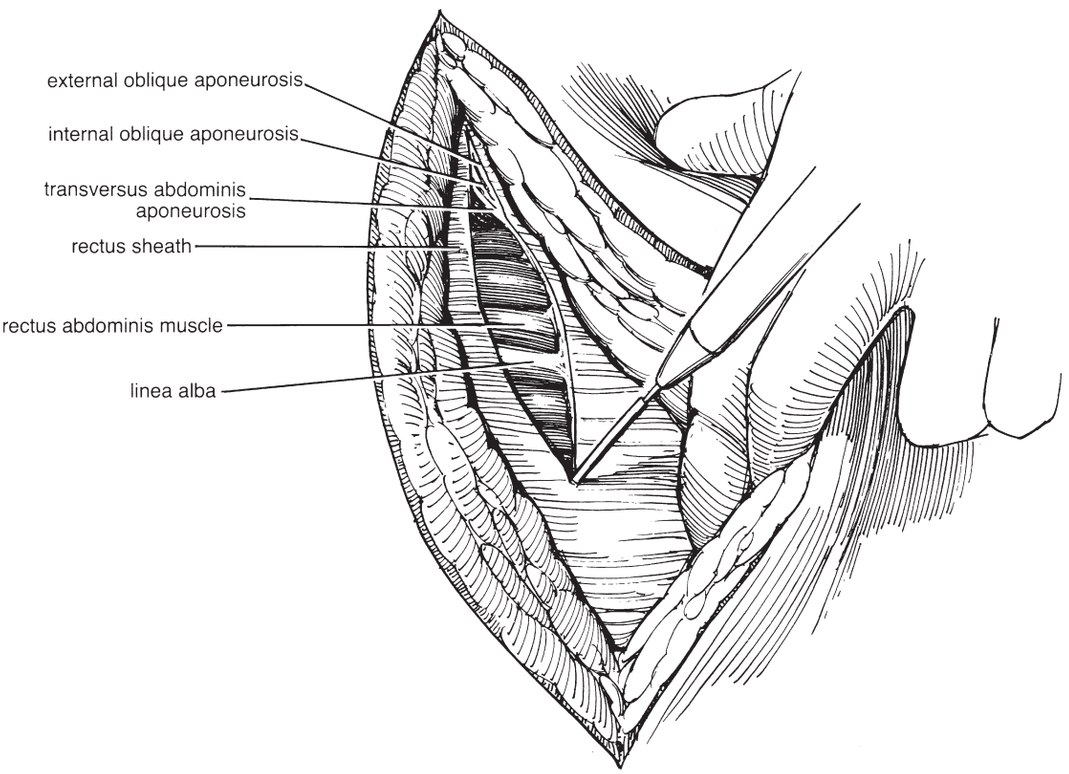

FIGURE 63-3.

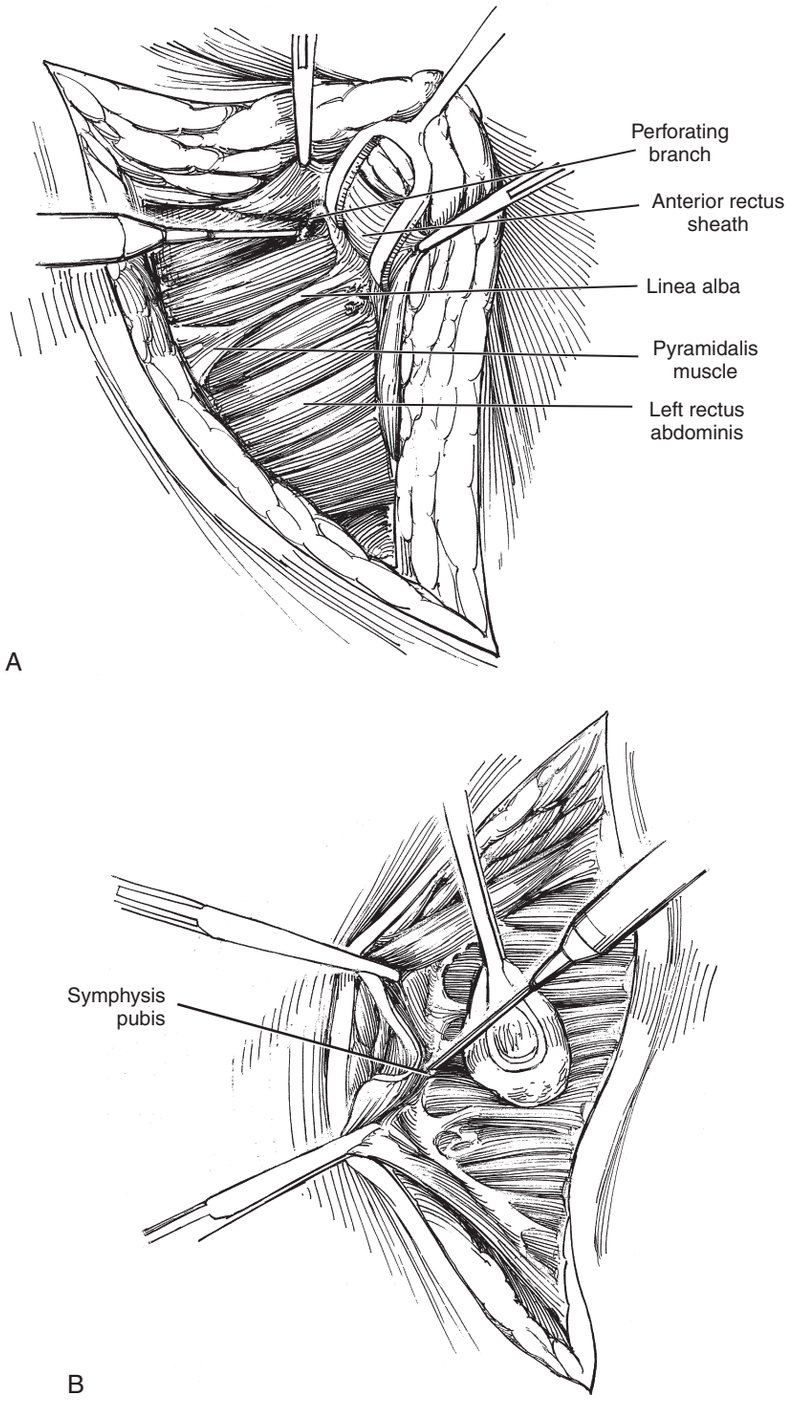
Perforating branch
Anterior rectus sheath
Linea alba
Pyramidalis muscle
Left rectus abdominis
A
Symphysis pubis
B

FIGURE 63-4.

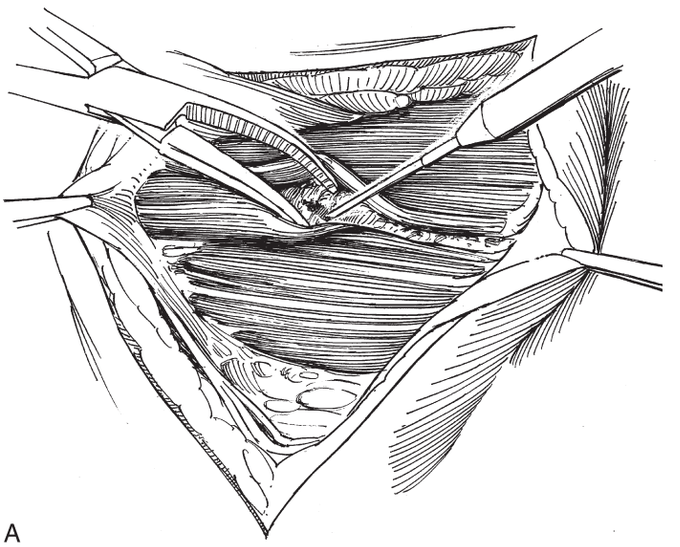

A

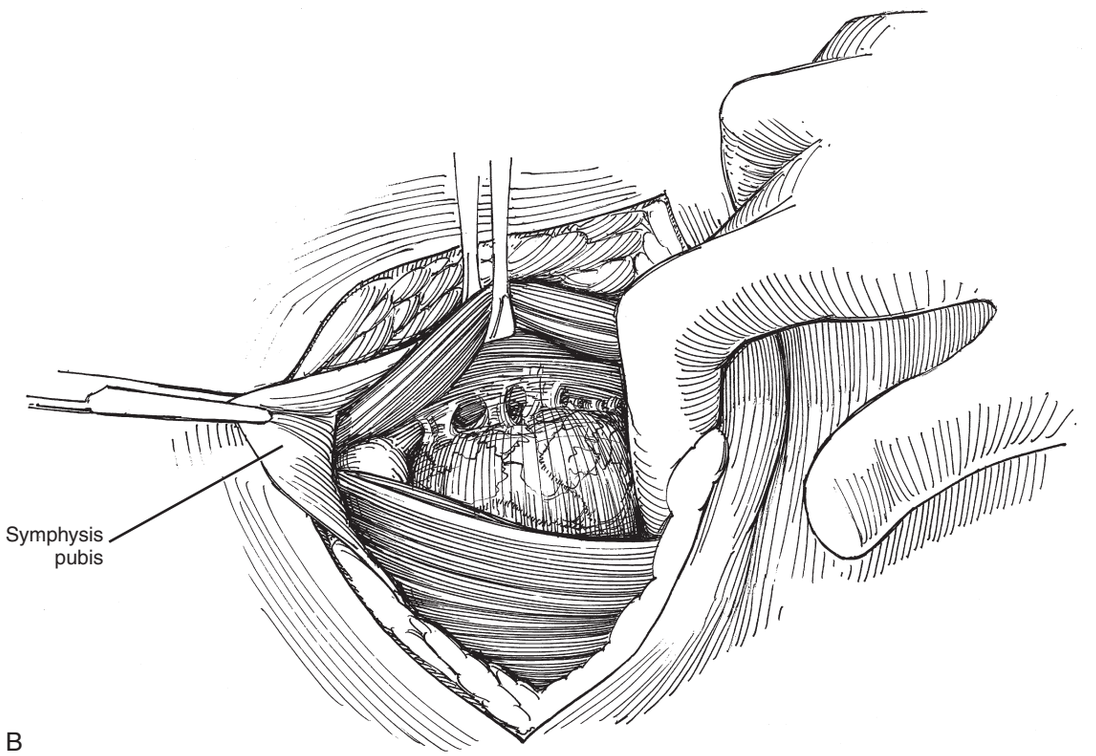

B

FIGURE 63-5.

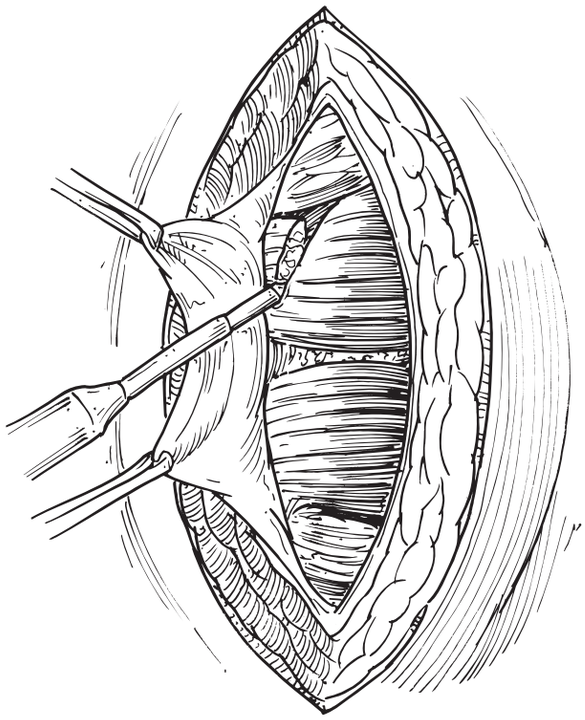

FIGURE 63-6.

This page intentionally left blank

Chapter 64

Gibson Incision

DAVID A. LEVY

The Gibson incision provides rapid exposure of the lower third of the ureter and is ideal for unilateral ureteral work when full exposure of the bladder is not necessary.

Position: The patient is supine with the lumbosacral junction over a break in the table. The table is flexed to provide additional exposure. Antiembolism devices should be considered.

Incision: A curvilinear incision starting 2 cm medial to the anterosuperior iliac spine and coursing inferomedially 1 fingerbreadth above the inguinal ligament to the lateral border of the rectus muscle is created with a knife (Fig. 64-1A). The incision is deepened to the fascia of the abdominal wall with electrocautery. Any small bleeders can be cauterized at this point.

The external oblique aponeurosis is exposed with retractors and then incised with a knife or cautery parallel to the course of the external oblique muscle fibers (see Fig. 64-1B).

The external oblique muscle fibers are split and retracted to expose the internal oblique aponeurosis, which is incised parallel to the course of the internal oblique muscle fibers. The internal oblique muscle is split to expose the aponeurosis of the transversus abdominis muscle. The transversus abdominis is opened with blunt dissection and retracted (Fig. 64-2). A fixed ring retractor can be placed for constant exposure. If additional exposure is needed then one can incise through the lateral border of the rectus muscle, or take the tendinous attachment of the rectus muscle off of the pubic symphysis.

Gentle dissection is carried out to reflect the peritoneum medially and thus expose the retroperitoneal structures. The inferior epigastric vessels may have to be sacrificed to allow for additional exposure. The peritoneum is sharply dissected off of the pelvic side wall at the level of the deep inguinal ring to allow for further medial retraction and exposure of the bifurcation of the iliac vessels and ureter as it courses over the iliac artery (Fig. 64-3).

The ureter is identified and gently dissected out of the retroperitoneum using a Kittner dissector and Jarrell forceps (Fig. 64-4). A vessel loop can be placed around the ureter to aid in retraction, thus preventing excessive tissue manipulation. The planned procedure can then commence.

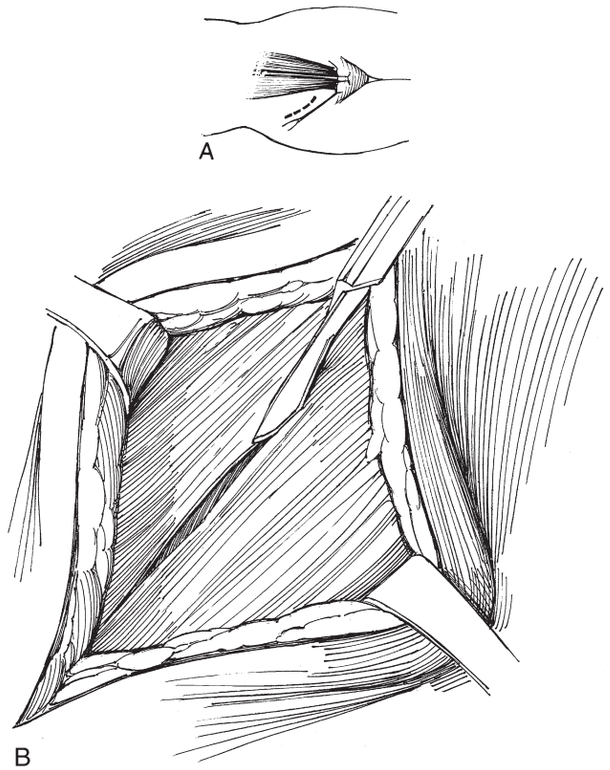

FIGURE 64-1.

Closure: If a ureteral suture line exists or an incision in the bladder was made, a drain is placed. Suction drains should not be placed adjacent to a suture line in the bladder or ureter because it may promote leakage from the closure. The retractor blades are removed and if the tendinous attachment of the rectus muscle was divided, it is reapproximated with 0 synthetic absorbable suture (SAS) or 2-0 SAS. The respective muscles of the abdominal wall are allowed to return to their normal positions and the individual aponeuroses are reapproximated with a running 2-0 SAS. Scarpa's fascia is reapproximated with 2-0 SAS and the wound is irrigated with antibiotic solution. The skin is closed.

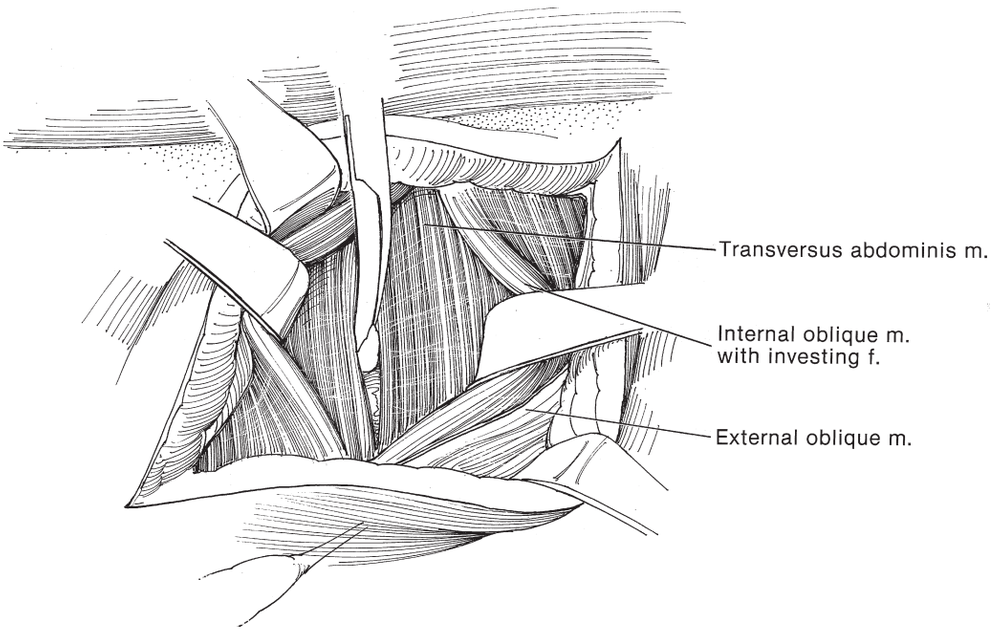

FIGURE 64-2.

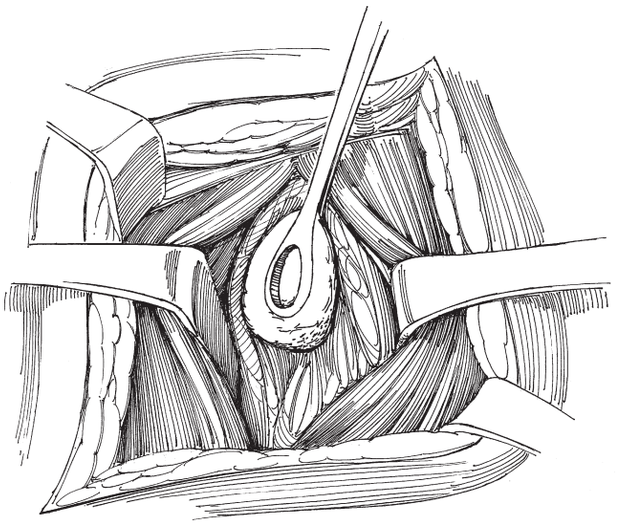

FIGURE 64-3.

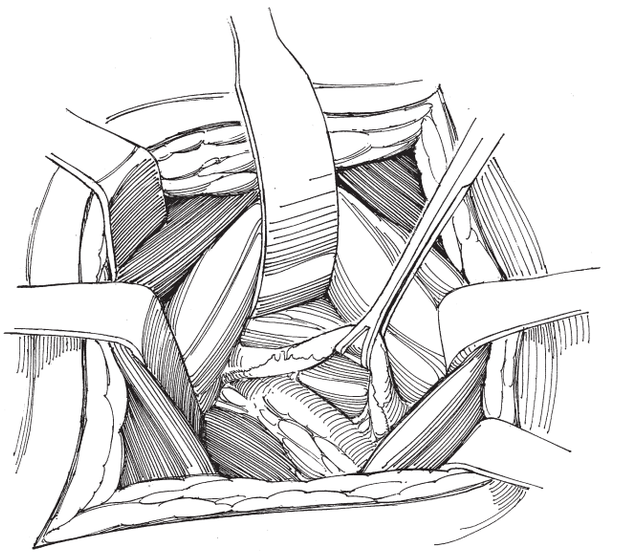

FIGURE 64-4.

Section XII

PROSTATE: MALIGNANCY

This page intentionally left blank

Chapter 65

Anatomy and Principles of Excision of the Prostate

MICHAEL S. COOKSON

SURGICAL APPROACHES

Radical prostatectomy remains a standard treatment option for men with localized prostate cancer. Even though this operation has developed over more than a century, it remains a technically challenging procedure. Thus technical refinements and innovative surgical approaches continue to evolve in an attempt to maximize cancer control while simultaneously reducing treatment-related side effects. In terms of open surgery, the prostate may be approached from either a retropubic or perineal direction. Currently, the open radical retropubic prostatectomy remains the most commonly performed surgical approach. This is due to a variety of reasons including familiarity with the anatomy, easy access to the pelvic lymph nodes, wide exposure to the pelvis, ability to identify and release the neurovascular bundles, and reduced risk of rectal injury.

The perineal approach, however, is also an important open technique that has potential advantages over the retropubic approach in experienced hands. Potential advantages of the perineal over a retropubic approach include a small, hidden incision, less blood loss, and excellent posterior and apical exposure to limit positive margins in these areas and facilitate the urethrovesical anastomosis. One definite disadvantage is the fact that lymph node dissection must be performed through a separate incision. When a pelvic lymph node dissection (PLND) is indicated, a laparoscopic or small open ("minlap") PLND can be performed before radical perineal prostatectomy.

Laparoscopic, particularly robotic-assisted laparoscopic radical prostatectomy, is another important surgical approach that has rapidly achieved equivalence and has surpassed open surgical approaches at many centers. Potential advantages of these minimally invasive approaches over traditional open surgery include smaller incisions that, in addition to improved cosmetic appearance, allow for a more rapid return to physical activity, significantly reduced blood loss, and enhanced optical magnification that could potentially result in improved functional outcomes. Most commonly, these procedures are performed from a transperitoneal approach with access anteriorly into the retropubic space, although it can be performed from a solely retropubic approach as well.

RELATIONSHIP TO ADJACENT STRUCTURES

Regardless of the surgical approach, a thorough understanding of the prostate anatomy and its relationship to surrounding structures is essential. The prostate gland is located in the true pelvis and is attached to the undersurface of the pubic symphysis by the puboprostatic ligaments (Fig. 65-1). Anteriorly, the puboprostatic ligaments are dense, fibrous connections that attach from the pubic bone to the prostate. They extend under the pubic bone and attach to the prostate and extend onto the urethra at the prostatourethral junction.

The apex of the prostate is intimately related to the urogenital diaphragm. The striated urethral sphincter surrounds the membranous urethral at the prostatic apex and forms a horseshoe-shaped muscular sleeve around it. On the lateral aspect of the prostate, the prostate is covered by the pelvic fascia and bordered by the levator ani muscle. The inner investing fascia of the levator ani fascia (endopelvic fascia) forms a fascial collar and is attached to the extraperitoneal connective tissue covering the prostate on its anterior and lateral aspects. Posteriorly, Denonvilliers' fascia is a thin layer of connective tissue that covers the prostate near the apex caudally and invests the seminal vesicles as it extends cranially.

At the apex, the prostate and membranous urethra are attached to the underlying rectum by the rectourethralis muscle, which extends laterally at the apex for a variable distance. The base of the prostate is intimately related to the bladder neck. The deepest portion of the trigone extends into the prostatic urethra. Consequently, the median lobe of the prostate may project into the bladder base and trigone. Posteriorly and cranially, the ampulla of the vas deferens and seminal vesicles are attached to the prostate base.

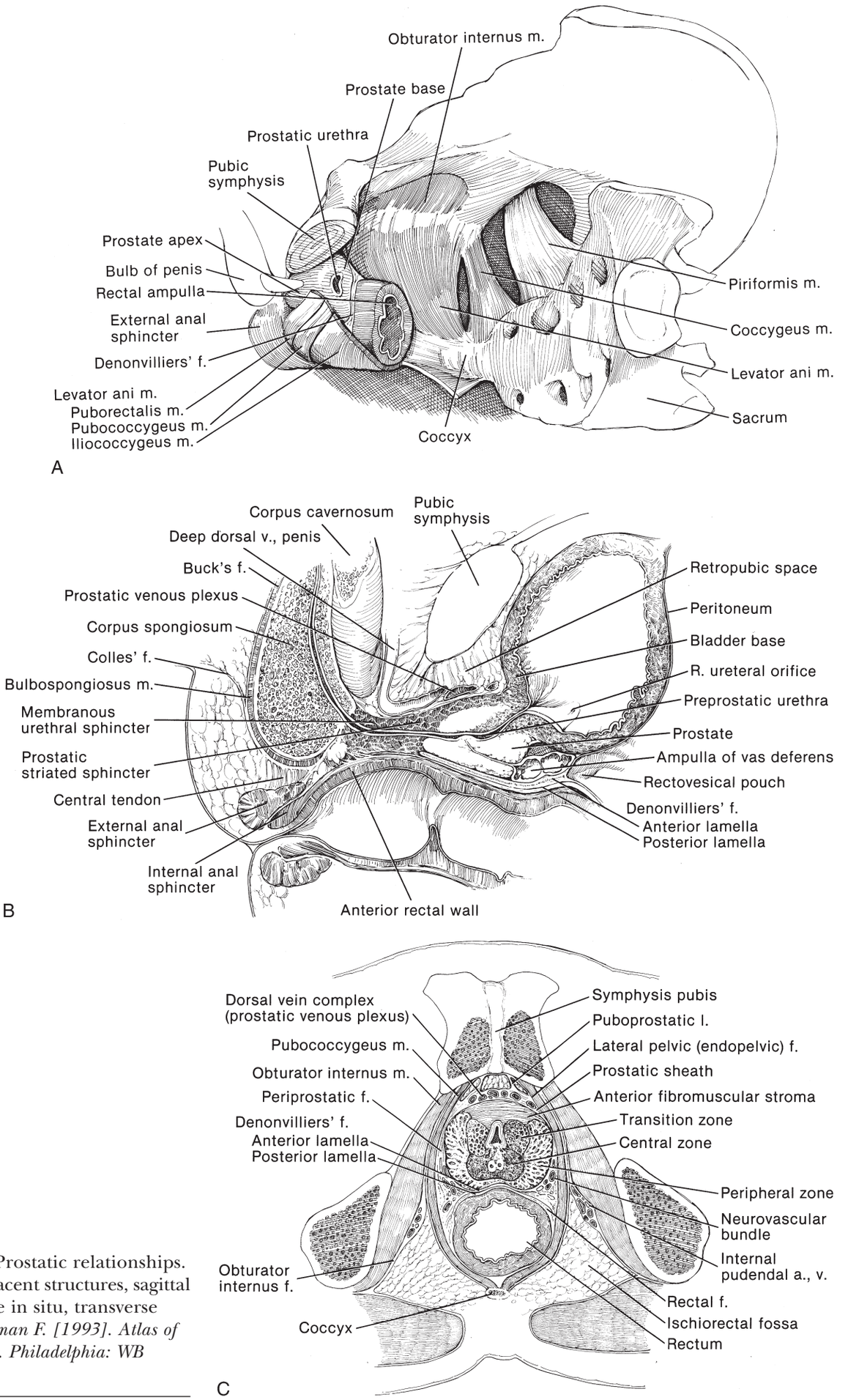

FIGURE 65-1. A, Prostatic relationships. **B,** Prostate and adjacent structures, sagittal section. **C,** Prostate in situ, transverse section. *(From Hinman F. [1993]. Atlas of urosurgical anatomy. Philadelphia: WB Saunders.)*

ARTERIAL BLOOD SUPPLY TO THE PROSTATE

The prostate receives its blood supply primarily from the prostatovesical artery (Fig. 65-2). Although this artery has a well-defined trunk, it may be of variable origin and most commonly is derived from the gluteopudendal. The prostatovesicular artery passes obliquely downward, forward, and medially along the anteroinferior surface of the bladder toward the prostate.

The pudendal artery and accessory pudendal branches may be encountered during radical retropubic prostatectomy. The pudendal artery arises variably from the inferior vesicular, superior vesicular, and obturator arteries. The main pudendal artery or aberrant branches may travel along the lateral portion of the bladder and course anterior and laterally in close proximity to the prostatic capsule. Historically, these were divided to facilitate exposure during radical prostatectomy, but it is now recognized that they may be of functional importance with respect to erectile function as they supply branches the corpus cavernosa. Accordingly, these branches should be preserved if possible during performance of radical prostatectomy.

VENOUS DRAINAGE OF THE PROSTATE

Radical prostatectomy is an operation that can be associated with significant blood loss, the majority of which is attributed directly to venous bleeding at the time of surgery from the large, dorsal venous complex which courses anteriorly over the prostate. The venous drainage of the prostate is derived mainly from lateral capsular vessels, and to a lesser extent several anteroinferior veins and veins of the vas deferens (Fig. 65-3). The capsular veins of the prostate drain directly into this previously mentioned dorsal venous complex, also known as the Santorini plexus.

The deep dorsal vein of the penis penetrates the urogenital diaphragm, dividing into three major branches: the

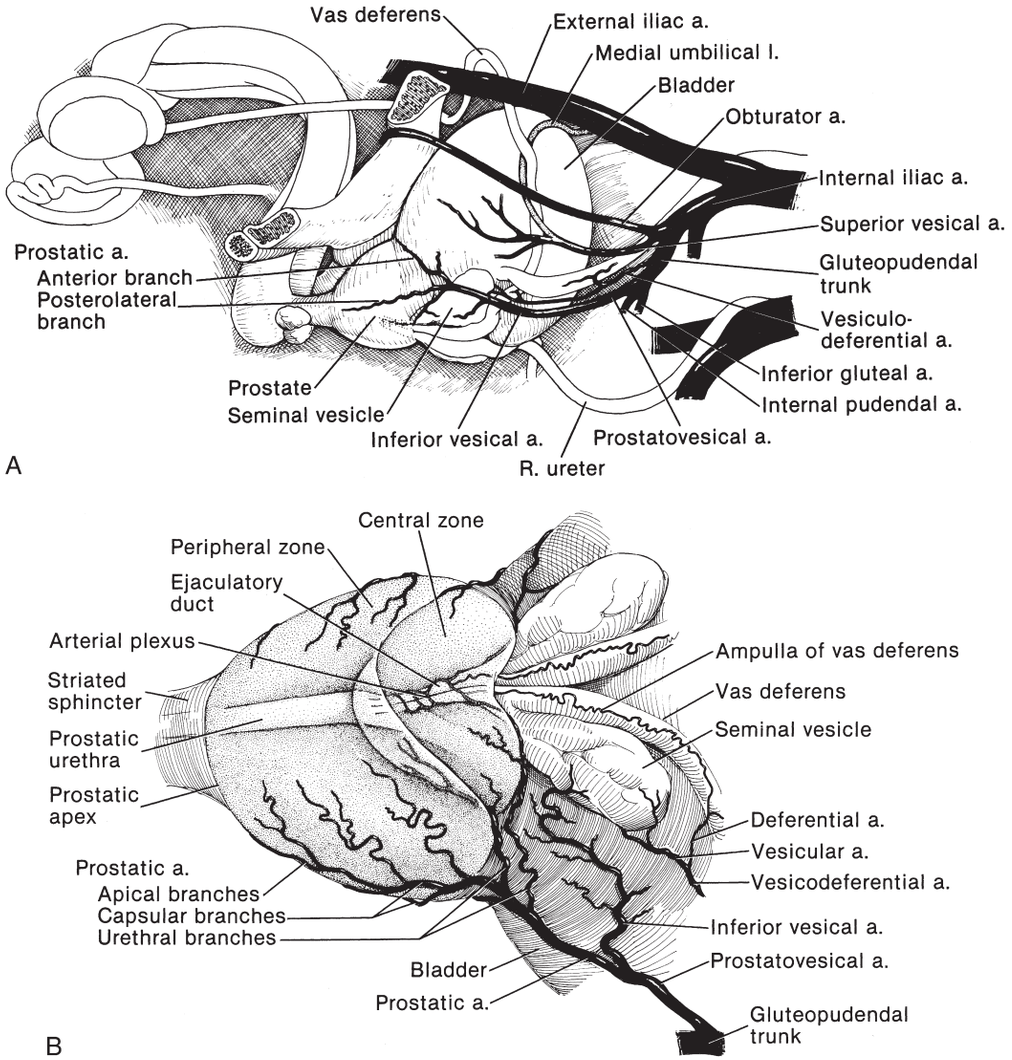

FIGURE 65-2. A, Arterial supply of the prostate, seminal vesicles, and vasa. **B,** Distribution of blood to the prostate, posterior view. *(From Hinman F. [1993]. Atlas of urosurgical anatomy. Philadelphia: WB Saunders.)*

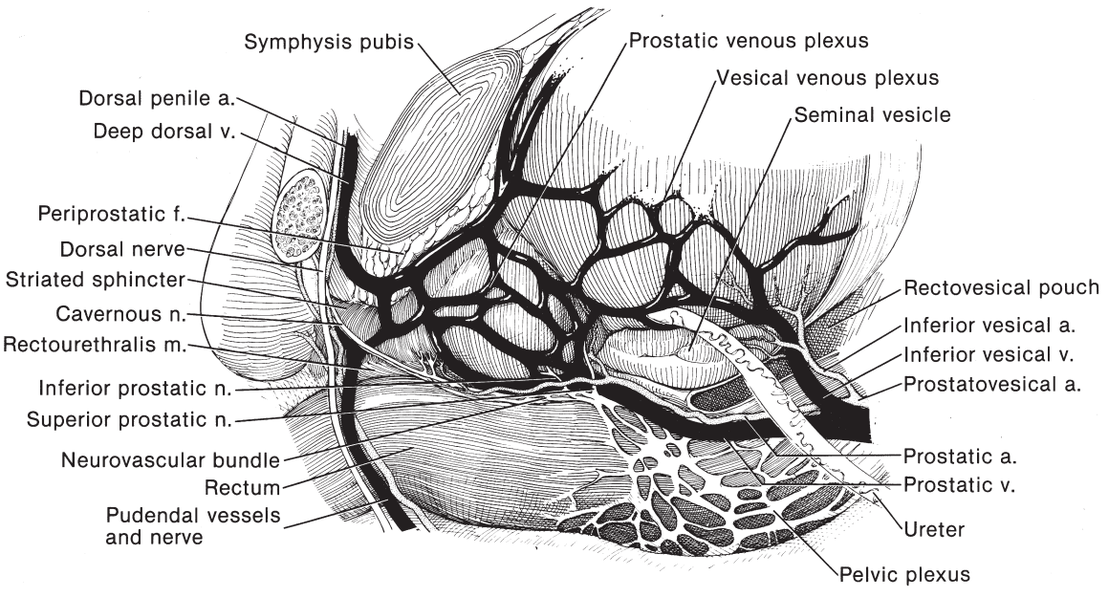

FIGURE 65-3. Venous drainage of the prostate. *(From Hinman F. [1993]. Atlas of urosurgical anatomy. Philadelphia: WB Saunders.)*

superficial branch and the right and left lateral branches. The superficial branch is centrally located over the bladder neck and urethra, and travels between the puboprostatic ligaments outside of the prostatic fascia. This is usually divided separately from the underlying lateral branches of the dorsal venous complex. The main dorsal veins and the lateral branches are seen under the lateral prostatic fascia and endopelvic fascia. In the deep pelvis in close proximity to the puboprostatic ligaments, the lateral branches of the dorsal venous complex may give off several small tributaries that penetrate into the pudendal venous drainage and pierce the pelvic sidewall. The lateral branches continue posterolaterally and may drain into the pudendal, obturator, and inferior vesicular plexus. In addition, there is thought to be valveless venous connection between the prostatic plexus and the extradural venous plexus, the Batson plexus, which is thought to be involved in the direct hematogenous spread of prostate cancer.

LYMPHATIC DRAINAGE

The lymphatic drainage of the prostate begins at the level of the prostatic acini, where they form slightly larger lymphatic channels (Fig. 65-4). These lymphatic channels travel to the level of the prostatic capsule where they join to form the periprostatic plexus. From this plexus, the lymphatic channels unite and follow the drainage path of major, named vascular channels. Lymphatic drainage from the superolateral prostate flows into the inferior vesicular and the internal iliac channels. There is also posterior drainage from the presacral lymphatics and from the posterior surface of the prostate to the internal iliac and external iliac nodes.

INNERVATION

The innervation of the prostate is derived from both sympathetic and parasympathetic origin and combine to form the pelvic plexus (Fig. 65-5). The sympathetic fibers are derived from the hypogastric plexus originating between T10 and L2 spinal segments, while the parasympathetic nerve fibers arise between S2 to S4. Thus the innervation of the prostate is of dual origin. The nerve fibers travel with the blood vessels and are contained within the extraperitoneal connective tissue. Both sympathetic and parasympathetic nerve fibers are concentrated in the smooth muscle around the prostatic ducts and acini.

Pelvic Fascia

In approaching the prostate from a retropubic technique, the endopelvic fascia is encountered as it courses anteriorly over the bladder and prostate and extends to the pelvic sidewall. It is believed to represent the inner investing fascia of the levator ani and contains two distinct layers. By opening this fascia layer, the pelvic sidewall and levator ani muscles are revealed (Fig. 65-6). The prostate is covered by three distinct and separate fascial layers: Denonvilliers' fascia, the prostatic fascia, and the levator fascia. Denonvilliers' fascia is a two-layered sheet of fibrous connective tissue located between the anterior rectum and the prostate. This layer extends superiorly to cover the seminal vesicles and ampulla of the vas deferens where it is thickest, and extends caudally to terminate at the urethral sphincter where it is the thinnest.

The lateral pelvic fascia, consisting of the levator fascia and the prostatic fascia, is intimately associated with the prostate. The prostatic fascia is directly connected to the

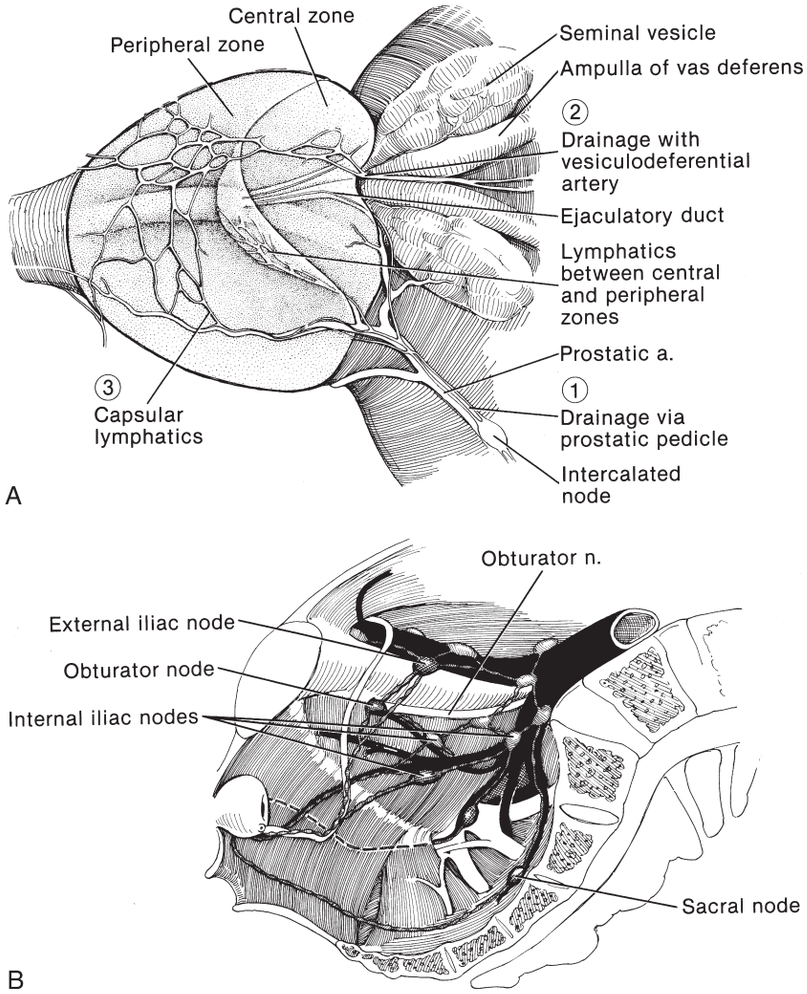

FIGURE 65-4. A, Lymphatic drainage from the prostate. **B,** Regional lymph nodes. *(From Hinman F. [1993]. Atlas of urosurgical anatomy. Philadelphia: WB Saunders.)*

prostate on the anterior and anterolateral surface. The dorsal venous complex and its branches travel within the anterior prostatic fascia. In the performance of a perineal prostatectomy, the anterior and pelvic fascia is dissected off of the prostate and if successful there is significantly reduced bleeding compared with bleeding in the retropubic approach.

The levator fascia fuses with the prostatic fascia laterally to form the lateral pelvic fascia. As it travels posterolaterally, the levator fascia becomes distinct from the prostate and courses along the musculature immediately adjacent to the rectum. An understanding of these fascial layers is an extremely important point as the vascular and autonomic innervation of the prostate travel between the prostatic and levator fascia.

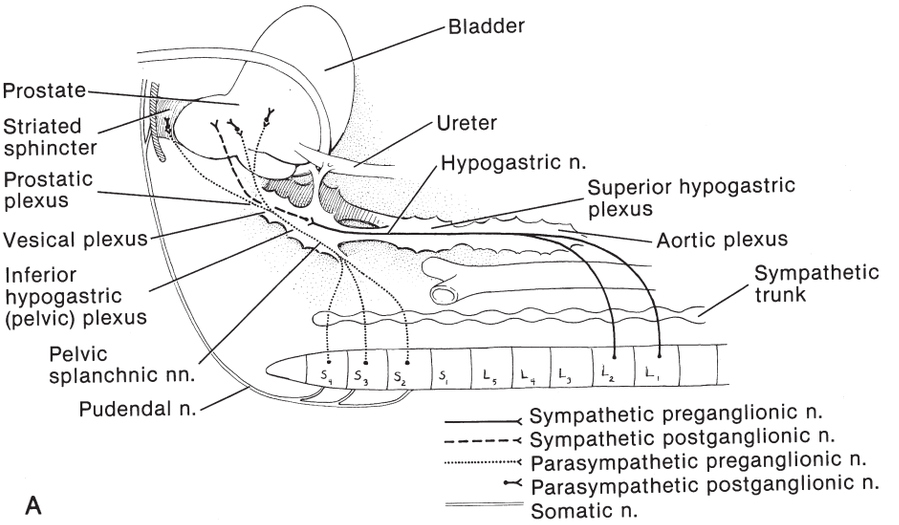

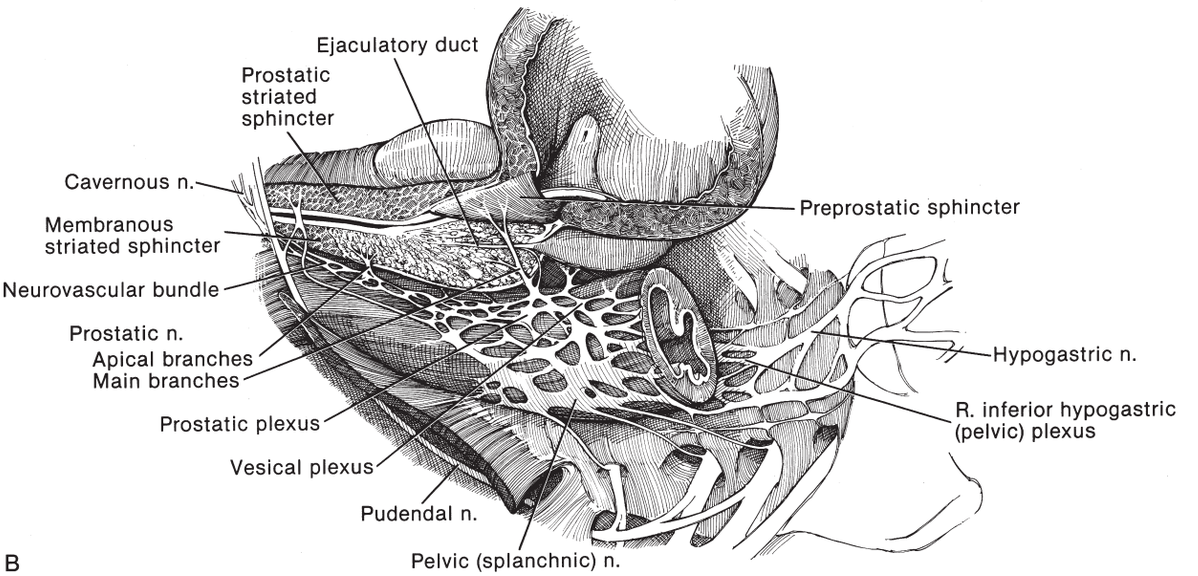

FIGURE 65-5. Innervation of the prostate. *(From Hinman F. [1993]. Atlas of urosurgical anatomy. Philadelphia: WB Saunders.)*

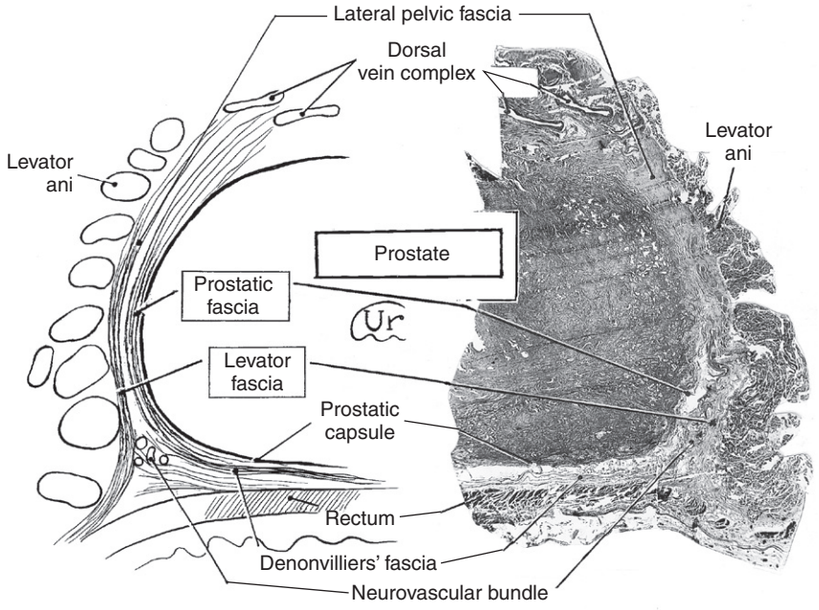

FIGURE 65-6. *(© Copyright 1996, Brady Urological Institute.)*

Commentary by

MICHAEL O. KOCH

The author of this chapter reviews the pertinent anatomy to the prostate gland. An adequate understanding of the anatomic relationships is perhaps more important in prostate surgery than in any other genitourinary malignancy. There is no other tumor that urologists treat that has such a small margin for error when a surgeon is trying to achieve an outcome of complete tumor removal while maintaining normal functions. A thorough understanding of the fascial relationships that surround the prostate and neurovascular bundles, the anatomy of the apex of the prostate, and the relationship of the prostate to the rectum and bladder are vital to achieving an optimal outcome. The reader will be will served by studying this chapter carefully to fully acquaint themselves with the anatomy of the prostate, which is pertinent to successful prostatectomy.

This page intentionally left blank

Chapter 66

Radical Retropubic Prostatectomy

MICHAEL S. COOKSON

Instruments: Include a basic set, GU long and GU vascular sets, prostatectomy specials including a McDougal clamp, medium and large clip appliers, long forceps, Russian forceps, long Allis and Babcock clamps including one with a 45-degree angled end, long Metzenbaum scissors and long needle holders. In addition, it is helpful to have available a 24-French Roth Greenwald suture guide, two Yankauer suctions, including one pediatric suction tip, a hand-controlled electrosurgery unit, 18-French Foley catheter with a 5-mL balloon, water-soluble lubricant, and a 15-mm rounded or 10-flat Jackson-Pratt drain. A Bookwalter retractor is useful for facilitating exposure and in most circumstances the entire operation can be performed using only four Richardson 1.5-inch retractor blades. The lower two blades are used to retract the body wall and the upper two blades are useful for retracting both the superior body wall and allowing for cephalad retraction of the bladder and peritoneum. In obese patients, the upper two blades may need to be longer (2.5 inches deep). A malleable blade or ribbon may be useful for retracting the bladder medially during the pelvic lymph node dissection. Vision in the pelvis is aided by the use of 2.5 power loupes head lamps that may be worn by both the surgeon and the first assistant.

Position: Place the patient in the supine position with his pubis centered over the break in the table (Fig. 66-1). Next, slightly hyperextend the patient by raising the kidney rest and reflexing or breaking the table, placing the patient in an approximately 20-degree Trendelenburg position to elevate the pelvis and facilitate exposure. Alternatively, when there is concern with regard to accessing the perineum or rectum, the legs may be spread and supported on spreader bars. In the latter position, place the perineum at the edge of the table to allow an assistant access for applying compression during urethral anastomosis or inspecting the rectum. A sterile preparation is performed of the abdomen, pelvis, and genitalia, and the drapes are placed. Empty the bladder with a 16-French Foley catheter and inflate the balloon; leave it in place for later manipulation of the prostatic apex.

Incision: A vertical midline incision is made extending from just above the symphysis to approximately halfway below the umbilicus. In general, excellent exposure is achieved through an incision that is only 6 to 8 cm (Fig. 66-2). Split the rectus muscles in the midline. Lift the semilunar line, and dissect the peritoneum and fascia off the posterior abdominal wall and remain in the extraperitoneal space. Be sure to carry the dissection beneath the transversalis fascia to avoid injury to the inferior epigastric vessels.

Exposure: Lift up the rectus abdominis gently with a handheld Richardson retractor while sweeping the bladder and lateral edge of the prostatic fascia medially with a sponge stick to expose the space of Retzius. Free the peritoneum from the internal inguinal rings. Sweep the spermatic cord cephalad to expose the lateral edge of the external iliac artery. This creates a pocket that allows for the spermatic

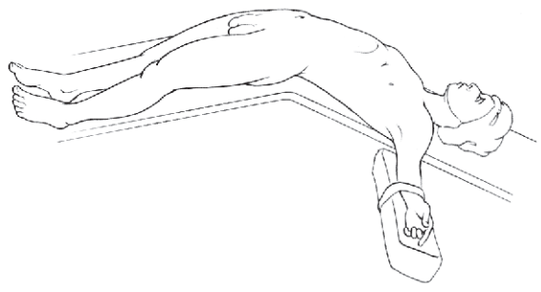

FIGURE 66-1.

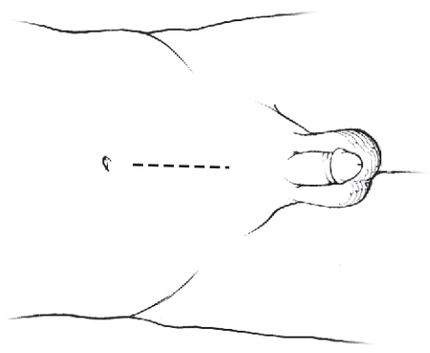

FIGURE 66-2.

cord and peritoneum to be retracted cephalad without risk of injury to the iliac vessels or genitofemoral nerve.

Retractor placement: Insert a self-retaining Bookwalter retractor. Before securing the oval ring to the fixed bar, ensure that it is properly positioned to allow for cephalad exposure and to allow for enough room for placement of a Roth Greenwald suture guide. Generally, the upper edge of the oval ring is 1 to 2 inches above the umbilicus. Next, place four right-angled Richardson blades to allow for lateral sidewall and cephalad bladder retraction. The two lower retractor blades are used to separate the rectus muscles while the two upper blades not only separate the rectus muscles but also facilitate exposure by applying traction to the lateral edges of the bladder and peritoneum cephalad. In obese patients, the two cephalad retractor blades may need to be deeper to allow for adequate exposure. Of note, if placed correctly at the beginning of the operation these four retractor blades will not require adjusting during the surgery.

Pelvic node dissection: If indicated, proceed with pelvic lymph node dissection, tailoring the extent of the dissection (modified vs. extended) based on clinical risk factors.

Endopelvic fascia: Gently tease the retropubic fat from the anterior and lateral prostatic surface. In the midline, the superficial branch of the dorsal venous complex will be identified within this fat and should be either cauterized or tied depending on its size. This allows for direct visualization of the lateral prostatic fascia and puboprostatic ligaments. Open the endopelvic fascia near the pelvic sidewall on both sides of the prostate with cautery or scissors (Fig. 66-3). Before incising the endopelvic fascia, it is best to place it on gentle stretch so that the fascia is taut when initially incised to avoid bleeding from any underlying blood vessels in the lateral pelvic sidewall and the medial prostatic fascia. Keeping away from the fascial attachment to the prostate and bladder avoids potentially significant bleeding from the large venous tributaries of the lateral aspect of Santorini's plexus. The incision in the endopelvic fascia is then extended medially to the level of the puboprostatic ligaments. Once the space has been opened, further develop it close to the bellies of the levator ani muscles and well lateral to the apex of the prostate by blunt dissection with either a finger or a Kittner sponge.

Incising the puboprostatic ligaments: Once the endopelvic fascia has been incised to level of the puboprostatic ligaments, a sponge stick can be used to place gentle downward traction on the prostate to distract it away from the undersurface of the pubic bone. Care must be taken to dissect free any small tributaries of the dorsal venous complex before dividing the puboprostatic ligaments. If the branches are intimately associated with the puboprostatic ligaments, they should be directly grasped with fine tissue forceps and

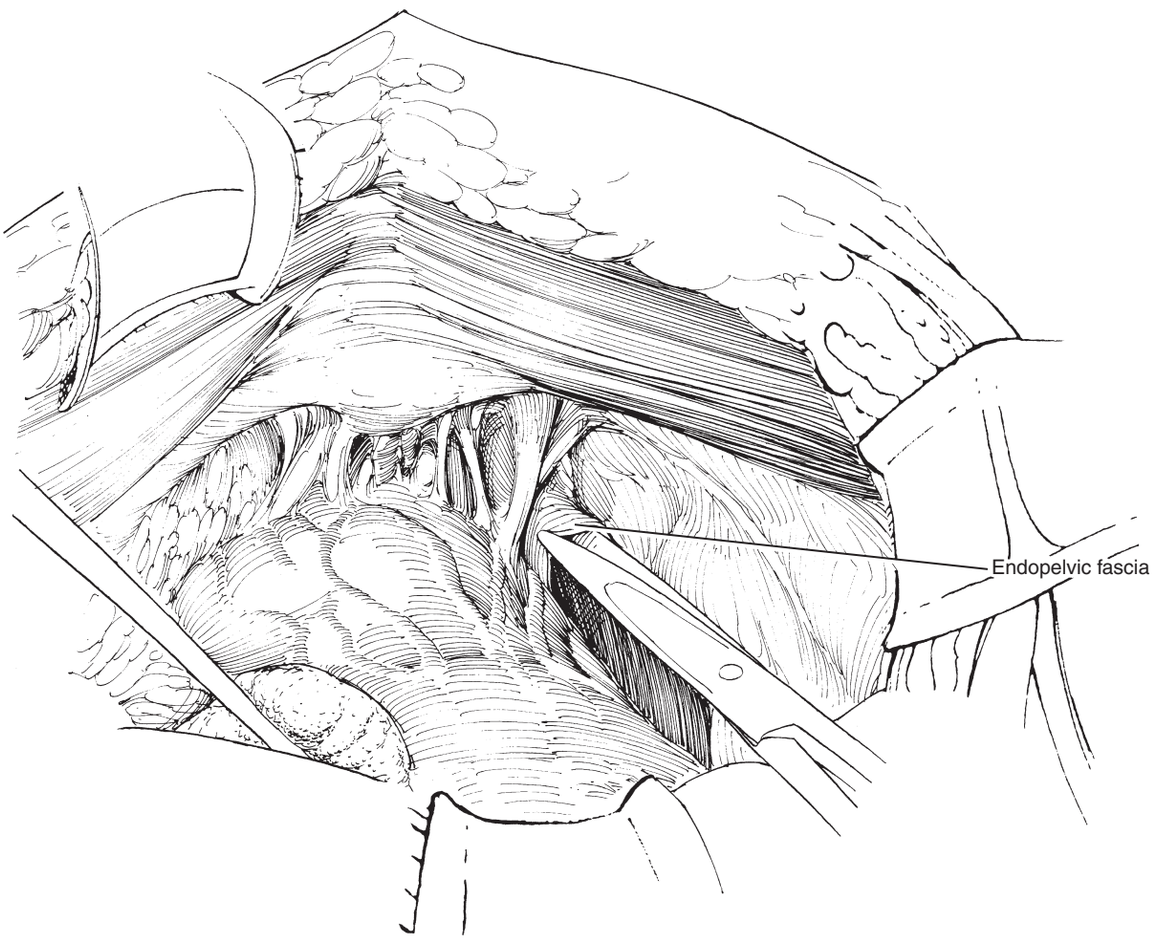

FIGURE 66-3.

cauterized. The puboprostatic ligaments are then partially transected with Metzenbaum scissors to allow for visualization of the prostatic apex (Fig. 66-4). Once the junction of the prostatic apex and urethra is visualized and the overlying dorsal venous complex can be visualized, division of the puboprostatic ligament is discontinued. Thus the puboure-thral extensions of the puboprostatic ligaments are left in place for structural support of the membranous urethra and striated urethral sphincter.

Bunching of the dorsal venous complex: To reduce bleeding during the division of the dorsal venous complex as well as to facilitate ligation of the complex as it courses over the prostatic apex, the dorsal venous complex may be gathered or "bunched" by grasping the dorsal venous complex as it courses over the junction between the bladder neck and prostatic base with a long Allis or Babcock clamp (Fig. 66-5). Care must be taken when grasping this complex both proximally and distally to avoid including the posterolateral tissue containing the lateral prostatic fascia and the neurovascular bundles. Place a figure-eight bunching suture of 1-0 Vicryl on a CT-1 needle on the dorsal venous complex as it courses under the clamp. Follow the dorsal venous

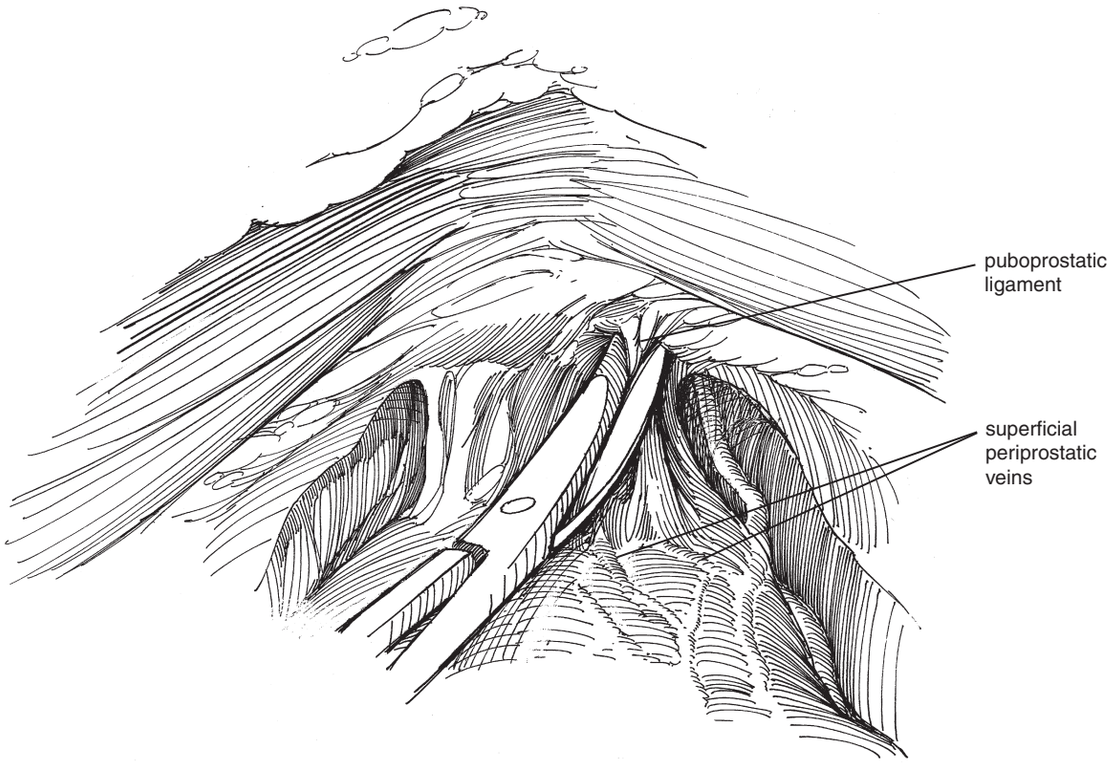

FIGURE 66-4.

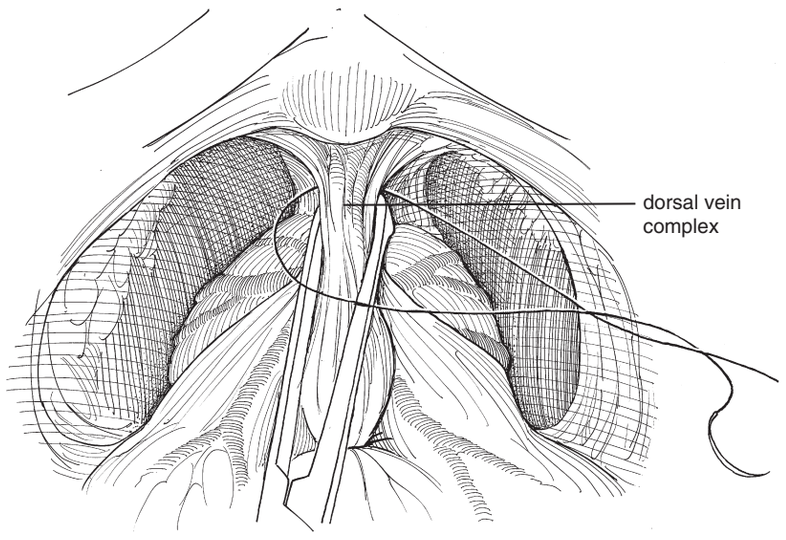

FIGURE 66-5.

complex distally as it courses over the prostatic urethral apex. Next, using a curved Allis to accommodate the angle of the pubic bone, the dorsal venous complex as it courses proximally over the urethra just distal to the prostatic urethral apex is grasped under the pubic bone. Using a sponge stick to gently retract the prostate away from the lateral pelvic sidewall, 1-0 Vicryl on a CT-1 needle is used to ligate the dorsal venous complex with either interrupted or figure-eight sutures.

Division of the dorsal venous complex: Divide the dorsal venous complex over the prostatic apex between the last bunching stitch on the proximal dorsal venous complex and the distal figure-eight dorsal venous complex stitch. This can be divided sharply with scissors or with the use of a Bovie electrocautery. Alternatively, before dividing the dorsal venous complex, a McDougall clamp may be insinuated between the undersurface of the dorsal venous complex and the anterior urethra and spread gently. The venous complex can then be divided. However, if bleeding ensues, pass a 1-0 Vicryl suture and secure the distal dorsal venous complex with an additional figure-eight suture before dividing the dorsal venous complex. If bleeding persists after dividing the dorsal vein, secure it with 2-0 Vicryl using a figure-eight stitch against the pubis, or secure it with the suture. Do not proceed with the apical prostatic dissection until hemostasis has been secured.

Apical prostatic dissection: Direct visualization of the prostatic apical dissection is critical to both cancer control and good functional outcomes. This is best accomplished with the use of optical magnification, use of a headlight, and maintenance of excellent hemostasis. Once the dorsal venous complex has been divided, the prostatic apex should be directly visualized with the use of some gentle cephalad retraction with a sponge stick and placement of the patient in reverse Trendelenburg position (Fig. 66-6A). Dissect closely around the urethra just below the apex of the prostate (see Fig. 66-6B). The lateral extensions of the striated musculature should be cut to allow for optimal apical exposure. Care

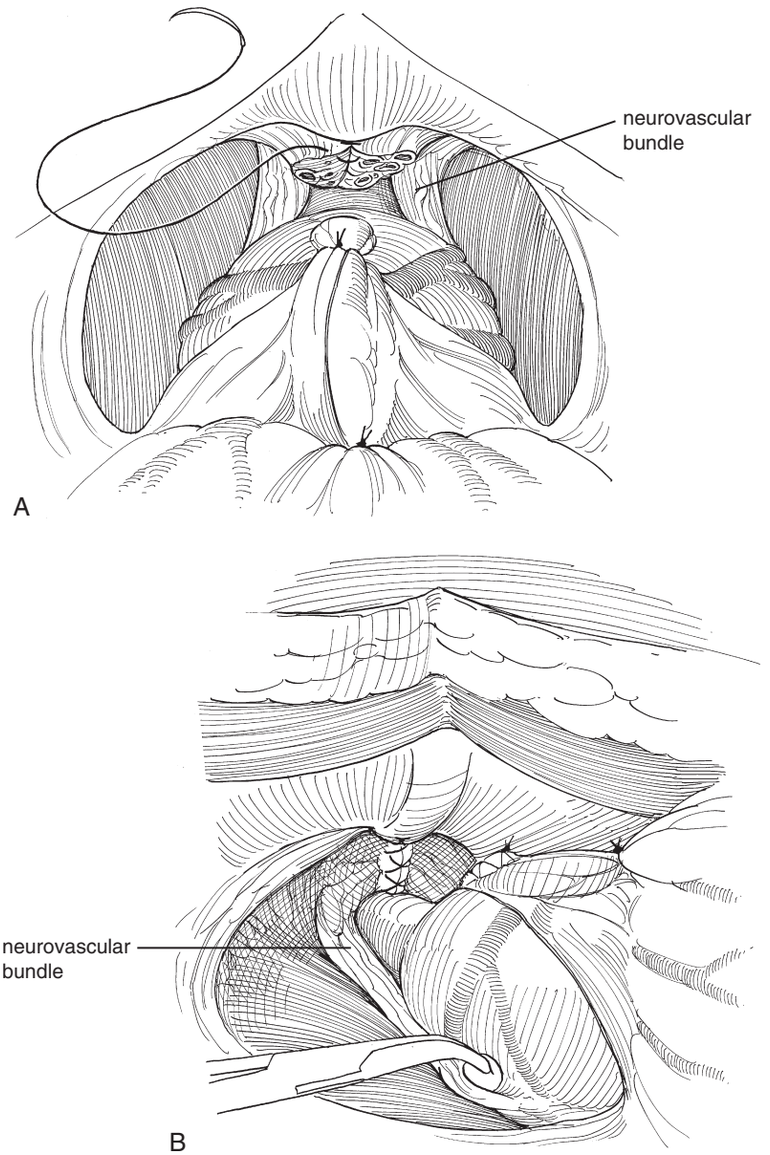

FIGURE 66-6.

should be given to avoiding damage to neurovascular bundles through inadvertent traction or thermal injury due to cautery. At this point, some authors advocate separating the neurovascular bundles, located posterolateral, from the urethra and prostatic apex. Use scissors then a right-angle clamp to push them off the surface of the prostate. Alternatively, the neurovascular bundles can be released after division of the urethra.

Division of the anterior urethra: Under direct vision, the anterior urethra is cut sharply, with care taken to preserve as much length on the striated urethral sphincter as possible. Cut the urethra obliquely with either Metzenbaum scissors or a #15 blade on a long handle because the apex of the prostate extends more distally on the lateral and posterior aspects of the urethra. Leave the posterior urethra intact to avoid retraction of the urethral stump. Grasp the now visible urethral Foley catheter and gently traction it cephalad. After clamping the Foley with a Kelly clamp, cut the Foley catheter in front of the urethral meatus and after lubricating it pull the now distal end through the urethra into the operative field and traction it gently cephalad. Great care should be taken to avoid aggressive pulling on the catheter that could result in damage to either the bladder neck or neurovascular bundles. Some surgeons prefer to transect the entire urethra at this point and will defer placement of the urethral stitches until after the radical prostatectomy has been completed.

Placement of the urethral sutures: After cutting the anterior two thirds of the urethral, the distal urethral anastomotic sutures may be placed. The advantage of placing the urethral stitches at this point is to take advantage of the fact that with the posterior urethral still intact the proximal urethra is easily visualized. To facilitate the anastomosis, a Roth Greenwald suture guide can be passed into the urethra. Alternatively, a urethral catheter can be used to help accentuate the urethral mucosa. Next, place five sutures of 2-0 Vicryl or 3-0 Monocryl on a curved UR-6 needle at the 12-, 2-, 5-, 7-, and 10-o'clock positions in the distal urethral stump and hold them in place with rubber-shod clamps. The urethral sutures are placed to allow for the final knots to be secured on the outside, so the 7- and 10-o'clock stitches are placed from outside to inside the urethral lumen with a single arm stitch while the 12-, 2-, and 5-o'clock stitches are placed from inside to outside with double-armed needles. Very carefully, these anastomotic sutures are then wrapped in a towel and protected to avoid accidental pulling or disruption. An alternative method in which the urethral stitches are placed after bladder neck reconstruction follows herein.

Division of the posterior urethra and rectourethralis muscle: Change the angle of the table to Trendelenburg to allow for visualization of the posterior plane of dissection. Sharply divide the posterior one third of the urethra to expose the posterior leaf of Denonvilliers' fascia and the rectourethralis muscle. In the midline, sharply divide the rectourethralis muscle and Denonvilliers' fascia with scissors to develop the plane posteriorly between the posterior prostate and the anterior rectal surface. Once started, use a combination of sharp and blunt dissection to separate the posterior layer of Denonvilliers' fascia from the anterior wall of the rectum.

Preservation and dissection of the neurovascular bundles: Preservation of one or both of the neurovascular bundles is essential to preserving potency among men undergoing radical prostatectomy. The neurovascular bundles lie anatomically outside the prostate between layers of lateral pelvic fascia (the levator fascia and prostatic fascia). To maintain the proper plane of dissection, the prostatic fascia should remain on the prostate. When there is a palpable nodule or induration extending into the lateral pelvic fascia, wide excision of the pelvic fascia along with the neurovascular bundles is recommended.

While many techniques are described to identify and preserve the neurovascular bundles during performance of radical prostatectomy, they have in common several important principles that should be adhered to. First, during dissection and release of the neurovascular bundle, the surgeon should avoid applying significant traction on the prostate and/or bundle or else risk nerve injury. Second, there should be a strict avoidance of electrical cautery or devices that can transmit thermal energy to the neurovascular bundle. Third, use of optical magnification through the use of loupes and a headlight to aid in visualization is highly recommended.

The first step is the release of the lateral levator fascia to expose the neurovascular bundle. This can be performed in an antegrade or retrograde approach. In the former, the lateral surface of the prostate is exposed as the level of the bladder neck and a fine right angle is placed into the plane under the levator fascia that is then incised along the plane of the lateral edge of the prostate to the level of the prostatic apex. Alternatively, the dissection may be started at the prostatic apex and carried back to the bladder neck. Once the levator fascia is opened, the neurovascular bundles can be visualized. At the level of the prostatic apex, the groove between the bundle and the prostatic fascia can be seen. Next, using a fine right-angle clip, divide the small vascular tributaries that tether the neurovascular bundle to the lateral edge of the prostate by placing clips parallel to the bundle beginning at the apex and continuing to the base of the prostate near the bladder neck. This allows the prostate with attached lateral prostatic fascia to separate off of the neurovascular bundle. As the lateral planes begin to develop, the previously initiated posterior dissection between the posterior prostate and the anterior rectum is further developed using a combination of sharp and blunt dissection.

Ligation of lateral prostatic pedicles: After release of the neurovascular pedicles or when wide excision of the pedicles is planned, the prostate is retracted cephalad via the Foley catheter to expose the posterior aspect of the prostate, including the base of the prostate and Denonvilliers' fascia overlying the ampulla of the vas deferens and the seminal vesicles. Next, the vascular pedicles are divided along the lateral aspect of the prostate by placing a right angle clamp medially and gently spreading between the prostate and the pedicle. The pedicles can then be ligated with suture ties or clips and then divided. The pedicles are divided along the lateral aspect of the seminal vesicles to the level of the bladder neck.

Dissection of the seminal vesicles and vas deferens: Open Denonvilliers' fascia covering the ampulla of the vas deferens

and the seminal vesicles. Identify, dissect, and divide the vas deferens near the ampulla (Fig. 66-7). Apply traction on the vas deferens and dissect down to the medial border of the base of the seminal vesicle. Mobilize the seminal vesicle laterally by passing a right-angle clamp in the plane between the bladder and the seminal vesicle. Place a clip on the artery at the tip of the seminal vesicle before to dividing it.

Bladder neck dissection: Once the seminal vesicles are dissected free the ligation and division of the lateral pedicles is completed, dissection is then directed toward the remaining bladder neck attachment (Fig. 66-8). The circular fibers of the bladder neck may be preserved during this dissection (Fig. 66-9). This dissection may be initiated either anteriorly or posterolaterally. Posteriorly, at the junction of the bladder neck and base of the prostate, dissection is begun to separate the prostate off of the bladder neck (Fig. 66-10). The dissection is continued anteriorly without entering the bladder. Once the groove has been created between the prostate base and bladder neck, the bladder is entered anteriorly and the catheter is grasped through this opening elevated superiorly.

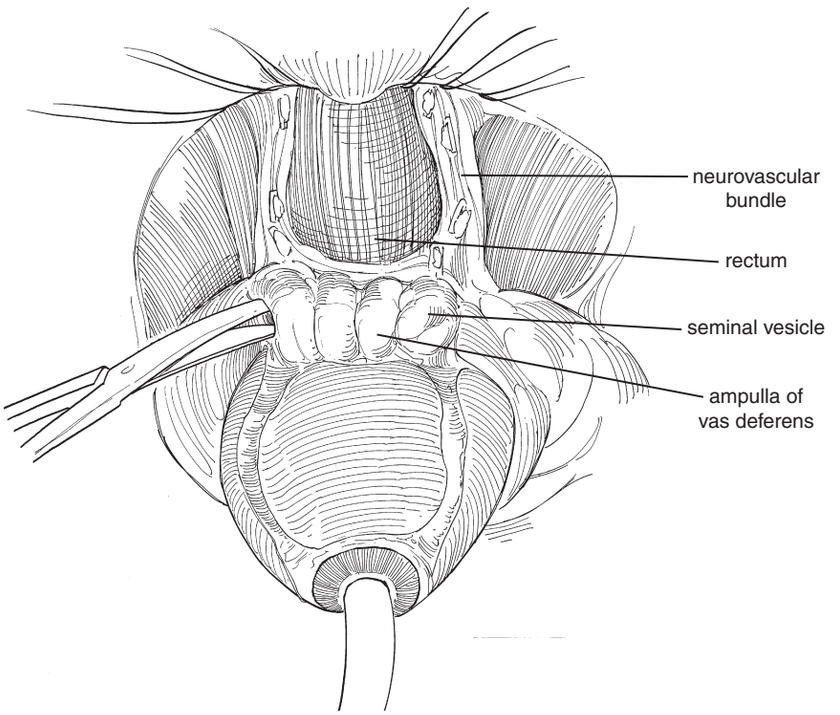

FIGURE 66-7.

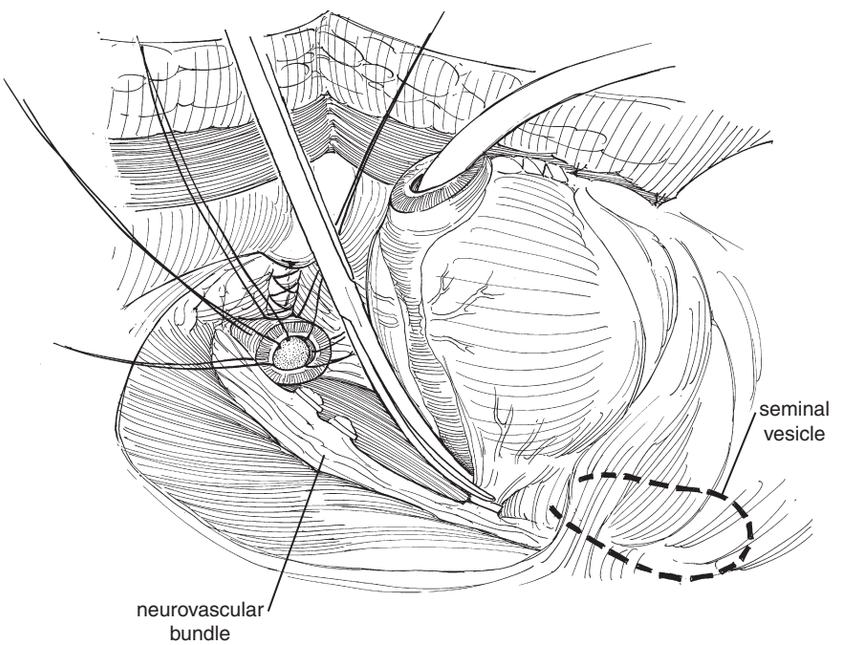

FIGURE 66-8.

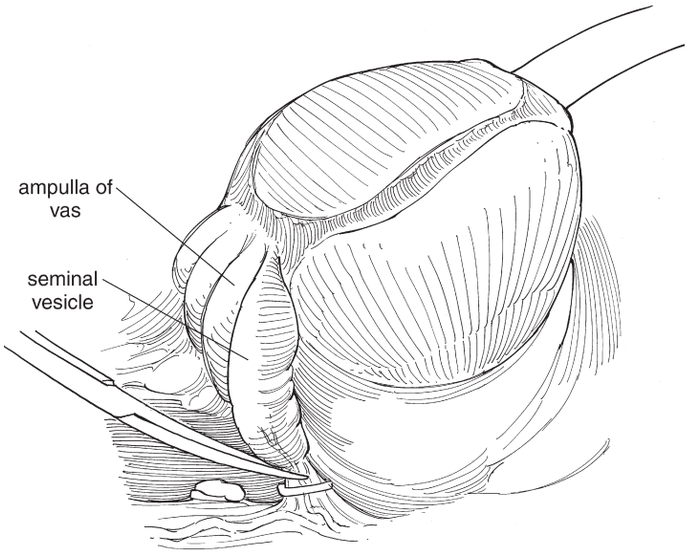

FIGURE 66-9.

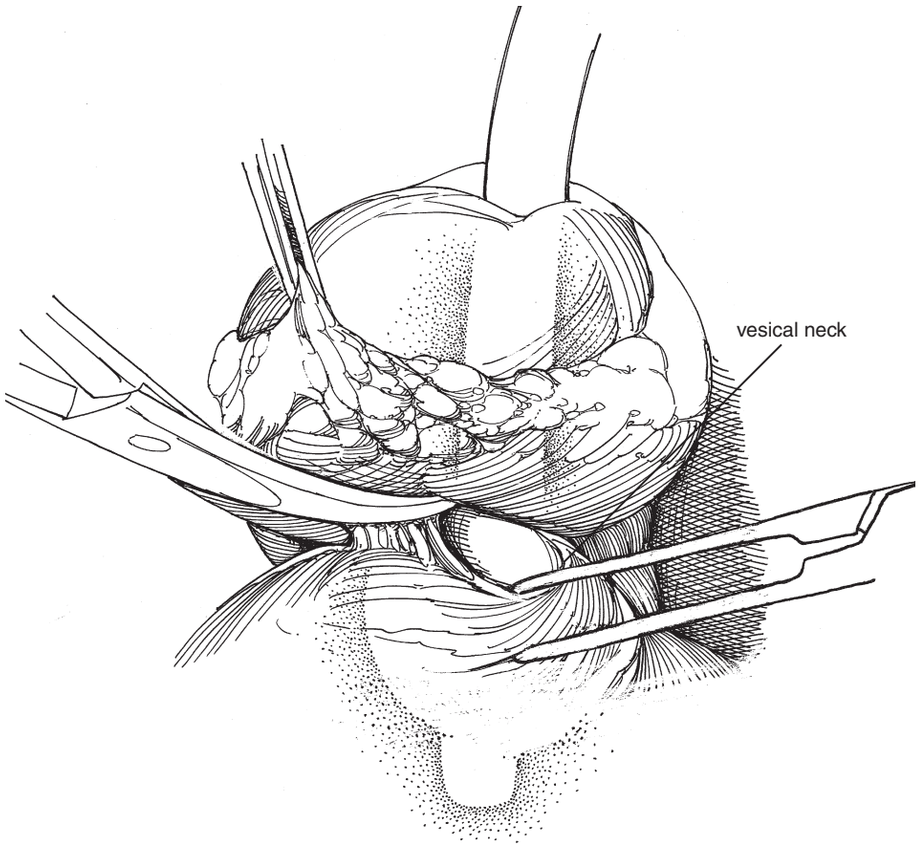

FIGURE 66-10.

Thus both ends of the catheter are being used to gently elevate the prostate (Fig. 66-11). The bladder neck opening is maintained circumferentially and extended inferiorly while the ureteral orifices are inspected and identified.

Alternatively, if there is concern regarding direct tumor extension onto the bladder or if there is a median lobe extending into the bladder, the bladder neck may excised widely. The administration of 1 mL of intravenous indigo carmine may help when the ureteral orifices are difficult to identify, particularly if a large median lobe is present. If there is further concern over identification of the ureteral orifices, pass either a small feeding tube or a ureteral catheter up one or both orifices. Once the ureteral orifices are identified and clearly out of harm's way, the bladder mucosa posteriorly is incised and the dissection is continued full thickness until the prostate is completely excised (Fig. 66-12).

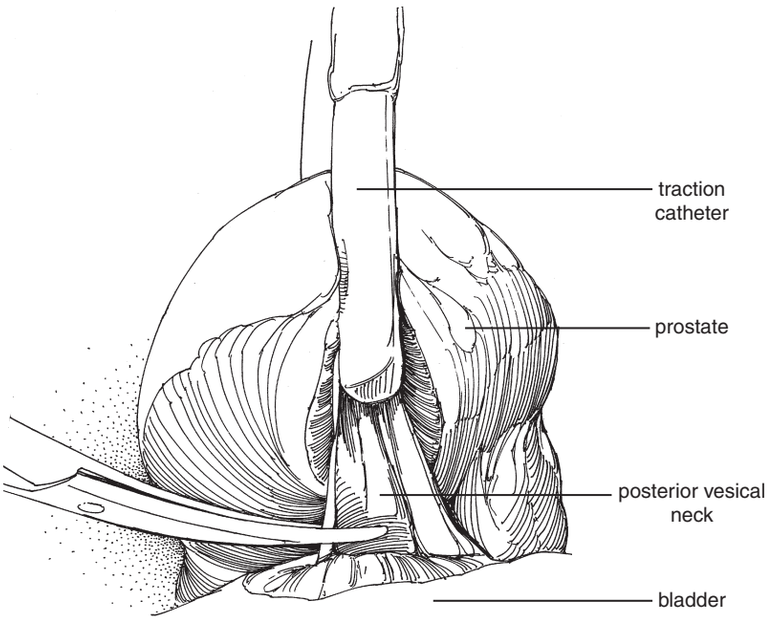

FIGURE 66-11.

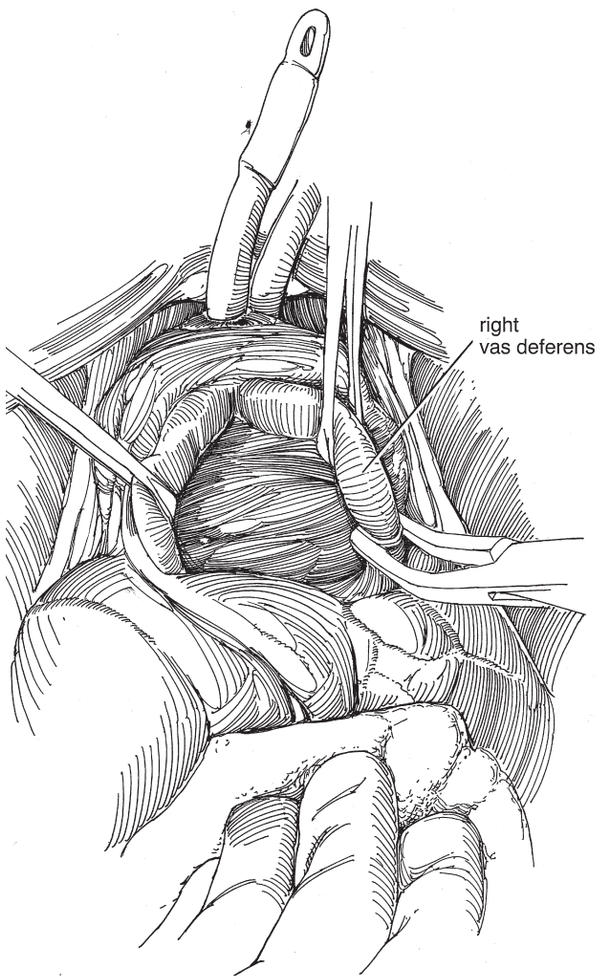

FIGURE 66-12.

Bladder neck reconstruction: When bladder neck fibers are preserved, there is no reconstruction required. However, everting the bladder mucosa with 4-0 absorbable sutures may facilitate healing by establishing bladder mucosa to urethral mucosal apposition. If the bladder neck is excised widely, bladder closure should be performed. This is most commonly referred to as *tennis racket closure* in which the handle of the tennis racket resembles the closure and the opening of the bladder neck resembles the racket. Begin inserting interrupted 2-0 absorbable sutures from the posterior margin of the bladder neck, which includes the full thickness of bladder wall (Fig. 66-13). Continue anteriorly

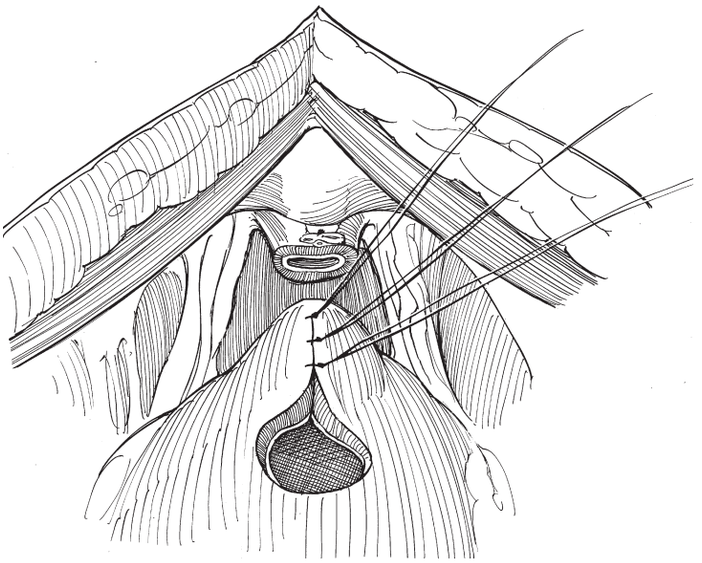

FIGURE 66-13.

until the opening is approximately 1 cm in diameter, such that it admits the tip of the index finger. Stomatize the opening by everting the bladder mucosa as previously described (Fig. 66-14).

Bladder neck anastomosis: After completing any necessary bladder neck reconstruction and having ensured excellent hemostasis in the pelvis and prostatic bed, attention is directed toward completing the urethrovesical anastomosis. Begin by placing the five previously placed urethral anastomotic stitches into their corresponding positions in the bladder neck (Fig. 66-15). Since the knots are to be tied on the outside of the bladder, these needles are passed from inside to outside. After ensuring that the urethral stitches are untangled, they are systematically placed in their corresponding positions within the bladder neck. All sutures are placed before tying them down to facilitate exposure. The posterior stitch at the 7-o'clock position is placed first, followed by the 10-o'clock stitch. Next, the 5-o'clock and 2-o'clock stitches are placed. Pass a new18-French 5-mL Foley catheter through the urethra into the bladder, taking care to pass the Foley in the middle to avoid entrapping the catheter in the suture. Inflate the Foley balloon to between 13 and 15 cc.

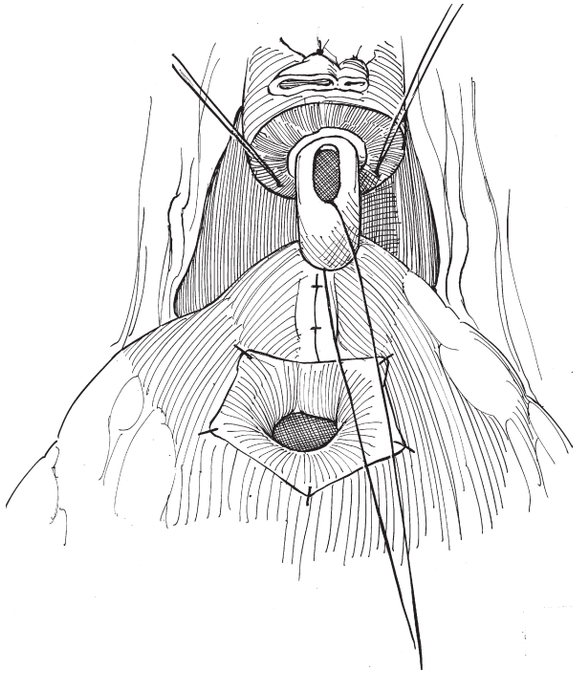

FIGURE 66-14.

Ensure that none of the sutures are twisted or tangled. Begin tying sutures. Release the two cephalad retractor blades to allow for the bladder to reach the urethra in the pelvis. When tension on the anastomosis is anticipated, the kidney rest on the bed may be lowered and some of the flex in the table may also be undone. In addition, if there is still tension on the bladder, the peritoneal attachments should be released from the bladder to further allow for extension of the bladder into the pelvis. After removing all of the slack from the individual sutures and removing all tangles, tie all of the urethrovesical anastomotic sutures starting anteriorly and continuing posteriorly while an assistant gently retracts the lateral aspect of the bladder medially. After securing all of the ties, irrigate the Foley catheter to ensure patency and to assess for any urine leaks.

Alternative urethral suture method: Wait until the bladder neck defect is partially closed before placing urethral sutures (Fig. 66-16). Insert a 24-French Roth Greenwald suture guide or 22-French catheter into the urethra through the penis to a point at which the tip is just visible emerging from the cut end. Place five or six 2-0 or 3-0 Vicryl or Monocryl sutures into the urethral stump and into the margin of the bladder neck, starting posteriorly, and hold them in rubber-shod clamps. Insert a new 18-F 5-mL balloon catheter into the bladder and inflate the balloon. Push the bladder down while pulling on the catheter and tie the sutures, beginning posteriorly (Fig. 66-17).

Drain placement and wound closure: The operative field is meticulously inspected and hemostasis in ensured. The wound is irrigated with normal saline and inspected one final time. A closed suction drain (Jackson-Pratt type) is inserted in the pelvis through a separate small skin incision

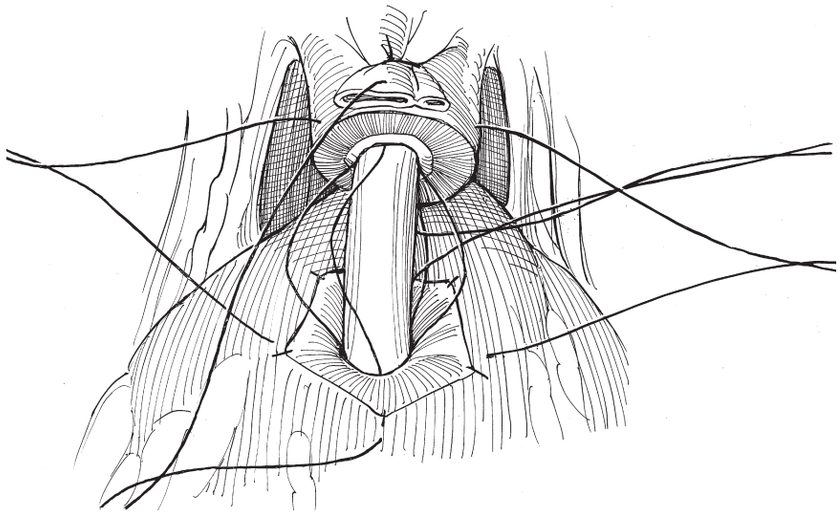

FIGURE 66-15.



FIGURE 66-16.

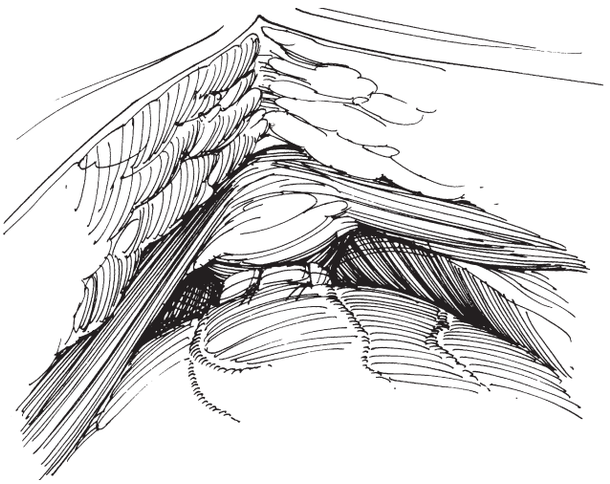

FIGURE 66-17.

and secured to the skin with a stitch. Care is taken not to injure the inferior epigastric vessels during drain placement. The wound is closed. The fascia is closed with either a running #1 Vicryl or PSDS suture. The subcutaneous tissue is irrigated and reapproximated, and the skin may be reapproximated with either 4-0 Vicryl or skin clips.

PERIOPERATIVE AND POSTOPERATIVE CARE

Advances in the perioperative and postoperative care of patients undergoing radical retropubic prostatectomy continue to evolve. Most patients are discharged on postoperative day 1 or 2. Most patients will have their drains removed before discharge, but in situations in which the drainage is persistent, the drain remains in place when drainage is minimal. The Foley catheter remains in place for 10 to 14 days, although in cases where there is a prolonged anastomotic leak it may remain until the leakage has resolved. The use of collaborative care pathways with standardized order sets have greatly facilitated the perioperative management of patients at our institution, and these have been further enhanced by the incorporation of evidence-based order sets.

INTRAOPERATIVE PROBLEMS

Intraoperative hemorrhage is common in their performance of radical prostatectomy, but massive, possibly life-threatening hemorrhage is rare. Accordingly, patients undergoing radical

prostatectomy should have a blood type and screen available for crossmatching if necessary. While transfusion rates vary by surgeon and institution, overall rates of transfusion are approximately 5% for most contemporary series. While bleeding may occur from multiple sites, including the pelvic sidewall and iliac vessels, the most common site of significant problematic bleeding is the dorsal venous complex. While there are many strategies for dividing and ligating this complex, when there is uncontrolled bleeding from this area the best method of controlling the dorsal venous complex is to completely transect it and sew the entire complex. Temporarily, packing the pelvis with laparotomy pads or direct manual compression may allow enough time for the anesthesiologist to adequately resuscitate the patient. Again, the use of optical magnification and a headlight are particularly helpful. Bleeding from pelvic sidewall branches of the iliac veins can be repaired with small 3-0 or 4-0 Prolene sutures after applying manual compression with sponge sticks proximally and distally to control bleeding.

Ureteral injury may occur during lymph node dissection or at the level of the bladder neck. The presence of a large medial prostatic lobe may cause the ureter to pursue a J-course, where it could be involved during transection of the posterior aspect of the bladder neck. The injury must be recognized intraoperatively, aided by the intravenous injection of indigo carmine as the bladder neck is transected. In the setting of a recognized ureteral injury, most commonly ureteral reimplantation should be performed.

Obturator nerve injury may occur during the pelvic lymphadenectomy. If possible, the two cut ends of the obturator nerve should be realigned with 7-0 or 8-0 Prolene sutures.

Rectal injury is uncommon but may occur due to inflammation, desmoplastic reaction, locally advanced tumor, or iatrogenic injury during dissection at the prostatic apex. When recognized, it may be closed primarily if the bowel has been prepared. It requires a meticulous closure preferably in two layers. Debridement of any nonviable edges is recommended before closing. Close the defect transversely with interrupted 3-0 PDS supplemented by omental interposition if possible. It is helpful to place the patient in a modified lithotomy position and to inspect the rectum with a proctoscope. In addition, air insufflation may be useful after filling the pelvis with normal saline to assess for a watertight closure and to ensure that the rectum has been completely repaired. Irrigate the pelvis copiously with antibiotic solution, and place a drain to the area. A diverting colostomy should be considered if the repair is tenuous, if the bowel was not prepared, if gross fecal contamination is present, or if the injury is related to prior irradiation.

POSTOPERATIVE PROBLEMS

Catheter replacement in the early postoperative period is necessary but potentially hazardous. While an initial attempt at gentle catheter replacement is reasonable, the best approach is to perform flexible cystoscopy and place a guidewire once safe passage is confirmed within the bladder. Next, remove the cystoscope and pass a 16- or 18-French Council-tip catheter over the guidewire. In rare cases, a suprapubic tube may be necessary if the bladder cannot be accessed.

Postoperative hemorrhage, evidenced by significant hypotension even though 2 or 3 units of blood were given during surgery, requires blood replacement; early reoperation may be necessary if bleeding persists to stop the bleeding. More importantly, in cases of significant postoperative pelvic bleeding, reoperation to evacuate a *pelvic hematoma* and to repair a *disrupted anastomosis* may be necessary to prevent bladder neck contracture and incontinence.

Persistent drainage from the Jackson-Pratt drain is either lymph or urine. Test the fluid for creatinine concentration. Lymph fluid has a creatinine value similar to that of serum, whereas urine creatinine is significantly higher. If drainage is lymph, stop suction and slowly advance the drains; if it is urine, it most likely comes from the urethrovesical anastomosis. Check the site with cystography. If the cystogram confirms leakage, no additional testing is needed. However, if the cystogram is normal, an intravenous pyelogram or computed tomography urogram should be performed to assess for ureteral injury. If the fluid is lymphatic in origin, stop the suction and move the drain away from the anastomosis. Spontaneous closure may take several weeks, and sclerosing agents or surgical correction of the lymphocele may eventually be necessary. Once the drain is removed, a lymphocele could develop. Lymphoceles can be diagnosed by ultrasonography or CT scan and treated most often by percutaneous, laparoscopic, or open drainage.

Urinary extravasation and *wound infection* occur in a small percentage of patients. *Ureteral obstruction* may occur from edema of the floor of the bladder or in rare cases from extrinsic compression. It is rarely possible to catheterize the orifices, so a percutaneous nephrostomy and an antegrade stent must be placed. In difficult cases in which the vesical neck repair was close to the orifices, a ureteral stent should be left in place at the time of surgery.

Deep vein thrombosis and *pulmonary embolism* are potential causes of major morbidity and mortality, respectively. Risk factors for developing thromboembolic events include cancer diagnosis, stasis, pelvic surgery, and obesity. Maintaining the head-down position and intermittent compression stockings during surgery and on postop day 1 help in prevention, as do early ambulation and avoidance of sitting in a chair without elevation of the legs. The necessity for postoperative anticoagulation remains debated due in part to the efficacy of compression stockings balanced against concerns over increased hemorrhagic complications and prolonged lymphatic drainage in the setting of early ambulation and 1- to 2-day hospital stays.

Bladder neck contracture has an incidence of 3% to 12%. It may be secondary to inadequate apposition of the epithelial edges during the anastomosis. In addition, it is increased among patients with prolonged urinary leakage, prior transurethral prostatic resection, or radiation therapy. Another cause may be disruption of the anastomosis in the postoperative period. Initially, the stricture may be treated with gentle filiform-guided dilation. If this fails, incise the bladder neck transurethrally either anteriorly or at 4- and 8-o'clock positions with a cold knife, Collin's knife, or laser. Extend the incision to, but not into, the normal sphincteric fibers because incontinence may result. Obtain hemostasis with a small electrode, and leave a catheter in place for 3 to 5 days. If the stricture recurs, the patient should be instructed to intermittently catheterize himself until the stricture stabilizes.

Commentary by

MICHAEL O. KOCH

Radical retropubic prostatectomy was the gold standard for the surgical treatment of prostate from the mid-1980s until the mid-2010s. In 2010, it still accounts for about 30% of the prostate cancer surgeries performed in the United States. While it has been supplanted to some degree by laparoscopic approaches, it behooves all prostate surgeons to be very familiar with the open approach as unforeseen circumstances during laparoscopic surgery such as hemorrhage or equipment failure could force conversion. Furthermore, there will always be patients in whom laparoscopic surgery is not feasible due to body habitus, previous surgery, and so on.

In addition, it is important to note that it is the outcome of surgery that is most important, not the approach taken. The meaningful differences between laparoscopic and open surgical approaches are small in the big scheme and open surgical prostatectomy has outstanding results in experienced hands. Each surgeon should determine that approach whereby they can achieve the optimal outcomes for their patients. In some cases, that will be best accomplished by open prostatectomy.

Chapter 67

Radical Perineal Prostatectomy

DAVID HARTKE

Hugh Hampton Young performed the first perineal extirpation of the prostate in 1905 for treatment of cancer; this was further modified by Belt in 1939. Today, the radical perineal prostatectomy continues to provide excellent long-term cancer control, rapid reconvalescence, and low morbidity with similar continence and potency rates compared with the radical retropubic and laparoscopic approaches. If indicated, a pelvic lymphadenectomy may be performed immediately before the perineal prostatectomy or as a separate procedure, also with little morbidity.

PREPARATION AND POSITION

On the day before surgery, the patient administers a bowel preparation per surgeon preference with magnesium citrate, polyethylene glycol, or phosphosoda enema and is also placed on a clear liquid diet. Historically, preoperative neomycin has been given orally at noon, 2 PM, 4 PM, 6 PM, 8 PM, and 10 PM on the day before surgery. However, many surgeons today are deviating from this regimen and give antibiotics only on the day of surgery. Although the need for blood transfusion occurs in less than 5% of cases, a blood type and antibody screen are obtained before surgery.

In the preoperative suite, antithromboembolic surgical stockings and sequential compression devices are placed. A second-generation cephalosporin is administered for perioperative antibiotic prophylaxis; alternatively, in the setting of a cephalosporin allergy, intravenous gentamicin and vancomycin may be given. Although regional anesthesia is a definite option, most patients receive a general anesthetic.

INSTRUMENTS

GU long and fine sets are necessary and include the following instruments: long Allis clamps, curved and straight Lowsley tractors, an irrigating syringe, a 14-French red-rubber catheter, a 22-French Foley catheter, and a 1-inch Penrose drain. In addition, it is imperative to use a special self-retaining retractor such as the Mini-Crescent (Omni-Tract Surgical, Minneapolis, MN) or Thompson (Thompson Surgical Instruments, Traverse City, MI). Finally, the use of a headlight allows for maximal visualization.

STEP 1

After successful induction of anesthesia, the legs are secured in Allen stirrups and the patient is placed into an exaggerated lithotomy position (Fig. 67-1). A wedge or sandbag may assist in elevating the perineum with the table in Trendelenburg position. In this position, the perineum is elevated, and the buttocks should extend beyond the end of the table. Many surgeons require the perineum to be positioned parallel to the floor; however, the author modifies the position so that the perineum is only moderately elevated. It is thought that this modification may reduce the

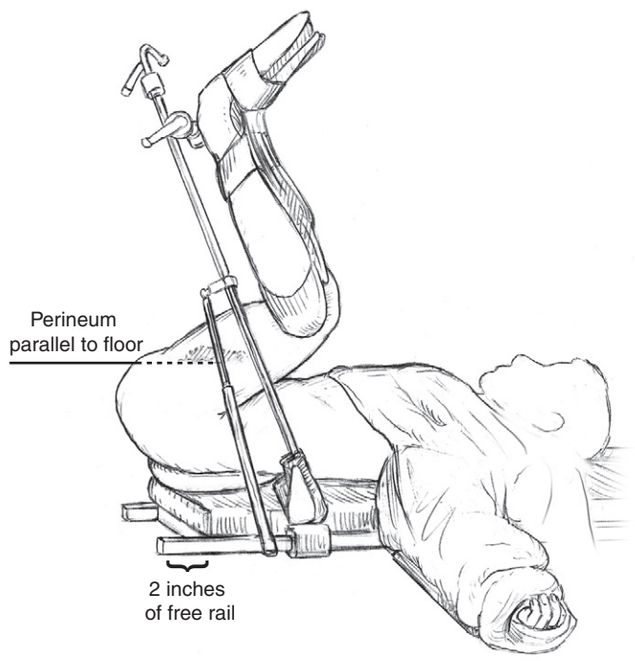

FIGURE 67-1.

incidence of neurapraxia. All points of contact should be well padded. The use of shoulder braces is at the discretion of the surgeon, but is not necessary in the modified position. Finally, of vital importance, approximately 2 inches of the rail must be available at the end of the table for placement of a self-retaining retractor.

The perineum and scrotum are shaved. The perineum, anus, thighs, penis, scrotum, and infraumbilical abdomen are scrubbed and painted with povidone-iodine paint. Next, a sterile towel is sewn around the anus from the 9-o'clock to the 3-o'clock position at the mucocutaneous pigmentation line, helping to maintain a sterile environment. Application of an O'Connor drape yields the same result. After sterile draping, the pole of the self-retaining retractor is secured to the rail at the end of the table. Finally, a curved Lowsley tractor is inserted into the bladder and the wings are opened, securing it in place. The first assistant should stand to the left of a right-handed surgeon and the second assistant stands on the right.

STEP 2

The ischial tuberosities are palpated and used as landmarks. Anterior to the anus, a curvilinear incision is made from a point medial to the right ischial tuberosity to a point medial to the left ischial tuberosity (Fig. 67-2). The incision is medial to the tuberosities so that the patient does not apply pressure to the incision upon sitting.

STEP 3

A number 10-blade scalpel is used to penetrate upward and laterally through the superficial perineal fascia into the ischiorectal fossa on each side. Each ischiorectal fossa is then further developed bluntly and, working a finger forward and cephalad along each side of the rectum, an index finger is passed beneath the central tendon (Fig. 67-3). If the fingers do not penetrate the tissue easily, move more posteriorly. The central tendon is then divided either sharply or with electrocautery.

STEP 4

The Young approach (open dashes) enters anterior to the superficial and deep portions of the external anal sphincter. The Belt approach (closed dashes) enters over the subcutaneous portion and then proceeds beneath the superficial and deep portions of the external anal sphincter (Fig. 67-4A).

Employing a Belt approach, as preferred by the author, the fibers of the external anal sphincter are retracted anteriorly and gentle dorsal countertraction is placed on the rectum (see Fig. 67-4B). This reveals a plane anterior to the rectum, which is easily recognized by the whitish longitudinal fibers of the rectal lamina propria (see Fig. 67-4C). When developed by pushing the levator ani

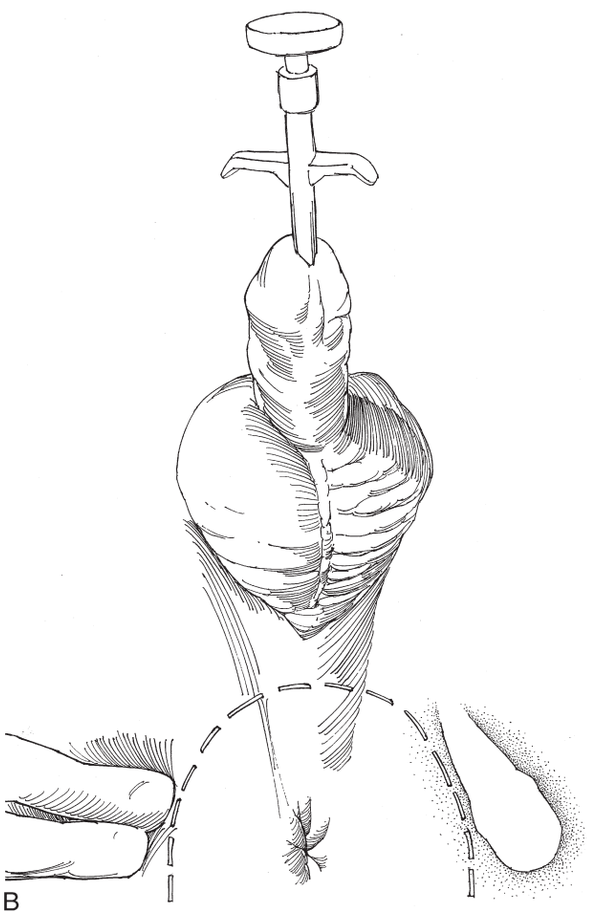

B

FIGURE 67-2.

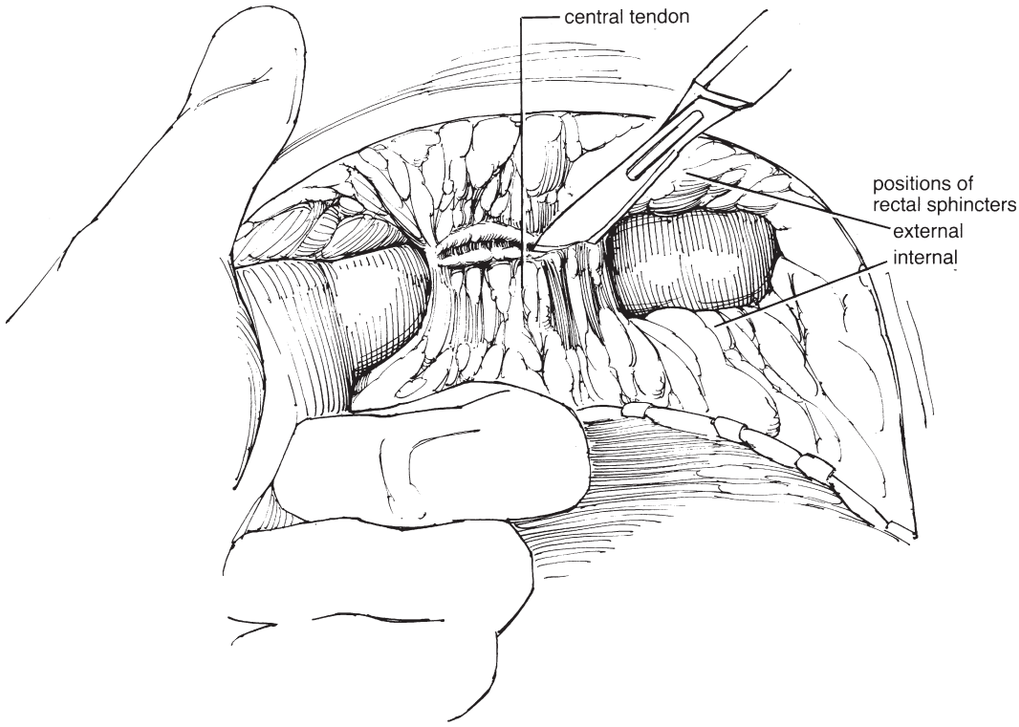

FIGURE 67-3.

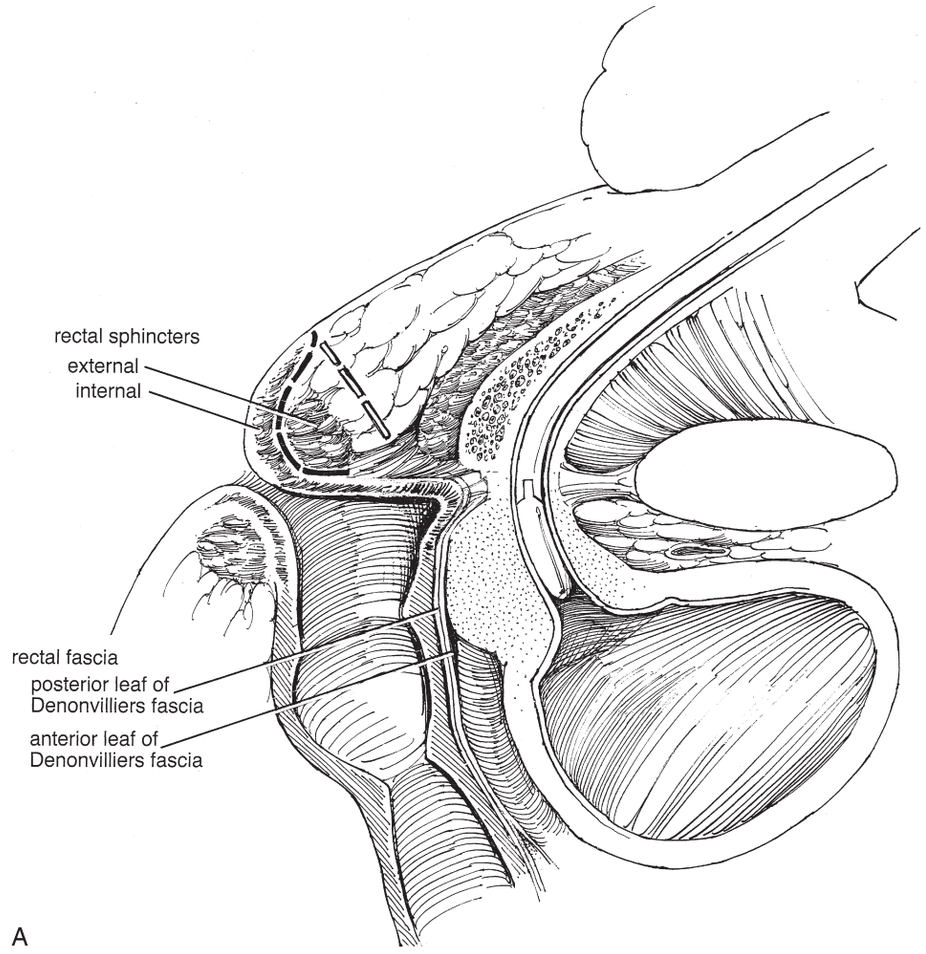

A

FIGURE 67-4.

Continued

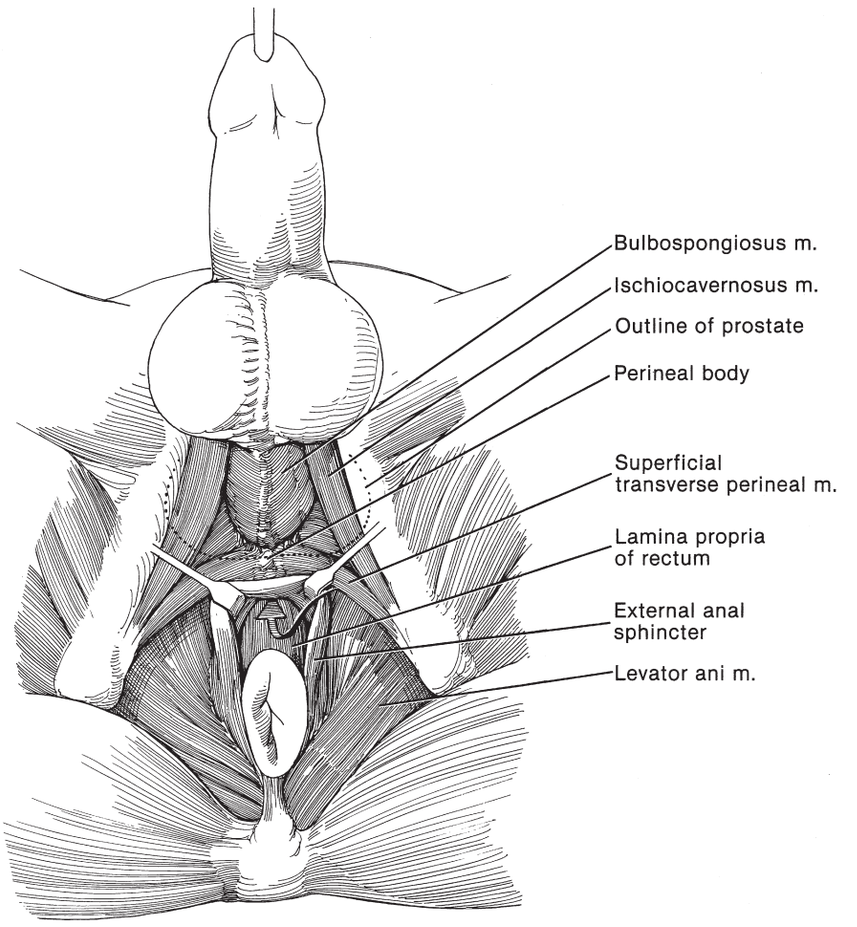

B

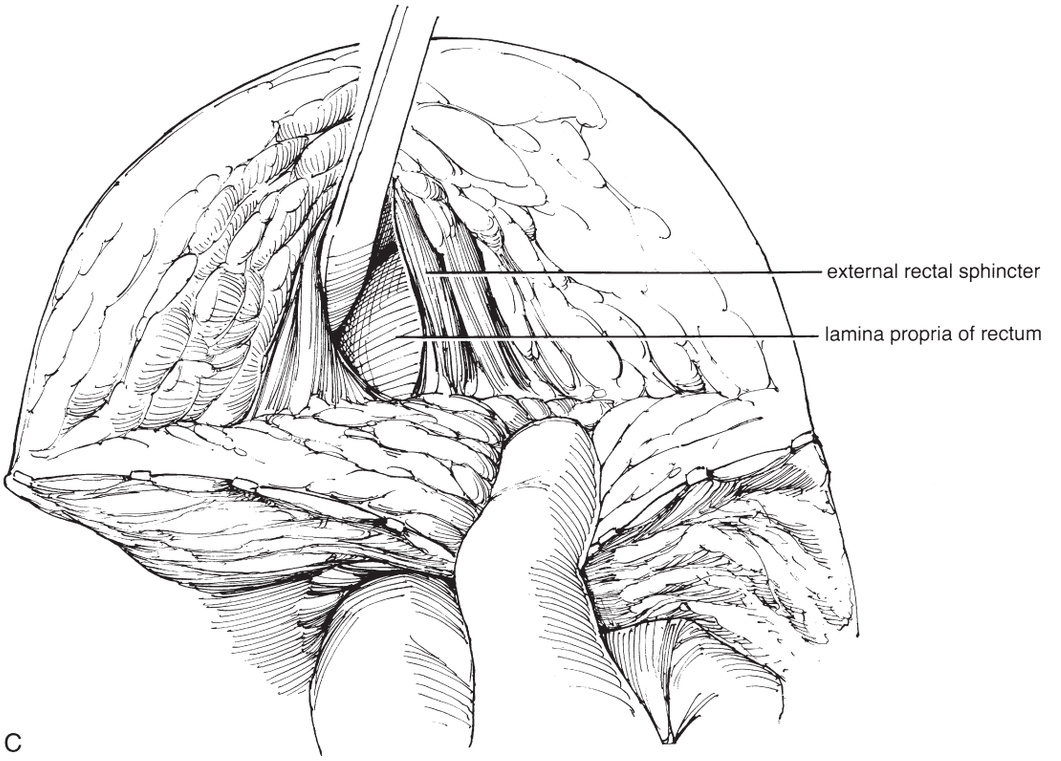

C

FIGURE 67-4, cont'd.

muscles laterally and anteriorly, this plane leads directly to the rectourethralis muscle.

STEP 5

The rectourethralis muscle is exposed in the midline. Without any traction on the Lowsley tractor, the rectourethralis muscle is sharply divided with vertically oriented scissors at its junction with the rectum (Fig. 67-5). The rectourethralis muscle tents the rectum anteriorly, risking injury to the rectum. Any downward traction on the Lowsley further elevates the rectum and increases the chance of rectal injury during this step. However, if this structure is divided too far anteriorly, the bulbar urethra may be in jeopardy.

STEP 6

After dividing the rectourethralis muscle, the rectum falls posteriorly and gentle traction placed on the Lowsley tractor (toward the anterior abdominal wall) delivers the prostate into the field. Blunt dissection using a finger further frees the prostate from the underlying rectum (Fig. 67-6).

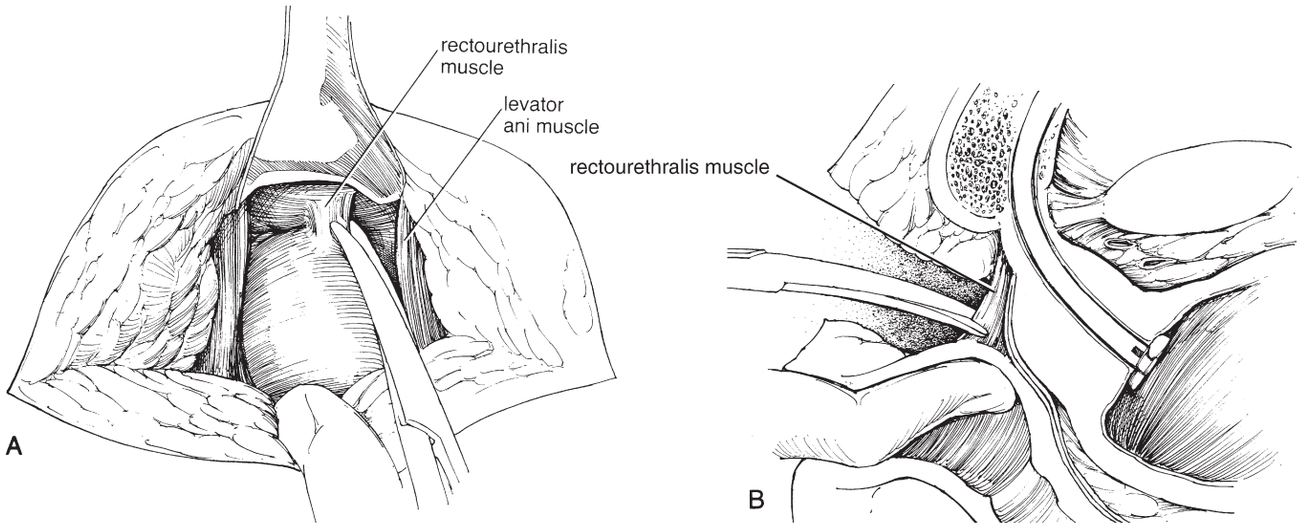

FIGURE 67-5.

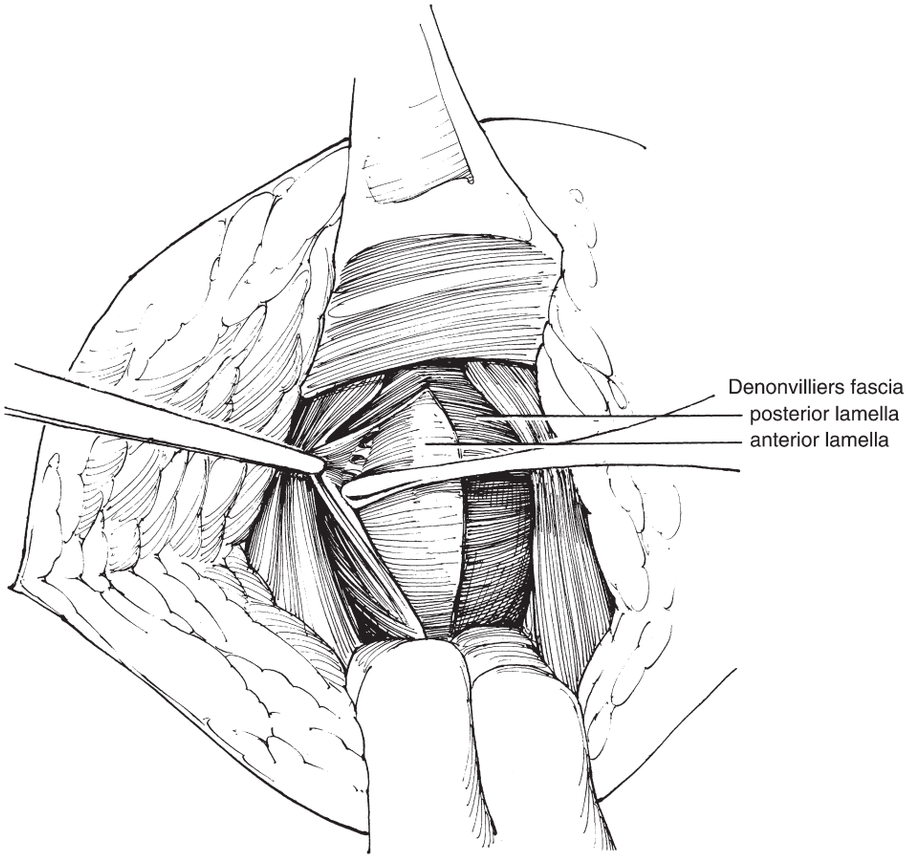

FIGURE 67-6.

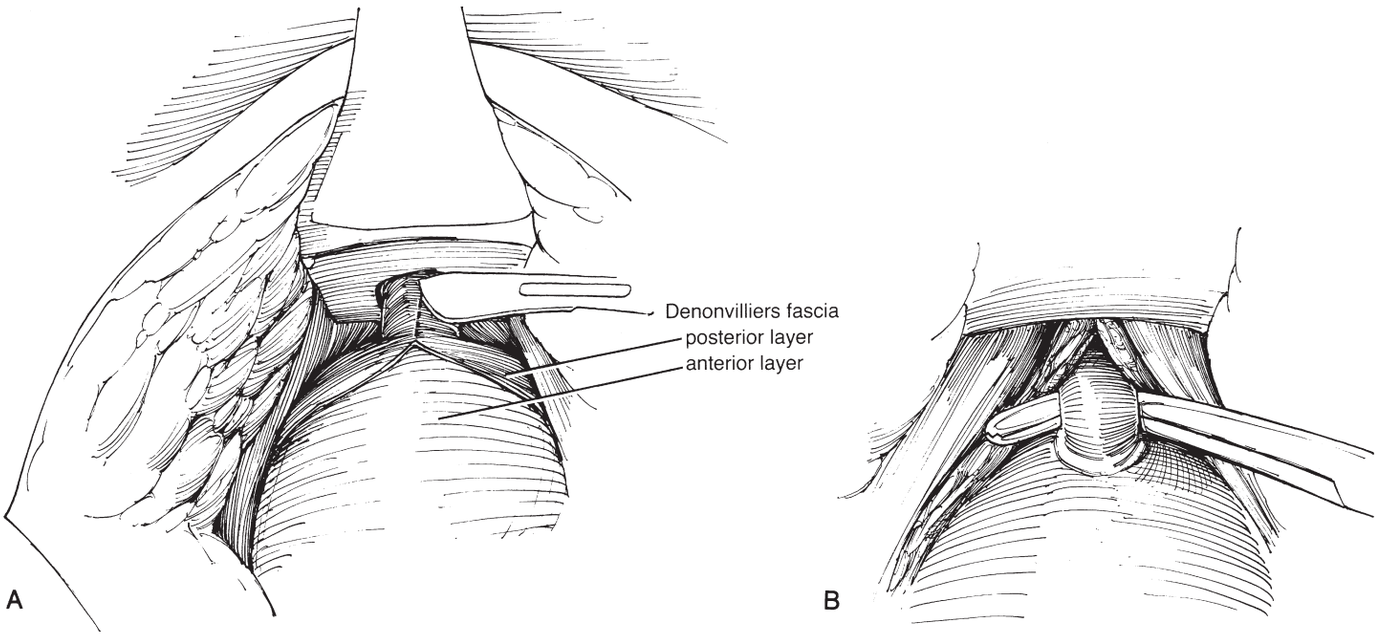

FIGURE 67-7.

With Denonvilliers fascia exposed (these are the "Pearly Gates of Young" that admit you to the prostate), a vertical incision is made through just the posterior leaf of Denonvilliers fascia. Historically, a transverse incision was employed, which carried greater risk for neurovascular injury.

STEP 7

After making the vertical incision, this layer is mobilized and bluntly swept laterally, protecting the neurovascular bundles in the process. Near the prostatic apex, the two layers of Denonvilliers fascia may be adherent and sharp dissection must divide these adhesions (Fig. 67-7). The dissection should be continued laterally and posteriorly to the level of the seminal vesicles. Gentle blunt dissection laterally and at the apex further mobilizes the prostate.

STEP 8

Next, the Lowsley tractor is palpated just distal to the prostatic apex. The pelvic fascia overlying the true urethra is incised vertically to expose the shiny urethral surface. The pelvic fascia is swept laterally to protect the distal course of the neurovascular bundles.

STEP 9

Using a #15 blade scalpel, the posterior aspect of the urethra is then incised, exposing the Lowsley tractor (Fig. 67-8). Next, the curved Lowsley tractor is removed and replaced with a straight Lowsley tractor, positioned through the apex of the prostate and into the bladder.

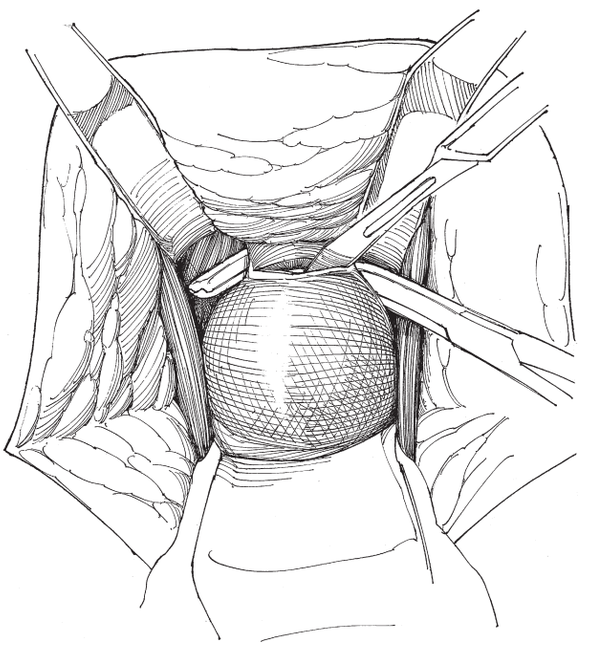

FIGURE 67-8.

The wings are again opened. Finally, the anterior aspect of the urethra is incised as well.

STEP 10

A self-retaining retractor is then used and blades are positioned at 3-, 9-, and 12-o'clock. Dorsal traction is placed on the straight Lowsley tractor and the anterior prostate is

dissected from the apex to the bladder neck (Fig. 67-9A). The dorsal venous complex lies ventral to this area of dissection and, fortunately, is left undisturbed.

By palpating the wings of the Lowsley tractor, the bladder neck is identified and entered anteriorly. The Lowsley tractor is then removed and a right-angle clamp is placed through the urethra with the tips passing through the area of bladder neck entry. A red rubber catheter is then grasped and looped through the prostatic urethra around the anterior aspect of the prostate and secured with a Kelly clamp (see Fig. 67-9B). Traction on this catheter further assists dissection.

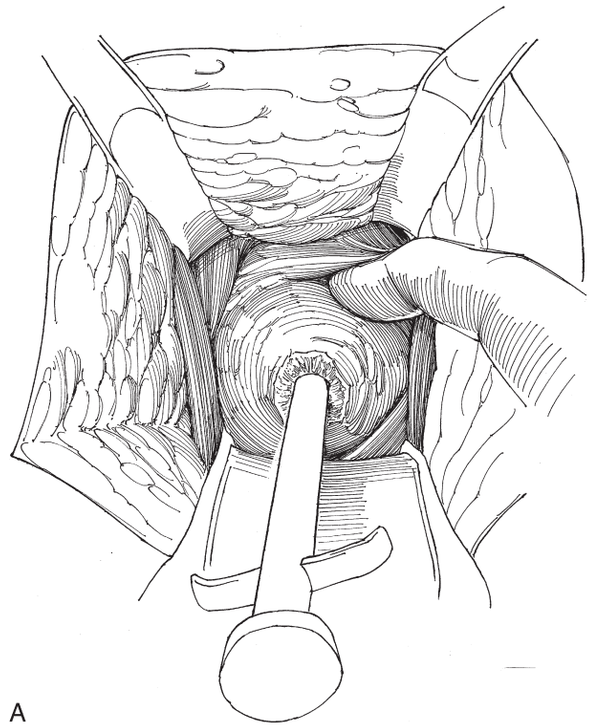

A

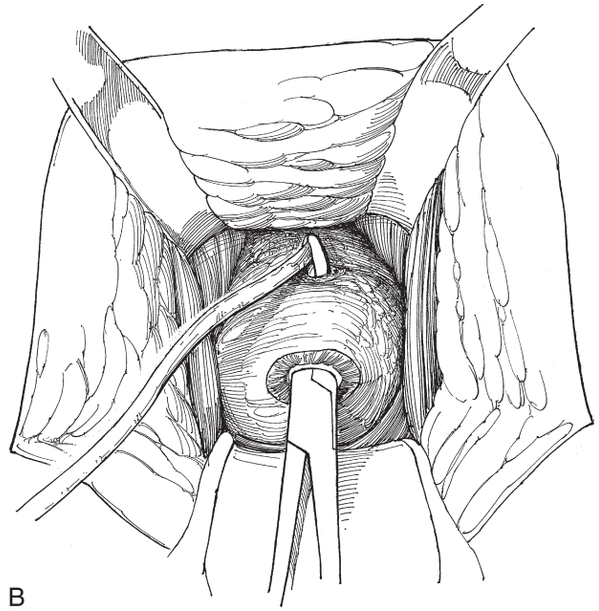

B

FIGURE 67-9.

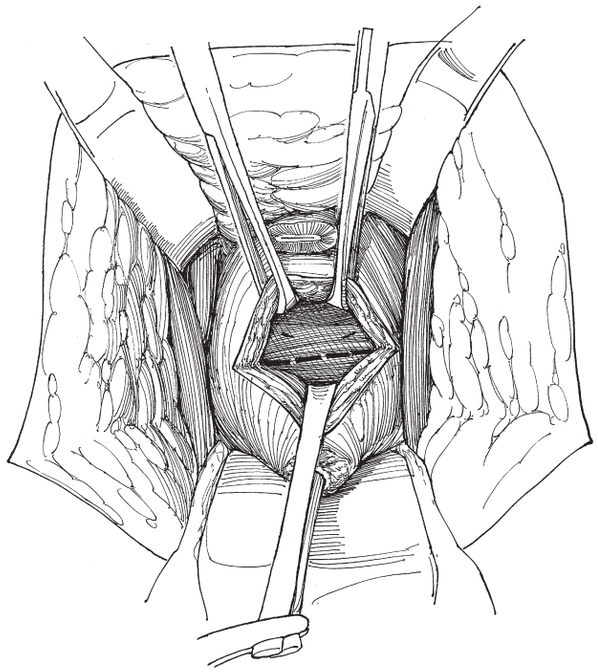

FIGURE 67-10.

STEP 11

With traction on the prostate, the anterior bladder wall is further divided at its junction with the prostate (Fig. 67-10). As they are encountered, vessels may be cauterized or ligated. At this time, the anesthesiologist may administer 5 mL of indigo carmine intravenously; this will assist in ureteral orifice identification later.

STEP 12

The bladder neck is then circumferentially divided from the base of the prostate, exposing the seminal vesicles and ejaculatory ducts (Fig. 67-11). The lateral pedicles are identified bilaterally and sequentially clamped, ligated with polyglycolic suture or surgical clips, and divided close to the prostate. Each lateral pedicle will require several clips; mass ligation should be avoided.

STEP 13

Dissection is continued along the posterior prostate and an appendiceal retractor is placed beneath the trigone, displacing it anteriorly. This exposes the underlying ejaculatory ducts, which are dissected, individually ligated, and divided (Fig. 67-12).

STEP 14

Gentle traction on the prostate allows blunt dissection of the seminal vesicles, which are subsequently clipped at their tips and divided (Fig. 67-13). At this point, the specimen is completely freed and delivered from the field.

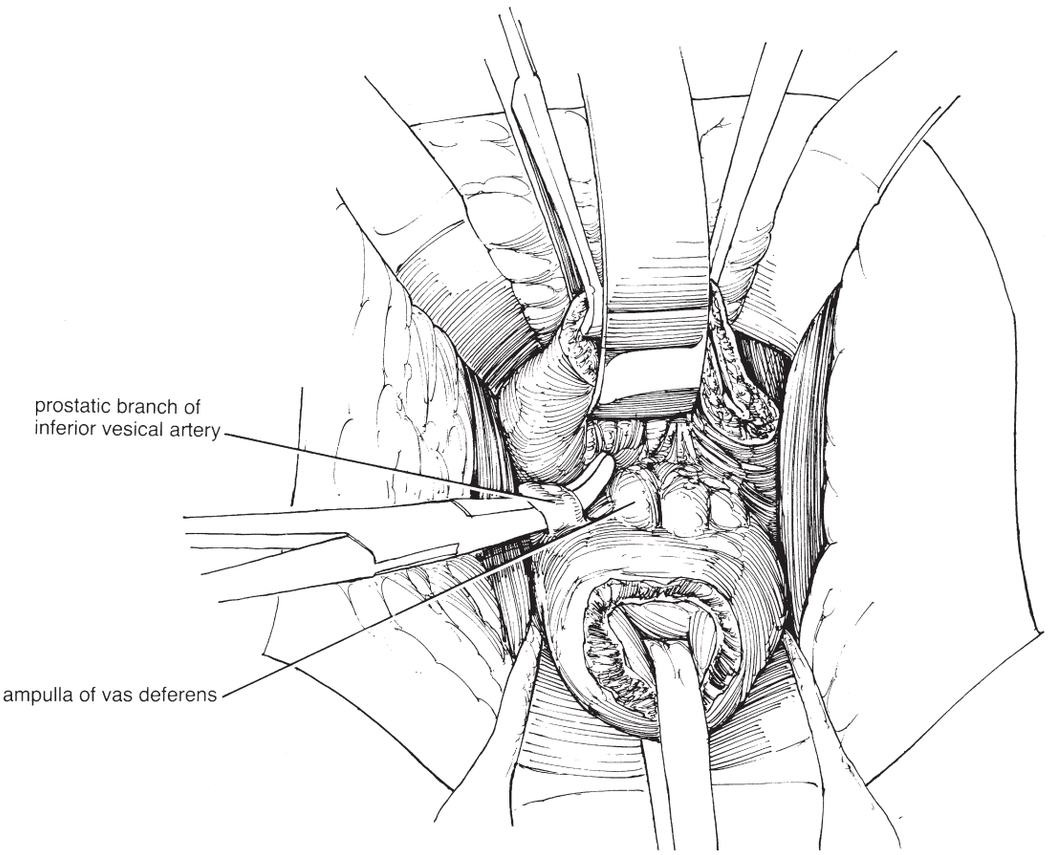

FIGURE 67-11.

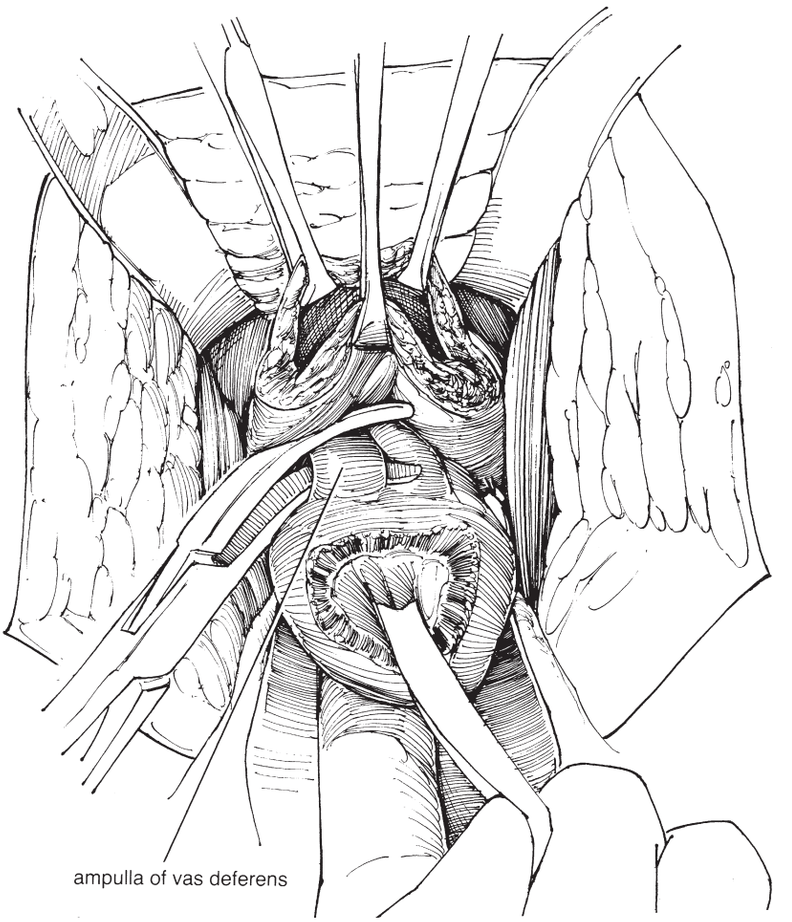

FIGURE 67-12.

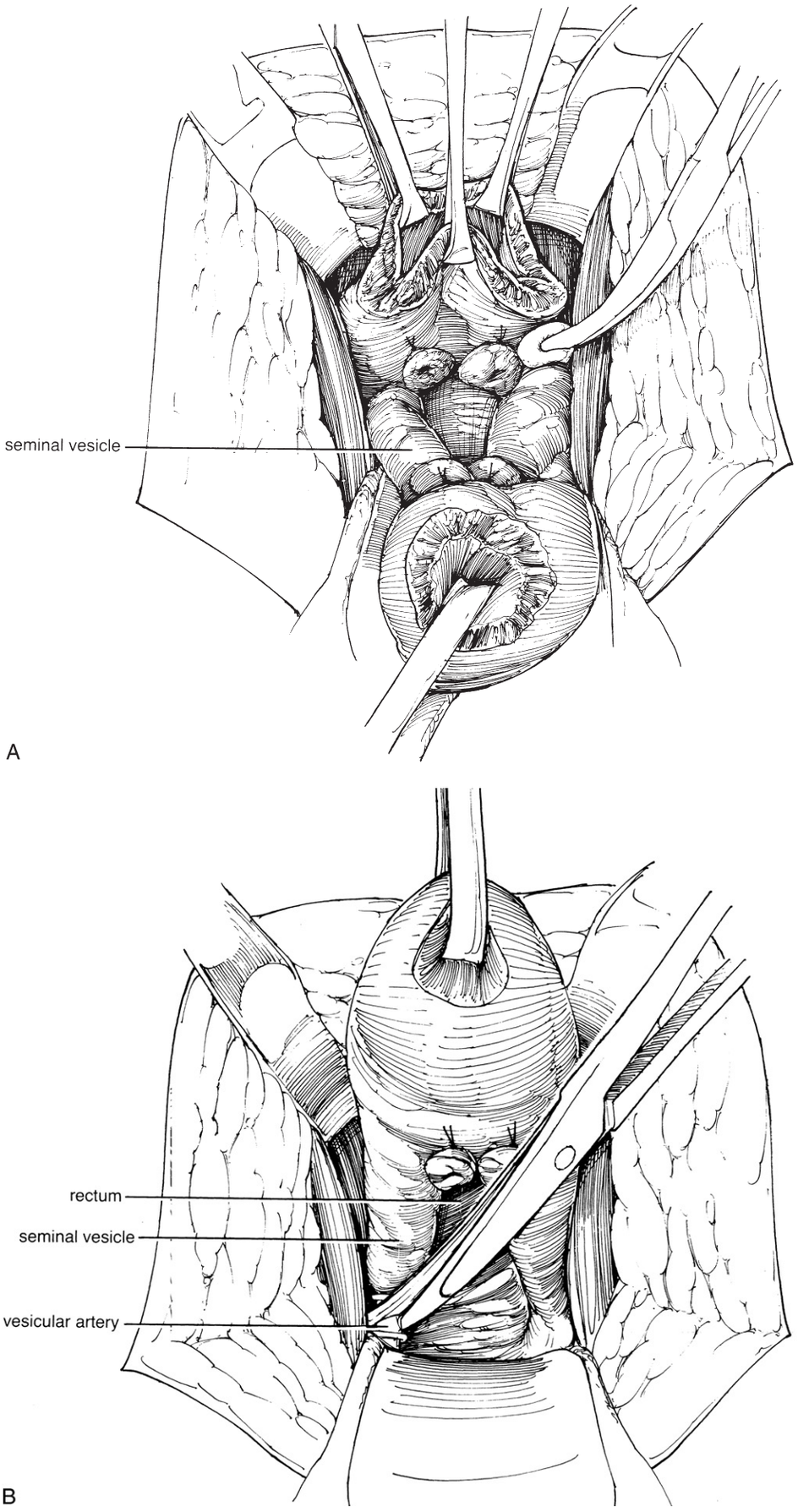
seminal vesicle
A
rectum
seminal vesicle
vesicular artery
B

FIGURE 67-13.

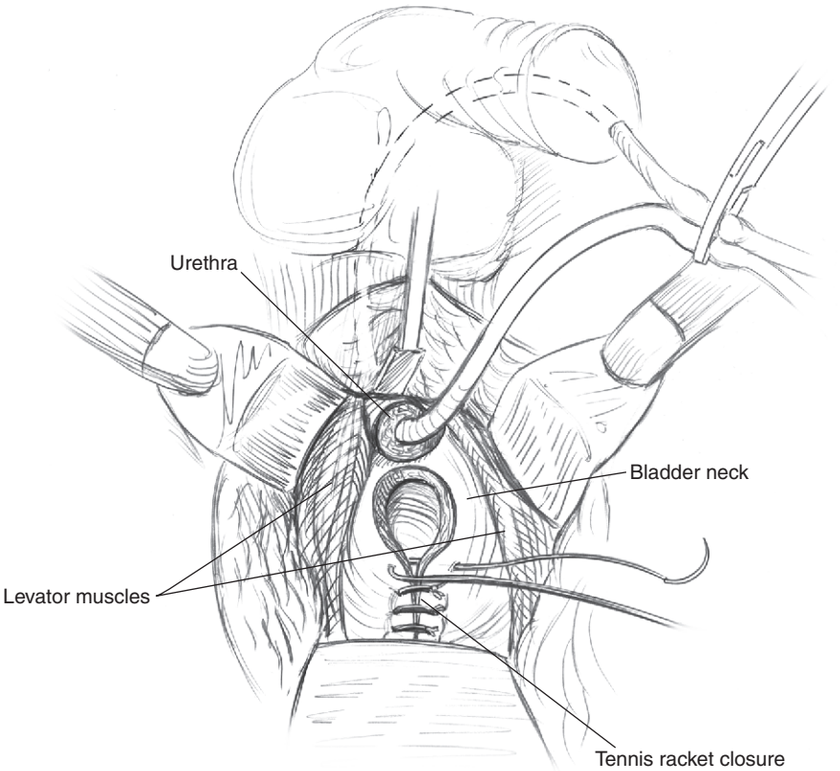

FIGURE 67-14.

STEP 15

If necessary, the posterior bladder neck is reconstructed using 2-0 absorbable suture in a standard tennis racquet fashion, taking care not to injure the ureteral orifices (Fig. 67-14). The indigo carmine, which was administered earlier, assists with this identification.

STEP 16

The retractor at the 12-o'clock position is removed and the red rubber catheter is then passed retrograde through the urethra and clamped at the level of the penis.

A 3-0 polyglycolic acid suture is placed at the 12-o'clock position of the bladder neck from outside to inside and then from inside to outside at the 12-o'clock position of the membranous urethra, and the suture is tied. Sutures are then placed at the 2- and 10-o'clock positions and tied (Fig. 67-15).

The red rubber catheter is removed and replaced by a 22-French Foley catheter, and directed transurethrally into the bladder, and the balloon is inflated with 15 mL of sterile water. Then, 3-0 polyglycolic acid sutures are placed at the 4-, 6-, and 8-o'clock positions and tied snugly.

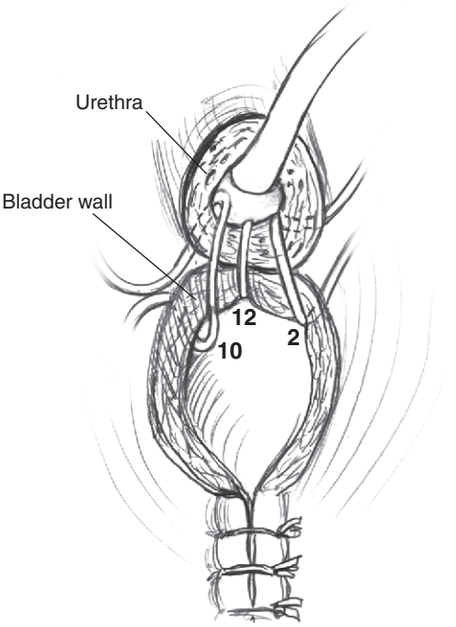

FIGURE 67-15.

STEP 17

The field is inspected thoroughly for rectal injury. A Penrose drain is positioned near the vesicourethral anastomosis and brought through the lateral aspect of the incision (Fig. 67-16). The levators are approximated using 2-0 absorbable suture. The central tendon and Colles' fascia is also reapproximated with 2-0 absorbable suture. Finally, the skin is closed with interrupted 4-0 absorbable suture.

POSTOPERATIVE CARE

Unless a rectal injury occurred, patients are immediately started on clear liquid diet and advanced as tolerated. Early ambulation is encouraged and the patient is prescribed oral pain control and stool softeners. However, rectal stimulation or manipulation is strictly prohibited. Patients are typically discharged within 1 to 3 days postoperatively and the drain is removed at that time. The catheter is removed in 1 to 2 weeks.

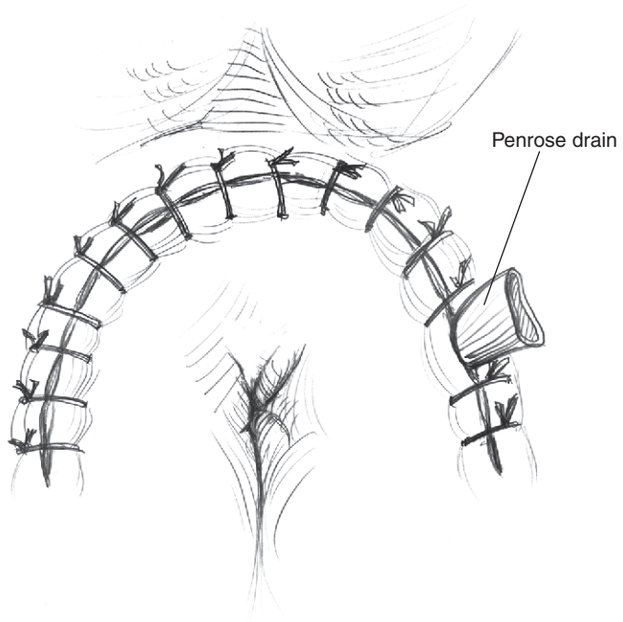

FIGURE 67-16.

Commentary by MICHAEL O. KOCH

Radical perineal prostatectomy is the most uncommon form of surgical prostatectomy performed in the United States today. Still there is a small committed group of oncologic surgeons who have mastered this technique and are able to achieve excellent functional outcomes. Most young surgeons today have not been adequately trained in perineal prostatectomy because the approach has grown out of favor because of popularity initially of the nerve-sparing retropubic approach and now the laparoscopic techniques. While the perineal approach suffers from a higher rate of rectal injury than open surgery and makes nerve sparing more difficult, it is also associated with outstanding exposure for the anastomosis, a minimal blood loss, and a very rapid postoperative recovery.

All surgeons occasionally encounter patients who may benefit from this approach, such as those with "hostile" abdomens and those who are morbidly obese.

This page intentionally left blank

Chapter 68

Pelvic Lymph Node Dissection

S. DUKE HERRELL

Pelvic lymph node dissection (PLND) remains the gold standard to assess anatomically for the presence of early metastatic disease. In the modern era, PLND is typically performed at the time of radical prostatectomy. Isolated PLND, by either minimally invasive or open approaches, is performed in far fewer circumstances than in previous decades. The advent of PSA and the stage migration of the majority of patients presenting with prostate cancer has heralded a major reduction in patients presenting with positive lymph nodes and metastatic disease. Despite the noted stage migration, dissection and pathologic examination of the pelvic lymph nodes remains the gold standard for assessing early metastatic disease and providing accurate staging information. While a variety of noninvasive or augmented imaging modalities are being investigated for potential to either replace or improve nodal staging, none has yet reached widespread use.

INDICATIONS

For patients with prostate cancer who have a Gleason sum ≤ 6 and a PSA ≤ 10, findings by Partin and colleagues suggest that in their nomogram, the rate of metastatic disease is approximately 0 to 3%. A number of surgeons and investigators have proposed avoiding PLND in these patients, due to the low incidence of positive lymph nodes and to avoid any potential morbidity. Of note, the majority of nomograms and data regarding the incidence of pelvic lymph metastasis are based on a modified dissection template and may underrepresent the true incidence of lymph node metastases; a portion of these patients will re-present with PSA recurrence and initially had probable undetected microscopic pelvic nodal disease.

More recently, a variety of authors have proposed the use of an extended PLND (EPLND) template in the treatment of presumed localized prostate cancer. Arguments for this strategy include a more accurate staging assessment and the possibility that extended lymph node dissection might result in cure in select patients with local nodal disease only. At present, there seems little controversy that a lymph node dissection of some type should be performed bilaterally in patients with high-risk disease. The role and extent of lymph node dissection remains controversial, at present, for low-risk patients.

Before the mid-1990s, a standard, modified bilateral template PLND, consisting of the external obturator lymph node packet, was simply considered part of radical prostatectomy. In some circumstances, laparoscopic PLNDs were performed separately from radical prostatectomies to stage disease. While the role of the PLND as a separate staging procedure has declined with the widespread use of biomarkers such as PSA, nomograms predicting nodal involvement, and the stage migration phenomenon that has occurred in the past decade, the role of PLND as both a staging and possibly therapeutic intervention during radical prostate surgery remains highly controversial. The two types of PLND—modified and extended—as well as technical details for each approach are discussed here.

Tracing studies have shown that the lymphatic drainage of the prostate takes place to the external iliac lymph nodes, the hypogastric nodes, and the presacral lymph nodes. Newer techniques, such as monoclonal antibody-based imaging and radioisotope tracing, are under investigation to establish their possible role in defining lymphatic drainage and sentinel nodes as an adjunct to surgery. The role of EPLND, which in the literature significantly increases the yield of lymph nodes and potentially the detection of lymph node metastasis, is still controversial. Several European authors have advocated the use of EPLND for all levels of risk classifications. While some studies have proposed a potential therapeutic and survival benefit, this remains a controversial issue.

ANATOMY

Anatomic Templates

PLND in prostate cancer has been described in several terms. A minimal or modified PLND consists only of the nodes present in the area bordered by the obturator nerve and external iliac vein. Anatomic boundaries include the external iliac vein; the obturator nerve; the node of Cloquet distally, the hypogastric artery posteriorly, and the common iliac vein proximally.

EPLND includes removal of the lymph node tissue contained within the area bounded by the genitofemoral nerve laterally, the internal iliac artery posteriorly, the common iliac artery in the superior cranial area, and the origin of the epigastric vessels distally. The entire modified template PLND area and the nodes inferior to the obturator nerve are cleared from the pelvic sidewall. In addition, the nodes overlying the internal iliac vessels and in some cases the presacral area are included. The majority of series describing EPLND have increased nodal yields to approximately 20 lymph nodes.

OPEN TECHNIQUE

Modified PLND

Incision: A midline, lower extraperitoneal incision is typically made.

Step one. The prevesical space is entered. The space of Retzius is dissected carefully and bluntly between the sidewall of the bladder and the iliac vasculature, using either finger dissection or a sponge stick.

Step two. A self-retaining retractor is placed with the abdominal wall retracted laterally and superiorly using shallow rake or bladder-blade retractors. The bladder is retracted away from the operative side using a padded deeper retractor blade (Fig. 68-1).

Step three. The external iliac vein wall is identified and the fibrofatty tissue overlying it is opened toward the inguinal canal (Fig. 68-2). The node of Cloquet and the inferior epigastric vessels serve as the distal landmark. The fibrofatty tissue is cleared off of the vein by splitting it along the vein's medial border and dissecting down underneath the vein until the obturator sidewall musculature is reached. Care should be taken to avoid the circumflex iliac vein, which is distal. A vein retractor placed carefully under the inferior edge of the vein may aid in retraction and dissection.

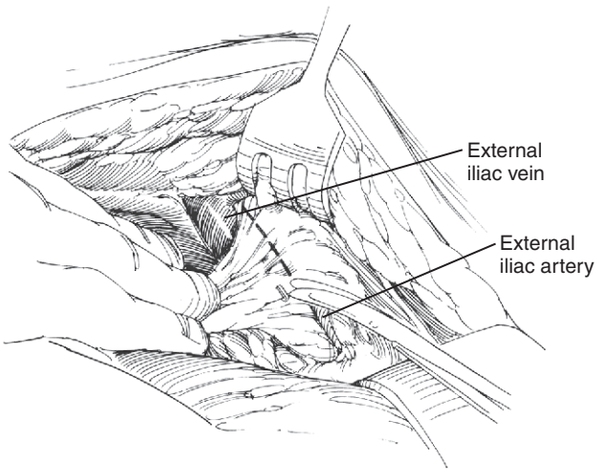

FIGURE 68-2.

Step four. The obturator nerve is identified by dissecting open the fibrofatty tissue present in the obturator fossa several centimeters below the iliac vein inferiorly (Fig. 68-3). Once the nerve is identified, it is skeletonized on its superior surface proximally and distally. Care must be taken to avoid injury to the obturator artery and vein. Clips can be used on any small, anomalous vasculature. Once the superior and inferior borders of the packet have been developed, the distal extent of the packet, which is narrowing as it approaches the inguinal area, can be ligated and divided using either sutures or clips. Care should be taken to leave a clip or suture distally to prevent lymphocele formation. The packet is then retracted superiorly and medially and the dissection carried posteriorly toward the internal iliac artery and the bifurcation of the common iliac vein. At this point, care should be taken to avoid a vascular injury. The lymphatic and fibrofatty tissue often tapers down to several lymphatic trunks, which can be controlled with either sutures or clips. Once removed, the

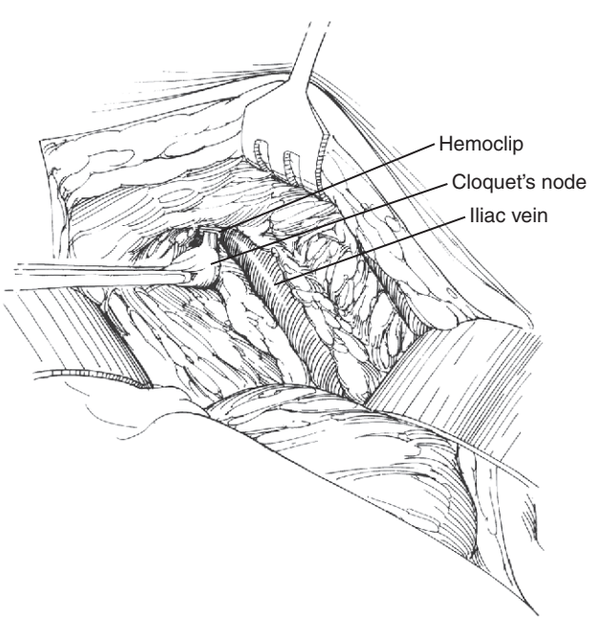

FIGURE 68-1.

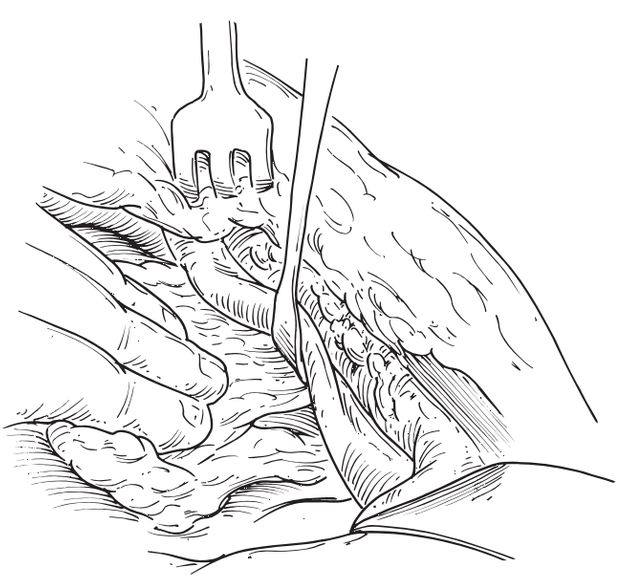

FIGURE 68-3.

packet is examined for pathologic nodes. Use of frozen section, intraoperative pathology is controversial, given the potential for false-negative results and the increasing use of radical prostatectomy for local control measures.

The site is carefully inspected for hemostasis. Small amounts of oozing can be controlled with hemostatic agents or cellulose packing.

Extended Pelvic Lymph Node Dissection

For the EPLND, the template is increased (Fig. 68-4). Initially, the dissection is begun along the external iliac artery. The small amount of tissue between the genitofemoral nerve and the external iliac artery can be dissected and removed. The tissues overlying the artery are split and rolled from around the vessel along with those around the external iliac vein. The dissection of the obturator nodes proceeds in the same manner as the modified template dissection, except that all lymphatic tissue from the level of the genitofemoral nerve and that surrounding the external iliac artery and vein is brought around with the obturator packet. Inferiorly below the obturator nerve, the extended packet is cleared down to the level of the offtake of the obturator artery posteriorly and the medial umbilical ligament offtake. The fibrofatty tissues overlying the internal iliac artery and vein are also split and rolled up for inclusion with the extended pelvic lymph node packet (Fig. 68-5). Clips and ties are used where necessary. Care is taken to avoid damage to the obturator nerve.

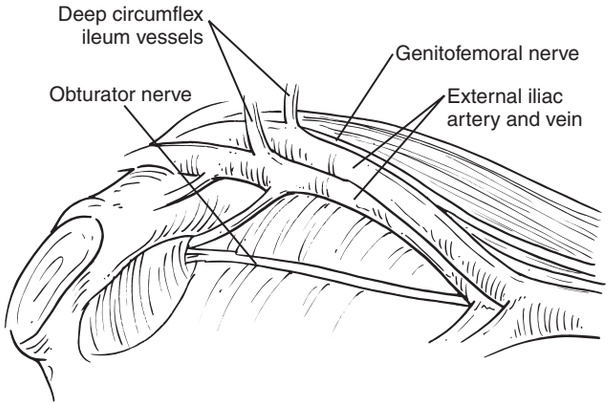

FIGURE 68-4.

Whereas an increased number of nodes are typically obtained in this dissection, the complication rate is increased in some studies. Interestingly, there is no consensus regarding what constitutes an EPLND. Some authors advocate leaving some lymphatic tissue intact anterior to the external iliac artery to prevent lower extremity lymphedema, while other authors include this zone and also recommend removal of the presacral nodes bilaterally. In some series, the method by which the nodes are sent in separate packets and/or pathologically analyzed has had a major impact on the number of nodes pathologically detected.

Laparoscopic/Robotic (MIS) Pelvic Lymph Node Dissection

Both the modified and the extended pelvic lymph node resection can be performed via a variety of minimally invasive routes (MIS = laparoscopic or robotic-assisted). MIS

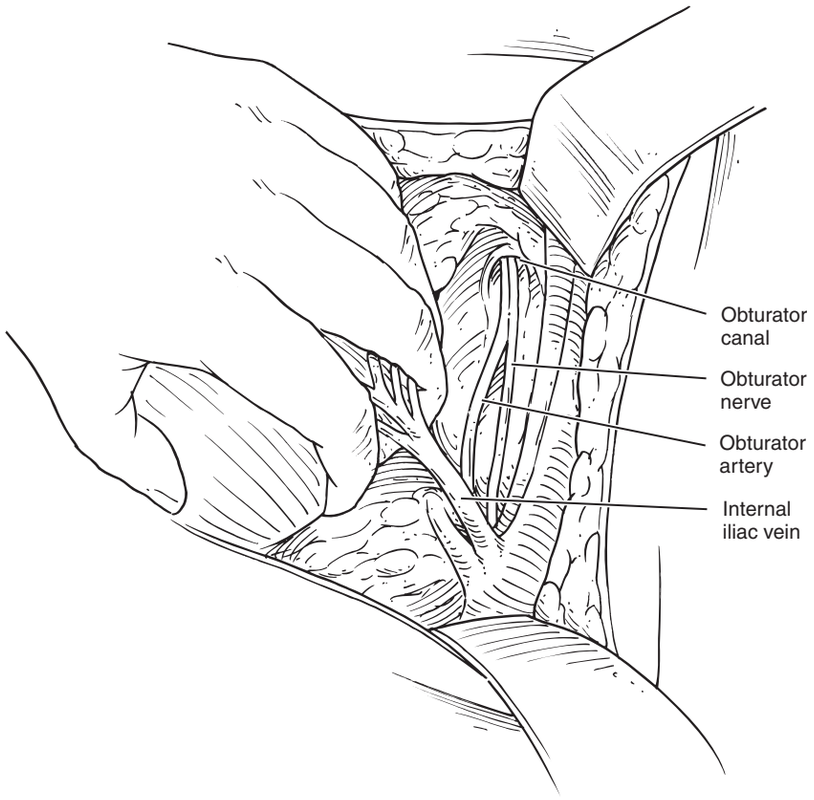

FIGURE 68-5.

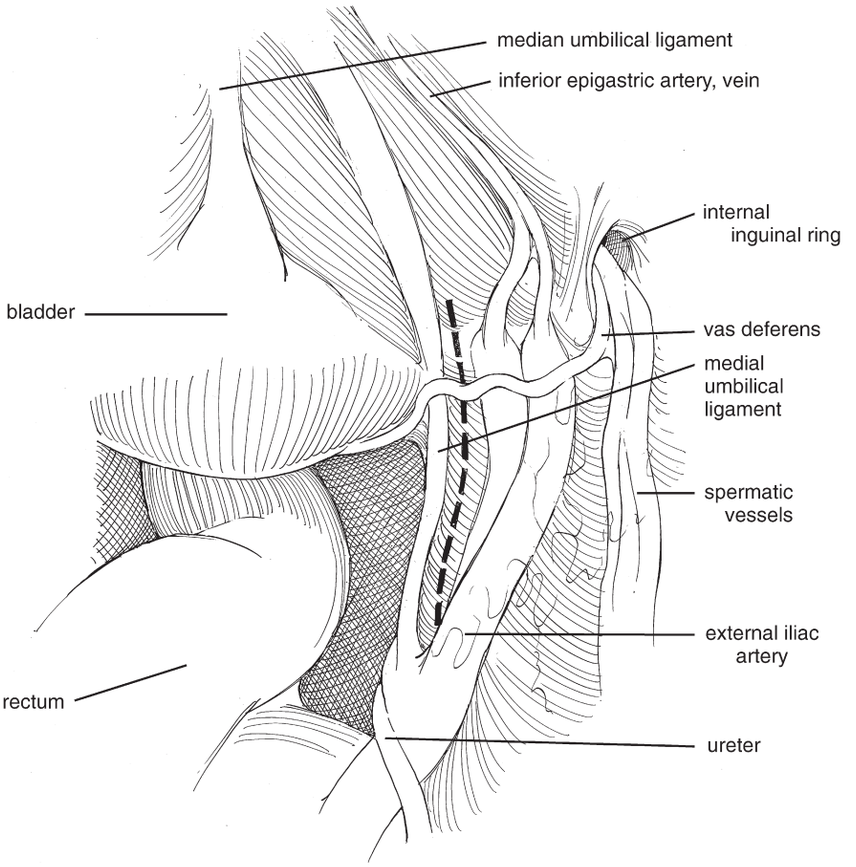

FIGURE 68-6.

PLND was initially described as a separate staging procedure, although this is currently typically incorporated into performance of an MIS radical prostatectomy. In general, the steps and boundaries for performance of each type of PLND for prostate cancer are similar to those of the open procedure once access to the space of Retzius and pelvic sidewall are obtained (Fig. 68-6). Trocar and port placement is typically in a fan-shaped configuration. Both transperitoneal and extraperitoneal approaches are described elsewhere in the literature.

While some critics have proposed that EPLND may not be possible using laparoscopic or robotic techniques, the performance of extensive and complete PLNDs during MIS radical cystectomy and laparoscopic retroperitoneal lymph node dissections for testicular malignancy via laparoscopic and robotic methods have shown this concern to be unfounded.

TECHNIQUE

Transperitoneal Exposure

The lymph node dissection can be performed either at the beginning of the procedure before performance of the radical prostatectomy or at the conclusion of the procedure after removal of the prostate but before performance of the vesicourethral anastomosis.

If the procedure is to be performed before radical prostatectomy, it can be performed before initial mobilization of the bladder and exposure of the endopelvic fascia or after this mobilization is performed.

If the surgeon desires to perform it at the beginning of the procedure before bladder mobilization, the posterior peritoneum is incised midway between the medial umbilical ligament and the internal inguinal ring and is extended cephalad to the level of the vas deferens. A second peritoneotomy incision can be made in an inverted V fashion and may increase exposure. The vas deferens can be clipped, ligated and divided, cauterized and divided, or simply elevated and mobilized to provide additional access to the obturator node area and the iliac vessels (Fig. 68-7).

For transperitoneal performance either immediately after bladder mobilization or after removal of the prostate, the exposure is similar in both scenarios. Care should be taken to extend the bladder mobilization inverted U posteriorly to at least the level of the vas deferens as they cross the iliac vasculature. Dissection of the space between the lateral wall of the bladder and the iliac vasculature should be performed (Fig. 68-8). Much of this mobilization can be performed in a blunt fashion. Ensuring that the bladder is completely empty and mobilized laterally allows medial retraction via a contralateral port on the bladder and reduces tension during the vesicourethral anastomosis.

Dissection is initiated by clearing the fibrofatty tissue off of the medial aspect of the external iliac vein similar dissection done in the open procedure (Fig. 68-9). We use the fourth arm of the robot to retract medially on the bladder, or for laparoscopic PLND, an assistant can retract using a

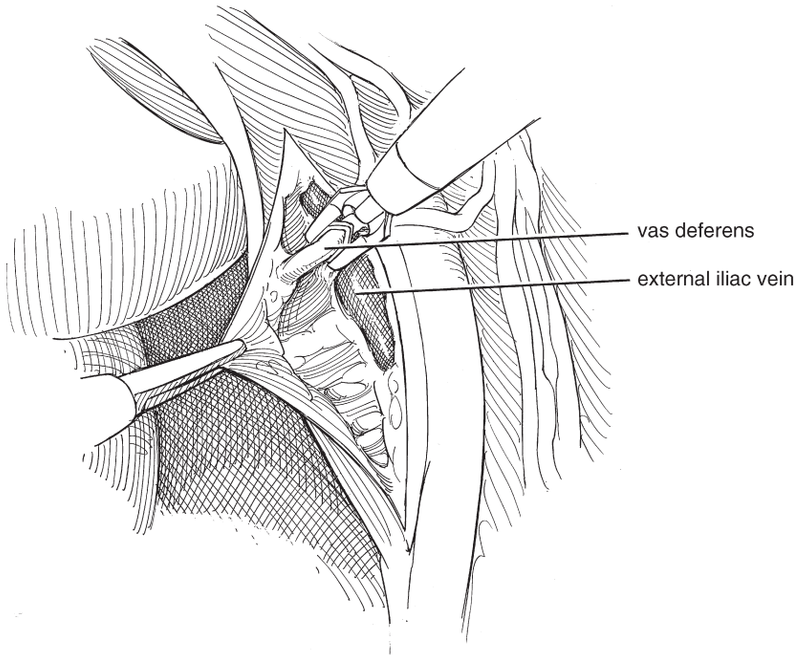

FIGURE 68-7.

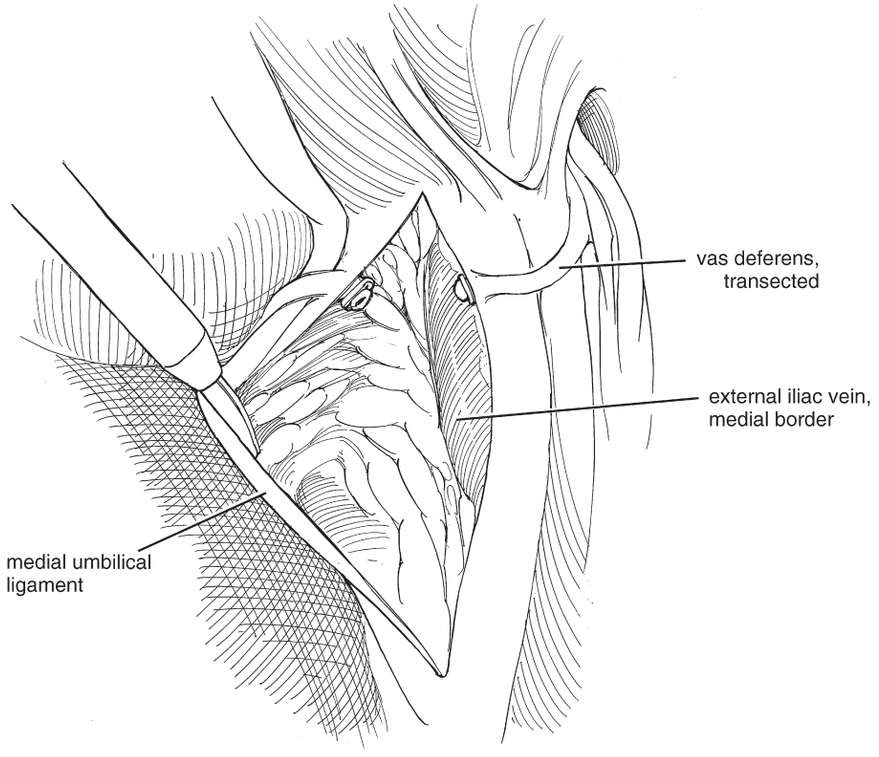

FIGURE 68-8.

contralateral laparoscopic port. This allows for use of a blunt grasper and cautery scissors to clear the fibrofatty tissue off of the external iliac vein. The vein is then gently elevated with a blunt grasper and the dissection carried down onto the pelvic sidewall beneath the vein. This dissection is carried distally to the node of Cloquet and proximally to the hypogastric vessels. Next, the obturator nerve is identified and dissected distally and proximally on its superior surface. The distal packet is then clipped distally and divided just proximal to the clip using locking endoscopic clips. The entire packet is then retracted superiorly and medially, allowing dissection back to the level of the hypogastric artery. One to two locking clips are placed on the proximal lymph channels and left in situ with division distal to the clips of

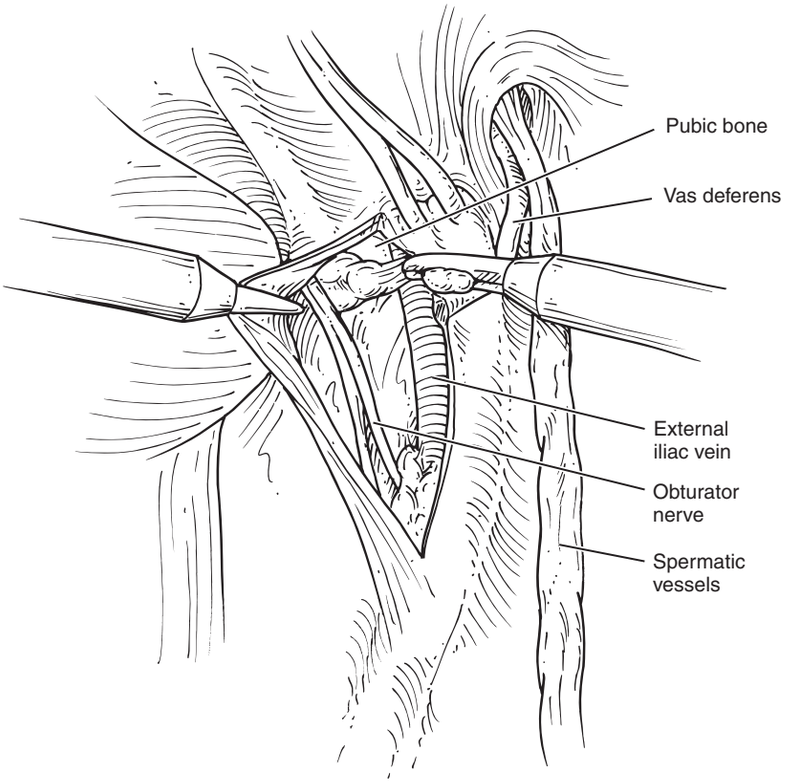

FIGURE 68-9.

the remaining tissue anchoring the packet. The lymph node packets are then either placed in specialized retrieval bags for later removal or if small enough removed using laparoscopic 10-mm biopsy forceps.

Extraperitoneal Technique

Use of an extraperitoneal exposure has been described for both robotic and laparoscopic PLND and Retropubic Radical Prostatectomy (RRP). Refer to the chapters discussing the extraperitoneal approach to MIS RRP. While the advantages of the extraperitoneal approach include avoidance of encroaching bowel, rapid exposure, and familiar anatomy to urologists, disadvantages are a smaller working space and the need for highly skilled assistance, for example, for suctioning due to the confined working space.

Technically, the dissection proceeds in the same manner as the intraperitoneal dissection but requires the surgeon to retract the bladder medially and to bluntly expose the space posteriorly toward the internal iliac vessels. While we have successfully used this approach in some patients, exposure seems especially challenging when the patient is morbidly obese.

MIS Extended Pelvic Lymph Node Dissection

As stated previously, what constitutes an EPLND for prostate cancer is the subject of great controversy. A growing amount of literature both for prostate cancer and bladder cancer has shown that the dissection and removal of both malignant organs and the surrounding nodal tissue dissections can be performed via MIS techniques and can completely recapitulate the open technique.

For the MIS EPLND, the peritoneum is incised laterally to the medial umbilical ligament over the external iliac artery. This incision is carried back to the level of the common iliac artery. The vas is identified and divided as previously described. Distally the superior pubic ramus is identified. Proximally the umbilical ligament is followed back to its offtake from the internal iliac artery. During this portion of the dissection, the ureter and the superior vesical artery crossing over the ureter are identified and preserved. The ureter is swept medially to protect it from harm. The node dissection proceeds in a standard fashion comparable to the open EPLND. The fibrofatty tissue and lymphatics over the external iliac artery are split and rolled, as are those over the external iliac vein. Retraction medially on the superior lateral side of the bladder exposes the internal iliac vessels. The fibrofatty and lymphatic tissue over the internal iliac vessels is split and rolled similarly. Meticulous hemostasis using electrocautery, bipolar, or clip ligation should be performed. The obturator nerve is identified and skeletonized, and the packets of lymph node tissue present in the obturator fossa superior to the nerve and inferior to the nerve are dissected from the lateral pelvic sidewall musculature. Clips are applied distally to the node of Cloquet. Any proximal lymphatic channels and trunk are similarly ligated. Specimens can either be removed en bloc or as separate specimens depending on the needs of the dissection.

Some surgeons place bilateral drains after EPLND and leave these in for more extended periods of time, usually

4 to 7 days. Other studies have not noted the increased risk for lymphocele seen in some experiences and do not advocate extensive or prolonged drainage.

COMPLICATIONS

The major intraoperative complications related to PLND include all standard risks of prostatectomy, including hemorrhage, vascular injury, bowel injury, and nerve injury.

Nerve injury: Special care should be taken in relationship to identifying and protecting from harm the obturator nerve and its associated vessels. Injury to the obturator nerve causes difficulty with adduction of the leg and thigh. Care should be taken during the lymphadenectomy to identify the obturator nerve coursing in the fibrofatty tissue inferior to the external obturator lymph node packet. If the nerve is transected, intraoperative consultation with the neurosurgery department can be obtained for nerve repair.

If extended lymphadenectomy is performed, care should be taken to avoid injury to the genitofemoral nerve. In addition, caution should be used during the positioning of all patients for open, laparoscopic, and robotic RRP/PLND, because neurapraxia due to flexed positioning and retractor placement has been observed.

Hemorrhage: Injury to the obturator vessels can typically be controlled with the use of clips, sutures, or bipolar cautery. Care should be taken to avoid injury of the obturator nerve. For more substantial injuries to the iliac vasculature, formal vascular repair should be performed. Temporary occlusion via noncrushing vascular clamps may be needed, and intraoperative vascular surgery consultation for significant injuries may be requested. During robotic and laparoscopic surgery, the pneumoperitoneum often collapses the iliac veins significantly, allowing for sutured repair.

Deep venous thrombosis (DVT)/thrombus: As with any pelvic organ surgery, there is a risk of thrombus formation in the iliac vessels. Prophylactic use of sequential compression devices should be initiated before the induction of anesthesia and continued during the postoperative period. In high-risk patients, the use of subcutaneous injection of anticoagulants, such as low molecular weight heparin, should be considered. There is significant controversy regarding the risk-to-benefit ratio of universal use of anticoagulation.

POSTOPERATIVE COMPLICATIONS

Lymphocele: Lymphocele formation can occur in up to 12% of patients. Many surgeons leave a temporary closed-suction drain in the pelvis after open and minimally invasive prostatectomy/PLND. Lymphocele formation is probably more common after extraperitoneal procedures, such as open and extraperitoneal minimally invasive prostatectomy. The rate of asymptomatic lymphoceles is probably not appreciated due to the rarity of postoperative imaging of the pelvis in these patients. Symptomatic lymphoceles can present with infection, pain, leg edema/swelling, and/or DVT. Management typically incorporates immediate percutaneous drainage for any infected or symptomatic lymphoceles. Symptomatic recurrent lymphoceles can be managed by aspiration sclerosis or more formal management techniques, such as laparoscopic or open marsupialization into the peritoneal cavity. Use of ligation techniques, such as suture or clip ligation of lymph chains during the dissection is encouraged to prevent the formation of lymphoceles.

Other injuries: Rarely, the ureter or other surrounding organ structures such as the bowel or bladder can be injured during lymph node dissection. Standard operative management of these rare injuries is indicated.

Commentary by

MICHAEL O. KOCH

Proper performance of PLND is a critical component of the accurate surgical staging of prostate cancer. In this chapter, the author describes some of the controversies surrounding who needs lymphadenectomy and how extensively it should be performed. Accurate knowledge of the normal drainage patterns is critical to accurate staging and a complete understanding of the anatomic relationships with the surrounding structures is vital to avoiding vascular or nerve injury.

This page intentionally left blank

Chapter 69

Robotic-Assisted Laparoscopic Prostatectomy

JOSEPH A. SMITH, JR.

Although a pure laparoscopic approach to radical prostatectomy is feasible, the operation is formidable for a surgeon without advanced laparoscopic skills. The surgical robot is a computerized system of mechanical arms controlled remotely by the surgeon who is seated at a console. Currently, there is only a single robotic system available for surgical use, the da Vinci surgical robot (Intuitive Surgical, Sunnyvale, Calif.). The da Vinci system provides three-dimensional magnification of the operative field and permits precise tissue handling and easy suturing. It can greatly facilitate performance of radical prostatectomy.

Candidates for robotic-assisted laparoscopic prostatectomy (RALP) in general are the same as those eligible for open surgery. Wide surgical resection margins can be achieved with robotic prostatectomy and an extended pelvic lymph node dissection can be performed when desirable. There may be particular advantages to RALP for obese men and those with prior laparoscopic hernia repair with mesh. A large prostate volume can create some exposure difficulties as the prostate may fill the pelvis but prostate size alone or the presence of a large median lobe do not preclude successful performance of RALP.

SURGICAL TECHNIQUE

Patient Positioning

With all operations, proper patient positioning is key but this is particularly important with robotic prostatectomy. A steep Trendelenburg position helps provide easy access to the pelvis for instruments but also helps displace the bowel cephalad. The patient's legs must be carefully placed in a lithotomy position. With the steep Trendelenburg, it is important to use an egg crate or other nonslipping surface to prevent the patient from sliding to the head of the table. After positioning, the table should be placed temporarily in steep Trendelenburg to make certain the patient does not slide and then repositioned without tilt for placement of the laparoscopic ports.

Port Placement

Comparable results have been achieved for both extraperitoneal and intraperitoneal laparoscopic access. The intraperitoneal approach is used most commonly and is described in this chapter.

A 12-mm vertical incision is made superior to the umbilicus and a Veress needle is carefully introduced through the abdominal wall. The needle is aspirated and a drop test is performed to confirm the intraperitoneal location of the needle. The insufflation tubing is connected and careful attention is paid to the opening pressure, which should be less than 7 to 8 mm Hg. The abdomen is insufflated to 15 mm Hg and a 12-mm trocar is introduced through the previously fashioned 12-mm incision. The robotic camera is inserted and the abdomen is inspected to show the absence of vascular or bowel injury. The patient is then placed in a steep Trendelenburg position.

The patient is marked approximately 15-cm superior to the pubic symphysis (Fig. 69-1). There is some variability in the distance from the symphysis to the umbilicus; however, this mark will generally fall just below the level of the umbilicus. This reference mark will guide the placement of the robotic trocars. Attention is initially paid to the left side of the patient's abdomen, which will accommodate two 8-mm robotic trocars (arm 2 and arm 3). The patient is marked approximately 7 to 8 cm lateral to the reference mark, and an 8-mm robotic trocar is introduced under direct vision. A second 8-mm robotic trocar is placed 7 to 8 cm lateral to the first robotic trocar. These trocars will accommodate robotic arms 2 and 3, respectively. Attention is then turned to the right side of the patient's abdomen. The table side assistant is on the right side, so two assistant ports and one robotic trocar will be placed. An 8-mm robotic trocar is placed under direct vision approximately 7 to 8 cm lateral to the reference mark. This trocar will accommodate robotic arm 1. Once the final robotic trocar has been placed, attention is turned to placement of the 12-mm lateral assistant port. The anterior superior iliac spine is palpated and serves as a landmark for placement of the lateral-most right-sided

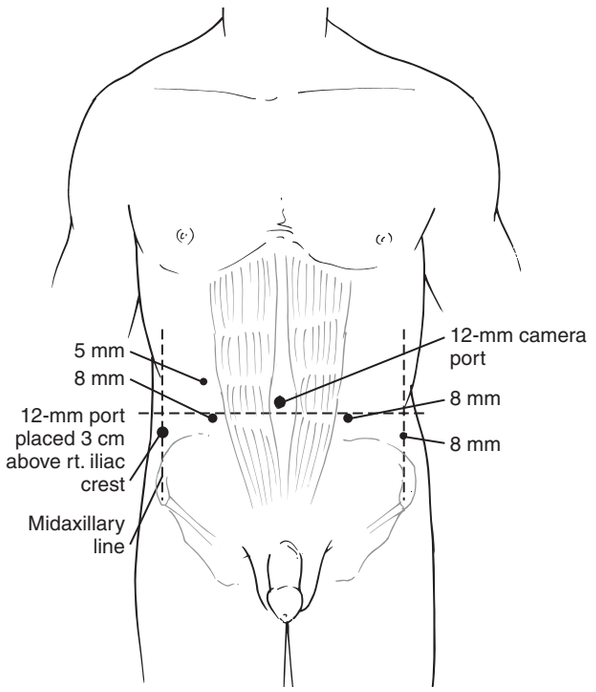

FIGURE 69-1. Port placement for a robotic assisted laparoscopic prostatectomy. Proper port placement provides optimal access to the pelvis and avoids clashing of instruments.

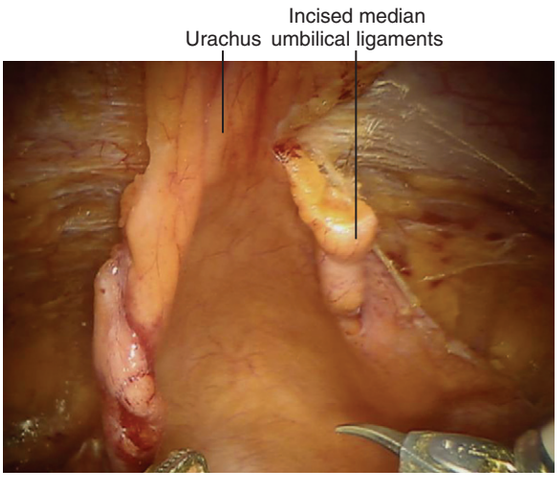

FIGURE 69-2. View of the partially incised peritoneum overlying the pelvis. The median umbilical ligaments have been divided and the urachus is seen in the midline.

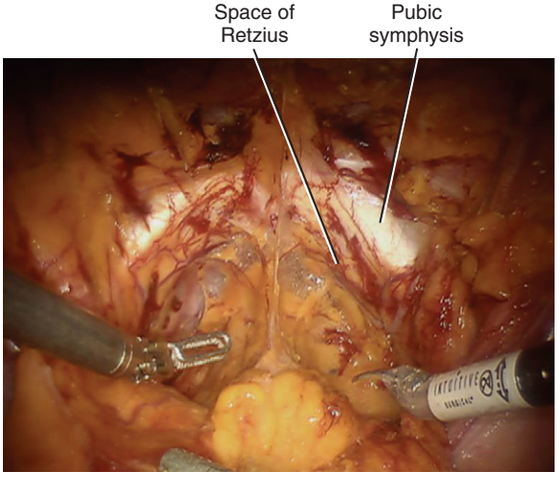

FIGURE 69-3. The space of Retzius is revealed posterior to the arch of the pubic symphysis.

trocar. A 12-mm trocar is placed approximately 3 to 4 cm superomedial to the iliac crest in a line drawn directly between the iliac crest and the camera port. Lastly, a 5-mm assistant port is placed directly between the two previously placed right-sided ports approximately 3 cm superior to a line drawn between the two trocars.

Exposure of the Prostate

Key anatomic landmarks to note are the median umbilical ligaments, the urachus, and the internal inguinal ring. Using either the straight or the 30-degree up lens, an incision is made in the peritoneum above the level of the pubic symphysis. The median umbilical ligaments and the urachus are divided (Fig. 69-2). This reveals the pubic symphysis and helps develop the space of Retzius (Fig. 69-3). The peritoneal incision is carried along the lateral pelvis all the way up to the level of the vas deferens at the internal inguinal ring. A dissection that is too far lateral could injure the epigastric vessels. The lateral attachments of the bladder are bluntly and sharply developed. This allows the bladder to fall posteriorly and expose the prostate in the space of Retzius. Caution must be used to identify an accessory pudendal artery, which may course through the tissues just lateral to the prostate and enter the genitourinary diaphragm at the dorsal vein complex (Fig. 69-4).

Control of the Dorsal Vein Complex

The fatty tissue overlying the prostate should be carefully excised, further defining not only the anatomic boundaries of the prostate but also the superficial dorsal vein and the puboprostatic ligaments. The superficial dorsal vein can be divided with electrocautery.

Two basic techniques have been described for control of the dorsal vein complex, one that involves sutures and the other staples. As with open surgery, suture control of the dorsal vein complex is used more commonly. After the endopelvic fascia is incised (Fig. 69-5), a 0 polydioxanone suture (PDS) or Vicryl suture is placed around the dorsal vein complex using a CT-1 needle. Careful identification of an anatomic notch between the venous complex and the anterior urethra facilitates placement of the suture (Fig. 69-6). A slip-knot tie can help ensure that the knot is secure. A second more proximal suture may be placed. Suspension of the urethra is accomplished by passing the suture through the pubic symphysis and securing it with a laparoscopic clip (Fig. 69-7). Once the sutures are secured, it is not necessary to divide the dorsal vein complex at this point. The vascular venous control achieved

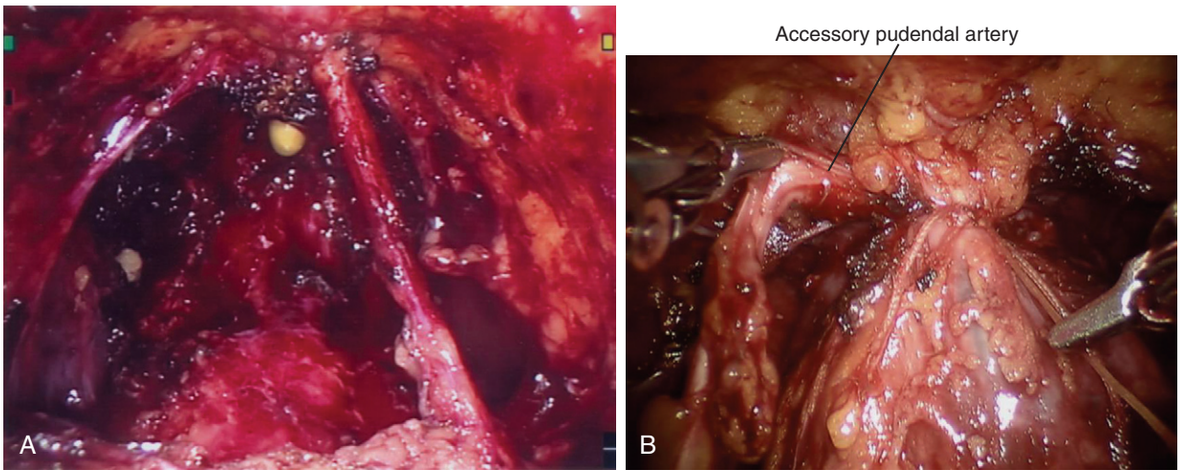

FIGURE 69-4. A, A large accessory pudendal artery is seen on the right side of the pelvis. **B,** A left-sided accessory pudendal artery is shown piercing the genitourinary diaphragm just distal to the dorsal vein complex sutures. Care must be taken to mobilize the artery sufficiently so that the sutures can be placed without entrapping the artery. *(**A**, From Smith JA Jr, Tewari A. [2008]. Robotics in urologic surgery. Philadelphia: Saunders.)*

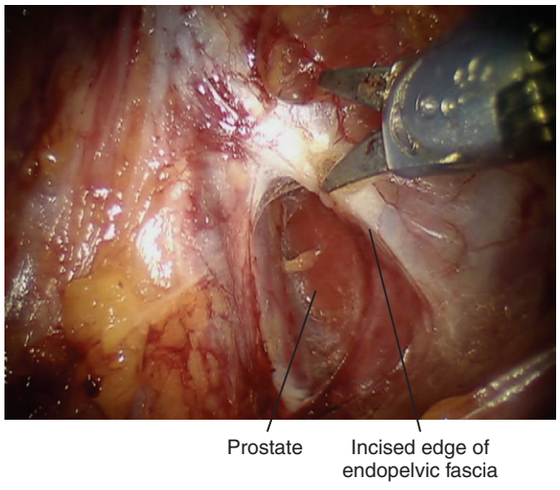

FIGURE 69-5. The right endopelvic fascia has been incised showing the lateral margin of the prostate.

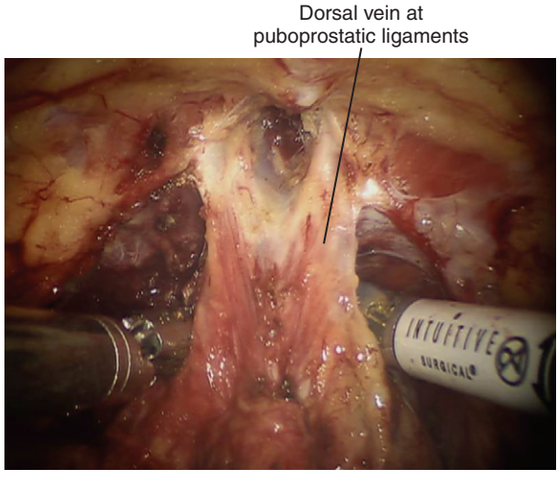

FIGURE 69-6. The dorsal vein complex and the puboprostatic ligaments are shown after the endopelvic fascia has been incised bilaterally.

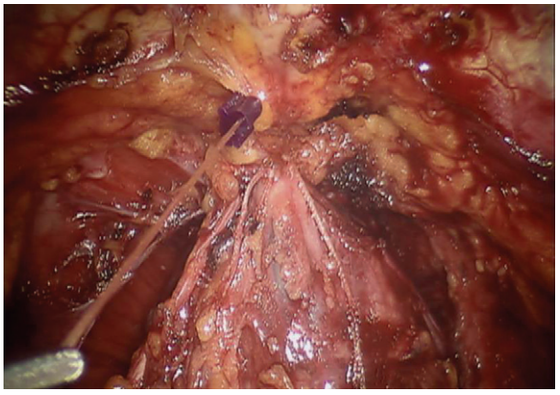

FIGURE 69-7. A suture from the dorsal vein complex passed through the cartilage of the pubic symphysis is secured with a laparoscopic tie to elevate and lengthen the urethra.

by the suture placement helps avoid blood loss during the remainder of the operation while division of the dorsal vein complex and urethra is reserved for later in the procedure.

With the stapling technique, the puboprostatic ligaments and dorsal vein complex are controlled in a similar manner. The stapling device is vertically placed with care to avoid incorporation of the anterior urethra or sphincter muscle in the staple line (Fig. 69-8).

Dissection of the Bladder Neck

Proper identification of the anatomic plane between the bladder neck and the prostate is essential to avoid entry into the prostate base or result in an overly large bladder neck. Several visual cues are used. Grasping the more proximal bladder with the fourth arm and a ProGrasp instrument can place some tension on the bladder and help with exposure. Typically, the perivesical fat ends at an anatomically defined point at the prostatovesical junction.

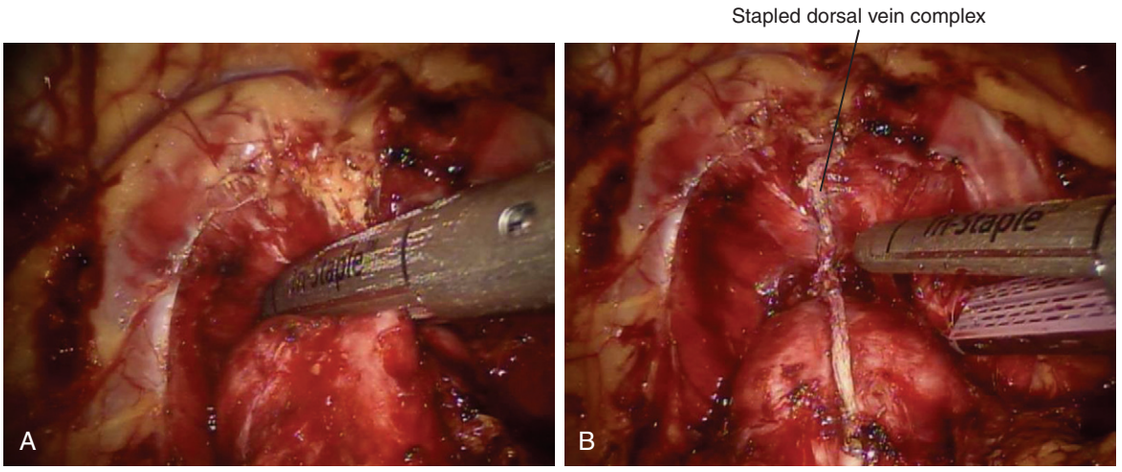

FIGURE 69-8. A, The stapler is passed around the dorsal vein complex. **B,** The dorsal vein complex has been separated from the prostatic apex after firing of the stapler.

Some surgeons pull on the Foley catheter gently and use the balloon to help define the bladder neck. An important technique is to use the right and left arms of the robot to indent or "pinch" the bladder at the prostatovesical junction (Fig. 69-9). This helps define the contour of the lateral prostate and allows the surgeon to visualize the point of division anteriorly.

Monopolar electrocautery scissors are used to begin the dissection of the prostatovesical tissue (Fig. 69-10). Typically, there are some veins that require cautery control coursing from the dorsal vein complex and into the perivesical tissue. Most surgeons either use a Maryland bipolar forceps in the left arm or a bipolar grasper. The prostate tissue has quite a characteristic appearance to alert the surgeon when the dissection is too close to the prostate. It is more vascular, thicker in quality, and often exudes a bubbly white secretion when the incision is into the prostate tissue. The entry into the bladder should be proximal to the prostatovesical junction. The Foley catheter is deflated and withdrawn into the urethra to expose the bladder trigone. The trigone should be readily visible. Careful inspection should be performed to make certain that there is not a median lobe. If so, the median lobe is grasped with the fourth arm and lifted anteriorly to expose the trigone (Fig. 69-11). Exposure is facilitated either by using the fourth arm or an assistant to elevate the Foley catheter or by directly grasping and elevating the prostate itself.

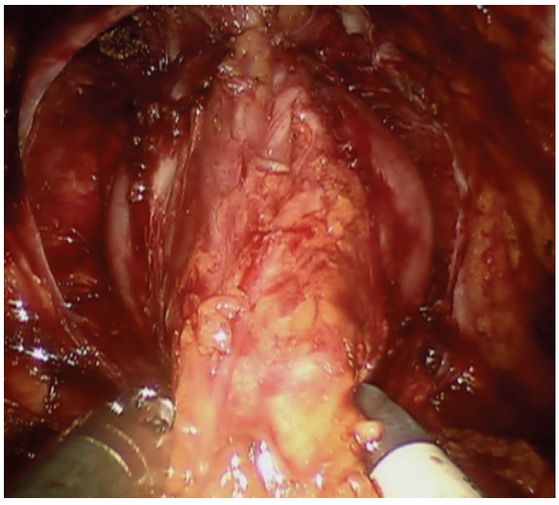

FIGURE 69-9. The right and left arms of the robot are used to pinch the bladder and help identify the contour of the prostate and the prostatovesical junction.

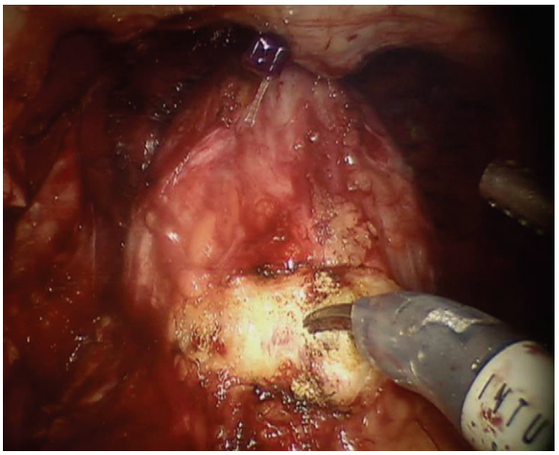

FIGURE 69-10. Monopolar scissors are used to separate the prostate from the bladder.

Once the posterior bladder neck and trigone are clearly identified, the incision is carried through the posterior bladder neck. The posterior bladder wall should be carefully visualized and the thickness should approximate that of the remainder of the bladder wall (Fig. 69-12). Dissection too close to the bladder risks injury to the ureters or buttonholing of the posterior bladder. Using the scissors as a cutting device but with some monopolar cautery helps provide good tissue separation and avoids excessive electrocautery, which can change the visual characteristics of the tissue and make the dissection more difficult. A longitudinal muscle layer between the base of the prostate and the detrusor is visible and should be divided sharply. Immediately beneath this tissue lie the vasa deferentia and seminal vesicles.

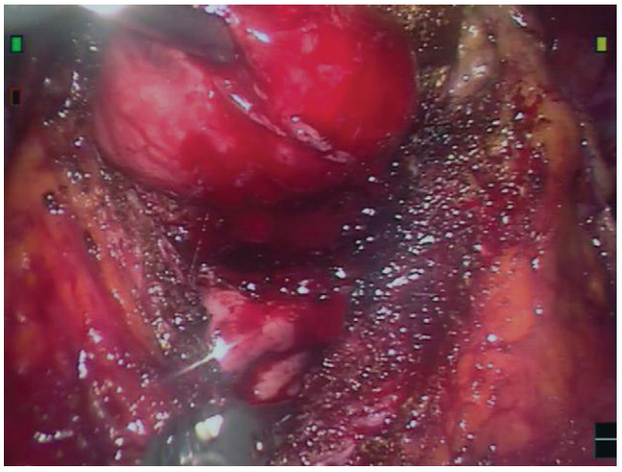

FIGURE 69-11. A large median lobe is grasped and elevated with the fourth arm to show the bladder trigone. *(From Smith JA Jr, Tewari A. [2008]. Robotics in urologic surgery. Philadelphia: Saunders.)*

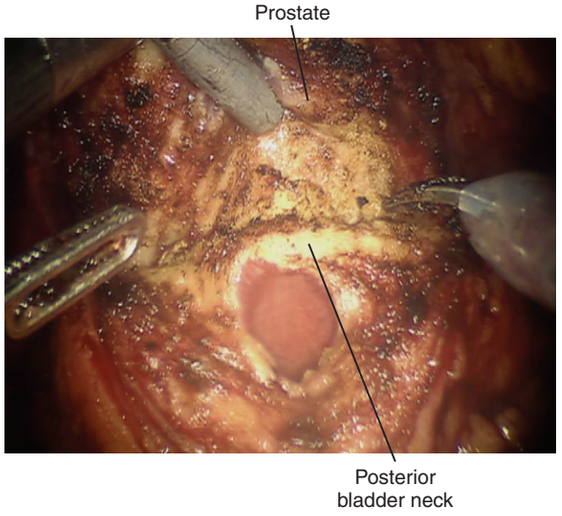

FIGURE 69-12. The prostate has been dissected from the bladder. The width of the posterior bladder muscle should approximate that of the remainder of the bladder neck to avoid excessive thinning of the bladder.

Seminal Vesicle Dissection

Once the anterior portion of the vasa deferentia and seminal vesicles are exposed, the vas deferens is grasped with the fourth arm. The anterior tissue over the proximal seminal vesicle can be swept aside easily. The vas deferens is then divided and the small artery along the side of the vas controlled with the cautery. The distal vas deferens is then grasped with the fourth arm and elevated. Dissection of the seminal vesicle can be facilitated by grasping and elevating the proximal vas deferens. Dissection is carried immediately along the anterior surface of the seminal vesicle. A surgical assistant can be quite helpful in providing proximal exposure. The tip of the seminal vesicle is visualized and a clip is placed across the artery (Fig. 69-13). Use of electrocautery

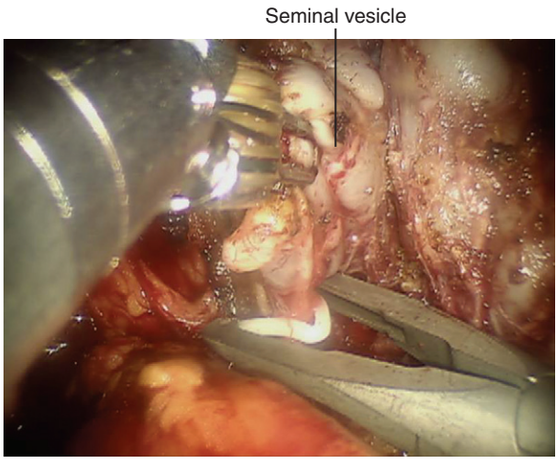

FIGURE 69-13. A clip is placed at the tip of the seminal vesicle to control bleeding and avoid the need for electrocautery.

should be minimized during the seminal vesicle dissection to avoid damage to the nerves and neurovascular bundle which course nearby. Once both seminal vesicles are freed completely and the vas deferens is divided bilaterally, they are grasped with the fourth arm and elevated superiorly.

An alternative method for seminal vesicle exposure is to develop the rectovesical space immediately upon entering the peritoneum. An incision is made in the peritoneal surface overlying the bladder just above the pouch of Douglas. The vasa deferentia are identified laterally and grasped. This leads directly to the tip of the seminal vesicle. The dissection can then be carried forward just anterior to the rectum and posterior to the bladder. With this method, the initial step of the operation is to completely free the vas deferens and seminal vesicles. The remainder of the operation then proceeds as described above except that the seminal vesicles are already free once the posterior bladder neck is divided.

Development of the Posterior Plane

Denonvilliers fascia covers the prostate and anatomically is derived from an extension of the peritoneum in the cul-de-sac of the pouch of Douglas. Several different methods have been described for dissection of the prostate relative to the fascial coverings that surround it. In general, the terminology used is as follows:

- *Intrafascial:* The dissection posteriorly is between Denonvilliers fascia and the prostate and laterally courses beneath the prostatic fascia. Because there is no true prostatic capsule, this approach leaves no fascial layer overlying the prostatic tissue.
- *Interfascial:* The dissection posteriorly is between the prostate and Denonvilliers fascia and laterally between the prostatic fascia and the lateral pelvic fascia.
- *Extrafascial:* The posterior dissection is carried posterior to Denonvilliers fascia and along the perirectal fat. Laterally, the dissection incorporates all of the lateral pelvic fascia and extends to the levator fascia.

When nerve sparing is performed, an interfascial approach is most commonly used. The rectal plane is established just anterior to a thick and readily identifiable Denonvilliers fascia. Typically, this is an avascular plane and bleeding usually implies that the dissection is too far anterior. This risks entry into the base of the prostate. The dissection can progress all the way to the prostatic apex using a combination of blunt and sharp dissection, and care should be taken to avoid overdissection either beyond the prostatic apex or laterally to the neurovascular bundle. The rectum lies immediately behind this plane of dissection and excessive cautery should be avoided. If difficulty is encountered when entering the proper plane of dissection at one point, it is better to move either laterally or medially to a fresh area in an attempt to initiate the dissection. Grasping the more proximal tissue with the left arm places Denonvilliers fascia on stretch and can facilitate identification of the proper plane (Fig. 69-14). Once the proper plane of dissection is entered, it can then be extended more readily across the entire base of the prostate (Fig. 69-15).

With an extrafascial approach, which is appropriate for more advanced or high-grade tumors, the dissection plane is posterior to Denonvilliers fascia. The fascia should be sharply incised, exposing the perirectal fat (Fig. 69-16). This plane typically develops quite easily, although there may be some adherence of the tissues as a consequence of prior needle biopsies or even tumor extension.

Preservation of the Neurovascular Bundle

It is commonly agreed that thermal energy should be limited or avoided entirely during dissection of the neurovascular bundle. Also, the nerves are quite fragile and susceptible to stretch injury so care must be taken to avoid excessive traction as the prostate is manipulated within the pelvis to provide exposure. Understanding and exposing the relationship between the neurovascular bundle and the pedicle is crucial. Initial identification of the neurovascular bundle along the lateral prostate before dividing the pedicle can be quite helpful. The lateral pelvic fascia is incised sharply along the anterolateral prostate (Fig. 69-17). Even though there may be very few nerves of consequence in this tissue,

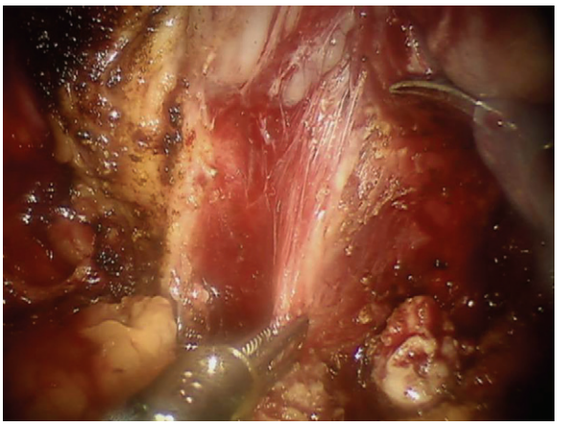

FIGURE 69-14. The left arm is used to place the tissue on stretch and facilitate entry into proper fascial plan posterior to the prostate.

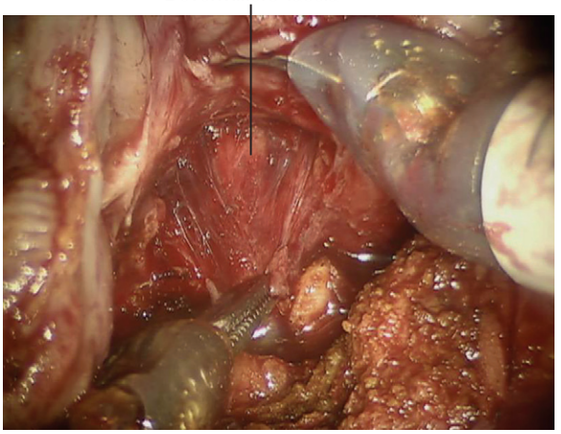

FIGURE 69-15. An interfascial posterior dissection between the prostate which is elevated anteriorly and Denonvilliers fascia.

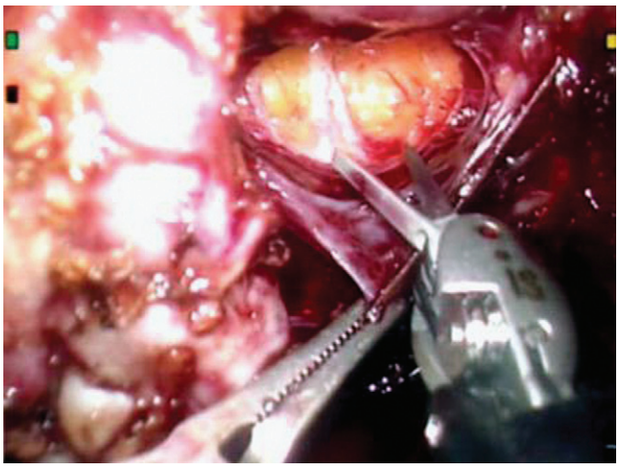

FIGURE 69-16. An extrafascial dissection shows incision through Denonvilliers fascia to expose the perirectal fat. *(From Smith JA Jr, Tewari A. [2008]. Robotics in urologic surgery. Philadelphia: Saunders.)*

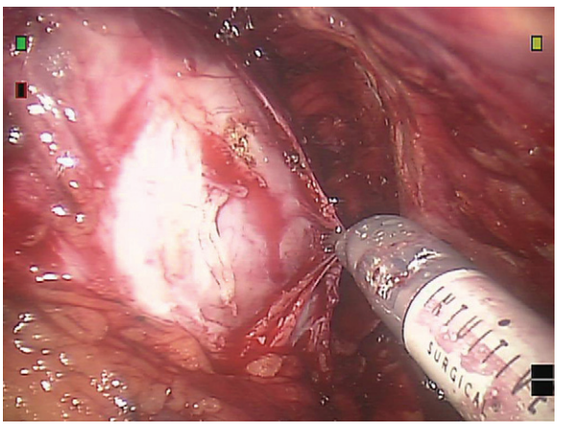

FIGURE 69-17. Incision along the right side of the prostate to release the lateral pelvic fascia.

establishing a leading edge of tissue permits the surgeon to grasp the edge during the dissection without crushing the nerves. The incision of the lateral pelvic fascia is carried down to the prostatic apex and along the posterolateral prostate and toward the base. The prostatic pedicle can then be identified. The remainder of the neurovascular bundle dissection occurs once the pedicle is divided. The key is to base the dissection on visualization of the prostate (Fig. 69-18). By maintaining a plane of dissection immediately alongside the prostatic fascia, limited dissection or damage occurs to the periprostatic tissue, including the nerves which course throughout this tissue and which can be quite variable in their anatomic location.

Control of the Pedicle

Various methods have been described for control of the vascular pedicle. Some surgeons simply incise it with electrocautery but this risks propagation of the thermal energy to the adjacent nerve tissue, even with bipolar cautery. The pedicles can be temporarily occluded with bulldog clamps and then sutured once the prostate is removed. A stapling device can control the pedicle. Some surgeons simply perform suture ligation of the pedicle itself. Most commonly, locking Weck clips are used.

Proper placement of the clips is crucial. Such placement is facilitated by exposing the pedicles by the posterior dissection and the lateral dissection of the neurovascular bundle (Fig. 69-19). The ipsilateral seminal vesicle can be grasped with the fourth arm and elevated, clearly exposing the pedicle (Fig. 69-20). The scissors can be placed around the pedicle to thin the tissue such that the locking mechanism at the tip of the clip can activate. Typically, several clips are required on each side to provide full control of the vascular pedicle (Fig. 69-21).

Once the pedicle is divided, the remaining posterolateral attachments between the neurovascular bundle and the prostate can be incised sharply with scissors. Electrocautery is not necessary. Some bleeding occurs during this dissection but it rarely requires suture control. The

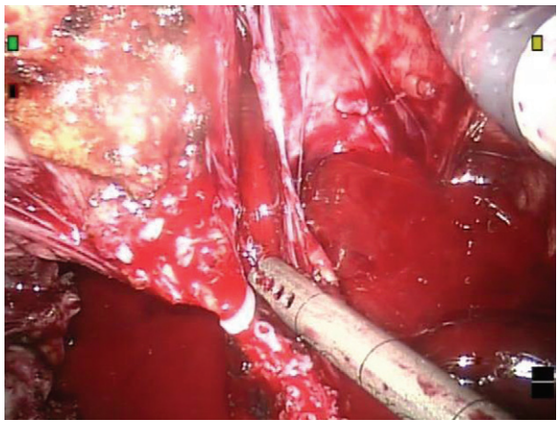

FIGURE 69-18. The prostate surface is used to guide the dissection of the curtain of tissue, which released the neurovascular bundle.

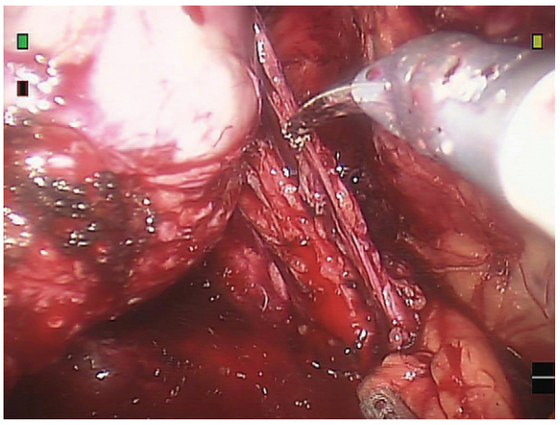

FIGURE 69-19. The relation between the right prostatic pedicle and the neurovascular is shown.

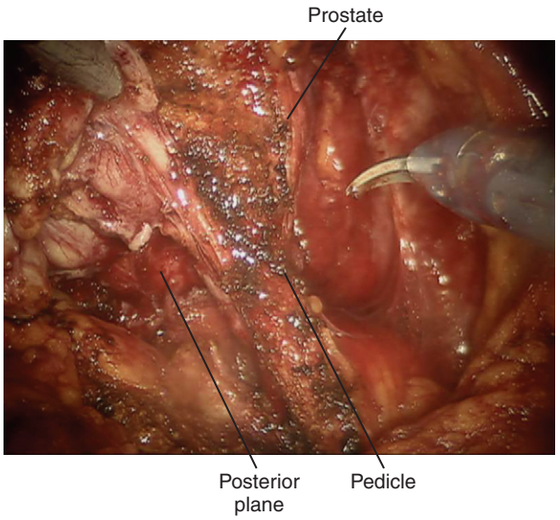

FIGURE 69-20. Elevation of the seminal vesicle helps demonstrate the right prostatic pedicle.

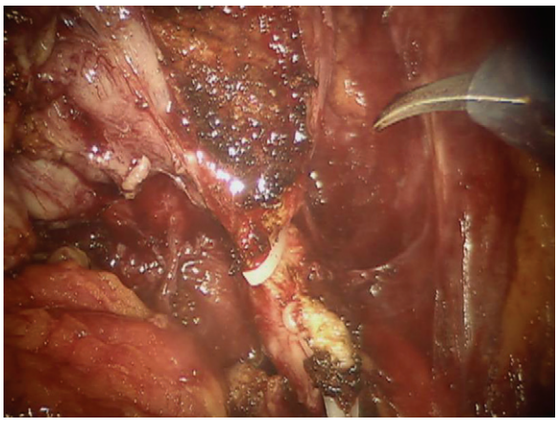

FIGURE 69-21. Locking clips are placed on the prostatic pedicle.

surgeon must exercise judgement in deciding how much bleeding is permissible and will stop spontaneously versus how much vascular control to achieve at the possible expense of damage to the neurovascular bundle.

Division of the Urethra

At this point in the operation, the prostate gland should be attached only by the previously controlled but undivided dorsal vein complex and the urethra. If the 30-degree down lens has been used for the bladder neck and posterior dissection, it may be preferable to switch to the straight telescope for the remainder of the apical dissection. The dorsal vein complex should be divided sharply immediately proximal to the hemostatic sutures. Great care should be taken to avoid entry into the anterior apical prostate in an effort to maintain length on the dorsal vein complex. Sometimes, the suture placement does not permit division of the dorsal vein complex with a sufficient distance from the prostatic apex that the sutures can be maintained. If the sutures are cut or dislodged, they are relatively easily replaced with a 2-0 Vicryl on an SH needle. The pneumoperitoneum typically keeps the bleeding at a minimal level until additional hemostatic sutures are placed.

Once the dorsal vein complex is completely divided, the prostatic apex should be easily visualized along with the urethra. Any remaining anterior apical prostatic tissue should be dissected free. The urethra can then be divided sharply with scissors at the prostatic apex. The catheter is withdrawn and the posterior urethra divided (Fig. 69-22). At this point, the operative field should be carefully inspected. There can be posterior extension of the prostate beyond the prostatourethral margin and this must be excised completely. There may be a few remaining attachments of the tissue commonly termed rectourethralis muscle and the posterior urethral plate which are incised and then the surgical specimen is removed (Fig. 69-23). It can be placed in a laparoscopy bag or left free in the pelvis and placed subsequently in the bag along with the pelvic lymph nodes if a pelvic lymph node dissection is to be performed.

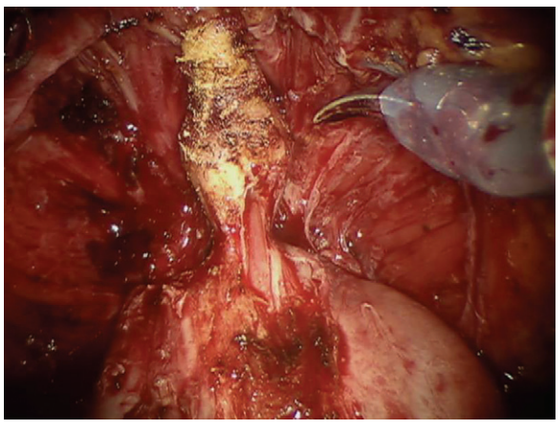

FIGURE 69-22. The posterior urethra is seen after partial division of the urethra at the prostatic apex.

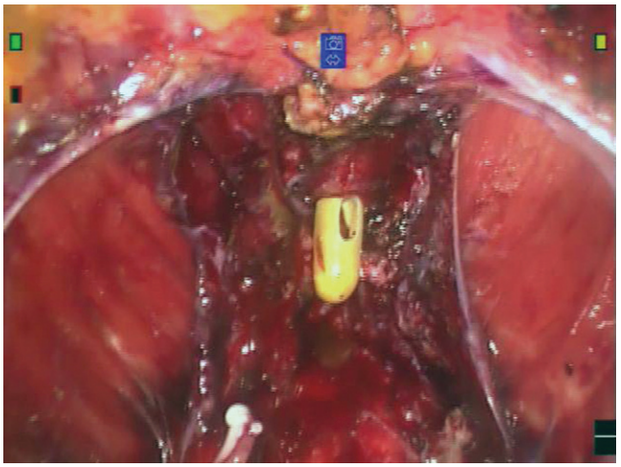

FIGURE 69-23. View of the pelvis after specimen removal. Clips are seen on the pedicle and the neurovascular bundle is shown coursing distally to the posterolateral urethra. *(From Smith JA Jr, Tewari A. [2008]. Robotics in urologic surgery. Philadelphia: Saunders.)*

Vesicourethral Anastomosis

Attainment of a secure, mucosal-to-mucosal vesicourethral anastomosis with a running suture is an important aspect of RALP to avoid postoperative problems and provide optimal outcomes. Hemostasis in the pelvis typically is good at this point but careful inspection should be performed and small sutures placed on any identifiable arterial bleeders along the neurovascular bundle or pedicle. A modification of a van Velthoven suture is commonly used for the anastomosis. Most surgeons either use 2-0 or 3-0 Monocryl and an RB-1 or SH needle. Two different suture colors are used with an 8-inch strand on each side. Another method is to use a barbed suture, which maintains tissue approximation because the barb prevents the suture from slipping (Fig. 69-24).

The initial sutures are placed in the bladder neck. The trigone should be readily visible and care must be taken to

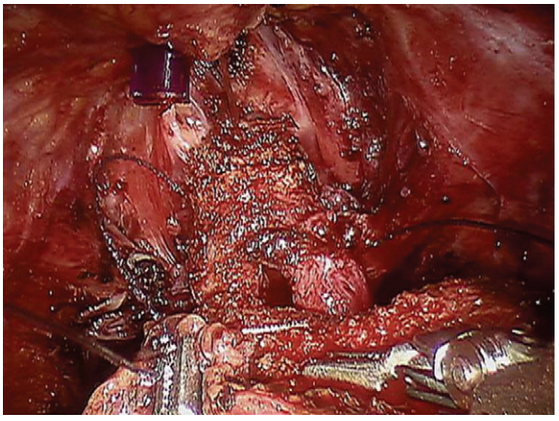

FIGURE 69-24. A barbed suture for the anastomosis maintains tissue approximation, preventing tissue slippage and loss of tension between suture throws.

avoid incorporation of the ureteral orifice. Sometimes the orifice can be quite close to the posterior bladder. If bladder neck reconstruction is required, it can be done with a posterior-based racket handle, a laterally based closure, or a simple anterior closure once the anastomosis is complete. It is important to obtain sufficiently large bites of tissue spaced far enough apart that the bladder neck tissues will hold as the sutures are tightened and the bladder is displaced toward the urethra.

The urethral sutures are then placed. They should be placed posterolateral on both sides of the urethra and incorporate sufficient tissue that they will not pull through as the anastomosis is tightened (Fig. 69-25). The neurovascular bundle can be damaged if the sutures are placed too deep and too far laterally. It is important for the assistant to periodically withdraw the Foley catheter partially to make certain that it has not been entrapped with one of the urethral or anastomotic sutures.

Many surgeons will place several sutures and then progressively lace them down with periodic tightening of the sutures to maintain the posterior tension. An alternative approach is to place a single suture through the bladder neck and urethra on both sides and then use the fourth arm to grasp the left-handed suture and the assistant to grasp the right. This allows the bladder to descend into the pelvis and be directly opposed to the urethra (Fig. 69-26). The proper direction of pull is straight up anteriorly to avoid excessive tension, which can tear the urethra. The sutures can then be progressively placed along the right side and then the left while good tension is maintained to keep good mucosal-to-mucosal approximation. A parachuting effect of the bladder neck to the urethra occurs because the bladder neck typically is larger than the urethra. If there is too much disparity in size, the bladder neck can be closed anteriorly with a running racket handle approach.

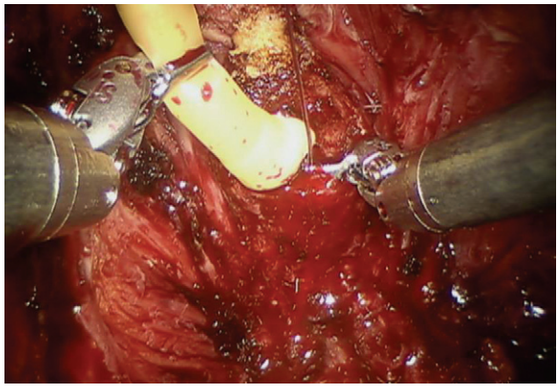

FIGURE 69-25. Placement of the urethral sutures for the anastomosis is facilitated by the left arm to grasp and lift the Foley catheter to expose the posterior urethra.

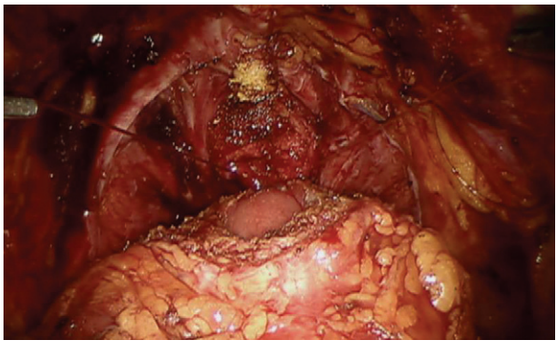

FIGURE 69-26. Gentle, progressive upward directed tension on the anastomotic brings the bladder neck into good approximation with the posterior urethra, which is maintained using the fourth arm and the table side assistant.

Once the anastomosis is complete, the Foley catheter is inserted and the bladder is filled to make certain that there is no anastomotic leak.

Undocking of the Robot and Wound Closure

Placement of a drain is not mandatory but a drain can be easily placed through the left lower quadrant port site and does not require a new incision. The string attached to the laparoscopy bag is transferred to the camera port site. The other abdominal ports are then removed and the camera is used to inspect the anterior abdominal wall to make certain that there is not any bleeding at the individual port sites. The abdomen is then desufflated.

The specimen is extracted at the umbilical port. This typically requires enlargement of the fascial incision depending upon the size of the prostate. It is withdrawn using the string and the laparoscopy bag and sent for pathologic analysis. The fascia of the umbilical port site is then closed directly and securely with a running #1 Vicryl suture to prevent a port-site hernia. The skin of the surgical incisions can be closed with Dermabond or a subcuticular absorbable suture.

POSTOPERATIVE CARE

Patients usually require only a single night of hospitalization and can have relatively rapid advancement in diet and activity. However, some degree of ileus is common for a few days after surgery. Postoperative bleeding is uncommon and transfusion is required in fewer than 1%. The catheter may be left in place for a week, although early removal is feasible if a cystogram is performed to ensure security of the anastomosis. Patients typically can resume their normal activities within a couple of weeks of surgery.

Commentary by

MICHAEL O. KOCH

Robotic-assisted laparoscopic radical prostatectomy has rapidly become the predominant form of prostatectomy performed in the United States. In this chapter, a widely recognized expert in the field describes his technique using an anterior approach. There are several pearls in this chapter for the surgeon studying to develop this approach such as how to identify the bladder neck, how to optimally expose and dissect the seminal vesicles, how to achieve optimal potency outcomes, and how to vary the fascial dissection according the risk of the individual patient's disease.

Even though many techniques have been described for the performance of the Robotic-assisted laparoscopic radical prostatectomy, there are unifying principles, such as release of the neurovascular bundles prior to the transection of the prostatic pedicle, the avoidance of traction and electrocautery around the neurovascular bundles, and techniques to avoid injury to the urethral stump during the anastomosis. The reader should study the techniques of the author and then with experience adopt those techniques consistent with the underlying principles that allow them to achieve their optimal results.

Chapter 70

Cryotherapy

KATSUTO SHINOHARA

PATIENT SELECTION

As with any other treatment for prostate cancer, appropriate patient selection is critical to the success of cryotherapy. Patients with low-risk tumor features (i.e., serum PSA ≤ 10 ng/mL, diagnostic biopsy Gleason score ≤ 6, and clinical stage T1c or T2a) have the best cryotherapy outcomes. Patients with higher grade tumors or higher PSA levels are at increased risk for localized extension of disease and/or metastatic spread. In most patient series, cryotherapy is associated with higher rates of impotence than are other localized treatment alternatives. Consequently, patients for whom preservation of erectile function is a high priority are less appropriate candidates.

Cryoablation has also been used for palliative maneuvers for local symptoms.

Even with a multiprobe cryotherapy device, a large prostate gland may be difficult to treat because of prolonged freezing time. A gland in excess of 50 mL may be best treated with neoadjuvant hormone therapy to reduce the target volume before the procedure.

PREOPERATIVE PREPARATIONS

Patients should discontinue anticoagulant or antiplatelet medications before cryotherapy is done. Light bowel preparation is recommended before the procedure and consists of administration of oral magnesium citrate the day before treatment and an enema just before the treatment.

CRYOTHERAPY PROCEDURE

Cryosurgery may be performed under general or regional anesthesia. After anesthesia is induced, the patient is placed in the lithotomy position.

A 20-French Council-tip catheter is placed in the urethra, and the bladder is distended with saline solution to displace the peritoneal contents away from the treatment area. A transrectal ultrasound (TRUS) probe is inserted into the rectum and the anatomic configuration of the prostate and tumor, if ultrasonically identifiable, are confirmed. Tacking the scrotum to the suprapubic area using 2-0 nylon suture helps expose the perineum for insertion of the cryo probes.

Current cryotherapy uses small-gauge needle-shaped probes that can be placed directly into the prostate gland through the perineum (Fig. 70-1). Probe placement is carried out under TRUS guidance and can be performed with a freehand technique or with a perineal template similar to the brachytherapy technique.

Depending on the cryo probes used, maximum ice ball size is different. To achieve complete tissue necrosis, at least achieving a temperature of −40°C once or −20°C twice is required. Within the ice ball, −20°C zone and −40°C zone are much smaller than actual ice ball size. For example, the EndoCare 4.0 cm V-probe is 2.4 mm in diameter and creates an ice ball with maximum diameter of 39 mm and length of 57 mm. However, -20°C zone is 28 mm in diameter and 45 mm in length, and -40°C zone is 21 mm in diameter and 40 mm in length (Figure 70-2). It is important to know the maximum size of ice as well as −20°C zone size in order to cover the edge of the prostate completely without damaging the adjacent organ.

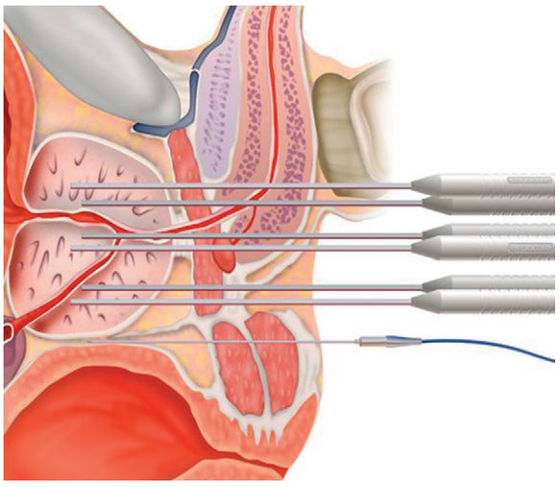

FIGURE 70-1. *Courtesy of Endocare, Inc., a wholly-owned subsidiary of Health Tronics, Inc.*

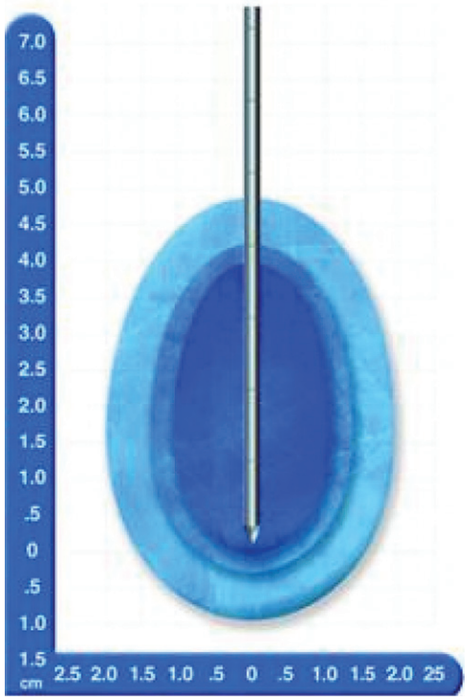

FIGURE 70-2. *Courtesy of Endocare, Inc., a wholly-owned subsidiary of Health Tronics, Inc.*

Before probe placement, a urethral warming catheter is connected to a pump and a water heater, and water is circulated to confirm the correct function of the catheter. Transrectal probe is inserted in the rectum and fixed onto the brachytherapy stepping device appropriately. Before insertion, cryo probes are connected to the cryo machine and a test run of circulating argon gas is performed to confirm the proper freezing of probes.

Based on the maximum cross-sectional image on TRUS, the probe placement sites are determined (Fig. 70-3). Probes are also distributed evenly, but less than 20 mm distance each other in order to cover the prostate edge completely by the ice ball's −20°C zone. Probes are also placed at least 8 mm away from the urethra to avoid freezing the urethral mucosa. Posterior probes are at least 5 mm away from the posterior edge of the gland. The CryoCare system usually requires six probes, two placed anteriorly and four posteriorly. The SeedNet system uses 17-gauge needle-shaped probes, which may be placed more than 6 probes to achieve a freezing zone more conformal to the prostate.

TRUS images with superimposed perineal template grid will guide the appropriate probe placement location (Fig. 70-3). Probes are placed through the template of the desired location and carefully inserted in the prostate through the perineal skin (Fig. 70-4). TRUS monitoring is continuously performed with scanning from the apex to the base during the probe insertion. The TRUS scanning plane is changed to the longitudinal view to confirm the probe tip is to be placed at the base of the gland or in the seminal vesicles, if necessary. In the end of the placement, the probe end should be all leveled each other to create symmetrical ice ball. After cryoprobe placements are completed, thermosensors are placed to monitor the temperature of the gland apex, the external sphincter, along Denonvilliers' fascia, and the neurovascular bundle. Again, the location of the sensor is determined using the perineal template grid position and ultrasound guidance.

After completing the insertion of probes and thermosensors, a flexible tip 0.035-inch guidewire is placed into the bladder lumen through the Council-tip Foley catheter. The Council-tip urethral catheter is exchanged with a urethral warming catheter over a guidewire. The urethral warming catheter is secured to the surgical sheets by towel clip, and the catheter end is connected to extension tubing to drain excessive urine and prevent overdistention of the bladder. At this point, warm saline of about 42°C is circulating in the warming catheter continuously (Fig. 70-5).

Freezing is started from the anterior two probes. Once freezing is initiated, ice within the prostate casts a dense acoustic shadow, obscuring all anatomic detail anterior to the ice. For this reason, the anterior probes must be activated first. Once the anterior ice balls reach to the posterior probes, the posterior probes are activated. The ice balls are extended posteriorly and laterally, including a 2- to 4-mm margin into the lateral periprostatic tissues and beyond the gland apex. If an extra capsular extension of tumor is suspected, the ice is propagated further laterally on the involved side. If seminal vesicle involvement is suspected, probes should be placed

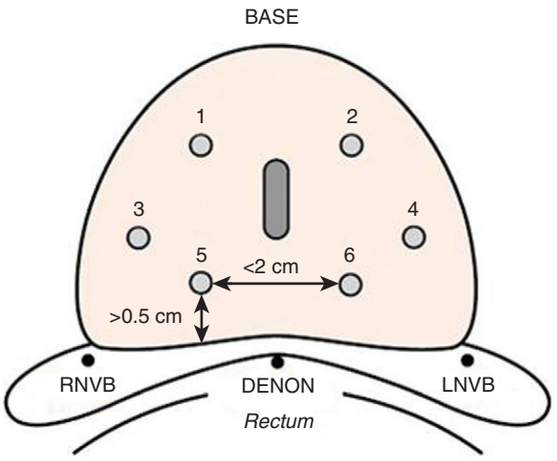

FIGURE 70-3. *Courtesy of Endocare, Inc., a wholly-owned subsidiary of Health Tronics, Inc.*

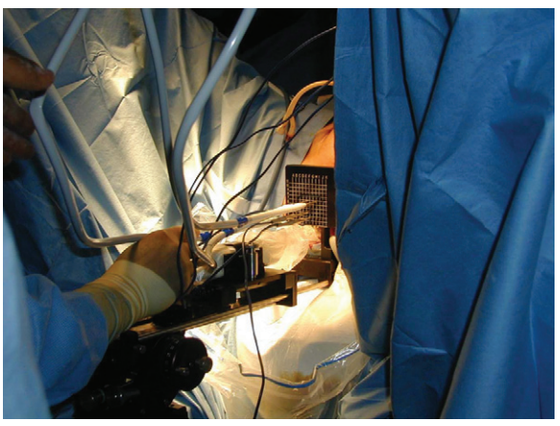

FIGURE 70-4. *Courtesy of Endocare, Inc., a wholly-owned subsidiary of Health Tronics, Inc.*

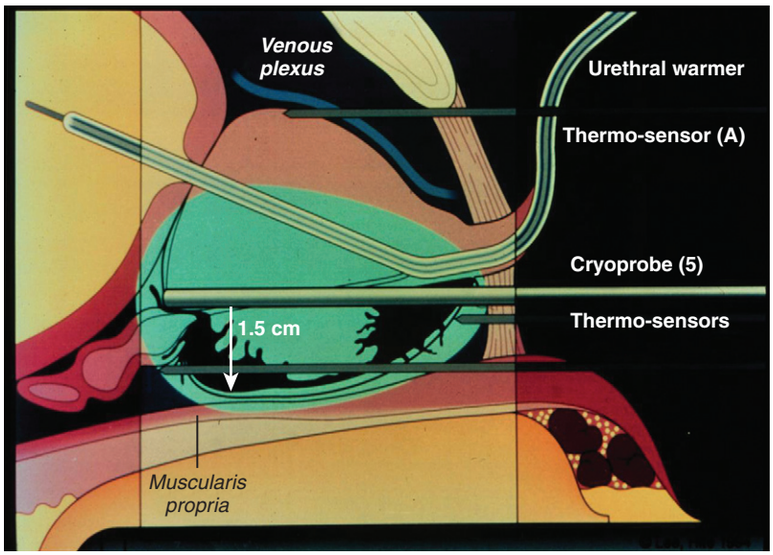

FIGURE 70-5. *Courtesy of Drs. Duke Bahn and Fred Lee.*

deeper into that organ. The posterior ice balls are extended into, but not beyond, the rectal muscularis propria. Once freezing is completed, the ice is allowed to actively thaw by circulating helium instead of argon gas through the probe. Two freeze-thaw cycles are generally carried out to achieve maximum tissue ablation. The edge of the prostate gland should achieve −20°C twice.

If the apex is inadequately frozen, the probes may be withdrawn an appropriate length toward the apex and additional freezing cycles are repeated (Fig. 70-6). After completing the last freezing cycle, the probes are changed to active thawing mode and continue thawing until the prostate gland is completely visualized without any ice ball shadowing on ultrasonography. The urethral warmer remains in place until all thawing is completed; it is then exchanged for a Foley catheter.

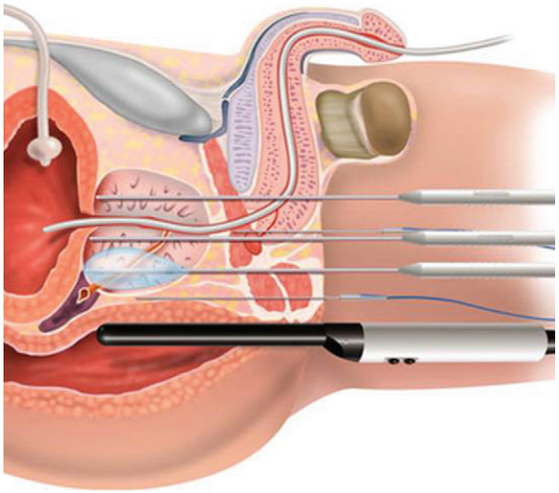

FIGURE 70-6. *Courtesy of Endocare, Inc., a wholly-owned subsidiary of Health Tronics, Inc.*

POSTOPERATIVE CARE

Cryotherapy is usually performed as an outpatient procedure. A urethral catheter should be left in place for 1 to 2 weeks following treatment until urinary retention resolves. Oral antibiotics coverage is given until the Foley catheter is removed.

Commentary by

MICHAEL O. KOCH

Cryotherapy of the prostate offers some unique advantages to patients with prostate cancer, especially in terms of early convalescence. While complete prostatic ablation with cryotherapy is associated with high rates of impotence, short-term results suggest that it can achieve reasonable rates of prostate cancer control. In this chapter, the author describes the general technique for cryoablation of the prostate.

This page intentionally left blank

Section XIII

PROSTATE: BENIGN DISEASE

This page intentionally left blank

Chapter 71

Transurethral Resection of the Prostate

DOUGLAS F. MILAM

INDICATIONS

Transurethral resection of the prostate (TURP) has played a storied role in American urology. Many of the same individuals who were crucial players in the development of the specialty of urology played important roles in the development of and widespread training of residents to perform TURP. While the number of procedures performed has decreased in recent years, TURP was probably the most important urologic surgical procedure in the twentieth century. A recent move to office-based therapy has decreased the frequency of operating room treatment of benign prostatic hyperplasia (BPH). Nevertheless, TURP remains the gold standard treatment for bladder outlet obstruction caused by BPH. This is the technique to which all other therapies are compared. Indeed, TURP produces the largest decrease in urinary symptoms, the largest increase in urinary flow rate and the largest decrease in urodynamically measured voiding pressure of any therapy.

PREOPERATIVE MANAGEMENT

The patient is given a single dose of perioperative intravenous antibiosis before beginning the resection. Consideration should be given to broader and longer antibiotic coverage for the patient in total urinary retention who has had prolonged urethral catheter drainage. Several clinicians have advocated the use of a 5α-reductase inhibitor for at least 1 month before therapy. There is at least anecdotal evidence that this decreases bleeding during TURP and may be especially helpful for large resections.

TURP can be performed with either general or spinal anesthesia. As recently as 1989, seventy-nine percent of procedures were performed under spinal or epidural anesthesia. Regional anesthesia was the preferred method in the past, because an awake patient facilitated earlier diagnosis of dilutional hyponatremia. Evolution in operative technique and equipment has made dilutional hyponatremia less of a problem. Bipolar electroresection eliminates the possibility of hyponatremia in that the technique uses normal saline irrigant during the procedure. Also, many surgeons now use less aggressive tissue resection. Less aggressive resection leading to less irrigant absorption also lowers the possibility of dilutional hyponatremia. Given either of these methods, general anesthesia can be good anesthetic choice.

PATIENT POSITIONING

The patient is placed on the edge of the operative table in the dorsal lithotomy position. Locating the perineum at the bottom edge of the operative table is important to allow the resectoscope to be angled upward for access to anterior prostatic tissue. An O'Connor drape can be placed to facilitate rectal examination during the procedure if one feels this helpful. Skin preparation and placement of surgical drapes is routine.

DESCRIPTION OF SURGICAL TECHNIQUE

Careful cystourethroscopy to visualize the entire prostatic and bladder urothelium should be performed before any tissue resection is begun. The presence of other lesions such as bladder tumor, lithiasis, or stricture must be excluded. Once the entirety of the bladder has been visualized, the resectoscope sheath can be passed into the bladder using either the blunt tip or visualizing obturator. Passage of a resectoscope sheath without an obturator should not be attempted. Some patients require gentle dilation of the meatus and fossa navicularis with well-lubricated Van Buren sounds before the resectoscope can be passed smoothly. In the absence of overt stricture disease, sequential dilation from 18 French to a size 2 French larger than the chosen resectoscope sheath is sufficient. Adequate urethral dilation and periodic lubrication of the resectoscope sheath are necessary to minimize development of postoperative urethral stricture disease.

Several cutting loop options are available for either monopolar or bipolar electrosurgical cutting and coagulation. These can be subdivided into the traditional "thin loops,"

which are firm wires, and "thick loops," which can be up to several times the diameter of the thin loops. Thin loops have higher current density and cut more cleanly, but do not coagulate blood vessels as well as thick loops. Increasing the electrosurgical generator output can compensate somewhat for the increased tissue drag experienced when using a thick loop. One typically can begin resection on power settings of 70 cut and 70 coagulation when cutting with a thin loop. Power output can be increased as need when using a thicker loop.

Some patients with bladder outlet obstruction due to BPH have substantial median lobe enlargement (Figs. 71-1 and 71-2). If this is the case, the median lobe requires early resection to permit irrigation of prostatic chips out of the operative field (Fig. 71-3). Typically, the median lobe is resected down to the point where circular bladder neck fibers are encountered. At this point the bladder neck and prostatic fossa is flat with the bladder floor that extends from the trigone (Fig. 71-4). Overresection of this area may undermine the bladder neck and should be avoided. Once the median lobe has been resected appropriately, the resection continues in the floor of the prostate to the proximal aspect of the verumontanum. The verumontanum is the key landmark used during resection of the prostate and should not be resected (Fig. 71-5).

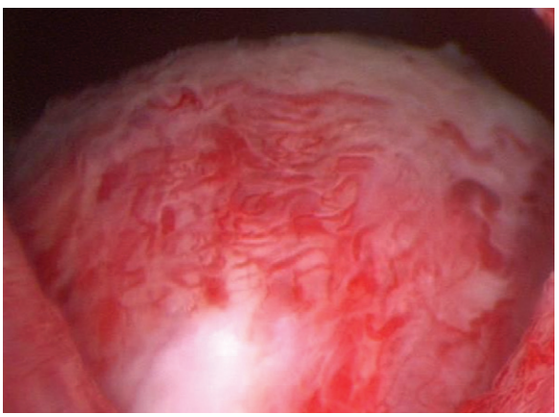

FIGURE 71-1.

Once the bladder neck and prostatic floor have been resected, then attention can be turned to the anterior prostate. Many individuals have only a small amount of anterior tissue. Resection begins just inside the bladder neck and continues to a point near the verumontanum. One is best served by waiting until the end of the procedure to complete the most distal resection. Often only one or two loop depths are required in the anterior portion of the prostate.

Once the prostate has been opened by the initial resection at the 6- and 12-o'clock positions, one can begin taking down the lateral lobes. The resectionist should perform the procedure the same way every time in order to develop a style that is thorough and repetitive. One typically begins at th 6- or 12-o'clock position and resects from the bladder neck for one loop length. The resectoscope is rotated without advancing or withdrawing the scope after each loopful (Fig. 71-6). On small prostates this may be the entirety of the prostate. Larger prostates, however, may require multiple loop lengths (Fig. 71-7). In that case, one should resect the first loop length all the way around 360 degrees. Once this is done to near the appropriate depth, one can progress more distally. It should be noted that if the prostate is

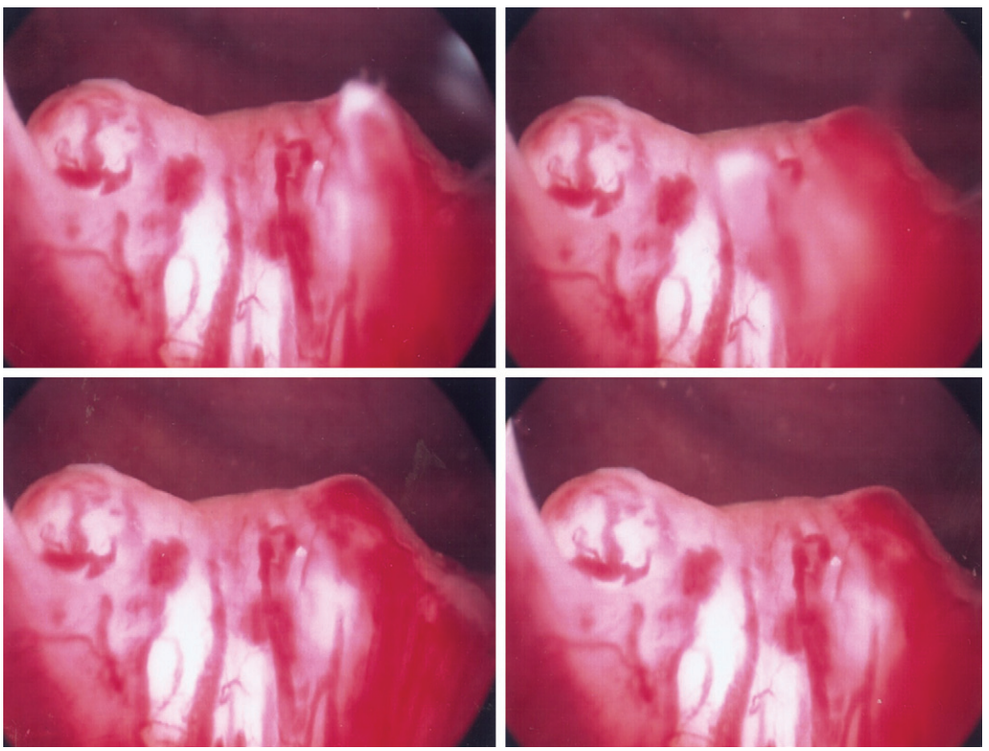

FIGURE 71-2.

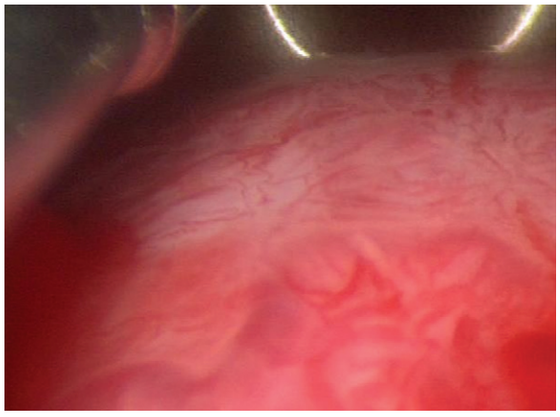

FIGURE 71-3.

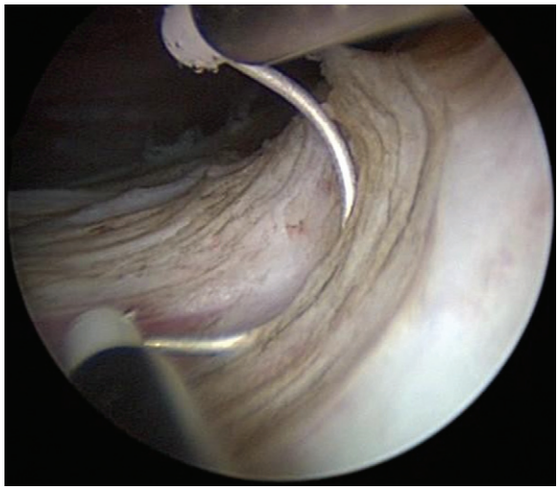

FIGURE 71-4.

extremely large, care should be given not to resect too deeply and to open venous sinuses early in the case (Fig. 71-8). These can, under the pressure of the irrigating fluid, lead to absorption of large amounts of irrigant fluid. If one is using saline as the irrigant, this leads only to volume dilution, but if one is using glycine or sterile water as the irrigant, profound dilutional hyponatremia may result. Venous sinuses are usually encountered when the resection extends too deep into the prostatic tissue. The character of the prostate tissue usually changes when the surgical capsule is encountered. The foamy prostate tissue becomes more stromal and fibrous (Fig. 71-9). One then progresses distally until the distal aspect of the loop length reaches the proximal verumontanum. Short scalloping resection "bites" are to be avoided. Long loop lengths of appropriate depth leave a smooth prostatic fossa. Avoid coagulating small bleeding vessels in tissue that will be soon resected. At this point, one should complete the resection of the lateral lobe tissue and develop thorough hemostasis.

The final aspect of the procedure is trimming the apical tissue. Many urologists find it helpful to gently withdraw the resectoscope distal to the verumontanum to visualize exactly the edge of the existing resected tissue (Fig. 71-10). One can then place the resectoscope at the proximal aspect of the veru and then without moving the resectoscope in or out, resect the lateral lobe apical tissue by sequentially rotating the scope. It is helpful to visualize the verumontanum several times during this procedure to prevent resecting too distally. How much tissue to resect from the prostatic apex is up to one's own training and experience. When adequately resected, the apex should appear open when viewed from the distal aspect of the verumontanum even in the very large prostate (Fig. 71-11). After the more typical 20- to 30-g resection, the prostatic fossa should appear wide open when viewed from the distal verumontanum (Fig. 71-12). Nevertheless, substantial resection distal to the veru often leads to either transient or permanent incontinence due to intrinsic sphincter dysfunction.

Following the bulk of tissue resection, the bladder is irrigated with an Ellik evacuator, which produces a Venturi effect, allowing chips of prostate tissue to settle to the bottom of the bulb. Many urologists prefer the older style glass evacuator. Many hospitals, however, do not carry these and use the softer plastic Ellik evacuators. After chips and clots are evacuated from the bladder, the prostate and bladder must be reexamined. Prostatic chips retained in the bladder can be removed individually by grasping them with the resectoscope loop and removing them through the sheath. The process of evacuating prostate chips usually triggers mild bleeding. A few minutes of coagulation of these small bleeding vessels, paying particular attention to the bladder

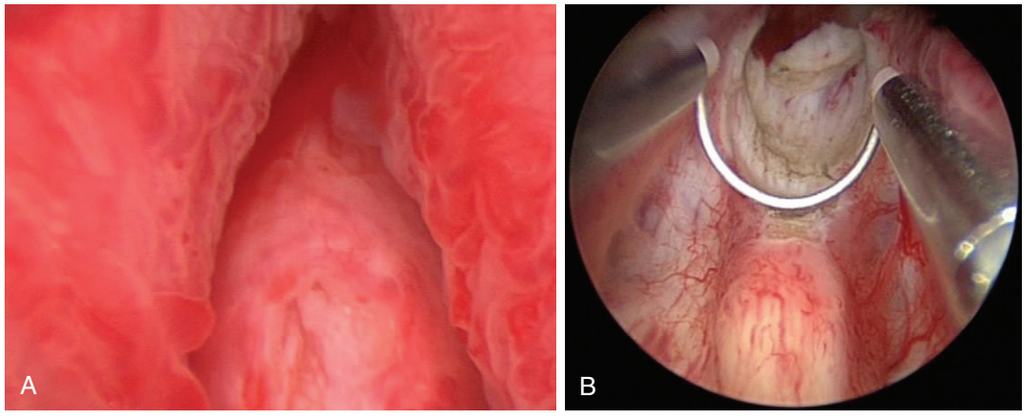

FIGURE 71-5.

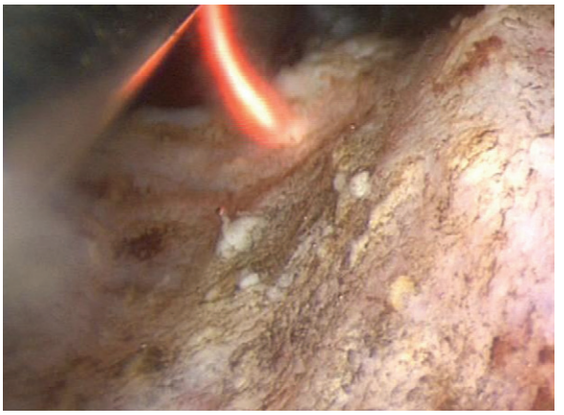

FIGURE 71-6.

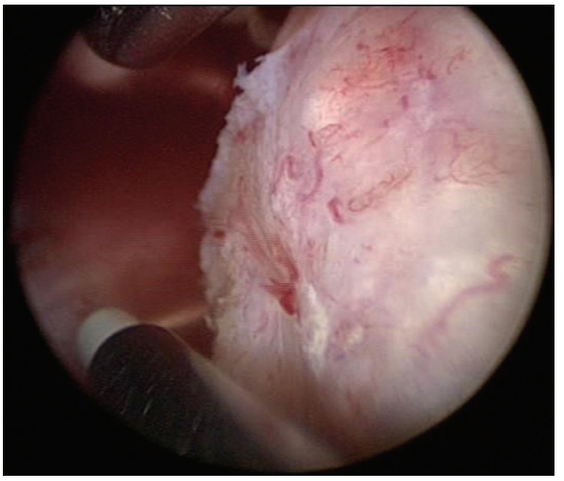

FIGURE 71-7.

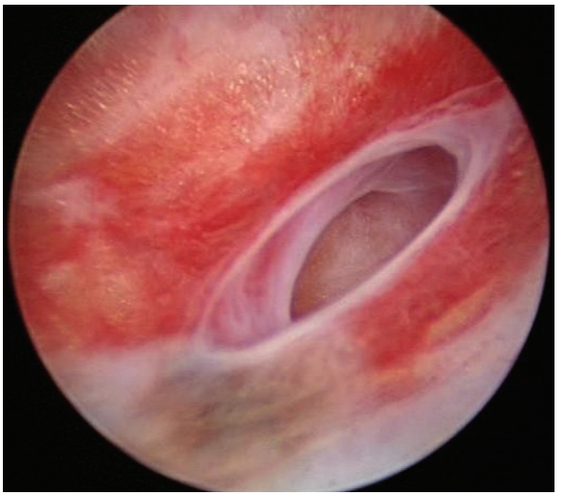

FIGURE 71-8.

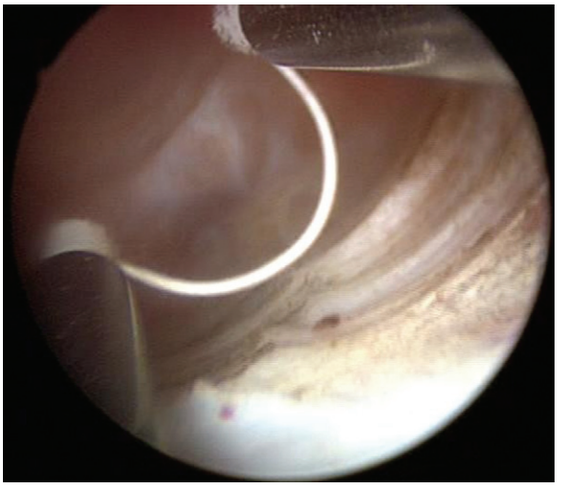

FIGURE 71-9.

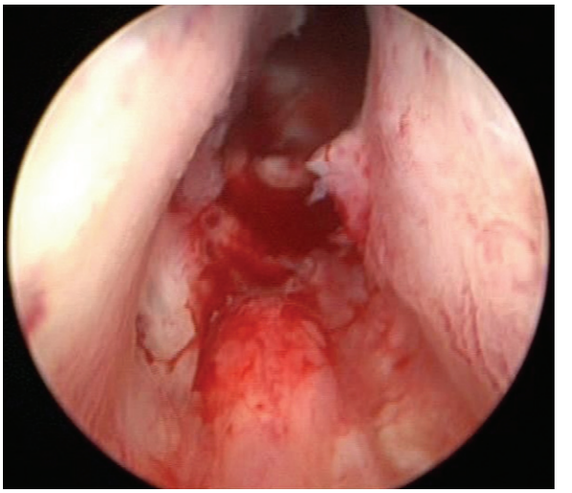

FIGURE 71-10.

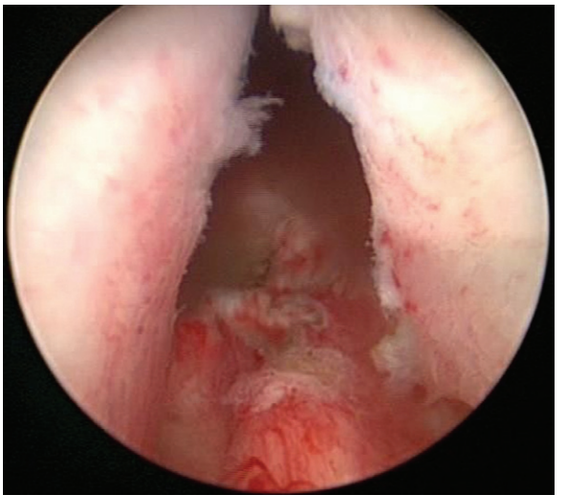

FIGURE 71-11.

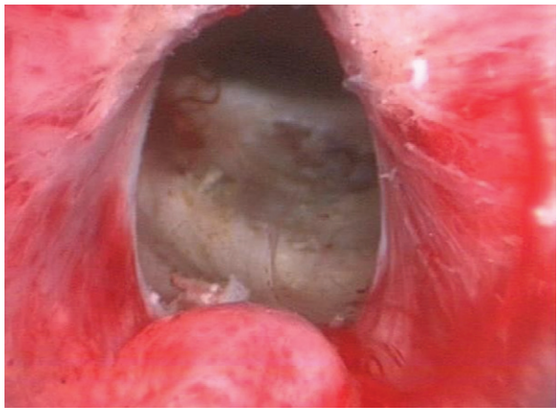

FIGURE 71-12.

neck and the anterior tissue, usually allows the prostatic fossa to be quite hemostatic.

COMPLICATIONS AND THEIR MANAGEMENT

- Hemorrhage, either during the procedure or delayed until after TURP, is one of the more frequent major complications. As discussed earlier, many urologists believe that placing the patient on a 5α-reductase inhibitor at least 1 month before TURP can decrease the bleeding during the procedure. With the advent of newer modalities and less aggressive intraoperative technique, severe hemorrhage during TURP has become uncommon. Nevertheless, older database studies demonstrated that about 8% of patients required transfusion during or after the procedure. Bipolar electrosurgical technique has minimized the frequency of intraoperative hemorrhage. Delayed hemorrhage probably has little to do with the intraoperative technique. This type of hemorrhage is more patient related. Usually within the first four weeks, the patient may return to the emergency room or hospital due to hemorrhage and clot retention. This usually does not require return to the operating room but can often be handled by placement of a large-bore catheter of 24 French or greater and subsequent hand irrigation using a catheter tip syringe. Following clot evacuation and return of clear urine, the patient may be placed on continuous bladder irrigation. Usually within 24 to 48 hours the bleeding stops and a voiding trial can be performed.
- Extravasation of irrigating fluid into the periprostatic tissue and the space of Retzius can occur. This occurred more frequently in the past due to very aggressive resection technique. One should inspect the suprapubic region during and immediately following TURP. If substantial suprapubic tension or distention is noted, then a Penrose drain may be placed through a suprapubic stab wound. This is done by creating a 2-cm transverse suprapubic skin incision with a scalpel. A Kelly clamp is then "popped" through the fascia immediately above the pubic bone and spread 2 cm wide in the space of Retzius. This maneuver usually yields a substantial amount of bloody fluid, which decompresses the suprapubic region. Again using the Kelly clamp, a ¾-inch Penrose drain can be left through the fascial opening to allow continued drainage. The Penrose drain can be removed the following day.
- Retrograde ejaculation should be looked at as an inevitability, not as a complication, of TURP. One of the reasons that TURP is the most effective procedure to decrease bladder outlet resistance and voiding pressure is likely the fact that the bladder neck is resected and is completely open after the procedure. Care should be made to make sure that the prostate is large enough that the normal scarring and contracture process will not leave the patient with a bladder neck contracture. If the prostate is small, one should consider other techniques such as transurethral incision of the prostate that preserve the bladder neck tissue and minimize the chance of bladder neck contracture.
- Urinary incontinence is uncommon following TURP. Two different causes are seen when patients do experience incontinence. Many individuals develop detrusor overactivity (DO) as a consequence of longstanding bladder outlet obstruction. Involuntary bladder contraction may cause urinary urgency, frequency and urge incontinence. Decreasing the bladder outlet resistance will often lead to a transient period of substantial urge incontinence in those individuals. After treatment of bladder outlet obstruction, however, changes in the bladder usually lead to a marked decrease in DO, leading to resolution of urinary frequency, urgency, and urge incontinence. The length of time to resolution can be frustrating, however. Some patients have been known to experience urge incontinence for several months before resolution.
- Intrinsic sphincter dysfunction can also occur following TURP. This can occur due to overly aggressive apical resection or due to individual variations in sphincter function. Usually, if one limits the resection to the proximal aspect of the verumontanum, permanent intrinsic sphincter dysfunction will not occur. There is a subset of patients who are particularly at risk for intrinsic sphincter dysfunction. These are individuals who have experienced either brachytherapy, cryotherapy or external beam radiation therapy. In these individuals, the sphincter area may have decreased function. Because most men do not experience any leakage of urine past the bladder neck during urinary storage, substantial external smooth deficits may not be apparent until they are unmasked by resection of the bladder neck tissue.
- Rectal injury can occur following TURP. This most commonly occurs in patients who require re-resection of their prostate or in individuals who have had radiation therapy to either the prostate or rectum. If a small rectal injury occurs, an initial trial of nonoperative therapy with urethral drainage, bowel rest, and antibiosis is reasonable. If a persistent fistula develops, it should be handled by diverting colostomy and fistula repair.
- TUR syndrome is a potentially life-threatening event caused by dilutional hyponatremia. During prostatic resection, substantial fluid can be absorbed through open venous channels into the bloodstream. If one uses either sterile water or glycine as the irrigant, intravascular

volume dilution and subsequent hyponatremia may occur. Successful treatment of TUR syndrome requires early identification. If one is using either glycine or sterile water irrigant, then consideration should be given to use of spinal anesthesia. This permits communication with the patient during surgery and identification of signs of hyponatremia, including dizziness, nausea, and headache. If one is suspicious for substantial irrigant absorption through open venous sinuses, a stat serum sodium should be sent from the operating room. With early diagnosis, treatment can be initiated before the lowered sodium concentration crosses the blood-brain barrier. For moderate hyponatremia (serum sodium greater than 120 mEq/L), a free water diuresis with intravenous furosemide (10 to 40 mg) can be initiated. Often this prevents symptomatic hyponatremia in individuals with moderately decreased serum sodium levels. If one diagnoses a profound hyponatremia, less than 120 mEq/L, before the patient becomes symptomatic, one can combine free water diuresis from furosemide with intravenous infusion of hypertonic 3% saline. Infusion of a small volume (50 to 200 mL) of hypertonic saline produces a marked effect. As mentioned earlier, when using a sodium-free irrigant, there should be a low threshold for sending a stat serum sodium and for beginning treatment with furosemide.

POSTOPERATIVE MANAGEMENT

A large-bore 22- or 24-French Foley urethral catheter is left in place following TURP. Some urologists use two lumen catheters, although most use triple-lumen catheters to facilitate continuous postoperative bladder irrigation. Assuming there were not a large number of venous sinuses opened during the case, either sterile water or saline can be used for postoperative continuous irrigation. If a large number of sinuses were opened, one should consider using normal saline as the irrigant. Immediately after placement of the catheter, the balloon should be inflated. One always uses a 30-cc balloon catheter, but often inflates the balloon with more than 30 cc. With a very large resection, the balloon may be inflated to 50 cc in order to minimize the chance that the balloon will be pulled down through the open bladder neck into the prostatic fossa. Once the balloon is snugged down to the bladder neck, then a catheter tip syringe is used to irrigate the bladder until the irrigant is clear. Some urologists prefer placement of a small amount of traction on the Foley at this point. This is done by taping the catheter to the patient's leg using a tape mesentery. Care should be taken not to tape this too tightly in order to minimize the chance of pulling the balloon down into the prostatic fossa or causing sphincter damage. Most of the time, however, traction is not necessary. Continuous irrigation is often performed overnight, but can usually be stopped on the morning of the first postoperative day. At this point, the patient can be discharged from the hospital. Urologists differ in whether to leave the urethral catheter in place or to attempt a voiding trial on postoperative day 1. If a voiding trial is performed and the patient is able to successfully void, then the patient can be discharged from the hospital without a catheter in place. However, if there is a substantial but normal amount of blood in the urine or there are any clots, usually it is advantageous to discharge the patient with a urethral catheter in place. In that case, the urethral catheter can be removed after a few days. Most patients with large prostatic resections require a urethral catheter at discharge.

CLINICAL EFFICACY

As mentioned earlier, transurethral resection of the prostate is the gold standard treatment for bladder outlet obstruction caused by BPH. This is the most efficacious treatment for BPH, only rivaled by open simple prostatectomy used for extremely large prostatic glands. Using bipolar technique and saline irrigant, the upper extent of prostatic size that can be handled endoscopically has increased in recent years. In years past, even experienced resectionists typically selected open technique for patients who had prostate glands greater than 100 cc volume. With the advent of newer technique and equipment, this size has increased somewhat. Coupling preoperative treatment with 5α-reductase inhibitors and use of bipolar technique and saline irrigant, the experienced resectionist can now often safely resect glands as large as 120 to 150 g.

The myriad of techniques with which to address bladder outlet obstruction has fragmented the market for BPH therapy. Nevertheless, TURP will continue to play an important role in the management of patients with a severe bladder outlet obstruction. TURP remains the gold standard treatment and continues to produce the most improvement of any technique in urinary symptoms, urinary flow rate, and voiding pressure.

Commentary by

CLAUS G. ROEHRBORN

The transurethral resection of the prostate or TURP remains the gold standard in the surgical treatment of male lower urinary tract symptoms (LUTS) and benign prostatic hyperplasia (BPH), using either monopolar or bipolar [saline based] resection techniques. While the use of either 1.5 glycine or 3% sorbitol eliminates the changes in osmolality associated with the irrigation of water when using sterile water as irrigant, the use of 0.9% saline addresses the rightfully feared complication of dilutional hyponatremia. I have found the bipolar saline-based resection to be slightly less efficient in terms of tissue removal, and the coagulation is somewhat less effective. A surgeon switching from one to the other may have to adjust his style, stop more frequently during the resection to coagulate blood vessels, as otherwise the irrigation solution will become cloudy and visibility will decrease, making hemostasis more difficult to achieve.

Regarding the use of 5α-reductase inhibitors before TURP to reduce intraoperative or postoperative bleeding, several placebo-controlled trials have been performed, the last and perhaps best executed of them finding in essence no advantage in this approach (Hahn et al, 2007). I personally do not postpone or adjust scheduling to allow for a several week treatment course with 5α-reductase inhibitors before TURP.

Hemostasis is a very important part of the TURP procedure. In my interactions with learners, it has become evident that the concept of the hydrostatic pressure inside the bladder and prostatic fossa is not imminently intuitive. During the resection, the pressure in the fossa is approximately equal to the distance between the symphysis pubis and the lower edge of the bag of irrigation fluid, which may be 70 to 100 cm H_2O. When embarking on the final hemostasis, I stress the importance of lowering the irrigation pressure by adjusting the height of the bags, such that smaller vessels that do not bleed under the higher pressure condition actually have the opportunity to manifest and be appropriately addressed. I have found this to be helpful in reducing the duration of continuous bladder irrigation, the number of times that hand irrigation may have to be performed, and the number of returns to the operating room.

Hahn RG, et al. (2007). Blood loss and postoperative complications associated with transurethral resection of the prostate after pretreatment with dutasteride. BJU Int 99(3):587-594.

This page intentionally left blank

Chapter 72

Transurethral Incision of the Prostate

DOUGLAS F. MILAM

INDICATIONS

The concept of transurethral incision of the prostate (TUIP) has been discussed for more than 100 years; however, the first modern series of patients was published by Orandi in 1973. TUIP is a technique ideally suited for younger individuals without significant prostatic hyperplasia, but with urodynamically proved primary bladder neck obstruction. It also is useful as a lesser invasive technique for those with bladder outlet obstruction from benign prostatic hyperplasia. General belief among resectionists is that TUIP may be considered when the prostatic gland size is less than 30 g. Although this cutoff in prostatic size seems reasonable, no clinical series has demonstrated 30 g to be the upper limit of size. In TUIP, no tissue is actually removed, but one or more incisions are made from inside the bladder neck to the prostatic verumontanum. This allows the bladder neck and prostate tissue to separate, functionally widening the channel through the prostatic urethra.

PREOPERATIVE MANAGEMENT INCLUDING ANESTHESIA

Preoperative management is similar to that for other treatments for bladder outlet obstruction. Intravenous antibiosis is given immediately before administration of anesthesia. General, spinal, or epidural anesthesia may be appropriately used. The patient is positioned in the dorsal lithotomy position.

SURGICAL PROCEDURE

Careful cystourethroscopy is performed in the usual way. All areas of the bladder and prostatic urothelium should be examined and both ureter orifices are visualized. Attention is especially focused on the bladder neck. One often encounters a high bladder neck in young men with urodynamically proved bladder neck obstruction. This finding especially lends itself to TUIP (Fig. 72-1). The bladder neck will also be elevated on the bladder side. TUIP causes the bladder neck to spring apart, leaving the prostatic floor at the same level as the bladder trigone.



FIGURE 72-1.

Various surgical tools can be used to perform TUIP. The most common is the Collings knife. This is a single bladed electrosurgical knife that connects to a standard resectoscope. The most common settings used for TUIP are 70 cut and 70 coagulation. Use of blend current is surprisingly unhelpful. Holmium or KTP lasers may also be used for TUIP. This can be done using either a straight fiber or a side-firing fiber. The technique is similar to that for the Collings knife. Many believe that better hemostasis is obtained if the incision is performed with either a holmium or KTP laser. With the holmium laser, a setting of 1.4 J and 5 to 10 pulses per second is appropriate for this type of incision. A bipolar knife or a modified bipolar loop can also be used for TUIP. Bipolar electrosurgical incision can be used to perform a fine TUIP, but the improvement in hemostasis relative to standard electrosurgical resection is not as great as that seen with TURP. With any modality, the selection of length and depth of cut is the same and is the most critical determinant of success.

The most important decision when performing a TUIP is whether to do a single-incision or two-incision TUIP. The

principal reason to choose single-incision over two-incision TUIP is to minimize the possibility of retrograde ejaculation. Two-incision TUIP probably has a slightly higher success rate, although controlled clinical trials comparing the two techniques are lacking.

When performing a single-incision TUIP, many physicians use an incision in the 7- or 8-o'clock position or a similarly placed incision on the contralateral side (Fig. 72-2). Incisions positioned slightly laterally allow the tissue to spring apart better than a midline incision in the 6-o'clock position. Two-incision TUIP most commonly involves incisions at the 4- and 8-o'clock positions. It is important to keep in mind the amount of median lobe tissue that a patient has before performing TUIP. Patients with a substantial median lobe would be better treated with other modalities such as TURP, TUNA, or interstitial laser ablation. Occasionally, however, a patient has a mild amount of median lobe tissue at the bladder neck that can be managed with TUIP. One needs to decide whether to leave that tissue intact or remove that tissue. If using a holmium laser, the laser can be focused into the median lobe tissue holding the fiber tip in a constant location just off the tissue surface. Involution of the tissue is seen as desiccation proceeds. The entire median lobe can be "removed" by desiccating areas about 5 to 10 mm apart.

The incision begins at a point about ½ to 1 cm inside the bladder and continues through the bladder neck to the proximal aspect of the prostatic verumontanum (Fig. 72-3). The illustration depicts the use of a laser fiber, but any other cutting tool can be used in the same location. An initial groove is cut into the bladder neck (Fig. 72-4). Continue in the same lateral location as the incision progresses distally to the level of the proximal verumontanum. If one does not remain aware of remaining lateral, it is easy to skive toward the midline. It is helpful to progressively make the entire length of the incision at near uniform depth (Fig. 72-5). Progressive deepening of the cut through the length of the incision causes the circular fibers in the bladder neck and prostate to spring apart (Fig. 72-6). Eventually the surgical capsule fibers are encountered. These fibers are unmistakable by their appearance (Fig. 72-7). Many urologists deepen the incision until fat is encountered. Whether or not one continues through the surgical capsule and encounters fat, the incision must be deep enough that the circular bladder neck fibers spring apart widely. Failure to achieve that result will doom the procedure to failure. Figure 72-8 demonstrates the appearance of the prostate from the verumontanum when the incision has not been carried far enough distally. Extending the incision slightly farther opens the prostate, giving a wide open appearance (Fig. 72-9).

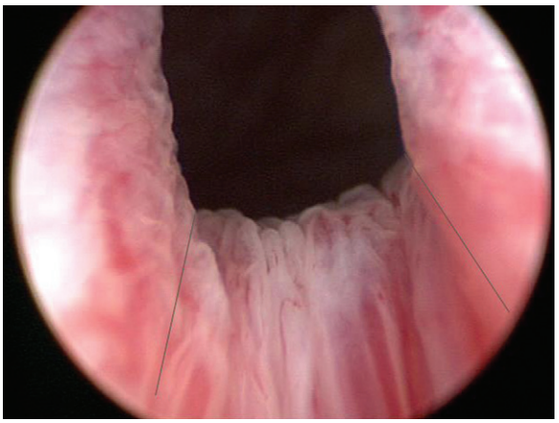

FIGURE 72-2.

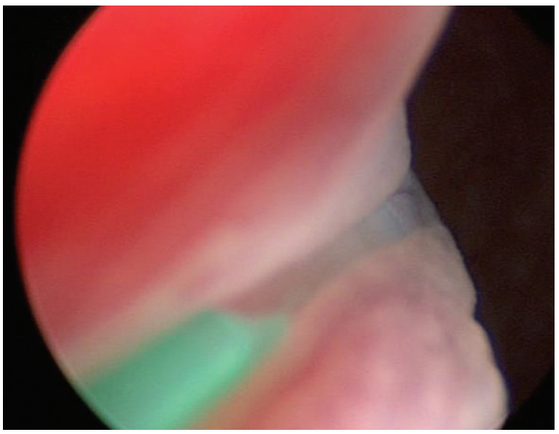

FIGURE 72-3.

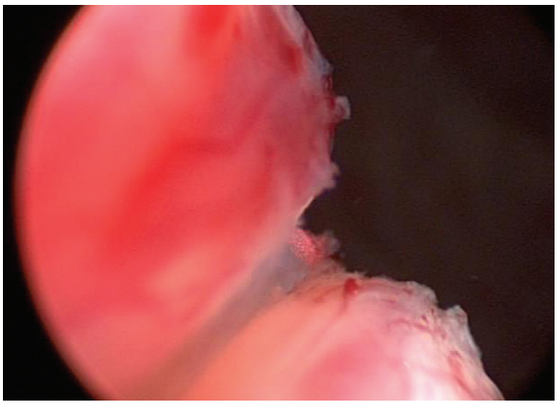

FIGURE 72-4.

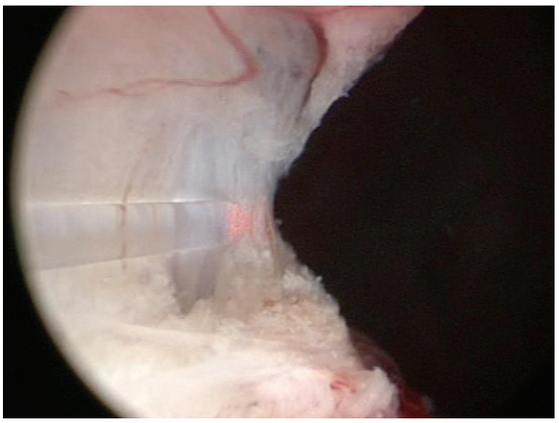

FIGURE 72-5.

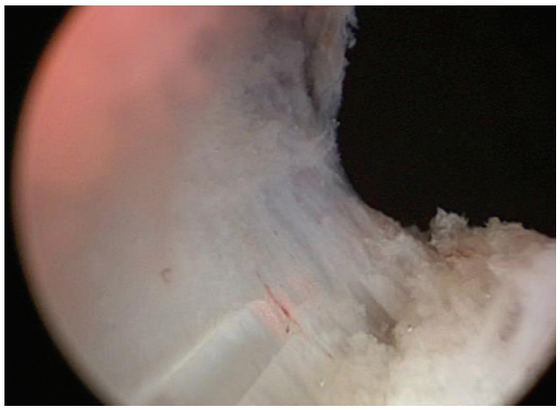

FIGURE 72-6.

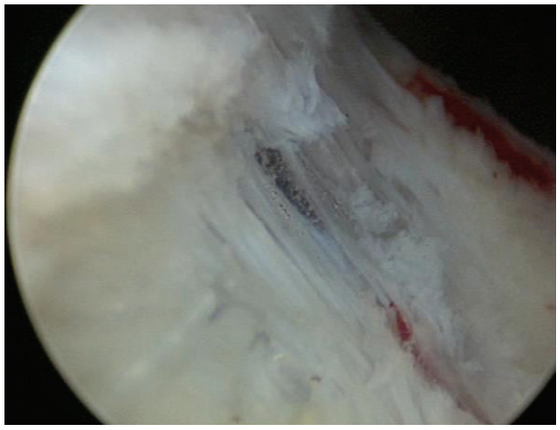

FIGURE 72-7.

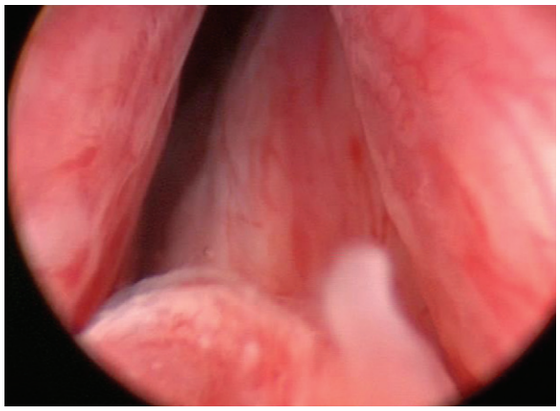

FIGURE 72-8.

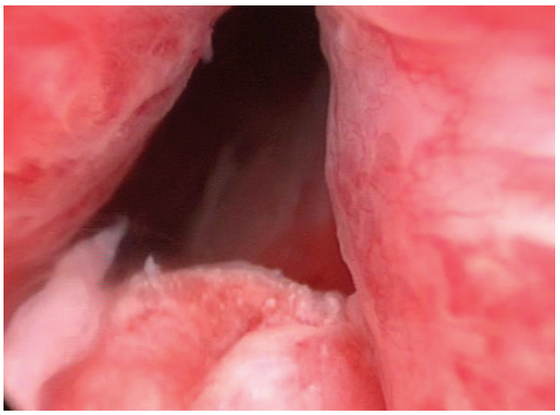

FIGURE 72-9.

COMPLICATIONS

- The most complication is post-TUIP hematuria. This can be severe enough to form clot retention; however, the need for transfusion is uncommon. Wider perforation and extravasation of urine and irrigation fluid into the periprostatic space is extremely uncommon with TUIP.
- Retrograde ejaculation is a possibility with TUIP. Single-incision TUIP carries an 8% to 10% chance of retrograde ejaculation while a two-incision TUIP carries roughly a 25% chance of retrograde ejaculation. If desiccation or resection of the median lobe tissue is required between the incisions of a two-incision TUIP, the risk of retrograde ejaculation is substantially increased.
- Urinary incontinence from intrinsic sphincter dysfunction following TUIP is extremely rare. Occasionally, lowering bladder outlet resistance will convert the overactive bladder patient from urinary urgency to urge incontinence. Detrusor overactivity will usually resolve without intervention in a few months if bladder outlet resistance and subsequently voiding pressure were satisfactorily lowered.
- Erectile dysfunction does not appear to occur as a consequence of TUIP.

Postoperative management of the TUIP patient involves the decision whether to leave an indwelling urethral catheter. For most physicians, this decision depends on the hemostasis at the time the procedure is finished. In any case, the Foley urethral catheter can almost always be removed on the morning of the first postoperative day. Many do not use a Foley catheter postoperatively unless there is substantially more than the usual amount of hematuria.

Commentary by

CLAUS G. ROEHRBORN

The TUIP procedure remains an underused tool in the urologist's armamentarium when treating men with lower urinary symptoms (LUTS) and BPH. While the often stated upper limit of prostate size of 30 g may not be valid, I firmly believe that most patients with an intravesical lobe are poorly treated by TUIP, which is essentially ideally suited to the patient with a high or elevated bladder neck but no to minimal intravesical protrusion.

What has changed in the last 10 to 15 years in the practice of urology is the fact that learners and practitioners use nearly universally a flexible cystoscope in the office. There are several questions I ask myself when doing a diagnostic flexible cystoscopy in the office in patients refractory to medical therapy. First, does the amount of lateral lobe tissue preclude a TUIP and thus require a resection rather than incision? Second, if the lateral lobes are not significantly enlarged, is the bladder neck elevated, that is, do I have to move the scope upward to enter the bladder across the bladder neck? Third, and most importantly, upon complete retroflection, is there a significant amount of intravesical prostate tissue (also called intravesical lobe, ball-valving middle lobe, and intravesical protrusion)? Only if the answer to questions one and three is "no" do I consider a TUIP procedure, while patients with obstructing lateral or intravesical lobes usually do much better with a TURP. Because flexible cystoscopy has become commonplace, I do not support the 30-g threshold for or against TUIP any longer.

A helpful experience for teaching and learning the TUIP procedure is to have seen or done a laparoscopic or robotic prostatectomy. Nearly every resident has seen or done this procedure and is familiar with the appearance of the tissue when the posterior bladder neck is transversely incised and the space between bladder and prostate further developed until vas deferens and seminal vesicles are identified. The appearance of the tissue in that gap is so characteristic that most learners will immediately remember it when mentioned, and that is the tissue quality I strive for when doing a TUIP. In other words, the circular fibers of the bladder neck are transected to the point where one enters the loosely organized fatty tissue in this very space.

While not wishing to claim one technique being superior to another, I myself prefer the 6-o'clock single incision, which I carry out from the interureteric ridge to the verumontanum.

Chapter 73

Laser Treatment of Benign Prostatic Disease

NICOLE MILLER AND DOUGLAS F. MILAM

RATIONAL CHOICE OF OPERATING ROOM OR OFFICE-BASED THERAPY

Surgical treatment of bladder outlet obstruction caused by benign prostatic hyperplasia has evolved into either operating room– or office-based therapy. Use of laser energy to perform prostatectomy for benign disease began with the use of free beam neodymium:YAG energy for tissue coagulation. The original treatment methodologies have been supplanted by more effective therapies including high-energy KTP laser photo ablation, holmium laser enucleation of the prostate, and interstitial laser coagulation. Of these three therapies, high-energy KTP photo ablation and holmium laser enucleation of the prostate are operating room–based therapies while interstitial laser coagulation is most commonly performed in the office setting. When choosing how to approach prostate disease, one's first decision is whether to perform an operating room–based therapy or an office-based treatment. Because of that, interstitial laser coagulation, which is office based, is often offered to a somewhat different treatment group than the other two operating room–based therapies.

HIGH-ENERGY PHOTO VAPORIZATION

High-energy photo vaporization, or photoablation (green light laser, photo selective vaporization of prostate [PVP]), requires specific equipment. This technique uses either a high energy diode pumped solid-state laser (80 to 120 W, 532 nm, Greenlight HPS) or a high-energy KTP laser. Power requirement is 30 A at 208 to 240 V). The 120-W systems produce more rapid tissue ablation than earlier 80-W systems. Typically, a KTP laser generates a 120-W continuous wave beam using a frequency doubling crystal. In essence, this is a neodymium:YAG laser with a potassium-titanyl-phosphate (KTP) crystal, which doubles the 1064-nm neodymium:YAG laser frequency, causing a brilliant green 532-nm beam to be produced. The beam is directed through a 70-degree side-firing fiber into tissue.

The laser beam is directed into tissue at a 70-degree angle.

Preoperative Management

Candidates for photo vaporization of the prostate are usually the same group of people who would otherwise be candidates for transurethral resection of the prostate (TURP). As such, the preoperative requirements are the same as described previously for TURP.

Procedure

The procedure begins with careful cystourethroscopy using both the 30- and 70-degree lenses. This eliminates the possibility of unknown lesions such as bladder tumors and bladder stones. After cystourethroscopy is performed, the 70-degree side-firing fiber may be passed through the cystoscope. One uses the 30-degree foreoblique lens for this treatment. Most urologists use a video camera during treatment. If one chooses to view directly through the lens, then wavelength-specific eye protection is mandatory. Much like for TURP, one should develop a personal regimen that is performed similarly every time. Nevertheless, most surgeons begin at the bladder neck and create a channel.

The high-energy laser beam is directed into tissue at the bladder neck immediately lateral to the median lobe, if one is present, or at the 5- and 7-o'clock positions to create a channel. This channel width is increased by slight rotation of the fiber while the scope is slowly withdrawn from the bladder neck toward the verumontanum. Do not dwell in one area; this may produce charring, which can limit laser effectiveness.

Laser energy is directed into tissue lateral to the median lobe. Speed of travel differs due to the characteristics of prostatic tissue, but the speed of travel must be slow enough to produce complete vaporization and desiccation of the tissue without producing carbon char.

Once the channel is created on both sides by high energy, photo vaporization, and desiccation, then the median lobe can be addressed. At this point, the median lobe will be very discrete and separate from the rest of the prostate.

Good visualization and access to the median lobe should be obtained. Because the beam projects forward 20 degrees from perpendicular relative to the tissue, one needs to be careful about forward treatment and injury to the ureteral orifices. These need to be very carefully identified and their position known throughout the entire procedure. The median lobe is then methodically photo vaporized beginning on one side and the other working to the midline. Once the median lobe is taken down, the lateral lobes can be treated.

Treatment progresses toward the veru montanum.

Most individuals begin on the edge of the groove created earlier and work their way axially from the floor of the prostate to the anterior region. Due to the 20-degree forward nature of the beam, it is safe to bring the fiber out to the proximal or midportion of the verumontanum to treat apical tissue. At the end of treatment, the prostate appears open when viewed from a position at the distal aspect of the verumontanum looking toward the bladder. The prostatic fossa is lined by a shaggy coat of desiccated tissue, which sloughs off almost imperceptibly to the patient and reepithelializes smoothly within 6 weeks. A unique characteristic of the KTP laser energy is that the high-energy beam is absorbed within 3 to 4 mm of the surface. Because of this, there is not extensive photo coagulation deep to the area that was resected. This is likely the reason why photo vaporization of the prostate does not create the frequency urgency syndrome that was commonly seen after Nd:YAG laser free beam prostatectomy.

The end result is a open prostatic fossa similar to that produced by TURP.

Postoperative Management

PVP is often quite bloodless. Patients with small prostates may be discharged home on the day of treatment. Many urologists, however, keep the patient overnight. If an indwelling urethral catheter is placed at the end of the procedure, it can almost always be removed on the morning of the first postoperative day. Oral antibiotics are routinely given for several days following therapy.

HOLMIUM LASER ABLATION OF THE PROSTATE (HoLAP)

The holmium laser has a wavelength of 2140 nm, which falls within the infrared portion of the spectrum and is invisible to the naked eye. Holmium laser energy is delivered in pulses through small vapor bubbles. A vapor bubble is created at the tip of the fiber when operating in a fluid medium, and water within the target tissue acts as a chromophore. Holmium laser energy results in thermal vaporization of the tissue.

The tissue penetration is only 0.5 mm in water, and the laser is capable of vaporizing, cutting, or coagulating tissue. Laser settings for holmium laser ablation of the prostate (HoLAP) range from 2 to 3.2 J and 25 to 50 Hz resulting in 80 to 100 W of power. The most common laser settings for HoLAP include 2 J and 50 Hz or 3.2 J and 25 Hz. A 550-μ side-firing DuoTome holmium laser fiber is used for HoLAP that emits laser energy at a 70-degree angle into the prostate tissue. One advantage of the holmium laser over other lasers used to treat benign prostatic hypertrophy (BPH) is the multipurpose nature of the laser that allows treatment of coexisting conditions such as urethral stricture or bladder stone at the same setting.

Equipment

- 100-W holmium laser
- DuoTome SideLite 550-μ holmium laser fiber
- 26-French continuous flow resectoscope
- Laser bridge/fiber stabilizing guide > 7.5 French
- Saline irrigant
- Video monitoring system

SURGICAL TECHNIQUE

Introduction of Resectoscope into Prostate

The operation begins with cystourethroscopy to visualize all of the appropriate landmarks as well as evaluate for the existence of any unknown conditions such as urethral stricture, bladder tumor, or stone. Important landmarks for HoLAP include the bladder neck, ureteral orifices, trigonal ridge of the bladder, verumontanum, and urinary sphincter. In addition, the configuration of the prostate should be ascertained, paying particular attention to the presence or absence of a significant median lobe. Multiple passes over the bladder neck should be avoided as this may induce scope trauma with resultant bleeding and impairment of visualization.

Ensure Proper Irrigation

Continuous flow of irrigation is an integral component of the procedure to allow proper visualization. To ensure continuous flow, the bladder should be distended, followed by opening of the outflow port of the resectoscope to gravity drainage.

Insertion of the Laser Fiber

A DuoTome SideLite 550-μ laser fiber is inserted through the working channel of the resectoscope (Fig. 73-1A). There is an adjustable handpiece on the fiber that can be manipulated to allow for adequate fiber length through the scope. One should check for the presence of the red aiming beam at the fiber tip. The handpiece is tightened so that it can be manipulated during the case for rotation of the laser fiber. The DuoTome SideLite 550-μ laser fiber has a torque device that allows rotation of the fiber. There is a solid center line that runs the length of the fiber as well as a solid circumferential line that runs around the cap of the fiber (see Fig. 73-1B). The solid center line indicates the top of the laser, which is 180 degrees from the laser energy exit window. The solid circumferential line on the fiber cap marks the distance at which the fiber must be extended to prevent laser damage to the scope lens. However, if the fiber is extended too far beyond the scope, excess vibration may

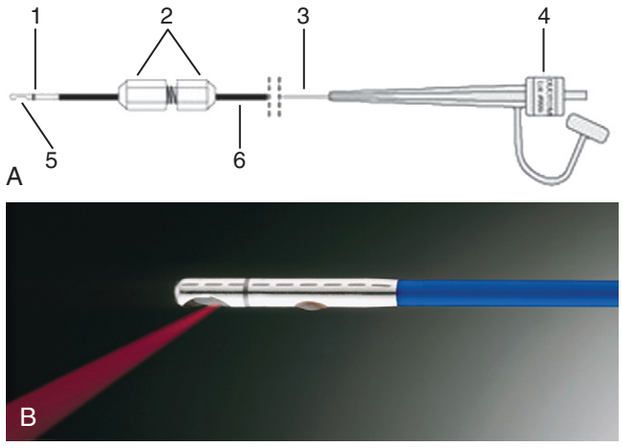

FIGURE 73-1.

occur during HoLAP and can potentially damage the fiber. Therefore, the solid circumferential line marks the distance at which the fiber should extend from the end of the resectoscope for correct fiber positioning. There are also two dashed lines present 90 degrees from the laser energy exit window. Each dashed line indicates a 180-degree rotation of the fiber.

Bladder Neck Incision and Holmium Laser Ablation of Median Lobe Tissue

HoLAP begins with treatment of the median lobe prostatic tissue. Using laser settings of 2 J and 50 Hz (alternatively 3.2 J and 25 Hz), incisions are made in the bladder neck at the 5- and 7-o'clock positions (Fig. 73-2). An important procedural point is that the laser fiber should be near but not touching the tissue for efficient ablation. Burying the fiber tip into the tissue may cause the fiber to overheat and potentially degrade. A slow, sweeping rotational motion of the laser fiber will create a smooth surface of prostatic tissue as well as efficient ablation. Approximately 1 g of prostate tissue can be ablated per minute using these laser settings. The bladder neck incisions are deepened and widened into grooves to better identify the bladder neck fibers. Extension of these grooves is continued out to the verumontanum and to the depth of the surgical capsule. The capsule is identified by the appearance of transverse circumferential fibers. The two incisions are then connected by ablation of the central remaining prostate tissue or median lobe.

Holmium Laser Ablation of the Lateral Lobes

A similar technique is employed to ablate the lateral lobes of the prostate. After the capsular fibers have been identified, ablation of the lateral lobes continues from the 5- and 7-o'clock positions upward toward the 11- and 1-o'clock positions (Fig. 73-3). The capsular fibers are again used to judge the depth of ablation. Using a slow rotational motion of the fiber as well as a forward and backward motion of the resectoscope, the lateral lobes are ablated from the bladder neck to the verumontanum. Great care is taken when approaching the prostatic apex to be sure the resectoscope is always kept proximal to the verumontanum when the laser is activated. These maneuvers will prevent any inadvertent injury to the urinary sphincter. If any bleeding points occur during HoLAP, they can be controlled by defocusing the laser tip 2 to 3 mm away from the bleeding vessel while activating the laser. The creation of a wide open prostatic fossa with visualization of the prostatic capsule completes the ablation procedure (Fig. 73-4).

Postoperative Care

An 18- to 20-French Foley catheter is left indwelling at the end of the procedure. Typically, patients treated early in the day and who have no significant history of urinary retention have their catheters removed in the afternoon of the day of surgery and a voiding trial initiated. Those treated later in the day will generally be discharged home on the day of surgery with a catheter in place with plans to remove it on the morning following surgery. The vast majority of HoLAP patients are treated on an outpatient basis. Pain medications are generally not needed,

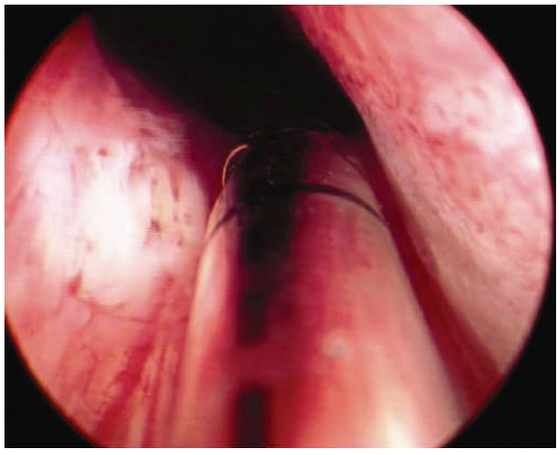

FIGURE 73-2.



FIGURE 73-3.

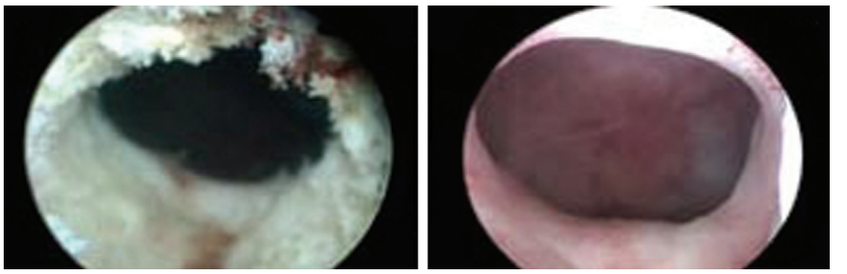

FIGURE 73-4.

and antibiotics are prescribed for approximately 1 week postoperatively.

HOLMIUM LASER ENUCLEATION OF THE PROSTATE (HoLEP)

HoLEP represents the endourologic procedure for treatment of BPH that most closely approximates simple open prostatectomy. The cutting characteristics of the holmium laser are used to develop a plane between the prostatic adenoma and the surgical capsule of the prostate. The enucleated tissue is removed through a process of morcellation. The reported advantages of HoLEP are reduced catheter times, hospitalization, and blood loss. The hemostatic nature of the holmium laser has also allowed HoLEP to be performed on anticoagulated patients. While HoLEP can be used to treat prostates of any size, it is particularly advantageous for the treatment of large prostates. Randomized controlled trial data have demonstrated outcomes of HoLEP to be equivalent to that of TURP and simple open prostatectomy. Furthermore, similar to HoLAP TUR syndrome is not a risk of HoLEP because normal saline is used for irrigation.

Equipment

- Holmium laser (100 W)
- 550 μ end-firing quartz Holmium laser fiber
- 26- to 28-French continuous flow resectoscope
- Laser bridge modified resectoscope sheath
- 7-French laser fiber stabilizing catheter
- Offset rigid nephroscope
- Tissue morcellator
- Saline irrigant
- Video monitoring system

SURGICAL TECHNIQUE

HoLEP is performed with the 100-W holmium laser. The aiming beam is turned off, and various laser settings are employed based on the step of the operation: 2 J and 50 Hz for enucleation of the median and lateral lobes, 2 J and 40 Hz for the apical dissection, 2 J and 20 Hz to divide the apical mucosal bridge, and 2.5 J and 40 Hz for capsular bleeding points. The cutting characteristics of the holmium laser are employed during HoLEP using a 550 μ end-firing holmium laser fiber at the aforementioned settings.

Inspection of the Bladder and Prostatic Fossa

Similar to HoLAP, HoLEP begins with careful cystourethroscopy to inspect the bladder and urethra for the existence of any unknown conditions such as urethral stricture, bladder tumor, or stone, and identify important landmarks for the operation including the bladder neck, ureteral orifices, trigonal ridge of the bladder, verumontanum, and urinary sphincter. The presence of any significant median lobe tissue is also of importance because it dictates the initial surgical approach to enucleation. A three-lobe technique is used for patients with a large median lobe, while a two-lobe technique is used for small or absent median lobe tissue.

Bladder Neck Incision and Enucleation of the Median Lobe

In the presence of trilobar prostatic hyperplasia, HoLEP begins with enucleation of the median lobe of the prostate. With the continuous flow resectoscope in the bladder, a 550-μ end-firing holmium laser fiber is passed through the laser stabilizing catheter in the working channel of the resectoscope. The end of the fiber is positioned just beyond the end of the scope with the aiming beam turned off. At laser settings of 2 J and 50 Hz, incisions are made at the 5- and 7-o'clock positions along the sulci lateral to the median lobe (Fig. 73-5A). The initial incisions are developed into grooves from the bladder neck distally to the verumontanum and then deepened to the level of the surgical capsule of the prostate (see Fig. 73-5B). The end of the resectoscope should be kept pointing downward into the groove to aid visualization of the tissue planes. The distal points of the 5- and 7-o'clock grooves are then connected by incising the remaining mucosa in a transverse fashion just proximal to the verumontanum. The beak of the resectoscope is used to place upward traction on the median lobe adenoma. This maneuver helps define the tissue attachments to the capsule. These attachments are divided in a retrograde fashion using a combination of sharp dissection (laser) and blunt dissection (beak of the resectoscope). To maintain appropriate orientation, it is helpful to work on the floor of the prostate from one lateral incision to the other, maintaining the same tissue plane and depth of enucleation. As one approaches the bladder neck, the median lobe is displaced upward into the bladder and care is taken not to undermine the bladder neck (Fig. 73-6). The remaining attachments of the median lobe to the bladder

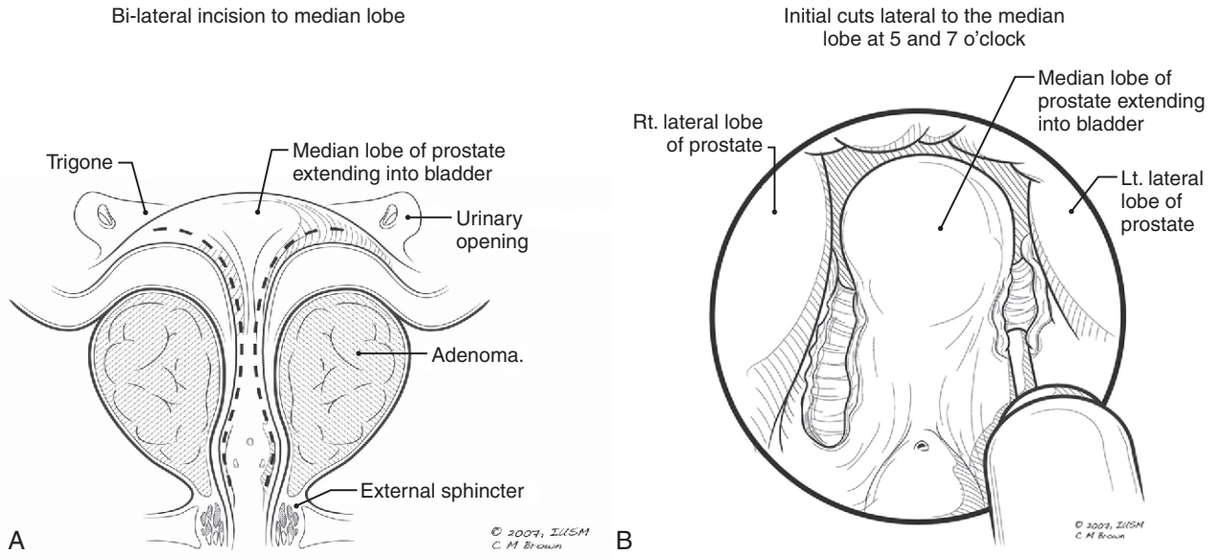

FIGURE 73-5. *(Courtesy of the Indiana University School of Medicine.)*

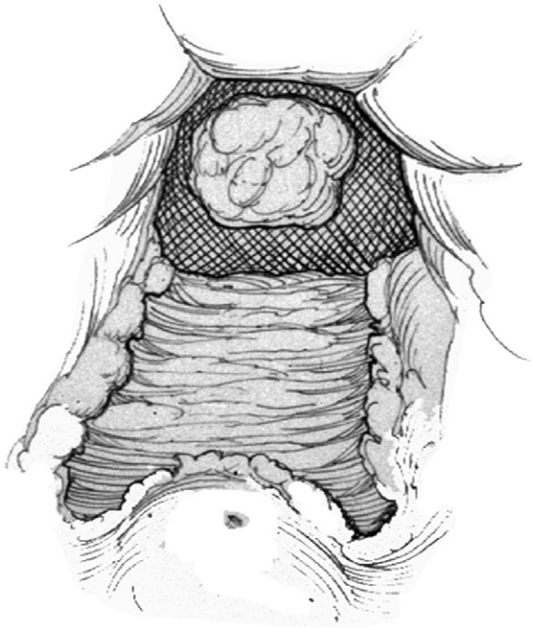

FIGURE 73-6. *From Moody JA, Lingeman JE: Holmium laser enucleation for prostate adenoma greater than 100 grams: comparison to open prostatectomy. J Urol 165:459-462, 2001.*

neck are best incised by working laterally to medially starting from the 5- or 7-o'clock groove. Particularly with large median lobes, it is important to again identify the position of the ureteral orifices so as to avoid any inadvertent injury while dividing the remaining median lobe attachments to the bladder neck. The median lobe should now be free floating in the bladder. The floor of the prostatic fossa is examined for any capsular bleeding points. Control of these bleeding points is accomplished by defocusing the laser tip 2 to 3 mm away from the bleeding vessel. Laser settings of 2.5 J and 40 Hz is recommended for capsular bleeding points.

Lateral Lobe Enucleation

One of the most critical steps in performing HoLEP is defining the correct plane of enucleation between the adenoma of the lateral lobe and the surgical capsule at the prostatic apex. This is accomplished by incising the mucosa directly lateral to the verumontanum (Fig. 73-7). Care should be taken to avoid carrying this incision distal to the verumontanum to prevent any injury to the striated sphincter. Complete enucleation of one lateral lobe at a time is recommended. Determining the correct plane for lateral lobe enucleation is aided by matching the depth of the distal end of the 5- or 7-o'clock groove, and working beneath the apex of the lateral lobe. Following incision lateral to the verumontanum, the beak of the resectoscope can then be positioned beneath the lateral lobe adenoma (Fig. 73-8).

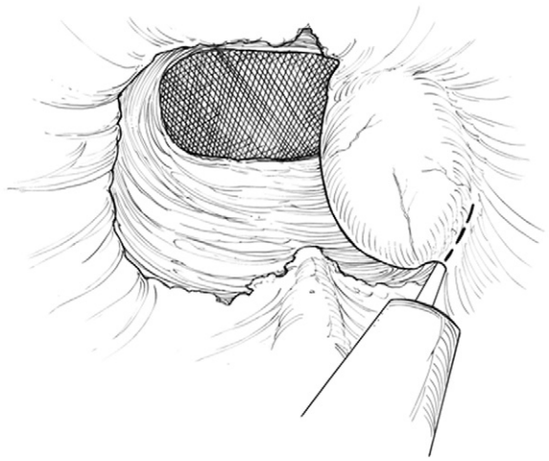

FIGURE 73-7. *From Das A: Holmium laser prostatectomy: a review of techniques. Atlas of the Urologic Clinics 10:81-92, 2002.*

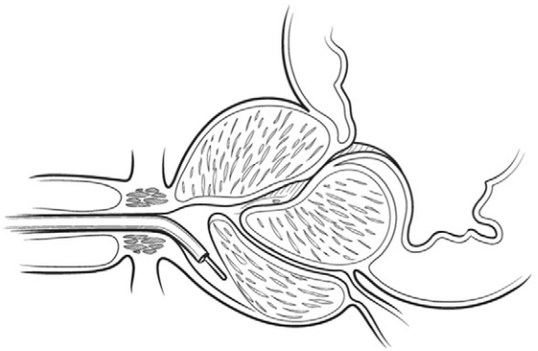

FIGURE 73-8. *From Das A: Holmium laser prostatectomy: a review of techniques. Atlas of the Urologic Clinics 10:81-92, 2002.*

Using a combination of blunt dissection with the beak of the resectoscope and cutting with the laser, the apical dissection is carried circumferentially toward the 1-o'clock position for the left lateral lobe or 11-o'clock position for the right lateral lobe. A reduction in laser energy to settings of 2 J and 40 Hz is recommended for the apical dissection. The circumferential incision is accomplished by rotation of the resectoscope up to 90 degrees and is continued in a retrograde fashion toward the bladder neck. Extension of the dissection forward allows separation of the lateral lobe from the bladder neck. The video camera should always remain perpendicular to the floor in order to maintain proper orientation. Rotation involves only the resectoscope and the laser fiber, which is to be pointed toward the capsular side. Enucleation is carried around as close to 12 o'clock as is possible so that the midline of the prostate is reached anteriorly. An important point of technique is that the beak of the resectoscope must remain wedged in between the adenoma and the surgical capsule to provide countertraction of the lobes. This maneuver aids visualization of the correct plane as well as mobilizes the lobe off the surgical capsule and away from the sphincter (Fig. 73-9). When in the correct tissue plane, gentle torque on the adenoma with the beak of the resectoscope will result in blunt enucleation, which simulates the action of the surgeon's finger during simple open prostatectomy.

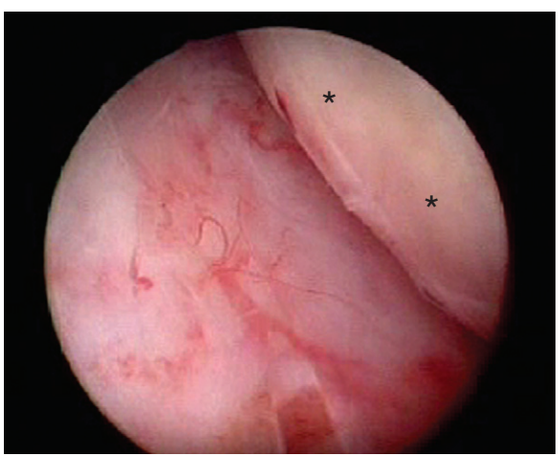

FIGURE 73-9.

Incision of the Anterior Commissure

A single incision is made in the anterior commissure at the 12-o'clock position from the bladder neck to the level of the verumontanum (Fig. 73-10). Before proceeding with this incision, it is important to withdraw the resectoscope distally to identify the location of the striated sphincter. This incision is deepened and widened until a 12-o'clock groove is created. If the circumferential incision that began at the apex of the prostate (inferior enucleation) was carried around far enough anteriorly, one will often encounter this plane while developing the 12-o'clock groove. If this plane is not encountered, then the 12-o'clock incision is extended circumferentially around the anterior surface of the adenoma toward 3 o'clock for the left lateral lobe or 9 o'clock for the right lateral lobe (Fig. 73-11). The goal at this stage of the operation is to match up the anterior superior plane of enucleation with the inferior plane of enucleation.

Division of the Apical Mucosal Bridge

Once the majority of the lateral lobe has been enucleated, it remains suspended distally by a strip of mucosa connected at the apex of the prostate. Rotation of the resectoscope laterally from the 12-o'clock to the 6-o'clock position will trap this bridge of mucosa so that it can be divided with the laser (Fig. 73-12). A strip of mucosa is present for each lateral lobe. Due to the close proximity of the apical mucosal bridge to the sphincter, the laser fiber is always pointed downward toward the mucosal strip, and laser settings are reduced to 2 J and 20 Hz for division. Leaving a small amount of anteroapical tissue is not a problem and may even be beneficial in preventing stress urinary incontinence.

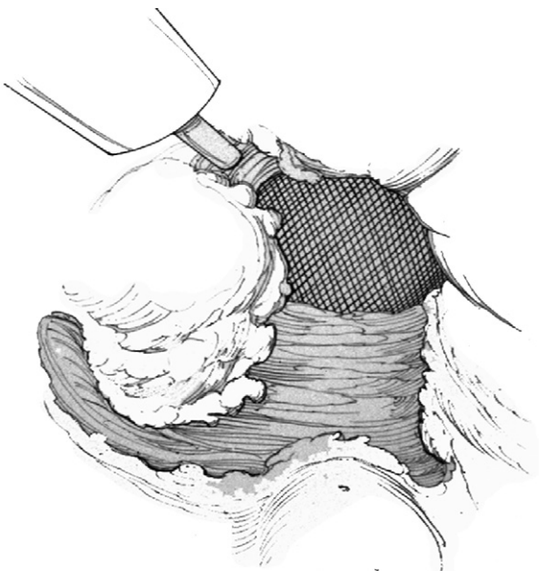

FIGURE 73-10. *From Moody JA, Lingeman JE: Holmium laser enucleation for prostate adenoma greater than 100 grams: comparison to open prostatectomy. J Urol 165:459-462, 2001.*

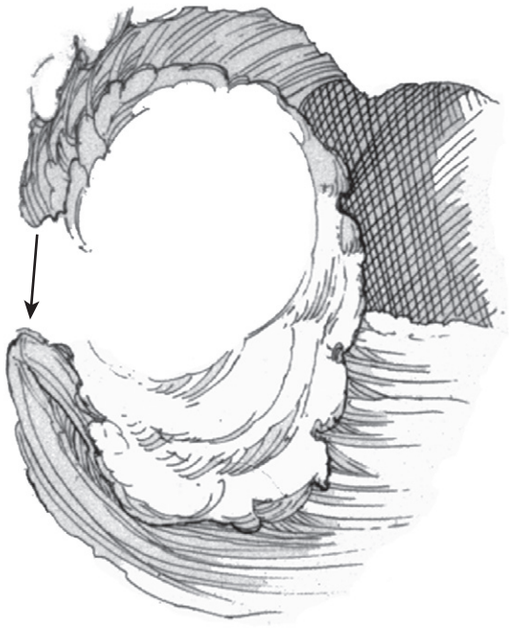

FIGURE 73-11.

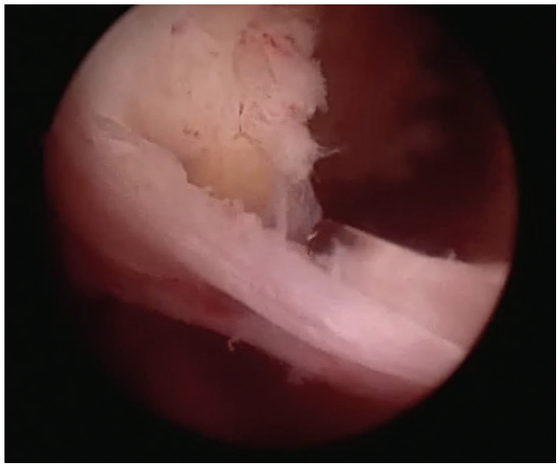

FIGURE 73-12.

Completion of the Lateral Lobe Enucleation

Any remaining attachments of the lateral lobes are divided with laser settings of 2 J and 50 Hz. The enucleated lobes are pushed into the bladder, and should be free floating when lateral lobe enucleation is completed. Prior to morcellation, inspection of the fossa is performed to identify any bleeding points and achieve hemostasis.

Tissue Morcellation

One of the benefits of HoLEP over other laser treatments for BPH, is the ability to retrieve suitable tissue for pathologic analysis. The enucleated tissue is removed through a process of tissue morcellation. Hemostasis must be achieved prior to proceeding with morcellation as a clear endoscopic field is essential. A standard tissue morcellator with reciprocating blades is introduced through the working channel of an offset nephroscope. The nephroscope connects easily to the outer sheath of the existing resectoscope. The bladder must be thoroughly distended during morcellation which is accomplished by running irrigant through both inflow ports. Slow depression of the morcellator pedal will activate the suction component of the morcellator. Further depression of the pedal activates the morcellator blades which can be seen at the end of the scope. Continuous suction ensures adequate visualization during morcellation and assists in engaging the enucleated tissue. Safe morcellation is performed by avoiding activation of the blades when near the bladder mucosa and directing the morcellator up toward the center of the bladder when the tissue is engaged (Fig. 73-13). If small fragments of tissue remain that are difficult to engage with the morcellator blades, these fragments can be morcellated in the prostatic fossa. The morcellated tissue is collected in a specimen trap, and sent for pathologic analysis.

Final Inspection of the Prostatic Fossa

Final inspection of the prostatic fossa is performed to identify any bleeding points. The creation of a wide open prostatic fossa with visualization of the prostatic capsule completes HoLEP.

In the case of a small median lobe, a two-lobe technique is used. This is a modification of the three-lobe technique described above where a single 5-o'clock incision is made from the bladder neck to the verumontanum. The left lateral lobe is enucleated as described, and the small median lobe is then enucleated along with the remaining right lateral lobe (Fig. 73-14).

Postoperative Care

A 20- or 22-French three-way catheter is secured in the bladder with a 60-mL balloon. If necessary, the catheter is placed on continuous bladder irrigation and is typically removed

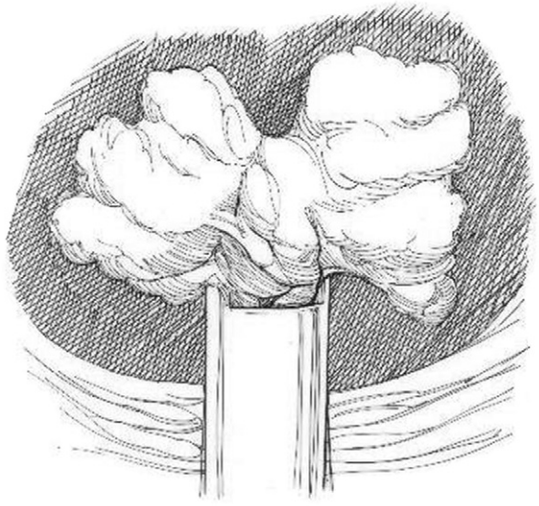

FIGURE 73-13. *Gilling PJ, Aho TF, Frampton CM, et al: Holmium laser enucleation of the prostate: results at 6 years. Eur Urol 53:744-749, 2008.*

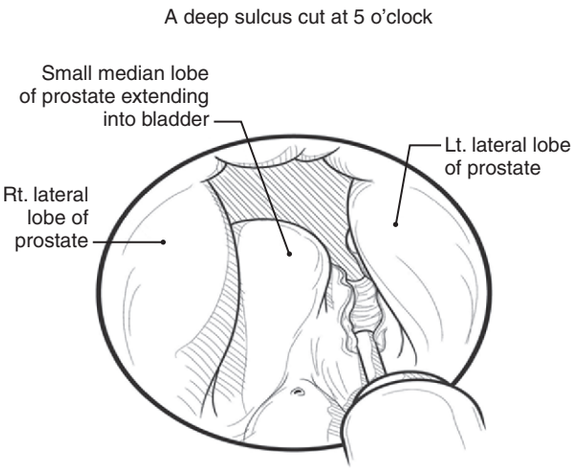

FIGURE 73-14. *Gilling PJ, Aho TF, Frampton CM, et al: Holmium laser enucleation of the prostate: results at 6 years. Eur Urol 53:744-749, 2008.*

early on the morning of the first postoperative day. Pain medications are generally not needed, and antibiotics are prescribed for approximately 1 week postoperatively.

TECHNIQUE OF INTERSTITIAL COAGULATION

Interstitial coagulation (ILC) is an office-based therapy that should be considered as an alternative to transurethral needle ablation (TUNA) of the prostate or transurethral microwave thermotherapy (TUMT). ILC is a minimally invasive thermotherapy used to heat prostatic tissue, forming a zone of coagulation. The ILC device incorporates a diode laser using a gallium-aluminum-arsenide lasing medium, which generates an 830-nm wavelength laser beam. The power can range from 2 to 20 W. The generator is small, almost briefcase size, and weighs approximately 28 lb. The laser fiber is attached to the generator box and threaded through the cystoscope for insertion directly into tissue. The fiber employs a diffuser tip to maximize the volume of treated tissue.

Pretreatment Requirement

Local intraurethral lidocaine anesthetic is administered. Most urologists pretreat the patient with an oral benzodiazepine 60 minutes before the treatment and often use hydrocodone supplementation. ILC can be performed without the use of transperineal or transrectal block. Most urologists, however, find that an ultrasonically guided transrectal block identical to that used for prostate biopsy is extremely helpful.

Procedure

A careful cystourethroscopy is then performed in order to visualize the prostate and bladder to eliminate the possibility of unrecognized lesions. A 21-French cystoscope sheath allows easy insertion of the laser fiber through the scope. A laser bridge is necessary to deflect the fiber laterally. Like TUNA, the urologist can visualize the prostate and insert the laser fiber directly into hyperplastic or median lobe regions (Fig. 73-15). Within a few seconds of beginning treatment, intraprostatic temperatures reach 85° C. Temperature is maintained for the remainder of 150 seconds of treatment. Like any endoscopic prostatectomy, one should develop a methodology that is used every time. Many urologists begin by inserting a laser fiber into lateral lobe tissue near the bladder neck. Care should be taken to make sure the fiber depth is sufficient to avoid prostatic urethral coagulation. Naturally, there is some debate about how many lesions to produce per treatment session. For 20- to 30-g prostate, many urologists select four lateral lobe lesions. Moderate-sized prostates are often treated with six lesions and larger prostates can be treated with a larger number of lesions as necessary (Fig. 73-16). Median lobe treatment can be performed, although one needs to be careful to limit the treated tissue to the median lobe.

Postoperative Management

ILC produces substantial prostatic edema and most urologists leave an indwelling urethral catheter for a few days. After 5 to 7 days, the incidence of urinary retention postcatheter removal is quite low. Patients should be covered by oral antibiosis through the time of catheterization and for another 2 to 3 days. Narcotic pain medication is not routinely used or prescribed. Nonsteroidal anti-inflammatory medications produce sufficient analgesia, if necessary. Patients should expect an increase in lower urinary tract symptoms for 1 to 2 weeks following treatment. After that, symptomatic improvement becomes noticeable and continues for 6 to 12 weeks.

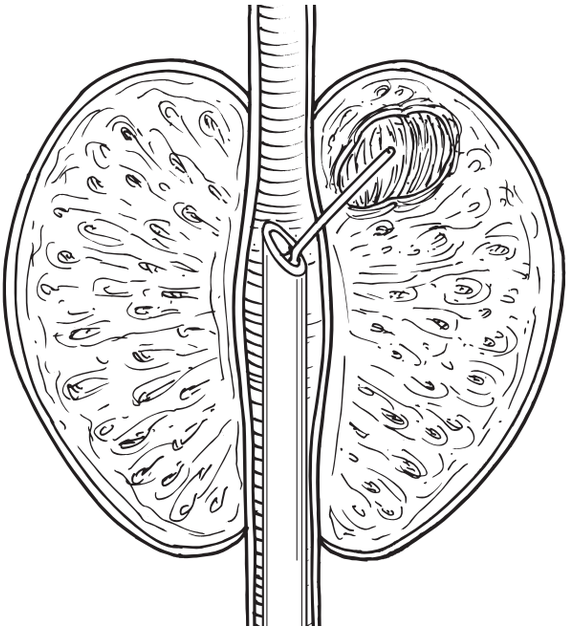

FIGURE 73-15.

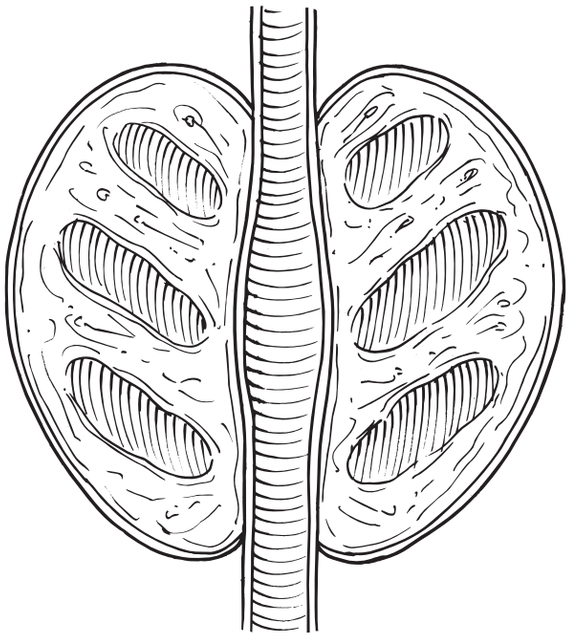

FIGURE 73-16.

Commentary by CLAUS G. ROEHRBORN

Several randomized trials and meta-analyses have demonstrated that there are no significant differences between the KTP, or green light, laser ablation and the holmium laser ablation of the prostate, and it is largely the surgeon's preference or the availability of the instrumentation that is the deciding factor in which method is chosen. The results in properly chosen patients are uniformly good as long as the technical aspects of the procedure as outlined in this chapter are followed. In interacting with learners, I am all too aware of common mistakes using the KTP laser for vaporization ablation:

- "Sitting" on the tissue and drilling a hole in the prostate
- Hovering too long and causing coagulation that leads later to tissue sloughing and irritative voiding symptoms
- Moving the fiber too fast without achieving visible bubble formation and thus vaporization
- Leaving behind the apical tissue for fear of sphincter damage, which results in less than ideal outcomes
- Aiming to create a "funnel" rather than a "barrel" appearance of the prostatic fossa, that is, achieving the ideal of a bilateral cavity by angling the cystoscope and thus the fiber quite lateral
- Forgetting to lower the irrigation fluid pressure (lowering the bag) toward the end of the procedure to coagulate precisely the smaller vessels

The holmium enucleation procedure is equivalent to the suprapubic or retropubic enucleation of the adenoma and requires considerable skills and experience, which of course is equally true for the open surgical approaches. In the hands of an expert, however, it results in shorter hospitalization with significantly less bleeding.

This page intentionally left blank

Chapter 74

Suprapubic Prostatectomy

JOSHUA K. MODDER AND KEVIN T. McVARY

The indications for a suprapubic prostatectomy for benign disease are the same as for the retropubic approach, namely symptomatic benign prostatic hypertrophy (BPH) or urinary retention along with a markedly enlarged prostate gland (>75 g). The suprapubic approach may be preferred in cases involving a prominent intravesical component of the prostate and/or where direct access to the bladder is required, such as with bladder calculi or a large, narrow-necked bladder diverticulum.

PREOPERATIVE CONSIDERATIONS

Preoperative evaluation should include measurement of postvoid residual, a urinalysis and urine culture, prostate-specific antigen (PSA), American Urological Association (AUA) symptom score, and urodynamics if indicated. Urinary retention should be treated with indwelling or clean intermittent catheterization preoperatively, and any urinary tract infection should be treated with antibiotics. The prostate size should be measured with transrectal ultrasonography, and in cases of an elevated PSA or suspicious prostate examination, a prostate biopsy should be performed to rule out adenocarcinoma. Overestimation of prostate size using transrectal ultrasonography is a common occurrence, and one should be aware of the volume of the transition zone alone compared with the total volume of the prostate.

The procedure requires either a general or spinal anesthetic (general is preferred), and preoperative cardiac clearance should be obtained. Preoperative laboratory studies should include a complete blood count, chemistry panel, and coagulation studies if indicated. Medications and allergies should be reviewed, and any medications that affect coagulation should be discontinued before surgery. Although transfusion rates are low, this procedure has the potential for significant blood loss, and typed and cross-matched blood products should be available for intraoperative and postoperative transfusion if necessary.

Instruments include a prostatectomy set with lobe forceps or a four-pronged tenaculum, Allis clamps, three Deaver retractors, a Balfour or other self-retaining retractor (Omni or Buchwalter), 2-inch vaginal packing, and a cystoscopy set. Perform cystoscopy if not already done.

Antibiotic prophylaxis should be administered before surgery. General recommendations include a first or second generation cephalosporin given intravenously (IV) within 1 hour of incision for uncomplicated cases. For higher risk patients, including those at risk for endocarditis, those with an indwelling Foley catheter, and those with prosthetics including an artificial heart valve of any age or artificial hips or knees within 2 years, a broad-spectrum regimen of ampicillin 2 g IV plus gentamicin 1.5 mg/kg (up to 120 mg) IV is recommended. In cases of a penicillin allergy, vancomycin 1 g IV (infused slowly over 1 hour before surgery) can be substituted for ampicillin. IV antibiotics should be continued for 24 hours following the procedure and then converted to an oral regimen postoperatively until the Foley catheter is removed.

PROCEDURE

Positioning and prep (Fig. 74-1): After the induction of satisfactory general or regional anesthesia, position the patient supine with the anterosuperior iliac spine located over the kidney rest. The table should be slightly flexed in the modified Trendelenburg position to facilitate exposure of the male pelvis and retraction of the peritoneal reflection. Shave the patient from above the umbilicus to the pubis, prep with Betadine scrub and paint, and drape using towels, clamps, and a laparotomy drape. Place an 18-French Foley catheter, fill the balloon with 10 mL of saline, fill the bladder with 200 to 300 mL of saline, and clamp to facilitate exposure of the bladder. Use of a fiberoptic headlight may aid visualization of the prostatic fossa after enucleation.

Incision and exposure: A transverse (Pfannenstiel) or lower midline incision may be used depending on the patient's build and presence of previous surgical scars. The authors prefer a transverse incision; however, extending the incision too far laterally should be avoided to decrease the risk of postoperative hernia. Awareness of potential injury to the underlying superficial inferior epigastric vessels is important with either incision. Expose

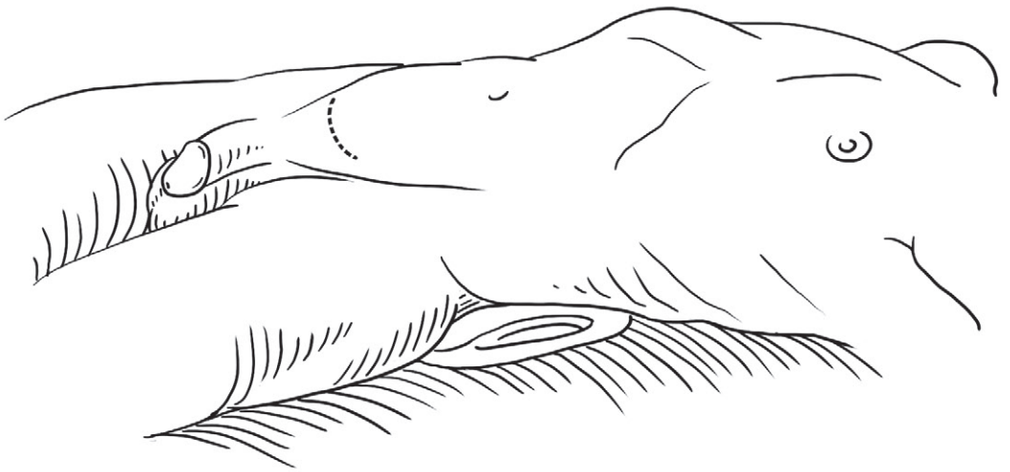

FIGURE 74-1.

and incise the anterior rectus fascia in the same direction and same length as the skin incision. In the case of the transverse incision, grasp the superior flaps of rectus fascia with Kocher clamps on either side of the midline. Using the Kocher clamps for retraction, separate the rectus muscle bellies from the fascia with blunt finger dissection and electrocautery (Fig. 74-2). Repeat on the inferior aspect of the incision to the symphysis pubis. Separate the rectus muscle bellies in the midline and retract them laterally, using electrocautery to open the underlying transversalis fascia. Use sponge sticks or fingers and a lap pad to gently develop the space of Retzius anterior to the bladder by pushing the peritoneal reflection superiorly and perivesical tissue laterally and posteriorly (Fig. 74-3). Avoid injuring the deep inferior epigastric vessels during this maneuver. Place a padded Balfour or other self-retaining retractor.

Cystotomy and exposure: Select a site on the anterior surface of the bladder, approximately 2 to 3 cm superior to the bladder neck, to open the bladder. Determine whether the bladder is sufficiently distended (add or remove saline if necessary) and remove the Foley catheter. Place stay sutures of 2-0 synthetic absorbable suture (SAS) inferior and superior to the planned incision. Avoid placing these too low to prevent tearing the prostatic capsule. Open the bladder transversely with a knife or electrocautery

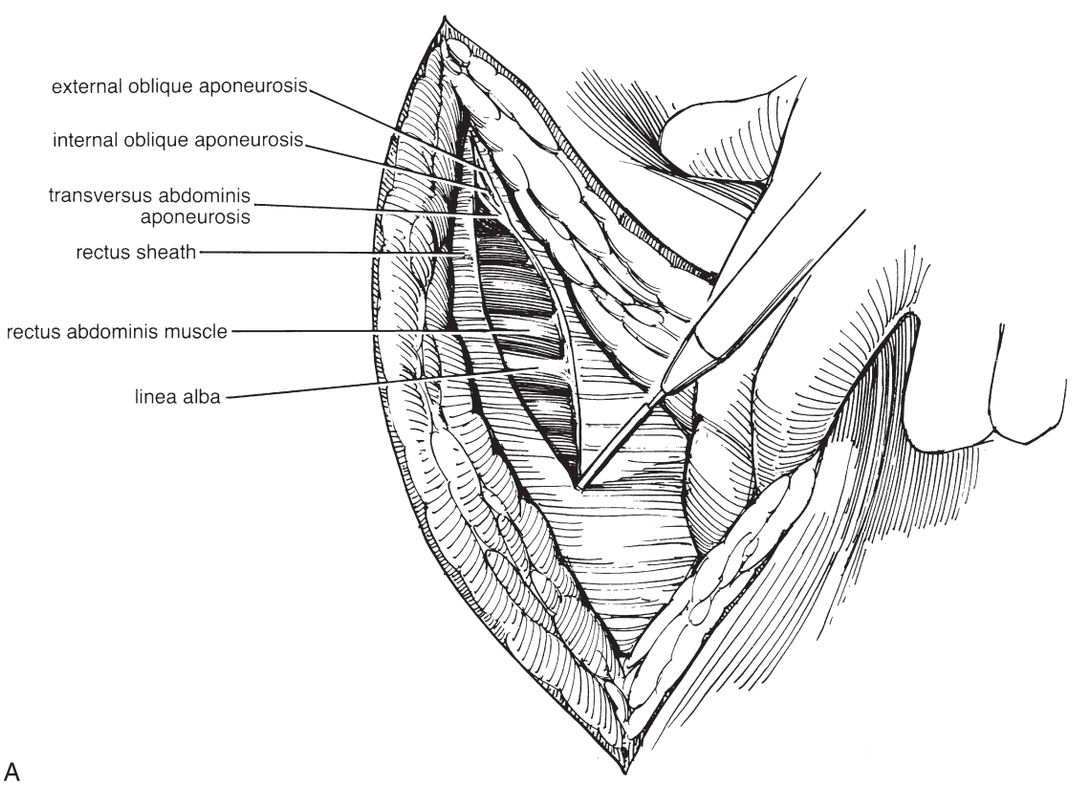

A

FIGURE 74-2.

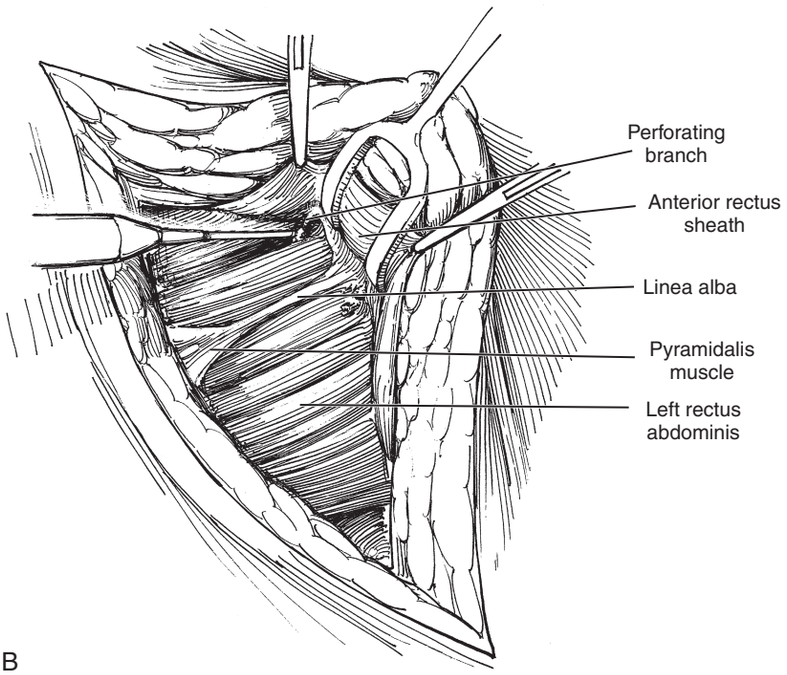

B

FIGURE 74-2, cont'd.

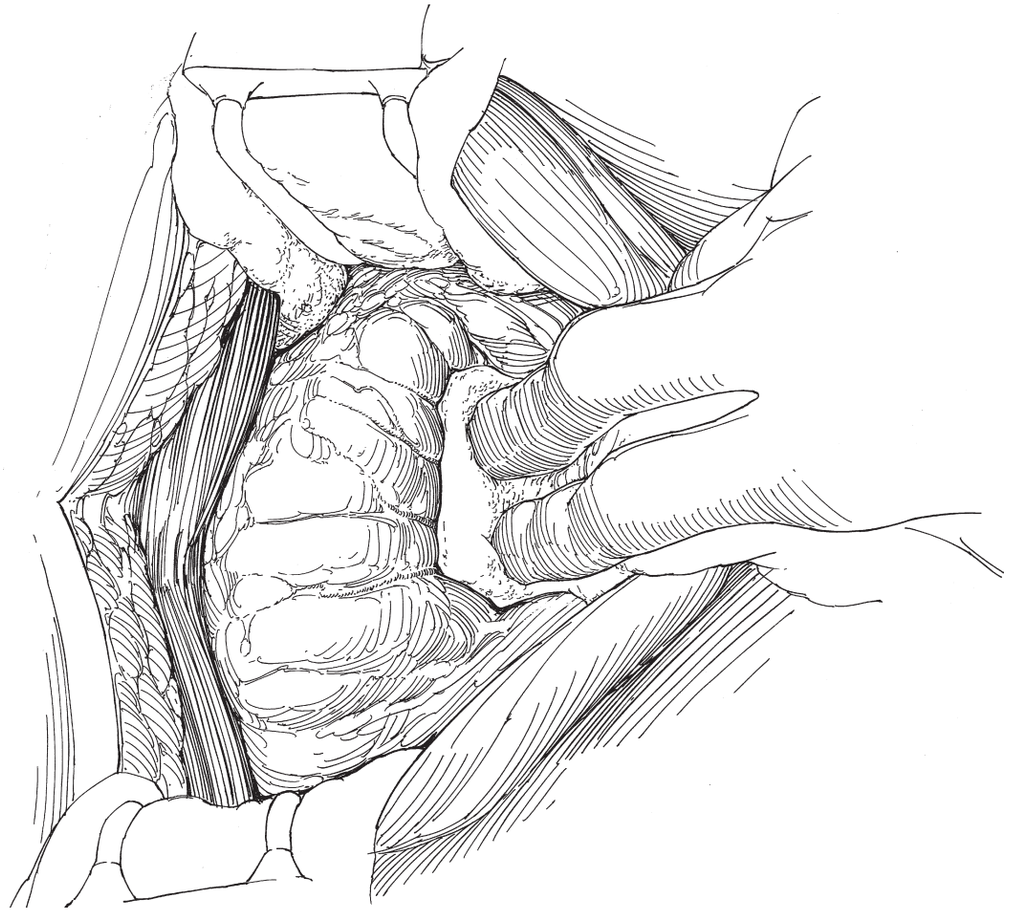

FIGURE 74-3.

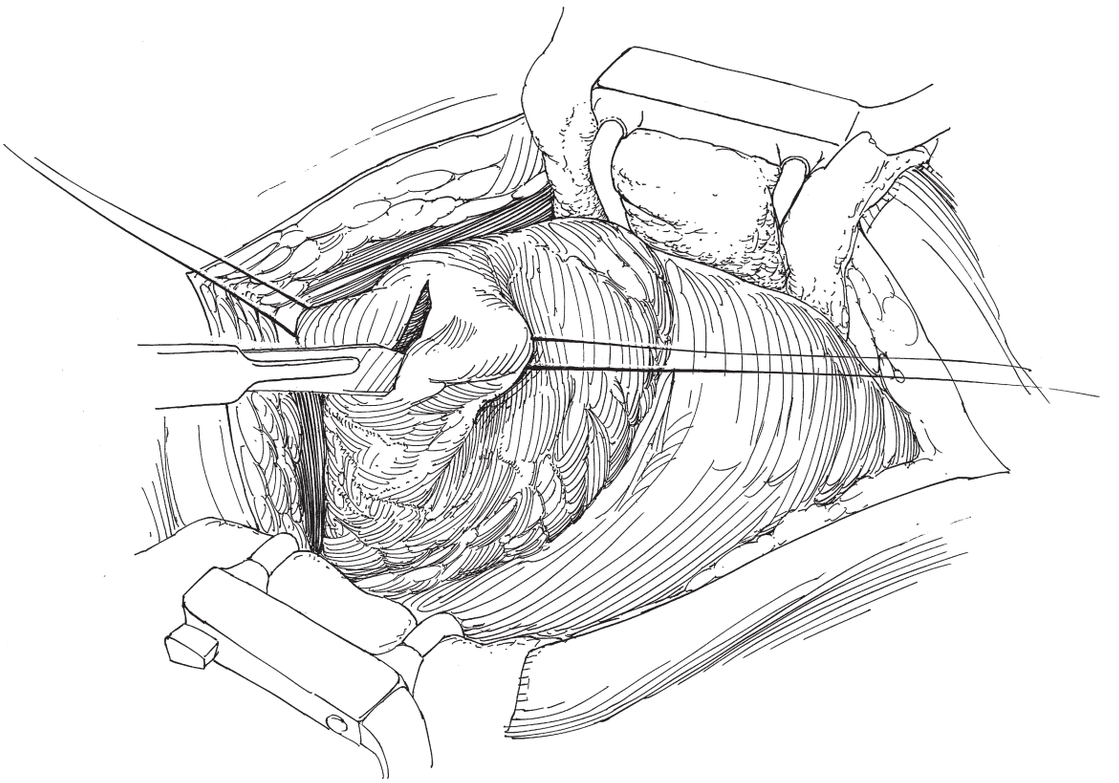

FIGURE 74-4.

between the stay sutures (Fig. 74-4). Immediately enlarge the opening by inserting a Mayo clamp and spreading. Empty the bladder contents with suction. Insert two fingers and stretch the opening wider (this technique is preferred because fewer vessels are injured). After cursory inspection of the interior of the bladder, pack the dome with lap pads and retract using the bladder blade attachment for the Balfour or a wide Deaver. Expose the trigone and bladder neck using narrow Deavers placed on either side. An Omni or Buchwalter retractor can also be used in place of a Balfour and Deavers. Identify the ureteral orifices (use intravenous indicarmine if necessary), remove any vesical calculi, and more closely inspect the bladder mucosa.

Dissection and removal of the adenoma: Identify and palpate the adenoma protruding at the bladder neck. Incise the bladder epithelium circumferentially around the protruding adenoma using the cutting current of the Bovie (Fig. 74-5). Separate the epithelium from the adenoma using a curved scissors. Remove the retractors and shift the patient into Trendelenburg position.

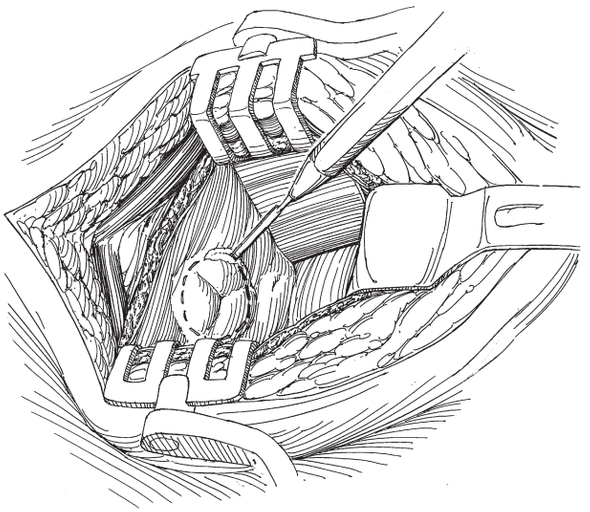

FIGURE 74-5.

The enucleation should be initiated by inserting the index finger into the prostatic fossa and cracking the anterior commissure with anterolateral pressure against the larger adenoma (Fig. 74-6). Blunt enucleation should be carried out in the cleavage plane between the surgical capsule and the adenoma with pressure primarily directed against the adenoma to avoid capsular tears or extraadenoma misadventures. Sweep and roll the finger laterally, working side-to-side, proximal and distal, until the lobes have been freed (posteriorly as well) (Fig. 74-7). If adhesions are met, try angling the elbow or turning your body to come at the area from a different angle. Use either hand. Do not persist if an area is stuck; leave that for last. Unusual adherence of the adenoma to the capsule should increase suspicion of carcinoma. Come across the midline posteriorly, making sure to stay within the confines of the capsule and enucleate the middle lobe. Be careful to avoid hooking and tearing the prostatic capsule with a sharp fingertip. The urethra should be divided sharply or bluntly by "pinching" between two fingers just proximal to the distal apical adenoma (Fig. 74-8).

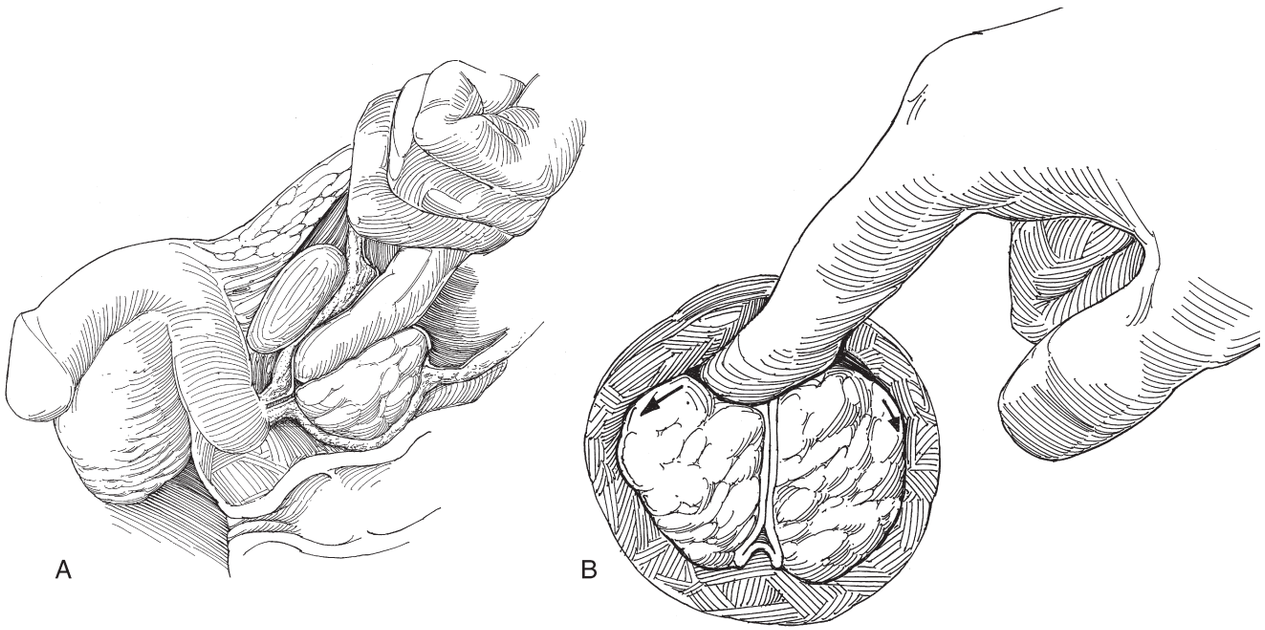

FIGURE 74-6.

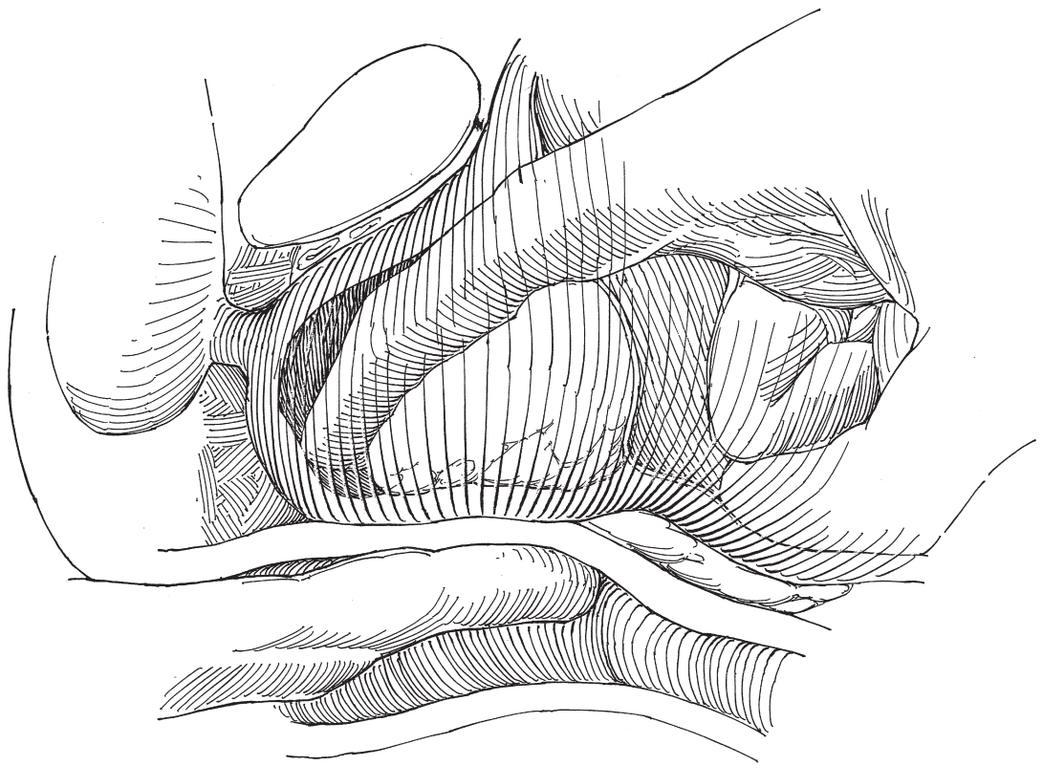

FIGURE 74-7.

Avoid traction on the distal urethra to minimize external sphincter or "traction" injury. Sharply divide any remaining attachments with care from the bladder neck, especially posteriorly in the area of the ureteral orifices. Grasp the adenoma with a four-pronged tenaculum, sponge, or lobe forceps and remove it (Fig. 74-9).

Enucleation may be facilitated by placing the fingers of the free hand or an assistant's hand or sponge stick on the perineum to push the prostate ventral and cephalad. A four-pronged tenaculum can also be used to grasp the adenoma and provide exposure of adherent areas for sharp dissection with long curved scissors. The sequence of the enucleation should be varied, depending on the configuration of the adenoma and the ease of enucleation. In a large gland with multiple adenomas, sequential removal is preferable to traumatic removal in toto.

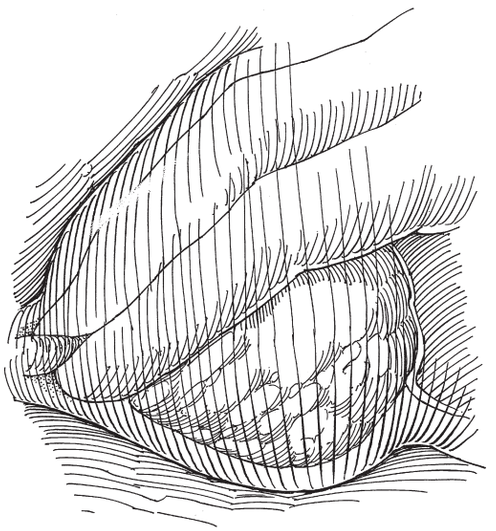

FIGURE 74-8.

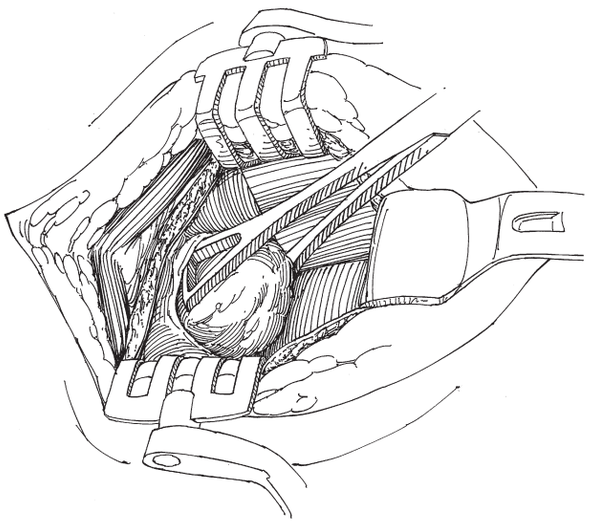

FIGURE 74-9.

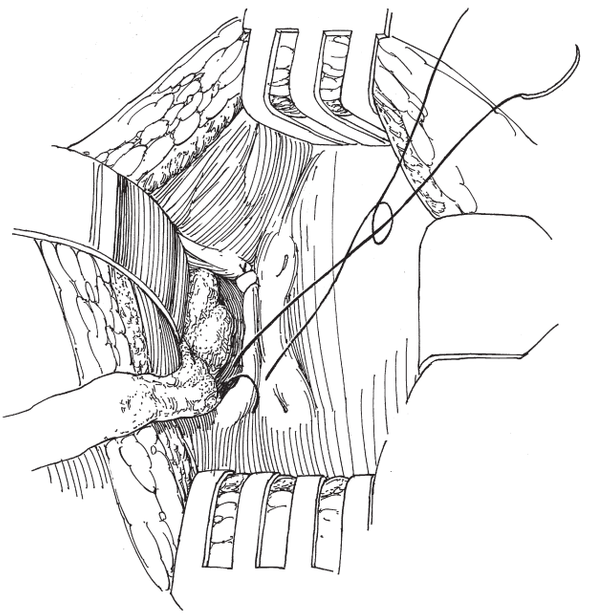

FIGURE 74-10.

Hemostasis and repair: Once the adenoma is removed, rapid control of bleeding becomes the major concern. Often a portion of the blood supply is identifiable as the adenoma is being removed and can be clamped and ligated. Unless bleeding is massive, rapid inspection of the prostatic fossa with supplemental lighting, a narrow Deaver, and partially open ring forceps to aid in the exposure is usually advisable at this time. Sharply remove irregular tissue tags or fragments and control sizable bleeders with suture ligatures or fulguration. Introduction of a gauze pack into the prostatic fossa with blunt-tipped forceps, a standard hemostatic procedure in the past, is now used selectively. It is, however, an excellent maneuver to achieve rapid control of significant bleeding. Place figure-eight or side-on (Halsted) hemostatic mattress sutures of 2-0 chromic or SAS at the 5- and 7-o'clock positions, avoiding the ureteral orifices (Fig. 74-10). These sutures should incorporate bladder mucosa, bladder neck, and prostatic capsule, extending 1 cm deep and 1 cm caudad so as to include the main prostatic arteries that enter there. Use of a GU (5/8) curved needle helps facilitate their placement. Leave these sutures uncut to help during further inspection for hemostasis. The needle-bearing end can be used to anchor the bladder neck to the prostatic fossa.

Inspect the fossa again by retraction, as before, and control further bleeding with suture ligatures or fulguration. If hemostasis is less than adequate, consider placing plication sutures as described by O'Conor (see Intraoperative Hemostatic Procedures). In the case of a small or fibrous bladder neck, excise a V-shaped wedge from the 6-o'clock position before trigonalization of the prostatic fossa. Tack the vesical epithelium over the rim of the fossa using the uncut hemostatic sutures or fine plain catgut or SAS sutures. This facilitates hemostasis, prevents the formation of an obstructing membrane and bladder neck contracture, and aids in proper Foley catheter placement. Insert a 22- or 24-French Foley catheter with a 30-mL balloon, inflate to the appropriate size for the bladder neck, and apply traction. If bleeding continues to be problematic, consider the use of hemostatic agents such as microfibrillar collagen (Avitene), oxidized cellulose (Surgicel), thrombin-soaked Gelfoam, or commercially available tissue sealants placed into the prostatic fossa with or without a temporary gauze packing and traction on the catheter balloon. On rare occasions, one may also need to place a pursestring closure of the bladder neck (see Intraoperative Hemostatic Procedure).

For cases that involve significant bleeding, place either a three-way Foley catheter or a cystostomy tube to allow for bladder irrigation. To place the cystostomy tube, make a stab wound in the skin lateral to the incision and direct a Mayo clamp through this incision, through the body wall, and through the bladder wall in a location near the dome. Cut the end obliquely from a 30-French Malecot catheter and draw it out through the tract. Secure the catheter against the bladder wall away from the trigone with a pursestring suture

of plain catgut at the site of exit from the bladder. Suture the catheter to the skin with heavy silk and fix it with tape.

Remove all sponges and place one or two large drains near the bladder neck brought through separate stab wounds just above and away from the symphysis, securing them at the skin. Close the bladder in two or three layers. Approximate the mucosa with a running suture of 3-0 or 4-0 chromic catgut, incorporating some muscle as well. Reapproximate the superficial and deep muscle layers with interrupted Lembert sutures of 2-0 chromic catgut or SAS. Assess the adequacy of closure and hemostasis with irrigation; the effluent should be pink to clear. Complete routine wound closure with absorbable suture, including approximation of the rectus muscle. Repeat catheter irrigation as the patient awakens from anesthesia and maintain traction on the urethral catheter with adhesive taping to the thigh. Attach the catheters to separate drainage systems and use intermittent or continuous irrigation as needed.

Intraoperative Hemostatic Procedures

Excessive bleeding, if bright red, probably comes from the urethral branches of the prostatic arteries that enter near the vesical neck at the 5- and 7-o'clock positions and constitute the blood supply to the adenoma (Fig. 74-11). Dark blood suggests venous bleeding from the posterior capsule, which has not contracted adequately due to clot or interference from a catheter. Another potential source of bleeding is the deep dorsal vein of the penis.

Capsular plication (O'Conor): Persistent bleeding from deep in the posterior aspect of the prostatic fossa without an obvious source can be controlled at times with capsular plication. Place a 1-0 chromic catgut suture on a GU needle in the posterior capsule, one near the neck and another more distally, running from one side of the fossa to the other (Fig. 74-12). This will bring the capsule together and mimic physiologic contraction.

Purse string partition closure (Malament): Using a double-swaged 1-0 nylon or polypropylene suture, place a pursestring suture, beginning at the posterior margin of the bladder neck. Take bites to include both mucosa and muscle, carry it around the bladder neck in both directions to the midline anteriorly, and exit through the entire thickness of the bladder wall (Fig. 74-13). Be careful not to cross the stitches or the suture will be difficult to remove. Insert a 24- or 26-French catheter with a 30-mL balloon, inflate the balloon, and draw the pursestring suture around the catheter to close the neck. Partially close the bladder, taking care that the closure stitches do not catch the pursestring suture (or the balloon of the catheter). Cut the needle from each end of the nylon suture and thread both ends on a large curved free cutting needle. Pass the sutures through the body wall above the symphysis, and put them under enough tension to close the bladder neck around the catheter to partition the fossa from the bladder. Tie them over a button or gauze pledget (Fig. 74-14). Insert a Malecot cystostomy tube and complete closure of the bladder. Insert a drain retropubically and close the wound. Withdraw the pursestring suture the following day, taking care to cut only one end. Remove the catheters according to the usual postoperative care timeline.

Postoperative Care

The patient should be observed as his blood pressure normalizes following anesthesia to ensure adequate hemostasis has been achieved and patency of the catheters is maintained. Ordinarily the traction on the Foley catheter can be released within 12 hours and the catheter removed on the second or third postoperative day. The drains may be removed when clinically apparent drainage ceases or after removal of the suprapubic catheter. The latter has generally been discontinued on the sixth or seventh postoperative day following a voiding trial, and this schedule is commonly advanced currently. If voiding is not adequately resumed and the suprapubic site is closed by 48 to 72 hours, reinsertion of the urethral catheter may be necessary. Persistent suprapubic drainage usually requires endoscopic and, at times, cystographic

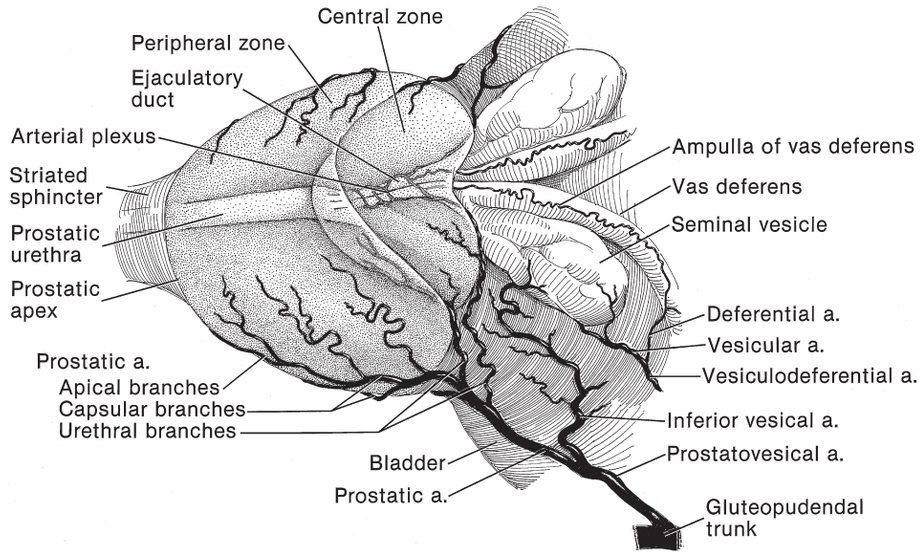

FIGURE 74-11.

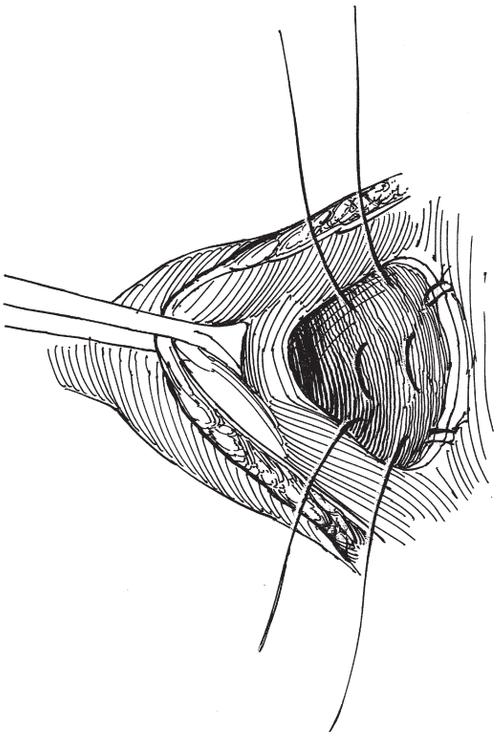

FIGURE 74-12.

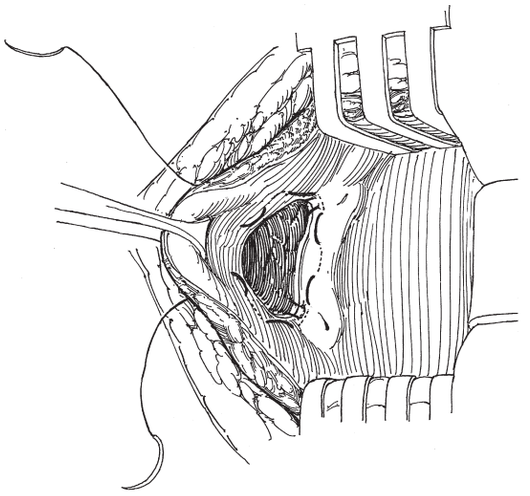

FIGURE 74-13.

assessment to evaluate the possible presence of obstructing tissue or a foreign body at the bladder neck.

Postoperative Problems

Bleeding may persist and require endoscopic fulguration if tamponade fails because tamponade itself prevents capsular retraction. Order appropriate tests to evaluate for clotting disorders. The administration of clotting substrates, including platelets, FFP, and aminocaproic acid (Amicar), may be necessary. Although rarely needed, packed red blood cells should also be available for transfusion.

One should be aware of excessive urinary output following prostatectomy. This may indicate postobstructive diuresis, which can occur following the release of chronic obstruction and result in significant losses of salt and water. The patient should be strictly monitored for fluid balance, blood pressure, heart rate, and serum electrolytes, with replacement as necessary. In general, for urine output of less than 100 mL/hr, treat with oral fluids and salt. For urine output of 100 to 200 mL/hr, replace the urine volume with 0.075 M NaCl in 5% dextrose. If body weight is stable the next day, cut the infusion rate in half, making further cuts as the weight declines. If the urine output is more than 200 mL/hr, measure the urine sodium concentration and use a proportionately more concentrated NaCl solution for 2 days, then progressively decrease it as the urine flow falls and the blood pressure remains stable. If this does not occur, go back to the earlier rate of infusion for 2 more days. For rates of diuresis greater than 300 mL/hr proceed as above for 4 days. Then reduce the infusion rate no more than 25% while monitoring blood pressure and pulse as well as urinary potassium and serum electrolytes.

Infectious and inflammatory complications, including wound infection, urinary tract infection, epididymo-orchitis, and osteitis pubis, are rare. With more prolonged follow-up, a bladder neck contracture may be recognized. This is uncommon and generally, in contrast to bladder neck contracture following transurethral resection of the prostate, responds well to dilation. Urethral stricture is also found in a few cases. The incidence of new onset postoperative impotence or incontinence is low; however, retrograde ejaculation following prostatectomy occurs in the majority of cases.

Although uncommon, the group of patients who are unable to void have persistent drainage from the suprapubic site, unchanged or troublesome symptoms, or chronic urinary tract infection requiring prompt evaluation. This usually includes endoscopic, cystourethrographic, and/or urodynamic studies.

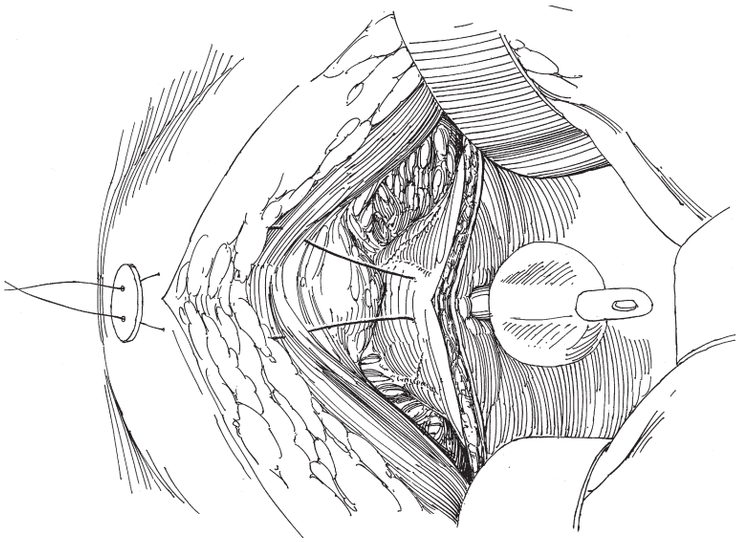

FIGURE 74-14.

Commentary by CLAUS G. ROEHRBORN

Over the last 10 years I have performed exclusively retropubic enucleations for larger adenoma and favor this approach over the suprapubic approach. While there are several reasons for this, I recognize that both procedures in the hand of an experienced surgeon are highly successful and the appropriately chosen patients are usually amongst the most grateful in my practice. I have successfully removed single or multiple bladder stones by the retropubic approach, and even large intravesical lobes. Concerning the suprapubic approach, several technical aspects deserve reinforcement: It is crucial particularly for the learner to identify the correct enucleation plane after breaking through the anterior commissure, because removal of adenomatous tissue left behind after an incomplete enucleation in the wrong plane is exceedingly difficult using the suprapubic approach with its limited visibility in the prostatic fossa. Second, a clear identification of the ureteral orifices, if needed by giving an intravenous dye or placing ureteral stents, is crucial, and the urothelium should be incised by cautery or sharply distal of the orifices before embarking on the enucleation to avoid any injury. Following the enucleation itself, the surgical field can be bloody and later identification of the ureteral orifices may be difficult. Furthermore, the concept of cutting or pinching the prostate off distally without causing a "traction" injury to the external sphincter is very important to impart upon the learner, as it is, incidentally in the retropubic enucleation.

This page intentionally left blank

Chapter 75

Retropubic Prostatectomy

RAJIV SAINI AND STEVEN A. KAPLAN

The transverse capsular incision for retropubic prostatectomy was first described by Terence Millin in 1945. Many descriptions and retrospective studies have been done, however, only minor modifications have been made in the operation since its original description. This retropubic approach through the prostatic capsule allows better control of the prostatic vessels at the bladder neck after enucleation of the adenoma. Other incisions through the prostatic capsule will also be described.

PREOPERATIVE MANAGEMENT

Most patients undergoing open prostatectomy are older with many comorbid medical problems. Medical and, if necessary, cardiac evaluation should be considered in all cases. Upper tract evaluation and cystoscopy should be done in patients with a history of hematuria.

A urine culture should be obtained before the operation and the urine should be sterile at the time of surgery. In addition, preoperative antibiotic coverage should be used to prevent infection from skin flora. A bowel prep and/or enema should be given to patients to prevent stool contamination in case of rectal injury.

POSITIONING AND APPROACH

Position the patient supine on the operating room table. The table should be placed in a flexed position to increase the space between the umbilicus and symphysis pubis, allowing better exposure to the anterior surface of the bladder and prostate. In addition, the table should be placed in Trendelenburg position to displace the peritoneum and intraabdominal organs in a cephalad direction. Padding the lower back may help prevent nerve injury. Compression stockings or sequential compression devices should be applied to the lower extremities to prevent deep venous thrombosis.

The abdomen and genitalia should be prepped under sterile conditions for surgery. Cystoscopy, if not done preoperatively, should now be done. Place a Foley catheter to drain the bladder and inflate the balloon with 30 mL of fluid. Palpating the Foley balloon allows identification of the bladder neck.

Incision

Simple open retropubic prostatectomy is approached through a low midline infraumbilical incision that extends below the level of the symphysis pubis (Fig. 75-1). Alternatively, a Pfannenstiel incision can be made. These incisions allow entry to the space of Retzius and access to the anterior surface of the prostate. A right-handed surgeon should stand on the patient's left side.

After the skin incision, dissection should continue through subcutaneous tissue with electrocautery to the level of the anterior rectus sheath (Fig. 75-2). The rectus sheath is opened in the midline, and the two bellies of the rectus muscle are retracted laterally. The loose fascia overlying the rectus muscle is incised to expose the extraperitoneal tissue overlying the bladder and prostate. Gently dissect the peritoneum away from the bladder. Place a self-retaining retractor (e.g. Balfour or Omni-Tract) to retract the rectus muscles laterally and the bladder and peritoneum superiorly. A

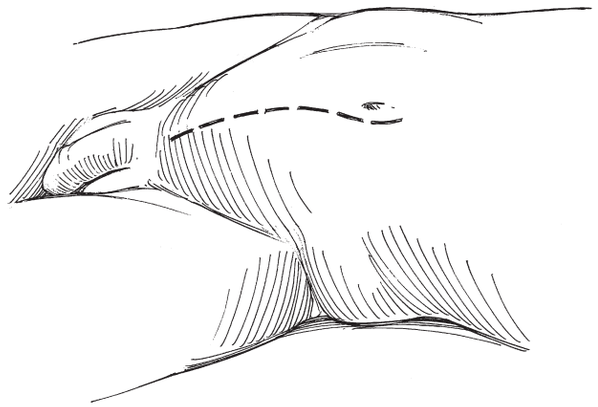

FIGURE 75-1.

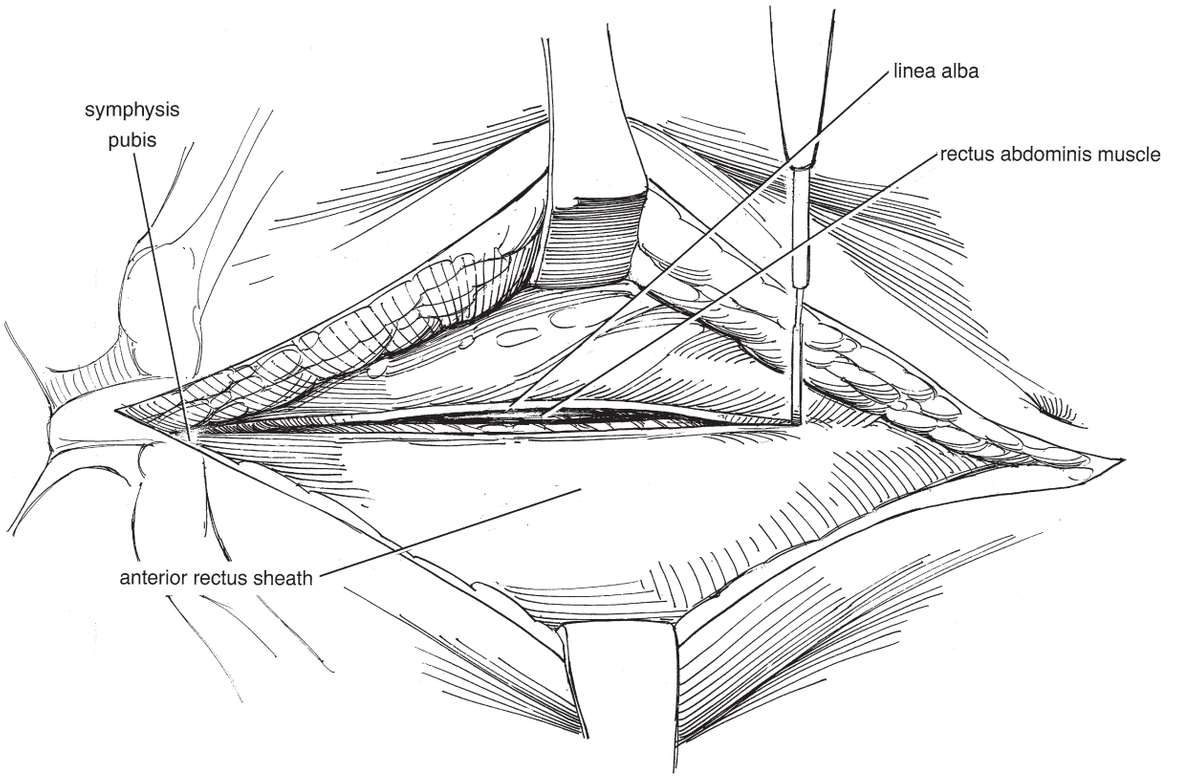

FIGURE 75-2.

moist lap pad should be placed over the bladder and peritoneum retractor blade to prevent traction injury.

Transverse capsular incision (Millin Technique): Gently tease away the loose areolar and fatty tissue overlying the anterior surface of the prostate. Palpate the Foley balloon at the bladder neck. Place parallel rows of 0-chromic sutures transversely along the anterior prostate near the bladder neck and distally near the apex of the prostate. The sutures should be placed deeply through the capsule into the adenoma (Fig. 75-3). These sutures help control bleeding from vessels on the surface of the prostate. Tag the middle sutures of each row with a small clamp. Separate sutures can be placed laterally at the edges of the planned incision to prevent lateral tearing of the prostate during enucleation. Remove the Foley catheter.

Hemostasis can be improved by ligating the dorsal venous complex as is done before radical prostatectomy. In addition, the lateral pedicles can be ligated by placing figure-eight sutures at the posterolateral surface of the prostate at the junction of the seminal vesicles. These methods together should control most arterial and venous bleeding encountered during adenectomy.

Using a blade or cutting electrocautery, make a transverse incision between and parallel to the suture lines over the anterior capsule (Fig. 75-4). Larger prostates require a longer incision. Using a sponge stick, compress the upper portion of the capsule to compress bleeding vessels. Slowly release the pressure to allow fulguration of vessels to maintain a dry field. In addition, use suction to keep the surgical field dry. Continue the incision down to the level of the adenoma.

Enucleation of adenoma: Once the adenoma is reached, identify the plane between the capsule and the adenoma.

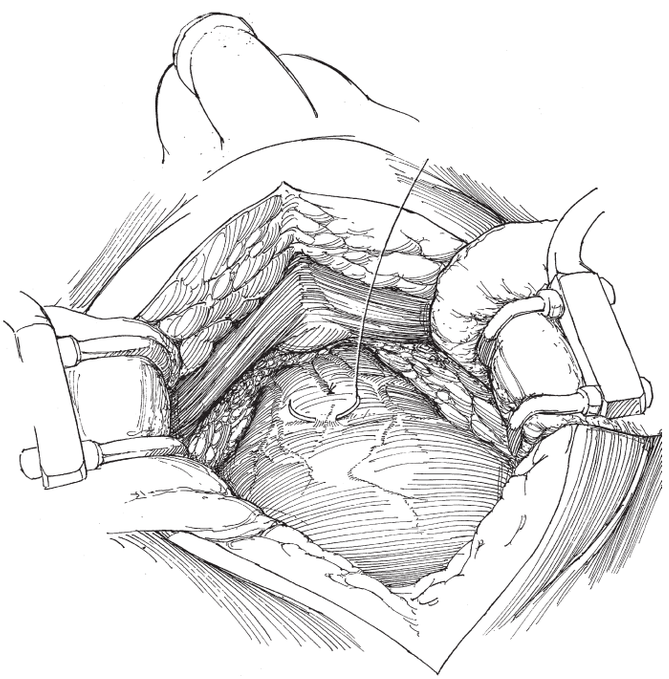

FIGURE 75-3.

Place a Babcock clamp on the lower lip of capsule and use Metzenbaum scissors to separate the adenoma from the capsule. Next use blunt dissection (finger) to further separate the adenoma circumferentially (Fig. 75-5). After separating the adenoma laterally, posteriorly, and superiorly away from the bladder, approach the apical portion. Under

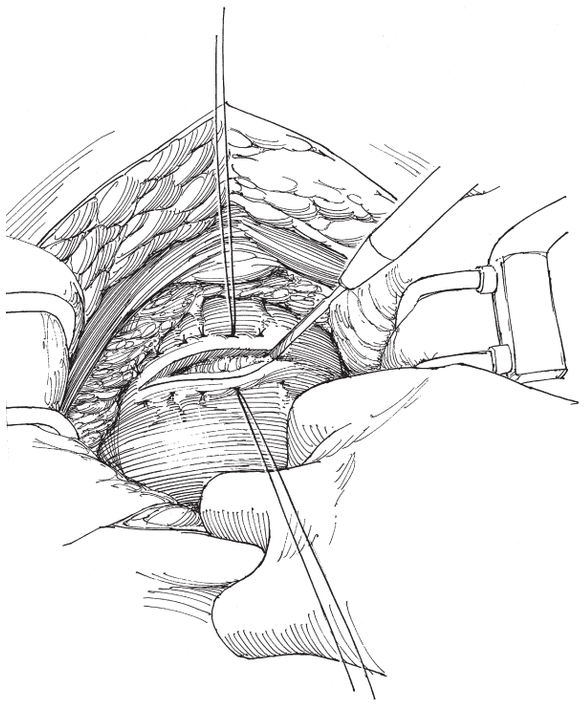

FIGURE 75-4.

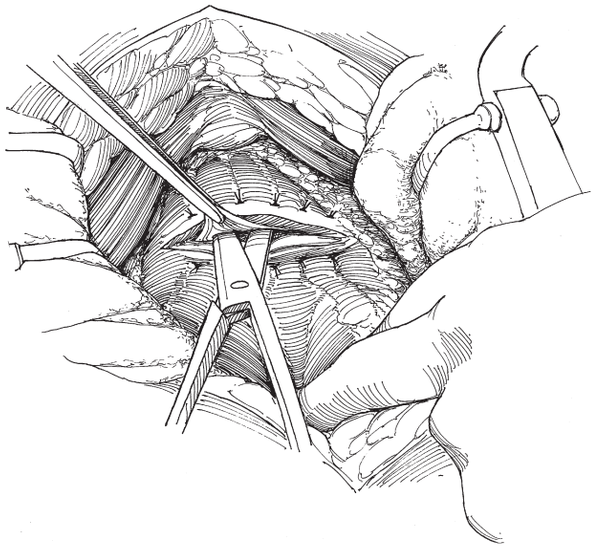

FIGURE 75-5.

direct vision, divide the adenoma proximal to the membranous urethra with sharp dissection to prevent injury to the sphincter (Fig. 75-6). After the adenoma is divided, remove it from the surgical field and ensure that no tissue is left adherent to the capsule. Once the adenoma has been completely removed, the prostatic fossa should be packed with a warm moist gauze pack for 5 minutes.

During enucleation, it is important to not tear the posterior layer of the capsule because an injury to the rectum may occur. If a bowel prep has been given, the tear can be closed in two layers. A layer of omentum should be placed between the rectum and capsule to help prevent fistula formation. If the tear is large or if no bowel prep was given and there is fecal spillage, a temporary colostomy may be required to divert the fecal stream away from the surgical site.

Trigonization of the bladder neck: After removal of the gauze pack, the fossa is inspected for hemostasis. Individual vessels can controlled with electrocautery or suture ligature as necessary. Figure-eight sutures can be placed at the 5- and 7-o'clock positions to control urethral branches of the prostatic arteries (Fig. 75-7). Inspect the bladder and trigone. Identify the ureteral orifices. If not easily visualized, indigo carmine can be administered intravenously to identify the ureteral orifices. If the orifices are too close to the distal edge of the bladder neck, ureteral catheters can be inserted in a retrograde fashion to prevent suturing the orifices.

Using 2-0 chromic suture, the posterior lip of the bladder neck is sutured to the posterior surface of the prostatic capsule. The bladder neck edge should be brought as far distally as possible. Excess posterior bladder neck tissue can be excised as necessary (Fig. 75-8). The trigonization technique is not only helpful with hemostasis, but also aids in keeping a wide junction between the bladder and prostatic cavity, hastens the epithelialization of the fossa, reduces the risk of postadenectomy urethral stricture, and decreases the duration of urethral catheterization postoperatively.

Closure of the capsule: Place a large-bore (22 or 24 French) three-way catheter per urethra and guide it into the bladder. Leave the balloon deflated. Beginning laterally, use two 0-chromic sutures to close the anterior capsule in a continuous fashion. Tie the sutures to each other (Fig. 75-9). Inflate the Foley balloon with 20 to 30 mL (or more if the bladder neck is wide) of fluid. Pull the balloon to the bladder neck, allowing the catheter to tamponade the prostatic fossa. Gentle traction may be applied if hematuria is present. A cystotomy tube may be placed; however, it is not necessary unless there is a large amount of bleeding. A Penrose or Jackson-Pratt drain is left in the space of Retzius anterior to the capsulotomy and brought out though a separate skin site. Recent reports have shown that liquid fibrin sealants can be used to ensure a watertight closure of the capsule and obviate the need for a drain. The Foley catheter is then connected to continuous bladder irrigation with normal saline. The skin is closed in the usual manner.

Alternative capsular incision (vesicocapsular technique): This technique incorporates the anterior bladder wall and the prostatic capsule as one continuous incision. There is an increased risk for urinary leakage after closure of the incision and for downward extension of the incision into the urethral sphincter. Place a Foley catheter after draping the patient. Leave the bladder partially distended.

Gently tease away the loose areolar and fatty tissue overlying the anterior surface of the prostate. After exposing the capsule, place a 0-chromic stitch as low as possible over the midline of the prostatic capsule (Fig. 75-10). Tie the suture and hold the ends on a clamp. Move to the anterior aspect of the bladder. Palpate the Foley balloon at the bladder neck and place two 1-0 chromic sutures as stay sutures over the bladder neck. Make a vertical incision with electrocautery in the midline of the bladder neck between the two sutures (Fig. 75-11). Carefully

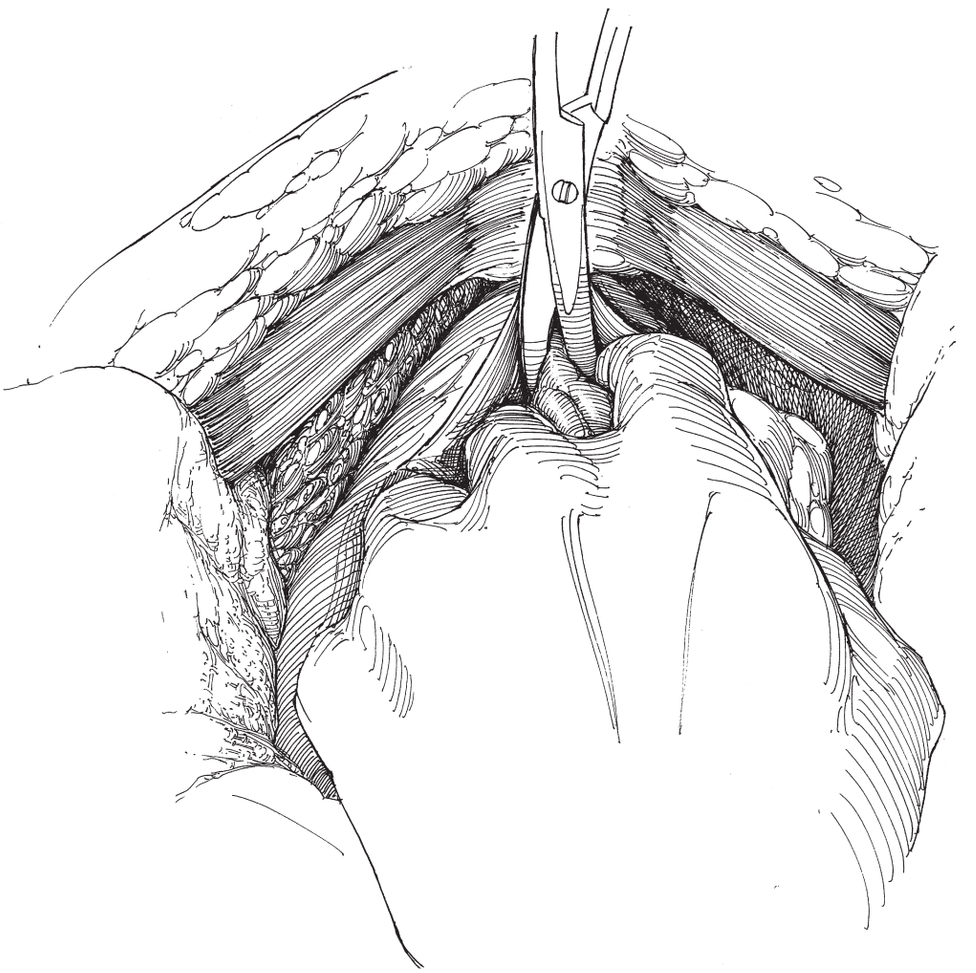

FIGURE 75-6.

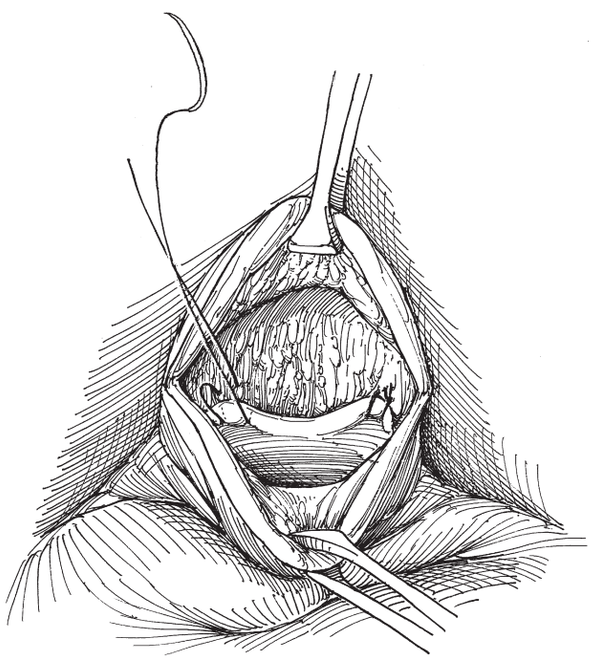

FIGURE 75-7.

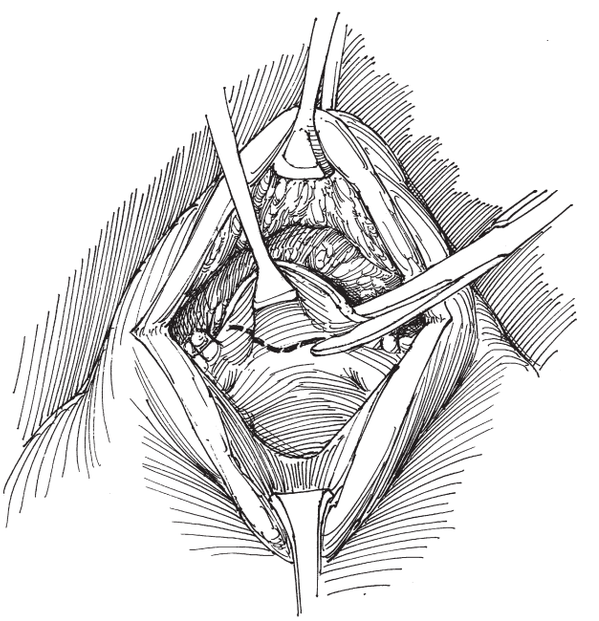

FIGURE 75-8.

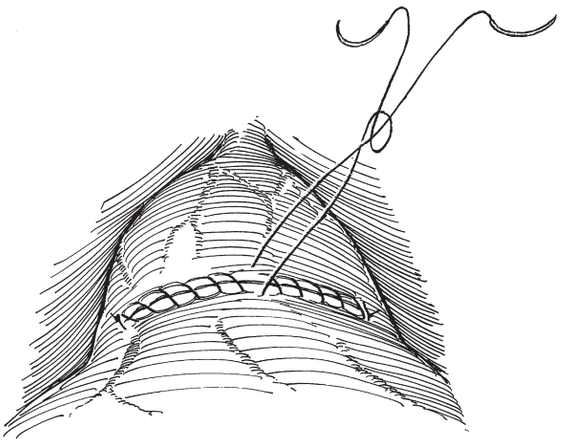

FIGURE 75-9.

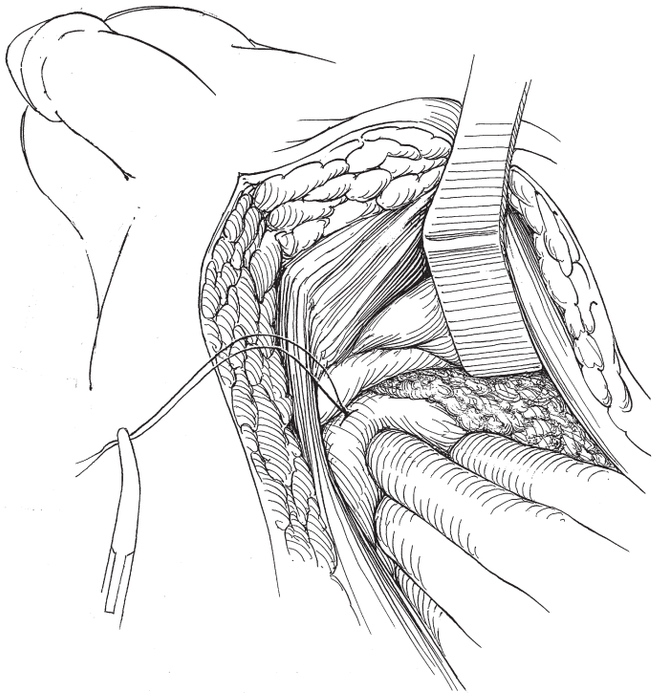

FIGURE 75-10.

enter the bladder. Use suction as necessary to keep the field dry.

Enucleation of adenoma: Place a finger into the bladder and enter the prostatic urethra. Bluntly dissect anteriorly to break the adenoma away from the inner aspect of the capsule (Fig. 75-12). Move circumferentially along the plane between the capsule and the adenoma to dissect the adenoma free. It is important not to dissect down into the apex to prevent sphincter injury. Once the adenoma is removed, use a curved Mayo scissor to incise the prostatic capsule down the midline toward the previously placed 0-chromic stitch (Fig. 75-13). Gently retract open the two lateral edges of the capsule to expose the apical portion of the adenoma. Under vision, divide the apical portion of the adenoma proximal to the sphincter (Fig. 75-14). After the adenoma is divided, remove it from the surgical field and ensure that no tissue is left adherent to the capsule. Once the adenoma has been completely removed, the prostatic fossa should be packed with a warm moist gauze pack for 5 minutes.

Trigonization of the bladder neck. Remove the gauze pack and inspect the fossa for hemostasis. Control bleeding with electrocautery or suture ligature as necessary. Figure-eight sutures can be placed at the 5- and 7-o'clock positions to control urethral branches of the prostatic arteries (Fig. 75-15). Inspect the bladder, trigone, and ureteral orifices. Indigo carmine and ureteral catheters can be used as previously described.

Using 2-0 chromic suture, the posterior lip of the bladder neck is sutured to the posterior surface of the prostatic capsule. The bladder neck edge should be brought as far distally as possible.

Closure of the bladder and capsule. Place a large bore (22 or 24 F) three-way catheter per urethra and guide it into the bladder. Leave the balloon deflated. Place a running 2-0 plain catgut suture in a pursestring fashion in the opened portion of the bladder. Begin at the one end of the bladder neck and move circumferentially to the other end of the neck. Tie this suture to close the bladder incision. Beginning distally, use two 0-chromic sutures to close the anterior capsule in an interrupted fashion. Using 2-0 chromic suture, imbricate the outer surface of the bladder over the previous layer (Fig. 75-16).

Inflate the Foley balloon with 20 to 30 mL (or more if the bladder neck is wide) of fluid. Pull the balloon to the bladder neck, allowing the catheter to tamponade the prostatic fossa. Gentle traction may be applied if hematuria is present. Irrigate the bladder to remove any clots. A Penrose or Jackson-Pratt drain is left in the space of Retzius anterior to the capsulotomy and brought out through a separate skin site (Fig. 75-17). The Foley catheter is then connected to continuous bladder irrigation with normal saline. The skin is closed in the usual manner.

POSTOPERATIVE MANAGEMENT

Deep venous thrombosis prophylaxis with compression stockings, sequential compression devices, or subcutaneous heparin should be used for all patients. Continuous bladder irrigation should be discontinued when the urine is clear. The drain should be removed when output is minimal, and the Foley can be removed 3 to 5 days after drain removal. Alternatively, the Foley can be removed 3 to 5 days postoperatively, and the drain can be removed 24 hours after Foley removal if output is minimal. If the drain output persists after Foley removal, replace the Foley catheter.

If the Foley is removed or inadvertently comes out of the urethra, it should be gently replaced with a smaller catheter. If this cannot be easily accomplished, cystoscopy and Foley placement may be necessary.

Continued bleeding from the fossa can be managed with traction on the Foley catheter. If bleeding persists, transurethral fulguration may be necessary. Antibiotics should be continued until the Foley is removed.

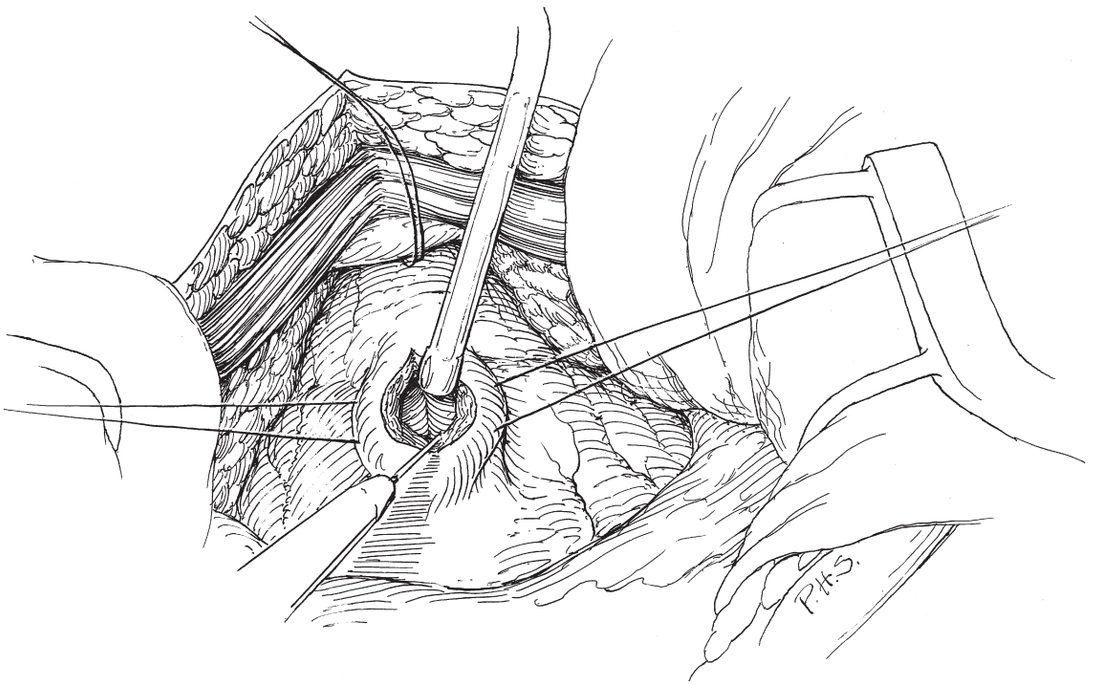

FIGURE 75-11.

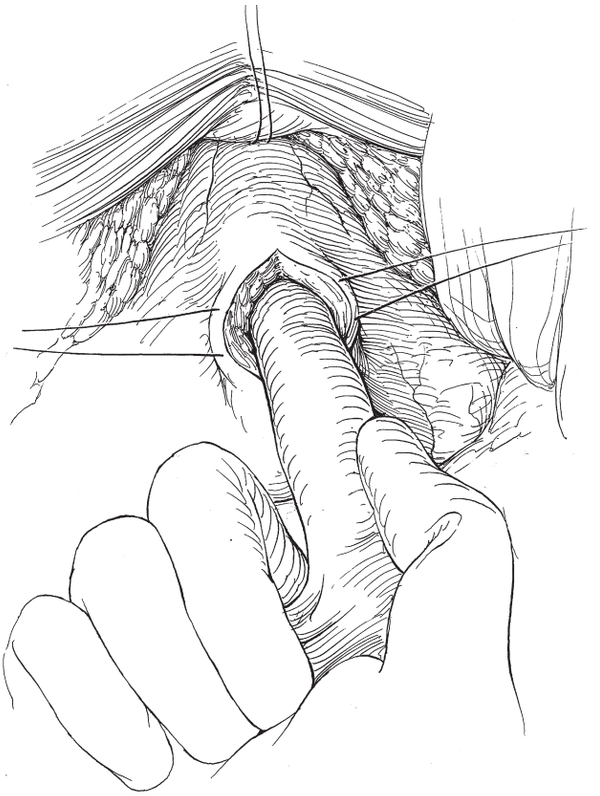

FIGURE 75-12.

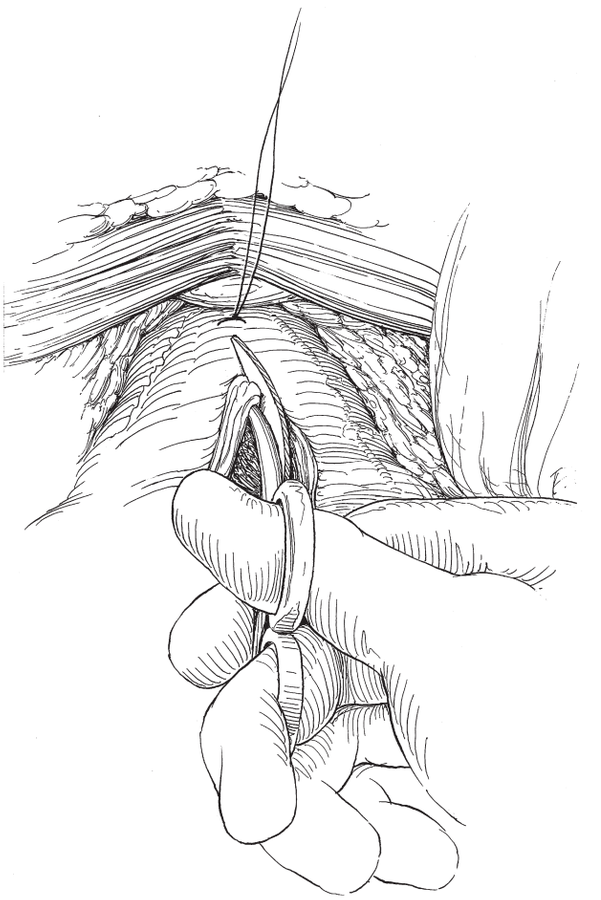

FIGURE 75-13.

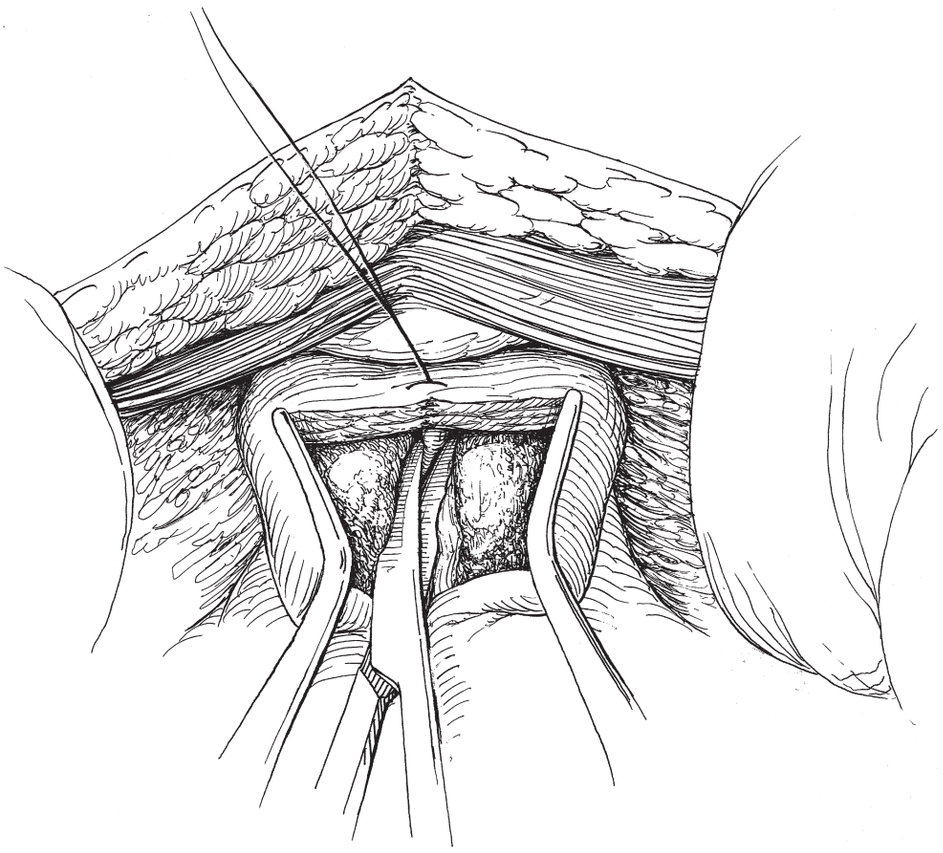

FIGURE 75-14.

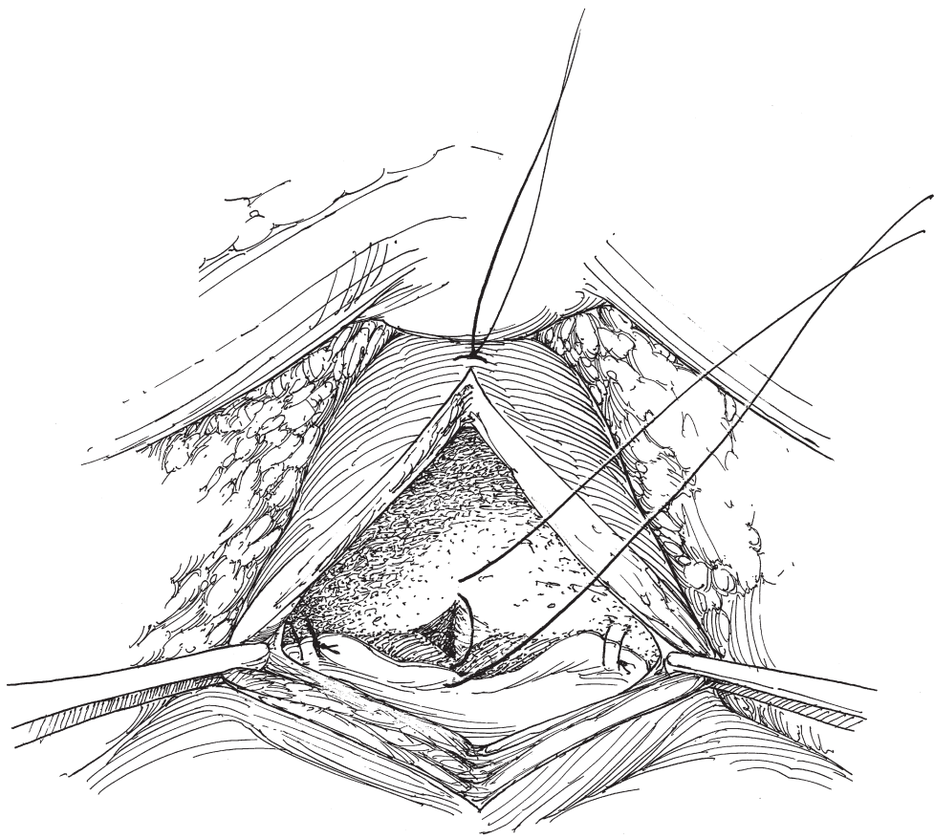

FIGURE 75-15.

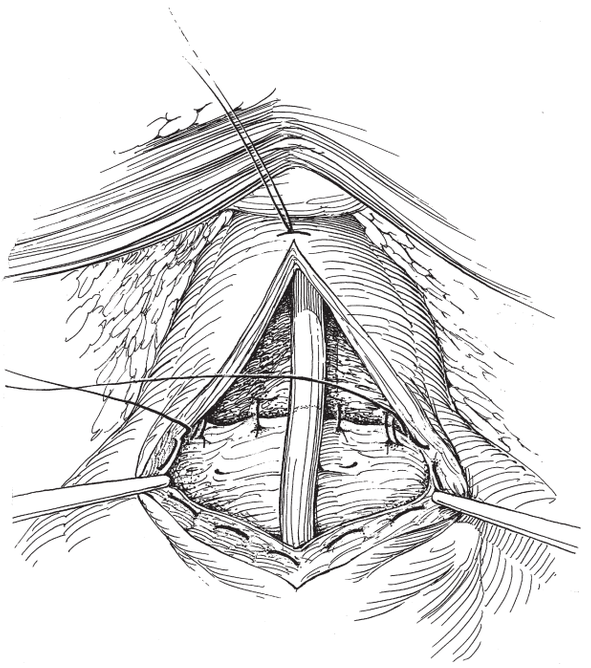

FIGURE 75-16.

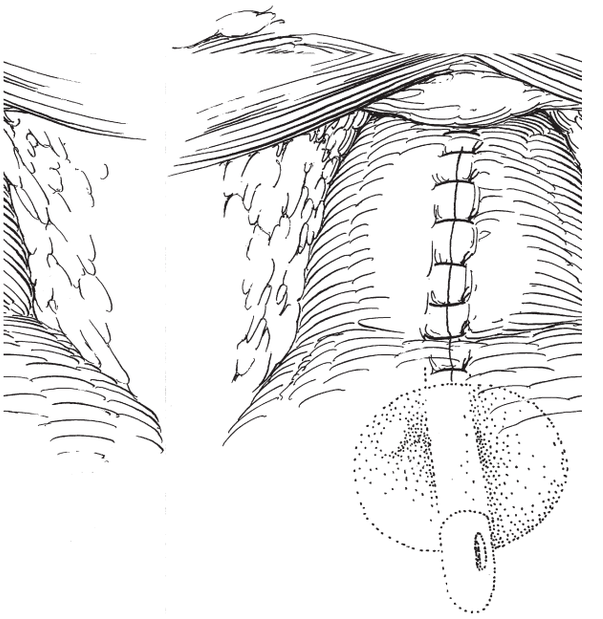

FIGURE 75-17.

Commentary by

CLAUS G. ROEHRBORN

I routinely schedule patients with an ultrasound measured *transition zone* of the prostate of more than 75 g for a retropubic partial prostatectomy or enucleation of the adenoma (considering that the transition zone is rarely greater than 75% of the total prostate size, the total prostate volume threshold is therefore approximately 100 g). It is generally recommended to limit resection time during transurethral resection of the prostate (TURP) to less than 60 minutes or 60 g of tissue for fear of the TURP syndrome, and I have found the KTP laser ablation of such larger glands tedious and less rewarding for the patient, leaving behind often an unsatisfactory rough and uneven surface in the prostatic fossa. In contrast, patients who undergo a retropubic enucleation are amongst the most satisfied in my practice. The retropubic approach allows a more controlled hemostasis and a beautiful trigonalization of the bladder neck, which in my experience results in superb hemostasis as the end of the case. I use continuing bladder irrigation overnight and remove the catheter on the morning of the second postoperative day. Once the patient has voided and the drain output remains low, I then remove the drain, and nearly all patients are discharged home on the second postoperative day. I attribute the successful early discharge to meticulous hemostasis inside the fossa under direct vision, trigonalization of the bladder neck with shortening of the fossa, and a watertight running closure of the capsule. To avoid bladder neck contractures, I usually employ three 3-0 chromic sutures to evert the mucosa of the bladder neck at the 3-, 9-, and 12-o'clock positions, similar to the open radical prostatectomy (the posterior bladder neck between the 5- and 7-o'clock positions is used in the trigonalization procedure and a contracture in this location is very unlikely).

Section XIV

BLADDER: EXCISION

This page intentionally left blank

Chapter 76

Transurethral Resection of Bladder Tumors

ALISON M. CHRISTIE

Transurethral resection of a bladder tumor (TURBT) is indicated upon diagnosis of a new or recurrent lesion in the bladder that is suspicious for malignancy and requires tissue confirmation of histopathology and therapeutic resection. This technique can be performed under general or regional anesthetic. Resection of lateral wall bladder tumors should be performed under general anesthetic with a paralytic agent to avoid inadvertent bladder wall perforation from an obturator nerve reflex. Complete resection of the tumor or tumors is the primary goal and may require staged resection in the case of some large tumors.

Choice of irrigant for TURBT depends on the type of resectoscope being used. Monopolar resectoscopes require sterile water or glycine for conduction of electricity, while newer bipolar resectoscopes can be operated with saline.

Position: Place the patient in the modified dorsal lithotomy position. Perform a bimanual examination with the patient under anesthesia and assess for palpable or fixed pelvic masses. Prepare and drape the genitals in a sterile fashion.

TRANSURETHRAL RESECTION

1. Perform a thorough cystoscopy at the beginning of every TURBT, including visual inspection of the bladder and urethra. This should be performed even when the patient has undergone a prior office cystoscopy. Use the 70-degree cystoscope lens if visualization of some areas of the bladder is difficult (i.e., anterior bladder wall).
2. Exchange the cystoscope for a resectoscope. Leave the bladder full when removing the cystoscope and place the resectoscope sheath with either a blind obturator or a visual obturator if needed. Removal of the obturator and return of fluid confirms appropriate positioning of the sheath in the bladder.

Place the resectoscope with a 24-French loop into the bladder. Confirm the location of the bladder trigone and ureteral orifices in relation to the bladder tumor. Resect tumors in a systematic fashion. Smaller papillary tumors can often be resected in one swipe at their base, sometimes without the use of electrical current. Use suprapubic pressure and minimal bladder filling to resect anterior wall tumors that are hard to reach. Resect larger sessile tumors in several layers, starting at the periphery. Once the base of a large tumor has been reached, perform one swipe at the tumor's edge to set an appropriate depth of the resection. This should include muscularis propria without extending through its entire thickness (Fig. 76-1). Continue to resect the entire base at the same preset depth. Resect tumors at or near the ureteral orifice with pure cutting current. If resection is being performed without continuous flow, stop to empty the bladder every three to five swipes to ensure that it does not become too full or too thin.

Collect the bladder tumor chips with an Ellik evacuator and send them for pathologic analysis. If there are only a few chips, capture the chips with the resectoscope loop and remove them individually.

Visualization of perivesical adipose tissue during resection indicates a bladder perforation. For large perforations, stop resection immediately, empty the bladder, and perform a cystogram. This will distinguish extraperitoneal from intraperitoneal perforations. For smaller perforations and small resections, consider finishing the resection under low pressure with minimal irrigation. Then perform a cystogram. Decision for surgical correction versus catheter drainage should be based on the clinical status of the patient and the extent and type of perforation.

3. Inspect the resection site(s) for hemostasis. Cauterize the edges and the base. Empty the bladder and inspect the resection site again with the flow turned off. There should be no visible bleeding.
4. For large resections, consider sending the patient home with a large (20- to 22-French) catheter. Remove the catheter in 1 to 7 days. For smaller resections, no catheter is required. Ensure that the patient is able to void in recovery before discharge to home.

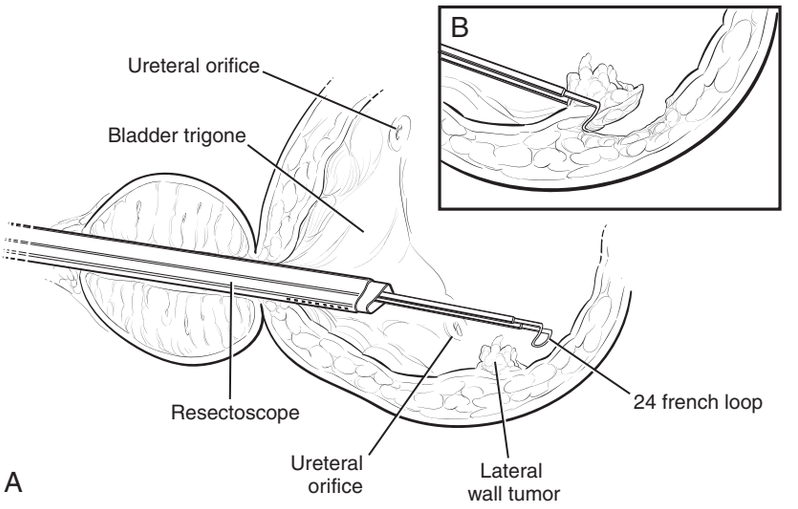

FIGURE 76-1.

POSTOPERATIVE PROBLEMS

Urinary retention usually resolves spontaneously within 1 to 2 days. Send the patient home with an indwelling urethral catheter. Perform a voiding trial and catheter removal in the clinic in several days. *Irritative symptoms* are common in the postoperative period and can be treated medically.

Bleeding occurs most often with large resections. For particularly large resections in which hemostasis was difficult or inadequate at the conclusion of the case, admit the patient for overnight observation with a catheter in place. Start continuous bladder irrigation if needed. This type of bleeding usually resolves spontaneously. Delayed bleeding may occur several days to weeks following the resection. Perform manual bladder irrigation through a large-caliber catheter, start continuous bladder irrigation, and consider cystoscopy with fulguration of bleeding as appropriate.

Commentary by JAMES E. MONTIE

TURBT is an underappreciated operation. An inadequate TURBT can lead to inadequate local therapy and understaging, leading to potentially serious error in therapy. Bladder cancer is often seen in the unfit, elderly patient with little physiologic reserve for untoward events. A large tumor on the anterior wall in an obese patient can be a remarkably challenging procedure with a substantial risk for either an incomplete resection or a bladder perforation. The extra-long resectoscope is indispensible in many such patients.

Bleeding in the postanesthesia care unit after a TURBT requires a lower threshold for intervention with return to the operating room for fulguration than that applied to a TUR prostate. A bladder filled with clot can turn a weak area in a recently resected bladder into a frank perforation; continuous flow irrigation can sometimes exacerbate the problem; tamponade of venous bleeding is less likely. It is often far safer to return the patient to operating room within 1 to 2 hours than to spend 5 to 6 hours with multiple irrigations that can be quite unpleasant and potentially dangerous for the patient.

Chapter 77

Partial Cystectomy

EDWARD CHERULLO

Partial cystectomy is suitable for single tumors of high grade, not deeply infiltrating by computed tomography (CT) scan, and situated away from the bladder base. It is an alternative to radical cystectomy in carefully selected patients with appropriately located lesions in the absence of carcinoma in-situ (CIS). Patient compliance for surveillance interval cystoscopy is mandatory as transitional cell carcinoma is a panurothelial disease.

Preoperatively, the lesion should be examined cystoscopically and samples for biopsy obtained from the lesion and randomly from the adjacent mucosa to identify depth of invasion and the presence of CIS.

Either a transperitoneal or an extraperitoneal approach may be used. The transperitoneal approach is suitable for more posteriorly situated tumors. The same surgical principles apply to both. Consider continuous epidural block for anesthesia.

Position: Place the patient supine, moderately flexed to open the pelvic inlet, in a slight Trendelenburg position. Perform bimanual palpation with the patient under anesthesia. Drape the genitalia into the field, and insert a balloon catheter. Flush the bladder several times with sterile water through a catheter, then partially drain the bladder, clamp the catheter, and immediately attach the catheter to a sterile drainage bag to avoid spillage. If localization may be a problem, insert a flexible cystoscope and fulgurate around the tumor, or inject methylene blue around it through a 25-cm, 21-gauge needle to stain the serosal surface.

TRANSPERITONEAL APPROACH

Incision: Make a midline transperitoneal incision (see Chapter 129) that extends from just above the umbilicus to well over the pubis (Fig. 77-1A).

Open the peritoneum in the midline (see Fig. 77-1B). A peritoneal flap is not necessary.

Incise the peritoneum over the iliac vessels and the nodes (Fig. 77-2). Unilateral lymph node dissection may be of value for staging (see Chapter 68). With positive nodes, partial cystectomy may still be a reasonable procedure for local control; completion radical cystectomy should be discussed as a possibility preoperatively.

Follow the obliterated hypogastric artery to the take-off of the superior vesical artery. Divide and use the vas as a guide (Fig. 77-3). It is important to mobilize the bladder for tumors near the base by dividing most of the lateral leash of vessels emerging from the hypogastric artery and vein, which are best seen before dividing the superior vesical artery. Clip and divide them to the entrance of the ureter into the bladder. Clamp, divide, and ligate the superior vesical artery. Bluntly and sharply free the bladder farther posteriorly as needed, leaving the peritoneum attached. Incise the peritoneal reflection behind the bladder and displace the rectum posteriorly. Pack the wound edges and hold them away from the bladder with the blades of a retractor. Isolate the bladder with plastic drapes to reduce the risk of tumor implantation.

Protect the rectum with a moist gauze pack in the cul-de-sac. Drain the bladder and open it between stay sutures at a site known from cystoscopic examination to be distant from the tumor. Mark the wall 2 cm from the tumor by coagulation while the bladder is mildly stretched. Circumscribe the entire lesion with the electrosurgical knife, and remove it en bloc with the perivesical fat and with overlying peritoneum if necessary (Fig. 77-4). Place Allis clamps both for exposure and for control of the brisk bleeding while the bladder wall is divided with the cutting current. Release the Allis clamps successively, and fulgurate or clamp and ligate the bleeding vessels in the bladder wall. Send multiple biopsy samples of the margin for frozen section examination; if they are positive, resect more of the bladder wall.

If a 2-cm margin from the ureteral orifice is not possible, consider proceeding with completion radical cystectomy rather than resect the orifice and reimplant the ureter.

Avoid placing a suprapubic catheter because of possible tumor spread; a large urethral catheter should be adequate. Flush the bladder with sterile water, and close it with a running 3-0 absorbable Vicryl suture subepithelially and interrupted or running 2-0 Vicryl suture for the remainder of the thickness of the wall (Fig. 77-5). Close the peritoneum with a running 3-0 plain catgut suture. Irrigate the wound thoroughly with sterile water. Drain well through stab wounds with two Penrose

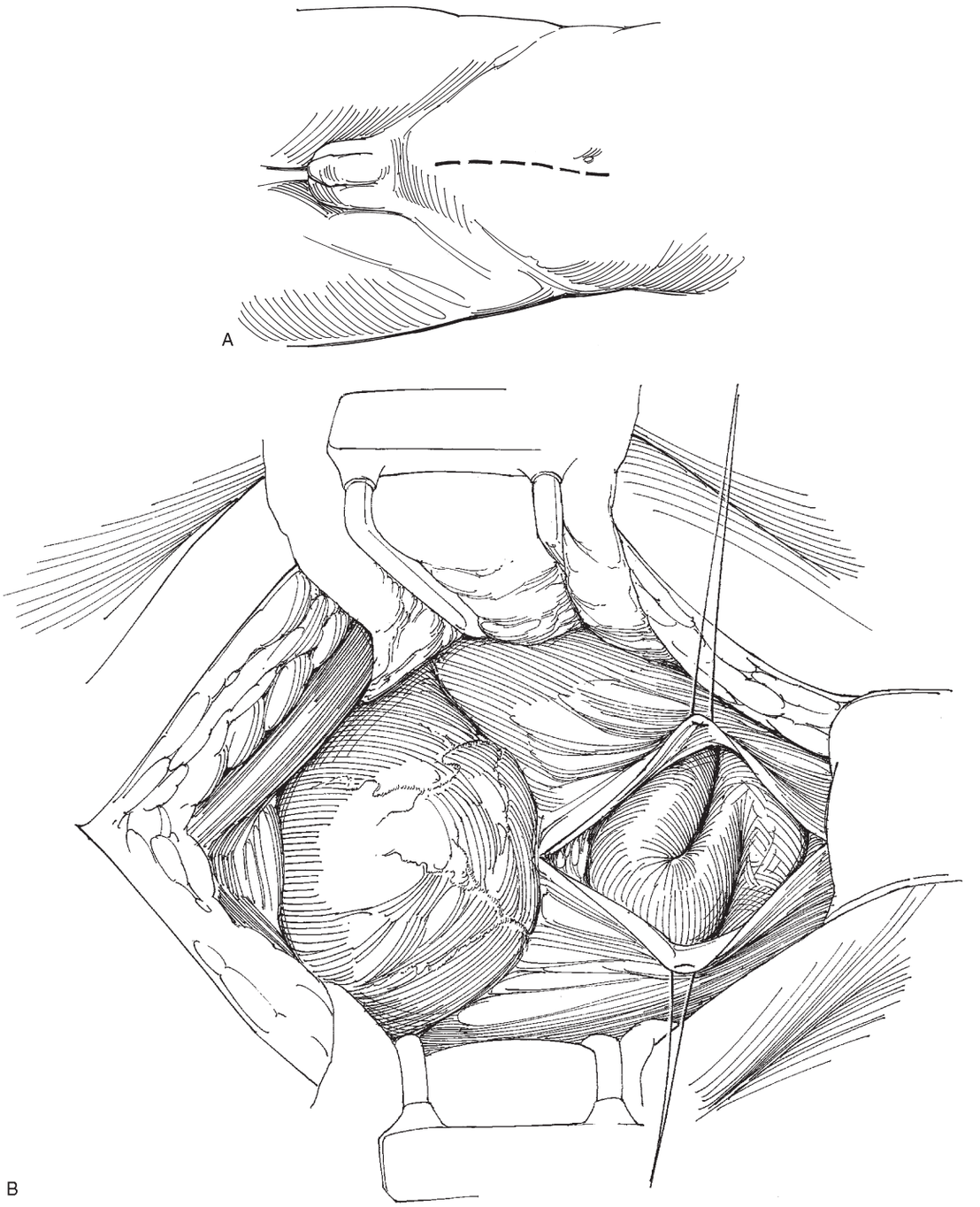

FIGURE 77-1.

drains or one Jackson-Pratt suction drain in the perivesical space. Close the abdominal wound. Remove the catheter in 7 to 10 days after a cystogram shows no urinary extravasation.

EXTRAPERITONEAL APPROACH

For the extraperitoneal approach, expose the anterior surface of the bladder and bluntly enter the space of Retzius. Over the dome it may be necessary to circumcise a patch of peritoneum, leaving it attached to the bladder. Free the bladder from its connective tissue attachments laterally and posteriorly, well beyond the site of the tumor. If necessary, expose and divide the superior vesical pedicle (see Chapter 78). Leave the perivesical fat attached to the bladder over the area of the tumor. Proceed as for transvesical excision.

POSTOPERATIVE PROBLEMS

Urinary leakage from the vesicotomy suture line usually stops with conservative management if drainage is maintained. Avoid removing the drain until minimal fluid is draining or a

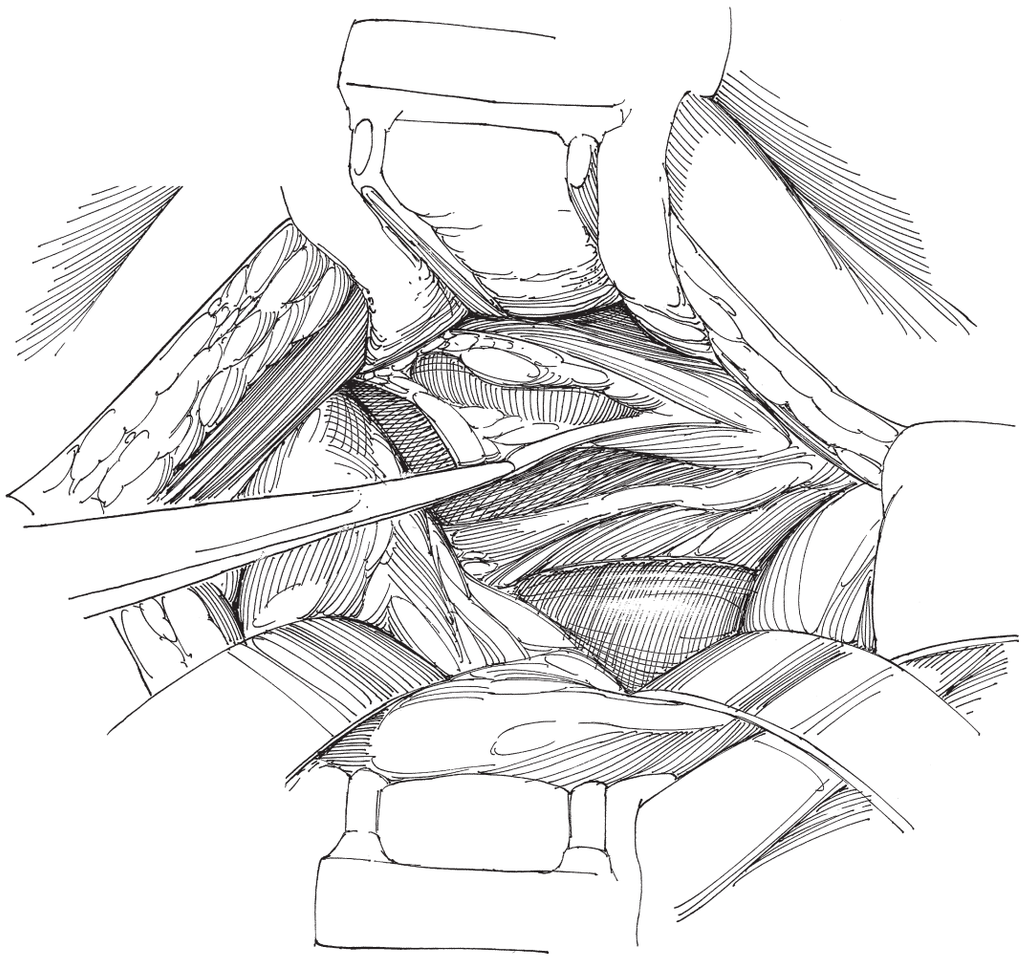

FIGURE 77-2.

cystogram is negative. *Bleeding* is uncommon with a two-layer closure, but clot retention can be a problem. *Prevesical infection* with formation of an abscess may require wound exploration with drainage or percutaneous drainage under CT guidance.

Ureteral obstruction should be suspected if the patient has flank pain; ultrasonography or CT urography can make the diagnosis. Endoscopic stent placement is the first line therapy for this problem, but percutaneous nephrostomy tube placement may be required. Complete ureteral obstruction secondary to iatrogenic injury or ligation will require surgical exploration. *Urge incontinence* from poor detrusor compliance and uninhibited contractions improves with time and anticholinergic medication.

Implantation of tumor cells is a feared complication. Flushing the bladder with water preoperatively, protecting the wound edges, using care in manipulation of the tumor, and copiously irrigating the wound with water before closure are measures that reduce this risk. Preoperative irradiation can be considered as a method to decrease implantation of tumor cells which may be spilled at surgery.

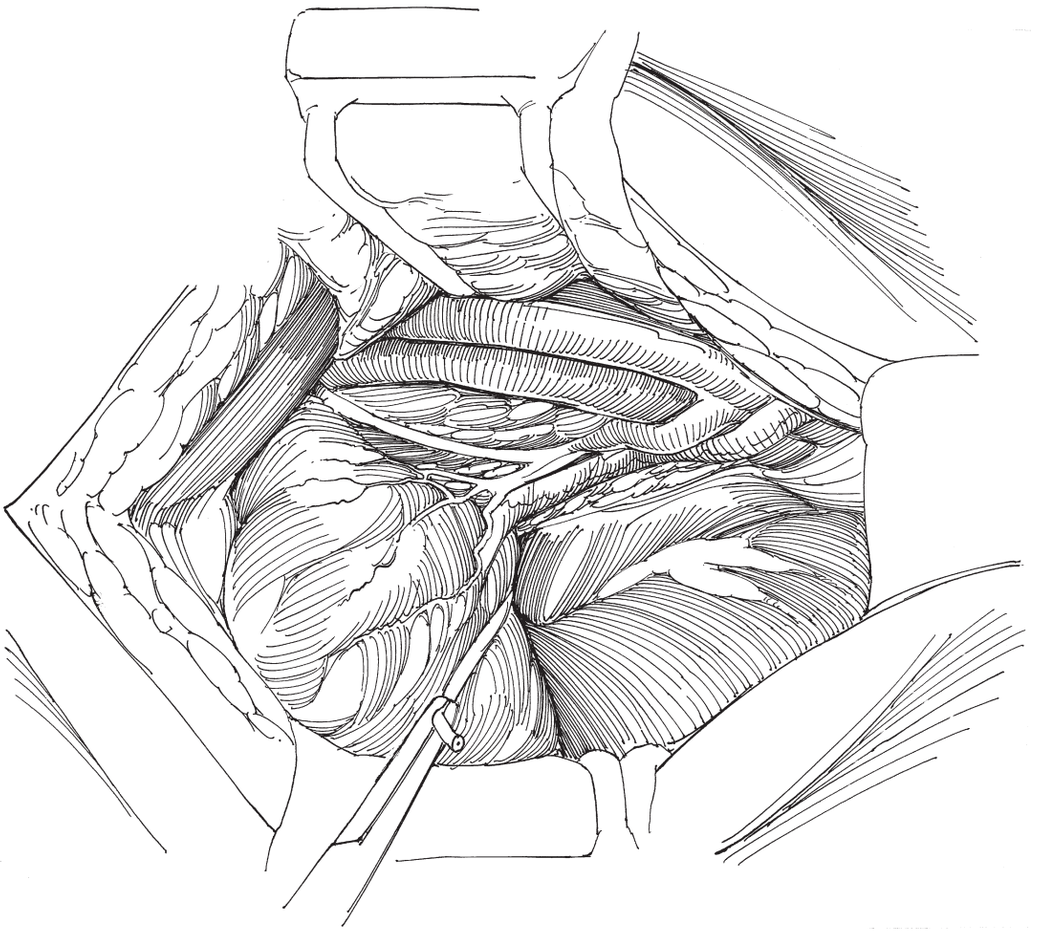

FIGURE 77-3.

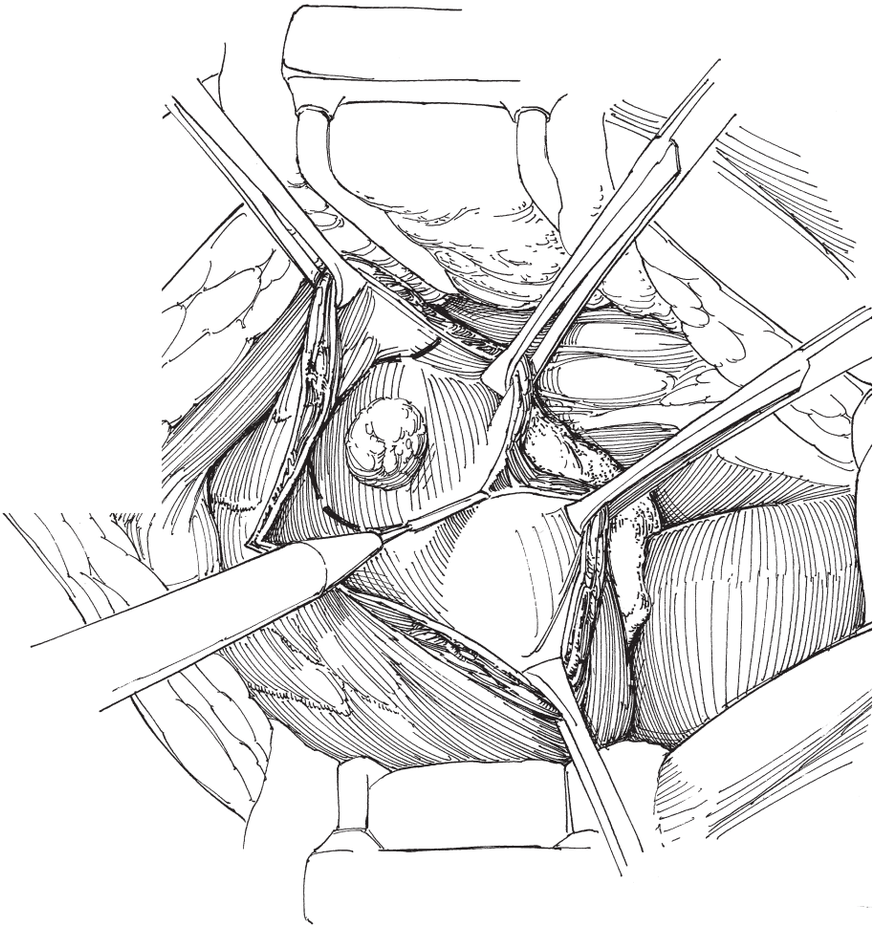

FIGURE 77-4.

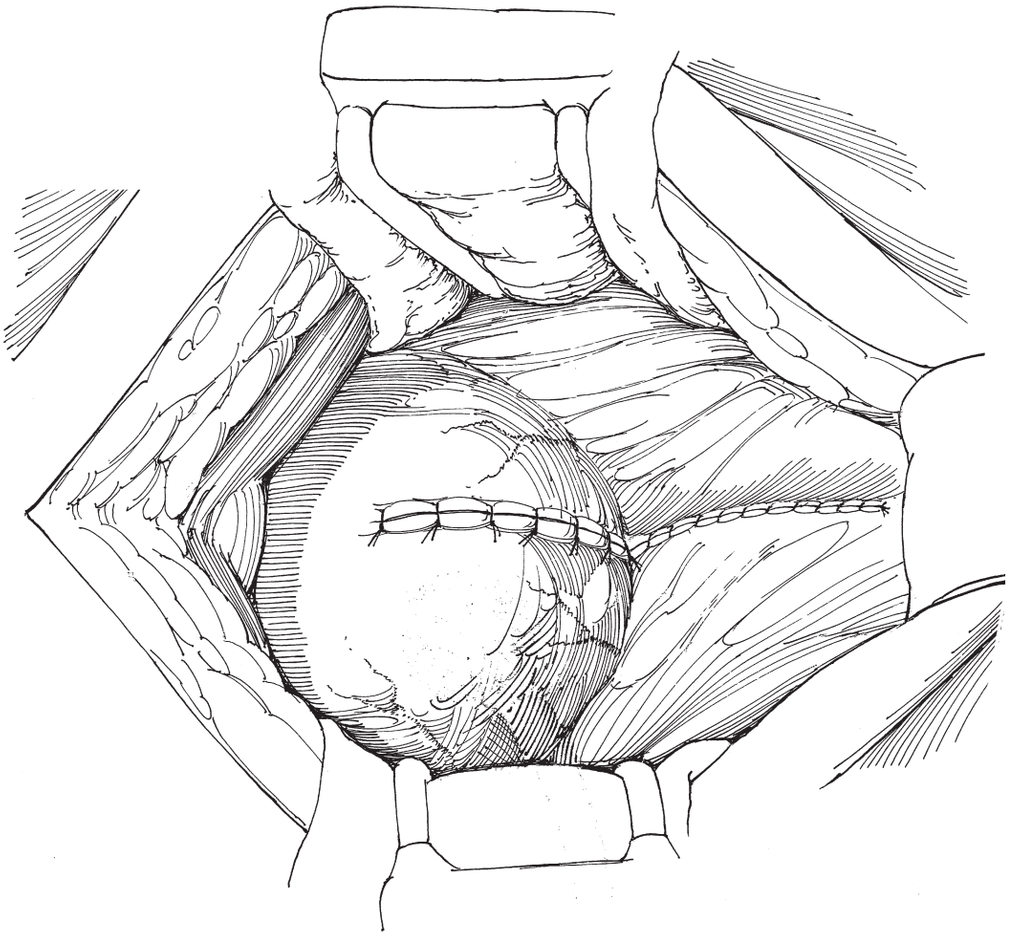

FIGURE 77-5.

Commentary by JAMES E. MONTIE

Partial cystectomy is appropriate for only a limited subgroup, probably only 2% to 3% of patients requiring an operation for invasive bladder cancer. An ill-advised partial cystectomy can turn into a disaster with an extravesical recurrence or extension to the abdominal wall. The tumor should be a "single tumor in space and time" and there should be no associated CIS, which implies more diffuse mucosal disease. Age should be not the indication for a partial cystectomy. A poor operation for cancer control in a 65-year-old does not become a good cancer operation in an 80-year-old. The soft tissue margins around the cancer, including the paravesical soft tissue and peritoneum, should be similar to that obtained with a total cystectomy if the patient has been properly selected. The patient's overall bladder capacity needs to be considered because, although there will be some stretching of the bladder with time after surgery, there are limits.

I believe a bilateral node dissection, similar to that performed with a radical cystectomy, should be performed in essentially all cases unless there is a prohibitive reason. There is abundant evidence for bilateral lymphatic drainage from all areas of the bladder so a unilateral dissection is not sufficient.

This page intentionally left blank

Chapter 78

Radical Cystectomy

SAM S. CHANG

PREPARATION AND EVALUATION

Preoperative Evaluation

Thorough preoperative medical and metastatic evaluation is an important priority. Cardiac and pulmonary optimization with careful collaboration with the anesthesiology service is mandatory. Breathing exercises, cessation of smoking, and nutrition optimization are important. Those patients with significant hydronephrosis associated with renal compromise may require either ureteral stent placement or nephrostomy drainage. Careful palpation of the abdomen may detect large masses. Careful bimanual examination can give valuable information as to stage of tumor and resectability.

Preoperative education cannot be underestimated in light of the magnitude of this procedure. Not only should possible complications and risks be discussed but also lifestyle and psychosocial changes should be anticipated and discussed. It is imperative that the patient meet with an enterostomal therapist, even if internal reconstruction is planned, to become familiar with urinary diversion and appliances. Select a site for a stoma with the patient in sitting and standing positions and this should be marked (Fig. 78-1).

Metastatic evaluation although not highly sensitive or specific should include careful pelvic clinical examination, radiographic examination of the chest, abdomen and pelvis, and serum studies (complete metabolic panel, complete blood count, coagulation parameters). If alkaline phosphatase is normal and there are no symptoms, then a bone scan is not necessary because the likelihood of bony metastatic disease is low. If there is any history of preexisting gastrointestinal disease, then colonoscopy should be performed, especially prior to diversion utilizing large bowel and if there is an adenocarcinoma suspected.

PREOPERATIVE PREPARATION

Although not mandatory, for a mechanical bowel preparation, give polyethylene glycol electrolyte solution (GoLYTELY). A parenteral antibiotic should be administered just prior to surgery. When possible, medications such as aspirin, Plavix, and anticoagulants like warfarin should be stopped.

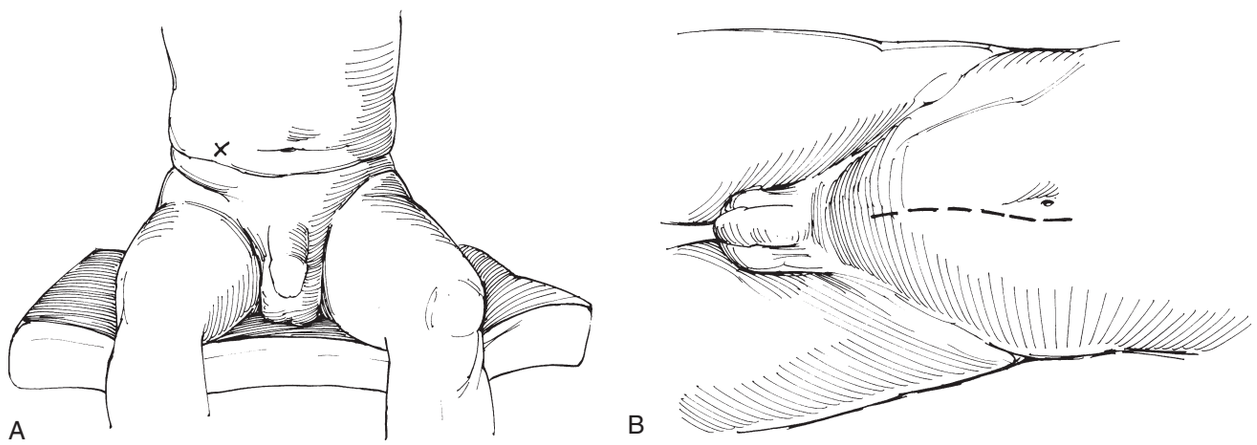

FIGURE 78-1. Patient abdomen appropriately marked for stoma and with incision.

Apply pneumatic compression boots to remain until the patient is fully ambulatory. Unless significant contraindication such as a bleeding diathesis exists, preoperative subcutaneous heparin or low molecular weight heparin should be administered. General endotracheal anesthesia is standard at our institution but epidural anesthesia is also appropriate. Central venous monitoring is not required but should not be deferred when necessary. During the initial perioperative period intravenous prophylactic antibiotics should be given, but not for more than 24 hours.

INSTRUMENTS AND SUTURES

Provide a basic set; a GU long set; a GU fine set; a Buchwalter retractor with an oval ring; a suction tip; smooth and toothed Cushing forceps; 9-inch vascular forceps; 11-inch Mayo scissors; long straight and curved Allis clamps; smooth Adson forceps; tenotomy scissors; 7-French single-J diversion stents; 4-0 Vicryl or Monocryl sutures on RB needle (ureter); 2-0 and 3-0 Vicryl sutures (stoma); #1 PDS suture (closure); articulating GIA stapler; a urostomy set; large, medium, and small hemoclips with long clip appliers; a right-angle clip applier for large clips; and a Jackson-Pratt drain with medium Hemovac needle.

CYSTECTOMY IN THE MALE

Position: Supine. Place the patient with the umbilicus over the break in the table in a hyperextended position with the aid of a kidney rest and flexion of the table. Fix and pad the legs abducted and very slightly flexed at knees.

For urethrectomy, subsequently elevate the padded legs in stirrups in a low lithotomy position.

Sterile preparation: Prepare the abdomen, scrotum, and perineum, and drape these areas. Insert a preconnected 18-French urethral catheter and maintain access of this on the surgical field. Clip the catheter to the drapes for accessibility. Drape out the perineum with a folded towel. The primary surgeon should stand on the left side with the assistant on the right side.

Incision: Make a lower midline abdominal incision from the symphysis pubis to the periumbilical area. Incise the anterior rectus fascia and the transversalis fascia.

Bluntly with a Kittner sponge stick but under direct visualization open the space of Retzius and establish the potential space between the bladder/prostate and the pelvic sidewall and the external iliac vessels. Examine the lymph nodes; if concern for disease exists and neoadjuvant chemotherapy has not been given, proceed with lymph node dissection and frozen section; otherwise, lymph node dissection can be completed after bladder/prostate removal.

Incise the peritoneum in the line of the abdominal incision; locate, ligate, and then divide the urachus, then incise the peritoneum in a V shape dissecting the "wings" of the bladder peritoneal attachment. A Kocher clamp on the urachus is useful for traction (Fig. 78-2).

Check the mobility of the tumor and bladder (should have been assessed preoperatively as well via exam under anesthesia (EUA) and rectal exam). Explore the abdomen, palpating especially the liver and preaortic and pelvic nodes. Release intra-abdominal adhesions at this time.

As the lateral attachments are divided in a posterior direction, the vasa deferentia will be encountered and should be ligated and divided (Fig. 78-3).

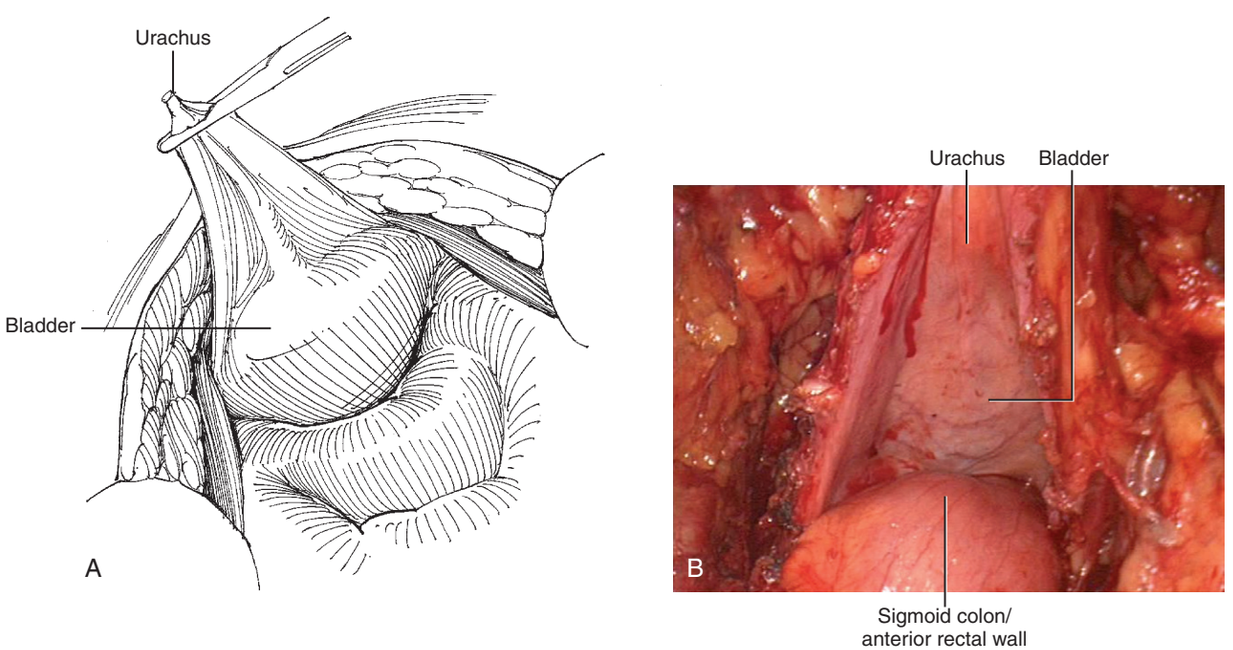

FIGURE 78-2. Peritoneal cavity opened with marking of the V-"wings" of the bladder peritoneal attachments and with Kocher clamp on the urachus.

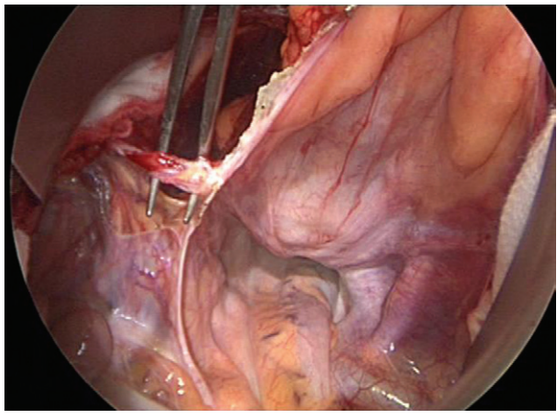

FIGURE 78-3. Clip placed on identified vas deferens with clip appliers.

Mobilization of Bowel and Exposure

Mobilize the sigmoid colon to allow exposure for dissection of the left ureter. The small bowel should then be packed into the upper abdomen using several laparotomy towels with a symmetric exposure of the left and right side and sigmoid colon in the middle (Fig. 78-4). The Buchwalter retractor provides excellent exposure. Extensive mobilization of the right colon is not necessary.

Identification of Ureters

A malleable blade can be used to retract the sigmoid colon either way when dissecting the ureter. For the right ureter, the peritoneum can then be incised parallel to the common iliac vessels and the ureter can be easily identified as it crosses the iliac vessels. The ureter can then be isolated with a vessiLoop and dissected with preservation of as much periureteral tissue as possible to avoid devascularization. Grasping the ureteral tissue with instruments should be avoided. The ureter should then be dissected to the level of entry into the bladder. The obliterated umbilical artery/superior vesical artery is encountered as the ureter will always run underneath this vessel, which is ligated to help provide adequate ureteral length (Fig. 78-5). The ureter is then ligated and divided with avoidance of any spillage from the bladder side.

If desired, frozen section biopsy can be performed. If the ureter is a small caliber, the distal end can be clipped/tied to allow for some dilatation during the dissection prior to urinary diversion. A tacking suture should be placed to help with manipulation and to avoid ureteral trauma.

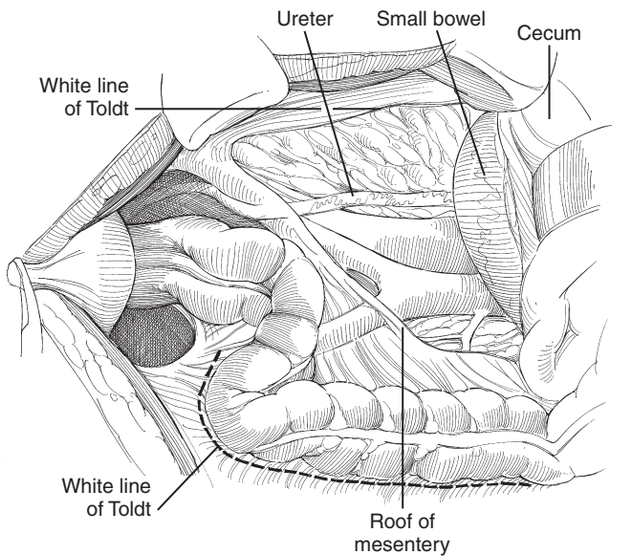

FIGURE 78-4. A view from above showing the sigmoid colon in the middle and right-angle retractor on each side of the sigmoid colon. Symmetry clarified.

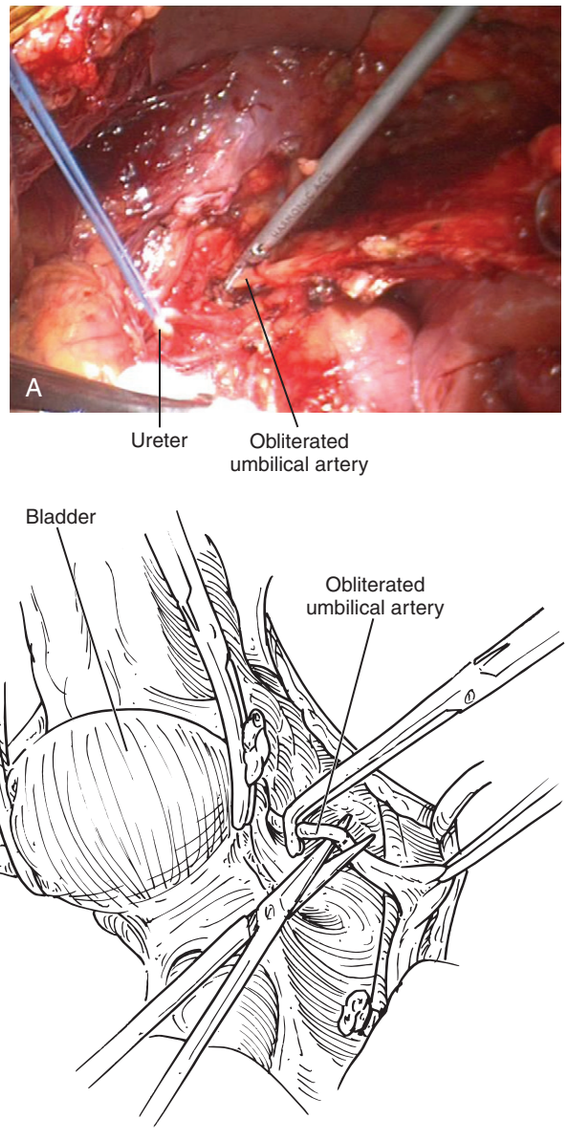

FIGURE 78-5. Ureter wrapped in vessiLoop as it crosses the iliac vessels. It runs underneath the tunnel of the obliterated umbilical vessel. The harmonic scalpel is on the obliterated umbilical artery/superior vesical artery.

Dissect similarly the left ureter more proximally than on the right and transect it similarly. With blunt finger dissection, establish an opening from one retroperitoneal opening to the other under the sigmoid colon, making a generous passage; this should be done just anterior to the sacrum and posterior to the aorta. Place a McDougal clamp or any curved clamp and then bring the ureter to the right side (Fig. 78-6). Be sure that the ureter is not twisted and that it runs in a smooth curve nor is it kinked in any way by the peritoneum or vessels.

Division of Posterolateral Pedicle

The posterior peritoneum should be divided sharply or with electrocautery under direct visualization at the level of the ampulla of the vasa and seminal vesicles. The plane should be established between the anterior rectal wall and posterior bladder/prostate initially visually and can be continued this way or blunt finger dissection with the palm up, sweeping the rectum from the bladder (Fig. 78-7). Dissect on the rectal wall, leaving the doubled fascial fold composed of the anterior and posterior lamellae of Denonvilliers' fascia (rectal fascia) anteriorly and seminal vesicles will be exposed. Enter the plane under (posterior to) Denonvilliers' fascia, and bluntly sweep the rectum back from the seminal vesicles and prostate.

Dissect the pedicles lateral to the seminal vesicles and avoid the neurovascular bundles. The bundles are seen on the ventrolateral surface of the rectum. If extravesical extension of the tumor is encountered, widely excise the neurovascular bundle on that side close to the pelvic sidewall. At this point, a reticulating GIA stapling device can be used on each side to control and divide the posterolateral pedicles (Fig. 78-8). Sequential fires of the stapler can be used to move distally as the bladder is retracted anteriorly and up out of the wound.

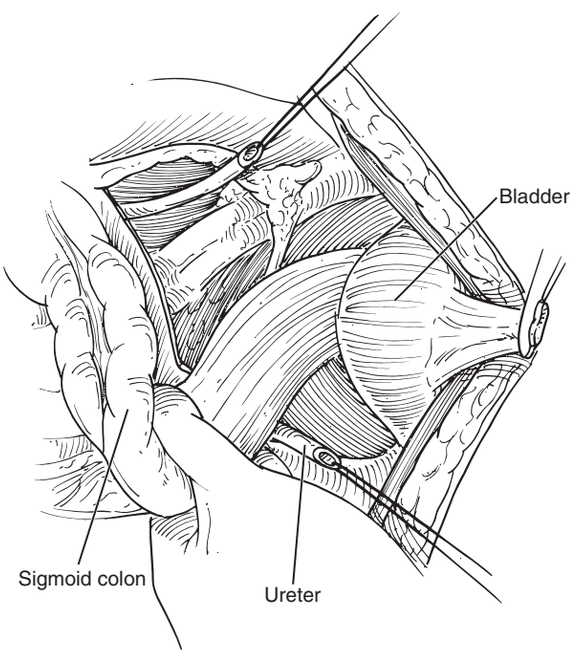

FIGURE 78-6. Ureter coming underneath sigmoid mesentery.

If a GIA stapler is not available, then clear the internal iliac artery and identify its branches, the superior gluteal. Dissect distal to the gluteal branch. Pass a right-angle clamp gingerly behind the arterial and venous branches, draw a 2-0 silk suture through, and ligate the artery. Clip, tie, or suture-ligate the remainder of the vesical pedicle down to the endopelvic fascia using finger dissection to develop the plane between the posterior bladder and the rectum (Fig. 78-9). Do not ligate the internal iliac artery.

Avoid the autonomic nerves from the superior internal iliac, pelvic, and vesical plexuses when dividing the superior and inferior vesical pedicles. These innervate the sphincteric mechanisms.

Dissect the pedicles lateral to the seminal vesicles to avoid the neurovascular bundles. The bundles are seen on the ventrolateral surface of the rectum. Clip and divide the pedicles along the anterolateral border of the seminal vesicle until the endopelvic fascia is reached. If extravesical extension of the tumor is encountered, widely excise the neurovascular bundle on that side, including the pelvic plexus, and divide the pedicle close to the pelvic wall.

Anterior Dissection and Urethral Division

Return anteriorly to proceed as for a radical retropubic prostatectomy. The endopelvic fascia should be incised sharply on each side of the prostate and levator ani muscle fibers should be dissected off. Dissect the prostate from the pubis and control the dorsal vein complex by passage of a McDougal clamp (Fig. 78-10). Suture ligation or use of a hemostatic device (e.g., harmonic scalpel) can be used for hemostasis. Sponge stick retraction can be helpful.

The urethra is the identified. Clamp the urethra near the prostate using a long Kelly clamp with care to avoid injury to the rectum. With long Mayo scissors, the urethra/urethral catheter can be divided sharply distal to the clamp or with electrocautery (Fig. 78-11).

Under visualization, sharply divide the rectourethralis muscle.

Remove the Specimen

It is important to avoid urine spillage.

Check for bleeding elsewhere and proceed with lymphadenectomy and urinary diversion.

After thorough irrigation, the pelvis is inspected carefully. The pelvis is then packed with a moist laparotomy pads. If there is question of rectal injury, an assistant can perform a rectal exam and/or fill the pelvic cavity with water and instill air through a catheter placed in the rectum to detect a leak. (If the rectum is injured, close the defect in two layers, thoroughly irrigate with antibiotic irrigation. Consider proximal colostomy and general surgery consult.)

If there is no obvious lymphadenopathy, performing this after cystectomy facilitates a complete node dissection and allows for careful examination of the cystectomy site to ensure hemostasis.

After urinary diversion is performed, replace the bowel carefully after carefully running the bowel, and pull the

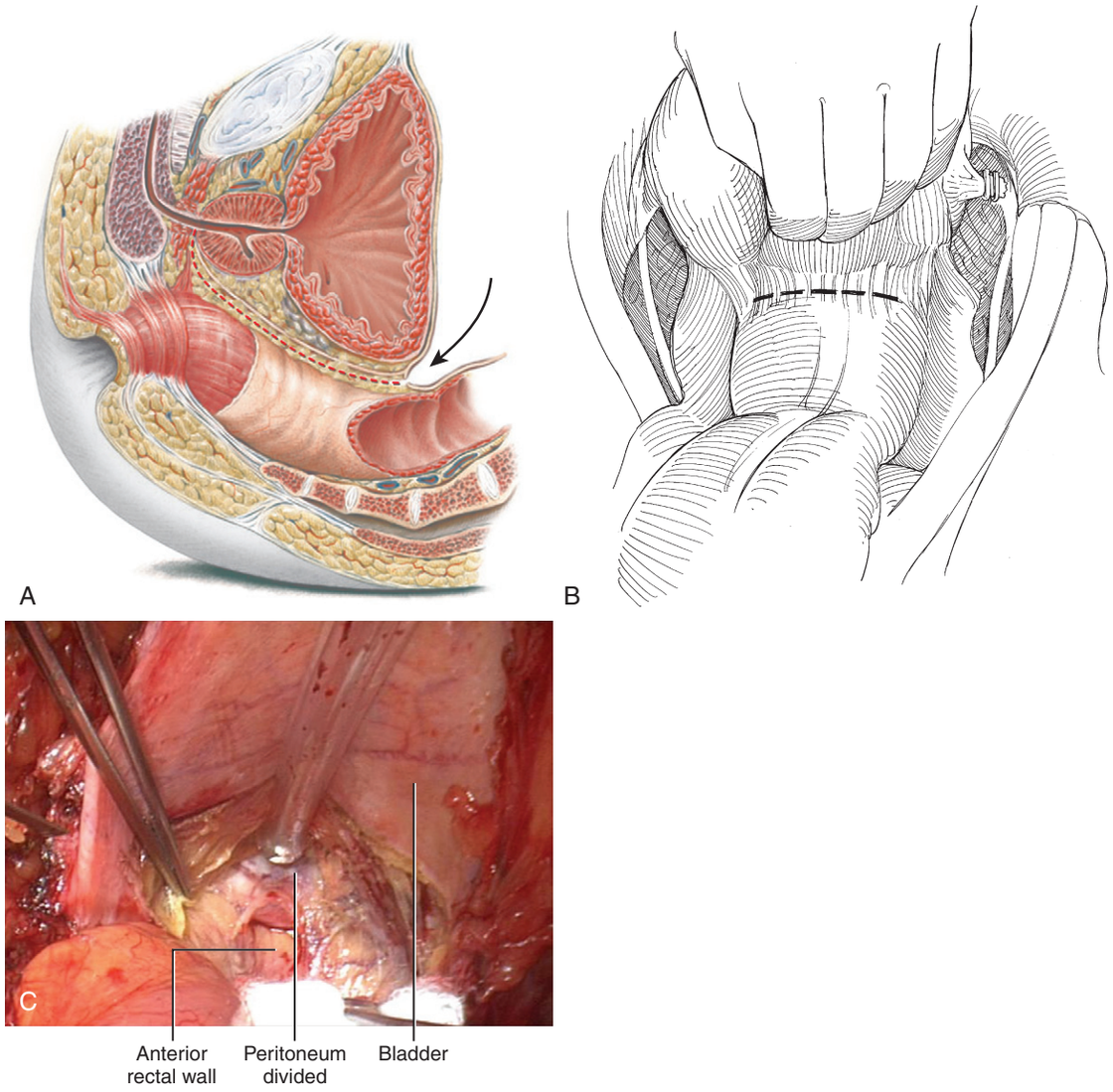

FIGURE 78-7. Marking and dividing the posterior peritoneum. *(From Walsh PC, Schlegel PN. Radical cystectomy. In Marshall FF [ed]. [1996]. Textbook of operative urology. Philadelphia: WB Saunders.)*

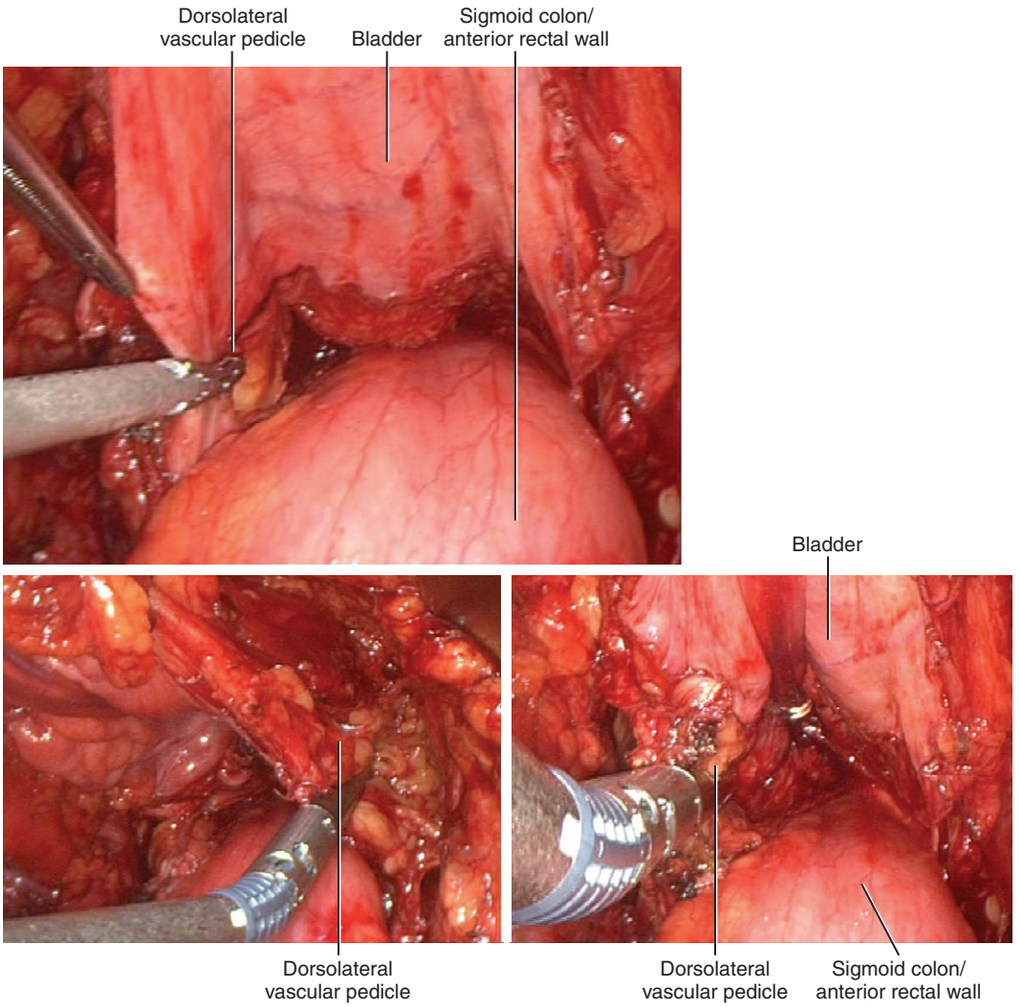

FIGURE 78-8. Stapler around a lateral pedicle on one side.

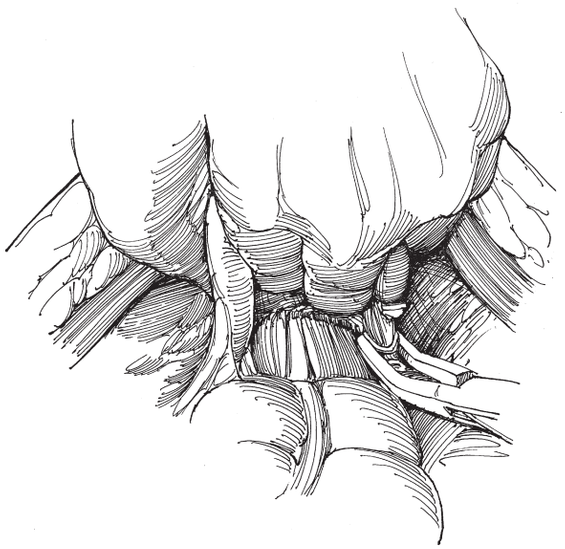

FIGURE 78-9. *(From Walsh PC, Schlegel PN. Radical cystectomy. In Marshall FF [ed]. [1996]. Textbook of operative urology. Philadelphia: WB Saunders.)*

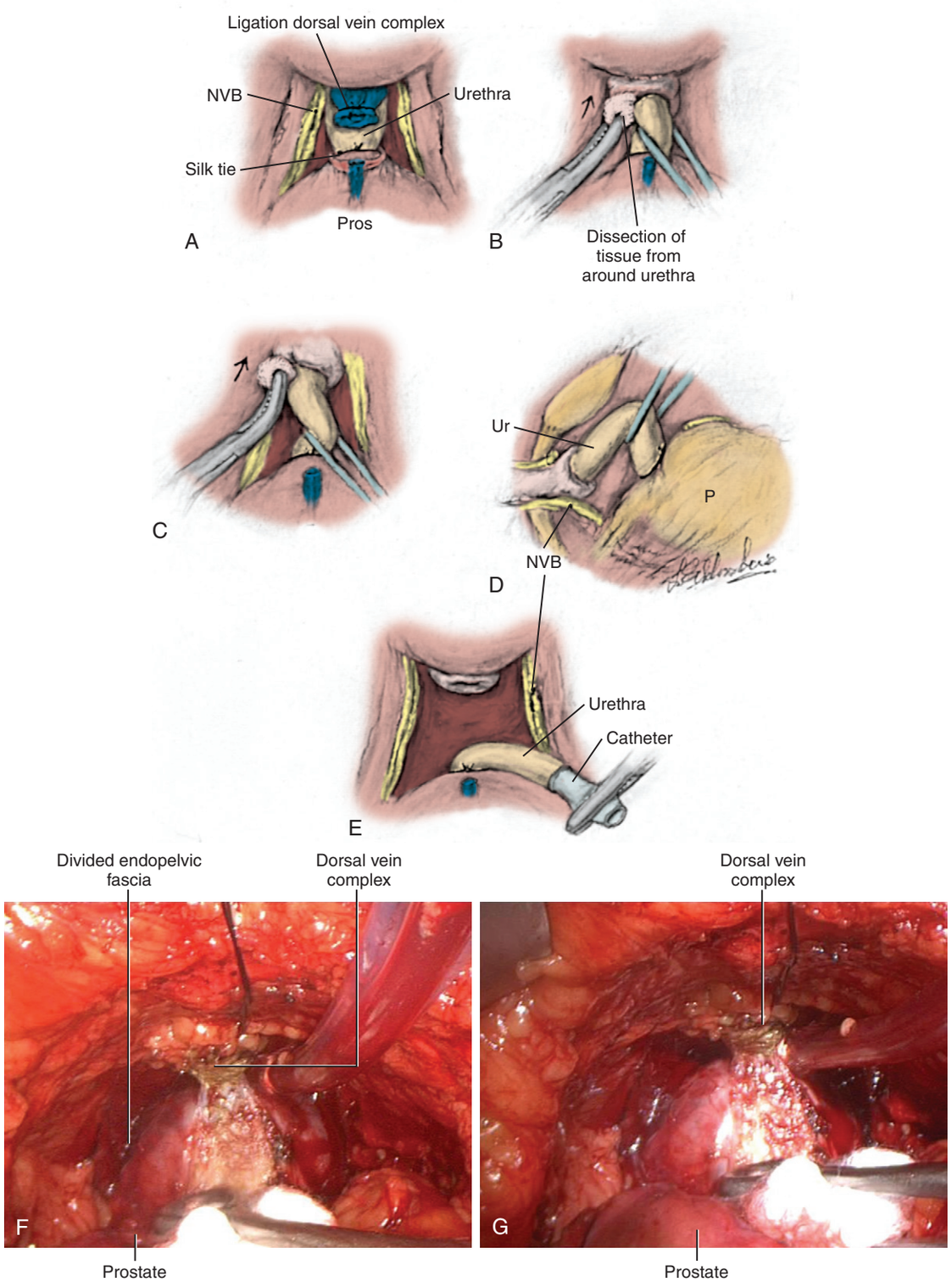

FIGURE 78-10. Dorsal vein, prostate, and divided endopelvic fascia. *(From Wein AJ, et al. [2007]. Campbell-Walsh urology, 9th ed. Philadelphia: Saunders.)*

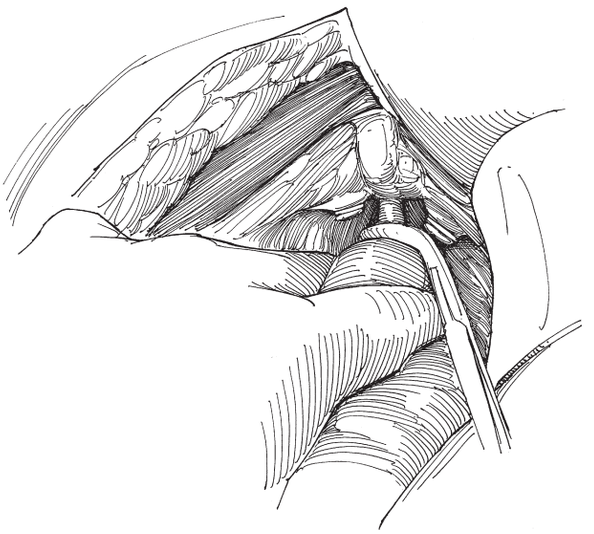

FIGURE 78-11. Division of the urethra. *(From Walsh PC, Schlegel PN. Radical cystectomy. In Marshall FF [ed]. [1996].: Textbook of operative urology. Philadelphia: WB Saunders.)*

omentum down to cover the anastomoses. An omental flap can be utilized to help prevent fistula. Suction drainage is usually needed for protection of the diversion. Close the wound appropriately.

PREPARATION FOR ORTHOTOPIC DIVERSION/ANTERIOR DISSECTION AND URETHRAL DIVISION

When orthotopic diversion is to be performed, great care should be taken to protect the urethra and preserve urethral length. Manipulation of the urethra should be avoided. The prostatic apex is approached laterally directly along the prostatic capsule and electrocautery is avoided. The urethra is divided sharply with a #15 blade to assist in a smooth urethral stump. If additional hemostasis of Santorini's/dorsal venous plexus is required, figure-eight type of sutures placed in the coronal plane can incorporate the cut edge of the endopelvic fascia on each side. Care is taken to avoid ensnaring the neurovascular bundles located posterolaterally. Also, one should not take too large bites or too deep bites to avoid injury to the sphincter mechanism.

NERVE-SPARING MODIFICATIONS

For nerve-sparing cystectomy in the male, the nerve fibers in the dorsomedial pedicles lateral to the seminal vesicles as well as the paraprostatic neurovascular bundle have to be spared.

Care should be taken to avoid even minimal trauma to the pelvic plexus through clamping or pinching of the tissue located on the dorsolateral aspect of the seminal vesicles. After that, a nerve-sparing prostatectomy must be performed. For optimal visualization of the neurovascular bundles and to avoid damage to the autonomic nerves running into the membranous urethra, a lateral approach with incision of the endopelvic and periprostatic fascia and bunching of Santorini's plexus at the level of the prostate and not distal to it is of utmost importance. The prostatic apex is approached laterally directly along the prostatic capsule and electrocautery is avoided. The urethra is divided sharply.

URETHRECTOMY

If the tumor in the prostatic stroma or prostatic urethra, urethrectomy should be considered. A two-team approach saves time and allows removal of the urethra en bloc with the radical cystectomy specimen.

POSTOPERATIVE CARE

Postoperatively, intensive care monitoring is not mandatory nor is a nasogastric tube drainage. Continue intravenous antibiotics for 24 hours is recommended. Maintain compression boots until the patient is ambulatory and continue subcutaneous heparin or low molecular heparin until discharge. Remove the stents after 7 to 10 days and the Jackson-Pratt if not without significant output. When stents are removed, a single dose of a fluoroquinolone is recommended. If there is a concern regarding excess output or possible urine leak, Jackson-Pratt fluid can be checked for creatinine.

Aggressive pulmonary toilet and ambulation is essential. Initiation of feeding at physician discretion.

CYSTECTOMY IN THE FEMALE

Intraabdominal Exposure (Fig. 78-12)

The peritoneum lateral to the bladder is incised, and the round ligament is ligated and divided. The ovarian vessels in the infundibulopelvic ligament are identified, ligated, and divided (Fig. 78-13).

These maneuvers allow the peritoneal contents to be packed away from the pelvis (Fig. 78-14). A moist pack and rolled towel combined with a ring retractor or Omni-Tract retractor provide excellent superficial and deep exposure.

Traction can be placed on the uterus anteriorly, with concomitant posterior and superior retraction on the rectosigmoid. This provides good exposure for incision of the cul-de-sac, and the vaginal wall is mobilized off the rectosigmoid colon. The classic anterior pelvic exenteration includes removal of the bladder, uterus, bilateral fallopian tubes and ovaries, anterior vaginal wall, and urethra. a povidone-iodine–soaked swabstick should be placed in the vagina and pushed into and upward/anteriorly. This maneuver facilitates identification of the cervix in the posterior vagina (Fig. 78-15). The cervix can usually be palpated easily, so that with electrocautery an incision can be made into the vagina posterior/below the cervix.

Once done, stapler fires can then be taken on each side to the level of the endopelvic fascia. If the primary tumor is small, resection of a large segment of the vagina can be avoided because of the adjacent pelvic plexus and some of the autonomic innervation that runs along its lateral aspect.

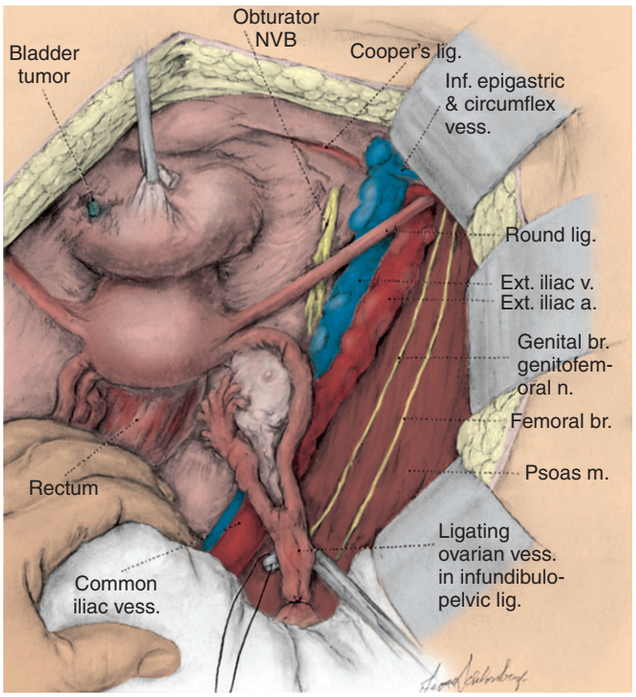

FIGURE 78-12. Exposure of female anatomy *(From Marshall FF, Treiger BF. [1991]. Radical cystectomy [anterior exenteration] in the female patient. Urol Clin North Am 18:765-775.)*

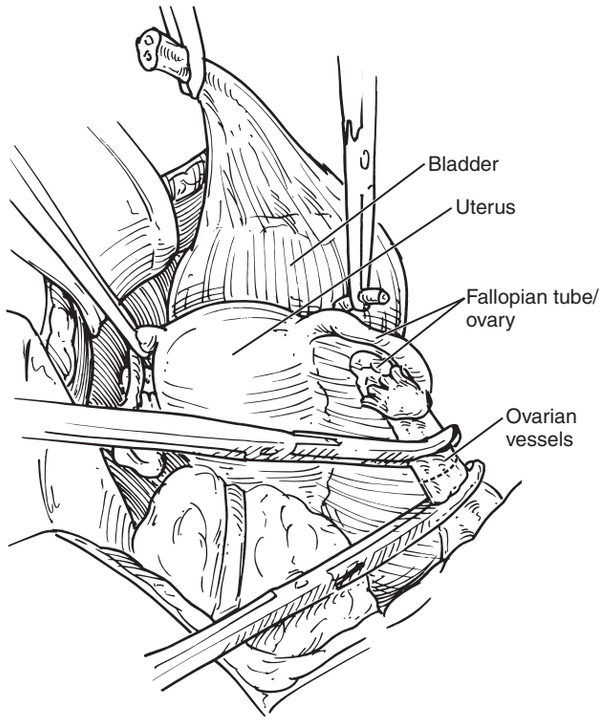

FIGURE 78-13. When fallopian tubes/ovaries are present, the ovarian vessels are ligated and divided cephalad to ovary.

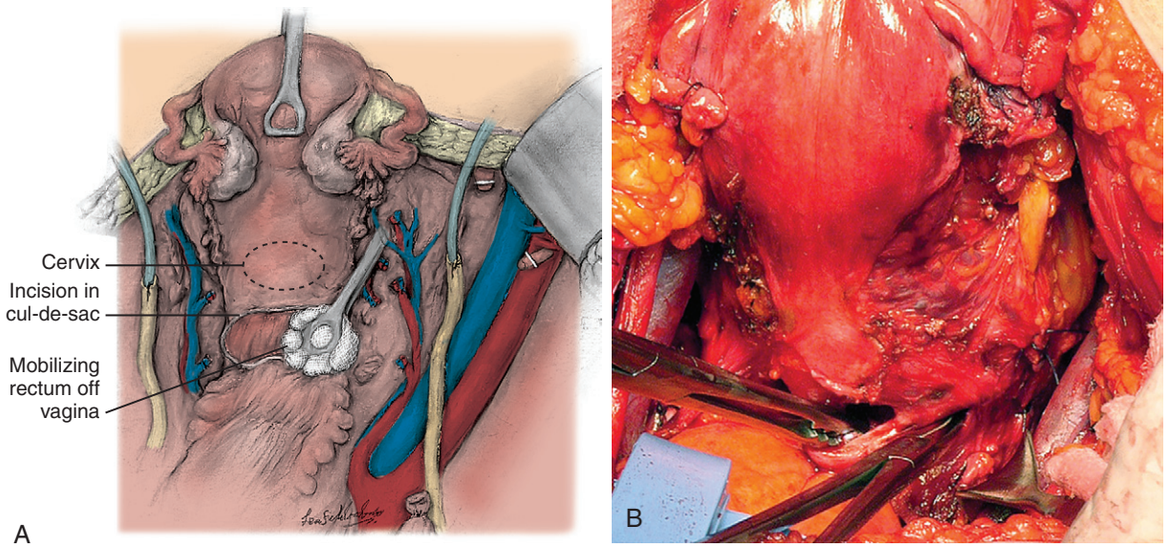

FIGURE 78-14. Retraction of uterus and ovaries with empty sponge stick allows visualization of the uterine-cervical junction. *(From Marshall FF, Treiger BF. [1991]. Radical cystectomy [anterior exenteration] in the female patient. Urol Clin North Am 18:765-775.)*

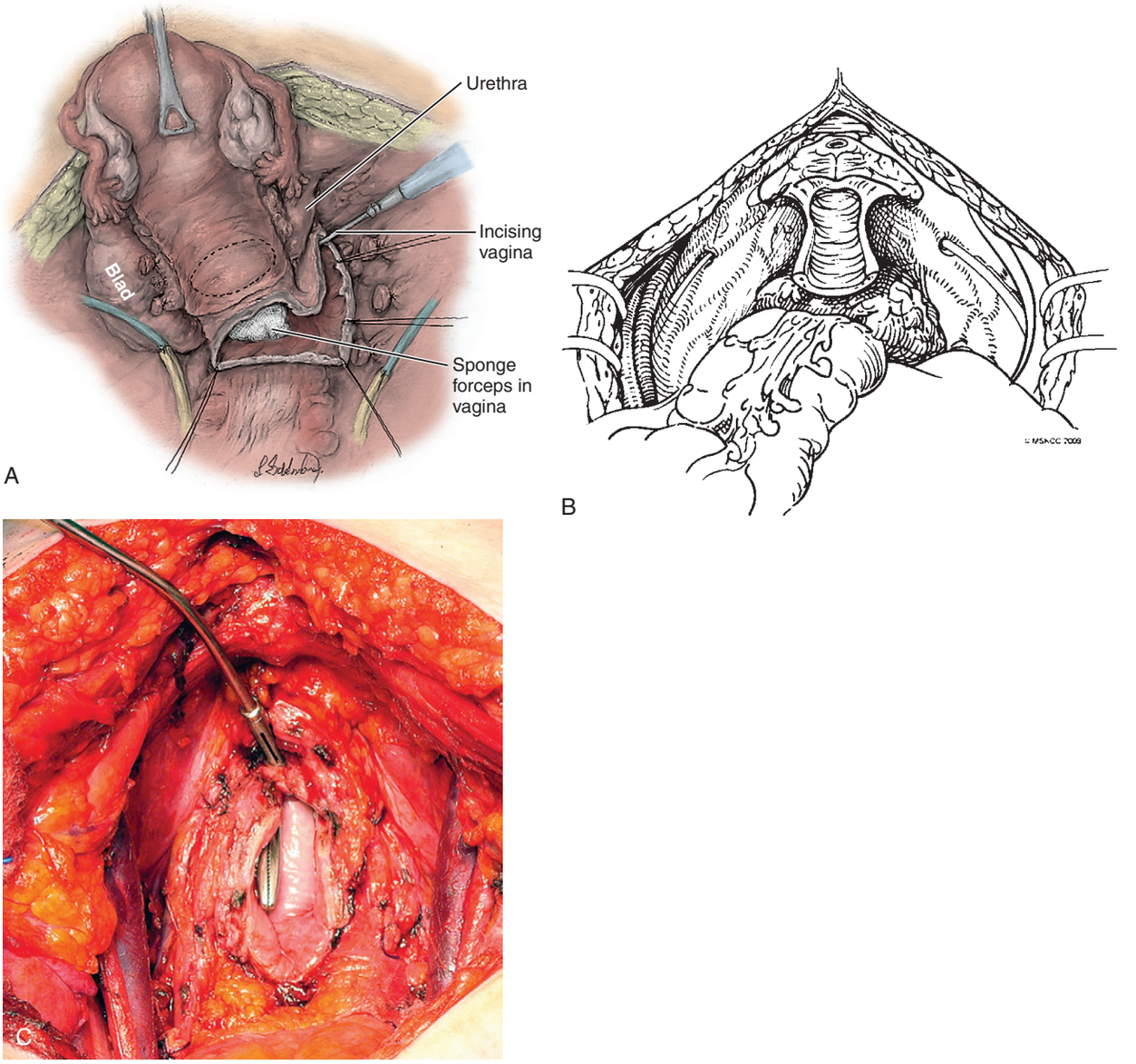

FIGURE 78-15. Placement of sponge stick into vaginal vault with exposure of cervix. *(From Marshall FF, Treiger BF. [1991]. Radical cystectomy [anterior exenteration] in the female patient. Urol Clin North Am 18:765-775.)*

The pelvic plexus provides some of the autonomic innervation to the smooth muscle of the female urethra. The pudendal nerve provides the innervation to the rhabdosphincter.

Anterior Dissection and Urethral Dissection with Urethrectomy

If a urethrectomy is to be performed, then the pubourethral suspensory ligaments are identified and divided (Fig. 78-16). These are analogous to the puboprostatic ligaments in the male. The division of the pubourethral ligaments allows the urethra and bladder to drop inferiorly. The dorsal vein complex can be identified and ligated. The urethra is then dissected from under the dorsal vein complex so the only remaining attachments of the specimen are the urethral meatus and a small portion of the vagina (Fig. 78-17). The completed specimen is passed off the table, and the vagina is closed (Fig. 78-18).

Vaginal-Sparing Approach

A vaginal-sparing procedure is most appropriate for patients undergoing orthotopic urinary diversion and/or those patients who are sexually active. The control of pedicles is different. No stapling device should be used. Division of the lateral pedicle is one of the more important technical aspects of the procedure. The endopelvic fascia should be well exposed. A perirectal fat pad lying adjacent to the rectum defines the lower limit of the lateral pedicle coursing from the internal iliac vessels. As in men, the ureter travels below the "bridge" of the superior vesicle artery, which can easily be seen and felt with medial traction on the urachus/bladder but the remainder of the small vessels can be controlled with a hemostatic device such as a LigaSure or harmonic scalpel and (Fig. 78-19).

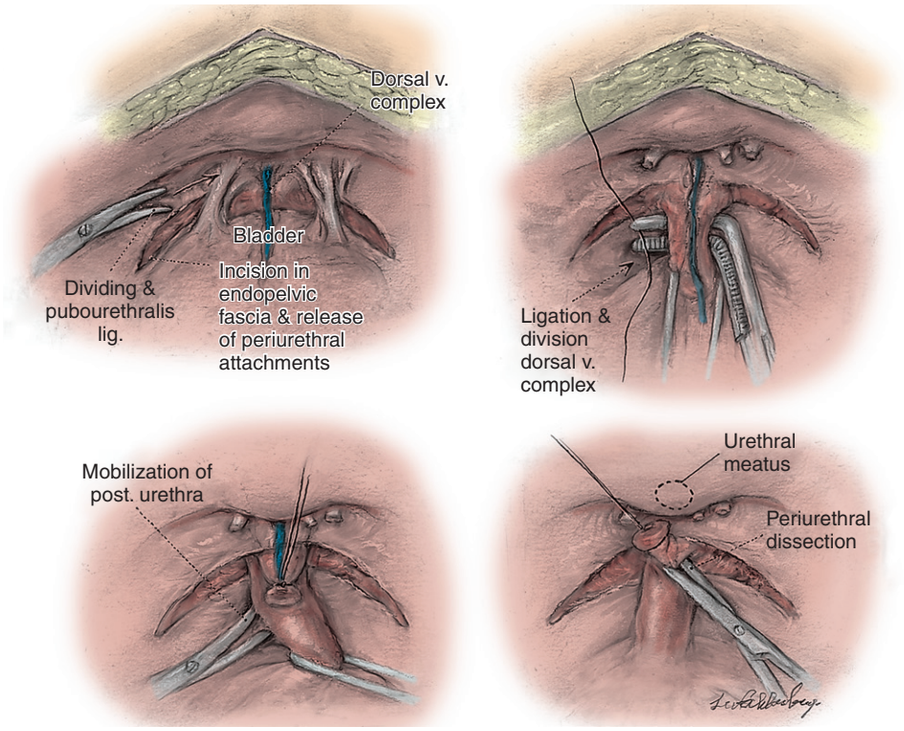

FIGURE 78-16. Urethral dissection. *(From Marshall FF, Treiger BF. [1991]. Radical cystectomy [anterior exenteration] in the female patient. Urol Clin North Am 18:765-775.)*

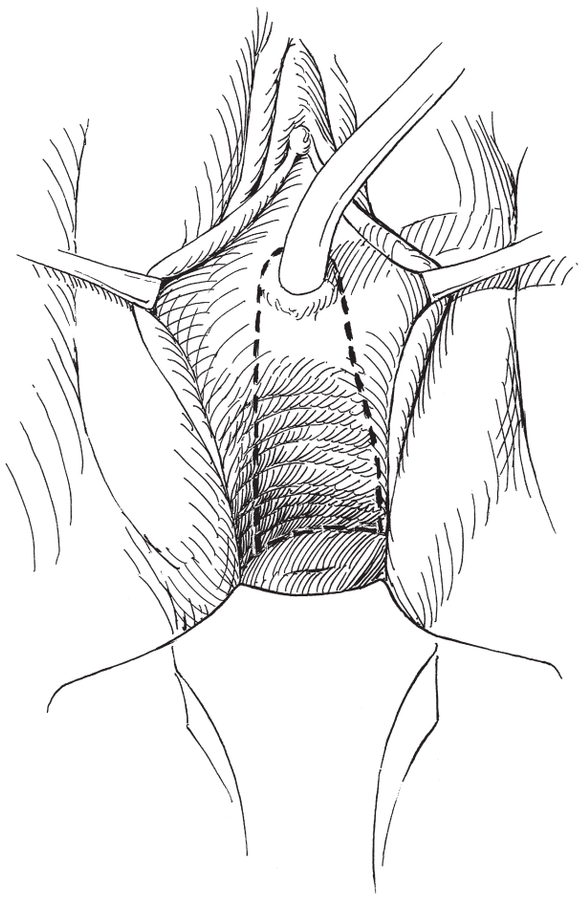

FIGURE 78-17. Perineal dissection of the urethra.

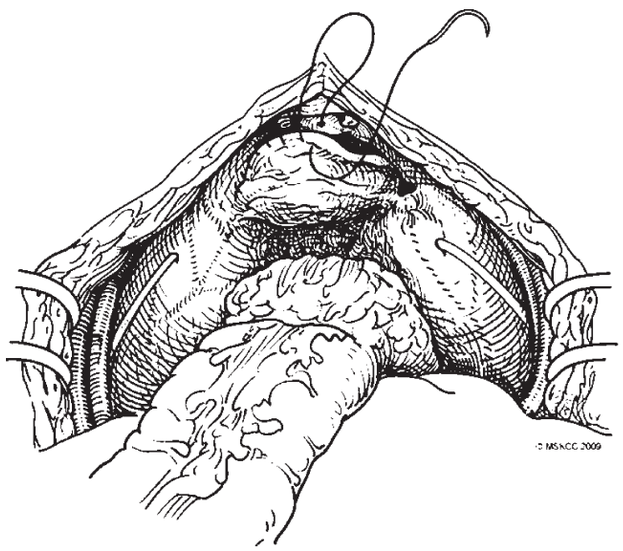

FIGURE 78-18. Closure of vaginal defect in clam-shell type fashion.

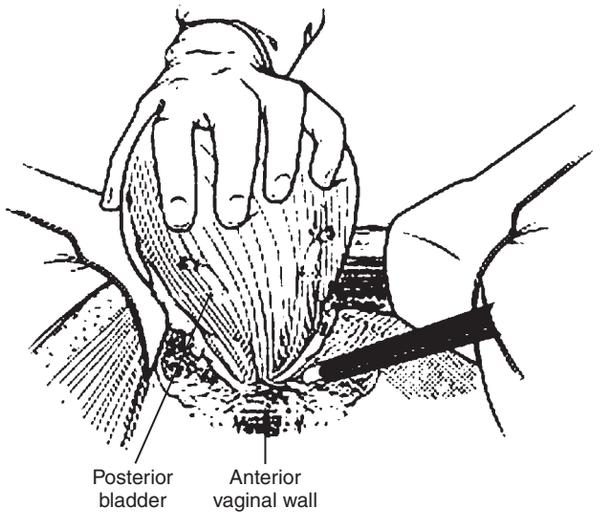

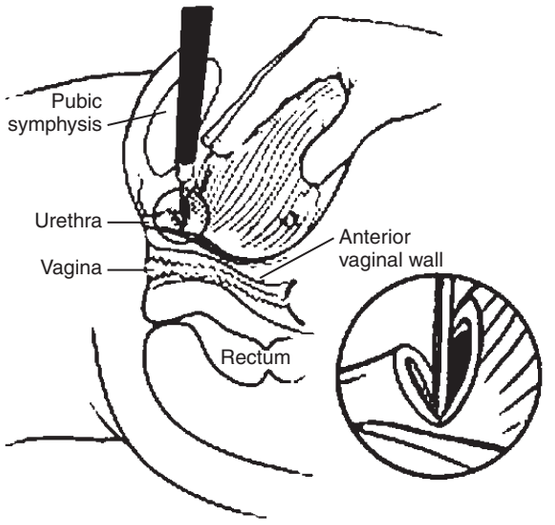

FIGURE 78-19. Urethral dissection of vaginal sparing approach. *(From Chang SS, Cole E, Cookson, MS, et al. [2002]. Preservation of the anterior vaginal wall during female radical cystectomy with orthotopic urinary diversion: technique and results. J Urol 168 (4, pt 1):1442-1445.)*

Orthotopic Urinary Diversion

If a continent orthotopic diversion is being considered, only the bladder neck and the initial 1 cm of urethra are removed (Fig. 78-20). Carefully avoiding a more extensive dissection provides for better preservation of the muscularity and innervation of the urethral sphincter. The dorsal vein complex can be identified and ligated.

If frozen section of the urethral margin is positive, perform urethrectomy (Figs. 78-16 and 78-17) and orthotopic diversion should not be performed. Otherwise, continue and vaginal-sparing approach as described is preferable, however, if the anterior vaginal wall is removed with the bladder specimen, the vagina can be reconstructed. It is important to place some type of tissue, preferably an omental flap to avoid fistula.

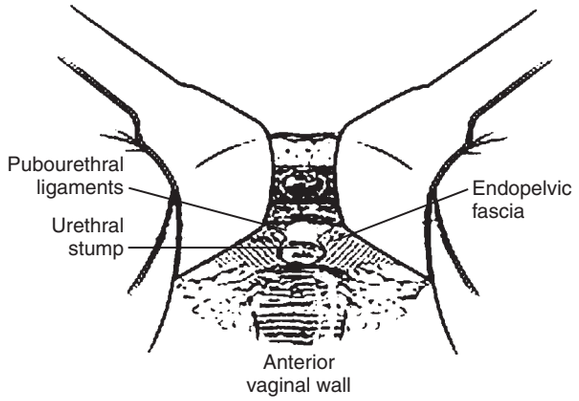

FIGURE 78-20. Urethral stump following preservation of anterior vaginal wall. *(From Chang SS, Cole E, Cookson, MS, et al. [2002]. Preservation of the anterior vaginal wall during female radical cystectomy with orthotopic urinary diversion: technique and results. J Urol 168 (4, pt 1): 1442-1445.)*

Commentary by

JAMES E. MONTIE

Radical cystectomy and urinary diversion takes a big toll on a patient. While 30-day perioperative mortality may be in the range of 1% to 2%, the 90-day mortality may be 6% to 10% and the 90-day readmission rate may be as high as 40%. Elderly patients represent the higher risk spectrum because of less physiologic reserve to adapt to complications if they do occur. All complications cannot be prevented so, often, early identification and intervention can prevent the real disaster, such as identification of a deep venous thrombosis before a pulmonary embolism or identification of fluid overload on physical exam before congestive heart failure, an arrhythmia, or a myocardial infarct. Large volume hospitals may have better outcomes because of ready availability of ancillary services such as interventional radiology and cardiology, dialysis, and wound management teams.

High volume surgeons may have better results because they can develop intraoperative and postoperative pathways that limit variability and allow everyone on the team in the operating room and on the floor to understand what their roles are and what to expect as milestones in the patient's recovery. Deviations from the pathway may be needed in special circumstances but less variability usually implies higher quality.

Chapter 79

Urethrectomy

CHRISTOPHER B. DECHET

URETHRECTOMY IN THE MALE

The indications for urethrectomy include carcinomatous involvement of the urethra. This can be done at the completion of a cystectomy or performed after subsequent urethral recurrence or staged following cystectomy.

Position: The patient should be placed in a lithotomy position. For most patients, hip flexion at 60 to 90 degrees should suffice; however, an exaggerated lithotomy can be used if additional exposure is necessary.

Incision: Following placement of the Foley catheter, a vertical perineal incision can be made over the palpable urethral bulb (Fig. 79-1). The incision can extend onto the base of the scrotum to provide better exposure; however, it is rarely needed as the distal urethra can easily be exposed due to the scrotal skin mobility. If greater exposure is necessary, an inverted "U" incision or a midline incision with lateral extension can be performed (see Fig. 79-1). Once the skin incision is made, a Scott ring retractor or similar retractor works well to expose the urethra.

Divide the subcutaneous tissue and the bulbospongiosus muscle until the corpus spongiosum is encountered. Grasp the urethra and Foley and perforate behind the urethra with a right angle instrument. Pass a large Penrose drain behind the urethra (Fig. 79-2). The arteries to the bulb will be encountered. These can be easily clipped or ligated.

Separate the distal urethra from the glans first, which will facilitate the more difficult proximal urethral dissection. The retractor hooks can be moved further proximal on the urethra to facilitate exposure and a retractor pulling the apex of the incision over the scrotum can be used for visualization of the distal urethra. The distal urethra should be separated from the corpora cavernosa. Inadvertent injury of the corpora cavernosa can be closed with interrupted Vicryl sutures. Dissection of the distal urethra is greatly facilitated by incising the surrounding investing fascia of the corpus spongiosum with Metzenbaum scissors in the midline (Fig. 79-3). Side retraction of the urethra with the Penrose drain will facilitate exposure of the urethra and its attachments which can be separated with cautery.

Invaginate the penis to the base of the glans. This can be facilitated with downward retraction of the Penrose drain around the urethra (Fig. 79-4). Carry the dissection up to the base of the glans. Let the penis return to its normal position and proceed to excise the distal urethra to remove the entire urethra en bloc. Alternatively, one can divide the urethra where it enters the proximal portion of the glans and proceed with the distal urethral excision separately.

Excise the distal urethra including the fossa navicularis by wedge resection (Fig. 79-5). Resection into the glans can be quite bloody and hinder visualization. Placement of a tourniquet around the base of the penis can facilitate the

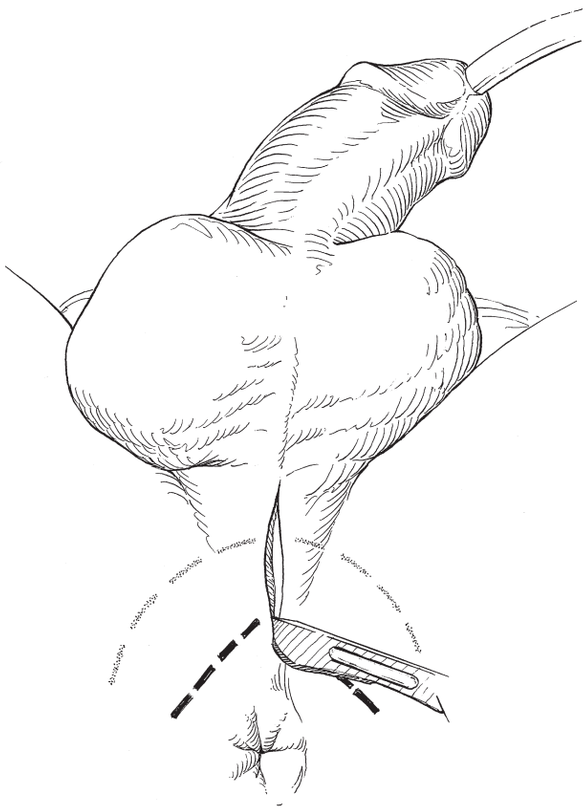

FIGURE 79-1.

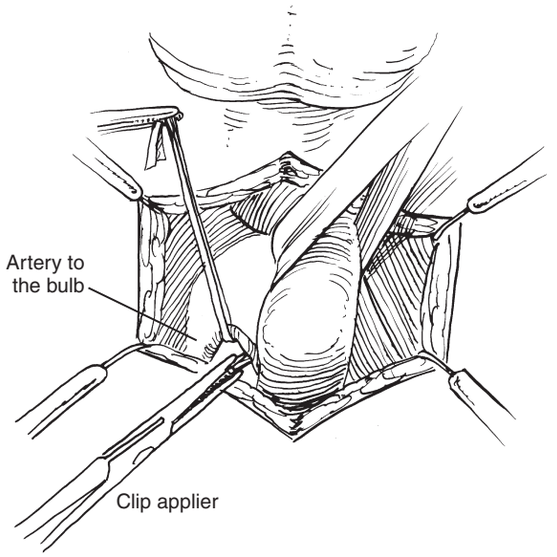

FIGURE 79-2.

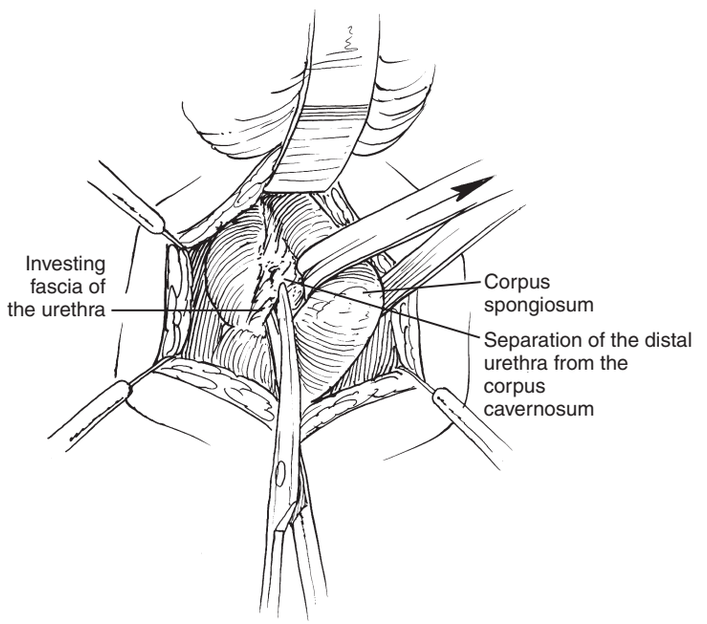

FIGURE 79-3.

dissection in these cases. One can carry this distal with Metzenbaum scissors until the area of previous dissection is encountered. Remove the entire distal urethra en bloc. Close the glans with interrupted sutures.

The proximal dissection is by far the most difficult. Incise the bulbocavernosus muscle to the perineal membrane. Once the bulbar urethral dissection is completed, dissection is carried into the deep perineal space (Fig. 79-6). It is possible to save the neurovascular bundles providing for potency if one stays close to the urethra. Bulbourethral branches from the internal pudendal arteries will be encountered. These can be clipped where they enter the bulb at the 4- and 8-o'clock position. Complete excision of the remaining membranous urethra involves entering the pelvic floor. Care must be taken to avoid cautery at this position as the proximal urethral stump

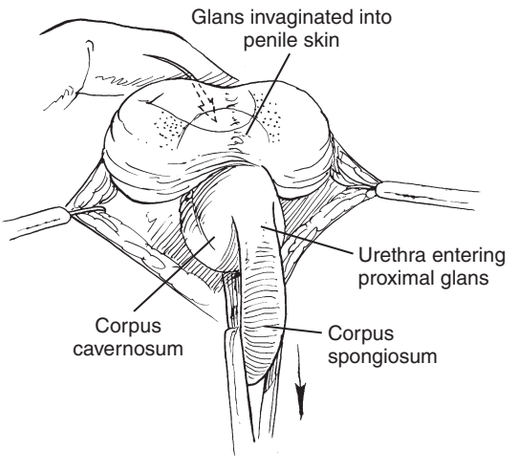

FIGURE 79-4.

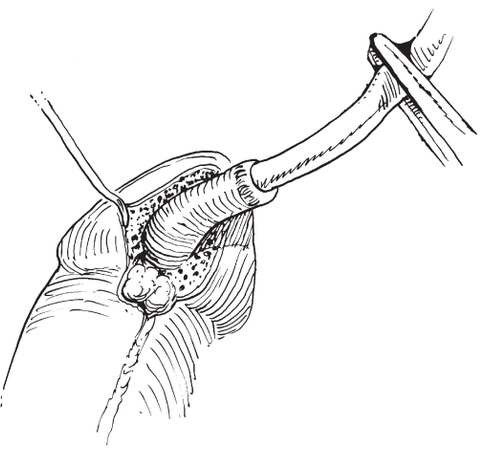

FIGURE 79-5.

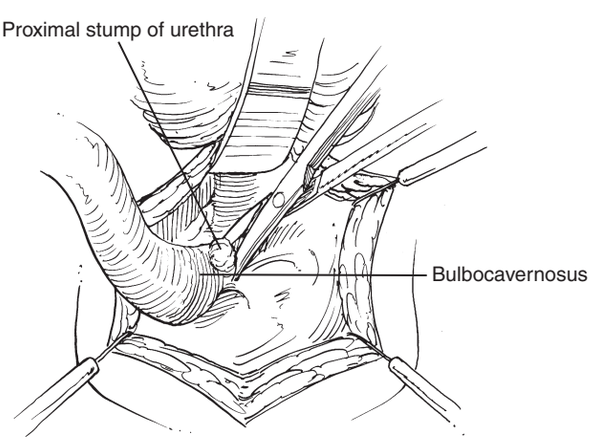

FIGURE 79-6.

can be very close or adherent to bowel, especially if a cystectomy has previously been accomplished. Circumferential sharp dissection of the remaining attachments will eventually free the proximal urethra. It is important to excise the entire proximal urethral stump. One must be careful not to avulse the proximal urethra with excessive retraction on the urethra.

Postoperative Problems

Penile edema and hematoma are common. A drain can be placed in the superficial and deep perineal space. The penis can be wrapped with a compressive dressing if there is significant glandular bleeding. Delayed bleeding is not common. A perineal hernia can appear through the urogenital diaphragm especially in cases with previous infection or radiation treatment. In closure, attempt to bring the ischiocavernosus muscles together in the midline and reapproximate the bulbospongiosus muscle to prevent herniation.

URETHRECTOMY IN THE FEMALE

Urethral carcinoma in a female is an extremely rare entity. Most commonly, a urethrectomy is performed in conjunction with a cystectomy.

To facilitate urethral resection at the time of cystectomy, make a horseshoe incision around the urethra and connect its limbs to the vaginal incisions made from above (Fig. 79-7). Dissect sharply with Metzenbaum scissors lateral to the urethra and Foley catheter entering the pelvic space. The vagina can be retubularized with absorbable sutures or by bringing the posterior inferior vaginal edge to the subclitoral edge. In cases where the tumor is not involving the floor of the bladder or bladder neck, consideration can be given to sparing the anterior vaginal wall, especially in young sexually active women.

Treatment of Distal Urethral Tumors

A distal urethrectomy can be used for patients with urethral tumors that are clinically localized to the distal one-third of the urethra. Ideally, the tumors should be restricted to the meatus, as extensive urethral dissection can result in incontinence. The patient is placed in lithotomy position and a Foley catheter is placed. A Scott retractor as well as a weighted speculum can be used for vaginal exposure. A circumscribing incision can be made around the urethral meatus (Fig. 79-8A). Metzenbaum scissors and a cautery should be used to dissect along the urethra in a circumferential manner until beyond the tumor (Fig. 79-8B). The distal urethra can then be amputated and the proximal urethra sutured to the vaginal mucosa. The remaining defects of the vaginal wall can then be reanastomosed. A vaginal pack and Foley catheter are left in place.

Complications

Hematoma and edema are common. Patients should be aware of a high risk of, incontinence especially with extensive urethral resection.

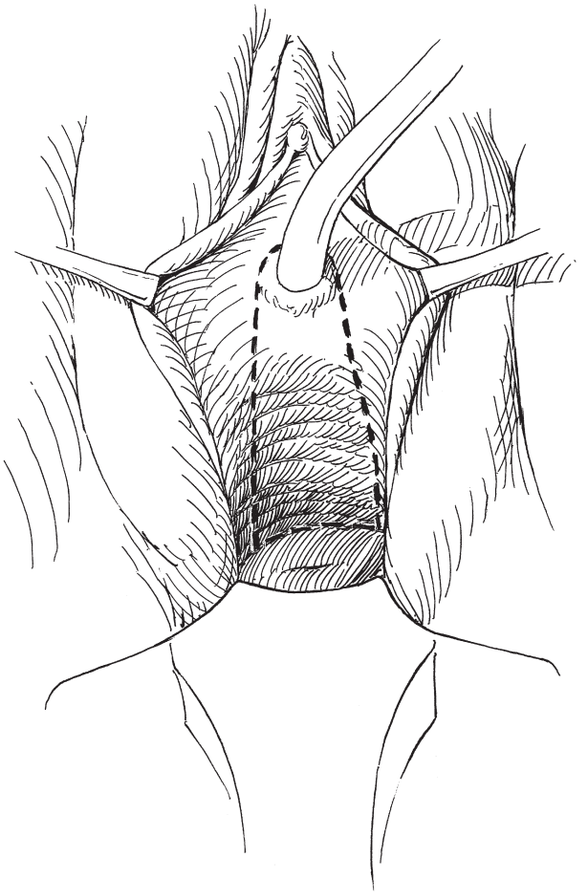

FIGURE 79-7.

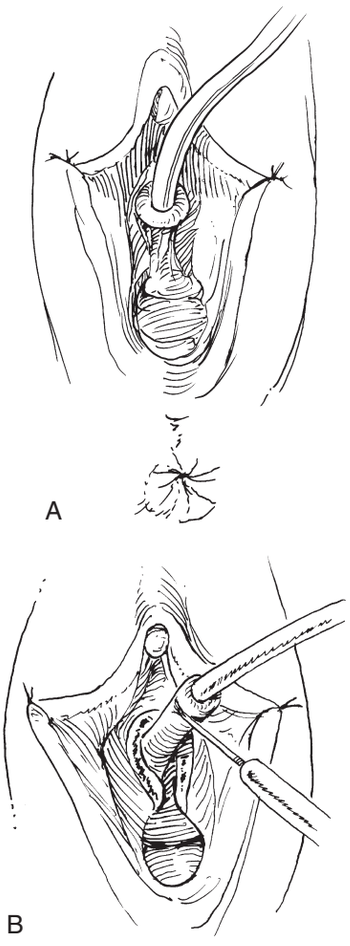

FIGURE 79-8.

Commentary by

JAMES E. MONTIE

A simultaneous male urethrectomy with a cystectomy is tedious, adding additional time and blood loss to an already difficult procedure. Concurrent urethrectomy is generally reserved for a patient with overt urethral cancer in addition to the bladder cancer. If orthopic diversion and potency are not issues, dissection of membranous urethra as distally as possible at the time of the cystoprostatectomy makes a subsequent urethrectomy easier.

In women, the urethra should be removed entirely unless there is an orthotopic urinary diversion. It is not always necessary to remove the anterior vaginal wall with the urethra. Preservation of the anterior vaginal wall provides a far better potential for sexual function recovery, a rehabilitative feature often overlooked in women, than does a reconstructed vagina.

Chapter 80

Pelvic Lymphadenectomy

PETER E. CLARK

This chapter describes the operative steps to performing an open bilateral pelvic lymphadenectomy as part of a radical cystoprostatectomy/anterior exenteration. The laparoscopic approaches to the pelvis and pelvic lymph nodes are discussed in other chapters.

The limits of dissection can be bound superiorly at several different levels, including at the bifurcation of the common iliac arteries, at the bifurcation of the aorta, or at the level of the inferior mesenteric artery (IMA) with or without inclusion of the presacral lymph nodes. The technique described herein is the maximum extent described in the literature, which is to the IMA with inclusion of the presacral lymph nodes. The approach can be modified as needed if the upper bound of dissection is lower.

LYMPHADENECTOMY IN THE MALE

Position: Patient is generally in the supine position. The patient is modestly flexed at the hip. If desired, the kidney rest can be positioned at the level of the sacrum and raised. The patient is then prepped and draped sterilely. A Foley catheter is sterilely placed in the bladder from the operative field after the patient is draped.

Incision: Midline incision is made from the level of the symphysis pubis to the level approximately 2 cm cephalad of the umbilicus. The incision should traverse around the umbilicus on the side opposite the stoma marking (Fig. 80-1A). If the patient has elected to undergo a continent cutaneous diversion or if this is a possibility and the umbilicus is to be the stoma site for the afferent limb, then be sure to stay wide of the umbilicus and preserve the fascia in that area. If a more limited pelvic lymphadenectomy is anticipated (e.g., to the level of the bifurcation of the common iliac arteries), then the incision can go superiorly to just below the umbilicus rather than around and above it. Divide the subcutaneous tissues down to the level of the fascia, which is divided in the midline. As with the incision, if a continent cutaneous diversion is a possibility and the umbilicus is to be used as the stoma site, then the periumbilical fascia should be preserved.

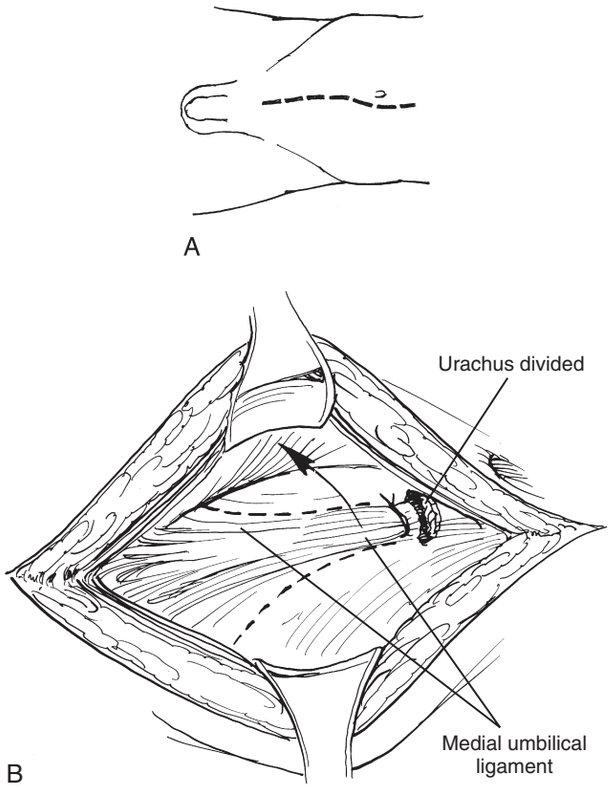

FIGURE 80-1.

Enter the peritoneum in the midline above the umbilicus. Open the peritoneum superiorly. Ligate and divide the urachus (see Fig. 80-1B). Incise the peritoneum inferiorly laterally to the medial umbilical ligaments bilaterally. Be sure not to incise too far lateral and injure the inferior epigastric vessels. At this point the incision of the peritoneum need only be carried inferiorly to approximately the level of the confluence of the vas deferens and spermatic chord bilaterally.

Explore the abdominal contents. Start in the right paracolic gutter, move superiorly, palpating the anterior and posterior aspects of the liver. Palpate the stomach. If a

nasogastric tube has been placed and is to remain postoperatively, its proper position in the stomach can be verified now. Continue left and inferiorly, palpating the retroperitoneal nodes overlying the great vessels and the left pericolic gutter. Continue inferiorly and assess the resectability of the bladder (i.e., ensure it is not fixed to the pelvic sidewall or rectum).

Retract the divided urachus inferiorly, which partially mobilizes the bladder out of the pelvis (Fig. 80-2A). Begin dissection by mobilizing the cecum along the white line of Toldt and dissecting the root of the small bowel mesentery off of the retroperitoneum cephalad. This should go no further than the level at which the third portion of the duodenum is identified. Attention is turned to the left side where the left colon and sigmoid colon are mobilized off the left pelvic side wall and retroperitoneum, starting again at the white line of Toldt on that side.

A plane is developed between the root of the sigmoid mesentery and the sacral promontory by gently passing the surgeon's hand between this space, starting on the left side of the root of the sigmoid mesentery and passing to the right. The overlying peritoneum on the right is divided, extending into the pelvis inferiorly and superiorly to the level of the inferior mesenteric artery. A self-retaining retractor may be placed if desired. Retractor blades would be placed on the body wall bilaterally as well as superiorly to retract the small bowel and cecum, which are packed with open moist laparotomy sponges. The sigmoid colon should be left mobile and not retracted with the self-retaining retractor blades.

Begin dissection of the right ureter by identifying it as it traverses anterior to the right common iliac artery. Dissect the ureter down into the pelvis, being sure to include sufficient periureteral tissue to ensure adequate blood supply. The dissection should continue approximately 2 to 3 cm beyond the common iliac artery. The ureter should be ligated and divided at this point. The proximal end may be sent for frozen section. The ureter is then dissected superiorly, focusing mainly on dividing its medial attachments, leaving the tissue between it and the spermatic chord laterally as intact as possible. The ureter is then packed in a moist sponge and placed in a pocket in the retroperitoneal space posterior to the retracted cecum and small bowel. The sigmoid colon is retracted to the right. The left ureter is dissected in essentially the identical fashion, continuing at least 2 to 3 cm into the pelvis beyond where the ureter passes over the left common iliac artery (see Fig. 80-2B). It is again ligated and divided, and the proximal end may be sent for frozen section analysis. Again it is dissected superiorly, again focusing mainly on dividing the medial attachments to preserve the blood supply in the tissue between it and the spermatic chord laterally. The ureter is again wrapped in a moist sponge and packed in the retroperitoneal space posterior the retracted small bowel and left colon.

With the sigmoid colon and mesentery still retracted to the right, incise the tissue lying just lateral to the left common iliac artery starting at the bifurcation of the common iliac artery and moving superiorly, bearing in mind the lateral border of dissection is the genitofemoral nerve. Continue the dissection cephalad, sweeping the lymphatic tissue

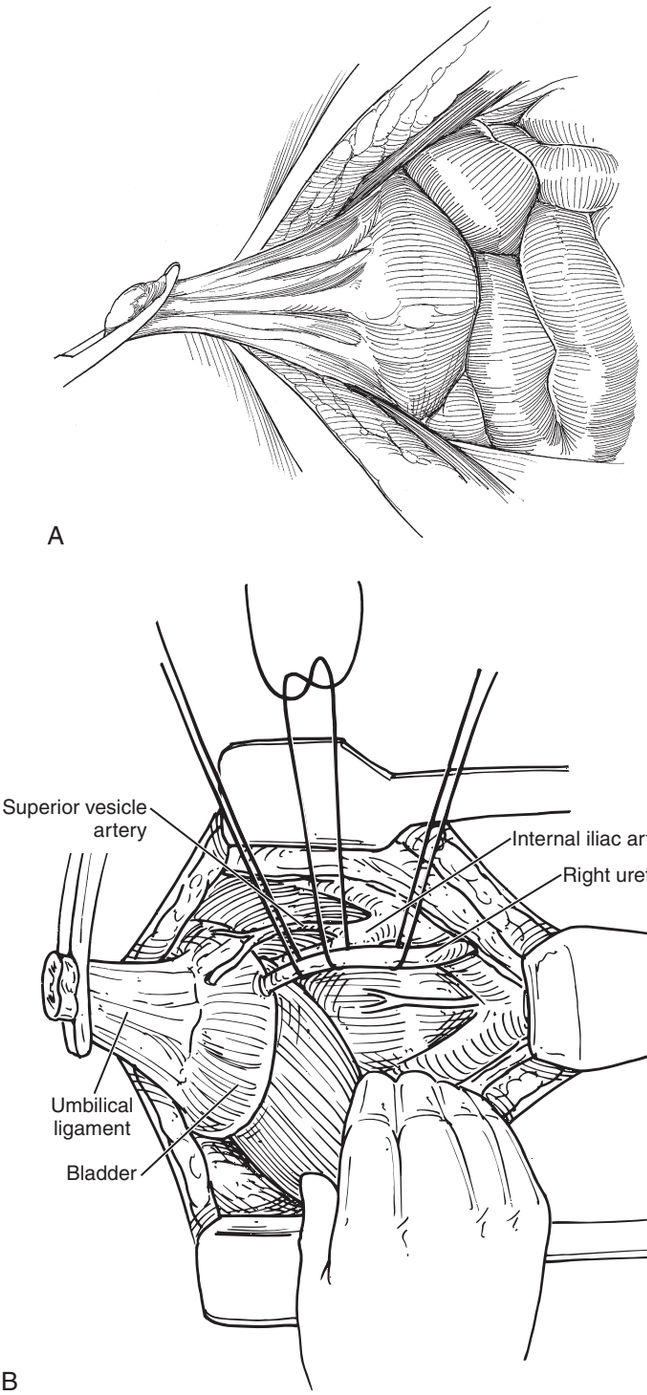

FIGURE 80-2.

inferiorly and medially off the anterior aspect of the left common iliac artery and then lower aorta up to the level of the inferior mesenteric artery (Fig. 80-3A). This will require at some point retracting the sigmoid colon and its mesentery to the left laterally, either with a hand or with a retractor blade placed in the space created earlier anterior to the sacral promontory. At the level of the inferior mesenteric artery, dissect to the right, sweeping the lymphatic tissue off of the anterior surface of the lower aorta and inferior vena cava, using Hemoclips along the superior border of dissection. When the right genitofemoral nerve is

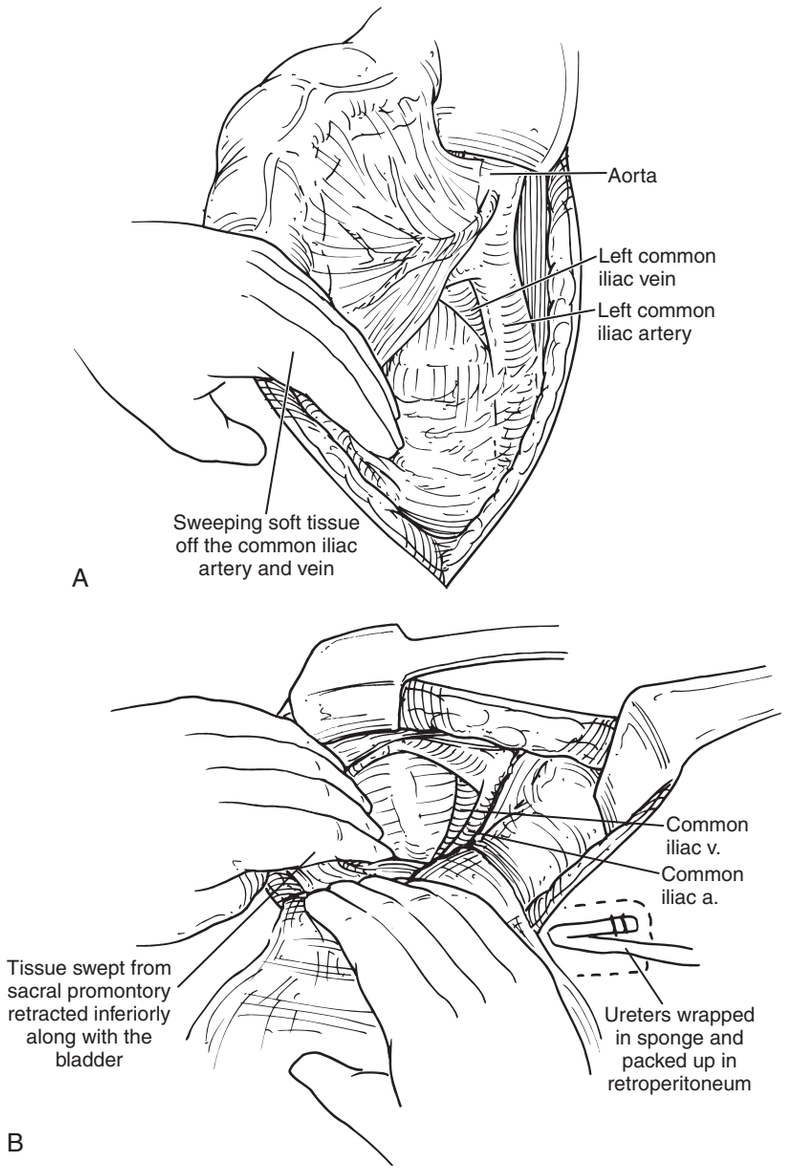

FIGURE 80-3.

reached, this is the lateral limit of dissection on the opposite side. Dissection now proceeds inferiorly, sweeping the lymphatic tissue off of the anterior surface of the right common iliac artery to the level of the bifurcation of the common iliac artery on the right.

Sweep the lymphatic tissue off of the anterior surface of the right common iliac artery and continue along the medial surface of the artery until the left common iliac vein is identified (see Fig. 80-3B). Divide the lymphatic tissue over the left common iliac vein and sweep this inferiorly in conjunction with the tissue off of the medial most aspect of the right common iliac artery down to the level of the sacrum. Identify, ligate, and divide the one or two middle sacral veins that enter into the left common iliac vein. Sweep the lymphatic tissue off of the sacral promontory, using Hemoclips as needed. Once the lymphatic tissue has been removed, a Raytec sponge may be placed in this space and removed later after the bladder is excised.

Turn attention now to the left hemipelvis. The sigmoid colon should be retracted to the right. A finger is placed in the space of Retzius and passes cephalad, mobilizing the bladder medially off of the pelvic side wall (Fig. 80-4A). Almost simultaneously, pass a finger from the opposite hand anterior to the iliac artery starting at the cut edge of the peritoneum, medial to the spermatic chord, and passing caudally. The fingers meet each other and the bladder is retracted medially. The peritoneal reflection is now divided, being careful to avoid injury to the spermatic chord until the vas deferens is isolated. This is now ligated and divided.

At this point the external iliac vessels should be well exposed. Divide the lymphatic tissue over the external iliac vein and sweep this medially (see Fig. 80-4B). Dissect the

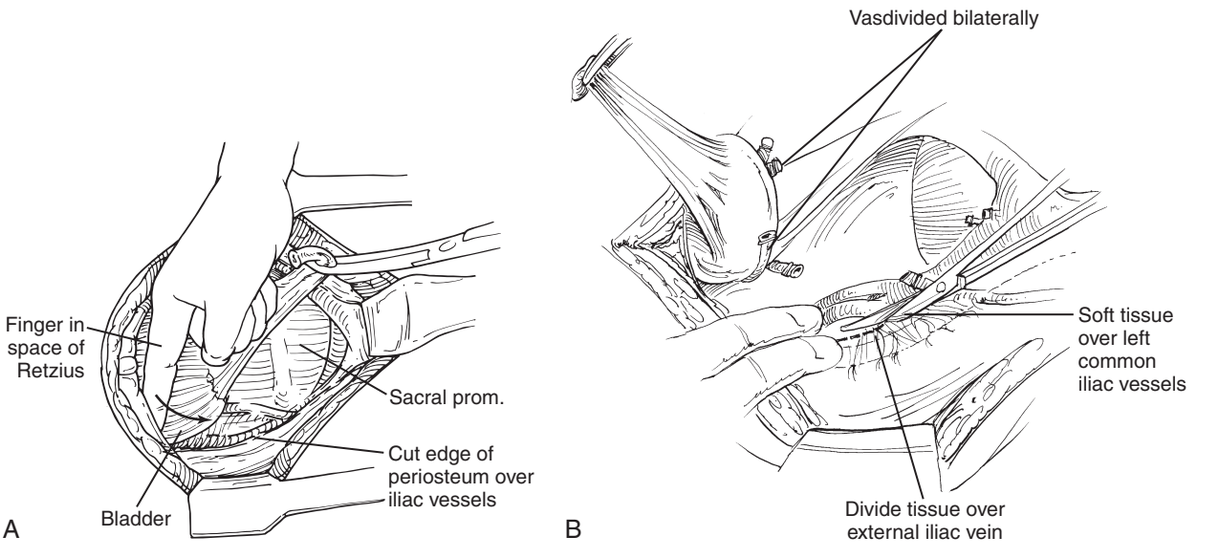

FIGURE 80-4.

tissue just distal to the lymph node of Cloquet, which represents the inferior limit of dissection. Hemoclips should be used at the inferior border of dissection. Mobilize the lymphatic tissue now off of the lower aspect of the pelvic side wall posteriorly to the level of the obturator vessels and nerve. Be alert for an accessory obturator vein, which should be ligated and divided if encountered.

Divide the lymphatic tissue overlying the external iliac artery and in a split and roll fashion isolate this vessel and retract it medially. Mobilize the lymphatic tissue medial to the genitofemoral nerve off of the pelvic side wall, using Hemoclips as necessary for perforating vessels. The remaining lymphatic tissue lying over the external iliac vein is now divided with the external iliac artery retracted medially.

Use a Raytec sponge that has been opened and pass this in the space lateral to the external iliac vessels, starting at the level of the bifurcation of the iliac artery and passing inferiorly and posteriorly into the obturator fossa (Fig. 80-5A). This will sweep all the lymphatic tissue into the obturator fossa. The lymphatic packet is now retracted medially and any remaining attachments to the external iliac vein can be divided. Dissect free the obturator nerve, which is now retracted superiorly along with the external iliac vein with a vein retractor. Isolate the obturator artery and vein as they egress the pelvis at the obturator foramen. Ligate and divide these vessels, which will allow the entire lymph node packet to be retracted medially out of the obturator fossa (see Fig. 80-5B). It can now be removed separately or keep attached with the bladder to be removed en bloc.

At this point the lateral pedicle of the bladder on the left side can be readily isolated and divided as per the radical cystectomy. If the bladder is not going to be removed, then the lymph node packet can be removed at this point.

The previous two steps are now repeated in mirror image on the right hand side. Again, as in Figure 80-5B, once the lymph node packet has been retracted medially and the obturator vessels ligated and divided, the lateral pedicle of the bladder is well exposed and can be ligated and divided as per the radical cystectomy. Otherwise, the lymph node packet can be removed, drains placed, and the incision closed after ensuring good hemostasis.

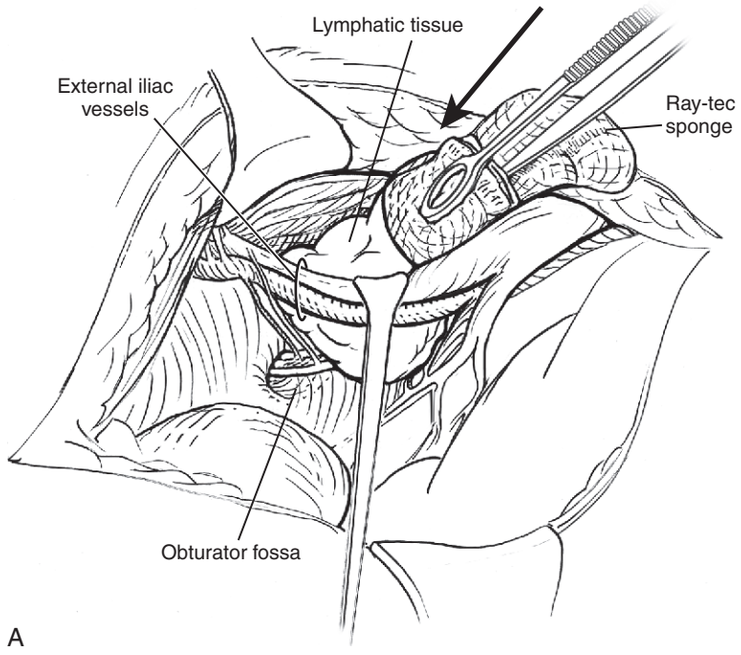

A

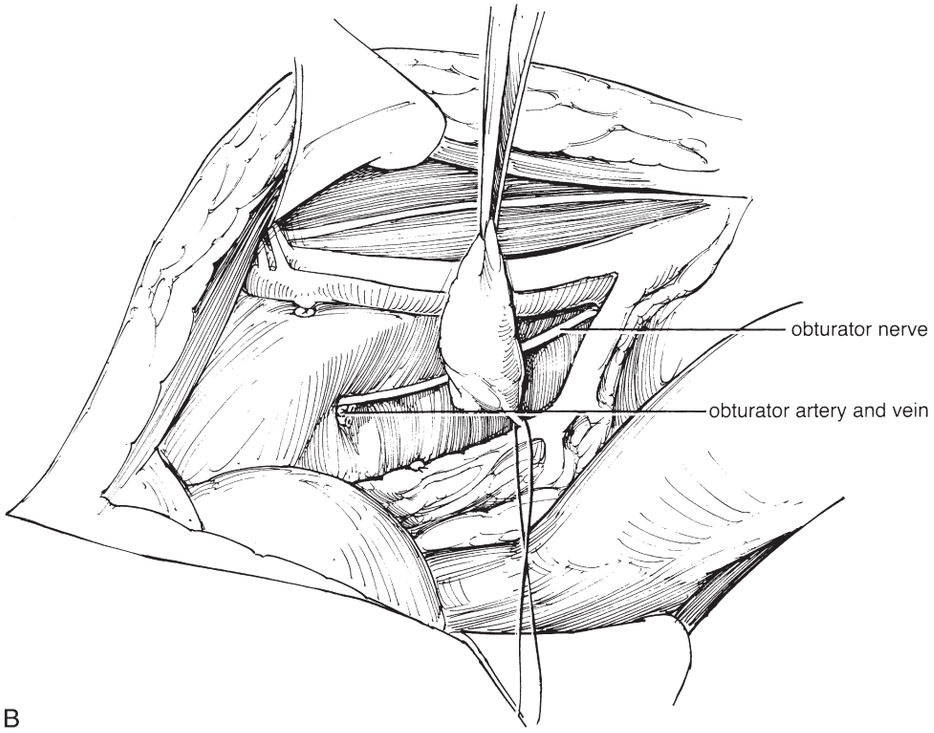

B

FIGURE 80-5.

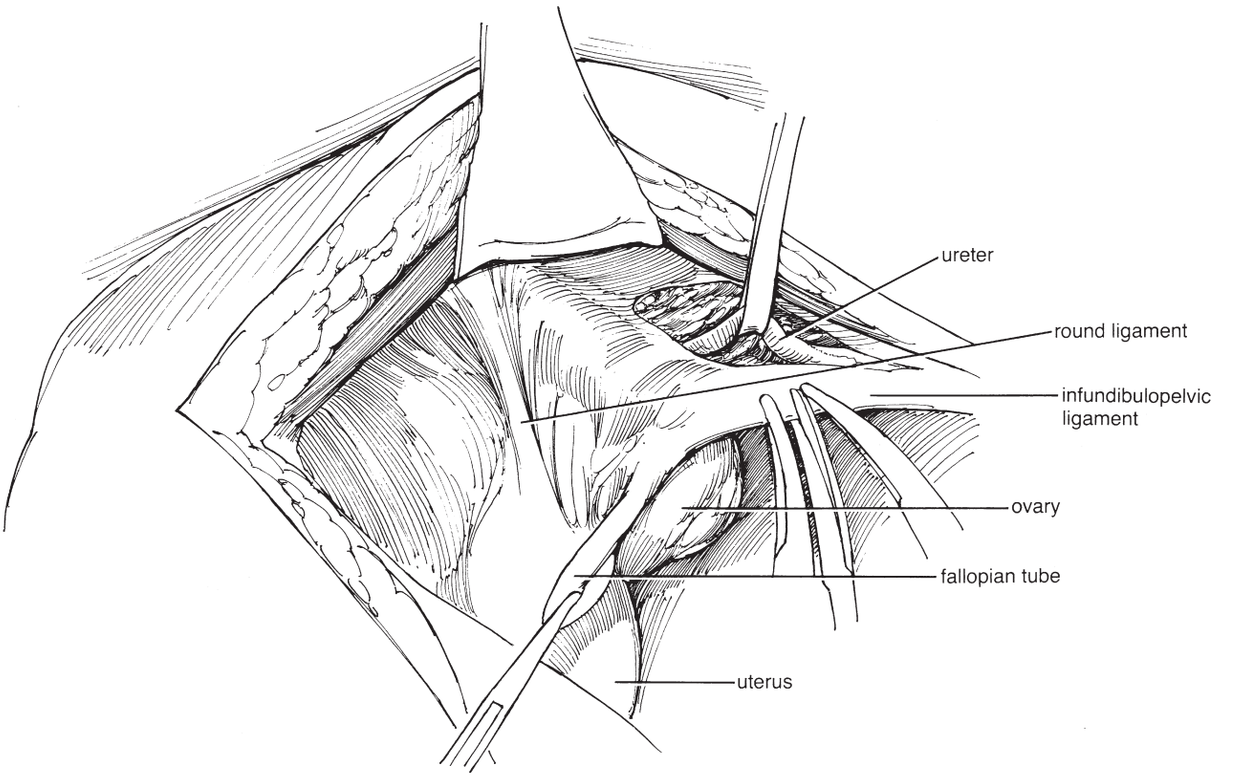

FIGURE 80-6.

LYMPHADENECTOMY IN THE FEMALE PELVIS

The pelvic lymphadenectomy in the female patient is similar to that of the male, but certain specific differences warrant attention. One is the positioning of the patient, which in a female patient is either in a frog-leg position (ensuring good support at the knees) or in a low lithotomy position, depending on the surgeon preference and the size and location of the tumor.

In the male, the spermatic chord is preserved and dissection proceeds medial to these structures. In the female patient, the infundibulopelvic ligament is identified, ligated, and divided before beginning dissection of the ureter into the pelvis (Fig. 80-6). In addition, the round ligament rather than the vas deferens will be the structure that is divided once the bladder has been mobilized off of the pelvic side wall.

POSTOPERATIVE PROBLEMS

Lymphocele: The potential complications after pelvic lymphadenectomy include hemorrhage and lymphocele formation. Lymphocele formation should be substantially less frequent than after procedures such as open retropubic prostatectomy in which the peritoneum is not entered. Small incidental lymphoceles noted during routine postoperative follow-up can generally be observed. Symptomatic lymphoceles and/or collections that may be infected should be drained. Infected lymphoceles should be percutaneously drained and usually resolve. For uninfected but symptomatic lymphoceles, the options for management include percutaneous drainage, laparoscopic drainage, or rarely open drainage.

Nerve injury: Care should be taken to avoid injury to the obturator nerve or genitofemoral nerve. Division of the obturator nerve can cause problems with adduction of the thigh. This can often be rehabilitated with physical therapy as other muscle groups can compensate for the loss of the obturator nerve function. Division of the genitofemoral nerve can cause pain or paresthesias of the upper thigh, groin, or scrotum. Care should be taken that any self-retaining retractor blades are not placed too deep in the pelvis to avoid compression injury to the femoral nerve.

Thrombus formation: There is a risk of thrombus formation as with any pelvic operation, especially when being performed for malignancy. Use of sequential compression devices, started prior to initiating anesthesia, and early postoperative ambulation are interventions that can help alleviate thrombus formation. Consideration can also be given to routine postoperative anticoagulation with low molecular weight heparin.

Chapter 81

Pelvic Exenteration

PETER E. CLARK

This chapter will outline the operative steps to performing a total pelvic exenteration in the male or female. In the majority of cases this procedure is not done for a genitourinary primary malignancy. For example, in men it is most frequently indicated for locally advanced rectal carcinoma with invasion into the bladder or prostate, while in women it is in locally advanced malignancies of the reproductive tract. As a consequence, and due to the nature of the procedure, a total pelvic exenteration is most often accomplished using a multidisciplinary team of surgeons from different specialties, as well as radiation oncologists, and medical oncologists. As an example, there are numerous different approaches to filling the space left in the deep pelvis after removal of the specimen. These include a myocutaneous flap based on the rectus abdominus or gracilis musculature, an omental flap, and absorbable mesh. Depending on the approach chosen, coordination may need to include pre-operative evaluation by a plastic surgeon.

Preoperative preparation: The patient will need to have undergone pre-operative evaluation and counseling by the enterostomal therapy team and marked for two stomas. It is prudent to mark the patient in all four quadrants so that all options for stoma placement are available at the time of the operation for placement of the colostomy and urinary conduit. If a myocutaneous flap will be utilized to fill the space in the deep pelvis, then a plastic surgeon should and evaluate the patient. Careful coordination is needed between the urologic surgeon and other involved surgical services, depending on the primary lesion (for example general/color-rectal/surgical oncology for colorectal carcinoma or gynecology oncology for malignancies of the female reproductive tract). If the patient requires pre-operative neoadjuvant therapy in the form of chemotherapy, radiation therapy, or (as is often the case in colorectal carcinoma) a combination of the two, then further careful coordination is also needed with medical and/or radiation oncology.

The patient will undergo a full pre-operative mechanical bowel preparation and broad spectrum intravenous prophylactic antibiotics should be given just prior to skin incision.

Total Pelvic Exenteration in the Male

Position: The patient should be placed in lithotomy position and prepped and draped such that the anus is separated from the anterior abdomen. To what degree the thigh is prepped and draped will depend on whether or not a gracilis myocutaneous flap will be used to fill the deep pelvis after specimen removal. A foley catheter is placed sterilely into the bladder on the operative field after the patient is draped.

Incision: Midline incision is made from the level of the symphysis pubis to the level approximately 2 cm cephalad of the umbilicus. Divide the subcutaneous tissues down to the level of the fascia which is divided in the midline.

Enter the peritoneum in the midline above the umbilicus. Open the peritoneum superiorly. Ligate and divide the urachus. Incise the peritoneum inferiorly laterally to the medial umbilical ligaments bilaterally. Be sure not to incise too far lateral and injure the inferior epigastric vessels. At this point the incision of the peritoneum need only be carried inferiorly to approximately the level of the confluence of the vas deferens and spermatic chord bilaterally.

Explore the abdominal contents. Start in the right paracolic gutter, move superiorly palpating the anterior and posterior aspects of the liver. Palpate the stomach and if a nasogastric tube has been placed and is to remain postoperatively its proper position in the stomach can be verified now. Continue now left and inferiorly palpating the retroperitoneal nodes overlying the great vessels and the left pericolic gutter. Continue inferiorly and assess the resectability of the specimen (invasion posteriorly into the coccyx or sacrum or laterally into the pelvic sidewall). It should be noted that in most cases extra-pelvic lymph node spread of disease for colorectal carcinoma is a relative contraindication to proceeding with total pelvic exenteration, although bowel and/or urinary diversion may be indicated.

Retract the divided urachus inferiorly which partially mobilizes the bladder out of the pelvis. Begin dissection by mobilizing the cecum along the white line of Toldt and dissecting the root of the small bowel mesentery off of the retroperitoneum cephalad. This should go no further than the level at which the third portion of the duodenum is identified. Attention is now turned to the left side where the

left colon and sigmoid colon are mobilized of off the left pelvic side wall and retroperitoneum, starting again at the white line of Toldt on that side. This needs to be extended more superiorly than would typically be done for a radical cystectomy alone in order to ensure sufficient mobility of the colon for a colostomy and possibly a colon conduit, depending on the choice of bowel segment for urinary diversion. A self retaining retractor can be placed at this time if desired. The small bowel and cecum should be retracted superiorly, but the distal left colon and sigmoid colon are left mobile.

A plane is now developed between the root of the sigmoid mesentery and the sacral promontory by gently passing the surgeons hand between this space starting on the left side of the root of the sigmoid mesentery and passing to the right. The overlying peritoneum on the right is now divided, extending into the pelvis inferiorly and superiorly to the level of the inferior mesenteric artery. Divide the colon using a gastrointestinal anastomosis (GIA) stapler (Fig. 81-1). The colon mesentery will now need to be divided. Care must be taken to preserve sufficient blood supply to the proximal colon (Fig. 81-2). The inferior mesenteric artery bifurcates into the left colic artery and the sigmoid artery. The sigmoid artery in turn bifurcates to give the lower left colic arteries and the superior rectal artery. The most common scenario for a total pelvic exenteration in the male is locally advanced rectal carcinoma. In this case, most often the sigmoid mesentery is divided such that the superior rectal artery and inferior left colic arteries are divided, but the left colic artery is preserved. The latter can supply the proximal most sigmoid colon via the marginal artery.

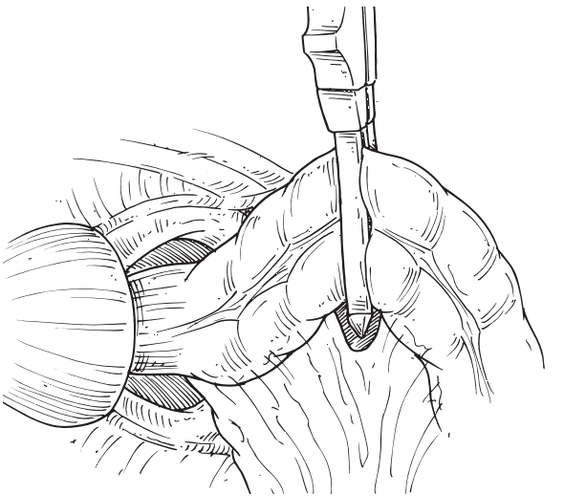

FIGURE 81-1.

Begin dissection of the right ureter by identifying it as it traverses anterior to the right common iliac artery. Dissect the

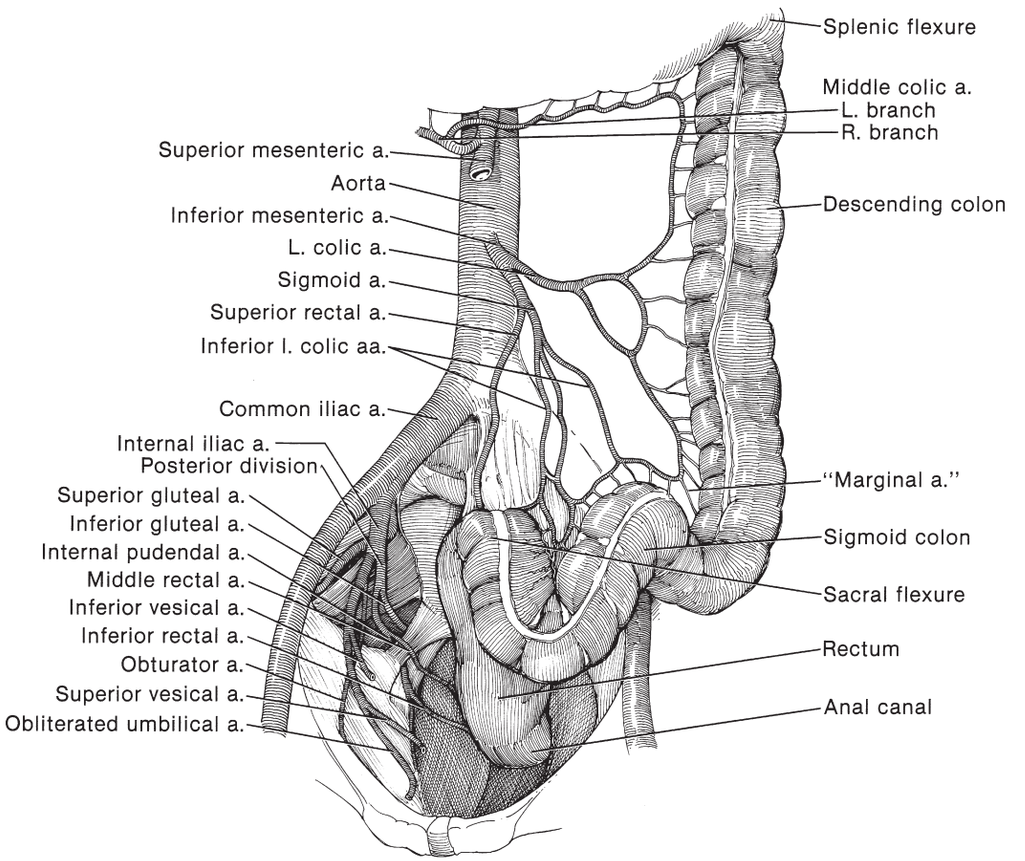

FIGURE 81-2.

ureter down into the pelvis, being sure to include sufficient peri-ureteral tissue to ensure adequate blood supply. The dissection should continue approximately 2-3 cm beyond the common iliac artery. The ureter should be ligated and divided at this point (Fig. 81-3). The ureter is then dissected superiorly, focusing mainly on dividing its medial attachments leaving the tissue between it and the spermatic chord laterally as intact as possible. The ureter is then packed in a moist sponge and placed in a pocket in the retroperitoneal space posterior to the retracted cecum and small bowel. The left ureter is dissected in essentially the identical fashion, continuing at least 2-3 cm into the pelvis beyond where the ureter passes over the left common iliac artery. It is again ligated, and divided. Again it is now dissected superiorly, again focusing mainly on dividing the medial attachments to preserve the blood supply in the tissue between it and the spermatic chord laterally. The ureter is again wrapped in a moist sponge and packed in the retroperitoneal space posterior the retracted small bowel and left colon.

Turn attention now to the left hemi-pelvis. A finger is placed in the space of Retzius and passes cephalad mobilizing the bladder medially off of the pelvic side wall. Almost simultaneously, a finger from the opposite hand passes anterior to the iliac artery starting at the cut edge of the peritoneum, medial to the spermatic chord, and is passed caudally. The fingers meet each other and the bladder is retracted medially. The peritoneal reflection is now divided, being careful to avoid injury to the spermatic chord and inferior epigastric vessels, until the Vas Deferens is isolated. This is now ligated and divided.

The bladder is now retracted medially and the lateral pedical of the bladder is isolated by passing the third finger posterior and the index finger anterior to the superior vesicle artery and advancing these toward the endopelvic fascia while simultaneously retracting the bladder medially (Fig. 81-4). The medial directed branches of the internal iliac artery are now ligated and divided, including the superior vesicle artery and the inferior vesicle artery as well as the associated veins in the lateral pedicle.

The steps for dissecting out and ligating the lateral pedicle are now duplicated on the right hand side. Attention is then turned to lateral mobilization of the prostate and division of the urethra.

If identified the superficial dorsal vein is ligated and divided. The endopelvic fascia is now exposed on the left side of the prostate and incised in a manner analogous to that performed in a radical retropubic prostatectomy. The levator muscle fibers are swept laterally away from the prostate. The endopelvic fascia is incised also over the prostate more superiorly to meet the dissection and ligation of the lateral pedicle of the bladder. This is then repeated on the right hand side. The incised edges of the endopelvic fascia are bunched anteriorly using a clamp such as a Babcock clamp and a back bleeding figure of eight suture is placed in the veinous complex (Fig. 81-5A).

A figure of eight suture is then placed in the deep dorsal veinous complex distally, again analogous to the step in a radical retropubic prostatectomy or radical cystoprostatectomy. Divide the dorsal veinous complex. Ensure good hemostasis, including placing additional sutures in the deep dorsal veinous complex as needed (Fig. 81-5B). The urethra may now be divided.

Retract the distal end of the sigmoid colon/rectum anteriorly and inferiorly and develop the plane between the sacrum and the rectum. This is accomplished by a combination of blunt and sharp dissection (Fig. 81-6). This should be continued posteriorly mobilizing the mesorectum off of the sacrum. Typically the dissection will remain

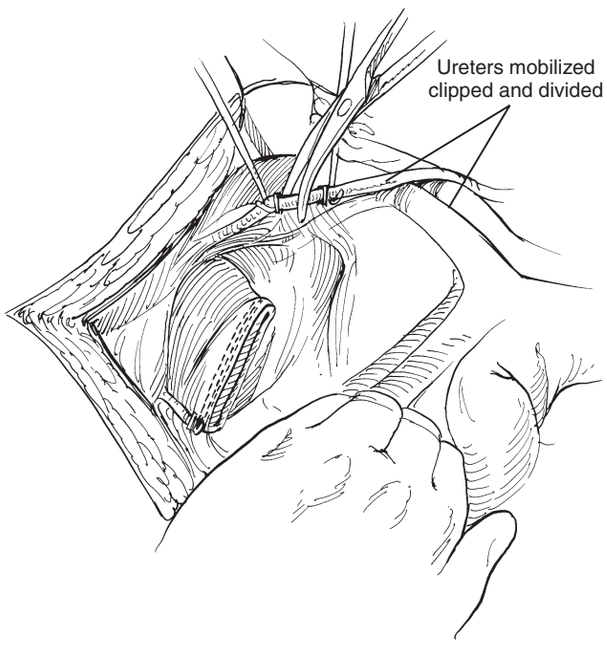

FIGURE 81-3.

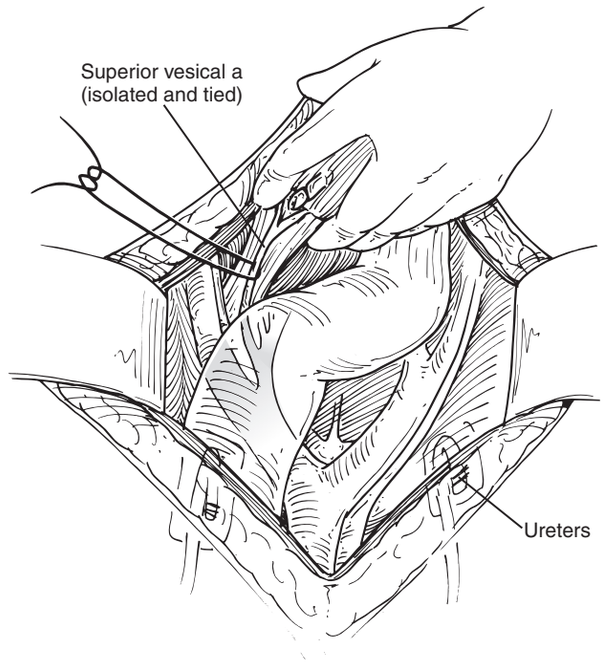

FIGURE 81-4.

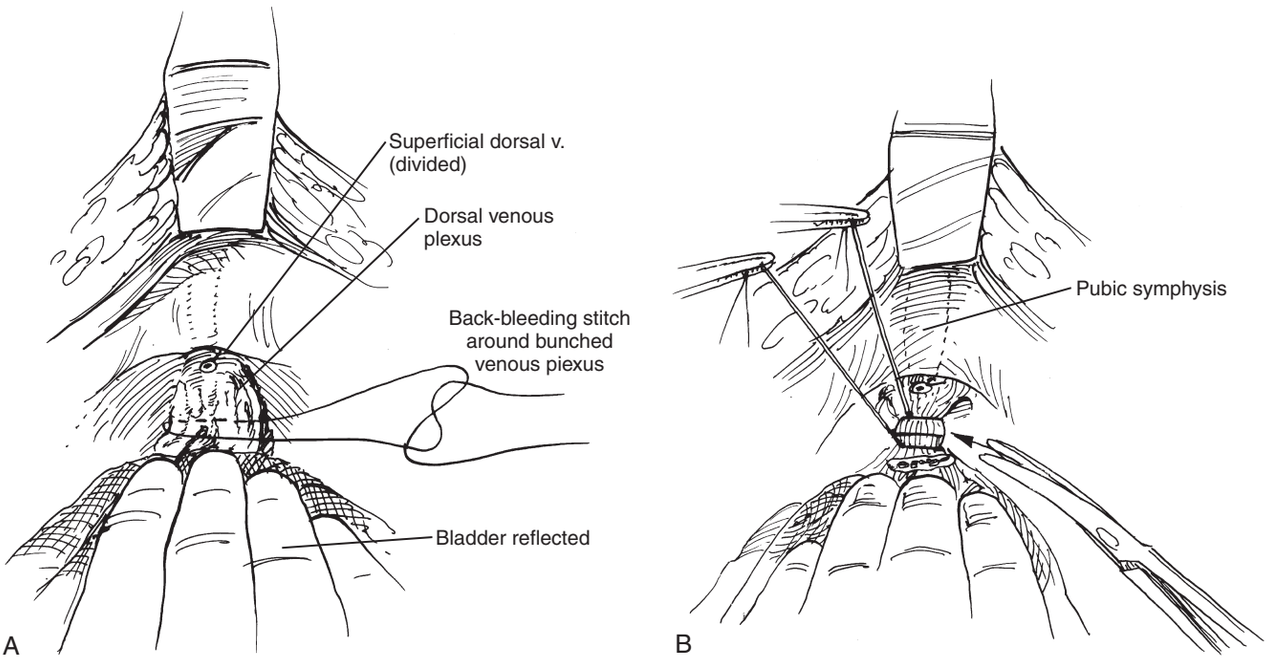

FIGURE 81-5.

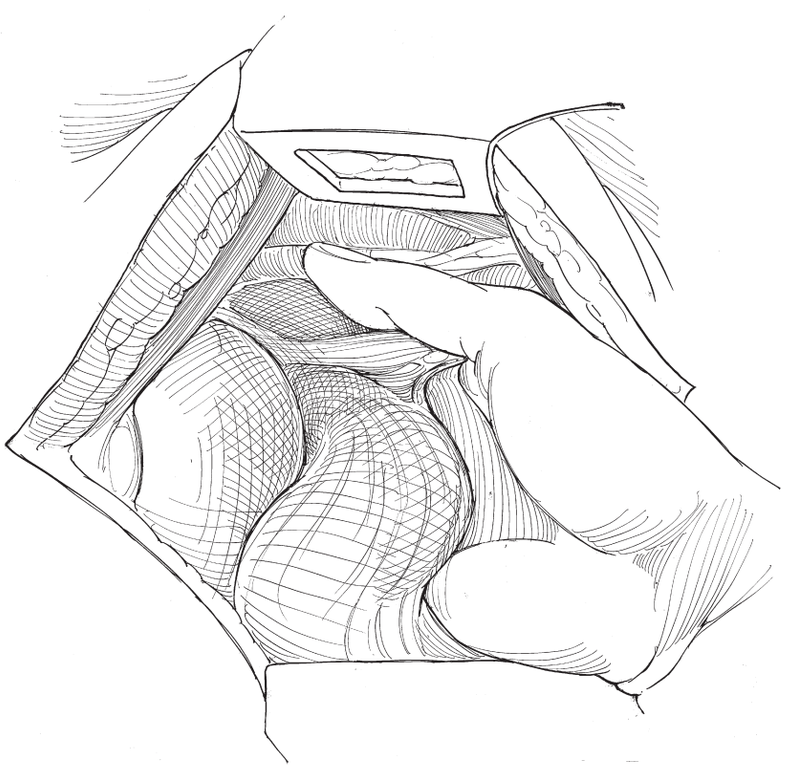

FIGURE 81-6.

anterior to the hypogastric plexus overlying the sacral promontory.

During the course of this posterior dissection the middle rectal artery will be identified arising from the internal iliac artery (Fig. 81-7). This must be ligated and divided. Particular care must be taken to ensure the superior gluteal artery that arises from the internal iliac artery and traverses posteriorly out of the pelvis is preserved.

Attention is now turned to the perineal dissection. This should include a new set of instruments that are kept distinct from the instruments used for the anterior based portions of the case already described. This includes changing sterile gown and gloves prior to anyone going from the perineal dissection to the anterior/abdominal dissection. A working understanding of the peri-rectal anatomy is important to ensure dissection in the proper planes (Fig. 81-8).

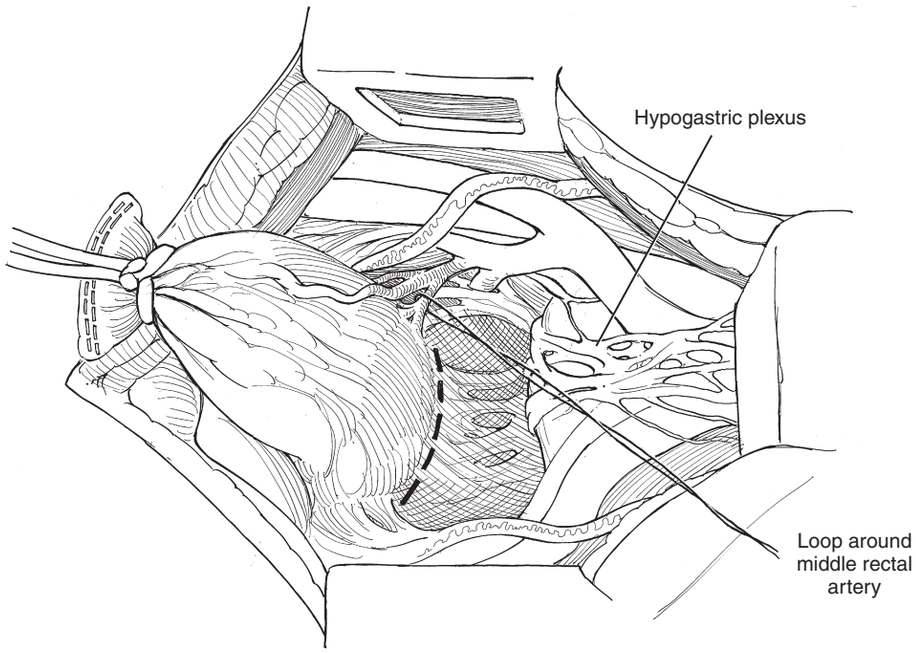

FIGURE 81-7.

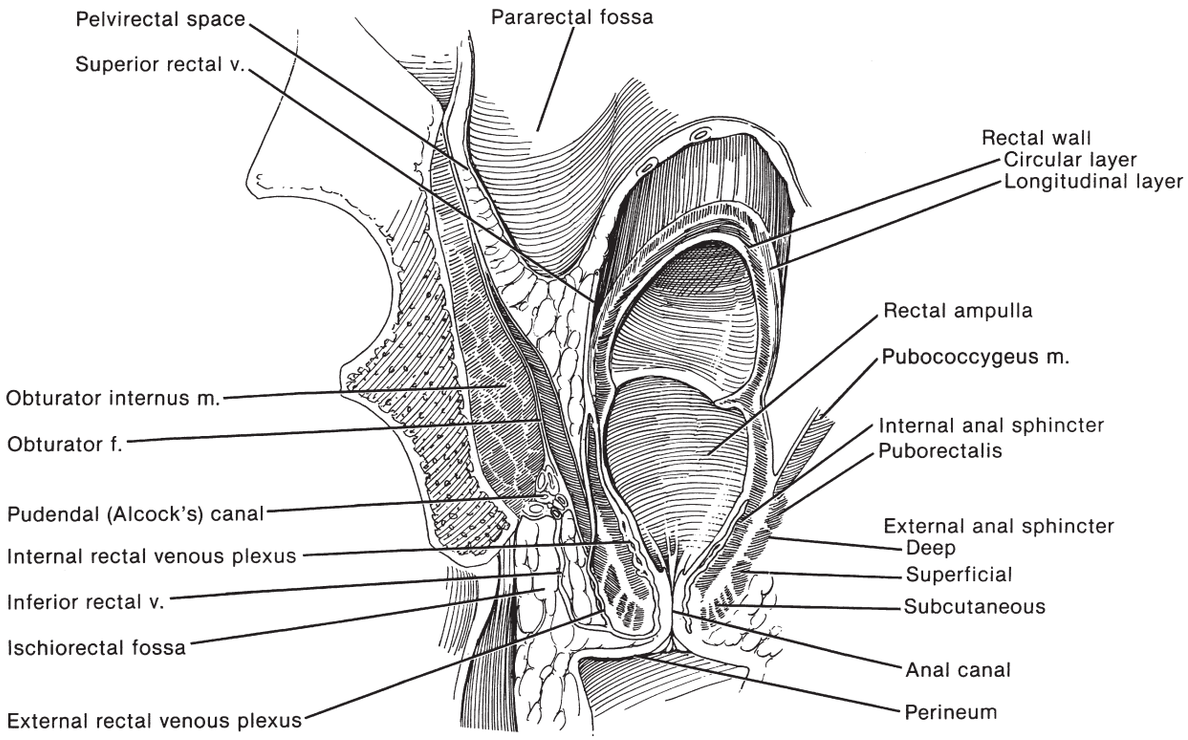

FIGURE 81-8.

Make an elliptical incision around the anus. The fat overlying the ischiorectal fossa is incised and this space is developed. The posterior central tendon is divided and the pubococcygeous portion of the levator ani is exposed. The pubococcygeous and iliococcygeous muscles are divided posterior and lateral to the rectum. This is continued until the perineal dissection is made contiguous with the abdominal dissection. This can be facilitated by a surgeon passing a hand posterior and/or lateral to the rectum from the abdominal side of the dissection. The plan of dissection is also developed anterior to the rectum with the levator ani divided lateral to the prostate and at the level of the urethral sphincter complex where the urethra has been divided previously at the prostatic apex. This allows removal of the specimen en-bloc (Fig. 81-9).

At this point attention can be turned to creation of an urinary diversion. Factors to consider in placement of the urinary conduit stoma include whether a colon or ileal conduit will be utilized. A colon conduit has the advantage of eliminating the need for a bowel anastomosis and associated risk of anastomotic leak. Conversely, the sigmoid colon may have been heavily irradiated depending on the neo-adjuvant therapy the patient received and the colon mesentery and/or amount of colon that had to be resected may not allow sufficient length to create a satisfactory stoma. A further consideration has to do with the method of filling the pelvic defect once the specimen has been removed. If a rectus myocutaneous flap is utilized, then of necessity both stomas will have to be either to the left or right of the midline (typically they will be on the left, and this makes the use of a colon conduit urinary diversion more attractive in that particular scenario). On the other hand, if the pelvic defect is to be managed with a gracilis myocutaneous flap, omental flap, or absorbable mesh, then it is preferable to have the urinary diversion stoma in the right lower quadrant and the colostomy in the left. This is much easier for the patient to manage than if both stoma appliances have to be placed on the same side of the abdomen. These details, and appropriate contingency plans, should be worked out in advance.

Following completion of the urinary diversion, the distal colon is brought out through a separate stoma site. The defect in the pelvis must now be filled. One option is a myocutaneous flap, typically a rectus abdominus or gracilis based flap. This is usually accomplished in collaboration with a plastic surgeon. An alternative is to fill the pelvis with an omental flap. This is faster and easier to accomplish than a myocutaneous flap and can often provide healthy viable tissue to fill this space but typically won't fill the defect as well as a myocutaneous flap. If omentum is not available and a myocutaneous flap is not feasible, an alternative is to use absorbable mesh to fashion a sling or hammock like support across the lower pelvis. Once the pelvic space has been filled, drains are brought out through separate incisions. The abdominal and perineal incisions are closed. Once the wounds are all closed, the colostomy stoma is matured, dressings are applied and the patient is awoken from anesthesia.

Total Pelvic Exenteration in the Female Patient

The positioning of the patient for a total pelvic exenteration is similar in both men and women. The procedure overall is very similar to that in the male, though there are several specific differences. In the male, the spermatic chord is preserved and dissection proceeds medial to these structures. In the female patient, the infundibulopelvic ligament is identified, ligated and divided prior to beginning dissection of the ureter into the pelvis (Fig. 80-6). In addition, the round ligament will be the structure that is divided once the bladder has been mobilized off of the pelvic side wall rather than the Vas Deferens.

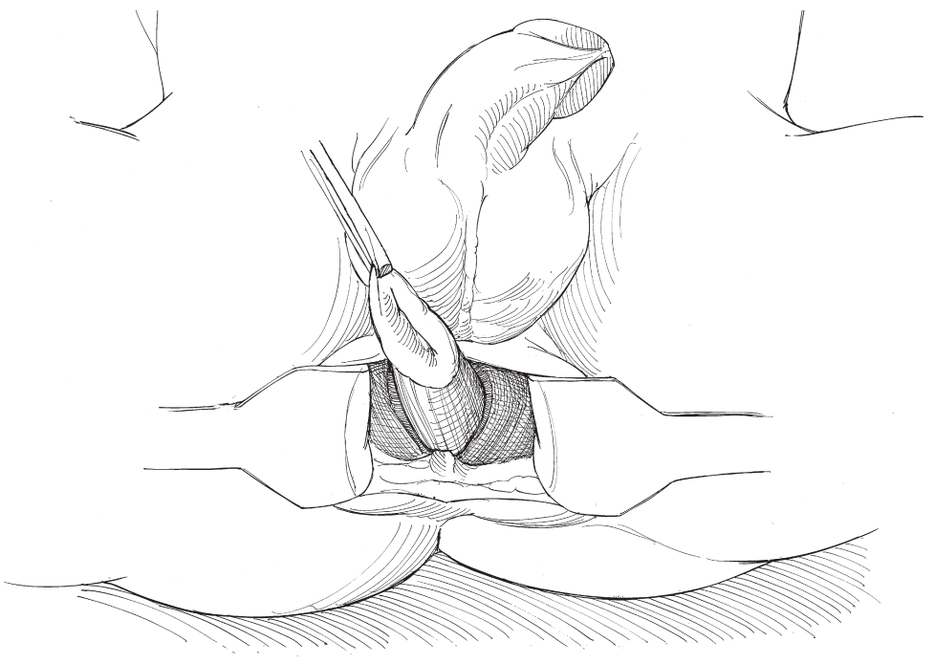

FIGURE 81-9.

As is the case for anterior exenteration in the female patient done for bladder cancer, it will be necessary to identify and divide the ueterosacral ligaments as the plane is developed lateral to the uterus (Fig. 81-10). The cardinal ligaments must also be identified, ligated, and divided (Fig. 81-11). The endopelvic fascia is incised as is the case in the male patient and the small dorsal venous complex identified, ligated, and divided. The vagina is now divided (Fig. 81-12). The amount of vagina that is spared depends to a large degree on the size and location of the primary malignancy. The remainder of the operation is similar to that in the male.

Post-operative problems

Lymphocele: The potential complications after pelvic exenteration include hemorrhage and lymphocele formation. Lymphocele formation should be substantially less frequent than after procedures such as open retropubic prostatectomy in which the peritoneum is not entered. Small incidental lymphoceles noted during routine post-operative follow up can generally be observed. Symptomatic lymphoceles and/or collections that may be infected should be drained. Infected lymphoceles should be percutaneously drained and will usually resolve. For un-infected

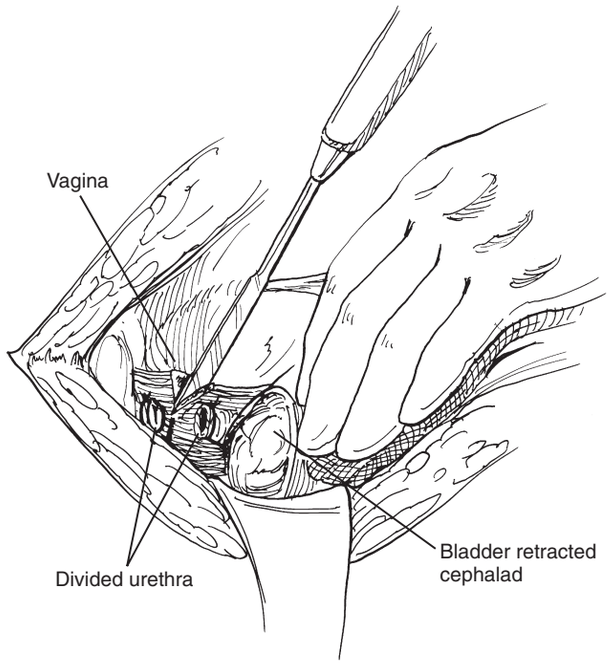

FIGURE 81-12.

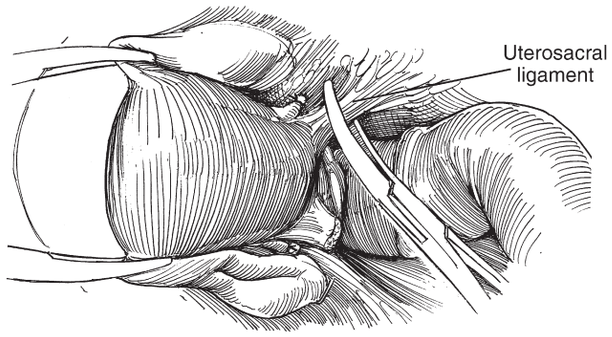

FIGURE 81-10.

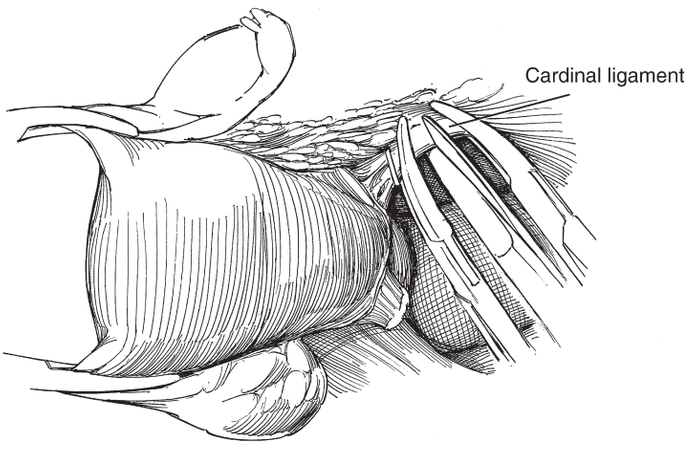

FIGURE 81-11.

but symptomatic lymphoceles the options for management include percutaneous drainage, laparoscopic drainage, or rarely open drainage.

Anastomotic leak can occur at the ureteroenteric anastomosis. This is usually managed by pelvic drainage, maintaining a stent if one is in place, and possibly antegrade percutaneous nephrostomy tube placement with or without antegrade stent placement. Additional potential problems include stricture formation at the ureteroenteric anastomosis, hernia formation at the ventral incision, or parastomal hernia around either stoma.

If a myocutaneous flap has been used to fill the pelvic defect particular attention should be paid that the flap remains viable.

Nerve injury: Care should be taken to avoid injury to the obturator nerve or genitofemoral nerve. Division of the obturator nerve can cause problems with adduction of the thigh. This can often be rehabilitated with physical therapy as other muscle groups can compensate for the loss of the obturator nerve function. Care should be taken that any self retaining retractor blades used are not placed too deep in the pelvis to avoid compression injury to the femoral nerve.

Thrombus Formation: There is a risk of thrombus formation as with any pelvic operation, especially when being performed for malignancy. Use of sequential compression devices, started prior to initiating anesthesia and early post-operative ambulation are some of the interventions that can help alleviate thrombus formation. Consideration can also be given to routine post-operative anticoagulation with low molecular weight heparin.

This page intentionally left blank

Chapter 82

Excision of Vesical Diverticulum

HARRIETTE M. SCARPERO AND DENA L. WALSH

INDICATIONS

Bladder diverticula are a herniation of bladder mucosa through the muscular wall. Due to the lack of muscular tissue located on the diverticula, they usually empty poorly or incompletely, creating urinary stasis and risk for infection. Diverticula also carry a risk for malignancy.

Bladder diverticula are classified as either congenital or acquired. Congenital diverticula are usually solitary and located lateral and posterior to the ureteral orifice. Acquired diverticula most commonly occur in patients with bladder outlet obstruction, neurogenic voiding dysfunction, or impaired compliance and are usually associated with significant bladder trabeculation.

Bladder diverticula are often asymptomatic and found on studies investigating hematuria, infection, or lower urinary tract symptoms. When a bladder diverticulum is suspected, voiding cystourethrography (VCUG) provides information about location, size, reflux, and emptying of the diverticulum upon voiding. Cystoscopy should be used to thoroughly evaluate the bladder and diverticula for mucosal abnormalities to rule out malignancy. In addition to a cystoscopy and VCUG, upper tract imaging with intravenous pyelography, ultrasound, or computed tomography should be performed to rule out hydronephrosis or ureteral obstruction.

Urodynamics should be strongly considered before any surgical therapy for bladder diverticula to identify any underlying functional abnormality. It can provide crucial information on the presence of bladder outlet obstruction and bladder contractility. The addition of fluoroscopy (video-urodynamics) provides information about the ability to empty the diverticulum.

The urologic abnormality causing the diverticula should be treated either before or during surgical treatment of the diverticula. In some cases, treatment of the urologic abnormality results in symptom resolution and no further treatment is needed for the diverticula. Asymptomatic diverticula that empty on urodynamics may not require excision but should be monitored over time.

Surgical management of the bladder diverticula is only necessary when the patient is symptomatic or has a recurrent infection, stones, urinary obstruction, vesicoureteral reflux, or malignant disease. Asymptomatic patients may be followed conservatively with urine cultures, urine cytology, and endoscopic surveillance.

In all patients, begin with a clean urinalysis and urine culture before any surgical procedure. All patients should receive culture-appropriate antibiotics. Patients should also have appropriate preoperative clearance before surgery to minimize surgical risk.

TECHNIQUE

Combined intravesical and extravesical diverticular excision: Ideal for larger diverticula with associated inflammation or fibrosis:

1. Place the patient in the supine position with the buttocks over the kidney rest. Prep and drape the penis/urethra into the field. Insert a 22-French balloon catheter and partially fill the bladder. Cover the penis/urethra and catheter with a towel.
2. Make a lower midline extraperitoneal incision (Fig. 82-1A).
3. Incise the linea alba and enter the abdomen between the recti and separate them. Divide the transversalis fascia with scissors and move laterally. Push the peritoneal fold upward, revealing the perivesical fat. Place a self-retaining retractor, such as a Bookwalter, for optimal exposure (see Fig. 82-1B). Through the Foley, fill the bladder to capacity with sterile water. Develop the retropubic space.
4. Place two stay sutures in the detrusor well above the pubic symphysis. Ensure that there is adequate suction in hand. Incise the detrusor muscle in a vertical fashion between the stay sutures using electrocautery. Use the suction to remove excess irrigation.
5. Adjust retractors as necessary to reveal the diverticulum and ureteral orifices. Place ureteral catheters to aid in avoiding ureteral injury.
6. Locate and incise the mucosa at the diverticular neck circumferentially with electrocautery. Place a finger in

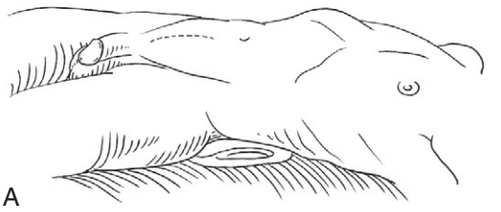

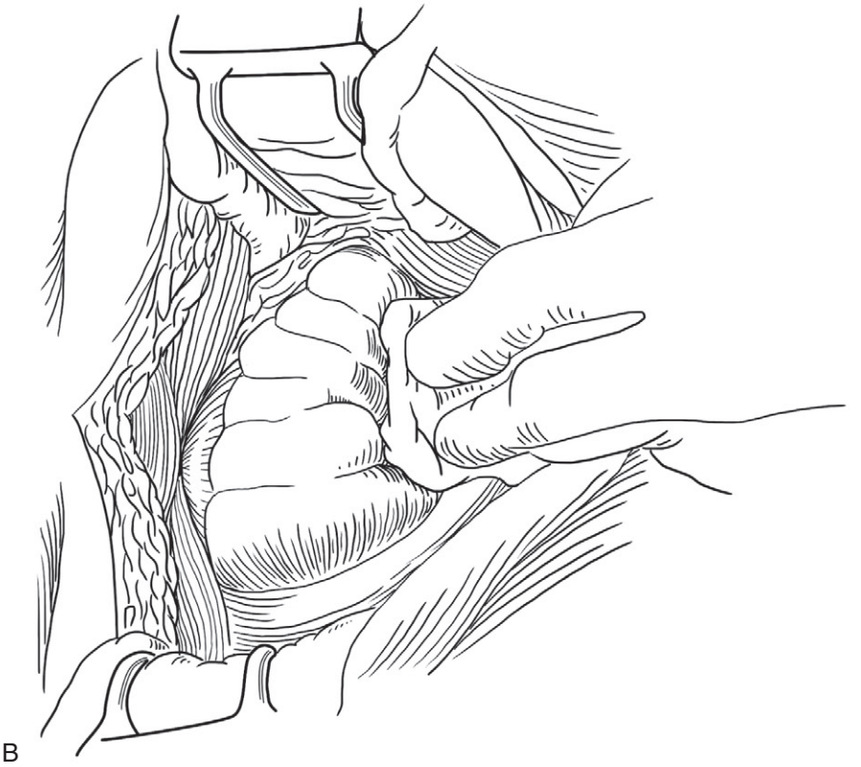

FIGURE 82-1.

the diverticulum (Fig. 82-2A). Using the finger for traction, bring the diverticular neck outside the bladder so the diverticulum can be palpated anteriorly though the wound. Dissect the overlying tissue to expose the anterior portion of the diverticular neck. Dissect the perivesical tissue away from the bladder wall down to the palpable fingertip (see Fig. 82-2B). Incise the anterior portion of the diverticular neck around the finger (Figs. 82-3 and 82-4).

7. Use fine Allis clamps to grasp the urothelium edges and progressively dissect the neck of the diverticulum circumferentially from the bladder (Fig. 82-5).
8. Once the diverticular neck has been freed from the mucosa, mobilize and dissect the walls of the diverticulum from the capsule until it can be completely removed (Fig. 82-6). These steps are carried out carefully in order to make identification of the mucosa and detrusor layers easier at the time of closure of the bladder defect. Where the diverticulum is densely adherent to the capsule portions may be left in situ. There is no need to leave a drain in the diverticular cavity.
9. Close the bladder wall at the diverticular mouth in two layers, ensuring closure of the muscular/serosal layer to prevent a recurrent diverticulum (Fig. 82-7).
10. Place a 24-French Malecot catheter or a large Foley in the bladder with a cystotomy and through the abdominal wall. Suture in place at the bladder with a purse-string suture and with a nonabsorbable suture at the skin (Fig. 82-8).
11. Close the bladder in two layers using 3-0 Vicryl on the mucosa and 2-0 Vicryl on the detrusor layer. The mucosal layer is closed first with a running suture. Close the detrusor/serosals layer, also using a running suture. Test the closure by filling the bladder with sterile water.
12. Place a Penrose or closed suction drain near the bladder closure, exiting next to the wound. Stitch in place to the skin with nonabsorbable suture to prevent inadvertent removal.

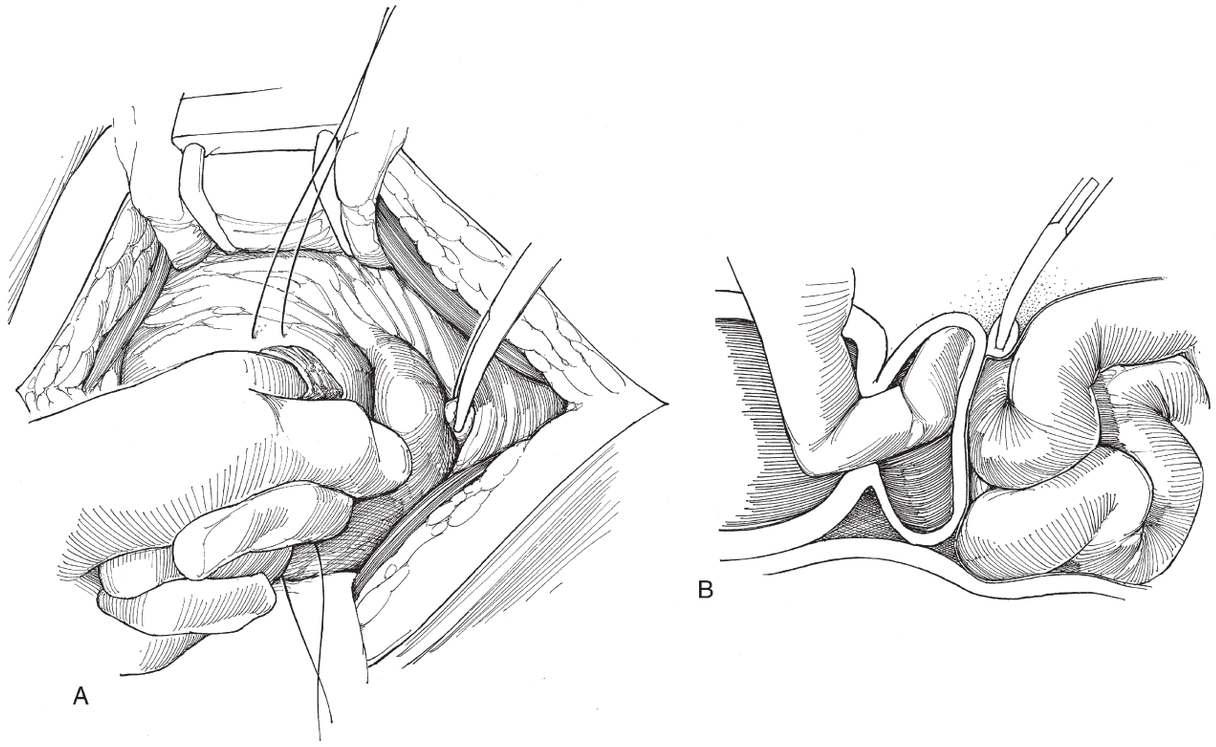

FIGURE 82-2.

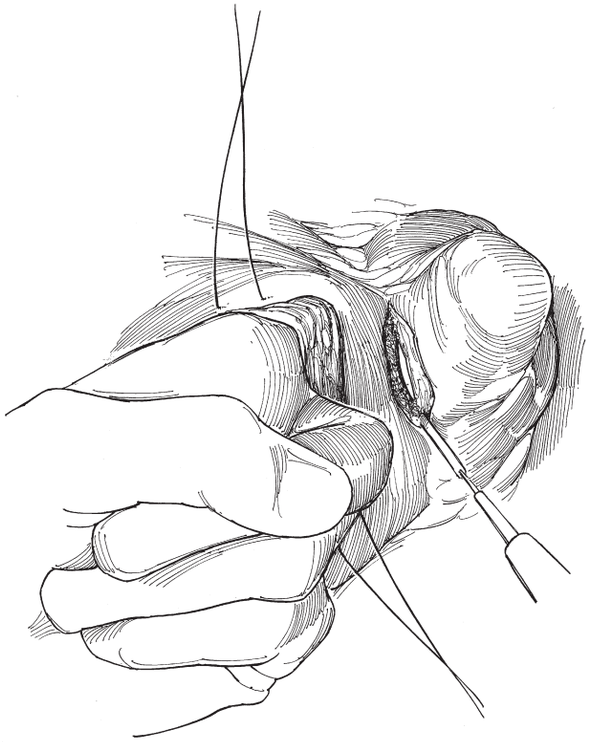

FIGURE 82-3.

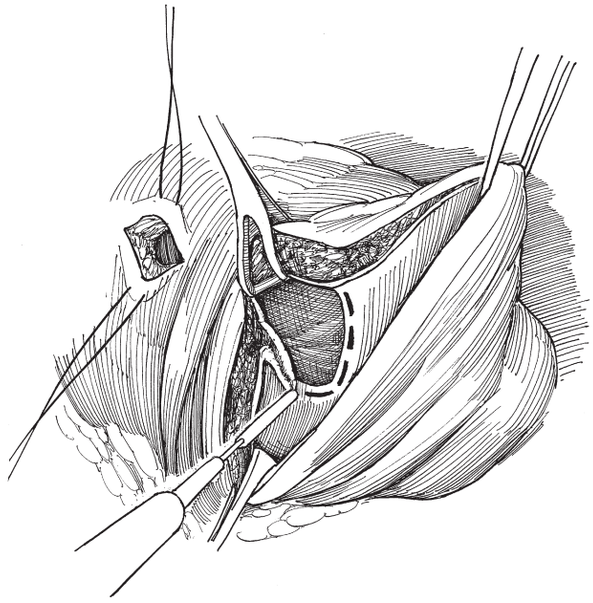

FIGURE 82-4.

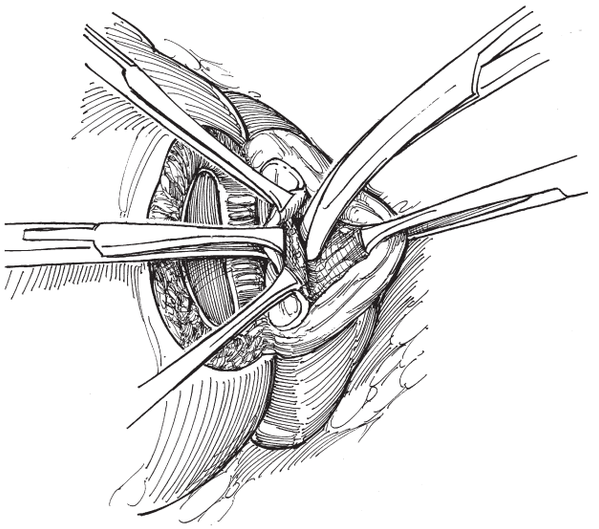

FIGURE 82-5

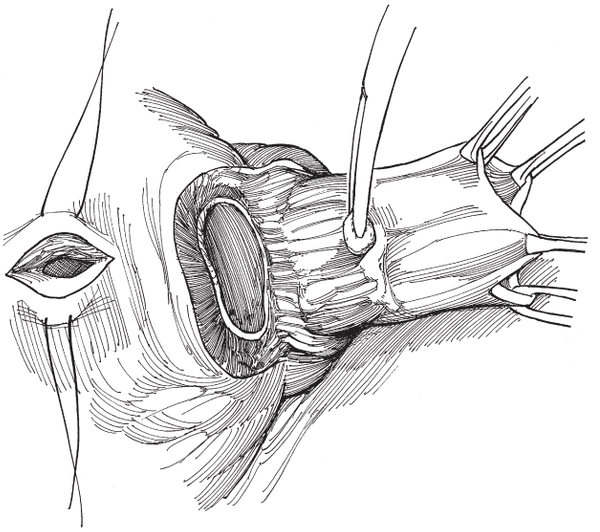

FIGURE 82-6

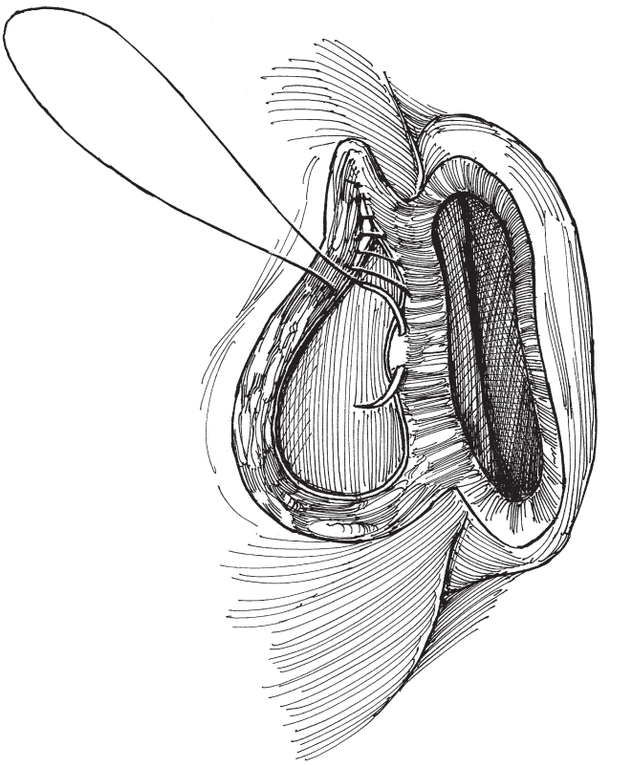

FIGURE 82-7

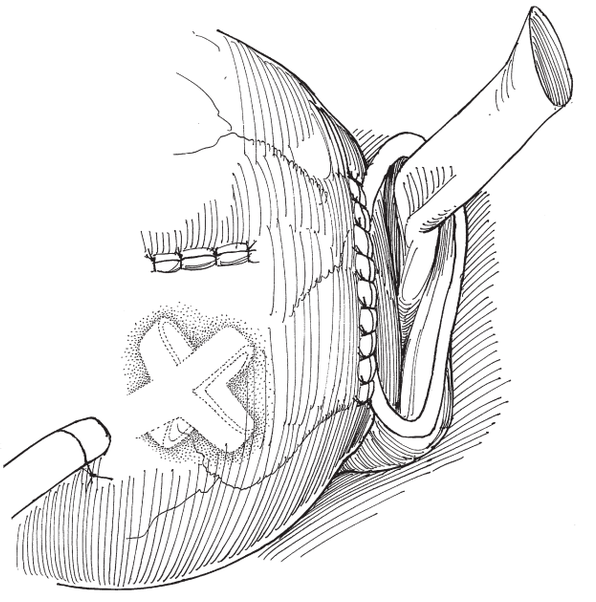

FIGURE 82-8

13. Leave a catheter for drainage for 8 to 10 days. Obtain a cystogram before catheter removal.
14. Close the fascia with zero polydioxanone suture (PDS). Skin closure is by surgeon preference.

Intravesical technique. Ideal for smaller diverticula:

1. Place the patient in the supine position with the buttocks over the kidney rest. Prep and drape the penis/urethra into the field. Insert a 22-French balloon catheter and partially fill the bladder. Cover the penis/urethra and catheter with a towel.
2. Make a lower midline extraperitoneal incision (see Fig. 82-1).
3. Incise the linea alba and enter the abdomen between the recti and separate them. Divide the transversalis fascia with scissors and move laterally. Push the peritoneal fold upward, revealing the perivesical fat. Place a self-retaining retractor such as a Bookwalter, for optimal exposure. Through the Foley, fill the bladder to capacity with sterile water. Develop the retropubic space.
4. Place two stay sutures in the detrusor well above the pubic symphysis. Ensure that there is adequate suction in hand. Incise the detrusor muscle in a vertical fashion

between the stay sutures using electrocautery. Use the suction to remove excess irrigation.

5. Place a retractor to visualize the divertiuclum. Pass a curved or Allis clamp through the neck to the base of the divertiuclum, which is grasped and everted back into the bladder (Fig. 82-9). Incise the mucosa at the diverticular neck circumferentially. Remove the divertiuclum.
   a. If the diverticulum cannot be everted into the bladder, a submucosal excision may be performed.
   b. Using electrocautery, incise the mucosa circumferentially around the divertiuclum neck. Place traction on the neck with an Allis clamp, dissecting a plane between the diverticula and the surrounding capsule. Continue to mobilize the diverticulum from the capsule until the diverticulum can be delivered into the bladder lumen. Once the diverticulum has been completely freed from the capsule, remove it from the bladder.
   c. If the diverticulum is located near the trigone, which is often the case, insertion of ureteral catheters can be helpful to avoid damage to the ureters (Fig. 82-10).
6. Close the bladder wall at the divertiuclum defect in two layers, ensuring closure of the muscular/serosal layer to prevent recurrent diverticulum.
7. Place a 24-French Malecot catheter or a large Foley in the bladder with a small cystotomy and through the abdominal wall. Suture in place at the bladder with a pursestring suture and with a nonabsorbable suture at the skin.
8. Close the bladder in two layers using 3-0 Vicryl on the mucosa and 2-0 Vicryl on the detrusor layer. The mucosal layer is closed first with a running suture. Close the detrusor/serosals layer also using a running suture (Fig. 82-11). Test the closure by filling the bladder with sterile water.
9. Place a Penrose or closed suction drain near the bladder closure, exiting next to the wound. Stitch in place to the skin with nonabsorbable suture to prevent inadvertent removal.
10. Leave a catheter for drainage for 8 to 10 days. Obtain a cysto gram before catheter removal.
11. Close the fascia with zero PDS. Surgeon preference for skin closure.

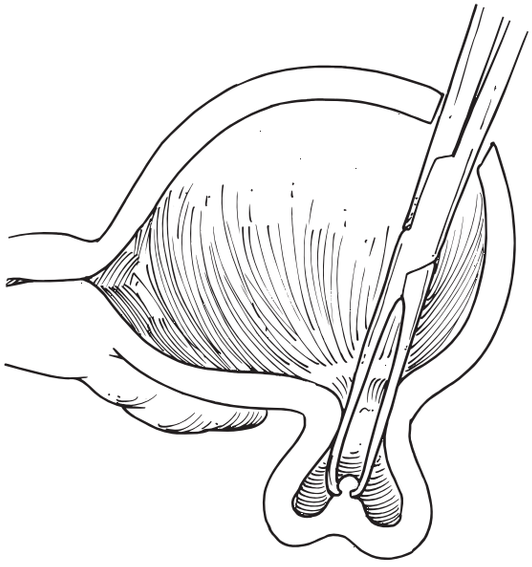

FIGURE 82-9

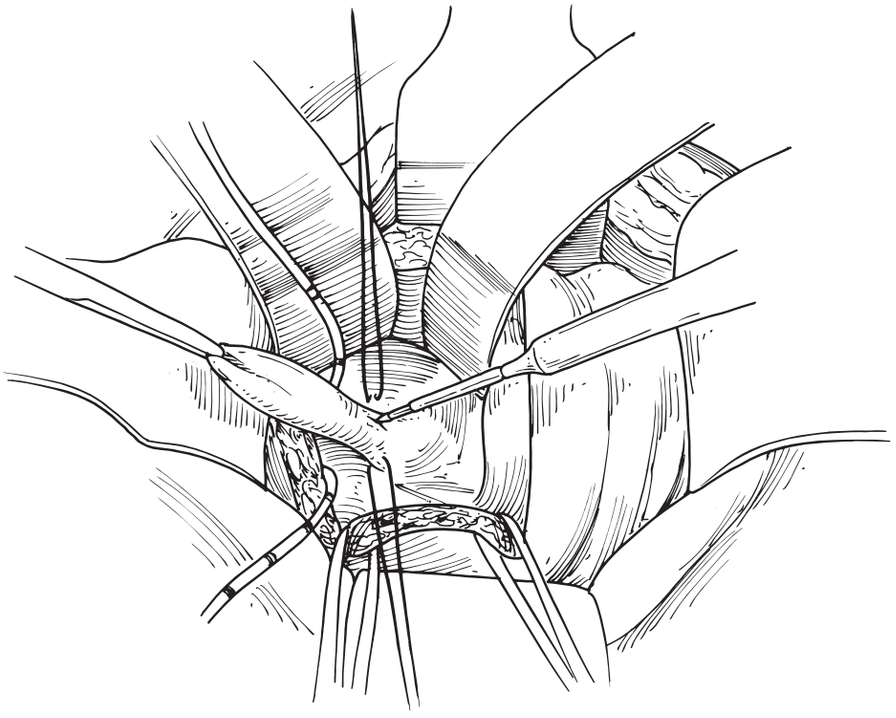

FIGURE 82-10

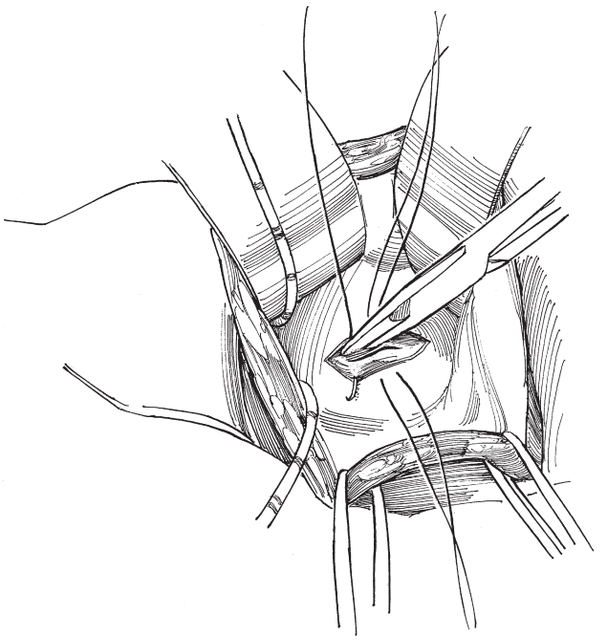

FIGURE 82-11

Laparoscopic/Robotic-Assisted Bladder Diverticulectomy

1. The patient is placed in supine position with the patient slightly flexed. Perform cystoscopy. Ureteral catheter(s) or stent(s) can be placed if the diverticulum is in proximity to the ureters. Using fluoroscopy and a ureteral catheter as a guide, place a 14-French Foley into the diverticulum and inflate the balloon with 30 mL of saline. Place a 10-French Foley into the bladder and secure in place.
2. Place ports: Pneumoperitoneum is obtained either by Veress needle or open Hasson access. A 10-mm trocar is placed supraumbilically for the laparoscope, a 10-mm trocar is placed at the lateral border of the rectus two fingerbreadths below the umbilicus on each side, and a 5-mm port is placed on each side two fingerbreadths below and lateral to the 10-mm port on each side. For the robotic-assisted technique, a standard arrangement of transperitoneal trocars for pelvic surgery is performed.
3. Place the patient in exaggerated Trendelenburg. Occlude the diverticulum with gentle traction on the 14-French Foley and distend the diverticulum with normal saline.
4. Incise the peritoneal peritoneum over the diverticulum transversely. Dissect a plane between the peritoneum and the perivesical fat. Identify the ipsilateral ureter and dissect away from the diverticulum.
5. Dissect the diverticulum down to the diverticular neck. Transect the diverticulum directly at its neck. Deflate the Foley balloon and remove the 14-French catheter. Place the diverticulum in a retrieval bag and remove the diverticulum through a trocar site.
6. Close the mouth of the diverticulum in two layers with 3-0 absorbable running suture.
7. Remove the ureteral catheter. Place an 18-French Foley catheter into the bladder and distend to test the anastomosis.
8. Place a closed suction drain through the 5-mm trocar site and secure into place.
9. Leave a catheter for drainage for 8 to 10 days. Obtain a cystogram before catheter removal.
10. Close the fascia and skin per surgeon preference.

Suggested Readings

Myer EG, Wagner JR. (2007). Robotic assisted laparoscopic bladder diverticulectomy. J Urol 178:2406.

Nadler RB, Pearle MS, McDougall EM, et al. (1995). Laparoscopic extraperitoneal bladder diverticulectomy: initial experience. Urology 45:524.

Parra RO, Jones JP, Andrus CH, et al. (1992). Laparoscopic diverticulectomy: preliminary report of a new approach for the treatment of bladder diverticulum. J Urol 148:869.

Wein AJ. (2007). Campbell-Walsh Urology, 9th ed. Philadelphia: Saunders.

Chapter 83

Cystolithotomy

HARRIETTE M. SCARPERO AND DENA L. WALSH

INDICATIONS

Bladder stones account for 5% of all urinary calculi and the prevalence varies among different demographic areas. In the United States, calcium oxalate stones are the majority of bladder calculi, whereas in Europe, uric acid and urate stones predominate. In Africa and the Middle East, dehydration, diarrhea, infection, and nutritional deficiencies increase the incidence of bladder stone formation.

Most bladder stones are asymptomatic and are found incidentally. In adults, bladder stones rarely occur spontaneously; usually a predisposing factor promotes stone formation. Bladder outlet obstruction, neurogenic voiding dysfunction, infection, and foreign bodies are all risk factors for bladder calculi. In children, uncorrected anatomic abnormalities, posterior urethral valves, voiding dysfunction, and vesicoureteral reflux are predisposing factors for bladder calculi formation.

Patients with a bladder augmentation or an intestinal neobladder are also predisposed to stone formation due to mucus production, urinary stasis, and instrumentation. Ileum and colon tissues are also colonized by urease-producing organisms, producing an alkaline pH that promotes stone formation.

Plain radiographs or an intravenous pyelogram can be used to diagnose a bladder stone, but a significant number of stones can be missed due to either radiolucency of the stone or bowel gas. Computed tomography is superior to plain radiographs in detection of calculi in the setting of lower tract reconstruction. Despite radiologic advances, cystoscopy is still considered the gold standard for diagnosis of bladder calculi and aids in surgical planning by identifying either prostatic enlargement or urethral abnormalities.

Urodynamics are indicated in all patients with neurologic disease, lower urinary tract symptoms (LUTS) suggestive of bladder outlet obstruction, or LUTS refractory to medications, and in those with incontinence. The goal in performing urodynamics is to answer specific questions related to the patient's storage and voiding function, which will ultimately guide surgical decisions in the treatment of the bladder stone as well as the treatment of the predisposing factor.

Despite the tremendous advancement in endoscopic technology, cystolithotomy is indicated for patients with a large stone burden (i.e., greater than 6 cm), hard stones, abnormal anatomy, failure of an endoscopic approach, and concomitant open prostatectomy or diverticulectomy. Patient comorbidities, previous surgery, and available instrumentation also guide treatment decisions.

In all patients, begin with a clean urinalysis and urine culture before undertaking any surgical procedure. All patients should receive appropriate antibiotics according to culture results.

TECHNIQUE

1. Place the patient in the supine position with the buttocks over the kidney rest. Prep and drape the penis/urethra into the field. Insert a 22-French balloon catheter and partially fill the bladder. Cover the penis/urethra and catheter with a towel.
2. Make a lower midline extraperitoneal incision (see Fig. 62-1).
3. Incise the linea alba and enter the abdomen between the recti and separate them (Fig. 83-1). Divide the transversalis fascia with scissors and move laterally. Push the peritoneal fold upward, revealing the perivesical fat. Through the Foley catheter, fill the bladder to capacity with sterile water. Develop the retropubic space and place a retractor if needed.
4. Place two stay sutures in the detrusor well above the pubic symphysis. Ensure that there is adequate suction in hand. Incise the detrusor muscle in a vertical fashion between the stay sutures using electrocautery (Fig. 83-2). Open the bladder enough to visualize the stones. The entire bladder need not be incised. Use the suction to remove excess irrigation.
5. Using the ring forceps, grasp the stone and remove it from the bladder (Fig. 83-3).
6. When a large incision has been made, place a suprapubic tube through a small cystotomy in the bladder and through the abdominal wall. Suture in place at the bladder with a pursestring suture and with a nonabsorbable

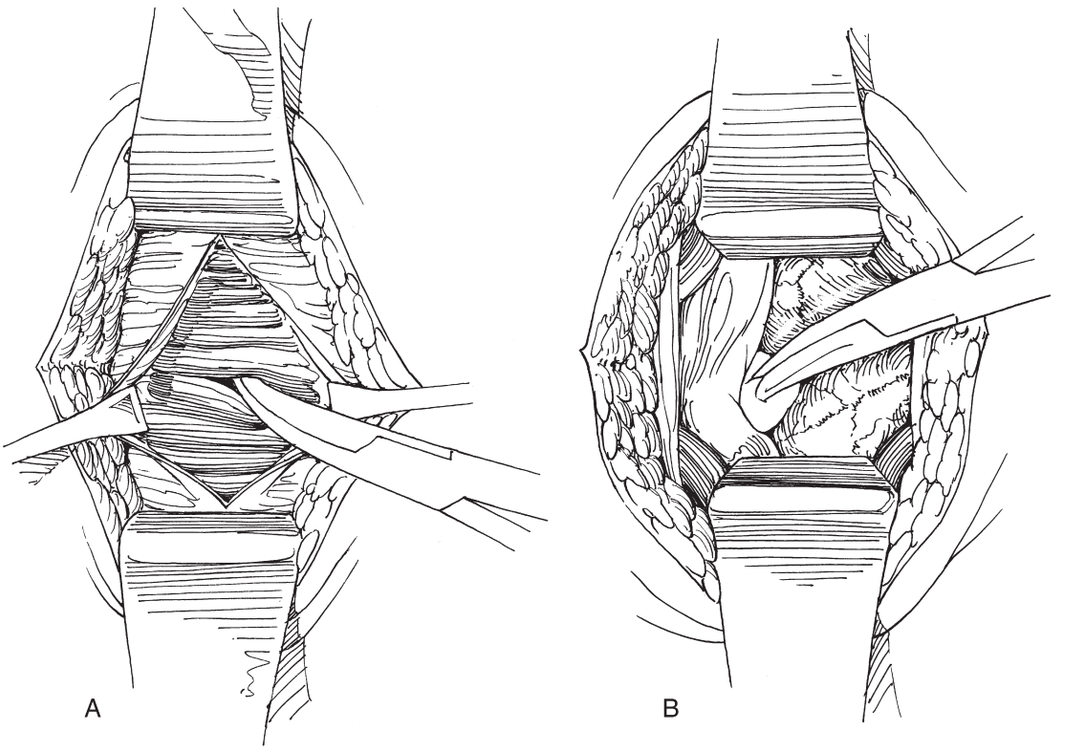

FIGURE 83-1.

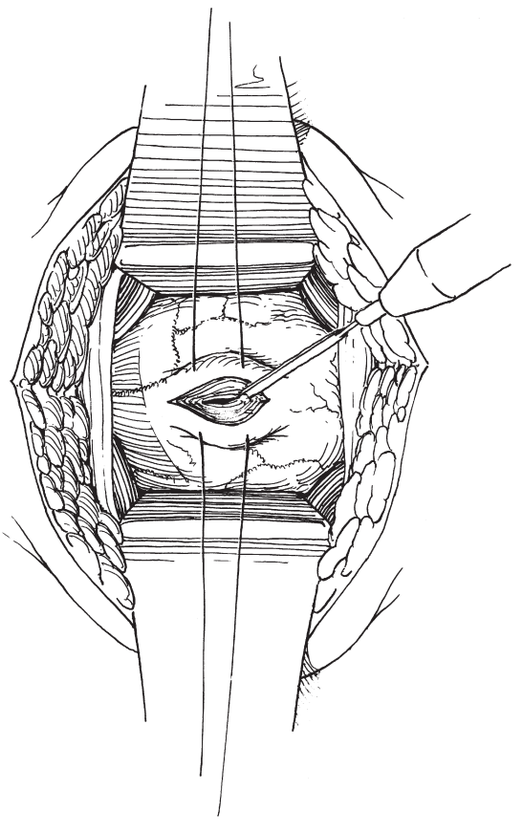

FIGURE 83-2.

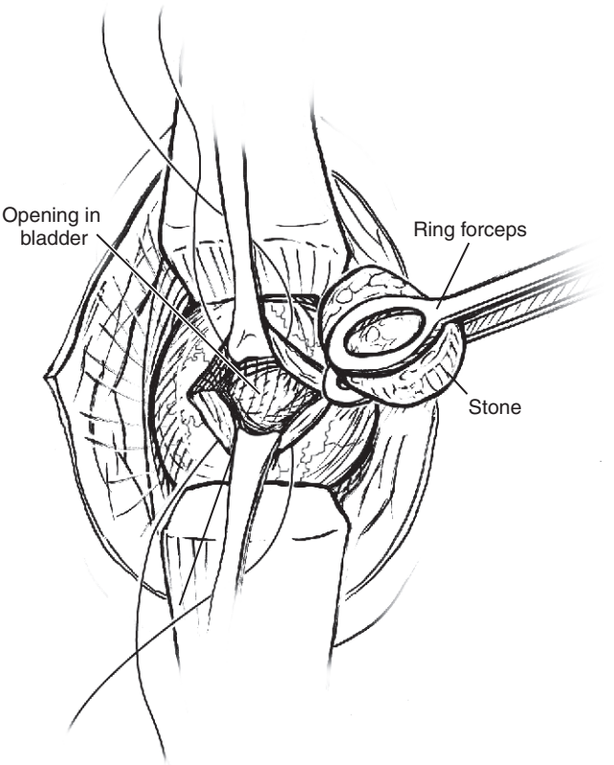

FIGURE 83-3.

suture at the skin. If a smaller incision has been made and adequate drainage can be maintained through a large Foley catheter, it is possible to forego the suprapubic tube at the discretion of the surgeon.

7. Close the bladder in two layers using 3-0 Vicryl on the mucosa and 2-0 Vicryl on the detrusor layer. The mucosal layer is closed first with a running suture. Close the detrusor/serosals layer also using a running suture. Test the closure by filling the bladder with sterile water.
8. Place a Penrose or closed suction drain near the bladder closure, exiting next to the wound. Stitch in place to the skin with nonabsorbable suture to prevent inadvertent removal.
9. Leave the catheter for drainage for 8 to 10 days. Obtain a cystogram before catheter removal.
10. Close the fascia with zero polydioxanone suture. Skin closure is by surgeon preference.

This page intentionally left blank

Chapter 84

Laparoscopic/Robotic Radical Cystectomy

ERIK P. CASTLE, MICHAEL E.WOODS, RAJU THOMAS, AND RODNEY DAVIS

PATIENT AND PREOPERATIVE PREPARATION

Patients being considered for laparoscopic radical cystectomy (LRC) or robot-assisted radical cystectomy (RARC) should undergo complete metastatic and staging evaluation. Particular attention needs to be paid to an abdominal and pelvic computed tomography (CT) or magnetic resonance imaging (MRI) to evaluate for lymphadenopathy, local extension of tumor, and anatomic abnormalities. Patients with extravesical disease or lymph node involvement should be considered for neoadjuvant chemotherapy. Neoadjuvant chemotherapy may also be considered for any patient with muscle invasive disease with or without clinical evidence of regional or systemic extension of disease. Currently it is the not the practice of the authors to perform any pre-operative bowel preparation. If small intestine is to be used for an ileal conduit or ileal neobladder then a bowel preparation is not needed. Simply making the patients "NPO" or nothing by mouth after midnight before surgery is all that is needed. While the current literature supports that even for elective colorectal surgery mechanical bowel preparation is not necessary, many urologists still use some version of a mechanical bowel preparation for urinary diversions that employ colon. Most would recommend the use of enemas especially in the pre-operative holding area if a patient has had pelvic radiation to eliminate most fecal contents from the rectum and sigmoid colon. All patients should be strategically marked immediately prior to surgery for the potential urostomy site. All patients are educated preoperatively regarding care and maintenance of a urostomy or neobladder based on choice of urinary diversion.

Preoperative Preparation/Checklist

- Laboratory
  - Basic metabolic panel
  - Liver transaminases
  - Complete blood count
- Radiologic imaging
  - Chest radiograph
  - CT or MRI of abdomen and pelvis
- Additional
  - Electrocardiogram
  - Anesthesia and/or cardiac clearance

Anesthesia and patient positioning: LRC/RARC is performed under general endotracheal anesthesia. Broad-spectrum antibiotics covering gram-negative, gram-positive, and anaerobic organisms are administered within 60 minutes of making the operating room. Sequential compression stockings are placed on the lower extremities. Pre-operative deep venous thrombosis prophylaxis should be employed per institutional practice (standard heparin or low-molecular weight heparin). A nasogastric tube is placed for decompression of the stomach. An arterial line may be inserted in order to monitor blood gases for developing potential acidosis and hypercapnia. The Foley catheter is placed after the patient is prepped and positioned.

The patient is placed in low lithotomy position with arms tucked to the side. Care must be taken to ensure the patient's hands and elbows are adequately padded as they often lie between the patient's thigh and attachment of the stirrup. This will allow access to the abdomen and perineum. The patient will be placed in extreme/maximal Trendelenburg during the case and this must be tested prior to prepping and draping the patient. A chest strap may be employed; however, patients rarely move on the bed with the arms tucked and the legs in low lithomy stirrups. Shoulder harnesses are not needed and may actually cause impingement complications.

Positioning of operating room equipment and personnel: If a robot assisted approach is used, then a daVinci 3 or 4 arm system may be used (the additional arm is beneficial by providing additional bowel retraction during lymphadenectomy). A 0 and 30-degree lens is required. The required robotic instruments are as follows: monopolar robotic scissors, Maryland bipolar, cadieré forceps, and two needle drivers. In addition, an endovascular GIA stapler, Hem-o-lok clips (Weck Closure Systems, Research Triangle Park NC), a suction-irrigator, and an atraumatic grasper are needed. The daVinci system is docked between the patients legs with the robotic arms oriented in a cephalad direction. The primary assistant operates from the patient's right. The robotic fourth arm is positioned on the patient's right side if an

intracorporeal diversion is to be performed. If an extracorporeal diversion is to be performed then it can be positioned based on surgeon preference. If a three arm system is being used, then a second assistant must be on the left side in order to assist with retraction of the bowel and other pelvic contents. It is strongly encouraged to perform this surgery with a four arm system. The control tower for the daVinci system is placed just left of the patient's left leg. Adjacent to the control tower is the instrument table. This leaves ample room for the scrub nurse and a second assisted, if needed, on the left side of the patient. A viewing monitor is located on top of the control tower as well as one to the opposite side of the first assistant (it is preferable if this second monitor is on a ceiling boom). The surgeon console may be placed according to surgeon preference.

If a traditional laparoscopic approach is used, then a 0 and 30-degree lens is used. A laparoscopic harmonic scalpel and/or bipolar can be used for dissection. In addition, an endovascular GIA stapler, Hem-o-lok clips (Weck Closure Systems, Research Triangle Park, NC), a suction irrigator, and an atraumatic grasper are needed. A camera can be held by an assistant or by a bedside robotic holder or camera arm. The right-handed surgeon will do most of his/her operating from the left side of the table. The assistant will be on the right side of the table.

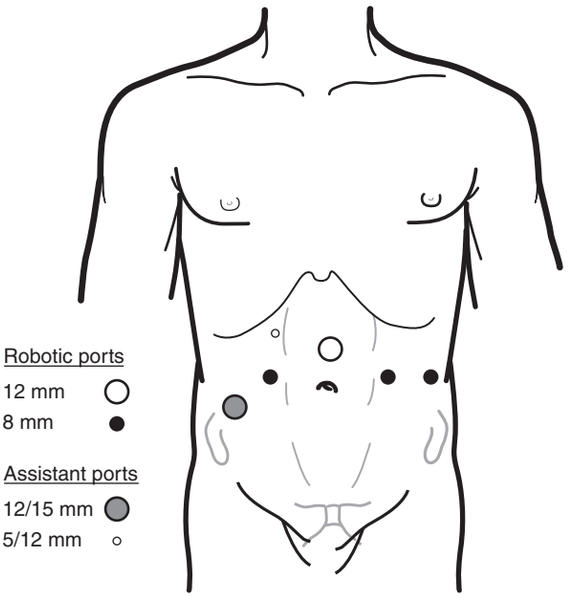

FIGURE 84-1. Port placement. The assistant ports are placed on the opposite side if intracorporeal diversion is to be performed. *(Modified from Bishoff JT, Kavoussi LR. [2007]. Atlas of laparoscopic urologic surgery. Philadelphia: Elsevier.)*

TECHNIQUE

Note: In female patients undergoing a cystourethrectomy, periurethral incision can be performed prior to the laparoscopic/robotic portion of the procedure to facilitate the vaginal dissection during the robotic approach.

Port placement: A total of six ports are utilized during the operation. One 12-mm camera port, three 8-mm robotic arm ports, and two assistant ports on the side opposite the 4th robotic arm. The assistant ports should be a 15 mm port and 5 mm port.

The ports are arranged in an "inverted-V" fashion as diagrammed (Fig. 84-1). The camera port is placed in the midline cephalad to the umbilicus. The port is 3 to 4 cm cephalad for ileal conduits and lowered slightly to 3 cm for neobladder diversions. The two 8 mm robotic ports are placed 8 to 9 cm lateral from the midline and approximately 1 cm above the superior aspect of the umbilicus to allow for proximal ureteral and lymphadenectomy dissection. With newer daVinci S surgical systems the cephalad placement still allows for access to the deeper pelvic structures. In cases where a neobladder is planned then the robotic ports may placed in line with the umbilicus to facilitate suturing if the anastomosis is to be performed with robotic assistance. The two assistant ports are placed lateral and caudad to the right robotic port. The left assistant port or fourth arm port is placed directly lateral to the left robotic port. Access and establishment of the pneumoperitoneum can be performed with a Veress or Hassan technique.

Mobilization of the sigmoid and left colon: Once ports are in place and the robot is docked, the surgeon should orient himself/herself to the pelvic anatomy by identifying specific landmarks. A 30-degree lens is used at the outset of the procedure and allows for better visualization of the retroperitoneum and pelvic structures. This will be changed to a 0 lens once the posterior and lateral portions of the bladder are dissected. Identification of the urachus and its relationship to the internal inguinal ring is helpful. By following the peritoneal fold of the medial umbilical ligaments posteriorly, the lateral aspect of the bladder and the umbilical ligaments become apparent. The relationship of the iliac vessels to the internal ring and umbilical ligaments is initially easier on the right as the sigmoid colon obscures the left iliac vessels. The procedure is begun by incising peritoneum lateral to the left colon (Fig. 84-2). The left colon and sigmoid colon should be released from the left side wall to allow access to the left iliac vessels and left ureter.

Development of the left paravesical space: With the left medial umbilical ligament identified, the peritoneum just

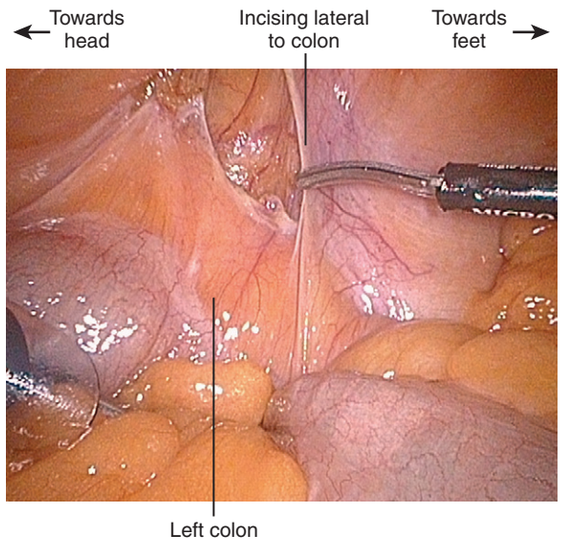

FIGURE 84-2.

lateral to the ligament and medial to the left iliac vessels should be incised. Blunt dissection can be employed to develop the left paravesical space. The dissection can often be carried caudad to expose the endopelvic fascia. In male patients, dividing the vas deferens is necessary to allow the bladder to be retracted medially. During this maneuver the sigmoid colon is retracted medially.

Identification, mobilization and division of the left ureter: The left ureter is identified crossing over the iliac vessels (Fig. 84-3a). The ureter should be dissected free of its underlying structures while preserving as much periureteral tissue as possible. The distal end can be dissected down to its insertion into the bladder. The left umbilical artery or left superior vesical artery should be seen just lateral to the insertion of the ureter into the bladder and can be clipped and divided to allow for greater ureteral length. The ureter can be clipped with a locking clip that has a pre-tied suture to the crotch of the clip (Fig. 84-3B). One may use a different color suture for the left and right sided clips. The ureter is divided and a margin may be sent for frozen section. The ureter should be dissected free of its lateral attachments as far cephalad as possible but preservation of some medial blood supply from the common iliac artery is preferred. Once again, the surrounding periureteral tissue should be preserved. If a pre-tied suture of the clip is not used then the distal ureter can be tagged with an 8–10 cm 2–0 vicryl suture.

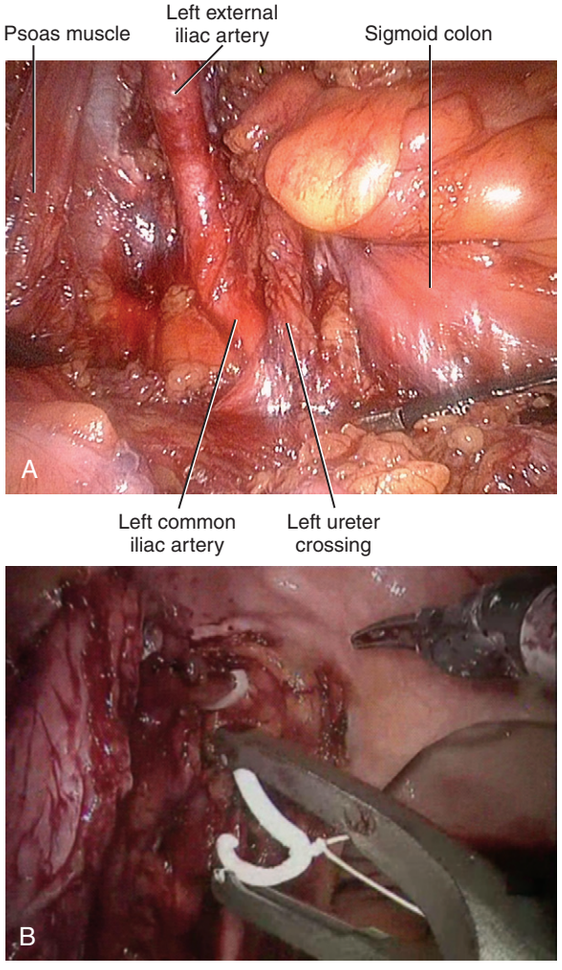

FIGURE 84-3.

Identification of the left iliac vessels: Optimal visualization of the left iliac vessels is achieved with medial retraction of the sigmoid colon and the bladder. The surgeon should be oriented by the lateral aspect of the bladder and umbilical artery that have already been identified.

Perform the left pelvic lymphadenectomy: The left pelvic lymphadenectomy can be performed with a variety of instruments. The authors currently use a Maryland bipolar in one hand and monopolar scissors in the dominant hand. The dissection is begun on the left external iliac artery. A "split-and-roll" technique is utilized. The dissection should be carried proximally along the common iliac artery up to the bifurcation of the aorta. Great care should be taken during dissection along the external and common iliac veins due to the collapsed nature of the veins from the pressure of the pneumoperitoneum. The dissection on the external iliac vessels should be carried lateral to the vessels and medial to the psoas muscle. By developing this space and retracting the vessels medially, a more extensive pelvic dissection can be performed. The obturator artery can in fact be identified from "behind" the external iliac vessels with this dissection. Furthermore, the obturator dissection will be much more complete when returning medial to the vessels. The obturator nerve is easily identified by orienting oneself with the pubic ramus. By following a line directly posterior to the point where the external iliac vein crosses the pubic ramus, one can find the obturator nerve and vessels. The hypogastric artery can be skeletonized down to the take-off of the umbilical artery. Lymph nodes can be removed in separate packets with 10 mm specimen retrieval bags. There are multiple use specimen retrieval bags such as the anchor™ tissue retrieval system (Anchor™, Addison, IL) that prevents the need to open several different bags.

Development of the right paravesical space: Once the left pelvic lymphadenectomy is completed, attention is directed to the right hemipelvis. The right paravesical space is developed similar to the left paravesical space. The peritoneum is incised between the right medial umbilical ligament and right iliac vessels (Fig. 84-4).

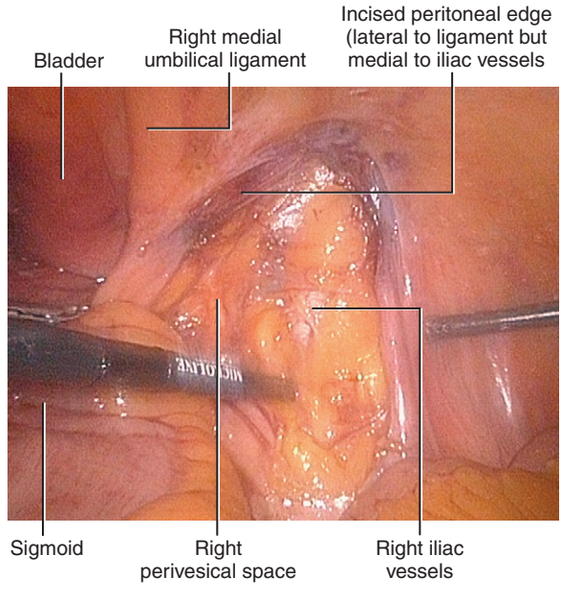

FIGURE 84-4.

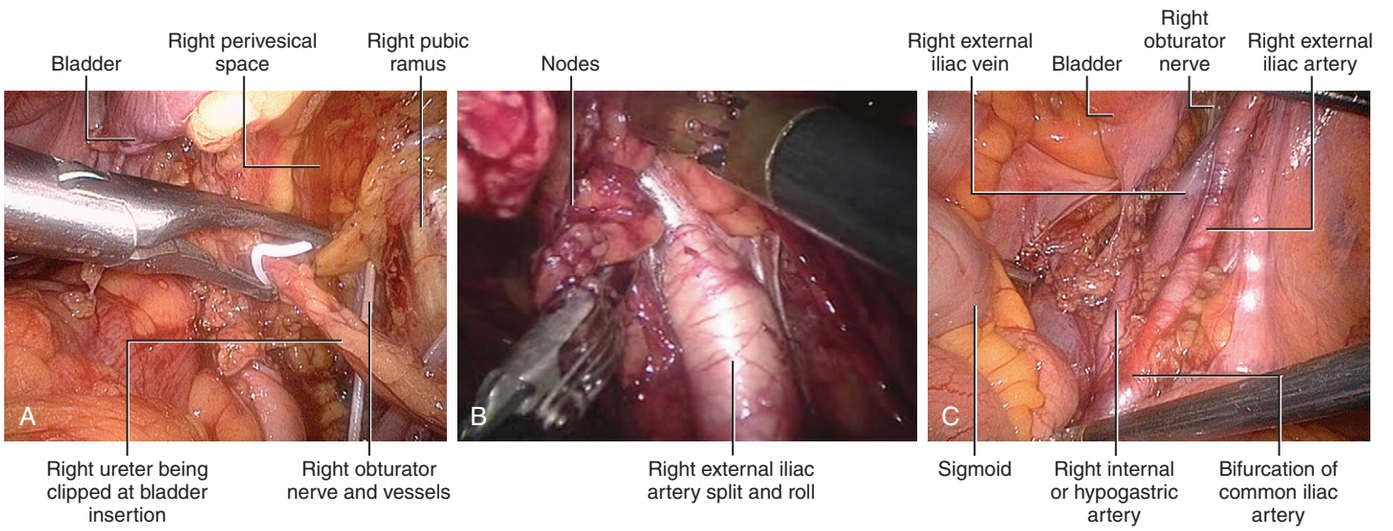

FIGURE 84-5. A, Right ureter being clipped at bladder insertion. **B,** Right external iliac artery split and roll.

The right ureter and right pelvic lymphadenectomy: The right iliac vessels and ureter are easier to identify and dissect due to less intrusion of the colon. The peritoneum covering the iliac vessels and right ureter is incised. The ureter is dissected free of its surrounding attachments and the distal end is clipped and divided at its insertion into the bladder (Fig. 84-5A). The right pelvic lymphadenectomy should be performed in similar fashion to the left side. It should be noted that the right common iliac artery crosses over the right common iliac vein. This is important to remember when performing "split-and-roll" along the common iliac artery as the common iliac vein will be encountered (see Fig. 84-5B). Dissection proximally up to the aortic bifurcation is easier on this side (see Fig. 84-5C).

Identification, ligation, and division of the superior vesical arteries: The umbilical and superior vesical arteries are clearly seen at the completion of the lymphadenectomy (Fig. 84-6). These vessels can be clipped with a locking clip or taken with an endovascular staple load.

Tagging both ureters with 8- to 10-inch 2-0 Vicryl suture: If the ureters have not already been tagged via pre-tied clip then one should switch instruments to needle drivers. A 2-0 Vicryl suture on an SH needle can be used to tag the distal ends of both ureters (Fig. 84-7). The suture should be a minimum of 8 to 10 cm in length to facilitate delivery into the extraction incision. It is important for the ureters to have some sort of suture tag to allow for extracorporeal creation of the diversion and for retraction needs.

Transferring the left ureter through the sigmoid mesentery: The left ureter can be transposed behind the sigmoid mesentery with the help of the right side assistant or additional robotic arm. The anterior aspect of the aortic bifurcation should already be visible due to the right extended lymphadenectomy. The peritoneum overlying the sigmoid mesentery can be incised if the window is not large enough. The right side grasper should gently and bluntly advance a blunt-tipped instrument through the mesentery (Fig. 84-7A). The sigmoid can be retracted to the right and the advanced instrument tip should be visualized. The tag on the left ureter can be grasped and the ureter should easily pass through the mesenteric window (see Fig. 84-7B). The surgeon may opt to place a locking clip onto both ureteral tags to facilitate delivery of the ureters into the abdominal incision.

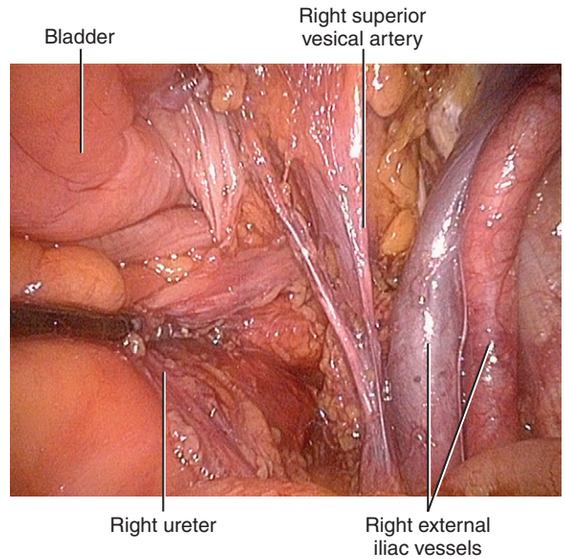

FIGURE 84-6. Right ureter being retracted medially, you can see that the right superior vesical artery is lateral to its insertion to the bladder.

Tagging the distal ileum with 8- to 10-inch 2-0 Vicryl suture: The ileum should be tagged with a 2-0 Vicryl suture if creation of an extracorporeal diversion is planned. There should be two tags placed with the one distal and closer to the ileo-cecal valve a different length to allow for orientation during extracorporeal work. One should be left at least 8 to 10 cm in length. It is often helpful to mobilize the lateral attachments of the cecum so as to make delivery of the ileum into the abdominal incision easier and make identification of the distal portion of the ileum easier. This

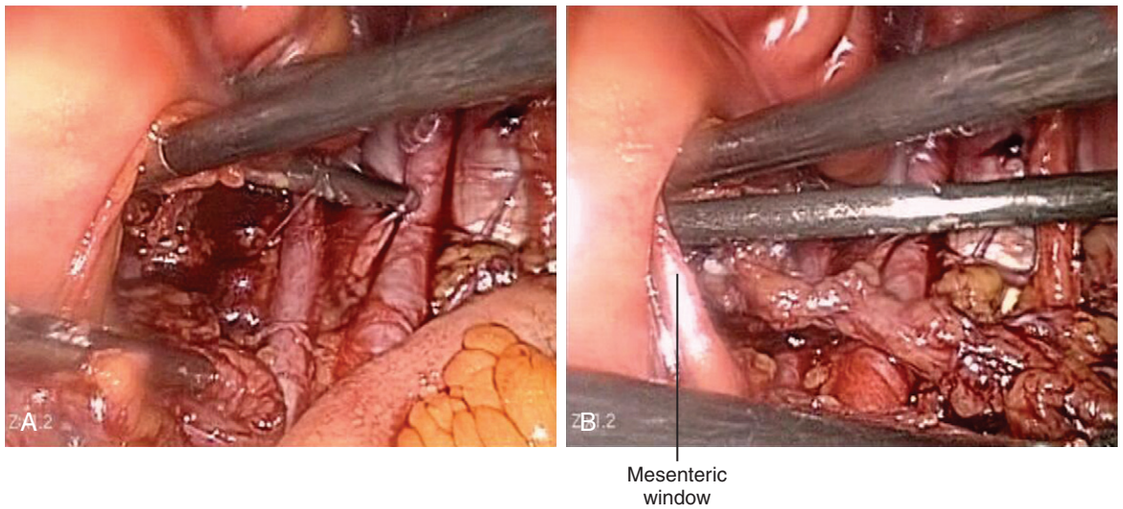

FIGURE 84-7. A, Creating mesenteric window for passage of grasper to transpose left ureter. **B,** Left ureter brought through mesenteric window.

tagging is very important to allow for identification of the ileum.

Development of the prerectal and posterior vesical space: The camera lens can be changed to a 0 degree lens for optimal visualization (Fig. 84-8A). The peritoneum extending from the posterior bladder to the anterior sigmoid should be incised. Using blunt and careful cautery dissection, the prerectal space is developed (see Fig. 84-8B). One must employ the assistant(s) or additional robotic arm to retract the bladder and its posterior structures anteriorly. In male patients, Denovillier's fascia needs to be incised to carry the dissection as far caudad as possible. The dissection should be carried down to the rectourethralis muscle.

In female patients, the dissection is carried along the anterior vaginal mucosa in a vaginal sparing procedure. If the anterior vaginal wall will not be spared then a sponge-stick in the vagina allows identification of the vaginal cuff. Incision of the vaginal apex can be performed with the monopolar cautery. Although some gas may escape through vaginal opening, a sponge-stick seems to occlude the vagina sufficiently. The dissection is then carried down to the posterior aspect of the periurethral incision made at the beginning of the operation. In a nerve sparing procedure for women, the incision of the vagina should be as anteriolateral as possible. Lateral vaginal tissue should be preserved to spare any neurovascular tissue coursing along the anteriolateral aspect of the vagina.

Division of the remaining inferior vesical vessels: Once the limits of dissection are reached along the posterior aspect of the bladder, the lateral attachments of the bladder can be divided. In a non-nerve sparing procedure, this can be done with a combination of the bipolar instrument and the hook

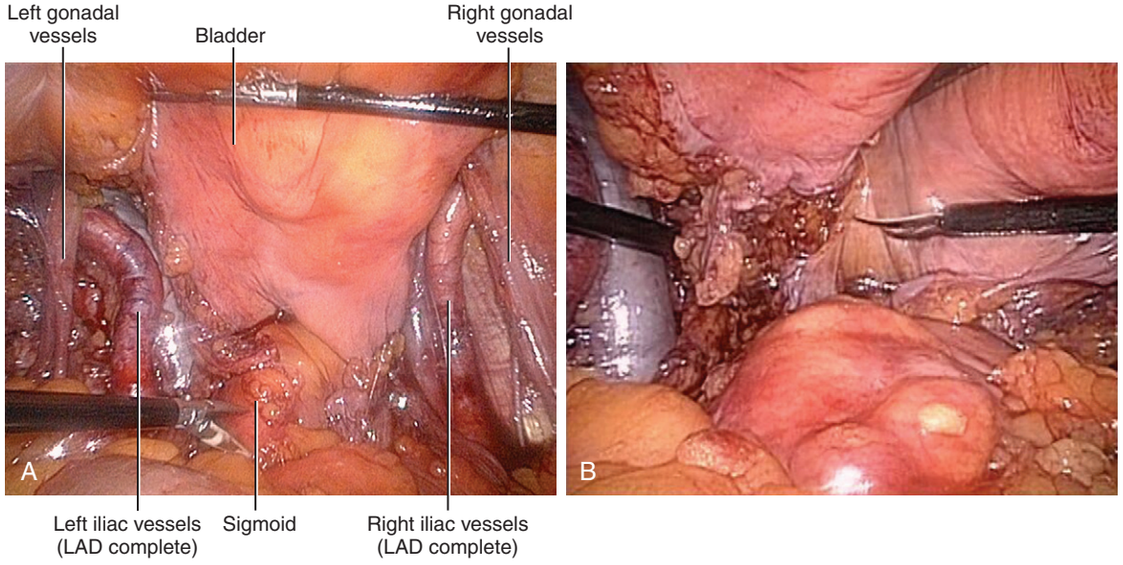

FIGURE 84-8. A, Visualization of area to be incised. **B,** Incising for posterior dissection and reveal seminal vesicles and prerectal space.

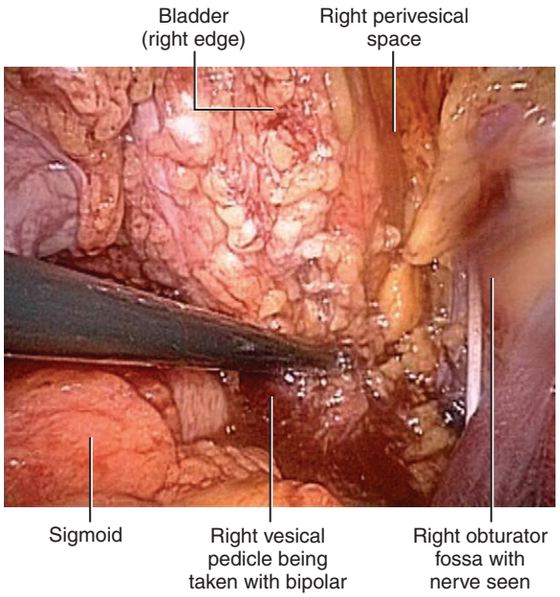

FIGURE 84-9.

electrode or monopolar scissors (Fig. 84-9). An endovascular stapler can be used on both sides as well. It should be remembered that the dissection should be carried caudad through the endopelvic fascia thereby completely mobilizing the bladder from its lateral attachments and the rectum. Often a combination of lateral and posterior dissection is used in an alternating fashion to complete the dissection.

Preservation of the neurovascular bundles: In nerve-sparing procedures, the neurovascular bundles are encountered as they project off the posterior-lateral aspects of the prostate down to the anterior surface of the colon. The bundles can be mobilized by releasing lateral fascia anterior to the bundles along the surface of the prostate or vagina. The inferior vesical pedicles and prostate pedicles should be clipped and divided with cold scissors to avoid neurovascular injury. The nerve sparing should be carried down to the genitourinary diaphragm to prevent injury during the apical and urethral dissection. Once the nerves are mobilized posteriolateral, the remaining posterior and lateral attachments of the bladder and/or prostate can be completed. At this point, the remaining bladder attachments should only be the urachus, anterior attachments, prostate, and urethra.

Mobilize the urachus: The medial and median umbilical ligaments should be divided as far proximally as possible with electrocautery (Fig. 84-10A). The dissection and peritoneal incision is carried lateral to the medial umbilical ligaments caudad to the anterior surface of the bladder (see Fig. 84-10B).

Complete the apical dissection: If not already done, the endopelvic fascia should be incised bilaterally (Fig. 84-11A). The apical dissection of the prostate or vagina is then completed. At this point the dorsal venous complex is ligated with a 1 Vicryl suture in a figure of eight fashion (see Fig. 84-11B). Although an endovascular stapler can be employed for this step, the authors feel the suture ligation allows for better visualization and identification of the urethra (see Fig. 84-11C).

Dissection, ligation and division of the urethra: It is very important to dissect out a generous urethral stump. This is important even in cases without a planned neobladder. A generous urethral stump allows for easier application of a locking clip or suture ligation to prevent tumor spillage during division (Fig. 84-12). If the previous posterior dissection was adequate, there should be minimal posterior tissue other than some minor remnants of rectourethralis. A frozen section can be taken from the proximal portion of the divided urethra prior to creation of a neobladder.

Specimen extraction: The entire specimen can be entrapped in a 15-mm specimen retrieval bag. It will be extracted though a 5- to 6-cm infraumbilical or periumbilical incision. Prior to extraction, the tags on the ureters and the ileum should be grasped in a locking grasper to allow delivery of all tags into and through the extraction incision. This will allow for extracorporeal creation of the urinary diversion of the surgeons choice.

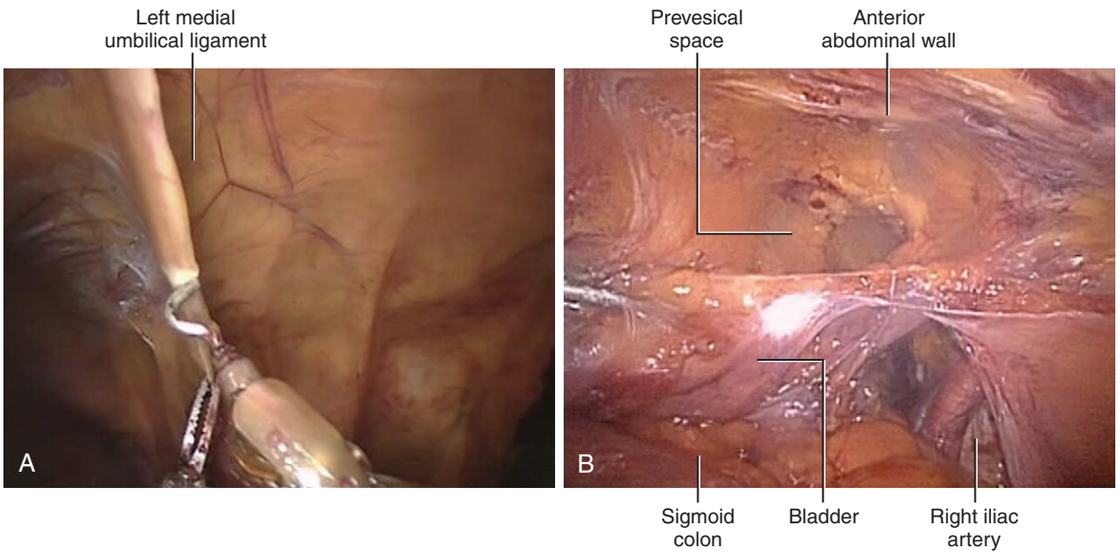

FIGURE 84-10.

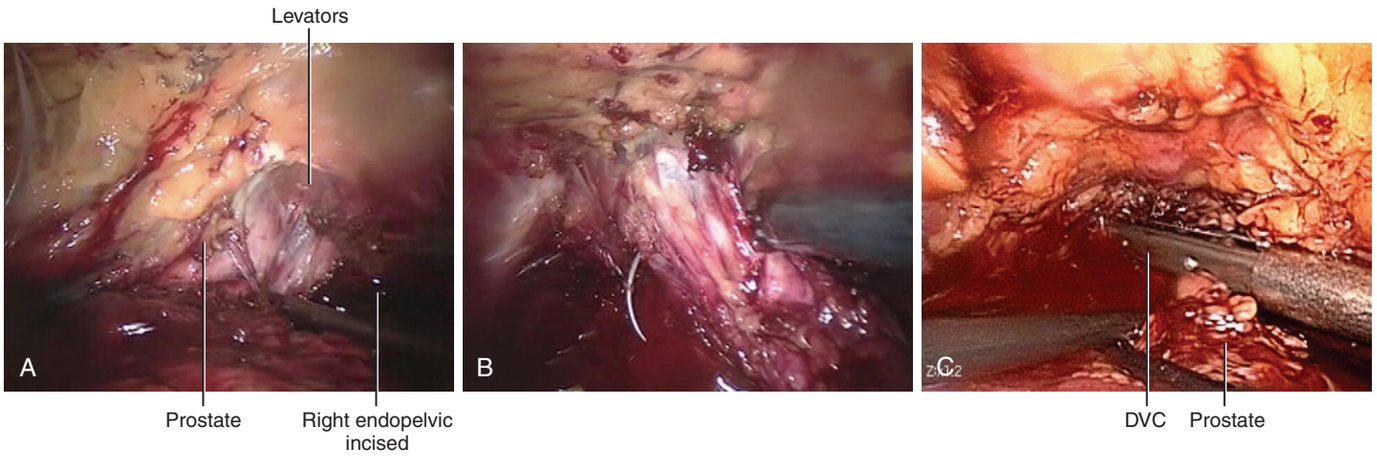

FIGURE 84-11.

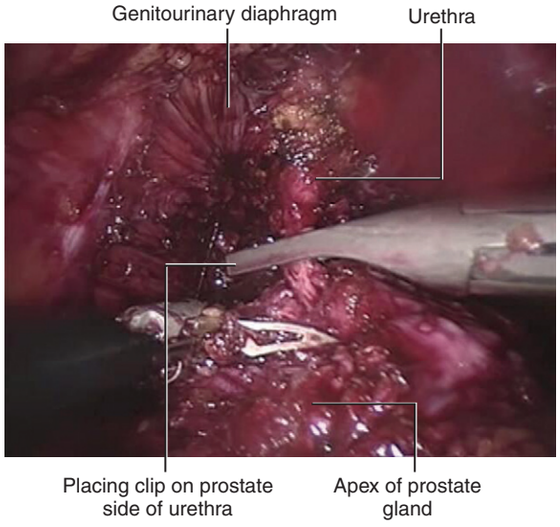

FIGURE 84-12. Placing clip on prostate side of urethra.

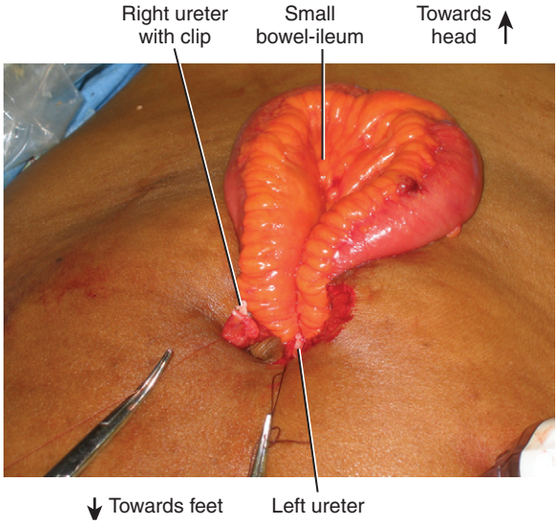

FIGURE 84-13.

Creation of ileal conduit/neobladder urinary diversion: The urinary diversion can be created through the extraction incision (Fig. 84-13). The choice of diversion is based on surgeon preference and patient characteristics. In most average sized patients, the ureters can be easily delivered into the extraction incision. In obese patients, wither a larger incision may be required or intracorporeal anastamoses of ureters to the bowel segment may be undertaken. It is very important to minimize traction on the ureters as well as making the incision for creation of the diversion generous if needed. One must cut back on the ureters enough to minimize the risk of post-operative ureteral-ileal ischemic stricture formation. The authors make a larger incision than previously to allow for working "within" the abdomen rather than working at the skin level. This allows for less traction on the ureters.

Placement of abdominal drains and/or suprapubic tube: One or two abdominal drains can be placed through one or more port sites. If the surgeon chooses to place a suprapubic tube, the urethral catheter should be withdrawn into the urethra to prevent damage to the balloon of the catheter. Ports should be closed based on surgeon preference.

POSTOPERATIVE CARE

A nasogastric tube is not routinely left in place. Antibiotic management has evolved to the standard initial perioperative antibiotic based on current recommendations. Use of oral prophylactic antibiotics for the stents is up to surgeon preference, but not recommended. All that should be needed is antibiotic coverage during stent removal. Epidural catheters are not used. Intravenous morphine and/or ketorolac are usually adequate for pain management and can be promptly switched to oral medications once the patient is tolerating a diet.

It is important to increase patient activity as early as the day of surgery. Patients are encouraged to sit in a chair the same night of surgery. They are ambulated

on the first post-operative day. Rectal suppositories are administered each morning starting on the first post-operative day until bowel function returns. This may help stimulate rectal motility in some patients. A liquid diet is started once bowel function returns which may be as early as the second or third post-operative day. Daily serum chemistry and hematocrits may be followed until discharge based on surgeon preference. Most patients do not seem to have significant third spacing and will rarely require additional fluid replacement other than standard maintenance fluids especially since pre-operative bowel preparation is not used. Although postoperative hemorrhage and delayed bowel injury have not been an issue to date, patients need to be monitored closely for these complications.

Ureteral stents and abdominal drains should be managed according to surgeon preference. Currently, the authors remove stents from a urostomy at 10 to 14 days. Foley catheters are removed from neobladders in 14 to 21 days. If the stents were not secured to the Foley during creation of the neobladder, then they are removed cystoscopically at the time of Foley removal in the office. The decision to perform a cystogram at the time of Foley removal is based on surgeon preference and can be decided on an individual case basis.

It should be noted that patients can be discharged home rather quickly which may require leaving drains or stents in place until the first office follow-up. The authors have found that some patients may have a continued leak of lymphatic fluid through a drain site, urethra or vagina for several days after discharge. We believe this is seen because patients are discharged home before their lymphatic channels have completely sealed. Whether this is due to the use of cautery and/or bipolar dissection during lymphadenectomy remains to be seen. Consequently, the abdominal drain may be left in place until their first post-operative follow-up which is on post-operative day seven to ten. If the drain is removed before discharge, then a urostomy appliance can be placed over the drain site to collect the fluid until the incision heals and drainage ceases. We have found this drainage to be self-limiting and uniformly resolves spontaneously as the lymphatic fluid is absorbed intraperitoneally. If there is any concern of a urine leak, the fluid may be sent for creatinine analysis.

Commentary by

JAMES E. MONTIE

The role of robotic cystectomy remains to be seen. In some cases, the patient's body habitus may be such that the robotic approach can improve visualization in the pelvis. The diminished blood loss compared to an open procedure may be beneficial. Cystectomy patients are generally older with far more comorbidity and less able to tolerate an excessively long operation so the robotic team should be quite proficient before undertaking a cystectomy.

National standards for perioperative antibiotics prescribe only 24 hours of postoperative antibiotics and there is no convincing evidence that longer treatment is beneficial. *Clostridium difficile* infection has become a major concern in our institution after cystectomy and minimization of unnecessary antibiotics is important.

Section XV

BLADDER RECONSTRUCTION

Pubovaginal Sling for Stress Urinary Incontinence

This page intentionally left blank

Chapter 85

Autologous Pubovaginal Sling

E. ANN GORMLEY

Historically the autologous pubovaginal sling was used to treat intrinsic sphincter dysfunction (ISD). ISD was initially described in women who had undergone multiple bladder neck suspensions and had fixed "stove pipe" urethras. In latter years, the term ISD described women with open bladder necks and low Valsalva leak point pressures. The autologous pubovaginal sling remains the ideal surgical treatment for ISD, and it may also be used to treat women whose stress incontinence is due to bladder neck mobility with or without an open bladder neck.

A physical examination or assessment of urodynamics can detect the presence or absence of mobility; urodynamic assessment is used to diagnose ISD. Urge incontinence is not a contraindication to a pubovaginal sling in the patient with documented stress urinary incontinence, but it will affect how the patient is counseled, in that approximately 30% of patients will continue to have urgency or urge incontinence after placement of the sling. Patients with residual urine, a history of difficulties voiding, or poor detrusor contractility are at higher risk for needing long-term intermittent catheterization postoperatively. In neurogenic patients with stress incontinence and poor compliance or intractable detrusor overactivity, augmentation cystoplasty can be performed in addition to the sling procedure. In the era of synthetic slings, the autologous fascial sling remains the sling of choice in patients who may need a "tighter" sling or in patients in whom a synthetic should be avoided, including the patient with a concomitant diverticulectomy or urethral reconstruction. Autologous rectus fascia is the ideal material in the patient who wishes to avoid a synthetic or in the patient who has had a prior problems with synthetic mesh.

Exhaust medical approaches using α-adrenergic and anticholinergic medications. Inform the patient about complications such as the possible need for intermittent catheterization, persistent stress incontinence, de novo or persistent urge incontinence, upper urinary tract damage, and urinary tract infection. Teach the patient to perform clean intermittent catheterization.

Two surgeons perform a combined abdominal and vaginal approach, although the procedure can easily be done with a single surgeon.

Position: Place the patient in the low lithotomy position. Use Allen or Yellow Fin stirrups, which place the weight of the leg on the sole of the foot, ensuring that no pressure is placed on the calf. Prepare the lower abdomen, perineum, and vagina. Drape to provide access to the vagina. Place a Foley catheter in the bladder with 5 to 10 mL in the balloon to allow for palpation of the bladder neck. Drain the bladder.

Suprapubic operator: Make a 6- to 8-cm long transverse suprapubic incision 4 cm above the symphysis. Expose the rectus sheath. Incise the sheath transversely above the symphysis for a distance of 6 to 8 cm. The fascia is lifted off the rectus muscle bellies and a strip of fascia measuring 1.5 to 2 cm by 6 to 8 cm is taken from either the upper or lower leaf (Fig. 85-1).

At each end, a 0 nonabsorbable running suture is whipstitched and tied down, leaving the ends as long as possible (Fig. 85-2). Alternatively a suture that is slowly absorbed can be used. The sutures are tested by firmly pulling to ensure that they will not pull through the fascia. Cover the strip with moist gauze and put it aside. Ideally the sling should be harvested and ready to be inserted before completion of the retropubic tunnels.

The suprapubic operator then retracts the lateral border of the rectus muscle just above the insertion into the symphysis

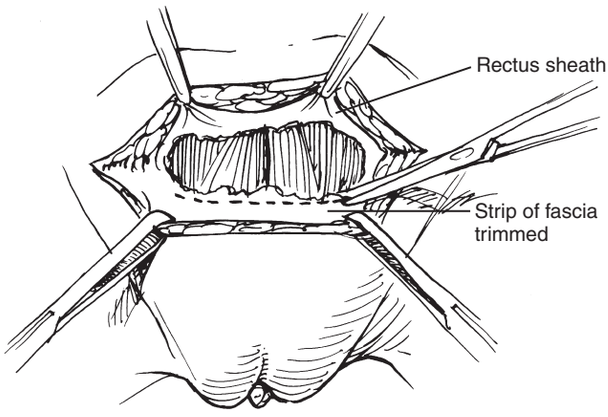

FIGURE 85-1.



FIGURE 85-2.

toward the midline. A triangular area is visualized, permitting easy access to the retropubic space (Fig. 85-3).

Vaginal operator: Insert a weighted vaginal retractor such as a Scherback. Infiltrate the vagina with normal saline or a dilute vasopressin solution. Make a 4- to 5-cm vertical midline incision in the vaginal wall from the midurethra to the bladder neck. (Alternatively, make a small inverted U-incision and reflect it posteriorly.) Using Metzenbaum or Church scissors, sharply dissect the vaginal wall off the underlying glistening white surface of the periurethral fascia (Fig. 85-4). Dissection in this plane is relatively bloodless and prevents inadvertent entry into the bladder or urethra. The vaginal wall is dissected laterally toward the ischium. The pubocervical fascia is perforated sharply on either side of the urethra by keeping the scissors parallel to the perineum and aiming for the patient's ipsilateral shoulder, thus gaining entry into the retropubic space. Finger dissection is used to create a tunnel for the sling into the retropubic space toward the rectus muscle bellies.

Suprapubic operator: The retropubic space is entered by "popping" the index finger through the triangular space (Fig. 85-5A). Retropubic tunnels are developed in continuity with the vaginal dissection by palpating the fingertip of the vaginal operator behind the rectus muscle.

Vaginal operator: Insert the index finger of the left hand in the vagina into the right side of the vaginal incision. Grasp a curved clamp, such as a Crawford, and advance it through the right retropubic tunnel from above down using the vaginal finger as a guide (see Fig. 85-5B). The nose of the clamp is kept in constant contact with the posterior surface of the symphysis to avoid entering the bladder.

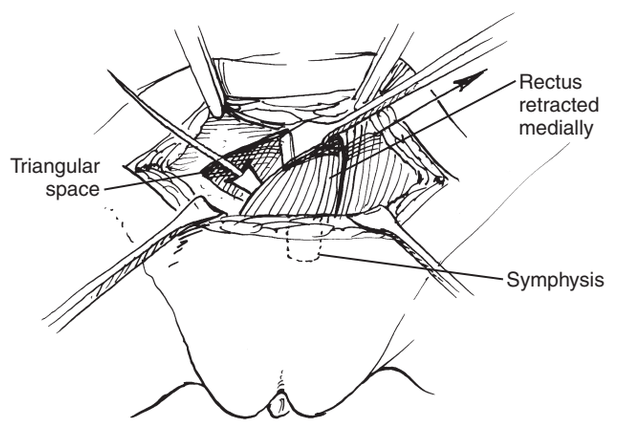

FIGURE 85-3.

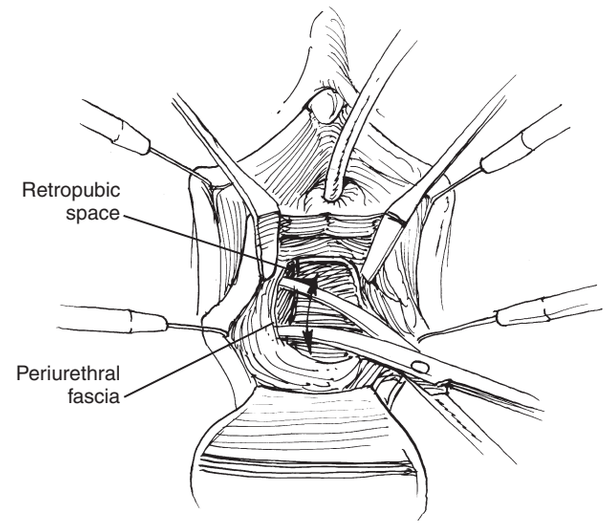

FIGURE 85-4.

Open the clamp and grasp the sling sutures from one end of the sling and draw it retropubically into the upper wound (Fig. 85-6). Repeat the procedure on the opposite side, passing the clamp down that side and drawing up the other end of the sling suture. Check for vesical injury by performing cystoscopy. If perforation has occurred, remove the sling. A new sling tunnel is constructed. Perform subsequent cystoscopy with the Crawford clamp in situ. Visualization of a clamp in the bladder is dramatic, whereas it is possible to miss seeing a piece of suture peeking through a small hole.

If no perforation is seen, the sling is gently pulled into the retropubic space bilaterally. This seats the sling at the bladder neck. The sling is sutured to the periurethral fascia to prevent dislocation and to spread the bearing surface of the fascia on the urethra as widely as possible. This is done with a 3-0 or 000 absorbable suture.

The sutures at either end of the sling are brought through two small defects in the inferior leaf of the rectus fascia (Fig. 85-7). The abdominal fascia is closed and the vaginal wound is closed.

A Foley catheter is placed per urethra if it was not replaced after the cystoscopy. The sling tension is adjusted so that gentle traction on the Foley catheter does not result in inferior and posterior urethral mobility (Fig. 85-8). Obtaining correct tension requires considerable judgment because no exact criteria can be used. The sling is loose and the surgeon can place two to three fingers between the fascia and the knot. Close the suprapubic wound. Place a vaginal pack. Remove the pack and Foley catheter on the first postoperative day. Ensure that the patient can perform intermittent catheterization.

Alternative techniques:

1. Harvest fascia from the fascia lata using a fascial stripper. A Peyrera type needle may be used to pass the sling and limit the abdominal dissection.
2. In patients with severe ISD, some tension may be applied while tying the sling. If the urethra is felt to be very rigid, a longer piece of fascia may be used and the fascia can be crossed by further freeing up the urethra and encircling

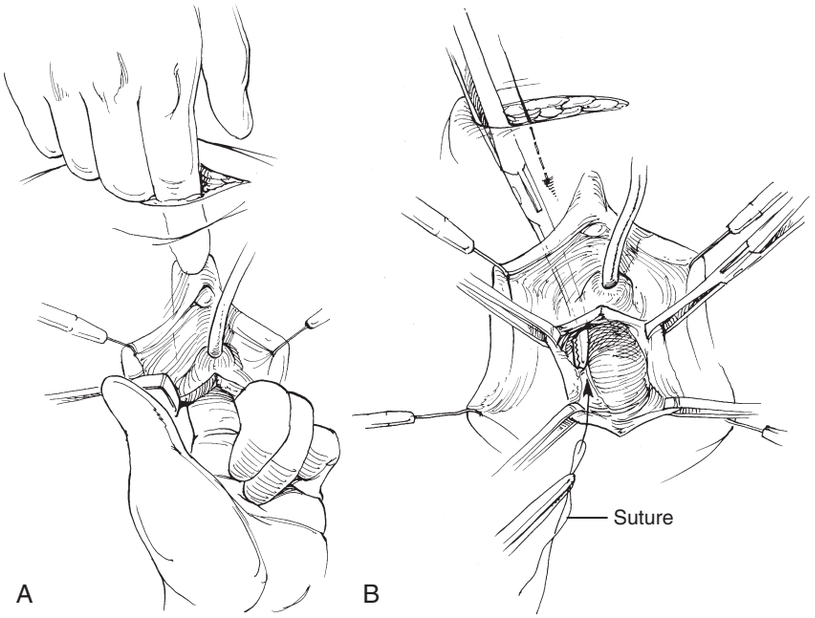

FIGURE 85-5.

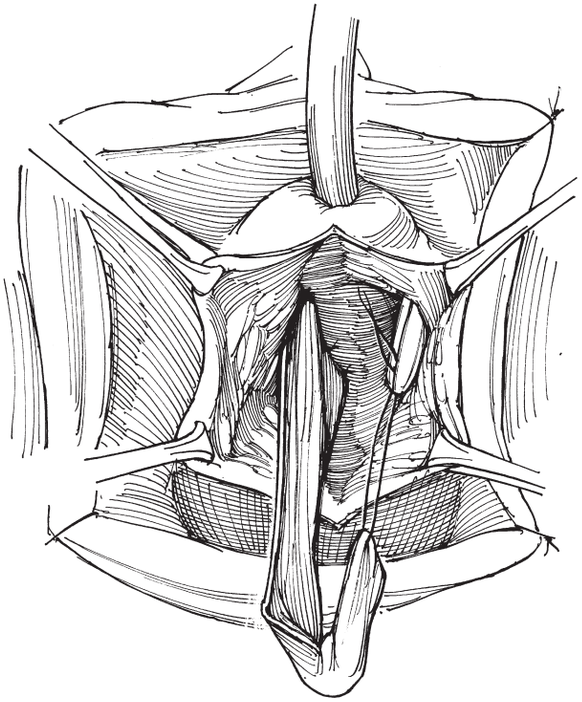

FIGURE 85-6.

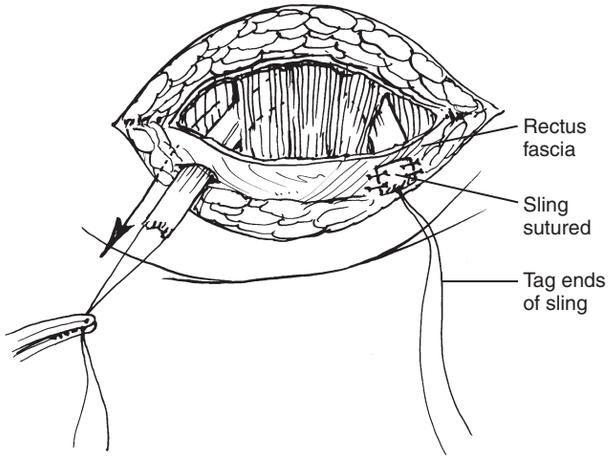

FIGURE 85-7.

it. A buttonhole is made approximately 2 cm back from one end of the fascia and the other end of the fascia is pulled through it.

POSTOPERATIVE PROBLEMS

Urinary retention, which is usually the result of too much tension at the urethrovesical junction is the greatest concern. Straining to void causes the sling to tighten. The patient must learn to void by relaxing and allowing the detrusor to contract. Clean intermittent catheterization is used until normal voiding occurs. Patients are advised to catheterize every 3 to 4 hours until their postvoid residuals are consistently low, less than 60 mL. If the patient is unable to resume normal voiding in 4 to 8 weeks, division of the sling vaginally will often result in resumption of normal emptying. Recurrent stress incontinence is very rare following sling incision. Untreated obstruction can lead to detrusor overactivity and/or a reduction in bladder *compliance.* Patients with borderline compliance preoperatively may benefit from concomitant augmentation.

Urge incontinence will persist in 20% to 30% of patients who had urge incontinence preoperatively, but it will respond to anticholinergic medication. Approximately 10% of patients will develop de novo urgency postoperatively. *Stress incontinence* can persist if the sling is not tight enough

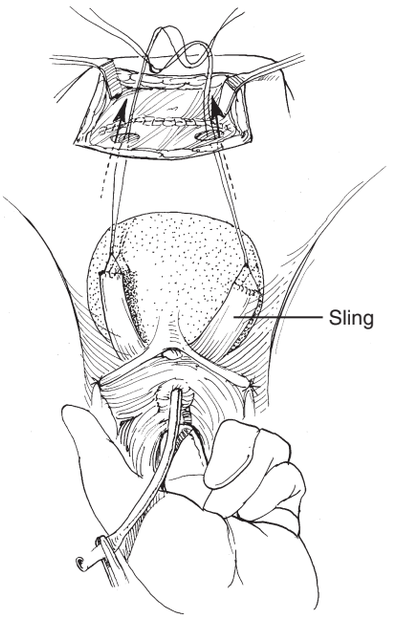

FIGURE 85-8.

to sufficiently compress the urethra, particularly if there is excessive scarring from previous procedures. Rarely recurrent stress incontinence develops when the sling suture pulls out of the fascia or breaks in the early postoperative period. To prevent this complication, patients are advised to refrain from lifting for 4 to 6 weeks.

There are only two case reports of *urethral erosion* with autologous fascial slings, and in one of these cases, the sling was inadvertently placed at the midurethra rather than at the bladder neck.

Wound problems—infection or wound hematoma—occur rarely but can be particularly problematic in the obese patient. Very rarely, pain develops where the sling suture comes through the rectus. Persistent pain is treated by removal of the sling sutures after 6 weeks.

Urinary tract infection is often a result of incomplete emptying. Patients with persistent infection should undergo cystoscopy to ensure that there is no sling or suture material in the bladder or urethra.

Commentary by VICTOR W. NITTI, MD

The pubovaginal sling remains an excellent procedure to treat stress urinary incontinence in women. While it is used less frequently than in the pre synthetic mid urethral sling era, it remains the procedure of choice in several instances such as: simultaneous urethral reconstruction, neurogenic voiding dysfunction for women already on self catheterization, prior mesh complication (particularly urethral erosion) and severe ISD with a fixed urethra (usually after multiple prior surgeries). In addition, it remains a good choice for those women who want to avoid a synthetic.

We generally preform the procedure first suprapubically, then vaginally. After the rectus fascia is incised at the superior and inferior border of the sling, we mobilize each end about halfway to the midline. Then the polypropylene whipstitches are placed through each of the sling, before the sling is detached. We find this easier than placing the sutures after detachment. Then we close the rectus fascia (unless extensive scarring in the retropubic space is expected. Then we proceed to the vaginal incision. After sharp perforation of the retropubic space, the plane from the vagina to the undersurface of the rectus fascia can usually be developed bluntly with a finger. Then either a Pereyra-type needle or long clamp can be used to perforate the inferior rectus fascia and guided through the retropubic space under direct finger guidance. Using this method, bladder perforation is a relative rare occurrence.

While many women will resume normal voiding after 24-48 hours, it is not unusual for it to take 2 weeks (or even a little longer) for patients to empty normally. This is different then what is seen for mid urethral synthetic slings and it is important that patients be made aware of

Section XV

BLADDER RECONSTRUCTION

Synthetic

This page intentionally left blank

Chapter 86

Tension-Free Vaginal Tape/Suprapubic Midurethral Sling Pubovaginal

ROGER R. DMOCHOWSKI AND CHRISTOPHER E. WOLTER

INDICATIONS

Relative to other treatments for surgical management of stress incontinence in women, the polypropylene midurethral sling is a new development in the treatment of stress urinary incontinence. The minimally invasive nature of the intervention, ease of implantation, and efficacy all contribute to the widespread use of this intervention. In addition, it can be performed under local anesthesia if desired, and convalescence from this procedure is much more rapid than traditional fascial slings and retropubic suspensions. Even though the sling itself is a synthetic mesh, there is a low incidence of erosion of the sling material (due to the specific mesh characteristics of the monofilament, widely porous material) if placed correctly and in a tension-free manner. A midurethral sling is best suited for a patient with mild to moderate severity incontinence, although it can be used in more severe cases with the expectation of somewhat decreased efficacy.

SET UP

1. After induction of the selected type of anesthesia, the patient is placed in the lithotomy position. A full vaginal as well as lower abdominal antibiotic skin preparation should then be performed, and the patient should be draped to expose the vagina and lower third of the abdomen. A weighted vaginal speculum should be used, and the labia minora should be retracted with sutures or a self-retaining ring retractor to maximize visualization of the anterior vaginal wall. Place a catheter at this time.
2. Starting 1 cm below the urethral meatus, measure a 2-cm incision vertically. If desired, inject normal saline or dilute lidocaine with epinephrine for hydrodissection. By grasping the vaginal wall just above the incision with an Allis clamp, upward traction can be gained, and this will also aid in visualization. Incise the vaginal mucosa with a #15 blade.
3. *Dissection* (Fig. 86-1): Grasp one edge of the incision with another Allis clamp. Dissect a flap of vaginal mucosa away from the underlying urethra. This is accomplished using a combination of sharp and blunt dissection. Carry the dissection lateral and superior to the incision, toward the inferior ramus of the pubis. In the proper plane, the glistening white surface of the vaginal wall is seen. If the dissection is too deep, the urethra can be violated or venous bleeding can be encountered. Dissect in this direction until the inferior ramus of the pubis is clearly palpable. Do not pierce the endopelvic fascia. Repeat this dissection on the opposite side.
4. *Suprapubic needle pass* (Fig. 86-2): Ensure that the bladder is completely drained of urine. Make paired 1-cm suprapubic incisions directly over the symphysis and 2 cm from midline. Place the index finger of one hand in the vagina and deflect the catheterized urethra away from the side that the needle is being passed from. With the opposite hand, pass the needle through the suprapubic incision. The first resistance to be overcome is the rectus fascia. Staying close to the bone, pierce the fascia. Once through this, ensure that the needle is oriented toward the vaginal incision, and direct it behind the pubis and toward the finger in the vagina, keeping the needle tip in contact with the bone for the entire retropubic excursion. The endopelvic fascia will provide the last resistance. Pass the needle through this and use the finger in the vagina to guide it out through the vaginal incision (Fig. 86-3). Ensure that the needle did not pierce the vaginal mucosa. Repeat on the opposite side, switching hands for the needle passage.
5. *TVT vaginal pass (catheter guide optional)* (Fig. 86-4): Ensure that the bladder is completely drained of urine. Make paired 1-cm suprapubic incisions directly over the symphysis and 2 cm from midline. Guide the tip of the trans vaginal tape (TVT) needle into one side of the vaginal incision up against the endopelvic fascia at the inferior ramus. Protect the catheterized urethra with a finger, or use the catheter guide to deflect it away. Pass the needle through the endopelvic fascia and behind the pubic bone, ensuring that the

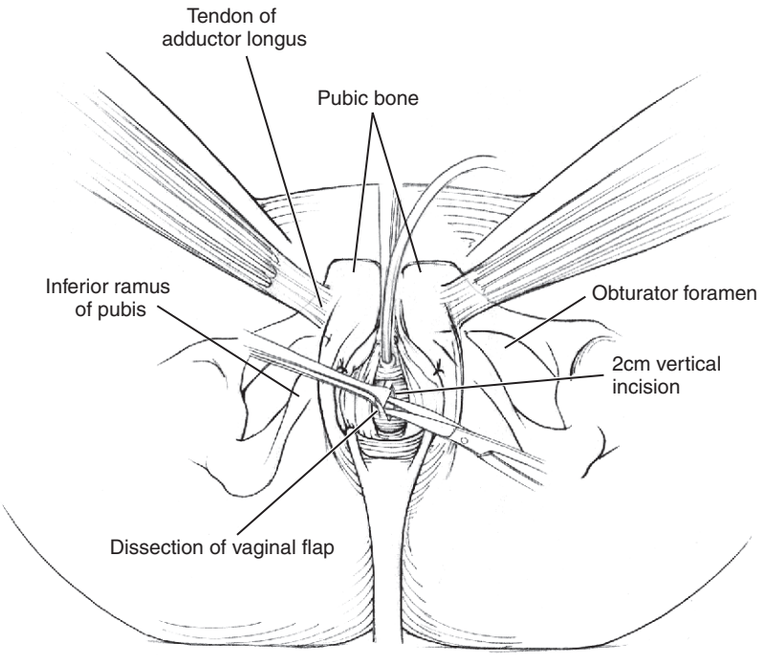

FIGURE 86-1.

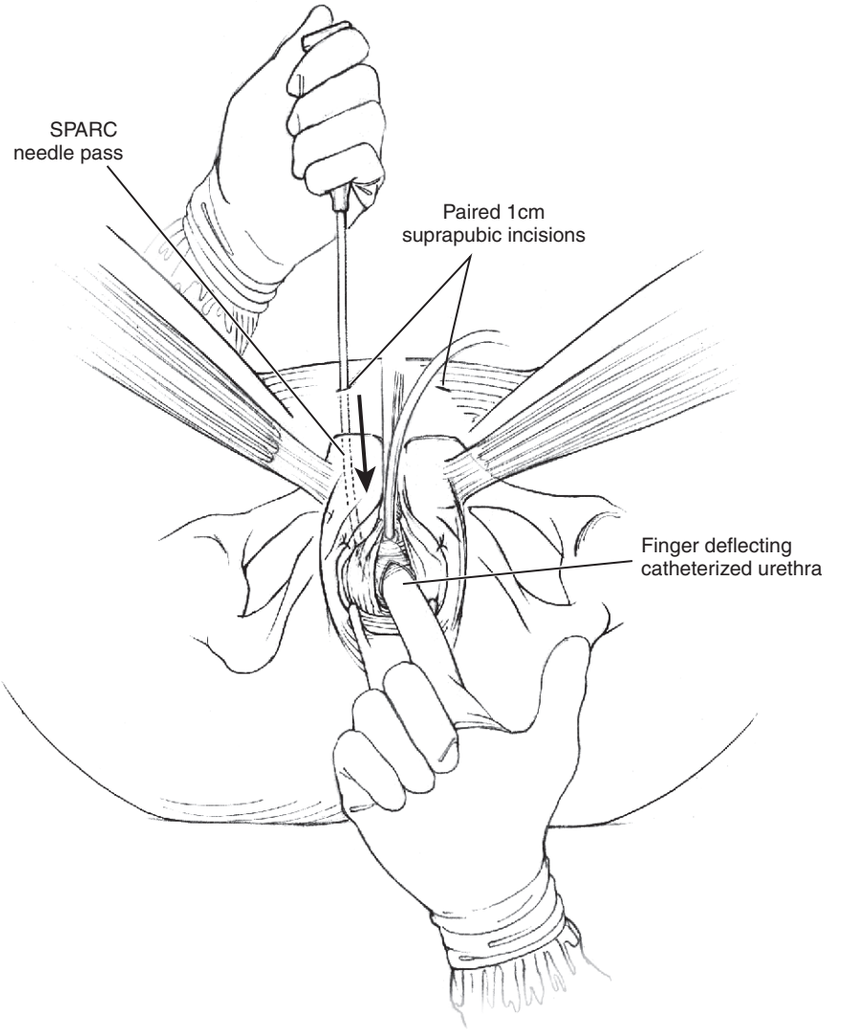

FIGURE 86-2.

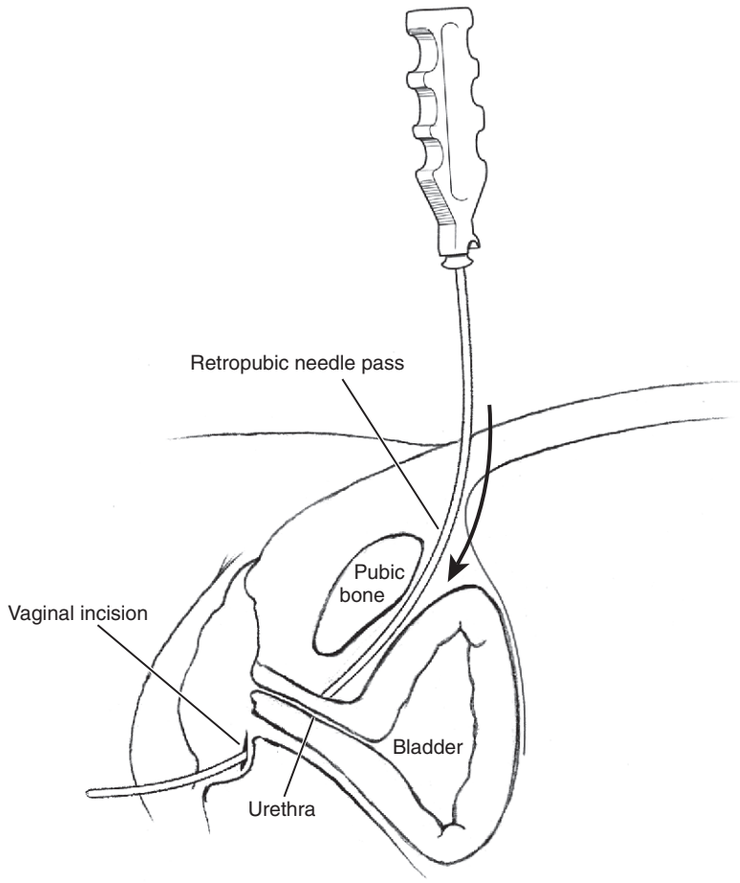

FIGURE 86-3.

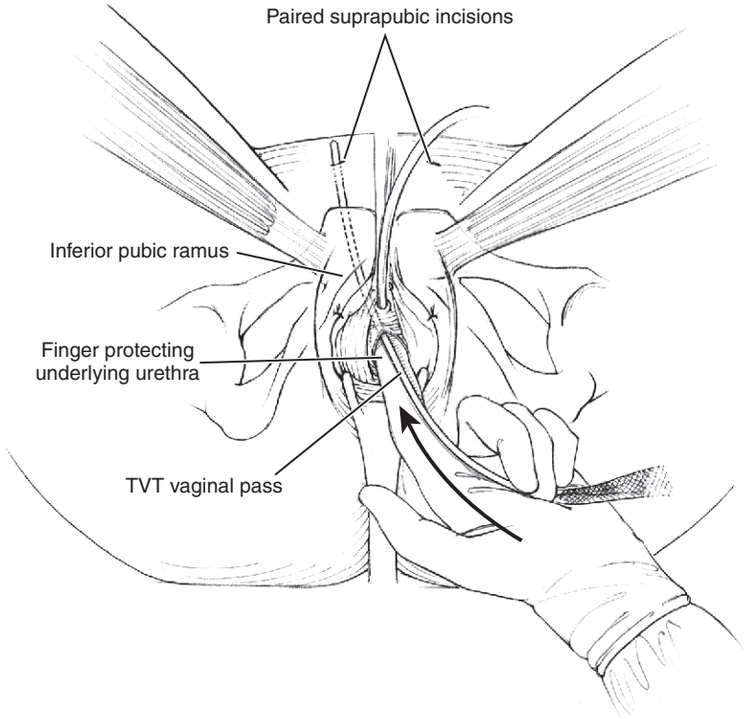

FIGURE 86-4.

needle is in contact with bone for the entire course. Be mindful of the direction of the needle. The next resistance will be the rectus fascia. After passage through the rectus fascia, use the opposite hand to guide the needle out from the skin incision. Repeat on the opposite side.

6. Cystoscopy should be performed. Fill the bladder with at least 300 mL of urine to visualize the entire bladder and mucosa. Use the 30- and 70-degree lenses to definitively see the entire surface. Inspect the urethra as the cystoscope is withdrawn. If a perforation is seen, withdraw the needle and attempt passage again. After correct passage, leave the catheter in for at least 7 days to ensure that the bladder heals. If no perforations are seen, remove the cystoscope and replace the catheter.
7. *Sling passage* (Fig. 86-5): Attach the sling to the suprapubically placed needles and withdraw them to pull the sling into the incision or pull the TVT needles up because the TVT needles already have the sling attached. First, however, grasp the sling in the middle with a small clamp. Leave the plastic sheath over the sling intact. Place an instrument between the sling and the catheterized urethra. A right-angle clamp or Kelly clamp is typically used. Pull up on the sling equally from each side until it is snugged up to the clamp. Trim the ends of the plastic sheath on each side, and grasp one edge of sheath with a hemostat and remove the plastic sheath from over the sling on each arm. Ensure that excessive upward tension is not placed on the sling by holding the instrument between the sling and the urethra firmly. After the plastic sheath is removed, the Kelly clamp should pass easily between the sling and the urethra.
8. *Closure:* Trim the ends of the sling where they emerge from the abdominal incision. Depress the skin when trimming the ends to ensure that the mesh is not protruding from the skin incisions. Curved Mayo scissors work best. Close the abdominal incisions with 4-0 subcuticular synthetic absorbable sutures (SAS) or wound glue. Close the vaginal incision with a running 2-0 SAS. Place antibiotic or estrogen cream–soaked vaginal packing at this time. Postoperatively, the Foley catheter can remain in anywhere from an hour to overnight, unless there was a bladder perforation. The patient must pass a voiding trial before going home. If not, the catheter should remain in and the voiding trial can be repeated in a few days.

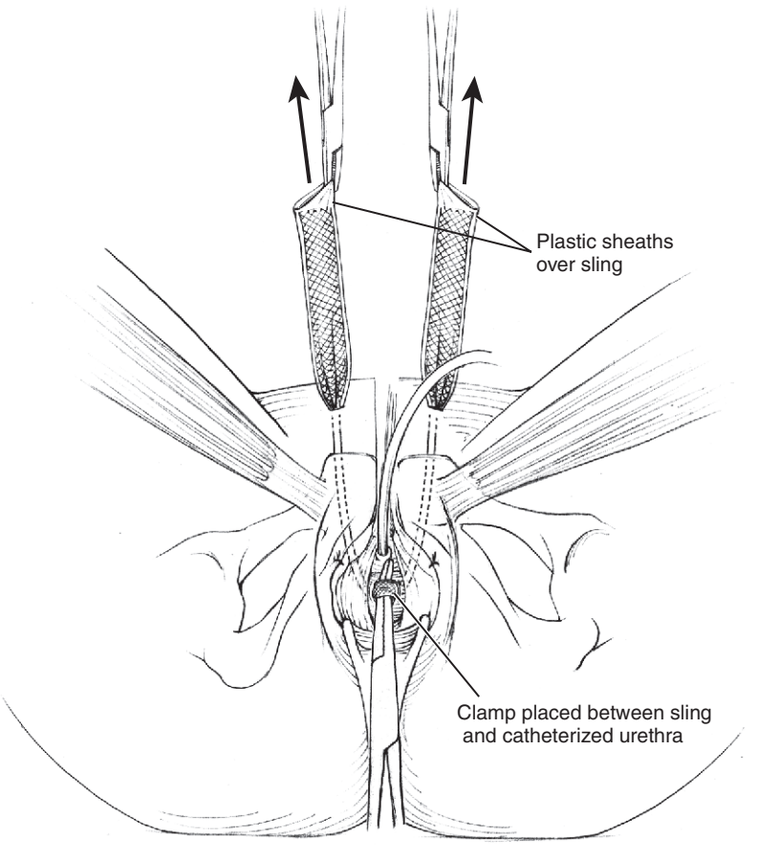

FIGURE 86-5.

Commentary by

VICTOR W. NITTI, MD

The retropubic mid urethral synthetic sling has become the gold standard for the treatment of most types of stress incontinence in women. It is relatively simple, with low morbidity, and a quick recovery. It has a relatively short learning curve for the experienced vaginal surgeon and can be preformed from down to up or up to down at the surgeon's discretion. Since the risk of bladder perforation is about 5-10% it is very important to recognize it. When discovered intraoperatively, the trocar (or sling) can be removed and replace without any compromise in outcomes. However, unrecognized bladder or urethral perforation (sometime falsely called "erosion") can have significant consequences. In cases of bladder perforation, after removal and replacement of the trocar or sling, we generally leave a catheter for 24 hours unless there is significant trauma, in which case a catheter can be left longer. Others have reported not leaving a catheter at all. This may be acceptable in cases on minimal trauma. We have not found the need for routine vaginal packing, unless bleeding is more excessive than normal.

This page intentionally left blank

Chapter 87

Transobturator Midurethral Sling

ROGER R. DMOCHOWSKI AND CHRISTOPHER E. WOLTER

INDICATIONS

Midurethral synthetic slings have become increasingly popular. Initial placement was by the retropubic route; however, alternative approaches, including transobturator, prepubic, and single incision vaginal, now are routinely used. The position of the synthetic mesh relative to the urethra is the same for all sling approaches, although the site of introduction, the route of needle passage, and the potentially damaged structures are different, albeit not mutually exclusive. The indications for placing a transobturator midurethral sling are the same as for those placed via the retropubic route, although this approach may not be as effective in more severe cases of stress incontinence. In addition, this type of sling may be considered when the surgeon wants to avoid the retropubic space, such as in cases of obesity, lower ventral hernia, or history of extensive retropubic or bladder surgery. These slings can also be placed under local anesthesia (usually with sedation) if desired.

SET UP

1. After induction of the selected type of anesthesia, the patient is placed in the lithotomy position. Stirrups that can easily be repositioned during the case are recommended. A full vaginal, lower abdominal, and inner thigh antibiotic skin prep should then be performed, and the patient should be draped to expose the vagina. Access to the obturator region should be made ready. A weighted vaginal speculum should be used, and the labia minora should be retracted with sutures or a self-retaining ring retractor to maximize visualization of the anterior vaginal wall. Place a catheter at this time.
2. Starting 1 cm below the urethral meatus, measure a 2-cm incision vertically. If desired, inject normal saline or dilute lidocaine with epinephrine for hydrodissection. By grasping the vaginal wall just above the incision with an Allis clamp, upward traction can be gained. This also aids visualization. Incise the vaginal mucosa with a #15 blade.
3. *Dissection* (Fig 87-1): Grasp one edge of the incision with another Allis clamp. Dissect a flap of vaginal mucosa away from the underlying urethra using a combination of sharp and blunt dissection. Carry the dissection laterally and superiorly from the incision, toward the inferior ramus of the pubis. In the proper plane, the glistening white surface of the vaginal wall is seen. If the dissection is too deep, the urethra can be injured or venous bleeding can be encountered. Dissect in this direction until the inferior ramus of the pubis is clearly palpable. Do not pierce the endopelvic fascia. Repeat this dissection on the contralateral side.
4. *Outside to inside needle pass* (Fig 87-2): Ensure that the bladder is completely drained of urine. Palpate the obturator foramen. At the horizontal level of the clitoris, make a 1-cm incision immediately below the tendinous insertion of the adductor longus. The sling, when place, should not be in contact with nor through any portion of the tendon so as to avoid postoperative pain syndromes. This should be easily palpated. The incision should be very close to or over the bone. Insert the point of the needle into the incision. Make sure to stay below the adductor longus tendon, and absolutely do not pass the needle through any portion of it. Stay as medial in orientation as possible and pierce the obturator membrane; remain close to bone on the inner aspect of the obturator foramen. Place the opposite index finger in the vaginal incision. Liken the position of the finger to trying to hook the obturator foramen from the inside. Holding the needle device at a 45-degree angle, rotate it into the vaginal incision. Use index finger to guide needle out incision, while protecting the urethra. Stay close to bone through rotation.
5. *Inside to out needle passage* (Fig. 87-3): Ensure that the bladder is completely drained of urine. Make the obturator incision as described for the "outside to inside" needle passage. Place the point of the needle in the vaginal incision and direct it against the inferior ramus of the pubis. Slide the needle tip around the bone and against the endopelvic fascia. Pierce the endopelvic fascia close to the bone. Rotate the needle toward the obturator incision. Pay careful attention to the direction, and ensure that the needle is sliding against the bone. Again, do not pass the needle through any portion of the adductor longus tendon. Also ensure that the path of the needle tip does not stray too far

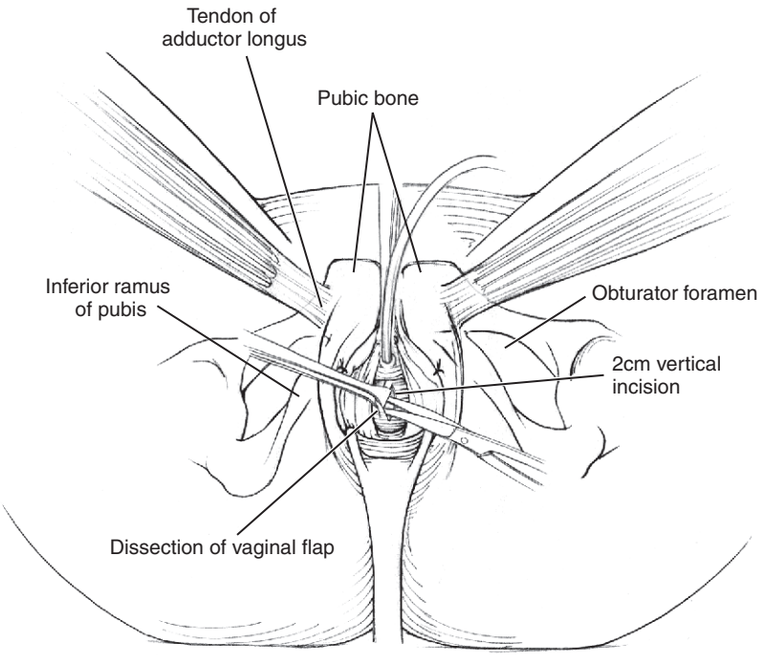

FIGURE 87-1.

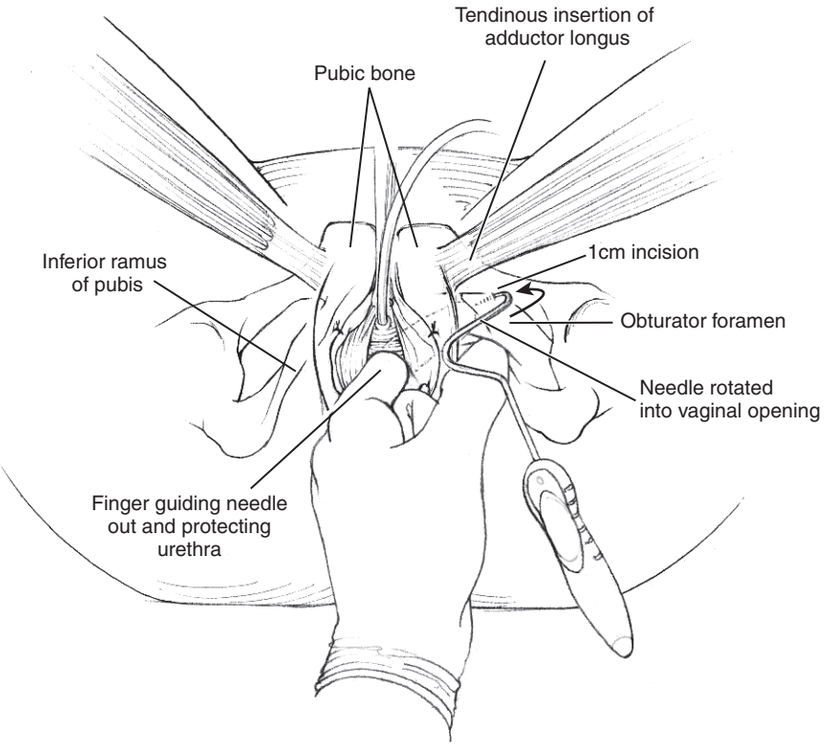

FIGURE 87-2.

lateral into the obturator foramen. Palpate over the obturator incision with the opposite hand and guide the needle out. Repeat on the opposite side.

6. *Cystoscopy*: This part of the procedure should routinely be performed. Make sure that the bladder is filled with at least 300 mL of irrigant so complete visualization can be attained. The 30- and 70-degree lenses should be employed in this. Be sure to carefully inspect the urethra as the scope is withdrawn. If a bladder perforation is found, remove the needle and repeat passage. If the urethra is injured, strongly consider not placing the sling. Replace the catheter at this point.
7. *Pass sling material* (Fig. 87-4): Connect the sling to the needles, or in the case of an "inside to outside" device,

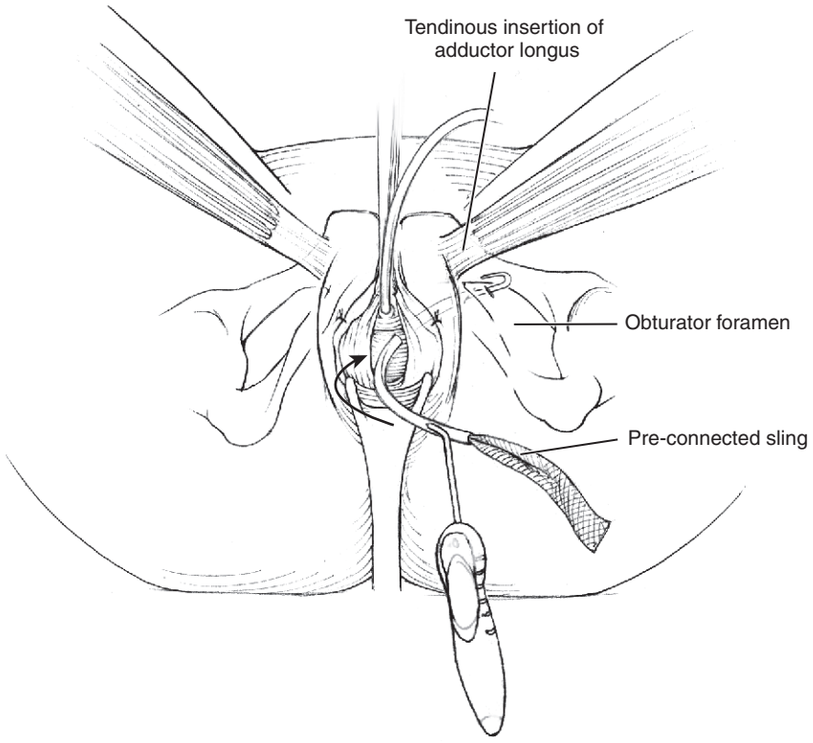

FIGURE 87-3.

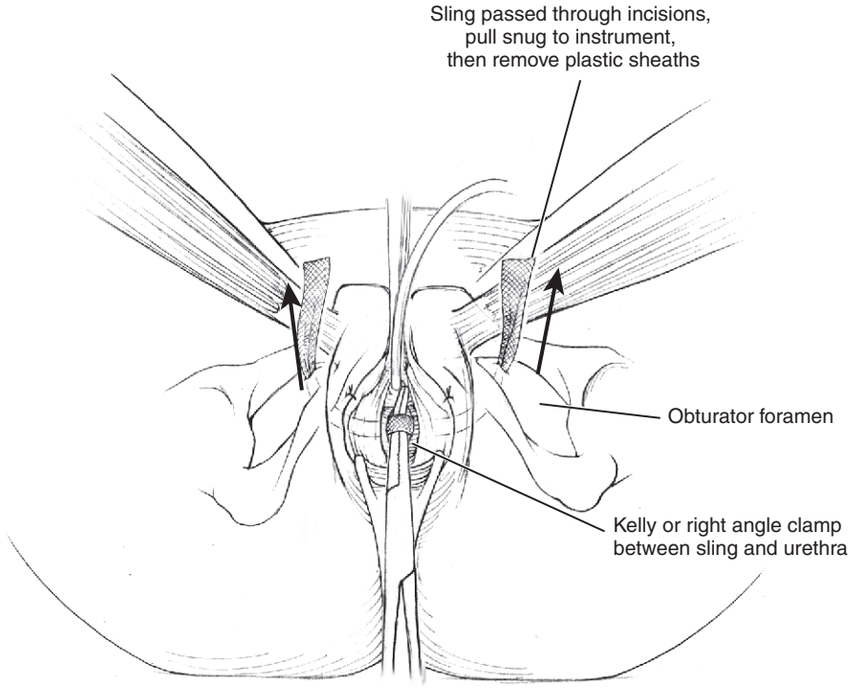

FIGURE 87-4.

the sling should be preconnected. Pass the sling out through the incisions. It is helpful to grasp the middle of the sling with a small clamp. Leave the plastic sheath intact. Place the instrument between the sling and the catheterized urethra. A right-angle clamp or Kelly clamp is typically used. Pull up on the sling material equally from both sides so that it is just snug to the instrument. Trim the ends of the plastic sheath on each side, grasp one edge of sheath with a hemostat, and remove the plastic sheath from over sling. Ensure excessive tension is not placed on the sling by holding the instrument between the sling and the urethra firmly. Tension on the

sling can cause not only incomplete emptying or urinary retention but also chronic pain. After the protective sheath is removed, a Kelly clamp or a right-angle clamp should pass easily between the sling and the urethra.

8. *Closure*: Cystoscopy should be performed to exclude sling entry into the urethra or bladder. This is a recommendation in the current AUA Guidelines for stress incontinence surgery. Trim the ends of the sling where they emerge from the thigh incisions with a curved Mayo scissor. Depress the skin while trimming to ensure that the mesh does not protrude through the incision. Close the thigh incisions with a subcuticular 4-0 synthetic absorbable sutures (SAS) or wound glue. Close the vaginal incision with a running 2-0 SAS. Place an antibiotic or estrogen cream–soaked vaginal packing at this time. The catheter can stay in for anywhere from 1 hour to overnight. Ensure that patient passes a voiding trial before discharge.

Commentary by VICTOR W. NITTI, MD

Transobturator slings have become increasing popular because of ease of surgery, reduced voiding dysfunction and reduced morbidity associated with staying out of the retropubic space. Multiple controlled trails (Level 1 and 2 evidence) have shown the results of transobturator mid urethral slings to be equivalent to retropubic slings in the index patient. Although bladder and urethral injuries are rare, we absolutely agree with the recommendation to perform cystoscopy in all patients during surgery after initial sling/trocar placement. It is also beneficial to position the patient at bit more flexed at the hip (100-110 degrees) to avoid aberrant needle/trocar placement, especially with the inside-out technique. We have found that transobturator slings tend to "tighten" at bit more than retropubic slings when the plastic sheath is removed. We like to place a Hagar dilator (#11) between the sling and the urethra before removing the sheath.

Chapter 88

Bulking Agents for Incontinence and Reflux

EDWARD J. McGUIRE

Bulking agents injected into the submucosal plane of the urethra can improve continence function at least transiently. The most commonly used agents are collagen suspension and carbon-coated metal beads in a gel suspension. There are other agents as well but none is clearly better than the others.

STRESS INCONTINENCE

The best results with these agents have been noted in women with stress incontinence and relative immobility of the urethra, and in elderly women with vaginal atrophy related to estrogen deficiency.

INJECTION TECHNIQUE

The material is injected into the submucosal plane in the urethra in an area just distal to the bladder neck and extending down to the midurethra. Transurethral injection is more accurate and less likely to involve injection deep to the submucosal plane or outside of the urethra proper. Injection sites near the bladder neck are likely to be associated with extravasation into the bladder; if the injection site is distal, into the volitional sphincter, it may be quite painful.

Patients are in the lithotomy position; 2% Xylocaine jelly is injected into the urethral lumen and left there for 5 to 6 minutes. We use a Wolf cystourethroscope modified for bulking agent injection with a needle and a working element requiring only one hand for operation. The instrument is suitable for urethral or ureteral injection. The latter is done to prevent reflux.

The endoscope is advanced into the bladder and then slowly withdrawn until the lens is positioned such that the operator sees the entire proximal urethra from a point just cephalad to the iris like closure of the midurethra related to distal sphincter activity. Turn the endoscope 90 degrees, which puts the tip of the injection needle pointed at the 3- or 9-o'clock position of the urethra. The scope is then tilted so that the lens and needle tip are pointed at the urethral wall at a 30- to 45-degree angle. The needle is advanced until it just indents the urethral mucosa. The entire scope with the needle fixed so it cannot retract is then moved sharply toward the urethral wall until the needle pops into the submucosal space. Return the scope to the neutral position parallel to the long axis of the urethra. Under vision, inject 1 mL 1% lidocaine into the submucosal plane, and then follow with a slow injection of the bulking agent. Fast injections are painful. The needle or the entire scope may be moved slightly forward and back to create more space for the agent. Repeat the sequence on the other side. The urethra will appear to close during the injection; as it does so, the injection can be stopped.

URETERAL INJECTION

Find the orifice. Keep the endoscope in the normal position, advance the needle until it appears at the 6-o'clock position (Fig. 88-1). Position the needle tip just below the orifice and slightly to one side of the orifice—medial is easiest (Fig. 88-2). Indent the bladder mucosa by gently advancing the needle. Penetrate the bladder mucosa with a sharp push of the entire scope with the needle fixed so it cannot retract. Inject 0.2 mL of the agent, usually collagen, so the orifice appears to close into a slit (Fig. 88-3).

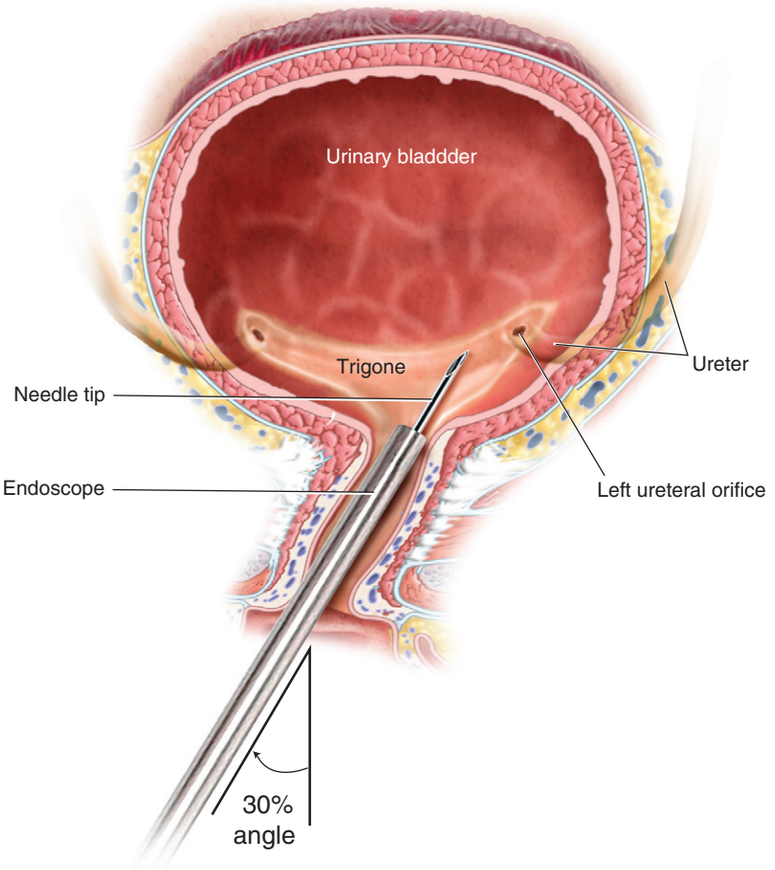

FIGURE 88-1.

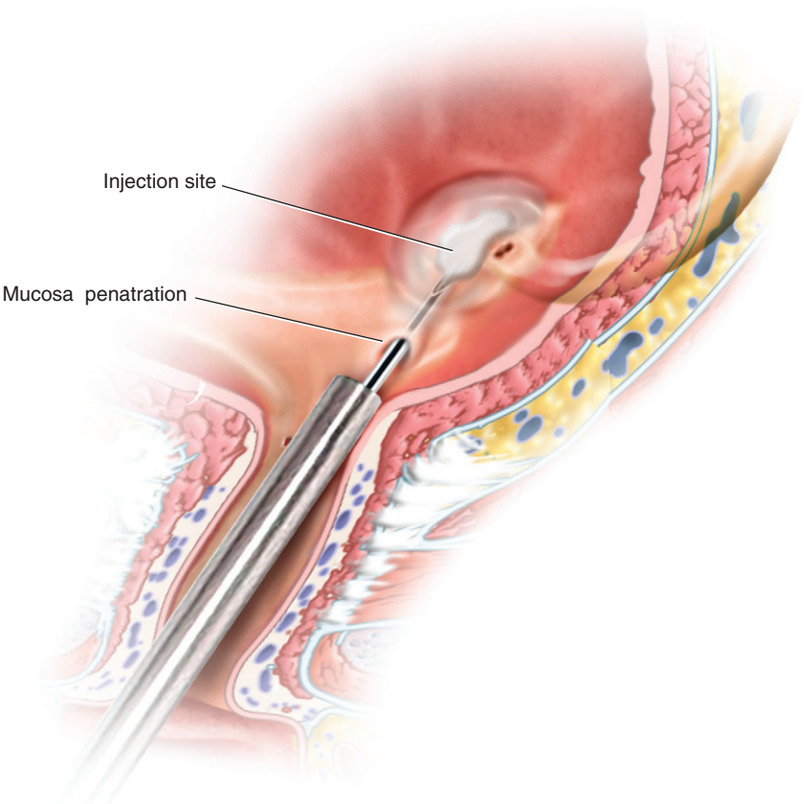

FIGURE 88-2.

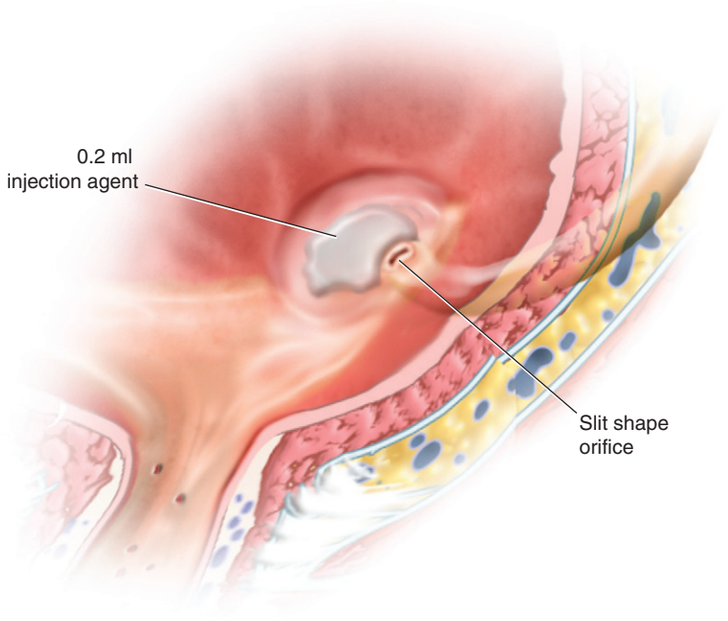

FIGURE 88-3.

This page intentionally left blank

Chapter 89

Technique for Insertion of Artificial Urinary Sphincter

MELISSA R. KAUFMAN

PREOPERATIVE EVALUATION

Although occasional indications for placement of an artificial urinary sphincter (AUS) in females exist, the vast majority of procedures are performed in males and are usually associated with incontinence secondary to prior surgical interventions. First introduced by American Medical Systems in 1973, the current model AMS 800 Urinary Control System has been utilized since 1983. Although AUS implants are also used for posttraumatic incontinence and neurologic compromise, the majority of implants are placed for moderate to severe stress urinary incontinence resulting from radical prostatectomy for prostate cancer. Several alternatives have emerged in the past decade with regard to minimally invasive therapies for male stress urinary incontinence, including placement of a bulbar urethral sling. Although these technologies may be highly effective in the appropriately selected patient with mild to moderate levels of incontinence, the AUS remains the established device for treatment of severe incontinence in this population. Preoperative evaluation often includes assessment with validated questionnaires, voiding diaries, pad weight testing, and functional bladder analysis with urodynamics to rule out primary detrusor dysfunction and identify issues that may adversely influence outcomes. Office cystoscopy is critical for anatomic appraisal of the urethra, urethral sphincter, and bladder neck to identify issues such as vesicourethral anastomotic stricture, which may require intervention before AUS implantation.

Preoperative concerns should additionally include evaluation for urinary infection with treatment if necessary before the day of surgery. Preoperative antibiotics, including coverage for both common urinary and skin pathogens, is recommended as the primary risk for device compromise due to infection is colonization at the time of implantation. The contemporary AMS 800 device is available with impregnation of rifampicin and minocycline (InhibiZone). Current AUA guidelines for perioperative antimicrobial treatment include an aminoglycoside combined with either a first- or second-generation cephalosporin or vancomycin. Deep venous thrombosis prophylaxis should be employed per AUA guidelines; however for the majority of patients, pneumatic compression devices are sufficient.

BULBAR URETHRAL PLACEMENT OF CUFF

Current practice patterns include several common methods for cuff placement, namely perineal and transverse scrotal. Occasional indications for bladder neck placement, such as with neurologic etiologies for incontinence, require an open approach similar to suprapubic prostatectomy. The technique used should be tailored to patient concerns, such as the need for concomitant penile prosthesis placement, as well as surgeon experience. For post-prostatectomy indications, the cuff is designed for optimal outcomes when encircling the bulbar urethra immediately proximal to the bifurcation of the corporal bodies. A perineal approach often provides optimal exposure for this delicate dissection, particularly in patients who have tissue atrophy following radiation therapy.

INSTRUMENTS

A basic instrument set designed for urethroplasty containing smooth Gerald forceps, DeBakey forceps, 3-inch Mayo scissors, Deaver retractors, Richardson retractors, a blunt Adson-Beckman retractor, or a self-retaining scrotal retraction system such as a Scott or Lone Star Retractor System will provide adequate instruments for exposure and placement. Sterile normal saline is used to fill the reservoir and de-gas device components. For surgeons desiring use of contrast agents in the device, a list of approved agents is contained within the manufacturer's operating room manual. Sixty-milliliter syringes are used in conjunction with the blunt needles and tubing connectors supplied in the manufacturer's accessory kit for filling of the pressure-regulating balloon and to create the connections. Additionally included in the

accessory kit is silicon tubing to create rubber-shod hemostats required for clamping of device tubing. A second plastic-draped Mayo stand or stainless steel tray is often used for device preparation to diminish influx of fibers from paper or cloth drapes, which may interfere with the fluid flow, decrease contamination of the device, and protect the components from sharps, which may be present on the sterile field. A polyethylene drape or polyester antimicrobial drapes may also be used to keep the device free from lint and other contaminants on the operative field. Sutures required include several sizes (1-0, 3-0, and 4-0) of absorbable synthetic braided suture.

POSITION FOR PERINEAL APPROACH

Dorsal lithotomy position provides adequate exposure with the surgeon and assistant seated between the legs. Extreme lithotomy is usually unnecessary. Following shaving of the operative site, the infraumbilical abdomen, genitalia, and perineum are prepped with a 10-minute scrub with either iodine or chlorhexidine based skin preparation. A mixture of 50% iodine-based paint solution may be used with a spray bottle to further treat the field during the surgery, with care taken to not spray the antibiotic-treated portions of the AUS device. A 14-French balloon catheter is placed before the initiation of the incision for bladder drainage and urethral identification during dissection. The scrotum may be elevated with towel clips attached to the towels and drapes to improve exposure of the perineum.

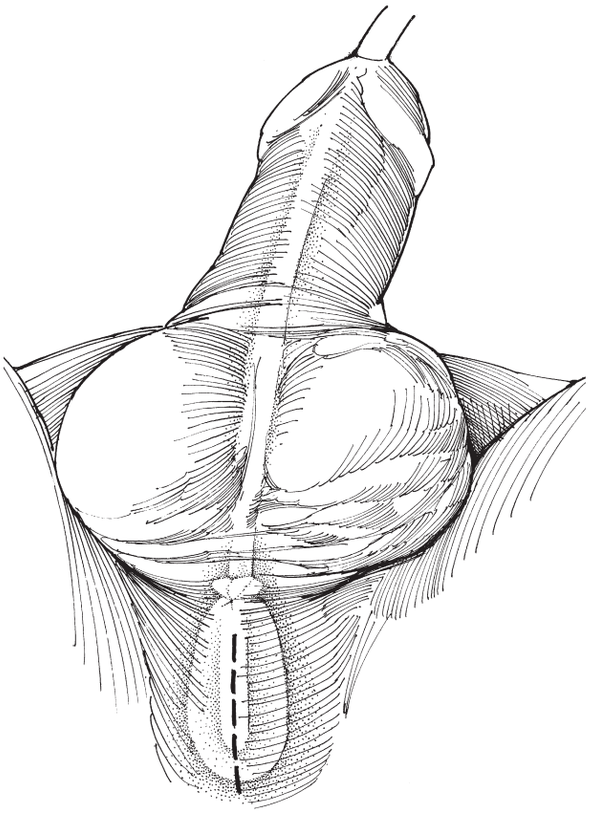

FIGURE 89-1.

INCISION

Use a midline perineal incision, incise vertically onto the bulbospongiosus muscle (Fig. 89-1). Dissect laterally around the bulbocavernosus muscle to preserve the tissue surrounding the urethra and spongiosum (Fig. 89-2). Identify the corporal bodies and use this landmark to begin dissection around the dorsum of the urethra. Using loupe magnification and sharp dissection with Metzenbaum scissors, stay close to the tunica albuginea to avoid injury to the urethra as it passes between the separating corporal bodies. Sharp dissection is highly recommended in that blunt dissection may split the urethra in this position because the tissue may be thin and friable. If the urethra has been entered, it is the standard practice to repair the injury with 4-0 or 5-0 synthetic absorbable sutures, abort the procedure, and delay cuff placement following complete urethral healing. However, in select instances, some surgeons advocate immediate repair of the urethra, moving the proposed cuff site, and delaying activation. For any question regarding site or extent of injury, AUS implantation should be avoided as the risks of erosion and infection are significant in these situations.

Once the urethra has been dissected circumferentially, pass a right-angle clamp and vessel loop to define the space and assist in further dissection. Enlarge the space around the urethra sharply to approximately 2 cm to accommodate the cuff width, working proximally to enable the occlusive cuff to be placed as near to the crura as possible. Measure the circumference by passing the cuff sizer supplied by the

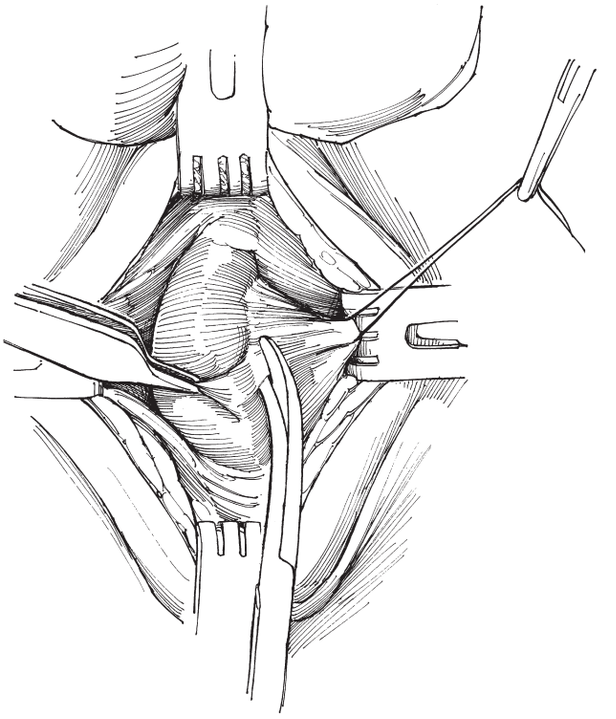

FIGURE 89-2.

manufacturer. It is critical to hold one portion of the sizer fixed against the urethra and pull the alternate tab to determine size. If both sides are deflected in opposite directions, compression may be too great and too small a cuff may be chosen. Alternatively, pass an umbilical tape, vessel loop, or Penrose drain around the urethra to measure circumference (Fig. 89-3). Practice patterns vary with regard to removal of the urethral catheter during sizing, with most surgeons preferring to size the occlusive cuff without the catheter; however, the presence of a small catheter alters this measurement minimally in that excessive tension should not be applied during measurement. A 4- to 4.5-cm cuff is standard for bulbar urethral placement, although sizes from 3.5 to 11 cm are available. Select the appropriate cuff and draw it under the urethra with the right-angle clamp, with the tab end first and mesh backing toward the outside. The right angle should start the pass on the side where the pressure-regulating balloon has been placed to allow the tubing to rotate into appropriate position. Pass the tubing through the locking tab and ensure it is seated appropriately on the connector (Fig. 89-4).

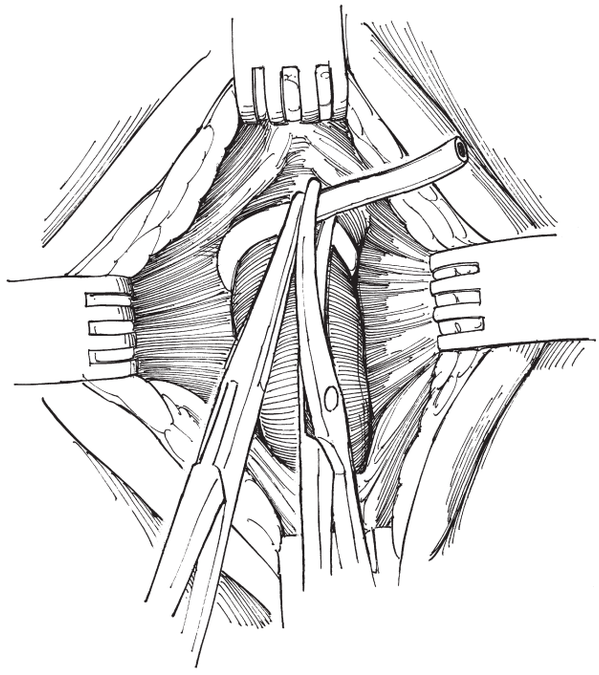

FIGURE 89-3.

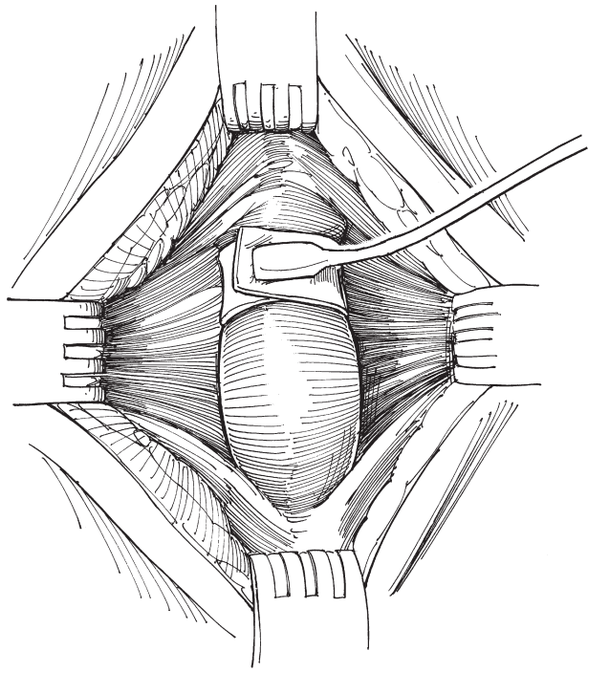

FIGURE 89-4.

PRESSURE-REGULATING BALLOON PLACEMENT

Placement of the pressure-regulating balloon (PRB) may be via a scrotal, perineal, or transverse lower abdominal incision depending on surgical approach, surgeon preference, patient body habitus, or prior surgical interventions. For abdominal placement, a horizontal incision is created on the ipsilateral side to pump placement. After ensuring bladder drainage, rectus or external oblique fascia is incised, underlying muscle is spread, and a small pocket is bluntly created in the preperitoneal or retropubic space. Alternatively, the PRB may be placed through the external inguinal ring by penetrating the floor of the inguinal canal with a fingertip or instrument. Contraindications to this approach for PRB placement may include prior inguinal mesh hernia repair or extensive intra-abdominal surgery. In select circumstances, such as a morbidly obese patient, it may be necessary to place the PRB in an ectopic location such as above the fascia. Select a reservoir with an appropriate pressure range, with 61 to 70 mm Hg used for the majority of patients. Several additional options of pressure ranges are available and the infrequent indications for use of these pressure ranges include bladder neck placement or concern for urethral atrophy and risk of erosion. The fascial incision is closed with absorbable suture (Fig. 89-5). Immediately after seating the reservoir in through the external ring or closing the fascial incision, fill the reservoir with 23 mL of sterile saline. Place a rubber-shod hemostat on the tubing until the connections are to be created.

SCROTAL PUMP

Bluntly dissect a pocket in the anterior scrotum from the inguinal incision and evert the pocket into the incision to clean off the dartos layer and ensure appropriate hemostasis. The pump is placed into the pocket from the inguinal incision and a Babcock clamp may be used to facilitate seating in a dependent location during creation of connections (Fig. 89-6). Tubing is passed from the perineal dissection to the inguinal incision using either a tubing trocar supplied by the manufacturer or a tonsil clamp passed close to the pubic bone (Fig. 89-7). Connect the cuff to the PRB and control pump with the manufacturer-supplied quick connectors (Fig. 89-8). Cycle the device two to three times to ensure appropriate function. In addition to visual confirmation of external cuff compression, many surgeons remove the catheter and perform urethroscopy during the cycling to ensure adequate urethral coaptation when activated. Before closing the incision, deactivate the cuff and lock it into the open position. Close the wound in several layers of absorbable suture to obliterate dead space. Do not place drains. Continue parenteral antibiotics for 24 hours during the inpatient observation. Current AUA guidelines do not recommend continuation of outpatient antibiotics for prosthetic placement; however, many high volume prosthetic surgeons continue to use oral broad-spectrum antibiotics for up to a week following discharge. If used, the urinary catheter is routinely removed the morning after surgery. Maintain AUS deactivation at least until the patient can comfortably manipulate the device and adequate healing has occurred, routinely between 4 and 6 weeks postoperatively. If the tissues are atrophic or affected by radiation, some surgeons would advocate prolonging the period of deactivation.

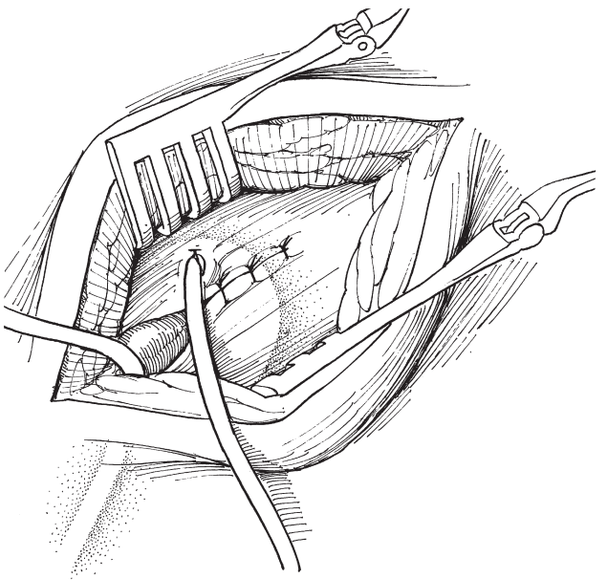

FIGURE 89-5.

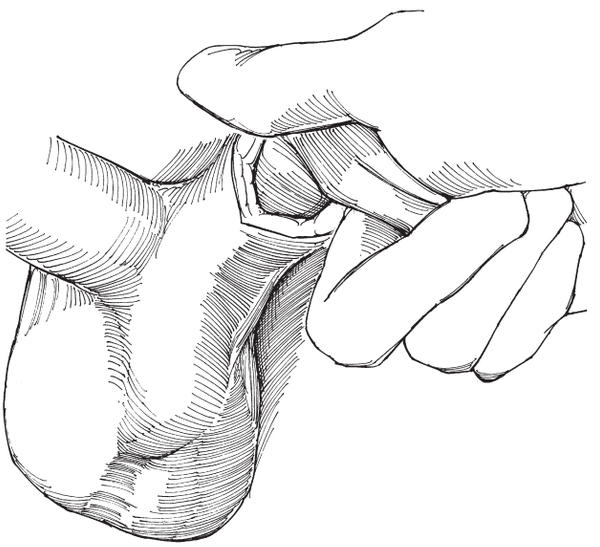

FIGURE 89-6.

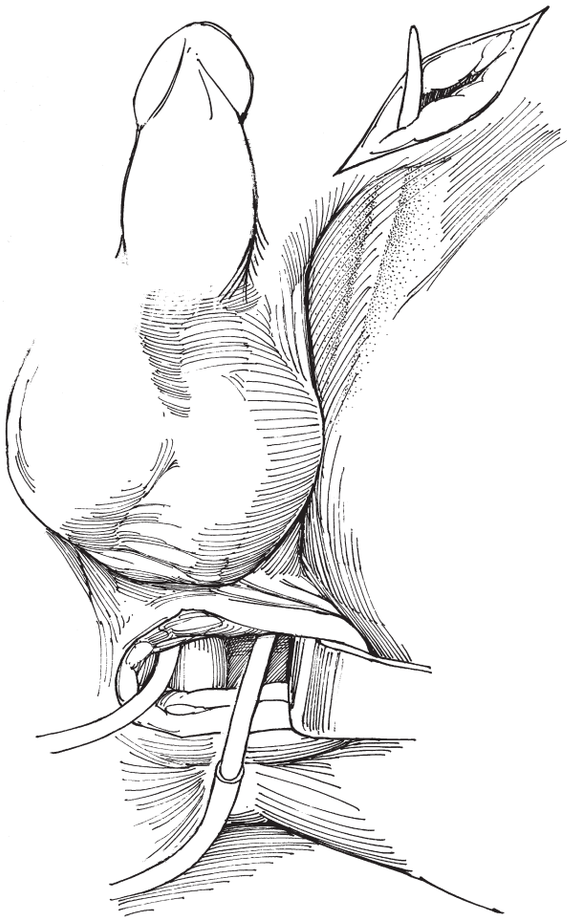

FIGURE 89-7.

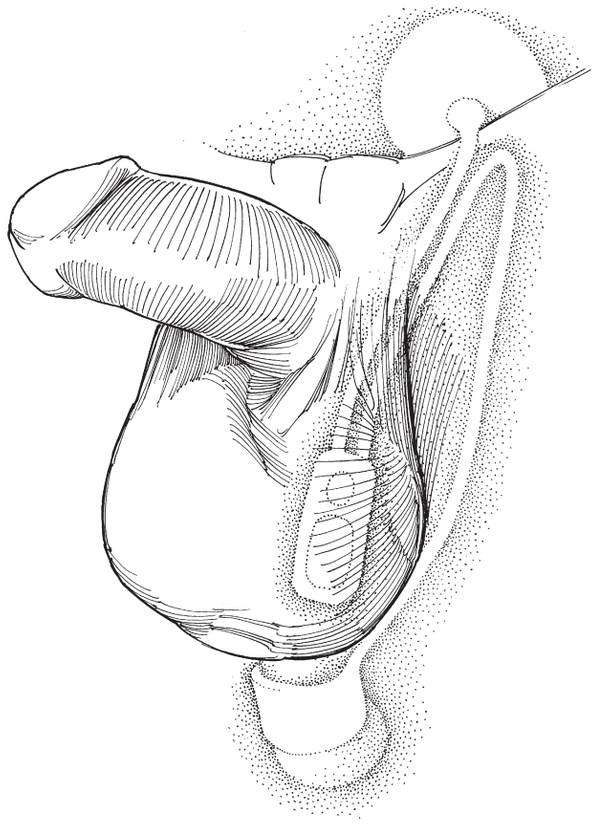

FIGURE 89-8.

POSTOPERATIVE PROBLEMS

Surgeons must remain vigilant to address issues that arise following device implantation, including urinary retention, AUS infection, urethral erosion, urethral atrophy, recurrent incontinence, and mechanical failure.

Infection remains the greatest hazard for prosthetic loss. For this reason, maintain strict asepsis perioperatively and postoperatively. The majority of AUS infections are caused by *Staphylococcus epidermidis* and *Staphylococcus aureus* from skin contamination. General consensus indicates early infections evolve from skin contamination and later infections are due to hematogenous seeding. Early postoperative AUS infections are often accompanied by scrotal or perineal pain, pump fixation, often in combination with erythema, edema, purulent exudate, and possible systemic manifestations such as fever. Traditional management calls for immediate and complete device removal, although in select circumstances without urethral erosion some surgeons may advocate copious irrigation and device reimplantation. Later infections and erosions may be more subtle in onset with a wide variety of presentations, although malfunction of the device is often reported. Cystourethroscopy is critical for evaluation of patients presenting with AUS malfunction to rule out urethral erosion. Long-term catheterization, catheterization without cuff deactivation, and repeated endoscopic manipulations are all risk factors for AUS erosion. Erosions necessitate removal of all components of the device along with catheterization, usually for 1 to 2 weeks to allow urethral healing. Following repeat anatomic evaluation, another device may be placed at 3 to 6 months following explantation.

In the absence of infection or erosion, recurrent stress urinary incontinence after a period of successful AUS may be secondary to urethral atrophy or mechanical malfunction. If fluid loss is not revealed by device interrogation, cystoscopy combined with urodynamics with the device deactivated for catheter placement and reactivated to test for incontinence can provide critical information before further operative interventions. Common techniques to correct for urethral atrophy include downsizing of the cuff, placement of a tandem cuff, or transcorporeal cuff placement.

For urinary retention immediately postoperatively, first ensure cuff deactivation. If catheterization is required, with a deactivated cuff, place a small 10- to 12-French catheter and leave indwelling for as short a period as feasible (<48 hours).

Suggested Readings

Ballert K. (2010). Complications of surgery for male incontinence. In: Taneja S, ed. Complications of urologic surgery, 4th ed. Philadelphia: Saunders, pp. 593-603.
Bauer RM, et al. (2011). Contemporary management of postprostatectomy incontinence. Eur Uro 59(6):985-996.
Chartier-Kastler E, et al. (2011). Artificial urinary sphincter (AMS 800) implantation for women with intrinsic sphincter deficiency: a technique for insiders? BJU Int 107(10):1618-1626.
Flynn BJ, Peterson AC, Webster GD. (2007). Evaluation and management of intrinsic sphincter deficiency after radical prostatectomy. AUA Update Series 26 (Lesson 15).
Forrest JB, et al. (2009). AUA Best Practice Statement for the prevention of deep vein thrombosis in patients undergoing urologic surgery. J Urol 181(3):1170-1177.
Peterson AC, Webster GD. (2011). Artificial urinary sphincter: lessons learned. Urol Clin North Am 38(1):83-88.
Wessells H, Peterson AC. (2007). Surgical procedures for sphincteric incontinence in the male: the artificial genitourinary sphincter and perineal sling procedures. In: Walsh PC, Retik AB, Vaughan ED, Jr., Wein AJ, eds. Campbell's urology, 9th ed. Philadelphia: WB Saunders, pp. 2290-2305.
Wilson SK, et al. (2010). New enhancements of the scrotal one-incision technique for placement of artificial urinary sphincter allow proximal cuff placement. J Sex Med 7(10):3510-3515.
Wilson LC, Gilling PJ. (2011). Post-prostatectomy urinary incontinence: a review of surgical treatment options. BJU Int 107(Suppl 3):7-10.
Wolf JS Jr, et al. (2008). Best practice policy statement on urologic surgery antimicrobial prophylaxis. J Urol 179(4):1379-1390.

Commentary by

VICTOR W. NITTI, MD

After almost 3 decades the current artificial urinary sphincter still remains the gold standard for the treatment of male stress urinary incontinence. It can be implanted via a single incision (penoscrotal) or two-incision (perineal and suprapubic). In the majority of cases we prefer the two-incision approach which gives a bit more flexibility as to where the cuff can be placed. The reservoir can also be implanted by opening the rectus fascia, either in the midline or lateral to the midline, and entering the retropubic space. We usually make a small (4 cm) transverse incision about 3 cm above the pubic bone beginning at the midline and extending laterally. The lateral border of the rectus muscle is identified and retracted medially. The transversalis fascia can be visualized and opened under direct vision so that a pocket can be made in the retropubic space. We like to tunnel the tubing of the reservoir under the rectus muscle exiting at the medial border. This protects the tubing during closure of the rectus fascia.

Section XV

BLADDER RECONSTRUCTION

Vesicovaginal Fistulas

This page intentionally left blank

Chapter 90

Transvaginal Repair of Vesicovaginal Fistula

FRANK HINMAN, JR. AND ROGER R. DMOCHOWSKI

TIMING OF REPAIR

Proceed as soon as the patient has recovered enough to physically allow reoperation, usually within 2 or 3 weeks. Otherwise wait until the inflammation around the fistula tract subsides. For small fistulas less than 2 to 3 mm in diameter, try fulgurating the lining by inserting a Bugbee electrode into the tract vaginally or cystoscopically and applying minimal current; then leave a catheter in place for 2 to 3 weeks.

Preliminaries

Perform intravenous urography or retrograde pyelography to be sure that the upper tract is normal. A displaced or partially obstructed ureter suggests a ureterovaginal fistula, in which case retrograde ureterography is needed to be certain such a fistula is not missed. Perform cystoscopy on the patient and ascertain the degree of induration and fibrosis related to the fistula and also the proximity of the fistula to the ureteral orifices. Examination of the vagina with the cystoscope may also be useful. For detection of small fistulas, pack the vagina and instill dilute methylene blue intravesically. Blue stain on the pack proves the presence of a vesicovaginal fistula. If the pack is not stained, the diagnosis is ureterovaginal fistula unless reflux is present. If all else fails because the fistula is so minute, place the patient in the knee-chest position, fill the bladder with air, and perform cystoscopy of the vagina looking for air bubbles. Alternatively, perform vaginography with the introitus occluded by a balloon, or instill air in the vagina and look for bubbles cystoscopically. If, on intravenous urography, the ureter appears involved and preliminary tests for vesicovaginal fistula are negative, suspect a ureterovaginal source for the leakage.

Caution the patient about the chance for successful closure (90% for an initial repair). The possibility of ureteral injury, the possibility of change in vaginal caliber, and the chance for changed voiding habits in the postoperative period.

Approaches

The first operation is the one most likely to succeed. Select an approach with which you feel comfortable. The *vaginal approach*, with the patient in the lithotomy position, is easiest on the patient. Increased visualization and easier access are found with the jack-knife (Kraske) position, although administration of anesthesia is more difficult. Previous attempts at closure or prior radiation may preclude a vaginal approach.

An *abdominal approach* is better for fistulas at the apex of the vaginal vault; for those larger than 1 cm, especially with indurated margins; for multiple fistulas, and for patients with intra-abdominal conditions that require procedures such as cystoplasty. A history of prior pelvic radiation and/or multiple abdominal procedures may also indicate the need for abdominal approach.

The patient may douche with povidone-iodine solution the night before surgery. Give gentamicin and ampicillin intravenously 1 hour before the operation. Apply intermittent compression stockings.

TRANSVAGINAL REPAIR

Instruments: Provide a Basic pack, a GU fine set, a cystoscopy set, a weighted posterior vaginal retractor, a Lowsley prostatic tractor, a 4-French tapered ureteral catheter, an 8-French 3-mL balloon catheter, and a 24-French 5-mL silicone balloon catheter.

If the fistula is close to the orifices, place ureteral catheters cystoscopically.

Position: Use the overflexed lithotomy position. Prepare and drape the patient. Place a suprapubic catheter by the Lowsley tractor technique. Consider inserting ureteral catheters if the defect is near the trigone. Suture the labia to the inner thighs (Fig. 90-1), or retract them with the hooks of a Scott ring retractor. Place a weighted posterior vaginal retractor. If more exposure is needed, make a Schuchardt relaxing incision at the 5- or 7-o'clock position. Place a tenaculum or two heavy sutures in the cervix for traction. Insert a 4-French tapered ureteral catheter directly through the fistula from below or, if that is not possible, cystoscopically from above. Or try traversing it with a lacrimal probe. If possible the tract should be cannulated with an appropriate instrument such as a catheter or stent or guide wire for purposes of identification. Infiltrate the area with epinephrine solution or injectable

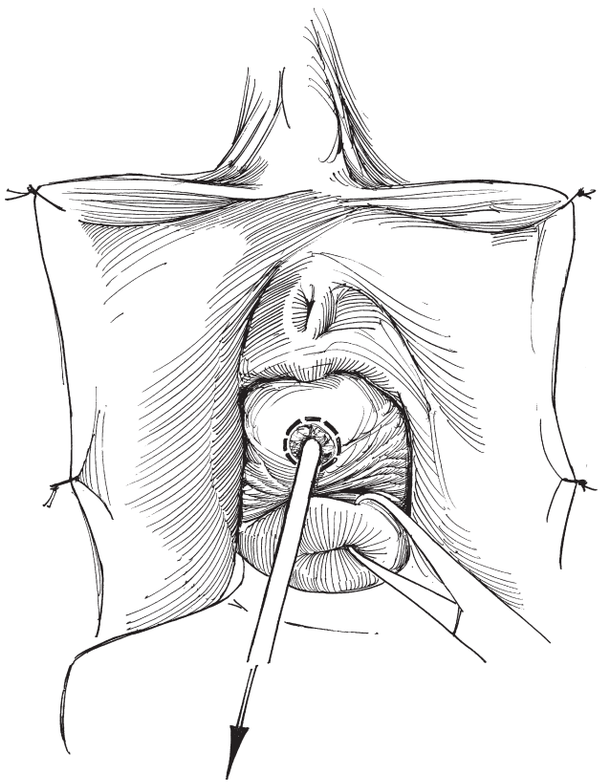

FIGURE 90-1.

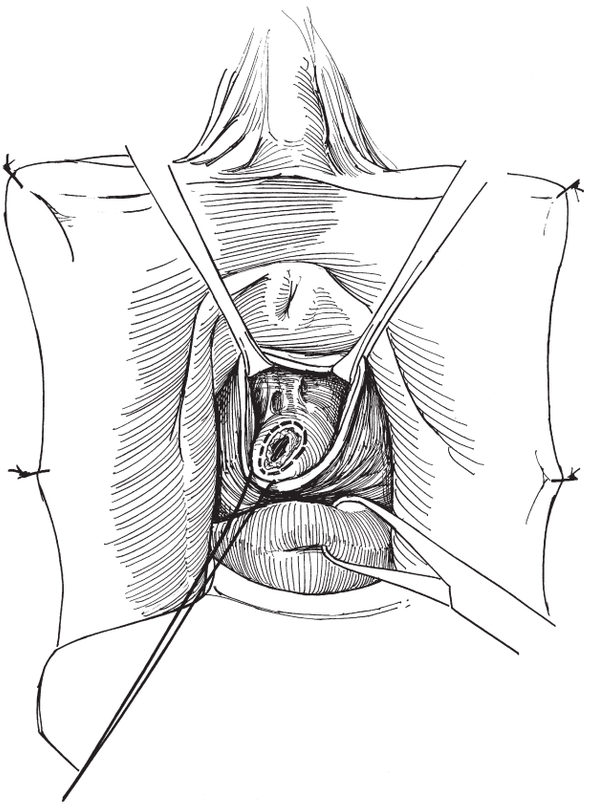

FIGURE 90-2.

solution. Incise the vaginal mucosa and perivesical fascia around the fistula well outside the scarred tissue. Using a delicate technique to avoid further tissue damage, develop a plane between the mucosa and fascia and another between the fascia and the bladder wall.

Thoroughly mobilize the bladder wall, but do not excise the fistula. Rather, trim its edges and use the scarred margins for placement of sutures (Fig. 90-2).

Develop a peritoneal flap (Raz) by dissecting along the anterior vaginal wall until the anterior cul-de-sac is reached and mobilizing the peritoneal edge from the back wall of the bladder without opening into the peritoneum. After closing the vesical opening, tack the double flap over the repair with interrupted 2-0 synthetic absorbable sutures (SAS). Also, it may be possible to use a rotational flap of de-epithelialized vaginal wall for purposes of interposition graft. This is usually best obtained in the immediate area next to the incision for fistula closure. The graft should be rotated on a separate vascular pedicle for purposes of interposition over the primary repair.

Close the vesical defect vertically with one layer of carefully placed interrupted 3-0 chromic catgut (CCG) sutures, inverting the scarred edges (Fig. 90-3). *Alternatively*, close the defect transversely with a running locking 3-0 SAS that includes the full thickness of the vaginal wall and some of the bladder wall. Add a vertical row of Lembert sutures (see Fig. 4-9), folding the surface upon itself.

Bring the layer of perivesical fascia together with a transverse row of 3-0 CCG sutures. Bring the vaginal flap over the repair, and close the vaginal mucosa (Fig. 90-4A). Place a vaginal pack that has been soaked in antibiotic. Tape the suprapubic and urethral catheters in place, and connect them to drainage (Figures 90-4B, C).

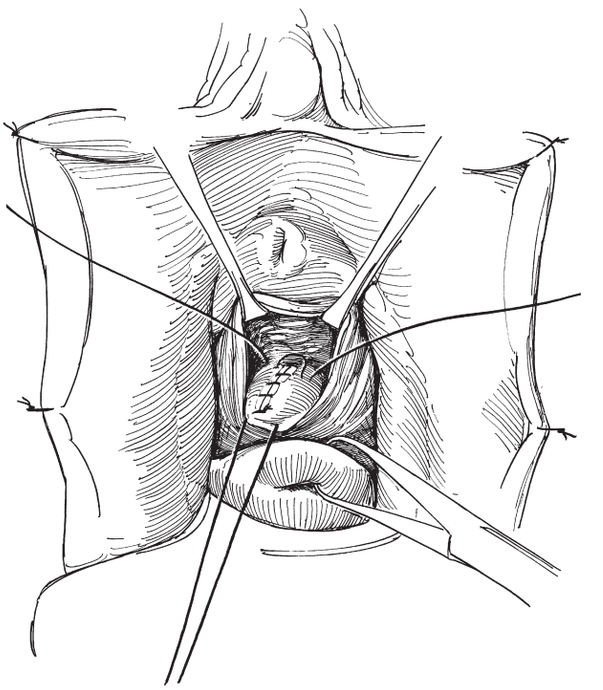

FIGURE 90-3.

INVERTED U-INCISION FLAP REPAIR

An inverted flap not only gives more exposure for the repair but also completely covers the area of the defect, especially if a portion of the vaginal mucosa is excised proximally (Fig. 90-5).

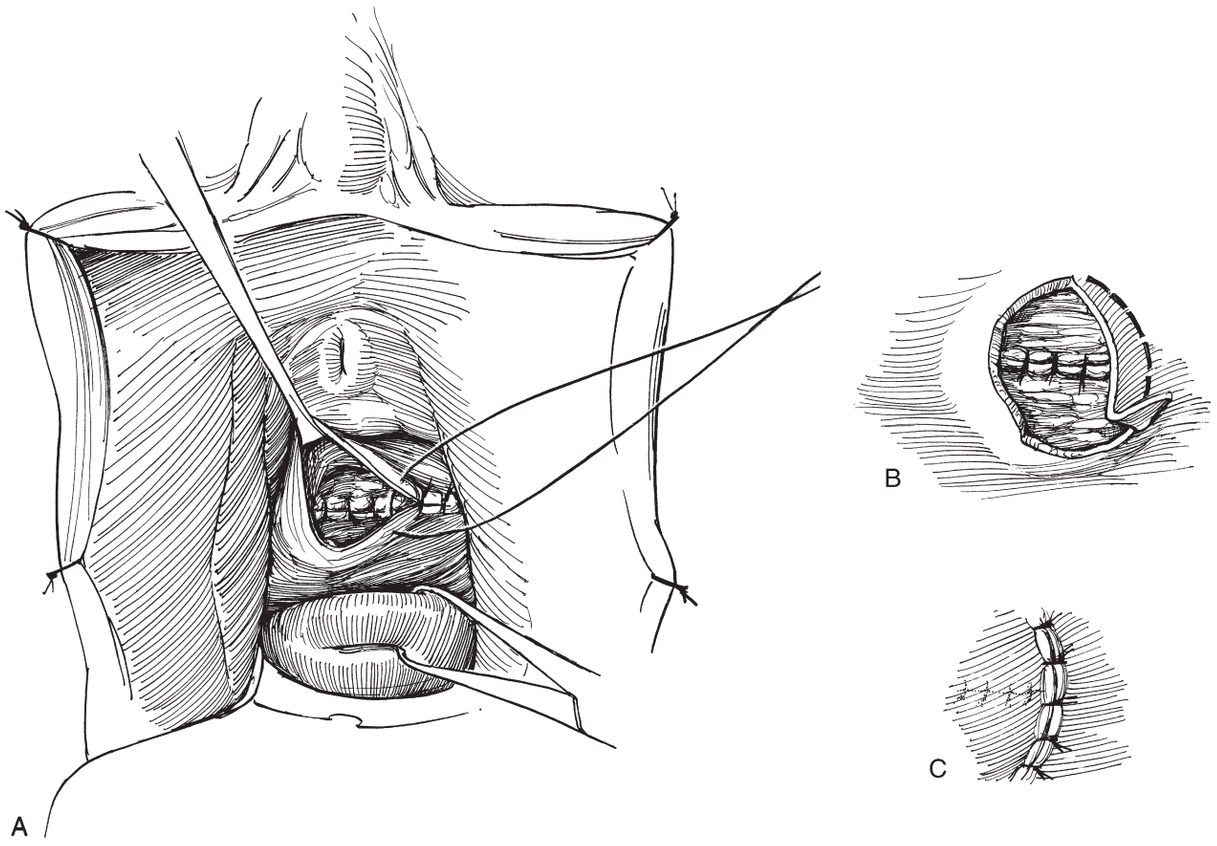

FIGURE 90-4.

Place a suprapubic tube with the Lowsley tractor technique and a urethral catheter. Infiltrate the anterior vaginal wall with saline, and raise a U-shaped flap with the apex adjacent to the fistula. Insert a balloon catheter through the fistula. Dissect the vaginal wall around the fistula, and trim it in the area superior to the fistula so that with closure the suture lines do not overlap. Trim the edges of the fistula. Put traction on the catheter to allow closure of the fistula transversely with a running locking 3-0 SAS through the full thickness of the vaginal wall and including part of the bladder wall. Withdraw the catheter as the last stitches are placed. Reinforce the closure with interrupted inverting 3-0 Lembert sutures (see Fig. 4-9) placed vertically in the prevesical fascia (not shown). Test the closure by instilling dilute methylene blue through the cystostomy tube. If the closure looks tenuous or is a repeat procedure, insert a Martius labial flap (see Figs. 90-6 and 90-7). Bring the vaginal flap over the suture line and approximate it with interrupted 3-0 SAS. Pack the vagina with povidone-iodine gauze.

Care After Vaginal Repair

Suture the suprapubic catheter to the skin. Connect both catheters to bag drainage by sterile technique. Continue antibiotic coverage. Discharge the patient in 3 to 4 days, after giving instruction on the care of the catheter and the risks of vesical overfilling. Provide anticholinergic medication. Stop the medication after 10 to 14 days, wait a day, remove the urethral catheter, and perform voiding cystourethrography through the suprapubic tube. If healing is satisfactory, clamp the catheter for a trial of voiding. (Expect frequent voiding because the bladder has contracted after long disuse.) Local topical estrogens may be used, especially after the acute healing phase. (In the post menopausal woman, topical estrogen should also be considered in the pre-operative phase to establish an appropriate environment for wound healing). Instruct the patient to abstain from intercourse for 6 weeks. For bleeding, pack the vagina and place the patient at bed rest.

COLPOCLEISIS (LATZKO)

Consider partial colpocleisis if the fistula lies in the vault of a deep vagina. Perform a Schuchardt incision for access. Extensively excise the scar tissue of the vaginal wall around the fistula both proximally and distally. Invert the vesical opening into the bladder lumen in two layers. Obliterate the vaginal vault by approximating the edges of the denuded area of the vaginal wall with two transverse rows of interrupted sutures. Colpocleisis should only be considered in individuals who are not sexually active given the likelihood of vaginal shortening associated with this procedure. Although these techniques are largely successful, they can substantially change vaginal caliber and capacity.

INSERTION OF FLAPS

Closure with Bulbospongiosus Muscle Flap (Martius)

Close the bladder defect, leaving the vagina open to receive the flap. Mark a vertical incision in the labium minus (Fig. 90-6).

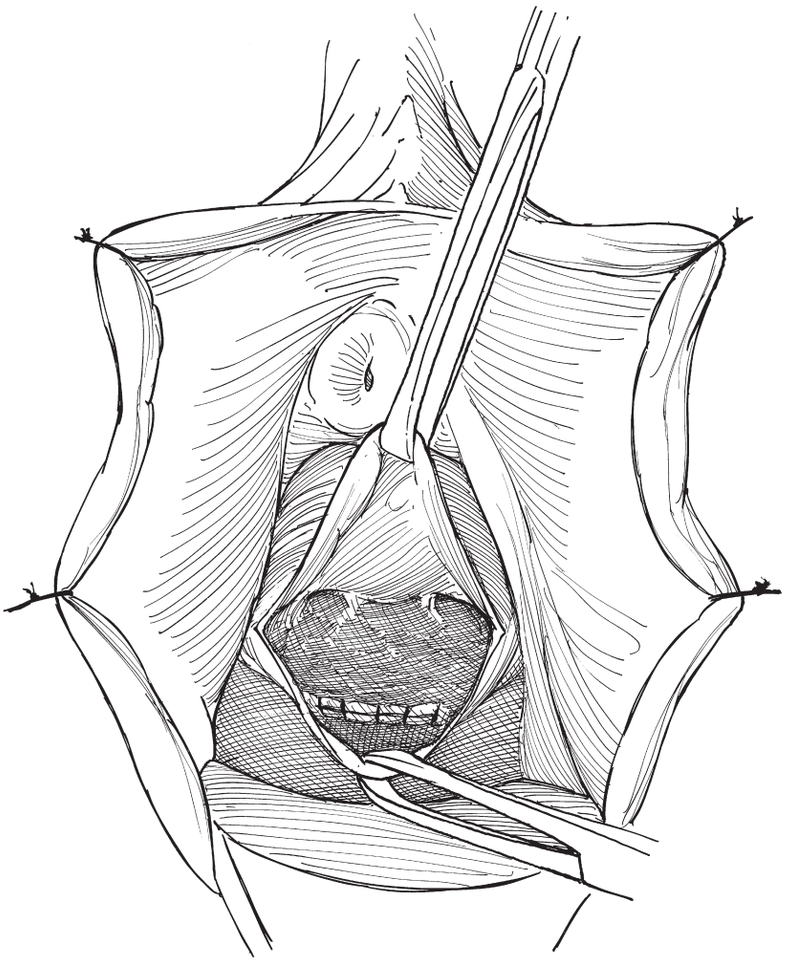

FIGURE 90-5.

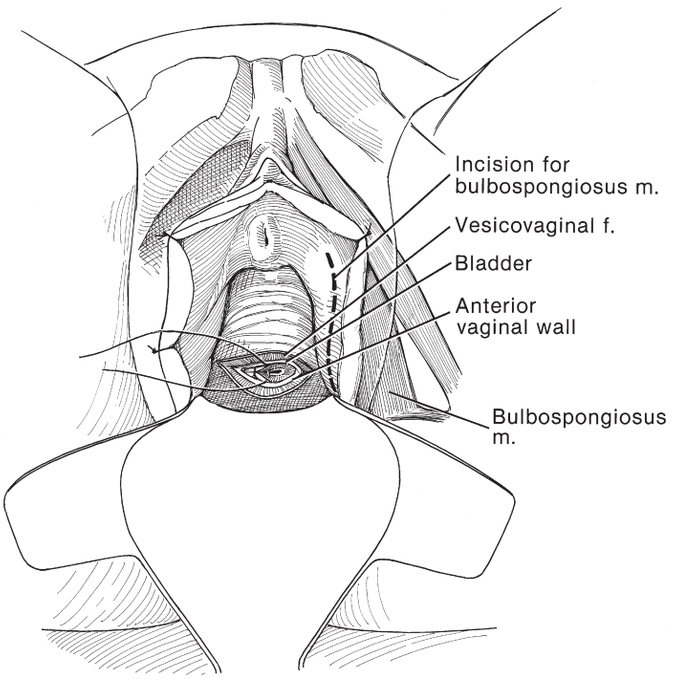

FIGURE 90-6.

Incise the labium minus vertically, and expose the bulbospongiosus muscle with its covering of fat. Mobilize both muscle and fat with part of the vestibular bulb on its posterior pedicle. The complex is supplied by the deep perineal branch of the external pudendal artery that enters the muscle near its point of origin. Divide the muscle anteriorly and check its viability. Bluntly tunnel along the upper portion of the descending pubic ramus beneath the vaginal vault, and draw the muscle flap to the site. Suture it over the repair with 3-0 SAS (Fig. 90-7). For additional security, fasten it to the periosteum of the opposite pubic ramus. Close the labial incision over a small Penrose drain, and close the vaginal wound by approximating the full thickness of the vaginal wall.

Closure with Labial Fat Pad Flap

Instead of mobilizing the bulbospongiosus muscle itself, dissect through the subcutaneous fat to reach the labial fat pad overlying the muscle. Preserve the blood supply from the pudendal vessels that enters posteriorly, and proceed as in the previous paragraph.

If a defect is present in the vaginal surface, leave a patch of labial skin attached to the Martius graft, and use it to fill the defect.

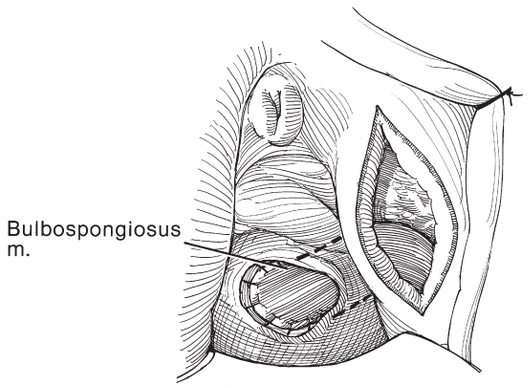

FIGURE 90-7.

Closure with Island Flap (Lehoczky)

Make a Schuchardt episiotomy incision. Proceed to close the fistula as described in Steps 1 to 4. Raise a 3-to 4-cm skin island from the labium majus on the side opposite the episiotomy, to include the underlying adipose tissue and the internal pudendal artery and pudendal nerve (Lehoczky island flap). Make a tunnel under the bulbocavernosus muscle, and suture the island in the defect. Close the episiotomy and the donor site. Leave a catheter in place for 2 to 3 weeks.

Closure with Gracilis Myocutaneous Flap

Prepare the left (or right) leg from the lower abdomen to below the knee. Also prepare the vulva and vagina. Drape the area appropriately. A cystostomy tube may be placed. Insert a 22-French 5-mL balloon catheter urethrally. Place a weighted retractor.

First trim the rim of the fistula. Enter the plane of cleavage between the bladder and the anterior vaginal wall, and continue dissecting until the bladder is freely mobilized so that the edges of the fistula can be brought together without tension (Fig. 90-8A). Dissect especially deeply on the left side where the new muscle will enter. With large fistulas, this much mobilization may not be possible and dependence must be placed on the transplanted muscle. Place a vaginal cystostomy unless the fistula is near the bladder neck, in which case insert a 24-French 5-mL balloon catheter through the urethra, or, preferably, place a suprapubic cystostomy.

Close the fistula in one layer with interrupted 4-0 SAS (see Fig. 90-8B) (extra layers merely add extra suture material without adding strength).

Raise a gracilis myocutaneous flap (see Fig. 5-9).

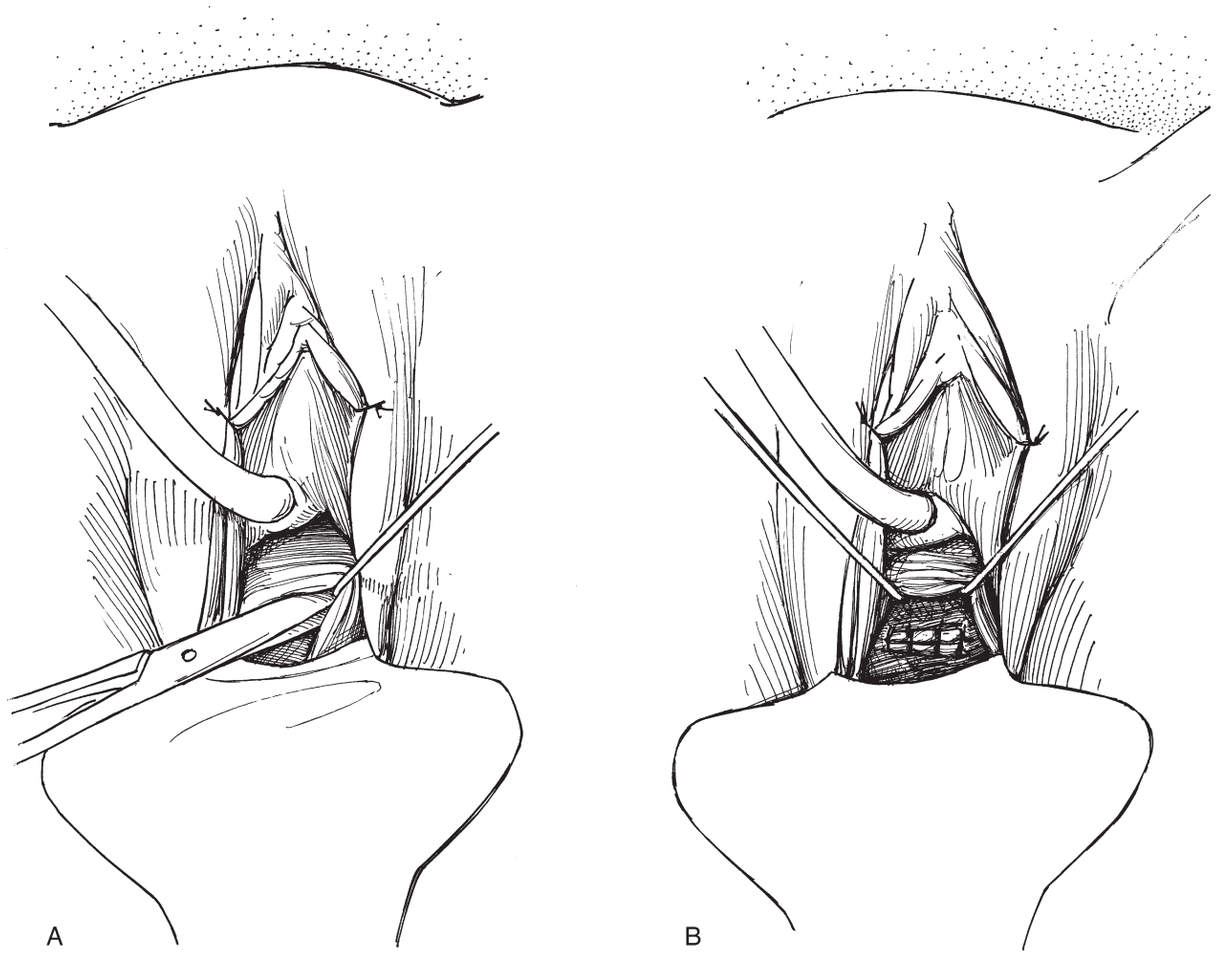

FIGURE 90-8.

VICTOR W. NITTI, MD

Commentary by

It is our practice to repair most uncomplicated vesicovaginal fistulae that are amenable to a vaginal repair at the time of presentation. Allaying the patient's anxiety and discomfort produced by the fistula is well worth the extra time it may take to preform a repair in the early post- operative period. Several authors have demonstrated equivalent result with early vs. delayed repair. Regardless of the type of vaginal repair that it chosen, we believe that success starts with proper identification and control of the fistula prior to making any incisions. The technique described above, placing a small Foley catheter into the fistula, is extremely helpful.

In many cases it is beneficial to place a tissue flap between the repair bladder and the vagina. The easiest flap to utilize is the peritoneal flap. This works well for high fistulae. The peritoneum can be mobilized off of the vaginal wall at the most posterior (proximal) vaginal flap. Be sure that enough peritoneum is mobilized to allow for a tension-free advancement over the fistula. In cases of immediate fistula repair after hysterectomy, the surgeon may enter the peritoneum during creation of vaginal flaps and mobilization of the fistula. When this happens, there is abundant peritoneum to create a flap.

Chapter 91

Transvesical Repair of Vesicovaginal Fistula

WENDY W. LENG AND SHELBY N. MORRISROE

TRANSVESICAL REPAIR

Timing of Repair

Optimal time between fistula diagnosis and repair remains controversial. However, if an iatrogenic injury is diagnosed early, repair can be attempted as soon as the patient has recovered physically to allow reoperation. Otherwise, wait a minimum of 6 to 8 weeks for inflammation to subside. Complex irradiation fistulas require an entirely different timetable for repair. The general consensus is that spontaneous fistula manifesting after radiotherapy should not be repaired in less than 12 months to allow the early and late stages of radiation injury to run its course. However, in the setting of preoperative radiotherapy with extirpative surgery leading to fistula formation, earlier repair can be attempted.

Preoperative Evaluation

Primary transvesical repair of uncomplicated vesicovaginal fistulas above the inter-ureteric ridge is highly successful with minimal morbidity and hospital stay comparable to those of the transvaginal approach. Thorough vaginal examination and cystoscopy may require the administration of intravesical dye to pinpoint the fistula site. It is then important to evaluate the relation of the fistula to the ureteral orifices. Upper tract studies are essential to assess the integrity of the entire collecting system as other fistulas may coexist. Any question of cancer recurrence as a cause of fistula formation demands a biopsy before reconstruction. Complex fistulas require unique preoperative considerations. The need for staged repairs or the use of pedicle flaps for interposition between the vaginal and bladder mucosa should also be assessed in the subset of patients with a history of pelvic irradiation.

Inform the patient about the chance for successful closure (>90% for an initial repair), the possibility of ureteral injury, and the chance for changed voiding habits in the postoperative period.

Instruments: Provide a basic set, a GU plastic set, stirrups, a headlight, an angled needle holder, vascular forceps, a Balfour retractor, a vascular tip sucker, a sponge stick, Potts-Smith 50-degree angled scissors, an angled scalpel handle open-ended ureteral catheters, an 18-French 5-mL balloon catheter and bag, 3-0 synthetic absorbable sutures, and 4-0 plain catgut (PCG) sutures.

Position: Place the patient in low lithotomy position with adjustable leg stirrups and the table tilted into moderate Trendelenburg position. Prepare and drape the perineum, vagina, and abdomen. If the defect is near the ureteral orifices, place ureteral catheters endoscopically or intraoperatively. Insert a sponge stick into the vagina in order to elevate the bladder trigone.

Incision: Make a vertical midline incision or use a transverse lower abdominal incision (Fig. 91-1). Insert a Balfour retractor.

Open the bladder with a 6-cm vertical cystotomy of the anterior bladder wall. This allows for gentle retraction by the Balfour retractor with the aid of attachable blade retractors as well as full visualization of the bladder base interior, the ureteral orifices, and the fistula (Fig. 91-2). A vaginal sponge stick is then pressed upward against the anterior vaginal wall to provide upward mobilization of the bladder

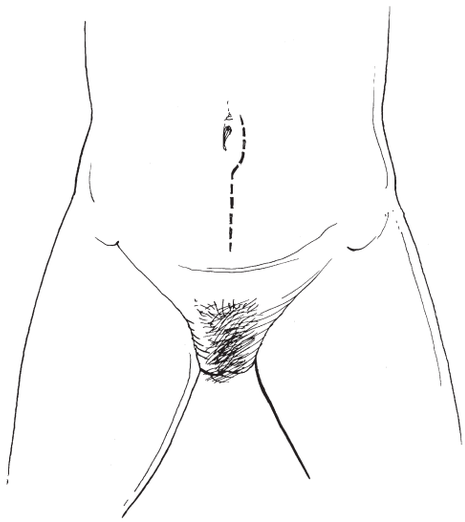

FIGURE 91-1.

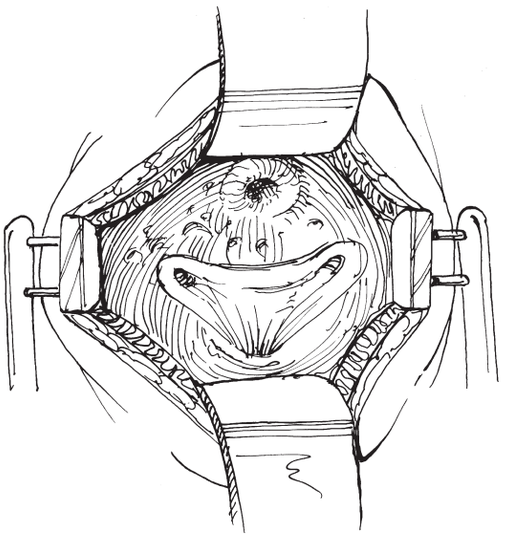

FIGURE 91-2.

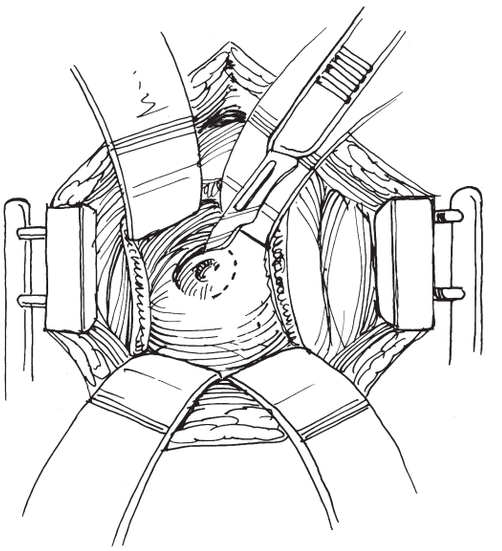

FIGURE 91-4.

base (Fig. 91-3). This maneuver often improves visualization and access to fistula dissection.

Place a stay suture above and below the fistula site. Incise the full thickness of the bladder wall circumferentially around the fistula and stay suture with an angled knife handle and #15 blade to the depth of the vaginal wall (Fig. 91-4). The plane between the detrusor wall and vaginal wall is then circumferentially mobilized for a 2-cm distance with the angled dissecting scissors. Excise the bladder wall portion of the fistula. The entire length of the fistulous tract does not need to be excised.

Close the vaginal mucosal layer by inversion with interrupted 3-0 delayed absorbable sutures. Now mobilize the intervening layer of combined perivaginal and perivesical tissue with the scissors (Fig. 91-5). It must be dissected enough so that no tension is present on the closure.

Close this intermediate layer with interrupted 3-0 delayed absorbable sutures, taking care to reapproximate this layer in a line perpendicular to the first closure. At this point, interposition of biomaterials might be considered. There are recent reports that suggest fibrin tissue sealant can be placed between the vaginal and bladder layers as an interposition bolster during cystotomy repair to promote tissue plane adherence and wound healing.

Reapproximate the detrusor layer with another layer of interrupted 3-0 absorbable sutures, and close the vesical urothelium with a running subepithelial 4-0 PCG suture (Fig. 91-6). Close the original cystotomy with a running

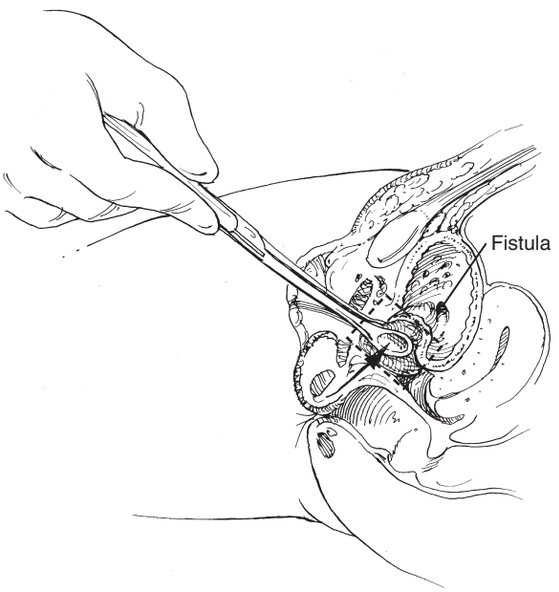

FIGURE 91-3.

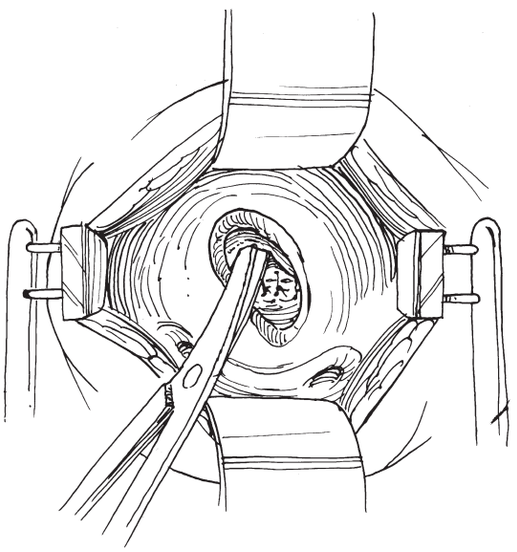

FIGURE 91-5.

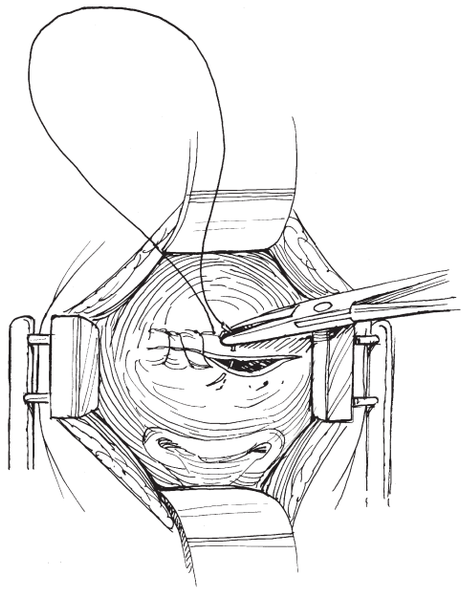

FIGURE 91-6.

subepithelial 3-0 PCG suture and place interrupted sutures to the muscle. Close the abdominal wound and place a Foley catheter to gravity drainage. A suprapubic tube is not necessary for uncomplicated fistula repair but may be placed at the surgeon's discretion. Provide broad-spectrum perioperative antibiotics. Postoperative uninterrupted drainage and continuous anticholinergic therapy to prevent bladder spasms are crucial to success. By remaining extraperitoneal, patients are ready for discharge home within 1 to 2 days. At 7 to 10 days after surgery, perform voiding cystography to ensure fistula closure. If the closure is seen to be intact, remove the Foley catheter. In postmenopausal women, provide estrogen cream for vaginal application.

VICTOR W. NITTI, MD

Commentary by

While waiting one year after radiation therapy to repair a vesicovaginal fistula may optimize tissue quality, we have found it impractical to leave patients with severe incontinence for that period of time. We will usually attempt an earlier repair or opt for some form of urinary diversion is that is not possible. While a suprapubic tube is optional, in many cases we prefer one no matter what approach is taken to repair the fistula. If the patient has excessive bladder spasms or discomfort, the urethral catheter can be removed and the suprapubic catheter left in place. Depending on the location of the fistula, this may also avoid direct contact of the tube with the repair.

This page intentionally left blank

Chapter 92

Transperitoneal Vesicovaginal Fistula Repair

SANDIP P. VASAVADA

Place the patient in the lithotomy position in Yellowfin leg holders. Place a urethral Foley catheter and fill the bladder with saline mixed with 3 or 4 drops of methylene blue. Expose the vaginal cuff and watch for egress of blue saline. Cannulate the fistula with a 10 to 14 silastic Foley catheter. Be sure blue fluid fills the catheter. Pull the catheter down and occlude the fistula so the bladder can be filled. Take the patient out of lithotomy position and make a midline incision; open the peritoneum. Fill the bladder and open it (Fig. 92-1).

Look in the bladder to locate the fistula, pull the catheter up so the balloon is out of the way, and open the bladder and adherent peritoneum right down to the fistula marked by the small catheter (Fig. 92-2). Take both catheters out for better exposure.

Cut the peritoneum transversely to create a flap to protect the bladder and vaginal suture lines and separate them. Dissect on the vagina to completely separate the bladder from the vagina. This dissection is through the open fistula (Fig. 92-3). Once the bladder is quite free, closure can begin.

Continue freeing the bladder from the vagina widely for 1 to 2 cm to allow mobility for separate closure. It is prudent to place ureteric feeding tubes or catheters to identify the ureters and their intravesical course during bladder flap mobilization and then closure. Close the vagina in two layers vertically or transversely with inverting interrupted 3-0 synthetic absorbable sutures (SAS). Avoid tension (Fig. 92-4).

Swing the peritoneal flap into the defect, and suture it in place to retroperitonealize the repair. If it is inadequate, elevate a long peritoneal flap or use a free peritoneal graft (Fig. 92-5). If this is not possible, then one can rely on the omental interposition to separate the two repairs. To prepare the field, place two separate 2-0 SAS sutures into the vagina *just distal* to the vaginal defect closure to anchor the omental interposition in place.

Close the bladder uroepithelium-subepithelium with a running 3-0 or 2-0 plain catgut suture, and approximate the muscularis and adventitia from the outside with interrupted 2-0 SAS (Fig. 92-6). Ensure that there is no tension, because success depends on the effectiveness of the bladder approximation, not on the vaginal closure. If the repair is tenuous or if the area has been radiated, bring the omentum behind the right colon for an omental graft,

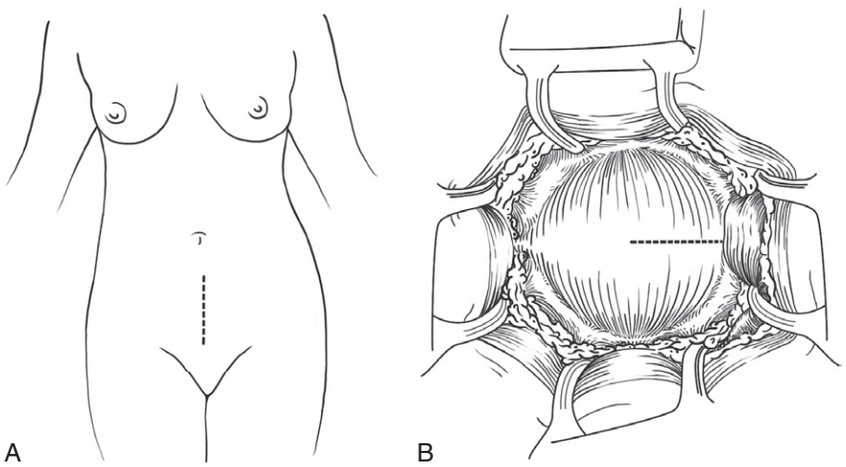

FIGURE 92-1.

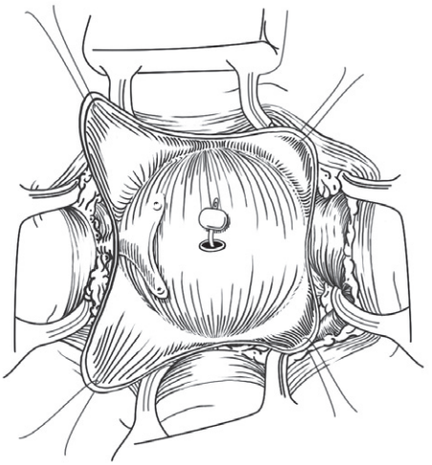

FIGURE 92-2.

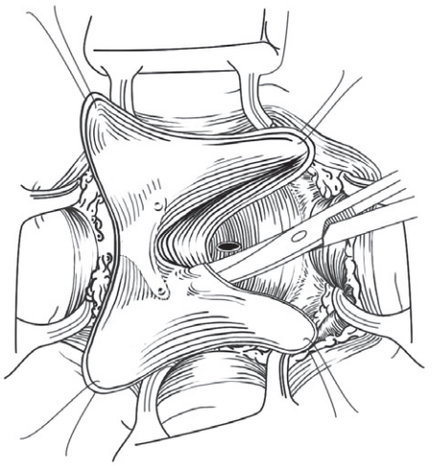

FIGURE 92-3.

and tack it between the bladder and vagina in the area of the defect. A fistula from radiation necrosis, however, is best managed with a musculocutaneous graft. Remove the ureteral catheters. If they were not placed, ask the anesthetist to inject indigo carmine intravenously to check ureteral patency. Although a balloon catheter may suffice, a suprapubic tube is safer and is less likely to press on the suture line. Insert a 22-French Malecot or Foley catheter

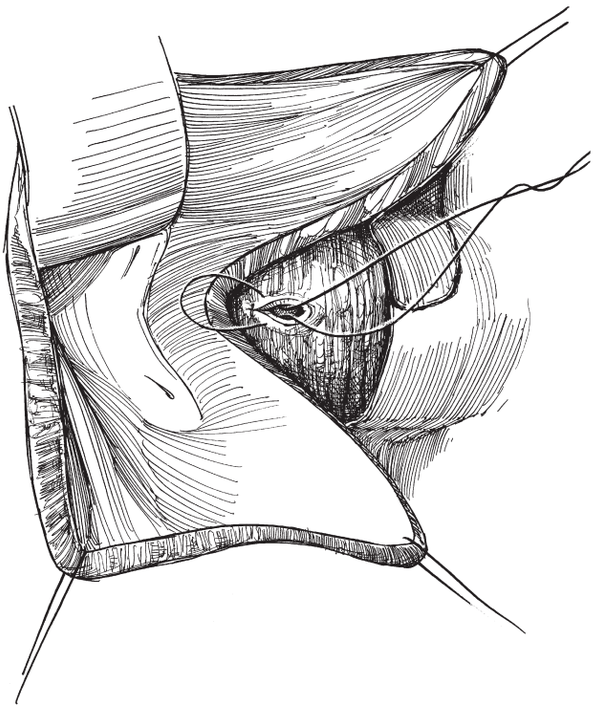

FIGURE 92-4.

through a stab wound in the bladder wall, and place a Penrose (or vacuum) drain; both should exit through stab wounds in the body wall and be sutured to the skin. Close the bladder in two layers with a continuous subepithelial suture and interrupted sutures to the muscularis placed from the outside. Close the wound in layers. Remove the urethral catheter when the urine clears, usually in a few days, and leave the suprapubic tube, if one was placed, to gravity; take out the suprapubic tube in 2 weeks after a cystogram confirms closure of the fistula. Advise the patient against engaging in sexual intercourse for 6 weeks.

Alternative: To avoid closing a long posterior vesical incision that could compromise vesical function and capacity, do not bisect the bladder. Instead, incise the peritoneum in the vesicouterine pouch, and establish a plane between bladder and vagina by sharp dissection. Do this before or after opening the bladder. Insert catheters into the ureters and a small Foley or Fogerty catheter through the fistula into the vagina. Continue the retrovesical dissection for at least 1 or 2 cm beyond the fistula. Trim the edges of the fistula just enough to remove inflammatory tissue, but not to try to debride it of all scar tissue. Complete the operation as described in Chapter 91.

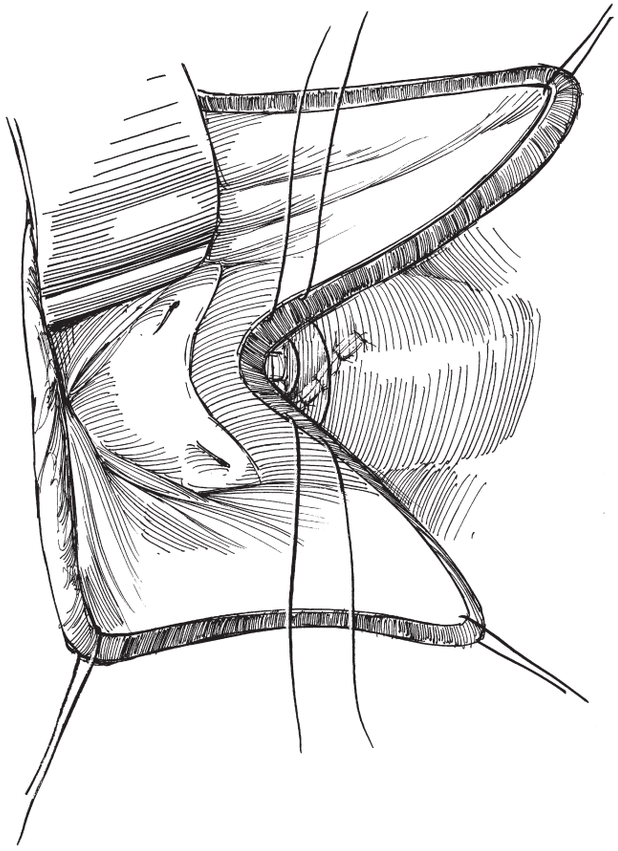

FIGURE 92-5.

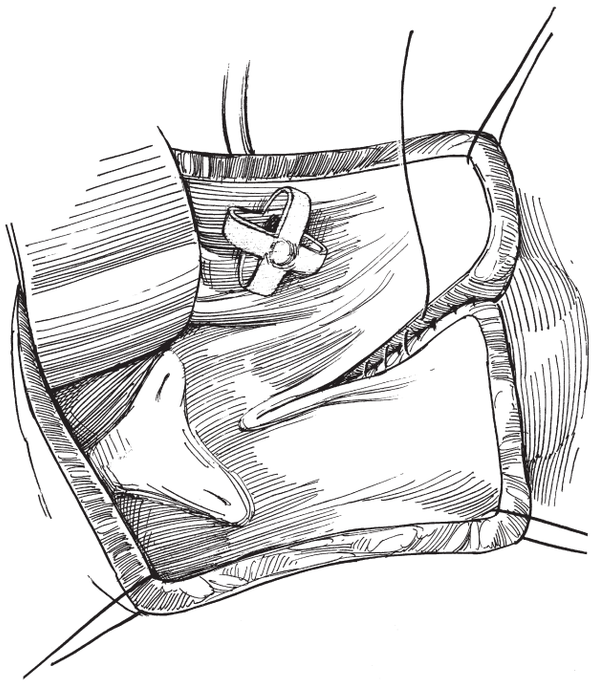

FIGURE 92-6.

Commentary by VICTOR W. NITTI, MD

The transperitoneal vesicovaginal fistula repair may also be preformed laparoscopically or robotically following the same basic operative technique.

Chapter 93

Female Vesical Neck Closure

ROGER R. DMOCHOWSKI AND CHRISTOPHER E. WOLTER

INDICATIONS

There are a number of conditions where female vesical neck closure is indicated. These include neurogenic voiding dysfunction, urethral mural loss due to failed incontinence surgery, and failed urethral diverticulum resection. Additionally, long-term catheterization can lead to urethral erosion and necrosis, leading to total urethral incompetence and loss of the continence mechanism. Frequently, patients have been put through an array of catheter and retention balloon sizes, as well as escalating doses of anticholinergic medications (invariably unsuccessfully) for symptomatic control. Additionally, in patients who have had multiple failed urethral reconstructive procedures for conditions such as recurrent urethrovaginal fistulae or urethral strictures, the urethra may be beyond repair. Vesical neck closure in the female patient requires a concomitant urinary diversion such as a suprapubic tube, an ileovesicostomy, or a bladder augmentation with a continent catheterizable stoma.

In all patients, begin with a clean urinalysis and urine culture. All patients should receive culture appropriate antibiotics, and if performing any bowel work, with appropriate bowel preparation if concomitant bowel surgery is to be performed. Deep venous thrombosis prophylaxis should be strongly considered.

Abdominal Approach

1. Place the patient in the low lithotomy position. After an appropriate antibiotic skin and vaginal prep, drape the patient so that the vagina is accessible. Place a Foley catheter at this time. The procedure can be done through either a low midline or transverse (Pfannenstiel) incision. After entering the abdomen, bluntly dissect the space of Retzius. Do this as widely as possible to ensure greatest mobility and working space. Take care not to avulse the dorsal venous complex. Next, enter the endopelvic fascia, and ligate the dorsal venous complex with 0 synthetic absorbable sutures (SAS) ties. Dissect the borders of the urethra as extensively as possible. The pubourethral ligaments should be sharply transected at this time for complete urethral mobility.
2. Transect the urethra at the level of the pelvic inlet (maximizing urethral length), exposing the Foley catheter (Fig. 93-1). This can be done sharply or with cautery. Divide the catheter so that it may be drawn retrograde into the operative field, taking care not to let the balloon deflate. Clamp the catheter and place upward traction on the bladder neck. Transect the posterior urethra. The distal urethra can be closed at this point in two layers using a running 3-0 polyglycolic acid (PGA) suture on the mucosa and an interrupted 2-0 PGA inverting layer.
3. Remove the catheter from the bladder at this time. Next, identify the urethral orifices. Urethral catheters can be placed to identify them, or indigo carmine can be administered intravenously to aid in visualization. Continue the dissection posterior to the bladder neck in the vesicovaginal space. Mobilize the bladder off the vaginal wall until it is rolled away from the inlet (Fig. 93-2).
4. Place cystostomy tube or construct diversion at this time.

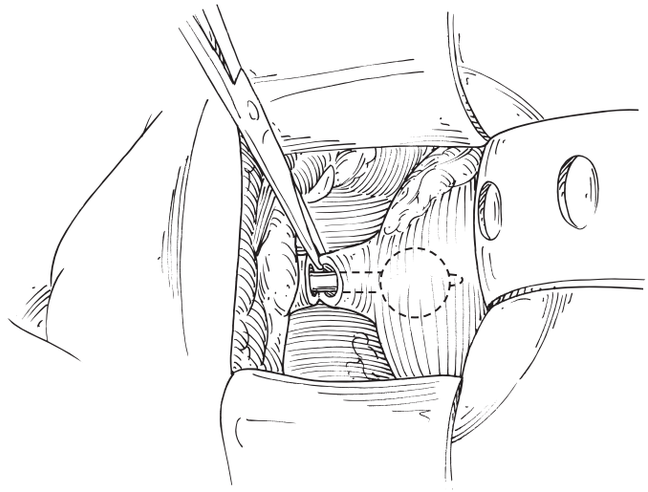

FIGURE 93-1.

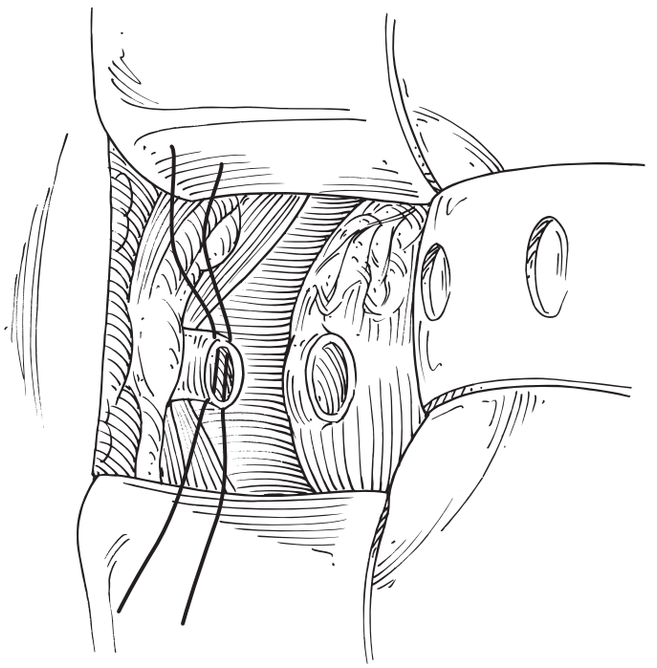

FIGURE 93-2.

5. Trim any nonviable or redundant urethral length, and begin a two-layer closure. The first layer should invert the mucosa and is placed in a vertical running fashion with 3-0 PGA. The second layer should be done horizontally with 2-0 PGA suture. Exaggerate suture bites on the upper side so the closure rolls up and away from the dependent position and the closed distal urethra (Fig. 93-3). If possible, an omental or peritoneal flap can be placed over the closure for more security.

Abdominal Approach with Urethral Inversion

1. Approach bladder as above (steps 1 and 2). Dissect the urethra circumferentially. This is made easier by first dividing the pubourethral ligament in order to gain length. Dissect the urethra away from the vagina. This can be aided by dissecting over a finger placed in the vagina.
2. Pass a right angle clamp beneath the urethra and place two 2-0 SAS ties, proximally and distally. Divide the urethra, and leave the proximal tie long and loose, and this will aid in urethral inversion in step 5 (Fig. 93-4).
3. Next, open the bladder and identify the ureteral orifices. Again, this can be aided by ureteral catheters or by giving indigo carmine intravenously. Place four 3-0 traction sutures at outlet of bladder neck through the epithelium. Using a hook blade, incise the bladder epithelium circumferentially outside of the traction sutures. Using the sutures to guide the dissection, dissect the epithelium from the incision toward the outlet (Fig. 93-5).
4. Transect the epithelial flap flush with the bladder outlet, placing tension on the traction sutures to ensure the outlet is inverted slightly into the bladder. Ensure that all epithelium is removed from the outlet. Next, pass a clamp through the outlet and grasp the long suture left on the proximal urethral stump. Pull the urethral stump into the bladder, inverting it, and trim the urethra (Fig. 93-6).
5. Close the trimmed end of the urethra with a running 4-0 PGA suture. Now secure the urethral stump to the surrounding detrusor with additional sutures to prevent it from prolapsing back to its native location. Invert the closed uroepithelium of the urethral stump with a purse-string suture. Repeat a second time 1 cm beyond this layer, further inverting it. Close the epithelium of the bladder with 4-0 PGA suture (Fig. 93-7).

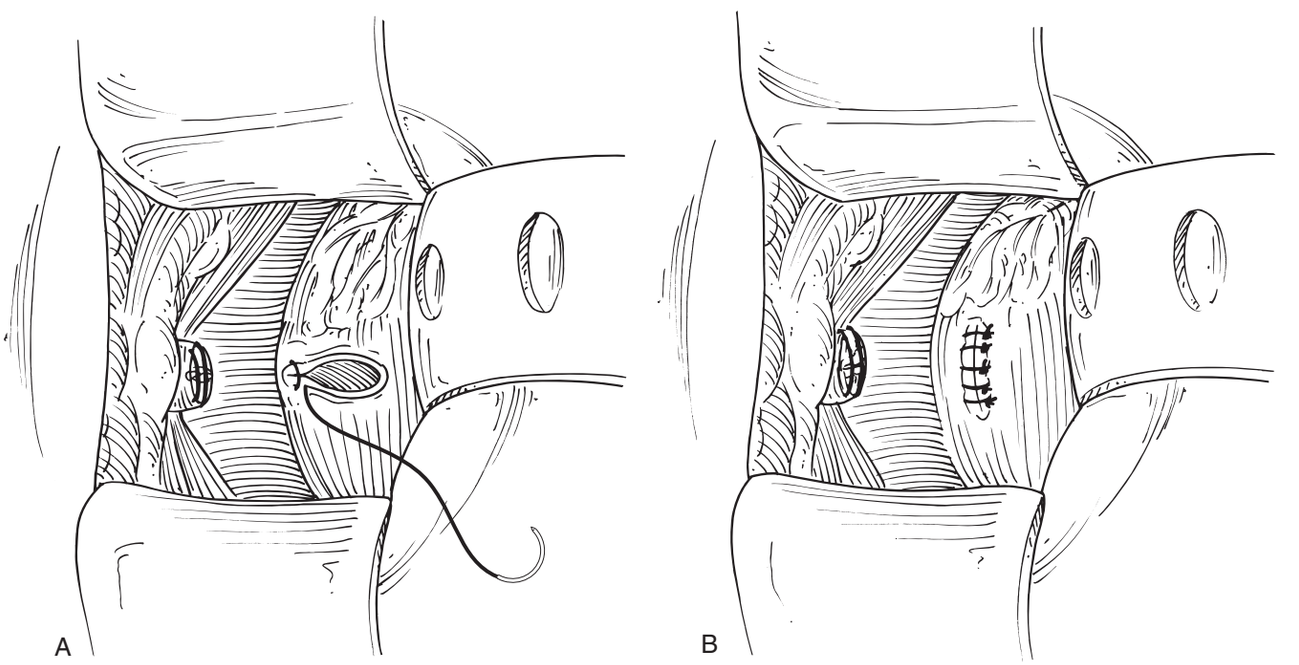

FIGURE 93-3.

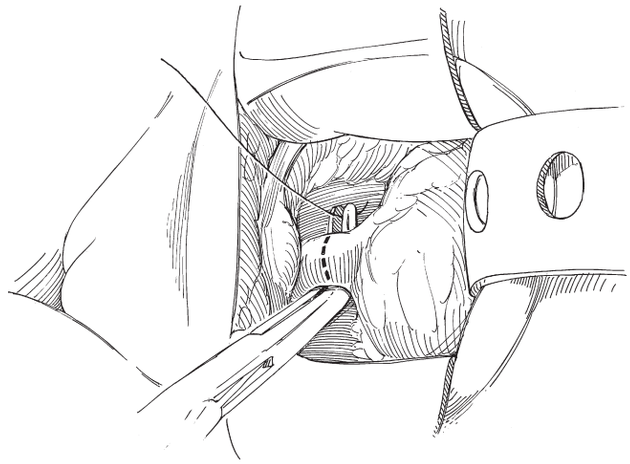

FIGURE 93-4.

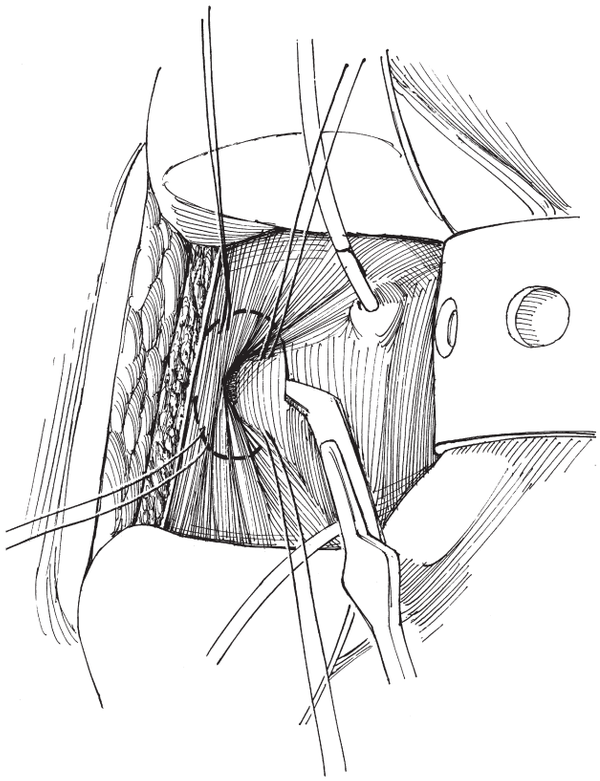

FIGURE 93-5.

6. Place a cystostomy tube or construct the urinary diversion at this time. Omentum can be mobilized and placed over the closure if desired.

Urethral Approach

1. This can be done if an abdominal incision is to be avoided or not desired. Place a suprapubic cystostomy tube prior to closure via this route. Start by placing the patient in the lithotomy position. Retract the labia with sutures or self-retaining ring retractor, and place a weighted vaginal speculum.

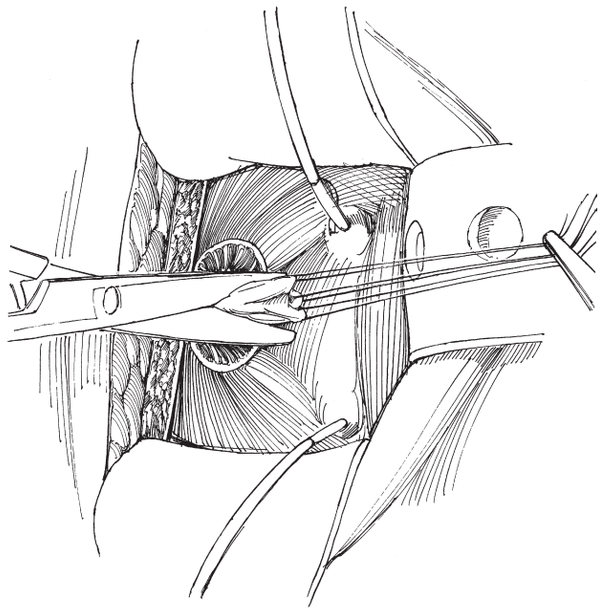

FIGURE 93-6.

2. Place four traction sutures around the meatus in quadrants. Incise around these circumferentially through the full thickness of the surrounding skin and vaginal mucosa (Fig. 93-8).
3. Sharply dissect the urethra from the vagina. Continue this dissection to the level of the bladder neck. Now free the bladder neck attachments in the retropubic space including the pubourethral ligaments. At this point, the urethra and the bladder neck should be free and mobile. If not, continue to mobilize and areas fixed in the vaginal side or in the retropubic space.
4. The distal urethral should be trimmed. After excision of this portion, the remaining urethra needs to be inverted. Begin this by placing three 2-0 PGA mattress sutures so that the mucosal edge is rolled into the lumen of the urethra. This should exclude the mucosa from the operative field. Next, place a 2-0 PGA pursestring suture around the bladder neck. Invert the urethra into the bladder and tie the pursestring down (Fig. 93-9).
5. Close the periurethral fascia over the bladder neck. Every attempt should be made to do this in alternating layers, further inverting the urethra. Last, the urethral hiatus should be closed with interrupted 3-0 CCG suture. Place a vaginal packing soaked in estrogen or antibiotic petroleum-based cream (Fig. 93-10).

Vaginal Approach

1. This is an alternative approach to closing the vesical neck that can avoid entry into the abdomen. Suprapubic tube placement or suitable diversion should be performed before to closure of the vesical neck. Begin by positioning the patient in the same manner as the urethral approach.
2. Begin with a wide inverted U-shaped incision on the anterior bladder wall. If desired, the anterior vaginal wall can be injected with saline or a dilute lidocaine with

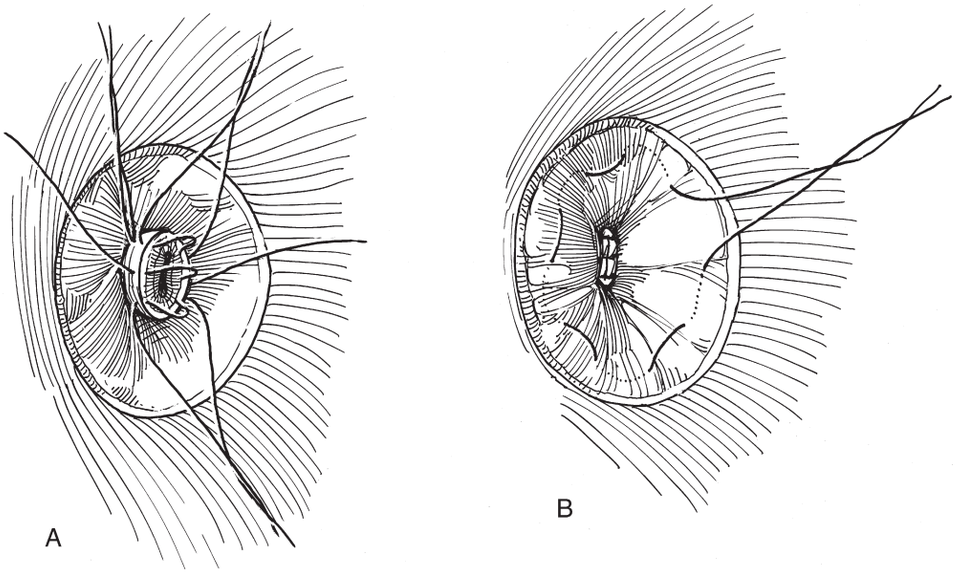

FIGURE 93-7.

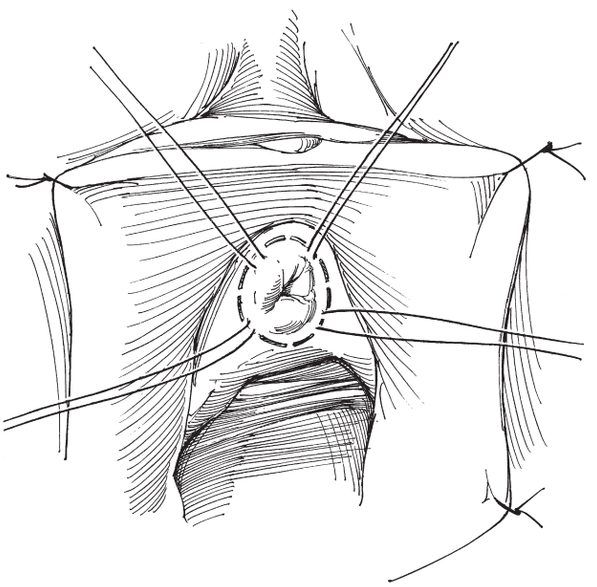

FIGURE 93-8.

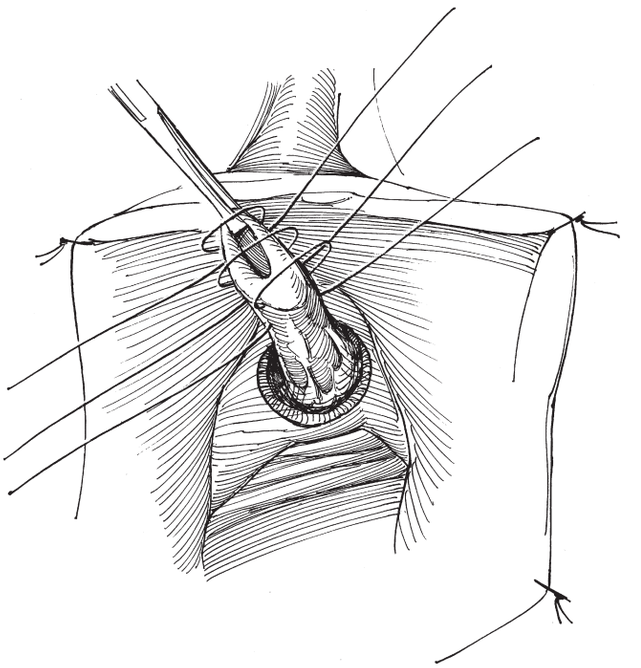

FIGURE 93-9.

epinephrine solution to hydro dissect the vesicovaginal space. Make the apex of the U-incision close to the urethral meatus, and extend it proximally as far into the introitus as possible. The longer this flap can be made, the less tension there will be at the time of closure. Develop the vaginal flap from this incision. The correct level of dissection should reveal the glistening white surface of the vaginal wall. If the flap is taken too thick, venous or detrusor bleeding will occur (Figs. 93-11 and 93-12).

3. Incise circumferentially around the urethra. The bottom edge of this incision is already started as it is the top edge of the vaginal flap incision. Sharply dissect along the length of the urethra to the level of the bladder neck. From this level, separate the bladder neck from its retropubic attachments, including the pubourethral ligament. Now excise the urethra close to the bladder neck (Fig. 93-13).
4. Close the bladder neck in multiple layers. Start with a running 3-0 PGA layer on the mucosa in a vertical fashion. Place a second 3-0 PGA layer over this, imbricating the first layer. Follow this with an interrupted layer of 2-0 PGA arranged horizontally through the perivesical fascia. An optional Martius flap can be placed over the closure at this time. Close the vaginal flap with two running 2-0 PGA sutures and tie in the middle. Place a vaginal packing soaked in estrogen or antibiotic petroleum-based cream (Figs. 93-14 and 93-15).

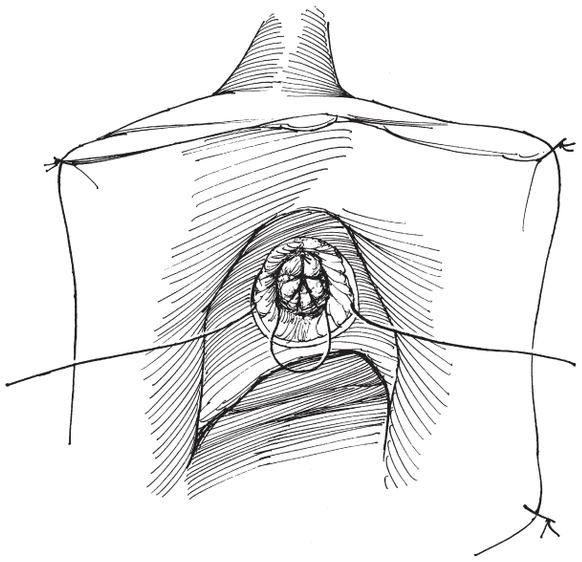

FIGURE 93-10.

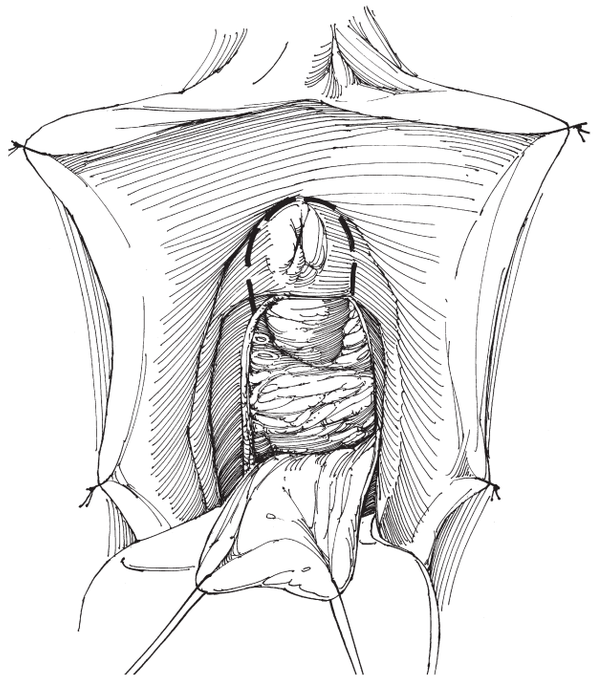

FIGURE 93-12.

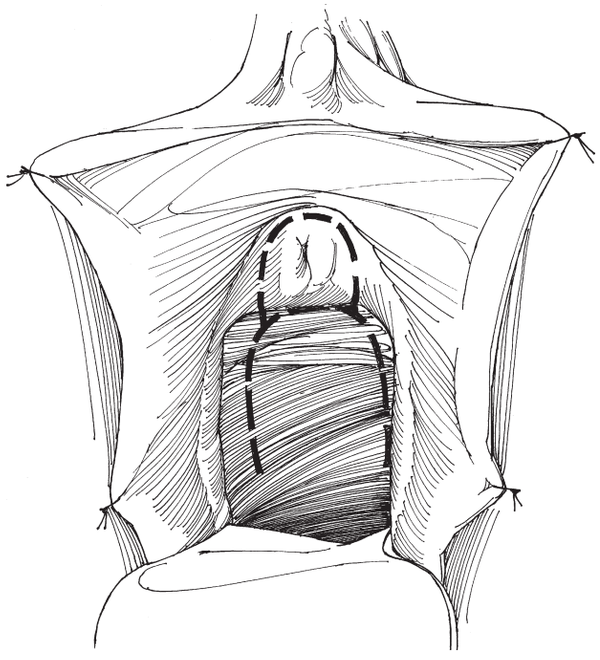

FIGURE 93-11.

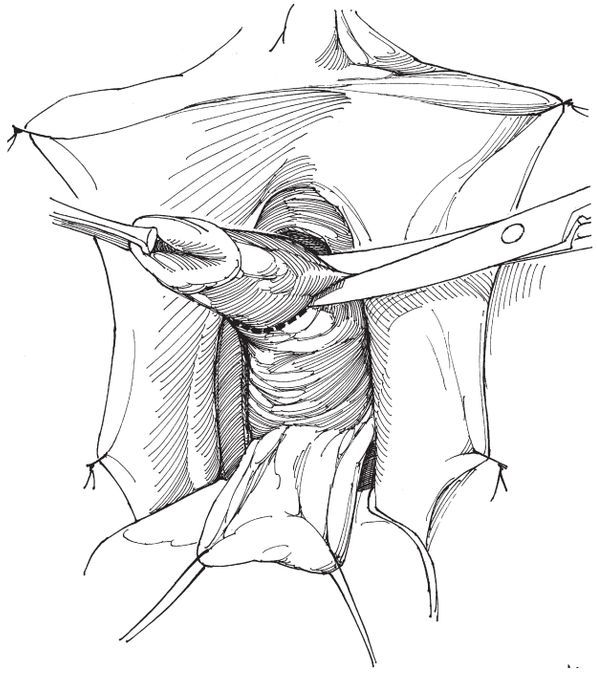

FIGURE 93-13.

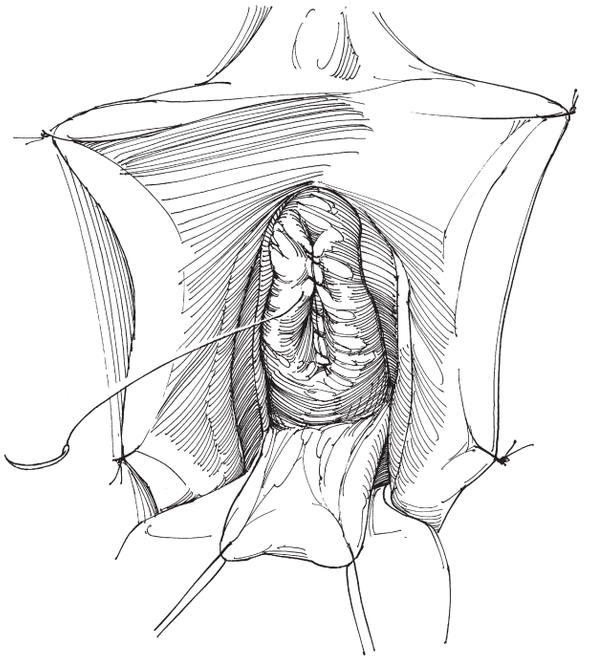

FIGURE 93-14.

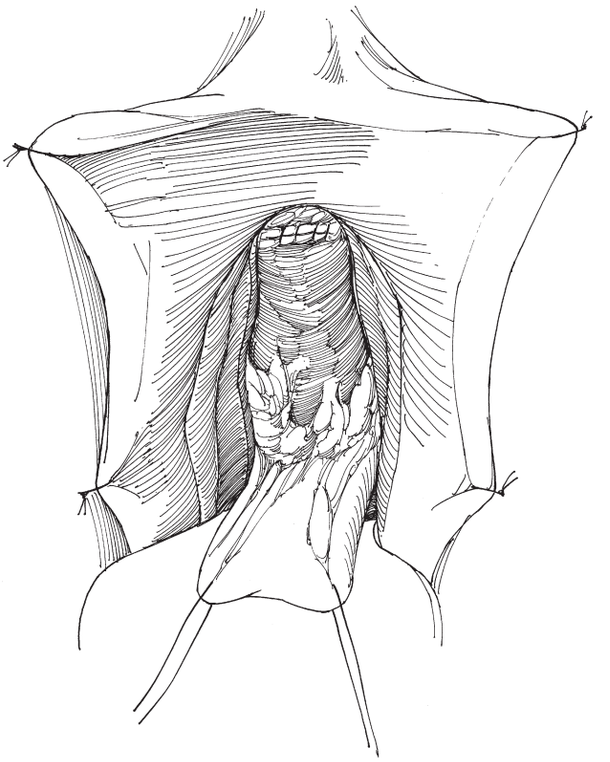

FIGURE 93-15.

Commentary by

VICTOR W. NITTI, MD

Female bladder neck closure (often with urethral excision is an excellent salvage operation when the urethra is destroyed or eroded to the point where continence cannot be practically achieved (e.g. with a pubovaginal sling or other reconstructive procedure). Our preference is to use the transvaginal approach when placing a suprapubic tube for urinary diversion and the abdominal approach when preforming a simultaneous continent or incontinent stoma.

Chapter 94

Neuromodulation

TRAVIS L. BULLOCK AND STEVEN W. SIEGEL

Neuromodulation in the form of sacral nerve modulation (SNM) for the treatment of refractory voiding dysfunction was first described by Tanagho and Schmidt in 1998. A commercially available device for SNM, InterStim (Medtronic, Minneapolis, Minn.), was approved by the Food and Drug Administration for the treatment of urge urinary incontinence in 1997, and for treatment of urgency-frequency syndrome and idiopathic nonobstructive urinary retention in 1999. Since its inception, the procedure has evolved from a one-stage open approach to access the appropriate nerve roots, to a two-stage procedure, including either a tined or non-tined percutaneous lead trial. It is our preference to perform a two-stage procedure with a tined lead implant as the initial therapeutic trial. The benefits of this approach include the ability to place a potentially permanent lead under minimal anesthesia. Additionally, it is our impression that this technique results in a lower rate of false-positive outcomes and more accurate placement of the potentially permanent lead, which may also result in a higher rate of appropriate patient selection and a decreased need for future revision surgery.

We usually perform the procedure in the operating room under monitored anesthesia care (MAC) with local anesthesia to allow the patient to give sensory feedback during the positioning of the lead, which serves to increase accuracy of site selection and decrease the risk of uncomfortable sensations with long-term use of the device. We typically conduct the staged lead implant over a 1-month time period. When there is at least a 50% improvement of the target symptoms, this justifies conversion to a permanent implantable neurostimulator (INS). A detailed explanation of the steps involved in the two-stage implantation of a sacral nerve stimulator (InterStim) follows.

FIRST STAGE

Positioning and Prep

Preoperatively the patient should have completed baseline diaries documenting specific voiding dysfunction and/or incontinence. These include quantification of urinary frequency, voided volumes, degree of urgency, number and severity of incontinence episodes, and number and type of pads used daily. Before the start of the procedure, a prophylactic dose of antibiotic effective against skin flora, such as cephazolin (Ancef), is administered. The patient is placed on a "fluoro-friendly" table in the prone position with chest rolls to assist with respiration and with pillows under the pelvis and beneath the shins to pad pressure points (Fig. 94-1). The feet must remain uncovered to allow for direct observation during the procedure. The lower back and buttocks are prepped with an antiseptic solution and draped into the operative field.

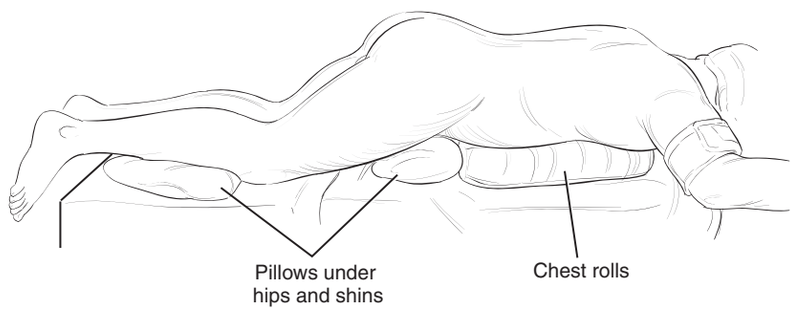

FIGURE 94-1. Proper patient positioning.

Selecting the Appropriate Spinal Foramen

As a rule, the target spinal foramen is the one that corresponds to the third sacral nerve root (S3). In rare instances, the fourth sacral nerve (S4) is preferable. In general, the second sacral nerve (S2) is not appropriate for long-term stimulation. If the patient has a lateralizing pain component, the S3 nerve root on that side is usually chosen for lead placement. Initially, an anteroposterior (AP) fluoroscopic view is obtained to determine the medial edge of the sacral foramina. A skin mark is made at this level on one side, and then by estimating two fingerbreadths over to the other side of the midline, the second site is marked. An imaginary line parallel to the spine at the level of either mark is where the foramina "line up" (Figs. 94-2 and 94-3).

A cross-table fluoroscopic view is next obtained to locate to the target foramen (S3). On the lateral view, the S2 level (B) is readily identified as where the sacroiliac joint fuses, forming a characteristic shadow (A) (Fig. 94-4). The first anterior protrusion or "hillock" from the surface of the sacrum below this shadow is typically S3 (C).

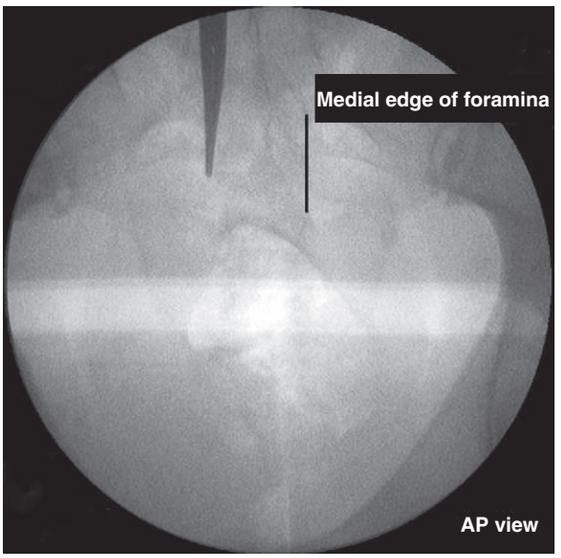

FIGURE 94-2. Fluoroscopic view of sacrum with marker at medical edge of foramen.

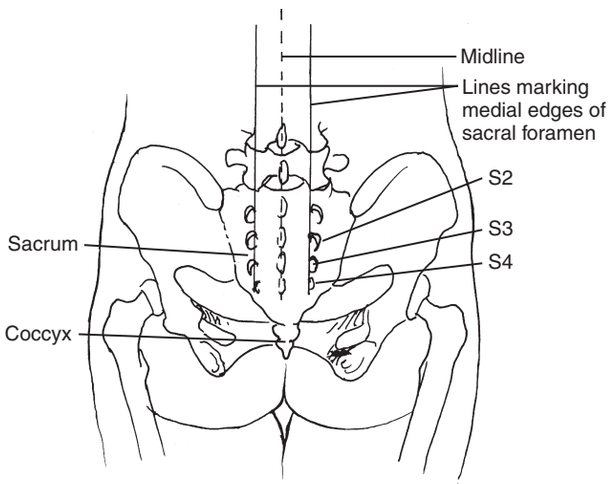

FIGURE 94-3.

Needle Location of the S3 Spinal Foramen

Once the starting point has been estimated with the aid of fluoroscopy, the skin is anesthetized with 0.25% bupivacaine (Marcaine) to create a dime-sized wheel. It may also be necessary to numb the sacral periosteum if the patient exhibits discomfort. At a 60-degree angle, a specialized foramen needle is then "walked" up or down along the line of the foramina, which was determined on the AP view, until it drops into the S3 foramen (Fig. 94-5). As the aim of the needle is adjusted up or down, it is important to pull it out and reinsert, rather than torquing or bending it. Once it enters the foramen, fluoroscopy is used to gauge the depth. The foramen needle is then stimulated with the screening device to check sacral root responses (Table 94-1).

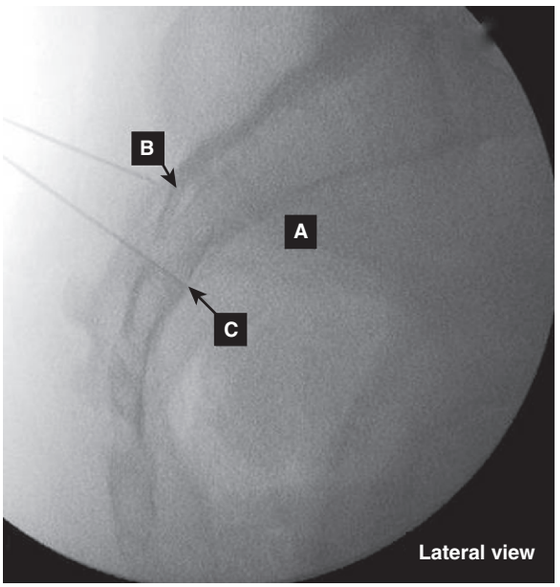

FIGURE 94-4. Fluoroscopic view showing sacroiliac shadow **(A),** location of the S2 foramen **(B),** and S3 foramen **(C).**

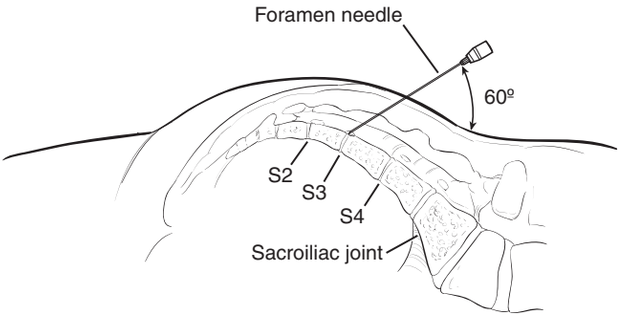

FIGURE 94-5. Locating the S3 foramen with the foramen needle.

TABLE 94-1 RESPONSES GENERATED BY SPECIFIC NERVE ROOT STIMULATION

Level	Motor	Sensory
S2	Bellows (inward going of intergluteal fold), Clamp (A-P pinching of perineum/coccyx), dorsiflexion of foot, heel rotation, calf cramping	Genital
S3	Bellows, dorsiflexion of great toe, bottom of foot	Genital, perineal, anal
S4	Bellows	Anal

If responses are not appropriate at this level (i.e., consistent with S2 or S4), the point of introduction at the skin level is reestimated in order to aim for the next foramen above or below to correctly enter the S3 spinal foramen. A bellows (rolling inward and deepening of the intergluteal fold due to levator contraction) response and dorsiflexion of the ipsilateral great toes confirms that the S3 nerve is being stimulated.

Placement of the Introducer Sheath Under Fluoroscopy

Once the course of the nerve has been fathomed using the foramen needle a skin nick is made at this insertion point, a stylette is placed, and the foramen needle is exchanged for the lead introducer sheath (Fig. 94-6). The tip of the introducer sheath has a radiopaque marker, and the depth of this should be about ½ to ⅔ through the bone table (Figs. 94-7 and 94-8).

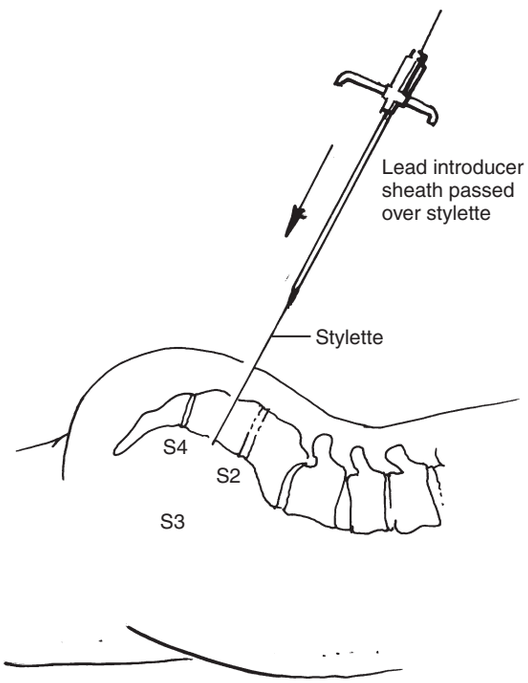

FIGURE 94-6. Lead introducer sheath passed over stylette.

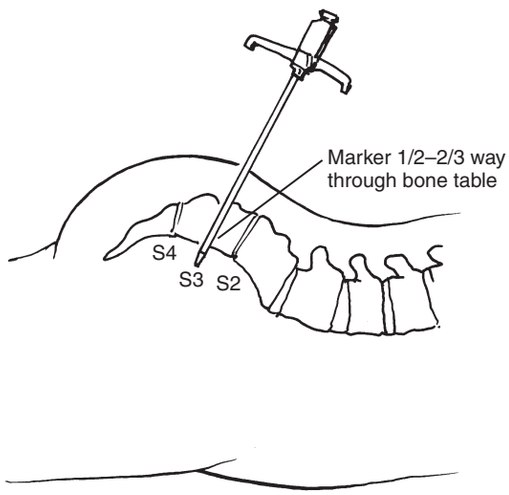

FIGURE 94-7. Radiopaque marker of lead introducer sheath one-half to two-thirds through bone table

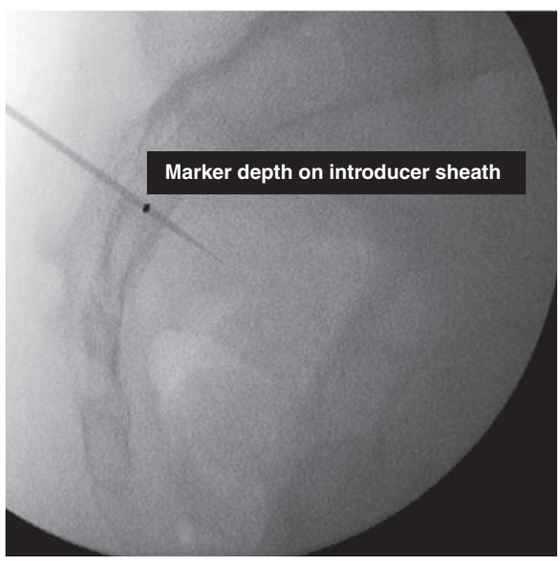

FIGURE 94-8. Fluoroscopic view of Figure 94-7.

Deployment of Tined Lead

After proper placement of the introducer sheath has been confirmed by fluoroscopy, the tined lead can be placed through its lumen. It is also helpful to use the curved stylet, included in an accessory kit (Medtronic Accessory Kit),

because it is softer than the one packaged with the lead and is less likely to force the electrode out of the proper plane (Fig. 94-9). When deployed properly, the lead should always point caudally and laterally. We always straddle the bone table with lead sites 2 and 3 (Fig. 94-10). This allows for a consistent lead depth, prevents premature deployment of the tines, and provides a point of future reference.

Once a satisfactory trajectory of the lead has been obtained, each lead site is stimulated and the threshold of response is measured. If each site elicits an appropriate response at a relatively low threshold, the position of the nerve has been appropriately paralleled by the lead. If not, the lead should be pulled back under fluoroscopy until the tip is proximal to the end of the introducer sheath and then reinserted under fluoroscopic control, making sure that it takes a different course. It is then retested at each contact point. The goal is to get all four contact points yielding an appropriate response at a similar, relatively low threshold. Once the ideal position is determined, the tines are deployed by pulling back the introducer sheath under fluoroscopic guidance.

Setting Up the Connection Between the Tined Lead and Lead Extension

Next the right lateral edge of the sacrum (easiest for a right-handed surgeon) and the posterior superior iliac crest are marked. The future site of the INS incision is marked diagonally so that the INS may be placed in a plane of fat away from boney prominences. This also provides for a course of the tunneled lead extension, which is away from the presacral lead insertion site. After infiltration with a local anesthetic, a 1- to 2-cm incision at the lateral aspect of the future INS incision is made and will be the site of future connections (Fig. 94-11). Care must be taken to deepen the incision completely through the skin into fat, preventing the lead from getting caught too superficially.

Next a lead extension wire must be tunneled to a separate area, on the contralateral side of the lower back, to be later attached to a portable generator for the test stimulation. Once the distance from the connection incision to the lead extension skin exit point has been determined (as long as the tunneler will allow), the tunneler is then placed into the future INS incision site and directed toward the preanesthetized exit point. As long as the tunneler is kept in the fatty tissue beneath the skin, there is little discomfort during this maneuver, and only the entry and exit points require local anesthesia. The sheath is left in place and the lead extension can be guided through to the exit point (Fig. 94-12).

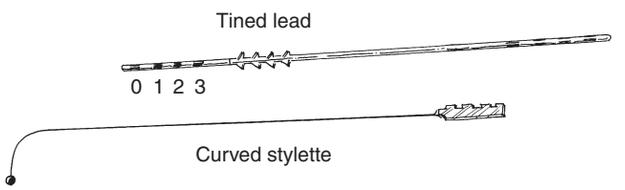

FIGURE 94-9. Tined lead and curved stylette.

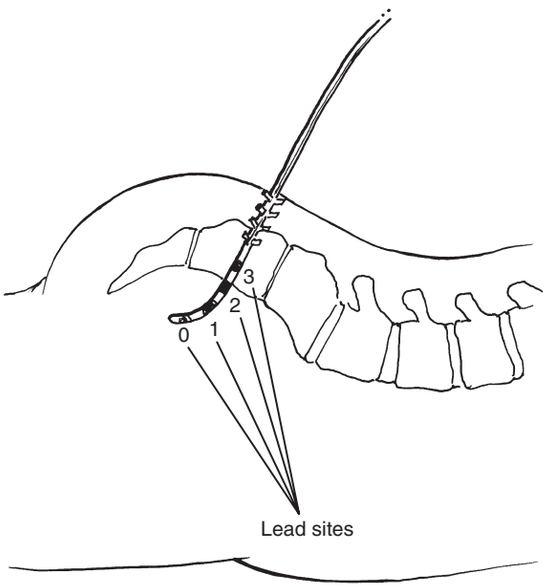

FIGURE 94-10. Deployment of tined lead with lead sites 2 and 3 straddling bone table.

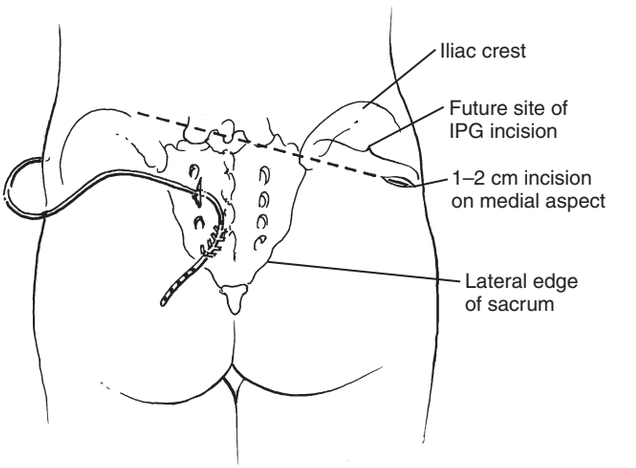

FIGURE 94-11. Incision made at lateral aspect of future INS site.

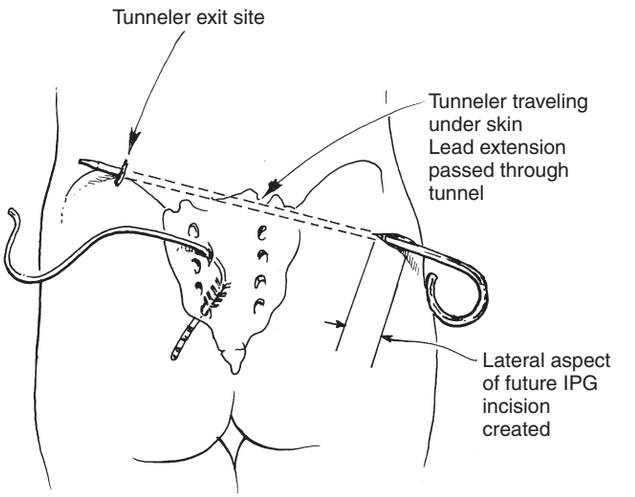

FIGURE 94-12. Tunneling the lead extension wire.

Tunneling of Tined Lead to the Connection Site

The tined lead is tunneled to the connection incision again using the tunneling device. We typically curve the tunneling device to cause the lead to sweep down and back up toward the incision to take up some of the redundant lead length and to allow for the lead to be placed in a predictable position for future reference (Fig. 94-13).

The connection hub between the tined lead and lead extension electrode is formed and placed in the subcutaneous fat underneath the future INS incision site. This allows for the connecting hub to be immediately located during the second phase procedure where the tined lead can be removed or the incision extended medially to allow for INS placement (Fig. 94-14).

Completion of Stage 1

The procedure is completed by irrigating the wound with antibiotic solution, achieving final hemostasis, and closing the incisions with staples. We believe use of staples is important to avoid having a knot of suture material from a subcuticular closure remaining in the future INS placement site. Patients are discharged after programming, and they return in 1 week for staple removal and reprogramming as needed. A 1-month trial period is used routinely to ensure that programming is optimized and for evaluating the response in terms of the target symptoms. At the end of the trial period, the second stage of the procedure is performed, wherein the INS may be inserted if appropriate efficacy is achieved or the tined lead and lead extension wire may be explanted if urinary symptoms are not improved to a point to justify permanent implantation.

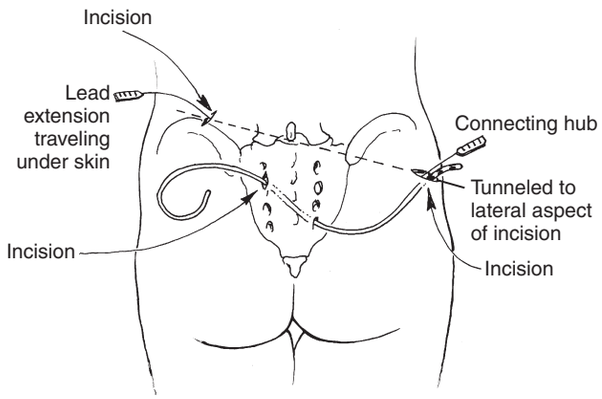

FIGURE 94-13. Tunneling the tined lead to the connection site.

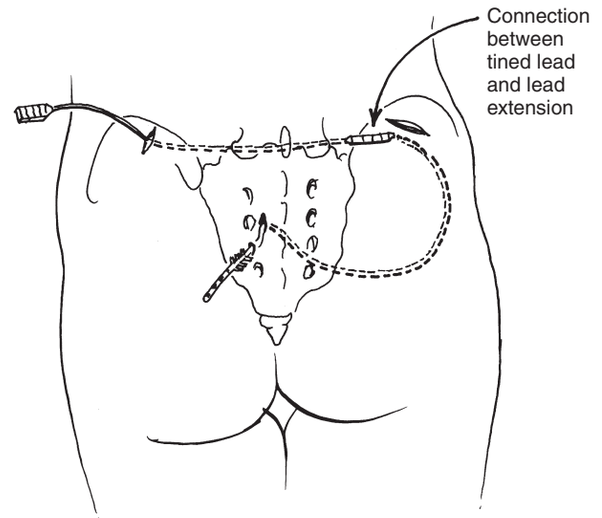

FIGURE 94-14. Final configuration of tined lead and lead extension wire at completion of stage 1.

SECOND STAGE

Explantation of Tined Lead and Lead Extension Wire

We schedule a completion phase procedure 4 weeks after the first stage. If symptoms have not been sufficiently improved, the tined lead and lead extension wire is removed under MAC and local anesthesia by infiltrating the connection incision with 0.25% bupivacaine (Marcaine), opening the incision, and discovering the connection hub. It is pulled into the incision and the lead extension electrode is cut. The tined lead is then pulled sharply from the connection incision, and usually comes out without resistance. If it is pulled slowly, it tends to elongate and thin out, potentially increasing the risk fracturing the lead. There is no risk for nerve injury if the lead is deployed as discussed, because the tines are all outside of the foramen. Finally, the connecting incision is closed loosely to minimize risk of infection.

Placement of Implantable Neurostimulator

If there has been a sufficient improvement in the target symptoms, implantation of the permanent INS is justified. The connection incision is marked and extended medially long enough to accommodate placement of the generator. The entire area is infiltrated with 0.25% bupivacaine (Marcaine), creating a skin wheel over the areas to be surgically dissected. The incision is then made and hemostasis is carefully maintained to minimize the risk of hematoma formation. The connection hub is identified and the lead extension wire is cut and removed. A subcutaneous pocket is created using cautery and blunt dissection. This should be 2 cm beneath and parallel to the skin, just large enough to comfortably house the INS and lead assembly (Fig. 94-15). The wound is irrigated with antibiotic solution, and the INS and previously placed tined lead are connected. The device is positioned in the pocket, taking care to tuck excess wire behind the generator. This step prevents superficial migration of the connection site, as well as potential lead injury if a revision surgery is needed (Fig. 94-16). The subcutaneous tissues are then closed with absorbable sutures and the skin is reapproximated. The patient can then be discharged home after device programming, which typically replicates the successful settings during the trial period.

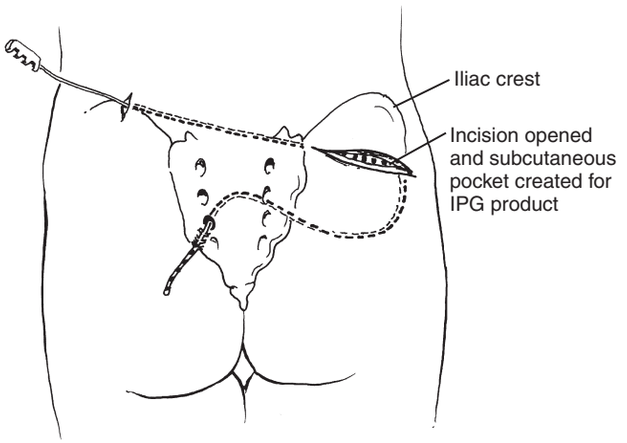

FIGURE 94-15. INS placement.

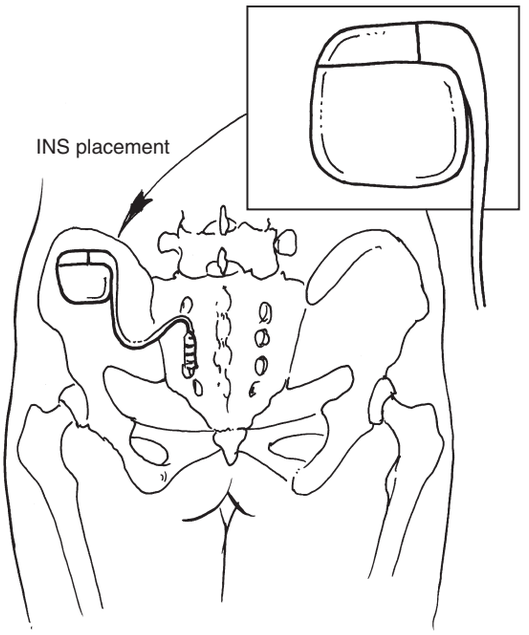

FIGURE 94-16.

Section XVI

URINARY AND BOWEL DIVERSION

This page intentionally left blank

Chapter 95

Vesicostomy

ROMANO T. DeMARCO

A vesicostomy is a successful and durable method of creating either temporary or permanent urinary diversion. This procedure is typically reserved for patients with neurogenic bladder who are unable to spontaneously void and who either cannot void, and or are not able to be catheterized.

LAPIDES VESICOSTOMY

After adequate anesthesia is administered, prep and drape the patient from the genitalia to the costal margins. Place a 20-French catheter in the bladder and fill the bladder with 250 to 300 mL of saline.

Position: Supine

First incision: Make a transverse lower abdominal incision approximately 2 to 3 fingerbreadths above the symphysis pubis 10 cm in length. Incise through the underlying subcutaneous tissue to expose the anterior sheath of the rectus muscle. Make a transverse incision through the anterior rectus sheath the length of the skin incision. Place Allis clamps on the edges of the superior flap of the rectus fascia and dissect it free from the underlying rectus muscles for several centimeters. Mobilize the inferior flap of the rectus fascia to a lesser degree and expose the bladder by separating the rectus muscles in the midline. Place stay sutures through the anterior bladder wall and displace the peritoneum superiorly.

Second incision: Make an inverted U-shaped skin flap measuring approximately 3.25 cm in length and slightly wider at the base approximately halfway between the transverse incision and the umbilicus (Fig. 95-1). Carefully dissect and mobilize the skin flap with its accompanying subcutaneous tissue off the rectus fascia. Place stay sutures through the exposed rectus

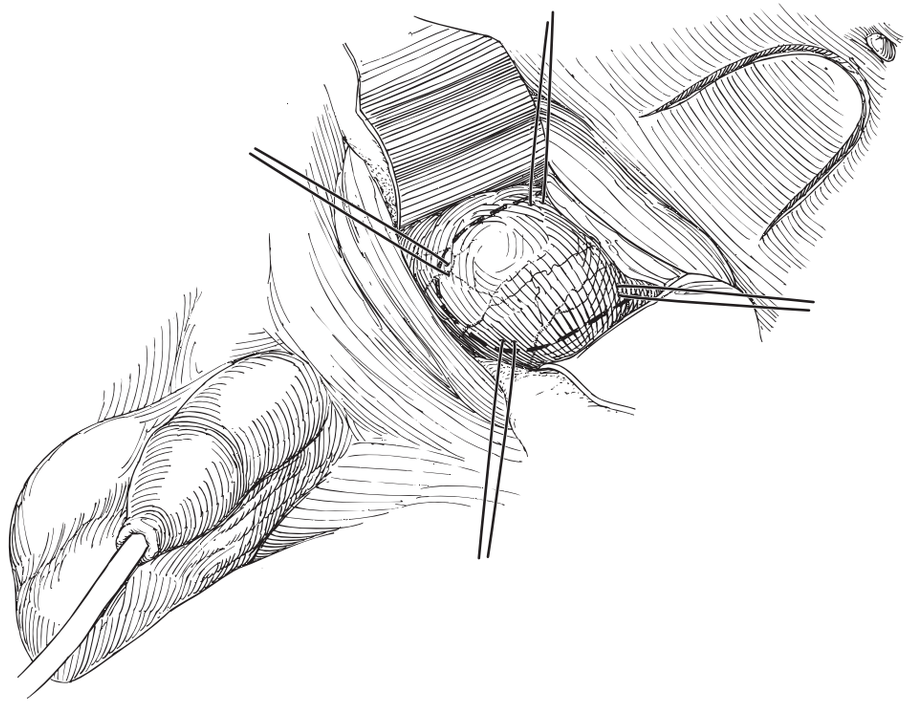

FIGURE 95-1.

fascia and incise through the fascia longitudinally in the midline. Separate the rectus muscles in the midline. If the posterior rectus fascia is encountered, incise through it in a similar fashion. Displace the peritoneum superiorly and posteriorly. To make room for the bladder and skin flaps, excise a segment of the anterior rectus sheath and rectus muscle in the midline.

Create a 4- by 4-cm U-shaped bladder flap off the anterior wall of the bladder. The base of the flap should be wider than the apex and extend superiorly just short of the dome of the bladder. Multiple stay sutures outlining the bladder flap help with mobilization (Fig. 95-2).

Pass the bladder flap beneath the skin bridge and secure the apex of the bladder flap to the superior skin edge of the abdominal incision with interrupted absorbable sutures. Several interrupted sutures placed through the rectus fascia and secured to the serosa of the flap anchor the flap in place. Complete the anastomosis of the bladder flap to the skin with interrupted absorbable sutures. Next, pass the skin flap underneath the bridge of skin and sew it to the bladder with interrupted absorbable suture (Fig. 95-3). The flaps are positioned in such a way that the skin and bladder mucosa outline the conduit for the expression of urine. Place a 20-French Foley catheter

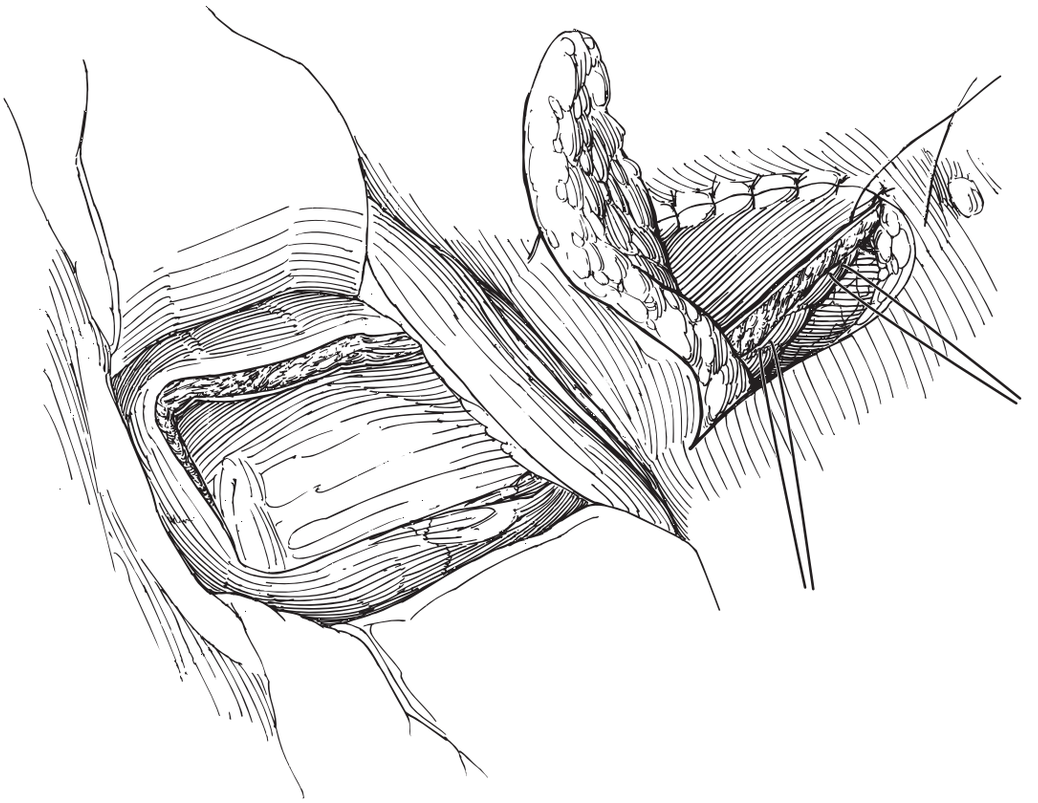

FIGURE 95-2.

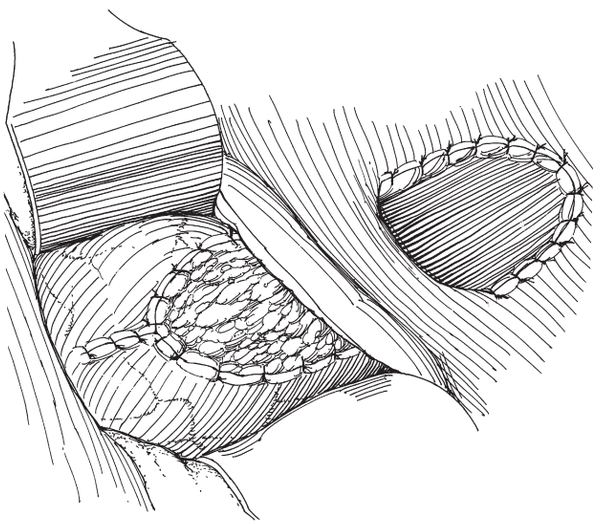

FIGURE 95-3.

into the bladder and inflate the balloon for 1 to 2 days of postoperative drainage. Close the incision in routine fashion.

MODIFICATIONS OF VESICOSTOMY TECHNIQUE

Ross described a modification of the Lapides technique which involves creating a superiorly based U-shaped skin and separate fascial flap halfway between the symphysis and the umbilicus. The fascial flap is then sewn to the posterior bladder wall. The apex of the skin flap is then sewn to the superior aspect of the bladder, and the inferior bladder margin is sewn to the inferior aspect of the skin incision. Paquin reported a modification which involves creating a fascial flap from the superior edge of the rectus fascia. This fascial flap is then anchored to the posterior aspect of the bladder just inferior to the base of the bladder flap. The skin and bladder flaps are then created as described by Lapides (Fig. 95-4).

BLOCKSOM VESICOSTOMY

This vesicostomy technique is the preferred means of temporarily diverting urine in children who cannot catheterize or despite catheterizations have worsening bladder dynamics and upper tract deterioration. Following adequate anesthesia, prep the patient from the genitalia to the costal margin. Place an 8-French catheter and fill the bladder to three fourths of the calculated bladder capacity.

Position: Supine.

Incision: Make a small 2-cm midline incision approximately 2 fingerbreadths above the symphysis pubis in the midline (Fig. 95-5).

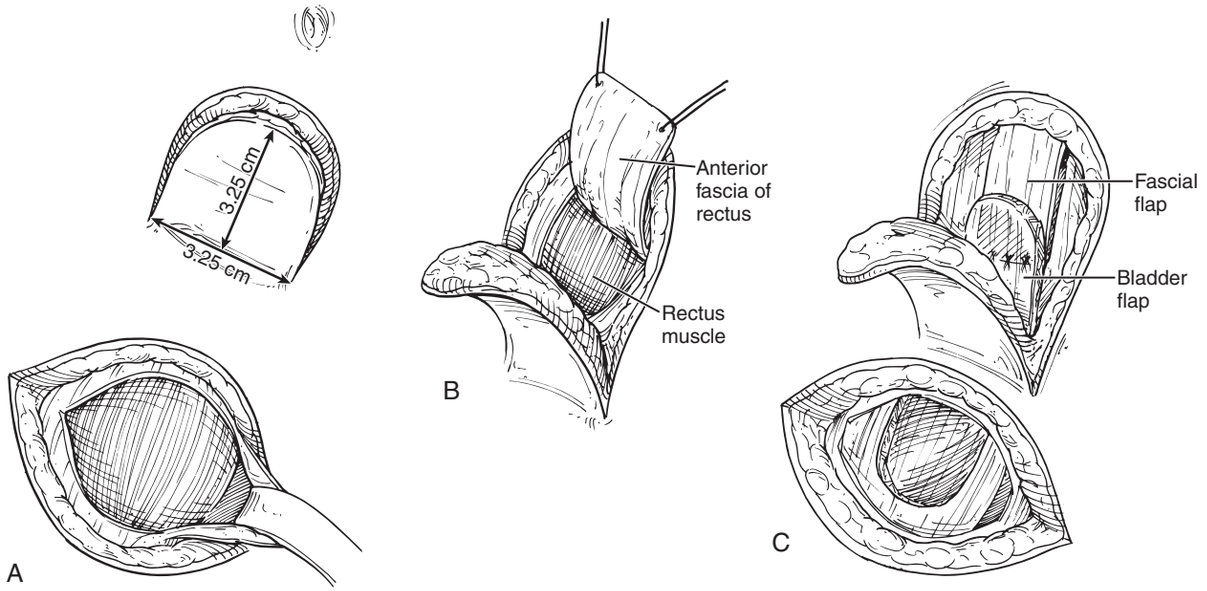

FIGURE 95-4. *(Redrawn from Paquin AJ Jr, Howard RS, Gillenwater JY. [1968]. Cutaneous vesicostomy: a modification of a technique. J Urol 99:270.)*

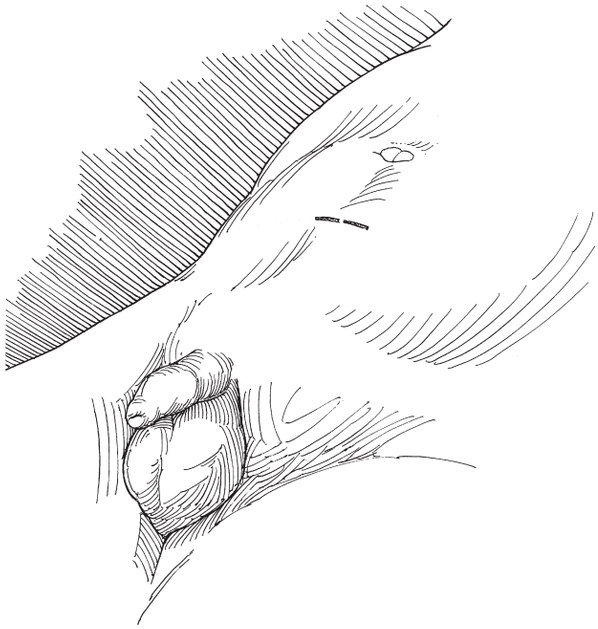

FIGURE 95-5.

Divide the subcutaneous tissue to expose the anterior rectus fascia. Incise through the rectus fascia transversely the length of the skin incision and separate the rectus muscle incising through the linea alba (Fig. 95-6). If needed, triangular segments of the rectus fascia and muscle may be excised to allow adequate space for the anterior bladder wall.

Place stay sutures through the anterior wall of the bladder to help pull the bladder inferiorly during dissection (Fig. 95-7).

Mobilize the bladder to expose the dome of the bladder, displacing the peritoneum superiorly. Find the urachus and the obliterated umbilical arteries. These structures will mark the superior extent of the dissection. Divide the urachus and umbilical arteries and place a hemostat on the urachus (Fig. 95-8).

Use the hemostat as a handle to retract the bladder. Circumscribe the urachus with the electrocautery device and enter into the bladder. The cystotomy should be large enough to accommodate the passage of a 20-French catheter (Fig. 95-9).

Secure the bladder serosa and muscle to the anterior rectus fascia with interrupted absorbable sutures, careful not to the cinch the bladder too tightly at the fascial level. (Fig. 96-10).

When securing the bladder to the fascia, allow for some redundancy of the bladder above the fascial level. The bladder above the fascial anchoring sutures will be matured to

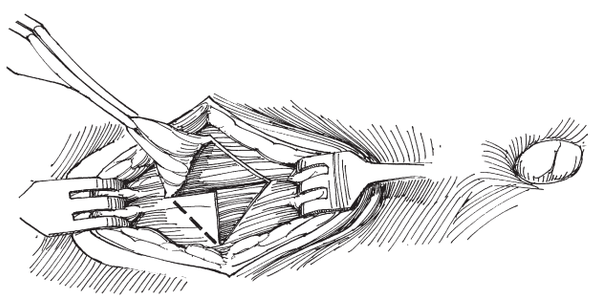

FIGURE 95-6.

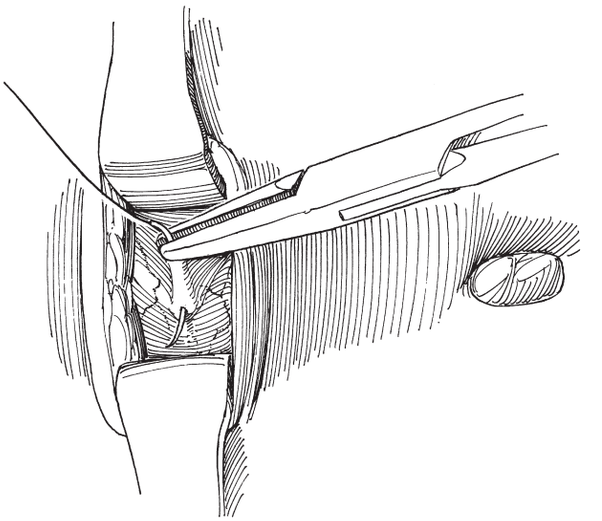

FIGURE 95-7.

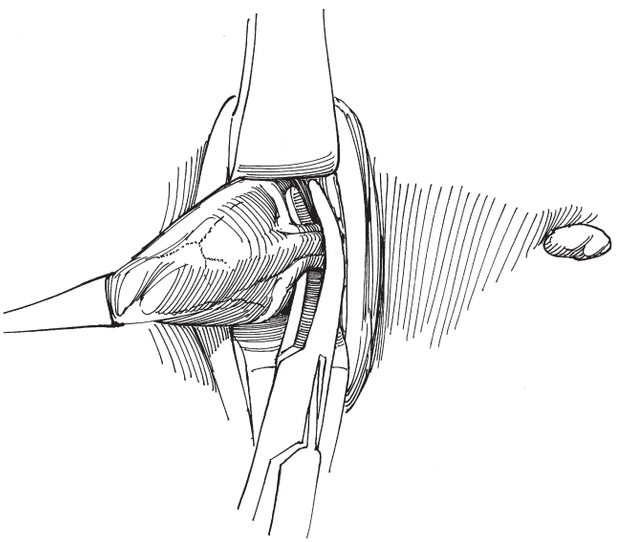

FIGURE 95-8.

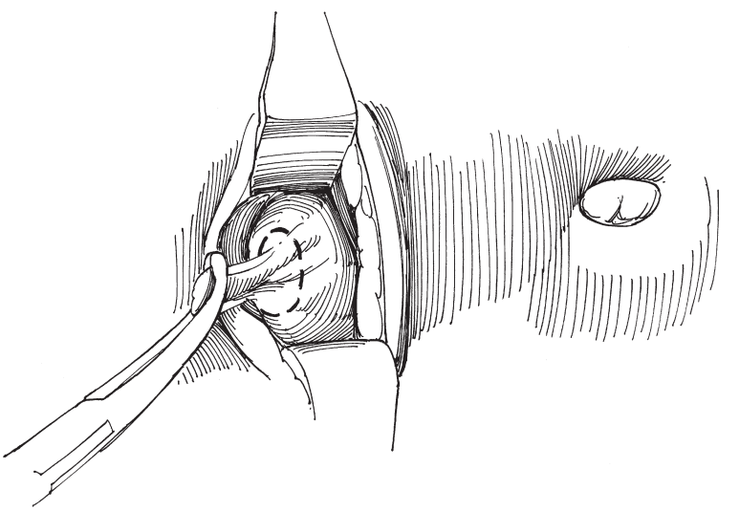

FIGURE 95-9.

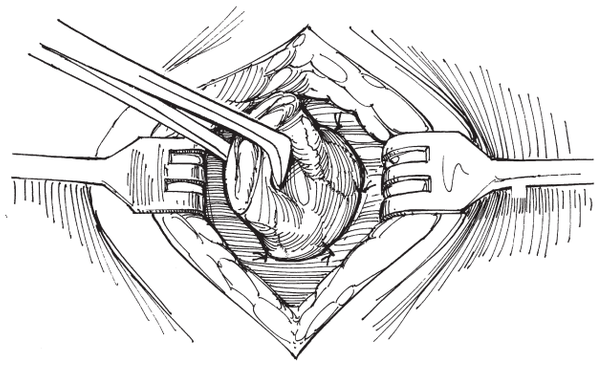

FIGURE 95-10.

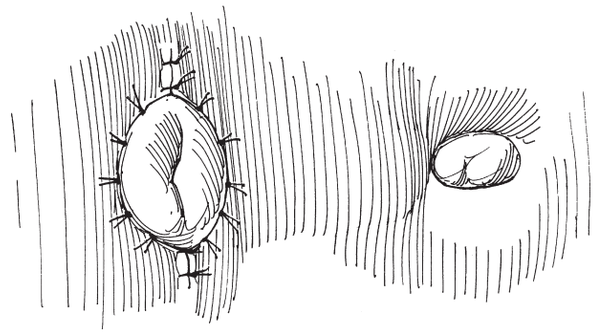

FIGURE 95-11.

create the cutaneous stoma by placing interrupted absorbable sutures through the bladder in full thickness fashion and secured to the skin. Place an 18-French catheter through the newly created vesicostomy and instill with 5 mL of sterile water for overnight drainage to be removed the next day (Fig. 95-11).

CLOSURE OF VESICOSTOMY

The most important aspect of closing a vesicostomy is the preoperative assessment. Clinical history, radiographic studies, and urodynamic data are all important diagnostic tools, but investigation of the patient and/or caregiver's ability to perform either scheduled clean intermittent catheterization or other appropriate care is essential.

Insert an appropriate sized catheter based on patient size into the stoma and inflate the balloon with 5 mL of sterile water. Make an elliptical incision around the stoma with the electrocautery device and mobilize the stoma and bladder below the level of the fascia (Fig. 95-12).

Once freed from the overlying fascia, excise the stoma, redundant bladder limb, and skin flaps if present (Fig. 95-13).

Close the bladder in two layers with a running, locked absorbable suture. Secure a suprapubic catheter exiting out a separate incision in the bladder. Leave a Penrose drain in the perivesical space and close the fascia and skin in routine fashion. Remove the Penrose drain and suprapubic catheter once the bladder has healed properly (Fig. 95-14).

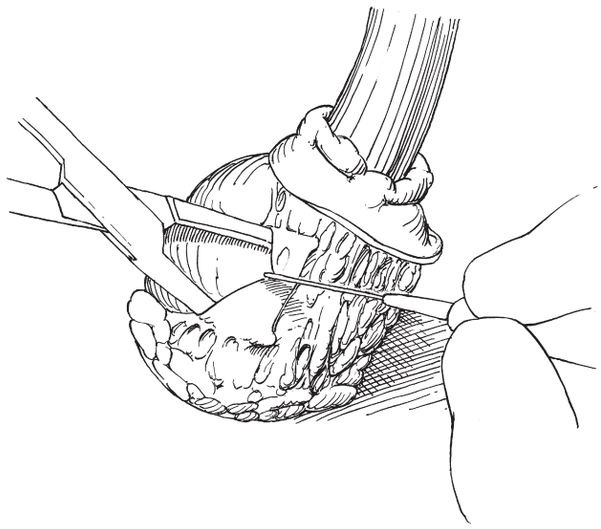

FIGURE 95-12.

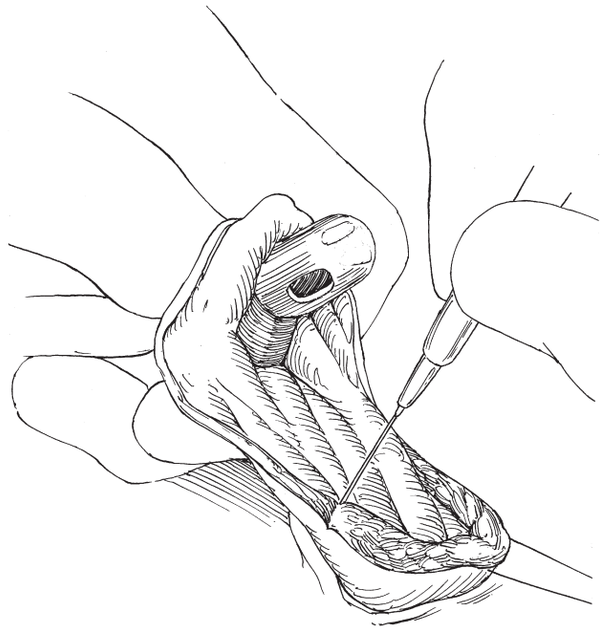

FIGURE 95-13.

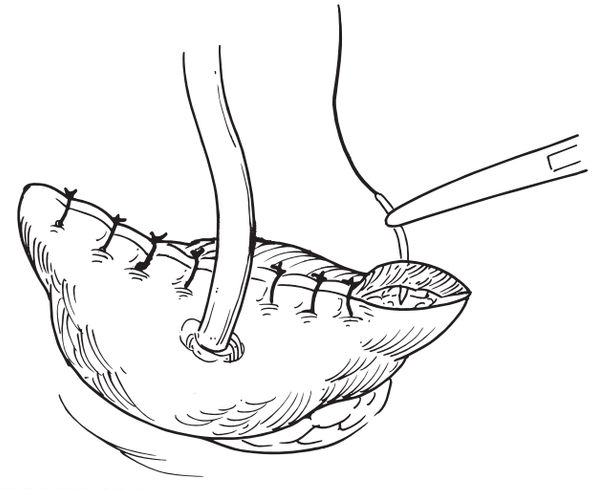

FIGURE 95-14.

INCONTINENT ILEOVESICOSTOMY

This procedure is typically employed in patients with high spinal lesions with resultant quadriplegia or those with limited upper extremity dexterity who cannot perform clean intermittent catheterization. The resultant rosebud stoma is managed similarly to an ileal loop with a secure ostomy device. It is pivotal that a trained enterostomal therapist evaluates the patient and marks an appropriate site for the stoma prior to surgery. Additionally, home bowel preparation is completed before surgery.

Position: Supine.

The patient is placed supine and prepped from the costal margins to the genitalia. A 16-French catheter is placed and a midline incision is made from the symphysis pubis to just below the umbilicus. The fascia is opened in the midline and the peritoneum entered (Fig. 95-15).

The terminal ileum is located with a mobile mesentery and an appropriate length of ileum is isolated dependent on the patient's body habitus. Bowel continuity is reestablished and the ileal segment is arranged in an isoperistaltic fashion with the proximal end spatulated approximately 4 to 6 cm on the antimesenteric side.

The bladder is filled with 300 mL of sterile irrigant and the catheter occluded. A wide U-shaped bladder flap is created with the base of the flap originating from the portion of the anterior bladder wall that allows for a smooth, tension-free anastomosis to the ileal segment. The vesicoileal anastomosis is performed with interrupted absorbable sutures. The distal end of the ileum is then brought through a cruciate incision in the rectus fascia and matured at the marked stomal site. A 22-French catheter is placed across the ileal segment into the bladder and left indwelling for 3 weeks. Close the incision in routine fashion. Perform a cystogram 2 weeks after surgery and then remove the catheter. To aid in the egress of urine, an ileovesicostomy requires a wide-mouthed anastomosis at the bladder level and minimal redundancy of the bowel segment from the bladder to fascia. An everted rosebud stoma makes for easy ostomy application.

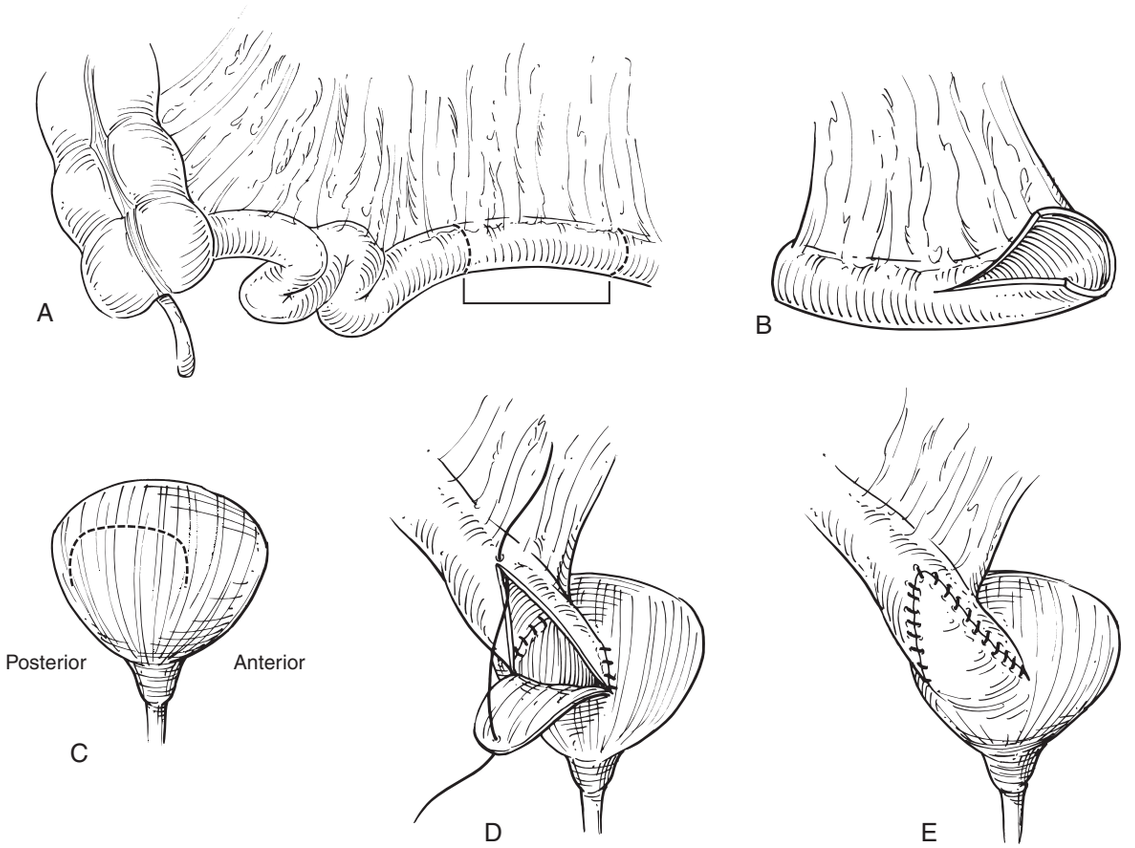

FIGURE 95-15. *(Redrawn from Schwartz SL, Kennelly MJ, McGuire EJ, Faerber GJ. [1994]. Incontinent ileo-vesicostomy urinary diversion in the treatment of lower urinary tract dysfunction. J Urol 152:99.)*

COMPLICATIONS

Minor skin irritation or dermatitis around the stoma occurs in many patients and may require moisture barriers, antifungals or antibacterial agents, and/or urinary acidification. Enterostomal therapists are a great resource when dealing with these skin problems. If stomal stenosis occurs routine dilation is curative in many instances. If stenosis is progressive with cicatricial scar formation a revision of the stoma is required. Prolapse of the bladder may respond to the placement of a large catheter with reduction of the bladder tissue, however this is usually a temporary fix. A significant prolapse of the bladder typically occurs because of poor posterior bladder wall fixation and requires revision.

Suggested Readings

Blocksom BH Jr. (1957). Bladder pouch for prolonged tubeless cystostomy. J Urol 78:398.

Lapides J, Ajemian EP, Lichtwardt JR. (1960). Cutaneous vesicostomy. J Urol 84:609.

Paquin AJ Jr, Howard RS, Gillenwater JY. (1968). Cutaneous vesicostomy: a modification of a technique. J Urol 99:270.

Ross G Jr, Michener FR, Brady C Jr, Thompson IM. (1965). Cutaneous vesicostomy: a review of 36 cases. J Urol 94:402.

Schwartz SL, Kennelly MJ, McGuire EJ, Faerber GJ. (1994). Incontinent ileo-vesicostomy urinary diversion in the treatment of lower urinary tract dysfunction. J Urol 152:99.

This page intentionally left blank

Chapter 96

Ileal Conduit

DOUGLAS S. SCHERR AND DANIEL A BAROCAS

Ileal conduit was popularized by Bricker in the 1950s and remains the most common form of urinary diversion after cystectomy, even as the indications for continent and orthotopic diversion continue to expand. The procedure remains popular because it is relatively easy to perform, allows for a rapid recovery and stabilization of function, is easy to maintain, and is widely applicable. In addition, it has the advantage that the proximal end may be attached at any site along the upper urinary tract and the distal end may surface anywhere on the abdomen.

PREPARATION FOR SURGERY

Patient Education

Patient counseling and education serves several purposes. First, it enables the patient and surgeon to arrive at a mutually satisfactory decision regarding the type of urinary diversion. Examples of each type of diversion can be provided (by picture, video, or model), and explanations on their care and maintenance can be given.

Preoperative education is the first opportunity for the patient to be introduced to the care team, which typically includes a nurse and/or specially trained enterostomal therapist. The enterostomal therapist is involved in preoperative education, marking of the stoma site, postoperative management of appliances, stomal health, and skin care.

Bowel Preparation

Most colorectal and urologic reconstructive surgeons agree that mechanical bowel preparation is indicated before bowel surgery, although there remains debate in the literature. A standard mechanical bowel preparation includes 3 to 4 L of polyethylene glycol solution, namely Go-LYTELY or NuLYTELY (Braintree Laboratories, Braintree, Mass.) or two doses of 45 mL of oral sodium phosphate solution, namely Fleet Phospho Soda (C.B. Fleet Co., Lynchburg, Va.). Oral sodium phosphate solutions appear to be equally effective and are better tolerated, leading to better compliance. However, they are contraindicated in congestive heart failure, renal insufficiency, and liver failure, among other comorbidities. Newer data suggest that a 2-L volume of NuLYTELY combined with 20 mg of bisacodyl (Half Lytely) may be equally effective.

Antibiotic bowel preparation appears to be important in colon surgery, but its role in ileal surgery is not clear. We favor the use of a Nichols-Condon oral neomycin and erythromycin base antibiotic combination. One gram of each is given at 1 PM, 2 PM, and 11 PM the day before surgery. Some authors advocate the use of 1 g each of oral metronidazole and neomycin at 5 PM and 11 PM the day before surgery, suggesting that it is equally effective, easier to administer, and has fewer gastrointestinal side effects.

Stoma Site Selection

An appropriate site for the stoma is selected, typically incorporating input from an enterostomal therapist. The importance of this step cannot be underestimated, in that poor position of the stoma can lead to a lifetime of poorly fitting appliances and urine leakage with all of its attendant social stigmata and skin complications. The standard location for the stoma is in the right lower quadrant (Fig. 96-1). In order for the wafer to adhere to the skin without leakage, the stoma must be situated at a distance from the umbilicus, the incision, other abdominal

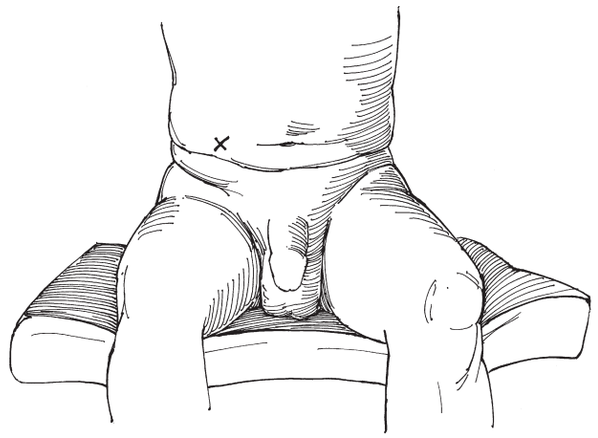

FIGURE 96-1.

scars, bony protuberances, such as the anterosuperior iliac spine, and other abdominal appliances and tubes. In addition, the stoma must be positioned away from any natural folds of the skin and be either above or below the waistline of clothing. For this reason, the person marking the patient must assess the patient in multiple positions (including sitting) and must determine where the patient's waistband would be on the abdomen. Finally, the conduit should traverse the rectus muscle, so the stoma should be positioned no farther lateral than the rectus muscle.

URETERAL MOBILIZATION

Left Ureteral Identification and Mobilization

Identification and transection of the ureters is typically performed at the beginning of the cystectomy procedure. Retract the sigmoid colon medially and incise parietal peritoneum vertically, lateral to the sigmoid mesocolon. Identify the ureter as it crosses the iliac vessels (Fig. 96-2). It will sometimes have lifted up with the peritoneum. Elevate the ureter with a Babcock clamp, pass a right angle clamp beneath the ureter, and encircle it with a Penrose drain or vessel loop. Dissect the ureter down to the level of the bladder and upward toward the kidney without disturbing its adventitial circulation. Use clips to ligate tethering blood vessels, but take care to preserve as many of these vessels as possible.

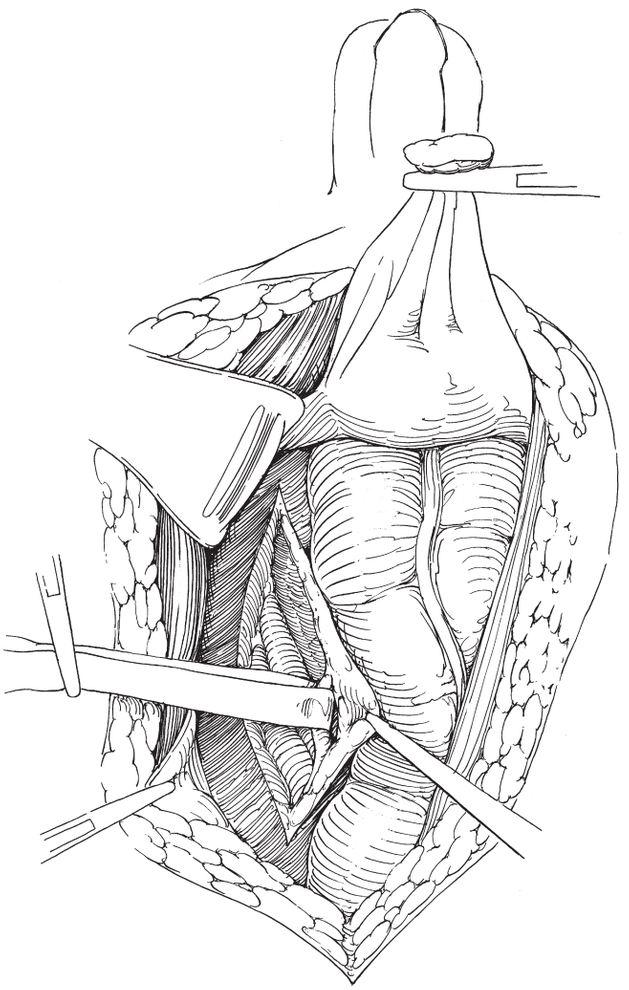

FIGURE 96-2.

Transection of Left Ureter

Place a right-angle clamp distally on the ureter where it enters the intramural tunnel. This is most readily visualized after dividing the anterior pedicle of the bladder. Place a surgical clip and transect the ureter between the clamp and the clip. Ligate the bladder side (distal) with a zero silk tie. Place a 2-0 chromic stay stitch just below the clip on the proximal side (Fig. 96-3). Some surgeons send the distal most portion of the ureter for frozen pathologic analysis and resect more proximally if carcinoma is present. The ureter is then wrapped in a 4 × 8 gauze and tucked up into the retroperitoneal space for protection during the cystectomy.

Right Ureteral Identification, Mobilization, and Transection

A similar procedure is performed on the right side. Length is not as crucial on the right side, because the conduit itself lies on the right. Therefore less mobilization is required on the right. The right ureter should also be protected with a 4 × 8 gauze and tucked up into the retroperitoneal space during the cystectomy.

Pass left ureter behind sigmoid mesentery.

Tunnel gently between the two peritoneal openings with the index and middle fingers of each hand, staying below the sigmoid mesentery. This creates a window for the left ureter to pass to the right side. The opening should accommodate at least 2 to 3 fingers in width. Pass a right-angle clamp from the right to the left and grasp the stay suture on

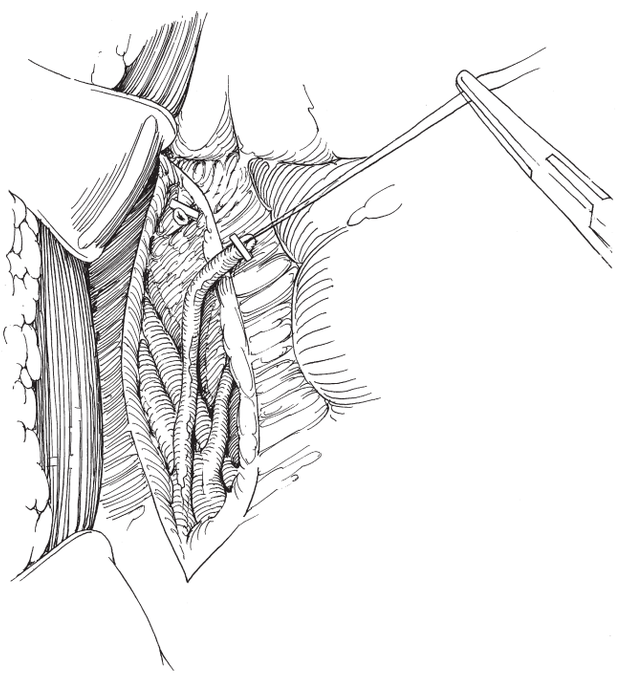

FIGURE 96-3.

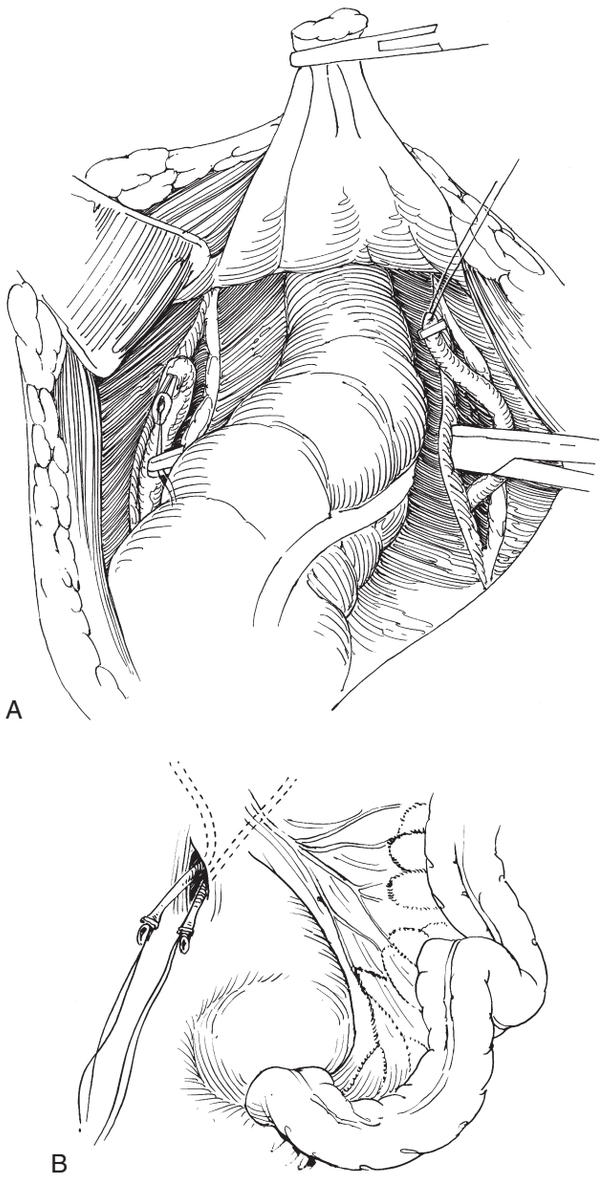

FIGURE 96-4.

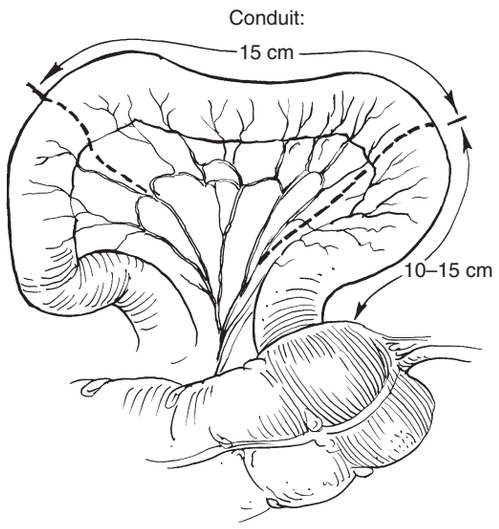

FIGURE 96-5.

the left ureter, drawing the left ureter behind the sigmoid mesocolon (Fig. 96-4). Be sure that the left ureter sweeps from left to right in a smooth arc, without angulation or twisting that could later result in obstruction.

HARVESTING THE BOWEL

Identify the Bowel Segment

In general, the bowel segment should be approximately 15 cm in length and its distal end should be approximately 15 cm from the ileocecal valve (Fig. 96-5). It should be generously supplied with at least two vascular arcades. Begin by identifying the ileocecal junction. Elevate the terminal ileum in your hands and identify the natural avascular plane in the mesentery between the ileocecal artery and the terminal branch of the superior mesenteric artery. The avascular plane can be found by shining a light through one side of the mesentery while looking at the other side, but the ridges made by these vessels may be apparent just by elevating the bowel and the avascular plane lies between them. An imaginary line drawn through this avascular plane intersects the ileum approximately 10 to 15 cm from the ileocecal valve. Place a 3-0 silk pop-off stay suture on the antimesenteric aspect of the ileum at this point and leave a long tail to mark the distal end of the conduit. Measure a length of approximately 15 cm (two fists) for the conduit. Use a longer length for a thicker abdominal wall and add 8 to 10 cm if a loop stoma is planned. Place a 3-0 silk stay suture; leave the tail short to mark the proximal end of the conduit. Reassess the blood supply to the planned conduit, ensuring that it contains at least two robust vascular arcades. Move the stay sutures if necessary.

Divide the Mesentery

The assistant shines his or her headlight through the mesentery to reveal the vascular anatomy to the surgeon. Make windows in the mesentery at intervals between vessels using the Bovie electrocautery (Fig. 96-6). The incision in the distal portion of the mesentery can go back nearly to the root of the mesentery, if necessary, and should be interrupted by only one or two anastomotic loops as one approaches the bowel. The incision in the proximal portion of the mesentery will be shorter in length, but this is not limiting, because it will remain within the abdomen. Incise the peritoneum between windows using the Bovie electrocautery and divide the vessels between hemostats using 3-0 silk ties to ligate the vessels. Alternatively, use the Ligasure device to ligate and divide mesenteric vessels. Whichever method is used, this is a delicate step, because unnecessary bleeding can lead to mesenteric hematomas or the need to place suture ligatures, both of which can compromise blood supply to the conduit. Next, clear the mesentery away from the bowel longitudinally enough to accommodate the stapler (for stapled anastomosis) or to accommodate bowel clamps (for hand-sewn anastomosis).

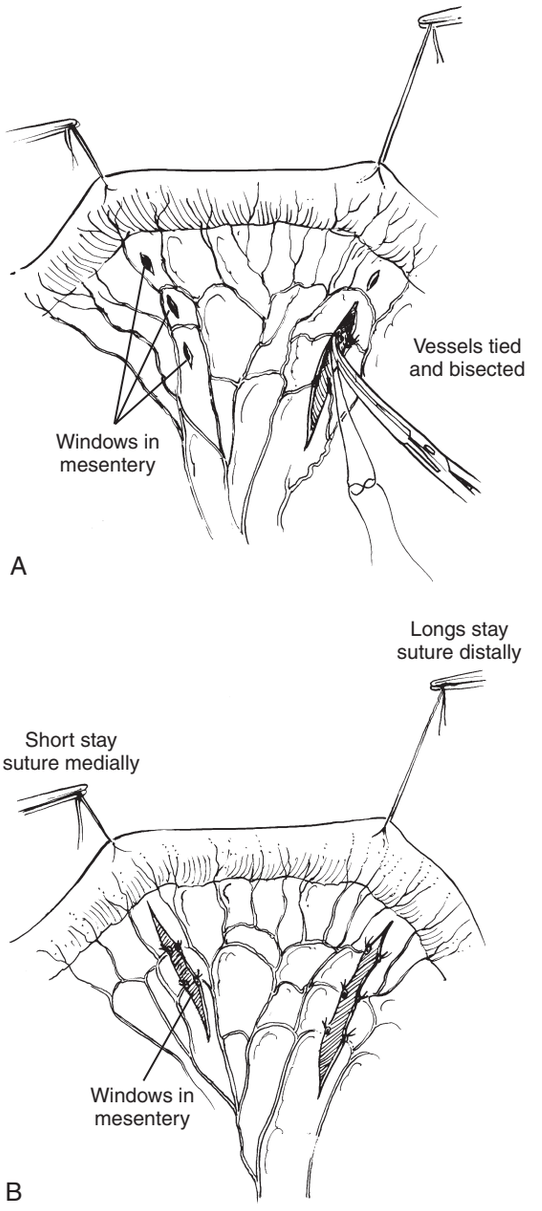
Vessels tied
and bisected
Windows in
mesentery
A
Longs stay
suture distally
Short stay
suture medially
Windows in
mesentery
B

FIGURE 96-6.

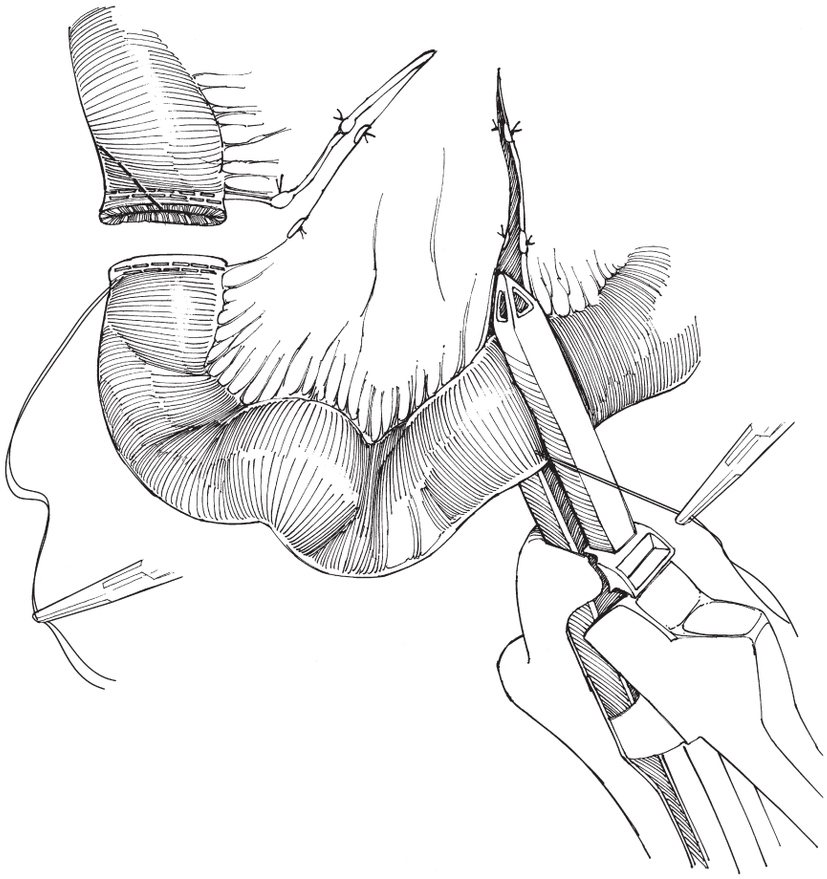

FIGURE 96-7.

Harvest the Bowel with GIA

Fire the GIA distally to staple and divide the bowel. Using a reload of the GIA, deploy the second load on the proximal end, again stapling and dividing the bowel (Fig. 96-7). Drop the conduit into the pelvis and elevate the proximal and distal ends of the ileum.

ILEOILEAL ANASTAMOSIS

Side-to-Side Functional End-to-End Stapled Ileoileostomy with GIA 80 Stapler

The aim is to reestablish bowel continuity and close the butt end of the anastomosis in a fail-safe way. Put down blue towels to isolate bowel work from the peritoneal cavity. Excise the antimesenteric corner on the proximal and distal segments of the ileum with curved Mayo scissors, just enough to allow the GIA to enter. Insert one end of the GIA stapler into each enterotomy and rotate the bowel so that the antimesenteric sides are facing and close the GIA to maintain this position (Fig. 96-8). Check on both sides that the mesentery is excluded. Fire the stapler for the third and final time. Open the GIA and withdraw both sides slowly while examining for bleeding on the staple line

Firing the TA Stapler on the Ileoileostomy

Grasp both sides of the enterotomy with three Allis clamps, being sure that each corner of the enterotomy is within the clamps and that the longitudinal staple lines are offset (Fig. 96-9). Alternatively, use stay sutures on the corners and an Allis clamp to offset the staple lines. Use a TA-60 or TA-90, depending on the width of the enterotomy. Check that the corners are included. Fire the TA, excise the stump, and discard it. Wipe the freshly cut end with a Betadine-soaked gauze.

Completing the Ileoileostomy

Next, a series of maneuvers is performed to reinforce the staple lines. First, two U-stitches of 3-0 braided synthetic absorbable suture are placed around each of the longitudinal staple lines, just below the TA staple line. Then, Lembert stitches of 3-0 silk are used to dunk TA staple line and reinforce it. A 3-0 silk stitch is placed at the crotch of the anastomosis to take tension off the longitudinal staple line (Fig. 96-10).



FIGURE 96-8.

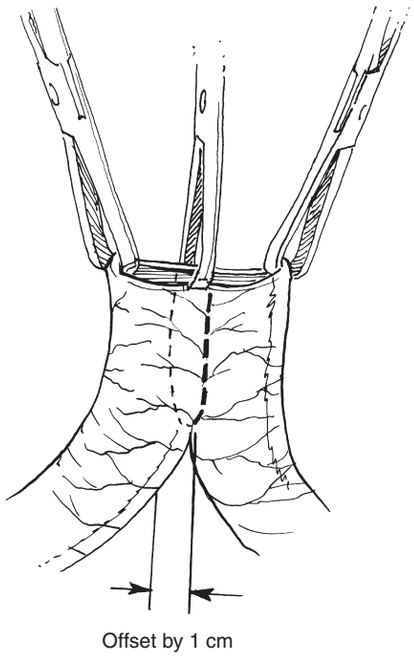

FIGURE 96-9.

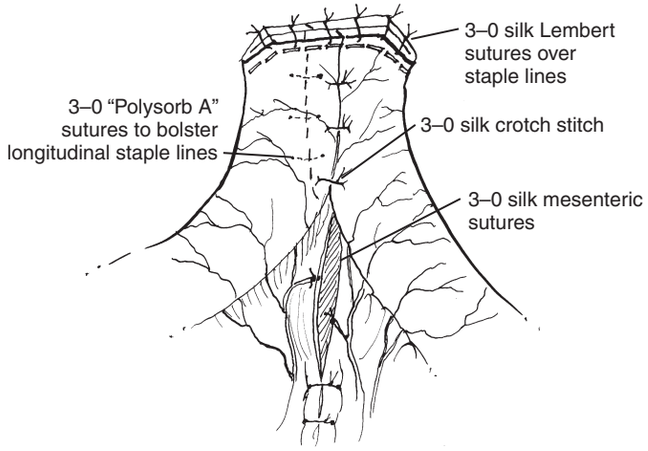

FIGURE 96-10.

Close the Mesenteric Trap

Next, 3-0 silk interrupted stitches are placed in the peritoneum to close the mesenteric trap and avoid internal hernias (Fig. 96-11). Take care to avoid placing sutures through the mesentery because these can cause bleeding or compromise blood supply. Discard the blue towels and dirty instruments before proceeding.

URETEROILEAL ANASTOMOSIS

Position the conduit and determine where the ureters will enter without tension or kinking.

The bowels are packed up high in the abdomen with malleable retractors. We prefer to position both ureteroileal

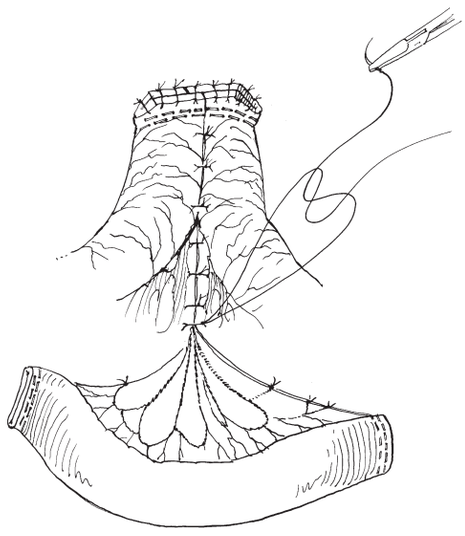

FIGURE 96-11.

anastomoses on the lateral aspect of the conduit, but alternative positions seem to be equally effective as long as there is no tension or kinking (Fig. 96-12). First, position the conduit as it will lie when it is completed (i.e., with the butt end deep and the distal end up to the anterior abdominal wall with some excess). Determine where (on the lateral aspect) the ureters will enter without tension or kinking. Then lay the conduit back down with the distal end pointed medially so that this lateral aspect is up and can be visualized. Exclude the proximal staple line by running a horizontal mattress stitch of 2-0 chromic just below it. Place fresh blue towels down. Excise the distal staple line and irrigate the conduit using a bulb syringe and a pool suction. Once you are ready to begin the ureteroenteric anastomosis, the conduit may be held in position by placing a Babcock clamp distally on the conduit and using a second clamp on the drape to secure the Babcock.

Excise or Incise a Window in the Conduit

Estimate once again where ureters will insert into conduit with tension or kinking. The left ureter will insert more toward the proximal end of the conduit. To excise a window, grasp an area of serosa with DeBakey forceps and tap the forceps with the Bovie before using the tenotomy scissors to excise a small window. To incise a window, grasp the conduit with the nondominant hand and incise a small window with the #15 blade (Fig. 96-13).

Open Bowel Mucosa

Grasp the mucosa with forceps and excise a small window (Fig. 96-14). Forceps can be used to evert the mucosa a bit, although some surgeons prefer to evert it with sutures.

Prepare the Ureter (Left Side First)

Hemitransect the ureter using tenotomy scissors, keeping the distal tip with stay suture and surgical clip as a "handle" (Fig. 96-15). Spatulate the ureter with Potts or tenotomy

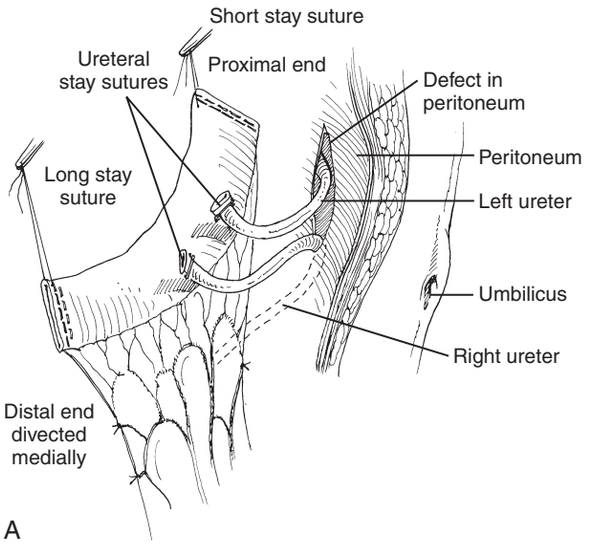

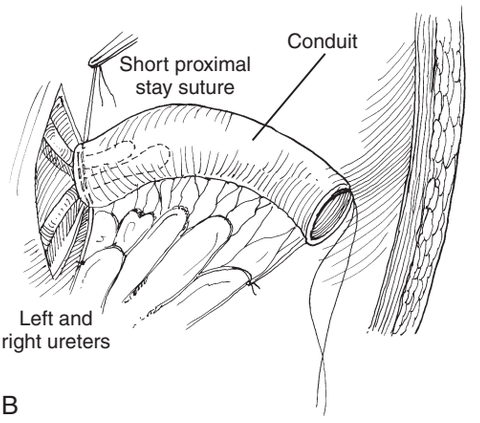

FIGURE 96-12.

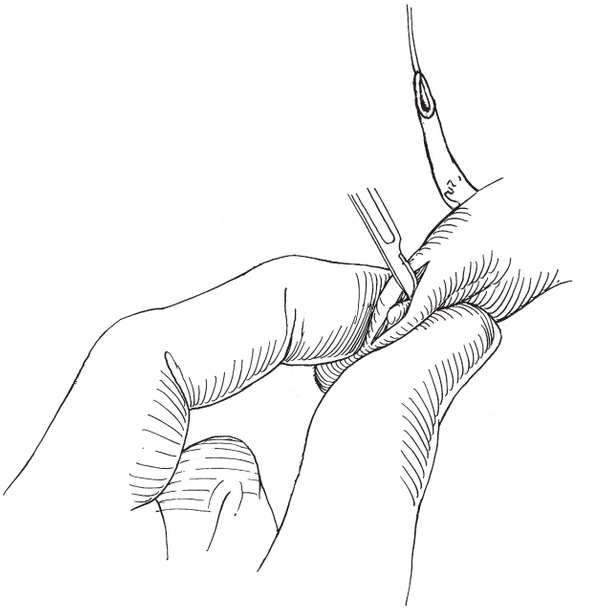

FIGURE 96-13.

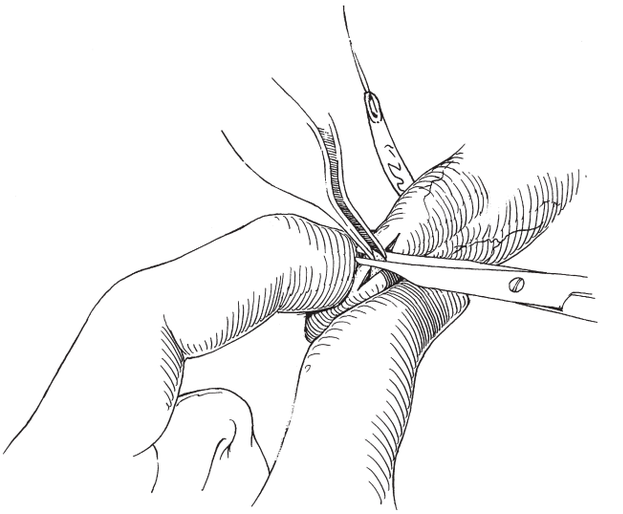

FIGURE 96-14.

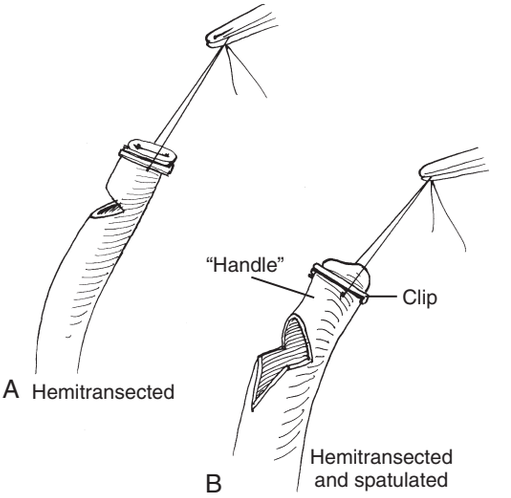

FIGURE 96-15.

scissor. We favor a relatively deep spatulation, so that the diameter of the anastomosis will be about 1 cm.

Implant the Left Ureter

A total of about 10 to 12 interrupted 4-0 braided synthetic absorbable stitches on small cutting needles are used. We prefer to use all interrupted sutures, even though others use running suture lines for all or part of the anastomosis.

The first suture is placed at the crotch of the spatulation, from out to in on ureter, then in to out on bowel (Fig. 96-16). Three or four additional sutures are placed on each side of the crotch, alternating sides with each suture. A suture guide or Jerold forceps is place inside the ureter to avoid catching the back wall of the ureter in the stitch. The assistant moves the stay suture on the distal end of the ureter away from the conduit to provide exposure when placing sutures, then toward the conduit

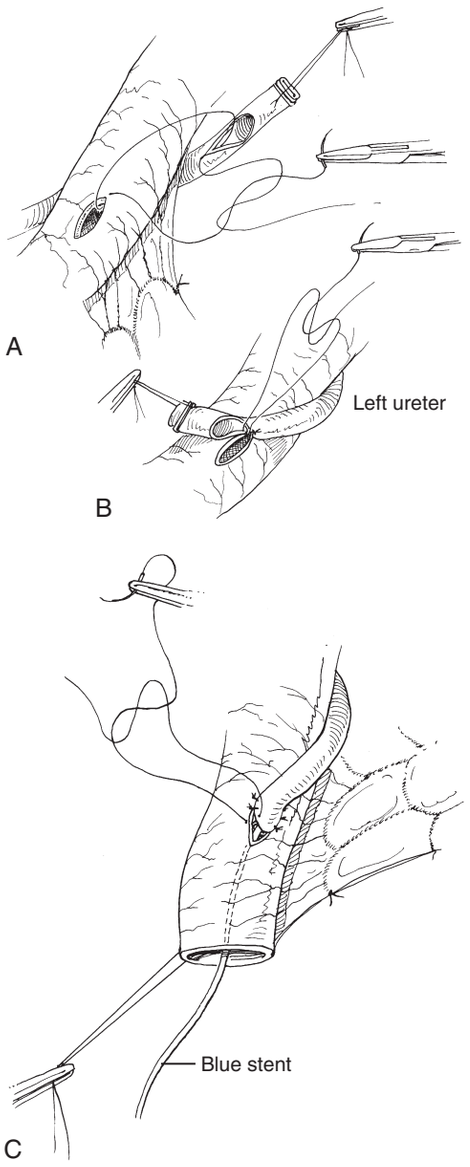

FIGURE 96-16.

to approximate the ureter and bowel while tying. When the anastomosis is more than half complete, a 7-French single-J stent is placed up the ureter (blue on the left, red on the right) with a wire loaded (stiff side up). The distal aspect of the stent can be drawn through the window and out through the distal opening in the conduit using a right-angle clamp or an empty Yankauer suction tip. The "handle" on the distal ureter is excised, including the clip and stay suture and sent for permanent pathology. The final three or four stitches are placed, but not tied until the last one is placed. The conduit is then irrigated with a bulb syringe to test the anastomosis for watertightness.

The right ureter is prepared and implanted in an identical fashion. Less length is required on the right side, so the ureter will be transected more proximally. The site of implantation of the ureter will be more distal on the conduit than the left and will also be on the lateral aspect.

CREATION OF THE STOMA

Excise the Skin and Subcutaneous Tissue

Place Kocher clamps on the rectus fascia on the patient's right side and draw the fascia to its orthotopic position in the midline. Place a Kocher clamp on the skin where the stoma is expected to emerge, preferably where the enterostomal therapist has marked the patient (Fig. 96-17A). Reconfirm that the conduit can lie in that position without tension on the ureteroileal anastomoses or mesentery. Incise the skin in a circular fashion, sized just smaller than the diameter of the ileal conduit. Use the Bovie on cutting or use a skin knife. Excise the skin with a cylinder of subcutaneous fat down to fascia (see Fig. 96-17B).

Cruciate Incision in the Fascia

Clean off the fascia and expose it well with retractors from above, using a finger from below for countertraction (Fig. 96-18). Make a cruciate incision in the anterior rectus fascia. Place four 2-0 braided synthetic absorbable sutures, one on each corner of the fascia, outside to inside, and leave the needle on for later use as fascia to seromuscular stitches.

Tack and Mature the Stoma

Spread the rectus fibers to expose the posterior sheath and peritoneum. Incise the posterior sheath and peritoneum against the surgeon's finger with the Bovie. Insert a Babcock clamp through the defect and carefully draw the stents through; then reinsert the Babcock and draw the distal end of the conduit through, leaving 5 to 7 cm above the fascia. Throw the previously placed 2-0 sutures into seromuscular layer of the conduit at four points to tack the conduit to the fascia at a level 5 to 7 cm proximal to the end of the conduit (Fig. 96-19A). Evert the mucosa by placing a Babcock clamp about 4 cm deep within the conduit, grasping the mucosa, and using smooth forceps to peel down the edge of the mucosa, thus forming the rosebud (see Fig. 96-19B). Place fresh 2-0 braided synthetic absorbable sutures into skin, serosa, and mucosa at four points to complete the eversion (see Fig. 96-19C). Place additional 2-0 or 3-0 sutures into skin and mucosa at 5-mm intervals to complete the stoma (see Fig. 96-19D).

Completed Conduit

The conduit is shown with the ureters emerging from the defect in the parietal peritoneum and inserting on the lateral aspect of the conduit. The stoma is completed, with the stents emerging from it (Fig. 96-20).

Retroperitonealize the Proximal End of Conduit

The medial peritoneal flap is tacked to the conduit, to the lateral peritoneal flap and to the mesentery with 3-0 silk sutures (Fig. 96-21).

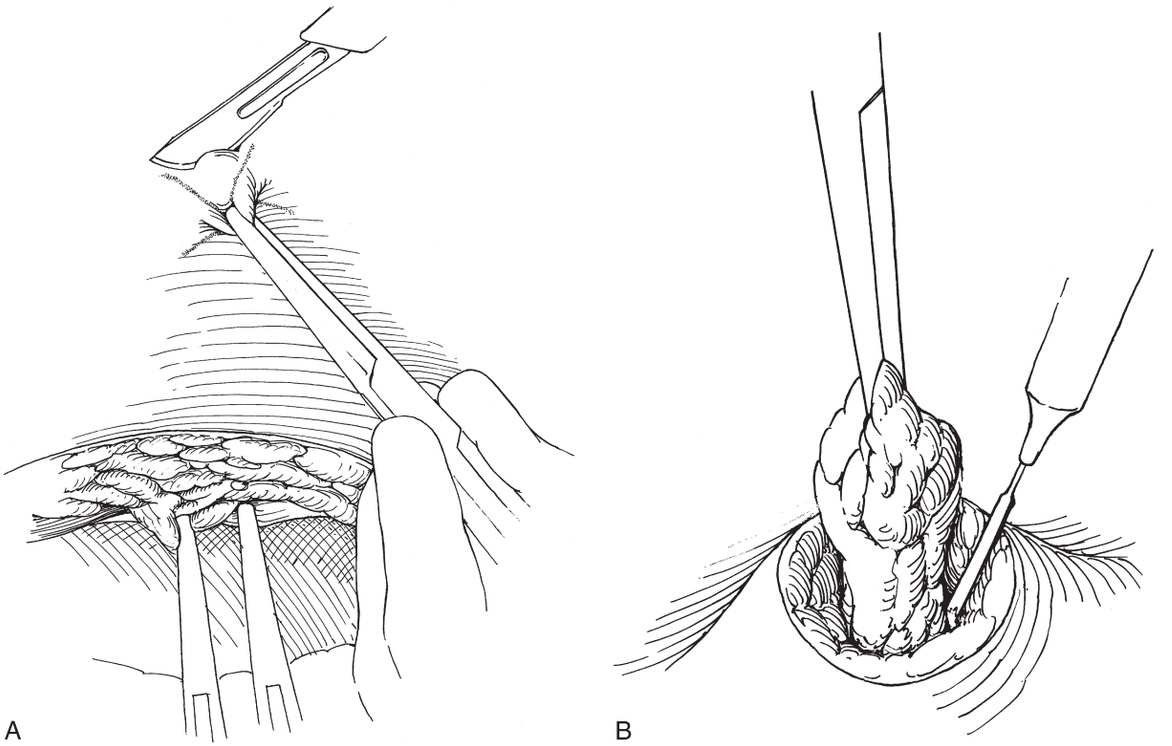

FIGURE 96-17.

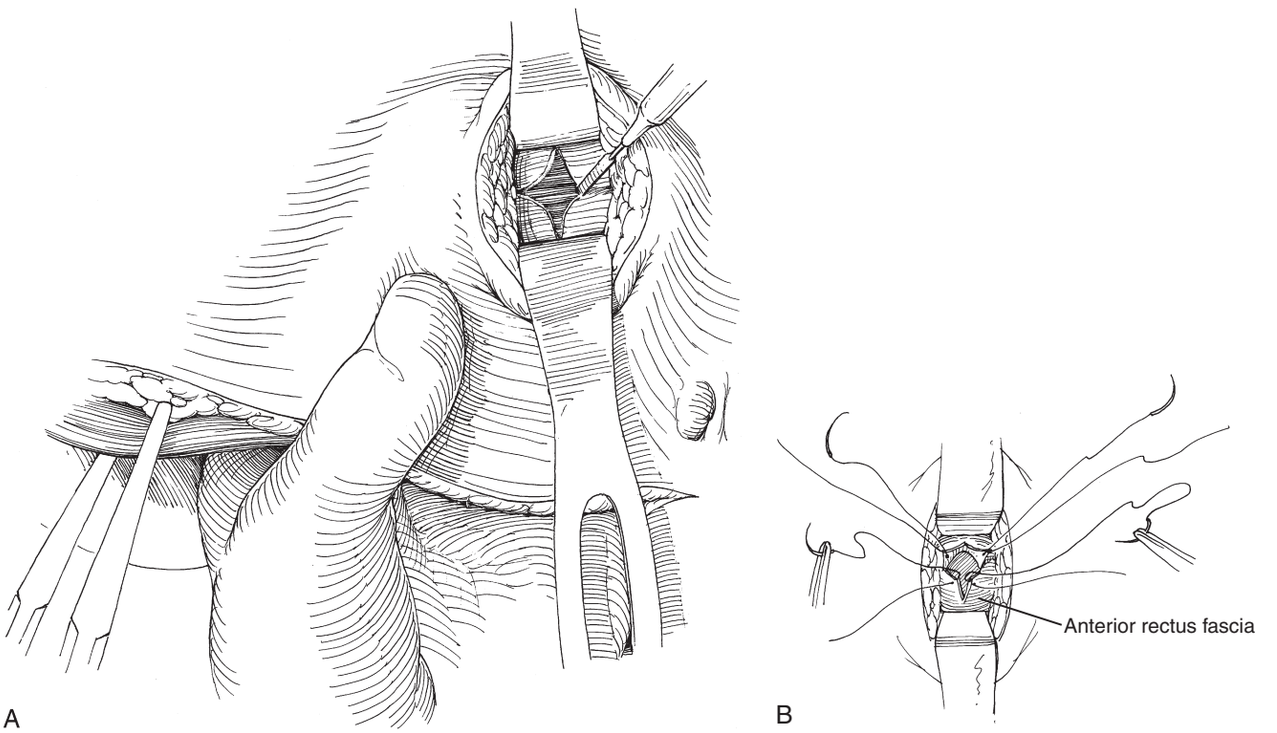

FIGURE 96-18.

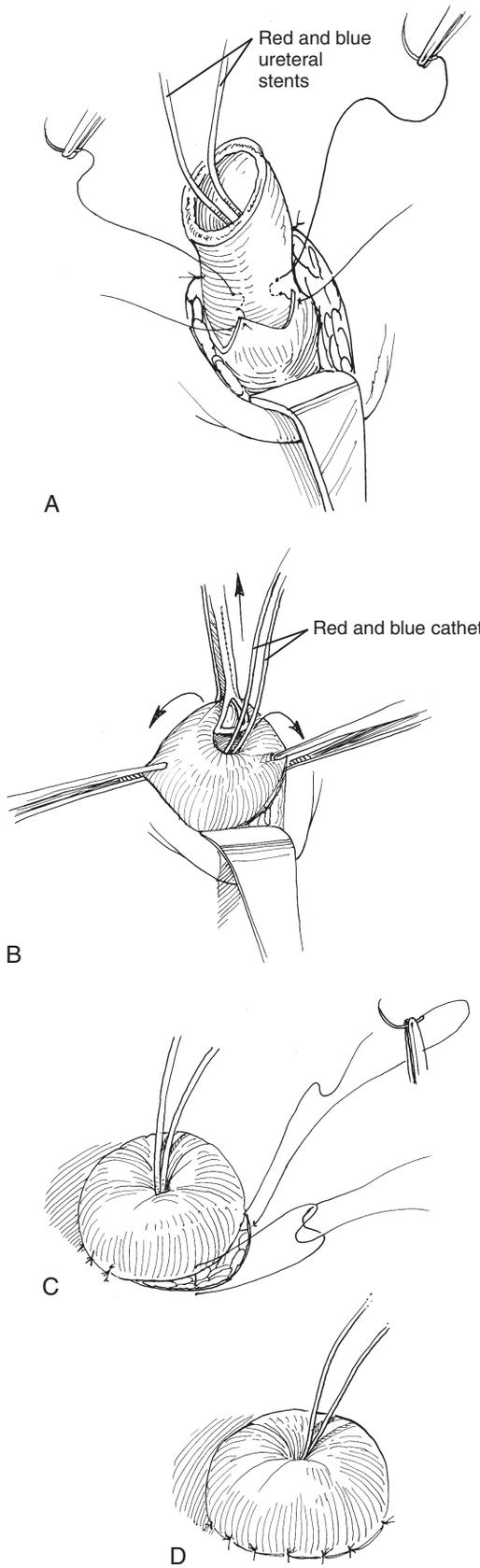

FIGURE 96-19.

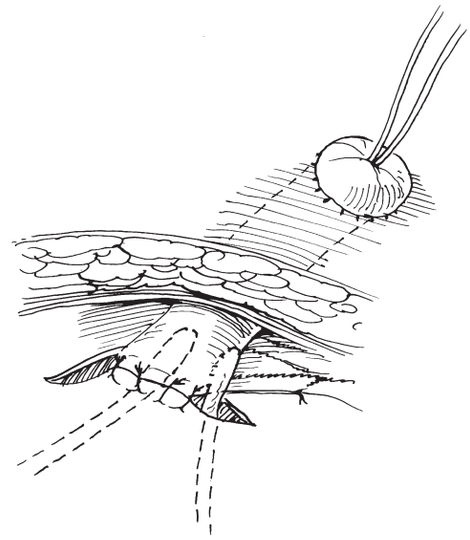

FIGURE 96-20.

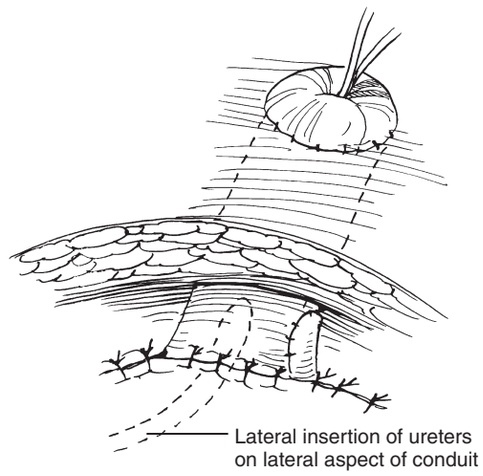

FIGURE 96-21.

Completed Conduit with Ileoileal Anastomoses Visible

A frontal view of the completed conduit and ileoileal anastomosis is shown. Closure is performed in standard fashion after irrigation of the abdomen and placement of a drain (Fig. 96-22).

Conjoined (End-to-End)

Spatulate each ureter for a distance slightly more than the diameter of the ileum (Fig. 96-23A).

Join their posterior edges with two running 4-0 chromic catgut sutures, starting in the middle and continuing around each end (only one suture is shown) (see Fig. 96-23B).

Continue the sutures to join the back walls of the bowel and ureter, taking care to invert the angles (see Fig. 96-23C). Then complete the closure anteriorly. Reinforcing sutures may be added.

An alternative technique can provide a nonrefluxing ileal conduit (Grossfield). After isolating the ileal segment, make a

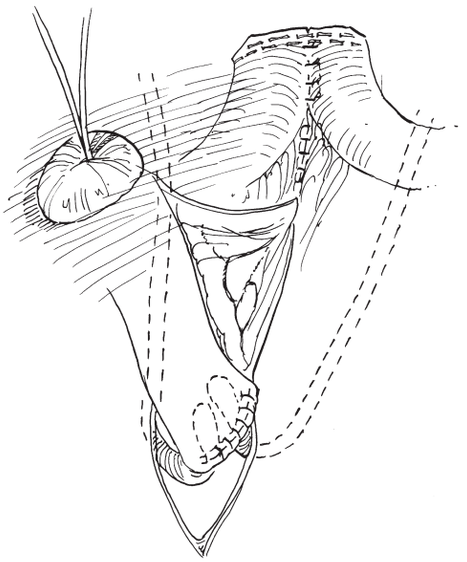

FIGURE 96-22.

5-cm enterotomy just distal to the afferent limb and intussusceptthe ileum through it. Fix the intussusception to itself with two rows of staples from the GIA stapler, and fix it to the back wall with a third set. Place a polyglycolic acid collar at the base of the nipple valve, and close the enterotomy in two layers.

STOMA ALTERNATIVES

Umbilical

Z-Incision Stoma

Make a Z-incision in the skin at the stomal site (Fig. 96-24A). Raise two flaps (see Fig. 96-24B). Incise the mucosa and submucosa of the bowel, or the entire thickness of the bowel, on either side (see Fig. 96-24C). Insert the flaps in the defects and suture them in place with 3-0 SAS (Fig. 96-24D).

Loop Stoma

This procedure is useful for obese patients with a short mesentery, but can be used in any patient. Initially provide a longer (8 to 10 cm) ileal segment.

Loop Stoma (Fig. 96-25)

For hand-sewn, close the distal end of the conduit absorbable suture or use an absorbable suture to exclude the staple line. In obese patients, carefully undercut the mesentery of the distal end to obtain adequate mobility. Pass a clamp bluntly through the most mobile and well-vascularized part of the mesentery in order to loop it with a Penrose drain (see Fig. 96-25A).

Draw the bowel loop through the body wall for at least several centimeters without tension or twisting (see Fig. 96-25B).

Loop Stoma (Fig. 96-26)

Replace the Penrose drain with a plastic rod (see Fig. 96-26A). Open the loop transversely four fifths of the distance along the exposed bowel, nearest the defunctionalized (distal) limb. Reach inside the opening with an Allis clamp and pull out the mucosa.

Suture the mucosa to the subcuticular layer of skin with interrupted 4-0 SAS, catching the seromuscular layer of the bowel to evert the stoma (see Fig. 96-26B). The defunctionalized portion requires only superficial sutures. Fasten the rod in place with two silk sutures; withdraw it 1 to 2 weeks postoperatively.

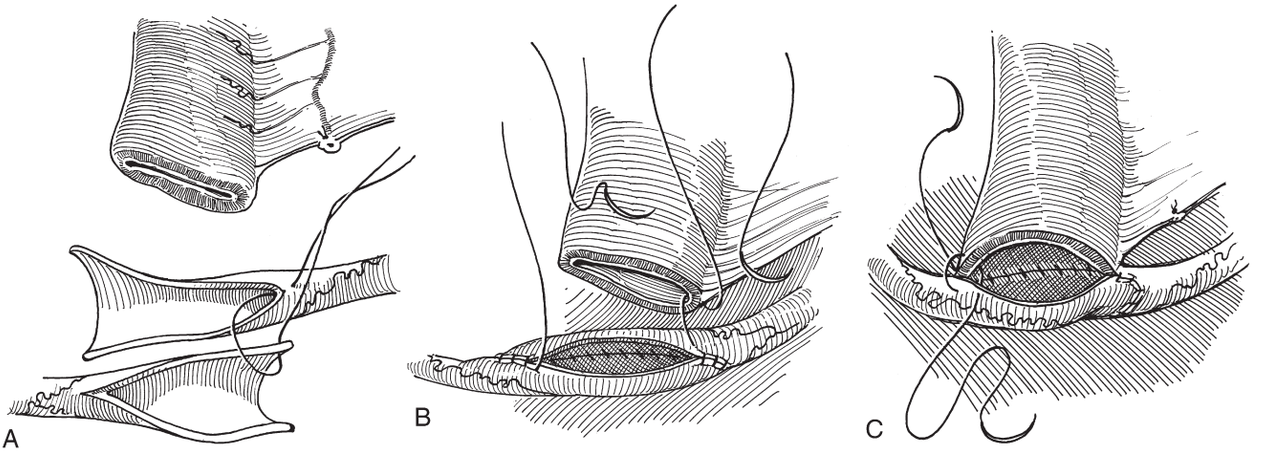

FIGURE 96-23.

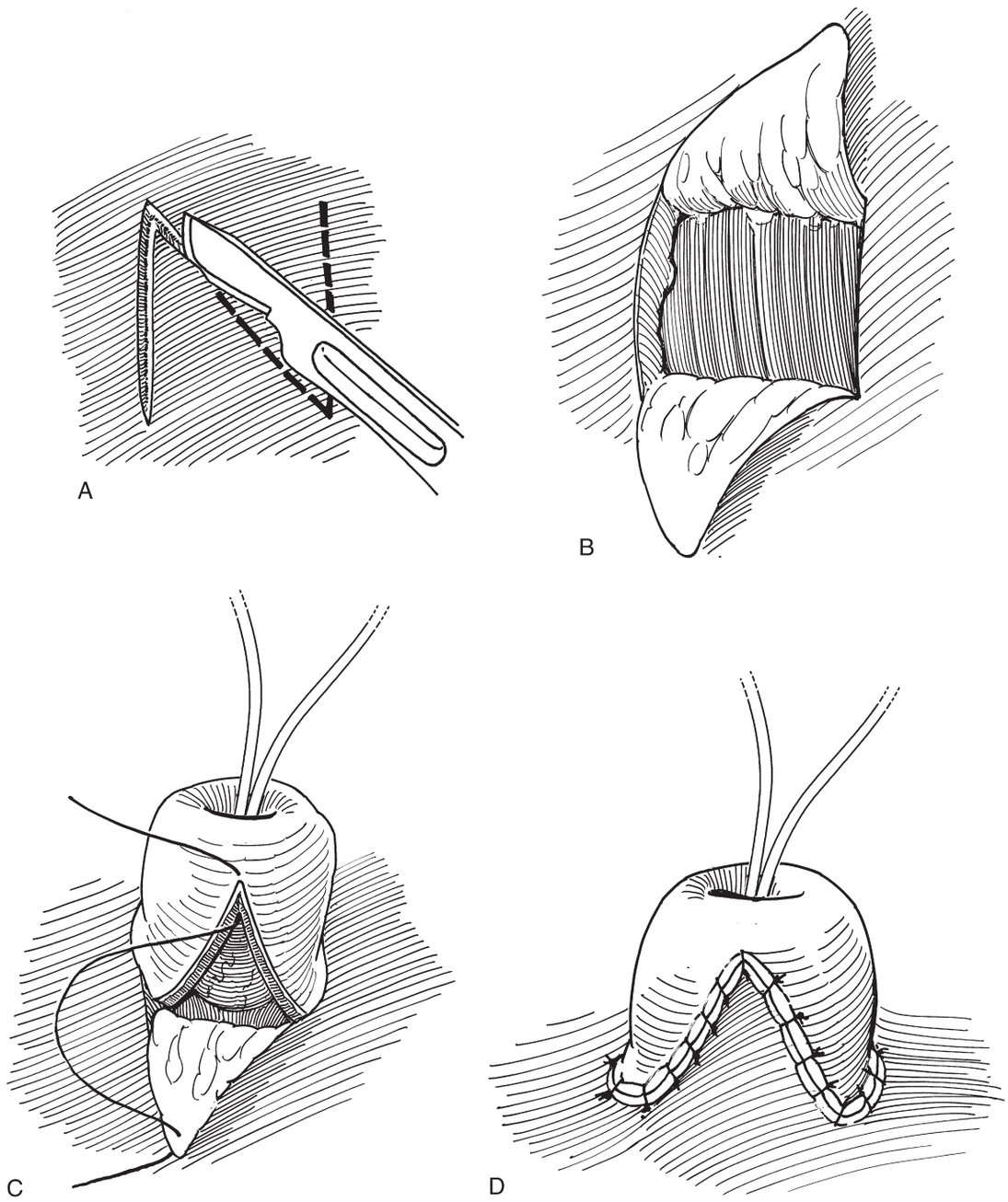

FIGURE 96-24.

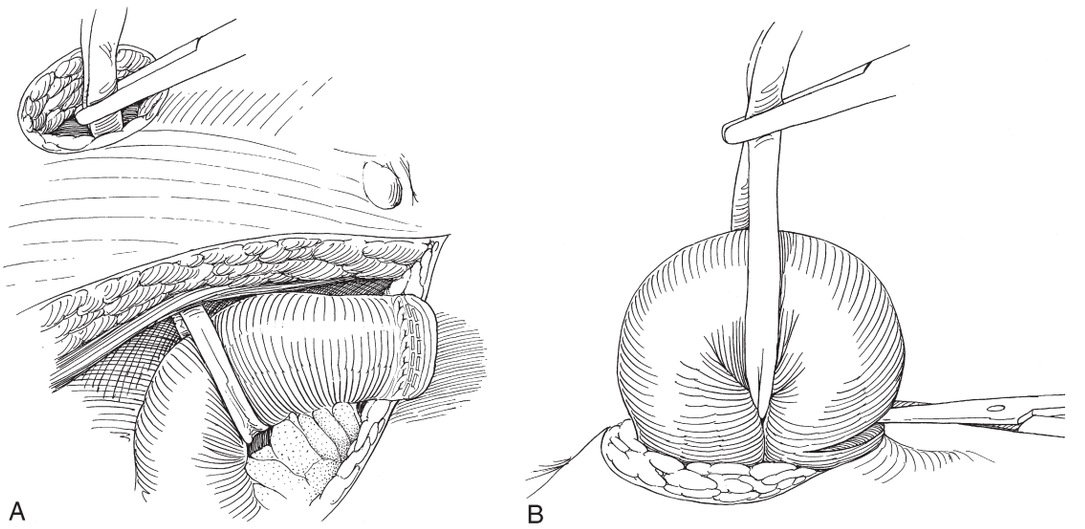

FIGURE 96-25.

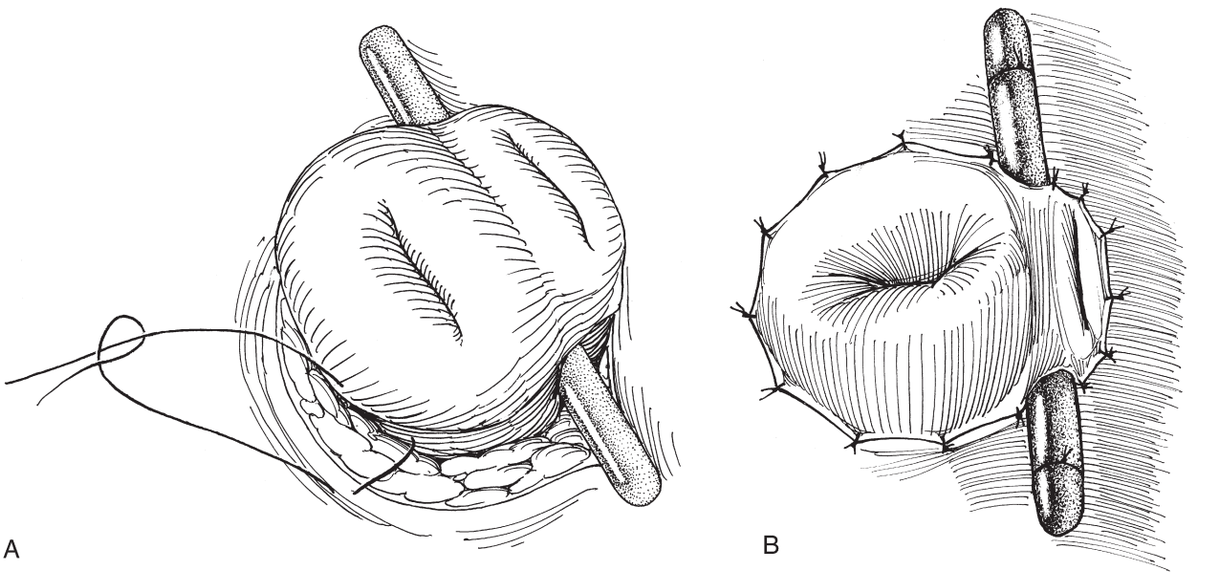

FIGURE 96-26.

Chapter 97

Laparoscopic/Robotic Ileal Conduit

ERIK P. CASTLE, MICHAEL E. WOODS, RAJU THOMAS, AND RODNEY DAVIS

ISOLATION OF THE ILEAL SEGMENT

When performing an ileal conduit along with radical cystectomy, please refer to Chapter 84, Laparoscopic/Robotic Radical Cystectomy, for steps prior to this segment. For this portion of the procedure, it is important that the bedside assistant be placed on the left side to allow for the ideal angle of passage of the stapler and insertion of the diversion stents. The ileal segment should be measured with a precut (15 cm) silk suture that is inserted into the peritoneal cavity. The suture can then be used to run the length of the distal ileum and select a 15- to 20-cm segment.

BOWEL DIVISION AND REANASTOMOSIS

In most cases, it is not necessary to identify the vascular arcades during division of the bowel segments. However, if desired, the surgeon may use a second laparoscope and light source, the mesentery of the ileum can be transilluminated to identify the vascular arcades. Once the arcades are visualized, a laparoscopic bipolar instrument can be used to incise and open the mesentery (Fig. 97-1A). The authors currently use vascular loads for the endovascular stapler (2.5 and 60 mm length) to divide the bowel and the mesentery. This allows for adequate hemostasis of the mesentery (see Fig. 97-1B and C). It is paramount that the stapler be placed perpendicular to the antimesenteric border of the ileum and the mesentery. This prevents devascularization of the ileal segment and the bowel anastomosis.

The two ends of the ileum that will be used for the bowel anastomosis should be grasped and 2-0 Vicryl suture should be used to bring the antimesenteric borders together at 5 and 10 cm proximal to the ends (Fig. 97-2). The medial corners should be tagged with short 2-0 Vicryl sutures for retraction. The corners can be cut to allow for insertion of another laparoscopic stapler. The stapler to be used here should be a laparoscopic 60 mm length and 3.5 mm bowel load to create a side-to-side anastomosis (Fig. 97-3). A second load can be fired down the anastomosis further to create larger a side-to-side anastomosis if desired. The open end can then be closed with one or two final 60-mm loads (Fig. 97-4). The mesenteric window can be closed with interrupted or running sutures and the staple line that is there can facilitate that.

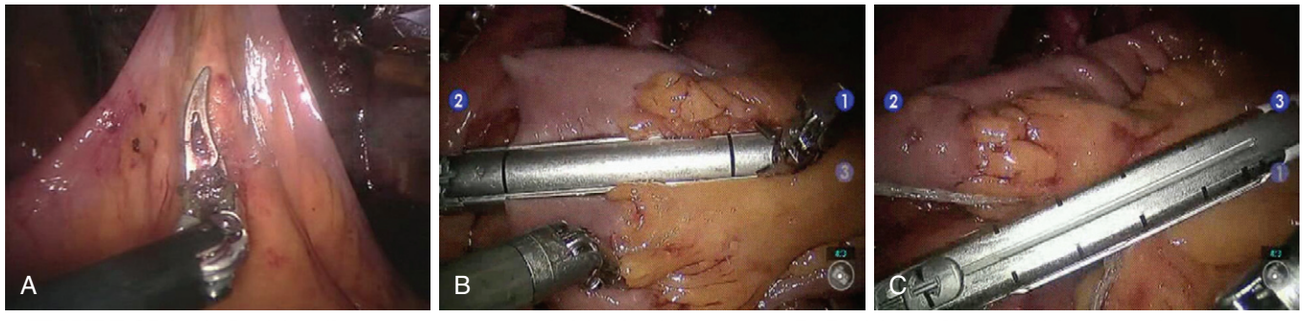

FIGURE 97-1. A, Incising ileum mesentery with bipolar instrument. **B,** Division of bowel with a vascular load. **C,** Division of mesentery with a vascular load.

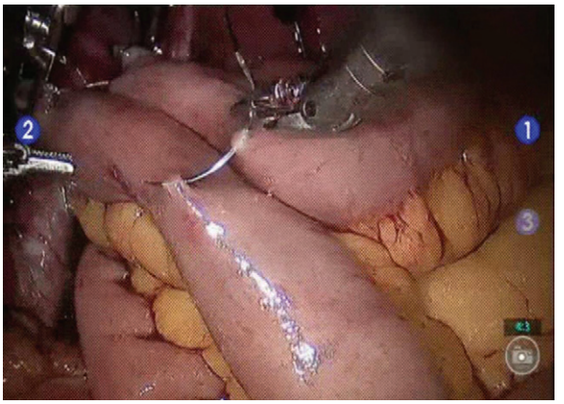

FIGURE 97-2. Antimesenteric tagging and approximation of bowel segments.

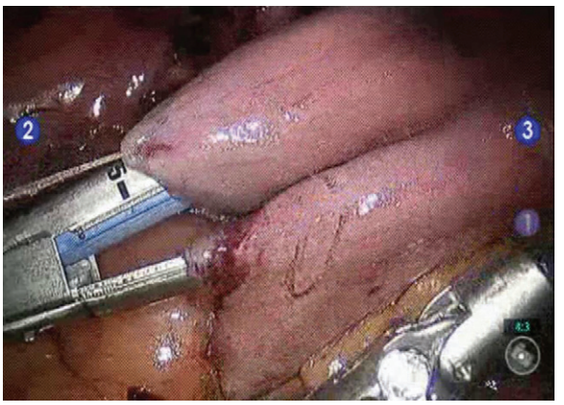

FIGURE 97-3. Creating side-to-side bowel anastomosis with a bowel load.

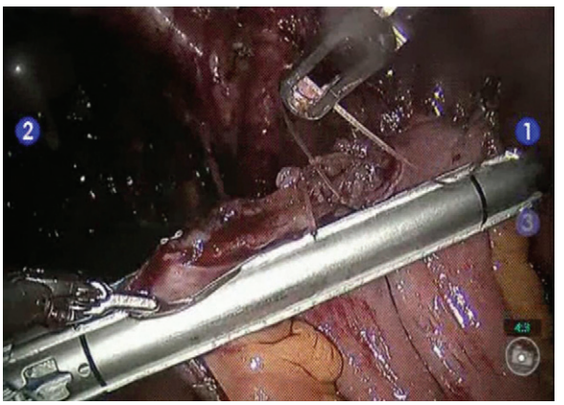

FIGURE 97-4. Completing side-to-side bowel anastomosis with a bowel load.

STOMA AND URETERAL ANASTOMOSES

The stoma should can be created first to allow for the ileal segment to be fixed at one point and the butt end can be used for the anastomosis. This is generally used more in the laparoscopic approach. With the robotic approach, one simply leaves the patient in Trendelenburg position and performs the desired ureteroileal anastomosis.

If a laparoscopic Bricker anastomosis is desired, then using the laparoscopic scissors/Endoshears one can spatulate the ureteral ends and the anticipated sited along the ileal segment. One should begin with the left ureteral anastomosis from the left side of the table and left-sided ports. Using a 4-0 Monocryl or Vicryl suture, either an interrupted or running anastomosis can be performed. The ureteral diversion stents should be inserted from extracorporeal into the stoma and into the open ureteral ends after performing each half of the ureteral anastomoses. This can be more difficult with a Bricker anastomosis than with a Wallace anastomosis because the conduit butt end is open into the peritoneum and the stents can be inserted into the ureters more easily. Alternatively, the surgeon can elect not to use stents and to simply place a red rubber catheter into the stomal end and allow for a low pressure system.

Generally the robotic approach is much easier and once the bowel anastomosis is complete the ureteroileal anastomosis is straight forward. The surgeon can cut back on the ureters significantly because the anastomosis is performed at the level of the retroperitoneum. The fourth robotic arm can be used to hold traction of the tags that were previously placed on the distal ends of the ureters. The anastomosis can be completed with a 4-0 absorbable suture (Fig. 97-5). Recently, double-armed and single-armed barbed sutures have become available and facilitate the anastomosis. The insertion of the stents can be challenging but with the assistant on the left side of the table, passage of an instrument through the ileal loop is feasible (Fig. 97-6).

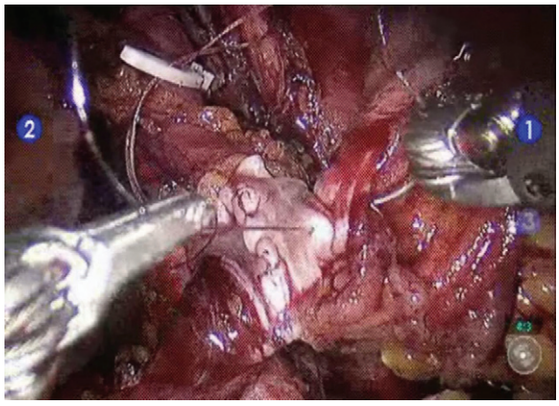

FIGURE 97-5. Suturing the ureteroileal anastomosis (Wallace type).

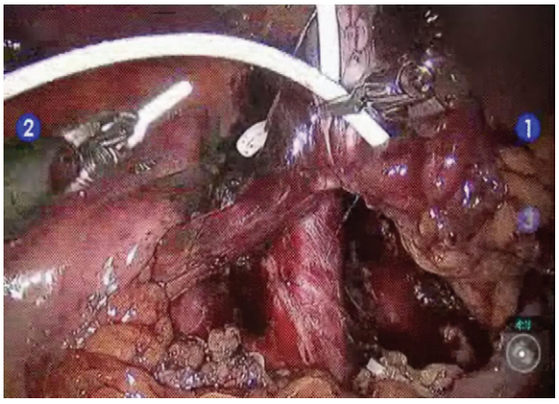

FIGURE 97-6. Stent passage into ureteroileal anastomosis.

This page intentionally left blank

Chapter 98

Sigmoid and Transverse Colon Conduits

WESLEY M. WHITE, FREDERICK A. KLEIN, AND W. BEDFORD WATERS

OPERATIVE INDICATIONS

Ureteroileostomy and orthotopic continent urinary diversion have largely rendered use of the colon conduit obsolete. In appropriate patients, however, sigmoid and transverse colon conduits can offer significant advantages. In general, colon conduits demonstrate little to no stomal complications and their facile nature affords the surgeon considerable flexibility in positioning of the stoma. Equally as important, the ability to create an antirefluxing ureteral anastomosis may prevent delayed renal deterioration often seen with ureteroileostomy and some forms of continent diversion. Although this is particularly significant in children, the routine use of augmentation enterocystoplasty has limited the role of colon conduits in this population.

Operative indications for sigmoid and transverse colon conduits are primarily predicated on contraindications to ureteroileostomy or orthotopic continent diversion. That is, the majority of patients who undergo colon conduit diversion are considered poor operative candidates for small bowel diversion owing to radiation enteritis, regional enteritis (i.e., Crohn's disease), and/or any type of short bowel syndrome. A very common indication is the need for urinary diversion in a patient with an existing colostomy or in a patient requiring pelvic exenteration for which a colostomy will also be formed. In these situations, no additional bowel anastomosis is required. Ideal use of the transverse colon includes patients with a history of prior pelvic irradiation (it avoids the irradiated field and requires shorter lengths of ureter), patients who require an intestinal pyelostomy, and in morbidly obese patients for which a long segment of bowel is necessary. In all other situations, the sigmoid colon should be considered the preferred segment.

Contraindications to colon conduit diversion include a history of large bowel inflammatory disease and, specific to the sigmoid colon, those who have had extensive pelvic irradiation involving the sigmoid colon or when the hypogastric arteries have been ligated and the rectum is left in situ (increased risk of rectal sloughing).

PREOPERATIVE PREPARATION

All patients should undergo counseling with an enterostomal therapist before operative intervention. Patients should be marked and educated on stomal care. Patients should be optimized nutritionally and should meet with a nutritionist as needed. Preoperative parenteral nutrition may be required. Patients should have undergone a recent colonoscopy and have been cleared by their gastroenterologist.

Patients should receive a preoperative bowel prep as well as oral neomycin and erythromycin. A second-generation cephalosporin and metronidazole should be administered intravenously within 2 hours of surgery.

SIGMOID COLON CONDUIT

Incision

Make an infraumbilical, midline, transperitoneal incision (Fig. 98-1). Anticipate placement of the stoma on the patient's left side.

Mobilization and Division of the Ureters

The ureters should be dissected down to the level of the bladder with careful attention paid to the blood supply (Fig. 98-2). Divide the ureters sharply on a broad base of

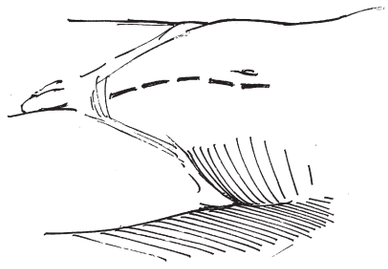

FIGURE 98-1.

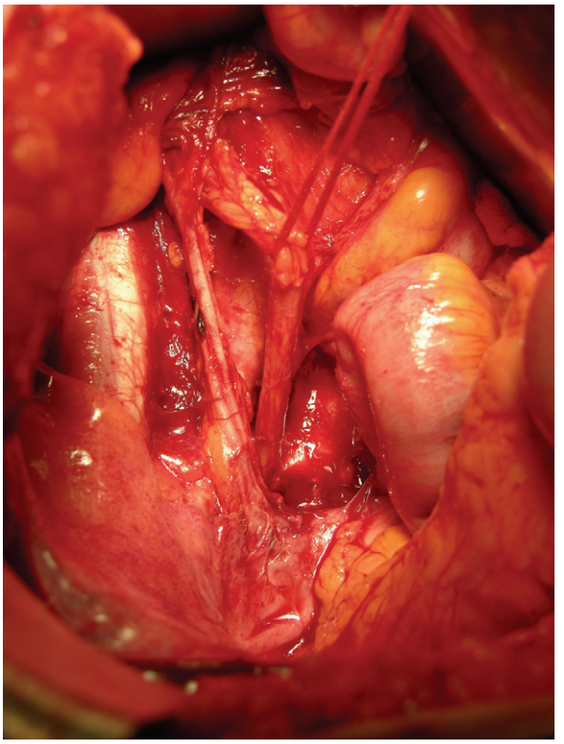

FIGURE 98-2.

adventitia, placing a titanium clip on the distal stump. Place a 3-0 chromic suture and titanium clip on the proximal end.

Selection and Isolation of Bowel Segment

Reflect the sigmoid colon along the lateral white line of Toldt from below the sacral promontory to the splenic flexure. Select a segment of sigmoid colon spanning approximately 10 cm (shorter or longer depending on the patient's body habitus). In general, it is important to isolate a longer bowel segment because it tends to shorten after division (Fig. 98-3). Pay close attention to the blood supply of the sigmoid colon, especially following cystectomy, because the superior rectal artery must be preserved to maintain the vascular integrity of the remaining rectum. Place a 3-0 silk stay suture at the proximal and distal limits of the bowel segment. Transillumination of the bowel mesentery can help facilitate identification of branching arteries to the sigmoid colon. Incise the mesenteric peritoneum and create a mesenteric window at the base of the incised peritoneum. Cross-clamp and divide the mesentery employing either a GIA stapler or a 4-0 Vicryl reel. Next, divide the bowel segment with a GIA stapler proximally and distally (Fig. 98-4). Oversew the "butt end" of the conduit (proximal end) with imbricating Lembert sutures of 3-0 silk. Restore continuity of the sigmoid colon using GIA and TA 60 staplers (as one would do for an ileal conduit) (Fig. 98-5). Reinforce the staple line, as needed, with interrupted mattress sutures of 3-0 silk. Close the mesenteric trap carefully with 3-0 silk sutures. Translocate the right ureter to the left side, staying close to the sacral promontory and deep to the hemorrhoidal vessels.

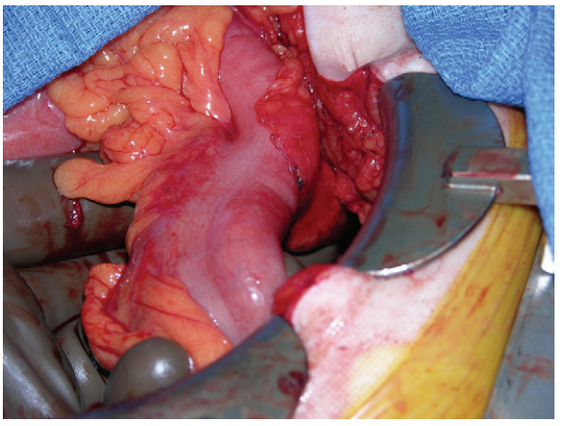

FIGURE 98-3.

Ureteral Anastomosis

After thoroughly cleansing the bowel segment, incise the tenia and bowel mucosa. The bowel mucosa may be everted with interrupted 3-0 chromic sutures. Next, anastomose the

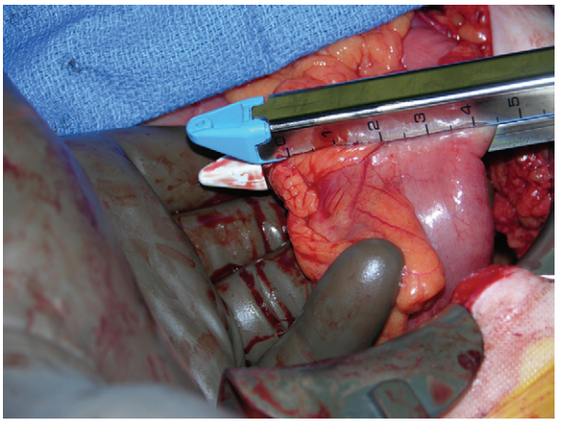

FIGURE 98-4.

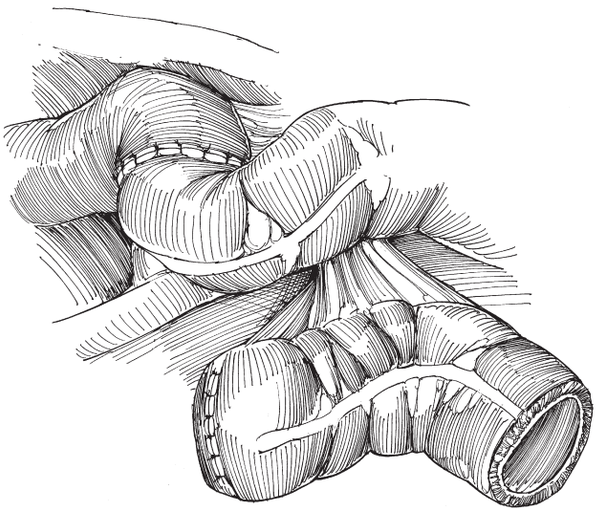

FIGURE 98-5.

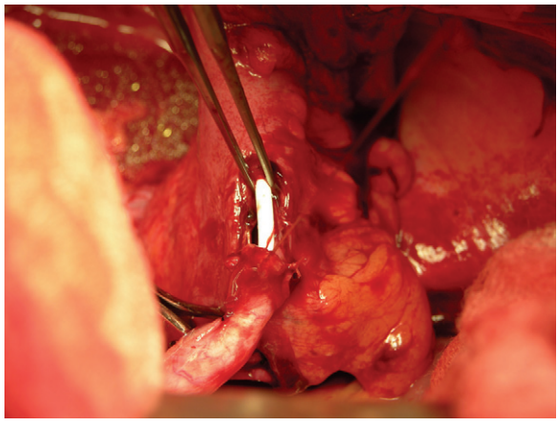

FIGURE 98-6.

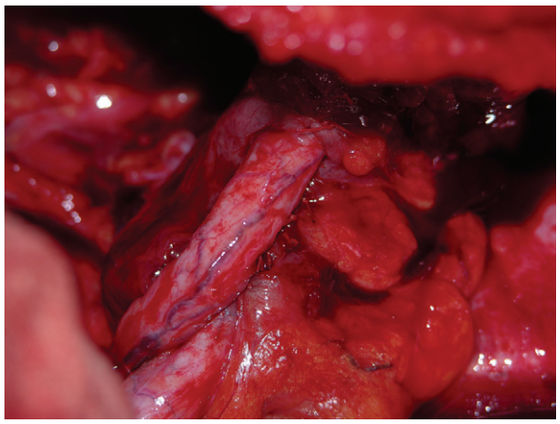

FIGURE 98-7.

ureters with interrupted 4-0 Vicryl using a submucosal tunnel technique (Fig. 98-6). A 5- to 6-cm tunnel is ideal. Ureteral stents are placed and brought out the distal end of the conduit. Carefully close the tenia, being careful not to constrict the ureter (Fig. 98-7).

Creation of Stoma

At the previously marked stoma site, excise a quarter-size piece of skin and underlying fatty tissue. Visualize the rectus fascia and create a cruciate incision with electrocautery. Place 2-0 chromic stay suture through the leaves of the fascia. Create a window through to the peritoneum and bring the conduit carefully to the skin surface. Suture the butt end of the conduit to the psoas muscle and/or retroperitoneum. Affix the fascial sutures to the proximal end of the stoma. Next, create an umbilical stoma (Fig. 98-8).

Closure

Close the incision with polydioxanone suture (PDS) or Prolene suture. Place a drainage appliance on the conduit. A surgical drain is generally not employed.



FIGURE 98-8.

TRANSVERSE COLON CONDUIT

Incision

Make an infraumbilical, midline, transperitoneal incision (Fig. 98-9). The incision may be extended as needed. The stoma may be placed on either the left or right side of the patient.

Mobilization and Division of the Ureters

The ureters should be dissected down to the level of the bladder with careful attention paid to the blood supply (see Fig. 98-2). Divide the ureters sharply on a broad base of adventitia, placing a titanium clip on the distal stump. Place a 3-0 chromic suture and titanium clip on the proximal end.

Selection and Isolation of Bowel Segment

Mobilize the transverse colon, dissecting the gastrocolic ligament and greater omentum from its superior surface. Mobilization of the splenic and hepatic flexures may be required. Transilluminate the transverse mesocolon to identify an appropriate 12-cm segment of bowel (Fig. 98-10). Incise the peritoneum of the mesocolon with electrocautery. Insinuate an opening at the base of the mesentery in an avascular area. Cross-clamp and divide the mesentery employing either a GIA stapler or a 4-0 Vicryl reel. Next, divide the bowel segment with a GIA stapler proximally and distally (see Fig. 98-4). Oversew the butt end of the conduit (proximal end) with imbricating Lembert sutures of 3-0 silk. Bring the conduit caudad to the bowel ends unless an intestinal pyelostomy is planned.

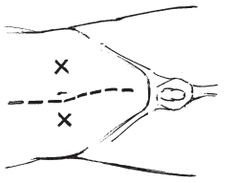

FIGURE 98-9.

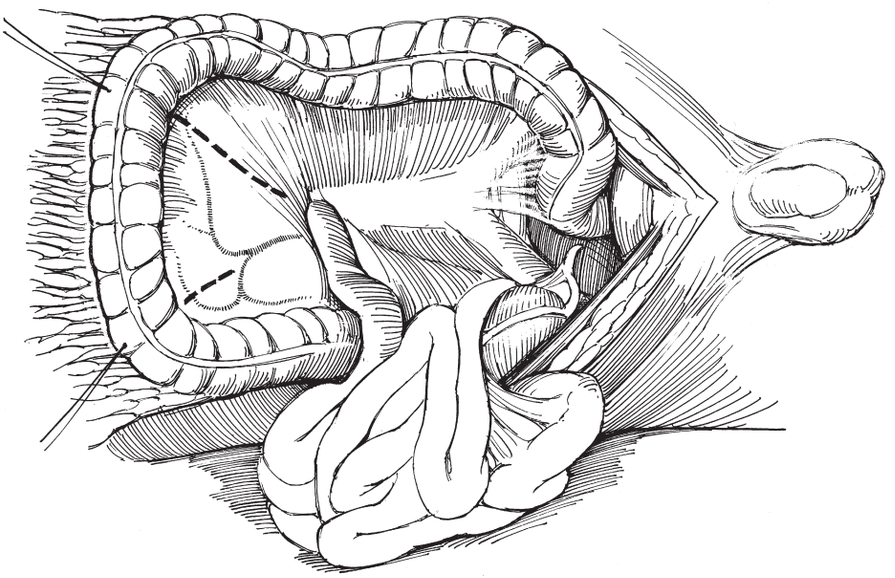

FIGURE 98-10.

Restore continuity of the colon using GIA and TA 60 staplers (as one would do for an ileal conduit). Reinforce the staple line, as needed, with interrupted mattress sutures of 3-0 silk. Close the mesenteric trap carefully with 3-0 silk sutures. Affix the butt end of the conduit to the peritoneum near the midline. Translocate the contralateral ureter to the side of the stoma through a peritoneal window.

Ureteral Anastomosis

After thoroughly cleansing the bowel segment, incise the tenia and bowel mucosa. The bowel mucosa may be everted with interrupted 3-0 chromic sutures. Next, anastomose the ureters with interrupted 4-0 Vicryl using a submucosal tunnel technique (see Fig. 98-6). A 5- to 6-cm tunnel is ideal. Ureteral stents are placed and brought out the distal end of the conduit. The stents are affixed to bowel mucosa with 3-0 chromic. Carefully close the tenia, being careful not to constrict the ureter (see Fig. 98-7).

Creation of Stoma

At the previously marked stoma site, excise a quarter-size piece of skin and underlying fatty tissue. Visualize the rectus fascia and create a cruciate incision with electrocautery. Place 2-0 chromic stay suture through the leaves of the fascia. Create a window through to the peritoneum and bring the conduit carefully to the skin surface. Suture the butt end of the conduit to the psoas muscle and/or retroperitoneum. Affix the fascial sutures to the proximal end of the stoma. Next, create an umbilical stoma (see Fig. 98-8).

Closure

Close the incision with PDS or Prolene suture. Place a drainage appliance on the conduit. A surgical drain is generally not employed.

POSTOPERATIVE COMPLICATIONS AND FOLLOW-UP

Although colon conduits are widely regarded as having fewer stomal complications and less renal deterioration than ureteroileostomy and/or continent reservoirs, recent data suggest that these differences are minimal. In the immediate postoperative setting, the incidence of urine leakage tends to be less than with ileal conduit. In the long-term, ureteral stricture is encountered more commonly with colon conduits owing to the nature of the ureteral reimplant. Stents are therefore helpful. All patients should undergo periodic renal sonography and/or computed tomography to assess for upper tract obstruction. The patient's creatinine should be checked at regular intervals.

Chapter 99

Fecal Diversion

KETSIA PIERRE AND PAUL E. WISE

UROLOGIC INDICATIONS FOR FECAL DIVERSION

Indications for fecal diversion are many. They are performed to divert from a distal obstruction or to decrease contamination of perineal or perianal wounds after trauma or infection. They are used to minimize contamination from a distal leak or fistula or to allow for healing and minimization of any leak consequences after creation of an obviously tenuous distal anastomosis. One of the more common urologic and gynecologic indications for fecal diversion occurs following an initial failed attempt at surgical repair of rectourethral, colovesical, or rectovaginal fistulas to allow the repair to heal while minimizing contamination. Additionally, diversion may be indicated due to iatrogenic rectal or colonic injuries. In the setting of Fournier's gangrene, there is no consensus on indications for fecal diversion, although it can be used selectively to prevent soilage and to allow the perineum to heal following debridement and flap repair or skin grafting.

ILEOSTOMY VERSUS COLOSTOMY

The decision to perform a diverting ileostomy or colostomy (loop or end for either) depends primarily on the disease being treated. Loop transverse colostomies were traditionally used to protect low-lying colorectal anastomoses; however loop ileostomies are now more widely used for temporary fecal diversion. Reasons cited include more difficult management of loop colostomies due to their bulk, lower peristomal hernia and/or prolapse occurrence with loop ileostomies, and fewer odors with an ileostomy than with a colostomy. Also cited is a lower overall complication rate with ileostomy takedown when compared with colostomy takedown. Because of this, loop transverse colostomies are considered a procedure of historical interest by most surgeons, except in the setting of a distal obstruction requiring proximal decompression of the distal limb. Additionally, loop ileostomies are more easily closed, often with a minimally invasive local procedure, whereas colostomies (especially end colostomies) usually require a full laparotomy. Divided loop sigmoid colostomies, on the other hand, avoid many of the complications of the traditional transverse and sigmoid loop colostomies and offer excellent distal diversion. The ability to perform the creation as well as closure of these ostomies laparoscopically has even further expanded the surgical options for patients in need of fecal diversion.

SELECTION OF STOMA SITE

There are several key principles to consider when choosing the location of the stoma. Proper placement is important to reduce complications including stomal herniation, which is reported in up to 36.7% of all stomas. Usual placement is through the rectus muscle. A flat area of skin is required for adequate adhesion of a stoma appliance, therefore skin creases, folds, previous scars and bony prominences should be avoided. Avoidance of placing the ostomy at the level of the beltline also prevents potential difficulties in maintaining an ostomy appliance seal when the patient is clothed normally. It is important to consult with a stoma nurse (wound, ostomy, and continence nurse, or WOCN) before surgery for proper marking to ensure patient comfort with the location of the ostomy. The stoma site is identified with the patient standing, sitting, and lying down. The position is then rechecked while the patient is clothed if possible.

In general, ileostomies are placed in the right iliac fossa, sigmoid colostomies (loop or end) in the left iliac fossa, and transverse loop colostomies in the left or right upper quadrant.

TECHNIQUES AND POSTOPERATIVE CARE

Loop Ileostomy

Trephine Incision

A loop ileostomy is usually created to rest the distal bowel or as protection for a fresh distal anastomosis or fistula or leak repair. Following the main procedure, attention is turned to construction of the loop ileostomy. A trephine incision is

made by grasping and elevating the skin at the chosen site and excising a circular area of skin approximately the size of a quarter.

The subcutaneous fat need not be excised but is separated down to the level of the rectus sheath. However, fat excision may be helpful in the morbidly obese patient to facilitate bringing the bowel to the skin. A cruciate or vertical incision is then made in the anterior rectus sheath (Fig. 99-1). The rectus muscle is partially divided using blunt dissection or electrocautery and the muscle fibers are then split longitudinally with care to avoid the inferior epigastric vessels (Fig. 99-2).

The peritoneum is subsequently opened vertically using electrocautery. The adequacy of the abdominal wall defect is checked by passing two fingers through the opening.

Delivery of the Bowel Through the Abdominal Wall

An avascular window is created in the mesentery of the small bowel to be used as the stoma. A piece of umbilical tape or a red rubber catheter or Babcock clamp can be used to deliver the bowel loop through the hole created in the abdominal wall (Fig. 99-3). Care should be taken to maintain proper orientation of the bowel loop during passage through the abdominal wall. A marking stitch can be used to identify the proximal end of the loop if necessary.

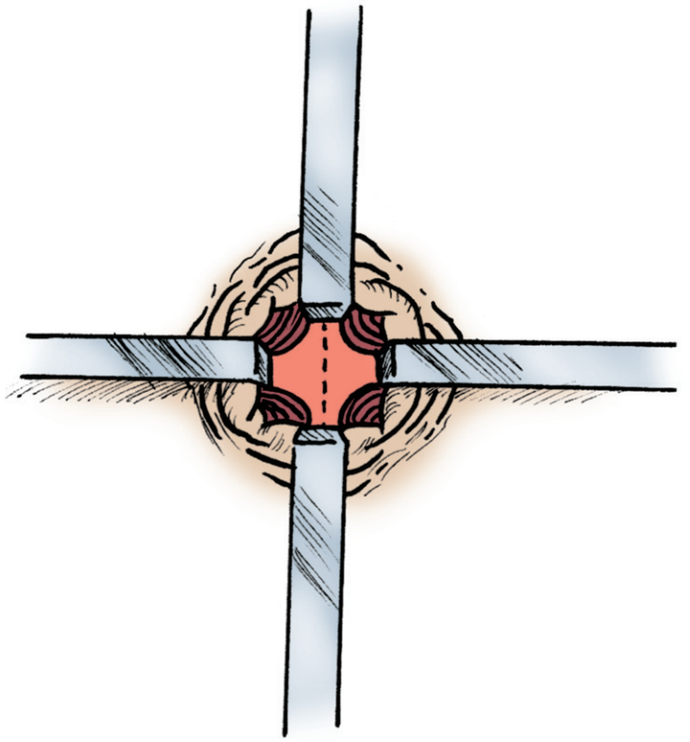

FIGURE 99-1. Cruciate incision in anterior rectus sheath. *(From Cassim R, McFadden DW. Ileostomy. In Yeo CJ [ed]. [2007].Shackelford's surgery of the alimentary tract, 6th ed. Philadelphia: Elsevier.)*

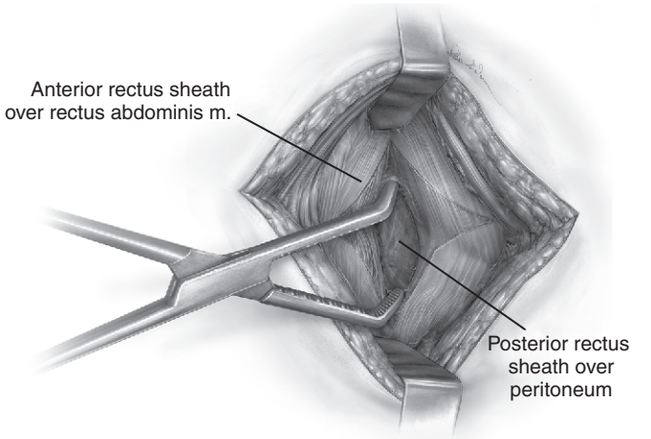

FIGURE 99-2. Rectus muscle fibers split longitudinally. *(From Schuler JG. [2008]. Proximal diversion for failed rectal anastomosis. Operat Techn Gen Surg 10[1]:11-20.)*

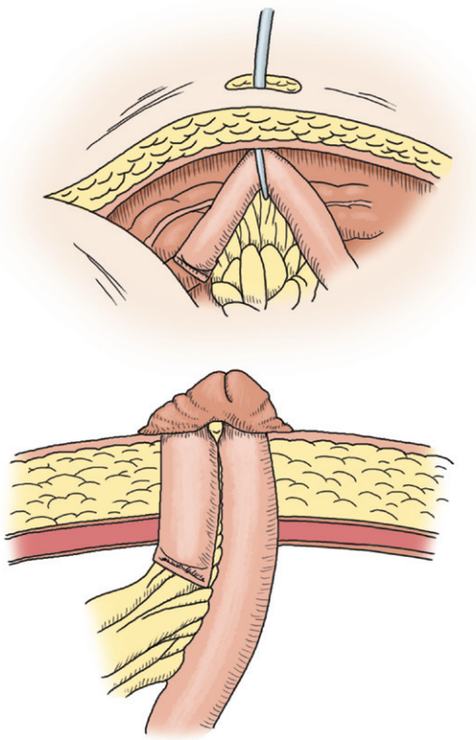

FIGURE 99-3. Bowel delivery through anterior abdominal wall. *(From Evans S. [2009]. Surgical pitfalls: prevention and management. Philadelphia: Elsevier. As adapted from Wu JS. [2003]. Ileostomy. Oper Tech Surg 5:257-263.)*

Stoma Creation

The ileostomy is created by making a near-circumferential transverse incision in the distal or efferent limb on the antimesenteric side almost at skin level (Fig. 99-4). If under tension at the skin, an ostomy rod or cut-and-curved (into an "S" shape) sterile endotracheal tube stylet can facilitate its creation as well as maintenance and elevation to the

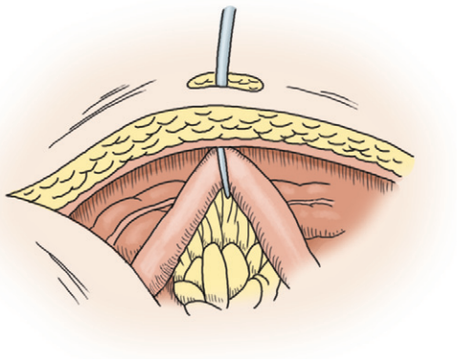

FIGURE 99-4. Antimesenteric circumferential incision. *(From Cassim R, McFadden DW. Ileostomy. In Yeo CJ [ed]. [2007].Shackelford's surgery of the alimentary tract, 6th ed. Philadelphia: Elsevier.)*

skin postoperatively. This is not necessary in all patients, however.

At least three interrupted, simple subcuticular absorbable (usually 3-0 Vicryl or chromic) fixation sutures are placed to approximate the cut edge of the distal limb to the skin. On the proximal side, the edge of the emerging bowel is fixed to the skin and more proximal serosa (approximately 3 to 4 cm proximal to the cut edge, if possible) using interrupted three-point "Brooke" sutures. A right-angle forceps or scalpel handle can be used to evert the mucosal side of the proximal limb to assist with the "Brooking" of the stoma. This eversion improves the ability to pouch the ostomy and capture its effluent postoperatively.

The final appearance of the stoma should be a spout created by the proximal afferent limb (active stoma) and a thin, flush, distal efferent limb opening (Fig. 99-5).

Divided Loop Colostomy

The divided loop colostomy avoids the complications of the standard loop colostomy as described earlier (e.g., pouching difficulties) but still provides a "pop-off" for evacuation of any distal obstruction.

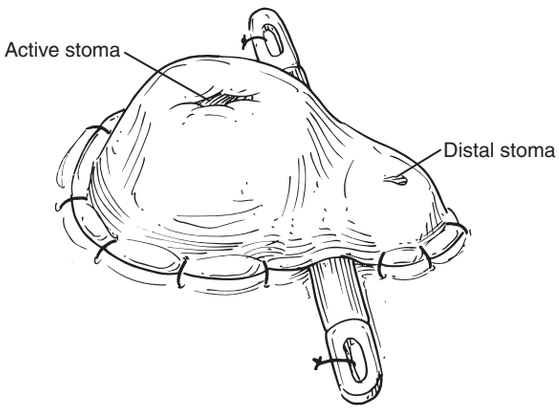

FIGURE 99-5. Final ileostomy appearance.

A trephine incision is created as described earlier. After pulling the colonic loop through the opening, the colon is totally divided using a GIA stapler without dividing the underlying mesentery of the sigmoid colon (Fig. 99-6).

An end colostomy is then matured with interrupted absorbable simple sutures leaving the inferior aspect of the trephine free to mature a corner of the antimesenteric staple line of the distal colonic segment with at least three sutures—one to the edge of the proximal colon to keep the distal mucus fistula open (Fig. 99-7). Using the three-point Brooke sutures as described earlier for ileostomies is not necessary for colostomies because of the less caustic nature of the colostomy effluent.

End Colostomy

The typical site for an end colostomy is the left iliac fossa using the left colon or the sigmoid colon for the stoma. If necessary, mobilization of the lateral peritoneal attachments

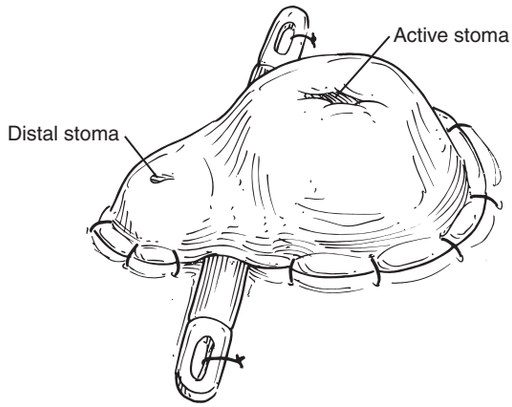

FIGURE 99-6. Construction of a divided loop colostomy. *(From Cassim R, McFadden DW. Ileostomy. In Yeo CJ [ed]. [2007].Shackelford's surgery of the alimentary tract, 6th ed. Philadelphia: Elsevier.)*



FIGURE 99-7. Final appearance of a divided loop colostomy.

and even the splenic flexure is performed to provide enough length to create a stoma without tension.

The colon is divided at the chosen site with a linear stapler. A Babcock tissue forceps is used to grasp the proximal end of the colon to pull it through the trephine opening in the abdominal wall (described earlier) while taking care to avoid twisting the mesentery. The end of the colon should be pulled out approximately 2 cm above skin level.

The main incision is closed and a clean dressing applied before construction of the colostomy to prevent wound contamination.

The stapled end of the colon is excised. A fresh bleeding edge confirms adequate blood supply. The stoma is matured by everting the bowel wall using simple full-thickness interrupted absorbable sutures. As with the loop colostomies, Brooke sutures can be used but are not necessary. An ostomy bag is applied once maturation of the stoma is complete.

Postoperative Care

Postoperatively, the patient can be started on clear liquids and advanced as tolerated. In cases where the procedure has been performed for an acute obstruction, a nasogastric tube may be left in place if needed. The patient should receive postoperative education on proper stoma maintenance by a WOCN, just as a patient with an ileostomy would.

Laparoscopic Stomas

The laparoscopic approach has shown some advantages over the conventional open technique. Laparoscopy allows complete inspection of the abdominal cavity and avoidance of a larger abdominal incision that may slow recovery and increase wound infection rates. In the hands of surgeons with advanced laparoscopic skills, these techniques can be performed with minimal complication risk.

Laparoscopic Loop Ileostomy

Placement of the monitor is important for adequate visualization. The monitor is placed to the right of the patient at the level of the feet. The operating surgeon stands on the patient's left and the assistant stands to the patient's right (Fig. 99-8).

Access to the peritoneal cavity can be obtained via Veress needle insertion or Hasson technique above the umbilicus. After insufflation of the abdomen, the laparoscope is introduced. A 5-mm trocar is then introduced into the left iliac fossa. A Babcock clamp is then used to grasp the distal loop of terminal ileum, which is directed toward the previously chosen stoma site. Adequate length of ileum (usually 30 to 40 cm) should separate the chosen section and the ileocecal valve to ensure adequate length for subsequent closure. A trephine incision is made at this site and carried down to the fascia, which is opened as previously described. The chosen loop is externalized. A final inspection of the peritoneal cavity is performed, paying particular attention to the loop to avoid a missed torsion of the bowel and to confirm that the correct (proximal) limb will be matured as the stoma. The stoma is then matured as previously described once the trocars are removed and the wounds closed and dressed.



FIGURE 99-8. Set-up for laparoscopic ileostomy.

Laparoscopic Loop/End Colostomy

The monitor is placed to the patient's left at the level of the feet. The surgeon stands to the right of the patient and the assistant stands to the left (Fig. 99-9). Again, the method of gaining access to the peritoneum is surgeon dependent. This can be done by Veress needle or Hasson technique in the right upper quadrant of the abdomen or above the umbilicus in the midline. The abdomen is insufflated and the laparoscope (usually 30 degrees) is introduced into the peritoneal cavity. One 5-mm and one 10/12-mm trochar are introduced

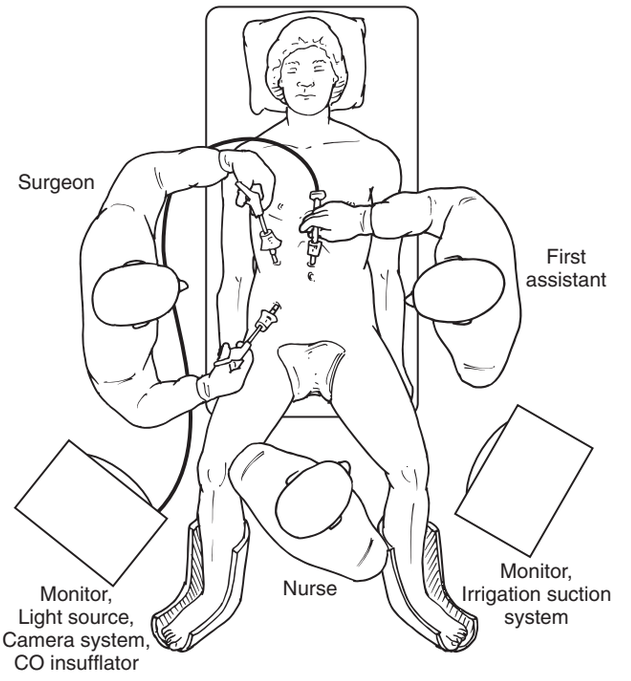

FIGURE 99-9. Set-up for laparoscopic colostomy.

lateral to the rectus muscle (one at the level of the umbilicus and one in the right iliac fossa). The sigmoid colon is then mobilized with division of the white line of Toldt to provide sufficient length to avoid tension on the colon once elevated up to the abdominal wall. A clamp is used to grasp the loop, taking care to maintain proper orientation. The previously chosen colostomy site is excised as described earlier and the loop is externalized. To create a divided loop colostomy, the loop is completely divided intracorporeally without dividing the underlying mesentery. Alternatively, the sigmoid can be divided once the chosen segment is externalized to ensure easier identification of the distal and proximal limbs. Once the trocars are removed and the wounds closed and dressed, the divided loop colostomy is then matured as described for the open procedure. For a simple end colostomy, the underlying mesentery is divided, the distal bowel segment is reintroduced into the peritoneum (if divided extracorporeally), and the proximal limb is matured.

Ostomy Reversal

Ostomy reversal is routinely performed by general surgeons, colorectal surgeons, and surgical oncologists. Most Urologists, even those willing to perform the procedures outlined above (whether laparoscopic or open), will refer their patients for stoma reversal once the underlying pathology that lead to the need for diversion has resolved. Therefore, the details of the reversal procedures will not be outlined in this text.

The timing of the reversal of an ostomy will be guided by the disease process being treated. In general, stoma reversal should not occur for at least 8 weeks following the original procedure. This allows time for inflammatory adhesions to settle and edema resolution. Clearly, the underlying condition should be resolved or healed with appropriate confirmation through radiographic (e.g., barium enema, cystogram, etc.) or endoscopic or cystoscopic studies as appropriate prior to closing the ostomy.

Commentary by

WILLIAM T. LOWRANCE

The five chapters in this section address urinary and bowel diversion, ranging from vesicostomy diversion to various bowel conduits and fecal diversion. The authors carefully outline the technical procedures necessary to perform each diversion, highlighting key considerations for the surgeon. Collectively, the authors of this section do an outstanding job of describing their surgical techniques as well as graphically representing their points.

Choice of urinary diversion after cystectomy is largely dependent upon patient/disease characteristics, prior medical/surgical history, and patient/surgeon preference. With radical cystectomy, the vast majority of postoperative complications are directly related to the urinary diversion and not the extirpative portion of the procedure. Surgical precision and attention to detail may help minimize such complications and improve long-term patient outcomes and satisfaction.

Popularized by Bricker, the ileal conduit is the most commonly performed urinary diversion after cystectomy. Scherr and Barocas clearly describe their preferred technique for creating an ileal conduit in Chapter 96 and provide superb illustrations to supplement their text. The importance of the ureteroenteric anastomosis cannot be overstated, as serious complications may result from poor surgical technique in this portion of the procedure. Anastomotic strictures may compromise renal function, result in infectious complications, and subject patients to multiple corrective procedures. Strictures are less likely with a well-vascularized ureter; therefore, during mobilization of the ureter, the surgeon should preserve an ample amount of periureteral tissue and use stay sutures to minimize handling of the ureter with forceps. A water-tight, mucosa-to-mucosa anastomosis is critical. To bolster the anastomosis and to help avoid urine leaks, the surgeon can often close an additional layer of redundant periureteral tissue over the anastomosis. Although frequently used, ureteral stents are unnecessary and are not proven to reduce strictures or short-term complications. Proper stoma positioning and avoidance of both stomal retraction and parastomal hernias can greatly impact patients' quality of life. A trained enterostomal therapist can facilitate optimal stoma positioning and provide patients with pre-and postoperative urostomy instruction and care. In obese patients with a short mesentery, a Turnbull stoma may prove advantageous over a conventional rosebud stoma by providing the extra length needed to reach the skin surface.

Creation of an ileal conduit by purely minimally invasive methods is technically challenging, but the general surgical principles and overall technique are similar to those used to create an open ileal conduit. As a result, many minimally invasive surgeons perform the cystectomy laparoscopically, often robotically, and then complete the urinary diversion through a small open incision. Castle and colleagues describe their minimally invasive, intracorporeal method for creating an ileal conduit after cystectomy in Chapter 97. Time will tell whether or not minimally invasive cystectomy and urinary diversion techniques will reduce postoperative complications and lead to improved long-term outcomes.

Colon conduits, although not commonly used, are useful in certain clinical situations, as described in Chapter 98 by White, Klein, and Waters. In patients with radiated small bowel, a segment of the transverse colon can be used for urinary diversion. In those undergoing pelvic exenteration, a bowel anastomosis can be avoided by creating a sigmoid colon conduit instead of an ileal conduit. The colostomy and colon conduit can be placed on the same or opposite sides of the patient, depending on body habitus and other anatomical considerations. Because of the tunneled, antirefluxing, ureteroenteric anastomosis, patients with colon conduits are more prone to ureteral obstruction than those with ileal conduits, where a refluxing anastomosis is typically created. Problems with stomal stenosis tend to be less common with colon conduits compared with ileal conduits, especially in children. Nonetheless, in adults our preference is to use a segment of ileum for the conduit unless otherwise contraindicated.

The multitude of urinary diversion options available for today's urologists creates unique challenges, requiring surgeons to be adept at various diversion procedures. Whether it is an ileal or colon conduit, a continent cutaneous diversion, or an orthotopic neobladder, diversions are technically challenging and necessitate surgical precision in order to minimize postoperative complications and maximize quality of life. Like most surgical procedures, successful outcomes after urinary diversion often hinge on patient selection. The authors of Chapters 95 through 99 provide a sound technical guide to these common incontinent urinary and bowel diversions and highlight many of the key patient selection criteria used today.

Section XVII

CONTINENT RECONSTRUCTION

This page intentionally left blank

Chapter 100

Principles of Continent Reconstruction

JERILYN M. LATINI AND JAMES MONTIE

Intestinal segments can be incorporated into the urinary tract to provide a urinary conduit if both urethra and ureterovesical junctions are gone (noncontinent diversion), to provide a continent reservoir (continent diversion), to enlarge the bladder if both the urethra and the ureterovesical junctions are present (augmentation), or to replace the entire bladder down to the urethra (substitution) (Tables 100-1 and 100-2). All require a bowel segment of adequate capacity at physiologic pressure. To avoid overfilling and rupture, the ideal system for continent diversion would have a pop-off mechanism to prevent filling beyond 600 mL or 60 cm H_2O of pressure. Additionally, the conduit should be easy to catheterize, and the stoma should be relatively inconspicuous. In order to simplify, methods of urinary diversion can be divided into two main groups, continent and noncontinent. These may be further subdivided into incontinent cutaneous, continent cutaneous, and finally continent diversion with intact native urethra (orthotopic neobladder). The remainder of this chapter focuses on the principles of the continent reconstruction.

The *superior mesenteric artery* gives off in succession, working clockwise, the jejunal and ileal arteries to those structures; the ileocolic artery to the cecum, first part of the ascending colon, and the terminal ileum; the right colic artery to the main portion of the ascending colon; and the middle colic artery to the right part of the transverse colon. The *inferior mesenteric artery* supplies the left colic artery to a limited part of the transverse colon and the descending colon, the sigmoid artery to that organ via inferior colic arteries, and the superior rectal artery to the rectum. The circulation of the large bowel differs from that of the small bowel. The small bowel has a microcirculation that supports it after its straight arteries have been resected. In the large bowel, the straight arteries do not give off collateral vessels that spread longitudinally along the bowel wall so that more of the vascular supply must be preserved.

BLOOD SUPPLY TO THE ILEOCECAL REGION AND APPENDIX

The more proximal part of the ileum is supplied by a system of ileal arcades terminating in long straight arteries that supply the entire circumference. In contrast, the terminal ileum has a distinct and highly variable blood supply. It lies at the center of the loop formed between terminal branches from the superior mesenteric artery to the ileum and the ileocolic artery, a major branch of that artery. The network that branches from this loop provides the opportunity for several forms of distribution. The trunk of the ileocolic artery as it terminates gives off branches in several sequences, one being ascending colic artery, ileal artery, appendicular artery, and anterior and posterior cecal arteries. Alternatively, the ileal artery may be given off prior to the ascending artery, or the ileocolic artery may bifurcate into trunks to terminate as the anterior and posterior cecal arteries after releasing branches to the other structures (Fig. 100-1).

The surgical significance of these details of arterial supply is that the mesentery must first be examined to see the orientation of the branches of the loop. For ileocecocystoplasty, it is especially important to look for a high bifurcation of the ileocolic artery so that the artery itself is ligated, not its branches; this leaves intact the arcades of the ileal artery and the ascending colic artery. Finally, the mesentery must be detached by dividing the terminal arterial branches very close to the ileum to preserve the smaller arcades.

The appendicular artery originates directly from the ileocolic artery (or its ileal branch) or from the cecal artery. Usually only one artery is present, but there may be two. The base of the appendix may be supplied by the anterior or posterior cecal arteries. The appendicular vein accompanies the artery to the cecal vein, which drains into the ileocolic vein. Chains of lymph channels and nodes along the arteries drain the lymph to the celiac nodes.

TABLE 100-1

PROCEDURES FOR BLADDER DIVERSION, AUGMENTATION, AND SUBSTITUTION

Noncontinent diversion: neither urethra nor ureterovesical junctions present (Section XVI)
Ureterostomy (cutaneous, loop); pyelostomy
Pediatric loop ureterostomy
Ileal conduit
Pediatric high ileal conduit
Sigmoid conduit
Transverse colon conduit
Continent diversion: neither urethra nor ureterovesical junctions present (Section XVII)
Ileal reservoir—open: Kock pouch
Cecoileal reservoir
Intact: Gilchrist, Mansson, Stevens
Open: Mainz, Penn pouch, LeBag, Indiana pouch
Appendiceal urethra
Ureterosigmoidostomy, intact
Augmentation: urethra and ureterovesical junctions present (Section XVIII)
Ileocystoplasty—open: Tasker patch, Goodwin cup, hemi-Kock
Colocystoplasty—intact or open
Cecocystoplasty—intact or open
Ileocecocystoplasty—open: Mainz pouch, LeBag, Indiana pouch
Substitution: urethra present
Ileal bladder substitution
Intact: Camey
Open: Camey, Ghoneim-Kock
Ileocecal bladder substitution
Intact: Mansson, Stevens
Open: Mainz pouch, LeBag, Indiana pouch

EPONYMS FOR RESERVOIRS, AUGMENTATIONS, AND SUBSTITUTIONS

TABLE 100-2

Camey	Detubularized U-shaped ileal bladder
Florida	Ileocecal pouch
Ghoneim	Modified rectal bladder
Goodwin	Ureterosigmoidostomy, transcolonic
Hautmann	W-shaped neobladder, sutured
Indiana	Ileocecal pouch
Kelalis	Ureterosigmoidostomy, spatulated
Kock	Hemi-Kock pouch
Kock	Ileal reservoir
Leadbetter	Ureterosigmoidostomy, closed
Mainz	Ileocecal pouch
Mainz II	Sigma rectum pouch
Mitchell	Gastric reservoir
Montie	W-shaped neobladder, stapled
Penn	Ileocecal pouch
Studer	Cross-folded pouch
Zingg	S-pouch

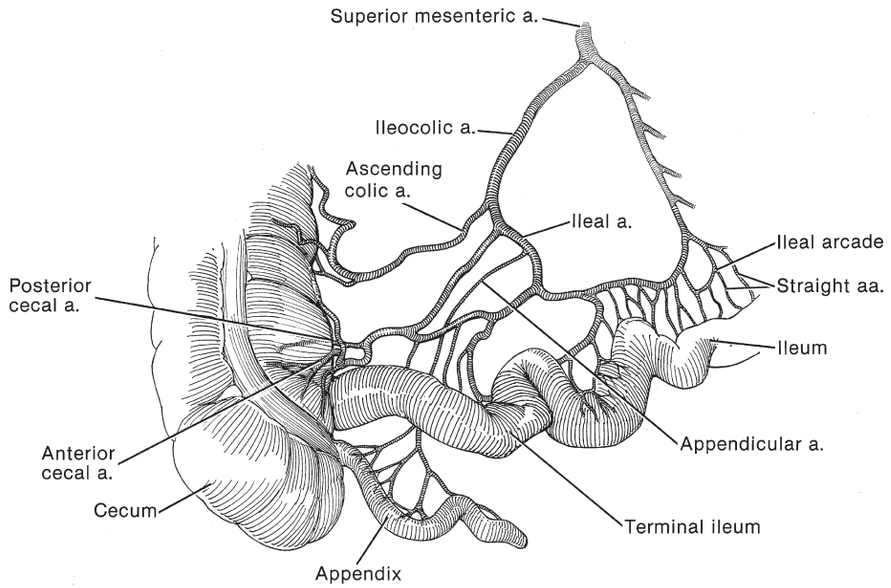

FIGURE 100-1.

BLOOD SUPPLY TO THE ASCENDING AND TRANSVERSE COLON

Arterial blood to this part of the colon, a derivative of the midgut, is delivered by the superior mesenteric artery. Three branches are involved: the ileocolic artery, as the lowest branch of the right-side system; the right colic artery; and the middle colic artery as far as the hepatic flexure (Fig. 100-2).

The *ileocolic artery* divides into a superior and an inferior branch. The superior branch joins the descending branch of the right colic artery. The inferior branch divides into the ascending colic artery that supplies the lower part of the ascending colon, the anterior and posterior cecal arteries that supply the cecum, the artery to the appendix, and an ileal artery that supplies the terminal ileum.

The *right colic artery*, which originates from the superior mesenteric artery cephalad to the ileocolic artery, divides into a descending branch that joins the ileocolic artery and an ascending branch that joins the middle colic artery. They supply the hepatic flexure as well as that part of the ascending colon not supplied by the ileocolic artery.

The *middle colic artery*, after leaving the superior mesenteric artery below the pancreas, divides into right and left branches. The right branch supplies the right half of the transverse colon and joins the right colic artery. The left branch supplies the left half of the transverse colon and joins the inferior mesenteric system through the left colic artery. Venous drainage is through the superior mesenteric vein.

BLOOD SUPPLY TO THE JEJUNUM AND ILEUM

As derivatives of the midgut, the jejunum and ileum are supplied from the superior mesenteric artery. This artery emerges from the aorta 1 cm below the celiac trunk and passes ventral to the left renal vein to give off 12 to 15 jejunal and ileal arteries. As these arteries divide and each member of the pair joins an adjacent branch, they form arches. The divisions continue until, especially in the more distal ileum, as many as five arches are developed to form an arcade. From the arches, short terminal arteries called *straight arteries* join the bowel, distributed more or less equally to each side.

BLOOD SUPPLY TO THE DESCENDING AND SIGMOID COLON

The inferior mesenteric artery supplies the remainder of the large bowel, the part that is not supplied by the superior mesenteric artery (Fig. 100-3). Its first branch,

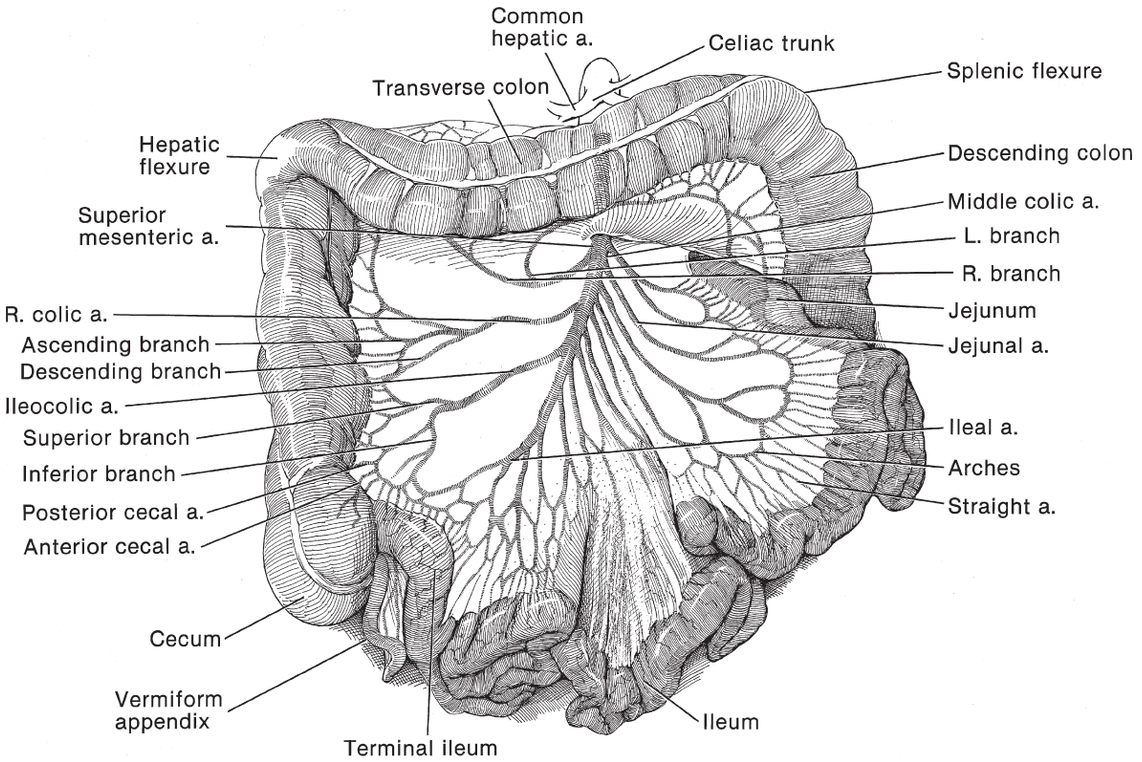

FIGURE 100-2.

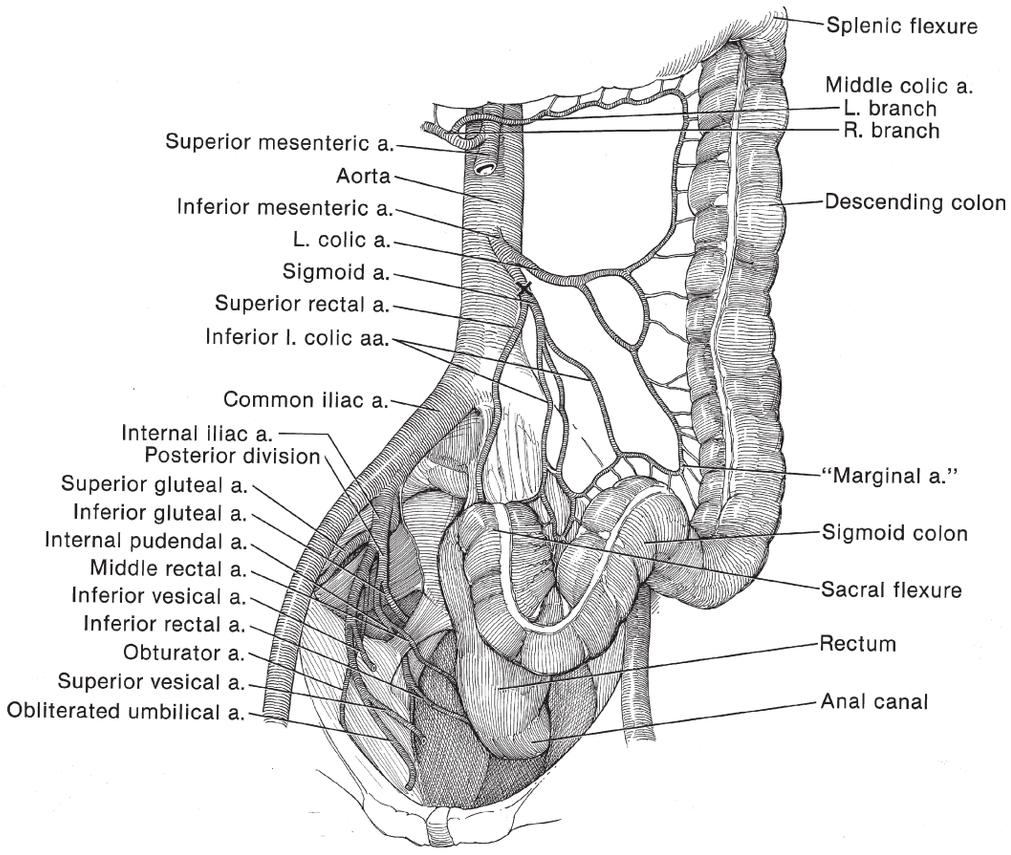

FIGURE 100-3.

the left colic artery, supplies a limited part of the transverse colon near the splenic flexure and the first part of the descending colon. The next branch, the sigmoid artery, after giving off the superior rectal artery, splits into two or three inferior left colic arteries that supply the sigmoid colon. The anastomoses between these arteries appear to form a "marginal artery" near the mesenteric margin of the colon.

BLOOD SUPPLY TO THE RECTUM

The rectum and upper half of the anal canal receive blood from the most distal branch of the inferior mesenteric artery, the superior rectal (hemorrhoidal) artery. These structures are also supplied by the middle rectal (hemorrhoidal) artery, a branch of the posterior division of the internal iliac artery, and the inferior rectal artery, a branch of the internal pudendal artery.

This page intentionally left blank

Chapter 101

Ileal Reservoir (T-Pouch)

JOHN P. STEIN

The Kock ileal reservoir was one of the first continent urinary reservoirs applied for lower urinary tract reconstruction in urology. The intussuscepted nipple valve provides the continence and antireflux mechanism in this ileal reservoir. Most complications associated with the Kock ileal reservoir relate to the intussuscepted limb; either the antireflux (afferent limb) or the continent catheterizable (efferent limb) nipple. Complications associated with the afferent intussuscepted antireflux nipple (Kock nipple valve) are seen in approximately 10% of patients. The three most common complications associated with the intussuscepted afferent nipple included (1) calculi formation (associated with exposed staples that secure the afferent nipple valve) in 5%, (2) afferent nipple stenosis (thought to be caused by ischemic changes resulting from the mesenteric stripping required to maintain the intussuscepted limb) in 4%, and (3) extussusception (prolapse of the afferent limb) in 1% of patients. The need to improve upon the intussuscepted nipple valve became increasingly obvious. Based on the principles of the ureteral serous-lined extramural tunnel technique, the serous-lined extramural ileal flap-valve technique was developed called the T-mechanism. The T-mechanism was first successfully incorporated as the afferent antireflux limb of an orthotopic reservoir (*T-pouch ileal neobladder*). The flap-valve T-mechanism should eliminate the complications associated with the intussuscepted Kock nipple valve while maintaining an effective antireflux mechanism. The surgical technique of the orthotopic T-pouch ileal neobladder is described.

SURGICAL TECHNIQUE

Step 1

The terminal portion of the ileum is used to construct the orthotopic T-pouch ileal neobladder (Fig. 101-1). The distal mesenteric division is best made along the avascular plane of Treves between the ileocolic artery and terminal branches of the superior mesenteric artery. This division should extend deep into the avascular portion of the mesentery. The proximal mesenteric division however, is short and provides a broad vascular blood supply to the reservoir. A small window of mesentery and a 5- to 7-cm portion of small bowel most proximal to the overall ileal segment are discarded to ensure mobility to the pouch and small bowel anastomosis.

The T-pouch reservoir is created from a 44-cm segment of distal ileum placed in an inverted V-configuration. Each limb of the V measures 22 cm. A proximal 8- to 10-cm segment of ileum (afferent limb) is used to form the afferent antireflux mechanism. Note, if ureteral length is short or compromised, a longer afferent ileal segment (proximal ileum) may be harvested to bridge the ureteral gap.

The ileum is divided between the proximal afferent ileal segment and the 44-cm segment that will form the reservoir portion of the neobladder. The mesentery between these ileal segments is carefully incised for 1 to 2 cm with preservation of all major vascular arcades. This mesenteric incision is directed toward the base of the mesentery and provides mobility to the afferent ileal segment, which will ultimately be advanced into the serosal-lined ileal trough formed by the base of the two adjacent 22-cm segments of ileum.

The proximal end of the isolated afferent ileal segment is closed and a standard small bowel anastomosis is performed to reestablish bowel continuity, and the mesenteric trap closed.

Step 2

The isolated 44-cm ileal segment is then laid out in an inverted V-configuration, with the apex of the V lying caudally with a suture marking a point between the two 22-cm adjacent segments of ileum (Fig. 101-2). The opened end (base) of the V is directed in a cephalad manner. Note, the serosal-lined ileal trough formed at the base of the 44-cm segment.

Step 3

The antireflux (flap-valve) mechanism is created by anchoring the distal 4 cm of the afferent ileal segment into the serosal-lined ileal trough formed by the two adjacent 22-cm ileal segments. First, mesenteric windows of Deaver are opened between the vascular arcades (carefully excising mesenteric fat adjacent to the serosa of the ileum, which facilitates the development of these mesenteric windows) for

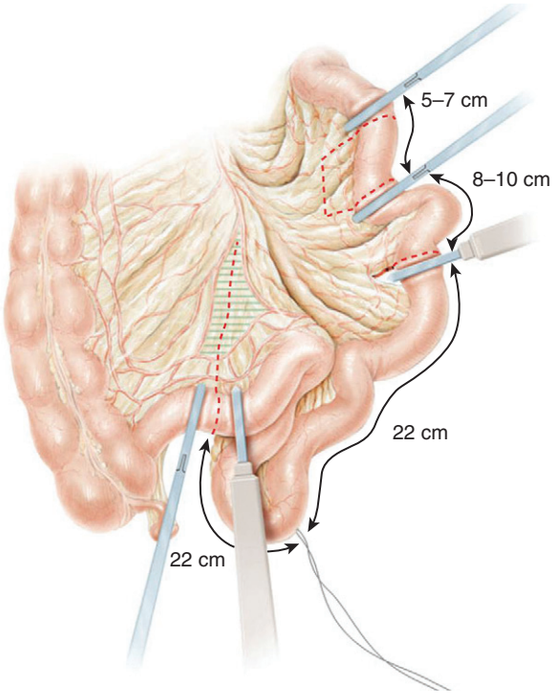

FIGURE 101-1. *(From Stein JP, Skinner DG: Surgical Atlas: The orthotopic T-pouch ileal neobladder. BJU Int 98(2):469-482, 2006.)*

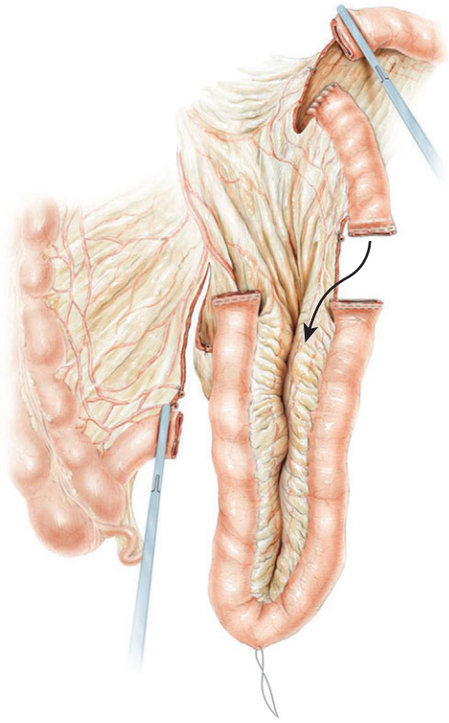

FIGURE 101-2. *(From Stein JP, Skinner DG: Surgical Atlas: The orthotopic T-pouch ileal neobladder. BJU Int 98(2):469-482, 2006.)*

4 cm proximal to the distal most portion of the isolated afferent ileal segment (Fig. 101-3). Preserving these arcades (blood vessels) maintains a vascularized afferent limb and will allow permanent fixation of this portion of the limb into the serosal-lined ileal trough with complete preservation of the mesentery and blood supply. Note, the use of small Penrose drains through each mesenteric window helps identify and facilitates passage of suture through each.

A series of 3-0 silk sutures are then used to approximate the serosa of the two adjacent 22-cm ileal segments at the base of the V with the sutures being passed through the previously opened windows of Deaver in the afferent ileal limb. This will anchor the afferent limb into the serosal-lined ileal trough. Specifically, a silk suture is placed into the seromuscular portion of the bowel (adjacent to the mesentery) at the base (most cephalad portion of the V) of one of the 22-cm ileal segments. The suture is then passed through the most proximal window of Deaver opened in the afferent ileal limb (Fig. 101-3A) and placed in a corresponding seromuscular site of the bowel (next to mesentery) of the adjacent 22-cm ileal segment. The suture is brought back through the same window of Deaver and tied down (see Fig. 101-3B). Generally, two to three silk sutures are placed within each window of Deaver to ensure that the back wall of the reservoir does not separate. This process is repeated through each individual window of Deaver until the distal 4 cm of the afferent segment is permanently fixed in the serosal-lined ileal trough (see Fig. 101-3C). Note, that placement of small (¼ inch) Penrose drains through each

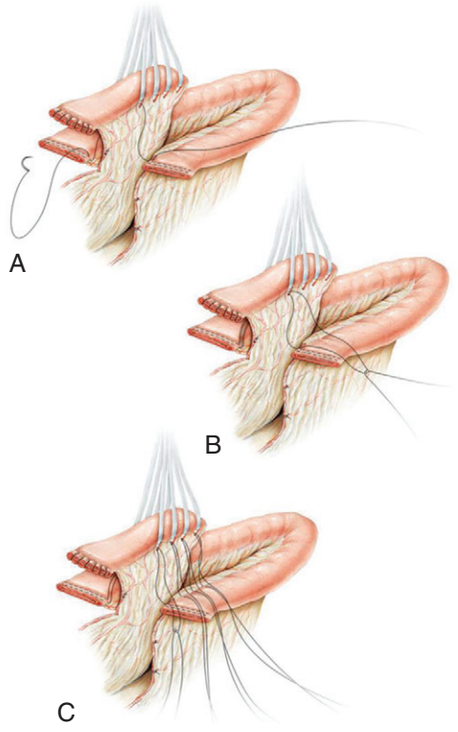

FIGURE 101-3. *(From Stein JP, Skinner DG: Surgical Atlas: The orthotopic T-pouch ileal neobladder. BJU Int 98(2):469-482, 2006.)*

window of Deaver facilitates passage of the silk suture back and forth through the mesentery without difficulty. The Penrose drains are systematically removed as the afferent limb is fixed within the serosal-lined ileal trough.

Step 4

Next, the previously anchored portion of the afferent ileal segment (distal 4 cm) is tapered on the antimesenteric (anterior) border over a 30-French catheter (Fig. 101-4). Tapering this portion of the afferent ileal segment reduces the bulk and lumen of the afferent limb, and facilitates later coverage of the anchored afferent limb with ileal flaps. This tapering of the afferent limb will also increase the tunnel-length to lumen diameter ratio, providing a more effective flap-valve mechanism.

Step 5

After the distal 4 cm of the afferent ileal segment has been tapered, the remaining portions of the adjacent 22-cm ileal segments are approximated with a side-to-side 3-0 polyglycolic acid suture. This suture line reapproximates the two ileal limbs and should be placed adjacent to the mesentery (Fig. 101-5). This can be performed in a running or interrupted fashion.

Step 6

Starting at the apex of the V, the ileum is then opened immediately adjacent to the previously placed serosal suture line using electrocautery. This incision is carried upward toward the ostium of the afferent limb where the afferent limb is anchored (Fig. 101-6A). Once this incision

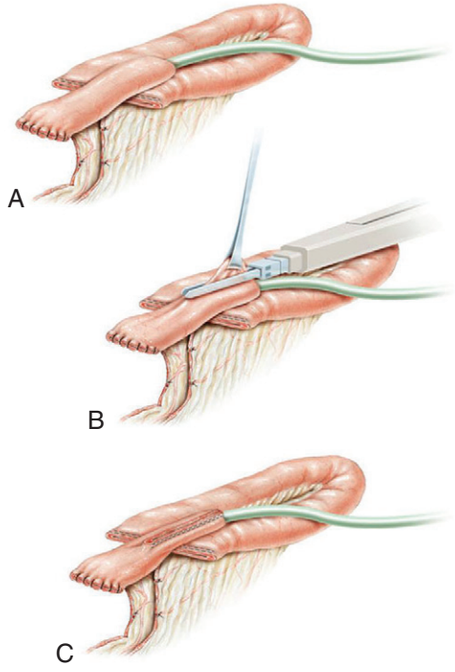

FIGURE 101-4. *(From Stein JP, Skinner DG: Surgical Atlas: The orthotopic T-pouch ileal neobladder. BJU Int 98(2):469-482, 2006.)*

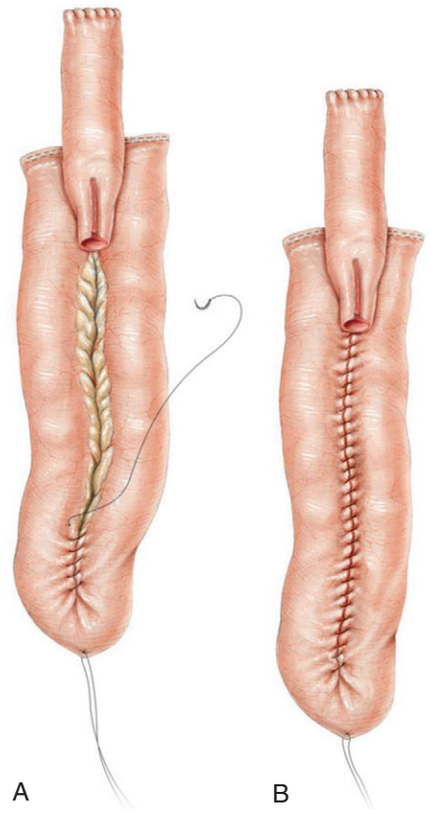

FIGURE 101-5. *(From Stein JP, Skinner DG: Surgical Atlas: The orthotopic T-pouch ileal neobladder. BJU Int 98(2):469-482, 2006.)*

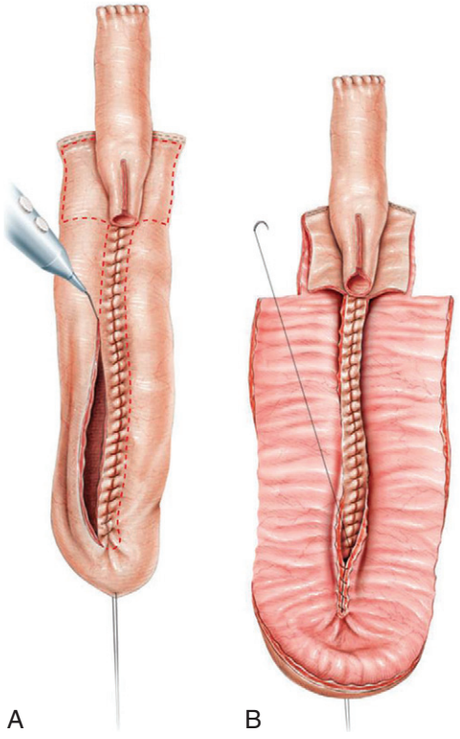

FIGURE 101-6. *(From Stein JP, Skinner DG: Surgical Atlas: The orthotopic T-pouch ileal neobladder. BJU Int 98(2):469-482, 2006.)*

reaches the level of the afferent ostium, the incision is then extended directly lateral to the antimesenteric border of the ileum, and carried upward (cephalad) to the base of the ileal segment. An incision is made in similar fashion on the contralateral 22-cm ileal segment. These incisions provide wide flaps of ileum that will ultimately be brought over and cover the tapered afferent ileal segment to create the antireflux mechanism in a flap-valve technique (see Fig. 101-6B).

Step 7

The previously incised ileal mucosa is oversewn with two layers of a running 3-0 polyglycolic acid suture starting at the apex and running upward toward the ostium of the afferent limb (Fig. 101-7A). Once the ostium of the afferent limb is reached, the running suture is tied. An interrupted mucosa-to-mucosa anastomosis is then performed between the ostium of the afferent ileal limb and the incised intestinal ileal flaps with 3-0 polyglycolic acid sutures (see Fig. 101-7B). The mucosal edges of the ileal flaps are then approximated over the tapered portion of the afferent ileal limb (4 cm) with a running suture in two layers (see Fig. 101-7C). This suture line completes the posterior wall of the reservoir and creates the effective flap-valve T-mechanism: the serosal-lined ileal antireflux limb.

Step 8

The reservoir is then closed by folding the ileum in half in an opposite direction to which it was opened (Fig. 101-8). This effectively creates a low-pressure, high-capacity urinary reservoir.

Step 9

The anterior wall is closed with a running, two-layer 3-0 polyglycolic acid suture that is water tight (Fig. 101-9). This anterior suture line is stopped just prior to the end of the right side to allow insertion of an index finger. This is the most mobile and dependent portion of the reservoir and will later be anastomosed to the urethra. Once the pouch has been closed, each ureter is spatulated and a standard, bilateral end-to-side ureteroileal anastomosis is performed to the proximal portion of the afferent limb using interrupted 4-0 polyglycolic acid suture. A tension-free mucosa-to-mucosa urethroileal anastomosis is performed after the ureteroileal anastomosis is performed.

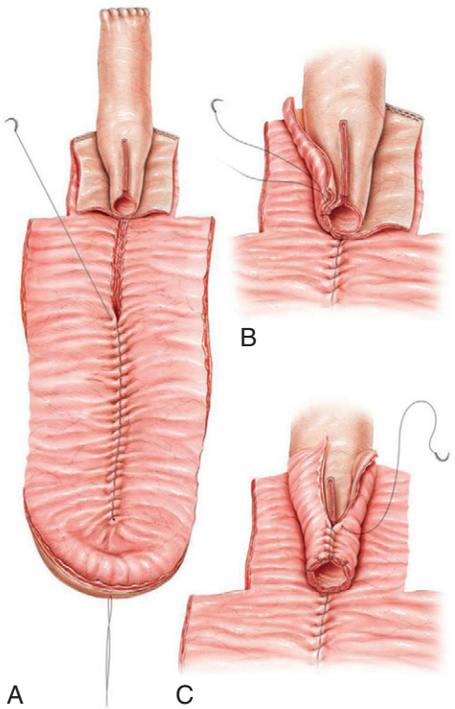

FIGURE 101-7. *(From Stein JP, Skinner DG: Surgical Atlas: The orthotopic T-pouch ileal neobladder. BJU Int 98(2):469-482, 2006.)*

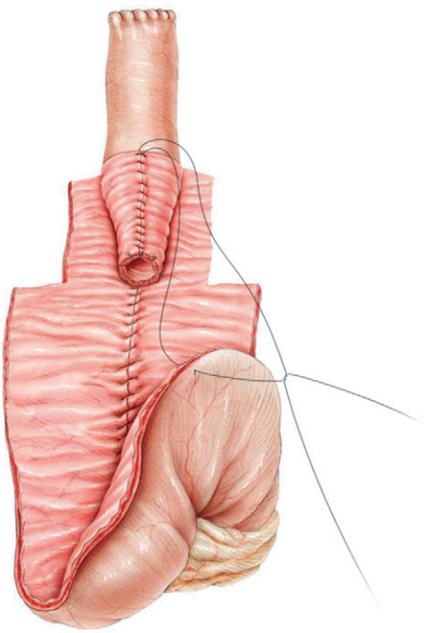

FIGURE 101-8. *(From Stein JP, Skinner DG: Surgical Atlas: The orthotopic T-pouch ileal neobladder. BJU Int 98(2):469-482, 2006.)*

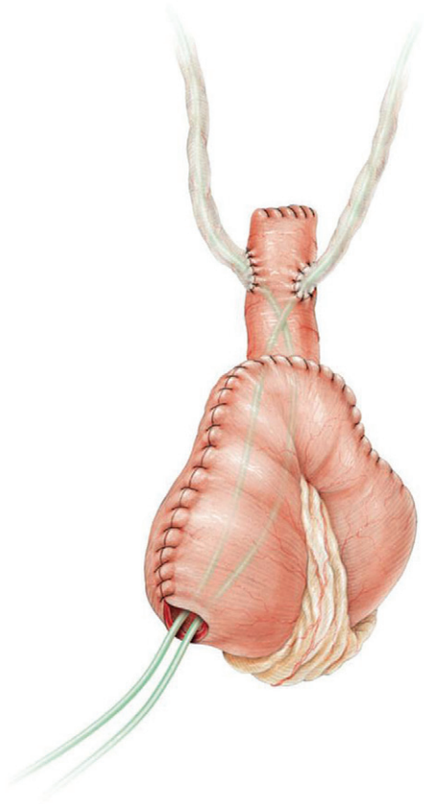

FIGURE 101-9. *(From Stein JP, Skinner DG: Surgical Atlas: The orthotopic T-pouch ileal neobladder. BJU Int 98(2):469-482, 2006.)*

Commentary by JEFFREY HOLZBEIERLEIN

The T-pouch as described by John Stein in this chapter is an orthotopic neobladder whose purported advantage is antireflux. The theory that reflux in patients with an orthotopic neobladder ultimately results in decreased renal function remains debatable. Previous studies that have examined whether patients with antireflux ureteral anastomoses versus refluxing anastomoses have demonstrated higher rates of renal deterioration from ureteral obstruction in the antireflux group.[1,2] Intuitively, procedures that supposedly decrease the likelihood of reflux place patients at higher risk for strictures.

The advantage of the T-pouch in circumventing this problem is that it uses the afferent limb into which the ureters are anastomosed to provide the antireflux by essentially "collapsing" on itself from pressure from the neobladder. This ingenious design allows for no tapering, nippling, or tunneling of the ureters, therefore reducing the risk of stricture formation. The trade-off, however, is a more complex reconstruction being performed to prevent problems of unclear significance.

1. Shaaban AA, Abdel-Latif M, Mosbah A, et al. (2006). A randomized study comparing an antireflux system with a direct ureteric anastomosis in patients with orthotopic ileal neobladders. BJU Int 97(5):1057-1062.
2. Aleksic P, Bancevic V, Stijelja B, et al. (2008). On 10 year experience in the use of direct and antireflux techniques of ureter and orthoptic intestinal neoblader after radical cystectomy. Vojnosanit Pregl 65(2):163-166.

This page intentionally left blank

Chapter 102

Ileocecal Reservoir

RANDALL G. ROWLAND AND FRANCES M. MARTIN

MAINZ POUCH

Urologists who know more than one technique are equipped to adapt to unanticipated findings.

Locate the stomal site before the patient goes to the operating room. Patients may prefer to catheterize the penis, perineum, or umbilicus, the last being especially suitable for the obese or wheelchair-bound patient.

Incision: Stand on the right side of the table. Make a long midline incision (Fig. 102-1A). Mobilize the cecum and ascending colon all the way beyond the hepatic flexure.

Starting from the cecum, measure 10 to 15 cm on the ascending colon and mark that point with a stay suture. Measure and mark three segments on the ileum starting at the ileocecal valve: 10 to 15 cm, 10 to 15 cm, and 20 to 25 cm (see Fig. 102-1B). Divide the mesentery of the ascending colon above the ileocolic artery and the mesentery of the ileum at the most proximal stay suture; then divide the bowel at each end.

Spatulate the antimesenteric border of the ileum, and anastomose it to the cecum with staples using the EEA and TA 55 staplers. Let the loop drop behind the anastomosis; do not leave it anterior to the anastomosis as is done with ureteroileostomy (Fig. 102-2).

Irrigate the bowel segment and open the cecum and ileum on the antimesenteric border with scissors, but leave the proximal 20 to 25 cm of ileum intact to provide for the construction of nipple and stoma (Fig. 102-3).

Suture the medial edge of the ascending colon to the first part of the ileum, then suture that first ileal segment to the second, as identified by the marking stay sutures (Fig. 102-4A). Use a single row of through-and-through running 4-0 synthetic absorbable suture (SAS) swaged on a straight needle. Mobilize the left ureter to the level of the lower pole of the kidney, insert a stay suture, and pull it through retroperitoneally below the duodenum. The right ureter needs less dissection and remains retroperitoneal.

Mark the site of *ureteral implantation* with four stay sutures through the mucosa and submucosa placed at the margin of the opened segment to tent the edges (see Fig. 102-4B and C). Enter the free edge between submucosa and mucosa with blunt-tipped scissors, and form a 4- to 5-cm pocket. Invert the scissors, and cut down on the tip with a knife to create a tunnel for the ureter.

Insert a clamp through this opening, and direct it back to the free edge. Grasp the ureteral stay suture, and draw the ureter into the tunnel (see Fig. 102-4C). Spatulate it, fasten the tip to the submucosa and muscularis with a deep stitch, and approximate the edges epithelium to mucosa. Tack the ureter at its site of entry into the tunnel. Repeat the procedure for the second ureter. Place a 6- or 8-French infant feeding tube in each, and bring the ends of the tubes out through the intact portion of bowel (see Fig. 102-4A).

Intussusception Through the Ileocecal Valve

Open the loop of ileum and the cecum (Fig. 102-5).

Intussuscept the ileum, and fix it with two rows of staples. Denude a portion of mucosa over the intussuscepted segment (Fig. 102-6).

Draw the intussuscepted ileum through the ileocecal valve, and fix it with a third row of staples (Fig. 102-7).

Close the anterior wall of the pouch in a single layer with a running stitch of 3-0 SAS. At the sites of ureteral exit, take care to close only the mucosa and to use interrupted sutures in that area (Fig. 102-8).

Stretch the ileal spout lengthwise because it will have contracted during the operation. Run a 2-cm strip of PGA mesh through the second mesenteric window and around the ileum. Fix it in place with multiple interrupted 3-0 SAS on both sides (Fig. 102-9). Make an opening in the body wall, the umbilicus, or the right lower quadrant within the future hair line. Place three mattress sutures in the mesh, and fasten them to the external oblique or rectus fascia.

Trim excess ileum and suture the ileum flush with the skin with sutures that include mucosa and submucosa, then some muscularis proximal to the edge, and finally the skin edge. Remove the retractor after the intussusception has been sutured in place, to allow the abdominal wound to assume its normal alignment for a trial of catheterization of the new stoma.

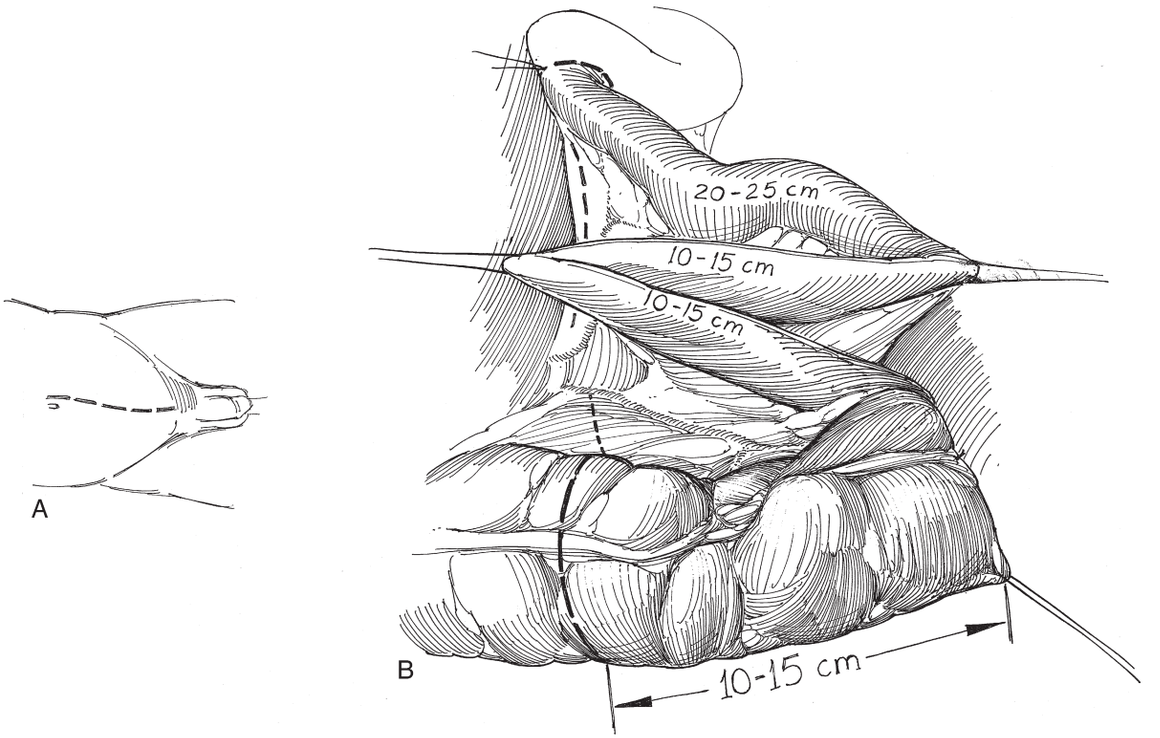

FIGURE 102-1.

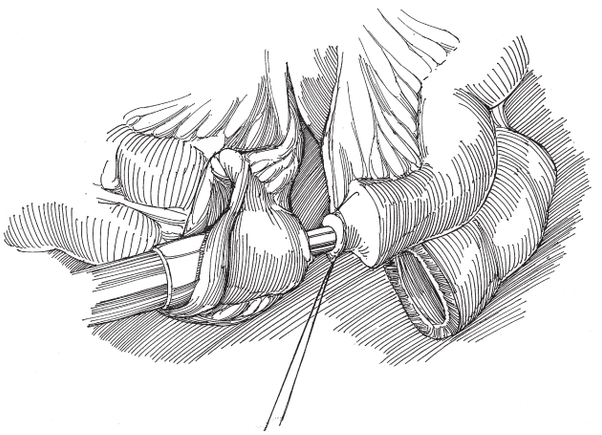

FIGURE 102-2.

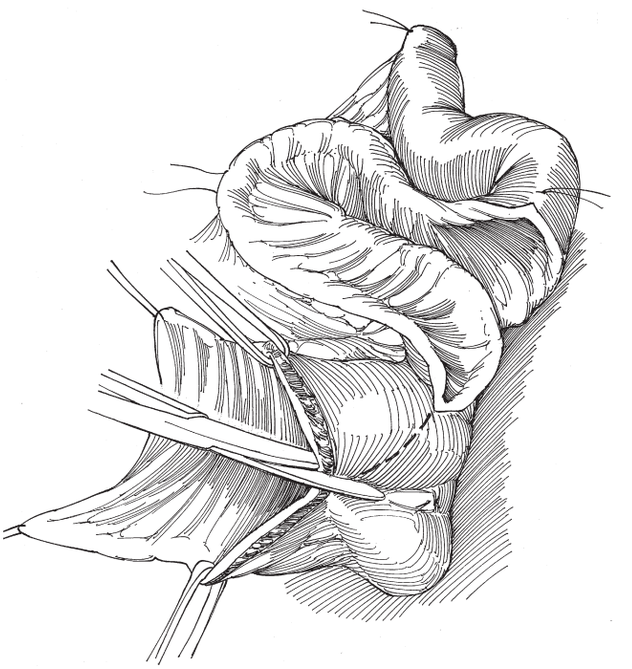

FIGURE 102-3.

Irrigate and test for leaks. Drain the pouch with a 26-French 5-mL balloon catheter, and drain the site of ureteral anastomosis with a Jackson-Pratt drain on gravity drainage. Cycle the reservoir with 20 to 30 mL of saline three times a day while the patient is in the hospital. Remove the stents one at a time in 10 days and the catheter in 2 to 3 weeks. If a suprapubic tube is used, be sure to keep it clamped when the urethral catheter is removed so that urination prevents the anastomosis from sealing (Fig. 102-10).

Alternative: Construct a flap-valve from an 18-cm segment of ileum by bringing 4 cm of the end that has been cut diagonally through an opening in the cecal wall. Anchor it circumferentially to the wall intraluminally at the site of entrance. Make two parallel mucosal incisions in the wall of the cecum, each beginning beside the site of ileal entrance. Suture the edges of the diagonal cut to the mucosal edges, making a flap-valve.

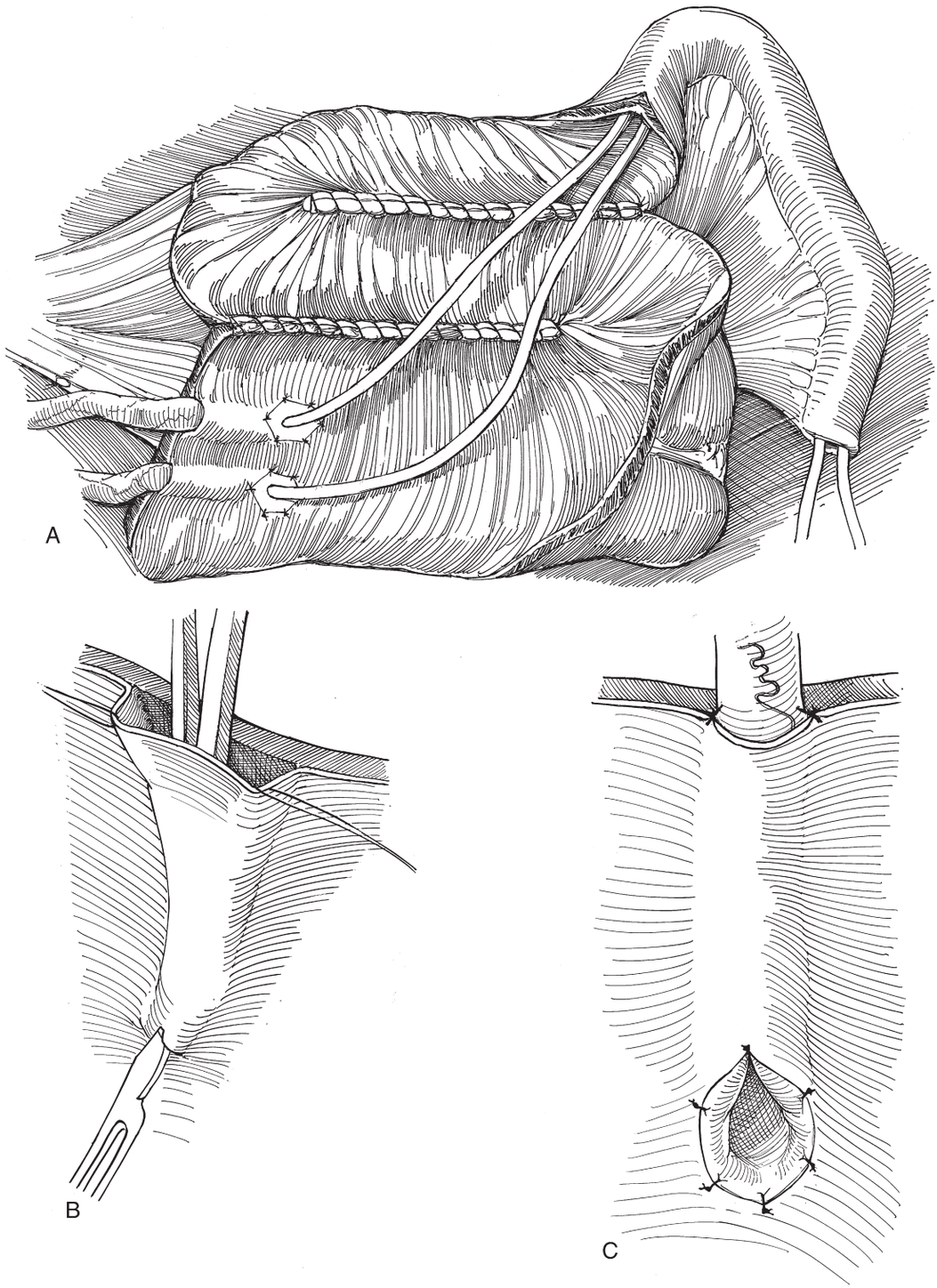

FIGURE 102-4.

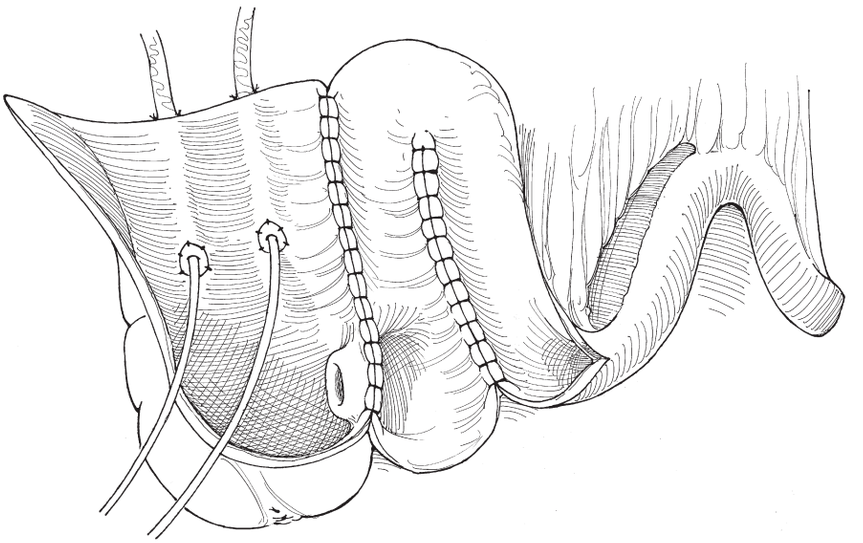

FIGURE 102-5.

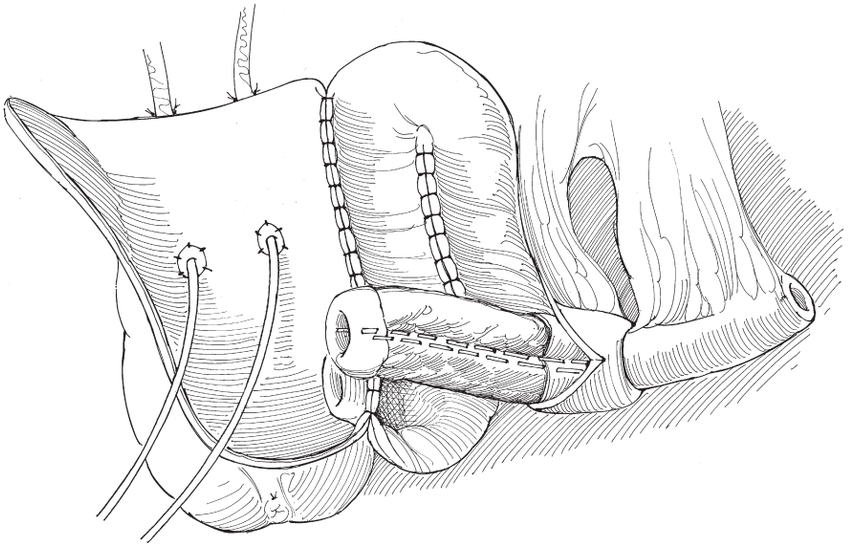

FIGURE 102-6.

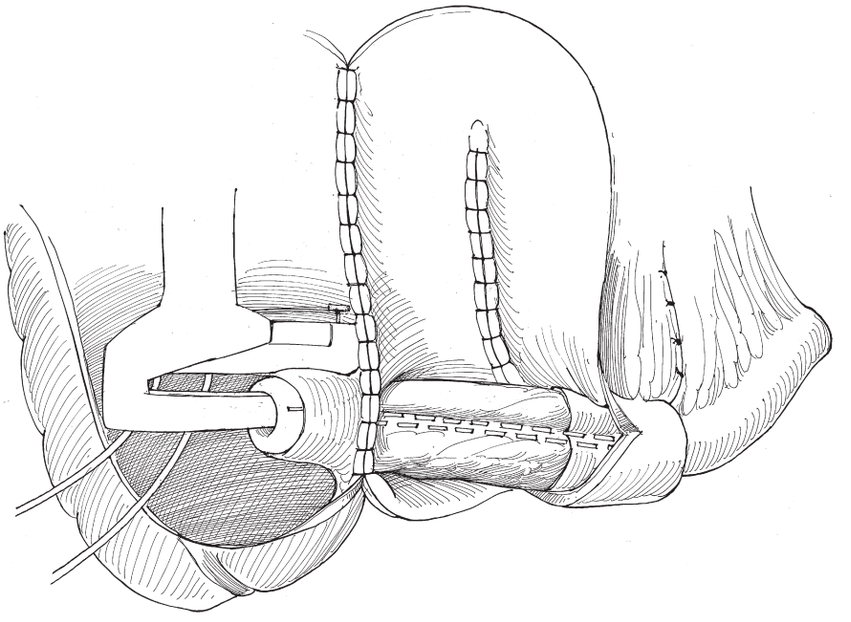

FIGURE 102-7.

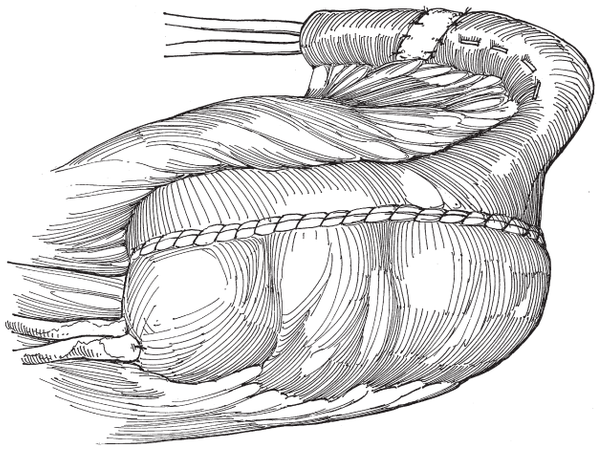

FIGURE 102-8.

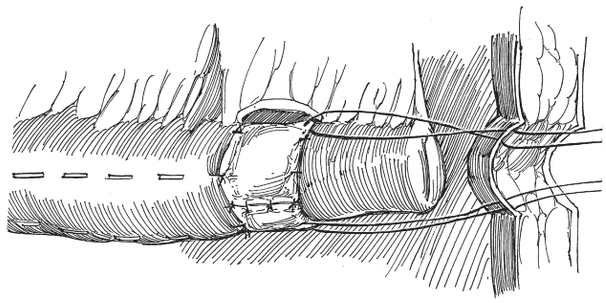

FIGURE 102-9.

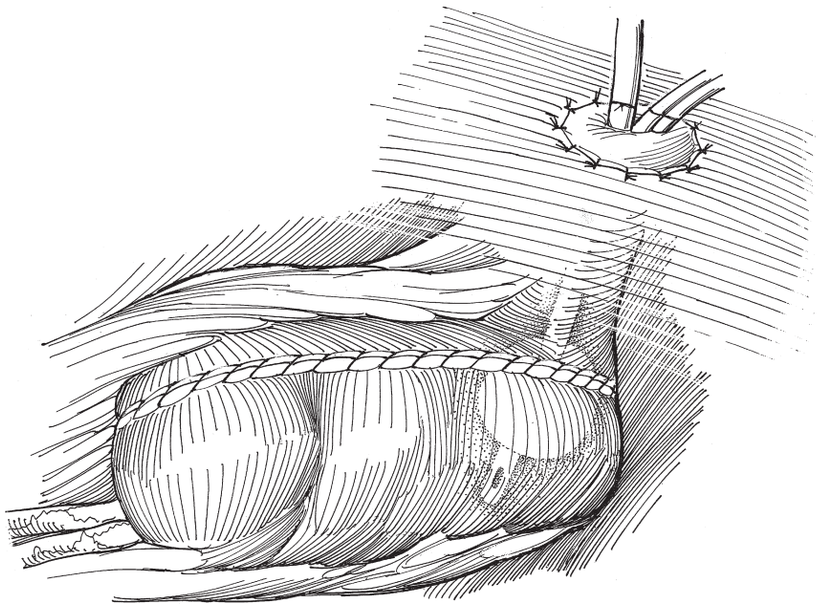

FIGURE 102-10.

MAINZ POUCH WITH APPENDICEAL STOMA

Check the appendix to be sure that it has not been inflamed and is of adequate length and caliber.

Proceed as shown in Figures 102-1 through 102-4, but do not open the last 4 cm of the cecum. Close the pouch (as shown in Fig. 102-8). Clean the mesentery of the appendix to skeletonize the vessels while preserving the appendicular artery on a branch of the anterior or posterior cecal artery. Form a trough in the cecum that ends at the base of the appendix by incising the seromuscular layer of the taenia libera to the depth of the mucosa. Turn the appendix up, and embed it in the trough. Close the seromuscular layer over it with 2-0 SAS.

Make a V-plasty in the umbilicus to form a funnel for connection of the skin to the appendix. Attach the pouch to the anterior abdominal wall to keep the course of the appendix straight.

IN SITU TUNNELED BOWEL FLAP TUBES

Techniques other than intussusception are available to achieve continence. *Seromuscular bowel flap tube*: Make a tube from a seromuscular bowel flap in the lower pole of the cecum, anastomose one end to an opening in the cecum, bury it in the cecal wall, and bring the other end to the skin as a stoma. *Full-thickness bowel flap tube*: Raise a full-thickness flap from the wall of the cecum, and form it into a tube. Close the resulting defect in the cecum, and place the tube in a submucosal tunnel extending laterally on the cecum.

INDIANA POUCH

After incision, mobilize the left ureter adequately, preserving the adventitia, and pass it retroperitoneally without twisting

at the level of the inferior mesenteric artery to the right side. The right ureter can be freed less extensively.

Mobilize the cecum and ascending colon beyond the hepatic flexure. Isolate a 25- to 30-cm segment of cecum and ascending colon in continuity with 8 to 10 cm of terminal ileum. Be sure not to make the reservoir too small (Fig. 102-11A).

Divide the mesentery after identifying and preserving the ileocolic artery. Restore bowel continuity by performing ileocolostomy by a suture technique or by a staple method with the isolated segment of bowel lying inferolateral to the anastomosis. Close the mesentery defect to prevent internal hernia. Then, encircle the appendiceal base and perform an appendectomy, if present. Irrigate bowel segment.

Create a cecostomy on the antimesenteric anterior border of the cecum. To taper for catheterizable channel, place a 12-French red rubber catheter into the efferent limb of the ileum through the cecostomy (see Fig. 102-11B).

Apply three Allis clamps to the antimesenteric border of the ileal segment, leaving enough room to move the catheter in and out of the limb. Staple using the GIA with metal staples to remove excess tissue. Fan out as the ileal cecal valve is approached (see Fig. 102-11C).

Place five to six imbricating sutures in Lembert fashion beginning just distal to the bend in the staple line near the ileal cecal valve. Widen the Lembert stitches as the IC valve is approached (see Fig. 102-11D). Catheterize the ileal limb with 18-French catheter. The catheter should pass with a "pop" through the ileal cecal valve, but it should not feel tight.

Place stay sutures through the cecostomy and through the open end of distal colon to fold colon into a U-shaped segment (see Fig. 102-11E, part1). *Detubularize* the colon by using an absorbable GIA stapler; staple and cut along the antimesenteric border to double the diameter of the lumen. Place Vicryl bridging sutures in between each stapled segments to prevent leak (see Fig. 102-11E, part 2). Usually three 75-mm long staple loads will be required (see Fig. 102-11E, part 3).

Place a 22-French Malecot catheter through the wall of the lowest part of the complex and secure with a pursestring suture. The position should allow direct exit through the abdominal wall near the exit of the ureteral stents. Close the U-shaped defect by folding the distal portion of the colon into the proximal end and suturing it in place with running 3-0 SAS full-thickness sutures with occasional lock stitches. Irrigate and evaluate for leaks (see Fig. 102-11F).

Insert the ureters by a submucosal technique or by an end-to-side technique with a spatulated ureter. Use an 8-French feeding tube as a stent through the ureteroenteric anastomosis; the stents will then pass through the anterior wall of the pouch and later pass through the abdominal wall (see Fig. 102-11G).

Alternatively, if the cecum and ascending colon prove to be too short or especially narrow in diameter, take an additional 15- to 20-cm segment of ileum, open it, and place it as

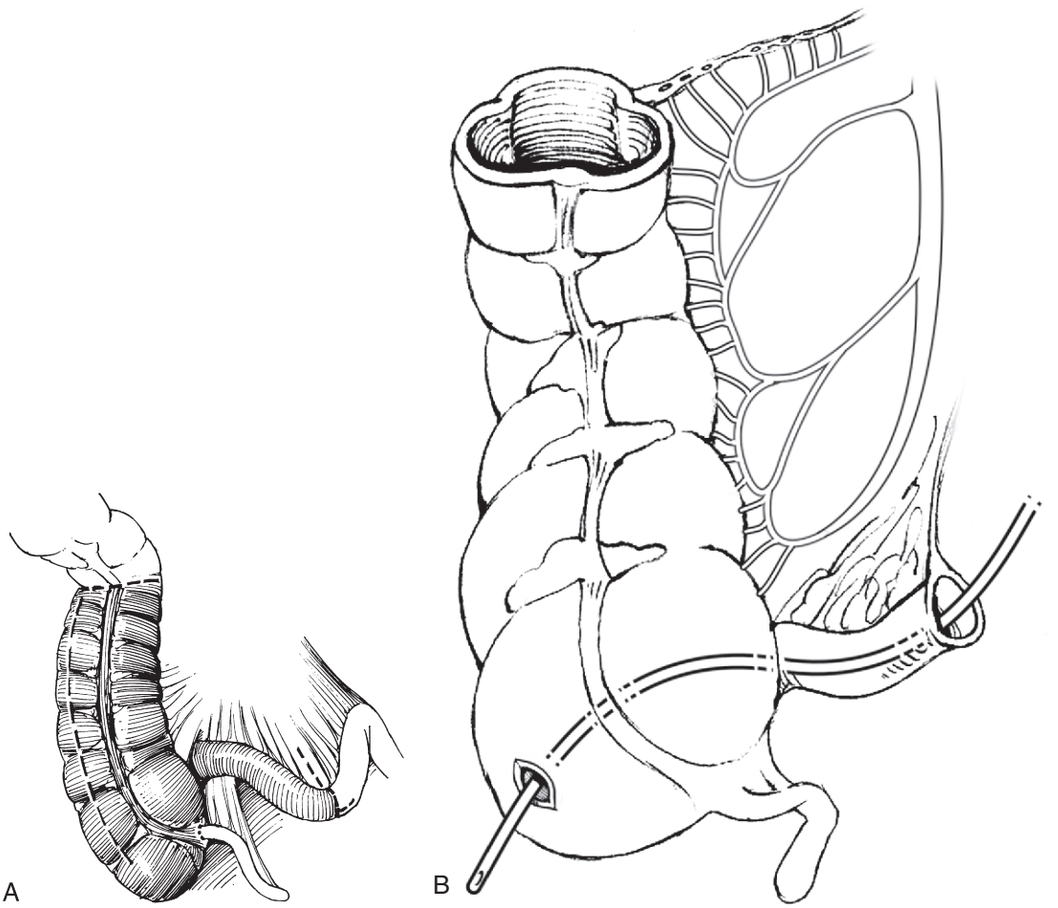

FIGURE 102-11.

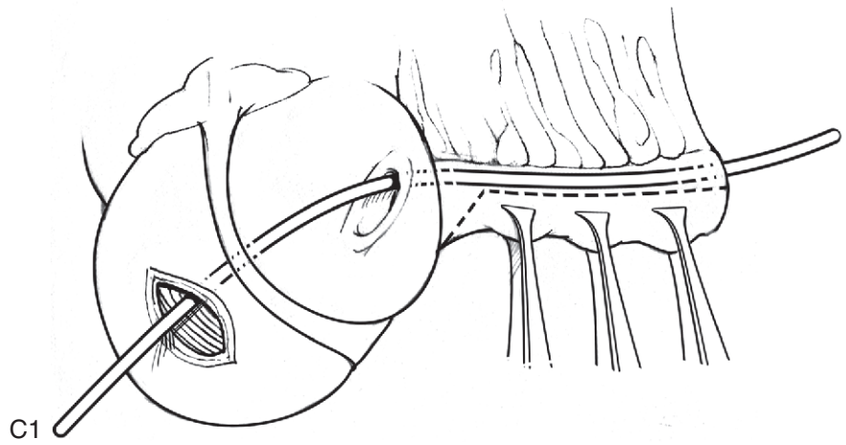

C1

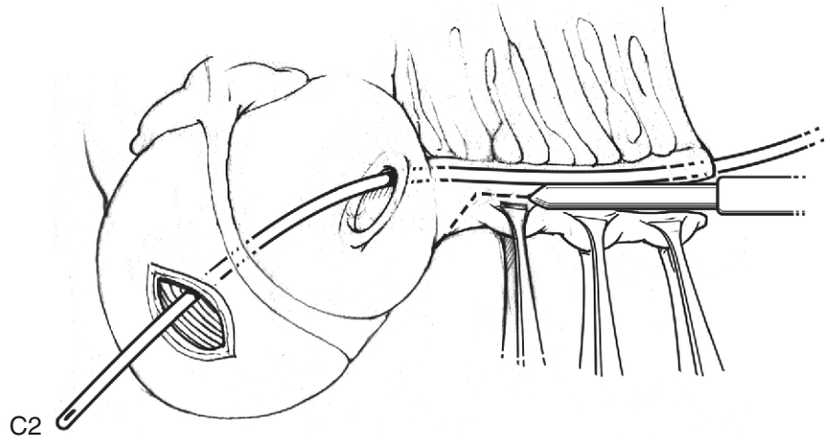

C2

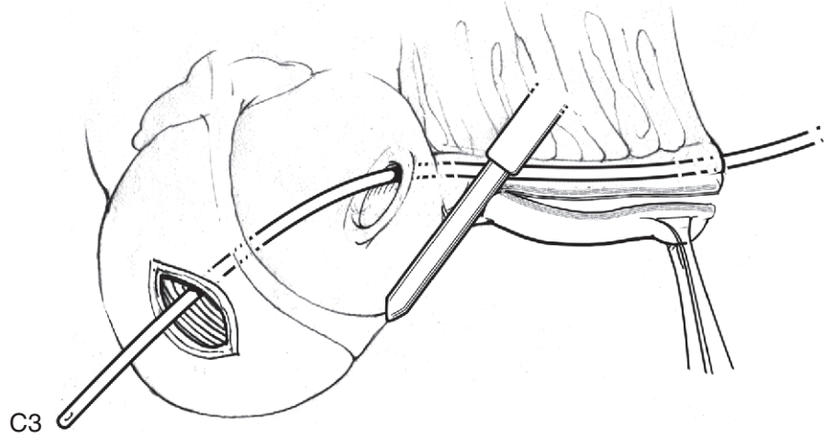

C3

FIGURE 102-11, cont'd.

Continued

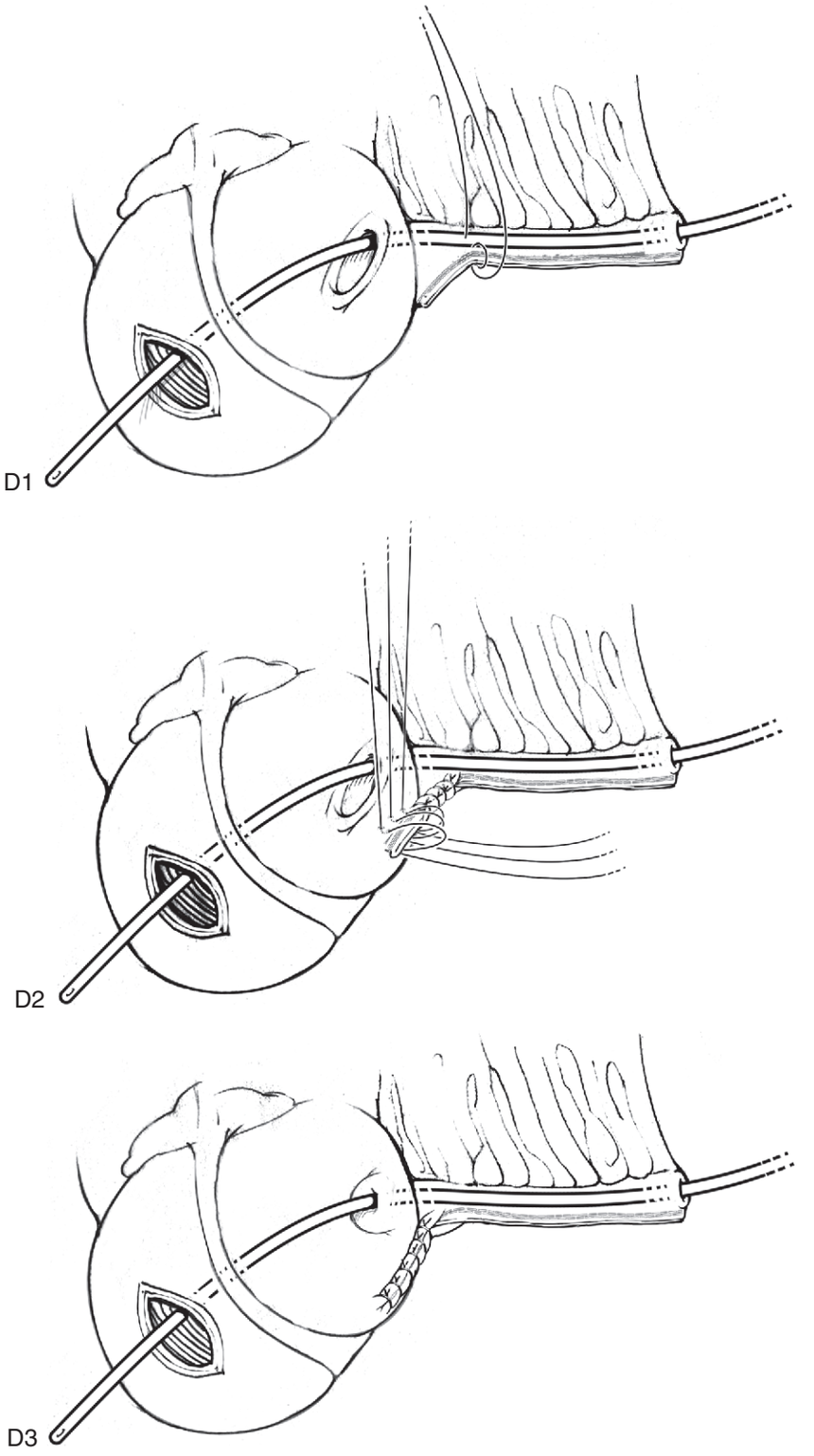

FIGURE 102-11, cont'd.

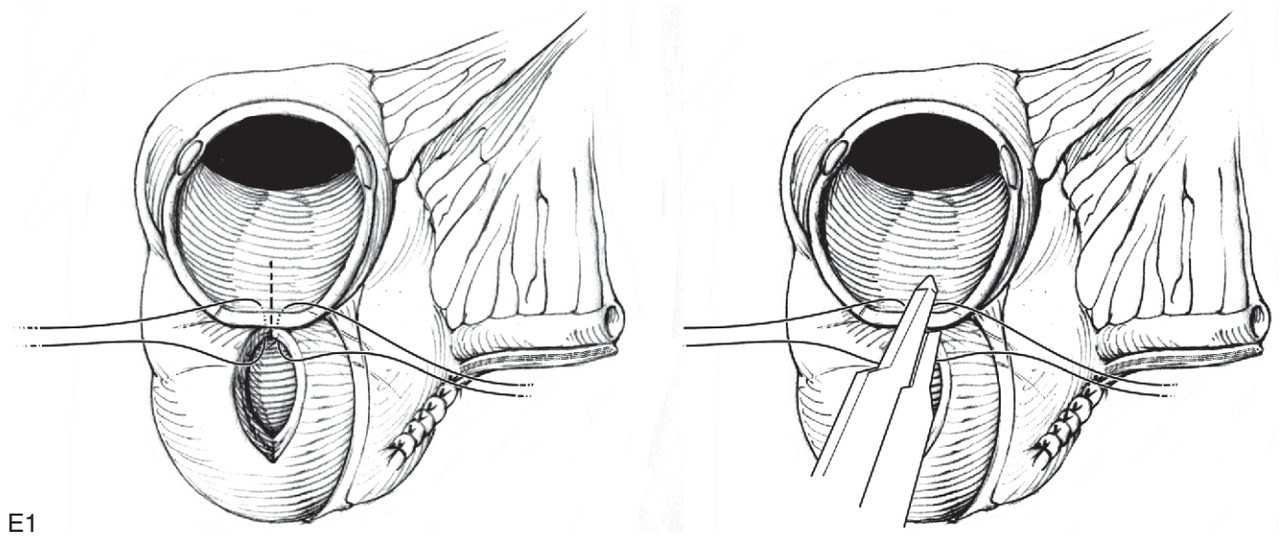

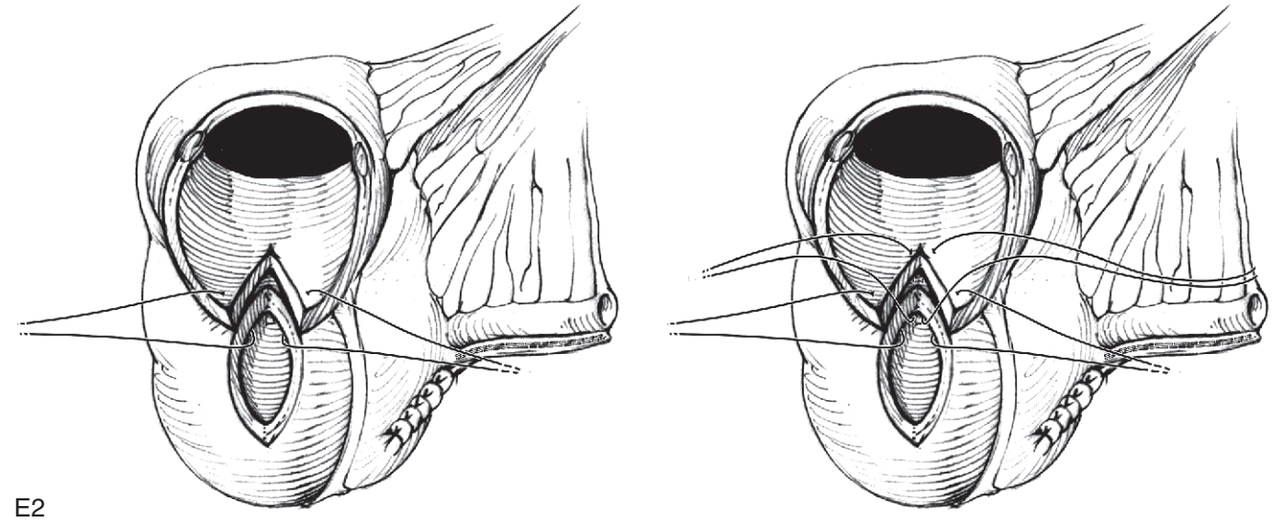

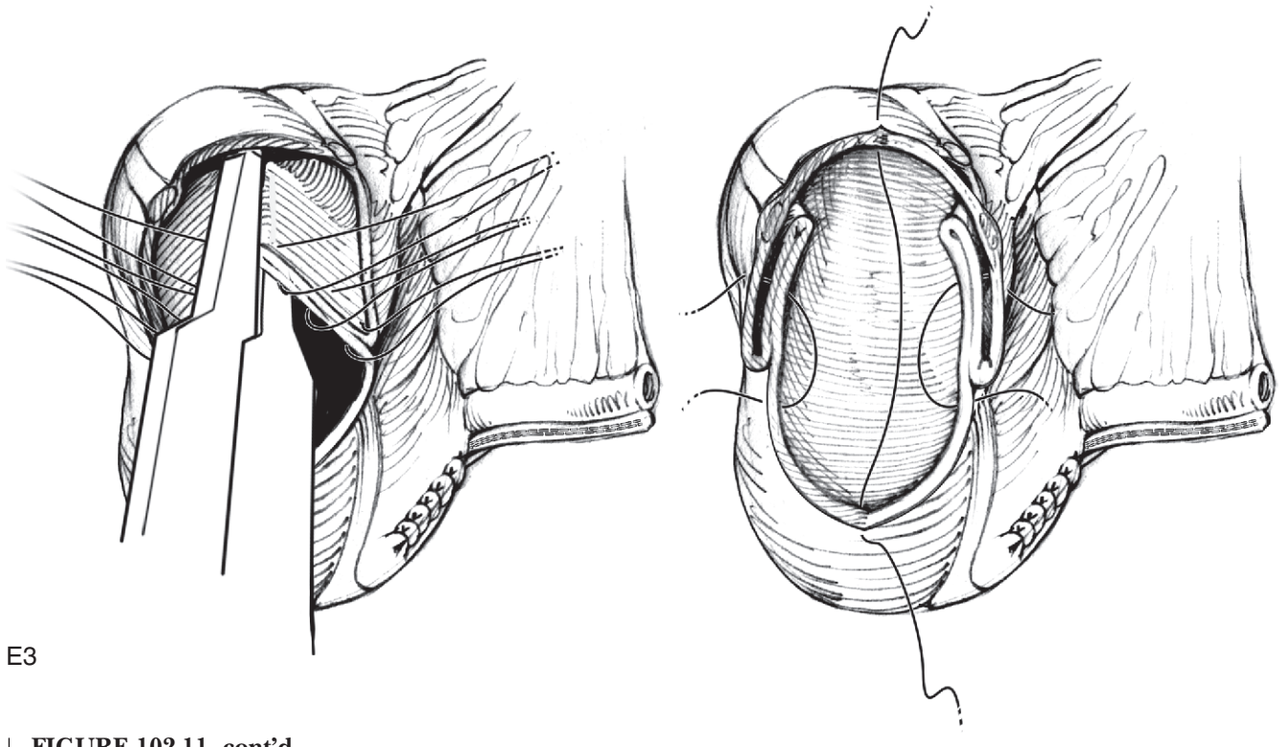

FIGURE 102-11, cont'd.

Continued

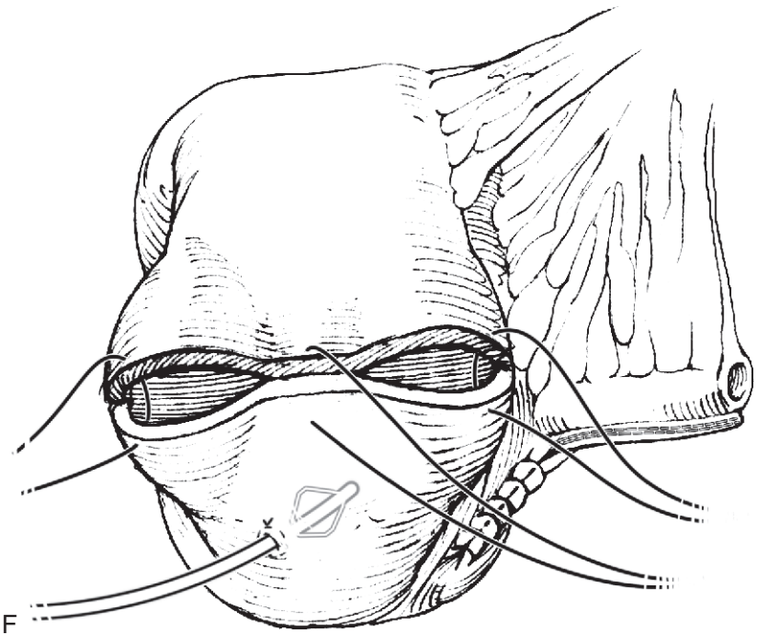

F

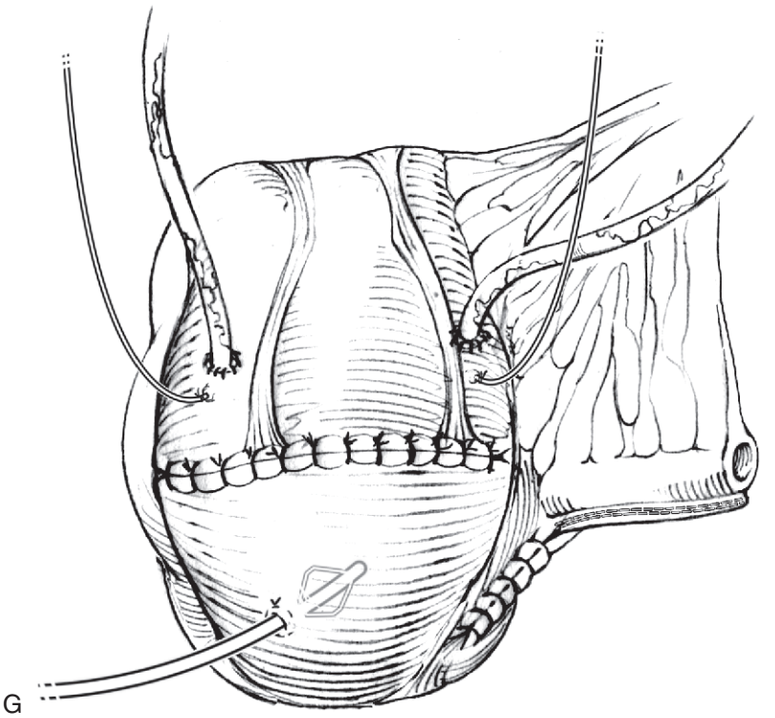

G

FIGURE 102-11, cont'd.

a patch over the open cecum to augment the reservoir. One can also take a longer segment of ileum and use the proximal part for an intussuscepted conduit (Bellevue pouch). Alternatively, tunnel the appendix into a taenia to serve as the conduit and so release the terminal ileum for use as a patch.

GASTROILEOILEAL POUCH

(Lockhart)

This pouch is best for patients with short bowel syndrome, acidosis, and an ileocecal segment made unusable by radiation damage.

Obtain a segment of stomach and a 32-cm length of ileum. Divide the ileum into two segments, 20 to 22 cm and 12 to 14 cm. Open the long segment on its antimesenteric border. Fold it into a U-shape, and anastomose it to the gastric segment with a running 3-0 SAS. Taper the short segment around a 14-French red rubber catheter with nonabsorbable staples (see Fig. 102-13) for 9 to 10 cm and absorbable sutures (see Fig. 102-12) for the remainder. Implant the short tapered segment into the gastric wall in a 3- to 4-cm submucosal tunnel. Reimplant the ureters into the gastric segment submucosally from inside. Stent with a single J-stent; place a Malecot catheter in the reservoir and a 12-French straight catheter in the conduit.

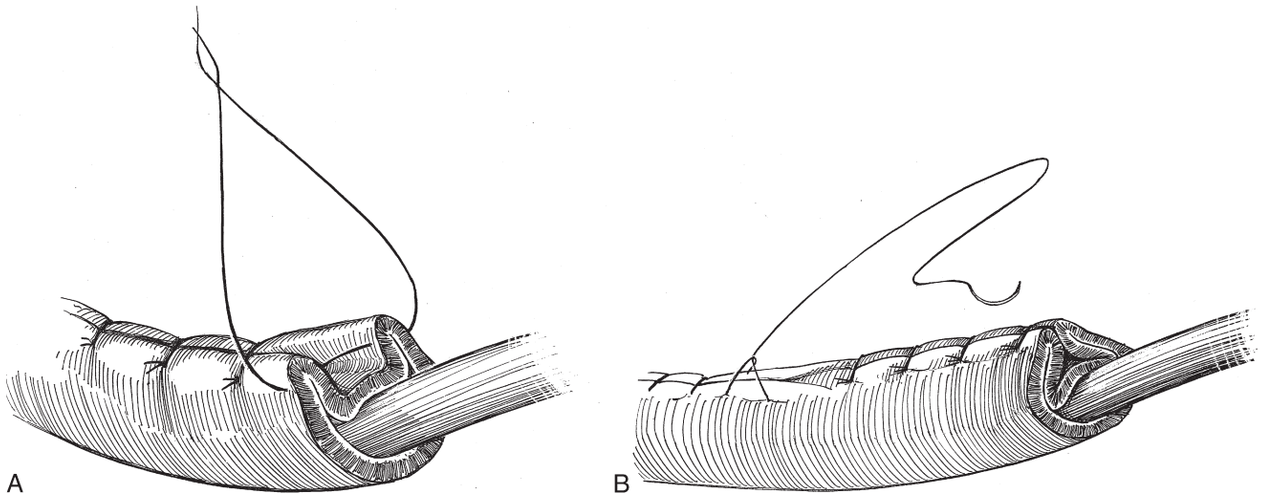

FIGURE 102-12.

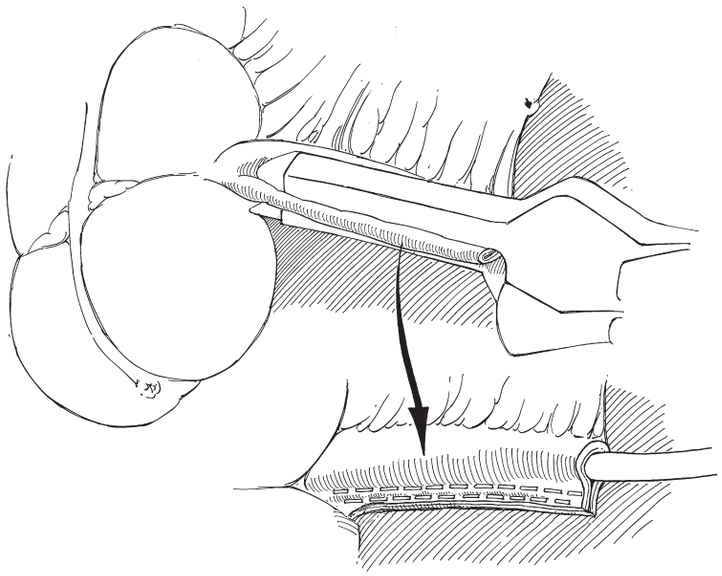

FIGURE 102-13.

CONDUITS FOR CONTINENT RESERVOIRS

Sutured Continent Conduit

Insert a 12-French Robinson catheter in the terminal ileum and ileocecal valve, and place Lembert sutures of 3-0 silk 0.5 cm apart for the entire length. Place a second layer, a running 3-0 silk suture. Fill the pouch to a volume of 300 to 400 cm. Remove the catheter, and press firmly on the reservoir to test for continence (Fig. 102-12).

If there is leakage, reinforce the suture line with interrupted 3-0 silk sutures at the ileocecal valve area. Insert a 12- and a 14-French catheter to test for ease of catheterization.

Stapled Continent Conduit (Bejany and Politano)

To form a narrow conduit from the terminal ileum, place the GIA 90-mm stapler on the antimesenteric border firmly against a 14-French Robinson catheter. It is usually necessary to apply the stapler more than once because the staple line should extend right down to the ileocecal valve. At the ileocecal valve, angle the stapler to cut off that portion. During the stapling process, make traction along the long axis of the terminal ileum to make sure that the catheterizing channel is straight and without folds. With the catheter in place, several interrupted sutures may be inserted in the angled cut at the ileocecal junction to maintain the continence mechanism of the ileocecal valve, not necessarily to "nipple" the terminal ileum into the cecum. Remove the catheter after filling the reservoir. There should be no leakage into the terminal ileum (Fig. 102-13).

POSTOPERATIVE PROBLEMS FROM URINARY RESERVOIRS

Immediate problems: Whichever form of continent diversion is used, it is extremely important before the patient leaves the operating table to prove that the continence mechanism is effective and that the conduit can easily be catheterized with suitable catheters of various types at various degrees of reservoir filling. If there is any difficulty catheterizing a conduit in the operating room, it will be that much harder later. Leaving a silicone catheter indwelling, sutured to the skin, is good insurance for the first week.

Late problems: Bacteriuria is inevitable in systems requiring self-catheterization, but pyelonephritis is rare. *Reflux* is present in a small number. *Ureteral obstruction* is more common and may require balloon dilation or revision. *Mucus secretion* is greater in reservoirs of cecum than of ileum, requiring more frequent and vigorous irrigation over a more prolonged time. In contrast, the ileal mucosa tends to atrophy. Mucus is often obstructive and requires daily irrigations with sterile water or bicarbonate solution. Occasional obstruction during catheter drainage may be overcome if the patient coughs. *Stomal stenosis or eversion* may require revision of the stoma. *Stone formation* is secondary to residual urine and may be managed by direct-vision lithotripsy or percutaneous techniques. The *metabolic changes* of increased serum chloride and decreased bicarbonate occur frequently. An occasional patient must be managed by ingestion of bicarbonate, more frequent emptying of the reservoir, and continuous drainage at night. Loss of potassium is not a problem. Renal function must be monitored. These metabolic problems typically improve after 6 months.

Commentary by JEFFREY HOLZBEIERLEIN

As Rowland and Martin describe in this chapter, a large arsenal of options for continent diversions exist, and choices should be made based on anatomy, renal function, and individual patient preferences and capabilities. Although these diversions can provide excellent outcomes in patients who cannot undergo orthotopic reconstruction but who desire continence, long-term complications appear quite frequently. In order to minimize these complications, several technical points should be stressed.

First, as the authors mention, it is critical that throughout the procedure one pass a catheter through the catheterizable limb at multiple steps throughout the procedure. If at any point the catheter does not go through smoothly, then the last step should be revisited to determine what has hampered catheterization. Kinking due to redundancy or angulation appear to be most commonly associated with this. Second, it is critical to imbricate mucosa over staples in these urinary diversions. If left exposed, stones, which can be quite complex to manage, may form. Personally, I think this should be performed in the catheterizable limb as well even though there is not urine in constant contact with the staple line. It is simple to do this step and reduces the risk long-term of stone formation or catching of the catheter on a staple. Lastly, it is particularly important when using the appendix for any catheterizable stoma that vascularity be carefully maintained. This is especially true in adult patients in whom there can be high rates of stricture of the appendix when used as the efferent limb.

Chapter 103

Appendicovesicostomy

JOHN C. THOMAS

The Mitrofanoff principle is based on implantation of a supple tube within a submucosal tunnel with firm muscular backing. Reservoir pressure during filling coapts the catheterizable channel to prevent leakage and provide continence. Although this principle has been applied most commonly for procedures in the appendix, other substitutes have included transversely tubularized bowel segments (Yang-Monti), ureteral remnants, or even müllerian structures. Careful patient selection is critical in that these channels have a high rate of continence and failure to catheterize regularly may cause infection, hydronephrosis, or reservoir perforation.

The patient will require a formal bowel preparation, appropriate preoperative antibiotic coverage, and a latex-free environment when indicated. A balloon catheter is placed transurethrally.

Incision: Make a lower midline or transverse incision (Pfannenstiel) (Fig. 103-1).

Develop the prevesical space and mobilize the right colon along the white line of Toldt to gain adequate mobilization of the appendix and mesoappendix.

Remove the appendix with a cuff of cecum to provide length and a wider stoma to help minimize stenosis at the skin level. Close the cecum in two layers with 3-0 self-absorbable suture (SAS) in a similar fashion as for an open appendectomy. Preserve the appendiceal artery at all times; however, the mesoappendix should be mobilized until the desired stomal location can be reached without tension (Fig. 103-2).

An alternative to a short appendix is to incorporate some tubularized cecal wall with the appendix. This can be done in a uniform fashion using a stapler (Fig. 103-3), which is a useful maneuver in obese patients. Care should be taken not to injure the blood supply.

Typically, the appendix is tunneled into the bladder into a posterolateral position (Fig. 103-4). However, the ultimate location should be determined by appendiceal length, stoma location, and mobility of the bladder. Open the bladder in a clamshell configuration. Alternatively, if the stomal location is to be the umbilicus, a superiorly based U-shaped bladder flap can be employed that is similar to a Boari flap (see Chapter 113).

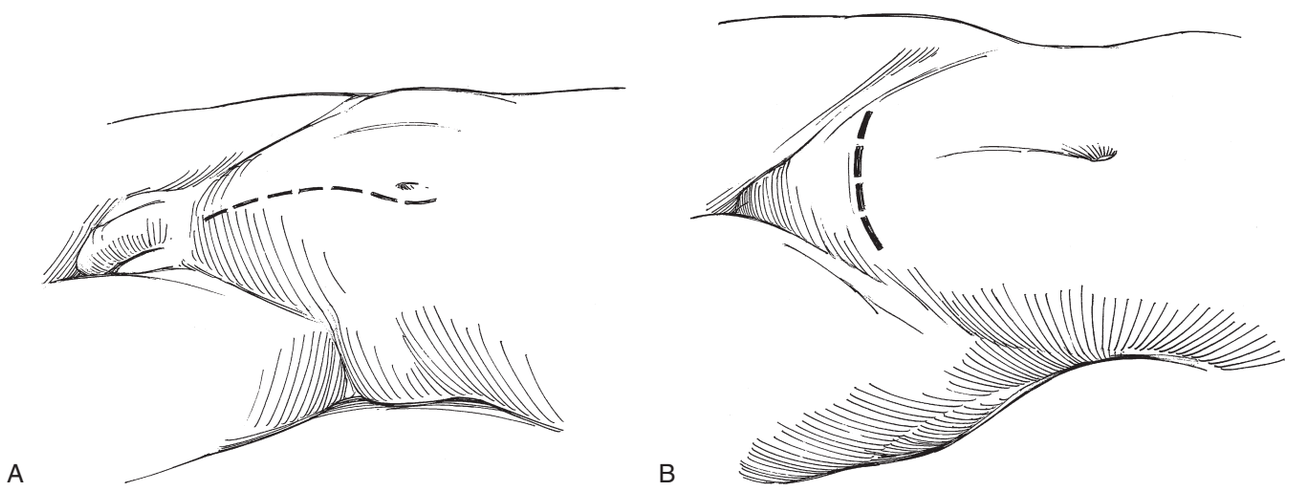

FIGURE 103-1.

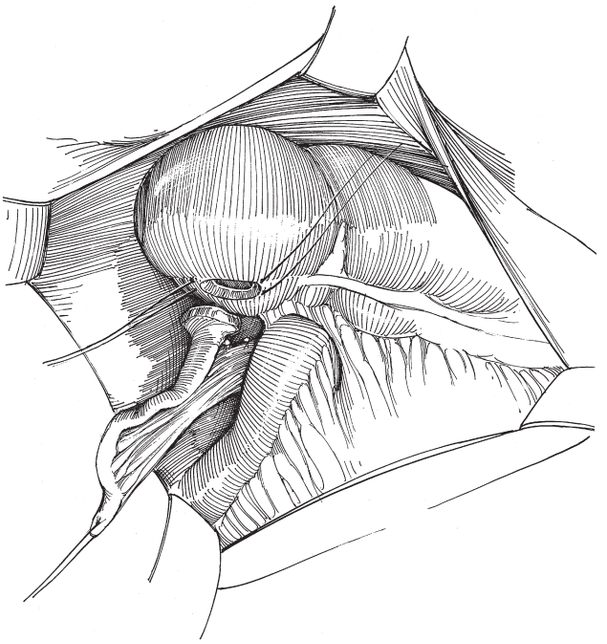

FIGURE 103-2.

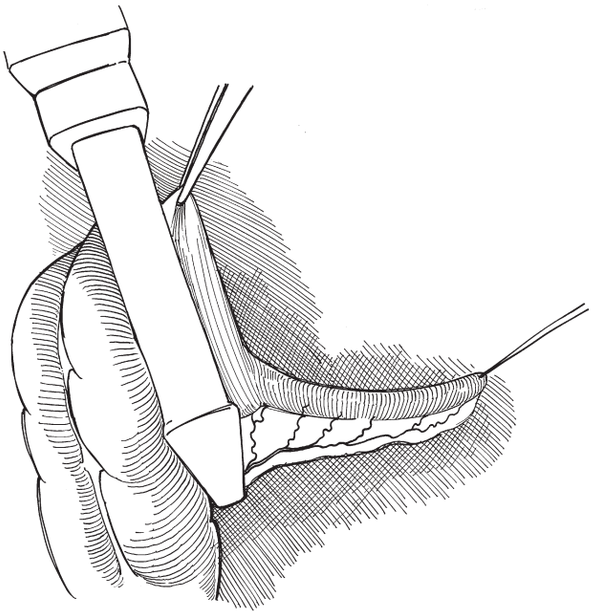

FIGURE 103-3.

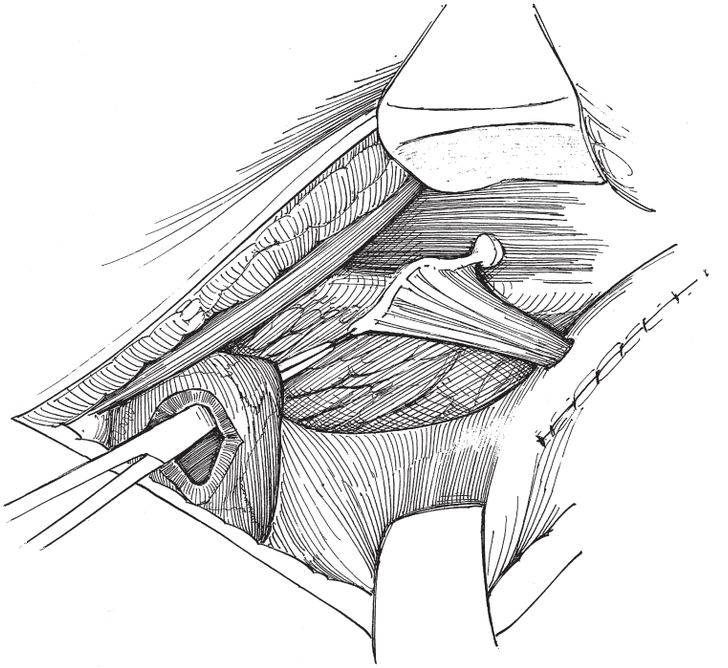

FIGURE 103-4.

IMPLANTATION INTO THE BLADDER

Trim the distal tip of the appendix and make sure it can be catheterized with a 10-14 French catheter. Tunnel the distal end of the appendix into the bladder with a minimal submucosal tunnel length of 2 cm. Place full thickness SAS to secure the distal appendiceal lumen to the bladder wall. Close the mucosal tunnel with 4-0 or 5-0 chromic running suture if applicable, and secure the appendix to the outer bladder wall at the entry hiatus with 3-0 SAS to minimize channel retraction (Fig. 103-5). Proceed with bladder augmentation when necessary.

Depending on stomal location, guide the appendiceal base to the umbilicus or through the rectus muscle after creating a cruciate incision in the rectus fascia. Mature the

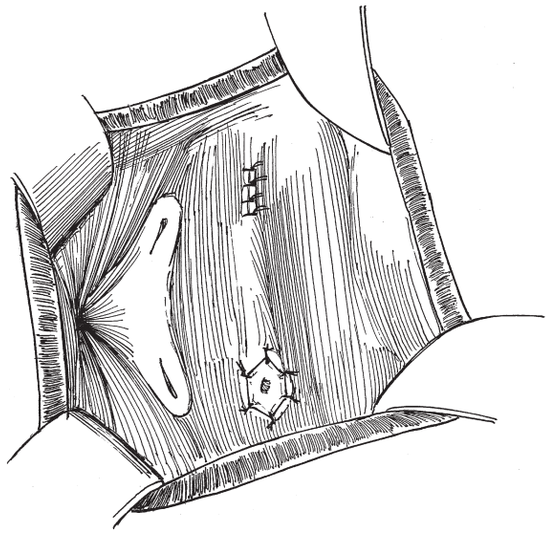

FIGURE 103-5.

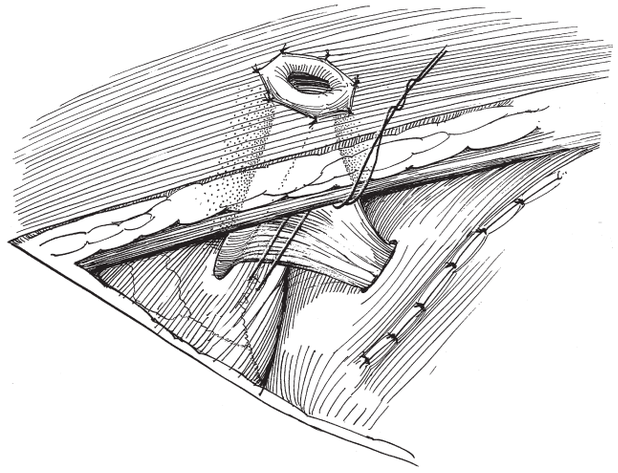

FIGURE 103-6.

stoma at the skin level (see later). Key technical points are to maintain the shortest channel possible to facilitate ease of catheterization, avoid kinking, and if possible, fix the bladder to the undersurface of the abdominal wall (Fig. 103-6). *Be sure to catheterize the channel each time an operative step is completed.*

STOMAL MATURATION

Depending on stomal location, the proximal end of the appendix is spatulated and secured to a wide-based V- or U-shaped skin flap at the apex of the spatulation. If the stoma is at the umbilicus, the umbilicus can be excised or used as part of the flap. Mature the stoma to the skin flap with 4-0 SAS or chromic catgut full thickness sutures. Leave a stent for 3 weeks until a static cystogram is obtained. If there is no leak, plug the cystostomy tube and have the patient catheterize every 4 hours. If there are no problems, remove the cystostomy tube.

ALTERNATIVES TO THE APPENDIX

Transversely Tubularized Bowel Segments (Yang-Monti Channel)

Harvest a 2-cm segment of ileum and open transversely along the antimesenteric border. Limb length can be altered depending on where one opens the segment (Fig. 103-7).

Tubularize the segment in a longitudinal fashion over a 10-14 French catheter in two layers using 5-0 SAS (Fig. 103-8). Tunnel the channel and mature the stoma in a similar fashion as the appendix.

A longer channel (spiral Monti) can be constructed by harvesting a 3- to 4-cm segment of ileum and partially dividing it as shown in Figure 103-9.

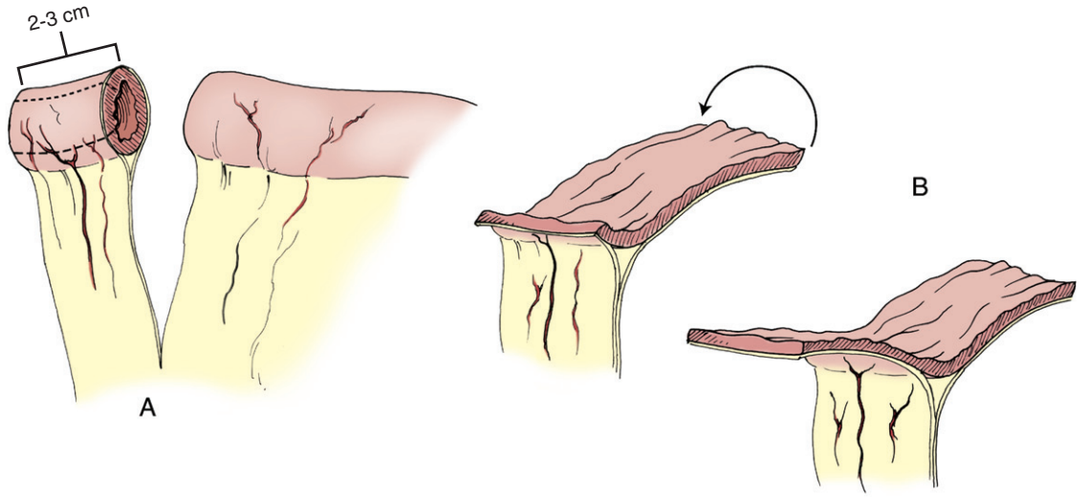

FIGURE 103-7. *(From Adams MC, Joseph DB. [2007]. Urinary tract reconstruction in children. In: Wein AJ, Kavoussi LR, Novick AC, Partin AW, Peters CA, eds. Campbell-Walsh urology, 9th ed. Philadelphia: Saunders Elsevier, pp 3656-3702.)*

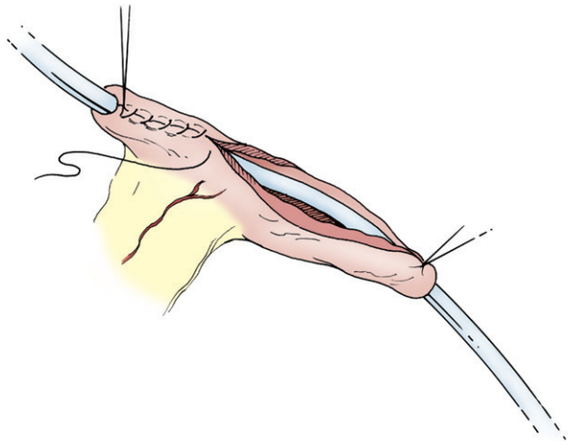

FIGURE 103-8. *(From Adams MC, Joseph DB. [2007]. Urinary tract reconstruction in children. In: Wein AJ, Kavoussi LR, Novick AC, Partin AW, Peters CA, eds. Campbell-Walsh urology, 9th ed. Philadelphia: Saunders Elsevier, pp 3656-3702.)*

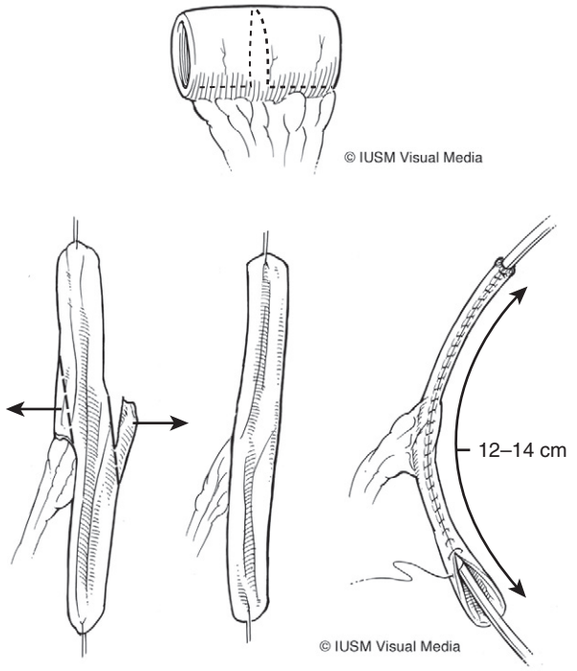

FIGURE 103-9. *(From Yerkes E, Metcalfe P, Rink RC. [2006]. Incontinent and continent urinary diversion. In: Grosfeld JL, O'Neill JA Jr., Coran AG, Fonkalsrud EW, eds. Pediatric surgery, 6th ed. Philadelphia: Mosby Elsevier, pp 1791-1804.)*

POSTOPERATIVE PROBLEMS

Stomal stenosis at the skin level is the most common problem with a reported incidence between 10% and 40%. Management consists of dilation with an indwelling catheter or formal revision. *False passages* can also occur from repeated erroneous catheterizations or excessive angulation within the channel and can usually be managed with a temporary indwelling catheter. *Fistulas* between the bladder and catheterizable channel are rare, but typically require formal revision. *Incontinence or stomal leakage* is rare, occurring in fewer than 5% of patients. This may be due to a short intravesical tunnel, persistently elevated reservoir pressures, or fistula. Although endoscopic management with Deflux has been reported, long-term outcomes are lacking. Therefore formal revision is usually necessary in these cases. *Appendiceal perforation, necrosis, and stricture* have also been reported.

Suggested Readings

Adams MC, Joseph DB. (2007). Urinary tract reconstruction in children. In: Wein AJ, Kavoussi LR, Novick AC, Partin AW, Peters CA, eds. Campbell-Walsh urology, 9th ed. Philadelphia: Saunders Elsevier, pp 3656-3702.

Cain MP, Metcalfe PD, Rink RC. (2007). Urinary diversion. In: Docimo SG, Canning DA, Khoury A, eds. Clinical pediatric urology, 5th ed. London: Informa Healthcare, p 937.

Yerkes E, Metcalfe P, Rink RC. (2006). Incontinent and continent urinary diversion. In: Grosfeld JL, O'Neill JA Jr., Coran AG, Fonkalsrud EW, eds. Pediatric surgery, 6th ed. Philadelphia: Mosby Elsevier, pp 1791-1804.

Chapter 104

Ureterosigmoidostomy

STEPHEN ANTHONY BOORJIAN AND DIPEN J. PAREKH

BACKGROUND

Ureterosigmoidostomy was introduced in 1852 by Simon and remained popular as a choice for urinary diversion until Bricker described the ileal conduit a century later. Given the risks of infection, electrolyte imbalance, incontinence, and secondary malignancy that had been reported with ureterosigmoidostomy, its application subsequently decreased significantly. Moreover, the popularization of orthotopic neobladder reconstruction in recent years has provided patients with an alternative diversion that allows preservation of volitional voiding and body image. Nevertheless, given the technical simplicity and absence of catheters or external appliances associated with ureterosigmoidostomy, the procedure has remained in use, particularly for patients in whom stoma bags and catheters are culturally or personally unacceptable. Moreover, a recent modification of the classic ureterosigmoidostomy, known as the Mainz Pouch II, has decreased storage pressures and thereby improved postoperative continence, thus helping restore interest in the procedure. Therefore, we describe the techniques here for both the classic ureterosigmoidostomy and Mainz Pouch II, options for urinary diversion that the urologist should be familiar with.

PATIENT SELECTION

While ureterosigmoidostomy has been used in patients with a history of bladder exstrophy, particularly after failed bladder reconstruction, we are reluctant to perform this diversion in children because of the associated long-term risks of malignancy and of upper tract deterioration, risks that increase with the length of time the diversion has been in place. Instead, we generally reserve ureterosigmoidostomy for older patients, most commonly following radical cystectomy for urothelial carcinoma. In particular, ureterosigmoidostomy may be used in patients who are not candidates for an orthotopic neobladder based on locally advanced tumor pathology, and for whom an external appliance or the potential need for self-catheterization may not be culturally, financially, or personally acceptable. Moreover, ureterosigmoidostomy may be used when intestinal adhesions or prior bowel resections preclude alternative diversions, or when intraoperative complications during cystectomy mandate prompt completion of the surgery.

Contraindications to ureterosigmoidostomy include a history of colorectal carcinoma, sigmoid diverticulitis, extensive pelvic irradiation, renal insufficiency, or an incompetent anal sphincter. This last criterion makes ureterosigmoidostomy a poor choice for diversion in patients with neurogenic bladder dysfunction, because of the increased frequency of associated anal malfunction. A number of different methods have been described to evaluate competency of the anal sphincter preoperatively, including anal manometry, digital palpation, and testing patients' ability to retain an enema. Our practice has been to have patients attempt to hold an enema while walking up and down two flights of stairs; if they are able to retain the enema with this exercise, we believe they are candidates for ureterosigmoidostomy.

PREOPERATIVE PREPARATION

Patients are placed on a clear liquid diet for 24 hours before surgery. Both antibiotic and mechanical bowel preparation are given the evening before surgery. We place support hose and intermittent compression stockings in the operating room as prophylaxis against the development of deep venous thrombosis. Central venous monitoring may be used particularly for patients with any element of preexisting cardiovascular disease, in whom postoperative volume status is paramount to assess carefully. Intravenous broad spectrum antibiotics are administered prior to incision.

SURGICAL TECHNIQUE

Ureterosigmoidostomy with Closed Extracolonic Technique for Ureterocolonic Anastomosis (Leadbetter)

1. Position the patient supine on the operating table, with the anterosuperior iliac spine over the break in the table. Flex the table, and placed the patient in slight Trendelenburg

position. Insert nasogastric and rectal tubes. A right-handed surgeon stands on the right side of the patient.

2. Make a lower midline incision (paramedian if there is history of exstrophy) starting just below the umbilicus and extending to the pubic bone, down to the anterior rectus fascia (Fig. 104-1). Divide the fascia in the midline. Enter the peritoneal cavity, and pack the small bowel out of the operative field. At this point, radical cystectomy and pelvic lymphadenectomy (described elsewhere) are performed if indicated, leaving the cut ureters open to drain freely.
3. Retract the sigmoid medially and incise the posterior peritoneum just lateral to where it meets the bowel edge, allowing entry into the left retroperitoneal space (Fig. 104-2). Identify the left ureter and mobilize it proximally and distally, taking care to preserve the adventitial vessels of the ureter and as much of the surrounding fat, which contains further blood supply, as possible. Distal dissection of the ureter should be carried down to the bladder, where additional length may be gained by dividing the ipsilateral superior vesical artery. At this point, clip the ureter as it enters the bladder, place a 4-0 chromic "tagging" suture into the ureter just proximal to the clip, and divide the ureter between the clip and the suture (Fig. 104-3). Frozen section analysis of the ureter may be obtained if indicated. Repeat the procedure for the right ureter, moving the sigmoid laterally and incising the pelvic peritoneum just to the right of the midline, allowing identification of the right ureter as it crosses the bifurcation of the iliac vessels. Expose and free the right ureter as was done on the left.
4. Elevate the antimesenteric border of the sigmoid by grasping the bowel with the left hand and gently pinching up on opposite sides using the left thumb and forefinger. Stay sutures may be used to help elevate the bowel. Using a #15 blade scalpel, make an incision on the anterior taenia of the sigmoid, approximately 5 to 6 cm in length, extending down through seromuscular layer of bowel until white submucosa is encountered (Fig. 104-4). Separate the seromuscular layer along each cut edge from the underlying submucosa, using a curved mosquito clamp. The flaps on each side should extend back approximately 1 cm from the incision. These flaps will ultimately be reapproximated to create a seromuscular "tunnel," which will cover the ureterocolonic anastomosis and act as an antirefluxing mechanism (Fig. 104-5). Of note, the tunnel for the left ureterocolonic anastomosis is usually located in the mid-sigmoid colon, while the right ureter is usually reimplanted about 4 cm distal to that, at approximately the rectosigmoid junction.
5. Excise a small "button" of submucosa plus mucosa at the distal end of the incision in the taenia using fine forceps and scissors (Fig. 104-6). This marks the site of the ureteral anastomosis. Sigmoid mucosa should extrude out, indicating entry into the bowel lumen. Insert a right-angle clamp into this opening and spread gently to widen the site.
6. Trim the ureters to a length that allows for a tension-free anastomosis but removes excess ureter to prevent kinking, and then spatulate the cut edge of each ureter to provide a wide area for the anastomosis. We use a running, double-armed 5-0 polydioxanone suture (PDS) for the ureterocolonic anastomosis. The first suture is placed "outside-in" through the apex of the spatulated ureter, then "inside-out," full thickness through the mucosa,

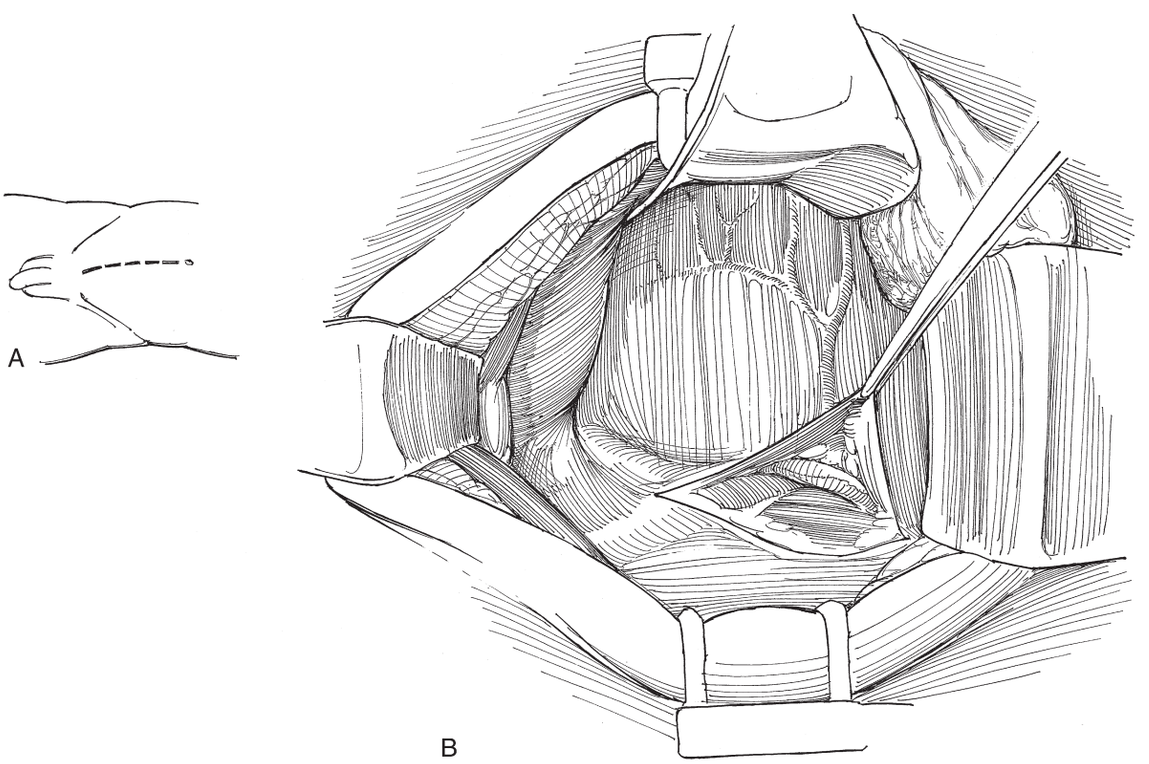

FIGURE 104-1. Lower midline incision used for ureterosigmoidostomy with or without radical cystectomy.

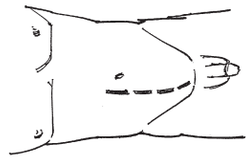

A

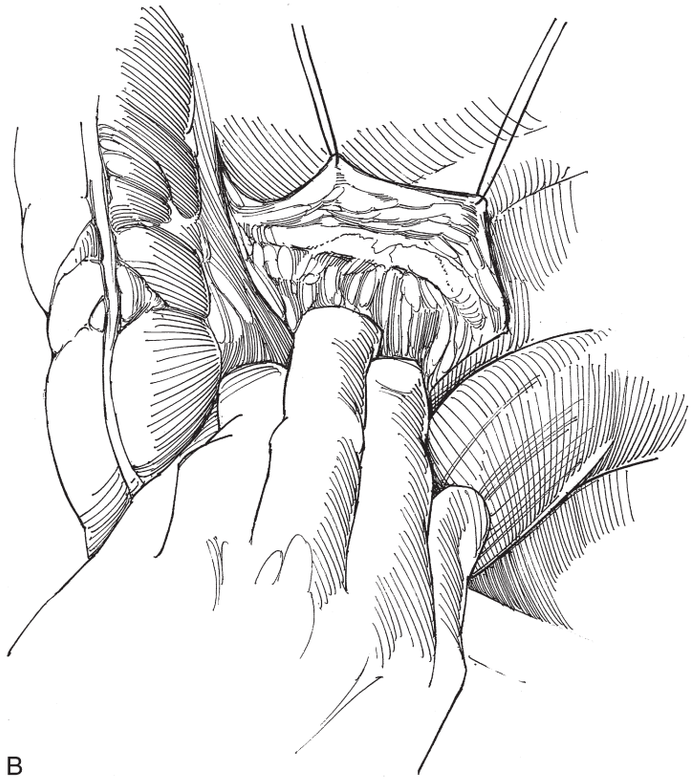

B

FIGURE 104-2. Incision in the peritoneal reflection just lateral to taenia of sigmoid, allowing entry into left retroperitoneal space and identification of the left ureter.

submucosa, muscle, and serosa of the bowel, and tied down with three knots (Fig. 104-7). Each arm of the suture is then run along one side of the ureter, and the two arms are tied together on the opposite side to complete the anastomosis. Single J stents (7 French) are placed across the anastomosis after the first arm of the suture has been run (Fig. 104-8). Stents may be introduced through the anus inside the rectal tube, after which the rectal tube should be removed and reinserted. Three or four "reinforcing" interrupted 4-0 PDS sutures are placed across the anastomosis after the running suture has been tied down.

7. The seromuscular "tunnel" is then closed over the ureter using interrupted 3-0 Lembert sutures to reapproximate the flaps created in step 4 (Fig. 104-9). The site of ureteral exit from this "tunnel" should be left twice the diameter of the ureter to prevent constriction or angulation, particularly from postoperative edema. Retroperitonealize the ureterocolonic anastomosis by drawing the cut lateral edge of posterior peritoneum over the site of the reimplant and suturing it loosely to serosa of the colon with interrupted 3-0 chromic stitches. Repeat for the contralateral ureter.
8. At the conclusion of the procedure, we leave a Jackson-Pratt drain within the pelvis, and then close the abdominal incision in layers. Separately fix the rectal tube and ureteral stents to the skin around the anus using nonabsorbable sutures.

Ureterosigmoidostomy with Transcolonic Technique for Ureterocolonic Anastomosis (Goodwin)

Positioning, incision, and ureteral dissection as for the Leadbetter procedure.

1. Using a #15 blade scalpel, make a full-thickness incision in the bowel along the anterior taenia at the rectosigmoid junction, approximately 8 cm long (Fig. 104-10).

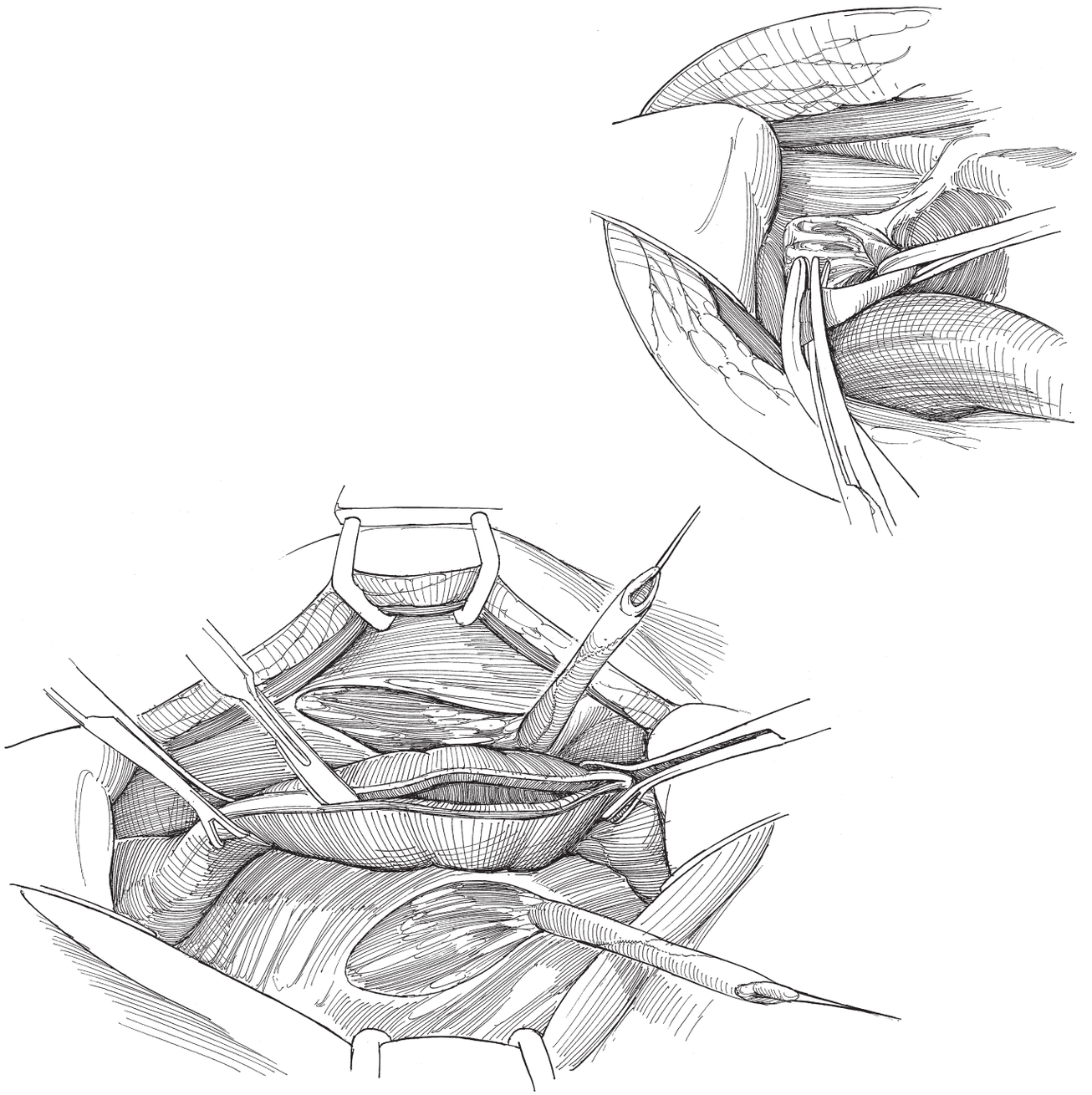

FIGURE 104-3. Division of the right ureter as it enters the bladder. Clip the stump of ureter at the bladder, and place a tagging stitch on the proximal end of the ureter for later identification.

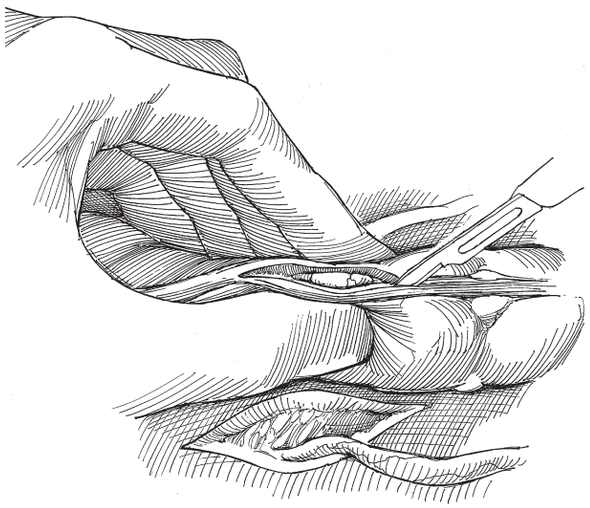

FIGURE 104-4. Incision along the taenia, through the seromuscular layers of bowel, down to the submucosa.

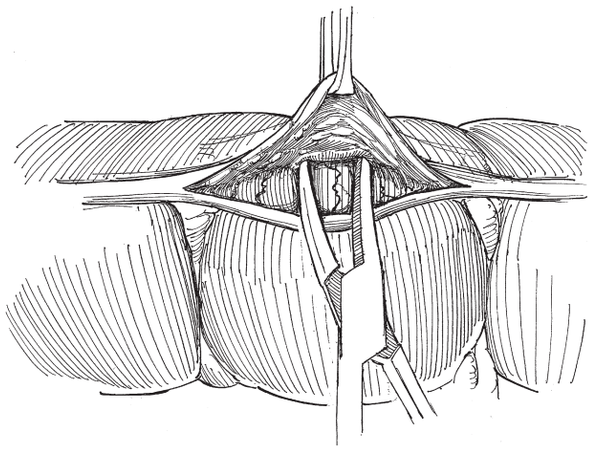

FIGURE 104-5. Creation of seromuscular tunnel, using a small curved clamp to elevate flaps approximately 1 cm on either side of the incision.

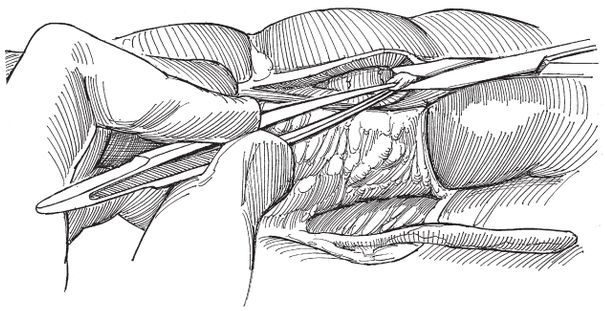

FIGURE 104-6. Excision of submucosa/mucosa to create site for ureterocolonic anastomosis.

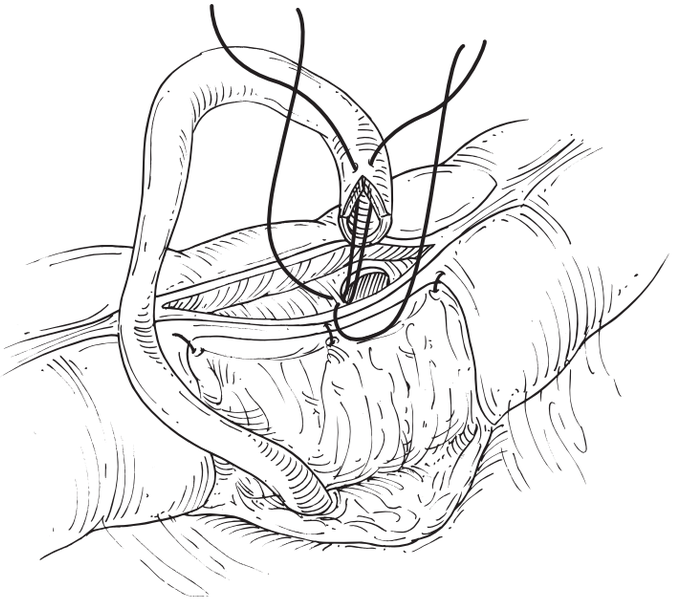

FIGURE 104-7. Ureterocolonic anastomosis, using a single, double-armed 5-0 PDS suture, starting at apex of spatulated ureter.

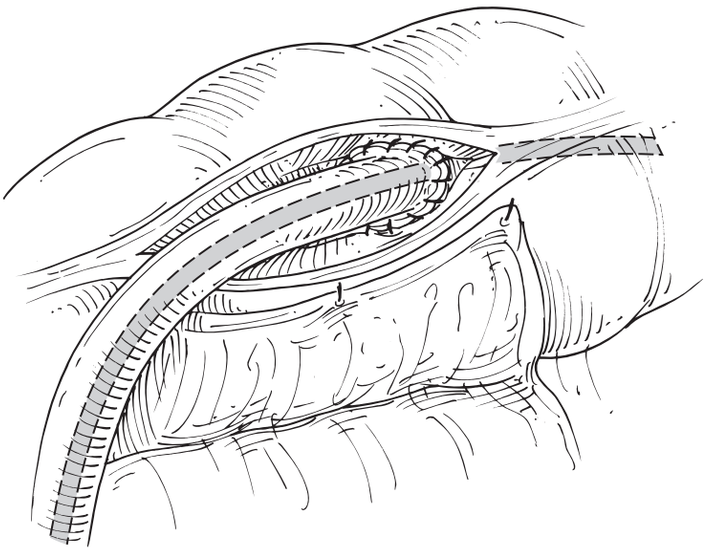

FIGURE 104-8. Running ureterocolonic anastomosis, completed, with stent in place.

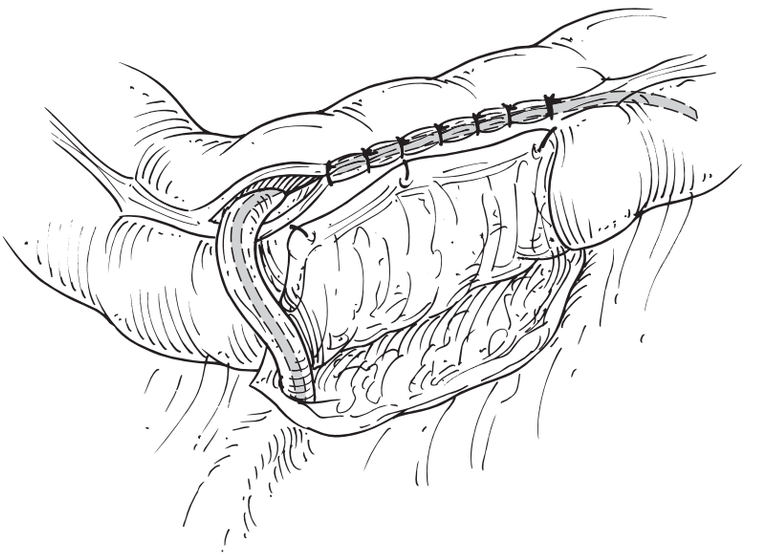

FIGURE 104-9. Closure of the seromuscular tunnel over the re-implanted ureter, taking care not to constrict the ureteral hiatus.

2. Insert the left hand through the lateral opening in the peritoneal reflection, beneath the sigmoid, and tent up the posterior wall of the opened bowel segment with the left index finger. Place stay sutures approximately 1 cm apart near the distal edge of the posterior bowel wall, and make a transverse incision through the mucosa and submucosa between the sutures to create the new ureteral orifice (Fig. 104-11). In a manner similar to the technique for a Politano-Leadbetter ureteroneocystostomy, infiltrate the submucosa proximally with saline to distend this layer, and then introduce a small curved clamp with the tips pointed upward into the mucosal incision. Gently spread to separate the mucosa and muscularis layers, and then gradually advance the clamp proximally and spread again, thus creating an antirefluxing submucosal tunnel, approximately 3 to 4 cm long (Fig. 104-12).
3. Once the proximal extent of the tunnel has been reached, rotate the clamp so that the tips point posteriorly. Push the clamp through the right lateral bowel wall and into the retroperitoneum, using the left index finger to guide. Spread the jaws of the clamp to create an opening for the ureter, then grasp the stay suture on the right ureter with this clamp and slowly draw the ureter into the bowel lumen (Fig. 104-13). Repeat this process for the left ureter to bring it into the bowel adjacent to the right one.
4. Spatulate each ureter to allow for a wide anastomosis. Trim excess ureteral length to prevent kinking. Reimplant the spatulated ureters into the posterior bowel wall using interrupted 4-0 synthetic absorbable sutures (SAS), taking care to ensure mucosa-to-mucosa apposition with the stitches. We recommend placing single J stents up each

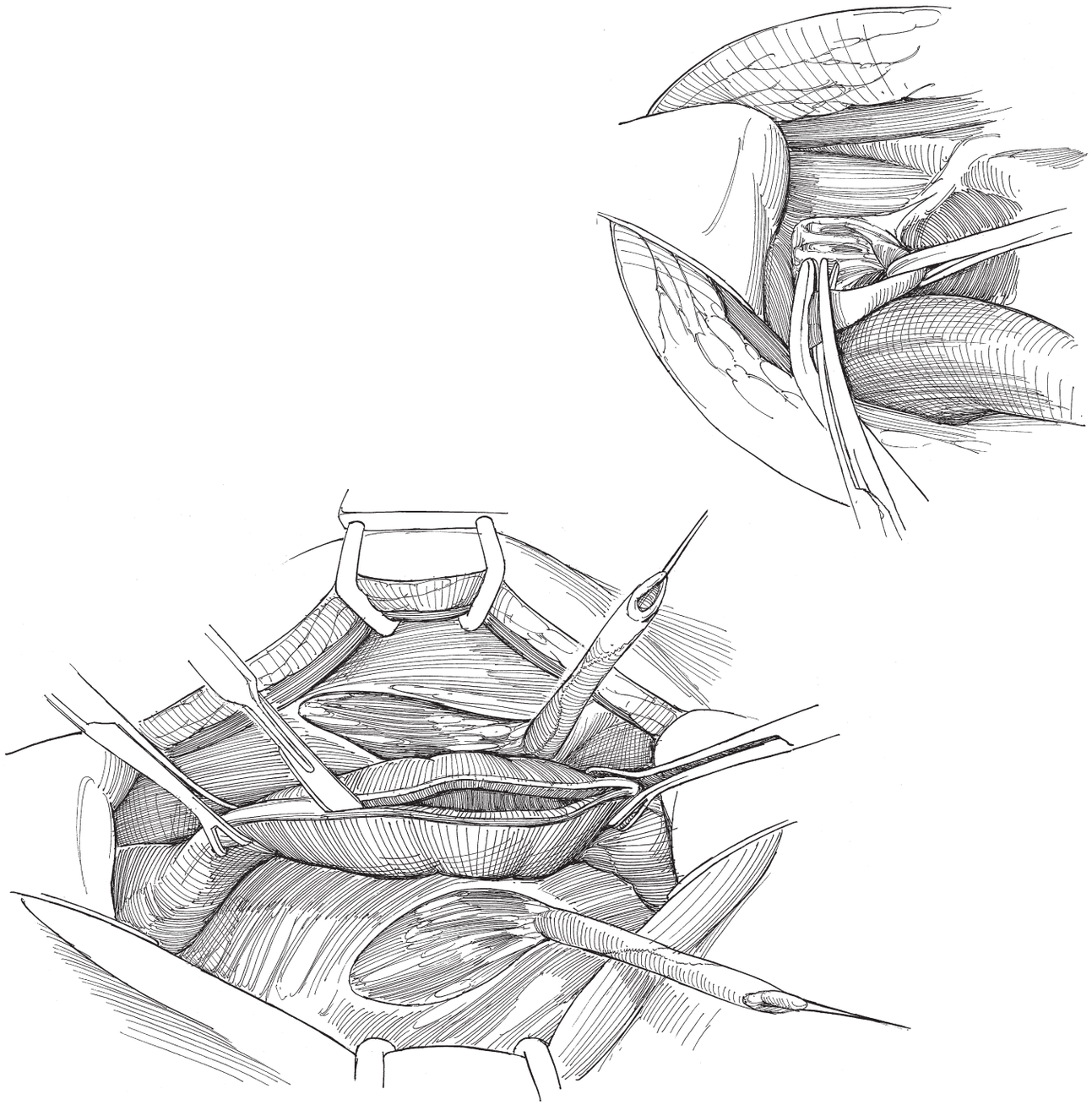

FIGURE 104-10. Full-thickness incision (approximately 8 cm in length) along the anterior taenia at the rectosigmoid junction.

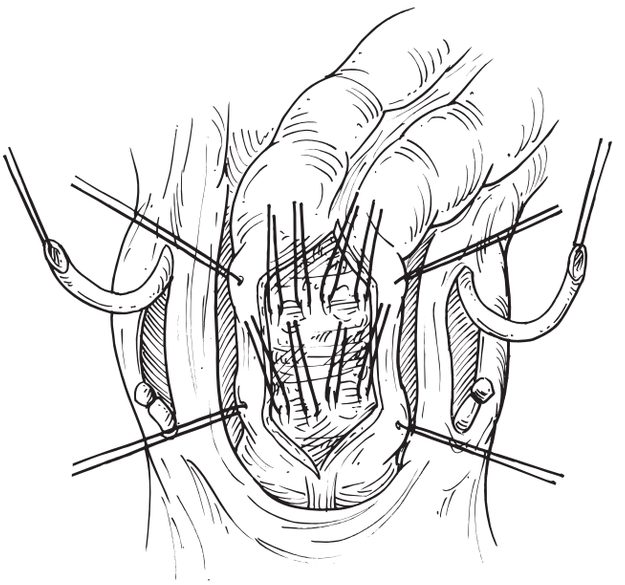

FIGURE 104-11. Sites of entry and exit for ureteral reimplantation into the posterior bowel wall. Ureters are spaced approximately 3 cm apart from one another, marked with stay sutures.

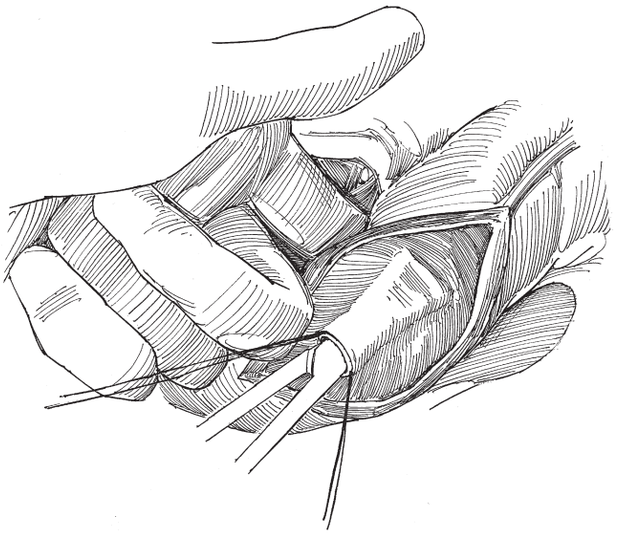

FIGURE 104-12. Dissection to create antirefluxing submucosal tunnel for the ureter in posterior bowel wall.

ureter after the anastomosis is complete (Fig. 104-14). Stents may be secured to the mucosa of the bowel using a single 4-0 chromic suture. Stents should then be inserted into the rectal tube and pulled out through the anus; thereafter, the rectal tube is reinserted.

5. Close colotomy in the anterior rectosigmoid wall in two layers, using a 3-0 or 4-0 running chromic stitch for the mucosa of the bowel, followed by a 2-0 running SAS suture for the seromuscular layer. Reapproximate the lateral edges of peritoneum. Drainage and closure is as for the Leadbetter procedure above.

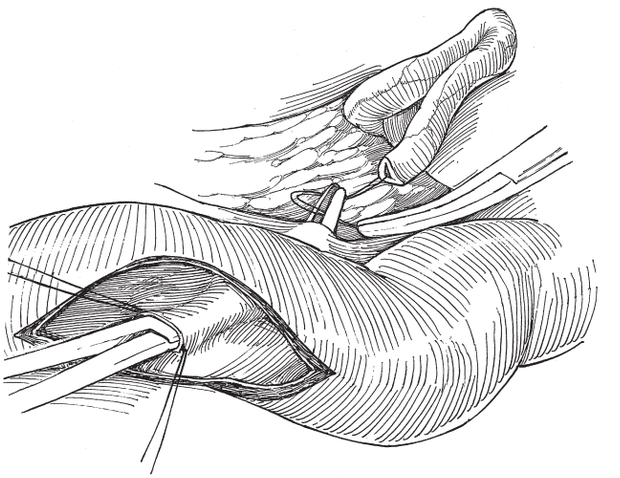

FIGURE 104-13. Grasp tagging suture on ureter with clamp to bring into the bowel lumen.

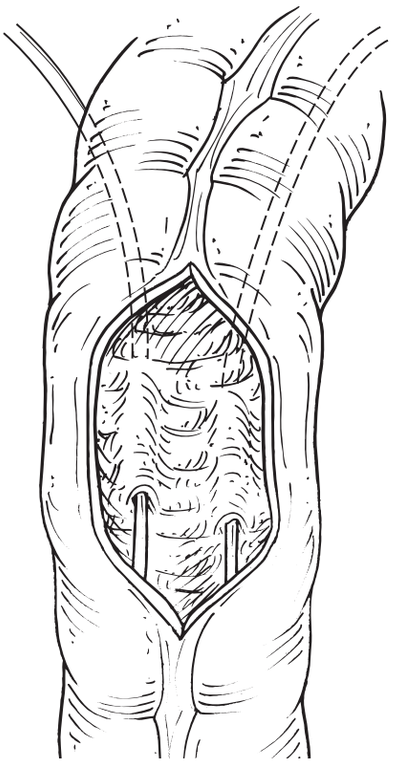

FIGURE 104-14. Ureters reimplanted into posterior bowel wall over stents, using interrupted 4-0 absorbable sutures.

Mainz Pouch II (Sigma Rectum Pouch)

The Mainz Pouch II, described by Fisch and colleagues in 1993, is a modification of the ureterosigmoidostomy that involves detubularizing the rectosigmoid colon and reconfiguring the detubularized segment into a spherical shape, while maintaining bowel continuity. Similar to the orthotopic neobladder, the spherical reconstruction interrupts circular bowel

contractions and decreases storage pressures. The resultant decrease in colonic storage pressure improves urinary continence and protects against upper tract deterioration.

1. Exposure and ureteral identification is identical to steps 1 through 3 for the Leadbetter ureterosigmoidostomy above.
2. Make a full-thickness incision in the bowel along the anterior taenia approximately 12 cm proximal and distal to the rectosigmoid junction (Fig. 104-15).
3. Fold the opened bowel segment into an inverted U, and then close the posterior wall of the U with a side-to-side anastomosis of the medial margins (Fig. 104-16), using two layers of full-thickness 2-0 Vicryl sutures, the first layer running and the second layer interrupted.
4. Pull the left ureter behind the sigmoid mesentery from the left to the right side. Implant the ureters (Fig. 104-17) according to the technique described above in steps 2 through 4 of the Goodwin ureterosigmoidostomy, with one ureter on either side of the medial suture line of the posterior wall of the pouch created in step 3.
5. Fix the posterior wall of the pouch to the anterior longitudinal band at the sacral promontory for stabilization (Fig. 104-18). If this is not possible to do without tension, the pouch may alternatively be fixed to the psoas tendon. Fixation in either case is important to prevent later dislocation of the pouch and kinking of the ureters.
6. Close the anterior wall of the pouch in the same manner as the posterior wall. The suture lines of the closed anterior wall form a Y shape (Fig. 104-19).
7. Drainage and closure are as for ureterosigmoidostomy.

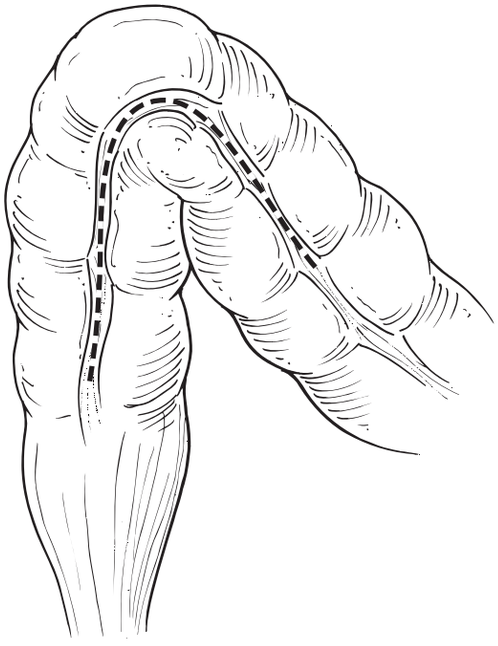

FIGURE 104-15. Incision in the anterior taenia coli approximately 12 cm proximal and distal to the rectosigmoid junction for creation of the Mainz Pouch II.

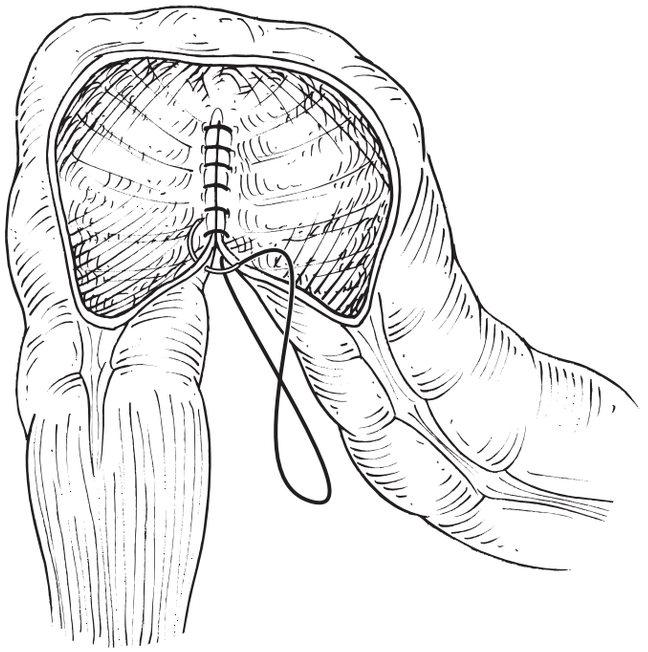

FIGURE 104-16. Creation of the posterior wall of the inverted U by sewing the medial edges of the detubularized bowel segment together.

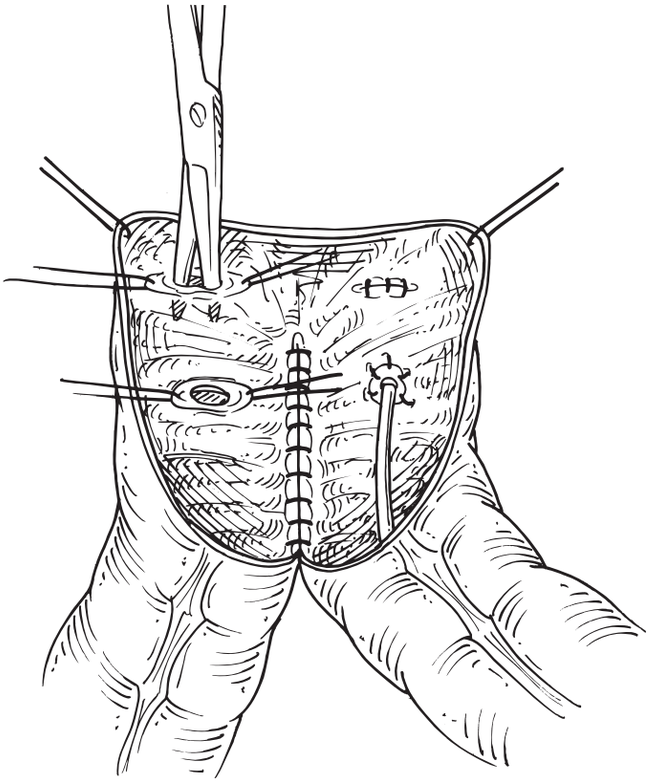

FIGURE 104-17. Submucosal tunnel for ureteral re-implantation into the Mainz Pouch II.

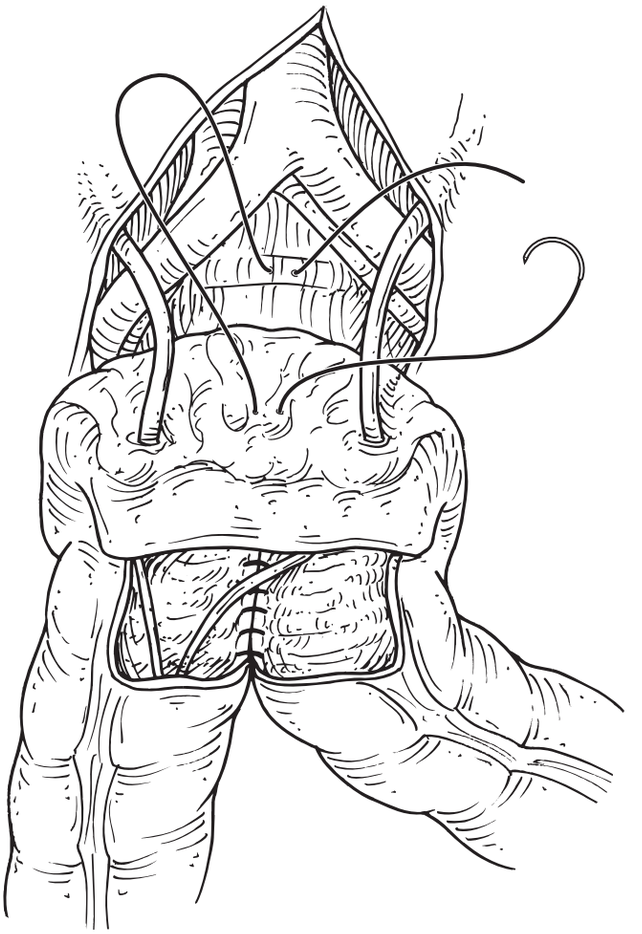

FIGURE 104-18. Fixation of the pouch to the sacral promontory, after the ureters are reimplanted but before closure of the anterior wall of the pouch, using one or two 3-0 nonabsorbable sutures.

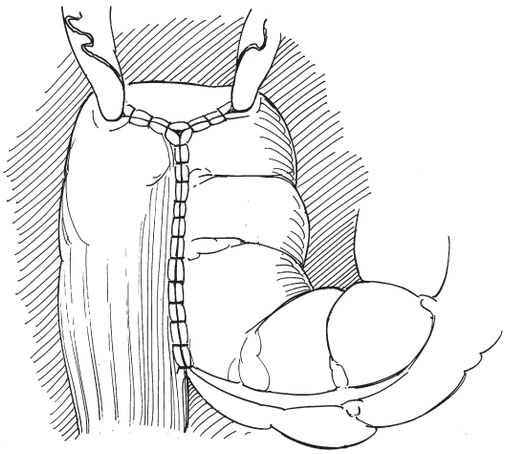

FIGURE 104-19. Completed Mainz Pouch II, with suture lines of the anterior wall closure intersecting in a Y-shape.

POSTOPERATIVE CARE

Ambulation and aggressive pulmonary toilet are started on postoperative day 1. Diet is advanced as bowel function returns. Ureteral stents are removed starting on postoperative day 7, as long as the patient is tolerating a regular diet and ambulating. The Jackson-Pratt drain is then removed if the output does not increase after stent removal. The rectal tube is subsequently removed on postoperative day 10.

Patients should be instructed to evacuate their bowels at frequent intervals after discharge from the hospital, which maintains a low intracolonic pressure and thereby protects the upper tracts and minimizes the likelihood of incontinence. Frequent evacuation also limits urinary contact time and reabsorption. Patients are followed with periodic serum electrolytes, creatinine, and contrast imaging studies, depending in part on the indication for diversion (e.g., bladder cancer surveillance). In addition, screening with colonoscopy is initiated on the 10th postoperative year and continued every 2 to 3 years thereafter.

OUTCOMES

Functional outcomes reported after ureterosigmoidostomy or Mainz Pouch II urinary diversion, albeit in small series, have demonstrated complete daytime urinary continence in 90% to 95% of patients, while, similar to the results following orthotopic neobladder reconstruction, nighttime continence rates have been consistently below that range. Nevertheless, social life, daily activities, and work are unaffected in the majority of patients after ureterosigmoidostomy, according to questionnaires. In one recent study, 97% of patients retrospectively stated they would undergo the same urinary diversion knowing its advantages and disadvantages.

Suggested Readings

Abol-Enein H and Ghoneim M. A novel uretero-ileal reimplantation technique: the serous lined extramural tunnel. A preliminary report. J Urol 1994; 151: 1193-1197.

Bastian PJ, Albers P, Haferkamp A, Schumacher S, and Müller SC. Modified ureterosigmoidostomy (Mainz Pouch II) in different age groups and with different techniques of ureteric implantation. BJU Int 2004; 94: 345-349.

D'Elia G, Pahernik S, Fisch M, Hohenfellner R, and Thüroff JW. Mainz Pouch II technique: 10 years' experience. BJU Int 93; 2004: 1037-1042.

Fisch M, Wammack R, Müller S, and Hohenfellner R. The Mainz Pouch II (Sigma Rectum Pouch). J Urol 1993; 149: 258-263.

Nitkunan T, Leaver R, Patel HRH, and Woodhouse CRJ. Modified ureterosigmoidostomy (Mainz II): a long-term follow-up. BJU Int 2004; 93: 1043-1047.

Commentary by

JEFFREY HOLZBEIERLEIN

Despite the attractiveness of using a "natural" sphincter to control urinary continence, a ureterosigmoidostomy should only be used in circumstances that prevent the construction of another type of diversion. As such, I believe it should be the "last option" for urinary reconstruction. This is primarily due to several risks:

1. The risk for development of adenocarcinomas at the site of ureterocolonic anastomoses. Even though this risk is estimated at only 10% and may take 20 years to develop, outcomes with these tumors have been poor and annual colonoscopies must be undertaken for evaluation.
2. The risk for electrolyte imbalances that occur with this diversion. Particularly over time or in patients with compromised renal function, a high incidence of electrolyte disturbances requiring hospitalization and treatment with intravenous fluid and electrolyte replacement may occur.
3. The risk for fecal/urine incontinence, which unlike many urinary diversions, is typically unacceptable, and much like a bowel ileostomy may result in significant irritation to the skin, particularly the perineum.
4. The risk for recurrent infections due to the high volume of bacteria in the colon. These infections may become difficult to treat, as it is not possible to obtain urine cultures completely devoid of fecal material, thus making it hard to identify pathogenic organisms.

This page intentionally left blank

Chapter 105

Ileal Orthotopic Bladder Substitution

URS E. STUDER AND FIONA C. BURKHARD

In this chapter we describe the surgical technique to construct an ileal orthotopic bladder substitute combined with an afferent tubular segment. This orthotopic bladder substitute is a low pressure, high compliance reservoir which achieves continence and preserves renal function while keeping a low risk of fluid and electrolyte imbalances. The length of ileum resected is relatively short and since both the terminal ileum and ileocecal valve are left in situ, the risk of malabsorption and diarrhea is minimized.

A low pressure system is created because the reservoir is constructed form double folded ileum which is transected along its antimesenteric border resulting in bowel wall contractions that are asynchronous and uncoordinated. Because the reservoir is spherical, maximum capacity and the lowest possible pressure for the given surface of bowel is achieved. As illustrated by Laplace's law (pressure = tension/radius), intraluminal pressure is low for a given tension since conversion of a tubular structure into a spherical reservoir increases the radius. Furthermore, the spherical shape obtains maximal capacity while the surface/volume ratio limits the reabsorbing surface and therefore minimizes associated metabolic issues.

The 14-16 cm afferent tubular limb allows for the ureters to be resected at a safe oncological distance from the bladder and for removal of periureteral lymphatics which may harbor micrometastasis. In addition, by removing most of the ureter, ureteral ischemia is precluded and thereby subsequent stricture formation. Under normal physiological conditions, the segment's isoperistaltic contractions decrease the possibility of ureteral reflux and transmission of reservoir pressures into the renal pelvis. Also, in case of urethral recurrence or functional problems (incontinence, pelvic recurrence, inability to void, etc.), the afferent limb can easily be converted into an ileal conduit.

PATIENT SELECTION

As is true for all bladder substitutes, specific selection criteria must be fulfilled. The table contains contraindications for orthotopic ileal bladder substitutions. While a creatinine of 1.5mg/dl is considered the upper limit, some patients with significant creatinine elevations due to primary bladder cancer may recover sufficient function to allow for continent diversion once the obstruction is relieved. Placement of a percutaneous nephrostomy tube in these patients before surgery may provide a better idea of the true renal function. As with all bladder substitutes, the cancer operation must not be compromised by the orthotopic reconstruction (Table 105-1).

TABLE 105-1

CONTRAINDICATIONS FOR ORTHOTOPIC ILEAL BLADDER SUBSTITUTIONS ARE:

Urinary stress incontinence
A damaged rhabdosphincter or incompetent urethra
Impaired renal function (serum creatinine > 150 μmol/l)
Severely impaired liver function
Severe intestinal diseases (e.g., Crohn's disease, short bowel syndrome)
Tumor infiltration of the distal prostatic urethra in men or bladder neck in females
Unwillingness to be regularly followed postoperatively

Previous radiation therapy or chronologic age should not be considered absolute contraindications for continent urinary diversion. Even octogenarians do not necessarily have to be excluded but the time needed for postoperative recovery and for achieving urinary continence maybe longer than in younger patients. This could be explained by a relatively weaker rhabdosphincter muscle due to old age. The ileal orthotopic bladder substitute is also particularly well suited for patients in whom the sequelae of ileocecal resection must be avoided.

PREOPERATIVE PATIENT PREPARATION

Patients consume a regular diet until the evening of surgery at which point they then eat only a light meal. Bowel preparation consists of two enemas late in the afternoon before day of surgery. Antegrade rinses of the bowel and neomycin-erythromycin intestinal preparations are avoided. Such preparations can increase the risk of fluid inbalances. In the elderly patient, this can produce cardiovascular instability due to intravascular volume depletion as well potentially placing the patient in a catabolic state prior to surgery.

All patients receive perioperative and postoperative prophylactic antibiotics. Subcutaneous heparin is administered in the arm the evening before surgery and continued postoperatively. In addition, to prevent a deep venous thrombosis of the lower extremities or broncho-pneumonia, patients wear stockings and are taught appropriate exercises by a physical therapist.

OPERATIVE TECHNIQUE

Under general and epidural anesthesia, the later placed for postoperative pain control, the patient is placed in a dorsal Trendelenburg position with overextension of the pelvis for optimal operative exposure. On the sterile operative field, an 18 F urethral foley catheter is placed into the bladder. The surgical approach is through a lower midline incision. The technique of radical cystectomy with bilateral pelvic lymphadenectomy has been described elsewhere. For nerve-sparing cystectomy in the male, the nerve fibers in the dorsomedial pedicles lateral to the seminal vesicles as well as the paraprostatic neurovascular bundle have to be spared. The pelvic plexus can be preserved by sectioning the dorsomedial pedicle along its ventral aspect, anterolateral to the seminal vesicles, and terminating the dissection at the base of the prostate. A nerve-sparing prostatectomy must also be performed which requires a lateral approach with incision of the endopelvic and periprostatic fascia. The bunching of Santorini's plexus is done at the level of the prostate and not distal to it. The dorsolateral neurovascular bundle must be separated from the prostatic capsule. The prostatic apex needs to be approached laterally directly along the prostatic capsule, and the membranous urethra is delivered sharply out of the donut-shaped prostatic apex. It has been shown that nerve sparing radical cystectomy does have a positive impact on erectile function and urinary continence after ileal bladder substitute.

For nerve sparing in women the vaginal wall dissection at the cervical level is in the anteroventral plane of the vagina, that is, at the 2 or 10 o'clock position. An empty sponge-holding forceps in the vagina helps facilitate dissection along the whitish vaginal wall. It is important to remain in close contact with the whitish wall of the vagina thereby ensuring that the paravaginal venous plexus is hemostatically controlled before the dorsomedial bladder pedicle is transsected. The endopelvic fascia is disturbed as little as possible to minimize damage to the intrapelvic branch of the pudendal nerve, which also contributes to urethral innervation. In general, nerve sparing should be performed on the non–tumor-bearing side and extensive surgery on the tumor-bearing side.

Preparation of the Ileal Segment for the Bladder Substitute

The ileal bladder substitute is performed by isolating 55 cm of ileum, 25 cm proximal to the ileocecal valve (Fig. 105-1). The ileocecal valve and the most distal 25 cm of ileum are preserved so to reduce the associated risk of malabsorption and bile acid induced diarrhea**.** One hour prior to bladder substitute construction, administration of anesthetics via the epidural catheter is stopped. This prevents increased

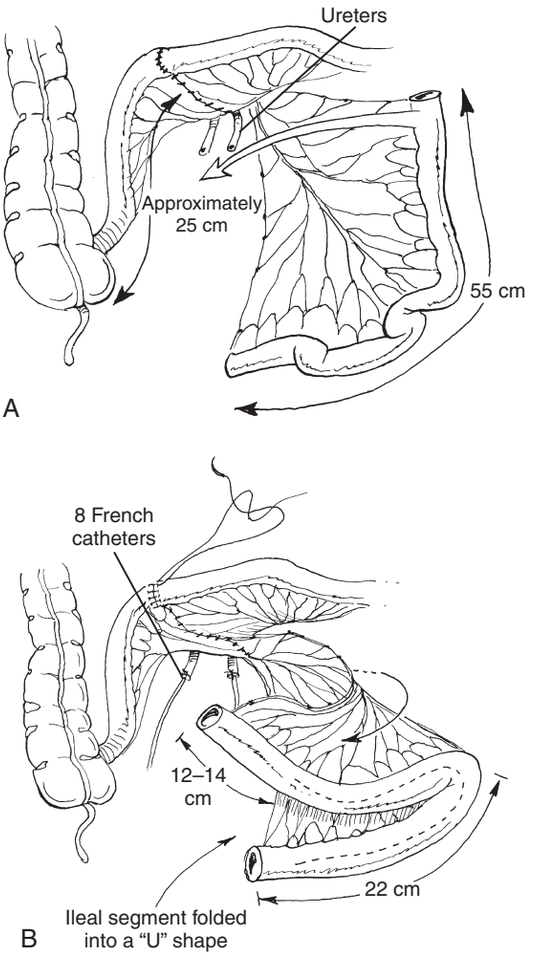

FIGURE 105-1.

muscle tone and activity which would result in an artificial shortening of bowel and thereby avoids removal of more bowel than is necessary for reservoir construction. The ileum used for the bladder substitute is measured with a 10 cm ruler along the mesoilium and without over stretching of the bowel.

The distal mesenteric division which is important for adequate mobility of the reservoir should extend deep into the mesentery. The proximal mesenteric division, however, is short and assures a broad vascular blood supply to the bladder substitute by at least two separate vascular arcades. Bowel continuity is re-established with a standard small bowel anastomosis performed end-to-end with a running (4-0 vicryl) suture through the seromuscular layers. The same technique is used to close both ends of the resected ileal segment. The mesenteric gap is then closed. The proximal part of the harvested ileum is left as a tubular shape to become the afferent segment. The distal 42-45 cm segment that will form the reservoir of the bladder substitute is opened with scissors along the antimesenteric line (Fig. 105-2).

Ureteroileal Anastomosis

The left ureter is mobilized up to the lower pole of the kidney together with the peri-ureteric tissue to maintain its surrounding blood supply and thereby prevent ischemia. It is then brought without tension to the right side of the abdomen retroperitoneally by crossing the aorta above the inferior mesenteric artery. If the ureters need to be resected close to the kidney (e.g., carcinoma in situ, compromised vascular supply, previous radiation history), a longer afferent ileal segment can be harvested to bridge the necessary distance.

The ureters are anastomosed, using the Nesbit technique, in an end-to-side fashion to the proximal isoperistaltic (nonincised) afferent tubular segment and are placed paramedial to the antimesenteric border (Fig. 105-3). To prevent bowel ischemia between the ureteral anastomosis, the right ureter is placed approximately 1 cm distal to the left ureter.

The ureteral ends are spatulated over a length of 1.5–2 cm. After placing a suture (4-0 polyglycolic acid) at each end of the spatulated ureter and ileal incision, the anastomosis is performed with running suture on either side (Fig. 105-3). To preclude a fistula resulting from ureteral mucosal prolapse

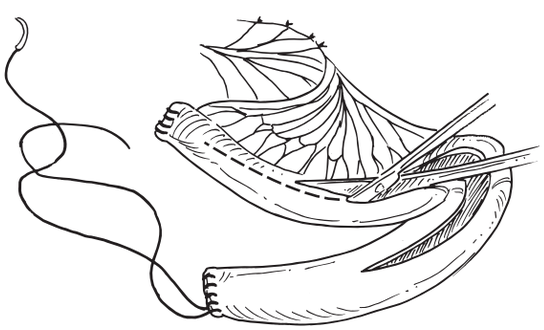

FIGURE 105-2.

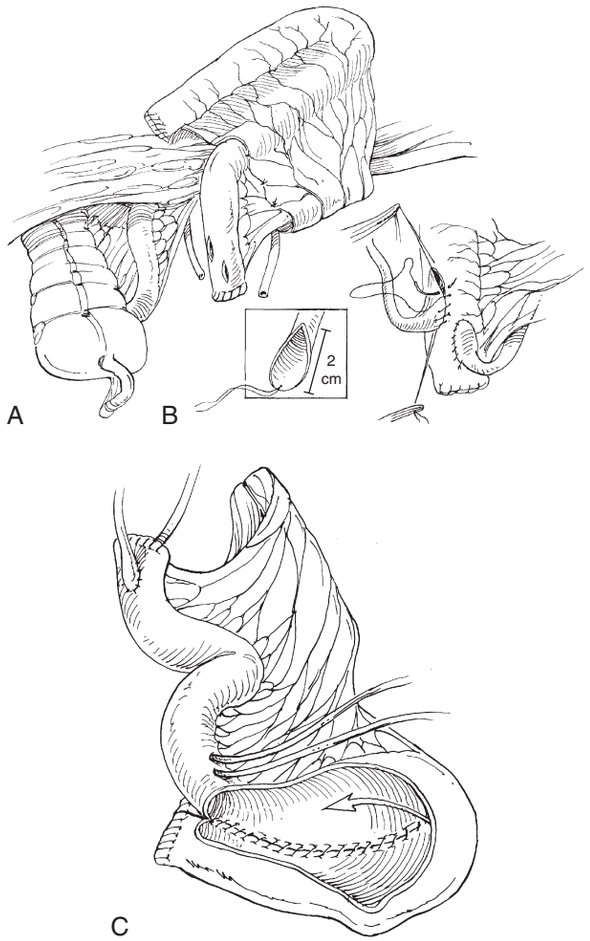

FIGURE 105-3.

and to establish a watertight anastomosis, care should be taken to have the ureteral wall lie between the mucosa and seromuscularis of the bowel. This is accomplished by starting each anastomsis on the ureteral wall. At the proximal angle, with running 4.0 Vicryl suture, a minimal amount of ureteral wall tissue is anastomosed to the seromuscular layer of bowel so as to prevent narrowing of the ureter. Gradually the amount of ureteral wall tissue incorporated increases in order to secure the anastomosis.

Prior to anastomotic completion, each ureter is stented with an 8 Fr ureteral catheter which is secured with 5.0 Rapid Vicryl through the wall of the ureter and stent. It is loosely tied so as to prevent ischemia. Tension on the anastomosis is reduced with three interrupted sutures placed between the distal peri-ureteral tissue and the ileal afferent tubular segment. By doing so, the peri-ureteral tissue also covers the suture line. The stents are then passed through the distal tubular wall where their exit sites are covered with mesenteric fat so as to prevent urine leakage when they are removed (Fig. 105-3C).

Bladder Substitute Construction

The previously opened portion of the ileal segment is folded into a U shape and the two medial borders are sewn together at the seromuscular layers with running 2.0 Vicryl suture (Fig. 105-3C). The tip of the U is crossfolded towards the

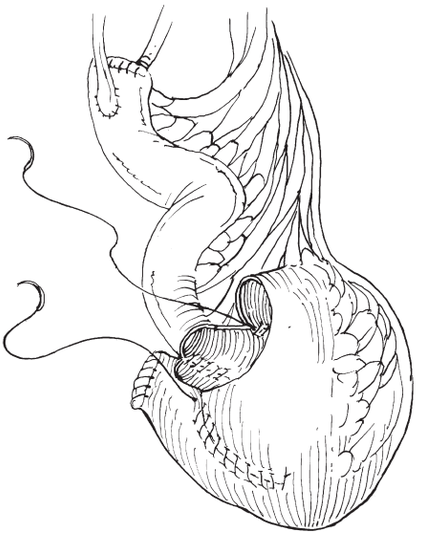

FIGURE 105-4.

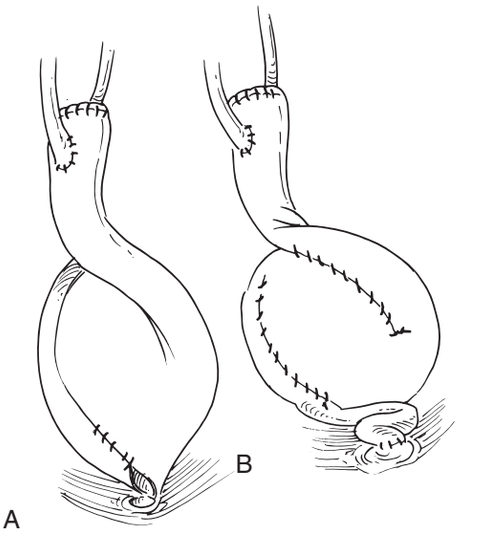

FIGURE 105-6. A, Use of the funneled end of the reservoir for the anastomosis should be avoided. **B,** Kinking and obstruction can occur when the reservoir fills if there is too much redundancy because of a funneled anastomosis.

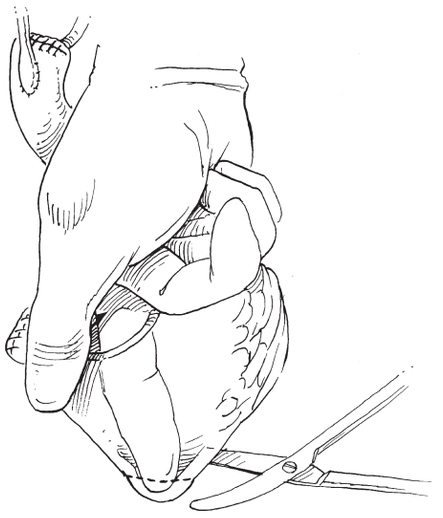

FIGURE 105-5.

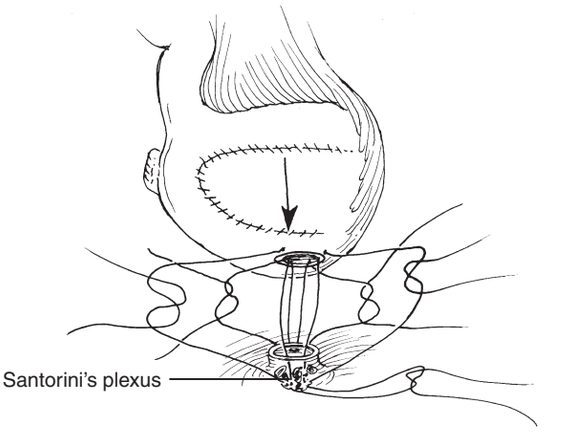

FIGURE 105-7.

opposite side (Fig. 105-4). This creates a low pressure spherical reservoir with an initial capacity of approximately 120 ml. Prior to reservoir closure, the surgeon's forefinger is introduced to determine its most dependant portion and a 1 cm diameter hole is excised from the wall as shown in (Fig. 105-5). Importantly, although it may appear easier to perform, it is imperative that the anastomosis of the urethra to the bladder substitute is not to the funnel shaped end of the reservoir. This error would increase the risk of kinking and obstruction at the anastomosic site when the reservoir is full (Fig. 105-6). To obtain optimal voiding, the anastomosis should sit broadly on the pelvic floor.

After placement of a silicone 18 Fr foley urethral catheter, six 2.0 vicryl sutures anastomose the previously made hole in the bladder substitute with the urethra (Fig. 105-7). When placing these sutures, the needle incorporates only 3–4 mm of the sphincter but exits at the mucosal edge of the membranous urethra, thereby bringing the two mucosal edges close together and maximizing urethral length as well as reducing the incidence of anastomotic strictures. Two posterior sutures are passed through Denonvillier's fascia and medial to the neurovascular bundles, two laterally to them through the lateral portion of the urethra and two anteriorly taking only a little of the urethra but also through the ligated Santorini's plexus. Sutures are loosely tied to prevent cutting, ischemia, shortening of the membranous urethra, or stenosis. Before complete closure of the reservoir, a cystostomy tube is passed through the bladder substitute wall and its exit site is covered with mesenteric fat (Fig. 105-8).

Postoperative Care

Ureteral stents are removed 5–7 days post surgery. If at 8–10 days postoperatively after a pouchography documents no evidence of urinary leakage, the cystostomy tube is removed. The foley catheter remains for additional 2 days to provide

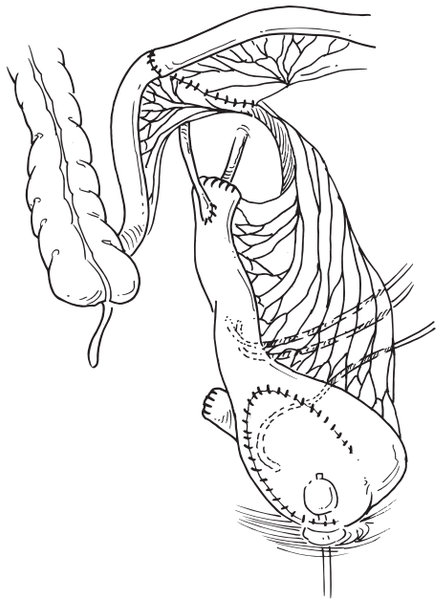

FIGURE 105-8.

adequate time for closure of the cystostomy tube exit site. Although our patients are on antibiotics, all drains are removed as early as possible to prevent infections. After all drains are removed, any bacteriuria is treated with antibiotics until the urine is sterile.

Jagenburg et al. reported that the iso-osmolality between urine in the reservoir and serum was established within two to six hours. This explains why, initially, when the urine is hypo-osmolar, the bladder substitute will secrete sodium chloride resulting in a salt loosing syndrome, hypovolemia, and metabolic acidosis. To prevent this metabolic cascade, patients are instructed to increase salt intake (pretzels, chips, etc.), namely because they are also encouraged to consume 2–3 liters of fluids a day to prevent a metabolic acidosis resulting from highly concentrated acidotic urine. Our patients are carefully followed with regular assessments of venous blood gasses and body weight. Base excess should be +2. With time, the villi will atrophy and this syndrome will become less pronounced.

Patients are carefully instructed on how to void. Initially, they are taught to empty the bladder substitute every 2 h during the daytime in a sitting position by relaxing the pelvic floor and if necessary by also increasing the intra-abdominal pressure. At night, they are encouraged to use an alarm clock to void every 3 hours. Patients without metabolic acidosis (base excess +2) or those managed with oral sodium bicarbonate are instructed to retain urine thereafter for 3h and later for 4 h in order to obtain a bladder capacity of up to 500 ml. During this exercise, increased bladder substitute pressures may cause incontinence, but the elevated pressures are required to increase the reservoir's capacity. Therefore, patients are advised not to void when they experience such incontinence. It is essential to increase the capacity to approximately 500 cc in order to have low end fill pressures to ensure urinary continence. Reservoirs with larger diameters have increased wall tension for any given intra-reservoir pressure compared to smaller reservoirs. Thus it is more likely to get the sensation of fullness when the end-fill pressure is achieved.

With increasing capacity, night time continence will improve but on the other hand, a bladder substitute capacity of greater than 500 ml should be prevented. Over distension of the reservoir will result in a floppy pouch unable to adequately empty, increased residual urine, and the potential for urinary retention. Residual urine should be monitored, recognized early, and promptly managed. The most common reasons for residual urine are protrusion of ileobladder mucosa into the urethra and urethral anastomotic strictures. Both of these can be managed endoscopically. Twenty percent of our male patients required such interventions within the first 10 years postoperatively, however 94% of these patients were still able to void spontaneously after 10 years. Permanent indwelling catheters and intermittent straight catherizations are not adequate therapies and are reserved only for patients for personal preferences or for nursing purposes.

Bacteriuria must be appropriately treated. Infected urine can cause reservoir instability with subsequent urinary incontinence as well as increased mucous production which can lead to increased postvoid residuals and even urinary retention.

Critical components to good long term results requires not only surgical finesse but also patient compliance and meticulous postoperative care. Our patients are followed regularly at every 6 months for 5 years and then at yearly intervals.

COMPLICATIONS

We recently published our twenty years experience with the ileal bladder substitute. In our experience, early diversion related complications (within 30 days) occurred in 13% of patients. Pyelonephritis was the predominant complication noted (6.0 %). Diversion related late complications (greater than 30 days) requiring re-hospitalization were metabolic acidosis, pyelonephritis, and sepsis in 4%, 4%, and 2%, respectively, and urinary retention due to infection and consequent mucus production in 4.5%. Typical late complications requiring surgery were bladder substitute outlet obstruction and incisional or inguinal hernias in 10%.

EXPERIENCE WITH THE TECHNIQUE

After 25 years experience and a median follow up of 40 months in > 700 patients, our results are encouraging. In this series, 93% could void spontaneously at the last visit, and 90% had daytime and 78% night-time continence with 3 to 4 hour voiding intervals. However, 20% of patients living longer than 10 years required at least one trans-urethral procedure secondary to increased post void residual urine. The remaining 7% were on intermittent self-catheterization or had an indwelling catheter for nursing home reasons. In addition to performing the above detailed surgical technique, success with this method of substitution demands active postoperative management and regular follow-up.

Suggested Readings

Jagenburg R, Kock NG, Norlén L., et al: Clinical significance of changes in composition of urine during collection and storage in continent ileum reservoir urinary divrsion. Scan J urol Nephrol (suppl) 49:43-48, 1978.

Kessler TM, Burkhard FC, Perimenis P, Danuser H, Thalmann GN, Hochreiter WW, Studer UE. Attempted nerve sparing surgery and age have a significant effect on urinary continence and erectile function after radical cystoprostatectomy and ileal orthotopic bladder substitution. J Urol. 2004 Oct;172(4 Pt 1):1323-7.

Mills RD, Studer UE. Metabolic consequences of continent urinary diversion. J Urol. 1999 Apr;161(4):1057-66.

Mills RD, Turner WH, Fleischmann A, Markwalder R, Thalmann GN, Studer UE.: Pelvic lymph node metastases from bladder cancer: Outcome in 83 patients after radical cystectomy and pelvic lymphadenectomy. J Urol 166:19–23, 2001.

Turner WH, Danuser H, Moehrle K, Studer UE. The effect of nerve sparing cystectomy technique on postoperative continence after orthotopic bladder substitution. J Urol. 1997 Dec;158(6):2118-22.

Section XVIII

BLADDER AUGMENTATION

This page intentionally left blank

Chapter 106

Ileocystoplasty

JOHN W. BROCK III

The ileum remains the preferred segment for augmentation. One must take into account several factors when using a bowel segment in the urinary tract. First, the patient must have reasonable renal function as there will be urinary absorption from the bowel segment. Second, in disease processes such as cloacal exstrophy, one must ascertain the amount of small bowel the patient has in order not to exacerbate a situation of short-gut syndrome. Finally, it is imperative to preserve the terminal ileum to preserve B_{12} and effective bile salt reuptake.

The decision to perform an ileal augment is a multifold one. It is important that the patient and family understand that in almost all instances the patient will have to catheterize to empty. A noncompliant patient with an augment can lead to a disastrous situation with rupture and resultant complications such as death. The preoperative education that is necessary to ensure compliance is extensive. The decision to proceed with augmentation is based on multiple findings and factors. Videourodynamics provides the hard data necessary to understand bladder function capacity, compliance, and outlet resistance. From these data one can determine not only need for augmentation but also necessity for increasing outlet resistance to provide continence.

After the decision is made to proceed with augmentation, the patient and family must be informed about several factors that they face in the postoperative period. There will be mucus problems that will require irrigation. They need to understand that noncatheterization on a regular basis may result in rupture of the augment with potential serious complications of peritonitis and possibly death. Finally there is clearly an increased risk of malignancy and the patient must be counseled as to the necessity of the surveillance and the possibility of this occurring in the future.

ILEOCYSTOPLASTY

Position: Supine.

An incision is made in the midline or an extended Pfannenstiel fashion (Fig. 106-1A). The patient is placed in the Trendelenburg position and the peritoneum opened and the bowel packed off into the upper abdomen using a Bookwalter retractor. At this point the bladder is opened in a fashion to allow placement of a continent catheterizable channel if one so desires. Usually this is done by making an inverted U-shaped incision on the bladder. After this the ureters are reimplanted in the bladder if necessary and the bladder neck is tightened by one of multiple methods if this is required. The continent catheterizable channel is placed as well if this is being employed.

Following the prep of the bladder as noted above, a 20- to 25-cm segment of ileum is chosen at least 20 cm from the ileocecal valve. The mesentery is then taken down and the segment to be utilized is isolated either with a GIA stapler or with Kocher clamps. The GI integrity is reestablished and the mesenteric trap closed. The segment for augmentation is then irrigated copiously with saline with 1 amp of GU irrigant per 500 mL. After this, the segment is completely opened on the antimesenteric border using the cutting current of the cautery (see Fig. 106-1B).

The mucosal edges of the cup of ileum are then anastomosed using a 3-0 polydioxanone suture (PDS) (Fig. 106-2). This is done by a single full thickness layer using a technique of locking every third suture. After the suture line is completed, the entire bowel segment is enfolded on itself and a cup is again created with a running, locking 3-0 PDS suture (Fig. 106-3). After this is completed, one is now ready to suture the bowel cup to the open bladder.

Before completing the anastomosis of the bowel to the bladder, a determination of use of tubes must be made. If one has performed reimplant of the ureters, ureteral catheters may be used and brought out through the bladder wall and skin (Figs. 106-4 and 106-5). Furthermore, depending on the necessity of bladder neck reconstruction or placement of a continent catheterizable channel, one may have catheters in each of these segments. Finally a suprapubic tube is brought out through the augment and then the lower abdominal wall. This must be of adequate caliber and completely nonlatex to allow proper drainage.

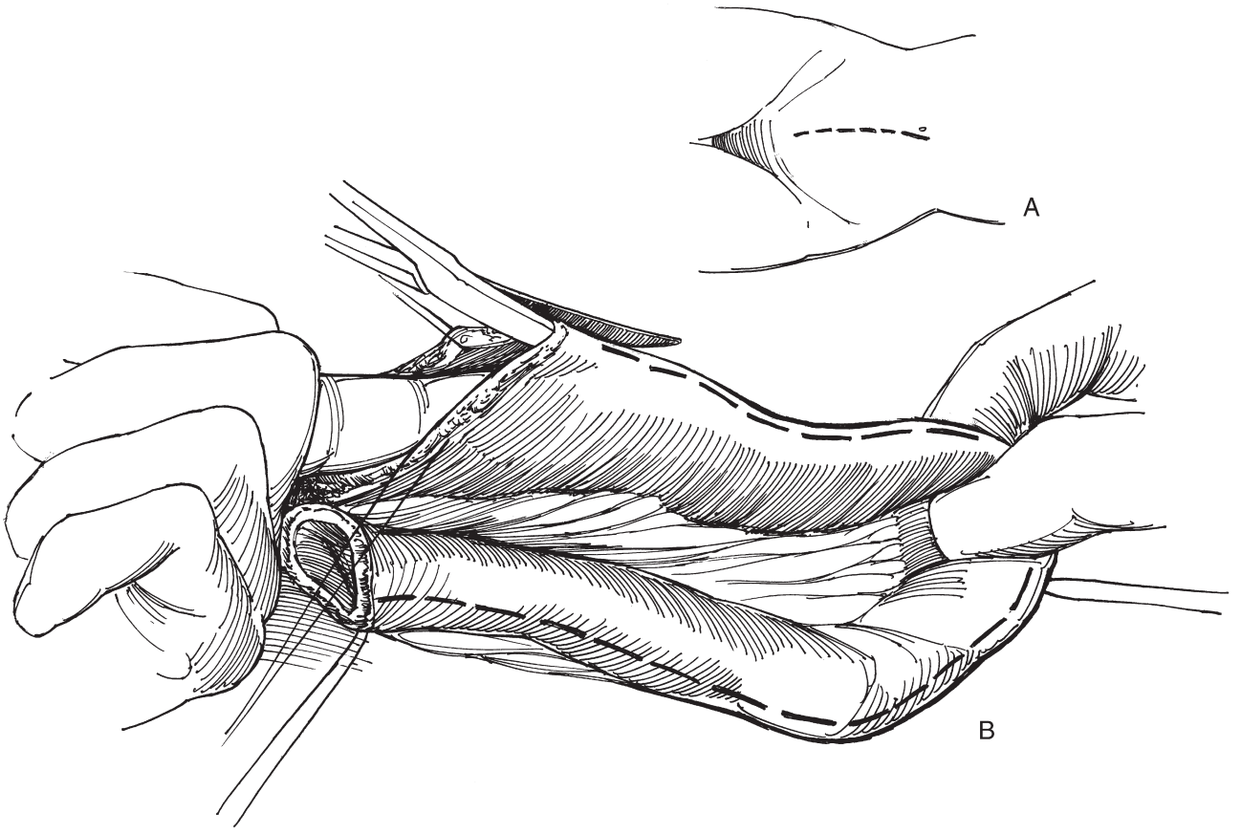

FIGURE 106-1.

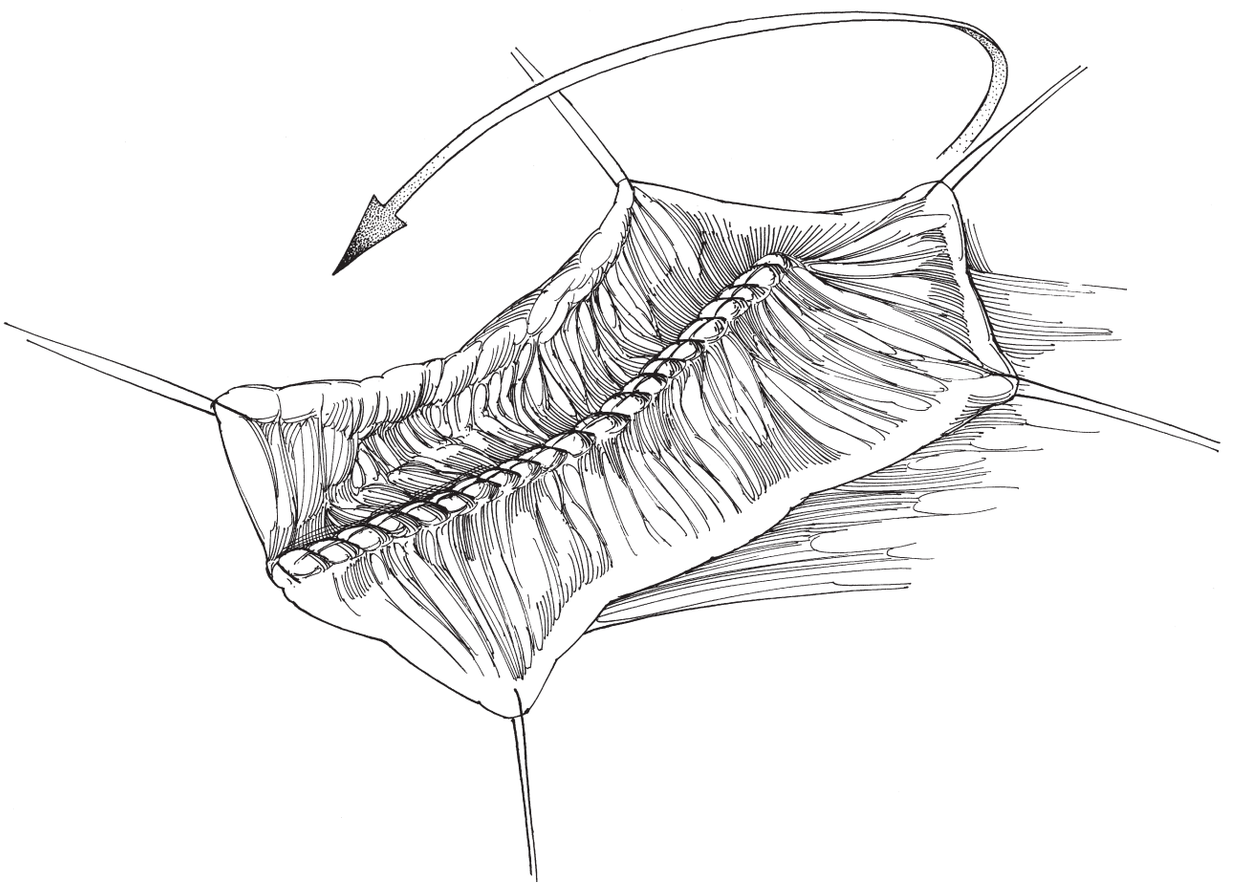

FIGURE 106-2.

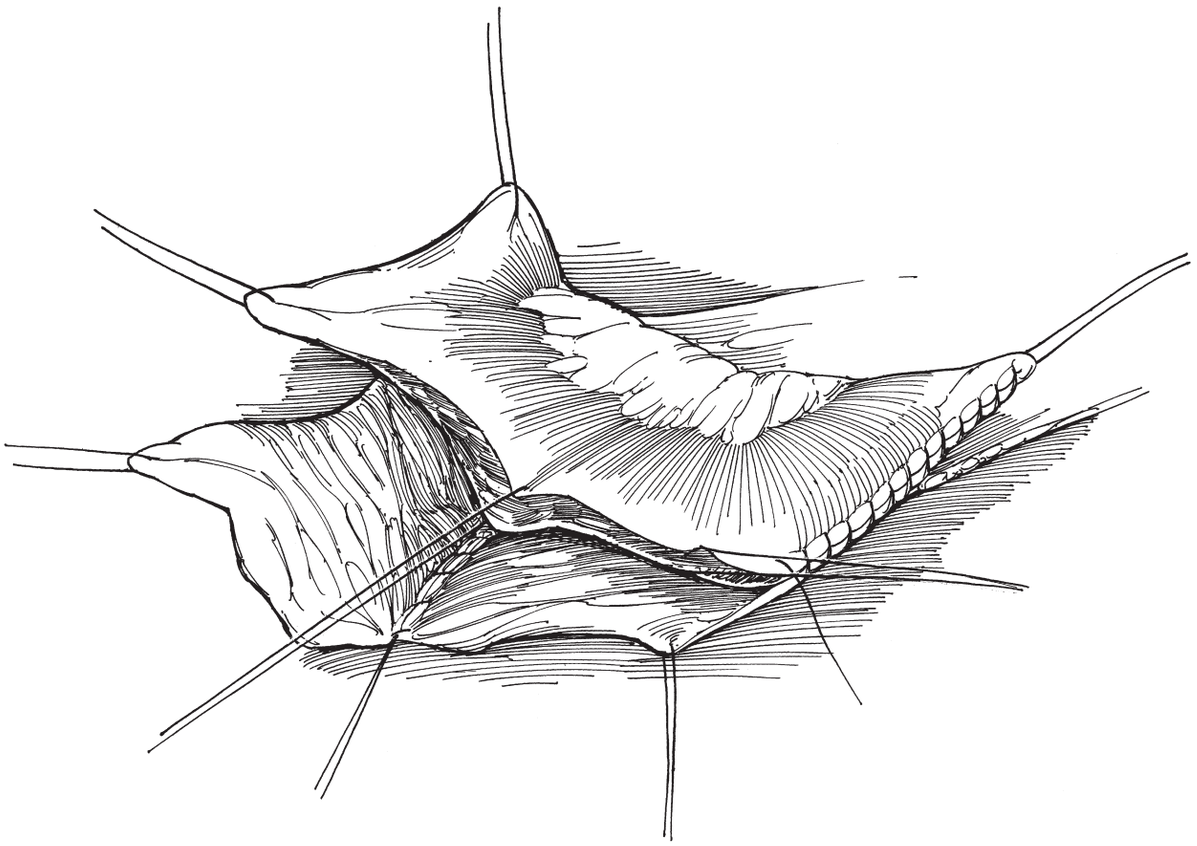

FIGURE 106-3.

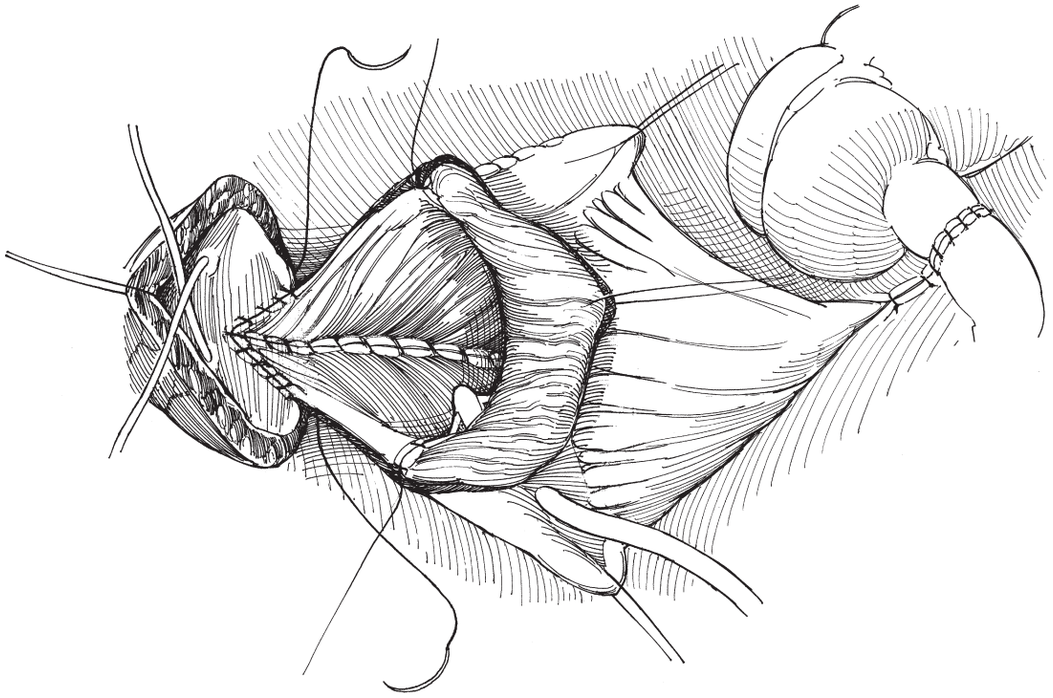

FIGURE 106-4.

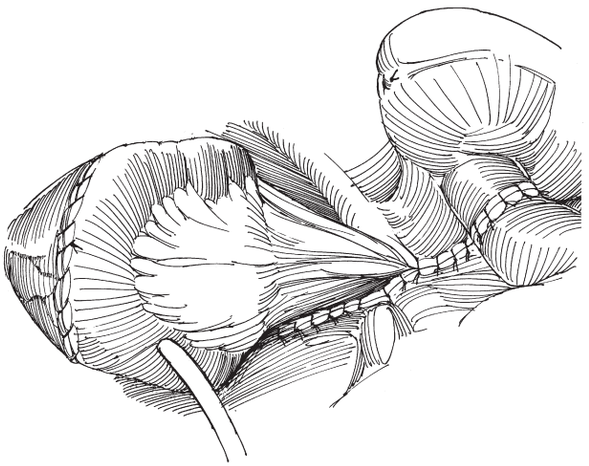

FIGURE 106-5.

POSTOPERATIVE CARE

Postoperatively the patient will be hospitalized for 5 to 7 days. Antibiotics are used for 3 to 5 days. The suprapubic tube is irrigated daily to prevent mucus accumulation. A perivesical drain is left in place and removed at 3 to 5 days postoperatively if there is no drainage. The patient is then discharged with the suprapubic tube in place. This is left in for approximately 3 weeks. A cystogram is obtained prior to removal of the suprapubic tube.

Suggested Readings

Adams MC, Joseph DB. (2007). Urinary tract reconstruction in children. In Wein AJ, Kavoussi LR, Novick AC, et al, eds. Campbell-Walsh urology, vol 4, 9th ed. Philadelphia: Saunders, Elsevier; 3675-3677.

Snyder HMcC III. (1987). Principles of pediatric urinary reconstruction: a synthesis. In Gillenwater J, Grayhack J, Howards S, et al, eds. Adult and pediatric urology, vol 2. Chicago: Yearbook Medical Publishing; 1738-1739.

Yerkes E, Metcalf P, Rink RC. Incontinent and continent urinary diversion. In Grosfeld J, O'Neill J, Fonkalsrud E, et al, eds. Pediatric surgery, vol 2, 6th ed. Philadelphia: Mosby, Elsevier; 1796-1797.

Commentary by

DAVID B. JOSEPH

The need for bladder augmentation has decreased with aggressive proactive medical management using intermittent catheterization and pharmacotherapy. However, refractory bladder hostility may persist and require reconstructive measures. While much has been written regarding augmentation cystoplasty, there is little evidence-based data to support one intestinal segment as superior to another. When considering all variables including metabolic issues, production of mucus, compliance, and proximity to the bladder, ileum is a logical first choice. The most critical aspect of any augmentation is the recognition, of the need to perform intermittent catheterization, particularly in the neurogenic population. It is mandatory that families and patients understand the importance of catheterization and have incorporated the technique into their preoperative routine.

The technique of ileal augmentation has been eloquently described. Reconfiguring the ileal segment into a cup maximizes the final volume of the reservoir, improves the compliance, and dampens any inherent peristaltic activity of the augment. More important than the location and direction of the cystotomy is the need to achieve the widest possible opening preventing an hourglass configuration that can occur due to contraction along the anastomotic line between bowel and bladder. Based on personal preference only, I typically create a cystotomy that begins just proximal to the bladder neck and extends posteriorly to the interureteric ridge above the native ureteral orifice or the position of the reimplanted ureters. The ileal segment is opened along the antimesenteric border asymmetrically creating a short and long limb of bowel in relation to the mesentery. The shorter limb of bowel is folded into the U and secured to the posterior bladder floor. The longer anterior segment is brought to the apex of the cystotomy and the anastomosis to the bladder is completed. The asymmetry of the limbs allows a little greater mobility for the ileum to reach the bladder apex and positions the mesenteric pedicle deeper within the pelvis with less tension. After the augment is secured to the bladder, the lateral edges of the ileal segment are closed completing the cup. Placing the segment on the bladder prior to creating a cup allows the bladder to dictate the diameter of the anastomosis. The suprapubic tube is placed through the thickened muscle of the bladder thinking that a more rapid seal of the cystotomy will occur postoperatively after removal of the tube. The augmentation is checked for leaks and spot closure is undertaken if needed. The suprapubic tube acts as a pelvic drain and no other drains are used.

Postoperative daily irrigation of mucus is strongly recommended in order to decrease long term bladder stone formation. Metabolic assessment is obtained on a routine basis and evaluation of B_{12} deficiency begins 3 to 5 years after augmentation. Cystoscopic surveillance for bladder tumors is initiated 10 years following augmentation cystoplasty.

Chapter 107

Colocystoplasty

MARK C. ADAMS

Sigmoid cystoplasty has been a cornerstone of experience with bladder augmentation since being described by Lemoine in 1912. The sigmoid colon's proximity to the bladder and reliable blood supply have made it an attractive option for cystoplasty. A suitable segment can be used with minimal, if any, effect on native bowel function. Use of sigmoid colon does not influence vitamin B metabolism as potentially does the use of ileum, and it is the technique least likely to result in chronic diarrhea of all conventional forms of cystoplasty. Good results can be anticipated when an adequate sized segment is used, reconfigured, and anastomosed to bladder appropriately. Nonetheless, potential morbidity does exist from colocystoplasty and should be familiar to urologists interested in reconstructive surgery.

TECHNIQUE

After thorough preoperative evaluation, the patient should undergo effective mechanical bowel preparation. Urine culture should document the absence of infection before surgery. Exposure is generally achieved by lower midline abdominal incision, although some patients may be a candidate for sigmoid cystoplasty through a lower transverse incision.

The sigmoid colon has greater circumference than ileum, and a shorter segment is usually used for cystoplasty. The length of segment chosen should somewhat be determined by the size of the native bladder and the additional volume needed. In general, a 15- to 20-cm segment is used, but the surgeon should use a larger rather than smaller segment. To choose the particular segment, the colonic mesentery should be transilluminated to identify an adequate blood supply based on branches of the inferior mesenteric artery. Likewise, the surgeon should inspect the mobility of the potential segment to ensure that it will reach the bladder without tension, although such an issue is not usually a problem when using sigmoid colon (Fig. 107-1A). Windows in the mesentery at either end of the intended segment are created with the mesenteric border of the bowel cleared of mesentery for 2 cm at each of those positions. The colon is incised at each end between atraumatic bowel clamps after the abdominal cavity is packed with moist sponges to prevent contamination. Colocolostomy using either a two-layer hand-sewn anastomosis or stapled side-to-side (functional end-to-end) anastomosis based on surgeon preference is performed lateral to the isolated segment. The isolated segment is then incised for its entire length along the antimesenteric border using the electrosurgical cautery and rinsed clear.

Since Hinman and Koff's descriptions, it has been clear that there are advantages to effective reconfiguration of any bowel segment used in cystoplasty. Such manipulation maximizes the volume achieved using a given surface area of bowel and blunts effective pressure contractions inherent in any intact gastrointestinal segment. Colon certainly has powerful unit contractions that may be problematic if persistent. Mitchell suggested that the two open ends of the sigmoid segment could be oversewn when the antimesenteric border was incised and that the resultant patch fit nicely on a bivalved bladder (see Fig. 107-1B); however, most surgeons have chosen to fold the open segment in a U-shape similar to that described for ileocystoplasty to more effectively reconfigure the colonic patch (see Fig. 107-1C). Longer segments may occasionally be folded in an S-shape. Once folded, the common limbs of bowel wall are sewn together using absorbable suture. This is easily done in a single full-thickness layer from within the luminal side using a running locked suture. Each purchase of bowel wall should contain more of the seromuscular layer than mucosa to ensure that the mucosa is inverted in the lumen. The native bladder is usually incised longitudinally or bivalved from a point just short of the bladder neck anteriorly to within centimeters of the interureteric ridge posteriorly. It is critical that a wide anastomosis of bowel patch to bladder be achieved, and a second transverse incision into the bladder near the dome can be performed when necessary to increase the area of anastomosis. The reconfigured colonic patch is mobilized to the open bladder and, at times, rotated 90 degrees in order to better fit onto the bladder without tension. Watertight approximation of the colonic segment to bladder is performed again using absorbable suture in one or two running layers, taking care to invert the mucosa of both bowel and bladder (Fig. 107-2).

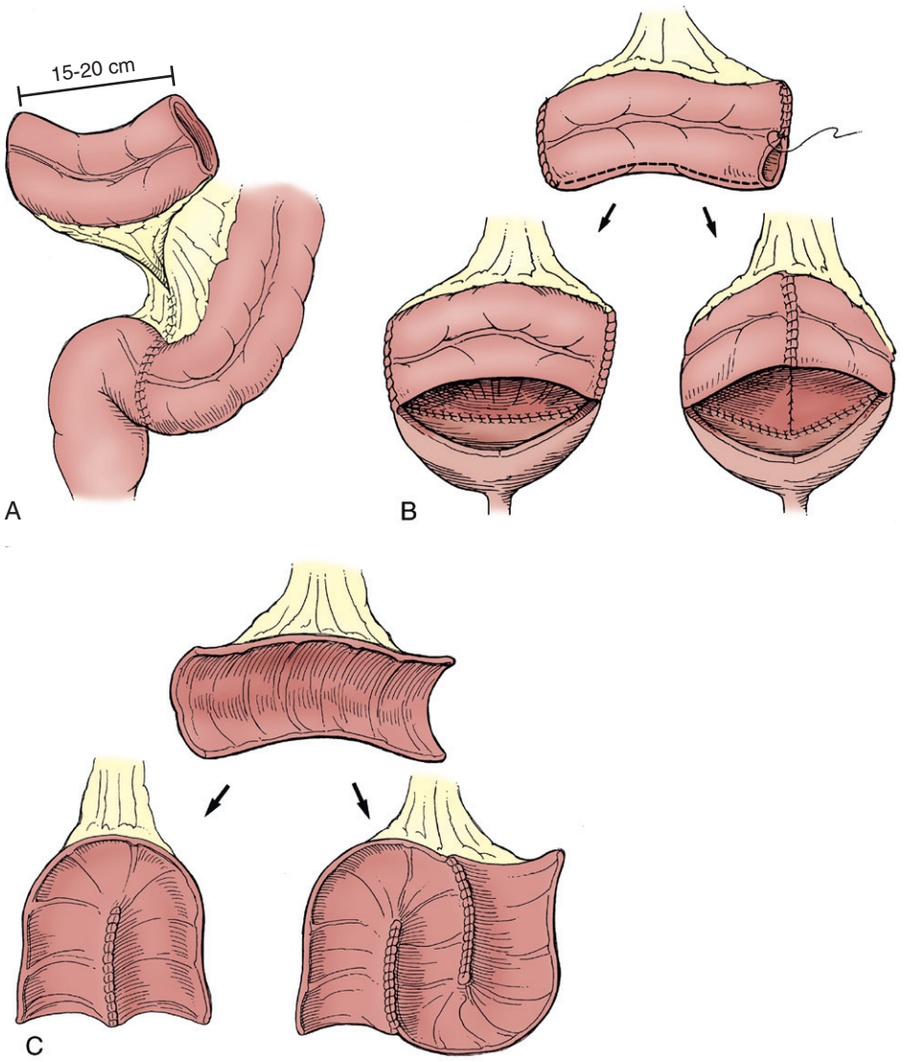

FIGURE 107-1. A, A 15- to 20-cm segment of sigmoid colon is chosen and isolated after careful inspection of the mesentery for blood supply and mobility. Colocolostomy is performed lateral to the isolated segment. **B,** Mitchell[4] described closure of the ends of the segment after complete incision along the mesenteric border. The segment may occasionally better fit the bladder when rotated 90 degrees. **C,** More effective reconfiguration may be achieved by folding the open colonic segment in a U- or S-shape. *(From Wein AJ, et al. [eds]. [2012]. Campbell-Walsh urology, 10th ed. Philadelphia, Saunders.)*

A large caliber suprapubic cystostomy tube is left in place and usually brought out of the bladder through the native bladder wall. It is left in place for approximately 3 weeks to keep the bladder decompressed during healing. Cystography is performed at that point to document healing and the absence of any leakage. The tube can be removed once intermittent clean catheterization (ICC) is performed on a regular and reliable basis. Most patients requiring cystoplasty will perform ICC long-term to empty and should be ready and capable to do so before any consideration of cystoplasty. Nasogastric suction is usually used for the first few days after sigmoid cystoplasty until bowel motility resumes.

Seromuscular colocystoplasty lined with urothelium (SCLU) has been performed in relatively small series in an effort to avoid some morbidity of conventional sigmoid cystoplasty. A segment of sigmoid similar to that described earlier is isolated in an identical fashion, although the colonic mucosa is then sharply excised. Care should be taken to completely excise the mucosa to prevent colonic mucosal regrowth while preserving the submucosa. Preservation of the submucosa may be important to avoid contracture of the intestinal segment. The demucosalized sigmoid segment is reconfigured and approximated to bladder muscle. Preparation of the bladder, however, is entirely different (Fig. 107-3). The bladder muscle of the dome is excised to a position just short of the level of the interureteric ridge circumferentially while the bladder mucosa is preserved. The seromuscular sigmoid patch is then applied over the bulging mucosa and approximated to the bladder muscle.



FIGURE 107-2. The reconfigured sigmoid patch is approximated to the widely opened bladder using absorbable suture. Here, the closure is done in two layers, taking care to invert both bladder and bowel mucosa.

RESULTS

Augmentation cystoplasty using an intestinal segment is not a perfect substitute for native bladder and carries potential morbidity. Effect on native bowel function after sigmoid cystoplasty is minimal. Bowel obstruction should be rare and no different in risk when compared with any major intraabdominal procedure. Potential complications, such as acidosis, systemic growth delay, infection, and bladder stone disease appear similar in incidence and severity whether colon or ileum are used for augmentation. Similarly, no difference in the risk of tumor formation has yet been noted for the two different segments.

The major goal of augmentation cystoplasty is to provide a compliant reservoir of adequate capacity. Review of at least one very large series of pediatric patients undergoing augmentation cystoplasty at Indiana University has suggested that more patients after colocystoplasty demonstrate significant uninhibited pressure contractions post-operatively and require secondary reaugmentation than do patients after ileocystoplasty. Most patients in that series did not undergo complete reconfiguration at the sigmoid segment with folding. It is possible that such reconfiguration may have improved the results, particularly when considering that other large series of patients have not shown inferior results when using sigmoid colon. Certainly, no prospective

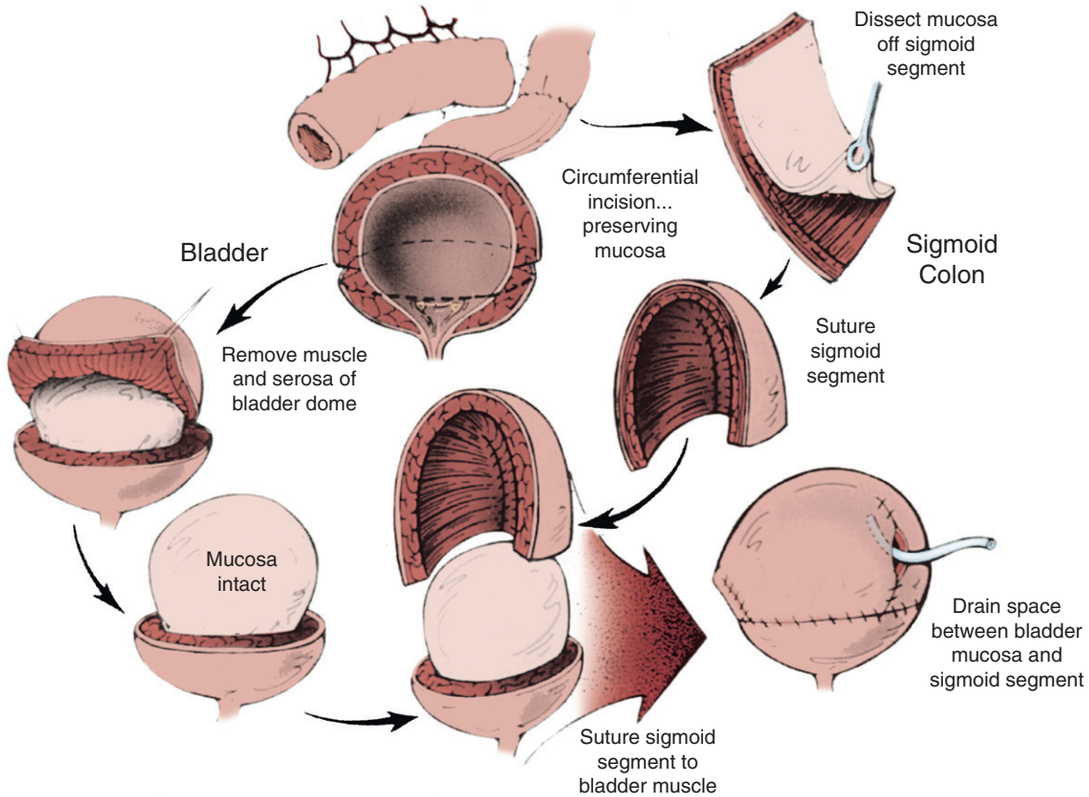

FIGURE 107-3. Seromuscular cystoplasty with urothelial lining (SCLU). Muscle of the bladder dome is excised and mucosa left intact. The sigmoid segment is reconfigured after sharp excision of colonic mucosa and then sutured to bladder muscle over the transitional cell lining. *(From Buson H, Manivel JC, Dayanc M, et al. [1994]. Seromuscular colocystoplasty lined with urothelium: experimental study. Urology 44:745.)*

study using identically sized segments with identical technique has been performed to truly show a difference in compliance between the two segments. Failure due to persistent pressure after cystoplasty should not much exceed a rate of 5%.

Delayed spontaneous perforation of the augmented bladder is a significant failure of an intestinal segment as a urinary reservoir and can result in patient death. The experience at Indiana University again suggests that sigmoid colon has had a four-time higher rate of perforation than has ileum in a pediatric patient population largely consisting of children with spina bifida. Other series have not shown colon to be at higher risk and have even noted a higher incidence when using ileum. It is not clear that any segment is consistently associated with a higher risk for this catastrophic complication.

Early results with seromuscular colocystoplasty lined with urothelium have been good but not necessarily equivalent to standard sigmoid cystoplasty. Failures due to persistent pressure requiring secondary ileocystoplasty have occurred. Endoscopic biopsy done postoperatively has shown both islands of colonic mucosa and complete intestinal mucosal regrowth in some patients. Although Denes and colleagues have shown that the persistent transitional lining will protect from metabolic problems and mucus production, regrowth of intestinal mucosa would make the added surgical time and blood loss associated with this technique prohibitive.

CONCLUSIONS

Experience with sigmoid cystoplasty has shown that it deserves its role in bladder reconstruction. The sigmoid colon is readily available for use with little effect on native bowel function. An adequate sized segment can usually be isolated and reach the bladder without tension. The segment used should be fully reconfigured to achieve optimal results. When used properly in well-selected patients, good results can be expected. As with all gastrointestinal segments used for cystoplasty, potential morbidity and complications do occur and should be familiar to the reconstructive surgeon. More critical analysis may determine whether sigmoid colon is as compliant as ileum when used for cystoplasty or carries any greater risk for delayed spontaneous perforation. The appropriate role of seromuscular colocystoplasty with intact urothelium is yet to be defined.

Commentary by

DAVID B. JOSEPH

Using sigmoid colon is enticing due to its close proximity to the bladder and redundancy, particularly encountered in patients with neurogenic disorders. However, I reserve the use of colon for patients in whom ileum may be contraindicated or those patients with a short, thick ileal mesentery that does not allow for a tension-free anastomosis. It is extremely important that the peristaltic activity of the colon is disrupted as described with either an "S" or "U" configuration creating a wide anastomosis to the native bladder. Mucus production can be problematic when using colon, particularly in the immediate post operative period; frequent irrigation is required. Transitory changes in bowel activity can occur with a return to baseline continence within several weeks, particularly if the patient has been given a catheterizable cecostomy channel to be used for bowel irrigation.

Suggested Readings

Bauer SB, Hendren WH, Kozakewich H, et al. (1992). Perforation of the augmented bladder. J Urol 148:699.

Chargi A, Charbonneau J, Gauthier G. (1967). Colocystoplasty for bladder enlargement and substitution: a study of late results in 31 cases. J Urol 97:849.

Denes ED, Vates TS, Freedman AL, Gonzalez R. (1997). Seromuscular colocystoplasty lined with urothelium protects dogs from acidosis during ammonium chloride loading. J Urol 158:1075.

Gonzalez R, Buson H, Reid C, Reinberg Y. (1994). Seromuscular colocystoplasty lined with urothelium: experience with 16 patients. Urology 45:124.

Hinman F Jr. (1988). Selection of intestinal segments for bladder substitution: physical and physiological characteristics. J Urol 139:519.

Hollensbe DW, Adams MC, Rink RC, et al. (1992). Comparison of different gastrointestinal segments for bladder augmentation. Presented at the American Urological Association Meeting, Washington, DC.

Koff SA. (1988). Guidelines to determine the size and shape of intestinal segments used for reconstruction. J Urol 140:1150.

Mitchell ME. (1986). Use of bowel in undiversion. Urol Clin North Am 13:349.

Pope JC 4th, Albers P, Rink RC, et al. (1999). Spontaneous rupture of the augmented bladder from silence to chaos. Presented at the European Society of Pediatric Urologists Meeting, Istanbul, Turkey.

Pope JC 4th, Keating MA, Casale AJ, Rink RC. (1998). Augmenting the augmented bladder: treatment of the contractile bowel segment. J Urol 160:854.

Shekarriz B, Upadhyay J, Demirbilek S, et al. (2000). Surgical complications of bladder augmentation: comparison between various enterocystoplasties in 133 patients. Urology 55:123.

Chapter 108

Ureterocystoplasty

JOHN POPE

Ureterocystoplasty is generally the procedure of choice for patients requiring bladder augmentation when a remarkably dilated ureter is present. This procedure clearly has advantages over the use of bowel for bladder augmentation, in that it is free of mucus and the problems of electrolyte absorption and subsequent metabolic abnormalities are avoided. In addition, bladder compliance and capacity can be restored with urothelial lined tissue, which also appears to work synergistically with the native bladder to allow more physiologic filling and emptying. It appears that children are more likely to void spontaneously after ureterocystoplasty than after intestinal cystoplasty, although postvoid residuals must be checked to ensure adequate emptying. The typical scenario for ureterocystoplasty is a patient with posterior urethral valves in whom the refluxing ureter is massively dilated, draining a poorly functioning or nonfunctioning kidney. Preoperatively, urodynamic evaluation of the bladder should be performed as for all patients requiring potential augmentation. In addition, adequate bowel preparation should be performed in case there is inadequate ureter available and the use of bowel becomes necessary at the time of surgery.

Incision: A single midline transperitoneal incision or a lower abdominal transverse (Pfannenstiel) incision should be used. This incision provides access to the intestine in case mobilization of the ureter for augmentation is unsatisfactory. Other authors have shown that ureterocystoplasty can be done through two incisions, remaining completely extraperitoneal. If the ipsilateral kidney is to be preserved as shown in Figure 108-1, only the lower portion of the ureter should be used for augmentation and a transureteroureterostomy should be used, using the proximal segment of ureter. Alternatively, the proximal ureter can be tapered and reimplanted into the native bladder. If the ipsilateral kidney is without function, it should be removed by dividing the renal vessels near the parenchyma and carefully dissecting the pelvis away while preserving as much of the ureteropelvic blood supply as possible. It is critical to conserve the ureteral blood supply along its entire length.

Dissect the ureter from the retroperitoneal tissues, keeping the segmental blood supply intact. All adventitia and periureteral tissue should be swept from the peritoneum toward the ureter during mobilization to protect the ureteral blood supply. Proximally, this blood supply typically arises medially. As the ureter enters the true pelvis, the blood supply arises posterior and laterally. It is important to remember that ureteral blood supply comes from numerous sources including the aorta, the iliac, vesical, and the gonadal vessels. If previous surgery has been done on the distal ureter, preserving the proximal blood supply is even

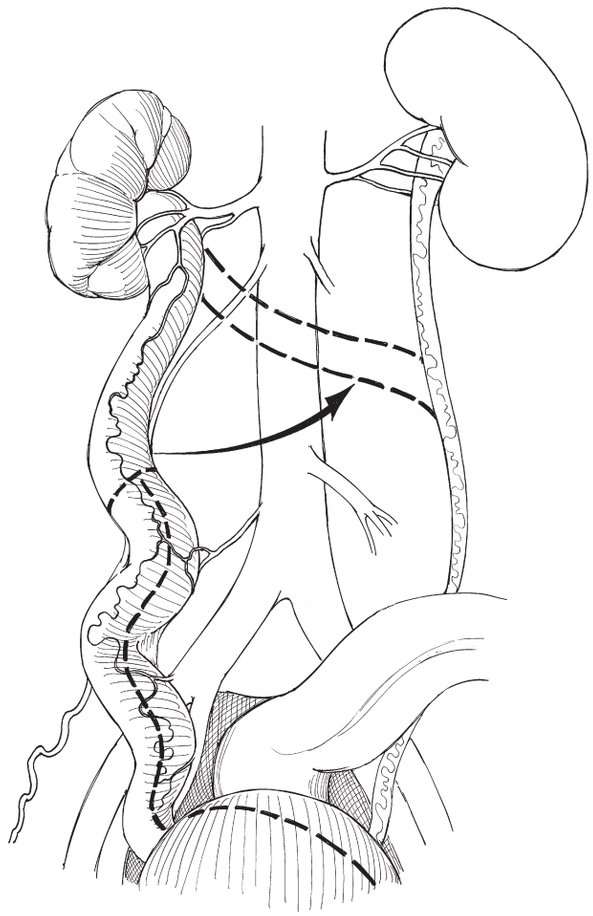

FIGURE 108-1.

more critical. It is also important to not disturb the connective tissue between the ureter and the bladder at the ureterovesical junction. The ureter should be divided at a site that leaves enough length for anastomosis to the contralateral ureter if a transureteroureterostomy is to be used.

The working ureteral segment should then be opened along its anterolateral border, and classically the incision is extended through the ureterovesical junction. Again, it is critical to stay in the coronal plane to preserve all the blood supply entering there. After mobilization of the ureter into the pelvis, the bladder is opened in the sagittal plane in a clamshell fashion. Posteriorly, this incision has typically been carried off-center directly into and through the ureteral orifice of the ureter used for cystoplasty. The ureter is *not* detached from the bladder but rather is opened longitudinally along its entire length.

Double the ureter upon itself to form a U-shaped cup (Fig. 108-2A); insert a suprapubic catheter in the bladder (not into the ureter). As with intestinal cystoplasty, folding the ureter into a more spherical configuration maximizes the volume that can be achieved. Apply the cup patch to the bivalved bladder with running 3-0 absorbable suture (see Fig. 108-2B). A drain should be placed in the perivesical space and the cystostomy tube should be connected to drainage for 14 to 21 days. Before removing the suprapubic catheter, cystography should be performed to confirm that the suture line is intact and that there is no urine leak.

An alternative technique proposed by Adams and colleagues, leaves the distal ureter intact. This avoids potential interruption of the distal blood supply. This "teacup" modification leaves the distal 3 cm of ureter intact, avoids an incision through the ureterovesical junction and is sound from a physiologic standpoint, technically easier, and associated with good results. The proximal ureter is bivalved and folded similar to that previously described. Leaving the distal 3 cm of ureter intact does not deleteriously affect the ultimate bladder capacity; however, it avoids potential injury to the blood supply of the mobilized ureter near the ureterovesical junction (Fig. 108-3).

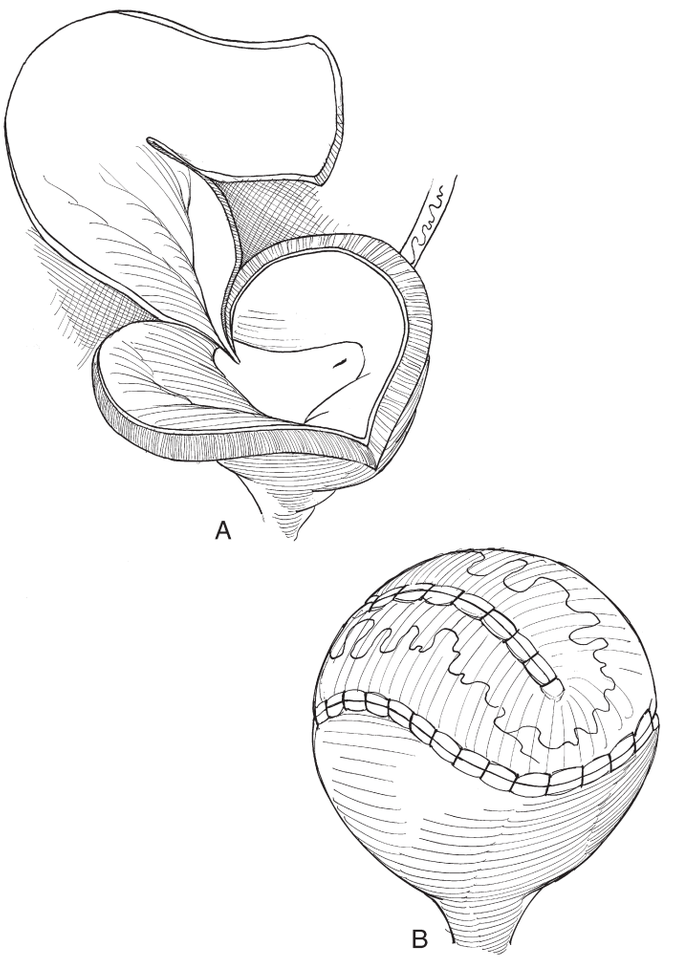

FIGURE 108-2.

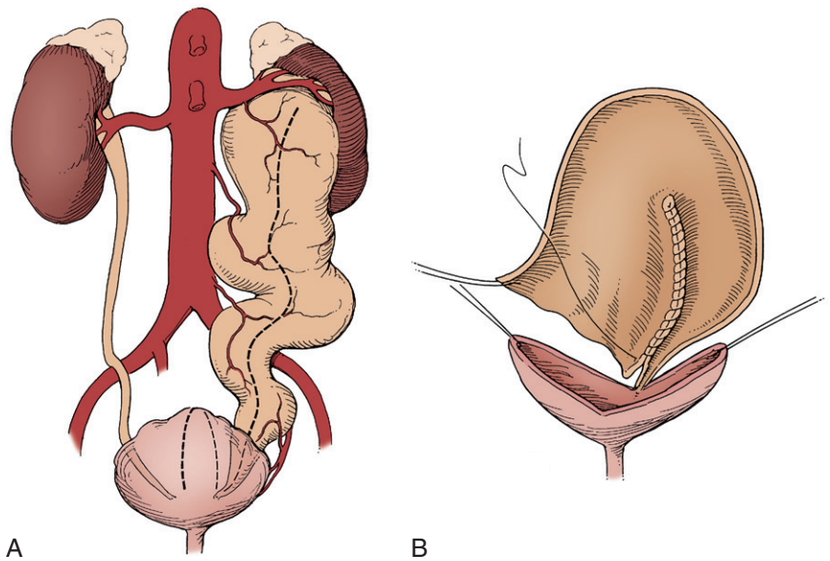

FIGURE 108-3.

Commentary by DAVID B. JOSEPH

The ureter provides an ideal source of tissue to be used for increasing the capacity and compliance of a bladder reservoir. In order to effectively accomplish this task, a substantial surface area of ureter is required. Often one of the kidneys will be sacrificed when using ureteral tissue for augmentation purposes. If both kidneys are taken in preparation for renal transplantation, it is critical to maintain a suprapubic tube postoperatively in order to cycle the bladder (filling the bladder with a predetermined volume of normal saline, holding for a period of time, and then emptying) to maximize the potential expansion of the ureteral tissue. If the kidney is going to be sacrificed, the renal pelvis can be incorporated into the augmentation. Successful mobilization of the ureter is achieved through meticulous dissection of the ureter from surrounding tissue, leaving substantial adventitia to enhance anastomotic blood supply and limiting the dissection on the distal third of the ureter. It is important to avoid spatulating the ureter along one straight line and best to follow an avascular meandering course along the ureter. Once the ureter is splayed open, it can be folded upon itself in a serpentine fashion to maximize its surface area. While ureter is theoretically an ideal tissue for augmentation, realistically there are few clinical situations that accommodate such an approach.

This page intentionally left blank

Chapter 109

Autoaugmentation by Seromyotomy

PATRICK C. CARTWRIGHT

Bladders with poor compliance and hyperreflexia but with only modestly reduced capacity are candidates for autoaugmentation.

Position: Supine. Insert a two-way urodynamics catheter connected to a Y-tube with a saline filling bag held at a height of 30 cm above the bladder.

Incision: Make a transverse lower abdominal incision. Dissect the peritoneum from the dome of the bladder.

With the electrocautery set for coagulation, incise through three fourths of the thickness of the detrusor with a vertical midline incision over the entire dome (Fig. 109-1). Separate the remaining detrusor fibers with a hemostat to expose the suburothelial layer. Release the clamp on the catheter, and allow the bladder to fill. Control any leaks with fine figure-eight absorbable sutures.

Grasp the edge of the detrusor with two-three Allis clamps on each side for countertraction during the submucosal dissection (Fig. 109-2). Bluntly and sharply dissect laterally in the plane between muscle and urothelium until half of the wall is peeled back. Fill and drain the bladder intermittently to aid the dissection. Close any holes created by oversewing with 5-0 or 6-0 synthetic absorbable sutures (SAS). Excise the detrusor flaps.

Hitch each of the posterior edges of the bladder to the respective psoas muscles (this is optional, see Chapter 112) with 3-0 SAS (Fig. 109-3). Drain the bladder with either a urethrally placed balloon catheter or a suprapubic tube emerging from an area of intact bladder wall. Place a Penrose drain paravesically. Two other suggestions have been made to help improve post-op compliance and capacity increases. Immediate bladder cycling several times each day either by catheter clamping with spontaneous distension or via direct installation of saline through the indwelling bladder catheter may lead to the urothelial bulge remaining more compliant. More recently, insertion of a large, intravesical silastic balloon/tissue expander at the time of surgery (and left for 14 days) has been reported with promising results in terms of functional improvement.

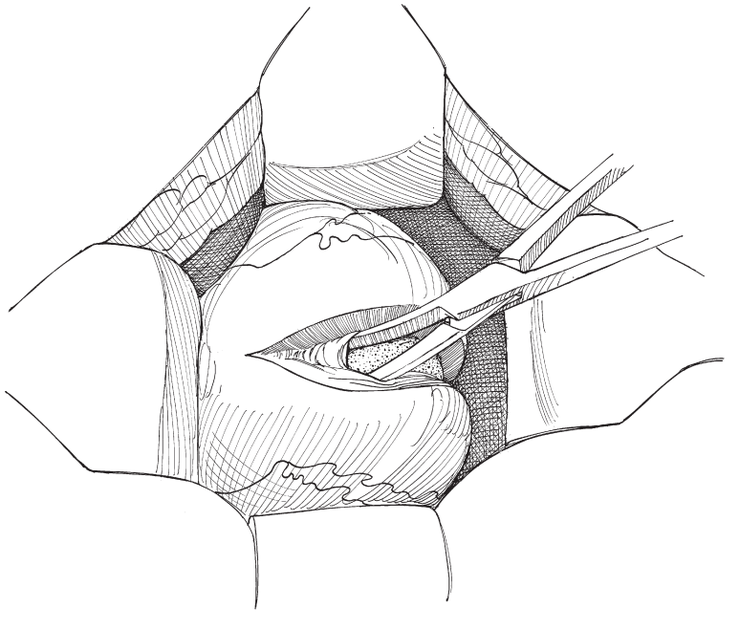

FIGURE 109-1.

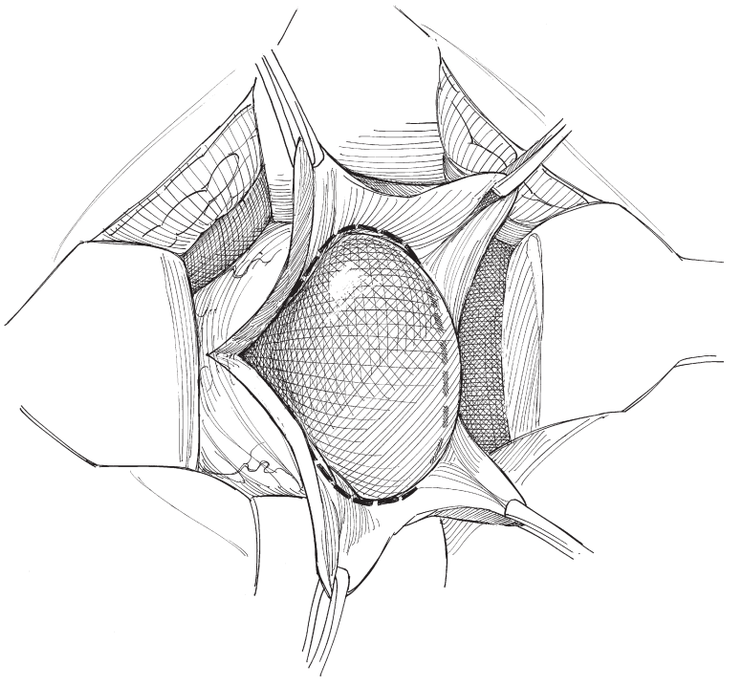

FIGURE 109-2.

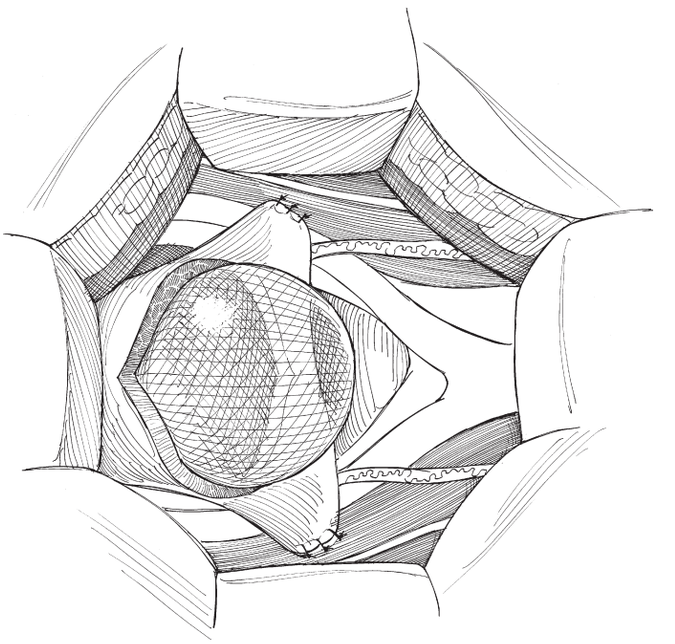

FIGURE 109-3.

Perform cystography in 1 week; if no extravasation is seen, remove the catheter and have the patient resume intermittent catheterization or voiding.

LAPAROSCOPIC AUTOAUGMENTATION

Create a pneumoperitoneum of 10 mm Hg. Insert one 10-mm trocar below the umbilicus, two in the right and left lower quadrants in the midaxillary line halfway between the umbilicus and the iliac crest, and a fourth in the right lower quadrant medial to the other trocar. Insert a balloon catheter, and fill the bladder with normal saline to which a vial of methylene blue has been added to help identify the mucosa. Alternatively, distend a balloon in the bladder to reduce the immediate consequences of puncture of the epithelium. Be sure to check for leaks by filling with saline after removing the balloon.

Incise the peritoneum over the dome of the bladder, and excise the perivesical fat. Clip the right and left medial umbilical ligaments to allow the bladder to fall posteriorly. Incise the serosa and muscularis with a harmonic scalpel in the sagittal plane to expose the mucosa. Dissect the muscularis from the mucosa with a uretero-scope using electrodissection and blunt dissection with the beak of the instrument. A few muscle strands may be left behind. Oversew any punctures; postoperative leakage produces harmful perivesical fibrosis. The fibrin glue Tisseel may be applied over the exposed epithelial layer to reduce leakage. Evacuate the bladder. Place a Penrose drain through one of the ports, and sew it in place. Close the portal sites with 2-0 SAS. Leave the urethral catheter in place for 1 week. Perform cystography to check for leaks, and remove the catheter if the repair is intact.

Commentary by DAVID B. JOSEPH

Autoaugmentation is technically challenging and requires a substantial amount of patience when dissecting the submucosal interface between the bladder epithelium and detrusor. The time spent cautiously developing this plane has a benefit of improving the integrity of an intact epithelium. Frequently applying saline to the exposed epithelium enhances its pliability. Unfortunately in my limited experience I never achieved the improved compliance and increased capacity that I had anticipated. In retrospect this could have been due to a fairly conservative epithelial diverticulum that I created. I suspect improved results might occur with aggressive dissection, removing the entire dome and a significant portion of the lateral detrusor walls. Postoperative bladder cycling (filling the bladder with a predetermined volume of normal saline, holding for a period of time, and then emptying) may prevent early contraction of the exposed epithelium and enhance long-term results.

Section XIX

URETERAL RECONSTRUCTION AND EXCISION

This page intentionally left blank

Chapter 110

Principles of Ureteral Reconstruction

GEORGE D. WEBSTER AND ELIZABETH ANOIA

URETERAL ANATOMY

Ureteral anatomy has been well-described from our experience in open ureteral surgery. We now have the benefit of adding to that knowledge as endoscopic and other minimally invasive techniques allow us to visualize the ureter from a different perspective. The anatomic arrangement of the ureteral sheath, muscular layer, and vascular supply is important to surgical manipulation. The ureter is encased in a loose *ureteral sheath*, a layer of intermediate stratum of the retroperitoneal connective tissue lying just under the peritoneum to which it is adherent (Fig. 110-1). Proximally, both the ureteral sheath and adventitia are continuous with the corresponding layers of the renal pelvis.

Distally, the sheath and adventitia are more prominent in the terminal portion of the ureter, where they join Waldeyer's sheath formed from the deep trigone as it extends from the bladder wall around the ureter. In the female, the sheath is closely associated with the ureterovaginal and vesicovaginal plexuses of veins within the parametrium, making the ureter more difficult to mobilize gynecologic procedures. It is, therefore, susceptible to injury in multiple ways (direct transection, cautery, or devascularization) as well as to subsequent fixation in fibrous tissue. After violation of the ureteral sheath, adherence of the ureter to adjacent structures may result in functional obstruction. The sheath supplements the adventitia to act as a barrier to periurethral neoplastic and inflammatory processes. This is best appreciated after

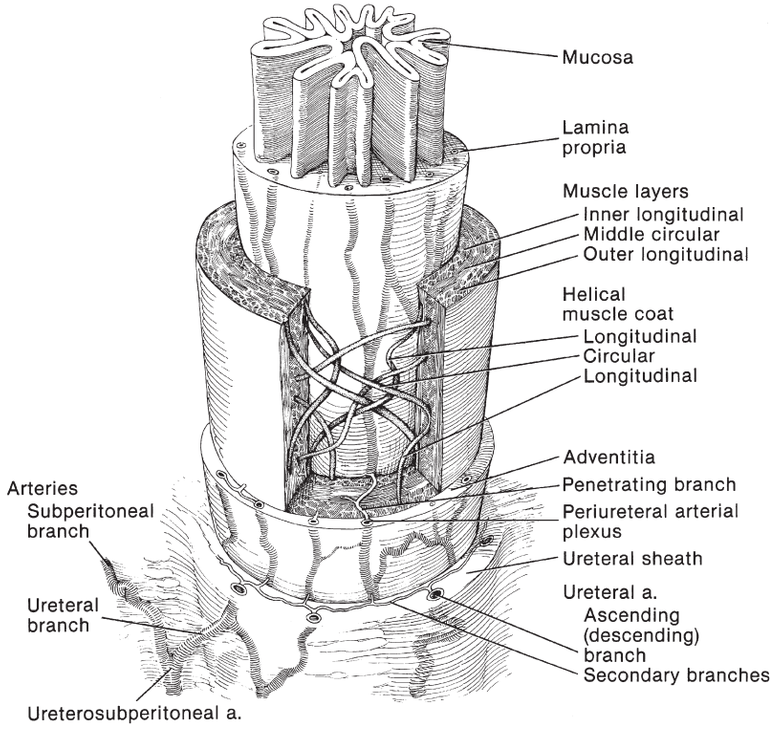

FIGURE 110-1.

retroperitoneal inflammation, when the sheath is found to be composed of a series of onion-skin layers that allow some peristaltic movement of the ureteral wall to continue. The *adventitia* is loosely attached to the underlying muscularis layer, leaving it free to move.

The *uretero-subperitoneal arteries* are supplied by several retroperitoneal vessels. Proximally, the blood supply arises medially from the renal artery, the aorta, and the gonadal arteries. Distally, the blood supply is lateral and the most frequent sources are the superior and inferior vesical arteries, but ureteral vessels also arise from internal iliac arteries, vessels that provide the richest supply to the lower portion of the ureter. The midureter between the lower pole of the kidney and the brim of the pelvis is the most poorly vascularized.

A uretero-subperitoneal artery divides into a subperitoneal and a ureteral branch. The ureteral branch has ascending and descending branches in the ureteral sheath that enter the adventitia through secondary branches. The secondary branches pass to a deeper layer to penetrate the adventitial layer of the ureter and there form a freely anastomotic periureteral arterial plexus that extends for the entire length of the ureter. The ureteral arteries branching from the uretero-subperitoneal vessels usually divide into long ascending and descending branches. These branches anastomose with descending branches from above and with the ascending branches from below.

This vascular arrangement does not limit the sites of division of the ureter because anastomoses within a sectioned ureter prevent ischemia. On the other hand, interference with the arterial plexus jeopardizes the viability of the end of the ureter. Viability of the distal ureter may be especially tenuous in secondary operations on the previously mobilized or resected ureter.

The preservation of the ureteral trunks in the ureteral sheath is essential when operating on long segments of the ureter, as when transplanting a kidney or tapering a megaureter. However, in about one quarter of the cases, the vessels do not have long branches but immediately form plexuses and therefore are more readily rendered avascular by division.

The subperitoneal arteries from the uretero-subperitoneal vessels supply the periureteral tissue and also provide some distribution to the peritoneum. They freely anastomose with neighboring vessels as they contribute blood to the ureter. Separation of the ureter from the peritoneum by division of the arterial twigs may compromise ureteral blood supply, especially in the lower ureter.

MANAGEMENT OF THE INTRAOPERATIVE INJURY TO THE URETER

A repertoire of procedures is needed when the ureter must be repaired following an injury. Location and length of the injury is key in determining the best technique. Ureteroureterostomy is an option if the injury is in the midureter and mobilization allows the anastomosis to adhere to the basic principles of a water-tight, tension-free anastomosis. Reimplantation into the ipsilateral posterolateral aspect of the bladder is generally used if the injury involves the distal third of the ureter. Mobilization followed by tubularization of a bladder flap or a trans-uretero-ureterostomy are alternatives. If such procedures are unable to be performed, then other options such as mobilization of the kidney, autotransplantation, or an ileal ureter can also be undertaken. Ureteral injury during a difficult abdominal operation may be less likely to occur if the ureters are stented at the beginning. The injury from cross-clamping the ureter in situ for an appreciable length of time should be treated with insertion of a double-J stent for at least 10 days, but if the ureter has already been isolated, resection and anastomosis are advisable. Inadvertent ligation of a ureter, even if recognized immediately, usually warrants ureteral stenting. If the involved segment is obviously ischemic, it is better to excise and anastomose it. If the ureter is cauterized, inspect it for damage to the adventitial vessels. Such ischemic tissue must be excised.

A severed ureter requires spatulation and anastomosis over a stent, but avulsion or extensive damage makes the use of a psoas hitch or bladder flap necessary. Ureteral injury is suspected postoperatively by the presence of flank pain and tenderness in the costovertebral angle, low-grade fever, and ileus. Contrast-enhanced computed tomography scan and urography may reveal the site and extent. Ultrasonography may detect the presence of hydronephrosis. Retrograde passage of a double-J stent should be tried first with a guidewire. Percutaneous nephrostomy is an alternative, to await the dissolution of obstructing absorbable sutures or while awaiting surgery. If the patient is in good condition, consider immediate surgical correction.

Chapter 111

Ureteroneocystostomy

JOHN POPE AND JOHN H. MAKARI

In children, ureteroneocystostomy is utilized primarily for the treatment of vesicoureteral reflux. In the setting of vesicoureteral reflux, operative indications for ureteroneocystostomy are breakthrough febrile urinary tract infections despite compliance with appropriate prophylactic antibiotics, persistence of vesicoureteral reflux despite prolonged medical management, and parenteral preference for surgical intervention as the primary treatment for vesicoureteral reflux.

The treatment options for vesicoureteral reflux include medical management, endoscopic submucosal injection of a bioimplant, and ureteroneocystostomy. Ureteroneocystostomy offers the most definitive surgical management available for vesicoureteral reflux. It may be performed via an intravesical or extravesical approach, or through a combination of the two. Choice of technique is largely dependent on the location of the ureteral orifice.

Ureteroneocystostomy is also indicated for the treatment of primary obstructive megaureter as a primary treatment or following cutaneous ureterostomy. In adults (as well as children) ureteroneocystostomy is indicated during renal transplantation and for the treatment of ureteral injury. In the setting of renal transplantation ureteral injury, performance of a nonrefluxing ureterovesical anastomosis may not be required.

Successful ureteroneocystostomy, regardless of approach or procedure, depends on adherence to common surgical principles. The ureter must be handled carefully: initial mobilization and subsequent manipulation must be atraumatic to avoid devascularization and subsequent stricture formation. The ureter must be adequately mobilized to produce a sufficiently long submucosal tunnel. To avoid postoperative vesicoureteral reflux, the submucosal tunnel to ureteral diameter ratio should be at least 5:1. The ureter must enter the bladder without significant angulation nor kink and must not be twisted to prevent postoperative obstruction. Additionally, before any surgical intervention for vesicoureteral reflux, secondary causes must aggressively be investigated and treated when present.

APPROACH TO THE BLADDER
(Figs. 111-1, 111-2, and 111-3)

Position: Place the patient supine on the operating table with a bump under the pelvis. Prep the patient from the umbilicus to the midthighs, making sure to include the external genitalia in the prep, so that access for urethral catheterization, if desired, is available from the sterile field.

Incision: Make a Pfannenstiel incision along Langer's lines, approximately 1 fingerbreadth above the symphysis pubis with a scalpel. Dissect the underlying subcutaneous tissue with a combination of blunt and electrocautery dissection. Incise Scarpa's fascia sharply or with electrocautery. Dissect the adipose tissue overlying the external oblique aponeurosis using blunt and electrocautery dissection.

Incise the anterior rectus abdominis sheath (aponeurosis of the external and internal oblique muscles, which are fused medially) either longitudinally or transversely. (We prefer a transverse fascial incision.) Elevate fascial flaps

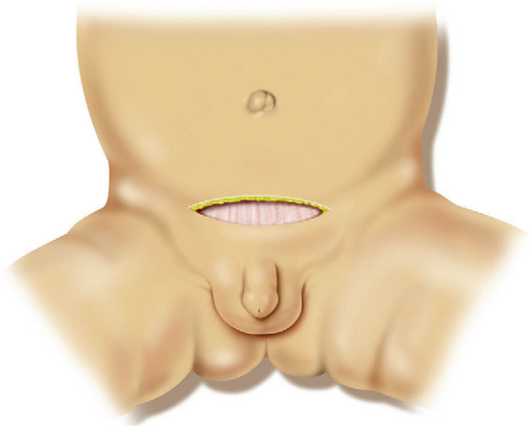

FIGURE 111-1.

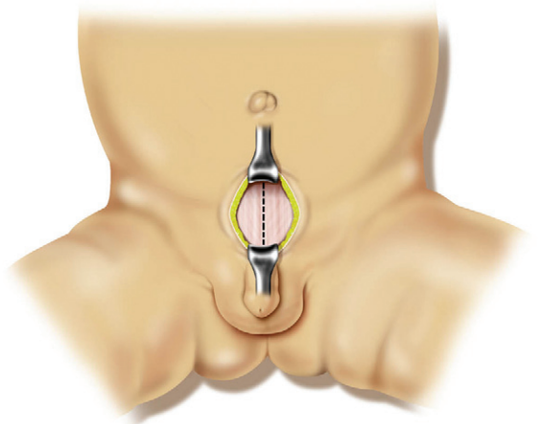

FIGURE 111-2.

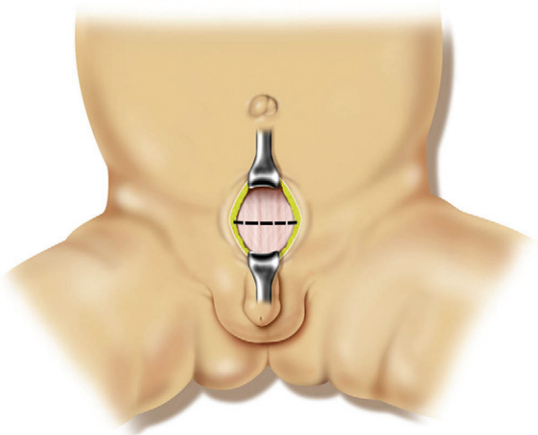

FIGURE 111-3.

laterally or cephalad and caudally using electrocautery to separate the fascia from the rectus abdominis muscle. Place a self retaining Denis Browne to retract the facial flaps. Identify the bilateral bellies of the rectus abdominis muscles and incise the midline sharply or with electrocautery. Incise the transversalis fascia in the midline. Identify the bladder and develop the space of Retzius bluntly with lateral retraction of each belly of the rectus abdominis muscle. Retract the bilateral bellies of the rectus abdominis muscle with the Denis Browne retractor.

Stabilize the bladder initially with either Allis clamps or 3-0 chromic stay sutures. Make a vertical cystotomy with electrocautery and evacuate the urine from the bladder. Place 3-0 chromic retraction sutures from the bladder, through the full thickness of the anterior wall lateral to the caudal apex of the cystotomy, to the skin lateral to the midline. Pack the dome of the bladder with two or three moistened sponges and retract it with a deep blade of the Denis Browne retractor. Reposition the lateral blades of the Denis Browne retractor within the bladder to provide exposure of the posterior wall and trigone of the bladder.

TRANSVESICAL TECHNIQUES

Ureteral Mobilization (Figs. 111-4, 111-5, and 111-6)

Intubate the ureter with a 3.5- or 5-French feeding tube and secure it to the adjacent bladder tissue with a 3-0 silk suture, initially placing the suture through the full thickness of

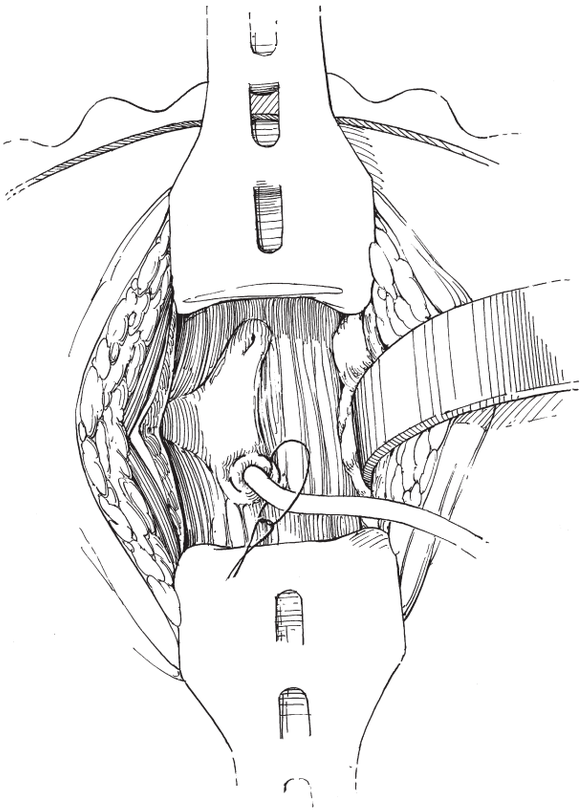

FIGURE 111-4.

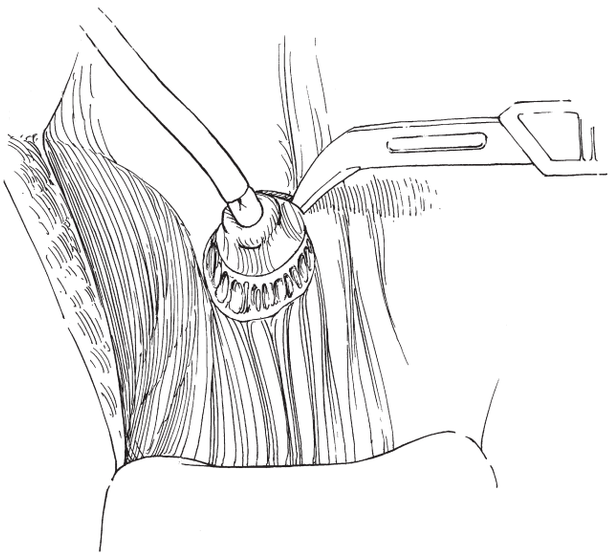

FIGURE 111-5.

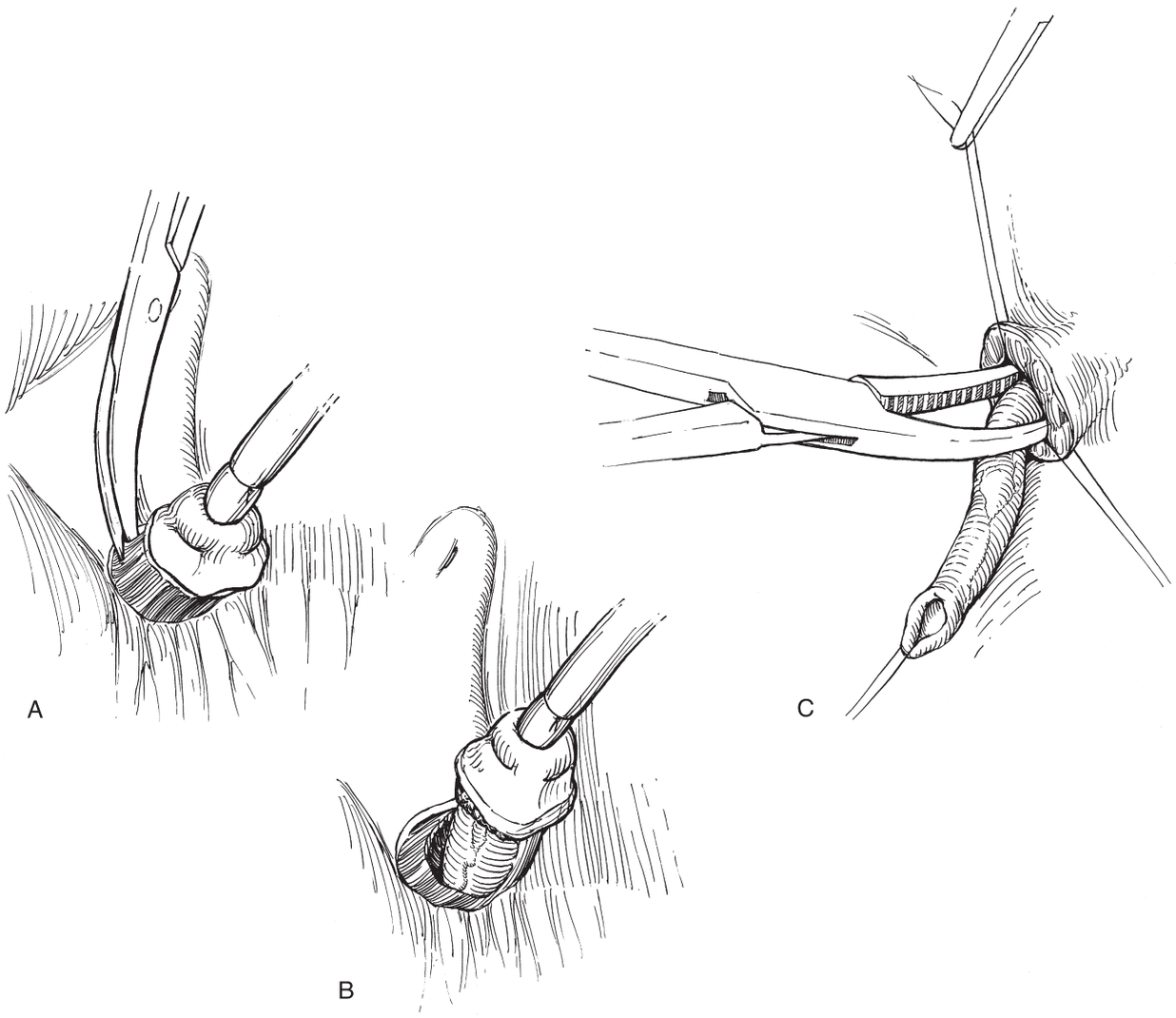

FIGURE 111-6.

the feeding tube. Score the bladder urothelium circumferentially around the ureteral orifice with electrocautery, leaving a rim of urothelium around the ureteral orifice. Begin sharp dissection of the ureter within Waldeyer's sheath caudally, distal to the ureteral orifice. Mobilize the ureter with traction on the feeding tube by dissecting the bladder muscle fibers away from Waldeyer's sheath using a combination of blunt and electrocautery dissection. Once the ureter has been dissected away from the bladder muscle fibers, dissect the extravesical ureter away from the adjacent peritoneum using a combination of blunt and electrocautery dissection. Carefully cauterize the small branches of the superior vesical artery running along the peritoneal reflection.

Intraextravesical Technique (Politano-Leadbetter) (Figs. 111-7, 111-8, 111-9, and 111-10)

Following mobilization of the intramural ureter, begin extraperitoneal blunt dissection of the extravesical ureter with a right-angle clamp. Mobilize the ureter initially in a plane between the posterior bladder wall and the anterior wall of the ureter, keeping caudal traction on the ureter with the feeding tube. Once adequate ureteral mobilization has been accomplished, make a transmural incision through the posterior bladder wall with electrocautery at the intended site of the neohiatus over the tip of the right angle clamp. Transfer the distal ureter to the neohiatus. Close the original hiatus with running interrupted 2-0 polyglactin suture.

Dissect a submucosal tunnel from the neohiatus to the original hiatus sharply, using tenotomy scissors. Transfer the distal ureter through this tunnel. Excise the most distal ureter sharply with heavy scissors, thereby dividing the feeding tube used initially to cannulate the ureter. Take care to apply external pressure to the ureter proximally and to the feeding tube to prevent cephalad migration of the feeding tube into the ureter.

Spatulate the distal anterior ureter sharply with tenotomy or Potts scissors. Anchor the distal posterior ureter to the neohiatus with 4-0 chromic sutures—place interrupted sutures at the 6-, 5-, and 7-o'clock positions approximating the transmural ureteral tissue and the ureteral orifice comprising deep muscular and urothelial bladder tissue. Approximate the urothelium of the orifice to the spatulated ureter at the 12-o'clock position with 5-0 chromic suture, making sure to incorporate the full thickness of the ureter. Approximate the intervening tissue with similar 5-0 chromic sutures. Close the urothelium overlying the ureter at the neohiatus with a running 5-0 chromic suture.

In some cases, it may be necessary to extend the length of the submucosal tunnel. This can be accomplished by creating a second submucosal tunnel toward the bladder neck. If a second tunnel is made caudally, the ureter is transferred to location of the new orifice and the ureterovesical anastomosis is performed as above; the urothelium overlying the ureter at the original orifice is closed as well with 5-0 chromic suture. Intubate the ureteral orifice with a 3.5- or 5-French feeding tube and pass it proximal to the hiatus to ensure that there is no obstruction, either from kinking or twisting of the ureter along its course. Close the bladder in two layers, using a running 3-0 absorbable suture

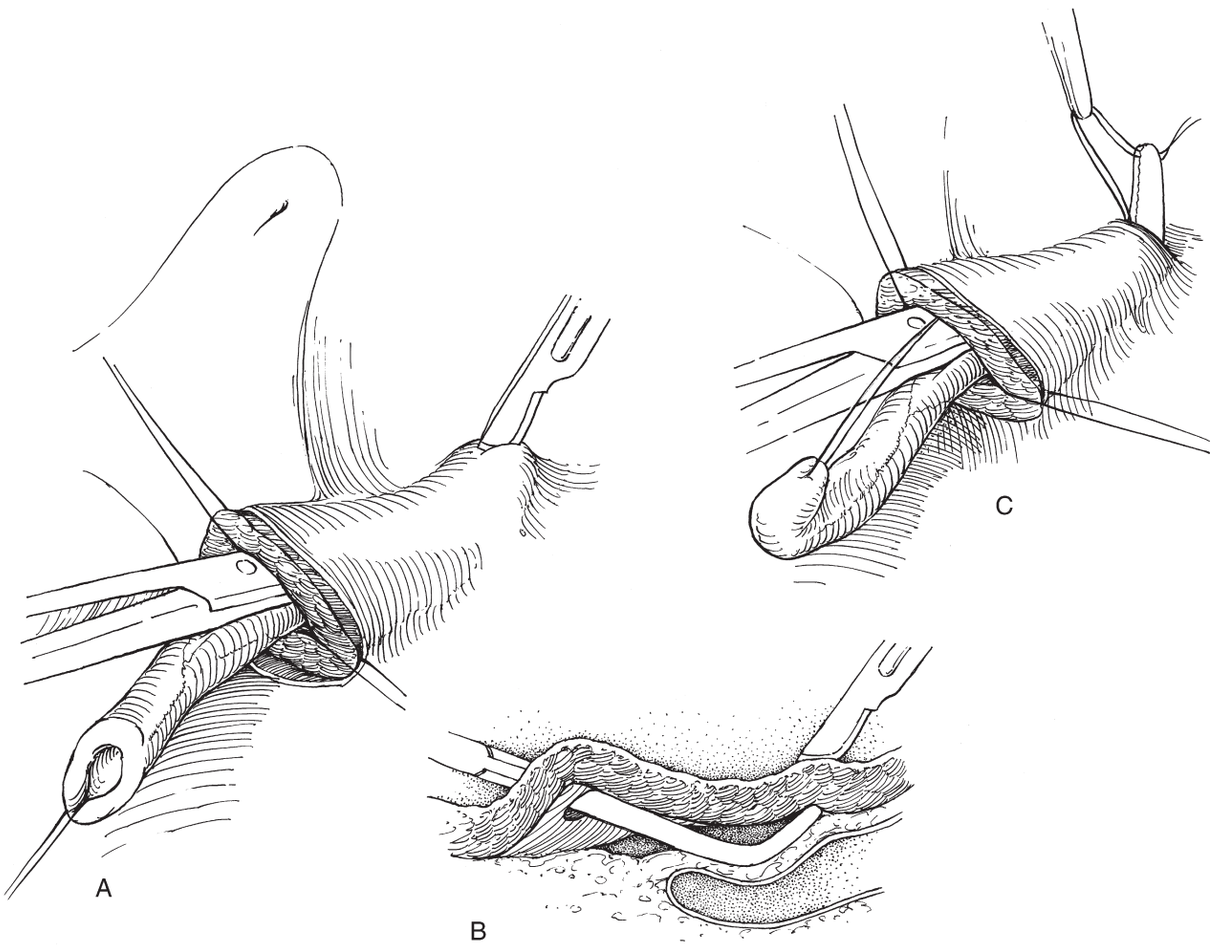

FIGURE 111-7.

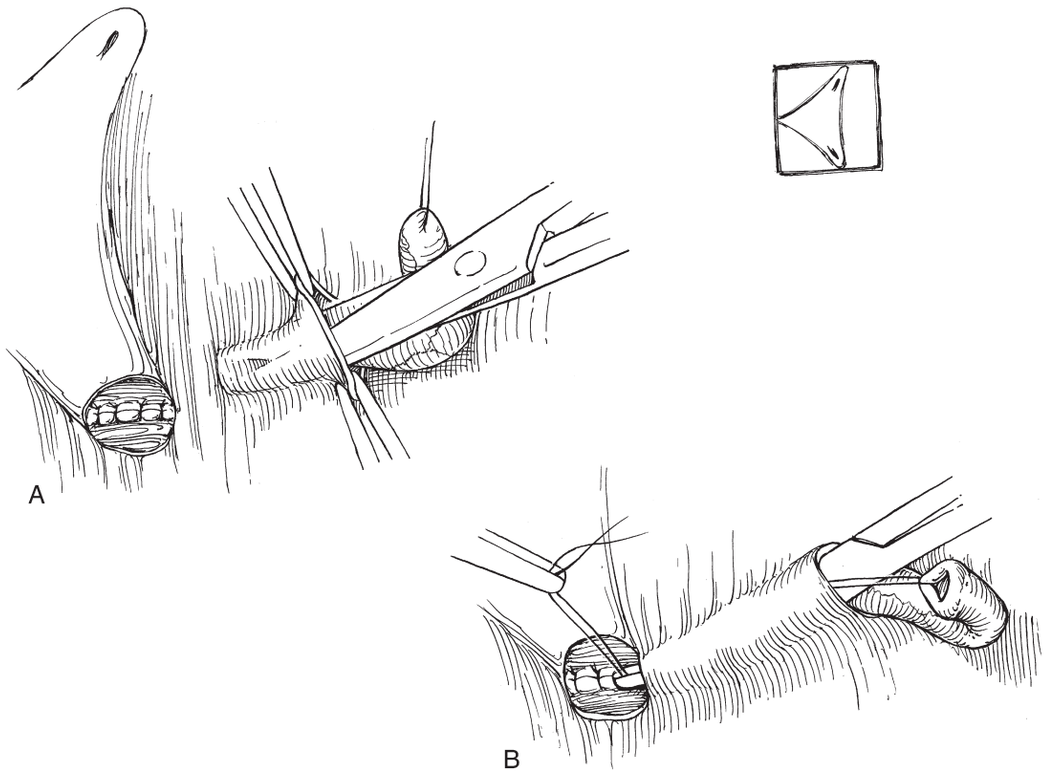

FIGURE 111-8.

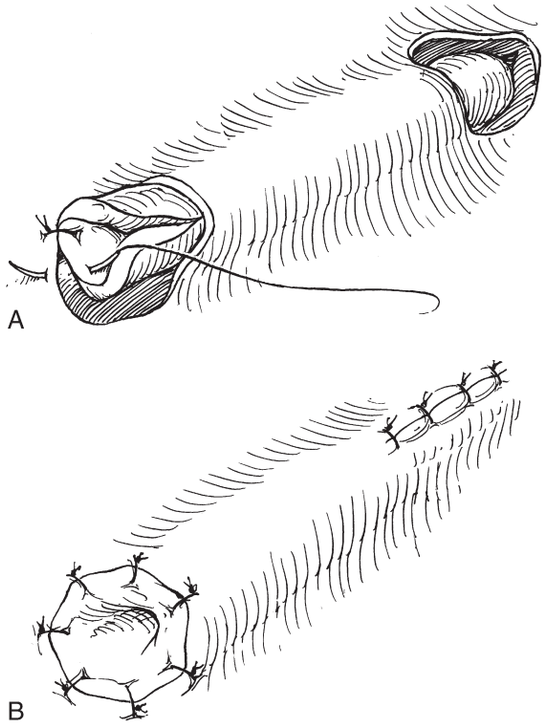

FIGURE 111-9.

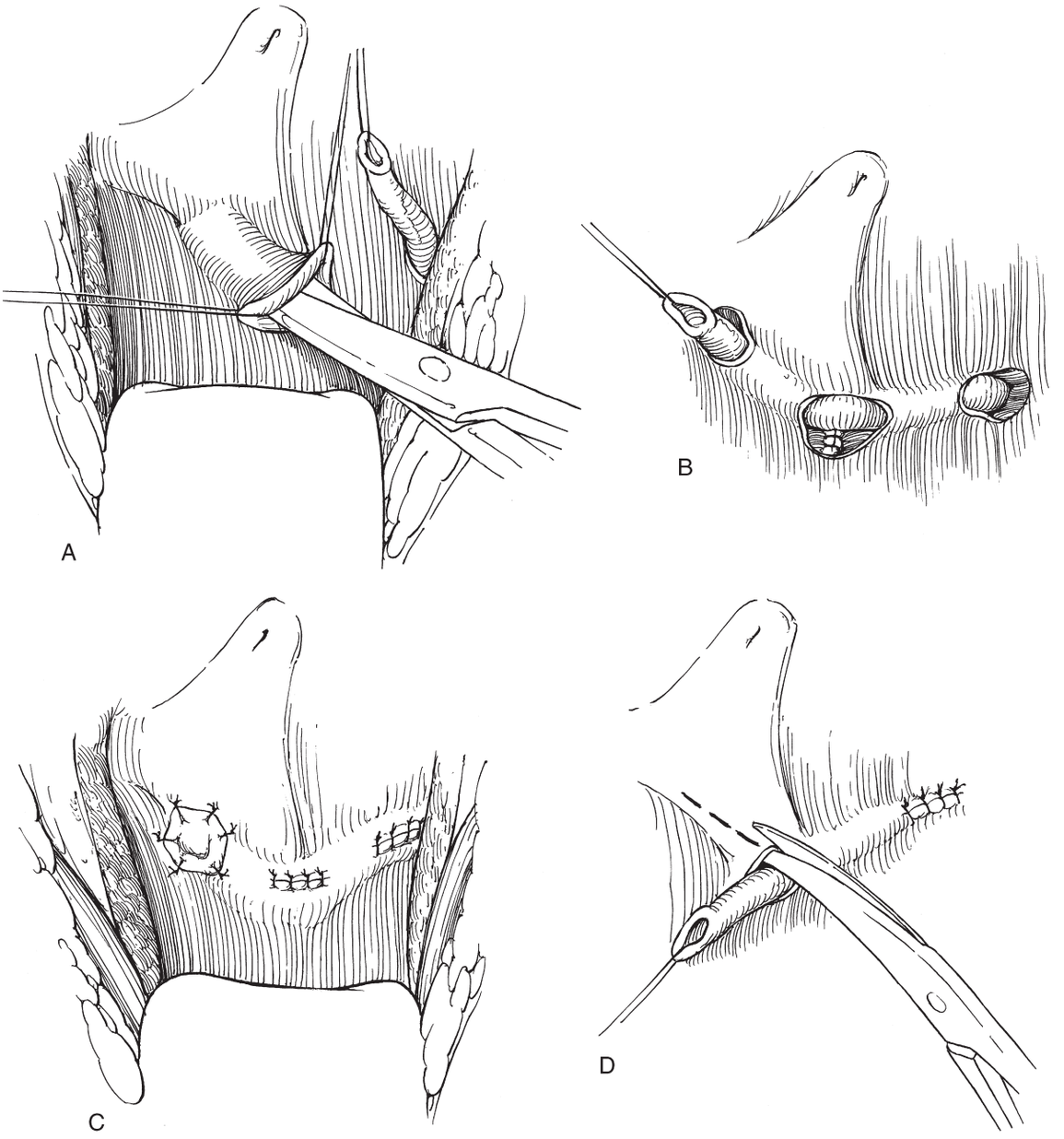

FIGURE 111-10.

for the urothelial layer and a running 2-0 absorbable suture for the seromuscular layer.

Modification of the Intra-Extravesical (Politano-Leadbetter) Technique

We typically perform a modified Politano-Leadbetter technique, in which the original hiatus is opened sufficiently to allow for posterior dissection under direct vision. The neohiatus may then be created by further cephalad extravesical dissection under direct visualization or by opening the posterior wall of the bladder to the intended neohiatus. The floor of the bladder caudal (distal) to the neohiatus, as well as the original hiatus, is closed with either interrupted or running 2-0 polyglactin suture. Care must be taken to avoid closing the neohiatus too tightly to prevent obstruction of the ureter at this point.

Ureteral Advancement Technique (Glenn-Anderson) (Fig. 111-11)

Once adequate ureteral mobilization has been accomplished, create a submucosal tunnel sharply toward the bladder neck. Incise a portion of the posterior wall of the bladder cephalad to the hiatus and transfer the ureter cephalad. Close the floor of the bladder with interrupted 2-0 absorbable sutures, beginning cephalad. Take care to avoid excessive compression of the ureter with these sutures. Transfer the distal ureter caudally through the submucosal tunnel. The ureterovesical anastomosis is

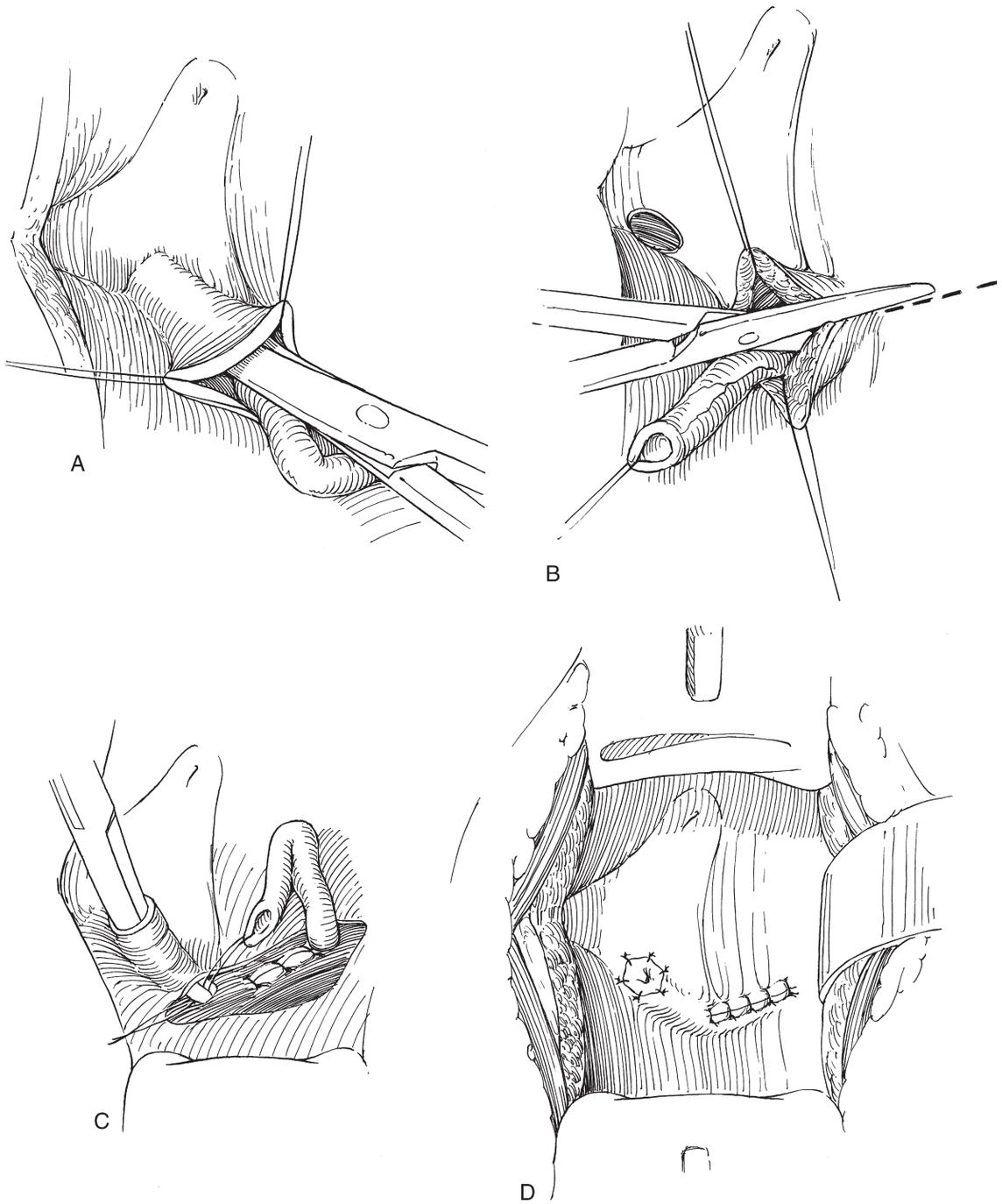

FIGURE 111-11.

performed as for the combined intra-extravesical technique, above. Close the urothelium overlying the exposed ureter with running 5-0 chromic suture. Intubate the ureteral orifice with a 3.5- or 5-French feeding tube and pass it proximal to the hiatus to ensure that there is no obstruction, either from kinking or twisting of the ureter along its course. Close the bladder in two layers, using a running 3-0 absorbable suture for the urothelial layer and a running 2-0 absorbable suture for the seromuscular layer.

Transtrigonal Technique (Cohen)

Unilateral Ureteroneocystostomy (Fig. 111-12)

Mobilize the ureter to be reimplanted and close any laxity of the hiatus with simple 2-0 absorbable sutures (chromic or polyglactin). Create a submucosal tunnel sharply from the hiatus of the ureter to be reimplanted to a point just cephalad to the contralateral ureteral orifice. Transfer the ureter across the trigone through the submucosal tunnel. Perform

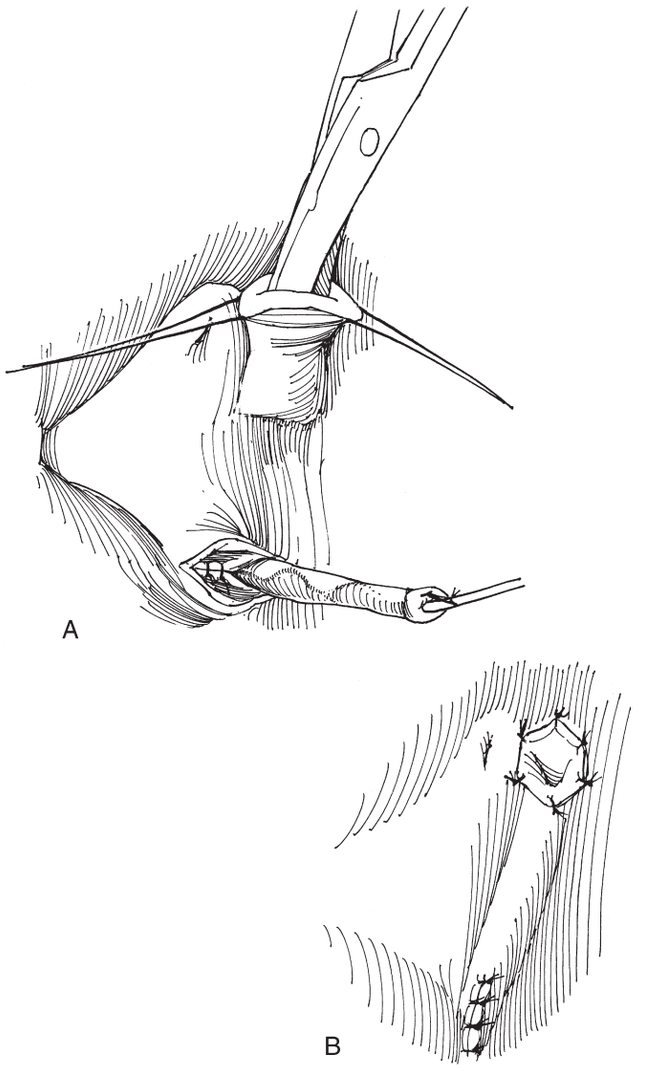

FIGURE 111-12.

a ureterovesical anastomosis by approximating transmural ureteral tissue with urothelial bladder tissue using 5-0 chromic or 6-0 polyglactin simple interrupted sutures. Intubate the ureteral orifice with a 3.5- or 5-French feeding tube and pass it proximal to the hiatus to ensure that there is no obstruction, either from kinking or twisting of the ureter along its course. Close the bladder in two layers, using a running 3-0 absorbable suture for the urothelial layer and a running 2-0 absorbable suture for the seromuscular layer.

Bilateral Ureteroneocystostomy (Fig. 111-13)

Following mobilization of the bilateral ureters, close any laxity of the hiatuses with simple interrupted 2-0 absorbable sutures (chromic or polyglactin). Create a submucosal tunnel sharply from the hiatus of the left ureter to a point just cephalad to the right ureteral orifice. Transfer the left ureter across the trigone through the submucosal tunnel. Perform a ureterovesical anastomosis by approximating transmural ureteral tissue with urothelial bladder tissue using 5-0 chromic or 6-0 polyglactin simple interrupted sutures. Create a submucosal tunnel sharply from the hiatus of the right ureter to the location of the original left ureteral orifice. Transfer the right ureter across the

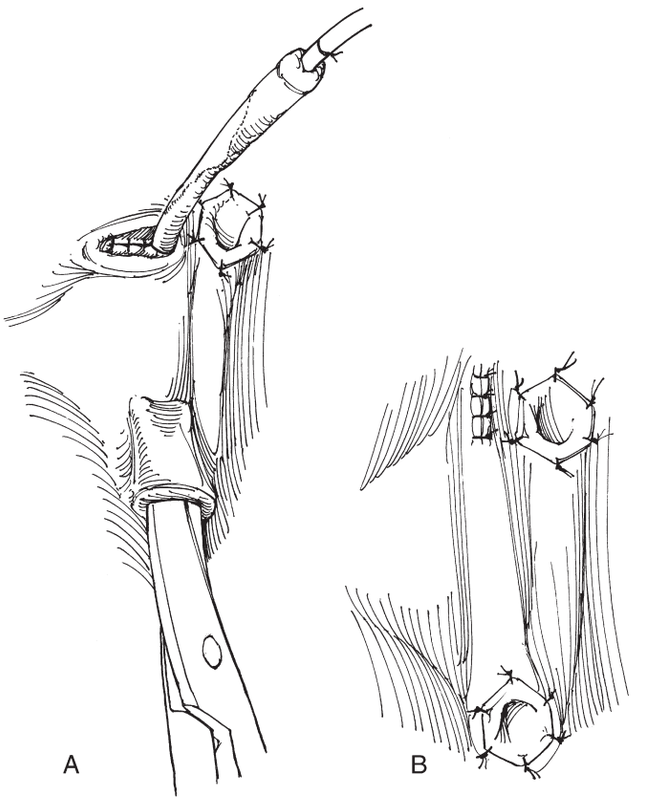

FIGURE 111-13.

trigone through the submucosal tunnel. Perform a ureterovesical anastomosis as above. Close the urothelium overlying the exposed right ureter with running 5-0 chromic suture. Intubate each ureteral orifice with a 3.5- or 5-French feeding tube and pass it proximal to the hiatus to ensure that there is no obstruction, either from kinking or twisting of the ureter along its course. Close the bladder in two layers, using a running 3-0 absorbable suture for the urothelial layer and a running 2-0 absorbable suture for the seromuscular layer.

Sheath Approximation Technique (Gil Vernet)

Make a transverse incision between the two laterally placed orifices to expose the underlying trigonal muscle. Catch the periurethral sheath at the inferior margin of the first ureter and then the other ureter with a single nonabsorbable mattress suture. Tie the suture to draw the ureters together in the midline.

Spatulated Nipple Technique (Fig. 111-14)

When bladder capacity is inadequate to provide an effective tunnel length to ureteral diameter ratio, despite ureteral tailoring or tapering techniques, the spatulated nipple technique may be employed, especially in instances where delayed surgical intervention is contraindicated. Bring approximately 2 cm of ureter directly through the bladder. Fix the ureter to the neohiatus with simple interrupted 4-0 absorbable sutures that approximate seromuscular ureteral tissue to muscular bladder tissue. Spatulate the distal ureter and evert the distal ureteral lumen. Approximate the distal ureteral margin to the

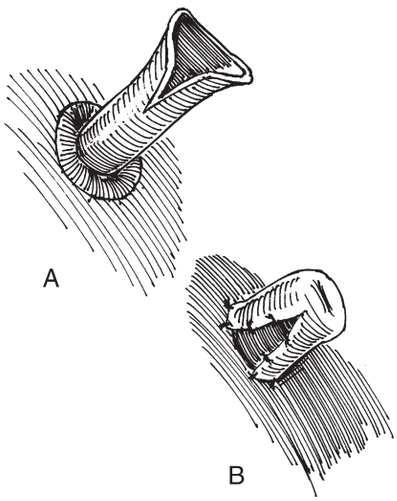

FIGURE 111-14.

bladder urothelium surrounding the original ureteral orifice with simple interrupted 5-0 chromic or 6-0 polyglactin sutures. Reapproximate the spatulation, now over the more proximal ureter, with simple interrupted 5-0 chromic or 6-0 polyglactin sutures. Intubate the ureteral orifice with a 3.5- or 5-French feeding tube and pass it proximal to the hiatus to ensure that there is no obstruction, either from kinking or twisting of the ureter along its course. Close the bladder in two layers, using a running 3-0 absorbable suture for the urothelial layer and a running 2-0 absorbable suture for the seromuscular layer.

Choice of Transvesical Technique (Figs. 111-15, 111-16, and 111-17)

Our philosophy regarding choice of transvesical technique relates to the location of the ureteral orifice in the ureter to be repaired. We believe that the location of the

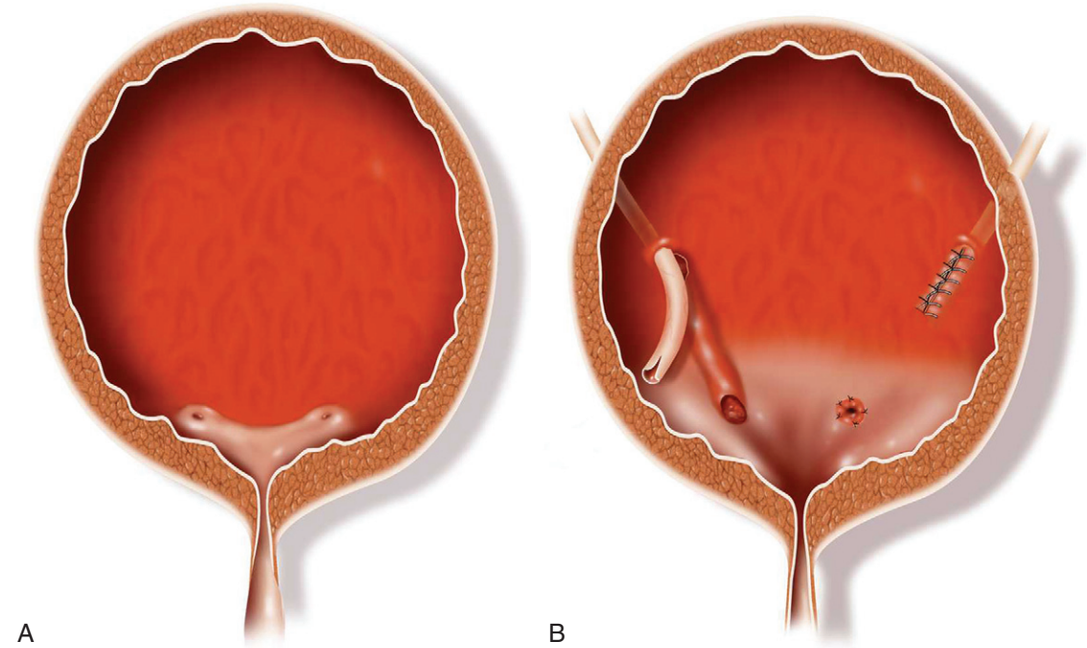

FIGURE 111-15.

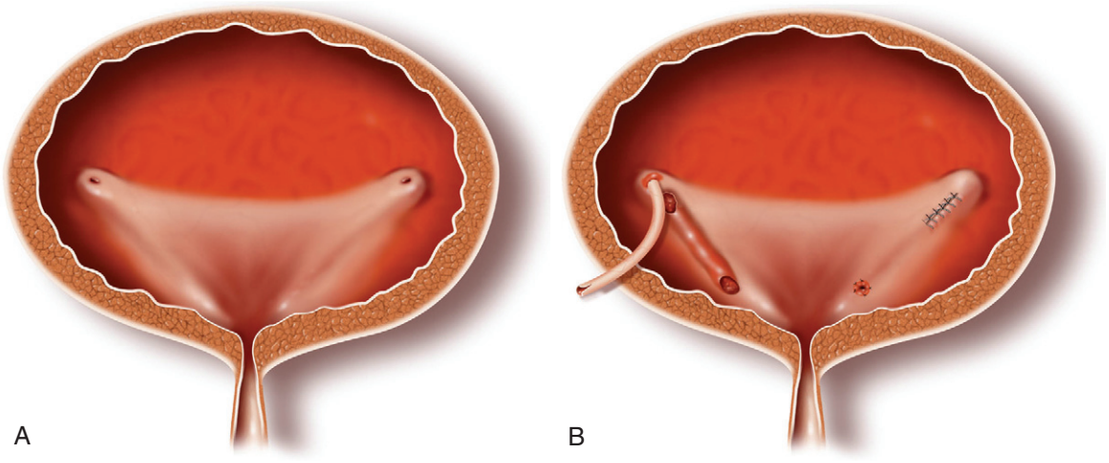

FIGURE 111-16.

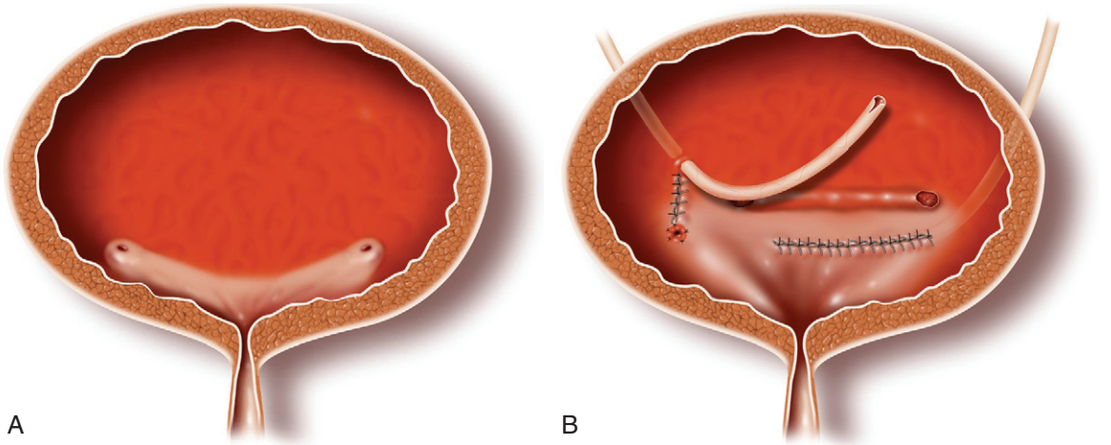

FIGURE 111-17.

ureteral orifice dictates the most appropriate technique. Our ultimate goal is to recapitulate the normal intramural ureteral anatomy. Our bias is that this facilitates endoscopic intervention, if necessary, at a later date. To this end, we reserve cross-trigonal techniques for only select situations, when existing anatomy precludes other techniques.

When the ureteral orifice is located in an orthotopic position, the intraextravesical (Politano-Leadbetter) technique is ideally suited to recapitulate normal intramural ureteral anatomy (see Fig. 111-15). Repositioning the hiatus in a more cephalad position allows for a longitudinally oriented intramural/submucosal ureteral tunnel. Similarly, when the ureteral orifice is located ectopically in a cephalad position, ureteral advancement (Glenn-Anderson) allows for a longitudinally oriented intramural/submucosal ureteral tunnel (see Figs. 111-16). Creation of a longitudinally oriented intramural/submucosal ureteral tunnel facilitates retrograde endoscopic intervention with flexible or semirigid instrumentation. This allows the urologist maximal access to the upper urinary tract throughout the patient's life.

Nonetheless, when the ureteral orifice is located in an extreme laterally ectopic position, the intraextravesical (Politano-Leadbetter) and ureteral advancement (Glenn-Anderson) techniques may be contraindicated. Repositioning the ureteral hiatus to a more cephalad position, as in the intra-extravesical technique (Politano-Leadbetter) may cause undesired tortuosity or kinking of the ureter as it enters the bladder. Repositioning the ureteral orifice to a more caudal location closer to the bladder neck, as with the ureteral advancement technique (Glenn-Anderson), may not provide an adequate submucosal tunnel to ureteral diameter ratio. Therefore, the extreme laterally ectopic ureteral orifice may warrant transtrigonal (Cohen) reimplantation. Although this technique does not recapitulate the normal intramural ureteral anatomy, it does, in selected situations, provide for an adequate submucosal tunnel to ureteral diameter ratio without causing potentially obstructing anatomy.

EXTRAVESICAL TECHNIQUES

Extravesical Tunnel, Open Technique (Lich-Gregoir) (Figs. 111-18, 111-19, and 111-20)

Place a Foley catheter per urethra sterilely on the operative field into the bladder. Fill the bladder by gravity with sterile irrigant. (Alternatively, if cystoscopy is performed before ureteroneocystostomy, leave the bladder distended after completion of cystoscopy.) Approach the bladder extraperitoneally as described for the transvesical techniques described above. Isolation of the ureter is facilitated by identification of the obliterated umbilical artery, which may be ligated and divided; the course of the ureter is just below this landmark. Identify and isolate the ureter, passing a vessel loop posterior to the ureter to provide atraumatic traction. Dissect caudally toward the bladder hiatus.

Incise the detrusor muscle along the intended path of the submucosal tunnel with electrocautery. Continue dissection of the ureter outside of Waldeyer's sheath down to the urothelium, which will appear as a translucent bluish layer with the bladder full. Dissect detrusor flaps from the urothelium perpendicular to the submucosal tunnel with a combination of blunt and electrocautery dissection. Any small violation of the urothelium can be repaired with 5-0 chromic figure-eight sutures. Lay the ureter into the tunnel and close the detrusor muscle over the ureter with 2-0 polyglactin simple interrupted sutures.

External Tunnel (Barry) (Figs. 111-21, 111-22, and 111-23)

This technique has been described for use in renal transplantation. Approach the bladder as described for the extravesical tunnel, open technique. Place a traction suture cephalad and medial to the intended site of reanastomosis. Make two 2-cm transverse incisions, 3 cm apart, through the seromuscular layers of the bladder down to the mucosa. Pass a right-angle clamp in the submucosal space between

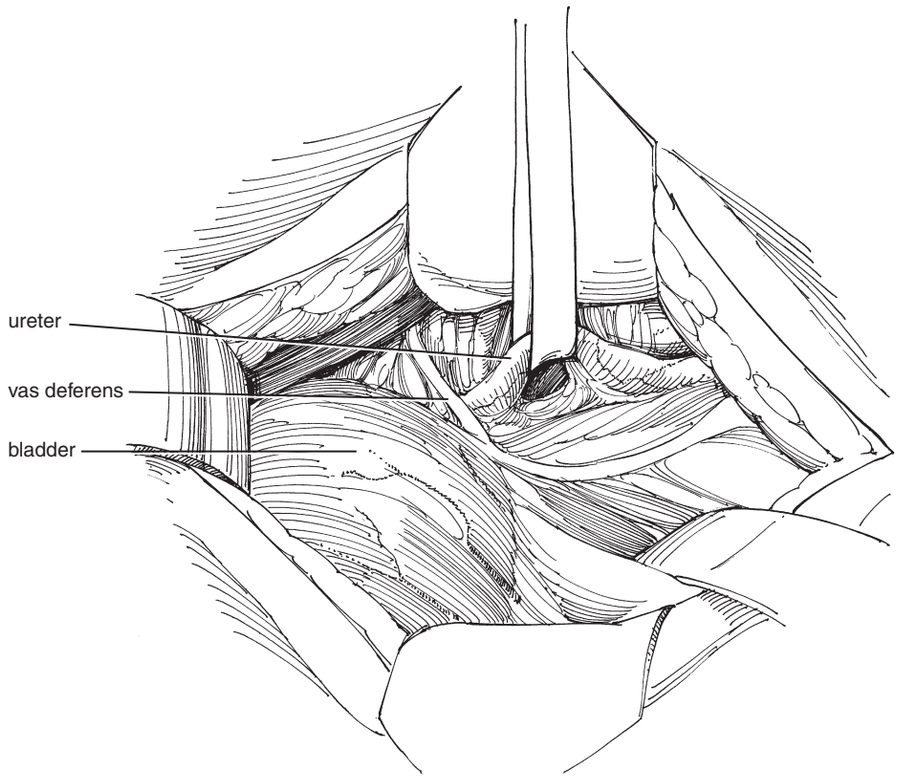

FIGURE 111-18.

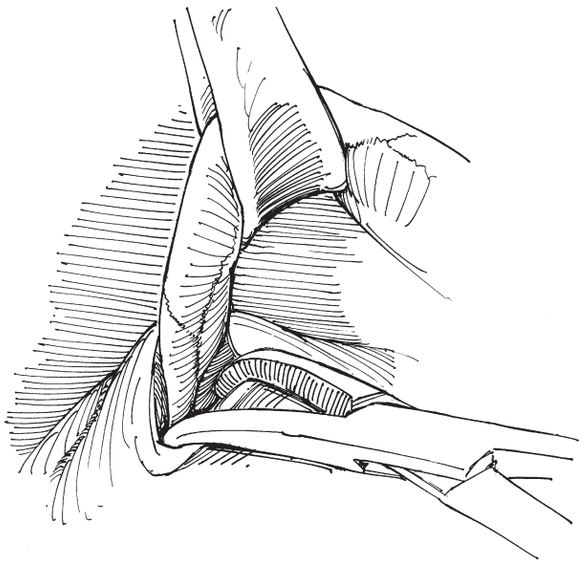

FIGURE 111-19.

these two incisions. Spread the right-angle clamp in this submucosal tunnel to the full 2 cm width of the two transverse incisions. Incise the mucosa of the caudal incision sharply. Spatulate the ureter to be reimplanted and pass it from the cephalad to the caudal incision. Place 4-0 polyglactin sutures approximating the ureter to the urothelium at the apex and at the 3- and 9-o'clock positions. Place one 4-0 polyglactin suture at the 12-o'clock position as a horizontal mattress suture through the full thickness of the bladder beginning on the serosal side of the bladder. Close the caudal incision with 3-0 polyglactin simple interrupted sutures reapproximating the seromuscular layers.

For duplicated ureters, spatulate both ureters on the side that will ultimately be placed toward the bladder lumen. Approximate the adjacent walls of the spatulated ureters with simple interrupted 6-0 polyglactin sutures. When anastomosing the ureters to the bladder, initially approximate both apices to urothelium with 4-0 polyglactin simple interrupted sutures.



FIGURE 111-20.

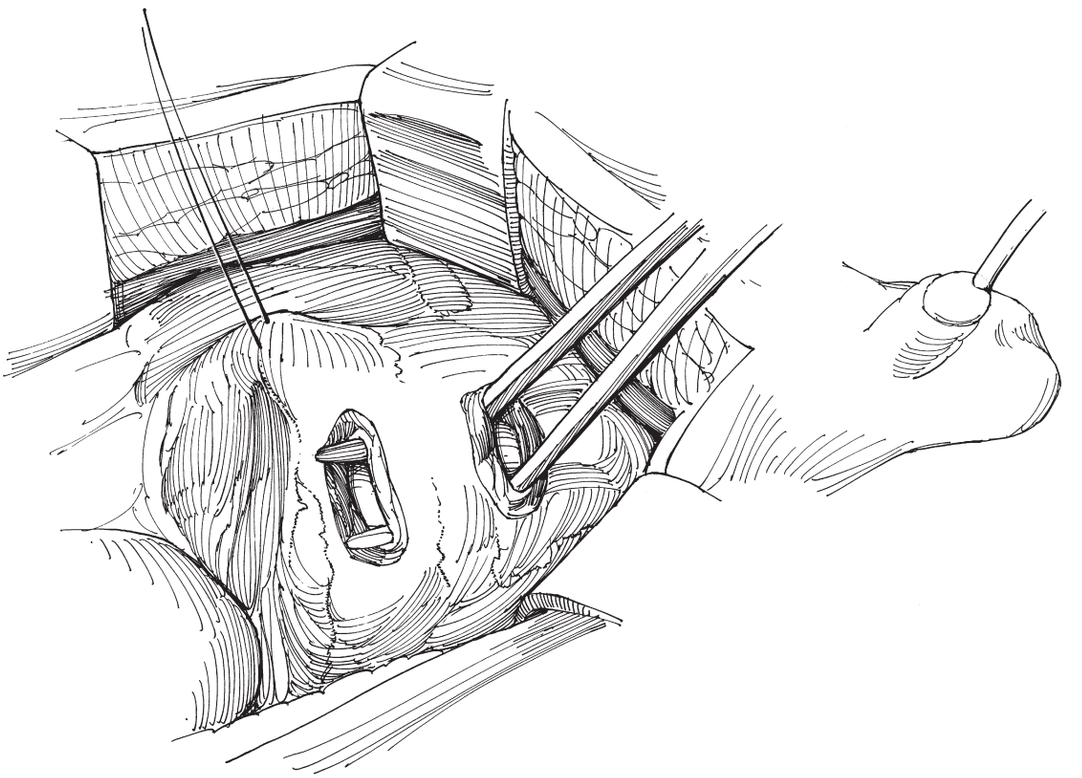

FIGURE 111-21.

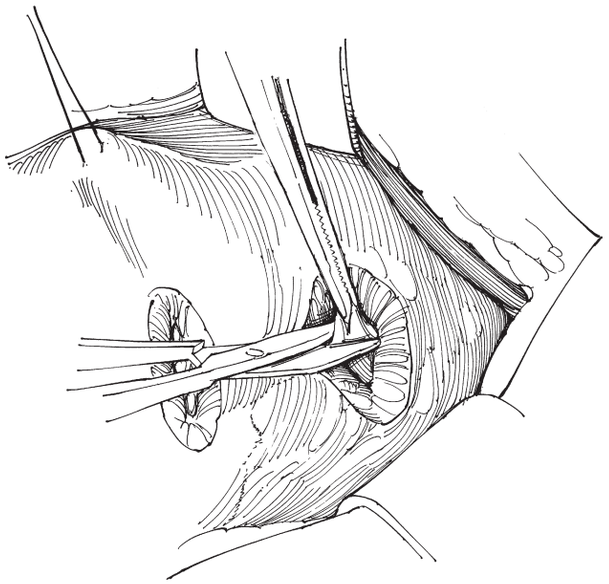

FIGURE 111-22.

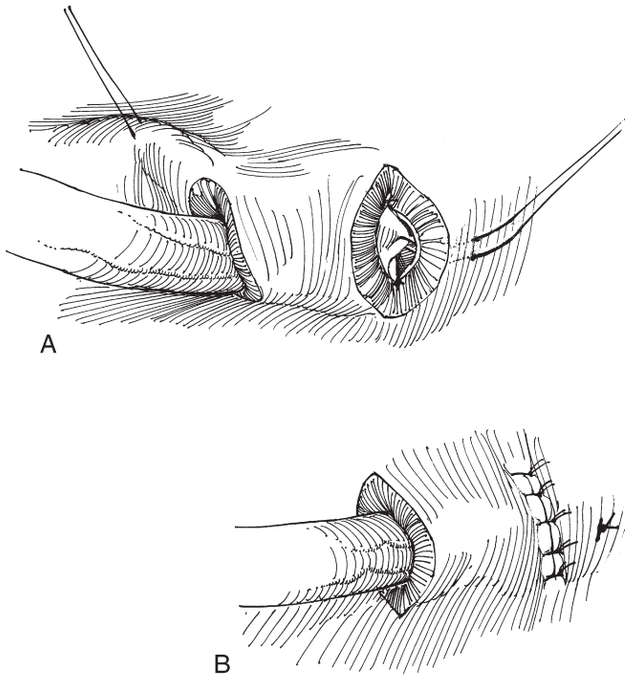

FIGURE 111-23.

Detrusorrhaphy (Hodgson-Firlit-Zaontz) (Figs. 111-24 and 111-25)

Approach the bladder and ureter to be reimplanted as described for the extravesical tunnel, open technique. Place a vessel loop around the ureter for traction. Dissect the ureter distally to the bladder. Incise the seromuscular layers of the bladder using electrocautery, following the course of the ureter down to the submucosa, remaining outside of Waldeyer's sheath. Dissect the submucosa from the detrusor circumferentially around the ureteral orifice. Place two 4-0 polyglactin sutures through the seromuscular layers of the bladder and ureter. Begin at the 5-o'clock position outside the bladder. Pass the suture through the serosa and muscularis and proceed through the seromuscular layer of the ureter in a caudal to cephalad orientation. Finally, pass this suture through the seromuscular layers of the bladder near the site of entry to produce a mattress type vest suture. Repeat this process at the 7-o'clock position. Close the detrusor muscle over the ureter with 3-0 polyglactin sutures, thereby producing the submucosal tunnel.

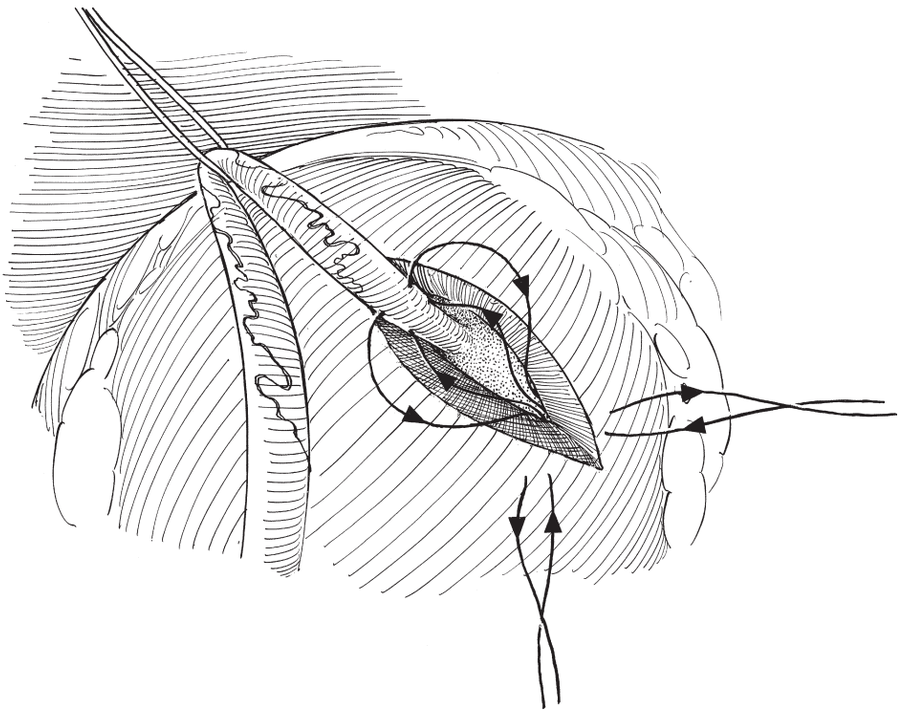

FIGURE 111-24.

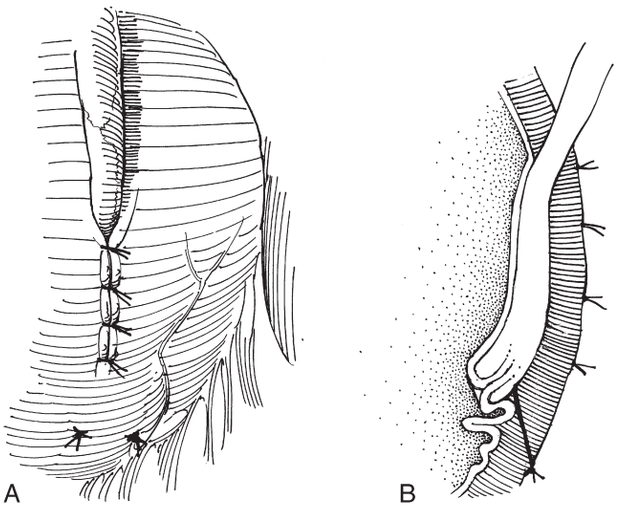

FIGURE 111-25.

Intra-Extravesical Technique (Paquin)

Approach the bladder and ureter to be reimplanted as described for the extravesical tunnel, open technique. Place a vessel loop around the ureter for traction. Dissect the ureter distally to the bladder serosa. Ligate the ureter just outside the bladder and divide it from the bladder with electrocautery.

Make an oblique cystotomy, beginning just anterior to the dome of the bladder on the intended side of reimplantation. Extend this incision posteriorly to the site of the neohiatus. From this point, develop a submucosal tunnel towards the original ureteral orifice. Perform a ureterovesical anastomosis by approximating transmural ureteral tissue with urothelial bladder tissue using 5-0 chromic or 6-0 polyglactin simple interrupted sutures. Close the bladder in two layers using a running 3-0 absorbable suture to reapproximate the urothelium and a running 2-0 absorbable suture to close the seromuscular layer.

POSTOPERATIVE PROBLEMS

Obstruction

In the early postoperative period, obstruction may present with symptoms of oliguria, anuria (following bilateral ureteroneocystostomy), flank pain, acute abdominal pain, nausea, vomiting, prolonged ileus, or sepsis. Acute obstruction following ureteroneocystostomy is most often caused by edema; however, it may also result from bladder spasms, intramural or submucosal hematoma, or ureteral kinking or twisting. The diagnosis of obstruction is made by the finding of hydroureteronephrosis by sonography. Although mild hydroureteronephrosis in the first few weeks is not unexpected postoperatively, hydronephrosis which appears greater on sonography than on preoperative voiding cystourethrography is particularly concerning for obstruction. The diagnosis of obstruction is confirmed by nuclear renography.

Acute obstruction can often be managed conservatively, in that the vast majority of cases are transient. When urine output remains adequate, observation alone may be sufficient. In the presence of oliguria, or even anuria, management by fluid boluses with or without diuretics may suffice. Alternatively, when drainage is indicated, it may be accomplished either by percutaneous nephrostomy tube placement or by endoscopic

placement of indwelling ureteral stents. Drainage is mandatory in the presence of sepsis. Endoscopic ureteral stent placement may be difficult in the acute postoperative period when edema and hematuria are maximal or when cross trigonal reimplantation is performed. One advantage of percutaneous nephrostomy tube drainage is the ability to perform antegrade nephrostography, which may ultimately reveal resolution of obstruction. When percutaneous nephrostomy tube drainage is performed, some advocate early internalization to prevent a "dry anastomosis."

Obstruction, which persists or develops beyond the early postoperative period (up to three weeks) is most often caused by ureteral angulation or kinking, ureteral twist, ischemia, or extravesical scar tissue. Ureteral angulation or kinking can be produced by creation of a neohiatus in a position which is too high or lateral or when the ureter traverses the peritoneum. With the "high reimplant phenomenon," when the neohiatus is placed too high or lateral, ureteral drainage may improve when the bladder is empty; it may ultimately resolve but often requires reoperation. Ischemia, produced by aggressive ureteral dissection, too tight of a neohiatus, or ureteral twist, leads to stricture formation. Urinary diversion by percutaneous nephrostomy tube drainage or ureteral stenting can serve as a temporizing measure, but persistent obstruction often requires reoperation. Ischemia at the level of the ureteral orifice most often occurs at the apex of the ureteral spatulation. This may be treated by endoscopic dilation and stenting or by incision of the ureteral roof, provided that the resultant submucosal tunnel length remains sufficient. Extravesical scarring, exacerbated by extravasation (usually following ureteral tapering), causes extrinsic obstruction and often requires reoperation.

Persistent or Recurrent Vesicoureteral Reflux

Persistent vesicoureteral reflux following ureteroneocystostomy for up to 3 months may be observed while postsurgical inflammation resolves. The majority of early persistent reflux will resolve without any further intervention. Vesicoureteral reflux which persists beyond this period is rare when the preoperative grade is low. Persistent vesicoureteral reflux beyond 3 months or reflux that recurs after postoperative imaging confirms resolution occurs most commonly in high grades of reflux and rarely resolves spontaneously. It occurs most often when the length of the submucosal tunnel is inadequate for the diameter of the reimplanted ureter, resulting from either a short tunnel or insufficient tapering. An inadequate submucosal tunnel to ureteral diameter ratio may also occur when the ureter retracts secondary to poor fixation of the orifice. When technical failure results in persistent or recurrent vesicoureteral reflux, reoperation is usually required.

Before any intervention for persistent or recurrent vesicoureteral reflux, secondary causes (i.e., neuropathic bladder, voiding dysfunction, and posterior urethral valves) must be ruled out or treated. Whether or not treatment of previously unrecognized secondary causes leads to resolution of persistent or recurrent vesicoureteral reflux, it facilitates successful reoperation, if necessary.

Contralateral Vesicoureteral Reflux

When unilateral ureteroneocystostomy is performed, postoperative vesicoureteral reflux may be discovered in the contralateral ureter between 3% and 18% of the time. It is the most common complication of ureteroneocystostomy. It is more common with higher grades of reflux or duplication in the ipsilateral ureter. It may be the result of failure to be detected on preoperative imaging.

The hallmark of treatment for contralateral reflux is observation, as a high rate of resolution has been observed. Patients should be maintained on prophylactic antibiotics until resolution is documented. Voiding dysfunction should be aggressively investigated and treated. When patients remain asymptomatic without further urinary tract infections, performance of voiding cystourethrography to document resolution of contralateral reflux has become a point of controversy.

Because of the high rate of spontaneous resolution, routine prophylactic reimplantation of the contralateral ureter is not indicated. However, risk factors including history of reflux in the contralateral ureter or abnormal configuration of the contralateral ureteral orifice have been shown to demonstrate significant predisposition for the development of vesicoureteral reflux following unilateral ureteroneocystostomy. Prophylactic reimplantation of such ureters is justified.

REOPERATION

When obstruction persists and is refractory to conservative management, reoperative ureteroneocystostomy is usually the treatment of choice. In the setting of persistent or recurrent vesicoureteral reflux, once secondary causes of reflux have been either eliminated, definitive treatment options include endoscopic management (see Chapter 156) or reoperative ureteroneocystostomy. In general, reoperative ureteroneocystostomy performed for persistent or recurrent vesicoureteral reflux has a higher success rate than when performed for obstruction.

Reoperative ureteroneocystostomy is technically more difficult than initial ureteroneocystostomy, especially when the bladder has undergone multiple operative procedures. Successful reoperative ureteroneocystostomy relies on careful surgical technique and strictly following the principles of adequate ureteral mobilization without skeletonizing its blood supply, positioning the hiatus posteriorly, production of a submucosal tunnel to ureteral diameter ratio of at least five to one, and ensuring that the ureteral course avoids tension, twist, angulation, or kinking. Reoperative ureteroneocystostomy requires long-term follow-up with imaging, as delayed obstruction can develop up to ten years postoperatively.

Although any of the open techniques of ureteroneocystostomy may be used in the reoperative setting, higher success rates have been reported with a combined intravesical and extravesical approach (e.g., Paquin). A lower abdominal, vertical midline incision should be made for reoperative ureteroneocystostomy. This allows excellent exposure for the combination of transvesical and extravesical

techniques and permits cephalad extension to provide more proximal exposure of the ureter. This is especially important when ureteral length is compromised by ischemia or scar tissue. Any such ischemic segment should be dissected and excised and adequate vascularity of the remaining ureter should be assured. A new hiatus and submucosal tunnel should be constructed during reoperative ureteroneocystostomy.

Management of the shortened ureter can be particularly challenging in reoperative ureteroneocystostomy. Use of a psoas hitch (which can be combined with Boari flap) can be a useful adjunct for gaining additional length. Additionally, immobilizing the neohiatus helps to overcome issues with angulation related to filling and emptying of the bladder. To reduce the incidence of angulation, it should be performed prior to construction of the neohiatus. The limitation of psoas hitch is that it can only be used for unilateral reimplantation.

Another technique which can be useful in the setting of bilateral shortened ureters, both in need of reoperative ureteroneocystostomy, is transureteroureterostomy with reimplantation of one ureter. Transureteroureterostomy can be combined effectively with psoas hitch and/or Boari flap techniques to maximize length. Use of a split nipple valve can be useful for reoperative ureteroneocystostomy when the affected ureter is short and dilated (which makes creation of an adequate submucosal tunnel length to ureteral diameter ratio difficult).

Finally, in the case of extreme foreshortening of the ureter, ureteral substitution with colon or ileum reconfigured as a Monti channel can be particularly effective. Reconfiguration of bowel into a Monti channel produces a long, narrow tube with a very short segment of bowel. This facilitates creation of an adequate submucosal tunnel length to ureteral diameter ratio and avoids the majority of metabolic consequences associated with the use of bowel for urinary diversion.

Commentary by

GARY J. FAERBER

In adults the importance of creating a non-refluxing anastomosis is not as paramount as it is in the pediatric patient where the primary indication for ureteroneocystostomy is vesicoureteral reflux. Adult distal ureteral injury is often of iatrogenic etiology, and the primary goal of the surgeon should be a patent anastomosis. A refluxing anastomosis in the adult population is rarely clinically important. Spatulation (if the ureter is of normal caliber) or direct reimplantation (if already dilated) with a tension-free anastomosis using interrupted 4-0 absorbable sutures (chromic, polyglactin, or polydioxanone) can be performed using either an intravesical or extravesical approach.

Chapter 112

Psoas Hitch

NEIL D. SHERMAN

The psoas hitch procedure is used when injury to the distal one third of the ureter precludes a direct reimplant. With this technique, the defect may be bridged by bringing the bladder to the healthy proximal ureter and anchoring it to the psoas muscle. Compared with other upper tract reconstructive procedures, the psoas hitch procedure is relatively simple and requires minimal mobilization to the proximal ureter. Not uncommonly, a psoas hitch is used in conjunction with other complex ureteral reimplants, requiring a Boari flap, transureteroureterostomy, or ileal substitution. There are no absolute contraindications to the technique, although a small, contracted bladder may not allow for adequate bladder mobilization. In addition, bladders that have been exposed to previous pelvic irradiation or surgery may have a compromised blood supply from excessive mobilization.

Preoperatively, the ureteral defect may be imaged with intravenous pyelogram, antegrade nephrostogram, and/or retrograde pyelogram. A preoperative cystogram can be performed to evaluate bladder size. Urodynamic studies may be indicated to evaluate detrusor capacity and compliance. Outlet obstruction and neurogenic voiding dysfunction should be treated preoperatively. If the patient has an internal ureteral stent consider removing it and draining the kidney with a percutaneous nephrostomy tube to allow the full extent of diseased ureter to manifest itself. The urine should be sterilized preoperatively.

Position: The patient is placed supine on the operating table and sequential compressive devices are placed on the lower extremities. The Foley catheter should be placed such that the surgeon has access, during the procedure, to fill and drain the bladder.

The bladder is infused with 200 mL of sterile water via Foley catheter at the start of the procedure. Exposure is via a midline or Pfannenstiel incision, preferably remaining extraperitoneal. The peritoneum is reflected medially to expose the ureter and bladder dome (Fig. 112-1). Reoperations may require an intraperitoneal approach. The healthy ureter is identified proximal to the obstruction and a vessel loop is placed around it. Free the vas in males or the round ligament in females. Ureteral dissection continues distally to the level of obstruction, with care being taken not to disrupt the blood supply of the ureter.

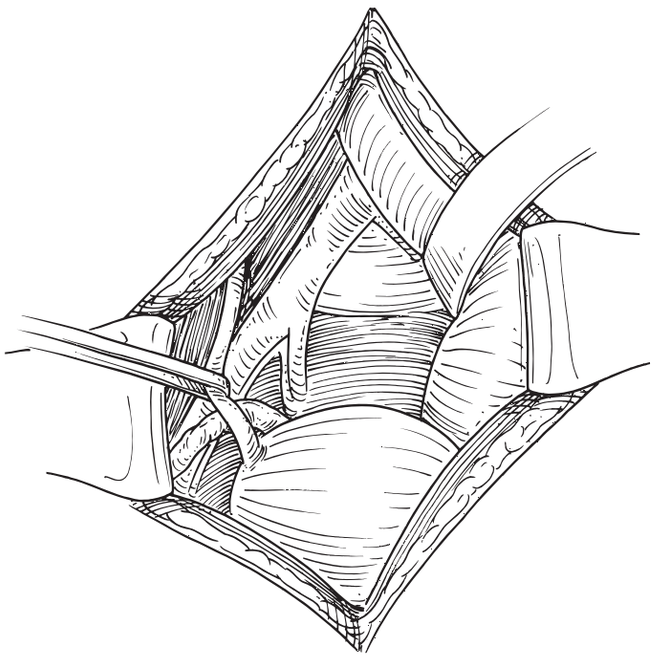

FIGURE 112-1.

The ureter is transected at the proximal limit of disease and a stay suture is placed in it. If necessary, a ureteral biopsy may be performed. The distal ureteral stump is ligated with a 2-0 absorbable suture.

Before bladder incision, evaluate the bladder's mobility by placing the dome on traction to ensure that it will reach above the level of the ipsilateral iliac vessels. Once mobility is confirmed, place stay sutures above the midpoint of the anterior bladder wall. Using cutting current, an oblique bladder incision is carried out between the stay sutures at the maximum diameter of the bladder (see inset in Fig. 112-1). The incision should be extended just more than halfway around the bladder (Fig. 112-2). If the cystotomy is not large enough, then cephalad movement of the bladder may be limited.

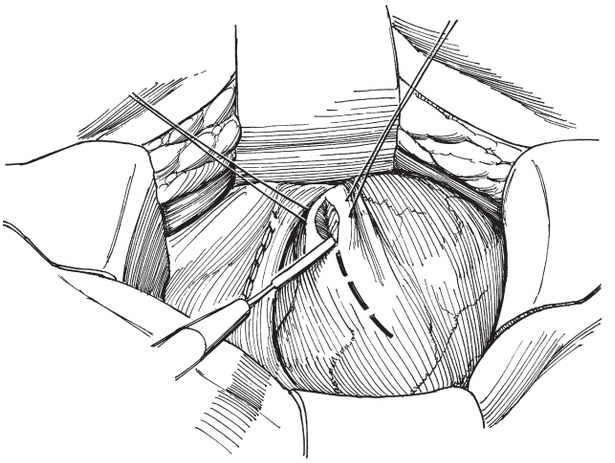

FIGURE 112-2.

Bladder mobility can be improved by releasing peritoneal attachments and the contralateral perivesical attachments. Often these maneuvers provide enough bladder flexibility. When necessary, the contralateral superior vesical artery may be ligated. Via the cystotomy, two fingers are placed into the bladder dome and it is elevated above the iliac vessels and onto the psoas muscle (Fig. 112-3).

If it appears that the anastomosis will be on tension, lateral relaxing incisions can be made into the oblique bladder incision, which is vertically oriented once it is placed on stretch. Although not routinely needed, the kidney can also be mobilized downward. If, after these maneuvers, the ureteral anastomosis remains on tension, then another procedure should be considered.

Three to five slowly absorbing sutures (2-0 Vicryl) are placed into the bladder muscle (not into mucosa) and then into the psoas muscle. Attempt to incorporate psoas minor tendon, if present, into the suture. Avoid the genitofemoral nerve. All sutures should be placed before individual sutures are tied (Fig. 112-4). Deliver the ureter into the bladder (see next step) before tying the psoas sutures. An assistant should elevate the bladder while the sutures are tied. Avoid tying sutures too tightly so that psoas muscle necrosis does not occur.

The ureter is delivered into the bladder at the superolateral aspect of the bladder dome. A traction suture on the ureter assists in this maneuver (Fig. 112-5). This location is less mobile than the lateral bladder and allows for a straight ureteral course that will not kink with bladder filling. A tunneled

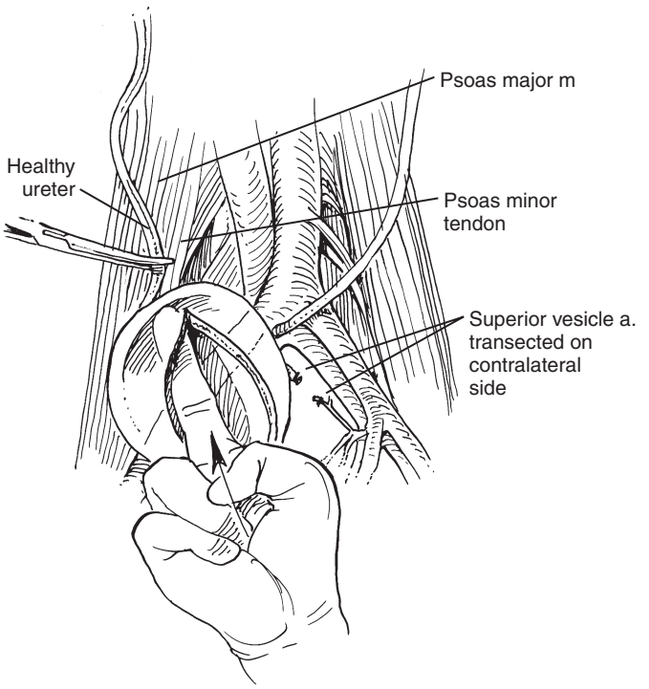

FIGURE 112-3.

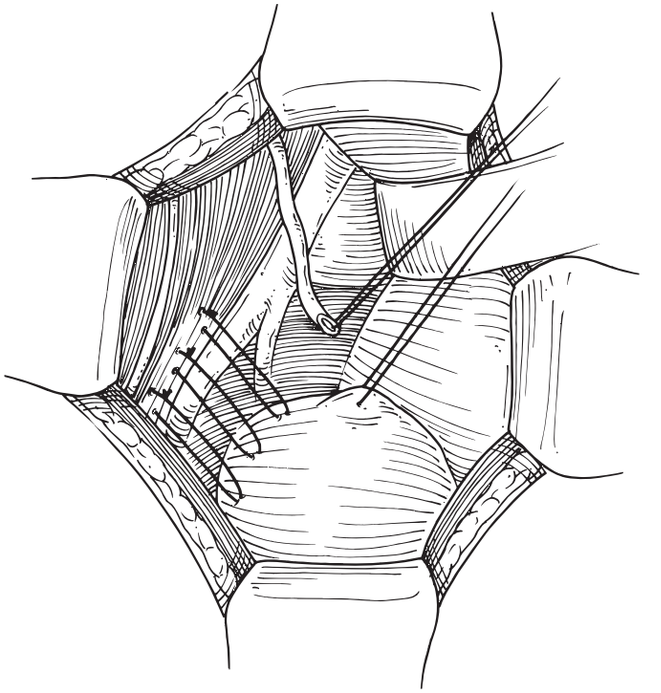

FIGURE 112-4.

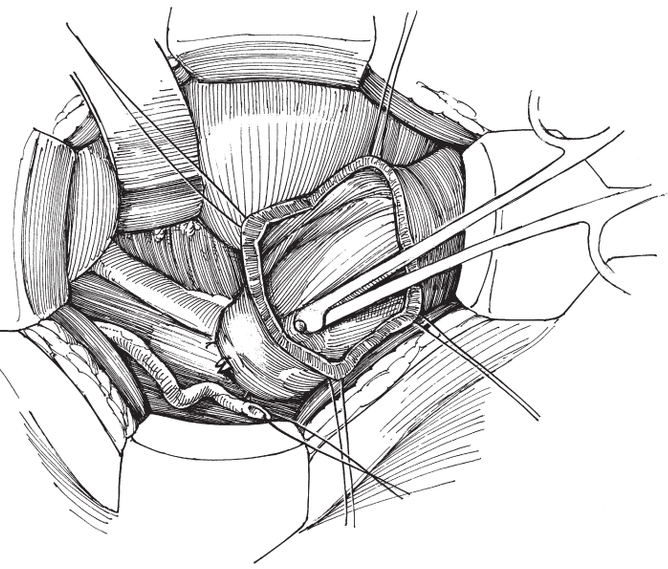

FIGURE 112-5.

nonrefluxing ureteral anastomosis is preferred, but not mandatory.

Once passed into the bladder, the ureter is spatulated on the anterior surface. Interrupted 4-0 Vicryl suture is used to complete the ureteral anastomosis. At the distal aspect of the anastomosis at least one suture should incorporate the posterior ureteral wall and detrusor muscle to ensure that the ureter does not retract. The remaining sutures are through ureteral and bladder mucosa only (Fig. 112-6).

Use interrupted 4-0 Vicryl to tack the ureteral adventitia to the bladder wall at the exit site.

The ureter is generally stented with either an internal ureteral stent or an externalized tube. Typically a urethral catheter is all that is necessary for bladder drainage. If there is concern for hematuria or if bladder closure is tenuous, then a suprapubic tube may be placed. A watertight bladder closure is performed in two layers (mucosal and seromuscular) with absorbable suture (Fig. 112-7). A drain may be left for postoperative monitoring.

Follow-up. Before removing the Foley catheter, a cystogram (Fig. 112-8) is performed, 7 to 10 days after surgery, to confirm bladder healing. A ureterogram via an externalized stent, or a retrograde pyelogram if a JJ stent is used, should be performed prior to stent removal.

COMPLICATIONS

Persistent urine leakage is the most common problem. Typically the leak seals with appropriate drainage and time. Consider radiographic imaging if a urinoma is suspected. Patients should have routine radiographic follow-up because of the risk for recurrent obstruction from ureteral stricture.

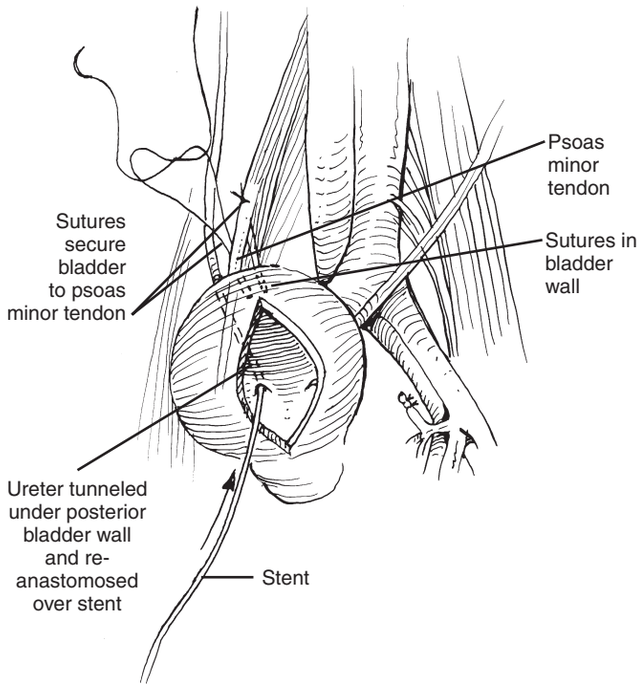

FIGURE 112-6.

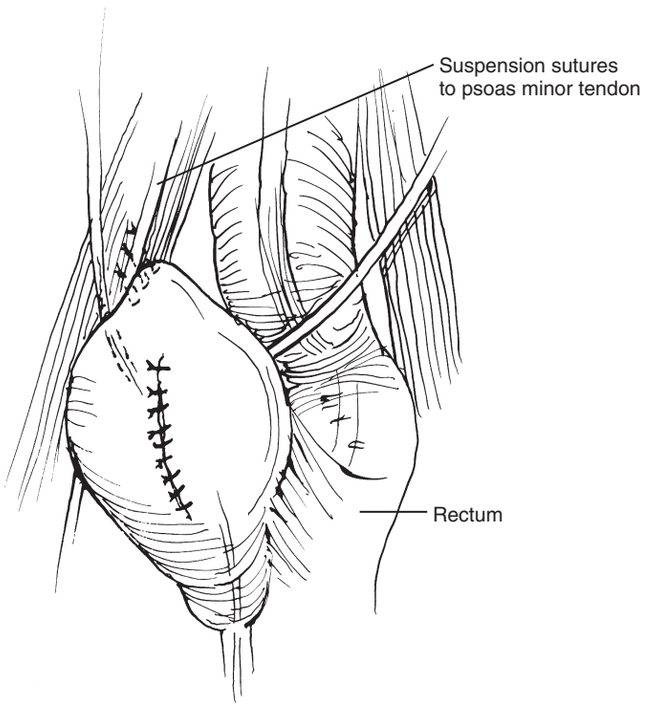

FIGURE 112-7.



FIGURE 112-8. Cystogram displaying bladder configuration after psoas hitch procedure.

Suggested Readings

Hsu THS, Streem SB, Nakada SY. (2007). Management of upper urinary tract obstruction. In Wein AJ, Kavoussi LR, Novick AC, Partin AW, Peters CA, eds. Campbell-Walsh urology, 9th ed. Philadelphia: WB Saunders.

Mathews R, Marshall FF. (1997). Versatility of the adult psoas hitch ureteral reimplantation. J Urol 158:2078.

Turner-Warwick R, Worth PHL. (1996). The psoas hitch procedure for the replacement of the lower third of the ureter. Br J Urol 41:701.

This page intentionally left blank

Chapter 113

Bladder Flap Repair (Boari)

JENNIFER T. ANGER

The psoas hitch is often sufficient to bridge most distal ureteral gaps. However, rarely a gap is of such length that a psoas hitch is not sufficient. In such instances, a Boari-Ockerblad flap provides the needed length to create a tension-free anastomosis between the ureter and the bladder. If both ureters are diseased or injured, bilateral Boari flaps may be created if bladder capacity permits.

Position: Supine. Sterile placement of a Foley catheter facilitates intraoperative bladder filling.

Incision: Either a lower midline incision or a Pfannenstiel is suitable. The incision may be determined by a previous surgical scar from the operation that caused the distal ureteral injury.

When minimal ureteral fibrosis is present, an extraperitoneal approach is ideal. The peritoneum is mobilized medially, along with either the round ligament or the vas deferens, to expose the proximal ureter. When extensive ureteral scarring has occurred, an intraperitoneal approach through a midline abdominal incision is ideal, in that a retroperitoneal approach may risk injury to the iliac vein during ureteral mobilization. In order to expose the normal ureter above the defect, it is usually best to identify the ureter at or above the level of the bifurcation of the common iliac artery. The colon is reflected medially and the posterior peritoneum is opened along the lateral gutter. Identify and encircle the ureter with either a Penrose or a vessel loop, then dissect the ureter distally as far as possible, until the defect or diseased portion is reached.

The bladder flap is prepared by freeing the peritoneum off the posterolateral surface of bladder. This can be aided by infiltration with saline. If possible, this peritoneum can later be used to cover the Boari flap anastomosis. Bladder mobilization is also facilitated by isolation and division of the urachal remnant.

If practical and necessary, excise the diseased portion of ureter and ligate the distal ureteral stump. Place a fine stay suture on the distalmost aspect of the proximal healthy ureter. The bladder must be fully mobilized on the opposite side of the planned Boari flap. This includes division of the superior vesicle pedicles and, rarely, the inferior vesicle pedicles. A psoas hitch alone may be feasible once the bladder is fully mobilized. If the bladder does not reach the ureter, then proceed with the Boari flap creation. With the bladder distended, use an umbilical tape to measure the length of flap needed to bridge the defect, extending from the posterior bladder wall to the proximal cut end of the ureter. Mark the outline of the flap with a marking pen. The flap length will depend on the size of the ureteral defect, and the base should be slightly broader than the apex. The flap should be at least 4 cm wide at the base and 2 to 3 cm at the tip (or three times the diameter of the ureter) to avoid constriction of the ureter after tubulization. The longer the flap, the wider must be the base. If greater length is required and bladder capacity permits, an oblique or S-shaped incision can be made.

Place stay sutures just outside of the four corners of the planned flap. Weak coagulating current can be used to re-outline the flap. Empty the bladder and recheck the flap dimensions. With the cutting current, cut through the bladder wall across the distal (narrow) side of the flap (Fig. 113-1), and place two stay sutures in the free corners of the flap. After the flap is created, a 5-French infant feeding tube or stent should be placed in the contralateral ureter to avoid injury during flap closure. Hitch the bladder to the psoas tendon at a location distal to the base of the flap in order to take tension off the ureteral anastomosis and make the anastomosis technically easier.

To allow for a proper submucosal tunnel, the flap should overlap the ureter by at least 3 cm. Ureteral mobilization may be necessary to achieve a tunnel, but care must be taken to leave the adventitia of the ureter intact to avoid ischemia. If the ureter is too short and creating a tunnel results in tension on the anastomosis, omission of a tunnel and creation of a refluxing anastomosis is preferred. This involves a direct anastomosis of the spatulated distal ureteral stump to the edge of the bladder flap with multiple 4-0 Vicryl sutures. If the ureter is still too short or if there is tension on the anastomosis, the kidney can be freed inside Gerota's fascia and moved down to gain an additional 4 to 5 cm of ureteral length.

Dissect the 3 cm submucosal tunnel with Lahey or Metzenbaum scissors after submucosal injection of saline.

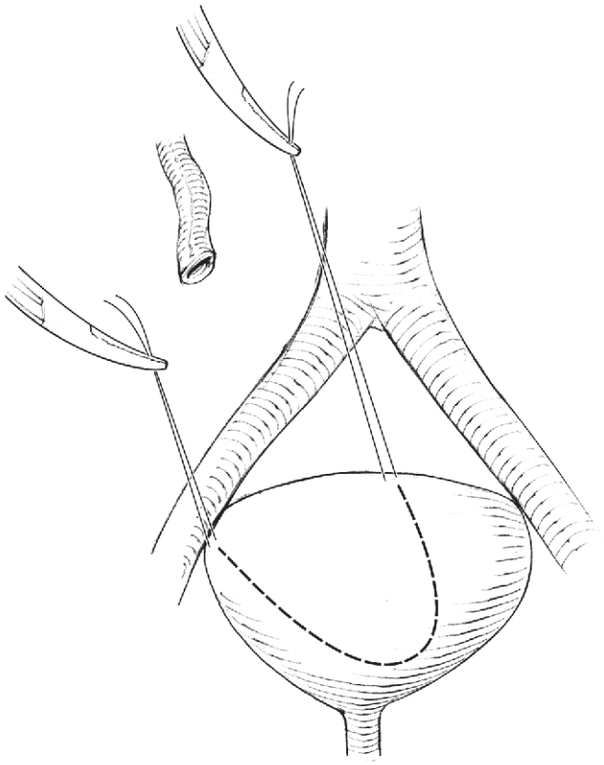

FIGURE 113-1.

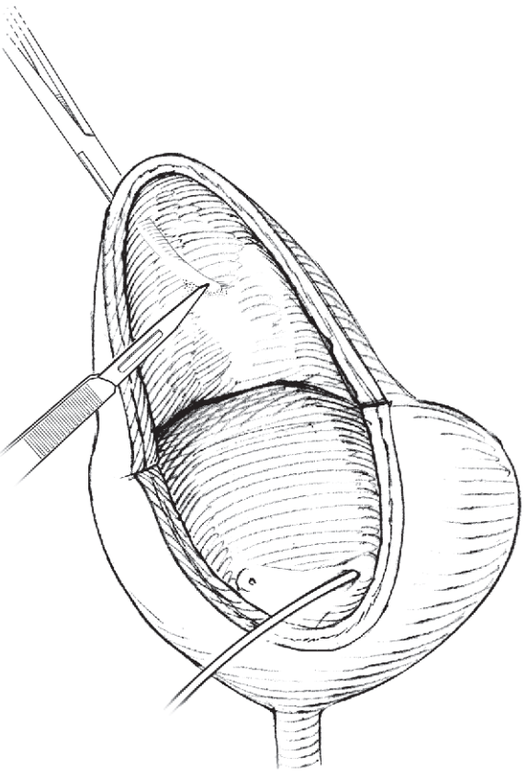

FIGURE 113-2.

Bring the tips of the scissors through the mucosa. The ureter is brought through the tunnel with the use of an 8 French infant feeding tube. The broad end of the feeding tube is installed on the closed scissors tips and drawn up through the tunnel (Fig. 113-2). Suture the tube to a ureteral stay suture, and draw the ureter through the tunnel (Fig. 113-3). The ureter is then spatulated obliquely. The superior end of the Boari tube is fixed the psoas minor muscle and tendon with 3-0 Vicryl, with care taken to avoid the ilioinguinal and genitofemoral nerves. This further prevents tension on the anastomosis. The apex of the ureter is then anchored to the bladder wall (mucosa and muscularis) with a 4-0 Vicryl suture, and the anastomosis is completed with multiple interrupted sutures (Fig. 113-4).

Before closing the bladder tube, a stent must be placed. Traditionally, a feeding tube is placed in the ureter, tacked to the bladder mucosa, brought through a stab incision through the bladder and body wall, and fixed to the skin with a 2-0 silk suture. Alternatively, a double-J stent can be placed into the renal pelvis over a wire before closing the bladder, avoiding the need for external drainage. Close the bladder tube and bladder in two layers. A running 4-0 Vicryl suture can be used to close the mucosal layer, followed by a second row of interrupted 4-0 Vicryl sutures through the muscularis and adventitia. Peritoneum overlying the bladder can be further mobilized and used to cover the anastomosis by tacking it to the bladder serosa with multiple absorbable sutures. Drain the bladder with either a suprapubic or urethral catheter. Place

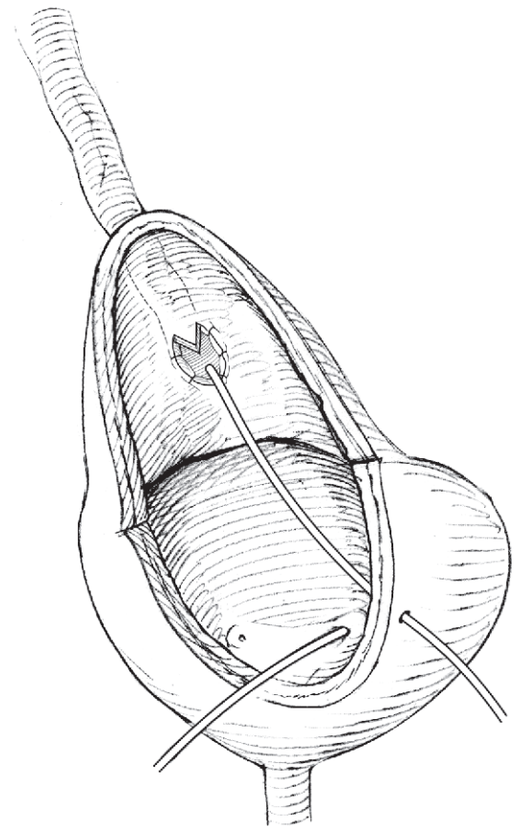

FIGURE 113-3.

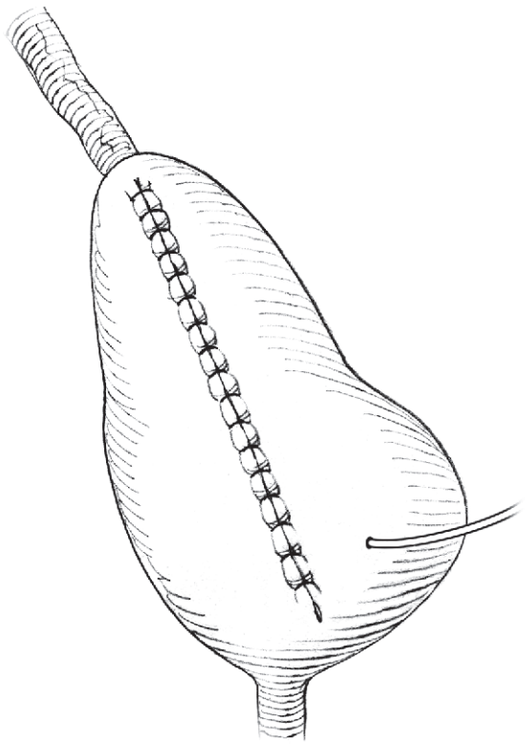

FIGURE 113-4.

additional sutures to approximate the superior end of the Boari flap to the adventitia of the ureter. Verify that the bladder is well secured to the psoas tendon at the base of the tube (psoas hitch). Place a Penrose or closed suction drain retroperitoneally. For an externalized stent, the stent is typically removed on the eighth postoperative day and the bladder catheter 2 days later if there is no increase in Penrose drainage. For an internalized double-J stent, it is prudent to perform a cystogram before stent and catheter removal.

Postoperative complications. Anastomotic leakage may occur after the Boari flap, so ureteral stenting, a bladder catheter (either urethral or suprapubic), and external pelvic drainage are crucial. Injury to the opposite ureter may occur and should be suspected if the patient develops flank pain. Intraoperative catheterization of the opposite ureter before Boari flap closure can aid in avoiding this complication. Stricture of the anastomosis of the ureter to the bladder can occur if ureteral spatulation is inadequate, the blood supply to the distal ureter is compromised, or the anastomosis is under tension. An inadequate tunnel may result in vesicoureteral reflux, which may not be clinically significant. In cases of a long distal ureteral defect in which a tunnel cannot be created without tension, the Boari is purposefully placed in a refluxing fashion without a tunnel.

Commentary by GARY J. FAERBER

The Boari flap is a dependable and versatile surgical technique that should be in all urologists' armamentarium when managing ureteral injury or stricture. Assessment of bladder volume is very helpful when entertaining the use of a Boari flap. I recommend performing a cystometrogram to assess bladder volume. Patients with a history of prior bladder surgery, pelvic irradiation, or neurogenic bladder may have small capacity or poorly compliant bladders, rendering them poor candidates for Boari flap reconstruction.

I use a Y-type connector to the Foley catheter to allow for easy emptying a filling of the bladder which is extremely helpful in planning out the bladder flap. I prefer a midline, intraabdominal approach, especially for mid or proximal ureteral strictures. I also widely develop the space of Retzius using blunt dissection. This provides easier access to the anterior bladder to create the bladder flap. As the authors stated, division of the contralateral superior vesical pedicles allows significant mobilization of the bladder and this maneuver alone may result in sufficient length enough for a psoas hitch and preclude the need to perform a bladder flap.

I anastomose my ureteral stump to the bladder mucosa with two running vascular anastomotic sutures using a 4-0 polydioxanone (PDS, Ethicon). If the ureter is dilated (often the case in patients with long-standing distal ureteral obstruction), spatulation is not necessary. Postoperative management consists of a cystogram on postop days 10 to 14. If negative, the Foley is removed and the indwelling stent is left in place for an additional 2 to 3 weeks. A follow-up functional study (intravenous pyelogram, nuclear renal scan, computed tomography urogram) is performed in 4 to 8 weeks following stent removal.

Suggested Readings

Blandy JP, Badenoch DF, Fowler CG, Jenkins BJ, Thomas NW. Early repair of iatrogenic injury to the ureter or bladder after gynecological surgery. J Urol 146:761.

Bowsher WG, Shah PJ, Costello AJ, Tiptaft RC, Paris AM, Blandy JP. (1982). A critical appraisal of the Boari flap. Br J Urol 54:682.

Flynn JT, Tiptaft RC, Woodhouse CR, Paris AM, Blandy JP. (1979). The early and aggressive repair of iatrogenic ureteric injuries. Br J Urol 51:454.

O'Flynn, JD. (1998). Bladder flap repair. In Hinman F. Atlas of urologic surgery, 2nd ed. Philadelphia: WB Saunders, p 822.

Sties JW, Johnson CW, Wilson CS. (1932). Reconstruction of the ureter by a bladder flap. Proc Soc Biol Med 30:425.

Stone AR, Moran ME. (1993). Management of the ureteral defect. In Webster GD. Reconstructive urology. Boston: Blackwell Scientific, Vol 1, pp 343-359.

This page intentionally left blank

Chapter 114

Ureteral Stricture Repair and Ureterolysis

ANDREW C. PETERSON

Ureteral strictures may arise from multiple etiologies including trauma, surgery, infections and malignancy. It is imperative that an accurate diagnosis for the etiology, location, length and possible involvement of surrounding structures is obtained before embarking on any operative repair. Computed tomography, intravenous urography, retrograde pyelography and functional assessment of the involved kidney should all be carried out. We prefer to combine the antegrade nephrostogram with the retrograde pyelogram to obtain an "up and down-o-gram" of the involved segment. This clearly delineates the location and length of the stricture in order to plan the appropriate surgical approach. Function of the involved renal unit must be established, preferably through nuclear medicine imaging before surgery in that less than 20% function indicates a lower success rate for cure and nephrectomy should be considered.

The options for surgical treatments of ureteral stricture ranges from minimally invasive endoscopic techniques (long-term indwelling stent, percutaneous drainage, balloon dilation, laser incision, endoureterotomy) to more complex surgical options including open and laparoscopic technique, which is the subject of this chapter.

The choice of repair is dependent on the location of the stricture. Distal strictures located below the iliac vessels are best managed with ureteral reimplant into the bladder (see later). Strictures of the proximal to midureter may be managed with pyeloplasty (see later), primary ureteroureterostomy, transureterostomy, bowel interposition (see later), nephrectomy (see later), and cutaneous ureterostomy.

Patient position and incision depend again on the location of the diseased segment. For proximal strictures, the flank incision, tip of the 12th rib incision, and subcostal and midline incision all provide adequate exposure. A periumbilical midline incision and extended Gibson incision provide ample exposure for midureteral strictures. Distal strictures needing reimplantation into the bladder are best managed with the infraumbilical midline incision, Gibson incision, or Pfannenstiel incision.

URETEROURETEROSTOMY

"The ureter is a surgically forgiving structure with good vascular supply" (Turner-Warwick). Meticulous surgical dissection and careful technique are required. A spatulated repair can be used in strictures of up to 3 to 4 cm in length because of the ability to mobilize the ureter.

For the proximal to midureteral stricture, place the patient in the supine position and make a midline incision in the abdomen. Place a Bookwalter abdominal retractor in position for adequate exposure.

Incise the white line of Toldt and mobilize the colon, exposing the ureter in the retroperitoneum. The ureter may always be identified lying anterior to the bifurcation of the common iliac artery (Fig. 114-1A).

Mobilize the ureter and place stay sutures (3-0 silk, 18 inch) on the anterior portion of the ureter to help with tissue handling and to identify the anterior portion for the reconstruction after mobilization. These stay sutures also help one avoid handling the ureter and to provide an anastomosis with the no-touch technique (see Fig. 1141B, C). Resect the damaged area (see Fig. 114-1D) and spatulate the two ends for 1.5 cm into good ureter (see Fig. 114D, E). Perform a tension-free, watertight anastomosis using 4-0 and 5-0 polyglycolic acid suture. Do not place suture knots at the apex; put them at the lateral suture margin, starting the running suture line in the middle of the wall and not at the apex (see Fig. 114-1F). Interrupt runs of two to four sutures, locking every third throw. After completing the posterior anastomosis, roll the anterior edges together to complete the repair (see Fig. 114-1G, H).

Place a standard stent (6 French double-J ureteral stent) to be left in place for 6 weeks. Place a suction drain in the vicinity of the repair but not directly on it, and drain the bladder with a Foley catheter. Consider the use of tissue sealant and an omental wrap (see later).

Postoperatively, remove the Foley catheter on day 1. If the suction drain output increases, replace the Foley back into the bladder. Remove the suction drain 24 hours

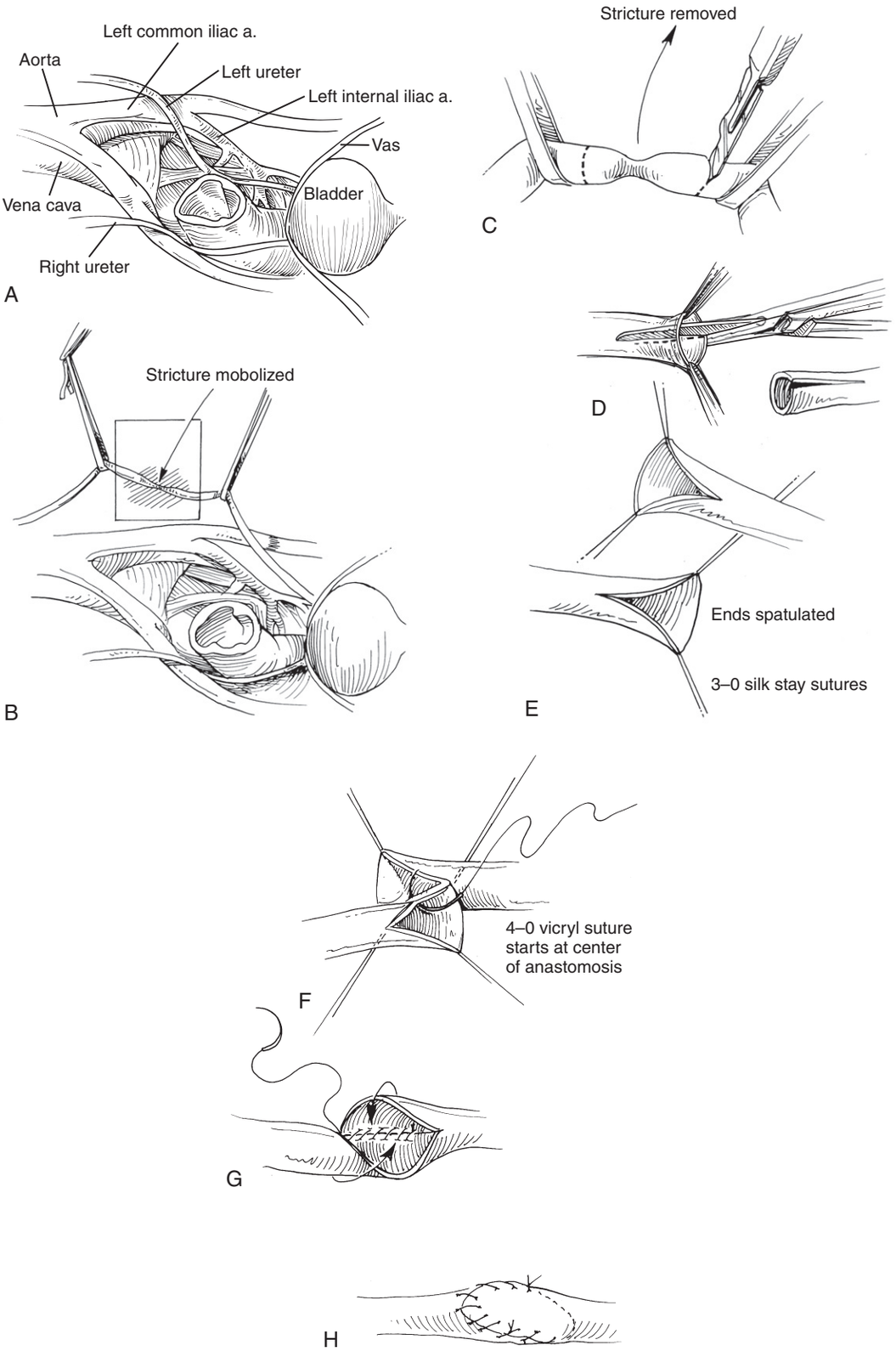
Left common iliac a.
Aorta
Left ureter
Left internal iliac a.
Vas
Bladder
Vena cava
Right ureter
A
Stricture removed
C
Stricture mobolized
B
D
Ends spatulated
3–0 silk stay sutures
E
4–0 vicryl suture
starts at center
of anastomosis
F
G
H

FIGURE 114-1.

after the Foley catheter is removed to ensure a watertight repair.

TRANSURETEROURETEROSTOMY

Transureteroureterostomy is indicated when the distal ureter is obliterated or not suitable for repair. Contraindications for this procedure include any process that may place both of the kidneys at risk for disease or obstruction. These include prior nephrolithiasis, upper tract transitional cell carcinoma, infectious diseases such as tuberculosis, and bilateral ureteral stricture disease. This procedure may also be used for duplicated systems.

Place the patient in the supine position and make a midline incision in the abdomen. Place a Bookwalter abdominal retractor in position for adequate exposure.

Incise the white line of Toldt and mobilize the colon, exposing the ureter in the retroperitoneum. The ureter may always be identified lying anterior to the bifurcation of the common iliac artery into the internal and external iliac arteries (Fig. 114-2A).

Mobilize the ureter and place stay sutures (3-0 silk, 18 inch) on the anterior portion of the ureter to help with tissue handling to provide an anastomosis with the no-touch technique.

Using blunt dissection and a tonsil clamp, create a tunnel in the retroperitoneum posterior to the mesentery of the small bowel inferior to the inferior mesenteric artery. Spatulate the end of the implanted ureter for 1.5 cm into normal ureter. Make a medial ureterotomy to match the spatulated ureter in the recipient ureter (see Fig. 114-2B). Perform a tension-free, watertight anastomosis using 4-0 and 5-0 polyglycolic acid suture. Do not place suture knots at the apex; put them at the lateral suture margin, starting the running suture line in the middle of the wall and not at the apex (see Fig. 114-2C).

Place a standard stent (6 French double J ureteral stent) into the implanted kidney (see Fig. 114-2D) to be left in place for 6 weeks. Place a suction drain in the vicinity of the repair but not directly on it, and drain the bladder with a Foley catheter. Consider the use of tissue sealant and an omental wrap (see later).

Graft and Flap Ureteroplasty

Consider graft and flap substitution for partially obliterating strictures in any location of the ureter. It is essential to rule out malignant etiologies for the ureteral stricture. For the ureter to successfully accept a graft or flap, there must be enough residual lumen within the diseased segment to sew the graft in place.

The choice of tissue is based on availability and surgeon preference. Buccal mucosa, preputial skin, and bladder mucosa all make excellent grafts. Flaps based on bladder (bladder mucosa flap) and bowel have been used with success.

The choice of incision is based on the location of the stricture as described earlier. The patient should have a mechanical bowel prep before surgery and broad spectrum antibiotics given before incision.

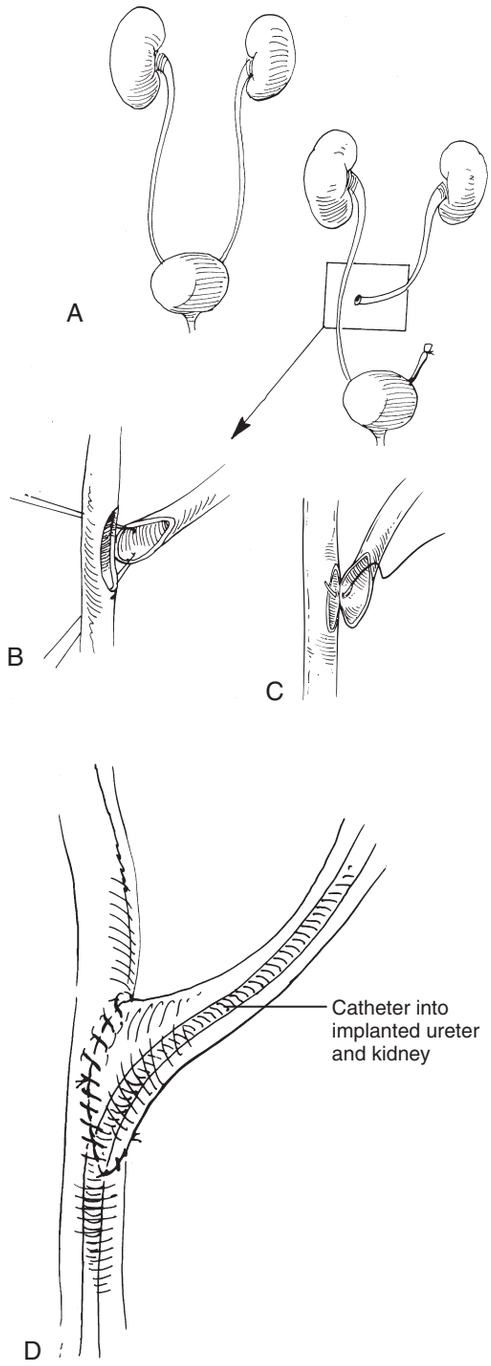

FIGURE 114-2.

Mobilize the bowel from the peritoneum off the strictured segment of ureter leaving the ureter in situ in the retroperitoneum to preserve the blood supply (Fig. 114-3A). Make an anterior ureterotomy with scissors through the diseased portion, extending the incision 1.5 cm into normal ureter both proximally and distally (see Fig. 114-3B, C).

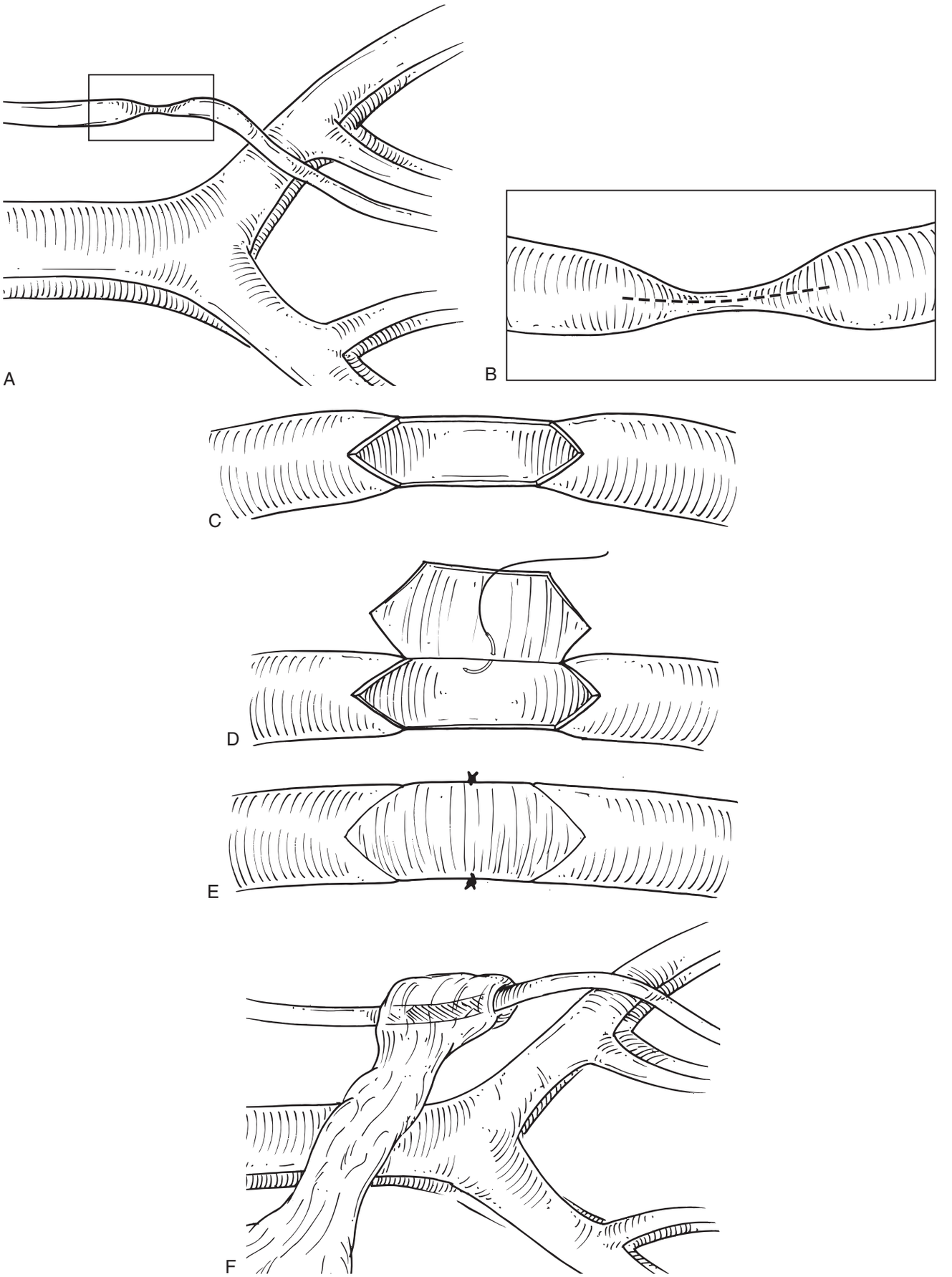

FIGURE 114-3.

Harvest the tissue of choice (e.g., buccal mucosa, preputial skin). Place the tissue anterior onto the strictured segment of ureter, performing a ventral onlay repair with 4-0 and 5-0 polyglycolic acid suture. Do not place suture knots at the apex, put them at lateral suture margin starting the running suture line in the middle of the wall and not at the apex (see Fig. 114-3D, E).

Augment the repair by wrapping it with omentum (see Fig. 114-3F) (see later for omental mobilization). Consider the use of fibrin tissue sealant to aid in performing a watertight repair. Place a standard stent (6-French double-J ureteral stent) to be left in place for 6 weeks. Place a suction drain in the vicinity of the repair but not directly on it, and drain the bladder with a Foley catheter.

Postoperatively, remove the Foley catheter on day 1. If the suction drain output increases, place the Foley back into the bladder. Remove the suction drain 24 hours after the Foley catheter is removed to ensure a watertight repair.

Ureterolysis

Ureterolysis for retroperitoneal fibrosis was first described by Albarran in 1905 and again by Ormind in 1948. The etiology of this disorder may be diverse, with 30% to 40% of cases being idiopathic. However, 10% to 20% are reported to be of a malignant etiology; therefore, it is extremely important to biopsy the retroperitoneal mass before or at the time of ureterolysis. Other known etiologies include trauma, surgical misadventure, abdominal aneurism, medications (methysergide, LSD, amphetamines, phenacetin, bromocriptine, beta blockers), prior radiation therapy, autoimmune diseases, appendicitis, and connective tissue disease.

Procedure: The best long-term results are obtained with surgical displacement of the ureters from the retroperitoneal fibrosis process (ureterolysis).

Make a midline incision from the xiphoid process to the pubic symphysis (Fig. 114-4). Mobilize both the ascending

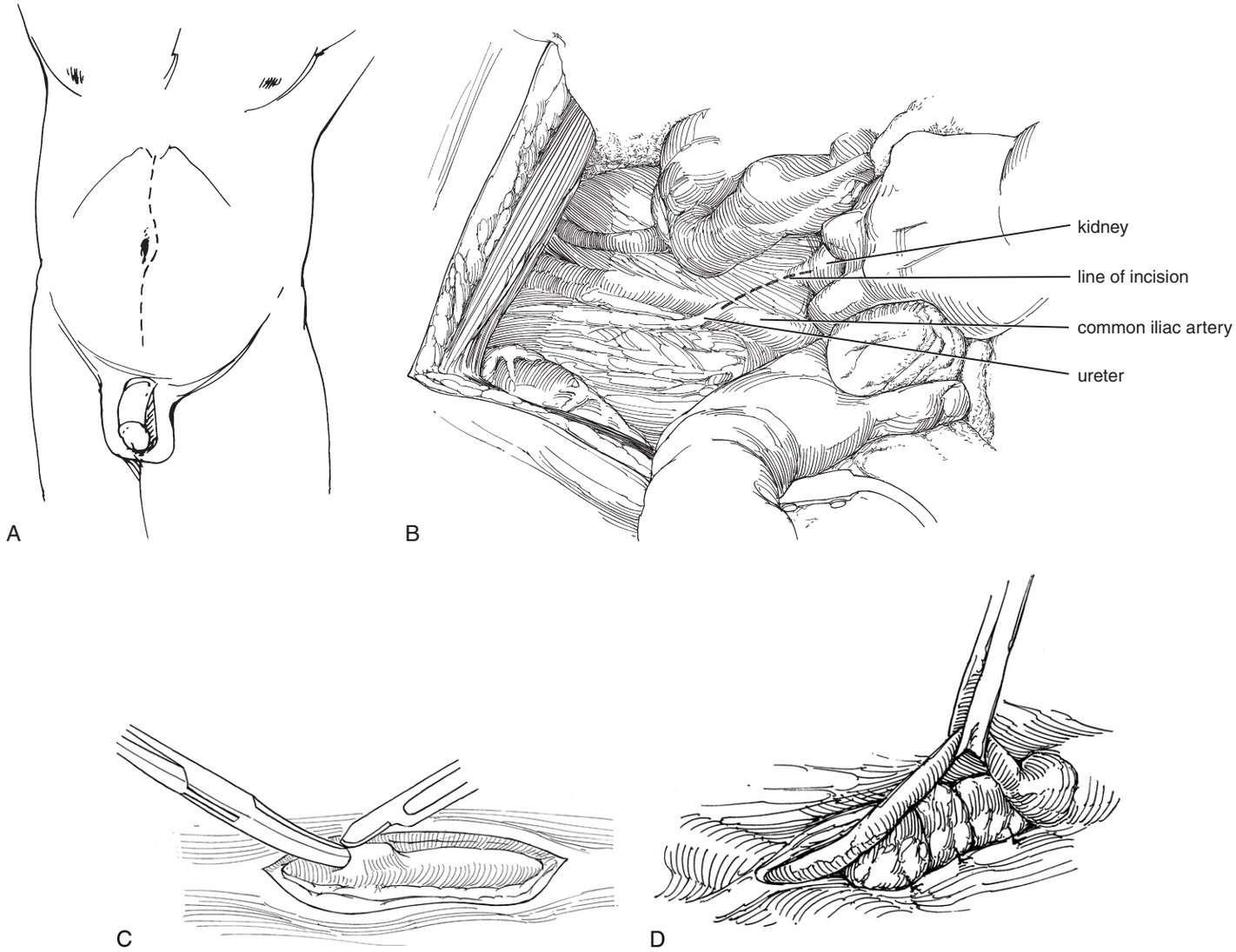

FIGURE 114-4.

Continued

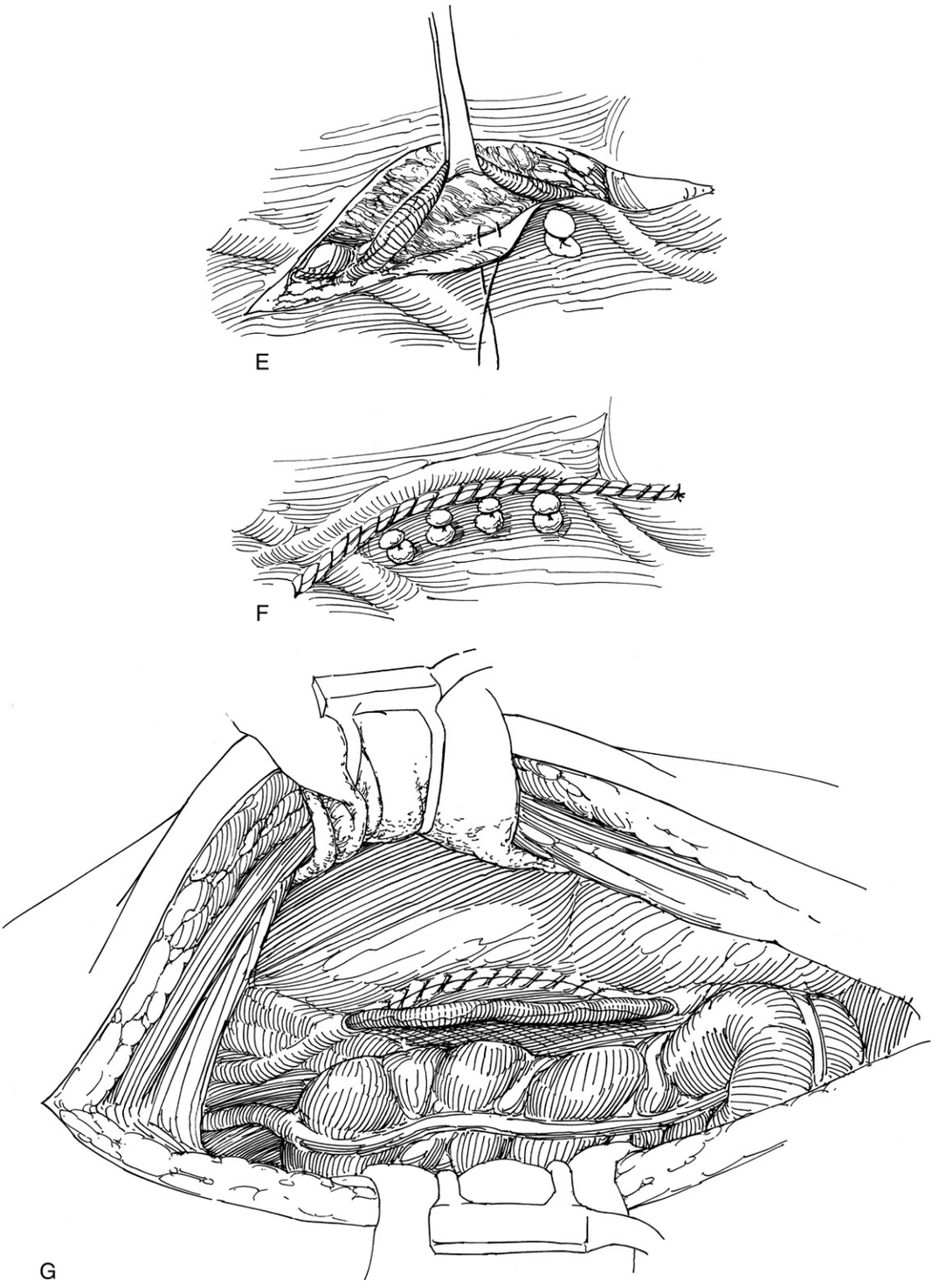

FIGURE 114-4, cont'd.

and descending colon along the white line of Toldt. Start from normal ureter, isolating it and mobilizing it. Hold it in a vessel loop. Work distally or proximally, mobilizing the ureter as it enters into the encased retroperitoneal fibrosis.

Place a right-angle clamp anterior, ventral, and parallel to the ureter and incise sharply through the retroperitoneal fibrosis with Metzenbaum scissors to free the ureter. As the ureter is mobilized and freed from the fibrosis, it often changes color from a constricted white to a healthy pink appearance as blood flow is restored back into the ureter.

Mobilize the ureter laterally and exclude it from the peritoneum.

Obtain deep biopsies of the mass at the time of exploration to ensure that no malignant process is involved. If one ureter is involved in the retroperitoneal fibrosis, consider

bilateral ureterolysis to prevent problems with the uninvolved side in the future.

Perform a Whittaker test to ensure that there is no residual obstruction after ureterolysis.

Laparoscopic Ureterolysis

Bilateral laparoscopic ureterolysis can be performed with three to four laparoscopic ports placed in the midline (Fig. 114-5). Mobilize both ascending and descending colons along the white line of Toldt with sharp dissection and Bovie electrocautery. Send biopsy specimens of the retroperitoneal mass to ensure the diagnosis. Identify the normal ureter bilaterally and mobilize it with a combination of blunt and sharp dissection as described for the open procedure to peel the retroperitoneal fibrosis away from the ureter.

If needed, fix the colon to the anterior abdominal wall with a stapler for retraction during mobilization. Perform either intraperitonealization of the ureter, lateral fixation, or omental wrap to ensure ureterolysis.

Omental Wrap

Divide and bifurcate the omentum by suture-ligating blood vessels with fine silk suture (Fig. 114-6A). Alternatively, tissue-sealing forceps may be used to ensure hemostasis while facilitating dissection. Ligate the short gastric vessels at the level of the gastric wall in the same manner (see Fig. 114-6B). The vasculature is based on the right and left gastroepiploic artery.

Mobilize the bilaterally bifurcated omentum to wrap around the ureter in a 360-degree fashion (see Fig. 114-6C). Secure the ureter to the omental wrap with fine absorbable suture of 4-0 or 5-0 Vicryl.

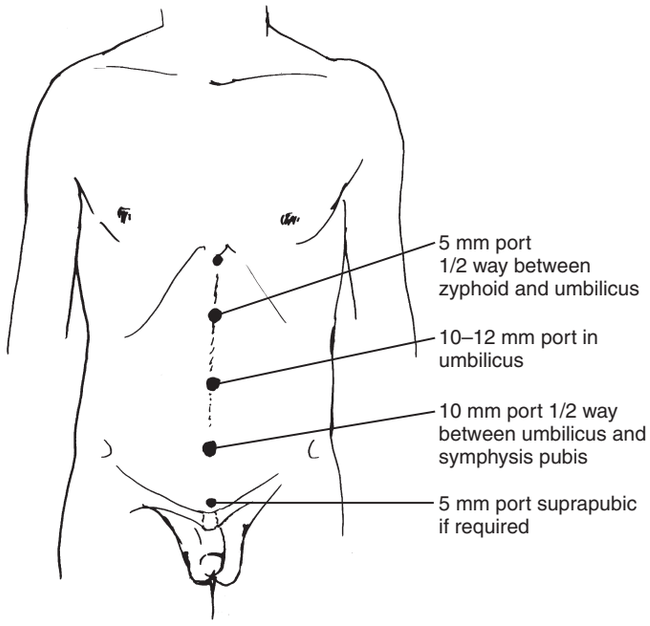

FIGURE 114-5.

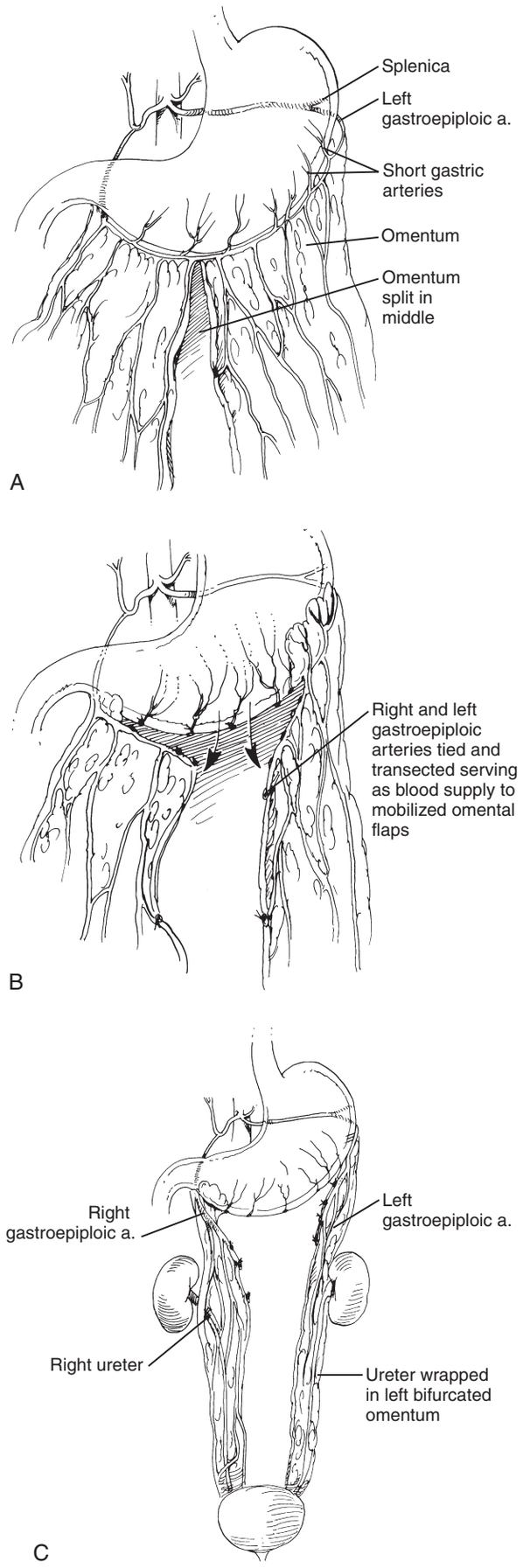

FIGURE 114-6.

This page intentionally left blank

Chapter 115

Repair of Ureterovaginal Fistula

BRIAN J. FLYNN

Ureteral injuries that result in ureterovaginal fistula are almost always iatrogenic, occurring after abdominal, vaginal, or laparoscopic pelvic surgery. Iatrogenic trauma to the ureter may be the result of ligation, laceration, transaction, electrocautery, or a crush injury. Complete ligation results in acute ureteral obstruction, causing abdominal or flank pain, low-grade fever, and ileus. These injuries, if recognized early in the postoperative period (0 to 7 days) are usually amenable to ureteral stenting or open repair with ureteral reimplantation or ureteroureterostomy. However, ureteral transaction often goes unrecognized, resulting in urinoma, ileus, and subsequent fistula to the vaginal cuff. Ureteral crush or cautery injury to the ureter can result in sloughing or perforation of the ureter and a delayed presentation of urinoma or ureterovaginal fistula. Due to the delay in presentation in these cases (after the 7th to 10th postoperative day), intense inflammation and eventual fibrosis occurs, necessitating a delayed approach to repair (6 to 12 weeks) that usually requires a more complex repair, such as psoas hitch, Boari flap, transureteroureterostomy, or ileal ureteral interposition.

Antegrade urography, retrograde urography, or preferably a simultaneous study performed within a few weeks of the planned reconstruction will define the length and location of the ureteral defect, stricture, or fistula. Imaging helps plan the repair and properly prepare the patient for surgery. The operating surgeon's armamentarium should include the full spectrum of ureteral reconstructive procedures as the length of the defect and surrounding fibrosis may be underestimated. The patient should be consented for the spectrum of possible repairs and a bowel preparation is ordered if an ileal ureter is even remotely possible. Prophylactic antibiotics with a β-lactam and aminoglycoside is administered, and general anesthesia is required.

MOBILIZATION OF THE URETER

Position: Supine or low lithotomy to allow identification of the vagina with a sponge stick. The bed is flexed and slight Trendelenburg positioning optimizes access to the pelvis. Insert an 18-French three-way Foley catheter and attach a drainage bag to one port and cystoscopy tubing with a liter bag of saline to the other to allow sterile intraoperative bladder distention, which facilitates the dissection and aids in planning the repair. The irrigation port is clamped and the bladder is placed on drainage.

Incision: In general, the existing abdominal incision may be utilized (either Pfannenstiel or low midline). If the prior surgical approach was vaginal or laparoscopic, then a Pfannenstiel incision with a midline fascial incision is preferable for surgery on the lower one third of the ureter. A transperitoneal appoach allows superior exposure and placement of a fixed-table retractor. The bowel is packed cephalad and the ureteral mobilization ensues.

The ureter is readily located at the pelvic rim where it crosses the bifurcation of the common iliac artery. The peritoneum anterior to the ureter is opened and the ureter is traced distally. The retropubic space is opened and then developed bilaterally (Fig. 115-1). Next, on the side of the injury, divide the bladder attachments to the pelvic sidewall, progressing posterior under successive bridges of connective tissue and vessels. The superior vesical pedicle is identified and usually needs to be ligated to access the juxtavesical ureter. There is usually a significant amount of inflammation or fibrosis surrounding the injured ureter. If the ureter is not found retrovesically, keep the dissection lateral to the ureter to preserve its blood supply.

Divide the ureter just above the fistula. Close the distal ureteral stump with a 2-0 polyglycolic acid (PGA) ligature. Debride the ureter and place a 3-0 silk traction suture posteriorly, spatulate the ureter anteriorly for 5 mm, and mobilize the ureter carefully to limit devascularization. It is not always necessary to close the vaginal defect, but if the bladder is involved (vesicovaginal fistula), close the vagina with 2-0 PGA and the bladder with two layers of sutures 3-0 and 2-0 PGA. Fill the bladder with 300 mL of saline and measure the length of the defect between the anticipated reimplant site and the ureter.

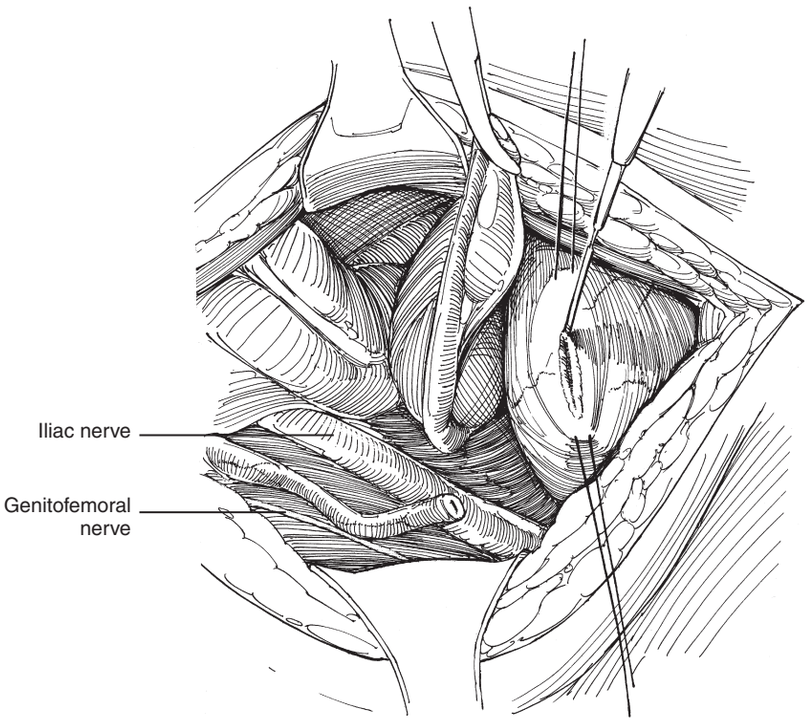

FIGURE 115-1.

URETERONEOCYSTOSTOMY COMBINED WITH A PSOAS HITCH

Open the bladder anteriorly near its equator at its greatest transverse width with a semioblique incision between stay sutures (Fig. 115-2). Make the transverse incision using electrocautery on cutting current. Complete the psoas hitch. Hold the bladder wall against the psoas tendon 2 cm above the site where the ureter would enter the bladder by elevating it with two fingers from within. Place three or four 2-0 polydioxanone sutures (PDS) from the bladder dome (partial thickness including the detrusor muscle) to the psoas minor tendon and to the psoas muscle above and lateral to the iliac vessels, and leave them untied.

From within the bladder, incise the urothelium transversely at the proposed site of the new meatus and tunnel under the urothelium for 3 cm with Metzenbaum scissors. Angle the scissors, and pass the tips obliquely through the bladder wall. Substitute a right-angled clamp for the scissors, grasp the stay suture, and draw the ureter into the bladder. Tie the psoas hitch sutures. Place one 4-0 PDS through the tip of the ureter posteriorly, then deeply into the bladder wall. Complete the anastomosis with six or eight interrupted 5-0 PDS to include the vesical urothelium and half the thickness of the ureteral wall (Fig. 115-3). Tack the

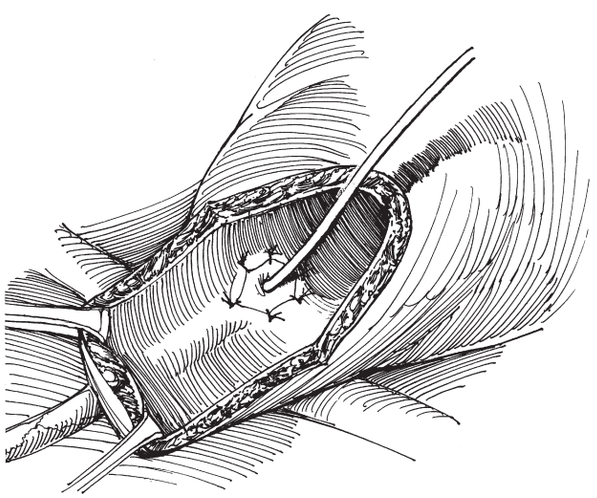

FIGURE 115-2.

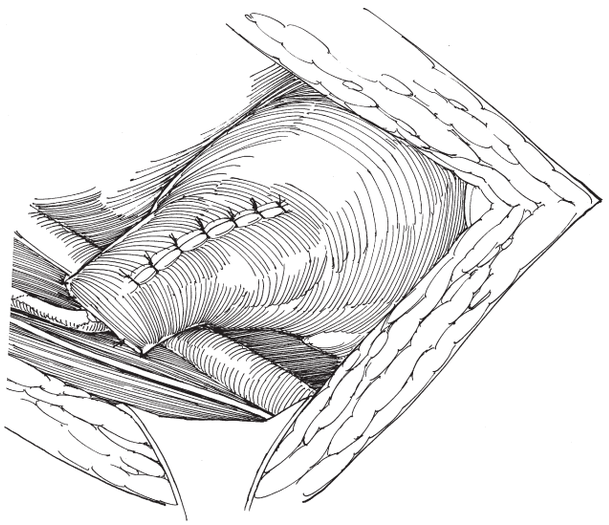

FIGURE 115-3.

ureteral adventitia to the bladder wall at the exit site with two or three interrupted 4-0 PGA sutures. I place a 4.7-French multilength double pigtail stent across the anastomosis for 3 to 4 weeks. Close the cystotomy longitudinally in two layers with a layer of running 3-0 PGA suture in the mucosa and muscularis and a running layer of 2-0 PGA in the muscularis and adventitia using a Lembert technique. Place a round 15-French Jackson-Pratt drain lateral to the repair and remove the drain when the output is minimal. Remove the Foley catheter at 7 to 10 days.

Alternative for longer ureteral defects. If a Boari flap is needed to bridge a long ureteral defect, a rhomboid anterior bladder wall flap can be created from the cephalad aspect of the existing semioblique incision. Cut a Boari flap, and make the tunnel by inserting the Metzenbaum scissors beneath the urothelium at the edge of the defect. Have the tips emerge after a 3-cm tunnel and draw the ureter through with a tonsil clamp. Complete the ureteral reimplant and place a larger stent than is customary. Close the anterior bladder wall flap in two layers over the stent.

Laparoscopic reimplantation (see page ***) is possible in selected cases using an extravesical transperitoneal approach, particularly if the repair is early before reactive fibrosis or infection sets in.

POSTOPERATIVE COMPLICATIONS

Urinary leakage at the ureteral hiatus is usually minimal when the ureter is stented and usually ceases when urinary drainage is adequate. Bladder spasms are amenable to long-acting anticholinergics and are often related to larger more rigid stents. *Stenosis* at the anastomosis is usually due to attenuated ureteral blood supply, tension on the anastomosis, kinking of the ureter in a psoas hitch or compression of the intramural ureter in a tunneled reimplant. This is often amenable to ureteral balloon dilation and stenting. If unsuccessful or recurrent stenosis occur, then ureteral reconstruction using a more advanced technique may be necessary.

This page intentionally left blank

Chapter 116

Ureteroureterostomy and Transureteroureterostomy

ELIZABETH A. MILLER

URETEROURETEROSTOMY

The technique of primary anastomosis of the ureter is used to repair upper to mid-ureteral injuries when the proximal and distal segments on either side of the injury are healthy and when the injured segment is relatively short. This can be determined with a combination of retrograde and antegrade fluoroscopic studies. The injuries commonly described that are appropriate for ureteroureterostomy include congenital anomalies of the ureter such as retrocaval ureter, penetrating injuries to the ureter from gunshot, for example, or iatrogenic injuries usually incurred during surgical missteps. The latter may either be identified at the time of surgery or delayed, in which case the presentation is often of a urinoma and/or ureteral stricture.

Position/incisions: Position: either flank or supine.

For mid to upper ureteral lesions, a *subcostal flank incision* using a retroperitoneal approach allows good exposure to the ureteral segment. For mid to lower ureteral pathology, a *Gibson incision* can be used (see flank and Gibson incisions in prior chapters). Choice of incision should be determined by the level of ureter to be accessed, which can be determined based on preoperative imagining. Either incision requires the colon to be reflected medially, and once done, the ureter becomes apparent, coursing along the psoas muscle lateral to the gonadal vessels. For lower ureteral exposure, the ureter crosses the iliac bifurcation and then traverses medially toward the bladder (Fig. 116-1).

A transperitoneal approach using a vertical midline incision may also be used to access the ureter at any level. However, the small bowel needs to be packed and the colon mobilized medially to expose the retroperitoneum. Alternatively, the left leaf of the small bowel mesentery can be opened to access either ureter. If this approach is chosen, the inferior mesenteric artery can be ligated for better exposure.

To confirm the tubular structure in question is ureter, gently squeeze it with forceps and watch for peristalsis. Dilated ureters can appear similar to bowel or vessels, and can be confirmed to be ureter by aspiration.

Surgical Technique

Identifying the area of ureteral damage can be challenging. If the injury is old, the exact level of stricture or pathology can usually be identified by its association with significant retroperitoneal and periureteral fibrosis. The affected segment of ureter can be mobilized sharply and incised to determine the length of ureteral injury and the affected segment excised completely (Fig. 116-2). In cases of acute injury, one or both ureteral ends can be found by injecting indigo carmine intravenously to identify the proximal end and by instilling methylene blue into the bladder either directly or via a Foley catheter to identify the distal end (although if the ureter fails to reflux, this technique will be ineffective). In cases of a blast injury to the ureter due to a gunshot penetration, radiation, or infection, debridement into healthy ureter is important to avoid failure of the repair. In cases of gunshot wounds, damaged tissue may not be easily differentiated from healthy tissue; therefore this author recommends debriding 1 cm of ureter above and below the injury. In addition, the full length of the ureter should be inspected to confirm the absence of secondary injury.

Once the damaged ureter is excised, mobilize proximal and distal ureter with a combination of sharp and blunt dissection, taking care to avoid cauterizing the ureter and maintaining integrity of the periureteral adventitia and blood supply. Mobilize enough ureter to allow a tension-free anastomosis. The entire ureter can be mobilized without affecting the blood supply if the periureteral adventitia is preserved; however, mobilize only what is needed to effectively anastomose. Place a stay suture on each ureteral end and spatulate by 1 cm at opposing sides (Fig. 116-3). Before beginning the anastomosis, ensure the ureteral ends are not twisted, as can happen inadvertently during mobilization of the ureteral ends. To anastomose, several methods can be used, all of which require placement of interrupted or running 4-0 to 6-0 absorbable suture. Orient the ureters such that the unspatulated end of one ureteral end is sewn to the spatulation of the other ureteral end (Fig. 116-4). This author prefers placing sutures at both ends or corners

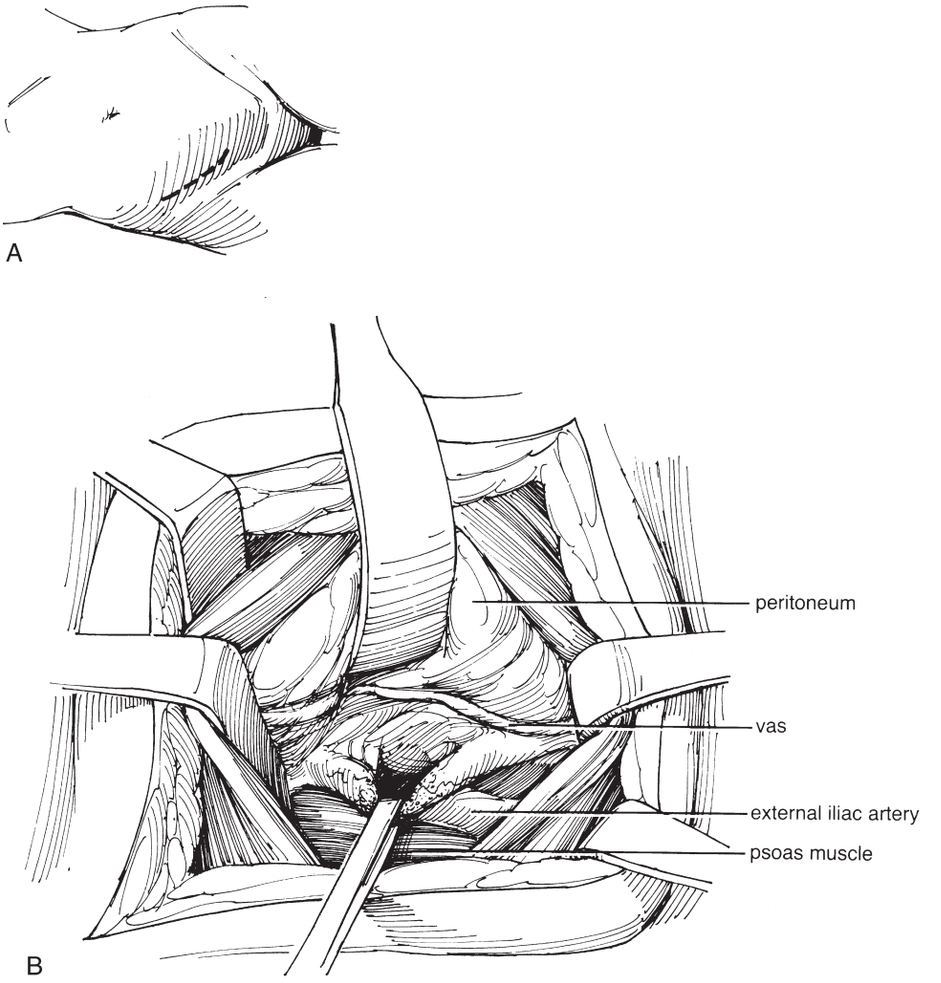

FIGURE 116-1. A, Incision to access distal ureter. **B,** Identification of ureteral segment to be excised.

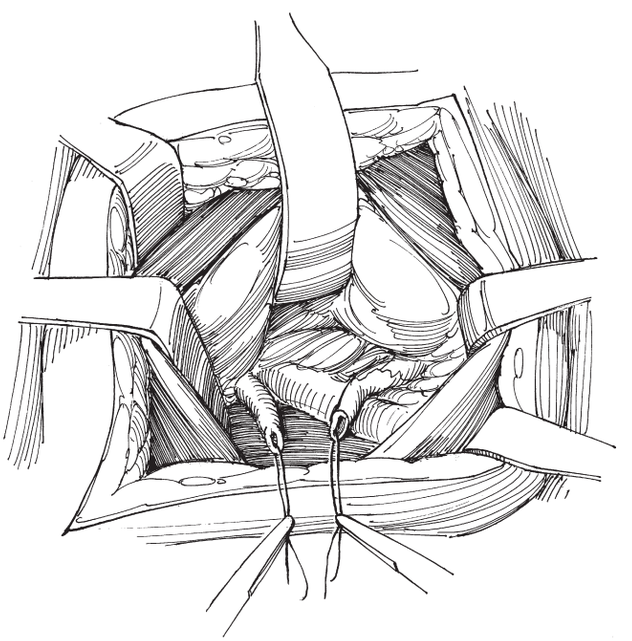

FIGURE 116-2. Excision of ureteral segment.

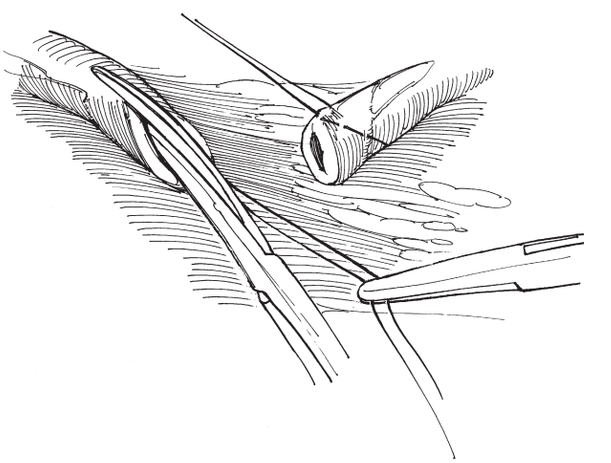

FIGURE 116-3. Spatulation of proximal ureteral segment.

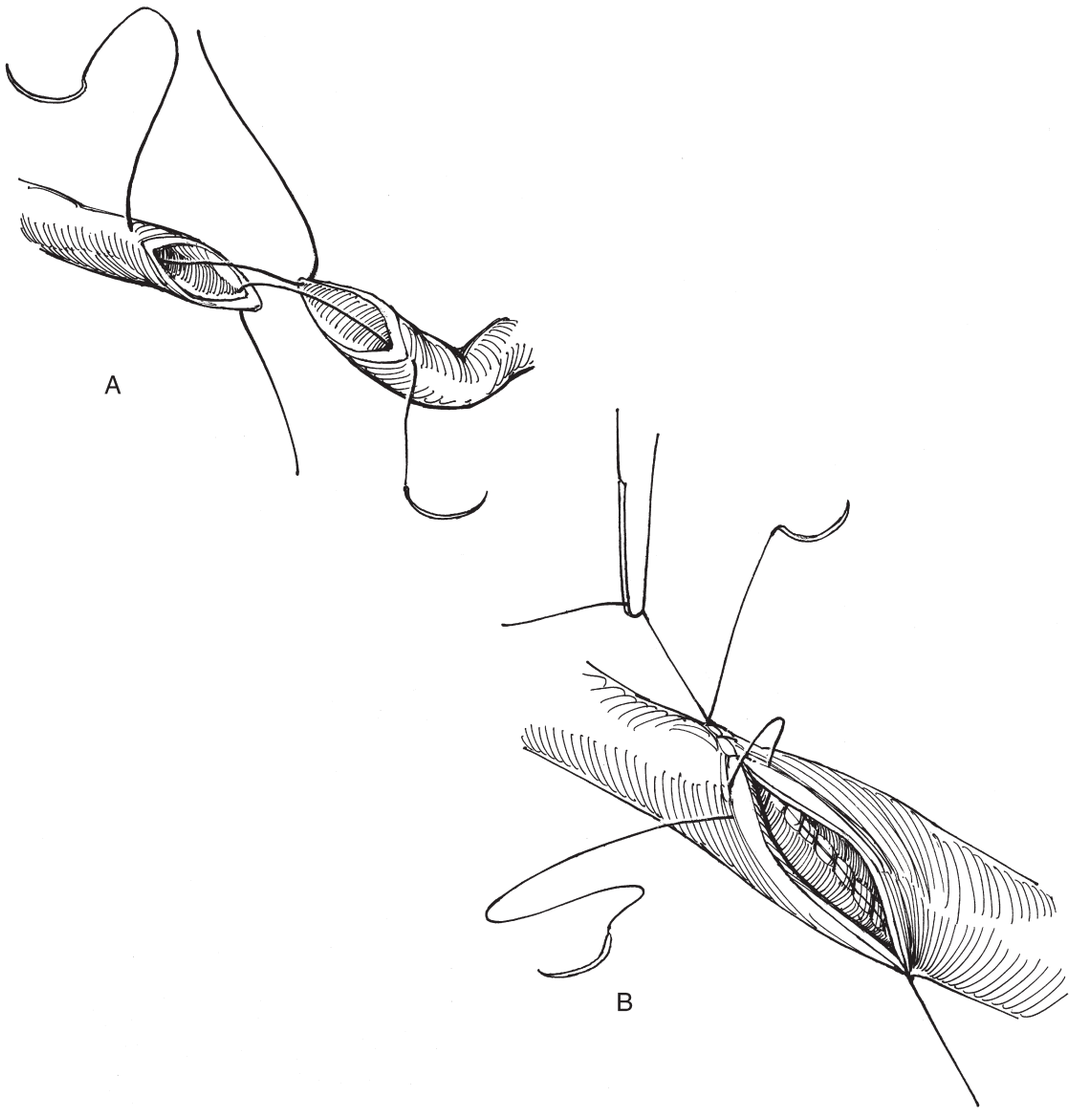

FIGURE 116-4. Unspatulated end of one ureteral end is sewn to the spatulation of the other ureteral end.

of the ureteroureterostomy, sewing one side from corner to corner while the assistant holds the corner sutures for exposure, and then flipping the ureter to sew the other side.

Stenting the anastomosis is recommended but not always needed. However, in cases of gunshot wound, extensive cautery or radiation injury, stenting is imperative. Place the stent after the first side of the anastomosis is complete and the ureter is flipped to expose the backside of the anastomosis. Pass a floppy tipped wire through the open ureteroureterostomy until resistance is met, then advance the stent over the wire until resistance is met. Confirm placement in the renal pelvis by observing urine from the other end of the stent. To pass the distal end of the stent into the bladder, cut a side hole in the stent, and then pass the floppy end of the wire into the bladder and the firm end of the wire through the distal end of the stent and through the previously cut hole in the midportion of the stent. Advance the stent over the wire into the bladder and remove the wire. If confirmation of stent placement is needed, obtain a kidney-ureter-bladder scan intraoperatively.

TRANSURETEROURETEROSTOMY

This technique is used in cases of an obliterated or severely injured distal ureter, such as in cases of radiation damage, ischemia, or total distal ureteral loss (e.g., ureteral avulsion during ureteroscopy). The health of the distal ureter is assessed with retrograde pyelography, computed tomography intravenous pyelography, or ureteroscopy. The recipient ureter should be of adequate caliber, free of significant vesicoureteral reflux, and without significant stricture.

Position/incision: Supine position with a vertical midline incision is best.

Surgical Technique

In cases of left-to-right transureteroureterostomy, pack the small bowel to the right and incise the retroperitoneum lateral to the left colon. Mobilize the left colon and expose the left (donor) ureter (Fig. 116-5). Identify the site of pathology in the left ureter and incise the ureter proximal

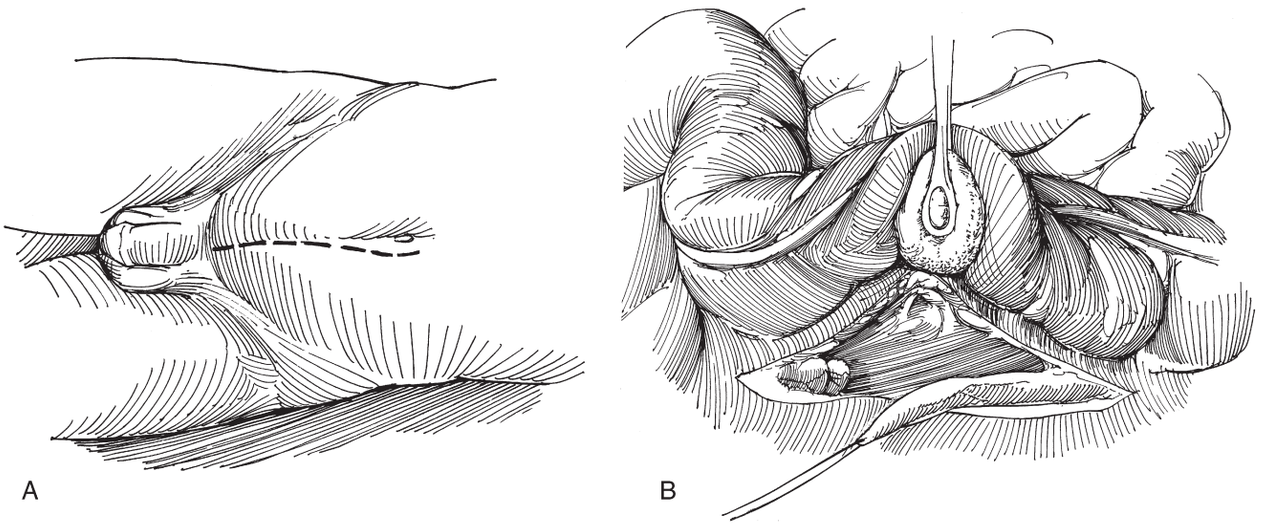

FIGURE 116-5. Mobilization of left colon to expose left ureter.

to this site. Place a stay suture through the proximal ureter to aid in mobilization and ligate the distal ureteral stump. Mobilize the donor ureter by 9 to 12 cm, preserving ureteral adventitia.

Free the cecum and right colon to expose the right (recipient) ureter (Fig. 116-6). Mobilize enough ureter to allow for the anastomosis, usually just 3 to 4 cm, preserving the ureteral adventitia. If the cecum cannot be mobilized, make a large window in the right retroperitoneum. Pass the left ureter using the stay suture across midline to the recipient ureter underneath the cecum and right colon. The ureter can be passed over (preferable) or under the inferior mesenteric artery (IMA), taking care to avoid kinking or angulating the ureter. Passing the ureter under the IMA may cause fibrosis and kinking where the ureter is wedged between aorta and artery.

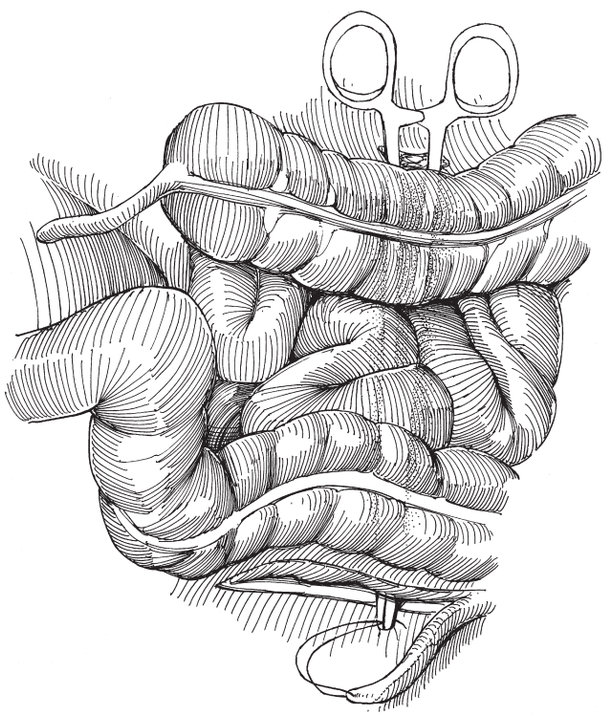

FIGURE 116-6. Exposure of right (recipient) ureter.

Open the recipient ureter along its medial border with a hook or 11 blade and extend the ureterotomy with Potts scissors for a distance of about 1.5 cm. Spatulate the donor ureter by a similar margin and perform the anastomosis by placing two stay sutures, one at each end of the anastomosis, of 4-0 to 6-0 absorbable suture. Run the upper stay suture along the inner side of the back wall first, then run the lower suture up the outer side of the front wall. Again, a stent can be placed in the donor ureter in a similar way as described above. Stenting the recipient ureter is usually not necessary.

A Penrose or low suction drain can be placed near the anastomosis, but is not necessary. Consider draining if the integrity of the anastomosis is in question.

Perform a cystogram or instill contrast through an open stent or nephrostomy tube 10 to 14 days postoperatively to confirm adequacy of the repair, at which time the stent can be removed.

Chapter 117

Ileal Ureteral Replacement

MICHAEL GURALNICK AND R. COREY O'CONNOR

Intestinal interpositioning is generally considered a surgery of last resort in ureteral repair. Surgical alternatives not involving bowel should be explored before using intestine to bridge any ureteral defects due to the potential for metabolic derangements that may accompany the procedure. Depending on location of the ureteral defect, preference should be given to performing ureteroureterostomy, a psoas hitch, Boari flap, or transureteroureterostomy before resorting to ileal interpositioning.

PATIENT PREPARATION

Preoperative antegrade and retrograde ureteral imaging is imperative to delineate the anatomy and defect length. We routinely have a nephrostomy tube placed preoperatively in patients undergoing planned ureteral repair. This aids in performing antegrade ureterography and allows for postoperative drainage. The nephrostomy tube is not removed until ureteral patency has been confirmed postoperatively. Furthermore, adequate renal function of the affected kidney needs to be determined to justify salvage. As a result, a preoperative nuclear renogram or a differential creatinine clearance should be performed. Ideally, patients should have adequate renal function in order to compensate for potential metabolic derangements that can occur with interposition of intestine into the urinary tract. Use of the Yang-Monti technique is theoretically advantageous in this regard due to shorter segment of bowel needed, which may minimize solute reabsorption and metabolic abnormalities.

In select patients, the bladder should be evaluated preoperatively for its capacity and function. In patients with large bladders and normal function, a psoas hitch or Boari flap should be performed to help shorten the ureteral defect needed to be bridged by bowel.

Although conflicting data exist in the literature, we routinely perform a mechanical bowel prep on all patients undergoing intestinal interpositioning. The presence of coexisting gastrointestinal disorders (e.g., Crohn's disease) should be ascertained to avoid using a segment of diseased bowel to repair to urinary tract.

INCISION AND IDENTIFICATION OF URETERAL DEFECT

Place the patient in a supine or low lithotomy position with the arms either tucked or at right angles to the table. Consider antegrade or retrograde placement of a guidewire to aid in identification of the diseased ureter. Place a urethral catheter using sterile technique and maintain access to the catheter during the case. Make a midline abdominal incision that may be extended to the xiphoid process and/or pubic symphysis and enter the peritoneal cavity. Place body wall retractors to aid visualization.

Divide the lateral attachments of the ascending/descending colon in the white line of Toldt up to and beyond the hepatic/splenic flexure, depending on the laterality of ureteral injury. Dissecting the omentum from the transverse colon may aid in further bowel mobilization. Rotate the colon medially to expose the retroperitoneum.

Measure the length of ureter to be replaced using a sterile ruler or umbilical tape. The length of bowel required depends on the size of the ureteral defect, the caudal mobility of the kidney, and the cephalad mobility of the bladder. Downward mobilization of the kidney with cephalad mobilization of the bladder by creation of a psoas hitch or Boari flap minimizes the length of bowel segment needed to reconstruct the ureter. At this time during the surgery, a decision is made as to which type of ileal interpositioning to perform: intact, isoperistaltic segment or a Yang-Monti tube. No published studies have confirmed superiority either way; the choice is based on surgeon preference. The isoperistaltic segment is less technically demanding; however, a Yang-Monti tube carries the advantage of requiring a shorter bowel segment (which may minimize metabolic derangements). In addition, the Yang-Monti tube is smaller in diameter and may allow for greater ease of performing a non-refluxing bladder anastomosis (if desired).

INTACT, ISOPERISTALTIC ILEAL SEGMENT

Select the desired segment of distal ileum. If possible, avoid the terminal ileum to minimize the risk of B_{12} and bile salt

malabsorption. It is generally advisable to overestimate the length of bowel needed and trim excess. Isolate the segment of bowel (Fig. 117-1). Tag each end of the ileal segment with a long (distal) and short (proximal) stay suture to ensure placement is isoperistaltic. Close the mesenteric defect with 3-0 silk suture to prevent internal herniation. Irrigate the isolated bowel segment free of enteric contents using copious amounts of saline until the effluent is clear.

For *right* ureteral replacement, place the ileal segment in the right retroperitoneum by lifting the previously mobilized cecum forward and medial. Adequate mobilization of the ascending colon should prevent the need for passing the ileal segment through the mesentery of the cecum. For *left* ureteral replacement, create a 5-cm window in the mesentery of the left colon and pass the ileal segment through. Ensure that the mesenteric window is small enough to minimize the risk of internal herniation but large enough to prevent ischemia of the ileal segment. Confirm that the bowel segment is positioned in an isoperistaltic orientation.

End-to-end anastomosis of the proximal ileal segment to the renal pelvis is performed in patients with a dilated, mobile renal pelvis (Fig. 117-2). Spatulate the ureteropelvic junction as needed to correspond to the luminal size of the ileal segment. Alternatively, the antimesenteric border of the proximal ileal segment can be closed with 3-0 absorbable suture until the opening is the same size as the defect in the renal pelvis. If the pelvis is intrarenal or obscured by scar, ileocalycostomy may be advisable. The anastomosis is performed with a single layer of running or interrupted full thickness 3-0 absorbable sutures. The renal pelvis is filled with saline via the nephrostomy tube to ensure a water-tight anastomosis. Additional reinforcing 3-0 absorbable sutures are used as needed. Occasionally, surgical sealants or glues can be used to aid in obtaining a watertight closure.

The distal anastomosis to the bladder is begun by creating an anterior cystotomy. Suture the distal end of the ileal segment to a similarly sized opening at the posterior dome of the bladder with full thickness, interrupted 3-0 absorbable suture (Fig. 117-3). In our opinion, the prevention of reflux is not necessary. Once again, consider a psoas hitch or Boari flap to minimize the defect length. Placement of a ureteral stent is optional.

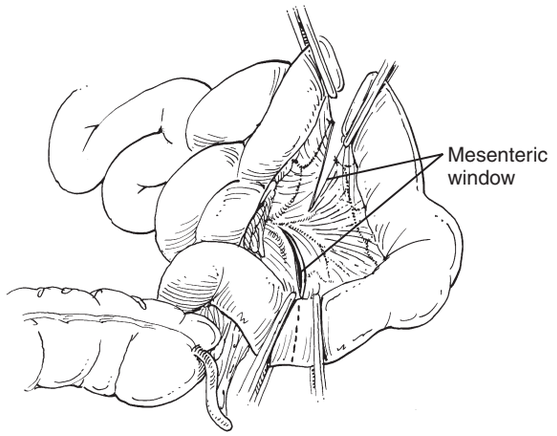

FIGURE 117-1. Harvesting of the intact ileal segment.

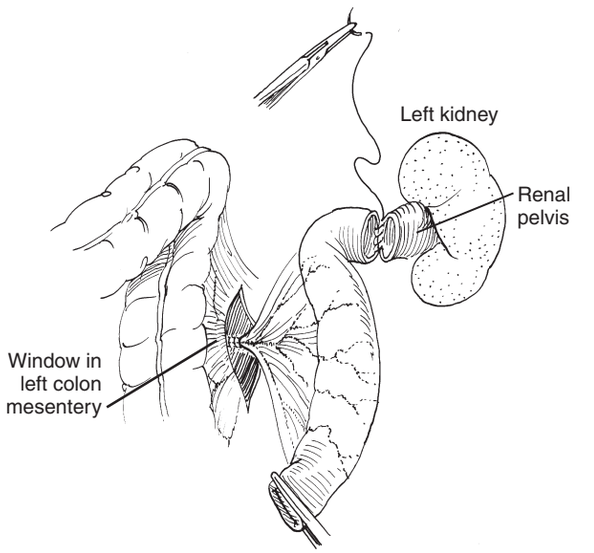

FIGURE 117-2. Anastomosis of the ileal segment to the renal pelvis.

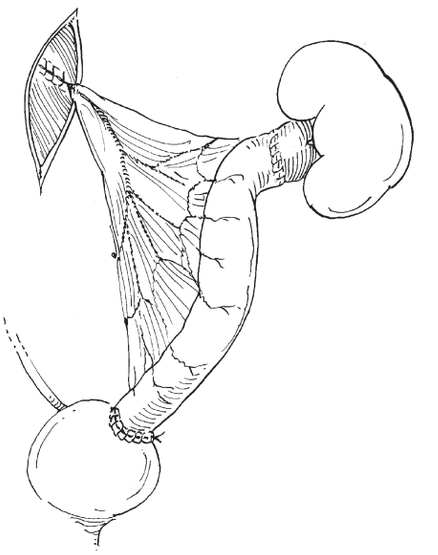

FIGURE 117-3. Anastomosis of ileal segment to bladder.

YANG-MONTI TUBE

The Yang-Monti principle involves the reconfiguration of a short, wide intestinal segment into a long, narrow tube. This is achieved by detubularizing a 2- to 3-cm length of bowel along its antimesenteric border. The bowel is then retubularized in the opposite axis, creating a long, narrow tube of bowel with a centrally located mesentery. The length of the newly created tube is proportional to the circumference of the original bowel segment while the diameter of the tube is proportional to the length of the bowel segment used. To increase tube length, several segments can be joined together to create a "double" or "triple" Yang-Monti.

Once the ureteral defect has been measured, an appropriate segment of bowel (typically the distal ileum) is selected. In

general, the 2- to 3-cm section of intestine provides about 8 to 10 cm of reconfigured length. The mesenteric vasculature is transilluminated to identify its branches. A 2- to 3-cm segment with an adequate central vascular supply is marked with stay sutures. The bowel and corresponding mesentery are isolated and divided. Bowel continuity is reestablished and mesenteric defects are closed. The bowel segment is incised along its longitudinal axis. If only one segment is used, it can be incised on the antimesenteric border and detubularized. If multiple segments are required, the most proximal and distal segments should be opened close to the mesenteric attachments and rotated so that the mesentery lies centrally (Fig. 117-4).

The adjacent bowel segments are sewn together with continuous 3-0 absorbable suture, creating a strip of bowel with a central mesentery (Fig. 117-5).

The bowel is retubularized along its opposite axis over a 16-French catheter using 3-0 absorbable suture (Fig. 117-6). It is important to use interrupted sutures at each end to allow for spatulation. The result is an intestinal tube of sufficient length and diameter to replace the ureteral defect. The ends of the retubularized bowel are free of mesenteric attachments, which facilitate anastomosis to the renal pelvis/ureter proximally and to the bladder distally.

Similar to the isoperistaltic ileal segment, the Yang-Monti tube can be re-retroperitonealized.

The proximal anastomosis to the upper ureter/renal pelvis is accomplished in an identical fashion to a ureteroureterostomy or dismembered pyeloplasty using continuous or interrupted 3-0 absorbable suture. The anastomosis is typically performed over a ureteral stent.

The distal anastomosis to the bladder can be performed in a direct or antirefluxing fashion. For a direct anastomosis the distal end of the Yang-Monti ileal tube is attached the bladder in the same way that one would perform the anastomosis for an isoperistaltic ileal tube (see earlier). One advantage of the Yang-Monti tube is the ability to easily create a nonrefluxing anastomosis. If prevention of reflux is desired, any type of nonrefluxing anastomosis (e.g., Leadbetter-Politano, Lich-Gregoir) technique can be used.

Place a Malecot cystostomy tube through the anterior bladder wall. Close all remaining bladder defects. A urethral catheter should remain to maximally drain the bladder. Percutaneous drains should be left near the pyeloureteroileal and vesical anastomoses. Irrigate the peritoneal space copiously to minimize the risk for infection. Tack the

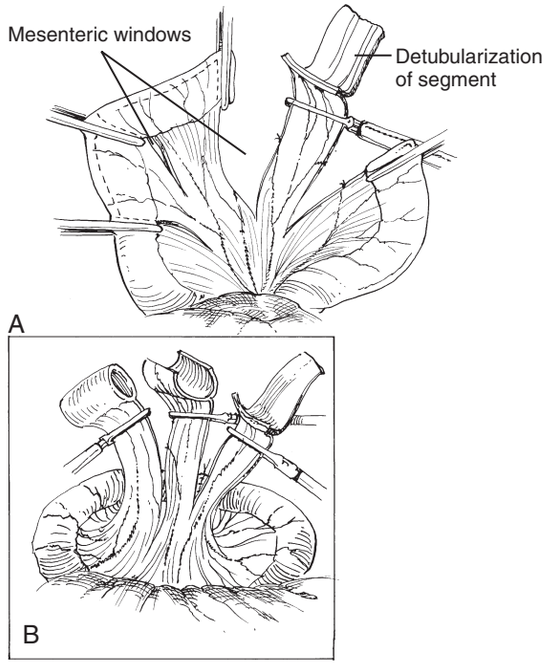

FIGURE 117-4. Creation of the Yang-Monti ileal tube. *(Redrawn from Ghoneim MA, Ali-El-Dein B. [2005]. Replacing the ureter by an ileal tube, using the Yang-Monti procedure. BJU Int 95:455-470.)*

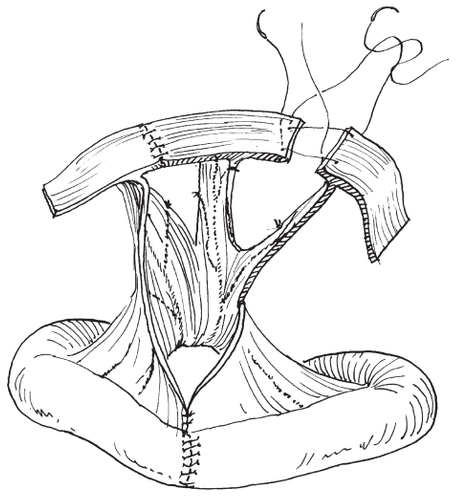

FIGURE 117-5. Sewing of adjacent bowel segments to form a "triple" Yang-Monti. *(Redrawn from Ghoneim MA, Ali-El-Dein B. [2005]. Replacing the ureter by an ileal tube, using the Yang-Monti procedure. BJU Int 95:455-470.)*

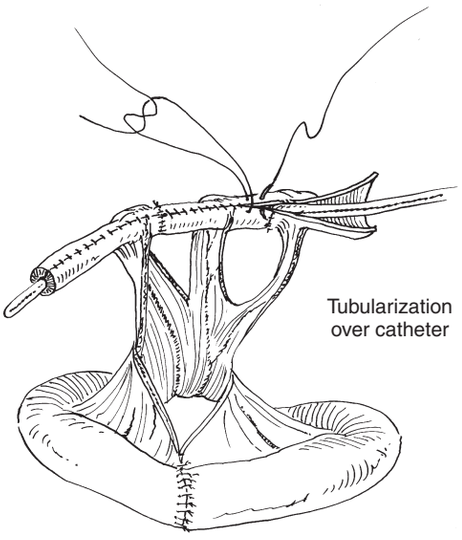

FIGURE 117-6. Tubularization over a catheter. *(Redrawn from Ghoneim MA, Ali-El-Dein B. [2005]. Replacing the ureter by an ileal tube, using the Yang-Monti procedure. BJU Int 95:455-470.)*

colon laterally to the peritoneal edge to re-retroperitonealize the ileal ureter. Close the rectus fascia and the skin. Finally, secure all tubes and drains to the skin with 2-0 nylon suture.

BILATERAL URETERAL REPLACEMENT

If needed, one segment of intestine can be used to replace both ureters. The bowel segment is positioned in an isoperistaltic L-shape (Fig. 117-7A). The proximal end of ileum is anastomosed to the proximal left ureter/renal pelvis. The right ureter/renal pelvis is connected to the bend of the L (see Fig. 117-7B). The distal portion of the bowel segment is anastomosed to the bladder as described earlier.

POSTOPERATIVE MANAGEMENT

The urethral catheter can be removed once the urine is clear and the pelvic drain output is minimal. Cystography via the suprapubic catheter is typically performed after 10 to 14 days. The patient can be allowed to void and the suprapubic tube removed following a negative cystogram. Persistent contrast extravasation from the bladder necessitates the need for longer catheter drainage. An antegrade nephrostoureterogram is performed 2 to 4 weeks after the procedure. If the antegrade study confirms patency and the absence of extravision, the ureteral stent may be removed. At this time, we cap the nephrostomy tube for 1 to 2 weeks to ensure the absence of problems (e.g., obstruction, flank pain) before removal. A urogram is performed 3 months later to verify an adequate functional and anatomic result.

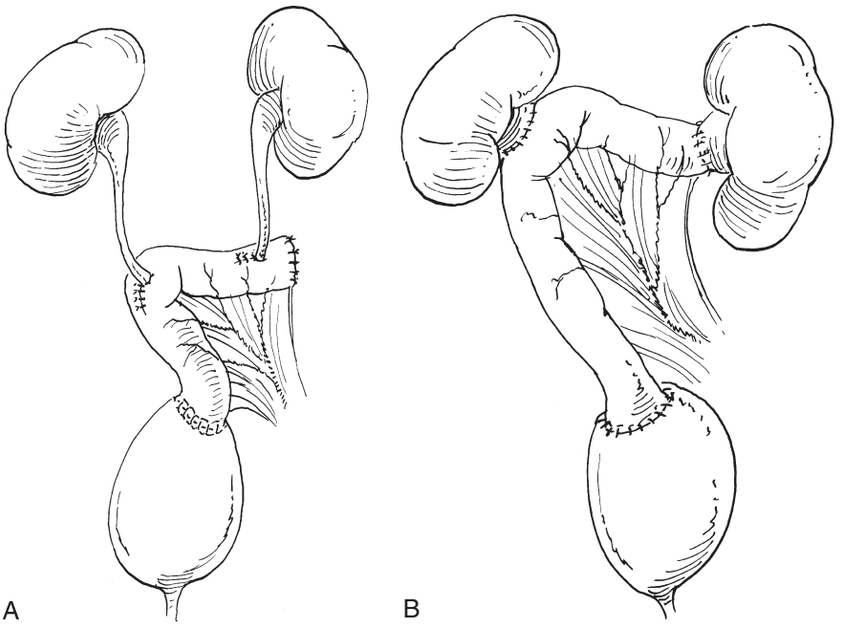

FIGURE 117-7. Bilateral ureteral replacement.

Chapter 118

Open Ureterolithotomy

J. PATRICK SPIRNAK AND PHILLIP S. KICK

Until the mid 1980s, ureterolithotomy was the primary procedure performed for the removal of ureteral stones. With the emergence of endoscopic techniques and extracorporeal shockwave lithotripsy (ESWL), ureterolithotomy is now rarely performed.

Ureterolithotomy is still useful in situations in which endoscopic access to the ureter is not technically possible and the targeted stone is not amenable to ESWL or has failed ESWL.

Radiographic identification of the stone at the time of surgery is crucial, as the location for the incision is determined by the location of the calculus. A kidney-ureter-bladder (KUB) study is obtained on the day of surgery to help plan the approach.

SURGICAL APPROACHES

Upper third of ureter: A flank incision with or without rib resection, lumbotomy incision, subcostal incision, or supracostal incision may be used. A midline incision with intraperitoneal or extraperitoneal approach can be used if the patient has extensive prior retroperitoneal surgery.

Middle third of ureter: A Foley incision or a midline extraperitoneal incision is most useful.

Lower third of ureter: A lower midline incision with extraperitoneal approach is most useful. A Gibson incision can also be used, and it has the advantage of allowing access to the midureter. A Pfannenstiel incision could also be used for stones in this segment.

For all approaches, it is very important not to let the stone migrate from the operative field during the course of the procedure. It is also paramount to consider the anatomy of the ureteral blood supply. The ureteral vascular supply originates medially above the iliac vessels and laterally below the iliac vessels. Attempts should be made to use muscle splitting incisions whenever possible to decrease postoperative pain.

URETEROLITHOTOMY

To begin, approach the ureter using whichever incision is deemed most appropriate based on patient anatomy, stone location, and prior surgical history. In general, the dissection will take place in the extraperitoneal space; however, transperitoneal dissection can be used if necessary. Manipulate the ureter minimally during dissection to lessen chance for stone migration or ureteral devascularization.

When the stone is located by visualizing a bulge or with gentle fingertip palpation of the stone, secure proximal control of the ureter with either a Babcock clamp or a vessel loop (Fig. 118-1). The distal ureter is then controlled with either a Babcock clamp or a vessel loop. Two 4-0 absorbable sutures are then placed on either side of the site of ureterotomy. Do not open the ureter until the stone is confirmed to be present at the site. The ureter is opened longitudinally over the stone with a hooked blade (Fig. 118-2). The incision can be extended using Potts scissors.

Loosen the stone from the ureteral wall and deliver it using forceps or a right-angle clamp (Fig. 118-3). When stones migrate from the operative field, intraoperative ureterograms are often of little use. Tactile exploration of the ureter with a ureteral catheter can occasionally be of some use. A counter incision may be necessary to complete the procedure. If the stone cannot be located, a stent should be left in place to ensure adequate renal drainage.

Once the stone is removed, the ureter is irrigated with normal saline proximally and distally using a red rubber catheter to ensure that there are no remaining fragments. A stent can then be passed, although this is a matter of surgeon preference and is likely unnecessary for a simple ureterolithotomy.

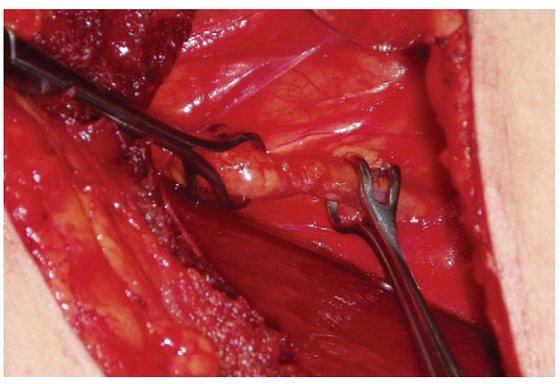

FIGURE 118-1.

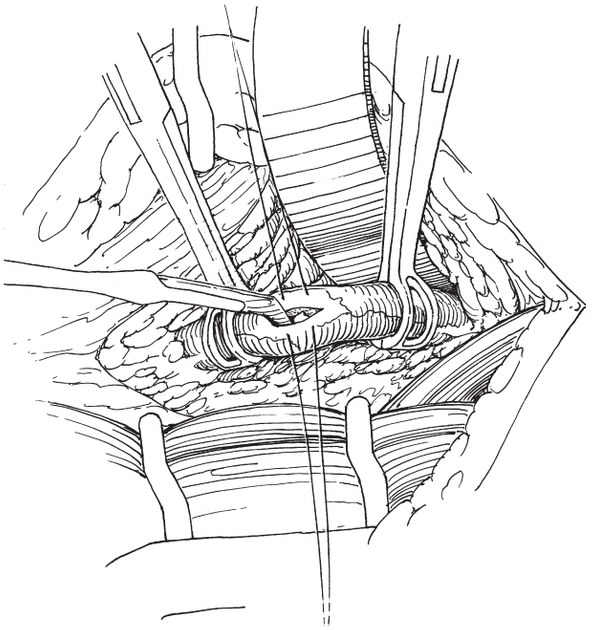

FIGURE 118-2.

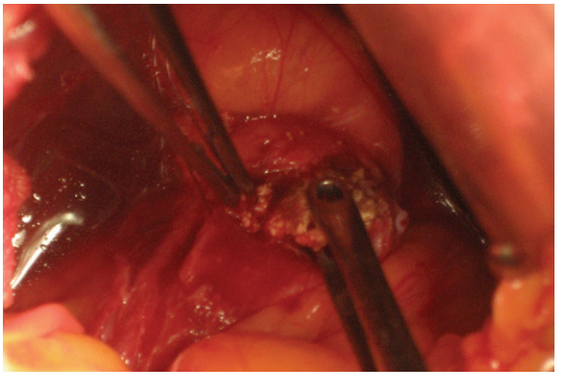

FIGURE 118-3.

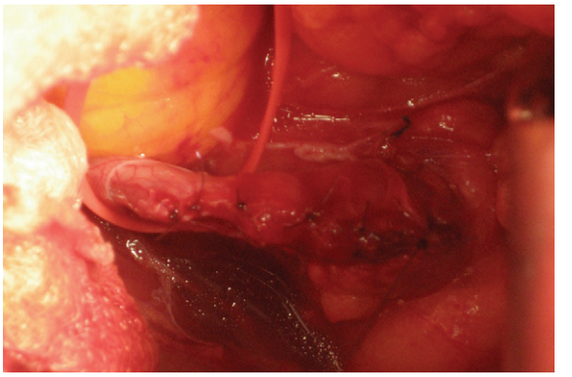

FIGURE 118-4.

The ureterotomy is then closed with several interrupted absorbable sutures (Fig. 118-4). The ureter is then wrapped in the adjacent periureteral fat. A drain should be placed. The drain should be close to the ureterotomy but not in direct contact. A Penrose drain or a closed suction drain can be used based upon surgeon preference. The incision is closed in layers with muscle reapproximation as appropriate.

POSTOPERATIVE PROBLEMS

Sepsis is a risk of any stone manipulation and use of culture-specific or broad-spectrum antibiotics is important in the perioperative period.

Prolonged drainage suggests distal ureteral obstruction or ureteral devascularization. Management options include placement of a ureteral stent (if not placed at the time of surgery). If drainage persists despite adequate stenting, then open surgical intervention may be required for repair of the ureter.

Any manipulation of the ureter can lead to stricture formation. Strictures are most likely caused by ureteral devascularization. The location of the stricture is going to determine the most suitable management options, which may include endoscopic as well as open surgical techniques.

Section XIX

URETERAL RECONSTRUCTION AND EXCISION

Principles of Endoscopic Ureteral Surgery

This page intentionally left blank

Chapter 119

Ureteral Access

MANOJ MONGA

Ureteral access is the initial step for any upper tract endoscopic procedure, including placement of a ureteral stent and ureteroscopy. The technique and instrumentation depend on the site, size, and type of pathology to be addressed.

PLACEMENT OF A SAFETY WIRE

Choice of Wire

Guidewires are essential in acquiring and maintaining ureteral access. An ideal guidewire would require little force to bend in response to resistance as it traverses a tortuous path and would require a large force to perforate through tissue. A recent in vitro study measured these properties from nine commercially available guide wires. If one defines the "margin of error" of a guidewire as the difference between the force required to perforate the ureter and the force required to bend the tip of the guidewire, the nitinol Glidewire (Boston Scientific Corp., Natick, Mass.) is the safest wire for initial access, whereas the polytetrafluoroethylene guidewire (Bard Urological Division, Covington, Ga.) has little margin for error and should be used with caution. Our guidewire of choice is the Sensor wire (Boston Scientific), a hybrid that combines three segments: a smooth, hydrophilic distal tip for bypassing impacted ureteral stones, a kink-resistant body (nitinol core with PTFE coating), and a flexible proximal tip for back-loading of the wire through the working channel of the ureteroscope. In general, a straight 0.035-inch guidewire is used, although if difficulty is encountered due to J-hooking of the ureter, an angled guidewire may be helpful.

Identifying the Ureteral Orifice

A rigid cystoscope is used to inspect the bladder and identify the ureteral orifice. Withdraw the cystoscope to the bladder neck and torque downward to inspect the trigone, then sweep laterally until the ureteral orifice is identified. If patient body habitus (e.g., lower extremity contractures) prevent placing the patient in a dorsolithotomy position, then a flexible cystoscope can be used. If a large median lobe prevents visualization of the ureteral orifice, a 70-degree angled lens with an Albarran's bridge can help with cannulation, or a flexible cystoscope can be used. If trabeculations in the bladder or prior ureteral reimplantation impedes identification of the orifice, 1 ampule of intravenous methylene blue or indigo carmine is administered intravenously.

Cannulating the Ureteral Orifice

Most commonly one is able to cannulate the ureteral orifice directly with the floppy tip of the guidewire. On occasion it may be necessary to use a 5-French open-ended ureteral catheter over the guidewire to help stabilize it at the ureteral orifice. Keeping the bladder decompressed with minimal irrigation inflow will also facilitate identification and cannulation of the orifice. Lastly, rotating the cystoscope to align the working channel with the lateral path of the transmural ureter (90 degrees clockwise for the left orifice, 90 degrees counterclockwise for the right orifice) may help with passage through this portion of the ureter. Alternatively, an angled-torqueable catheter, such as a Kumpe catheter or JB-1, may be used to assist in cannulating a difficult to access orifice.

Advancing the Wire

The wire should be advanced under fluoroscopic guidance. Do not activate the fluoroscopy unit while the c-arm unit or table is moving—movement increases the radiation exposure to the patient and personnel—rather, pause and activate fluoroscopy once the unit has been repositioned. Maintain a distance of 10 cm between the patient and the c-arm image intensifier to minimize radiation exposure.

Resistance to passage of the guidewire may be appreciated by tactile feedback or visual feedback, as noted on fluoroscopy, or by detecting buckling of the wire in the bladder under direct vision through the cystoscope. Advance a 5-French open-ended catheter to the site of obstruction. Remove the guidewire. Inject radiographic contrast to delineate the "road map" for the path of the ureter. At this point, a 0.035-inch straight-tip hydrophilic Glidewire (Boston Scientific) should be advanced through the open-ended catheter. If attempts to maneuver past the site of obstruction are unsuccessful, an angled guidewire of an angled torqueable catheter (Kumpe, JB-1)

may be used. If the wire cannot be advanced past the site of obstruction, a semirigid ureteroscope is advanced alongside the wire and the guidewire is placed under direct vision through the working channel of the scope.

CANNULATION OF THE URETERAL ORIFICE WITH A SEMIRIGID URETEROSCOPE

The ureteroscope is advanced under direct vision until it reaches the level of the ureteral orifice. The tip of the ureteroscope is used to engage the guidewire by rotating the tip until it is under the wire and lifting up. This helps open up the orifice so that the scope can be advanced under direct vision. If this is not successful, a superstiff guidewire is advanced through the working channel of the ureteroscope and passed through the ureteral orifice alongside the safety wire under fluoroscopic monitoring. Once the wire has been advanced into the proximal ureter such that the stiff segment of the shaft is in the distal ureter, the ureteroscope is rotated until it lies in between the two guidewires and the ureteroscope is then advanced over the "railroad" of guidewires (Fig. 119-1).

If resistance is met to this maneuver, then the ureteroscope is removed and a ureteral balloon is advanced over the wire and positioned fluoroscopically over the ureteral orifice and inflated with contrast until waisting of the balloon subsides. Ureteral balloon dilation is commonly used to overcome ureteral strictures, but because of the popularity of access sheaths, they are less commonly used to dilate a ureteral orifice or intramural ureter (~5% of cases) than in the past. The ideal ureteral balloon would dilate to 100% of the expected diameter while under any amount of radial constrictive force. A recent in vitro analysis of 14 different balloons showed three balloons that attained close to 100% of the expected diameter at low inflation pressure with high reproducibility: the UroMax Ultra 7 mm × 4 cm and 7 mm × 6 cm (BSCI) and the Cook Pursuit (6 mm × 4 cm). At burst inflation pressure, the Cook Ascend AQ was the most reliable balloon, achieving expected inflation diameters with minimal pressure and a small coefficient of variation.

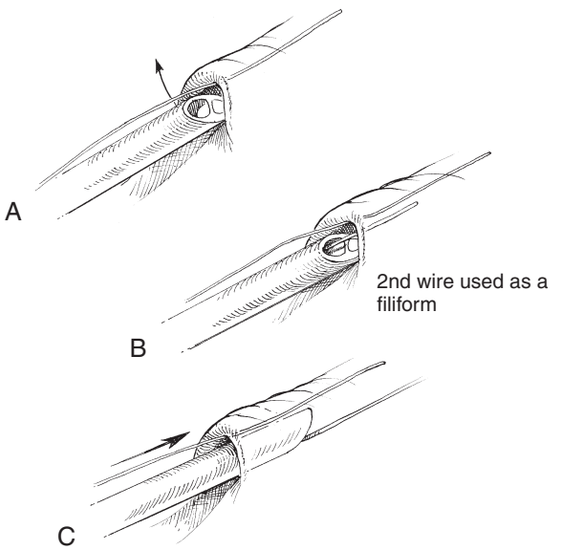

FIGURE 119-1. Tenting the ureteral orifice open by lifting up on the guidewire. Using a second wire as a filiform to open up the orifice.

PLACEMENT OF A WORKING WIRE:

Once the semirigid ureteroscope has been advanced to the point where further excursion is hampered by the course, caliber, or length of the ureter, a superstiff guidewire is advanced through the working channel of the semi-rigid ureteroscope and the scope is removed. Alternatively, if a semirigid ureteroscope is not used to inspect the distal ureter, an 8- to 10-French coaxial dilator or a 6- to 10-French dual lumen catheter can be placed over the safety wire for advancement of the superstiff working wire under fluoroscopic guidance. It is our preference to use the semirigid ureteroscope to inspect for unanticipated pathology in the distal ureter and to passively dilate the ureteral orifice such that subsequent passage of a ureteral access sheath is facilitated.

PLACEMENT OF A FLEXIBLE URETEROSCOPE OVER A GUIDEWIRE

The flexible ureteroscope can be advanced over a double floppy tip superstiff guidewire. This technique is used if one anticipates the need of less than three insertions of the flexible ureteroscope to the upper tract (i.e., diagnostic ureteroscopy, ureteral biopsy, endopyelotomy, stone burden < 8 mm). Otherwise our preference is to place a ureteral access sheath (see later).

It is critical to advance the flexible ureteroscope under fluoroscopic guidance if placed over a guidewire. In particular one should stop if buckling is noted in the bladder and then rotate the scope to realign the working channel with the ureteral orifice (Fig. 119-2A). It is helpful to keep the scope straight during advancement over a guidewire. Ureteroscopes that are stiffer (e.g., Storz, Gyrus ACMI, Wolf) are less likely to buckle when advanced over a wire than scopes that are softer (e.g., Olympus URF-P3).

PLACEMENT OF A URETERAL ACCESS SHEATH

Ureteral access sheaths are used to ease access to the upper urinary tract and to facilitate insertion of the scope during extraction of multiple stone fragments (see Fig. 119-2B). Routine use of a ureteral access sheath has been demonstrated to decrease operative time and costs, minimize morbidity to the patient, and optimize success with intrarenal ureteroscopic surgery. A 12- to 14-French (ID/OD) ureteral access sheath maintains intrapelvic pressures below 20 cm H_2O and optimizes irrigant flow, even when the irrigant fluid is pressurized to 200 cm H_2O. A 14- to 16-French ureteral access sheath should be reserved for patients with

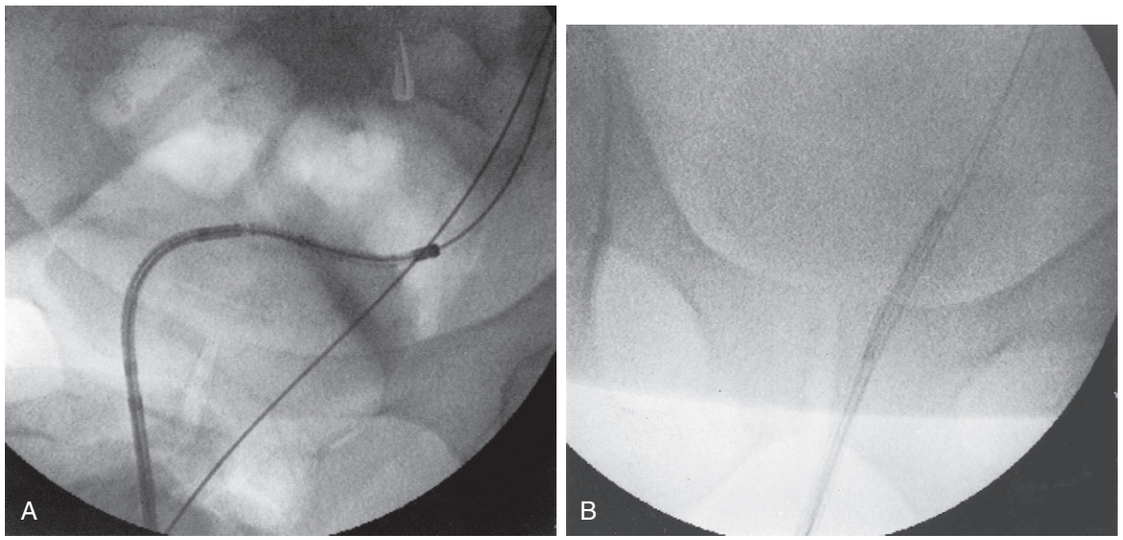

FIGURE 119-2. A, Flexible ureteroscope buckling in the bladder when advanced over a guidewire. **B,** "Straight shot" through a ureteral access sheath.

greater than 15 cm of stone burden who have been prestented. In general, a 35-cm length sheath is used in women while a 45-cm length sheath is used in men; the target is to have a sheath sufficiently long to reach the ureteropelvic junction if the site of pathology is in the kidney. The longer 55-cm sheaths may make it difficult to maneuver the flexible ureteroscope, in particular the shorter 64-cm long Gyrus-ACMI DUR-8 series.

Clinical failure of an access sheath can occur if the sheath buckles in the bladder, if it kinks when the inner dilator is removed, or if it is difficult to pass instruments through it. A prospective randomized comparison between the Flexor and Access Forte XE showed the performance of the Flexor sheath was superior with regard to overall failure and ease of use. In vitro studies have demonstrated that the Cook Flexor Sheath and the Gyrus-ACMI UroPass facilitate stone extraction because they have the largest inner diameters in the most common bending positions (straight and 30-degree bend). The Cook Flexor Sheath is most resistant to buckling during insertion (Fig. 119-3), while the Gyrus-ACMI is most resistant to kinking after removal of the inner dilator (Fig. 119-4).

The use of the ureteral access sheath may prolong the lifespan of flexible ureteroscopes by allowing easier entry and easier reentry through the intramural ureter, preventing buckling of the ureteroscope, and minimizing working channel trauma associated with the traditional backloaded guidewire technique for ureteroscope insertion. This has not been evaluated, however, in a prospective manner.

It is important to activate the hydrophilic coating of the ureteral access sheath using a "sloppy wet" gauze. The sheath is then loaded on a superstiff guidewire and advanced under fluoroscopic guidance. Care should be taken to monitor for buckling in the bladder as the sheath reaches the ureteral orifice and then the iliac vessels. If resistance or buckling is encountered, use a "jiggle" on the sheath, taking care not to rotate the sheath with advancement. The tip of the ureteral access sheath should be positioned close to the

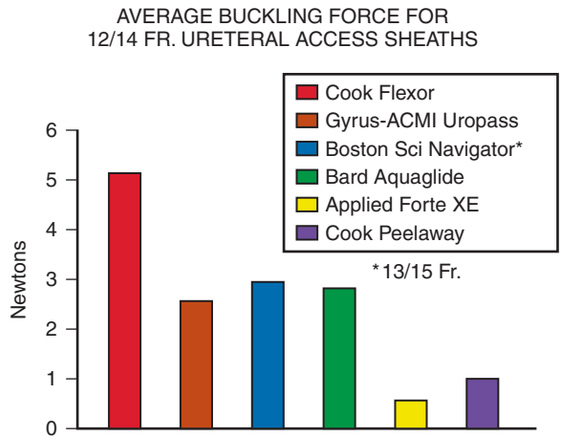

FIGURE 119-3. Average buckling force for 12- to 14-French ureteral access sheaths.

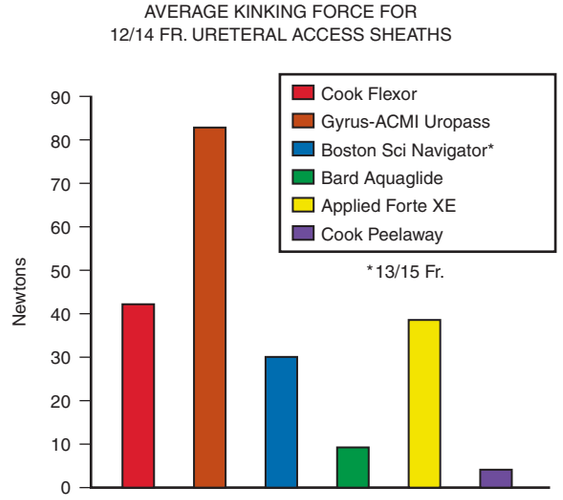

FIGURE 119-4. Average kinking force for 12- to 14-French ureteral access sheaths.

site of ureteral pathology or at the level of the ureteropelvic junction for intrarenal ureterorenoscopy. On completion of the procedure the sheath should gradually be withdrawn together with the flexible uretersocope so that the ureter can be inspected for signs of trauma.

SPECIAL CHALLENGES:

Under specific conditions, one may anticipate difficulty in identification and cannulation of the ureteral orifice. Examples include a neurogenic bladder, chronic indwelling catheter, transitional cell cancer of the bladder, trabeculations secondary to bladder outlet obstruction, or ureteral reimplantation. In this situation the use of intravenous methylene blue or indigo carmine may be required to identify efflux from the orifice. This should be administered early in the search for the orifice, especially in the face of renal insufficiency. An Albarran's bridge with a 70-degree lens or a flexible cystoscope may be necessary to facilitate identification of the orifice in the face of a large median lobe of the prostate, transplant kidney wherein the reimplant is at the dome of the bladder, or ureteroenteric anastomosis.

If the patient has a partially duplicated system, it may be desired to specifically advance a guidewire to the lower pole moiety. In this situation, a torqueable catheter may assist in selectively cannulating the lower pole ureter at the level where they conjoin. Alternatively, it may be necessary to place a safety wire to the upper pole and then place a second wire to the lower pole under direct ureteroscopic vision. Placement of a ureteral access sheath may be challenging due to a smaller caliber ureter, in which case pre-stenting for 2 weeks may be needed.

For ureteroscopic inspection as part of the evaluation of lateralizing hematuria or positive urine cytology, it is critical to use a "no touch technique" to ureteral access. In this situation, the ureteral orifice is cannulated with a semirigid ureteroscope without the assistance of a guidewire. The semirigid ureteroscope is advanced until the lumen can no longer be visualized, at which point a guidewire is advanced through the scope to the level that was visualized. The scope is then removed and a flexible ureteroscope is backloaded over the guidewire to the level inspected and direct visualization resumed after removal of the guidewire. As such, a guidewire is not advanced before inspection of the collecting system so that inadvertent guidewire trauma is not misconstrued as the source of hematuria.

See commentary at the end of Chapter 120.

Suggested Readings

Beiko DT, Watterson JD. (2005). From bench top to ureteroscopy: a comparison of ureteral access sheath physical properties. Presented at Annual Meeting of the Engineering and Urology Society. San Antonio, TX. May 21, 2005.

Clayman M, Uribe CA, Eichel L, et al. (2004). Comparison of guide wires in urology. Which, when and why? J Urol 171:2146-2150.

Hendlin K, Lund B, Dockendorf K, Ramani R, Monga M. (2005). Radial dilation of ureteral balloons: a comparative in vitro analysis. J Endourol 19:575-578.

Kourambas J, Byrne RR, Preminger GM. (2001). Does a ureteral access sheath facilitate ureteroscopy? J Urol 165:789-793.

Monga M, Anderson JK, Durfee W. (2004). Physical properties of flexible ureteroscopes: implications for clinical practice. J Endourol 18:462-465.

Monga M, Best S, Venkatesh R, et al. (2004). Prospective randomized comparison of 2 ureteral access sheaths during flexible retrograde ureteroscopy. J Urol 172:572-573.

Monga M, Gawlik A, Durfee W. (2004). A systematic evaluation of physical characteristics of ureteral access sheaths. Urology 63: 834-836.

Pedro R, Hendlin K, Durfee W, Monga M. (2007). Physical characteristics of next-generation ureteral access sheaths: buckling and kinking. Urology 70:440-442.

Pietrow PK, Auge BK, Delvecchio FC, Silverstein AD, Weizer AZ, Albala DM, Preminger GM. (2002). Techniques to maximize flexible ureteroscope longevity. Urology 60(5):784-788.

Rehman J, Monga M, Landman J, et al. (2003). Characterization of intrapelvic pressure during ureteropyeloscopy with ureteral access sheaths. Urology 61:713-718.

Chapter 120

Ureteroscopic Instrumentation

GEORGE E. HALEBLIAN

TYPES OF URETEROSCOPES

Ureteroscopes come in two forms and can be divided into conventional and digital categories. Within the conventional group, one can find semi-rigid, and flexible ureteroscopes. Within the digital classification, semi-rigid and flexible ureteroscopes are available.

CONVENTIONAL URETEROSCOPES

Semirigid Ureteroscopes

Semirigid ureteroscopes greatly advanced the art of ureteroscopy by allowing for excellent image quality in small caliber scopes due to the development of fiberoptic technology in which a bundle of glass fibers relay the image from a distal lens to a proximal lens in the eye piece.

Flexible Ureteroscopes

Since the mid-1980s, tremendous advances in scope development have led to the miniaturization of the scope to as narrow as 6 French with improved visualization through advances in fiberoptic technology. Moreover, the agility of these scopes have improved and models are available with both single and compound deflection with models having compound deflection mechanisms touting easier and improved access to lower pole calyces (Figs. 120-1 and 120-2).

DIGITAL TECHNOLOGY

The advent of digital video technology has ushered in a new era of endoscopy. With the miniaturization of CCD and CMOS technology, manufacturers are capable of placing high-resolution digital sensors at the tip of the endoscope, allowing for surgeons to have a large, clear, and bright image when performing endoscopic procedures (Fig. 120-3).



FIGURE 120-1. Single deflection.



FIGURE 120-2. Compound deflection of ureteroscope tip.

There are significant advantages related to a completely digital image, including improved resolution, no pixilation of the image, and no image degradation along the course of the scope due to air/glass interfaces seen with traditional lens systems. In addition, because the image is acquired at the tip of the scope and converted to a digital signal, damage to the imaging fiberoptic bundle is no longer of concern, which may enhance the durability of the device. Both semirigid and flexible digital ureteroscopes are available.

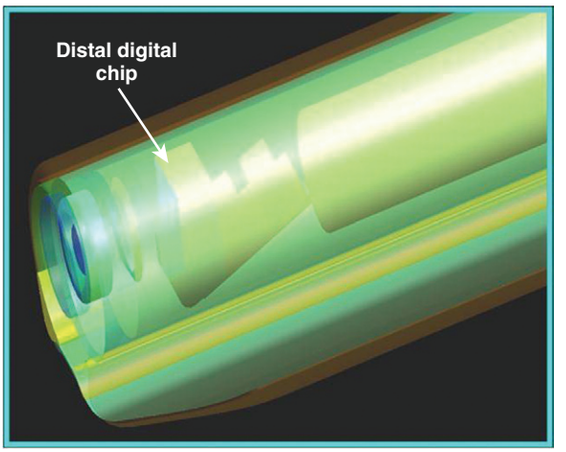

FIGURE 120-3. Digital chip at the tip of the scope captures and digitizes images at the point of acquisition.

URETEROSCOPY ACCESSORIES

Ureteral Access Sheath

The ureteral access sheath has greatly facilitated flexible ureteroscopy. The access sheath is comprised of an inner obturator with an outer sheath that is designed to resist compression while remaining flexible. The ureteral access sheath is advanced over the wire under fluoroscopic guidance to the level of interest. The obturator is then removed, with care taken to leave the wire in place. The flexible scope can then be advanced through the access sheath without concern about cannulating the ureteral orifice.

SELECTION OF VARIOUS URETEROSCOPES

As a general rule, semirigid ureteroscopy is performed for diagnostic and therapeutic procedures in the distal and mid ureter, while flexible ureteroscopy is reserved for procedures requiring access to the mid or proximal ureter and the renal collecting system.

Commentary by

S. DUKE HERRELL

Perhaps no area of surgery has undergone as many profound technological advances as those witnessed in the area of endoscopic disease treatment. Advancements in endoscopic imaging, ranging from rod lens to flexible fiber bundles and to distal chip technology have allowed for unprecedented access and visualization into even the most complex renal collecting system anatomy. Simultaneously, advanced engineering solutions, such as hydrophilic wires, small diameter manipulation tools, such as the Nitinol basket, and advancements in laser technology (holmium) have given the modern endoscopic urologic surgeon a useful and potent arsenal of weapons for stones, strictures, and tumors.

Dr. Monga (see Chapter 119) and Drs. Lyon and Halebian provide an excellent review of current techniques of access and endoscopic instrumentation for ureteroscopy, which are the basics for all the following more complex interventions. As cited, Dr. Monga's research on precise measurement of force and performance characteristics for many of these basic devices has added a needed element of science to the selection and evaluation process.

Chapter 121

Ureteroscopic Management of Ureteral Calculi

ROGER L. SUR AND GLENN M. PREMINGER

The introduction and adoption of both flexible ureteroscopes and smaller semirigid ureteroscopes (6.9 French) has revolutionized the now accepted endoscopic management of ureteral calculi. Other innovations such as newer baskets, stone entrapment devices, array of different wires, access sheaths, and Ho:YAG laser have contributed to the excellent outcomes in endoscopic management of ureteral calculi.

URETEROSCOPY FOR LOWER URETERAL STONES (BELOW ILIAC VESSELS)

Ureteral calculi below the iliac vessels are best treated with semirigid ureteroscopy, which affords maximum irrigation and visualization, as well as larger working channels to accommodate the largest lithotripsy devices. A retrograde pyelogram via a rigid cystoscope provides a map of stone location as well as collecting system anatomy and potential pitfalls that may be encountered during ureteroscopy. Safety wire placement is the necessary next step. Ureteroscopy should not proceed without a safety wire, which provides access to the collecting system when a case is terminated early and a stent is placed. Hydrophilic wires with different tips (curved, straight, or polytetrafluoroethylene (PTFE)/hydrophilic) can be used for impacted stones that do not permit passage of routine PTFE wires.

The semirigid ureteroscope should be placed down the urethra and alongside the safety wire. The ureteroscope is then placed into the ureteral orifice again alongside the safety wire. The distal ureter does not always accommodate the ureteroscope and at times must be dilated with a balloon dilating device or a ureteral dilating sheath under fluoroscopy.

Several devices provide stone entrapment to minimize retropulsion of the calculus. Retropulsion of calculi can convert a relatively uncomplicated distal ureteroscopy into a more complicated proximal ureteroscopy and even leave residual fragments in the kidney, hence decreasing stone removal outcomes. Either one is deployed through the ureteroscope just above the stone under direct visualization and the ureteroscope is then repassed to the calculus alongside both the safety wire and entrapment device. Lithotripsy then commences.

Types of intracorporeal lithotripsy include a variety of technologies, although Ho:YAG laser is clearly the current most efficacious and safe laser available. Other technologies include pneumatic/ballistic, ultrasound, and EHL (electrohydraulic). These other forms of lithotripsy can be equally effective but have limitations, and we therefore recommend Ho:YAG as first line option.

Second only to safety, visualization is paramount, and several techniques can increase visualization. Continuous controlled high irrigation pressure (<200 mm H_2O) with automatic irrigation devices or hand pump irrigation and gentle repositioning of the stone into the hydronephrotic area with the ureteroscope facilitate maximal visualization. Best results are obtained by "painting" the stone rather than immediately breaking the stone into large fragments (Fig. 121-1C). The laser should initially be set at the lowest settings (0.6 joules and 6 Hz) and gradually increased

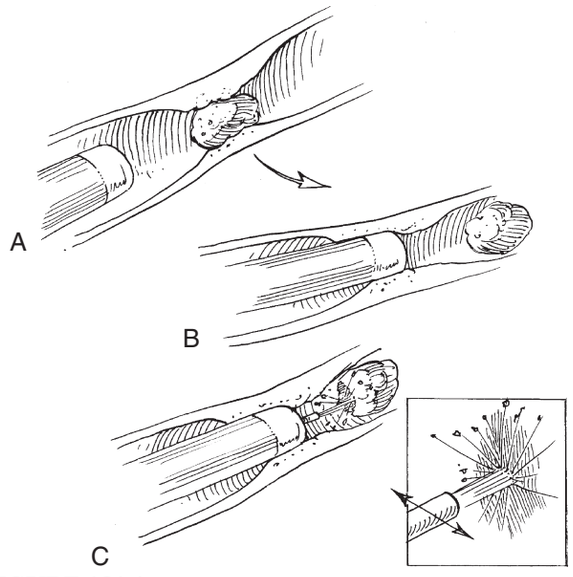

FIGURE 121-1.

if necessary, thus ensuring the gradual fragmentation of the stone and minimizing retropulsion.

Lastly, the choice of anesthesia can affect outcomes in that laryngeal mask anesthesia can introduce significant uncontrolled respiratory motion and interfere with continuous visualization of the stone. General anesthesia or regional anesthesia are better choices for ureteroscopy.

Ureteral lithotripsy can either be performed with pure fragmentation of stones (Fig. 121-2A) or lithotripsy in combination with basket removal of smaller fragments. However, we caution against the use of basket removal because it increases likelihood of ureteral avulsion (see Fig. 121-2B). Both techniques are acceptable but the urologist must recognize the potential for a significant adverse event when basketing stones.

The decision to place a double pigtail ureteral stent is purely clinical in that the literature supports an unstented ureter for uncomplicated distal ureteral lithotripsy. There are two techniques for placing a ureteral stent: (1) The stent may be placed through the working channel of cystoscope over a wire or (2) the stent may be placed only under fluoroscopy over a wire without a cystoscope. Regardless of technique, a good curl in the renal pelvis and bladder should be obtained to ensure proper placement.

URETEROSCOPY FOR UPPER URETERAL STONES (ABOVE ILIAC VESSELS)

Endoscopic treatment of ureteral calculi above the iliac vessels is very similar to treatment for distal ureteral calculi except semirigid ureteroscopy is often not practical in males due to the more acute angle posed by the pelvic bone; therefore flexible ureteroscopy is the preferred choice. Semirigid ureteroscopy is usually possible in females, although flexible ureteroscopy is necessary occasionally. Stones that are high in the proximal ureter are more easily accessed with an access sheath (Fig. 121-3). The access sheath affords improved irrigation and visualization, lowers intraureteral pressures, facilitates passage and repassage of flexible the ureteroscope, and decreases mechanical deterioration of the instrument. Safety wire access is still mandatory and can be accomplished with the wire through the lumen of the access sheath (use at least 12-French inner diameter sheath). Alternatively, the safety wire can be used outside the access sheath. Two wires are placed with a dual lumen catheter, the access sheath is passed over one safety wire under fluoroscopy, and this wire can then be removed. Sometimes the access sheath buckles during placement and requires use of a more stiff wire (Amplatz wire) or even distal ureteral balloon dilation to assist passage. Sheaths with outer diameters larger than 14 French can only be passed through ureters that have been previously stented. The access sheath should never be forced, which could result in ureteral injury.

A reasonable alternative is to simply pass the flexible ureteroscope over the working guidewire rather than use an access sheath. A single wire is placed with a rigid cystoscope, and the cystoscope is removed. A dual lumen catheter is then passed over the wire under fluoroscopy, and a second wire is placed through the catheter (Fig. 121-4A). The dual lumen catheter is removed, and a flexible ureteroscope is passed over one of the wires under fluoroscopy (see Fig. 121-4B). This "working" wire is then removed, leaving only a safety wire alongside the ureteroscope.

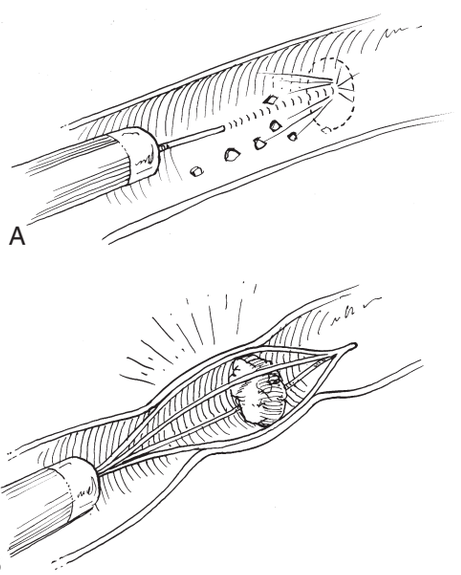

FIGURE 121-2.

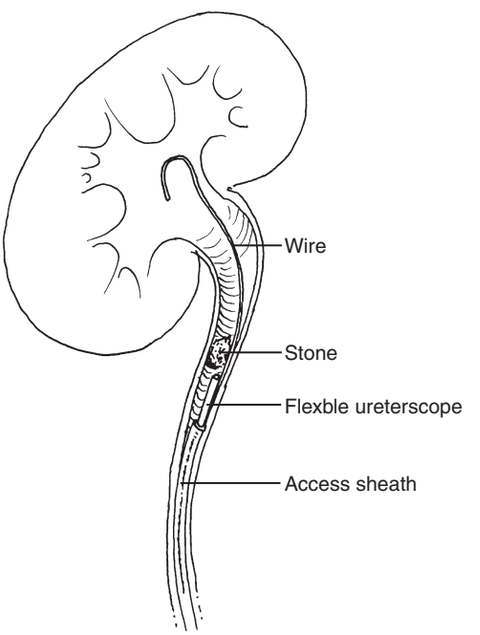

FIGURE 121-3.

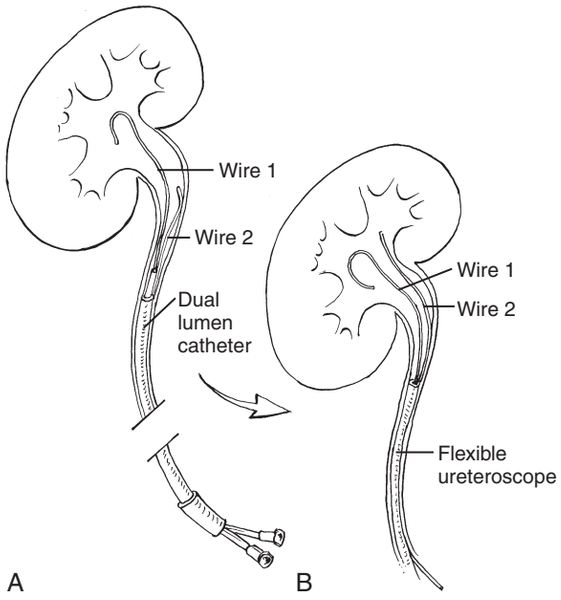

FIGURE 121-4.

Commentary by

S. DUKE HERRELL

Distal ureteroscopy has outperformed shock wave lithotripsy for ureteral stones in the majority of comparative literature studies in stone-free rates, albeit with increased potential for secondary procedures and complications. We favor a ureteroscopic approach for the majority of distal and upper ureteral stones as an expeditious and effective first line therapy.

We perform aggressive removal of fragmented particles in the majority of cases unless significant ureteral stricture or edema exists. The need for routine postoperative stenting after "uncomplicated" upper tract ureteroscopic stone management remains controversial in routine practice despite recent literature that suggests safety in some cases. While the studies have shown overall increased patient comfort and no significant increase in stricture, the risk of rehospitalization or emergency department visits for pain symptoms is increased postoperatively. This significant readmission rate combined with a lack of definitive data and selection criteria prevents us from adopting routine "stentless ureteroscopy" in our practice.

Preminger GM, Tiselius HG, Assimos DG, Alken P, Buck C, Gallucci M, Knoll T, Lingeman JE, Nakada SY, Pearle MS, Sarica K, Türk C, Wolf JS Jr., EAU/AUA Nephrolithiasis Guideline Panel. (2007). 2007 Guideline for the management of ureteral calculi. J Urol 178(6):2418-2434.

This page intentionally left blank

Chapter 122

Ureteroscopic Management of Renal Calculi

CHARLES G. MARGUET AND GLENN M. PREMINGER

The development of the flexible, deflectable ureterorenoscope allows for retrograde endoscopic treatment of renal calculi, even those in the lower pole calyx. In addition, retrograde ureteroscopy has allowed for the management of some larger stones (>1 cm), reducing the need even for percutaneous nephrostolithotomy. Herein we discuss our technique of ureteroscopy for renal calculi.

Preoperative considerations: General anesthesia with neuromuscular paralysis is preferred for renal endoscopy. This significantly reduces respiratory variation associated with spontaneous breathing and allows the anesthetist to hold respirations for stone fragmentation.

A retrograde pyelogram is performed under direct fluoroscopic guidance using half-strength water-soluble contrast. The pyelogram provides an anatomic "roadmap" for inspection of the collecting system. A guidewire is advanced through the ureteral catheter and up into the renal pelvis (Fig. 122-1). The ureteral catheter and cystoscope are then removed over the guidewire, leaving it in place.



FIGURE 122-1. Fluoroscopic image of safety guidewire into intrarenal collecting system.

A ureteral access sheath and obturator are then placed over the guidewire. The use of the access sheath facilitates passage of the flexible ureteroscope for removal of stones, and has been shown to decrease intrarenal pressures and ultimately lead to greater stone-free rates. If the ureteral orifice is noted to be narrow or stenotic, then the obturator may be passed initially by itself over the guidewire to gently dilate the lower ureter. In instances when this is unsuccessful, sequential ureteral dilators or a pressure-regulated ureteral dilating balloon may be used. Once the ureteral access sheath is in appropriate position, the obturator is removed. Care should be taken with each maneuver to ensure ureterorenal continuity with the guidewire.

A 7.5-French flexible ureteroscope with a pressurized water source is used for renal endoscopy. The ureteroscope is advanced through the ureteral access sheath, and the ureter is inspected in a retrograde fashion. The ureteropelvic junction is then traversed gently and the renal collecting system is entered. The calyces of the kidney are then systematically inspected (Fig. 122-2). Modern generation flexible ureteroscopes allow for complete inspection of the collecting system, including the lower pole calyces. A retrograde pyelogram may be performed through the ureteroscope at this point in case further delineation of the intrarenal anatomy is required.

When renal stones are encountered, intracorporeal lithotripsy may begin. Several lithotrites are currently available. We prefer the holmium:YAG laser, which allows efficient stone fragmentation with minimal tissue penetration, in case inadvertent contact with the collecting system mucosa occurs. A 200-micron laser fiber fits easily through the working channel of a flexible ureteroscope with only minimal loss of deflection and reduction of irrigation. In the case of a lower pole renal calculus, to which the scope with fiber inserted cannot be adequately deflected and therefore in situ fragmentation cannot be accomplished, the stone may be displaced with the use of a nitinol basket into a more accessible upper pole calyx.

After complete stone fragmentation, the entire collecting system is again inspected to ensure that no large stone fragments remain. At this point, the ureteroscope is slowly withdrawn across the ureteropelvic junction. The access

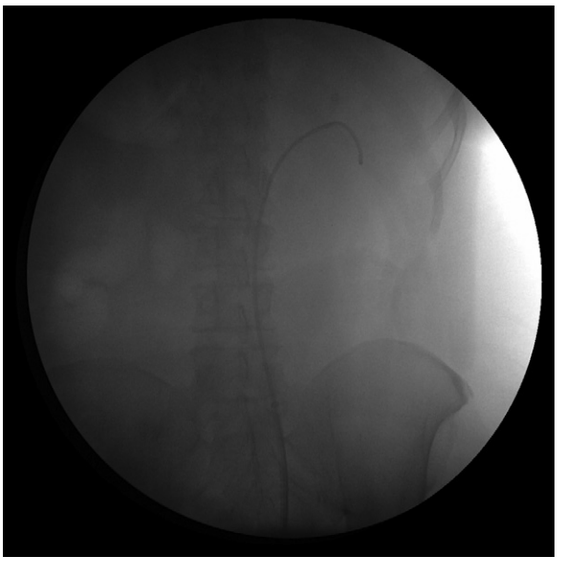

FIGURE 122-2. Fluoroscopic image of ureteroscope deflected into lower renal pole.

sheath is withdrawn with the ureteroscope down the entire length of the ureter, to facilitate inspection of the entire ureter. As stated previously, ureterorenal continuity is maintained throughout this process by the guidewire.

Although stent placement after routine ureterorenoscopy is somewhat controversial, the authors prefer to leave a ureteral stent in case of ureteral injury or after any dilation of the ureter or ureteral orifice.

Postoperative care: Routine ureterorenoscopy can almost always be performed in the outpatient setting, and hospital admission is rarely required. Postoperative pain is usually well managed with oral analgesics combined with anticholinergics for bladder spasm. If a stent is placed intraoperatively, it can be removed in 5 to 7 days via an office cystoscopic extraction or by the patient if a string is left attached to the stent.

CONCLUSIONS

Ureterorenoscopy has evolved into a powerful tool in the armamentarium of the urologist for the management of renal stones. Many larger stones once requiring either percutaneous or open renal surgery can now be managed with a less invasive outpatient procedure. Excellent stone-free rates can be achieved, often with a single procedure in the outpatient setting.

Commentary by S. DUKE HERRELL

Like many surgical engineering technology advances, the development of the double deflection ureteroscope has helped revolutionize modern urologic surgical care. Access to the important lower caliceal renal anatomy has paved the way for improvements in stone retrieval, repositioning, and treatment. Ability to access the difficult lower pole anatomy with the single deflection scope once defined the "master endourologist" but is now the purview of most urologists and even early trainees due to these endoscopes.

Like the authors, we routinely utilize small caliber access sheaths, which allow for ease of scope passage, reduction in overpressurization, repetitive fragment retrieval, and presumed reduction in scope damage. In most cases, the distal ureter is dilated with an $^{8}/_{10}$-French catheter and the $^{11}/_{13}$-French access sheath is passed to the mid-ureter for upper ureteral and renal stone treatment. However, in some cases, we have encountered increased difficulty in passing the access sheath next to a safety wire and find the intraluminal safety wire motion limiting within the small lumen access sheaths; therefore we prefer to work without a safety for some less complex cases. In rare cases, we employ no access sheath and use the two-wire technique. Certainly, if ureteral stricture is present, perforation is likely, or incision is planned, then options include a safety wire externally to the small sheath before placement, dilatation enough to place a larger diameter sheath with an internally parallel safety wire, use of the two wires with no access sheath, or stenting empirically with a plan for a secondary procedure with a larger sheath if none of the initial three maneuvers are successful.

Chapter 123

Ureteroscopic Endoureterotomy

BRIAN K. AUGE

Endoscopic incision of benign ureteral or ureteroenteric strictures is considered first line treatment with long-term success rates exceeding 65%. The majority of strictures develop secondary to iatrogenic ureteral injury during ureteroscopic procedures or urinary diversion; however, impacted stones and external inflammatory processes can also produce ureteral fibrosis, leading to stricture formation. Preoperative evaluation should include both antegrade and retrograde imaging to assess the degree of obstruction, the exact location, and stricture length. Antegrade imaging techniques known to be helpful are contrast-enhanced computed tomography, intravenous pyelography, and nuclear renography, while retrograde ureteropyelography aids in those with high-grade obstruction and to determine the extent of stricture disease. Success rates of endoureterotomy for strictures longer than 1 cm are uniformly poor compared with those shorter than 1 cm. Recurrence of malignancy must be ruled out before endoscopic management in patients having previously undergone urinary diversion following radical cystectomy for carcinoma. Knowledge of the ureteral blood supply and surrounding structures is of utmost importance when considering energy ablative techniques to avoid major vascular or intestinal injury. In general, ureteral strictures are incised laterally for proximal and mid segment strictures, and medially for distal strictures.

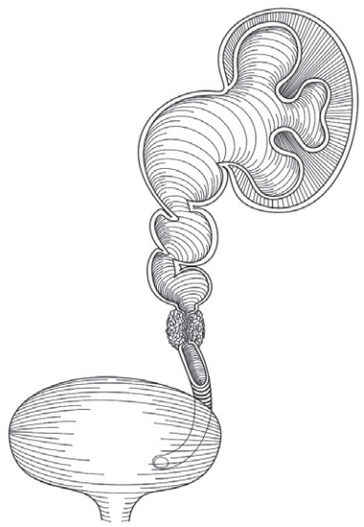

FIGURE 123-1. Demonstration of distal ureteral stricture with accompanying proximal hydroureteronephrosis.

1. Following induction of general or regional anesthesia and administration of prophylactic antibiotics, the patient is placed on a fluoroscopy table in the lithotomy position and cystoscopy with retrograde pyelography is performed. The location of the stricture is determined and the degree of hydronephrosis is assessed (Fig. 123-1). The operating surgeon selects the appropriate endoscope, typically choosing a semirigid scope for strictures within the distal one third of the ureter and a flexible ureteroscope for those within the proximal two thirds of the ureter.
2. A guidewire is inserted through the strictured segment and into the proximal portion of the collecting system under fluoroscopic control. If a standard Teflon-coated or combination wire cannot be advanced, then a hydrophilic wire with or without an angled tip may be required to traverse the stricture and gain access to the proximal collecting system. The hydrophilic wires require replacement with a standard working wire before further manipulation to ensure adequate and secure access. A 4- or 10-cm ureteral dilating balloon is then advanced over the wire and through the stricture so that the stricture is located at the midportion of the balloon. The balloon is partially inflated using full strength contrast to better evaluate the stricture length (Fig. 123-2). The balloon can then be deflated and removed, leaving the wire in situ.
3. If using a semirigid ureteroscope, the scope can then be advanced alongside the safety wire to the level of the stricture. If a flexible scope is used, a ureteral access sheath can be of assistance to allow repeated unencumbered advancement of the scope and facilitate placement of the stent at the conclusion of the procedure. The access sheath is placed over the wire to within 3- to 5-cm of the stricture. The inner obturator is removed, followed

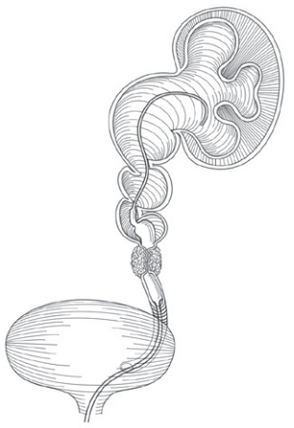

FIGURE 123-2. Ureteral dilating balloon partially inflated across ureteral stricture.

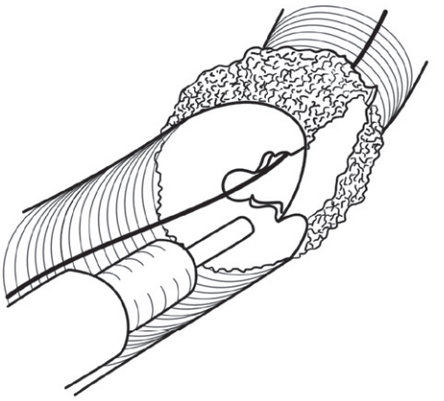

FIGURE 123-4. Full thickness incision of the stricture with holmium laser.

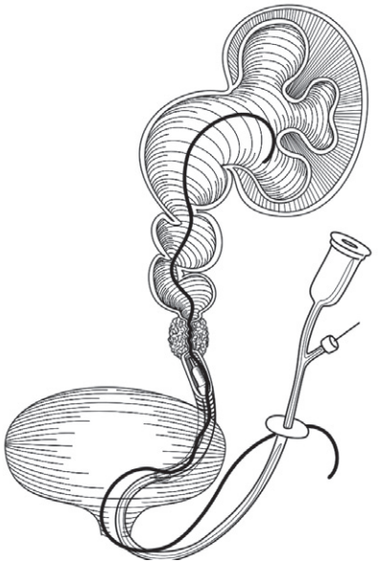

FIGURE 123-3. Flexible ureteroscope inserted through ureteral access sheath to the level of the stricture.

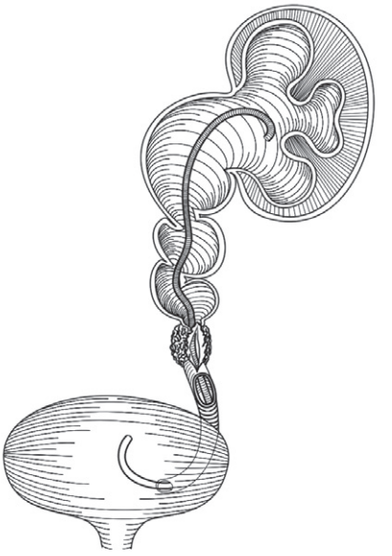

FIGURE 123-5. Ureteral stent noted to be in proper position within the collecting system, across the incised ureteral stricture.

by insertion of the flexible ureteroscope to the level of the stricture (Fig. 123-3).

4. The holmium laser is used to incise the stricture laterally in the upper two thirds and medially in the distal one third of the ureter (Fig. 123-4). The holmium laser settings are generally 1 to 2 J at 10 to 20 Hz. Full thickness incision is required, ensuring that the incision extends into the normal healthy-appearing ureter 0.5 to 1 cm proximal and distal to the fibrotic segment. Retroperitoneal adipose tissue or thin "spiderweb" periureteral attachments must be observed through the endoureterotomy to confirm adequate depth. Care must be exercised to avoid major vascular structures within the vicinity of the incision.
5. The ureteroscope is removed and ureteral stent is inserted over the safety wire under fluoroscopic guidance. Observation of the proximal and distal curl of the stent is mandatory to ensure proper positioning (Fig. 123-5). All pull-string tethers should be removed before placement to eliminate the potential for inadvertent stent removal. The stent is maintained for approximately 6 weeks to allow for adequate ureteral healing over the stent. A Foley catheter is inserted for temporary bladder drainage and minimization of retrograde urinary reflux through the ureterotomy.
6. Patients with ureteroenteric strictures (Fig. 123-6) generally require an antegrade approach or combined antegrade-retrograde approach to endoureterotomy, because identification of the anastomosis from within the bowel segment for a pure retrograde attempt can be challenging. Percutaneous access to the mid or upper portion of the intrarenal collecting system is made with the aid of ultrasonic or fluoroscopic guidance.
7. An antegrade ureterogram is performed, followed by advancement of two wires across the stricture and into the intestinal segment (Fig. 123-7). If a combined

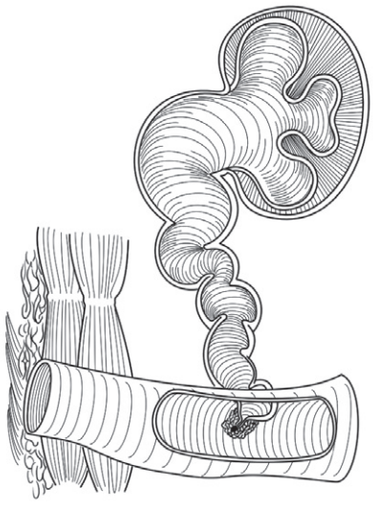

FIGURE 123-6. Ureteroenteric anastomotic stricture.

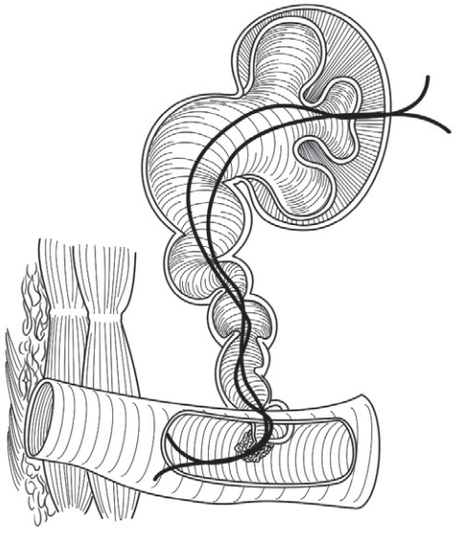

FIGURE 123-7. Safety and working wires across the ureteroenteric stricture.

antegrade-retrograde procedure is being performed, then the wires can be identified within the bowel segment and withdrawn out through the cutaneous ostomy site for through-and-through access.

8. The access tract is then dilated to an appropriate diameter to allow instrumentation to be easily passed. This can be done using a standard 30-French dilating balloon, sequential Amplatz dilators, or ureteral access sheath. Generally, a flexible ureteroscope is required to perform an antegrade endoureterotomy. The endoscope is advanced through the access sheath to the level of the stricture (Fig. 123-8). Biopsy specimens can be obtained if recurrent malignancy is suspected. Using the holmium laser or cautery device, a full thickness incision is made as previously described. Once an adequate incision is observed, the ureteroscope is withdrawn and a ureteral stent is inserted under fluoroscopic guidance. It is advised to maintain nephrostomy tube drainage until the stent is removed 6 weeks postoperatively to facilitate antegrade ureterogram imaging at the time of stent removal.

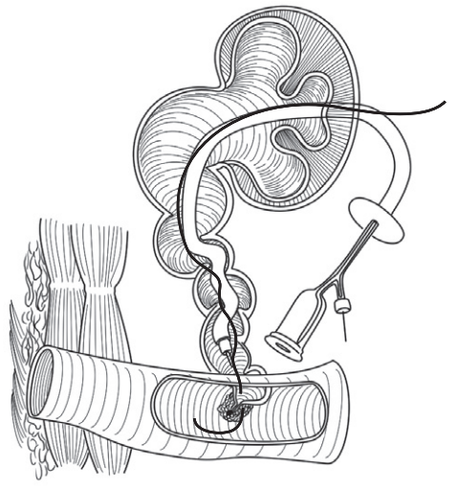

FIGURE 123-8. Percutaneous access with flexible ureteroscope through access sheath to level of stricture.

POSTOPERATIVE CARE

Endoureterotomy can be performed as an outpatient procedure in most situations. Patients are given appropriate antibiotics for 2 to 3 days following the procedure to avoid postoperative infection. Foley catheter and/or nephrostomy tube drainage is encouraged to reduce the extent of urinary extravasation and avoid the development of a urinoma within the retroperitoneum at the ureteral incision site. The Foley catheter can be removed 3 to 5 days postoperatively to allow adequate time for the urothelium to heal over the incision. The stent is maintained for a minimum of 6 weeks and can be removed via flexible cystoscopy in the office. If a nephrostomy tube is present, antegrade nephrostogram should be performed before the stent is removed.

Follow-up must include contrast imaging to ensure patency at the previous stricture site. This should be performed approximately 4 to 6 weeks after stent removal or at presentation for persistent or recurrent symptoms. Additional imaging at 3 months, 6 months, and 12 months after surgery is also mandatory. However, it remains unclear whether long-term follow-up beyond 12 months is required because the majority of patients fail within 3 months if the procedure is unsuccessful.

Commentary by

S. DUKE HARRELL

Dr. Auge provides an excellent review of modern techniques for endoscopic incision of ureteral stricture disease. Our technique is similar and we would stress the importance of maintaining a safety wire across the segment throughout all manipulations, especially incision.

While we continue to employ endoincision for short ureteral strictures (<1 cm) in select cases, our trend is to use laparoscopic and robotic reconstruction techniques for most upper and lower ureteral stricture disease.

Ureteroenteric stricture remains a rare but challenging complication of urinary diversion. We recently reviewed our institutional experience in the management of ureteroenteric strictures by primary endoscopic intervention or primary open revision. Twenty-eight patients with ureteroenteric strictures underwent endoscopic management (n = 21) or open revision (n = 7). Endoscopic intervention (balloon dilation, electroincision, or holmium endoureterotomy) was successful in six patients for an overall success rate of 27% with a median follow-up of 21 months. Open revision was successful in 87.5% (7 of 8) patients for whom initial endoscopic surgery had failed. The success rate of primary open revision was 71.4% (5 of 7 patients) with a mean follow-up of 18.1 months. Endoscopic management continues to have success rates that remain lower than that of open revision. However, despite low success rates, the potential avoidance of the difficult open reexploration of many of these diversion patients is often requested and likely warranted.

Milhoua PM, Miller NL, Cookson MS, Chang SS, Smith JA, Herrell SD. (2009). Primary endoscopic management versus open revision of ureteroenteric anastomotic strictures after urinary diversion—single institution contemporary series. J Endourol 23(3):551-555.

Suggested Readings

Gnessin, E, Yossepowitch, O, Holland, R, Livne, PM and Lifshitz, DA: Holmium laser endoureterotomy for benign ureteral strictures: a single center experience. J UroI 182(6): 2775-9, 2009.

Hibi, H, Ohori, T, Taki, T, Yamada, Y and Honda, N: Long-term results of endoureterotomy using a holmium laser. Int J Urol 14(9): 872-4, 2007.

Kurzer, E and Leveillee, RJ: Endoscopic management of ureterointestinal strictures after radical cystectomy. J Endourol 19(6): 677-82, 2005.

Razdau, Silberstein, IK and Bagley, DH: Ureteroscopic endoureterotomy. BJU Int Suppl 2: 94-101, 2005.

Chapter 124

Ureteroscopic Endopyelotomy

ILIA S. ZELTSER AND MARGARET S. PEARLE

Ureteropelvic junction obstruction (UPJO) is defined as functional or anatomic obstruction of urine flow from the renal pelvis into the ureter. UPJO may be caused by intrinsic or extrinsic anatomic anomalies classified as congenital or acquired and by functional impedance of urinary flow across the ureteropelvic junction (UPJ). Intrinsic causes of obstruction include congenital narrowing at the UPJ, a defect in ureteral musculature, persistent mucosal folds, high insertion of the ureter into the renal pelvis, and rarely, ureteral polyps. Congenital extrinsic obstruction is usually due to a crossing vessel, typically an accessory or aberrant arterial branch supplying the lower pole. Acquired obstruction can result from scarring due to ischemia from previous ureteral surgery, stone impaction, or traumatic injury, or it may be due to fibrosis or lymphadenopathy.

Historically, UPJO was corrected by open dismembered pyeloplasty with a high success rate; however, with popularization of percutaneous approaches, development of small diameter flexible and semirigid ureteroscopes, introduction of the holmium laser, and refinement of laparoscopic and robotic techniques, a variety of minimally invasive treatment options are now available. Endopyelotomy, by which a full-thickness incision is carried through the narrowed segment from normal ureter proximally into normal ureter distally, can be accomplished via a single-stage antegrade or retrograde approach using a cold knife, electrosurgical probe, or holmium laser or via a retrograde or antegrade incision using the Acucise (Applied Urology, Rancho Santa Margarita, Calif.) ureteral cutting balloon catheter consisting of a low-pressure balloon with a monopolar electrocautery cutting wire. The overall success rate for retrograde ureteroscopic endopyelotomy ranges from 67% to 100% and is negatively impacted by the presence of a crossing vessel, massive hydronephrosis, and poor ipsilateral renal function.

PATIENT SELECTION

The only absolute contraindications to retrograde endopyelotomy are active urinary tract infection and untreated bleeding diathesis. The presence of a crossing vessel, large renal pelvis, concurrent renal calculi, ipsilateral differential renal function of less than 20%, length of the narrow segment exceeding 2 cm, and stent intolerance comprise relative contraindications, and patients with these characteristics may be better served with an antegrade endopyelotomy or a laparoscopic pyeloplasty.

PREOPERATIVE PREPARATION

Preoperative ureteral stenting may alleviate flank pain, improve renal function, and passively dilate the ureter, thus facilitating ureteral access at the time of endopyelotomy, but this measure is not a necessary step in the procedure. Urine culture is obtained in all patients, and culture-specific antibiotics are administered to those with positive cultures. Sterile urine must be documented before endopyelotomy. Coagulation studies are obtained only as indicated by a history of bleeding diathesis, and in those with abnormal findings a formal hematology evaluation may be required. Preoperative imaging with a helical computed tomography (CT) angiogram is advisable to identify a crossing vessel that may preclude safe endoscopic incision or negatively impact outcome. On the day of the procedure, a parenteral antibiotic is administered in time to achieve therapeutic plasma levels before the intervention. The procedure can be performed under general or spinal anesthesia, but general anesthesia is preferred.

URETEROSCOPIC ENDOPYELOTOMY: THE PROCEDURE

Ho:YAG Laser

1. After placement of antiembolic stockings or compression devices, the patient is placed on a radiolucent table in the modified dorsal lithotomy position, and all of the pressure points are carefully padded.
2. A rigid cystoscope is introduced into the bladder and a retrograde pyelogram is performed to delineate anatomy



FIGURE 124-1. Retrograde pyelogram is performed.

of the ureter and the ureteropelvic junction, particularly defining the area of obstruction (Fig. 124-1). A total of 15 to 20 mL of dilute contrast may be necessary to adequately opacify the dilated renal pelvis. (At this point, some authors advocate examining the UPJ with endoluminal ultrasound to identify crossing vessels and to precisely define the location of the incision.)

3. A 0.035- or 0.038-inch Bentson guidewire is passed into the ureteral orifice and advanced up the ureter under fluoroscopic guidance until it coils in the renal pelvis (Fig. 124-2). A second, stiff-shafted guidewire, is passed into the renal pelvis using an 8/10-French coaxial introducer or a dual lumen catheter (Fig. 124-3). The Bentson wire is secured to the drape as a safety wire to safeguard against lost ureteral access, and the second wire is used to deliver an actively deflectable flexible ureteroscope to the level of the UPJ (Fig. 124-4). The working guidewire is removed after the ureteroscope is positioned in the collecting system.
4. The entire UPJ segment is then examined circumferentially to define the length of stricture and identify transmitted ureteral wall pulsations from a possible crossing vessel.
5. A 365-μm or 200-μm holmium:YAG laser fiber is passed through the working channel of the ureteroscope until the tip of the fiber is visible in the field of view of the ureteroscope (Fig. 124-5). Using energy setting of 1.0 to 1.5 J and a frequency of 10 to 15 Hz, a straight lateral incision is made that extends from the renal pelvis proximally into patent, healthy ureter distal to the obstructing segment. The incision should extend 1 cm proximal and distal to the narrowed segment into normal pelvis/ureter and should be carried through the full thickness of the ureteral wall into periureteral fat, incising the ureter layer by layer (see Fig. 124-5). The

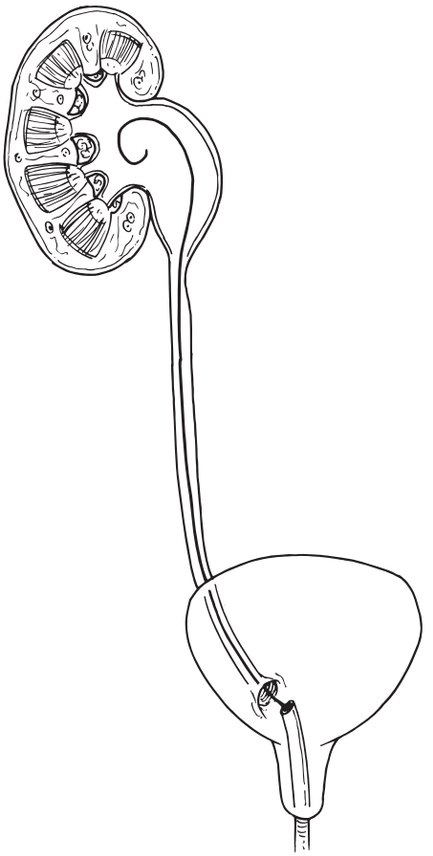

FIGURE 124-2. A safety guidewire is placed

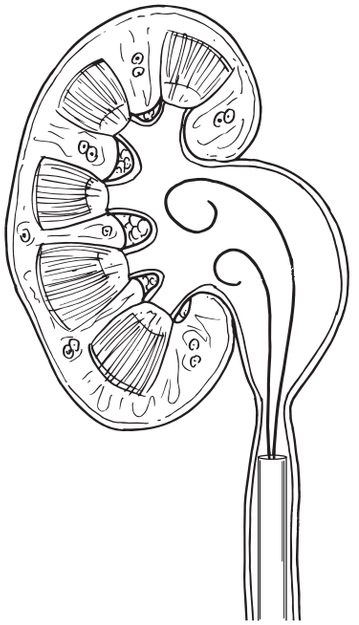

FIGURE 124-3. A working guidewire is inserted using an 8/10F coaxial introducer or a dual lumen catheter

ureteroscope is then removed and a 4-cm 24-French dilating balloon is passed over the guidewire to calibrate the incised segment and separate the cut edges (Fig. 124-6). The balloon should fully inflate at low pressure (1 to 2 Atm) if the incision is sufficiently deep and long (Fig. 124-7).

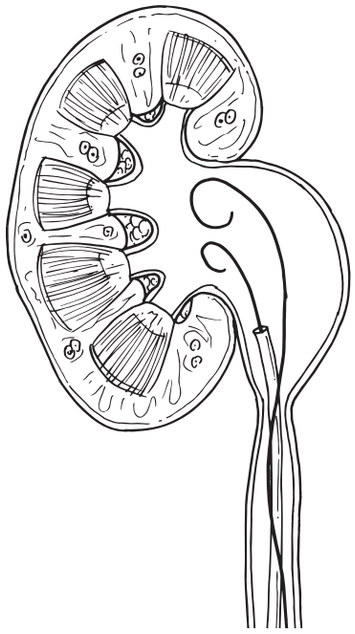

FIGURE 124-4. The flexible ureteroscope is placed over the working guidewire under fluoroscopic guidance and the obstructing segment is examined

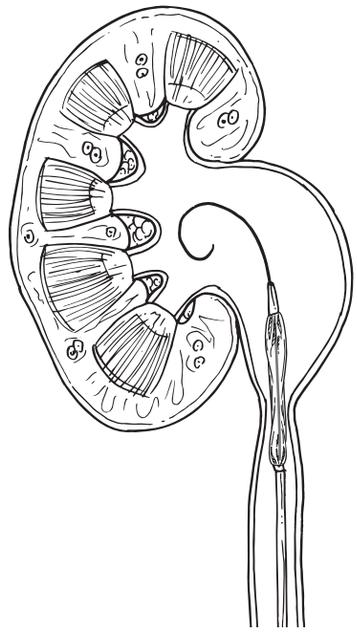

FIGURE 124-6. A ureteral dilating balloon catheter is passed over the wire and positioned under fluoroscopic guidance so that the radiopaque markers encompass the incised segment.

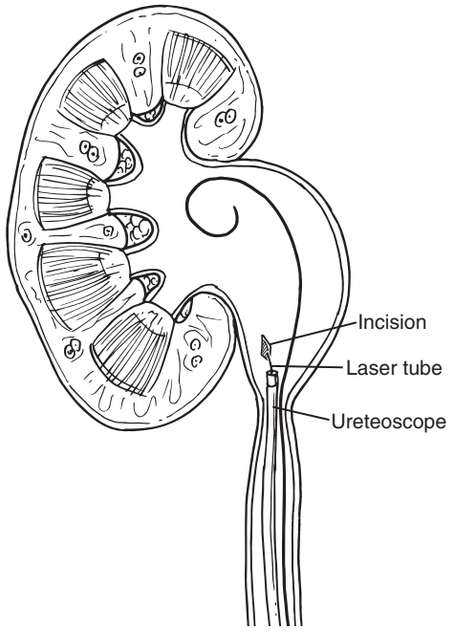

FIGURE 124-5. A laser fiber is inserted through the ureteroscope and its tip positioned a few millimeters beyond the end of the working channel. The ureteroscope is advanced proximal to the UPJ and rotated so that the tip of laser fiber faces laterally. The incision is made by activating the laser and simultaneously withdrawing the ureteroscope through the UPJ while maintaining the lateral orientation. Repeated passes are made until periureteral fat is visualized.

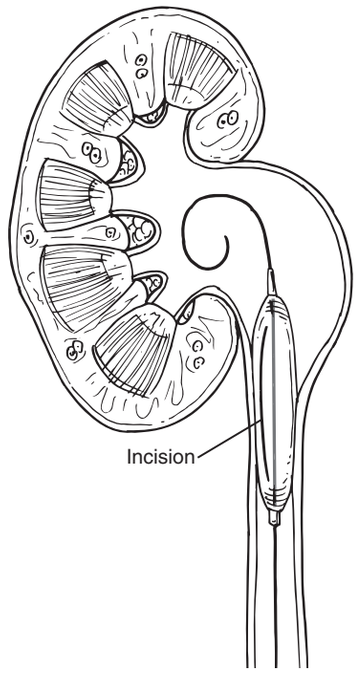

FIGURE 124-7. The balloon is inflated with dilute contrast under fluoroscopic control and the incised segment is dilated to 24 French. Proper incision is ensured by the absence of a waist.

Electrocautery

Steps 1 through 4 are as outlined above.

6. 5A. When electrocautery is used, an insulated guidewire (hydrophilic guidewire) is used as a safety wire. Alternatively, a small diameter ureteral catheter (5-French angiographic catheter) is passed over the guidewire to insulate it and prevent transmission of current along the wire. A small volume of sterile water or glycine replaces physiologic saline irrigation during the incision and should be replaced with saline after the incision is complete. A full-thickness incision is accomplished via a 2- or 3-French angled or straight tip electrosurgical probe with the generator set to 30 to 40 W of pure cutting current. Small bleeding vessels can be controlled by spot electrocoagulation. The ureteroscope is removed, and a 4-cm 24-French dilating balloon is passed over the safety guidewire to calibrate the incised segment and separate the cut edges.

Cold Knife

Steps 1 and 2 are as outlined above.

3B. A ureteroresectoscope fitted with a cold knife is advanced into the renal pelvis, alongside the safety guidewire.

7. 4B. Using short a shallow strokes, a lateral incision is carried from the renal pelvis distally through the narrowed segment into healthy patent ureter distal to the obstructing segment and extending through the full thickness of the ureteral wall until periureteral fat is visualized. The ureteroscope is removed and a 4-cm 24-French dilating balloon is passed over the safety guidewire to calibrate the incised segment and separate the cut edges.
8. A large diameter, graduated double pigtail ureteral stent (endopyelotomy stent, 12/7 French or 10/7 French) or, alternatively, a standard small-caliber stent (7 French) is inserted under fluoroscopic and/or cystoscopic guidance and left in place for 4 to 6 weeks (Fig. 124-8). An indwelling Foley catheter is placed to provide low-pressure drainage across the UPJ, to eliminate ureteral reflux, and to monitor bleeding over the next 12 to 24 hours.

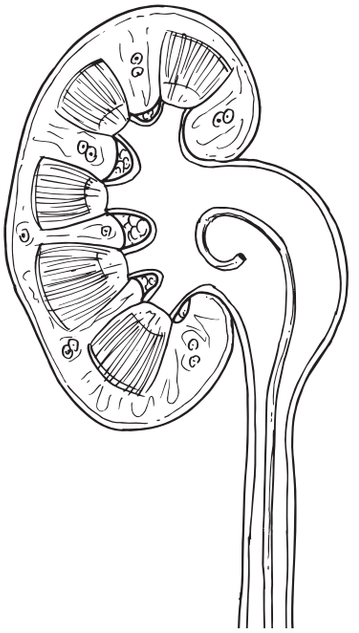

FIGURE 124-8. A double pigtail ureteral stent is inserted.

POSTOPERATIVE CARE

Patients are discharged home the same day or the next morning provided the urine is no darker than light pink in color. The Foley catheter is removed before discharge, after 12 to 24 hours, and the ureteral stent is removed cystoscopically at 4 to 6 weeks. Initial imaging is performed with a diuretic renal scan and/or excretory urography within 2 to 4 weeks of stent removal. If the study shows a patent UPJ, further follow-up with a diuretic renogram is obtained at 3 months, 6 months, and annually for at least 5 years to monitor ipsilateral renal function and to rule out silent reobstruction.

Commentary by

S. DUKE HERRELL

The management of UPJ obstruction has certainly undergone radical change over the past 2 decades. Antegrade and retrograde endopyelotomy were proposed in the 1980s and 1990s as minimally invasive alternatives to open pyeloplasty. Subsequent long-term study has revealed lower success rates than pyeloplasty with long-term follow-up, albeit with the benefit of improved cosmetics and recovery. There has now been significant drop-off in endoscopic endopyelotomy as laparoscopic pyeloplasty, initially described by Kavoussi and colleagues, has proven highly effective with the benefits of a minimally invasive approach. The robotic surgical platform has served as an enabling technology, allowing translation of these techniques out into the community and to larger numbers of surgeons and patients.

Suggested Readings

Bagley DH, Liu JB, Goldberg BB, et al. (1995). Endopyelotomy: importance of crossing vessels demonstrated by endoluminal ultrasonography. J Endourol 9:465.

Biyani CS, Cornford PA, Powell CS. (2000). Ureteroscopic endopyelotomy with the holmium:YAG laser. Mid-term results. Eur Urol 38:139.

Clayman RV, Basler JW, Kavoussi L, et al. (1990). Ureteronephroscopic endopyelotomy. J Urol 144:246.

Conlin MJ, Bagley DH. (1998). Ureteroscopic endopyelotomy at a single setting. J Urol 159:727.

Gerber GS, Kim JC. (2000). Ureteroscopic endopyelotomy in the treatment of patients with ureteropelvic junction obstruction. Urology 55:198.

Giddens JL, Grasso M. (2000). Retrograde ureteroscopic endopyelotomy using the holmium:YAG laser. J Urol 164:1509.

Karlin GS, Badlani GH, Smith AD. (1988). Endopyelotomy versus open pyeloplasty: comparison in 88 patients. J Urol 140:476.

Mendez-Torres FR, Urena R, Thomas R. (2004). Retrograde ureteroscopic endopyelotomy. Urol Clin North Am 31:99.

Meretyk I, Meretyk S, Clayman RV. (1992). Endopyelotomy: comparison of ureteroscopic retrograde and antegrade percutaneous techniques. J Urol 148:775.

Nakada SY. (2000). Acucise endopyelotomy. Urology 55:277.

Nakada SY, Johnson M. (2000). Ureteropelvic junction obstruction. Retrograde endopyelotomy. Urol Clin North Am 27:677.

Pearle MS. (1996). Use of ureteral stents after endopyelotomy. J Endourol 10:169.

Thomas R, Monga M. (1998). Endopyelotomy. Retrograde ureteroscopic approach. Urol Clin North Am 25:305.

Thomas R, Monga M, Klein EW. (1996). Ureteroscopic retrograde endopyelotomy for management of ureteropelvic junction obstruction. J Endourol 10:141.

This page intentionally left blank

Chapter 125

Ureteroscopic Management of Transitional Cell Carcinoma

RAYMOND W. PAK AND DEMETRIUS H. BAGLEY

Upper tract transitional cell carcinoma (TCC) has historically been managed by complete surgical resection (radical nephroureterectomy) without renal preservation. Increasing data support the role of renal preservation and ureteroscopic resection of ureteral and renal TCC lesions. Imperative indications for conservative, endoscopic management include a solitary renal unit, underlying renal insufficiency and bilateral upper tract TCC. With improvements in endourologic equipment, such as reduced size, improved optics, and increased mobility, ureteroscopic management has become a valid option and has been extended to patients with normal contralateral kidneys. Although recurrences are frequent, long-term data support the oncologic success of this modality. Progression to high-grade disease or a large unresectable tumor burden should still be managed with radical nephroureterectomy even in the face of rendering a patient anephric.

Successful endoscopic management of upper tract TCC is ultimately dictated by the patient's understanding and acceptance of the risk of recurrence and subsequent need for continued surveillance and retreatment. Therefore, the goal of ureteroscopy should be to diagnose the lesion visually, obtain tissue specimens for pathologic review, and ablate the lesion completely without causing undue harm to the patient. The ideal patient would have a negative urine cytology, indicating low-grade disease, and a single, small upper tract lesion on a papillary stalk with normal anatomy. Complex cases in endoscopic management include sessile lesions, large tumor burden, circumferential tumors, lesions in a lower pole calyx (limiting instrumentation), and abnormal anatomy (strictures, diverticula, narrow infundibula).

PREOPERATIVE PLANNING

All patients require preoperative evaluation including urine studies (urinalysis, cytology, culture, and/or other TCC markers), blood work (electrolytes and BUN/Cr), and radiographic imaging. Intravenous pyelography or computed tomography urograms are the best studies available for delineating ureteral and/or renal TCC lesions. A previous history of bladder TCC requires that preparation for possible bladder tumor resection be available intraoperatively.

General anesthesia with endotracheal intubation and paralysis is ideal, although spinal blockade or laryngeal mask anesthesia is adequate. Narcotics can be used to slow the patient's respiratory rate when working on a moving target such as a tumor in the renal pelvis. Patients are placed in dorsal lithotomy position with ample padding at all pressure points. The upper extremities are placed outside the radiation field to ensure unobscured views of both upper tracts. Monitors for endoscopy and fluoroscopy should be comfortably positioned for the surgeon. A laser generator capable of dual modalities such as holmium (Ho):YAG and neodymium (Nd):YAG is crucial because of their respective biophysical properties, specifically level of tissue penetration. Fluid irrigation should always be with sterile normal saline, unless an electrode for electrocautery is used. Fluid irrigation during ureteroscopy can be delivered by gravity, a pressurized bag, or a hand-controlled irrigation device. Ureteral access sheaths are not preferred secondary to loss of intrapelvic or ureteral pressures, leading to inadequate visualization and working room. Safety guidewires are generally helpful to maintain ureteral access, but must be used with care to avoid bleeding and tumor disruption. Containers with sterile normal saline for pathologic specimens should be prepared for frequent collections of tissue for cytology, histology, and/or cell block analysis.

ENDOSCOPIC TECHNIQUE

An initial thorough cystoscopy is crucial to rule out bladder TCC lesions. Initial urine cytology of the bladder should be collected. Any bladder lesion seen should be managed after the upper tract has been adequately visualized and/or treated. Using approximately 30% iodinated contrast, a

formal retrograde ureteropyelogram with a cone tip catheter is always useful despite adequate preoperative imaging studies. A small-diameter rigid ureteroscope (<7 French) or flexible ureteroscope (if the lumen is adequate) is initially passed into the ureter without a wire or dilation to avoid instigation of bleeding or tumor destruction (Fig. 125-1). The length of the ureter up to lower portions of the proximal ureter should be adequately visualized with the rigid ureteroscope depending on the sex of the patient. The rigid ureteroscope should be passed only to the level that can be reached easily. If unsuccessful, changing out to a flexible ureteroscope over a guidewire is safer and more efficient.

After completion of the proximal excursion of the rigid endoscope, a guidewire is placed to the level of the ureter that has already been inspected and left in place as the endoscope is removed. A flexible ureteroscope is then passed over the wire toward the last visualized segment under fluoroscopic guidance. The guidewire is then removed and the endoscope passed retrograde to the renal pelvis. At this level, the collecting system is systematically visualized, starting with the renal pelvis, then major and minor calyces of the upper-pole, mid-pole, and finally lower-pole (Fig. 125-2). Diluted contrast (20% to 30% iodinated contrast) in the irrigant can help outline the renal collecting system under fluoroscopic visualization to ensure complete inspection.

Any lesion encountered during ureteroscopy should be managed as the endoscope is passed retrograde, unless retrograde studies reveal more significant proximal lesions. After thorough visualization of a ureteral lesion, a sample should be obtained for pathology. An adequate tissue specimen can be obtained using a flatwire basket, a cup biopsy forceps, or occasionally a wire-prong grasper. The type of lesion dictates the ideal tool: flat (cup) or papillary (basket) (Fig. 125-3).

Using a flatwire basket in the ureter or kidney requires placement of the widest opening of the basket on the center of the lesion, closure of the basket snugly but not fully to avoid tumor shearing, withdrawal of the basket to avulse a fragment, and depending on specimen size, removal of the basket through the working channel or the entire unit (endoscope and basket) from the upper tract (Fig. 125-4).

Repeated tissue sampling acts as a mechanical debridement of the lesion and increases the specimen yield. A ureteral or renal aspirate postbiopsy should be obtained once again to increase tissue yield. Energy can then be used to ablate and coagulate the biopsy site for hemostasis and complete tumor ablation, while maintaining the integrity of the ureter Ho:YAG and Nd:YAG lasers are the ideal modality to achieve these two goals (Fig. 125-5).

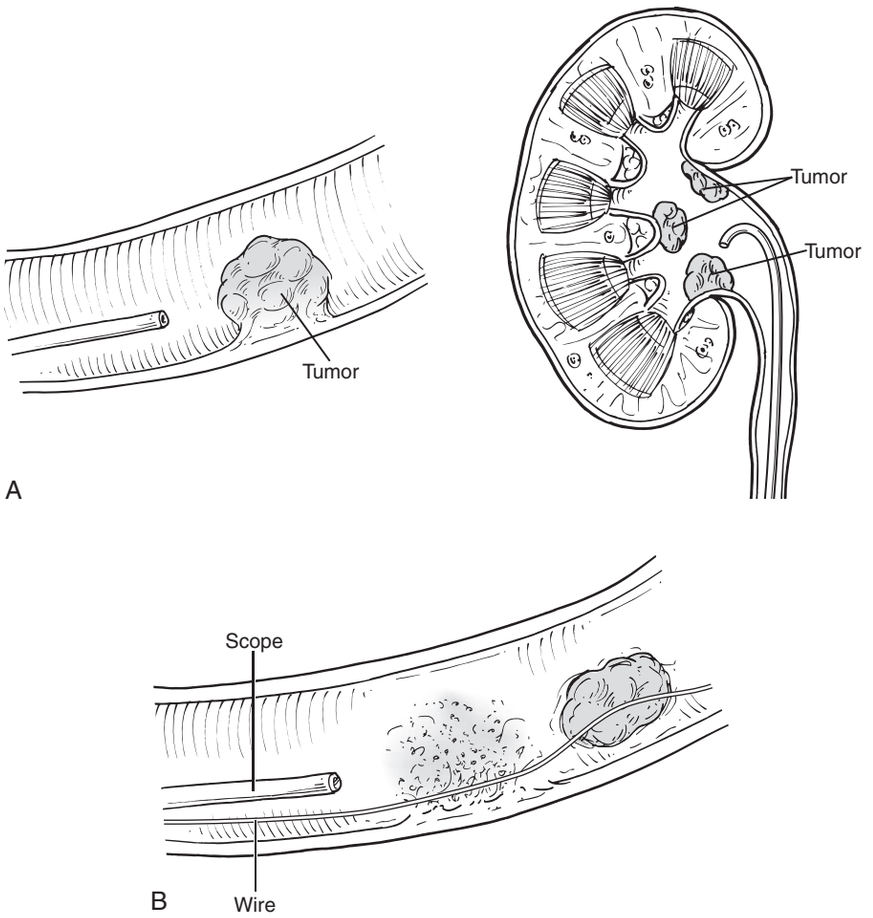

FIGURE 125-1. A, Rigid scope in ureter (left); flex scope in kidney (right). **B,** Wire causing tumor violation, leading to bleeding.



FIGURE 125-2.

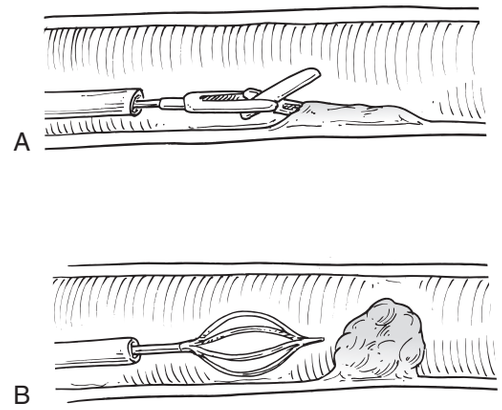

FIGURE 125-3.

Initial laser settings are 30 W continuous for Nd:YAG and energy setting of 0.5 KJ with a rate of 10 to 15 Hz for Ho:YAG. Small laser fibers (200 or 365 μ) can be passed through the working channel of a small-diameter rigid or flexible ureteroscope. When the laser is unavailable or the fiber cannot deflect into a lower pole, a 2-French electrode is used to fulgurate the tumor. Some holmium lasers have optional pulse duration settings, usually 350 or 700 msec.

When there is a large tumor burden in the upper tract, treatment of the lesion from a proximal to distal direction using laser energy is preferred to maintain visualization and orientation. Keep returning to the normal lumen as necessary to define the ureteral wall. For adequate tumor excision, carefully rotate the endoscope in an arc with the laser fiber aimed at the base of the lesion, conforming to the wall of the ureter (see Fig. 125-5B). Avoid deep excursions into the ureteral wall, which can lead to perforation and/or strictures. When in tubular structures such as the ureter or infundibulum, avoid coagulation with Nd:YAG laser or an electrode; Ho:YAG is preferred because of its minimal tissue

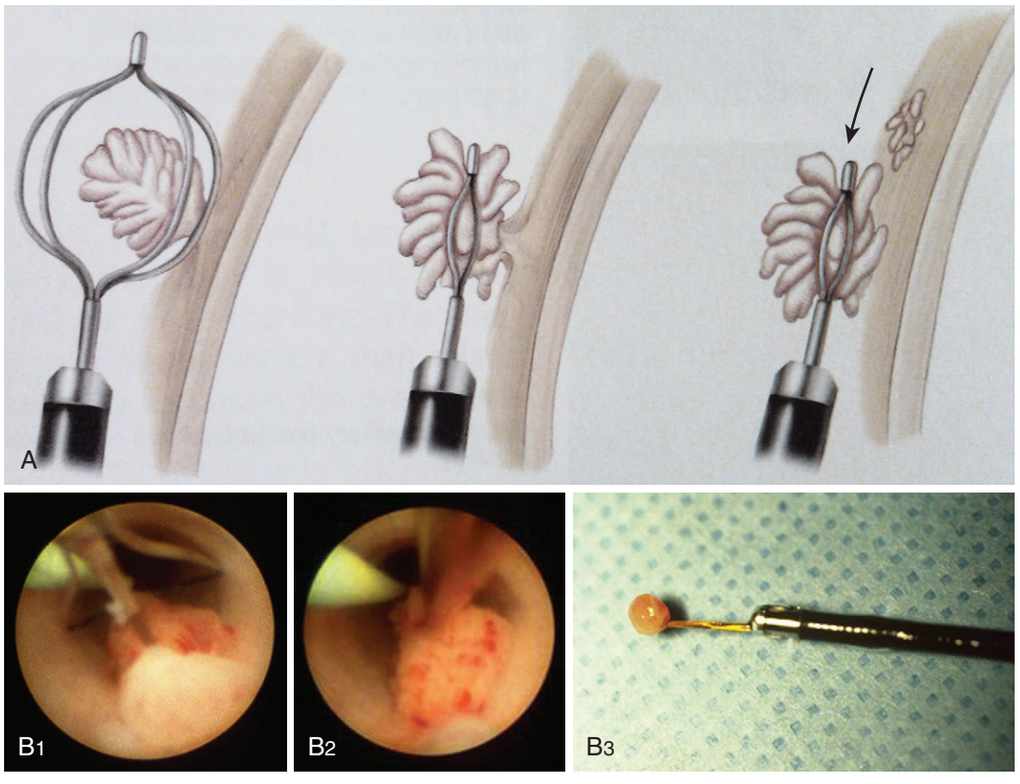

FIGURE 125-4. *(A, From Bagley DH, Grasso M. [2006]. Flexible ureteroscopy with the Flex-X2 Ureteroscope. Culver City, CA: Endo-Press. Illustrations by Molly Babich.)*

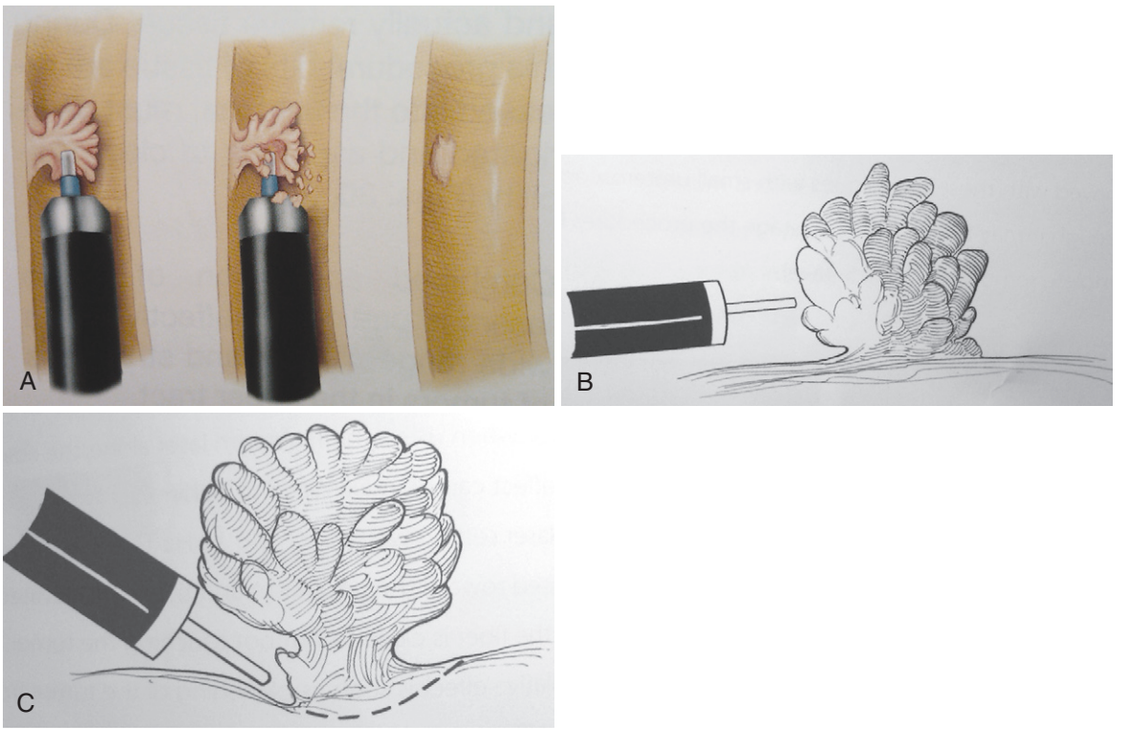

FIGURE 125-5. A, Ho:YAG laser destruction. **B,** Nd:YAG laser coagulation. **C,** Arcing to remove base of tumor. *(**A,** From Bagley DH, Grasso M. [2006]. Flexible Ureteroscopy with the Flex-X2 Ureteroscopy. Culver City, CA: Endo-Press. Illustrations by Molly Babich. **B** and **C,** From Bagley DH, Das A. [2001]. Endourologic use of the holmium laser. Jackson, WY: Teton NewMedia. Illustrations by Molly Borman-Babich.)*

penetration. Also, avoid circumferential treatment if possible. Within the renal pelvis and calyces, coagulation can be used more freely. Ureteral or renal pelvic aspirates for cytopathology should be collected at the conclusion of laser utilization and labeled appropriately.

An indwelling double pigtail ureteral stent should be left in the collecting system to allow drainage and healing, as well as to avoid strictures. The proximal end of a ureteral stent can be placed across a narrow infundibulum of a treated calyx to avoid stricture formation after laser treatment. Ureteral catheters can be placed if the patient is to receive adjuvant topical (i.e., mitomycin, BCG) therapy. A temporary indwelling Foley catheter is recommended to drain the upper tracts maximally and can be removed before the patient is discharged.

POSTTREATMENT AND SURVEILLANCE

Most patients can be discharged on the same day. Some may require admission for instillation of topical therapy and others because of fever. Those with a stent should have it removed by dangler string or cystoscopy within a few days. If there is a history of ureteral stricture or increased risk of stricture formation (e.g., larger tumors), the stent may be left longer.

All patients who had tumor present should have repeat endoscopy in 3 months. When the involved upper system shows no recurrence visually or on cytology, the surveillance interval is lengthened to 6 months. A contralateral retrograde ureteropyelogram is performed at each endoscopic interval.

Commentary by

S. DUKE HERRELL

Conservative endoscopic management of upper tract transitional cell cancers is an increasing trend in select patients with either imperative indications or low-grade low-volume disease despite the rarity of the disease process. Similar to the trend seen in partial nephrectomy for renal cell carcinoma, avoidance of renal insufficiency and its long-term consequences in the upper tract TCCA population merits consideration when oncologic outcomes are equivalent.

While we agree that patients with high-grade and high-volume disease should be recommended to undergo radical nephroureterectomy, there are situations in which patients adamantly refuse dialysis. Consideration must be given to the patient's ultimate desires, and renal conservative endoscopic management can be considered with appropriate patient informed consent. Dr. Bagley's extensive experience with ureteroscopic management of upper tract TCCA has helped guide improvements in endoscopic treatment, and this chapter provides an excellent technical review.

Suggested Readings

Bagley DH. Ureteroscopic treatment of upper tract neoplasms. In: Nakada S, Pearle MS (eds). (2006). Advanced endourology: the complete clinical guide. Totowa, NJ: Humana Press, 2006, pp 267-279.

Bagley DH. Ureteroscopic diagnosis and treatment of upper urinary tract neoplasms. In: Smith AD, Badlani GH, Bagley DH, et al. (eds). (2007). Smith's textbook of endourology, 2nd ed. Ontario, Canada: BC Decker Publishing, pp 271-280.

Bagley DH. Ureteroscopic upper—tract preserving approaches in urothelial cancer. In: Droller S. (2004). Urothelial tumors, Ontario, Canada: BC Decker Publishers, pp 353-368.

Elliott DS, Blute ML, Patterson DE, Bergstralh EJ, Segura JW. (1996). Long-term follow-up of endoscopically treated upper urinary tract transitional cell carcinoma. Urology 47(6):819-825.

Chen GL, El-Gabry EA, Bagley DH. Surveillance of upper urinary tract transitional cell carcinoma: the role of ureteroscopy, retrograde pyelography, cytology and urinalysis. (2000). J Urol 164(6):1901-1904.

Iborra I, Solsona E, Casanova J, Ricos JV, Rubio J, Climent MA. (2003). Conservative elective treatment of upper urinary tract tumors: a multivariate analysis of prognostic factors for recurrence and progression. J Urol 169(1):82-85.

Lee D, Trabulsi E, McGinnis D, Strup S, Gomella LG, Bagley DH. (2002). Totally endoscopic management of upper tract transitional-cell carcinoma. J Endourol 16(1):37-41.

Soderdahl DW, Fabrizio MD, Rahman NU, Jarrett TW, Bagley DH. (2005). Endoscopic treatment of upper tract transitional cell carcinoma. Urol Oncol Semin Orig Investig 23(2):114-122.

This page intentionally left blank

Chapter 126

Laparoscopic Ureterolithotomy

DAVID CANES, RENE SOTELO, AND MIHIR M. DESAI

Indications for laparoscopic ureterolithotomy are identical to its open counterpart. In the modern era, indications for laparoscopic ureterolithotomy include the following: (1) secondary treatment after failure of less invasive procedures (extracorporeal shock wave lithotripsy, retrograde ureteroscopy, percutaneous antegrade ureteroscopy); (2) primary treatment for a large (>1.5 cm) impacted stone, with a low likelihood of clearance by a reasonable number of less invasive procedures; (3) presence of an anatomic abnormality that precludes endourologic access; (4) presence of an anatomic abnormality requiring simultaneous reconstruction, such as a ureteral stricture requiring ureteroureterostomy or ureteroneocystostomy; (5) developing countries without access to ureteroscopic and/or lithotripter technology, or where a single laparoscopic procedure is the most cost-effective approach.

Cystourethroscopy. Position the patient in lithotomy position. Perform retrograde pyelography to ensure patency of the distal ureter. Place a double pigtail ureteral stent if the degree of stone impaction permits. If the stone is impassable, place an open ended ureteral catheter just below the stone, and drape the externalized portion into the surgical field.

Surgical planning. Laparoscopic ureterolithotomy can be accomplished via transperitoneal or retroperitoneal approaches. Contraindications to the retroperitoneal approach include prior retroperitoneal surgery. The ureter is divided in thirds for planning purposes, and suggested approaches are delineated in Figures 126-1 through 126-4. For stones in the upper ureter, either the trans- (see Fig. 126-1) or retroperitoneal approach (see Fig. 126-2) in flank position can be employed, depending on surgeon preference. For stones in the mid ureter, the flank position and a transperitoneal approach is more reliable, owing to space limitations in the retroperitoneum as one proceeds caudally (see Fig. 126-3). As the ureter dips over the iliac bifurcation it becomes inaccessible from the retroperitoneal flank position. Secure the patient in the standard flank position with the table flexed. Meticulously pad all bony prominences. For lower ureteral stones, position the patient supine and proceed transperitoneally.

Access, port placement. Refer to Chapters 170 and 171 for retroperitoneal and transperitoneal access techniques. For transperitoneal approaches, triangulate the expected location of the ureteral stone as shown in Figure 126-1. Place a 10/12-mm camera trocar centrally, a right-sided 10/12-mm trocar, and a left-sided 5-mm trocar. For retroperitoneal surgery, establish pneumoretroperitoneum from the primary 10/12-mm trocar at the tip of the twelfth rib. Place an anterior 10-mm port 2 to 3 cm cephalad to the iliac crest between the mid and anterior axillary line. Place a 5-mm

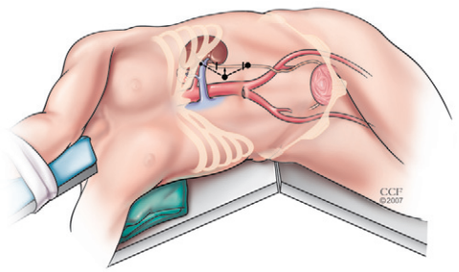

FIGURE 126-1. Port placement for transperitoneal access to the upper ureter (renal pelvis to the sacroiliac joint). Arrow depicts triangulation vector. *(Copyright © 2007, Cleveland Clinic Foundation.)*

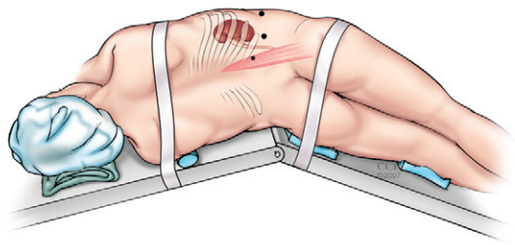

FIGURE 126-2. Port placement for retroperitoneoscopic access to the upper ureter (renal pelvis to the sacroiliac joint). Notice that the distal ureter cannot be accessed as it dives beyond the psoas muscle into the true pelvis. *(Copyright © 2007, Cleveland Clinic Foundation.)*

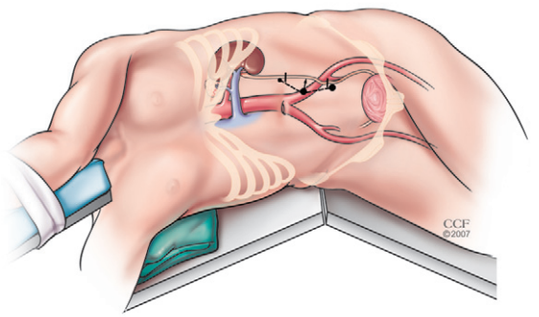

FIGURE 126-3. Port placement for transperitoneal access to the mid ureter (sacroiliac joint to the iliac bifurcation). *(Copyright © 2007, Cleveland Clinic Foundation.)*

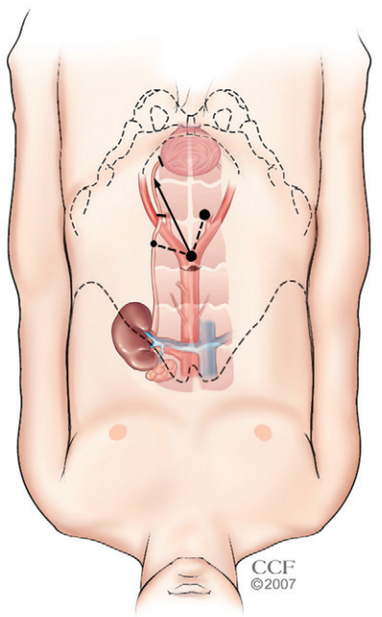

FIGURE 126-4. Port placement for transperitoneal access to the lower ureter (iliac bifurcation to the detrusor hiatus), with the patient supine. *(Copyright © 2007, Cleveland Clinic Foundation.)*

port at the angle between the twelfth rib and the lateral border of the paraspinal muscles. Avoid pleural or peritoneal transgression during placement of secondary ports.

Ureteral mobilization. In the retroperitoneal approach, identify the ureter on the psoas muscle. The ureter is best identified at the lower pole of the kidney. In some cases, the ureter may be adherent to the inferior aspect of parietal peritoneum. For right or left transperitoneal approaches, medialize the colon and mesocolon from Gerota's fascia. Mobilize the ureter, with care to preserve periureteral soft tissue. Identify the stone as a conspicuous bulge (Fig. 126-5). Obtain real-time fluoroscopic guidance for difficult cases. Encircle the ureter proximal to the stone with a 5-inch piece of vessel loop to avoid stone migration into the dilated ureteral segment during manipulation. Apply a hemolock clip to the vessel loop to secure it.

Ureteral incision. Clear the periureteral tissue over the stone. Incise the ureter longitudinally to minimize vascular

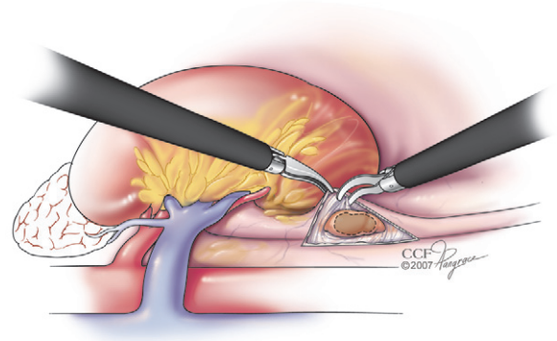

FIGURE 126-5. Ureteral dissection reveals the bulging impacted stone. *(Copyright © 2007, Cleveland Clinic Foundation.)*

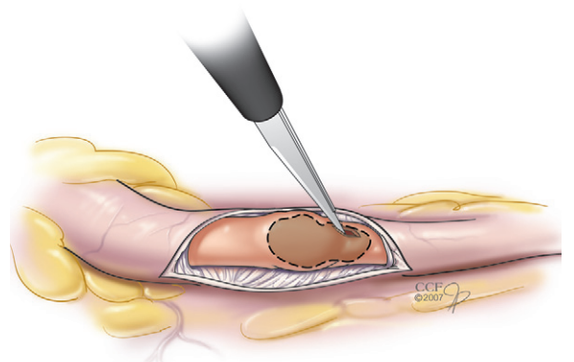

FIGURE 126-6. Longitudinal ureterotomy is made over the stone with a laparoscopic blade. *(Copyright © 2007, Cleveland Clinic Foundation.)*

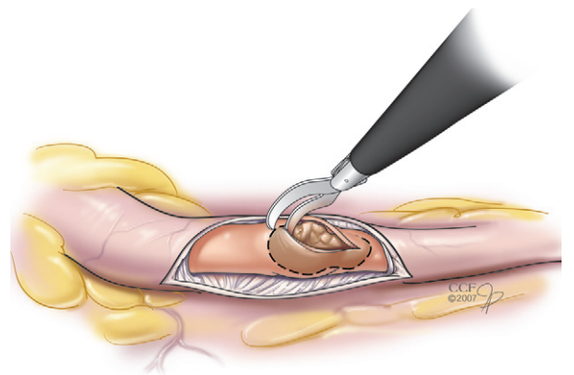

FIGURE 126-7. The ureterotomy is extended with shears. *(Copyright © 2007, Cleveland Clinic Foundation.)*

compromise and postoperative stricture. Incise with a cold laparoscopic knife or scissors (Figs. 126-6 and 126-7). Electrical diathermy with a cutting current is avoided as far as possible. Hemostasis from the incised edges may be obtained with spot bipolar coagulation.

Stone removal. Angle or leverage the ureter to deliver the stone (Fig. 126-8). Avoid breaking the stone into small fragments, which may migrate. Mucosal adherence can be

overcome with gentle manipulation using a blunt instrument. Extract the stone through the 10/12-mm port using 10-mm laparoscopic spoon forceps. Extract larger stones using an endocatch specimen bag. Wash the ureteral lumen using an open-ended catheter threaded through a 2-mm minisite port to remove stone debris and sludge.

Stent placement. If the stone is near the ureterovesical junction (UVJ) or ureteropelvic junction (UPJ), a stent can be placed antegrade through any of the existing trocars.

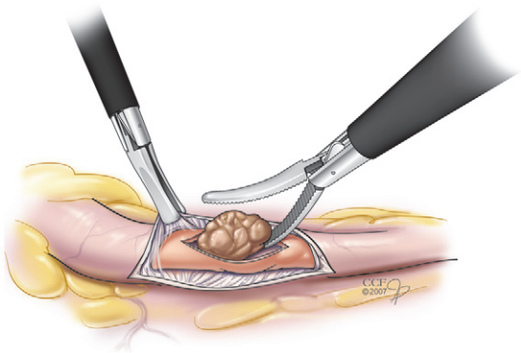

FIGURE 126-8. The stone is leveraged intact from the ureterotomy. *(Copyright © 2007, Cleveland Clinic Foundation.)*

When the angle is not optimal, place an additional 2-mm miniport in a position that affords a straight line to the ureterotomy in the direction of the distal ureter (stone near UPJ), or renal pelvis (stone near UVJ). Pass a glide wire, followed by a double pigtail ureteral stent over the wire, and remove the wire. Feed the excess stent into the remaining short segment of ureter. If the stone is in the mid ureter, either place a stent preoperatively or position an open-ended catheter to the lower aspect of the stone, with the externalized portion in the sterile field. Following ureterotomy and stone extraction, pass a wire across the defect under laparoscopic vision. Place a stent under fluoroscopy in a standard retrograde fashion at the conclusion of the procedure.

Ureteral repair. Close the ureterotomy with simple interrupted 4-0 polyglactin sutures (Fig. 126-9). Applying lubricant to the suture minimizes tissue trauma and facilitates intracorporeal suturing. Gentle mucosal approximation allows room for subsequent edema.

Drain placement. Exteriorize a flat 10-French Jackson-Pratt drain through the 5-mm skin site. Drape the drain in proximity to the ureterotomy. Secure the drain at the skin with a 3-0 nylon suture. After a transperitoneal approach, place the drain to bulb suction. After a retroperitoneal approach, allow passive gravity drainage into a bile bag.

Postoperative care. Sequentially remove the Foley catheter (1 to 2 days) followed by the surgical drain when output is minimal. Remove the ureteral stent 2 to 4 weeks later.

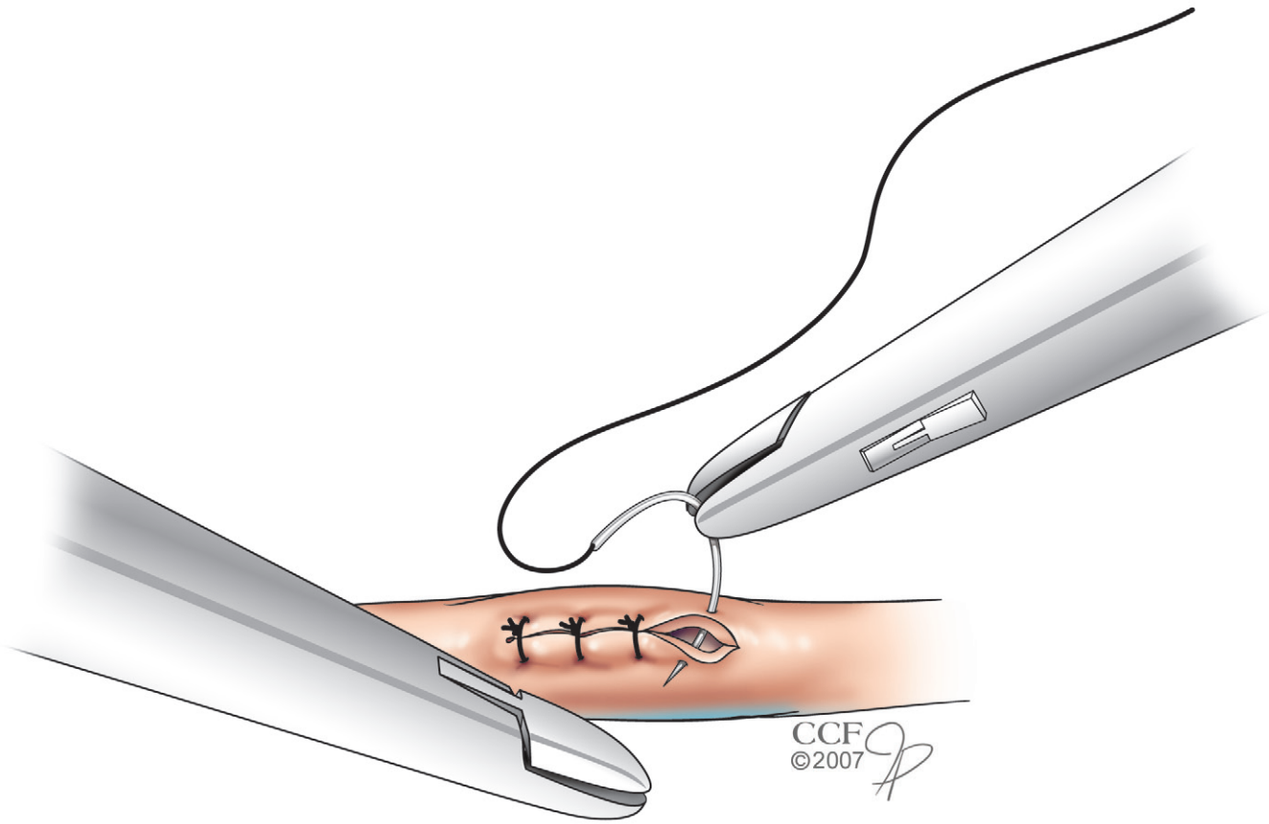

FIGURE 126-9. Simple interrupted sutures accomplishes watertight stented ureterotomy closure. *(Copyright © 2007, Cleveland Clinic Foundation.)*

Commentary by

S. DUKE HERRELL

While this should be a rare clinical scenario with modern ureteroscopic and percutaneous techniques and technology, the laparoscopic ureterolithotomy is obviously feasible. Key concepts are included by the authors and based on the extensive pre-shock wave lithotripsy open surgical experience of many authors. The authors are correct to mention care must be exercised in closure of the ureter with minimal incorporation of mucosa and avoidance of ischemic knots to avoid strangulation and narrowing of the lumen with subsequent stricture. In the past, closure of longitudinal ureterotomy was often done with loose serosal reapproximation interrupted sutures over a stent based on the principles for healing defined by the Davis intubated ureterotomy.

Chapter 127

Endoscopic Management of VUR

ANDREW J. KIRSCH

Endoscopic injection first described in 1984 by O'Donnell and Puri. The STING has been the most commonly described technique; however, the success rate has been approximately 75%. There are many pearls for the successful endoscopic correction of VUR. A significant improvement was first realized with the concept of ureteral hydrodistention and intraluminal submucosal injection (hydrodistention implantation technique, or HIT; Fig. 127-1), and further improved with injection of increased volume using two tandem intraluminal injection sites (double HIT). Our current success after one treatment for up to grade 5 VUR is 90% of patients and 93% of ureters, rivaling open surgical repair. Successful injection has also been achieved for duplex ureters, those associated with paraureteral diverticula, after failed open or endoscopic surgery, and in patients with bladder dysfunction or deficit.

PREPARATION

An offset cystoscope (straight working channel) with a distal tip of at least 9.5 French or above and a minimum 4-French working channel.

- Bladder should be half full or less.
- Flush needle with fluid and prime the needle with injectable agent.
- Evaluate both ureteral orifices before injecting.
- Surgeon should be the injector of the implant. This allows the surgeon to feel the sensation of the filling of the implant bleb. Inject agent very slowly. If the orifice seems difficult to inject, check to make sure that the bladder is not overfilled or the needle is not occluded.

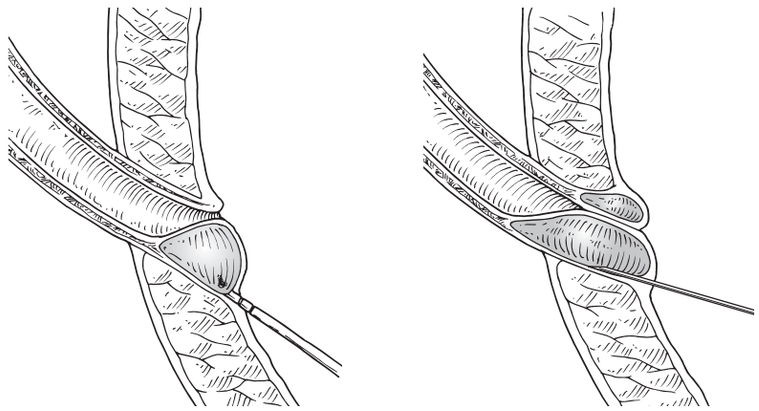

FIGURE 127-1.

Assess the intramural tunnel with full water jet from the cystoscope directed at the ureteral orifice. This technique, known as hydrodistention, requires that a pressurized steam of irrigation fluid be directed at the ureteral orifice, causing the orifice to open and allowing the surgeon to assess the competence of the ureteral orifice. Ureteral hydrodistention always causes the ureteral orifice to open before treatment and should remain closed after treatment when implantation is performed correctly (Fig. 127-2).

DOUBLE HYDRODISTENSION IMPLANTATION TECHNIQUE (DOUBLE HIT)

The first consideration is that the needle be directed in-line with ureteral tunnel. With hydrodistention, the needle should impinge the floor of the mid ureteral tunnel at the 6-o'clock position to a depth of approximately 2 to 4 mm within the submucosa. Positioning and gauging the depth of the needle is facilitated by placing the beak of the cystoscope flush with the ureteral orifice during hydrodistention. Once the needle is in place, the flow of irrigation fluid should be stopped and a small volume (less than 0.1 mL) is injected to confirm implant location. A combination of injection sites (1+2, 2+3, or 1+2+3) is often needed for optimal ureteral tunnel and orifice coaptation (Fig. 127-3).

The first injection site (proximal HIT, #1) should lead to coaptation of the proximal ureteric tunnel, converting all hydrodistending ureters to minimal (H1) or no hydrodistention (H0). The distal HIT (#2 injection site) is performed by placing the needle to the same depth just within the ureteral orifice and injecting slowly (while pulling the needle more superficially) until the ureteral orifice is coapted and elevated to the height of the ureteral tunnel (treated with the proximal HIT). The distal HIT should

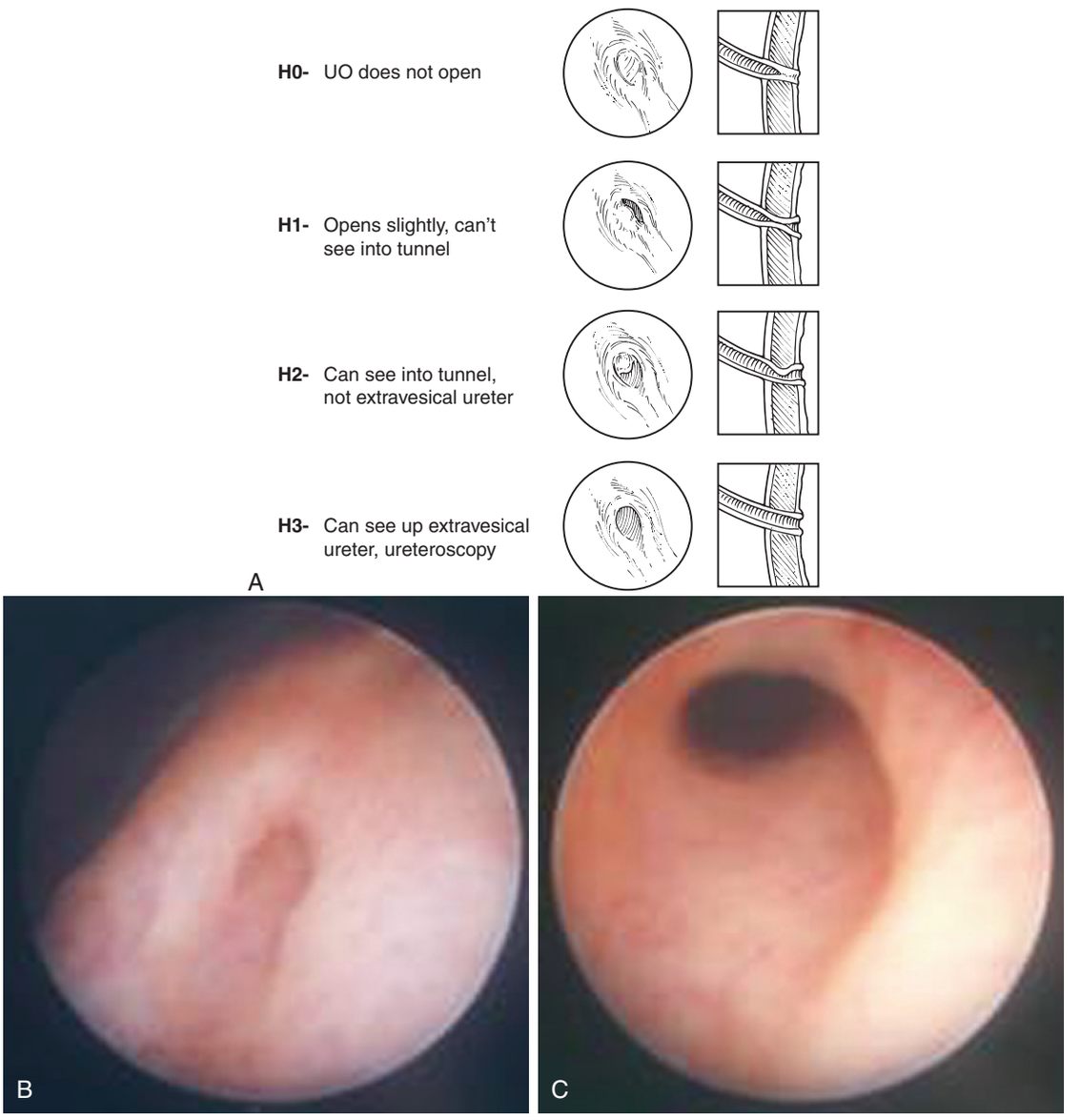

FIGURE 127-2. A, Hydrodistention (HD) grading technique. **B,** H1 ureter. **C,** H3 ureter.

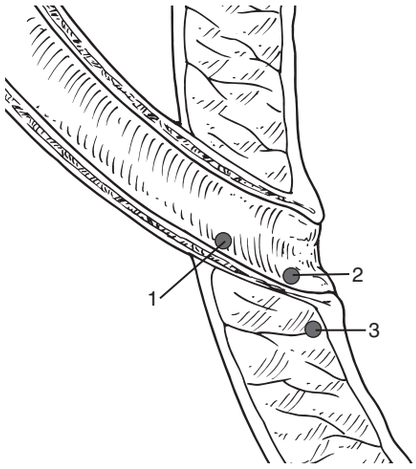

FIGURE 127-3. Needle placement. 1, proximal HIT; 2, distal HIT; 3, STING.

result in the complete absence of hydrodistention (H0). The end result is a mountain-range appearance of the tunnel and orifice. If the ureteral orifice does not completely coapt with intraureteric injection, a classic subureteric implantation (STING, #3) is conducted. After each injection, an attempt at ureteral hydrodistention will ensure proper technique as the ureter will remain coapted with irrigation. At least 0.8 mL of material per ureter may be needed, depending on the physical characteristics of the ureteral orifice.

For optimal correction, the procedure will produce a prominent bulge with a crescent-like orifice positioned on top of the bulge (Fig. 127-4).

Reasons for optimal and suboptimal results (Table 127-1)
Complications of endoscopic injection:

- VUR. Persistence of VUR may occur in 10% to 30% depending on technique used and patient selection; recurrent symptomatic VUR is unusual.
- Ureteral obstruction. <0.5% and considered rare.
- Transient flank pain, emesis. 2%.
- Urinary tract infection. 5% despite successful injection.
- New contralateral VUR. Up to 15% of previously nonrefluxing ureters develop VUR after unilateral treatment. This may justify contralateral treatment of abnormal ureters (e.g., location, configuration, hydrodistention grade).

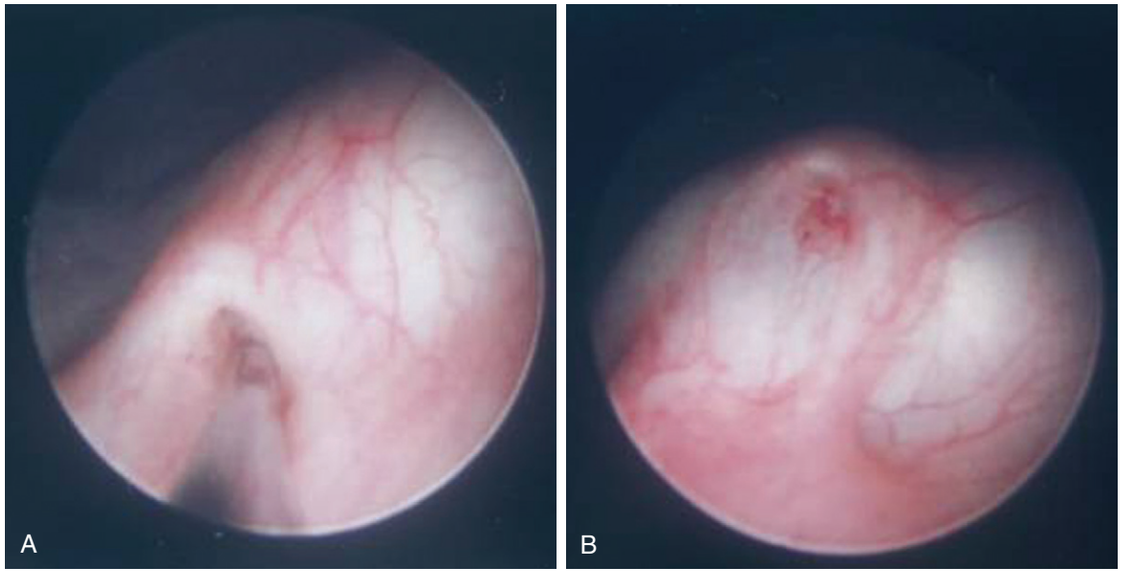

FIGURE 127-4. The mucosa surrounding the implant should be blanched with high turgor and will emit a light reflex off the mucosal surface. **A,** Injection completed at site 1. **B,** Injection completed at sites 1 and 2 (double HIT).

CAUSES OF FAILURE AND REASONS FOR SUCCESS AFTER ENDOSCOPIC INJECTION FOR VUR

TABLE 127-1

Causes of Endoscopic Failure	Reasons for Successful Treatment
Poor technique: improper injection site(s), low injected volume, endpoint of injection unclear	Improved injection technique (total ureteric tunnel coaptation, intraureteric injection); comprehensive algorithm for needle site(s) of injection
Absorption of material: 20% by 2 weeks, up to 40% by 1 year	Combination of flap, hydrostatic, and nipple valve configurations
Local bulking agent migration (displacement)	Loss of hydrodistention as an endpoint of injection
Associated conditions: bladder dysfunction, complete ureteral duplication, grade V VUR, bilateral VUR	Increased volume of injection: greater volume used for VUR and hydrodistention grades
Very superficial implant injection into the mucosa (mound takes on a blue reflection) may result in splitting of the mucosal tissue with implant expulsion upon increased bladder pressure	

Chapter 128

Endoscopic Incision of Ureterocele

EARL Y. CHENG

Most clinically significant cases of ureteroceles are going to be associated with duplex systems. There are different schools of thought as to how to approach these patients. Some prefer an upper tract approach in which hemine-phrectomy is performed, whereas others prefer a lower tract approach in which excision of the ureterocele and reimplantation of the ureters is performed. The presence or absence of reflux, as well determination of whether there is salvageable function of the upper pole segment that is associated with the ureterocele can help determine which approach is most appropriate in individual patients. Regardless of whether one favors an upper or lower tract approach, most patients have initial endoscopic incision of the ureterocele to decompress the obstructed upper pole system. In some patients, endoscopic incision alone is definitive therapy with no further need for surgery. This is especially true in those with an intravesical ureterocele that is not associated with reflux. In other patients, additional upper or lower tract surgery will be needed following initial endoscopic incision.

Positioning for surgery: Dorsal lithotomy.

Technique: Initial endoscopic inspection of the entire bladder and urethra should be done very carefully to determine numerous important anatomic factors: (1) the size of the ureterocele, (2) whether the ureterocele is entirely intravesical or whether there is an ectopic component in which there is extravesical extension into the urethra, and (3) the location of the ipsilateral lower pole orifice (in duplicated systems) and the contralateral orifice(s). The ureterocele should be inspected closely with various states of bladder filing because the ureterocele will decompress with the bladder full and will bulge and be more tense with the bladder empty. It is often much easier to see the associated ureteral orifices when the bladder is full with resultant decompression of the ureterocele.

Endoscopic decompression of the ureterocele can be accomplished with either a Bugbee electrode (puncture) or with a resectoscope peg (transverse incision). The location of the puncture/incision should be at the inferior and medial edge of the ureterocele (Fig. 128-1). This gives one the best chance of avoiding subsequent reflux. It is best to perform the puncture/incision with the bladder mostly empty to allow the ureterocele wall to be tense. If the ureterocele is not bulging and tense, then the Bugbee electrode or resectoscope peg is more likely to slide off the wall of the ureterocele, which can increase the risk of making the incision in the wrong place or inadvertently injuring the contralateral orifice. Many ureteroceles are thick-walled and require more than one pass with the Bugbee electrode or resectoscope peg to get entirely through the wall. Use of the cutting current with little to no cautery mix allows for a clean puncture/incision. One should observe full decompression of the ureterocele when puncture/incision is adequate. If this does not occur, then the defect in the ureterocele wall needs to be further enlarged.

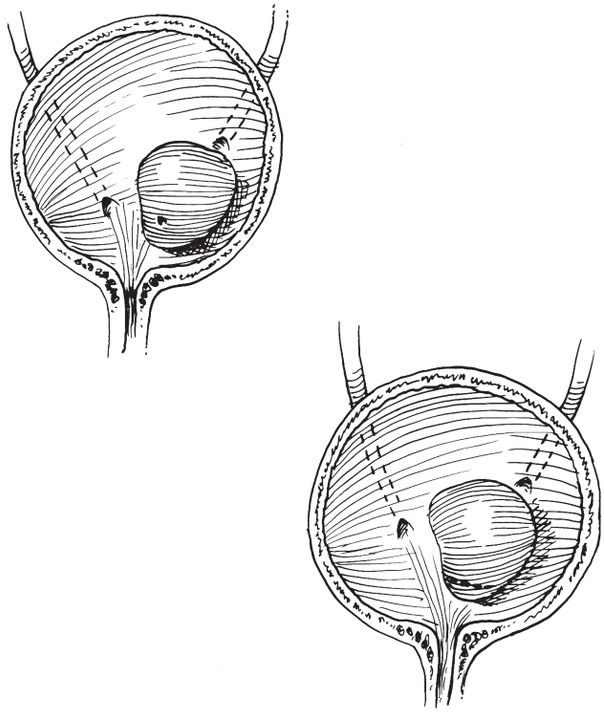

FIGURE 128-1.

When the ureterocele is ectopic and has an extravesical component in which there is extension into the urethra, an additional puncture/incision needs to be made to prevent accumulation of urine in the urethral portion of the ureterocele which can in turn cause secondary outflow obstruction (Fig. 128-2). To accomplish this, a second puncture with the Bugbee electrode can be made in the most inferior portion of the urethral extension or the resectoscope peg can be used to extend the ureterocele incision within the bladder longitudinally into the urethral extension with a T-configuration. A Crede maneuver should be performed afterwards to ensure that there is no outflow obstruction.

Postoperative problems: The most significant complication is inadvertent injury to adjacent structures. This most often occurs when the back wall of the ureterocele is injured due to continued forward motion of the Bugbee electrode or resectoscope peg once the ureterocele wall is incised. The bladder neck continence mechanism can also be injured with overaggressive incision at the level of the bladder neck, especially when attempting to extend the incision into the urethra in cases of an ectopic ureterocele.

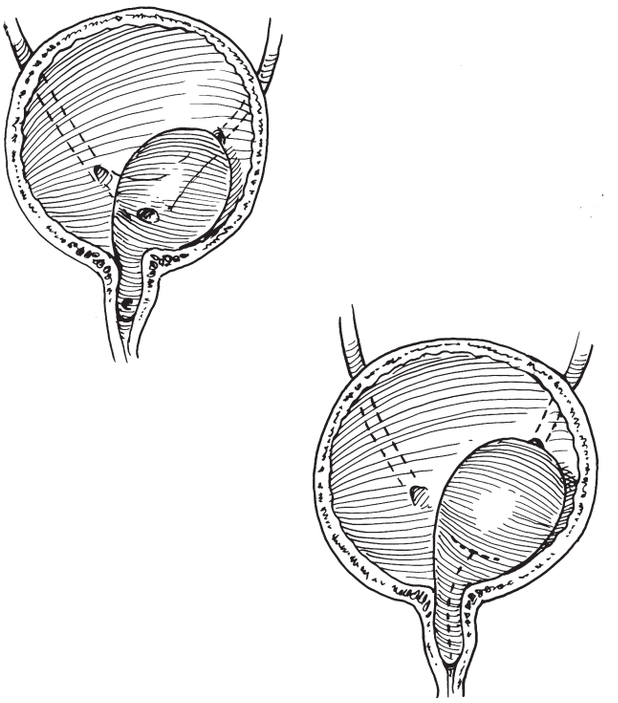

FIGURE 128-2.

Section XX

SURGICAL APPROACHES TO THE KIDNEY

Open Renal Surgery

This page intentionally left blank

Chapter 129

Surgical Approaches for Open Renal Surgery

EILA SKINNER

ANATOMIC BASIS FOR RENAL INCISIONS

Abdominal and Chest Wall

The abdominal and flank skin are supplied mainly by branches of the intercostals and lumbar vessels and nerves, which course from lateral to medial parallel to the lower ribs. Figure 129-1 shows the vascular and nervous supply to the abdominal wall muscles. Denervation of these muscles can result in anesthesia as well as a noticeable bulge in the abdominal wall or flank. As the intercostals nerves emerge from below the costal margin they run between the layers of the internal oblique and transversus abdominis muscles. Figure 129-2 shows the muscles of the back and flank.

Within the chest the inferior limit of the pleural cavity may lie anywhere between the tenth and the twelfth rib beds. An extrapleural approach through the eleventh or twelfth rib usually requires careful mobilization of the lower edge of the pleura to avoid entering it. Above the tenth rib, entry into the pleural cavity is usually inevitable.

The rectus abdominis is supplied superiorly by the superior epigastric artery, which originates from the inferior mammary artery (internal thoracic artery). As it runs caudad on the anterior surface of the posterior rectus sheath, it penetrates and supplies the rectus muscle and then passes through the anterior rectus sheath to supply the overlying skin. Perforating vessels are particularly noticeable around the umbilicus. The lower rectus muscle is supplied in a similar manner by the inferior epigastric artery, arising from the end of the external iliac artery. The rectus can be safely divided in the upper abdomen, and the body of the muscle should be retracted laterally (rather than medially) to maintain the lateral innervation from the lumbar nerves. The falciform ligament from the umbilicus to the liver contains vessels from a branch of the superior epigastric artery that are destined to enter the hepatic artery; the ligament therefore requires ligation after division.

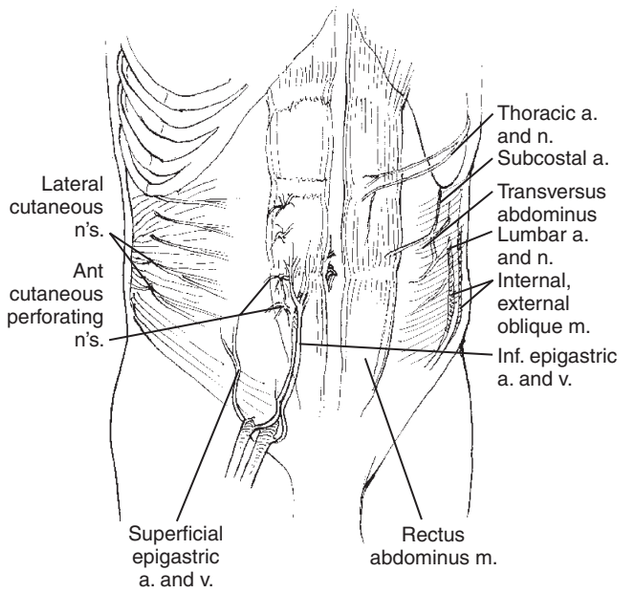

FIGURE 129-1.

RETROPERITONEAL SPACE

The retroperitoneal space is defined as the space posterior to the peritoneal envelope and anterior to the abdominal wall muscles. Figure 129-3 shows the retroperitoneal space in oblique view. The space is lined posteriorly by the transversalis fascia, a thin layer overlying the abdominal wall muscles, and the posterior pararenal fat. Gerota's fascia (perirenal fascia) is comprised of two layers, the anterior and posterior laminae. The kidney and adjacent structures lie in the perirenal space between these two sheets, enveloped in fat. The layers fuse laterally to form the lateroconal fascia, which then fuses with the peritoneum lateral to the colon to form the white line of Toldt. The two layers of Gerota's fascia also envelop the great vessels. Superiorly the two leaves of Gerota's fascia fuse and attach to the crura of the diaphragm. Inferiorly the fat thins out at the level of the common iliac arteries, and the ureter and gonadal vessels exit into the pelvis. The two layers of Gerota's fascia are not fused inferiorly. Thus a perinephric hematoma contained

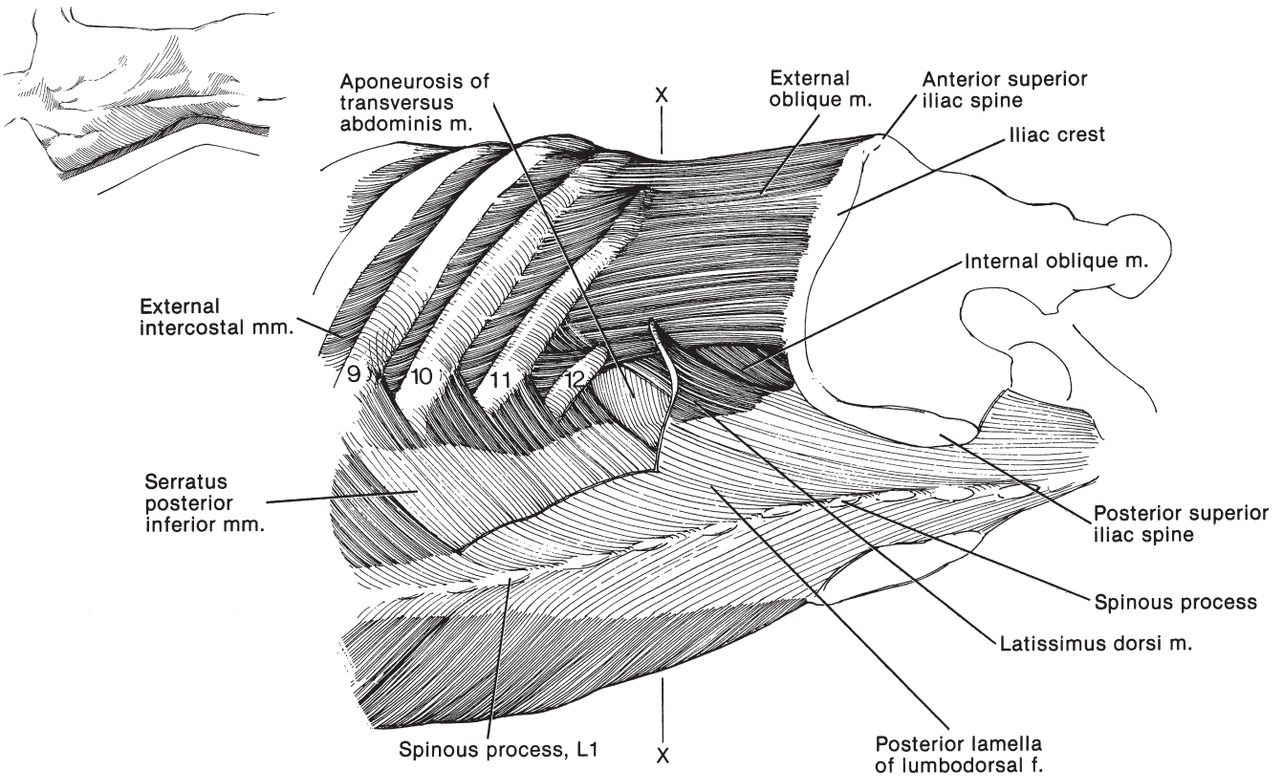

FIGURE 129-2.

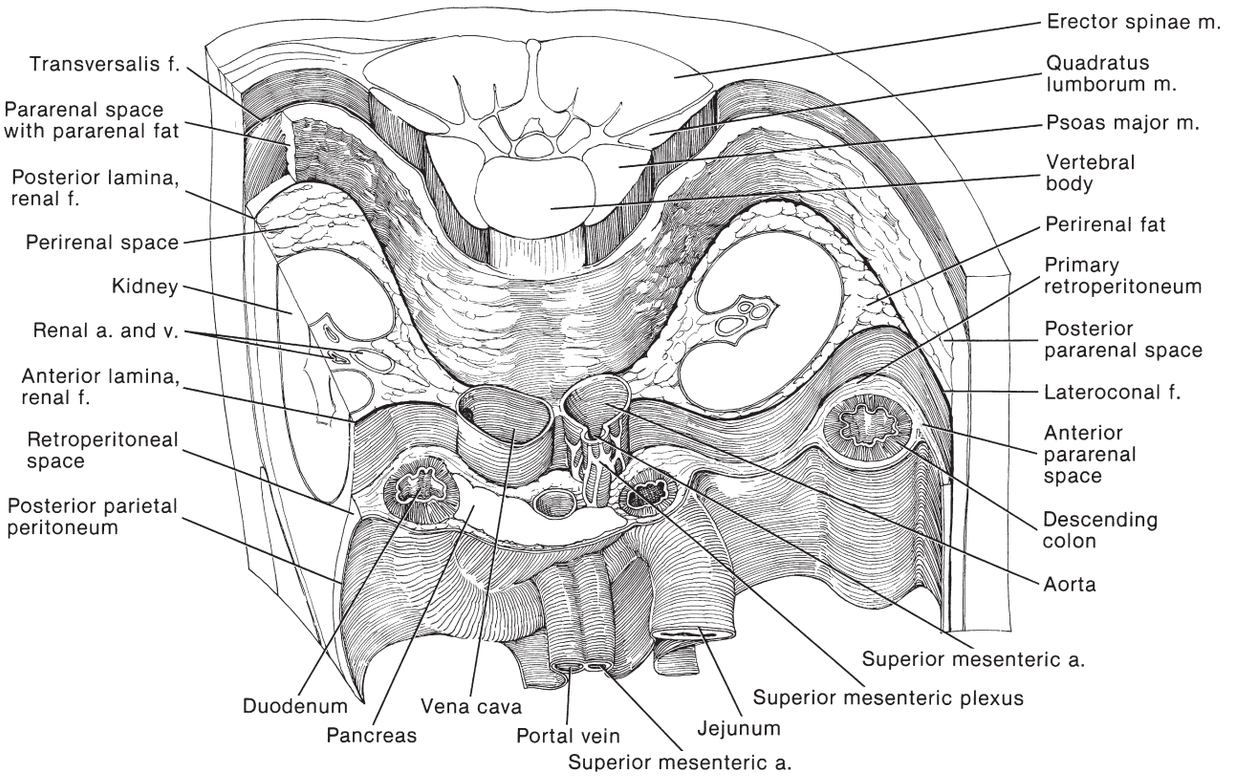

FIGURE 129-3.

within Gerota's fascia may extend over the midline or down into the pelvis.

Medially the posterior lamina of Gerota's fascia fuses with the transversalis fascia to close the pararenal space over the psoas major and quadratus lumborum. The line of fusion is encountered surgically as a dense band that usually must be divided. There is a thin fascial layer that encloses both the peritoneal envelope and Gerota's facia—this layer must be divided sharply to develop the avascular plane between these two packages. Only the superior and inferior mesenteric arteries penetrate from Gerota's fascia into the peritoneal envelope—if the inferior mesenteric artery is divided, the entire peritoneal envelope can be elevated off of Gerota's fascia and the retroperitoneum left intact. A filmy fibroareolar tissue is encountered in the anterior pararenal space and is the hallmark of the retroperitoneum for the surgeon. In cases of malignancy, after developing the pararenal spaces anterior and posterior to Gerota's fascia and dividing the hilar vessels, the kidney, adrenal, gonadal vessels, and ureter can all be removed while remaining completely encased within Gerota's fascia.

Three-Dimensional Relationships

A thorough knowledge of the three-dimensional relationships between the various abdominal structures is key to safe renal surgery. Figure 129-4 shows these relationships. The adrenal gland is within Gerota's fascia, but separated from the kidney by a layer of fat. The right adrenal is draped over the superior medial border of the kidney and tucked behind the lateral edge of the inferior vena cava at the level of the lower edge of the liver. The left adrenal lies between the lateral border of the aorta and the lower edge of the left crus of the diaphragm and the superior medial border of the left kidney. The left and right colon and colon mesenteries are directly anterior to both kidneys. The second portion of the duodenum overlies the hilum of the right kidney. The tail of the pancreas and splenic hilum overlie the superior portion of the left kidney. When approached from the flank, the peritoneal envelope wraps well posteriorly and superiorly around the lateral edge of the kidney on both sides. From an anterior transperitoneal approach the inferior mesenteric vein courses superiorly and joins the splenic vein just over the crossing of the left renal vein under the superior mesenteric artery (the latter structure is hidden in surrounding dense fat). The takeoff of both main renal arteries is generally encountered posterior to the left renal vein after it is mobilized off of the aorta. However, the renal arterial anatomy is variable, with multiple branches in approximately 40% of patients. The arterial branches may arise anywhere from above the level of the superior mesenteric artery down to the common iliac arteries. Although the right renal arteries generally course behind the vena cava, anomalous arteries may occasionally pass anterior to the inferior vena cava (IVC). Venous anatomy around the kidney is less variable, but a retroaortic left renal vein or a persistent left cardinal vein (duplicated or left-sided IVC) are not uncommon.

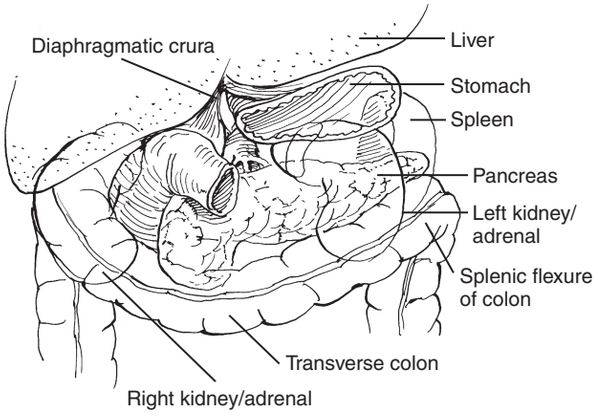

FIGURE 129-4.

Choice of Surgical Approach

The most common indications for open surgery today include radical or partial nephrectomy for malignancy, complex ureteropelvic junction (UPJ) obstruction, ureteral replacement for ureteral stricture disease, some cases of donor nephrectomy, trauma, and rarely, complex stone disease. Today many open surgeries are performed in the setting of previous failed endoscopic treatment, recurrent disease following previous excision, or the most advanced malignant processes such as renal or adrenal cancer associated with an extensive vena cava thrombus or bulky adenopathy. In many areas, the majority of radical and many partial nephrectomies are also performed laparoscopically. Because of this, many of the previously popular surgical approaches, such as dorsal lumbotomy and Foley muscle-splitting flank incisions, have become primarily of historical interest only.

In planning an open surgical approach to the kidney, the surgeon must take into account the disease process, the patient's body habitus, known anatomic anomalies, and previous surgical history. Fortunately, modern imaging techniques make a thorough preoperative understanding of the anatomy more available than in the past.

There are two primary open surgical approaches to the kidney—flank and anterior approaches. The approaches that are discussed in this atlas are listed in Table 129-1 and shown in Figure 129-5. This section also describes techniques for splenectomy and open repair of flank incisional hernias.

A standard flank incision has the advantage of direct access to the kidney and the ability to avoid entry into the peritoneal cavity. Injury to the spleen is easier to avoid, postoperative ileus is minimized, and late bowel obstruction is rare. The disadvantages of these lateral incisions are the need to divide large muscles, the risk of injuring nerves, and the fact that the vascular pedicle lies on the opposite side of the kidney from the one exposed. A horizontal line drawn from kidney over to the lateral edge of the rib marks the highest level that is easily accessed from that level of flank incision (Fig. 129-6). In the example, a twelfth rib incision would not afford reasonable access to the renal hilum. A flank incision can be painful, and late diastasis of the abdominal muscles due to injury of the intercostal nerve or actual hernia causing a bulge in the flank is not uncommon. In addition, it is more difficult through this approach to access the renal hilum or to do a complete lymphadenectomy.

APPROACHES TO THE KIDNEY

TABLE 129-1

Anterior
Midline transperitoneal (laparotomy)
Anterior subcostal
Bilateral subcostal chevron
Pediatric anterior transverse
Modified thoracoabdominal hockey-stick
Flank
Foley muscle-splitting
Subcostal
Supracostal
Transcostal
Combined
Thoracoabdominal

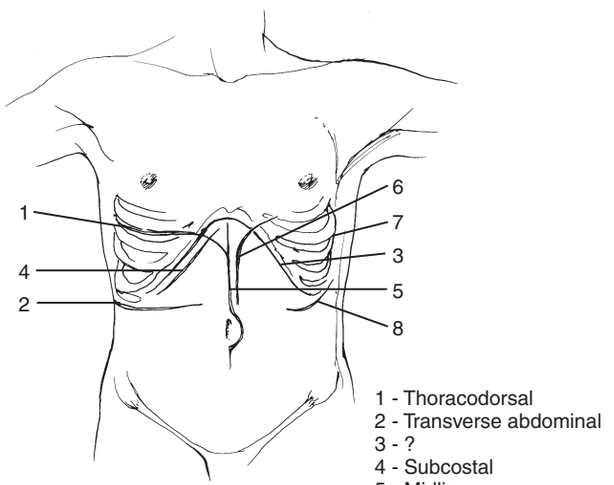

FIGURE 129-5.

The flank approach is most appropriate for partial nephrectomies, repair of UPJ obstruction, open stone surgeries, and drainage of renal or perirenal abscesses.

Of the flank incisions, the Foley muscle splitting incision and subcostal approach below the twelfth rib are the simplest but they afford the most limited exposure. It is not usually possible from these incisions to access the renal hilum, great vessels, or upper kidney. They are only really useful for simple procedures such as drainage of a lower perinephric or psoas abscess, open renal biopsy, or procedures

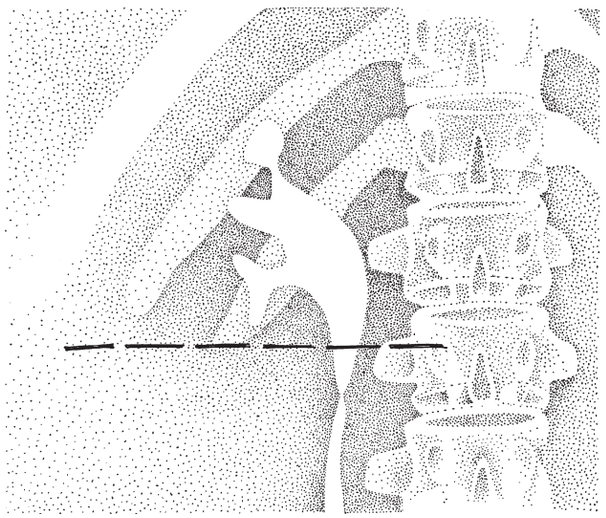

FIGURE 129-6.

on the proximal ureter. A supracostal twelfth or eleventh rib incision gives better exposure and still can be accomplished without entering the pleural or peritoneal cavities. The transcostal approach in which the involved rib is completely removed does not really add much exposure compared to a supracostal approach and results in a palpable chest wall defect for the patient. Removal of the rib is often performed in higher chest incisions such as the thoracoabdominal incision, where separation of the ribs is more difficult.

An anterior transperitoneal route (upper midline laparotomy incision) is a popular approach for major procedures on the kidney, ureter, and adrenal, and one that is familiar to most surgeons. Opening and closure are very rapid and provide an opportunity to evaluate other intraabdominal organs, allow rapid access to the renal vessels with early ligation of the vessels in case of malignancy, and afford good control of the great vessels if they are injured. Pain is also minimized by avoiding cutting any muscles. However, a standard midline laparotomy provides relatively poor access to the kidney because the renal hilum is at the upper limit of the incision and the overlying colon, liver, and spleen must be mobilized widely. Other disadvantages are the risk of late bowel obstruction and incisional hernia.

Similarly a standard anterior subcostal incision gives very limited visibility and is best limited to small renal tumors or benign conditions, although on the left side it may be possible to stay out of the peritoneal cavity with this incision. Better anterior access may be gained from incisions that include division of the rectus abdominis, such as the hockey-stick incision, extended subcostal, or bilateral subcostal (chevron). The hockey stick incision can be performed either intraperitoneally or extraperitoneally. In young children a transverse abdominal incision is commonly used for unilateral renal approach. For large and complex kidney tumors requiring access to the chest (e.g., a renal cancer with high vena cava thrombus), a bilateral subcostal incision with a cephalad median sternotomy extension (Mercedes incision) or a high thoracoabdominal incision can give maximal exposure.

ANTERIOR APPROACHES

Midline Transperitoneal Incision (Laparotomy)

This is the basic laparotomy incision that is familiar to all general and urologic surgeons. The advantage of this incision is that it is rapid and simple to open and close, and less painful than flank or transverse abdominal incisions that require division of major muscle groups. It gives good exposure to the peritoneal contents but affords relatively poor exposure to the kidneys because the renal hilum is generally at the superior end of the incision. It is ideal for addressing abdominal trauma that may involve the kidneys, problems related to both ureters (e.g., retroperitoneal fibrosis), or for approaching a horseshoe kidney. It can also be used for radical or partial nephrectomy.

Place the patient supine with the table extended at the patient's waist. Make an incision in the midline from the xiphoid to just below the umbilicus. For greater exposure, continue the incision down to the symphysis pubis *(dotted line)* (Fig. 129-7).

Divide the subcutaneous tissue down to the level of the fascia, and identify the fine decussations of the fused aponeuroses of the muscles of the anterior abdominal wall that form the linea alba (Fig. 129-8). Lifting up on the skin at the upper end of the incision helps identify the linea alba as a ridge in the fascia.

Incise through the linea alba into the loose properitoneal fat covering the peritoneum. Grasp the preperitoneal fat and underlying peritoneum between two forceps, taking care not to include the underlying loops of bowel. Incise the properitoneal tissue carefully between them (Fig. 129-9A). When the peritoneum is opened the loops of bowel will naturally drop away from the anterior abdominal wall, unless there are adhesions from a previous laparotomy. The remainder of the posterior rectus fascia and peritoneum may be opened (see Fig. 129-9B). If this is a reoperation, care must be taken to identify adhesions between the bowel and anterior abdominal wall and take these down sharply to avoid bowel injury.

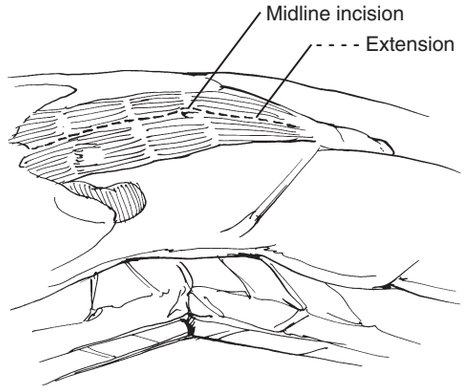

FIGURE 129-7.

In cases of trauma or malignancy, it is advisable to control the renal vessels before mobilizing the colon off of Gerota's fascia. The renal vessels may be approached through the posterior peritoneum. To access the posterior peritoneum, the small bowel contents are displaced to the patient's right and the descending colon to the left. The peritoneum is first divided over the aorta between the fourth portion of the duodenum and the inferior mesenteric vein (Fig. 129-10A). Both of these structures are usually easy to identify even in the case of severe retroperitoneal hemorrhage. There are no vessels arising off of the anterior aorta in this area as long as one stays above the takeoff of the inferior mesenteric artery. The retroperitoneal fat over the aorta is divided superiorly up to the left renal vein. Recall that the left renal vein crosses posterior to the aorta in a small percentage of patients. The vein is mobilized above and below, taking care not to injure the superior mesenteric artery (SMA) at its takeoff from the aorta right above the left renal vein (see Fig. 129-10B). The left and right renal arteries are usually encountered coursing directly lateral off of the aorta posterior to the left renal vein, though multiple arteries may arise anywhere from above the level of the SMA down to the common iliac arteries.

The right kidney is approached from the midline by incising along the lateral edge of the right colon on the avascular line of Toldt, continuing up around the hepatic flexure (Fig. 129-11). As the colon is mobilized medially, the second portion of the duodenum is encountered. Dissecting posteriorly it is mobilized medially as well (Kocher maneuver) over to the aorta. One then encounters the anterior aspect of the inferior vena cava and the anterior leaf of Gerota's fascia covering the right kidney.

The left kidney is similarly approached by incising lateral to the left colon and taking down the splenocolic

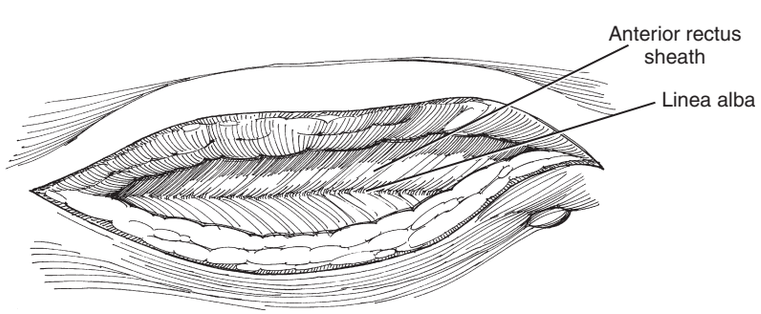

FIGURE 129-8.

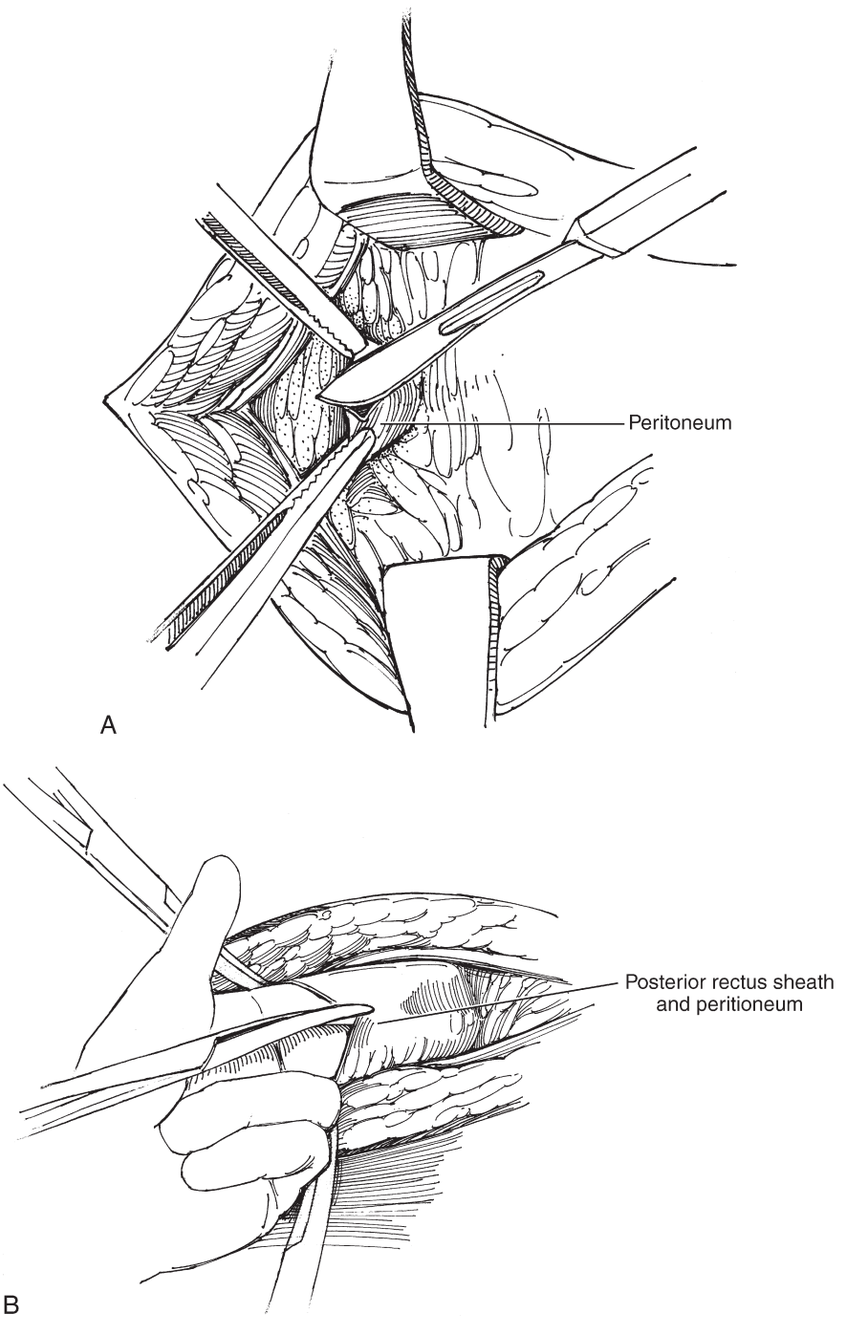

FIGURE 129-9.

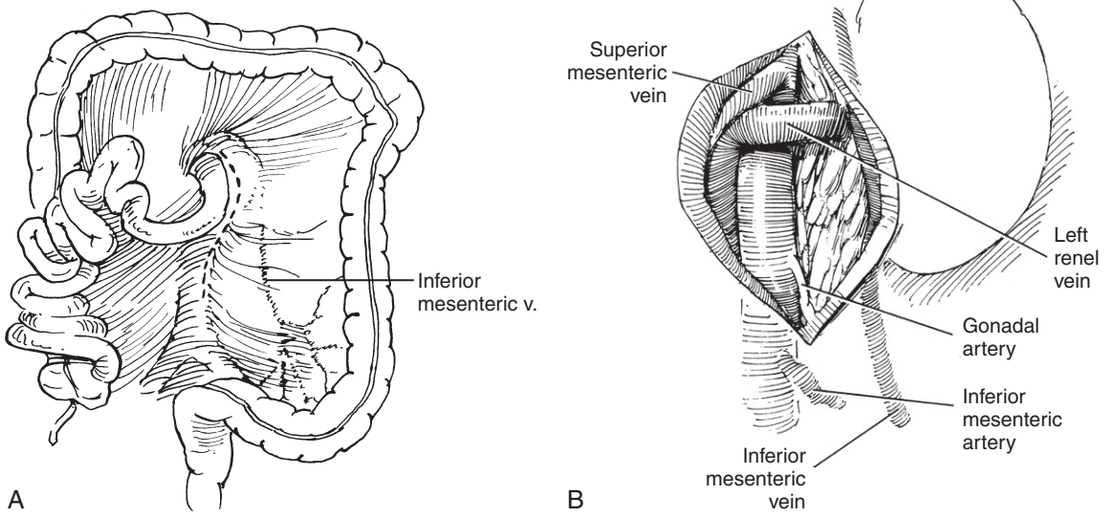

FIGURE 129-10.

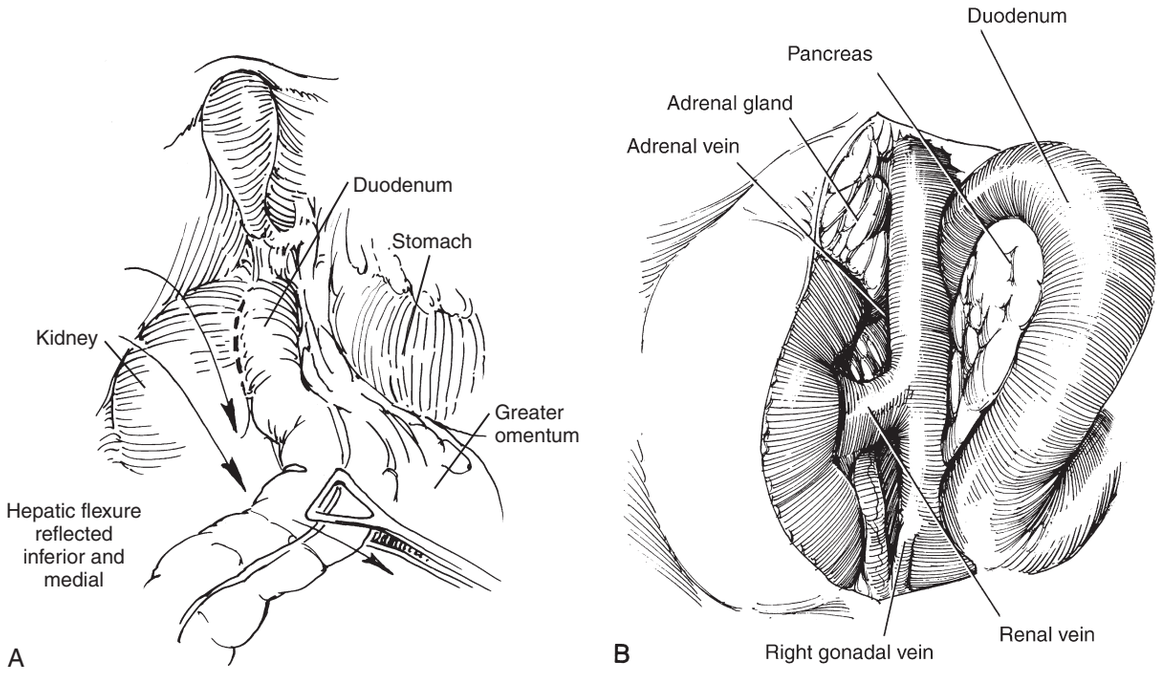

FIGURE 129-11.

ligament to mobilize the colon and spleen medially off of Gerota's fascia (Fig. 129-12A). In case of malignancy, there may be tumor involvement of the left colon mesentery as it is draped across the anterior border of the kidney, and resection of the mesentery may be required.

In a radical nephrectomy, the upper limit of Gerota's fascia must be separated from the lower edge of the pancreatic tail and splenic hilum. This is facilitated by keeping the peritoneum intact over the spleen. Once the abdominal contents are mobilized off of Gerota's fascia, a self-retaining retractor can be placed to keep the intestines out of the way for the remainder of the operation (see Fig. 129-12B).

Closure: The midline incision may be closed in a number of ways, from interrupted to continuous closures, using permanent or absorbable suture. Generally, a one-layer closure is performed. I prefer using #1 looped or straight absorbable monofilament in a running suture, using two or three segments. It is not necessary to close the peritoneum separately.

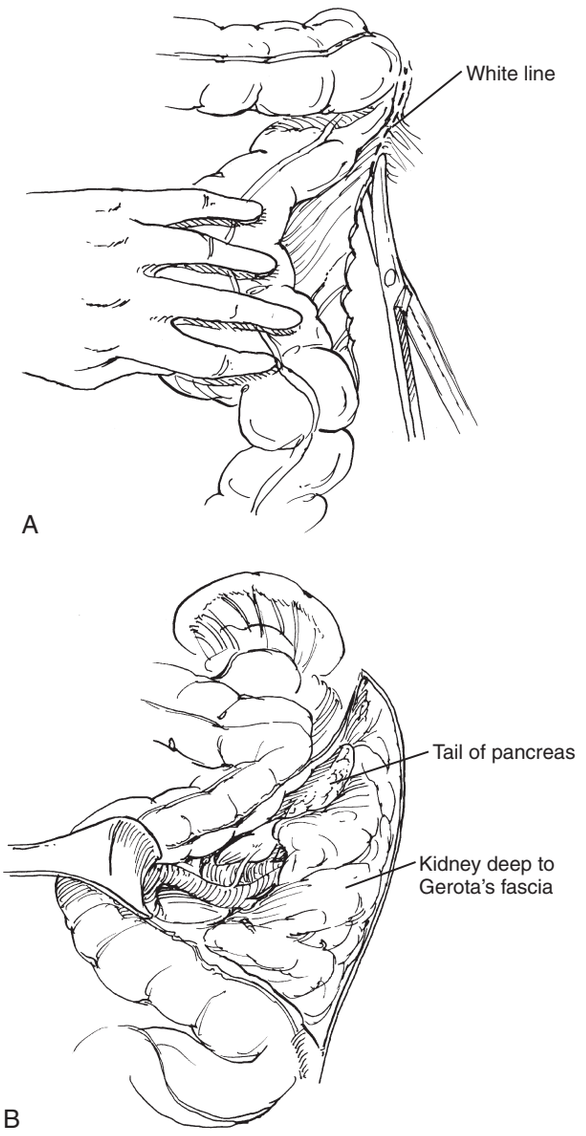

FIGURE 129-12.

If a subcuticular skin closure is planned, the subcutaneous fat can be approximated with 2-0 or 3-0 absorbable suture and the skin closed with fine absorbable monofilament. If skin staples are used, I prefer not to separately close the subcutaneous fat. In very obese patients, a closed suction drain may be placed in the subcutaneous tissue to decrease the risk of postoperative seroma.

POSTOPERATIVE PROBLEMS

Abdominal dehiscence should be rare and generally reflects a technical error in the initial closure. It is heralded by serosanguineous discharge from the wound, an indication that intestines are lying subcutaneously or visible in the wound. Place a nasogastric tube, and start intravenous fluids and parenteral antibiotics, and cover the wound with a sterile dressing. In the operating room under anesthesia, gently mobilize the edges of the fascia on either side of the wound and replace the bowel in the abdominal cavity. Irrigate extensively with sterile saline. Place through-and-through retention sutures of permanent heavy monofilament several centimeters back from the wound edge approximately 2 cm apart, taking care not to injure any loops of bowel. If the fascia can be reapproximated without tension, close it with permanent interrupted suture. The skin should generally be left open or very loosely closed to allow drainage. Thread a length of red rubber catheter on each retention suture before tying loosely over the skin to allow for subsequent edema.

SUBCOSTAL INCISION

Extraperitoneal Approach—Left Side

This approach is most practical on the left side, where the spleen and peritoneal contents can be readily mobilized anteriorly. On the right the liver limits the ability to mobilize the peritoneum off of Gerota's fascia from a subcostal approach. A transperitoneal subcostal, modified thoracoabdominal hockey-stick, or retroperitoneal flank approach is more useful on the right.

Position: Place the patient in the supine position with the table flexed at the patient's waist. If desired, the shoulder can be turned up 30 to 40 degrees and the ipsilateral arm placed over the head on a support.

Incision: Start the incision in the midline anteriorly, one third of the distance from the xiphoid to the umbilicus *(dashed line)*. End the incision on the left at the tip of the eleventh rib, near the anterior axillary line (Fig. 129-13).

Divide the left side of the anterior rectus sheath and the external oblique muscles in the line of the incision for a short distance (Fig. 129-14). The rectus muscle may be divided with electrocautery, controlling the superior epigastric artery with cautery or ligature.

Divide or bluntly split the internal oblique, and digitally separate the fibers of the transversus abdominis, starting as far laterally as possible, where the peritoneum is less adherent (Fig. 129-15). Incise the transversalis

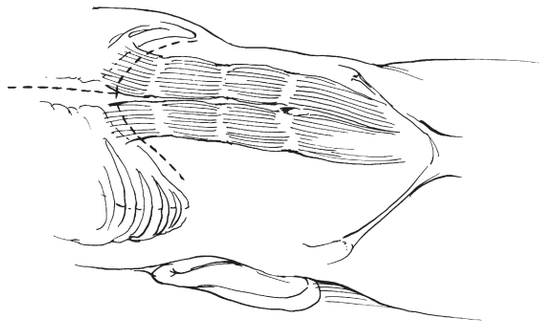

FIGURE 129-13.

fascia and free the peritoneum off above and below the incision.

Sweep the peritoneum bluntly off the abdominal wall laterally and inferiorly to the iliac crest. Continue posteriorly to the lateral edge of the psoas muscle in the extraperitoneal space; then bluntly strip the peritoneum from the overlying muscle layer. Some sharp dissection with the scissors may be required. To develop the plane between the peritoneum and the anterior leaf of Gerota's fascia, incise the transversalis fascia just outside the reflection of the peritoneum laterally (Fig. 129-16). One will encounter the filmy fibroareolar tissue that lies in this plane and allows the peritoneum to be reflected up off of Gerota's. This should be an avascular plan, and the gonadal vein complex and ureter will be left posteriorly.

For a noncancer operation such as a UPJ repair, one may enter Gerota's fascia over the lateral aspect of the kidney; reflect the fascia anteriorly (Fig. 129-17A). Dissect the perirenal fat from the kidney so that the posterior portion remains behind the kidney to isolate it from the posterior body wall after repair. Expose the renal pelvis (see Fig. 129-17B).

For a radical nephrectomy, the renal vessels may be encountered at the level of the aorta, ligated, and divided. Gerota's fascia is divided above the kidney, carefully mobilizing it off of the lower edge of the pancreas. The lower limit of Gerota's is divided above the common iliac artery, and the ureter and gonadal vessels divided. The posterior

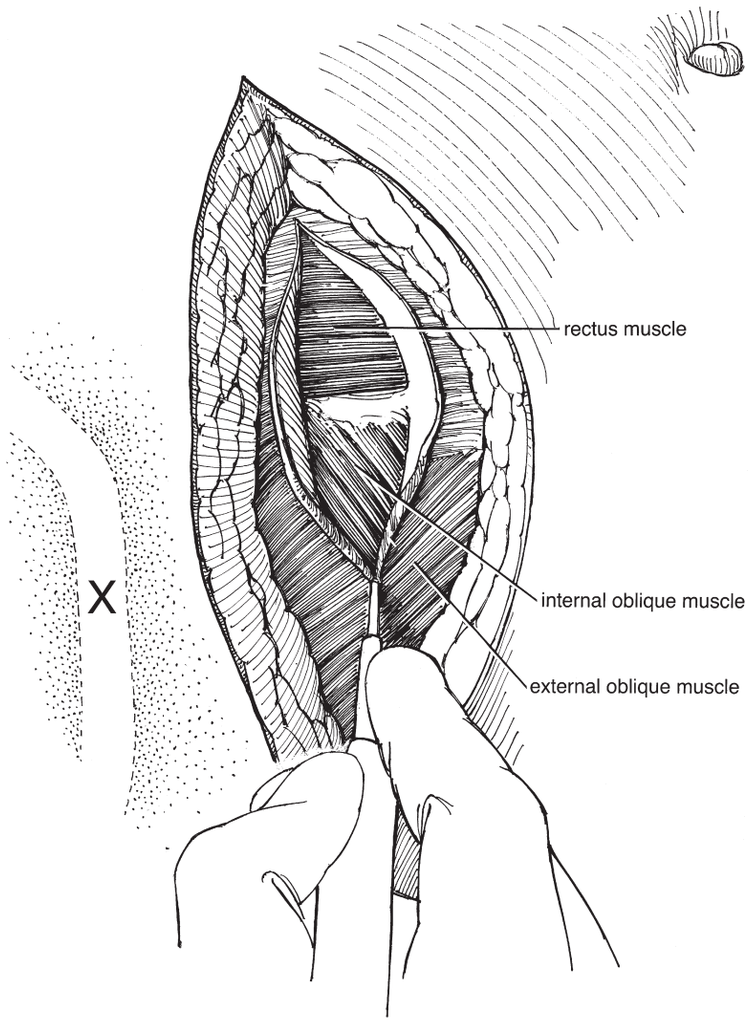

FIGURE 129-14.

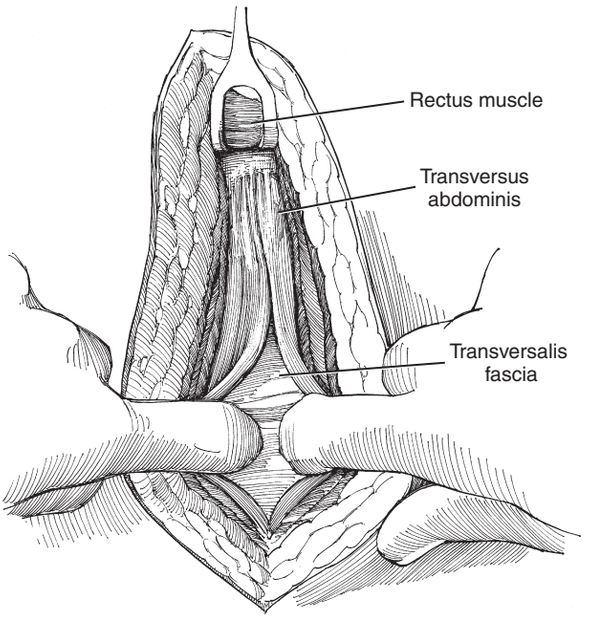

FIGURE 129-15.

and medial attachments are divided and the kidney removed within Gerota's fascia.

Closure: The wound may be closed in two layers, separately closing the internal oblique and external oblique and rectus fascias. I prefer a running closure with #1 absorbable monofilament. The skin may be closed with a subcuticular absorbable stitch or with skin staples.

If the exposure with this incision is found to be inadequate intraoperatively, further exposure can be gained by extending the incision medially and incising the opposite rectus sheath slightly, or converting it to a full chevron incision (see later). It also may be extended posteriorly over the twelfth or eleventh rib as a flank incision.

Transperitoneal Approach—Right Side

A transperitoneal approach for a subcostal incision is preferable for right-sided surgeries, because it is difficult to dissect lateral and behind the liver to reach the retroperitoneum on that side. With this approach, it is faster to open and set up the field. The disadvantage is the need to pack away the abdominal contents and the risk of ileus and bowel obstruction.

Make the same subcostal incision shown in Figure 129-13. Divide the fibers of the internal oblique and transversus muscles, and expose the outer surface of the peritoneum. Divide the peritoneum in the line of the incision to expose the liver, the ascending colon, and the greater omentum covering the transverse colon. The renal vessels may be approached through the posterior peritoneum as described for midline transperitoneal incision. Alternatively, incise along the lateral border of the hepatic flexure and mobilize the right colon and duodenum medially to expose the kidney (described under Midline Transperitoneal Incision).

Closure is identical that for the extraperitoneal subcostal incision described earlier.

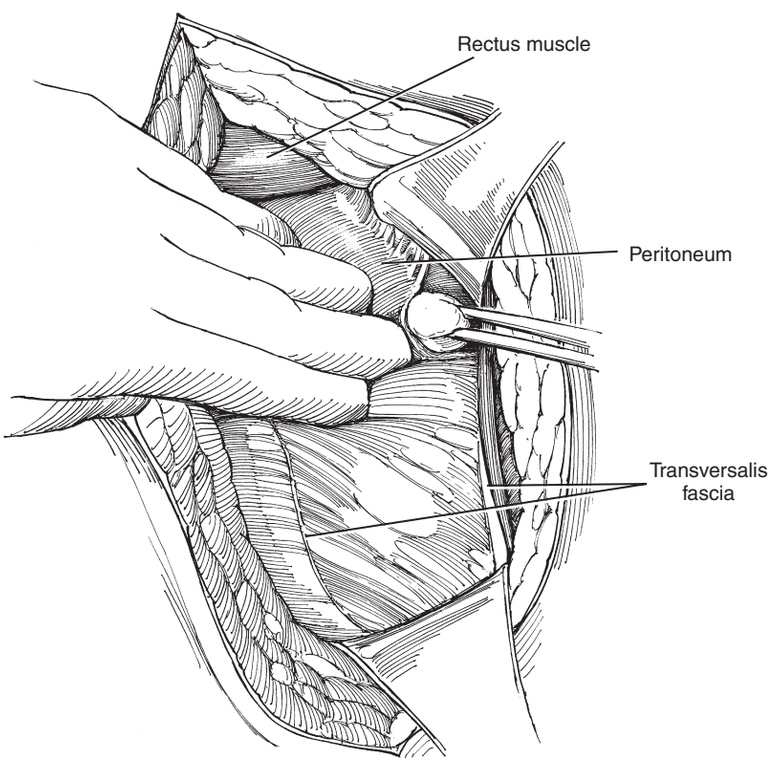

FIGURE 129-16.

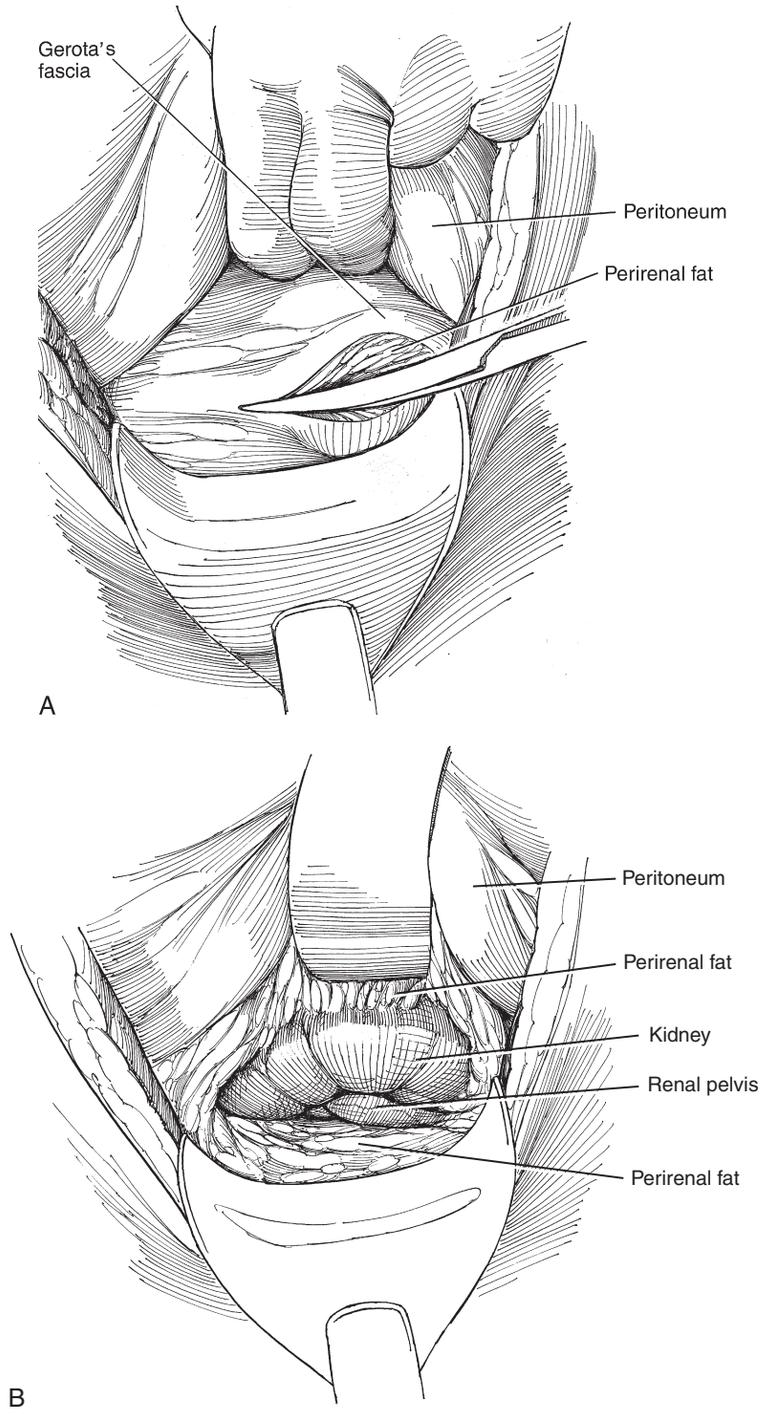

FIGURE 129-17.

CHEVRON INCISION

As an extension of an anterior subcostal incision across the midline, the bilateral subcostal or chevron incision provides excellent bilateral exposure of the upper portion of the retroperitoneum. The incision is most valuable when access to both sides of the retroperitoneum is required, such as for bilateral renal tumors or bilateral nephrectomies for large polycystic kidneys. It also allows wide exposure to the liver and spleen/pancreas in cases where those organs are involved by direct extension of a tumor. It is the incision preferred by most hepatic surgeons for liver resection and transplantation. Exposure to the lower abdomen and pelvis is limited with this incision, making it less valuable than a thoracoabdominal incision in cases of advanced testis cancer or renal tumors with vena cava involvement.

Wider exposure may be obtained by converting the incision to a thoracoabdominal approach by extending either limb over the bed of the tenth or eleventh rib, opening the chest and dividing the diaphragm to expose intrathoracic

extension of neoplasms. Or a formal median sternotomy may be performed to have full access to the heart for bypass in cases of a thrombus extending into the heart (Mercedes incision).

Position and incision: Place the patient in a supine position, hyperextended over a break in the table. From the tip of the eleventh rib, incise the skin toward the midline below the costal margin to just below the xiphoid process. Continue down the opposite side to the tip of the opposite eleventh rib *(dashed line)* (Fig. 129-18). If you are uncertain about operability or the need for such an extensive incision, make only half of it first.

After incising the subcutaneous tissue, divide both sides of the anterior rectus sheath (Fig. 129-19). Insinuate a finger under the rectus muscle and divide it with cautery. Ligate or cauterize the superior epigastric artery as it is encountered.

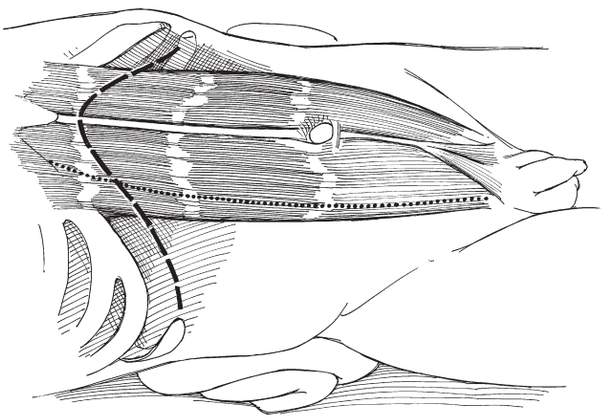

FIGURE 129-18.

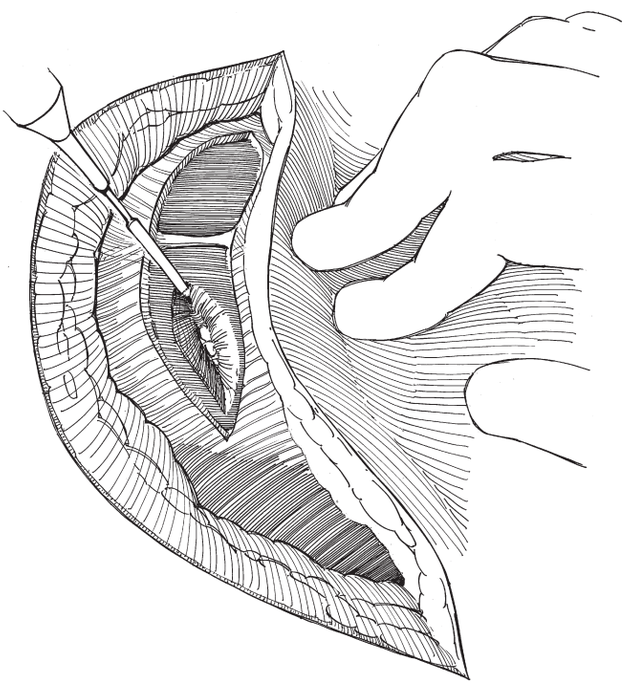

FIGURE 129-19.

Divide the investing fascia and muscles of the external and internal oblique muscles and split the fibers of the transversus abdominis muscle. Incise the transversalis fascia and peritoneum, and enter the peritoneal cavity (Fig. 129-20). Complete the incision with cutting current or scissors against one or two fingers inside the abdomen (Fig. 129-21). Divide the falciform ligament of the liver between clamps, and ligate each end. Exposure of the kidneys and retroperitoneum on the right and left sides is identical to that described above (midline transperitoneal incision).

Closure: Straighten the table and remove any pads under the patient. Approximate the linea alba in the midline with a place-holding suture that is tied after the fascial closure is completed. The incision may be closed in a single layer including the anterior and posterior rectus sheath in a single layer with running or interrupted sutures. Alternatively, a multilayer closure may be performed, separately closing the peritoneum and posterior rectus fascia, the internal and external oblique fascial layers laterally, and the anterior rectus sheath medially. Close the subcutaneous tissue and skin.

Complications: Unilateral and bilateral subcostal incisions may result in an incisional hernia, or diastasis of the ipsilateral muscles if the intercostals nerves are damaged. Damage to the liver or spleen may be more likely than in a midline incision. Limited exposure with the unilateral incision may lead to complications such as bleeding that may be difficult to manage.

PEDIATRIC TRANSVERSE ABDOMINAL INCISION

This incision allows early access to the renal pedicle and retroperitoneal nodes and provides excellent exposure for excision of Wilms tumor. It can also be used for simultaneous bilateral pyeloplasty, although two subcostal incisions may be just as easy to make and offer fewer complications.

Position and incision: The child may be positioned flat with a rolled bolster under the loin, and the table may be flexed. Alternatively he may be slightly rotated by placing small wedges or bolsters (rolled towels, padded sandbags, or gel pads) under the ipsilateral thorax at the shoulder and under the buttock, and place a larger pad under the loin (Fig. 129-22). The loin pad should be accessible to the circulating nurse for removal at the time of closure. Bend the elbow approximately 90 degrees, and suspend the forearm from the anesthesia screen to avoid stretch injury to the brachial plexus. Hyperextend the table if necessary to accentuate the renal area; raising the kidney rest may improve the position. Make a long transverse incision above the umbilicus, ending at the tip of the twelfth rib on the involved side. For large tumors, make the incision higher so that it may be extended through the eleventh or tenth intercostal space, or consider a thoracoabdominal approach (see later).

Divide the anterior rectus sheath and the ipsilateral rectus abdominis muscle. In neonates and infants, each muscle layer can be separated bluntly. Divide and ligate the superior epigastric vessels. If additional exposure is needed the incision can be extended across and the opposite rectus muscle divided. Open the peritoneum in line with the incision

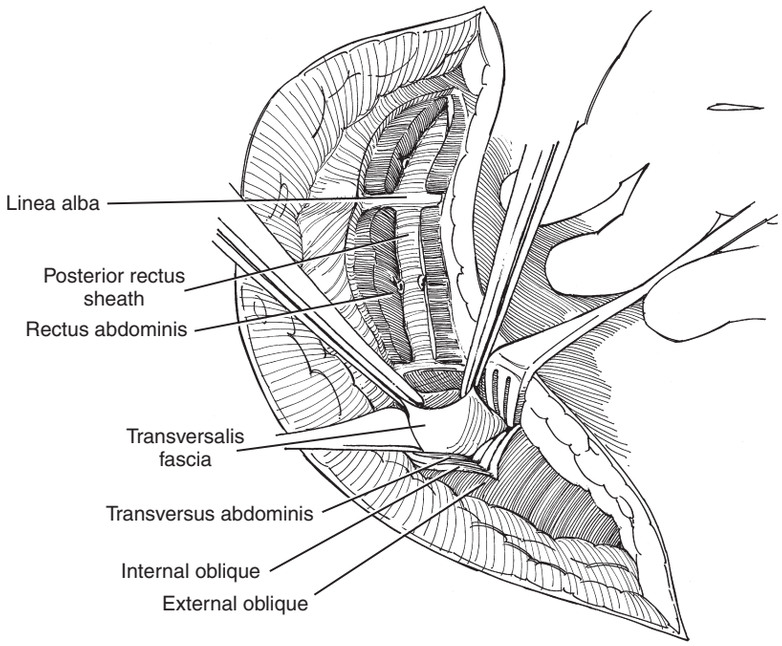

FIGURE 129-20.

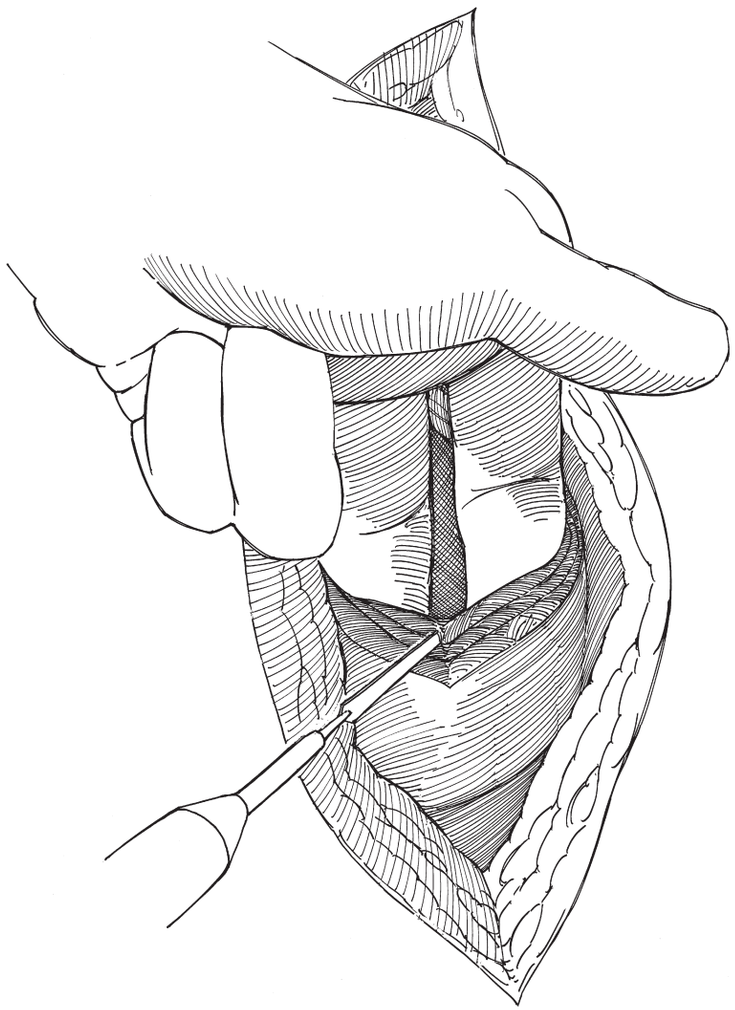

FIGURE 129-21.

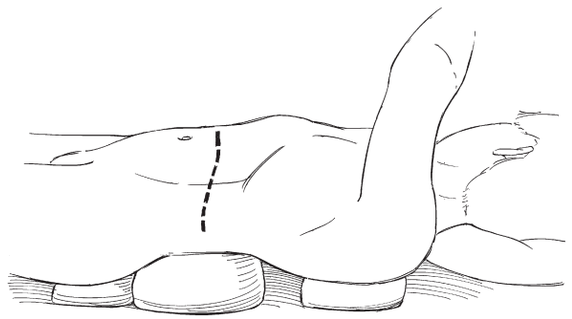

FIGURE 129-22.

and divide the falciform ligament (Fig. 129-23). Access to the retroperitoneal structures is identical to that described above (midline transperitoneal incision). Closure is done in one or two layers with absorbable suture.

Paramedian Incision

Some surgeons prefer a paramedian incision to a midline transperitoneal incision believing that the interposed muscle makes the closure stronger. Little evidence is available to prove this. The primary indication for a paramedian incision is the need to avoid a scar close to another structure such as a nearby colostomy. The paramedian approach also facilitates development of the preperitoneal space in an effort to approach the kidney in an extraperitoneal fashion (see the discussion on extraperitoneal transabdominal hockey-stick incision later).

Position and incision: Position is identical to the midline transperitoneal incision. The patient is flat with the table extended at his waist. The incision is made 2 cm lateral to the midline (Fig. 129-24).

The muscle belly of the rectus muscle is reflected laterally from the midline, allowing maintenance of the nerve and blood supply to the muscle (Fig. 129-25). The rectus muscle should not be reflected medially. Going through the middle of the rectus muscle risks injury to the superior epigastric artery.

The posterior rectus fascia is incised 1 to 2 cm lateral to the midline and the preperitoneal space opened (Fig. 129-26). The peritoneum may be opened or the

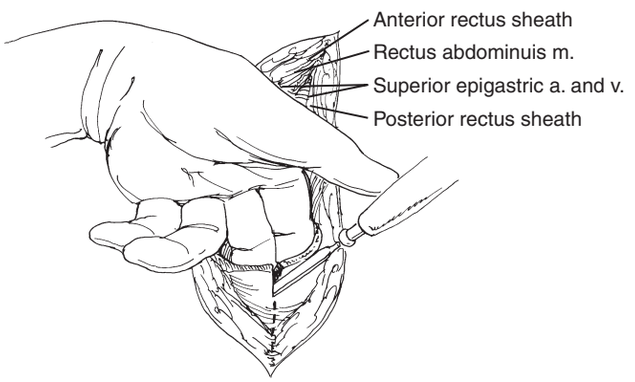

FIGURE 129-23.

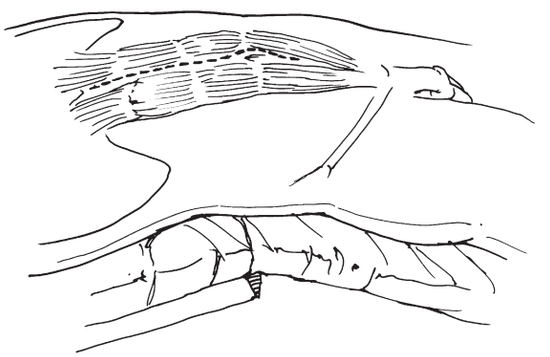

FIGURE 129-24.

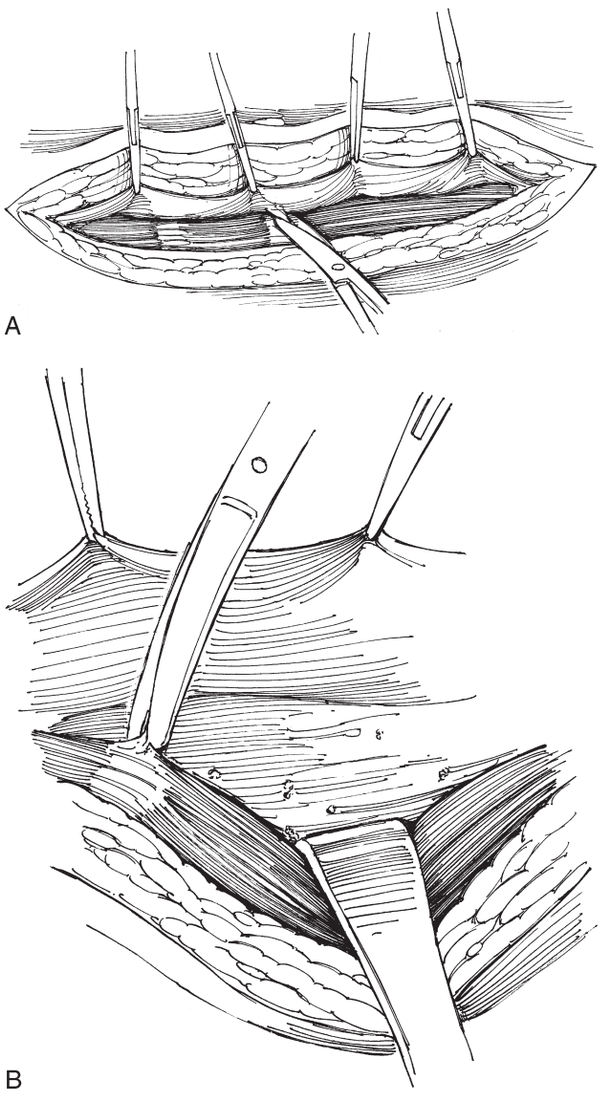

FIGURE 129-25.

extraperitoneal space developed around to the back, reflecting the peritoneal envelope medially.

Closure: Close the peritoneum and posterior sheath in one layer with a heavy running absorbable or nonabsorbable suture. Close the anterior sheath with running or interrupted sutures of the same material.

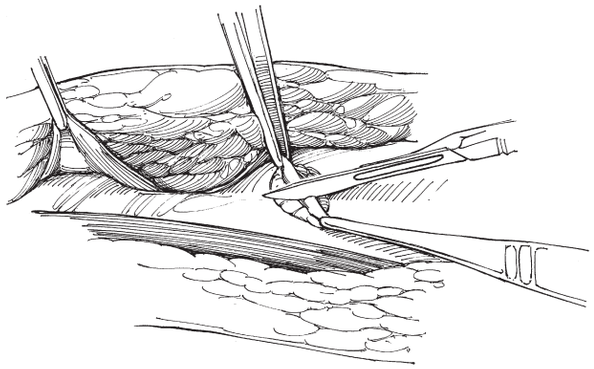

FIGURE 129-26.

Modified Thoracoabdominal, Extraperitoneal Hockey-Stick Incision

This is a versatile incision for radical nephrectomy or other surgeries requiring an anterior approach to the kidney. The transverse portion facilitates development of the extraperitoneal space. The incision may be extended inferiorly all the way to the pubic bone or laterally over the rib cage as a thoracoabdominal incision (Fig. 129-27).

Position and incision: If it is unlikely that the incision will need to be extended over the rib cage then the patient may be positioned supine with the table flexed at his waist, as shown for the midline transperitoneal approach. The position shown here is preferable for larger tumors in that the abdominal contents are deflected away by gravity and the chest is easily opened (Fig. 129-28). In this position the ipsilateral arm is suspended on an airplane over the chest. If desired a long roll can be placed under the chest and abdomen to elevate the ipsilateral side slightly.

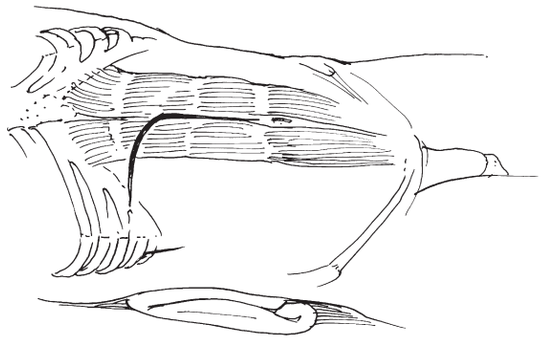

FIGURE 129-27.

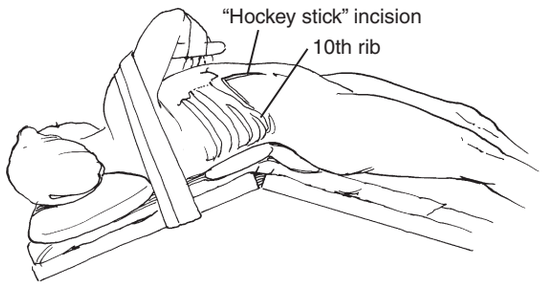

FIGURE 129-28.

The subcutaneous tissues and anterior rectus fascia are divided in line with the incision (Fig. 129-29).

The body of the rectus muscle is divided at the upper edge of the incision with electrocautery (Fig. 129-30).

The external oblique, external oblique, and transversalis muscles are divided near the costal margin and the retroperitoneum is entered there, lateral to the peritoneal reflection. The peritoneum can be swept off of the anterior abdominal muscles medially before opening the posterior rectus fascia. The abdominal wall flap can then be retracted inferiorly with a towel clamp.

The peritoneal envelope is then mobilized laterally all the way back to the psoas muscle (Fig. 129-31). Superiorly the peritoneum is mobilized off of the diaphragm, keeping the spleen within the peritoneal envelope.

The plane between the peritoneum and the anterior leaf of Gerota's fascia is developed by incising the thin fascial layer that envelopes them together (Fig. 129-32). This plane is most easily identified near the lower pole of the kidney and superiorly extends quite far posteriorly. An inadvertent peritoneotomy can be closed with fine absorbable suture.

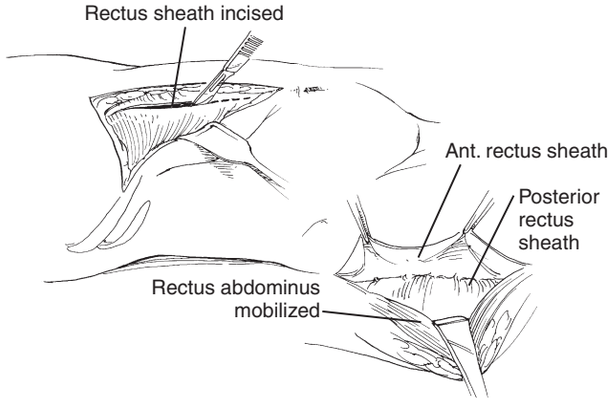

FIGURE 129-29.

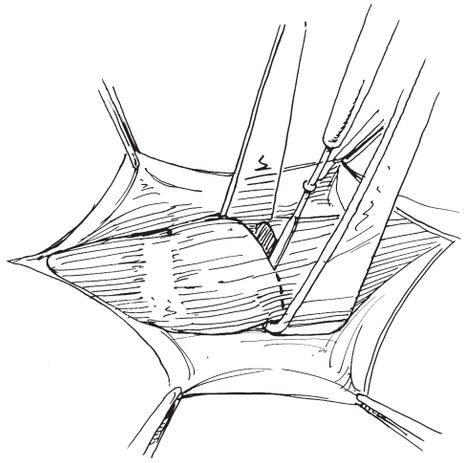

FIGURE 129-30.

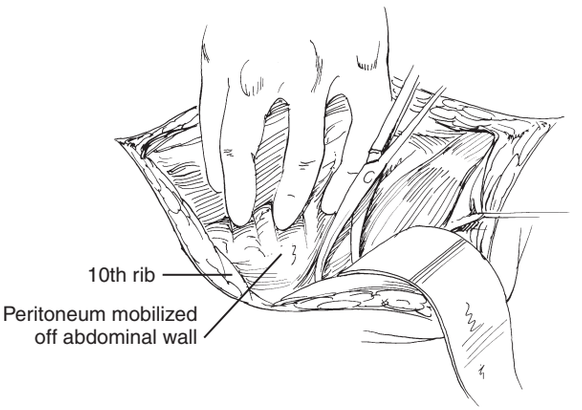

FIGURE 129-31.

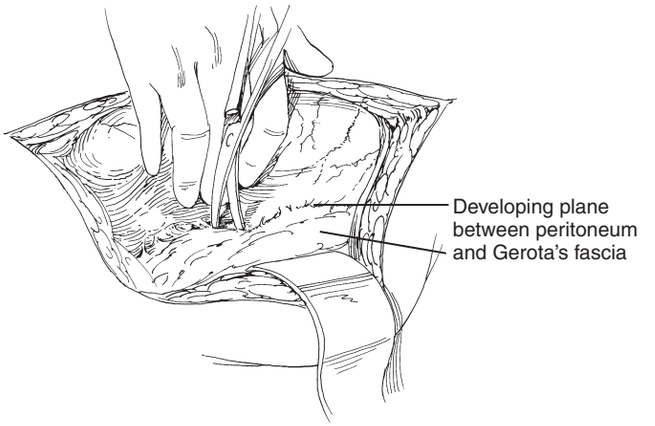

FIGURE 129-32.

Once the fascia is incised, the rest of the avascular plane is developed bluntly all the way over to the aorta or vena cava, reflecting the entire peritoneal envelope medially.

The kidney, ureters and gonadal vessels within Gerota's fascia remain lying on the psoas muscle. A self-retaining retractor such as a Buckwalter allows the peritoneum to be kept medially out of the way (Fig. 129-33). A radical nephrectomy with a node dissection may be performed with early ligation of the vessels, or Gerota's fascia may be opened to address a benign condition.

Closure: The transverse portion of the incision is closed in two layers taking care to keep the corner properly aligned.

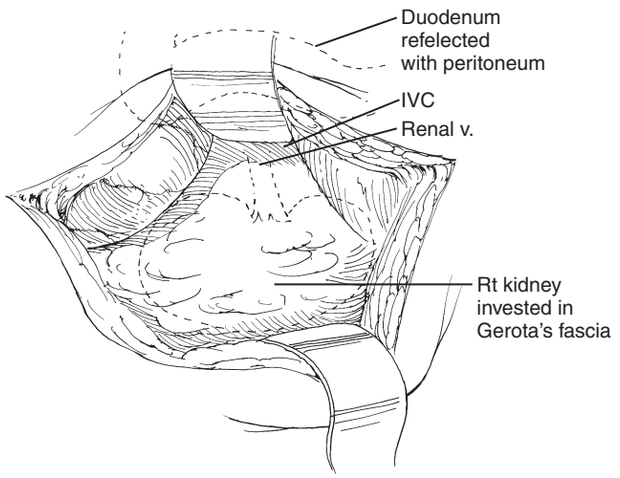

FIGURE 129-33.

FLANK APPROACHES

Foley Muscle-Splitting Incision

This incision is only useful for accessing the upper ureters and psoas muscle area, and was primarily used for open ureterolithotomy in the era before the advent of ureteroscopy. It is rarely used now except perhaps for open drainage of a psoas abscess.

Place the patient in the full flank position with the table flexed. The incision is made obliquely from the angle between the twelfth rib and spine, extending anteriorly and inferiorly to just above the iliac crest (Fig. 129-34).

The latissimus dorsi is reflected posteriorly and the free edge of the external oblique muscle reflected anteriorly. The internal oblique is encountered with the fibers running perpendicular to the incision (Fig. 129-35).

Incise the fascia overlying the internal oblique and separate the muscle fibers bluntly. The lumbodorsal fascia is then incised in line with the skin incision (Fig. 129-36).

The peritoneal envelope is reflected medially and the ureters encountered adherent to its posterior surface, overlying the psoas muscle (Fig. 129-37).

Flank Subcostal Incision (Below Twelfth Rib)

A subcostal flank incision provides limited access and its use has generally be supplanted by endoscopic and laparoscopic approaches. It is only useful for open renal biopsy, drainage of a perinephric abscess, or for a pyeloplasty in the

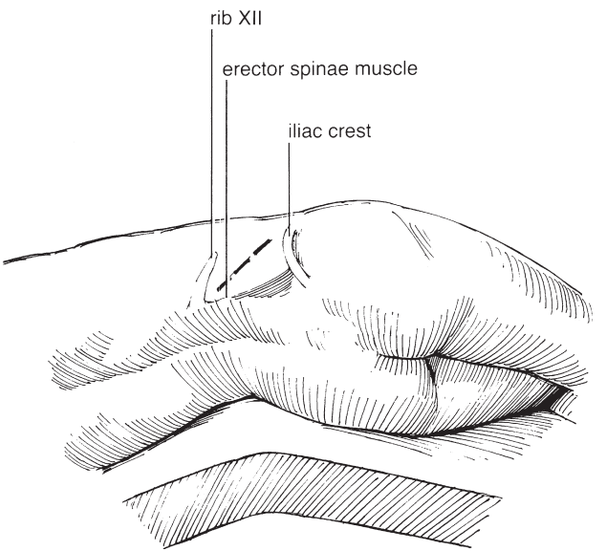

FIGURE 129-34.

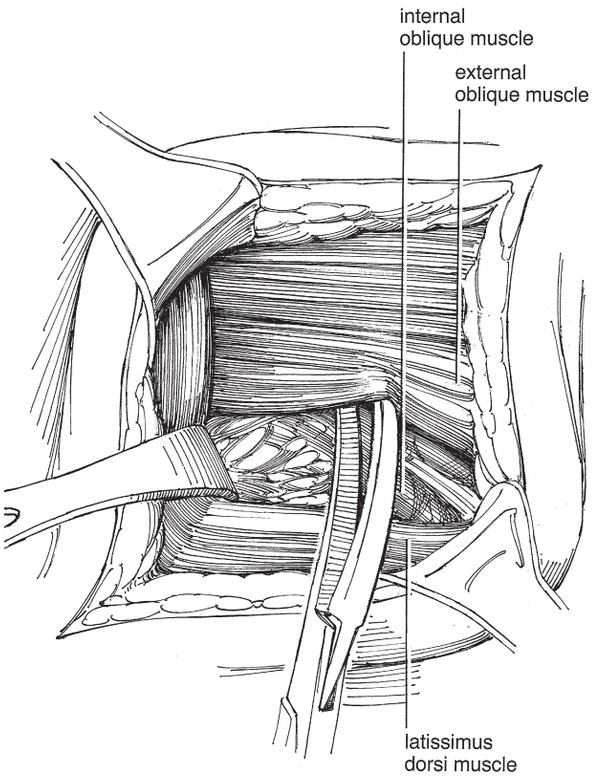

FIGURE 129-35.

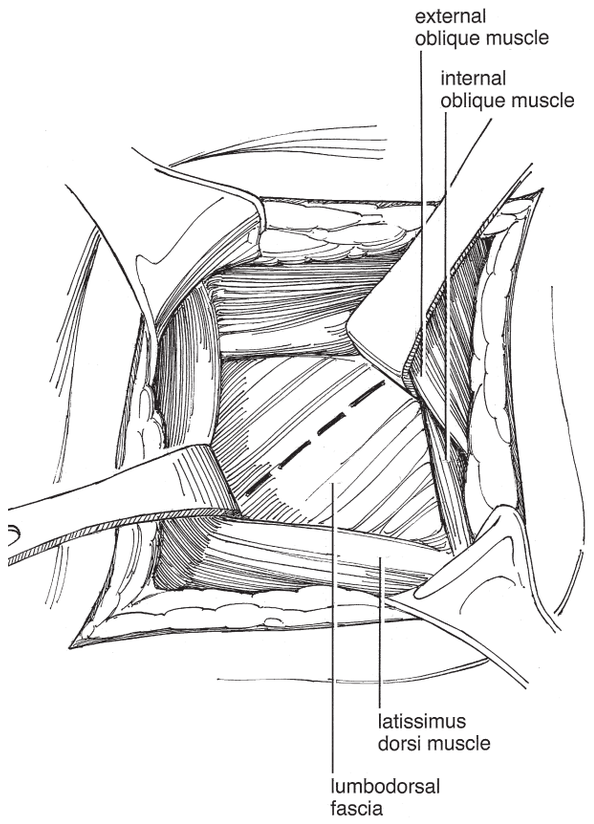

FIGURE 129-36.

presence of an extrarenal pelvis. Other incisions are more suitable for access to the renal pedicle.

Place the patient in the classical flank position, with the dependent twelfth rib directly over the kidney lift. Elevate the kidney lift in conjunction with table flexion. An axillary roll must be placed to avoid a brachial plexus injury. Watch for hypotension from poor venous return, mediastinal shift, and displacement of the liver. The top arm is carefully padded on an airplane or pillow. Fix the patient in position with broad tape extending from the table top anteriorly, over the hip, and to the table top posteriorly, placed after the table has been flexed (Fig. 129-38).

Start the incision at the lateral border of the sacrospinalis muscle, 1 cm below the lower edge of the twelfth rib. Follow the lower border of the rib anteriorly, curving the incision caudally as it crosses the anterior abdominal wall to avoid the subcostal nerve. Avoid extending it very far caudally until you are sure that access to the pedicle is not needed. End it at the lateral border of the rectus sheath (Fig. 129-39). With a rudimentary twelfth rib, place the incision well below the eleventh rib.

Incise the latissimus dorsi and serratus posterior inferior muscles with cautery. Incise the external oblique fascia and muscle fibers (Fig. 129-40).

After incising the internal oblique fascia and muscle fibers, identify the twelfth intercostal neurovascular bundle that lies between the internal oblique and transversus abdominis muscles. Free it and reflect it upward. Divide the small intercostal veins accompanying it (Fig. 129-41).

Split the muscle fibers of the transversus abdominis muscle and incise the firm white lumbodorsal fascia in the middle of the incision (Fig. 129-42). This allows insertion of two fingers to push the peritoneum forward and free it from the anterior abdominal wall before completing the incision. Sharply cut the fascia to its junction with the anterior musculature.

Incise the posterior layer of the lumbodorsal fascia, working back from the anterior border of the sacrospinalis muscle, along with a few fibers of the serratus posterior inferior muscle. Divide the sacrospinalis muscle posteriorly to expose the costotransverse ligament (Fig. 129-43).

Elevate the rib, and cut the costotransverse (costovertebral) ligament with partially opened Mayo scissors, advanced curved side down to avoid cutting the intercostal artery or entering the pleura, which lies beyond the tip of the transverse process. Free the subcostal nerve further, and move it superiorly. Insert a self-retaining retractor, and proceed with entry into Gerota's fascia (Fig. 129-44).

Extension of the Incision

Careful preoperative planning should ensure that this incision is not used when access to the center of the kidney or the renal hilum is necessary. However, if exposure is still inadequate, the incision can be extended anteriorly to the midline dividing the rectus muscle with cautery, and then up the midline to the xiphoid process. This creates a flap that can be reflected superiorly, allowing access to the renal hilum. The exposure is still inferior to the other anterior or higher flank approaches.

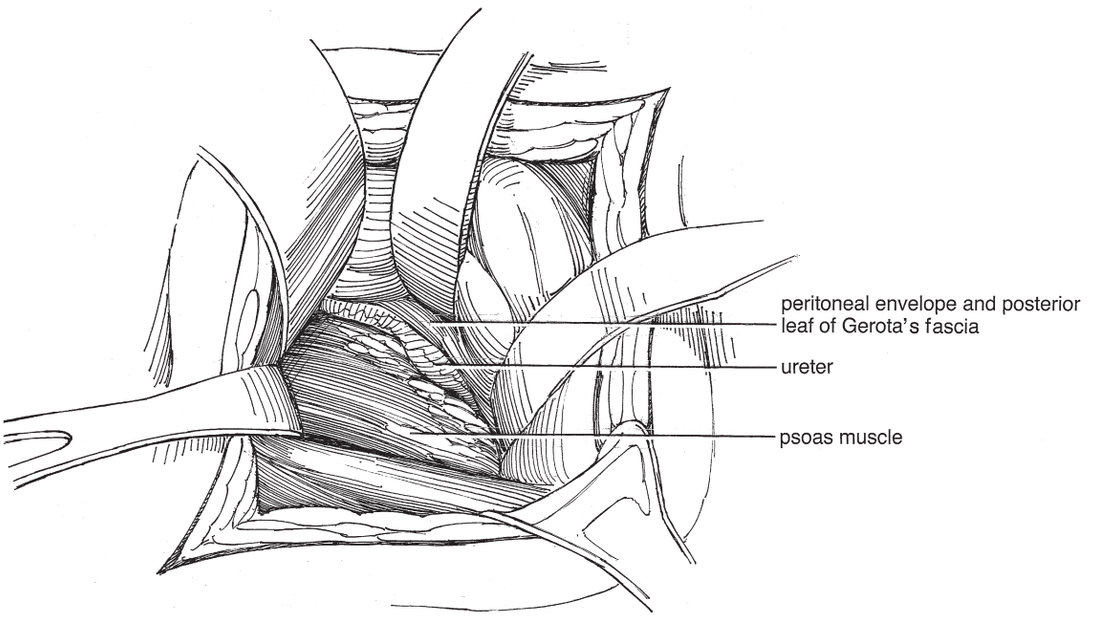

FIGURE 129-37.

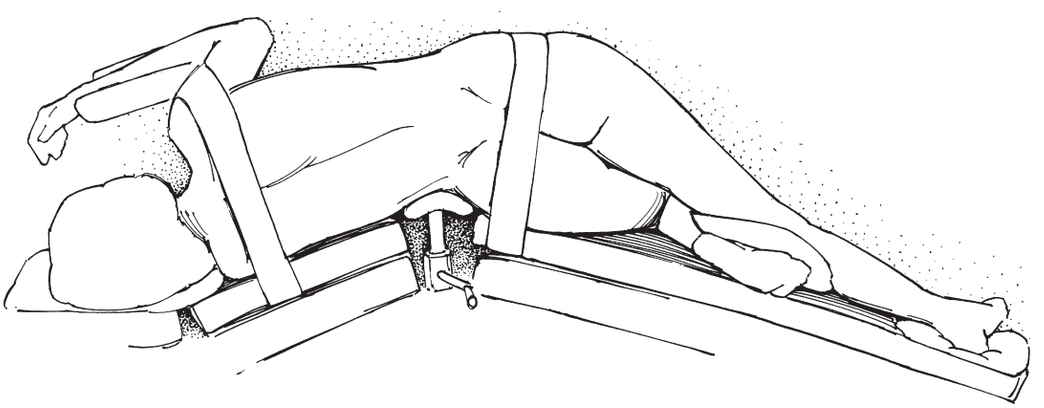

FIGURE 129-38.

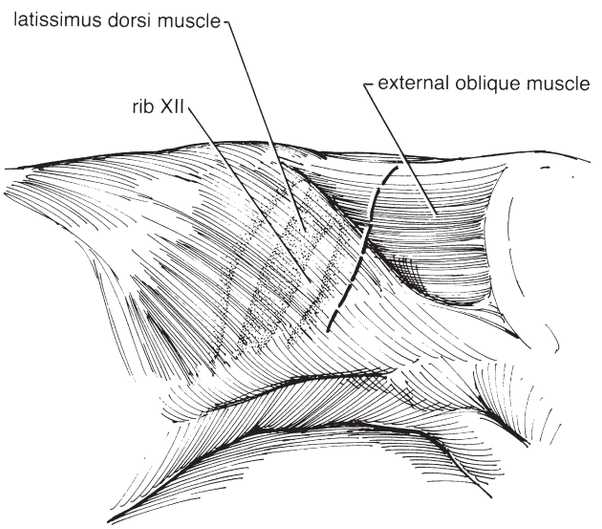

FIGURE 129-39.

Closure: Lower the kidney rest, and partially flatten the table top. Completely flatten it after the first layers of sutures have been placed and tied. Have the assistant pull the shoulder back if it has fallen forward. (Note that rotation of hips and shoulders in opposite directions opens or closes flank incisions.) Insert a Penrose or suction drain if required to exit through a stab wound. The wound may be closed in two layers (external and internal oblique) using running or interrupted absorbable or permanent suture, taking care to avoid the twelfth intercostal neurovascular bundle (Fig. 129-45). Injury to this nerve results in a weakness or diastasis of the abdominal wall muscles, causing an uncomfortable and unsightly bulge in the flank postoperatively.

Twelfth Rib Supracostal Incision

A flank incision immediately above the twelfth or, better, above the eleventh rib can be made more easily than a transcostal incision and gives equal exposure. The approach

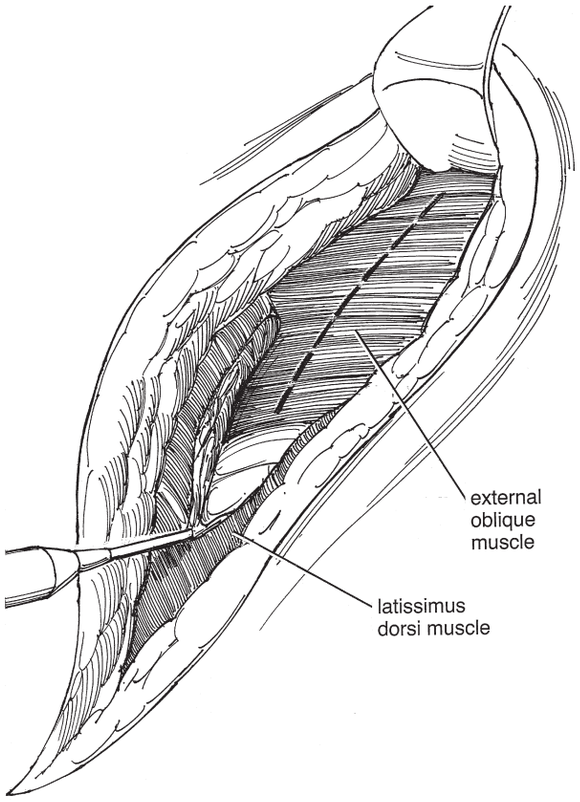

FIGURE 129-40.

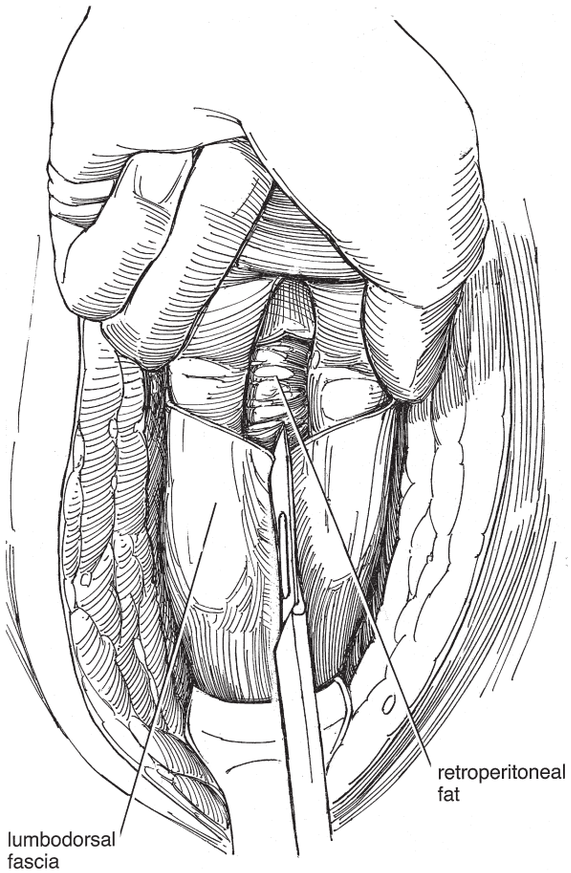

FIGURE 129-42.

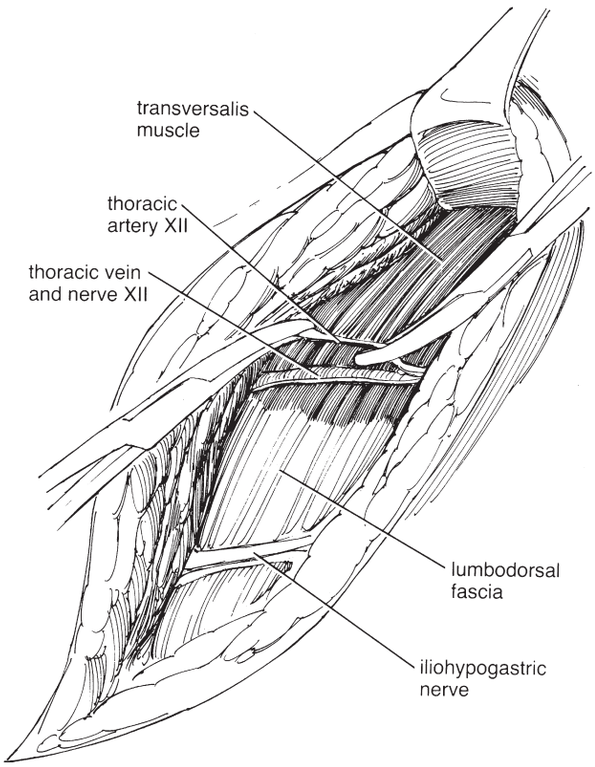

FIGURE 129-41.

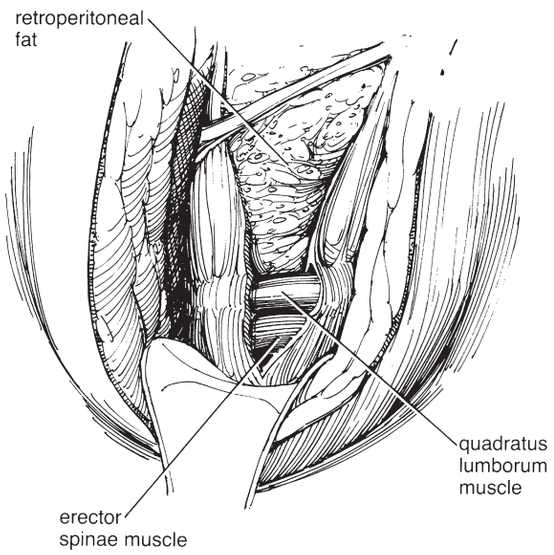

FIGURE 129-43.

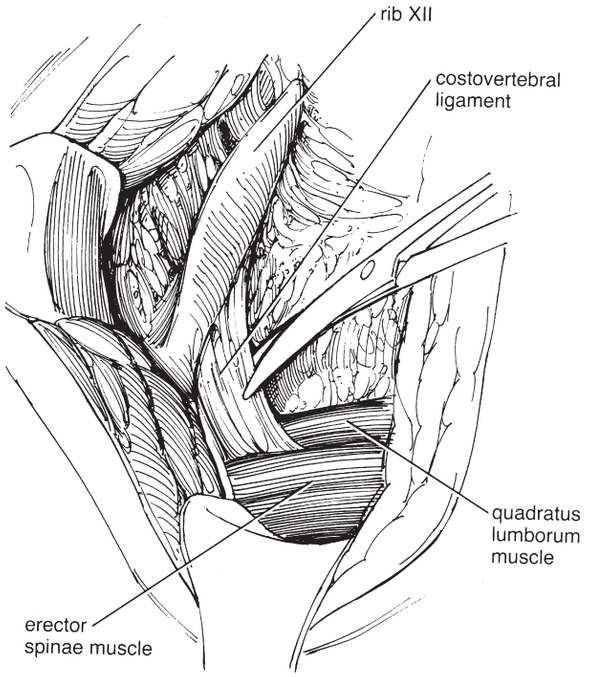

FIGURE 129-44.

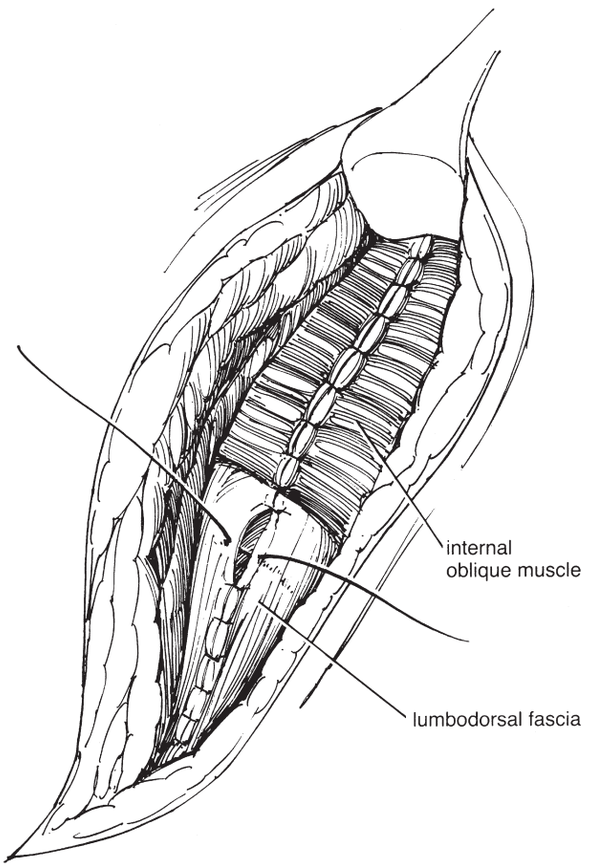

FIGURE 129-45.

described here can be used above the eleventh rib as well, although it may be challenging to mobilize the pleura without injury at that level.

Plan the incision carefully, taking into consideration that the pathology that is to be addressed as well as the individual patient's anatomy. Entering above the eleventh rib is advantageous in patients requiring greater exposure, such as for a complex partial nephrectomy. Place the patient in the full flank position. If the incision is to be extended anteriorly, the patient may be rocked back 30 degrees with a rolled towel providing support behind the back. The incision is made just above the rib from the posterior axillary line across to the lateral border of the rectus abdominis (Fig. 129-46).

Divide the latissimus dorsi, the serratus posterior inferior, and the external and internal oblique muscles over the top border of the rib (Fig. 129-47).

The intercostal muscles above the twelfth rib are carefully incised off of the top edge of the rib beginning at its tip, using cautery and proceeding posteriorly (Fig. 129-48).

Lifting the tip of the rib, the attachments of the diaphragm are teased off of the underside of the upper edge of the rib with scissors, watching for the edge of the pleura, which is usually encountered a few centimeters back from the tip of the rib (Fig. 129-49A). The edge of the pleura is mobilized off of the rib and is reflected superiorly. The intercostal nerve for the eleventh rib is left attached to the eleventh rib and is out of harm's way (see Fig. 129-49B-D).

Run the pad of the left index finger back along the top edge of the rib until it meets the sharp edge of the costovertebral ligament. Insert slightly opened heavy curved scissors, curve down, and hug the top of the rib with the blades to divide the ligament sharply, avoiding the intercostal bundle that lies below the upper (eleventh) rib (Fig. 129-50). The lower rib can pivot downward on its costovertebral joint and be retracted inferiorly to be held out of the way with a self-retaining retractor. Anterior to the tip of the rib, the fascia of the external and interal oblique muscles are divided. As the eleventh intercostal neurovascular bundle is encountered between the internal oblique and transversus abdominis, it is freed up and reflected superiorly. The transversus

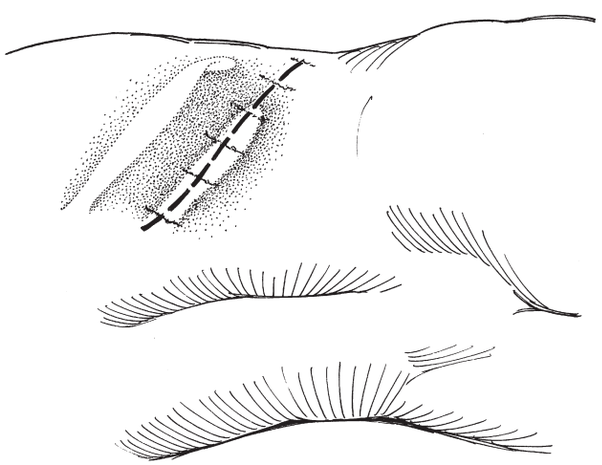

FIGURE 129-46.

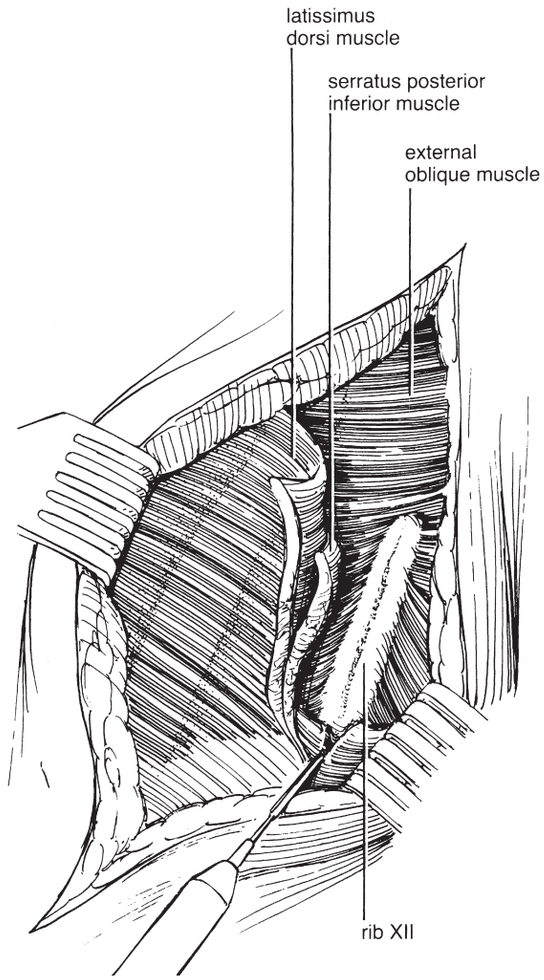

FIGURE 129-47.

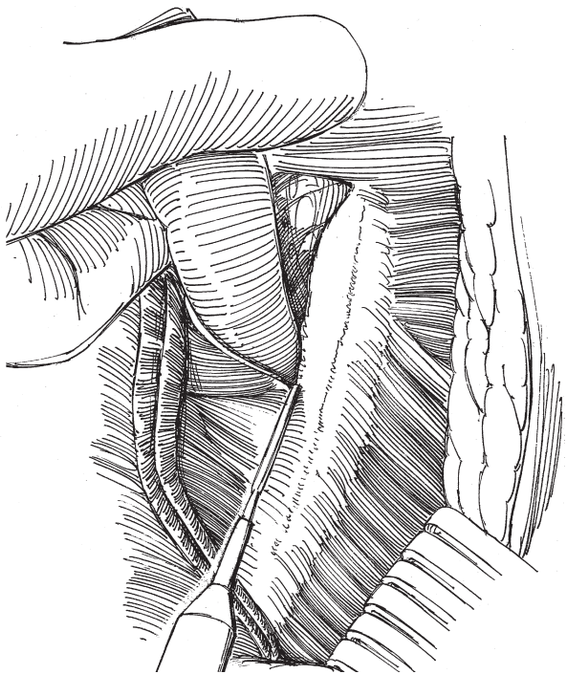

FIGURE 129-48.

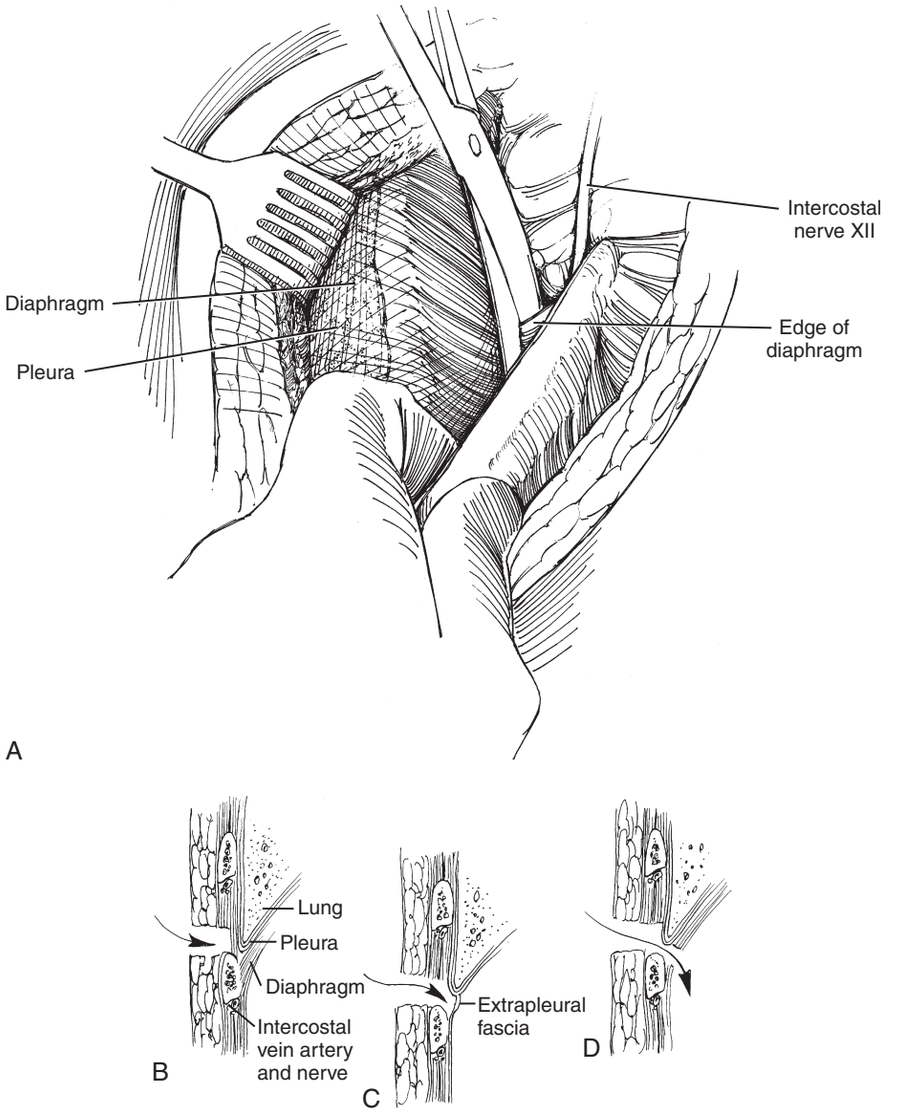

FIGURE 129-49.

abdominis muscle fibers are separated in line with their fibers and the lumbodorsal fascia divided, entering the retroperitoneum. The peritoneal envelope is reflected medially.

The supracostal eleventh rib incision is not shown, but it differs from the supracostal twelfth rib incision only in that the pleura extends lower and more anteriorly, and is more exposed to possible entry during its dissection from the inner aspect of the eleventh rib. However, it is often possible to make a supra-eleventh rib incision without entering the pleura. If the pleura is injured, it can generally be closed primarily (see later) without the need for a chest tube.

Closure. Partially straighten the table, just enough to allow the edges of the wound to come together but not enough to impede the insertion of sutures. If the pleura has been opened it should be closed with fine running PGA suture using a small catheter to let out the air with a big breath given by the anesthesiologist (see later). If a drain is required, it is placed through a stab incision well below the twelfth rib. We do not make any attempt to close the intercostal muscles individually. A running or interrupted suture closure of the external and internal oblique fascial layers may be made with heavy absorbable or permanent suture in one or two 2 layers (running or interrupted) through the abdominal wall muscles overlying the ribs (Fig. 129-51). Care must be taken to avoid the intercostal neurovascular bundle below the eleventh rib.

Eleventh Rib Transcostal Incision

The transcostal incision approaches the upper retroperitoneum through the bed of the eleventh rib. It may be used for simple or partial nephrectomy and for simple adrenalectomy, although an eleventh or twelfth supracostal incision is easier to make and gives equal or better exposure. When a large portion of the rib is removed it leaves a defect that is noticeable to the patient.

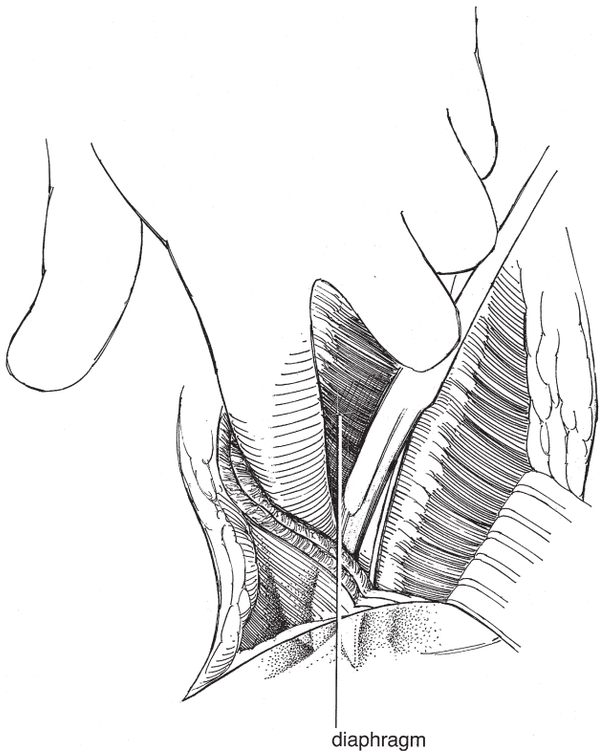

FIGURE 129-50.

Position: Place the patient in the flank position over the break in the table and elevate the kidney rest. Palpate the twelfth and eleventh ribs and mark out the course of the eleventh rib on the skin. Incise the skin starting at the margin of the erector spinae muscles, running obliquely forward, following the line of the eleventh rib and ending at the lateral border of the rectus abdominis. If the rib cannot be felt through a thick body wall, estimate its site, and cut through enough of the subcutaneous tissue that it can be palpated before dividing fascia and muscle. Divide the external oblique muscle and the latissimus dorsi muscle directly over the center of the rib all the way down through the anterior periosteum with electrocautery (Fig. 129-52).

Scrape the periosteum from the rib with the chisel end of the Alexander periosteal elevator, beginning posteriorly (Fig. 129-53A). Use small strokes to free it from the convex surface of the rib, and then free the upper and lower edges. Finally, run the elevator along both edges at an angle to free the periosteum under them. The curved blades on the other end of the Alexander elevator are useful to free the periosteum from the edges of the rib, dissecting anteriorly on the upper edge of the rib and posteriorly on the lower edge because of the direction of insertion of the intercostal muscles (see Fig. 129-53B).

Once the periosteum is freed off the posterior side of the rib posteriorly, a curved Doyen rib stripper can be inserted to encircle the rib posteriorly and pushed anteriorly

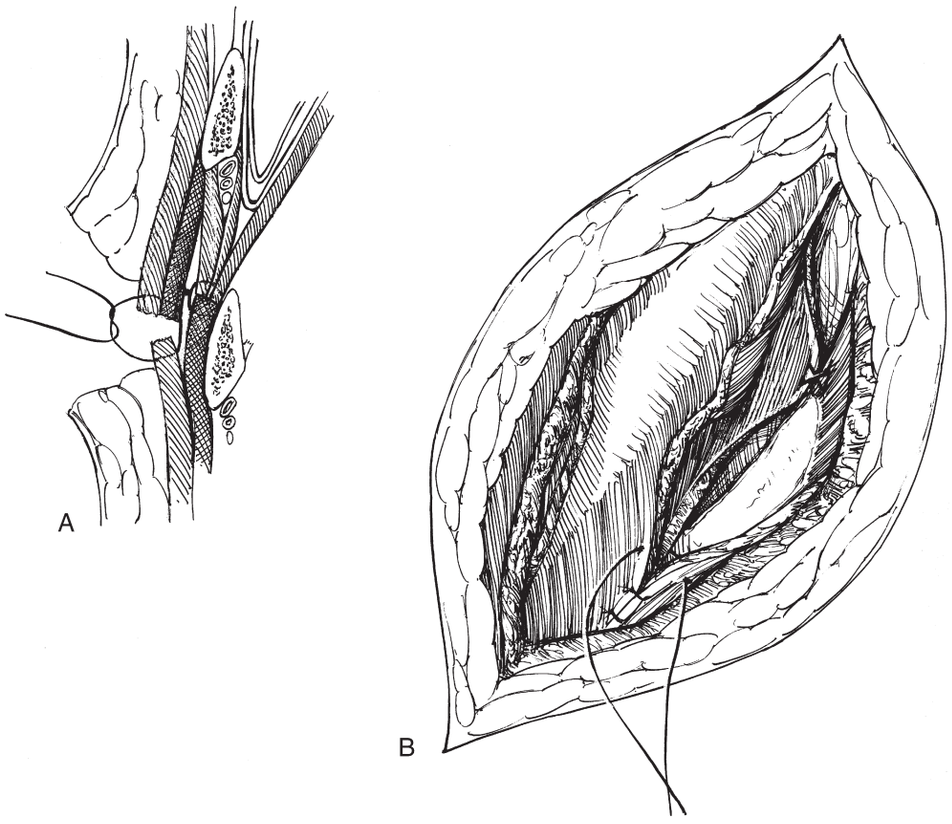

FIGURE 129-51.

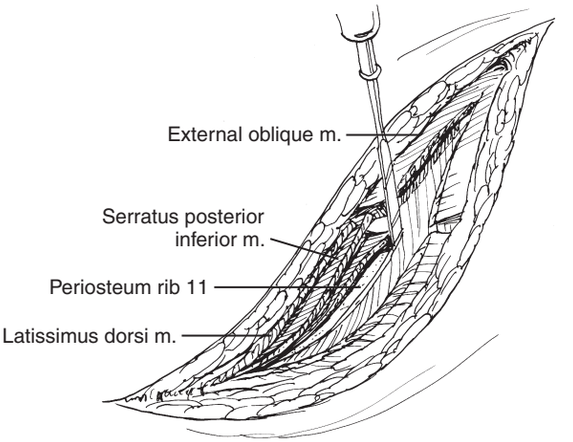

FIGURE 129-52.

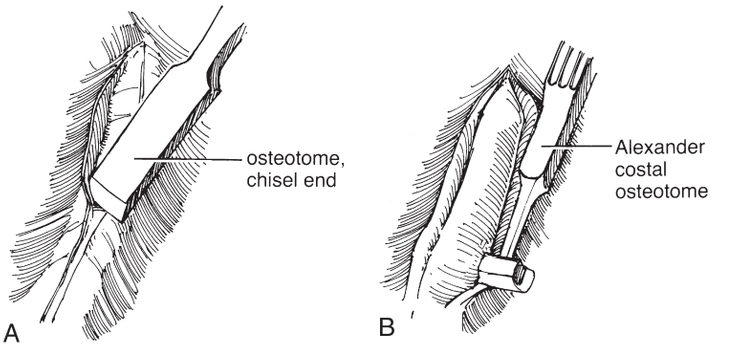

FIGURE 129-53.

to the tip of the rib to strip the off the periosteum (Fig. 129-54).

Insert the rib cutter with the blade on the medial side, and pull it well posteriorly to divide the rib as far back as possible. Cut the rib (Fig. 129-55). After division, use rongeurs to trim more of the rib if needed and to round the edges. Press bone wax into the cut end if it is bleeding. Cut the anterior fibrous attachment of the rib with Mayo scissors, and remove it.

Incise the posterior layer of periosteum at the anterior end under the site of the rib tip to enter the retroperitoneal space (Fig. 129-56). Insert a finger to depress the pleura and peritoneum; then extend the incision both ways with scissors. Spare the branches of the eleventh intercostal neurovascular

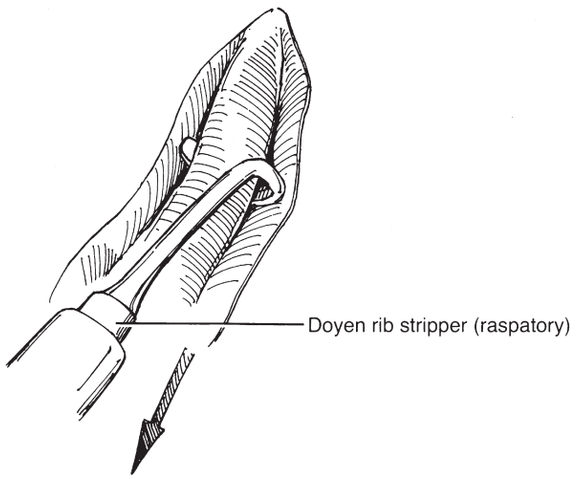

FIGURE 129-54.

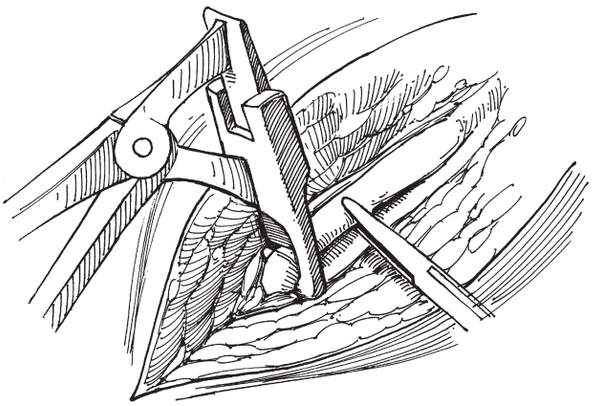

FIGURE 129-55.

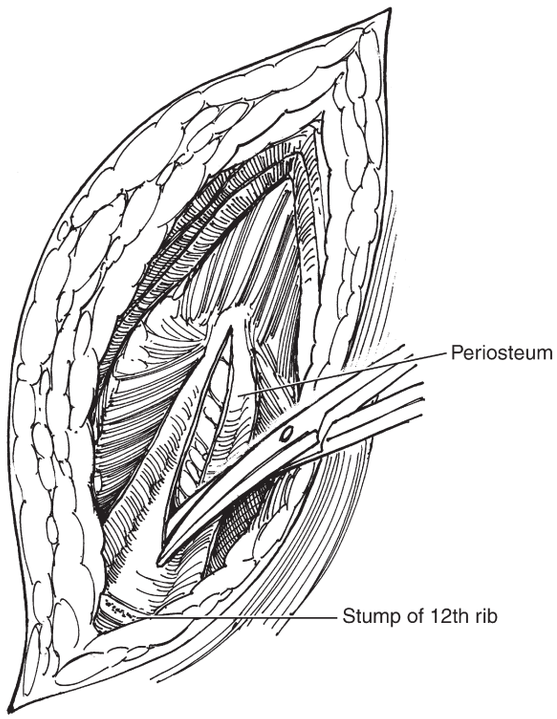

FIGURE 129-56.

bundle by palpating them and letting them move caudally. Watch out for a vessel joining the twelfth and eleventh bundles anteriorly.

Anterior to the rib tip, divide the external and internal oblique fascia and muscles with cautery. Separate the fibers of the transversus abdominis to the anterior end of the wound, which ends at the lateral border of the rectus abdominis (Fig. 129-57).

Identify the pleura posteriorly and gently dissect it from the endothoracic fascia beneath the eleventh rib, reflecting it superiorly (Fig. 129-58). Cut the attachments of the

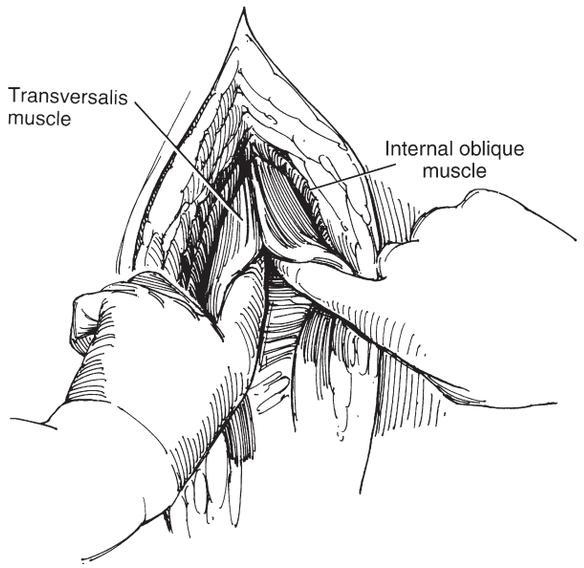

FIGURE 129-57.

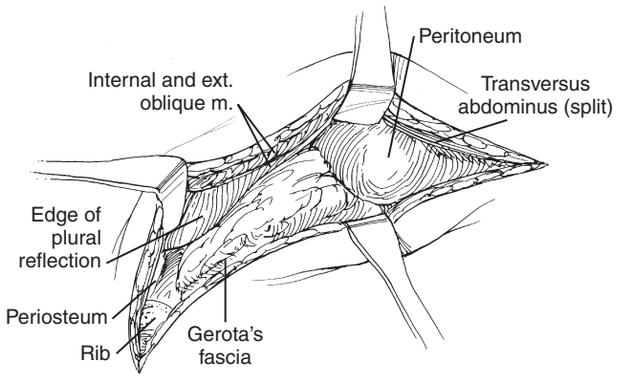

FIGURE 129-58.

diaphragm against the body wall with Metzenbaum scissors. Separate the diaphragm from the retroperitoneal connective tissue to allow its displacement superiorly. If a small pleural tear is made, it is best to repair it at the end of the procedure (see later). If it is not easily repaired, a small chest tube may be placed for 24 hours.

Free the peritoneum thoroughly by blunt dissection from the transversalis fascia on the undersurface of the abdominal wall, not only medially but superiorly and inferiorly as well. This facilitates placement of retractors and achieves optimal exposure.

Closure

Insert a Penrose drain through a separate stab wound well below the twelfth rib. The incised periosteum may be closed but it is not required. The abdomen may be closed in one or two layers, incorporating the external oblique and internal oblique with the transversalis fascia. Before tying the sutures, ask the anesthetist to lower the kidney rest and flatten the table. Close the external oblique along with the posterior inferior serratus muscles, and approximate the latissimus muscles with the same suture material. Approximate the subcutaneous tissue obliquely so that the caudal part of the wound does not sag posteriorly.

THORACOABDOMINAL INCISION

A thoracoabdominal incision is extremely useful for very large renal tumors with involvement of surrounding structures (spleen, pancreas, liver, colon) or extensive lymphadenopathy. When taken through the ninth rib, the renal hilum ends up right in the center of the incision, with outstanding exposure for difficult cases. For patients with a tumor thrombus in the inferior vena cava extending into or above the hepatic veins, this incision taken through the seventh or eighth rib on the right allows full access to the upper IVC above or below the diaphragm to facilitate obtaining vascular control. If access to the intraperitoneal contents is not required, this incision may also be approached completely extraperitoneally, handling the abdominal portion in the manner described for the modified thoracoabdominal hockey-stick incision.

Position: Place the patient flush with the ipsilateral (in this case, the right) side of the table, with the flank directly over the break in the table (Fig. 129-59). The opposite leg may be flexed 90 degrees at the knee under the ipsilateral leg, with a pillow between the legs. This raises the pelvis slightly on the ipsilateral side. Alternatively the down leg may be placed on a pillow. Rotate the upper torso slightly and support it with a rolled towel or sandbag. Place the upper arm across the chest onto a padded airplane support. Hyperextend the table, and hold the patient in position with wide strips of adhesive tape. Carefully pad all pressure points.

The incision is made over the bed of the ninth rib from the midaxillary line anteriorly to the midepigastrium, then down to the umbilicus or below as a midline or paramedian incision (Fig. 129-60). The latter is preferred if an extraperitoneal approach is planned, to decrease the risk of inadvertently entering the peritoneum. The choice of rib may be varied depending on the patient's pathology. The incision can also be extended across the midline to the contralateral costochondral junction if necessary. The latissimus dorsi, posterior inferior serratus, and external oblique muscles overlying the rib are incised with electrocautery (Fig. 129-61). The periosteum of the rib is incised down to the costal margin and a subperiosteal resection of the rib is performed as described above (transcostal incision). Alternatively, only a small segment of the rib can be excised posteriorly and the intercostal muscles divided above the remaining rib to the costal margin (Fig. 129-62). The pleural cavity is opened for the length of the incision and the cartilaginous costal margin is divided with straight scissors. A crossing artery is usually encountered just posterior to the costal margin, which must be cauterized or ligated.

The upper insertion of the rectus abdominis muscle is encircled with Army Navy retractors and divided with electrocautery, taking care to ligate or cauterize the superior epigastric vessels (Fig. 129-63). If an extraperitoneal approach is planned, the space between the peritoneum and the anterior abdominal wall can be identified just below the cut costal margin and the space developed bluntly before incising the abdominal wall muscles. The external oblique, internal oblique, and transverses abdominis muscles are incised between the costal margin and rectus. It is crucial to reflect the body of the rectus muscle laterally rather than medially to preserve its nerve supply.

If an extraperitoneal approach is planned, we sharply take down the attachments between the peritoneal envelope and the lower surface of the diaphragm all the way back to the central tendon of the diaphragm. This frees up the upper portion of the peritoneum with the liver or spleen inside and allows it to be reflected off of Gerota's fascia. The remaining peritoneum is dissected off of the anterior leaf of Gerota's fascia as described earlier.

Insert a self-retaining (Finochietto) retractor at the tip of the tenth rib, catching the ends of cartilage in its slots. The lower abdominal wall flap can also be retracted out of the way using a towel clamp on the corner of the cut rectus fascia, holding it laterally and inferiorly to the drapes with

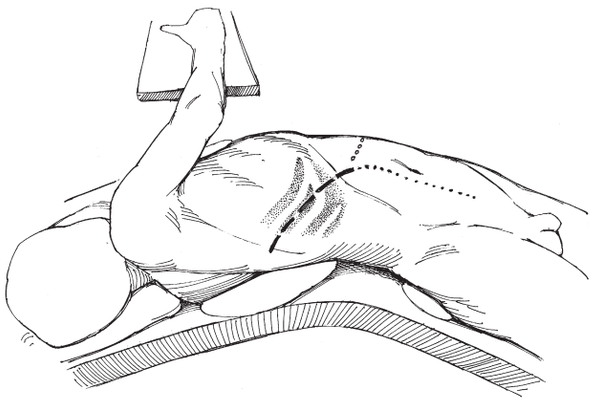

FIGURE 129-59.

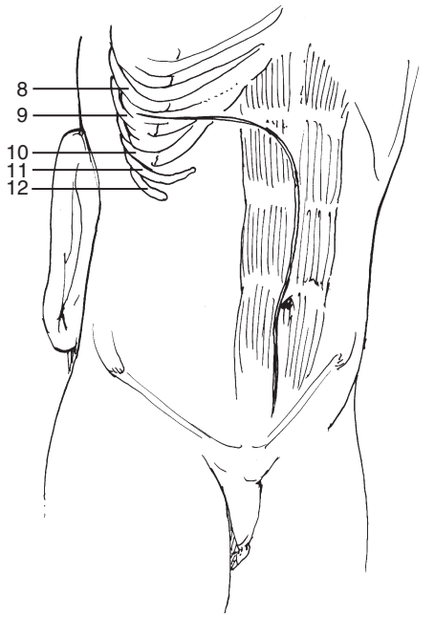

FIGURE 129-60.

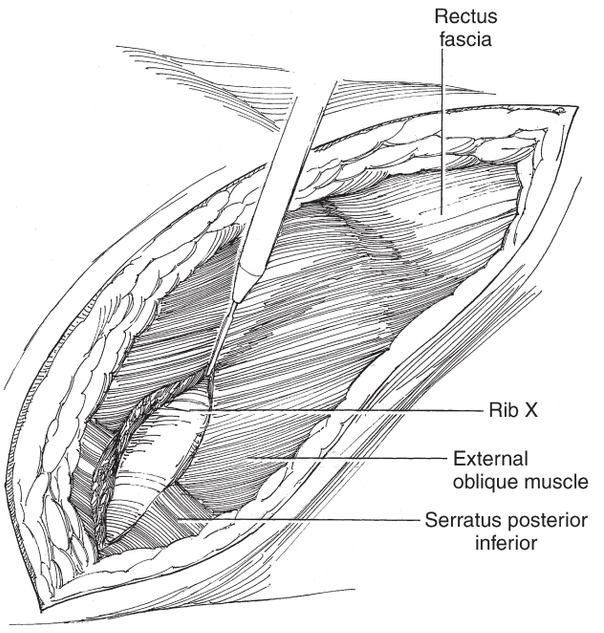

FIGURE 129-61.

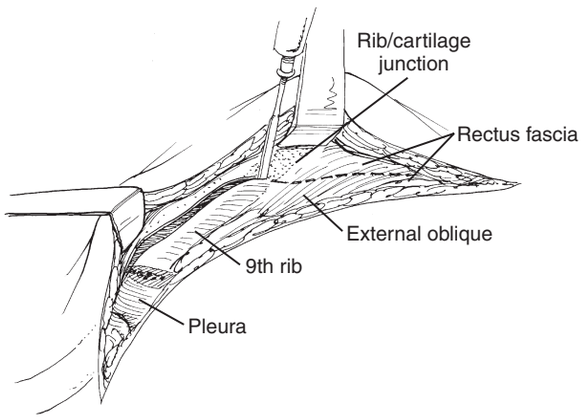

FIGURE 129-62.

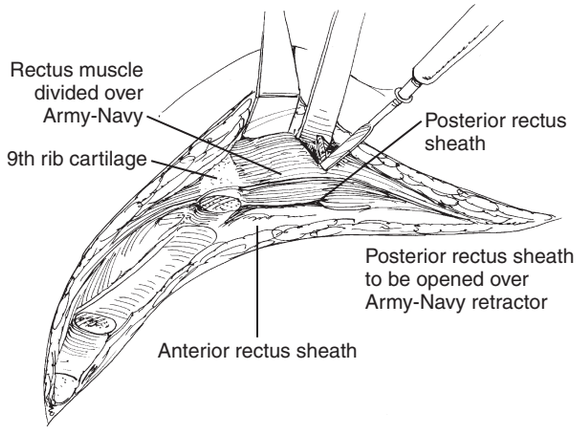

FIGURE 129-63.

another clamp. A large Buchwalter or similar retractor may also be used.

With an intraperitoneal approach, after opening the peritoneum, the right colon and small bowel mesentery are mobilized off of Gerota's fascia by incising the white line of Toldt lateral to the right colon (Fig. 129-64). Continue around the ileocolic area and up toward the aorta to the duodenum. The duodenum is Kocherized off of the great vessels. The right colon and small bowel are then placed into a bowel bag with a moist lap pad and placed up onto the chest.

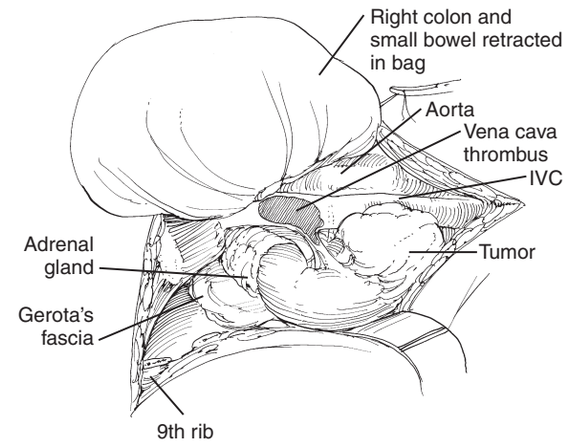

FIGURE 129-64.

Closure

If a drain is required it may be placed through a stab wound below the twelfth rib. After unflexing the table, the diaphragm should be closed in two layers with absorbable 1-0 running suture (Fig. 129-65). It is usually not possible to approximate the most medial edges of the diaphragm, and at that location the diaphragm should be incorporated into the chest closure to seal the pleural space. A small chest tube (20 French is adequate if there is no bleeding in the thoracic cavity) is placed over the top of the eighth rib and laid up along the lateral chest wall to the apex. Usually it can be removed the first postoperative day.

The costal margin should be carefully reapproximated using a horizontal mattress heavy permanent suture. A loose closure here will bother the patient as the edges move against each other. The repair can be reinforced with a strip of Marlex or Prolene mesh wrapped around the repaired costal junction. If a full rib resection is performed, we simply close the fascia of the external and internal oblique muscles over the top of the rib with interrupted permanent suture. If the rib has been dropped inferiorly, it can be reapproximated to the rib above with a few simple sutures of heavy nylon, taking care not to injure the intercostal nerves and vessels. The fascia of the external oblique can then be closed over the top of the ribs with a heavy absorbable running suture. The latter gives a better cosmetic result than the complete rib resection. The abdominal portion of the incision is closed in the usual manner with running or interrupted absorbable suture.

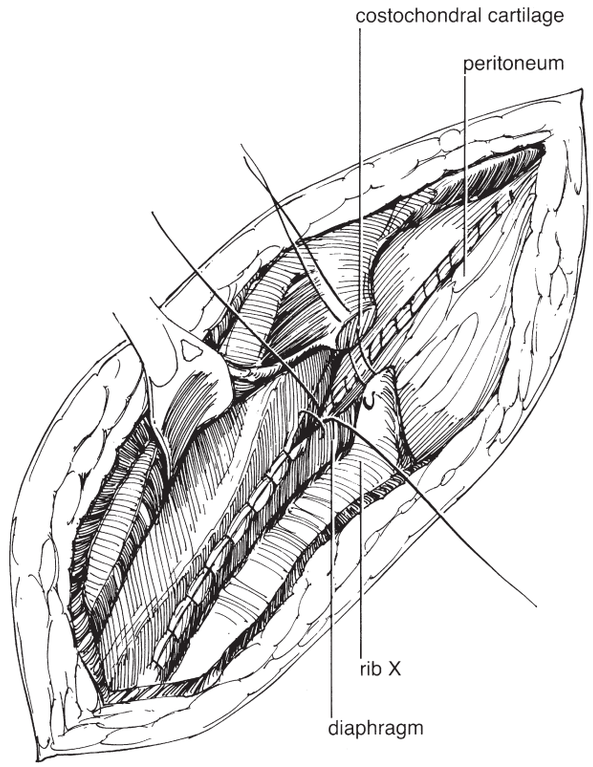

FIGURE 129-65.

REPAIR OF PLEURAL TEAR

If a pleural tear has been identified it is best repaired just prior to closing the incision. Have the anesthesiologist inflate the lung to identify the leak. Close the tear carefully with 4-0 absorbable suture down to a small hole. Insert a 12- or 14-French red Robinson catheter into the pleural space through the hole and encircle the catheter with the stitch. Tie a running 4-0 plain catgut suture beyond the anterior end of the pleural defect, continue it as a running suture around the catheter, and tie it beyond the end of the defect (Fig. 129-66). If the pleura is too flimsy, the diaphragm or intercostal muscle edge can be included in the repair.

Place the other end of the catheter under water, and have the anesthesiologist fully inflate the lung. Remove the catheter and quickly tie down the suture when no more bubbles appear (Fig. 129-67). The repair can be tested by filling the wound with water and having the anesthesiologist inflate the lung again to look for air bubbles. If the repair is unsuccessful intraoperatively or in cases of a large pleurotomy, it is safest to place a small chest tube to suction overnight.

If the postoperative chest film shows a small pneumoperitoneum, it can be observed and usually resolves spontaneously. A large symptomatic pneumoperitoneum can be managed by aspiration through the second interspace posteriorly while the patient is upright, or by placement of a small chest tube.

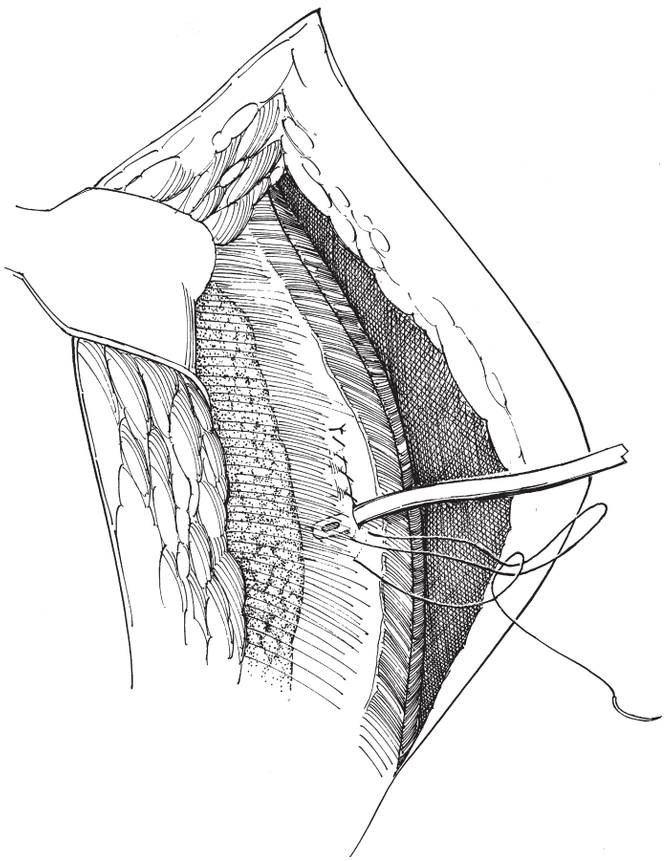

FIGURE 129-66.

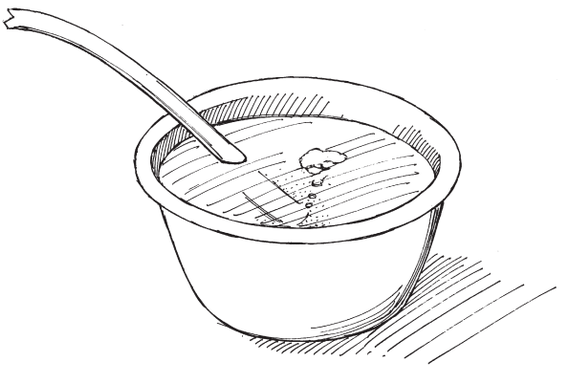

FIGURE 129-67.

SPLENORRHAPHY AND SPLENECTOMY

Splenorrhaphy After Intraoperative Injury

Injury of the spleen during an operation usually results from avulsion of the capsule by forcible retraction of the spleen away from the retroperitoneal surface, or by direct trauma to the spleen by a poorly placed retractor. The splenic capsule may also be torn by traction against the splenocolic and splenorenal ligaments. Care should be taken to avoid this injury because it usually results in significant, sometimes life-threatening blood loss, and removal of the spleen results in a lifelong susceptibility to infection.

Segmental splenectomy may be feasible because of the segmental distribution of the blood supply. It is the preferable alternative if the laceration itself cannot be repaired by splenorrhaphy.

Initial Control

Once an injury is identified start by covering the avulsed area with hemostatic gauze (e.g., Surgicel) and gentle pressure with a dry sponge or laparotomy pad. Avoid holding it with a retractor, which usually makes the tear worse or starts a new one. Fibrin sealants such as FloSeal are also sometimes helpful. If it is possible to control the bleeding with these agents, then the spleen can be left in place to complete the intended surgery, and the injury can be further repaired before closing.

If the bleeding is brisk and time is needed for repair, open the lesser sac and compress the tail of the pancreas over the splenic vessels by hand or with a padded noncrushing clamp. Mobilize the spleen by incising the lienorenal ligament to allow delivery of the spleen and tail of the pancreas into the wound. The splenic vessels are then readily compressed, and the splenic wound itself can be tamponaded and repaired under direct vision.

Splenorrhaphy

Repair of the spleen is similar to repair of renal lacerations. Carelessly placed sutures will tear through the flimsy splenic capsule and extend the injury. Place a horizontal mattress

3-0 SAS in the capsule 1 cm from the edge over hemostatic gauze bolsters. Bring the omentum over to cover the tear. Fix it in place with further mattress sutures (Fig. 129-68A).

To further reinforce the injury polyglycolic acid knitted mesh can be stretched over the spleen, sewing the edges of the mesh together (see Fig. 129-68B).

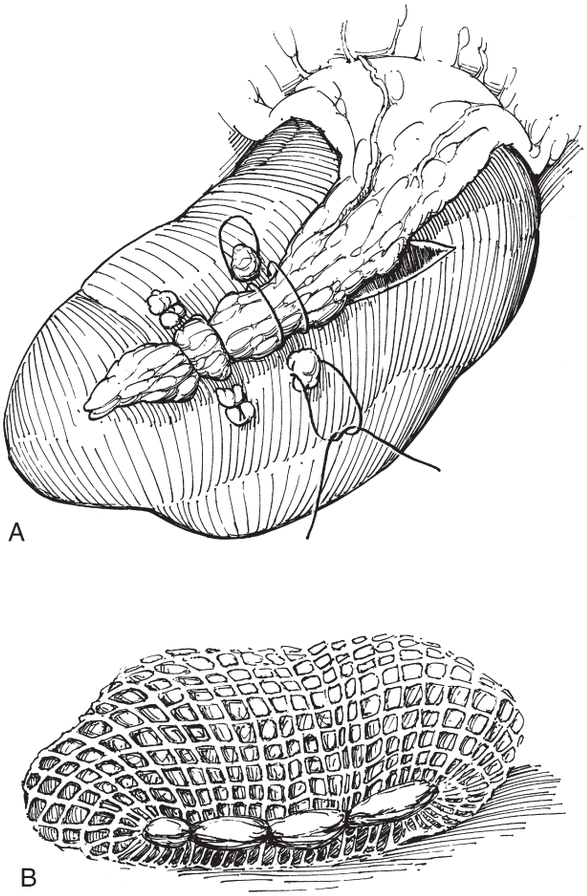

FIGURE 129-68.

Partial Splenectomy

The vasculature to the spleen, being somewhat like that of the kidney, allows segmental splenectomy (Fig. 129-69). Selective ligation is possible because the splenic artery, before it reaches the spleen, gives off a superior polar artery supplying the upper segment of the spleen. Near the hilus it divides again into two branches to the middle and lower polar segments. By preliminary ligation of one of these vessels, a segment of the spleen may be removed along a relatively avascular plane.

Isolate the main splenic artery, and encircle it with a vessel loop. Follow the artery to its main branch (to the upper pole) and into its two inferior divisions. Compress the appropriate vessel to find which one supplies the injured portion by observing immediate blanching there. Ligate and divide the selected artery.

Incise the capsule and divide the parenchyma with sharp and blunt dissection. Use a Frazier neurosurgical suction tip to help identify and clip the intrasplenic vessels. For dissection of the parenchyma, apply an argon-beam coagulator, although blunt dissection with hemostasis by pressure alone is usually adequate. Clip or ligate vessels as they are encountered. The arteries are obvious as they protrude from the parenchyma, where they can be damped and ligated. The veins lie flush with the surface and require figure-eight sutures. Control residual ooze with microfibrillar collagen. Place long mattress sutures in the edges of the capsule to occlude the parenchyma even if the capsule itself cannot be approximated. Drainage is not necessary.

Splenectomy

Removal of the spleen should be the last resort because the result is lifelong susceptibility to infection. If splenectomy is expected to be likely (for example with a large left upper pole renal mass) one should administer pneumococcal vaccine preoperatively to those older than 65 years. Any patient

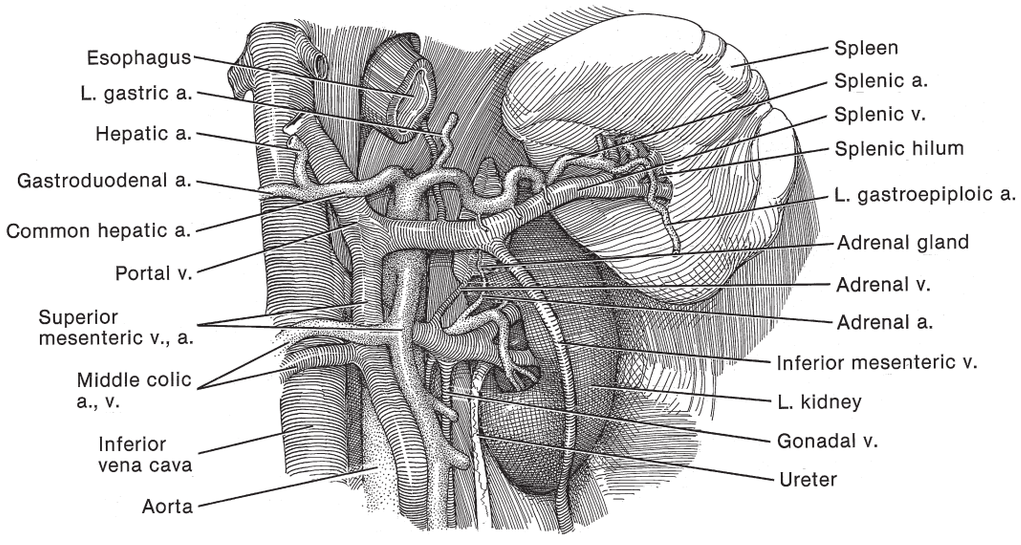

FIGURE 129-69.

undergoing unexpected splenectomy should receive the vaccine before leaving the hospital.

With the right hand, gently retract the greater omentum and transverse colon inferiorly (Fig. 129-70).

With the left hand, reach over the top of the spleen and rotate it anteriorly and medially. Incise the attachments to the lateral peritoneum, then those to the kidney (lienorenal ligament), diaphragm, and colon (splenocolic ligament) (Fig. 129-71).

Slide the left hand more laterally to hook the finger tips under the medial edge of the peritoneum that was just divided (Fig. 129-72). Avoid traction injury to the splenic capsule or vessels. Incise the posterior parietal peritoneum superiorly and inferiorly to the pancreas, and release the final attachments of the splenocolic and splenodiaphragmatic ligaments.

Identify the gastrosplenic ligament and the short gastric vessels where the spleen abuts the stomach. Be sure to work high on the greater curvature of the stomach in a caudad to cephalad direction to expose and avoid tearing the most cephalad short gastric vessels.

Lift the spleen with the left hand. Hold the tail of the pancreas out of the way with the left thumb and index finger during dissection of the vessels under direct vision (Fig. 129-73). Dissect the artery from the vein before it divides into its branches. Clamp and ligate the artery first; contraction of the spleen gives the patient a transfusion. Be sure not to clamp or ligate any part of the stomach.

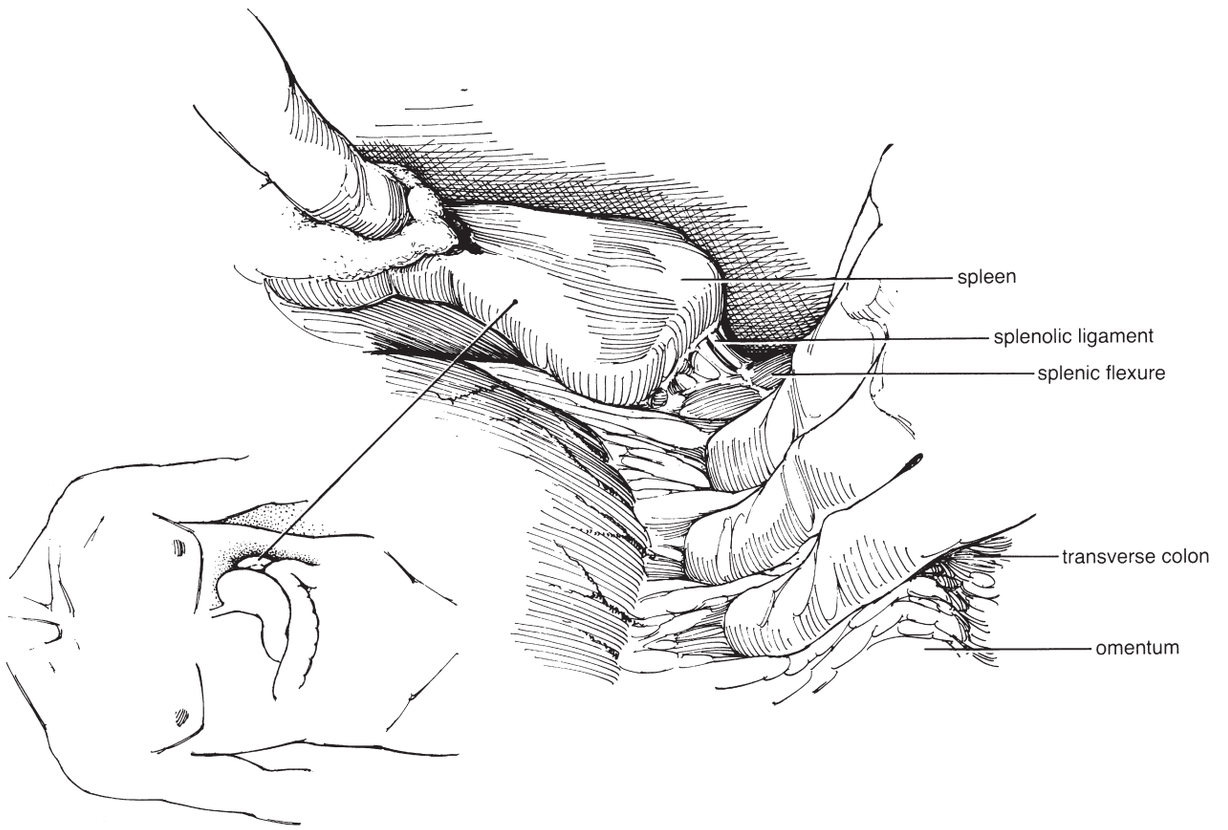

FIGURE 129-70.

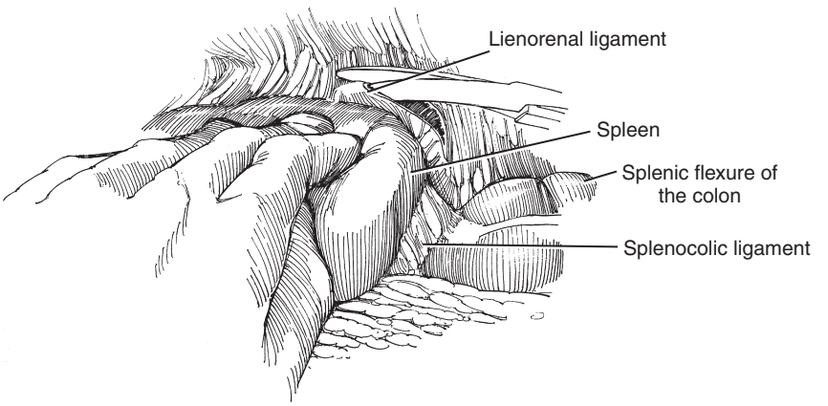

FIGURE 129-71.

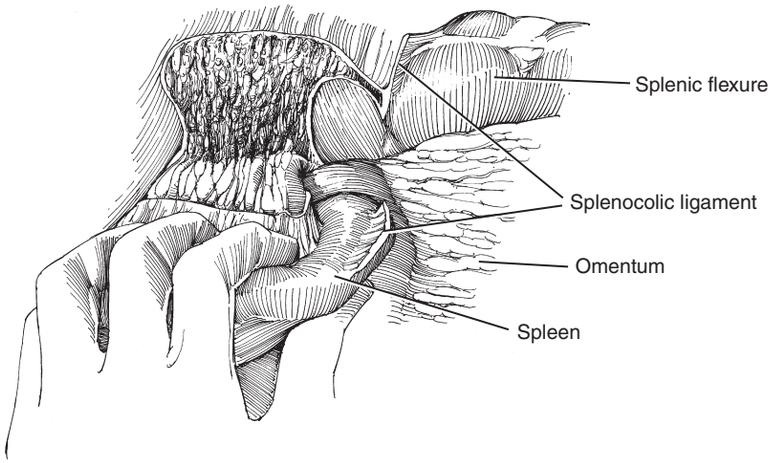

FIGURE 129-72.

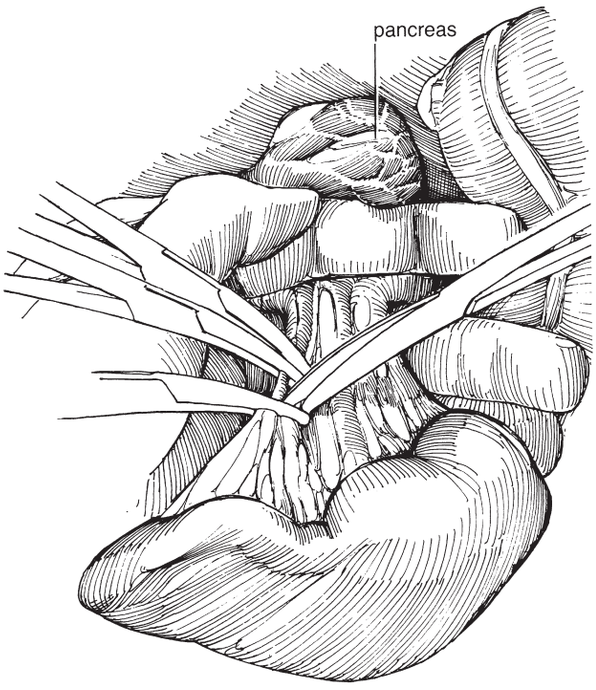

FIGURE 129-73.

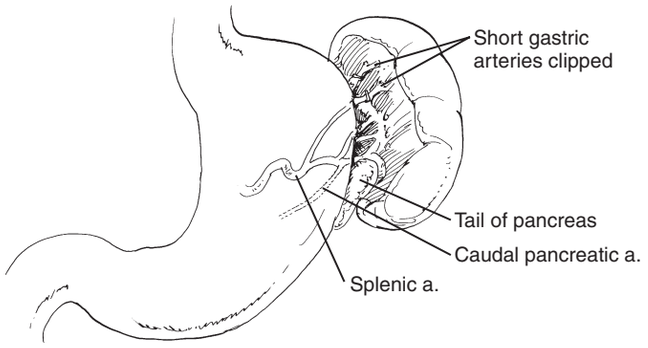

FIGURE 129-74.

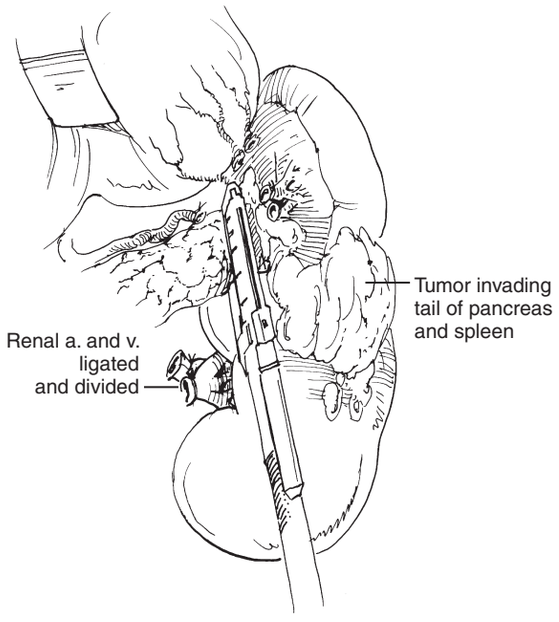

FIGURE 129-75.

The splenic vein pursues a tortuous course above the pancreas that allows it to be ligated at one of its anterior bends.

In patients with infiltrating upper pole renal tumors the tail of the pancreas and/or spleen may be involved with the tumor. In these cases first divide the short gastric arteries between the stomach and spleen (Fig. 129-74).

The pancreas may then be divided with a vascular endogastrointestinal stapler applied across the pancreas tail after individually ligating the splenic artery and vein (Fig. 129-75).

Postoperative Problems

If the pancreas has been divided or extensively manipulated it is wise to place a closed suction drain near the tail of the pancreas prior to closing. This drain is left in place until the patient is on a regular diet. The output can be tested for amylase to identify a potential pancreatic leak. All patients who undergo splenectomy should receive pneumococcal vaccine and perioperative antibiotics, and should be encouraged to obtain a Medic Alert bracelet.

REPAIR OF INCISIONAL HERNIA

Debility, perioperative deficiency of protein and vitamin C, wound infection, postoperative sepsis, vertical rather than transverse incisions, and excessive postoperative coughing are factors responsible for most postoperative incisional hernias.

Midline incisional hernias are generally true hernias. On the other hand, bulging of the flank after lateral incisions is more often denervation atrophy of the muscles of the ipsilateral body wall secondary to division of the subcostal nerve and rarely is an actual hernia in which the skin is lined only by peritoneum. Nevertheless, either one can be very uncomfortable for the patient. The risk of incarceration for flank hernias is very low.

The principles of hernia repair apply to both abdominal and flank hernias or defects. These include identification of strong surrounding fascia, reduction or resection of the hernia sac, closure with strong permanent suture without tension, and reinforcement when indicated with synthetic mesh fabric.

Flank hernias are difficult to repair because the defect may extend right up to the edge of the ribs or below to the iliac crest. These defects may ultimately be better repaired using a dual-sided mesh placed from inside using laparoscopic techniques.

Primary Repair

Position: Lateral or oblique, depending on the site of the hernia.

Incision: Make an elliptical incision, and excise the scar and excess skin (Fig. 129-76A). Alternatively the excess skin can be excised after the defect is repaired to ensure adequate closure.

Extend the incision through the subcutaneous layer circumferentially, exposing normal fascia and muscle layers around the defect (see Fig. 129-76B). Have your assistant elevate the wound edges with large rake retractors. Mobilize the fasciomuscular flaps, and define the margins of the defect. Do not open the hernia sac prematurely. Meticulous hemostasis is important.

Open the peritoneal sac, which comprises attenuated subcutaneous tissue and peritoneum (Fig. 129-77). Free the peritoneum from the intestinal contents if it is adherent. Trim the edges of the hernia sac until sound fascia and muscle layers are reached.

Imbricate the fascia in a vest-over-pants technique with heavy permanent suture placed as interrupted mattress stitches. Do this by entering the upper fascia 2 or 3 cm from its edge and then passing the suture through the lower fascia 1 cm from its edge. Exit from the lower flap 1 cm lateral to the site of entry; then exit from the upper flap 1 cm lateral to the original site of entry (Fig. 129-78). Clamp the ends of the suture. Repeat these stitches 1 cm apart for the length of the defect. Tie them sequentially while your assistant keeps tension on the remainder.

Run a heavy SAS under the flap just below the first row of sutures (Fig. 129-79). Take care not to go through the fascia and involve the underlying bowel in the stitch.

Place a row of interrupted figure-eight sutures of heavy synthetic absorbable material between the upper flap and the adjacent lower (posterior) flap (Fig. 129-80). Insert two suction drains in the subcutaneous space, but do not place sutures there in an attempt to close another layer. Close the skin with interrupted or subcuticular sutures.

Augmented Repair of Large Defects Using Synthetic Materials

Proceed as previously described, clearing the fascial surfaces of fat. If possible, close the peritoneum separately with 3-0 or 4-0 SAS. Cut to the necessary shape a piece of polypropylene mesh large enough to overlap the edges of the defect by 3 to 4 cm. While preparing for the closure, the mesh is soaked in antibiotic solution.

The mesh is first sewn along one edge of the defect at least 2 cm away from the fascial edge, using a running heavy permanent suture. A set of interrupted sutures of the same material are placed on the second side and tagged. These are placed before closing the fascia to ensure that

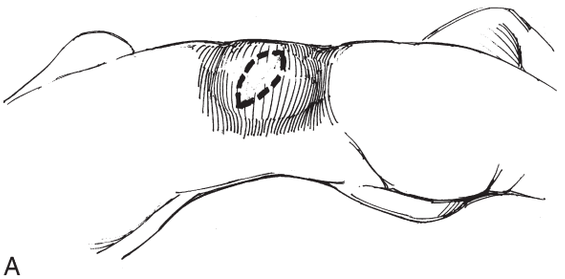
A

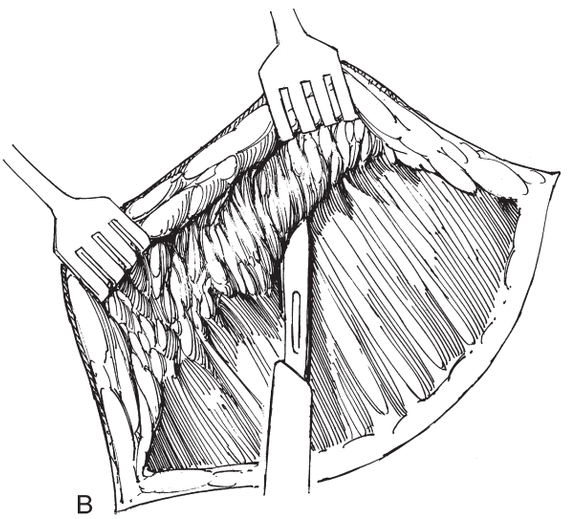
B

FIGURE 129-76.

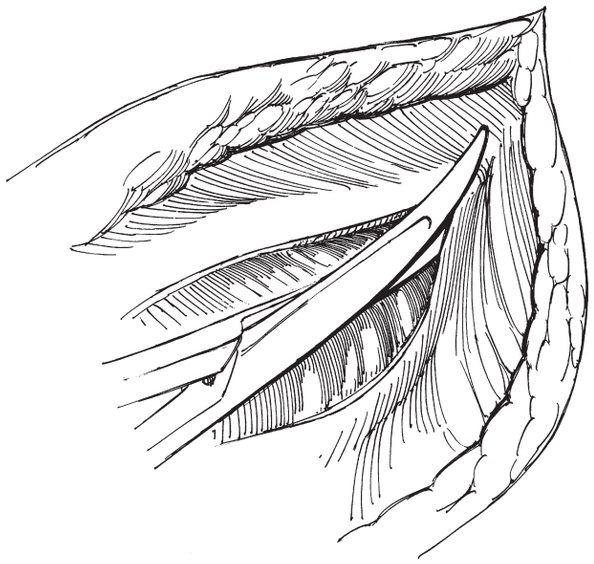

FIGURE 129-77.

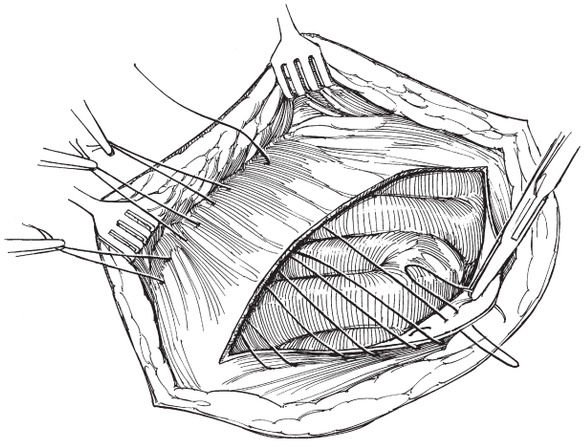

FIGURE 129-78.

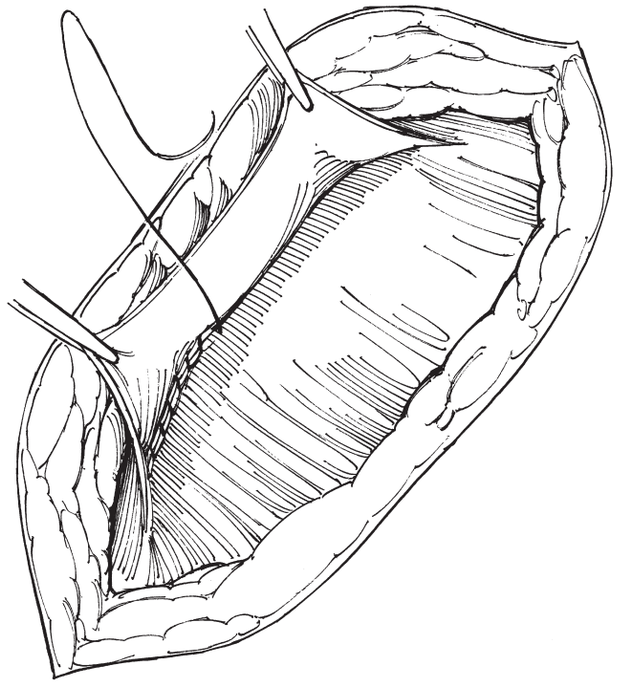

FIGURE 129-79.

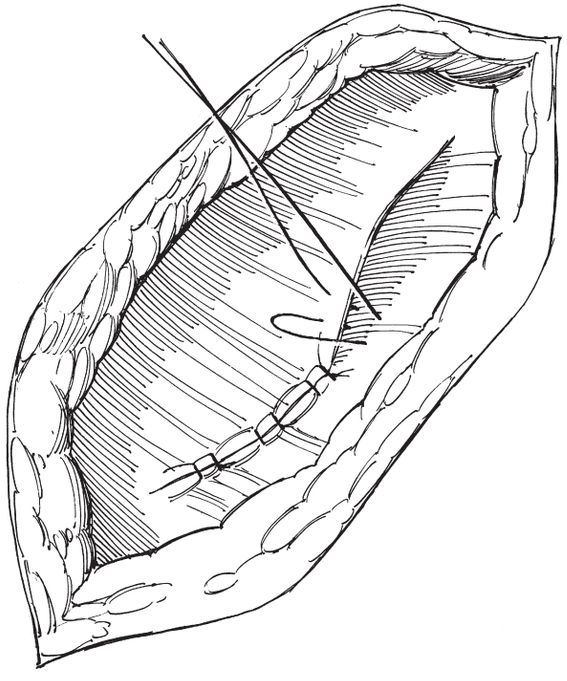

FIGURE 129-80.

through-and-through bites of the fascia are obtained without risk to intraabdominal injury.

The fascia is then closed primarily if possible with interrupted heavy permanent suture. Finally the mesh is brought over the top and the previously placed interrupted sutures are used to tack the mesh on the opposite side (Fig. 129-81). A subcutaneous closed suction drain should be placed over the mesh to decrease the risk of seroma.

Postoperative Problems

Infection is the greatest concern, especially if synthetic materials have been placed. It must be treated aggressively and is facilitated by opening the skin and applying a continuous suction device (Wound Vac). However, removal of the mesh may be necessary. *Recurrence* of the hernia is not as common as persistent bulging of the area—patients should be warned that it is not usually possible to make the affected side completely symmetrical with the other side.

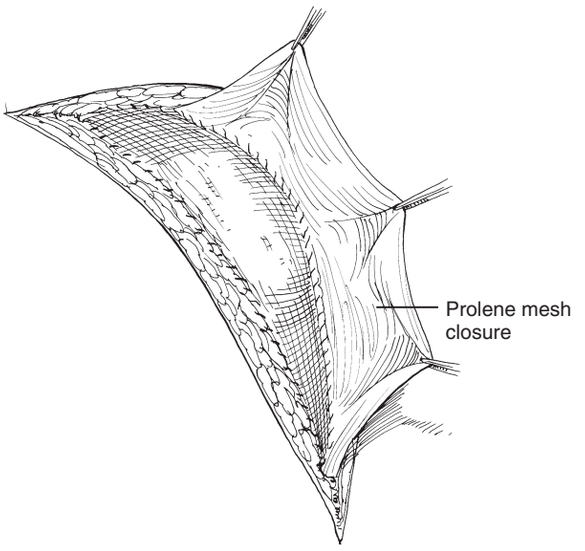

FIGURE 129-81.

Section XX

SURGICAL APPROACHES TO THE KIDNEY

Endoscopic Renal Surgery

This page intentionally left blank

Chapter 130

Anatomical Basis for Renal Endoscopy

FRANCISCO J. B. SAMPAIO

PELVIOCALYCEAL SYSTEM: ENDOUROLOGICAL IMPLICATIONS

Anatomical Background

To assist endourologists in making a mental image of the collecting system in three dimensions and learning the exact spatial position of the calices, before obtaining pelviocalyceal system corrosion endocasts, an iodinated contrast material was injected into the ureter to opacify the collecting system in order to obtain a pyelogram. After radiography, the contrast material was removed and the collecting system was filled with a polyester resin to obtain a three-dimensional endocast. These kidneys enabled a comparative study between the radiographic images and their corresponding three-dimensional endocasts.

Findings and Clinical Implications

The comparative study between pyelograms and three-dimensional endocasts of the collecting system enabled a perception of some remarkable anatomical aspects of the kidney collecting system that are very important to be considered by endourologists during the endourologic procedures.

Presence of Perpendicular Minor Calices

When a stone is located in a perpendicular minor calyx (Fig. 130-1), its removal presents additional difficulties for both shock wave lithotripsy (SWL) and percutaneous nephrolithotripsy (PNL). Patients with stones in such calices are not good candidates for SWL because these calices invariably present narrow infundibula (smaller than 4 mm in diameter); therefore the discharge of the disintegrated stone fragments will be difficult. Regarding the percutaneous removal, direct access into the calyx containing the stone is an easy approach; nevertheless it involves a puncture performed without considering the arterial and venous anatomical relationships to the collecting system. This kind of puncture carries a great risk of injuring a vascular structure. Therefore, in cases of stone in such calices, a variety of safe and refined accesses, techniques, and instruments should be used.

Position of the Calices Relative to the Lateral Kidney Margin

Because the place of choice to access the collecting system is through a posterior calyx, much effort has been dispensed in an attempt to determine preoperatively which calices are anterior and which calices are posterior. To solve this problem quickly and inexpensively, during endourological procedures, with the patient in the prone position, injection of room air into the collecting system will rise to the more posterior portions of the collecting system, determining which calices are placed posteriorly (radiolucent contrast).

Position of the Calices Relative to the Polar Regions and to the Kidney Midzone

The superior pole was drained by a midline calyceal infundibulum in 98.6% of the cases (Fig. 130-2). The midzone (hilar) was drained by paired calices that were arranged in two rows (anterior and posterior) in 95.7% of the cases (see Fig. 130-2). The inferior pole was drained by paired calices arranged in two rows in 81 casts (57.9%) (see Fig. 130-2A) and by a single midline calyceal infundibulum in 59 casts (42.1%) (see Fig. 130-2B).

Concerning the calyceal drainage of the kidney polar regions, many investigators affirmed that there usually is only one calyceal infundibulum draining each pole. In our study the superior pole was drained by only one midline calyceal infundibulum in 98.6% of the cases. However, the inferior pole was drained by paired calices arranged in two rows in 81 of 140 cases (57.9%) and by one midline calyceal infundibulum in 59 cases (42.1%) (see Fig. 130-2). These results are important to endourology; it will be easier to access endoscopically a polar region drained by a single infundibulum, which usually has suitable diameter, rather than a polar region drained by paired calices (see Fig. 130-2). Because the inferior

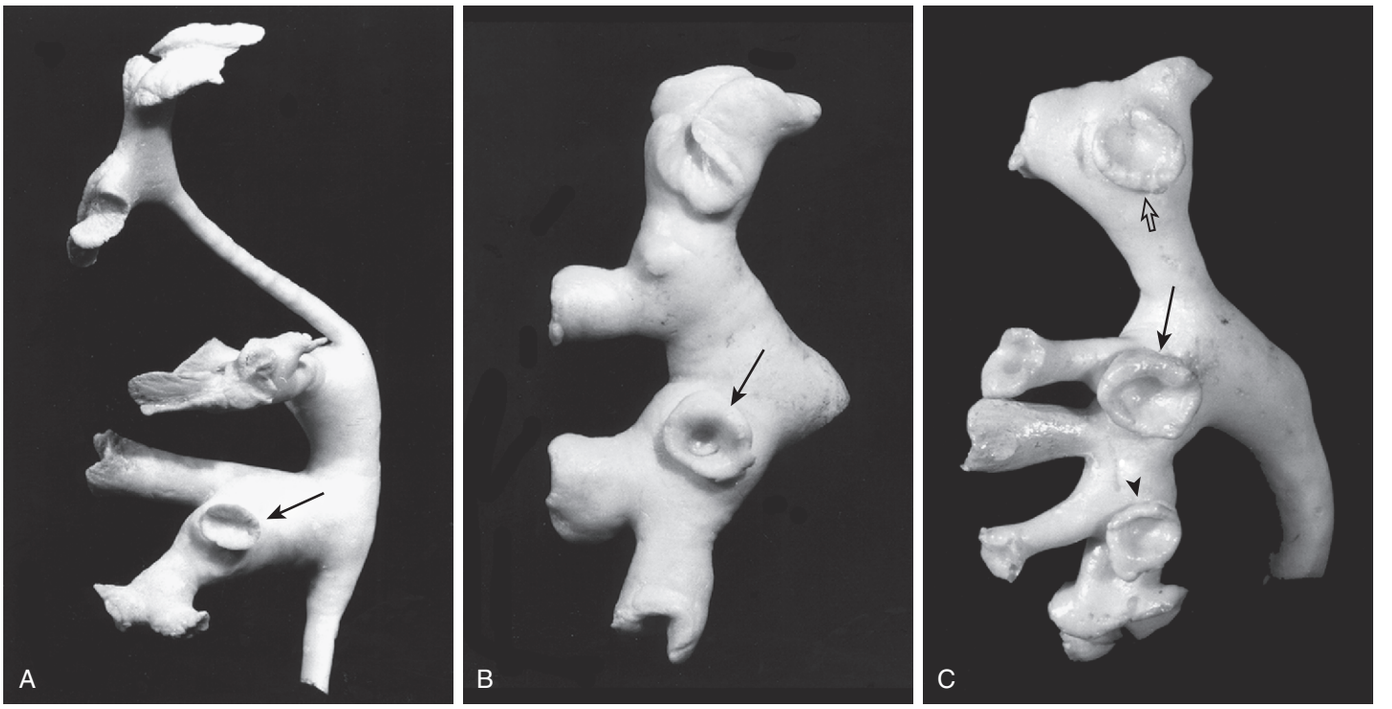

FIGURE 130-1. A, Anterior view of right pelviocalyceal endocast reveals perpendicular minor calyx draining into the inferior calyceal group *(arrow)*. **B,** Anterior view of right pelviocalyceal endocast reveals perpendicular minor calyx draining into the inferior calyceal group *(arrow)* very close to the renal pelvis. **C,** Anterior view of right pelviocalyceal endocast reveals perpendicular minor calyx draining into the renal pelvis *(arrow)*. This cast also shows a perpendicular minor calyx draining into the superior calyceal group *(open arrow)* and a perpendicular minor calyx draining into the inferior calyceal group *(arrowhead)*.

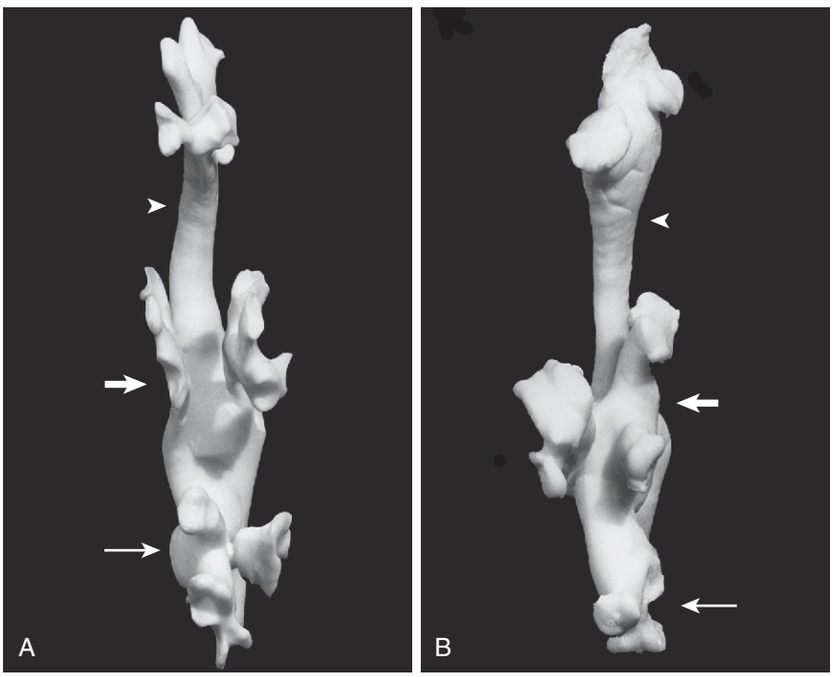

FIGURE 130-2. Position of calices related to the polar regions and kidney midzone. **A,** Lateral view of a left pelviocalyceal cast. The superior pole is drained by a single midline calyceal infundibulum *(arrowhead)*. The midzone (hilar) is drained by paired calices arranged in two rows *(short arrow)*; anterior and posterior. The inferior pole is drained by paired calices arranged in two rows *(long arrow)*. **B,** Lateral view of a right pelviocalyceal cast. The superior pole is drained by a single midline calyceal infundibulum *(arrowhead)*. The midzone is drained by paired calices arranged in two rows *(short arrow)*, anterior and posterior. The inferior pole is drained by only one midline calyceal infundibulum *(long arrow)*.

pole is drained by paired calices in 57.9% of the cases, one must keep in mind this anatomical detail, both to plan and perform the intrarenal access and the endoscopic procedures in the inferior pole. The calyceal drainage of superior and inferior poles is also of utmost importance in SWL and was fully discussed in previous papers.

Concerning the kidney midzone (hilar) drainage, our results show that this region is drained by paired calices arranged in two rows (anterior and posterior) in 95.7% of the cases (see Fig. 130-2). These results should also be retained by endourologists to access and work in the midkidney.

ANATOMICAL RELATIONSHIPS OF INTRARENAL VESSELS (ARTERIES AND VEINS) WITH THE KIDNEY COLLECTING SYSTEM

Relevance for the Intrarenal Access by Puncture

One of the most significant complications during percutaneous renal procedures is vascular injury. Therefore an anatomical depiction of refined details concerning intrarenal vessels and their relationships to the collecting system should better allow safe percutaneous intrarenal access by keeping as many renal vessels as possible intact during puncture.

Material Studied for the Anatomical Background

Studies included retrograde pyelograms and the corresponding three-dimensional polyester resin corrosion endocasts of the kidney collecting system together with the intrarenal arteries and veins obtained from fresh cadavers.

The kidneys were punctured under fluoroscopic guidance and the endocasts obtained with the needles positioned in the place of puncture (Fig. 130-3). For comparative analysis, we studied kidneys that had been punctured through a calyceal infundibulum and kidneys punctured through a calyceal fornix.

Intrarenal Access Through an Infundibulum

Superior pole. Puncture is most dangerous through the upper pole infundibulum because this region is surrounded almost completely by large vessels (Fig. 130-4). Infundibular arteries and veins course parallel to the anterior and posterior aspects of the upper pole infundibulum. In our series, injury to an interlobar (infundibular) vessel was a common consequence of puncturing the upper-pole infundibulum (67% of kidneys) (Fig. 130-5); the injured vessel was an artery in 26% of those cases.

The most serious vascular accident in upper infundibulum puncture is a lesion of the posterior segmental artery (retropelvic artery). This event may occur because this artery crossed and is related to the posterior surface of the upper infundibulum in 57% of the cases (Fig. 130-6A). Figures 130-6B and C show an upper infundibulum puncture in which the needle tract produced complete laceration of the posterior segmental artery. Because the posterior segmental artery (retropelvic artery) may supply up to 50% of the renal parenchyma, injury to it may result in significant loss of functioning renal tissue, in addition to causing hemorrhage.

Middle kidney. Intrarenal access through the midkidney infundibulum produced arterial lesion in 23% of kidneys studied. The middle branch of the posterior segmental artery was injured more often than any other vessel.

Inferior pole. The posterior aspect of the lower-pole infundibulum is widely presumed by endourologists and

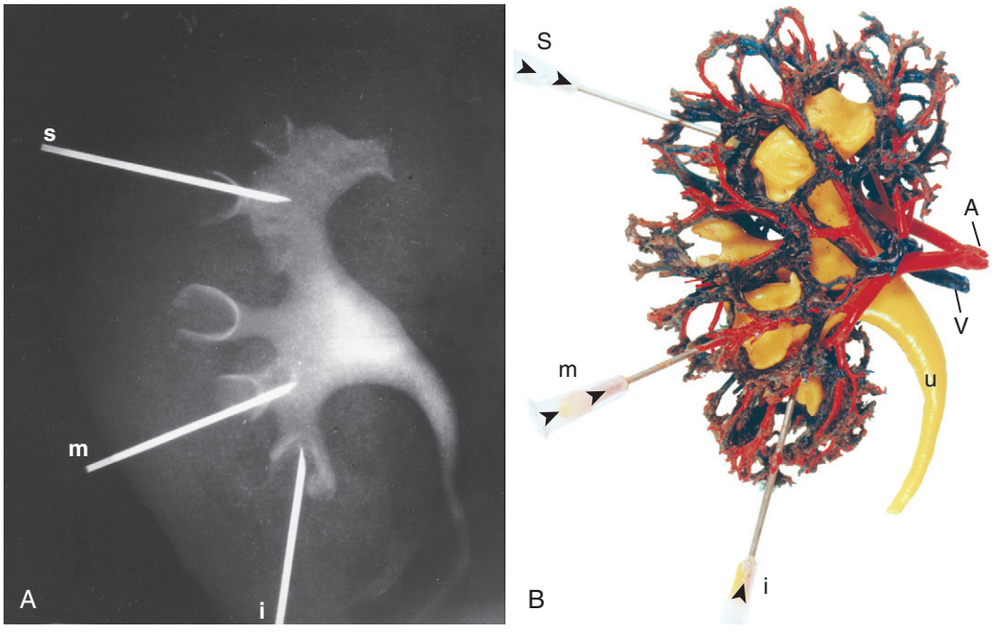

FIGURE 130-3. A, Anterior view of a retrograde pyelogram from a right kidney shows superior pole (s), midkidney (m), and inferior pole (i) punctures. These punctures were performed after polyester resin injections into the arterial and venous systems, while the resins were still in the gel state. Note that the injected resins are not opaque to x-rays. **B,** Anterior view of the corresponding corrosion endocast obtained after contrast removal and pelviocalyceal system injection with resin. The needles are maintained in their original places. s, superior pole puncture; m, midkidney puncture; i, inferior pole puncture. The arrowheads point out the tracts of the needles. A, renal artery; V, renal vein; u, ureter.

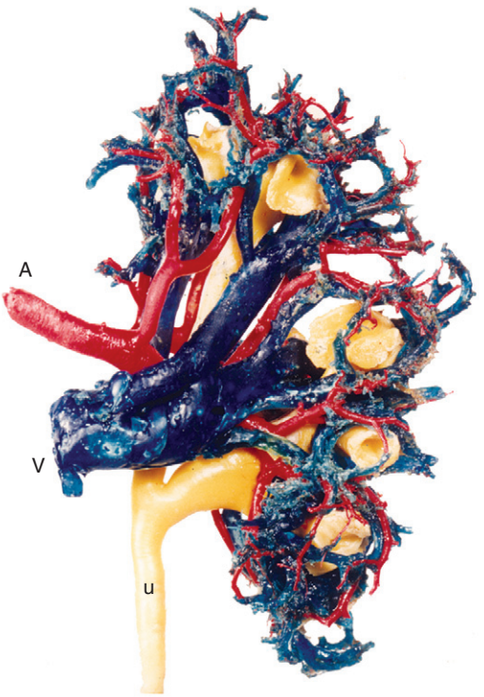

FIGURE 130-4. Oblique medial view of an endocast of arterial (A), venous (V), and pelviocalyceal systems from a left kidney reveals the upper infundibulum almost completely encircled by infundibular arteries and veins. This anatomic arrangement makes the upper pole infundibular puncture especially dangerous. u = ureter.

interventional radiologists to be free of arteries. It is considered, therefore, to be a safe region through which to gain access to the collecting system and to place a nephrostomy tube. In about 38% of the kidneys examined, however, an infundibular artery is found in this region. Thus significant complications may develop as a consequence of a posterior approach through the supposedly vessel-free lower infundibulum. In fact, we found an arterial injury in 13% of kidneys in which we had made a puncture through the lower pole infundibulum.

Concerning the veins, in many kidneys that we studied, we found large venous anastomoses—similar to collars—around the calyceal infundibula (the so-called calyceal necks). Puncture through the lower pole infundibulum therefore also risks injury to a venous arcade. A venous lesion usually heals spontaneously, but consequent hemorrhage may be cumbersome during the procedure.

Our findings clearly demonstrate that percutaneous nephrostomy through an infundibulum of a calyx is not a safe route, because this type of access poses an important risk of significant bleeding from interlobar (infundibular) vessels.

Infundibular puncture also creates the hazard of through-and-through (two-wall) puncture of the collecting system (see Fig. 130-5). Because major segmental branches of the renal artery, as well as major tributaries of the renal vein, are positioned on the anterior surface of the renal pelvis, marked hemorrhage may occur as a result of an anterior through-and-through perforation. In addition, effective tamponade of anterior vessels that have been

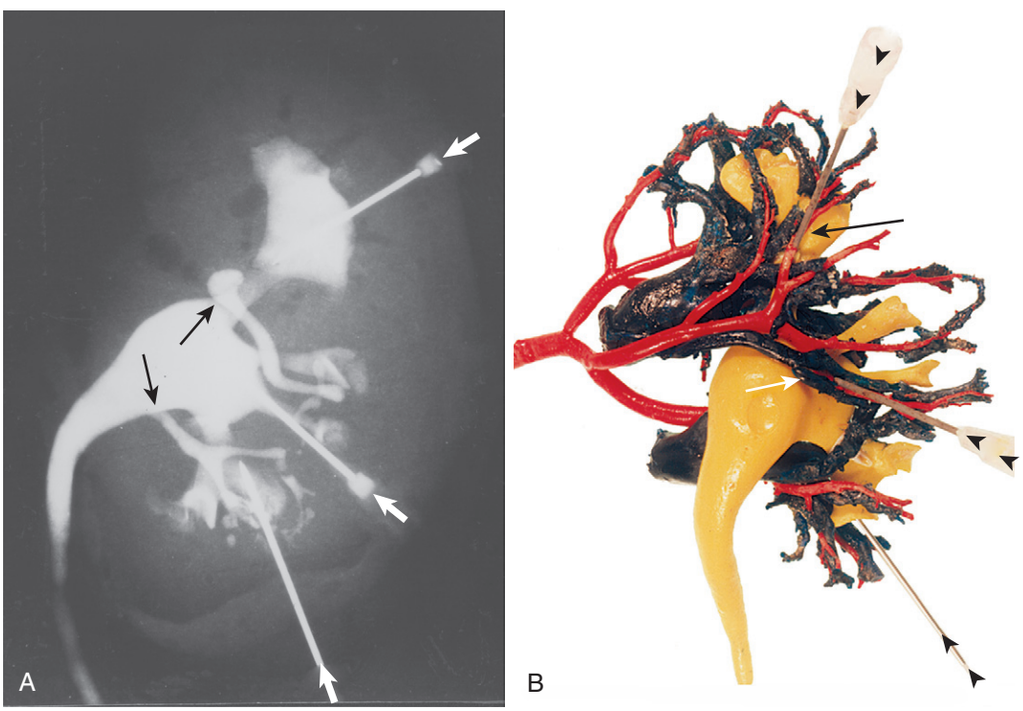

FIGURE 130-5. A, Posterior view of a retrograde pyelogram from a right kidney reveals superior, middle, and inferior punctures *(short arrows)* and the contrast material in the superior and inferior infundibular arteries *(black arrows)*. **B,** Posterior view of the corresponding endocast reveals injury to an upper infundibular artery *(black arrow)*. The midkidney puncture *(white arrow)* was a through-and-through (two walls) puncture and injured an anterior segmental artery. The injured vessel furnished the posteroinferior branch filled with contrast on the pyelogram. The arrowheads point out the tracts of the needles.

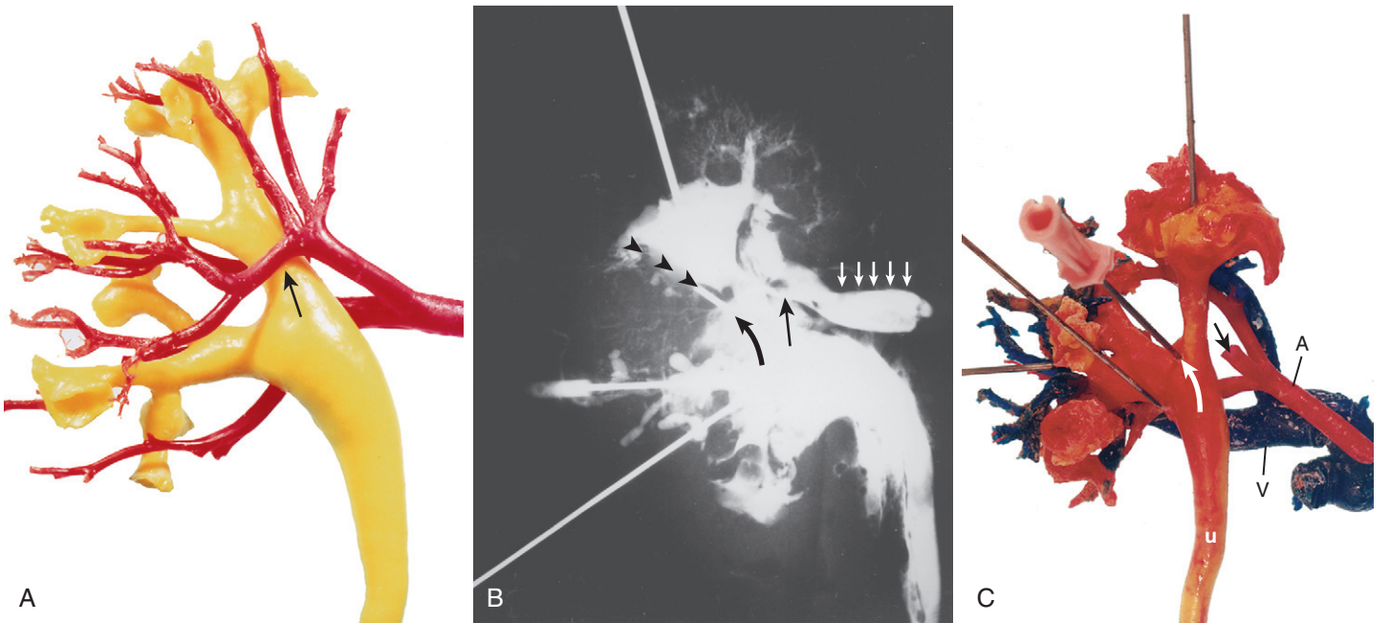

FIGURE 130-6. A, Posterior view of endocast (pelviocalyceal system and arteries) from a left kidney shows the posterior segmental artery (retropelvic artery) describing an arc and contacting the upper infundibulum *(arrow)*. **B,** Posterior view of a retrograde pyelogram from a left kidney shows contrast medium extravasation and contrast material in the arterial system and in the main trunk of the renal artery *(short arrows)*. The retropelvic artery was injured by the needle pointed by the arrowheads. The curved arrow shows the lesion site. Straight arrow points the retropelvic artery filled with contrast medium extravasated from the collecting system. **C,** Posterior view of the corresponding endocast reveals the retropelvic artery divided *(straight arrow)* and the needle responsible for the lesion (pink needle). The curved-arrow reveals the lesion site. A, renal artery; V, renal vein; u, ureter.

injured is difficult because they lie distantly in the nephrostomy tract.

Although the infundibular access is feasible in some circumstances and must be considered in specific situations (some difficult anatomical cases, for example), the surgeon must evaluate the risk of an arterial lesion, primarily in the superior pole and in the midkidney.

Intrarenal Access through the Renal Pelvis

Direct puncture of the renal pelvis for endourologic surgery should be excluded. Besides the fact that the nephrostomy tube inserted at this site is easily dislodged and difficult to reintroduce during the operative maneuvers, renal pelvis puncture has a prohibitive and unnecessary risk of injuring a retropelvic vessel (artery and/or vein).

Intrarenal Access Through a Calyceal Fornix

When we made a puncture through a fornix of a calyx, venous injury occurred in fewer than 8% of the kidneys. These injuries occurred indiscriminately, in the upper pole, midkidney, and lower pole calices. We did not detect any arterial lesions as a consequence of a forniceal puncture.

In conclusion, the high rate of vascular injury and the possibility of associated complications mean that a nephrostomy tube should not be placed through an infundibulum of a calyx (see Fig. 130-4). On the other hand, and regardless of the region of the kidney, puncture and placement of a nephrostomy tube through a fornix of a calyx is safe and must be the site chosen by the operator. Even in the superior pole, the intrarenal puncture through a calyceal fornix is harmless (Fig. 130-7A). In addition, when puncturing through a fornix of a calyx, in case of lesion, the injury was always to a periphery vessel, such as a small venous arcade (see Fig. 130-7B).

Relevance for Endopyelotomy

Since its clinical introduction, the endoscopic treatment of ureteropelvic junction (UPJ) obstruction—endopyelotomy—has almost completely replaced open pyeloplasty for the treatment of UPJ obstruction. It has a comparable success rate of the open surgery and is applicable to congenital and acquired conditions. Endopyelotomy has become a common procedure for both primary and secondary UPJ obstruction. Despite the recent great success rate of laparoscopic pyeloplasty, endopyelotomy continues to be more commonly performed in academic centers.

Because endopyelotomy is based on an intubated pyeloplasty (ureteropelvic incision followed by stenting for 1 to 6 weeks), to achieve success the endoscopist must incise the full thickness of the muscle at the stenotic wall of the UPJ until periureteral fat becomes visible. This deep incision must be carried out whether the approach is through a nephrostomy tract, by ureteroscopy or with an Acucise

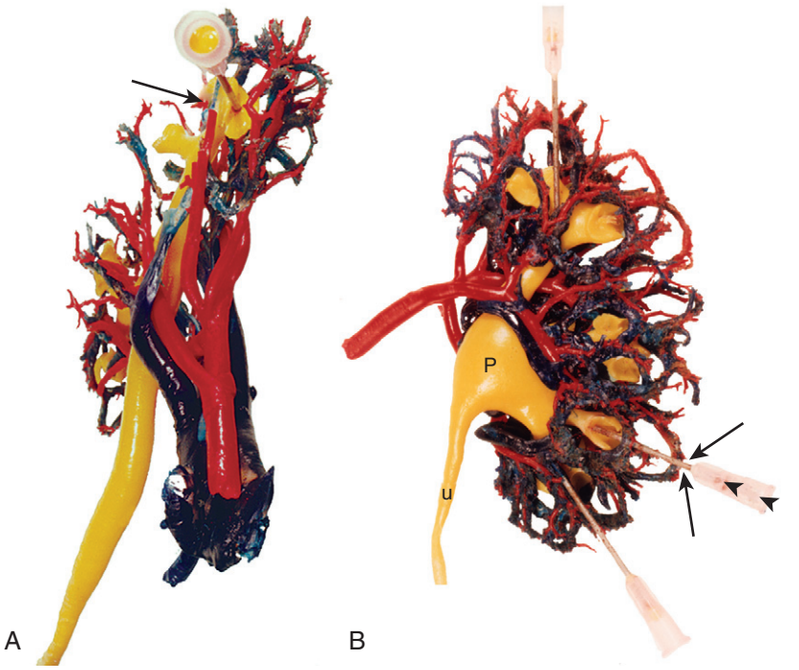

FIGURE 130-7. A, Superior view of an endocast from a left kidney shows that, even in the superior pole, a puncture through the fornix of a calyx *(arrow)* is safe. **B,** Posterior view of an endocast from a right kidney and an inferior puncture performed through a fornix of a calyx. The arrows show a lesion to a small peripheric venous arcade. The arrowheads demonstrate the needle tract. P, renal pelvis; u, ureter.

catheter, and whether the instrument used to incise the stricture is a cold knife or an electrosurgical probe.

Incising the UPJ until the perirenal space is entered obviously carries the risk of injuring a retroperitoneal vessel. In fact, the most significant complication of this procedure is vascular injury that is followed by severe hemorrhage and/or formation of an arteriovenous fistula. To protect the arteries from the lesion, it has been recommended to examine via intrarenal endoscopy the area to be incised for any arterial pulsation and to avoid incising this site. Nevertheless, arterial pulsations are not always readily identifiable endoscopically during surgery, mainly because patients may be hypotensive due to anesthesia. In addition, because the veins do not pulsate, endoscopic examination of the area to be incised is not effective in avoiding a venous lesion.

The risk of injuring a large vessel during endopyelotomy can be greatly reduced or even eliminated if the endourologist understands and keeps in mind the three-dimensional vascular relationships to the UPJ. This item provides background on the vascular anatomy of the UPJ to be applied in performing endopyelotomy safely and efficiently.

Vascular Background

We analyzed 146 three-dimensional, polyester resin corrosion endocasts of the pelviocalyceal system, together with the intrarenal arteries and veins simultaneously in the same kidney.

Anterior Vascular Ureteropelvic Junction Relationships

In 65% of the cases, there was a prominent artery, or vein, or both vessels in close relationship with the ventral surface of the UPJ (Fig. 130-8). Among these cases, in 45% the relationship was with the inferior segmental artery (see Fig. 130-8C).

Concerning patient selection for treatment of UPJ obstruction, it remains controversial whether it is important to diagnose anterior crossing vessels. Van Cangh and colleagues obtained preoperative digital angiography in patients before endopyelotomy and found an associated vessel in 39% of patients with UPJ obstruction. These authors stated that the presence of an anterior crossing vessel with either mild or severe hydronephrosis resulted in a success rate of only 50% and 39%, respectively. More recently, Van Cangh and colleagues stated that significant risk factors for endopyelotomy failure are crossing vessels, degree of hydronephrosis, length of stricture, and renal function. Rehman and colleagues emphasized the importance of spiral computed tomography (CT) angiography for delineating the renal vascular anatomy before open retroperitoneal UPJ obstruction repair. They described two patients with repair failure of UPJ obstruction in whom anterior vessels were missed during open retroperitoneal surgery. Laparoscopic transperitoneal secondary dismembered pyeloplasty with posterior displacement of the crossing vessel was successfully performed in each case.

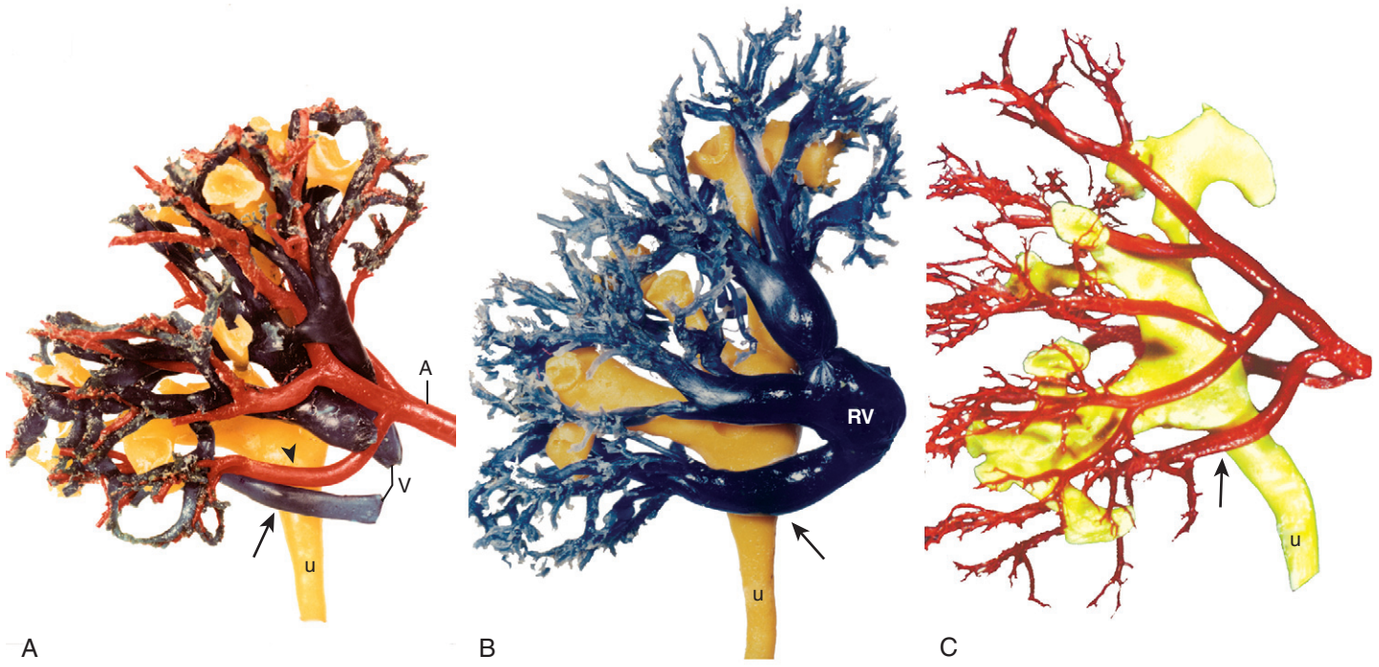

FIGURE 130-8. A, Anterior view of a right kidney endocast (pelviocalyceal system together with the intrarenal arteries and veins) reveals the anterior surface of the ureteropelvic junction (UPJ) in close relationship with the inferior segmental artery *(arrowhead)* and with a tributary of the renal vein *(arrow)*. A, renal artery; V, renal vein; u, ureter. **B,** Anterior view of a right kidney endocast (pelviocalyceal system together with the intrarenal veins) shows a close relationship between a vein draining the lower pole and the UPJ *(arrow)*. RV, renal vein; u, ureter. **C,** Anterior view of a right kidney endocast (pelviocalyceal system together with the intrarenal arteries) shows a close relationship between the inferior segmental artery and the anterior surface of the UPJ *(arrow)*. u, ureter.

On the other hand, Smith stated that this kind of study would be justified only if there was evidence that such vessels were etiological in UPJ obstruction or if there was a risk of incising the vessel during endopyelotomy. More recently, Gupta and Smith stated that the current data suggest that the finding of crossing vessels preoperatively need not significantly influence the treatment rendered. Corroborating the concept that crossing vessels have little impact on post-operative results, Nakada and colleagues reported that helical CT detected significant anterior or posterior crossing vessels in 38% of patients following successful endopyelotomy. In their opinion, the adverse influence of the crossing vessel is not sufficient to justify the added expense of preoperative angiography, spiral CT, or endoluminal ultrasound. Also, documenting the presence of a crossing vessel is inadequate to confirm that the vessel is causing obstruction. None of the current UPJ imaging techniques can distinguish crossing arteries that are the direct cause of obstruction from those that are not. Therefore, in the absence of a prospective randomized trial comparing the results of open pyeloplasty and endopyelotomy, including the investigation of crossing vessels, it is controversial the importance of imaging these crossing vessels before surgery.

It is worthy to point out that in Van Cangh's series, 39% of the patients presented a crossing vessel anteriorly to the UPJ and this author considered these vessels to be anomalous arteries. Considering these vessels anomalous is in disagreement with our extensive vascular anatomical studies. Analyzing 280 endocasts of the pelviocalyceal system together with the intrarenal arteries and veins, we found a close relationship between a normal artery, or vein, or both and the anterior surface of the UPJ in 65.1% of the cases (see Fig. 130-8). In 45.2% of the cases there was a close relationship between the inferior segmental artery and the anterior surface of the UPJ when this vessel passed in front of this region to enter the inferior pole (see Fig. 130-8C). This vessel is neither accessory nor aberrant, but, rather, a normal segmental artery that maintains a consistent anatomical relationship with the anterior surface of the UPJ without compressing the junction. The mere presence of crossing vessels in the UPJ does not mean that they are necessarily obstructive. We believe that an anomalous artery crossing the UPJ and causing obstruction in 39% of patients, as described by Van Cangh and colleagues is a quite high incidence. It is possible that many of the vessels seen close to the UPJ during angiography and described as anomalous were normal segmental arteries. They may not cause the obstruction but rather increase the dilatation of a redundant renal pelvis previously obstructed by a primary muscular defect at the UPJ. In such a situation, the dilated renal pelvis balloons over the anterior crossing vessel, and the resulting angulation appears to worsen the obstruction. Therefore the exact role of crossing vessels in obstruction and the success of endopyelotomy are yet to be determined.

With respect to the presence of multiple renal arteries, in 266 renal arterial pedicles analyzed, we found an inferior polar artery crossing anteriorly to the UPJ in only 6.8% of the cases. Also, in only a few cases did this inferior polar artery pass close to the UPJ. Therefore the presence of an anomalous vessel crossing the UPJ and causing obstruction is uncommon.

For patients with a crossing vessel and minimal to moderate hydronephrosis, laparoscopic clipping and incision of the crossing artery was reported. Nevertheless, we emphasize that this approach should be precluded, because it results in loss of functioning renal parenchyma. It was well demonstrated and stressed that all renal arteries, even in case of multiple arteries, are terminal vessels; therefore clipping the vessel will cause renal infarction. As we have shown previously, the artery supplying the inferior pole of the kidney (inferior segment) represents from 7.4% to 38% of the total kidney area of functioning renal parenchyma (median area of the inferior segment = 22.6%). For that reason, if one confirms that the UPJ obstruction is caused by a crossing artery, open surgery or a laparoscopic pyeloplasty with transposition of the crossing vessel should be proposed rather than clipping it.

Posterior Vascular Ureteropelvic Junction Relationships

In 6.2% of cases, we found a direct relationship between a large vessel (artery or vein, or both) and the dorsal surface of the UPJ (Fig. 130-9). In all cases in which an artery crosses the dorsal surface of the UPJ (3.5%), the vessel was the posterior segmental artery, also known as the retropelvic artery (see Fig. 130-9B).

Most authors recommend that the UPJ be incised alongside its posterolateral aspect, but our findings evinced that this poses a serious risk of injuring a retropelvic vessel. In fact, even when the procedure is performed by experienced endourologists, the incidence of severe hemorrhage when the UPJ is incised posterolaterally is 12%. A posterior or posterolateral incision at the UPJ stenosis also presents the possibility of injury to the posterior segmental artery (retropelvic artery), which in addition to causing severe hemorrhage, can be associated with loss of a great portion of functioning renal tissue as a consequence of renal infarction. It is important to note that in some individuals, the posterior segmental artery supplies as much as 50% of the renal parenchyma (Fig. 130-10A).

In addition to the 6.2% of vessels that had a direct dorsal relationship with the UPJ by crossing it just at the posterior surface, another 20.5% of cases were characterized by a vessel crossing less than 1.5 cm above the dorsal surface of the UPJ (see Fig. 130-10B). This is of great importance to surgeons who perform endopyelotomy, because to achieve a patent UPJ it is generally necessary to extend the endoscopic incision into the healthy tissue for 1 to 2 cm on each side (above and below) of the UPJ stenotic zone. This means that the risk of injury to a dorsal vessel is especially great in posterior and posterolateral incisions.

Furthermore, the risk of injury to a vessel that crosses less than 1.5 cm above the UPJ is particularly high in cases of extensive fibrosis and scarring tissue at the UPJ, because under such circumstances, it is necessary to make a long incision, sometimes extending into the renal parenchyma. Therefore posterior and posterolateral incisions at the UPJ must be avoided.

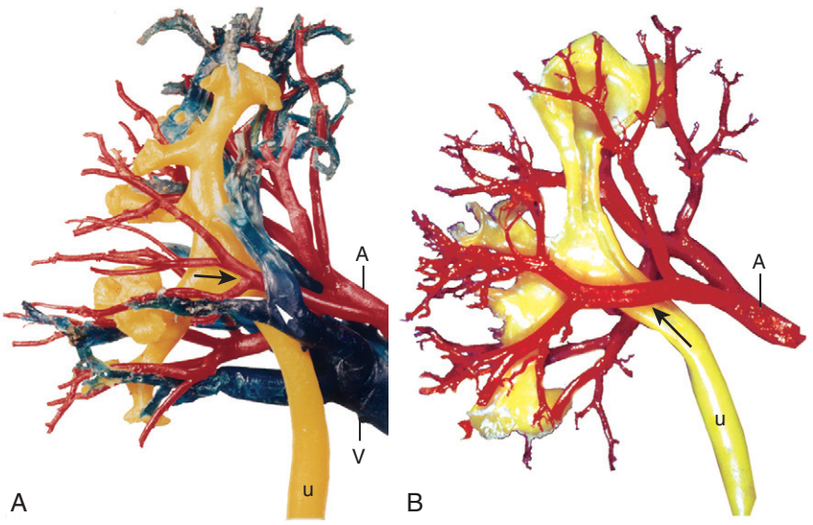

FIGURE 130-9. A, Posterior view of a left kidney endocast (pelviocalyceal system together with the intrarenal arteries and veins). A dorsal tributary of the renal vein *(arrowhead)* and the posterior segmental artery (retropelvic artery, *arrow*), are in close relationship to the posterior aspect of the ureteropelvic junction. A, renal artery; V, renal vein; u, ureter. **B,** Posterior view of a left kidney endocast (pelviocalyceal system together with the intrarenal arteries) reveals the posterior segmental artery (retropelvic artery) in close relationship to the posterior aspect of the ureteropelvic junction *(arrow)*. A, renal artery; u, ureter.

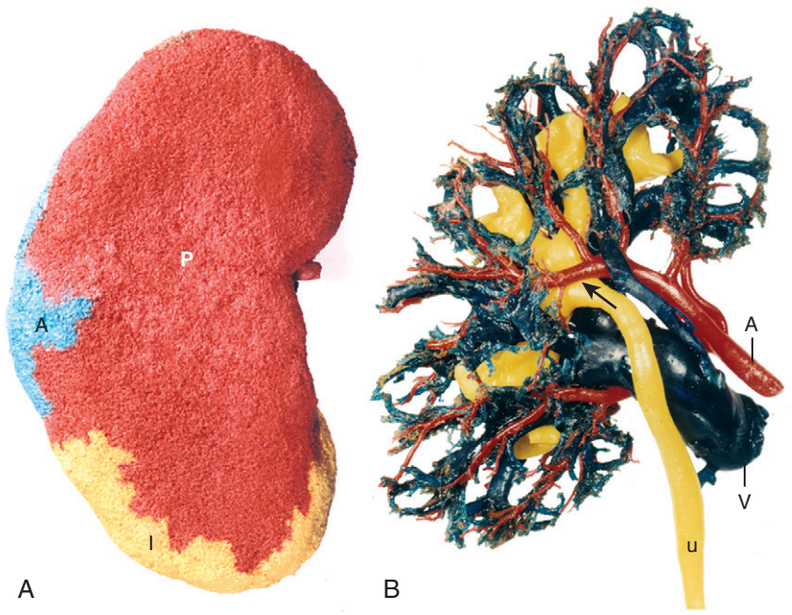

FIGURE 130-10. A, Posterior view of a left kidney endocast demonstrating the posterior segment in red (P), corresponding to 49.36% of the total kidney area. A, anterior segment; I, inferior segment. **B,** Posterior view of a left kidney endocast (pelviocalyceal system together with the intrarenal arteries and veins) reveals the posterior segmental artery (retropelvic artery) crossing lower than 1.5 cm (0.5 cm) above the posterior aspect of the ureteropelvic junction *(arrow)*. A, renal artery; V, renal vein; u, ureter.

Incision at the Ureteropelvic Junction Stenosis Based on the Vascular Anatomy

We recommend that the deep incision alongside the UPJ stenotic wall be done just laterally (Fig. 130-11A). An incision at this site, which we named "nonvascular area" of the UPJ, avoids all important vessels that can be related anteriorly, posteriorly, or less than 1.5 cm above the posterior surface of the UPJ.

Even in cases of extensive scar tissue at the UPJ and in cases of vessels that were transposed posteriorly in an earlier dismembered pyeloplasty, the lateral incision in the nonvascular area of the UPJ is safe and precludes preoperative angiographic examinations. Also, an unsuspected polar inferior artery crossing anteriorly or posteriorly at the UPJ will be protected from injury.

Maintaining complete anatomical orientation under endoscopic vision is sometimes difficult. Consequently, it is our practice and our recommendation, to position the cutting instrument laterally and under fluoroscopic guidance (see Fig. 130-11B) before starting the incision at the UPJ. Such a maneuver assures the surgeon that the incision will be made precisely in the lateral aspect—the nonvascular area—of the UPJ.

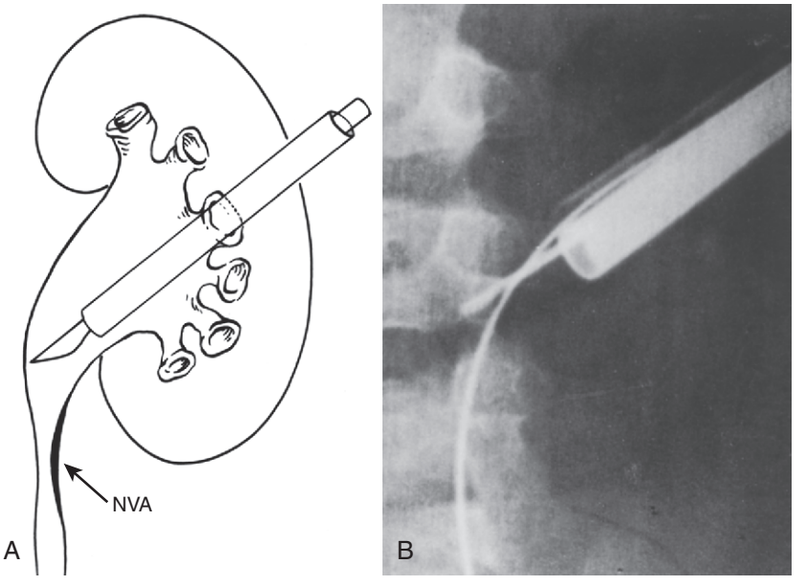

FIGURE 130-11. A, Anterior view of a schematic drawing from a left kidney shows the area to be incised in endopyelotomy *(arrow)*; nonvascular area (NVA) of the ureteropelvic junction. **B,** Note the cutting surface of a Sacks knife positioned laterally under fluoroscopic guidance during the procedure of endopyelotomy.

Suggested Readings

Badlani G, Eshghi M, Smith AD. (1986). Percutaneous surgery for ureteropelvic junction obstruction (endopyelotomy): technique and early results. J Urol 135:26-28.

Badlani G, Karlin G, Smith AD. (1988). Complications of endopyelotomy: analysis in series of 64 patients. J Urol 140:473-475.

Cassis AN, Brannen GE, Bush WH, Correa RJ, Chambers M. (1991). Endopyelotomy: review of results and complications. J Urol 146: 1492-1495.

Clayman RV, Basler JW, Kavoussi L, Picus DD. (1990). Ureteronephroscopic endopyelotomy. J Urol 144:246-252.

Clayman RV, Hunter D, Surya V, et al. (1984). Percutaneous intrarenal electrosurgery. J Urol 131:864-867.

Clayman RV, Picus DD. (1988). Ureterorenoscopic endopyelotomy. Preliminary report. Urol Clin N Amer 15:433-438.

Clayman RV, Surya V, Hunter D, et al. (1984). Renal vascular complications associated with the percutaneous removal of renal calculi. J Urol 132:228-230.

Davis DM. (1943). Intubated ureterotomy: a new operation for ureteral and ureteropelvic strictures. Surg Gynecol Obstet 76:513-514.

Frauscher F, Janetschek G, Helweg G, Strasser H, Bartsch G, zur Nedden D. (1999). Crossing vessels at the ureteropelvic junction: detection with contrast-enhanced color Doppler imaging. Radiology 210:727-731.

Gupta M, Smith AD. (1998). Crossing vessels. Endourologic implications. Urol Clin North Am 25:289-293.

Kausik S, Segura JW. (2003). Surgical management of ureteropelvic junction obstruction in adults. Int Braz J Urol 29:3-10.

Kaye KW, Goldberg ME. (1982). Applied anatomy of the kidney and ureter. Urol Clin N Am 9:3-13.

Kaye KW, Reinke DB. (1987). Detailed caliceal anatomy for endourology. J Urol 132:1085-1088.

Lee WJ, Smith AD, Cubelli V, Badlani GH, Lewin B, Vernace F, Cantos E. (1987). Complications of percutaneous nephro-lithotomy. AJR Am J Radiol 148:177-180.

Malden ES, Picus D, Clayman RV. (1992). Arteriovenous fistula complicating endopyelotomy. J Urol 148:1520-1523.

Marcovich R, Jacobson AI, Aldana JP, Lee BR, Smith AD. (2003). Practice trends in contemporary management of adult ureteropelvic junction obstruction. Urology 62:22-25.

Meretyk I, Meretyk S, Clayman RV. (1992). Endopyelotomy: comparison of ureteroscopic retrograde and antegrade percutaneous techniques. J Urol 148:775-783.

Nakada SY, Wolf Jr JS, Brink JA, Quillen SP, Nadler RB, Gaines MV, Clayman RV. (1998). Retrospective analysis of the effect of crossing vessels on successful retrograde endopyelotomy outcomes using spiral computerized tomography angiography. J Urol 159:62-65.

Rehman J, Landman J, Sundaram C, Clayman RV. (2001). Missed anterior crossing vessels during open retroperitoneal pyeloplasty: laparoscopic transperitoneal discovery and repair. J Urol 166:593-596.

Rouvière O, Lyonnet D, Berger P, Pangaud C, Gelet A, Martin X. (1999). Ureteropelvic junction obstruction: use of helical CT for preoperative assessment—comparison with intraarterial angiography. Radiology 213:668-673.

Rukin NJ, Ashdown DA, Patel P, Liu S. (2007). The role of percutaneous endopyelotomy for ureteropelvic junction obstruction. Ann R Coll Surg Engl 89:153-156.

Sampaio FJB. (1994). Endopyelotomy, guided by meticulous anatomy. Contemp Urol 6:23-26.

Sampaio FJ. (1992). Anatomic background for intrarenal endourologic surgery. J Endourol 6:301-304.

Sampaio FJ. (1993). Basic anatomic features of the kidney collecting system. Three-dimensional and radiologic study. In: Sampaio FJB, Uflacker R, eds. Renal anatomy applied to urology, endourology, and interventional radiology. New York: Thieme Medical Publishers, pp 7-15.

Sampaio FJ, Favorito LA. (1993). Ureteropelvic junction stenosis: vascular anatomical background for endopyelotomy. J Urol 150:1787-1791.

Sampaio FJ. (1994). How to place a nephrostomy, safely. Contemp Urol 6:41-46.

Sampaio FJ. (1993). Intrarenal access by puncture. Three-dimensional study. In: Sampaio FJB, Uflacker R, eds. Renal anatomy applied to urology, endourology, and interventional radiology. New York: Thieme Medical Publishers, pp 68-76.

Sampaio FJ. (1997). Kidney arterial vascularization. In: Uflacker R, ed. Atlas of vascular anatomy: an angiographic approach. Baltimore: Williams & Wilkins, pp 552-595.

Sampaio FJ. (1991). Relationship between segmental arteries and pelviureteric junction. Br J Urol 68:214-217.

Sampaio FJ. (2000). Renal anatomy: endourologic considerations. Urol Clin North Am 27:585-607.

Sampaio FJ. (2001). Renal collecting system anatomy: its possible role in the effectiveness of renal stone treatment. Curr Opin Urol 11:359-366.

Sampaio FJ. (2007). Surgical anatomy of the kidney. In: Smith's textbook of endourology, 2nd ed. Hamilton: BC Dekker, pp 79-99.

Sampaio FJ. (1996). The dilemma of the crossing vessel at the ureteropelvic junction: precise anatomic study. J Endourol 10:411-415.

Sampaio FJ. (2003). Ureteropelvic junction anatomy. In: Ureteropelvic junction obstruction. In: Preminger GM, ed. Atlas of the urologic clinics. Philadelphia: WB Saunders, Volume 11, Number 2: 129-140, 2003.

Sampaio FJ. (1998). Vascular anatomy at the ureteropelvic junction. Urol Clin North Am 25:251-258.

Sampaio FJ, Aragao AH. (1990). Anatomical relationship between the intrarenal arteries and the kidney collecting system. J Urol 143:679-681.

Sampaio FJ, Aragao AH. (1990). Anatomical relationship between the renal venous arrangement and the kidney collecting system. J Urol 144:1089-1093.

Sampaio FJ, Aragao AH. (1992). Inferior pole collecting system anatomy. Its probable role in extracorporeal shock wave lithotripsy. J Urol 147:322-324.

Sampaio FJ, Mandarim-de-Lacerda CA. (1988). 3-Dimensional and radiological pelviocalyceal anatomy for endourology. J Urol 140:1352-1355.

Sampaio FJ, Mandarim-de-Lacerda CA. (1988). Anatomic classification of the kidney collecting system for endourologic procedures. J Endourol 2:247-251.

Sampaio FJ, Passos MA. (1992). Renal arteries: anatomic study for surgical and radiological practice. Surg Radiol Anat 14:113-117.

Sampaio FJ, Schiavini JL, Favorito LA. (1993). Proportional analysis of the kidney arterial segments. Urol Res 21:371-374.

Sampaio FJ, Zanier JF, Aragao AH, Favorito LA. (1992). Intrarenal access: 3-dimensional anatomical study. J Urol 148:1769-1773.

Segura JW. (1992). Editorial comment. J Urol 148:782.

Segura JW. (1989). The role of percutaneous surgery in renal and ureteral stone removal. J Urol 141:780-781.

Smith AD. (1991). Editorial comment. J Urol 146:1495.

Streem SB, Geisinger MA. (1995). Prevention and management of hemorrhage associate with cautery wire balloon incision of ureteropelvic junction obstruction. J Urol 153:1904-1906.

Streem SD. (1998). Preface. Contemporary intervention for UPJ obstruction: which one, when and how? Urol Clin North Am 25:xiii-xv.

Uflacker R. (1993). Percutaneous kidney procedures. Endopyelotomy. In: Sampaio FJ, Uflacker R, eds. Renal anatomy applied to urology, endourology, and interventional radiology. New York: Thieme Medical Publishers, pp 90-96.

Van Cangh PJ, Nesa S, De Groote P. (2000). Current indications for endopyelotomy. Int Braz J Urol 26:54-63.

Van Cangh PJ, Wilmart JF, Opsomer RJ, Abi-Aad A, Wese FX, Lorge F. (1994). Long-term results and late recurrence after endopyelotomy: a critical analysis of prognostic factors. J Urol 151:934-937.

Wagner JR, D'Agostino R, Babayan RK. (1996). Renal arterioureteral hemorrhage: a complication of Acucise endopyelotomy. Urology 48:139-141.

Weyman PJ. (1986). Air as a contrast agent during percutaneous nephrostomy. J Endourol 1:16-17.

Chapter 131

Percutaneous Renal Access

NICOLE MILLER AND JAMES E. LINGEMAN

Percutaneous renal access was first described in 1955 by Goodwin and colleagues for the purpose of relieving obstruction in a hydronephrotic kidney. Rapid evolution of the techniques for percutaneous renal access has led to applications beyond simple drainage of the urinary tract. Percutaneous renal surgery now plays a prominent role in the treatment of a variety of urologic conditions. Performance of safe and efficient percutaneous access is the most critical aspect of successful percutaneous renal surgery.

INDICATIONS

Percutaneous renal access is performed for both diagnostic and therapeutic interventions. Diagnostic tests using percutaneous access include antegrade pyelography and pressure/perfusion studies (Whitaker test). Common therapeutic indications include drainage of an obstructed kidney, treatment of complex nephrolithiasis, antegrade endopyelotomy for ureteropelvic junction (UPJ) obstruction, endoscopic resection of upper tract transitional cell carcinoma, treatment of ureteral stricture, removal of foreign body (i.e., retained stent), and instillation of topical intrarenal agents (chemolytics, chemo/immunotherapy). Percutaneous nephrolithotomy (PNL) is by far the most common operation employing percutaneous renal access. PNL is indicated for the treatment of staghorn calculi, large stone burden (>2 cm), calculi composed of cystine, brushite, struvite, or calcium oxalate monohydrate, impacted or large proximal ureteral calculi, calyceal diverticular calculi, ectopic renal calculi (horseshoe kidney, pelvic kidney, or transplant kidney), coexisting UPJ obstruction and renal calculi, lower pole renal calculi greater than 1 cm and stones that have failed ureteroscopy or shock wave lithotripsy.

PREOPERATIVE EVALUATION

A complete medical history and physical examination should be performed in all patients before percutaneous access. Special attention is paid to identifying conditions in which percutaneous access is contraindicated such as bleeding disorders and active urinary tract infection (UTI) unless for obstruction or sepsis**.** If medically feasible, aspirin and other antiplatelet medications should be discontinued 7 days before surgery. Preoperative laboratory evaluation includes complete blood count, serum electrolytes, and renal function measurement. All patients should have a preoperative urine culture to exclude UTI. This is particularly important in patients with neurogenic bladder and urinary diversion who are often colonized with bacteria, and/or infected with organisms that are resistant to commonly prescribed antibiotics. In patients undergoing PNL, a 2-week course of a broad-spectrum antibiotic is recommended even in the presence of a negative urine culture because the calculi may be harboring bacteria. Cephalosporins are the most appropriate antibiotics for surgical prophylaxis immediately before surgical procedures in noninfected stone patients, because the most common secondarily infecting organism is *Staphylococcus epidermidis*. High-risk patients can be treated with intravenous ampicillin and gentamicin. Morbidly obese patients warrant special preoperative consideration because they often have cardiac and/or pulmonary disease that can represent a challenge for the anesthesiologist, especially when the patient is placed in the prone position.

Finally, preoperative imaging is essential in planning percutaneous access. Intravenous pyelography (IVP) has largely been supplanted by computed tomography (CT). CT is particularly useful in cases of congenital renal anomalies, transplant kidney, morbid obesity, and spinal cord deformities to allow evaluation of adjacent visceral structures. Although rare (<1%), CT can also identify a retrorenal colon, the incidence of which may be higher in patients with jejunoileal bypass or spinal cord injury. IVP and/or retrograde pyelography remain useful in patients with calyceal diverticulum to define the relationship between the diverticular cavity and the renal collecting system. A three-dimensional CT scan with reconstruction images or CT urogram may be helpful in planning percutaneous access for treatment of a urothelial neoplasm, UPJ obstruction, or calculi in an ectopic kidney.

ANATOMICAL CONSIDERATIONS

Familiarity with basic renal anatomy is essential for safe and efficient percutaneous renal access. The kidneys lie obliquely within the retroperitoneum anterior to the psoas and quadratus lumborum muscles. These muscle layers are thinner superiorly; therefore, the upper pole of the kidney lies more posterior than the lower pole. The right kidney is adjacent to the twelfth rib, liver, duodenum, and hepatic flexure of the colon, and is positioned 2 to 3 cm lower than the left due to the position of the liver. Structures bordering the left kidney include the eleventh and twelfth ribs, pancreas, spleen, and splenic flexure of the colon. The pleura normally attaches at the level of the eleventh rib, and is important to consider, particularly when planning supracostal access.

Knowledge of the principal renal vascular structures and their relationships to the renal collecting system can decrease the risk of hemorrhagic events. The main renal artery typically divides into an anterior and a posterior division. The avascular field between the anterior and posterior divisions, known as Brödel's bloodless line, is the ideal point of renal entry. Due to the orientation of the kidney in the retroperitoneum, entry through a posterior calyx usually traverses this line. For this reason, a posterior calyx is the preferred site of entry for percutaneous access in that it is associated with a lower risk of vascular injury and usually allows negotiation of a guidewire out of the calyx and down the ureter (Fig. 131-1). Positioning the patient prone will bring the posterior calyces into an end-on position facilitating puncture into a posterior calyx. Inadvertent puncture beyond the anterior aspect of the collecting system risks vascular injury of the large anterior segmental vessels, which is a problematic complication because these vessels cannot be readily tamponaded with a nephrostomy tube or occlusion balloon.

The preferred point of entry into a posterior calyx is through the papilla or fornix. Infundibular puncture or direct puncture into the renal pelvis should be avoided because of the increased risk for significant vascular injury. Furthermore, access directly into the renal pelvis may pose a risk for prolonged urinary leakage or easy tube dislodgment. When percutaneous access is created through the papilla or fornix and aligned with the infundibulum, the rigid nephroscope can be used efficiently without the need for excessive torque, which may cause renal trauma and bleeding. To reduce the risk of colonic injury, the puncture site should be medial to the posterior axillary line because the colon is usually anterior or anterolateral to the lateral most part of the kidney. A very medial puncture should also be avoided because it may traverse the paraspinal muscles, increasing postoperative pain. Finally, when performing supracostal access, the puncture should not be performed too close to the rib because it may injure the intercostal nerve and/or vessels.

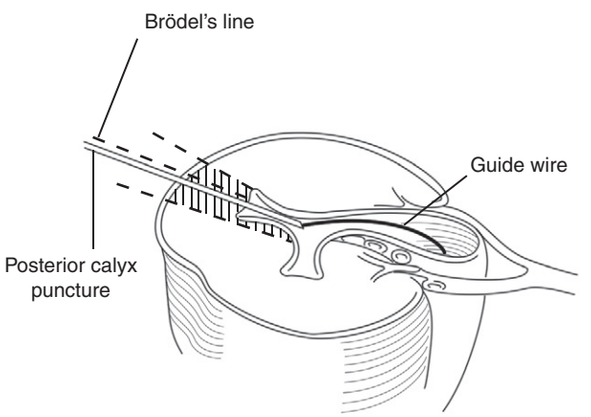

FIGURE 131-1. A posterior calyx is the preferred site of entry for percutaneous renal access as it normally traverses Brodel's line.

STANDARD LOWER POLE PERCUTANEOUS ACCESS

Instrumentation

C-arm fluoroscopy
22-French rigid cystoscope
5-French open-ended ureteral catheter or an occlusion balloon catheter
16-French Foley catheter
18-gauge diamond-tip access needle
Wires
- 0.035-inch straight tip glidewire
- 0.035-inch straight removable core wire
- 0.035-inch Amplatz superstiff wire
- 0.035-inch removable core J-wire

5-French angiographic catheter
8-French fascial dilator
$^{8}/_{10}$-French coaxial dilator
Nephromax balloon dilator
LeVeen syringe
30-French Amplatz sheath

CYSTOSCOPY, URETERAL CATHERIZATION

The first step in performing percutaneous renal access is cystoscopic placement of a ureteral catheter for retrograde opacification of the collecting system. Placement of the ureteral catheter is performed in the dorsal lithotomy position to ensure catheter placement is rapid and all anatomical conditions, such as urethral or ureteral strictures, can be easily addressed. A 5- or 6-French open-ended ureteral catheter is routinely used; however, a 7-French occlusion balloon catheter should be considered when stone burden is large, or the proximal ureter is dilated. A Foley catheter ensures bladder drainage during the percutaneous procedure.

Alternatively, some urologists prefer to place the patient in a prone split-leg position. This positioning is most often employed when percutaneous access is performed using a combined antegrade and retrograde approach. An operative table that allows abduction of the legs is necessary. Flexible cystoscopy is then performed to first establish retrograde access to the kidney, often via placement of a ureteral access sheath.

Patient Positioning

The patient is placed in the prone position with the side to be treated elevated on a foam pad at 30 degrees (Fig. 131-2). This position aids in ventilation of the patient and brings the posterior calyces into a vertical position. All pressure points are padded. The patient's arm on the side of the stone is flexed at the elbow and placed on an arm board, while the contralateral arm is placed at the patient's side. For bilateral PNL, the patient is placed in the straight prone position and the more symptomatic side or the side with the larger stone burden is addressed first. Intravenous extension tubing is connected to the ureteral catheter, or the occlusion balloon port, to allow inflation or deflation of the balloon, or the instillation of contrast dye.

Imaging Setup—Fluoroscopic

While ultrasound and CT-guided percutaneous renal access have been described, biplanar fluoroscopy is the most commonly used imaging method. The determination of calyceal orientation and the selection of the optimal calyx of entry are best determined using biplanar C-arm fluoroscopy. A C-arm fluoroscopic unit is preferable to a urotable with a fixed x-ray tube because it permits more active movement between anteroposterior and oblique views of the kidney and reduces operator exposure to radiation scatter in that the x-ray source is under the table rather than over it. A C-arm drape is used during the operation to maintain the sterile field.



FIGURE 131-2. Patient positioning. Chest roll/wedge for 30-degree elevation brings posterior calyces into vertical orientation.

Selection of Puncture Site and Needle Access

The determination of calyceal orientation and selection of the optimal calyx of entry is best determined intraoperatively using real time imaging. As mentioned previously, the preferred access site into the lower pole of the kidney is through a posterior calyx. Radiographic guidance for fluoroscopic percutaneous access is routinely performed using one of two techniques: eye of the needle and triangulation. Both techniques begin with retrograde opacification of the collecting system via instillation of contrast dye through the existing ureteral catheter.

Eye of the needle. An 18-gauge diamond-tip access needle is positioned so that the targeted calyx, the needle tip, and the needle hub are all in line with the image intensifier, giving a bulls-eye effect on the monitor (Fig. 131-3A). In effect, the surgeon is looking down the needle into the targeted calyx, hence the phrase "eye of the needle." The needle is advanced in this orientation, with continuous fluoroscopic monitoring to ensure that the needle maintains the proper trajectory. The needle depth is ascertained by rotating the C-arm to a vertical orientation (see Fig. 131-3B). If the needle is aligned with the calyx in this view, the urologist should be able to aspirate urine from the collecting system, confirming proper positioning.

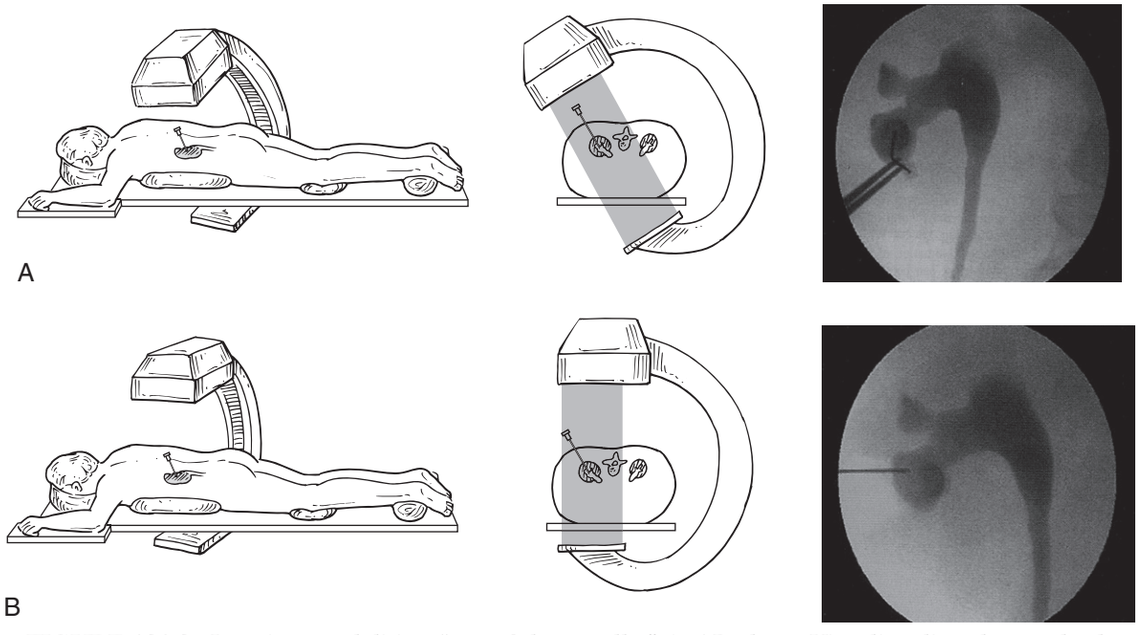

FIGURE 131-3. Imaging modalities: "eye of the needle." **A,** AP plane. Visualize directly over both needle and calyx of puncture. Will see a "bulls-eye" appearance as visualize down the shaft of the needle. **B,** Oblique plane. Allows evaluation of needle penetration depth.

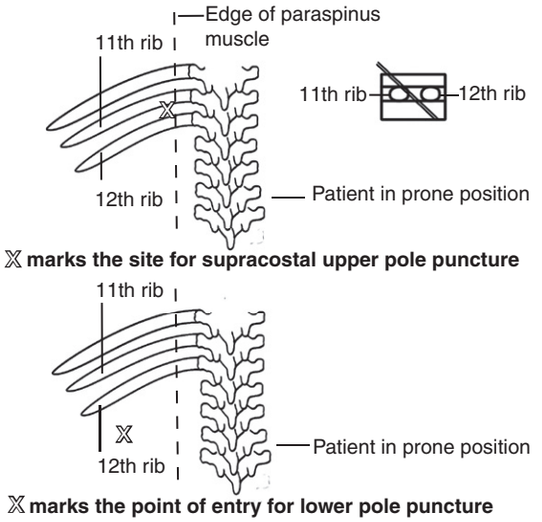

FIGURE 131-4. Anatomic land marks for upper and lower pole percutaneous renal access.

Triangulation technique. The skin puncture is usually performed approximately 1 cm inferior and 1 cm medial to the tip of the twelfth rib (Fig. 131-4). With the C-arm oriented parallel to the line of puncture, adjustments are made in the mediolateral (or left/right) direction (Fig. 131-5A). The C-arm is rotated to the oblique position and adjustments are made in the cephalad/caudad (or up/down) orientation of the line of puncture taking care not to alter the mediolateral orientation of the needle (see Fig. 131-5B). To reduce radiation exposure to the surgeon, the C-arm is angled away from the line of puncture with the image intensifier angled toward the patient's head. Once the proper orientation of the line of puncture has been obtained, respirations are suspended in full expiration. An 18-gauge diamond-tipped access needle is advanced toward the desired calyx in the oblique position to gauge the depth of puncture. Maintenance of needle orientation in one plane while making adjustments in the other plane is critical to preserve proper orientation. This maneuver is facilitated by resting the surgeon's forearm on the torso of the patient to minimize drift and stabilize the line of puncture. Before the renal capsule is entered, final adjustments are made. Manipulating the needle after entering renal parenchyma is discouraged because it may displace the kidney affecting the position of the target calyx. Once the needle is advanced into the collecting system, aspiration of urine will verify proper caliceal puncture.

Placement of Access Wires

A hydrophilic, nitinol core glidewire is passed through the access needle and into the collecting system. This type of wire is preferred for obtaining initial access because it is quite maneuverable and resists kinking. Under fluoroscopic guidance, an attempt is made to advance the glidewire down the ureter (Fig. 131-6). If the wire does not pass easily into the ureter, it can be coiled in the renal pelvis. An

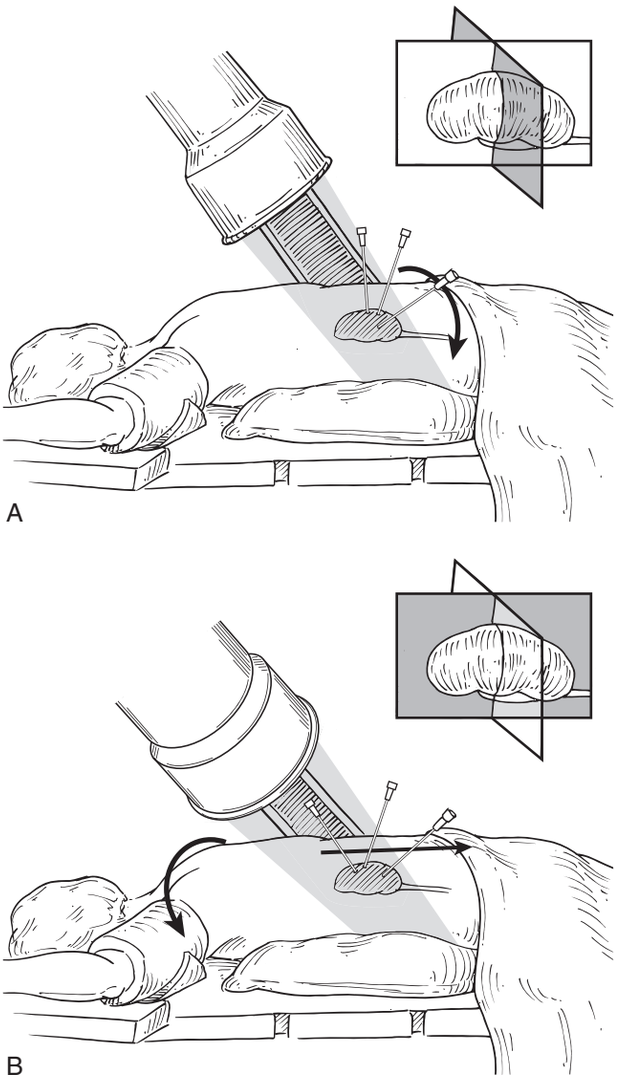

FIGURE 131-5. Imaging modalities: triangulation technique. **A,** AP plane (left-right adjustments). **B,** Oblique plane (up-down adjustments).

8-French fascial dilator is passed into the calyx, followed by a 5-French Cobra-tipped angiographic catheter. The angiographic catheter helps direct the glidewire toward the ureteropelvic junction, facilitating placement of the wire down the ureter (Fig. 131-7). Once the glidewire is positioned in the ureter, it is exchanged for a stiffer, Teflon-coated working wire such as an Amplatz super-stiff wire. The glidewire should not be used as a working wire because its lubricious nature makes it prone to displacement. At times it may not be possible to advance the glidewire down the ureter (impacted stone or UPJ narrowing); therefore the access wires are positioned in a calyx distant from the initial nephrostomy tract or coiled in the renal pelvis. An 8/10 French coaxial dilating system is then used to place a second safety wire, usually a 0.035-inch straight removal core wire (Fig. 131-8). The 8-French tapered portion is advanced first, followed by the 10-French outer portion. Removal of the 8-French inner dilator then allows passage of the safety wire. The safety wire should be secured to the drape with a clamp. Placement of a safety wire is imperative before

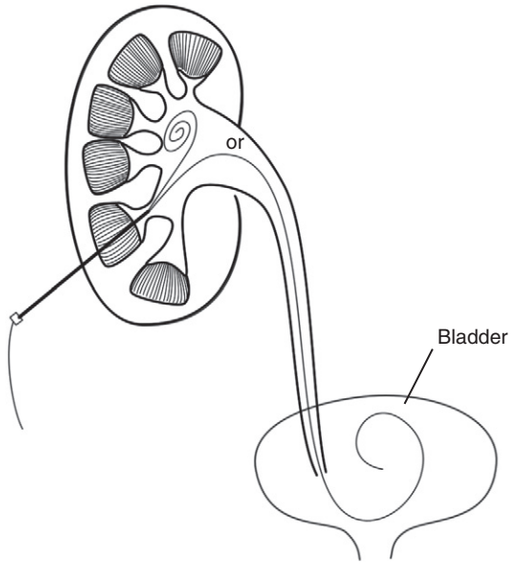

FIGURE 131-6. Initial needle puncture and placement of wire-coil in renal pelvis or, if possible, down ureter.

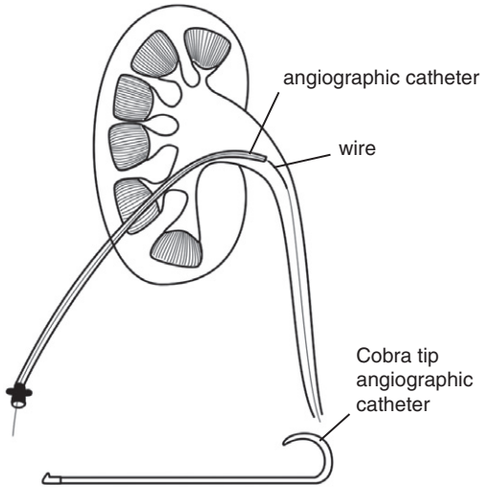

FIGURE 131-7. Using an angiographic catheter to place wire down the ureter and exchange to an Amplatz super-stiff wire.

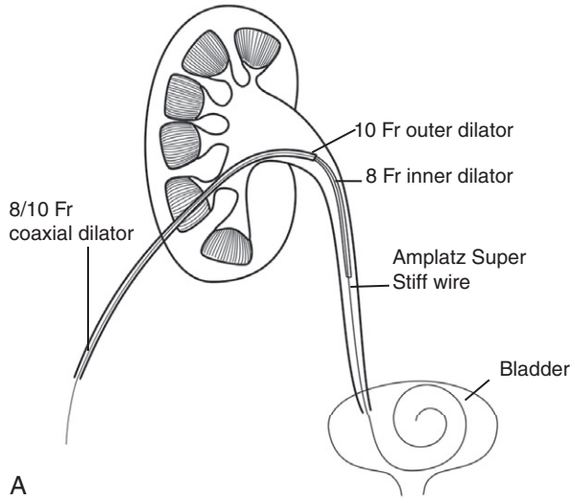

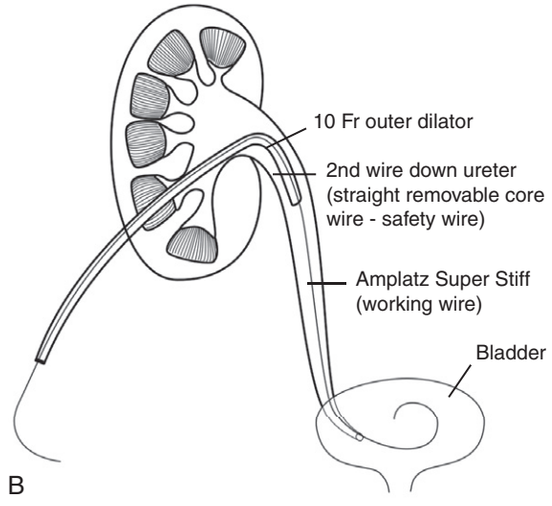

FIGURE 131-8. B, Two-wire access, using 10 French of $^{8}/_{10}$-French coaxial dilator.

proceeding with dilation of the percutaneous tract because it maintains access in the event that the working wire becomes displaced.

Tract Dilation

Several methods of tract dilation are available, including metal telescoping dilators, semirigid Amplatz dilators, and balloon dilators. Tract dilation must be performed over a stiff wire using fluoroscopic guidance. Balloon dilators have been reported to cause significantly less bleeding than sequential dilators because the radial force used to spread the renal parenchyma is less traumatic than the shearing or cutting action of sequential Amplatz dilators or metal telescoping dilators. The author's preference is to use a 12-cm, 30-French balloon dilator with a 30-French Amplatz sheath backloaded behind the balloon. The radiopaque marker located at the tip of the balloon is positioned under fluoroscopic guidance just inside the calyx of puncture, and the balloon is then inflated using a LeVeen syringe (Fig. 131-9A). The balloon is inflated to a maximum of 18 atmospheres. Persistent "waist" may indicate perirenal scarring. A 4.5-mm fascial incising needle (Cook Urological, Spencer, IN) can be placed over the working wire to incise the scar and facilitate balloon dilation. Alternatively, sequential dilators (Amplatz or metal dilators) may be useful; however, it can be difficult to control the amount of pressure exerted during dilation, which may result in renal pelvic perforation or hemorrhage. Following tract dilation, a 30-French Amplatz working sheath is advanced in a rotating fashion over the balloon or dilator until it is well positioned in the calyx of puncture (see Fig. 131-9B). Dilation of the nephrostomy tract should always be performed under fluoroscopic guidance, and care should be taken to avoid overadvancement of the sheath, which may cause bleeding and trauma

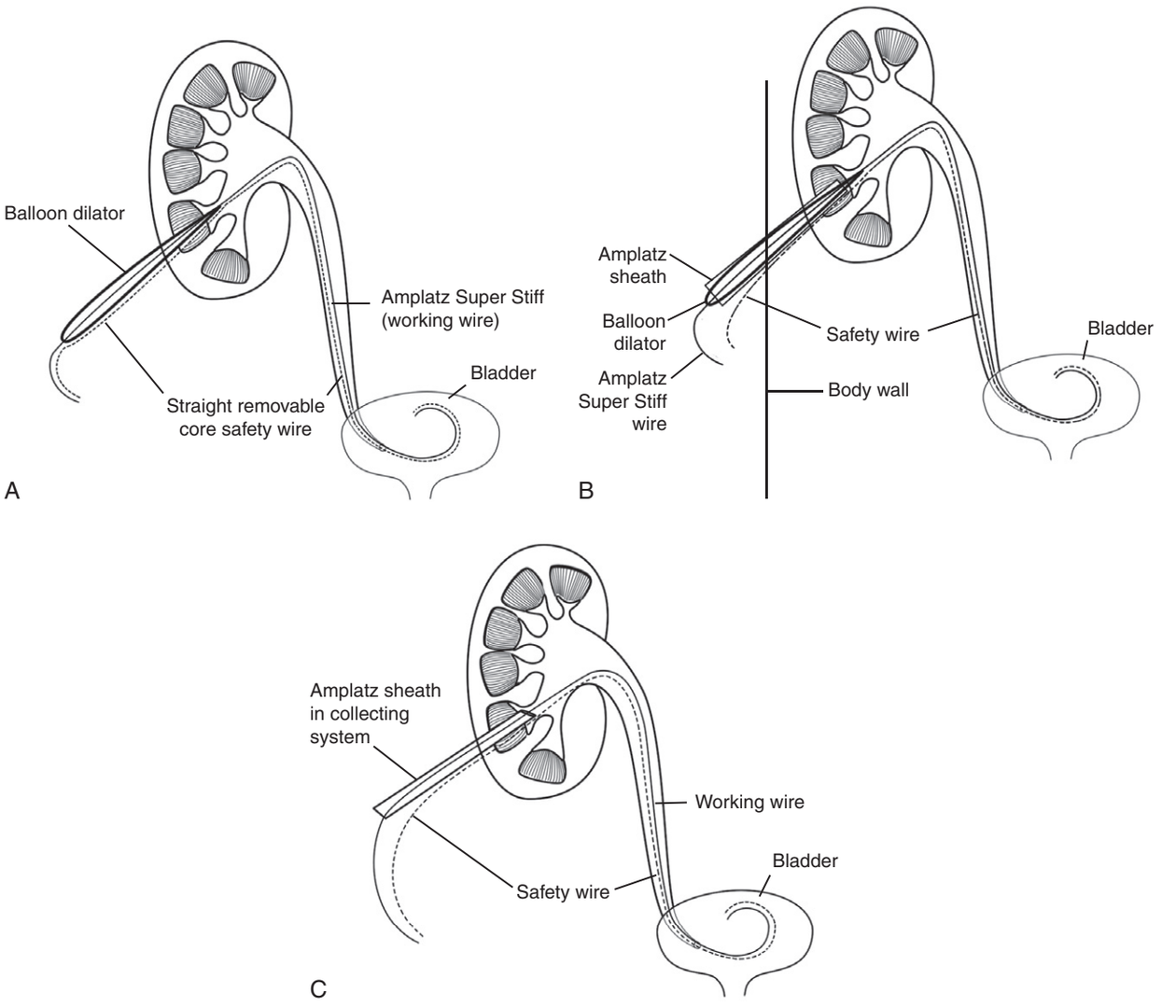

FIGURE 131-9. A, Balloon dilation of nephrostomy tract. **B,** Placement of the Amplatz sheath. **C,** Final access with the Amplatz sheath in place.

to the renal parenchyma or perforation of the collecting system.

Percutaneous renal access in the morbidly obese patient warrants special consideration because of the potential need for special equipment. In these cases, there is often a long distance from the skin to the collecting system, which may exceed the length of the working sheath and/or the length of the rigid nephroscope. Therefore when performing percutaneous access in these patients it is important to have an extra long Amplatz working sheath (20 cm) and rigid nephroscope readily available.

SPECIAL ACCESS SITUATIONS

Supracostal/Upper Pole Access

Supracostal or upper pole percutaneous access is advantageous in certain clinical situations because the line of puncture is directly aligned with the renal pelvis and UPJ (Fig. 131-10). This alignment allows for excellent visualization of the UPJ and proximal ureter. For this reason, it is advocated for the treatment of large impacted proximal ureteral calculi or UPJ obstruction when antegrade endopyelotomy is planned. Supracostal or upper pole access may be also be beneficial in cases where there is large stone burden located in the upper calyces such as a complete staghorn calculus, an upper pole calyceal diverticulum, or in the presence of multiple stone-containing lower pole calyces. In addition, percutaneous access of the horseshoe kidney is routinely performed using upper pole access; however, this is almost always via a subcostal approach due to the incomplete ascent of the kidney.

Although the percutaneous technique is similar to that described for the lower pole, certain aspects of supracostal or upper pole access are worthy of emphasis. The main risk of a supracostal puncture is injury to the lung and pleura because the upper poles of both kidneys lie immediately anterior to the posterior portion of the eleventh and twelfth ribs, and can even be as high as the tenth rib. The risk of

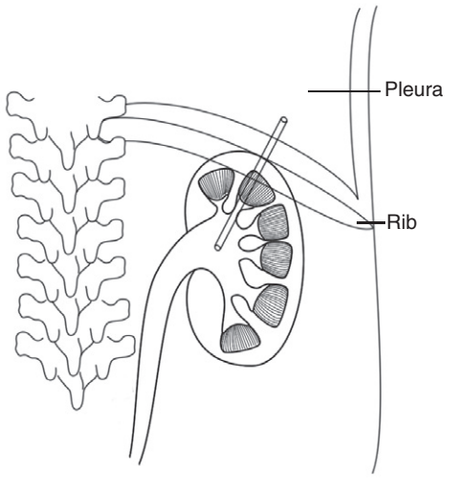

FIGURE 131-10. Upper pole access aligns with UPJ, but can violate the pleura.

pleural injury is greatest during the inspiratory phase of respiration; therefore general anesthesia is essential for control of respiratory movements during puncture. For supracostal access, the puncture site should be placed in the upper portion of the intercostal space, just lateral to the paraspinal muscles and puncture above the eleventh rib avoided when possible (Fig. 131-11). Occasionally, the upper pole can be accessed via a laterally situated tract between the tips of the eleventh and twelfth ribs or even by an infracostal approach. This type of intercostal access has been shown to decrease the risk of pleural injury when compared with a vertical supracostal puncture, but can limit visualization of the renal pelvis, lower pole, and UPJ.

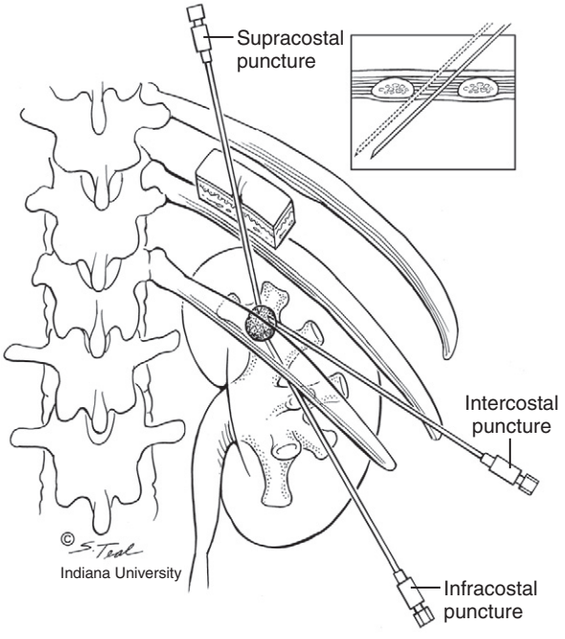

FIGURE 131-11. Upper pole access can be performed via a supracostal, intercostal, or infracostal approach. *(Drawn by Sharon Teal. Copyright Indiana University Trustees, used with permission.)*

The use of an Amplatz working sheath is mandatory in patients with supracostal access to reduce the risk of hydrothorax. Pulmonary complications have been reported in approximately 16% of cases with a need for intervention in 3% to 4%. Following supracostal access, intraoperative fluoroscopy should be used to detect any clinically significant hydrothorax or pneumothorax. Aspiration of the pleural fluid can then be performed while the patient is under general anesthesia. If intraoperative fluoroscopy of the chest is normal, a formal chest radiograph in the recovery room is recommended only if the patient is symptomatic. Minor pleural effusions can be managed conservatively, but larger effusions or the presence of significant pneumothorax will require a chest tube. Because injury to the lung is rare, small pigtail type catheters are usually sufficient and more comfortable than larger chest tubes.

Preoperative CT imaging is critical to rule out enlargement of the liver or spleen. In the absence of organ enlargement, injury to the liver or spleen is extremely rare with access below the twelfth rib. However, supracostal access can be associated with an increased risk of liver or spleen injury, particularly if the puncture is performed during the inspiratory phase of respiration or above the eleventh rib. To reduce the risk of hepatic or splenic injury, the puncture site should be located as far medial as possible, adjacent to the lateral border of the paraspinal muscles.

Calyceal Diverticulum/Obstructed Calyx

A special access technique is warranted when planning percutaneous treatment of a calyceal diverticulum or a calyx with an obstructed infundibulum containing stone material. Direct puncture of a calyceal diverticulum can be difficult when the diverticulum is small and/or located in the upper pole. Even when the diverticulum is successfully punctured, passing a guidewire through the communication with the renal collecting system is usually impossible.

The author's preferred technique involves a single-stage percutaneous approach that obviates placement of a ureteral catheter or entrance into the renal collecting system. The patient is positioned as described previously. A C-arm fluoroscopy unit is used to visualize the diverticular calculi, and a direct preferably infracostal puncture is performed using an 18-gauge diamond-tipped access needle and a biplanar fluoroscopic triangulation technique. When access is achieved, a 0.035-inch J-tipped removable core guidewire is coiled inside the diverticular cavity (Fig. 131-12A). The major advantage of the removable core J-wire is that the flexible distal end of the wire can be adapted to the size of the diverticulum, while the wire proximal to the removed core remains rigid enough to function as the working wire. With the J-wire in place, an 8/10-French coaxial dilator is passed over the J-wire in a sequential fashion. The 8-French dilator is removed, and a second 0.035-inch J-tipped removable core wire is curled inside of the diverticulum to be used as a safety wire (see Fig. 131-12B). Dilation of the nephrostomy tract is performed as previously described. Overadvancement of the balloon dilator and sheath should be avoided to prevent perforation of the opposite wall of the diverticulum. The tapered end of the balloon dilator often precludes

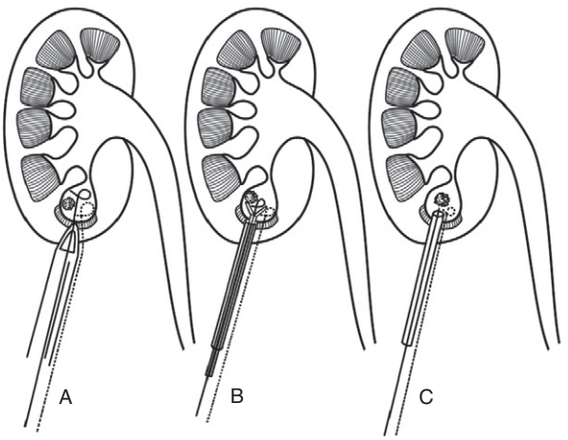

FIGURE 131-12. Access technique for calyceal diverticulum.

placement of the sheath directly into the diverticular cavity; therefore 11-French alligator forceps can be used through an offset rigid nephroscope to manually dilate the tract immediately adjacent to the diverticulum (see Fig. 131-12C).

Multiple Access

Multiple percutaneous access tracts are most often used during PNL for complex stones. Creation of additional access tracts is usually considered when a calyx contains a stone that is larger than 2 cm and cannot be approached with a rigid instrument via the primary access, or if a calyx contains stones of any size that cannot be reached with a flexible instrument via the primary access. For most situations, the additional accesses may be undertaken during the primary PNL using the techniques described previously, unless the procedure has been unduly prolonged, or if bleeding has been deemed excessive. If calculi are located in calyces that are in parallel with or adjacent to the calyx of initial puncture, a Y-puncture technique, in which the secondary puncture angles off the initial nephrostomy tract, may be considered (Fig. 131-13). Once the calyx of initial puncture has been cleared of stone, the working sheath is retracted outside of the renal capsule and angled toward the second targeted calyx. The second puncture is made through the working sheath. One of the attractions of the Y-puncture technique is that the cosmetic effects are minimized because the second puncture is created through the same skin incision as the first.

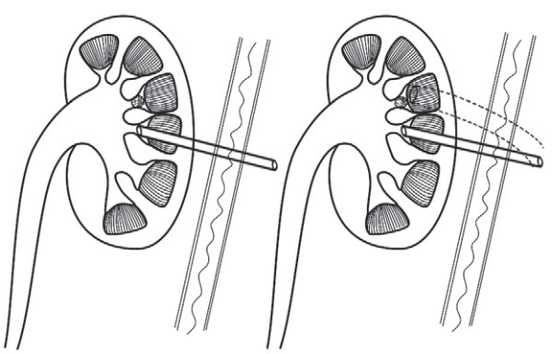

FIGURE 131-13. Y-puncture.

Nondilated Puncture

A nondilated puncture technique is preferred for certain percutaneous procedures including drainage of an obstructed hydronephrotic kidney, performance of pressure/perfusion studies (Whitaker test), instillation of chemolytic or topical chemotherapeutic agents, or as an adjunct to standard PNL techniques when an eccentric calyx that is difficult to identify is encountered. In these situations, needle puncture into the desired calyx is carried out as described previously; however, tract dilation is not performed. When percutaneous access is performed for drainage of the kidney or instillation of topical agents, a single guidewire is placed into the renal pelvis over which a nephrostomy tube is inserted. In the case of a stone-bearing calyx that cannot be identified via the existing access, a nondilated puncture is performed directly onto the stone. An attempt is made to pass a glidewire out of this calyx and into the renal pelvis where it can serve as a road map to the area of interest. Alternatively, methylene blue or carbon dioxide can be injected through the needle, and the colored stream or gas bubbles may be used to guide a flexible nephroscope into the desired calyx. Occasionally, a narrow infundibulum prevents advancement of the nephroscope into the calyx. In this instance, use of a flexible ureteroscope or balloon dilation of the infundibulum may be necessary. Back loading of the flexible nephroscope or ureteroscope over a guidewire into the desired calyx can be accomplished via a push-pull technique (Fig. 131-14). The advantage of this approach as an adjunct to PNL is that a nephrostomy tube is not needed through the nondilated tract. The nondilated puncture may also be useful for insertion of a small-diameter nephrostomy tube into a lower pole calyx in cases of "tubeless" upper pole or multiple accesses. The technique involves puncture of the lower pole onto a flexible nephroscope inserted through the upper pole access and directed into the desired lower pole calyx.

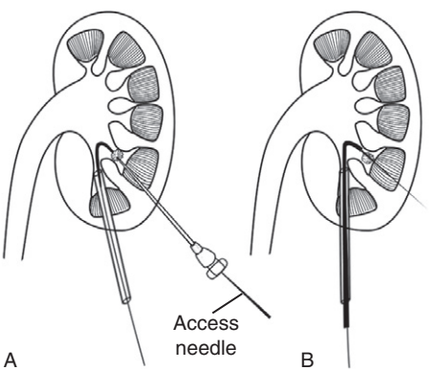

FIGURE 131-14. A, Nondilated puncture access needle guidewire with through and through access. **B,** Backloading of nephroscope/ureteroscope over guidewire into inaccessible desired calyx.

COMPLICATIONS

Hemorrhage. The most significant complication of percutaneous renal access is bleeding. Hemorrhage requiring blood transfusion has been reported to be 1% to 15%. When bleeding is encountered that impairs visualization, one should first check the position of the access sheath since placement short of the calyx of puncture may result in renal parenchymal bleeding. If the access sheath is properly positioned and substantial bleeding is still present, the procedure should be aborted and a nephrostomy tube placed. The bleeding is usually venous in nature and is often controlled by placement of the nephrostomy tube and/or clamping the nephrostomy tube to tamponade the bleeding. If these measures do not control the hemorrhage or bleeding is pulsatile, arterial bleeding should be suspected. Placement of a Kaye nephrostomy tamponade balloon catheter (Cook Urological, Spencer, IN) consisting of a low-pressure 12-mm balloon in the nephrostomy tract will usually control the bleeding; however, hemorrhage despite these maneuvers warrants urgent angiographic evaluation and superselective embolization of the bleeding source. Delayed hemorrhage occurs rarely (<0.5%); however, in these cases arteriovenous malformation or pseudoaneurysm should be suspected and angiography performed.

Infection. Although postoperative fever is found in almost one fourth of patients, sepsis occurs in only 0.3% to 2.5%. The risk of sepsis can be minimized by appropriate antibiotic therapy tailored to the preoperative urine culture. If purulent urine is encountered during percutaneous access, the tract should not be dilated. The best way to proceed is to send urine for culture, place a nephrostomy tube, and administer broad-spectrum antibiotics until a specific organism is identified. Antibiotic prophylaxis is recommended even in the face of a negative urine culture to reduce the risk of infectious complications. An intraoperative stone culture is also beneficial in selecting antibiotic therapy when fever or sepsis occurs postoperatively.

Perforation. Perforation of the renal pelvis can occur as a result of percutaneous renal access. Therefore physiologic solutions such as normal saline are mandatory to prevent electrolyte abnormalities. In the presence of minor perforation, it is usually unnecessary to terminate the procedure because the low pressure system created by the Amplatz working sheath limits retroperitoneal extravasation. More extensive perforations or those that are intraperitoneal are best treated by terminating the procedure and placing a nephrostomy tube.

Thoracic. Supracostal puncture is associated with a 4% to 16% risk of pneumothorax or pleural effusion. The risk can be minimized by suspending respirations in end expiration during needle puncture. Intraoperative fluoroscopy can be used to identify and treat pneumothorax or hydrothorax by immediate aspiration of the air and/or fluid. If the surgeon has a high index of suspicion or clinical findings postoperatively suggest a thoracic complication, a chest x-ray should be obtained, and a chest tube placed for drainage.

Visceral organ. Fortunately, visceral organ injury is a rare complication of percutaneous access. Colonic injury is the most common, occurring in less than 1% of cases. Signs of colonic perforation include passage of gas or feculent material through the nephrostomy tract, intraoperative diarrhea, hematochezia, peritonitis, or an unanticipated septic event. Because the injury is usually retroperitoneal, signs and symptoms of peritonitis may not be present, and diagnosis is not uncommonly made on postoperative CT or nephrostogram. Extraperitoneal perforation can be managed expectantly with placement of a ureteral catheter or double-J stent to decompress the collecting system and withdrawal of the nephrostomy tube from an intrarenal position to an intracolonic position to serve as a colostomy tube. The colostomy tube is left in place for a minimum of 7 days and is removed after an appropriate contrast study reveals no communication between the colon and the kidney. In cases of intraperitoneal injury or sepsis, abdominal exploration and colostomy are warranted. While less common than colonic injury, injury to the duodenum has been reported following percutaneous access of the right kidney. Duodenal perforation can usually be treated conservatively with placement of a nephrostomy tube, cessation of oral intake, nasogastric tube suction of gastric secretion, and parenteral hyperalimentation.

Injury to the liver and spleen are fortunately rare in the absence of organ enlargement. CT-guided percutaneous renal access is recommended in cases of hepatomegaly or splenomegaly. Splenic laceration often results in significant bleeding, and in severe cases may require surgical exploration. Liver injuries can usually be managed conservatively with placement of a nephrostomy tube and rarely require surgical intervention.

Suggested Readings

Kim SC, Kuo RL, Tinmouth WW, Watkins S, Lingeman JE. (2005). Percutaneous nephrolithotomy for caliceal diverticular calculi: a novel single stage approach. J Urol 173(4):1194-1198.

Lingeman JE, Matlaga BR, Evan AP. (2007). Surgical management of upper urinary tract calculi. In: Wein AJ, Kavoussi L, Novick AC, Partin AW, Peters CA, eds. Campbell-Walsh urology, 9th ed. Philadelphia: Saunders (an imprint of Elsevier Science), p 1431-1507.

Miller NL, Evan AP, Lingeman JE. (2007). Pathogenesis of renal calculi. Urol Clin North Am 34(2):295-313.

This page intentionally left blank

Chapter 132

Percutaneous Nephrolithotomy

RAMSAY L. KUO

PREOPERATIVE RADIOLOGIC EVALUATION

A successful percutaneous nephrolithotomy (PNL) procedure depends upon accurate assessment of the stone burden and its location. An intravenous pyelogram following appropriate bowel cleansing can delineate these factors; even radiolucent stones can be outlined by the presence of contrast within the collecting system. Patients with renal insufficiency should have either a retrograde pyelogram or a noncontrast computed tomography (CT) scan of the abdomen and pelvis preoperatively. A CT scan is also helpful in patients with unusual anatomy (myelomeningocele, severe scoliosis, horseshoe kidney) to ensure that safe percutaneous access can be established.

Choice of Percutaneous Tract Location and Number

The technical aspects of achieving percutaneous renal access is covered in Chapter 131. The location and number of accesses required should be determined with the ultimate goal of rendering the patient stone-free. To achieve this, each access tract should enable the surgeon to reach the maximal, if not entire amount, of the stone bulk using a rigid nephroscope. Patients with a large staghorn calculus filling multiple peripheral calyces, especially when long and narrow infundibula are present, will often require multiple simultaneous tracts to allow for optimal stone clearance.

The surgeon should always keep an upper pole access in mind as an alternative, especially when a patient has a large impacted stone burden involving the lower pole calyceal complex, or one where stone fills most of the renal pelvis with extension into the proximal ureter.

Management of Percutaneous Access Tract Before Dilation

Before any dilation attempt, guidewires must be properly positioned. Optimally, wires should be inserted down the ureter and their distal ends coiled within the bladder to avoid access loss during initial tract manipulation. Two wires should be inserted, with one serving as the "working" wire (preferably a super stiff wire to resist kinking or bending) over which catheters and dilators are inserted, and another "safety" wire to preserve the tract if the "working" wire is lost. Incomplete tract dilation can sometimes occur, especially when utilizing a radial balloon dilator.

NEPHROSCOPES

The surgeon should have both a rigid and flexible nephroscope available for every PNL procedure. The rigid nephroscope should be the initial instrument placed into the access tract. In general, rod lens rigid nephroscopes are preferred because of the superior visualization provided by these devices. Newer digital nephroscopes show promise as well. Various intracorporeal lithotripters can then be employed to fragment the stone burden.

The flexible nephroscope is used in a "clean-up" role, once the majority of the stone burden has been cleared.

Intracorporeal Lithotripters

A number of intracorporeal lithotripter (ICL) devices have been designed for PNL use.

There are a number of single modality ICL devices that use one form of energy to break apart calculi. The first of these is the ultrasonic lithotripter, which typically consists of a handpiece and a hollow metal probe. A piezoelectric crystal within the handpiece produces high-frequency vibrational energy up to 27,000 Hz, which is then transmitted through the probe. The probe is brought into direct contact with the stone surface to initiate fragmentation. Because the handpiece has a central lumen that is coupled to the hollow probe, suction can be applied through the handpiece/probe combination, allowing for concurrent removal of stone fragments. The ultrasonic lithotripter is also relatively atraumatic to the collecting system surface.

Another useful ICL is the pneumatic lithotripter, composed of a handpiece to which a solid probe is secured. A compressed air source drives a pellet within the handpiece

forcefully against the hollow probe, creating a ballistic or "jackhammer" effect that breaks the stone apart when the probe tip is brought into contact with the calculus surface. The pneumatic device is especially useful when dealing with a large volume stone of hard composition. The main disadvantage of the pneumatic device is that there is no method of concurrent stone removal. This necessitates a more tedious effort of using grasping forceps through the nephroscope to extract the fragments in a piecemeal fashion.

The holmium laser can also fragment stones during PNL. Unfortunately, laser treatment of large stones can be inefficient, because there is no efficient method of simultaneously removing fragments from the collecting system and the small fragments resulting from laser lithotripsy can be spread throughout the collecting system, making complete clearance more difficult.

Combination ICL Devices

More recently, combination ICL devices have been developed specifically for use during PN, which combine both the ultrasonic and pneumatic modalities through a dual handpiece and probe design.

FLEXIBLE NEPHROSCOPY

To ensure that stone fragments have not been dislodged into the peripheral calyces during intracorporeal lithotripsy, flexible nephroscopy should be used. This technique provides the most effective method of visualizing all accessible calyces within the collecting system. A 15-French flexible cystoscope is used along with a working channel sealing device that should have a side port. A side port sealing device enables the surgeon to use adjunctive instruments (baskets, laser fiber) concurrently with irrigation through the side port. Irrigation must be pressurized to optimize visualization within the collecting system, in that the working channel of the flexible instrument is much smaller than that of the rigid nephroscope. Typically, a pressure of 300 mm Hg is applied when a standard 34-French Amplatz sheath is used. A suggested setup involves use of cystoscopic Y-tubing to which two separate 3-L bags of normal saline irrigation are attached. One bag is compressed by a pressure bag, whereas the other bag is left to gravity drainage. This allows a seamless alternation from pressurized irrigant to gravity irrigant depending on whether flexible nephroscopy or rigid nephroscopy is used.

When calyces are visualized though the nephroscope, contrast can then be instilled and the location of the nephroscope confirmed fluoroscopically. In this manner, the surgeon can effectively "map" the entire collecting system and confirm that all peripheral areas have been examined and are free of stones.

Lastly, the ureteropelvic junction (UPJ) must be visualized. This allows for visual confirmation that no potentially obstructing fragments have lodged in the region. If the UPJ appears clear, contrast should be injected antegrade down the ureter and passage of contrast into the bladder confirmed fluoroscopically. If contrast is not seen down the length of the ureter, visualization of the ureter with a flexible ureteroscope should be considered to confirm that a more distal ureteral fragment is not present.

Placement of Nephrostomy Tube

A nephrostomy tube is traditionally placed into the renal collecting system at the conclusion of the PNL procedure. The nephrostomy tube serves a number of purposes, including tamponade of the percutaneous tract and direct drainage of the collecting system. Presence of a tube also allows the surgeon to place a wire back into the tract if needed to facilitate a second look nephroscopy. Tube placement should take place under fluoroscopic guidance, over a wire to facilitate positioning if needed. Contrast is then injected through the tube to confirm its proper location. The tube is secured to the skin with nonabsorbable suture.

Tubeless PNL

Leaving a patient without a nephrostomy tube is an option only if the surgeon is confident that all stone has been cleared and that the case has progressed without trauma to the collecting system. This option is generally most suitable for a solitary renal stone which has been cleared with minimal manipulation. If the tubeless approach is chosen, an indwelling stent and/or tract sealant can be used per the surgeon's discretion.

Chapter 133

Retroperitoneal Laparoscopic Access

PHILIPPE KOENIG, GEORGES-PASCAL HABER, AND INDERBIR S. GILL

Progress in retroperitoneal surgery during the last 15 years has allowed retroperitoneal laparoscopy to become the procedure of choice for endoscopic exploration of retroperitoneal organs. A wide range of retroperitoneoscopic procedures are now established: adrenalectomy, simple nephrectomy, nephroureterectomy, radical nephrectomy, partial nephrectomy, renal biopsy, renal cyst marsupialization, dismembered pyeloplasty, ureterolysis, ureterocutaneostomy, and retroperitoneal nerve-sparing lymphadenectomy. We describe herein the retroperitoneal laparoscopic access.

HISTORICAL CONSIDERATIONS:

Although retroperitoneoscopy was first described in 1969, it was not until Gaur and colleagues described a balloon dilation technique in 1992 that this approach became feasible and practical. The authors proposed that inflation of a balloon within the retroperitoneum displaces the retroperitoneal fat atraumatically, thus creating an adequate space for performing retroperitoneoscopic manipulation. Retroperitoneoscopy has been embraced slowly because it is thought by some to be technically challenging on account of the smaller working space, scarcity and unfamiliarity of anatomic landmarks, and considerable fat in the retroperitoneum.

CONTRAINDICATIONS AND CONCERNS

General contraindications for retroperitoneal laparoscopic access include major cardiopulmonary morbidity, resulting in high anesthetic risk and uncorrected coagulopathy. The presence of prior retroperitoneal scarring is a relative contraindication. Morbid obesity was previously considered a contraindication because of the increased retroperitoneal fat, suboptimal anatomic landmarks, and subsequent operator disorientation. Retroperitoneoscopy, however, may be preferable to the transperitoneal laparoscopic approach when approaching adrenal and renal pathology in morbidly obese patients. In our opinion, retroperitoneoscopy may offer a shorter and more rapid approach to the renal hilum in these patients.

ANATOMIC CONSIDERATIONS

A prerequisite for performing retroperitoneoscopic surgery well and minimizing complications is to have a clear and confident understanding of the relevant retroperitoneal surgical anatomy. The retroperitoneal space is fixed toward the posterior by the paraspinal, psoas, and quadratus lumborum muscles. Its anterior boundary is formed by the mobile posterior parietal peritoneum, which can be displaced by balloon dilation or finger dissection. Because the flank position doubles the dimensions of the potential retroperitoneal space in the anteroposterior plane, the peritoneal reflection is displaced toward the anterior by gravity. Further enlargement of the retroperitoneum using the balloon dilator creates an adequate working space. There are two consistent landmarks: the horizontally oriented psoas muscle and the horizontally oriented pulsations of the aorta or vena cava, which are clearly visible despite the retroperitoneal fat. During retroperitoneoscopy, the psoas muscle and posterior aspect of the kidney are identified first. This direct posterior approach allows rapid visualization of the main renal artery and vein. Our experience indicates that the following are reliable anatomic landmarks for identifying the renal hilum during retroperitoneoscopy: (1) the psoas muscle, (2) pulsations of the renal artery, (3) pulsations of the aorta or inferior vena cava, and (4) the ureter.

The major blood vessels seen initially during a right-sided retroperitoneal laparoscopic nephrectomy are the inferior vena cava and/or the renal artery, which are seen through the retroperitoneal fat. One must be careful not to confuse the partially collapsed vena cava for the duodenum. Conversely, during a left retroperitoneoscopic procedure, the pulsations of the fat-obscured aorta are often visualized initially and can act as a guide to the renal artery.

PATIENT PREPARATION AND POSITIONING

Bowel preparation for retroperitoneoscopic renal surgery involves administration of two bottles of magnesium citrate on the afternoon before surgery. Following general anesthesia, a urethral catheter is placed and the patient is positioned in the full 90-degree flank position (standard lateral decubitus). Meticulous padding and careful positioning in an ergonomically neutral position are critically important to preventing postoperative complications. Once access is gained and dissection is begun, the kidney bridge is first elevated and then the operating table is flexed to the least degree that will allow adequate separation of the costal margin and the iliac crest (Fig. 133-1). These measures help prevent rare but significant cardiovascular and dire neuromuscular consequences. The surgeon and the assistant stand facing the back of the patient.

RETROPERITONEAL LAPAROSCOPIC TECHNIQUE

Access. Port placement scheme is the same for every retroperitoneal procedure (Fig. 133-2). Initial access is obtained through a 1.5-cm transverse incision located below the tip of the twelfth rib. The muscle fibers are bluntly separated and the thoracolumbar fascia is incised to enter the retroperitoneum. Gentle blunt finger dissection is performed between Gerota's fascia and the psoas fascia and muscle (Fig. 133-3). A round preperitoneal distention balloon (US Surgical Corp., Norwalk, CT) is introduced and inflated with 800 mL of air. The laparoscope is inserted into the transparent balloon to confirm correct placement and expansion (Fig. 133-4). The balloon is deflated and removed, and a 10-mm Bluntip Cannula (US Surgical Corp., Norwalk, CT) with a retention balloon and external foam cuff is inserted

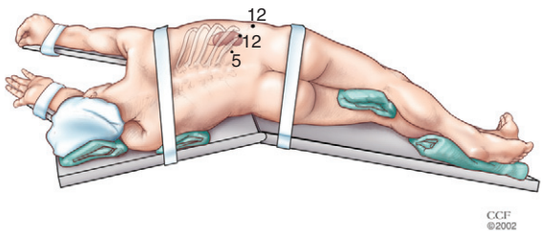

FIGURE 133-1. Patient positioning for a right retroperitoneal access. *(Reprinted with permission, Cleveland Clinic Center for Medical Art & Photography © 1999-2012. All Rights Reserved.)*

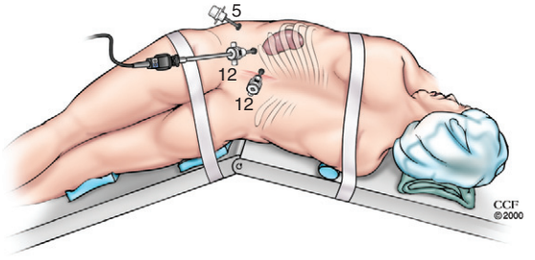

FIGURE 133-2. Patient positioning for a left retroperitoneal access with port placement. *(Reprinted with permission, Cleveland Clinic Center for Medical Art & Photography © 1999-2012. All Rights Reserved.)*

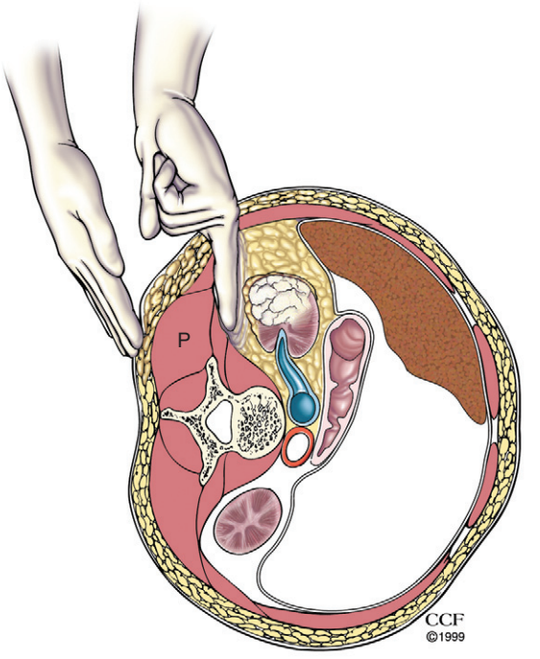

FIGURE 133-3. Retroperitoneal access: finger dissection. *(Reprinted with permission, Cleveland Clinic Center for Medical Art & Photography © 1999-2012. All Rights Reserved.)*

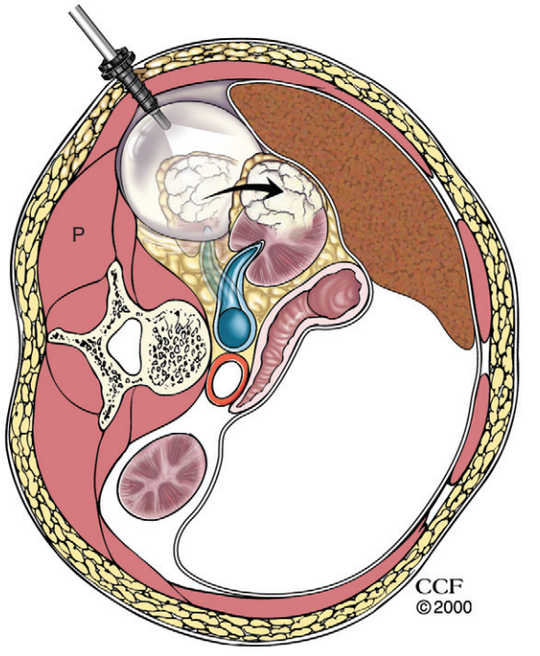

FIGURE 133-4. Retroperitoneal access: balloon dilation. *(Reprinted with permission, Cleveland Clinic Center for Medical Art & Photography © 1999-2012. All Rights Reserved.)*

and secured. Pneumoretroperitoneum (15 mm Hg) is established and a 10-mm 30-degree laparoscope is introduced.

Port placement. Two secondary ports are inserted and secured under laparoscopic visualization: a 5- or 12-mm port at the junction of the lateral border of the erector spinae muscle and the twelfth rib and a 5- or 12-mm port in the mid axillary line 3 cm cephalad to the iliac crest. On occasion, a 2-mm port is inserted anterior to the anterior axillary line at the tip of the eleventh rib to retract the peritoneum anteriorly. The ports should be placed as far away from each other as possible to avoid intraoperative clashing of the laparoscopic instruments, which can be quite frustrating during the procedure. Similarly, the anterior port should be located some distance (≥3 cm) cephalad to the iliac bone to allow free movement of the laparoscopic instrument without restriction by the rigid bone.

Dissection technique. The kidney is retracted anteromedially and the identifiable anatomic landmarks are documented. A major principle is to hold the camera in order to maintain proper horizontal orientation at all times. To that end, the horizon must be oriented to the horizontal psoas muscle rather than any vascular structures. The sequential operative strategy involves planned initial control of the vertically oriented renal artery, with its pulsations acting as an aid in locating its position (Fig. 133-5).

Once the renal artery is circumferentially mobilized, clipped-occluded, and divided, the renal vein, located more toward the anterior and usually caudal to the renal artery, is mobilized and secured with a laparoscopic vascular stapler. To avoid inadvertent ligation of the inferior vena cava, the stapler must never be fired without circumferentially visualizing the junction of the renal vein with the inferior vena cava. On the right side, the renal vein must be clearly seen heading from the vena cava toward the kidney with proper direction toward the top of the television monitor. Additionally, the clipped/transected renal artery stump, which does not retract, serves as an important guide to localizing the renal vein. When suprahilar is indicated, dissection along the medial aspect of the upper renal pole identifies the inferior adrenal vessels followed by the main adrenal vein, which may be precisely controlled using clips or the vascular stapler after lateral mobilization. The ureter, with or without the gonadal vein, is secured, and specimen mobilization, including the adrenal gland when indicated, is completed external to Gerota's fascia, mirroring established principles of open surgery.

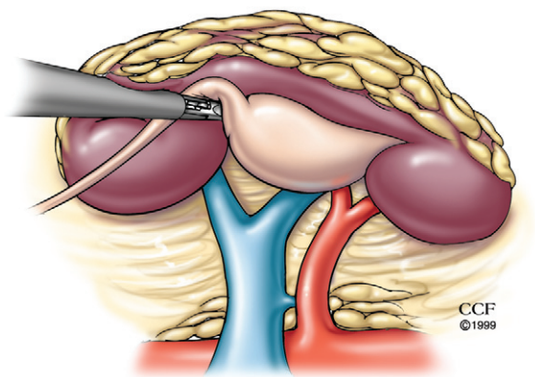

FIGURE 133-5 *(Reprinted with permission, Cleveland Clinic Center for Medical Art & Photography © 1999-2012. All Rights Reserved.)*

Inadvertent peritoneotomy is a minor event that should be disregarded because it usually does not interfere with the procedure.

Entrapment and exit. An EndoCatch device is introduced through the right-hand port incision, and the specimen is entrapped. For the largest specimens, an intentional peritoneotomy is occasionally created to facilitate intraperitoneal specimen entrapment. In males, we perform intact specimen extraction by either an extraperitoneal Gibson muscle-splitting incision or a low Pfannenstiel incision. In females, vaginal extraction of the intact specimen can additionally be performed efficaciously.

CONCLUSION

The retroperitoneal approach likewise has inherent disadvantages and advantages. Disadvantages include a smaller initial working space, closer proximity of trocar sites, and greater difficulty in specimen entrapment. As such, retroperitoneoscopy is possibly associated with a steeper learning curve. Because of these drawbacks, retroperitoneoscopy has not been favored by most laparoscopic surgeons. Increasing experience has allowed us to overcome the perceived difficulties associated with this approach. Balloon dilation allows rapid and atraumatic expansion of a viable working space within the retroperitoneum, which can be readily enlarged as the dissection proceeds.

The hallmark of the retroperitoneal approach is the rapid and straightforward access to the renal artery and vein. Because the bowel is not physically manipulated, paralytic ileus is minimized. Although the chances of visceral injury are decreased, it must be remembered that only the peritoneal membrane separates bowel from the retroperitoneum, and transperitoneal enteric injury remains a possibility. Postoperative fluid collections remain limited to the retroperitoneal space, thus avoiding contamination and spillage into the peritoneal cavity. The retroperitoneal approach is superior in patients with intraperitoneal adhesions secondary to prior abdominal surgery and is preferred in obese patients because it gives a shorter and more direct access to the different structures. Finally, when comparing retroperitoneal and transperitoneal radical nephrectomy in a prospective randomized study, the retroperitoneal access was associated with a shorter time to renal artery control, shorter time to renal vein control and shorter total operative time.

Suggested Readings

Bartel M. (1969). Retroperitoneoscopy. An endoscopic method for inspection and biopsic examination of the retroperitoneal space [in German]. Zentralbl Chir 94:377-383.

Desai MM, Strzempkowski B, Matin SF, Steinberg AP, Ng C, Meraney AM, Kaouk JH, Gill IS. (2005). Prospective randomized comparison of transperitoneal versus retroperitoneal laparoscopic radical nephrectomy. J Urol 173(1):38-41.

Gaur DD. (1992). Laparoscopic operative retroperitoneoscopy: use of a new device. J Urol 148(4):1137-1139.

This page intentionally left blank

Chapter 134

Transperitoneal Laparoscopic Access

J. STUART WOLF, JR. AND WILLIAM W. ROBERTS

CHOOSING SITES OF ACCESS

The first step in obtaining transperitoneal laparoscopic access is choosing the optimal site for initial access. Typically, the initial site is the one for the videolaparoscope. As such, consideration of the best viewing location is important. The view of the operative field should be unobstructed by anatomic structures and should provide appropriate angles that do not interfere with instruments. Additionally, the entry site should be free of adhesions (near surgical scars) or other anatomic problems (e.g., organomegaly, cysts) that might increase the risk of injury. Finally, knowledge of the abdominal wall configuration provides confidence in the "feel" of initial entry and reduces the chance of abdominal wall vessel injury. Figure 134-1 illustrates a cross section of the abdominal wall. The simplest entry is in the midline, where fascial layers are fused. The peritoneum is a separate layer, except at the umbilicus where it is adherent to the fused fascia. Laterally, several additional layers of muscle and fascia are interposed between the skin and the peritoneal membrane.

The location of abdominal wall vessels should be considered during access site selection. The superior and inferior epigastric vessels course posterior to the rectus muscle, with branches that perforate laterally and medially. A puncture through the rectus muscle risks damage to these vessels. The superficial epigastric and circumflex iliac vessels fan onto the lower abdominal wall above the fascial layers. Any lower quadrant puncture may injure these vessels. The periumbilical venous plexus is usually not problematic, but in some patients may be dilated and therefore may be more susceptible to injury.

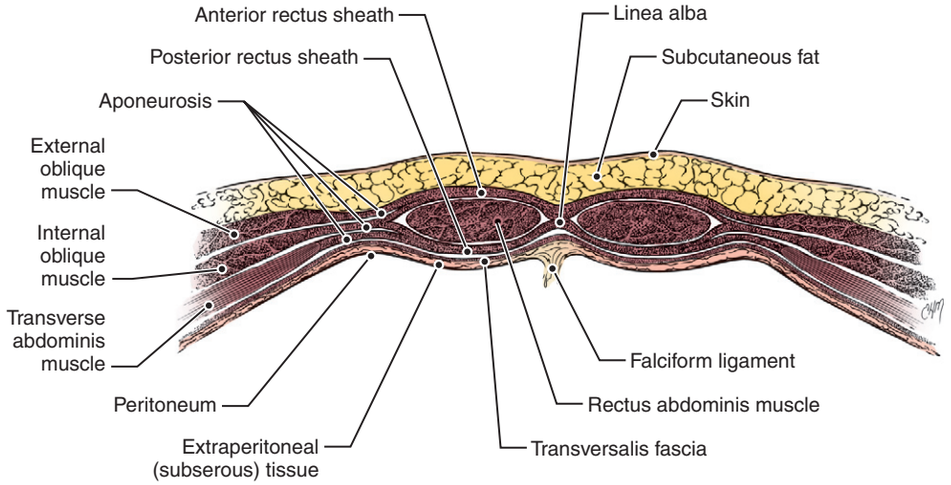

FIGURE 134-1. Cross-section of anterior abdominal wall. *(From Ellenbogen KA, et al. [2011]. Clinical cardiac pacing, defibrillation and resynchronization therapy, 4th ed. Philadelphia: Saunders.)*

INITIAL ACCESS

For laparoscopic renal surgery, the initial entry is usually made in the umbilicus, the upper midline, or the ipsilateral upper quadrant. The distance lateral from the midline and cephalad from the umbilicus is determined by the size of the patient and the kidney. In thin and small patients, entry at the umbilicus or elsewhere in the midline might be appropriate. For obese patients, the optimal entry site might be closer to the costal margin. Although the initial entry site is usually where the videolaparoscope is placed, if the preferred areas are complicated by scars from prior surgery, then initial access can be obtained anywhere that is safe. Once the abdomen is insufflated, then additional ports, including the one that will eventually be used for the videolaparoscope, can be placed.

Veress Needle

The most common tool for initial transperitoneal laparoscopic entry in urologic practice is the Veress needle, which has an inner, blunt-tipped obturator and an outer, sharply beveled sheath (Fig. 134-2). The obturator is spring-loaded, such that it retracts when pushed against fixed structures (fascia and peritoneum) and allows penetration of tissue by the sharp sheath, but when against mobile structures such as bowel, the obturator protrudes and prevents puncture. To insert the Veress needle, first make a small nick in the skin with a scalpel. Holding the needle with thumb and forefingers, insert it with a motion of the wrist and fingers. The direction of insertion generally should be perpendicular to the abdominal wall, although for midline insertion the needle should be angled away from the great vessels. The number of palpable layers of resistance until the peritoneal cavity is reached varies from one to three, depending on the site of insertion and the patient's body habitus. When resistance is lost, and the needle can be advanced a few centimeters freely, the correct space has likely been entered. Lifting up on the abdominal wall, as done by many surgeons, does not create more space in the peritoneal cavity, and may increase the depth of tissue that must be traversed to the peritoneal cavity, but it does create more abdominal wall tension against which to push the Veress needle, and likely increases the distance between the anterior peritoneum and the retroperitoneal vessels.

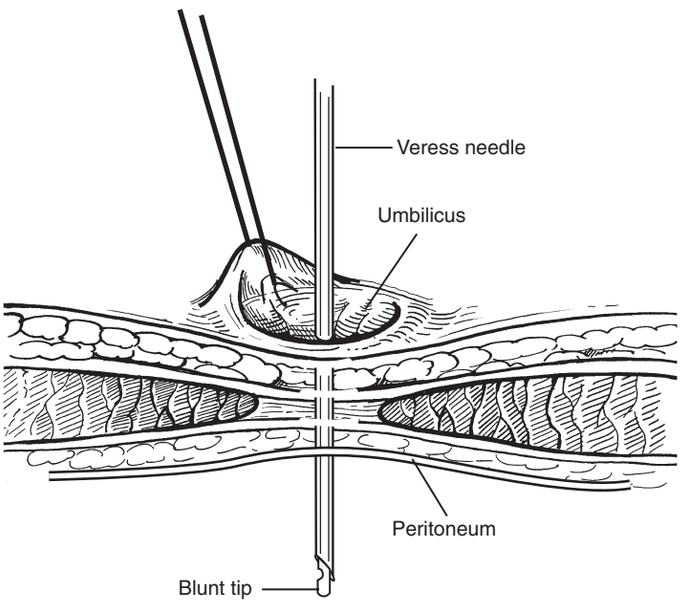

FIGURE 134-2. Veress needle. *(From Bishoff JT, Kavoussi LR. [2007]. Atlas of laparoscopic urologic surgery. Philadelphia: Elsevier.)*

Next, perform a series of tests to assess for correct needle placement. Place a 10-mL syringe containing 5 mL of saline on the Veress needle, and aspirate back. If blood, bowel contents, or urine is aspirated back, then placement is incorrect. If there is no such material, then inject the fluid through the Veress needle and aspirate; again, there should be no return of material. These maneuvers will determine whether the needle tip is in a luminal structure, but will be unremarkable if the needle is preperitoneal, which is the most common erroneous placement. This possibility is assessed by monitoring the intraabdominal pressure when insufflation is commenced. The pressure should not rise above 8 mm Hg within the first 500 ml of gas, or if it does, it should only be momentary and quickly corrected by a slight withdrawal, twist, and tilting up of the needle (which will free the needle tip from omental or mesenteric fat). If these conditions are met, continue insufflation. If these conditions are not met, then disconnect the insufflation tubing, allow the gas to escape, and withdraw the needle. One or two additional attempts are reasonable, perhaps at different locations, but continued failure should prompt the use of an alternative method of access.

"Open" Laparoscopy

The most common alternative method of initial transperitoneal entry for laparoscopy is "open" laparoscopy to insert a blunt (Hasson) trocar-cannula, a balloon-tipped port, or the sleeve for a radially expanding port. A blunt trocar-cannula (Fig. 134-3), which is available from various manufacturers in reusable and disposable versions, consists of a blunt trocar, a cannula with an adjustable conical sleeve, and suture-holding arms for fixation. Make a small incision through the skin and use small retractors to expose the fascia in order to make a 1.5-cm incision. Place retention sutures on both sides of the fascia, incise the peritoneum under vision, and explore with a finger to ensure that the peritoneal cavity is free of adhesions. Insert the trocar-cannula assembly, and bring the cone into the peritoneotomy to create a tight seal. Pull the fascial stitches up and tie them around the arms of the assembly to hold it in place. Insert the balloon-tipped port (Fig. 134-4), which is available as a disposable device from various manufacturers, in a similar manner, but with this device retention and gas-tightness is attained by an inflatable balloon at the tip of the port pulled up against the underside of the abdominal wall and held snugly in place by a locking foam cuff. The radially expanding port (Step ports, AutoSuture Co, Norwalk, Conn.; Fig. 134-5), which is more commonly used as a separate port rather than for initial entry, can also be used with "open" laparoscopy for initial access. For this port, make the incision in the fascia and peritoneum only



FIGURE 134-3. Traditional Hasson cannula. *(From Wein AJ, et al. [2011]. Campbell-Walsh urology, 10th ed. Philadelphia: Saunders.)*

a few millimeters wide. Insert the mesh sleeve into the peritoneotomy and advance the dilating trocar-cannula assembly through the sleeve (see later for more detailed explanation of this device). Because the initial incision is smaller than the final port diameter, gas leakage with this technique tends to be less than with the blunt trocar-cannula (gas leakage with the balloon-tipped port also tends to be minimal). Some laparoscopists obtain initial access with "open" laparoscopy in all cases, some use it when confronted with a patient with suspected abdominal adhesions or other anatomic abnormalities, and others use this technique only if Veress needle insertion fails.

Visualizing Trocar

Another alternative to using the Veress needle is use of a dilating, visualizing trocar (Endopath bladeless trocar, Ethicon Endo-surgery, Cincinnati, Ohio; Fig. 134-6). The clear plastic tip allows laparoscopic visualization of the tissue in front of the tip as the port is being inserted. This device is most commonly used after insufflation (see later for more detailed explanation of this device). Some authors have advocated use of a dilating, visualizing trocar for initial abdominal access, without prior insufflation, although injuries can still occur.

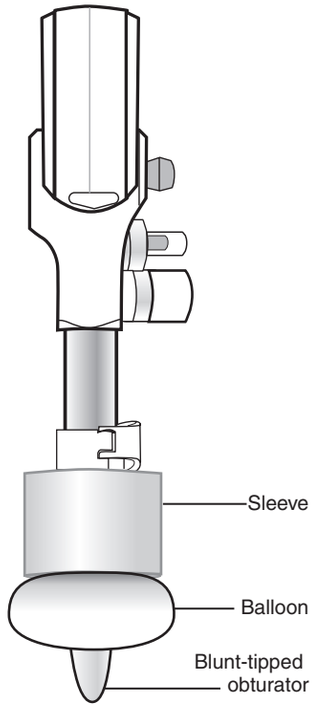

FIGURE 134-4. Balloon-tipped port. *(From Bishoff JT, Kavoussi LR. [2007]. Atlas of laparoscopic urologic surgery. Philadelphia: Elsevier.)*

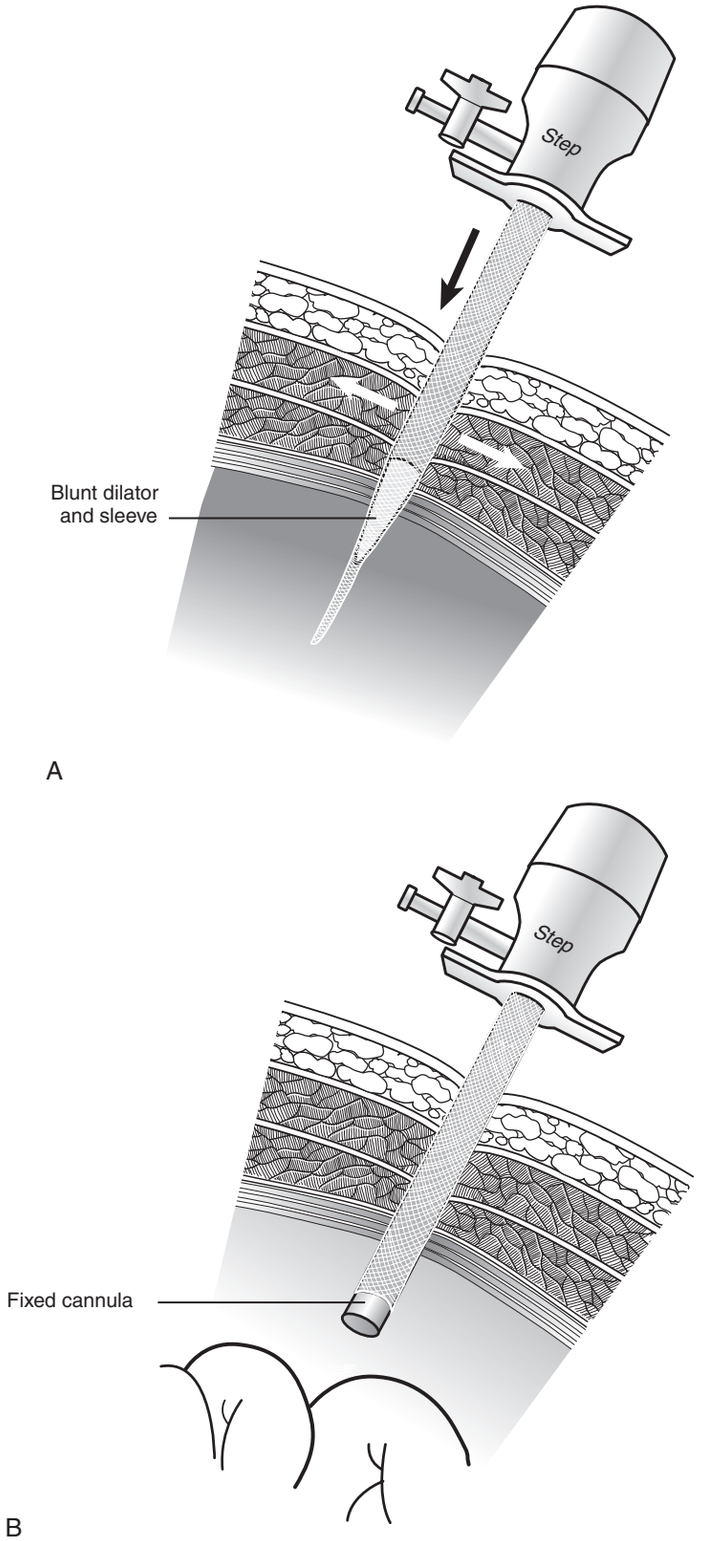

FIGURE 134-5. Radially dilating port system. *(From Bishoff JT, Kavoussi LR. [2007]. Atlas of laparoscopic urologic surgery. Philadelphia: Elsevier.)*



FIGURE 134-6. Visualizing dilating trocar. *(From Wein AJ, et al. [2011]. Campbell-Walsh urology, 10th ed. Philadelphia: Saunders.)*

PORT PLACEMENT

Once the peritoneal cavity has been insufflated through a Veress needle, place the first port. This port almost always should be inserted at the site of Veress needle placement. Although this is usually the port for the videolaparoscope, in some cases the videolaparoscope is better situated elsewhere. Once the first port has been inserted, inspect the abdominal contents and choose sites for the additional ports. Options for secondary ports (or primary ports after Veress needle insufflation), include those with bladed trocars, a variety of nonbladed trocars (radially dilating, visualizing, and nonvisualizing), and threaded ports.

Bladed trocars (Fig. 134-7) are most commonly disposable, although some sharp reusable metal trocars are available. Advantages of a disposable bladed trocar include its consistently sharp tip and the safety-shield mechanism, which is a spring-loaded plastic covering around the trocar point that retracts to expose the sharp tip. After the peritoneal cavity is entered, the shield springs forward and locks into position to protect abdominal contents from injury (see Fig. 134-7). Insert bladed trocars with a firm but controlled motion, without rotating or deviating the tip from a straight trajectory.

The radially dilating system (see Fig. 134-5) consists of a Veress needle, a mesh sheath, a conical tipped trocar, and a rigid cannula. Fit the mesh over the Veress needle, and insert the tip into the abdomen. After removing the needle, grasp the handle of the mesh sheath to provide fixation, and advance the trocar-cannula assembly through the mesh sheath, which dilates the small fascial incision (considerable force is often required) until the cannula is seated into the handle of the mesh sheath. Visualizing dilating trocars (see Fig. 134-6) have a conical plastic tip with flanges that allows visualization of the tissue in front of the trocar with a 0 degree videolaparoscope. Advance the laparoscope-trocar-cannula assembly through a skin incision, keeping the camera straight but rotating the trocar and cannula back and forth over a 120-degree range, to drive through fascia and muscle into the peritoneal cavity. There also are a number of nonvisualizing dilating trocars, with various tip configurations that are also used to dilate rather than cut the fascia. Insert these trocar-cannula assemblies with a straight trajectory, rotating the trocar and cannula back and forth over a 120-degree range. The dilating trocars carry a lower risk of injury to abdominal wall vessels and other structures. Additionally, the fascial defects are smaller than those produced by bladed trocars. The visualization of



FIGURE 134-7. Bladed trocar, with sharp blade extended **(A)** and retracted **(B).**

tissue in front of the trocar with the visualizing dilating trocars provides the additional safety feature of direct monitoring of the tissue being penetrated.

The final type of laparoscopic port is a threaded one (Ternamian EndoTIP Cannula, Karl Storz Endoskope, Germany; Fig. 134-8). This port incorporates a corkscrew thread and a flange that separates rather than cuts tissue. Initial abdominal entry has also been reported with this type of port.



FIGURE 134-8. Tip of threaded port. *(Ternamian EndoTIP Cannula, C Karl Storz Endoskope, Germany.)*

The radially dilating and threaded ports tend to remain in place very well in the abdominal wall, but the other ports, especially ones placed with a bladed trocar, can slip out easily. Some of these ports include features intended to improve fixation, such as threads or beveled ridges, but the simplest method to prevent port dislodgment is to suture the port to the abdominal skin in much the same way a drain would be sutured into place.

Priorities for secondary port placement include, in addition to the same anatomic considerations as for initial access: avoidance of clashes with the videolaparoscope and other instruments, comfortable position for the surgeon's arms, and providing more than one "angle of attack" to the operative site. The procedure chapters in this text provide recommended port placements, but as experience is gained surgeons should expect to alter the port locations to suit their particular technique.

Chapter 135

Hand-Assisted Laparoscopic Surgery

GEORGE E. HALEBLIAN, JAMES O. L'ESPERANCE, AND DAVID M. ALBALA

ROLE OF HAND-ASSISTED LAPAROSCOPIC SURGERY

Hand-assisted approach provides tactile feedback to the surgeon and improves the surgeon's three-dimensional orientation in the operative field. It allows the surgeon's hand into the operative field to facilitate dissection, retraction, and hemostasis. The tissues can be visualized and palpated. This method also facilitates resident education in the operation room. The hand-assisted approach allows the surgeon greater control in difficult situations, such as bleeding, where digital pressure can be applied, and helps reduce the conversion rate to open surgery.

Preoperative Considerations

Patient selection is of paramount importance in hand-assisted laparoscopic surgery (HALS). A complete history and physical examination is always performed with a focus on prior surgery, percutaneous procedures, endourologic procedures, history of peritonitis/bowel obstruction, abdominal wall infection, or radiation therapy. A history of coagulopathy, chronic obstructive pulmonary disease, or cardiac issues must also be ascertained. Informed consent must include the risk of open conversion. A full bowel preparation with Miralax or Fleets Phosphosoda is usually performed. Antiplatelet agents are discontinued 10 days before surgery. Laboratory tests to ensure adequate renal function and blood counts are obtained. If a difficult procedure is predicted, the patient is cross-matched for blood. Absolute contraindications for performing HALS are active peritonitis or bowel perforation, bowel obstruction and distention, uncorrectable coagulopathy, extensive adhesions often associated with multiple prior surgical procedures, shock/sepsis, abdominal wall infection, and severe cardiac or pulmonary disease. Relative contraindications include morbid obesity, abdominal aneurysmal disease, large intraabdominal mass, ascites, and umbilical abnormalities.

Patient Positioning

A Foley catheter and a nasogastric tube are placed after induction. For nephrectomy, partial nephrectomy, nephroureterectomy, or adrenalectomy, the patient is placed in a full flank or a modified flank position. A beanbag and an axillary roll are usually used. Flexion of the operating room table is usually not necessary. The authors prefer to create the hand-port incision and to insert the hand-assist device with subsequent insufflation and secondary port placement. The secondary ports can either be placed under direct vision after abdominal insufflation or they can be placed using the hand to palpate and guide the placement.

Devices Used for Hand-Assisted Laparoscopic Surgery

There are three second generation hand-assist devices utilized by most surgeons: the Lap Disc (Ethicon Endosurgery, Cincinnati, Ohio) (Fig. 135-1), the GelPort (Applied Medical, Rancho Santa Maria, Calif.) (Fig. 135-2), and the OmniPort (Weck Inc., Raleigh, NC) (Fig. 135-3). All of these devices allow for easy removal and reinsertion of the surgeon's hand. They are also all relatively easy to use and maintain pneumoperitoneum as long as they are used according to recommended techniques. Pneumoperitoneum is maintained by either an internal ring compressing the anterior abdominal wall or by compression against the wound.

Device Placement

Selecting Location for Hand-Assist Device Placement (Fig. 135-4)

The site of template placement is important but varies with surgeon preference and procedure being performed. Specific port placement for each procedure is outlined in subsequent chapters. In placing the template, the nondominant hand of the surgeon, the body habitus of the patient, the goals of the procedure, and the experience of the assistant are taken into account. The following template positions have been described:

Low Midline (Fig. 135-5)

The advantages with low midline device placement are that there is access to both sides with the nondominant hand. Access to the bladder is easy in nephroureterectomy. In



FIGURE 135-1.

addition, lower midline incisions appear to be less painful. One disadvantage is that access to the upper pole of the kidney and to the adrenal gland may be difficult.

Periumbilical (Fig. 135-6)

This is the ideal position for left nephrectomies for a right-handed surgeon or for right nephrectomies for a left-handed surgeon. It provides access to the upper pole of the kidney and adrenal gland and can provide access (though more challenging than the low midline location) to the bladder for nephroureterectomy.

Upper Midline (Fig. 135-7)

With this template placement, access to the right kidney is with the dominant hand and to the left kidney with the nondominant hand. This position also allows the assistant to insert a hand for renal hilar access. The disadvantage of this position is that the hand tends to be too close to the kidney, forcing the surgeon to work with less space and in an awkward position. The author uses this position only in unusual circumstances when prior surgery precludes a lower incision or in patients with very large upper pole tumors.

Gibson-Type or Paramedian (Figs. 135-8 and 135-9)

Gibson-type lateral incisions (see Fig. 135-8) are more suited for the right-side or for left-sided cases performed by left-handed surgeons. Access to the bladder is easy with this approach. These can be muscle-splitting incisions and are often associated with minimal pain.

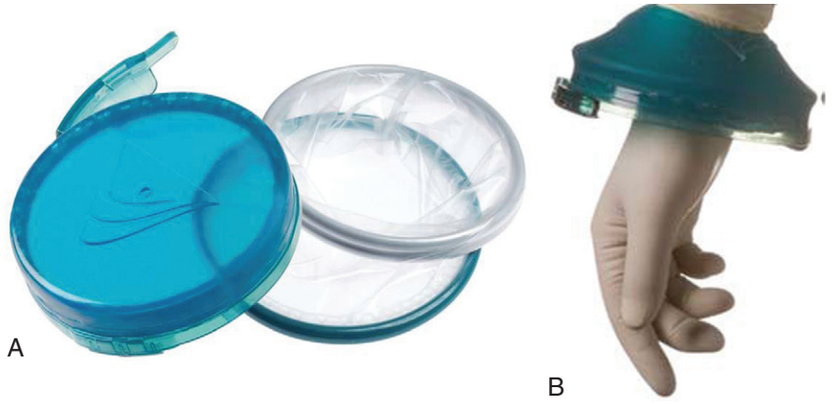

FIGURE 135-2.

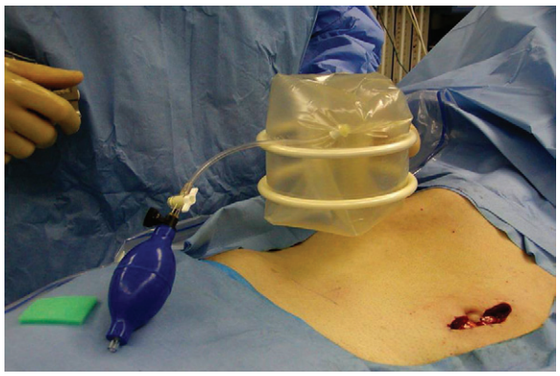

FIGURE 135-3.

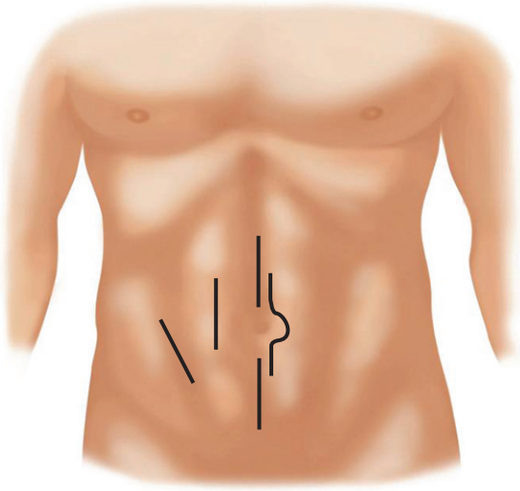

FIGURE 135-4.

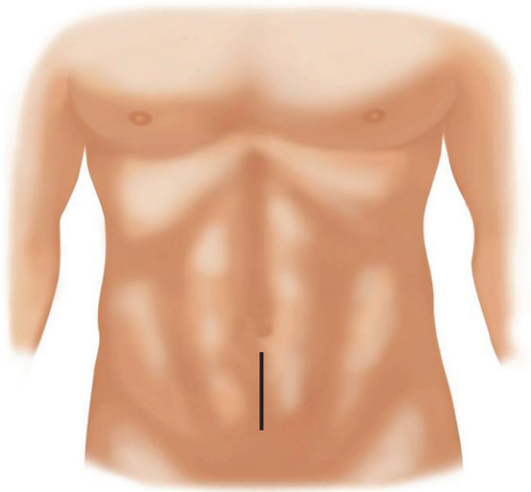

FIGURE 135-5.

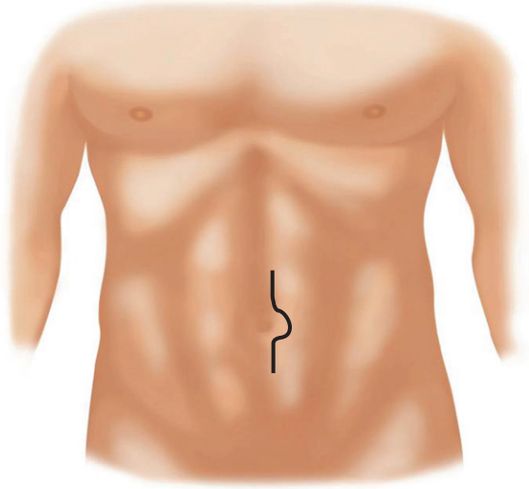

FIGURE 135-6.

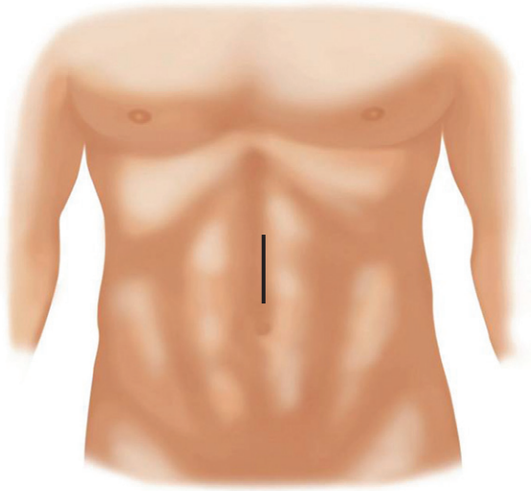

FIGURE 135-7.

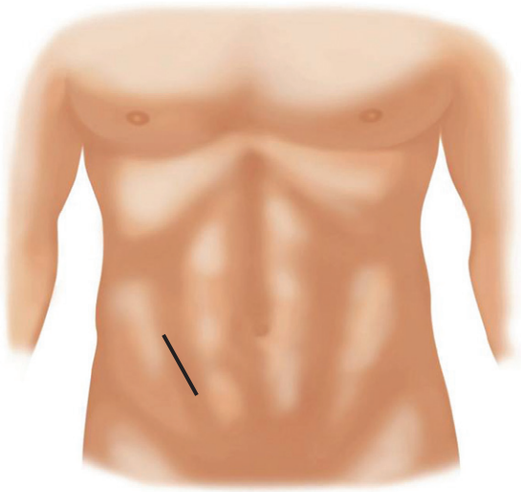

FIGURE 135-8.

It should be noted that a paramedian incision should be used on obese patients (see Fig. 135-9). In these situations, as the pannus falls to the side, the location of the paramedian incision is over the midline of the fascia and rectus musculature, resulting in a midline incision inside the abdominal cavity.

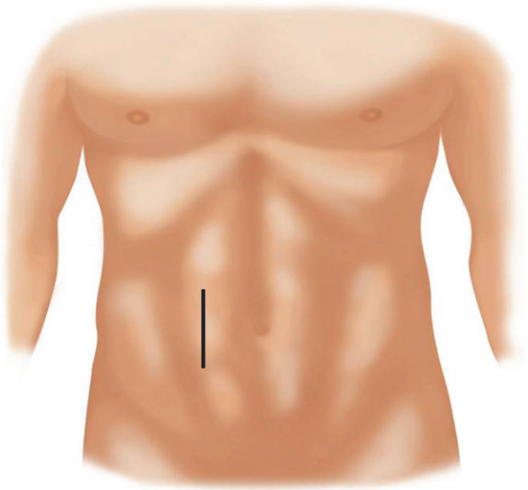

FIGURE 135-9.

In most cases for right-hand dominant surgeons, a Gibson incision for hand port placement is used on the right side and a periumbilical incision is used for the left side. Some authors prefer to perform the operation as a mirror image on each side. These surgeons employ the Gibson incision on both sides and use either the dominant or nondominant hand for dissection.

CONCLUSIONS

HALS is widely used in urology and provides many of the advantages of pure laparoscopy with the added benefit of tactile feedback, ease in training, and surgeon familiarity. It is critical that the surgeon familiarize himself or herself with the various hand-assist devices available. Numerous locations for hand port devices have been described all with successful outcomes. Highlights of each device location have been reviewed and further recommendations for specific procedures are provided in the ensuing chapters.

Chapter 136

Renal Cryosurgery

THOMAS J. POLASCIK

PRELIMINARIES

Indications: Current technology works best for tumor size less than 3.5 cm. Tumors between 3.5 and 4.5 cm will likely require additional probes and run a greater risk of incomplete ablation or complication when laparoscopically ablated and are not recommended for cryotherapy, although these larger tumors may be reasonable for a percutaneous approach depending on the clinical situation. For therapeutic ablation, patients should have an absence of local and systemic dissemination on magnetic resonance imaging (MRI) or computed tomography (CT), although palliative treatment may be offered under appropriate conditions.

In addition to routine preoperative assessment, a recent dual-phase renal CT or MRI delineating exact tumor dimensions and location is imperative. Mechanical bowel preparation is routinely done to decompress the intestines. Patients also receive a dose of a broad-spectrum cephalosporin.

Cryosurgery is an ablative technology and as such, can be used via an open surgical, percutaneous, or laparoscopic (transperitoneal, retroperitoneal, or hand-assisted) approach. The transperitoneal, pure laparoscopic approach is illustrated.

INSTRUMENTS

Argon-based cryotherapy unit with cryoprobes and thermocouples, intraoperative ultrasonography, laparoscopic ports and instruments, biopsy gun, and hemostatic agents.

ISOTHERMS

Temperatures within the iceball vary and represent a gradient from extremely cold (approximately −180°C) adjacent to the thermal shaft of the cryoprobe to 0°C at the outside edge of the iceball. An isotherm is a temperature zone colder than a specific cutoff temperature characterizing that temperature gradient (e.g., 0°C, −20°C, and −40°C isotherms). Approximately 2 to 3 mm inside the outer edge of the iceball begins the <−15° to −20°C isotherm, at which point temperatures become cold enough to be considered lethal to some cells. It is generally accepted that the <−40°C isotherm is sufficient for complete cellular destruction; however, in vitro studies have suggested that cellular death can occur at different temperatures depending on the type of tumor. Figure 136-1 provides an example of iceball dimensions according to the desired isotherm achieved.

Position: The patient is positioned in a 20- to 45-degree modified lateral position and is well secured to the table. The table can be rotated during the procedure (should be tested before draping) to achieve further lateral positioning. The patient should be toward the edge of the table facing the surgeon, tumor side up. General anesthesia is used.

Port placement: Typically three laparoscopic ports are used: a 5-mm port in the midline epigastrium, a 5- or 12-mm camera port at the umbilicus, and a 12-mm port in the lower quadrant on the side of the tumor (Fig. 136-2). Alternatively, the three ports can be placed at the lateral border of the rectus muscle beginning 2 cm below the costal margin (the superior port usually serves as the camera port), evenly spaced with a hands-width between each port. With either port configuration, one must use a 12-mm port to allow access of the laparoscopic ultrasound probe. A 5-mm liver retractor is used when appropriate. A pneumoperitoneum is created.

Mobilization: The overall principle is to mobilize sufficient tissue to (1) allow exposure of the tumor and (2) to place the cryoprobes perpendicular into the tumor, rather than obliquely. The rib cage is usually the limiting anatomical factor that prevents perpendicular probe placement, especially for upper pole tumors. Anatomically, for many patients the upper pole lies beneath the costal margin while the lower pole is unencumbered by the rib cage (see Fig. 136-2). Therefore, the amount of mobilization will depend on being able to attain perpendicular cryoprobe access to the tumor. As an example, for an anterior lower pole tumor, minimal mobilization is needed to both expose the tumor and directly access it with the cryoprobe(s) (Fig. 136-3A). For posterior or upper pole tumors, more extensive mobilization

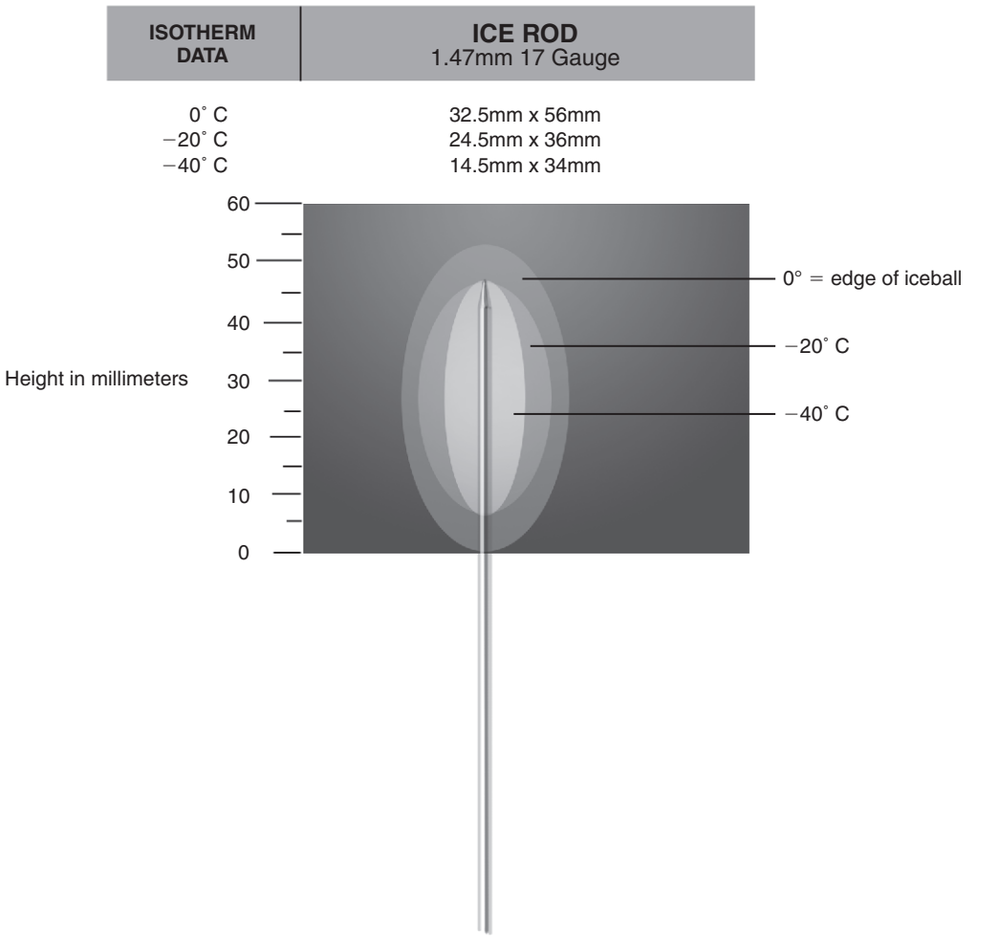

FIGURE 136-1.

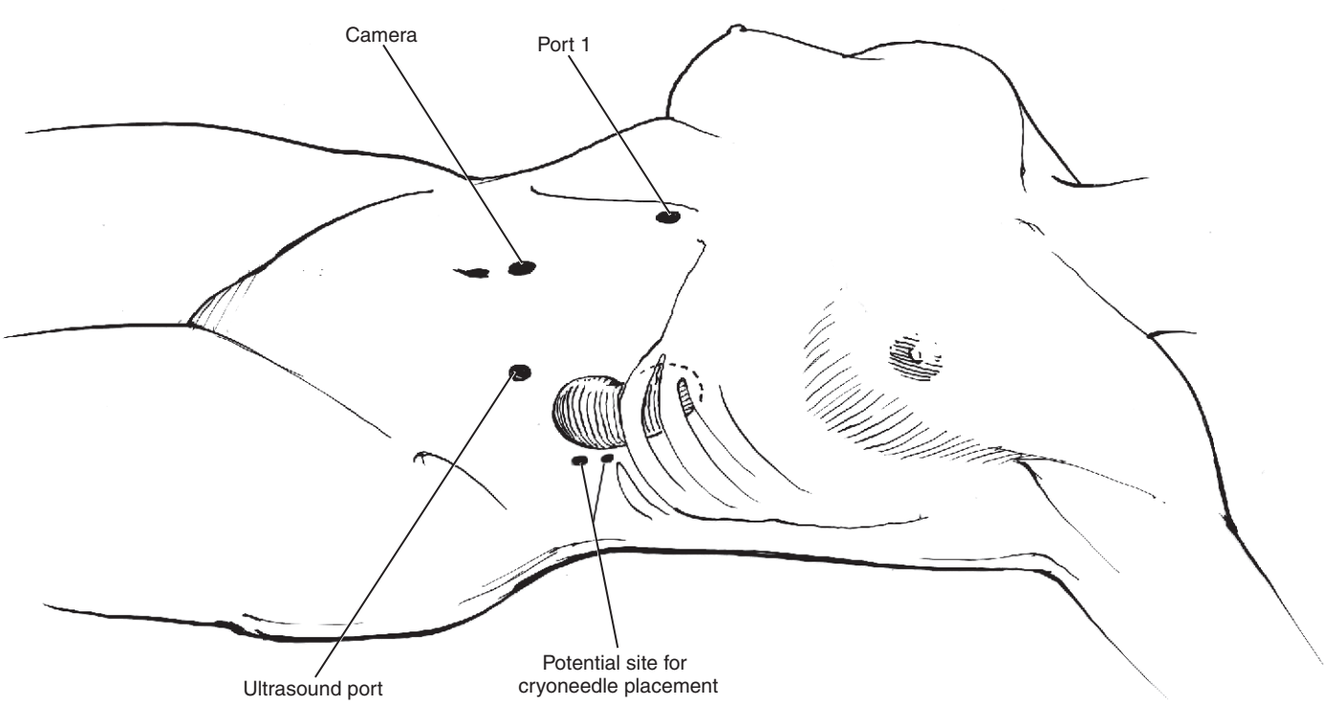

FIGURE 136-2.

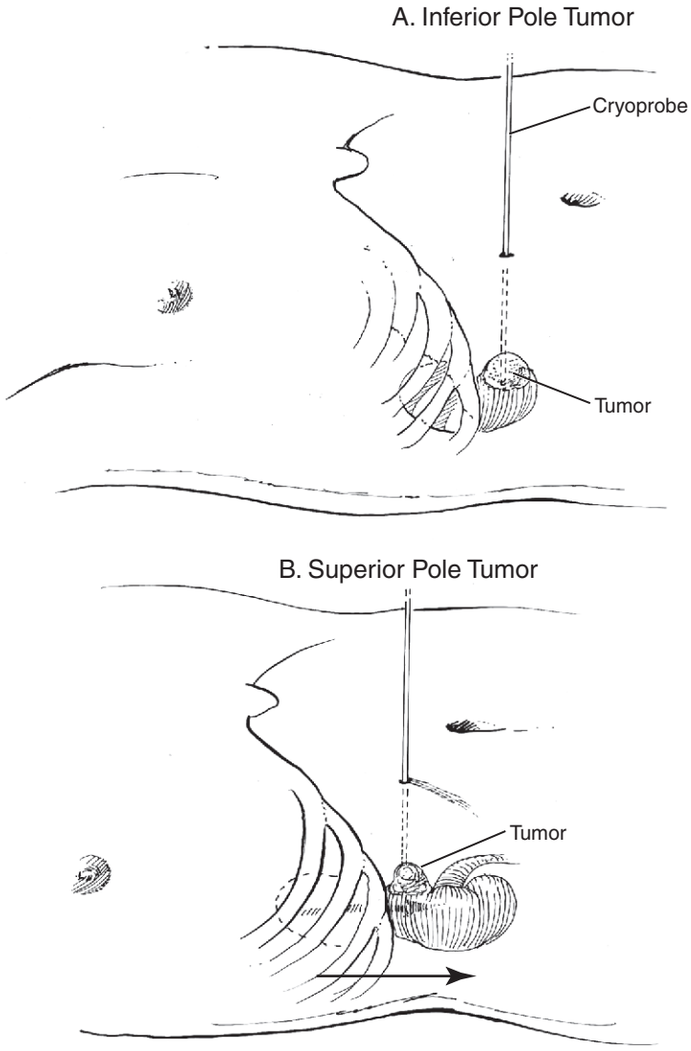

FIGURE 136-3.

may be necessary. For example, upper pole tumors will usually require greater mobilization to pull the kidney inferiorly below the rib cage, to prevent oblique cryoprobe placement into the tumor (see Fig. 136-3B). Retracting the upper pole beyond the rib cage can be accomplished by placing additional retractors or using a hand-assist device to pull the kidney inferiorly.

When mobilizing the kidney, the line of Toldt is incised only to the extent it need be to attain access to the tumor. For left-sided upper pole tumors, the spleen should be sufficiently mobilized to prevent inadvertent traction injury due to pulling on the lienorenal and lienocolic ligaments. The colon is reflected medially by incising the renocolic ligament. Hilar control is not necessary for cryosurgery. During the freezing phase the ultrasound probe is placed perpendicular to the cryoneedles (Fig. 136-4). Therefore, for anterior tumors, it may be necessary to mobilize an area posterior to the kidney to allow for subsequent placement of the ultrasound probe.

The tumor dimensions and location should already be known based upon a recent preoperative CT or MRI scan. For endophytic lesions, it may be necessary to locate the tumor solely using ultrasound guidance in contrast to exophytic tumors that can be visually identified. The location of endophytic tumors can be verified by frozen section biopsy. Once the tumor is identified, Gerota's fascia adjacent to the neoplasm is incised and the renal surface exposed. The perirenal fat overlying the tumor is removed, placed in a laparoscopic entrapment bag, and sent for histological evaluation. The renal surface is scanned with the laparoscopic ultrasound probe to define the exact dimensions of the lesion, its relationship to the calyceal system and vascular structures, and the presence of any satellite lesion(s). Raytech gauze can be temporarily placed through a 12-mm port to either provide a field around the tumor or protect other vital structures, such as bowel, during the freezing phase. The sponge can also retract and protect the ureter when treating medial, lower pole lesions.

Cryoprobes: Based upon the size of the lesion, the number of cryoprobes needed to ablate the tumor must be determined. For very small lesions, it may be possible to use a single cryoprobe for ablation. For larger lesions, triangulation of the probes may provide sufficient ice overlap to encompass the tumor (Fig. 136-5). For even larger lesions,

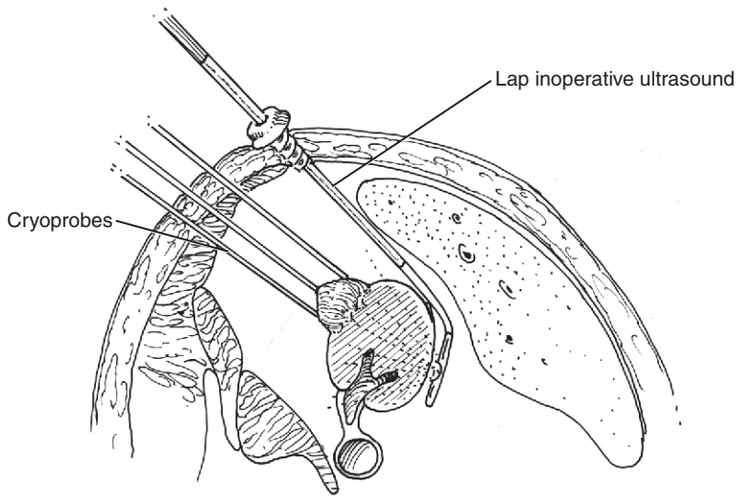

FIGURE 136-4.

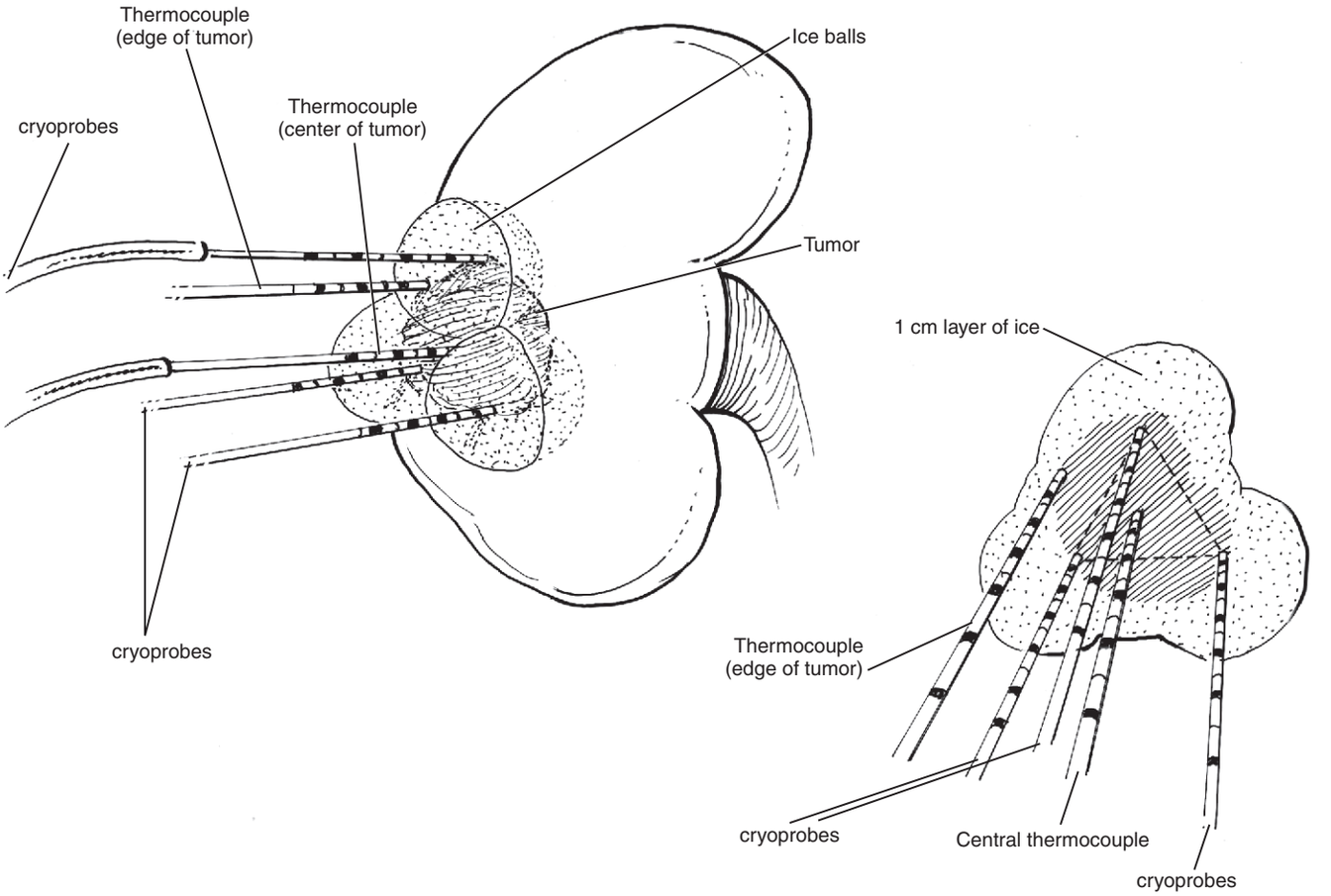

FIGURE 136-5.

cryosurgeons may use a 4-probe "square" or "box" configuration placed around the perimeter of the tumor, or a 5-6 probe pentagon/hexagon probe placement. It is important to consult with the manufacturer about the size of the ice generated and the isotherm data for a particular product when determining the number of cryoprobes or the positioning/configuration of probes needed to achieve cell kill. However, the principle remains the same: to ensure the tumor remains engulfed in a lethal isotherm and that adjacent ice balls overlap sufficiently to attain a lethal isotherm between ice balls. When using a single cryoprobe it is placed in the center of the tumor with sufficient depth to achieve an adequate deep parenchymal margin. This chapter illustrates a more complex multiprobe configuration. Figure 136-6A depicts three cryoprobes properly spaced apart so that there are even colder temperatures achieved

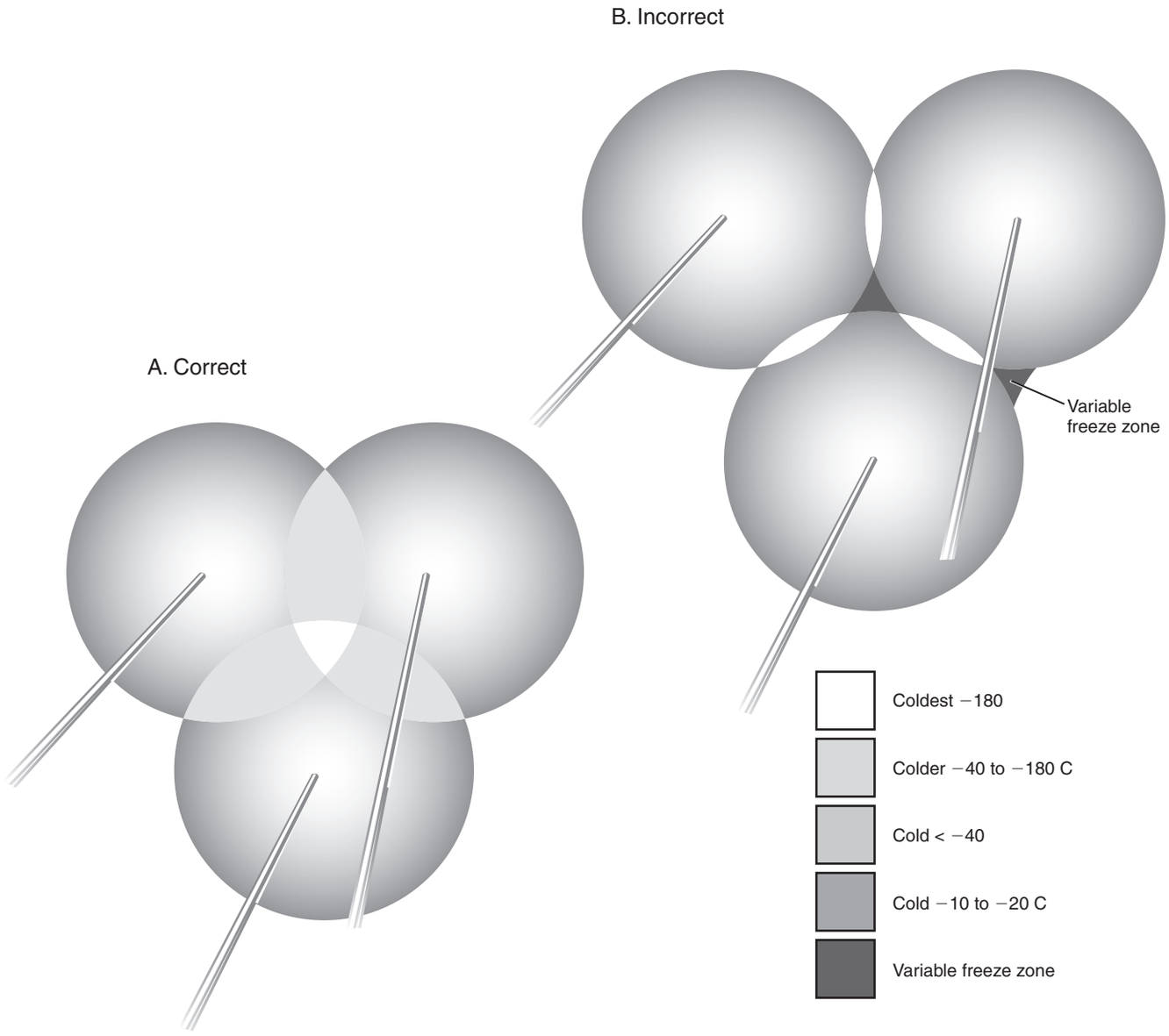

FIGURE 136-6.

where adjacent ice balls overlap. In contrast, Figure 136-6B demonstrates that, if adjacent cryoprobes are spaced too far apart, then one may have "warm pockets" called the "variable freeze zone" where two adjacent ice balls do not overlap to provide lethal temperatures.

Regarding depth of probe placement, because there may be little lethal ice generated beyond the tip of the needle, cryoprobes are placed either at the base of the tumor or up to 0.5 cm beyond the depth of the tumor when clinically appropriate. As an example, using 17-gauge needle technology, cryoneedles are placed no farther than 1.5 cm apart according to thermal mapping studies to achieve sufficient overlap of adjacent ice balls along with an adequate cryosurgical margin (up to 1 cm) beyond the edge of the tumor.

Thermocouples: A thermocouple is placed at the perimeter of the lesion as well as in the center (Fig. 136-7). If the temperature is measured at the tip of the thermocouple, then one would place the tip in the center of the tumor, representing the radius of the mass or half the distance of the depth of the tumor. Often the cryotherapy kit supplied by the manufacturer contains several thermocouples that can be placed in whatever locations the physician wishes to measure temperatures.

Cryoprobe placement into the skin: Before placement of cryoprobes, the surgeon needs to determine the most direct route between the skin surface and the renal mass. This may entail pulling the kidney inferiorly below the costal margin with retractors or rotation of the kidney in order to position the kidney in such a way that the tumor is directly in line with percutaneous placement of the cryoprobes. Once the configuration of the needles is determined, each cryoprobe and thermocouple is placed through the skin first in the same configuration as will be placed into the tumor. For example, if one wants a triangular configuration of probes placed in the tumor with a 1.5-cm distance between each

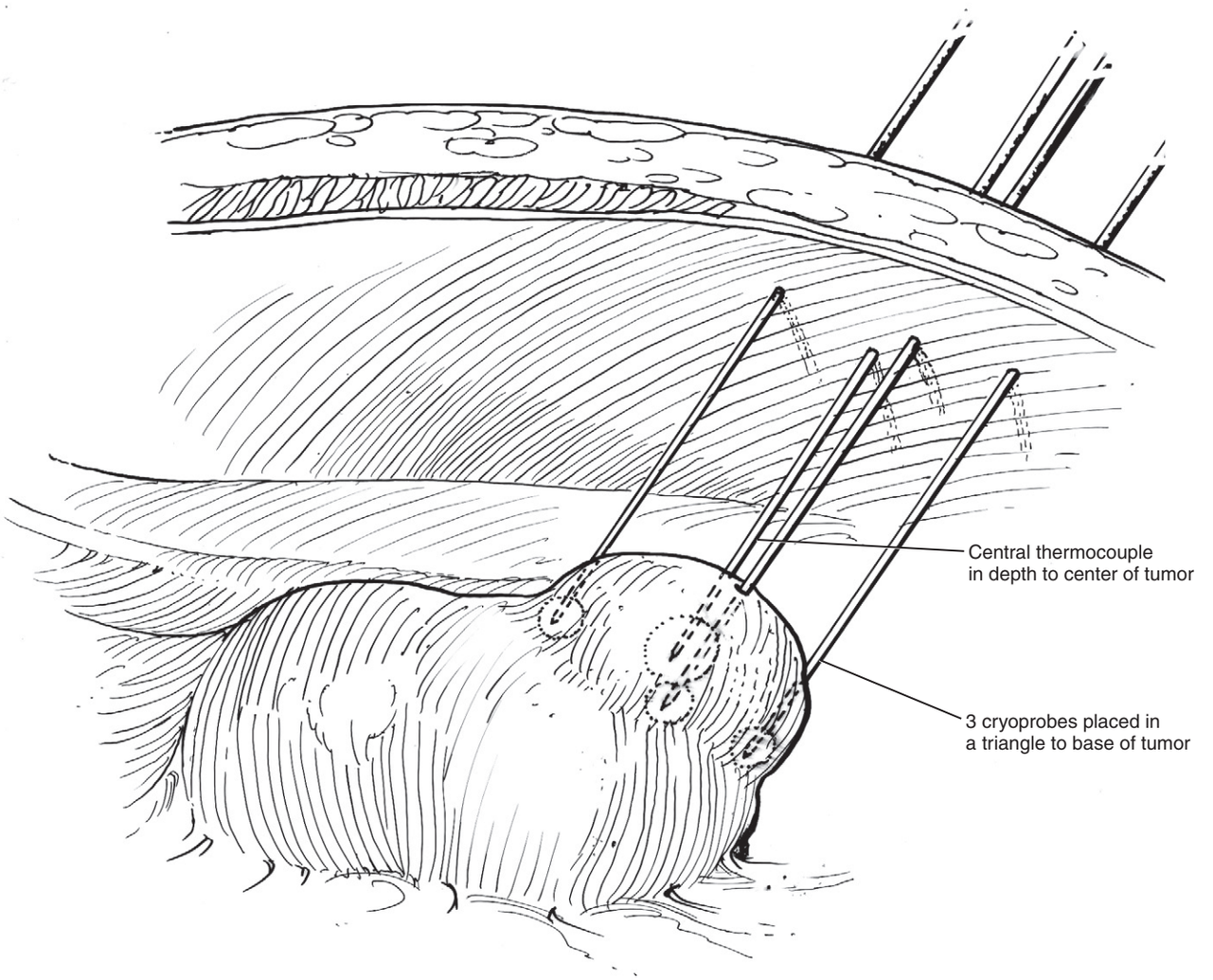

FIGURE 136-7.

probe, one will mark out the same configuration on the skin (Fig. 136-8). All probes are initially placed parallel to one another through the skin at predetermined sites.

Needle biopsy and insertion of cryoprobes into tumor: Before insertion of cryoprobes/thermocouples into the tumor, a small access sheath is placed approximately 5 to 10 cm away that will be used to provide access for renal tumor biopsy (the sheath provides a means to prevent the theoretical risk of "track seeding" with tumor biopsy). Sequentially, each cryoprobe is placed into the tumor to the appropriate depth followed by placement of the thermocouple(s). The ultrasound probe can assist with probe placement and is best used if the transducer is perpendicular to the probes. One should verify proper probe position and depth prior to commencement of freezing. Under direct vision or laparoscopic ultrasound guidance, needle biopsy of the renal mass is obtained (three or four cores) and sent for histological evaluation. The biopsy can be performed either before cryotherapy or after the first freeze/thaw cycle to decrease the chance of biopsy-induced bleeding.

Freezing: Two freeze-thaw cycles are performed. The freezing process is monitored by both temperature readings and ultrasonic guidance. Temperatures during freezing typically depress beyond −75°C centrally and are measured to be at least <−40°C at the perimeter of the tumor by thermocouple. The ultrasound will show a hyperechoic rim of the leading ice edge followed by loss of acoustic shadowing. As freezing time progresses, each of the ice balls coalesce and the treated area will become anechoic. One can sonographically visualize the coalescence of ice balls and follow the ice edge as it covers the tumor and beyond to include a surgical margin (see Fig. 136-5). Once this occurs, and temperatures depress beyond −40°C both inside and at the perimeter of the tumor, the freezing process can be stopped. A typical freeze for a 2- to 3-cm tumor using commercially available argon gas systems lasts 5 to 10 minutes. During the cryoablation procedure it is mandatory to use extreme care to prevent the ureter or other abdominal organs from coming into direct contact with the ice ball or cryoprobes. Additional retractors may need to be placed before freezing to safeguard normal structures from touching the probes. In addition, during the freezing process, one is establishing a frozen/solid interface adjacent to perfused, soft, normal

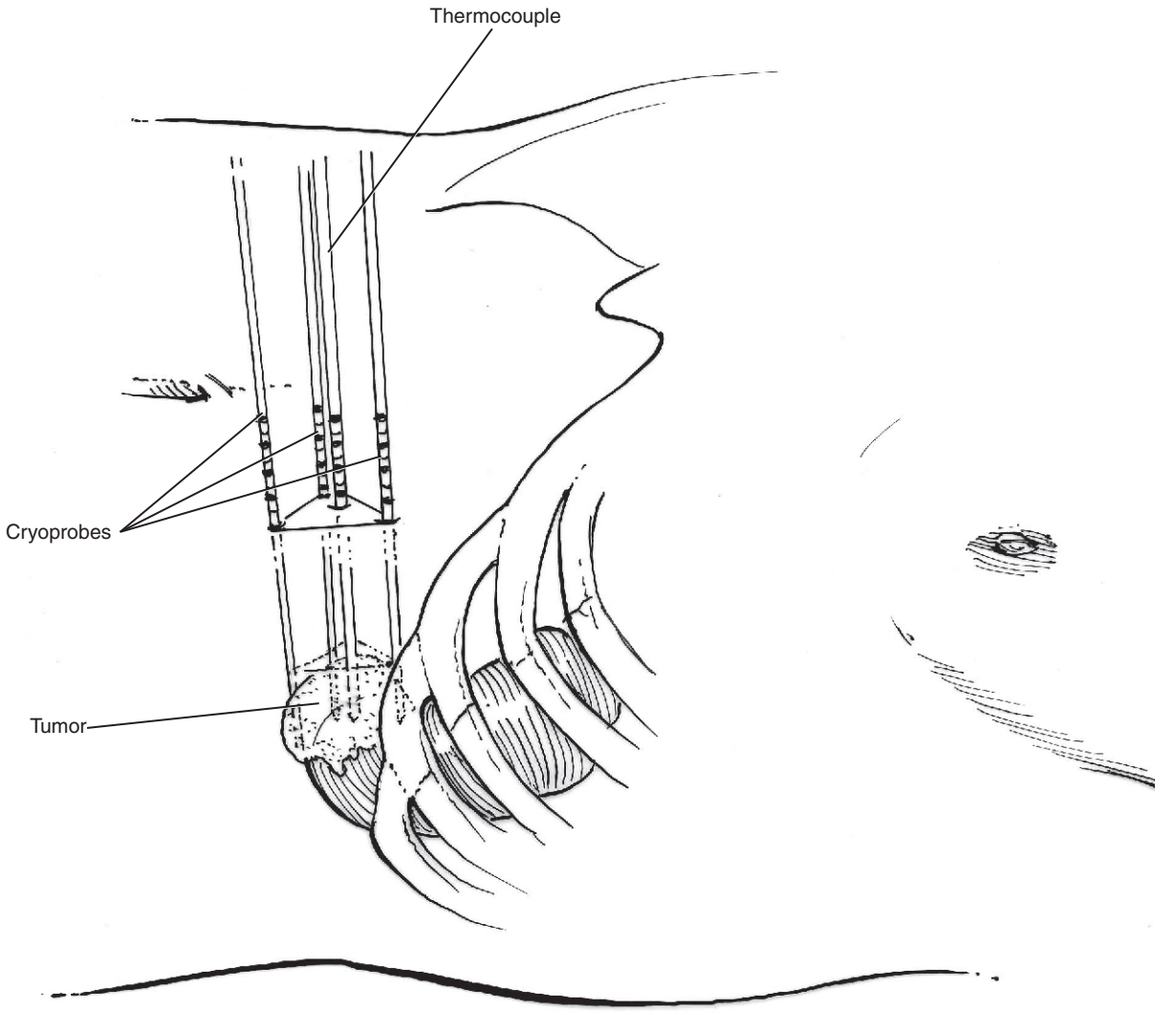

FIGURE 136-8.

parenchyma. This interface can "crack" if undue tension is placed on the probes thereby leading to a fractured kidney with subsequent bleeding. Care must be taken to prevent this from occurring.

After the first freeze, the kidney is thawed until the temperature thermocouples reach positive numbers (>0°C) and the ultrasound shows the iceball has melted. Thereafter, a second freeze is commenced. Following the second thaw cycle, the cryoprobes and thermocouples can be removed once the tissue reaches positive temperatures (>0°C). Hemostatic agents are applied to the treated site to control minor bleeding. A drain is not usually required but can be placed at the judgment of the surgeon.

Postoperative patient evaluation including physical examination, serum creatinine, chest roentgenogram and dual phase renal CT or MRI is performed every 6 months for 2 years after cryosurgery, and annually thereafter. Tumor control is usually radiographically defined as the absence of both contrast enhancement and growth in size of the treated lesion on contrast-enhanced CT or MRI.

This page intentionally left blank

Chapter 137

Renal Radiofrequency Ablation

ILIA S. ZELTSER AND JEFFREY A. CADEDDU

RENAL RADIOFREQUENCY ABLATION

Renal radiofrequency ablation (RFA) provides a minimally invasive approach to treatment of small renal masses. RFA utilizes monopolar alternating electrical current generated by the RFA generator that flows between the grounding pad and the RFA probe. Heat is generated as a result of ionic agitation of the tissue around the probe and cell death is achieved when the temperature within a tumor and a small rim of the surrounding tissue rises over 60 °C. High temperatures produce occlusion of the microvasculature and destruction of the cellular cytoskeleton, causing tissue ischemia, impaired DNA replication, and ultimately resulting in a predictable zone of coagulation necrosis around the RF electrode.

Based on the type of the feedback loop–modulating energy delivery to the probe, there are two types of RF generators: impedance-based (Valleylab, Boulder, CO, or Boston Scientific, Natick, MA) and temperature-based (RITA Medical Systems, Mountain View, CA). The feedback loops are designed to prevent an overly rapid tissue heating, which would produce charring and increase tissue resistance, thus decreasing the ablation zone.

To further minimize tissue charring, multiple probe designs have been developed. There are single- or multiple-tined electrodes that are subdivided further into wet-, dry-, or cooled-tip probes. Multiple tines distribute the current over a larger surface area, allowing more energy to be delivered to the tissue before charring occurs. Wet probes (StarBurst™ Xli-Enhanced and Talon™, RITA Medical Systems) infuse poorly resistive conductive fluid into the treated tissue, thus decreasing resistance and permitting deeper penetration of the current. The cooled-tip probe (Cool-tip™, Valleylab, Boulder, CO) is a single-tine electrode that minimizes tissue charring by circulating cooling liquid within the probe to decrease its surface temperature and allow more energy to be delivered into the tissue.

RFA can be used to treat exophytic as well as completely endophytic renal masses and can be done in an outpatient setting. It can be performed laparoscopically or percutaneously, and the selection of the approach depends on tumor location, patient's health status, and the surgeon's expertise. A percutaneous technique is suitable for patients with posterior or laterally located renal masses and those who cannot tolerate abdominal insufflation because of cardiac or pulmonary disease. Laparoscopic RFA is done under general anesthesia; however, percutaneous ablations can be performed under either general anesthesia or intravenous sedation. We prefer general anesthesia for the percutaneous approach because it prevents patients' movement as well as allows for a controlled respiratory expansion, thus stabilizing kidney location. We believe that these advantages provide for a more precise and expedited tumor targeting.

Prior to intervention patients are evaluated with a CT scan of the abdomen with and without intravenous contrast utilizing 3-mm axial cuts through the kidneys to determine the exact location and size of the renal lesion. In patients with poor renal function or intravenous contrast allergy, magnetic resonance imaging with gadolinium enhancement can be used instead.

PATIENT PREPARATION

Routine laboratory studies are obtained and include serum electrolytes, creatinine, liver function tests, and coagulation profile. Urine culture is sent, and culture-specific antibiotics are started in those with positive cultures. Chest radiography is performed per discretion of the anesthesiologist. Patients taking aspirin, warfarin, large doses of vitamin E, or other anticoagulation agents are instructed to discontinue them 5 to 7 days prior to the intervention although they may resume them immediately after RFA. Patients are made NPO (nothing per mouth) the night before the procedure and to those undergoing laparoscopic RF ablation, a light bowel preparation with one-half bottle of magnesium citrate is administered. A parenteral antibiotic with good coverage of skin flora is given in the morning of the procedure.

RFA TECHNIQUES

The techniques demonstrated employs the Starburst XL RFA probe and RITA 1500X Generator (RITA Medical Systems), which is our preferred technology. If the treating physician elects to utilize an alternative probe or manufacturer, the approach outlined below remains unchanged except for the probe and generator use instructions provided by the manufacturer.

Percutaneous RFA

1. After placement of antiembolic stockings, general endotracheal anesthesia is administered. The bladder is drained with a Foley catheter. The patient is secured in a prone or flank position on the CT table and all the pressure points are carefully padded. Two RF grounding pads are placed per manufacturer recommendation (Fig. 137-1).
2. A paper grid is placed on the back or flank over the kidney and a computed tomography (CT) of the abdomen is performed with a one-half normal contrast dose to accurately identify the lesion. Following the initial scan, the best percutaneous route to the tumor is planned to ensure that the probe will avoid the surrounding structures such as liver, spleen, colon, and pleura.
3. An RFA probe is inserted percutaneously through the predetermined point on the grid and directed toward the lesion (Fig. 137-2). Correct placement is confirmed with repeated CT imaging and adjustments are made to ensure that the deployed tines fully encompass the tumor and that the ablation zone will extend at least 5 mm beyond the tumor margin. Successful deployment must be confirmed on CT prior to ablation (Fig. 137-3). In cases where ablation of the entire tumor cannot be accomplished despite proper probe positioning and tine deployment, a repositioning prior to a second round of ablation may be required.
4. Although not necessary, core-needle biopsies of the tumor can now be performed once the correct probe position is verified. It is important to position the probe prior to placement of the biopsy needle, because bleeding from the biopsy may change the contour of the lesion and obscure its margins.



FIGURE 137-1. Patient positioned on computed tomography table.

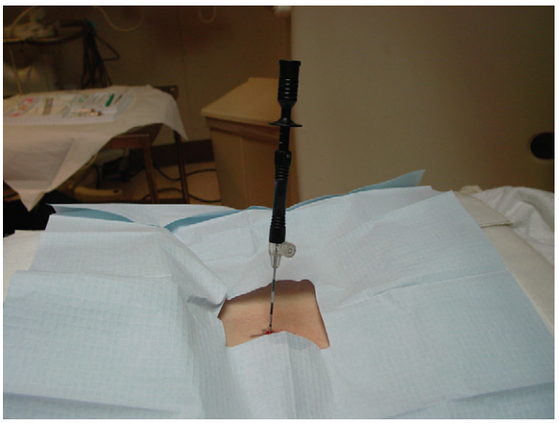

FIGURE 137-2. Probe placement.



FIGURE 137-3. Computed tomography with tines deployed.

5. Immediately following the biopsy, the RF generator (RITA) is activated and energy is delivered until the average temperature among all the tines reaches 105 °C. Depending on the size of the tumor (Table 137-1), the target temperature is maintained for 3 to 8 minutes.
6. Once the first treatment cycle is completed, a cool-down cycle is initiated and tissue temperature is monitored. Adequate ablation and cell death is confirmed if the treated tissue maintains passive temperatures above 70 °C during the cool down cycle.
7. For tumors larger than 1 cm, a second cycle of ablation is initiated to ensure ablation.
8. Following the second cool down cycle, track ablation is performed as the tines are withdrawn and the probe is simultaneously pulled back 5 to 10 mm.
9. Post-ablation CT with one-half dose of intravenous contrast is obtained to confirm successful tumor ablation (Fig. 137-4).
10. The Foley catheter is removed and the patient is discharged home the same day following recovery from anesthesia.

RFA PROTOCOL UTILIZING STARBURST XL (RITA) PROBE

TABLE 137-1

Tumor Size	Length of Treatment Cycle (minutes)	Number of Cycles
<1 cm	3	1 or 2
1–2 cm	5	2
2–3 cm	7	2
3–4 cm	8	2



FIGURE 137-4. Postablation computed tomography.

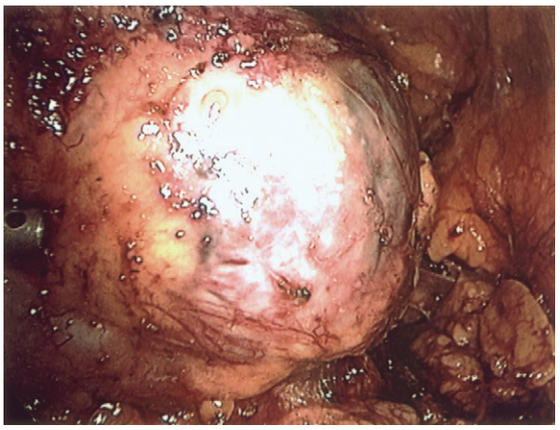

FIGURE 137-5. Tumor is exposed.

LAPAROSCOPIC RFA

1. After antiembolic stockings are placed, general endotracheal anesthesia induced, and the bladder is drained with a Foley catheter, the patient is positioned in the modified flank position and secured to the table with tape. All of the pressure points are carefully padded.
2. The abdomen is insufflated with a Veress needle, and three transperitoneal laparoscopic trocars are placed in the same configuration as for a laparoscopic nephrectomy.
3. The white line of Toldt is incised and the colon is reflected medially off the Gerota's fascia. Gerota's fascia is then opened and the perinephric fat is reflected off the renal surface to identify the tumor (Fig. 137-5).
4. Laparoscopic renal ultrasound is then used to define tumor margins. Ultrasound is imperative in helping to identify and define the margins of partially or completely endophytic renal tumors.
5. The location on the abdominal wall allowing the most perpendicular path of the probe to the tumor is identified. The probe is inserted through the abdominal wall and the kidney is then manipulated so that the probe enters the lesion at a right angle to the most exophytic point of the tumor. The probe is inserted into the tumor and the tines are deployed to encompass a diameter extending 5 to 10 mm beyond the measured margin of the tumor (Fig. 137-6). Tine placement is confirmed with laparoscopic ultrasound.
6. RF ablation is initiated utilizing the same protocol as for percutaneous RFA (Table 137-1).
7. Once ablation is completed (Fig. 137-7) the probe is removed and biopsies of the tumor with a laparoscopic 5-mm–toothed biopsy forceps are taken (Fig. 137-8).

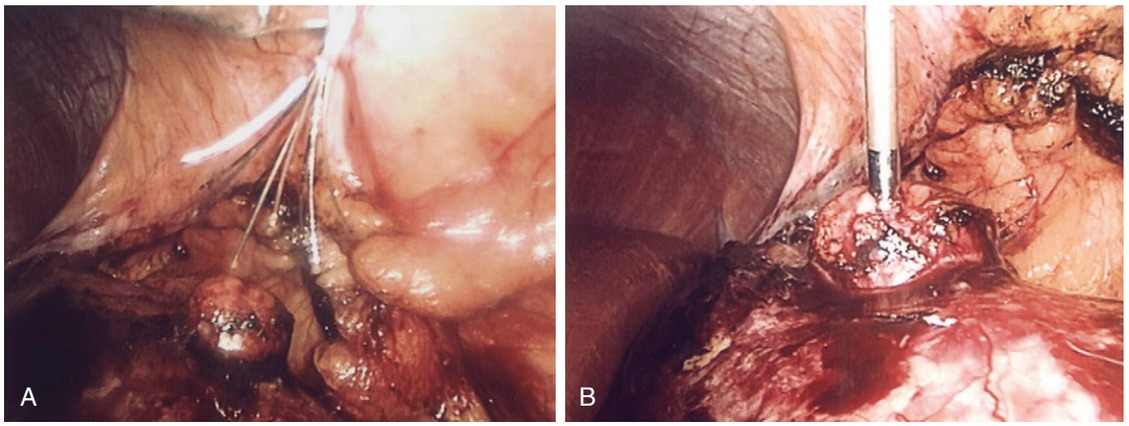

FIGURE 137-6. Probe placement.

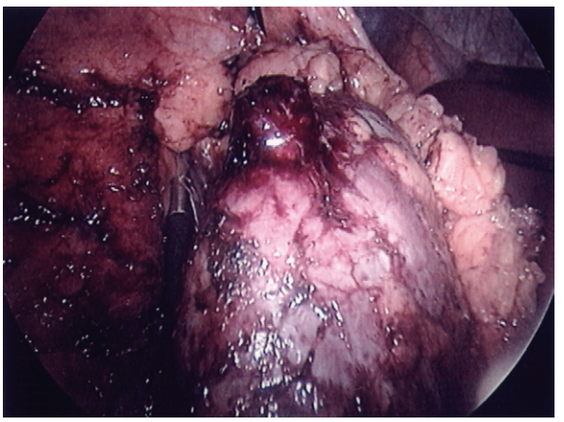

FIGURE 137-7. Postablation appearance.

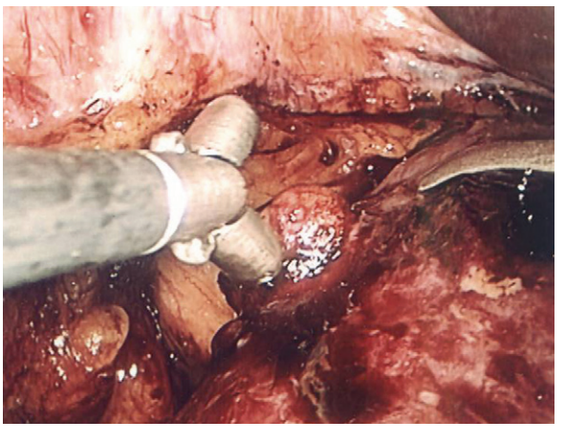

FIGURE 137-8. Biopsy of tumor.

Performing the biopsy following ablation, minimizes bleeding, reduces tumor seeding, and provides adequate tissue sample for accurate diagnosis.

8. The biopsy site on the surface of the kidney is examined: usually no or minimal bleeding results. Mild bleeding can be controlled by application of Tisseel™ and FloSeal™ (Baxter, Germany) hemostatic sealants; however, occasionally argon beam coagulation may be needed.
9. The colon is placed in its normal anatomic position and the incised edges of peritoneum are approximated with clips. The abdomen is dessuflated and the trocars are removed.
10. Postoperative care is the same as for a laparoscopic nephrectomy.

RADIOGRAPHIC FOLLOW-UP

Patients are imaged initially at 6 weeks following ablation with CT or magnetic resonance imaging (MRI) with intravenous contrast. Successful ablation is confirmed by the absence of contrast enhancement within the tumor and a narrow rim of normal parenchyma. Once successful ablation is established, the patients are reimaged with CT or MRI at 6 months and 12 months, and then every 6 months thereafter. Those with biopsy-confirmed benign tumors are scanned with CT or MRI at 6 weeks and then annually.

It is important to emphasize the RF lesion will persist on the follow-up scans, although it may contract slightly. Endophytic lesions may retract from the renal parenchyma, with a narrow rim of fat infiltrating the margin. Lesions treated with percutaneous RF may exhibit a peritumor halo in the perinephric fat surrounding the tumor probably caused by fibrosis at the margin of ablation zone.

Suggested Readings

Anderson JK, Matsumoto E, Cadeddu JA. Renal radiofrequency ablation: technique and results. *Urol Oncol.* 2005;23:355.

Anderson JK, Shingleton WB, Cadeddu JA. Imaging associated with percutaneous and intraoperative management of renal tumors. *Urol Clin North Am.* 2006;33:339.

Cosman ER, Nashold BS, Ovelman-Levitt J. Theoretical aspects of radiofrequency lesions in the dorsal root entry zone. *Neurosurgery.* 1984;15:945.

Gill IS, Hsu TH, Fox RL, et al. Laparoscopic and percutaneous radiofrequency ablation of the kidney: acute and chronic porcine study. *Urology.* 2000;56:197.

Margulis V, Matsumoto ED, Lindberg G, et al. Acute histologic effects of temperature-based radiofrequency ablation on renal tumor pathologic interpretation. *Urology.* 2004;64:660.

Ogan K, Jacomides L, Dolmatch B L, et al. Percutaneous radiofrequency ablation of renal tumors: technique, limitations, and morbidity. *Urology.* 2002;60:954.

Park S, Anderson J K, Matsumoto ED, et al. Radiofrequency ablation of renal tumors: intermediate-term results. *J Endourol.* 2006;20:569.

Section XXI

KIDNEY: RECONSTRUCTION

This page intentionally left blank

Chapter 138

Anatomy and Principles of Open Reconstructive Renal Surgery

JOHN F. REDMAN

The requisites for renal reconstructive surgery are a thorough understanding of renal anatomy. The challenges to the surgeon are the myriad variations and anomalies, which requires alertness and perception to successfully achieve the ultimate objective of preservation of renal parenchyma. A starting point is to understand the most commonly encountered renal anatomy, since in reality there is no true "normal."

The surgically important aspects of renal anatomy include:

- The gross morphology
- The position of the kidneys
- The macroscopic renal collecting structures
- The renal vasculature

GROSS MORPHOLOGY OF THE KIDNEYS

The kidney is bean shaped (Fig. 138-1) with a large elliptical, centrally and medially located depression, termed the *hilum*. The depression is the site of the opening into the central cavity of the renal corpus, known as the *renal sinus*. The renal sinus is lined by the investment of the kidney, the renal capsule, and is filled with the major renal collecting structures, renal vasculature, and fat. On the renal surface, just ventral to the convex border is located a longitudinal whitish depression, Brodel's white line, which demarcates the area between the anterior and posterior calyces (it does not overlie the relatively avascular plane between the anterior and posterior renal segments). If sectioned longitudinally, the renal corpus is seen to consist of a thick renal cortex surrounding equally spaced renal pyramids (medulla). Between the pyramids, the cortex extends to the renal sinus and is termed a *renal column of Bertin*.

Important Variations

The renal corpus may be duplex with two completely separate hila and sinuses of varying size.

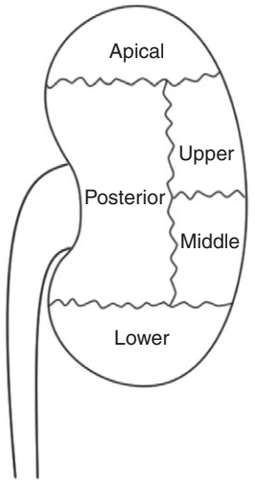

FIGURE 138-1.

Position of the Kidneys

The kidneys are usually located high in the retroperitoneum, dorsal to the great vessels. The lateral convex surface of the kidney is positioned more dorsal than the medial concave surface, on transverse cross section forming a 30-degree angle with a coronal plane at the dorsal skin level. The upper pole of the kidney tips medially 10 degrees and dorsally 10 degrees.

Macroscopic Renal Collecting Structures

The macroscopic renal collecting structures consist of the renal pelvis, infundibula and calyces. The renal pelvis may be located completely within the renal sinus (intrarenal pelvis) or largely outside of the renal sinus (extrarenal pelvis) or as a combination of both. The calyces are cuplike, whitish, elastic structures, which cover the tips of the renal papillae and receive the ducts of Bellini. As the papilla invaginates the calyx, it forms an arc, termed the *fornix*. The calyx connects

to the remainder of the renal collecting structures by a neck. If several calyceal necks join and then from a single elongated collecting structure, it is termed an *infundibulum*, which then drains into the renal pelvis. When viewed on cross section, it can be appreciated that the calyces numbering 6 to 10 are located in two parallel rows equally distributed in the dorsal and ventral aspects of the kidney.

Important Variations

The calyces may enter the renal pelvis directly. In the polar regions, several papillae and their calyces may join together to form a compound calyx. The infundibula may be short or elongated. There can be intrarenal duplications in which a large mass of renal cortex separates the lower pole collecting structures from that of the upper pole.

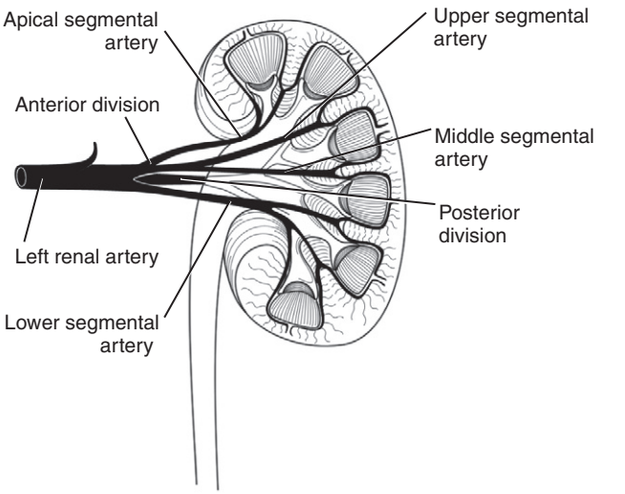

FIGURE 138-2.

THE RENAL VASCULATURE

Renal Veins

The renal veins differ from left to right. On the right side, the vein, which is usually short, drains from the renal hilum into the lateral aspect of the inferior vena cava with few tributaries. On the left side, the longer renal vein is joined on its caudal aspect, just lateral to the aorta, by a lumbar vein. A few centimeters medial to the renal sinus, the left renal vein is joined by the left central adrenal vein and the left gonadal vein, just opposite each other, on the cranial and caudal aspects of the renal vein, respectively. Within the renal sinus, the renal vein is joined by several large branches, which course over the ventrum of the renal pelvis. Because all of the renal veins communicate within the renal parenchyma, renal veins may be ligated with impunity without compromising the overall renal venous drainage.

Renal Arteries

The usual pattern of the renal arteries follows: The renal artery, which is shorter on the left side than the right, lies just dorsal to the renal vein. The artery, as it approaches the renal sinus over the ventral surface of the renal pelvis, divides into a posterior and anterior division. The anterior division then divides, usually, into four segmental arteries: an apical, upper, middle, and lower (Fig. 138-2). The apical and lower arteries may frequently be visualized extrarenally. Within the renal sinus, as the segmental artery approaches the kidney, the artery divides into interlobar arteries, which enter the parenchyma on either side of the renal pyramids. The interlobar artery gives off a short spiral artery, which vascularizes the tip of the papilla, and then courses along the lateral aspect of the pyramid. At the base of the pyramid, the artery curves medially over the base of the pyramid as an arcuate artery, which in turn gives off branches that enter the cortex, termed *interlobular arteries*.

One of the most important points in reconstructive renal surgery is that the renal arteries are end arteries. The segmental arteries vascularize distinct segments of the kidney. The posterior segment occupies the dorsal aspect of the kidney between the apical and lower segments. The apical and lower segments are smaller than the upper, middle, and posterior segments. On transverse cross section of the kidney, it can be appreciated that there exists a relatively avascular plane between the anterior and posterior segments of the kidney. This plane is located 1 to 2 cm dorsal to the convex surface of the kidney between the apical and lower segments. A similar avascular plane can exist between the lower and posterior renal segments. Incisions between the apical or upper and posterior renal segments risk injury to the posterior division of the renal artery, which typically courses over the cranial aspect of the renal pelvis.

Important Variations

In 30% of patients, accessory vessels will be found, frequently vascularizing the apical and lower renal segments. Accessory renal arteries may course dorsal to the renal pelvis.

Chapter 139

Open Pyeloplasty

JOHN S. WIENER

Ureteropelvic junction (UPJ) obstruction can present symptomatically or as a serendipitous radiologic finding in a fetus or asymptomatic patient. Initial imaging, most commonly by sonogram or computed tomography (CT), reveals pelvocaliectasis of the affected renal unit(s). Functional studies can assess differential renal function and drainage to confirm obstruction; diuretic nuclear renography is preferable over intravenous pyelography due to the former's ability to provide quantitative measurements. Neonatal presentation after a prenatal diagnosis of hydronephrosis is common, but a strict definition of UPJ obstruction in the asymptomatic infant remains elusive.

APPROACHES

Successful open pyeloplasty can be achieved through a variety of incisions. The approach most comfortable to urologists is through the flank. Because access is needed only to the UPJ and not to the entire kidney, the incision can be lower than for nephrectomy. The simplest approach is an anterior incision extending medially from the tip of the twelfth rib. This incision allows the greatest flexibility for more complex cases, such as those with extremely large or malrotated renal pelves. An anterior subcostal incision provides excellent visualization, but special care must be taken to keep the dissection extraperitoneal. Dorsal lumbotomy can reduce operative time and postoperative convalescence, but is an approach less familiar to urologists. Because of its limited adaptability to complex anatomy, percutaneous pyelography after prepping and draping has been employed to confirm the anatomy before the lumbotomy incision. In cases of bilateral UPJ obstruction, either approach can be used on both sides in the same setting instead of a midline transperitoneal approach.

INSTRUMENTS

Optimal magnification with loupes is preferred for precise dissection and closure to avoid postoperative leakage or anastomotic stricture.

A basic genitourinary (GU) instrument set is adequate for dissection to the renal pelvis and ureter, but finer instruments are required for the plastic portion of the repair. A self-retaining retractor is a great aid; retractor choice should be guided by the surgeon's preference (e.g., Denis-Browne, baby Balfour, Bookwalter, Omni). Gil-Vernet or vein retractors further aid in manipulation of the kidney. Sharp dissecting (tenotomy) scissors, Potts scissors, fine vascular forceps, and a hooked blade enhance the opening and closing of the urinary tract. Swaged 4-0 to 6-0 synthetic absorbable suture (SAS) allow a watertight closure; monofilament suture prevents dragging adjacent areolar tissue that can become trapped in the closure and promote leakage. Suture size for fascial closure is dictated by patient size. The need for internal stenting has been debated in straightforward cases but should be strongly considered for complex cases, such as solitary kidneys, bilateral cases, and revision surgery. A perinephric drain is suggested to allow egress of any leaked urine; a Penrose drain is preferred over a closed suction drain which may prolong leakage.

Position: A Foley catheter should be placed in the anesthetized patient to prevent bladder distention, which may impair ureteral emptying and lead to anastomotic leakage.

A straight flank position is ideal for the twelfth rib anterior incision (Fig. 139-1A). This is easily achieved in infants and young children by placing a rolled towel or intravenous fluid bag under the contralateral waist on a flat table. The position can be stabilized by strips of tape from each side of the table across the child at the shoulder and hip. Older children and adults are better positioned by placing the table in the flexed position with the kidney rest raised. If an anterior subcostal approach is desired, the patient can be rotated posteriorly in torque-flank position. The use of a beanbag to secure the patient can be beneficial. Meticulous attention to positioning with an axillary roll below the down (contralateral) shoulder, padding under all extremities, and support of the up (ipsilateral) arm cannot be emphasized enough.

Incision: The twelfth rib incision is made from the tip of twelfth rib anteriorly to no further than the lateral edge of the rectus muscle. In infants and small children, 4 to 6 cm should suffice. The incision line should follow the skin lines

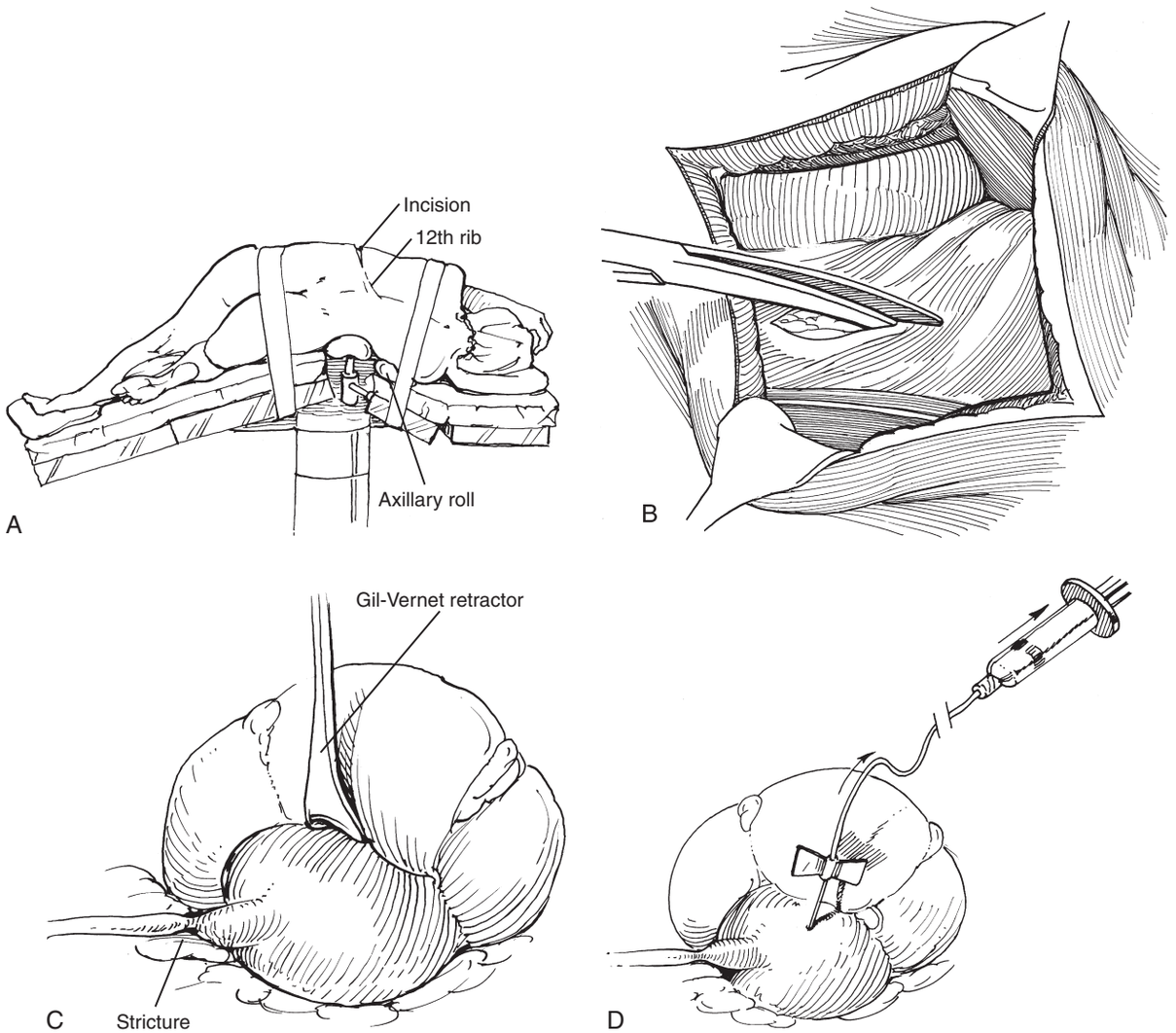

FIGURE 139-1.

to minimize the appearance of the scar postoperatively. A combination of cautery and fiber separation can be used to dissect through the three muscle/fascial layers: external oblique, internal oblique, and the transversus abdominis. Care must be taken to identify the intercostal nerves that lie between the latter two layers and protect them with a vessel loop, if necessary. Once opened, the transversalis fascia should be dissected from the underlying tissue overlying Gerota's fascia and the peritoneum to prevent tearing either when the self-retainer retractor is inserted.

Gerota's fascia should be opened vertically as far posteriorly as possible to avoid inadvertently entering the peritoneum (see Fig. 139-1B). Angle the cut posteriorly while proceeding cranially because the peritoneum sweeps more posteriorly to include the liver (on the right) and spleen (on the left). Leave the dorsal layer of perinephric fat undisturbed if possible, because this may be used later to cover the repair. Continue to work posteriorly by rotating the kidney anteriorly with a sponge stick.

Once the renal hilum is seen, greater exposure can be gained by placing a vein or Gil-Vernet retractor at the junction of the renal parenchyma and hilum (see Fig. 139-1C). Unlike a nephrectomy, there is no need to mobilize the entire kidney unless a long segment of ureter is excised. The pelvis is then cleaned of fat to expose the UPJ. A retraction suture of 4-0 SAS in the pelvis may further help in rotating the pelvis during dissection.

With a hugely dilated pelvis, decompression of the pelvis with a 21-23 gauge butterfly needle may be required to gain exposure to the entire pelvis (see Fig. 139-1D). In chronically obstructed systems, there is often a thick rind that must be dissected off the pelvis. Bleeding from the investing fine vasculature can be controlled with a bipolar or low current needle point cautery, using care not to injure the underlying pelvis.

Locate the ureter distal to the UPJ, taking care not to interfere with the segmental blood supply that enters the ureter medially. A vessel loop will aid in mobilization of the ureter for several centimeters below the UPJ (Fig. 139-2A). Dissect as short a length of the ureter as possible, and preserve all of its adventitial vessels to prevent devascularization, which could result in postoperative stenosis. For secondary procedures, it may be easier to find normal ureter distally and then dissect proximally from normal to abnormal.

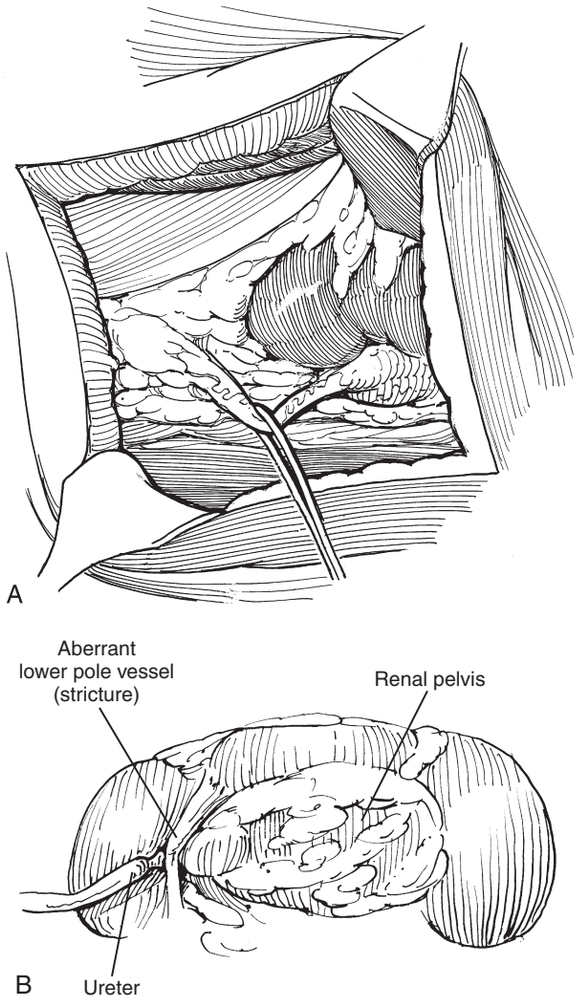

FIGURE 139-2.

Be on the lookout for an aberrant lower pole vessel crossing the UPJ (see Fig. 139-2B); palpation for pulsations can be helpful, to confirm the presence of a crossing vessel. Crossing lower pole vessels are a more common cause of UPJ obstruction in older children; isolated intrinsic narrowing of the UPJ is more commonly found in infants.

SELECTION OF PYELOPLASTY TECHNIQUE

Once the pelvis, UPJ, and upper ureter are free of surrounding fat and rind, the anatomy is carefully analyzed. The variations in obstruction location include (1) at the UPJ with a high insertion on the pelvis, with or without intrinsic narrowing, (2) at the UPJ due to intrinsic narrowing, and (3) in the upper ureter due to stricture, valve, or polyp. A crossing lower vessel causes extrinsic compression of the upper ureter/UPJ, but additionally, intrinsic narrowing within the lumen of the ureter can be found in association or as result of the crossing vessel. If there is doubt regarding the exact position of obstruction, the pelvis can be filled with saline through a butterfly needle to delineate the point of hold-up.

For a short stenotic segment, it is best to excise the narrowed and often dysplastic portion of ureter; therefore, a dismembered repair is ideal. The dismembered repair also allows for precise reduction in the size of the pelvis when indicated in widely dilated systems. Failure to adequately reduce the size of the pelvis in such cases can lead to postoperative obstruction due to kinking of the repaired UPJ segment. The dismembered pyeloplasty is the most widely used repair due to its simplicity and efficacy, but it does have greater potential for postoperative obstruction due to scar contracture of the circular anastomosis.

Nondismembered repairs can be used for specific defects. The Foley Y-V plasty is used in high insertion UPJ obstruction to remodel the UPJ into a funnel shape at a most dependent position on the pelvis. Flap techniques, such as the Culp and Scardino repairs, may solve the problem of insufficient ureteral length in long or more distal obstructions. The Davis intubated ureterostomy is reserved for the longest of obstructions.

DISMEMBERED PYELOPLASTY (ANDERSON-HYNES)

Place a stay suture of 4-0 SAS in the anterior surface of the ureter parallel to its course in healthy tissue below the obstruction. Transect the ureter in a healthy portion several millimeters below the abnormal segment (Fig. 139-3). If there is intrinsic narrowing of the ureter, no urine will drain from the pelvis at this point. In cases with a crossing vessel, cut the ureter below the crossing vessel and then pull the ureter to the opposite side of the obstructing vessel. To ensure patency of the distal ureter, gently pass a tube down the ureter but not though the ureterovesical junction. A 5-French feeding tube works well in most cases, but a 3.5-French umbilical vein catheter may be necessary for infants.

If not placed earlier during the dissection, a traction suture of 4-0 SAS is placed in the midportion of the anterior surface of the renal pelvis near the parenchyma. This allows further anterior rotation of the pelvis. A proposed diamond-shaped incision is then demarcated on the pelvis with a marking pen (Fig. 139-4A). A long caudal angle is created

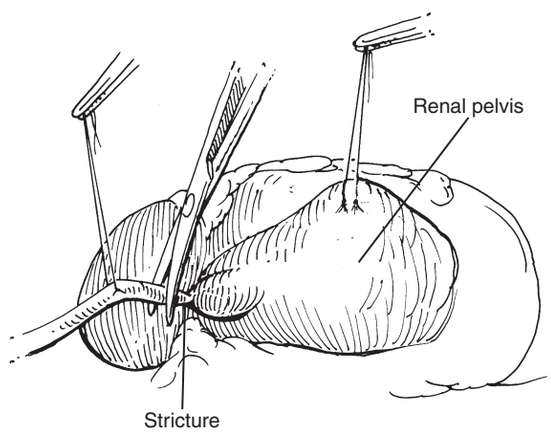

FIGURE 139-3.

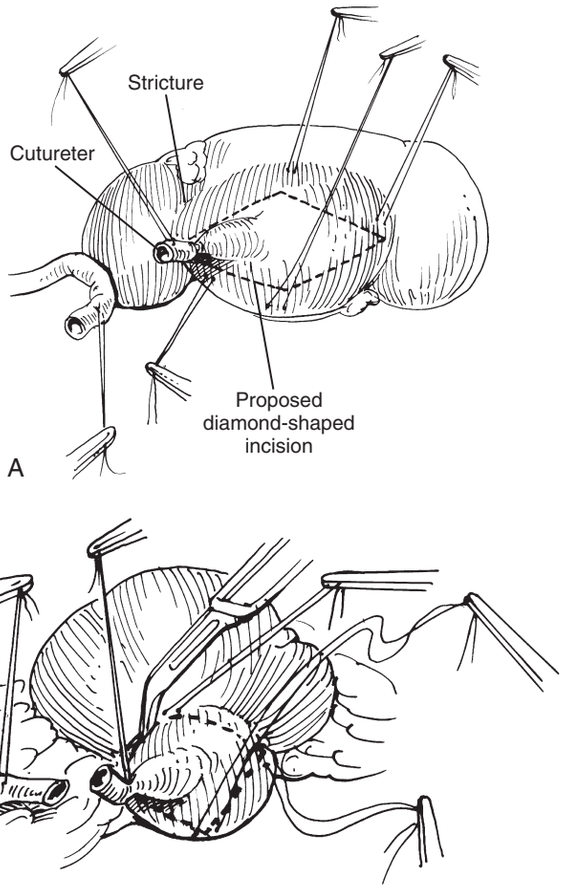

FIGURE 139-4.

for later anastomosis into the spatulated ureter. The ureter should be pulled cranially by its traction suture to visualize the length of pelvic caudal flap needed. Although inadequate pelvic reduction is potentially problematic, resection of too much pelvis will compromise closure, especially in bifid systems. Keep the incision well away from the caliceal necks, which can be surprisingly close to the edge of pelvic resection. Excision of only a small amount of the pelvis is needed in cases with little pelvic dilation or a crossing vessel without narrowing. Additional stay sutures are then placed outside of the remaining angles of the diamond before opening the pelvis.

The incision of the pelvis is then initiated along the demarcated lines using tenotomy scissors or a #11 hook scalpel (see Fig. 139-4B).

Complete the excision of the pelvis along the demarcated lines using tenotomy or angled Potts scissors (Fig. 139-5). The specimen containing the excised pelvis and obstructed UPJ is removed.

The ureter is then spatulated along its lateral segment (away from its vascular supply and toward the renal pelvis). Rotation of the ureter and pelvis can lead to disorientation depending on the approach, so one must take care to be certain of which side is appropriate before cutting. The traction suture on the anterior surface of the ureter can guide proper orientation. An exception to this rule may be in malrotated or horseshoe kidneys when the relationship

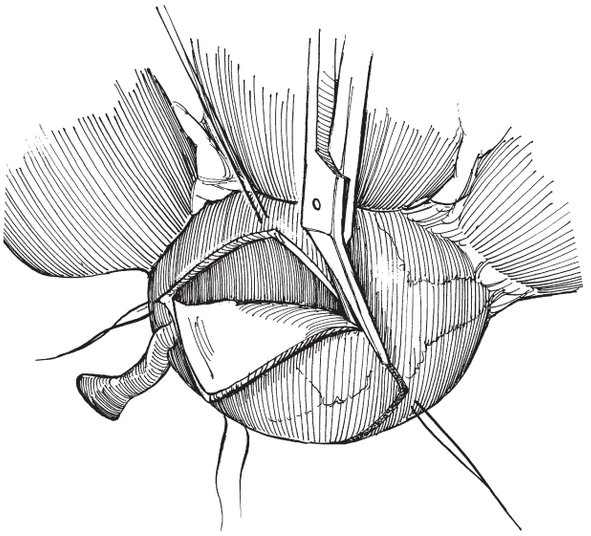

FIGURE 139-5.

between ureter and pelvis may be anterior:posterior rather than medial:lateral. Spatulation can be done with tenotomy or Potts scissors; avoid a spiral incision. The length of the incision should match the length of the caudal angle of the cut pelvis (Fig. 139-6).

Insert the feeding tube or umbilical vein catheter into the ureter to prevent "back-walling" the other side of the ureter. Place a 6-0 SAS suture from the apex of the caudal angle of the renal pelvis into the crotch of the spatulated ureter (Fig. 139-7A). A 4-0 or 5-0 suture may be substituted in larger patients with larger ureters. The knot should be tied on the outside of the collecting system and the suture tagged for traction. Alternatively, place a mattress stitch with a double-armed suture; run one end up the far wall from inside the lumen and the other up the near wall from outside.

To prevent constricting the anastomosis, angle the needle in order to catch a minimal amount of urothelium while including more muscularis and adventitia (see Fig. 139-7B). Use the most minimal diameter needle possible to avoid placing holes in the wall larger than the diameter of the suture. Cutting needles may be more precise but risk tearing the ureteral and pelvic wall.

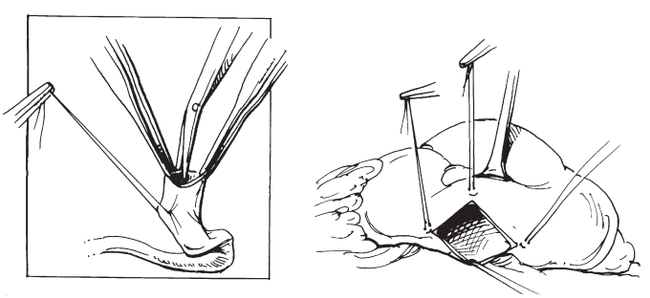

FIGURE 139-6.

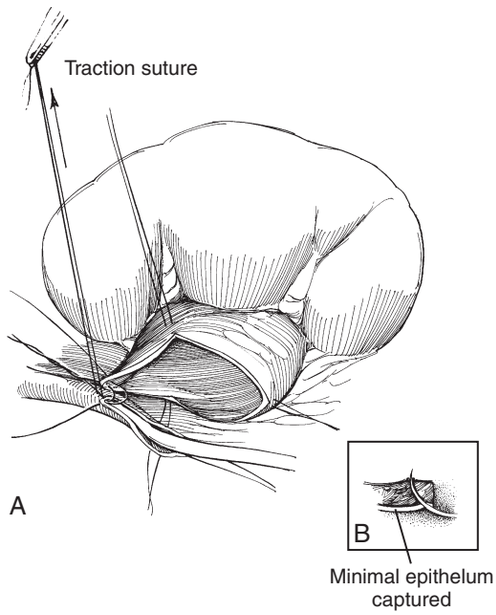

FIGURE 139-7.

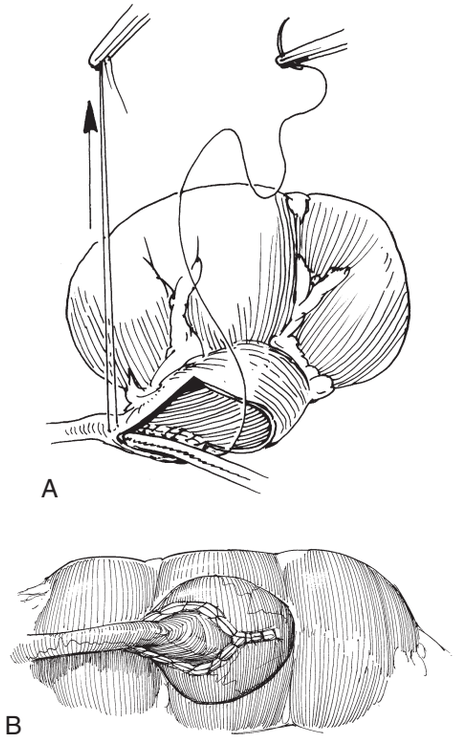

FIGURE 139-8.

Place the next stitch of equivalent-sized suture or one size larger 2 mm posterior to the apical suture (Fig. 139-8A). This is facilitated by passing the apical traction stitch underneath and medial to the anastomosis, thus rotating the far wall into better view and allowing closure from the outside. This suture is then run as a continuous stitch up the far wall of the repair, locking every fourth or fifth stitch. The suture is then tied to itself once the top of the ureter is reached. Irrigate the pelvis and calyces free of clot.

The apical traction suture is then brought back into its original orientation to provide optimal exposure of the near wall. Once the near wall is partially closed, the feeding tube in the ureter is pulled. If a stent or nephrostomy tube is desired, it should be placed at this point (see later). This suture is continued up the near wall until the suture on the far wall is encountered. The near suture can be run up the entirety of the repair or tied to itself above the ureteropelvic anastomosis, and a third suture is used to close the pelvic defect cranially (see Fig. 139-8B).

STENTING

In difficult repairs or in solitary kidneys, placing a ureteral stent or nephrostomy tube allows greater safety. Internal stents are preferable because they reduce discomfort, anxiety, and risk of infection or dislodgment. Straightforward repairs in children rarely require stenting, avoiding the need for a second anesthetic to remove the internal double-J stent. When needed, a double-J stent is slid over a wire that has been placed down the ureter into the bladder. Radiographic confirmation of position is difficult with the patient in the flank position, but return of colored urine up the stent after filling the bladder with indigo carmine-dyed saline via the Foley catheter indicates that the distal end is indeed in the bladder. Another alternative is placement of a KISS (kidney internal stent splint), which acts as a nephrostomy tube with a half circumference portion of the stent extending across the anastomosis and part way down the ureter (Fig. 139-9A).

When a nephrostomy tube is desired, a Malecot catheter can be brought into the pelvis by tying it to a small straight catheter placed from the pelvis out through a calyx and parenchyma (see Fig. 139-9B). An external nephroureteral stent can be placed across the anastomosis in a similar manner to avoid an unstented "dry" anastomosis.

Insert a Penrose drain to a position near but not touching the anastomosis. Because the incision is clean, the Penrose drain can be brought through the incision to avoid an additional scar at the exit wound (Fig. 139-10). If there is concern about potential infection or a weakened closure, bring the Penrose drain out through a separate stab wound below the incision. It should be located laterally but not in a place on which the patient lies.

If the kidney has been completely mobilized, nephropexy stitches can be placed to prevent excessive renal mobility that could kink the ureter (see Fig. 139-14). Place fat over the repair and close Gerota's fascia with fine SAS, if possible. Close each muscle layer separately, taking care not to entrap the intercostal nerves. Progressively decrease the flexion of the table, if used, to reduce tension on the closure. Use local anesthetic to infiltrate the tenth, eleventh, and twelfth intercostal nerves under direct vision or percutaneously; also infiltrate the wound edges. After skin closure, secure the Penrose with nonabsorbable suture.

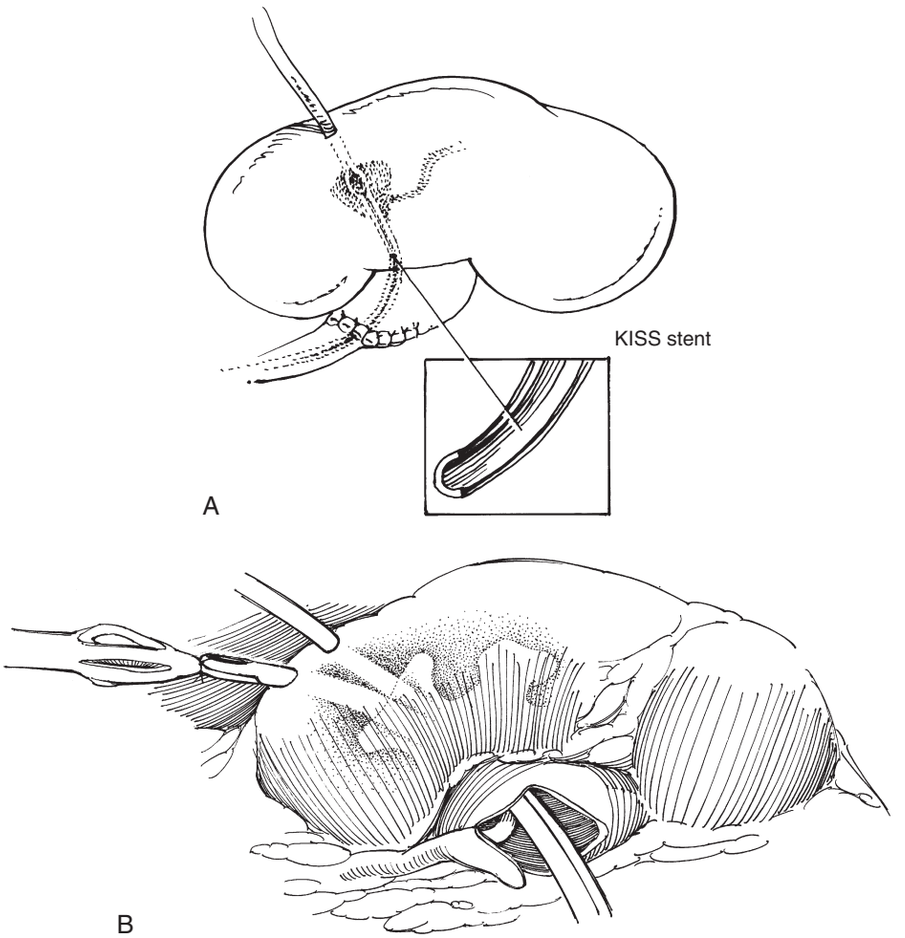

FIGURE 139-9.

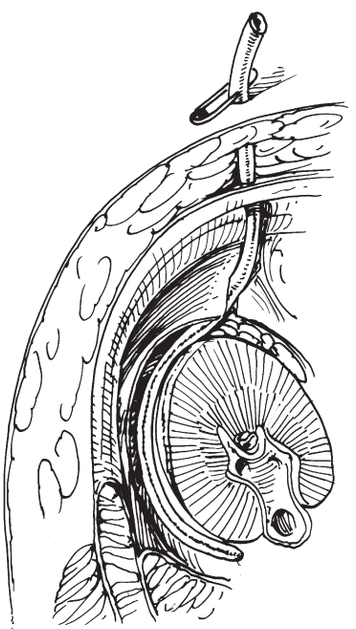

FIGURE 139-10.

FOLEY Y-V PLASTY

The Foley Y-V plasty is best used in cases with a high insertion of the ureter, particularly in the absence of a dysplastic upper ureter/UPJ segment. It requires more ability to conceptually visualize the remodeling than does a dismembered repair.

Free the ureter but preserve the adventitia (Fig. 139-11A). Carefully clear the lower pelvis of fat and inflammatory rind.

Pull the ureter cranially with a vessel loop. Mark a long Y-shaped incision between stay sutures (see Fig. 139-11B). Incise the pelvis between the sutures using a hooked scalpel blade and open the remainder of the incision with Potts scissors. The limbs of the V-flap on the pelvis should be equal in length to the ureteral incision. Consider placing a nephrostomy tube or internal stent at this point.

Suture the apex of the V-flap to the apex of the ureteral incision using 6-0 SAS (see Fig. 139-11C).

Place interrupted 5-0 or 4-0 SAS down each limb of the repair to create a watertight anastomosis (see Fig. 139-11D, E). This can alternatively be closed with running suture, taking care to avoid dog-ears. Cover the anastomosis with perirenal fat and place a Penrose drain.

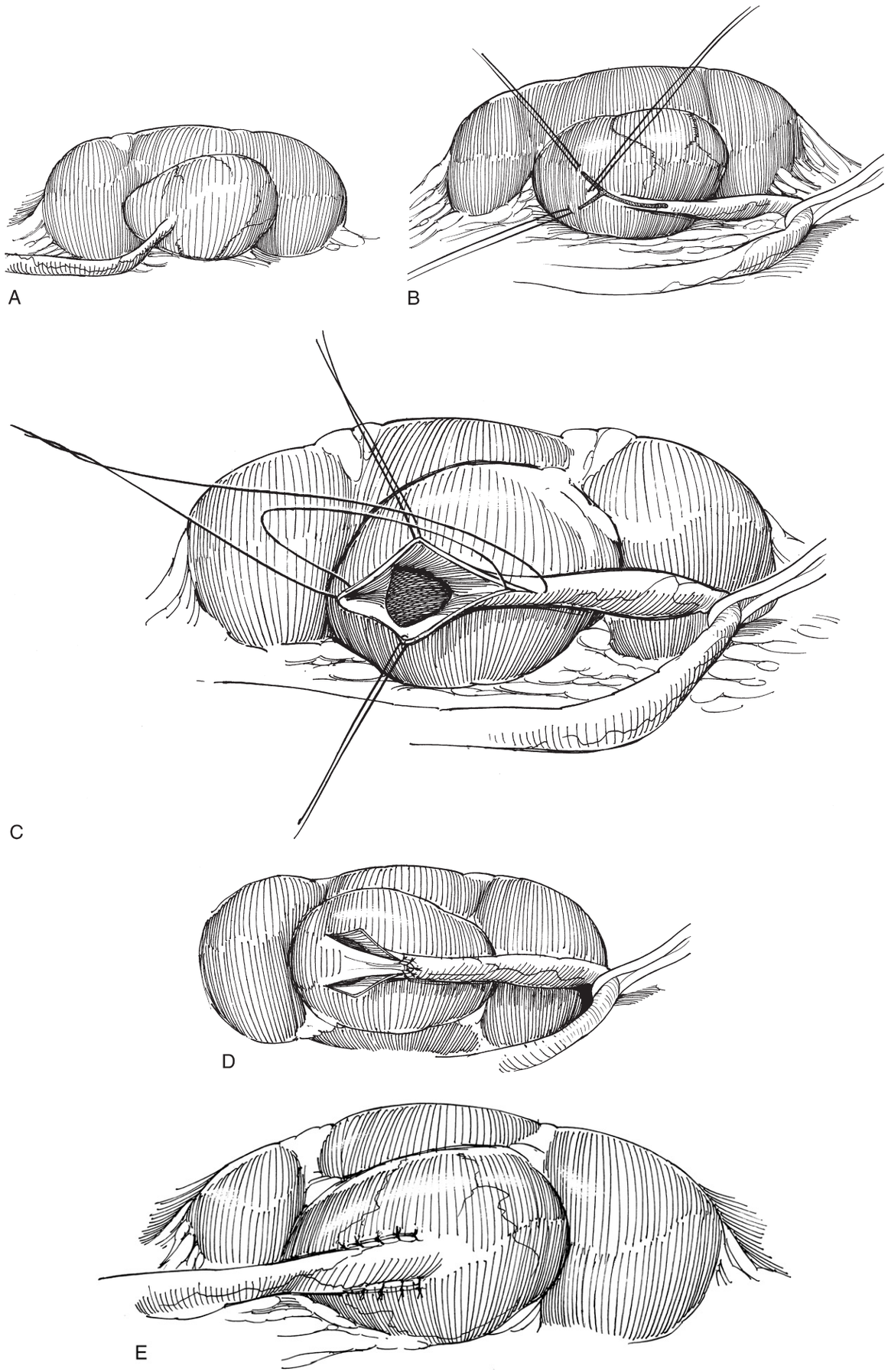

FIGURE 139-11.

PELVIC FLAP PYELOPLASTY

Culp-DeWeerd Spiral Flap

A flap procedure is used for long, low defects with a dilated pelvis when a dismembered pyeloplasty would result in excessive tension on the repair. The Scardino-Prince variation uses a vertical instead of spiral flap and is more suitable for cases with higher ureteral insertion. An alternative for long defects or extensive pelvic scarring is ureterocalycostomy.

Mark a spiral flap running obliquely around the enlarged pelvis. Extend the incision line down the ureter for a distance equal to the length of the flap (Fig. 139-12A).

Incise the flap and swing it caudally with a stay suture (see Fig. 139-12B).

Approximate the far edge of the flap to the lateral edge of the ureter with running 5-0 SAS (see Fig. 139-12C). Use a feeding tube down the ureter as a guide (not shown).

Close the near edge of the flap and pelvis with similar suture (see Fig. 139-12D). Stent and/or drain appropriately.

Intubated Ureterotomy (Davis)

Intubated ureterotomy has been used historically for scarred defects near the UPJ, but it has been largely replaced by endoscopic incision unless the defects are very long.

Incise the pelvis just above the UPJ between two stay sutures with a hooked scalpel blade (Fig. 139-13A). Open the ureter distally with Potts scissors until healthy ureter of normal caliber is reached.

Insert an external or internal 8-French ureteral stent over a guidewire (see Fig. 139-9) and a nephrostomy tube. Tack the edges of the defects together loosely over the stent with interrupted 5-0 SAS sutures (see Fig. 139-13B). Tack perirenal fat or omentum from the peritoneal cavity around the repair. Carefully place a Penrose drain near the repair without touching it. Leave the stent for 6 weeks, then exclude extravasation with an antegrade nephrostogram before and after removing it.

NEPHROPEXY

If extensive mobilization of the kidney is required to create a tension-free repair, the lower pole of the kidney should be fixed to prevent it from sliding medially and angulating the repair. The lower pole can be fixed to the posterior body wall with two sutures of 2-0 SAS. The suture is placed in the renal capsule in a mattress fashion on the posterolateral aspect and tied over bolsters of fat or absorbable sponge. The suture is then placed as a horizontal mattress at the appropriate position in the quadratus lumborum, taking

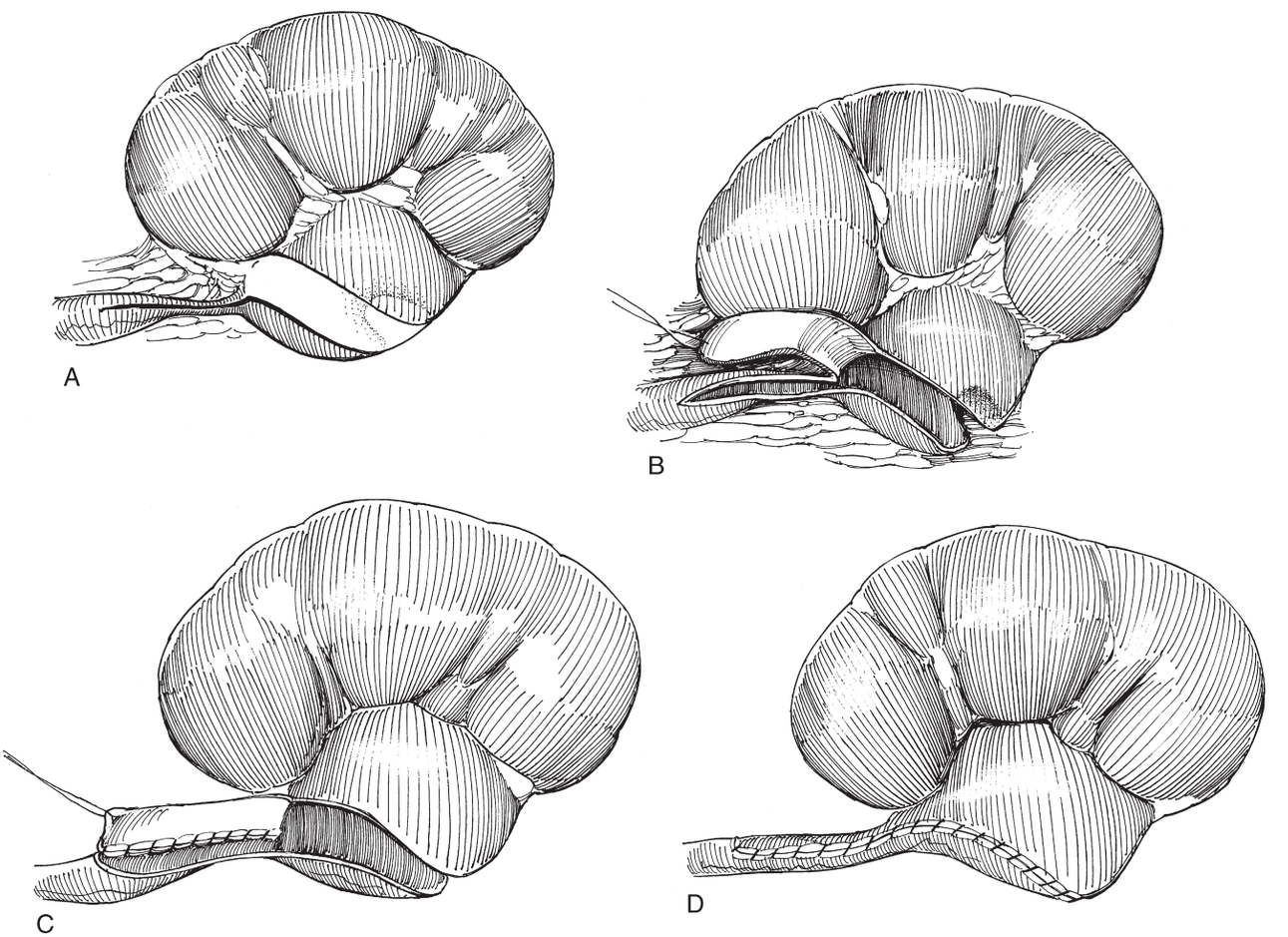

FIGURE 139-12.

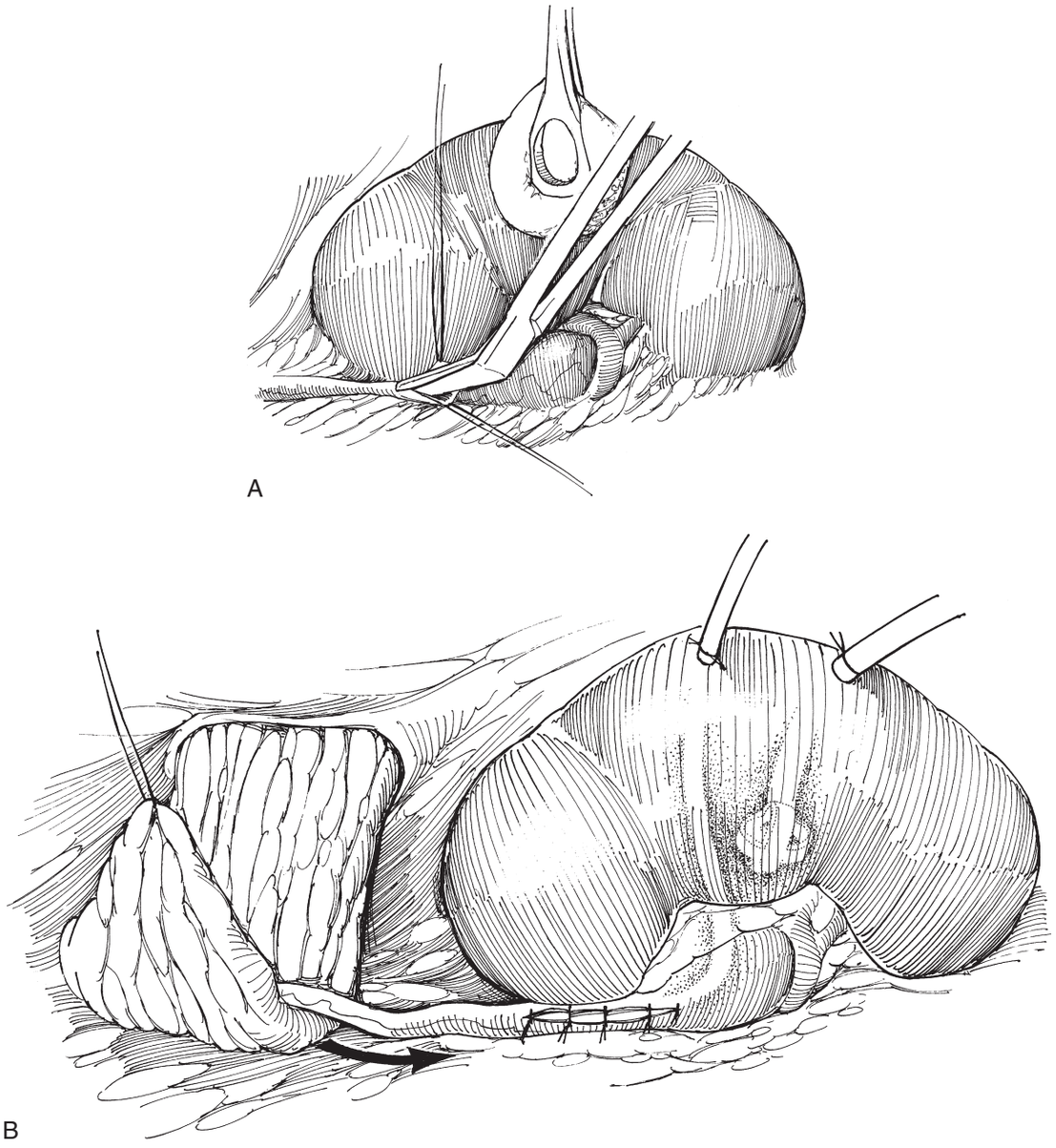

FIGURE 139-13.

care not to entrap the overlying nerves (Fig. 139-14). The kidney is rotated into its natural position and the sutures tied.

POSTOPERATIVE CARE

Drainage from Penrose can be monitored by frequency of dressing changes. Remove drain when drainage is minimal, usually 1 to 2 days postoperatively. In cases with excessive drainage, placement of Montgomery straps on the flank simplifies frequent dressing changes and protects skin from tape excoriation. If drainage persists, the drain often is sitting on the anastomosis and should be gently advanced ½ to 1 inch per day sequentially until drainage abates.

If a nephrostomy tube is used, the tube can be capped after several days. Patency of the anastomosis can be confirmed by (1) lack of symptoms, (2) unplugging the tube to check residual urine volume in the renal pelvis, (3) taping the tube to the chest and observing urine fluid level, or (4) pressure-flow (Whitaker) test in troublesome cases.

Sonography is performed 1 month later to exclude urinoma formation. Improvement in sonographic appearance of the kidney is not usually seen this early and often takes more than 6 months. In cases with initial symptomatic presentation, the combination of resolution of symptoms and improved sonographic appearance may be sufficient to prove successful repair; otherwise, repeat diuretic renography should be repeated 3 to 6 months postoperatively. Long-term sonographic follow-up periodically is warranted, but failures after 2 years are unusual.

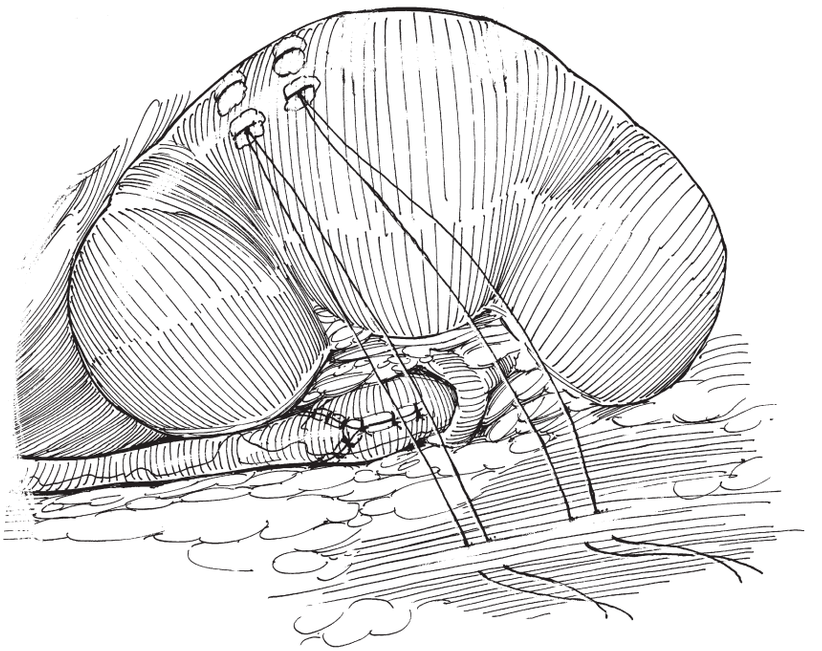

FIGURE 139-14.

Commentary by ALLEN F. MOREY

The techniques described in this chapter are also of great benefit in adults. The dismembered pyeloplasty procedure outlined is usually the best first choice. I have found it helpful to begin the reconstruction by applying a small hemostat to the amputated UPJ, which can then be placed on traction, thus facilitating the dissection. It is important to mobilize the entire renal pelvis completely to enable exposure for tailoring and to begin the anastomosis in the most dependant portion of the pelvis.

The surgeon must be familiar with all the techniques mentioned, especially in the reoperative setting where some creativity may be required. Ureterocalicostomy is another useful technique for salvage of failed pyeloplasty, but caution and adjunctive techniques may be warranted when the stricture extends below the level of the lower renal pole.

Chapter 140

Surgery of the Horseshoe Kidney

ZEPH OKEKE, LINDSAY FOSSETT, AND ARTHUR D. SMITH

EMBRYOLOGY

The horseshoe kidney is the most common renal fusion abnormality. It is composed of two distinct functional renal moieties, joined in the midline by an isthmus that varies from a fibrous band to a parenchymatous isthmus with associated calyces. Embryologically, it is thought to result from abnormal migration of the metanephric blastema across the midline during weeks 4 to 6 of development. The inferior poles then fuse to form the isthmus, and the ascent of the kidney is arrested by the inferior mesenteric artery, preventing normal rotation of the kidney (Fig. 140-1).

VASCULAR ANATOMY

The horseshoe kidneys often lie lower than normal and the isthmus usually lies anterior to the great vessels, at the level of the third to fifth lumbar vertebrae. The vascular anatomy is variable and can arise from the aorta, the iliac arteries, or the inferior mesenteric artery. Normal hilar arterial anatomy can be seen in about one third of cases, with variable arterial anatomy present in greater than two thirds of cases. The isthmus may have a separate blood supply arising from the aorta, iliacs, or inferior mesenteric artery. The renal pelvis lies anteriorly and the calyceal system is oriented medially (Fig. 140-2).

INDICATIONS FOR SURGERY

The indications for surgery in the horseshoe kidney are similar to indications for anatomically normal kidneys. The incidence of malignancy in patients with horseshoe kidney

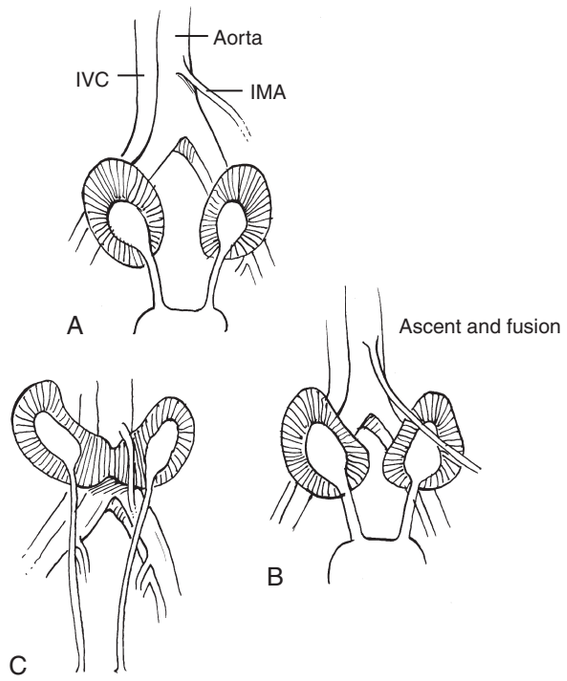

FIGURE 140-1.

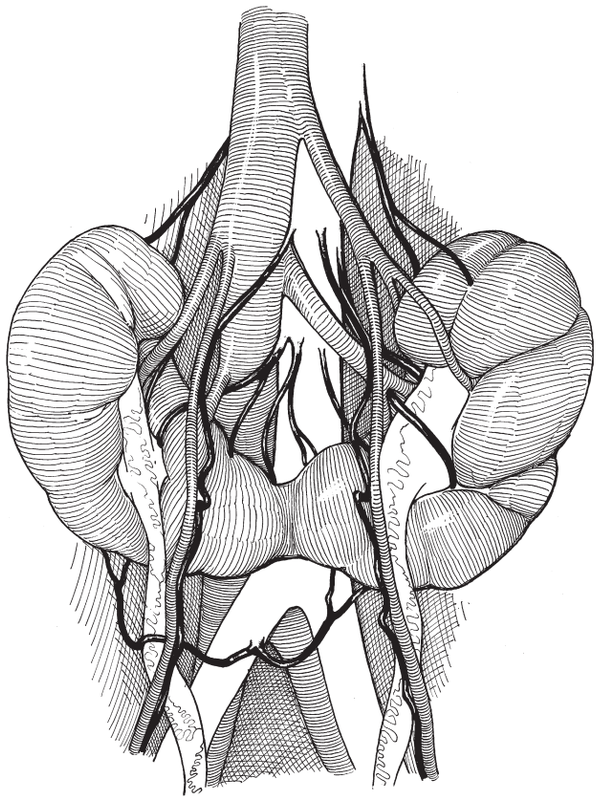

FIGURE 140-2.

is the same as in the general population, although there is an increased incidence of Wilms' tumor and transitional cell carcinoma of the renal pelvis. Ureteropelvic junction (UPJ) obstruction is a common finding in the horseshoe kidney, as is urolithiasis.

Nephrolithiasis occurs more commonly in the horseshoe kidney, at an incidence of 21% to 60%. It is postulated that the horseshoe kidney is more susceptible to stone formation due to several factors. The calyceal anatomy, anteriorly located renal pelvis, abnormal course of the ureter over the isthmus, and the occasional high inserting ureter all favor urinary stasis, leading to increased risk for stone formation.

Shock Wave Lithotripsy

Shock wave lithotripsy is the preferred first line management of small stones in the horseshoe kidney. The patient is placed in the supine position and the stone is localized at the focal point.

If the stone cannot be localized, due to body habitus or projection of the calculus over the spine, it may be helpful to place the patient in the prone position. Insertion of a retrograde catheter with instillation of radiopaque contrast may aid in stone localization in difficult cases. Additionally, dependent drainage in the horseshoe kidney may impair the passage of stone fragments and necessitate retrograde placement of a ureteral stent to aid in passage.

PERCUTANEOUS APPROACH AND URETEROSCOPY

Nephrolithotomy

The operating table should be configured to permit C-arm fluoroscopy or should have built-in overhead fluoroscopy. The patient is initially positioned in the dorsal lithotomy position for cystoscopy and insertion of an open-ended ureteral catheter or balloon catheter into the renal pelvis to allow the use of air or contrast to opacify the collecting system to aid in the identification and targeting of the involved calyces. A Foley catheter is placed at the end of the cystoscopic portion. The patient is then positioned prone on the operating table with the aid of a stretcher. Chest rolls are placed, if the table is not equipped with such. The extremities and torso are padded. The flank is prepared and draped with a nephrostomy drape. The procedure begins with the injection of approximately 10 cc of contrast or air, or a mixture. The air bubbles rise to the top of the posterior calyces. The air bubble is then targeted with an 18-gauge nephrostomy needle. The access tract is more posterior and vertical when targeting the upper pole calyx in a horseshoe kidney (Fig. 140-3). This compensates for the incomplete rotation and lower position of the kidney. Dilation is done with Amplatz type fascial dilators up to 30 French or with balloon dilators such as the NephroMax High Pressure Balloon Dilatation Catheter. The 30-French Amplatz sheath is left in place. Nephroscopy is performed with a 24-French rigid nephroscope, and ultrasonic lithotripsy is used for stone fragmentation. Residual fragments are extracted with a rigid grasping forceps via the working

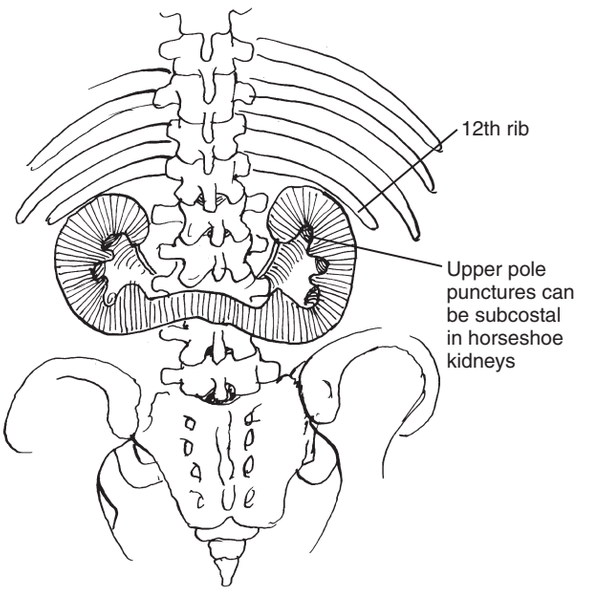

FIGURE 140-3.

port of the nephroscope. Extra long nephroscopes and Amplatz sheaths may be required because of the deeper renal pelvis and its more medial location within the abdomen. After completing the procedure, a 20- to 24-French nephrostomy tube may be placed. Nephrostomy tubes can be removed 24 to 48 hours after the surgery.

Endopyelotomy

An open-ended ureteral catheter is inserted as described earlier. The goal is to pass the catheter beyond the obstructed UPJ, although this effort can be fraught with difficulty at times. The collecting system is outlined by retrograde pyelography under fluoroscopic guidance. The posterior middle or upper pole calyx is chosen and punctured. The access tract is established as described previously. Rigid nephroscopy is used to visualize the UPJ and the ureteral catheter is grasped and pulled through the nephrostomy tract. The ureteral catheter is exchanged for a guidewire traversing the tract and exiting through the urethra. A lateral incision is made at the UPJ until the periureteral fat is visualized. The incision can be made with an endopyelotome or with the Acucise balloon system. An endopyelotomy stent is placed at the termination of the procedure.

Ureteroscopy

The procedure starts with a cystourethroscopy. The ureteral orifice of interest is identified. A PTFE guidewire or a hydrophilic guidewire is placed, with the aid of an open-ended ureteral catheter, and advanced up into the renal pelvis. Fluoroscopy aided by retrograde pyelography obtained by injecting radiopaque contrast media through the open-ended catheter is used to guide proper placement. A second safety guidewire is placed alongside the first wire. A dual-lumen ureteral catheter can be used to facilitate placement of the safety guidewire. A ureteral access sheath is placed over one of the wires. The safety wire remains

outside of the access sheath to maintain collecting system access. The PTFE wire is preferred over the glide wire as the safety wire. Renoscopy can then be performed. The extraction of stones or treatment of tumors can then proceed as with a normal kidney.

LAPAROSCOPIC APPROACH

Laparoscopy can be applied for the excision of renal masses, pyeloplasty, renal cyst unroofing. The general approach is the same for the exposure of the lesion. Preoperative contrast-enhanced imaging such as computed tomography (CT) or magnetic resonance imaging (MRI) should be done to aid in delineating the anomalous vasculature, particularly the vessels supplying the isthmus.

Access and Exposure

The transabdominal approach is preferred, although the retroperitoneal approach has been described. A Foley catheter is inserted and the patient is positioned in a semilateral decubitus position by rotating the operative side up by about 45 degrees axially. Pneumoperitoneum is initiated. Three or four trocars are inserted as illustrated (Fig. 140-4A). An 11- or 12-mm port is placed at the paraumbilical position for

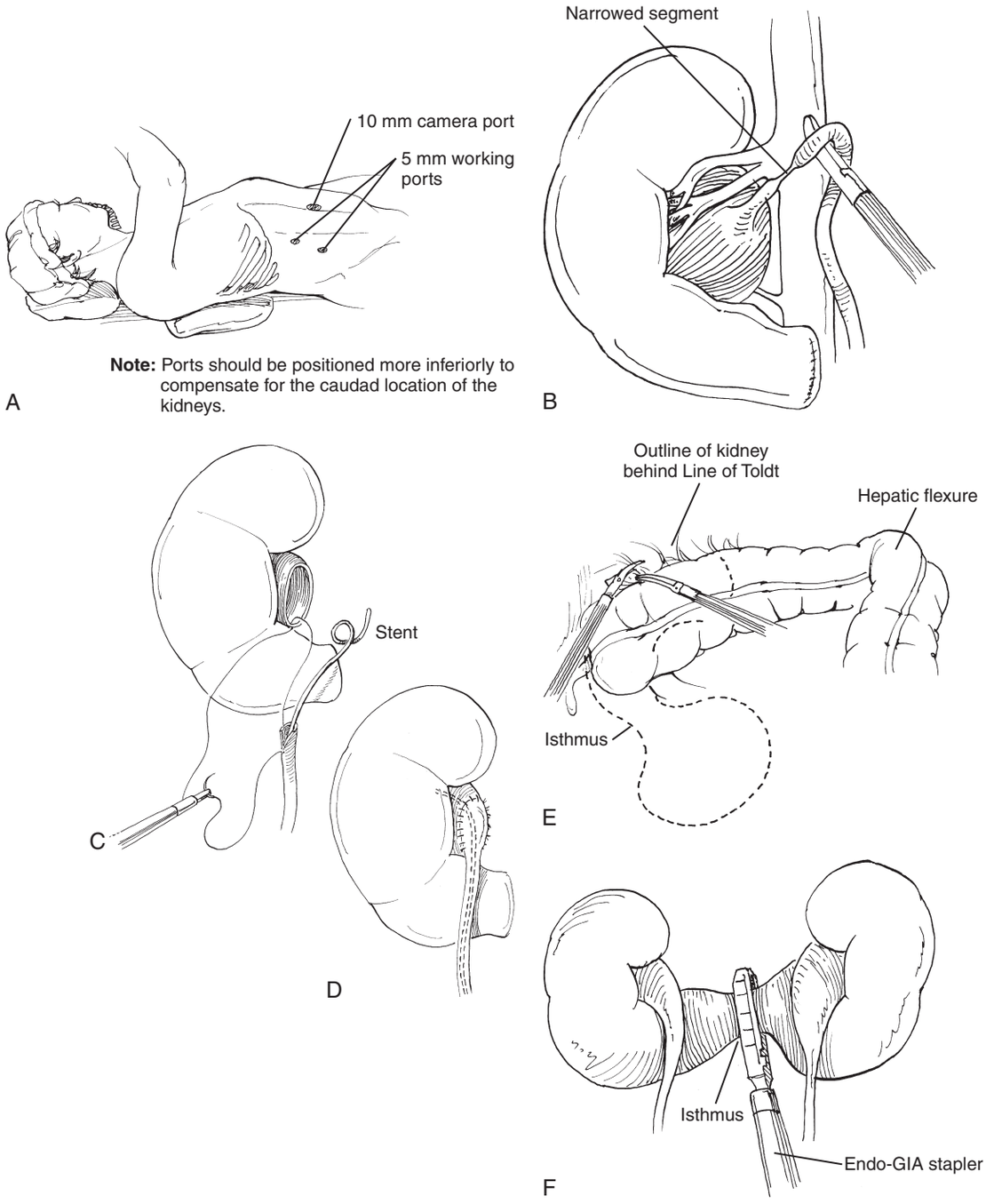

FIGURE 140-4.

the camera. Two 5- or 10-mm working ports are placed. Bipolar scissors, or any energy device of the surgeon's choosing, are used to take down Toldt's line and release the colorenal attachments. Gerota's fascia is then opened and dissected to expose the target lesion.

Pyeloplasty

Expose the kidney as described; incise Gerota's fascia. Locate the renal pelvis and the diseased UPJ (see Fig. 140-4B). The renal pelvis is transected with Endoshears scissors, the diseased segment of the UPJ is excised, and tailoring may be performed by excision of the redundant renal pelvis. Any renal stones can be extracted at this point with the renal pelvis well exposed. If the stones are difficult to extract using the laparoscopic instruments, a flexible cystoscope or ureteroscope can be inserted through larger working ports and the stones can then be extracted using flexible graspers or a stone basket. The ureter is spatulated on its posterior aspect. The new UPJ is reconstructed by placing running 4-0 absorbable sutures posteriorly. The anterior portion of the anastomosis is then sutured with another running 4-0 absorbable suture (see Fig 140-4C and D). The isthmus may need to be divided to allow dependent drainage of the newly constructed UPJ. The repair is retroperitonealized by reapproximating Gerota's fascia with 4-0 synthetic absorbable sutures (SAS). A suction drain such a Jackson-Pratt drain is draped over the area of the repair and brought out through a separate stab wound.

Nephrectomy

The patient may be placed in a modified flank position or semilateral decubitus position. Three ports are placed using the transperitoneal technique (see Fig. 140-4A). The colon is reflected along Toldt's line (see Fig. 140-4E). The main renal artery followed by the vein should be identified, ligated and divided with staples. Other accessory arteries and veins supplying the upper and lower poles of the moiety of interest are then identified and stapled. Next, the artery to the isthmus is identified and controlled as well. The isthmus can be divided using endo-GIA staples or with bipolar cautery (see Fig. 140-4F). Care must be taken not to injure the great vessels that are in close proximity. Parenchymal sutures are placed in the isthmus of the remaining moiety before division. Small bleeders can be controlled with cautery or argon beam and larger vessels need to be sutured as is done for a partial nephrectomy.

OPEN APPROACH

Pyeloplasty

The renal pelvis is approached through an anterior subcostal incision (Fig. 140-5). The colon is mobilized and Gerota's fascia is moved medially. Several vessels are encountered as described previously. A standard Anderson-Hynes (Fig. 140-6) or Foley YV-plasty can be performed. The UPJ is exposed and stay sutures are placed in the anterior portion of the upper ureter and the anterior portion of the renal pelvis to aid in mobilizing and further dissection. The UPJ is transected above the traction suture. The renal pelvis is similarly transected, leaving the traction suture in place at the most dependent portion of the inferior renal pelvis. A 2- to 3-cm spatulating incision is made in ureter on its inferior border. The redundant renal pelvis may be trimmed. A 5-French ureteral stent may be placed at this point to aid in the anastomosis and to protect the back wall of the ureter from being incorporated into the

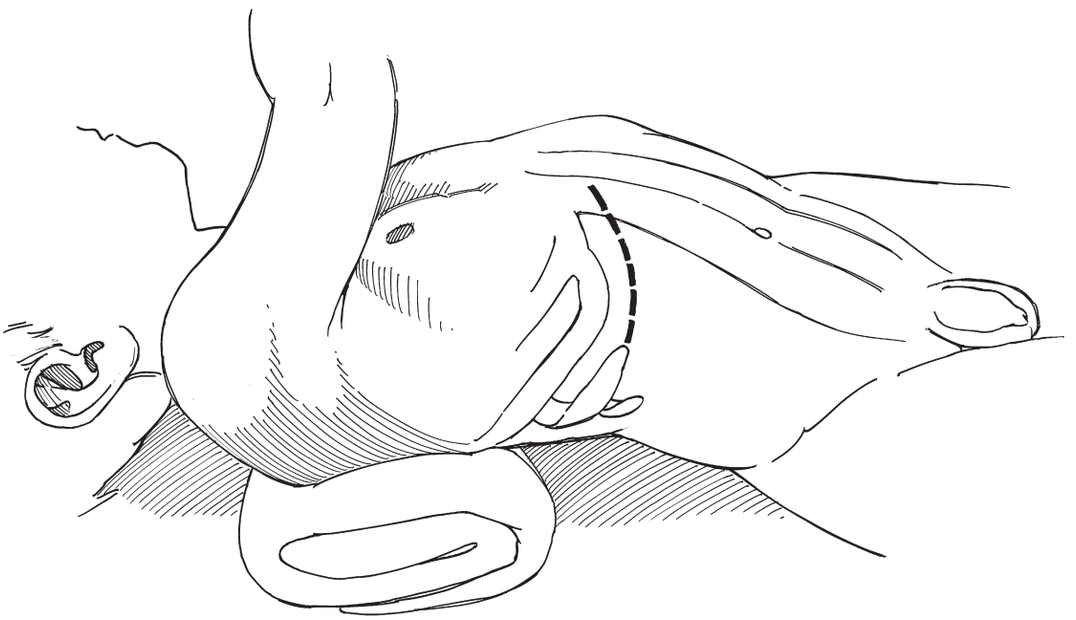

FIGURE 140-5.

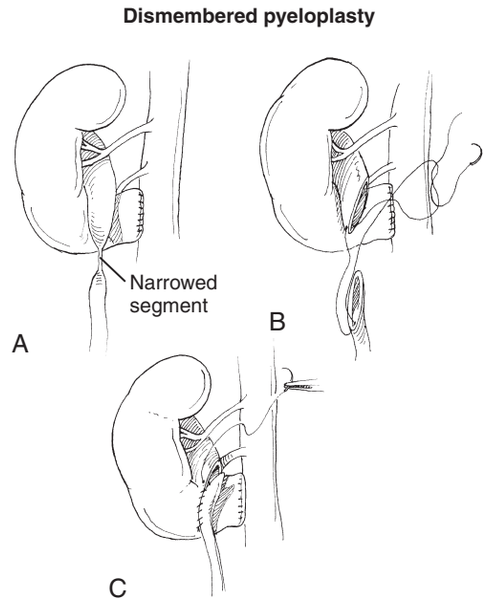

FIGURE 140-6.

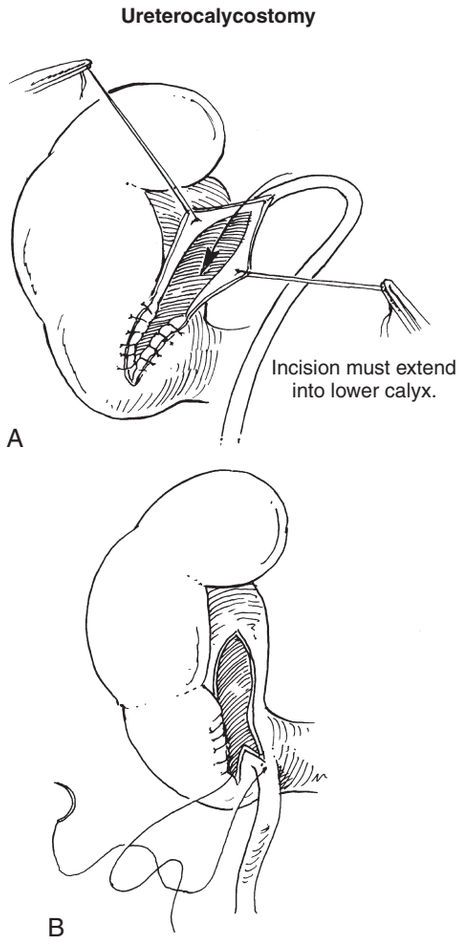

FIGURE 140-7.

anastomosis. The anastomotic suture line is made with a combination of interrupted sutures at the most dependent portion of the ureter and renal pelvis and a running suture up either side of the spatulating incision. A surgical drain such as Jackson-Pratt or Penrose drain is placed near the area of anastomoses at the completion of the repair. In cases of foreshortened ureters, secondary repairs, high insertions, and aberrant vessels precluding a tension-free dependent anastomosis, a ureterocalicostomy can be performed (Fig. 140-7).

Nephrectomy

The transperitoneal approach is best for nephrectomy. The kidney is approached via a supraumbilical long transverse incision in children or midline incision in adults. The vascular pedicle is reached by incising the peritoneum overlying the aorta and inferior vena cava. The vascular distribution is variable. There are no vessels on the dorsal aspect of the kidney except for some arteries to the isthmus. In addition to the normal renal arteries, there will be three or more accessory arteries; originating from the distal aorta, aortic bifurcation, and common iliac artery. Aberrant arteries may also arise from the renal artery, aorta, bifurcation of aorta, middle sacral, and common iliac artery. The caliber of these arteries is usually smaller than those of a normal kidney.

The upper pole is freed and the ureter is divided. There is usually minimal mobility of the lower pole due to fixation by the vasculature. Each identified artery supplying the kidney is exposed, identified, and sacrificed; the same follows for the veins supplying that kidney (Fig. 140-8A). The isthmus is left for last. The middle of the isthmus is identified through palpation. The vascular supply to the isthmus is identified, clamped, and divided. Observe for blanching, then place Satinsky clamps on either side of the isthmus, incise the capsule between the clamps, and peel back to aid in closing. Divide the parenchyma bluntly (see Fig. 140-8B). Calyces are usually in close proximity and may be inadvertently entered. If a calyx is entered, it should be closed meticulously. Running or interrupted 4-0 SAS are used to close the capsule (see Fig. 140-8C). Alternately, hemostatic Surgicel bolsters may be used to reapproximate the defect. Gerota's fascia or perirenal fat should then be reapproximated over the repair.

Partial Nephrectomy

The mobilization and exposure of the kidney is as described for radical nephrectomy. Gerota's fascia is opened and the entire surface of the kidney is exposed, leaving the perirenal fat overlying the tumor undisturbed. The supplying vasculature is identified and secured with vessel loops. The artery is clamped with a bulldog clamp as needed, especially for nonperipheral tumors. Renal ischemia is achieved by placing a bowel bag around the kidney and filling the bag with slush ice. Furosemide (Lasix) or mannitol can be administered a few minutes before clamping the renal artery. It is not always necessary to clamp the vein. The renal capsule is incised circumferentially with at least a 2-mm margin around

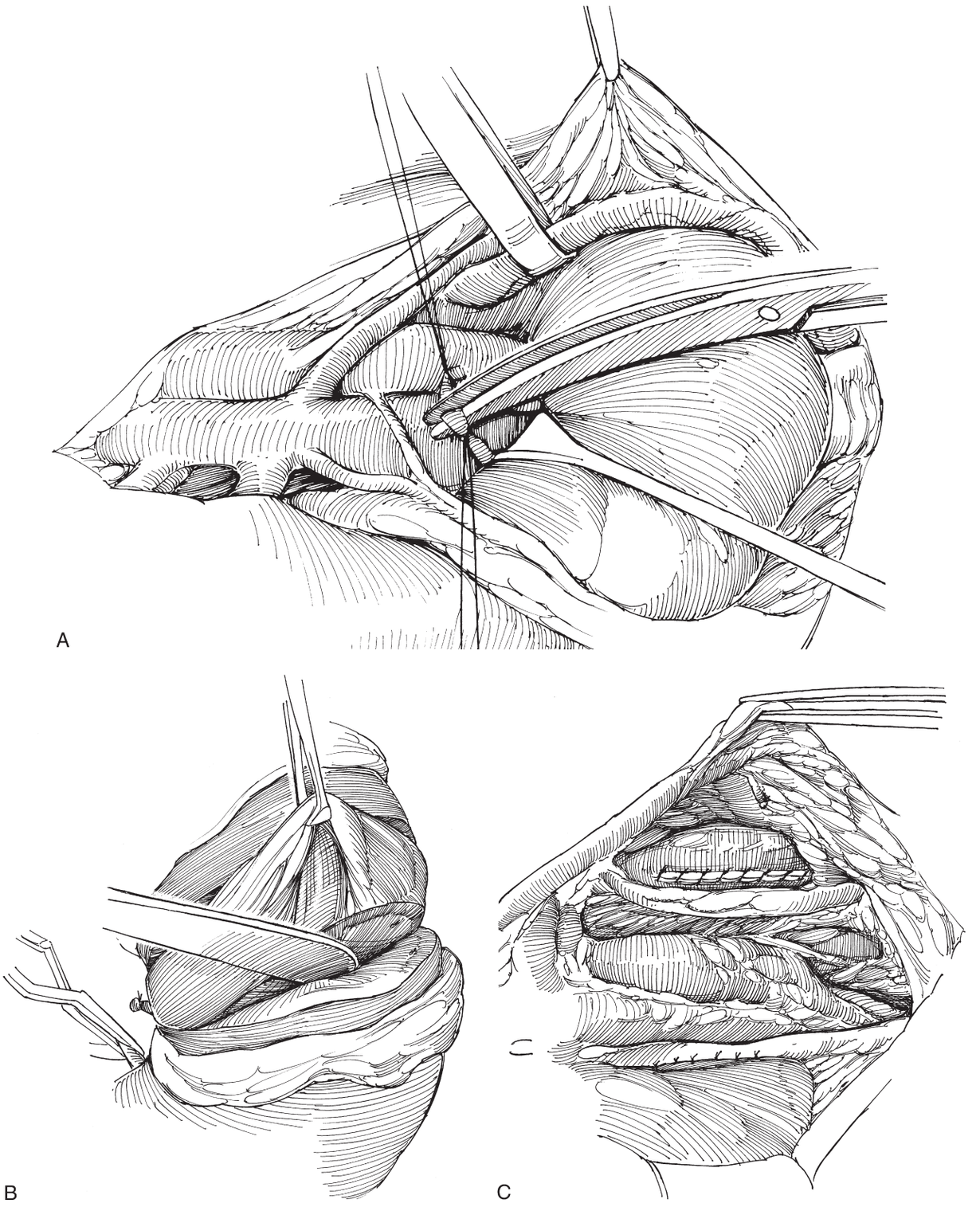

FIGURE 140-8.

the tumor. The tumor is excised with a margin of normal renal parenchyma in a wedge or cone to ensure that its entire intraparenchymal extent is removed with a margin (Fig. 140-9A). The tool instrument used for the resection is at the surgeon's discretion. Various methods, including energy based and mechanical means have been described. Small vessels can be coagulated, while larger vessels can be over-sewn with 4-0 SAS sutures. The tumors as well as biopsies of the base of the tumor are sent for frozen section. Calyces that are entered should be oversewn with 6-0 SAS sutures. The resection bed is coagulated using an argon beam coagulator, tissue-link device, or other suitable device. The kidney is closed by suturing the renal capsule (see Fig. 140-9B). Bolsters can be used as described in the Nephrectomy section.

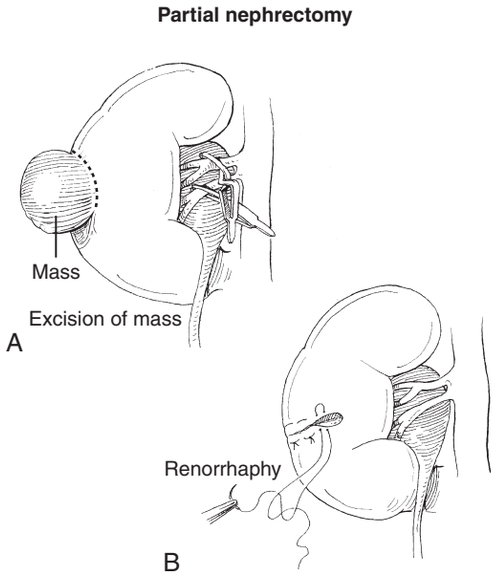

FIGURE 140-9.

Commentary by

ARTHUR I. SAGALOWSKY

The key to safe and successful surgery upon the horseshoe kidney, regardless of the pathology being treated (stones, obstruction, or tumor), lies in understanding its three-dimensional geometry with regard to the variation in orientation of the collecting system (calyces medial; renal pelvis anterior) and the fact that multiplicity of renal vascular supply is the rule rather than the exception. Modern three-dimensional imaging with CT angiography (CTA) and CT urography (CTU) is invaluable and should be obtained to plan the surgical approach. One may substitute MRI for CT except when treating stones, in which case CT is superior to MRI. When surgery is performed on one unilateral moiety of the horseshoe kidney, it is important to identify the origin of each renal artery and vein and to trace them to and from the segment being operated upon. This is particularly true near the medial portion of the kidney to avoid injury or inadvertent ligation of critical renovascular supply to the portion of the kidney that is to be spared, as well as failure to control bleeding from the portion being operated upon.

This page intentionally left blank

Chapter 141

Repair of Renal Injuries

JACK W. McANINCH AND JILL C. BUCKLEY

The first priority for all trauma patients is acute resuscitation stabilizing the airway, breathing, and circulation. Critically ill patients with severe hemodynamic instability undergo immediate operative exploration to control intraabdominal bleeding and may require a damage control nephrectomy to evade immediate mortality.

The remainder of severe renal injuries may present with abdominal or flank pain, ecchymosis, or tenderness. They can be associated with rib or spinous process fractures. Hematuria can be gross, microscopic, or absent and does not necessarily correlate with the degree of injury. Standard laboratory values are obtained.

In stable patients, computed tomography (CT) radiographic staging of renal injuries along with clinical presentation, mechanism of injury, presence of nonurologic intraabdominal injuries, and hemodynamic stability determine selective management. Grade I to III injuries are managed nonoperatively with excellent renal preservation and minimal risk of future morbidity. More severe renal injuries (grades IV to V) often occur with serious associated intraabdominal injuries that require operative exploration. Renal exploration and reconstruction is performed concurrently, providing a definitive repair and reducing the risk of late complications and a prolonged recovery phase with minimal increase in risk to the patient.

SURGICAL APPROACH TO RENAL EXPLORATION

A midline transabdominal incision from the xiphoid to the pubic symphysis (Fig. 141-1) provides optimal exposure for complete abdominal exploration, detection of associated intraabdominal injuries, and access to the great vessels in anticipation of renal exploration. Immediate bleeding should be controlled with laparotomy packs and surgical repair.

EXPOSURE, IMPORTANT LANDMARKS, AND RENAL HILAR CONTROL

The transverse colon is placed onto the chest over a moist laparotomy pack. The small bowel is extricated to the patient's right side and retracted superiorly to allow access to the

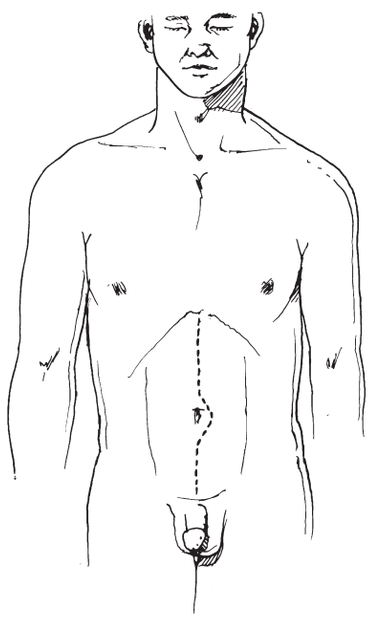

FIGURE 141-1.

retroperitoneum, inferior vena cava, and aorta for isolation of the injured renal unit hilar vessels (Fig. 141-2). The inferior mesenteric artery (IMA) is identified and an incision made superior to it directly down to the aorta. The dissection is carried cephalad to the left renal vein which reliably (~95%) crosses anterior to the aorta. When retroperitoneal anatomy is difficult to identify secondary to a large hematoma (Fig. 141-3), the inferior mesenteric vein (IMV) can be identified and used as a landmark to identify the aorta. An incision is made medial to the IMV and extended up to the ligament of Treitz on the anterior surface of the aorta to identify the anteriorly crossing left renal vein.

RENAL HILUM VESSEL ISOLATION

The left renal vein is always the first structure identified even for a right renal injury. Both the right and left renal artery are located posterior and slightly superior to the left renal vein. The right renal artery can be identified in the intra-aortocaval space by elevating the left renal vein and

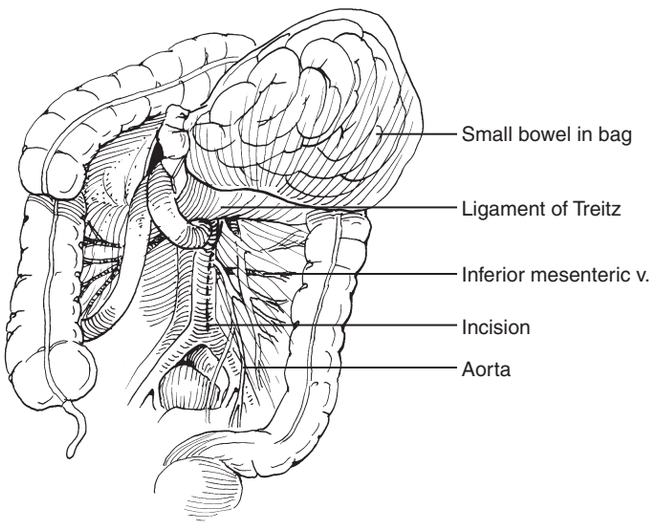

FIGURE 141-2.

dissecting on the medial aspect of the aorta (Fig. 141-4A). The right renal vein can be found on the lateral aspect of the vena cava at about the same level as the left renal vein. Vessel loops are placed around the artery and vein of the injured kidney in anticipation of opening the retroperitoneal hematoma (see Fig. 141-4B). Mobilization of the second portion of the duodenum is often necessary to visualize the right renal vein and should be performed if a right renal hilar injury is suspected.

ENTERING THE RETROPERITONEAL HEMATOMA AND RENAL EXPOSURE

The colon is mobilized medially by incising the white line of Toldt lateral to the colon. Gerota's fascia is opened sharply and the hematoma around the kidney is evacuated (Fig. 141-5). Unless severe bleeding is encountered that cannot be controlled with manual compression, the vessels are not clamped, thus avoiding warm ischemia. The kidney is completely mobilized and inspected to determine the full extent of the injury, to identify the entrance and exit wound of a penetrating injury, and to avoid a missed injury.

RECONSTRUCTIVE PRINCIPLES

Five basic renal reconstructive principles should be applied to all renal repairs: (1) complete renal exposure, (2) sharp debridement back to viable tissue, (3) hemostasis by oversewing end on vessels, (4) watertight collecting system closure, and (5) defect coverage.

Deep middle pole renal laceration can be reconstructed by renorrhaphy. The clot overlying the injury is removed to expose the full extent of injury, and the nonviable tissue edges are sharply debrided (Figs. 141-6 and 141-7). Individual suture ligation of bleeding parenchymal vessels and watertight continuous closure of the collecting system is performed with absorbable suture. Hemostatic and/or tissue sealants are placed directly onto the defect site for additional coverage and hemostasis (Fig. 141-8). Absorbable 3.0 capsular sutures are loosely placed over Gelfoam bolsters in an interrupted fashion. When available, the omentum can be used to cover the entire repair (Fig. 141-9).

A large upper or lower pole injury is best managed by a partial polar nephrectomy (Fig. 141-10). In a guillotine manner, the devitalized tissue is sharply removed. Applying the same reconstructive principles, end on bleeding vessels are oversewn and the collecting system is closed in a watertight fashion using a continuous suture. Hemostatic/sealant agents are applied directly to the defect site. Renal capsule is often not available or adequate to cover the renal defect, thus omentum and/or synthetic absorbable polyglactin mesh (Vicryl) is used for coverage. The mesh is tailored to the size of the defect and secured into place with interrupted sutures. If omentum is available, it is mobilized to cover the entire repair. Omentum provides a rich blood supply to the area, has excellent absorbant properties, and is beneficial to the wound healing process. The polyglactin mesh is absorbed through hydrolysis over a period of 55 to 70 days with minimal tissue reaction.

Sharp penetrating renal trauma, such as a stab wound, often causes significant bleeding but minimal displacement of renal tissue. Frequently, entrance and exit wounds can be oversewn and combined with viscous thrombogenic agents to achieve hemostasis (Fig. 141-11). Collecting system injuries that may have occurred usually resolve with closure of the overlying parenchyma and should not be aggressively pursued.

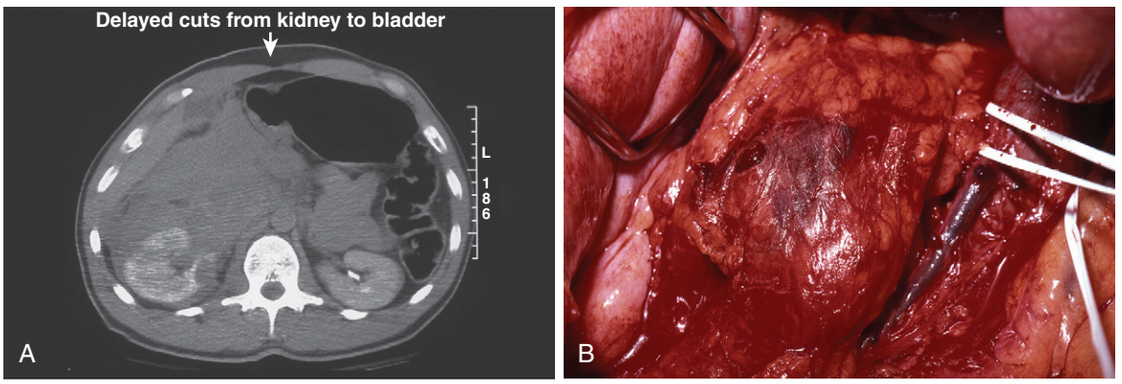

FIGURE 141-3. A, Computed tomography, right perirenal hematoma. **B,** Right perirenal hematoma. *(Courtesy of Jack W. McAninch, MD.)*

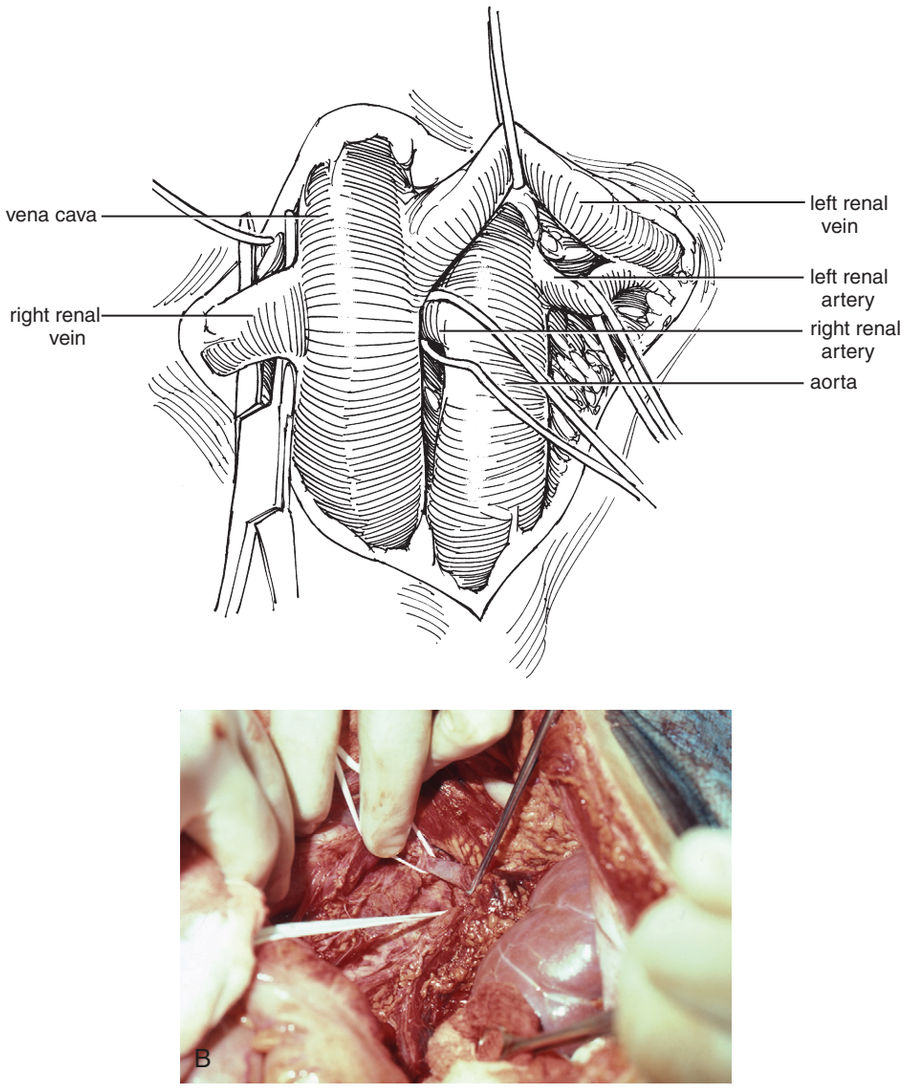

FIGURE 141-4. *(Part* **A,** *courtesy of Jack W. McAninch, MD.)*

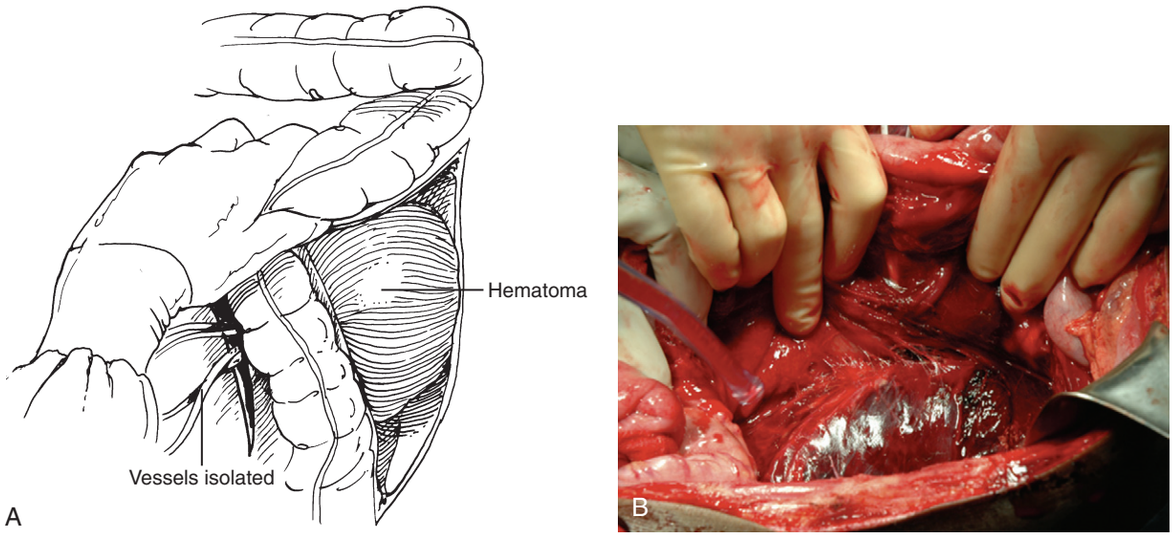

FIGURE 141-5. *(Part* **B,** *courtesy of Jill C. Buckley, MD.)*

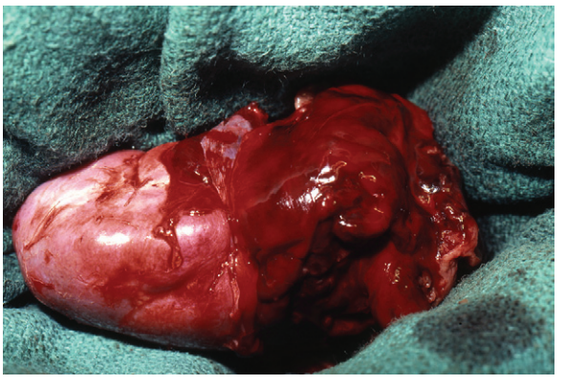

FIGURE 141-6. *(Courtesy of Jack W. McAninch, MD.)*

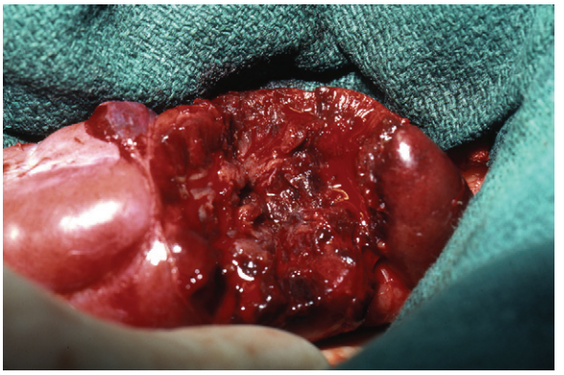

FIGURE 141-7. *(Courtesy of Jack W. McAninch, MD.)*



FIGURE 141-8. *(Courtesy of Jack W. McAninch, MD.)*

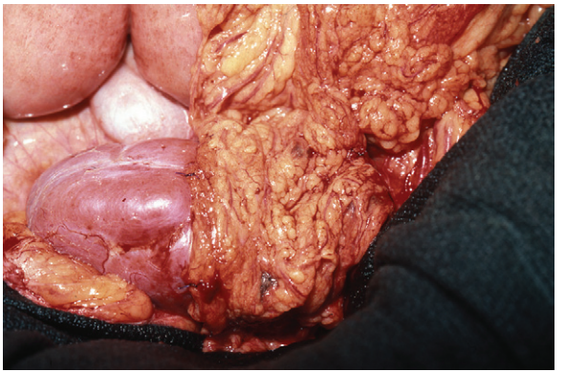

FIGURE 141-9. *(Courtesy of Jack W. McAninch, MD.)*

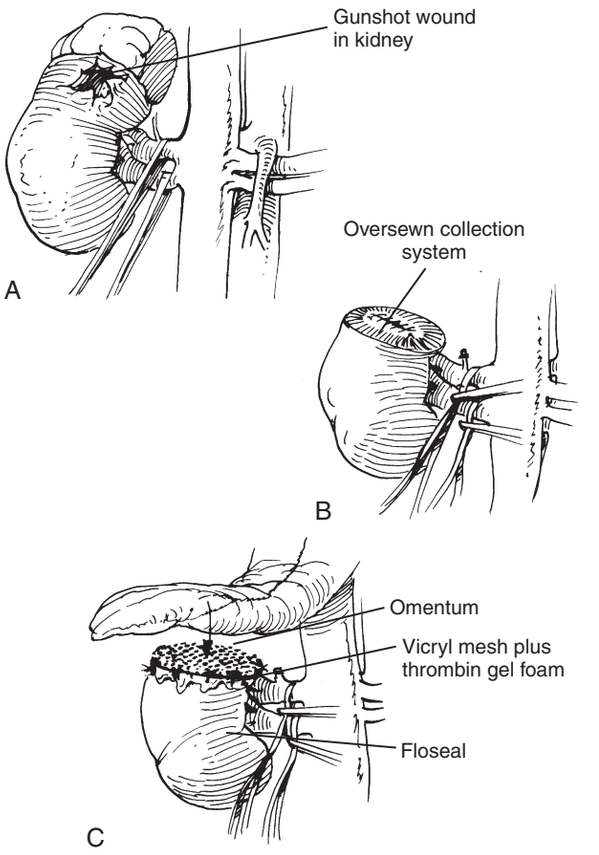

FIGURE 141-10. A, Gunshot wound injury. **B,** Hemi-nephrectomy with oversewing the collecting system. **C,** Liquid sealant (Floseal), thrombin gel foam and mesh sewn over coverage.

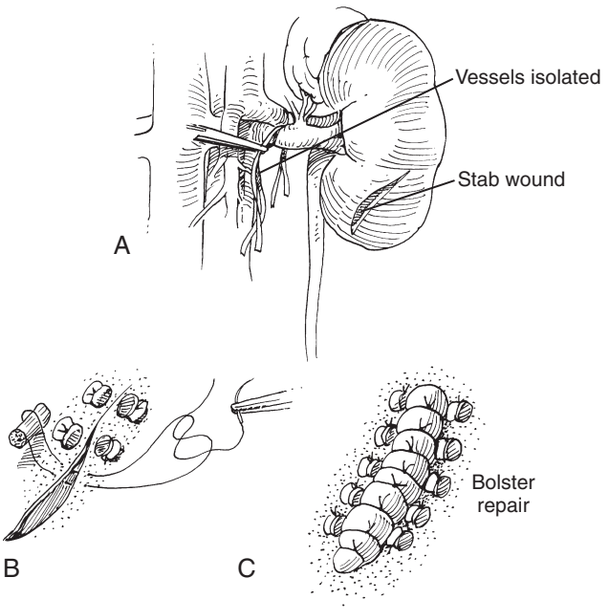

FIGURE 141-11.

TRAUMATIC RENAL VASCULAR INJURIES

Complex vascular reconstruction in the acute trauma situation is reserved for a solitary kidney or bilateral severe renal injuries. Conformation of a functioning contralateral kidney is necessary before performing a nephrectomy and can be achieved via imaging studies (intraoperative one-shot intravenous pyelogram [Fig. 141-12], CT) or with operative exploration.

Partial main renal vein or arterial injuries can be primarily repaired after proximal and distal control have been obtained. A continuous 4.0 Prolene suture is used to complete the repair (Fig. 141-13). Segmental arteries and veins are individually suture ligated to gain hemostasis.

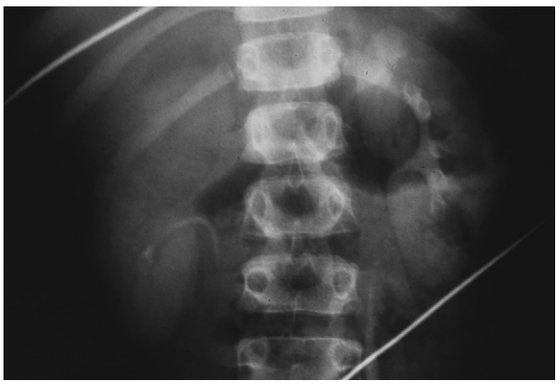

FIGURE 141-12. One shot intravenous pyelogram showing an intact contralateral renal unit. *(Courtesy of Jack W. McAninch, MD.)*

DRAINS AND URETERAL STENTS

If there is concern of a collecting system injury, either a ½-inch Penrose or a close passive suction flank drain is placed at the time of surgery through a separate incision. Suction drains are avoided because they may potentiate a urinary fistula. In the absence of a ureteral injury, a ureteral stent is not placed at the original exploration and repair.

POSTOPERATIVE CARE

A postoperative hematocrit is obtained and the patient is placed on bedrest until the hematuria clears (often within 24 hours). Perirenal drains are checked for creatinine and removed within 48 hours to prevent infecting the retroperitoneum. If a urinary leak is detected, a ureteral stent is placed to hasten closure of the collecting system. Persistent hematuria may indicate development of an arterial venous malformation or pseudoaneurysm requiring angioembolization. Patients are advised to avoid all strenuous activity for a 3-month period and are informed of the delayed risk of bleeding. A radionuclear renal scan or CT scan is obtained in the acute 3-month perioperative period to document postoperative function. These patients should be monitored regularly to detect hypertension.

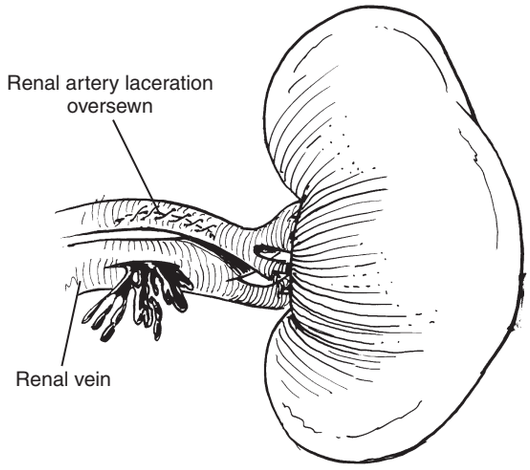

FIGURE 141-13.

Commentary by

ALLEN F. MOREY

The widespread adoption of CT for renal injury staging provides excellent anatomic information which has reduced the frequency of renal repairs required after trauma. Deep renal lacerations are now often safely observed without any intervention, even following penetrating trauma. Medial lacerations and those associated with large perirenal hematomas harboring vascular contrast extravasation are of particular concern. Angiographic embolization should be considered in lieu of open repair for cases involving injury to segmental renal vessels in stable patients. Persistence of urinary leakage from renal repairs can be expected when suction drains are used. Covering the repair with perirenal fat or omentum is prudent, as is the use of nonsuction drains. Finally, a variety of effective hemostatic topical agents may safely be used adjunctively in support of renal repair.

This page intentionally left blank

Chapter 142

Surgery for Renal Vascular Disease

AMR FERGANY AND ANDREW C. NOVICK

Renal artery disease is a surgically treatable cause of secondary hypertension and renal dysfunction. Significant stenosis of the renal artery or its branches results in activation of the renin-angiotensin-aldosterone system with resultant hypertension that may be associated with fluid retention, and can sometimes become severe and life threatening. Atherosclerotic disease of the renal arteries is the most common cause of renal artery stenosis (RAS), and fibrous dysplasia accounts for most of the remaining cases. Other rare causes include renal artery aneurysm, arteriovenous malformations, neurofibromatosis, middle aortic syndrome, and Takayasu arteritis.

The introduction of endovascular transluminal techniques for treating arterial stenosis has had a profound impact on the role of surgery for renal artery stenosis. The majority of patients with renal artery disease are currently treated with percutaneous transluminal angioplasty and intra-arterial stents. Open surgical revascularization remains the best option for patients with branch renal artery disease, renal artery aneurysm, or in cases of failed or complicated endovascular procedures. When used in properly selected patients, open surgical revascularization provides excellent long-term outcomes in patients with renal artery disease.

INDICATIONS FOR SURGERY

Renovascular hypertension (RVH) has been the traditional indication for surgery to repair RAS. More recently, renal dysfunction resulting from RAS (ischemic nephropathy) has become recognized as another indication for renal revascularization. Both RVH and ischemic nephropathy can present independently or concomitantly in the same patient.

Renovascular Hypertension

Clinical clues to suggest RVH include sudden onset and short duration, patient age less 30 or more than 50 at the onset of disease, presence of systemic vascular disease, end organ damage such as left ventricular hypertrophy or severe retinopathy, and renal function deterioration in response to treatment with angiotensin-converting–enzyme inhibitors.

Patients with clinical suspicion of RVH are usually tested with a variety of functional (plasma renin activity, captopril test, captopril renography, and renal vein renin assays) or anatomic (renal artery duplex ultrasound, magnetic resonance angiography, computerized tomography angiography) tests. Intra-arterial contrast angiography remains the definitive diagnostic study, and is necessary for planning surgical or endovascular intervention. Only lesions with hemodynamic significance should be treated. Such lesions cause more than 70% stenosis of the renal artery, and usually result in a measurable functional activation of the renin-angiotensin system.

In patients with fibrous dysplasia, angiography defines the type and extent of the lesions. This information is necessary to guide treatment and predict the natural history of the disease. Most patients with fibrous dysplasia are diagnosed with medial fibroplasia, which rarely progresses to loss of kidney function or complications. Such patients can be safely managed with medical treatment unless hypertension is severe. On the other hand, patients with intimal and perimedial fibroplasia usually have severe hypertension. These lesions have a tendency for progression with dissection, thrombosis, and loss of renal function. Intervention for revascularizing such lesions is usually recommended as an early treatment. Percutaneous angioplasty has excellent success rate, similar to that of open surgery, in the range of 90% to 95%. In these cases with fibrous dysplasia, surgery is usually reserved for patients with branch disease, associated renal artery aneurysm, or angioplasty failures.

Patients with RVH secondary to renal artery atherosclerosis (ASO) have a poorer blood pressure response to revascularization, with cure rates around 20% only, although the majority will have some improvement of blood pressure control. Management of these patients is usually complicated by the presence of medical comorbidity, extrarenal vascular disease, essential hypertension, glomerulosclerosis, and occasional cholesterol embolism. Medical management is more aggressively pursued in these patients. Renal artery ASO usually affects the ostium of the artery, and endovascular management usually includes stent placement

to improve patency rates. Surgical repair of these lesions is indicated for (uncommon) branch disease, and failed or complicated stent placement.

Ischemic Nephropathy

This is defined as the development of renal insufficiency from renal artery ASO, and occurs when there is high-grade (>75%) stenosis involving the entire renal mass. This entity is separate and distinct from RVH, although the two may coexist. Ischemic nephropathy usually occurs in older patients with generalized ASO. Because renal artery ASO is progressive and eventually results in loss of renal function of the affected unit, revascularization in such cases is recommended to improve or stabilize renal function. Clinical clues to the existence of ischemic nephropathy include unexplained azotemia in an older patient, azotemia associated with angiotensin converting enzyme inhibitor use, diminished renal size, and presence of atherosclerotic disease in extrarenal sites (cerebrovascular, coronary, or peripheral vascular disease).

PREOPERATIVE PREPARATION

Precise anatomic delineation of the arterial lesion by intraarterial angiography is necessary for planning and performing surgical revascularization. Selective renal arteriography is usually performed using iodinated contrast agents, although carbon dioxide can be used as a contrast agent in patients with renal dysfunction. Careful evaluation of the aorta and iliac arteries, as well as the origins of the celiac and superior mesenteric arteries (on lateral aortogram) is required to determine the optimal donor artery for revascularization.

Associated extrarenal vascular disease is common in patients with renal artery ASO. In these patients, correction of coronary or carotid disease preoperatively decreases morbidity and mortality in the perioperative period, and is an essential practice before renal revascularization.

Patients undergoing surgery should be well hydrated before surgery, and hypotension should be avoided intraoperatively and in the postoperative period, to minimize the possibility of graft thrombosis. Mannitol is administered before clamping and after unclamping of the renal artery, and postoperatively to optimize renal perfusion and maintain diuresis. A postoperative stay in an intensive care unit may be necessary for a day or two to manage postoperative fluctuations in blood pressure.

PATIENT POSITIONING

Revascularization of the kidney is most commonly performed through an anterior transperitoneal approach, which provides the best access to major vessels for vascular control. Consequently, patients are usually placed in the supine position. A roll may be placed underneath the patient's upper abdomen to facilitate surgery in the retroperitoneum. This roll is removed before closure of the abdomen. To allow harvesting of the saphenous vein, the patient is also placed in a mild frog-legged position, which provides access to the anteromedial aspects of both thighs. The abdomen, lower chest, and upper thighs should be shaved and prepped, with sterile surgical field allowing access to abdomen, both groins, and both thighs.

Depending on the particular planned bypass, a subcostal or a midline incision can be used. Midline incisions are versatile, allowing access to the renal vessels, as well as the entire length of the abdominal aorta, the iliac arteries, and the hypogastric artery to be harvested for use as a graft. Autotransplantation of the kidney can be performed through a midline incision as well. A right or left subcostal incision provides excellent access to the renal hilar area and the abdominal aorta, allowing easier reflection of the colon, and is a suitable incision for most renal bypass procedures, except iliorenal bypass. Splenorenal bypass can occasionally be performed through a modified left flank approach, which allows access to both splenic and left renal arteries. This can be performed retroperitoneally or transperitoneally. With this approach, exposure to the rest of the abdominal vasculature is limited, with minimal options for the surgeon if the planned procedure cannot be completed.

AORTORENAL BYPASS

Aortorenal bypass graft is an attractive and fairly straightforward renal revascularizton technique. Being the original source for the renal artery, the aorta makes the best donor vessel, with strong outflow. The required dissection is fairly simple, exposing aorta from the level of the renal arteries to the inferior mesenteric vein. Unfortunately, the aorta is commonly involved with atherosclerotic disease, which limits the application of aortorenal bypass in cases of atherosclerotic RAS. In this circumstance, care must be taken to ensure that a relatively disease-free portion of the aorta is used for the proximal arterial anastomosis, or an extraanatomic bypass procedure should be performed. On the left side, using the lower thoracic aorta (which is rarely affected by ASO) as a thoracic aortorenal bypass can also be performed.

Graft material for aortorenal bypass may be autologous or synthetic. Best results are obtained with autologous arterial grafts that withstand arterial pressure without long-term deterioration. The arterial graft most commonly used is the hypogastric artery. Its use is limited by short length, making it not suitable when a long graft is needed, and on the right side. Another limitation is the early effect by ASO on the hypogastric artery, which also makes it unsuitable for use. Venous grafts offer good results, and have proven durability. The saphenous vein is the most commonly used, being easy to procure, and of sufficient length for all required procedures. Aneurysmal dilatation of saphenous vein grafts can occur long term, and may be related to ischemic wall changes from arterial pressure. Such change is more common in children, and prevents the use of saphenous vein in this group of patients. If no autologous material is available, a synthetic graft of polytetrafluoroethylene or Dacron may be used.

Exposure for a right-sided aortorenal bypass is accomplished by mobilizing the right colon, and Kocherizing the duodenum. The liver is retracted superiorly, and the inferior

vena cava as well as the aorta are exposed. A self-retaining ring retractor is essential to maintain this exposure. A small area on the anterior surface of the kidney is exposed by excising the perinephric fat. This allows inspection and palpation of the kidney after revascularization, and can also be used to obtain an intraoperative renal biopsy when the extent of glomerulosclerosis is in question.

The anterolateral surface of the aorta is dissected, facilitated by lateral retraction of the inferior vena cava and superior retraction of the left renal vein. Dissection along the right side of the aorta in a cephalad direction leads to the origin of the right renal artery posterior to the left renal vein. The renal artery is dissected behind and lateral to the inferior vena cava by retracting the cava and the right renal vein. Lumbar vein injury damage should be carefully avoided. The renal artery is dissected distally toward the kidney, with the branches dissected as required from preoperative angiography.

A suitable donor area of the aorta is selected, and an appropriate length of saphenous vein harvested. This length should be more than the anticipated length, and it should not be trimmed to proper length until it is time to perform the distal anastomosis.

The proximal (aorta-graft) anastomosis is performed first. Vascular control of the aorta around the selected donor site can be obtained by cross clamping, or side clamping with a Satinsky clamp. We prefer the latter because it avoids the need for systemic heparinization, which is necessary if the aorta is totally occluded. An aortotomy is made with a scalpel or an aortic punch. This should be oval in shape, and placed on the anterolateral aspect of the aorta to allow a gentle curve over the vena cava without proximal kinking or angulation. The vein graft is spatulated for a short distance, and an end-to-side anastomosis is performed (Fig. 142-1). Various techniques can be used; we prefer interrupted vascular silk sutures (5-0 or 6-0) on the anterior and posterior walls after two apical sutures are placed. Purse-string narrowing is minimized using this technique. A continuous suture line using Prolene is commonly used as well.

After the proximal anastomosis is complete, the vein graft is clamped with a bull-dog clamp, and the aortic clamps are released. Any bleeding from the anastomosis can be secured at this time, and systemic heparinization can be reversed. The distal graft is flushed with heparinized saline to prevent clotting. The renal artery (previously mobilized) is ligated proximally, and clamped distally with a bull-dog clamp after injecting heparinized saline into the kidney. The diseased segment of renal artery is excised, and the vein graft can be trimmed at this time. Trimming should be done to allow enough length for a tension free anastomosis without any redundancy that may predispose to kinking and thrombosis. It is helpful to measure with the distal end of the graft occluded, as filling with arterial pressure will distend and lengthen the vein.

The distal anastomosis is then performed in an end-to-end fashion. End-to-side anastomoses are more difficult to perform, and result in suboptimal flow rates. Interrupted or continuous suture can be used, although narrowing tendency is minimized using interrupted sutures. The distal and proximal clamps are removed, and blood flow to the kidney is restored.

The procedure is similar on the left side. The descending colon and the splenic flexure are mobilized to expose the renal hilum and the aorta. The renal artery is identified on the lateral aspect of the aorta. The donor site is chosen on the lateral aspect of the aorta on the left side, instead of anterolaterally on the right. The shorter graft distance on the left side makes the hypogastric artery more useful.

Patients with multiple renal arteries or disease involving the branches of the renal artery outside the renal hilum can be revascularized with a branched graft in situ (Fig. 142-2).

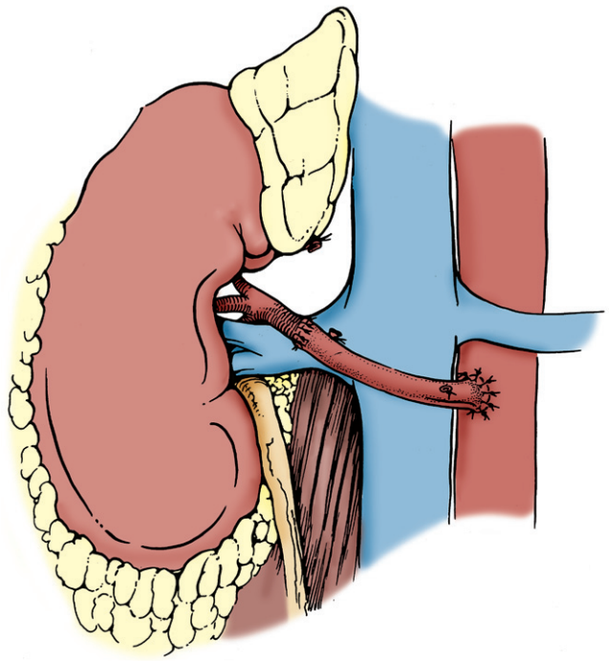

FIGURE 142-1. Completed right aortorenal bypass.

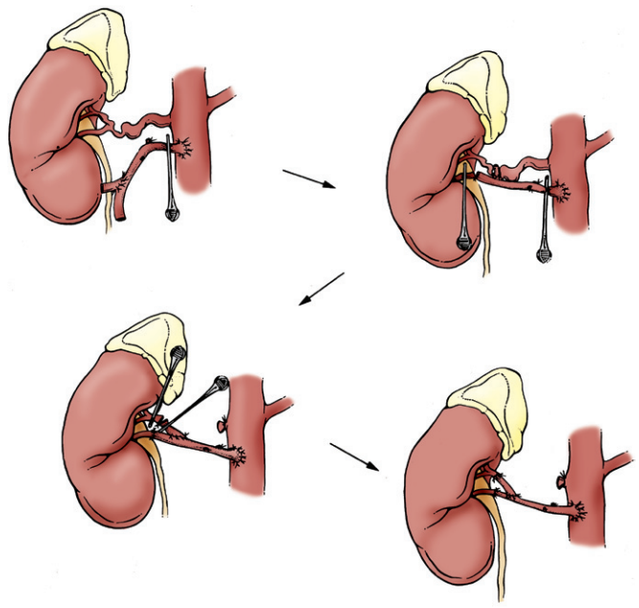

FIGURE 142-2. Aortorenal bypass with branched saphenous vein graft.

This technique is also used for patients with renal artery aneurysm that extends into the extrahilar portion of the renal artery branches. The saphenous vein provides good material for branched grafts, as it has enough length, and can be fashioned into the desired configuration before anastomosis to the aorta or the renal artery branches. The hypogastric artery can be harvested with its branches and used on the left side, but its use is limited by its fixed configuration, which might not fit the required branch configuration of the renal artery. In these cases the proximal aorta-graft anastomosis is performed in the usual manner, but the distal anastomoses to the renal artery branches is different. Such branch anastomoses are usually delicate, and finer suture (7-0) is required. Optical magnification, which is helpful but not necessary for main renal artery anastomosis, is essential for branch anastomosis. Ligation of the renal artery branches and anastomosis is performed one by one. The remainder of the kidney remains perfused through the renal artery while the branch anastomosis is performed, limiting the overall renal ischemia time. The branches are thus sequentially clamped, anastomosed, and revascularized before another branch is clamped.

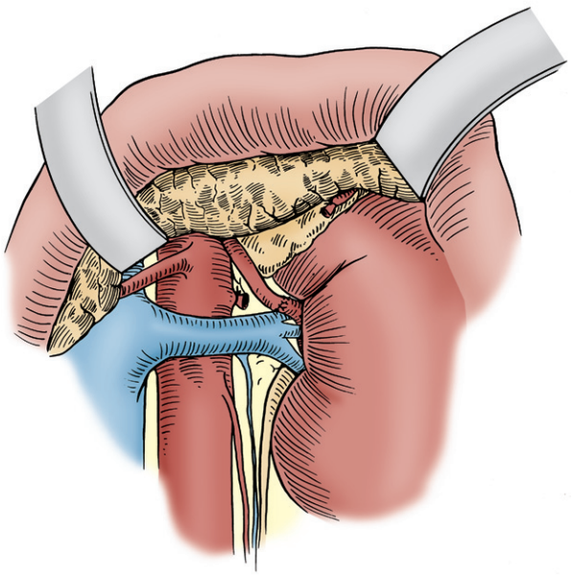

FIGURE 142-3. Splenorenal bypass.

EXTRA-ANATOMIC BYPASS TECHNIQUES

Although aortorenal bypass is the preferred bypass method of choice, it may not be possible to perform in a variety of situations. These include older patients with aortic atherosclerosis, aortic aneurysm, or fibrosis from previous surgery. In some of these cases, aortic replacement might not be required, and a renal artery bypass without utilizing the abdominal aorta avoids the potential hazards of operating on such diseased aorta. The morbidity of these extra-anatomic renal bypass procedures alone is significantly lower than the morbidity of a combined aortic replacement and renal revascularization, and the success rates are quite high. Such alternate bypass techniques are splenorenal, hepatorenal, and iliorenal bypass procedures. These potential donor arteries need to be evaluated radiographically before surgery by lateral aortography to show the celiac axis, as well as pelvic angiography to evaluate the iliac vessels.

Splenorenal Bypass

Splenorenal bypass is a useful bypass procedure for patients with a difficult aorta who need left renal revascularization (Fig. 142-3). The procedure has several advantages including surgery away from the aorta, the absence of graft material, a single arterial anastomosis, and close proximity of the splenic artery to the renal artery with similar caliber. Although rerouting of the splenic artery behind the duodenum for a right-sided splenorenal bypass has been described, the procedure is not considered to be suitable for right renal revascularization. Careful handling of the splenic artery is essential, to avoid troublesome spasm that can sometimes occur, especially in younger female patients.

After reflecting the left colon, and exposing the renal vein, the renal artery is located posterior to the vein, lateral to the aorta. Enough length of the renal artery should be dissected to allow sufficient mobility. Ligation of the renal vein branches will assist in retracting the vein to expose the artery. The splenic artery is identified cephalad to the splenic vein, behind the body of the pancreas. The splenic artery is dissected proximally and distally to allow enough mobility to reach the renal artery. Careful attention should be made to avoid tearing short pancreatic branches that arise from the artery and enter the body of the pancreas immediately. After this dissection is complete, a bull-dog clamp is placed on the splenic artery proximally, and it is ligated and divided distally. There is no need to perform a splenectomy, as the spleen will remain adequately vascularized through collateral arterial supply from the short gastric arteries.

The splenic artery is irrigated free of blood and debris with heparinized saline. A bull-dog clamp is placed across the distal renal artery. It is ligated and divided proximally, ensuring the distal end of the artery is free of disease, and irrigated with heparinized saline. The splenic artery is trimmed to the correct length, taking into consideration the elongation of the artery that occurs with distention, as well as shortening of the gap between the two vessels as self-retaining retractors are removed and the pancreas replaced anterior to the renal hilum. We prefer to perform an interrupted end-to-end anastomosis using 6-0 vascular silk, suturing the anterior and then posterior walls after two corner stay sutures are placed. End-to-side anastomosis of the splenic to the renal artery is more difficult, and associated with suboptimal hemodynamic flow. A continuous suture line using fine Prolene can also be performed. Finally, the bull-dog clamps are released, and the anastomosis checked for hemostasis and patency into the distal renal artery.

Hepatorenal Bypass

Hepatorenal bypass is a useful technique for right renal artery revascularization when an aortorenal bypass is not possible. The hepatic circulation is unique in that the liver derives a dual blood supply through the hepatic arterial and

portal venous systems. The hepatic artery contributes about 20% of the blood supply to the liver; when interrupted, oxygen extraction increases from the portal venous blood, and collateral arterial supply to the liver develops. Anatomic variation of the hepatic arterial tree is common, with separate origins of the right and left hepatic arteries from the superior mesenteric or left gastric artery.

Various techniques can be used for hepatorenal bypass according to the anatomic findings and the caliber of the hepatic vessels. Most commonly a saphenous vein graft is used in an end-to-side fashion to the common hepatic artery and an end-to-end fashion to the renal artery (Fig. 142-4). This provides the least reduction of hepatic arterial flow. Other variants include end-to-end anastomosis to the common hepatic, right hepatic, or gastroduodenal artery, with or without an interposition saphenous vein graft, as length permits. In such cases, the liver does not suffer ischemic damage, but the gallbladder needs to be removed to minimize the risk of necrosis. In some patients with severe mesenteric atherosclerosis, blood supply within the superior mesenteric bed may be dependent on collaterals through the gastroduodenal and pancreatico-duodenal anastomoses. Interruption of the gastroduodenal artery in these cases may result in ischemic injury to the bowel. When using the gastroduodenal artery, care must be taken to avoid proximal kinking at the origin, as well as direct injury to the duodenum or pancreas.

The right renal artery is exposed at the beginning of the procedure. The hepatic artery is dissected carefully in the porta-hepatic within the free edge of the lesser omentum (anterior margin of the foramen of Winslow). Sufficient length of the common hepatic artery should be exposed, including the hepatic branches and the gastroduodenal artery as needed. Care should be taken to avoid injuring the common bile duct or the portal vein, which lie close to the hepatic artery. Saphenous vein is harvested as needed, and the appropriate technique for the anatomic situation is performed.

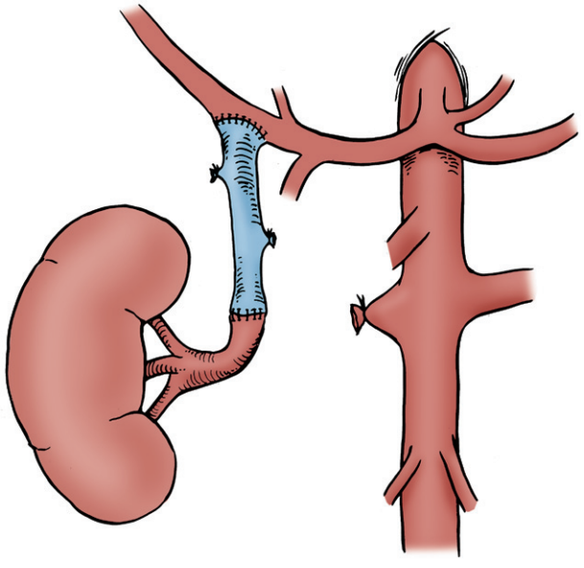

FIGURE 142-4. The most common method of performing hepatorenal bypass: vein graft anastomosed end to side to the common hepatic artery.

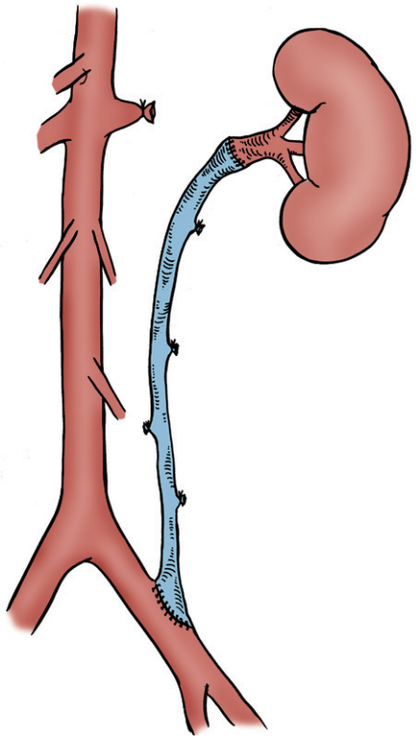

FIGURE 142-5. Iliorenal bypass.

Iliorenal Bypass

Iliorenal bypass is a technique that can occasionally be used when it is not possible to perform an aortorenal, hepatorenal, or splenorenal bypass. Occasionally the iliac artery will be relatively healthy in the presence of aortic atherosclerosis, although such disease can progress to involve the iliac vessels and compromise the bypass graft at a later time. The procedure is equally useful for the right and left sides; occasionally the contralateral iliac vessel can be used as a donor artery. A long midline incision is used, allowing simultaneous exposure of the renal and iliac vessels, and the bypass is carried out using a long reversed, saphenous vein graft (Fig. 142-5).

EX VIVO REPAIR WITH AUTOTRANSPLANTATION

Ex vivo microvascular repair and autotransplantation is a useful revascularization technique that is employed when arterial disease extends into the smaller branches of the renal artery. Such branches are usually small, and disease may extend into the renal sinus making in situ repair difficult. Branch renal artery disease is typically caused by fibromuscular dysplasia, arteriovenous fistula, renal artery dissection, and renal artery aneurysm. It is far less common in cases of renal artery atherosclerosis, which affects the renal artery in the ostial and proximal locations. The advantages of the technique include optimum exposure and illumination, a bloodless field, greater renal protection from ischemia, and easy use of optical magnification and microvascular technique. The nonperfused kidney is softer, allowing distal dissection of the renal artery branches a lot farther into the renal sinus. At the end of the reconstruction, the repair can

be tested with saline and any leaks can be repaired before autotransplantation.

Preparation includes detailed renal and pelvic arteriography. The extent of renal artery disease has to be fully delineated before surgery. The pelvic arterial anatomy has to be carefully mapped to ensure disease free iliac vessels as well as to delineate the hypogastric artery and branches. Patients with severe aortoiliac atherosclerotic disease are not candidates for this approach, as well as kidneys with parenchymal or diffuse small vessel disease. Such diseased kidneys perfuse poorly after removal, resulting in irreversible ischemic damage.

Surgery is usually performed through two separate incisions for the kidney removal and for the autotransplantation. In thinner patients, a single long midline incision can be used for both parts of the operation. Adequate perfusion of the kidney and brisk urine output before nephrectomy is essential, similar to live donor nephrectomy. The kidney is flushed with cold perfusate immediately after nephrectomy, and kept in an ice slush basin throughout the extracorporeal reconstruction. It is preferable to divide the ureter and work on the kidney at a separate workbench, than to work at the abdominal level with the ureter attached to the patient, which is rather cumbersome.

After the kidney is flushed and hypothermia maintained, the branches of the renal artery are dissected distally into the renal sinus beyond the diseased segments (Fig. 142-6A). Microsurgical instruments and optical magnification are essential, as well as careful technique to avoid injuring the delicate renal hilar vessels. After the full extent of disease is delineated, a graft material is chosen. If available and healthy, a hypogastric artery graft, harvested intact with its branches, can provide an optimal graft material (Fig. 142-6B). A long segment of saphenous vein can be used as

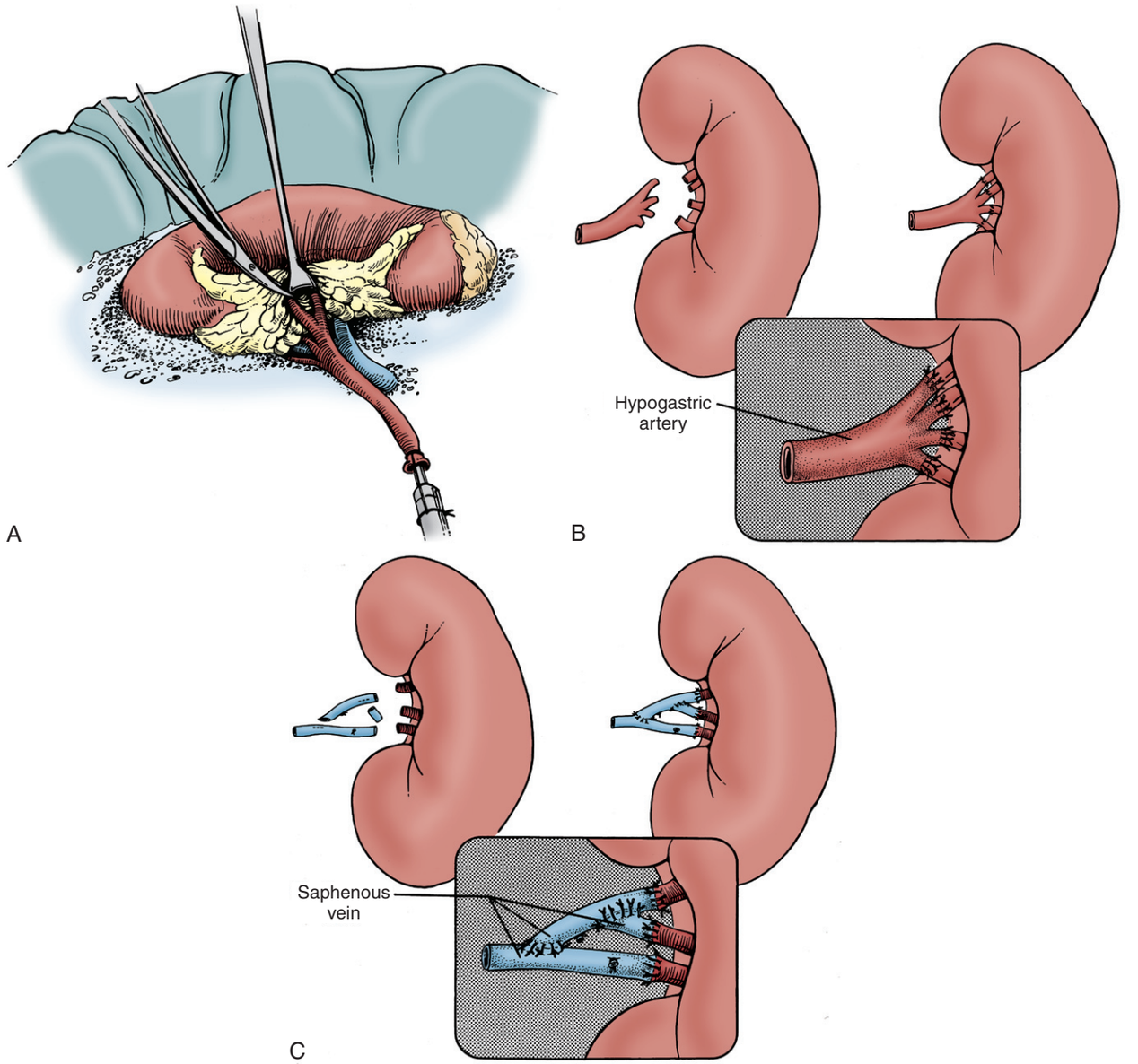

FIGURE 142-6. Extracorporeal microvascular repair of branch renal artery disease. **A,** Renal artery branches dissected into the renal hilum under hypothermia. **B,** Repair with branched hypogastric artery graft. **C,** Repair with branched saphenous vein graft.

well, multiple vein segments can be anastomosed end to side to the main vein, allowing a branched graft to be fashioned in any configuration (Fig. 142-6C). For smaller renal artery branches, the inferior epigastric artery can also be used as a graft. In all cases, positioning of the graft and branches should be kept in mind, and all anastomoses should be carried out in a manner that avoids kinking, malrotation, or twisting. Fine suture material (7-0 to 9-0) and interrupted suture technique are used for such anastomoses. After the repair is complete, the patency and integrity is tested by reflushing the new renal artery. The kidney is then autotransplanted into the renal fossa, and a ureteroneocystostomy is performed.

POSTOPERATIVE CARE AND COMPLICATIONS

Patients undergoing renal artery revascularization should be monitored in the intensive care unit postoperatively. Wide blood pressure fluctuations are common, and can predispose the patient to bleeding or graft thrombosis. Diastolic blood pressure should be maintained around 90 mmHg using short-acting intravenous antihypertensive medication or pressors as needed. A renal scan is performed 24 hours after surgery to confirm perfusion of the kidney. Patients are discharged from the intensive care unit after blood pressure stabilization, usually within 48 hours of surgery.

Postoperative bleeding usually occurs within the first 24 hours, and is detected by changes in vital signs and blood counts. Management depends on estimated severity, and ranges from conservation with blood transfusion to re-exploration with repair of the bleeding anastomosis or vessel. Delayed bleeding or false aneurysm may require re-exploration; these complications are uncommon with the use of autogenous graft material.

Graft thrombosis is estimated to occur in 2% to 4% of cases, and is more common with synthetic graft material and diseased kidneys with poor distal blood flow. It should be suspected when postoperative renal flow scan shows no perfusion to the kidney, or when severe unexplained hypertension develops suddenly. Attempts at salvage are rarely successful, and nephrectomy may be required for severe hypertension in these cases.

ARTHUR I. SAGALOWSKY

Commentary by

Few urologists will perform the renovascular repairs that are elegantly described by Fergany and Novick. However, every urologist should be knowledgeable about the pathophysiology of renovascular hypertension (RVH) (excess activation of the rennin-angiotensin axis secondary to reduced renal blood flow due to critical narrowing of the main renal artery or of its braches), and reduced renal function due to renal ischemic nephropathy secondary to decreased glomerular and renal tubular function due to chronically decreased renal blood flow. Functional hemodynamic significance must be demonstrated before deciding renal artery repair is indicated. The primary role of endovascular repair for many forms of main renal stenosis should be appreciated. Proper interpretation of the various forms of renal fibrous dysplasia shown on arteriography is important due to the distinct and different natural histories. Medial fibroplasias shows the "classic string of beads pattern," causes hypertension that is more responsive the medical therapy, and has low risk for loss of the kidney. In contrast, the more severe intimal and perimedial fibroplasias are associated with more severe and difficult to control hypertension, and are prone to sudden dissection, thrombosis, and loss of the kidney if not repaired first. Repair of renal ischemic nephropathy, which is usually caused by renal artery atherosclerosis, is only indicated if the kidney likely has recoverable parenchymal function. This is usually demonstrated by renal size greater than 7 cm and biopsy demonstrating viable glomeruli.

Suggested Readings

Chibaro EA, Libertino JA, Novick AC. Use of the hepatic circulation for renal revascularization. Ann Surg. 1984;199(4):406-411.

Fergany A, Kolettis P, Novick AC. The contemporary role of extra-anatomical surgical renal revascularization in patients with atherosclerotic renal artery disease. J Urol. 1995;153(6):1798-1801.

Khauli RB, Novick AC, Coseriu GV. Renal revascularization with polytetrafluoroethylene grafts. Cleve Clin Q. 1984;51(2):365-369.

Khauli RB, Novick AC, Ziegelbaum M. Splenorenal bypass in the treatment of renal artery stenosis: experience with sixty-nine cases. J Vasc Surg. 1985;2(4):547-551.

Novick AC. Percutaneous transluminal angioplasty and surgery of the renal artery. Eur J Vasc Surg. 1994;8(1):1-9.

Novick AC, Banowsky LH. Iliorenal saphenous vein bypass: an alternative for renal revascularization in patients with a surgically difficult aorta. J Urol. 1979;122(2):243-245.

Novick AC, Jackson CL, Straffon RA. The role of renal autotransplantation in complex urological reconstruction. J Urol. 1990;143(3):452-457.

Novick AC, Stewart BH, Straffon RA. Autogenous arterial grafts in the treatment of renal artery stenosis. J Urol. 1977;118(6):919-922.

Novick AC, Straffon RA, Stewart BH, et al. Diminished operative morbidity and mortality following revascularization for atherosclerotic renovascular disease. JAMA. 1981;246:749-753.

Novick AC, Ziegelbaum M, Vidt DG, et al. Trends in surgical revascularization for renal artery disease: ten years' experience. JAMA. 1987;257:498-501.

Ortenberg J, Novick AC, Straffon RA, Stewart BH. Surgical treatment of renal artery aneurysms. Br J Urol. 1983;55(4):341-346.

Schreiber MJ, Pohl MA, Novick AC. The natural history of atherosclerotic and fibrous renal artery disease. Urol Clin North Am. 1984;11(3):383-392.

Steinbach F, Novick AC, Campbell S, Dykstra D. Long-term survival after surgical revascularization for atherosclerotic renal artery disease. J Urol. 1997;158(1):38-41.

Stewart BH, Dustan HP, Kiser WS, Meaney TF, Straffon RA, McCormack LJ. Correlation of angiography and natural history in evaluation of patients with renovascular hypertension. J Urol. 1970;104(2):231-238.

Straffon R, Siegel DF. Saphenous vein bypass graft in the treatment of renovascular hypertension. Urol Clin North Am. 1975;2(2):337-350.

Streem SB, Novick AC. Aortorenal bypass with a branched saphenous vein graft for in situ repair of multiple segmental renal arteries. Surg Gynecol Obstet. 1982;155(6):855-859.

This page intentionally left blank

Chapter 143

Renal Transplant Recipient

JOHN M. BARRY

ADULT

Well in advance of renal transplantation, assess the patient for the following: risk of renal disease recurrence in the kidney transplant, active infection, active malignancy, probability of perioperative mortality, compliance, and unsuitable conditions for technical success. Evaluate the transplant candidate for vascular disease and for the status of the urinary bladder or its substitute.

Preparation

Just before surgery, perform a brief history and physical examination to be certain that no intervening problems have occurred that will compromise the transplant procedure and induction immunosuppression. Confirm that the donor and recipient are ABO-compatible and that the cytotoxic lymphocyte cross match results are acceptable. If necessary, dialyze the patient for hyperkalemia or fluid overload.

Instruments

Provide a self-retaining retractor that attaches to the operating room table; a general laparotomy set with vascular instruments; a variety of vascular clamps; 5-mm and 6-mm vascular punches; heparinized saline solution; bacitracin-neomycin irrigant for the bladder and the wound; 2-0 and 4-0 silk ties; small, medium, and large hemostatic clips; 0- or #1-synthetic absorbable monofilament sutures; 3-0 synthetic absorbable sutures; 4-0 synthetic absorbable sutures; 5-0 synthetic monofilament absorbable sutures; 5-0 and 6-0 monofilament vascular sutures; 3-0 monofilament nonabsorbable sutures; umbilical tapes; a Foley catheter; a flat, soft suction drain (two if the patient is obese); a Y-connector; cystoscopy tubing; and a urine drainage bag.

Position

The patient should be supine; break the table slightly to hyperextend the abdomen and rotate it slightly toward the surgeon. The kidney is preferably placed in the opposite iliac fossa so that the renal pelvis is the most medial of the hilar structures. Remove hair with clippers and prepare the entire abdomen. Insert a 20 Foley 5-ml balloon catheter into the bladder and with a Y-connector; hook it up to a drainage bag and cystoscopy tubing (Fig. 143-1). Connect the cystoscopy tubing to a liter bag that contains one ampule of bacitracin-neomycin solution. Rinse the bladder a

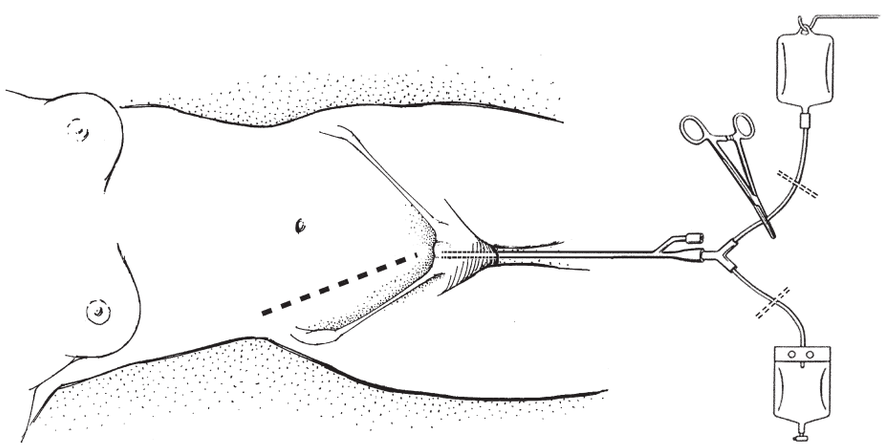

FIGURE 143-1.

time or two with the antibiotic solution and leave a 100-ml indwelling by clamping the in-flow and out-flow tubes. Place the clamped urine drainage bag under the head of the operating room table so the anesthesiologist can fill and empty the bladder for you later in the case. This will facilitate bladder identification in a scarred pelvis and performance of an extravesical ureteroneocystostomy.

Technique

1. Make a 20-cm straight lower quadrant (modified Gibson or Rutherford Morison) incision from the pubic notch toward the costal margin about 3 cm medial to the anterior superior iliac spine. Incise the anterior rectus sheath and external oblique in the directions of its fibers. Preserve the rectus abdominis muscle.
2. Divide the inferior epigastric vessels between 2-0 silk ligatures (Fig. 143-2). Leave the inferior epigastric artery long if it might be necessary to anastomose it to a lower-pole segmental renal artery. Divide the thin inner layer of the transversalis fascia and enter the extraperitoneal space between the partially filled bladder and the external iliac vessels. Sweep the peritoneum medially from the iliac vessels and posteriorly from the transversalis fascia and transversus abdominis muscle. Incise the internal oblique muscle, transversalis fascia, and transversus abdominis muscle in the line of the fibers of the external oblique.

   In the female, ligate and divide the round ligament. In the male, identify the spermatic cord and free it to its entry into the inguinal canal so that it can be retracted medially. Division of spermatic vessels or vas deferens is rarely necessary. Develop the extraperitoneal space over the iliac fossa to expose the distal common and external iliac arteries and the external iliac vein.
3. Insert a self-retaining Bookwalter or similar retractor (Fig. 143-3). A ring retractor with fixation to the operating table via a post permits many different exposures using a variety of fixed and adjustable blades. Be certain that a retractor blade does not compress the Psoas muscle and the underlying femoral nerve.
4. Palpate the iliac arteries and select a preliminary target for the arterial anastomosis (Fig. 143-4). Arteriosclosis of the internal iliac artery usually begins in the posterior common iliac artery. Start the dissection over the

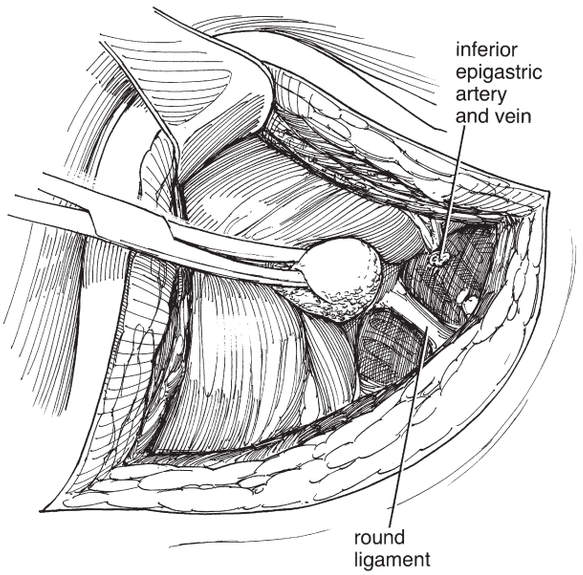

FIGURE 143-2.

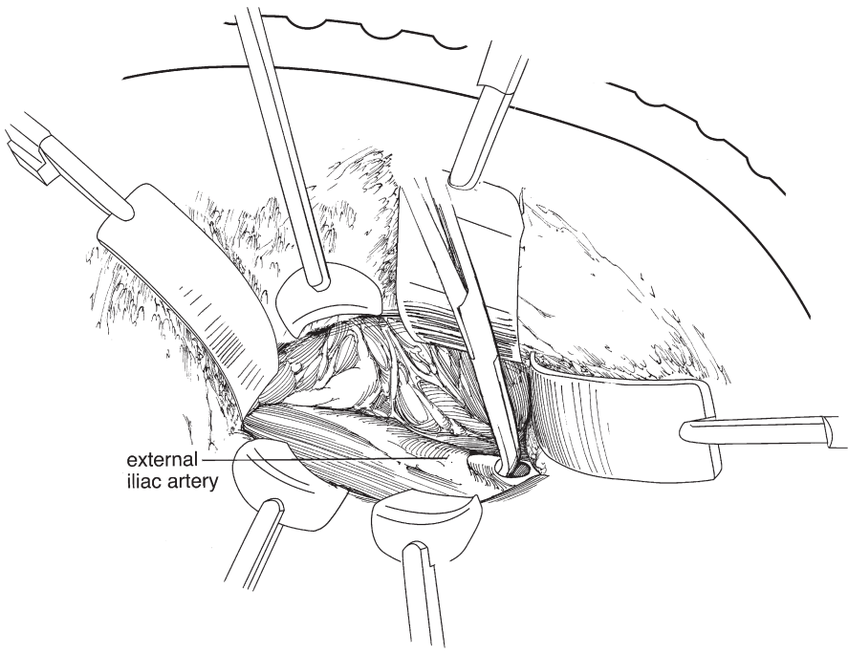

FIGURE 143-3.

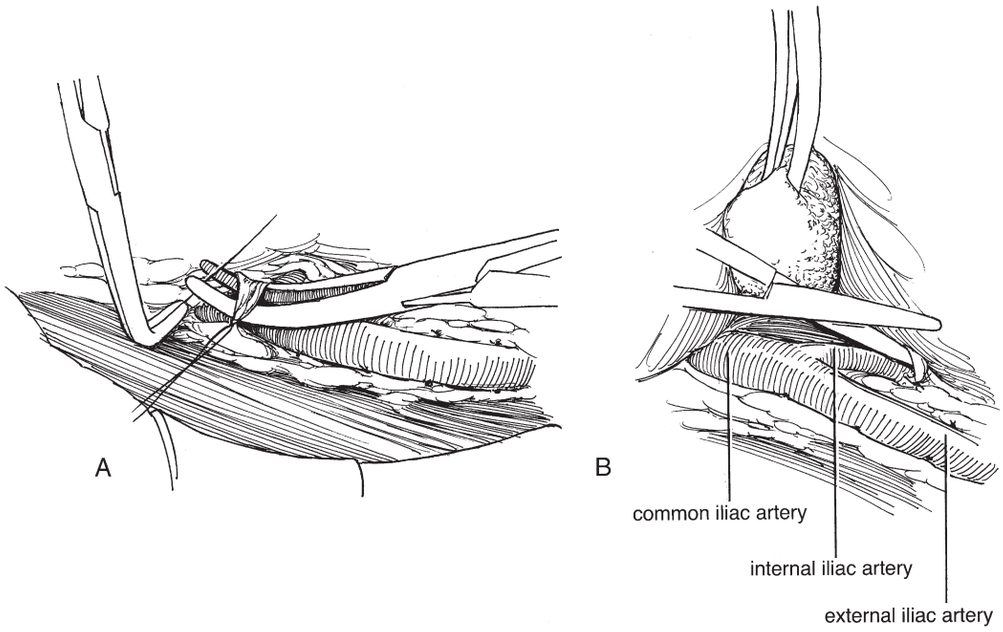

FIGURE 143-4.

external iliac artery, elevate the tissue anteriorly with right-angle forceps, and divide overlying lymphatics between 2-0 silk ligatures. Ties are better than clips to prevent lymphoceles because the former may be dislodged with the suction device. Continue up onto the common iliac artery for a few centimeters. The genitofemoral nerve lies lateral to the external iliac artery and may cross it distally. Do not mistake it for a lymphatic. Now dissect the internal iliac artery if that is to be used for the renal artery anastomosis.

5. Dissect the external iliac vein and consider dissection of the common iliac vein (Fig. 143-5). Ligate and divide the overlying lymphatics. Look for venous tributaries posteriorly. When they are found, doubly ligate and divide them. Avoid double clamping, this may avulse these delicate vessels. The iliac vein anastomosis site can be isolated with Rumel tourniquets or a large Satinsky clamp or with a bent-handled DeBakey curved aortic clamp on the vein proximally and an angled DeBakey clamp distally. Place the prepared, cold kidney graft into the wound, check for the best fit, make a final selection of the sites for the renal artery and venous anastomoses, and decide which anastomosis will be done first. Many surgeons prefer to do the arterial anastomosis first because it is the smaller of the two vascular anastomoses and the kidney can be moved about to better expose the arterial suture line than when the venous anastomosis has been completed first.

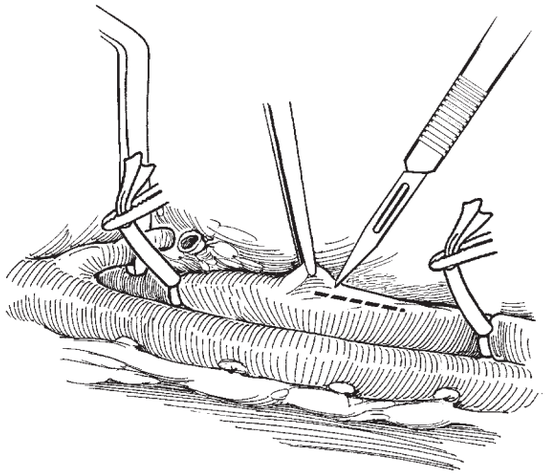

FIGURE 143-5.

End-to-Side Anastomosis to External Iliac Vein

6. Before the first vascular anastomosis, administer heparin to the recipient and start a mannitol infusion. Incise the external iliac vein longitudinally and irrigate the lumen with heparinized saline.
   a. Place four 5-0 double-needle cardiovascular sutures, one at each end and one at each side of the venotomy (quadrant technique) (Fig. 143-6A).
   b. Pass the four sutures from the iliac vein through the wall of the renal vein in the appropriate quadrants, and tie the ones at the ends (Fig. 143-6B). Leave the lateral and medial stay sutures untied. Pull on the medial and lateral sutures with shod clamps to separate the suture lines.
   c. Run the sutures up or down the lateral and medial sides and tie them. Pull on the stay sutures to be certain that the medial and lateral walls of the vein have not been sewn to one another (Fig. 143-6C). Tie or remove the lateral stay sutures.

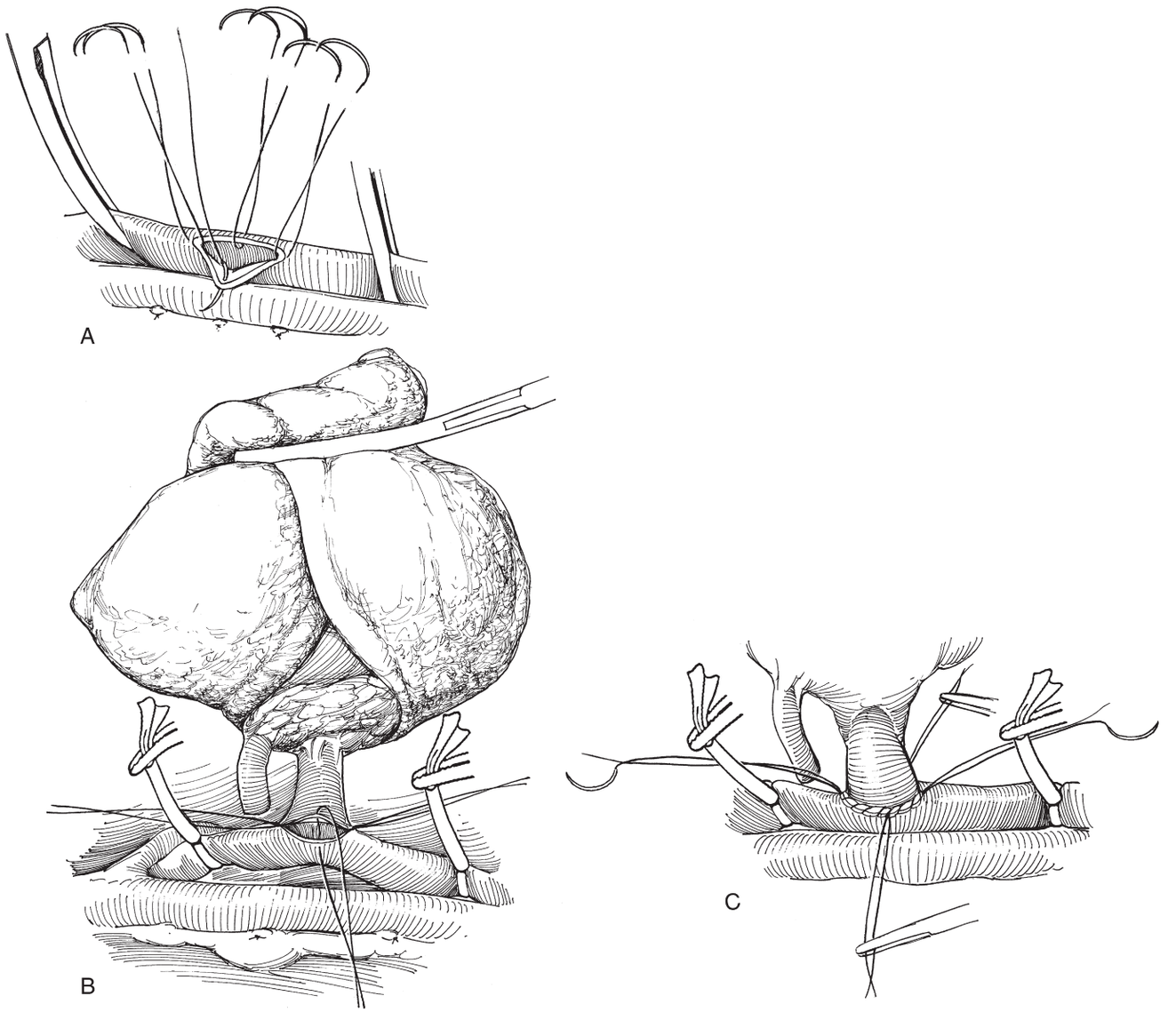

FIGURE 143-6.

End-to-End Anastomosis to Internal Iliac Artery

7. If the renal vein anastomosis was completed first, place a bull-dog clamp on the renal vein, and remove the vascular clamps or tourniquets from the iliac vein. Place vascular clamps on the external iliac and common iliac arteries to avoid injury to the internal iliac artery and its take-off. Spatulate the internal iliac and renal arteries or bevel-cut them.
   a. Bring the renal and internal iliac arteries together in a gentle curve (Fig. 143-7A). Place 5-0 or 6-0 vascular sutures in the opposite ends of both vessels and leave them untied. Place stay sutures at the midway points of the proposed suture lines.
   b. Run the first suture line or use interrupted sutures if the anastomosis is small (Fig. 143-7B).
   c. Change sides of the table or have the assistant do the other suture line (Fig. 143-7C). Tie the sutures.

Alternative: End-to-Side Arterial Anastomosis

8. If the internal iliac artery is unsuitable because it is too short, arteriosclerotic, or the opposite internal iliac artery was used in a prior transplant in a man, do an end-to-side anastomosis to the external or common iliac artery. Pick an anastomosis site that will result in a smooth, unkinked renal artery after revascularization.
   a. Occlude the iliac arteries with vascular clamps; try to avoid atheromatous plaques. Make a longitudinal incision in the anterior surface of the artery with a #11 knife blade (Fig. 143-8A).
   b. Enlarge it with a vascular punch that will match the diameter of the renal artery (usually 5 or 6 mm) (Fig. 143-8). Irrigate the lumen with heparinized saline.
9. Insert a superior and an inferior suture of 5-0 or 6-0 cardiovascular suture through the iliac and renal arteries and

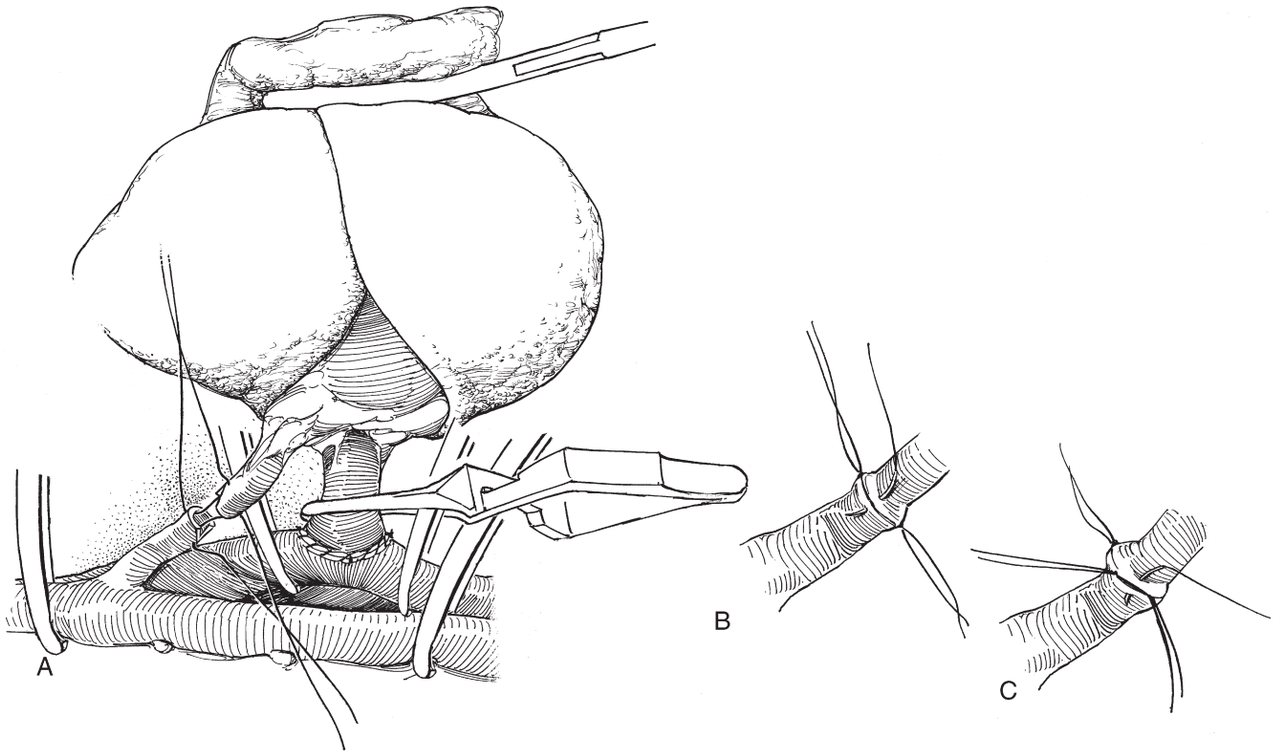

FIGURE 143-7.

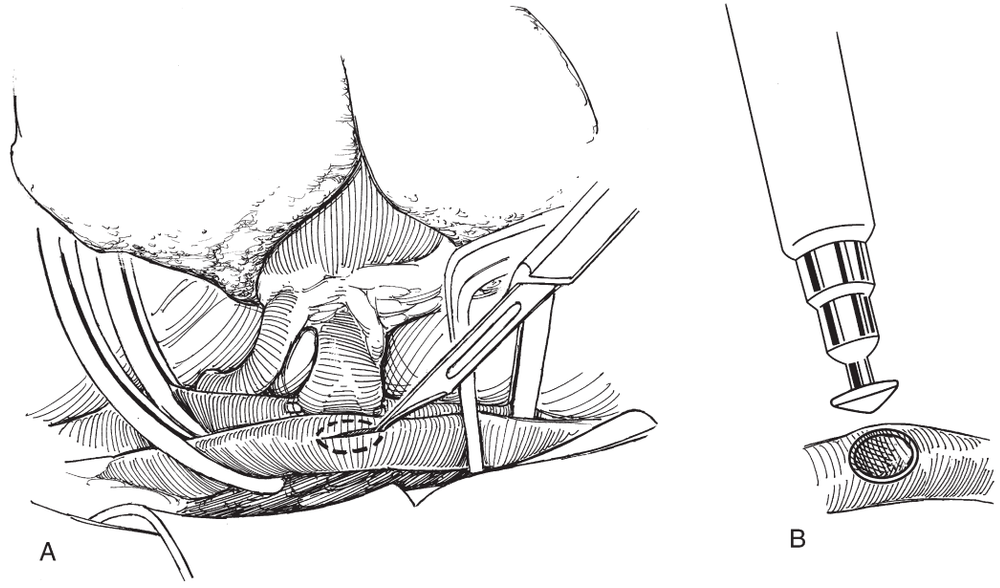

FIGURE 143-8.

leave them untied (Fig. 143-9). Place quadrant sutures. Run the suture lines as you did for the venous anastomosis (Fig. 143-9B). Administer furosemide to the recipient as the second suture line is being completed.

Release the cephalad venous clamp or tourniquet first, followed by the distal arterial clamp, proximal arterial clamp, and finally, the distal venous clamp or tourniquet. Check for hemostasis and a pulse in the iliac artery distal to the anastomosis.

Multiple Renal Arteries

10. For cadaver kidneys harvested with a Carrel patch, make an arteriotomy to match the size of the patch (Fig. 143-10). If the renal arteries are widely separated

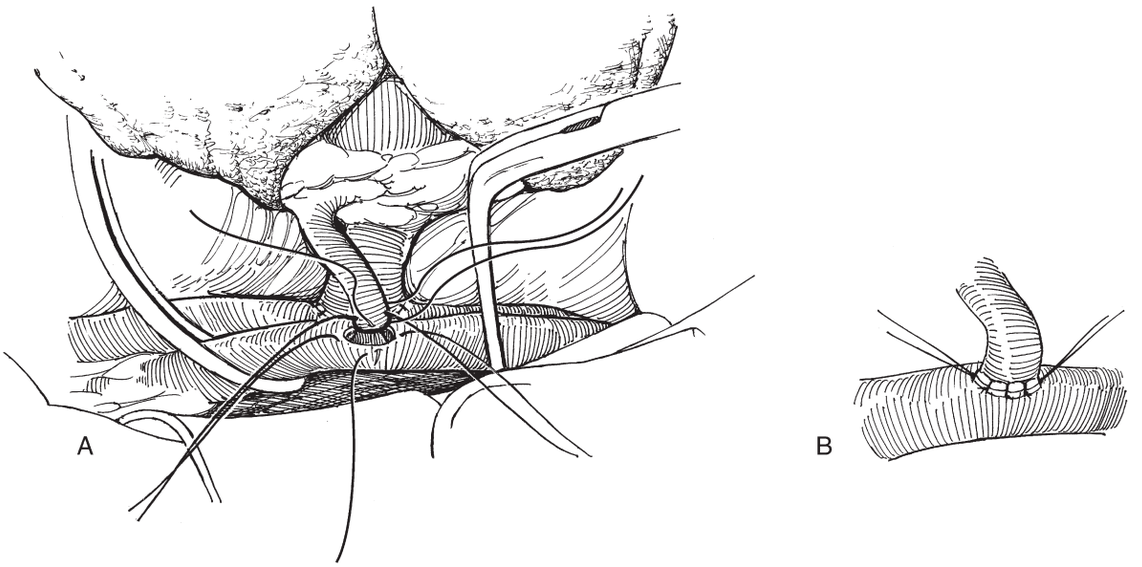

FIGURE 143-9.

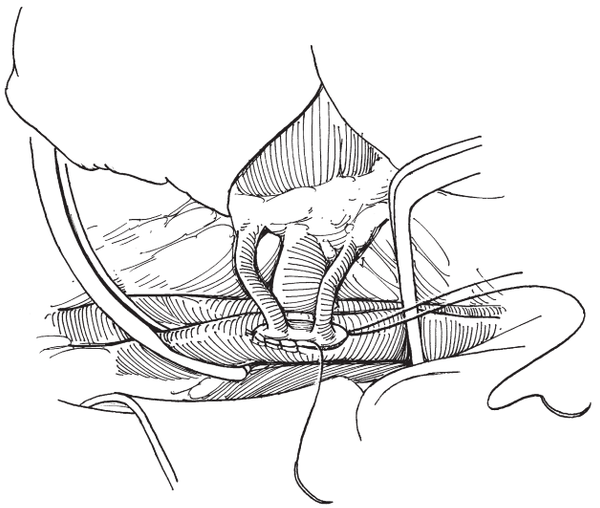

FIGURE 143-10.

on the patch, make two patches and sew them separately, or remove a segment of aorta between the renal arteries and sew the small patches together before anastomosis of the reconfigured patch to the iliac artery.

11. Kidneys from live donors with adjacent renal arteries are managed with side-to-side anastomosis because they cannot be harvested with a Carrel patch of donor aorta.
    a. Slit both arteries for a distance of 5 to 10 mm. Pass a 6-0 cardiovascular double-armed suture through both apices and tie it (Fig. 143-11A). Place stay sutures in the two arteries to set up the suture lines.
    b. Run each end of the suture down the corresponding side, and tie each to itself (Fig. 143-11B). Check the lumens with a small vessel dilator to be certain they are open.
    c. Anastomose the conjoined vessels as described for the single artery in Steps 8 and 9 (Fig. 143-11C). The same technique may be applied to triple renal arteries.
12. Alternatively, anastomose one of the renal arteries to the common or external iliac arteries and the other to the internal iliac artery (Fig. 143-12A). If there is a lower pole segmental renal artery, it can be anastomosed end-to-end to the ipsilateral inferior epigastric artery (Fig. 143-12B).

Short Right Renal Vein

13. Kidneys recovered during *excision of the liver from a deceased multiorgan donor* may have a short right renal vein when the inferior vena cava is transected through the cephalic portion of the renal vein to provide a wide inferior vena cava cuff for caudal inferior vena caval anastomosis. To fill the defect, use a patch graft from the vena cava distally to patch the superior defect, and use a portion of the cava to extend the lower margin of the renal vein. Alternatively, create a rotation flap from the inferior vena cava and discard the excess cava. When the right renal vein of a deceased donor kidney is short, it can be extended with the attached inferior vena cava or with donor external iliac vein. A short right renal vein is common with laparoscopic-retrieved kidneys from living donors. This can be managed by complete mobilization of the iliac veins to bring the venous anastomosis site up out of the pelvis, or by extending the right renal vein with one of the recipient's native renal veins.

Small Children's Kidneys into Adults

14. Resect the kidneys en bloc, and close the proximal ends of the aorta and the inferior vena cava (Fig. 143-13). Anastomose the distal ends of the aorta and the inferior vena cava to the external iliac artery and vein, respectively. Alternatively, split both or one of the great vessels

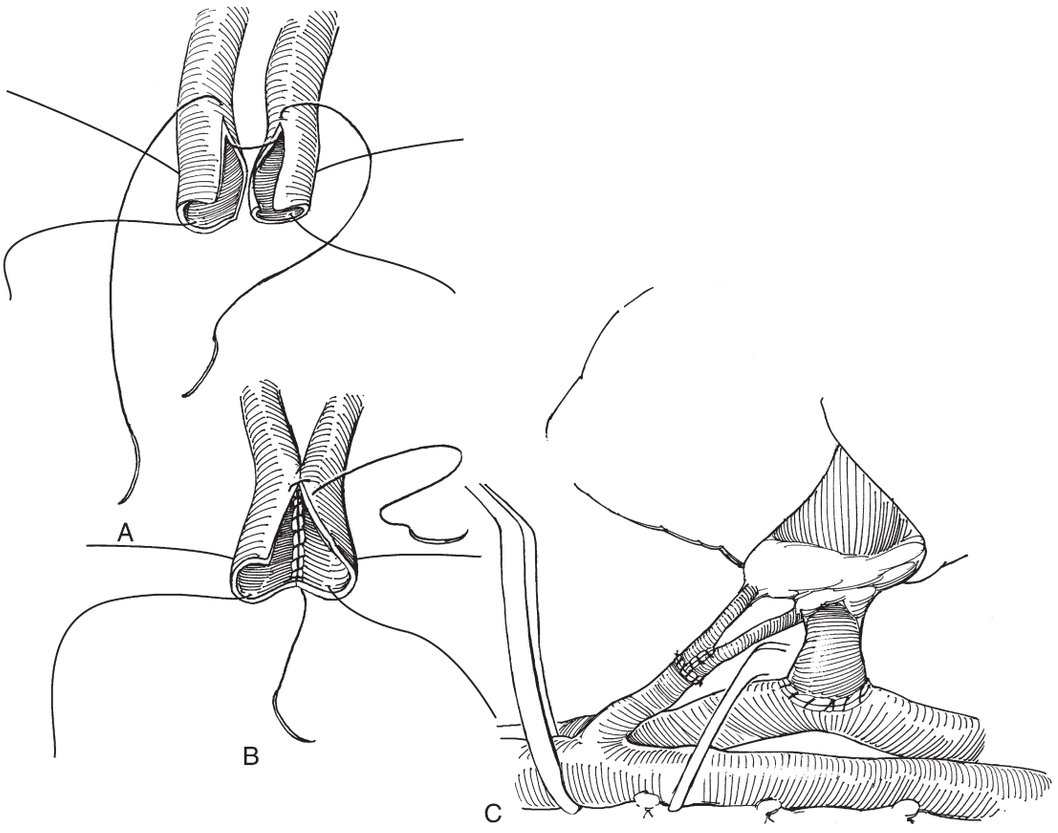

FIGURE 143-11.

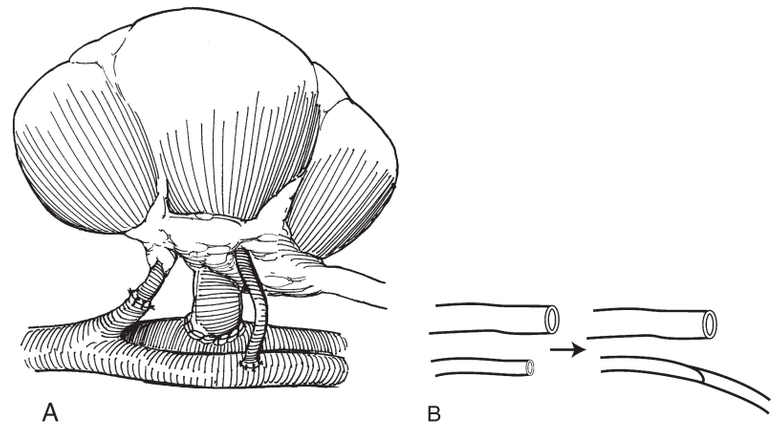

FIGURE 143-12.

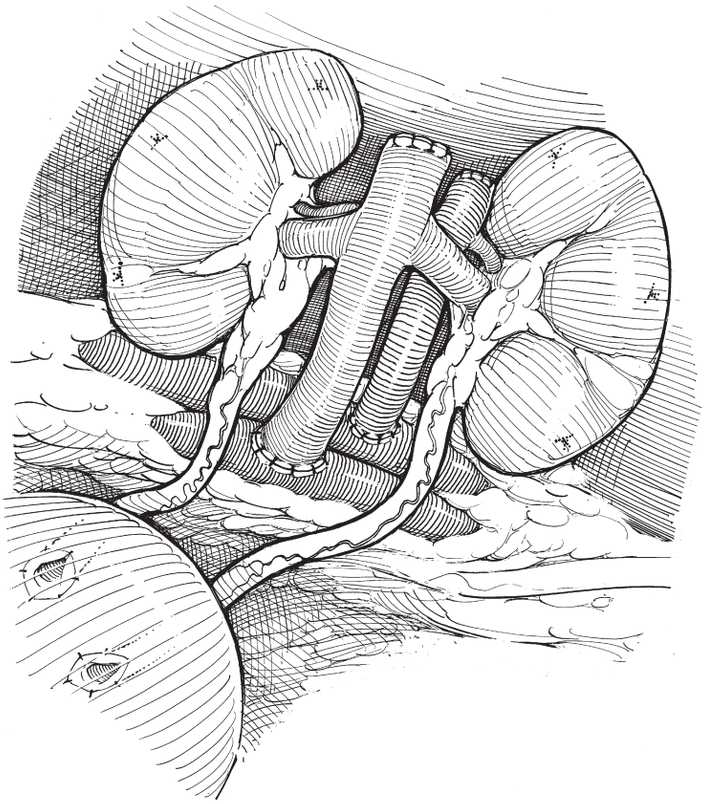

FIGURE 143-13.

and anastomose the vascular patch or patches to the recipient's external iliac artery and external iliac vein. Implant the ureters in the bladder.

CHILDREN

In children with voiding dysfunction or prior urinary diversion, formal urodynamic studies will be compromised if the child is anuric. Cycling the defunctionalized bladder in such cases for a week or two through a suprapubic trocar catheter allows assessment of its potential. Do any necessary bladder augmentation at least 3 months before transplantation; then check to make sure the storage and evacuation system works. Hydroureteronephrosis and grade 4 or 5 reflux are indications for nephrectomy before or at the time of kidney transplantation.

An adult kidney is usually used for renal transplantation in a small child. Either a transperitoneal midline approach or an extraperitoneal Rutherford Morison incision extended to the right costal margin can be used. With either approach, the kidney is positioned behind the cecum. In a small child, anastomoses to the vena cava and the aorta or common iliac artery are necessary. Ureteral implantation may be difficult because of multiple previous procedures.

Position and Incision

The patient's position is supine. The incision is made at midline, from the xiphoid to the symphysis pubis or lateral from pubic notch to costal margin (Fig. 143-14). Develop the right retroperitoneal space down to the lateral aspect of the bladder and up under the liver either by incising the lateral posterior parietal peritoneum if a transperitoneal approach is used, or by retracting the peritoneum and its contents cephalad and medially if a lateral extraperitoneal approach has been selected (Fig. 143-15).

Technique

Remove the right kidney if necessary. Free the inferior vena cava from the level of the right renal vein to its bifurcation. Mobilize both proximal common iliac veins. Doubly ligate and divide the lumbar veins. Place Rumel tourniquets loosely around the proximal inferior vena cava and both common iliac veins. The left common iliac tourniquet should be to the left of the common iliac artery. Mobilize both common iliac arteries, the proximal inferior mesenteric artery, and the aorta to just below the renal arteries. Ligate and divide the middle sacral artery and the lumbar arteries. Place vascular tapes around the common iliac arteries and the inferior mesentric artery. Select a vascular clamp for the proximal aorta. Consider starting a blood transfusion because of the relatively large blood volume that will be required to fill the adult kidney.

Place the cold kidney graft in the wound and select the anastomotic sites (Fig. 143-16A). They are usually the distal aorta or right common iliac artery and the inferior vena cava and proximal right common iliac vein. Shorten the donor renal vein, if necessary. Administer intravenous heparin and start a mannitol infusion.

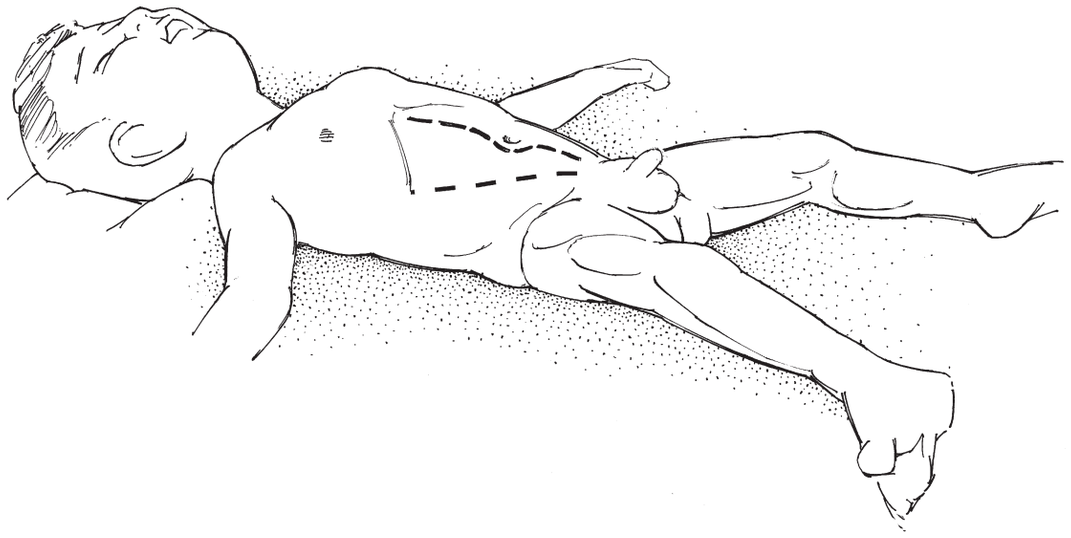

FIGURE 143-14.

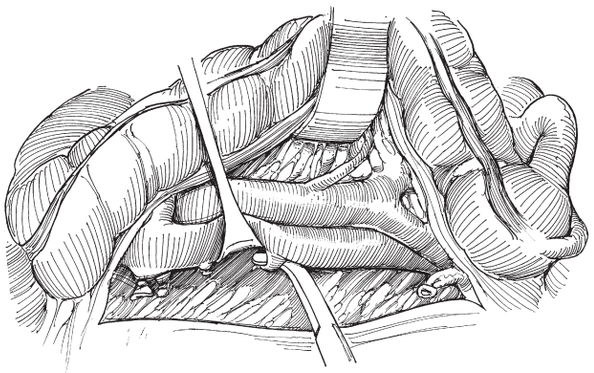

FIGURE 143-15.

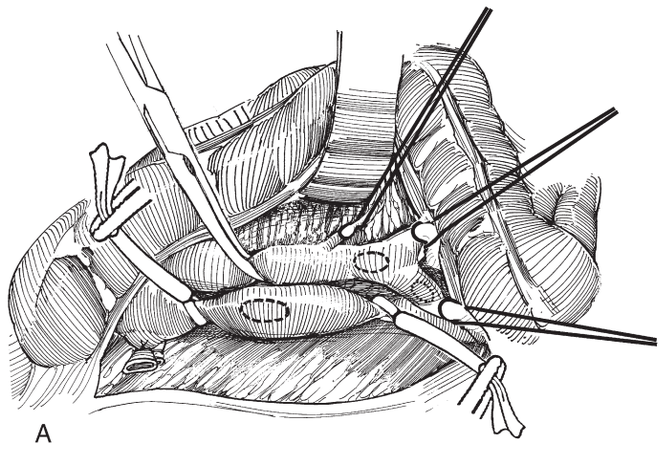

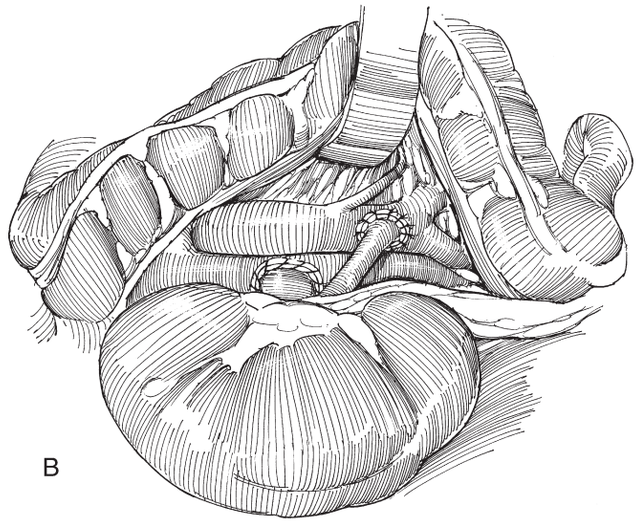

FIGURE 143-16.

Tighten the common iliac artery and inferior mesenteric artery vascular tapes and secure them to the retractor ring. Apply the proximal aortic clamp. Make an incision in the aorta or common iliac artery. Enlarge it with a 5-mm or 6-mm aortic punch. Irrigate the lumen with heparinized saline. Perform an end-to-side anastomosis of the spatulated renal artery to the lower aorta (as shown, Fig. 143-16B) or common iliac artery with running or interrupted 5-0 or 6-0 cardiovascular sutures. Tighten the proximal inferior vena cava tourniquet. Tighten both common iliac venous tourniquets. Incise the inferior vena cava and, if necessary, the right proximal common iliac vein. Irrigate the lumen with heparinized saline. Perform an end-to-side anastomosis of the renal vein, using 5-0 or 6-0 cardiovascular sutures as for adult transplantation (see Steps 5 and 6). Administer furosemide to the recipient as the second suture line is being completed. Loosen the tourniquet on the inferior vena cava first, then loosen the common iliac and inferior mesenteric artery vascular tapes, then release the aortic clamp. As the kidney becomes pink, loosen the iliac vein tourniquets. If the kidney is slow to pink up, tighten the common iliac artery vessel loops to divert the arterial blood flow to the kidney and release them as soon as the kidney assumes a normal, well-vascularized appearance.

URETERAL IMPLANTATION

Extravesical Technique

An *extravesical* ureteroneocystostomy with or without a stent is commonly performed. When the donor ureter is short or its circulation is compromised, anastomose a shortened donor ureter or donor renal pelvis to the recipient ureter over a stent.

Reposition the retractor blades and have the anesthesiologist fill the bladder with 100 to 200 ml of antibiotic irrigation through the Y-connector set up and clamp the tubing. Score the seromuscular layer with the electrocautery for two parallel incisions 2.5 cm apart. Make two incisions 2 cm long through the adventitia and muscularis until the mucosa bulges into the incisions. Have the anesthesiologist drain 50 ml from the bladder and reclamp the drainage tube. With a right-angle clamp or curved scissors, make a submucosal tunnel between the incisions (Fig. 143-17). If the bladder mucosa is entered, close it with fine absorbable sutures. If it's a small entry, lift it up with forceps and ligate it with a fine absorbable ligature.

Grasp the epithelium in the distal incision with vascular forceps (Fig. 143-18). Have the anesthesiologist unclamp the drainage tube and drain the bladder. Incise the urothelium or excise a small button of it.

As seen in Fig. 143-19A and B, draw the ureter through the tunnel, spatulate it, and suture it to the opening in the bladder mucosa with fine absorbable sutures, one at the apex, and the others at the 9-o'clock and 3-o'clock positions. If it's a large anastomosis, put additional sutures between them. Place an anchoring stitch through the full thickness of the tip of the ureter with a double-armed fine absorbable suture. Pass one needle through the full thickness of the bladder to exit 5 to 10 mm distal to the incision, and pass the other through the seromuscular layer. Tie the two ends together. Close the distal seromuscular opening with a fine absorbable running suture.

Transvesical Technique

Drain the bladder by having the anesthesiologist unclamp the tube that leads to the drainage bag. Incise the anterior bladder and swab the interior for culture. Select a site on the floor of the bladder near to the ipsilateral ureteral orifice. Make a short transverse incision through the mucosa. Dissect a 2- to 2.5-cm tunnel superolaterally with curved scissors or a right-angle clamp (Fig. 143-20).

Pass a long right-angle clamp obliquely through the bladder wall from inside-out just above the upper end of the tunnel. The tract must provide a smooth oblique exit for the ureter. Stretch the hiatus so it will not obstruct the ureter. Draw an 8 Foley Robinson catheter through the tunnel and fasten it to the tip of the ureter with a 2-0 suture (Fig. 143-21). Pull the ureter gently into the bladder (posterior to the spermatic cord in males), and leave a little redundancy outside the bladder.

Trim and spatulate the end of the ureter, leaving 1 cm protruding. Anchor the apex with a 5-0 monofilament absorbable suture to the trigonal muscle and bladder mucosa. Place several mucosal sutures on either side and at the apex (Fig. 143-22). Test for absence of constriction with an infant feeding tube. If desired, a 12-cm double-J stent can be placed.

Close the cystotomy in a single layer with a running full-thickness 3-0 synthetic monofilament absorbable suture (Fig. 143-23). Catch just the edge of the epithelium, and

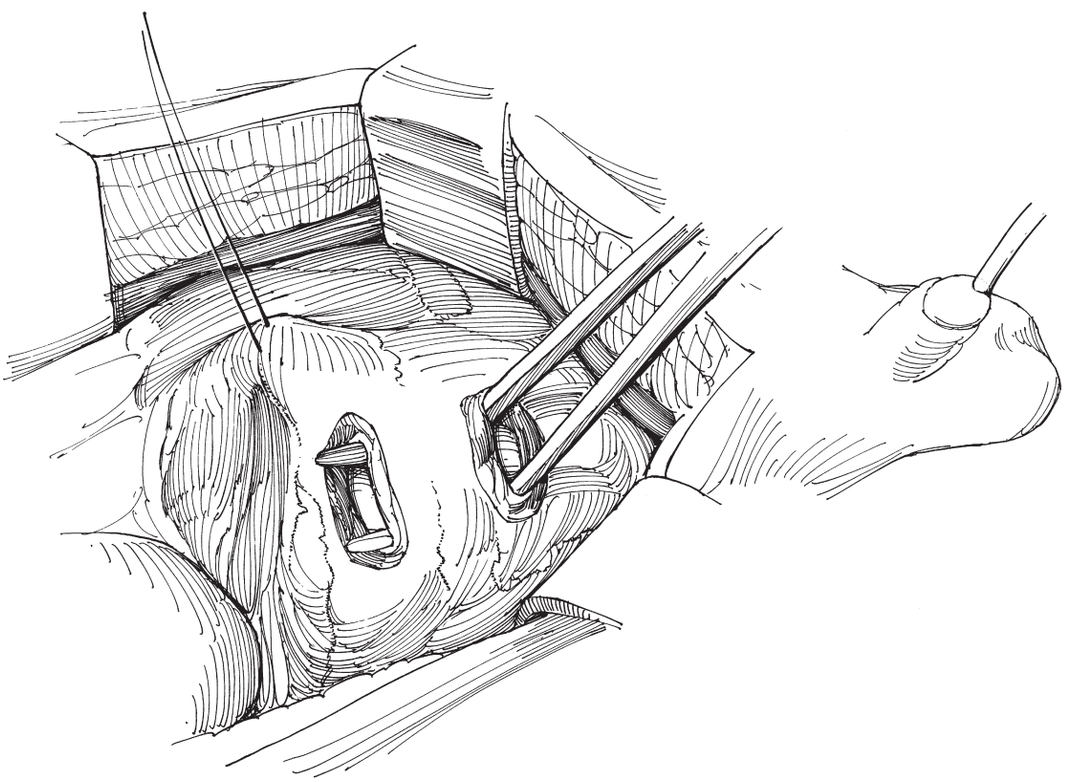

FIGURE 143-17.

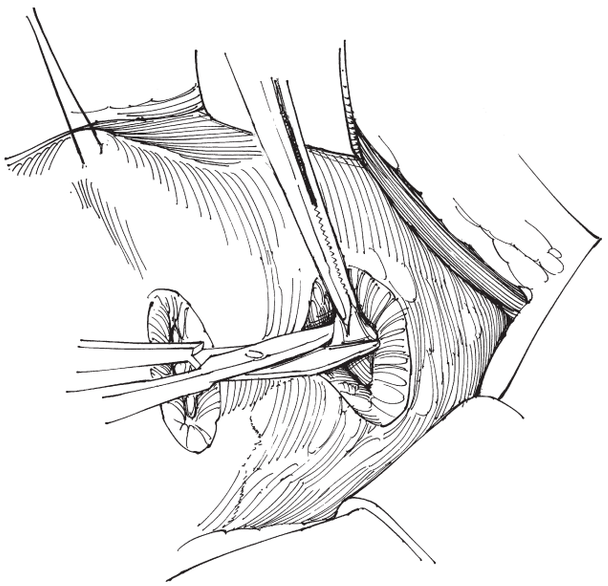

FIGURE 143-18.

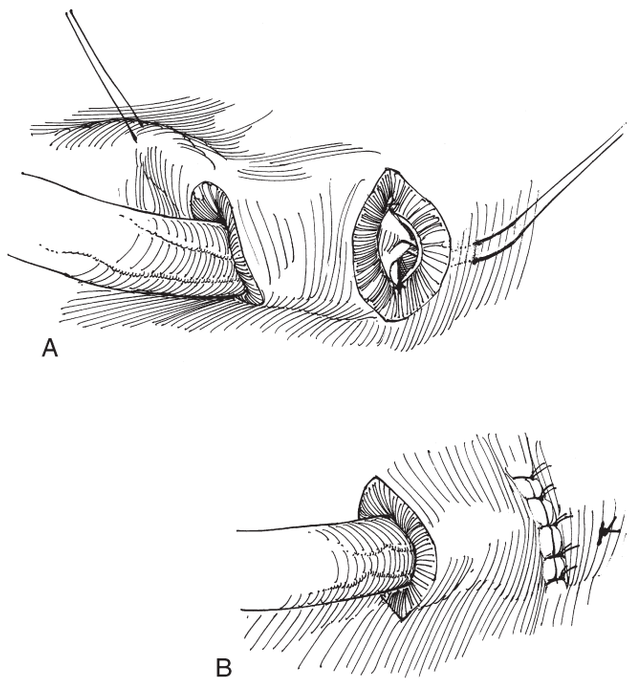

FIGURE 143-19.

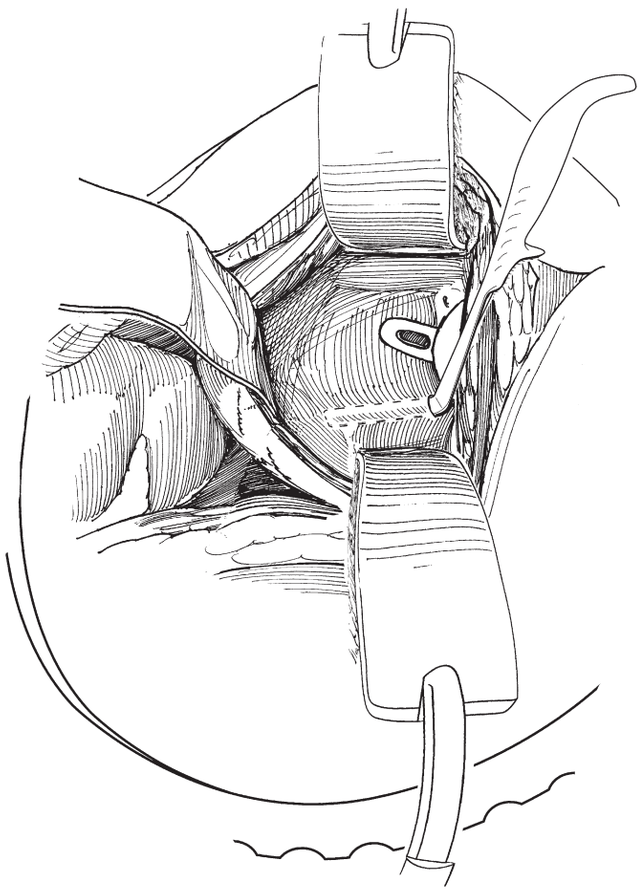

FIGURE 143-20.

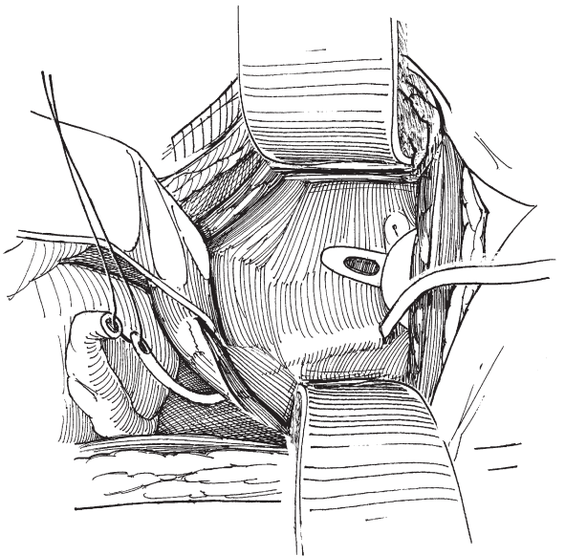

FIGURE 143-21.

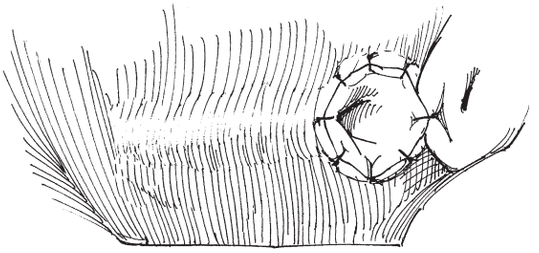

FIGURE 143-22.

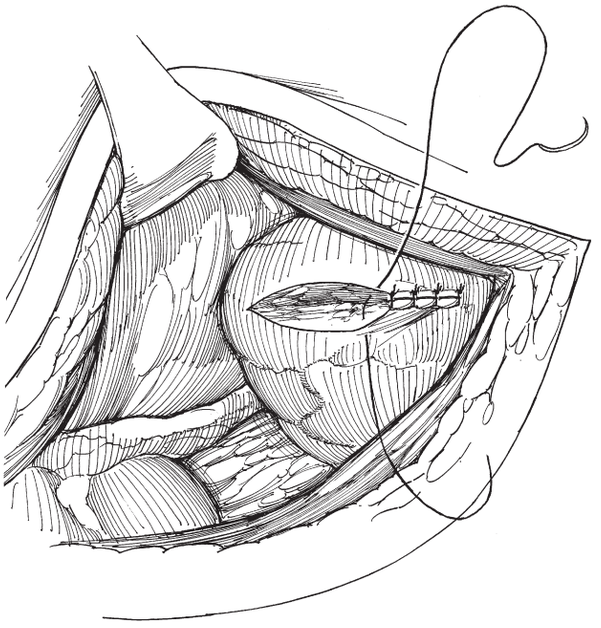

FIGURE 143-23.

take a good bite of the muscularis and adventitia. Carry the closure beyond the ends of the incision to avoid leakage. The closure can be tested by clamping the drainage tube and having the anesthesiologist run in antibiotic solution with the Y-system. Consider a retroperitoneal suction drain. It's always easier to remove a drain than wish that one had placed on at the time of operation. Close the abdomen appropriately.

Double Ureter

Spatulate the ureters along their medial edges for 5 to 10 mm. Suture the dorsal edges together with a running fine absorbable suture. Bring the double-barreled ureter through the submucosal tunnel and suture it to the mucosal opening as described above. Add a mattress suture through the full thickness of the conjoined ureters and the seromuscular layer of the bladder distal to the implantation.

Tubes and Drains

The bladder catheter is usually removed early on the 5th postoperative day. If a ureteral stent was inserted during the transplant procedure and attached to the Foley catheter, it will come out when the Foley is pulled. Use ultrasonography to check for postvoid residual urine if there is concern about urinary retention. Indwelling stents are usually removed in the outpatient clinic 4 to 6 weeks after renal transplantation. Suction drains are removed when the 24-hour drainage is less than 50 ml or in 3 weeks, whichever occurs first.

Operative and Postoperative Support

It is important that the graft be supplied with adequate fluids and electrolytes and that the patient be supported with packed red blood cells and colloid solutions, if necessary.

POSTOPERATIVE PROBLEMS FROM RENAL TRANSPLANTATION

Bleeding is the most frequent cause for re-exploration of the graft. A small hematoma in the iliac fossa is common. Significant bleeding is heralded by pain and the signs of blood loss, followed by a distended wound, an unstable blood pressure, and usually anuria. Reopen the wound, dissect the peritoneum from the surface of the kidney, and evacuate the hematoma. Explore the arterial and venous anastomoses, the renal hilum, the surface of the kidney, the ureter, the ligated inferior epigastric vessels, the posterior iliac venous branches, and the wound edges. Often no source for the bleeding is found.

Allograft rupture due to acute rejection or renal vein thrombosis is suggested by acute, severe pain over the graft. Nephrectomy is usually necessary. *Hyperacute rejection* is heralded by swelling and discoloration of the kidney soon after it is revascularized. It must be differentiated from renal vein obstruction or thrombosis. Take a biopsy specimen to confirm the diagnosis of hyperacute rejection. If the finding is positive, removing the kidney may be advisable; if the situation is

doubtful, leave the kidney in place and hope for reversal. Both problems are rare.

Try not to confuse the signs and symptoms of *rejection* with those of *urologic complications*. Use ultrasonography, renal scintigraphy, and computerized axial tomography to differentiate among acute tubular necrosis, rejection, and urinary obstruction. Percutaneous nephrostomy with antegrade pyelography with or without ureteral stent placement is the definitive diagnostic test for ureteral obstruction, and it provides initial therapy.

Urinary leakage is heralded by bulging of the wound, decreased urine output, weight gain, and rising serum creatinine. Evaluation by ultrasonography will document a fluid collection, and radioisotope renography with or without a determination that the creatinine level of the aspirate or wound drainage is near that of urine will make the diagnosis. Leakage may occur at the ureterovesical anastomosis or from the bladder closure, or, later, directly from a necrotic ureter. A vesical source can be diagnosed by cystography. A ureteral source can be diagnosed by antegrade neprostogram. If the ureteral disruption is partial, it may be possible to treat it with antegrade placement of a ureteral stent. If it is extensive, treatment options are ureterovesical or pyelovesical anastomosis with a psoas hitch or a Boari flap and ureteroureterostomy or pyeloureterostomy to the native ureter. Fistulas can occur from a calyx if a renal pole is devascularized. In that case an omental flap with a nephrostomy tube and a ureteral stent may be effective.

Vesicocutaneous fistulas are not common when the bladder has been opened through a normal wall and has been closed carefully. Conservative treatment of bladder fistulas by inserting a balloon catheter and suction drainage and antibiotics is sometimes effective.

Ureteral obstruction in the first week or so is usually from edema, but hematoma, lymphocele, or technical error may be the cause. A common cause, with later subtle onset of obstruction, is periureteral fibrosis or contraction of the ureter from ischemia. The immediate treatment is percutaneous diversion or occasionally transurethral insertion of a silicone stent. Some cases may respond to percutaneous transluminal ureteroplasty. If these measures are inapplicable or if they fail, reoperate and reimplant the ureter. Alternatively, use the patient's own structures. Anastomose the native ureter to the grafted pelvis (pyeloureterostomy), anastomose the grafted ureter to the native ureter ipsilaterally or contralaterally (ureteroureterostomy or crossed ureteroureterostomy), bring the native renal pelvis down for anastomosis to the grafted pelvis (pyelopyelostomy), or perform calicocystostomy combined with a psoas hitch.

Lymphoceles, usually appear several weeks after renal transplantation. Look for impaired renal function due to compression of the ureter, lower abdominal fullness, genital edema, and edema of the ipsilateral leg from compression of the iliac vein. Ipsilateral iliofemoral venous thrombosis may occur. Aspirate the lymphocele with the aid of ultrasonography. Identify the fluid as lymph by finding levels of creatinine that are nearly the same as those in serum or plasma. If the lymphocele recurs, consider percutaneous sclerosis, inserting a tube for drainage, or marsupialization of the lymphocele into the peritoneal cavity.

Renal artery stenosis comes from a defective anastomosis, from chronic rejection, or from kinking or torsion due to excessive renal artery length. In children, the cause may be inadequate size of the recipient vessels. Stenosis can occur both early and late. Look for hypertension and decreased renal function. Delay treatment if renal function is stable and hypertension can be controlled medically. Try transluminal angioplasty before proceeding with a difficult surgical procedure that carries a real chance for loss of the graft.

Arterial thrombosis usually comes from tearing of the intima either when the kidney is secured or during perfusion, but rejection and poor anastomotic technique may be factors, as well as hypercoagulability, arteriosclerotic disease in the recipient artery, and embolus. Treatment is usually prompt nephrectomy. *Venous thrombosis* is secondary to such errors as kinking of the renal vein when the kidney is put in its final position and faulty anastomotic technique. Distinguishing the venous thrombosis from rejection can be difficult. Perform renal venography when suspicion is aroused, and re-explore immediately to do a thrombectomy.

Acute tubular necrosis is a complication in the immediate postoperative period. Follow the patient with nuclear scans to check on blood flow and evidence of rejection and with sonograms to rule out obstruction and extravasation.

Be alert for *wound complications*. Wound infections are uncommon even though patients are immunocompromised, but infections may have serious sequelae. If fever persists, look for a pelvic or retroperitoneal abscess by sonography and computed tomograpy (CT) scans, as well as for urinary leakage and rejection of the graft.

In patients with poorly controlled renin-mediated hypertension, persistent urinary tract infections, significant renal stone disease, prior urinary diversion, or severe reflux, the *native kidneys usually* should be removed before transplantation. The native kidneys can be removed by bilateral posterior incisions, laparoscopic-assisted procedures, an open transperitoneal approach, or flank approaches. Indications for nephrectomy in autosomal dominant polycystic kidney disease are recurrent pyelonephritis, hemorrhage, early satiety, indeterminate renal mass or size that will not allow renal transplantation into the pelvis. Native nephrectomy is usually performed weeks before transplantation unless the recipient is a child or an adult who is to receive a kidney from a living renal donor and there is no active renal infection.

NEPHRECTOMY AFTER FAILED TRANSPLANTATION

Removal of the failed graft is not always necessary. Once the patient requires maintenance dialysis, stopping the immunosuppressive drugs that are no longer needed can result in the development of anti-HLA antibodies and symptomatic rejection with fever and painful swelling of the graft.

Nephrectomy soon after transplantation is straightforward. Reopen the transplant incision, mobilize the kidney, and ligate and divide the renal artery. If the entire renal

artery is removed at the site of an end-to-side anastomosis where a vascular punch was used to enlarge the arteriotomy, a vein patch may be necessary to prevent iliac artery stenosis. The low-pressure renal vein may simply be ligated and divided beyond the anastomosis. Ligate and divide the ureter where it enters the bladder. If the entire ureter is removed, it can be pulled out of the bladder and the defect closed with 3-0 absorbable sutures. Maintain bladder drainage for 1 or 2 days with a balloon catheter.

Late nephrectomy can be very difficult because of the rejection reaction and the adherence of the kidney to the recipient artery and vein. Allograft nephrectomy more than 90 days after transplantation is usually best done subcapsularly because of perinephric fibrosis. Incise the capsule over the anterolateral lateral surface, and bluntly dissect the kidney parenchyma from the capsule. At the hilum, incise the capsule circumferentially, dissect the branch arteries and veins and ligate and divide them. Ligate and divide the ureter. Leave a portion of the donor ureter if necessary. Coagulate oozing spots within the capsule. Irrigate with antibiotic solution, and dust the capsule with thrombin. Placement of a soft suction drain is optional.

BLADDER AUGMENTATION AND RENAL TRANSPLANTATION

For an-end stage renal disease patient with a small, scarred, contracted bladder that does not become compliant with bladder cycling, perform bladder augmentation a few months prior to transplantation. Left nephrectomy can be done at the same time. At the time of renal transplantation, mobilize the right colon, remove the right kidney, and transplant the donor kidney into the right iliac fossa. Anastomotic alternatives include ureteroureterostomy, implantation into the bladder or an ileal nipple, if that has been formed.

Commentary by

ARTHUR I. SAGALOWSKY

Use of a self-retaining retractor such as the Bookwalter as described by Barry here is invaluable in facilitating exposure, and freeing hands to mentor others in the surgical technique. One simple modification in using the retractor that I have found to be helpful follows. No retractor blade is placed inferolaterally toward the iliac crest on the ipsilateral side where the primary surgeon stands. Rather, a long figure-of-eight, 2-0 silk suture is placed through the muscle and fascia of the inferior edge of the incision, and this stitch is pulled over the Bookwalter ring and clamped on traction, which provides the same exposure as if a retractor blade had been placed. This substitution accomplishes two things. First, the surgeon's hand has easier access into the pelvis for performance of the vascular anastomoses. Second, the possible risk of compression of the femoral nerve against the iliac crest by a retractor blade, which may produce a transient femoral neuropathy, is avoided.

Chapter 144

Open Donor Nephrectomy/Cadaver Donor Nephrectomy

DAVID A. GOLDFARB AND VENKATESH KRISHNAMURTHI

OPEN DONOR NEPHRECTOMY

Open donor nephrectomy avoids the acute renal compromise related to pneumoperitoneum and warm ischemia which may occur during laparoscopic donor nephrectomy. The vasculature, in general, is longer with the open technique. In cases where there has been extensive transabdominal surgery, laparoscopy may not be feasible. Other circumstances include a short renal vein (<1.5 cm). The preponderance of early technical losses in laparoscopic donor nephrectomy were right-sided kidneys. If the extra 5 to 10 mm of renal vein is felt to be required for successful transplantation, an open technique should be considered. Finally, any circumstance in the donor or recipient deemed to be a potential source of technical compromise that would be more optimized by open procurement should be considered.

Preoperative donor evaluation should ensure the absence of renal disease or a condition that may affect future renal function. Glomerular filtration should exceed 80 ml/min and there should be no proteinuria (<150 mg/L). Anatomic evaluation is performed using a computed tomography (CT) angiography technique. This integrated exam combines features of arteriography, venography, and parenchymal assessment in a single examination. Post-CT intravenous pyelogram is used to demonstrate the collecting system anatomy. Catheter arteriography is rarely needed.

Patients are operated as a same-day surgery. The night before surgery, patients are encouraged to take fluids liberally, but are given a magnesium citrate bowel prep. On arrival at the preoperative area, donors are administered 1 liter of intravenous normal saline before anesthetic induction. At the time of renal hilar manipulation, 25 g mannitol are given intravenously for renal protection. Following procurement, kidneys are flushed with a Euro-Collins solution and cooled in an ice bath.

Postoperative care includes early ambulation. Clear liquids can be introduced in most patients on the first postoperative day. Satisfactory intake by 3 to 4 days is normal and most patients can be discharged by day 4. Laboratory studies to assess renal function and blood counts are monitored in the hospital, and then at a return office visit in 4 to 6 weeks. Donors also need follow-up at 6 and 12 months, in compliance with United Network for Organ Sharing (UNOS) guidelines.

Right Donor Nephrectomy

The patient is placed in the classic flank position for right donor nephrectomy, following anesthetic induction and Foley placement (Fig. 144-1). The down side is supported by the kidney rest of the table, and then the table is flexed and placed in slight Trendelenberg position until the flank is parallel to the floor. A roll is placed in the down-side axilla to prevent brachial plexus injury. Legs are appropriately padded. A Turner-Warwick approach may be used, taking the incision between the 11th and 12th rib. Total incision length should be no more than 15 to 18 cm. The retroperitoneum is entered and the diaphragm and pleura are dissected free from under the lateral aspect of the 11th rib. The 12th rib is dissected close to its articulation with the spine so that it acts like a hinged retractor for the remainder of the operation.

The retroperitoneum is dissected using blunt and sharp dissection, and the ureter is identified with surrounding tissue down to the level of the ipsilateral iliac vessels. The

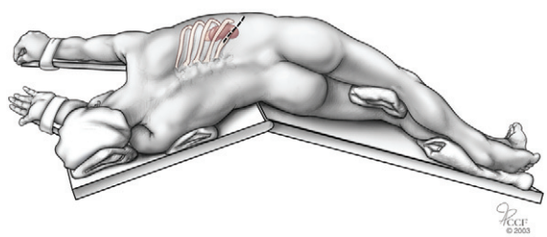

FIGURE 144-1. Patient positioning. *(From Cleveland Clinic Center for Medical Art & Photography, © 2003–2012. Reprinted with permission, all rights reserved.)*

ureter is not divided until later in the case. Gerota's fascia is entered, and the kidney is mobilized (Fig. 144-2). The adrenal is spared. Hilar dissection of the renal vein is then carried out. The renal artery is usually in a retrocaval position, and additional length may be achieved by dissection laterally and behind the vena cava.

After confirmation with the recipient room that the recipient has favorable vasculature and is medically stable, the ureter can be divided. As much length as possible should be preserved. The triangle of tissue bordered laterally by the lower pole of the kidney, medially by the inferior vena cava (IVC) and superiorly by the renal hilum represents the territory of the ureteral vasculature. The right renal artery is controlled with a right angle clamp and divided. The right renal vein encompassing a portion of adjacent IVC is then secured (Fig. 144-3). Using a scissor, the vein is divided including a cuff of the IVC with the donor kidney. The inclusion of the IVC cuff is a distinct advantage of the open technique for the right side. The kidney is delivered to the recipient surgeon where it is perfused in an ice bath. The renal artery is ligated with an 0 silk-free ligature and a large-caliber polypropylene suture ligature.

The renal vein is oversewn with a continuous 4-0 polypropylene suture as depicted (Fig. 144-4). Closure of the flank incision is in multiple layers using polydioxanone suture. Skin is approximated with clips.

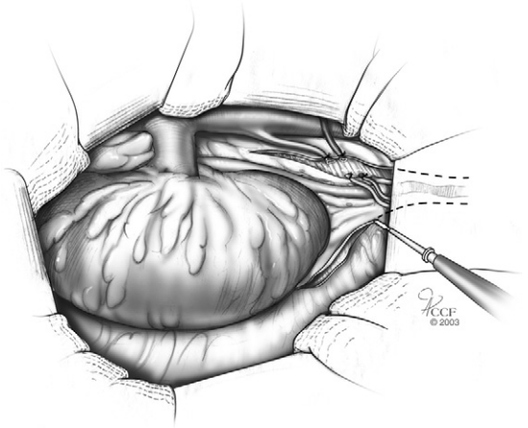

FIGURE 144-2. Exposure of the kidney with mobilization of the ureter. *(From Cleveland Clinic Center for Medical Art & Photography, © 2003–2012. Reprinted with permission, all rights reserved.)*

Left Donor Nephrectomy

The flank incision for the left side is similar to the right. The gonadal vein is identified and ligated in the pelvis. A tissue plane is developed between the aorta and gonadal vein to encompass the periureteral blood supply. The gonadal vein can be used as a tracer to dissect superiorly until the renal vein is visualized. The ureter is also identified and traced to the lower pole of the kidney (Fig. 144-5). The peritoneum is then swept medially off Gerota's fascia.

The kidney is mobilized within Gerota's fascia. At the upper pole the kidney is separated from the spleen and the adrenal gland carefully. The adrenal vein is ligated and divided between 4-0 silk tie to facilitate full mobilization of the renal vein. The ureter is ligated and divided in the pelvis as far down as possible after confirmation that there are no problems with the recipient operation. Any lumbar veins originating from the renal vein are controlled using clips or permanent suture (Fig. 144-6).

The renal artery is clamped as close to the aorta as feasible, ensuring adequate space to permanently control the stump (Fig. 144-7). The renal vein can be clamped over the medial aspect of the aorta to ensure a good length of vein. The artery and vein are then divided. The renal artery is doubly secured using an 0-silk free ligature and a large caliber polypropylene suture ligature. The vein can be tied with 0 silk ligatures or oversewn with 4-0 polyproproylene suture if it is too wide. The wound is irrigated, and then closed in a manner similar to the right side.

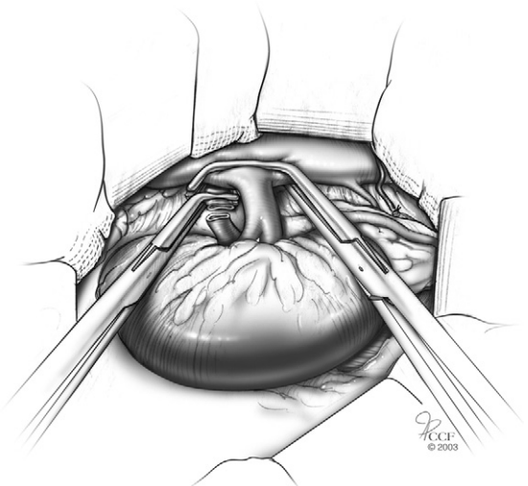

FIGURE 144-3. Securing the vessels. *(From Cleveland Clinic Center for Medical Art & Photography, © 2003–2012. Reprinted with permission, all rights reserved.)*

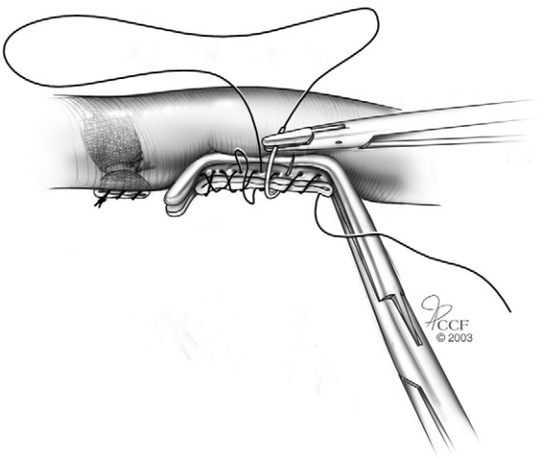

FIGURE 144-4. Reconstructing the inferior vena cava. *(From Cleveland Clinic Center for Medical Art & Photography, © 2003–2012. Reprinted with permission, all rights reserved.)*

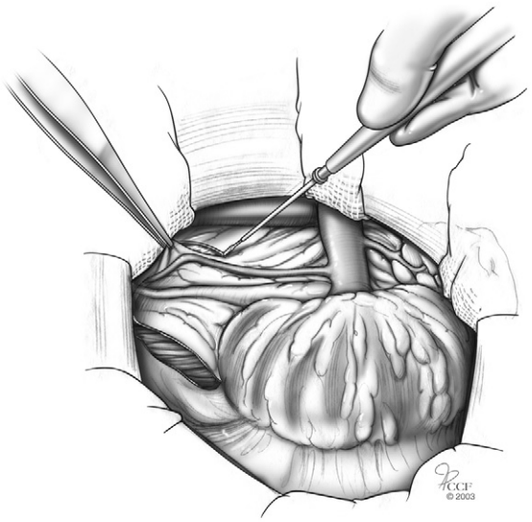

FIGURE 144-5. Left renal exposure and mobilization of the ureter/left gonadal vein. *(From Cleveland Clinic Center for Medical Art & Photography, © 2003–2012. Reprinted with permission, all rights reserved.)*

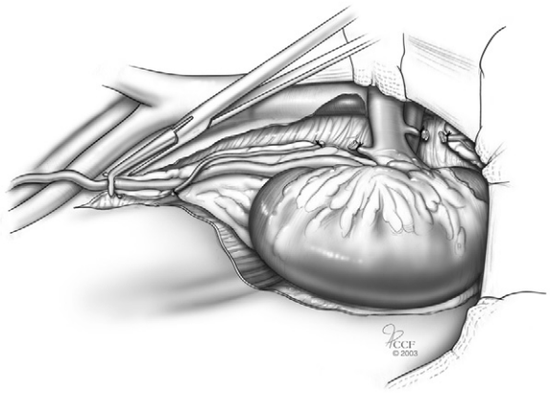

FIGURE 144-6. Renal hilar dissection. *(From Cleveland Clinic Center for Medical Art & Photography, © 2003–2012. Reprinted with permission, all rights reserved.)*

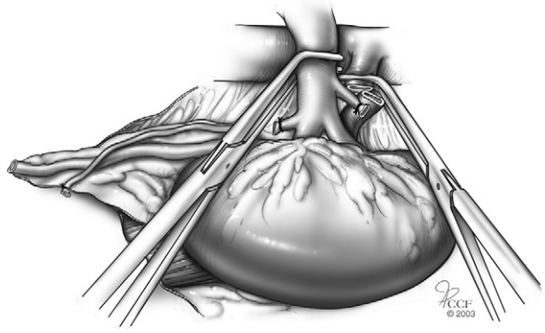

FIGURE 144-7. Securing the renal vessels. *(From Cleveland Clinic Center for Medical Art & Photography, © 2003–2012. Reprinted with permission, all rights reserved.)*

CADAVERIC DONOR NEPHRECTOMY

Surgical Technique

Deceased donor nephrectomy is most often performed in conjunction with procurement of other solid organs for transplantation. The principles of abdominal organ procurement, regardless of the organs being removed, include wide exposure, cannulation for in-situ perfusion, isolation of organs to be removed in continuity with their central vascular structures and orderly removal of the organs under cold perfusion. In the setting of a combined thoracic and multiple abdominal organ donor, the initial dissection is performed by the thoracic and liver procurement teams. After aortic cross-clamping and in-situ perfusion, the organs are removed in the following order: heart, lungs, liver, pancreas, and kidneys. This chapter focuses on the operative technique of kidney procurement in kidney-only deceased organ donors.

Exposure and Initial Dissection

The organ donor is placed in the supine position. A small rolled towel may be placed between the shoulder blades and the neck can then be hyperextended to facilitate median sternotomy. A long midline incision from the suprasternal notch to the symphysis pubis is utilized to obtain exposure (Fig. 144-8). A median sternotomy, though not absolutely

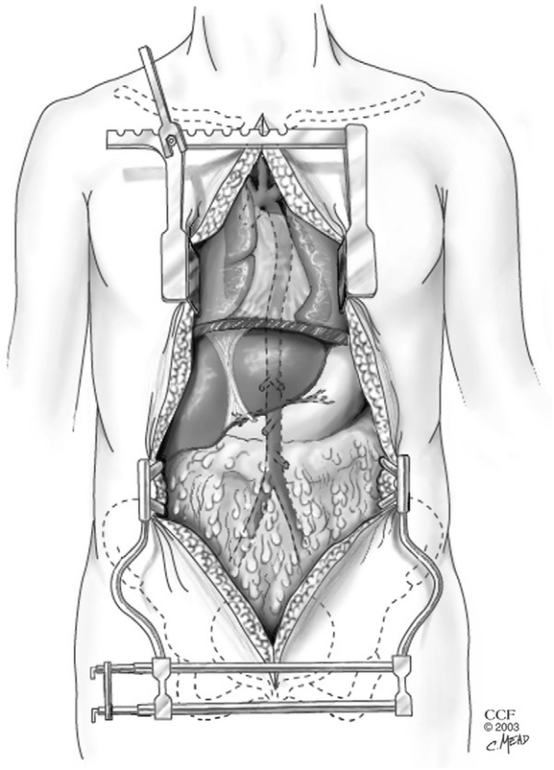

FIGURE 144-8. Exposure for deceased donor organ procurement. *(From Cleveland Clinic Center for Medical Art & Photography, © 2003–2012. Reprinted with permission, all rights reserved.)*

necessary in kidney-only procurement procedures, improves exposure and enables easier control of proximal aorta and allows for venous outflow in the chest. The chest and abdomen are exposed with a sternal retractor and large Balfour retractor. Complete neuromuscular blockade is essential to maximizing exposure.

The initial steps in the dissection should be directed towards exposure of the retroperitoneal structures and isolation of the distal aorta for cannulation. The retroperitoneum is exposed by incising the posterior peritoneum beginning near the root of the small bowel mesentery and continuing around the hepatic flexure**.** The viscera are then generously retracted superiorly and the impulse of the superior mesenteric artery (SMA) should be palpable directly superior to the left renal vein. In a kidney only procurement, isolation of the SMA may maximize kidney perfusion (through occlusion of the SMA). The SMA can be isolated at this point, but it is important to remember that this maneuver can be difficult and is not necessary for satisfactory kidney procurement. Additionally, the SMA can be occluded (without isolation) by placing a large clamp across the root of the small bowl mesentery, which should also improve renal perfusion.

The distal aorta (3 to 4 cm proximal to the bifurcation) is isolated and encircled with two umbilical tapes. The IMA can be divided after ensuring that it is not an aberrant, low-lying renal artery. Posterior lumbar arteries, visualized by gently pulling up on the aorta with the umbilical tapes, can be clipped or tied. The left kidney is exposed by medial mobilization of the left colon. This ensures that both kidneys will be in direct contact with iced slush. At this point no further dissection is performed on the kidneys until after cross-clamp and perfusion.

Control of the supraceliac aorta is most often obtained in the abdomen (Fig. 144-9); however, supradiaphragmatic control can be obtained in certain situations. Isolation of the supraceliac aortic is begun by dividing the left triangular ligament with the electrocautery. The gastrohepatic omentum (lesser omentum) is incised from the lesser curvature of the stomach to the diaphragm. The aortic impulse should palpable beneath the crural fibers and immediately to the right of the esophagus. The crural fibers are divided and the anterior and lateral surfaces of the aorta are exposed for clamping.

Alternatively, the aorta can be controlled in a supradiaphragmatic location even in the setting of lung procurement. Collaboration with the thoracic team is essential to control the distal thoracic aorta. When the lungs are not being procured, the supradiaphragmatic aorta can be isolated by retracting the left lung and palpating the aorta at the level of the diaphragm.

The anesthesiologist and other organ procurement teams are now notified that cross clamping can proceed. Mannitol (25 g) and heparin (250–300 U/kg) are administered intravenously. A distal aorta is then exposed and the umbilical tape along the distal aspect is secured. An aortic cannula is placed on the field and connected via tubing to cold preservation solution. The cannulation line should be flushed to remove any retained air. The distal aorta is in controlled with the thumb and the forefinger of non-dominant hand. The anterior wall of the aorta is generously incised, the cannula is placed within the aorta and secured by tying the proximal umbilical tape (Fig. 144-10). The cannula must be passed far enough to be secured at its flange but passage too far proximally may prevent perfusion of lower pole renal arterial branches. Additionally, cannulation of an atherosclerotic aorta must be done with great care as aggressive cannulation can cause an intimal dissection and thrombosis of donor organs.

When all procurement teams are ready, exsanguination is achieved by the dividing vena cava at its junction with the

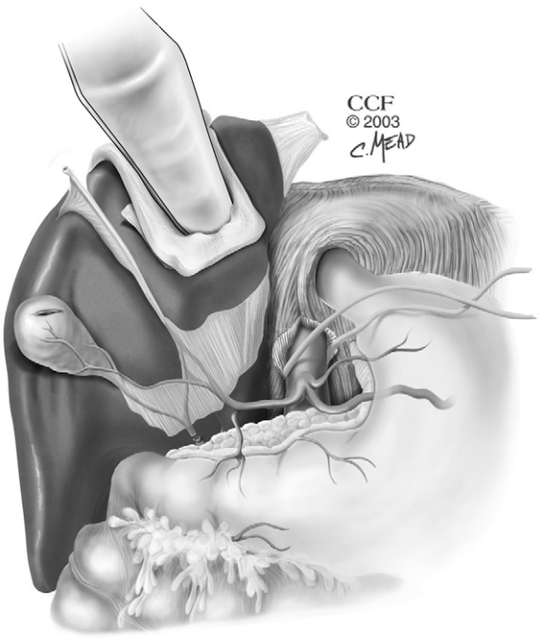

FIGURE 144-9. Isolation of the supraceliac aorta for cross-clamping. *(From Cleveland Clinic Center for Medical Art & Photography, © 2003–2012. Reprinted with permission, all rights reserved.)*

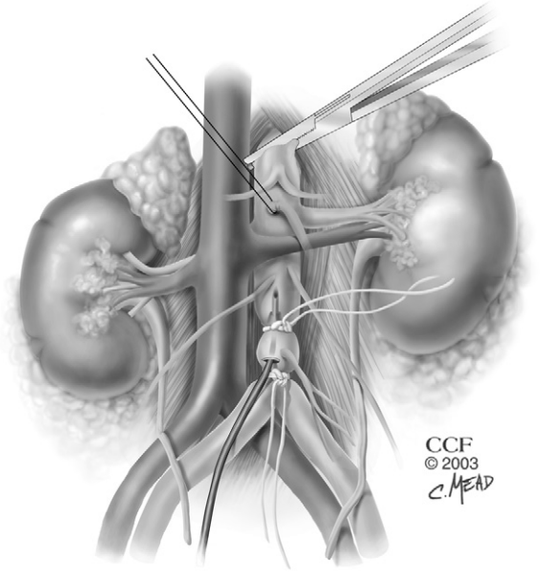

FIGURE 144-10. Cannulation of the distal aorta. *(From Cleveland Clinic Center for Medical Art & Photography, © 2003–2012. Reprinted with permission, all rights reserved.)*

right atrium, the supraceliac aorta is clamped and, simultaneously, cold preservation solution is infused. Surface hypothermia is then achieved by liberally placing iced slush solution on and around both kidneys.

As mentioned previously, occlusion of the SMA, although not essential, improves perfusion to the kidneys. Consideration can also be given to occluding hepatic and pancreatic inflow by placement of a large clamp across the porta hepatis (Pringle maneuver). Approximately 4 to 5 liters of preservation solution are perfused through the aortic cannula and can be discontinued when the venous effluent is clear or slightly blood tinged.

En-bloc removal of the kidneys is a preferred technique in that the surgeon can quickly place both kidneys in cold preservation solution. The ureters are identified deep in the pelvis and divided. Abundant periureteral tissue should be included in the dissection of the ureters, which are mobilized to the level of the kidneys. The posterior and lateral attachments to the kidney are sharply divided. The attachments superior to each adrenal gland and upper pole kidney are similarly divided. A window is made in the left colon mesentery through which the left kidney and ureter are passed medially. The proximal aorta and suprarenal vena cava are divided as are the distal aorta and vena cava. The great vessels are freed off the spine by sharply dividing all the posterior attachments.

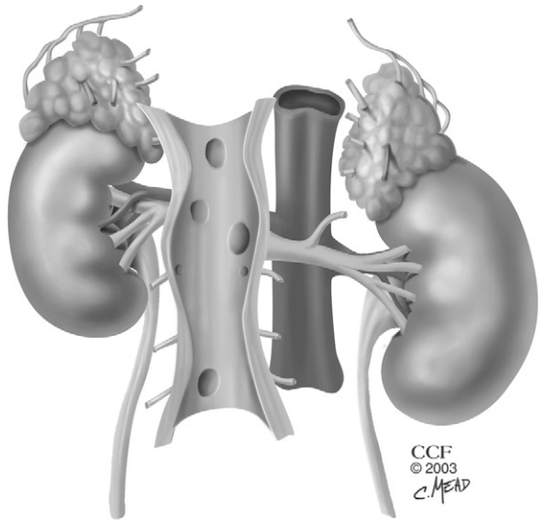

FIGURE 144-11. Appearance of en-bloc kidney specimen following division of posterior aorta. *(From Cleveland Clinic Center for Medical Art & Photography, © 2003–2012. Reprinted with permission, all rights reserved.)*

Separation of the Kidneys

After en-bloc removal, the kidneys are immediately placed in an iced slush solution. The posterior wall of the aorta is then divided longitudinally between the lumbar arteries (Fig. 144-11). The aorta is inspected to verify the position and number of the renal arteries. The anterior aspect of the aorta is then divided.

The left renal vein is divided at its entry into the inferior vena cava (Fig. 144-12). The entire IVC should be maintained with the right kidney. Pediatric (<7 years) donor kidneys should be maintained en-bloc as this may be the preferred method of transplantation.

After removing the perinephric fat, the kidneys are individually inspected for the presence of tumors, cysts, or other abnormalities. The number, length and size of the vessels are verified prior to packaging. Each kidney is then placed in two sterile isolation bags and then packaged in a sterile plastic labeled container. Ten to 15 lymph nodes and the spleen are removed for histocompatibility testing. Numerous mesenteric lymph nodes can be harvested and, if inadequate, additional lymph nodes can be found in the pelvis or mediastinum.

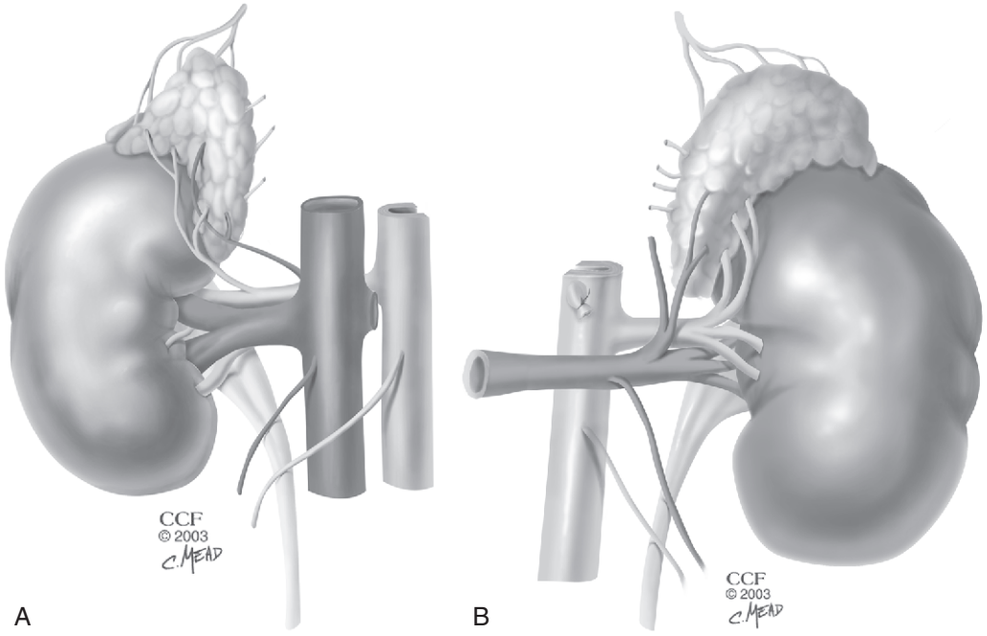

FIGURE 144-12. A, Right kidney (anterior view) following separation. An intact inferior vena cava is included with the right kidney. **B,** Left kidney (anterior view) following separation. *(From Cleveland Clinic Center for Medical Art & Photography, © 2003–2012. Reprinted with permission, all rights reserved.)*

Commentary by

ARTHUR I. SAGALOWSKY

The authors accurately describe some of the functional and anatomic considerations in the decision making process for open versus laparoscopic donor nephrectomy. The latter procedure is described elsewhere in this text. Despite the exceptional safety record for open live donor nephrectomy, which is a testament to the added burden that every donor surgeon feels toward the healthy living donor, one must acknowledge how greatly the public has embraced laparoscopic kidney donation. The number of willing live kidney donors has more than doubled in recent years thanks to the laparoscopic option. This single procedure, which reduces the acuity of an ever growing shortage of kidneys compared to the growing transplant waiting list, is one of the single greatest improvements in renal transplantation over the past two decades.

Chapter 145

Percutaneous Endopyelotomy

GEOFFREY R.WIGNALL AND JOHN D. DENSTEDT

Ureteropelvic junction obstruction (UPJO) may result from intrinsic causes such as an aperistaltic segment of ureter or from extrinsic causes such as fibrosis or tumor. While pyeloplasty remains the gold standard for surgical repair of UPJO, minimally invasive techniques offer an attractive alternative with minimal morbidity. Percutaneous endopyelotomy offers the advantages of reduced postoperative pain and quicker recovery time.

PREOPERATIVE PREPARATION

Indications for surgical intervention in patients with UPJO include symptomatic obstruction, chronic infection, presence of proximal calculi, and deteriorating renal function. Contraindications include uncorrected coagulopathy and active infection. While not an absolute contraindication, obstructive segments >2 cm and the presence of lower-pole-crossing vessels have been associated with lower long-term success rates. Spiral computed tomography with three-dimensional reconstruction is helpful to assess for the presence of lower-pole-crossing vessels. Retrograde pyelography is often useful to help define the distal extent and length of the strictured segment. We usually reserve retrograde pyelography until the day of surgery.

Instrumentation

Specific equipment utilized for the procedure at our institution includes an 18-gauge Chiba needle, 0.038-inch Bentson, 0.038-inch extra-stiff and 0.035-inch hydrophilic guidewires, 5F Kumpe Access angiographic catheter (Cook Incorporated, Bloomingdale, IN), and a fascial dilator (either one-step balloon or serial rigid dilators) with 30F working sheath. Additionally, we use an 8-mm by 10-cm ureteral balloon dilator for calibration of the ureter following endopyelotomy. The endopyelotomy incision itself may be performed with various endopyelotomes, although our preference is to use either a cold hook knife or the holmium:YAG laser.

Positioning and Percutaneous Access Technique

1. Following induction of general anesthesia, the patient is placed in the prone position. Care is taken to ensure that all pressure points are adequately padded and that the chest is supported to allow for optimal ventilation. The genitals are prepped and draped in a sterile fashion.
2. Flexible cystoscopy is carried out in the prone position and the appropriate ureteral orifice is identified. Under fluoroscopic guidance, a 0.038-inch Bentson guidewire is passed in a retrograde fashion as far cephalad as possible. A 5F ureteral catheter is advanced over the wire and the wire is removed. A 16F Foley catheter is placed in the bladder, and the ureteral catheter is secured to the Foley with waterproof adhesive tape. Finally, a syringe filled with dilute contrast media is secured to the ureteral catheter to allow injection of contrast during the procedure.
3. The flank area is widely prepped and draped from the midline to the ipsilateral midaxillary line. Under fluoroscopy, contrast is injected in a retrograde fashion through the ureteral catheter to define the calyceal anatomy. A posterior, lateral mid- or upper-pole calyx is preferred to give a more direct route to the ureter and to allow easier passage of instruments during the procedure. Occasionally, a small amount of air injected through the catheter may aid in identification of the posterior calyces as these will preferentially fill with air while the anterior calyces will retain contrast. Initially fluoroscopy is performed in the AP plane to position the 18-gauge Chiba needle over the desired calyx and the needle is advanced through the skin. The C-arm is then rotated 30 degrees laterally and the needle is advanced to an appropriate depth to enter the calyx. Urine may be seen flowing from the needle confirming correct positioning. Alternatively, a 0.035-inch hydrophilic guidewire may be gently passed through the needle to assess for correct positioning. If the tip of the needle is not in the collecting system, the needle should be removed and access reattempted as above. Once in the renal parenchyma, it is advisable to avoid unnecessary

torquing of the needle as this may cause lacerations in the parenchyma and increase the risk of hemorrhage.

4. Once position in the calyx has been confirmed, the 0.035-inch hydrophilic guidewire is advanced into the renal pelvis and preferably into the ureter. We find a 5F-angled catheter (5F Kumpe access angiographic catheter) to be invaluable to assist in guiding the wire into the ureter. The angled catheter is then advanced over the wire into the ureter, and the hydrophilic wire is exchanged for a 0.038-inch, extra-stiff wire that is advanced to the bladder and the angled catheter removed. In the event that a wire cannot be passed down the ureter due to a large, redundant renal pelvis or a very tight UPJ, a Bentson wire may be coiled in the renal pelvis and later passed into the ureter under direct vision. A 2-cm skin incision is made and a one-step balloon dilator is advanced under fluoroscopy until the opaque marker is visible in the renal pelvis. Care should be taken to avoid advancing the dilator beyond the pelvis and into the UPJ and ureter. The tract is dilated to 30F and a 30F working sheath is advanced over the balloon. The balloon is removed and nephroscopy is carried out using a rigid nephroscope.

Endopyelotomy Technique

1. Prior to performing the endopyelotomy, any calculi should be dealt with as per standard percutaneous nephrolithotomy detailed elsewhere in this text. The UPJ is visualized at which time a wire may be passed down the ureter under vision if necessary (Fig. 145-1). We will often employ an extra-long "exchange wire" advanced through the ureteral catheter from below and grasped and brought out through the tract. This maneuver provides optimal "through-and-through" access to the urinary tract. Our preferred endopyelotome is a cold hook knife (Figs. 145-2 and 145-3); however, other options such as the holmium:YAG laser or wire-guided knife may be used as per surgeon preference. In the event of an extremely tight obstruction, the UPJ may be gently dilated using a 12F ureteral balloon dilator prior to endopyelotomy.
2. Under direct vision, a full thickness endopyelotomy is made in a true lateral direction. Any pulsations that might indicate a crossing vessel should be noted and avoided. The incision should be deepened until retroperitoneal fat and tissue are visible. The UPJ is then dilated to 24F using an 8-mm by 10-cm ureteral dilator balloon over the guidewire. Contrast injected retrograde through the ureteral catheter should demonstrate extravasation on fluoroscopy if the incision is of sufficient depth. At this point a 12/6F endopyelotomy stent is placed with the widest portion crossing the UPJ. Finally, a nephrostomy tube is placed under fluoroscopy and secured at the skin with suture.

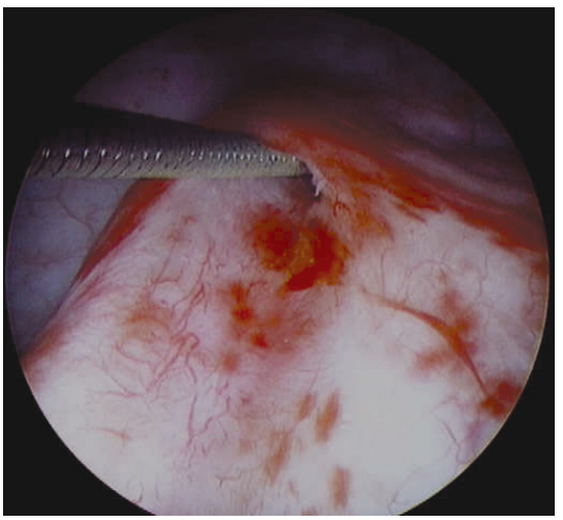

FIGURE 145-1. Ureteropelvic junction viewed through rigid nephroscope.

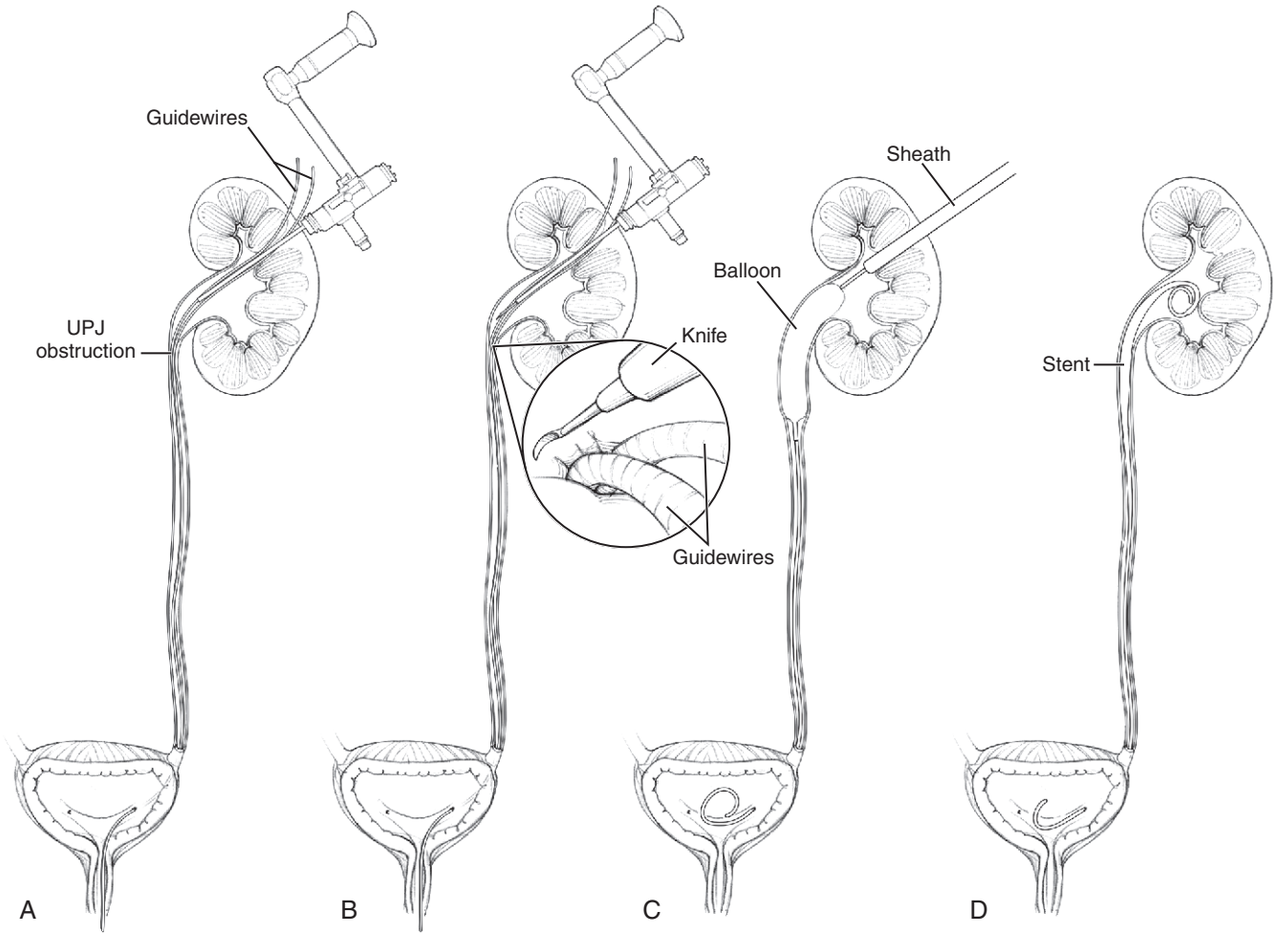

FIGURE 145-2. A, Percutaneous nephroscopy with visualization of the ureteropelvic junction (UPJ). **B,** Incision of the UPJ with endopyelotome. **C,** Following endopyelotomy, the UPJ is calibrated with a balloon dilator. **D,** The endopyelotomy stent is placed with the widest portion across the UPJ.

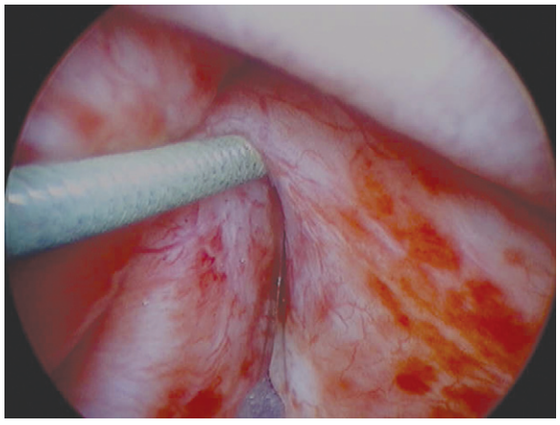

FIGURE 145-3. Incision of the ureteropelvic junction under vision with the cold knife.

POSTOPERATIVE CARE

We routinely admit our patients postoperatively and leave the nephrostomy tube to straight drainage for 24 to 48 hours. Antegrade nephrostogram is performed on the first postoperative day to ensure adequate drainage and absence of extravasation. Prior to removal, the nephrostomy tube is clamped and the patient monitored for pain or fever. Provided that the clamping is well tolerated, the tube is removed and a dressing applied. The ureteral endopyelotomy stent remains in place for 4 to 6 weeks, at which time it is removed with flexible cystoscopy in the clinic. Our routine is to obtain a renal ultrasound 4 weeks post stent removal and a diuretic renal scan 6 to 8 weeks later to assess for resolution of obstruction. The patient is seen in the clinic at the time of the renal scan for clinical assessment and to discuss the treatment outcome and further follow-up plans if required.

Commentary by JEAN JOSEPH

Establishing through-and-through guide wire access, pulling the end of the retrogradely placed ureteral wire through the nephrostomy tract is not only a safe measure, but also removes unnecessary wire coils out of the renal pelvis. Endopyelotomy is associated with adequate success rates, with most failures seen within the first year. Late failures beyond 5 years have been reported warranting long-term follow-up. Poor renal function, high-grade hydronephrosis, presence of crossing vessels, and long strictures have been associated with poor success rates.

One of the main advantages of this technique is the ability to concurrently treat associated stones through the established nephrostomy tract. However, all stones fragments should be removed to eliminate the possibility of stones lodging at the site of ureterotomy, or pyeloureteral tissue, resulting in fibrosis or granuloma affecting ureteral patency.

Chapter 146

Percutaneous Endopyeloplasty

MAHESH R. DESAI, MIHIR M. DESAI, AND ARVIND P. GANPULE

Endopyelotomy has been widely used for the management of selected patients with ureteropelvic junction (UPJ) obstruction. Endopyelotomy, which is associated with a 10% to 15% failure rate, is based on the principle of Davis's intubated ureterotomy. The steep learning curve with laparoscopic suturing has restricted laparoscopic pyeloplasty to centers with high volume. Percutaneous endopyeloplasty consists of horizontal suturing of a standard vertical endopyelotomy incision performed through a percutaneous renal tract via a nephroscope. Our technique of percutaneous endopyeloplasty incorporates the use of a novel laparoscopic suturing device (SewRight SR5, LSI Solutions, Victor, NY) that was modified to enable use with a 26 French nephroscope (Karl Storz, Culver City, CA) for meticulous intrarenal suturing.

TECHNIQUE

The SewRite 5SR (SewRight SR5, LSI Solutions, Victor, NY) is a 5-mm suturing instrument used for placing interrupted sutures (Fig. 146-1A and B). The device was modified in length and diameter to enable its use through the working channel of a 26 French Storz nephroscope.

Step 1. Retrograde contrast study and placement of ureteral catheter. Retrograde ureteral access is obtained cystoscopically by placing a 6 French open-ended ureteral catheter into the pelvicalyceal system.

Step 2. Renal access. Percutaneous renal access is obtained through an upper or midpole calyx, which provides direct access to the UPJ (Fig. 146-2). A 30 French Amplatz sheath is positioned within the renal pelvis.

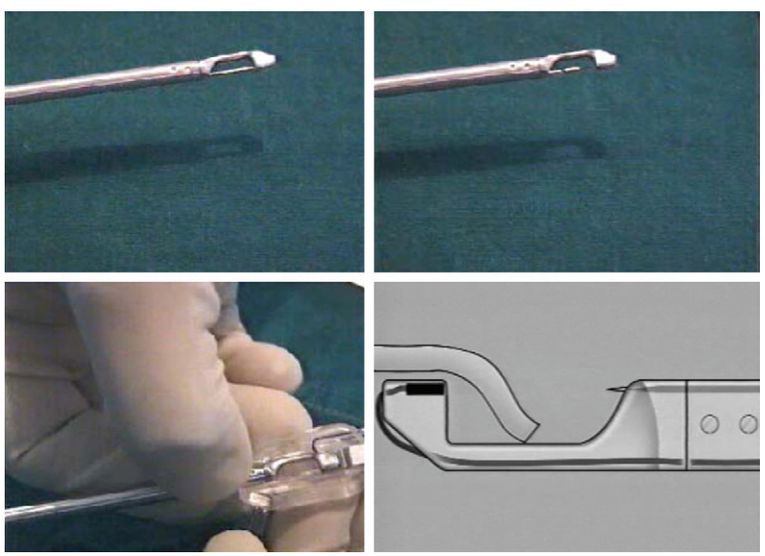

FIGURE 146-1. Each end of the suture used with the SewRight SR5 has a metal ferrule, and comes prepacked in a cartridge. The tip of the suturing device fits on a groove on the suture cartridge and the loop of the main body of suture is threaded through the length of the shaft and exits through an opening on the handle.

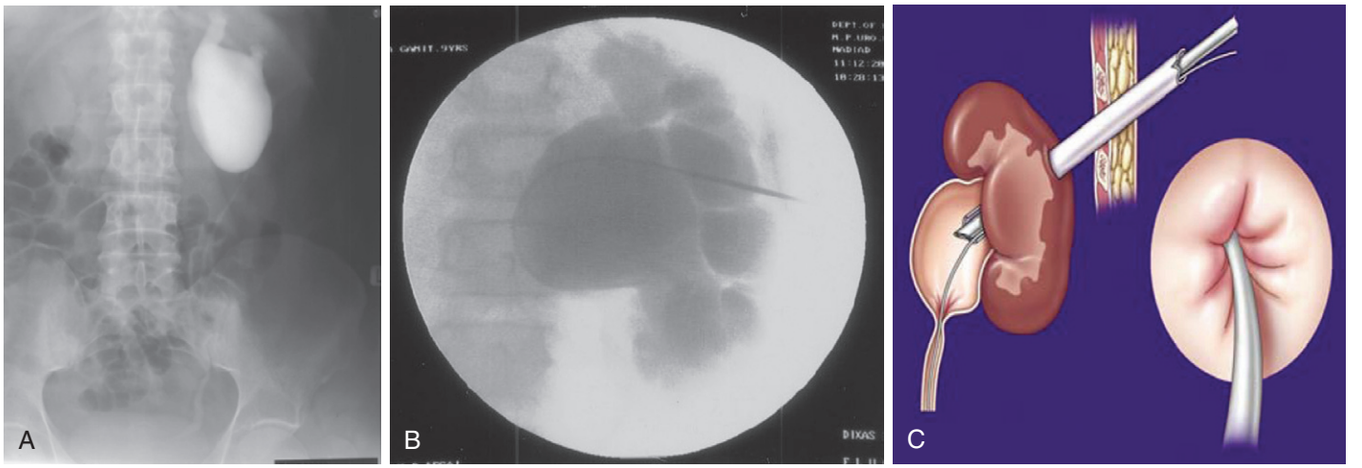

FIGURE 146-2. Percutaneous renal access is obtained through left middle calyx.

Step 4. Conventional endopyelotomy. A laterally placed, full-thickness endopyelotomy incision is made using cutting current and a bugbee electrode (Fig. 146-3). The incision is made across the stricture segment and extends for approximately 1 cm into the normal ureter distally and normal pelvis proximally. Care is taken to ensure a clean and sharp cut to facilitate subsequent endopyeloplasty suturing.

Step 5. Mobilizing the distal ureteral lip. This is an important step for suturing (Fig. 146-4). The periureteral fibroareolar tissue is carefully dissected away from the incised ureteral margin and the adjacent un-incised ureter. This is performed carefully under vision using a 5-mm laparoscopic Endoshears (USSC, Norwalk, CT). Recently we have used the 3-mm MicroEndoshears (USSC, Norwalk, CT), which enables even more precise dissection. Care is taken not to excessively thin out the ureteral wall during this step. The entire dissection is performed "cold," without cautery. Only specific spot coagulation of bleeding points is carried out as required. Occasionally one can encounter a vessel of significant size, which can be gently dissected away from the ureteral wall. This step serves three important purposes. First, it provides space for the suturing device while placing the distal bites. Second, it defines the distal ureteral lip enabling precise full thickness suturing. Third, it releases tension on the horizontal suture line.

Step 5. Endopyeloplasty suturing. The loaded SewRight SR5 is passed through the working channel of the 26 French nephroscope (Karl Storz, Germany). The initial suture approximates the distal and proximal angles of the endopyelotomy incision, thereby dividing the horizontal sutureline into two equal halves (Fig. 146-5A, B, and C). Additional sutures are placed on either side of the initial stitch to complete the procedure (Fig. 146-6A and B). The number of sutures depends on the length of the endopyelotomy

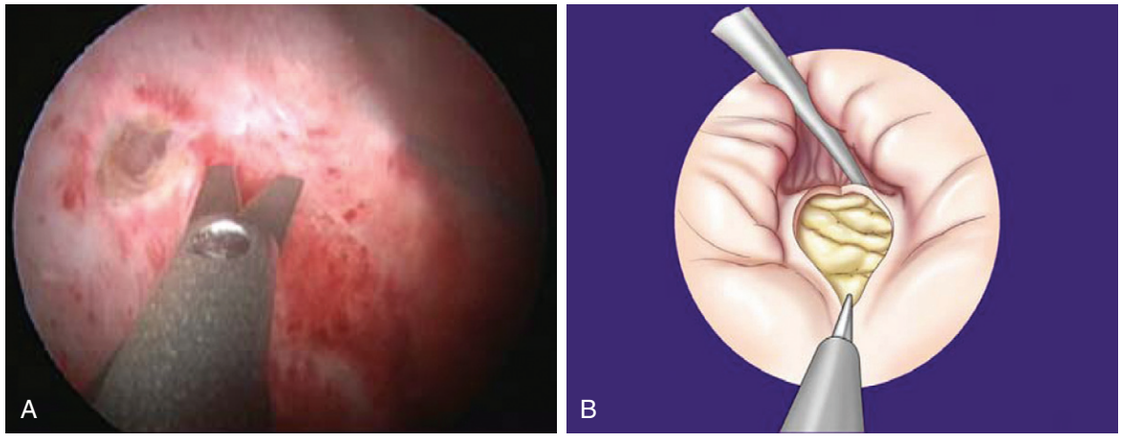

FIGURE 146-3. A laterally oriented, full-thickness, endopyelotomy button-hole incision is made using a hook electrode and cutting current. This incision is extended toward the ureteropelvic junction with a"cold"endoshears.

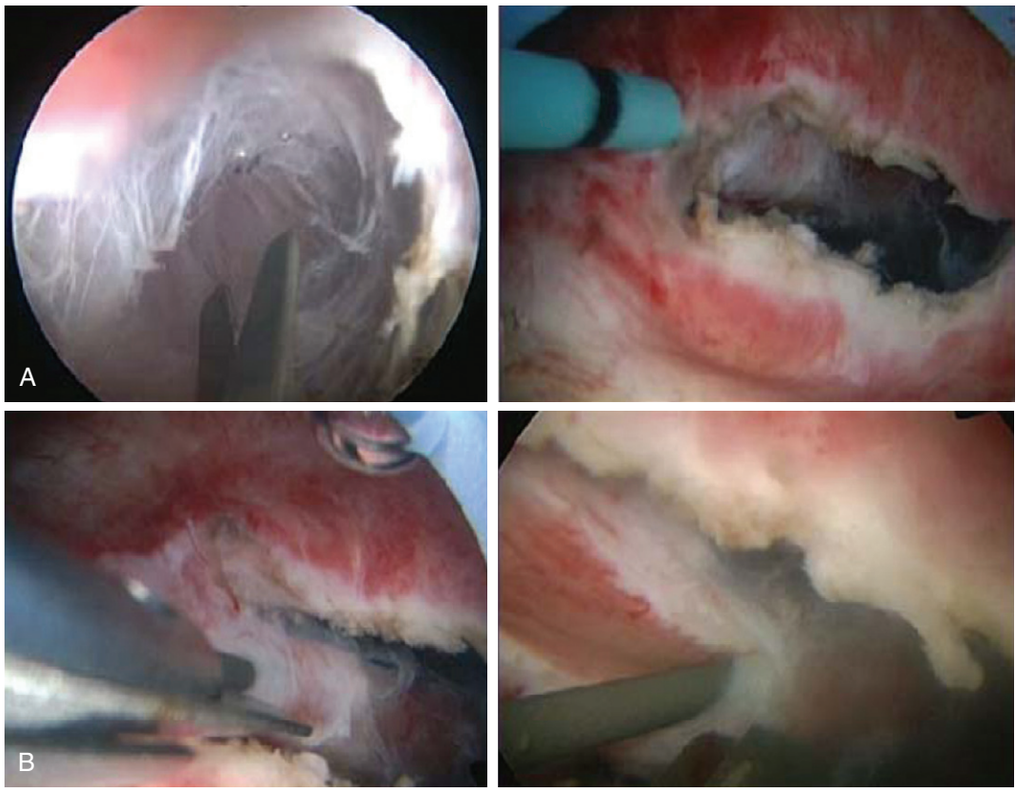

FIGURE 146-4. A, The extraluminal aspect of the ureter is dissected by a combination of sharp and blunt dissection with minimal use of electrocautery and preserving a reasonable amount of periureteral tissue. The ureter is spatulated with the help of endoshears. **B,** Mobilization of the distal ureteral margin is performed using a 5-mm microendoshears. The ureter is spatulated with the help of endoshears.

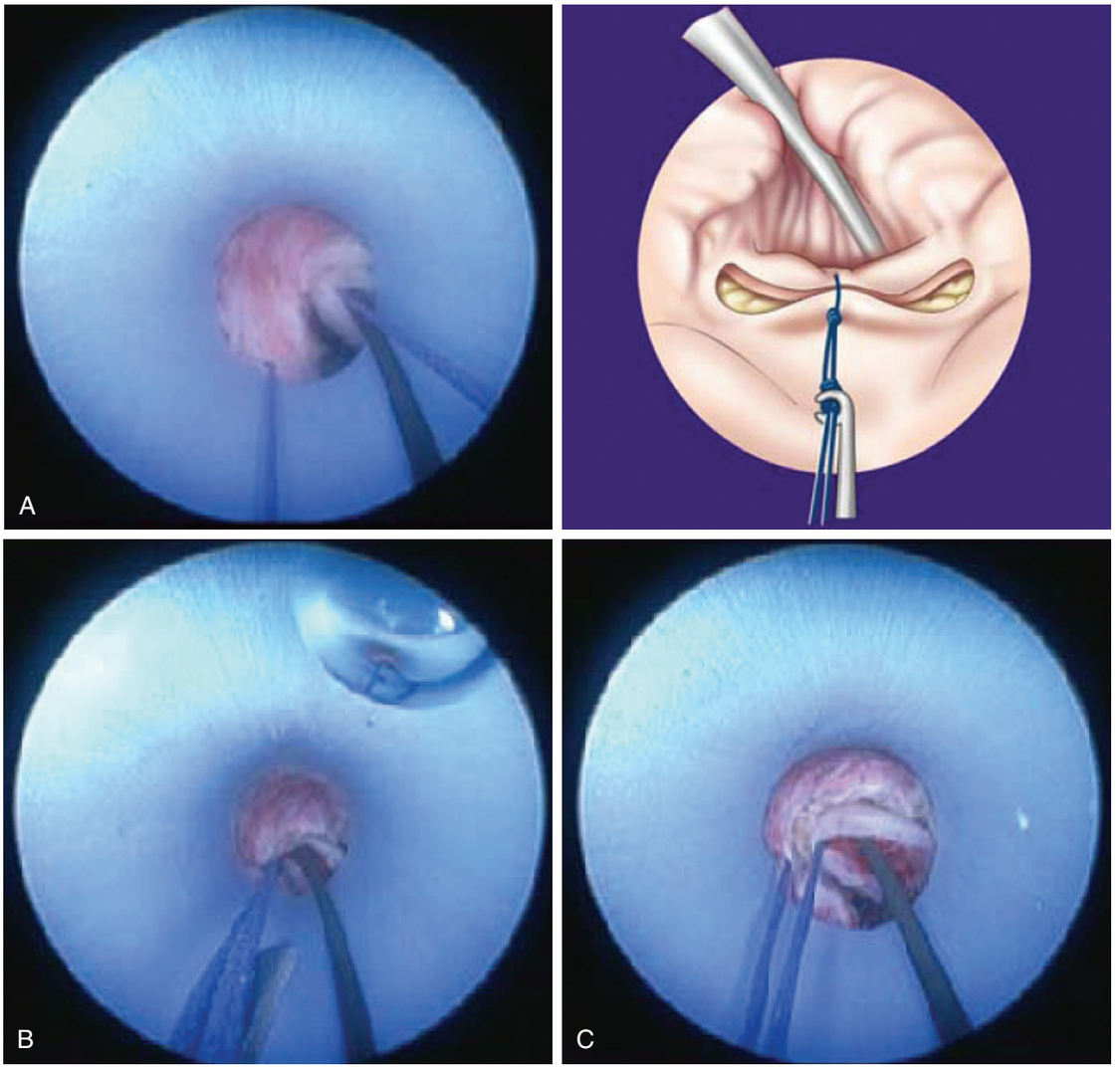

FIGURE 146-5. A to **C,** Placement of the first suture during an endopyeloplasty. The initial suture approximates the proximal and distal angle of the endopyelotomy incision, thereby dividing the incision into two equal halves.

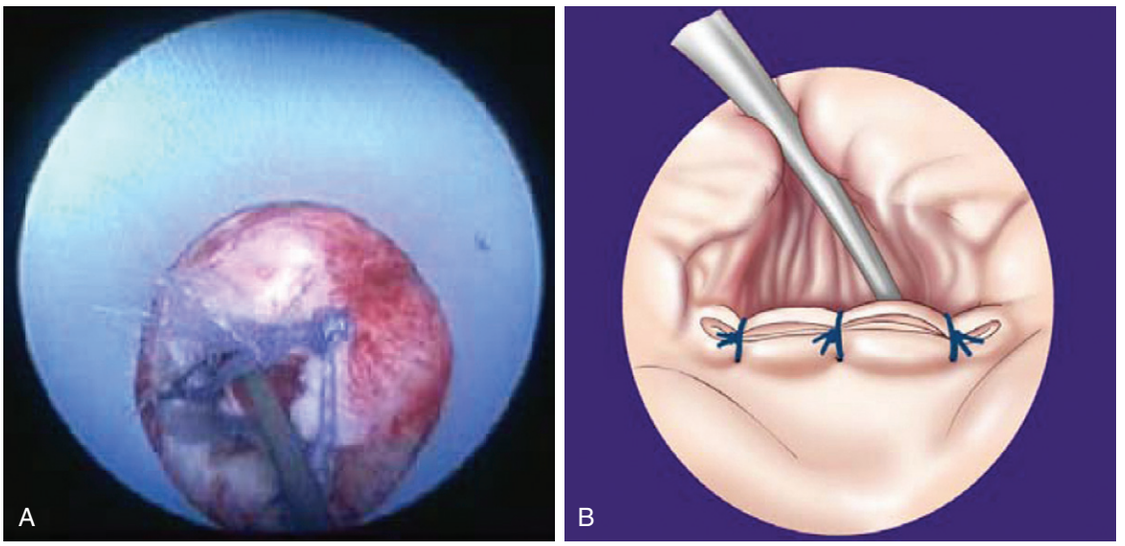

FIGURE 146-6. A and **B,** Nephroscopic view of a completed endopyeloplasty. Typically, two additional sutures are placed on either side of the initial suture providing precise mucosa-to-mucosa approximation.

incision. Typically, three sutures are required, one on either side of the initial stitch. However, anywhere from one to four sutures may be placed in the individual case.

Step 6. Placement of a JJ stent and nephrostomy tube. After obtaining precise mucosa-to-mucosa coaptation, a JJ ureteral stent is placed antegradely, and a 20 French nephrostomy tube is placed.

CONCLUSIONS

Percutaneous endopyeloplasty is technically feasible and safe. The initial clinical experience with percutaneous endopyeloplasty is encouraging. However, these data need to be validated by further studies from multiple centers with longer follow-up.

Commentary by

JEAN JOSEPH

With this technique, a Fenger pyeloplasty is carried out in a minimally invasive manner. The initial steps are identical to a percutaneous endopyelotomy. The Sew-Right device provides an adequate way of reapproximating the longitudinal endopyelotomy cut transversely. However, adequate training in the proper usage of this instrument is necessary.

As with an antegrade pyelotomy, an upper pole calyx provides the most direct approach to the UPJ. The needle from the Sew-Right device must capture an equal amount of tissue on either side of the ureter. Similar to a Heineke-Mikulicz repair, the initial midline suture is under the most tension. Subsequent sutures on either side can be tied without difficulty. These can be done extracorporally and set in place under direct vision using a knot pusher. Proper mobilization of the ureteral lips is necessary to facilitate their reapproximation.

This technique has the advantage of faster healing, with a shorter time required for ureteral stenting.

This page intentionally left blank

Chapter 147

Laparoscopic Renal Biopsy

DAVID I. LEE

In the rare instances where a patient may be of significant risk for bleeding after a percutaneous needle biopsy, a laparoscopic renal biopsy may be performed. Benefits of this procedure include the definitive procurement of tissue and hemostasis confirmed by direct visualization.

Give an intravenous dose of broad-spectrum antibiotics before the surgery. After induction of general anesthesia, an orogastric tube and Foley catheter are placed. The patient is placed in a flank position with all pressure points well padded. Prep the flank, abdomen, and back sterilely.

A 12-mm trocar is placed off the tip of the twelfth rib (Fig. 147-1). Place secondary 5-mm ports lateral and posterior to the camera port first. Use a blunt dissector through this port to sweep the peritoneum away to allow placement of another port anteriorly. Using blunt dissection, the lower pole of the kidney can be identified. Excise the fat overlying the lower pole to prepare the biopsy specimen. Use a Tru-Cut needle or biopsy gun to obtain a needle biopsy (Fig. 147-2). Alternatively a small wedge can be obtained with a laparoscopic spoon. After adequate specimens are obtained, observe the kidney carefully for signs of bleeding. Once hemostasis is obtained, lower the pneumoperitoneum to 5 mm Hg to ensure hemostasis. Remove the ports under direct vision. Close the fascia of the 12-mm port with 2-0 absorbable suture and the skin of all port sites with subcuticular suture.

Alternative: A transperitoneal approach may also be performed. In a similar fashion as a transperitoneal laparoscopic nephrectomy, the lower pole of the kidney is exposed and needle biopsy or wedge biopsy can be completed.

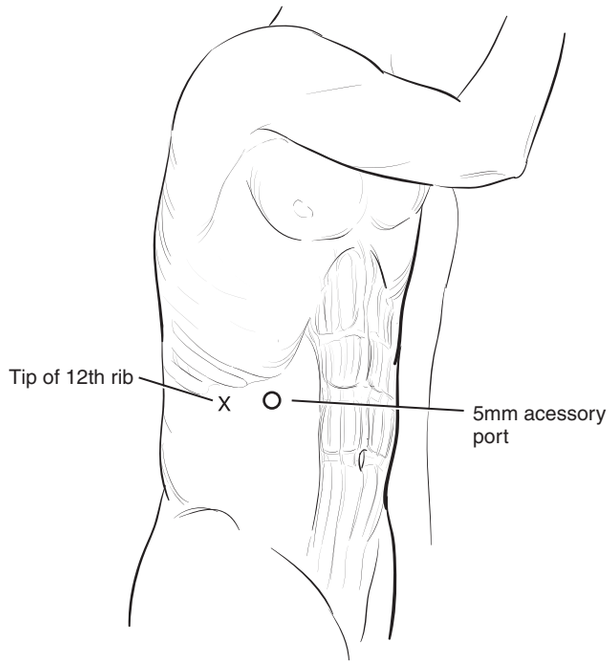

FIGURE 147-1.

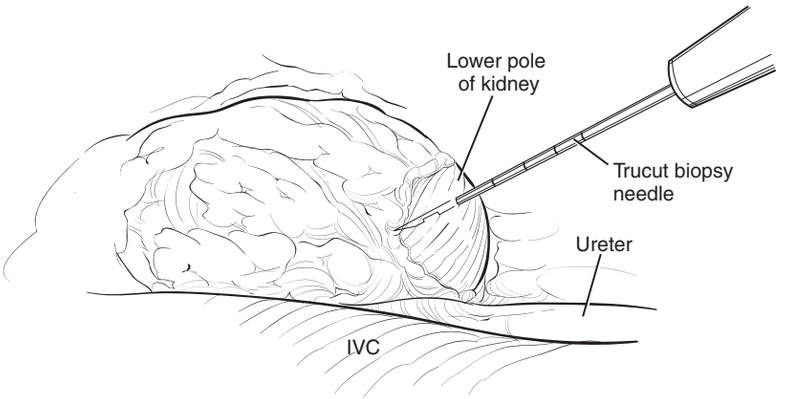

FIGURE 147-2.

Commentary by JEAN JOSEPH

This is a safe alternative approach to open biopsy when percutaneous biopsy is not possible. A cup biopsy forceps can provide adequate tissue without the risk of injuring deep vessels or the collecting systems. Adequate sampling of the renal cortical tissue can be performed, with the biopsy site thoroughly cauterized under direct vision.

The retroperitoneoscopic approach is my preferred route. There is a reduced risk for injury to intraperitoneal structures. No colonic mobilization is necessary to expose the kidney. In patients with prior abdominal surgeries, lysis of adhesions with associated risks can complicate the procedure if performed transperitoneally.

Chapter 148

Laparoscopic Pyeloplasty

RICHARD W. SUTHERLAND

Indications for laparoscopic pyeloplasty in a child do not differ significantly than the indications for an open pyeloplasty. The need to document obstruction and/or renal function deterioration must be made before proceeding with reconstruction. Failure has been noted in the neonate, but after 3 months of age, good results should be expected. Laparoscopic pyeloplasty in itself, when done with fixed instruments rather than robotically, can be particularly demanding with respect to suturing secondary to the loss of distal degrees of movement freedom at the tip of the needle driver. Because this a reconstructive technique, it is imperative that the surgeon performing the procedure be comfortable with suturing and knot tying.

Patient position in the pediatric population is very similar to patient positioning in the adult population. Care must be taken to protect the lower extremities with appropriate padding. The child is placed at approximately a 45-degree angle on the table (Fig. 148-1).

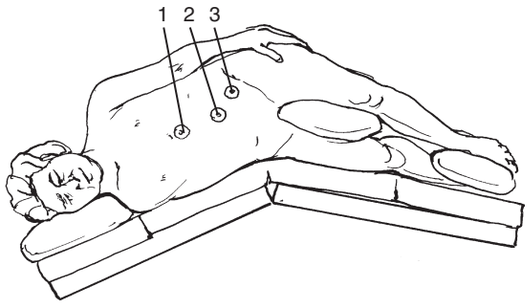

FIGURE 148-1.

The most important aspect is port placement. Unlike in an adult in whom the ports are frequently placed 5 to 10 cm apart, in pediatric cases it is not uncommon to place the ports too close to each other, resulting in instruments becoming entangled. I use a subxiphoid midline port, an umbilical port that I place directly through the umbilicus rather than a semilunar incision, and then a lower quadrant port in a triangulation position toward the ureteropelvic junction (UPJ).

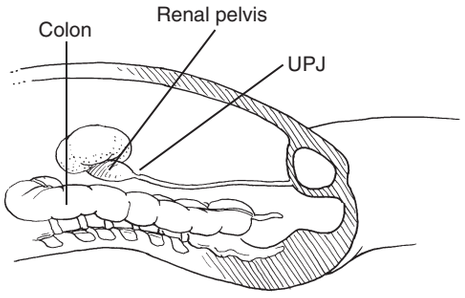

FIGURE 148-2.

Dissection of the kidney and the pelvis is an important part of the procedure. Good mobilization of the colon off either the splenic or hepatic flexure greatly facilitates dissection of the kidney and the renal pelvis (Fig. 148-2). Transmesenteric approaches can be performed in extremely hydronephrotic kidneys.

In children who have had a stent or percutaneous nephrostomy tube placed prior to this dissection, it can be difficult to identify the renal pelvis as it frequently completely collapsed. I do not routinely recommend placing a stent at the beginning of the case because the hydronephrotic kidney helps with the initial dissection.

Once the dissection of the renal pelvis and the kidney has been completed, it can be mobilized to the anterior abdominal wall (Fig. 148-3). This allows for excellent

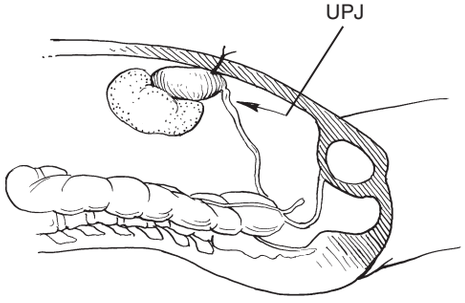

FIGURE 148-3.

visualization and reconstruction of the UPJ. This is usually done with a 4-0 polydioxanone suture (PDS) on Keith needle that is passed through the abdominal wall and then through the renal pelvis above the area of the UPJ and then back through the abdominal wall immediately adjacent to the entry suture. The eventual spatulation of the ureter will be on its medial border so the Keith needle is placed to pull the kidney slightly lateral rather than medial. A hemostat can then be used to adjust the tension to pull the renal pelvis up out of the retroperitoneum toward or actually on the abdominal wall.

Once the renal pelvis has been elevated, entry into the hydronephrotic renal pelvis above the UPJ can be performed. The eventual anastomosis should be at least 15 mm in size (Fig. 148-4). The opening should be slightly larger to accommodate the tissue used during suturing. Complete transection of the UPJ at this point is not done. A short posterior segment is left intact to prevent the ureter from falling back down into the retroperitoneum.

With the ureter still attached posteriorly to the renal pelvis, it is spatulated onto the medial to anterior surface with fine Metzenbaum scissors or a hook electrode down through the narrowing until normal diameter ureter is reached (Fig. 148-5).

The base of the spatulation "A'" is then brought to the medial aspect of the renal pelvis "A" with a single interrupted stitch (Fig. 148-6). A 5-0 PDS or a similar absorbable suture is used. This fixes the ureter to the renal pelvis and allows for incision of the posterior portion of the UPJ and remaining atretic ureter from the healthy ureter. This portion of the ureter is then discarded.

The posterior wall of the anastomosis can then be approximated (Fig. 148-7). I use 5-0 PDS for this anastomosis or 6-0 PDS depending on the size of the ports used, 5FR or 3FR, that are being used and the needle available.

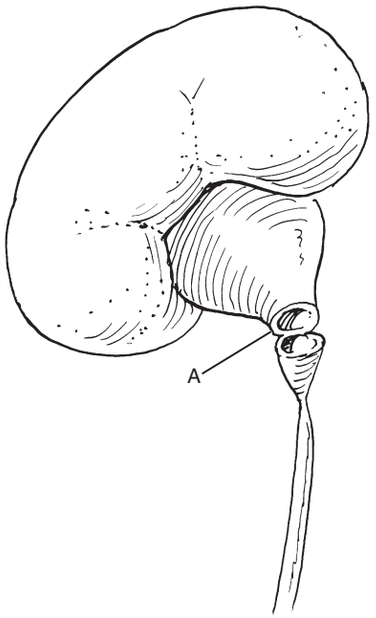

FIGURE 148-4.

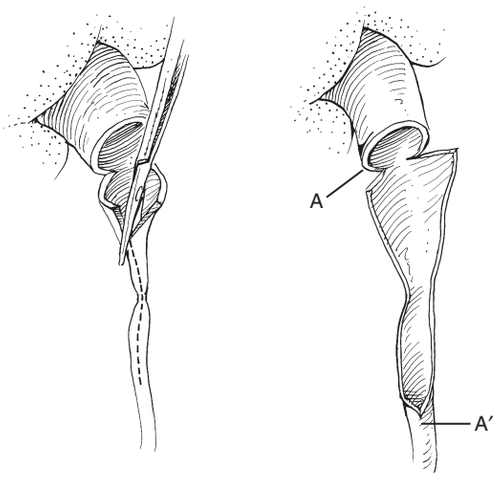

FIGURE 148-5.

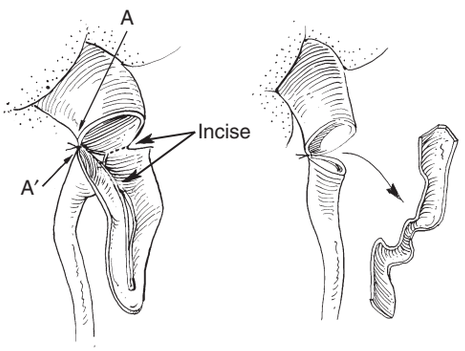

FIGURE 148-6.

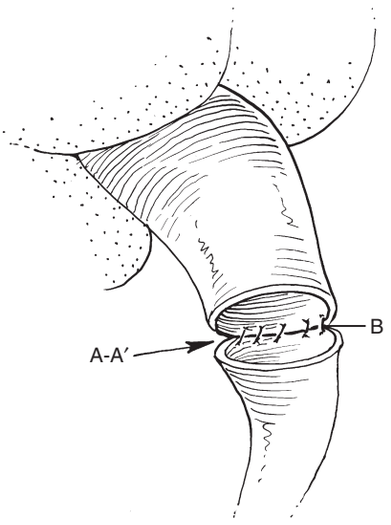

FIGURE 148-7.

Once the posterior wall has been approximated, a stent is then placed into the ureter down into the bladder. This is done by placing a 14-gauge Angiocath through the abdominal wall and directing it toward the open ureter. A wire is passed down through the ureter into the bladder (Fig. 148-8). The Angiocath is then removed and the

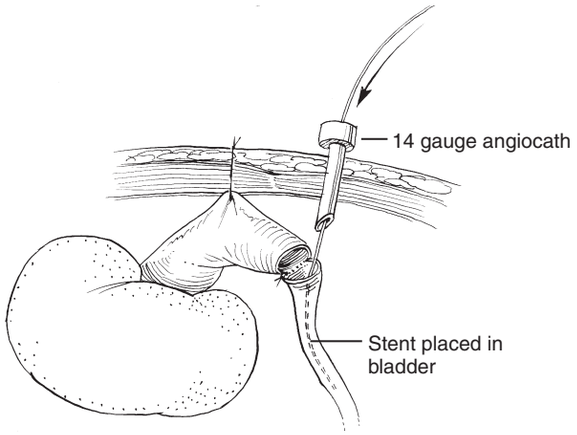

FIGURE 148-8.

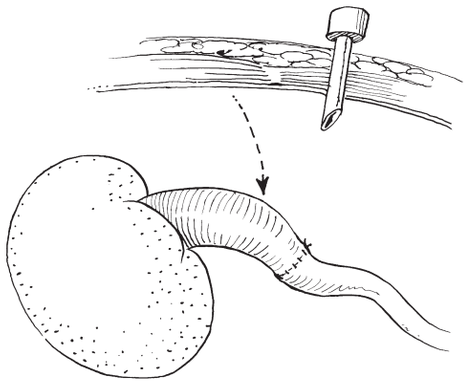

FIGURE 148-9.

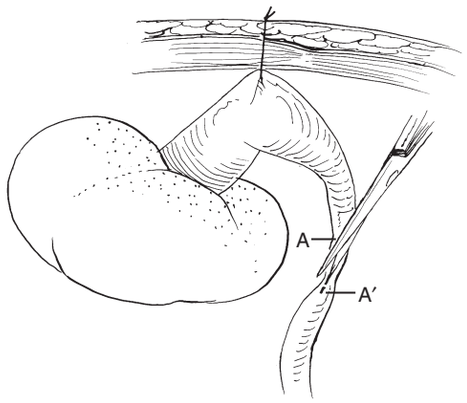

FIGURE 148-10.

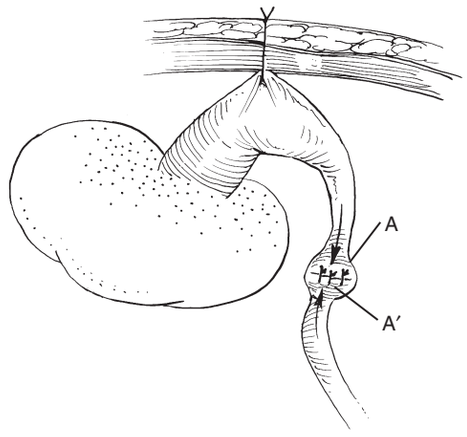

FIGURE 148-11.

double-J stent is placed through the skin over the wire down into the bladder. The top of the double-J stent is then placed into the renal pelvis. The anterior wall of the anastomosis is then completed.

The renal pelvis is then released from the abdominal wall by removing the 4-0 PDS, allowing the kidney to fall back into the retroperitoneum (Fig. 148-9).

FENGER PYELOPLASTY

While the dismembered pyeloplasty is the choice of many pediatric urologists, the Fenger pyeloplasty can also be considered, particularly for a short narrowing of the UPJ. Using initially scissors or the hook electrode, an opening is made in the renal pelvis above the stricture in a normal diameter region of the renal pelvis (Fig. 148-10). This then allows for the wall of the ureter to be opened through the stricture for a distance down to normal sized lumen.

Using three individual interrupted PDS sutures, the incision is closed in a Heinecke-Mikulicz type fashion after the double-J stent is placed (Fig. 148-11). While a single suture has been recommended in previous descriptions, I place two or three sutures to protect against suture dislodgment of a single stitch and subsequent complete breakdown.

POSTOPERATIVE PROBLEMS

Laparoscopic pyeloplasties done in an open fashion are almost always preformed with a Penrose drain to allow the minor amount of leakage that can sometimes occur at the anastomosis to drain away from the repair. In the laparoscopic pyeloplasty, I do not generally recommend leaving a drain that is, in essence, an intraperitoneal drain. In the occasional patient in whom significant anastomotic leak does occur, a chemical peritonitis will develop. The patient will complain of peritoneal signs and discomfort. It is for this reason that I leave a Foley in place overnight until discharge the following morning.

Obstruction can occur in any pyeloplasty case. It is unusual in the immediate because the stent is generally left in place for at least 2 weeks to allow the surgical edema to subside. Early obstruction would suggest some failure in the anastomotic process and require possibly some restenting or retrograde ureteropyelogram. Obstruction can occur up to 6 months after the pyeloplasty and a routine ultrasound at approximately 1 month and then at 6 months after surgery is recommended to ensure that the degree of hydronephrosis is stable or improved after the pyeloplasty.

Infection is also a secondary complication with acute pyelonephritis after any procedure on the kidney. Routine urine cultures are obtained at the beginning of the case before initiating antibiotics. Once the urine culture is obtained, intravenous antibiotics are started in the operating room and continued until the initial 24-hour urine culture comes back without growth. If there is suggestion of infection, which could clearly affect the success of the repair, intravenous antibiotics are continued until the isolation and sensitivity pattern of the bacteria is identified.

Herniation of the port sites is extremely rare when a 5-mm and certainly 2- and 3-mm ports are used. The most common site for herniation in this population of port placements tends to be the umbilical port. There is no muscle to coapt the opening to the skin. Closure of the fascia in the lateral or lower quadrant ports may not be necessary because of the muscle that is present. The midline ports that have only fascia and no muscle associated with them are at risk for a herniation. I would recommend a 4-0 Vicryl suture be placed into the fascia at least as a single stitch if not a figure-8 when 5-mm ports are used midline. This should prevent possible herniation before closure with either a subcuticular stitch or Dermabond.

Commentary by

JEAN JOSEPH

Laparoscopic pyeloplasty has been a well-accepted alternative to the open technique. Surgeon and family preference remain the deciding factors. In children younger than 1 year old, an extraperitoneal dismembered pyeloplasty performed via a dorsal lumbotomy remains a popular option. To many, the cosmetic benefits are negated because the incision used is often close to the same size as a 10-mm trocar or port incision. The slow adoption of laparoscopy is likely due to the associated long learning curve. In trained hands, the outcomes between open and laparoscopy have been equal. While laparoscopy may be associated with longer operative time, shorter hospital stay has been noted.

Chapter 149

Robot-Assisted Laparoscopic Pyeloplasty

CHARLES R. MOORE, RAYMOND J. LEVEILLEE, AND JOHN SHIELDS

Robotic-assisted laparoscopic pyeloplasty is an alternative to laparoscopic pyeloplasty, affording the patient with the benefit of decreased morbidity of open surgery and the surgeon with the benefit of an easier technique to perform the delicate intracorporeal suturing required for the anastomosis.

SURGICAL TECHNIQUE

1. Cystoscopy with retrograde pyelogram, ureteral stent, and foley placement (optional). We prefer to perform this prior to the reconstruction to evaluate the anatomy and place a ureteral stent. Alternatively, this step can be omitted and an antegrade wire/stent can be placed after the pyelotomy.
2. Position (for right pyeloplasty). Pneumatic compression stockings and oro-gastric tube are placed. Patients are put in a modified flank position with the right side up and a 30-degree tilt. The patient is held in place with a conformal bean bag (Olympia, Seattle, Washington) and a subaxillary roll is positioned. The left arm is placed on an arm board with padding and the right arm draped over the chest on a padded Krause arm hanger or pillows. Secure both arms by wrapping elastic wraps around each individually to secure to arm board and hanger. The patient's right arm, chest, hips, and legs are secured to the table with 3-inch silk tape. Place padding and pillows (as needed) under bent left leg, and then three pillows on top of left leg and straight right leg on top of the pillows. The table is tilt tested 30 degrees to and fro to ensure that the patient is secured to the table (Fig. 149-1).
3. Trocar placement and robot docking. An infraumbilical incision is made in a semicircular fashion and a 12-mm trocar is placed for the camera. After the abdomen is examined and lysis of adhesions performed, if needed, the remainder of the trocars are placed. Typically, two 8-mm robotic trocars are placed—one 8 to 10 cm cephalad to the camera port and the second 8 to 10 cm lateral with a 10-degree inferior angle from the camera trocar. A third robotic trocar may be utilized for additional retraction (optional). A fourth assistant trocar is placed between the umbilicus and subxiphoid trocar (Fig. 149-2). The robot is docked by bringing the robot from the patients back at approximately 30 degrees to the table and the robotic arms are brought over the patient and docked to the trocars. The #1 arm of the robot has monopolar scissors (cephalad arm) and



FIGURE 149-1. Positioning.

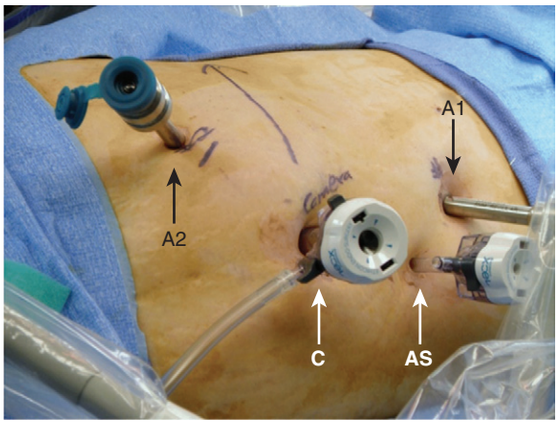

FIGURE 149-2. Trocar placement. (A1, cephalad robotic arm; A2, caudad robotic arm; AS, assistant trocar; C, camera trocar.)

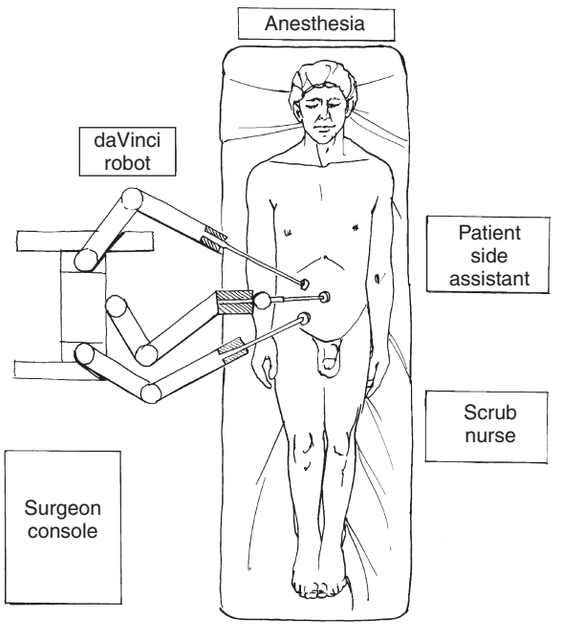

FIGURE 149-3. Room set-up.

the #2 arm (caudad arm) has bipolar Maryland forceps. Fig. 149-3 illustrates the room setup.

4. Exposure. Release the peritoneal attachments from the liver (spleen for left pyeloplasty) as needed for exposure. Mobilize the right colon. Kocherize the duodenum with cold scissors. There must be no thermal energy here because unrecognized duodenal injuries can be life threatening. Skeletonization of the inferior vena cava while identifying the gonadal and renal vein may reveal anterior crossing vessels (Fig. 149-4A). Preoperative imaging (computed tomography or magnetic resonance imaging arteriograms) may assist in helping to localize these vessels, which should be preserved (Fig. 149-4B).
5. Dissection. Prior to mobilization we clamp the Foley and give the patient 20 mg of furosemide and a fluid bolus to distend the renal pelvis and aid in dissection. The ureter is identified and mobilized to the renal pelvis: carefully dissect overlying areolar tissue from the ureter without devascularizing it. The renal pelvis is skeletonized anteriorly and posteriorly. During mobilization of the ureter and renal pelvis, one must be cautious to avoid inadvertent injury to a crossing vessel. After mobilization of the ureter and renal pelvis, the technique for the pyeloplasty is determined. We typically perform a dismembered pyeloplasty, except with high insertions of the ureter where we may perform a YV-plasty.
6. Anastomosis: The anterior wall of the ureter is transected with caution to avoid inadvertent transection of the ureteral stent. The stent is pulled out of the renal pelvis and the posterior wall of the ureter is transected (Fig. 149-5). (Optional: If no stent was pre-placed it can be placed antegrade now.) If renal calculi are present, a flexible cystoscope may be introduced through a trocar at this time and renoscopy performed to basket renal calculi. Move the ureter anterior to the crossing vessel, if needed. Reduction of the renal pelvis as needed with cold scissors. Spatulate the ureter laterally for 2 cm with Potts scissors or monopolar scissors (Fig. 149-6). Change robotic instruments to needle drivers in both robotic arms. The anastomosis is performed tension-free in a dependent manner. An anchor suture with a 3-0 polyglactin on a RB-1 needle is placed at the apex of the ureteral spatulation and the renal pelvis and tied down (Fig. 149-7). The anchor suture is cut 1 cm long to serve as a retractor. Interrupted sutures are placed on each side of the initial anchor suture. The posterior wall is closed with interrupted sutures, the ureteral stent placed back in the renal pelvis (Fig. 149-8), and the anterior wall is closed. The anastomosis is completed with interrupted 3-0 polyglactin on a RB-1 needle (Fig. 149-9). Any defect remaining in the renal pelvis after completion of the

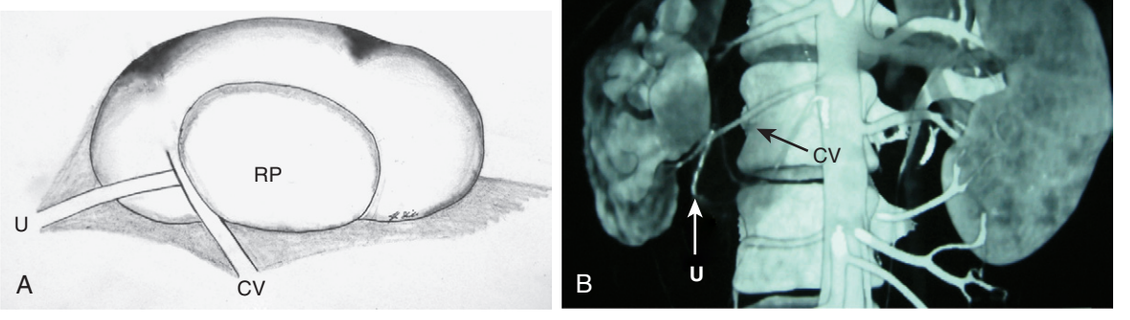

FIGURE 149-4. A, Drawing illustrating a ureteropelvic junction obstruction secondary to an anterior crossing vessel. **B,** Computed tomography scan illustrating ureteropelvic junction obstruction secondary to a crossing vessel *(Part A Courtesy of John Martin Shields, MD, MRCS-I.)* (CV, anterior crossing vessel; RP, renal pelvis; U, ureter.)

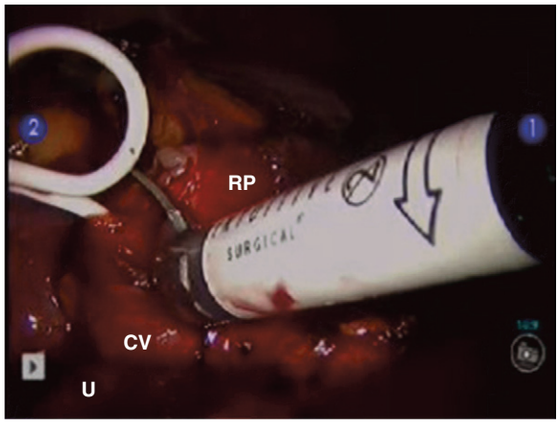

FIGURE 149-5. Incision of posterior wall of ureteropelvic junction. (CV, anterior crossing vessel; RP, renal pelvis; U, ureter.)

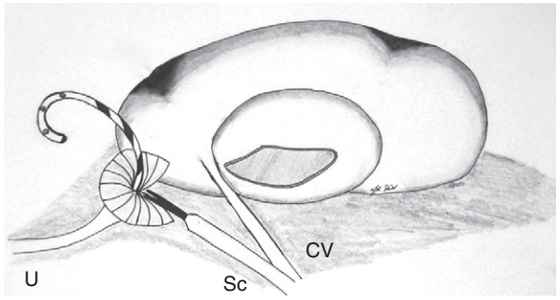

FIGURE 149-6. Lateral ureteral spatulation. *Courtesy of John Martin Shields, MD, MRCS-I.)* (CV, anterior crossing vessel; Sc, scissors; U, ureter.)

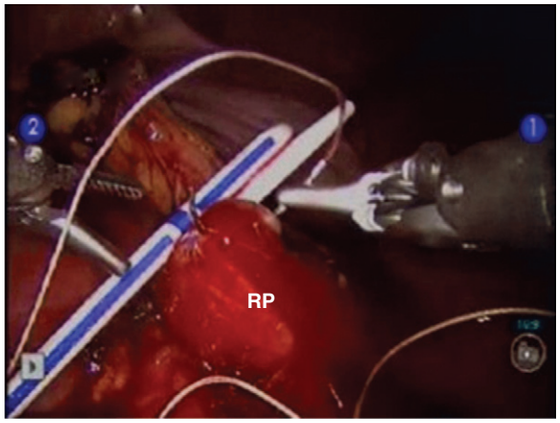

FIGURE 149-7. Lateral ureteral spatulation. (RP, renal pelvis.)

anastomosis can be closed with a running or interrupted 3-0 polyglactin. Alternatively, a running ureteropelvic junction (UPJ) anastomosis can be done. We prefer an interrupted anastomosis to minimize the potential risks of decreasing the lumen of the anastomosis when a running suture is tightened/tied down.

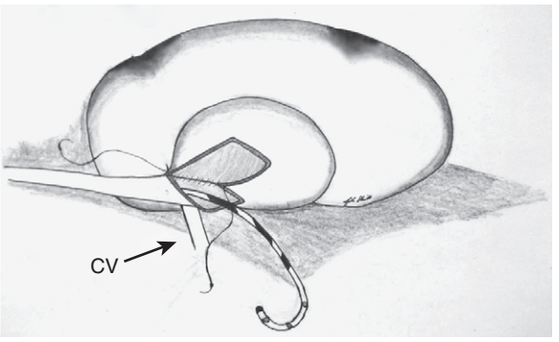

FIGURE 149-8. A complete posterior anastomosis with a running suture; we prefer interrupted sutures. *(Courtesy of John Martin Shields, MD, MRCS-I.)* (CV, anterior crossing vessel.)

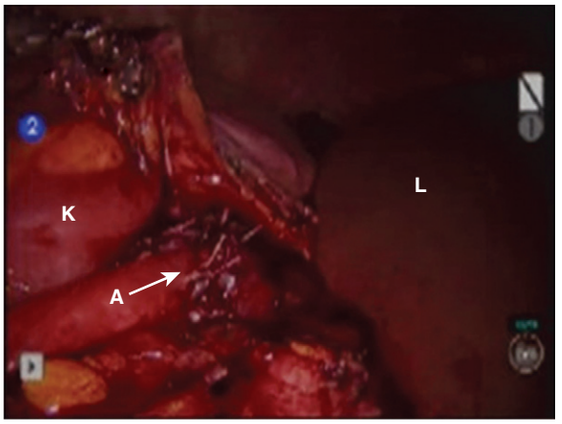

FIGURE 149-9. Completed anastomosis. (A, anastomosis; K, kidney; L, liver.)

7. The pneumoperitoneum is lowered to 5 mmHg to inspect for bleeding. The 12-mm trocar is closed with a 0 polyglactin suture, a 19 French JP drain is placed through the most lateral trocar and secured with a drain stitch to the skin. The other skin incisions are closed with a 4-0 absorbable monofilament (poliglecaprone) and dermabond.

POSTOPERATIVE CARE

The patient is given a clear liquid diet the day of surgery, and thereafter the diet is advanced as tolerated. On postoperative day 1 the Foley is removed. If the drain output remains low, the drain is removed the afternoon of postoperative day 1 and the patient is discharged from the hospital. The ureteral stent is removed 4 to 6 weeks after surgery. A Mag3 renal scan with furosemide is obtained 1 month after ureteral stent removal. Thereafter, follow-up renal scans occur initially at 6 months and then yearly.

Commentary by JEAN JOSEPH

Keeping the arm on the operative side adducted and secured to the patient's side eliminates the possibility that the robotic arm would place pressure on the patient's arm. I do not routinely perform cystoscopy or stent placement at the beginning of the procedure. Keeping the renal pelvis dilated often facilitates the dissection. Adequate stent length selection is a must to ensure the stent reaches the bladder during antegrade placement.

The entire renal hilum should be exposed during the dissection. Proper identification of the UPV is necessary with visualization of the funneling renal pelvis. Large crossing vessels to the lower pole should not be confused for the main renal vessels. In thin patients, and particularly patients with a horseshoe kidney, a transmesentaric approach provides quick access to the UPV obstruction. When this approach is under consideration, it is helpful to leave the renal pelvis without drainage. I prefer a dismembered pyeloplasty, with adequate spatulation on either side in most cases. In cases when there are stones present in the renal pelvis, flexible air pyeloscopy can be done to facilitate stone retrieval or basketing. Once the flexible cystoscope is positioned into the pyelotomy, carbon dioxide used for peritoneal insufflation is transferred to the cystoscope. This circumvents the need for fluid irrigation of fluid, stone flushing, and instilling large amounts of fluid in the abdominal cavity. The pressure from the carbon dioxide fixes the stones to the wall of the renal pelvis, which are easily retrieved.

During the reconstructive phase, grasping of the ureteral edges by the strong robotic instruments should be avoided to limit crush injury, which would compromise the repair. I generally place the ureteral stent in an antegrade manner once the posterior wall is completed. The ease of suturing provided by the robotic technology has allowed many urologists to offer this minimally invasive technique to their patients.

Chapter 150

Laparoscopic Live Donor Nephrectomy

GRANT DISICK, STUART KESLER, AND RAVI MUNVER

Laparoscopic live donor nephrectomy is more appealing to potential donors than the traditional open approach in that it provides decreased postoperative pain, improved cosmesis, and a shorter convalescent period. Furthermore, laparoscopic kidney procurement has been shown to have equivalent graft function compared with open excision. As such, laparoscopic live donor nephrectomy is gaining popularity and is becoming the new standard for renal transplantation.

Preoperative assessment. Multiplicity of renal vessels or anomalous renal vasculature are not contraindications. The surgeon must thoughtfully assess each individual's vascular anatomy to determine whether successful ex vivo reconstruction is feasible. Dual phase helical computed tomography angiography with three-dimensional reconstruction is extremely useful for radiographic imaging of renal anatomy and vasculature. Renal function measurements may be determined by nuclear renal imaging studies.

Patient preparation: Patients are instructed to maintain a clear liquid diet for 12 to 24 hours before surgery and to administer a bowel preparation consisting of 300 mL of magnesium citrate on the prior day. Sequential compression devices are placed on the lower extremities and a single dose of intravenous antibiotics is given. Patients are aggressively hydrated upon induction of general anesthesia and throughout the operative procedure to maintain adequate diuresis. Prophylactic antibiotics are administered 60 minutes before surgical incision.

Operating room preparation and instrumentation: Operating room preparation, as well as necessary instrumentation required, is similar to that required for laparoscopic radical nephrectomy.

CONVENTIONAL LAPAROSCOPIC DONOR NEPHRECTOMY

Left Laparoscopic Donor Nephrectomy

1. Position
   a. Patient: Before positioning the patient, a marking pen is used to mark a 5- to 7-cm Pfannenstiel incision approximately 2 to 3 fingerbreadths above the pubic symphysis. This incision will be used as the eventual extraction site of the kidney and the site should be marked before rotating the patient to ensure symmetry. The patient is placed in a modified right lateral decubitus position (45 to 60 degrees) with the flank situated over the kidney rest. The table may be flexed to increase the area between the iliac crest and costal margin. A bean bag or large gel rolls are used to support the patient in this position. Pillows are placed between the legs and the right leg is flexed at the knee while the left leg is placed straight. The arms are placed parallel onto well-padded arm boards. The ankles, knees, dependent hip, shoulders, and brachial plexus are adequately padded. After verifying that all areas prone to pressure injury are well padded, the patient is secured to the operating table using 3″ cloth tape across the left shoulder and arm as well as across the hip.
   b. Trocar: Figure 150-1 illustrates the trocar placement for conventional laparoscopic donor nephrectomy (left and right), and hand-assisted laparoscopic donor nephrectomy (left and right). A 5- or 10-mm trocar is inserted under direct vision at the umbilicus. The primary camera trocar (5 or 10 mm) is placed slightly left of midline, approximately 2 cm below the xiphoid process. The primary working trocar (12 mm) is placed along the midclavicular line, 2 cm below the level of the umbilicus. An accessory trocar (5 mm) may be placed along the anterior axillary line approximately 2 cm below the costal margin. A 0- or 30-degree laparoscope is used throughout the procedure.
2. The descending colon is mobilized along the white line of Toldt using ultrasonic shears or an alternate thermal energy device. The superficial peritoneal attachments between the colon and lateral sidewall should be released initially. Lateral renal attachments to the sidewall should not be released because this will result in medial mobilization of the kidney. This maneuver will obscure the renal hilum and interfere with further dissection. The colon is further dissected medially using the suction-irrigator device, exposing the proper plane

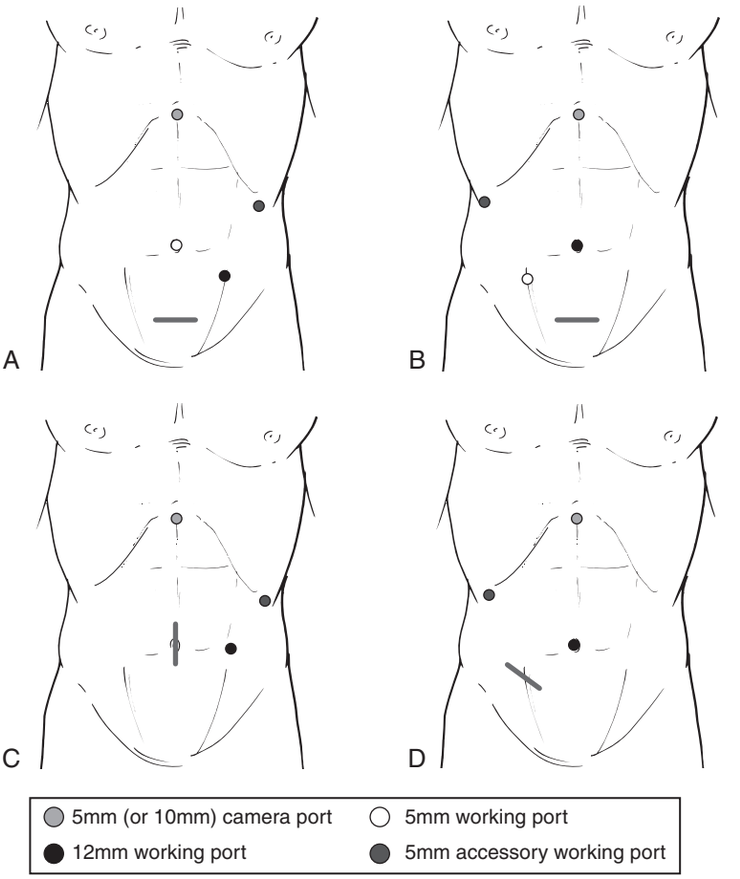

FIGURE 150-1. Trocar placement for conventional laparoscopic donor nephrectomy (left and right), and hand-assisted laparoscopic donor nephrectomy (left and right). **A,** Conventional laparoscopic donor nephrectomy. **B,** Conventional laparoscopic right donor nephrectomy. **C,** Hand-assisted laparoscopic left donor nephrectomy. **D,** Hand-assisted laparoscopic right donor nephrectomy.

between the colonic mesentery and Gerota's fascia, shown in Figure 150-2. Recognition of this plane is important, in that inadvertent entry into the mesentery can lead to bleeding as well as mesenteric defects with potential for internal herniation. Premature entry into Gerota's fascia can create bleeding and limit visualization of the renal hilum. The dissection is carried cephalad towards the upper pole of the kidney. Extensive splenic mobilization is required to provide adequate exposure of the upper pole of the kidney.

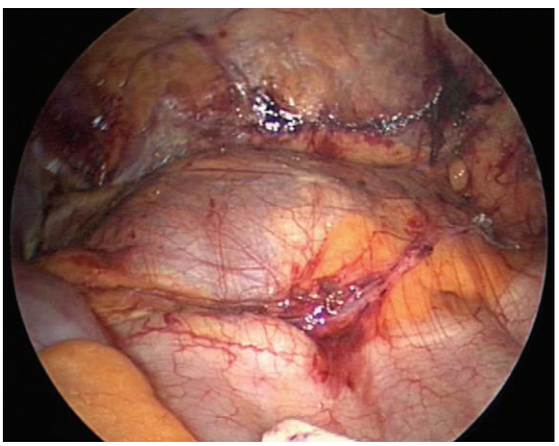

FIGURE 150-2. The colon is further dissected medially using the suction-irrigator device, exposing the proper plane between the colonic mesentery and Gerota's fascia.

3. The psoas muscle is exposed below the lower pole of the kidney. This muscle functions as an important landmark for locating the ureter. The ureter and gonadal vein are identified along the medial border of the psoas muscle. Care should be taken to avoid entering the psoas muscle fascia which may lead to unnecessary bleeding or damage to the genitofemoral nerve. The ureter is dissected to the level of the iliac artery bifurcation. Meticulous care is taken to avoid ureteral devascularization. Following distal ureteral transection, the remaining blood supply to the ureter arises proximally from the renal artery, and therefore excessive dissection of the periureteral tissue is avoided. The ureter is not divided at this time. By gently elevating the ureter and lower pole of the kidney with an instrument, the medial border of the kidney is dissected in a cephalad direction to the level of the renal hilum. The correct plane of dissection lies medial to the gonadal vein. Figure 150-3 shows the initial exposure of the renal vein, adrenal vein, gonadal vein, and lumbar branch after the colon has been fully mobilized medially.

   Alternative: When both lateral traction of the kidney and medial traction of spleen are needed, placement of an accessory trocar (as discussed) may be beneficial.
4. Dissection
   a. The gonadal vein is then dissected using a Maryland dissector or right angle dissector at its insertion into the renal vein. The gonadal vein can be ligated and

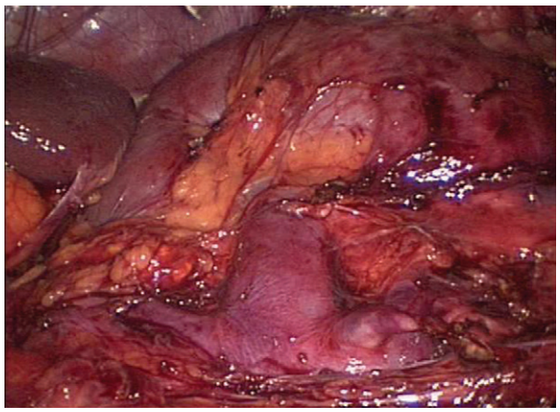

FIGURE 150-3. Initial exposure of the renal vein, adrenal vein (on left), gonadal vein (on right), and lumbar branch after the colon has been mobilized medially.

divided with titanium or polymer clips. Alternatively, the vein can be divided with a bipolar vessel sealing device. The stump of the gonadal vein may serve as a handle for superior traction of the renal vein to help identify the lumbar vein and renal artery posteriorly. An alternative technique is to divide the gonadal vein at the level of the iliac artery bifurcation.

b. The adrenal vein is dissected at its insertion into the renal vein. The adrenal vein is ligated and divided with clips or a bipolar vessel sealing device. An advantage of the vessel sealing device is that it eliminates the presence of clips that may interfere with stapling devices. The lumbar vein, when present, enters the renal vein posteriorly, as seen in Figure 150-4. This vein must be ligated and divided in order to identify the renal artery that lies immediately posterior.

5. Renal vein/artery
   a. The renal vein is dissected from all surrounding perivascular tissues to a point medial to the adrenal vein. This maneuver provides maximal venous length for the vascular anastomosis.
   b. The renal artery is identified posterior to the renal vein and is dissected from the surrounding tissues using a Maryland dissector, right angle clamp, and suction-irrigator device.
6. Gerota's fascia is entered along the anterior aspect of the upper pole, exposing the renal capsule, as shown in Figure 150-5. With gentle displacement of the adrenal gland medially, meticulous dissection between the adrenal gland and the upper pole of the kidney is carried out. The use of clips, ultrasonic shears, or a bipolar vessel sealing device is beneficial in this area due to the highly vascular nature of the adrenal gland. If bleeding is encountered in this area, the application of gentle pressure is usually effective in obtaining hemostasis. In addition, renal artery branches to the upper pole of the kidney are not uncommonly encountered during this portion of the dissection, and one should be careful about inadvertent vascular injury.
7. The upper pole of the kidney is released by dividing medial and superior attachments. Lateral retraction of the upper pole using the suction-irrigator, while using ultrasonic shears to release attachments, can assist in these maneuvers. The remaining posterior and lateral attachments of the kidney are released last.
8. The kidney is rotated medially in order to expose the posterior surface of renal artery and vein, shown in Figure 150-6. Any remaining perihilar tissue is dissected posteriorly. It is important to verify that all attachments are divided before hilar clamping.
9. The specimen extraction incision is made before hilar clamping. A 5- to 7-cm Pfannenstiel incision is optimal, unless prior abdominal surgery and adhesions are prohibitive. The fascia is incised in the midline to expose the peritoneum. A 15-mm trocar is placed through the peritoneum and a laparoscopic extraction bag is placed behind the kidney in order to elevate the kidney by providing lateral traction.
10.
    a. A clip is placed on the ureter at the level of the pelvic brim and the ureter is divided proximally. In a well-hydrated patient, urine is usually seen

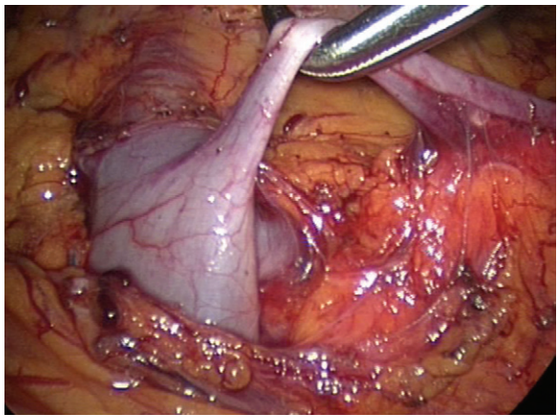

FIGURE 150-4. Dissection of the lumbar vein, with ligation and division, is required and is helpful in locating the renal artery posteriorly.

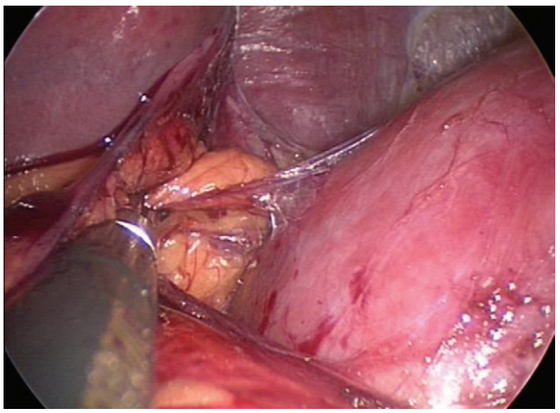

FIGURE 150-5. Gerota's fascia is entered along the anterior aspect of the upper pole to expose the renal capsule as the adrenal gland is retracted medially.

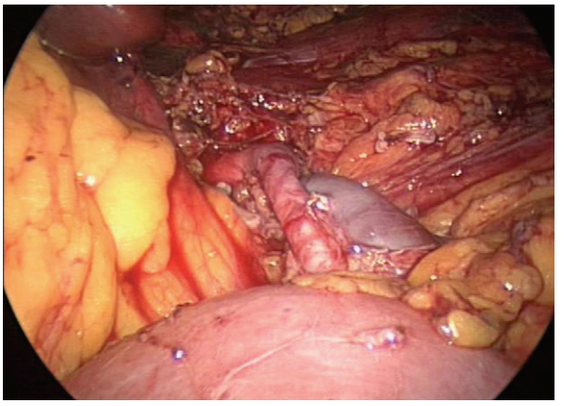

FIGURE 150-6. The kidney is rotated medially in order to expose the posterior surface of the renal artery and vein.

emanating from the proximal end of the ureter after transection.

b. An endoscopic TA linear stapling device is used to ligate the renal artery at its origin from the aorta. The artery is immediately divided lateral to the staple line using laparoscopic scissors. Figure 150-7 shows the kidney rotated medially and the TA stapler is placed at its origin from the aorta. *Note:* If bleeding arises through the staple line, a reinforcing clip may be applied to the renal artery stump.

Warning: Hem-o-lok ligating clips are contraindicated for use in ligating the renal artery during laparoscopic nephrectomies in living donor patients. Teleflex Medical (Research Triangle Park, NC), manufacturers of the Weck Hem-o-lok clip, issued a memo in April 2006 stating that the Hem-o-lok ligating clips may become dislodged following ligation of the renal artery after laparoscopic donor nephrectomy.

c. An endoscopic TA linear stapling device is used to ligate the renal vein medial to the adrenal and gonadal branches. The vein is then divided lateral to the staple line using laparoscopic scissors.

Alternative: When adequate length of the renal artery or vein is likely to be compromised due to the inability of the TA stapler to achieve the appropriate angle, an endoscopic roticulating GIA stapler may be used.

Warning: While exceedingly rare, stapler malfunctions have been reported. In such situations, an additional 12-mm trocar may be used to place a second stapling device. If possible, a second row of staples is applied more proximal. When sufficient vessel length does not permit this salvage method, open conversion may be required.

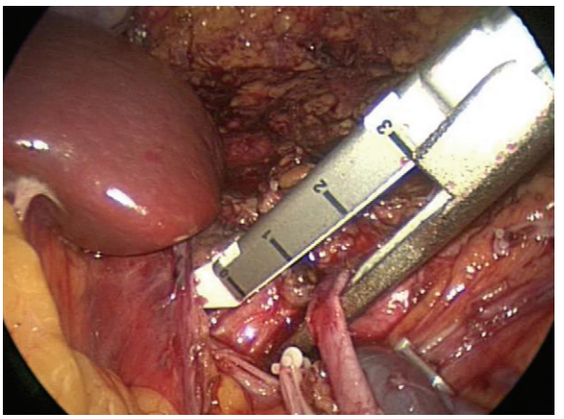

FIGURE 150-7. The kidney is rotated medially and the TA linear stapling device is placed at its origin from the aorta.

11. The specimen is placed in the laparoscopic extraction bag following division of the renal hilar vessels. The peritoneum is incised and the kidney is extracted and placed on ice. The kidney is then passed to the awaiting transplant surgical team.
12. After the extraction site fascia is closed, the abdomen is re-insufflated to 5 mm Hg and the peritoneal cavity is laparoscopically inspected for bleeding or visceral injury. After inspection, all trocar sites 10 mm or larger are closed with a fascial closure device. Finally, the pneumoperitoneum is evacuated and the skin incisions are closed.

Right Laparoscopic Donor Nephrectomy

Introduction: While the positioning and procedure for a right-sided donor nephrectomy is similar to a left-sided donor nephrectomy, some of the differences are highlighted below.

1. Position
   a. Patient: The patient is placed in a modified left lateral decubitus position (45 to 60 degrees). Positioning details described in the previous section should be modified to reflect the contralateral side.
   b. Trocar: The peritoneal cavity is insufflated to 15 mm Hg using a Veress needle or Hassan technique. Figure 150-1 illustrates the trocar placement for conventional laparoscopic donor nephrectomy (left and right), and hand-assisted laparoscopic donor nephrectomy (left and right). A 12-mm trocar is inserted under direct vision at the umbilicus and is used as the primary working port. The primary camera trocar (5 or 10 mm) is placed slightly right of midline, approximately 2 cm below the xiphoid process. A 5-mm trocar is placed at the midclavicular line, 2 cm below the level of the umbilicus. An accessory trocar (5 mm) is placed along the anterior axillary line approximately 2 cm below the costal margin and is used for liver retraction. A 0- or 30-degree laparoscope is used throughout the procedure.
2. The triangular ligament is incised to release the right lobe of the liver from the sidewall. If significant adhesions exist between the liver and anterior surface of Gerota's fascia, they are incised at this time using ultrasonic shears. A liver retractor is placed through the lateral subcostal port, and the liver is retracted

superiorly to expose the upper pole of the kidney. Several types of liver retractors are commercially available. The liver retractor is held in place by an assistant or a self-retaining device that is attached to the operating table.

3. The right colon is reflected medially using ultrasonic shears or an alternative thermal energy device as described for the left-sided procedure. A Kocher maneuver is performed to mobilize the duodenum medially. The peritoneal layer overlying Gerota's fascia is incised in a cephalad direction medially, and then in a lateral direction after reaching the upper pole of the kidney. The suction-irrigator is used to bluntly dissect medially, helping to develop the medial plane between the kidney and inferior vena cava and the superior plane between the kidney, adrenal gland, and liver.
4. The psoas muscle is exposed below the lower pole of the kidney. The ureter and gonadal vein are identified along the medial border of the psoas muscle. The ureter is dissected to the level of the iliac artery bifurcation. The ureter is not divided at this time. By gently elevating the ureter and lower pole of the kidney with an instrument, the medial border of the kidney is dissected in a cephalad direction to the level of the renal hilum. The correct plane of dissection lies lateral to the gonadal vein.
5. Gerota's fascia is entered along the anterior aspect of the upper pole, exposing the renal capsule. Meticulous dissection between the adrenal gland and the upper pole of the kidney is carried out. The right adrenal vein enters directly into the inferior vena cava and is not dissected during a right-sided donor nephrectomy.
6. Because of the anatomic limitations of a short right renal vein, a fervent attempt is made to salvage as much renal vein length as possible. Ligation and division of the ureter and renal hilum, and extraction of the specimen is performed as described previously. Figure 150-8 shows exposure of the right-sided renal artery and vein, with the ureter coursing toward the pelvis.

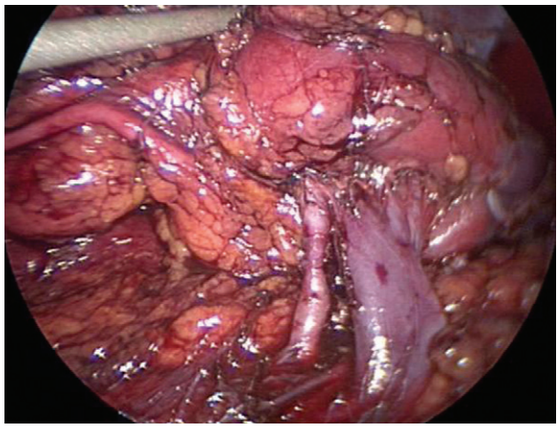

FIGURE 150-8. Exposure of right-sided renal artery and vein, with the ureter coursing toward the pelvis.

HAND-ASSISTED LAPAROSCOPIC DONOR NEPHRECTOMY

Introduction: Hand-assisted laparoscopy has transformed the field of operative urology over the past decade, and its applications have been applied to a variety of procedures since its introduction. In this technique, the surgeon's nondominant hand is introduced into the surgical field through a hand-access device while the dominant hand uses laparoscopic instruments that are introduced through standard laparoscopic trocars. The nondominant hand facilitates dissection by providing the surgeon with tactile feedback and manual retraction, while additionally allowing prompt hemostasis, vascular control, and rapid specimen extraction.

Left Hand–Assisted Laparoscopic Donor Nephrectomy

Trocar and hand-access device placement. A 7-cm left periumbilical midline incision is made for insertion of the hand-access device. The fascia and peritoneum are incised and the hand-access device is inserted. The abdomen is then insufflated to 15 mm Hg using a trocar placed temporarily through the hand-access device. The primary camera trocar (5 or 10 mm) is placed under laparoscopic surveillance slightly left of midline, approximately 2 cm below the xiphoid process. The primary working trocar (12 mm) is placed at the mid-clavicular line, 2 cm below the level of the umbilicus. An accessory 5 mm trocar, placed along the anterior axillary line approximately 2 cm below the costal margin, may assist with lateral retraction of the kidney. At the conclusion of the procedure, the specimen is manually extracted via the hand-access device incision. Figure 150-1 illustrates the trocar placement for conventional laparoscopic donor nephrectomy (left and right), and hand-assisted laparoscopic donor nephrectomy (left and right).

Right Hand–Assisted Laparoscopic Donor Nephrectomy

Trocar and hand-access device placemen: A 7-cm muscle-splitting Gibson incision is made in the right lower quadrant for insertion of the hand-access device. The fascia and peritoneum is incised and the hand-access device is inserted. The abdomen is then insufflated to 15 mm Hg using a trocar placed temporarily through the hand-access device. The primary camera trocar (5 or 10 mm) is placed under laparoscopic surveillance slightly right of midline, approximately 2 cm below the xiphoid process. The primary working trocar (12 mm) is placed at the midline, just above the umbilicus. An accessory trocar (5 mm), placed along the anterior axillary line approximately 2 cm below the costal margin, may assist with liver retraction. At the conclusion of the procedure, the specimen is manually extracted via the hand-access device incision. Figure 150-1 illustrates the trocar placement for conventional laparoscopic donor nephrectomy (left and right), and hand-assisted laparoscopic donor nephrectomy (left and right).

Adjunctive Measures Used During Laparoscopic Donor Nephrectomy

The pneumoperitoneum created during laparoscopic surgery can have transient negative effects on urine output and renal function. This is cause for concern because low urine output in the donor may lead to delayed graft function in the recipient. Therefore certain measures during laparoscopic donor nephrectomy have been described to promote urine production and allograft function. Adequate hydration is mandatory, and many centers use loop or osmotic diuretics to promote a diuresis. Our preference is to administer one dose of 12.5 g of mannitol during the dissection of the gonadal and adrenal vein, and an additional 12.5 g of mannitol during renal artery dissection. Other groups have described the use of other combinations of mannitol and furosemide, as well as continuous infusions of mannitol and dopamine during laparoscopic donor nephrectomy.

The use of systemic heparin to prevent vascular thrombosis during donor nephrectomy remains controversial. An intravenous dose of 5000 IU, with or without protamine reversal (50 mg IV), is routinely advocated by many centers. However, recent literature suggests that the use of heparin, given either alone or with protamine reversal after the graft is removed, does not offer any clinical benefit in terms of preventing graft thrombosis or improving allograft function. Additionally, due to the potential for exacerbating hemorrhagic complications, some groups have abandoned this practice altogether.

Finally, in order to maintain adequate arterial blood flow during renal artery dissection, some surgeons advocate the use of topical application of papaverine (30 mg/mL solution, 10 to 20 mL total) to prevent arterial vasospasm.

Postoperative Considerations

The orogastric tube is removed at the completion of the procedure. A chemistry panel and complete blood count are obtained in the recovery room and on the first postoperative day. The Foley catheter is removed on the first postoperative day. A clear liquid diet is started on the first postoperative day and the diet is advanced as tolerated.

Commentary by

JEAN JOSEPH

At many centers, laparoscopic live donor nephrectomy has effectively replaced open donor nephrectomy. Surgeon preference dictates the technique used. Both hand-assisted and pure laparoscopic approaches are standard of care in experienced hands. Specimen retrieval time should not add to warm ischemia time, which would potentially affect graft function. I prefer a hand-assisted technique, where the specimen can be quickly retrieved once it is freed.

The uniqueness of a live donor nephrectomy is that it is being performed on a healthy, heavily screened individual performing an altruistic act. Proper skills acquisition is necessary to perform as safe a procedure as possible, resulting in a high-quality renal transplant, and provide the intended gift to the recipient.

Section XXII

KIDNEY: EXCISION

This page intentionally left blank

Chapter 151

Anatomy and Principles of Renal Surgery

MICHAEL L. BLUTE, SR. AND BRANT INMAN

RENAL ANATOMY FOR RENAL RESECTION

Anatomic Relationships of the Kidney (Fig. 151-1)

The renal hila are located roughly at the level of the L1 vertebra and move by approximately 3 cm with breathing. Anteriorly, the right kidney is related to the liver, duodenum, and ascending colon, whereas the left kidney is related to the spleen, pancreas, stomach, and descending colon. Posteriorly, both kidneys are adjacent to the muscles and nerves of the posterior abdomen as well as the diaphragm, pleura, and lungs. These are the key structures that can be injured during renal surgery.

Surgical Planes of the Kidney (Fig. 151-2)

Safely approaching the kidney during surgery requires a detailed knowledge of the normal anatomic planes that separate the structures of the retroperitoneum. The kidney may be approached through two separate planes: through the anterior pararenal space and through the posterior pararenal space. The posterior pararenal space is usually fat filled while the anterior pararenal space is often empty. The *anterior pararenal space* is best accessed by incising the *posterior parietal peritoneum* though the *white line of Toldt*. The white line of Toldt is the site where the posterolateral reflection of the parietal peritoneum fuses with the ascending and descending mesocolon and the lateroconal fascia. Developing the anterior pararenal space involves mobilizing the colon off the *anterior renal fascia* (Gerota's fascia, Toldt's membrane, anterior perirenal fascia, prerenal fascia). Medially, the anterior renal fascia crosses the midline and fuses with its contralateral counterpart while laterally it fuses with the posterior renal fascia to form part of the *lateroconal fascia*. Superiorly, the renal fascial layers fuse with the diaphragmatic fascia. Controversy exists regarding the inferior continuation of the renal fascia in that some studies have shown pelvic fusion of the anterior and posterior layers of the renal fascia, whereas others have not. Once the anterior pararenal space is developed, the anterior renal fascia can be incised medially to access the renal hilum posteriorly. On the right side, colonic mobilization and development of the right anterior pararenal space is often coupled with small bowel mobilization, a procedure known as the *Cattel-Braasch maneuver*, a procedure that is commonly used for vena caval thrombectomy and retroperitoneal lymph node dissection.

The *posterior pararenal space* is developed by bluntly dissecting between the *posterior renal fascia* (Zuckerkandl's fascia, posterior perirenal fascia, retrorenal fascia) and the transversalis fascia that lines the posterior abdominal wall. The posterior and anterior renal fasciae are often collectively referred to as Gerota's fascia, but this is incorrect since Zuckerkandl first described the posterior layer, a fact recognized by Gerota himself. We prefer to avoid these eponyms altogether because they only create confusion. The posterior renal fascia is continuous medially with the psoas major and quadratus lumborum fasciae, laterally with the lateroconal fascia, superiorly with the diaphragmatic fascia, and inferiorly with the anterior renal fascia (see earlier). To access the renal hilum, the posterior renal fascia is incised medially and the vessels are found anteriorly. On the left side, colonic mobilization with development of the left posterior pararenal space is known as the *Mattox maneuver*, a procedure used to rapidly address the suprarenal aorta in trauma cases.

The compartment contained between the anterior and posterior layers of the renal fascia is called the *perirenal space*. The perirenal space contains the perirenal structural/anchoring fat, the kidney and its vessels, the ureter, and the adrenal gland (suprarenal gland). The renal fasciae form a natural barrier to the spread of urine, blood, infection, and malignancy. For this reason the entire perirenal space and its enveloping renal fascia, with the possible exception of the separate adrenal compartment, should be excised in radical nephrectomy.

When approaching the posterior pararenal space using either the flank or the lumbotomy approach, the musculofascial planes of the posterolateral abdomen must be negotiated. The three main muscles of the abdominal wall—the *external oblique*, *internal oblique*, and *transversus abdominis*—as well as the *transversalis fascia* all terminate posteriorly by inserting into the *thoracolumbar fascia* (lumbodorsal fascia). The thoracolumbar fascia has three distinct layers. In the flank the *posterior layer* (superficial layer) is derived from the aponeurosis of the

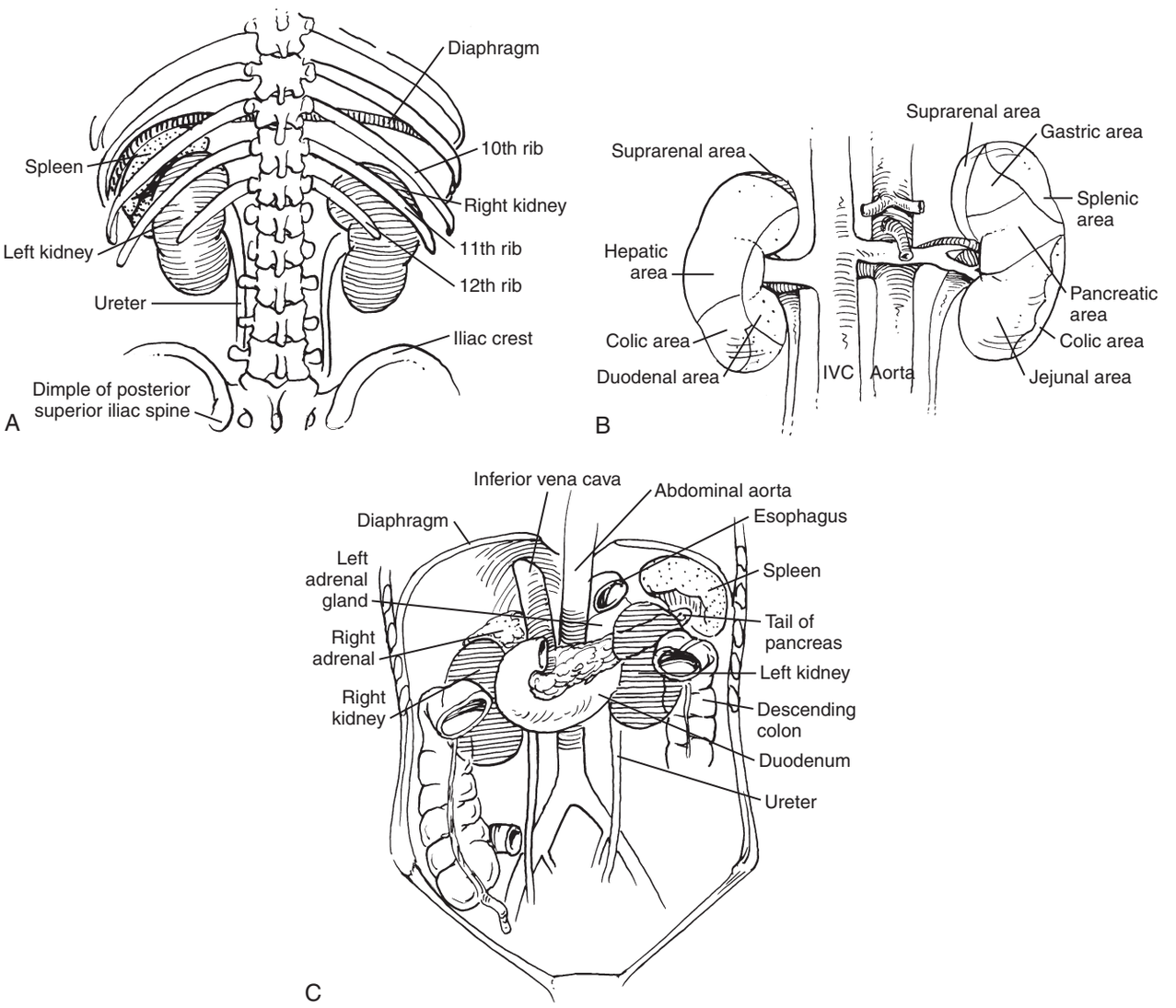

FIGURE 151-1. A, Normal kidney position. **B,** Organs adjacent to the kidneys. **C,** Relationship of the kidneys to adjacent organs.

external oblique (occasionally), internal oblique, latissimus dorsi, and erector spinae muscles and inserts onto the spinous processes of the vertebrae and the supraspinous ligament. The *middle layer* is derived from the aponeurosis of the transversus abdominis, erector spinae, and quadratus lumborum muscles. The middle layer of the thoracolumbar fascia inserts on the tips of the transverse processes of the vertebrae and is the boundary that separates erector spinae (sacrospinalis muscle) from quadratus lumborum. The *anterior layer* (deep layer) is the thinnest of the three layers and is derived from the aponeurosis of the transversus abdominis muscle, the transversalis fascia, and the fasciae of the psoas and quadratus lumborum muscles. This layer is the coating that covers the posterior abdominal wall and inserts onto the anterior aspect of the transverse processes of the vertebrae.

Renal Vasculature (Fig. 151-3)

The aorta and inferior vena cava (IVC) contribute the principal inflow and outflow vessels to the kidneys. Veins commonly encountered during renal surgery include the gonadal, lumbar, and adrenal veins. All of these veins can be safely ligated if troublesome bleeding occurs. Additionally, the minor hepatic veins from the caudate lobe of the liver can be ligated during IVC dissection for tumor thrombectomy. Arteries that are occasionally identified during renal surgery include the celiac trunk, superior mesenteric, inferior mesenteric, adrenal, lumbar, and gonadal arteries. Even though the celiac trunk and superior mesenteric artery should be preserved at all costs, the other arteries can usually be safely sacrificed if actively bleeding or otherwise compromising surgical resection of the kidney.

Although each kidney usually is fed by a single renal artery and vein, anatomic anomalies of the renal vasculature are much more common than usually appreciated and can pose problems for control of the renal pedicle. Anomalies of importance include multiple renal arteries in 25%, multiple renal veins in 15%, early division of the renal artery in 8%, circumaortic left renal vein in 5%, precaval right renal artery in 5%, and retroaortic left renal vein in 4%.

The renal artery forms an anterior division that typically carries three fourths of the blood and a posterior division

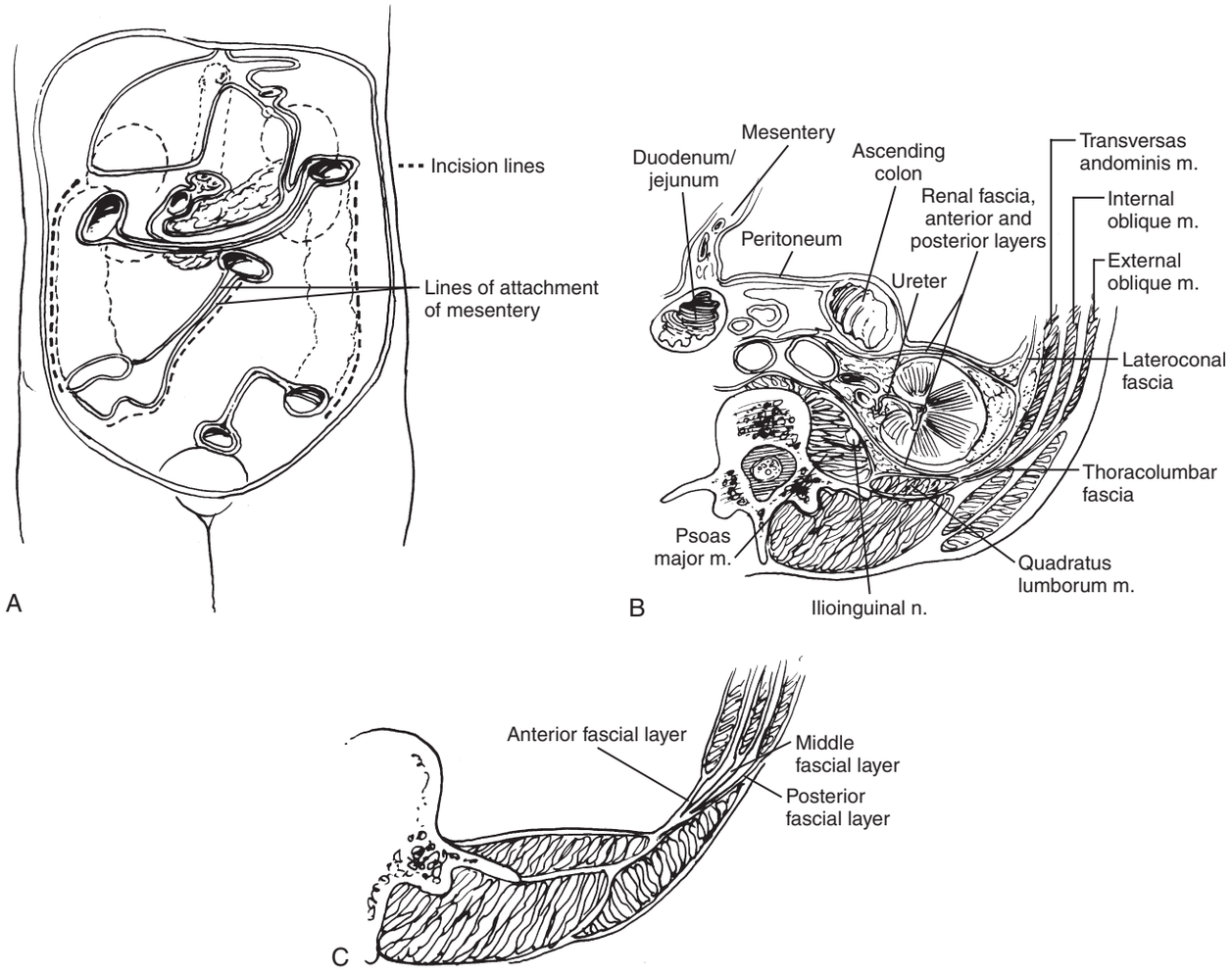

FIGURE 151-2. A, Lines of incision in the posterior parietal peritoneum. **B,** Cross-sectional view of the retroperitoneum. **C,** Layers of the thoracolumbar fascia.

that carries the rest. The *avascular plane of Brödel* between these divisions lies in the axis of the posterior calyces and can be used when performing nephrotomy for access to intraparenchymal lesions. Four to five segmental renal arteries are derived from the anterior and posterior divisions of the renal artery and may be dissected during nephron-sparing surgery. The *apical segmental artery* originates from the anterior division and supplies the upper pole of the kidney. The *anterior segmental artery* originates from the anterior division and feeds the anterior surface of the kidney. This artery often branches into an *anterior superior segmental artery* (upper segmental artery) and an *anterior inferior segmental artery* (middle segmental artery). An aberrant anterosuperior segmental artery is usually responsible for Fraley's syndrome (vascular obstruction of an anterior upper calyx). The *basilar segmental artery* (lower segmental artery) originates from the anterior division and supplies the lower pole of the kidney. The *posterior segmental artery* arises from the posterior division and supplies both the posterior aspect of the kidney as well as the majority of the renal pelvis and proximal ureter. The segmental arteries are end arteries without collateral circulation; therefore their division necessarily implies devitalization and ischemic necrosis on nonresected segmental parenchyma. During an operation, clamping or injection of indigo carmine into a segmental artery accurately outlines the segment supplied.

In contrast to the renal arterial system, the renal venous system is redundant and collateralized down to the level of the interlobular veins. Interlobular veins also drain into the subcapsular stellate venous plexus, which communicates with venous branches in the perirenal fat. Division of segmental renal veins therefore does not damage the renal parenchyma. Venous collateralization is important to consider when treating a process that is slowly obstructing the renal vein (e.g., a contralateral venous tumor thrombus). In such circumstances, progressive collateralization into the lumbar, adrenal, gonadal, inferior phrenic and hemiazygous venous drainage systems may allow ligation of the main renal vein distal to these collaterals without parenchymal compromise.

Renal Collecting System (Fig. 151-4)

The kidney is organized into lobes that are comprised of a *renal pyramid* and its associated *papilla* and *minor calyx* and the overlying renal cortex. Segmental renal arteries branch into *interlobar arteries* that enter the renal parenchyma from the renal sinus between the renal pyramids in the *columns of*

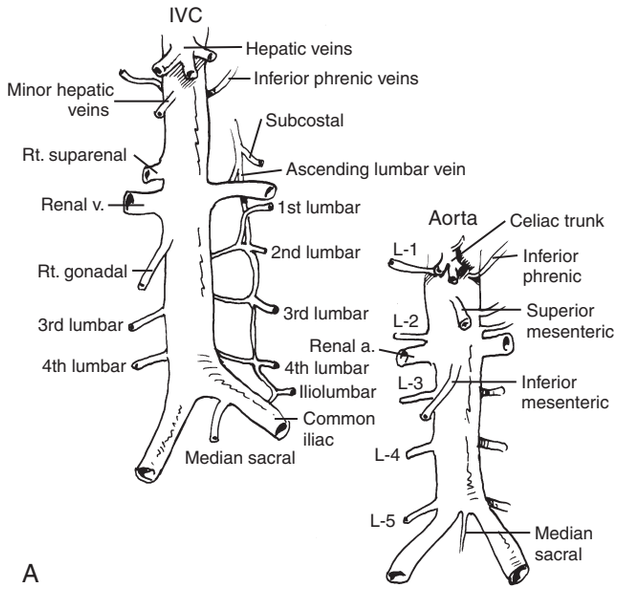

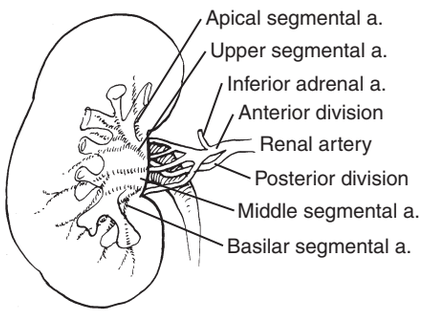

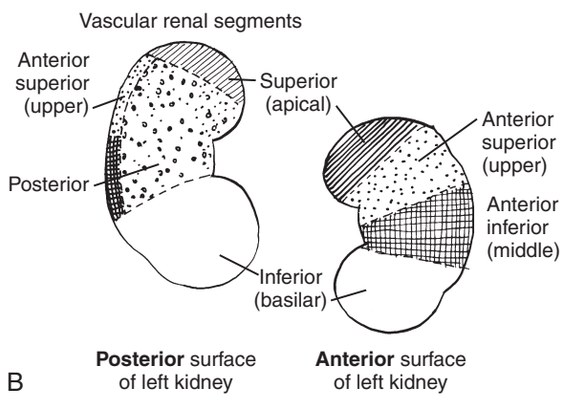

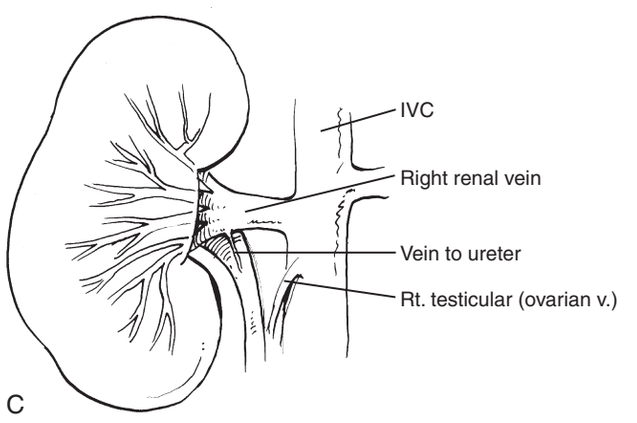

FIGURE 151-3. A, Branches of the aorta and inferior vena cava. **B,** Branches of the renal artery. **C,** Venous drainage of the kidney and collateralization.

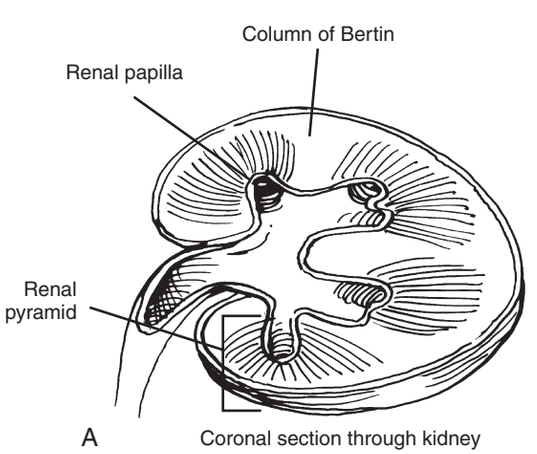

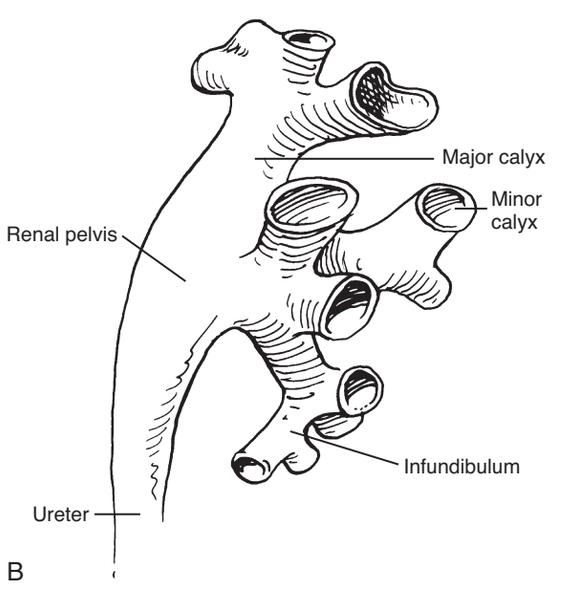

FIGURE 151-4. A, Coronal section through kidney. **B,** Renal calyceal anatomy.

Bertin. The renal collecting system starts in *Bowman's capsule*, proceeds through the *proximal convoluted tubule, loop of Henle,* and *distal convoluted tubule* to eventually arrive in *cortical collecting tubules*. The cortical collecting tubules coalesce into *collecting ducts* that extend into the renal pyramid to empty at its papillary tip. A typical kidney has seven to nine renal pyramids, each with its own papilla and minor calyx (the first collecting structure visible to the naked eye). *Compound papillae* occur when two pyramids drain into one minor calyx. The minor calyces are generally organized into an anterior column and posterior column with a solitary apical calyx in the midline. The minor calyces narrow into a neck called a *calyceal infundibulum*, which is of variable length and width. The confluence of two to three calyceal infundibula results in the formation of a *major calyx*, which typically numbers two to three per kidney. These major calyces then join to form the *renal pelvis,* which drains urine into the ureter. Calyceal anatomy is highly variable, both in number and in orientation, so the surgeon must carefully consider each patient's anatomy before declaring that there is collecting system pathology. The collecting system blood supply is derived from the renal artery with the posterior segmental branch often being the major supply to the renal pelvis.

The *ureter* then courses on top of the psoas muscle from the *ureteropelvic junction* to the bifurcation of the common iliac artery, where it enters the pelvis and makes it way to the posterolateral bladder. The ureter is clinically divided into proximal/abdominal (from the ureteropelvic junction to the common iliac artery) and distal/pelvic (from the common iliac artery to the bladder) segments. The blood supply of the proximal ureter arrives medially from small branches off the renal, gonadal, and aortic arteries, whereas that of the distal ureter arrives laterally from small arterioles originating from the iliac arteries and their superior vesicle, middle rectal, and inferior vesicle branches.

Lymphatic Drainage of the Kidney and Ureter (Fig. 151-5)

Renal interstitial fluid is drained by lymphatics that course in the columns of Bertin until they arrive at the renal sinus. In the renal sinus, the lymphatics coalesce into a few large trunks that exit the renal hilum alongside the renal blood vessels. On the right side, the renal lymphatic trunks drain into the paracaval, precaval, retrocaval, and interaortocaval lymph nodes, extending from the right crus of the diaphragm to the right common iliac artery. On the left side, the renal lymphatics drain into the paraaortic, preaortic, and retroaortic nodes, extending from the left crus of the diaphragm to the inferior mesenteric artery. On both sides, lymphatics may drain directly into the suprahilar nodes, retrocrural nodes, and thoracic duct, skipping the normal landing zones (although this is not common). The cisterna chyli is located on the right anterolateral surface of the L-1 vertebra, posterior to the right diaphragmatic crus, and medial to the aorta and azygous veins. It drains lymph into the thoracic duct.

Even though the lymphatic drainage of the renal pelvis is identical to that of the kidney, the drainage of the ureter is substantially more extensive because it parallels the ureteral blood supply. Hence, the proximal right ureter drains to the paracaval, interaortocaval, and presacral nodes, while the proximal left ureter drains to the paraaortic, preaortic, and presacral nodes. The distal ureters drain to the common iliac, external iliac, obturator, and internal iliac nodes.

Nerves of the Retroperitoneum (Fig. 151-6)

The major source of the somatic retroperitoneal nerves is the *lumbosacral plexus*. The lumbosacral plexus is composed of nerve fibers originating from the lumbar, sacral, and coccygeal plexuses of T_{12} to Co_1. The *subcostal* (twelfth intercostal

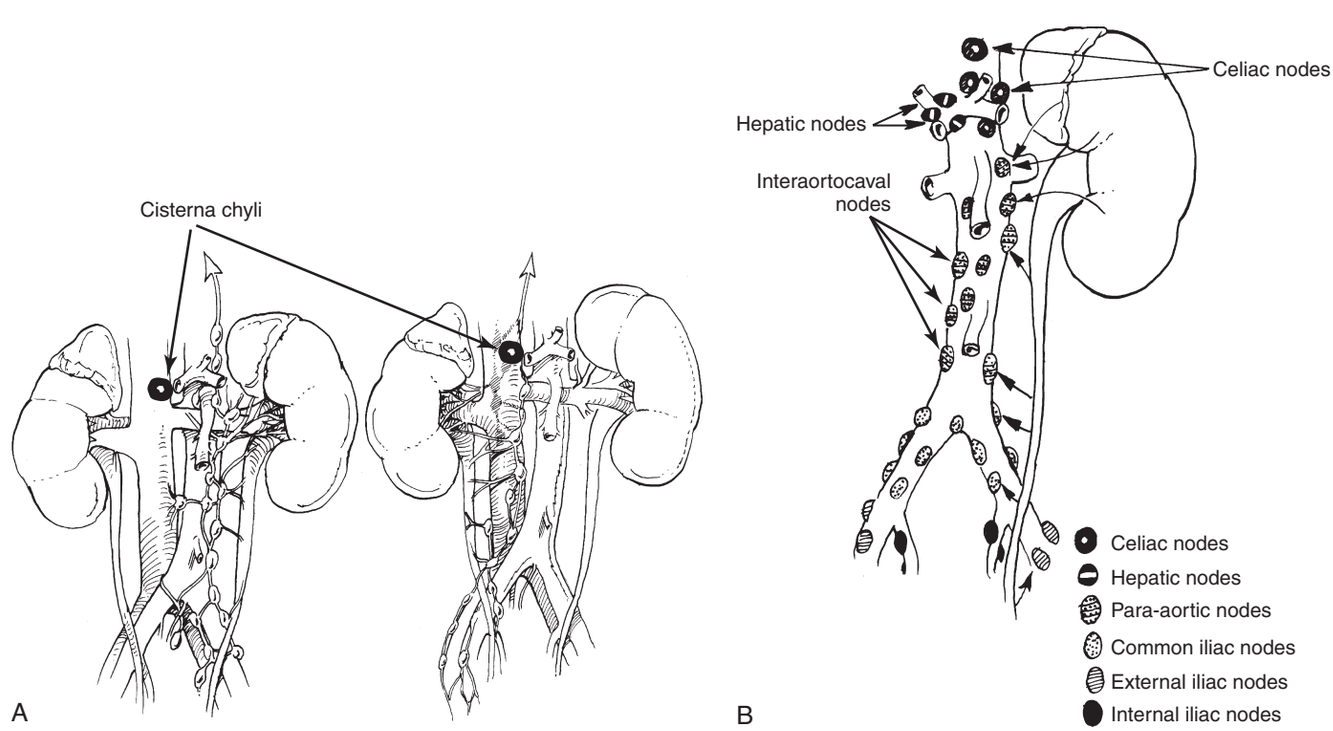

FIGURE 151-5. A, Renal lymphatic drainage. **B,** Ureteral lymphatic drainage.

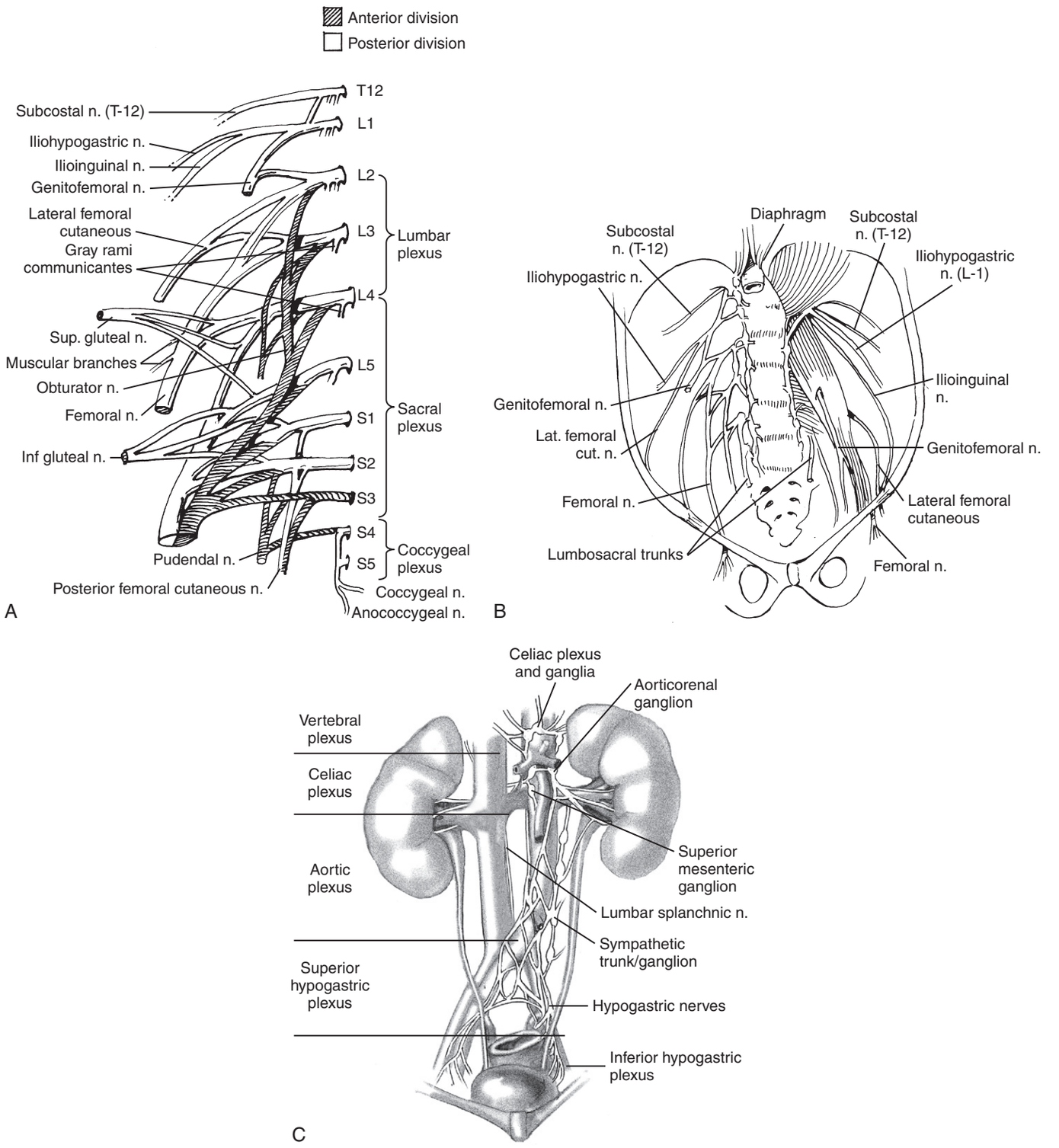

FIGURE 151-6. A, Lumbosacral plexus. **B,** Nerves of the posterior abdominal wall. **C,** Cross-sectional relationships of nerves to surrounding structures.

nerve), *iliohypogastric,* and *ilioinguinal nerves* are the first components of the lumbosacral plexus. These three nerves emerge from beneath the psoas muscle on top of quadratus lumborum and course inferomedially around the abdomen between the transversus abdominis and internal oblique muscles to provide motor and sensory innervation to the anterior abdominal wall.

The *lumbar plexus* contributes four branches that emerge from within the substance of the psoas muscle: the lateral femoral cutaneous, femoral, genitofemoral, and obturator nerves. While the *lateral femoral cutaneous nerve* and *femoral branch of the genitofemoral nerve* provide sensation to the anterior thigh and genitalia, the *genital branch of the genitofemoral nerve* supplies the cremaster and dartos muscles. The *femoral*

nerve supplies the hip flexors (psoas, iliacus, and pectineus) and knee extensors (sartorius, rectus femoris, vastus lateralis, vastus medialis, and vastus intermedius), and provides sensation to the anteromedial thigh. The *obturator nerve* supplies the adductors of the thigh (adductor longus, adductor brevis, adductor magnus, and gracilis) and a lateral rotator of the thigh (obturator externus).

The *sacral plexus* also contributes four branches to the lumbosacral plexus that emerge from within the piriformis muscle: the superior gluteal, inferior gluteal, sciatic, and pudendal nerves. The *superior and inferior gluteal nerves* provide motor innervation to the abductors and extensors of the hip (gluteus minimus, gluteus medius, and gluteus maximus). The *sciatic nerve* is the largest nerve in the body and is composed of the tibial and common fibular nerves. The *tibial nerve* supplies the flexors of the knee (semitendinosus, semimembranosus, biceps femoris, and popliteus) and the plantarflexors of the foot (gastrocnemius, soleus, plantaris, tibialis posterior, flexor digitorum longus, and flexor hallucis longus), and supplies sensation to the posterior leg. The *common peroneal nerve* hooks around the head of the fibula and supplies the dorsiflexors of the foot (tibialis anterior, extensor hallucis longus, extensor digitorum longus, and fibularis) and the evertors of the foot (peroneus longus and brevis), as well as sensation to the anterolateral leg. The *pudendal nerve* supplies sensation to the perineum. The *coccygeal plexus* supplies the coccygeus muscle and the skin overlying the coccyx.

Significant autonomic nerves are also found in the retroperitoneum. The *thoracolumbar sympathetic chain* receives input from T-1 to L-2 and courses in the medial groove between the psoas muscle and the vertebral column. Nerves from this chain supply most of the sympathetic outflow to the abdominal and pelvic organs and its branches join the various autonomic nerve plexuses. The *celiac plexus* is the largest autonomic plexus in the abdomen and surrounds the celiac trunk. It supplies the adrenal, kidney, renal pelvis, and ureter. Occasionally, a small *renal plexus* may surround the renal artery and supply the kidney. The *superior hypogastric plexus* is located on the anterior surface of the aorta near its bifurcation. The autonomic nerves that feed this plexus arrive from the right in the interaortocaval area and on the left from the paraaortic area. Paired *hypogastric nerves* leave the superior hypogastric plexus and course caudally to join the *inferior hypogastric plexus* on the lateral wall of the rectum near the tip of the seminal vesicles.

PERIOPERATIVE MANAGEMENT OF THE PATIENT UNDERGOING RENAL SURGERY

Perioperative laboratory testing: A urinalysis and culture should be obtained preoperatively, as should a serum creatinine and hemoglobin. Patients with renal tumors should be screened for hepatic dysfunction (Stauffer syndrome) and coagulopathies. Other laboratory testing is obtained only if clinically indicated. A postoperative creatinine measurement is useful for determining new baseline renal function and a hemoglobin test should be repeated if there was major bleeding.

Preoperative imaging: It is extremely unusual to proceed with renal surgery without some form of renal imaging for guidance. Cross-sectional imaging with computed tomography or magnetic resonance imaging is particularly useful for planning the operative course.

Dialysis counseling and preparation: Patients who are otherwise in good health with two normally functioning kidneys are at very low risk of requiring dialysis following nephrectomy. Patients with a functionally or anatomically solitary kidney should be referred to a nephrologist before surgery for dialysis counseling, as should be patients with a glomerular filtration rate less than 60 mL/min or significant proteinuria. If postoperative dialysis is deemed likely, placement of a dialysis central line or a peritoneal dialysis catheter can be done at the time of surgery (depending on the surgical pathology being treated).

Surgical site infection prophylaxis: The Centers for Disease Control and Prevention guidelines for surgical site infection risk assessment, prevention, and antimicrobial prophylaxis should be followed. A single preoperative dose of a cefazolin or clindamycin for patients undergoing renal surgery with negative urine cultures is prescribed. Active urinary tract infections should be adequately treated preoperatively.

Postoperative diet and ambulation: An abundance of evidence now exists to suggest that there is no benefit to keeping patients NPO (nothing by mouth) following elective abdominal surgery, including surgery directly on the gastrointestinal tract. Rather, allowing patients to ambulate as soon as they desire (including postoperative day 0) and to eat when they feel hungry results in lower complication rates and faster departure from hospital.

Gastrointestinal prophylaxis: Mechanical bowel preparation is not indicated for renal surgery unless (1) there is reason to suspect intestinal involvement of the pathologic process or (2) iatrogenic intestinal trauma is probable (e.g., multiple previous abdominal operations with a likely requirement for lysis of adhesions). Postoperative prophylaxis with an H_2-receptor blocker, proton pump inhibitor, or sucralfate is warranted if the patient is admitted to the intensive care unit or is not eating for prolonged periods.

Thromboembolism prophylaxis: No level 1 evidence exists to support the use of thromboembolism prophylaxis for renal surgery. However, the American College of Chest Physicians believes that extrapolation from other similar surgeries is reasonable and for major open urologic procedures advocates routine prescription of thigh-high thromboembolic deterrent (TED) stockings and/or intermittent pneumatic compression devices. Subcutaneous heparin or low molecular weight heparins should be administered to high-risk patients.

Respiratory prophylaxis: To prevent respiratory complications, low-risk patients should be managed postoperatively with deep breathing exercises, while high-risk patients should be prescribed incentive spirometry. When timing permits, enroll patient in a 4- to 6-week preoperative smoking cessation program because it reduces postoperative complications.

Instruments

Provide a basic set; a GU long set; a GU vascular set; a GU chest set, if taking a rib; renal pedicle clamps; Satinsky vascular clamps; bulldog clamps; self-retaining retractor; Balfour retractor; surgical clips; and suction drain.

Commentary by

PAUL RUSSO

A fundamental knowledge of basic kidney anatomy is essential for the urologic surgeon performing complex partial nephrectomy. For example, for renal tumors located in the upper or lower pole of the kidney, regional ischemia covering the area of the tumor can often be achieved by placing a bulldog vascular clamp on a segmental artery. This maneuver allows for the advantages of a bloodless field without the ischemic insult to the non–tumor-bearing elements of the kidney. Once common in anatrophic nephrolithotomy, knowledge of the avascular plane of Brödel allows ready access to renal sinus and is effective route for excision of endophytic renal cortical tumors with minimal collateral damage. Renal vein anatomy is more forgiving than renal artery anatomy during partial nephrectomy with the exception of hilar or endophytic tumors involving the major branch point of the renal vein as it tees off to each pole. A resection of a tumor at the branch point can leave no renal venous drainage and hence a radical nephrectomy would need to be performed. Lastly, in repair of the kidney after extensive partial nephrectomy, care must be taken not to exclude a renal papilla from a renal calyx and the collecting system. This can lead to a prolonged urinary leak as manifested by drainage from a perinephric drain but a retrograde pyelogram indicating no leak and an intact collecting system. Stenting will not ameliorate this problem and gradually, often over months, the papilla cease to function and the leak subsides.

Suggested Readings

Andersen, H. K., S. J. Lewis, and S. Thomas. 2006. Early enteral nutrition within 24h of colorectal surgery versus later commencement of feeding for postoperative complications. Cochrane Database Syst ev:CD004080.

Chesbrough, R. M., T. K. Burkhard, A. J. Martinez, and D. D. Burks. 1989. Gerota versus Zuckerkandl: the renal fascia revisited. Radiology 73:845.

Cook, D. J., B. K. Reeve, G. H. Guyatt, D. K. Heyland, L. E. Griffith, L. Buckingham, and M. Tryba. 1996. Stress ulcer prophylaxis in critically ill patients. Resolving discordant meta-analyses. Jama 275:308.

Geerts, W. H., G. F. Pineo, J. A. Heit, D. Bergqvist, M. R. Lassen, C. W. Colwell, and J. G. Ray. 2004. Prevention of venous thromboembolism: the Seventh ACCP Conference on Antithrombotic and Thrombolytic Therapy. Chest 126:338S.

Goldfarb, D. A., S. F. Matin, W. E. Braun, M. J. Schreiber, B. Mastroianni, D. Papajcik, H. A. Rolin, S. Flechner, M. Goormastic, and A. C. Novick. 2001. Renal outcome 25 years after donor nephrectomy. J Urol 166:2043.

Gore, R. M., D. M. Balfe, R. I. Aizenstein, and P. M. Silverman. 2000. The great escape: interfascial decompression planes of the retroperitoneum. AJR Am J Roentgenol 175:363.

Hall, J. C., R. A. Tarala, J. Tapper, and J. L. Hall. 1996. Prevention of respiratory complications after abdominal surgery: a randomised clinical trial. BMJ 312:148.

Koc, Z., S. Ulusan, L. Oguzkurt, and N. Tokmak. 2007. Venous variants and anomalies on routine abdominal multi-detector row CT. Eur J Radiol 61:267.

Mangram, A. J., T. C. Horan, M. L. Pearson, L. S. Silver, W. R. Jarvis, and the Hospital Infection Control Practices Advisory Committee. 1999. Guideline for the prevention of surgical site infection, 1999. Infect Control Hosp Epidemiol 20:247.

Moller, A. M., N. Villebro, T. Pedersen, and H. Tonnesen. 2002. Effect of preoperative smoking intervention on postoperative complications: a randomised clinical trial. Lancet 359:114.

Munro, J., A. Booth, and J. Nicholl. 1997. Routine preoperative testing: a systematic review of the evidence. Health Technol Assess 1:i.

Ozkan, U., L. Oguzkurt, F. Tercan, O. Kizilkilic, Z. Koc, and N. Koca. 2006. Renal artery origins and variations: angiographic evaluation of 855 consecutive patients. Diagn Interv Radiol 12:183.

Yeh, B. M., F. V. Coakley, M. V. Meng, R. S. Breiman, and M. L. Stoller. 2004. Precaval right renal arteries: prevalence and morphologic associations at spiral CT. Radiology 230:429.

Chapter 152

Simple Nephrectomy

MICHAEL L. BLUTE, SR. AND BRANT INMAN

INDICATIONS FOR SIMPLE NEPHRECTOMY

Simple nephrectomy is an operation that is a last resort for nonmalignant renal diseases that cannot be adequately managed otherwise. Indications for simple nephrectomy are shown in Table 152-1.

Preoperative Considerations

Assess preoperative renal function to determine whether postoperative dialysis might be required. Adequately hydrate the patient preoperatively and have blood available in case of a vascular accident. General anesthesia with endotracheal intubation is required.

The surgeon must decide preoperatively which surgical approach and incision to use. There are a number of options that are available, each with advantages and disadvantages (Table 152-2). The skilled surgeon will choose the approach and incision that best suits the pathology being treated and that minimizes patient morbidity.

THE FLANK APPROACH

Patient Positioning

For the flank position (kidney position, lateral decubitus position), place the patient on the operating table with the thorax in a true lateral orientation and the pelvis rotated posteriorly about 20 to 40 degrees. The lower leg should be fully flexed with the knee near the front edge of the table, the upper leg extended perfectly straight over a pillow (acting as a cantilever to tense the flank), and the space between the twelfth rib and the iliac crest centered over the

TABLE 152-1 INDICATIONS FOR SIMPLE NEPHRECTOMY

Active infection: Renal tuberculosis in a non-functioning kidney
Chronic pyelonephritis (end-stage reflux nephropathy)
Xanthogranulomatous pyelonephritis
Emphysematous pyelonephritis
Trauma: Life-threatening renal injury in a critically unstable patient
Nonreconstructible kidney
Urolithiasis: High stone burden in a nonfunctioning kidney
Transplantation: Donor nephrectomy
Pretransplant debulking of a large nonfunctioning kidney
Renal autotransplantation
Renovascular: Renovascular hypertension in nonfunctioning kidney
Refractory, nonreconstructible renovascular hypertension
End-stage kidneys: Painful cysts or hydronephrosis in nonfunctioning kidney
Severe hematuria in a nonfunctioning kidney
Severe proteinuria in a nonfunctioning kidney

TABLE 152-2

SURGICAL APPROACHES TO THE KIDNEY: ADVANTAGES, DISADVANTAGES

	Advantages	Disadvantages	Relative Indications	Relative Contraindications
Anterior approaches				
Subcostal	Early vascular control Ventilation Pneumothorax rare Extendible incision	Postoperative ileus Intestinal injury Adhesions and bowel obstruction	Anterior partial nephrectomy Colonic tumor involvement Multiple flank surgeries Very large kidney	Multiple abdominal surgeries
Midline abdominal	Early vascular control Repair of abdominal pathology Extendible incision Access both kidneys	Renal parenchymal exposure Postoperative ileus Intestinal injury Adhesions and bowel obstruction	Trauma Bilateral renal disease IVC thrombus Renovascular disease	Partial nephrectomy Multiple abdominal surgeries
Chevron	Early vascular control	Extensive muscle transection Postoperative ileus Intestinal injury Adhesions and bowel obstruction	Very large tumors IVC thrombus	Multiple abdominal surgeries
Lateral approaches				
Standard flank	Parenchymal visualization No peritoneal cavity breech Anterior or posterior pedicle	Rib resection and flank bulge Ventilation compromise Pneumothorax Vascular control Interaortocaval nodes Right adrenal access Pressure related complications	Posterior partial nephrectomy Infectious process Multiple abdominal surgeries Obese patient	Spinal deformity Cardiopulmonary disease Large anteromedial tumors
Thoracoabdominal	Parenchymal visualization IVC dissection Adrenal access	Extensive muscle transection Increased complications Pneumothorax Prolonged incision/closure time	Large right upper pole tumor IVC thrombus	
Posterior approaches				
Dorsal lumbotomy	No muscle transection Fast Minimal pain No flank bulge No rib resection	Vascular control poor	Small kidney Pediatric patient Previous flank incision	Tumor Trauma Large kidney

IVC, inferior vena cava.

break in the table. Flex the table until the flank muscles become tense. Optionally, raise the kidney bar before flexing the table. Place the lower arm on a padded arm board extending 90 degrees from the table and the upper arm on either a stack of pillows or a second padded arm board, also extending out 90 degrees. Fix the patient to the table by applying a 4-inch-wide cloth adhesive tape across the across the greater trochanter of the hip and another across the upper back and shoulder. Optionally, a suctionable bean bag may be placed beneath the patient to help maintain position. Tilt the entire table into the Trendelenburg position until the flank skin is parallel to the floor.

Since the weight of the body is being supported on a much narrower body surface area than in the supine and prone positions, there are several pressure points in the flank position that must be adequately protected to avoid musculoskeletal and neurologic injury.

1. The head must be supported so that the cervical spine is in alignment with the thoracic spine. This helps maintain adequate cerebral blood flow and prevents brachial plexus, sympathetic chain, and cervical spine injury.
2. Pad the lower ear to avoid pressure-induced ischemia.
3. An axillary roll should be placed under the lateral chest just below the axilla to take tension off the shoulder and brachial plexus. The term *axillary roll* is a misnomer in that this roll must not be placed in the axilla, which would result in neurovascular compromise. The roll must not be compressible and a 1-L bag of intravenous fluid wrapped in a towel is an inexpensive and excellent option for the roll. The roll must elevate the thorax and distribute the pressure over several ribs in the midaxillary line.
4. Shoulder supports should be avoided because they increase the risk for brachial plexus injury.
5. Both elbows should be padded circumferentially to avoid ulnar nerve compression on the arm boards.
6. The lower knee must be adequately padded to avoid peroneal nerve compression.
7. The upper foot must be supported so that the toes are not subject to pressure-induced ischemia.

The flank position can have several important physiologic sequelae. From a circulatory standpoint, lateral flexion can cause inferior vena cava stretching and kinking (especially when the right side is down) and will also cause venous blood to pool in the dependent extremities. When both of these factors are combined in an anesthetized patient, they can cause an immediate reduction in cardiac preload, which manifests as severe hypotension. In prolonged cases, dependent venous pooling can also lead to lower extremity edema and to the formation of a large third space, which requires intraoperative volume loading. When the patient is returned to a normal supine position postoperatively, the third space can be reabsorbed rapidly, leading to volume overload and cardiorespiratory compromise. From a respiratory standpoint, the flank position results in mechanical interference with chest movement during breathing. In particular, there is a 10% to 15% reduction in pulmonary compliance, tidal volume, and vital capacity in the flank position. The axillary roll has a secondary benefit of improving the compliance of the downside hemithorax. Postoperative atelectasis is a common finding in patients who underwent surgery in the flank position. Lastly, from a neuromuscular standpoint, the flank position results in temporary postoperative back pain in roughly 10% to 20% of patients. More serious injuries have been observed to the brachial plexus (resulting in motor and sensory defects of the upper extremity), the cervical sympathetic chain (resulting in Horner's syndrome), the ulnar nerve (resulting in motor and sensory defects of the hand), the common peroneal nerve (resulting in foot drop), and rarely the sciatic nerve (resulting in motor and sensory defects of the lower extremity).

Development of the Pararenal Space

Make a flank incision. Place a self-retaining retractor (good options include the Finochietto, Bookwalter, or Omni-Tract retractors) into the wound to expose the renal fascia.

Bluntly dissect the posterior layer of the renal fascia from the muscles of the posterior abdominal wall. Small fibrovascular bands in this posterior plane should be cauterized and divided as they are encountered. Next, bluntly dissect the anterior layer of the renal fascia away from the colonic mesentery and peritoneum, leaving a fascial compartment in which the kidney, adrenal gland and perirenal fat lie (Fig. 152-1). Exposing the renal fascia as described is helpful in preventing adjacent organ injury.

Renal Exposure and Mobilization

Open the renal fascia like a book along its lateral curvature, exposing the perirenal fat. Dissect the perirenal fat from the kidney using a combination of blunt dissection and electrocautery (Fig. 152-2). Do the easy parts of the renal dissection first, gradually working toward the more adherent

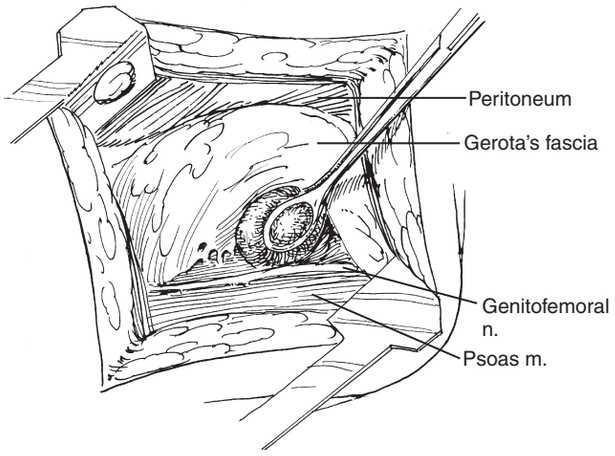

FIGURE 152-1.

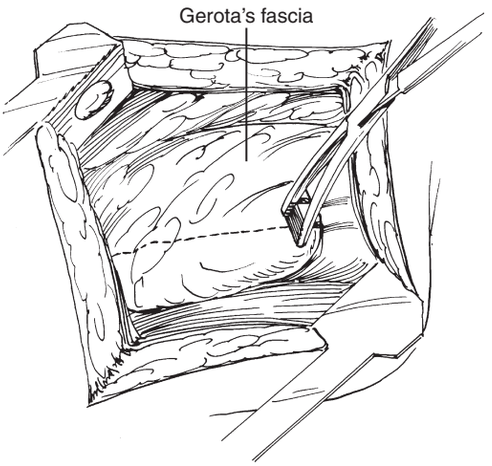

FIGURE 152-2.

areas. Try not to get beneath the capsule, which makes the remainder of the dissection more difficult. Watch for aberrant blood vessels, which are usually found near the poles and in areas resistant to blunt dissection. Posterior adherence to the psoas fascia can be very great and require inclusion of the psoas fascia with the specimen. If exposure of a large hydronephrotic kidney is difficult, puncture the kidney and aspirate its contents.

Dissect the adrenal gland from the upper pole of the kidney by maintaining the dissection plane directly on the renal capsule (Fig. 152-3). Free the superior attachments of the kidney to the spleen, pancreas, and liver to allow safe caudal retraction of the kidney.

Mobilize the lower pole of the kidney and isolate the ureter on the peritoneal side of the wound. Encircle the ureter with a vessel loop and retract it laterally (Fig. 152-4). The gonadal vein is usually found adjacent to the ureter and should be left medially because it is easily torn with lateral traction. Once the inferior pole is mobilized, the ureter can

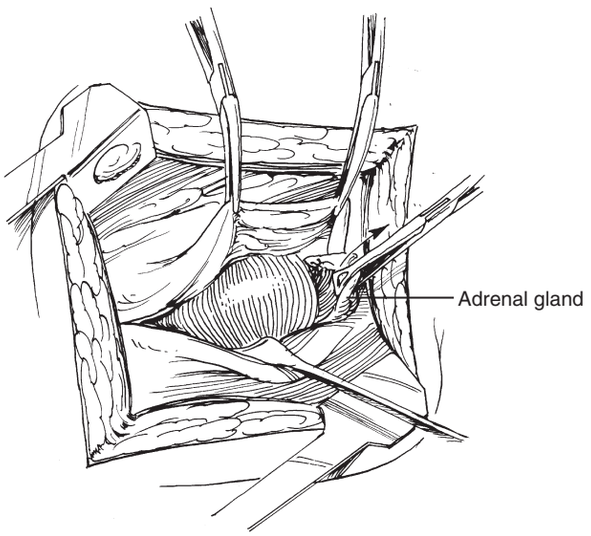

FIGURE 152-3.

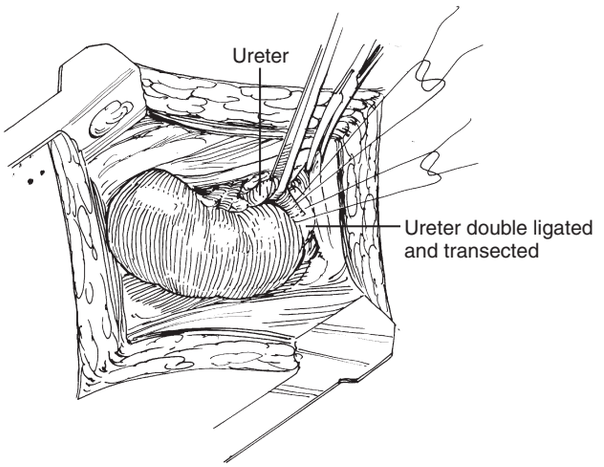

FIGURE 152-4.

be divided, although some surgeons prefer to wait until after division of the renal vasculature to divide it.

Renal Vasculature Control

Retract the kidney posterolaterally to visualize the renal hilum medially. Bluntly dissect the renal vein and artery away from hilar lymphatics and fat.

ANTERIOR SUBCOSTAL APPROACH

Patient Positioning

For the anterior subcostal approach, the patient must be placed in the supine position (dorsal decubitus position) with or without hyperlordosis. Hyperlordosis can be achieved by placing blankets underneath the lumbar spine, by raising the kidney bar slightly or by flexing the operating table over the lumbar spine. A small amount of hyperlordosis can be used to help open the thoracolumbar angle and improve the surgical access to the upper abdomen. However, it can also place stress on the lumbar spine resulting in postoperative lower back pain and can stretch the great vessels which reduces their blood flow. Hyperlordosis is not recommended in patients with spinal stenosis and should not exceed 10 to 15 degrees. In the supine position, the arms can be tucked alongside the torso or abducted 90 degrees or less from the body and placed on padded armboards. In either case, the elbows should receive extra padding to prevent ulnar nerve injury.

In the supine position, the weight of the body is borne principally by the occiput, dorsal torso, scapulae, sacrum, dorsal legs, and heels. All of these sites should be adequately padded so that the weight of the body is evenly distributed. The supine position can cause several important complications. From a cardiovascular perspective, supine positioning can result in supine hypotension (aortocaval syndrome) if excess adiposity or abdominal masses compress the great vessels. From a musculoskeletal perspective, low back pain is frequent, particularly in patients with scoliotic and kyphotic spine

deformities. Artificial hip and knee joints may also be placed under great stress in the supine position; this should be verified while the patient is awake. The slight flexion of the hip and knee that results from placing a small pillow under the knees can help reduce stress on the spine, hips, and knees. Lastly, the supine position can result in pressure ischemia of the skin. Pressure ischemia of the occiput can cause occipital alopecia while ischemia at the heels can cause heel blisters and plantar flexion problems of the calcaneal/Achilles tendon. Good padding of the heels and head prevents these complications.

Renal Exposure

Make a subcostal incision. Place a self-retaining retractor (good options include the Finochietto, Bookwalter, or Omni-Tract retractors) into the wound to expose the peritoneal cavity (Fig. 152-5). Inspect the peritoneal cavity for metastatic disease and other pathology.

Right: Incise the white line of Toldt from the hepatic flexure to the common iliac artery and reflect the ascending colon medially (Fig. 152-6). Divide the renocolic ligaments.

Left: Incise the white line of Toldt from the splenic flexure to the common iliac artery and reflect the descending colon medially (Fig. 152-7). Divide the renocolic ligaments.

Right: Expose then reflect the duodenum medially by means of a Kocher maneuver (Fig. 152-8).

Left: Divide the lienocolic and lienorenal ligaments to allow the spleen and pancreas to be safely mobilized cranially (Fig. 152-9). If the descending colon is not adequately mobile, the greater omentum can be freed from the distal third of the transverse colon, allowing for easy division of the lienocolic ligaments and improved medial reflection of the splenic flexure.

Renal Vasculature Control

Right: Use the anteromedial surface of the inferior vena cava as a guide to identify the short right renal vein. The right renal artery is usually located deep to the right renal

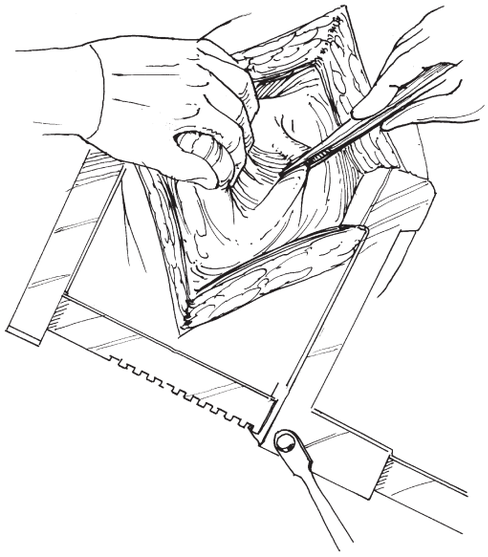

FIGURE 152-5.

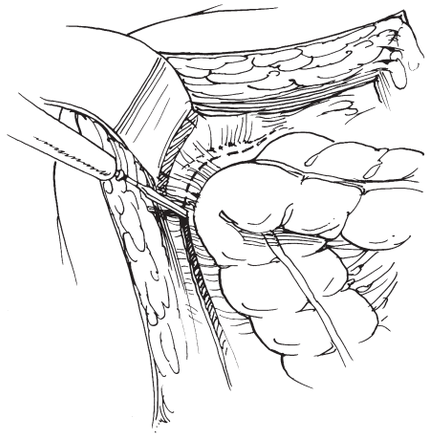

FIGURE 152-6.

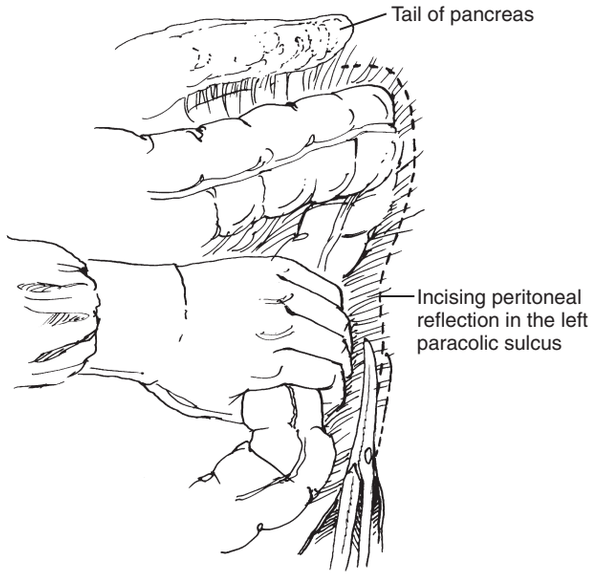

FIGURE 152-7.

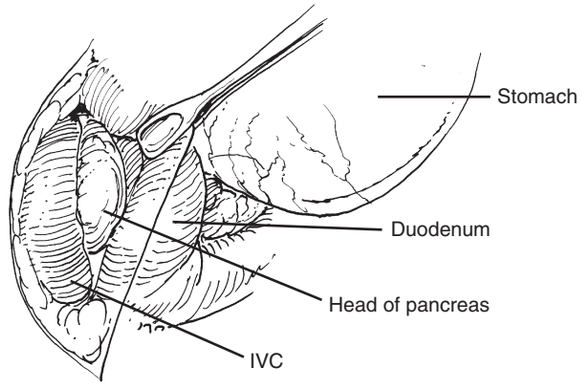

FIGURE 152-8.

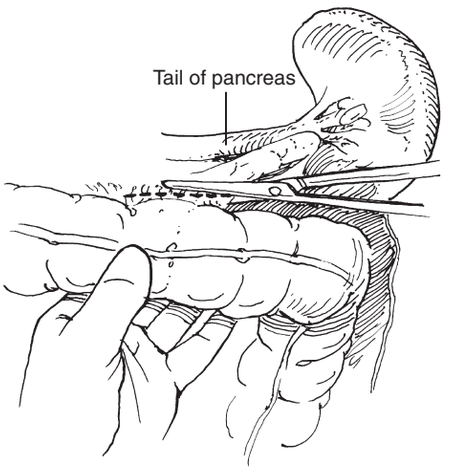

FIGURE 152-9.

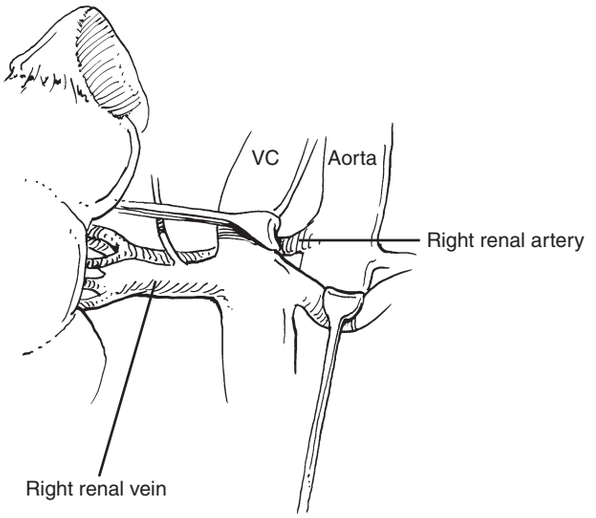

FIGURE 152-10.

vein and is sometimes easier to identify in the interaortocaval groove (Fig. 152-10). Control the vascular pedicle using the techniques described later in this chapter.

Left: Use the anterior surface of the aorta as a guide to identify the long left renal vein (Fig. 152-11). The left renal artery is usually located cranial and deep to the renal vein on the left lateral side of the aorta. Control the vascular pedicle.

Renal Mobilization

Dissect the adrenal gland from the upper pole of the kidney by maintaining the dissection plane directly on the renal capsule. Free the superior and posterolateral attachments of the kidney to allow safe caudal retraction of the kidney. Mobilize the lower pole of the kidney and divide the ureter.

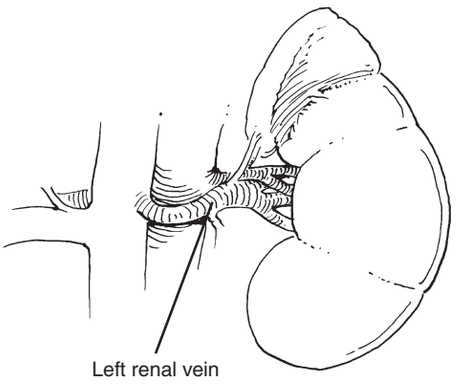

FIGURE 152-11.

KOCHER MANEUVER

For exposure of the right kidney and adrenal from a transabdominal approach, perform a Kocher maneuver to mobilize the duodenum and head of the pancreas to the left.

First have your assistant elevate the second portion of the duodenum to put tension on its retroperitoneal connections. Incise the retroperitoneal surface in a semicircle adjacent to the duodenum. Medially and caudally, continue the incision under the superior mesenteric artery and vein, and have it approach the right gastric artery above the duodenum (Fig. 152-12A).

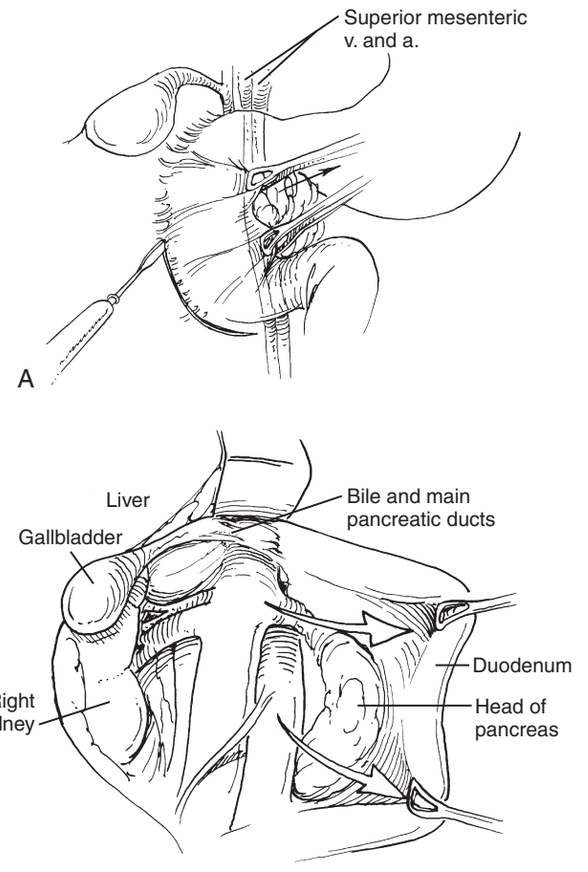

FIGURE 152-12.

Bluntly dissect the duodenum and head of the pancreas from the posterior body wall, and move them to the left, carrying the common bile duct and main pancreatic duct with them (see Fig. 152-12B).

THE MIDLINE TRANSPERITONEAL APPROACH

This approach is typically reserved for large renal masses, bilateral renal surgery, renal surgery requiring concomitant gastrointestinal or vascular surgery, and acute renal trauma. Normal supine positioning (described earlier) is used.

Make a midline laparotomy incision and insert a self-retaining retractor (Bookwalter or Omni-Tract work best).

Option A, nonemergent case: Divide the parietal peritoneum on the white line of Toldt lateral to the descending or ascending colon. Enter the plane between the peritoneum and the anterior renal fascia and bluntly separate these structures until the aorta or vena cava is approached. Enter the renal fascia near the hilum of the kidney and dissect the renal artery and vein (Fig. 152-13).

Option B, emergent retroperitoneal bleeding: Move the transverse colon cranially and the small bowel to the right. Incise the parietal peritoneum over the aorta from the ligament of Treitz superiorly to the inferior mesenteric artery inferiorly (Fig. 152-14). Rapidly control the left renal vein with a vessel loop and retract it superiorly. At the level of the left renal vein, control both the renal arteries on the lateral sides of the aorta with vessel loops. Next, expose the anterior IVC and control the right renal vein with a vessel loop. Once all the renal vessels are isolated and controlled, incise the white line of Toldt, mobilize the colon, evacuate the hematoma, and inspect the damaged kidney. If the defect is a renovascular injury or grade 5 parenchymal injury and is nonrepairable, nephrectomy is usually indicated.

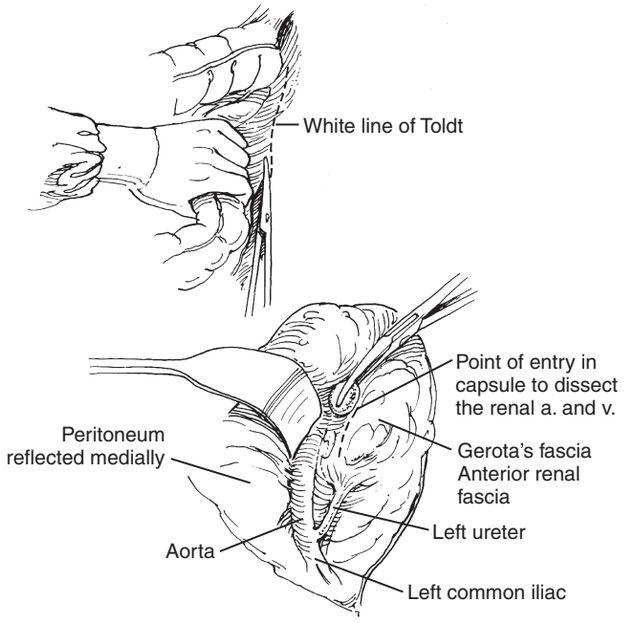

FIGURE 152-13.

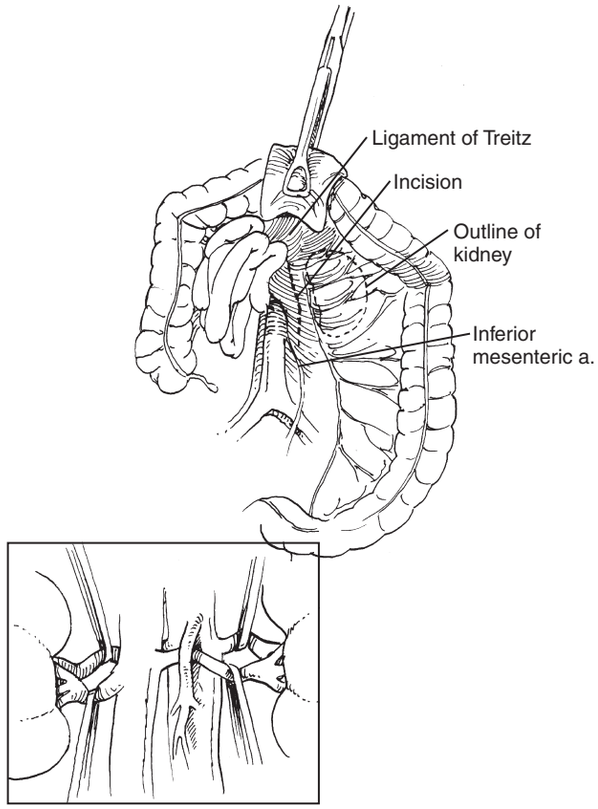

FIGURE 152-14.

Consider the possibility of delayed repair instead of nephrectomy in the hemodynamically unstable patient with an otherwise salvageable kidney.

Divide the renal pedicle using the methods described later in this chapter. Dissect the adrenal gland from the upper pole of the kidney by maintaining the dissection plane directly on the renal capsule. Free the superior and posterolateral attachments of the kidney to allow safe caudal retraction of the kidney. Mobilize the lower pole of the kidney and divide the ureter.

DORSAL LUMBOTOMY APPROACH

This approach is typically reserved for pediatric patients and for thin adults requiring bilateral nephrectomy. The key advantage of this approach is its low morbidity in that no muscle is transected. The key disadvantage of this approach is exposure, particularly to the renal hilum and its vessels, which is notably poor in obese and muscular individuals and patients with high-riding or enlarged kidneys.

Patient Positioning

To perform the dorsal lumbotomy, the patient must be placed in the prone position (ventral decubitus position, ventral recumbent position) with the operating table flexed by roughly 10 degrees ventrally. The patient is first anesthetized and intubated in the supine position and is later rolled into the prone position with the aid of several personnel. The

arms may be tucked lateral to the thorax or positioned and supported cranially in an overhead swimming position. The key to the prone position is adequate padding, in that the pressure points are very different than in the supine position.

1. To protect the face and endotracheal tube, a C-shaped face support, a doughnut-shaped foam pad, or a horseshoe head rest may be used. Depending on the padding used, the head may be rotated to one side or the other, or may face downward.
2. Ensure that the eyes and eyelids are protected from abrasion and compression to avoid ischemic optic neuropathy and blindness.
3. The downside ear should be padded to avoid pressure ischemia.
4. The humerus should not be forced into the axilla, which should be loose at all times to avoid axillary plexus injury.
5. The elbow should be flexed 90 degrees and padded circumferentially to prevent ulnar nerve injury.
6. The knees must be adequately padded to avoid pressure ischemia.
7. To avoid pressure ischemia to the toes, the ankles should be supported and the toes should not touch the table.
8. Breasts should be displaced medially and cranially if possible. Women who are pregnant or lactating, have breast implants, are obese or otherwise have true mammomegaly are at risk for lateral displacement and trauma to the breasts. Longitudinal torso frames/rolls designed to relieve pressure on abdominal viscera or a padding placed beneath the clavicles may be useful in such cases.
9. The anterior iliac crest and spines should be protected with padded iliac supports to prevent pressure ischemia to the pelvis and inguinal canals. Injury to the lateral femoral cutaneous nerve of the thigh can occur if padding is inadequate.
10. The penis and scrotum should not be compressed by the weight of the body.
11. Bowel and urinary stomas should not be compressed against hardware or bear the weight of the patient.

The prone position may be poorly tolerated by older adults, patients with cervical spine pathology, patients with unstable chest walls following trauma, and patients with a known thoracic outlet syndrome. Furthermore, the prone position has several important physiologic sequelae. From a cardiovascular standpoint, the thoracic outlet syndrome (due to an anomalous cervical rib or some other anatomic reason) can occur, particularly when the arms are located in the swimmer's position and the head is turned to one side. Similarly, closure of the retroclavicular space can occur in the prone position and the subclavian vessels and brachial plexus can be compressed. The mediastinum can also be squashed against the sternum, resulting in ischemic compression of the coronary arteries. Hemodynamically, the central venous pressure typically rises when in the prone position resulting in venous engorgement and increased surgical bleeding. Occasionally, compression of the IVC results in hypotension. From a respiratory standpoint, an increased amount of work is required to breathe when prone and the risk for displacement of the endotracheal tube is increased. The risk for venous air embolism due to central lines is also increased. From a neurologic standpoint, rotation of the head can modify the cerebral blood flow and place the patient at risk cerebral ischemia.

Make a dorsal lumbotomy incision and insert a Richardson retractor to visualize the posterior renal fascia (Fig. 152-15). Divide the costovertebral ligaments if additional exposure is needed.

Open the posterior renal fascia and mobilize the kidney completely from its attachments (Fig. 152-16). This allows the kidney to be brought into the wound.

Approach the renal vessels posteriorly, dissect them from the hilar fat and lymphatics, and divide them using the methods discussed later in this chapter (Fig. 152-17). Close the lumbodorsal fascia and skin.

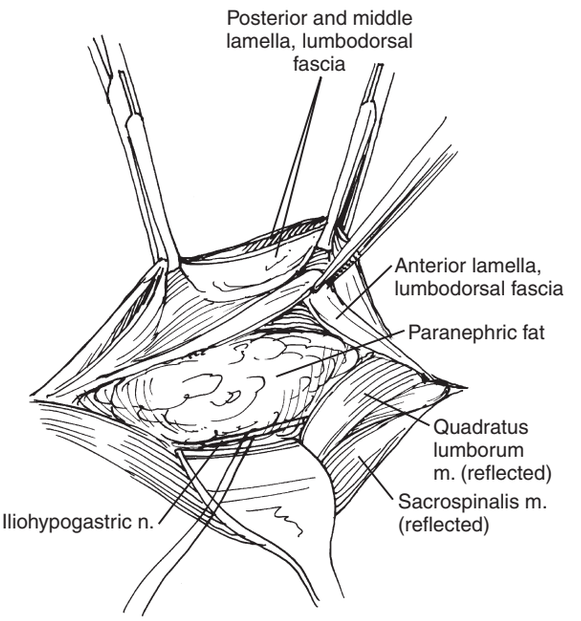

FIGURE 152-15.

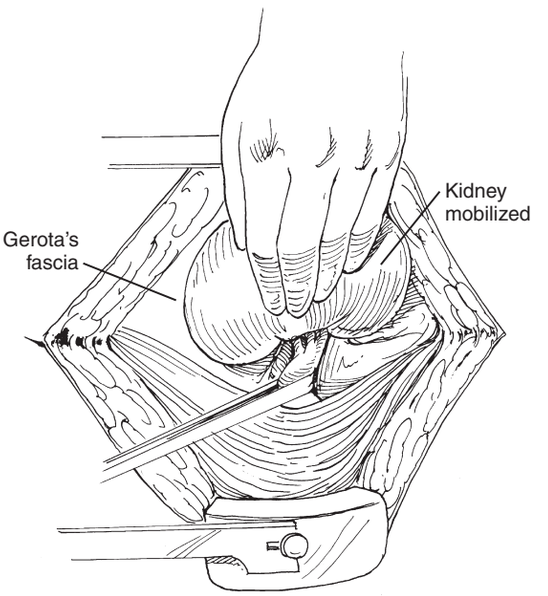

FIGURE 152-16.

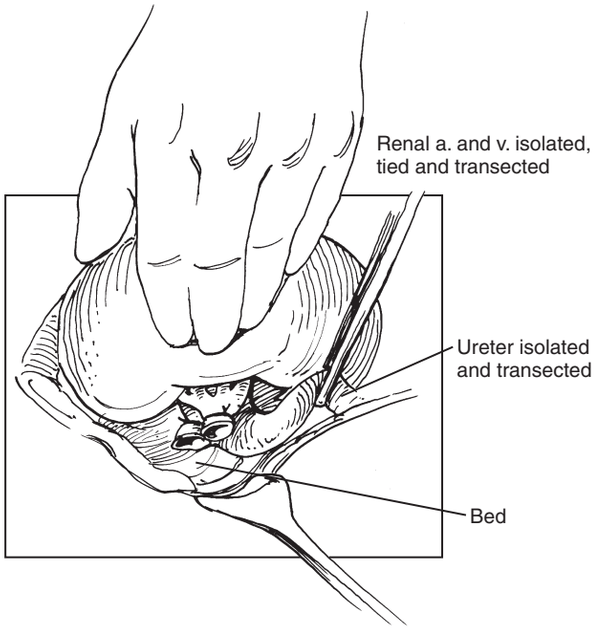

FIGURE 152-17.

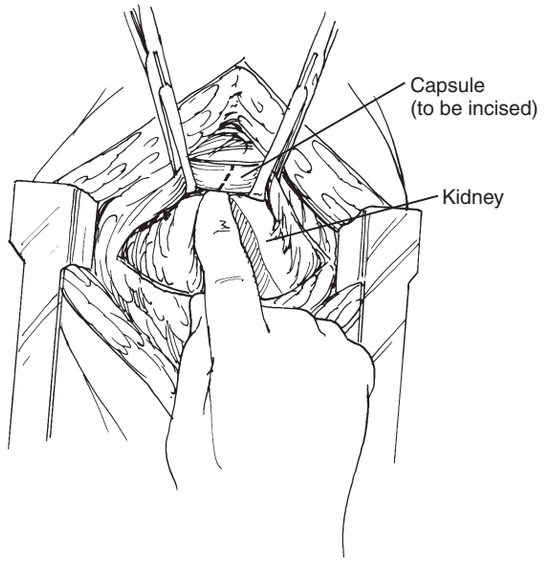

FIGURE 152-18.

SUBCAPSULAR NEPHRECTOMY

The subcapsular simple nephrectomy is a last resort method of removing the kidney that is reserved for cases in which the normal anatomic planes surrounding the kidney are obliterated by fibrotic tissue. The decision to use this technique is usually made intraoperatively and the most common reasons for its use include a previously operated kidney, chronic renal infection, and transplant nephrectomy.

If the kidney was previously operated, choose a different approach than previously used (flank if previously subcostal; subcostal if previously flank). Be careful in making the incision because the pararenal and perirenal fat are usually sparse in the retroperitoneum following previous renal surgery and the renal parenchyma can be inadvertently incised immediately beneath the transversalis fascia (Fig. 152-18). Work at separating the perirenal fat from the capsule with blunt and sharp dissection in the usual way before concluding that subcapsular nephrectomy is absolutely necessary.

Identify the ureter at the lower pole of the kidney and tag it with a vessel loop. Incise the perirenal fibrosis, including the capsule of the kidney, along the convex border of the kidney and grasp the edge with Allis clamps. Insert a finger beneath the renal capsule and bluntly peel it from the parenchyma on the anterior surface of the kidney. Dissect in this plane toward the hilum medially, incising the fibrotic capsule as needed to gain adequate exposure.

Hold the kidney posterolaterally while retracting the capsule anteromedially (Fig. 152-19). Palpate the renal vessels, which are often small because the kidney is diseased. As the dissection progresses, continue to incise the turned-back capsular flap directly toward the artery. If possible, dissect the renal artery first, even though it lies behind the vein. Ligate the artery in continuity and divide it. Treat the renal vein similarly. Alternatively, take the pedicle en bloc as described later in this chapter.

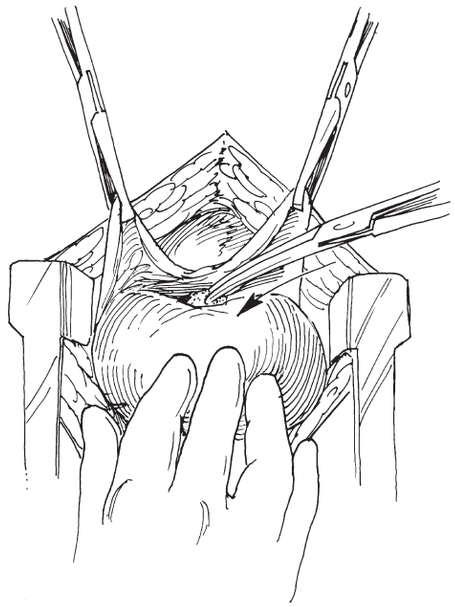

FIGURE 152-19.

Divide and ligate the ureter below the scar tissue (Fig. 152-20). Dissect cranially along the ureter until you reach the renal hilum that was previously dissected. Trim as much (devascularized) perirenal tissue as feasible but be careful not to injure the gonadal veins and great vessels that lie medially.

Once the inferior and medial portions of the kidney are mobilized, gentle caudal traction will displace the kidney into the operating field so that the superior border can be freed. Occasionally the fibrosis will be so thick that long curved clamps (e.g., Crawford) will be needed to clamp and cut the renal fibrosis from the adjacent structures. Leave a closed-suction drain before closing the wound.

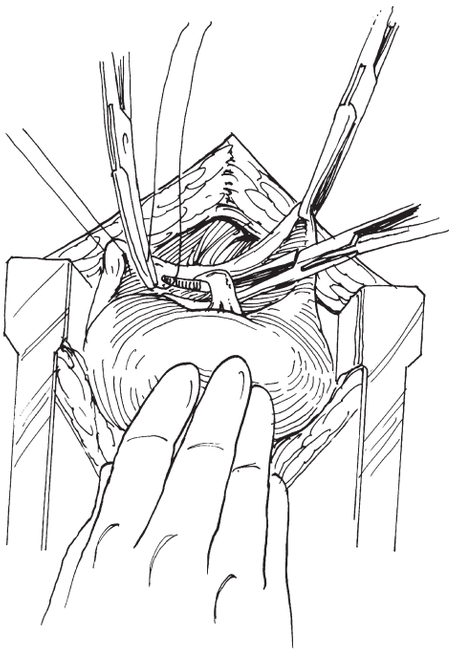

FIGURE 152-20.

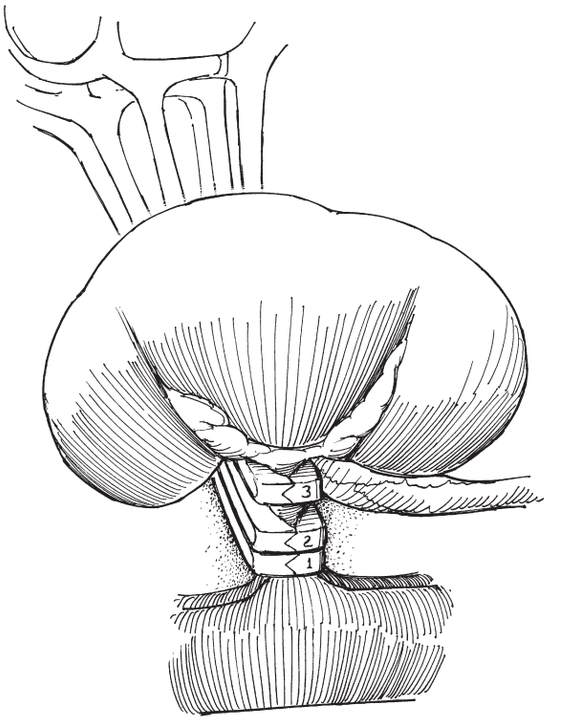

FIGURE 152-21.

CONTROLLING THE RENAL VASCULAR PEDICLE

With an arterial inflow of 1.2 L/min (roughly 20% of the cardiac output), the kidney receives the highest blood flow per gram of tissue of any organ in the body. An improperly controlled renal vascular pedicle can produce catastrophic and life-threatening quantities of bleeding.

Whole Pedicle Clamp Method

This is a simple method, especially for urologic surgeons without experience in handling large vessels, but it does carry an increased risk of damaging the duodenum or creating an arteriovenous fistula. It is also very useful when major bleeding is occurring and the kidney must be rapidly removed.

Bluntly (and blindly if necessary) isolate the pedicle (i.e., both the artery and vein) until it has a diameter of 2 or 3 cm (Fig. 152-21). Use a long, curved, locking vascular clamp (e.g., Satinsky, DeBakey) or a renal pedicle clamp (e.g., Crawford, Young, Mayo) to occlude the renal artery and vein. Pinch the pedicle between the first and second finger of the left hand, and guide the blades of the lowermost clamp around the pedicle and above the fingers while they keep neighboring structures away. This finger technique also ensures that sufficient pedicle remains to allow ligation and that the tip of the clamp extends far enough beyond the pedicle to engage the suture. Close the first clamp to the first notch on the ratchet. Place a second clamp above and adjacent to the first; under direct vision, divide the pedicle just below the upper clamp with scissors, leaving vascular stumps protruding from the lower clamp.

Preferred technique: Dissect the vessels within the clamp and individually suture-ligate them using a 2-0 silk suture on a tapered ½ circle needle such as an RB-1 needle (17 mm) or SH needle (26 mm) (Fig. 152-22).

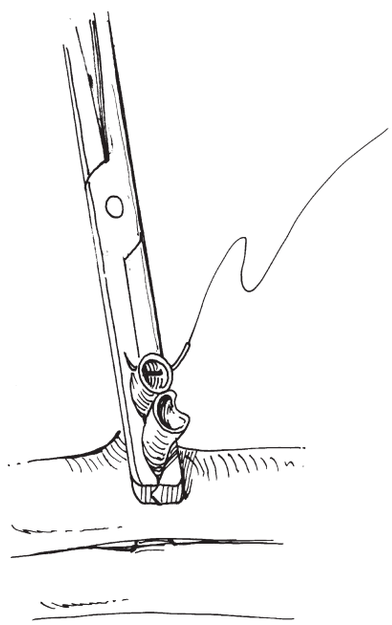

FIGURE 152-22.

Alternative technique: Loop a 0 silk suture below the lower clamp, and tie it as the assistant slowly releases the clamp (Fig. 152-23). It is usually prudent to tie the pedicle twice when this technique is used.

Cut First, Ligate Second Method

Double clamp the artery and vein separately and divide the vessels between the clamps (Fig. 152-24). If the right renal vein is too short to permit the accurate placement of

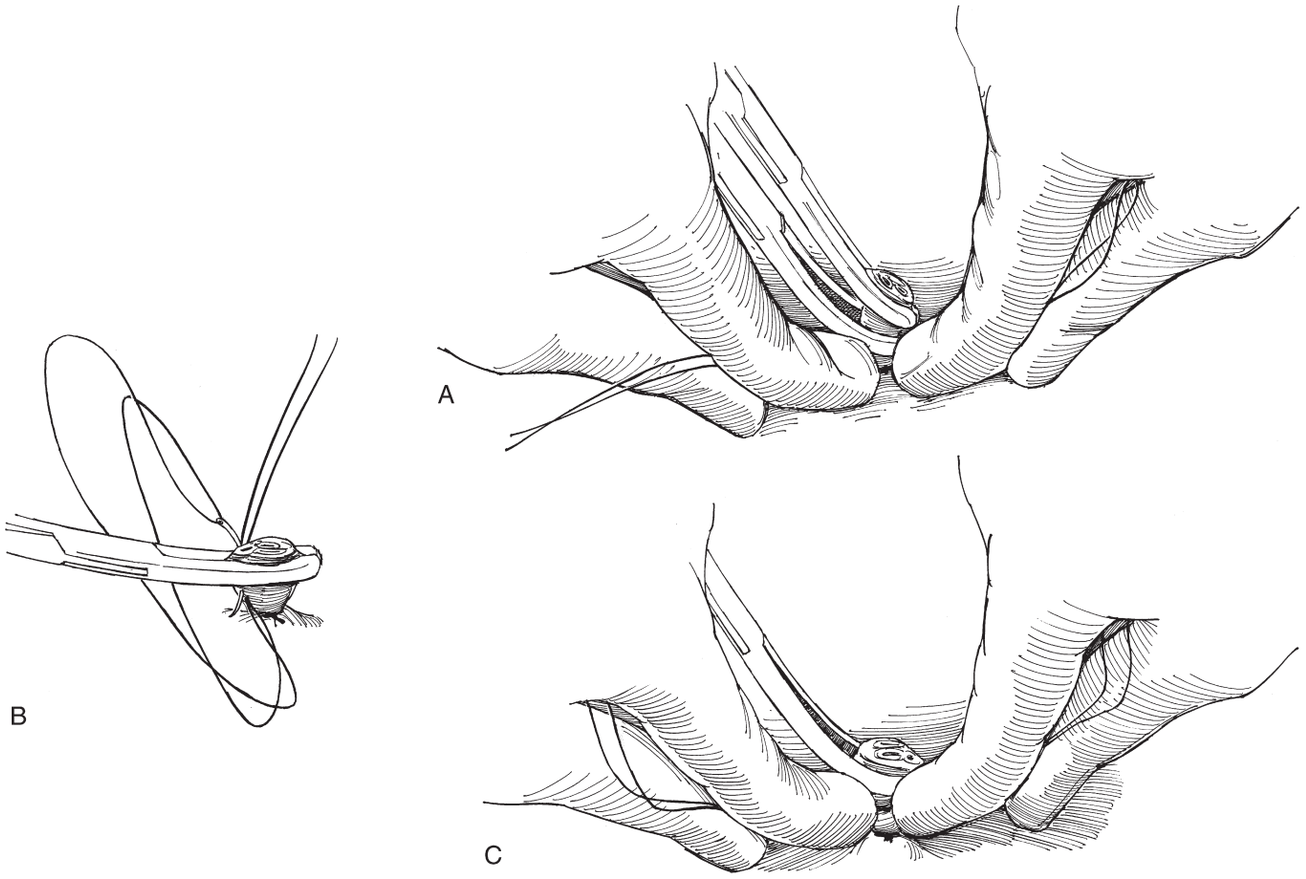

FIGURE 152-23.

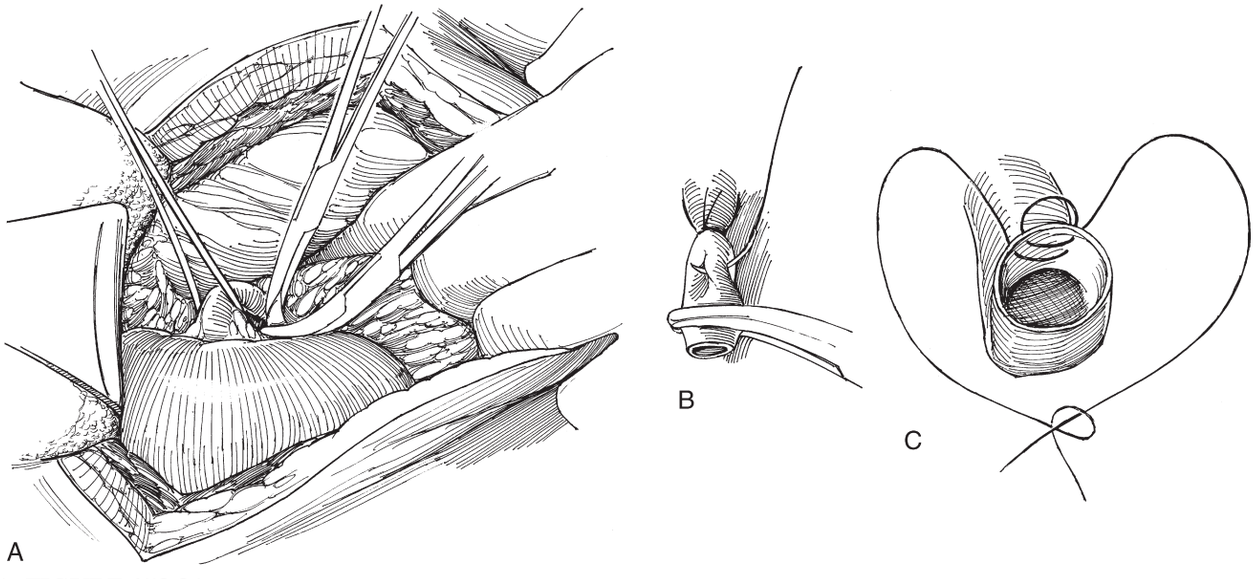

FIGURE 152-24.

two clamps, use a curved Satinsky clamp on the inferior vena cava, and oversew the cuff after dividing the vein. Tie the vessels with a 2-0 silk ligature or a 2-0 silk suture ligature.

Ligate First, Cut Second Method

Pass a right-angle clamp under the artery, and successively draw two ligatures around it. Use them to doubly ligate the artery with 2-0 silk. Do the same for the vein. Cut the ligated vessels with scissors or a long scalpel (Fig. 152-25).

Loss of Control of the Pedicle

Stay calm. Inform all personnel in the operating room that major bleeding is occurring and that their strict attention is required. Ask that two suction devices (typically Yankauer) be placed in the wound and that the surgical site be kept as clear of blood and clot as possible. Ask that vascular sutures be opened. We recommend using a 30- or 36-inch (75 or 90 cm) polypropylene (Prolene) suture, 3-0 or 4-0 size for IVC and aortic repairs and 4-0 or 5-0 for renal vessel repairs. We also recommend that the suture have double-armed tapered needles, ⅜ circle BB (17 mm) for arterial repairs (because they are less likely to fracture a calcific arterial plaque) and ½ circle RB-1 (17 mm) or SH (26 mm) for venous repairs. Also ask that vascular occlusion clamps be retrieved if they are not in the open instrument tray.

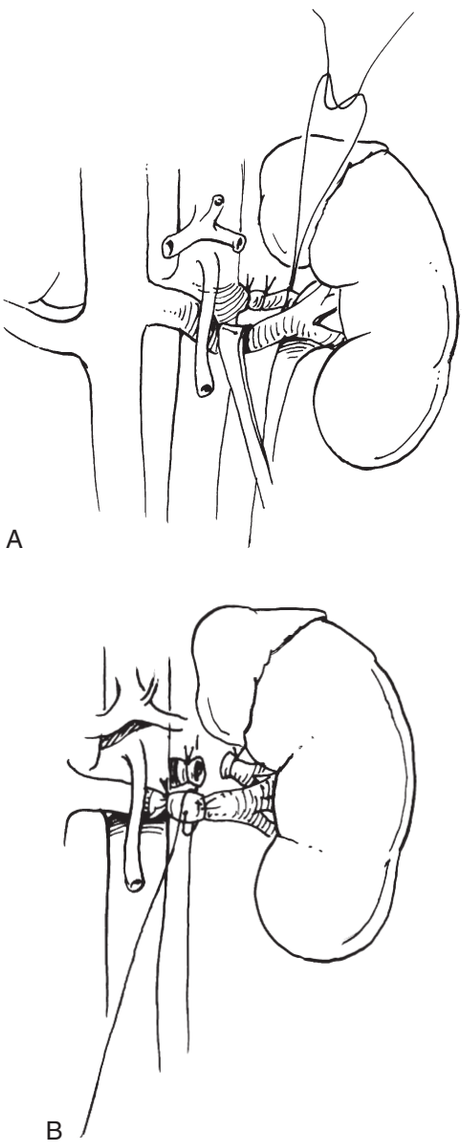

FIGURE 152-25.

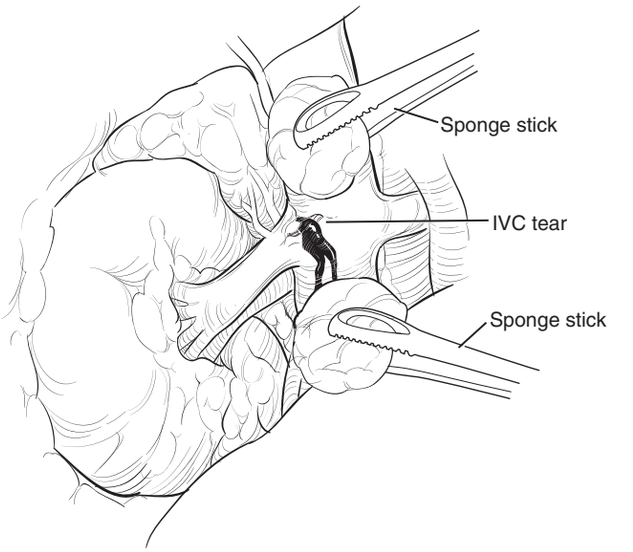

FIGURE 152-26.

Stop the active bleeding. This can be achieved by putting a fingertip on the vascular defect or by compressing the aorta and IVC with sponge sticks (Fig. 152-26). Do not clamp blindly, but suction, pack, retract, and dissect to get more exposure. If the renal artery is bleeding, have the assistant compress the aorta above the renal arteries and clamp the arterial stump with a vascular clamp. Try to visualize one end of the vessel, and put a suture in it. Tie the suture and hold it up as you put a stitch in the part that your assistant exposes next. Run the vascular suture up the defect and down again as your assistant slowly rolls the packs away and suctions.

If the bleeding is occurring from the IVC due to an avulsed or lacerated renal vein, hold a finger on the hole and grasp the hole with an Allis clamp. Pulling up on the clamp will normally stop the bleeding, allowing the defect to be sutured. This technique also works well for avulsed gonadal and lumbar veins.

WOUND CLOSURE

Control any outstanding bleeding vessels and investigate adjacent organs for signs of injury. Pay particular attention to the diaphragm and pleura as these tissues can easily be damaged with the incision and retraction required for the flank approach. Bubbling in saline irrigation indicates a pneumothorax. Although there is no conclusive evidence in humans proving that irrigating clean surgical wounds with saline or antibiotic solutions prevents surgical site infection,

saline irrigation is cheap, unlikely to be harmful, and potentially helpful; therefore it is recommended.

Placing a closed-suction drain (we use a 17-Frecnch Jackson-Pratt drain) following abdominal operations should not be routine because it increases cost and complications. However, there are instances when a drain should be left, including difficult cases with poor hemostasis, in patients with a bleeding diatheses, an infectious reason for nephrectomy, nephrectomy for trauma, and when adjacent organ injury occurs. The drain should be brought out through a separate stab incision, usually anterior and inferior to the flank incision.

Inject 0.5% bupivacaine around the intercostal nerves and into the incision site. This contributes significantly to postoperative pain management. Straighten the table and lower the kidney bar for wound closure. Numerous randomized trials have shown that laparotomy wounds should be (1) closed in one layer with (2) a slowly absorbable monofilament suture (we use a looped double-stranded 0 polyglyconate/Maxon suture on a GS-26 needle), and (3) a suture to wound length ratio of 4:1. It is not clear whether these principles also apply to flank and lumbotomy incisions, although the assumption seems reasonable. Take care not to injure any nerves during closure. The skin can be closed with staples, a 4-0 Monocryl subcuticular suture on a ⅜ circle reverse cutting needle (e.g., PS-1 or PS-3) or with bioadhesives, and a dry dressing should be applied.

Commentary by PAUL RUSSO

The traditional open partial nephrectomy utilized a large flank incision with resection of the distal third of the eleventh rib. Although this approach provided wide exposure to the kidney and retroperitoneum, patients complained of significant postoperative pain, a prolonged recovery, and for many an uncomfortable and unsightly flank bulge usually from muscle atony from nerve damage as opposed to fascial hernia. Canadian investigators described 70 patients who underwent formal flank or thoracoabdominal incision for RN (69%) or PN (31%). Fifty percent of patients experienced a flank bulge. Besides the associated discomfort and poor cosmetic appearance, paresthesias and neuralgic pain around the incision were also reported, often lasting for months postoperatively. For the surgeon, resection of the rib and closure of the large incision also added significant operating time. These significant wound difficulties were major drivers for the development of laparoscopic RN for small renal tumors and a normal contralateral kidney in the late 1990s.

An effective alternative to the classic flank incision or laparoscopic RN for small renal tumors is the supra-eleventh rib "mini-flank" retroperitoneal approach, which provides rapid and excellent exposure to the kidney without the need for a rib resection. With the patient in the standard flank position, an 8- to 10-cm extraperitoneal incision is performed between the bed of the tenth and eleventh. The latissimus dorsi, external oblique, and internal oblique muscles are transected and the transversus abdominis is divided in the direction of its fibers while preserving the intercostal neurovascular bundle. Using blunt dissection, the peritoneal cavity is mobilized medially, the perinephric soft tissues laterally, and the diaphragmatic fibers and pleura superiorly. A small incision in the plane between the soft tissues overlying the psoas muscle and Gerota's fascia is then bluntly developed, exposing the kidney, ureter, and ipsilateral great vessel (vena cava, aorta). The Bookwalter retractor (Codman and Shurtleff, Inc., Raynham, Mass.) is placed using the bladder blade attachment to retract the tenth rib and rib cage superiorly, while the short right-angle blade retracts the eleventh rib inferiorly. A malleable blade retracts the peritoneal cavity and its intestinal contents medially. Careful dissection is conducted to isolate the ureter, renal artery, and renal vein, each of which is surrounded by a different colored vessel loop. On the left side, division of the gonadal vein and adrenal vein liberates the renal vein more fully, facilitates identification and isolation of the renal artery, and allows for substantial upward mobilization of the renal hilum and easy access to the entire kidney. Dense lymphatic vessels that commonly surround the renal artery are ligated and divided further, facilitating upward mobilization of the kidney, which allows a decrease in venous bleeding during the tumor resection and allows easy identification and repairs of rents in renal sinus veins. After the renal hilum has been fully dissected, the upper pole of the kidney is separated from the adrenal, using blunt dissection between the two and perforating vessels and soft tissues are ligated and divided. The surgeon can then readily proceed with either total or partial nephrectomy.

Suggested Readings

Ceydeli A, Rucinski J, Wise L. (2005). Finding the best abdominal closure: an evidence-based review of the literature. Curr Surg 62(2):220-225.

Chesbrough RM, Burkhard TK, Martinez AJ, Burks DD. (1989). Gerota versus Zuckerkandl: the renal fascia revisited. Radiology 173(3):845-846.

Crawford ED, Skinner DG. (1982). Intercostal nerve block with thoracoabdominal and flank incisions. Urology 19(1):25-28.

Gurusamy KS, Samraj K. (2007). Routine abdominal drainage for uncomplicated open cholecystectomy. Cochrane Database Syst Rev (2):CD006003.

Gurusamy K, Samraj K, Davidson B. (2007). Routine abdominal drainage for uncomplicated liver resection. Cochrane Database Syst Rev (3): CD006232.

Gurusamy K, Samraj K, Mullerat P, Davidson B. (2007). Routine abdominal drainage for uncomplicated laparoscopic cholecystectomy. Cochrane Database Syst Rev (3):CD006004.

Lawson NW, Meyer DJ. (1997). Lateral positions. In Martin JT, Warner MA, eds. Positioning in anesthesia and surgery, 3rd ed. Philadelphia: WB Saunders.

Martin JT. (1997). The ventral decubitus (prone) positions. In Martin JT, Warner MA, eds. Positioning in anesthesia and surgery, 3rd ed. Philadelphia: WB Saunders.

Warner MA. Supine positions (1997). In Martin JT, Warner MA, eds. Positioning in anesthesia and surgery, 3rd ed. Philadelphia: WB Saunders.

Chapter 153

Radical Nephrectomy

MICHAEL L. BLUTE, SR. AND BRANT INMAN

INDICATIONS FOR RADICAL NEPHRECTOMY

Radical nephrectomy is an operation reserved for renal tumors that are not amenable to partial nephrectomy because of tumor or patient characteristics. Contemporary indications for radical nephrectomy are listed in Table 153-1. Note that large tumor size is not, per se, an indication for radical nephrectomy.

Preoperative Considerations

Preoperative tumor staging. All renal tumors that are suspicious for malignancy should be staged with an abdominopelvic computed tomography (CT) or magnetic resonance imaging (MRI) scan and a chest x-ray study. If any sign of metastatic disease is present in the chest or abdomen, a bone scan and head CT should be obtained. The cross-sectional imaging should be scrutinized for tumor thrombus, enlarged retroperitoneal lymph nodes, and the presence of embryologic abnormalities of the renal collecting system and vasculature.

Percutaneous renal biopsy: Although percutaneous renal biopsy has historically been controversial, this is changing. Indications include bilateral renal masses (rule out metastases), a new renal mass occurring in a patient with another known malignancy (rule out renal metastasis), a renal mass associated with extensive retroperitoneal lymphadenopathy (rule out, e.g., lymphomas, germ cell tumors), a renal mass associated with new systemic metastases (establish histologic tumor type for systemic therapy), complex renal cysts (rule out malignancy), and solid renal masses that will be managed nonoperatively with radiofrequency ablation, cryotherapy, or observation.

Preoperative angioembolization: Indications for renal tumor angioembolization include palliation of unresectable tumors, definitive treatment of large or symptomatic renal angiomyolipomas, and the preoperative infarction of large (>10 cm) tumors, symptomatic (i.e., bleeding) tumors, and tumors complicated by venous tumor thrombi. The goal of angioembolization before planned surgery is to make the procedure easier. With this in mind, potential advantages of preoperative angioinfarction include less blood loss, the ability to ligate the renal vein before the artery (important when extensive hilar disease is present), shrinkage of the primary tumor and tumor thrombus (improving resectability), development of edema in the surgical planes (improving dissection), and the formation of a better antitumor immune

TABLE 153-1 INDICATIONS FOR RADICAL NEPHRECTOMY

Patient characteristics	Renal tumor occurring in a nonfunctional kidney Patient would not tolerate complications of partial nephrectomy
Tumor characteristics	Large tumor replacing most of the kidney Central renal tumors in a patient with a normal contralateral kidney Numerous tumors involving most of the parenchyma Tumors associated with regional lymphadenopathy (debatable) Tumors associated with tumor thrombus Tumors associated with metastases (cytoreductive nephrectomy)
Other	Difficult partial nephrectomy requiring intraoperative conversion Patient preference

response that may possibly improve outcomes. Disadvantages include increased cost, painful postinfarction syndrome, risk of tumor lysis syndrome, risk for embolization of tumor thrombi, and risk for vascular trauma or an ineffective procedure.

Bilateral renal tumors: Percutaneous needle biopsy should be considered for diagnostic purposes. Bilateral renal surgery can be conducted in one operative setting (our preference) or can be staged as sequential operations. Bilateral partial nephrectomy with adrenal preservation is the best management technique if technically possible. One could also consider performing radical nephrectomy on one side and partial nephrectomy on the other. Bilateral radical nephrectomy is only indicated in about 5% of bilateral tumor cases and carries higher morbidity and mortality rates.

Adrenalectomy: Ipsilateral adrenalectomy is not required in every radical nephrectomy because the overall incidence of adrenal metastasis is only about 5%. Rather, it should be reserved for those cases in which the probability of adrenal involvement is sufficiently high. Because preoperative CT and MRI miss roughly 20% to 25% of adrenal metastases, one must consider clinical indicators of potential adrenal involvement. The probabilities of ipsilateral adrenal metastasis for different tumor characteristics are listed in Table 153-2. Contemporary indications for adrenalectomy are (1) diffuse renal involvement by tumor, (2) tumor size greater than 10 cm, (3) extrarenal tumor extension, (4) tumor thrombus, (5) positive lymph nodes, (6) metastases, (7) adrenal mass on imaging, and (8) direct tumoral invasion of adjacent organs (including the adrenal gland itself). Contrary to conventional lore, upper pole tumors do not require routine adrenalectomy.

Regional lymphadenectomy: Lymphadenectomy is not required in every radical nephrectomy in that the overall incidence of positive regional lymph nodes is only about 5%. Rather, regional lymphadenectomy should only be performed in those patients who have a reasonable chance of benefiting from it. The probability of regional node involvement for various clinical states is listed in Table 153-3. Current indications for regional lymphadenectomy are (1) enlarged nodes on imaging, (2) metastases (i.e., cytoreductive nephrectomy), (3) tumor size greater than 10 cm, (4) nuclear grade ≥ 3, (5) sarcomatoid histology, (6) presence of tumor necrosis, (7) extrarenal tumor extension, (8) tumor thrombus, and (9) direct tumoral invasion of adjacent organs (including the adrenal gland).

Adjacent organ involvement. If the colon or the spleen is involved, consider removing them because leaving tumor behind will not help the patient. Owing to the presence of its bilaminar capsule (Glisson's capsule), renal tumors do not usually invade the liver directly, which is why preoperative imaging suggesting hepatic invasion is often misleading. However, in the rare circumstance in which the tumor

TABLE 153-2 PROBABILITY OF IPSILATERAL ADRENAL METASTASIS

Tumor Characteristic	Probability of Adrenal Metastasis
Stage	
T1	1%
T2	3%
T3a	8%
T3b/c	11%
T4	45%
N+	15%
M+	26%
Location	
Upper pole	5%
Middle	3%
Lower pole	4%
Diffuse	10%
Bilateral	25%

TABLE 153-3 PROBABILITY OF POSITIVE REGIONAL LYMPH NODES

Tumor Characteristic	Probability of Positive Regional Lymph Nodes
Stage	
T1	1%
T2	4%
T3a	8%
T3b/c	9%
T4	27%
M+	27%
Nuclear grade	
1 or 2	1%
3 or 4	9%
Other features	
Sarcomatoid histology	28%
Tumor necrosis	11%

is actually invading the liver parenchyma, a hepatobiliary surgeon should be contacted to either perform a hepatic wedge resection or a right hepatectomy (usually done with the kidney en bloc).

Choice of incision: Several options exist for approaching the kidney and the benefits and disadvantages of each (see Table 152-2) should be considered before deciding on any particular case.

ANTERIOR SUBCOSTAL APPROACH, RIGHT SIDE

Place the patient in the supine position and proceed with an anterior subcostal incision (Fig. 153-1). Insert a Balfour or Bookwalter retractor and pack the liver and gallbladder superiorly. If the liver is large, incise its avascular right triangular ligament to make it easier to shift it superomedially. Inspect and palpate the abdominal viscera for metastases.

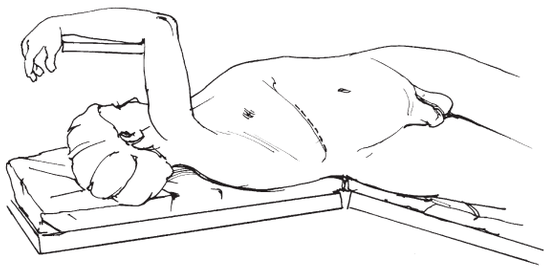

FIGURE 153-1.

Incise the posterior parietal peritoneum on the line of Toldt from the common iliac artery to the hepatic flexure (Fig. 153-2). Develop the anterior pararenal space by dissecting in the plane between the anterior renal fascia and the mesentery of the ascending colon. With large or inflammatory masses, the anterior pararenal space may be obliterated by tumor or occupied by numerous large collateral vessels, making this step tedious and difficult. It is important to stay out of the ascending mesocolon if possible because trauma to the right colic and ileocolic arteries (and their branches) can devitalize this segment of the colon. It is also important to keep the renal fascia intact to ensure a complete resection and to avoid tumor spillage. It is of little use to excise part of the tumor; complete removal provides the patient's only chance for cure.

Mobilize the hepatic flexure of the colon using sharp and blunt dissection (Fig. 153-3). The second part of the duodenum may be closely connected to the medial part of the tumor and the Kocher maneuver is useful for mobilizing it further medially and away from the mass. The duodenum is fragile and is in danger of injury, with necrosis and perforation as a consequence. Avoid using electrocautery around the duodenum, but, if necessary, light bipolar coagulation can safely achieve hemostasis.

Incise the anterior renal fascia on the medial aspect of the kidney and identify the inferior vena cava (IVC). Dissect anteriorly on the IVC, both cranially and caudally, until the left renal vein, right renal veins, and right gonadal vein are identified. Dissect the right renal vein and place a vessel loop around it so that it can be gently and atraumatically retracted (Fig. 153-4). Palpate the vein and IVC for evidence of tumor thrombus. Next, identify and dissect the right renal artery which is usually located deep and superior to the right renal vein on the lateral side of the IVC. If the

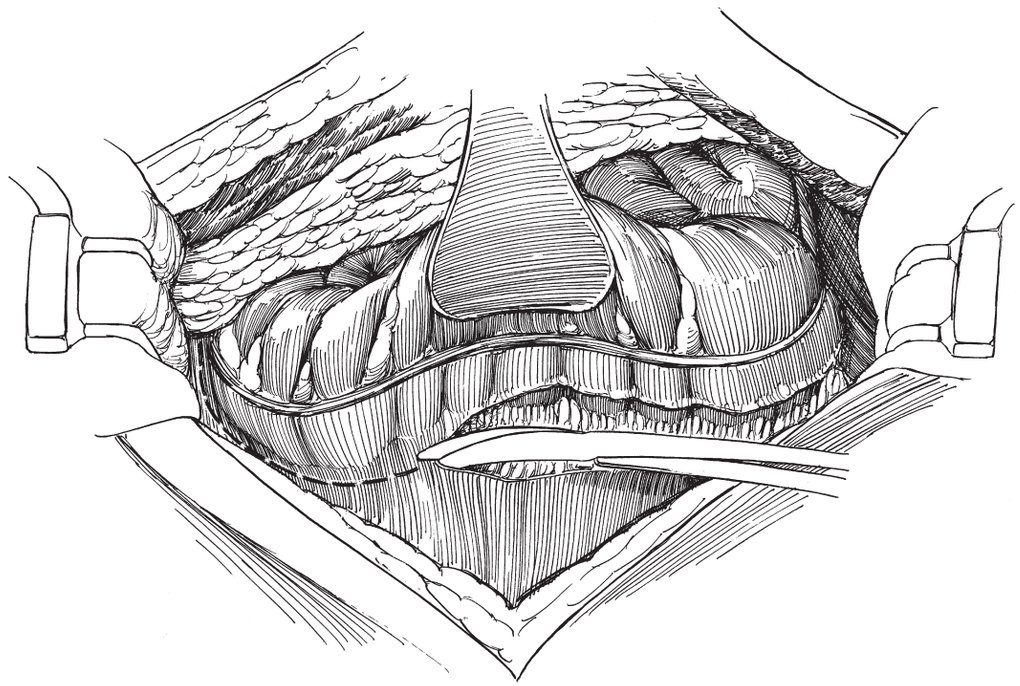

FIGURE 153-2.

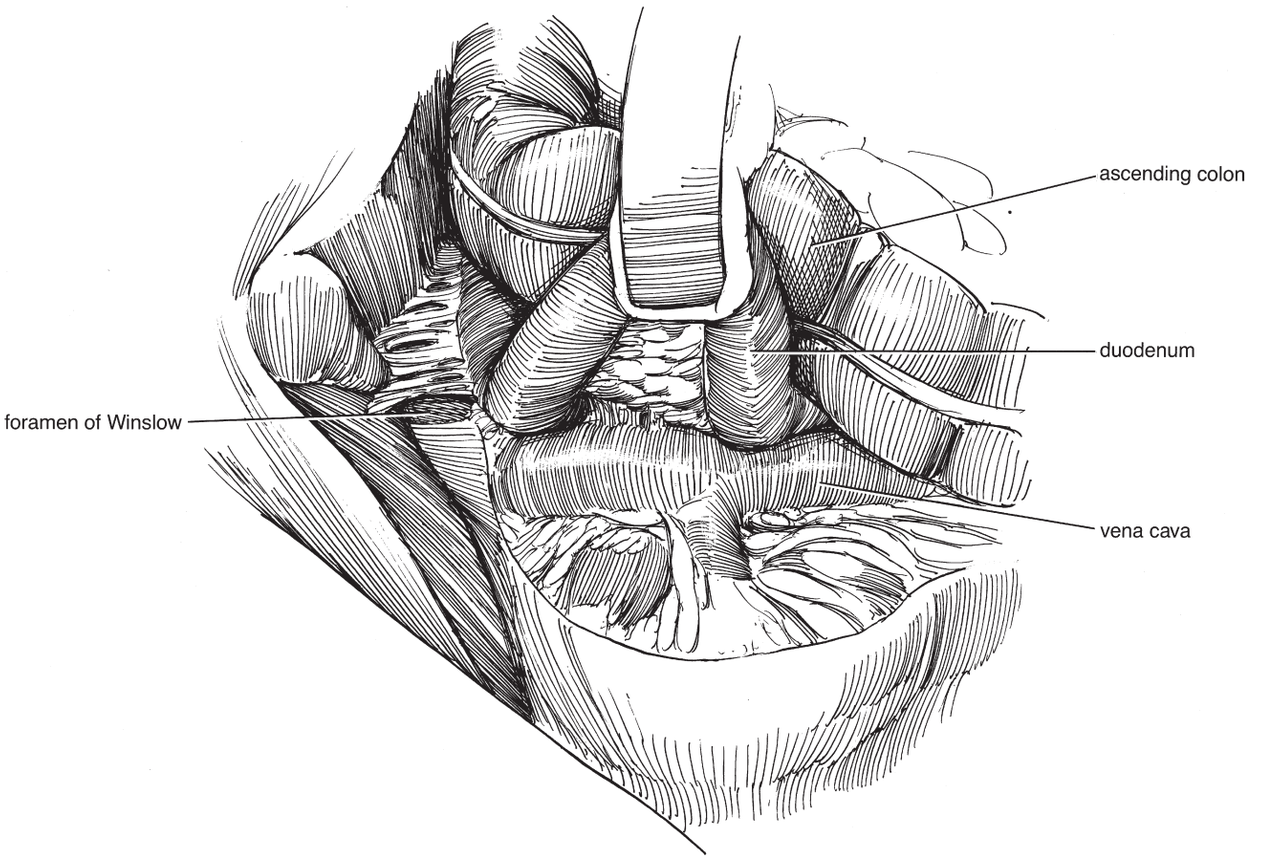

FIGURE 153-3.

right renal artery is hard to isolate because tumor is encroaching medially on the renal hilum or because troublesome hilar bleeding is occurring, identify the artery in the interaortocaval region and control it with either a 2-0 silk ligature or a large straight clip (if emergent). Once the right renal artery is controlled in the interaortocaval region, the right renal vein should deflate and become more flaccid. It should be palpated to rule out an occult tumor thrombus and then ligated with 2-0 silk and divided. This provides much better exposure to the right renal artery lateral to the IVC, which can then be ligated and divided. Watch for *lumbar veins* that come into the renal vein or vena cava at this level. When you encounter them, do not secure them with clips that may become displaced, but pass a 0 silk ligature on a right-angle clamp and tie it. Techniques for pedicle control are discussed in Chapter 152.

Bluntly develop the posterior pararenal space (Fig. 153-5). Normally this is easily done by gently sliding the left hand underneath the kidney while retaining contact with the fascia of the muscles of the posterior abdominal wall. Little vessels in the posterior pararenal space that perforate through the posterior renal fascia should be slipped or cauterized as this plane is gently developed. Occasionally the renal tumor will invade the psoas muscle posteriorly, making the posterior dissection difficult. In these circumstances, ensure that the renal pedicle is adequately controlled before dissecting the tumor away from the muscle sharply.

Bluntly dissect the inferior pole of the kidney (with its investing fat and renal fascia) (Fig. 153-6). Identify the ureter, doubly ligate it with 2-0 silk or a large clip, then divide it between the ligatures. Also identify and protect the gonadal vein by gently pushing it medially. This vein is friable and its avulsion from the IVC is a common cause of hemorrhage during nephrectomy. Dissect the inferomedial kidney away from the IVC until it is free up to the renal hilum superiorly. With the exception of the upper pole, the entire kidney, with the perirenal fat and renal fascia intact, should now be mobilized.

Grasp the kidney with the left hand and gently pull it caudally into the wound to expose the upper pole attachments (Fig. 153-7). Working laterally to medially, free the kidney from its cranial attachments. If adrenalectomy is indicated, remove the gland en bloc with the kidney, within the renal fascia. Otherwise, if the adrenal can be spared, dissect it off the anterior, superior, and medial surface of the kidney. The cranial connections to the adrenal gland must be divided carefully step by step between clips. Clip the small vessels and especially the lymphatics. If the adrenal gland is injured, oversew the edge with 4-0 Monocryl on a tapered ½ circle SH needle. Beware the short right adrenal vein that typically enters the IVC posterolaterally, high in the retroperitoneum, near the hepatic veins. If avulsed, this little vein can lead to significant hemorrhage before it is controlled.

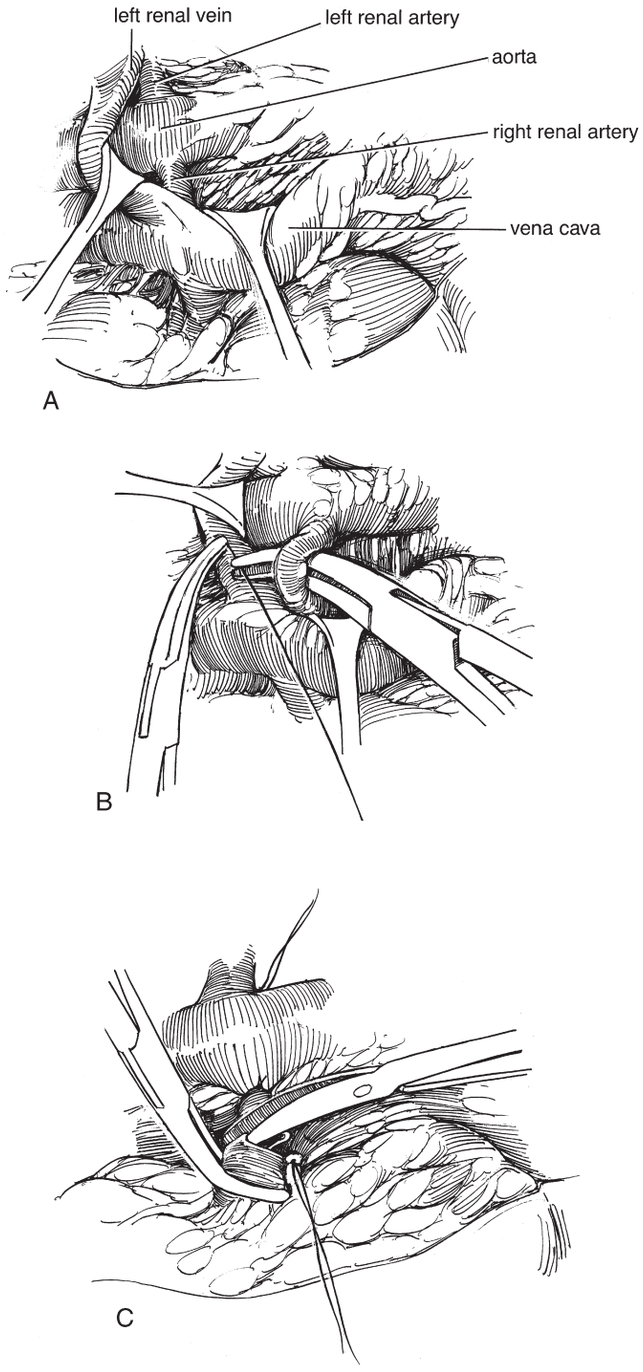
left renal vein
left renal artery
aorta
right renal artery
vena cava
A
B
C

FIGURE 153-4.

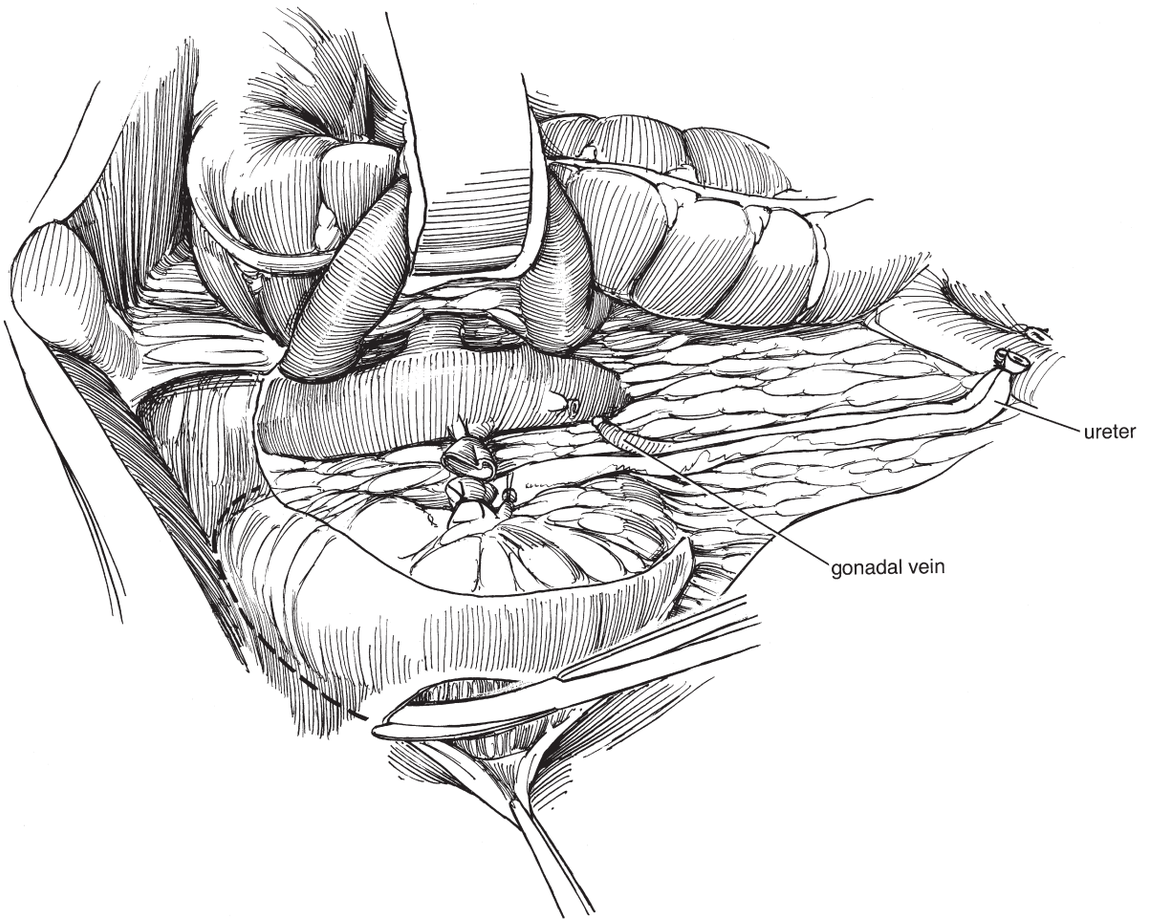

FIGURE 153-5.

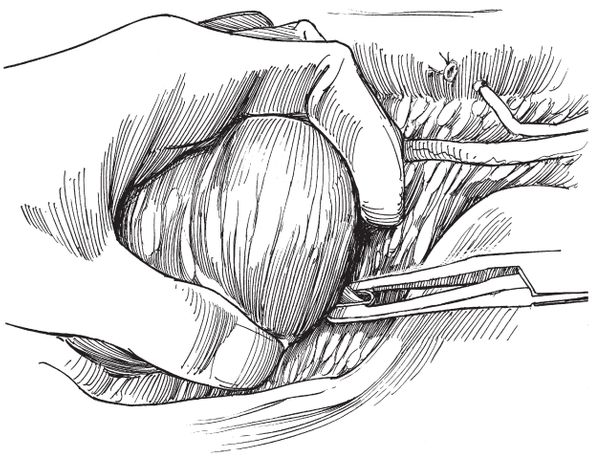

FIGURE 153-6.



FIGURE 153-7.

LEFT RADICAL NEPHRECTOMY, MINI-FLANK APPROACH

A nephrectomy using the flank approach can be accomplished by three different incisions: eleventh rib, twelfth rib and subcostal. The subcostal incision is rarely an appropriate choice for radical nephrectomy because it does not provide optimal access to the hilum (for pedicle control) and upper retroperitoneum (for lymphadenectomy). Three important points should be noted regarding flank access. First, a small (8 to 10 cm) mini-flank incision reduces morbidity while providing adequate access to the kidney in most cases. We recommend its use whenever possible. Second, resection of the eleventh or twelfth rib is not always necessary because they can often be retracted out of the wound after sharp transection of the intercostal structures (external and internal intercostal muscles, subcostal muscle, serratus posterior muscle, and the costotransverse ligament). Third, the flank approach provides the flexibility of attacking the renal pedicle either posteriorly (through the posterior pararenal space) or anteriorly (through the anterior pararenal space). Although we prefer the anterior approach which provides better access to the great vessels, we do not hesitate to use the posterior approach or a combined approach when the surgical anatomy is difficult.

Make a mini-flank incision on the upper border of the twelfth rib, starting from a point 3 to 5 cm from the tip of the twelfth rib and extending 8 to 10 cm anteromedially (Fig. 153-8). Transect the intercostal attachments between the eleventh and twelfth ribs, taking care not to injure the pleura or the intercostal neurovascular bundle. Resect the distal part of the twelfth rib if required for exposure.

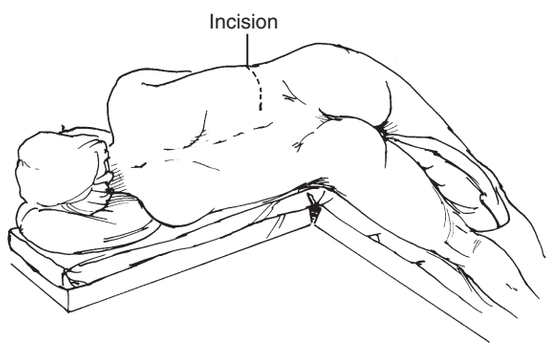

FIGURE 153-8.

Bluntly develop the pararenal space, protect the ribs with moist sponges, and insert a self-retaining retractor (e.g., Finochietto, Bookwalter, or Omni-Tract). Gently push the peritoneum anteromedially with a moist sponge stick to further develop the anterior pararenal space medially to the aorta (Fig. 153-9). Open the anterior renal fascia overlying the aorta and dissect superiorly until the left renal vein is found. Using right angle dissection, place a vessel loop around the left renal vein for retraction. Palpate the vein for evidence of tumor thrombus. Dissect and mobilize the left renal vein while ligating its lumbar, adrenal and gonadal branches with 3-0 silk. These branches of the left renal vein, particularly the lumbar branch, are common sources of operative hemorrhage during left nephrectomy.

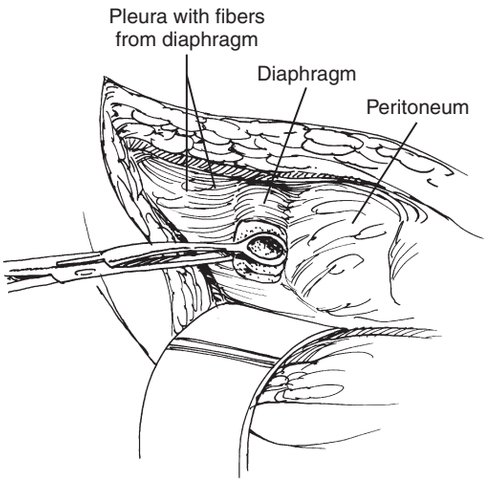

FIGURE 153-9.

Identify the left renal artery as it comes off the lateral surface of the aorta deep to the left renal vein, doubly ligate it with 2-0 silk, then divide (Fig. 153-10). With the left renal artery controlled, the left renal vein should decompress. If it remains engorged, the possibility of an accessory renal artery needs to be considered and the lateral aorta should be further dissected before ligating the vein. Otherwise, the vein can be safely ligated with 2-0 silk and divided. Other methods of pedicle control are described in Chapter 152.

Completely mobilize the kidney outside of the renal fascia, starting with the posterior pararenal space (Fig. 153-11). Progress inferiorly and identify then divide the ureter while mobilizing the lower pole. Pull the upper pole into the wound and dissect the adrenal gland off the superoanteromedial kidney, progressing laterally to medially. Alternatively, if adrenalectomy is indicated, identify and ligate the left middle adrenal artery on the lateral surface of the aorta. Proceed from the superolateral surface of the renal fascia medially, progressively clipping and dividing the attachments and blood supply to the left adrenal gland. Retract the specimen and close the wound.

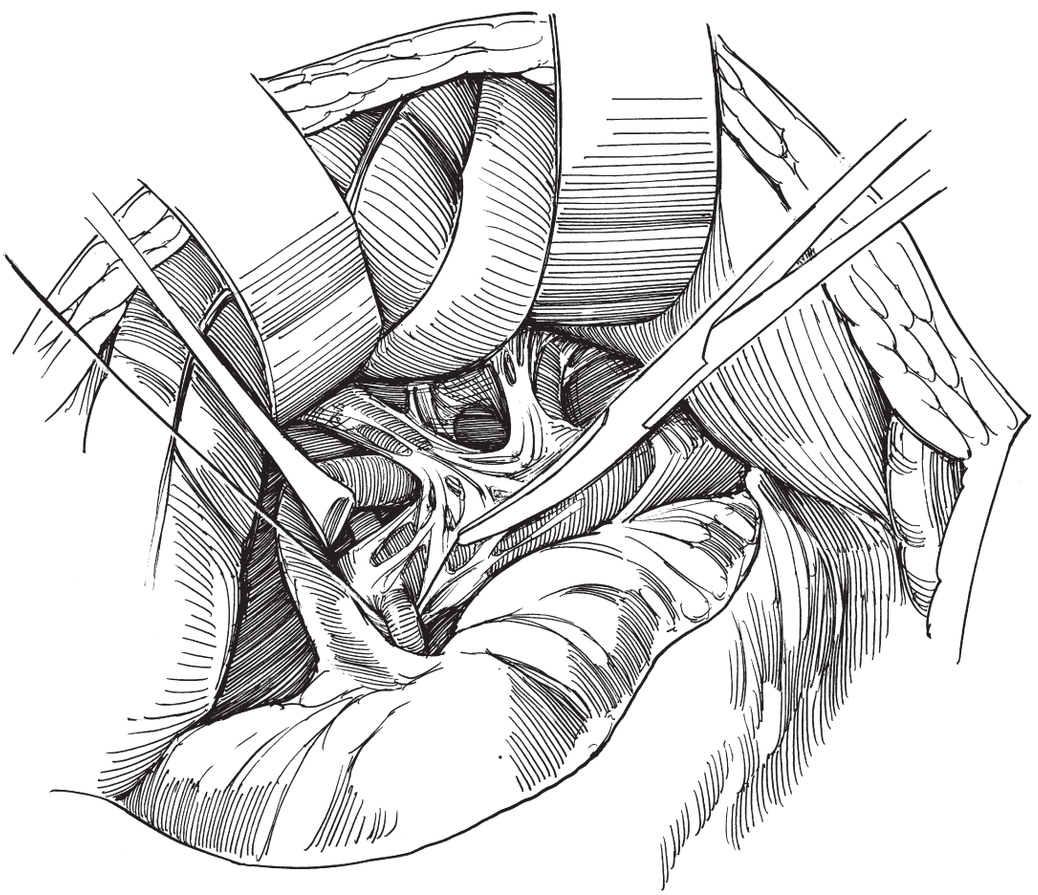

FIGURE 153-10.

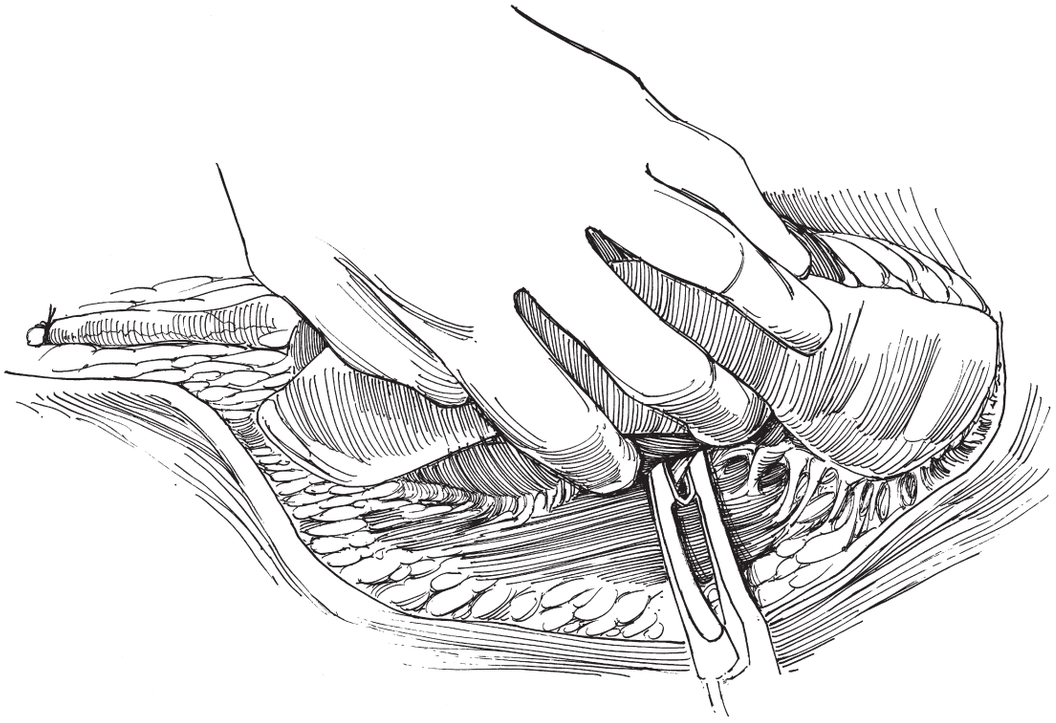

FIGURE 153-11.

REGIONAL LYMPHADENECTOMY FOR RENAL MASSES

The indications for regional lymphadenectomy are detailed earlier in this chapter. The regional lymphatic drainage of the kidneys is described in Chapter 151 and forms the basis of the extended template for a regional lymphadenectomy of the kidney. On the right side, the paracaval, precaval, retrocaval, and interaortocaval nodes from the right crus of the diaphragm to the bifurcation of the IVC are sampled. On the left side, the paraaortic, preaortic, and retroaortic nodes from the left crus of the diaphragm to the bifurcation of the aorta are sampled.

Right Side

Use a right-angle clamp and electrocautery to split the fleshy tissue on the anterior surface of the IVC. Clear the anterior surface of the IVC cranially to the level of the right crus of the diaphragm (which is located medial to the IVC, 3 to 4 cm above the right renal vein) and caudally until the level of the bifurcation of the IVC. Ligate the right gonadal vein at its insertion on the IVC with 2-0 silk and divide. Even though the right gonadal vein can be preserved, its avulsion during mobilization of the IVC can be a major source of bleeding during retroperitoneal lymphadenectomy. The gonadal artery should be preserved.

Clear the lymphatic tissue off the lateral aspect of the IVC (paracaval nodes). As you proceed, have the assistant use a Cushing vein retractor or a Love nerve root retractor to gently elevate the IVC on either side of each lumbar vein (there are usually four to five). Pass a right-angle clamp around each lumbar vein and doubly ligate them with 3-0 silk before transection. Ligate or clip the large lymphatic tributaries that are located above the right renal vein in the interaortocaval and paracaval areas. These lymphatic trunks can drain large quantities of lymph and chyle into the cisterna chyli and thoracic duct, and failure to appropriately control them can result in chylous ascites. Have the assistant use two sponge sticks to carefully roll the IVC medially. Clear the lymphatic tissue off the posterior IVC and the anterior longitudinal vertebral ligament (retrocaval nodes). Occasionally, the contralateral lumbar veins are easily accessed and ligated through this retrocaval plane.

Use a right-angle clamp to split the nodal tissue on the anteromedial surface of the aorta. Follow the aorta up to the level of the left renal vein and progressively clip and divide the lymphatic tissue overlying this vein, moving toward the IVC. Retract the lymphatic tissue medially off the IVC and aorta and dissect and ligate any remaining lumbar veins. Clear the interaortocaval space of its lymphatic tissue to the level of the bifurcation of the great vessels.

Left Side

Use a right-angle clamp and electrocautery to split the lymphatic tissue on anteromedial surface of the aorta and roll it laterally (Fig. 153-12). Continue the split cranially along the aorta to the level of the superior mesenteric artery (SMA) and caudally past the inferior mesenteric artery (IMA) to the bifurcation of the aorta. In general, the IMA, SMA, and celiac trunk should all be preserved. However, in the case of lymphadenopathy involving the IMA, this vessel can be safely resected (see discussion on mesenteric vessel injury later).

Dissect the lymphatic tissue off the anterior and lateral surfaces of the aorta (Fig. 153-13). Have the assistant use a Cushing vein retractor or a Love nerve root retractor to gently

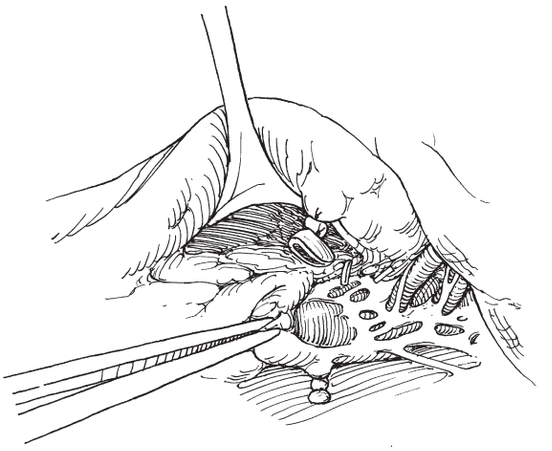

FIGURE 153-12.

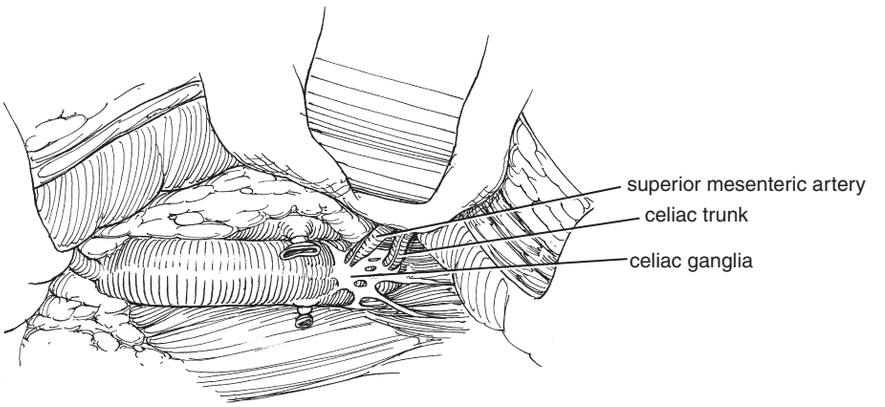

FIGURE 153-13.

elevate the aorta on either side of each lumbar artery (there are usually three to four). Ligate the left lumbar arteries with 3-0 silk as the dissection proceeds along the lateral aorta. Once the lumbar arteries are properly controlled, roll the aorta medially and resect the tissue located between the anterior longitudinal vertebral ligament and the aorta (retroaortic lymph nodes). The interaortocaval nodes are resected only if they are palpable or visualized on preoperative imaging, or if there is extensive nodal involvement around the aorta.

INTRAOPERATIVE AND POSTOPERATIVE PROBLEMS

Suprahilar and Retrocrural Lymphadenectomy

Dissecting the lymphatic tissue located above the left renal vein (suprahilar and retrocrural nodes) in the interaortocaval space should be undertaken with great caution and care because the duodenum, pancreas, superior mesenteric artery, celiac trunk, superior mesenteric autonomic plexus, and cisterna chyli can all be easily damaged in this area with serious sequelae. In general, we only resect the suprahilar and retrocrural nodes if they are palpable, clearly enlarged on preoperative imaging, or if there is a large volume of retroperitoneal lymphadenopathy.

Injury to the Vasculature of the Gut

During radical nephrectomy, a number of important gastrointestinal blood vessels may be encountered which can be involved in the tumoral process or fall victim to iatrogenic injury. The *inferior mesenteric artery* provides the blood supply to the distal transverse, descending, and sigmoid colon. It can be safely ligated as long as the marginal artery of the colon (artery of Drummond, arch of Riolan) is patent and can bring blood from the superior mesenteric artery to the left colonic arcades, which is normally the case. The *superior mesenteric artery* provides the blood supply to the entire small bowel as well to the cecum and ascending and transverse colon, whereas the *celiac trunk* feeds the esophagus, stomach, pancreas, liver, spleen, and part of the duodenum. Ligation of either the SMA or the celiac trunk is a catastrophic event that occurs predominantly with left-sided nephrectomy and that must be rapidly reversed if the patient is to survive. A vascular surgeon should be immediately called to the operating room and the vessel in

question should be repaired. If a vascular surgeon is not available, the urologist should attempt repair. All bleeding must be controlled, the vessel adequately exposed, and the aorta temporarily occluded with vascular clamps to allow for repair. Heparin should be given intraoperatively. Options for repairing an arterial laceration include a simple running closure (with 6-0 Prolene on a tapered ½ circle BB needle) and vascular patching (using renal vein, bovine pericardium, or polytetrafluoroethylene/Gore-Tex). Options for repairing a completely transected vessel include aortic reimplantation, celiac artery to SMA bypass, and splenic artery bypass. If additional vessel length is needed, a 6- to 10-mm Gore-Tex graft can be used to make the bypass easier. Intraoperative Doppler ultrasound confirms patency of the repaired vessel. The patient should be heparinized and emergently air-lifted to a center where vascular surgeons are available for postoperative follow-up.

The *inferior mesenteric vein (IMV)* is found in the mesentery of the descending colon, immediately lateral to the ligament of Treitz. It is a useful landmark for the Cattel-Braasch maneuver (complete mobilization of the right colon and small bowel mesentery to access the retroperitoneum) because the posterior peritoneum is incised immediately medial to the IMV in this maneuver. The IMV can be safely ligated during surgery without consequence.

In stark contrast, the *superior mesenteric vein (SMV)* is not a vein that should be sacrificed unless this is the only option. It runs in the root of the small bowel mesentery and joins with the splenic and inferior mesenteric veins to form the portal vein. Repair of SMV lacerations is done by first clipping the small venous branches entering the SMV and then isolating the injury with atraumatic vascular clamps. Venorrhaphy using 6-0 Prolene is usually adequate to repair the vein. If the vein has been ligated and transected, serious bowel edema and venous engorgement will result, which can impair venous return through the portal venous system. The net result is the development of the systemic hypotension/splanchnic hypertension syndrome, which is characterized by venous thrombosis, bowel ischemia, and necrosis. If possible, a ligated SMV should be reanastomosed primarily or repaired using autologous venous grafting. Gore-Tex grafts should only be used when autologous veins are not available because the thrombosis rate is high. The abdomen should not be closed primarily in cases of SMV injury because abdominal compartment syndrome will occur.

Injury to the Liver and Spleen

Small hepatic and splenic injuries (capsular tears and minor lacerations) can usually be managed effectively by argon beam coagulation or electrocautery (with generator set to spray at 60 to 90 watts). Fibrin glue and topical hemostatic meshes (e.g., Surgicel) are useful adjuncts. More serious splenic injuries can be managed by splenorrhaphy or splenectomy. Minor hepatic lacerations can be repaired using the same basic principles as a partial nephrectomy closure: use a synthetic absorbable suture on a ½ circle tapered needle, perform an interrupted horizontal mattress closure, use Nu-Knit pledgets to prevent capsular tearing by the suture, and use a tubular Nu-Knit bolster if the defect is large (see page ***). A closed suction drain should be left to monitor for delayed bleeding. Major hepatic lacerations should be managed by an experienced gastrointestinal surgeon.

Injury to the Duodenum

Most intramural hematomas of the duodenum should be managed expectantly. However, if the hematoma is large and narrowing the duodenal lumen, incision of the serosa and muscularis (but not the mucosa) can be performed to drain the hematoma and achieve hemostasis. The defect should be closed in one layer of interrupted 3-0 silk. The involved segment may initially appear nonviable, but no resection should be done because this perception is usually false. Minor electrocautery or laceration injuries should be managed by careful debridement of the nonviable tissue and closure in two layers (mucosal layer: continuous 4-0 chromic on a ½ circle tapered needle; serosa and muscularis layer: interrupted 3-0 silk on a ½ circle tapered needle). Place an omental flap over the injury and insert a closed suction drain. Major duodenal injuries can be extremely complex to repair and manage correctly and a gastrointestinal surgeon should be consulted intraoperatively.

Injury to the Pancreas

The first step in the management of any pancreatic injury is a thorough inspection of the organ. Very superficial lacerations and contusions can usually be managed by applying fibrin glue and inserting a closed suction drain. Monitor the drain fluid for an alkaline pH and lipase/amylase to determine whether a pancreatic fistula is developing. If the laceration is more than superficial or if there appears to be injury to a pancreatic duct, the pancreas must be more carefully assessed and it is wise to consult a gastrointestinal surgeon intraoperatively. To inspect the pancreas, perform a wide Kocher maneuver (see Chapter 152), open the lesser peritoneal sac by dividing the insertion of the omentum onto the transverse colon, and retract the stomach cranially. Incise the parietal peritoneum overlying the inferior border of the pancreas and use a finger to develop the avascular plane behind the pancreas. Carefully inspect both the anterior and posterior surfaces of the pancreas for injury. If the injury involves the head or body of the pancreas or the ampulla of Vater, the repair will be complex and should involve a gastrointestinal surgeon. If the injury involves the tail of the pancreas, a distal pancreatectomy should be performed. This can be done by mobilizing the splenic artery and vein off the posterior surface of the pancreas (there will be several pancreatic branches requiring ligation) and stapling across the distal pancreas with a GIA-80 stapler. Alternatively, the spleen can be resected along with the distal pancreas. The stump of the pancreatic duct should be suture ligated with 5-0 silk, the stapled end of the pancreas oversewn with 4-0 silk, and fibrin glue applied over the injury site. Two closed suction drains should be left near the pancreas to monitor for pancreatic fistulization. Postoperatively,

prophylactic measures that can be instituted to reduce the incidence of pancreatic fistulae (which is about 20% to 25%) include giving total parenteral nutrition for 2 to 3 weeks with the patient given nothing by mouth (NPO) and administering octreotide 100-300 μg SC Q8h for 10 days.

Pulmonary Complications

Large postoperative pleural effusions can be managed by aspiration initially, followed by chest tube drainage if refractory.

Commentary by PAUL RUSSO

An estimated 57,760 new cases and 12,980 deaths due to renal cancer were expected in the United States in 2009. Approximately 30% to 40% of patients with malignant renal cortical tumors will either present with or later develop metastatic disease. The vast majority of mRCC patients have large, locally advanced tumors often with regional nodal, renal vein, and or inferior vena caval extension. Approximately 90% of metastatic renal cancer (mRCC) patients have the conventional clear cell histological subtype. Cytotoxic chemotherapy and hormonal therapies alone or in combinations are ineffective in treating patients with mRCC. Cytokine therapy, including interleukin-2 and interferon-alpha, used widely in the past 20 years in clinical trials and oncologic practice, have some activity but overall response rates are low (10% to 15%) and only rarely associated with durable complete remission. Median patient survival for mRCC ranges from 10 to 12 months. New systemic agents, including multitargeted tyrosine kinase (TKI) inhibitors (sunitinib, sorafenib) and mammalian target of rapamycin (mTOR) kinase inhibitors (temsirolimus, everolimus) have improved overall progression-free survival in 40% of patients in clinical trials of both previously treated and treatment-naive patients and are now FDA approved for use in patients with mRCC. Interestingly, these new targeted therapies can cause significant responses in the primary tumor, unlike the cytokines, as well as in the metastatic sites.

The role of surgical intervention in patients with metastatic renal cancer is twofold: (1) to render a patient clinically free of all sites of primary disease and metastases, termed *nephrectomy/metastasectomy,* or (2) to resect the primary tumor in the face of unresectable metastatic disease before the initiation of systemic therapy, termed *cytoreductive nephrectomy* (CRN). The occasionally unpredictable natural history of renal cancer and varying patient selection criteria can make the interpretation of results from different centers difficult. Controversies regarding the effectiveness of CRN and its timing (presystemic therapy or after a clinical response in metastatic sites following systemic therapy) are longstanding. Carefully selected patients with good performance status undergoing nephrectomy and subsequent metastasectomy may experience prolonged survival in the range of 30 months, which could be attributed to a combination of patient selection factors and the surgical resections. Randomized clinical trials in the United States and Europe have demonstrated a small but significant survival benefit to cytoreductive nephrectomy and cytokine therapy vs. cytokine therapy alone, measured in the range of 3 to 6 months and associated with overall survival of approximately 12 months. The precise mechanism by which cytoreductive nephrectomy improves survival is not known but may relate to reduction in the large primary immunosuppressive burden. Patient selection factors including performance status and serum factors (Hgb, corrected Ca^{++}, LDH) stratify metastatic patients into risk groups that are strongly associated with survival time in both medically and surgically treated metastatic renal cancer patients. The development of multi-kinase and mTOR inhibitors has markedly improved survival in treatment-naive and previously treated metastatic renal cancer patients and these agents are currently under active clinical investigation in the neoadjuvant and adjuvant setting.

It is essential for urologists to perform a thorough operation when resecting a massive renal tumor. Ipsilateral adrenalectomy and thorough regional lymphadenectomy (ipsilateral great vessel and interaortocaval nodes) to maximize local tumor control as well as to provide eligibility for patients in ongoing adjuvant clinical trials using these new mTOR and TKI inhibitors.

Suggested Readings

Blute ML, Amling CL, Bryant SC, Zincke H. (2000). Management and extended outcome of patients with synchronous bilateral solid renal neoplasms in the absence of von Hippel-Lindau disease. Mayo Clin Proc 75(10):1020-1026.

Blute ML, Leibovich BC, Cheville JC, Lohse CM, Zincke H. (2004). A protocol for performing extended lymph node dissection using primary tumor pathological features for patients treated with radical nephrectomy for clear cell renal cell carcinoma. J Urol 172(2):465-469.

Schwartz MJ, Smith EB, Trost DW, Vaughan ED Jr. (2007). Renal artery embolization: clinical indications and experience from over 100 cases. BJU Int 99(4):881-886.

Siemer S, Lehmann J, Kamradt J, et al. (2004). Adrenal metastases in 1635 patients with renal cell carcinoma: outcome and indication for adrenalectomy. J Urol 171(6 Pt 1):2155-2159; discussion 2159.

Volpe A, Kachura JR, Geddie WR, et al. (2007). Techniques, safety and accuracy of sampling of renal tumors by fine needle aspiration and core biopsy. J Urol 178(2):379-386.

Chapter 154

Partial Nephrectomy

MICHAEL L. BLUTE, SR. AND BRANT INMAN

Partial nephrectomy is the preferred method of managing most renal masses. While in the past partial nephrectomy was reserved for imperative indications (bilateral tumors, tumor in a solitary kidney, patient at high risk of future renal failure) and small tumors less than 4 cm in diameter, contemporary indications have widened considerably to include most renal masses that can be safely and completely removed, independent of their size. In fact, it is easier to consider relative contraindications to partial nephrectomy than to consider its indications (Table 154-1). A larger debate is whether partial nephrectomy is best done laparoscopically or with the open technique. Although the laparoscopic technique appears to provide similar short-term cancer control and reduced operative blood loss, postoperative complications are two to three times as common, second procedures are three times as common, and renal ischemia times are increased by 70%. In summary, open partial nephrectomy is an excellent operation and remains the standard of care for the management of renal masses.

RELATIVE CONTRAINDICATIONS TO PARTIAL NEPHRECTOMY

TABLE 154-1

Technical	Cold ischemia time > 45 min (consider extracorporeal approach)
	Less than 20% of global nephron mass retained
Cancer related	Diffuse encasement of the renal pedicle by tumor
	Diffuse invasion of the central collecting system
	Tumor thrombus (cT3b/c)
	Adjacent organ invasion (cT4)
	Regional lymphadenopathy (cTxN1)
	Metastases (cTxNxM1)

PREOPERATIVE CONSIDERATIONS

In addition to the preoperative considerations of radical nephrectomy (see Chapter 153), there are additional things to consider when contemplating partial nephrectomy.

Hyperfiltration injury: When a significant portion of renal parenchyma is removed, the renal blood flow is delivered to a smaller number of nephrons, which causes an increased glomerular capillary perfusion pressure that results in an increased single nephron glomerular filtration rate called *hyperfiltration.* Over decades, this hyperfiltration can injure the remaining nephrons, resulting in focal segmental glomerulosclerosis and the clinical manifestations of proteinuria and progressive renal failure. Hyperfiltration injury is most common when the total nephron mass (both kidneys combined) is reduced by more than 80%.

Renal ischemia and hypothermia: To minimize blood loss and allow for adequate surgical visibility, it is often necessary to employ some method of vascular compression during partial nephrectomy. Options include manual compression, a renal compression clamp (e.g., Kaufmann clamp), selective clamping of the renal artery, and en bloc clamping of the entire renal pedicle. Manual and clamp compression of the renal parenchyma should be favored because vascular clamping is associated with a higher incidence of renal complications. It is unclear whether leaving the renal vein unclamped for retrograde renal perfusion offers any tangible benefit. Attempts to limit warm ischemia to 20 minutes and cold ischemia to 35 minutes should be used when vascular clamping is necessary. Adequate renal hypothermia (core renal temperature of ~20°C) takes at least 15 min to occur if the kidney is packed with ice slush. To help prevent acute postoperative renal failure, intravenous mannitol (250 mL bolus of 20% solution) and furosemide (40 mg) should be given about 15 minutes before renal artery clamping. Even though evidence supporting this practice is somewhat limited, both drugs are quite safe as long as the patient is well hydrated.

Enucleation and surgical margins: Simple tumor enucleation can be safely conducted in small renal tumors while preserving a small rim of normal tissue and a negative surgical margin. Although opinions vary, we do not believe that

local recurrence rates are higher for enucleation procedures than for wedge resections.

Multifocality and tumor size: The incidence of multifocality is roughly 2% for clear cell and chromophobe renal cell carcinoma (RCC) and 10% for papillary RCC. Multifocal tumors are also more common as the primary tumor increases in size. It is important to recognize these multifocal tumors because their persistence accounts for the 5% local recurrence rate that is observed following partial nephrectomy. Careful inspection of the entire renal surface should be done at partial nephrectomy to ensure that imaging has not missed any small renal tumors. Partial nephrectomy is still the treatment of choice for multifocal tumors as long as they can all be resected with negative surgical margins.

Hereditary renal malignancy: Hereditary renal tumors are usually multifocal, bilateral, and highly likely to recur. Except patients with hereditary leiomyomatous RCC that should be aggressively managed, most patients with hereditary syndromes can be safely observed until the largest renal tumor reaches about 3 cm in size. When partial nephrectomy is performed, the perirenal fat and renal fascia should be preserved to make subsequent reoperation easier. The entire renal surface should be visualized and all visible tumors should be resected. Intraoperative ultrasound should be used to identify any subcortical tumors that could also be resected. Hypothermia is nearly always required for these cases.

Urothelial carcinoma of the renal collecting system: Before considering partial nephrectomy for urothelial carcinoma, the collecting system must be carefully evaluated for multifocal lesions with computed tomography (CT) or magnetic resonance (MR) urography, ureteroscopy, and cystoscopy. To be a candidate for partial nephrectomy, collecting system tumors should be unifocal, polar, and not manageable by endoscopic means (whether antegrade or retrograde). It is critical to assess surgical margin status intraoperatively with frozen section in that local recurrences are common. Neoadjuvant chemotherapy should be strongly considered.

ENUCLEATION FOR SMALL CORTICAL TUMORS

Ensure that renal cooling is available, even though ischemia time seldom exceeds 30 minutes. Prepare two 5- to 10-cm cigarette-shaped bolsters by rolling Nu-Knit into a cylinder and tying the two ends with a 4-0 absorbable suture. Prepare two pledgets by folding Nu-Knit into a double-layer strip 5 to 10 cm long and 1 cm wide. We prefer Nu-Knit because it is absorbable, it does not immediately shrink away when wet, and has tremendous tensile strength when sutured.

Expose the kidney, using either an anterior subcostal approach or a flank approach (our preference). Insert a self-retaining retractor. Dissect the entire surface of the kidney free of the perirenal fat, with the exception of palpable tumors which should remain fat covered (Fig. 154-1). Administer intravenous mannitol and furosemide, then isolate the renal pedicle sufficiently to allow safe application of a vascular clamp. Control the renal vessels with vessel loops.

Circumferentially score the renal cortex surrounding the tumor with electrocautery. Identify a plane outside of the tumor pseudocapsule and within the normal parenchyma and

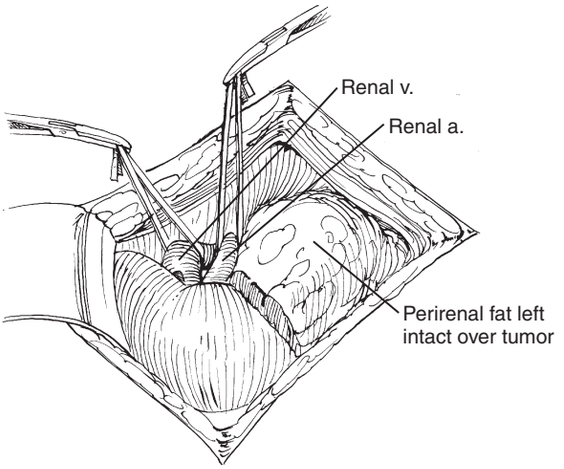

FIGURE 154-1.

bluntly dissect it with small closed Metzenbaum scissors (Fig. 154-2). Renal occlusion is not usually necessary, but if bleeding results that hampers vision, use manual compression of kidney or clamp the renal pedicle to control it. When small vessels are encountered, use the scissors to sharply divide them. Excise the tumor and examine it immediately for evidence of visible tumor. Biopsy the deep margins of the tumor bed for frozen section. Control any small bleeding vessels by figure-eight sutures with a 4-0 absorbable monofilament on a tapered needle or by coagulation with an argon beam coagulator or bipolar electrocautery. Verify the collecting system for injury and repair with the same suture if necessary.

Place a Nu-Knit pledget along each border of the crater and place a Nu-Knit bolster into the bottom of the crater (not required if the defect is very small). Close the defect with a horizontal mattress using a 2-0 absorbable suture (e.g., oiled Vicryl, Maxon) on a large, tapered ½ circle needle (e.g., CTX, GS-25) (Fig. 154-3). The sutures should be placed through the pledgets and about 1 to 2 cm into the renal parenchyma to prevent capsular and parenchymal tearing. The pledgets

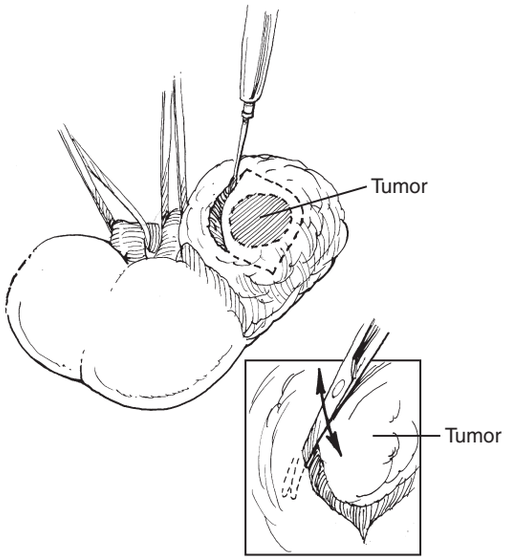

FIGURE 154-2.

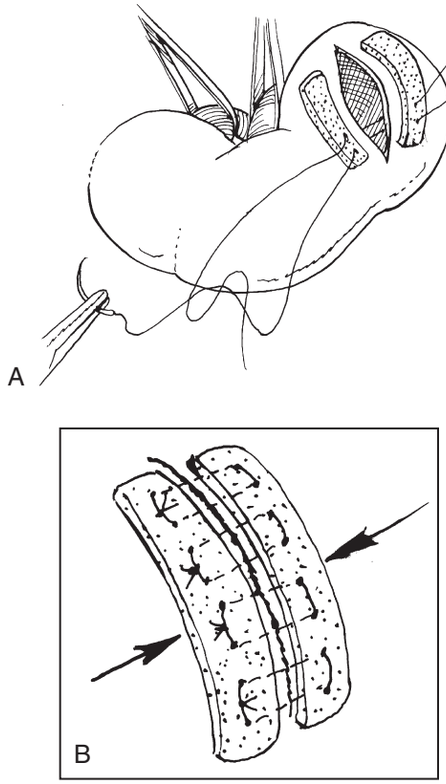

FIGURE 154-3.

allow tension to be more evenly distributed along the renal capsule, therefore making tearing less likely. If clamping was used, unclamp the pedicle and inspect the kidney for bleeding, ischemia, urine leakage, or adjacent trauma.

Perform regional lymphadenectomy if indicated (see Chapter 153). Replace the perirenal fat and renal fascia around the kidney. Leave a closed suction drain in the pararenal space to monitor for delayed bleeding and urine leaks; remove only after 7 to 10 days of minimal output (Fig. 154-4). A Foley catheter is used to monitor urine output. No ureteral catheter is required unless there was a large defect in the collecting system.

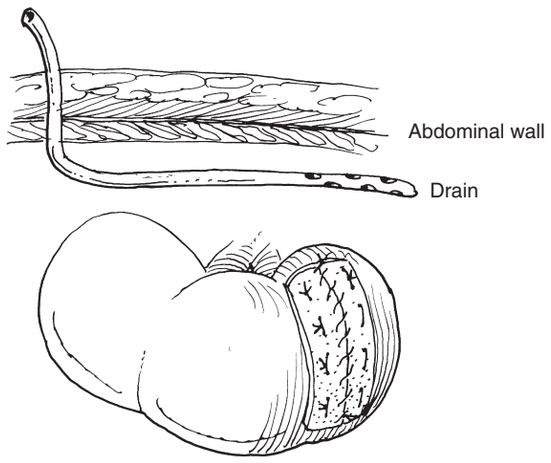

FIGURE 154-4.

WEDGE RESECTION FOR LARGE CORTICAL TUMORS

Administer intravenous mannitol and Lasix, then clamp the renal artery with a vascular bulldog clamp. Place a plastic bag or sheet around the kidney and fill it with ice slush (Fig. 154-5). Allow the kidney to cool for 15 minutes to 20°C.

Circumferentially incise the renal capsule 5 to 10 mm peripheral to the tumor with electrocautery. Use a combination of blunt and sharp dissection with Metzenbaum scissors to excise the tumor with a small rim of normal parenchyma (Fig. 154-6). Inspect the specimen for visible tumor, then biopsy the tumor bed for frozen section.

Control bleeding vessels with figure-eight sutures, argon beam coagulation, or bipolar electrocautery (Fig. 154-7). Inspect the tumor crater for any evidence of collecting system injury. If there is any doubt, inject 10 to 20 mL of diluted indigo carmine into the renal pelvis while occluding the

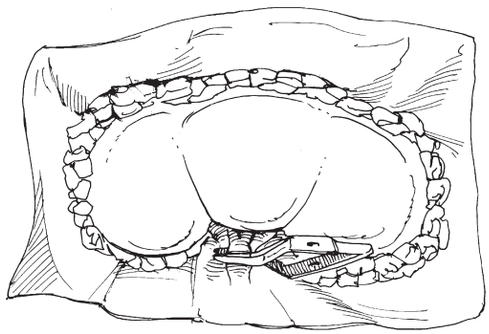

FIGURE 154-5.

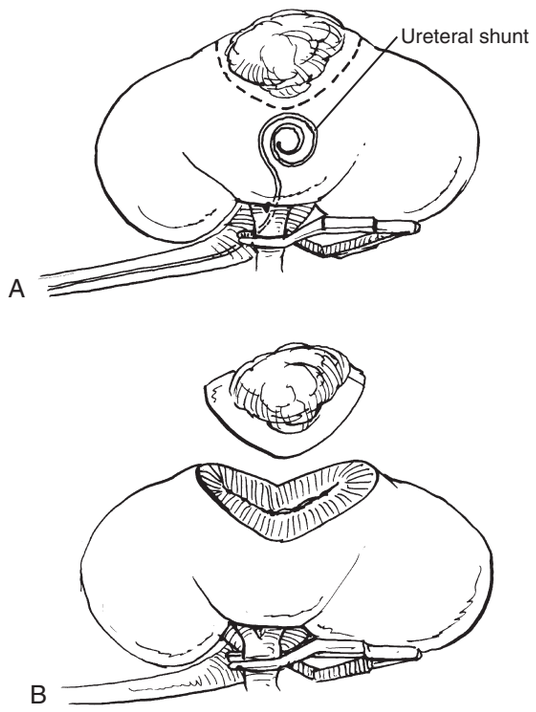

FIGURE 154-6.

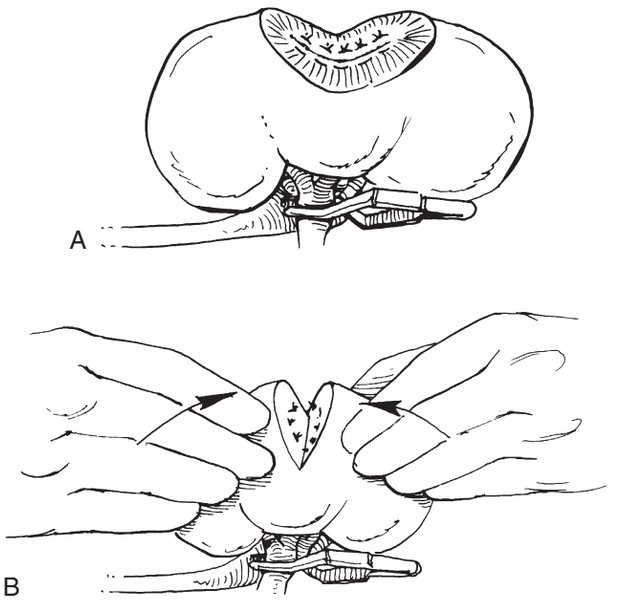

FIGURE 154-7.

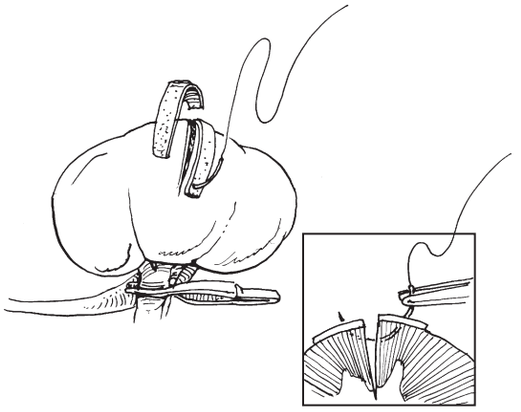

FIGURE 154-8.

ureter to look for leaks. Close the collecting system with a 4-0 absorbable monofilament on a ½ circle tapered needle.

Reconstruct the defect using Nu-Knit bolsters and pledgets (Fig. 154-8). Have the assistant approximate the edges of the defect while deep horizontal mattress sutures are tied through the pledgets, securing the bolsters in place and closing the defect. Apply fibrin glue to the crater if desired. Unclamp the renal artery and inspect for evidence of bleeding. Remove the plastic sheet and ice slush. Leave a closed suction drain and Foley catheter.

SEGMENTAL NEPHRECTOMY FOR LARGE POLAR TUMORS

Administer intravenous mannitol and Lasix. Dissect the renal pedicle completely, including the segmental branches. Apply a bulldog clamp to the apical segmental artery (or basilar segmental artery for lower pole tumors) and observe the line

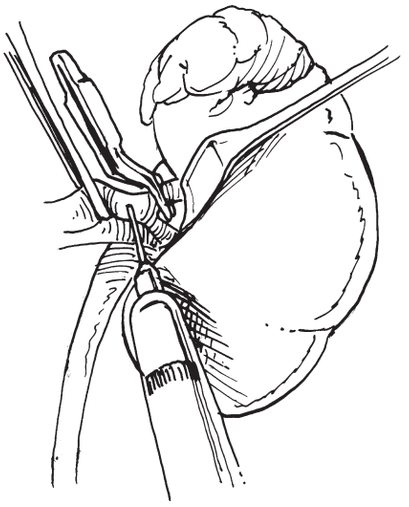

FIGURE 154-9.

of ischemia. The avascular line can be further demarcated by injecting 5 mL of indigo carmine directly into the clamped artery (Fig. 154-9). The line of ischemia is the optimal site for transection of the kidney and should be lightly marked with electrocautery. Ligate the apical segmental artery, then clamp the renal pedicle en bloc with a curved Satinsky clamp. Place a plastic bag or sheet around the kidney and fill it with ice slush. Allow the kidney to cool for 15 minutes to 20°C.

Incise the renal capsule along the line of ischemia with electrocautery. Use blunt and sharp dissection to excise the pole of kidney (Fig. 154-10). Control all bleeding vessels, working rapidly and accurately. Release the clamp momentarily to check for uncontrolled vessels. If hemostasis is adequate, proceed to collecting system repair; otherwise reclamp and continue vascular control.

Inspect the collecting system for injury. If the defect in the collecting system is large, insert a guidewire into the defect and manually guide it into the ureter and bladder. Insert a 6-French double-J stent over the guidewire and ensure that it is coiled within the renal pelvis. Close the collecting system with a running 4-0 absorbably monofilament (Fig. 154-11). Inject indigo carmine into the renal pelvis (while pinching the ureter and stent) to ensure that the collecting system is closed. Apply fibrin glue to the crater if desired.

Close the renal capsule using two Nu-Knit pledgets and a horizontal mattress suture of 2-0 absorbable suture (Fig. 154-12). Because the defect is much larger, we use a larger needle (e.g., XLH, GS-27) for segmental polar nephrectomies and heminephrectomies than for enucleations and wedge resections. Consider nephropexy if the kidney is quite mobile, but remember that several nerves run in the psoas muscle and can be damaged by suture placement (see Chapter 151). Replace the kidney within the perirenal fat and the renal fascia. Leave a Foley catheter and a closed suction drain. Remove the Foley catheter when the patient is mobile and stable. Remove the drain after 7 to 10 days of minimal drainage, but leave the stent in place for 4 to 6 weeks. If abundant urine collects in the drain, reinsert the Foley catheter to decompress the bladder and reduce the intrapelvic urine pressure.

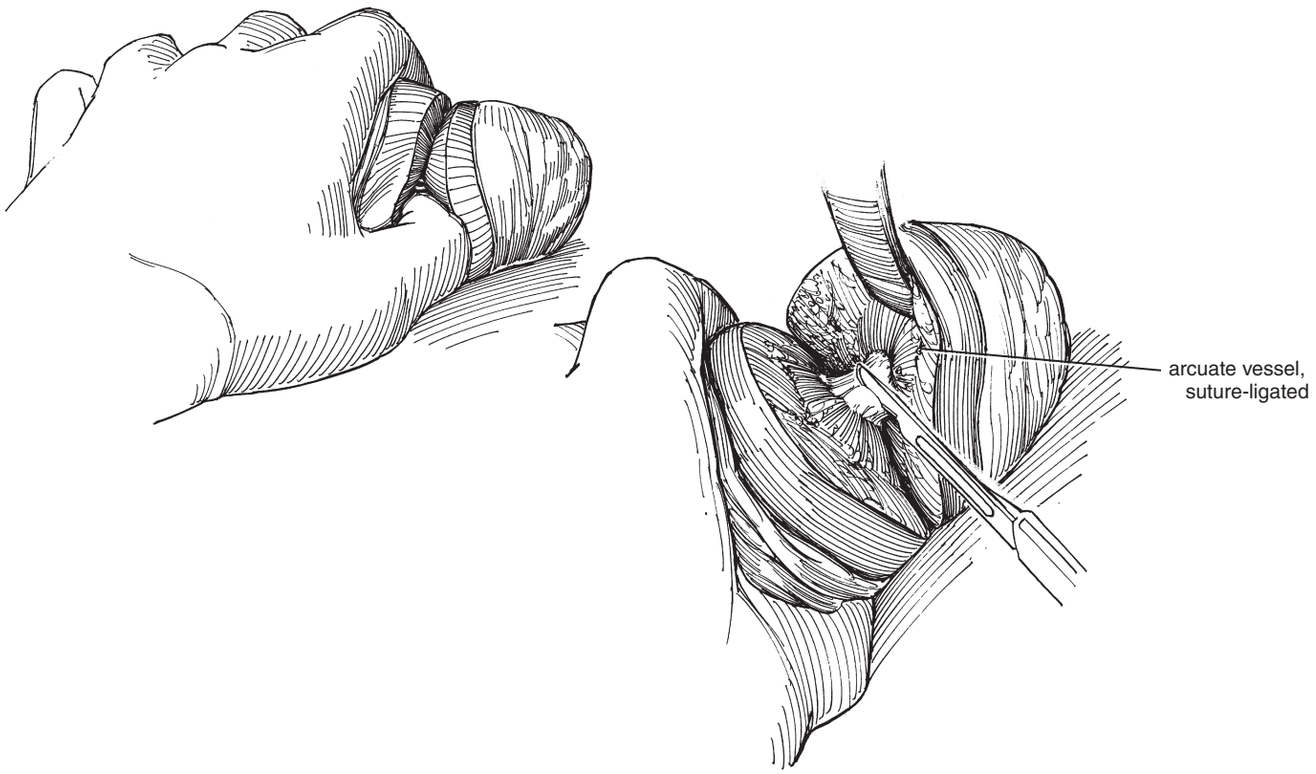

FIGURE 154-10.

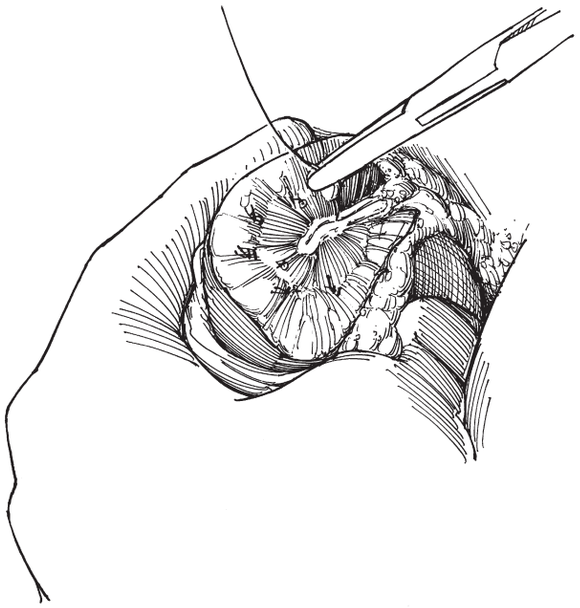

FIGURE 154-11.

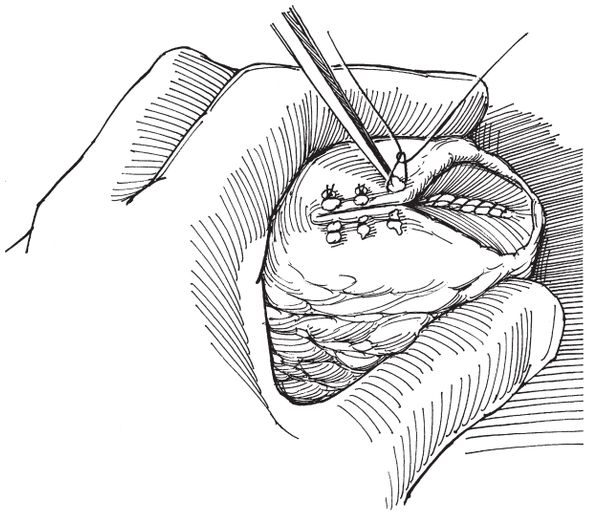

FIGURE 154-12.

HEMINEPHRECTOMY FOR LARGE TUMORS

Heminephrectomy (major transverse resection) is most often performed to resect nonfunctional parenchyma associated with an obstructed and infected upper pole of a duplex collecting system. It is also used to resect large polar tumors that exceed the bound of segmental polar nephrectomy and for urothelial carcinomas of the renal pelvis (see earlier discussion).

Place a double-J stent before making the incision (Fig. 154-13). Clear the kidney of the perirenal fat and completely dissect the renal pedicle. Administer intravenous mannitol and furosemide. Identify the major branches of the renal vasculature that are feeding the tumor then ligate and divide them. Clamp the renal artery the place a plastic sheet around the kidney and cool it with ice slush for 15 minutes.

Score the renal capsule with electrocautery circumferentially between the margin of the tumor and the margin of the renal hilum. Try not to get too close to the main renal artery and vein. Use blunt and sharp dissection to transect the kidney. Large vessels and parts of the collecting system will be encountered and should be divided sharply. Excise the specimen and examine it for visible tumor at the margin. Place figure-eight sutures with an absorbable 4-0 suture on large bleeding vessels then unclamp the artery (Fig. 154-14). Argon beam coagulation is useful to coagulate small vessels. Close the collecting system with the same suture, ensuring that the ureteral stent is in good position and that no collecting system sutures inadvertently catch the stent.

Close the capsular defect using a horizontal mattress sewn over Nu-Knit pledgets with 2-0 absorbable suture on a very large XLH or GS-27 tapered needle (Fig. 154-15).

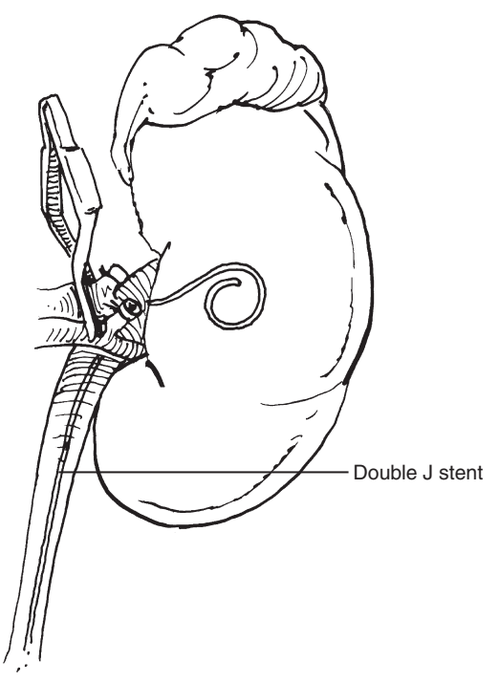

FIGURE 154-13.

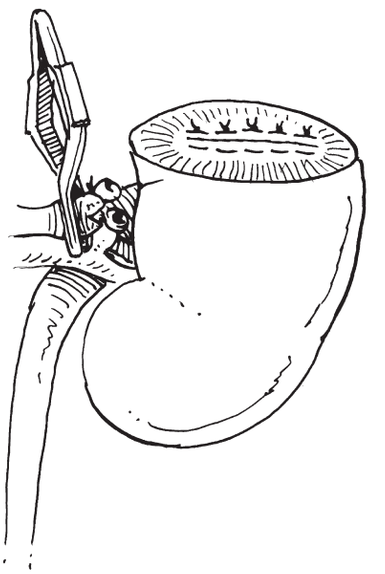

FIGURE 154-14.

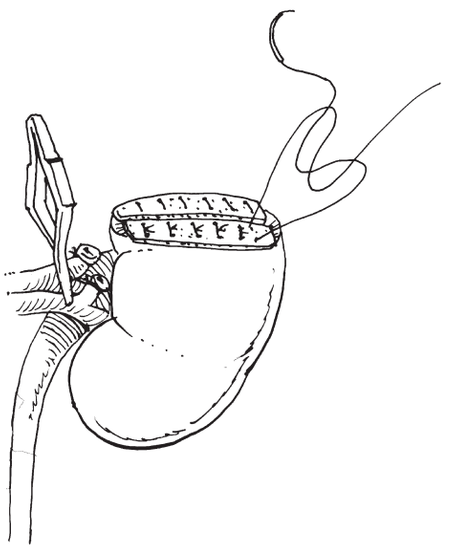

FIGURE 154-15.

Consider nephropexy. Wrap the renal remnant with perirenal fat and place a closed suction drain in the pararenal space before closing the skin and fascia.

POSTOPERATIVE PROBLEMS

Urinary Fistulas

Whenever the collecting system is entered, the possibility exists for breakdown of the suture repair with subsequent urine leakage. Most leaks happen at around 1 week after surgery, so it is wise to keep the postoperative drain for 7 to 10 days before removing it. Proof of a urine leak is straightforward when a drain is present: simply check the effluent drainage for creatinine (which will be an order of magnitude larger than the serum level) or administer an ampule

of intravenous indigo carmine and check the drainage fluid for blue color. If a urine leak is suspected in a patient without a drain, an intravenous or retrograde pyelogram is required to make the diagnosis. Imaging is also useful to rule out ureteral obstruction (usually by a blood clot) if drainage is sudden, severe, or prolonged. When a drain is not in place, leaking urine can collect in the retroperitoneum and cause a *urinoma* or can flow into the peritoneal cavity and cause *urinary ascites*. The treatment of urinary fistulas requires three tubes, a retroperitoneal closed suction drain (to drain any collections that might get infected or cause symptoms), a double-J ureteral stent (to ensure good upper tract emptying), and a Foley catheter (to keep the entire collecting system at low pressure). Most urinary fistulas resolve within a month with conservative management. Reoperation is rarely required.

Postoperative Bleeding

Delayed bleeding can occur following partial nephrectomy, particularly in patients who require postoperative anticoagulation for comorbid medical conditions. If a drain is in place, initial management is conservative and consists of bed rest, hydration, frequent blood counts, and close clinical monitoring. The requirement of more than 1 to 2 units of transfused blood is an indication of more serious bleeding and renal angioembolization should be promptly attempted. Usually, bleeding segmental or subsegmental arteries can be selectively embolized and the kidney salvaged. Life-threatening hemorrhage can also occur and require complete angioinfarction of the kidney or reoperative exploration.

Renal Insufficiency

Acute renal failure may follow partial nephrectomy in a solitary kidney, related to large size of the tumor, excessive removal of parenchyma, and prolonged ischemia time. Obstruction of the collecting system, drug toxicity, vascular thrombosis, and vascular disruption are other causes that should be considered. While most cases of postoperative renal insufficiency are mild and temporary, some cases are severe and require hemodialysis for electrolyte and fluid management. Hyperfiltration injury can also cause a gradual decrease in renal function over time, typically associated with proteinuria.

Commentary by PAUL RUSSO

From its historical description as an operation to be performed only for the essential conditions for a patient with a tumor in a functionally or anatomically solitary kidney, a patient with bilateral renal tumors, or a patient with a renal tumor and chronic kidney or stone disease. However, in the past decade, several factors have changed these traditional views of essential partial nephrectomy toward the liberal application of kidney or "nephron sparing" partial nephrectomy. Secondary to the liberal use of modern imaging techniques of CT, ultrasound, and MRI during the evaluation of nonspecific abdominal and musculoskeletal complaints or during unrelated cancer care, 70% of renal tumors are now detected incidentally and are small with a median tumor size of less than 4 cm. It is also now known that 20% of renal cortical tumors are benign (i.e., renal oncocytoma, metanephric adenoma) and 25% are indolent (papillary or chromophobe carcinoma) with limited metastatic potential. If the tumor is a small conventional clear cell carcinoma, despite its malignant potential, the overall prognosis for survival is excellent, with greater than 90% of T1 tumors (<7 cm) achieving long-term survival.

Well-done studies have indicated that partial nephrectomy provides equivalent oncologic results as radical nephrectomy with the added benefits of preventing or delaying chronic kidney disease status and its associated cardiovascular morbidity and mortality. A historical misconception exists that radical nephrectomy (RN) can cause a permanent rise in serum creatinine due to the sacrifice of normal renal parenchyma not involved by tumor but will not cause serious long-term side effects as long as the patient has a normal contralateral kidney. The renal transplant literature is cited as the clinical evidence to support this view in that patients undergoing donor nephrectomy have not been reported to have higher rates of death or kidney failure requiring dialysis. However, distinct differences between kidney donors and kidney tumor patients exist. Donors tend to be carefully screened for medical comorbidities and are generally young (age 45 years or younger). In contrast, renal tumor patients are not screened, are older (mean age 61 years), and many have significant comorbidities affecting baseline kidney function, including metabolic syndrome, hypertension, coronary artery disease, obesity, vascular disease, and diabetes. In addition, as patients age, particularly beyond 60 years, nephrons atrophy and glomerular filtration rate progressively decreases. It now appears clear that whether a patient develops chronic kidney disease from medical comorbidities or is effectively placed in chronic kidney disease status by the overzealous use of radical nephrectomy, the deleterious impact on cardiovascular health and overall survival is the same. These factors have also effectively ended the notion that radical nephrectomy can be performed to settle diagnostic dilemmas (i.e., complex cystic mass).

In addition, partial nephrectomy provides a buffer for patients going forward who are at an approximately 5% risk for developing a contralateral renal tumor regardless of whether a partial or radical nephrectomy was performed on the tumor-bearing kidney. Despite complications of partial nephrectomy of approximately 10% relating to urinary fistula, bleeding, or infection, the combination of renal functional preservation and excellent oncologic control has made partial nephrectomy the treatment of choice for the small renal mass whenever technically feasible.

Suggested Readings

Blute ML, Thibault GP, Leibovich BC, Cheville JC, Lohse CM, Zincke H. (2003). Multiple ipsilateral renal tumors discovered at planned nephron sparing surgery: importance of tumor histology and risk of metachronous recurrence. J Urol 170(3):760-763.

Carini M, Minervini A, Masieri L, Lapini A, Serni S. (2006). Simple enucleation for the treatment of PT1a renal cell carcinoma: our 20-year experience. Eur Urol 50(6):1263-1268; discussion 1269-1271.

Gill IS, Kavoussi LR, Lane BR, et al. (2007). Comparison of 1,800 laparoscopic and open partial nephrectomies for single renal tumors. J Urol 178(1):41-46.

Hanley MJ, Davidson K. (1981). Prior mannitol and furosemide infusion in a model of ischemic acute renal failure. Am J Physiol 241(5):F556-564.

Nicholson ML, Baker DM, Hopkinson BR, Wenham PW. (1996). Randomized controlled trial of the effect of mannitol on renal reperfusion injury during aortic aneurysm surgery. Br J Surg. 83(9):1230-1233.

Novick AC, Gephardt G, Guz B, Steinmuller D, Tubbs RR. (1991). Long-term follow-up after partial removal of a solitary kidney. N Engl J Med 325(15):1058-1062.

Thompson RH, Frank I, Lohse CM, et al. (2007). The impact of ischemia time during open nephron-sparing surgery on solitary kidneys: a multi-institutional study. J Urol 177(2):471-476.

Tiggeler RG, Berden JH, Hoitsma AJ, Koene RA. (1985). Prevention of acute tubular necrosis in cadaveric kidney transplantation by the combined use of mannitol and moderate hydration. Ann Surg 201(2):246-251.

van Valenberg PL, Hoitsma AJ, Tiggeler RG, Berden JH, van Lier HJ, Koene RA. (1987). Mannitol as an indispensable constituent of an intraoperative hydration protocol for the prevention of acute renal failure after renal cadaveric transplantation. Transplantation 44(6):784-788.

Chapter 155

Nephroureterectomy

MICHAEL L. BLUTE, SR. AND BRANT INMAN

Nephroureterectomy is the standard of care for treating carcinoma of the upper urinary tract and consists of the removal of the kidney, renal pelvis, ureter, and a cuff of bladder mucosa. Although less aggressive nephron-sparing resections are sometimes indicated for treating upper tract malignancy, it should always be remembered that leaving residual cancer in exchange for nephrons is not a good deal for the patient. Other indications for nephroureterectomy include infectious diseases that destroy the kidney and that can persist within the ureter. In such cases, removal of the entire ureter in addition to the kidney reduces the risk of infection persistence or recurrence. General indications for nephroureterectomy are listed in Table 155-1.

TABLE 155-1 INDICATIONS FOR NEPHROURETERECTOMY

Malignancy	Carcinoma of the renal pelvis
	Carcinoma of the ureter
Infection	End-stage renal tuberculosis
	Pyelonephritis in a nonfunctional, refluxing kidney

PREOPERATIVE CONSIDERATIONS

Proving that the upper tract mass is malignant. Upper tract masses can be safely assumed to be malignant if (1) they are very large or invasive on imaging, (2) they are associated with metastases or lymphadenopathy, (3) they are associated with urothelial carcinoma of the bladder, (4) there is an associated positive urine cytology, or (5) a characteristic lesion is seen on ureteroscopy. Ureteroscopic visualization and biopsy (brush, basket, or cold cup) should be considered in cases where the diagnosis is not clear. Percutaneous approaches can also be used to confirm the presence of tumor, but these approaches are more invasive than ureteroscopy and have the added (albeit rare) risk of nephrostomy tract seeding.

Staging of malignancy. Carcinoma of the upper urinary tract, regardless of the histology, should be considered a panurothelial disease that can metastasize. This means that the epithelium of the urinary tract must be inspected from the tips of the renal papillae to the tip of the penis, usually with a CT or MR urogram and a cystoscopy, and that the chest and abdomen should be screened for nodal and organ involvement. Intravenous or retrograde pyelography may provide finer anatomic detail of the renal collecting system. The prevalence of various forms of multifocal urothelial carcinoma is shown in Table 155-2.

TABLE 155-2 PREVALENCE OF MULTIFOCAL UPPER TRACT UROTHELIAL CARCINOMA

	Synchronous	Metachronous
Ipsilateral upper tract	10%	—
Contralateral upper tract	1.5%	3%
Bladder	15%	50%

Neoadjuvant chemotherapy. Neoadjuvant chemotherapy has been shown to be of benefit in urothelial carcinoma of the bladder and it is reasonable to expect that a benefit could also be observed in the upper tract. One major difference distinguishes chemotherapy for upper tract lesions from that of bladder lesions: renal insufficiency. Patients undergoing nephroureterectomy always experience a postoperative reduction in renal function, often one that is significant enough to necessitate important modifications in the chemotherapy regimen, such as a dose reduction or a change to a less nephrotoxic agent. These changes can compromise the efficacy of chemotherapy or even obviate its use. Therefore, all patients that might reasonably be expected to benefit from chemotherapy (positive nodes, metastases, locally invasive tumors, large tumors, high grade tumors, multifocal tumors) should receive the bulk of their chemotherapy prior to surgery. It is our experience that the majority of patients in whom nephroureterectomy is planned should receive neoadjuvant chemotherapy.

Lymphadenectomy. Extended lymphadenectomy has been shown to be of benefit in urothelial carcinoma of the bladder treated by cystectomy. Extrapolating this effect to upper tract carcinomas and considering small studies in upper tract patients, we recommend extended regional lymphadenectomy for upper tract tumors when certain criteria are present: (1) tumor stage is pT2-T4, (2) there are multifocal tumors, (3) the tumor is high grade, or (4) the tumor shows lymphovascular invasion. The lymphatic drainage of the renal pelvis and ureter are discussed on page 971. The presacral, common iliac, external iliac, obturator, and internal iliac nodes should be removed in an extended regional lymphadenectomy. In addition, for right-sided tumors the paracaval, precaval, retrocaval, and interaortocaval nodes should be removed and for left-sided tumors the para-aortic, preaortic, and retroaortic nodes should be removed.

TECHNIQUES OF NEPHROURETERECTOMY

No other oncologic procedure in urology has the diversity of techniques of nephroureterectomy. Although it goes without saying that the optimal technique is open for debate, we generally favor laparoscopic nephroureterectomy over the open approach since it is less morbid. However, in cases where a high-quality lymphadenectomy will be required (large invasive tumors, lymphadenopathy, metastases), open nephroureterectomy remains an excellent operation. We prefer a two-incision technique and complete extravesical cuff resection. Table 155-3 describes some of the possible variations in technique that can be used to remove the kidney and ureter in an open manner.

TABLE 155-3 TECHNIQUES OF OPEN NEPHROURETERECTOMY

	Advantages	Disadvantages
Single Incision		
Thoracoabdominal	Excellent access for very large masses	Increased pulmonary complications Long incision, slower recovery Transection of large muscles Reduced access to contralateral retroperitoneum
Midline laparotomy	No muscle transection Bilateral renal access Excellent access to aorta and inferior vena cava	Suboptimal access to upper pole Long incision, slower recovery
Paramedian laparotomy	No muscle transection Lower incidence of hernia Excellent access to aorta and inferior vena cava	Suboptimal access to upper pole Long incision, slower recovery Reduced access to contralateral retroperitoneum Transection of deep inferior epigastric vessels
Flank and endoscopic pluck	Short incision, faster recovery	Increased bladder recurrences Local wound seeding and recurrences

TABLE 155-3

TECHNIQUES OF OPEN NEPHROURETERECTOMY—cont'd

	Advantages	Disadvantages
Two Incisions		
Upper Incision		
Flank	Excellent parenchymal visualization No peritoneal cavity breech Pedicle approached anteriorly or posteriorly	Rib resection and flank bulge Ventilation compromise and pneumothorax Difficult interaortocaval node dissection Positioning related complications
Anterior subcostal	Excellent vascular control Extendible incision	Postoperative ileus Intestinal injury Adhesions and bowel obstruction
Lower Incision		
Paramedian or Gibson	Excellent access to distal ureter Extendible to lower pole of kidney Rare herniation and dehiscence	Ilioinguinal and iliohypogastric nerve injury Transection of deep inferior epigastric vessels
Midline or Pfannenstiel	No muscle transection Excellent cosmesis (Pfannenstiel) Rare herniation and dehiscence (Pfannenstiel) Quick entry (midline)	Rectus muscle hematoma (Pfannentiel) Limited exposure (Pfannenstiel)
Distal Ureteral Resection		
Endoscopic pluck	Avoid a second incision No cystotomy (decreased spasms)	Increased bladder recurrences Local tumor seeding and recurrences Defect not closed
Endoscopic intussusception	Avoid a second incision No cystotomy (decreased spasms)	Local tumor seeding and recurrences Technical failure requiring incision Defect not closed
Transvesical cuff	Ensures complete upper tract excision	Urine leaks Bladder spasms Prolonged Foley catheterization
Extravesical cuff	No cystotomy (decreased leaks and bladder spasms) Fast	Complete removal of intramural ureter can be tricky
Extravesical transection	No cystotomy (decreased leaks and bladder spasms) Faster (since no cuff is removed)	Intramural tunnel remains (increased recurrence risk)

Single-Incision Thoracoabdominal Approach with Intravesical Dissection of the Ureteral Cuff

We rarely use a single incision to perform nephroureterectomy since we find these incisions to be excessively morbid, cosmetically unappealing and the exposure inferior to the two incision technique.

1. Place the patient in the flank position (see page 975) but rotate the hips posteriorly until the pelvis is nearly in a supine position. The rules of padding for the flank position apply. Insert a three-way catheter into the bladder to allow for bladder irrigation and filling during the case. Make a thoracoabdominal incision (Fig. 155-1) starting at the angle of the 11th rib in the posterior axillary line, run it inferomedially to the lateral border of the rectus muscle, and continue it paramedially to the symphysis pubis. Cut directly onto the palpable 11th rib through the latissimus dorsi and serratus muscles posteriorly and the external and internal oblique and transversalis muscles anteriorly.
2. Excise the rib or free its superior margin (Fig. 155-2).

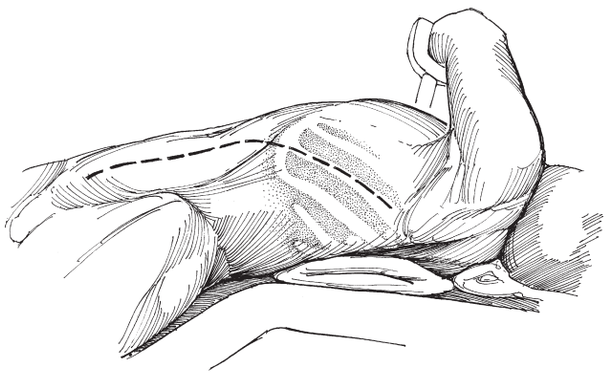

FIGURE 155-1.

3. Sharply divide the costochondral junction (Fig. 155-3). Incise the bed of the rib, opening the pleura. Alternatively, use an extrapleural approach. Continue the incision anteriorly to the border of the rectus muscle; then carry it to the symphysis.
4. Bluntly dissect under the edge of the diaphragm, and open it in the direction of the incision (Fig. 155-4). This approach should spare injury to the phrenic nerve.
5. Mobilize the peritoneum medially, freeing it first from the transversalis fascia and then from the anterior rectus fascia, where it is quite adherent and must be sharply separated (Fig. 155-5). Also free the peritoneum from the undersurface of the diaphragm to allow the spleen, pancreas, and left lobe of the liver to be moved medially within the peritoneal envelope, out of the way of the dissection. Enter the avascular plane between the peritoneum and the anterior surface of the renal fascia in the thin layer of loose areolar tissue. Carry the dissection medially across the aorta bluntly.
6. Dissect the left renal vein lying beneath the SMA (Fig. 155-6). Divide the adrenal, gonadal, and lumbar veins at their origins from the renal vein for left-sided tumors. (This division is not necessary for right-sided tumors.) Expose the renal artery.
7. Ligate the renal artery and divide it, then ligate and divide the renal vein (Fig. 155-7). Mobilize the posterior surface of Gerota's fascia from the lumbar and psoas muscles. Begin dissection of the retroperitoneal areolar and nodal tissue at the diaphragm. Spare the adrenal gland unless gross pathology exists. As the dissection proceeds, clip generously to prevent lymphatic leakage.
8. Continue the dissection posteriorly outside Gerota's fascia (Fig. 155-8).
9. Continue the dissection caudally to just above the aortic bifurcation (Fig. 155-9). Clamp, divide, and ligate the remaining tongue of tissue.
10. Draw the ureter aside, and clip and divide its vascular connections within the pelvis (Fig. 155-10). Continue to dissect the ureter distally until you reach the posterior

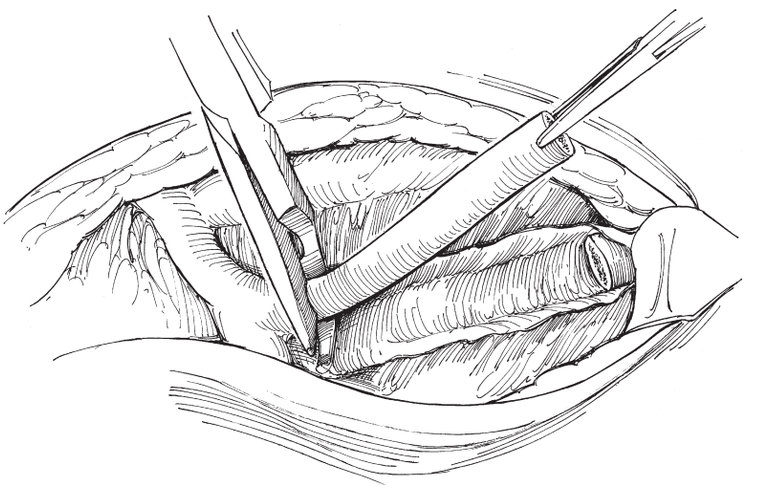

FIGURE 155-2.



FIGURE 155-3.

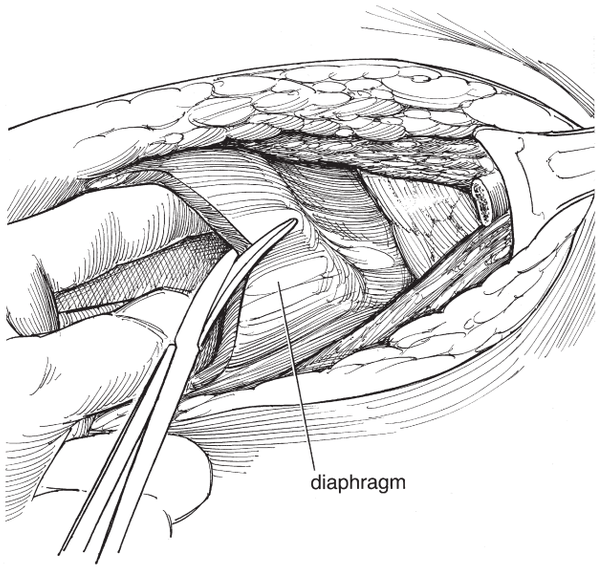

FIGURE 155-4.

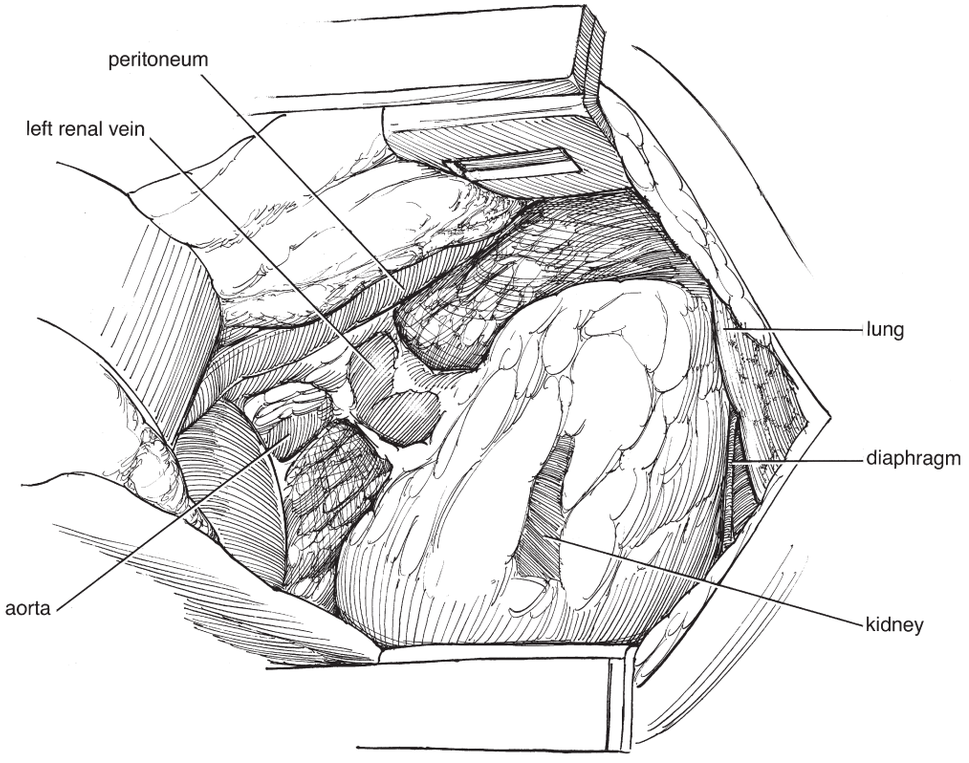

FIGURE 155-5.

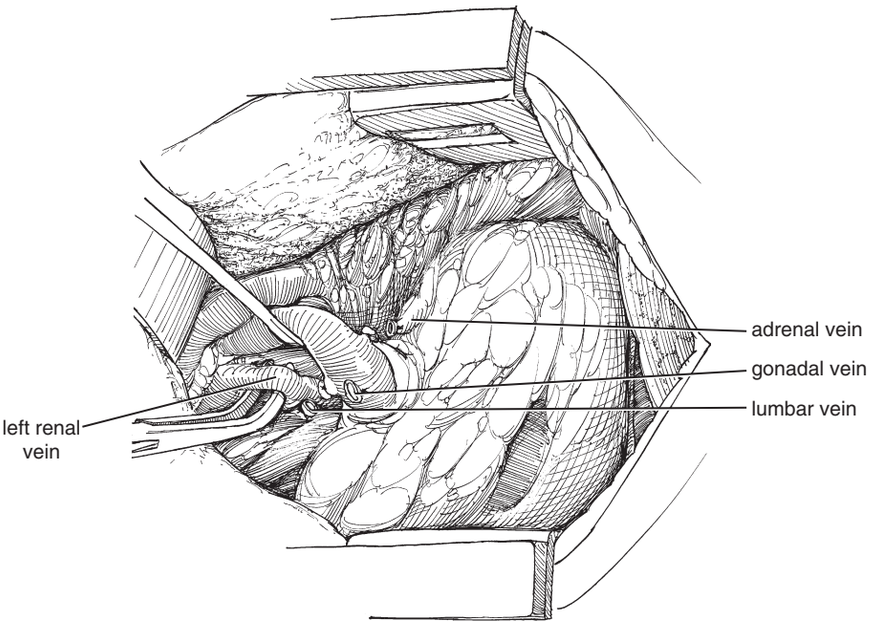

FIGURE 155-6.

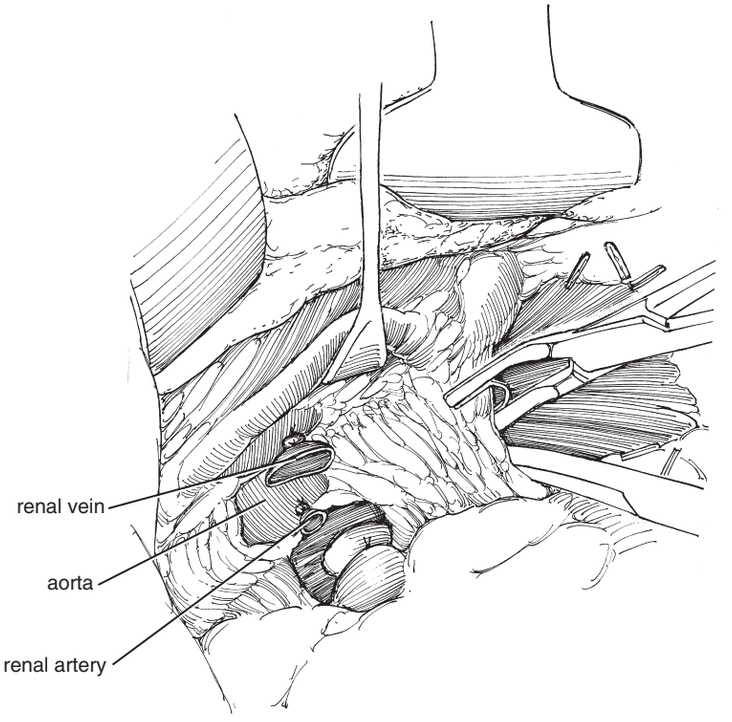

FIGURE 155-7.

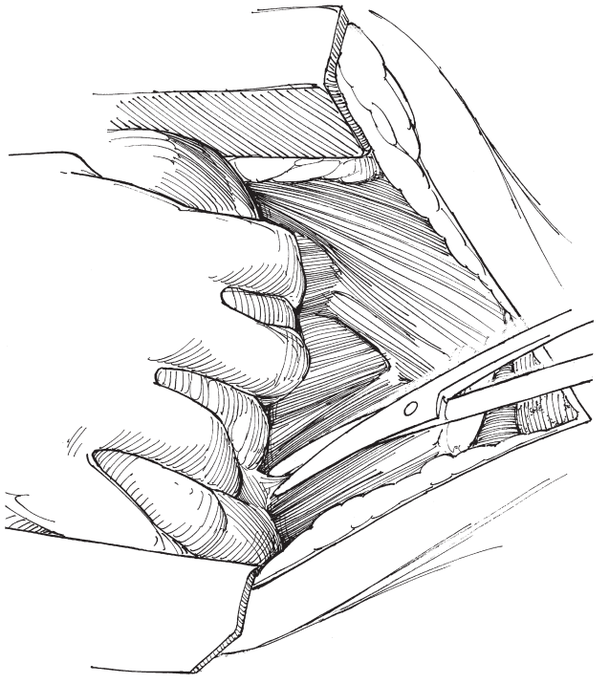

FIGURE 155-8.

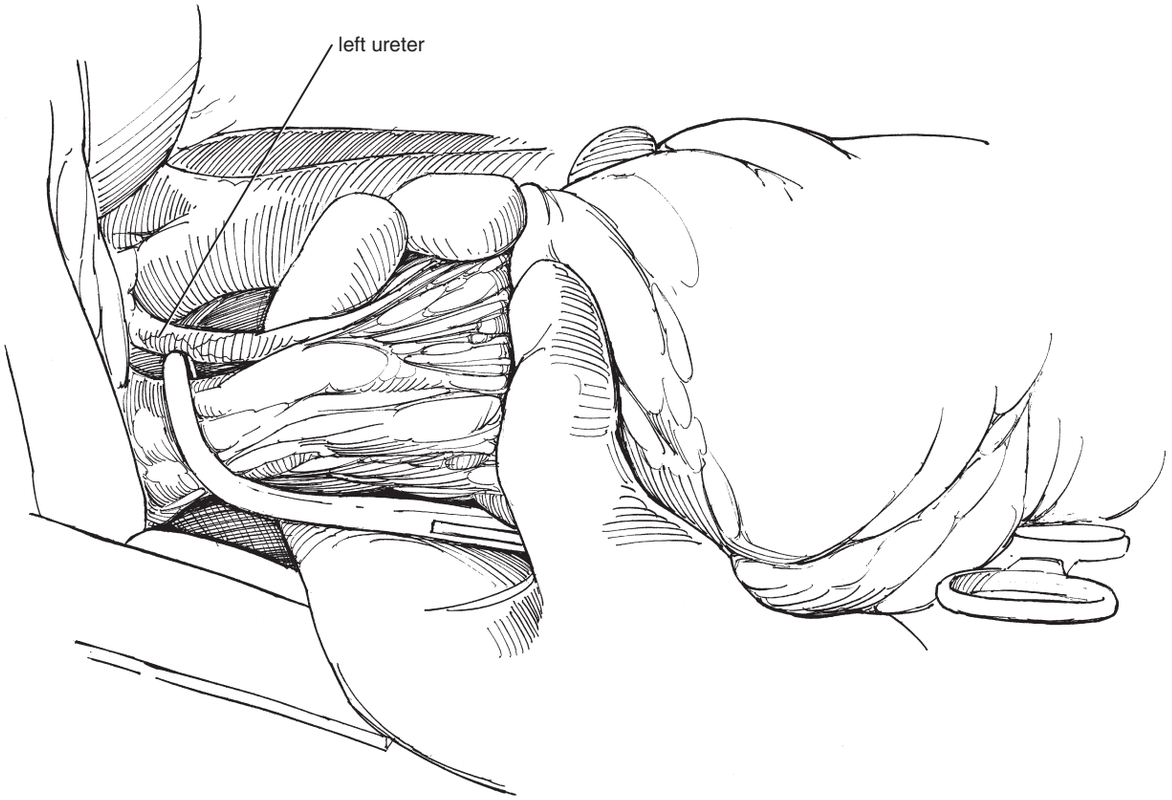

FIGURE 155-9.

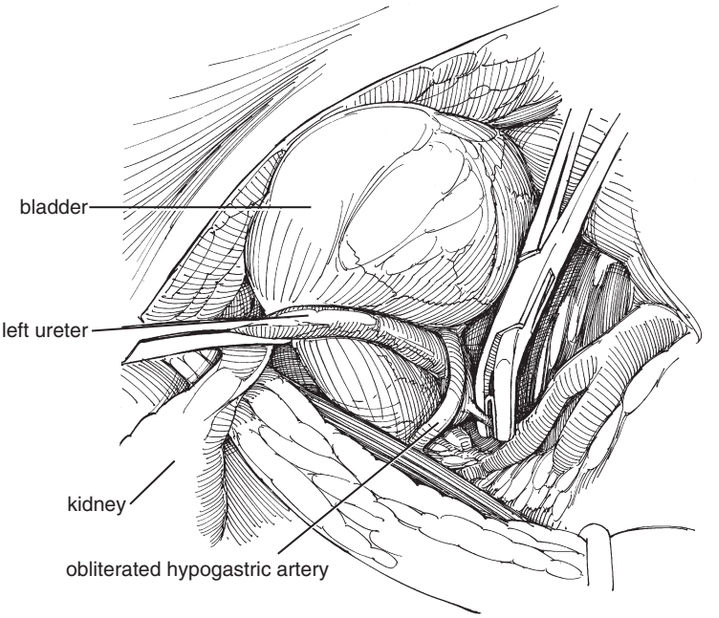

FIGURE 155-10.

bladder wall. In the female, the ovarian artery is anterolateral to the ureter as it crosses the pelvic brim. Although it can be safely ligated in most women due to collateral circulation from the uterine artery, the ovarian artery is the sole blood to the ovary in some women. The superior vesical and uterine arteries cross the ureter as it approaches the posterolateral wall of the bladder. Both may be safely ligated and divided if they obstruct ureteral dissection. At about the same time that pelvic ureteral dissection commences, fill the bladder with sterile water or a chemotherapeutic agent (e.g., Mitomycin C, Thiotepa) and clamp the Foley catheter. By allowing roughly 15 minutes of dwell time with a cytotoxic or hypotonic solution prior to incising the urinary bladder, free-floating urothelial carcinoma cells capable of seeding the operative site will be lysed, reducing the risk of a local recurrence.

11. Clip the ureter on the posterior bladder wall (to close the upper tract; Fig. 155-11) and pack the pelvis surrounding the bladder with sponges or towels to catch any urine spillage. Circumferentially incise the detrusor muscle surrounding the posterolateral ureter with electrocautery to loosen Waldeyer's sheath.
12. Empty the bladder and then incise and perform a midline cystotomy over a 3- to 4-cm length with electrocautery. Use suction to aspirate any residual urine and be careful not to spill urine into the wound. Gently pull the bladder open using vein retractors or 3-0 silk stay sutures. Place a figure-of-eight suture in the ureteral orifice using a 3-0 silk suture to close the orifice and to serve as a traction suture. Excise a 5- to 10-mm cuff of urothelium surrounding the orifice using a scalpel (Fig. 155-12). Use scissors to dissect the complete intramural tunnel of the ureter away from the bladder and remove the kidney and ureter en bloc.

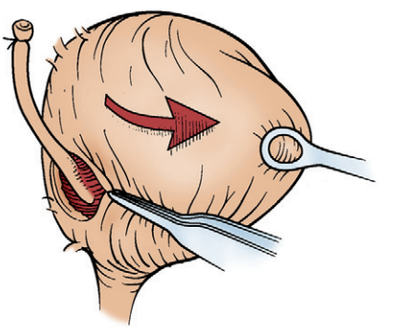

FIGURE 155-11. *(Modified from Wein AJ, Kavoussi LR, Novick AC, Partin AW, Peters CA, eds., Campbell-Walsh Urology, 10th ed., Philadelphia, Saunders, 2012.)*

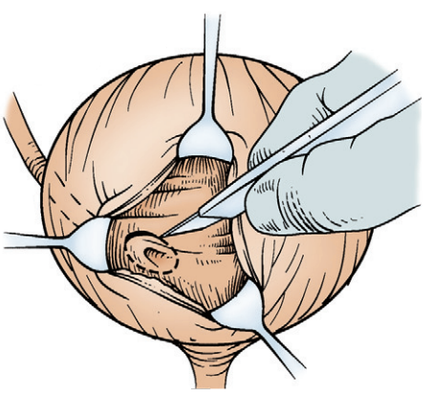

FIGURE 155-12. *(Modified from Wein AJ, Kavoussi LR, Novick AC, Partin AW, Peters CA, eds., Campbell-Walsh Urology, 10th ed., Philadelphia, Saunders, 2012.)*

13. Close the bladder mucosa overlying the ureteral orifice and the anterior cystotomy intravesically with a running suture of 4-0 absorbable monofilament (e.g., Maxon, Monocryl) on a tapered needle (Fig. 155-13). Close the detrusor muscle and adventitia extravesically in a single layer with a running suture of 3-0 absorbable monofilament. Insert a new urethral catheter and fill the bladder with water to check for leaks. Leave the urethral catheter in place for 7 to 10 days to allow for bladder healing. A closed suction drain placed in the pelvis is usually a good idea to monitor for delayed bleeding, lymphoceles, and urine leaks.
14. Since the renal pelvis and upper ureter drain to the same lymph nodes as the kidney, perform a regional retroperitoneal lymph node dissection as described on page 997. In addition, since the middle and distal ureter drain to the same nodes as the prostate and bladder, perform an extended pelvic lymph node dissection. It is important to remember that a complete lymphadenectomy for upper tract urothelial carcinoma requires the resection of both the pelvic and retroperitoneal nodes. Close the abdominal wound.

Two-Incision Approach (Mini-Flank with Gibson) with Extravesical Dissection of the Ureteral Cuff

1. Position the patient in flank position with the pelvis rotated posteriorly until it is nearly supine in position. Perform a mini-flank incision and proceed with adrenal-sparing nephrectomy as described on page 995. Do not divide the ureter at the inferior pole of the kidney (Fig. 155-14).
2. Dissect the ureter as far distally as possible (usually to the level of the common iliac artery), clipping its medial vascular and lymphatic attachments. Be careful not to pull too hard on the ureter, which can result in its avulsion and seeding of the wound with urine containing tumor cells.
3. Perform a regional retroperitoneal lymphadenectomy as described on page 997.
   Option 1: Doubly clip the ureter as distal as possible and transect it with electrocautery (to kill any tumor cells at this surgical margin) between the clips. Remove the kidney and proximal ureter and close the flank.
   Option 2: Clip the ureter as distally as possible but do not divide it (the clip will serve a landmark for the pelvic portion of the case). Place the kidney and proximal ureter in a laparoscopic specimen bag and gently place this bag as caudal as possible in the wound. Close the flank leaving the kidney and ureter in the body. Inflate the bladder with sterile water or cytotoxic agents.
4. Rotate the table to make pelvis more accessible. If access is inadequate, repositioning and redraping of the patient in the supine position will be required. Perform a small Gibson incision and bluntly develop the retroperitoneal space of Retzius. Mobilize the peritoneum off the iliac vessels and identify the ureter as it crosses the common iliac artery. Search for the previously placed clip on the ureter and mobilize the ureter (with or without an attached bagged kidney) into the wound.
5. Dissect the pelvic ureter to its attachment to the bladder and rotate the bladder anteriorly so that the posterolateral ureteral insertion site is better seen (Fig. 155-15). Traction sutures around the site can help to rotate the bladder. If necessary, ligate the superior vesicle artery to improve visualization and bladder mobility.
6. Circumferentially dissect the ureter away from the detrusor muscle and Waldeyer's sheath using cutting current electrocautery in a fashion analogous to an extravesical detrusorrhaphy (Fig. 155-16). Continue to develop the

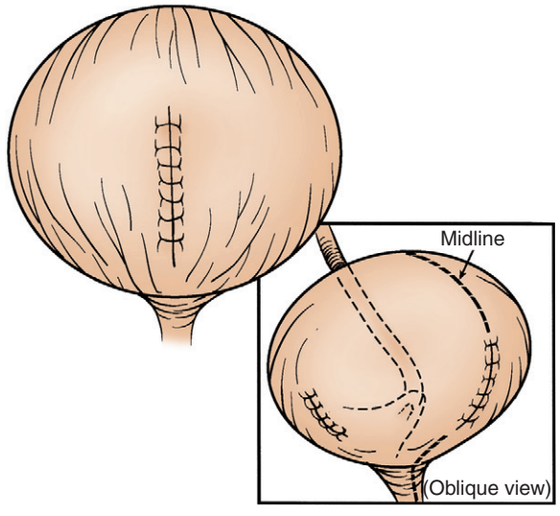

FIGURE 155-13. *(Modified from Wein AJ, Kavoussi LR, Novick AC, Partin AW, Peters CA, eds., Campbell-Walsh Urology, 10th ed., Philadelphia, Saunders, 2012.)*

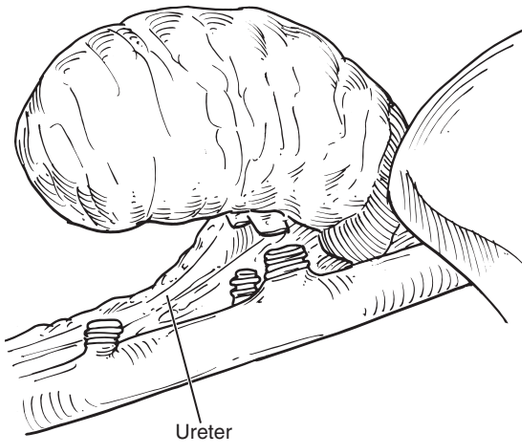

FIGURE 155-14. *(Modified from Bishoff JT, Kavoussi LR, Atlas of Laparoscopic Urologic Surgery, Philadelphia, Elsevier, 2007.)*

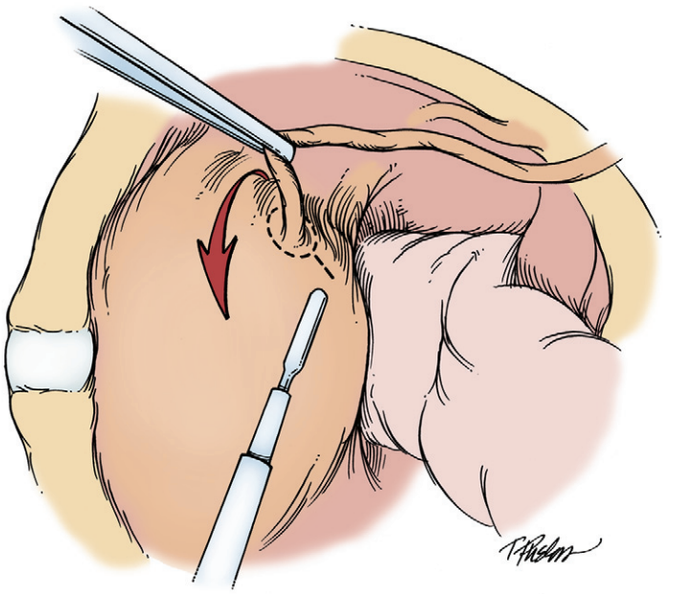

FIGURE 155-15. *(From Wein AJ, Kavoussi LR, Novick AC, Partin AW, Peters CA, eds., Campbell-Walsh Urology, 10th ed., Philadelphia, Saunders, 2012.)*

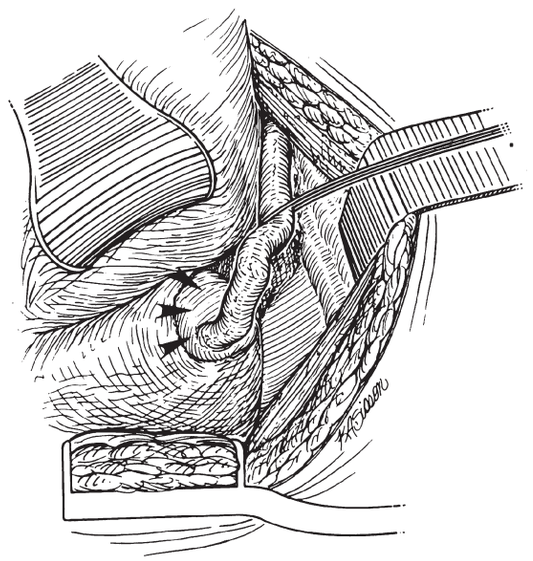

FIGURE 155-16. *(Modified from Zaontz MR, Maizels M, Sugar E, Firlit CF, Detrusorrhaphy: extravesical ureteral advancement to correct vesicoureteral reflux in children, J Urol. 1987;138:947949, with permission.)*

ureteral orifice until a large rim of bulging bladder mucosa completely surrounds it.

7. Empty the bladder and excise the ureteral orifice with a 5- to 10-mm cuff of bladder mucosa. Close the mucosa with a running 4-0 absorbable monofilament and the detrusor/adventitia with a 3-0 running absorbable monofilament. Leave a fresh urinary catheter for 7 to 10 days and consider placing a closed suction drain. Close the abdominal incision in layers.

ALTERNATIVE METHODS OF DISTAL URETERECTOMY

Excising the distal ureter with a cuff or bladder mucosa, whether done intravesically or extravesically, is the standard of care for resection of malignancy. All other methods of management of the distal ureter are associated with higher cancer recurrence rates and a risk of seeding the wound. There is no good reason in open nephroureterectomy to perform a sub-optimal distal ureterectomy. In fact, there is no good reason in laparoscopic nephroureterectomy not to excise a cuff of bladder since the renal extraction incision can double as access to the distal ureter. Though we strongly advocate removing the complete ureter with a bladder cuff in all cases of malignancy, benign conditions may be appropriately treated with less aggressive distal ureterectomies.

Transurethral Resection of the Ureteral Orifice (a.k.a. Pluck Technique)

Prior to nephrectomy, place the patient in lithotomy position and use an endoscopic resectoscope to resect the ureteral orifice and intramural ureter until the extravesical fat is seen (Fig. 155-17). Ensure that the ureter is completely

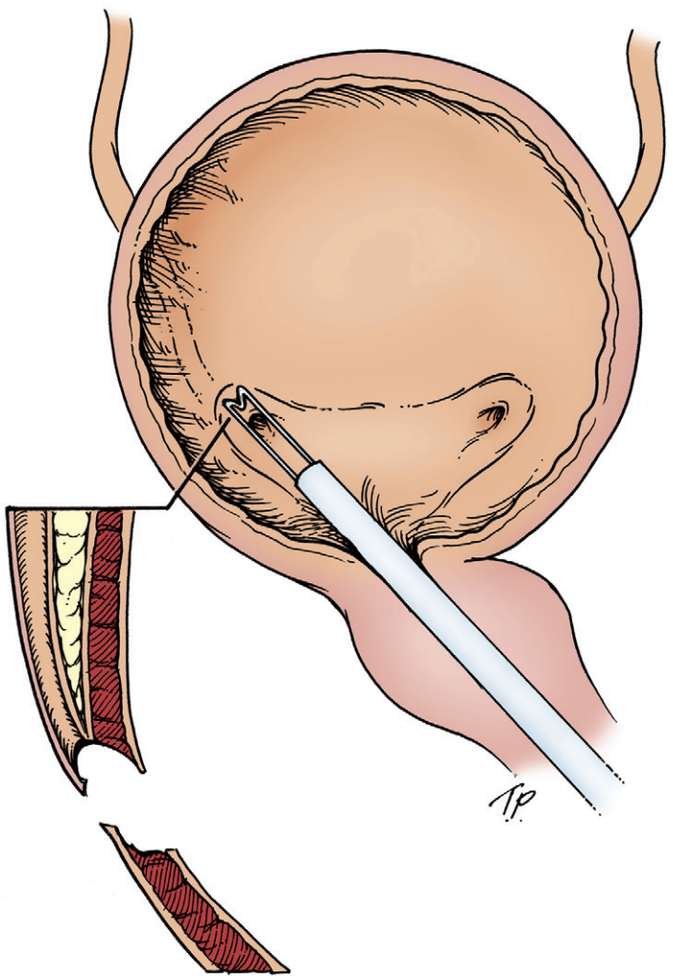

FIGURE 155-17. *(From Wein AJ, Kavoussi LR, Novick AC, Partin AW, Peters CA, eds., Campbell-Walsh Urology, 10th ed., Philadelphia, Saunders, 2012.)*

free of the bladder. Insert a Foley catheter to reduce (but certainly not eliminate) the risk of urine seepage through the hole in the bladder into the perivesical space.

Reposition the patient, perform nephrectomy (through a flank or anterior subcostal approach) and dissect the ureter distally into the pelvis (Fig. 155-18). Keep traction on the ureter as you dissect distally and eventually it will pull free of its perivesical attachments, the so-called "pluck." Excess tension can result in avulsion of the ureter, which requires a second pelvic incision to safely retrieve the retained ureteral stump. The bladder is not closed primarily, but heals secondarily with Foley drainage.

Ureteral Intussusception (a.k.a. Stripping Technique)

Prior to nephrectomy, place the patient in lithotomy position and insert a long straight 6 F ureteral catheter endoscopically into the renal pelvis. Reposition the patient, perform nephrectomy, and singly ligate the ureter as far distal as possible. Cut the ureter distal to the ligature and remove the kidney and proximal ureter. Pull out 2- to 4-cm length of the ureteral catheter from the open distal ureter, fold it over on itself outside the ureter, and secure the catheter to the ureter with several 2-0 silk ligatures (Fig. 155-19). Close the flank and replace the patient in lithotomy position.

Insert and endoscopic resectoscope and resect around the ureteral orifice into the extravesical fat. Pull on the ureteral catheter to extract the intussuscepted distal ureteral stump (in a fashion analogous to varicose vein stripping, Fig. 155-20). Too much traction on the ureteral catheter can tear the ureter or result in the avulsion of pelvic vascular structures upon which the catheter may be hooked. The bladder is not closed primarily but heals secondarily with Foley drainage.

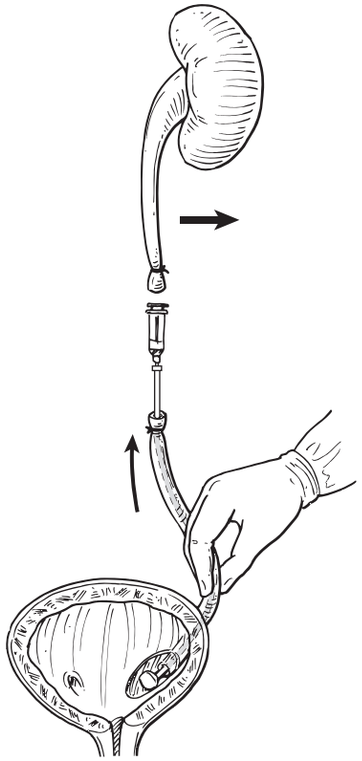

FIGURE 155-18. *(From Willis RG, Embolectomy catheter-assisted nephroureterectomy Br J Urol Int. 1999;83:709-710, Fig. 1.)*

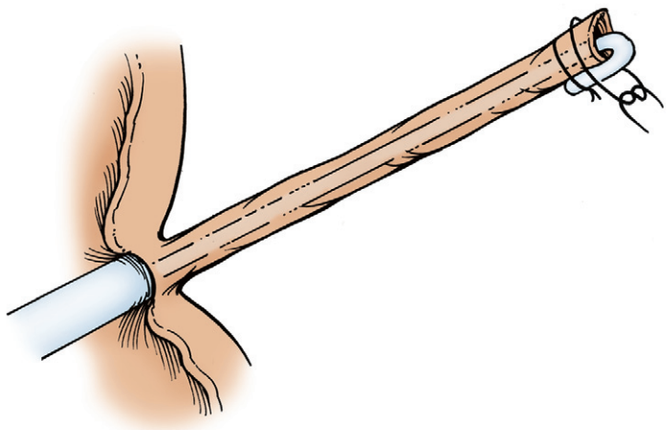

FIGURE 155-19. *(Modified from Wein AJ, Kavoussi LR, Novick AC, Partin AW, Peters CA, eds., Campbell-Walsh Urology, 10th ed., Philadelphia, Saunders, 2012.)*

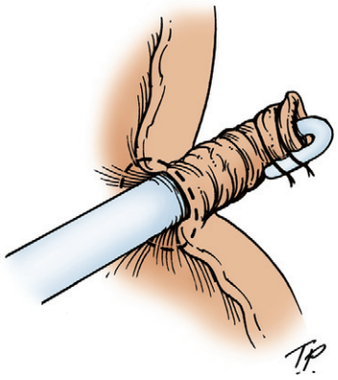

FIGURE 155-20. *(Modified from Wein AJ, Kavoussi LR, Novick AC, Partin AW, Peters CA, eds., Campbell-Walsh Urology, 10th ed., Philadelphia, Saunders, 2012.)*

Extravesical Transection without a Bladder Cuff

Perform nephrectomy and ureteral dissection using either one or two incisions. Dissect the ureter to the level of the posterolateral bladder wall (Fig. 155-21). Place the ureter on traction and ligate the ureter as close to the bladder as possible. Alternatively, clips or a stapler can be used to control the distal ureter. Transect the ureter and remove the specimen, leaving the intramural tunnel and orifice in situ.

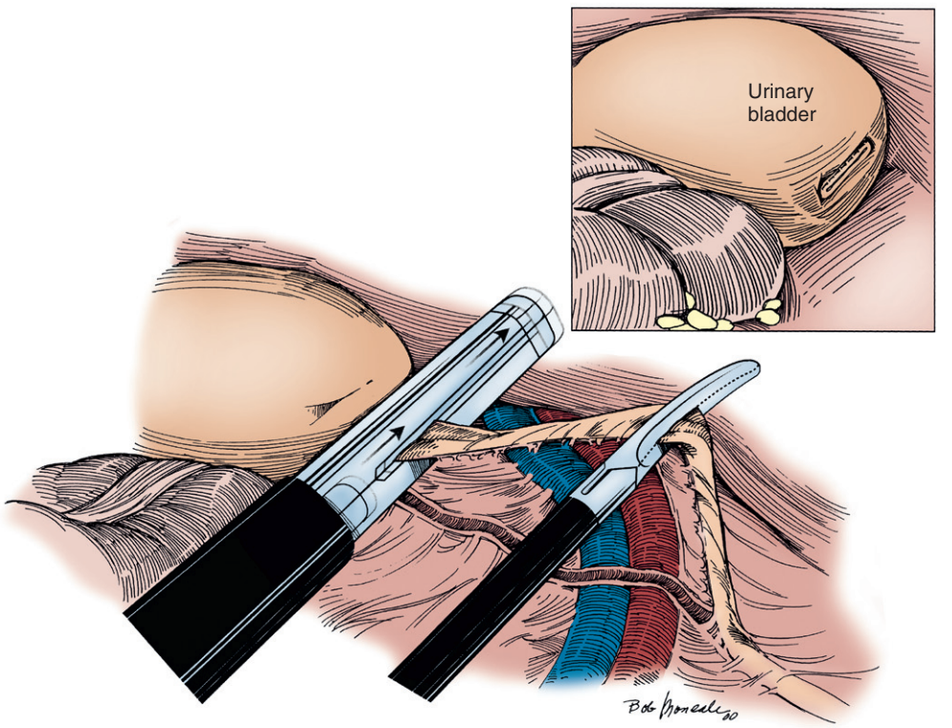

FIGURE 155-21. *(From Wein AJ, Kavoussi LR, Novick AC, Partin AW, Peters CA, eds., Campbell-Walsh Urology, 10th ed., Philadelphia, Saunders, 2012.)*

Suggested Readings

Advanced Bladder Cancer Meta-analysis Collaboration. Neoadjuvant chemotherapy in invasive bladder cancer: a systematic review and meta-analysis. *Lancet.* 2003;361:1927-1934.

Holmang S, Johansson SL. Synchronous bilateral ureteral and renal pelvic carcinomas: incidence, etiology, treatment and outcome. *Cancer.* 2004;101:741-747.

Holmang S, Johansson SL. Bilateral metachronous ureteral and renal pelvic carcinomas: incidence, clinical presentation, histopathology, treatment and outcome. *J Urol.* 2006;175:69-72; discussion 72-63.

Kondo T, Nakazawa H, Ito F, Hashimoto Y, Toma H, Tanabe K. Impact of the extent of regional lymphadenectomy on the survival of patients with urothelial carcinoma of the upper urinary tract. *J Urol.* 2007; 178(4 Pt 1):1212-1217; discussion 1217.

Koppie TM, Vickers AJ, Vora K, Dalbagni G, Bochner BH. Standardization of pelvic lymphadenectomy performed at radical cystectomy: can we establish a minimum number of lymph nodes that should be removed? *Cancer.* 2006;107:2368-2374.

Miyake H, Hara I, Gohji K, Arakawa S, Kamidono S. The significance of lymphadenectomy in transitional cell carcinoma of the upper urinary tract. *Br J Urol.* 1998;82:494-498.

Chapter 156

Extracorporeal Renal Surgery

MICHAEL L. BLUTE, SR. AND BRANT INMAN

Extracorporeal renal surgery (ECRS) with autotransplantation is an operative technique that is rarely used in contemporary urologic practice since open in situ renal exposure with vascular clamping and hypothermia provides excellent access to the kidney for nearly all forms of renal surgery. The advantages of ECRS are better exposure and illumination, a bloodless surgical field, the ability to protect the kidney from prolonged ischemia, and the opportunity to use an operating microscope. Currently, ECRS is reserved for the reconstruction of complex renal pathologies where (1) there is a solitary kidney, (2) percutaneous approaches are not appropriate or possible, and (3) routine in situ operative exposure is inadequate. Additionally, ECRS is used when addressing anatomic problems in a donated kidney that is destined for allogeneic transplantation. Specific indications where ECRS may be a valid option are listed in Table 156-1.

Although ECRS has been used in the past to manage complex staghorn nephrolithiasis, contemporary endourologic instrumentation for antegrade and retrograde access to the collecting system have made this indication obsolete. Renal autotransplantation can also be used without ECRS to manage cases where the ureter is lost and not amenable to reconstruction or stenting (e.g., total ureterectomy for cancer, severe ureteral stricture), to treat the loin pain-hematuria syndrome, and to permit pyelovesicostomy in cases of severe metabolic stone disease. These indications are discussed elsewhere.

PREOPERATIVE CONSIDERATIONS

Obtain a contrast study of the renal and iliac vasculature to rule out unrecognized anatomic abnormalities and to characterize the pathology being treated. Typically, a computed tomography (CT) or magnetic resonance (MR) angiogram is sufficient, although conventional digital subtraction arteriography may be beneficial in select cases.

Assess renal function with serum creatinine (and/or a 24-hour urine collection) and obtain a preoperative

TABLE 156-1 INDICATIONS FOR EXTRACORPOREAL RENAL SURGERY AND AUTOTRANSPLANTATION

Renovascular disease	Prolonged ischemia time (>45 minutes) anticipated
	Segmental renal artery disease
	Multivessel disease
	Arteriovenous malformations refractory to embolization
	Large intrarenal arterial aneurysms
Renal transplantation	Repair of a vascular anomaly
	Repair of a collecting system anomaly
Malignancy in solitary kidney	Large, central mass encroaching on the renal pedicle
	Large, central renal pelvic tumor
	Multiple subcortical neoplasms

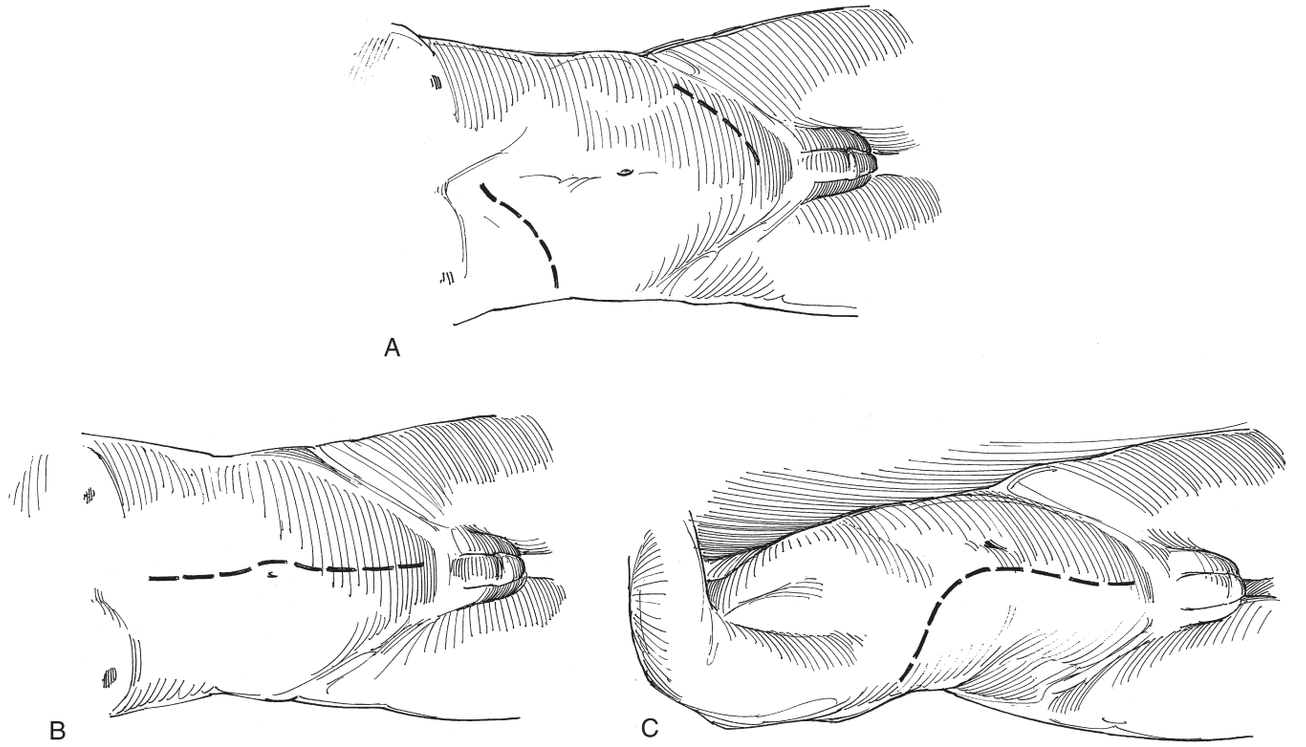

FIGURE 156-1.

nephrology evaluation for possible postoperative dialysis. Ensure that the patient is adequately hydrated. Ask that the anesthetist insert a large bore central line that can handle hemodialysis and that mannitol, lasix, and heparin be available for the case. Ask the surgical staff to prepare a seated operative work bench, ice slush, renal transplant preservation solution (e.g., EuroCollins or UW solution), and microvascular surgical instruments. The surgeon and assistants should wear surgical loupes with high magnification.

Since the surgeon will need to access both the retroperitoneum (for renal extirpation) and iliac foss (for autotransplantation), a number of single-incision and double-incision approaches are possible (Fig. 156-1). The rationale for the choice of surgical incision(s) is identical to that of open nephroureterectomy. Following incision and abdominal exploration, expose the kidney as for a living-related donor nephrectomy. Once the kidney is completely mobilized and that the only remaining attachments to the patient are the ureter, renal vein and renal artery, rapidly infuse 12.5 g of mannitol and 20 mg of furosemide intravenously. Ligate the ureter as far distally as possible and transect it, preserving as much periureteral tissue as possible. Though the ureter can be preserved intact, we do not favor this approach since it imposes two main problems for the subsequent transplantation: (1) placing the kidney in the contralateral iliac fossa can be difficult (and this may be the preferred site), and (2) the ureter is usually too long and is therefore prone to ischemia and kinking. Apply vascular clamps to each renal vessel directly where they exit the aorta and IVC (a C-shaped clamp is useful to gain length on the right renal vein) and transect the renal vessels directly on the clamps.

Immediately after dividing the renal vessels, place the kidney on the workbench in a pan of ice slush covered with a towel. Flush the kidney intra-arterially by gravity flow with renal preservation solution at 6° C (Fig. 156-2).

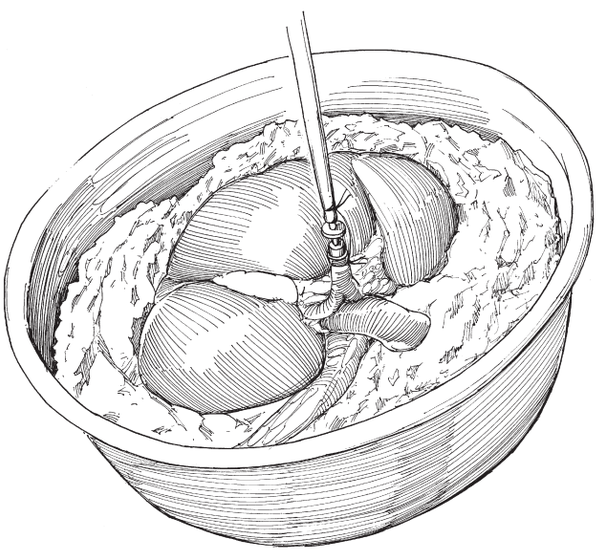

FIGURE 156-2.

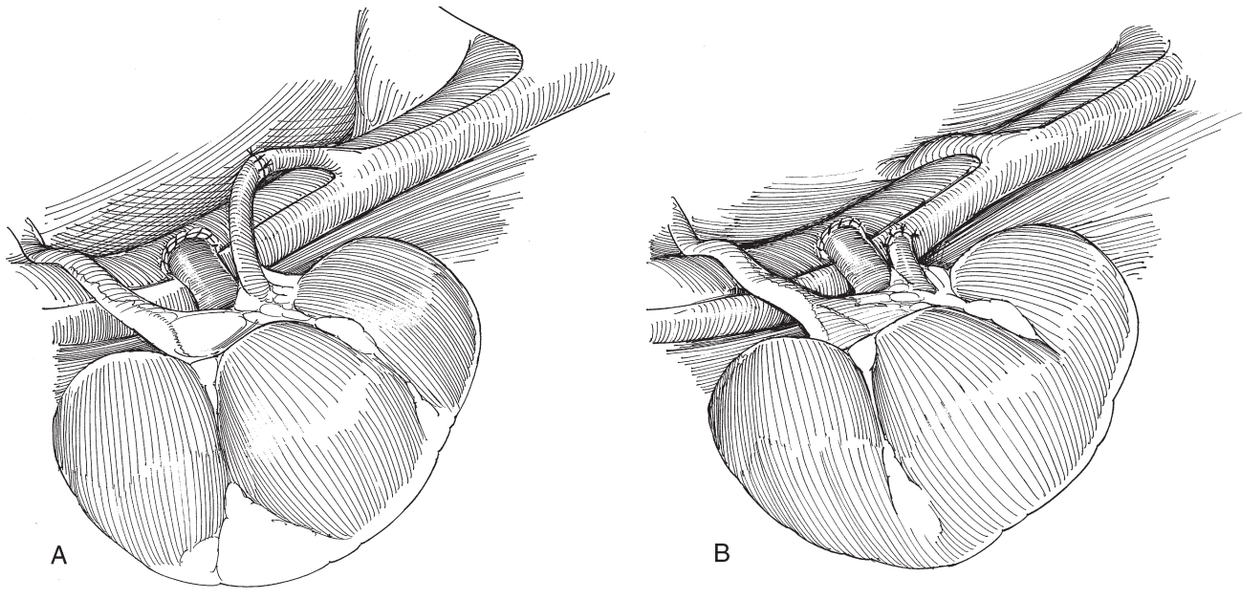

FIGURE 156-3.

Continue flushing until the kidney is cool and the renal vein effluent is clear (usually 500 to 1000 ml). Keep the kidney in the ice slush basin during the procedure to maintain hypothermia.

For renovascular disease, dissect the vasculature of the renal hilum and proceed with the vascular repair. For neoplasms, remove Gerota's fascia and the perirenal fat and proceed with partial nephrectomy. After reconstruction of the renal vasculature or the nephrectomy parenchymal defect is achieved, flush the renal artery and vein independently with preservation solution to look for potential sites of bleeding. Retrograde flush the ureter to look for collecting system leaks which should be repaired if identified.

Transplant the kidney into either lower quadrant. Transfer the kidney to the iliac fossa, and anastomose the renal vein to the external iliac vein and the renal artery either end to end with the hypogastric artery (Fig. 156-3A) or end to side with the external iliac artery (Fig. 156-3B). During the anastomosis, irrigate the vessels liberally with heparin solution (mix 10,000 U of heparin in 100 ml of normal saline), and consider injecting 10 mg of verapamil into the renal artery following the anatomosis to ensure vasodilation. Implant the ureter into the bladder. Leave a closed suction drain and a ureteral stent.

RENOVASCULAR DISEASE

For repair, select one of several alternative autologous vascular grafts, such as the saphenous vein graft.

The hypogastric artery, when not involved in atherosclerosis, may be used intact with its branches (Fig. 156-4).

Anastomose each branch end to end to a distal branch of the renal artery (Fig. 156-5).

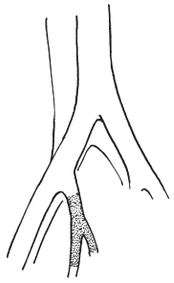

FIGURE 156-4.

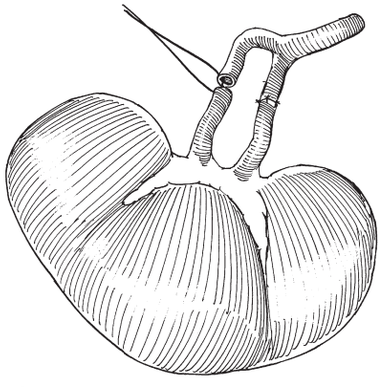

FIGURE 156-5.

RENAL NEOPLASMS

Extracorporeal partial nephrectomy has very limited application in oncology and there are almost always better ways to proceed. The technique is reserved for patients with a solitary kidney, whether anatomic or functional. Extracorporeal partial nephrectomy may be appropriate

for cases where prolonged ischemia would be required, such as a large centrally located tumor that is diffusely encroaching on the renal vasculature, a kidney that is involved with multiple subcortical neoplasms, or a large central renal pelvic tumor that will be resected while preserving maximal parenchyma. Regardless of the indication for surgery, the local recurrence rate is very high (20% to 25%) despite the presence of negative surgical margins.

The partial nephrectomy is performed using the same principles as the *in situ* technique (see Chapter 154). Clear the fat from the capsule to evaluate the extent of the disease and from the hilum to assess the vascular supply. Begin dissection of the tumor at the hilum and proceed peripherally (Fig. 156-6). Dissect and suture-ligate with 4-0 Maxon the small arteries and veins that supply the tumor. Although the surgical margin needs to be negative at every site, this does *not* require the resection of a rim of normal tissue (which amounts to wasting nephrons for no benefit). Frozen section must be performed to ensure an adequate resection. Close the collecting system with running 4-0 Maxon. Perform regional lymphadenectomy if indicated (see page 997).

Check the security of the vasculature by flushing renal preservation solution through the artery and the vein. Suture-ligate the transected vessels on the renal surface (Fig. 156-7). Fill the defect with a Nu-Knit bolster and reapproximate the capsule with a horizontal mattress closure sewn with Nu-Knit capsular pledget. Autotransplant the kidney into the iliac fossa and restore urinary continuity by ureteroneocystostomy. Pyelovesicostomy is an alternative for patients that have had the majority of the collecting system resected. A ureteral stent and a closed suction drain are left in most cases.

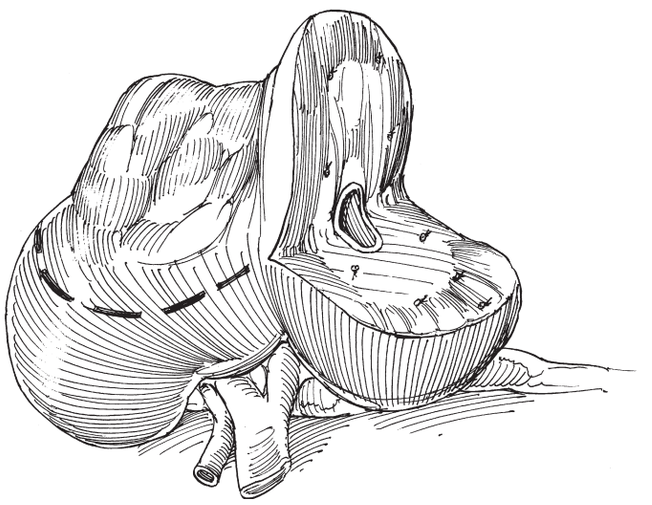

FIGURE 156-6.

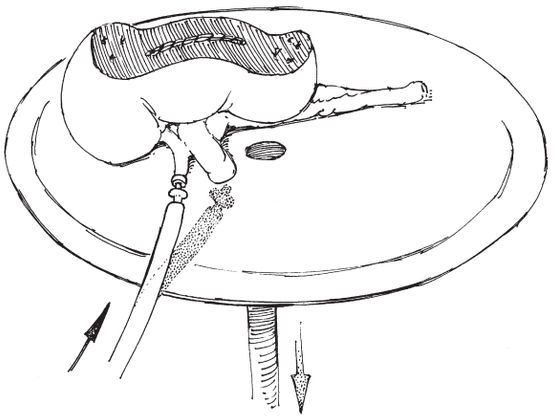

FIGURE 156-7.

POSTOPERATIVE PROBLEMS

The postoperative ECRS kidney should be managed in a fashion analogous to a postoperative allogeneic renal transplant. Obtain daily serum electrolytes and creatinine. Monitor urine output hourly to ensure adequate hydration and provide diuretics as needed, the goal being a high urine output (100 ml/hr). Oliguria can be a sign of a vascular problem (renal artery thrombosis, renal vein thrombosis, bleeding), a ureteral problem (ureteral obstruction, ureteral necrosis, leakage from ureteroneocystostomy) or a nephron problem (hypovolemia, acute tubular necrosis, acute interstial nephritis). Obtain a Doppler ultrasound of the kidney if the patient is oliguric, has a rising serum creatinine or if there is any reason to suspect a surgical problem. Anticoagulation should be considered on a patient by patient basis. Monitor the lower extremities for edema and evidence of distal embolization.

Complications are common following ECRS and include technical failure requiring nephrectomy (5% in renovascular disease, 20% in malignancy),[2-4] temporary and permanent renal failure requiring dialysis, local recurrence of malignancy, as well as the common surgical complications of renal transplantation (vascular thrombosis and bleeding, ureteral obstruction and leakage, lymphocele, and infection).

Suggested Readings

1. Holmang S, Johansson SL. Tumours of the ureter and renal pelvis treated with resection and renal autotransplantation: a study with up to 20 years of follow-up. BJU Int. 2005;95:1201-1205.
2. Novick AC, Jackson CL, Straffon RA. The role of renal autotransplantation in complex urological reconstruction. J Urol. 1990;143:452-457.
3. Stormont TJ, Bilhartz DL, Zincke H. Pitfalls of "bench surgery" and autotransplantation for renal cell carcinoma. Mayo Clin Proc. 1992;67:621-628.
4. Zincke H, Sen SE. Experience with extracorporeal surgery and autotransplantation for renal cell and transitional cell cancer of the kidney. J Urol. 1988;140:25-27.

Chapter 157

Vena Caval Thrombectomy

MICHAEL L. BLUTE, SR. AND BRANT INMAN

Thrombus in the venous drainage system of the kidney can occur with many retroperitoneal tumors. In children, Wilm's tumor, clear cell sarcoma of the kidney, adrenocortical carcinoma, and neuroblastoma can all cause inferior vena cava (IVC) thrombi. In adults, urothelial carcinoma of the renal pelvis, lymphoma, retroperitoneal sarcoma, adrenocortical carcinoma, pheochromocytoma, and angiomyolipoma are all potential sources of an IVC thrombus, though renal cell carcinoma (RCC) is by far the most common cause (18% of RCC cases will have venous thrombi). IVC thrombi have two components: *tumor thrombus* (tumor cells contained within a blood coagulum) and *bland thrombus* (blood coagulum without tumor cells). Tumor thrombus encourages the formation of bland thrombus because it alters venous drainage hemodynamics. The distinction between these two components is critical and forms the basis of the operative management of IVC thrombi.

The management of IVC thrombi is complicated by an additional concern: the necessity of managing the underlying tumor. This is not a minor consideration since tumors associated with IVC thrombi are typically quite aggressive. In the case of RCC with venous thrombus, 10% have associated positive regional lymph nodes, 25% have associated metastases, and 50% show perirenal fat invasion. Radical nephrectomy with regional lymph node dissection should accompany thrombectomy in nearly all cases.

PREOPERATIVE CONSIDERATIONS

Pulmonary embolism, anticoagulation, and IVC filters. Patients with renal tumors are at increased risk of pulmonary embolism due to malignancy-associated hypercoagulability and venous thrombus embolization. We recommend that anticoagulation with intravenous or low molecular weight heparin (not coumadin) be instituted as soon as a tumor thrombus is detected. Though evidence supporting this recommendation is limited, we have noted several important benefits to perioperative anticoagulation, including (1) a reduced risk of pulmonary embolism, (2) tumor thrombus shrinkage, and (3) bland thrombus shrinkage and/or prevention. Temporary suprarenal IVC filters are also an option for patients with level 0, I, and II tumor thrombi. However, due to the risk of contralateral renal and hepatic vein thrombosis, the risk of provoking embolization, and the impediment that these devices can pose to future IVC thrombectomy, we do not recommend this approach. The risk of intraoperative thrombus detachment and the possibility of interval thrombus growth in the period immediately preceding surgery leads us to recommend transesophageal echography (TEE) for level II to IV thrombi.

Preoperative angioembolization. In about one third of cases, tumor thrombi have an independent blood supply arising from the renal artery or the aorta itself. Angiographic infarction of the blood supply to the tumor thrombus can help shrink a large thrombus to a more reasonable size, sometimes allowing bypass and/or hepatic mobilization to be avoided. Angioembolization can be considered for caval thrombi when (1) the thrombus appears to invade the IVC, (2) the thrombus is intrahepatic or suprahepatic and cannot be immediately excised, (3) the thrombus is associated with a bleeding kidney, and (4) when deep hypothermic arrest is planned since the status of the coronary arteries can be evaluated simultaneously. The optimal timing between thrombus angioembolization and operative vena caval thrombectomy is unknown. There is a theoretical risk of causing an iatrogenic pulmonary embolization of the tumor thrombus when angiography is done, but this appears to be minimal. Also, severe ischemia-related flank pain and tumor lysis syndrome can result from angioembolization. We use angioembolization sparingly when a decision for definitive management of an IVC thrombus has been made.

Preoperative consultations. Urologists that do not routinely handle the IVC and aorta should consult a vascular surgeon for level II–III thrombi to aid in vena cava control and reconstruction. A cardiothoracic surgeon must be consulted preoperatively for all level III–IV thrombi since access to the mediastinal compartment for vascular bypass and thrombus removal may be required. A cardiologist or cardiac anesthetist should also be consulted for level II–IV thrombi to allow for intraoperative TEE.

Tumor thrombus level. Traditionally, IVC thrombi have been defined and managed according to the cranial extent extent of the tumor thrombus (Table 157-1, Fig. 157-1). Magnetic resonance imaging (MRI) is probably the best overall method of imaging a suspected tumor thrombus since it is noninvasive and avoids the risk of thrombus embolization associated with percutaneous venocavography. However, modern three-dimensional reconstructed computed tomography (CT) angiograms can also produce excellent results. Though classification by thrombus level is clinically useful in most cases, it does not consider the presence of bland thrombus in the infrarenal IVC, a factor that can dramatically complicate patient management.

Bland thrombus group. A grouping system that complements tumor thrombus levels and helps with intraoperative decision making has been devised at Mayo Clinic (Table 157-2, Fig. 157-2). The key addition of this grouping system is the consideration of the location and extent of bland thrombus and its impact on IVC management.

TABLE 157-1 TRADITIONAL STAGING AND MANAGEMENT OF VENA CAVAL THROMBI

Thrombus Level	Incidence Rate in RCC	Proportion of Thrombi	Cranial Extent of Thrombus	Management of Tumor Thrombus
0	12%	65%	Confined to renal vein	Radical nephrectomy
I	2%	10%	Within 2 cm of renal vein ostium	IVC milking, partial IVC occlusion, ostial cavotomy
II	3%	15%	Below hepatic veins	Complete IVC mobilization/control, infrahepatic cavotomy
III	1%	5%	Between hepatic veins and diaphragm	Complete occlusion: suprahepatic IVC clamping, infrahepatic cavotomy Partial occlusion: veno-venous bypass, infrahepatic cavotomy
IV	1%	5%	Above diaphragm	Deep hypothermic arrest, infrahepatic cavotomy, right atriotomy

Source: Blute ML, Leibovich BC, Lohse CM, Cheville JC, Zincke H. The Mayo Clinic experience with surgical management, complications and outcome for patients with renal cell carcinoma and venous tumour thrombus. BJU Int. 2004;94:33-41.

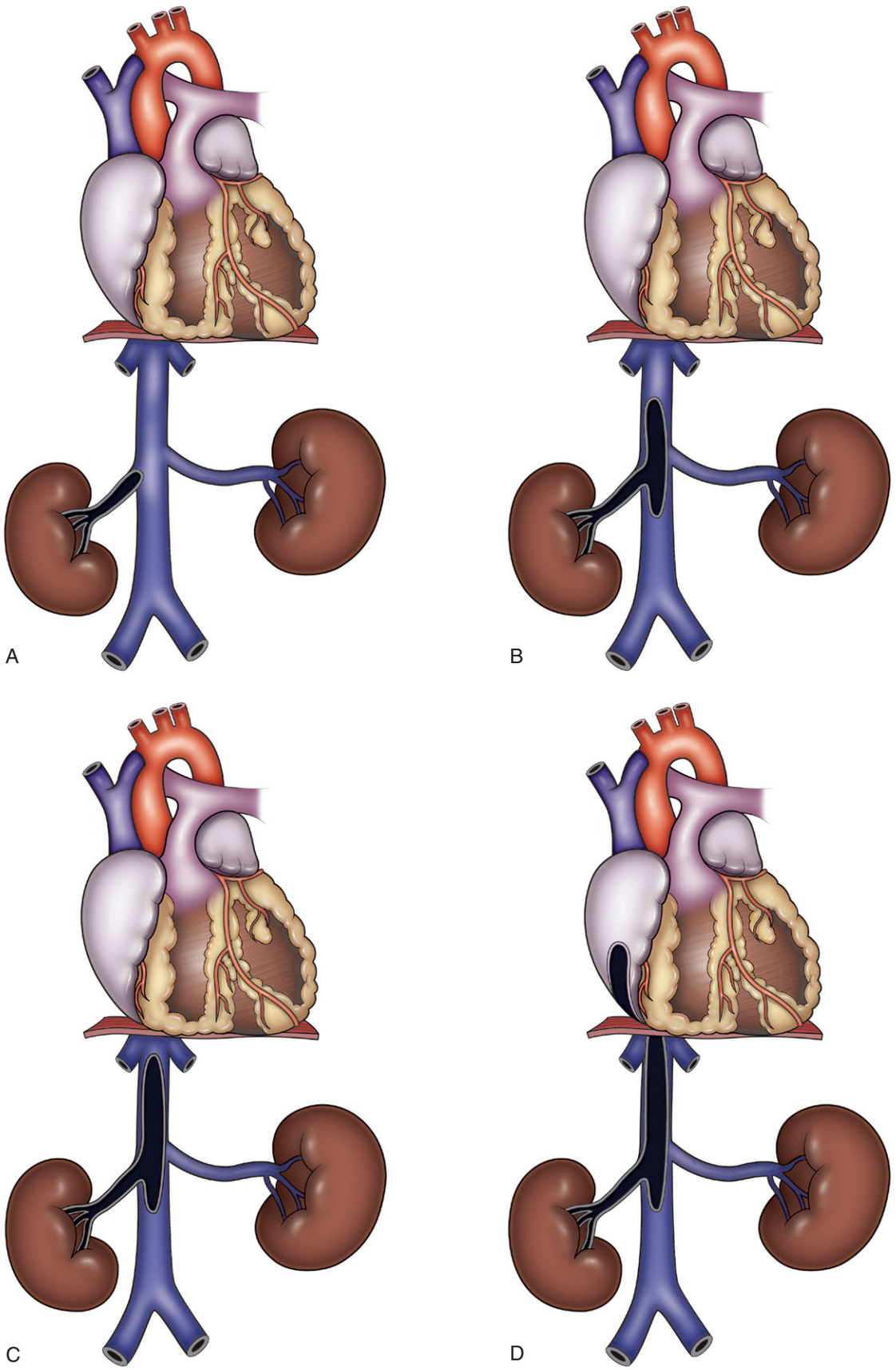

FIGURE 157-1. *(From Montie JE. Inferior vena cava tumor thrombus. [1990]. In: Montie JE, Pontes JE, Bukowski RM, eds. Clinical management of renal cell cancer. St. Louis: Mosby-Year Book.)*

TABLE 157-2 MAYO CLINIC THROMBUS GROUPING SYSTEM FOR VENA CAVAL THROMBI

Mayo Thrombus Group	Incidence Rate in RCC	Proportion of Thrombi	Associated Bland Thrombus	Additional IVC Management
A	17%	90%	None	None
B	<1%	1%	At or below common iliac veins	Infrarenal IVC filter (e.g., Greenfield)
C	1%	5%	Infrarenal IVC, separate from tumor thrombus	Infrarenal IVC interruption with vena cava clip
D	0.5%	4%	Infrarenal IVC, mixed with tumor thrombus	Infrarenal IVC resection

Source: Blute ML, Leibovich BC, Lohse CM, Cheville JC, Zincke H. The Mayo Clinic experience with surgical management, complications and outcome for patients with renal cell carcinoma and venous tumour thrombus. BJU Int. 2004;94:33-41.

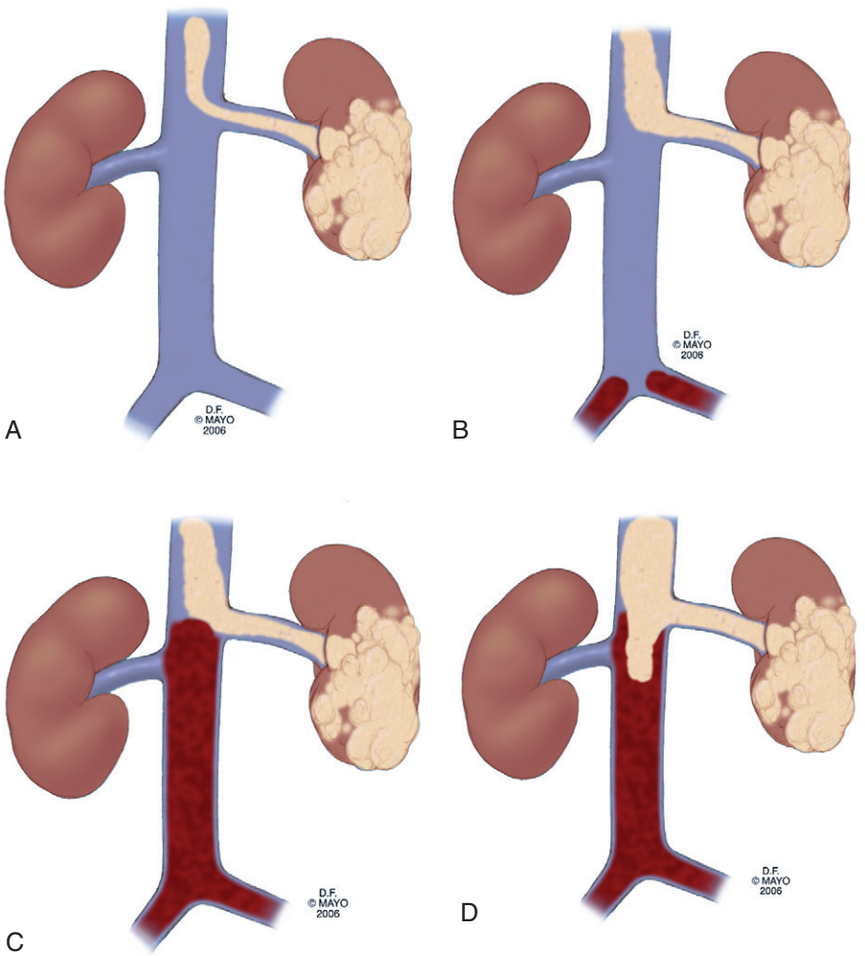

FIGURE 157-2. *(By permission of Mayo Foundation for Medical Education and Research. All rights reserved. In: Blute ML, et al. [2007]. Results of inferior vena caval interruption by Greenfield filter, ligation or resection during radical nephrectomy and tumor thrombectomy. J Urol. 2007;178:440-445.)*

LEVEL I VENA CAVAL THROMBECTOMY: RIGHT SIDE

As a rule, level I caval thrombi are partially occlusive, nonadherent, and do not require extensive IVC dissection or any form of bypass. Some groups mobilize the kidney only after the thrombectomy is complete in order to minimize embolization, while others mobilize the kidney first and then perform thrombectomy.

Perform a midline or anterior subcostal incision, install a self-retaining retractor, reflect the colon, Kocherize the duodenum, develop the anterior pararenal space, and expose the great vessels (Fig. 157-3). Using care not to mobilize the renal vein or IVC too much, find the renal artery in the interaortocaval region and secure it with a 2-0 silk ligature or a large clip. This is an important first step toward reducing blood loss and complications.

Gently mobilize the kidney outside the renal fascia and dissect the IVC above and below the right renal vein (Fig. 157-4). Identify the left renal vein and place a vessel loop around it, and then place another vessel loop around the suprarenal and infrarenal IVC. These vessel loops can then be passed through a short (3–6 inch) 18 F red rubber catheter and used as Rummel tourniquets. We prefer Rummel tourniquets over vascular clamps since they are more easily adjustable and less likely to pinch and fracture the tumor thrombus. This degree of vascular control is not necessary for most level I thrombi but is prudent if there is doubt about the thrombus level or if a significant amount of time has passed since the imaging studies were completed. Starting as cranially as possible, place the left hand on the IVC, gently pinch it closed, and then apply the Rummel tourniquets so that the infrarenal IVC, left renal vein and suprarenal IVC are closed (in that order). Milk the IVC with the left hand towards the ostium of the right renal vein. Take a C-shaped Satinsky vascular clamp in the right hand and place it around the ostium of the right renal vein, approaching from lateral to medial and partially occluding the IVC. Ensure that the thrombus is located entirely within jaws of the clamp before closing it. Palpate the IVC for evidence of any other thrombus. Ready the suction and two sponge sticks (to compress the IVC if needed) and place laparotomy sponges around the renal vein to catch any malignant cells that may drip from the open renal vein. Circumferentially incise the renal ostium using a scalpel or fine-tip Metzenbaum or Potts scissors. Be careful not to cut away too much IVC or to cut into tumor thrombus.

Extract the thrombus intact by gentle downward traction on the renal vein (Fig. 157-5). Wrap a gauze around the

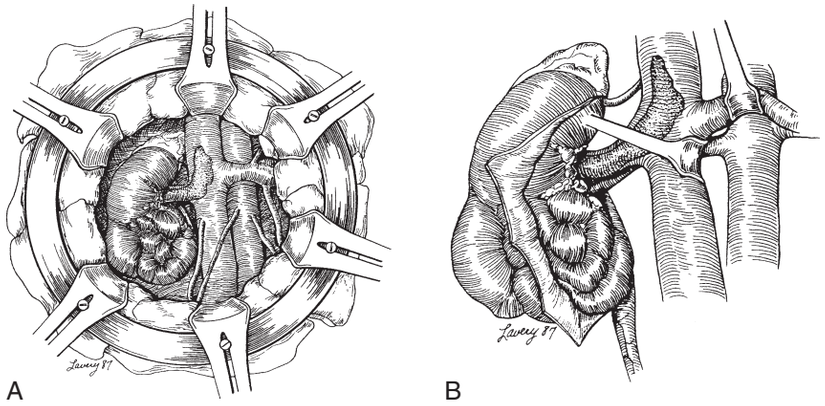

FIGURE 157-3. *(From Novick AC, Streem SB, Pontes E. [1989]. Stewart's operative urology, 2nd ed. Baltimore: Williams & Wilkins.)*

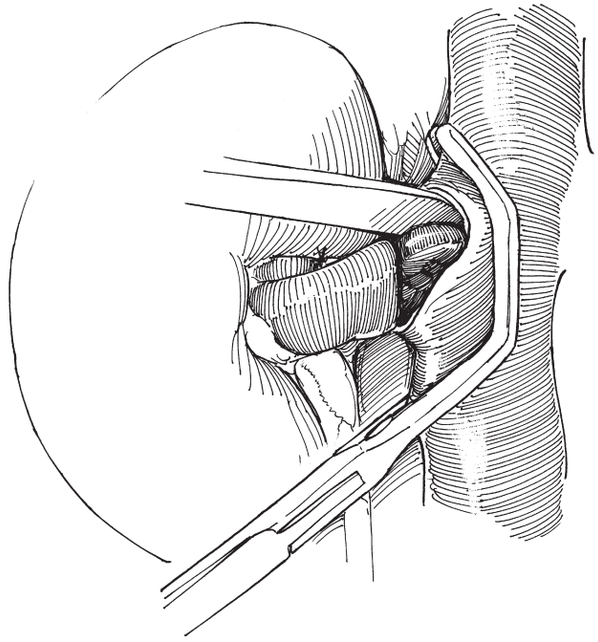

FIGURE 157-4.

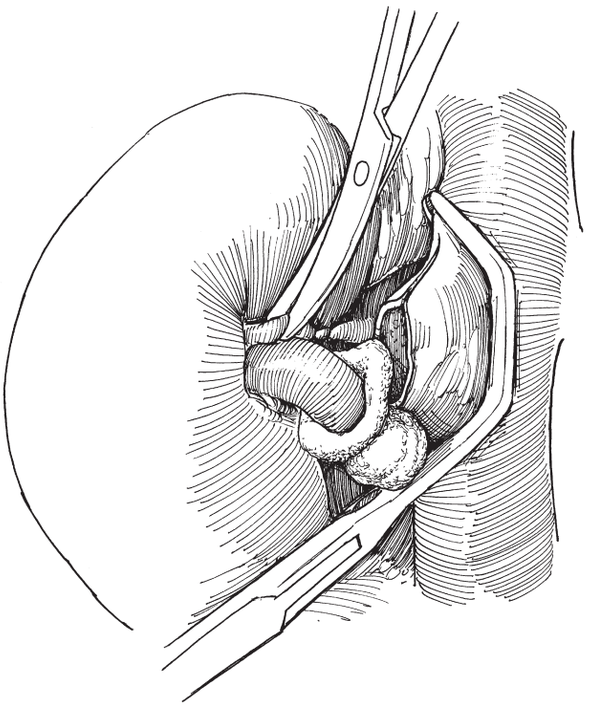

FIGURE 157-5.

renal vein stump and thrombus and secure it with a silk ligature. This helps prevents tumor spillage. Dissect the medial attachments of the kidney, ligating the renal artery again before division.

Inspect the IVC for evidence of residual tumor thrombus, irrigating its lumen with heparinized saline solution (100 U/ml) for improved visualization. Close the IVC defect with a running closure using a 4-0 Prolene on a BB vascular needle (Fig. 157-6). Prior to tying the knot, ask the anesthetist to apply positive airway pressure, pinch the infrarenal IVC closed, and then release the Satinsky clamp. Allow 5 to 10 ml of blood to escape from the caval defect to flush out any residual thrombus fragments and debris before pulling the the suture tight and tying the closure down. Perform a right regional lymphadenectomy. Irrigate the wound copiously with sterile water. Leave a closed suction drain to monitor for postoperative bleeding.

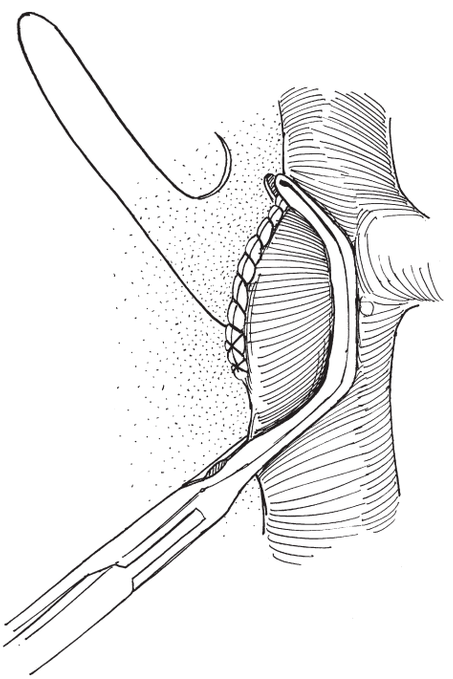

FIGURE 157-6.

LEVEL II VENA CAVAL THROMBECTOMY: LEFT SIDE

Exposure for a level-sided tumor thrombus case is more difficult since the IVC is best accessed from the right retroperitoneum while the tumor is best accessed from the left. Both the right and left colons must be mobilized to get adequate exposure. The midline and chevron incisions provide the best access for left-sided tumors.

Make a subcostal chevron incision, mobilize the left colon, develop the left anterior pararenal space, and then identify and ligate the left renal artery (Fig. 157-7). Ligate and divide the adrenal, lumbar, and gonadal branches of the left renal vein. These branches are often dilated and friable and occasionally contain thrombus, which is usually bland but can also be malignant (frozen section can be used to confirm). Mobilize the kidney outside of the renal fascia and divide the ureter.

Mobilize the right colon and small bowel, perform a Kocher maneuver, develop the right anterior pararenal space, and expose the great vessels. Carefully dissect the IVC from the liver to its bifurcation, ligating the right gonadal



FIGURE 157-7. *(From Richie JP, D'Amico AV. [2005]. Urologic oncology. Philadelphia, Saunders.)*

vein on its anterior surface. (Note: While dissecting the IVC, the surgeon has essentially started the regional lymphadenectomy. Taking a few extra moments to fully dissect the IVC of its fatty lymphatics can save time later in the case.) Obtain vascular control sequentially in the following order: (1) ligate the ipsilateral (left) renal artery, (2) clamp the infrarenal IVC, (3) clamp the contralateral (right) renal vein, (4) clamp suprarenal IVC, and (5) ligate accessory hepatic veins to caudate lobe (optional maneuver to gain 2 to 3 cm of extra infrahepatic IVC exposure) (Fig. 157-8). Optionally, one can clamp the contralateral renal artery to prevent renal engorgement while the venous outflow is temporarily clamped. This is more of an issue for left-sided tumors since the right kidney does not have significant venous collateralization to shunt blood when the right renal vein is clamped. While obtaining vascular control be very gentle to avoid dislodging the thrombus. Ligate and divide lumbar veins as required. Prior to clamping, some surgeons give 0.5 mg/kg of intravenous heparin to prevent clamp-related thrombotic complications. Our experience has been that bleeding, not clotting, is the principal problem encountered with vena caval thrombectomy and we do not routinely heparinize our patients.

Circumferentially excise the left renal vein ostium and extend the incision superiorly onto the anterior surface of the IVC using Potts scissors (Fig. 157-9). Use a Penfield dissector to carefully extract the tumor thrombus from the IVC. Lumbar veins can be a source of troublesome bleeding at this stage and should be ligated or sutured as needed.

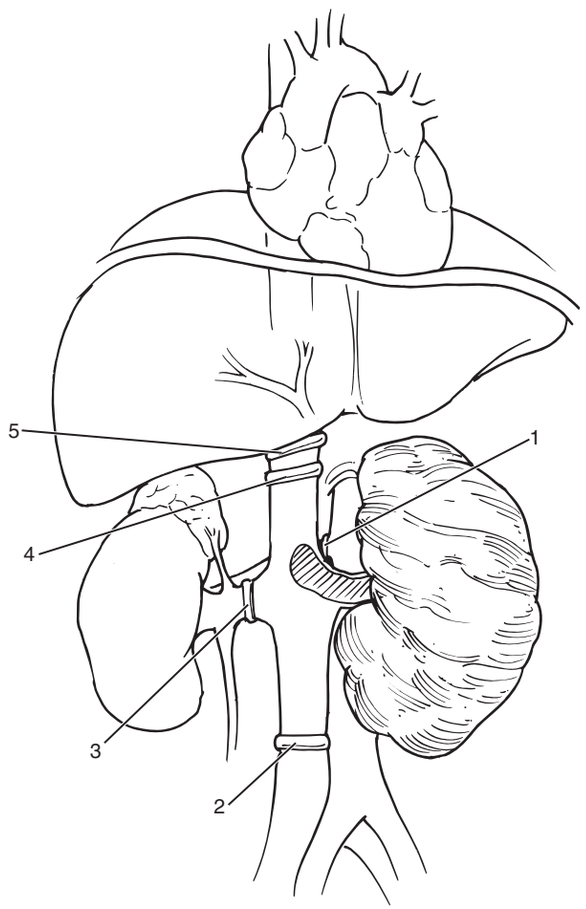

FIGURE 157-8.



FIGURE 157-9.

Remove the gross tumor thrombus and kidney en bloc. Flush the IVC with heparinized saline and inspect the intima for signs of caval invasion. Biopsy or resect suspicious areas. The IVC lumen can be safely narrowed to about 50% of its preoperative size without requiring special measures.

Close the caval defect with a running 4-0 Prolene (Fig. 157-10). Prior to tying the knot, release the infrarenal

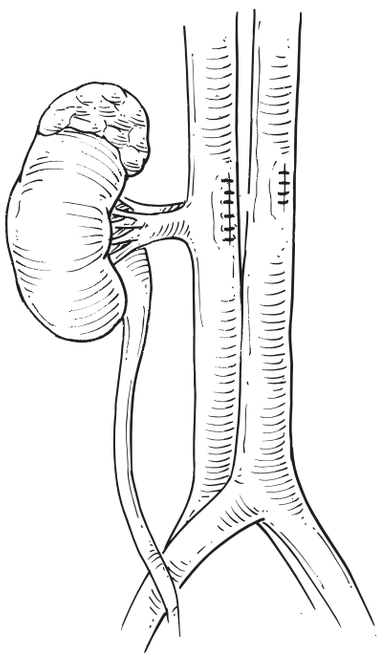

FIGURE 157-10.

clamp and allow 5 to 10 ml of blood to seep from the cavotomy to clear the IVC of air and debris. Release the contralateral renal clamp followed by the suprarenal IVC clamp and perform regional lymphadenectomy. Leave a closed suction drain to monitor for postoperative bleeding.

LEVEL III–IV VENA CAVAL THROMBECTOMY: INTRA-ABDOMINAL APPROACH

Intrahepatic tumor thrombi are very challenging to treat. We prefer the midline incision for level III and IV thrombi, though a chevron incision with T-extension (i.e., sternotomy) can also be used. The operating room should be set up for possible bypass, including deep hypothermic arrest. Intraoperative TEE should be available to measure the cranial extent of the thrombus and to monitor the thrombus for fracture and embolization. Cardiac function can also be evaluated with TEE so that the anesthetist can more easily manage patient hemodynamics.

The key decision for level III thrombi is whether to attempt an intra-abdominal thrombus extraction with complete hepatic mobilization or use a combined intrathoracic/intra-abdominal approach with bypass. This decision can only be made intraoperatively, after the renal artery is ligated, the liver mobilized and the IVC exposed and evaluated. If the IVC can be clamped below the hepatic veins this is preferable, since the venous return from the liver is considerable. As a rule of thumb, patients with free floating partially occlusive thrombi (as assessed on TEE) will not tolerate suprahepatic clamping very well and should probably undergo bypass. Contrarily, patients with completely occlusive thrombi will typically have developed extensive collateral venous drainage networks and therefore tolerate clamping much better. Occasionally, a level IV thrombus can be milked into the abdomen through a small diaphragmatic incision and treated intra-abdominally. It is crucial that IVC control not compromise the operation since bleeding and hypotension can lead to an incomplete tumor resection, a result that is universally fatal. Techniques of bypass are discussed in the following section, Bypass Techniques for Inferior Vena Cava Surgery.

Expose the right kidney and great vessels as described for the level I thrombus and ligate the right renal artery in the interaortocaval area. Gently dissect the infrahepatic IVC. Isolate and place Rummel tourniquets around the infrarenal IVC and left renal vein (Fig. 157-11).

Start mobilizing the liver by ligating and dividing the ligamentum teres, the remnant of the obliterated left umbilical vein, which is located at the lower free border of the falciform ligament (Fig 157-12). Divide the falciform ligament with electrocautery up to the upper border of the liver where it branches into the coronary ligament (on the right) and left triangular ligament (on the left). Divide the superior layer of the coronary ligament with scissors or electrocautery, taking care not to injure the liver or the IVC, which is located just behind this ligament in the bare area of the liver. Continue dividing the superior layer of the coronary ligament along the right border of the liver until it forms the right triangular ligament (the fused superior and inferior layers of the coronary ligament), which should also be divided. Finish mobilizing the right lobe of the liver by dividing the inferior layer of the coronary ligament, the attachment that ties the liver to the diaphragm, upwards toward the IVC.

Divide the left triangular ligament anteriorly and complete hepatic mobilization by dividing the posterior aspects of the left triangular ligament towards the IVC (Fig. 157-13). The right lobe of the liver can now be safely and gently rotated towards the midline so that the IVC can be evaluated on the posterior surface of the liver. For tumors of the left kidney, it may be necessary to divide the diaphragmatic attachments of the spleen so that it can be

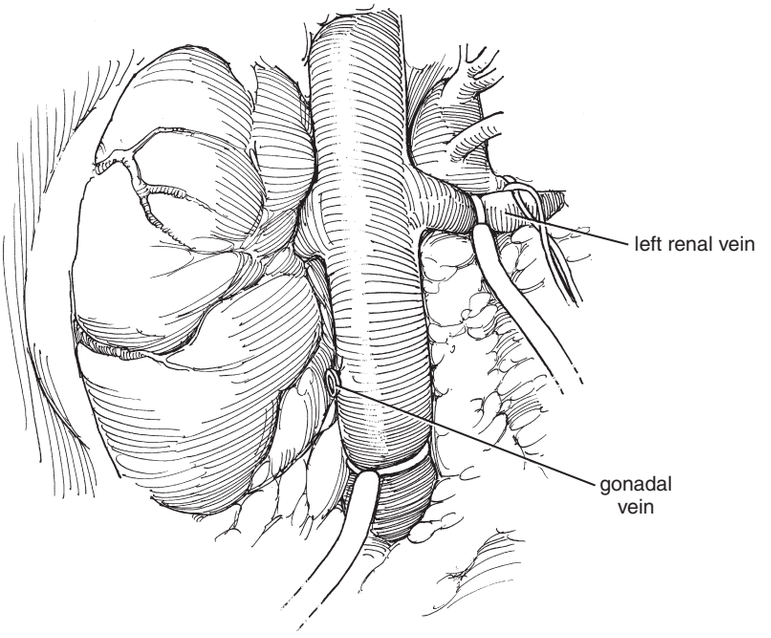

FIGURE 157-11.

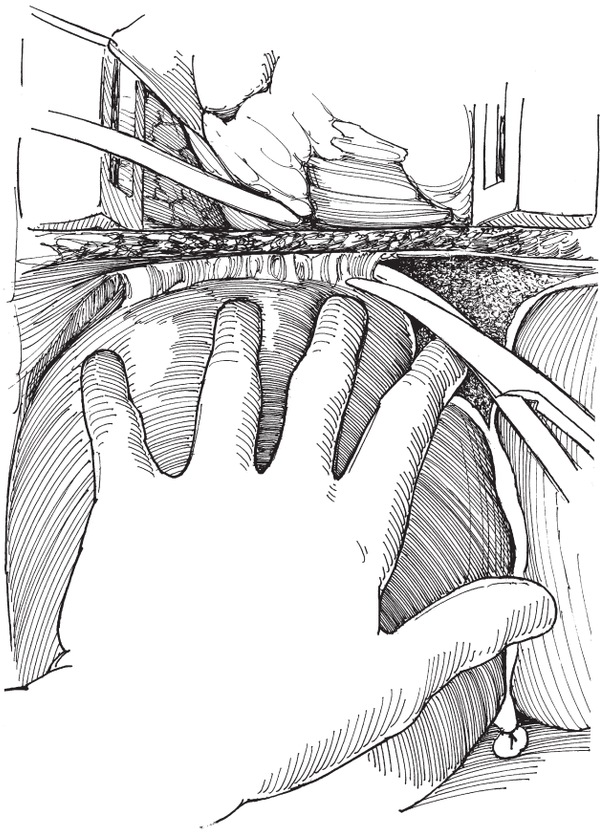

FIGURE 157-12.

rotated towards the midline with the pancreas without being traumatized.

There is a plane between the posterior surface of the liver and the anterior surface of the IVC that can be developed (consider the aid of a hepatic surgeon with this portion of the procedure) (Fig. 157-14). This plane contains venous branches from the liver that are divided in the upper and lower groups. The most important group is the upper group that contains the right, middle, and left hepatic veins, the principal outflow from the liver, and therefore cannot be divided. Tumor thrombus can extend into these veins and they must be carefully inspected and cleared of any thrombus during thrombectomy. Obstruction of these three veins leads to the Budd-Chiari syndrome. The lower group of hepatic veins (a.k.a., accessory hepatic veins) drains blood principally from the caudate lobe (with a small contribution from the right lobe) and can be safely divided. Ligate the accessory hepatic veins with 2-0 silk and develop the plane between the IVC and liver. Additionally, ligate the lumbar veins with 2-0 silk and develop the plane between the IVC and the posterior abdominal wall. The IVC is now fully mobilized.

Create a window in the lesser omentum and encircle the porta hepatis (a.k.a., portal triad, hepatic pedicle), which contains the portal vein, common hepatic artery, and common bile duct, with a Rummel tourniquet. Clamping the porta hepatis (a.k.a., the Pringle maneuver) is necessary to prevent massive blood loss if the IVC is clamped above the major hepatic veins (Fig. 157-15). Clamping the IVC above and below the hepatic veins while performing a Pringle maneuver is called total hepatic vascular occlusion. If the IVC is clamped below the major hepatic veins and the accessory hepatic veins are ligated, the Pringle maneuver may not be necessary. Under normothermic conditions, the porta hepatis can be clamped for up to 60 minutes, although a clamping time of 20 minutes or less is preferred since ischemic hepatic injury and portal vein thrombosis can result. Another complication of the Pringle maneuver is splenic engorgement and rupture due to backup of venous drainage from the splenic vein, which normally empties into the portal vein.

Determine the resectability of the tumor and thrombus using TEE and a thorough intraoperative assessment of the anatomy (Fig. 157-16). If the thrombus is below the hepatic veins or can be milked below these veins, it is usually safe to proceed without bypass. If the thrombus involves the hepatic veins or extends above the liver, bypass is often required. Occlude the IVC above the liver and thrombus

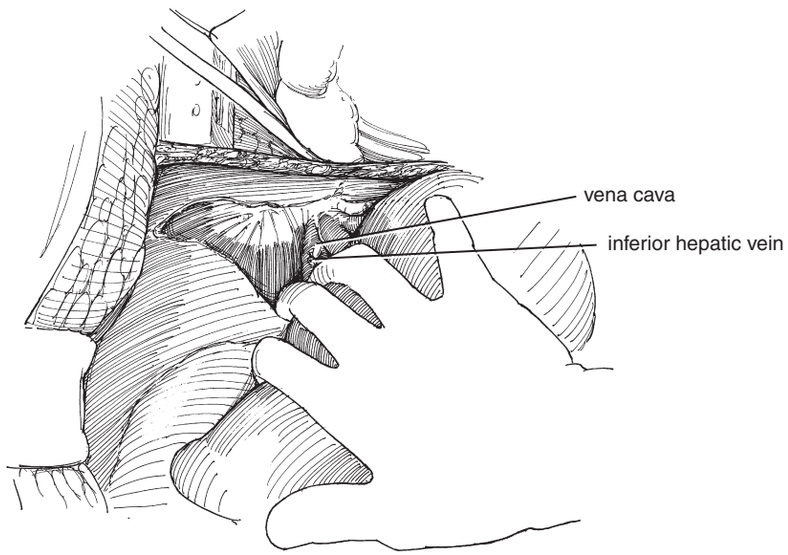

FIGURE 157-13.

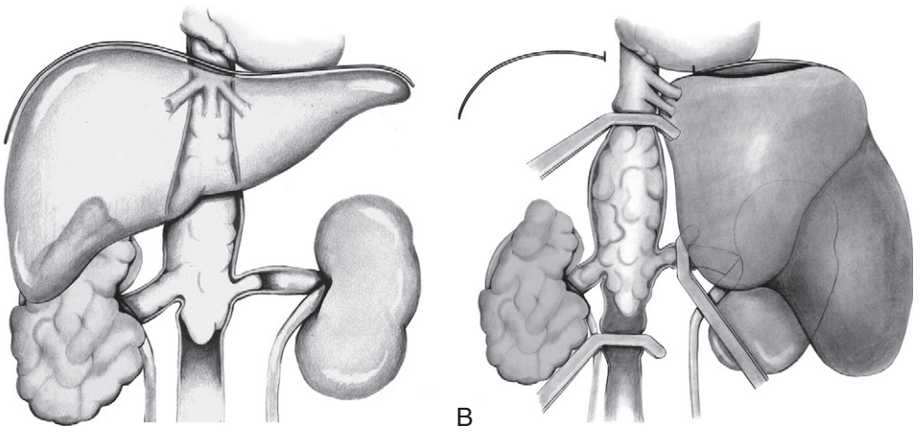

FIGURE 157-14. *(From Ciancio G, Livingstone AS, Soloway M: Surgical management of renal cell carcinoma with tumor thrombus in the renal and inferior vena cava: the University of Miami experience in using liver transplantation techniques. European Urology. 2007;51:988-995.)*

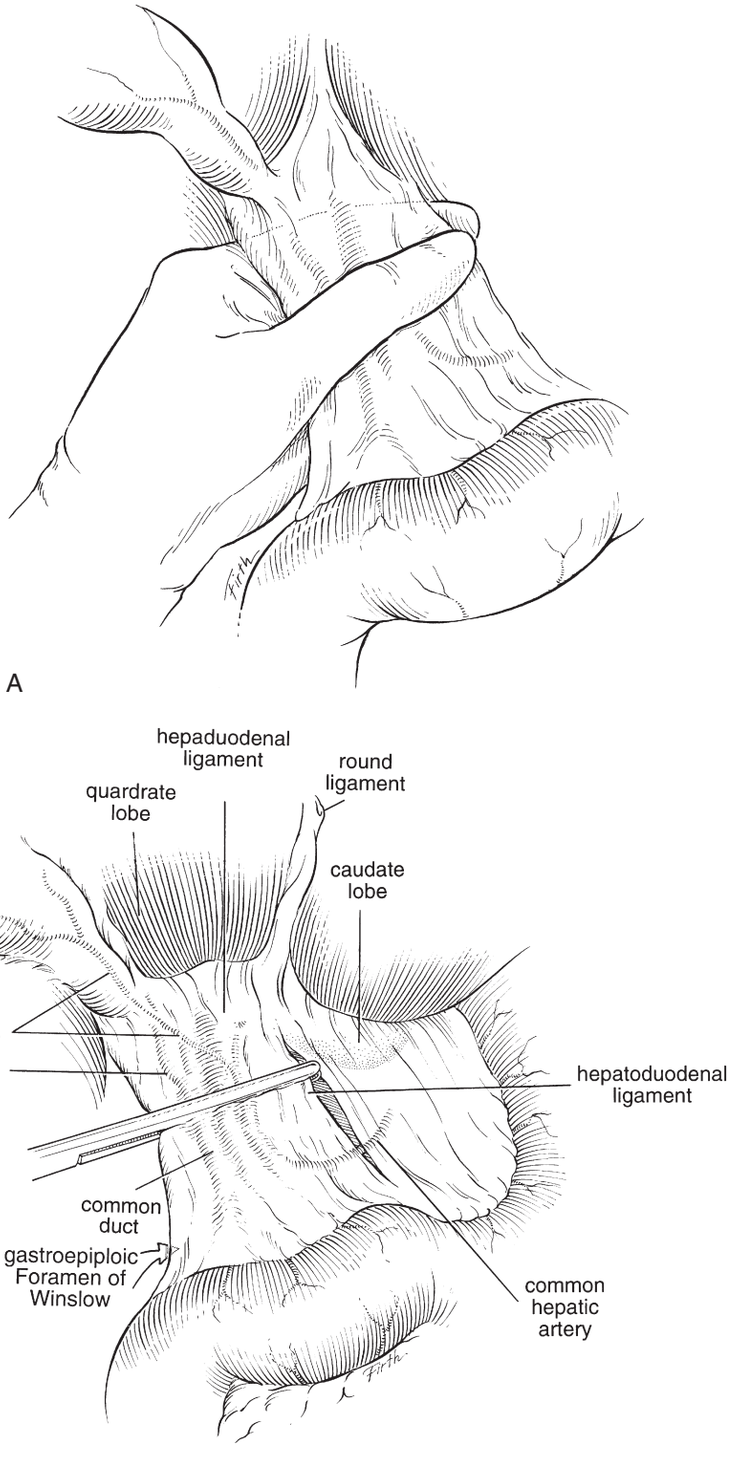

FIGURE 157-15. *(From Asensio J, Trunkey D: Current Therapy of Trauma and Surgical Critical Care. Philadelphia, Mosby, 2008.)*

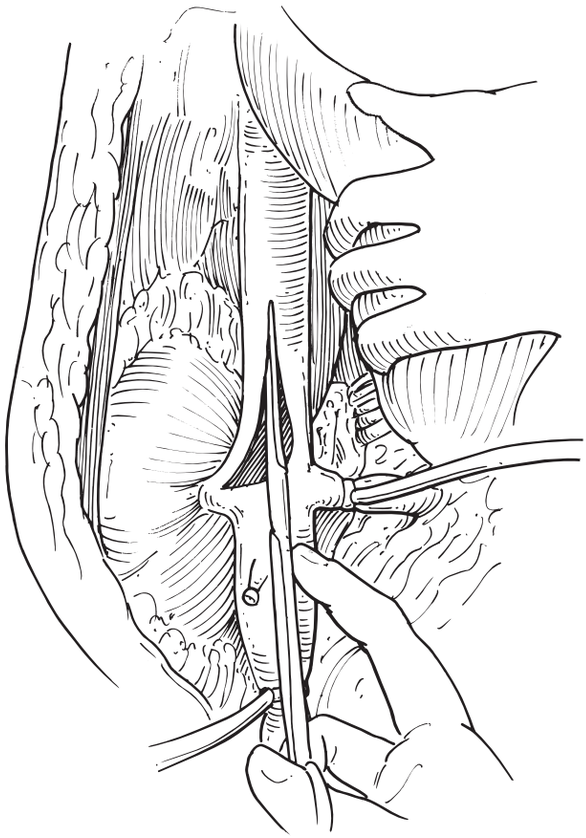

FIGURE 157-16.

and observe the patient's hemodynamic response over 2 to 5 minutes. Clamping the suprahepatic IVC results in a 60% reduction in cardiac preload, an increase in peripheral vascular resistance of 80%, an increase in heart rate of 50%, a drop in cardiac output of 40%, and a drop in mean arterial blood pressure of 10% to 20%. If the cardiac output drops more than 50% or the mean arterial blood pressure drops more than 30%, the patient will not tolerate suprahepatic IVC clamping. Options for managing this situation include bypass (our preference) and clamping of the supraceliac aorta.

If the IVC clamping trial is tolerated and the thrombus can be removed in less than 30 minutes, it is safe to proceed with the intra-abdominal procedure. In sequence, clamp the infrarenal IVC, the contralateral (left) renal vein, the porta hepatis, and the suprahepatic IVC. For left-sided tumors, the right renal artery should be clamped prior to the right renal vein since there is no good collateral venous drainage for the right kidney. Circumferentially incise the ostium of the right renal vein and extend the incision upwards toward the intrahepatic IVC. The incision should be large enough to permit extraction all the tumor thrombus and careful inspection on the intima of the IVC. Excise the thrombus and kidney. Use a Penfield dissector to help clear the IVC of adherent thrombus. A 20 F Foley catheter can be used as an embolectomy catheter if thrombus is out of reach. If involved with tumor that cannot be scraped away, the IVC should be completely or partially resected and reconstructed. During deep hypothermic arrest a cystoscope can be used to inspect the hepatic veins and suprahepatic IVC and allows for a smaller caval incision. Close the IVC as described for a level II thrombus. Tack the hepatic ligaments back into place to prevent torsion of the liver. Perform a regional lymphadenectomy and leave a closed suction drain. Postoperative monitoring in the ICU is recommended.

LEVEL III–IV VENA CAVAL THROMBECTOMY: COMBINED INTRA-ABDOMINAL AND INTRATHORACIC APPROACH

Level III thrombi that cannot be removed intra-abdominally and most level IV thrombi are managed with a combined intra-abdominal and intrathoracic approach. The three incisions that can be used for combined access to the abdomen and chest are (1) the thoracoabdominal, (2) chevron laparotomy with sternotomy, and (3) midline laparotomy with sternotomy (Fig. 157-17). Our preference is for the midline laparotomy with sternotomy. A cardiothoracic surgeon needs to be involved.

The abdominal portion of the case is identical to the intra-abdominal approach described above. Once the abdominal phase is completed, the thoracic surgeon is called, a median sternotomy is performed, the pericardium opened and the right heart is exposed (Fig. 157-18). It is often easier to mobilize the liver and IVC once the sternotomy is completed so if

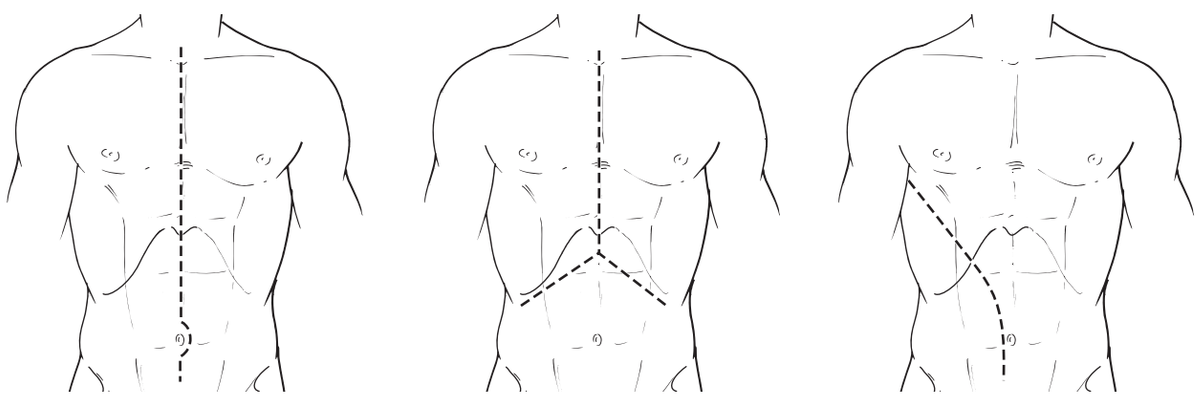

FIGURE 157-17.

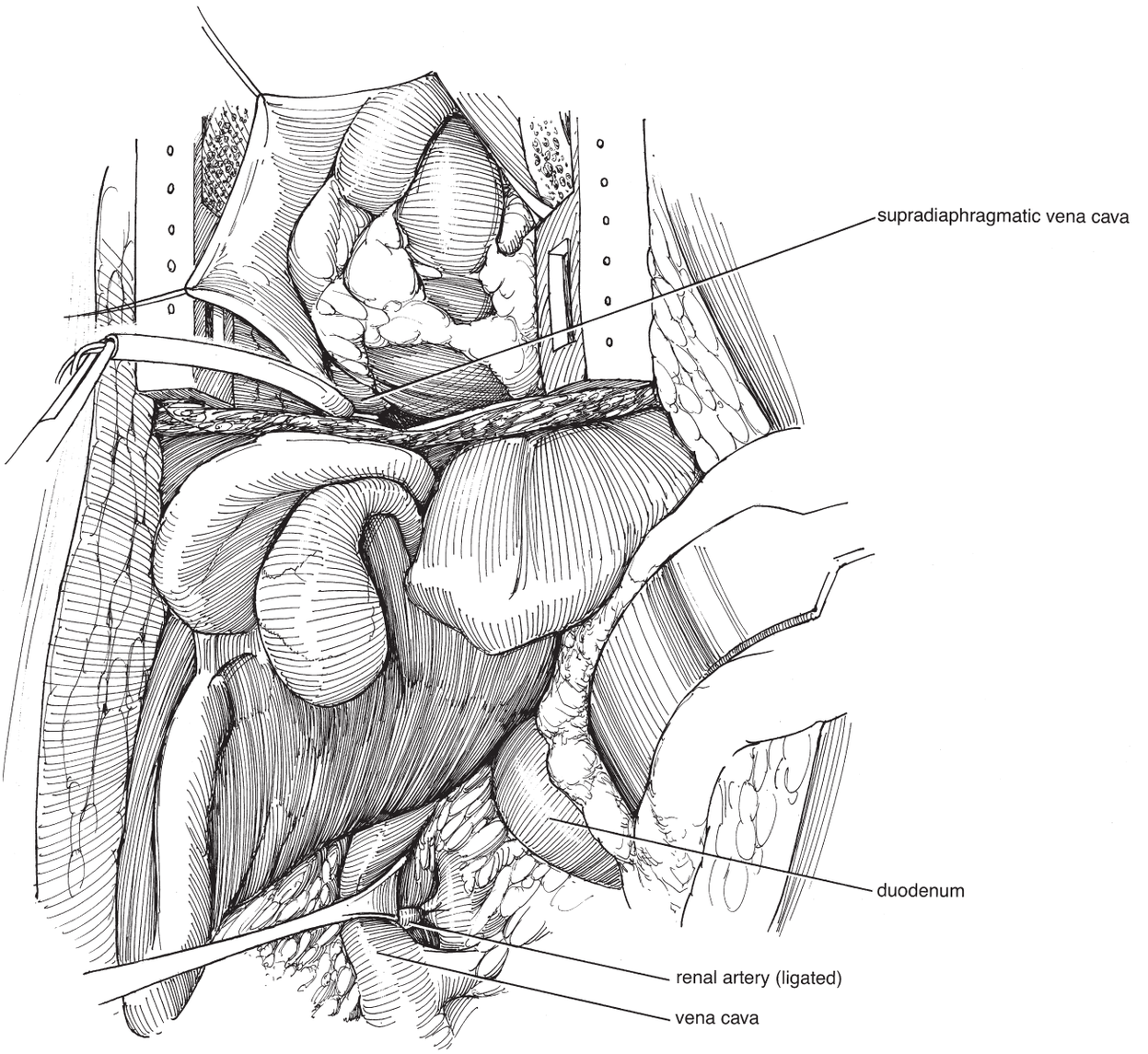

FIGURE 157-18.

there is a clear preoperative indication for bypass, perform the sternotomy before dissecting the liver.

Bypass the blood supply using one of the techniques described in the following section. Circumferentially excise the ostium of the renal vein, extend the incision cranially on the IVC and extract the thrombus. A right atriotomy is usually performed to help remove suprahepatic thrombus. Close the atrium and IVC (Fig. 157-19). Bring the patient off bypass and place thoracostomy tubes and closed suction abdominal drains. Tack the hepatic ligaments back into place to prevent torsion of the liver and perform regional lymphadenectomy. Postoperative monitoring in the ICU is required.

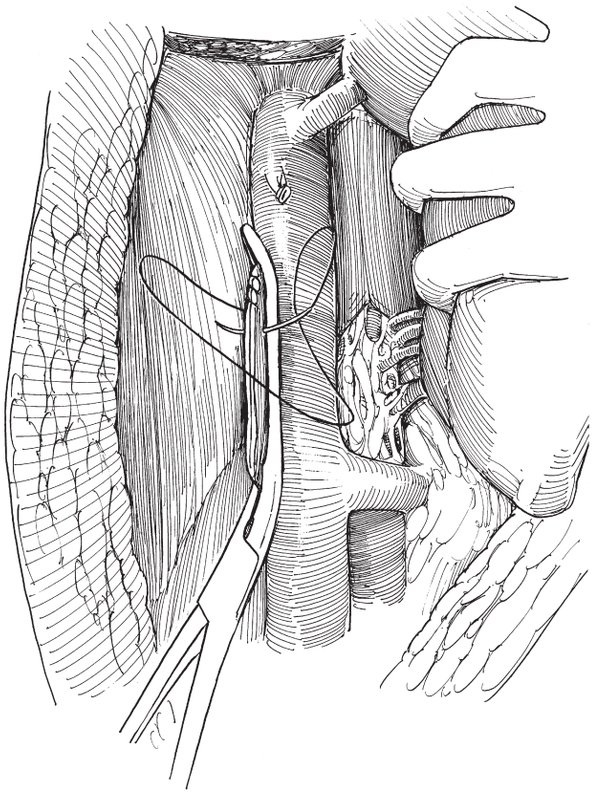

FIGURE 157-19.

BYPASS TECHNIQUES FOR INFERIOR VENA CAVA SURGERY

The requirement of bypass significantly complicates and prolongs IVC thrombectomy. However, the use of bypass is often critical to performing the procedure safely and completely and should be used whenever required. Bypass should be considered in patients where (1) the IVC cross clamping trial causes serious hypotension, (2) there is preoperative cardiac dysfunction, (3) there is preoperative contralateral renal dysfunction, (4) there is preoperative hepatic dysfunction, (5) there is preoperative portal venous hypertension, and (6) there is major intraoperative bleeding that is difficult to control.

Veno-Venous Bypass

This is the least invasive bypass technique for IVC thrombi and involves shunting the venous blood from the below the renal veins to the venous return of the heart with the aid of a pump. Veno-venous bypass (VVB) can be done without opening the chest, which is a key advantage that it has over traditional cardiopulmonary bypass. Two main options are available for infrarenal cannulation: a percutaneous approach through the femoral vein or a direct intraoperative approach through the IVC just above its bifurcation. When cannulating the IVC, it is important to position the tip of the cannula as far from the tumor thrombus as possible to avoid dislodging it (causing a massive pulmonary embolism) and to avoid aspirating and recirculating tumor cells. Several options are available for delivering the shunted blood back to the heart: a percutaneous approach via the internal jugular vein, a cut-down approach to the brachial/axillary vein, and a direct intraoperative approach through the right atrium. One advantage of VVB is that full heparinization is not required, which may help minimize postoperative bleeding problems. However, a key disadvantage is that the blood flow to the intercostal and lumbar arteries (and hence the intercostal and lumbar veins) is not interrupted during VVB, a problem that can lead to major bleeding once the cavotomy is performed to extract the thrombus. VVB should not be used when atrial thrombi cannot be completely milked into the IVC, when there is extensive bland thrombus in the iliac veins or infrarenal IVC, or when there is a pre-existing Budd-Chiari syndrome.

For *percutaneous VVB*, immediately following intubation have the anesthetist insert an 8–18 French heparin-bonded arterial cannula into the internal jugular vein using the Seldinger technique (Fig. 157-20). Insert a 6-cm, 18-gauge hollow needle into the femoral vein, place a guidewire, dilate the tract (incising the skin as needed), and advance a 14–20 French heparin-bonded arterial cannula into the common iliac vein. Connect both cannulae to a perfusion pump using heparin bonded tubing. The portal vein can also be cannulated with a 20-French cannula and its venous flow returned to the pump, though this is usually not necessary. Perform the incision, dissect the kidney and IVC, and then start the perfusion pump once all the vessels are clamped and you are ready for thrombectomy. Perform thrombectomy under pump, ligating any troublesome lumbar and intercostal

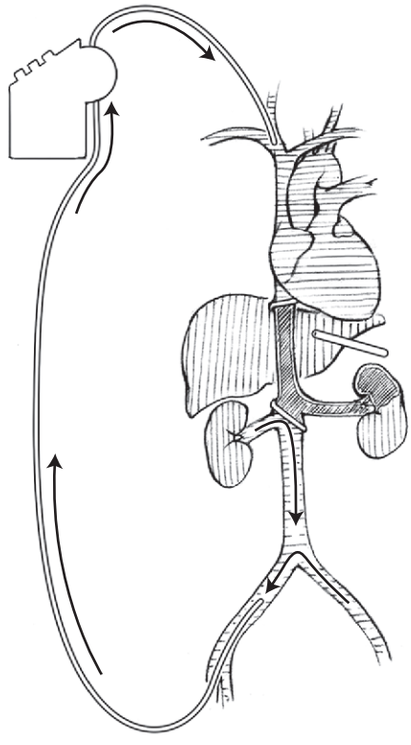

FIGURE 157-20.

veins. Once thrombectomy and IVC repair are complete, unclamp the vessels in the same order that they were clamped.

For *open VVB*, dissect the kidney and IVC, mobilize the liver, and perform sternotomy. Insert a 20 French cannula into the infrarenal IVC well away from the tumor thrombus, and then insert a 14–20 French cannula into the auricle of the right atrium (Fig. 157-21). Clamp the infrarenal IVC, renal vein, porta hepatis, and suprahepatic IVC, and then start bypass. Perform thrombectomy as quickly as possible.

Cardiopulmonary Bypass with and without Deep Hypothermic Arrest

Cardiopulmonary bypass (CPB) can be performed with or without deep hypothermic arrest. CPB with hypothermic arrest involves stopping the heart and starting bypass, cooling the patient to 16 to 18°C, and draining all the blood from the patient. Although certainly quite invasive, CPB with hypothermic arrest offers several benefits. First, it can be used in cases where the thrombus cannot be milked below an intrapericardial IVC clamp. Second, there is no need to clamp the aorta or porta hepatis or to ligate as many lumbar and hepatic veins since blood flow to these structures is no longer present. However, all vessels that have been traumatized or transected must be controlled since they will bleed once the patient is taken off bypass. Third, the absence of active blood flow allows for complete inspection of the IVC and hepatic veins, thereby aiding to achieve a complete thrombectomy. Fourth, the risk of embolization during thrombectomy is lower. Fifth, the surgeon is allowed up to 60 minutes to perform thrombectomy (although <40 minutes is certainly a better target), whereas IVC clamping without bypass is only tolerated for about 30 minutes. Complications following CPB can be serious and are detailed in Perioperative Complications section.

For *CPB with deep hypothermia*, dissect the kidney and IVC and mobilize the liver. Call the thoracic surgeon to perform the sternotomy, open the pericardium and expose the heart and its vessels. Place heparin-bonded cannulae in the infrarenal IVC and in the right atrium to collect venous blood and place a cannula into the aortic arch for outflow (Fig. 157-22). Heparinize the patient and start bypass. Clamp the aorta and administer cardioplegia solution. Drop the temperature of the recirculated blood to 10 to 14 °C and cool the patient for 15 to 30 minutes until a core temperature of 16 to 18 °C is reached. Perform intraoperative electroencephalography (EEG) to determine when the brain has been adequately cooled. Stop the perfusion pump and drain 95% of the patient's blood volume into the pump reservoir. Perform tumor thrombectomy as fast as possible, taking great care to ligate all potential bleeders. If the patient has known coronary artery disease, perform coronary artery bypass at the same time. If the case is taking longer than anticipated, consider allowing a 10-ml/kg/min trickle of blood to flow to the organs or using retrograde cerebral perfusion.

Once the IVC and right atrium are repaired, reinfuse warm blood from the pump reservoir and restart CPB.

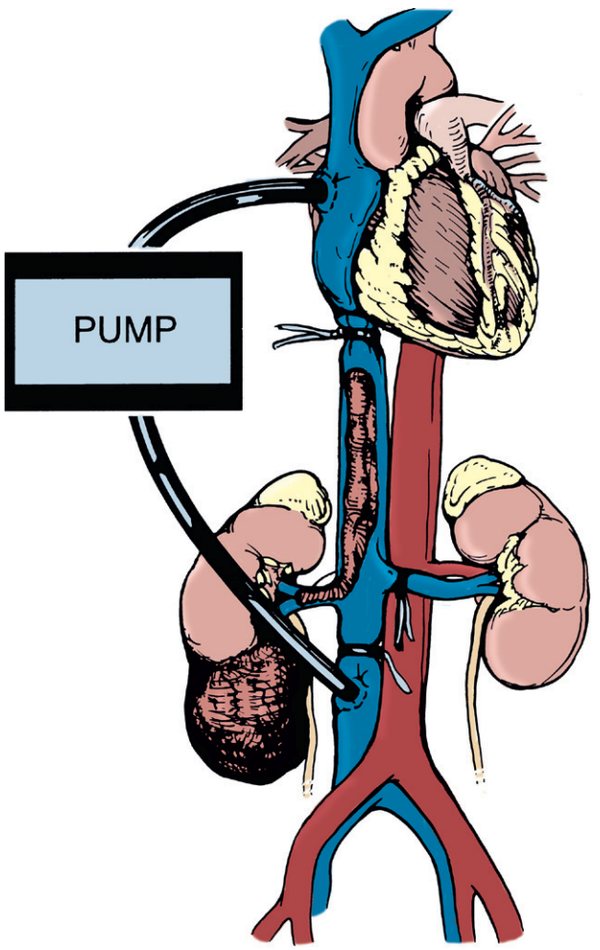

FIGURE 157-21. *(From Wein AJ, et al. Campbell-Walsh urology, 10th ed. Philadelphia: Saunders.)*

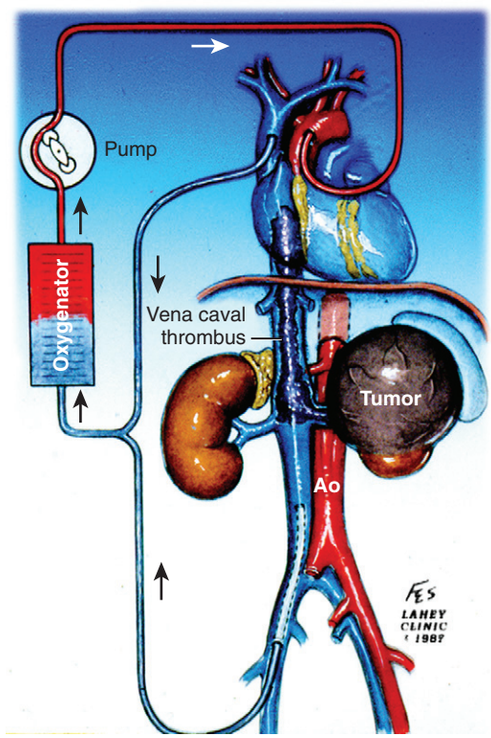

FIGURE 157-22. *(©The Lahey Clinic.)*

Peform hemostasis while the patient warms to 37 °C over the next 30 to 45 minutes. Once the heart has restarted pumping, stop bypass, remove the cannulae and administer protamine sulfate. Coagulopathy is common and fresh frozen plasma, platelets and packed red blood cells should be available to administer. Insert thoracostomy tubes and closed-suction abdominal drains.

PATCHING, REPLACING AND INTERRUPTING THE INFERIOR VENA CAVA

Patch Cavoplasty

If a piece of IVC was resected and the circumference of the IVC is expected to be less than 50% of its original size, a patch cavoplasty must be performed to prevent IVC stenosis and thrombosis related events. Material available for patching the IVC includes autologous and bovine pericardium, PTFE, collagen impregnated Dacron, and autologous saphenous vein. Despite being readily available, the gonadal veins should be avoided in patch angioplasty since they are very thin and prone to aneurysmal dilation.

Cut the patch so it is slightly larger than the defect being covered and is generally ovoid in shape (Fig. 157-23). Use a double-armed 5-0 Prolene on a BB needle to sew the patch in place. Keep the distance between suture bites small and regular. Avoid intraluminal inversion of the edges of the patch since this will be thrombogenic. Some surgeons prefer tacking both apices of the defect first and then running a strand of suture from each apex to the midpoint between the apices. This technique requires four knots. Alternatively, the graft can be parachuted into position and sewn into place circumferentially. This technique requires one knot. In either case, a no-touch policy is helpful to prevent damaging the patch and liberal use of heparinated saline irrigation can help make visualization easier. Before tying the last knot, the inferior IVC clamp should be released and 5 to 10 ml of venous blood should be allowed to escape from the cavotomy. This removes air, debris, and clot from the IVC prior to unclamping the cranial clamp.

Vena Caval Replacement

If a circumferential section of IVC has been removed or if a vena caval defect is too large for simple patching, vena caval replacement is indicated. We generally use PTFE grafts to replace the IVC, although others have described spiraled saphenous vein, superficial femoral vein and tubularized pericardium as options. IVC replacement typically requires a graft that is 16 to 20 mm in diameter. The large diameter of the IVC graft significantly reduces the risk of graft thrombosis, despite the relatively slow flow rate of venous blood.

Mobilize the liver and expose the IVC completely (Fig. 157-24). Use bypass if clinically indicated and then administer 5000 units of intravenous heparin. Cleanly transect and excise the affected portion of the clamped IVC. Perform the upper IVC anastomosis first. Clamp the graft and unclamp the suprahepatic IVC to test the anastomosis. Cut the graft so that it is as short as possible, and then perform the lower IVC anastomosis. Prior to tying the knot, unclamp the graft and allow 5 to 10 ml of blood to escape from the graft through the cavotomy. Reclamp the graft and

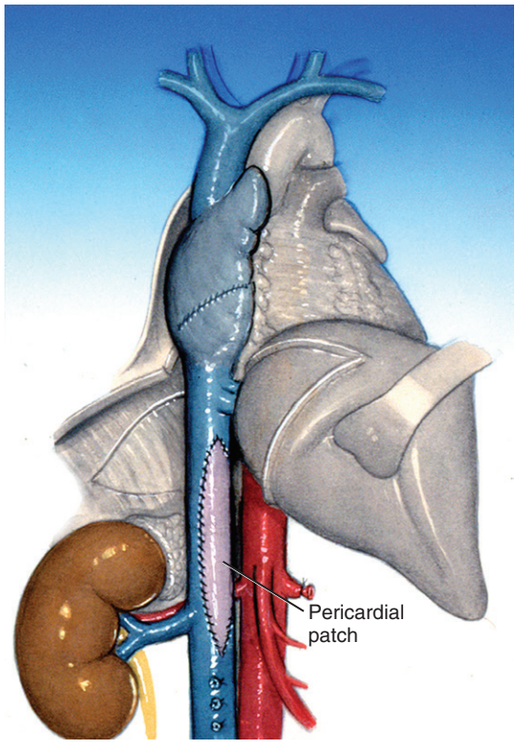

FIGURE 157-23. *(From Wein AJ, et al. [2012]. Campbell-Walsh urology, 10th ed. Philadelphia: Saunders.)*

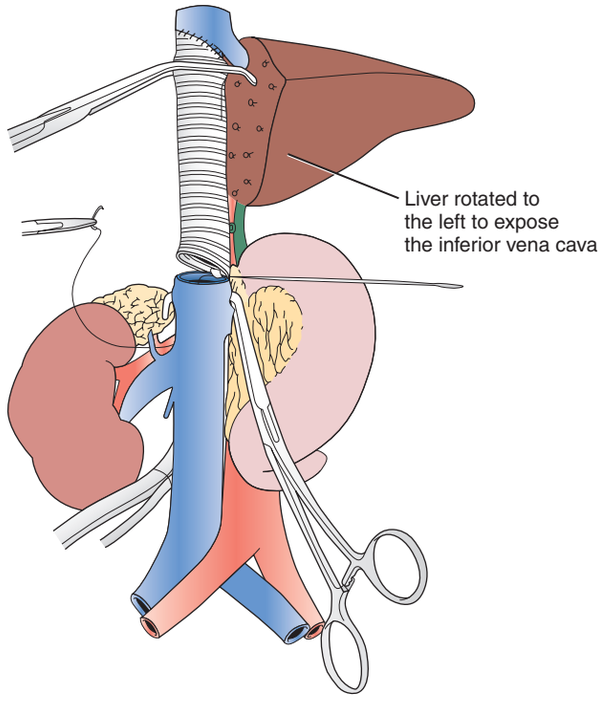

FIGURE 157-24. *(From Bower TC, Nagorney DM, Toomey BJ, et al. Vena cava replacement for malignant disease: is there a role? Ann Vasc Surg. 1993;7:51-62, with permission.)*

unclamp the infrarenal IVC and allow 5 to 10 ml of blood to escape from the infrarenal IVC. Tie the knot down and unclamp all the vessels. Wrap the graft with omentum or retroperitoneal fat and then reapproximate the hepatic ligaments to prevent vascular torsion.

Postoperatively, the patient should be placed on a low-dose intravenous heparin nomogram or a reduced dosage of low molecular weight heparin. Once the diet has resumed, start lifelong oral warfarin and maintain an INR of 2 to 3.

Inferior Vena Cava Filtration and Permanent Interruption for Bland Thrombus

Occasionally a patient will have infrarenal bland thrombus that requires management (see Table 157-2 and Fig. 157-2 for grouping system) at the time of tumor thrombectomy. For bland thrombus that is limited to the pelvic veins (Mayo group B), the intraoperative placement of an infrarenal vena cava filter (a.k.a., Greenfield filter) is indicated (Fig. 157-25).

When the bland thrombus diffusely involves the infrarenal IVC (Mayo group C), the optimal management is permanent interruption of the IVC (Fig. 157-26). In such cases, intraoperative care is required during thrombectomy to preserve the collateral venous drainage from the IVC (i.e., lumbar veins), since these veins provide a release valve for the impaired caval blood flow. When the infrarenal IVC is occluded with bland thrombus that is distinct and separate from the tumor thrombus, the best form of management is usually *permanent interruption of the IVC without resection* since attempts at completely removing diffuse organized bland thrombus are almost always unsuccessful and often result in vascular injury. Options for permanent interruption of the IVC include serrated vena cava clips (e.g., Adams-DeWeese clip, Moretz clip), cross stapling with a vascular GIA stapler, suture plication, and suture ligation. Serrated vena cava clips offer the advantage of allowing partial blood flow through the IVC and ease of application. Stapling is also a fast and simple technique.

When the bland thrombus in the infrarenal IVC is admixed with tumor thrombus that has undergone retrograde growth (Mayo group D), *segmental resection of the IVC with permanent interruption of the IVC* will maximize the chance of cure since it is not possible to accurately dissect tumor thrombus from bland thrombus and guarantee a complete resection (Fig. 157-27). For this reason, resection of the IVC below the level of the contralateral renal vein ostium is recommended. The resection should be as close to the renal vein ostium as is possible to prevent turbulent and thrombogenic flow in the upper stump. Maximal preservation of the lumbar veins in the lower stump is important to ensure good collateral drainage.

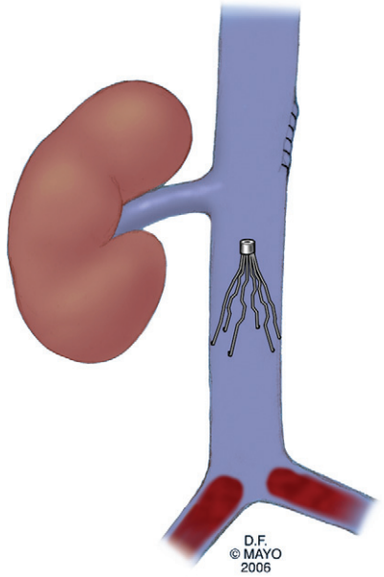

FIGURE 157-25. *(By permission of Mayo Foundation for Medical Education and Research. All rights reserved. From Blute ML, et al. [2007]. Results of inferior vena caval interruption by Greenfield filter, ligation or resection during radical nephrectomy and tumor thrombectomy. J Urol. 2007;178:440-445.)*

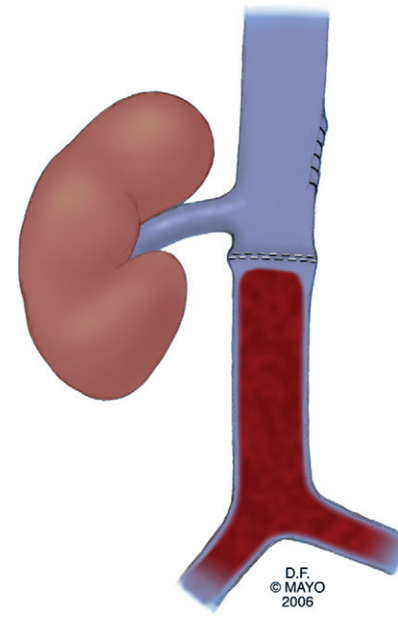

FIGURE 157-26. *(By permission of Mayo Foundation for Medical Education and Research. All rights reserved. From Blute ML, et al. [2007]. Results of inferior vena caval interruption by Greenfield filter, ligation or resection during radical nephrectomy and tumor thrombectomy. J Urol. 2007;178:440-445.)*

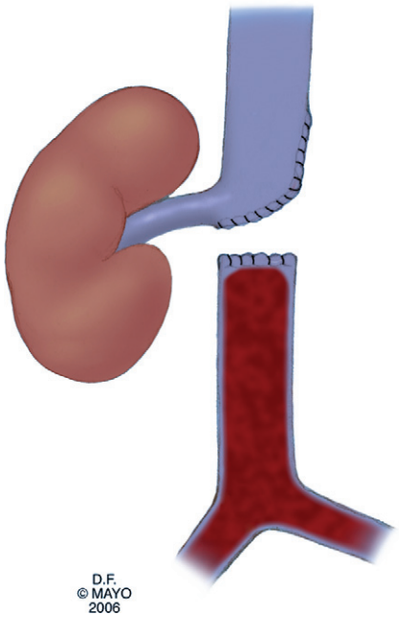

FIGURE 157-27. *(By permission of Mayo Foundation for Medical Education and Research. All rights reserved. From Blute ML, et al. [2007]. Results of inferior vena caval interruption by Greenfield filter, ligation or resection during radical nephrectomy and tumor thrombectomy. J Urol. 2007;178: 440-445.)*

PERIOPERATIVE COMPLICATIONS

Air embolism. A serious complication of IVC surgery is embolism of air to the right heart and pulmonary arteries. Air embolism can be prevented by releasing the caudal IVC clamp first and allowing air (and some blood) to escape from the IVC repair prior to removing the cranial clamp.

Acute pulmonary embolism. Tumor and bland thrombus can embolize during and after the case. Minimizing intraoperative manipulation of the kidney and IVC too much before vascular control has been achieved helps to reduce this complication. The early intraoperative placement of a Greenfield filter in a patient with pelvic bland thrombus can also be helpful. If respiratory distress is noted during the operation, consider prompt thoracotomy, pulmonary arteriotomy, and extraction of the thrombus.

Massive hemorrhage. Major bleeding can occur during and after the case. If uncontrolled major bleeding occurs in a patient who is not on bypass, consider clamping the aorta above the celiac trunk or initiating deep hypothermic cardiopulmonary bypass. Remember that bypass also causes a coagulopathy that can make a relatively minor bleed much worse. Fresh frozen plasma, platelets, and red blood cells should be transfused liberally in hemorrhaging patients. Using a Cell-Saver is not recommended for oncologic surgery since tumor cells can be disseminated.

Hepatic dysfunction. Temporary hepatic dysfunction, characterized by elevated transaminases and alkaline phosphatase, is common in patients with levels III or IV thrombi that require suprahepatic IVC clamping and/or bypass. This can be minimized by reducing porta hepatis clamping times and hepatic ischemia. Liver enzymes typically peak at 2 to 3 days postoperatively and slowly resolve thereafter.

Organ ischemia. Cardiac ischemia is most common in patients undergoing suprahepatic IVC clamping without bypass. Patients with poor preoperative cardiac function are probably best managed with bypass. Renal and intestinal ischemia can also result during thrombectomy, and postoperative creatinine monitoring is clearly indicated.

Suggested Readings

Blute ML, Leibovich BC, Lohse CM, Cheville JC, Zincke H. The Mayo Clinic experience with surgical management, complications and outcome for patients with renal cell carcinoma and venous tumour thrombus. *BJU Int.* 2004;94:33-41.

Schwartz MJ, Smith EB, Trost DW, Vaughan ED Jr. Renal artery embolization: clinical indications and experience from over 100 cases. *BJU Int.* 2007;99:881-886.

Smyrniotis V, Farantos C, Kostopanagiotou G, Arkadopoulos N. Vascular control during hepatectomy: review of methods and results. *World J Surg.* 2005;29:1384-1396.

This page intentionally left blank

Chapter 158

Open Stone Surgery: Anatrophic Nephrolithotomy and Pyelolithotomy

RAHUL A. DESAI AND DEAN G. ASSIMOS

The development of shock-wave lithotripsy, ureteroscopic, percutaneous, and laparoscopic stone removal has resulted in very few current indications for open surgical stone removal. There are a small number of patients who have extremely large staghorn stones with complex collecting system anatomy who may be still candidates for anatrophic nephrolithotomy, the steps for which are subsequently outlined. An even fewer number of patients are candidates for pyelolithotomy, which is also described below. It is recognized that these procedures are undertaken in portions of the world where the aforementioned technologies are not available.

ANATROPHIC NEPHROLITHOTOMY

Preoperative

The spatial orientation of the stone in the kidney is best defined with computed tomography and three-dimensional reconstruction. If the former does not adequately define collecting system anatomy, intravenous or retrograde pyelography is performed. Nuclear renography is performed if the involved kidney is thought to be functioning poorly. Antibiotic therapy is prescribed preoperatively if infection stones are suspected. The antibiotic should cover the cultured organism from urine and be broad spectrum due to the known discordance between stone and urine cultures. Type and cross for blood is obtained, as transfusion may be required. The utilization of a sequential lower-extremity compression device to prevent thromboembolic complications is advocated. General anesthesia is administered and a Foley catheter is inserted just prior to positioning.

Positioning

The patient is placed in a flank position. Cushions are placed along the spine, just below the axilla and in between the legs. The patient is secured to the table with pads and wide tape encircling the midchest and hips.

Incision

An 11th rib incision is generally used. The flank fascial layers are opened and the diaphragm and pleura are mobilized superiorly and the peritoneum medially. The utilization of a self-retaining retractor is recommended.

Renal Dissection

Gerota's fascia is longitudinally opened over the posterior aspect of the kidney. Perinephric fat is carefully dissected off the kidney taking care to not enter a subcapsular plane. The utilization of loupe magnification facilitates this process and other portions of the operation. The ureter(s), renal artery(ies) and vein(s) are dissected out and encircled with vessel loops (Fig. 158-1). The posterior segmental artery is isolated by distal dissection of the main renal artery. This vessel is typically the first segmental branch and it courses around the posterior aspect of the renal sinus.

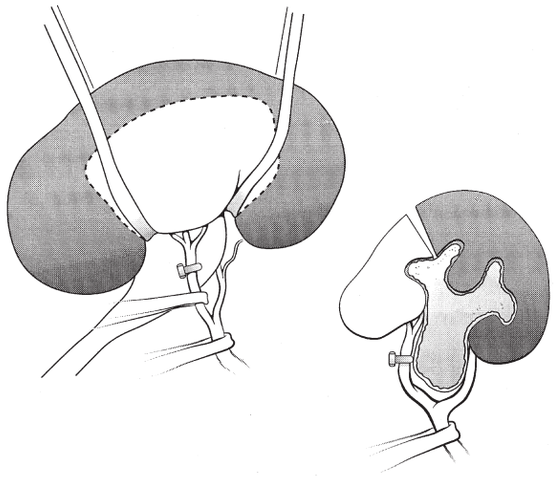

FIGURE 158-1. *(From Assimos DG. Anatrophic nephrolithotomy. Urology. 2001;57(1):161-165, Figure 1.)*

Intraoperative Imaging

Intraoperative imaging is undertaken before embarking on stone removal (Fig. 158-2). Ideally, this is done with sterilized small-film placed posterior to the kidney. However, nowadays, this is not available in most institutions, and alternative imaging is utilized (digital fluoroscopy or direct contact ultrasonography). The imaging provides information about stone location and may help direct nephrotomy.

Identifying Anatrophic Plane

The posterior segmental artery is temporarily occluded with a bull-dog clamp and the patient is administered one ampule of methylene blue intravenously. This typically results in blanching the posterior segment of the kidney, which contrasts with the blue-colored parenchyma in the remainder of the kidney. The defined plane is then marked on the renal surface with topical application of methylene blue. The bull-dog clamp is removed. If an anatrophic plane is not defined, intraoperative Doppler ultrasonography may help define the best plane for nephrotomy.

Institution of Ischemic Renal Hypothermia

The patient is administered mannitol intravenously (12.5-g dose for adults). The main renal artery is occluded 10 minutes later with a plastic bull-dog clamp. The kidney is surrounded with a plastic drape and subsequently packed in iced slush for 10 minutes.

Nephrotomy and Stone Removal

A superficial incision is made along the previously defined anatrophic plane. The parenchyma is bluntly separated using brain spatulas or scalpel handles until the collecting system is entered. This is further opened to expose the stone. The stone is manipulated out using stone forceps. The nephrotomy may need to be enlarged and the collecting system incised further to deliver the branched stone without fracture. Other stones present are removed with forceps. Stenotic infundibula containing stones are incised open and the calculi are removed with forceps. Exposure to these areas is facilitated through the use of nerve hooks and drum elevators. Separate incisions should be made in each moiety to prevent injury to the anterior segmental artery branch in kidneys with a bifid collecting system. Iced slush is applied as necessary to keep the kidney adequately cooled. The renal vein can be occluded if bleeding obscures visualization. Imaging is repeated once all visible stone is removed. If residual stone is demonstrated, the targeted portion of the kidney is explored. These stone are typically located behind stenotic infundibula, which can found with gentle probing and sometimes gentle palpation of the parenchyma. Complete removal is confirmed with a repeat imaging study. After this, a hydrophilic wire is passed down the ureteropelvic junction, down the ureter and into the bladder. A double-J stent is then passed in an antegrade manner over the wire.

Renal Closure

All transected vessels are ligated with absorbable 4-0 to 6-0 suture (Figs. 158-3 through 158-6). Running absorbable 5-0 or 6-0 monofilament can be used to close the collecting system. Two different techniques are used to reconstruct incised stenotic infundibula. Calicorrhaphy involves suturing the mucosal edges of the infundibulum to the adjacent renal pelvis, which shortens and widens the infundibulum. Calicoplasty is utilized for reconstruction of two adjacent stenotic infundibula. The adjacent mucosa from each infundibulum is approximated with suture forming one common conduit. After reconstruction of the stenotic infundibula, the remainder of the collecting system is closed with using a running suture. 4-0 to 6-0 absorbable suture is used for reconstructing the collecting system. The renal capsule is closed with running 3-0 to 4-0 absorbable suture.

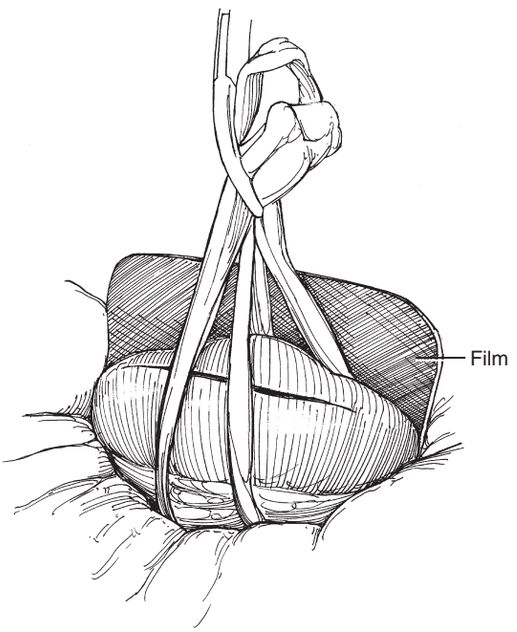

FIGURE 158-2.

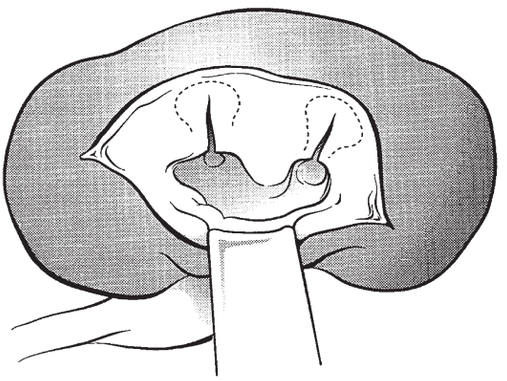

FIGURE 158-3. *(From Assimos DG, Anatrophic nephrolithotomy, Urology. 2001;57(1):161-165, Figure 3A.)*

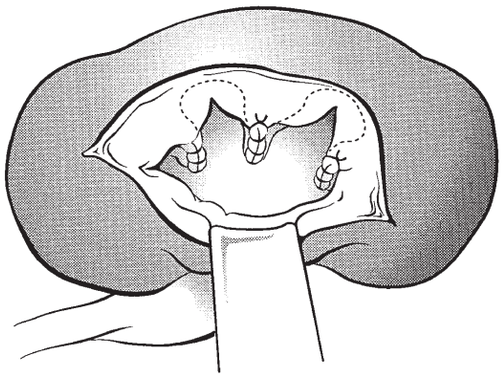

FIGURE 158-4. *(From Assimos DG, Anatrophic nephrolithotomy, Urology. 2001;57(1):161-165, Figure 3B.)*

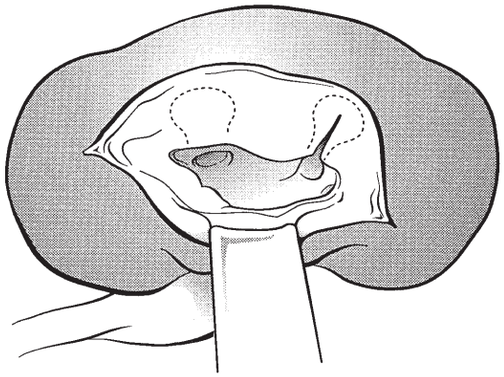

FIGURE 158-5. *(From Assimos DG, Anatrophic nephrolithotomy, Urology. 2001;57(1):161-165, Figure 4A.)*

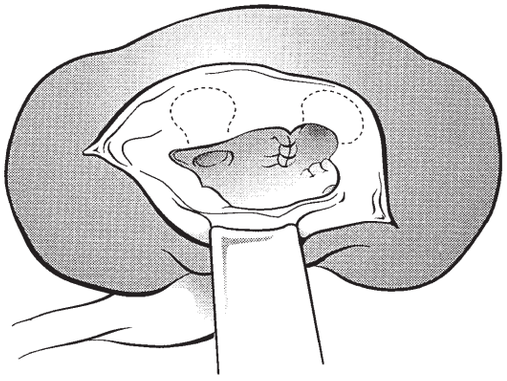

FIGURE 158-6. *(From Assimos DG, Anatrophic nephrolithotomy, Urology. 2001;57(1):161-165, Figure 4B.)*

Termination of Ischemic Hypothermia

The bull-dog vascular clamps and iced slush are subsequently removed. The patient is administered another dose of intravenous mannitol (12.5 g in adults) to attenuate reperfusion injury. The kidney is bathed in warm sterile saline. Return of good turgor typically occurs promptly. Bleeding may be seen through the nephrotomy and usually ceases with application of gentle pressure for 5 to 10 minutes. Tissue sealants may be applied to the suture line if low volume bleeding persists. If there is persistent high volume bleeding, ischemic hypothermia is reinstituted, the nephrotomy is opened, and a search for transected vessels is undertaken. The renal artery clamp may need to be removed to find the source of bleeding, which is subsequently oversewn. Once hemostasis is achieved, Gerota's fascia is re-approximated around the kidney with absorbable 2-0 to 3-0 suture. A closed suction drain is placed posterior to the kidney and brought through a small separate incision. The fascial layers and skin are closed in a standard fashion.

Postoperative Care

The patient is closely monitored for signs of hemorrhage or renal insufficiency. The drain is typically removed when there is no indication of a urine leak. The patient is maintained on antibiotic therapy. The stent is usually removed 2 to 3 weeks after discharge.

Complications

Perioperative complications may include wound infection, sepsis, acute tubular necrosis, damage of the main or segmental renal arteries and veins, injury to the collecting system ureter and surrounding structures, neuropraxia, rhabdomyolysis, hydrothorax/pneumothorax, atelectasis, pneumonia, venous thromboembolic events, and renal hemorrhage. Renal angiography and selective embolization may be required for management of the latter.

PYELOLITHOTOMY

Preoperative Evaluation, Patient Preparation, and Incision

Preoperative evaluation and preparation are similar to those for anatrophic nephrolithotomy. This procedure should not be undertaken if the patient has an intrarenal pelvis. The kidney may be accessed through a flank, subcostal, dorsal lumbotomy, or midline incision.

Exposure of Renal Pelvis

Gerota's fascia is incised posteriorly and the perinephric fat is dissected off the posterior surface of the kidney. The proximal ureter is isolated and the dissection is carefully extended proximally and the posterior surface of the pelvis is delineated. The utilization of Gil-Vernet retractors is used to expose the renal sinus (Fig. 158-7). Care is taken not to injure the posterior segmental artery, which typically courses just inside the posterior renal sinus.

Stone Removal

A "U"-shaped curvilinear incision is made with a hooked scalpel or Pott's scissors with the lower extent at least 1 cm

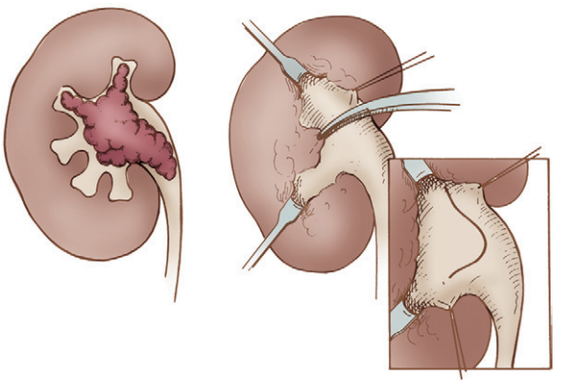

FIGURE 158-7. *(Modified from Gillenwater JY, et al., Adult and Pediatric Urology, 3rd ed., Elsevier, 1996. Copyright J.Y. Gillenwater, MD.)*

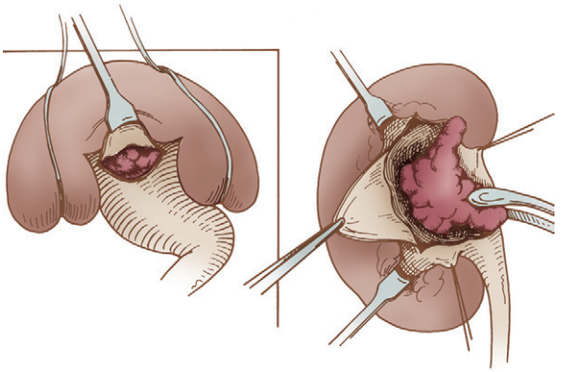

FIGURE 158-8. *(Modified from Gillenwater JY, et al., Adult and Pediatric Urology, 3rd ed., Elsevier, 1996. Copyright J.Y. Gillenwater, MD.)*

above the ureteropelvic junction. The stone(s) are extracted with stone forceps taking care to not extend the pyelotomy. The collecting system can be examined with a flexible nephroscope or intraoperative imaging can be utilized to confirm complete stone removal. The technique of extended pyelolithotomy can be used to obtain further exposure and facilitate stone removal. In this modification, the pyelotomy is carefully extended superiorly into the respective infundibula. Inferior exposure can be enhanced by delineating the anatrophic demarcation as previously described and making a small nephrotomy along the inferior edge of the anatrophic plane (Fig 158-8).

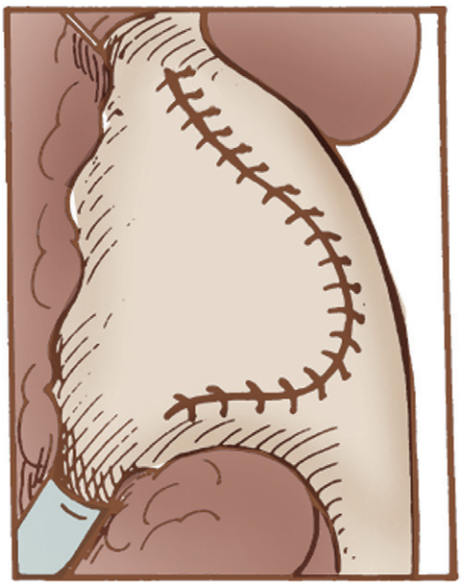

FIGURE 158-9. *(Modified from Gillenwater JY, et al., Adult and Pediatric Urology, 3rd ed., Elsevier, 1996. Copyright J.Y. Gillenwater, MD.)*

Closure of Pyelotomy and Wound Closure

An internalized ureteral stent can be inserted at the discretion of the surgeon. The pyelotomy is closed with running or interrupted 4-0 to 6-0 absorbable suture (Fig. 158-9). A closed suction drain is placed posterior to the kidney and brought out a separate small incision. Routine wound closure techniques are employed.

Postoperative Care

This is similar to that described for patients subjected to anatrophic nephrolithotomy.

Complications

The complications are similar to those with anatrophic nephrolithotomy but the risks of acute tubular necrosis are negligible as renal circulation is not interrupted. The posterior segmental artery can be injured during manipulation in the proximal portion of the renal pelvis and renal sinus. Urine leak may develop and the patient is managed using standard approaches. Ureteropelvic junction obstruction and proximal ureteral stricture development are also amongst possible complications.

Chapter 159

Laparoscopic Simple Nephrectomy

Anatomy and Principles of Laparoscopic Kidney Excision

COURTNEY K. PHILLIPS AND JAIME LANDMAN

PREOPERATIVE CONSIDERATIONS

Patients should understand both the benefits and complications associated with laparoscopic renal surgery. Intraoperative complications associated with laparoscopic simple nephrectomy include vascular and visceral injuries as well as failure to progress. Any of these complications may necessitate open conversion, and, as such, patients should be consented for possible open conversion. Postoperative complications include neurapraxias, rhabdomyolysis, deep venous thrombosis, and cardiac events associated with pneumoperitoneum (e.g., CO_2 embolism). The operating theater should be prepared with two units of packed red blood cells and an open surgical tray for emergent conversions. Currently, the authors do not use any special bowel preparation for laparoscopic renal surgery. Both the transperitoneal and retroperitoneal approaches are reasonable for the majority of simple nephrectomy procedures.

PATIENT POSITIONING

Lower extremity sequential compression devices are placed and started before the induction of anesthesia. A single dose of an intravenous antibiotic, such as cefazolin, is administered on induction. Once adequate general endotracheal anesthesia is obtained, an orogastric or nasogastric tube and a Foley catheter are placed to decompress the stomach and bladder, respectively.

Proper positioning is important to minimize the risk of postoperative complications (Fig. 159-1A). The patient is moved along the longitudinal plane of the table until the iliac crest is over the break in the table. The patient is then placed in a 70-degree semilateral decubitus position, with the pathologic kidney away from the table. An axillary roll is placed under the patient, just caudal to the axilla to minimize the risk of brachial plexus injury. For all transperitoneal procedures, the patient's anterior abdominal wall is situated flush to the edge of the table. The patient's lower leg is flexed at the knee, and the patient's upper leg is extended.

Because table rotation (airplaning) is used to help with laparoscopic exposure, it is important that the patient's hips, knees, and shoulders are padded and circumferentially secured to the table with 3-inch tape to prevent shifting.

PRIMARY ACCESS

The abdomen is widely prepared and draped from the symphysis pubis to a level just above the xiphoid process and from the posterior axillary line of the upward side to the midclavicular line of the downward side. If specimen extraction through a Pfannenstiel incision is a consideration, the appropriate area must be shaved and prepared as well.

TROCAR POSITIONING

Templates for trocar placement on both sides are shown in Figure 159-1B. Each patient's anatomy is different, so trocar templates must be adapted to the individual's body habitus and site of pathology. In general, the lower quadrant 12-mm trocar is placed approximately 2 fingerbreadths medial and superior to the anterior superior iliac spine. A second 10- or 12-mm trocar is placed in the midclavicular line approximately 2 cm below the costal margin. A third 10- or 12-mm trocar is then placed in the midline between the two working trocars. If the patient is obese, the template is moved laterally with the midline trocar being moved lateral to the rectus abdominis muscle. After the colon is reflected medially, a fourth 5-mm trocar is placed along the posterior axillary line at the level of the twelfth rib.

REFLECTION OF THE COLON

There are a variety of instruments that can be used for dissection. The authors prefer a 5-mm ultrasound energy device, such as the Harmonic Scalpel (Ethicon Endo-Surgery, Cincinnati, Ohio) and a 5-mm bipolar grasper (Aesculap, Center Valley, Pa.), which is an effective combination for safe and efficient dissection. The initial dissection should be focused on the release of any adhesions tethered to the anterior abdominal wall. These adhesions are common in the

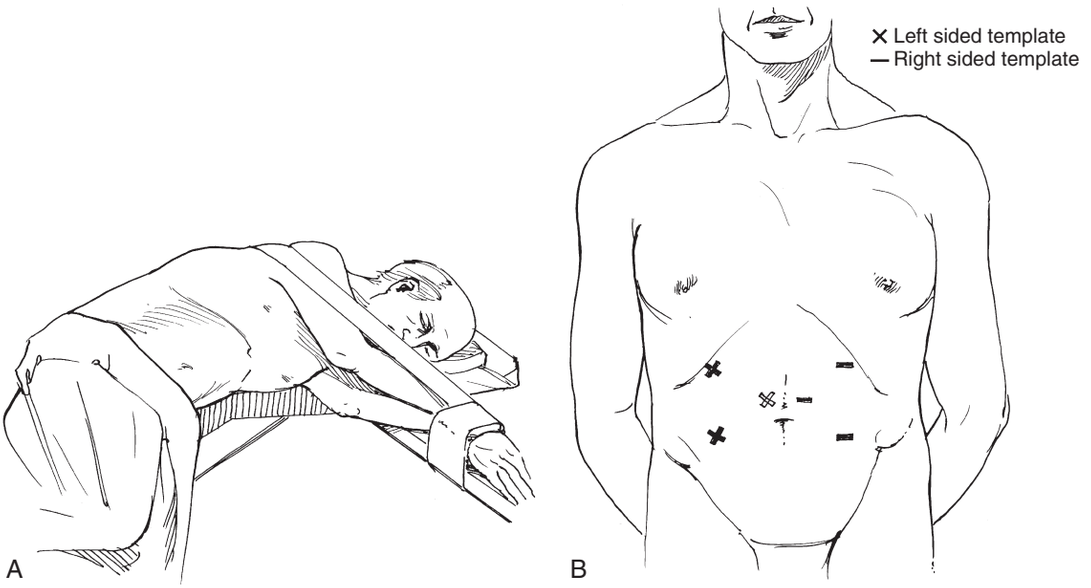

FIGURE 159-1.

region of the splenic flexure. Caution must be used when releasing these attachments, which can appear insignificant, but may contain bowel structures.

Once adhesions are released, the subhepatic attachments on the right, or the splenorenal ligaments on the left, are divided, allowing these organs to be rotated superiorly and medially, respectively. A self-retaining retractor, such as a PEER retractor (JARIT Surgical Instruments, Hawthorne, N.Y.) and the Endoholder (Codman, Raynham, Mass.) or the Diamond Flex retractor (Genzyme Surgical Products, Tucker, Ga.) can be placed through the posterior 5-mm trocar and are critical for the reflection of these organs away from the kidney.

The mesentery attaching the colon to Gerota's fascia is incised using a harmonic scalpel and divided up to the diaphragm and down to the lower pole of the kidney. As the colon is swept medially, it is important to maintain dissection in the avascular plane between Gerota's fascia and the mesentery. Visually, this can be achieved by staying in the thin areolar tissue lying between the pale yellow fat of Gerota's fascia and the darker yellow fat of the mesentery. This plane is often most easily identified at or just below the lower pole of the kidney. Deviation from this plane results in increased blood loss. The colon is reflected medially until the medial portion of the kidney is exposed.

MEDIAL DISSECTION OF THE KIDNEY

Once the medial portion of the kidney is visualized on the right side, it is imperative to identify and carefully dissect the duodenum, which is almost always anterior to the inferior vena cava (IVC) (Fig. 159-2). The duodenum will overlie the IVC and its extent must be carefully identified in order to avoid injury. With the duodenum safely mobilized medially and out of the operative field, the posterior coronary hepatic ligament can be incised from the white line of Toldt. This maneuver improves access to the anterior IVC

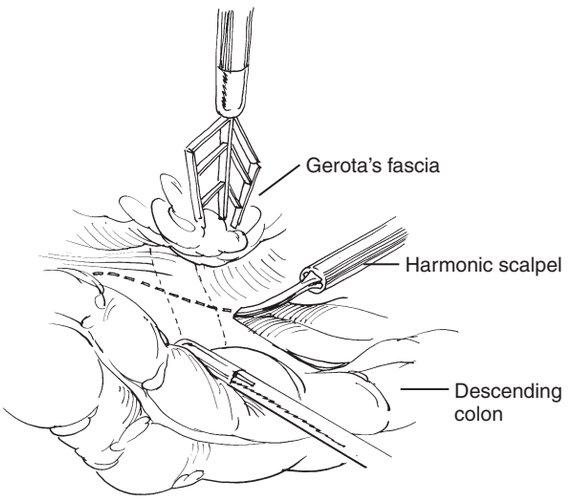

FIGURE 159-2.

above the duodenum and adrenal gland. By using the self-retaining retractor to hold the kidney laterally, the insertion of the renal vein can be identified.

On the left side, dissection is continued toward the aorta, although visualization of the aorta is not critical. Early identification of the pancreas, however, is critical to avoid injury. On the left side, the gonadal vein is an excellent landmark to use to prevent dissecting too far laterally or too far medially. Identification of the gonadal vein at its insertion into the left renal vein helps orient the surgeon to the local anatomy and helps minimize the risk of surgical misadventure.

IDENTIFICATION OF THE PROXIMAL URETER

On the right side, dissection of the IVC is continued inferiorly until the insertion of the gonadal vein is identified. The ureter courses posterior and lateral to the right gonadal

vein. Blunt dissection back to the iliopsoas will expose the ureter and provide a window to the posterior abdominal wall that can later be used to apply traction on the kidney.

On the left side, the gonadal vein can be identified at the level of the lower pole of the kidney and traced all the way to its insertion in the renal vein. Once the gonadal vein is isolated, the ureter can be identified in a manner identical to the right side. Early identification of the ureter is helpful as it can be used to help orient the surgeon to the local anatomy.

SUPERIOR DISSECTION

The upper and medial border of the kidney can be precisely identified by incising the overlying Gerota's fascia. Once the upper pole is visualized, an EndoGIA stapler can be used to dissect and separate the kidney from the adrenal gland superiorly and laterally. Alternatively, energy-based dissection with any surgical energy modality can be used to separate the superior and medial portion of the kidney from surrounding structures.

THE RENAL HILUM

Before dissection of the renal hilum, mobilization of the lower pole of the kidney is prudent. Mobilization of the lower pole and medial aspect of the kidney allow for improved access to the hilum, in that gentle retraction provides access to both the medial and inferior components of the renal artery and vein.

The renal vein is encountered during dissection of the IVC on the right and by tracing the gonadal vein proximally on the left. Once identified, circumferential dissection of the renal vein can be completed with a Maryland dissector and a right-angle dissector. During left renal vein dissection, particular attention must be focused on the posterior dissection. A lumbar vein, or veins, frequently insert into the renal vein posteriorly or may insert directly into the gonadal vein in the region of the renal vein. A 30-degree lens may aid in visualizing these tributaries.

The renal artery is located posterior to the vein, but it may be cranial, caudal, or directly posterior to the vein. Occasionally the renal artery may appear to be anterior to the vein; more thorough dissection usually reveals that the artery in question is not the renal artery, but the superior mesenteric artery, which is present in the region of the left hilum. Additionally, the pancreas lies medial to the left renal hilum. Early identification of the pancreas can help prevent pancreatic injury during the hilar dissection (Fig. 159-3).

Dissection of the artery must focus on obtaining enough length to comfortably place five 11-mm vascular clips or a vascular stapler across the artery. When using clips, the artery is divided between the second and third clips, leaving three clips proximally. When using a vascular stapler, the surgeon must be careful not to fire the stapler over any clips.

Once the artery has been successfully ligated and divided, the vein can be divided using a laparoscopic stapler. On the left, meticulous dissection of the renal vein

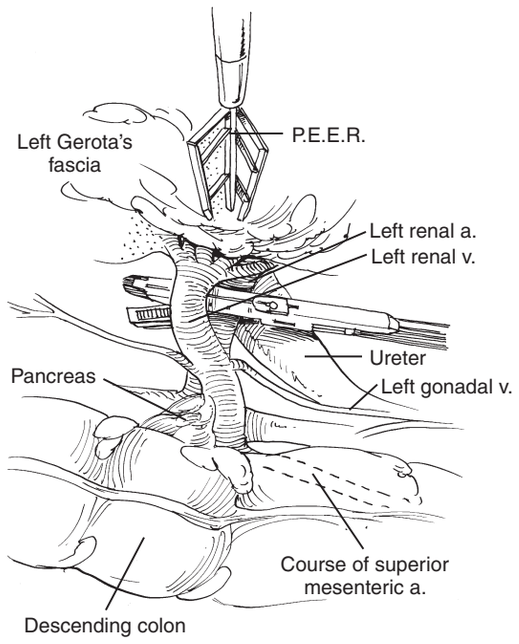

FIGURE 159-3.

can often allow the gonadal and adrenal veins to be spared; however, this is not imperative and should not be attempted if there is inadequate left renal vein length.

When the artery cannot be adequately dissected due to the position or length of the renal vein, the artery can be occluded with one to two clips, and then the vein can be divided first. With division of the vein, the artery should be dissected more extensively to allow for appropriate ligation and division.

Once the hilum is divided, the proximal ureter, which has already been identified, can be clipped and divided.

LATERAL AND INFERIOR DISSECTION

With adequate medial mobilization of the colon, the lateral and inferior kidney should be easily visualized. These renal attachments are often areolar in nature with minimal vasculature and require little more than blunt dissection and occasional electrocautery for focal hemostasis.

SPECIMEN RETRIEVAL AND REMOVAL

The renal specimen can be extracted many ways depending on specimen size, surgeon preference, patient body habitus, and prior surgical history, but in all cases the kidney should be removed in an entrapment sack such as a 15-mm Endocatch II (U.S. Surgical Inc., Norwalk, Conn.) or a LapSac (Cook Urological, Spencer, Ind.). This entrapment sack should be placed through the inferior 10-mm trocar site under direct vision once the trocar has been removed. Once safely placed into the entrapment bag, the specimen can be delivered through a separate Pfannenstiel, midline, or Gibson incision (Fig. 159-4). Alternatively, if the specimen is small or atrophic, the lowermost trocar site can be



FIGURE 159-4.

expanded 1 to 2 cm. Even though smaller incisions and scars are more desirable, it is important that no more than slight pressure be used to remove the specimen to prevent bag rupture.

With the specimen removed, the abdomen should be inspected for hemostasis. The pressure of the pneumoperitoneum can tamponade venous bleeding. As such, the abdomen is inspected with the intraabdominal pressure lowered to 5 mm. Often, in the time it takes to open and close an extraction incision, this has effectively already been done. Additionally, the anesthesia team can be asked to Valsalva the patient three times to inspect for bleeding incited by strain. Once adequate hemostasis has been achieved, trocar sites can be closed. Drainage of the renal bed is unnecessary in most instances.

HEMOSTASIS AND CLOSURE

Extraction incisions should be closed in the manner preferred by the surgeon. Fascial closure is not required for 5-mm trocars and those sites created with dilating trocars. Fascia should be reapproximated when Hasson access or nondilating trocars have been used. Skin incisions can be closed with subcuticular stitches or with skin adhesives such as Dermabond (Ethicon Endosurgery, Cincinnati, Ohio).

POSTOPERATIVE COURSE

Postoperatively patients can be maintained on oral or intravenous analgesia. In the absence of renal insufficiency, 15 mg of intravenous ketorolac (Toradol) can be given every 6 hours as needed for 36 hours as an adjunct for pain control. Sequential compression devices should be kept in place until the patient is ambulatory. Postoperative pulmonary toilet is also critical. Diet can be advanced as tolerated. Most patients tolerate clear liquids once fully awake, and a regular diet is usually well tolerated on the first postoperative day. Intravenous antibiotics, such as cephalexin, are continued 24 hours postoperatively and the Foley catheter is removed on the morning of postoperative day 1. Patients are usually discharged in 2 to 3 days on oral pain medications.

POSTOPERATIVE COMPLICATIONS

Patients undergoing laparoscopic nephrectomy do not usually need intensive care unit beds but should be monitored for signs and symptoms of myocardial infarction, stroke, and deep vein thrombosis per hospital protocol. Shoulder pain (focused around the area of the scapula) is a common complaint and results from diaphragmatic irritation caused by residual pneumoperitoneum. The shoulder pain should not, however, be accompanied by sensory or motor deficit, which could indicate a neurologic injury from inappropriate positioning. Additionally, any patient complaining of isolated lower extremity or buttock pain or weakness should immediately be assessed for rhabdomyolysis. Risk factors for this rare but serious condition include exaggerated flexion position, obesity, and prolonged operative time.

Bleeding is rare, but should be suspected in the appropriate clinical setting. Subcutaneous emphysema is not uncommon, especially if initial port placement was complicated. This condition is usually self-limited and can appear alarming, particularly if it extends into the subcutaneous tissues of the face and neck. Although traditional teaching dictates that patients with air in the subcutaneous tissue of the head and neck should be left intubated postoperatively, this is often unnecessary.

Unrecognized visceral injury must be suspected in any patient with pain at a particular port site and leukopenia. Contrary to the classic presentation of peritonitis, which is associated with open visceral injuries, patients who sustain laparoscopic bowel injury are frequently afebrile and do not have diffuse pain or an acute abdomen. Trocar site pain and leukopenia are the most common presentation of bowel injury after a laparoscopic procedure and should prompt immediate imaging with computed tomography. In this setting, an expeditious evaluation is critical because, as a rule, these patients' condition rapidly deteriorates when left untreated.

RETROPERITONEAL SIMPLE NEPHRECTOMY

The retroperitoneal approach is a reasonable alternative to the transperitoneal approach for simple nephrectomy. Indeed, for patients with multiple prior transabdominal surgeries or with known infection of the kidney, a retroperitoneal approach to the kidney may be advantageous. The limitations of the retroperitoneal approach are the limited working space and lack of orienting anatomic landmarks. Relative contraindications for retroperitoneal laparoscopic

surgery include history of recent open retroperitoneal surgery or inflammatory processes of the kidney, which can result in intense perirenal fibrosis (e.g., xanthogranulomatous pyelonephritis).

Initial access to the retroperitoneum is obtained through a transverse 2-cm incision off the tip of the twelfth rib. Once the flank muscle fibers are bluntly divided, the anterior thoracolumbar fascia is entered. Digital dissection cephalad to the incision, immediately posterior to Gerota's but anterior to the psoas fascia creates a space for a dilating balloon to be placed. It is critical to ensure that the dilating balloon lie outside Gerota's fascia, before inflating the balloon with 800 cc of air. A second dilation cranial or caudal to this initial site may be required depending on the clinical situation. A 10- to 12-mm trocar with an internal fascial retention balloon and external adjustable foam collar, such as the Bluntip trocar (Origin Medsystems, Menlo Park, Calif.), is particularly helpful in retroperitoneal cases, because it minimizes air leaks and subcutaneous emphysema. Alternatively, a Hasson trocar may be used to form a seal and maintain insufflation.

Once a 15-mmHg pneumoretroperitoneum is established, a 30-degree lens is inserted through the initial trocar. Upon initial entry, the psoas muscle and Gerota's fascia can consistently be identified, while the ureter, gonadal vein, peritoneal reflection, renal artery, aorta (on the left), and attenuated vena cava (on the right) can occasionally be identified. Once access is obtained, two additional 10- or 12-mm trocars are deployed. One trocar is placed at the costovertebral angle. This trocar can be used to insert a blunt instrument to gently peel the peritoneum off of the anterior abdominal wall. Mobilization of the peritoneum allows deployment of the third 10- or 12-mm trocar, which is placed near the anterior axillary line.

Once access has been established, the dissection proceeds along the medial margin of the psoas muscle where the renal artery is usually easily identified. The artery is circumferentially dissected and taken as previously described. The renal vein can then be dissected from surrounding structures and divided. Once the renal hilum has been addressed, the cephalad aspect of the medial dissection can be continued to separate the adrenal gland from the upper pole of the kidney.

With the adrenal gland spared, the upper and lower poles of the kidney are mobilized with sharp and blunt dissection. The ureter is identified, clipped, and cut. Finally, the lateral and anterior attachments of the kidney are taken. Care should be taken to avoid perforation of the peritoneum because it can further limit the working space. However, if the peritoneal cavity is entered, the procedure can still usually be completed without difficulty. If the working space becomes too limited, an additional 5-mm trocar can be placed for retraction.

Once the kidney is completely mobilized, the kidney can be extracted in a 10-mm Endocatch or 15-mm Endocatch II bag. Because of the limited space available in the retroperitoneum, it may be necessary to create an intentional peritoneotomy, which allows the specimen to be placed into the peritoneum for entrapment. The entire specimen can then be extracted by making a muscle-splitting extension of the primary port-site incision.

MORCELLATION

Although the vast majority of surgeons extract an intact specimen, the specimen may also be removed in a piecemeal fashion. Morcellation can be achieved mechanically by using a high-speed morcellator or manually by using a large ring forceps. While a morcellator produces smaller fragments than the ring forceps, both techniques allow for specimen extraction through an unextended port site. The major limitation of morcellation is its obfuscation of accurate pathologic staging. Additionally, any attempts at morcellation must be performed within a double-layered, impermeable nylon entrapment sack (LapSac) to minimize the risk of bag rupture, puncture, or injury to the surrounding viscera.

This page intentionally left blank

Chapter 160

Laparoscopic Transperitoneal Radical Nephrectomy

LESLIE A. DEANE, JAMES F. BORIN, AND RALPH V. CLAYMAN

PATIENT SELECTION AND CONTRAINDICATIONS

Laparoscopic radical nephrectomy has been accepted as the alternative to traditional open radical nephrectomy in the treatment of many renal cell carcinomas. Accepted indications currently include T1 to T3a lesions with even very large tumors (25 cm) being safely and effectively removed. Cases with limited renal vein involvement (T3b) can also be excised via a laparoscopic approach, albeit by the most experienced laparoscopic surgeons. If metastases have developed, there is survival benefit conferred by nephrectomy prior to adjuvant immunotherapy, and a laparoscopic approach allows for a more expedient recovery. Sound clinical judgment remains the mainstay in deciding whether a particular tumor is most amenable to a laparoscopic versus an open approach.

PREOPERATIVE PREPARATION

Patients are admitted to hospital on the morning of surgery. We routinely recommend intake of only clear fluids for the preceding 24 hours in addition to one bottle of magnesium citrate the evening before surgery, and nothing by mouth after midnight. A cephalosporin within 1 hour of the incision will usually suffice for surgical prophylaxis. In patients at increased risk for deep venous thrombosis, Heparin 5000 IU is given subcutaneously, just prior to surgery, in addition to sequential compression devices in all patients.

PATIENT POSITIONING AND PROTECTION

Following the induction of general endotracheal anesthesia, a urethral catheter and orogastric tube are placed. Patients are placed in the lateral decubitus position with the table half flexed. The kidney rest is only elevated for the first 30 minutes, or until the pneumoperitoneum is established, whichever occurs sooner. The operating table is reinforced with either gel padding or egg crate. Hip grips (SunMedica, AZ) are placed on the table at the level of the buttocks and shoulder. The patient's lower leg is flexed to 90 degrees and separated from the upper leg by pillows. Next an axillary roll is put at the level of the nipple. It is important that the axilla is empty and this roll does not occupy the axilla to avoid the potential development of a brachial plexus palsy. The ipsilateral arm is draped across the torso and separated from the dependent arm by multiple pillows. We are careful to place extra padding under the lateral malleolus and the fibular head of the dependent leg, again for prevention of compression injury. The patient is then secured to the table with Velcro straps and 3-inch cloth tape at the shoulders, hips, and knees.

ESTABLISHING AND REGULATING PNEUMOPERITONEUM (VERESS, HASSON)

Two techniques are generally available to achieve the pneumoperitoneum. We currently routinely obtain the pneumoperitoneum by using a 15-cm Veress needle placed two finger-breadths superior and medial to the anterior superior iliac spine (Fig. 160-1). At this point there is a soft spot that indicates the site of the interdigitation of the external oblique aponeurosis and the lateral edge of the rectus muscle at the linea semilunaris. A 12-mm incision is then made and the subcutaneous fat separated with a hemostat until the fascia is visualized. This is then grasped with two Allis clamps and gently lifted. The Veress needle is then advanced into the peritoneum with its tip directed slightly medially and inferiorly. There are usually three "pops" as the needle is inserted, but this solely depends on the state of development of the musculofascial

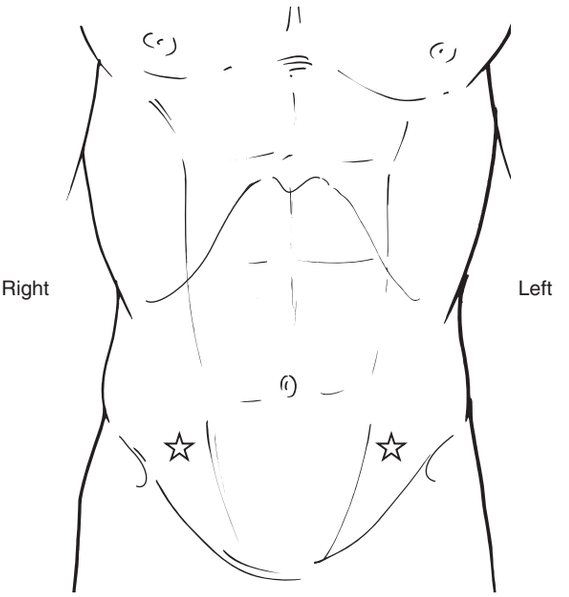

FIGURE 160-1. Veress needle access is gained at a point two finger-breadths superior and two finger-breadths medial to the anterior superior iliac spine. This is the site where the anterolateral abdominal wall muscles interdigitate with the lateral aspect of the rectus sheath at the linea semilunaris. A 12-mm incision is made followed by insertion of the Veress needle.

layers and is largely patient dependent. Next the Veress needle should be aspirated with a 10-cc syringe followed by irrigation with up to 3 cc of saline, a second aspiration, and removal of the syringe, thus allowing the column of saline to fall under gravity into the peritoneum. Following this, the insufflator tubing is connected to the needle and the expected opening pressure should be less than 10 mmHg. The insufflator is then switched to high flow until an initial pressure of 20 mmHg is achieved. This higher pressure is maintained for no longer than 10 minutes by the clock, or until all primary ports are placed, whichever comes first. The pressure is then lowered to 12 mmHg for the remainder of the case.

In cases where there has been a previous appendectomy, colectomy, or lower abdominal/pelvic surgery, Veress access will be gained at a point one finger-breadth below the costal margin and in the midclavicular line. Through this site a 5-mm Ternamian Endo-Tip (Karl Storz Endoscopy America, Culver City, CA) port is inserted. This provides a safe and controlled way to enter the abdomen. This is done under visual control with a zero-degree 5-mm lens. This 5-mm port may be upsized to a 12-mm port as necessary. If there has been more extensive prior surgery, a Hasson technique with a balloon port (Covidien, Norwalk, CT) is considered.

PORT PLACEMENT FOR LEFT AND RIGHT NEPHRECTOMY

Next, the sites for placement of the working ports are selected. Typically, the first port is placed one finger-breadth below the costal margin in the mid-clavicular line. This is a 12-mm port with a visual obturator allowing a 10-mm, zero-degree lens, to view the subcutaneous tissue followed by the external fascia, internal fascia, preperitoneal fat and finally the peritoneal cavity, in a controlled rotating fashion. This lens is immediately switched to a 10-mm, 30-degree lens, and the site of Veress entry is inspected for any obvious injury. The needle is removed and a second 12-mm port is inserted at the previous site of Veress entry, under direct vision. In most patients, the primary 12-mm camera port is placed under direct vision at least 6 cm from the midline to avoid the epigastric vessels and usually superior to the umbilicus.

For right radical nephrectomy, two additional 5-mm ports are required (Fig. 160-2). The first of these is placed in the epigastrium, just inferior to the xiphoid process, entering the peritoneum on the right side of the falciform ligament. This is used to retract the liver cephalad, after it has been mobilized. The second 5-mm port is placed

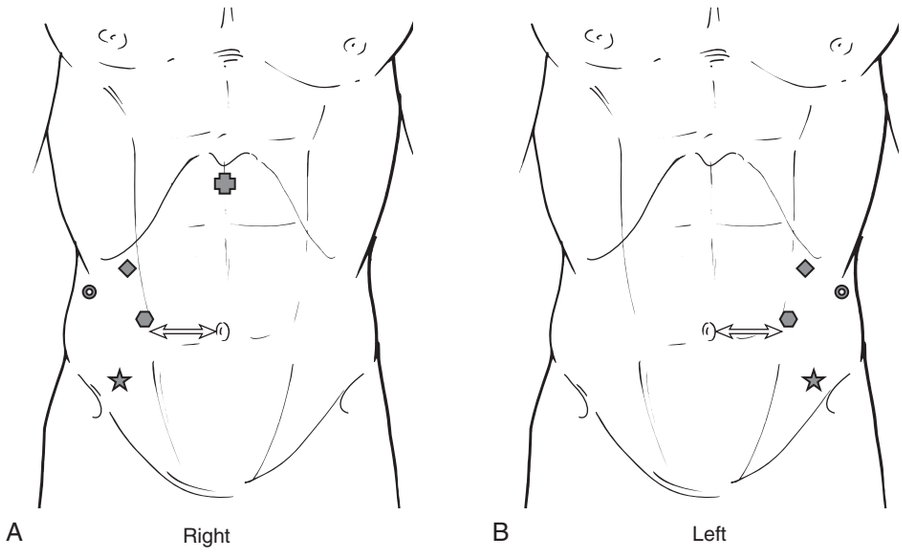

FIGURE 160-2. Port placement for right and left laparoscopic radical nephrectomy. Hexagon, 10-mm camera port placed at least 6 cm from the midline and lateral to the rectus to avoid the inferior epigastric vessels. If the patient is thin, the upper outer quadrant of the umbilicus can be used to place the 10-mm camera port. Star, 12-mm port placed at the site of previous Veress needle insertion. Diamond, 12-mm port placed 1 cm inferior to the costal margin in the mid clavicular line. Donut, Optional 5-mm port placed in the anterior axillary line at 1 to 2 cm subcostal to facilitate use of the Jarit retractor for exposure of the renal hilum. Cross, Optional 5-mm subxiphoid port can be placed for right radical nephrectomy to aid liver retraction.

laterally in the midaxillary line to provide lateral traction on the renal hilum during its dissection and also to facilitate specimen entrapment.

For left radical nephrectomy, only one of these, the lateral 5-mm port, is placed in the midaxillary line.

STEPS FOR LEFT NEPHRECTOMY

The steps for left radical nephrectomy begin with complete mobilization of the left colon, initiated by incision of the white line of Toldt from the level of the iliac vessels inferiorly, through the spleno-phrenic attachments (Fig. 160-3). Proceeding as far cephalad as the spleno-phrenic attachments allows the spleen and subsequently the pancreatic tail and body to fall medially away from Gerota's fascia. Further dissection and incision of the spleno-colic ligament followed by the spleno-renal ligaments, defines the dissection of the upper pole (Fig. 160-4). At this point, the muscles of the posterior body wall and diaphragm are visualized.

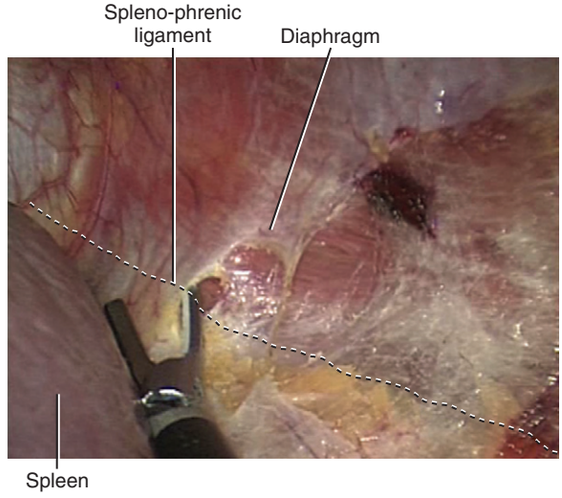

FIGURE 160-3. Incision of the white line of Toldt extending to the spleno-phrenic ligament.

Next, the plane between the mesentery of the descending colon and the anterior surface of Gerota's fascia is identified. Identifying these natural tissue planes is greatly facilitated by traction–counter-traction maneuvers using either a 5- or 10-mm laparoscopic Kittner dissector (Covidien, Norwalk, CT, and Ethicon Endosurgery, Cincinnati, OH, respectively). This medial reflection of the colon, combined with the mobilization of the spleen, allows the spleen and colon to fall medially, carrying the tail and body of the pancreas with them away from Gerota's fascia. This dissection also allows the gonadal vein and the ureter to then be approached. The gonadal vein is then traced by proceeding carefully along its anterior surface to its insertion into the left renal vein (Fig. 160-5). Any troublesome minor oozing can be effectively dealt with using the argon beam coagulator. One should be aware that the pneumoperitoneum should be vented through a port, when the argon beam is in use, to avoid overpressurizing the abdomen.

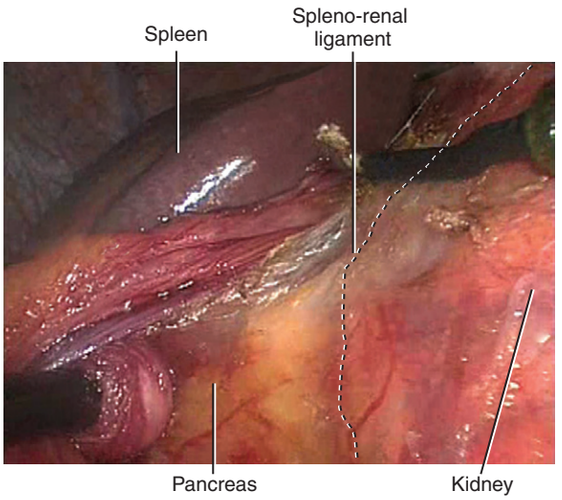

FIGURE 160-4. Incision of the spleno-renal ligament defines the upper pole of the left kidney. When this incision is deepened, the posterior body wall will be seen.

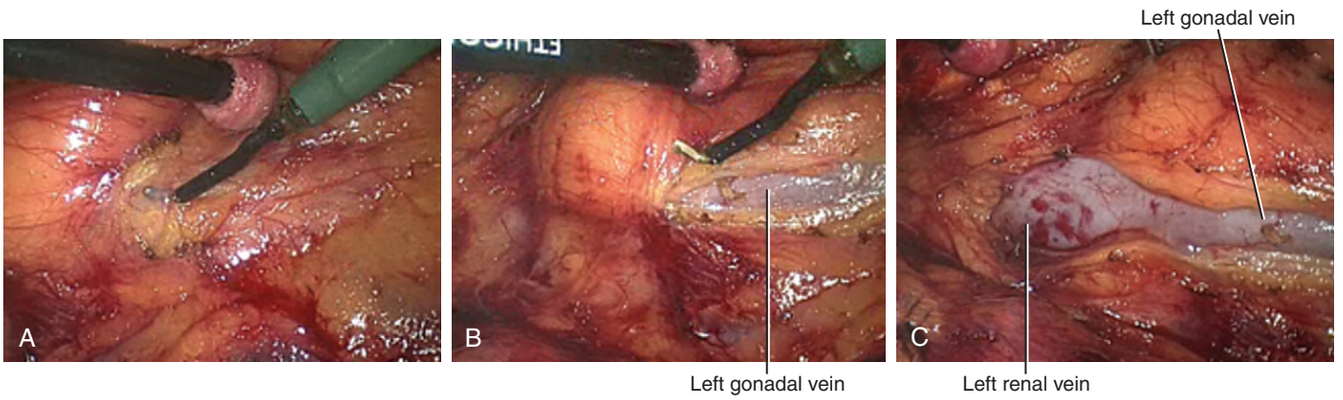

FIGURE 160-5. A, First view of the left gonadal vein. **B,** Surface of vein visualized. **C,** Gonadal vein traced cephalad to its insertion into the left renal vein.

STEPS FOR RIGHT NEPHRECTOMY

The steps for right radical nephrectomy begin with incision of the white line of Toldt from the base of the cecum, extending cephalad to and then through the triangular ligament of the liver, continuing cephalad to the bare area of the liver (Fig. 160-6). Next, a shallow incision is made from medial to lateral just above the colon; this incision is connected with the initial incision in the line of Toldt. The colon, which covers only the lower half of the right kidney, is thus mobilized along with its mesentery medially and inferior off of Gerota's fascia. At this point, the 5-mm port in the epigastrium becomes key, as it is used to pass a locking traumatic 5-mm forceps; the forceps is passed beneath the edge of the liver and affixed to the upper edge of the incision in the line of Toldt, thereby retracting the inferior liver edge cephalad to expose the posterior coronary ligament of the liver. The posterior coronary hepatic ligament is then incised from lateral to medial. The lateral incision is connected to the incision in the line of Toldt. The medial extent of the incision ends at the inferior vena cava; if there

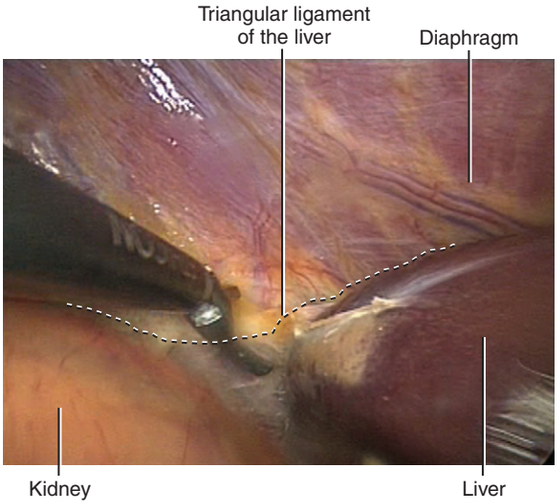

FIGURE 160-6. Incision of white line of Toldt extending to the triangular ligament of the liver.

is any difficult with continuing this incision medially, the surgeon is advised to stop and proceed with the following steps in order to clearly identify the anterior surface of the inferior vena cava (Fig. 160-7). Now the duodenum is carefully dissected from the surface of Gerota's fascia overlying the kidney (i.e., Kocher maneuver), in order to expose the anterior surface of the vena cava (Fig. 160-8). It should be noted that the vena cava is never seen prior to Kocherizing the duodenum. At times, with the liver retracted, the inferior vena cava can be identified where it enters the liver. This lies well above the point of insertion of the adrenal vein. By careful dissection with hook electrode along the anterior surface of the vena cava, the main right renal vein and then superior to this, the right adrenal vein insertion is identified. If the adrenal gland is being removed en-bloc with the kidney, the adrenal vein can be secured either with the Ligasure device (Covidien, Boulder, CO) or with three 5-mm titanium clips, being careful to leave two clips on the "stay" side. In many instances, it is possible, once the adrenal vein is secured, to dissect the entire upper pole of the kidney in Gerota's fascia away from the posterior abdominal wall musculature and lower insertions of the diaphragm. As the dissection proceeds caudally along the inferior vena cava, the next vessel emanating laterally from the inferior vena cava is the right renal vein. Anterior and approximately at the same level or slightly lower than the renal vein is the insertion of the right gonadal vein into the anterior surface of the inferior vena cava (Fig. 160-9). This vessel can either be spared if the pathology being treated permits, or secured in a similar fashion to that described for the adrenal vein above. It is important not to injure this vessel at its insertion as this will require a sutured repair of the vena cava.

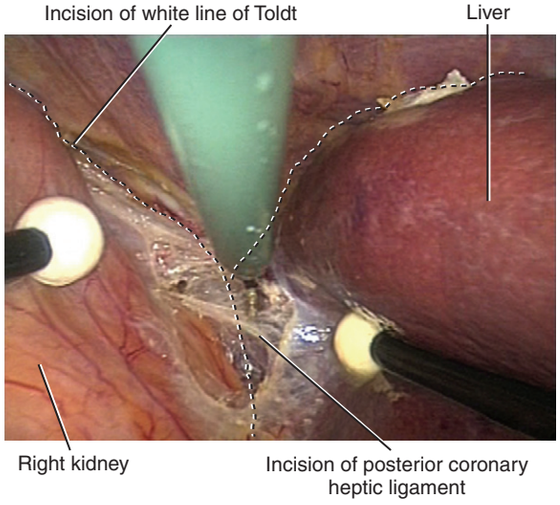

FIGURE 160-7. Incision of the posterior coronary hepatic ligament, which is joined by the incision of the white line and the triangular ligament.

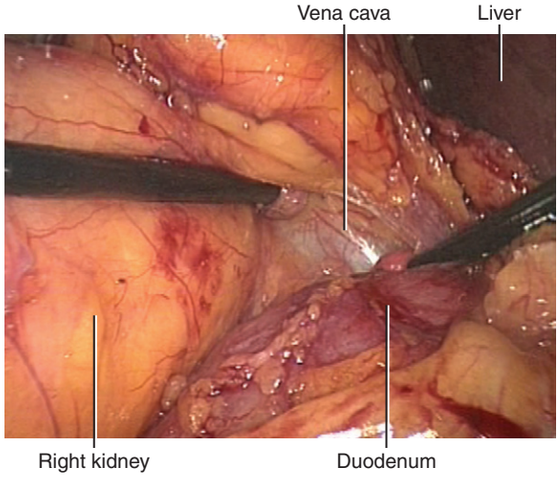

FIGURE 160-8. Kocherization of the duodenum reveals the inferior vena caval surface for the first time. The anterior surface of the vena cava can be dissected cephalad to connect with the medial extent of the incision in the posterior coronary hepatic ligament.

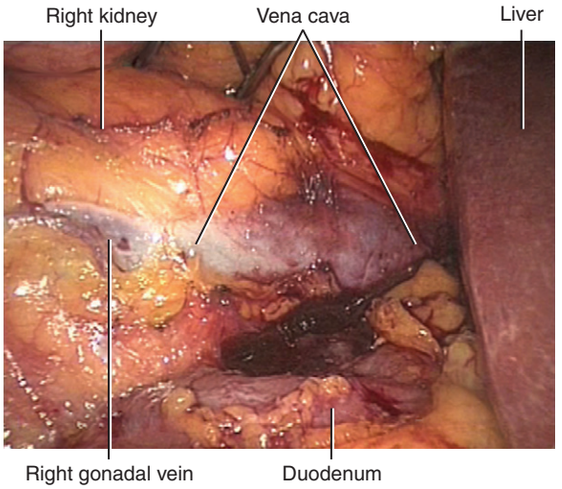

FIGURE 160-9. Complete Kocherization of the duodenum and dissection of the anterior surface of the vena cava allows identification of the right gonadal vein insertion. In this photograph, the liver is not retracted cephalad yet, thereby obscuring vision of the posterior coronary hepatic ligament.

HILAR DISSECTION

There are generally three ways to address the renal hilum, namely anterior, posterior, and inferior approach with a "renal lift" maneuver. It should be noted, that while the renal vein is usually clearly seen and is readily exposed by blunt dissection, the renal artery is invested with a thick layer of lymphatic tissue that requires sharp dissection before it is clearly exposed. The kidney can be retracted laterally using a 5-mm Jarit PEER retractor (Jarit Surgical Instruments Inc., Hawthorne, NY) passed through the lateral 5-mm port, which is fixed to an external holding device such as the Endoholder (Codman, Raynham, MA) or CIVCO Laparostat Laparoscope holder (CIVCO Medical Solutions, Kalona, IA). These instruments maintain the non-fatiguing retraction needed for the dissection and prevent the kidney from falling medially.

For an anterior approach, on the right side, the vena cava is dissected to expose the origin of the renal vein. Its anterior surface is then dissected. The renal artery is usually located directly posterior or slightly inferior to the right renal vein and with gentle superior traction on the renal vein, can be identified as it emerges from behind the vena cava.

For an anterior approach, on the left side, the renal vein is found by identifying and following the left gonadal vein superiorly, to its insertion into the renal vein. At this time, the ascending lumbar vein can also be identified, sealed, and transected; this vein may enter the renal vein directly, usually posterior and lateral to the gonadal vein, or it may join the gonadal vein directly or rarely, insert on the renal vein medial to the gonadal vein (Fig. 160-10). Identifying and securing this vein is essential prior to dissecting the renal artery; if this vein is inadvertently torn, it has a tendency to retract into the muscular tissues of the back, making hemostasis difficult. The left adrenal vein, located superior and opposite, or slightly medial, to the gonadal insertion, is then dissected sealed and transected. This gives access to the left renal artery in most instances.

If an anterior approach proves unsuccessful in identifying the renal artery, the gonadal vein/ureteral complex is isolated at the level of the lower pole of the kidney and a Kittner dissector or other atraumatic clamp, is passed beneath this complex to the psoas muscle. Next, this instrument is used to raise up the ureter and renal lower pole laterally. Now the entire inferior surface of the renal hilum is exposed, revealing the vein and artery lying parallel to each other. The one caveat is that on the left side, the ascending lumbar vein, if present and not already secured, will need to be identified and secured prior to visualization of the left renal artery (Fig. 160-11).

The third way to identify the renal hilum, the posterior approach, requires the release of the lateral attachments of the kidney. This allows for complete medial rotation of the kidney within Gerota's fascia. One must proceed cautiously at this point, carefully observing for the subtle pulsations of the renal artery, which will now be encountered prior to seeing the renal vein. On the left side, the artery can be traced to the sidewall of the aorta; however, on the right side, one must be aware that the body of the artery crosses posterior to the inferior vena cava. Identification of the lateral wall of the vena cava is advised prior to full dissection of the right renal artery in order to preclude inadvertent caval injury due to passage of the right angle clamp. The artery can then be dissected and secured (vide infra). The renal vein is then secured from this approach or the kidney is returned to its normal position and the vein is taken by an anterior approach.

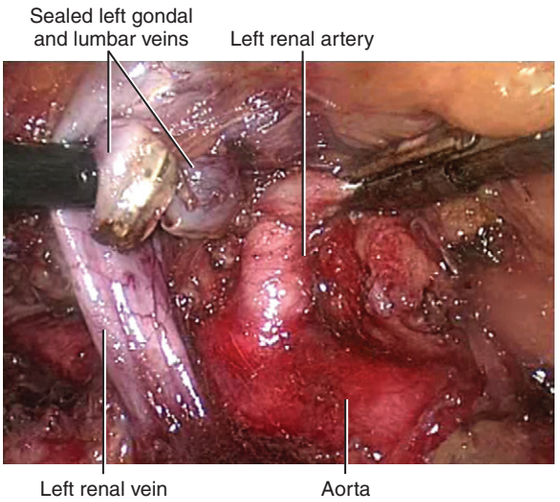

FIGURE 160-11. Left renal artery seen following transection of the gonadal and posterior lumbar veins.

METHODS TO LIGATE RENAL ARTERY AND VEIN

Once the renal artery and vein have been identified, dissected and isolated, it is our preference to staple these individually, artery followed by vein, using an Endo-GIA (Ethicon Endosurgery, Cincinnati, OH; Covidien, Norwalk, CT) with a vascular load (Figs. 160-12 and 160-13). When applying the

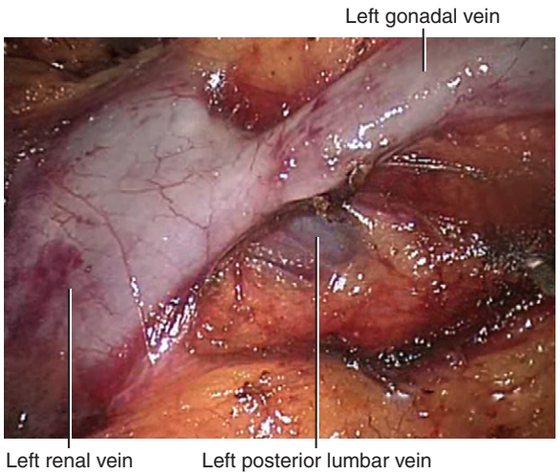

FIGURE 160-10. The anatomic relationship of left gonadal, posterior lumbar, and renal veins.

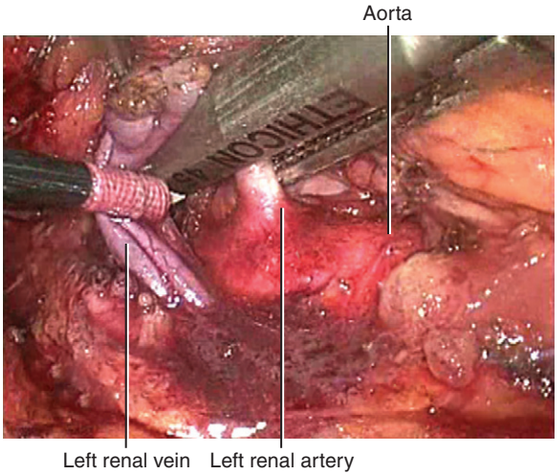

FIGURE 160-12. Renal artery being stapled with vascular Endo-GIA.

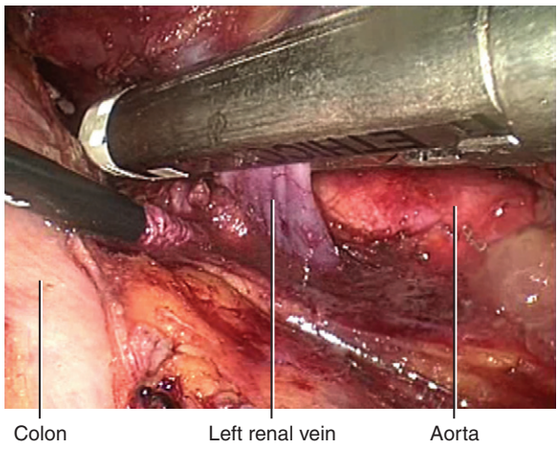

FIGURE 160-13. Renal vein being stapled with vascular Endo-GIA.

stapler, we have found it helpful to first close the handles of the stapler and then wait for 10 seconds prior to firing the staples; in theory this allows for full compression of the occluded tissues and possibly better deployment of the staples.

An ideal method of aiding the dissection of the artery and vein in preparation for stapling, involves a gentle twisting followed by the back and forth motion of the laparoscopic Kittner dissector, to create an appropriate space to apply and deploy the stapling device. In the preparation of the vasculature for transection, numerous small lymphatics are encountered and these should be secured with either a bipolar sealing device or an ultrasonic shears, to minimize the risk of a lymphatic leak, as opposed to monopolar cautery. A second method of arterial control is the application of multiple 10-mm titanium clips (Fig. 160-14). Typically, five clips are placed and the artery is divided between the third and fourth clips. The vein can then be stapled as above. Alternatively, two Hem-O-lock (Teleflex Medical, Research Triangle Park, NC) clips can be applied to the artery. When using these clips it is important not to use the ultrasonic shears for nearby dissection as this can result in clip failure and catastrophic hemorrhage.

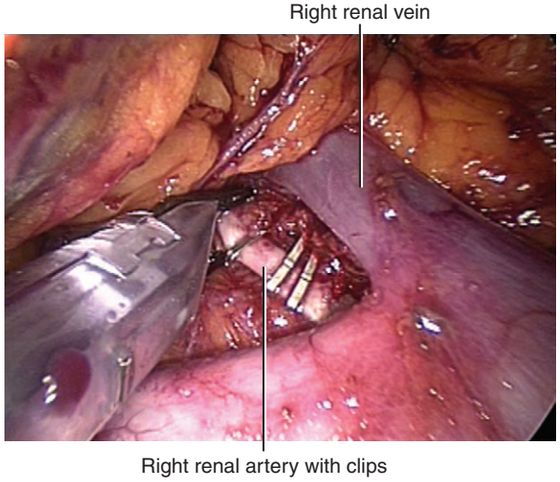

FIGURE 160-14. Titanium clips applied to right renal artery. A third clip has yet to be applied to "stay" side.

ADRENAL GLAND

Adrenal Removal

On the right side, the adrenal vein is sealed and transected as previously discussed. Once the adrenal vein is secured, the previous incision of the posterior coronary ligament of the liver is deepened to reveal the posterior body wall musculature. On the left side this plane corresponds to the splenorenal ligament, which is incised and the dissection is continued until again the posterior body wall musculature comes into view. The plane between Gerota's fascia and the muscle is dissected caudally as the upper pole is lifted. Next, the lateral attachments are incised and the two planes of dissection joined. Now the specimen is only attached by the ureter.

Adrenal Sparing

If the clinical circumstance warrants preservation of the adrenal gland, its venous drainage is preserved. Once the renal hilum has been addressed, all efforts are focused on identifying the renal capsule of the upper pole. This is followed to the posterior aspect of the inside of Gerota's fascia using the Ligasure device or ultrasonic shears. When the latter is incised, the posterior body wall will be seen. This effectively leaves the adrenal gland protected within the sleeve of Gerota's fascia. From here the dissection proceeds as detailed above.

URETERAL DISSECTION, OCCLUSION, AND DIVISION

Now the only remaining attachment is the ureter; the ureter is grasped using a locking grasping toothed forceps passed via the upper lateral 5-mm port and is sealed and transected with the Ligasure device (Fig. 160-15). Alternatively, two

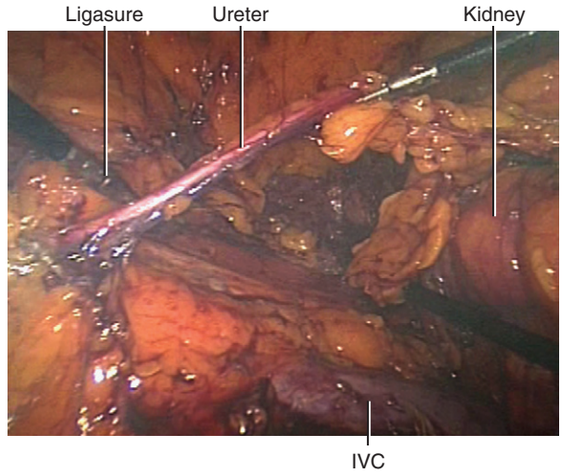

FIGURE 160-15. Ureter grasped with toothed forceps and about to be sealed and transected with Ligasure device (Covidien, Boulder, CO). The ureter is being held by a locking grasping forceps passed through the lateral upper 5-mm port. Once transected, the specimen is then moved onto the surface of the liver or spleen, using this forceps.

10-mm titanium clips can be used to ligate the ureter prior to its transection. The specimen is then placed on the liver or spleen for entrapment following right and left nephrectomy, respectively.

SPECIMEN ENTRAPMENT (ENDOCATCH VS LAPSAC)

When the specimen is completely free, the entrapment sack used largely depends on the size of the specimen and whether the specimen will be morcellated or removed intact. This sack is passed via the 12-mm port just opposite the umbilicus. Specimens weighing less than 1000 grams can be entrapped in the Endocatch; while specimens up to 1800 grams can be entrapped in a LapSac sack. If one is morcellating, the LapSac (Cook Urological, Spencer, IN) must be used, as it is the only sack that is durable enough for this mechanical process.

When entrapping the kidney, the specimen is placed on the spleen or liver, via the 5-mm locking grasping forceps that was placed on the ureter. For intact removal, the 15-mm Endocatch (Ethicon Endosurgery, Cincinnati, OH) is inserted via the middle 12-mm port site; to do this, the port must be removed and the Endocatch is inserted under endoscopic control through the bare port site. The Endocatch is opened beneath the edge of the liver or spleen; the spring opening mechanism keeps the neck of the sack wide open while the kidney is then rolled into the sack. Next, the drawstring on the sack is pulled closed as the Endocatch device is withdrawn.

For morcellation, the 8×10-inch LapSac is used. This sack is mounted onto a two-tined introducer system with a nitinol glidewire threaded through the holes along the neck of the sack; the glidewire will facilitate opening of the sack once it is deployed within the abdomen. The LapSac is then opened in a triangular configuration, with a 5-mm locking grasping forceps affixed to each of the equidistant tabs on the neck of the sack. A lateral and medial grasping forceps are used to create the base of the "tent," which is brought cephalad until it rests under the edge of the liver or spleen. The third forceps is in between the first two and holds the third tab upward, creating the apex of the tent.

At this point, the laparoscope is passed via the upper 12-mm port and is passed deeply into the sack; as the laparoscope is removed from the sack, it is moved in an ever widening circular pattern in order to further open the sack. Then, with the clamp on the ureter, the specimen is maneuvered into the sack. It is helpful to aim the 5-mm forceps, holding the ureter, toward the apex of the sack while the two forceps creating the base of the sack are pushed cephalad and anterior thereby pushing the specimen deeper into the sack. The nitinol glidewire is then pulled taught, closing the mouth of the sack.

SPECIMEN REMOVAL (MORCELLATION OR INTACT REMOVAL)

When the specimen is to be morcellated, the nitinol wire on the LapSac is grasped and brought out through the lowermost port, that is, the site of previous Veress needle insertion, and this port site incision is extended to 20 to 25 mm. Next, the mouth of the sack is exteriorized and the neck of the sack is passed through a perforated green towel; additional green towels are placed over the abdomen to cover the other ports following which an Ioban drape (3M United States, St. Paul, MN), which is perforated at its center is also passed over the neck of the sack. Lastly, to complete the triple draping of the neck of the LapSac, the opening of a disposable, adhesive percutaneous nephrostomy drape is placed over the mouth of the sack. A Sopher clamp is then used to manually fragment the specimen in the sack and remove pieces of the kidney and tumor. This process is monitored with the laparoscope, and if there is any sign of a breach in the integrity of the sack or a sudden loss of the pneumoperitoneum, morcellation is aborted, the incision is further extended, and the specimen is removed. Following morcellation, the triple drapes are removed and the wound is lavaged with Betadine solution. The entire team, except for the camera person, then changes gowns and gloves. The extraction site is closed in two layers.

For intact removal, the drawstring on the Endocatch is transferred to the lower 12-mm port site and a 7- to 10-cm horizontal incision is made to pull the specimen and sack out intact. Alternatively, a 7- to 10-cm lower midline or Pfannenstiel incision can be made to remove the tumor and entrapment sack intact.

TECHNIQUE OF HEMOSTATIC INSPECTION

Once the specimen has been removed, the extraction incision is closed and a final check for hemostasis is made. The retroperitoneum and operative site are flooded with saline irrigant; the pneumoperitoneum is reduced to 5 mmHg. The observance of thin red swirls coming to the surface of the pooled irrigant (i.e., "rivulets") is a sure sign of bleeding. The red swirl must be traced to its origin and hemostasis achieved. Hemostatic adjuncts, such as Floseal, are liberally used in the resection bed for added hemostatic security.

PORT-SITE CLOSURE (CARTER THOMASON DEVICE) OR NONE

As a rule, all midline ports greater than or equal to 10 mm and all nonmidline ports larger than 12 mm, are closed. In thin patients, the fascia is easily seen and a single figure-of-eight suture will suffice. In more obese patients, the Carter-Thomason (Inlet Medical, Eden Prairie, MN) device is used to place one to two simple sutures through the fascia under direct vision.

POSTOPERATIVE CARE

As long as renal function is normal preoperatively, 15 to 30 mg of Toradol are administered intravenously every 6 hours for up to 36 hours. Narcotics are minimized in order to avoid an ileus. Patients are given a clear liquid diet

on the first evening postoperatively and are advanced to a normal diet once they have passed flatus. Early ambulation is encouraged and the urethral catheter is removed when they are sufficiently mobile (usually postoperative day 1). Discharge is typically within 2 to 3 days.

IDENTIFYING PROCEDURE-SPECIFIC COMPLICATIONS

Right Side: Adrenal, Liver, Caval, Right Colon, or Duodenal Injury

The major structures that may be injured during radical nephrectomy are both vascular and visceral. On the right side these include the short right adrenal vein, the inferior vena cava, colon, liver, and the duodenum. To avoid a vascular injury, it is important that the vena cava be completely dissected along its anterior surface prior to proceeding laterally. This allows for identification of the gonadal vein as it enters the vena cava, as well as the laterally directed right renal vein and the short right adrenal vein. If hemorrhage occurs from any venous structure, pressure over the stump with a 10-mm Kittner followed by increasing the pneumoperitoneum pressure to 20 mmHg, gives the surgeon enhanced visibility. For minor venous ooze, argon beam coagulation may suffice. For marked venous bleeding, the site of bleeding can be tamponaded with a 10-mm Kittner. The area of injury can be secured with a clip or more commonly by suturing; to do this, the surgeon may use either an Endostitch with a 4-0 silk suture and a Lapra-Ty clip or a free suture with a Lapra-Ty clip; the latter is used with an SH needle, which enhances one's ability to see the tip of the needle after it has been passed through the tissue. If there is difficulty controlling the venous bleeding, one can convert to hand-assist or to open; if the injury is arterial, open conversion is recommended (Fig. 160-16).

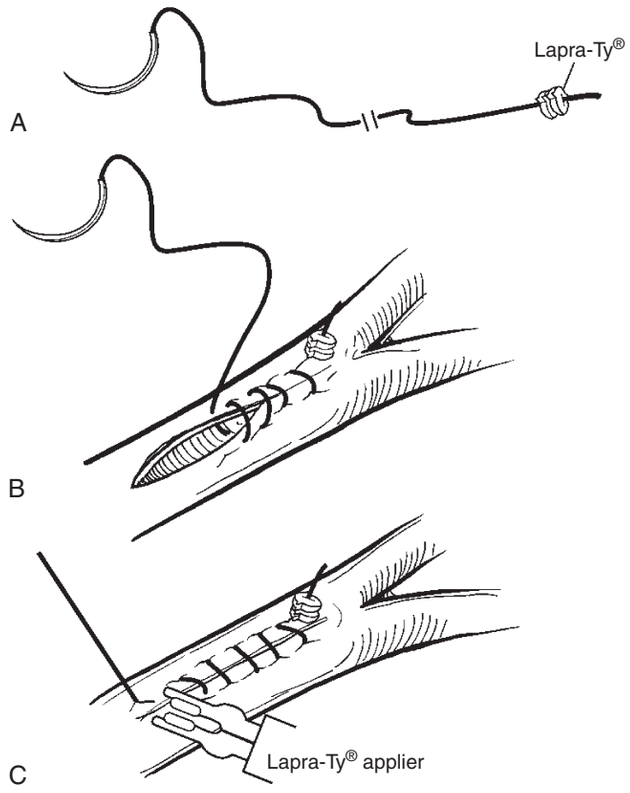

FIGURE 160-16. A, Steps for repair of inferior vena caval injury using Endostitch device or free hand laparoscopic suturing (Covidien, Norwalk, CT). **B,** Endostitch device or free hand laparoscopic suturing used to close laceration of vena cava with 4-0 silk with Lapra-Ty on free end. **C,** Second Lapra-Ty clip applied when closure complete. *(From Bishoff JT, Kavoussi LR. [2007]. Atlas of laparoscopic urologic surgery. Philadelphia, Elsevier.)*

With regards to the liver, anything more significant than a capsular tear or minor laceration warrants a general surgery consultation. Minor injuries can be treated with a combination of argon beam coagulation, Surgicel strips and Floseal.

Transmural injury to the duodenum requires a general surgical consult. Serosal tears can be oversewn with 2-0 silk Lembert sutures followed by an omental patch. Minor electrocautery injuries can also be treated as per serosal tears. Colon injuries can be similarly treated. Any full thickness bowel injury requires a two-layer transverse closure. Likewise, any extensive electrocautery injury to the bowel requires wide resection of the affected area, with a proper bowel anastomosis as these injuries are more extensive than what meets the eye.

Left Side: Spleen, Pancreas, Colon, Aorta, Superior Mesenteric Artery, and Stomach

Splenic injuries can be addressed in the same fashion as hepatic injuries—specifically, argon beam coagulation and fibrin glue accompanied by general surgical consultation. Recognized pancreatic injury warrants an immediate surgical consultation. Very minor pancreatic injuries can be oversewn but deeper injuries, especially those deep enough to involve the ductal system, may require distal pancreatic resection; a drain is placed in all cases.

The superior mesenteric artery (SMA) is at risk during left radical nephrectomy as it passes anterior to the third part of the duodenum and the left renal vein. Complete mobilization of the spleen allows the spleen, pancreas, and SMA to be displaced medially. The rule of following the left gonadal vein to its insertion into the renal vein and dissection posterior to the renal vein to identify the renal artery should ensure that the SMA is not inadvertently ligated. To be sure, when the surgeon "stumbles" upon the "renal artery" or sees the "renal artery" before identifying the renal vein, the likelihood is strong that one is dealing with the SMA and not the renal artery. If the SMA is ligated and transected, open conversion and vascular surgery consultation for possible immediate repair are mandatory. Aortic injury almost inevitably requires open conversion for repair. An attempt at treating this laparoscopically, either with the Endostitch device or free-hand suturing, should only be considered by

the most facile and experienced laparoscopic surgeons, provided that the injury can be immediately controlled by compression.

Also, the stomach may be encountered during the dissection of the upper pole of the kidney, if the surgeon enters the plane under the pancreas. This leads to the lesser omentum and the greater curvature of the stomach will come into view (Fig. 160-17). The stomach may also be noted as the spleen is mobilized medially. Finally, the left colon is at risk during the dissection; injury to the colon is handled as previously described for right nephrectomy.

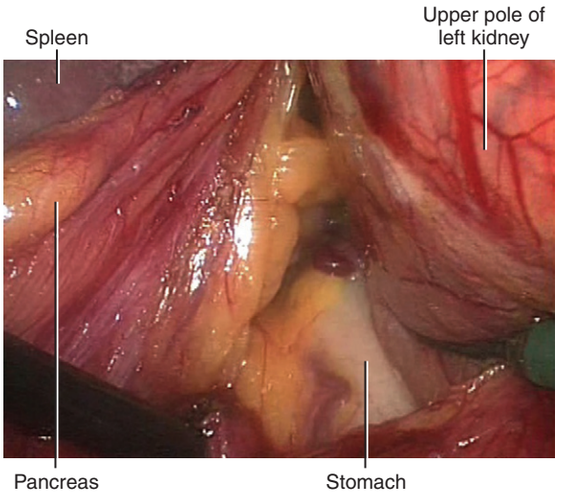

FIGURE 160-17. When the dissection proceeds under the pancreas, the greater curvature of the stomach will come into view.

Chapter 161

Laparoscopic Heminephrectomy

JEFFREY B. CAMPBELL AND BRADLEY P. KROPP

INDICATIONS

The primary indications for a laparoscopic heminephrectomy in the pediatric population are a nonfunctioning upper-pole moiety associated with an ureterocele or ectopic ureter. Additional indications include a nonfunctioning lower-pole moiety associated with an ureteropelvic junction obstruction or high-grade vesicoureteral reflux. Patient selection is extremely important. Ruling out concomitant lower tract pathology that could eventually require repair may make lower tract reconstruction a more attractive option for the patient. Finally, in the presence of infection associated with a nonfunctioning moiety, a laparoscopic or combined laparoscopic and open total heminephroureterectomy may be preferable.

PATIENT PREPARATION

A preoperative urine specimen is obtained for culture and sensitivities. Bowel laxatives are instituted the day before surgery if there is a history of constipation.

INSTRUMENTS

A general rule of thumb is to use the smallest instruments possible to accomplish the task at hand. This allows more precise dissection and minimizes damage to adjacent tissues. With this in mind, we typically use 5-mm ports and 3-mm instruments for dissection. We have found the Harmonic Scalpel (Ethicon) to be useful for both dissection and hemostasis and prefer to have an Argon Beam Coagulator (ConMed) on hand for managing bleeding from the exposed renal parenchyma. We have also found the Endoloop (Ethicon) to be a useful instrument for ligation of the distal ureteral stump.

APPROACH

Both transperitoneal and retroperitoneal approaches have been described, each with its own advantages and disadvantages. The transperitoneal approach offers the advantages of a larger working space, more familiar anatomy, easier access to the renal hilum in the setting of marked ureterectasis, and more distal mobilization of the ureter, particularly in older patients. The retroperitoneal approach offers the advantages of less mobilization of adjacent structures and working within a contained space that is more effectively drained in the setting of a compromised collecting system. The authors typically prefer a transperitoneal approach and describe the technical aspects herein.

CYSTOSCOPY/STENT PLACEMENT

In selective cases, to aid in identification and preservation of the lower-pole ureter, we will place a ureteral catheter in the lower-pole ureter, the upper-pole ureter, or both. This decision is based primarily on the size of the upper-pole ureter and laparoscopic experience. There have been no adverse events associated with the placement of these ureteral catheters except for the additional surgical time and, therefore, we highly recommend their use. With the patient in the dorsal lithotomy position, cystourethroscopy is performed. Retrograde ureteropyelography is then performed to delineate the ureteral anatomy. Ureteral catheters are then placed with fluoroscopic guidance if deemed necessary. The cystoscope is removed, a Foley catheter is placed, and the ureteral and Foley catheters are prepped into the field.

PATIENT POSITIONING/ PORT PLACEMENT

The patient is placed in a modified (30 degrees) lateral decubitus position with a small roll under the flank. In older patients, the kidney may be raised and the table flexed to achieve the same effect. Intraperitoneal access is gained via the umbilicus. A 5-mm umbilical port is placed. Laparoscopy is performed to confirm atraumatic access. Two additional 5-mm ports are placed: the first either in the midline, superior to the umbilicus or in the upper quadrant in the midclavicular line, and the second in the

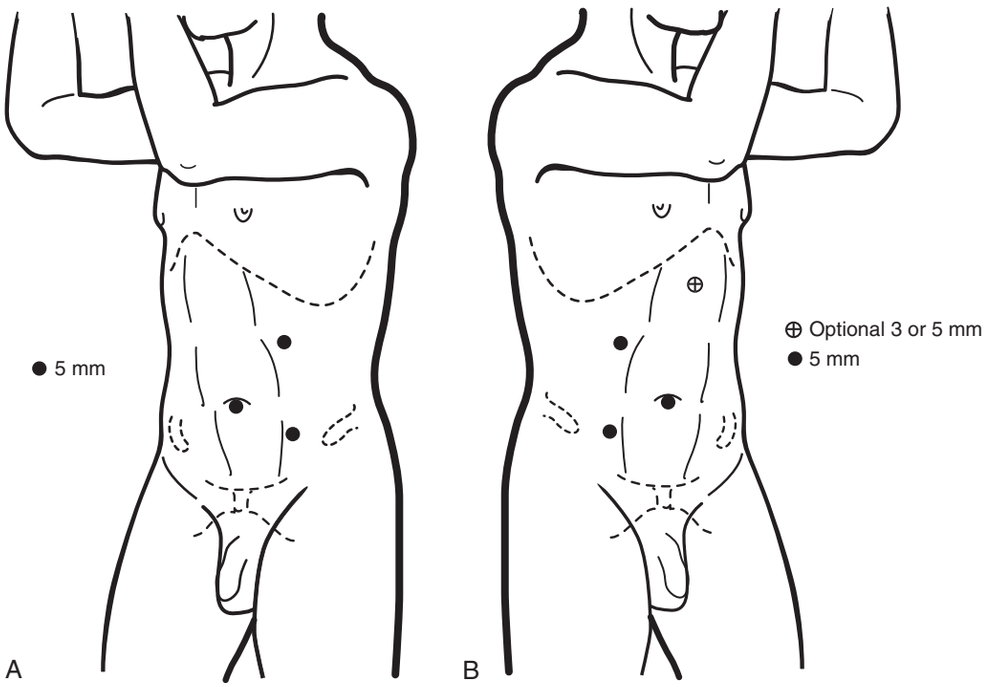

FIGURE 161-1 *(Modified from Bishoff JT, Kavoussi LR. [2007]. Atlas of laparoscopic urologic surgery. Philadelphia: Elsevier, Figure 5-2A and B.)*

lower quadrant in the midclavicular line. A right hemine-phrectomy often requires placement of an additional port for use in retraction of the liver. This port is typically placed in the midline just inferior to the xiphisternum (Fig. 161-1). The ports are secured to the abdominal wall to prevent displacement during movement or exchange of instruments.

EXPOSURE

The colon is mobilized medially. The gonadal vessels are identified and followed up to the renal hilum. Alternatively, the upper- and lower-pole ureters are identified where they pass under the gonadal vessels. Placement of the ureteral catheters, as describe above, can greatly facilitate this step and ensure proper identification and preservation of the lower-pole ureter. The upper-pole ureter can than be traced to the level of the renal hilum. Gerota's fascia in incised inferior to the renal hilum and extended superiorly around the upper-pole moiety. The renal vasculature and upper-pole moiety are mobilized (Fig. 161-2). Care is taken to minimize traction on the renal artery in an effort to minimize vasospasm and avoid an intimal tear, which could lead to devitalization of the lower-pole moiety.

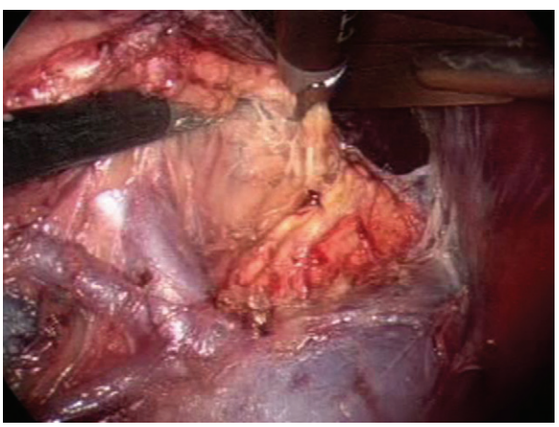

FIGURE 161-2.

MOBILIZATION OF URETER

The ureter is mobilized circumferentially beneath the renal vasculature. It is extremely important that all adventitial attachments between the renal vasculature and the ureter are divided before proceeding to the next steps. Failure to release these attachments can result in undue traction on the renal vasculature and transient ischemia

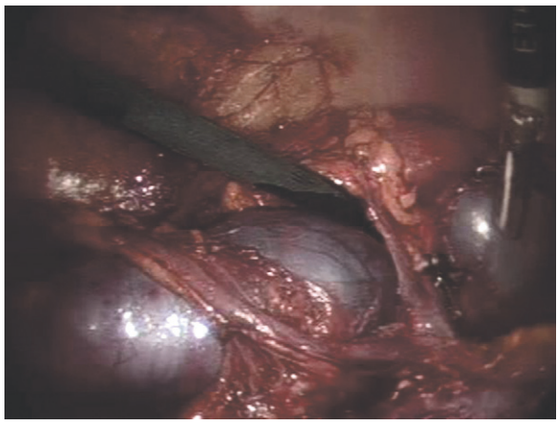

FIGURE 161-3.

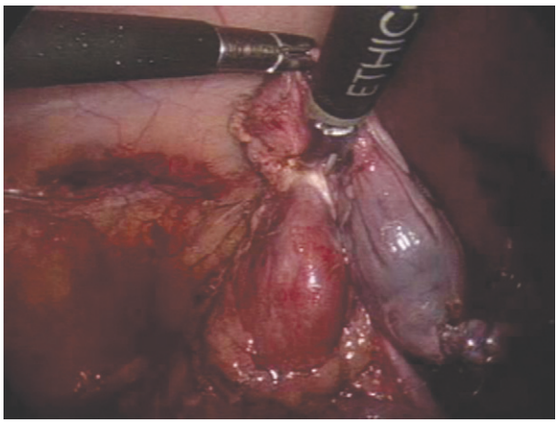

FIGURE 161-4.

to the lower-pole moiety when passing the ureter behind the vessels as described in the next steps of the procedure. The ureter is clipped/ligated and divided inferior to the renal hilum. Care should be taken to maintain distension of the upper-pole ureter and renal pelvis as this can greatly facilitate subsequent dissection. The upper-pole vessels are clipped and divided. The upper-pole ureter is then passed superiorly, inferior to the lower-pole vessels (Fig. 161-3).

EXCISION OF UPPER POLE MOIETY

Cephalad retraction of the upper-pole ureter exposes the junction of the upper and lower-pole moieties, which is usually well demarcated following division of the upper-pole vessels (Fig. 161-4). The upper and lower-pole moieties are separated with the Harmonic Scalpel. Intermittent use of the Argon Beam Coagulator may be required for hemostasis. Venting of the abdomen during use of the Argon Beam Coagulator is essential to avoid sudden increases in intra-abdominal pressure.

Suspicion of an injury to the lower-pole moiety collecting system may be confirmed with injection of methylene blue into the lower-pole renal pelvis with subsequent efflux across the resection bed. Injuries to the collecting system are closed with a running absorbable suture. The surgical site is then drained with a JP drain brought out through the inferior 5-mm port site and the Foley catheter is left to gravity drainage.

Some advocate nephropexy upon completion of an open heminephrectomy, stating an increased risk of torsion about the renal vasculature. The authors feel that this is not necessary given the minimal mobilization required in a laparoscopic heminephrectomy.

MANAGEMENT OF DISTAL URETER

The upper-pole ureter is dissected free from the lower-pole ureter down to Waldeyer's sheath. The dissection is carried out close to the upper-pole ureter taking care to preserve the intervening adventitial vasculature for the lower-pole ureter. The vas deferens, when applicable, is identified and preserved. An Endoloop is used for distal ligation of the upper-pole ureter, which is then excised (Fig. 161-5).

REMOVAL OF SPECIMEN

The surgical site is inspected and hemostasis in ensured. Once decompressed, the surgical specimen is extracted through the umbilical incision with a hemostat. Alternatively, the umbilical port is exchanged for a 10-mm port to accommodate an Endocatch specimen retrieval pouch (Autosuture). The specimen is placed in the pouch and extracted through the umbilical incision. Occasionally, the umbilical incision may need to be extended to accommodate the specimen. The remaining ports are removed and the incisions are closed in two layers with absorbable sutures.

These technical considerations apply to both upper-pole and lower-pole heminephrectomies. However, with a lower-pole heminephrectomy, one must take great care to identify and preserve the upper-pole renal vasculature, which are usually branches or tributaries of the lower-pole vessels.

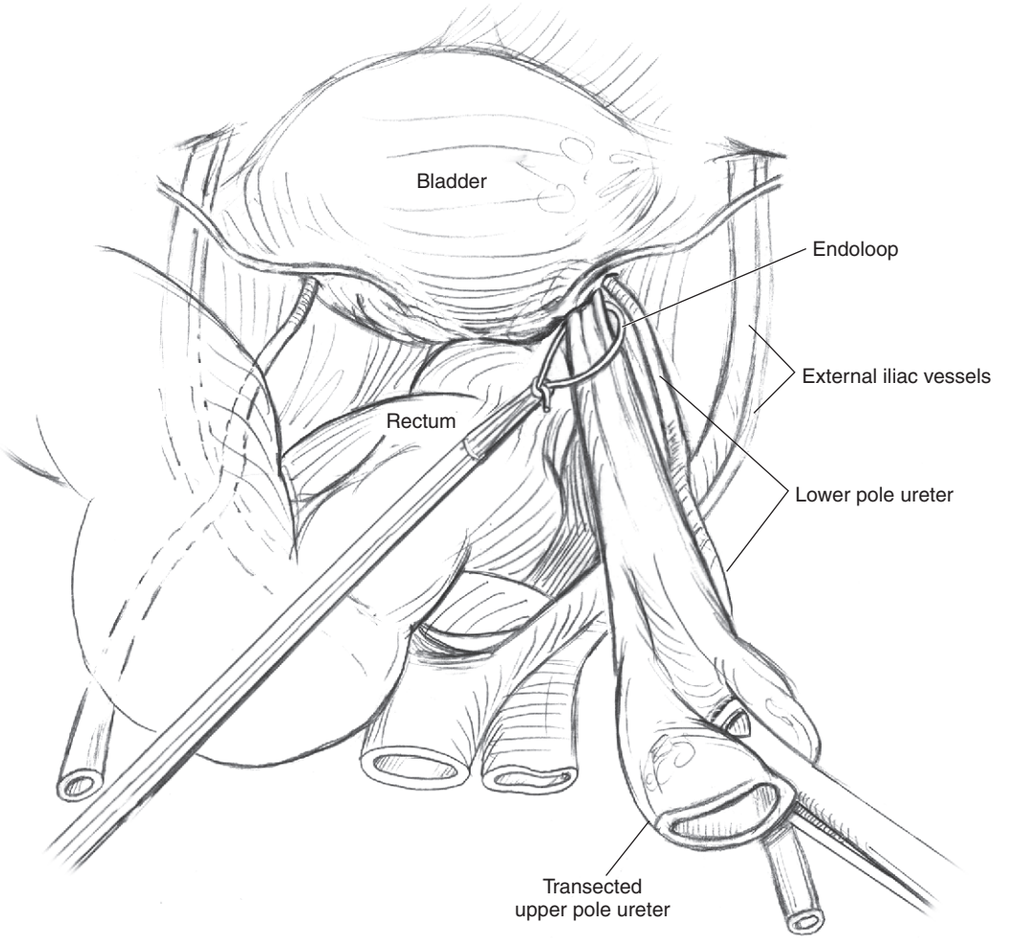
Bladder
Endoloop
External iliac vessels
Rectum
Lower pole ureter
Transected
upper pole ureter

FIGURE 161-5.

Chapter 162

Laparoscopic Partial Nephrectomy

DAVID D. THIEL AND HOWARD N. WINFIELD

Laparoscopic partial nephrectomy has matured into the oncologic equivalent of open partial nephrectomy for small (<4 cm) and peripherally located renal masses. Important limitations of the laparoscopic approach to partial nephrectomy are techniques of cooling the kidney which are still cumbersome and in early stages of development. Anticipated prolonged warm ischemia time beyond 30 to 45 minutes should direct the surgeon to consider open surgical intervention from the outset. Surgical indications are the same as open partial nephrectomy.

Our preferred method of preoperative imaging if the patient's renal function is acceptable is computerized tomography with three dimensional angiographic reconstructions. A magnetic resonance angiography (MRA) with three-dimensional vascular reconstruction is utilized in patients with compromised renal function. Changes in surgical approach are contemplated if the mass encroaches on the renal hilar vessels or with extensive collecting system involvement. All patients should be consented for possible radical nephrectomy or conversion to an open procedure.

1. A 5 French open-ended catheter is placed cystoscopically into the proximal ureter over a guide-wire prior to beginning the procedure. The ureteral catheter is anchored to a 16 French urethral catheter for the duration of the procedure. Injection of methylene blue into this catheter facilitates identification of collecting system violation. This step is eliminated for small exophytic masses and in those were collecting system violation seems unlikely.

   Positioning is the same as for laparoscopic radical nephrectomy and laparoscopic hemi-nephrectomy. The patient is placed in a modified lateral decubitus position assisted by an inflatable bean bag covered with a gel pad. Proper cushioning of all pressure points including the use of an axillary roll is a necessity. An orogastric or nasogastric tube is placed as well.

   Pneumoperitoneum is established using the Veress needle or Hasson open cannula technique. Fig. 162-1A and 1B represent the port placement for right and left side resections, respectively. If the lesion is located posterior, a retroperitoneal approach may be employed.
2. The kidney is mobilized within Gerota's fascia and the mass identified. Attempts should be made to spare the perirenal fat overlying the lesion, although clear delineation of tumor borders must be ascertained.
3. Intraoperative laparoscopic ultrasound is used to clearly delineate the extent and depth of the mass (Fig. 162-2A). The periphery of the mass is scored with monopolar cautery with care to give an approximately 5-mm margin. For peripheral lesions under 2 cm, a TP-1 needle (Ethicon, Inc.) may be placed under the deepest extent of the tumor and its position confirmed by ultrasound (Fig. 162-2B). The mass and needle will be subsequently resected en bloc.
4. The renal artery and vein are isolated in a similar fashion to laparoscopic radical nephrectomy. Prior to clamping the renal vessels, good intravenous hydration is established and mannitol (12.5 g) is given followed by 20 mg of intravenous lasix. For right sided lesions, the right renal artery and vein are clamped either en bloc with a laparoscopic curved Satinski clamp (Fig. 162-3) or individually with bulldog vascular clamps. For left renal tumors, our approach is to clamp only the artery. The venous backflow from the left renal vein is very low and we have found that we save warm ischemia time obviating the need for removal of the second bulldog clamp.

   Renal hilum dissection and clamping are not typically performed for peripherally located lesions. The clinical decision to gain vascular control is based on the predicted requirement of collecting system closure and anticipated difficulty of attaining complete hemostasis. Collecting system repair and complete tumor excision are far easier when performed in a bloodless field.
5. The mass is excised from the kidney (Fig. 162-4). If hilar control was acquired, sharp cold laparoscopic scissors are used. If hilar control has not been established, the mass is excised with a harmonic scalpel or monopolar scissors in combination with an argon beam coagulator. Numerous techniques have been proposed for this step with varying success including ultrasonic shears, lasers, microwaves, and radiofrequency coagulation.

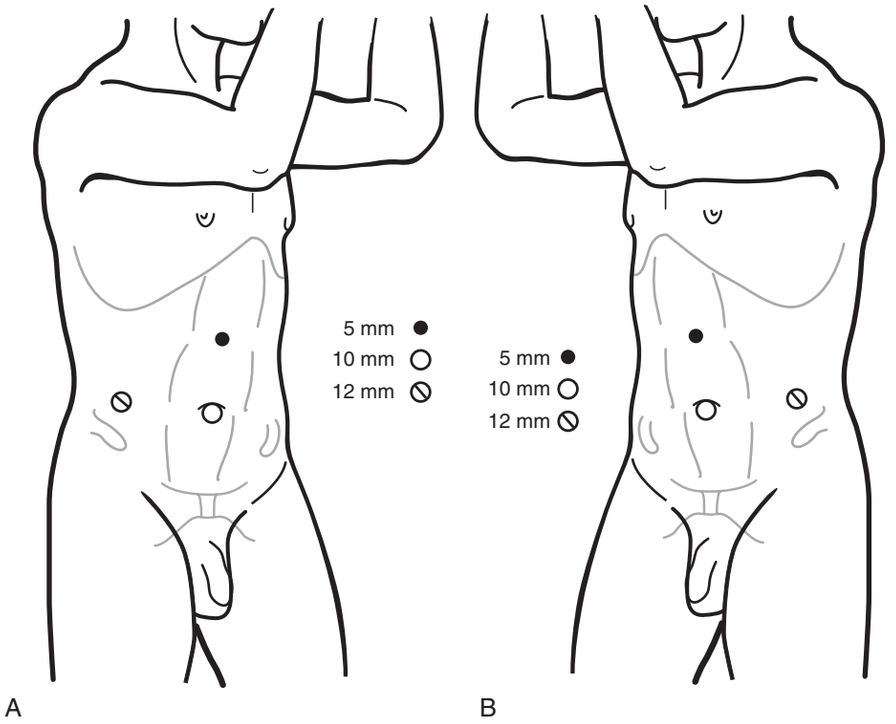

FIGURE 162-1. A, Right side port placement for laparoscopic partial nephrectomy. Patient is positioned with right flank up. There is a 12 mm port at mid-clavicular line at around level of umbilicus (see symbol); 10 mm ports (open circle) close to umbilicus and right upper mid clavicular port. Two 5 mm ports are placed in the anterior and posterior axillary lines, respectively, for lateral retraction of the kidney as well as superior retraction of the liver. **B,** Left side port placement for laparoscopic partial nephrectomy. Patient is positioned with left flank up. A 12 mm port (see symbol) is placed in the mid clavicular line at the level of the umbilicus. A 10 mm port (open circle) is placed near the umbilicus. A 5 mm port (black circle) is placed in left upper mid-clavicular line as well as a 5 mm port in the anterior axillary line, 2 finger breadths about the level of the umbilicus.

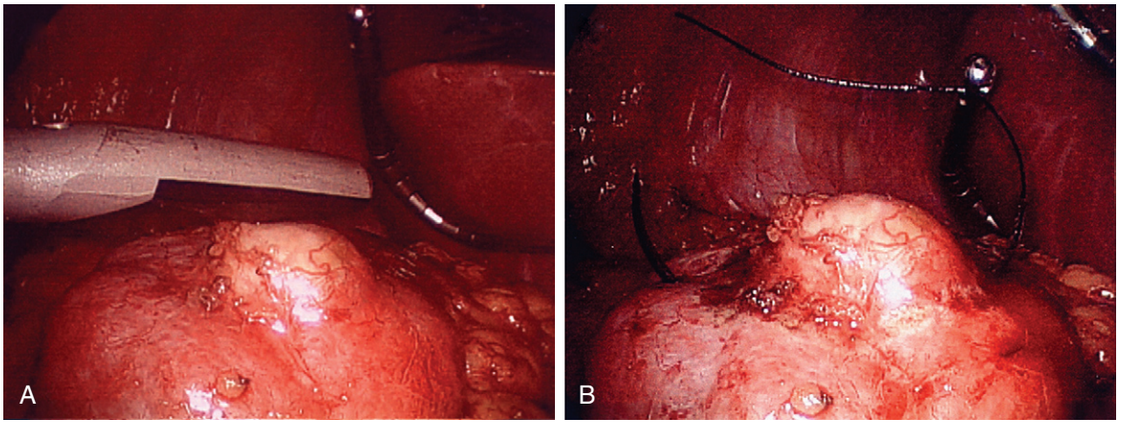

FIGURE 162-2. A, Laparoscopic needle technique on small renal masses to ensure negative margins. Intraoperative laparoscopic ultrasound is used to evaluate the full depth and extent of the mass. **B,** A TP-1 needle is placed below the mass under ultrasound guidance to ensure proper depth.

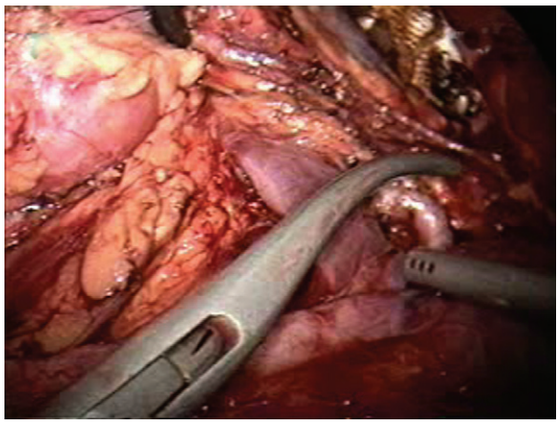

FIGURE 162-3. Clamping renal hilum for vascular control. A laparoscopic Satinsky clamp is placed across the right renal hilum. The dissected renal artery and vein are included in the clamp. The laparoscopic suction device aids in vessel exposure. Note that the laparoscopic Satinsky clamp must come in through a 10- or 12-mm port in the suprapubic region.

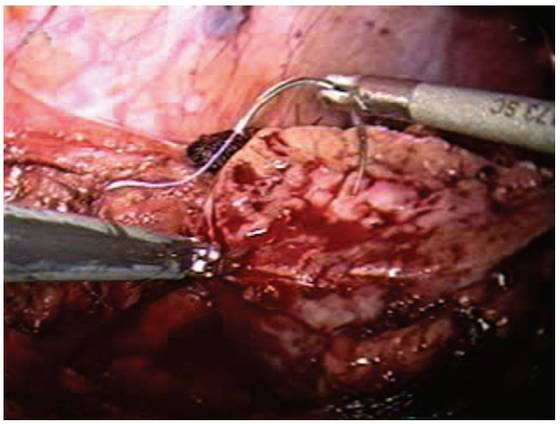

FIGURE 162-5. Laparoscopic suturing of collecting system and resection base. The base of the resection site is sutured with a running 2-0 Vicryl stitch. The first stitch is tied free-handed and the last stitch is anchored with a HemoLok clip and absorbable Vicryl clip. Injection of methylene blue into the previously placed ureteral catheter will demonstrate collecting system violation that requires repair.

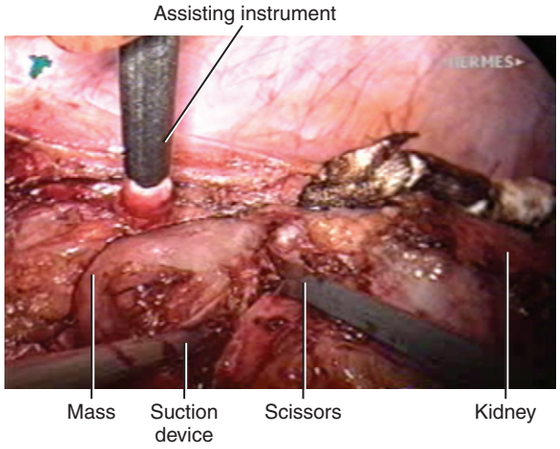

FIGURE 162-4. Renal mass excision. Laparoscopic scissors are utilized to excise the mass from the kidney. The mass is grasped by an assistant with laparoscopic grasping forceps to aid in traction. The laparoscopic suction device aids in visualization and retraction.

6. The raw surface of the resection crater is examined. Blue dye injected into the previously placed ureteral catheter will identify collecting system rents. For collecting system reconstruction and suturing of the crater base a 2-0 Vicryl on a CT-2 needle is placed in a running fashion (Fig. 162-5).
7. A bolster made of oxidized cellulose phosphate is sutured into the resection crater using interrupted 0 Vicryl on a CT-1 needle (Fig. 162-6). A gelatin matrix hemostatic sealant can be placed into the resection site during this step to insure hemostasis. The clamps are removed from the renal vessels and the resection site observed for hemostasis.
8. The mass is entrapped within a laparoscopic sac and removed through one of the 12-mm port sites. The mass is sent for frozen section to insure negative margins. A half-inch Penrose drain or a 10-ml Jackson Pratt drain is placed in proximity to the resection site and brought out through one of the lateral 5-mm port sites. All port sites 10 mm and larger are closed with 0 Vicryl suture using a Carter-Tomlinson port closure device.

The patients are kept at bed rest for one complete day. The urethral catheter is removed and diet is advanced on the first postoperative day. The drain is removed once output has subsided to acceptable levels. Patients are usually discharged home on postoperative day 2 or 3. A baseline follow-up CT scan is obtained at 4 to 8 weeks following surgery. Persistent flank drainage could signal a urinary fistula that may require ureteral stenting and bladder catheterization for complete healing. Wound infections and delayed bleeding are not common. Vascular injuries such as renal artery thrombosis are rare.

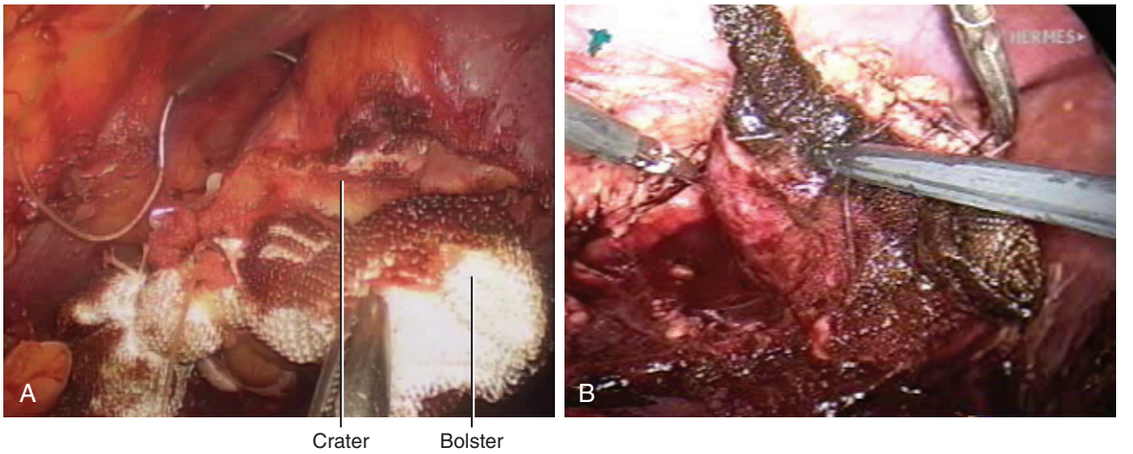

FIGURE 162-6. Surgical bolster placement for hemostasis. A bolster composed of oxidized regenerated cellulose is sutured into the crater in an interrupted fashion with 0 Vicryl. HemoLok clip as well as absorbable Vicryl clips are used to anchor the stitches to avoid knot tying and reduce warm ischemia time.

Chapter 163

Laparoscopic Nephroureterectomy

JAY T. BISHOFF AND THOMAS W. JARRETT

The goal of this chapter is to outline our technique for laparoscopic nephroureterectomy (LNU) and to describe our preferred approach using transperitoneal access. The chapter concludes with a description of several different methods to remove the distal ureter and bladder cuff. This technique mimics the standard established by the open technique, while offering the usual benefits of laparoscopic surgery.

INDICATIONS AND CONTRAINDICATIONS

The indications for LNU remain the same as those for open nephroureterectomy. Confirmed urothelial carcinoma of the upper tract (renal collecting system or ureter) by either visual inspection or biopsy is an indication for LNU. Biopsy specimens may be nondiagnostic, due to the small sample size of tissue obtained through standard ureteroscopes.

PATIENT POSITIONING AND OPERATING ROOM CONFIGURATION

LNU is performed in two stages, which require careful planning when positioning the patient: (1) laparoscopic dissection and isolation of the kidney and ureter to the level of the pelvis, and (2) complete dissection of the distal ureter and bladder cuff. Proper positioning allows the completion of both stages and intact specimen removal without the need for repositioning. However, the surgeon's preference for management of the distal ureter may require that the patient be moved to the lithotomy position for resection or destruction of the distal ureter and bladder cuff.

A modified lateral position with the targeted side slightly elevated allows intraoperative access to the kidney and the distal ureter with out the need to reposition the patient. The ipsilateral hip, flank, and shoulder are bumped up to approximately 20 degrees and the ipsilateral arm is brought across the table and either placed on a padded arm board or flexed in front of face on a pillow (Fig. 163-1). It is not necessary to place an axillary roll, flex the table, or elevate the kidney rest. All extremity pressure points must be padded. The patient is carefully fixed to the bed with wide cloth tape at the shoulders, chest, hips, thighs, and distal lower extremities. Prior to application of the surgical prep and draping, the bed is rotated to ensure that the patient is secured to the table.

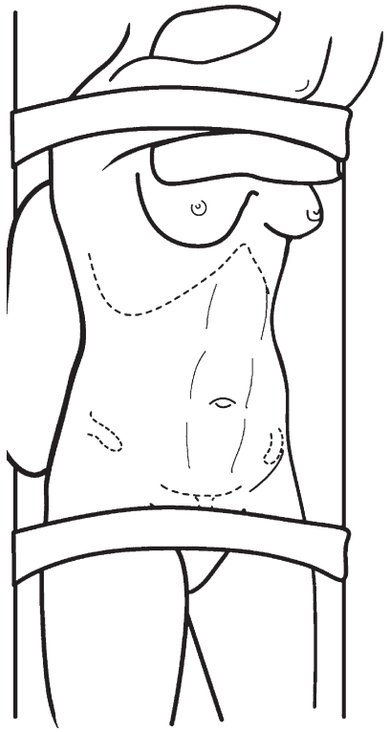

FIGURE 163-1. For laparoscopic nephroureterectomy, the patient is placed in the supine position with the ipsilateral arm across the chest. The patient is secured to the table and may be rotated during the case to the contralateral side. *(From Bishoff JT, Kavoussi LR. [2007]. Atlas of laparoscopic urologic surgery. Philadelphia: Elsevier.)*

The sterile skin prep is carried wide enough to accommodate conversion to an open procedure through an incision placed over the flank or pelvis if needed. Both an orogastric tube and bladder catheter are placed prior to trocar insertion. The surgeon and assistant stand on the side contralateral to the tumor (Fig. 163-2).

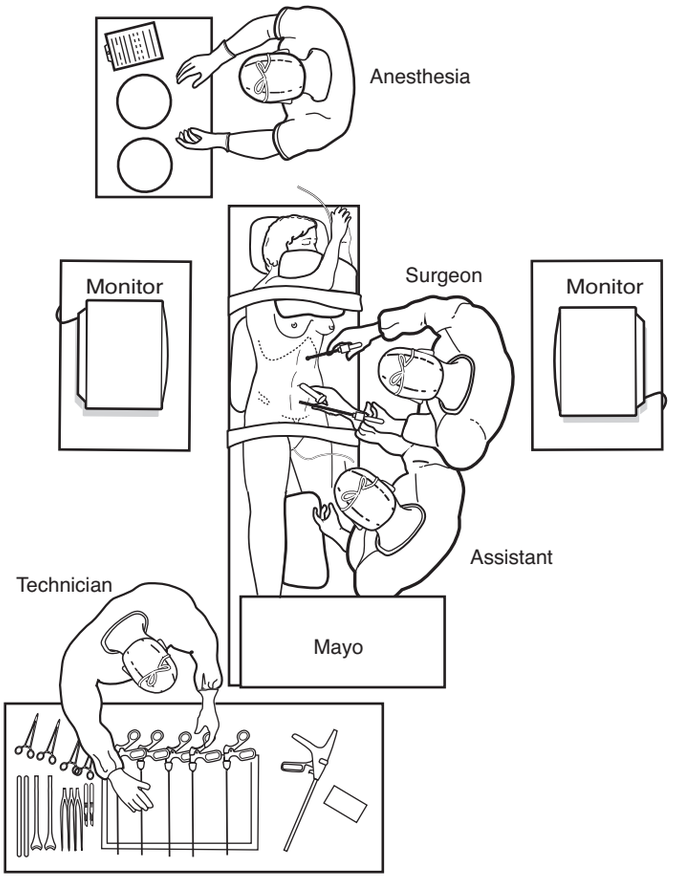

FIGURE 163-2. The surgeon and assistant stand on the contralateral side of the table with the scrub person at the foot of the table. *(From Bishoff JT, Kavoussi LR. [2007]. Atlas of laparoscopic urologic surgery. Philadelphia: Elsevier.)*

INSUFFLATION AND TROCAR PLACEMENT

In the absence of prior midline abdominal surgery, a Veress needle is placed at the umbilicus or as far from prior abdominal incisions as possible. A transperitoneal four-trocar approach is generally utilized. The trocar position depends mainly on the patient's body habitus (Fig. 163-3). A 10- to 12-mm trocar with a visual obturator is placed under direct vision through the umbilicus. For a right handed surgeon operating on a left kidney, a second 10- to 12-mm trocar is placed at the level of the umbilicus just lateral to the rectus muscle, is used for dissection and is large enough for passing the vascular stapler. A 5-mm trocar is placed in the midline between the umbilicus and the xiphoid process and a fourth trocar is (usually 10 to 12 mm) placed between the umbilicus and the pubis.

For a right-handed surgeon operating on a right-side kidney the 10- to 12-mm trocars are placed at the umbilicus, midway between the umbilicus and the xiphoid process, midway between the pubis and the umbilicus and a 5-mm trocar lateral to the rectus in line with the umbilicus.

For obese patients, placement in the modified flank position can create a significant shift in the pannus such that trocars placed at the umbilicus will actually enter the peritoneum below the midline and further away from the retroperitoneum. In the obese patient, all trocars are shifted laterally.

During the nephrectomy portion of the procedure, the camera is placed in the umbilical port and the surgeon operates through the superior midline and lateral trocar sites. Once the kidney dissection is complete, the 10- to 12-mm trocar between the umbilicus and pubis is used to reach the distal ureter and bladder cuff and the superior, midline trocar used for traction of the ureter (Fig. 163-4). For assistance with retraction, a suture on a straight needle can be passed through the abdominal wall and under a structure to be elevated or retracted, and passed back out through the anterior abdominal wall (Fig. 163-5).

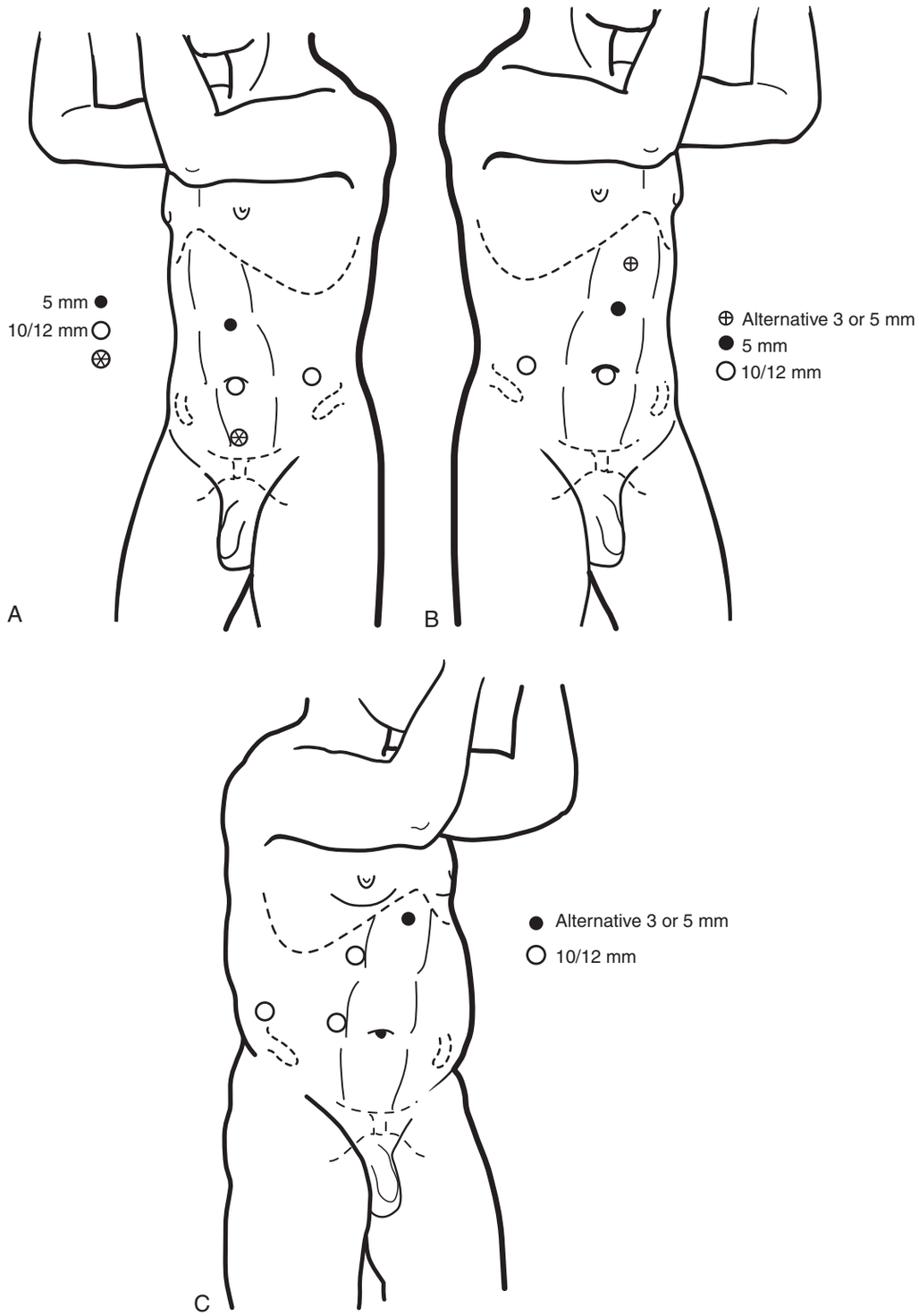

FIGURE 163-3. A, Trocar placement for left-side procedure. **B,** Right-side procedure. **C,** In obese patients the trocars are moved lateral to the rectus. *(From Bishoff JT, Kavoussi LR. [2007]. Atlas of laparoscopic urologic surgery. Philadelphia: Elsevier.)*

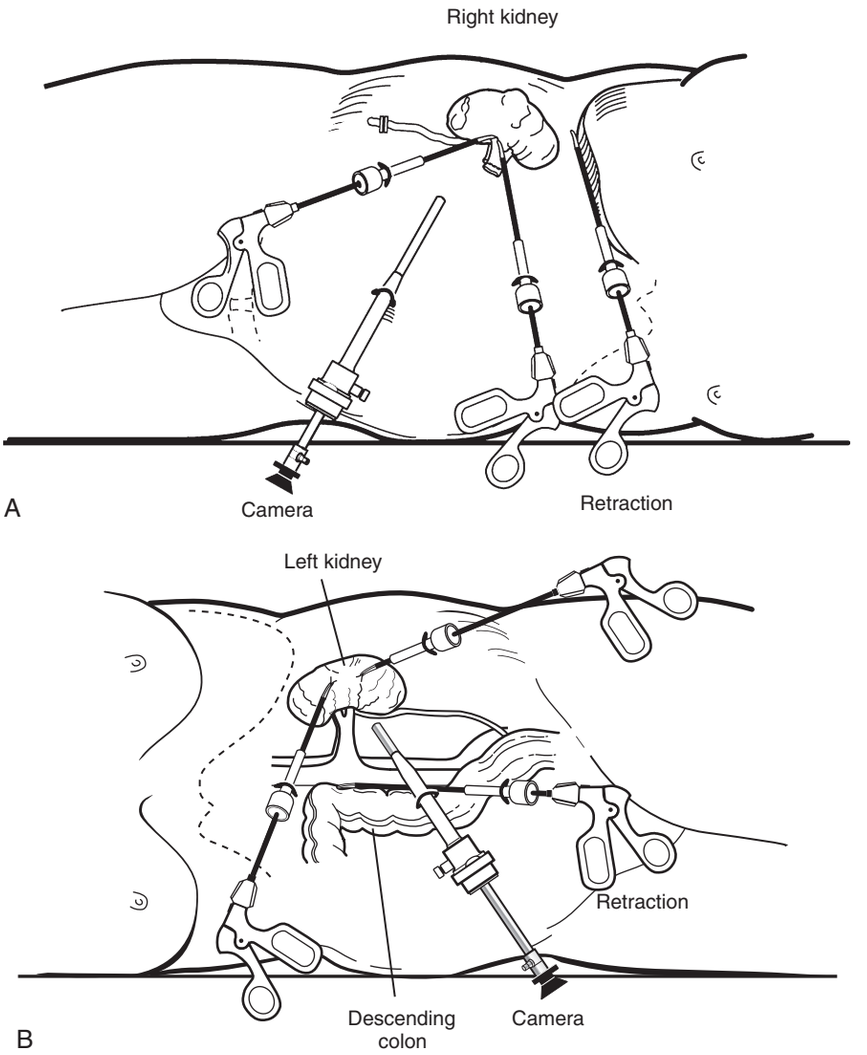

FIGURE 163-4. Accessory ports are placed as needed to retract surrounding organs. **A,** For right-side lesions, a port below the xiphoid is helpful for retracting the liver. **B**, On the left side, a lower midline port is helpful for retracting the descending colon. *(From Bishoff JT, Kavoussi LR. [2007]. Atlas of laparoscopic urologic surgery. Philadelphia: Elsevier.)*

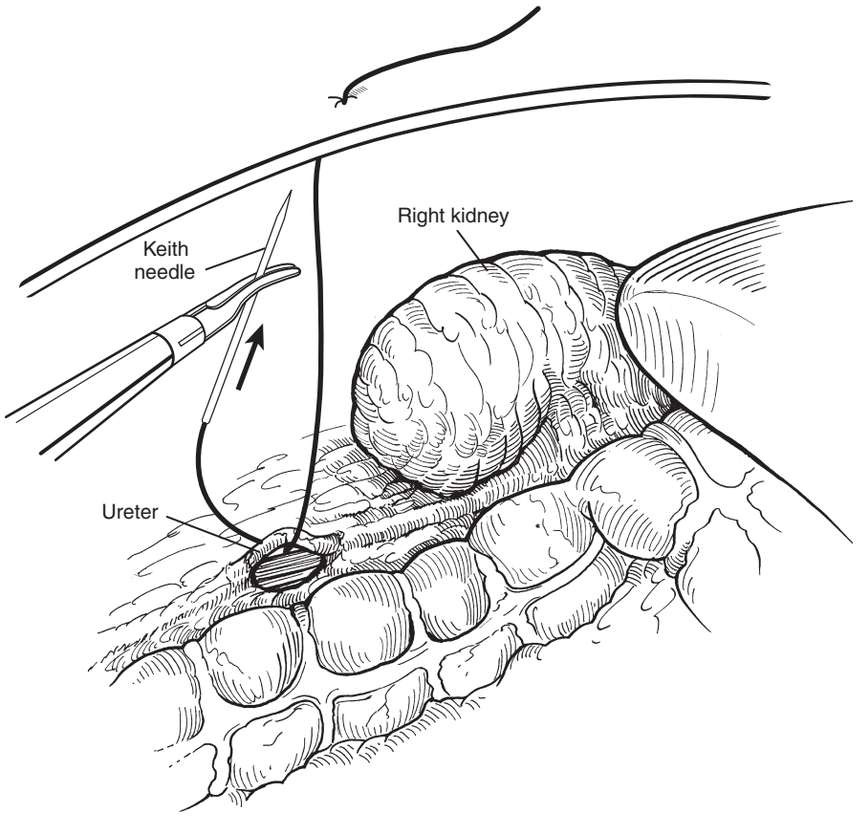

FIGURE 163-5. A suture on a straight needle can be used to elevate the ureter and assist with dissection. *(From Bishoff JT, Kavoussi LR. [2007]. Atlas of laparoscopic urologic surgery. Philadelphia: Elsevier.)*

PROCEDURE

Colon Mobilization

The posterior peritoneum is incised at the line of Toldt using ultrasonic energy or bipolar cautery allowing mobilization and displacement of the colon mesentery medial to the aorta on the right and vena cava on the left. With the colon reflected medially, the surgeon has to be careful not to create a hole in the "back wall" or posterior aspect of the large bowel mesentery which is a common site of persistent, troublesome bleeding.

For a right-side dissection, the incision is carried from hepatic flexure to the iliac vessels. On the left it is taken cephalad to the splenic flexure. The renocolic ligaments are divided to allow further mobilization of the colon off the lower pole of the kidney. The lateral attachments of Gerota's fascia are left intact to prevent the kidney from falling medially during the dissection of the hilum.

Nephrectomy

Once the colon is mobilized, the midsection of the ureter is identified medial to the lower pole of the kidney, elevated, clipped distal to the tumor location (but not divided), and dissected toward the renal hilum. A wide margin of tissue should be maintained if an invasive ureteral tumor is known or suspected (Fig. 163-6). The dissection is carried cephalad to the renal hilum.

First the renal artery is divided with an endovascular stapler (Fig. 163-7) followed by the renal vein (Fig. 163-8). The kidney is then fully mobilized either inside or outside Gerota's fascia depending on the tumor location and stage (Fig. 163-9).

Distal Ureteral Dissection

During the initial dissection, the ureter is clipped distal to the tumor location to prevent migration of tumor cells during renal manipulation. The peritoneal incision is continued inferiorly over the iliac vessels and medial to the median umbilical ligament to completely expose the ureter (Fig. 163-10). At this point, the dissection trocars are the lateral trocar and the trocar located between the umbilicus and the pubis. An atraumatic locking grasper can be placed through the superior midline trocar and used to deliver traction on the ureter during subsequent dissection. Ureteral dissection is carried as far distally as possible, keeping wide margins of tissue at areas of known tumor. The ureter is dissected circumferentially, while gentle cranial traction provides exposure to the ureteral vessels and attachments, which are divided with bipolar or ultrasonic energy as the dissection proceeds towards the bladder. The circumferential dissection continues into the intramural tunnel as the

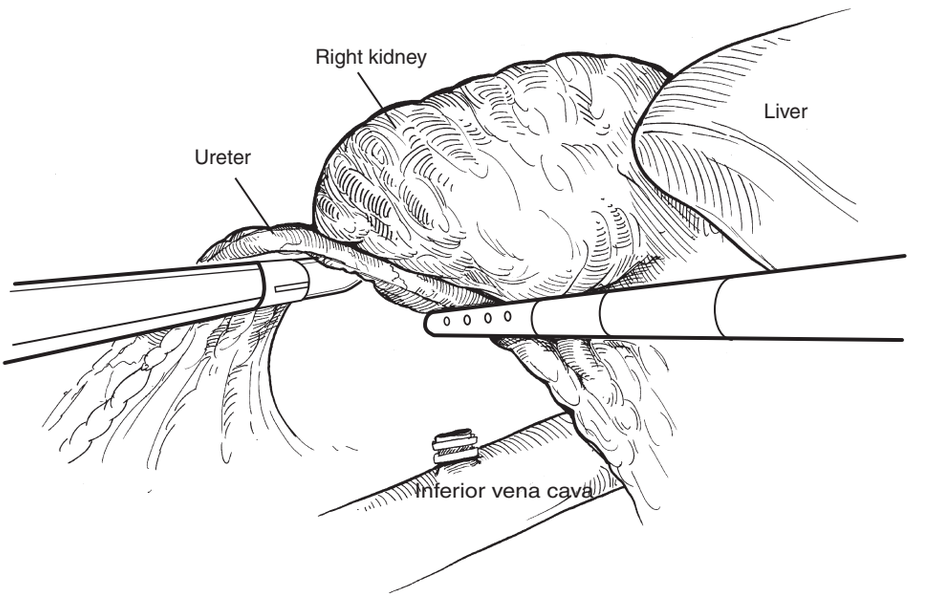

FIGURE 163-6. Once the bowel is reflected medially, a grasper is placed under the lower pole of the kidney placing the renal vessels on stretch. The renal hilum can then safely be dissected. *(From Bishoff JT, Kavoussi LR. [2007]. Atlas of laparoscopic urologic surgery. Philadelphia: Elsevier.)*

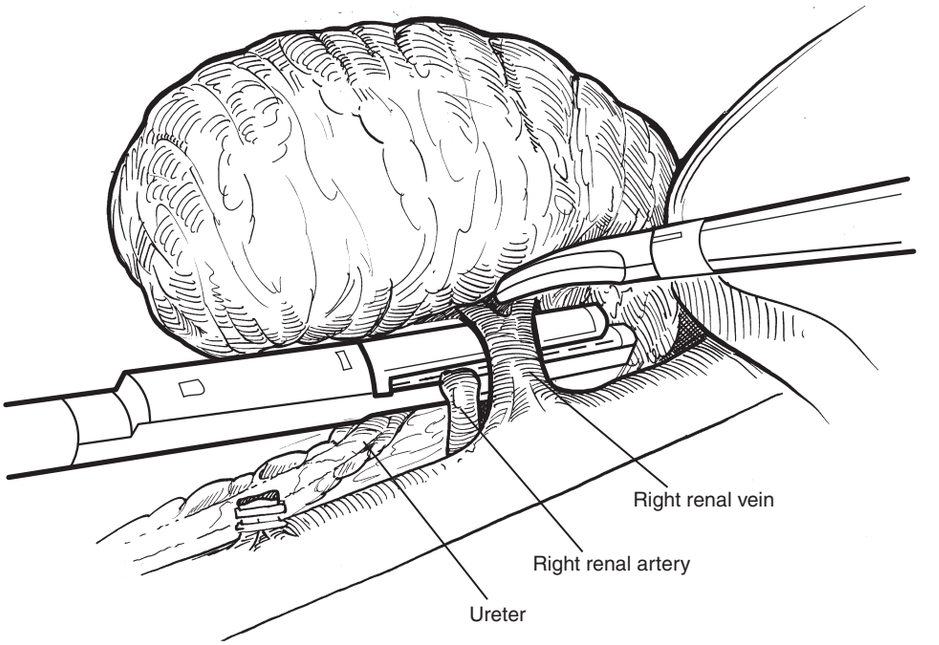

FIGURE 163-7. The renal artery is divided with an endovascualar stapler. *(From Bishoff JT, Kavoussi LR. [2007]. Atlas of laparoscopic urologic surgery. Philadelphia: Elsevier.)*

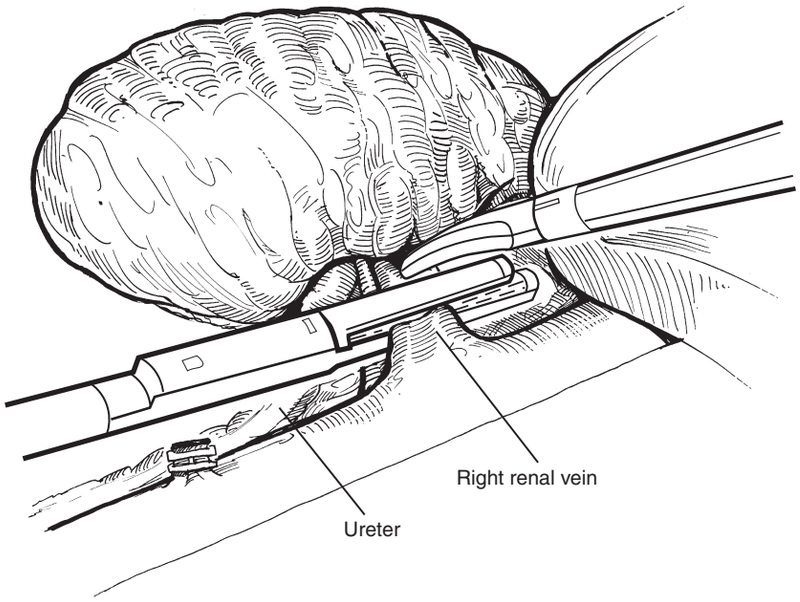

FIGURE 163-8. The renal vein is divided after the renal artery using the endoscopic vascular stapling device. *(From Bishoff JT, Kavoussi LR. [2007]. Atlas of laparoscopic urologic surgery. Philadelphia: Elsevier.)*

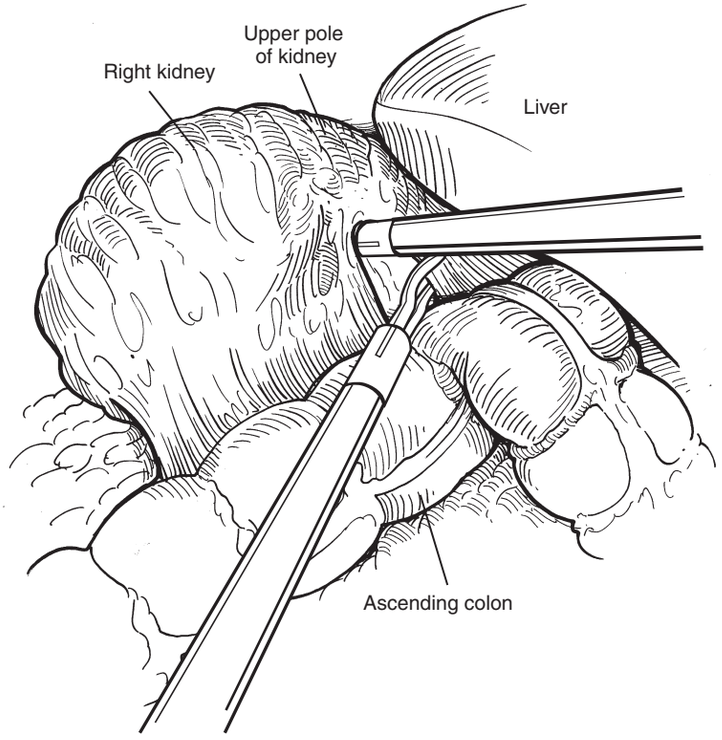

FIGURE 163-9. The remaining posterior, lateral, and upper pole attachments are divided freeing the entire kidney. *(From Bishoff JT, Kavoussi LR. [2007]. Atlas of laparoscopic urologic surgery. Philadelphia: Elsevier.)*

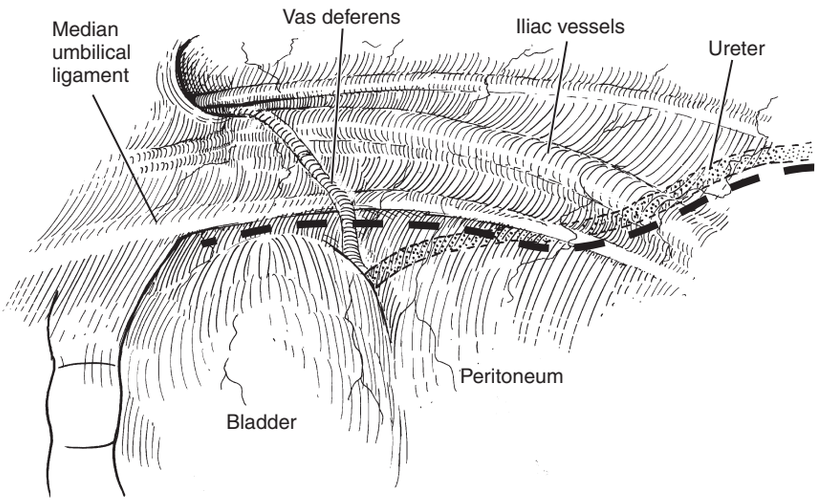

FIGURE 163-10. The peritoneal incision is extended deep into the pelvis over the iliac vessels and medial to the median umbilical ligament.*(From Bishoff JT, Kavoussi LR. [2007]. Atlas of laparoscopic urologic surgery. Philadelphia: Elsevier.)*

ureter enters the bladder. If needed, the vas deferens in the male or the round ligament in the female can be divided to allow easier subsequent dissection of the distal ureter. The final dissection of ureter and bladder cuff depends upon the surgeon's preference and the location of the tumor. Tumors near the junction of the bladder are best treated with open resection of the distal segment, while renal and proximal tumors are amenable to laparoscopic resection of the distal ureter.

Organ Entrapment and Extraction

Once the kidney and ureter are freed of all attachments the specimen is placed above the liver or spleen and then entrapped in a 15-mm Endocatch bag (Tyco, Norwalk CT). The intact specimen is removed through an extended midline or lateral incision at one of the trocar sites. After closing the extraction site, the abdomen should be reinsufflated and the extraction site inspected for entrapped bowel and to assess closure integrity.

If an open excision of the distal ureter is chosen, the ureter dissection should be carried as far as can be comfortably done and the extraction incision placed to maximize exposure of the distal ureter. Mobilizing the ureter as close to the bladder as possible will facilitate subsequent open completion of the operation.

Management of Distal Ureter/Bladder Cuff

1. *Open technique.* The traditional method of open distal ureteral dissection and excision with a cuff of bladder remains a good choice for management of the ureter with a tumor in the distal ureter or near the intramural tunnel. With the patient is the same modified lateral position, the table is rotated as close to the supine position as possible (Fig. 163-11). If a low midline incision is

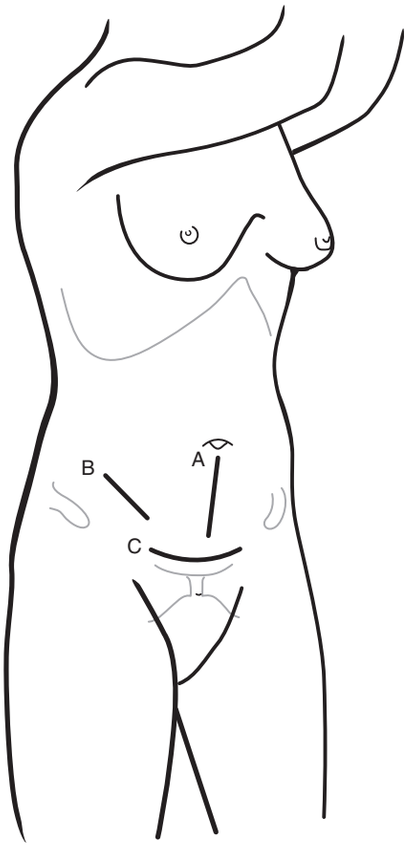

FIGURE 163-11. The type of incision for extraction largely depends on the distal extent of the ureteral dissection. A low midline of Pfannenstiel is adequate for dissecting the most distal ureter. A Gibson incision may give better visualization of the midureter. *(From Bishoff JT, Kavoussi LR. [2007]. Atlas of laparoscopic urologic surgery. Philadelphia: Elsevier.)*

chosen, an anterior cystotomy is made and the ipsilateral orifice visualized. The orifice to be resected is then circumscribed and the intramural ureter dissected intravesically (Fig. 163-12). With the bladder mobilized medially, the ureter is then dissected cephalad to the level of the initial dissection. The specimen is then delivered en bloc through the incision. The cystotomies are then closed with a standard two-layer closure.

For cases where the distal ureter was not dissected below the level of the iliac vessels, a Gibson incision may allow better exposure. The bladder is exposed and mobilized to allow a posterolateral incision. The incision is carried around the ureter in a "tennis racket" shape. The entire intramural ureter and orifice is then dissected extravesically and removed (Fig. 163-13). The cystotomy is then closed with a standard two layer closure. A perivesical drain and a large-caliber Foley catheter are left for either approach and the incision closed in the standard fashion.

2. *Laparoscopic extravesical.* The ureter is laparoscopically dissected through the detrussor at or very near the level of the orifice. The ureter is tented up on slight tension, the endoscopic gastrointestinal anastomosis stapler is used to ligate and divide the ureter at or near the level of the ureteral orifice (Fig. 163-14). The specimen is then removed through a low abdominal incision and the incision closed.

Next, the patient is moved to the lithotomy position and an aggressive transurethral resection of the ipsilateral ureter performed. This technique prevents urine spillage and more closely adheres to oncologic principles. A Collins knife or a roller ball is inserted into the orifice to be resected and pure cutting current employed to unroof or open the small segment of ureter remaining in the bladder. The ureter incision continues until

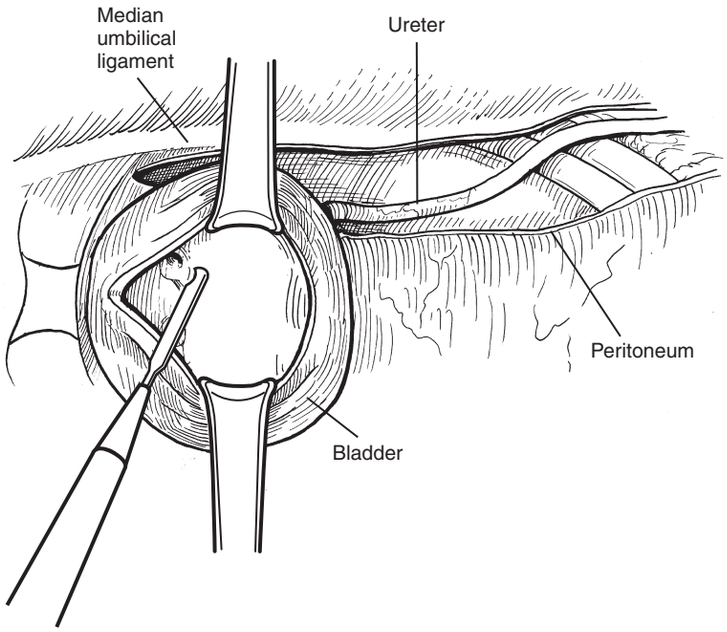

FIGURE 163-12. With a low abdominal incision, an anterior cystotomy can be used for transvesical dissection of the intramural ureter and bladder cuff. *(From Bishoff JT, Kavoussi LR. [2007]. Atlas of laparoscopic urologic surgery. Philadelphia: Elsevier.)*

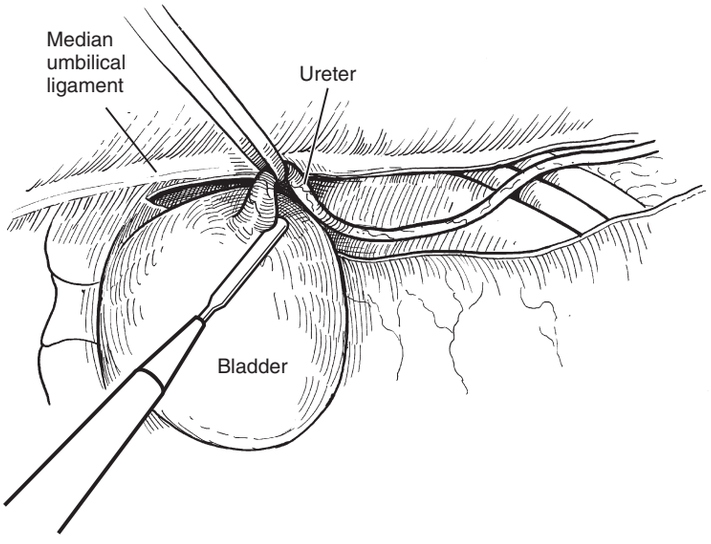

FIGURE 163-13. For an extravesicular open approach the ureter is retracted superiorly and electrocautery used to circumscribe the ureter as it enters the muscle of the bladder. *(From Bishoff JT, Kavoussi LR. [2007]. Atlas of laparoscopic urologic surgery. Philadelphia: Elsevier.)*

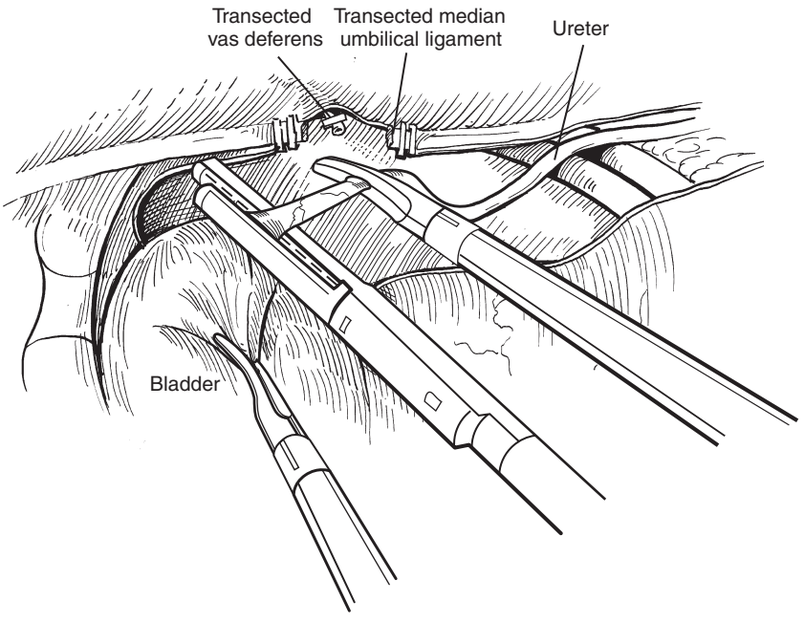

FIGURE 163-14. In the laparoscopic extravesicle technique, the ureter is dissected down to the bladder and retracted superiorly while the laparoscopic vascular gastrointestinal anastomosis stapler is placed as distally as possible to remove the entire ureter and a bladder cuff. *(From Bishoff JT, Kavoussi LR. [2007]. Atlas of laparoscopic urologic surgery. Philadelphia: Elsevier.)*

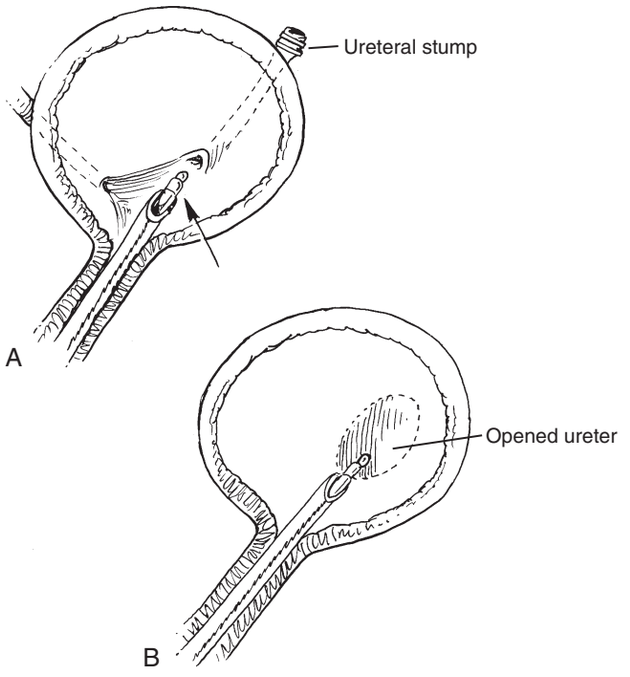

FIGURE 163-15. A, The distal ureter is opened by placing a resectoscope into the bladder and then a roller ball or Collin's knife into the opening of the ureter and any remaining tunnel. Directing the device superiorly while applying cutting current will open the remaining ureter. This is continued until the staple line is visualized. **B,** All underlying tissue, including the staple line, is cauterized with the roller ball.

the staple line in identified. The entire surface and staple line is fulgurated with electrocautery delivered with the roller ball (Fig. 163-15) and a bladder catheter is placed for 7 days.

POST OPERATIVE CONSIDERATIONS

A perivesical closed suction drain is left in place for 1 to 3 days postoperatively until there is minimal drainage. The orogastric or nasogastric tube is removed at the end of the case unless there is concern for prolonged recovery of bowel function. Oral fluids are given when there are signs of bowel activity, and the diet level advanced after passage of flatus.

Regardless of the technique implemented to manage the distal ureter and bladder, the Foley catheter remains in place for 7 to 10 days after surgery. A cystogram is routinely obtained prior to removal to ensure complete closure of the cystotomy.

COMPLICATIONS

Potential complications related to laparoscopic nephroureterectomy and their management are similar to those associated with other abdominal laparoscopic procedures and open procedures. Intraoperative complications include blood loss requiring transfusion, injury to liver, spleen, pancreas, bowel, or vascular structures. Careful attention to the contralateral ureteral orifice must be given during dissection to prevent inadvertent injury.

Chapter 164

Laparoscopic Pyelolithotomy

CARL K. GJERTSON AND CHANDRU P. SUNDARAM

Appropriate candidates for laparoscopic pyelolithotomy include (1) patients with a large solitary stone in a dilated renal pelvis, (2) patients requiring a simultaneous laparoscopic (or robotic-assisted laparoscopic) pyeloplasty, (3) patients with a large stone in an ectopic kidney, which could be managed with laparoscopic surgery alone or laparoscopy to assist percutaneous access to the ectopic kidney in conjunction with percutaneous nephrostolithotomy (PCNL), and (4) patients for whom PCNL is contraindicated. In patients with a large stone in a caliceal diverticulum with a thin overlying renal cortex, a laparoscopic nephrolithotomy is an option.

Computed tomography (CT) imaging with and without intravenous contrast and preferably a CT urogram is essential to delineate location of stones, calyceal and vascular anatomy. A nuclear renal scan with furosemide washout helps identify obstruction or nonfunctioning kidneys that may be appropriate for nephrectomy rather than pyelolithotomy. All patients must have a preoperative urine culture, and any infection should either be eradicated or treated with 5 to 7 days of culture-specific antibiotics before surgery. On the day before surgery, we sometimes prescribe a "mini bowel-prep" (300 mL of magnesium citrate).

TECHNIQUE OF LAPAROSCOPIC TRANSPERITONEAL PYELOLITHOTOMY

A 5-French open-ended ureteral catheter is used to measure the length of the ureter from ureteropelvic junction (UPJ) to ureterovesical junction. Next a 6-French double-J ureteral stent that is at least 4 cm longer than the measured length of the ureter is placed with its proximal end in an upper pole calyx, if possible. An open-ended ureteral catheter could be placed instead, allowing for retrograde distention of the renal pelvis and injection of methylene blue, which could aid in dissection of the ureter and pelvis during the laparoscopic portion of the procedure. However, this would also necessitate the additional step of laparoscopic antegrade double-J stent placement before pyelotomy closure.

The patient is placed in a modified flank position over a bean bag. Exact positioning instructions have been noted in previous chapters.

Planned trocar placement is illustrated for a left-sided pyelolithotomy. Initial Veress needle access is obtained at the supra-umbilical incision and a 10-12 mm trocar placed. Three additional self dilating trocars are placed using laparoscopic guidance: a 10-12 mm working port at the level of the umbilicus in the mid-clavicular line, a 5 mm midline working port midway between the sternum and umbilicus, and a 5 mm port in the anterior-axillary line just under the costal margin that will allow for insertion of a retractor. There should be at least 4 finger breadths distance between the umbilical and working ports to prevent clashing of instruments and camera during surgery. For large or obese patients the camera and working ports should be moved laterally and sometimes superiorly so that the trocars are an appropriate working distance from the kidney. For right-sided procedures, trocar placement is similar except for the addition of a 5 mm port in the midline just inferior to the xiphisternum through which a locking grasping forceps is inserted as a liver retractor. The forceps retracts the liver anteriorly and holds the desired position by grasping a fold of the diaphragm or peritoneum at the lateral abdominal wall.

The renal hilum is identified to prevent inadvertent injury during the subsequent pyelolithotomy. The peripelvic fat surrounding the renal pelvis may be densely adherent. This tissue should be cleared with meticulous blunt and sharp dissection, ensuring that renal vessels or their branches are not injured. The suction irrigator, the bipolar forceps, and ultrasonic shears are effective instruments

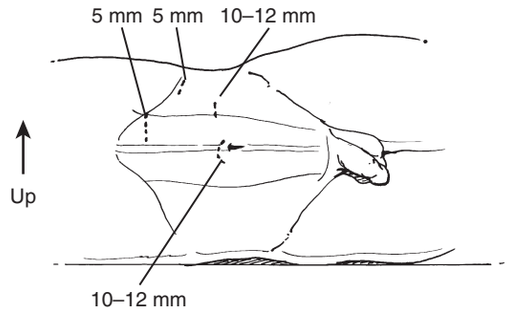

FIGURE 164-1. Port placement.

during this step. If the renal pelvis is opened before completion of this dissection, final watertight closure will be difficult. The ureter is identified near the lower pole and followed superiorly to the renal pelvis. Clamping the Foley catheter and administering intravenous furosemide to distend the pelvis and ureter may aid with this dissection. If an open-ended ureteral catheter had been placed during the initial cystoscopy instead of a double pigtail stent, irrigation with saline or methylene blue at this point will have a similar effect. After the renal pelvis and UPJ are adequately exposed, pyelotomy is performed with laparoscopic scissors (Fig. 164-2). The suction tip is placed just under the incision in the renal pelvis to evacuate urine and small stone debris.

A 2-0 braided polyglactin (on an RB-1 needle, cut to 6 inches) traction suture at the apex of the pyelotomy aids in further manipulation of the renal pelvis, and when tied down prevents unintentional tearing of the incision. Large stones may be difficult to deliver from the pelvis. The stone can be dislodged by gentle to and fro movement with a grasper. The pelvic incision may need to be extended toward the infundibulum containing the stone. A Maryland forceps can be used to dilate the infundibulum if there is infundibular stenosis. Excessive traction on the stone can cause significant intrarenal bleeding. A spoon or grasping forceps can be used to remove stones that are visible in the renal pelvis. If the proximal end of the double pigtail stent is interfering, it can be pulled medially out of the incision. Stones that are too large to remove through the trocars can be placed into a laparoscopic specimen bag for extraction, and extreme care should be taken not to lose any stones in the peritoneal cavity. For calculi that are not readily visible through the pyelotomy, the laparoscopic lens can be driven into the renal pelvis as illustrated (Fig. 164-3).

For stones that continue to elude extraction, flexible nephroscopy can be performed through the 10- to 12-mm working port using a standard 14 to 16 Fr flexible cystonephroscope. Remaining calculi are grasped with a calyceal basket or three-pronged grasper and removed. For very large or impacted stones, holmium laser lithotripsy may be required. Placing multiple stone fragments in a spoon grasper or specimen bag for later extraction is quicker than withdrawing

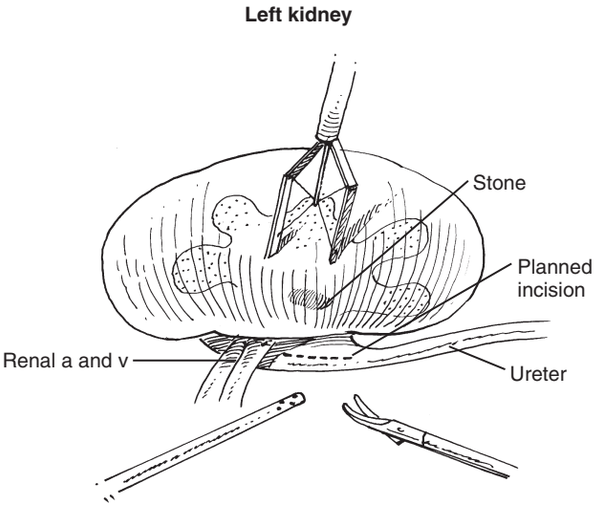

FIGURE 164-2. Incision of renal pelvis.

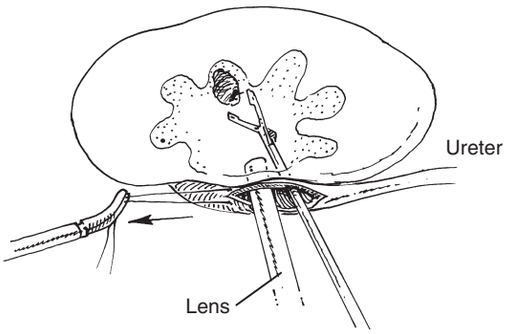

FIGURE 164-3. Extraction of stones with spoon/traction suture.

and reinserting the nephroscope for each calculus. Smaller debris can be irrigated through the nephroscope and then removed from the renal pelvis and retroperitoneum with the laparoscopic suction. Even though we do not perform this routinely, C-arm fluoroscopy at this time with or without retrograde pyelography could help confirm stone-free status.

After all stones have been removed, the proximal end of the double pigtail stent is placed into an upper pole calyx so as not to interfere with suture closure of the renal pelvis (Fig. 164-4). The additional length chosen for the stent prevents the distal end from pulling into the ureter. Stones may be sent for culture and chemical analysis.

The pyelotomy is closed with a running 4-0 braided polyglactin suture on an RB-1 needle cut to 6 inches. Alternatively, a laparoscopic single-use suturing device (Endo Stitch, Autosuture, US Surgical, Norwalk, Conn.) can be used instead of a traditional suture. After pyelotomy closure, the insufflation pressure is reduced to 5 mm Hg and the abdomen is inspected for hemostasis and any evidence of damage to adjacent organs. The insufflation pressure is returned to 15 mm Hg. The 5 mm subcostal trocar is removed and a closed suction drain placed through the incision with the aid of a handheld Kelly clamp. We prefer a 10- or 15-French Blake or a 7-mm Jackson-Pratt drain. A grasper placed through one of the working ports pulls the distal portion of the drain into the abdomen. The drain should be positioned near the renal pelvic incision but not directly on it.

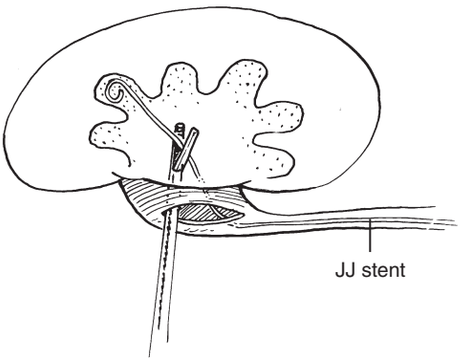

FIGURE 164-4. Double-J stent replaced into upper pole.

If a specimen bag has been used to collect the stone material, the string attached to the bag is brought out of the umbilical port and the trocar removed. The umbilical incision is widened with Bovie cautery to permit removal of the specimen bag, and the fascia is then closed with a 0 or #1 running polydioxanone suture. Pneumoperitoneum is reestablished and the 10-mm laparoscope placed through the 10- to 12-mm working port. Laparoscopic examination ensures adequate closure and no entrapment of bowel or omentum in the umbilical closure. The remaining laparoscopic trocars are removed while examining for hemostasis with the laparoscope.

Prophylactic intravenous antibiotics are continued for 24 hours. The Foley catheter is removed on the morning of the first postoperative day. If the drain output does not increase substantially after the patient is voiding, the drain is also removed. The patient is discharged and returns to have cystoscopy and double pigtail stent removal after 6 weeks.

TECHNIQUE OF RETROPERITONEOSCOPIC PYELOLITHOTOMY

Patient position and operating room setup is similar to what is described previously for laparoscopic transperitoneal pyelolithotomy, with a few important differences. The patient is placed on a bean bag in full flank position over the break in the table. The kidney bridge is raised and the table flexed to increase the distance between iliac crest and costal margin.

Planned trocar placement is illustrated for a left sided pyelolithotomy. Access is gained to the retroperitoneum through a horizontal incision 1 fingerbreadth inferior to the tip of the 12th rib. An open technique and a 10-12 mm blunt tip trocar are used as described by Hasson. Three additional ports are placed: a 5 mm working port is placed in line with the blunt tip trocar at the lateral border of the erector spinae muscle, a 5 mm working port 3 cm superior to the iliac crest in the anterior axillary line, and a 5 mm port for a retractor in the anterior axillary line in the subcostal region.

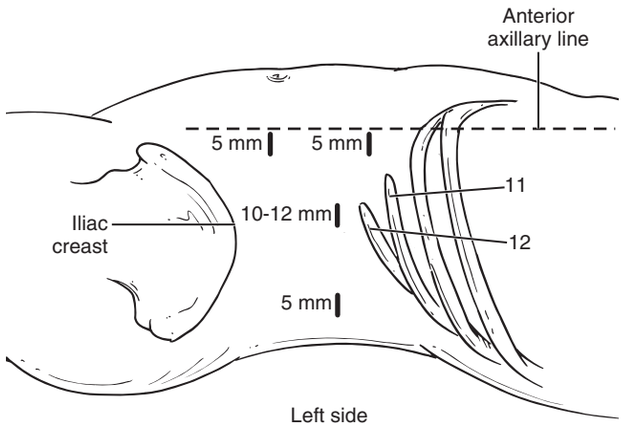

FIGURE 164-5. Port placement, left retroperitoneoscopy.

The remaining steps for identification and dissection of the ureter and renal pelvis, pyelotomy, stone extraction, and closure are similar to those described for the transperitoneal approach.

SIMULTANEOUS PYELOPLASTY

Patients with UPJ obstruction and stones may be candidates for simultaneous laparoscopic pyeloplasty and pyelolithotomy.

This page intentionally left blank

Chapter 165

Laparoscopic Caliceal Diverticulectomy

PATRICK W. MUFARRIJ AND MICHAEL D. STIFELMAN

Indications and goals: Treatment of caliceal diverticula should be considered when pain, infection, calculi, hematuria, or compromised renal function is present. The goals of surgical treatment are complete stone clearance and obliteration of the infundibular neck and diverticular cavity. Laparoscopic caliceal diverticulectomy is a particularly useful approach for anterior lesions inaccessible to, or unsuccessfully managed by, endourologic techniques, or for diverticula with thin overlying renal parenchyma, which make stabilization of guidewires and sheaths during percutaneous approaches difficult.

Alternatives to laparoscopic approach: For posterior caliceal diverticula, percutaneous endoscopic management may be considered. Anterior caliceal diverticula are not as suitable for percutaneous approaches due to overlying bowel and vessels, but can be alternatively managed with open diverticulectomy. In general, open excision is always an option, especially when other approaches are not practical or risky.

Patient preparation: The patient is initially placed in dorsal lithotomy position for rigid cystoscopy, retrograde pyelography, and 5-French ureteral catheter placement on the side of interest. A urethral catheter is passed into the bladder, and the 5-French ureteral catheter is tied to it externally. Next, the patient is repositioned, and laparoscopic trocars are placed depending on the location of the caliceal diverticulum. For an anterior diverticulectomy, the patient is placed in a semilateral decubitus position, and port placement is similar to that for a transperitoneal laparoscopic nephrectomy. For a posterior diverticulectomy, the patient is placed in a flank position, and ports are placed as for a retroperitoneal laparoscopic nephrectomy.

Exposure: The kidney is identified and exposed. Routine use of intraoperative ultrasound to locate the diverticulum allows us to subsequently dissect and clear off the portions of Gerota's fascia and perirenal fat overlying it. Saline mixed with indigo carmine can be injected through the previously inserted 5-French ureteral catheter to distend and better identify the thin-walled diverticulum. Ultrasound is further utilized to delineate the borders of the diverticulum once it is exposed as well as localizing calculi that may be present.

Excisional technique: Using either electrocautery or the harmonic scalpel (Ethicon Endosurgery, Cincinnati, Ohio), an incision is made through the parenchyma and into the diverticulum. Excess cortex and capsule are trimmed. At this time, any calculi present within the diverticulum can be grasped with forceps or ablated by a laser via a flexible or rigid nephroscope inserted through one of the ports (Fig. 165-1). If inspection of the diverticulum reveals no suspicious lesions requiring biopsy, then an argon beam coagulator or the Tissue-Link device (Dover, NH) is employed to destroy the remaining epithelium on the floor and walls of the diverticulum as well as control any parenchymal bleeding (Fig. 165-2). Once the neck of the diverticulum is identified, it can be enlarged by a laser

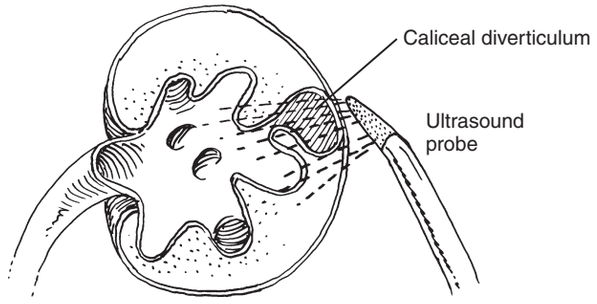

FIGURE 165-1.

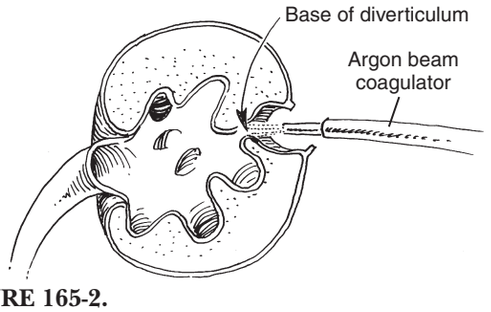

FIGURE 165-2.

to allow entry into the proximal collecting system for inspection or to address any other calculi. We then close the diverticular neck with interrupted figure-eight 3-0 polyglactin sutures (Fig. 165-3). Hemostatic matrices, surgical sealants, or fibrin sealants can be injected over the suture closure line to ensure a watertight anastomosis, which can be confirmed by reinjection of indigo carmine through the ureteral catheter. A vascularized flap of perirenal fat is then packed into the excisional cavity and secured with 4-0 polyglactin sutures. A self-suction drain is passed through one of the trocar sites and positioned adjacent to the repair. The port sites are then closed, and both catheters are left to drainage.

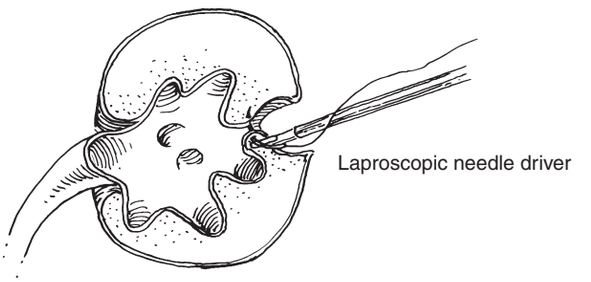

FIGURE 165-3.

Postoperative management: The urethral and ureteral catheters are removed on the second postoperative day, as long as the output from the surgical drain is minimal or not consistent with urine. The surgical drain can then be removed after two consecutive shifts of minimal drainage once its fluid has been sent for creatinine analysis to ensure it is consistent with serum. If a urine leak is suspected, the drain, urethral catheter, and ureteral catheter remain until the anastomosis has sealed. If needed, the ureteral catheter can be exchanged for a double-J stent. Antibiotics are discontinued once the drain has been removed. A computed tomography urogram is performed 4 weeks after surgery to confirm no collections or extravasation.

Chapter 166

Laparoscopic Renal Cyst Ablation

YEH HONG TAN

Renal cysts are a common incidental radiologic finding. Usually asymptomatic, the cysts may be associated with pain, infection, abdominal mass effect, and collecting system obstruction. Symptomatic cysts can be treated with percutaneous aspiration with or without instillation of a sclerosant or laparoscopic surgery. Laparoscopic cyst ablation is indicated for symptomatic renal cysts that have failed medical treatment and unsuccessful percutaneous cyst aspiration. Laparoscopy is also indicated for symptomatic peripelvic cysts where percutaneous aspiration and instillation of sclerosant is contraindicated due to potential risks of urinary fistula and stricture formation. In general, a transperitoneal approach is recommended for anteriorly located cyst and retroperitoneoscopy for the posterior cysts. However, a retroperitoneal approach can be used for most renal cysts, and this technique has been the preferred approach at our institution.

POSITION

Under general anesthesia, the patient is catheterized and nasogastric tube is inserted to decompress the stomach. In selected cases, an open ended ureteral catheter may be placed to perform retrograde pyelography to confirm that the cyst is not communicating with the collecting system. The patient is then placed in the lateral decubitus position with the side of the operated kidney facing upward. The patient is stabilized by strapping the body to the operating table with adequate padding to the extremities. The operating table is flexed at the center to maximize the space between the 12th rib and iliac crest. A kidney rest may be put underneath the contralateral kidney.

PORT PLACEMENT

For the retroperitoneal approach, a three-port technique is used. A 1.5-cm transverse incision is made just below the tip of 12th rib for the primary port. The incision is deepened until the thoracolumbar fascia is incised to enter the retroperitoneal space. Blunt finger dissection is used to sweep the peritoneum medially. A balloon dilator is inserted posterior to the Gerota's fascia and anterior to the psoas muscle. About 500 to 800 cc of air is used to inflate the balloon to expand the retroperitoneal space. After removal of the balloon dilator, a 10- to 12-mm trocar is inserted and a 0-degree laparoscope is inserted into the trocar to inspect the retroperitoneal working space. A 5-mm trocar is placed posteriorly between the inferior border of 12th rib and the lateral border of erector spinae muscle. Peritoneum is mobilized medially to avoid transperitoneal insertion of trocar. A second 10- to 12-mm trocar is placed anteriorly using digital guidance or under laparoscopic vision about three to four fingerbreadths, anterior to the primary port, along the anterior axillary line. A fourth working port is usually not required. Carbon dioxide pneumo-retroperitoneum is maintained at about 12 mmHg (Fig. 166-1).

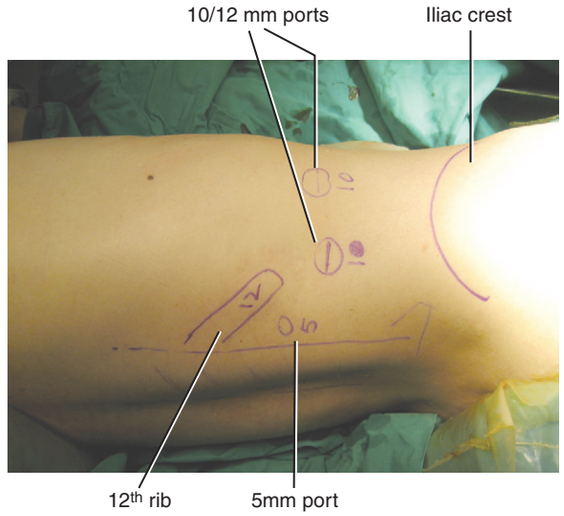

FIGURE 166-1. Ports placement for retroperitonescopy.

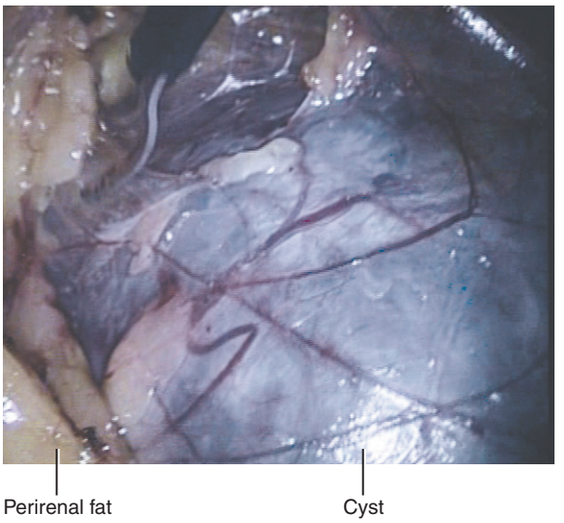

FIGURE 166-2. Exposure of renal cyst after dissection of perirenal fat. Note the blue dome appearance.

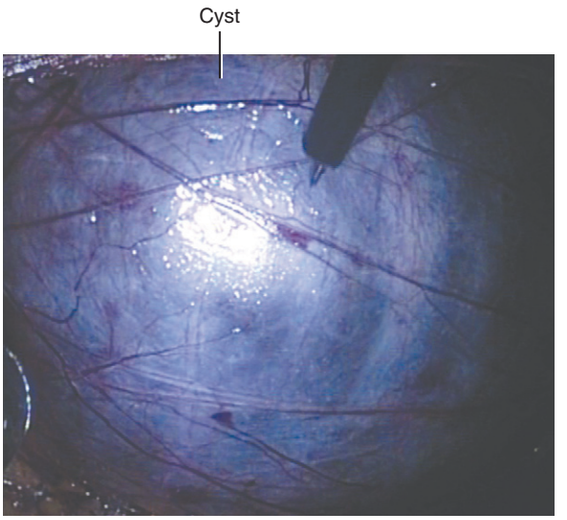

FIGURE 166-3. Aspiration of renal cyst using laparoscopic aspirator.

EXPOSURE OF RENAL CYST

The exophytic renal cyst may be identified by the bulge in the Gerota fascia. The Gerota fascia and perirenal fat overlying the renal cyst is excised sharply using electrocautery scissor or ultrasonic dissector to expose the renal parenchyma around the renal cyst. Renal cysts usually have a typical blue dome appearance (Fig. 166-2). A laparoscopic ultrasound may be employed to identify the intraparenchymal renal cyst. For peripelvic cysts, it is useful to dissect the renal hilum completely, expose the renal vessels and the proximal ureter carefully to avoid injuring them during cyst ablation.

ASPIRATION OF RENAL CYST

The renal cyst is carefully aspirated using a needle aspirator without spillage. The fluid content is sent for cytologic examination. For a simple cyst, the fluid is usually straw colored. However, purulent or bloody fluid may indicate infection or malignancy, respectively (Fig. 166-3).

EXCISION OF CYST WALL

The renal cyst wall (usually the exophytic part) is excised using electrocautery scissor or ultrasonic dissector and the wall is sent for histologic examination. The intraparenchymal portion of the cyst wall is usually not excised because of increased risk of bleeding (Fig. 166-4).

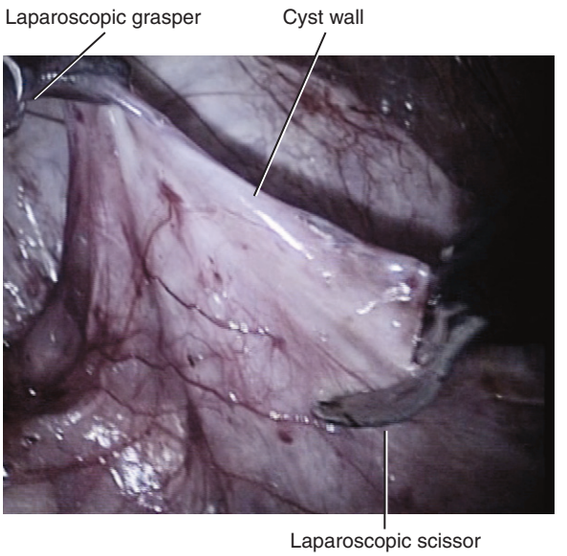

FIGURE 166-4. Excision of renal cyst wall.

INSPECTION OF CYST WALL AND BIOPSY OF BASE OF RENAL CYST

The cyst wall is examined carefully for the presence of suspicious lesions. Biopsies of the base of the renal cyst wall are done and the tissues are sent for histological examination (Fig. 166-5). If malignancy is detected during frozen section

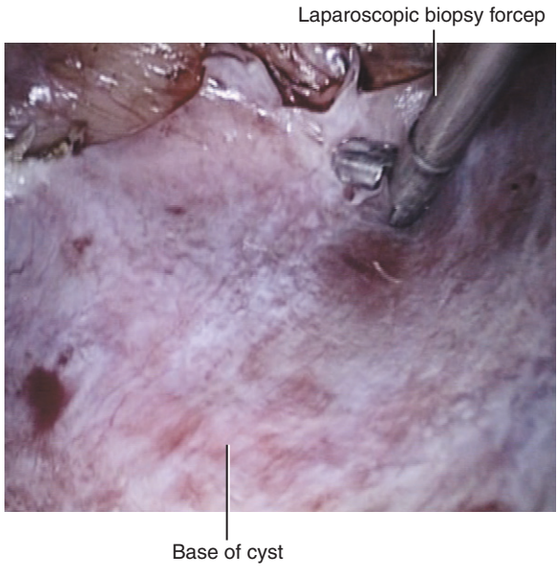

FIGURE 166-5. Biopsy of base using laparoscopic biopsy forcep.

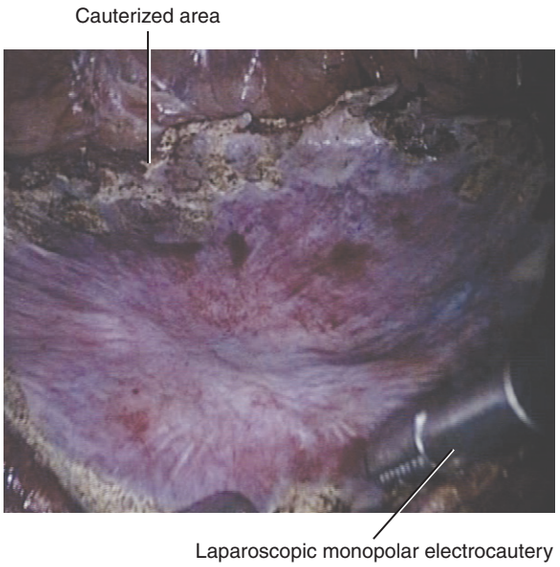

FIGURE 166-6. Fulguration of base of cyst wall using electrocautery.

analysis, immediate partial or radical nephrectomy may be performed.

FULGURATION OF BASE OF RENAL CYST

For the parenchymal cyst, the base is fulgurated using a monopolar electrocautery with care to avoid injuring the collecting system (Fig. 166-6). However, fulguration is usually not performed for peripelvic cyst to reduce the risk of fistulation with the collecting system. Retrograde injection of methylene blue through the ureteral catheter may be performed if there is suspicion of communication with the collecting system.

CLOSURE OF RENAL CYST DEFECT

To reduce the risk of recurrence, a Surgicel is placed in the cyst defect. In addition, the perirenal fat is sutured to the base of the renal cyst using a 2-0 polyglactin suture (Fig. 166-7). A closed suction drain may be placed in situ at the end of procedure.

WOUND CLOSURE

The surgical site is inspected for hemostasis at low insufflation pressure (e.g., 8 mmHg). The trocars are removed under laparoscopic vision. The 10- to 12-mm ports are closed with 2-0 polyglactin sutures. The skin is closed with subcuticular 3-0 polyglactin sutures and Steri-Strips.

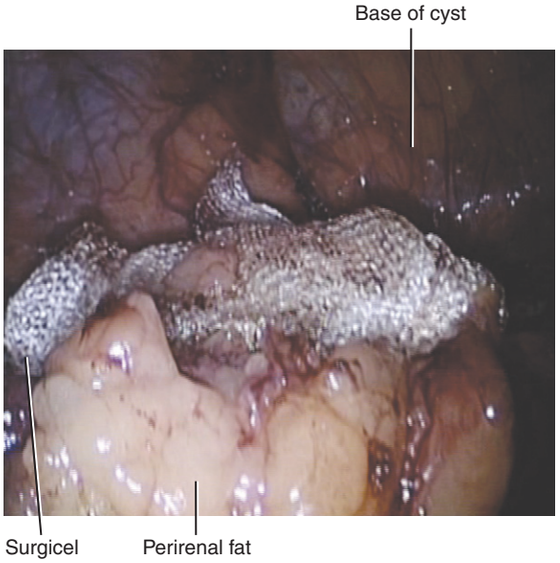

FIGURE 166-7. Perirenal fat is sutured to the base of cyst.

POSTOPERATIVE CARE

At the end of the procedure, the nasogastric tube is removed. Diet may be started on the same day and advanced as tolerated. A prophylactic antibiotic may be continued for first 24 hours. The patient is encouraged to ambulate as soon as possible. The urinary catheter is removed when the patient is ambulatory. The drain may be removed when there is minimal drainage. The patient is discharged one or two days after the surgery.

This page intentionally left blank

Chapter 167

Percutaneous Resection of Upper Tract Urothelial Carcinoma

KRISTOFER R. WAGNER AND THOMAS W. JARRETT

This nephron-sparing approach to urothelial carcinoma of the renal calyx, pelvis, or proximal ureter offers an alternative to total nephroureterectomy in well-selected patients. Appropriate indications include low-grade superficial disease in patients with a solitary kidney or renal insufficiency. In addition, some small tumors that cannot be treated with retrograde ureteroscopy (lower pole) may be resectable through an upper pole nephrostomy tract. Patients with a healthy contralateral kidney should be counseled extensively and understand the increased recurrence risk as compared to nephroureterectomy. Contraindications include uncorrectable bleeding diatheses, extensive bulky disease, and invasive or metastatic disease. Whereas an aggressive approach may be feasible in some bladder tumors, conservative resection is the key to success and minimizing complications with this procedure.

Instruments: Use a radiolucent orthopedic spine operating table with lower extremity spreader bars. Provide a rigid and flexible nephroscope set as well as a transurethral resection tray, including cold cup forceps, loop, Rollerball, and Bugbee electrodes. In addition, have a 30-French nephrostomy balloon-dilating catheter and sheath or Amplatz renal dilator set. Extra-long endoscopes, dilators, and sheaths may be necessary in obese patients. Perform flexible cystoscopy and place a 5-French open-ended ureteral catheter over a hydrophilic guidewire. Place a Foley catheter and secure the ureteral catheter to the Foley with 2-0 silk ties. Keep a Kaye nephrostomy tamponade catheter available at all times to control hemorrhage if needed.

Access: Inject 5 mL of radiopaque contrast into the open-ended catheter, and then inject 5 cc of air. Use C-arm fluoroscopy to select a posterior (air-filled) calyx for puncture (Fig. 167-1). For posterior calyceal tumors, direct access into the calyx is best. For anterior calyceal tumors, it may be preferred to enter via a posterior calyx in the opposite pole. For renal pelvic tumors, mid or upper pole access provides the best angles for complete nephroscopy, resection, and access to the ureter. Use an 18-gauge diamond-tipped needle to access the calyx of interest using the bull's-eye technique (see Chapter 131).

Nephroscopy: Examine the collecting system first using the rigid nephroscope, and then perform flexible nephroscopy if needed. Extensive multifocality or very bulky tumors may not be amenable to percutaneous resection. If a guidewire could not be passed into the bladder initially, grasp the open-ended catheter and bring it out through the sheath to establish through-and-through access.

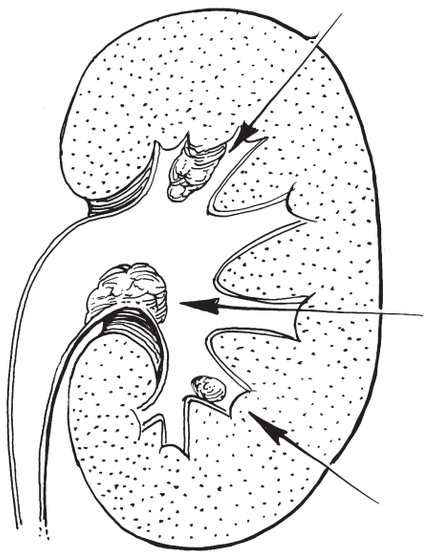

FIGURE 167-1. Selection of access.

Resection: Resect the tumor piecemeal using cold cup biopsy forceps to debulk the tumor (Fig. 167-2). Use the resectoscope and loop cautery for very bulky tumors (Fig. 167-3). Take small swipes and avoid resecting deeply. Minimize contact between the cautery device and safety wire, or use an open-ended catheter instead to prevent cautery arc to the wire. Use sterile water irrigation throughout the procedure and avoid extravasation, which may lead to hyponatremia. When using the loop, remove each chip as it is resected, one at a time. Once resected nearly flush, use the cold cup forceps to resect the remainder and biopsy the tumor base to assess for invasion. Do not biopsy deeply or significant hemorrhage may occur. The Rollerball or Bugbee electrode is then used to fulgurate the tumor base. For tumor in an adjacent calyx, use a flexible nephroscope

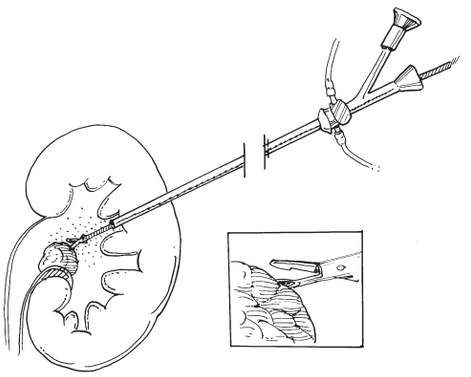

FIGURE 167-2. Use of cold cup forceps for piecemeal tumor resection.

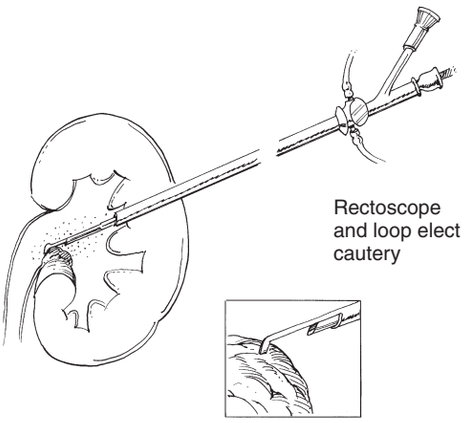

FIGURE 167-3. Use of continuous-flow resectoscope and loop electrocautery for tumor resection.

with cup forceps and Bugbee cautery, or place a second nephrostomy access if needed.

Drainage: Remove the open-ended ureteral catheter from the urethra. Place a large 24-French Malecot reentry nephrostomy tube and secure it to the skin with 0-silk. Alternatively, a 24-French Councill-tip Foley may be advanced over an open-ended ureteral catheter; however, clot may not drain as well as when using the Malecot type. Perform an antegrade nephrostogram to confirm placement of the nephrostomy with the tip in the renal pelvis, then dress the site with 4-inch Kerlix roll gauze on either side of the tube to prevent kinking and discomfort.

Postoperative care: Obtain a hematocrit postoperatively and the following morning. Provide antibiotic prophylaxis for 24 hours. Resume regular diet and remove the Foley catheter the following morning. Unless hematuria is severe or the patient develops fever, clamp the nephrostomy tube and the patient may be discharged home.

Second-look procedure: Review the final pathology report. If there is any evidence of invasion, perform a total nephroureterectomy. Perform the flexible nephroscopy and take advantage of the bloodless field to carefully inspect the collecting system for any residual disease. Small foci may be ablated with cold cups, Bugbee electrode, or holmium laser fulguration (Fig. 167-4). Larger foci may require replacement of a working sheath and rigid nephroscope or resectoscope. Consider placing an antegrade double-J ureteral stent if there is significant hematuria or edema in the proximal ureter, or if intravesical chemotherapy is planned to treat the upper tracts via the refluxing stent. Place a 10-French pigtail nephrostomy catheter for drainage or administration of adjuvant topical therapy. The nephrostomy is then removed when no longer needed.

Adjuvant topical therapy: Consider the administration of either mitomycin C or BCG postoperatively. This may be done via the nephrostomy tube (Fig. 167-5) or intravesically with a refluxing double-J stent. Before intravesical instillation, perform a cystogram to confirm the presence of reflux.

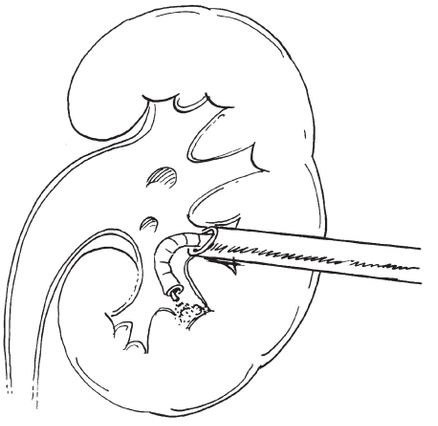

FIGURE 167-4. Flexible nephroscopy is useful to examine and treat adjacent and anterior calyces through a single access. The holmium-YAG laser may be used to ablate tumor and achieve hemostasis. Flexible cup biopsy forceps may be used to resect the tumor base to assess for the presence of invasion. A Bugbee electrode may also be used for hemostasis.

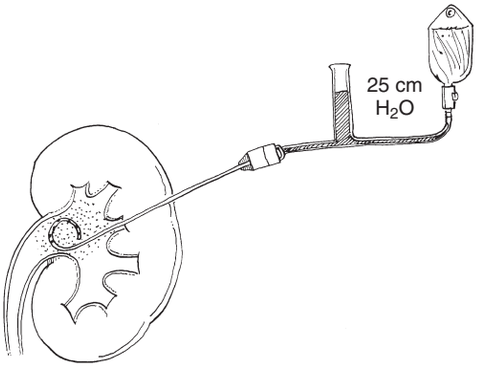

FIGURE 167-5. Setup for percutaneous instillation of topical therapy by gravity. A 10-French Cope loop type nephrostomy is used in conjunction with a manometer to monitor intrarenal pressures, which must be maintained below 25 cm H_2O.

Perform instillation 2 weeks following resection. For percutaneous instillations of BCG, give therapy weekly for 6 weeks. Give prophylactic intravenous antibiotics to prevent urosepsis from bacterial colonization. Do not use fluoroquinolones, gentamicin, or doxycycline with BCG because they may inactivate the bacillus. Infuse normal saline via the nephrostomy starting at 10 mL per hour and increase by 10 mL per hour until the rate equals 50 mL per hour. Monitor the intrarenal pressure as shown and maintain pressures below 25 cm H_2O. If saline infusion is well tolerated, then give 50 mL of 1×10^8 colony forming units of BCG over 1 hour. The patient may be discharged home the following day. Two weeks after completion of therapy, perform a third-look nephroscopy via the established tract.

This page intentionally left blank

Section XXIII

ADRENAL EXCISION

This page intentionally left blank

Chapter 168

Adrenal Anatomy and Preparation for Adrenal Surgery

E. DARRACOTT VAUGHAN, JR.

At the present time the majority of adrenalectomies are performed utilizing a laparoscopic approach. However the open techniques are still utilized for the removal of large adrenal adenomas, carcinomas, and some pheochromocytomas. Regardless of the surgical technique required, the surgeon must have thorough knowledge of adrenal anatomy, including relationships with adjacent organs, and must have carefully established the diagnosis and prepared the patient for the operation in order to avoid complications.

ANATOMY AND EMBRYOLOGY

The adrenal glands are paired retroperitoneal organs that lie within perinephric fat at the anterosuperior and medial aspects of the kidney. They measure up to 5 cm in length by 3 cm in width and are 1 cm thick. In the healthy, nonstressed adult, the glands weigh about 5 g each. In contrast, the adrenal weight at birth is quite large (5 to 10 g) because of the fetal adrenal cortex, which may play a major role of fetal embryogenesis and homeostasis. The fetal adrenal cortex regresses rapidly during the first 6 weeks of life; adrenal tissue remodeling is due to apoptotic cell death at birth after the fetal adrenal serves as a reservoir of progenitor cells that move centrally to populate the definitive zones of the adult adrenal. The adrenal is susceptible to hemorrhage at the time of birth, a condition now readily diagnosed by magnetic resonance imaging (MRI).

Sectional imaging has provided a better understanding of the precise appearance of the adrenals. Both glands are flattened anteriorly with a thick central ridge and thinner medial and lateral rami. Cortical infoldings, especially seen on sagittal sections, may be confused for small adenomas, especially in primary aldosteronism, in which the lesions are small.

The right adrenal lies above the kidney posterolateral to the inferior vena cava. The anterior surface is in immediate contact with the inferior-posterior surface of the liver. Thus, from an anterior approach, the anterior surface of the adrenal can be exposed extraperitoneally by gently lifting the liver cephalad, the inferior vena cava being medial. The posterior surface of both adrenals is in contact with the posterior diaphragm (Fig. 168-1).

Both adrenals lie more posteriorly as they follow the lumbar curve of the spine, thus falling away from the surgeon for the superior dissection.

The left adrenal is in more intimate contact with the kidney, and the main left renal artery often lies deep to the left adrenal vein as it enters the left renal vein. The gland overlies the upper pole of the kidney, with its anterior surface and medial aspects behind the pancreas and splenic vein (see Fig. 168-1). The anterior surface of the left adrenal can be exposed by remaining retroperitoneal and by gently retracting the spleen cephalad within the peritoneum. Division of the spleno-renal ligament facilitates this dissection.

The adrenals have a delicate and rich blood supply, estimated to be 6 to 7 ml/g/min, without a dominant single artery. The inferior phrenic artery is in the main blood supply, with additional branches from the aorta and the renal artery (Fig 168-2). In addition, there can be an adrenal arterial supply arising from the gonadal arteries in 60% of fetal adrenal vascular dissections. The small arteries penetrate the gland in a circumferential stellate fashion, leaving both anterior and posterior surfaces avascular. The venous drainage is usually a common vein on the right, exiting the apex of the gland and entering the inferior vena cava; the vein is short, fragile, and the most common source of troublesome bleeding during right adrenalectomy (Fig 168-3). Uncommonly the right adrenal vein is joined by a hepatic vein, which enters the undersurface of the liver.

The left vein empties directly into the left renal vein, about 3 cm from the inferior vena cava and often opposite the gonadal vein. Not well recognized is the left inferior phrenic vein, which typically communicates with the adrenal vein but then courses medially and can be injured during dissection of the medial edge of the gland (Fig 168-3).

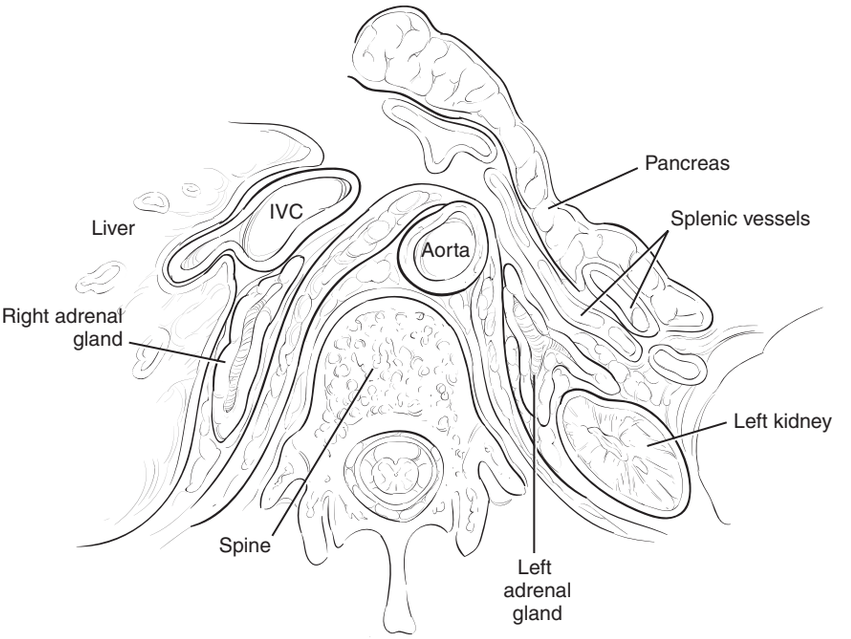

FIGURE 168-1. Line schematic of an anatomic specimen showing position of the adrenal glands in relationship to the diaphragm, inferior vena cava (IVC), aorta, and kidneys.

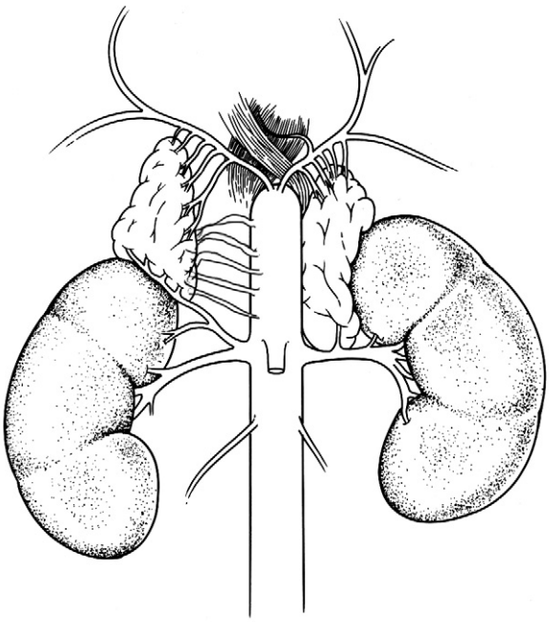

FIGURE 168-2. Arterial supply of the left and right adrenal glands.

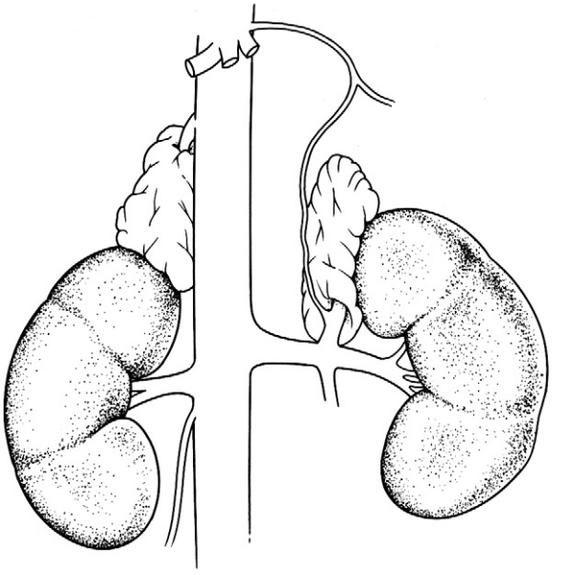

FIGURE 168-3. Venous drainage of the left and right adrenal glands with particular attention to the intercommunicating vein on the left, which is medial and drains into the phrenic system. *(From Vaughan ED Jr, Carey RM, eds. [1989]. Adrenal disorders. New York: Thieme Medical.)*

ANATOMIC RELATIONSHIPS

The relationships of the adrenals to the kidney, paraspinal musculature diaphragm, and inferior vena cava (IVC) are shown in anatomical dissections. On the right side, small vessels emerge from behind the IVC (Fig. 168-4) entering the gland medially. During adrenalectomy careful control of these vessels with hemostatic clips prevents retraction of the vessels behind the IVC and troublesome bleeding. On the left side, the apical branch of the renal artery to the upper pole can course behind the lower border of the adrenal and be ligated mistakenly as an inferior branch artery to the adrenal.

The relationship to the liver, pancreas, and splenic vein are shown in Figs. 168-1 and 168-5. The lateral wing of the right adrenal, especially when involved in the pathologic

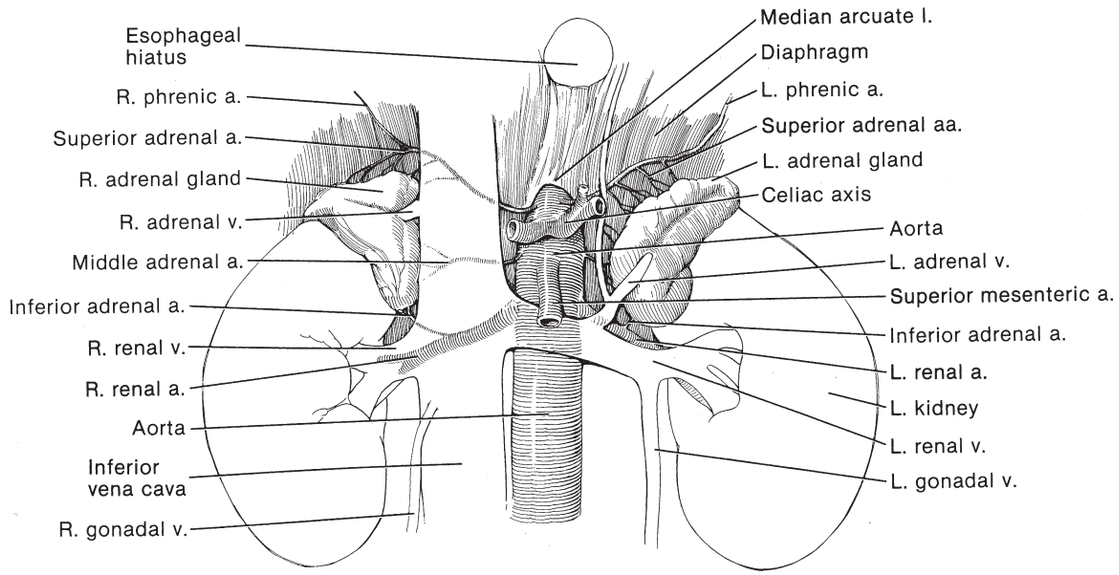

FIGURE 168-4. Vascular anatomy of the right adrenal showing aortic arterial branches entering the adrenal from behind the inferior vena cava.

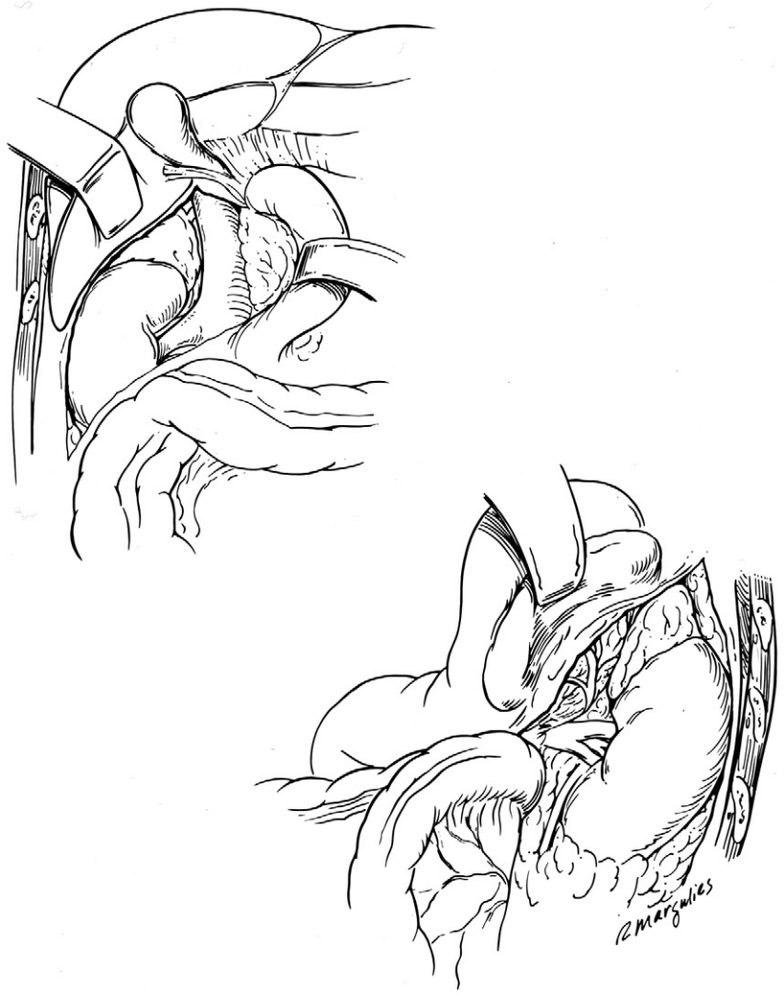

FIGURE 168-5. Intraperitoneal anatomy showing the relationship of the adrenals to the bowel, liver, pancreas, and spleen.

process may actually invade the liver. Removal can lead to hepatic bleeding usually controlled with the Argon Beam Coagulator.

On the left, especially during exposure with a transperitoneal approach (Fig. 168-5), the tail of the pancreas and the splenic vein are located just anterior to the adrenal and must be dissected free carefully.

PREPARATION FOR ADRENAL EXCISION

Success in the treatment of adrenal disorders requires precise metabolic definition of the underlying disorder, proper patient preparation, and precise surgical adrenal removal with a clear understanding of the anatomy in each specific case. Thus, complications can arise if there are errors in diagnosis and preparation. A thorough discussion of the pathophysiology and diagnosis of adrenal disorders are given elsewhere.

DIAGNOSTIC PROCEDURES AND PATIENT PREPARATION

The term *hyperaldosteronism* was originally coined by Conn. The clinical syndrome was initially characterized by hypertension, hypokalemia, and alkalosis. The biochemical triad that characterizes the disease is hypokalemia, a high aldosterone level with patient sodium replete, and a low plasma renin activity when the patient is sodium depleted. In evaluating patients with primary hyperaldosteronism, one must make sure that they are sodium replete because some patients will realize that they feel worse when sodium loaded, and therefore maintain themselves on a low-sodium diet, which can lead to normalization of plasma potassium. Therefore, before ruling out the entity, the patients should have sodium loading. If the patient is found to have hypokalemia, there should be diagnostic evaluation for primary aldosteronism. The next step is to measure plasma renin activity; if it is low, one should be sure to replete the patient with potassium before measuring aldosterone because hypokalemia can limit aldosterone production.

After establishing that the patient has hyperaldosteronism, one must delineate between the entity being caused by a solitary adenoma versus bilateral adrenal hyperplasia. Patients with an adenoma have a paradoxical fall or stabilization of aldosterone with posture; however, this test is accurate in only 70% of cases and thus is not totally reliable. Computed tomography scanning and adrenal vein sampling are used and plasma cortisol should be measured to validate correct positioning, particularly in the small right adrenal vein. A minimum amount of contrast solution should be used during sampling to avoid damage to the fragile adrenal, and cases of adrenal infarction have been reported. Patients with adenomas or the rare patient with bilateral hyperplasia and unilateral aldosterone secretion are candidates for adrenalectomy. Before bringing the patient to the operating room, the patient should have potassium repletion and blood pressure control, which is usually obtained using spironolactone, 100 to 200 mg per day, and possibly the use of calcium channel blocker.

Patients with Cushing's syndrome resulting from adrenal adenoma or carcinoma comprise only about 20% of all patients with Cushing's syndrome. A plan for evaluation was described by Orth. The role of the physical examination in evaluating patients with Cushing's syndrome, with particular emphasis on virilization as a marker for adrenal carcinoma, cannot be underestimated. A careful history is mandatory because the occult use of steroids, even in a steroid cream, can cause exogenous Cushing's syndrome, and this problem must be ferreted out with a careful history. An additional point in the history is the determination of alcohol intake or depression, which can cause mild elevations of cortisol level. In these patients, a low-dose dexamethasone suppression test (2 mg/day) should suppress plasma cortisol to normal and lead to the diagnosis of pseudo-Cushing's syndrome. A concurrent measurement of corticotropin (ACTH) and plasma cortisol leads to the differentiation between adrenal Cushing's syndrome in which ACTH is suppressed and pituitary Cushing's syndrome or Cushing's syndrome resulting from ectopic ACTH secretion in which both hormones are elevated. Patients with adrenal Cushing's syndrome then undergo computed tomography scanning to identify the site of the tumor.

If the patients have severe manifestations of Cushing's syndrome, they should be treated preoperatively with an adrenal blocking agent such as metyrapone to minimize the metabolic consequences of the disease. These patients have multiple manifestations of glucocorticoid excess, and the resulting diabetes needs to be controlled. They are also prone to postoperative infections. Preoperative steroid administration usually is begun at surgery and is not needed before that time. Endocrinologists use different replacement regimens, but many believe that a combination of both intramuscular and intravenous administration is useful in the event there is an error in administration. In patients with large adrenal lesions, particularly with adrenal carcinoma, the consent should include the need for adjacent organ resection, particularly the kidney. The patient should realize that the tumor may have invaded adjacent organs, which may need to be removed. Obviously, thorough metastatic evaluation is mandatory in a patient with adrenal carcinoma.

Incidentally found adrenal lesions are quite common. It is mandatory that all of these patients have catecholamine levels measured to rule out occult pheochromocytoma. Patients should also be investigated for Cushing's syndrome if they have physical stigmata of the diseases and for hyperaldosteronism if hypokalemia is identified. If the patient has a nonfunctioning lesion, I personally believe that (MRI) should be done; if the lesion is not typical of benign adenoma, exploration is indicated. However, there is considerable controversy, and certainly adrenal cancers are not uniformly delineated from other adrenal lesions by MRI.

As stated, all patients with sustained hypertension should be evaluated with urinary catecholamine levels and their metabolites to rule out pheochromocytoma. A number of situations can lead to false elevations of urinary catecholamines, and a careful history should be taken to rule out

these entities. Once the elevated catecholamines have been identified, the appropriate imaging study is an MRI not only because it identifies the site of the lesion, but because coronal and sagittal studies give excellent imaging of adjacent organ relationships. Care should be taken to identify multiple lesions, particularly in children, patients with familial pheochromocytoma, and those with multiple endocrine adenopathy.

Patients with pheochromocytoma should have preoperative catecholamine blockade, with the agent choice being phenoxybenzamine (Dibenzyline), increasing the dose until the blood pressure normalizes. If the patients have severe increases in catecholamine levels, particularly if they have any evidence of catecholamine cardiomyopathy, then double blockade adding ά-methylparatyrosine, a hydroxylase inhibitor, should be instituted.

Anesthetic management is critically important, and all patients with suspected pheochromocytoma should have a preoperative anesthesia consult before the operation. All patients should be closely monitored both preoperatively and intraoperatively.

Careful diagnostic studies and preoperative preparation should lead to a successful surgical outcome whether open or laparoscopic with avoidance of the complications.

Commentary by

DUANE BALDWIN

ANATOMY AND EMBRYOLOGY SECTION

The left adrenal vein usually joins the left renal vein slightly medial to the site where the left gonadal vein drains into the left renal vein. In about 10% to 15% of patients, there may be another smaller adrenal vein located more lateral to the main adrenal vein, which also drains into the renal vein. On the left side, there may be accessory renal arteries or early branches of the left renal artery that course very close to the adrenal. These should be sought carefully on preoperative imaging and if seen, should be anticipated at the time of surgery.

ANATOMIC RELATIONSHIPS

On the left side, the adrenal gland may be very close to the kidney in a young thin patient or it may be separated by several centimeters of fat in the morbidly obese patient. This fat may be thick, dense, and well vascularized. Determining the correct plane to separate the adrenal from the kidney can be challenging in these patients. If there are no renal arteries or early upper pole branches coursing through this plane, the surgeon can use a bipolar coagulation device to define this plane. This will routinely provide adequate hemostasis even in this well-vascularized fat. In some adrenal lesions, the caudal edge of the adrenal may extend down behind the main renal vessels. This can make the dissection more complicated if the relationship is not anticipated, as dissecting toward the kidney in the usual location could fracture some adrenal parenchyma and result in bleeding. On the right side, a metastatic neoplasm or adenoma located in the medial part of the adrenal can present a challenge during the dissection when approached transperitoneally. Occasionally, ligation of some lumbar veins may be required to get good caval mobilization to dissect these tumors located behind the vena cava.

DIAGNOSTIC PROCEDURES AND PATIENT PREPARATION

In patients with an elevated aldosterone level, low plasma renin and a definite adenoma seen with cross sectional imaging, one does not always have to perform adrenal vein sampling prior to proceeding with adrenalectomy. Certainly if bilateral lesions are seen one should proceed with adrenal vein sampling.

Patients with only mildly elevated 24-hour urine catecholamines probably do not have pheochromocytoma. True pheochromocytoma patients will usually have 24-hour urine catecholamine levels that are two to three times normal. In patients with familial forms of pheochromocytoma, I also routinely order an MIBG scan to search for extra adrenal sites that will be difficult to identify during a laparoscopic adrenalectomy.

When blocking with phenoxybenzamine one can start with 10 mg orally twice a day and titrate up the dosage until the patient is mildly dizzy upon standing. Patients often don't like this medication, but it is highly effective in preventing the catastrophic blood pressure swings that can be encountered during surgery. These cases should only be attempted with skilled anesthesiologists familiar with the blood pressure extremes potentially encountered with these patients.

In the evaluation of incidentally detected adrenal lesions, CT may be very helpful in identifying patients with either pheochromocytoma or adrenocortical carcinoma. A benign adenoma is routinely less than 10 Hounsfield units on noncontrast CT, while a cancer or pheochromocytoma will often be 30 Hounsfield units or greater on noncontrast CT. A benign myelolipoma will show macroscopic fat with negative Hounsfield unit attenuation.

This page intentionally left blank

Chapter 169

Open Approaches to the Adrenal Gland

E. DARRACOTT VAUGHAN, JR.

Currently, the vast majority of patients with surgical adrenal disorders undergo a laparoscopic adrenalectomy. For those of us schooled in the nuances of adrenal surgery, it has been with pleasure that we've seen the evolution of elegant laparoscopic techniques.

The complication rate of laparoscopic technique is low, 6% in 370 cases, including complications that did not require surgical intervention. Conversion to open surgery only occurred in 3.5%.

However, remaining indications for open adrenalectomy include selected patients with adrenal carcinoma, patients with large pheochromocytoma where the blood pressure may be difficult to control, and patients requiring simultaneous abdominal procedures. Moreover, there are medical indications including bleeding disorders, morbid obesity, and patients who have had multiple previous abdominal procedures and require an open procedure.

In addition, if the surgeon understands specific complications that can occur with open adrenal surgery, the surgeon will be aware of their existence and will be prepared to react even if a patient is undergoing a laparoscopic adrenalectomy. For example, it has been demonstrated that there is significant catecholamine and cytokine response to laparoscopic adrenal surgery in patients with pheochromocytoma.

ADRENAL SURGERY

The management of patients with an adrenal disorder is approached on a team basis involving experienced endocrinologists, radiologists, anesthesiologists, and urologists or general surgeons.

Numerous open approaches can be made to the adrenal gland. The proper approach depends on the underlying cause of adrenal pathology, the size of the adrenal, the site of the lesion, the habitus of the patient, and the experience and preference of the surgeon. In most cases, there are a number of different options available and a careful review of all the variables is required before a choice is made. Thus each case should be considered individually although some approaches are preferable for a given disease. For example, in patients with large adrenal tumors a thoracoabdominal approach is often utilized. In contrast, a posterior or modified posterior approach is preferred for small localized lesions. Finally, a patient with multiple lesions, either extra-adrenal or bilateral, will be explored using a transabdominal chevron incision.

Before describing the specific techniques a number of unifying concepts warrant attention. First, adequate visualization is imperative; the adrenal glands lie high in the retroperitoneum and quite posterior. Therefore, the use of a headlight by both the surgeon and first assistant is critical and hemostasis should be maintained rigorously. The operator should bring the adrenal down by initially exposing the cranial attachments and dividing the right blood supply between either right-angled clips or utilizing a forceps cautery. If available, the harmonic scalpel (as used in laparoscopic surgery) is very useful for both dissection and coagulation. Thus, it is often simplest to begin the dissection laterally, identifying the vascular supply and working around the cranial edge of the gland. The posterior surface is generally devoid of vasculature and, after the gland is freed superiorly with gentle traction on the kidney, the gland can be brought inferiorly for control of the adrenal vein. The only tumor that would be handled in a different fashion would be a pheochromocytoma where the intent should be to obtain control of the adrenal vein early so as to stabilize the patient from a burst of catecholamine release during manipulation. The adrenal gland is extremely friable and fractures easily, which can cause troublesome bleeding. Therefore, tension or traction should be maintained on the kidney or surrounding structures and not on the adrenal itself. The concept has been expressed as "the patient should be dissected from the tumor," a view that is particularly true in patients with pheochromocytomas where the gland should not be manipulated.

POSTERIOR APPROACH

The posterior approach can be used for either bilateral adrenal exploration or unilateral removal of small tumors. The bilateral approach is rarely utilized today because of

our excellent localization techniques. It is now utilized primarily for ablative total adrenalectomy. The options for incisions are shown in Fig. 169-1; generally, rib resection is preferable in order to gain high exposure. After a standard subperiosteal rib resection, care should be taken with the diaphragmatic release; the pleura should be avoided and the diaphragm swept cranially.

The fibrofatty tissues with Gerota's fascia are swept away from the paraspinal musculature, exposing a subdiaphragmatic "open space" that is at the posterior apex of the resection. The liver within the peritoneum is dissected off the anterior surface of the adrenal and the cranial blood supply is divided. Medially on the right, the inferior vena cava (IVC) is visualized. The short, high adrenal vein entering the cava in the dorsolateral position is identified and can be clipped or ligated. The adrenal can then be drawn caudally by traction on the kidney. The adrenal arteries will issue from under and from behind the IVC and these must be carefully clipped; otherwise, troublesome bleeding can occur.

Finally, the adrenal is removed from the superior aspect of the kidney and care must be taken to avoid apical branches of the renal artery. On the left, the approach is similar with division of the spleno-renal ligament giving lateral exposure.

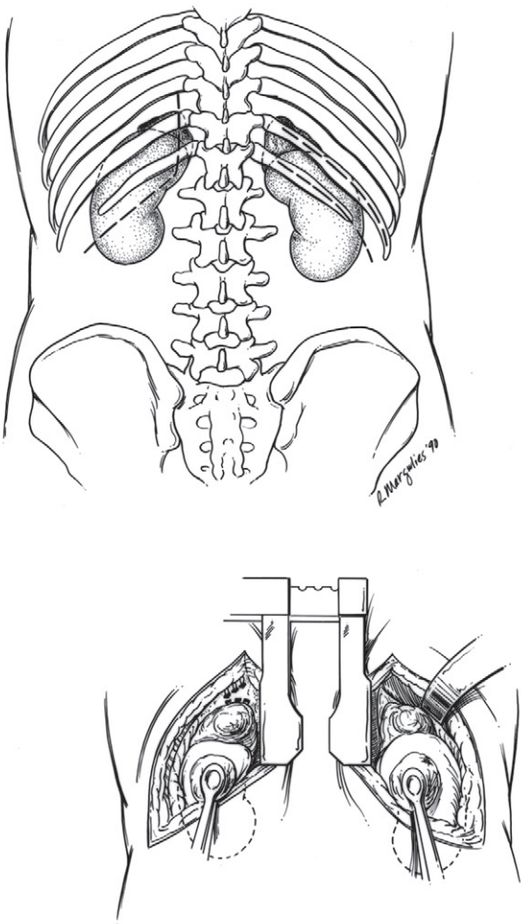

FIGURE 169-1. Posterior approach to the adrenals: options for incisions and bilateral adrenal exposure.

The posterior approach can be modified for a transthoracic adrenal exposure to the diaphragm; however, this more extensive approach is rarely necessary for small adrenal tumors.

MODIFIED POSTERIOR APPROACH

Although the posterior approach has the advantage of rapid adrenal exposure and low morbidity, there are definite disadvantages. This approach may impair respiration, the abdominal contents are compressed posteriorly, and the visual field is limited. In addition, if bleeding occurs it is difficult to extend the incision to gain better exposure. Therefore, we have developed a modified posterior approach for right adrenalectomy utilizing the Gil-Vernet position.

The approach is based on the anatomical relationship with the right adrenal which lies deeply posterior and high in the retroperitoneum behind the liver (Fig. 169-2). In addition, the short, stubby right adrenal vein enters the IVC posteriorly at the apex of the adrenal. Hence, we utilize an approach that is posterior, but the patient is in a modified position, similar to that used for a Gil-Vernet dorsal lumbotomy incision (Fig. 169-3). The patient is first placed in a formal lateral flank position and then allowed to fall forward into the modified posterior position. Subsequently, the 11th or 12th rib is resected with care to avoid the pleura. The diaphragm then is dissected off the underlying peritoneum and liver in order to gain mobility. Similarly, the inferior surface of the peritoneum, loosely associated with the liver, is sharply dissected from Gerota's fascia, which is gently retracted inferiorly. It is of note that the adrenal gland is not identified during the early portion of the dissection and, because of the modified posterior approach, the surgeon can become disoriented if not thoroughly familiar with anatomical relationships.

The adrenal will become visible in the depth of the incision as the final hepatic attachments are divided. The lateral, empty space can be found exposing the posterior abdominal musculature and often the IVC. Multiple, small arteries course behind the IVC and emerge over the paraspinal muscles and these arteries are clipped and divided. At this point the adrenal usually can be moved posteriorly against the paraspinal muscles exposing the surface of the IVC below the adrenal gland.

The major advantage of this approach is that the adrenal vein is easily identified because it emerges from the exposed segment of the IVC and courses up to the adrenal, which now rises toward the surgeon. In other flank or anterior position, the adrenal vein resides in its posterior relationship, requiring caval rotation and the chance of adrenal vein avulsion. After adrenal vein exposure, it is doubly tied and divided or clipped with right-angled clips and divided. The remaining removal of the adrenal occurs as was previously described for the posterior approach.

On the left side, we do not use this modified approach and use a standard flank approach with a fairly small incision.

We have used the modified posterior approach for all patients with right adrenal aldosterone-secreting tumors and for other patients with benign adenomas of less than

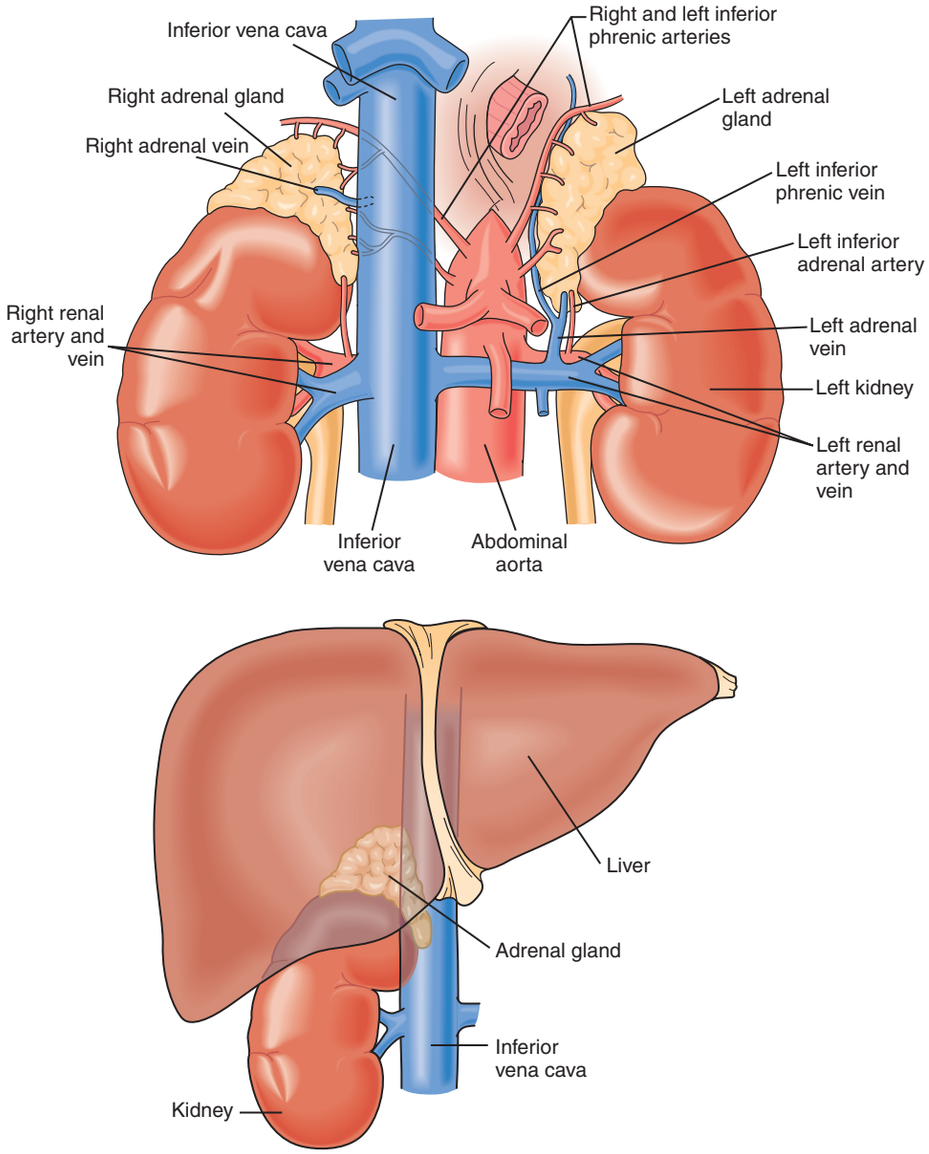

FIGURE 169-2. Anatomic relationships of the right adrenal, the adrenal vein, the inferior vena cava, and the liver.

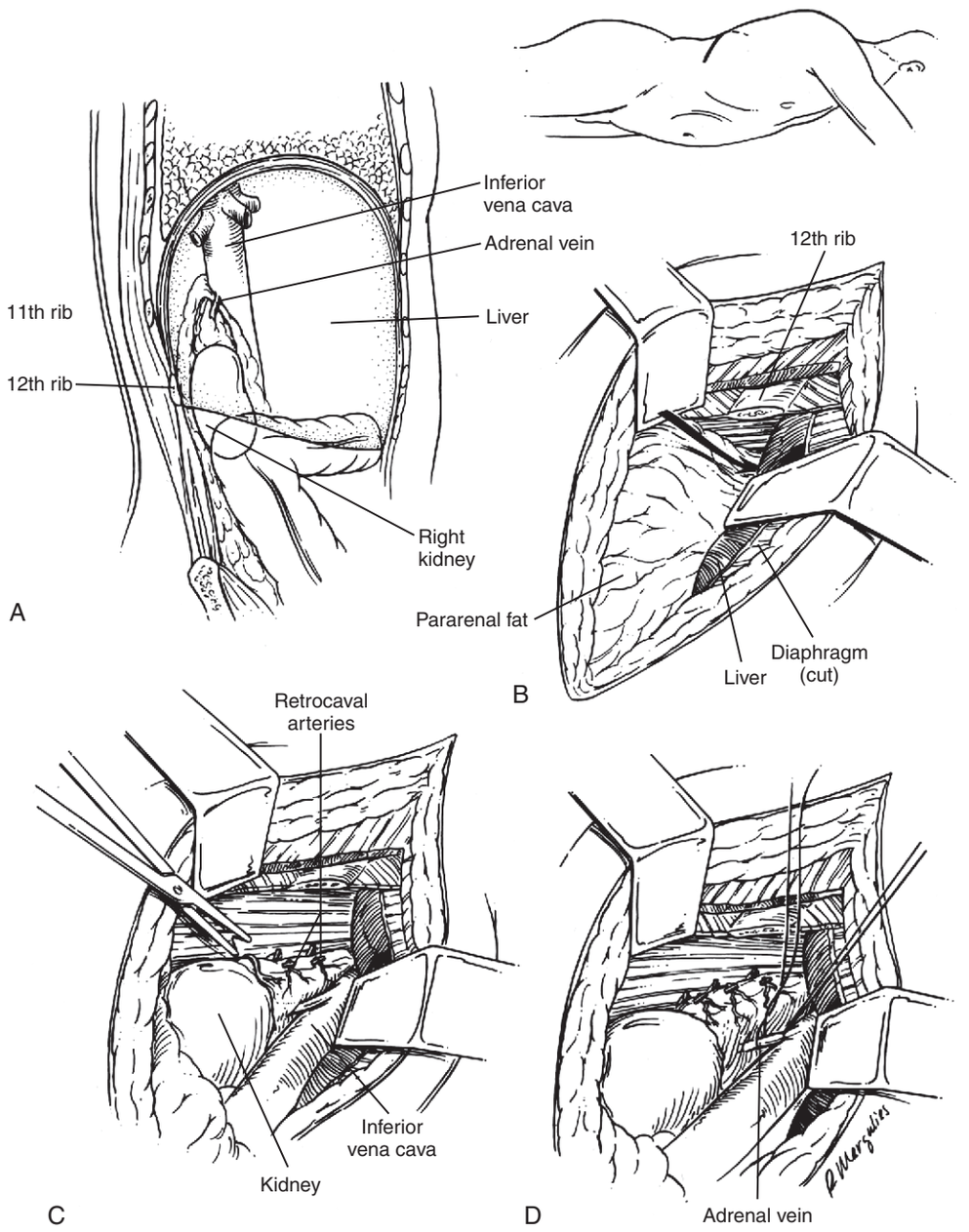

FIGURE 169-3. The modified right adrenal approach showing the patient positioning and steps of adrenal dissection.

6 cm. We do not recommend the approach for patients with large lesions or malignant adrenal neoplasms. The approach has been used for patients with relatively small pheochromocytomas.

FLANK APPROACH

The standard extrapleural, extraperitoneal, 11th rib resection is excellent for either left or right adrenalectomy. After completion of the incision, the lumbocostal arch is utilized as a landmark showing the point of attachment of the posterior diaphragm to the posterior abdominal musculature. Gerota's fascia, containing the adrenal and kidney, can be swept medially and inferiorly, giving exposure to the spleno-renal ligament on the left, which should be divided to avoid splenic injury (Fig. 169-4). Working anteriorly on the left, the pancreas and spleen within the peritoneum can be lifted cranially, exposing the anterior surface of the adrenal gland.

On the right side, a similar maneuver is used to lift the liver within the peritoneum off the anterior surface of the adrenal. Quite often, the adrenal gland cannot be identified precisely until these maneuvers are performed. One should not attempt to dissect into the body of the adrenal or to dissect the inferior surface of the adrenal off the kidney. The kidney is useful for retraction. The dissection should continue from lateral to medial along the posterior

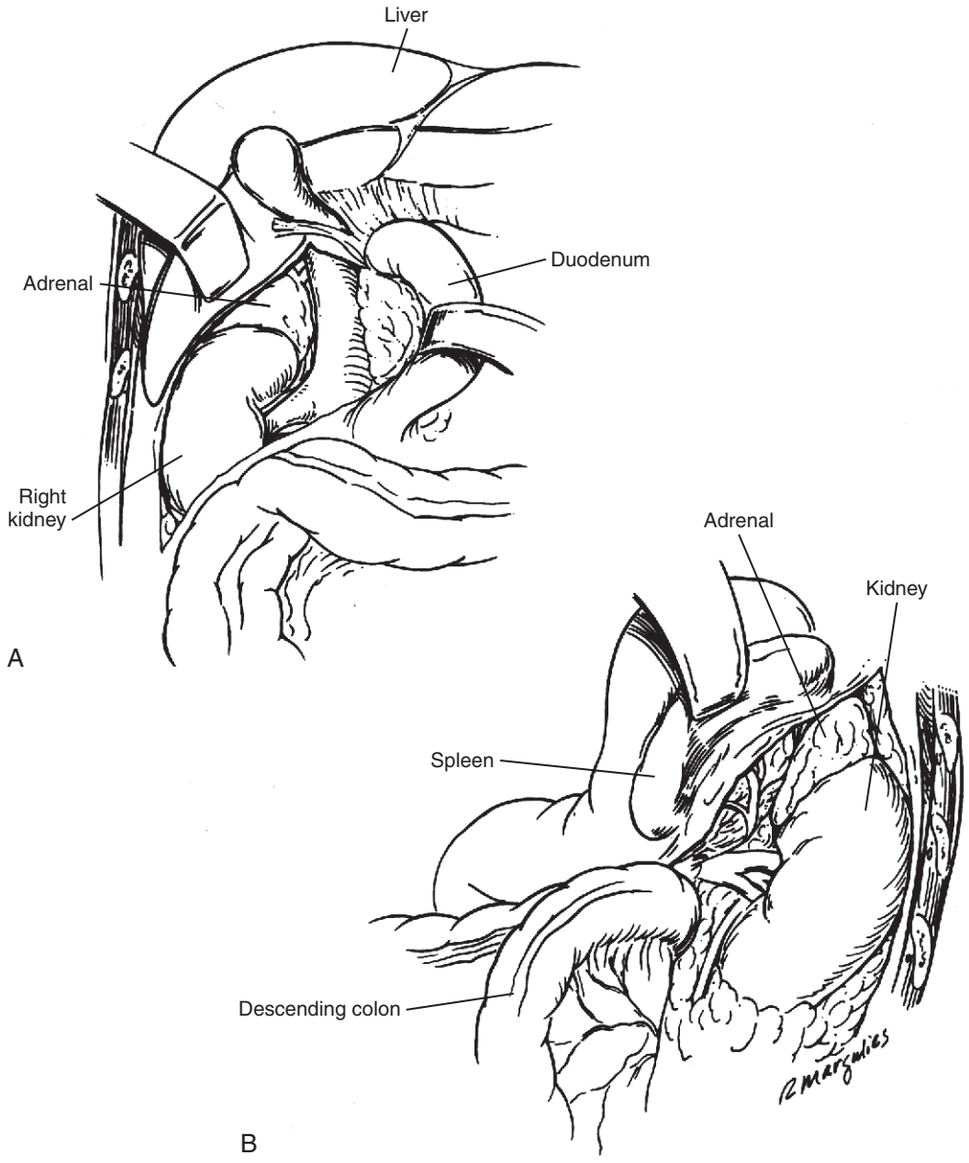

FIGURE 169-4. Exposure of right and left adrenal: dissection of colon, duodenum, pancreas, and spleen.

abdominal and diaphragmatic musculature, with precise ligation or clipping of the small but multiple adrenal arteries. While the operator clips these arteries with one hand, the opposite hand is employed to retract both adrenal and kidney inferiorly. With release of the superior vasculature, the adrenal is visualized. On the left medially, the phrenic branch of the venous drainage must be carefully clipped or ligated. This vessel is not noted in most atlases, but can cause troublesome bleeding if divided. The medial dissection along the crus of the diaphragm and aorta will lead to the renal vein; finally, the adrenal vein is controlled, doubly tied, and divided. The adrenal is then removed from the kidney with care to avoid the apical branches of the renal artery.

On the right side, the dissection is similar. However, after release of the adrenal from the superior vasculature, it is helpful to expose the IVC and divide the medial arterial supply. This maneuver allows mobilization of the cava for better exposure of the high posterior adrenal vein, which is doubly tied or clipped and divided. Patients with large adrenal carcinomas may require en bloc resection of the adrenal and kidney following the principles of radical nephrectomy (Fig. 169-5).

A major deviation from this technique is used for the patient with pheochromocytoma, in whom the initial dissection should be aimed toward early control and division of the main adrenal vein on either side. Obviously, in this setting, the anesthesiologist should be notified when the adrenal vein is divided because a marked drop in blood pressure often occurs, even when the patient is adequately hydrated.

After removal of the adrenal, inspection should be made for any bleeding and for pleural tears. The kidney should also be inspected. The incision is closed without drains with interrupted 0 polydioxanone sutures.

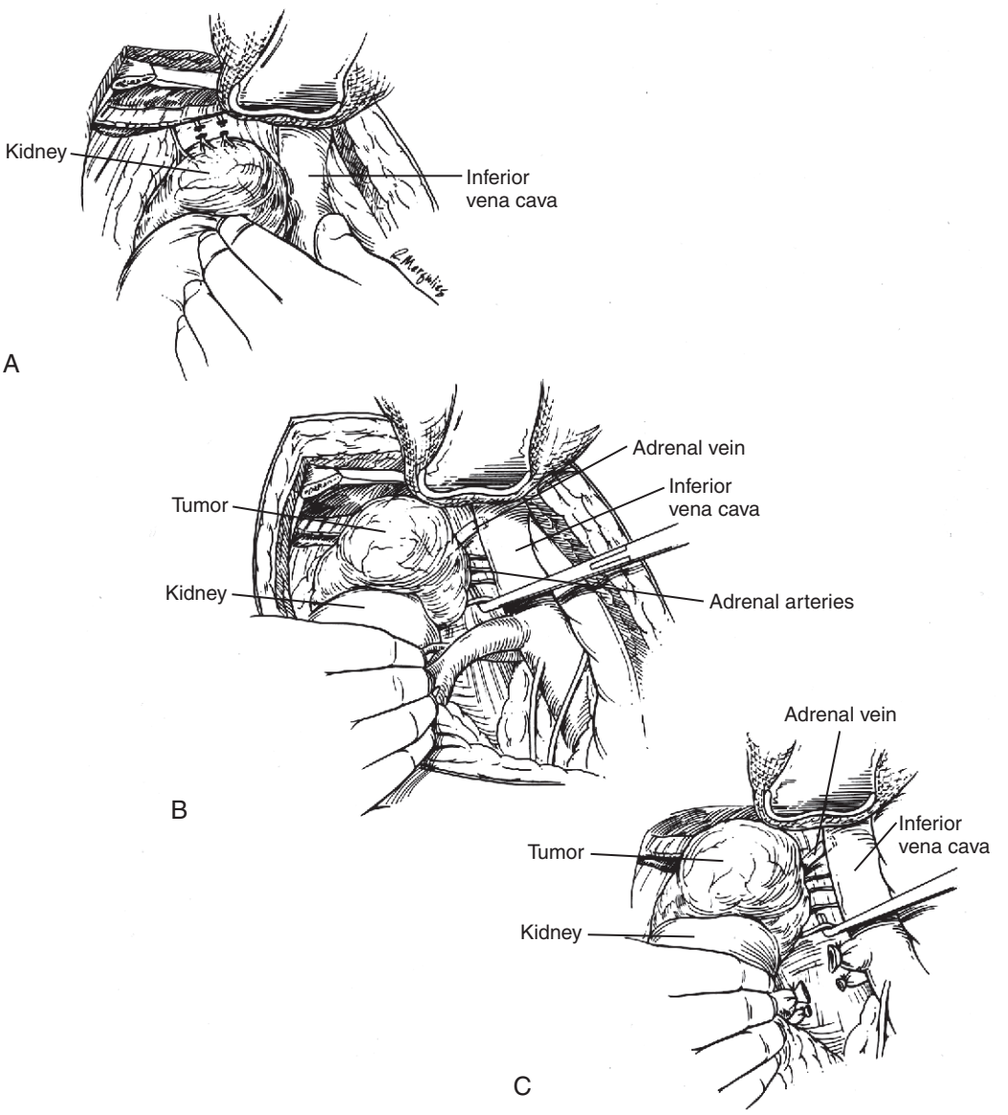

FIGURE 169-5. Right adrenalectomy with en bloc resection of the right kidney.

THORACOABDOMINAL APPROACH

The thoracoabdominal 9th or 10th rib approach is utilized for large adenomas, for some large adrenal carcinoma, and for well-localized pheochromocytomas. The incision and exposure is standard, with a radial incision through the diaphragm and a generous intraperitoneal extension. The techniques described for adrenalectomy with the 11th rib approach are used.

TRANSABDOMINAL APPROACH

The transabdominal approach is commonly selected for patients with pheochromocytomas, bilateral cortical tumors, for children, and for some patients with adrenal carcinomas. The concept is to have the ability for complete abdominal exploration to identify either multiple pheochromocytomas or adrenal metastases.

I use the transverse or chevron incision (Fig. 169-6), which I believe gives better exposure of both adrenal glands than a midline incision. The rectus muscles and lateral abdominal muscles are divided, exposing the peritoneum. Upon entering the peritoneal cavity, the surgeon should gently palpate the para-aortic areas and the adrenal areas. Close attention is given to blood pressure changes in an attempt to identify any unsuspected lesions if the patient has a pheochromocytoma. This maneuver is less important today because of the excellent localization techniques. In fact, with precise preoperative localization of the offending tumor, the chevron incision does not need to be completely symmetrical and may be limited on the contralateral side.

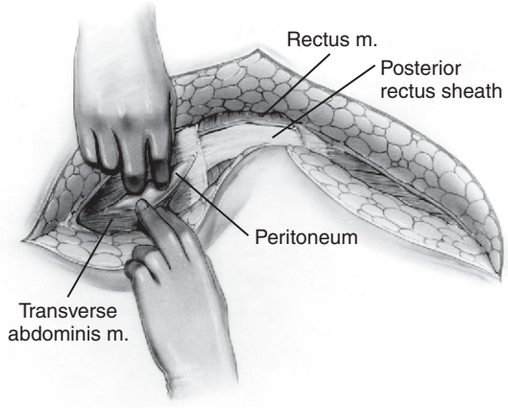

FIGURE 169-6. Chevron incision.

If the patient has a lesion on the right adrenal, the hepatic flexure of the colon is reflected inferiorly. The incision is made in the posterior peritoneum lateral to the kidney and carried superiorly, allowing the liver to be reflected cranially (Fig. 169-7). Incision in the peritoneum is carried downward, exposing the anterior surface of the IVC to the entrance of the right renal vein. Once the cava is cleared, one or two accessory hepatic veins are often encountered, which should be secured. These veins are easily avulsed from the cava and may cause troublesome bleeding. Ligation of these veins gives 1 to 2 cm of additional caval exposure, which is often useful during the exposure of the short posterior right adrenal vein. Small accessory adrenal veins may also be encountered or the adrenal and a hepatic vein may enter the cava with a common trunk. The cava is then rolled medially, exposing the adrenal vein, which should be doubly tied or clipped and divided.

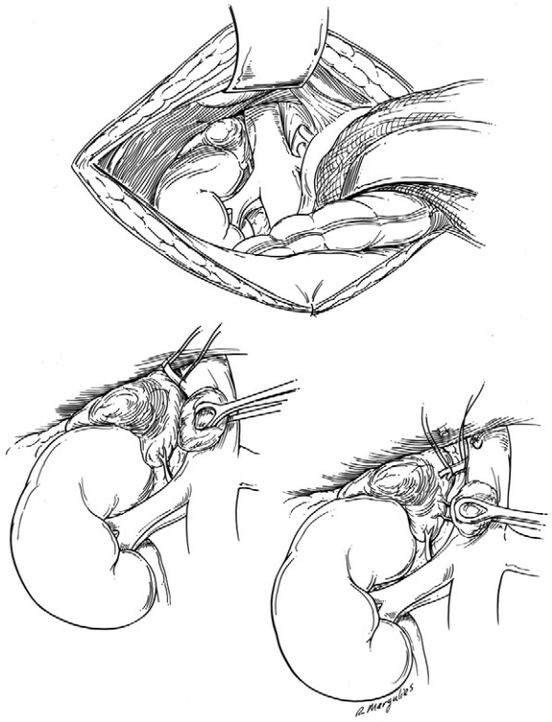

FIGURE 169-7. Transabdominal right adrenal exposure showing ligation of a small hepatic vein and the adrenal vein.

After control of the adrenal vein, it is simplest to proceed with the superior dissection, lifting the liver off the adrenal and securing the multiple small adrenal arteries arising from the inferior phrenic artery, which is rarely seen. The adrenal can be drawn inferiorly with retraction on the kidney, and the adrenal arteries transversing to the adrenal from under the cava can be secured with right-angled clips. The final step is removing the adrenal from the kidney.

The left adrenal vein is not as difficult to approach because it lies lower, partially anterior to the upper pole of the kidney, and the adrenal vein empties into the left renal vein. Accordingly, on the left side, the colon is reflected medially, exposing the anterior surface of Gerota's capsule; the initial dissection should involve identification of the renal vein. In essence, the dissection is the same as for radical nephrectomy for renal carcinoma. Once the renal vein is exposed, the adrenal vein is identified, doubly ligated, and divided. After this maneuver, the pancreas and splenic vasculature are lifted off the anterior surface of the adrenal gland. Because of the additional drainage from the adrenal into the phrenic system, I generally continue the medial dissection early to control the phrenic vein. I then work cephalad and lateral to release the splenorenal ligament and the superior attachments of the adrenal. The remainder of the dissection is carried out as previously described.

After removal of the tumor, regardless of size, careful inspection is made to ensure hemostasis and the absence of injury to adjacent organs. Careful abdominal exploration is carried out, after which the wound is closed with the suture material of choice. No drains are used.

Patients with multiple endocrine adenopathy or family histories of pheochromocytoma, as well as pediatric patients, should be considered at high risk for multiple lesions. Preoperative evaluation should identify these lesions but, regardless, a careful abdominal exploration should be carried out.

In patients with suspected malignant pheochromocytomas, en bloc dissections may be necessary to obtain adequate margins, a concept that also applies inpatients with adrenal carcinomas. Evaluation with magnetic resonance imaging (MRI) to obtain transverse, coronal, and sagittal images is extremely useful to define clearly the adrenal relationships to the IVC and renal vessels as well as to localize the adrenal vein.

In patients with pheochromocytomas, postoperative management includes maintenance of arterial and venous lines in an intensive care setting until they are stable. Often, 24 to 48 hours are required for the full effect of phenoxybenzamine, the alpha-blocking agent commonly given, to wear off and for normal alpha-receptor activity to be restored (Table 169-1).

TABLE 169-1 POSTOPERATIVE COMPLICATIONS AFTER ADRENAL SURGERY

Primary aldosteronism
Hypokalemia secondary to continued potassium loss immediately postoperative
Hyperkalemia secondary to failure of contralateral adrenal to secrete aldosterone
Cushing's syndrome
Inadequate steroid replacement leading to hypocorticoidism
Fracture secondary to osteoporosis
Poor wound healing
Increased risk of infection
Pheochromocytoma
Hypotension secondary to alpha-adrenergic blockade after tumor removal
Generic complications
Hemorrhage (inferior vena cava; adrenal arteries)
Pneumothorax
Pancreatitis
Pneumonia
Hiccoughs

PARTIAL ADRENALECTOMY

The standard treatment for patients with the adrenal lesions described has been total adrenalectomy. I have not used partial adrenalectomy in a patient with a normal contralateral adrenal, but certainly have used the technique in patients with bilateral disease. Thus, in one patient with a pheochromocytoma on one side and a nonfunctioning adenoma on the other, the adenoma was simply enucleated from the adrenal. Ina second patient with bilateral pheochromocytomas, the larger lesion was totally excised and partial adrenalectomy was utilized to remove the contralateral tumor. Care has to betaken to obtain thorough hemostasis when performing a partial adrenalectomy because of the vasculature nature of the adrenal.

An additional appropriate use for partial adrenalectomy has been reported in patients known to have the potential for multiple adrenal lesions. The group at the U.S. National Institute of Health reported 13 consecutive von Hippel-Lindau disease patients with pheochromocytoma who underwent 14 partial and 6 complete unilateral adrenalectomies. In addition, Mugiya et al. have utilized partial adrenalectomy in patients with multiple endocrine neoplasia type II A.

SUMMARY

The management of these adrenal disorders with precise surgical precision following localization is highly successful, resulting in a reversal of both metabolic abnormalities and the hypertension that often accompanies these diseases.

Chapter 170

Laparoscopic Approaches to the Adrenal Gland

KAZUO SUZUKI, NOBUO TSURU, AND HIROYUKI IHARA

Laparoscopic adrenalectomy is a safe and effective treatment for adrenal disorders, excluding primary adrenal cancer. There are no differences of the various operative parameters between the transperitoneal and retroperitoneal approaches, so the choice of approach should depend on the surgeon's preference or the patient's circumstances. It is important for the surgeon to remove the tumor and the surrounding fat en bloc, especially in the case of large or irregular tumors because of the potential for malignancy. The surgeon must also immediately switch to an open procedure if the laparoscopic operation becomes difficult.

ANATOMY OF THE PERITONEAL MEMBRANE AND FASCIAS

The correlation among the peritoneum, fusion fascia, renal fascia, and lateroconal fascia is shown in Fig. 170-1. Incise the peritoneal membrane, fusion fascia, and renal fascia in transperitoneal approach (arrow A) and incise the lateroconal fascia and renal fascia in extraperitoneal approach (arrow B).

TRANSPERITONEAL APPROACH TO THE ADRENAL GLAND

The transperitoneal lateral approach is appropriate for primary adrenal tumors with a diameter of 6 cm or more because it provides a wide operating field and clearly exposes the adrenal gland. For both left and right adrenalectomy, it is important to reflect the intestines, liver, and spleen medially so as to obtain a wide field of view, to dissect the adrenal gland en bloc with the surrounding fat, and to never touch the tumor or the normal adrenal tissue. Use of an ultrasonic coagulating shears or ultrasonic aspirator requires extreme care to avoid touching the tumor surface because of the risk of disseminating tumor cells.

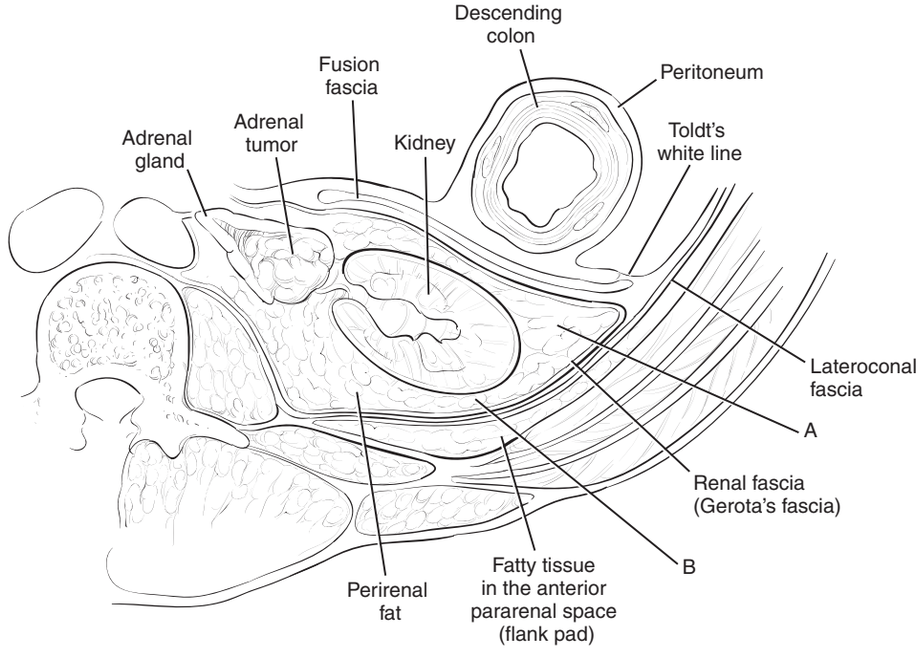

FIGURE 170-1. Anatomy.

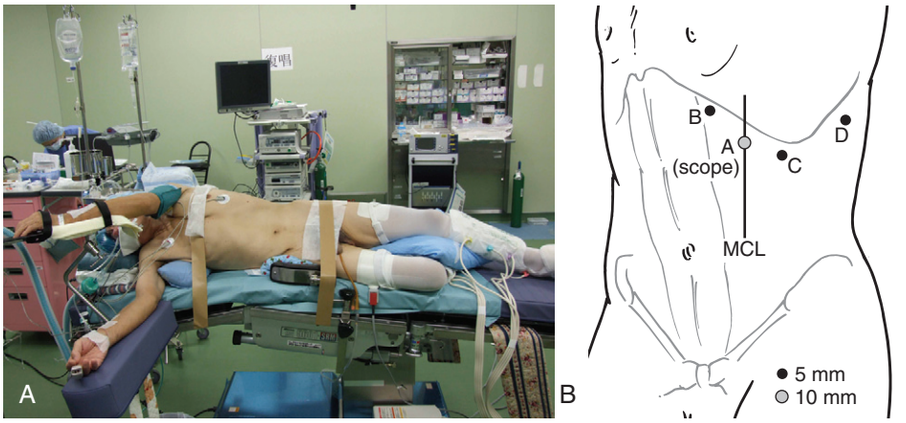

FIGURE 170-2. A, Patient position. **B,** Trocars placement.

A flexible laparoscope or rigid laparoscope (30-degree and 0-degree) is used. A bipolar forceps for the surgeon's left hand is required, and for the right hand a coagulating and cutting device (monopolar electrocautery scissors or hock forceps, ultrasonically activated scalpel, vessel sealer with knife, etc.) is needed. A snake retractor is preferable for reflecting the liver. A 5-mm metal clip is adequate for clipping the adrenal vein.

Left Adrenal Gland

Place the patient in the right semilateral position (about 70 degrees) (Fig. 170-2). Extend the tumor side slightly, and place the left arm on an airplane-type arm board. Hyperextension of the abdominal wall is not necessary because carbon dioxide gas insufflation (pneumoperitoneum) will elevate the abdominal wall.

Make an approximately 2-cm skin incision on the midclavicular line slightly below the costal arch to place the first 10- to 12-mm blunt tip trocar (open method). Insufflate carbon dioxide gas with a pressure of 10 to 14 mmHg. Insert a laparoscope via the trocar (A in Fig. 170-2B) to carefully inspect the peritoneal cavity and examine the bowel condition, adhesion, ascites, and so on. Place an additional three 5-mm trocars along the costal arch under laparoscopic monitoring. Insert the second trocar about 5 cm below the xiphoid process at slightly lateral to midline to avoid the falciform ligament (B in Fig. 170-2B). The third trocar is inserted just below the costal arch on the anterior axillary line (C in Fig. 170-2B), and the forth trocar inserts just below the costal arch on the mid-axillary line (D in Fig. 170-2B).

The surgeon stands on the opposite side of the pathology and uses two trocars that are placed just below the costal margin (B and C in Fig. 170-2B). After completing the trocar placement, the insufflation pressure should be lowered during the procedure to 8 to 12 mmHg. The 10-mm laparoscope is inserted via a trocar (A in Fig. 170-2B). The surgeon holds in the right hand a 5-mm coagulating and cutting device that is inserted through trocar C, and in the left hand a 5-mm forceps that is inserted through trocar B. The assistant inserts a 5-mm forceps through trocar D.

Incise the phrenocolic ligament first. Cut the peritoneum, fusion fascia, and renal fascia, and then extend the incision upward along the lateral border of the spleen until the greater curvature of the stomach is exposed (Fig. 170-3).

Allow the spleen to fall away in the medial direction by its own gravity until the posterior surface of the pancreas is exposed (Fig. 170-4). These procedures expose the adrenal gland and surrounding fat at the center of the endoscopic view.

Clearly expose the diaphragm at the lateral and superior aspects of the spleen (Fig. 170-5A). Dissect the fat around the upper pole of the adrenal gland along the diaphragm. Expose the superior adrenal vein draining into the inferior phrenic vein at the upper median site of the adrenal gland,

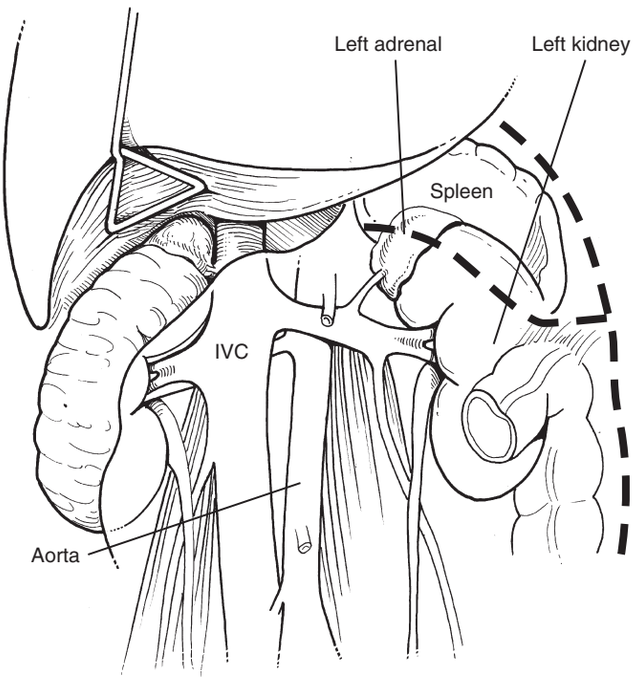

FIGURE 170-3. Cut line of peritoneum. *(From Bishoff JT, Kavoussi LR. [2007]. Atlas of laparoscopic urologic surgery. Philadelphia: Elsevier.)*

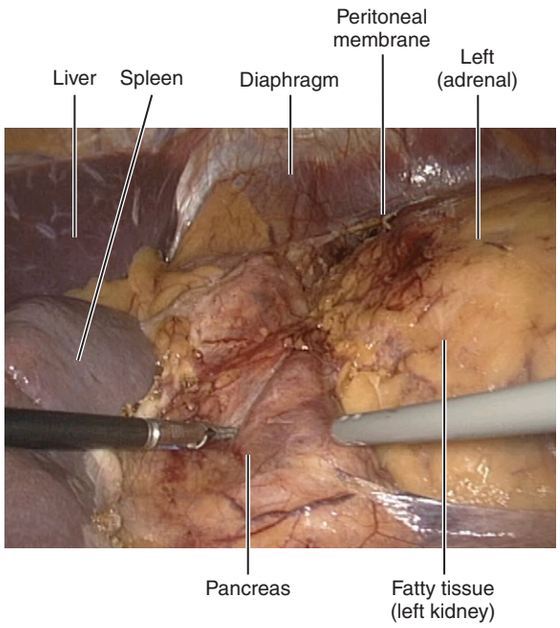

FIGURE 170-4. Reflect the spleen medially

and transect. Detach the fat including the adrenal gland at the upper lateral site and lateral site of the gland. Dissect the fatty tissue and small vessels (inferior and posterior adrenal vessels) between the adrenal gland and the upper pole of the kidney by using a coagulating and cutting device. Reflect the kidney downward and expose the quadrate lumbar muscle and major psoas muscle.

After dissecting the circumference of the adrenal gland, grasp the surrounding fat or insert the forceps between the surrounding fat and psoas muscle to lift the gland, and continue detaching the adrenal gland caudally and medially (Fig. 170-5B).

Expose the adrenal vein after careful dissection of the surrounding fat at the lower median site of the adrenal gland (Fig. 170-6). Clip the adrenal vein and cut. Use the 5-mm metal clip or non-absorbable polymer clip and put two clips on the proximal and one clip on the distal site.

Dissect the adrenal gland from the posterior surface of the pancreas at the final step of surgery. Push the upper pole of the kidney downward and reflect the adrenal gland laterally by grasping the surrounding fat, and then extend the dissection between the adrenal gland and pancreas until the superior adrenal vein is exposed (Fig. 170-7). Put the freed adrenal gland en bloc with the surrounding fat into the entrapment sac and retrieve it from the abdominal cavity through the small skin incision for the first trocar. Extend the trocar wound if necessary. Tissue morcellation for large tumors is not recommended because of the possibility of malignancy. Re-insufflate the peritoneal space by carbon dioxide gas with a low pressure of 5 to 6 mmHg and confirm complete hemostasis. Remove the trocars under laparoscopic observation. If there are some hemorrhages from the trocar ports, stop the bleeding by electrocautery. Insert a drain tube via the 5-mm trocar port (trocar D) for one night. Close the peritoneal membrane and fascia at the first trocar port with 2-0 absorbable sutures. Wash and close the 5-mm trocar ports in the usual fashion.

When the incision of the peritoneum, fusion fascia, and renal fascia is fully extended upward along the outer border of the spleen until the greater curvature of the stomach can be seen, the spleen is displaced in the medial direction by its own weight to provide a clear visual field. Key points to this surgical technique are to dislocate the spleen medially, to expose the diaphragm first, and to start gradually dissecting the adrenal gland from an easy site.

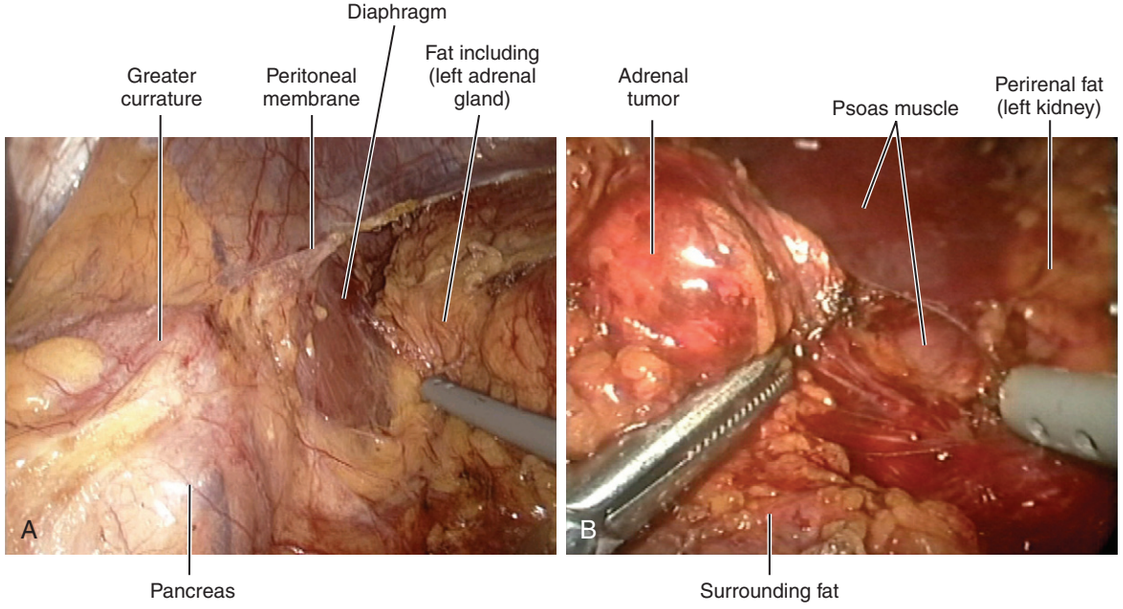

FIGURE 170-5. A, Adrenal gland dissection (1), expose diaphragm. **B,** Adrenal gland dissection (2), between adrenal and psoas muscle.

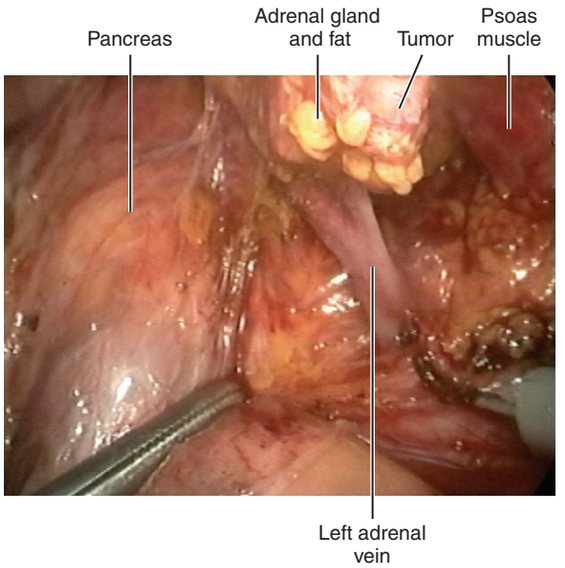

FIGURE 170-6. Dissect and transect adrenal vein.

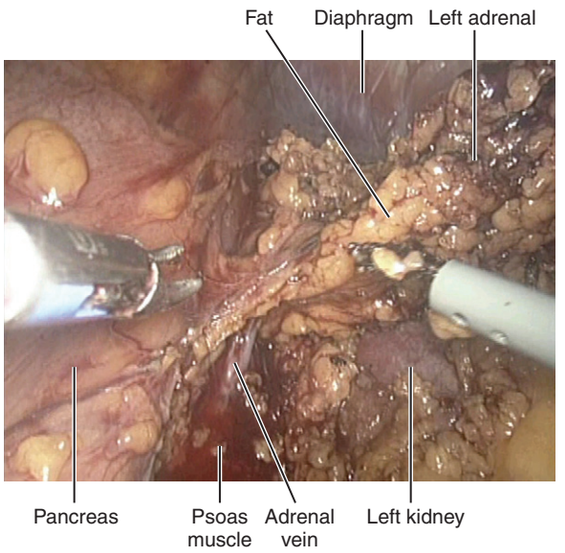

FIGURE 170-7. Dissection between adrenal and pancreas.

If the patient is slender and the identification of the renal vein is easy, transection of the adrenal vein at the first step of procedure is occasionally performed. However, first ligation of the adrenal vein causes congestion of the adrenal gland and makes it difficult to perform further pathological examination. Additionally, hypotensive crisis could be triggered just after the first clipping of the adrenal vein in patients with pheochromocytoma. First-step transection of the adrenal vein is not strongly recommended for left adrenalectomy.

Right Adrenal Gland

Patient position and trocar placement are nearly identical with that of the left adrenalectomy. Place the patient in the left semi-lateral position. Make an approximately 2-cm skin incision on the midclavicular line slightly below the costal arch to place the first 10- or 12-mm blunt-tip trocar (open method). Place an additional three 5-mm trocars along the costal arch under laparoscopic monitoring.

The surgeon stands on the opposite side of the pathology and uses two trocars (A and B in Fig. 170-8). After completing the trocar placement, the insufflation pressure should be lowered to 8 to 12 mmHg during the procedure. The 10-mm laparoscope is inserted via trocar (A in Fig. 170-8). The surgeon holds in the right hand a 5-mm cutting and coagulating device that is inserted through trocar B, and in the left hand, a 5-mm forceps that is inserted through trocar C. The assistant inserts a snake-head retractor through trocar 4 and elevates the liver or reflects the upper pole of the kidney downwardly. Occasionally, the surgeon stands on the right side of the patient and uses two trocars (D and A). In that case, a laparoscope is inserted through trocar C and assistant insert a retractor through trocar B.

Lift the liver by using a 5-mm snake retractor. Incise the hepatocolic ligament first and then cut the peritoneal membrane vertically along with the vena cava (Fig. 170-9). If the adrenal tumor is small (<4 to 5 cm in size), this cut line is adequate for adrenalectomy. If the tumor is large (>5 to 6 cm in size), extend the incision of the hepatocolic ligament along the liver from the lateral to upper surfaces. Expose the diaphragm at the lateral border of the liver and detach the liver along the diaphragm. Incise the hepatic triangular ligament to allow the right lobe of the liver to fall away in the medial direction. This will allow medial mobilization of the liver by pressure to a position near the inferior vena cava, thereby providing a wide visual field.

The diaphragm is an important initial landmark for dissecting the adrenal gland (Fig. 170-10A). After opening the

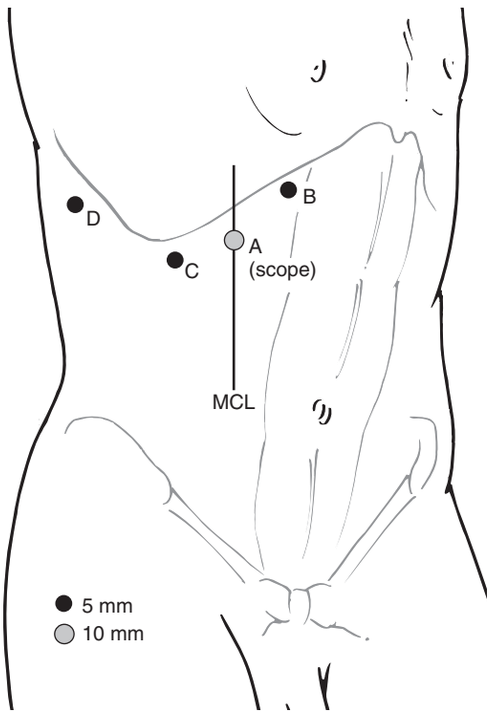

FIGURE 170-8. Trocars placement.

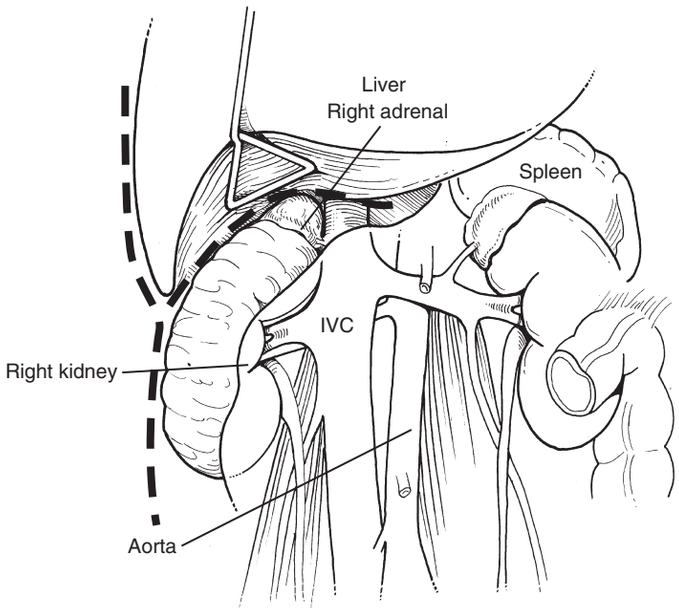

FIGURE 170-9. Cut line of peritoneum. *(From Bishoff JT, Kavoussi LR. [2007]. Atlas of laparoscopic urologic surgery. Philadelphia: Elsevier.)*

hepatocolic ligament and the peritoneal membrane vertically along with the vena cava, dissect the fat surrounding the adrenal gland on the superior and lateral borders of the gland along the diaphragm. If the upper pole of the adrenal gland is impacted in, or strongly adherent to, the inferior surface of the liver, do not try to dissect it. Instead, detach the lateral border of the adrenal gland and leave dissection of the upper pole until the last step.

Incise the peritoneal membrane between the adrenal gland and kidney (Fig. 170-10B). Then separate the upper pole of the kidney from the adrenal gland.

Cut the inferior and posterior adrenal vessels between the adrenal gland and the upper pole of the kidney by using electrocautery or an ultrasonic device. Push down the kidney and expose the quadrate lumbar muscle and major psoas muscle (Fig. 170-11). After dissecting the circumference of the adrenal gland, push down the kidney and grasp the surrounding fat of the adrenal gland or insert the forceps between the surrounding fat and psoas muscle to lift the gland. Detach the adrenal gland from the psoas muscle caudally and medially.

With the left hand, the surgeon lifts the adrenal gland and reflects the kidney downward with the help of the assistant. Carefully dissect the inferior vena cava and then expose the adrenal vein at the level of the short hepatic vein (Fig. 170-12). Clip the adrenal vein using three metal clips (two clips on the proximal site, and one clip on the distal), and cut. Occasionally, a non-absorbable polymer clip is not suitable because the length of the right adrenal vein directly draining into the vena cava is too short. During the clipping, do not strongly retract the gland laterally to avoid tearing the adrenal vein.

After clipping the adrenal vein, dissect the adrenal gland in the cranial direction along the inferior vena cava to expose and treat the superior adrenal vein draining into the inferior phrenic vein. After treating the superior adrenal vein, dissect the upper pole of the adrenal gland from the psoas muscle and the liver bed (Fig. 170-13). If the upper pole of the normal adrenal gland is impacted in, or strongly adherent to, the inferior surface of the liver, a small part of normal adrenal gland could be separated from the adrenal gland by using a vessel sealing device or bipolar electrocautery. If injury occurs to the liver bed, stop the bleeding by using an argon beam coagulator or a bipolar coagulating device.

It is sometimes very easy to identify the vena cava in a slender patient. In that case, expose the vena cava first, and divide the fat including the inferior and posterior adrenal

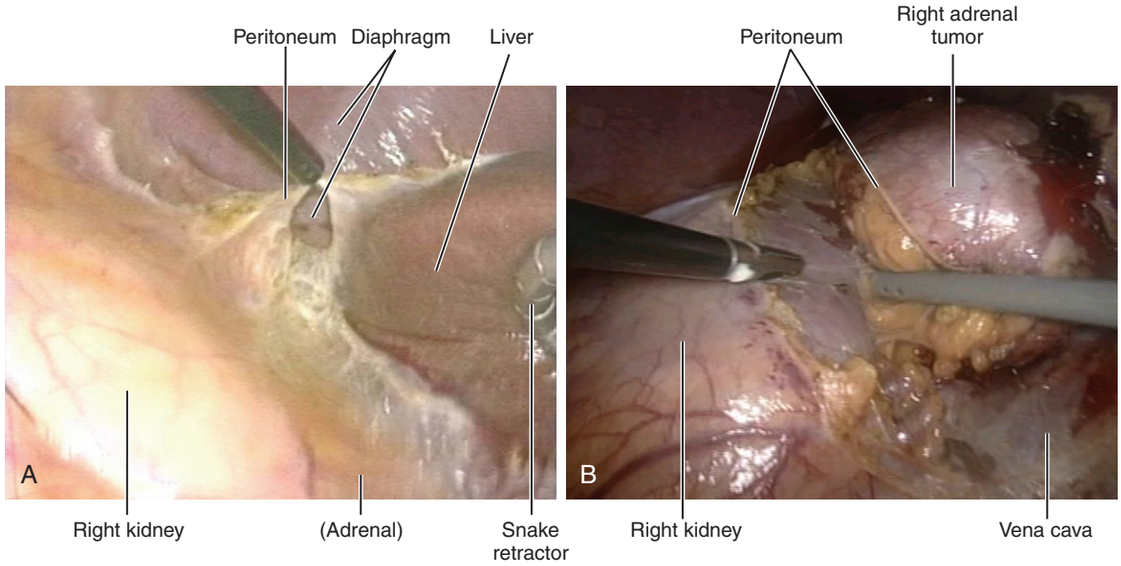

FIGURE 170-10. A, Dissection of adrenal gland (1), expose diaphragm. **B,** Dissection of adrenal gland (2), dissect between adrenal and kidney.

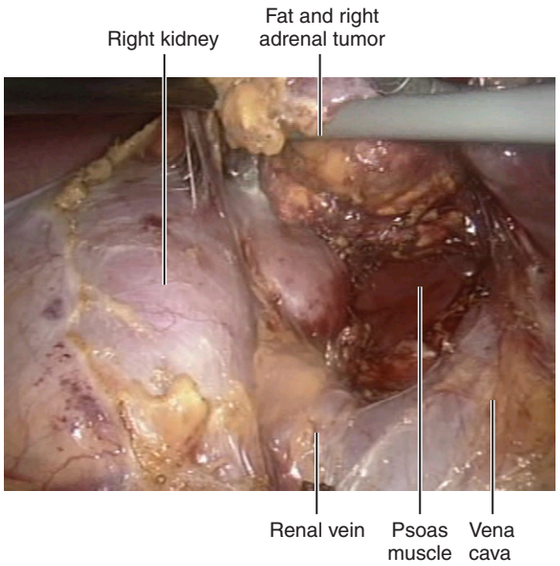

FIGURE 170-11. Expose psoas muscle and vena cava.

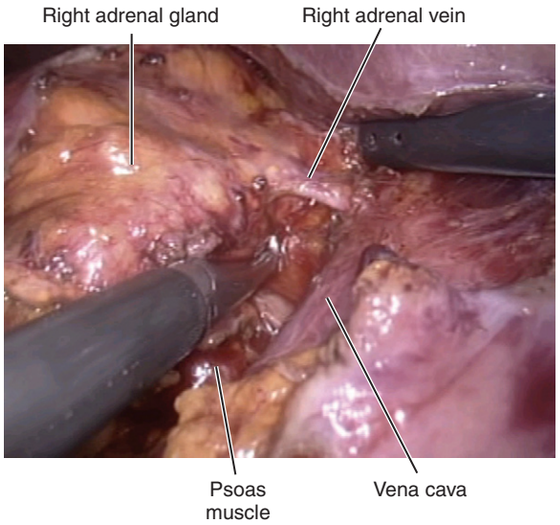

FIGURE 170-12. Expose and cut right adrenal vein.

vessels between the adrenal gland and upper pole of the kidney. After decreasing the blood flow to the adrenal gland by cutting the inferior, posterior, and middle adrenal arteries, clip and cut the adrenal vein. Then, dissect the adrenal gland upwardly. Landmarks for the procedure are the quadrate lumbar muscle, psoas muscle, vena cava, and diaphragm.

EXTRAPERITONEAL APPROACH TO THE ADRENAL GLAND

Retroperitoneoscopic adrenalectomy is performed with the patient in the full lateral position. Changing the position is necessary for simultaneous bilateral adrenalectomy. Also, the working space is smaller than with the transperitoneal approach. Therefore, large tumors (more than 5 to 6 cm)

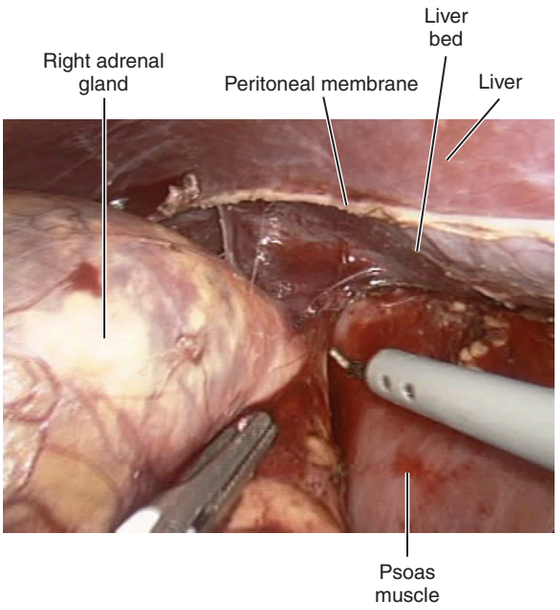

FIGURE 170-13. Dissect between adrenal and liver, and freed adrenal gland.

and symptomatic pheochromocytoma seem to be unsuitable for the lateral retroperitoneoscopic approach.

Taking such factors into consideration, retroperitoneoscopic adrenalectomy should be indicated for unilateral and relatively small (<4 to 5 cm in diameter) adrenal tumors, excluding symptomatic pheochromocytoma. It is also better to avoid the procedure in obese patients or patients with Cushing's syndrome until the surgeon has sufficient experience of laparoscopic adrenalectomy.

Left Adrenal Gland

Place the patient in the full lateral position (Fig. 170-14A). Extend the tumor side slightly so that the space between the costal margin and the iliac crest is exposed. Hyperextension is not necessary because carbon dioxide gas insufflation elevate the abdominal wall. The surgeon stands on the backside of the patient and uses two trocars and assistant stand on the opposite the pathology and handle a laparoscope and a forceps.

Make a 2-cm skin incision below the costal arch on mid axillary line and dilate the posterior pararenal space by the index finger. Use an index finger to penetrate the transverse muscle and enter the retroperitoneal cavity. The fingertip can easily detect the point of entry into the cavity. By this technique, a small hole that tightly fixes the balloon trocar can be made and the subcutaneous emphysema is prevented. Expand the pararenal space using a balloon dilator just outside the fatty tissue in the pararenal space (sometimes called as a flank pad). Insert a 5-mm trocar blindly with finger guide technique just below the costal margin on posterior axillary line (at point B in Fig. 170-14B). Next, insert a blunt-tip trocar via the skin incision (at point A of Fig. 170-14B) and insufflate carbon dioxide gas with a pressure of 14 mmHg. After dissecting the peritoneal membrane medially by a forceps inserted through the trocar B, insert a 5-mm trocar on anterior axillary line under the

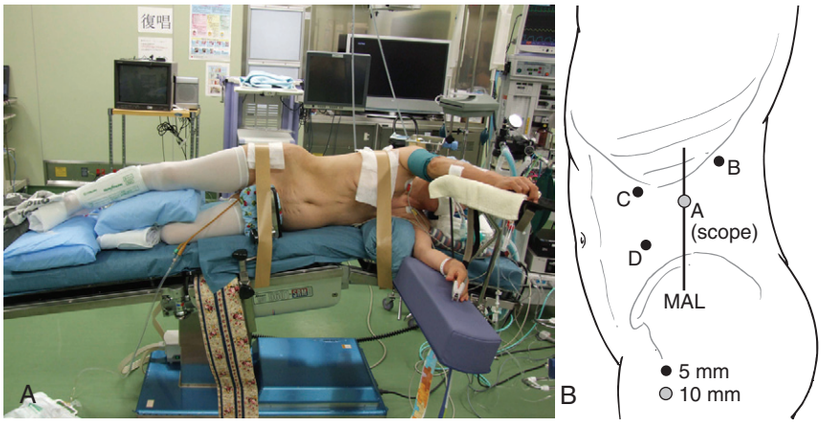

FIGURE 170-14. A, Patient position. **B,** Trocars placement.

endoscopic observation (at point C of Fig. 170-14). Insert an additional 5-mm trocar above the iliac crest on anterior axillary line if necessary (at point D in Fig. 170-14B).

After completing the trocar placement, the insufflation pressure should be lowered to 8 to 12 mmHg during the procedure. The 10-mm laparoscope is inserted via trocar A of Fig. 170-14B. The surgeon holds a 5-mm coagulating and cutting device inserted through the trocar B in the right hand, and a 5-mm forceps inserted through trocar C in the left hand. The assistant holds a laparoscope and inserts a 5-mm forceps through trocar D if necessary.

Since the retroperitoneal space is fully occupied by the kidney, adrenal gland, and fatty tissue, how to make the wide space in the retroperitoneal cavity is an important point (Fig. 170-15). The pararenal space is expanded using a balloon dilator just outside the flank pad. The posterior pararenal space is gradually dilated by balloon, so the risk of vascular or organ injury is low. It is also possible to get a well-lighted and clear visual field because the balloon squashes the fatty tissue and thin connective tissue. Exfoliation of the peritoneal membrane to median side is necessary when insert the third trocar (see point C of Fig. 170-14B) without injury of the peritoneum. Reflect the abundant flank pad downwardly. Renal fascia conjoined with lateroconal fascia is clearly exposed after removing the flank pad.

Incise the renal fascia conjoined with lateroconal fascia (Fig. 170-16). The incision should be made upwardly to near the diaphragm to make a wide opening of renal fascia. Then expose the perirenal fat, including the kidney and adrenal gland. Renal fascia should also be incised along with the transverse muscle to prevent the opening of the peritoneal membrane. Once the peritoneal membrane is penetrated, the window should be opened wide. If the window is pinhole size, the direction flow of the carbon dioxide gas goes one way, from the retroperitoneal space to the peritoneal cavity. After repeating gas insufflation and deflation, the gas vigorously flows into the peritoneal cavity, and the peritoneal membrane expands more and more so that the working space becomes extremely narrow.

If the procedure is performed in accordance with the following steps, the dissection of the adrenal gland without a laparoscopic ultrasound scanner is not difficult. First, create

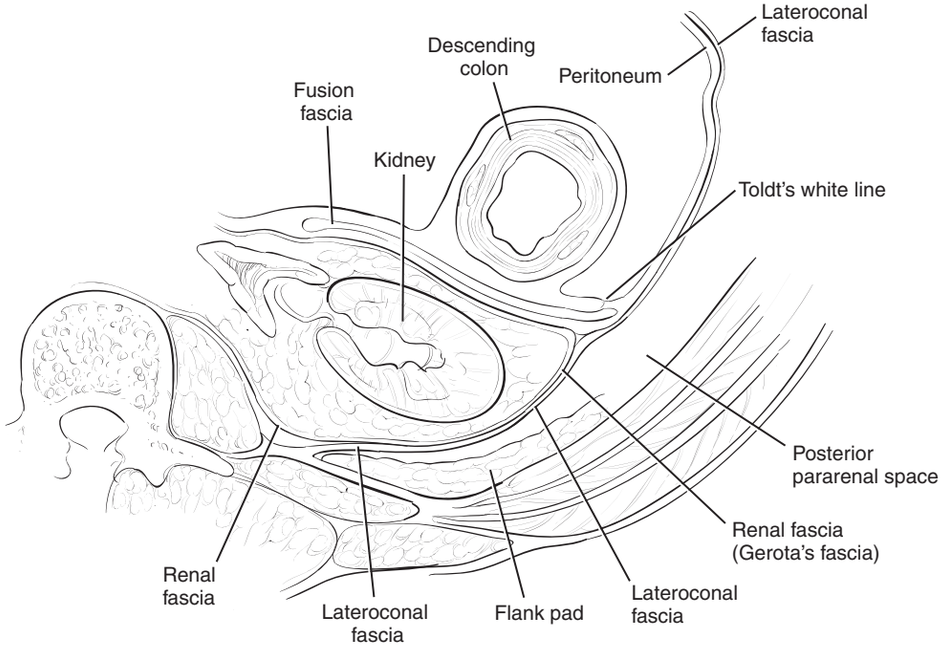

FIGURE 170-15. Make working space in retroperitoneum.

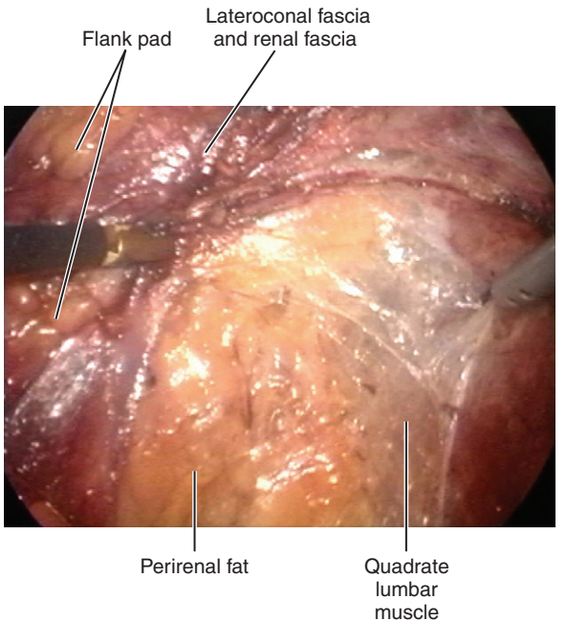

FIGURE 170-16. Open renal fascia.

a large retroperitoneal space. Second, open wide the renal fascia. Third, perform en bloc dissection together with the adrenal gland, upper pole of the kidney, and perirenal fat (do not attempt to first directly locate the adrenal gland). The perirenal fat including the adrenal gland and the kidney should be dissected from the transverse muscle (lateral side), the diaphragm (upper side), the quadrate lumbar muscle and psoas muscle (posterior side), and the pancreas (left) or the liver (right) just inside the renal fascia. After these steps, the perirenal fat floats upward in bold relief against the surrounding tissues, looking somewhat oval shaped, or like a snowman. Next, divide the fatty tissue between the adrenal gland and the upper pole of the kidney (Fig. 170-17).

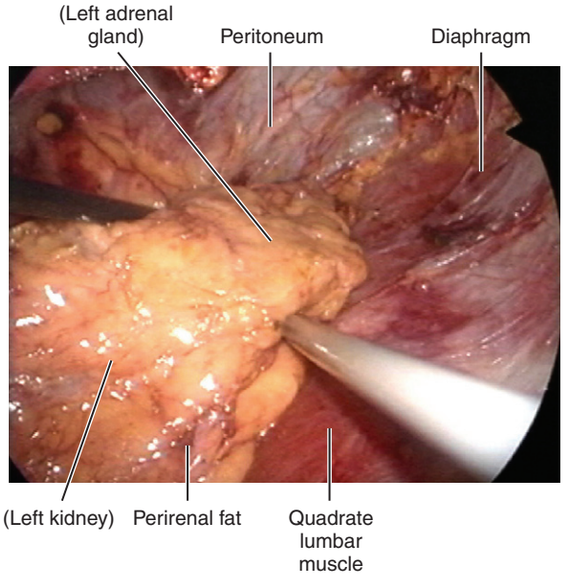

FIGURE 170-17. En bloc dissection of upper pole of kidney and adrenal gland.

At the separation of perirenal fat from the diaphragm in upper site of the adrenal gland, the superior adrenal vessels are usually exposed. Clip and transect the superior adrenal vessels carefully (Fig. 170-18). The superior adrenal vessels are sometimes become thick in patients with a large adrenal tumor and the preparation should be done very carefully to avoid bleeding. In some patients having spars perirenal fat, the adrenal gland and the surface of upper pole of the kidney can be identified at this step and the following procedure become easy.

After en bloc dissection, divide the perirenal fat between the adrenal gland and upper pole of the kidney (Fig. 170-19). Then, expose the kidney and proceed with the dissection

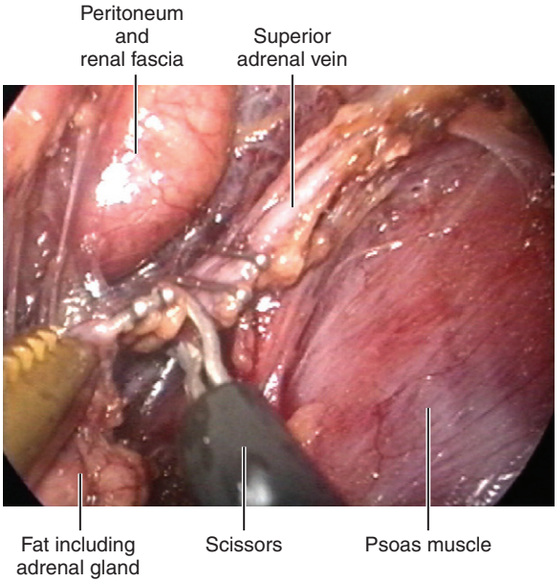

FIGURE 170-18. Cut superior adrenal vein.

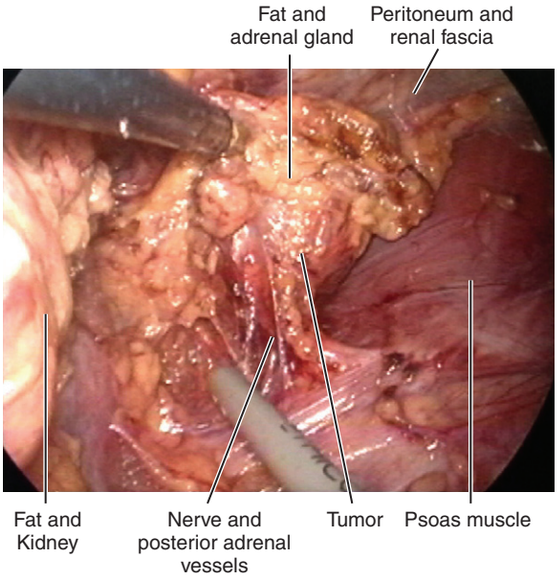

FIGURE 170-19. Dissect between kidney and adrenal.

along with the surface of the kidney. Reflect the kidney downwardly, and lift the adrenal gland by grasping the surrounding fat. Transect the inferior and posterior adrenal vessels that are located at the lower median site of the adrenal gland by using a coagulating and cutting device.

After transection of the inferior and posterior adrenal vessels, carefully dissect the fat around the left adrenal vein at the lower median site of the adrenal gland. Expose the adrenal vein, place three clips, and transect (Fig. 170-20).

Finally, separate the remaining inner part of the adrenal gland from the posterior surface of the pancreas (Fig. 170-21). In some cases, there is a thickened communicated vein (from adrenal vein to inferior phrenic vein) in this part. Put the freed adrenal gland en bloc with the surrounding fat into the entrapment sac and retrieve it from the retroperitoneal cavity through the small skin incision for the first trocar. Re-insufflate the retroperitoneal space by carbon dioxide gas with a low pressure of 5 to 6 mmHg and confirm complete hemostasis.

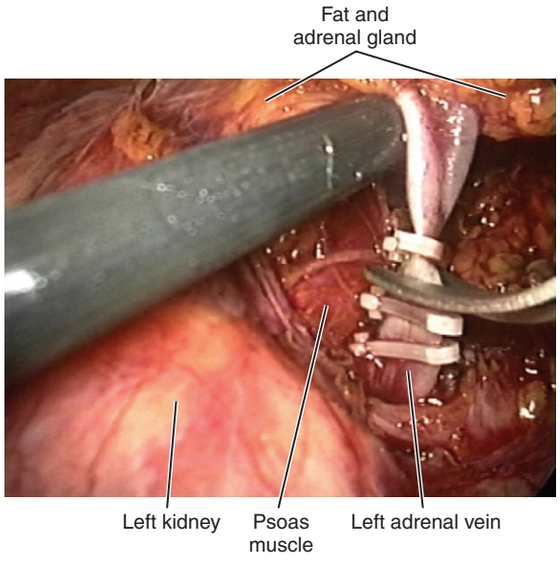

FIGURE 170-20. Cut left adrenal vein.

Right Adrenal Gland

Patient position, trocar placement, creation of the working space, the opening of the renal fascia, en bloc dissection of the adrenal gland together with the upper pole of the kidney and perirenal fat, and dissection between the kidney and adrenal gland are virtually the same as with the left adrenalectomy.

Divide the perirenal fat between the adrenal gland and upper pole of the kidney (Fig. 170-22). Dissect the fatty tissue along the surface of the kidney. Reflect the kidney downwardly and lift the adrenal gland by grasping the surrounding fat. Transect the inferior and posterior adrenal vessels that are located at the lower median site of the adrenal gland. After exposing the psoas muscle, continue the dissection medially to identify the vena cava.

Dissect the fibrous tissue along the right side of the vena cava (Fig. 170-23). Then, expose and cut the right adrenal vein. The clipping of the right adrenal vein is slightly difficult because it is short and diverges directly from the vena cava. The vena cava and adrenal vein should be carefully and clearly dissected out before transection. Also, lateral retraction of the adrenal gland by grasping the surrounding fat should be gently done to avoid tearing the vena cave at a diverging point of the right adrenal vein.

Separate the remaining inner part of the adrenal gland from the vena cava and liver (Fig. 170-24). In some cases, there is a thickened communicated vein (from the adrenal vein to the inferior phrenic vein) in this area. Carefully transect the superior adrenal vein. If the tumor is large and located at the upper pole of the adrenal gland, the tumor

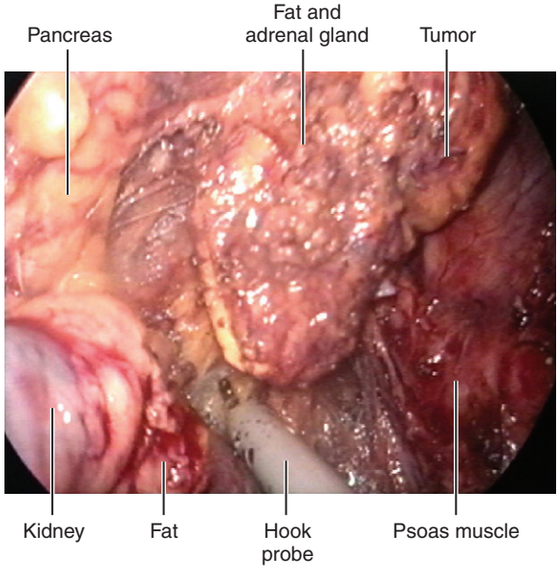

FIGURE 170-21. Dissection between pancreas and adrenal gland.

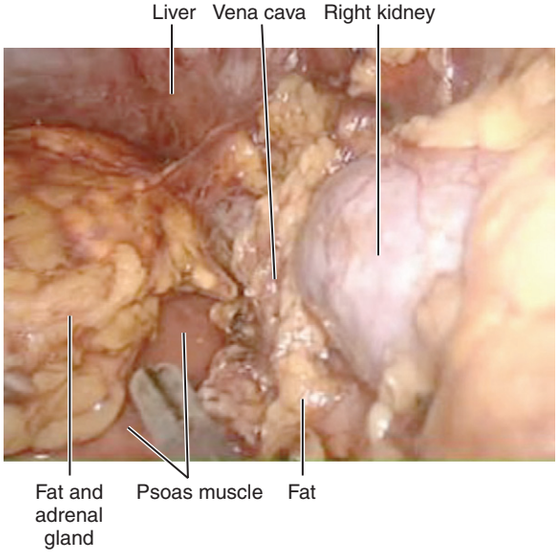

FIGURE 170-22. Dissection between kidney and adrenal gland.

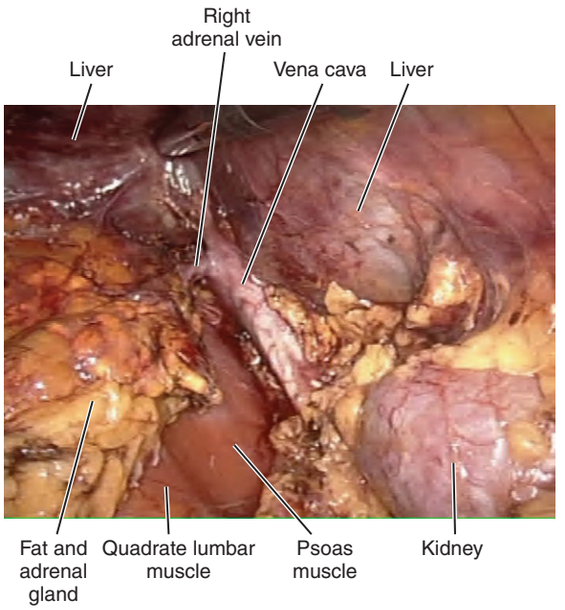

FIGURE 170-23. Cut the right adrenal vein.

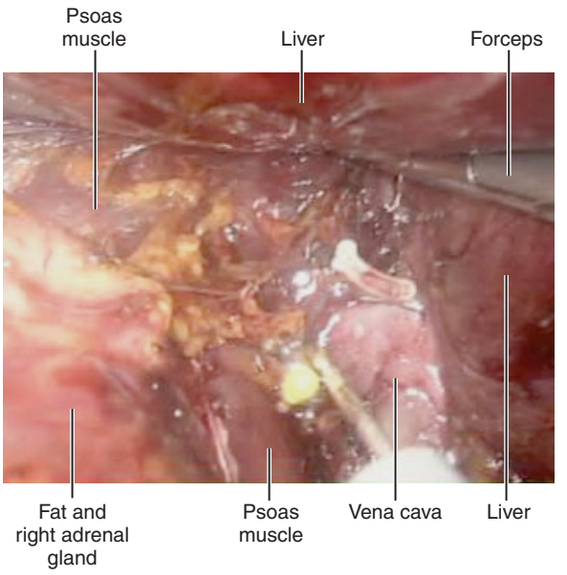

FIGURE 170-24. Dissection among vena cava, liver, and adrenal gland.

adheres to the liver. In this case, lift the liver bed, and reflect the adrenal gland downwardly by grasping the surrounding fat, and then dissect the tumor from the liver bed and psoas muscle. In comparison with the transperitoneal approach, the dissection of the upper pole of the adrenal gland is easier in the retroperitoneal approach. Finally, the adrenal tumor is completely freed together with the normal adrenal gland and surrounding fat.

The most important point of retroperitoneoscopic adrenalectomy is en bloc dissection of the perirenal fat, including the upper pole of the kidney and adrenal gland against the surrounding muscles (transverse muscle, quadrate lumbar muscle, psoas muscle, and diaphragm) just inside the Gerota's fascia. Do not attempt to directly find out the adrenal gland at the first step of the operation. Transection of the adrenal vein at the first step of procedure is not strongly recommended in retroperitoneoscopic adrenalectomy because identification of the renal vein, vena cava, and adrenal vein in the initial phase of the surgery is difficult and dangerous. As already mentioned, first ligation of the adrenal vein causes congestion of the adrenal gland and makes it difficult to perform further pathological examination.

Retroperitoneoscopic lateral approach promises to be a safer and more minimally invasive treatment for patients with unilateral, small adrenal tumor because it avoids intestinal injuries and/or intestinal adhesions. In all cases, careful patient selection and correct choice of surgical approach according to tumor size, patient's condition, and the surgeon's skill are the most important points in order to avoid any complications in laparoscopic adrenalectomy.

Commentary by

DUANE BALDWIN

TRANSPERITONEAL APPROACH TO THE ADRENAL GLAND

On the right side the position of the colon is variable, but sometimes the right adrenal gland can be removed without extensive dissection or mobilization of the duodenum or colon.

Although the goal is to have minimal manipulation of the adrenal gland, gentle retraction of the adrenal gland may sometimes be required. It is best not to grab the adrenal itself, as it is fragile and prone to tearing, which can result in bleeding that in turn can obscure visualization. This is most pronounced with pheochromocytoma and adrenocortical carcinoma. Use of a suction device or closed grasper to simply retract the adrenal is less likely to tear the adrenal and provides adequate exposure. The adrenal venules coalescing into the right adrenal vein are very thin and excessive traction can result in devastating bleeding.

Certainly, a 5-mm clip, harmonic scalpel, or bipolar sealing device alone has been successfully used to control the adrenal vein. In my experience, some right adrenal veins are quite large and I think that the 10-mm hem-o-lok clips provide a little extra margin of safety when securing the right adrenal vein. Often there is not enough space for easy application of a large automatic stapling device in the small spaces particularly around the right adrenal gland. It is important for the surgeon to proceed cautiously during this step and try to get room for at least two clips on the vena cava or renal vein side of the adrenal vein and one clip on the adrenal side of the adrenal vein.

I start with the patient in a 45-degree lateral decubitus position with an axillary roll, careful padding of all pressure points, with the lower arm on a straight arm-board and the upper arm on a thoracotomy arm holder at a 90-degree angle. After securing

the patient to the bed with 3-inch cloth tape, I rotate the patient as close to supine as possible during the Veress insufflation and then rotate into a similar 70-degree lateral decubitus position following port placement. I add slight flexion to the table to open up the space between the costal margin and the hip but do not elevate the kidney rest. I routinely use a pneumoperitoneum of 15 mmHg for adults for the duration of the case. In children I use 12 mmHg. I believe that the 30-degree, 10-mm rigid laparoscope works well, particularly in obese patients, and can allow the surgeon to see over the fatty bowel and mesentery. Although this procedure can certainly be performed with only 5-mm ports and has even been described with needlescopic and LESS instrumentation, I routinely use two or three 12-mm ports to give me a little flexibility with instrumentation. I find that the 10-mm Ligasure is particularly effective in separating the adrenal gland from the kidney in obese patients. I think it is important to have a low threshold for the placement of additional ports when they might assist in retraction and exposure and agree with the authors that there should be a low threshold for conversion in the face of failure to progress or complications.

LEFT ADRENAL GLAND

A key step in the procedure of the left side is complete mobilization of the spleen in order to obtain exposure to the adrenal gland. This can be particularly difficult in morbidly obese patients with an enlarged spleen. There are certainly many ways to approach the surgical steps and the surgeon should be flexible in his approach as unique anatomic challenges are encountered.

On the left side, I usually mobilize the colon medially enough to identify the renal and gonadal veins. Identification of the location of the gonadal vein joining the renal vein helps the surgeon predict the location of the left adrenal vein. In contrast to the authors, I usually begin the adrenal dissection with transection of the left main adrenal vein. I think that ligation of the adrenal vein first ameliorates the severe episodes of hypertension that can occur during manipulation of the tumor in a pheochromocytoma. In an appropriately blocked patient, there is little risk for hypotension, and if it occurs, the skilled anesthesiologist with fluids and pressers can control this hypotension. I have not encountered problems due to engorgement of the adrenal gland.

I use a right-angle dissector to come around the adrenal vein and place hem-o-lok clips around the vein and transect it. I then extend the dissection posteriorly to identify the fascia overlying the psoas muscle. This early separation of the adrenal vein allows the surgeon to quickly identify some key boundaries of the dissection including the left renal vein, the Crus of the diaphragm covering the aorta, and posteriorly the psoas muscle and diaphragmatic fascia.

Once these landmarks are identified, I follow the muscular plane cephalad first, separating the adrenal gland from the pancreas. I leave the adrenal attached to the kidney to act as a handle allowing the assistant to retract caudal and lateral on the fat overlying the upper pole of the kidney, which provides separation of the plane between the adrenal and the pancreas without putting direct pressure on the adrenal gland. In thin patients the upper surface of the adrenal is easy to identify and this dissection can be performed easily with a hook electrode. In morbidly obese patients, a thick layer of fat may cover the adrenal gland. In these patients the plane may be difficult to identify. It is important not to deviate too high to avoid injury to the splenic vessels. One option in this difficult situation is to use a bipolar sealing device to free up the cephalad surface of the adrenal gland. This dissection is extended laterally until the cephalad surface of the adrenal gland is free. The avascular posterior surface of the adrenal is also mobilized with a hook electrode. If bleeding in the plane posterior to the adrenal gland is encountered, the surgeon may be either too shallow (getting into the adrenal) or too deep (dissection below the fascia). Finally, the adrenal is separated from the hilar vessels and the kidney. This is also a difficult step particularly in older male patients with significant retroperitoneal fat. Knowledge of the relationship of the adrenal gland to the renal vessels based on preoperative imaging may help the surgeon to safely dissect in this area. The branches from the renal artery to the adrenal gland are ligated using a bipolar sealing device. I do not routinely morcellate adrenal tumors but prefer to remove them intact. No drain is left unless there is a suspicion for pancreatic injury.

RIGHT ADRENAL GLAND

In right-sided tumors, I start by mobilizing the liver at the junction with the vena cava. I usually start by opening the peritoneal covering over the inferior vena cava at the point immediately below the liver. This is a consistent landmark even in obese patients. Next, the dissection is extended laterally between the liver and the adrenal gland. I also take down the triangular ligament on the lateral surface of the liver. I usually dissect the liver away from the adrenal in a cephalad direction until I have freed the liver up enough to clearly define the upper surface of the adrenal gland. In obese patients, it may be difficult to clearly see the adrenal surface since it may be buried beneath a thick layer of adipose tissue.

After this mobilization of the liver is completed I suspend the liver on the triangular "snake" liver retractor inserted through a subxiphoid port placed just to the left of midline to avoid interference with the other ports. If this dissection has been performed completely the liver can be lifted anterior, medial, and cephalad and remain in the same position for the majority of the subsequent dissection, making this easier to perform.

After freeing and elevating the liver, I next extend the peritoneal opening on the vena cava in a caudal direction down to the renal vein. Working in a plane between the adrenal gland and the vena cava, I follow the vena cava posteriorly until I encounter the edge of the adrenal or the muscle is encountered. This dissection is done slowly and carefully as small arterial branches to the adrenal and small accessory adrenal veins may be encountered in this region. I usually ligate these with a 5-mm bipolar sealing device. Once this area has been opened there is room for the assistant to bring in a tool from a lateral 5-mm port that can retract

Continued

the kidney and adrenal lateral and caudal. This provides the exposure to allow the dissection to proceed cephalad until the adrenal vein is encountered. Some gentle tension in the lateral and caudal direction can assist in defining the location of the adrenal vein and also make the dissection easier. It also can stretch the vein slightly so that there is more room for clips. The position of the adrenal vein is usually very high at the upper apex of the triangle formed by the adrenal gland and often enters the posterior vena cava. I like to free up the tissues inferior to the vein, and then anterior and cephalad to the vein. It is important to define the upper and lower edges of the vein to avoid injury.

Next, I use a 10-mm right-angle dissector to dissect circumferentially around the adrenal vein and try to create adequate space for application of two 10-mm hem-o-lok clips on the cava side and one 10-mm hem-o-lok clip on the adrenal side. It is also important to have a 1- to 2-mm cuff of vein on the vena cava side after clipping. If the adrenal vein is very short a second titanium clip can be applied on the cava itself. Once the adrenal vein is transected the assistant can retract on the kidney pulling in a caudal direction to facilitate the final separation of the adrenal from the liver. The avascular posterior surface and the cephalad surface are dissected with a hook electrode or bipolar sealing device leaving only the inferior surface and the attachments to the kidney remaining.

The final dissection is the plane between the renal vessels and the most inferior surface of the adrenal gland. There is usually at least one arterial supply coming off of the renal artery and sometimes multiple arteries and small veins in this area. Review of preoperative cross sectional imaging will help to identify the caudal extent of the adrenal gland in relation to the renal hilar vessels. If the caudal surface of the adrenal gland is difficult to identify due to obesity, the surgeon can dissect down on the upper pole of the kidney and trace the medial edge of the kidney caudally until the renal hilar vessels are encountered. The surgeon can then use the bipolar sealing device to proceed from the vena cava toward the kidney. Finally the lateral attachments are freed and the gland placed in a sac for intact extraction.

EXTRAPERITONEAL APPROACH

This approach is more difficult in obese patients, and it should be kept in mind that this includes a high percentage of patients in Western countries. For this reason, the retroperitoneal approach for adrenal surgery appears to be more commonly employed in regions where patients have normal or low body mass indexes (BMIs). Surgeons not familiar with this approach, who are operating on high BMI patients, or with large adrenal tumors, will likely find the transperitoneal approach more reproducible. Comparative studies between transperitoneal and retroperitoneal adrenalectomy have shown little difference in outcomes and complications between approaches.

Index

Note: Page numbers in italics indicate boxes, figures and tables.

A
Abdominal colposacropexy 227
Acquired meatal stenosis 95
Active drains
  see drains/drainage tubes
Adenocarcinomas 473, 683
Adrenal gland
  anatomy
    embryology and vascular system 1097, 1098f, 1101
    peritoneal membrane and fascias 1111
    relation to other organs 1098–1100, 1099f, 1101
  diagnostics and patient preparation 1100–1101
  laparoscopic approaches
    commentary on left side procedure 1121
    commentary on right side procedure 1121–1122
    extraperitoneal approach 1116–1120, 1122
    extraperitoneal approach - left gland 1116–1119
    extraperitoneal approach - right gland 1119–1120
    transperitoneal approach 1111–1116, 1120–1121
    transperitoneal approach - left gland 1112–1114
    transperitoneal approach - right gland 1114–1116
  open surgery approaches
    about the procedure 1103
    complications, postoperative 1110t
    flank approach 1106–1107
    partial adrenalectomy 1110
    posterior approach 1103–1104
    posterior approach, modified 1104–1106, 1106f
    thoracoabdominal approach 1108
    transabdominal approach 1108–1109
Algorithms, hypospadias repair 90f, 97f
Allografts 187–188
American College of Chest Physicians 4
American Society of Anesthesiology 3–4, 4t
American Urological Association (AUA) 4, 7t, 12
Analgesic medications, postoperative 326
Anastomotic urethroplasty
  bulbar urethra reconstruction 238, 265, 274b
  membranous urethra reconstruction 275
  penile urethra reconstruction 247, 263b
Anatrophic nephrolithotomy
  about patient selection 1043
  incision and renal dissection 1043
  intraoperative imaging and stone removal 1044
  postoperative care 1045
  preoperative preparation and positioning 1043
  renal closure and hypothermia termination 1044, 1045
Androgen supplementation/replacement 88, 109, 326
Anesthesia
  fluid and electrolyte replacement 8
  general anesthesia 8
  for laparoscopic surgery 18
  local anesthesia 8
Anterior colporrhaphy 221–223
Antibiotics
  postoperative infections 12
  perioperative uses 6–8
  preoperative uses 415
  procedures and duration of therapy 7t
Aorta, repairs 74
Appendicovesicostomy
  implantation into the bladder 670–671, 671f
  incision and surgical procedure 669, 670f
  patient selection and preparation 669
  postoperative problems 672
  stomal maturation 671
  Yang-Monti channel 671, 671f, 672f
Arterial injury repairs
  aortic laceration 74
  arterial resection 75–76
  external iliac artery 74–75
  internal iliac artery 74
  renal artery 75
Arterial resection 75–76
Arterial revascularization, penile
  diagnosis and technique selection 173, 176b
  epigastric artery, exposing and harvesting 173–174
  epigastric artery-dorsal artery anastomosis 174–175, 175f
  epigastric artery-dorsal vein anastomosis 175, 176f
  exposing the penile vasculature 174
  instruments for 173
  postoperative problems 176
Artificial erection 88
Artificial urinary sphincter (AUS)
  bulbar urethral cuff placement 571
  incision and surgical procedure 572–573
  instruments for 571–572
  patient positioning 572
  postoperative problems 575
  preoperative evaluation 571
  pressure-regulating balloon placement 574
  scrotal pump placement 574
Autoaugmentation, bladder
  added commentary 706b
  laparoscopic technique 706
  postoperative care 706
  surgical technique 705
Autologous pubovaginal sling
  assessment for 551
  development of the technique 551
  patient positioning 551
  postoperative complications 551, 553–554
  surgical procedure 551–552
  technique alternatives 552–553
Automated suturing devices 22
Avulsion injuries 187

B
Balanitis xerotica obliterans 142, 241, 245
Balloon dissector 25
Barotrauma 25
Benign prostatic hyperplasia (BHP)
  laser phototherapy
    added commentary 471b
    choosing office-based vs. operating room 463
    high-energy photo vaporization 463–464
    holmium laser ablation (hoLAP) 464–466
    holmium laser enucleation (HoLEP) 466–470
    interstitial coagulation 470
  retropubic prostatectomy
    added commentary 490b

Benign prostatic hyperplasia *(Continued)*
patient positioning 483
postoperative management 487, 490b
preoperative preparation 483
surgical procedure 483–487
ultrasound and 490b
suprapubic prostatectomy
added commentary 481b
anesthesia 473
antibiotic prophylaxis 473
clinical efficacy 481b
diagnosis and technique selection 473
instruments for 473
intraoperative hemostatic procedures 479
postoperative care 479–480
postoperative problems 480
preoperative considerations 473
surgical procedure 473–480
transurethral incision of the prostrate (TUIP)
anesthesia 459
catheterization 461
cystoscopy examination 462
diagnosis and technique selection 459
laparoscopic surgery and 462, 462b
patient selection 462
postoperative complications 461
preoperative preparation 459
surgical technique 459–460
transurethral resection of the prostrate (TURP)
anesthesia 451
clinical efficacy 456
diagnosis and technique selection 451
patient positioning 451
postoperative care 456
preoperative preparation 451
surgical complications 455–456, 457
surgical technique 451–455, 457b
Benign tumors 351–352
ß-blockers 4, 739
Biopsy
kidneys 949–950
testis 293–298
Bite injuries 187
Bladder, augmentation
autoaugmentation
added commentary 706b
laparoscopic technique 706
postoperative care 706
surgical procedure 705
colocystoplasty
about the technique 697
added commentary 700b
postoperative considerations 699–700
surgical procedure 697–698
ileocystoplasty
added commentary 696b
patient selection and preparation 693
postoperative care 696
surgical procedure 693, 694f, 695f
ureterocystoplasty
added commentary 703b
patient selection and preparation 701
surgical procedure 701–702, 702f, 703f
Bladder, excision
benign prostatic hyperplasia (BHP)
clinical efficacy 456
diagnosis and technique selection 451
patient positioning 451
postoperative care 456
preoperative preparation 451
surgical complications 455–456, 457
surgical technique 451–455, 457b
Bladder, excision *(Continued)*
catheters and urinary drainage 10–11
cystectomy, laparoscopic
added commentary 548b
evaluation and preoperative preparation 541–542
postoperative care 547–548
surgical procedure 542–547
cystectomy, partial
added commentary 499b
bilateral node dissection 499
diagnosis and technique selection 495, 499
extraperitoneal approach 496
patient positioning 495
postoperative problems 496–497
transperitoneal approach 495–496
cystectomy, radical
added commentary 512b
evaluation and preparation 501–502
instruments and sutures 502
cystectomy, radical (female)
dissection and urethrectomy 510
orthotopic urinary diversion 512
surgical procedure 508–510
vaginal-sparing procedure 510
cystectomy, radical (male)
nerve-sparing modifications 508
orthotopic diversion and anterior dissection 508
postoperative care 508
surgical procedure 502–508
urethrectomy 508
cystolithotomy
antibiotic prophylaxis 537
diagnosis and technique selection 537
surgical procedure 537–539
pelvic lymphadenectomy
approaches to surgery 517
female procedure 522
male procedure 517–520
postoperative problems 522
total pelvic exenteration
evaluation and preoperative preparation 523
female procedure 528–529
male procedure 523–527, 528
postoperative problems 529
transurethral resection of Bladder tumors (TURBT)
added commentary 494b
anesthesia 493
diagnosis and technique selection 493, 494
patient positioning 493
postoperative problems 494
surgical procedure 493
urethrectomy, female
added commentary 516b
diagnosis and technique selection 515
sexual function and 516
surgical complications 515
treatment of distal tumors 515
urethrectomy, male
added commentary 516b
diagnosis and technique selection 513, 516
patient positioning 513
postoperative problems 515
surgical procedure 513–515
vesical diverticulectomy
diagnosis and preoperative preparation 531
laparoscopic technique 536
surgical technique 531–536
Bladder, flap repair
about selection of 731
added commentary 733b
postoperative complications 733
surgical procedure 731–733

Bladder, reconstruction
artificial urinary sphincter (AUS)
bulbar urethral cuff placement 571
incision and surgical procedure 572–573
instruments for 571–572
patient positioning 572
postoperative problems 575
preoperative evaluation 571
pressure-regulating balloon placement 574
scrotal pump placement 574
autologous pubovaginal sling
assessment for 551
development of the technique 551
patient positioning 551
postoperative complications 551, 553–554
surgical procedure 551–552
technique alternatives 552–553
bulking agents for incontinence 567–570
female vesical neck closure
abdominal approach 593–594, 593f, 594f
abdominal approach with urethral inversion 594–595, 595f, 596f
diagnosis and technique selection 593
preoperative preparation 593
urethral approach 595, 596f, 597f
vaginal approach 595–596, 597f, 598f
ileal reservoir (T-pouch)
advantages 655b
considerations for 651
steps in surgical procedure 651–654
sacral nerve modulation
anesthesia 599
development of the technique 599
patient selection 599
responses to nerve stimulation 601t
stage one 599–603
stage two 603
suprapubic midurethral sling
anesthesia 557
diagnosis and technique selection 557
patient positioning 557
surgical procedure 557–560
transobturator midurethral sling
anesthesia 563
closure 566
cystoscopy 564
diagnosis and technique selection 563
incision and dissection 563
needle passes 563–564
passage of sling material 564–566
patient positioning 563
transperitoneal vesicovaginal fistula repair
incision and surgical procedure 589–590, 591f
patient positioning 589
surgical alternative procedure 590
transvaginal repair of vesicovaginal fistula
abdominal approach 579, 580–581, 582f, 583f
diagnosis and timing of procedure 579
flap closure techniques 581–583
instruments for 579
inverted u-incision flap repair 580–581
partial colpocleisis 581
patient positioning 579–580
postoperative care 581
postoperative complications 579
preoperative preparation 579
vaginal approach 579–580, 580f, 581f
transvesical repair of vesicovaginal fistula
diagnosis and timing of procedure 585–587
incision and surgical procedure 585–587
instruments for 585
patient positioning 585
Bladder, reconstruction *(Continued)*
postoperative complications 585
preoperative evaluation 585
see also Continent reconstruction
Bladder stones
see Cystolithotomy
Bladder substitution, ileal orthotopic
about the technique 685, 686–689
contraindications 685t
ileal segment preparation 686–687
patient selection and preparation 685–686
postoperative care 688–689
postoperative complications 689
postoperative outcomes 689
substitute construction 687–688
ureteroileal anastomosis 687
Blood/blood vessels
aorta repairs 74
arterial repairs 75
clipping and stapling 23
laparoscopic surgery injury 27
surgical loss and transfusion 9–10
vascular system, intestines 645
colon, ascending and transverse 648, 648f
colon, descending and sigmoid 648–649, 649f
ileocecal region and appendix 645, 647f
jejunum and ileum 648
rectum 649
vascular system, renal 837–842, 843, 886
venous repairs 909
Bowel/bowels
basic surgical techniques 15
ileocystoplasty 693
laparoscopic procedures and peritonitis 1050
laparoscopic surgery injury 26, 27
large bowel repair 77–78
preoperative cleansing 6
rectal injuries 78–79
small bowel repair 77
stapling instruments
EEA (end-to-end anastomosis) 53, 54
GIA (gastrointestinal anastomosis) 53
TA (thoracoabdominal) 53–54
stapling techniques
development of 53
end-to-end anastomosis 53, 55–57, 58f, 59f, 60f
laparoscopic GIA 53
side-to-side anastomosis 54, 54f, 55f, 56f, 57f
suturing techniques 35–37
see also Urinary and bowel diversion
Bracka Grafts 109, 110–111
Bulbar urethra, reconstruction
anastomotic urethroplasty 265, 274
anatomy and adjacent structures 265, 266f
dorsal graft urethroplasty 270
onlay urethroplasty 274
staged repair 265
ventral graft urethroplasty 265–270, 267f, 268f, 269f, 270f, 271f, 272f, 273f, 274f
Bulbocavernosus muscle and fat pad supplement
added commentary 204b
classical Martius flap 199, 201–202
labial flap 203
in situ Martius flap 202
urethrovaginal fistula repair 199
Bulbospongious muscle flap (Martius flap), vesicovaginal fistula repair 581, 582, 583f
Bulking agents for incontinence 567–570
Buried penis
see Hidden penis
Burn injuries 187
Byars' Flaps 103, 105, 109, 110

C
Cadaveric skin grafts 187–188
Caliceal diverticulectomy 1085–1086
Cardiopulmonary disease, laparoscopy risks 17
Catheters and urinary drainage
  antibiotic prophylaxis 7t
  urethral damage 216b
Caudal blocks 11
Cecal vagina procedure 191–196
Checklists, preoperative 6t
Children
  hypospadias repair 88
  inguinal orchiopexy 327–330
  laparoscopic orchiopexy 339–340
  laparoscopic surgery 24–25, 344
  microvascular orchiopexy 338–339
  testicular torsion, repair 345–346
  use of local anesthesia 42
  vesicoureteral reflux 711
  see also Pediatric surgery
Chronic obstructive pulmonary disease (COPD) 17
Circumcision
  see Penis, circumcision
Clips and staples
  see Surgical staples
Clostridium difficile, postoperative infections 12
Coagulopathy
  hemostasis and hemostatic agents 9, 10t
  postoperative bleeding 11
  surgical blood loss and transfusion 10
Cold knife technique 289, 290
Colocystoplasty
  about the technique 697
  added commentary 700b
  postoperative considerations 699–700
  surgical procedure 697–698
Colon conduits
  sigmoid procedure 633f, 634f, 635f
    diagnosis and technique selection 633
    incision and ureter dissection 633–634
    postoperative complications 636
    preoperative preparation 633
    selection and isolation of bowel 634
    stoma creation and closure 635
    ureteral anastomosis 634–635
  transverse procedure 636f
    diagnosis and technique selection 633
    incision and ureter dissection 635
    postoperative complications 636
    preoperative preparation 633
    selection and isolation of bowel 635–636
    stoma creation and closure 636
    ureteral anastomosis 636
Colostomy
  see Urinary and bowel diversion, fecal diversion
Colpocleisis 227
Colporrhaphy 221–223, 224–226
computer-assisted laparoscopy
  see Da Vinci computer-assisted laparoscopic system
Concealed penis
  see Hidden penis
Congenital meatal stenosis 95, 96b
Continent reconstruction
  about choices and types 645, 646t
  appendicovesicostomy
    implantation into the bladder 670–671, 671f
    incision and surgical procedure 669, 670f
    patient selection and preparation 669
    postoperative problems 672
    stoma placement 671
    surgical alternatives 671
Continent reconstruction *(Continued)*
  blood supply 645
    colon, ascending and transverse 648, 648f
    colon, descending and sigmoid 648–649, 649f
    ileocecal region and appendix 645, 647f
    jejunum and ileum 648
    rectum 649
  ileal reservoir (T-pouch)
    advantages 655b
    considerations 651
    surgical procedure 651–654
  ileocecal reservoir
    added commentary 668b
    choices and patient preference 668
    conduits 667f, 668
    Indiana pouch 661–667, 662f
    in situ tunneled bowel flap tubes 661
    Lockhart gastroileoileal pouch 667
    Mainz pouch 657–658, 658f, 659f, 660f, 661f
    Mainz pouch with appendiceal stoma 661, 668
    postoperative problems 668
  ureterosigmoidostomy
    added commentary 683b
    background 673
    closed extracolonic technique 673–675, 678f
    functional outcomes 683
    Mainz Pouch II (sigma rectum pouch) 680–681, 681f, 682f
    patient selection 673
    preoperative preparation 673
    transcolonic technique 675–680, 679f, 680f
  see also Bladder, reconstruction; Incontinence; Urinary and bowel diversion
Crohn's disease 633
Cryosurgery, renal
  assessment of indications 871
  cryoprobe placement and technique 871–877
  instruments 871
  isotherms 871, 872f
  patient positioning 871
  postoperative evaluation 877
Cryotherapy, prostate
  added commentary 447b
  impotence 445, 447
  patient selection 445
  postoperative care 447
  preoperative preparation 445
  surgical procedure 445–447
  ultrasound 445–447
Curvature of the penis
  see Hypospadias repair; Penis, curvature of
Cystectomy
  laparoscopic surgery
    added commentary 548b
    evaluation and preoperative preparation 541–542
    postoperative care 547–548
    surgical procedure 542–547
  partial approach
    added commentary 499b
    diagnosis and technique selection 495, 499
    extraperitoneal approach 496
    patient positioning 495
    postoperative problems 496–497
    transperitoneal approach 495–496
  radical approach
    added commentary 512b
    evaluation and preparation 501–502
    instruments and sutures 502
  radical approach, female
    dissection and urethrectomy 510
    orthotopic urinary diversion 512

Cystectomy *(Continued)*
surgical technique 508–510
vaginal-sparing procedure 510
radical approach, male
nerve-sparing modifications 508
orthotopic diversion and anterior dissection 508
postoperative care 508
surgical techniques 502–508
urethrectomy 508
Cystocele repair 221–223
Cystography, antibiotic prophylaxis 7t
Cystolithotomy
antibiotic prophylaxis 537
diagnosis and technique selection 537
surgical procedure 537–539
Cystoscopy, bladder diverticula evaluation 531
Cystourethroscopy
antibiotic prophylaxis 7t
laparoscopic ureterolithotomy and 787
postoperative evaluation 575
preoperative staging 275, 451, 459
ureteroscopy and 898–899
urethrovaginal fistula repair 197

D

Da Vinci computer-assisted laparoscopic system
availability of training 81, 435
controls and environment 81–82
instrumentation 82, 83f
port access and placement 82–83
role of the robotic assistant 83
suturing and knot tying 83, 84f
Deep venous thromboembolism
early mobilization to prevent 129
pelvic surgery and 433
perioperative evaluation 4
positioning and compression devices 483, 487
postoperative complications 1047
preoperative preparation 673
prophylaxis 5t
use of compression stockings 18, 26, 124–125
Diarrhea
bladder stone symptom 537
postoperative infections 12
Direct vision internal urethrotomy (DVIU)
choices of modalities for 289
cold knife technique 290
holmium laser technique 290–291
postoperative care 291
preoperative evaluation 289–291
urethral stricture disease and 289
Disposal of clothing and instruments 9
Distal tip repair 99–100, 99f
Diverticulectomy, bladder
diagnosis and preoperative preparation 531
laparoscopic technique 536
surgical technique 531–536
Dorsal plication 97–98, 98f
Drains/drainage tubes
benefits and types 10
catheters and urinary drainage 10–11
postoperative infections 12
wound management 12
Drapes/draping 6
Duckett onlay flap procedure 104–105
Duckett tubularized flap procedure 105–107

E

Electrolyte replacement 8
Endopyeloplasty
about the procedure 943, 947
Endopyeloplasty *(Continued)*
added commentary 947b
surgical technique 943–947
Endopyelotomy
endoscopic renal reconstruction
about the procedure 939
added commentary 942b
instrumentation 939
patient positioning and access 939–940
postoperative care 941
preoperative preparation 939
surgical technique 940
horseshoe kidney 898
ureteroscopic technique
about the technique 775
added commentary 778b
cold knife technique 778
electrocautery 778
Ho:YAG laser procedure 775–776
patient selection and preparation 775
postoperative care 778
Endoscopic surgery
see also Laparoscopic surgery
Endoscopic surgery, renal
anatomy
added commentary 974b
pelviocalyceal system 835–836, 836f
renal vasculature 837–842
ureteropelvic junction 843
cryosurgery
assessment of indications 871
cryoprobe placement and technique 871–877
instruments 871
patient positioning 871
postoperative evaluation 877
percutaneous access
about the technique 845
anatomical considerations 846
calyceal diverticulum/obstructed calyx 851–852
cystoscopy and ureteral catherization 846–848, 849–850
diagnosis and preoperative evaluation 845
multiple access tracts 852
nondilated puncture 852
operative complications 853
standard lower pole access 846
supracostal/upper pole access 850–851
percutaneous endopyeloplasty
about the procedure 943, 947
added commentary 947b
surgical technique 943–947
percutaneous endopyelotomy
about the procedure 939
added commentary 942b
instrumentation 939
patient positioning and access 939–940
postoperative care 941
preoperative preparation 939
surgical technique 940
percutaneous nephrolithotomy (PNL)
flexible nephroscopy 856
nephroscopes 855–856
preoperative evaluation 855
radiofrequency ablation
about the technique 879
laparoscopic RFA 881–882
patient positioning 879
percutaneous RFA 880
postoperative follow-up 882
Starburst XL RFA probe 880, 881t
retroperitoneal laparoscopic access
about the technique 857, 859
anatomic considerations 857

Endoscopic surgery, renal *(Continued)*
contraindications 857
laparoscopic technique 858–859
patient positioning and prep 858
transperitoneal laparoscopic access
choosing access sites 861
insertion of veress needle 862
insertion of visualizing dilating trocar 863
"open" alternative entry 862–863
port placement 865–866
Endoscopic surgery, ureteral
accessing the ureter
cannulating the ureteral orifice 759, 760
identifying the ureteral orifice 759
placement, safety wire 759–760
placement, ureteral access sheath 760–762
placement, ureteroscope over a guidewire 760
placement, working wire 760
special challenges 762
endopyelotomy
about the technique 775
added commentary 778b
cold knife technique 778
electrocautery 778
Ho:YAG laser procedure 775–776
patient selection and preparation 775
postoperative care 778
endoureterotomy
postoperative care 773
surgical procedure 771–773
instrumentation
about the types of 763
added commentary 764b
digital video technology 763
flexible ureteroscopes 763
semirigid ureteroscopes 763
ureteroscopy accessories 764
management of renal calculi
about the technique 770
added commentary 770b
preoperative preparation 769
surgical procedure 769–770
management of ureteral calculi
about the technique 765
added commentary 767b
stones above the iliac vessels 766, 767f
stones below the iliac vessels 765–766, 766f
management of VUR
about the technique 791
causes of failure 794t
double hydrodistension implantation (double hit) 792–793
"Mountain range" technique 791f
preoperative preparation 791–792
reasons for success 794t
STING technique 791f
renal calculi
development of the technique 770
postoperative care 770
preoperative considerations 769
surgical procedure 769–770
transitional cell carcinoma (TCC)
about the technique 781
added commentary 785b
postoperative care 784
preoperative preparation 781
surgical procedure 781–784
ureterocele excision 795–796
ureterolithotomy
added commentary 790b
diagnosis and preoperative preparation 787
Endoscopic surgery, ureteral *(Continued)*
port access and placement 787–788, 787f, 788f
postoperative care 789
stone removal and closure 788–789
surgical procedure 788, 788f
Endoureterotomy
postoperative care 773
surgical procedure 771–773
Enteritis
see Crohn's disease
Enterocele repair 223–224
Epididymectomy
anatomy and physiology 325
indications for 325
postoperative care 326
surgical technique 325–326, 325f, 326f
Epidural anesthesia
partial cystectomy 495
postoperative pain management 11
transurethral incision of the prostrate 459
transurethral resection of the prostrate (Turp) 451
Epigastric artery 173–175
Erthroplasia of Queyrat 132–133
Estrogen deficiency 567
Extracorporeal suturing: pushed half knot 22
Extragenital grafts 110
Extraperitoneal access (Gauer) 25

F

Fascia, sutures 30–31, 33–35
Fecal diversion
see Urinary and bowel diversion
Female vesical neck closure
abdominal approach 593–594, 593f, 594f
abdominal approach with urethral inversion 594–595, 595f, 596f
diagnosis and technique selection 593
preoperative preparation 593
urethral approach 595, 596f, 597f
vaginal approach 595–596, 597f, 598f
Fevers, postoperative infections 12
Flap/flaps
hypospadias surgery
basic considerations 103
Byars' Flap/flaps 110
see also Graft (s)
onlay preputial transverse island flap repair 104–105, 105f
perimeatal-based flap repair 103, 104f
tubularized transverse preputial island flap repair 105–107, 106f
techniques
designs and shapes 41
dog ear corrections 42, 43f
fixation and dressings 48–49
flap preparation 41–42
local anesthesia 42
maintaining blood supply 41
postoperative complications 49–51
use of Langer's lines 42, 42f
transvaginal repair
bulbospongious muscle flap (Martius) 581, 582, 583f
gracilis myocutaneous flap 583
island flap (Lehoczky) 583
labial fat pad flap 582
types
composition and uses 40
fasciocutaneous flap 41
gracilis muscle flap 46, 47f
gracilis myocutaneous flap 43–46

Flap/flaps *(Continued)*
inferior rectus abdominis flap 46–48, 48f, 49f, 50f
island flap 41, 42, 42f
microvascular free transfer (MVFT) flap 41
musculocutaneous flap 41, 42–49, 43f
peninsula flap 41
urethral reconstruction 215–216
see also Graft/grafts
Flexible prosthesis
see Penis, flexible prosthesis
Fluid management
under anesthesia 8
blood loss and transfusion 9–10
monitoring fluid overload 10
postoperative care 11
Fluoroscopy
inducer sheath placement 601
needle placement 600–601
patient positioning and prep 599
selecting the target 600
Foreskin, hypospadias repair 87
Fossa navicularis, reconstruction
added commentary 245b
meatal stenosis 241
skin flap techniques 241, 242, 243
skin graft technique 243–244
skin island techniques 244
Free, partial thickness skin grafts (Bracka Grafts) 110–111

G
Gas embolism 26
General anesthesia 8
Genital injuries, male
allografts and cadaveric skin application 187–188
avulsion injuries 187
bite injuries 187
burn injuries 187
penile fracture 189f
penile reimplantation 189, 189f, 190f
penis meshed unexpanded split thickness skin graft 187–188, 188f
scrotum meshed split thickness skin graft 188
testicular rupture 190
Genital repair, female
see Vaginal reconstruction
Gibson incision 391–392
Glansplasty 100, 101, 112b
GoLYTELY® 6
Gomco clamp circumcision 141–142
Gonadal biopsy 297
Graft/grafts
allografts and cadaveric skin application 187–188
blood supply to the skin 39, 40f
Bracka grafts 109, 110–111
dermal grafts 39–40, 179
establishing vascular connections 39
extragenital grafts 110
fixation and dressings 48–49
full-thickness skin grafts 39, 40f
incision and vein grafts 177–179
meshed grafts 40, 41f
penis meshed unexpanded split thickness skin graft 187–188, 188f
postoperative complications 49–51
scrotum meshed split thickness skin graft 188
split-thickness skin grafts 39, 40f, 41f
see also Flap/flaps

H
Halstead, William Stewart 15
Hand-assisted laparoscopy (HALS)
about the technique 867, 870
choice of devices 867
GelPort 868f
Lap Disc 868f
OmniPort 869f
device placement
about selection of location 867, 869f
Gibson-type/paramedian 868–870, 869f, 870f
low midline 867–868, 869f
periumbilical 868, 869f
upper midline 868, 869f
patient positioning 867
preoperative considerations 867
Hasson (open) technique 20–21, 21f
Heminephrectomy
indications and patient preparation 1063
instruments 1063
positioning and port placement 1063–1064
procedural approach and cystoscopy 1063
procedural technique 1064–1065
specimen removal 1065
Hidden penis
appearance 152, 153f
diagnostic definitions 151, 151t
etiological classification 151
forms trapped from prior surgery 152
management or surgical correction 151–152
micropenis 151
obesity and 152
postoperative considerations 155
surgical considerations 152
surgical repair 152, 155, 155f, 156f
webbed or tethered penis 151
Holmium laser technology
direct vision internal urethrotomy 289, 290–291, 291f
penile lesion treatment 131, 132f
transurethral incision of the prostrate 459, 460
Horseshoe kidney
about the abnormality 897
added commentary 903b
anatomy/vascular anatomy 897
indications for surgery 897–898
laparoscopic approach
access and exposure 899–900
nephrectomy 900
pyeloplasty 900
open approach
nephrectomy 901
partial nephrectomy 901–903
pyeloplasty 900–901
percutaneous approach
endopyelotomy 898
nephrolithotomy 898
ureteroscopy 898–899
shock-wave lithotripsy 898
Hüld, Hümér 53
Hydration
fluid and electrolyte replacement 8
ischemic priapism 183
overhydration 26
postoperative care 1007
preoperative checklist 6t
Hydrocelectomy, caudal blocks 11
Hyperthermia, malignant 8
Hypospadias repair
age considerations 88
algorithm 90f, 97f

Hypospadias repair *(Continued)*
basic types and goals 87
meatal stenosis 95
nerve blocks 11, 88
outpatient surgery 88
practical conclusions 91
preoperative considerations 88, 109
problems and complications 90
surgeon training and experience 87–88
surgical considerations 88, 89
surgical technique selection 89, 90
two-stage technique 109–112
urinary diversion and dressings 88–89
see also Penis, curvature of
Hypotension/cardiovascular collapse 26
Hypothermia 10
Hypotonic hyponatremia 11
Hysterectomy 227

I
Ileal conduit, laparoscopic
cystectomy and 629
isolation of ileal segment 629
reanastomosis and bowel division 629, 630f
stoma and ureteral anastomoses 630, 631f
Ileal conduit, open surgery
development and advantages 615
harvesting the bowel 617f, 618f
dividing the mesentery 617
GIA stapling and division 619
identifying the bowel segment 617
ileoileal anastomosis 619f, 620f, 621f
stapling (GIA 80 and TA staplers) 619
stapling the ileoileostomy 619
suturing the ileoileostomy 619, 621
patient selection and education 615
preparation of the bowel 615
stoma, creation of the
appropriate site selection 615–616
completion of the conduit and closure 623, 625–626, 625f, 626f
preparing the site 623–626, 624f, 625f
stoma, technique alternatives
loop stoma procedure 626, 628f
umbilical procedure 626, 627f
ureteroileal anastomosis 622f, 623f
positioning and excising the bowel 621–623
prepping and implanting the left ureter 621–623
prepping and implanting the right ureter 623
urethral mobilization 616f, 617f
identifying and transecting left ureter 616
identifying and transecting right ureter 616–617
Ileal orthotopic bladder substitution
about the technique 685, 686–689
contraindications 685t
ileal segment preparation 686–687
patient selection and preparation 685–686
postoperative care 688–689
postoperative complications 689
postoperative outcomes 689
substitute construction 687–688
ureteroileal anastomosis 687
Ileal reservoir (T-pouch)
advantages 655b
considerations for 651
steps in surgical procedure 651–654
Ileal ureteral replacement
about the technique 751
harvesting an ileum segment 751–752
identification of the defect 751
Ileal ureteral replacement *(Continued)*
postoperative management 754
preoperative preparation 751
replacement of both ureters 754
surgical procedure 752
Yang-Monti tube 752–754
Ileocecal reservoirs
added commentary 668b
choices and patient preferences 668
conduits 667f, 668
gastroileoileal pouch (Lockhart) 667
Indiana pouch 661–667, 662f
Mainz pouch
incision and surgical procedure 657, 658f, 659f
intussusception, ileocecal valve 657–658, 660f, 661f
intussusception, valve alternative 658
pouch with appendiceal stoma 661, 668
preoperative site selection 657
postoperative problems 668
in situ tunneled bowel flap tubes 661
Ileocystoplasty
added commentary 696b
patient selection and preparation 693
postoperative care 696
surgical procedure 693, 694f, 695f
Ileostomy
see Urinary and bowel diversion, fecal diversion
Iliac vascular repairs 71–75
Ilioinguinal lymphadenectomy
evaluation and preoperative preparation 123
intraoperative precautions 129
modified lymphadenectomy 124–127
pelvic lymphadenectomy 127
postoperative problems 129
radical lymphadenectomy closure 127
sentinel node biopsy 123–124, 124f
Impotence
cryotheraphy 445, 447
penile reconstruction 179, 180
Peyronie's Disease 181
prostatectomy postoperative 480
Incentive spirometry (IS) 12
Inconspicuous penis
see Hidden penis
Incontinence
autologous pubovaginal sling 553–554
bulking agents 567–570
intrinsic sphincter dysfunction (ISD) 551
orthotopic continent urinary diversion 633
transurethral resection of the prostrate (TURP) 455
urethrectomy, female 515
see also Continent reconstruction
Incontinent ileovesicostomy 612
Infections, postoperative management 12
Inferior vena cava (IVF)
see Vena cava
Inflatable prosthesis
see Penis, inflatable prosthesis
Intestines, sutures 31–32
Intracorporeal suturing 23
Intrinsic sphincter dysfunction (ISD) 551
Intubation
assessment of risk 4
nephrectomy 975
transitional cell carcinoma surgery 781
vena caval thrombectomy 1037–1038

K
Kidneys
anatomy
added commentary 974b
anatomic relationships 885, 967, 968f
approaches to surgery 967–968, 969f
gross morphology 885–886
lymphatic drainage 971
macroscopic renal collecting structures 885–886
organ position 885
pelviocalyceal system 835–836, 836f
renal collecting system 969–971, 970f
renal vasculature 837–842, 886, 968–969, 970f
retroperitoneal nerves 971–973
ureteropelvic junction 843
approaches to open surgery 802t
anatomic basis for incisions 799
anterior approaches 803–806
chevron incision 809–810
flank approaches 814–823
incisional hernia repair 830–832
instruments for 973
pediatric transverse abdominal incision 810–814
pleural tear repair 826
postoperative problems 806
preoperative preparation 973
retroperitoneal space 799–802
splenorrhaphy and splenectomy 826–829
subcostal incision 806–808
thoracoabdominal incision 823–825
prevalence of upper tract urothelial carcinoma 1009t
probability of adrenal metastasis 990t
probability of positive lymph nodes 990t
see also Renal surgery
Kidneys, excision, laparoscopic
caliceal diverticulectomy 1085–1086
heminephrectomy
indications and patient preparation 1063
instruments 1063
positioning and port placement 1063–1064
procedural approach and cystoscopy 1063
procedural technique 1064–1065
specimen removal 1065
nephroureterectomy
indications and contraindications 1071
insufflation and trocar placement 1072, 1073f, 1074f, 1075f
mobilization of the colon 1075
nephrectomy procedure 1075, 1076f, 1077f
organ entrapment/extraction 1078–1080
positioning and operating room set-up 1071–1072
postoperative considerations 1080
potential complications 1080
ureter dissection and excision 1075–1080, 1078f, 1079f, 1080f
partial nephrectomy 1067–1070
pyelolithotomy
candidate selection and preparation 1081
retroperitoneoscopic approach 1083
simultaneous pyeloplasty 1083
transperitoneal approach 1081–1083
radical nephrectomy, transperitoneal
establishing pneumoperitoneum 1053–1054
hilar dissection 1057–1058
patient selection and contraindications 1053
port placement 1054–1055
postoperative care 1060–1061
postoperative complications, identifying 1061–1062
preoperative preparation and positioning 1053
removal/sparing of adrenal gland 1059
Kidneys, excision, laparoscopic *(Continued)*
renal artery and vein ligation 1058–1059
specimen removal 1060
steps for left side 1055
steps for right side 1056–1057
ureteral dissection and division 1059–1060
wound closure 1060
renal cyst ablation
about the technique 1087
positioning and port placement 1087
postoperative care 1089
procedure 1088–1089
wound closure 1089
simple nephrectomy 1047
identification of proximal ureter 1048–1049
lateral and inferior dissection 1049
medial dissection of kidney 1048
patient positioning 1047, 1048f
postoperative care and complications 1050
preoperative considerations 1047
primary access and trocar placement 1047
reflection of the colon 1047–1048
renal hilum dissection 1049
retroperitoneal approach 1050–1051
specimen morcellation 1051
specimen retrieval and removal 1049–1050
superior dissection 1049
wound closure 1050
urothelial carcinoma
about the technique 1091
instruments 1091
resection procedure 1091–1093
Kidneys, excision, open surgery
anatrophic nephrolithotomy
about patient selection 1043
incision and renal dissection 1043
intraoperative imaging and stone removal 1044
postoperative care 1045
preoperative preparation and positioning 1043
renal closure and hypothermia termination 1044, 1045
extracorporeal renal surgery
about the procedure 1021
indications and preop considerations 1021–1022
operative technique 1022–1023
postoperative problems 1024
renal neoplasms 1023–1024
renovascular disease 1023
nephroureterectomy
about the procedure 1009
approaches to 1010–1011t
indications and preop considerations 1009–1010, 1009t
single-incision with intravesical dissection 1012–1017
transection without a bladder cuff 1019
transurethra resection of ureteral orifice 1018–1019
two-incision approach with extravesical dissection 1017–1018
ureteral intussusception 1019
partial nephrectomy
added commentary 1007b
contraindications 1001t
indications and preop considerations 1001–1002
large cortical tumors, wedge resection 1003–1004
large polar tumors, heminephrectomy 1006

Kidneys, excision, open surgery *(Continued)*
large polar tumors, segmental nephrectomy 1004
postoperative fistulas and bleeding 1006–1007
renal insufficiency 1007
small cortical tumors, enucleation 1002–1003
pyelolithotomy
patient selection and preparation 1045
postoperative care 1046
stone removal and closure 1045–1046
radical nephrectomy
added commentary 1000b
indications and preop considerations 989–991, 989t
injury to liver and spleen 999
injury to the duodenum 999
injury to the gut vasculature 998–999
injury to the pancreas 999–1000
left side mini-flank approach 995–996
pulmonary complications 1000
rectrocrural lymphadenectomy 998
regional lymphadenectomy 997–998
right side anterior subcostal approach 991–992
suprahilar lymphadenectomy 998
simple nephrectomy
added commentary 987b
anterior subcostal approach 978–980
approaches to surgery 976t
dorsal lumbotomy approach 981–982
flank approach 975–978
indications and preop considerations 975, 975t
Kocher maneuver 980–981
midline transperitoneal approach 981
renal vascular pedicle, controlling 984–986
subcapsular approach 983
wound closure 986–987
vena caval thrombectomy
about the procedure 1025
bypass techniques 1037–1039
level I: right side 1029–1030
level II: left side 1030–1032
level III: intra-abdominal approach 1032–1035
level III-IV: combined intra-abdominal and intrathoracic approach 1035–1036
patch cavoplasty 1039
perioperative complications 1041
permanent interruption for bland thrombus 1040
preoperative considerations 1025–1026
thrombus grouping system (Mayo Clinic) 1028t
thrombus staging and management 1026t
vena caval replacement 1039–1040
Kidneys, reconstruction, endoscopic
laparoscopic pyeloplasty
about the procedure 951
added commentary 954b
Fenger pyeloplasty 953
positioning and port placement 951
postoperative problems 953–954
surgical technique 951–953
percutaneous endopyeloplasty
about the procedure 943, 947
added commentary 947b
surgical technique 943–947
percutaneous endopyelotomy
about the procedure 939
added commentary 942b
instrumentation 939
patient positioning and access 939–940
postoperative care 941
Kidneys, reconstruction, endoscopic *(Continued)*
preoperative preparation 939
surgical technique 940
renal biopsy 949–950
robot-assisted pyeloplasty
about the technique 955
added commentary 958b
exposure and anastomosis 956–957
positioning and trocar placement 955–956
postoperative care 957
Kidneys, reconstruction, open surgery
horseshoe kidney
about the abnormality 897
added commentary 903b
anatomy/vascular anatomy 897
indications for surgery 897–898
laparoscopic approach 899–900
open approach 900–903
percutaneous approach 898–899
shock-wave lithotripsy 898
pyeloplasty
about the technique 887
added commentary 896b
approaches to surgery 887
initial incision and access 887–888, 889
instruments 887
patient positioning 887
postoperative care 888
selection of technique 889
technique: dismembered pyeloplasty 887
technique: Foley Y-V plasty 887
technique: nephropexy 888, 896f
technique: pelvic flap pyeloplasty 887–888
technique: stenting 887
renal injury repair
about the techniques 905
added commentary 909b
approach to open surgery 905
exposure and injury assessment 906, 907f
landmarks and renal hilum isolation 905–906, 906f, 907f
postoperative care 909
reconstructive principles 906
repair: lower/upper pole injury 906, 908f
repair: middle pole injury 906, 908f
repair: penetrating wounds 906, 908f
stents and drains 909
vascular injuries 909
renal vascular disease
about the procedure 911
added commentary 917b
indications for surgery 911–912
patient positioning 912
postoperative care 917
preoperative preparation 912
procedure: aortorenal bypass 912–914
procedure: ex vivo repair with autotransplantation 915–917
procedures: extra-anatomic bypass 914–915
Kidneys, transplantation
cadaveric donor nephrectomy
about the technique 935–937
added commentary 938b
exposure and en-bloc removal 935–937
separation of the kidneys 937
laparoscopic nephrectomy
about the procedure 959
added commentary 964b
conventional left side donation 959–962
conventional right side donation 962–963
hand-assisted left side 963

Kidneys, transplantation *(Continued)*
hand-assisted right side 963
operative adjunctive measures 964
postoperative considerations 964
live donor nephrectomy
about the procedure 933–934
left side donation 934
right side donation 933–934
recipient
added commentary 932b
assessment and preparation 919, 922
instruments 919
patient positioning 919–920
postoperative problems 930
technique: adult 920–924
technique: adult from child donor 924–926
technique: child 926–927
technique: ureteral implantation 928–930
transplantation failure: nephrectomy 931–932

L

Labial flap
fistula repair 203, 204b
vesicovaginal fistula 582
Langer's lines 42, 42f
Laparoscopic surgery
antibiotic prophylaxis 7t
basic techniques
clipping and stapling 23
contraindications and patient selection 17
direct extraperitoneal access (Gauer) 25
GIA stapling instruments 53
Hasson (open) technique 20–21, 21f
hemostasis 23
initial transperitoneal access 18–20
insertion of primary port 20–21
insertion of secondary ports 21
intraoperative problems 25–27
irrigation 22
lysis of adhesions 22
monitoring equipment 17
organ entrapment 23
patient preparation and positioning 18
postoperative care 24
postoperative problems 27
procedures for children 24–25
retractors and graspers 22
site closure 23–24
suturing 22–23
Veress needle (closed) technique 19–20, 19f
see also Trocar insertion
bilateral ureterolysis 741
bladder diverticulectomy 536
caliceal diverticulectomy 1085–1086
cystectomy
added commentary 548b
evaluation and preoperative preparation 541–542
postoperative care 547–548
surgical procedure 542–547
hand-assisted laparoscopy (HALS)
about the technique 867, 870
choice of devices 867, 868f, 869f
device placement 867–870, 869f, 870f
patient positioning 867
preoperative considerations 867
heminephrectomy
indications and patient preparation 1063
instruments 1063
positioning and port placement 1063–1064
Laparoscopic surgery *(Continued)*
procedural approach and cystoscopy 1063
procedural technique 1064–1065
specimen removal 1065
horseshoe kidney
access and exposure 899–900
nephrectomy 900
pyeloplasty 900
ileal conduit
cystectomy and 629
isolation of ileal segment 629
reanastomosis and bowel division 629, 630f
stoma and ureteral anastomoses 630, 631f
instrumentation 17–18
management of VUR
about the technique 791
causes of failure 794t
double hydrodistension implantation (double hit) 792–793
"Mountain range" technique 791f
preoperative preparation 791–792
reasons for success 794t
STING technique 791f
nephrectomy, live donor
about the procedure 959
added commentary 964b
conventional left side donation 959–962
conventional right side donation 962–963
hand-assisted left side 963
hand-assisted right side 963
operative adjunctive measures 964
postoperative considerations 964
nephroureterectomy
indications and contraindications 1071
insufflation and trocar placement 1072, 1073f, 1074f, 1075f
mobilization of the colon 1075
nephrectomy procedure 1075, 1076f, 1077f
organ entrapment/extraction 1078–1080
positioning and operating room set-up 1071–1072
postoperative considerations 1080
potential complications 1080
ureter dissection and excision 1075–1080, 1078f, 1079f, 1080f
omentum mobilization 63–64
partial nephrectomy 1067–1070
pelvic lymph node dissection (PLND) 429–430
prostatectomy
added commentary 444b
candidate selection 435
positioning and port placement 435–436
postoperative care 443
surgical technique 436–438, 439–443
undocking and wound closure 443
pyelolithotomy
candidate selection and preparation 1081
retroperitoneoscopic approach 1083
simultaneous pyeloplasty 1083
transperitoneal approach 1081–1083
radical nephrectomy, transperitoneal
establishing pneumoperitoneum 1053–1054
hilar dissection 1057–1058
patient selection and contraindications 1053
port placement 1054–1055
postoperative care 1060–1061
postoperative complications, identifying 1061–1062

Laparoscopic surgery *(Continued)*
preoperative preparation and positioning 1053
removal/sparing of adrenal gland 1059
renal artery and vein ligation 1058–1059
specimen removal 1060
steps for left side 1055
steps for right side 1056–1057
ureteral dissection and division 1059–1060
wound closure 1060
renal biopsy 949–950
renal cyst ablation
about the technique 1087
positioning and port placement 1087
postoperative care 1089
procedure 1088–1089
wound closure 1089
renal reconstruction pyeloplasty
about the procedure 951
added commentary 954b
Fenger pyeloplasty 953
positioning and port placement 951
postoperative problems 953–954
surgical technique 951–953
retroperitoneal procedures
about the technique 857, 859
anatomic considerations 857
contraindications 857
laparoscopic technique 858–859
patient positioning and prep 858
robot-assisted pyeloplasty
about the technique 955
added commentary 958b
exposure and anastomosis 956–957
positioning and trocar placement 955–956
postoperative care 957
robot-assisted techniques
availability of training 81–83
controls and environment 81–82
instrumentation 82, 83f
port access and placement 82–83
role of the robotic assistant 83
suturing and knot tying 83, 84f
simple nephrectomy
identification of proximal ureter 1048–1049
lateral and inferior dissection 1049
medial dissection of kidney 1048
patient positioning 1047, 1048f
postoperative care and complications 1050
preoperative considerations 1047
primary access and trocar placement 1047
reflection of the colon 1047–1048
renal hilum dissection 1049
retroperitoneal approach 1050–1051
specimen morcellation 1051
specimen retrieval and removal 1049–1050
superior dissection 1049
wound closure 1050
testis, postoperative problems 344
transperitoneal access
choosing access sites 861
insertion of veress needle 862
insertion of visualizing dilating trocar 863
“open” alternative entry 862–863
port placement 865–866
ureterolithotomy
added commentary 790b
diagnosis and preoperative preparation 787
port access and placement 787–788, 787f, 788f
Laparoscopic surgery *(Continued)*
postoperative care 789
stone removal and closure 788–789
surgical procedure 788, 788f
urothelial carcinoma
about the technique 1091
instruments 1091
resection procedure 1091–1093
see also Endoscopic surgery
Large bowel repair 26, 77–78
Laser phototherapy
benign prostatic disease
added commentary 471b
choosing office-based vs. operating room 463
high-energy photo vaporization 463–464
holmium laser ablation (hoLAP) 464–466
holmium laser enucleation (HoLEP) 466–470
interstitial coagulation 470
penis
about the use of 131
common choices and types 131
erythroplasia of Queyrat 132–133
penile condylomata 131–132
postprocedural management 134–135
squamous cell carcinoma 133–134
Lichen sclerosus/balanitis xerotica obliterans 237–238, 241, 245
Lidocaine 65
Lithotripsy
shock-wave
antibiotic prophylaxis 7t
comparison to ureteroscopy 767b
horseshoe kidney 898
stone removal 755
ureteral calculi
about the technique 765
added commentary 767b
stones above the iliac vessels 766, 767f
stones below the iliac vessels 765–766, 766f
Local anesthesia 8
caudal blocks 11
nerve blocks 11
regional blocks 8, 42
Lumbar vein 74
Lymph node dissection, pelvic (PLND)
added commentary 433b
anatomic relationships 427–428
diagnosis and technique selection 427
extended PLND 429
extraperitoneal exposure 432
intraoperative complications 433
laparoscopic/robotic (MIS) 429–430
MIS extended PLND 432–433
modified PLND 428–429
postoperative problems 433
Prostate, anatomic relationships 433
transperitoneal exposure 430–432
Lymph node dissection, retroperitoneal (RPLND)
anatomy and templates 362, 362f, 363f, 365
nerve-sparing left-sided dissection 362, 364f
nerve-sparing right-sided dissection 362–364, 364f
diagnosis and therapuetic intent 365
drug complications and risks 365
full bilateral technique 358–362
laparoscopic approach
added commentary 377b
benefits, staging and preparation 367
left-sided dissection 374–376
operating room set-up 368f
positioning and trocar placement 367–368

Lymph node dissection, retroperitoneal *(Continued)*
postoperative care 376
potential complications 376
right-sided dissection 368–373
postchemotherapy approach 357–358
preoperative preparation 357
special considerations 364
Lymphadenectomy, pelvic
approaches to surgery 517
male procedure 517–520
postoperative problems 522

M

Malignancy
gonadal biopsy 297
horseshoe kidneys 897–898
ileocystoplasty and 693
laparoscopy contraindications 17
nephrectomy, radical 989, 1000b
nephrectomy, simple 975
open renal surgery and 801, 803
preoperative evaluation 4
rectourinary fistula 287
renal anatomy and 967
ureteral strictures and 735, 737, 739, 740–741
ureteroscopic endoureterotomy 771–773
ureterosigmoidostomy and 673
Malignancy, prostate
anatomy related to excision
added commentary 401b
adjacent structures 395, 396f
approaches to surgery 395
arterial blood supply 397f
innervation 398, 400f
lymphatic drainage 398, 399f
pelvic fascia 398–399, 401f
venous drainage 397–398, 398f
cryotherapy
cryotherapy procedure 445–447
impotence 445, 447
patient selection 445
postoperative care 447
preoperative preparation 445
ultrasound 445–447
pelvic lymphadenectomy
added commentary 433b
anatomic relationships 427–428, 433
diagnosis and technique selection 427
extended PLND 429
extraperitoneal exposure 432
intraoperative complications 433
laparoscopic/robotic (MIS) 429–430
MIS extended PLND 432–433
modified PLND 428–429
postoperative problems 433
transperitoneal exposure 430–432
radical perineal prostatectomy
added commentary 425b
alternative techniques 425
development of the technique 415
instruments for 415
obesity and 425
postoperative care 425
preoperative preparation 415
surgical procedure 415–421, 424, 425
radical retropubic prostatectomy
added commentary 414b
bladder neck dissection and reconstruction 408–409, 410–411
closure and drain placement 411–412
Malignancy, prostate *(Continued)*
instruments 403
intraoperative problems 412–413
positioning and initial incision 403–404
postoperative care 412
postoperative problems 413
preservation of neurovascular bundles 407
seminal vesicles and vas deferens dissection 407–408
surgical procedure 404–407
urethral suturing 407, 411
robotic-assisted prostatectomy
added commentary 444b
candidate selection 435
positioning and port placement 435–436
postoperative care 443
surgical technique 436–438, 439–443
undocking and wound closure 443
Malignancy, testis
orchiectomy, epididymis-sparing 349, 350f
orchiectomy, radical 353
added commentary 355b
examination and preoperative preparation 353
surgical procedure 353–355
orchiectomy, simple 349, 350f
testis-sparing surgery 351–352
Malignant hyperthermia 4, 8
Marsupialization technique (Spence-Duckett) 205, 206f
Martius flap procedure
classical technique 201–202
fistula repair 201–202
modifications 200
in situ technique 202
Mathieu flip-flap procedure 103
Meatal stenosis, indications for 95
Meatotomy
indications of stenosis 95
surgical technique 95, 95f, 96f
Membranous injuries, urethral
added commentary 285b
assessment 275
draping and positioning 276f
endoscopic realignment 275
perineal urethroplasty 275–282
preoperative planning 275
transpubic (abdominoperineal) urethroplasty 282–284
Michigan four-wall sacrospinous suspension
added commentary 233b
advantages over other techniques 228
comparison to other techniques 227
differences from other techniques 227t
key principles of 228t
operative technique 229–231
results and outcomes after 1 year 233
Micropenis
see Hidden penis
Midline lower abdominal peritoneal incision 379–384
Midshaft and proximal tip repair 100–101
Midurethral sling
pubovaginal procedure
closure 560
incision and dissection 557
sling passage 560
suprapubic needle pass 557
TVT vaginal pass 557–560
tension-free vaginal tape 560
transobturator placement
anesthesia 563

Midurethral sling *(Continued)*
closure 566
cystoscopy 564
diagnosis and technique selection 563
incision and dissection 563
needle passes 563–564
passage of sling material 564–566
patient positioning 563
Millin, Terence 483
Morbidity and Mortality conferences 11
Morcellator/morcellation 23, 1051
Morley, George W. 227

N
Narcotics, postoperative pain management 11, 12, 288, 317
Nephrectomy
cadaveric donor
about the technique 935–937
added commentary 938b
exposure and en-bloc removal 935–937
separation of the kidneys 937
horseshoe kidney 900, 901–903
intubation 975
live donor, laparoscopic
about the procedure 959
added commentary 964b
conventional left side donation 959–962
conventional right side donation 962–963
hand-assisted left side 963
hand-assisted right side 963
operative adjunctive measures 964
postoperative considerations 964
live donor, open surgery
about the procedure 933–934
left side donation 934
right side donation 933–934
obese patients 1050
partial nephrectomy, laparoscopic 1067–1070
partial nephrectomy, open
added commentary 1007b
contraindications 1001t
indications and preop considerations 1001–1002
large cortical tumors, wedge resection 1003–1004
large polar tumors, heminephrectomy 1006
large polar tumors, segmental nephrectomy 1004
postoperative fistulas and bleeding 1006–1007
renal insufficiency 1007
small cortical tumors, enucleation 1002–1003
radical nephrectomy, laparoscopic
establishing pneumoperitoneum 1053–1054
hilar dissection 1057–1058
patient selection and contraindications 1053
port placement 1054–1055
postoperative care 1060–1061
postoperative complications, identifying 1061–1062
preoperative preparation and positioning 1053
removal/sparing of adrenal gland 1059
renal artery and vein ligation 1058–1059
specimen removal 1060
steps for left side 1055
steps for right side 1056–1057
ureteral dissection and division 1059–1060
wound closure 1060
radical nephrectomy, open
added commentary 1000b
Nephrectomy *(Continued)*
indications and preop considerations 989–991, 989t
injury to liver and spleen 999
injury to the duodenum 999
injury to the gut vasculature 998–999
injury to the pancreas 999–1000
left side mini-flank approach 995–996
pulmonary complications 1000
rectrocrural lymphadenectomy 998
regional lymphadenectomy 997–998
right side anterior subcostal approach 991–992
suprahilar lymphadenectomy 998
simple nephrectomy, laparoscopic 1047
identification of proximal ureter 1048–1049
lateral and inferior dissection 1049
medial dissection of kidney 1048
patient positioning 1047, 1048f
postoperative care and complications 1050
preoperative considerations 1047
primary access and trocar placement 1047
reflection of the colon 1047–1048
renal hilum dissection 1049
retroperitoneal approach 1050–1051
specimen morcellation 1051
specimen retrieval and removal 1049–1050
superior dissection 1049
wound closure 1050
simple nephrectomy, open
added commentary 987b
anterior subcostal approach 978–980
approaches to surgery 976t
dorsal lumbotomy approach 981–982
flank approach 975–978
indications and preop considerations 975, 975t
Kocher maneuver 980–981
midline transperitoneal approach 981
renal vascular pedicle, controlling 984–986
subcapsular approach 983
wound closure 986–987
transplantation, removal following failure 931–932
Nephrolithotomy
about patient selection 1043
horseshoe kidney 898
incision and renal dissection 1043
intraoperative imaging and stone removal 1044
percutaneous 9
postoperative care 1045
preoperative preparation and positioning 1043
renal closure and hypothermia termination 1044, 1045
Nephroureterectomy, laparoscopic
indications and contraindications 1071
insufflation and trocar placement 1072, 1073f, 1074f, 1075f
positioning and operating room set-up 1071–1072
postoperative considerations 1080
potential complications 1080
procedure
colon mobilization 1075
distal ureteral dissection 1075–1078, 1078f
distal ureter/bladder cuff management 1078f, 1079f, 1080f
nephrectomy 1075, 1076f, 1077f
organ entrapment/extraction 1078–1080
specimen entrapment/extraction 1078–1080
Nephroureterectomy, open
about the procedure 1009
indications and preop considerations 1009–1010, 1009t

Nephroureterectomy, open *(Continued)*
techniques
about the selection of 1010–1018
advantages and disadvantages 1010–1011t
single-incision with intravesical dissection 1012–1017
two-incision approach with extravesical dissection 1017–1018
techniques, alternatives
rextravesical transection without a bladder cuff 1019
transurethra resection of ureteral orifice 1018–1019
ureteral intussusception 1019
Nerve blocks
genitofemoral 66–67
hypospadias repair 88
iliohypogastric 66–67
ilioinguinal 66–67
intercostal 65
penile 65–66
postoperative pain management 11
prostatic 68
pudendal 67
testis 67
transsacral 68
Neuromodulation, sacral nerve
anesthesia 599
development of the technique 599
patient selection 599
stage one
closure and postop evaluation 603
fluoroscopy placement of foramen needle 600–601
fluoroscopy placement of introducer sheath 601
preoperative preparation 599
selecting the target spinal foramen 600
tined lead connection to lead extension 602
tined lead deployment 601–602
tunneling tined lead to connection site 603
stage two
extension wire and tined lead removal 603
neurostimulator placement 603
Nutritional assessment, preoperative 4

O

Obese patients/obesity
bladder surgery and 494
hidden penis surgery 151, 151t, 152
ileal conduit surgery 626
inguinal varicocelectomy procedure 304
kidney function and 1007b
laparoscopic surgery
approach to 870
contraindications 17
nephrectomy risks 1050
patient positioning 18, 26, 82–83, 1047
pneumoperitoneum 19
preoperative issues 867
problems 344
trocar placement 1081
operative risk assessment 6t
pelvic lymph node dissection 432
postoperative complications 155
postoperative infections 12, 121, 554
renal surgery 806, 976t, 981, 1091
transobturator midurethral sling placement 563
wound closure 12, 23–24
Omentum, mobilization
anatomy 61
tissue physiology 61
Onlay preputial transverse island flap repair 104–105, 105f
Onlay urethroplasty
bulbar urethra reconstruction 274
penile urethra reconstruction 263b
Operating room
light intensity 9
room temperature 8
viral infection contamination 9
Operative site preparation
avoiding site contamination 6
bowel cleansing 6
draping 6
marking the site 5
preoperative checklist 5, 6t
shaving and epilation 6
skin preparation 6
vascular access 6
Orchiectomy, radical
added commentary 355b
control of gonadal vessels 355
diagnosis and technique selection 353
draping 355
preoperative evaluation 353
surgical procedure 353–355
Orchiopexy
abdominal testes
diagnosis and technique selection 331–335
extended inguinal approach 334
extraperitoneal approach 334
Laroque incision 334–335
transperitoneal approach 332–334
caudal blocks 11, 327
high ligation approach (Fowler-Stephens)
diagnosis and technique selection 335–336
open surgical technique 335–336, 336f, 337f
postoperative problems 336
inguinal (open technique) 329f, 330f, 331f, 332f
anesthesia 327
diagnosis and technique selection 327–330
surgical techniques 327–330, 328f
inguinal (open technique)
surgical procedure 328f
laparoscopic techniques
approaches in children 339–340
insertion of trocars 340–341
normal landmarks 341
postoperative problems 344
single-stage technique 342–343, 343f, 344f
two-stage technique (Fowler-Stephens) 343–344
unilateral nonpalpable testis 341–342
low ligation approach 336–337, 337f, 338f
microvascular approach 338–339
postoperative problems 327–330, 336, 344
redoing a previous procedure 337–338, 338f
scrotal technique 330, 332f
Organ entrapment 23
Orthoplasty
defined 87
first stage surgery 109
recurrence of curvature 112b
second stage surgery 111–112
techniques 109
Orthotopic continent urinary diversion 633
Outpatient surgery
hypospadias repair 88
preoperative checklist 5–6, 6t
Overhydration 26

P

Pain management
analgesic medications 11
intravenous narcotics 12
laparoscopic surgery 27
nerve blocks 11
Papoose board (restraining wrap) 8
Paraphimosis, dorsal slit procedure 145–146

Passive drains
see drains/drainage tubes
Pediatric surgery
hypospadias repair
lateral curvature and chordee 147–149
penile torsion 147
postoperative management 93–94
meatotomy
indications for 95
surgical technique 95, 95f, 96f
renal transplant
about the technique 926–927
positioning and initial incision 926
surgical technique 926–927
see also Children
Pedicled dorsal foreskin flaps
see Byars' Flaps
Pelvis
approaches to surgery
Gibson incision 391–392
midline lower abdominal peritoneal incision 379–384
transverse lower abdominal incision 385–390
lymph node dissection (PLND)
see Lymph node dissection, pelvic
lymphadenectomy 517
approaches to surgery 517
female procedure 522
male procedure 517–520
postoperative problems 522
total pelvic exenteration
evaluation and preoperative preparation 523
female procedure 528–529
male procedure 523–527, 528
postoperative problems 529
venous plexus injury repairs 71
Penectomy
partial approach
evaluation and preparation 119
goals 115
postoperative problems 116, 121
surgical technique 115, 119–121
total approach
evaluation and preparation 119
postoperative problems 121
surgical technique 119–121
Penis
arterial revascularization
diagnosis and technique selection 173, 176b
epigastric artery, exposing and harvesting 173–174
epigastric artery-dorsal artery anastomosis 174–175
epigastric artery-dorsal vein anastomosis 175
exposing the penile vasculature 174
instruments for 173
postoperative problems 176
circumcision
about the history of 139
adults 139
alternative to sleeve incision 140–141
anesthesia and caudal blocks 11, 139
changes in surface tissue 139
evaluation of babies 139
Gomco clamp technique 141–142, 142f
meatal stenosis 142–144
Mogen clamp circumcision 142–144
Plastibell technique 141, 141f
postoperative problems 142–144
preoperative preparation 139
repair and revisions 142
Penis *(Continued)*
sleeve incision (double incision) 139–140, 140f
undoing 144
condylomata 131–132, 132f
corrective procedures
dorsal slit for paraphimosis 145–146
dorsal slit for phimosis 145
hidden penis 151–152
curvature
added commentary 102b
basic causes and correction 87, 97–99
distal tip repair 99–100, 99f
dorsal plication 97–98, 98f
"fairy cuts" 98–99, 98f
lateral curvature and chordee 147–149
midshaft and proximal tip repair 100–101, 101f
onlay preputial transverse island flap repair 104–105
operative technique selection 89, 90
penile prostheses and 169
perimeatal-based flap repair 103
postoperative management 101
torsion curvature 147
tubularized transverse preputial island flap repair 105–107
two-stage repair 109
urethral plate elevation 98–99, 98f
ventral grafting 99, 99f
see also Peyronie's Disease
curvature, pediatric
dorsal midline plication 149, 149f
lateral curvature and chordee 147, 148, 148f
penile torsion 147
tunica albuginea plication 148–149, 148f
Yachia plication 149
fractures 188–189
genital injury, repair of
allografts and cadaveric skin application 187–188
avulsion injuries 187
bite injuries 187
burn injuries 187
fracture 189f
reimplantation 189, 189f, 190f
skin grafts 187–188, 188f
testicular rupture 190
hypospadias repair
added commentary 102b, 112b
age considerations 88
algorithm 90f, 97f
basic types and goals 87
meatal stenosis 95
nerve blocks 11, 88
outpatient surgery 88
postoperative management 93–94
practical conclusions 91
preoperative considerations 88, 109
problems and complications 90
surgeon training and experience 87–88
surgical considerations 88, 89
surgical technique selection 89, 90
two-stage technique 109–112
urinary diversion and dressings 88–89
laser phototherapy
about the use of 131
common choices and types 131
erythroplasia of Queyrat 132–133
penile condylomata 131–132
postprocedural management 134–135
squamous cell carcinoma 133–134
malignancy
ilioinguinal lymphadenectomy 123

Penis *(Continued)*
laser phototherapy 131
partial penectomy 115, 116
postoperative problems 116, 121, 129, 134–135
total penectomy 119
meatal stenosis
circumcision and 142–144
indications for 95
postoperative problems 103, 112, 116, 121
surgical technique 95, 95f, 96f
nerve blocks 65–66
Peyronie's Disease
added commentary 181b
criteria for correction 177
dermal grafts 179, 179f
incision and vein grafts 177–179, 178f
incisional plication 180
nonincisional plication 179–180, 179f, 180f
postoperative problems 181
prosthesis implantation 180–181
priapism
added commentary 186b
classification and diagnosis 183
corporoglanular (Al-Ghorab) shunt 184, 185f
corporoglanular (Ebbehoj and T-) shunt 184, 184f, 185f
corporoglanular (Winter) shunt 184, 184f
corporospongial shunt 184–185, 186f
nonischemic management 185
nonsurgical management 183
surgical considerations 185
prosthesis, flexible
about the selection and sizing 161, 161t
antibiotic prophylaxis 7t, 161–162
approaches for insertion 159
dorsal penile shaft approach 165–166
instruments for 162
perineal approach 164
postoperative problems 167
pubic approach 166
subcoronal approach 164–165
ventral approach 166
ventral penile approach 162–164
prosthesis, inflatable
added commentary 172b
antibiotic prophylaxis 7t, 169
implantation approaches 169–171
implantation of AMS 700 LGX prosthesis 170–171
options for Peyronie's Disease 180–181
postoperative care 171
preoperative preparation 169
types of 169
reconstruction
arterial revascularization 173–176
flexible prosthesis insertion 159–168
genital injury repair 187–190
inflatable prosthesis implantation 169–172
Peyronie's Disease procedures 177–182
priapism surgery 183–186
reimplantation 189, 189f, 190f
urethra reconstruction
anatomic and vascular diagram 247, 248f
distal penile circular fasciocutaneous flap (McAninch) 247–250, 249f, 250f, 251f
dorsally placed buccal mucosa graft (Barbagli) 254, 257f, 258f, 259f
fossa navicularis, skin flaps 241, 242, 243
fossa navicularis, skin graft 243–244
fossa navicularis, skin islands 244, 244
goals and patient factors 247
longitudinal ventral skin flap with lateral pedicle (Orandi) 250–254, 251f, 252f, 253f, 254f
Penis *(Continued)*
longitudinal ventral skin flap with ventral pedicle (Turner-Warwick) 254, 255f, 256f
two-stage urethroplasty (Johannson) 255, 260f, 261f, 262f
urethroplasty, anastomotic 247, 263b
urethroplasty, onlay 263b
Penoscrotal transposition 101
Percutaneous access, renal
anatomical considerations 846
cystoscopy and ureteral catherization
about the technique 846–850
imaging and patient positioning 847
needle access and puncture site 847–848
placement of access wires 848–849
tract dilation 849–850
diagnosis and preoperative evaluation 845
instrumentation 846
multiple access tracts 852
nondilated puncture 852
operative complications 853
special access situations
calyceal diverticulum/obstructed calyx 851–852
supracostal/upper pole access 850–851
Percutaneous endopyeloplasty
about the procedure 943, 947
added commentary 947b
surgical technique 943–947
Percutaneous nephrolithotomy (PNL)
evaluation, preoperative
about the procedure 855
choice of tract location and number 855
management before tract dilation 855
flexible nephroscopy
about the procedure 856
tube placement 856
tubeless approach 856
nephroscopes
about the choices 855–856
combination ICL devices 856
intracorporeal lithotripters 855–856
tissue sealants and glues 9
Perimeatal-based flap repair 103, 104f
Peritonitis
bowel injury and 1050
ileocystoplasty and 693
laparoscopic surgery and 17, 27, 867
Petz, Alädar 53
Peyronie's Disease
added commentary 181b
criteria for correction 177
dermal grafts 179, 179f
incision and vein grafts 177–179, 178f
incisional plication 180
nonincisional plication 179–180, 179f, 180f
postoperative problems 181
prosthesis implantation 180–181
Pfannenstiel incision 385, 386f
Phimosis, dorsal slit procedure 145
Plastibell circumcision 141
Plication techniques
Heineke-Mikuliez incision and closure 180
incisional (ventral tuck) 180
nonincisional (16-Dot) 179–180
Pneumomediastinum/pneumopericardium 25
Pneumothorax
closing surgical wounds 986–987
laparoscopic risks of 18, 19–20, 23, 25, 26
nerve block risks of 65
Polydioxanone Clip technique 22
Polyethylene glycol electrolyte 6

Posterior colporrhaphy 224–226
Postoperative bleeding 11
Postoperative management
  about the operative report 11
  avoidance of complications 11
  fluid requirements 11
  infections 12
  pain management 11–12
  wound management 12
Preperitoneal emphysema 25
Priapism
  added commentary 186b
  classification and diagnosis 183
  corporoglanular (Al-Ghorab) shunt 184, 185f
  corporoglanular (Ebbehoj and T-) shunt 184, 184f, 185f
  corporoglanular (Winter) shunt 184, 184f
  corporospongial shunt 184–185, 186f
  nonischemic management 185
  nonsurgical management 183
  surgical considerations 185
Procaine 65
Prostate
  anatomy related to excision
    added commentary 401b
    adjacent structures 395, 396f
    approaches to surgery 395
    arterial blood supply 397f
    innervation 398, 400f
    lymphatic drainage 398, 399f
    pelvic fascia 398–399, 401f
    venous drainage 397–398, 398f
  benign retropubic prostatectomy
    added commentary 481b, 490b
    development of the technique 483
    patient positioning 483
    postoperative management 487
    preoperative preparation 483
    surgical procedure 483–487
  brachytherapy 7t
  cryotherapy
    added commentary 447b
    antibiotic prophylaxis 7t
    cryotherapy procedure 445–447
    patient selection 445
    postoperative care 447
    preoperative preparation 445
  laparoscopic prostatectomy
    added commentary 444b
    candidate selection 435
    positioning and port placement 435–436
    postoperative care 443
    surgical technique 436–438, 439–443
    undocking and wound closure 443
  laser phototherapy
    added commentary 471b
    choosing office-based vs. operating room 463
    high-energy photo vaporization 463–464
    holmium laser ablation (hoLAP) 464–466
    holmium laser enucleation (HoLEP) 466–470
    interstitial coagulation 470
  pelvic lymph node dissection (PLND)
    anatomic relationships 427–428, 433
    diagnosis and technique selection 427
    extended PLND 429
    extraperitoneal exposure 432
    intraoperative complications 433
    laparoscopic/robotic (MIS) 429–430
    MIS extended PLND 432–433
    modified PLND 428–429
Prostate *(Continued)*
    postoperative problems 433
    transperitoneal exposure 430–432
  radical perineal prostatectomy
    added commentary 425b
    alternative techniques 425
    anesthesia 415
    development of the technique 415
    incontinence 571
    instruments for 415
    obesity and 425
    positioning 415f
    postoperative care 425
    preoperative preparation 415
    surgical procedure 415–421, 424, 425
  radical retropubic prostatectomy
    bladder neck dissection and reconstruction 408–409, 410–411
    closure and drain placement 411–412
    instruments 403
    intraoperative problems 412–413
    positioning and initial incision 403–404
    postoperative care 412
    postoperative problems 413
    preservation of neurovascular bundles 407
    seminal vesicles and vas deferens dissection 407–408
    surgical procedure 404–407
    urethral suturing 407, 411
  suprapubic prostatectomy
    added commentary 481b
    anesthesia 473
    antibiotic prophylaxis 473
    diagnosis and technique selection 473
    instruments for 473
    intraoperative hemostatic procedures 479
    postoperative care 479–480
    postoperative problems 480
    preoperative considerations 473
    surgical procedure 473–480
  tissue sealants and glues 9
  transurethral incision of the prostrate (TUIP)
    added commentary 462b
    anesthesia 459
    catheterization 461
    cystoscopy examination 462
    diagnosis and technique selection 459
    laparoscopic surgery and 462
    patient selection 462
    postoperative complications 461
    preoperative preparation 459
    surgical technique 459–460
  transurethral resection of the prostrate (TURP)
    added commentary 457b
    anesthesia 451
    clinical efficacy 456
    diagnosis and technique selection 451
    patient positioning 451
    postoperative care 456
    preoperative preparation 451
    surgical complications 455–456, 457
    surgical technique 451–455
Prostatic nerve block 68
Prosthesis
  see Penis, flexible prosthesis; Penis, inflatable prosthesis
Proximal tip repair 100–101, 101f
Psoas hitch
  considerations for use of 727
  postoperative complications 729
  surgical procedure 727, 728–729

Pubovaginal sling, autologous
assessment for 551
development of the technique 551
patient positioning 551
postoperative complications 551, 553–554
surgical procedure 551–552
technique alternatives 552–553
Pudendal nerve block 67
Pyelolithotomy
laparoscopic
candidate selection and preparation 1081
retroperitoneoscopic approach 1083
simultaneous pyeloplasty 1083
transperitoneal approach 1081–1083
open surgery
patient selection and preparation 1045
postoperative care 1046
stone removal and closure 1045–1046
Pyeloplasty
horseshoe kidney 900–901
laparoscopic reconstruction
about the procedure 951
added commentary 954b
Fenger pyeloplasty 953
positioning and port placement 951
postoperative problems 953–954
surgical technique 951–953
open surgery
about the technique 887
added commentary 896b
approaches to surgery 887
initial incision and access 887–888, 889
instruments 887
patient positioning 887
postoperative care 888
selection of technique 889
technique: dismembered pyeloplasty 887
technique: Foley Y-V plasty 887
technique: nephropexy 888, 896f
technique: pelvic flap pyeloplasty 887–888
technique: stenting 887
robot-assisted technique
about the technique 955
added commentary 958b
exposure and anastomosis 956–957
positioning and trocar placement 955–956
postoperative care 957

R

Radical perineal prostatectomy
alternative techniques 425
anesthesia 415
development of the technique 415
incontinence 571
instruments for 415
obesity and 425
positioning 415f
postoperative care 425
preoperative preparation 415
surgical procedure 415–421, 424, 425
Radiofrequency ablation, renal
about the technique 879
laparoscopic RFA 881–882
patient positioning 879
percutaneous RFA 880
postoperative follow-up 882
Starburst XL RFA probe 880, 881t
Ravitch, Mark M. 53
Reconstructive surgery
see Bladder, reconstruction; Fossa navicularis, reconstruction; Kidneys, reconstruction; Penis, reconstruction; Ureteral reconstruction and excision; Urethra, reconstruction; Vaginal reconstruction
Rectocele repair 224–226
Rectourinary fistula, York-Mason closure
diagnosis and technique selection 287
operative procedure 287–288
positioning for surgery 287f
postoperative care 288
Rectum
injury repairs 78–79
radical prostatectomy 395
retropubic prostatectomy 483
transurethral resection of the prostrate (TURP) 455
Renal calculi
about the technique 770
added commentary 770b
preoperative preparation 769
surgical procedure 769–770
Renal cyst ablation
about the technique 1087
positioning and port placement 1087
postoperative care 1089
procedure 1088–1089
wound closure 1089
Renal injury repair
about the techniques 905
added commentary 909b
approach to open surgery 905
exposure and injury assessment 906, 907f
landmarks and renal hilum isolation 905–906, 906f, 907f
postoperative care 909
reconstructive principles 906
repair: lower/upper pole injury 906, 908f
repair: middle pole injury 906, 908f
repair: penetrating wounds 906, 908f
stents and drains 909
vascular injuries 909
Renal surgery, endoscopic
anatomy
added commentary 974b
pelviocalyceal system 835–836, 836f
renal vasculature 837–842
ureteropelvic junction 843
caliceal diverticulectomy 1085–1086
cryosurgery
assessment of indications 871
cryoprobe placement and technique 871–877
instruments 871
patient positioning 871
postoperative evaluation 877
hand-assisted laparoscopy (HALS)
about the technique 867, 870
choice of devices 867, 868f, 869f
device placement 867–870, 869f, 870f
patient positioning 867
preoperative considerations 867
heminephrectomy
indications and patient preparation 1063
instruments 1063
positioning and port placement 1063–1064
procedural approach and cystoscopy 1063
procedural technique 1064–1065
specimen removal 1065
nephroureterectomy
indications and contraindications 1071
insufflation and trocar placement 1072, 1073f, 1074f, 1075f

Renal surgery, endoscopic *(Continued)*
mobilization of the colon 1075
nephrectomy procedure 1075, 1076f, 1077f
organ entrapment/extraction 1078–1080
positioning and operating room set-up 1071–1072
postoperative considerations 1080
potential complications 1080
ureter dissection and excision 1075–1080, 1078f, 1079f, 1080f
partial nephrectomy 1067–1070
percutaneous access
about the technique 845
anatomical considerations 846
calyceal diverticulum/obstructed calyx 851–852
cystoscopy and ureteral catherization 846–848, 849–850
diagnosis and preoperative evaluation 845
multiple access tracts 852
nondilated puncture 852
operative complications 853
standard lower pole access 846
supracostal/upper pole access 850–851
percutaneous nephrolithotomy (PNL)
flexible nephroscopy 856
nephroscopes 855–856
preoperative evaluation 855
pyelolithotomy
candidate selection and preparation 1081
retroperitoneoscopic approach 1083
simultaneous pyeloplasty 1083
transperitoneal approach 1081–1083
radical nephrectomy, transperitoneal
establishing pneumoperitoneum 1053–1054
hilar dissection 1057–1058
patient selection and contraindications 1053
port placement 1054–1055
postoperative care 1060–1061
postoperative complications, identifying 1061–1062
preoperative preparation and positioning 1053
removal/sparing of adrenal gland 1059
renal artery and vein ligation 1058–1059
specimen removal 1060
steps for left side 1055
steps for right side 1056–1057
ureteral dissection and division 1059–1060
wound closure 1060
radiofrequency ablation
about the technique 879
laparoscopic RFA 881–882
patient positioning 879
percutaneous RFA 880
postoperative follow–up 882
Starburst XL RFA probe 880, 881t
renal cyst ablation
about the technique 1087
positioning and port placement 1087
postoperative care 1089
procedure 1088–1089
wound closure 1089
retroperitoneal laparoscopic access
about the technique 857, 859
anatomic considerations 857
contraindications 857
laparoscopic technique 858–859
patient positioning and prep 858
simple nephrectomy
identification of proximal ureter 1048–1049
lateral and inferior dissection 1049
medial dissection of kidney 1048
patient positioning 1047, 1048f
postoperative care and complications 1050
preoperative considerations 1047
primary access and trocar placement 1047
Renal surgery, endoscopic *(Continued)*
reflection of the colon 1047–1048
renal hilum dissection 1049
retroperitoneal approach 1050–1051
specimen morcellation 1051
specimen retrieval and removal 1049–1050
superior dissection 1049
wound closure 1050
transperitoneal laparoscopic access
choosing access sites 861
insertion of veress needle 862
insertion of visualizing dilating trocar 863
"open" alternative entry 862–863
port placement 865–866
urothelial carcinoma
about the technique 1091
instruments 1091
resection procedure 1091–1093
Renal surgery, open
anatrophic nephrolithotomy
about patient selection 1043
incision and renal dissection 1043
intraoperative imaging and stone removal 1044
postoperative care 1045
preoperative preparation and positioning 1043
renal closure and hypothermia termination 1044, 1045
approaches to open surgery
about the choices 801–802, 802t
anatomy 799, 800f, 801
anterior approaches 803–806
chevron incision 809–810
flank approaches 814–823
incisional hernia repair 830–832
pediatric transverse abdominal incision 810–814
pleural tear repair 826
splenectomy 827–829
splenorrhaphy, intraoperative repair 826–829
subcostal incision 806–808
thoracoabdominal incision 823–825
extracorporeal surgery
about the procedure 1021
indications and preop considerations 1021–1022
operative technique 1022–1023
postoperative problems 1024
renal neoplasms 1023–1024
renovascular disease 1023
nephroureterectomy
about the procedure 1009
approaches to 1010–1011t
indications and preop considerations 1009–1010, 1009t
single-incision with intravesical dissection 1012–1017
transection without a bladder cuff 1019
transurethra resection of ureteral orifice 1018–1019
two-incision approach with extravesical dissection 1017–1018
ureteral intussusception 1019
partial nephrectomy
added commentary 1007b
contraindications 1001t
indications and preop considerations 1001–1002
large cortical tumors, wedge resection 1003–1004
large polar tumors, heminephrectomy 1006
large polar tumors, segmental nephrectomy 1004
postoperative fistulas and bleeding 1006–1007
renal insufficiency 1007
small cortical tumors, enucleation 1002–1003
pyelolithotomy
patient selection and preparation 1045
postoperative care 1046
stone removal and closure 1045–1046

Renal surgery, open *(Continued)*
radical nephrectomy
added commentary 1000b
indications and preop considerations 989–991, 989t
injury to liver and spleen 999
injury to the duodenum 999
injury to the gut vasculature 998–999
injury to the pancreas 999–1000
left side mini-flank approach 995–996
pulmonary complications 1000
rectrocrural lymphadenectomy 998
regional lymphadenectomy 997–998
right side anterior subcostal approach 991–992
suprahilar lymphadenectomy 998
simple nephrectomy
added commentary 987b
anterior subcostal approach 978–980
approaches to surgery 976t
dorsal lumbotomy approach 981–982
flank approach 975–978
indications and preop considerations 975, 975t
Kocher maneuver 980–981
midline transperitoneal approach 981
renal vascular pedicle, controlling 984–986
subcapsular approach 983
wound closure 986–987
vena caval thrombectomy
about the procedure 1025
bypass techniques 1037–1039
level I: right side 1029–1030
level II: left side 1030–1032
level III: intra-abdominal approach 1032–1035
level III-IV: combined intra-abdominal and intrathoracic approach 1035–1036
patch cavoplasty 1039
perioperative complications 1041
permanent interruption for bland thrombus 1040
preoperative considerations 1025–1026
thrombus grouping system (Mayo Clinic) 1028t
thrombus staging and management 1026t
vena caval replacement 1039–1040
Renal transplantation, donor
cadaveric donor nephrectomy
about the technique 935–937
added commentary 938b
exposure and en-bloc removal 935–937
separation of the kidneys 937
live donor nephrectomy
about the procedure 933–934
left side donation 934
right side donation 933–934
Renal transplantation, recipient
added commentary 932b
assessment and preparation
bladder augmentation 922
candidate evaluation 919
instruments 919
patient positioning 919–920
postoperative problems 930
technique: adult
about the technique 920–926
end-to-end anastomosis to iliac artery 922
end-to-side anastomosis to iliac vein 921
end-to-side arterial anastomosis 922–923
multiple renal arteries 923–924
short right renal vein 924
technique: adult from child donor 924–926
technique: child
about the procedure 926–927
positioning and initial incision 926
surgical technique 926–927
Renal transplantation, recipient *(Continued)*
technique: ureteral implantation
double ureter 930
drains and tubes 930
extravesical technique 928
postoperative care 930
transvesical technique 928–930
transplantation failure: nephrectomy 931–932
Renal vascular disease
about the procedure 911
added commentary 917b
indications for surgery 911–912
patient positioning 912
postoperative care 917
preoperative preparation 912
procedure: aortorenal bypass 912–914
procedure: ex vivo repair with autotransplantation 915–917
procedures: extra-anatomic bypass
about the techniques 914–915
hepatorenal bypass 914–915
iliorenal bypass 915
splenorenal bypass 914
Renal vascular system
anatomy and vasculature 837–842, 843, 886
arterial repairs 75
vascular repairs 909
Restraining wraps (papoose board) 8
Retroperitoneal lymph node dissection (RPLND)
see Lymph node dissection, retroperitoneal
Retroperitoneal surgery, laparoscopic
about the technique 857, 859
anatomic considerations 857
contraindications 857
laparoscopic technique 858–859
patient positioning and prep 858
Retropubic prostatectomy
benign
added commentary 490b
clinical efficacy 481b
patient positioning 483
postoperative management 487
preoperative preparation 483
surgical procedure 483–487
malignant
added commentary 414b
bladder neck dissection and reconstruction 408–409, 410–411
closure and drain placement 411–412
instruments 403
intraoperative problems 412–413
positioning and initial incision 403–404
postoperative care 412
postoperative problems 413
preservation of neurovascular bundles 407
seminal vesicles and vas deferens dissection 407–408
surgical procedure 404–407
urethral suturing 407, 411
Revascularization
see Arterial revascularization
Robotic surgery
see Endoscopic surgery; Laparoscopic surgery

S

Sacral nerve modulation (SNM)
anesthesia 599
development of the technique 599
patient selection 599
responses to nerve stimulation 601t
stage one
closure and postop evaluation 603
fluoroscopy placement of foramen needle 600–601

Sacral nerve modulation *(Continued)*
fluoroscopy placement of introducer sheath 601
preoperative preparation 599
selecting the target spinal foramen 600
tined lead connection to lead extension 602
tined lead deployment 601–602
tunneling tined lead to connection site 603
stage two
extension wire and tined lead removal 603
neurostimulator placement 603
Sacrospinous ligament suspension
comparison to Michigan technique 227
differences from Michigan technique 227t
postoperative issues 233b
see also Michigan four-wall sacrospinous suspension
Scientific Research Institute for Experimental Apparatus 53
Scrotum, hypospadias repair 87
Shaving and epilation 6
Shock-wave lithotripsy
antibiotic prophylaxis 7t
comparison to ureteroscopy 767b
horseshoe kidney 898
stone removal 755, 1043
Sigmoid colon conduit 633f, 634f, 635f
diagnosis and technique selection 633
incision and ureter dissection 633–634
postoperative complications 636
preoperative preparation 633
selection and isolation of bowel 634
stoma creation and closure 635
ureteral anastomosis 634–635
Skin
basic layers and structure 40f
dermal grafts 39–40
grafting techniques 39
maintaining blood supply 39
sutures 31, 32–33
Skin tape 41–42
Sleeve incision (double incision) circumcision 139–141
Small bowel
blood supply 998–999
ileocystoplasty 693
longitudinal lacerations 77
transverse or small puncture lacerations 77
Sperm retrieval
microdissection testicular extraction (microTESE) 300–301
microsurgical epididymal aspiration (MESA) 299–300
percutaneous epididymal aspiration (PESA) 299
testicular fine needle aspiration (TESE) 300
Spermatocelectomy 323–324
Split thickness grafts
allografts and cadaveric skin application 187–188
penis meshed unexpanded split thickness skin graft 187–188, 188f
scrotum meshed split thickness skin graft 188
Squamous cell carcinoma
laser therapy 133–134
Steichen, Felicien M. 53
Sterilization
see Vasectomy
Stone removal surgery
see Anatrophic nephrolithotomy; Pyelolithotomy
Stress incontinence 567
Subcutaneous tissue
sutures 31
Supra midurethral sling pubovaginal
anesthesia 557
diagnosis and technique selection 557
patient positioning 557
surgical procedure
incision and dissection 557
Suprapubic drainage 10
Suprapubic prostatectomy
added commentary 481b
anesthesia 473
antibiotic prophylaxis 473
diagnosis and technique selection 473
instruments for 473
intraoperative hemostatic procedures 479
postoperative care 479–480
postoperative problems 480
preoperative considerations 473
surgical procedure 473–480
Surgical safety procedures
"time out" procedures 5
Surgical staples
bowel stapling technique 53
laparoscopic surgery 23, 53
wound management 12
Surgical techniques
adherence to fundamental concepts 15
basic skills and techniques 15
laparoscopic surgery 17
omentum mobilization 61–63
urologist training for 15
Suture materials
absorption and reactivity of 29–32, 29t
selection by tissue type 32t
types and needle size 32
types and trade name 31t
Suture techniques
basic knot-tying 29
body tissue and selection of 29–32
bowel sutures 35–37
clipping and stapling 23
fascia tissue 30–31
fascial sutures 33–35
hypospadias repair 88
intestine tissues 31–32
robotic surgery 83
skin sutures 32–33
skin tissue 31
subcutaneous tissue 31
surgical staples 12
tissue sealants and glues 9
urinary tract 31
vascular tissue 32
Suture (s)
Connell suture 35, 35f
double-throw knot 29, 30f
everting interrupted suture 33, 33f
far-and-near sutures 34, 34f
figure-eight bowel suture 35, 37f
Halsted mattress suture 33, 33f
interrupted sutures 33–34, 34f
laparoscopic surgery 22–23, 35–37
Lembert suture 35, 36f
lock-stitch 35, 36f
near-and-far suture 34, 34f
pursestring suture 35, 36f
skin clips 34
Smead-Jones fascial closure 34, 34f
square knot 29, 30f
subcuticular closure 32, 33f
surgeon's knot 29, 30f
vertical mattress suture 32, 33f
vertical mattress suture (Gambee stitch) 34–35, 34f

T

Tension-free vaginal tape
anesthesia 557
diagnosis and technique selection 557
patient positioning 557

Tension-free vaginal tape *(Continued)*
surgical procedure
closure 560
incision and dissection 557
sling passage 560
suprapubic needle pass 557
TVT vaginal pass 557–560
Tension-free vaginal tape/midurethral sling
surgical procedure
cystoscopy 560
Testis
benign tumors 351–352
biopsy
incision technique 295, 296–297
infertility 295
intersexes 297
partial duct obstruction 295
percutaneous needle technique 295
epididymectomy
anatomy and physiology 325
indications for 325
postoperative care 326
surgical technique 325–326, 325f, 326f
malignancy
gonadal biopsy 297
radical orchiectomy 353, 355b
retroperitoneal lymph node dissection 357, 365b
testis-sparing surgery 351–352
orchiectomy, radical
control of gonadal vessels 355
diagnosis and technique selection 353
draping 355
preoperative evaluation 353
surgical procedure 353–355
orchiopexy
abdominal approach 331–335
high ligation approach (Fowler-Stephens) 335–336
inguinal (open technique) 327–330
laparoscopic techniques 339–344
low ligation approach 336–337
microvascular approach 338–339
postoperative problems 327–330, 336, 344
redoing a previous procedure 337–338
scrotal approach 330
retroperitoneal lymph node dissection
diagnosis and staging 357
retroperitoneal lymph node dissection (RPLND)
anatomy and templates 362, 365
diagnostic and therapuetic intent 365
drug complications and risks 365
full bilateral RPLND technique 358–362
nerve-sparing anatomy and templates 362f, 363f
nerve-sparing left-sided dissection 362, 364f
nerve-sparing right-sided dissection 362–364, 364f
postchemotherapy approach 357–358
preoperative preparation 357
special considerations 364
sperm retrieval
microdissection testicular extraction (microTESE) 300–301
microsurgical epididymal aspiration (MESA) 299–300
percutaneous epididymal aspiration (PESA) 299
testicular fine needle aspiration (TESE) 300
spermatocelectomy 323–324
testicular torsion
intravaginal vs. extravaginal 345
manual detorsion 345
scrotal fixation 345–346
utricular cyst excision
laparoscopic approach 321
posterior sagittal approach 322
transtrigonal approach 321
Testis *(Continued)*
varicocele ligation (varicocelectomy)
approaches and preparation 303
inguinal approach 304–305
laparoscopic approach 307
postoperative problems 307–308
retroperitoneal approach 305–306
subinguinal varicocelectomy 303–304
vasectomy
added commentary 314b
cautery or compression technique 313, 314
patient counseling and preparation 311
postprocedure considerations 313
postvasectomy semen analysis 314
scalpel technique 313
vas deferens, isolating and anesthetizing 311, 312f
vasovasostomy (vasectomy reversal)
incision and confirmation of patency 315
instruments for 315
modified one-layer closure 316
patient positioning 315
postoperative care 317
post-procedure semen analysis 317
two-layer anastomosis 316
vasoepididymostomy 316–317
Testis, malignancy
laparoscopic retroperitoneal lymph node dissection
added commentary 377b
benefits, staging and preparation 367
left-sided dissection 374–376
operating room set-up 368f
positioning and trocar placement 367–368
postoperative care 376
potential complications 376
right-sided dissection 368–373
orchiectomy, epididymis-sparing 349, 350f
orchiectomy, radical
added commentary 355b
control of gonadal vessels 355
diagnosis and technique selection 353
draping 355
preoperative evaluation 353
surgical procedure 353–355
orchiectomy, simple 349, 350f
retroperitoneal lymph node dissection (RPLND)
added commentary 365b
anatomy and templates 362, 362f, 363f, 365
diagnosis and therapuetic intent 365
drug complications and risks 365
full bilateral technique 358–362
nerve-sparing left-sided dissection 362, 364f
nerve-sparing right-sided dissection 362–364, 364f
postchemotherapy approach 357–358
preoperative preparation 357
special considerations 364
testis-sparing surgery 351–352
Testis nerve block 67
Testosterone
see Androgen supplementation/replacement
Tetracaine 65
Thermal burns/injury
electrocautery 26
treatment of 187
"Time out" procedures 5
Tissue dissection
instrument selection and use 9
tissue handling 9
Tissue sealants and glues 9
Torsion, penile
see Penis, torsion curvature

Total pelvic exenteration
evaluation and preoperative preparation 523
female procedure 528–529
male procedure 523–527, 528
Pelvis, postoperative problems 529
postoperative problems 529
T-pouch (ileal reservoir)
advantages 655b
considerations for 651
steps in surgical procedure 651–654
Transitional cell carcinoma (TCC)
about the management of 781
added commentary 785b
postoperative care 784
preoperative preparation 781
surgical procedure 781–784
Transobturator midurethral sling
anesthesia 563
closure 566
cystoscopy 564
diagnosis and technique selection 563
incision and dissection 563
needle passes 563–564
passage of sling material 564–566
patient positioning 563
Transperitoneal laparoscopy 17
Transperitoneal surgery, laparoscopic
choosing access sites 861
insertion of veress needle 862
insertion of visualizing dilating trocar 863
"open" alternative entry 862–863
port placement 865–866
Transperitoneal vesicovaginal fistula repair
incision and surgical procedure 589–590, 591f
patient positioning 589
surgical alternative procedure 590
Transplantation
see Kidneys, transplantation
Transsacral nerve block 68
Transureteroureterostomy
diagnosis and technique selection 735, 749
positioning and initial incision 735, 749
surgical procedure 737–741, 749–750
graft and flap ureteroplasty 737–739
laparoscopic ureterolysis 741
omental wrap 741
ureterolysis 739–741
Transurethral incision of the prostrate (TUIP)
added commentary 462b
anesthesia 459
catheterization 461
cystoscopy examination 462
diagnosis and technique selection 459
laparoscopic surgery and 462
patient selection 462
postoperative complications 461
preoperative preparation 459
surgical technique 459
Transurethral prostatectomy 3
Transurethral resection
bladder tumors (TURBT)
added commentary 494b
anesthesia 493
diagnosis and technique selection 493, 494
patient positioning 493
postoperative problems 494
surgical procedure 493
prostrate (TURP)
added commentary 457b
anesthesia 451
clinical efficacy 456
diagnosis and technique selection 451
Transurethral resection *(Continued)*
patient positioning 451
postoperative care 456
preoperative preparation 451
surgical complications 455–456, 457
surgical technique 451–455
Transvaginal excision, diverticulectomy 205–212
Transvaginal repair, vesicovaginal fistula
abdominal approach 579, 580–581, 582f
closure
bulbospongious muscle flap (Martius) 581, 582, 583f
gracilis myocutaneous flap 583
island flap (Lehoczky) 583
labial fat pad flap 582
diagnosis and timing of procedure 579
instruments for 579
inverted u-incision flap repair 580–581
partial colpocleisis 581
patient positioning 579–580
postoperative care 581
postoperative complications 579
preoperative preparation 579
vaginal approach 579–580, 580f, 581f
Transverse colon conduit 636f
diagnosis and technique selection 633
incision and ureter dissection 635
postoperative complications 636
preoperative preparation 633
selection and isolation of bowel 635–636
stoma creation and closure 636
ureteral anastomosis 636
Transverse lower abdominal incision 385–390
Transvesical repair, vesicovaginal fistula
diagnosis and timing of procedure 585–587
incision and surgical procedure 585–587
instruments for 585
patient positioning 585
postoperative problems 585
preoperative evaluation 585
Trocar insertion
intraoperative problems 25
port access and placement 82–83
primary port 20–21
procedures for children 24
Tubularized transverse preputial island flap repair 105–107, 106f
Tumor thrombectomy
about the procedure 1025
bypass techniques
cardiopulmonary bypass 1038–1039
considerations for 1037–1039
veno-venous bypass 1037–1038
level I: right side 1029–1030
level II: left side 1030–1032
level III: intra-abdominal approach 1032–1035
level III-IV: combined intra-abdominal and intrathoracic approach 1035–1036
patch cavoplasty 1039
perioperative complications 1041
permanent interruption for bland thrombus 1040
preoperative considerations 1025–1026
thrombus grouping system (Mayo Clinic) 1028t
thrombus staging and management 1026t
vena caval replacement 1039–1040

U

Ultrasound/ultrasound guidance
caliceal diverticulectomy 1085
colon dissection 1047–1048
cryotherapy procedure 445–447
inguinal varicocelectomy 305

Ultrasound/ultrasound guidance *(Continued)*
lymphadenectomy postoperative problems 998–999
nephrectomy preoperative evaluation 1002, 1007
priapism diagnosis and classification 183
prostate cryotherapy 445–447
prostatic nerve block 68
prosthesis postoperative problems 181
pyeloplasty postoperative problems 953
radical orchiectomy 353
retropubic prostatectomy 490
subinguinal varicocelectomy 303
testicular torsion 345
testis-sparing surgery 351
ureteroscopy 765
Uncircumcision 144
Undescended testis
see Orchiopexy
Ureteral calculi, management
about the technique 765
added commentary 767b
stones above the iliac vessels 766, 767f
stones below the iliac vessels 765–766, 766f
Ureteral endoscopic surgery
access and approaches
cannulating the ureteral orifice 760
placement, safety wire 759–760
placement, ureteral access sheath 760–762
placement, ureteroscope over a guidewire 760
placement, working wire 760
special challenges 762
renal calculi treatment
development of the technique 770
postoperative care 770
preoperative considerations 769
surgical procedure 769–770
Ureteral reconstruction and excision
anatomy and vascular arrangement 709–710
assessing intraoperative ureter injury 710
bladder flap repair
about selection of 731
added commentary 733b
postoperative complications 733
surgical procedure 731–733
ileal replacement
about the technique 751
harvesting an ileum segment 751–752
identification of the defect 751
postoperative management 754
preoperative preparation 751
replacement of both ureters 754
surgical procedure 752
Yang-Monti tube 752–754
psoas hitch
considerations for use of 727
postoperative complications 729
surgical procedure 727, 728–729
stricture repair and ureterolysis
diagnosis and technique selection 735, 747
omental wrap 741
patient positioning 735, 747
transureteroureterostomy 737–741, 749–750
ureterolysis 739–741
ureterolysis, laparoscopic 741
ureteroneocystostomy 747–749
ureteroplasty, graft and flap 737–739
ureteroureterostomy 735–737, 736f
transureteroureterostomy
about the technique 737, 749–750
positioning and initial incision 737, 749
surgical procedure 737, 749–750
Ureteral reconstruction and excision *(Continued)*
ureterolithotomy
about the technique 755
postoperative problems 756
surgical procedure 755–756
ureteroneocystostomy
about diagnosis and treatment 711, 726
added commentary 726b
choosing transvesical techniques 719–720
detrusorrhaphy (Hodgson-Firlit-Zaontz) 723, 724f
diagnosis and treatment options 711
external tunnel technique 720–721, 722f, 723f
extravesical tunnel, open technique 720, 721f, 722f
intraextravesical technique 714–716
intraextravesical modification (Politano-Leadbetter) 716
intra-extravesical technique (Paquin) 724
positioning and initial incision 711–712
postoperative problems 724–725
reoperation procedures 725–726
sheath approximation technique (Gil Vernet) 718
spatulated nipple technique 718–719
transtrigonal technique (Cohen) 717–718
ureteral advancement technique (Glenn-Anderson) 716–717
ureteral mobilization 712–713
ureteroureterostomy
diagnosis and technique selection 735, 747
positioning and initial incision 735, 747
surgical procedure 735–737, 747–749, 748f, 749f
ureterovaginal fistula
causes 743
choices and patient preparation 743
positioning and initial incision 743
postoperative complications 745
technique alternatives 745
ureteroneocystostomy with a psoas hitch 744–745
see also Endoscopic ureteral surgery
Ureterocele excision 795–796
Ureterocystoplasty
added commentary 703b
patient selection and preparation 701
surgical procedure 701–702, 702f, 703f
Ureteroileostomy 633, 636, 657
Ureterolithotomy
about the technique 755
added commentary 790b
diagnosis and preoperative preparation 787
port access and placement 787–788, 787f, 788f
postoperative care 789
postoperative problems 756
stone removal and closure 788–789
surgical procedure 755–756, 788, 788f
Ureteroneocystostomy
added commentary 726b
diagnosis and treatment options 711, 726
extravesical techniques
detrusorrhaphy (Hodgson-Firlit-Zaontz) 723, 724f
external tunnel technique 720–721, 722f, 723f
extravesical tunnel, open technique 720, 721f, 722f
intra-extravesical technique (Paquin) 724
positioning and initial incision 711–712
postoperative problems
contralateral vesicoureteral reflux 725
obstructions 724–725
persistent/recurrent vesicoureteral reflux 725
reoperation procedures 725–726
transvesical techniques
about the choices 719–720
intraextravesical technique (Politano-Leadbetter) 714–716
intraextravesical modification 716
sheath approximation technique (Gil Vernet) 718

Ureteroneocystostomy *(Continued)*
spatulated nipple technique 718–719
transtrigonal techniques (Cohen) 717–718
ureteral advancement technique (Glenn-Anderson) 716–717
ureteral mobilization 712–713
Ureteropelvic junction (UPJ) obstruction 887, 939, 943
Ureteroscopy
accessing the ureter
cannulating the ureteral orifice 759, 760
guiding and advancing the wire 759–760
identifying the ureteral orifice 759
placement of a working wire 760
placement of scope 760
placement of ureteral access sheath 760–762
special challenges 762
antibiotic prophylaxis 7t
endopyelotomy
about the technique 775
added commentary 778b
cold knife technique 778
electrocautery 778
Ho:YAG laser procedure 775–776
patient selection and preparation 775
postoperative care 778
endoureterotomy
postoperative care 773
surgical procedure 771–773
horseshoe kidney 898–899
instrumentation
about the types of 763
added commentary 764b
digital video technology 763
flexible ureteroscopes 763
semirigid ureteroscopes 763
ureteroscopy accessories 764
renal calculi
about the technique 770
added commentary 770b
preoperative preparation 769
surgical procedure 769–770
transitional cell carcinoma (TCC)
about the technique 781
postoperative care 784
preoperative preparation 781
surgical procedure 781–784
ureteral calculi
about the technique 765
added commentary 767b
stones above the iliac vessels 766, 767f
stones below the iliac vessels 765–766, 766f
ureterocele excision 795–796
Ureterosigmoidostomy
added commentary 683b
background 673
closed extracolonic technique 673–675, 678f
functional outcomes 683
Mainz Pouch II (sigma rectum pouch) 680–681, 681f, 682f
patient selection 673
preoperative preparation 673
transcolonic technique 675–680, 679f, 680f
Ureteroureterostomy
diagnosis and technique selection 735, 747
positioning and initial incision 735, 747
surgical procedure 735–737, 747–749, 748f, 749f
Ureterovaginal fistula, repair
causes 743
choices and patient preparation 743
positioning and initial incision 743
postoperative complications 745
surgical alternatives 745
ureteroneocystostomy with a psoas hitch 744–745
Urethra
diverticulectomy
described and diagnosis 205
Marsupialization technique (Spence-Duckett) 205, 206f
postoperative care 212
postoperative incontinence 213b
transection procedure 213
transvaginal excision 205–212
urethral mural reconstruction 213
urethral transection procedure 213
endoscopic realignment 275, 285b
meatus
hypospadias repair 87
penectomy postoperative problems 121
necrosis 121
plate elevation 98–99, 98f
prolapse-caruncle
conditions described 217
dissection and reconstruction 217, 218f, 219f
Urethra, reconstruction
anatomy, bulbar 266f
anatomy, penile 248f
bulbar urethra strictures
added commentary 274b
anastomotic urethroplasty 265, 274
anatomy 265, 266f
dorsal graft urethroplasty 270
onlay urethroplasty 274
staged repair 265
ventral graft urethroplasty 265–270, 267f, 268f, 269f, 270f, 271f, 272f, 273f, 274f
concept and techniques
added commentary 239b
bulbar anatomy 238f
distal reconstruction 237–239
instruments 237
positioning 237
preoperative considerations 237
surgical procedures 238–239
direct vision internal urethrotomy (DVIU)
choices of modalities for 289
cold knife technique 290
holmium laser technique 290–291
postoperative care 291
preoperative evaluation 289–291
urethral stricture disease and 289
fossa navicularis
added commentary 245b
meatal stenosis 241
skin flap techniques 241, 242, 243
skin graft technique 243–244
skin island techniques 244, 244
membranous injuries
added commentary 285b
assessment 275
draping and positioning 276f
endoscopic realignment 275
perineal urethroplasty 275–282
preoperative planning 275
transpubic (abdominoperineal) urethroplasty 282–284
penile strictures
anatomy 247, 248f
distal circular fasciocutaneous flap (McAninch) 247–250, 249f, 250f, 251f
dorsally placed buccal mucosa graft (Barbagli) 254, 257f, 258f, 259f
goals and patient factors 247
longitudinal ventral skin flap with lateral pedicle (Orandi) 250–254, 251f, 252f, 253f, 254f
longitudinal ventral skin flap with ventral pedicle (Turner-Warwick) 254, 255f, 256f

Urethra, reconstruction *(Continued)*
urethroplasty, anastomotic 247, 263b
urethroplasty, two-stage (Johannson) 255, 260f, 261f, 262f
rectourinary fistula 287–288
tissue sealants and glues 9
vaginal lateral flap procedure 215–216
Urethrectomy, female
added commentary 516b
diagnosis and technique selection 515
sexual function and 516
surgical complications 515
treatment of distal tumors 515
Urethrectomy, male
added commentary 516b
diagnosis and technique selection 513, 516
patient positioning 513
postoperative problems 515
surgical procedure 513–515
Urethroplasty
basic instrument set 571–572
hypospadias repair 87, 97
onlay technique 90, 274b
preoperative considerations 237
skin flap repairs 103
tubularized incised plate 103, 109
see also Anastomotic urethroplasty
Urethrovaginal fistula
bulbocavernosus muscle and fat pad supplement
labial flap 203, 204b
Martius flap 199
Martius flap, classical approach 201–202
Martius flap, in situ approach 202
Martius flap modifications 200
diagnosis 197
fistula repair 197–198
fistula repair closure 200
Urinary and bowel diversion
about choices and types 646t, 647t
fecal diversion
added commentary 642b
divided loop colostomy 639
end colostomy 640
end colostomy, laparoscopic 640, 640–641
ileostomy vs. colostomy 637
indications for 637
laparoscopic stoma, reversal 641
loop ileostomy 637–639
loop ileostomy, laparoscopic 640–641
stoma, site selection 637
stoma placement, laparoscopic 640–641
stoma reversal, laparoscopic 641
Ileal conduit, laparoscopic
cystectomy and 629
isolation of ileal segment 629
reanastomosis and bowel division 629, 630f
stoma and ureteral anastomoses 630, 631f
Ileal conduit, surgery
development and advantages 615
harvesting the bowel 617–619, 617f, 618f
ileoileal anastomosis 619–621, 619f, 620f, 621f
patient selection and education 615
preparation of the bowel 615
stoma, creation of the 623–626
stoma, procedure alternatives 626
stoma, site selection 615–616
ureteroileal anastomosis 621–623
urethral mobilization 616–617, 616f, 617
ileal orthotopic bladder substitution
about the technique 685, 686–689
contraindications 685t
ileal segment preparation 686–687
patient selection and preparation 685–686
Urinary and bowel diversion *(Continued)*
postoperative care 688–689
postoperative complications 689
postoperative outcomes 689
substitute construction 687–688
ureteroileal anastomosis 687
sigmoid colon conduit 633f, 634f, 635f
diagnosis and technique selection 633
incision and ureter dissection 633–634
postoperative complications 636
preoperative preparation 633
selection and isolation of bowel 634
stoma creation and closure 635
ureteral anastomosis 634–635
sutures 31
transverse colon conduit 636f
diagnosis and technique selection 633
incision and ureter dissection 635
postoperative complications 636
preoperative preparation 633
selection and isolation of bowel 635–636
stoma creation and closure 636
ureteral anastomosis 636
vesicostomy
blocksom technique 609–611
closure 611
incontinent ileovesicostomy 612
lapides technique 607–609
lapides technique modifications 609
postoperative complications 613
see also Continent reconstruction
Urinary reservoirs
choices and patient preferences 668
conduits 667f, 668
Gastroileoileal pouch (Lockhart) 667
Indiana pouch 661–667, 662f
Mainz pouch
incision and surgical procedure 657, 658f, 659f
intussusception, ileocecal valve 657–658, 660f, 661f
intussusception alternative 658
pouch with appendiceal stoma 661, 668
preoperative site selection 657
postoperative problems 668
in situ tunneled bowel flap tubes 661
Urinary sphincter, artificial (AUS)
bulbar urethral cuff placement 571
incision and surgical procedure 572–573
instruments for 571–572
patient positioning 572
postoperative problems 575
preoperative evaluation 571
pressure-regulating balloon 574
scrotal pump placement 574
Urologic operative procedures
about strategy and tactics of 3
anesthesia 8
evaluation by the anesthesiologist 4–5
fluid and electrolyte replacement 8
general anesthesia 8
local anesthesia 8
bowel preparation 6
management
role of first assistant 8
surgical techniques 9–10
urinary drainage and catheters 10–11
viral infections 8–9
nutritional assessment 4
operative site preparation 5–6
contamination 6
draping 6
marking the site 5

Urologic operative procedures *(Continued)*
shaving and epilation 6
skin preparation 6
outpatient surgery 5
perioperative antibiotics 6–8, 7t
preoperative checklist 5, 6t
preoperative evaluation 3–5
protection during surgery 8
risk evaluation 3–4
vascular access 6
venous thromboembolism prophylaxis 4, 5t
Urologic postoperative management
about the operative report 11
avoidance of complications 11
fluid requirements 11
infections 12
pain management 11–12
wound management 12
Urothelial carcinoma, laparoscopic resection
about the technique 1091
instruments 1091
procedure 1091–1093
Uterosacral ligament suspension 227
Utricular cyst excision
laparoscopic approach 321
posterior sagittal approach 322
transtrigonal approach 321

V

Vaginal atrophy 567
Vaginal reconstruction
antibiotic prophylaxis 7t
bulbocavernosus muscle and fat pad supplement
added commentary 204b
classical Martius flap 199, 201–202
labial flap 203
in situ Martius flap 202
cecal vagina procedure 191–196
colporrhaphy
anterior technique 221–223
concurrent enterocele repair 223–224
posterior technique 224–226
cystocele repair 221–223
enterocele repair 223–224
Michigan four-wall sacrospinous suspension
added commentary 233b
advantages over other techniques 228
comparison to other techniques 227
differences from other techniques 227t
key principles of 228t
operative technique 229–231
results and outcomes after 1 year 233
rectocele repair 224–226
urethral diverticulectomy
added commentary 213b
examination and diagnosis 205
marsupialization technique (Spence-Duckett) 205, 206f
postoperative care 212
transvaginal excision 205–212, 207f, 208f, 210f, 211f, 212f
urethral lateral flap 215–216
urethral prolapse-caruncle 217–220
urethrovaginal fistula repair 197–200
Vaginal vault eversion 227
Varicocele ligation (varicocelectomy)
approaches and preparation 303
inguinal approach 304–305
laparoscopic approach 307, 308f
postoperative problems 307–308
retroperitoneal approach 305–306
subinguinal approach 303–304
Vascular tissue
arterial repair 74–76
sutures 32
venous repair 71–74
Vasectomy
added commentary 314b
anesthetizing the vas deferens 311, 312f
cautery or compression technique 313, 314
patient counseling and preparation 311
postprocedural considerations 313
postvasectomy semen analysis 314
scalpel technique 313
Vasovasostomy (vasectomy reversal)
incision and confirmation of patency 315
instruments 315
modified one-layer closure 316
patient positioning 315
postoperative care 317
post-procedure semen analysis 317
two-layer anastomosis 316
vasoepididymostomy
confirmation of patency 316–317
end-to-end anastomosis 317
end-to-side anastomosis 316–317
intussusception anastomosis 317
Vena cava
bilateral lymphadenectomy 358
laceration repairs 71
laparoscopic surgery 19–20, 23
lymph node dissection 362–364
patch cavoplasty 1039
perioperative complications 1041
permanent interruption for bland thrombus 1040
renal surgery 801
renal vasculature 886, 968, 968f, 970f
replacement 1039–1040
thrombectomy
about the procedure 1025
bypass techniques 1037–1039
level I: right side 1029–1030
level II: left side 1030–1032
level III: intra-abdominal approach 1032–1035
level III-IV: combined intra-abdominal and intrathoracic approach 1035–1036
preoperative considerations 1025–1026
thrombus grouping system (Mayo Clinic) 1028t
thrombus staging and management 1026t
Venous injury repairs
iliac veins 71–74
laceration of the vena cava 71
lumbar vein 74
pelvic venous plexus 71
Ventral corporal lengthening 99, 99f
Veress needle (closed) technique 19–20, 19f
Vesical diverticulectomy
diagnosis and preoperative preparation 531
laparoscopic technique 536
surgical technique 531–536
Vesicostomy
blocksom technique 609–611
closure 611
incontinent ileovesicostomy 612
lapides technique 607–609
lapides technique modifications 609
postoperative complications 613
Vesicoureteral reflux 711
Vesicovaginal fistula
transperitoneal repair
incision and surgical procedure 589–590, 591f
patient positioning 589
surgical alternative procedure 590

Vesicovaginal fistula *(Continued)*
transvaginal repair
abdominal approach 579, 580–581, 582f, 583f
diagnosis and timing of procedure 579
flap closure techniques 581–583
instruments for 579
inverted u-incision flap repair 580–581
partial colpocleisis 581
patient positioning 579–580
postoperative care 581
postoperative complications 579
preoperative preparation 579
vaginal approach 579–580, 580f, 581f
transvesical repair
diagnosis and timing of procedure 585–587
incision and surgical procedure 585–587
instruments for 585
patient positioning 585
postoperative problems 585
preoperative evaluation 585
vesical neck closure
abdominal approach 593–594, 593f, 594f
abdominal approach with urethral inversion 594–595, 595f, 596f
diagnosis and technique selection 593
preoperative preparation 593
urethral approach 595, 596f, 597f
vaginal approach 595–596, 597f, 598f
Viral infections
operating room contamination 9
preoperative testing 8–9
protective gloves and clothing 9
Voiding cystourethrography (VCUG) 531
VUR, management of
about the technique 791
causes of failure 794t
double hydrodistension implantation (double hit) 792–793
"Mountain range" technique 791f
preoperative preparation 791–792
reasons for success 794t
STING technique 791f

W
Webbed or tethered penis
see Hidden penis
Wound management
postoperative care 12

Y
Yang-Monti procedure
appendicovesicostomy 671, 671f, 672f
ileal ureteral replacement 752–754
York-Mason closure, rectourethral fistula 287–288
Young, Hugh Hampton 3, 415