Student CONSULT
Activate at studentconsult.com
Searchable Full Text Online

KUMAR
ABBAS
ASTER

# Robbins BASIC PATHOLOGY

NINTH EDITION

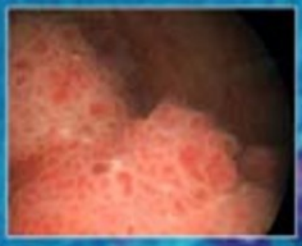
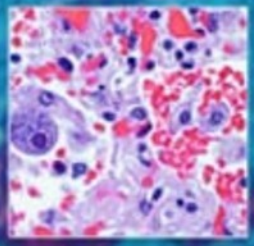
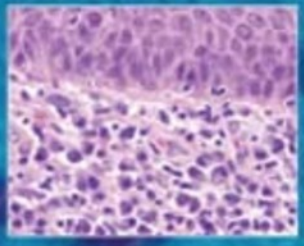
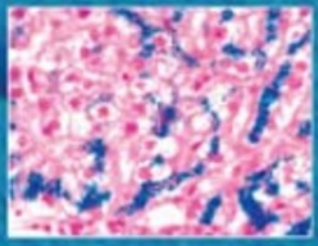
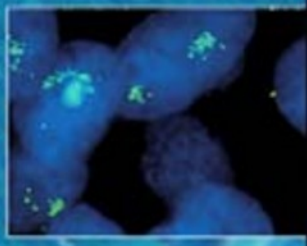

ELSEVIER
SAUNDERS

*Study smart* with **Student Consult**
Searchable full text online

# Register and activate this title today at studentconsult.com

Activation Code

- **Access the full text online**
- **Download images**
- Add your own **notes and bookmarks**
- Search across all the **Student Consult** resources you own online in one place

## ALREADY REGISTERED?

1. Go to studentconsult.com; Sign in
2. Click the "Activate Another Book" button
3. Gently scratch off the surface of the sticker with the edge of a coin to reveal your Pin code
4. Enter it into the "Pin code" box; select the title you've activated from the drop-down menu
5. Click the "Activate Book" button

## FIRST-TIME USER?

1. ***REGISTER***
   - Go to studentconsult.com; click "Register Now"
   - Fill in your user information and click "Activate your account"
2. ***ACTIVATE YOUR BOOK***
   - Click the "Activate Another Book" button
   - Gently scratch off the surface of the sticker with the edge of a coin to reveal your Pin code
   - Enter it into the "Pin code" box; select the title you've activated from the drop-down menu
   - Click the "Activate Book" button

Access to, and online use of, content through the Student Consult website is for individual use only; library and institutional access and use are strictly prohibited. For information on products and services available for institutional access, please contact our Account Support Center at (+1) 877-857-1047. Important note: Purchase of this product includes access to the online version of this edition for use exclusively by the individual purchaser from the launch of the site. This license and access to the online version operates strictly on the basis of a single user per PIN number. The sharing of passwords is strictly prohibited, and any attempt to do so will invalidate the password. Access may not be shared, resold, or otherwise circulated, and will terminate 12 months after publication of the next edition of this product. Full details and terms of use are available upon registration, and access will be subject to your acceptance of these terms of use.

For technical assistance: email online.help@elsevier.com
call 800-401-9962 (inside the US) / call +1-314-995-3200 (outside the US)

Robbins Basic Pathology

This page intentionally left blank

ROBBINS

# Basic Pathology

NINTH EDITION


## Vinay Kumar, MBBS, MD, FRCPath

Donald N. Pritzker Professor
Chair, Department of Pathology
Biologic Sciences Division and
Pritzker School of Medicine
University of Chicago
Chicago, Illinois

## Abul K. Abbas, MBBS

Distinguished Professor and Chair
Department of Pathology
University of California San Francisco
San Francisco, California

## Jon C. Aster, MD, PhD

Professor of Pathology
Harvard Medical School
Brigham and Women's Hospital
Boston, Massachusetts

ARTIST

James A. Perkins, MS, MFA



ELSEVIER
SAUNDERS

ELSEVIER
SAUNDERS

1600 John F. Kennedy Blvd.
Ste 1800
Philadelphia, PA 19103-2899

ROBBINS BASIC PATHOLOGY 978-1-4377-1781-5
International Edition: 978-0-8089-2432-6

**Copyright © 2013, 2007, 2003, 1997, 1992, 1987, 1981, 1976, 1971 by Saunders, an imprint of Elsevier Inc.**

No part of this publication may be reproduced or transmitted in any form or by any means, electronic or mechanical, including photocopying, recording, or any information storage and retrieval system, without permission in writing from the publisher. Details on how to seek permission, further information about the Publisher's permissions policies and our arrangements with organizations such as the Copyright Clearance Center and the Copyright Licensing Agency, can be found at our website: www.elsevier.com/permissions.

This book and the individual contributions contained in it are protected under copyright by the Publisher (other than as may be noted herein).

**Notices**

Knowledge and best practice in this field are constantly changing. As new research and experience broaden our understanding, changes in research methods, professional practices, or medical treatment may become necessary.

Practitioners and researchers must always rely on their own experience and knowledge in evaluating and using any information, methods, compounds, or experiments described herein. In using such information or methods they should be mindful of their own safety and the safety of others, including parties for whom they have a professional responsibility.

With respect to any drug or pharmaceutical products identified, readers are advised to check the most current information provided (i) on procedures featured or (ii) by the manufacturer of each product to be administered, to verify the recommended dose or formula, the method and duration of administration, and contraindications. It is the responsibility of practitioners, relying on their own experience and knowledge of their patients, to make diagnoses, to determine dosages and the best treatment for each individual patient, and to take all appropriate safety precautions.

To the fullest extent of the law, neither the Publisher nor the authors, contributors, or editors, assume any liability for any injury and/or damage to persons or property as a matter of products liability, negligence or otherwise, or from any use or operation of any methods, products, instructions, or ideas contained in the material herein.

**Library of Congress Cataloging-in-Publication Data**

Robbins basic pathology / [edited by] Vinay Kumar, Abul K. Abbas, Jon C. Aster. – 9th ed.
p. ; cm.
Basic pathology
Includes bibliographical references and index.
ISBN 978-1-4377-1781-5 (hardcover : alk. paper) – ISBN 978-0-8089-2432-6 (International ed. : hardcover : alk. paper)
I. Kumar, Vinay, 1944– II. Abbas, Abul K. III. Aster, Jon C. IV. Robbins, Stanley L. (Stanley Leonard), 1915–2003. V. Title: Basic pathology.
[DNLM: 1. Pathology. QZ 4]
616.07–dc23

2011048699

*Executive Content Strategist:* William Schmitt
*Content Development Manager:* Rebecca Gruliow
*Publishing Services Manager:* Patricia Tannian
*Senior Project Manager:* Sarah Wunderly
*Design Direction:* Louis Forgione

Printed in Canada

Last digit is the print number: 9 8 7 6 5 4 3 2 1

Working together to grow libraries in developing countries
www.elsevier.com | www.bookaid.org | www.sabre.org
ELSEVIER BOOK AID International Sabre Foundation

# DEDICATION

To
Our children and a special grandchild
Kiera Chapman Kumar

This page intentionally left blank

# Contributors


**Charles E. Alpers, MD**
Professor and Vice Chair
Department of Pathology
University of Washington
Seattle, Washington
*Kidney and Its Collecting System*

**Jonathan Epstein, MD**
Professor of Pathology, Urology, and Oncology
The Reinhard Professor of Urological Pathology
Director of Surgical Pathology
The Johns Hopkins Medical Institutions
Baltimore, Maryland
*Male Genital System and Lower Urinary Tract*

**Agnes B. Fogo, MD**
John L. Shapiro Chair of Pathology
Professor of Pathology, Microbiology, Immunology, Medicine, and Pediatrics
Director, Renal/EM Division of Pathology
Vanderbilt University School of Medicine
Nashville, Tennessee
*Kidney and Its Collecting System*

**Matthew P. Frosch, MD, PhD**
Lawrence J. Henderson Associate Professor of Pathology and Health Sciences & Technology
Harvard Medical School
Director, C.S. Kubik Laboratory for Neuropathology
Massachusetts General Hospital
Boston, Massachusetts
*Central Nervous System*

**Aliya Noor Husain, MBBS**
Professor
Department of Pathology
The University of Chicago
Chicago, Illinois
*Lung*

**Alexander J.F. Lazar, MD, PhD**
Associate Professor
Departments of Pathology and Dermatology
The University of Texas M.D. Anderson Cancer Center
Houston, Texas
*Skin*

**Mark W. Lingen, DDS, PhD**
Associate Professor
Department of Pathology
The University of Chicago, Chicago, Illinois
*Oral Cavity and Gastrointestinal Tract*

**Anirban Maitra, MBBS**
Professor of Pathology and Oncology
The Johns Hopkins University School of Medicine
Pathologist
The Johns Hopkins Hospital
Baltimore, Maryland
*Genetic and Pediatric Diseases*; *Pancreas*; *Endocrine System*

**Alexander J. McAdam, MD, PhD**
Associate Professor of Pathology
Harvard Medical School
Medical Director, Infectious Diseases Diagnostic Laboratory
Children's Hospital
Boston, Massachusetts
*General Pathology of Infectious Diseases*

**Richard N. Mitchell, MD, PhD**
Lawrence J. Henderson Professor of Pathology and Health Sciences & Technology
Department of Pathology
Harvard Medical School
Staff Pathologist
Brigham and Women's Hospital
Boston, Massachusetts
*Hemodynamic Disorders, Thromboembolism, and Shock*; *Blood Vessels*; *Heart*

**Peter Pytel, MD**
Assistant Professor
Department of Pathology
The University of Chicago
Chicago, Illinois
*Peripheral Nerves and Muscles*

**Andrew E. Rosenberg, MD**
Clinical Professor of Pathology
Director, Bone and Soft Tissue Pathology
Department of Pathology
Miller School of Medicine
University of Miami
Miami, Florida
*Bones, Joints, and Soft Tissue Tumors*

Husain A. Sattar, MD
Assistant Professor of Pathology
The University of Chicago
Chicago, Illinois
*Female Genital System and Breast*

Arlene H. Sharpe, MD, PhD
Professor of Microbiology and Immunobiology, and Pathology
Harvard Medical School and Brigham and Women's Hospital
Boston, Massachusetts
*General Pathology of Infectious Diseases*

Thomas Stricker, MD, PhD
Instructor
Department of Pathology
The University of Chicago
Chicago, Illinois
*Neoplasia*

Neil D. Theise, MD
Professor
Departments of Pathology and Medicine (Digestive Diseases)
Beth Israel Medical Center of Albert Einstein College of Medicine
New York, New York
*Liver, Gallbladder, and Biliary Tract*

Jerrold R. Turner, MD, PhD
Sara and Harold Lincoln Thompson Professor
Associate Chair
Department of Pathology
The University of Chicago
Chicago, Illinois
*Oral Cavity and Gastrointestinal Tract*

Wei-Lien Wang, MD
Assistant Professor of Pathology
Section of Soft Tissue and Dermatopathology
The University of Texas M.D. Anderson Cancer Center
Houston, Texas
*Skin*

Edward C. Klatt, MD
Professor and Academic Administrator
Department of Pathology
Florida State University College of Medicine
Tallahassee, Florida
*Photographic Editor*

Raminder Kumar, MBBS, MD
Chicago, Illinois
*Clinical Editor for Diseases of the Heart, Lung, Pancreas, Oral Cavity and Gastrointestinal Tract, and Liver*

Richard N. Mitchell, MD, PhD
Lawrence J. Henderson Professor of Pathology and Health Sciences & Technology
Department of Pathology
Harvard Medical School
Staff Pathologist
Brigham and Women's Hospital
Boston, Massachusetts
*Targeted Therapy (Online) Editor*

# Preface

## FORTY YEARS OF BASIC PATHOLOGY

As we reach the 40th year of the publication of *Robbins Basic Pathology,* it is useful to quote Stanley Robbins from the Preface of the first edition (1971):

"Of books as well as men, it may be observed that fat ones contain thin ones struggling to get out. In a sense, this book bears such a relationship to its more substantial progenitor, *Robbins Pathology*. It arose from an appreciation of the modern medical student's dilemma. As the curriculum has become restructured to place greater emphasis on clinical experience, time for reading is correspondingly curtailed. … In writing this book, rare and esoteric lesions are omitted without apology, and infrequent or trivial ones described only briefly. We felt it important, however, to consider rather fully the major disease entities."

The goals of this edition of "baby Robbins" remain true to this vision of Stanley Robbins.

This is an exciting time for students of medicine because the fundamental mechanisms of disease are being unveiled at a breathtaking pace. Pathology is central to understanding the molecular basis of disease, and we have tried to capture the essence of this new knowledge in the ninth edition of *Robbins Basic Pathology.* We firmly believe that pathology forms the scientific foundation of medicine, and advances in the basic sciences ultimately help us in understanding diseases in the individual patient. Thus, while many of the new discoveries in genomics and personalized medicine are covered in the initial chapters on general pathology, we have strived to include the impact of scientific advances on diseases of organ systems described throughout the text. To emphasize the importance of disease mechanisms in the practice of medicine, we have highlighted sections dealing with pathogenesis. In recent years an understanding of the molecular basis of disease has led to the development of "targeted therapies." These are highlighted in the form of "Targeted Therapy" boxes in the online edition of this book. We hope that this new feature will provide examples of "bench-to-bedside" medicine. Although many of the "breakthroughs" in the laboratory have not yet reached the bedside, we have included them in measured "doses" so that students can begin to experience the excitement that is ahead in their careers.

Realizing that the modern medical student feels inundated in trying to synthesize the essentials with the "state of the art," we have continued the use of Summary boxes designed to provide the students with key "take home" messages. These have been retained at the risk of adding a few additional pages to the book since students have uniformly told us that they find them useful.

Many new pieces of four-color art—schematics, flow charts, and diagrammatic representations of disease—have been added to facilitate the understanding of difficult concepts such as the control of the cell cycle, functions of cancer genes, interactions of HIV with its receptors, and the biochemical basis of apoptotic cell death. More illustrations have been added, bringing the total to more than 1,000. Formatting and color palettes of the tables have been changed for greater clarity.

Despite the extensive changes and revisions, our goals remain essentially unaltered. Although we have entered the genomic era, the time-honored tools of gross and microscopic analysis remain useful and morphologic changes are highlighted for ready reference. The strong emphasis on clinicopathologic correlations is maintained, and wherever understood, the impact of molecular pathology on the practice of medicine is emphasized. We are pleased that all of this was accomplished without any "bulge" in the waistline of the text.

We continue to firmly believe that clarity of writing and proper use of language enhance comprehension and facilitate the learning process. Generations of students have told us that they enjoy reading this book. We hope that this edition will be worthy of and possibly enhance the tradition of its forebears.

# Acknowledgments

First and foremost, we wish to thank and acknowledge our long-time friend and colleague Dr. Nelson Fausto for his contributions to the previous edition of this book. We continue to benefit from his writing and editing.

Any large endeavor of this type cannot be completed without the help of many individuals. We thank the contributors of various chapters. Many are veterans of the older sibling of this text, the so-called "Big Robbins," and they are listed in the table of contents. To each of them a special thanks. We are fortunate to continue our collaboration with Jim Perkins, whose illustrations bring abstract ideas to life and clarify difficult concepts, and we welcome Dr. Raminder Kumar who edited several chapters for accuracy and appropriateness of the clinical content.

Our assistants, Valerie Driscoll from Chicago, Ana Narvaez from San Francisco, and Muriel Goutas from Boston, deserve thanks for coordinating the tasks.

Many colleagues have enhanced the text by providing helpful critiques in their areas of interest. These include Dr. Rick Aster, who provided "late-breaking news" in the area of climate change science. Many others offered critiques of various chapters. They include Drs. Tony Chang and Neeraj Jolly at the University of Chicago; Drs. Ryan Gill, Andrew Horvai, Marta Margeta, Arie Perry, and Mike Rosenblum of the University of California at San Francisco; Dr. John Stone from Massachusetts General Hospital, Harvard Medical School; Dr. Diego H. Castrillon at UT Southwestern Medical School; and Dr. Victor J. Thannickal of the University of Alabama at Birmingham. Others have provided us with photographic gems from their personal collections. They are individually acknowledged in the credits for their contribution(s). For any unintended omissions we offer our apologies.

Many at Elsevier deserve recognition for their roles in the production of this book. This text was fortunate to be in the hands of Rebecca Gruliow (Manager, Content Development) who has been our partner for several editions. Others deserving of our thanks are Sarah Wunderly (Senor Project Manager) and Lou Forgione (Senior Book Designer). Bill Schmitt, Executive Content Strategist, continues to be our cheerleader and friend. We are especially grateful to the entire production team for tolerating our sometimes next to "impossible" demands and for putting up with our idiosyncrasies during the periods of extreme exhaustion that afflict all authors who undertake what seems like an endless task. We are thankful to the entire Elsevier team for sharing our passion for excellence.

Ventures such as this exact a heavy toll from the families of the authors. We thank them for their tolerance of our absences, both physical and emotional. We are blessed and strengthened by their unconditional support and love, and for their sharing with us the belief that our efforts are worthwhile and useful. We are especially grateful to our wives Raminder Kumar, Ann Abbas, and Erin Malone, who continue to provide steadfast support.

And finally, Vinay Kumar and Abul Abbas welcome Jon Aster, who cut his teeth on the eighth edition of *Pathologic Basis of Disease*, as a co-author and editor. Our partnership thrives because of a shared vision of excellence in teaching despite differences in opinions and individual styles.

**VK**
**AKA**
**JCA**

# Contents


| | | |
|---|---|---|
| CHAPTER 1 | Cell Injury, Cell Death, and Adaptations | 1 |
| CHAPTER 2 | Inflammation and Repair | 29 |
| CHAPTER 3 | Hemodynamic Disorders, Thromboembolism, and Shock<br>*Richard N. Mitchell* | 75 |
| CHAPTER 4 | Diseases of the Immune System | 99 |
| CHAPTER 5 | Neoplasia | 161 |
| CHAPTER 6 | Genetic and Pediatric Diseases<br>*Anirban Maitra* | 215 |
| CHAPTER 7 | Environmental and Nutritional Diseases | 269 |
| CHAPTER 8 | General Pathology of Infectious Diseases<br>*Alexander J. McAdam, Arlene H. Sharpe* | 309 |
| CHAPTER 9 | Blood Vessels<br>*Richard N. Mitchell* | 327 |
| CHAPTER 10 | Heart<br>*Richard N. Mitchell* | 365 |
| CHAPTER 11 | Hematopoietic and Lymphoid Systems | 407 |
| CHAPTER 12 | Lung<br>*Aliya Noor Husain* | 459 |
| CHAPTER 13 | Kidney and Its Collecting System<br>*Charles E. Alpers, Agnes B. Fogo* | 517 |
| CHAPTER 14 | Oral Cavity and Gastrointestinal Tract<br>*Jerrold R. Turner, Mark W. Lingen* | 551 |
| CHAPTER 15 | Liver, Gallbladder, and Biliary Tract<br>*Neil D. Theise* | 603 |


Chapters without author names were written by the editors.

CHAPTER 16 Pancreas 645
*Anirban Maitra*

CHAPTER 17 Male Genital System and Lower Urinary Tract 657
*Jonathan Epstein*

CHAPTER 18 Female Genital System and Breast 681
*Husain A. Sattar*

CHAPTER 19 Endocrine System 715
*Anirban Maitra*

CHAPTER 20 Bones, Joints, and Soft Tissue Tumors 765
*Andrew E. Rosenberg*

CHAPTER 21 Peripheral Nerves and Muscles 797
*Peter Pytel*

CHAPTER 22 Central Nervous System 811
*Matthew P. Frosch*

CHAPTER 23 Skin 851
*Alexander J.F. Lazar, Wei-Lien Wang*

See Targeted Therapy available online at studentconsult.com

CHAPTER 1

# Cell Injury, Cell Death, and Adaptations

CHAPTER CONTENTS

Introduction to Pathology 1
Overview of Cellular Responses to Stress and Noxious Stimuli 1
Cellular Adaptations to Stress 3
Hypertrophy 3
Hyperplasia 4
Atrophy 4
Metaplasia 5
Overview of Cell Injury and Cell Death 6
Causes of Cell Injury 6
The Morphology of Cell and Tissue Injury 8
Reversible Injury 8
Necrosis 9
Patterns of Tissue Necrosis 9
Mechanisms of Cell Injury 11
Depletion of ATP 12
Mitochondrial Damage and Dysfunction 13
Influx of Calcium 13
Accumulation of Oxygen-Derived Free Radicals (Oxidative Stress) 14
Defects in Membrane Permeability 16
Damage to DNA and Proteins 16
Clinicopathologic Correlations: Examples of Cell Injury and Necrosis 16
Ischemic and Hypoxic Injury 17
Ischemia-Reperfusion Injury 17
Chemical (Toxic) Injury 17
Apoptosis 18
Causes of Apoptosis 18
Mechanisms of Apoptosis 19
Examples of Apoptosis 20
Autophagy 22
Intracellular Accumulations 23
Pathologic Calcification 25
Cellular Aging 26

## INTRODUCTION TO PATHOLOGY

Literally translated, *pathology* is the study (*logos*) of disease (*pathos,* suffering). It involves the investigation of the causes of disease and the associated changes at the levels of cells, tissues, and organs, which in turn give rise to the presenting signs and symptoms of the patient. There are two important terms that students will encounter throughout their study of pathology and medicine:

- *Etiology* is the origin of a disease, including the underlying causes and modifying factors. It is now clear that most common diseases, such as hypertension, diabetes, and cancer, are caused by a combination of inherited genetic susceptibility and various environmental triggers. Understanding the genetic and environmental factors underlying diseases is a major theme of modern medicine.
- *Pathogenesis* refers to the steps in the development of disease. It describes how etiologic factors trigger cellular and molecular changes that give rise to the specific functional and structural abnormalities that characterize the disease. Whereas etiology refers to *why* a disease arises, pathogenesis describes *how* a disease develops.

Defining the etiology and pathogenesis of disease not only is essential for understanding a disease but is also the basis for developing rational treatments. Thus, by explaining the causes and development of disease *pathology provides the scientific foundation for the practice of medicine*.

To render diagnoses and guide therapy in clinical practice, pathologists identify changes in the gross or microscopic appearance (*morphology*) of cells and tissues, and biochemical alterations in body fluids (such as blood and urine). Pathologists also use a variety of morphologic, molecular, microbiologic, and immunologic techniques to define the biochemical, structural, and functional changes that occur in cells, tissues, and organs in response to injury. Traditionally, the discipline is divided into general pathology and systemic pathology; the former focuses on the cellular and tissue alterations caused by pathologic stimuli in most tissues, while the latter examines the reactions and abnormalities of different specialized organs. In this book we first cover the broad principles of general pathology and then progress to specific disease processes in individual organs.

## OVERVIEW OF CELLULAR RESPONSES TO STRESS AND NOXIOUS STIMULI

Cells are active participants in their environment, constantly adjusting their structure and function to accommodate changing demands and extracellular stresses. Cells normally maintain a steady state called *homeostasis* in which the intracellular milieu is kept within a fairly narrow range of physiologic parameters. As cells encounter physiologic stresses or pathologic stimuli, they can undergo

adaptation, achieving a new steady state and preserving viability and function. The principal adaptive responses are *hypertrophy, hyperplasia, atrophy,* and *metaplasia*. If the adaptive capability is exceeded or if the external stress is inherently harmful, *cell injury* develops (Fig. 1–1). Within certain limits, injury is *reversible,* and cells return to a stable baseline; however, if the stress is severe, persistent and rapid in onset, it results in *irreversible injury* and death of the affected cells. *Cell death* is one of the most crucial events in the evolution of disease in any tissue or organ. It results from diverse causes, including ischemia (lack of blood flow), infections, toxins, and immune reactions. Cell death also is a normal and essential process in embryogenesis, the development of organs, and the maintenance of homeostasis.

The relationships among normal, adapted, and reversibly and irreversibly injured cells are well illustrated by the responses of the heart to different types of stress (Fig. 1–2). Myocardium subjected to persistent increased load, as in hypertension or with a narrowed (stenotic) valve, adapts by undergoing *hypertrophy*—an increase in the size of the individual cells and ultimately the entire heart—to generate the required higher contractile force. If the increased demand is not relieved, or if the myocardium is subjected to reduced blood flow (*ischemia*) from an occluded coronary artery, the muscle cells may undergo injury. Myocardium may be reversibly injured if the stress is mild or the arterial occlusion is incomplete or sufficiently brief, or it may undergo irreversible injury and cell death (*infarction*) after complete or prolonged occlusion. Also of note, stresses

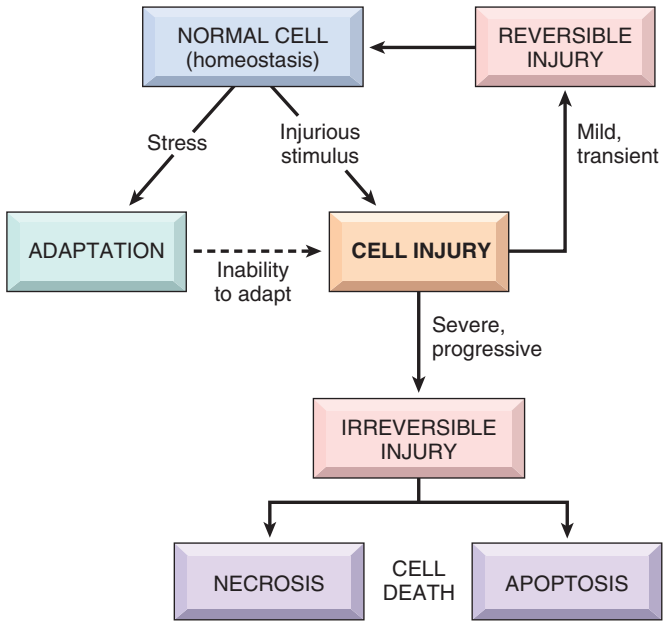


**Figure 1–1** Stages in the cellular response to stress and injurious stimuli.

and injury affect not only the morphology but also the functional status of cells and tissues. Thus, reversibly injured myocytes are not dead and may resemble normal myocytes morphologically; however, they are transiently noncontractile, so even mild injury can have a significant

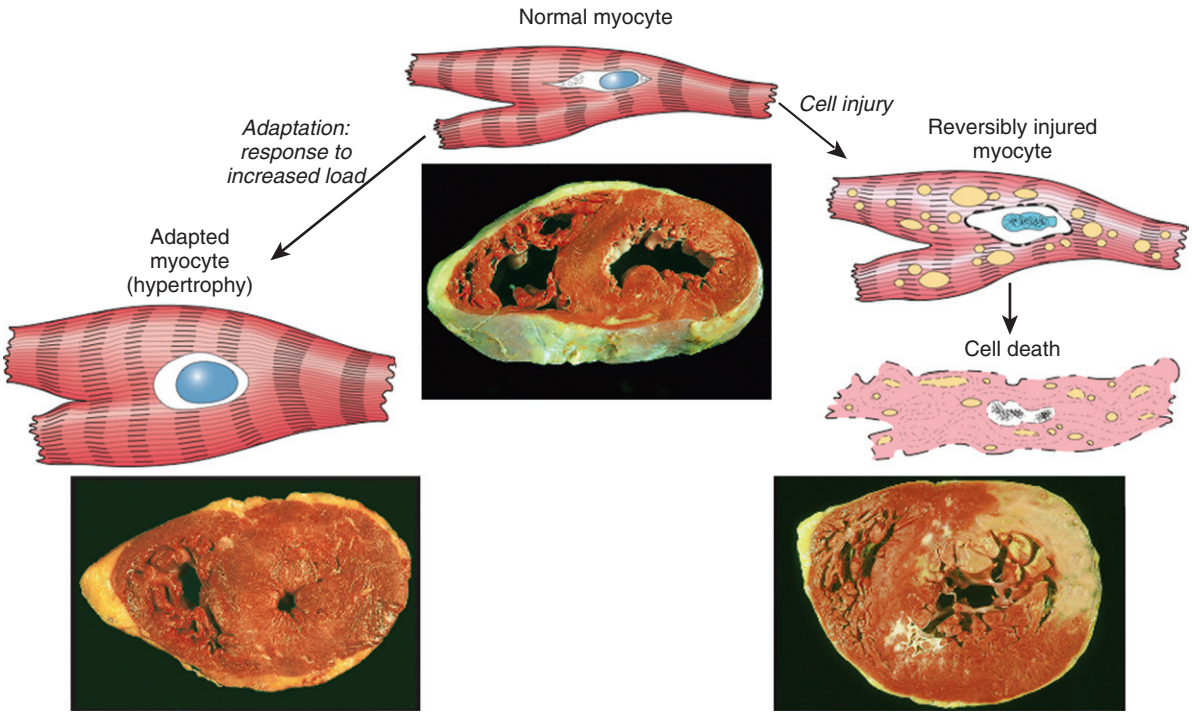


**Figure 1–2** The relationship among normal, adapted, reversibly injured, and dead myocardial cells. The cellular adaptation depicted here is hypertrophy, the type of reversible injury is ischemia, and the irreversible injury is ischemic coagulative necrosis. In the example of myocardial hypertrophy (*lower left*), the left ventricular wall is thicker than 2 cm (normal, 1–1.5 cm). Reversibly injured myocardium shows functional effects without any gross or light microscopic changes, or reversible changes like cellular swelling and fatty change (*shown here*). In the specimen showing necrosis (*lower right*) the transmural light area in the posterolateral left ventricle represents an acute myocardial infarction. All three transverse sections of myocardium have been stained with triphenyltetrazolium chloride, an enzyme substrate that colors viable myocardium magenta. Failure to stain is due to enzyme loss after cell death.

clinical impact. Whether a specific form of stress induces adaptation or causes reversible or irreversible injury depends not only on the nature and severity of the stress but also on several other variables, including basal cellular metabolism and blood and nutrient supply.

In this chapter we discuss first how cells adapt to stresses and then the causes, mechanisms, and consequences of the various forms of acute cell damage, including reversible cell injury, subcellular alterations, and cell death. We conclude with three other processes that affect cells and tissues: intracellular accumulations, pathologic calcification, and cell aging.

## CELLULAR ADAPTATIONS TO STRESS

Adaptations are reversible changes in the number, size, phenotype, metabolic activity, or functions of cells in response to changes in their environment. *Physiologic adaptations* usually represent responses of cells to normal stimulation by hormones or endogenous chemical mediators (e.g., the hormone-induced enlargement of the breast and uterus during pregnancy). *Pathologic adaptations* are responses to stress that allow cells to modulate their structure and function and thus escape injury. Such adaptations can take several distinct forms.

### Hypertrophy

*Hypertrophy is an increase in the size of cells resulting in increase in the size of the organ.* In contrast, hyperplasia (discussed next) is characterized by an increase in cell number because of proliferation of differentiated cells and replacement by tissue stem cells. Stated another way, in pure hypertrophy there are no new cells, just bigger cells containing increased amounts of structural proteins and organelles. Hyperplasia is an adaptive response in cells capable of replication, whereas hypertrophy occurs when cells have a limited capacity to divide. Hypertrophy and hyperplasia also can occur together, and obviously both result in an enlarged (*hypertrophic*) organ.

*Hypertrophy can be physiologic or pathologic* and is caused either by increased functional demand or by growth factor or hormonal stimulation.

- The massive physiologic enlargement of the uterus during pregnancy occurs as a consequence of estrogen-stimulated smooth muscle hypertrophy and smooth muscle hyperplasia (Fig. 1–3). In contrast, in response to increased demand the striated muscle cells in both the skeletal muscle and the heart can undergo only hypertrophy because adult muscle cells have a limited capacity to divide. Therefore, the chiseled physique of the avid weightlifter stems solely from the hypertrophy of individual skeletal muscles.
- An example of pathologic cellular hypertrophy is the cardiac enlargement that occurs with hypertension or aortic valve disease (Fig. 1–2).

The mechanisms driving cardiac hypertrophy involve at least two types of signals: *mechanical triggers,* such as stretch, and *trophic triggers,* which typically are soluble mediators that stimulate cell growth, such as growth factors and adrenergic hormones. These stimuli turn on signal transduction pathways that lead to the induction of a number of genes, which in turn stimulate synthesis of many cellular proteins, including growth factors and structural proteins. The result is the synthesis of more proteins and myofilaments per cell, which increases the force generated with each contraction, enabling the cell to meet increased work demands. There may also be a switch of contractile proteins from adult to fetal or neonatal forms. For example, during muscle hypertrophy, the α-myosin heavy chain is replaced by the β form of the myosin heavy chain, which produces slower, more energetically economical contraction.

Whatever the exact mechanisms of hypertrophy, a limit is reached beyond which the enlargement of muscle mass

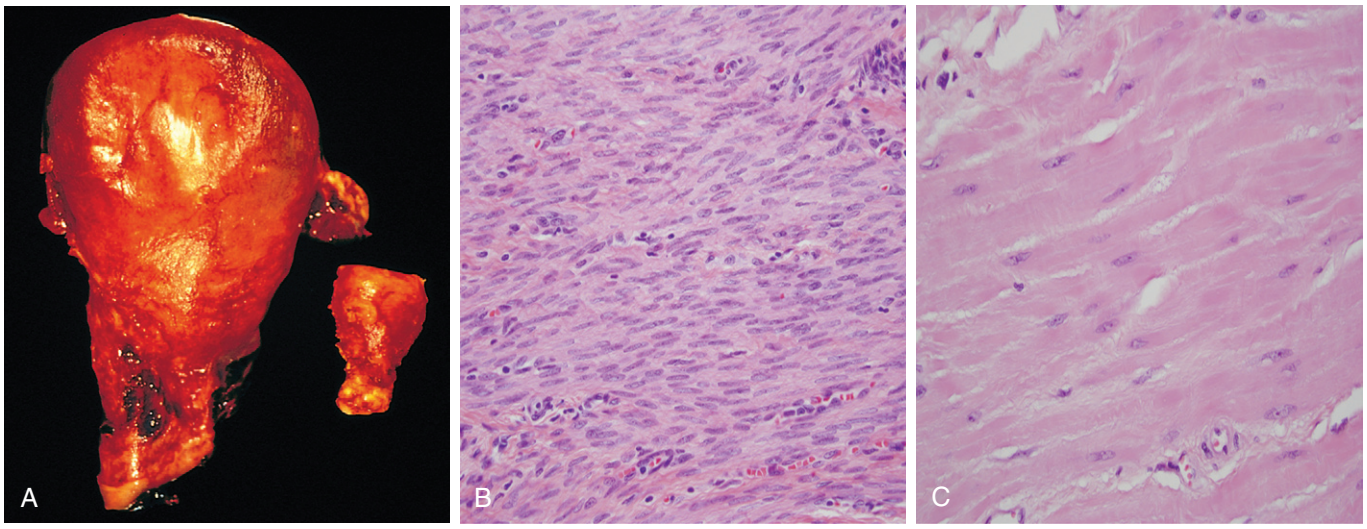


**Figure 1–3** Physiologic hypertrophy of the uterus during pregnancy. **A,** Gross appearance of a normal uterus (*right*) and a gravid uterus (*left*) that was removed for postpartum bleeding. **B,** Small spindle-shaped uterine smooth muscle cells from a normal uterus. **C,** Large, plump hypertrophied smooth muscle cells from a gravid uterus; compare with **B.** (**B** and **C,** Same magnification.)

can no longer compensate for the increased burden. When this happens in the heart, several "degenerative" changes occur in the myocardial fibers, of which the most important are fragmentation and loss of myofibrillar contractile elements. The variables that limit continued hypertrophy and cause the regressive changes are incompletely understood. There may be finite limits of the vasculature to adequately supply the enlarged fibers, of the mitochondria to supply adenosine triphosphate (ATP), or of the biosynthetic machinery to provide the contractile proteins or other cytoskeletal elements. The net result of these changes is ventricular dilation and ultimately cardiac failure, a sequence of events that illustrates how *an adaptation to stress can progress to functionally significant cell injury if the stress is not relieved.*

## Hyperplasia

As discussed earlier, hyperplasia takes place if the tissue contains cell populations capable of replication; it may occur concurrently with hypertrophy and often in response to the same stimuli.

*Hyperplasia can be physiologic or pathologic*. In both situations, cellular proliferation is stimulated by growth factors that are produced by a variety of cell types.

- The two types of *physiologic hyperplasia* are (1) *hormonal hyperplasia,* exemplified by the proliferation of the glandular epithelium of the female breast at puberty and during pregnancy, and (2) *compensatory hyperplasia,* in which residual tissue grows after removal or loss of part of an organ. For example, when part of a liver is resected, mitotic activity in the remaining cells begins as early as 12 hours later, eventually restoring the liver to its normal weight. The stimuli for hyperplasia in this setting are polypeptide growth factors produced by uninjured hepatocytes as well as nonparenchymal cells in the liver (Chapter 2). After restoration of the liver mass, cell proliferation is "turned off" by various growth inhibitors.
- Most forms of *pathologic hyperplasia* are caused by excessive hormonal or growth factor stimulation. For example, after a normal menstrual period there is a burst of uterine epithelial proliferation that is normally tightly regulated by stimulation through pituitary hormones and ovarian estrogen and by inhibition through progesterone. However, a disturbed balance between estrogen and progesterone causes endometrial hyperplasia, which is a common cause of abnormal menstrual bleeding. Hyperplasia also is an important response of connective tissue cells in wound healing, in which proliferating fibroblasts and blood vessels aid in repair (Chapter 2). In this process, growth factors are produced by white blood cells (leukocytes) responding to the injury and by cells in the extracellular matrix. Stimulation by growth factors also is involved in the hyperplasia that is associated with certain viral infections; for example, papillomaviruses cause skin warts and mucosal lesions composed of masses of hyperplastic epithelium. Here the growth factors may be encoded by viral genes or by the genes of the infected host cells.

An important point is that in all of these situations, *the hyperplastic process remains controlled; if the signals that initiate it abate, the hyperplasia disappears*. It is this responsiveness to normal regulatory control mechanisms that distinguishes pathologic hyperplasias from cancer, in which the growth control mechanisms become dysregulated or ineffective (Chapter 5). Nevertheless, in many cases, pathologic hyperplasia constitutes a fertile soil in which cancers may eventually arise. For example, patients with hyperplasia of the endometrium are at increased risk of developing endometrial cancer (Chapter 18).

## Atrophy

*Shrinkage in the size of the cell by the loss of cell substance is known as atrophy.* When a sufficient number of cells are involved, the entire tissue or organ diminishes in size, becoming atrophic (Fig. 1–4). Although atrophic cells may have diminished function, they are not dead.

Causes of atrophy include a decreased workload (e.g., immobilization of a limb to permit healing of a fracture),

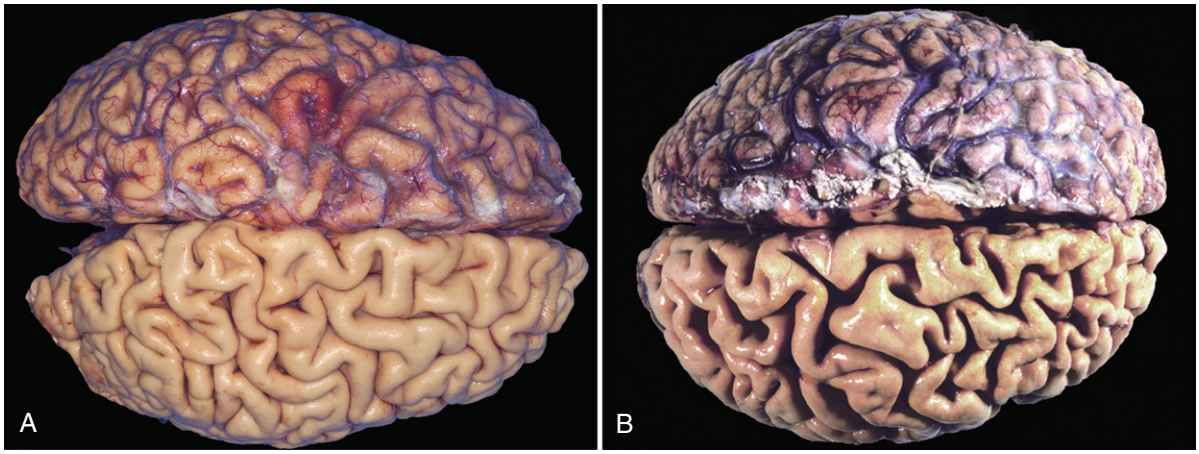


**Figure 1–4** Atrophy as seen in the brain. **A,** Normal brain of a young adult. **B,** Atrophy of the brain in an 82-year-old man with atherosclerotic disease. Atrophy of the brain is due to aging and reduced blood supply. Note that loss of brain substance narrows the gyri and widens the sulci. The meninges have been stripped from the bottom half of each specimen to reveal the surface of the brain.

loss of innervation, diminished blood supply, inadequate nutrition, loss of endocrine stimulation, and aging (senile atrophy). Although some of these stimuli are physiologic (e.g., the loss of hormone stimulation in menopause) and others pathologic (e.g., denervation), the fundamental cellular changes are identical. They represent a retreat by the cell to a smaller size at which survival is still possible; a new equilibrium is achieved between cell size and diminished blood supply, nutrition, or trophic stimulation.

*The mechanisms of atrophy consist of a combination of decreased protein synthesis and increased protein degradation in cells.*

- Protein synthesis decreases because of reduced metabolic activity.
- The degradation of cellular proteins occurs mainly by the *ubiquitin-proteasome pathway.* Nutrient deficiency and disuse may activate ubiquitin ligases, which attach multiple copies of the small peptide ubiquitin to cellular proteins and target them for degradation in proteasomes. This pathway is also thought to be responsible for the accelerated proteolysis seen in a variety of catabolic conditions, including the cachexia associated with cancer.
- In many situations, atrophy is also accompanied by increased *autophagy,* with resulting increases in the number of *autophagic vacuoles.* Autophagy ("self-eating") is the process in which the starved cell eats its own components in an attempt to survive. We describe this process later in the chapter.

## Metaplasia

*Metaplasia is a reversible change in which one adult cell type (epithelial or mesenchymal) is replaced by another adult cell type.* In this type of cellular adaptation, a cell type sensitive to a particular stress is replaced by another cell type better able to withstand the adverse environment. Metaplasia is thought to arise by reprogramming of stem cells to differentiate along a new pathway rather than a phenotypic change (transdifferentiation) of already differentiated cells.

Epithelial metaplasia is exemplified by the squamous change that occurs in the respiratory epithelium of habitual cigarette smokers (Fig. 1–5). The normal ciliated columnar epithelial cells of the trachea and bronchi are focally or widely replaced by stratified squamous epithelial cells. The rugged stratified squamous epithelium may be able to survive the noxious chemicals in cigarette smoke that the more fragile specialized epithelium would not tolerate. *Although the metaplastic squamous epithelium has survival advantages, important protective mechanisms are lost,* such as mucus secretion and ciliary clearance of particulate matter. Epithelial metaplasia is therefore a double-edged sword. Moreover, *the influences that induce metaplastic change, if persistent, may predispose to malignant transformation of the epithelium.* In fact, squamous metaplasia of the respiratory epithelium often coexists with lung cancers composed of malignant squamous cells. It is thought that cigarette smoking initially causes squamous metaplasia, and cancers arise later in some of these altered foci. Since vitamin A is essential for normal epithelial differentiation, its deficiency may also induce squamous metaplasia in the respiratory epithelium. Metaplasia need not always occur in the direction of columnar to squamous epithelium; in chronic gastric reflux, the normal stratified squamous epithelium of the lower esophagus may undergo metaplastic transformation to gastric or intestinal-type columnar epithelium. Metaplasia may also occur in mesenchymal cells but in these situations it is generally a reaction to some pathologic alteration and not an adaptive response to stress. For example, bone is occasionally formed in soft tissues, particularly in foci of injury.

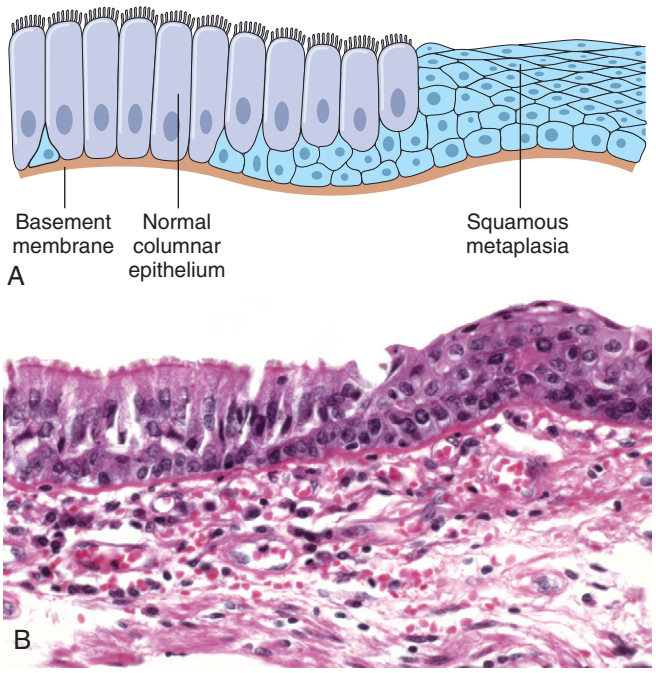


**Figure 1–5** Metaplasia of normal columnar (*left*) to squamous epithelium (*right*) in a bronchus, shown schematically (**A**) and histologically (**B**).

### SUMMARY

#### Cellular Adaptations to Stress

- *Hypertrophy:* increased cell and organ size, often in response to increased workload; induced by growth factors produced in response to mechanical stress or other stimuli; occurs in tissues incapable of cell division
- *Hyperplasia:* increased cell numbers in response to hormones and other growth factors; occurs in tissues whose cells are able to divide or contain abundant tissue stem cells
- *Atrophy:* decreased cell and organ size, as a result of decreased nutrient supply or disuse; associated with decreased synthesis of cellular building blocks and increased breakdown of cellular organelles
- *Metaplasia:* change in phenotype of differentiated cells, often in response to chronic irritation, that makes cells better able to withstand the stress; usually induced by altered differentiation pathway of tissue stem cells; may result in reduced functions or increased propensity for malignant transformation

## OVERVIEW OF CELL INJURY AND CELL DEATH

As stated at the beginning of the chapter, cell injury results when cells are stressed so severely that they are no longer able to adapt or when cells are exposed to inherently damaging agents or suffer from intrinsic abnormalities (e.g., in DNA or proteins). Different injurious stimuli affect many metabolic pathways and cellular organelles. Injury may progress through a reversible stage and culminate in cell death (Fig. 1–1).

- *Reversible cell injury.* In early stages or mild forms of injury the functional and morphologic changes are reversible if the damaging stimulus is removed. At this stage, although there may be significant structural and functional abnormalities, the injury has typically not progressed to severe membrane damage and nuclear dissolution.
- *Cell death.* With continuing damage, the injury becomes irreversible, at which time the cell cannot recover and it dies. *There are two types of cell death—necrosis and apoptosis—which differ in their mechanisms, morphology, and roles in disease and physiology* (Fig. 1–6 and Table 1–1). When damage to membranes is severe, enzymes leak out of lysosomes, enter the cytoplasm, and digest the cell, resulting in *necrosis.* Cellular contents also leak through the damaged plasma membrane into the extracellular space, where they elicit a host reaction (inflammation). Necrosis is the major pathway of cell death in many commonly encountered injuries, such as those resulting from ischemia, exposure to toxins, various infections, and trauma. When a cell is deprived of growth factors, or the cell's DNA or proteins are damaged beyond repair, typically the cell kills itself by another type of death, called *apoptosis,* which is characterized by nuclear dissolution without complete loss of membrane integrity. *Whereas necrosis is always a pathologic process, apoptosis serves many normal functions and is not necessarily associated with pathologic cell injury. Furthermore, in keeping with its role in certain physiologic processes, apoptosis does not elicit an inflammatory response.* The morphologic features, mechanisms, and significance of these two death pathways are discussed in more detail later in the chapter.

## CAUSES OF CELL INJURY

The causes of cell injury range from the gross physical trauma of a motor vehicle accident to the single gene defect that results in a nonfunctional enzyme underlying a

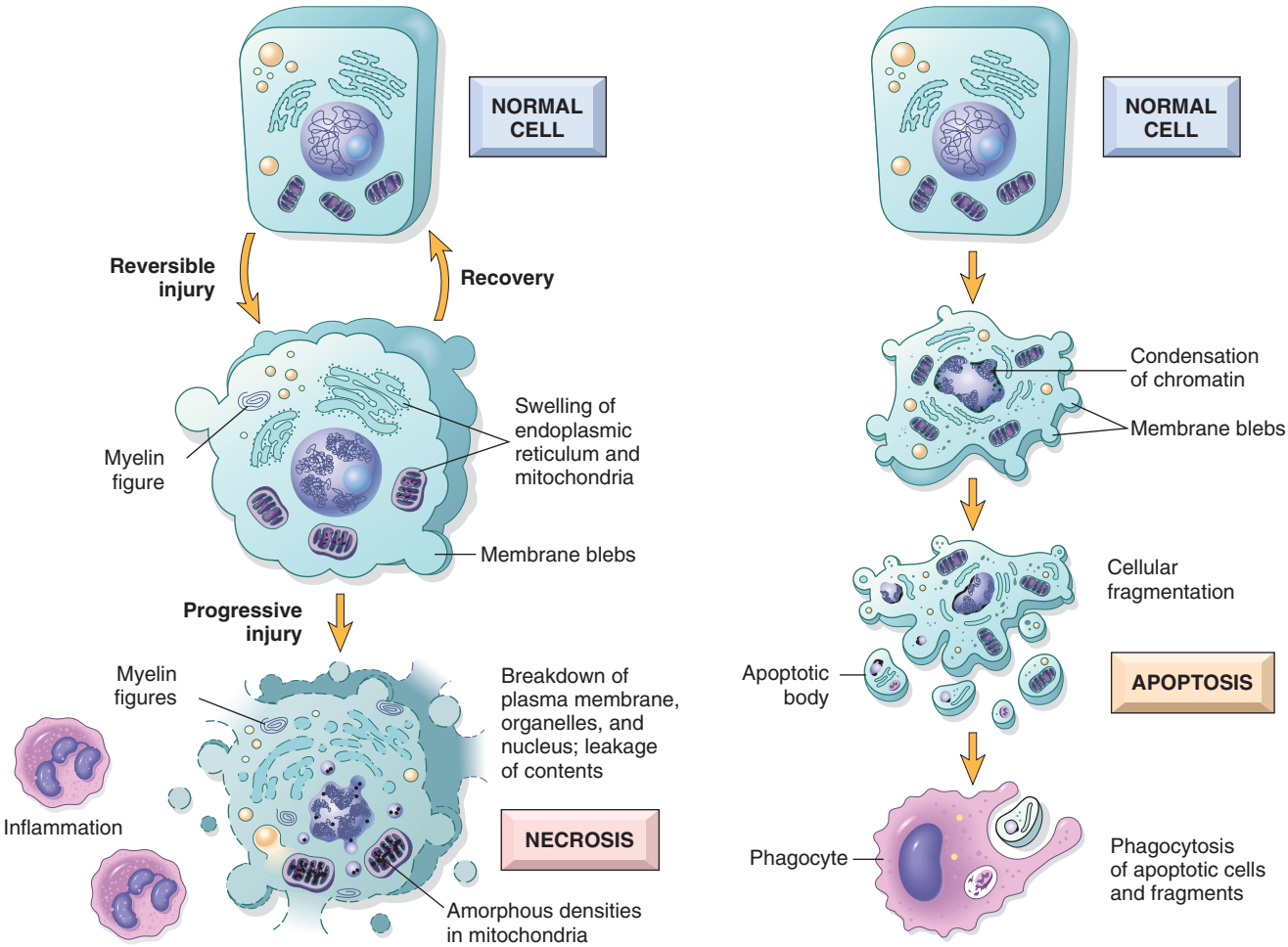


**Figure 1–6** Cellular features of necrosis (*left*) and apoptosis (*right*).

**Table 1–1** Features of Necrosis and Apoptosis

| Feature | Necrosis | Apoptosis |
|---|---|---|
| Cell size | Enlarged (swelling) | Reduced (shrinkage) |
| Nucleus | Pyknosis → karyorrhexis → karyolysis | Fragmentation into nucleosome size fragments |
| Plasma membrane | Disrupted | Intact; altered structure, especially orientation of lipids |
| Cellular contents | Enzymatic digestion; may leak out of cell | Intact; may be released in apoptotic bodies |
| Adjacent inflammation | Frequent | No |
| Physiologic or pathologic role | Invariably pathologic (culmination of irreversible cell injury) | Often physiologic; means of eliminating unwanted cells; may be pathologic after some forms of cell injury, especially DNA and protein damage |

DNA, deoxyribonucleic acid.

specific metabolic disease. Most injurious stimuli can be grouped into the following categories.

### Oxygen Deprivation

*Hypoxia,* or oxygen deficiency, interferes with aerobic oxidative respiration and is an extremely important and common cause of cell injury and death. Hypoxia should be distinguished from *ischemia,* which is a loss of blood supply in a tissue due to impeded arterial flow or reduced venous drainage. While ischemia is the most common cause of hypoxia, oxygen deficiency can also result from inadequate oxygenation of the blood, as in pneumonia, or from reduction in the oxygen-carrying capacity of the blood, as in blood loss anemia or carbon monoxide (CO) poisoning. (CO forms a stable complex with hemoglobin that prevents oxygen binding.)

### Chemical Agents

An increasing number of chemical substances that can injure cells are being recognized; even innocuous substances such as glucose, salt, or even water, if absorbed or administered in excess, can so derange the osmotic environment that cell injury or death results. Agents commonly known as poisons cause severe damage at the cellular level by altering membrane permeability, osmotic homeostasis, or the integrity of an enzyme or cofactor, and exposure to such poisons can culminate in the death of the whole organism. Other potentially toxic agents are encountered daily in the environment; these include air pollutants, insecticides, CO, asbestos, and "social stimuli" such as ethanol. Many therapeutic drugs can cause cell or tissue injury in a susceptible patient or if used excessively or inappropriately (Chapter 7). Even oxygen at sufficiently high partial pressures is toxic.

### Infectious Agents

Agents of infection range from submicroscopic viruses to meter-long tapeworms; in between are the rickettsiae, bacteria, fungi, and protozoans. The diverse ways in which infectious pathogens cause injury are discussed in Chapter 8.

### Immunologic Reactions

Although the immune system defends the body against pathogenic microbes, immune reactions can also result in cell and tissue injury. Examples are autoimmune reactions against one's own tissues and allergic reactions against environmental substances in genetically susceptible individuals (Chapter 4).

### Genetic Factors

Genetic aberrations can result in pathologic changes as conspicuous as the congenital malformations associated with Down syndrome or as subtle as the single amino acid substitution in hemoglobin S giving rise to sickle cell anemia (Chapter 6). Genetic defects may cause cell injury as a consequence of deficiency of functional proteins, such as enzymes in inborn errors of metabolism, or accumulation of damaged DNA or misfolded proteins, both of which trigger cell death when they are beyond repair. Genetic variations (polymorphisms) contribute to the development of many complex diseases and can influence the susceptibility of cells to injury by chemicals and other environmental insults.

### Nutritional Imbalances

Even in the current era of burgeoning global affluence, nutritional deficiencies remain a major cause of cell injury. Protein–calorie insufficiency among underprivileged populations is only the most obvious example; specific vitamin deficiencies are not uncommon even in developed countries with high standards of living (Chapter 7). Ironically, disorders of nutrition rather than lack of nutrients are also important causes of morbidity and mortality; for example, obesity markedly increases the risk for type 2 diabetes mellitus. Moreover, diets rich in animal fat are strongly implicated in the development of atherosclerosis as well as in increased vulnerability to many disorders, including cancer.

### Physical Agents

Trauma, extremes of temperature, radiation, electric shock, and sudden changes in atmospheric pressure all have wide-ranging effects on cells (Chapter 7).

### Aging

Cellular senescence leads to alterations in replicative and repair abilities of individual cells and tissues. All of these changes result in a diminished ability to respond to damage and, eventually, the death of cells and of the organism. The mechanisms underlying cellular aging are discussed separately at the end of the chapter.

## THE MORPHOLOGY OF CELL AND TISSUE INJURY

It is useful to describe the structural alterations that occur in damaged cells before we discuss the biochemical mechanisms that bring about these changes. All stresses and noxious influences exert their effects first at the molecular or biochemical level. *Cellular function may be lost long before cell death occurs, and the morphologic changes of cell injury (or death) lag far behind both* (Fig. 1–7). For example, myocardial cells become noncontractile after 1 to 2 minutes of ischemia, although they do not die until 20 to 30 minutes of ischemia have elapsed. These myocytes may not appear dead by electron microscopy for 2 to 3 hours, or by light microscopy for 6 to 12 hours.

The cellular derangements of reversible injury can be corrected, and if the injurious stimulus abates, the cell can return to normalcy. Persistent or excessive injury, however, causes cells to pass the nebulous "point of no return" into *irreversible injury* and *cell death.* The events that determine when reversible injury becomes irreversible and progresses to cell death remain poorly understood. The clinical relevance of this question is obvious; if the biochemical and molecular changes that predict cell death can be identified with precision, it may be possible to devise strategies for preventing the transition from reversible to irreversible cell injury. Although there are no definitive morphologic or biochemical correlates of irreversibility, *two phenomena consistently characterize irreversibility: the inability to correct mitochondrial dysfunction* (lack of oxidative phosphorylation and ATP generation) even after resolution of the original injury, and *profound disturbances in membrane function.* As mentioned earlier, injury to lysosomal membranes results in the enzymatic dissolution of the injured cell, which is the culmination of injury progressing to necrosis.

As mentioned earlier, different injurious stimuli may induce death by necrosis or apoptosis (Fig. 1–6 and Table 1–1). Below we describe the morphology of reversible cell injury and necrosis; the sequence of morphologic alterations in these processes is illustrated in Figure 1–6, *left*. Apoptosis has many unique features, and we describe it separately later in the chapter.

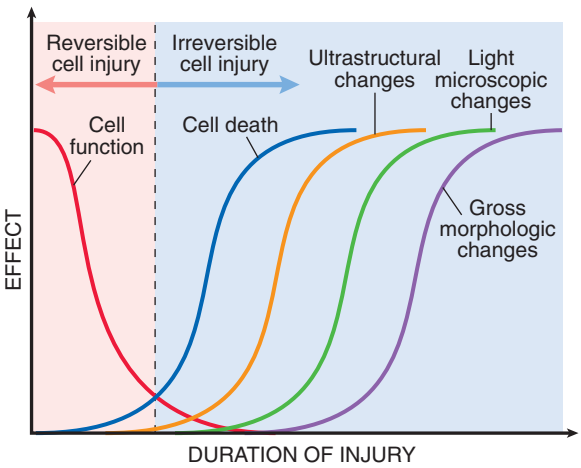


**Figure 1–7** The relationship among cellular function, cell death, and the morphologic changes of cell injury. Note that cells may rapidly become nonfunctional after the onset of injury, although they are still viable, with potentially reversible damage; with a longer duration of injury, irreversible injury and cell death may result. Note also that cell death typically precedes ultrastructural, light microscopic, and grossly visible morphologic changes.

### Reversible Injury

The two main morphologic correlates of reversible cell injury are *cellular swelling* and *fatty change.* Cellular swelling is the result of failure of energy-dependent ion pumps in the plasma membrane, leading to an inability to maintain ionic and fluid homeostasis. Fatty change occurs in hypoxic injury and in various forms of toxic or metabolic injury and is manifested by the appearance of small or large lipid vacuoles in the cytoplasm. The mechanisms of fatty change are discussed in Chapter 15.

In some situations, potentially injurious insults induce specific alterations in cellular organelles, like the ER. The smooth ER is involved in the metabolism of various chemicals, and cells exposed to these chemicals show hypertrophy of the ER as an adaptive response that may have important functional consequences. For instance, barbiturates are metabolized in the liver by the cytochrome P-450 mixed-function oxidase system found in the smooth ER. Protracted use of barbiturates leads to a state of tolerance, with a decrease in the effects of the drug and the need to use increasing doses. This adaptation is due to increased volume (hypertrophy) of the smooth ER of hepatocytes and consequent increased P-450 enzymatic activity. Although P-450–mediated modification is often thought of as "detoxification," many compounds are rendered *more* injurious by this process; one example is carbon tetrachloride ($CCl_4$), discussed later. In addition, the products formed by this oxidative metabolism include reactive oxygen species (ROS), which can injure the cell. Cells adapted to one drug have increased capacity to metabolize other compounds handled by the same system. Thus, if patients taking phenobarbital for epilepsy increase their alcohol intake, they may experience a drop in blood concentration of the antiseizure medication to subtherapeutic levels because of induction of smooth ER in response to the alcohol.

#### MORPHOLOGY

**Cellular swelling** (Fig. 1–8, *B*), the first manifestation of almost all forms of injury to cells, is a reversible alteration that may be difficult to appreciate with the light microscope, but it may be more apparent at the level of the whole organ. When it affects many cells in an organ, it causes some pallor (as a result of compression of capillaries), increased turgor, and increase in weight of the organ. Microscopic examination may reveal small, clear vacuoles within the cytoplasm; these represent distended and pinched-off segments of the endoplasmic reticulum (ER). This pattern of nonlethal injury is sometimes called **hydropic change** or **vacuolar degeneration. Fatty change** is manifested by the appearance of lipid vacuoles in the cytoplasm. It is principally encountered in cells participating in fat metabolism (e.g., hepatocytes, myocardial cells) and is also reversible. Injured cells may also show increased eosinophilic staining, which becomes much

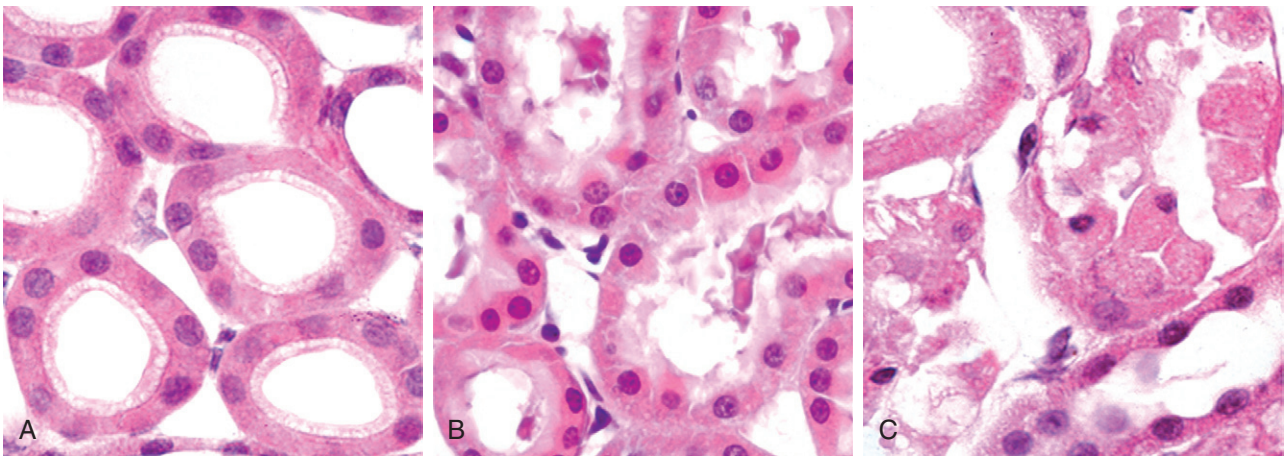


**Figure 1–8** Morphologic changes in reversible and irreversible cell injury (necrosis). **A,** Normal kidney tubules with viable epithelial cells. **B,** Early (reversible) ischemic injury showing surface blebs, increased eosinophilia of cytoplasm, and swelling of occasional cells. **C,** Necrotic (irreversible) injury of epithelial cells, with loss of nuclei and fragmentation of cells and leakage of contents.
*(Courtesy of Drs. Neal Pinckard and M.A. Venkatachalam, University of Texas Health Sciences Center, San Antonio, Tex.)*

more pronounced with progression to necrosis (described further on).

The intracellular changes associated with reversible injury (Fig. 1–6) include (1) plasma membrane alterations such as blebbing, blunting, or distortion of microvilli, and loosening of intercellular attachments; (2) mitochondrial changes such as swelling and the appearance of phospholipid-rich amorphous densities; (3) dilation of the ER with detachment of ribosomes and dissociation of polysomes; and (4) nuclear alterations, with clumping of chromatin. The cytoplasm may contain phospholipid masses, called myelin figures, which are derived from damaged cellular membranes.

## Necrosis

*Necrosis* is the type of cell death that is associated with loss of membrane integrity and leakage of cellular contents culminating in dissolution of cells, largely resulting from the degradative action of enzymes on lethally injured cells. The leaked cellular contents often elicit a local host reaction, called *inflammation,* that attempts to eliminate the dead cells and start the subsequent repair process (Chapter 2). The enzymes responsible for digestion of the cell may be derived from the lysosomes of the dying cells themselves and from the lysosomes of leukocytes that are recruited as part of the inflammatory reaction to the dead cells.

### MORPHOLOGY

Necrosis is characterized by changes in the cytoplasm and nuclei of the injured cells (Figs. 1–6, *left,* and 1–8, *C*).

- **Cytoplasmic changes.** Necrotic cells show **increased eosinophilia** (i.e., pink staining from the eosin dye—the E in the hematoxylin and eosin [H&E] stain), attributable in part to increased binding of eosin to denatured cytoplasmic proteins and in part to loss of the basophilia that is normally imparted by the ribonucleic acid (RNA) in the cytoplasm (basophilia is the blue staining from the hematoxylin dye—the H in "H&E"). Compared with viable cells, the cell may have a more glassy, homogeneous appearance, mostly because of the loss of glycogen particles. Myelin figures are more prominent in necrotic cells than during reversible injury. When enzymes have digested cytoplasmic organelles, the cytoplasm becomes vacuolated and appears "moth-eaten." By electron microscopy, necrotic cells are characterized by discontinuities in plasma and organelle membranes, marked dilation of mitochondria with the appearance of large amorphous densities, disruption of lysosomes, and intracytoplasmic myelin figures.
- **Nuclear changes.** Nuclear changes assume one of three patterns, all due to breakdown of DNA and chromatin. The basophilia of the chromatin may fade **(karyolysis),** presumably secondary to deoxyribonuclease (DNase) activity. A second pattern is **pyknosis,** characterized by nuclear shrinkage and increased basophilia; the DNA condenses into a solid shrunken mass. In the third pattern, **karyorrhexis,** the pyknotic nucleus undergoes fragmentation. In 1 to 2 days, the nucleus in a dead cell may completely disappear. Electron microscopy reveals profound nuclear changes culminating in nuclear dissolution.
- **Fates of necrotic cells.** Necrotic cells may persist for some time or may be digested by enzymes and disappear. Dead cells may be replaced by myelin figures, which are either phagocytosed by other cells or further degraded into fatty acids. These fatty acids bind calcium salts, which may result in the dead cells ultimately becoming **calcified.**

## Patterns of Tissue Necrosis

There are several morphologically distinct patterns of tissue necrosis, which may provide clues about the underlying cause. Although the terms that describe these patterns do not reflect underlying mechanisms, such terms are in common use, and their implications are understood by both pathologists and clinicians. Most of these types of necrosis have distinct gross appearance; fibrinoid necrosis is detected only by histologic examination.

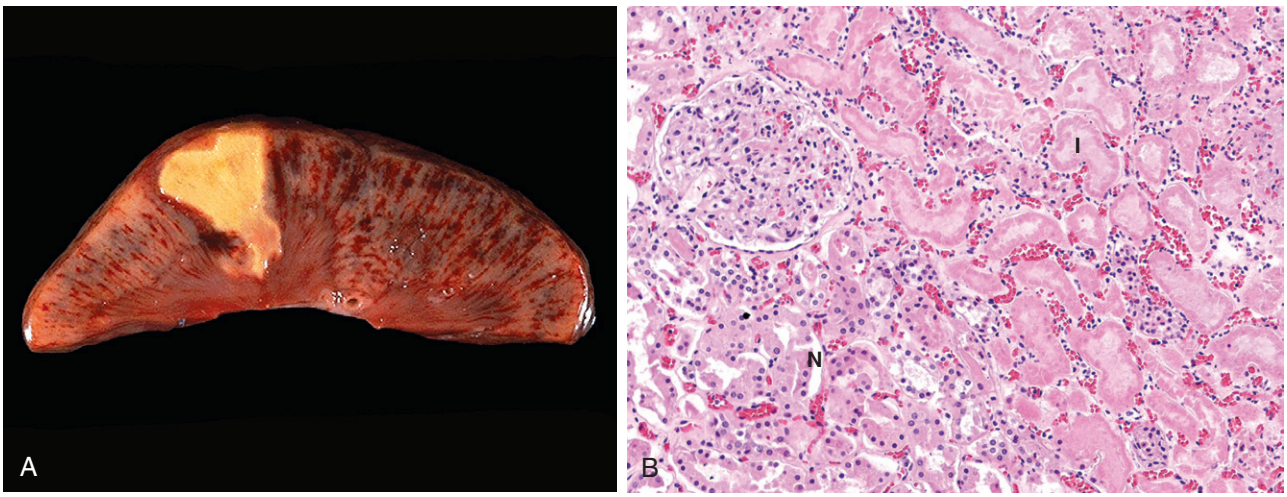


**Figure 1–9** Coagulative necrosis. **A,** A wedge-shaped kidney infarct *(yellow)* with preservation of the outlines. **B,** Microscopic view of the edge of the infarct, with normal kidney *(N)* and necrotic cells in the infarct *(I)*. The necrotic cells show preserved outlines with loss of nuclei, and an inflammatory infiltrate is present (difficult to discern at this magnification).

## MORPHOLOGY

- **Coagulative necrosis** is a form of necrosis in which the underlying tissue architecture is preserved for at least several days (Fig. 1–9). The affected tissues take on a firm texture. Presumably the injury denatures not only structural proteins but also enzymes, thereby blocking the proteolysis of the dead cells; as a result, eosinophilic, anucleate cells may persist for days or weeks. Leukocytes are recruited to the site of necrosis, and the dead cells are digested by the action of lysosomal enzymes of the leukocytes. The cellular debris is then removed by phagocytosis. Coagulative necrosis is characteristic of **infarcts** (areas of ischemic necrosis) in all of the solid organs except the brain.
- **Liquefactive necrosis** is seen in focal bacterial or, occasionally, fungal infections, because microbes stimulate the accumulation of inflammatory cells and the enzymes of leukocytes digest ("liquefy") the tissue. For obscure reasons, hypoxic death of cells within the central nervous system often evokes liquefactive necrosis (Fig. 1–10). Whatever the pathogenesis, the dead cells are completely digested, transforming the tissue into a liquid viscous mass. Eventually, the digested tissue is removed by phagocytes. If the process was initiated by acute inflammation, as in a bacterial infection, the material is frequently creamy yellow and is called pus (Chapter 2).
- Although **gangrenous necrosis** is not a distinctive pattern of cell death, the term is still commonly used in clinical practice. It usually refers to the condition of a limb, generally the lower leg, that has lost its blood supply and has undergone coagulative necrosis involving multiple tissue layers. When bacterial infection is superimposed, coagulative necrosis is modified by the liquefactive action of the bacteria and the attracted leukocytes (resulting in so-called **wet gangrene**).
- **Caseous necrosis** is encountered most often in foci of tuberculous infection. **Caseous** means "cheese-like," referring to the friable yellow-white appearance of the area of necrosis (Fig. 1–11). On microscopic examination, the necrotic focus appears as a collection of fragmented or lysed cells with an amorphous granular pink appearance in the usual H&E-stained tissue. Unlike with coagulative necrosis, the tissue architecture is completely obliterated and cellular outlines cannot be discerned. The area of caseous necrosis is often enclosed within a distinctive inflammatory border; this appearance is characteristic of a focus of inflammation known as a **granuloma** (Chapter 2).
- **Fat necrosis** refers to focal areas of fat destruction, typically resulting from release of activated pancreatic lipases into the substance of the pancreas and the peritoneal cavity. This occurs in the calamitous abdominal emergency known as acute pancreatitis (Chapter 16). In this disorder, pancreatic enzymes that have leaked out of acinar cells

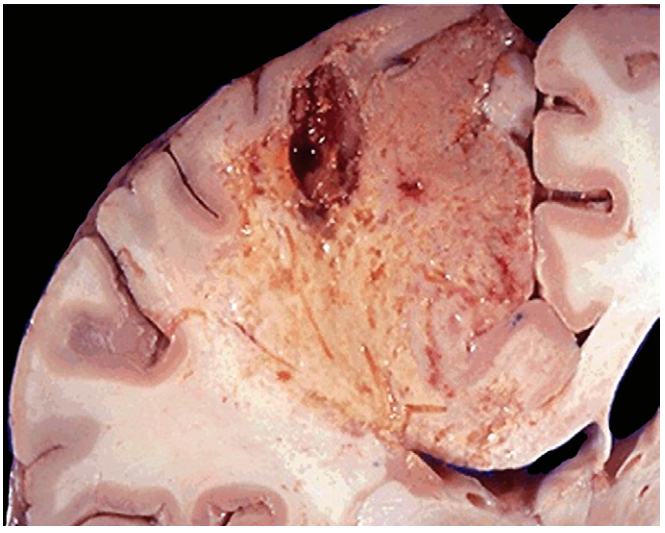

**Figure 1–10** Liquefactive necrosis. An infarct in the brain showing dissolution of the tissue.

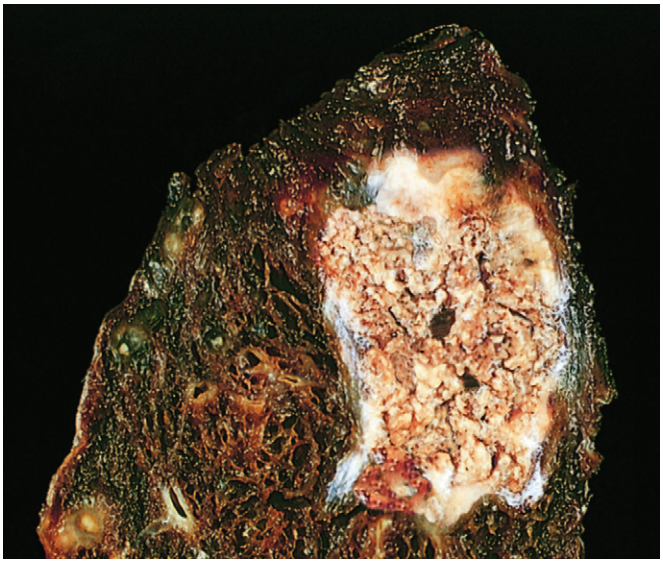

**Figure 1–11** Caseous necrosis. Tuberculosis of the lung, with a large area of caseous necrosis containing yellow-white (cheesy) debris.

and ducts liquefy the membranes of fat cells in the peritoneum, and lipases split the triglyceride esters contained within fat cells. The released fatty acids combine with calcium to produce grossly visible chalky white areas (fat saponification), which enable the surgeon and the pathologist to identify the lesions (Fig. 1–12). On histologic examination, the foci of necrosis contain shadowy outlines of necrotic fat cells with basophilic calcium deposits, surrounded by an inflammatory reaction.

- **Fibrinoid necrosis** is a special form of necrosis, visible by light microscopy, usually in immune reactions in which complexes of antigens and antibodies are deposited in the walls of arteries. The deposited immune complexes, together with fibrin that has leaked out of vessels, produce a bright pink and amorphous appearance on H&E preparations called **fibrinoid** (fibrin-like) by pathologists (Fig. 1–13). The immunologically mediated diseases (e.g., polyarteritis nodosa) in which this type of necrosis is seen are described in Chapter 4.

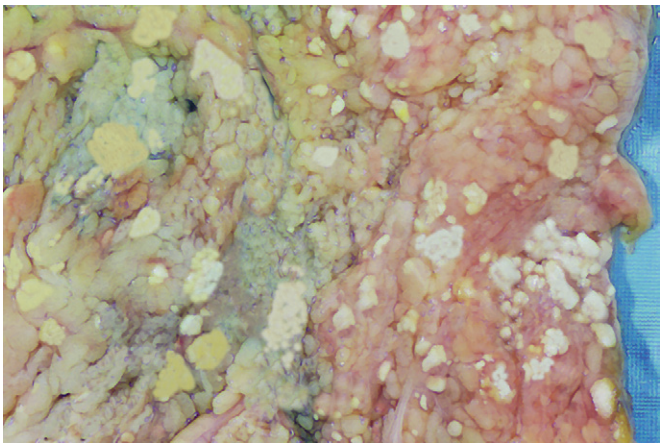

**Figure 1–12** Fat necrosis in acute pancreatitis. The areas of white chalky deposits represent foci of fat necrosis with calcium soap formation (saponification) at sites of lipid breakdown in the mesentery.

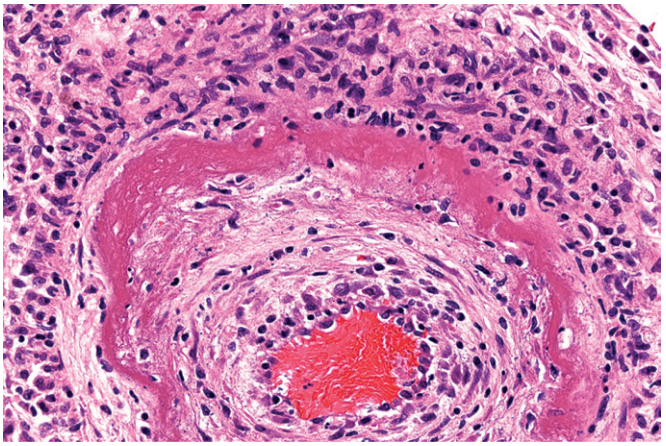

**Figure 1–13** Fibrinoid necrosis in an artery in a patient with polyarteritis nodosa. The wall of the artery shows a circumferential bright pink area of necrosis with protein deposition and inflammation.

*Leakage of intracellular proteins through the damaged cell membrane and ultimately into the circulation provides a means of detecting tissue-specific necrosis using blood or serum samples.* Cardiac muscle, for example, contains a unique isoform of the enzyme creatine kinase and of the contractile protein troponin, whereas hepatic bile duct epithelium contains a temperature-resistant isoform of the enzyme alkaline phosphatase, and hepatocytes contain transaminases. Irreversible injury and cell death in these tissues result in increased serum levels of such proteins, and measurement of serum levels is used clinically to assess damage to these tissues.

## SUMMARY

### Morphologic Alterations in Injured Cells and Tissues

- *Reversible cell injury:* cell swelling, fatty change, plasma membrane blebbing and loss of microvilli, mitochondrial swelling, dilation of the ER, eosinophilia (due to decreased cytoplasmic RNA)
- *Necrosis:* increased eosinophilia; nuclear shrinkage, fragmentation, and dissolution; breakdown of plasma membrane and organellar membranes; abundant myelin figures; leakage and enzymatic digestion of cellular contents
- *Patterns of tissue necrosis:* Under different conditions, necrosis in tissues may assume specific patterns: coagulative, liquefactive, gangrenous, caseous, fat, and fibrinoid.

## MECHANISMS OF CELL INJURY

Now that we have discussed the causes of cell injury and the morphologic changes in necrosis, we next consider in more detail the molecular basis of cell injury, and then illustrate the important principles with a few selected examples of common types of injury.

The biochemical mechanisms linking any given injury with the resulting cellular and tissue manifestations are complex, interconnected, and tightly interwoven with many intracellular metabolic pathways. Nevertheless,

several general principles are relevant to most forms of cell injury:

- *The cellular response to injurious stimuli depends on the type of injury, its duration, and its severity.* Thus, low doses of toxins or a brief duration of ischemia may lead to reversible cell injury, whereas larger toxin doses or longer ischemic intervals may result in irreversible injury and cell death.
- *The consequences of an injurious stimulus depend on the type, status, adaptability, and genetic makeup of the injured cell.* The same injury has vastly different outcomes depending on the cell type; thus, striated skeletal muscle in the leg accommodates complete ischemia for 2 to 3 hours without irreversible injury, whereas cardiac muscle dies after only 20 to 30 minutes. The nutritional (or hormonal) status can also be important; clearly, a glycogen-replete hepatocyte will tolerate ischemia much better than one that has just burned its last glucose molecule. Genetically determined diversity in metabolic pathways can contribute to differences in responses to injurious stimuli. For instance, when exposed to the same dose of a toxin, individuals who inherit variants in genes encoding cytochrome P-450 may catabolize the toxin at different rates, leading to different outcomes. Much effort is now directed toward understanding the role of genetic polymorphisms in responses to drugs and toxins. The study of such interactions is called pharmacogenomics. In fact, genetic variations influence susceptibility to many complex diseases as well as responsiveness to various therapeutic agents. Using the genetic makeup of the individual patient to guide therapy is one example of "personalized medicine."
- *Cell injury results from functional and biochemical abnormalities in one or more of several essential cellular components* (Fig. 1–14). The principal targets and biochemical mechanisms of cell injury are: (1) mitochondria and their ability to generate ATP and ROS under pathologic conditions; (2) disturbance in calcium homeostasis; (3) damage to cellular (plasma and lysosomal) membranes; and (4) damage to DNA and misfolding of proteins.
- *Multiple biochemical alterations may be triggered by any one injurious insult.* It is therefore difficult to assign any one mechanism to a particular insult or clinical situation in which cell injury is prominent. For this reason, therapies that target individual mechanisms of cell injury may not be effective.

With this background, we can briefly discuss the major biochemical mechanisms of cell injury.

## Depletion of ATP

ATP, the energy store of cells, is produced mainly by oxidative phosphorylation of adenosine diphosphate (ADP) during reduction of oxygen in the electron transport system of mitochondria. In addition, the glycolytic pathway can generate ATP in the absence of oxygen using glucose derived either from the circulation or from the hydrolysis of intracellular glycogen. The major causes of ATP depletion are reduced supply of oxygen and nutrients, mitochondrial damage, and the actions of some toxins (e.g., cyanide). Tissues with a greater glycolytic capacity (e.g., the liver) are able to survive loss of oxygen and decreased oxidative phosphorylation better than are tissues with limited capacity for glycolysis (e.g., the brain). High-energy phosphate in the form of ATP is required for virtually all synthetic and degradative processes within the cell, including membrane transport, protein synthesis, lipogenesis, and the deacylation-reacylation reactions necessary for phospholipid turnover. It is estimated that in total, the cells of a healthy human burn 50 to 75 kg of ATP every day!

*Significant depletion of ATP has widespread effects on many critical cellular systems* (Fig. 1–15):

- The activity of *plasma membrane ATP-dependent sodium pumps* is reduced, resulting in intracellular accumulation of sodium and efflux of potassium. The net gain of solute is accompanied by iso-osmotic gain of water, causing *cell swelling* and dilation of the ER.
- There is a compensatory *increase in anaerobic glycolysis* in an attempt to maintain the cell's energy sources. As a consequence, intracellular glycogen stores are rapidly depleted, and lactic acid accumulates, leading to decreased intracellular pH and decreased activity of many cellular enzymes.
- *Failure of ATP-dependent $Ca^{2+}$ pumps* leads to influx of $Ca^{2+}$, with damaging effects on numerous cellular components, described later.

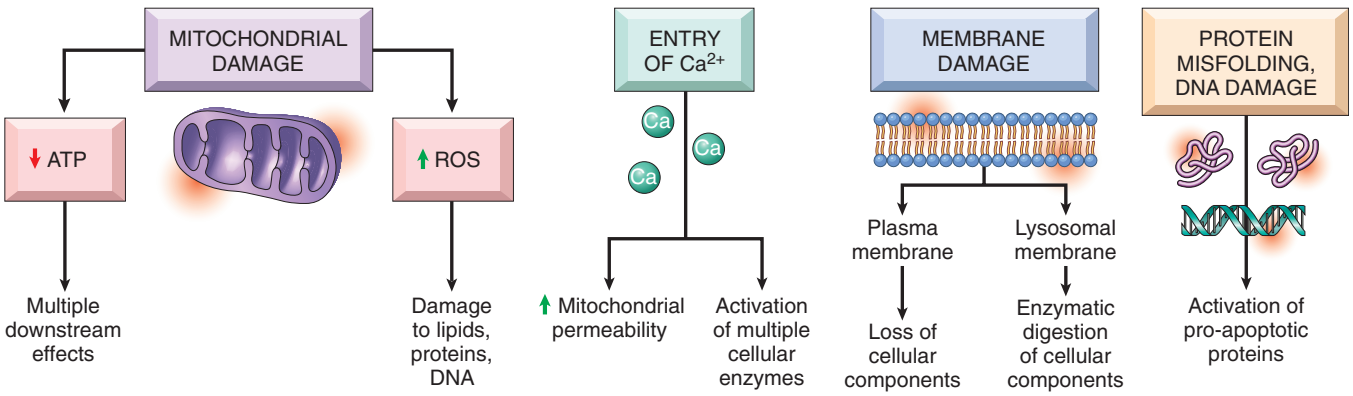


**Figure 1–14** The principal biochemical mechanisms and sites of damage in cell injury. ATP, adenosine triphospate; ROS, reactive oxygen species.

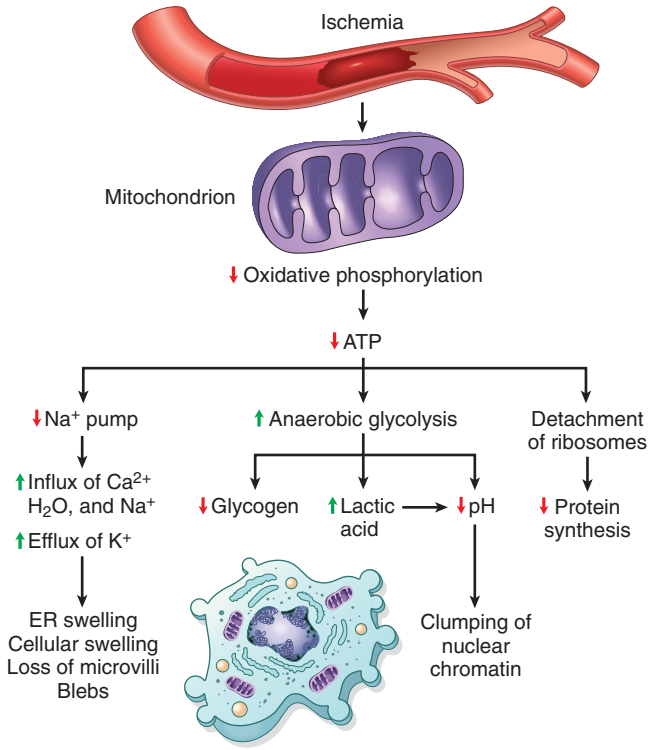


**Figure 1–15** The functional and morphologic consequences of depletion of intracellular adenosine triphosphate (ATP). ER, endoplasmic reticulum.

- Prolonged or worsening depletion of ATP causes *structural disruption of the protein synthetic apparatus,* manifested as detachment of ribosomes from the rough ER (RER) and dissociation of polysomes into monosomes, with a consequent reduction in protein synthesis. Ultimately, there is irreversible damage to mitochondrial and lysosomal membranes, and the cell undergoes necrosis.

## Mitochondrial Damage and Dysfunction

Mitochondria may be viewed as "mini-factories" that produce life-sustaining energy in the form of ATP. Not surprisingly, therefore, they are also critical players in cell injury and death (Fig. 1–16). Mitochondria are sensitive to many types of injurious stimuli, including hypoxia, chemical toxins, and radiation. Mitochondrial damage may result in several biochemical abnormalities:

- Failure of oxidative phosphorylation leads to progressive depletion of ATP, culminating in necrosis of the cell, as described earlier.
- Abnormal oxidative phosphorylation also leads to the formation of reactive oxygen species, which have many deleterious effects, described below.
- Damage to mitochondria is often associated with the formation of a high-conductance channel in the mitochondrial membrane, called the mitochondrial permeability transition pore. The opening of this channel leads to the loss of mitochondrial membrane potential and pH changes, further compromising oxidative phosphorylation.
- The mitochondria also contain several proteins that, when released into the cytoplasm, tell the cell there is internal injury and activate a pathway of apoptosis, discussed later.

## Influx of Calcium

The importance of $Ca^{2+}$ in cell injury was established by the experimental finding that depleting extracellular $Ca^{2+}$ delays cell death after hypoxia and exposure to some toxins. Cytosolic free calcium is normally maintained by ATP-dependent calcium transporters at concentrations as much as 10,000 times lower than the concentration of extracellular calcium or of sequestered intracellular mitochondrial and ER calcium. Ischemia and certain toxins cause an increase in cytosolic calcium concentration, initially because of release of $Ca^{2+}$ from the intracellular stores, and later resulting from increased influx across the plasma membrane. *Increased cytosolic $Ca^{2+}$ activates a number of enzymes,* with potentially deleterious cellular effects (Fig. 1–17). These enzymes include phospholipases (which cause membrane damage), proteases (which break down both membrane and cytoskeletal proteins), endonucleases (which are responsible for DNA and chromatin fragmentation), and adenosine triphosphatases (ATPases) (thereby hastening ATP depletion). Increased intracellular $Ca^{2+}$ levels may also induce apoptosis, by direct activation of caspases and by increasing mitochondrial permeability.

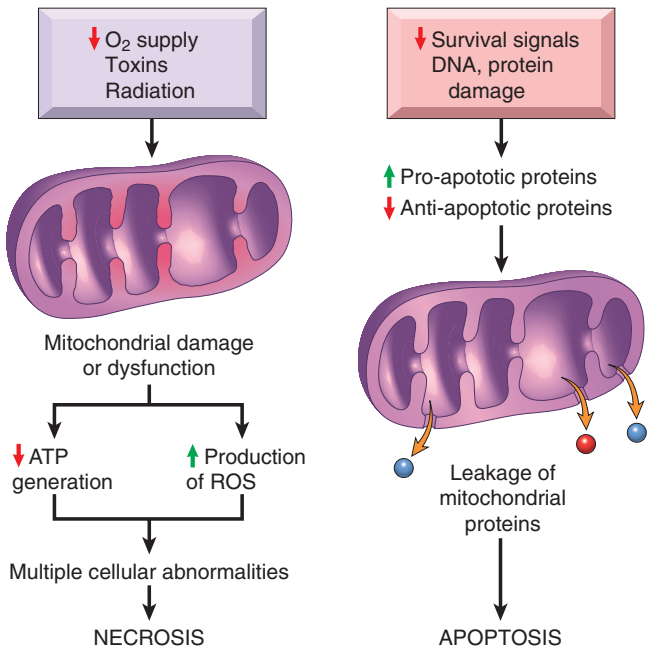


**Figure 1–16** Role of mitochondria in cell injury and death. Mitochondria are affected by a variety of injurious stimuli and their abnormalities lead to necrosis or apoptosis. This pathway of apoptosis is described in more detail later. ATP, adenosine triphosphate; ROS, reactive oxygen species.

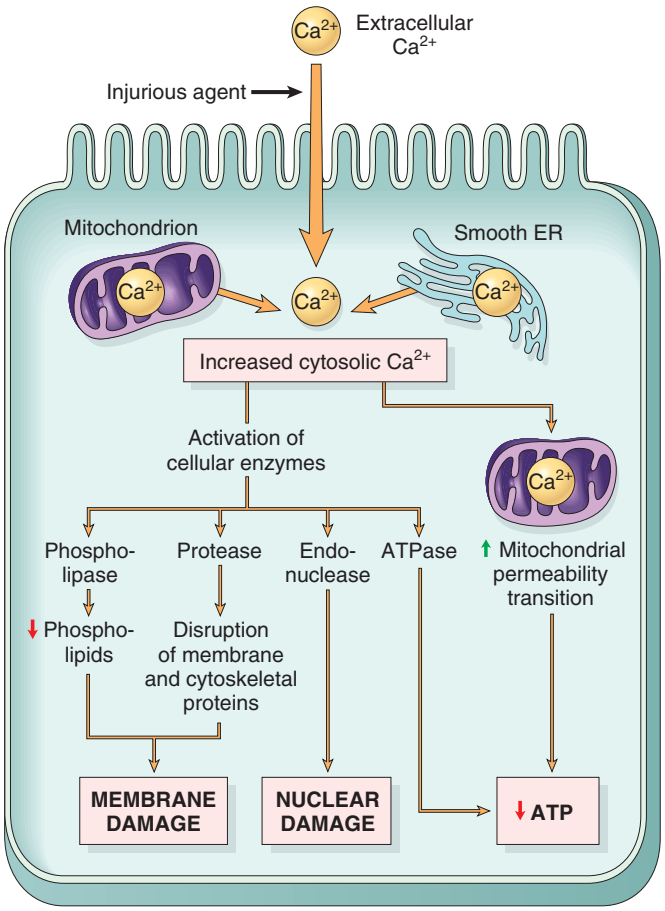


**Figure 1–17** Sources and consequences of increased cytosolic calcium in cell injury. ATP, adenosine triphosphate; ATPase, adenosine triphosphatase.

## Accumulation of Oxygen-Derived Free Radicals (Oxidative Stress)

Free radicals are chemical species with a single unpaired electron in an outer orbital. Such chemical states are extremely unstable, and free radicals readily react with inorganic and organic chemicals; when generated in cells, they avidly attack nucleic acids as well as a variety of cellular proteins and lipids. In addition, free radicals initiate reactions in which molecules that react with free radicals are themselves converted into other types of free radicals, thereby propagating the chain of damage.

*Reactive oxygen species (ROS)* are a type of oxygen-derived free radical whose role in cell injury is well established. Cell injury in many circumstances involves damage by free radicals; these situations include ischemia-reperfusion (discussed later on), chemical and radiation injury, toxicity from oxygen and other gases, cellular aging, microbial killing by phagocytic cells, and tissue injury caused by inflammatory cells.

There are different types of ROS, and they are produced by two major pathways (Fig. 1–18).

- *ROS are produced normally in small amounts in all cells during the reduction-oxidation (redox) reactions* that occur during mitochondrial respiration and energy generation. In this process, molecular oxygen is sequentially reduced in mitochondria by the addition of four electrons to generate water. This reaction is imperfect, however, and small amounts of highly reactive but short-lived toxic intermediates are generated when oxygen is only partially reduced. These intermediates include superoxide ($O_2^{\cdot-}$), which is converted to hydrogen peroxide ($H_2O_2$) spontaneously and by the action of the enzyme superoxide dismutase. $H_2O_2$ is more stable than $O_2^{\cdot-}$ and can cross biologic membranes. In the presence of metals, such as $Fe^{2+}$, $H_2O_2$ is converted to the highly reactive hydroxyl radical $^{\cdot}OH$ by the Fenton reaction.

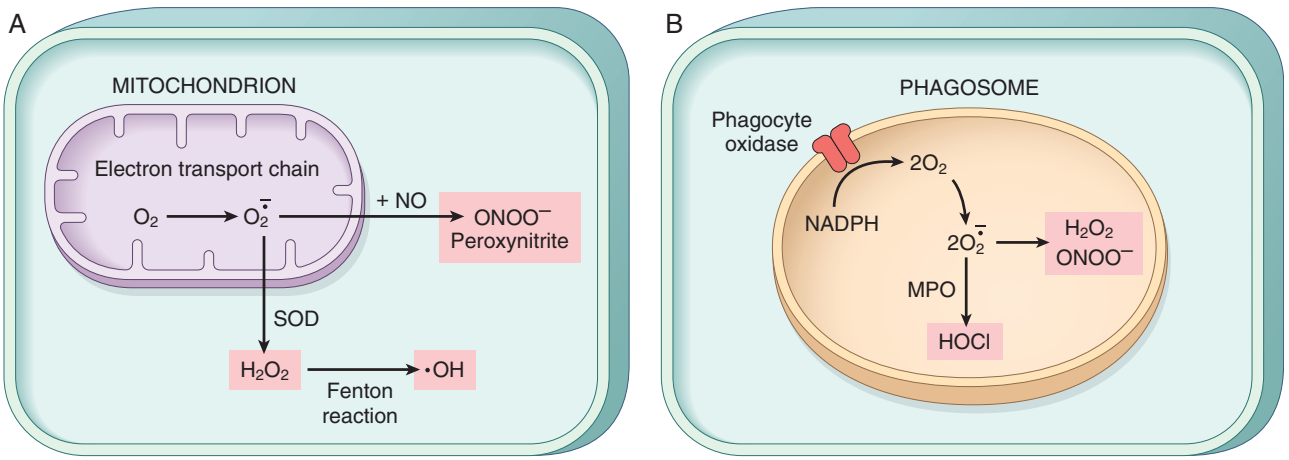


**Figure 1–18** Pathways of production of reactive oxygen species. **A,** In all cells, superoxide ($O_2^{\cdot-}$) is generated during mitochondrial respiration by the electron transport chain and may be converted to $H_2O_2$ and the hydroxyl ($^{\cdot}OH$) free radical or to peroxynitrite ($ONOO^-$). **B,** In leukocytes (mainly neutrophils and macrophages), the phagocyte oxidase enzyme in the phagosome membrane generates superoxide, which can be converted to other free radicals. Myeloperoxidase (MPO) in phagosomes also generates hypochlorite from reactive oxygen species (ROS). NO, nitric oxide; SOD, superoxide dismutase.

- *ROS are produced in phagocytic leukocytes, mainly neutrophils and macrophages,* as a weapon for destroying ingested microbes and other substances during inflammation and host defense (Chapter 2). The ROS are generated in the phagosomes and phagolysosomes of leukocytes by a process that is similar to mitochondrial respiration and is called the *respiratory burst* (or oxidative burst). In this process, a phagosome membrane enzyme catalyzes the generation of superoxide, which is converted to $H_2O_2$. $H_2O_2$ is in turn converted to a highly reactive compound hypochlorite (the major component of household bleach) by the enzyme myeloperoxidase, which is present in leukocytes. The role of ROS in inflammation is described in Chapter 2.
- *Nitric oxide (NO)* is another reactive free radical produced in leukocytes and other cells. It can react with $O_2^{\bullet-}$ to form a highly reactive compound, peroxynitrite, which also participates in cell injury.

*The damage caused by free radicals is determined by their rates of production and removal* (Fig. 1–19). When the production of ROS increases or the scavenging systems are ineffective, the result is an excess of these free radicals, leading to a condition called *oxidative stress.*

*The generation of free radicals is increased under several circumstances:*

- The absorption of radiant energy (e.g., ultraviolet light, x-rays). Ionizing radiation can hydrolyze water into hydroxyl ($^{\bullet}OH$) and hydrogen ($H^{\bullet}$) free radicals.
- The enzymatic metabolism of exogenous chemicals (e.g., carbon tetrachloride—see later)
- Inflammation, in which free radicals are produced by leukocytes (Chapter 2)

Cells have developed many *mechanisms to remove free radicals* and thereby minimize injury. Free radicals are inherently unstable and decay spontaneously. There are also nonenzymatic and enzymatic systems that contribute to inactivation of free radicals (Fig. 1–19).

- The rate of decay of superoxide is significantly increased by the action of superoxide dismutases (SODs) found in many cell types.
- Glutathione (GSH) peroxidases are a family of enzymes whose major function is to protect cells from oxidative damage. The most abundant member of this family, glutathione peroxidase 1, is found in the cytoplasm of all cells. It catalyzes the breakdown of $H_2O_2$ by the reaction 2 GSH (glutathione) + $H_2O_2$ → GS-SG + 2 $H_2O$. The intracellular ratio of oxidized glutathione (GSSG) to reduced glutathione (GSH) is a reflection of this enzyme's activity and thus of the cell's ability to catabolize free radicals.
- Catalase, present in peroxisomes, catalyzes the decomposition of hydrogen peroxide ($2H_2O_2 \rightarrow O_2 + 2H_2O$). It is one of the most active enzymes known, capable of degrading millions of molecules of $H_2O_2$ per second.
- Endogenous or exogenous antioxidants (e.g., vitamins E, A, and C and β-carotene) may either block the formation of free radicals or scavenge them once they have formed.

*Reactive oxygen species cause cell injury by three main reactions* (Fig. 1–19):

- *Lipid peroxidation of membranes.* Double bonds in membrane polyunsaturated lipids are vulnerable to attack by oxygen-derived free radicals. The lipid–radical interactions yield peroxides, which are themselves unstable and reactive, and an autocatalytic chain reaction ensues.
- *Cross-linking and other changes in proteins.* Free radicals promote sulfhydryl-mediated protein cross-linking, resulting in enhanced degradation or loss of enzymatic activity. Free radical reactions may also directly cause polypeptide fragmentation.
- *DNA damage.* Free radical reactions with thymine in nuclear and mitochondrial DNA produce single-strand breaks. Such DNA damage has been implicated in cell death, aging, and malignant transformation of cells.

In addition to the role of ROS in cell injury and killing of microbes, low concentrations of ROS are involved in numerous signaling pathways in cells and thus in many physiologic reactions. Therefore, these molecules are produced normally but, to avoid their harmful effects, their intracellular concentrations are tightly regulated in healthy cells.

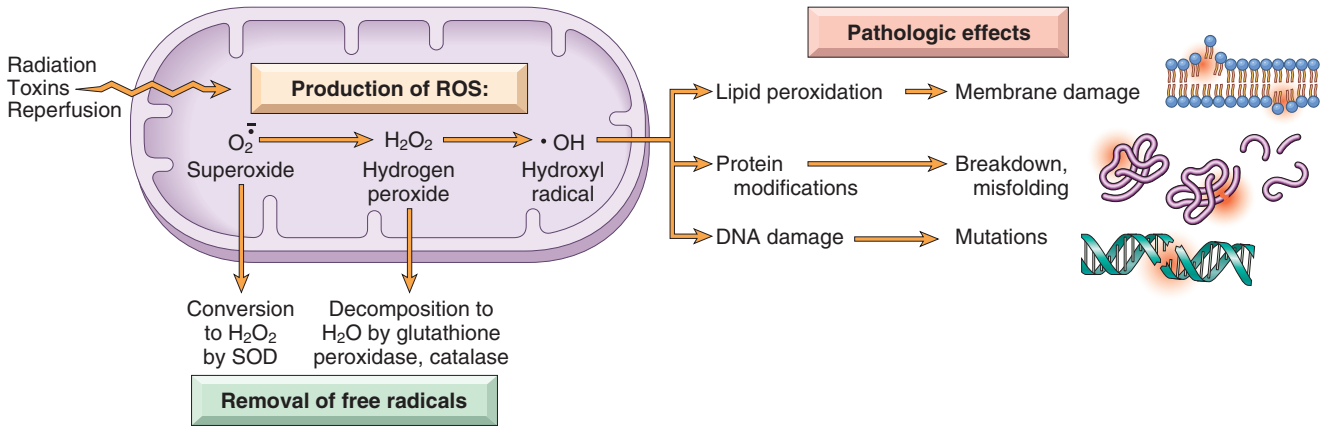


**Figure 1–19** The generation, removal, and role of reactive oxygen species (ROS) in cell injury. The production of ROS is increased by many injurious stimuli. These free radicals are removed by spontaneous decay and by specialized enzymatic systems. Excessive production or inadequate removal leads to accumulation of free radicals in cells, which may damage lipids (by peroxidation), proteins, and deoxyribonucleic acid (DNA), resulting in cell injury.

## Defects in Membrane Permeability

Increased membrane permeability leading ultimately to overt membrane damage is a consistent feature of most forms of cell injury that culminate in necrosis. The plasma membrane can be damaged by ischemia, various microbial toxins, lytic complement components, and a variety of physical and chemical agents. Several biochemical mechanisms may contribute to membrane damage (Fig. 1–20):

- *Decreased phospholipid synthesis.* The production of phospholipids in cells may be reduced whenever there is a fall in ATP levels, leading to decreased energy-dependent enzymatic activities. The reduced phospholipid synthesis may affect all cellular membranes, including the membranes of mitochondria, thus exacerbating the loss of ATP.
- *Increased phospholipid breakdown.* Severe cell injury is associated with increased degradation of membrane phospholipids, probably owing to activation of endogenous phospholipases by increased levels of cytosolic $Ca^{2+}$.
- *ROS.* Oxygen free radicals cause injury to cell membranes by lipid peroxidation, discussed earlier.
- *Cytoskeletal abnormalities.* Cytoskeletal filaments act as anchors connecting the plasma membrane to the cell interior, and serve many functions in maintaining normal cellular architecture, motility, and signaling. Activation of proteases by increased cytosolic $Ca^{2+}$ may cause damage to elements of the cytoskeleton, leading to membrane damage.
- *Lipid breakdown products.* These include unesterified free fatty acids, acyl carnitine, and lysophospholipids, all of which accumulate in injured cells as a result of phospholipid degradation. These catabolic products have a detergent effect on membranes. They may also either insert into the lipid bilayer of the membrane or exchange with membrane phospholipids, causing changes in permeability and electrophysiologic alterations.

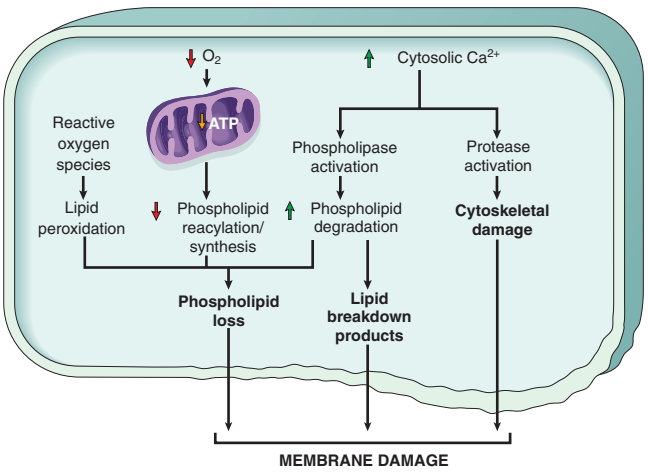


**Figure 1–20** Mechanisms of membrane damage in cell injury. Decreased $O_2$ and increased cytosolic $Ca^{2+}$ typically are seen in ischemia but may accompany other forms of cell injury. Reactive oxygen species, which often are produced on reperfusion of ischemic tissues, also cause membrane damage (*not shown*).

The most important sites of membrane damage during cell injury are the mitochondrial membrane, the plasma membrane, and membranes of lysosomes.

- *Mitochondrial membrane damage.* As discussed earlier, damage to mitochondrial membranes results in decreased production of ATP, with many deleterious effects culminating in necrosis.
- *Plasma membrane damage.* Plasma membrane damage leads to loss of osmotic balance and influx of fluids and ions, as well as loss of cellular contents. The cells may also leak metabolites that are vital for the reconstitution of ATP, thus further depleting energy stores.
- *Injury to lysosomal membranes* results in leakage of their enzymes into the cytoplasm and activation of the acid hydrolases in the acidic intracellular pH of the injured (e.g., ischemic) cell. Lysosomes contain ribonucleases (RNases), DNases, proteases, glucosidases, and other enzymes. Activation of these enzymes leads to enzymatic digestion of cell components, and the cells die by necrosis.

## Damage to DNA and Proteins

Cells have mechanisms that repair damage to DNA, but if this damage is too severe to be corrected (e.g., after radiation injury or oxidative stress), the cell initiates its suicide program and dies by apoptosis. A similar reaction is triggered by the accumulation of improperly folded proteins, which may result from inherited mutations or external triggers such as free radicals. Since these mechanisms of cell injury typically cause apoptosis, they are discussed later in the chapter.

### SUMMARY

#### Mechanisms of Cell Injury

- *ATP depletion:* failure of energy-dependent functions → reversible injury → necrosis
- *Mitochondrial damage:* ATP depletion → failure of energy-dependent cellular functions → ultimately, necrosis; under some conditions, leakage of mitochondrial proteins that cause apoptosis
- *Influx of calcium:* activation of enzymes that damage cellular components and may also trigger apoptosis
- *Accumulation of reactive oxygen species:* covalent modification of cellular proteins, lipids, nucleic acids
- *Increased permeability of cellular membranes:* may affect plasma membrane, lysosomal membranes, mitochondrial membranes; typically culminates in necrosis
- *Accumulation of damaged DNA and misfolded proteins:* triggers apoptosis

## CLINICOPATHOLOGIC CORRELATIONS: EXAMPLES OF CELL INJURY AND NECROSIS

To illustrate the evolution and biochemical mechanisms of cell injury, we conclude this section by discussing some commonly encountered examples of reversible cell injury and necrosis.

## Ischemic and Hypoxic Injury

Ischemia, or diminished blood flow to a tissue, is a common cause of acute cell injury underlying human disease. In contrast with hypoxia, in which energy generation by anaerobic glycolysis can continue (albeit less efficiently than by oxidative pathways), ischemia, because of reduced blood supply, also compromises the delivery of substrates for glycolysis. Consequently, anaerobic energy generation also ceases in ischemic tissues after potential substrates are exhausted or when glycolysis is inhibited by the accumulation of metabolites that would normally be removed by blood flow. Therefore, *ischemia injures tissues faster and usually more severely than does hypoxia.* The major cellular abnormalities in oxygen-deprived cells are decreased ATP generation, mitochondrial damage, and accumulation of ROS, with its downstream consequences.

*The most important biochemical abnormality in hypoxic cells that leads to cell injury is reduced intracellular generation of ATP, as a consequence of reduced supply of oxygen.* As described above, loss of ATP leads to the failure of many energy-dependent cellular systems, including (1) ion pumps (leading to cell swelling, and influx of $Ca^{2+}$, with its deleterious consequences); (2) depletion of glycogen stores and accumulation of lactic acid, thus lowering the intracellular pH; and (3) reduction in protein synthesis.

The functional consequences may be severe at this stage. For instance, heart muscle ceases to contract within 60 seconds of coronary occlusion. If hypoxia continues, worsening ATP depletion causes further deterioration, with loss of microvilli and the formation of "blebs" (Fig. 1–6). At this time, the entire cell and its organelles (mitochondria, ER) are markedly swollen, with increased concentrations of water, sodium, and chloride and a decreased concentration of potassium. *If oxygen is restored, all of these disturbances are reversible,* and in the case of myocardium, contractility returns.

*If ischemia persists, irreversible injury and necrosis ensue.* Irreversible injury is associated with severe swelling of mitochondria, extensive damage to plasma membranes, and swelling of lysosomes. ROS accumulate in cells, and massive influx of calcium may occur. Death is mainly by necrosis, but apoptosis also contributes; the apoptotic pathway is activated by release of pro-apoptotic molecules from mitochondria. The cell's components are progressively degraded, and there is widespread leakage of cellular enzymes into the extracellular space. Finally, the dead cells may become replaced by large masses composed of phospholipids in the form of myelin figures. These are then either phagocytosed by leukocytes or degraded further into fatty acids that may become calcified.

## Ischemia-Reperfusion Injury

If cells are reversibly injured, the restoration of blood flow can result in cell recovery. However, under certain circumstances, *the restoration of blood flow to ischemic but viable tissues results, paradoxically, in the death of cells that are not otherwise irreversibly injured.* This so-called *ischemia-reperfusion injury* is a clinically important process that may contribute significantly to tissue damage in myocardial and cerebral ischemia.

Several mechanisms may account for the exacerbation of cell injury resulting from reperfusion into ischemic tissues:

- New damage may be initiated during reoxygenation by increased generation of *ROS* from parenchymal and endothelial cells and from infiltrating leukocytes. When the supply of oxygen is increased, there may be a corresponding increase in the production of ROS, especially because mitochondrial damage leads to incomplete reduction of oxygen, and because of the action of oxidases in leukocytes, endothelial cells, or parenchymal cells. Cellular antioxidant defense mechanisms may also be compromised by ischemia, favoring the accumulation of free radicals.
- The *inflammation* that is induced by ischemic injury may increase with reperfusion because of increased influx of leukocytes and plasma proteins. The products of activated leukocytes may cause additional tissue injury (Chapter 2). Activation of the *complement system* may also contribute to ischemia-reperfusion injury. Complement proteins may bind in the injured tissues, or to antibodies that are deposited in the tissues, and subsequent complement activation generates by-products that exacerbate the cell injury and inflammation.

## Chemical (Toxic) Injury

Chemicals induce cell injury by one of two general mechanisms:

- *Some chemicals act directly by combining with a critical molecular component or cellular organelle.* For example, in mercuric chloride poisoning (as may occur from ingestion of contaminated seafood) (Chapter 7), mercury binds to the sulfhydryl groups of various cell membrane proteins, causing inhibition of ATP-dependent transport and increased membrane permeability. Many antineoplastic chemotherapeutic agents also induce cell damage by direct cytotoxic effects. In such instances, the *greatest damage is sustained by the cells that use, absorb, excrete, or concentrate the compounds.*
- *Many other chemicals are not intrinsically biologically active but must be first converted to reactive toxic metabolites, which then act on target cells.* This modification is usually accomplished by the cytochrome P-450 in the smooth ER of the liver and other organs. Although the metabolites might cause membrane damage and cell injury by direct covalent binding to protein and lipids, the most important mechanism of cell injury involves the formation of free radicals. *Carbon tetrachloride* ($CCl_4$)—once widely used in the dry cleaning industry but now banned—and the analgesic *acetaminophen* belong in this category. The effect of $CCl_4$ is still instructive as an example of chemical injury. $CCl_4$ is converted to the toxic free radical $CCl_3^{\bullet}$, principally in the liver, and this free radical is the cause of cell injury, mainly by membrane phospholipid peroxidation. In less than 30 minutes after exposure to $CCl_4$, there is breakdown of ER membranes with a decline in hepatic protein synthesis of enzymes and plasma proteins; within 2 hours, swelling of the smooth ER and dissociation of ribosomes from the smooth ER have occurred. There is reduced lipid export from the hepatocytes, as a result of their inability to synthesize

apoprotein to form complexes with triglycerides and thereby facilitate lipoprotein secretion; the result is the "fatty liver" of $CCl_4$ poisoning. Mitochondrial injury follows, and subsequently diminished ATP stores result in defective ion transport and progressive cell swelling; the plasma membranes are further damaged by fatty aldehydes produced by lipid peroxidation in the ER. The end result can be calcium influx and eventually cell death.

# APOPTOSIS

*Apoptosis is a pathway of cell death in which cells activate enzymes that degrade the cells' own nuclear DNA and nuclear and cytoplasmic proteins.* Fragments of the apoptotic cells then break off, giving the appearance that is responsible for the name (*apoptosis,* "falling off"). The plasma membrane of the apoptotic cell remains intact, but the membrane is altered in such a way that the cell and its fragments become avid targets for phagocytes. The dead cell and its fragments are rapidly cleared before cellular contents have leaked out, so *apoptotic cell death does not elicit an inflammatory reaction in the host.* Apoptosis differs in this respect from necrosis, which is characterized by loss of membrane integrity, enzymatic digestion of cells, leakage of cellular contents, and frequently a host reaction (Fig. 1–6 and Table 1–1). However, apoptosis and necrosis sometimes coexist, and apoptosis induced by some pathologic stimuli may progress to necrosis.

## Causes of Apoptosis

Apoptosis occurs in many normal situations and serves to eliminate potentially harmful cells and cells that have outlived their usefulness. It also occurs as a pathologic event when cells are damaged beyond repair, especially when the damage affects the cell's DNA or proteins; in these situations, the irreparably damaged cell is eliminated.

### *Apoptosis in Physiologic Situations*

*Death by apoptosis is a normal phenomenon that serves to eliminate cells that are no longer needed and to maintain a constant number of cells of various types in tissues.* It is important in the following physiologic situations:

- *The programmed destruction of cells during embryogenesis.* Normal development is associated with the death of some cells and the appearance of new cells and tissues. The term *programmed cell death* was originally coined to denote this death of specific cell types at defined times during the development of an organism. Apoptosis is a generic term for this pattern of cell death, regardless of the context, but it is often used interchangeably with programmed cell death.
- *Involution of hormone-dependent tissues upon hormone deprivation,* such as endometrial cell breakdown during the menstrual cycle, and regression of the lactating breast after weaning
- *Cell loss in proliferating cell populations,* such as intestinal crypt epithelia, in order to maintain a constant number
- *Elimination of cells that have served their useful purpose,* such as neutrophils in an acute inflammatory response and lymphocytes at the end of an immune response. In these situations, cells undergo apoptosis because they are deprived of necessary survival signals, such as growth factors.
- *Elimination of potentially harmful self-reactive lymphocytes,* either before or after they have completed their maturation, in order to prevent reactions against the body's own tissues (Chapter 4)
- *Cell death induced by cytotoxic T lymphocytes,* a defense mechanism against viruses and tumors that serves to kill virus-infected and neoplastic cells (Chapter 4)

### *Apoptosis in Pathologic Conditions*

*Apoptosis eliminates cells that are genetically altered or injured beyond repair and does so without eliciting a severe host reaction, thereby keeping the extent of tissue damage to a minimum.* Death by apoptosis is responsible for loss of cells in a variety of pathologic states:

- *DNA damage.* Radiation, cytotoxic anticancer drugs, extremes of temperature, and even hypoxia can damage DNA, either directly or through production of free radicals. If repair mechanisms cannot cope with the injury, the cell triggers intrinsic mechanisms that induce apoptosis. In these situations, elimination of the cell may be a better alternative than risking mutations in the damaged DNA, which may progress to malignant transformation. These injurious stimuli cause apoptosis if the insult is mild, but larger doses of the same stimuli result in necrotic cell death. Inducing apoptosis of cancer cells is a desired effect of chemotherapeutic agents, many of which work by damaging DNA.
- *Accumulation of misfolded proteins.* Improperly folded proteins may arise because of mutations in the genes encoding these proteins or because of extrinsic factors, such as damage caused by free radicals. Excessive accumulation of these proteins in the ER leads to a condition called *ER stress,* which culminates in apoptotic death of cells.
- *Cell injury in certain infections,* particularly viral infections, in which loss of infected cells is largely due to apoptotic death that may be induced by the virus (as in adenovirus and human immunodeficiency virus infections) or by the host immune response (as in viral hepatitis).
- *Pathologic atrophy in parenchymal organs after duct obstruction,* such as occurs in the pancreas, parotid gland, and kidney

### MORPHOLOGY

In H&E-stained tissue sections, the nuclei of apoptotic cells show various stages of chromatin condensation and aggregation and, ultimately, karyorrhexis (Fig. 1–21); at the molecular level this is reflected in fragmentation of DNA into nucleosome-sized pieces. The cells rapidly shrink, form cytoplasmic buds, and fragment into **apoptotic bodies** composed of membrane-bound vesicles of cytosol and organelles (Fig. 1–6). Because these fragments are quickly extruded and phagocytosed without eliciting an inflammatory response, even substantial apoptosis may be histologically undetectable.

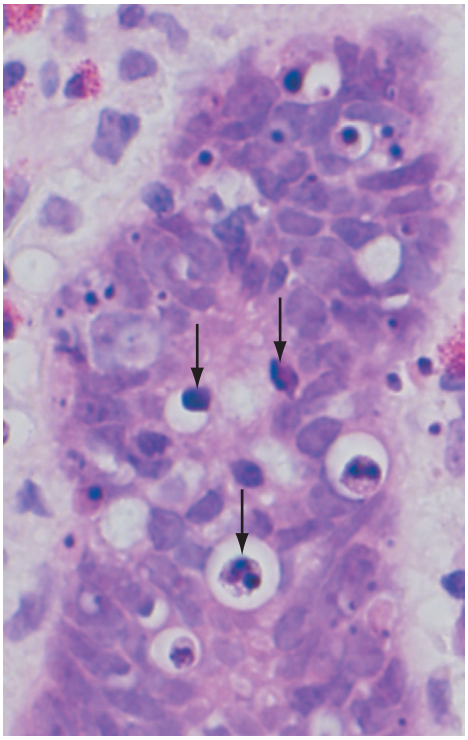

**Figure 1–21** Morphologic appearance of apoptotic cells. Apoptotic cells (some indicated by *arrows*) in a normal crypt in the colonic epithelium are shown. (The preparative regimen for colonoscopy frequently induces apoptosis in epithelial cells, which explains the abundance of dead cells in this normal tissue.) Note the fragmented nuclei with condensed chromatin and the shrunken cell bodies, some with pieces falling off.
*(Courtesy of Dr. Sanjay Kakar, Department of Pathology, University of California San Francisco, San Francisco, Calif.)*

## Mechanisms of Apoptosis

*Apoptosis results from the activation of enzymes called caspases* (so named because they are *c*ysteine proteases that cleave proteins after *asp*artic residues). The activation of caspases depends on a finely tuned balance between production of pro- and anti-apoptotic proteins. Two distinct pathways converge on caspase activation: the *mitochondrial pathway* and the *death receptor pathway* (Fig. 1–22). Although these pathways can intersect, they are generally induced under different conditions, involve different molecules, and serve distinct roles in physiology and disease.

### *The Mitochondrial (Intrinsic) Pathway of Apoptosis*

Mitochondria contain several proteins that are capable of inducing apoptosis; these proteins include cytochrome c and other proteins that neutralize endogenous inhibitors of apoptosis. The choice between cell survival and death is determined by the permeability of mitochondria, which is controlled by a family of more than 20 proteins, the prototype of which is Bcl-2 (Fig. 1–23). When cells are deprived of growth factors and other survival signals, or are exposed to agents that damage DNA, or accumulate unacceptable amounts of misfolded proteins, a number of sensors are activated. These sensors are members of the Bcl-2 family called "BH3 proteins" (because they contain only the third of multiple conserved domains of the Bcl-2 family). They in turn activate two pro-apoptotic members of the family called Bax and Bak, which dimerize, insert into the mitochondrial membrane, and form channels through which cytochrome c and other mitochondrial proteins escape into the cytosol. These sensors also inhibit the anti-apoptotic molecules Bcl-2 and Bcl-$x_L$ (see further on), enhancing the leakage of mitochondrial proteins. Cytochrome c, together with some cofactors, activates caspase-9. Other proteins that leak out of mitochondria block the activities of caspase antagonists that function as physiologic inhibitors of apoptosis. The net result is the activation of the caspase cascade, ultimately leading to nuclear fragmentation. Conversely, if cells are exposed to growth factors and other survival signals, they synthesize anti-apoptotic members of the Bcl-2 family, the two main ones of which are Bcl-2 itself and Bcl-$x_L$. These proteins antagonize Bax and Bak, and thus limit the escape of the mitochondrial pro-apoptotic proteins. Cells deprived of growth factors not only activate the pro-apoptotic Bax and Bak but also show reduced levels of Bcl-2 and Bcl-$x_L$, thus further tilting the balance toward death. The mitochondrial pathway seems to be the pathway that is responsible for apoptosis in most situations, as we discuss later.

### *The Death Receptor (Extrinsic) Pathway of Apoptosis*

Many cells express surface molecules, called death receptors, that trigger apoptosis. Most of these are members of the tumor necrosis factor (TNF) receptor family, which contain in their cytoplasmic regions a conserved "death domain," so named because it mediates interaction with other proteins involved in cell death. The prototypic death receptors are the type I TNF receptor and Fas (CD95). Fas ligand (FasL) is a membrane protein expressed mainly on activated T lymphocytes. When these T cells recognize Fas-expressing targets, Fas molecules are cross-linked by FasL and bind adaptor proteins via the death domain. These in turn recruit and activate caspase-8. In many cell types caspase-8 may cleave and activate a pro-apoptotic member of the Bcl-2 family called Bid, thus feeding into the mitochondrial pathway. The combined activation of both pathways delivers a lethal blow to the cell. Cellular proteins, notably a caspase antagonist called FLIP, block activation of caspases downstream of death receptors. Interestingly, some viruses produce homologues of FLIP, and it is suggested that this is a mechanism that viruses use to keep infected cells alive. The death receptor pathway is involved in elimination of self-reactive lymphocytes and in killing of target cells by some cytotoxic T lymphocytes.

### *Activation and Function of Caspases*

The mitochondrial and death receptor pathways lead to the activation of the *initiator caspases,* caspase-9 and -8, respectively. Active forms of these enzymes are produced, and these cleave and thereby activate another series of caspases that are called the *executioner caspases.* These activated caspases cleave numerous targets, culminating in activation of nucleases that degrade DNA and nucleoproteins. Caspases also degrade components of the nuclear matrix and cytoskeleton, leading to fragmentation of cells.

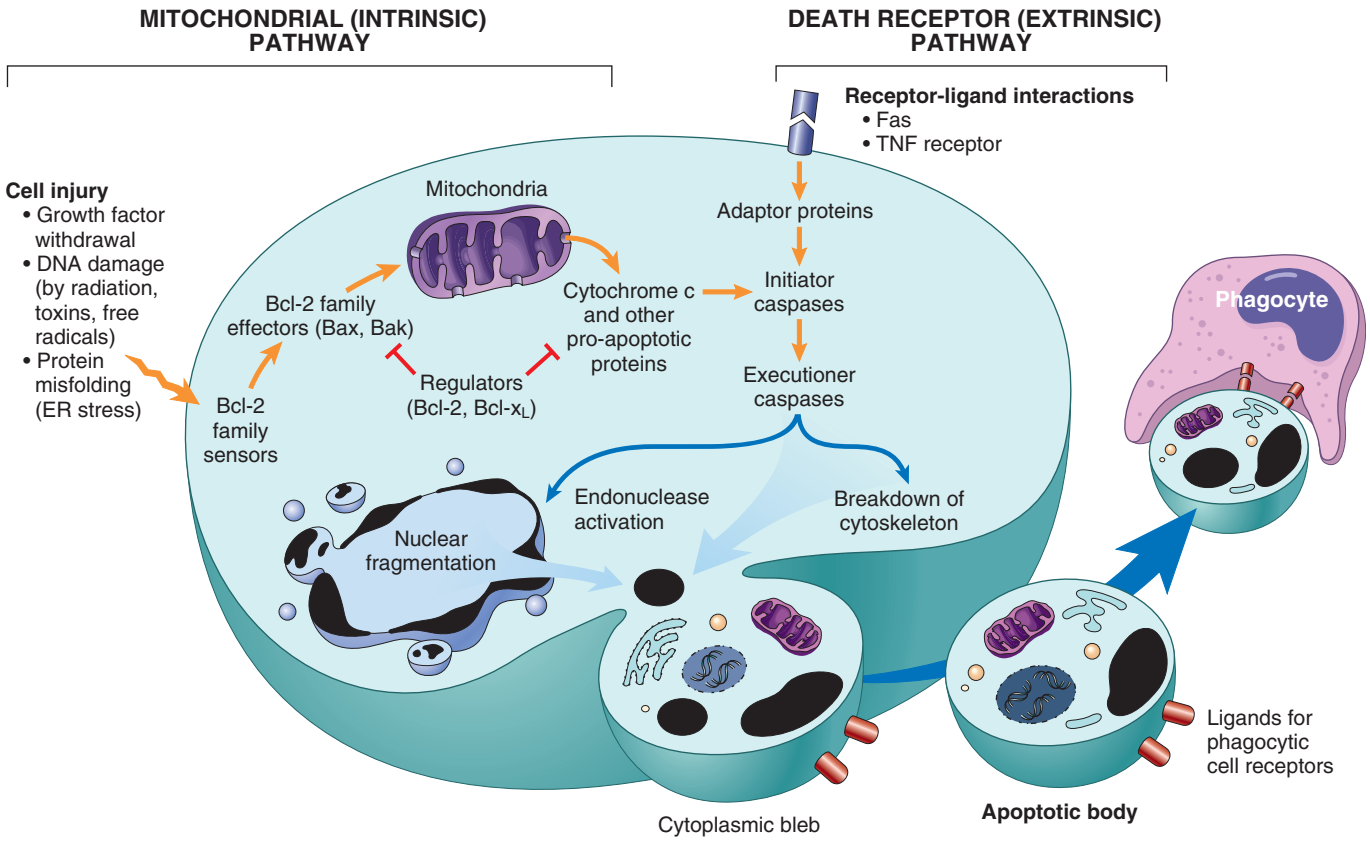


**Figure 1–22** Mechanisms of apoptosis. The two pathways of apoptosis differ in their induction and regulation, and both culminate in the activation of caspases. In the mitochondrial pathway, proteins of the Bcl-2 family, which regulate mitochondrial permeability, become imbalanced and leakage of various substances from mitochondria leads to caspase activation. In the death receptor pathway, signals from plasma membrane receptors lead to the assembly of adaptor proteins into a "death-inducing signaling complex," which activates caspases, and the end result is the same.

### *Clearance of Apoptotic Cells*

Apoptotic cells entice phagocytes by producing "eat-me" signals. In normal cells phosphatidylserine is present on the inner leaflet of the plasma membrane, but in apoptotic cells this phospholipid "flips" to the outer leaflet, where it is recognized by tissue macrophages and leads to phagocytosis of the apoptotic cells. Cells that are dying by apoptosis also secrete soluble factors that recruit phagocytes. This facilitates prompt clearance of the dead cells before they undergo secondary membrane damage and release their cellular contents (which can induce inflammation). Some apoptotic bodies express adhesive glycoproteins that are recognized by phagocytes, and macrophages themselves may produce proteins that bind to apoptotic cells (but not to live cells) and target the dead cells for engulfment. Numerous macrophage receptors have been shown to be involved in the binding and engulfment of apoptotic cells. This process of phagocytosis of apoptotic cells is so efficient that dead cells disappear without leaving a trace, and inflammation is virtually absent.

Although we have emphasized the distinctions between necrosis and apoptosis, these two forms of cell death may coexist and be related mechanistically. For instance, DNA damage (seen in apoptosis) activates an enzyme called poly-ADP(ribose) polymerase, which depletes cellular supplies of nicotinamide adenine dinucleotide, leading to a fall in ATP levels and ultimately necrosis. In fact, even in common situations such as ischemia, it has been suggested that early cell death can be partly attributed to apoptosis, with necrosis supervening later as ischemia worsens.

## Examples of Apoptosis

Cell death in many situations is caused by apoptosis. The examples listed next illustrate the role of the two pathways of apoptosis in normal physiology and in disease.

### Growth Factor Deprivation

Hormone-sensitive cells deprived of the relevant hormone, lymphocytes that are not stimulated by antigens and cytokines, and neurons deprived of nerve growth factor die by apoptosis. In all these situations, apoptosis is triggered by the mitochondrial pathway and is attributable to activation of pro-apoptotic members of the Bcl-2 family and decreased synthesis of Bcl-2 and Bcl-$x_L$.

### DNA Damage

Exposure of cells to radiation or chemotherapeutic agents induces DNA damage, which if severe may trigger apoptotic death. When DNA is damaged, the p53 protein accumulates in cells. It first arrests the cell cycle (at the $G_1$ phase) to allow the DNA to be repaired before it is replicated (Chapter 5). However, if the damage is too great to be

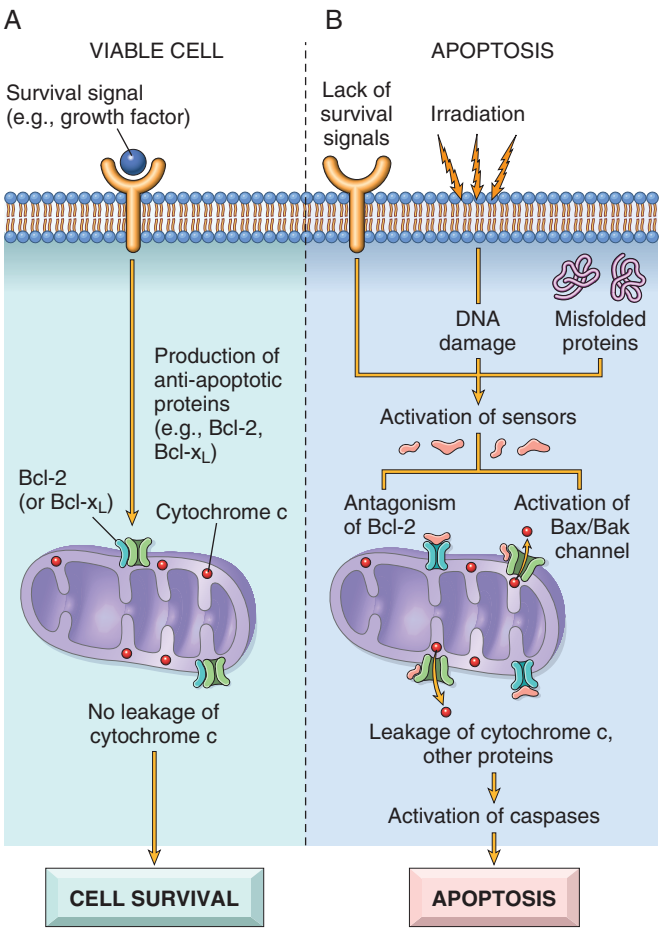


**Figure 1–23** The mitochondrial pathway of apoptosis.The induction of apoptosis by the mitochondrial pathway is dependent on a balance between pro- and anti-apoptotic proteins of the Bcl family. The pro-apoptotic proteins include some (sensors) that sense DNA and protein damage and trigger apoptosis and others (effectors) that insert in the mitochondrial membrane and promote leakage of mitochondrial proteins. **A,** In a viable cell, anti-apoptotic members of the Bcl-2 family prevent leakage of mitochondrial proteins. **B,** Various injurious stimuli activate cytoplasmic sensors and lead to reduced production of these anti-apoptotic proteins and increased amounts of pro-apoptotic proteins, resulting in leakage of proteins that are normally sequestered within mitochondria. The mitochondrial proteins that leak out activate a series of caspases, first the initiators and then the executioners, and these enzymes cause fragmentation of the nucleus and ultimately the cell.

repaired successfully, p53 triggers apoptosis, mainly by stimulating sensors that ultimately activate Bax and Bak, and by increasing the synthesis of pro-apoptotic members of the Bcl-2 family. When p53 is mutated or absent (as it is in certain cancers), cells with damaged DNA that would otherwise undergo apoptosis survive. In such cells, the DNA damage may result in mutations or DNA rearrangements (e.g., translocations) that lead to neoplastic transformation (Chapter 5).

### Accumulation of Misfolded Proteins: ER Stress

During normal protein synthesis, chaperones in the ER control the proper folding of newly synthesized proteins, and misfolded polypeptides are ubiquitinated and targeted for proteolysis. If, however, unfolded or misfolded proteins accumulate in the ER because of inherited mutations or environmental perturbations, they induce a protective cellular response that is called the *unfolded protein response* (Fig. 1–24). This response activates signaling pathways that increase the production of chaperones and retard protein translation, thus reducing the levels of misfolded proteins in the cell. In circumstances in which the accumulation of misfolded proteins overwhelms these adaptations, the result is *ER stress*, which leads to the activation of caspases and ultimately apoptosis. Intracellular accumulation of abnormally folded proteins, caused by mutations, aging, or unknown environmental factors, may cause diseases by reducing the availability of the normal protein or by inducing cell injury (Table 1–2). Cell death as a result of protein misfolding is now recognized as a feature of a number of neurodegenerative diseases, including Alzheimer, Huntington, and Parkinson diseases, and possibly type 2 diabetes. Deprivation of glucose and oxygen and stresses such as infections also result in protein misfolding, culminating in cell injury and death.

### Apoptosis of Self-Reactive Lymphocytes

Lymphocytes capable of recognizing self antigens are normally produced in all individuals. If these lymphocytes encounter self antigens, the cells die by apoptosis. Both the mitochondrial pathway and the Fas death receptor pathway have been implicated in this process (Chapter 4). Failure of apoptosis of self-reactive lymphocytes is one of the causes of autoimmune diseases.

**Table 1–2** Diseases Caused by Misfolding of Proteins

| Disease | Affected Protein | Pathogenesis |
|---|---|---|
| Cystic fibrosis | Cystic fibrosis transmembrane conductance regulator (CFTR) | Loss of CFTR leads to defects in chloride transport |
| Familial hypercholesterolemia | LDL receptor | Loss of LDL receptor leading to hypercholesterolemia |
| Tay-Sachs disease | Hexosaminidase β subunit | Lack of the lysosomal enzyme leads to storage of $GM_2$ gangliosides in neurons |
| Alpha-1-antitrypsin deficiency | α-1 antitrypsin | Storage of nonfunctional protein in hepatocytes causes apoptosis; absence of enzymatic activity in lungs causes destruction of elastic tissue giving rise to emphysema |
| Creutzfeld-Jacob disease | Prions | Abnormal folding of $PrP^{sc}$ causes neuronal cell death |
| Alzheimer disease | $A_\beta$ peptide | Abnormal folding of $A_\beta$ peptides causes aggregation within neurons and apoptosis |

Shown are selected illustrative examples of diseases in which protein misfolding is thought to be the major mechanism of functional derangement or cell or tissue injury.

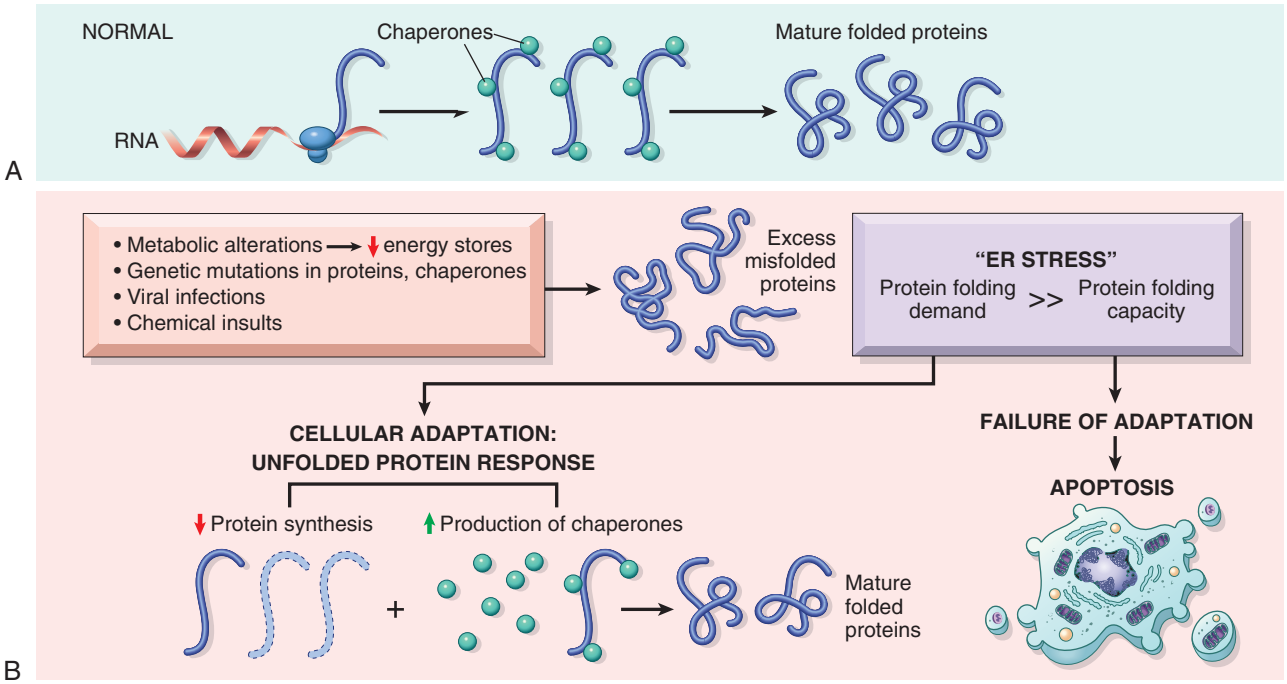


**Figure 1–24** The unfolded protein response and ER stress. **A,** In healthy cells, newly synthesized proteins are folded with the help of chaperones and are then incorporated into the cell or secreted. **B,** Various external stresses or mutations induce a state called ER stress, in which the cell is unable to cope with the load of misfolded proteins. Accumulation of these proteins in the ER triggers the unfolded protein response, which tries to restore protein homeostasis; if this response is inadequate, the cell dies by apoptosis.

### Cytotoxic T Lymphocyte–Mediated Apoptosis

Cytotoxic T lymphocytes (CTLs) recognize foreign antigens presented on the surface of infected host cells and tumor cells (Chapter 4). On activation, CTL granule proteases called *granzymes* enter the target cells. Granzymes cleave proteins at aspartate residues and are able to activate cellular caspases. In this way, the CTL kills target cells by directly inducing the effector phase of apoptosis, without engaging mitochondria or death receptors. CTLs also express FasL on their surface and may kill target cells by ligation of Fas receptors.

## SUMMARY

### Apoptosis

- Regulated mechanism of cell death that serves to eliminate unwanted and irreparably damaged cells, with the least possible host reaction
- Characterized by enzymatic degradation of proteins and DNA, initiated by caspases; and by recognition and removal of dead cells by phagocytes
- Initiated by two major pathways:
  - *Mitochondrial (intrinsic) pathway* is triggered by loss of survival signals, DNA damage and accumulation of misfolded proteins (ER stress); associated with leakage of pro-apoptotic proteins from mitochondrial membrane into the cytoplasm, where they trigger caspase activation; inhibited by anti-apoptotic members of the Bcl family, which are induced by survival signals including growth factors.
  - *Death receptor (extrinsic) pathway* is responsible for elimination of self-reactive lymphocytes and damage by cytotoxic T lymphocytes; is initiated by engagement of death receptors (members of the TNF receptor family) by ligands on adjacent cells.

## AUTOPHAGY

Autophagy ("self-eating") refers to lysosomal digestion of the cell's own components. It is a survival mechanism in times of nutrient deprivation, such that the starved cell subsists by eating its own contents and recycling these contents to provide nutrients and energy. In this process, intracellular organelles and portions of cytosol are first sequestered within an *autophagic vacuole,* which is postulated to be formed from ribosome-free regions of the ER (Fig. 1–25). The vacuole fuses with lysosomes to form an *autophagolysosome,* in which lysosomal enzymes digest the cellular components. Autophagy is initiated by multiprotein complexes that sense nutrient deprivation and stimulate formation of the autophagic vacuole. With time, the starved cell eventually can no longer cope by devouring itself; at this stage, autophagy may also signal cell death by apoptosis.

Autophagy is also involved in the clearance of misfolded proteins, for instance, in neurons and hepatocytes. Therefore, defective autophagy may be a cause of neuronal death induced by accumulation of these proteins and, subsequently, neurodegenerative diseases. Conversely, pharmacologic activation of autophagy limits the build-up of misfolded proteins in liver cells in animal models,

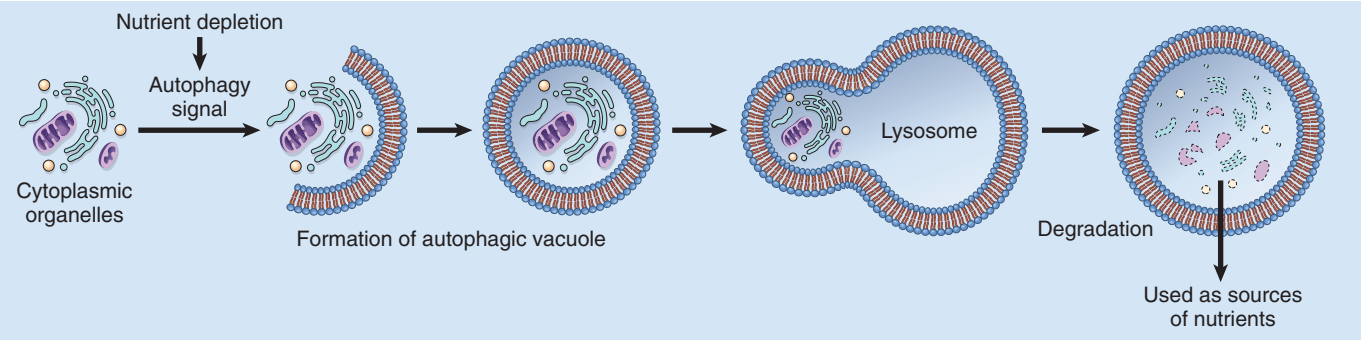


**Figure 1–25** Autophagy. Cellular stresses, such as nutrient deprivation, activate autophagy genes (*Atg* genes), which initiate the formation of membrane-bound vesicles in which cellular organelles are sequestered. These vesicles fuse with lysosomes, in which the organelles are digested, and the products are used to provide nutrients for the cell. The same process can trigger apoptosis, by mechanisms that are not well defined.

thereby reducing liver fibrosis. Polymorphisms in a gene involved in autophagy have been associated with inflammatory bowel disease, but the mechanistic link between autophagy and intestinal inflammation is not known. The role of autophagy in cancer is discussed in Chapter 5. Thus, a once little-appreciated survival pathway in cells may prove to have wide-ranging roles in human disease.

We have now concluded the discussion of cell injury and cell death. As we have seen, these processes are the root cause of many common diseases. We end this chapter with brief considerations of three other processes: intracellular accumulations of various substances and extracellular deposition of calcium, both of which are often associated with cell injury, and aging.

## INTRACELLULAR ACCUMULATIONS

Under some circumstances cells may accumulate abnormal amounts of various substances, which may be harmless or associated with varying degrees of injury. The substance may be located in the cytoplasm, within organelles (typically lysosomes), or in the nucleus, and it may be synthesized by the affected cells or may be produced elsewhere.

There are four main pathways of abnormal intracellular accumulations (Fig. 1–26):

- Inadequate removal of a normal substance secondary to defects in mechanisms of packaging and transport, as in fatty change in the liver
- Accumulation of an abnormal endogenous substance as a result of genetic or acquired defects in its folding, packaging, transport, or secretion, as with certain mutated forms of $\alpha_1$-antitrypsin
- Failure to degrade a metabolite due to inherited enzyme deficiencies. The resulting disorders are called *storage diseases* (Chapter 6).
- Deposition and accumulation of an abnormal exogenous substance when the cell has neither the enzymatic machinery to degrade the substance nor the ability to transport it to other sites. Accumulation of carbon or silica particles is an example of this type of alteration.

### Fatty Change (Steatosis)

*Fatty change* refers to any abnormal accumulation of triglycerides within parenchymal cells. It is most often seen in the liver, since this is the major organ involved in fat metabolism, but it may also occur in heart, skeletal muscle, kidney, and other organs. Steatosis may be caused by toxins, protein malnutrition, diabetes mellitus, obesity, or anoxia. *Alcohol abuse and diabetes associated with obesity are the most common causes of fatty change in the liver* (fatty liver) in industrialized nations. This process is discussed in more detail in Chapter 15.

### Cholesterol and Cholesteryl Esters

Cellular cholesterol metabolism is tightly regulated to ensure normal cell membrane synthesis without significant intracellular accumulation. However, phagocytic cells may become overloaded with lipid (triglycerides, cholesterol, and cholesteryl esters) in several different pathologic processes. Of these, atherosclerosis is the most important. The role of lipid and cholesterol deposition in the pathogenesis of atherosclerosis is discussed in Chapter 9.

### Proteins

Morphologically visible protein accumulations are much less common than lipid accumulations; they may occur when excesses are presented to the cells or if the cells synthesize excessive amounts. In the kidney, for example, trace amounts of albumin filtered through the glomerulus are normally reabsorbed by pinocytosis in the proximal convoluted tubules. However, in disorders with heavy protein leakage across the glomerular filter (e.g., nephrotic syndrome), there is a much larger reabsorption of the protein, and vesicles containing this protein accumulate, giving the histologic appearance of pink, hyaline cytoplasmic droplets. The process is reversible: If the proteinuria abates, the protein droplets are metabolized and disappear. Another example is the marked accumulation of newly synthesized immunoglobulins that may occur in the RER of some plasma cells, forming rounded, eosinophilic *Russell bodies.* Other examples of protein aggregation are discussed elsewhere in this book (e.g., "alcoholic hyaline" in the liver in Chapter 15; neurofibrillary tangles in neurons in Chapter 22).

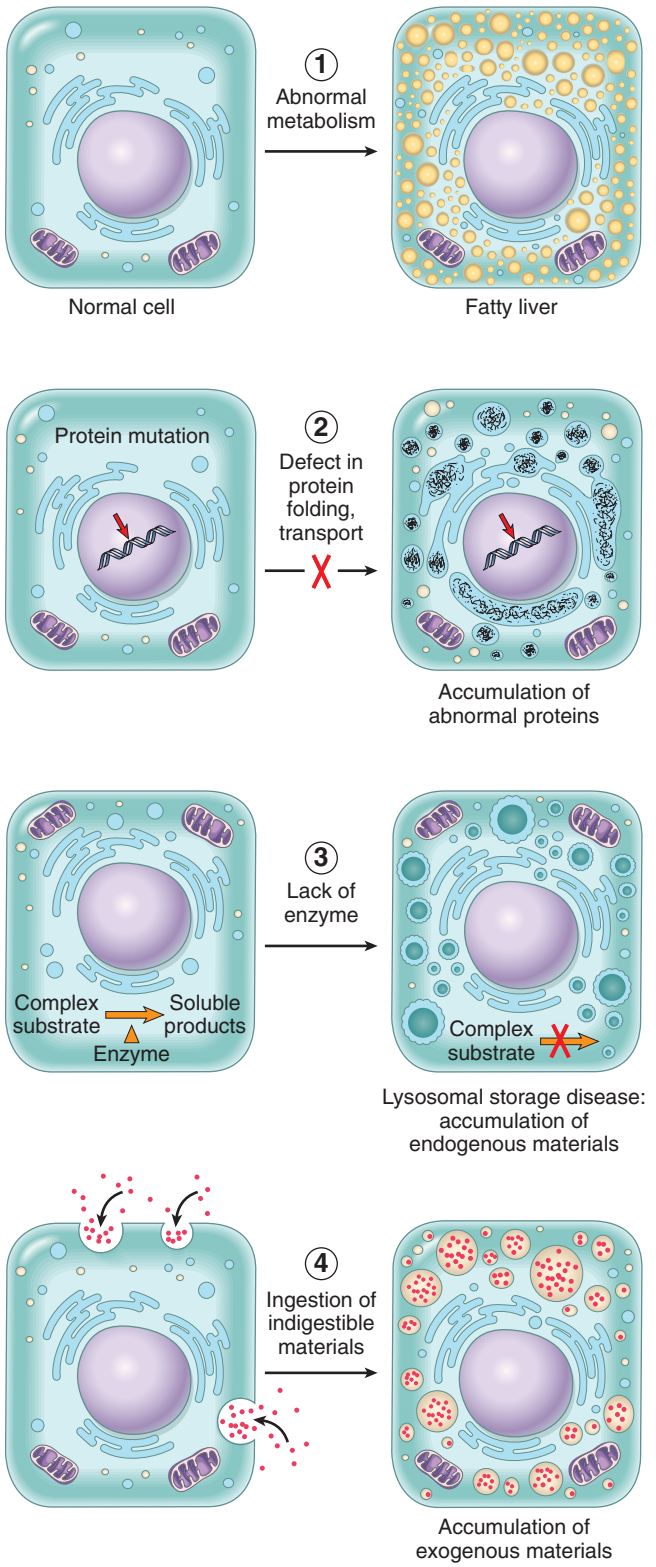


**Figure 1–26** Mechanisms of intracellular accumulation: *(1)* Abnormal metabolism, as in fatty change in the liver. *(2)* Mutations causing alterations in protein folding and transport, so that defective molecules accumulate intracellularly. *(3)* A deficiency of critical enzymes responsible for breaking down certain compounds, causing substrates to accumulate in lysosomes, as in lysosomal storage diseases. *(4)* An inability to degrade phagocytosed particles, as in carbon pigment accumulation.

### Glycogen

Excessive intracellular deposits of glycogen are associated with abnormalities in the metabolism of either glucose or glycogen. In poorly controlled diabetes mellitus, the prime example of abnormal glucose metabolism, glycogen accumulates in renal tubular epithelium, cardiac myocytes, and β cells of the islets of Langerhans. Glycogen also accumulates within cells in a group of closely related genetic disorders collectively referred to as *glycogen storage diseases,* or *glycogenoses* (Chapter 6).

### Pigments

Pigments are colored substances that are either exogenous, coming from outside the body, such as carbon, or endogenous, synthesized within the body itself, such as lipofuscin, melanin, and certain derivatives of hemoglobin.

- The most common exogenous pigment is *carbon* (an example is coal dust), a ubiquitous air pollutant of urban life. When inhaled, it is phagocytosed by alveolar macrophages and transported through lymphatic channels to the regional tracheobronchial lymph nodes. Aggregates of the pigment blacken the draining lymph nodes and pulmonary parenchyma (*anthracosis*) (Chapter 12).
- *Lipofuscin,* or "wear-and-tear pigment," is an insoluble brownish-yellow granular intracellular material that accumulates in a variety of tissues (particularly the heart, liver, and brain) as a function of age or atrophy. Lipofuscin represents complexes of lipid and protein that derive from the free radical–catalyzed peroxidation of polyunsaturated lipids of subcellular membranes. It is not injurious to the cell but is a marker of past free radical injury. The brown pigment (Fig. 1–27), when present in large amounts, imparts an appearance to the tissue that is called *brown atrophy.* By electron microscopy, the pigment appears as perinuclear electron-dense granules (Fig. 1–27, *B*).
- *Melanin* is an endogenous, brown-black pigment that is synthesized by melanocytes located in the epidermis and acts as a screen against harmful ultraviolet radiation. Although melanocytes are the only source of melanin, adjacent basal keratinocytes in the skin can accumulate the pigment (e.g., in freckles), as can dermal macrophages.
- *Hemosiderin* is a hemoglobin-derived granular pigment that is golden yellow to brown and accumulates in tissues when there is a local or systemic excess of iron. Iron is normally stored within cells in association with the protein *apoferritin,* forming ferritin micelles. Hemosiderin pigment represents large aggregates of these ferritin micelles, readily visualized by light and electron microscopy; the iron can be unambiguously identified by the Prussian blue histochemical reaction (Fig. 1–28). Although hemosiderin accumulation is usually pathologic, small amounts of this pigment are normal in the mononuclear phagocytes of the bone marrow, spleen, and liver, where aging red cells are normally degraded. Excessive deposition of hemosiderin, called *hemosiderosis*, and more extensive accumulations of iron seen in *hereditary hemochromatosis*, are described in Chapter 15.

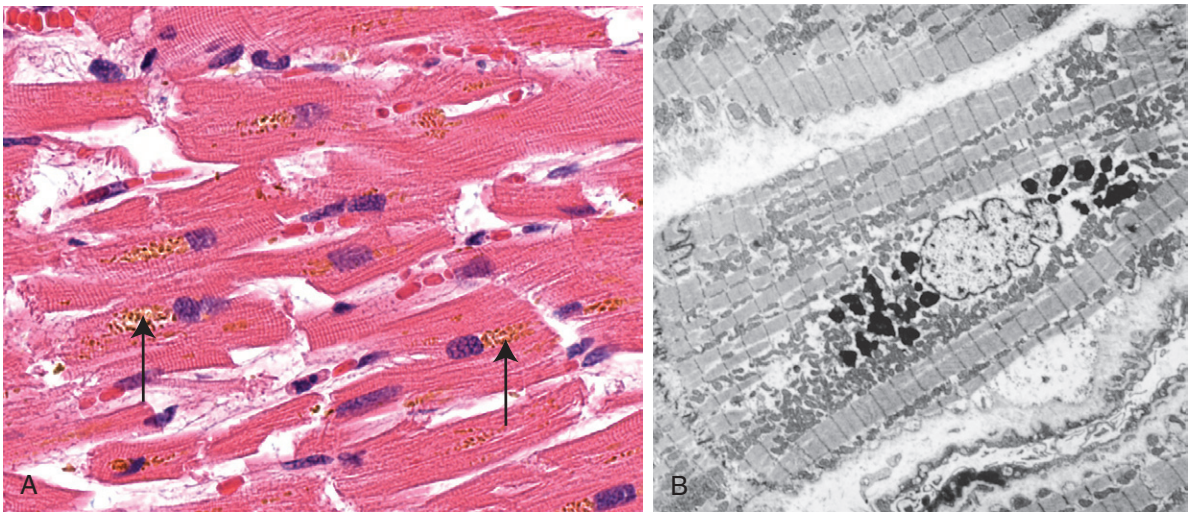


**Figure 1–27** Lipofuscin granules in a cardiac myocyte. **A,** Light microscopy (deposits indicated by *arrows*). **B,** Electron microscopy. Note the perinuclear, intralysosomal location.

## PATHOLOGIC CALCIFICATION

Pathologic calcification is a common process in a wide variety of disease states; it implies the abnormal deposition of calcium salts, together with smaller amounts of iron, magnesium, and other minerals. When the deposition occurs in dead or dying tissues, it is called *dystrophic calcification; it occurs in the absence of derangements in calcium metabolism* (i.e., with normal serum levels of calcium). In contrast, the deposition of calcium salts in normal tissues is known as *metastatic calcification and is almost always secondary to some derangement in calcium metabolism (hypercalcemia).* Of note, while hypercalcemia is not a prerequisite for dystrophic calcification, it can exacerbate it.

### Dystrophic Calcification

Dystrophic calcification is encountered in areas of necrosis of any type. It is virtually inevitable in the *atheromas* of advanced atherosclerosis, associated with intimal injury in the aorta and large arteries and characterized by accumulation of lipids (Chapter 9). Although dystrophic calcification may be an incidental finding indicating insignificant past cell injury, it may also be a cause of organ dysfunction. For example, calcification can develop in aging or damaged heart valves, resulting in severely compromised valve motion. Dystrophic calcification of the aortic valves is an important cause of aortic stenosis in elderly persons (Fig. 10-17, Chapter 10).

The pathogenesis of dystrophic calcification involves *initiation* (or nucleation) and *propagation,* both of which may be either intracellular or extracellular; the ultimate end product is the formation of crystalline *calcium phosphate.* Initiation in extracellular sites occurs in membrane-bound vesicles about 200 nm in diameter; in normal cartilage and bone they are known as *matrix vesicles,* and in pathologic calcification they derive from degenerating cells. It is thought that calcium is initially concentrated in these vesicles by its affinity for membrane phospholipids, while phosphates accumulate as a result of the action of membrane-bound phosphatases. Initiation of intracellular calcification occurs in the mitochondria of dead or dying

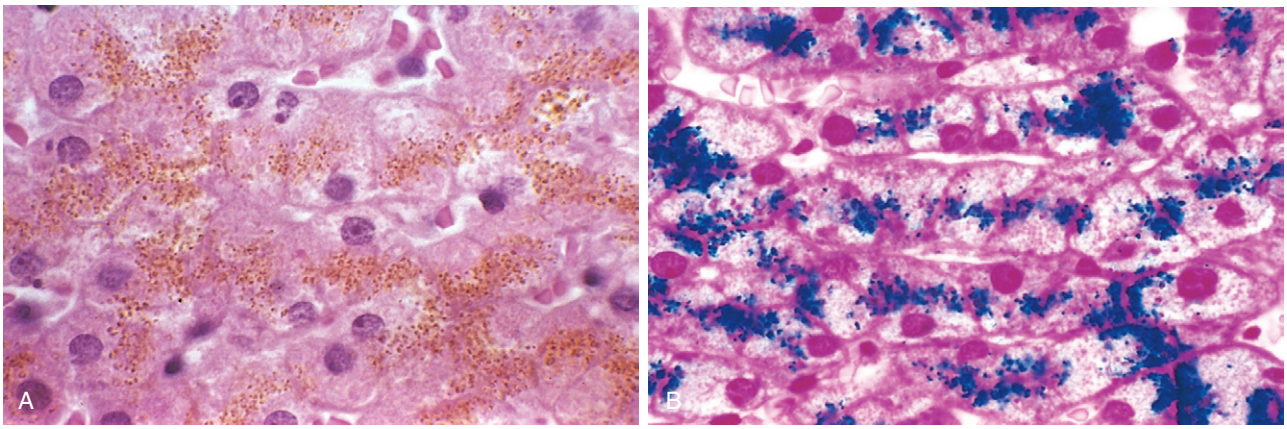


**Figure 1–28** Hemosiderin granules in liver cells. **A,** Hematoxylin-eosin–stained section showing golden-brown, finely granular pigment. **B,** Iron deposits revealed by a special staining process called the Prussian blue reaction.

cells that have lost their ability to regulate intracellular calcium. After initiation in either location, propagation of crystal formation occurs. This is dependent on the concentration of $Ca^{2+}$ and $PO_4^-$, the presence of mineral inhibitors, and the degree of collagenization, which enhances the rate of crystal growth.

Metastatic Calcification

Metastatic calcification can occur in normal tissues whenever there is hypercalcemia. The major causes of hypercalcemia are (1) *increased secretion of parathyroid hormone,* due to either primary parathyroid tumors or production of parathyroid hormone–related protein by other malignant tumors; (2) *destruction of bone* due to the effects of accelerated turnover (e.g., *Paget disease*), immobilization, or tumors (increased bone catabolism associated with multiple myeloma, leukemia, or diffuse skeletal metastases); (3) *vitamin D–related disorders* including vitamin D intoxication and *sarcoidosis* (in which macrophages activate a vitamin D precursor); and (4) *renal failure,* in which phosphate retention leads to *secondary hyperparathyroidism.*

## MORPHOLOGY

Regardless of the site, calcium salts are seen on gross examination as fine white granules or clumps, often felt as gritty deposits. Dystrophic calcification is common in areas of caseous necrosis in tuberculosis. Sometimes a tuberculous lymph node is essentially converted to radiopaque stone. On histologic examination, calcification appears as intracellular and/or extracellular basophilic deposits. Over time, heterotopic bone may be formed in the focus of calcification.

Metastatic calcification can occur widely throughout the body but principally affects the interstitial tissues of the vasculature, kidneys, lungs, and gastric mucosa. The calcium deposits morphologically resemble those described in dystrophic calcification. Although they generally do not cause clinical dysfunction, extensive calcifications in the lungs may be evident on radiographs and may produce respiratory deficits, and massive deposits in the kidney **(nephrocalcinosis)** can lead to renal damage.

## SUMMARY

### Abnormal Intracellular Depositions and Calcifications

Abnormal deposits of materials in cells and tissues are the result of excessive intake or defective transport or catabolism.

- Depositions of *lipids*
  - *Fatty change:* accumulation of free triglycerides in cells, resulting from excessive intake or defective transport (often because of defects in synthesis of transport proteins); manifestation of reversible cell injury
  - *Cholesterol deposition:* result of defective catabolism and excessive intake; in macrophages and smooth muscle cells of vessel walls in atherosclerosis
- Deposition of *proteins:* reabsorbed proteins in kidney tubules; immunoglobulins in plasma cells
- Deposition of *glycogen:* in macrophages of patients with defects in lysosomal enzymes that break down glycogen (glycogen storage diseases)
- Deposition of *pigments:* typically indigestible pigments, such as carbon, lipofuscin (breakdown product of lipid peroxidation), or iron (usually due to overload, as in hemosiderosis)
- Pathologic calcifications
  - *Dystrophic calcification:* deposition of calcium at sites of cell injury and necrosis
  - *Metastatic calcification:* deposition of calcium in normal tissues, caused by hypercalcemia (usually a consequence of parathyroid hormone excess)

# CELLULAR AGING

Individuals age because their cells age. Although public attention on the aging process has traditionally focused on its cosmetic manifestations, aging has important health consequences, because age is one of the strongest independent risk factors for many chronic diseases, such as cancer, Alzheimer disease, and ischemic heart disease. Perhaps one of the most striking discoveries about cellular aging is that it is not simply a consequence of cells' "running out of steam," but in fact is regulated by a limited number of genes and signaling pathways that are evolutionarily conserved from yeast to mammals.

*Cellular aging is the result of a progressive decline in the life span and functional capacity of cells.* Several mechanisms are thought to be responsible for cellular aging (Fig. 1–29):

- *DNA damage.* A variety of metabolic insults that accumulate over time may result in damage to nuclear and mitochondrial DNA. Although most DNA damage is repaired by DNA repair enzymes, some persists and accumulates as cells age. Some aging syndromes are associated with defects in DNA repair mechanisms, and the life span of experimental animals in some models can be increased if responses to DNA damage are enhanced or proteins that stabilize DNA are introduced. A role of free radicals in DNA damage leading to aging has been postulated but remains controversial.
- *Decreased cellular replication.* All normal cells have a limited capacity for replication, and after a fixed number of divisions cells become arrested in a terminally nondividing state, known as *replicative senescence.* Aging is associated with progressive replicative senescence of cells. Cells from children have the capacity to undergo more rounds of replication than do cells from older people. In contrast, cells from patients with *Werner syndrome,* a rare disease characterized by premature aging, have a markedly reduced in vitro life span. In human cells, the mechanism of replicative senescence involves progressive shortening of telomeres, which ultimately results in cell cycle arrest. *Telomeres* are short repeated sequences of DNA present at the ends of linear chromosomes that are important for ensuring the complete replication of chromosome ends and for protecting the ends from fusion and degradation. When somatic cells replicate, a small section of the telomere is not duplicated,

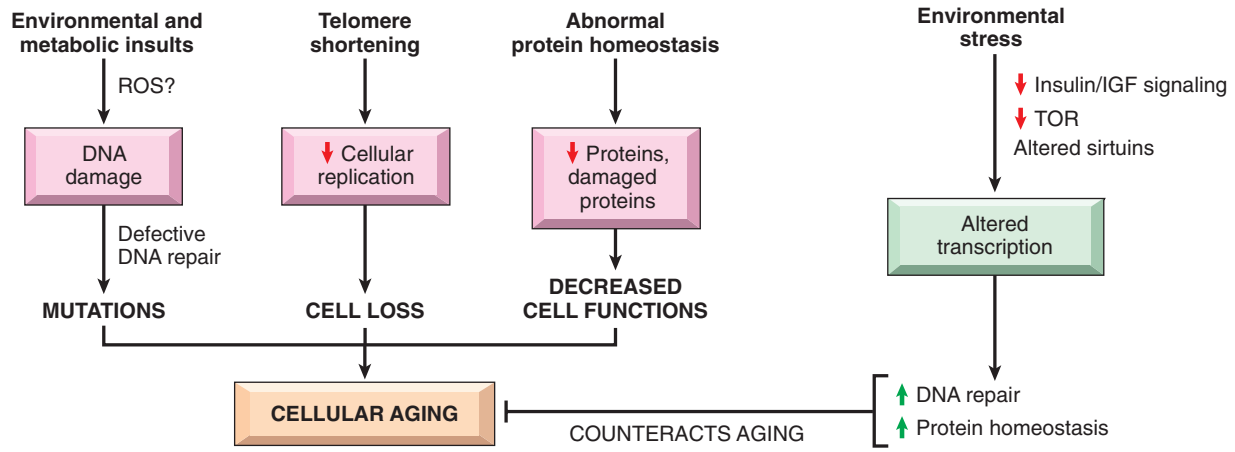


**Figure 1–29** Mechanisms that cause and counteract cellular aging. DNA damage, replicative senescence, and decreased and misfolded proteins are among the best described mechanisms of cellular aging. Some environmental stresses, such as calorie restriction, counteract aging by activating various signaling pathways and transcription factors. IGF, insulin-like growth factor; TOR, target of rapamycin.

and telomeres become progressively shortened. As the telomeres become shorter, the ends of chromosomes cannot be protected and are seen as broken DNA, which signals cell cycle arrest. Telomere length is maintained by nucleotide addition mediated by an enzyme called *telomerase.* Telomerase is a specialized RNA-protein complex that uses its own RNA as a template for adding nucleotides to the ends of chromosomes. Telomerase activity is expressed in germ cells and is present at low levels in stem cells, but it is absent in most somatic tissues (Fig. 1–30). Therefore, as most somatic cells age their telomeres become shorter and they exit the cell cycle, resulting in an inability to generate new cells to replace damaged ones. Conversely, in immortalized cancer cells, telomerase is usually reactivated and telomere length is stabilized, allowing the cells to proliferate indefinitely. This is discussed more fully in Chapter 5. Telomere shortening may also decrease the regenerative capacity of stem cells, further contributing to cellular aging. Despite such alluring observations, however, the relationship of telomerase activity and telomere length to aging has yet to be fully established.

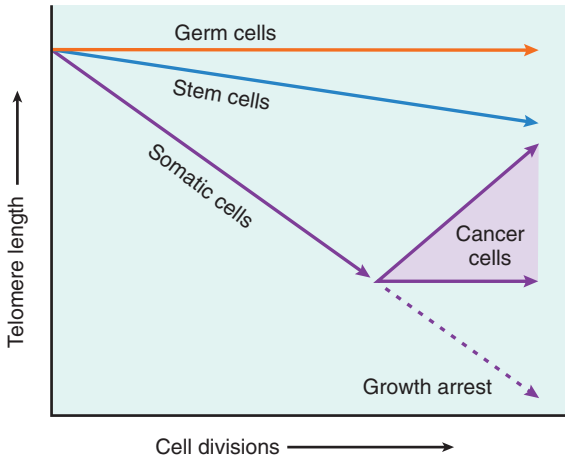


**Figure 1–30** The role of telomeres and telomerase in replicative senescence of cells. Telomere length is plotted against the number of cell divisions. In most normal somatic cells there is no telomerase activity, and telomeres progressively shorten with increasing cell divisions until growth arrest, or senescence, occurs. Germ cells and stem cells both contain active telomerase, but only the germ cells have sufficient levels of the enzyme to stabilize telomere length completely. In cancer cells, telomerase is often reactivated.

*(Data from Macmillan Publishers Ltd, from Holt SE, et al: Refining the telomer-telomerase hypothesis of aging and cancer. Nat Biotechnol 14:836, 1996.)*

- *Defective protein homeostasis.* Over time, cells are unable to maintain normal protein homeostasis, because of increased turnover and decreased synthesis caused by reduced translation of proteins and defective activity of chaperones (which promote normal protein folding), proteasomes (which destroy misfolded proteins) and repair enzymes. Abnormal protein homeostasis can have many effects on cell survival, replication, and functions. In addition, it may lead to accumulation of misfolded proteins, which can trigger pathways of apoptosis.

There has been great interest in defining signaling pathways that counteract the aging process, not only because of their obvious therapeutic potential (the search for the "elixir of youth") but also because elucidating these pathways might tell us about the mechanisms that cause aging. It is now thought that certain *environmental stresses, such as calorie restriction, alter signaling pathways that influence aging* (Fig. 1–29). Among the biochemical alterations that have been described as playing a role in counteracting the aging process are reduced signaling by insulin-like growth factor receptors, reduced activation of kinases (notably the "target of rapamycin," [TOR], and the AKT kinase), and altered transcriptional activity. Ultimately these changes lead to improved DNA repair and protein homeostasis and enhanced immunity, all of which inhibit aging. Environmental stresses may also activate proteins of the Sirtuin family, such as Sir2, which function as protein deacetylases. These proteins may deacetylate and thereby activate DNA repair enzymes, thus stabilizing the DNA; in the absence of these proteins, DNA is more prone to damage. Although the role of sirtuins has received a great deal of attention recently, their importance in the aging process is not yet established.

## SUMMARY

### Cellular Aging

- Results from combination of accumulating cellular damage (e.g., by free radicals), reduced capacity to divide (replicative senescence), and reduced ability to repair damaged DNA
- *Accumulation of DNA damage:* defective DNA repair mechanisms; conversely DNA repair may be activated by calorie restriction, which is known to prolong aging in model organisms
- *Replicative senescence:* reduced capacity of cells to divide secondary to progressive shortening of chromosomal ends (telomeres)
- *Other factors:* progressive accumulation of metabolic damage; possible roles of growth factors that promote aging in simple model organisms

It should be apparent that the various forms of cellular derangements and adaptations described in this chapter cover a wide spectrum, ranging from adaptations in cell size, growth, and function, to the reversible and irreversible forms of acute cell injury, to the regulated type of cell death represented by apoptosis. Reference is made to these many different alterations throughout this book, because all instances of organ injury and ultimately all cases of clinical disease arise from derangements in cell structure and function.

## BIBLIOGRAPHY


Auten RL, Davis JM: Oxygen toxicity and reactive oxygen species: the devil is in the details. Pediatr Res 66:121, 2009. *[A review of the production and degradation of reactive oxygen species, and their roles in cell injury.]*

Balaban RS, Nemoto S, Finkel T: Mitochondria, oxidants, and aging. Cell 120:483, 2005. *[A good review of the role of free radicals in aging.]*

Calado RT, Young NS: Telomere diseases. N Engl J Med 361:2353, 2009. *[An excellent review of the basic biology of telomeres, and how their abnormalities may contribute to cancer, aging, and other diseases.]*

Chipuk JE, Moldoveanu T, Llambl F, et al: The BCL-2 family reunion. Mol Cell 37:299, 2010. *[A review of the biochemistry and biology of the BCL-2 family of apoptosis-regulating proteins.]*

de Groot H, Rauen U: Ischemia-reperfusion injury: processes in pathogenetic networks: a review. Transplant Proc 39:481, 2007. *[A review of the roles of intrinsic cell injury and the inflammatory response in ischemia-reperfusion injury.]*

Dong Z, Saikumar P, Weinberg JM, Venkatachalam MA: Calcium in cell injury and death. Annu Rev Pathol 1:405, 2006. *[A review of the links between calcium and cell injury.]*

Elliott MR, Ravichandran KS: Clearance of apoptotic cells: implications in health and disease. J Cell Biol 189:1059, 2010. *[An excellent review of the mechanisms by which apoptotic cells are cleared, and how abnormalities in these clearance pathways may result in disease.]*

Frey N, Olson EN: Cardiac hypertrophy: the good, the bad, and the ugly. Annu Rev Physiol 65:45, 2003. *[Excellent discussion of the mechanisms of muscle hypertrophy, using the heart as the paradigm.]*

Galluzzi L, Aaronson SA, Abrams J, et al: Guidelines for the use and interpretation of assays for monitoring cell death in higher eukaryotes. Cell Death Differ 16:1093, 2009. *[A practical summary of the morphologic and other techniques for detecting and quantifying dead cells.]*

Haigis MC, Yankner BA: The aging stress response. Mol Cell 40:333, 2010. *[A review of the role of cellular stresses in controlling the aging process.]*

Hotchkiss RS, Strasser A, McDunn JE, Swanson PE: Cell death. N Engl J Med 361:1570, 2009. *[Excellent review of the major pathways of cell death (necrosis, apoptosis, and autophagy-associated death), and their clinical implications and therapeutic targeting.]*

Kenyon CJ: The genetics of ageing. Nature 464:504, 2010. *[An excellent review of the genes that influence aging, based on human genetic syndromes and studies with mutant model organisms.]*

Kroemer G, Marino G, Levine B: Autophagy and the integrated stress response. Mol Cell 40:280, 2010. *[An excellent discussion of the biology, biochemical pathways, and physiologic roles of autophagy.]*

Kundu M, Thompson CB: Autophagy: basic principles and relevance to disease. Annu Rev Pathol 3:427, 2008. *[A discussion of the biology of autophagy and its potential contribution to a variety of disease states.]*

Lin JH, Walter P, Yen TSB: Endoplasmic reticulum stress in disease pathogenesis. Annu Rev Pathol 3:399, 2008. *[A review of the biology and disease relevance of the unfolded protein response and ER stress induced by unfolded proteins.]*

Lombard DB, Chua KF, Mostoslavsky R, et al: DNA repair, genome stability, and aging. Cell 120:497, 2005. *[The role of DNA damage in cellular aging.]*

McKinnell IW, Rudnicki MA: Molecular mechanisms of muscle atrophy. Cell 119:907, 2004. *[Discussion of the mechanisms of cellular atrophy.]*

Newmeyer DD, Ferguson-Miller S: Mitochondria: releasing power for life and unleashing the machineries of death. Cell 112:481, 2003. *[Excellent review of the many functions of mitochondria, with an emphasis on their role in cell death.]*

Sahin E, DePinho RA: Linking functional decline of telomeres, mitochondria and stem cells during ageing. Nature 464:520, 2010. *[An excellent review of stem cell abnormalities that contribute to aging.]*

Tosh D, Slack JM: How cells change their phenotype. Nat Rev Mol Cell Biol 3:187, 2002. *[Review of metaplasia and the roles of stem cells and genetic reprogramming.]*

Valko M, Leibfritz D, Moncol J, et al: Free radicals and antioxidants in normal physiological functions and human disease. Int J Biochem Cell Biol 39:44, 2007. *[An interesting discussion of the biochemistry of reactive oxygen and nitrogen-derived free radicals, their roles in cell injury, and their physiologic functions as signaling molecules.]*

See Targeted Therapy available online at studentconsult.com

CHAPTER 2

# Inflammation and Repair

CHAPTER CONTENTS


**Overview of Inflammation and Tissue Repair 29**
**Acute Inflammation 31**
Stimuli for Acute Inflammation 31
Recognition of Microbes, Necrotic Cells, and Foreign Substances 32
Vascular Changes 33
Cellular Events: Leukocyte Recruitment and Activation 34
Leukocyte-Induced Tissue Injury 39
Defects in Leukocyte Function 40
Outcomes of Acute Inflammation 41
**Morphologic Patterns of Acute Inflammation 43**
**Chemical Mediators and Regulators of Inflammation 44**
Cell-Derived Mediators 46
Plasma Protein–Derived Mediators 50
Anti-inflammatory Mechanisms 52
**Chronic Inflammation 53**
Chronic Inflammatory Cells and Mediators 53
Granulomatous Inflammation 56
**Systemic Effects of Inflammation 57**
**Overview of Tissue Repair 58**
**Cell and Tissue Regeneration 59**
The Control of Cell Proliferation 59
Proliferative Capacities of Tissues 59
Stem Cells 60
Growth Factors 61
Role of the Extracellular Matrix in Tissue Repair 63
Role of Regeneration in Tissue Repair 65
**Scar Formation 65**
Steps in Scar Formation 65
Angiogenesis 66
Activation of Fibroblasts and Deposition of Connective Tissue 68
Remodeling of Connective Tissue 68
**Factors That Influence Tissue Repair 69**
**Selected Clinical Examples of Tissue Repair and Fibrosis 70**
Healing of Skin Wounds 70
Fibrosis in Parenchymal Organs 72


## OVERVIEW OF INFLAMMATION AND TISSUE REPAIR

The survival of all organisms requires that they eliminate foreign invaders, such as infectious agents, and damaged tissues. These functions are mediated by a complex host response called *inflammation. Inflammation is a protective response involving host cells, blood vessels, and proteins and other mediators that is intended to eliminate the initial cause of cell injury, as well as the necrotic cells and tissues resulting from the original insult, and to initiate the process of repair.* Inflammation accomplishes its protective mission by first diluting, destroying, or otherwise neutralizing harmful agents (e.g., microbes, toxins). It then sets into motion the events that eventually heal and repair the sites of injury. Without inflammation, infections would go unchecked and wounds would never heal. In the context of infections, inflammation is one component of a protective response that immunologists refer to as innate immunity (Chapter 4).

*Although inflammation helps clear infections and other noxious stimuli and initiates repair, the inflammatory reaction and the subsequent repair process can themselves cause considerable harm.* The components of the inflammatory reaction that destroy and eliminate microbes and dead tissues are also capable of injuring normal tissues. Therefore, injury may accompany entirely normal, beneficial inflammatory reactions, and the damage may even become the dominant feature if the reaction is very strong (e.g., when the infection is severe), prolonged (e.g., when the eliciting agent resists eradication), or inappropriate (e.g., when it is directed against self-antigens in autoimmune diseases, or against usually harmless environmental antigens (e.g., in allergic disorders). Some of the most vexing diseases of humans are disorders that result from inappropriate, often chronic, inflammation. Thus, the process of inflammation is fundamental to virtually all of clinical medicine.

*The cells and molecules of host defense, including leukocytes and plasma proteins, normally circulate in the blood, and the goal of the inflammatory reaction is to bring them to the site of infection or tissue damage.* In addition, resident cells of vascular walls and the cells and proteins of the extracellular matrix (ECM) are also involved in inflammation and repair (Fig. 2–1). Before we describe the process of inflammation in detail, some of the basic features will be highlighted.

*Inflammation can be acute or chronic* (Table 2–1). Acute inflammation is rapid in onset and of short duration, lasting

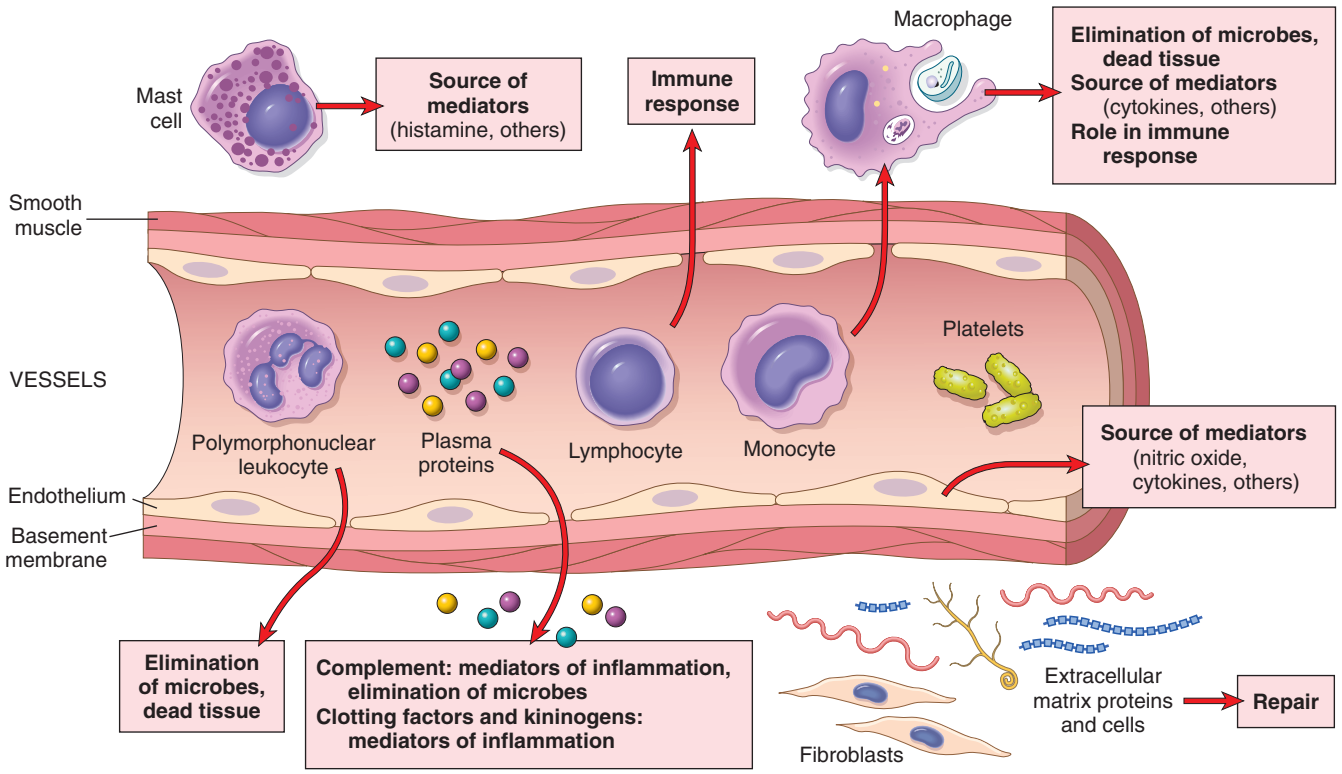


**Figure 2–1** The components of acute and chronic inflammatory responses and their principal functions. The roles of these cells and molecules in inflammation are described in this chapter.

from a few minutes to as long as a few days, and is characterized by fluid and plasma protein exudation and a predominantly neutrophilic leukocyte accumulation. Chronic inflammation may be more insidious, is of longer duration (days to years), and is typified by influx of lymphocytes and macrophages with associated vascular proliferation and fibrosis (scarring). As we shall see later, however, these two basic forms of inflammation may coexist, and many variables modify their course and histologic appearance.

*Inflammation is induced by chemical mediators that are produced by host cells in response to injurious stimuli.* When a microbe enters a tissue or the tissue is injured, the presence of the infection or damage is sensed by resident cells, mainly macrophages, but also dendritic cells, mast cells, and other cell types. These cells secrete molecules (cytokines and other mediators) that induce and regulate the subsequent inflammatory response. Inflammatory mediators are also produced from plasma proteins that react with the microbes or to injured tissues. Some of these mediators promote the efflux of plasma and the recruitment of circulating leukocytes to the site where the offending agent is located. The recruited leukocytes are activated and they try to remove the offending agent by phagocytosis. An unfortunate side effect of the activation of leukocytes may be damage to normal host tissues.

*The external manifestations of inflammation, often called its cardinal signs, are heat (calor), redness (rubor), swelling (tumor), pain (dolor), and loss of function (functio laesa).* The first four of these were described more than 2000 years ago by a Roman encyclopedist named Celsus, who wrote the then-famous text *De Medicina,* and the fifth was added in the late 19th century by Rudolf Virchow, known as the "father of modern pathology." These manifestations occur as consequences of the vascular changes and leukocyte recruitment and activation, as will be evident from the discussion that follows.

*Inflammation is normally controlled and self-limited.* The mediators and cells are activated only in response to the injurious stimulus and are short-lived, and they are degraded or become inactive as the injurious agent is eliminated. In addition, various anti-inflammatory mechanisms become active. If the injurious agent cannot be quickly eliminated, the result may be chronic inflammation, which can have serious pathologic consequences.

**Table 2–1** Features of Acute and Chronic Inflammation

| Feature | Acute | Chronic |
|---|---|---|
| Onset | Fast: minutes or hours | Slow: days |
| Cellular infiltrate | Mainly neutrophils | Monocytes/macrophages and lymphocytes |
| Tissue injury, fibrosis | Usually mild and self-limited | Often severe and progressive |
| Local and systemic signs | Prominent | Less prominent; may be subtle |

## SUMMARY

### General Features of Inflammation

- Inflammation is a defensive host response to foreign invaders and necrotic tissue, but it is itself capable of causing tissue damage.
- The main components of inflammation are a vascular reaction and a cellular response; both are activated by mediators derived from plasma proteins and various cells.
- The steps of the inflammatory response can be remembered as the five *R*s: (1) *r*ecognition of the injurious agent, (2) *r*ecruitment of leukocytes, (3) *r*emoval of the agent, (4) *r*egulation (control) of the response, and (5) *r*esolution (repair).
- The outcome of acute inflammation is either elimination of the noxious stimulus, followed by decline of the reaction and repair of the damaged tissue, or persistent injury resulting in chronic inflammation.

# ACUTE INFLAMMATION

The acute inflammatory response rapidly delivers leukocytes and plasma proteins to sites of injury. Once there, leukocytes clear the invaders and begin the process of digesting and getting rid of necrotic tissues.

Acute inflammation has two major components (Fig. 2–2):

- *Vascular changes:* alterations in vessel caliber resulting in increased blood flow (vasodilation) and changes in the vessel wall that permit plasma proteins to leave the circulation (increased vascular permeability). In addition, endothelial cells are activated, resulting in increased adhesion of leukocytes and migration of the leukocytes through the vessel wall.
- *Cellular events:* emigration of the leukocytes from the circulation and accumulation in the focus of injury (cellular recruitment), followed by activation of the leukocytes, enabling them to eliminate the offending agent. The principal leukocytes in acute inflammation are neutrophils (polymorphonuclear leukocytes).

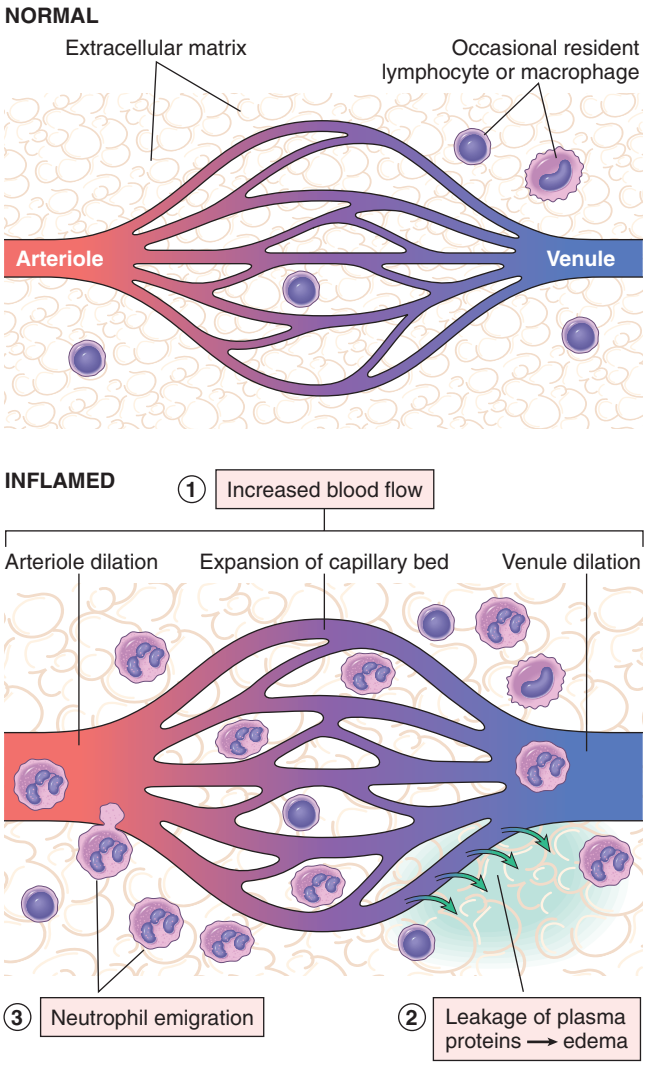


**Figure 2–2** Vascular and cellular reactions of acute inflammation. The major local manifestations of acute inflammation, compared with normal, are *(1)* vascular dilation and increased blood flow (causing erythema and warmth), *(2)* extravasation of plasma fluid and proteins (edema), and *(3)* leukocyte (mainly neutrophil) emigration and accumulation.

## Stimuli for Acute Inflammation

Acute inflammatory reactions may be triggered by a variety of stimuli:

- *Infections* (bacterial, viral, fungal, parasitic) are among the most common and medically important causes of inflammation.
- *Trauma* (blunt and penetrating) and various physical and chemical agents (e.g., thermal injury, such as burns or frostbite; irradiation; toxicity from certain environmental chemicals) injure host cells and elicit inflammatory reactions.
- *Tissue necrosis* (from any cause), including ischemia (as in a myocardial infarct) and physical and chemical injury
- *Foreign bodies* (splinters, dirt, sutures, crystal deposits)
- *Immune reactions* (also called *hypersensitivity reactions*) against environmental substances or against "self" tissues. Because the stimuli for these inflammatory responses often cannot be eliminated or avoided, such reactions tend to persist, with features of chronic inflammation. The term "immune-mediated inflammatory disease" is sometimes used to refer to this group of disorders.

Although each of these stimuli may induce reactions with some distinctive characteristics, in general, all inflammatory reactions have the same basic features.

In this section, we describe first how inflammatory stimuli are recognized by the host, then the typical reactions of acute inflammation and its morphologic features, and finally the chemical mediators responsible for these reactions.

## Recognition of Microbes, Necrotic Cells, and Foreign Substances

A fundamental question relating to activation of the host response is how cells recognize the presence of potentially harmful agents such as microbes in the tissues. It was postulated that microbes and dead cells must elicit some sort of "danger signals" that distinguish them from normal tissues and mobilize the host response. It is now established that *phagocytes, dendritic cells (cells in connective tissue and organs that capture microbes and initiate responses to them), and many other cells, such as epithelial cells, express receptors that are designed to sense the presence of infectious pathogens and substances released from dead cells.* These receptors have been called "pattern recognition receptors" because they recognize structures (i.e., molecular patterns) that are common to many microbes or to dead cells. The two most important families of these receptors are the following:

- *Toll-like receptors (TLRs)* are microbial sensors that are named for the founding member called *Toll,* which was discovered in *Drosophila.* There are ten mammalian TLRs, which recognize products of bacteria (such as endotoxin and bacterial DNA), viruses (such as double-stranded RNA), and other pathogens (Fig. 2–3, *A*). TLRs are located in plasma membranes and endosomes, so they are able to detect extracellular and ingested microbes. They are complemented by cytoplasmic and membrane molecules, from several other families, that also recognize microbial products. TLRs and the other receptors recognize products of different types of microbes and thus provide defense against essentially all classes of infectious pathogens. Recognition of microbes by these receptors activates transcription factors that stimulate the production of a number of secreted and membrane proteins. These proteins include mediators of inflammation, antiviral cytokines (interferons), and proteins that promote lymphocyte activation and even more potent immune responses. We return to TLRs in Chapter 4, when we discuss innate immunity, the early defense against infections.
- The *inflammasome* is a multi-protein cytoplasmic complex that recognizes products of dead cells, such as uric acid and extracellular ATP, as well as crystals and some microbial products. Triggering of the inflammasome results in activation of an enzyme called caspase-1, which cleaves precursor forms of the inflammatory

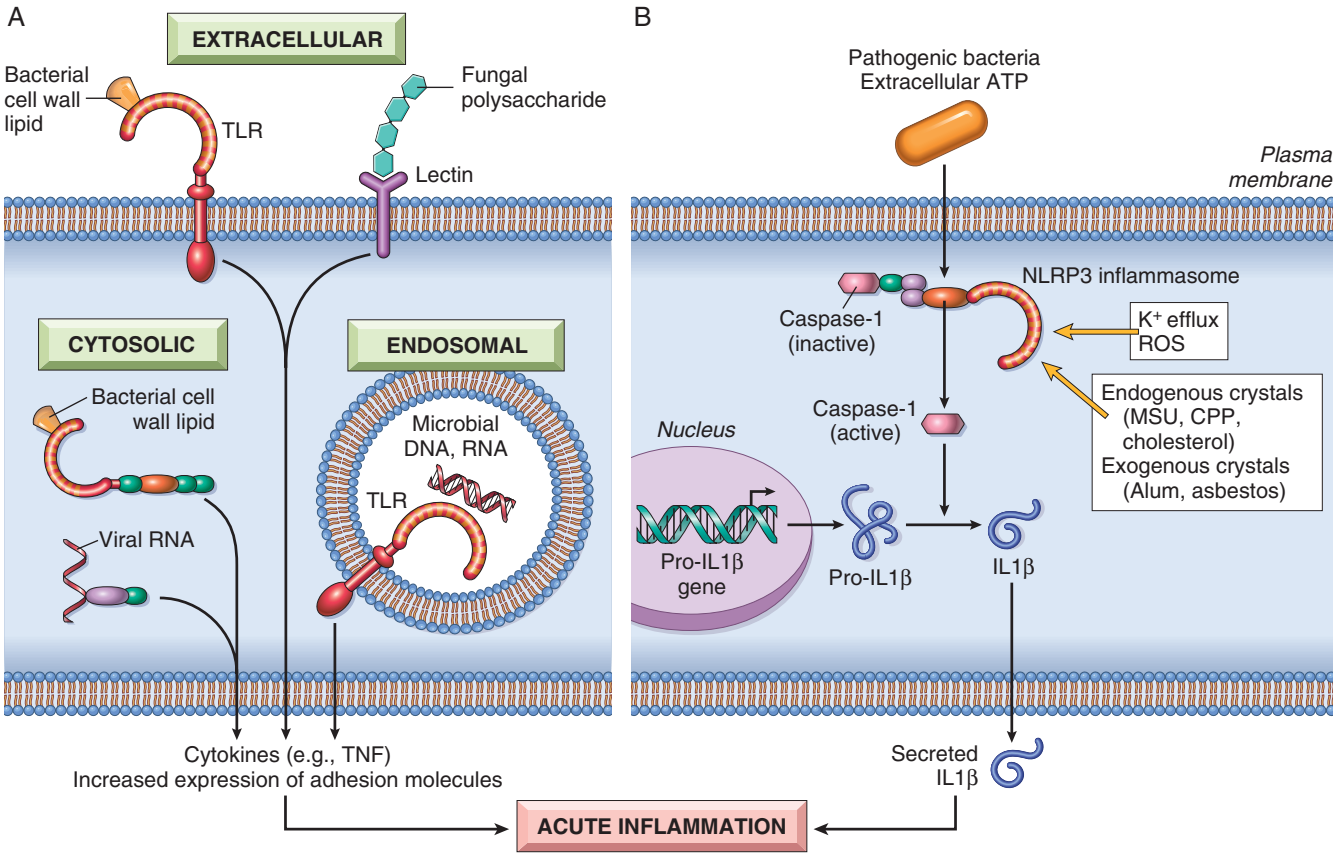


**Figure 2–3** Sensors of microbes and dead cells: Phagocytes, dendritic cells, and many types of epithelial cells express different classes of receptors that sense the presence of microbes and dead cells. **A, Toll-like receptors** (TLRs) located in the plasma membrane and endosomes and other cytoplasmic and plasma membrane receptors (members of families other than TLRs) recognize products of different classes of microbes. The proteins produced by TLR activation have numerous functions; only their role in inflammation is shown. **B,** The **inflammasome** is a protein complex that recognizes products of dead cells and some microbes and induces the secretion of biologically active interleukin-1 (IL-1). The inflammasome consists of a sensor protein (a leucine-rich protein called NLRP3), an adaptor, and the enzyme caspase-1, which is converted from an inactive to an active form. (Note that the inflammasome is distinct from phagolysosomes, which also are present in the cytoplasm but are vesicles that serve different functions in inflammation, as discussed later in the chapter.) CPP, calcium pyrophosphate; MSU, monosodium urate.

cytokine interleukin-1β (IL-1β) into its biologically active form (Fig. 2–3, *B*). As discussed later, IL-1 is an important mediator of leukocyte recruitment in the acute inflammatory response, and the leukocytes phagocytose and destroy dead cells. The joint disease, gout, is caused by deposition of urate crystals, which are ingested by phagocytes and activate the inflammasome, resulting in IL-1 production and acute inflammation. IL-1 antagonists are effective treatments in cases of gout that are resistant to conventional anti-inflammatory therapy. Recent studies have shown that cholesterol crystals and free fatty acids also activate the inflammasome, suggesting that IL-1 plays a role in common diseases such as atherosclerosis (associated with deposition of cholesterol crystals in vessel walls) and obesity-associated type 2 diabetes. This finding raises the possibility of treating these diseases by blocking IL-1.

The functions of these sensors are referred to throughout the chapter. We now proceed with a discussion of the principal reactions of acute inflammation.

## Vascular Changes

*The main vascular reactions of acute inflammation are increased blood flow secondary to vasodilation and increased vascular permeability, both designed to bring blood cells and proteins to sites of infection or injury.* While the initial encounter of an injurious stimulus, such as a microbe, is with macrophages and other cells in the connective tissue, the vascular reactions triggered by these interactions soon follow and dominate the early phase of the response.

### Changes in Vascular Caliber and Flow

Changes in blood vessels are initiated rapidly after infection or injury but evolve at variable rates, depending on the nature and severity of the original inflammatory stimulus.

- After transient vasoconstriction (lasting only for seconds), arteriolar vasodilation occurs, resulting in locally increased blood flow and engorgement of the down-stream capillary beds (Fig. 2–2). This vascular expansion is the cause of the redness (*erythema*) and warmth characteristic of acute inflammation, and mentioned previously as two of the cardinal signs of inflammation.
- The microvasculature becomes more permeable, and protein-rich fluid moves into the extravascular tissues. This causes the red cells in the flowing blood to become more concentrated, thereby increasing blood viscosity and slowing the circulation. These changes are reflected microscopically by numerous dilated small vessels packed with red blood cells, called *stasis.*
- As stasis develops, leukocytes (principally neutrophils) begin to accumulate along the vascular endothelial surface—a process called *margination.* This is the first step in the journey of the leukocytes through the vascular wall into the interstitial tissue (described later).

### Increased Vascular Permeability

Increasing vascular permeability leads to the movement of protein-rich fluid and even blood cells into the extravascular tissues (Fig. 2–4). This in turn increases the osmotic pressure of the interstitial fluid, leading to more outflow of

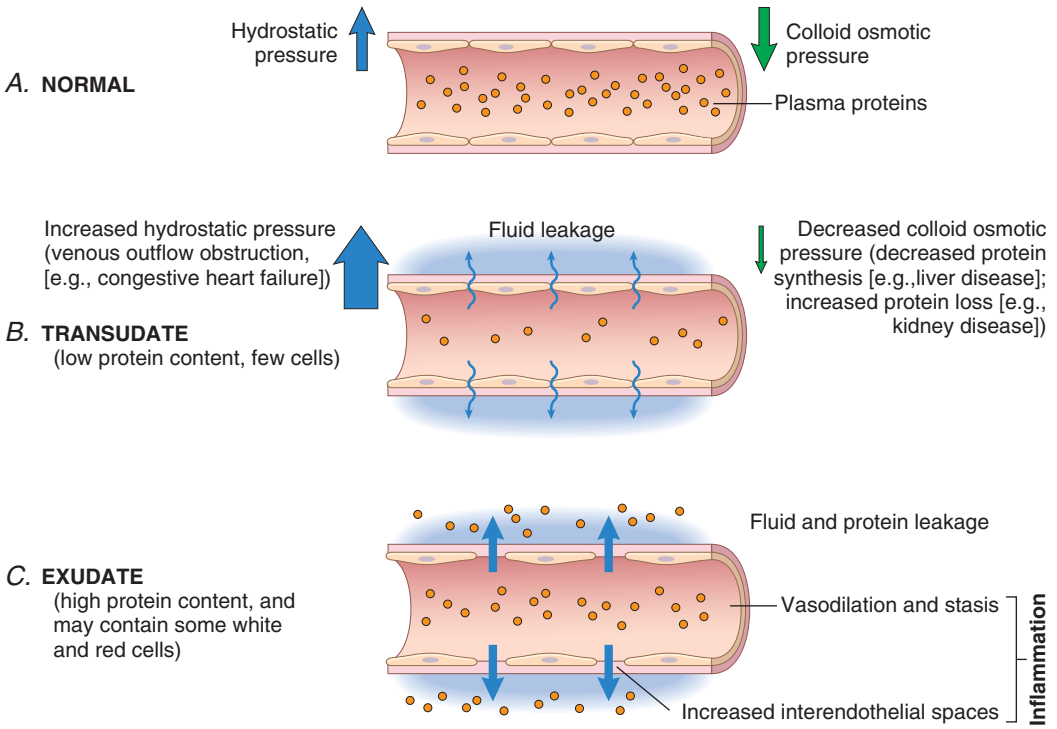


**Figure 2–4** Formation of transudates and exudates. *A*, Normal hydrostatic pressure (*blue arrows*) is approximately 32 mm Hg at the arterial end of a capillary bed and 12 mm Hg at the venous end; the mean colloid osmotic pressure of tissues is approximately 25 mm Hg (*green arrows*), which is nearly equal to the mean capillary pressure. Therefore, the net flow of fluid across the vascular bed is almost nil. *B*, A transudate is formed when fluid leaks out because of increased hydrostatic pressure or decreased osmotic pressure. *C*, An exudate is formed in inflammation because vascular permeability increases as a result of the increase in interendothelial spaces.

water from the blood into the tissues. The resulting protein-rich fluid accumulation is called an *exudate.* Exudates must be distinguished from *transudates,* which are interstitial fluid accumulations caused by increased hydrostatic pressure, usually a consequence of reduced venous return. Transudates typically contain low concentrations of protein and few or no blood cells. Fluid accumulation in extravascular spaces, whether from an exudate or a transudate, produces tissue *edema.* Whereas exudates are typical of inflammation, transudates accumulate in various noninflammatory conditions, which are mentioned in Figure 2–4 and described in more detail in Chapter 3.

Several mechanisms may contribute to increased vascular permeability in acute inflammatory reactions:

- *Endothelial cell contraction leading to intercellular gaps in postcapillary venules* is the most common cause of increased vascular permeability. Endothelial cell contraction occurs rapidly after binding of histamine, bradykinin, leukotrienes, and many other mediators to specific receptors, and is usually short-lived (15 to 30 minutes). A slower and more prolonged retraction of endothelial cells, resulting from changes in the cytoskeleton, may be induced by cytokines such as tumor necrosis factor (TNF) and interleukin-1 (IL-1). This reaction may take 4 to 6 hours to develop after the initial trigger and persist for 24 hours or more.
- *Endothelial injury* results in vascular leakage by causing endothelial cell necrosis and detachment. Endothelial cells are damaged after severe injury such as with burns and some infections. In most cases, leakage begins immediately after the injury and persists for several hours (or days) until the damaged vessels are thrombosed or repaired. Venules, capillaries, and arterioles can all be affected, depending on the site of the injury. Direct injury to endothelial cells may also induce a delayed prolonged leakage that begins after a delay of 2 to 12 hours, lasts for several hours or even days, and involves venules and capillaries. Examples are mild to moderate thermal injury, certain bacterial toxins, and x- or ultraviolet irradiation (i.e., the sunburn that has spoiled many an evening after a day in the sun). Endothelial cells may also be damaged as a consequence of leukocyte accumulation along the vessel wall. Activated leukocytes release many toxic mediators, discussed later, that may cause endothelial injury or detachment.
- *Increased transcytosis* of proteins by way of an intracellular vesicular pathway augments venular permeability, especially after exposure to certain mediators such as vascular endothelial growth factor (VEGF). Transcytosis occurs through channels formed by fusion of intracellular vesicles.
- *Leakage from new blood vessels.* As described later, tissue repair involves new blood vessel formation (angiogenesis). These vessel sprouts remain leaky until proliferating endothelial cells mature sufficiently to form intercellular junctions. New endothelial cells also have increased expression of receptors for vasoactive mediators, and some of the factors that stimulate angiogenesis (e.g., VEGF) also directly induce increased vascular permeability.

Although these mechanisms of vascular permeability are separable, all of them may participate in the response to a particular stimulus. For example, in a thermal burn, leakage results from chemically mediated endothelial contraction, as well as from direct injury and leukocyte-mediated endothelial damage.

### Responses of Lymphatic Vessels

In addition to blood vessels, lymphatic vessels also participate in the inflammatory response. In inflammation, lymph flow is increased and helps drain edema fluid, leukocytes, and cell debris from the extravascular space. In severe inflammatory reactions, especially to microbes, the lymphatics may transport the offending agent, contributing to its dissemination. The lymphatics may become secondarily inflamed (*lymphangitis*), as may the draining lymph nodes (*lymphadenitis*). Inflamed lymph nodes are often enlarged because of hyperplasia of the lymphoid follicles and increased numbers of lymphocytes and phagocytic cells lining the sinuses of the lymph nodes. This constellation of pathologic changes is termed reactive, or inflammatory, lymphadenitis (Chapter 11). For clinicians, the presence of red streaks near a skin wound is a telltale sign of an infection in the wound. This streaking follows the course of the lymphatic channels and is diagnostic of lymphangitis; it may be accompanied by painful enlargement of the draining lymph nodes, indicating lymphadenitis.

## SUMMARY

### Vascular Reactions in Acute Inflammation

- Vasodilation is induced by chemical mediators such as histamine (described later) and is the cause of erythema and stasis of blood flow.
- Increased vascular permeability is induced by histamine, kinins, and other mediators that produce gaps between endothelial cells; by direct or leukocyte-induced endothelial injury; and by increased passage of fluids through the endothelium. This increased permeability allows plasma proteins and leukocytes to enter sites of infection or tissue damage; fluid leak through blood vessels results in edema.

## Cellular Events: Leukocyte Recruitment and Activation

As mentioned earlier, an important function of the inflammatory response is to deliver leukocytes to the site of injury and to activate them. Leukocytes ingest offending agents, kill bacteria and other microbes, and eliminate necrotic tissue and foreign substances. A price that is paid for the defensive potency of leukocytes is that once activated, they may induce tissue damage and prolong inflammation, since the leukocyte products that destroy microbes can also injure normal host tissues. Therefore, host defense mechanisms include checks and balances that ensure that leukocytes are recruited and activated only when and where they are needed (i.e., in response to foreign invaders and dead tissues). Systemic activation of leukocytes can, in fact, have detrimental consequences, as in septic shock (Chapter 3).

### *Leukocyte Recruitment*

*Leukocytes normally flow rapidly in the blood, and in inflammation, they have to be stopped and brought to the offending agent or the site of tissue damage, which are typically outside the vessels.* The sequence of events in the recruitment of leukocytes from the vascular lumen to the extravascular space consists of (1) margination and rolling along the vessel wall; (2) firm adhesion to the endothelium; (3) transmigration between endothelial cells; and (4) migration in interstitial tissues toward a chemotactic stimulus (Fig. 2–5). Rolling, adhesion, and transmigration are mediated by the interactions of adhesion molecules on leukocytes and endothelial surfaces (see later on). Chemical mediators—chemoattractants and certain cytokines—affect these processes by modulating the surface expression and binding affinity of the adhesion molecules and by stimulating directional movement of the leukocytes.

*Margination and Rolling.* As blood flows from capillaries into postcapillary venules, circulating cells are swept by laminar flow against the vessel wall. Because the smaller red cells tend to move faster than the larger white cells, leukocytes are pushed out of the central axial column and thus have a better opportunity to interact with lining endothelial cells, especially as stasis sets in. This process of leukocyte accumulation at the periphery of vessels is called *margination.* If the endothelial cells are activated by cytokines and other mediators produced locally, they express adhesion molecules to which the leukocytes attach loosely. These cells bind and detach and thus begin to tumble on the endothelial surface, a process called *rolling.*

The weak and transient interactions involved in rolling are mediated by the *selectin* family of adhesion molecules (Table 2–2). Selectins are receptors expressed on leukocytes and endothelium that contain an extracellular domain that binds sugars (hence the lectin part of the name). The three members of this family are E-selectin (also called CD62E), expressed on endothelial cells; P-selectin (CD62P), present on platelets and endothelium; and L-selectin (CD62L), on the surface of most leukocytes. Selectins bind sialylated oligosaccharides (e.g., sialyl–Lewis X on leukocytes) that are attached to mucin-like glycoproteins on various cells. The endothelial selectins are typically expressed at low levels or are not present at all on unactivated endothelium, and are up-regulated after stimulation by cytokines and other mediators. Therefore, binding of leukocytes is largely restricted to endothelium at sites of infection or tissue injury (where the mediators are produced). For example, in unactivated endothelial cells, P-selectin is found primarily in intracellular Weibel-Palade bodies; however, within minutes of exposure to mediators such as histamine or thrombin, P-selectin is distributed to the cell surface, where it can facilitate leukocyte binding. Similarly, E-selectin and the ligand for L-selectin, which are not expressed on normal endothelium, are induced after stimulation by the cytokines IL-1 and TNF.

*Adhesion.* The rolling leukocytes are able to sense changes in the endothelium that initiate the next step in the reaction of leukocytes, which is firm *adhesion* to endothelial surfaces. This adhesion is mediated by *integrins* expressed on leukocyte cell surfaces interacting with their ligands on endothelial cells (Fig. 2–5 and Table 2–2). Integrins are

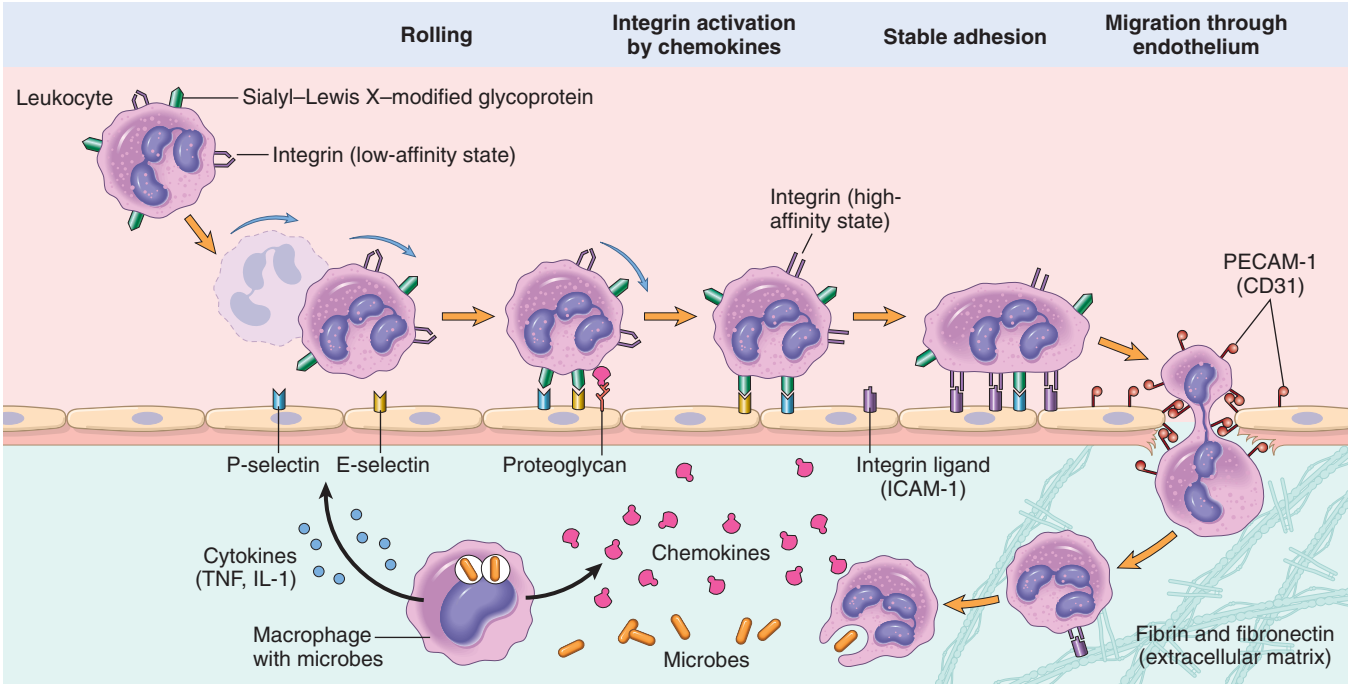


**Figure 2–5** Mechanisms of leukocyte migration through blood vessels. The leukocytes (neutrophils shown here) first roll, then become activated and adhere to endothelium, then transmigrate across the endothelium, pierce the basement membrane, and migrate toward chemoattractants emanating from the source of injury. Different molecules play predominant roles in different steps of this process: selectins in rolling; chemokines (usually displayed bound to proteoglycans) in activating the neutrophils to increase avidity of integrins; integrins in firm adhesion; and CD31 (PECAM-1) in transmigration. ICAM-1, intercellular adhesion molecule-1; IL-1, interleukin-1; PECAM-1, platelet endothelial cell adhesion molecule-1; TNF, tumor necrosis factor.

**Table 2–2** Endothelial and Leukocyte Adhesion Molecules

| Endothelial Molecule | Leukocyte Molecule | Major Role(s) |
|---|---|---|
| Selectins and Selectin Ligands | | |
| P-selectin | Sialyl–Lewis X–modified proteins | Rolling |
| E-selectin | Sialyl–Lewis X–modified proteins | Rolling and adhesion |
| GlyCam-1, CD34 | L-selectin* | Rolling (neutrophils, monocytes) |
| Integrins and Integrin Ligands | | |
| ICAM-1 (immunoglobulin family) | CD11/CD18 integrins (LFA-1, Mac-1) | Firm adhesion, arrest, transmigration |
| VCAM-1 (immunoglobulin family) | VLA-4 integrin | Adhesion |
| Others | | |
| CD31 | CD31 (homotypic interaction) | Transmigration of leukocytes through endothelium |

*L-selectin is also involved in the binding of circulating lymphocytes to the high endothelial venules in lymph nodes and mucosal lymphoid tissues, and subsequent homing of lymphocytes to these tissues.
ICAM-1, intercellular adhesion molecule-1; LFA-1, leukocyte function–associated antigen-1; Mac-1, macrophage-1 antigen; VCAM-1, vascular cell adhesion molecule-1; VLA-4, very late antigen-4.

transmembrane heterodimeric glycoproteins that mediate the adhesion of leukocytes to endothelium and of various cells to the extracellular matrix. They are normally expressed on leukocyte plasma membranes in a low-affinity form and do not adhere to their specific ligands until the leukocytes are activated by chemokines.

Chemokines are chemoattractant cytokines that are secreted by many cells at sites of inflammation and are displayed on the endothelial surface. (Cytokines are described later in the chapter.) When the adherent leukocytes encounter the displayed chemokines, the cells are activated, and their integrins undergo conformational changes and cluster together, thus converting to a high-affinity form. At the same time, other cytokines, notably TNF and IL-1 (also secreted at sites of infection and injury), activate endothelial cells to increase their expression of ligands for integrins. These ligands include intercellular adhesion molecule-1 (ICAM-1), which binds to the integrins leukocyte function–associated antigen-1 (LFA-1) (also called CD11a/CD18) and macrophage-1 antigen (Mac-1) (i.e., CD11b/CD18), and vascular cell adhesion molecule-1 (VCAM-1), which binds to the integrin very late antigen-4 (VLA-4) (Table 2–2). Engagement of integrins by their ligands delivers signals to the leukocytes that lead to cytoskeletal changes that mediate firm attachment to the substrate. Thus, the net result of cytokine-stimulated increased integrin affinity and increased expression of integrin ligands is stable attachment of leukocytes to endothelial cells at sites of inflammation.

***Transmigration.*** After being arrested on the endothelial surface, leukocytes migrate through the vessel wall primarily by squeezing between cells at intercellular junctions. This extravasation of leukocytes, called *diapedesis,* occurs mainly in the venules of the systemic vasculature; it has also been noted in capillaries in the pulmonary circulation. Migration of leukocytes is driven by chemokines produced in extravascular tissues, which stimulate movement of the leukocytes toward their chemical gradient. In addition, platelet endothelial cell adhesion molecule-1 (PECAM-1) (also called CD31), a cellular adhesion molecule expressed on leukocytes and endothelial cells, mediates the binding events needed for leukocytes to traverse the endothelium. After passing through the endothelium, leukocytes secrete collagenases that enable them to pass through the vascular basement membrane.

***Chemotaxis.*** After extravasating from the blood, leukocytes move toward sites of infection or injury along a chemical gradient by a process called *chemotaxis*. Both exogenous and endogenous substances can be chemotactic for leukocytes, including the following:

- Bacterial products, particularly peptides with *N*-formylmethionine termini
- Cytokines, especially those of the *chemokine* family
- Components of the complement system, particularly C5
- Products of the lipoxygenase pathway of arachidonic acid (AA) metabolism, particularly leukotriene B4 (LTB4)

These mediators, which are described in more detail later, are produced in response to infections and tissue damage and during immunologic reactions. Leukocyte infiltration in all of these situations results from the actions of various combinations of mediators.

Chemotactic molecules bind to specific cell surface receptors, which triggers the assembly of cytoskeletal contractile elements necessary for movement. Leukocytes move by extending pseudopods that anchor to the ECM and then pull the cell in the direction of the extension. The direction of such movement is specified by a higher density of chemokine receptors at the leading edge of the cell. Thus, leukocytes move to and are retained at the site where they are needed.

The type of emigrating leukocyte varies with the age of the inflammatory response and with the type of stimulus. In most forms of acute inflammation, *neutrophils predominate in the inflammatory infiltrate during the first 6 to 24 hours and are replaced by monocytes in 24 to 48 hours* (Fig. 2–6). Several factors account for this early abundance of neutrophils: These cells are the most numerous leukocytes in the blood, they respond more rapidly to chemokines, and they may attach more firmly to the adhesion molecules that are rapidly induced on endothelial cells, such as P- and E-selectins. In addition, after entering tissues, neutrophils are short-lived—they die by apoptosis and disappear within 24 to 48 hours—while monocytes survive longer. There are exceptions to this pattern of cellular infiltration, however.

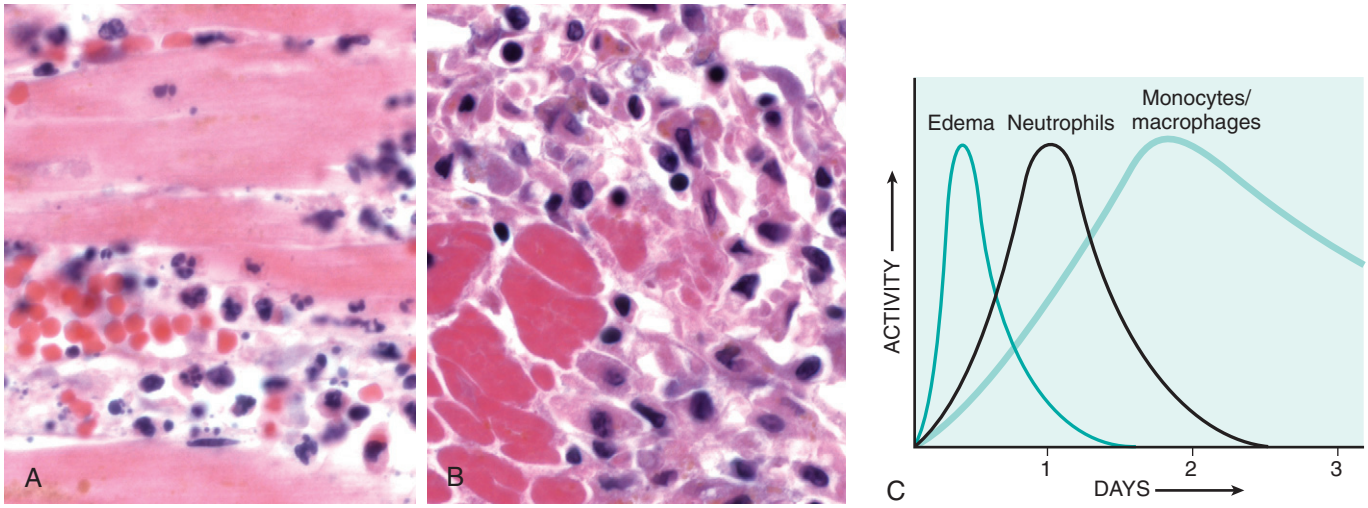


**Figure 2–6** Nature of leukocyte infiltrates in inflammatory reactions. The photomicrographs show an inflammatory reaction in the myocardium after ischemic necrosis (infarction). **A,** Early (neutrophilic) infiltrates and congested blood vessels. **B,** Later (mononuclear) cellular infiltrates. **C,** The approximate kinetics of edema and cellular infiltration. For sake of simplicity, edema is shown as an acute transient response, although secondary waves of delayed edema and neutrophil infiltration also can occur.

In certain infections (e.g., those caused by *Pseudomonas* organisms), the cellular infiltrate is dominated by continuously recruited neutrophils for several days; in viral infections, lymphocytes may be the first cells to arrive; and in some hypersensitivity reactions, eosinophils may be the main cell type.

## SUMMARY

### Leukocyte Recruitment to Sites of Inflammation

- Leukocytes are recruited from the blood into the extravascular tissue, where infectious pathogens or damaged tissues may be located, and are activated to perform their functions.
- Leukocyte recruitment is a multi-step process consisting of loose attachment to and rolling on endothelium (mediated by selectins); firm attachment to endothelium (mediated by integrins); and migration through interendothelial spaces.
- Various cytokines promote expression of selectins and integrin ligands on endothelium (TNF, IL-1), increase the avidity of integrins for their ligands (chemokines), and promote directional migration of leukocytes (also chemokines); many of these cytokines are produced by tissue macrophages and other cells responding to pathogens or damaged tissues.
- Neutrophils predominate in the early inflammatory infiltrate and are later replaced by macrophages.

### *Leukocyte Activation*

Once leukocytes have been recruited to the site of infection or tissue necrosis, they must be activated to perform their functions. Stimuli for activation include microbes, products of necrotic cells, and several mediators that are described later. As described earlier, leukocytes use various receptors to sense the presence of microbes, dead cells, and foreign substances. Engagement of these cellular receptors induces a number of responses in leukocytes that are part of their normal defensive functions and are grouped under the term *leukocyte activation* (Fig. 2–7). Leukocyte activation results in the enhancement of the following functions:

- *Phagocytosis* of particles
- *Intracellular destruction of phagocytosed microbes and dead cells* by substances produced in phagosomes, including reactive oxygen and nitrogen species and lysosomal enzymes
- *Liberation of substances that destroy extracellular microbes and dead tissues*, which are largely the same as the substances produced within phagocytic vesicles. A recently discovered mechanism by which neutrophils destroy extracellular microbes is the formation of extracellular "traps."
- *Production of mediators*, including arachidonic acid metabolites and cytokines, that amplify the inflammatory reaction, by recruiting and activating more leukocytes

***Phagocytosis.*** *Phagocytosis consists of three steps* (Fig. 2–8): *(1) recognition and attachment of the particle to the ingesting leukocyte; (2) engulfment, with subsequent formation of a phagocytic vacuole; and (3) killing and degradation of the ingested material.*

Leukocytes bind and ingest most microorganisms and dead cells by means of specific surface receptors. Some of these receptors recognize components of the microbes and dead cells and other receptors recognize host proteins, called *opsonins*, that coat microbes and target them for phagocytosis (the process called *opsonization*). The most important opsonins are antibodies of the immunoglobulin G (IgG) class that bind to microbial surface antigens, breakdown products of the complement protein C3 (described later), and plasma carbohydrate-binding lectins called collectins, which bind to microbial cell wall sugar groups. These opsonins either are present in the blood ready to coat

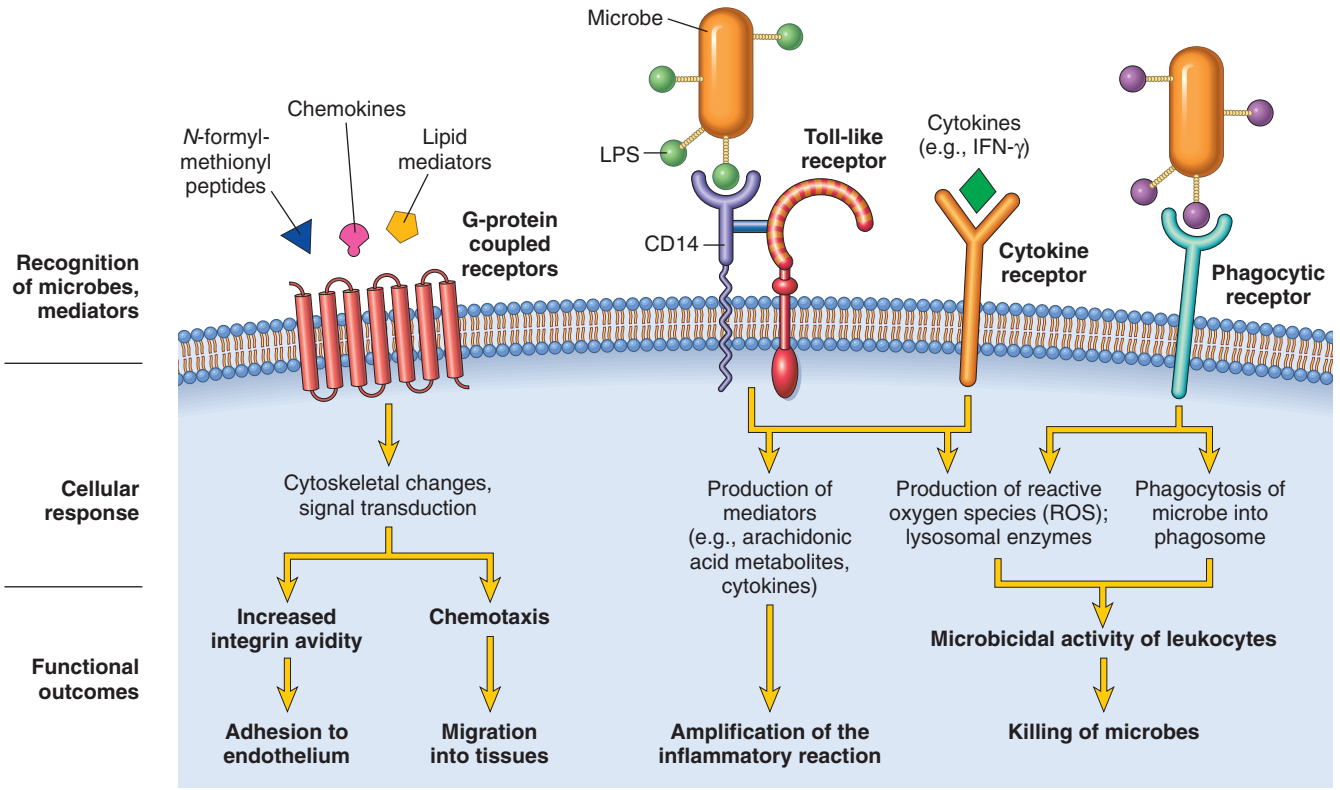


**Figure 2–7** Leukocyte activation. Different classes of cell surface receptors of leukocytes recognize different stimuli. The receptors initiate responses that mediate the functions of the leukocytes. Only some receptors are depicted (see text for details). Lipopolysaccharide (LPS) first binds to a circulating LPS-binding protein (*not shown*). IFN-γ, interferon-γ.

microbes or are produced in response to the microbes. Leukocytes express receptors for opsonins that facilitate rapid phagocytosis of the coated microbes. These receptors include the Fc receptor for IgG (called FcγRI), complement receptors 1 and 3 (CR1 and CR3) for complement fragments, and C1q for the collectins.

Binding of opsonized particles to these receptors triggers engulfment and induces cellular activation that enhances degradation of ingested microbes. In engulfment, pseudopods are extended around the object, eventually forming a phagocytic vacuole. The membrane of the vacuole then fuses with the membrane of a lysosomal granule, resulting in discharge of the granule's contents into the *phagolysosome*.

***Killing and Degradation of Phagocytosed Microbes.*** The culmination of the phagocytosis of microbes is killing and degradation of the ingested particles. The key steps in this reaction are the production of microbicidal substances within lysosomes and fusion of the lysosomes with phagosomes, thus exposing the ingested particles to the destructive mechanisms of the leukocytes (Fig. 2–8). The most important microbicidal substances are reactive oxygen species (ROS) and lysosomal enzymes. The production of ROS involves the following steps:

- Phagocytosis and the engagement of various cellular receptors stimulate an *oxidative burst,* also called the *respiratory burst,* which is characterized by a rapid increase in oxygen consumption, glycogen catabolism (glycogenolysis), increased glucose oxidation, and production of ROS. The generation of the oxygen metabolites is due to rapid activation of a leukocyte NADPH oxidase, called the *phagocyte oxidase,* which oxidizes NADPH (reduced nicotinamide adenine dinucleotide phosphate) and, in the process, converts oxygen to superoxide ion ($O_2^{\cdot-}$) (see Fig. 1–18, *B*, Chapter 1).
- Superoxide is then converted by spontaneous dismutation into hydrogen peroxide ($O_2^{\cdot-} + 2H^+ \rightarrow H_2O_2$). These ROS act as free radicals and destroy microbes by mechanisms that were described in Chapter 1.
- The quantities of $H_2O_2$ produced generally are insufficient to kill most bacteria (although superoxide and hydroxyl radical formation may be sufficient to do so). However, the lysosomes of neutrophils (called *azurophilic granules*) contain the enzyme myeloperoxidase (MPO), and in the presence of a halide such as $Cl^-$, MPO converts $H_2O_2$ to $HOCl^{\cdot}$ (hypochlorous radical). $HOCl^{\cdot}$ is a powerful oxidant and antimicrobial agent (NaOCl is the active ingredient in chlorine bleach) that kills bacteria by halogenation, or by protein and lipid peroxidation.

Fortunately, the phagocyte oxidase is active only after its cytosolic subunit translocates to the membrane of the phagolysosome; thus, the reactive end products are generated mainly within the vesicles, and the phagocyte itself is not damaged. $H_2O_2$ is eventually broken down to water and $O_2$ by the actions of catalase, and the other ROS also are degraded (Chapter 1). Reactive nitrogen species, particularly nitric oxide (NO), act in the same way as that described for ROS.

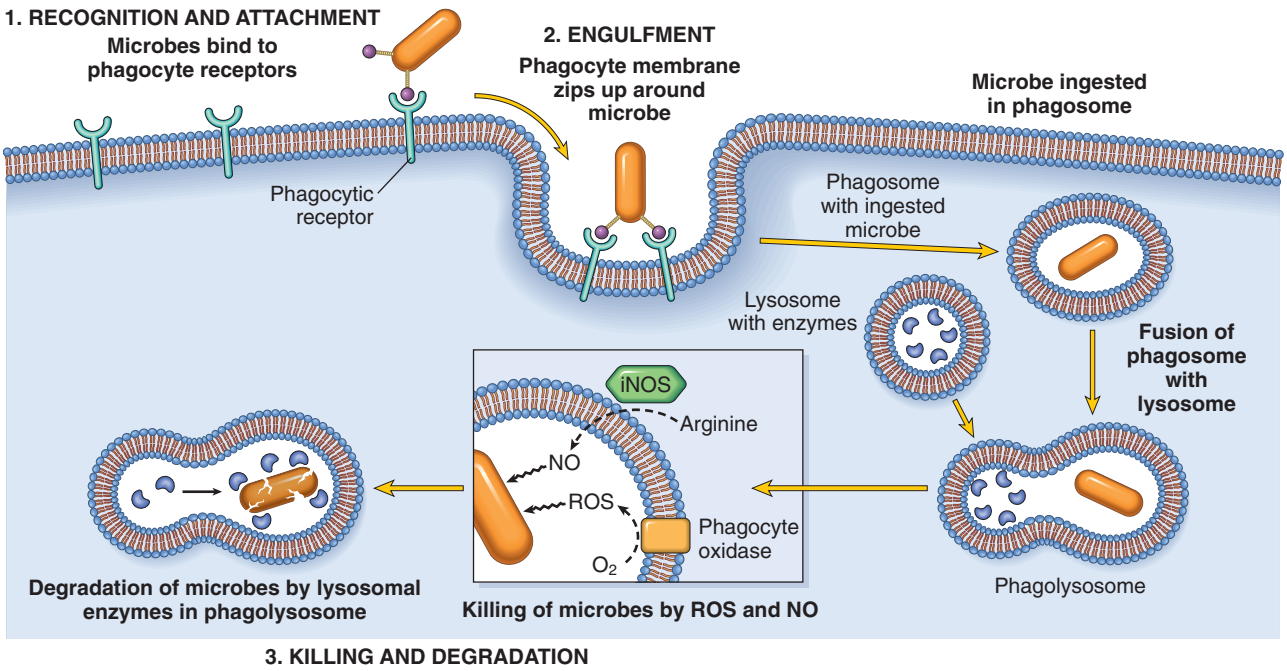


**Figure 2–8** Phagocytosis. Phagocytosis of a particle (e.g., a bacterium) involves (*1*) attachment and binding of the particle to receptors on the leukocyte surface, (*2*) engulfment and fusion of the phagocytic vacuole with granules (lysosomes), and (*3*) destruction of the ingested particle. iNOS, inducible nitric oxide synthase; NO, nitric oxide; ROS, reactive oxygen species.

The dead microorganisms are then degraded by the action of lysosomal acid hydrolases. Perhaps the most important lysosomal enzyme involved in bacterial killing is elastase.

Of note, in addition to ROS and enzymes, several other constituents of leukocyte granules are capable of killing infectious pathogens. These include bactericidal permeability-increasing protein (causing phospholipase activation and membrane phospholipid degradation), lysozyme (causing degradation of bacterial coat oligosaccharides), major basic protein (an important eosinophil granule constituent that is cytotoxic for parasites), and defensins (peptides that kill microbes by creating holes in their membranes).

***Secretion of Microbicidal Substances.*** The microbicidal mechanisms of phagocytes are largely sequestered within phagolysosomes in order to protect the leukocytes from damaging themselves. Leukocytes also actively secrete granule components including enzymes such as elastase, which destroy and digest extracellular microbes and dead tissues, as well as antimicrobial peptides. The contents of lysosomal granules are secreted by leukocytes into the extracellular milieu by several mechanisms:

- The phagocytic vacuole may remain transiently open to the outside before complete closure of the phagolysosome (regurgitation during feeding).
- If cells encounter materials that cannot be easily ingested, such as immune complexes deposited on immovable surfaces (e.g., glomerular basement membrane), the attempt to phagocytose these substances (frustrated phagocytosis) triggers strong leukocyte activation, and lysosomal enzymes are released into the surrounding tissue or lumen.
- The membrane of the phagolysosome may be damaged if potentially injurious substances, such as silica particles, are phagocytosed.

***Neutrophil Extracellular Traps (NETs).*** These "traps" are extracellular fibrillar networks that are produced by neutrophils in response to infectious pathogens (mainly bacteria and fungi) and inflammatory mediators (such as chemokines, cytokines, complement proteins, and ROS). NETs contain a framework of nuclear chromatin with embedded granule proteins, such as antimicrobial peptides and enzymes (Fig. 2–9). The traps provide a high concentration of antimicrobial substances at sites of infection, and prevent the spread of the microbes by trapping them in the fibrils. In the process, the nuclei of the neutrophils are lost, leading to death of the cells. NETs also have been detected in blood neutrophils during sepsis. The nuclear chromatin in the NETs, which includes histones and associated DNA, has been postulated to be a source of nuclear antigens in systemic autoimmune diseases, particularly lupus, in which affected persons react against their own DNA and nucleoproteins (Chapter 4).

## Leukocyte-Induced Tissue Injury

Because leukocytes are capable of secreting potentially harmful substances such as enzymes and ROS, they are important causes of injury to normal cells and tissues under several circumstances:

- As part of a normal defense reaction against infectious microbes, when "bystander" tissues are injured. In certain infections that are difficult to eradicate, such as tuberculosis and some viral diseases, the host response

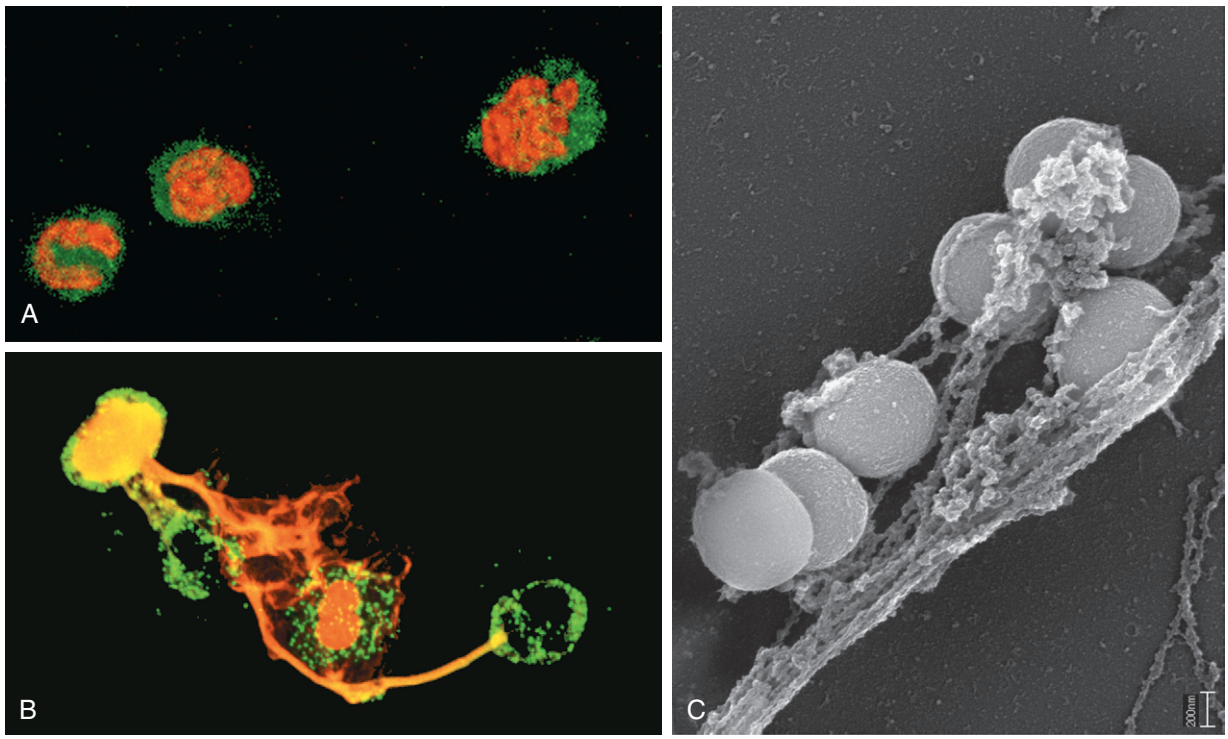


**Figure 2–9** Neutrophil extracellular traps (NETs). **A,** Healthy neutrophils with nuclei stained red and cytoplasm green. **B,** Release of nuclear material from neutrophils (note that two have lost their nuclei), forming extracellular traps. **C,** An electron micrograph of bacteria (staphylococci) trapped in NETs.

*(From Brinkmann V, Zychlinsky A: Beneficial suicide: why neutrophils die to make NETs. Nat Rev Microbiol 5:577, 2007, with the permission of the authors and publisher.)*

contributes more to the pathologic process than does the microbe itself.

- As a normal attempt to clear damaged and dead tissues (e.g., after a myocardial infarction). In an infarct, inflammation may prolong and exacerbate the injurious consequences of the ischemia, especially upon reperfusion (Chapter 1).
- When the inflammatory response is inappropriately directed against host tissues, as in certain autoimmune diseases, or when the host reacts excessively against nontoxic environmental substances, such as allergic diseases including asthma (discussed in Chapter 4)

In all of these situations, the mechanisms by which leukocytes damage normal tissues are the same as the mechanisms involved in the clearance of microbes and dead tissues, because once the leukocytes are activated, their effector mechanisms do not distinguish between offender and host. In fact, if unchecked or inappropriately directed against host tissues, leukocytes themselves become the main offenders. Leukocyte-dependent tissue injury underlies many acute and chronic human diseases (Table 2–3), as is evident in discussions of specific disorders throughout this book.

Activated leukocytes, especially macrophages, also secrete many cytokines, which stimulate further inflammation and have important systemic effects, to be discussed later.

## SUMMARY

### Leukocyte Effector Mechanisms

- Leukocytes can eliminate microbes and dead cells by phagocytosis, followed by their destruction in phagolysosomes.
- Destruction is caused by free radicals (ROS, NO) generated in activated leukocytes and lysosomal enzymes.
- Enzymes and ROS may be released into the extracellular environment.
- The mechanisms that function to eliminate microbes and dead cells (the physiologic role of inflammation) are also capable of damaging normal tissues (the pathologic consequences of inflammation).

## Defects in Leukocyte Function

Since leukocytes play a central role in host defense, it is not surprising that defects in leukocyte function, both acquired and inherited, lead to increased susceptibility to infections, which may be recurrent and life-threatening (Table 2–4). The most common causes of defective inflammation are bone marrow suppression caused by tumors or treatment with chemotherapy or radiation (resulting in decreased leukocyte numbers) and metabolic diseases such as

**Table 2–3** Clinical Examples of Leukocyte-Induced Injury

| Disorder* | Cells and Molecules Involved in Injury |
|---|---|
| **Acute** | |
| Acute respiratory distress syndrome | Neutrophils |
| Acute transplant rejection | Lymphocytes; antibodies and complement |
| Asthma | Eosinophils; IgE antibodies |
| Glomerulonephritis | Antibodies and complement; neutrophils, monocytes |
| Septic shock | Cytokines |
| **Chronic** | |
| Rheumatoid arthritis | Lymphocytes, macrophages; antibodies? |
| Asthma | Eosinophils; IgE antibodies |
| Atherosclerosis | Macrophages; lymphocytes? |
| Chronic transplant rejection | Lymphocytes, macrophages; cytokines |
| Pulmonary fibrosis | Macrophages; fibroblasts |

*Listed are selected examples of diseases in which the host response plays a significant role in tissue injury. Some, such as asthma, can manifest with acute inflammation or a chronic illness with repeated bouts of acute exacerbation. These diseases and their pathogenesis are discussed in much more detail in relevant chapters.
IgE, immunoglobulin E.

**Table 2–4** Defects in Leukocyte Functions

| Disease | Defect |
|---|---|
| **Acquired** | |
| Bone marrow suppression: tumors (including leukemias), radiation, and chemotherapy | Production of leukocytes |
| Diabetes, malignancy, sepsis, chronic dialysis | Adhesion and chemotaxis |
| Anemia, sepsis, diabetes, malnutrition | Phagocytosis and microbicidal activity |
| **Genetic** | |
| Leukocyte adhesion deficiency 1 | Defective leukocyte adhesion because of mutations in β chain of CD11/CD18 integrins |
| Leukocyte adhesion deficiency 2 | Defective leukocyte adhesion because of mutations in fucosyl transferase required for synthesis of sialylated oligosaccharide (receptor for selectins) |
| Chronic granulomatous disease | Decreased oxidative burst |
| X-linked | Phagocyte oxidase (membrane component) |
| Autosomal recessive | Phagocyte oxidase (cytoplasmic components) |
| Myeloperoxidase deficiency | Decreased microbial killing because of defective MPO–$H_2O_2$ system |
| Chédiak-Higashi syndrome | Decreased leukocyte functions because of mutations affecting protein involved in lysosomal membrane traffic |

$H_2O_2$, hydrogen peroxide; MPO, myeloperoxidase.
Modified from Gallin JI: Disorders of phagocytic cells. In Gallin JI, et al (eds): Inflammation: Basic Principles and Clinical Correlates, 2nd ed. New York, Raven Press, 1992, pp 860, 861.

diabetes (causing abnormal leukocyte functions). These are described elsewhere in the book.

The genetic disorders, although individually rare, illustrate the importance of particular molecular pathways in the complex inflammatory response. Some of the better understood inherited diseases are the following:

- *Defects in leukocyte adhesion.* In *leukocyte adhesion deficiency type 1 (LAD-1)*, defective synthesis of the CD18 β subunit of the leukocyte integrins LFA-1 and Mac-1 leads to impaired leukocyte adhesion to and migration through endothelium, and defective phagocytosis and generation of an oxidative burst. *Leukocyte adhesion deficiency type 2 (LAD-2)* is caused by a defect in fucose metabolism resulting in the absence of sialyl–Lewis X, the oligosaccharide on leukocytes that binds to selectins on activated endothelium. Its clinical manifestations are similar to but milder than those of LAD-1.
- *Defects in microbicidal activity.* An example is *chronic granulomatous disease,* a genetic deficiency in one of the several components of the phagocyte oxidase enzyme that is responsible for generating ROS. In these patients, engulfment of bacteria does not result in activation of oxygen-dependent killing mechanisms. In an attempt to control these infections, the microbes are surrounded by activated macrophages, forming the "granulomas" (see later) that give the disease its distinctive pathologic features and its somewhat misleading name.
- *Defects in phagolysosome formation.* One such disorder, *Chédiak-Higashi syndrome,* is an autosomal recessive disease that results from disordered intracellular trafficking of organelles, ultimately impairing the fusion of lysosomes with phagosomes. The secretion of lytic secretory granules by cytotoxic T lymphocytes is also affected, explaining the severe immunodeficiency typical of the disorder.
- Rare patients with defective host defenses have been shown to carry *mutations in TLR signaling pathways*. Inherited defects in components of adaptive immune responses also result in increased susceptibility to infections. These are described in Chapter 4.
- *Gain-of-function mutations in genes encoding some components of the inflammasome*, one of which is called *cryopyrin,* are responsible for rare but serious diseases called cryopyrin-associated periodic fever syndromes (CAPSs), which manifest with unrelenting fevers and other signs of inflammation and respond well to treatment with IL-1 antagonists.

## Outcomes of Acute Inflammation

Although the consequences of acute inflammation are modified by the nature and intensity of the injury, the site and tissue affected, and the ability of the host to mount a response, *acute inflammation generally has one of three outcomes* (Fig. 2–10):

- *Resolution: Regeneration and repair.* When the injury is limited or short-lived, when there has been no or minimal tissue damage, and when the injured tissue is capable of regenerating, the usual outcome is restoration

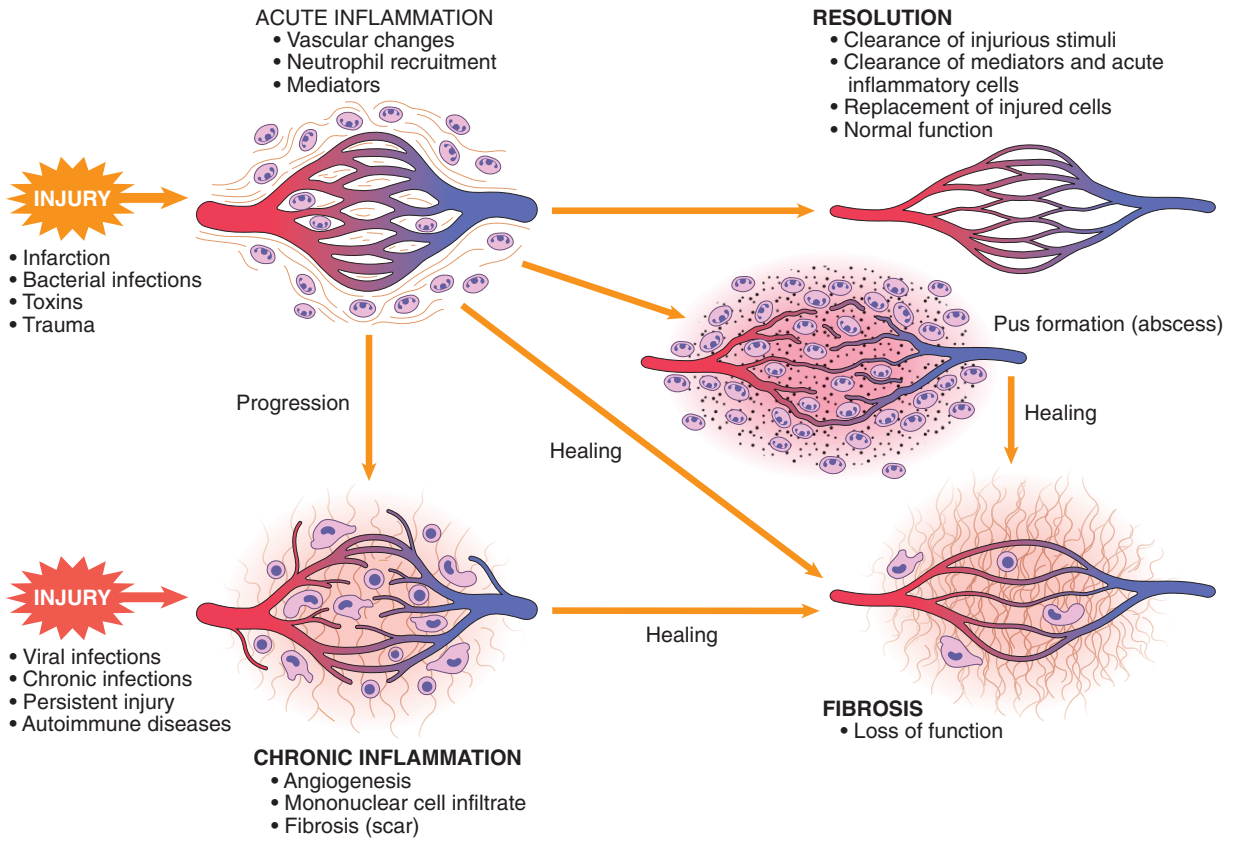


**Figure 2–10** Outcomes of acute inflammation: resolution, healing by scarring (fibrosis), or chronic inflammation (see text).

to structural and functional normalcy. Before the process of resolution can start, the acute inflammatory response has to be terminated. This involves neutralization, decay, or enzymatic degradation of the various chemical mediators; normalization of vascular permeability; and cessation of leukocyte emigration, with subsequent death (by apoptosis) of extravasated neutrophils. Furthermore, leukocytes begin to produce mediators that inhibit inflammation, thereby limiting the reaction. The necrotic debris, edema fluid, and inflammatory cells are cleared by phagocytes and lymphatic drainage, eliminating the detritus from the battlefield. Leukocytes secrete cytokines that initiate the subsequent repair process, in which new blood vessels grow into the injured tissue to provide nutrients, growth factors stimulate the proliferation of fibroblasts and laying down of collagen to fill defects, and residual tissue cells proliferate to restore structural integrity. This process is described later in the chapter.

- *Chronic inflammation* may follow acute inflammation if the offending agent is not removed, or it may be present from the onset of injury (e.g., in viral infections or immune responses to self-antigens). Depending on the extent of the initial and continuing tissue injury, as well as the capacity of the affected tissues to regrow, chronic inflammation may be followed by restoration of normal structure and function or may lead to scarring.
- *Scarring* is a type of repair after substantial tissue destruction (as in abscess formation, discussed later) or when inflammation occurs in tissues that do not regenerate, in which the injured tissue is filled in by connective tissue. In organs in which extensive connective tissue deposition occurs in attempts to heal the damage or as a consequence of chronic inflammation, the outcome is *fibrosis,* a process that can significantly compromise function.

## SUMMARY

### Sequence of Events in Acute Inflammation

- The vascular changes in acute inflammation are characterized by increased blood flow secondary to arteriolar and capillary bed dilation (erythema and warmth).
- Increased vascular permeability, as a consequence of either widening of interendothelial cell junctions of the venules or direct endothelial cell injury, results in an exudate of protein-rich extravascular fluid (tissue edema).
- The leukocytes, initially predominantly neutrophils, adhere to the endothelium via adhesion molecules and then leave the microvasculature and migrate to the site of injury under the influence of chemotactic agents.
- Phagocytosis, killing, and degradation of the offending agent follow.
- Genetic or acquired defects in leukocyte functions give rise to recurrent infections.
- The outcome of acute inflammation may be removal of the exudate with restoration of normal tissue architecture (resolution); transition to chronic inflammation; or extensive destruction of the tissue resulting in scarring.

# MORPHOLOGIC PATTERNS OF ACUTE INFLAMMATION

The vascular and cellular reactions that characterize acute inflammation are reflected in the morphologic appearance of the reaction. The severity of the inflammatory response, its specific cause, and the particular tissue involved all can modify the basic morphology of acute inflammation, producing distinctive appearances. The importance of recognizing these morphologic patterns is that they are often associated with different etiology and clinical situations.

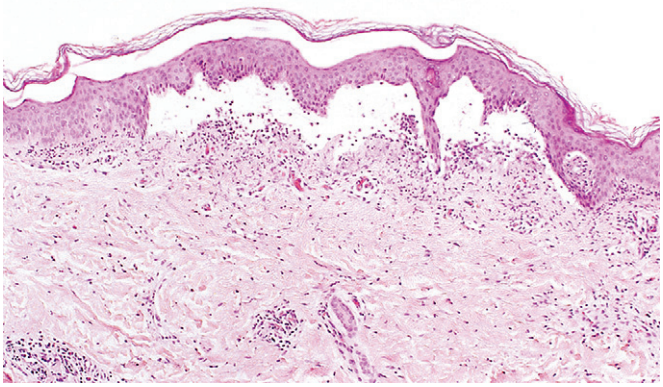

**Figure 2–11** Serous inflammation. Low-power view of a cross-section of a skin blister showing the epidermis separated from the dermis by a focal collection of serous effusion.

## MORPHOLOGY

- **Serous inflammation** is characterized by the outpouring of a watery, relatively protein-poor fluid that, depending on the site of injury, derives either from the plasma or from the secretions of mesothelial cells lining the peritoneal, pleural, and pericardial cavities. The skin blister resulting from a burn or viral infection is a good example of the accumulation of a serous effusion either within or immediately beneath the epidermis of the skin (Fig. 2–11). Fluid in a serous cavity is called an **effusion.**
- **Fibrinous inflammation** occurs as a consequence of more severe injuries, resulting in greater vascular permeability that allows large molecules (such as fibrinogen) to pass the endothelial barrier. Histologically, the accumulated extravascular fibrin appears as an eosinophilic meshwork of threads or sometimes as an amorphous coagulum (Fig. 2–12). A fibrinous exudate is characteristic of inflammation in the lining of body cavities, such as the meninges, pericardium, and pleura. Such exudates may be degraded by fibrinolysis, and the accumulated debris may be removed by macrophages, resulting in restoration of the normal tissue structure **(resolution).** However, extensive fibrin-rich exudates may not be completely removed, and are replaced by an ingrowth of fibroblasts and blood vessels **(organization),** leading ultimately to scarring that may have significant clinical consequences. For example, organization of a fibrinous pericardial exudate forms dense fibrous scar tissue that bridges or obliterates the pericardial space and restricts myocardial function.
- **Suppurative (purulent) inflammation and abscess formation.** These are manifested by the collection of large amounts of purulent exudate (pus) consisting of neutrophils, necrotic cells, and edema fluid. Certain organisms (e.g., staphylococci) are more likely to induce such localized suppuration and are therefore referred to as pyogenic (pus-forming). **Abscesses** are focal collections of pus that may be caused by seeding of pyogenic organisms into a tissue or by secondary infections of necrotic foci. Abscesses typically have a central, largely necrotic region rimmed by a layer of preserved neutrophils (Fig. 2–13), with a surrounding zone of dilated vessels and fibroblast proliferation indicative of attempted repair. As time passes, the abscess may become completely walled off and eventually be replaced by connective tissue. Because of the underlying tissue destruction, the usual outcome with abscess formation is scarring.

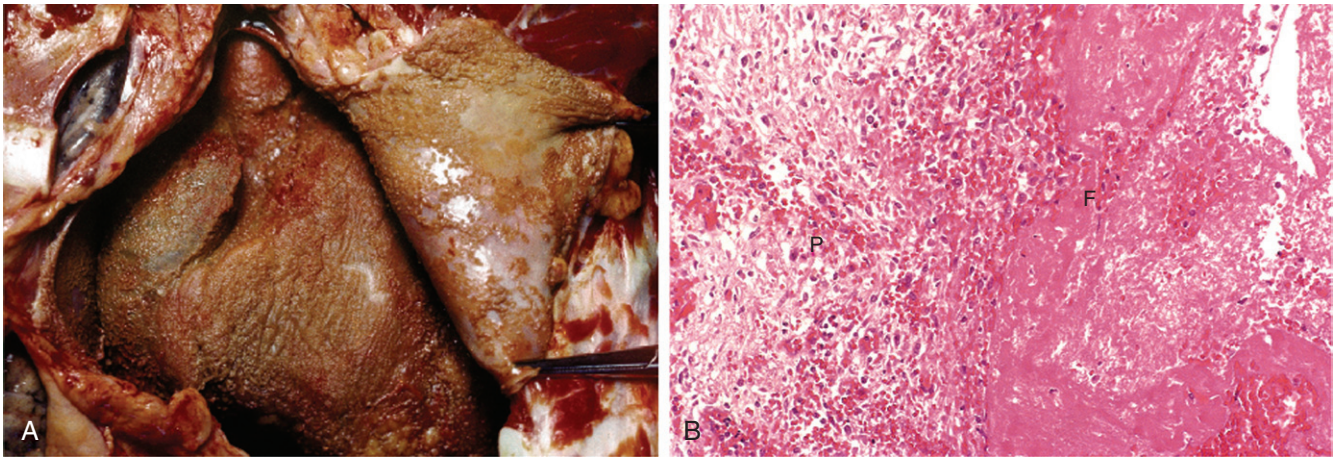


**Figure 2–12** Fibrinous pericarditis. **A,** Deposits of fibrin on the pericardium. **B,** A pink meshwork of fibrin exudate *(F)* overlies the pericardial surface *(P)*.

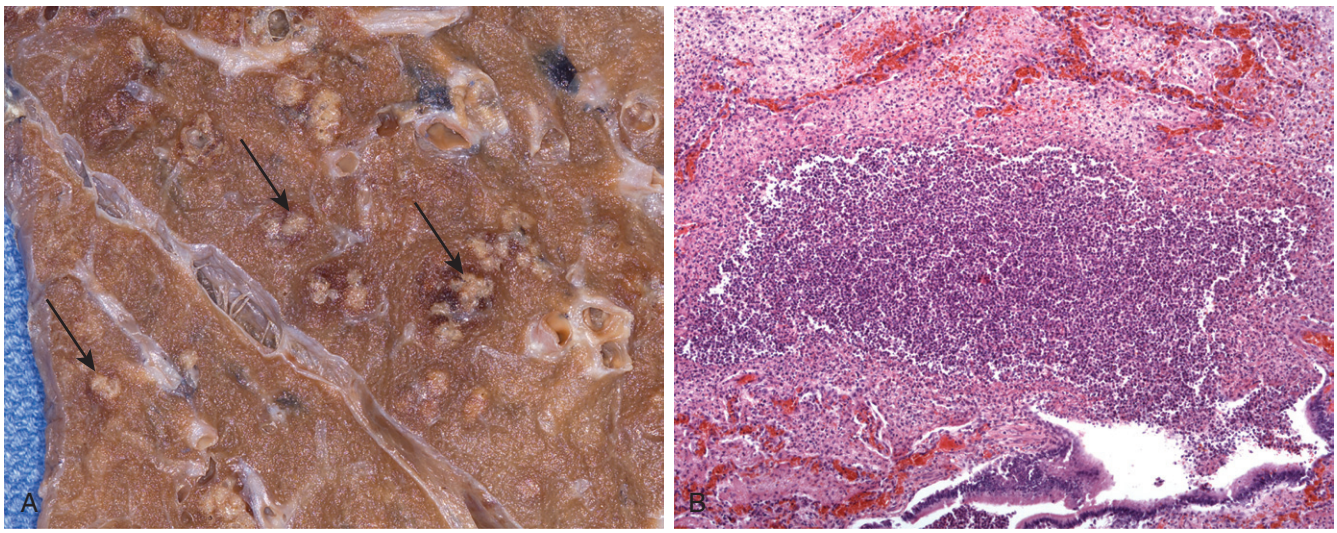

**Figure 2–13** Purulent inflammation with abscess formation. **A,** Multiple bacterial abscesses in the lung (*arrows*) in a case of bronchopneumonia. **B,** The abscess contains neutrophils and cellular debris and is surrounded by congested blood vessels.

- An **ulcer** is a local defect, or excavation, of the surface of an organ or tissue that is produced by necrosis of cells and sloughing (shedding) of necrotic and inflammatory tissue (Fig. 2–14). Ulceration can occur only when tissue necrosis and resultant inflammation exist on or near a surface. Ulcers are most commonly encountered in (1) the mucosa of the mouth, stomach, intestines, or genitourinary tract and (2) in the subcutaneous tissues of the lower extremities in older persons who have circulatory disturbances predisposing affected tissue to extensive necrosis. Ulcerations are best exemplified by peptic ulcer of the stomach or duodenum, in which acute and chronic inflammation coexist. During the acute stage, there is intense polymorphonuclear infiltration and vascular dilation in the margins of the defect. With chronicity, the margins and base of the ulcer develop scarring with accumulation of lymphocytes, macrophages, and plasma cells.

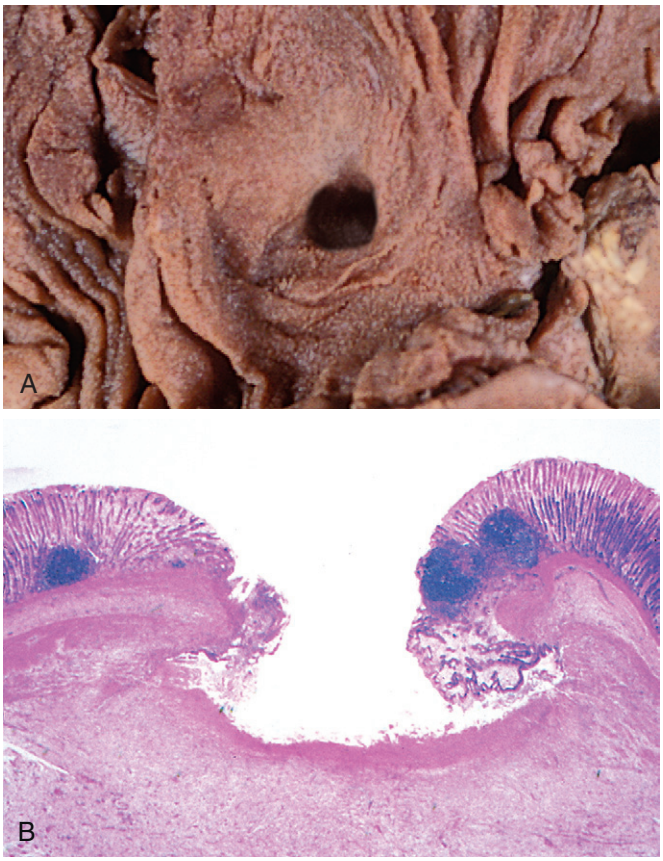

**Figure 2–14** Ulcer. **A,** A chronic duodenal ulcer. **B,** Low-power cross-section of a duodenal ulcer crater with an acute inflammatory exudate in the base.

## CHEMICAL MEDIATORS AND REGULATORS OF INFLAMMATION

Having described the vascular and cellular events in acute inflammation, and the accompanying morphologic alterations, we next discuss the chemical mediators that are responsible for these events. While the harried student may find this list daunting (as do the professors!), it is worthy of note that this knowledge has been used to design a large armamentarium of anti-inflammatory drugs, which are used every day by large numbers of people and include familiar drugs like aspirin and acetaminophen. In this section, we emphasize general properties of the mediators of inflammation and highlight only some of the more important molecules. We also touch upon some of the mechanisms that limit and terminate inflammatory reactions.

- *Mediators may be produced locally by cells at the site of inflammation, or may be derived from circulating inactive precursors (typically synthesized by the liver) that are activated at the site of inflammation* (Fig. 2–15 and Table 2–5). Cell-derived mediators are normally sequestered in intracellular granules and are rapidly secreted upon cellular activation (e.g., histamine in mast cells) or are

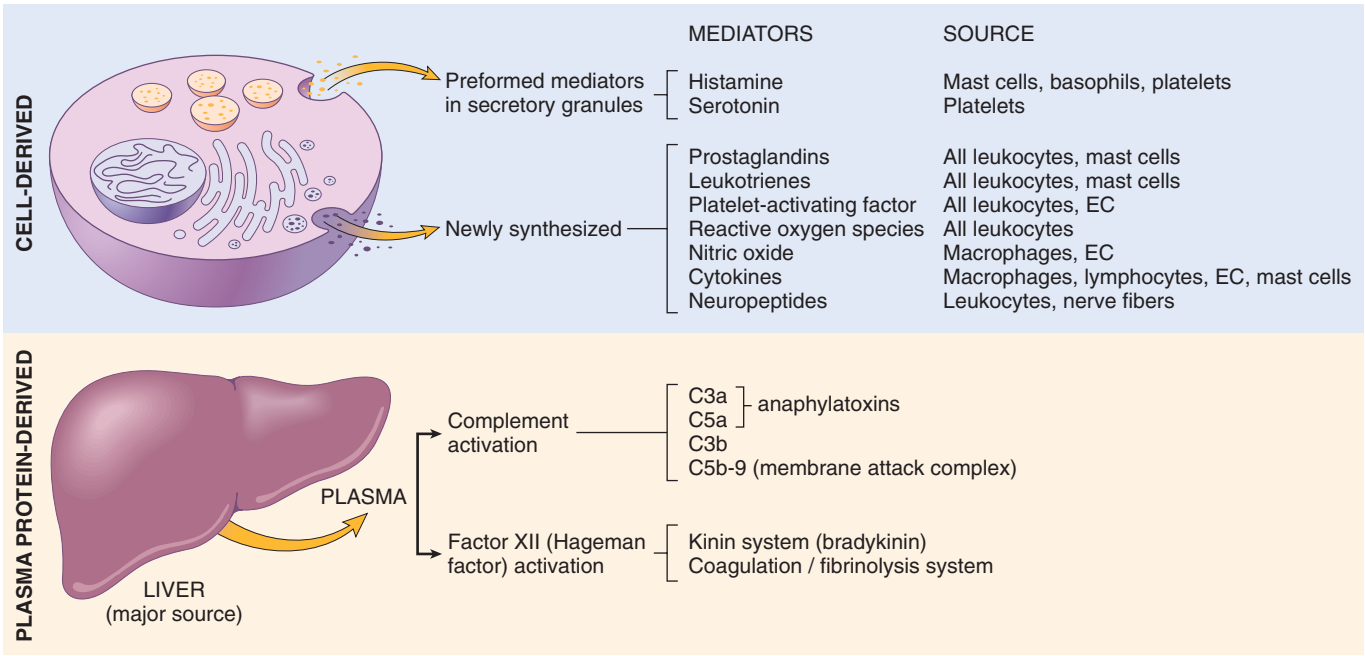


**Figure 2–15** Mediators of inflammation. The principal cell-derived and plasma protein mediators are shown. EC, endothelial cells.

synthesized de novo in response to a stimulus (e.g., prostaglandins and cytokines produced by leukocytes and other cells). Plasma protein–derived mediators (complement proteins, kinins) circulate in an inactive form and typically undergo proteolytic cleavage to acquire their biologic activities.

- *Most mediators act by binding to specific receptors on different target cells.* Such mediators may act on only one or a very few cell types, or they may have diverse actions, with differing outcomes depending on which cell type they affect. Other mediators (e.g., lysosomal proteases, ROS) have direct enzymatic and/or toxic activities that do not require binding to specific receptors.
- *The actions of most mediators are tightly regulated and short-lived.* Once activated and released from the cell, mediators quickly decay (e.g., arachidonic acid metabolites), are inactivated by enzymes (e.g., kininase inactivates bradykinin), are eliminated (e.g., antioxidants scavenge

**Table 2–5** Actions of the Principal Mediators of Inflammation

| Mediator | Source(s) | Actions |
|---|---|---|
| **Cell-Derived** | | |
| Histamine | Mast cells, basophils, platelets | Vasodilation, increased vascular permeability, endothelial activation |
| Serotonin | Platelets | Vasoconstriction |
| Prostaglandins | Mast cells, leukocytes | Vasodilation, pain, fever |
| Leukotrienes | Mast cells, leukocytes | Increased vascular permeability, chemotaxis, leukocyte adhesion and activation |
| Platelet-activating factor | Leukocytes, mast cells | Vasodilation, increased vascular permeability, leukocyte adhesion, chemotaxis, degranulation, oxidative burst |
| Reactive oxygen species | Leukocytes | Killing of microbes, tissue damage |
| Nitric oxide | Endothelium, macrophages | Vascular smooth muscle relaxation; killing of microbes |
| Cytokines (TNF, IL-1, IL-6) | Macrophages, endothelial cells, mast cells | *Local*: endothelial activation (expression of adhesion molecules). *Systemic*: fever, metabolic abnormalities, hypotension (shock) |
| Chemokines | Leukocytes, activated macrophages | Chemotaxis, leukocyte activation |
| **Plasma Protein–Derived** | | |
| Complement | Plasma (produced in liver) | Leukocyte chemotaxis and activation, direct target killing (MAC), vasodilation (mast cell stimulation) |
| Kinins | Plasma (produced in liver) | Increased vascular permeability, smooth muscle contraction, vasodilation, pain |
| Proteases activated during coagulation | Plasma (produced in liver) | Endothelial activation, leukocyte recruitment |

IL-1, IL-6, interleukin-1 and -6; MAC, membrane attack complex; TNF, tumor necrosis factor.

toxic oxygen metabolites), or are inhibited (e.g., complement regulatory proteins block complement activation).

## Cell-Derived Mediators

Tissue macrophages, mast cells, and endothelial cells at the site of inflammation, as well as leukocytes that are recruited to the site from the blood, are all capable of producing different mediators of inflammation.

### Vasoactive Amines

The two vasoactive amines, histamine and serotonin, are stored as preformed molecules in mast cells and other cells and are among the first mediators to be released in acute inflammatory reactions.

- *Histamine* is produced by many cell types, particularly mast cells adjacent to vessels, as well as circulating basophils and platelets. Preformed histamine is released from mast cell granules in response to a variety of stimuli: (1) physical injury such as trauma or heat; (2) immune reactions involving binding of IgE antibodies to Fc receptors on mast cells (Chapter 4); (3) C3a and C5a fragments of complement, the so-called anaphylatoxins (see later); (4) leukocyte-derived histamine-releasing proteins; (5) neuropeptides (e.g., substance P); and (6) certain cytokines (e.g., IL-1, IL-8). In humans, histamine causes arteriolar dilation and rapidly increases vascular permeability by inducing venular endothelial contraction and formation of interendothelial gaps. Soon after its release, histamine is inactivated by histaminase.
- *Serotonin* (5-hydroxytryptamine) is a preformed vasoactive mediator found within platelet granules that is released during platelet aggregation (Chapter 3). It induces vasoconstriction during clotting. It is produced mainly in some neurons and enterochromaffin cells, and is a neurotransmitter and regulates intestinal motility.

### Arachidonic Acid Metabolites: Prostaglandins, Leukotrienes, and Lipoxins

Products derived from the metabolism of AA affect a variety of biologic processes, including inflammation and hemostasis. AA metabolites, also called *eicosanoids* (because they are derived from 20-carbon fatty acids—Greek *eicosa*, "twenty"), can mediate virtually every step of inflammation (Table 2–6); their synthesis is increased at sites of inflammatory response, and agents that inhibit their synthesis also diminish inflammation. Leukocytes, mast cells, endothelial cells, and platelets are the major sources of AA metabolites in inflammation. These AA-derived mediators act locally at the site of generation and then decay spontaneously or are enzymatically destroyed.

**Table 2–6** Principal Inflammatory Actions of Arachidonic Acid Metabolites (Eicosanoids)

| Action | Eicosanoid |
|---|---|
| Vasodilation | Prostaglandins $PGI_2$ (prostacyclin), $PGE_1$, $PGE_2$, $PGD_2$ |
| Vasoconstriction | Thromboxane $A_2$, leukotrienes $C_4$, $D_4$, $E_4$ |
| Increased vascular permeability | Leukotrienes $C_4$, $D_4$, $E_4$ |
| Chemotaxis, leukocyte adhesion | Leukotriene $B_4$, HETE |

HETE, hydroxyeicosatetraenoic acid.

AA is a 20-carbon polyunsaturated fatty acid (with four double bonds) produced primarily from dietary linoleic acid and present in the body mainly in its esterified form as a component of cell membrane phospholipids. It is released from these phospholipids through the action of cellular phospholipases that have been activated by mechanical, chemical, or physical stimuli, or by inflammatory mediators such as C5a. AA metabolism proceeds along one of two major enzymatic pathways: Cyclooxygenase stimulates the synthesis of prostaglandins and thromboxanes, and lipoxygenase is responsible for production of leukotrienes and lipoxins (Fig. 2–16).

- *Prostaglandins and thromboxanes.* Products of the cyclooxygenase pathway include prostaglandin $E_2$ ($PGE_2$), $PGD_2$, $PGF_{2\alpha}$, $PGI_2$ (prostacyclin), and thromboxane $A_2$ ($TXA_2$), each derived by the action of a specific enzyme on an intermediate. Some of these enzymes have a restricted tissue distribution. For example, platelets contain the enzyme *thromboxane synthase,* and hence $TXA_2$, a potent platelet-aggregating agent and vasoconstrictor, is the major prostaglandin produced in these cells. Endothelial cells, on the other hand, lack thromboxane synthase but contain prostacyclin synthase, which is responsible for the formation of $PGI_2$, a vasodilator and a potent inhibitor of platelet aggregation. The opposing roles of $TXA_2$ and $PGI_2$ in hemostasis are discussed further in Chapter 3. $PGD_2$ is the major metabolite of the cyclooxygenase pathway in mast cells; along with $PGE_2$ and $PGF_{2\alpha}$ (which are more widely distributed), it causes vasodilation and potentiates edema formation. The prostaglandins also contribute to the pain and fever that accompany inflammation; $PGE_2$ augments pain sensitivity to a variety of other stimuli and interacts with cytokines to cause fever.
- *Leukotrienes.* Leukotrienes are produced by the action of 5-lipoxygenase, the major AA-metabolizing enzyme in neutrophils. The synthesis of leukotrienes involves multiple steps (Fig. 2–16). The first step generates leukotriene $A_4$ ($LTA_4$), which in turn gives rise to $LTB_4$ or $LTC_4$. $LTB_4$ is produced by neutrophils and some macrophages and is a potent chemotactic agent for neutrophils. $LTC_4$ and its subsequent metabolites, $LTD_4$ and $LTE_4$, are produced mainly in mast cells and cause bronchoconstriction and increased vascular permeability.
- *Lipoxins.* Once leukocytes enter tissues, they gradually change their major lipoxygenase-derived AA products from leukotrienes to anti-inflammatory mediators called lipoxins, which inhibit neutrophil chemotaxis and adhesion to endothelium and thus serve as endogenous antagonists of leukotrienes. Platelets that are activated and adherent to leukocytes also are important sources of lipoxins. Platelets alone cannot synthesize lipoxins $A_4$ and $B_4$ ($LXA_4$ and $LXB_4$), but they can form these mediators from an intermediate derived from adjacent neutrophils, by a transcellular biosynthetic pathway. By this mechanism, AA products can pass from one cell type to another.

***Anti-inflammatory Drugs That Block Prostaglandin Production.*** The central role of eicosanoids in inflammatory

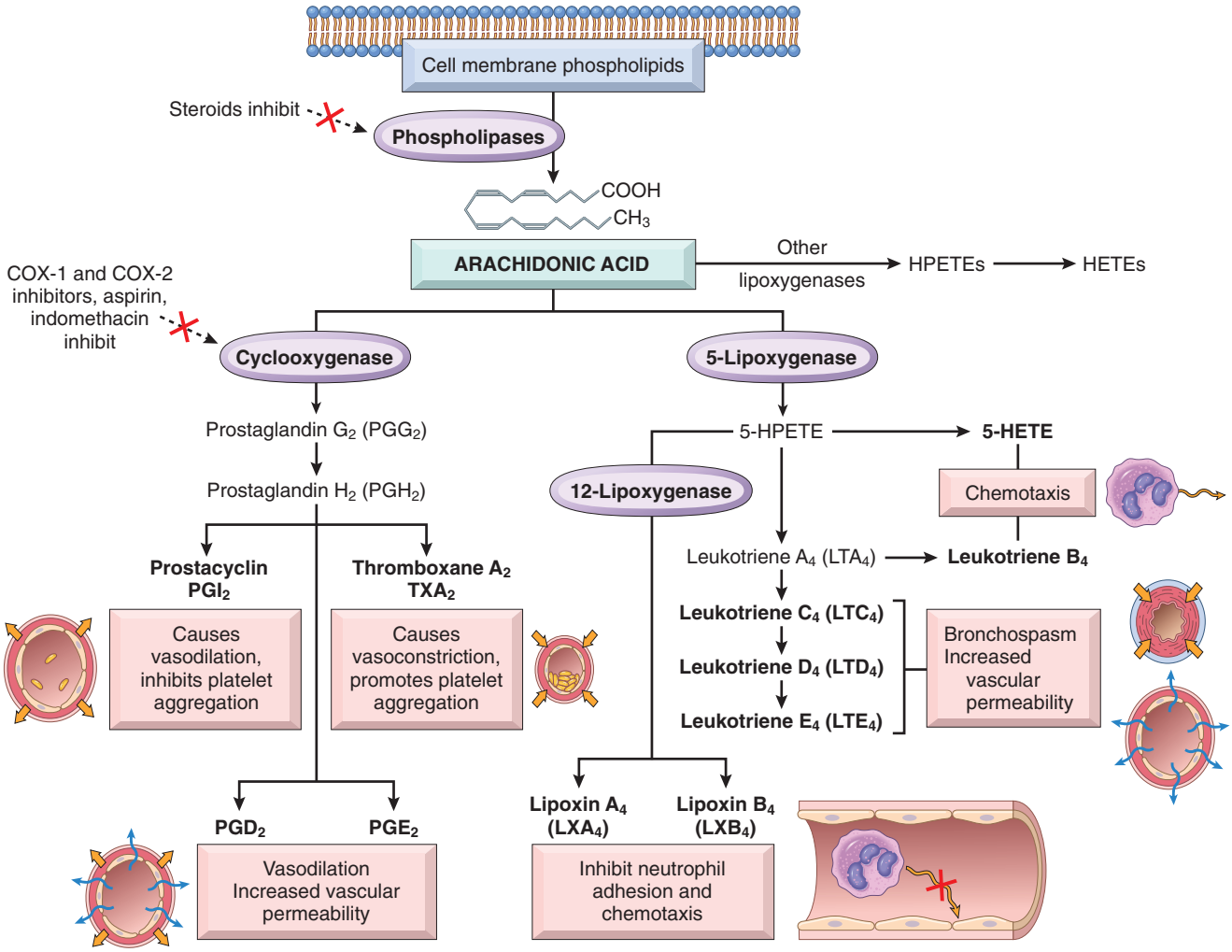


**Figure 2–16** Production of arachidonic acid metabolites and their roles in inflammation. Note the enzymatic activities whose inhibition through pharmacologic intervention blocks major pathways (denoted with a *red X*). COX-1, COX-2, cyclooxygenases 1 and 2; HETE, hydroxyeicosatetraenoic acid; HPETE, hydroperoxyeicosatetraenoic acid.

processes is emphasized by the clinical utility of agents that block eicosanoid synthesis. Nonsteroidal anti-inflammatory drugs (NSAIDs), such as aspirin and ibuprofen, inhibit cyclooxygenase activity, thereby blocking all prostaglandin synthesis (hence their efficacy in treating pain and fever). There are two forms of the cyclooxygenase enzyme, COX-1 and COX-2. COX-1 is produced in response to inflammatory stimuli and also is constitutively expressed in most tissues, where it stimulates the production of prostaglandins that serve a homeostatic function (e.g., fluid and electrolyte balance in the kidneys, cytoprotection in the gastrointestinal tract). By contrast, COX-2 is induced by inflammatory stimuli but it is absent from most normal tissues. Therefore, COX-2 inhibitors have been developed with the expectation that they will inhibit harmful inflammation but will not block the protective effects of constitutively produced prostaglandins. These distinctions between the roles of the two cyclooxygenases are not absolute, however. Furthermore, COX-2 inhibitors may increase the risk for cardiovascular and cerebrovascular events, possibly because they impair endothelial cell production of prostacyclin ($PGI_2$), an inhibitor of platelet aggregation, but leave intact the COX-1–mediated production by platelets of $TXA_2$, a mediator of platelet aggregation. Glucocorticoids, which are powerful anti-inflammatory agents, act in part by inhibiting the activity of phospholipase $A_2$ and thus the release of AA from membrane lipids.

### Platelet-Activating Factor

Originally named for its ability to aggregate platelets and cause their degranulation, platelet-activating factor (PAF) is another phospholipid-derived mediator with a broad spectrum of inflammatory effects. PAF is acetyl glycerol ether phosphocholine; it is generated from the membrane phospholipids of neutrophils, monocytes, basophils, endothelial cells, and platelets (and other cells) by the action of phospholipase $A_2$. PAF acts directly on target cells through the effects of a specific G protein–coupled receptor. In addition to stimulating platelets, PAF causes bronchoconstriction and is 100 to 1000 times more potent than histamine in inducing vasodilation and increased vascular permeability. It also stimulates the synthesis of other mediators, such as eicosanoids and cytokines, from platelets and other cells. Thus, PAF can elicit many of the reactions of inflammation,

including enhanced leukocyte adhesion, chemotaxis, leukocyte degranulation, and the respiratory burst.

### Cytokines

Cytokines are polypeptide products of many cell types that function as mediators of inflammation and immune responses (Chapter 4). Different cytokines are involved in the earliest immune and inflammatory reactions to noxious stimuli and in the later adaptive (specific) immune responses to microbes. Some cytokines stimulate bone marrow precursors to produce more leukocytes, thus replacing the ones that are consumed during inflammation and immune responses. Molecularly characterized cytokines are called interleukins (abbreviated IL and numbered), referring to their ability to mediate communications between leukocytes. However, the nomenclature is imperfect—many interleukins act on cells other than leukocytes, and many cytokines that do act on leukocytes are not called interleukins, for historical reasons.

*The major cytokines in acute inflammation are TNF, IL-1, IL-6, and a group of chemoattractant cytokines called chemokines.* Other cytokines that are more important in chronic inflammation include interferon-γ (IFN-γ) and IL-12. A cytokine called IL-17, produced by T lymphocytes and other cells, plays an important role in recruiting neutrophils and is involved in host defense against infections and in inflammatory diseases.

***Tumor Necrosis Factor and Interleukin-1.*** TNF and IL-1 are produced by activated macrophages, as well as mast cells, endothelial cells, and some other cell types (Fig. 2–17). Their secretion is stimulated by microbial products, such as bacterial endotoxin, immune complexes, and products of T lymphocytes generated during adaptive immune responses. As mentioned earlier, IL-1 is also the cytokine induced by activation of the inflammasome. The principal role of these cytokines in inflammation is in endothelial activation. Both TNF and IL-1 stimulate the expression of adhesion molecules on endothelial cells, resulting in increased leukocyte binding and recruitment, and enhance the production of additional cytokines (notably chemokines) and eicosanoids. TNF also increases the thrombogenicity of endothelium. IL-1 activates tissue fibroblasts, resulting in increased proliferation and production of ECM.

Although TNF and IL-1 are secreted by macrophages and other cells at sites of inflammation, they may enter the circulation and act at distant sites to induce the systemic acute-phase reaction that is often associated with infection and inflammatory diseases. Components of this reaction include fever, lethargy, hepatic synthesis of various acute-phase proteins (also stimulated by IL-6), metabolic wasting (cachexia), neutrophil release into the circulation, and fall in blood pressure. These systemic manifestations of inflammation are described later in the chapter.

***Chemokines.*** The chemokines are a family of small (8 to 10 kDa), structurally related proteins that act primarily as chemoattractants for different subsets of leukocytes. The two main functions of chemokines are to recruit leukocytes to the site of inflammation and to control the normal anatomic organization of cells in lymphoid and other tissues. Combinations of chemokines that are produced transiently in response to inflammatory stimuli recruit particular cell

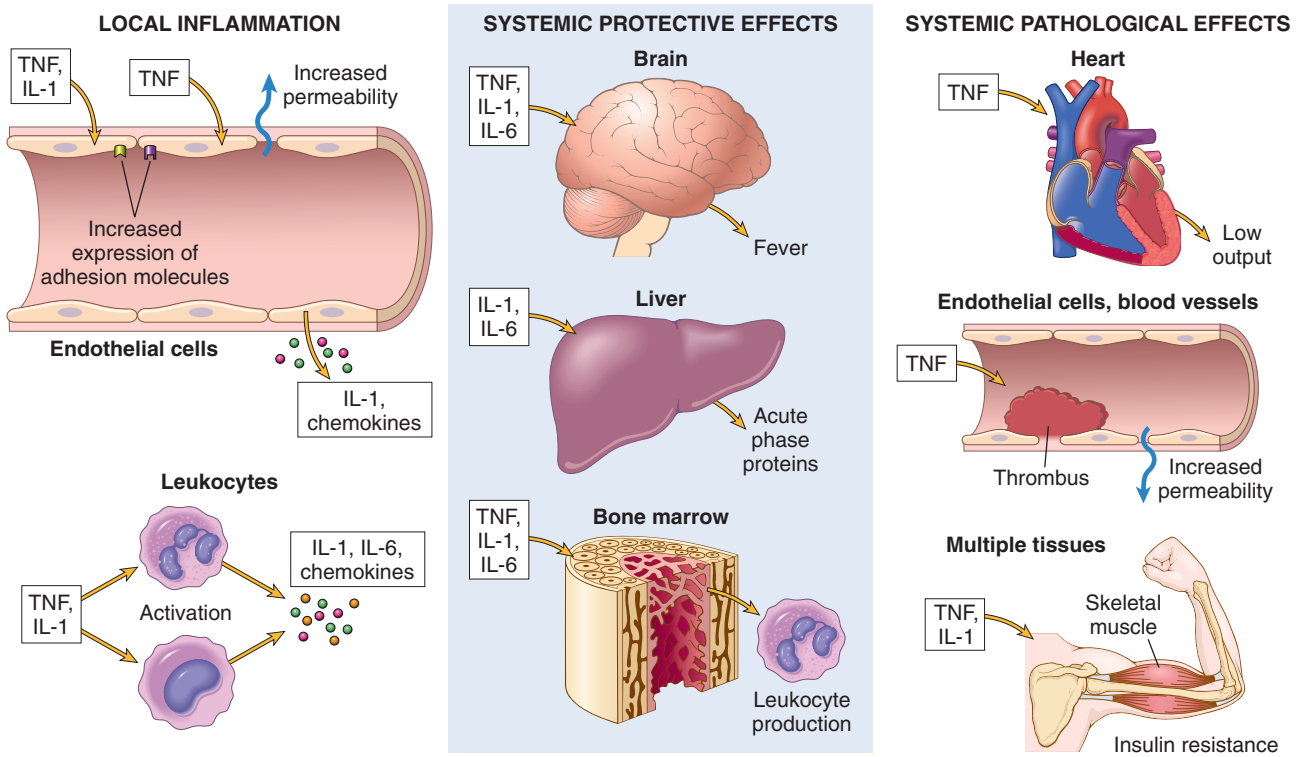


**Figure 2–17** The roles of cytokines in acute inflammation. The cytokines TNF, IL-1, and IL-6 are key mediators of leukocyte recruitment in local inflammatory responses and also play important roles in the systemic reactions of inflammation.

populations (e.g., neutrophils, lymphocytes or eosinophils) to sites of inflammation. Chemokines also activate leukocytes; one consequence of such activation, as mentioned earlier, is increased affinity of leukocyte integrins for their ligands on endothelial cells. Some chemokines are produced constitutively in tissues and are responsible for the anatomic segregation of different cell populations in tissues (e.g., the segregation of T and B lymphocytes in different areas of lymph nodes and spleen). Chemokines mediate their activities by binding to specific G protein–coupled receptors on target cells; two of these chemokine receptors (called CXCR4 and CCR5) are important coreceptors for the binding and entry of the human immunodeficiency virus into lymphocytes (Chapter 4).

Chemokines are classified into four groups based on the arrangement of conserved cysteine residues. The two major groups are the CXC and CC chemokines:

- *CXC chemokines* have one amino acid separating the conserved cysteines and act primarily on neutrophils. IL-8 is typical of this group; it is produced by activated macrophages, endothelial cells, mast cells, and fibroblasts, mainly in response to microbial products and other cytokines such as IL-1 and TNF.
- *CC chemokines* have adjacent cysteine residues and include monocyte chemoattractant protein-1 (MCP-1) and macrophage inflammatory protein-1α (MIP-1α) (both chemotactic predominantly for monocytes), RANTES (*r*egulated on *a*ctivation, *n*ormal *T* cell–*e*xpressed and *s*ecreted) (chemotactic for memory CD4+ T cells and monocytes), and eotaxin (chemotactic for eosinophils).

### Reactive Oxygen Species

ROS are synthesized via the NADPH oxidase (phagocyte oxidase) pathway and are released from neutrophils and macrophages that are activated by microbes, immune complexes, cytokines, and a variety of other inflammatory stimuli. The synthesis and regulation of these oxygen-derived free radicals have been described in Chapter 1, in the context of cell injury, and earlier in this chapter in the discussion of leukocyte activation. When the ROS are produced within lysosomes they function to destroy phagocytosed microbes and necrotic cells. When secreted at low levels, ROS can increase chemokine, cytokine, and adhesion molecule expression, thus amplifying the cascade of inflammatory mediators. At higher levels, these mediators are responsible for tissue injury by several mechanisms, including (1) endothelial damage, with thrombosis and increased permeability; (2) protease activation and antiprotease inactivation, with a net increase in breakdown of the ECM; and (3) direct injury to other cell types (e.g., tumor cells, red cells, parenchymal cells). Fortunately, various antioxidant protective mechanisms (e.g., mediated by catalase, superoxide dismutase, and glutathione) present in tissues and blood minimize the toxicity of the oxygen metabolites (Chapter 1).

### Nitric Oxide

NO is a short-lived, soluble, free radical gas produced by many cell types and capable of mediating a variety of functions. In the central nervous system it regulates neurotransmitter release as well as blood flow. Macrophages use it as a cytotoxic agent for killing microbes and tumor cells. When produced by endothelial cells it relaxes vascular smooth muscle and causes vasodilation.

NO is synthesized de novo from L-arginine, molecular oxygen, and NADPH by the enzyme nitric oxide synthase (NOS). There are three isoforms of NOS, with different tissue distributions.

- Type I, neuronal NOS (nNOS), is constitutively expressed in neurons, and does not play a significant role in inflammation.
- Type II, inducible NOS (iNOS), is induced in macrophages and endothelial cells by a number of inflammatory cytokines and mediators, most notably by IL-1, TNF, and IFN-γ, and by bacterial endotoxin, and is responsible for production of NO in inflammatory reactions. This inducible form is also present in many other cell types, including hepatocytes, cardiac myocytes, and respiratory epithelial cells.
- Type III, endothelial NOS, (eNOS), is constitutively synthesized primarily (but not exclusively) in endothelium.

An important function of NO is as a microbicidal (cytotoxic) agent in activated macrophages. NO plays other roles in inflammation, including vasodilation, antagonism of all stages of platelet activation (adhesion, aggregation, and degranulation), and reduction of leukocyte recruitment at inflammatory sites.

### Lysosomal Enzymes of Leukocytes

The lysosomal granules of neutrophils and monocytes contain many enzymes that destroy phagocytosed substances and are capable of causing tissue damage. Lysosomal granule contents also may be released from activated leukocytes, as described earlier. Acid proteases generally are active only in the low-pH environment of phagolysosomes, whereas neutral proteases, including elastase, collagenase, and cathepsin, are active in extracellular locations and cause tissue injury by degrading elastin, collagen, basement membrane, and other matrix proteins. Neutral proteases also can cleave the complement proteins C3 and C5 directly to generate the vasoactive mediators C3a and C5a and can generate bradykinin-like peptides from kininogen.

The potentially damaging effects of lysosomal enzymes are limited by antiproteases present in the plasma and tissue fluids. These include $\alpha_1$-antitrypsin, the major inhibitor of neutrophil elastase, and $\alpha_2$-macroglobulin. Deficiencies of these inhibitors may result in sustained activation of leukocyte proteases, resulting in tissue destruction at sites of leukocyte accumulation. For instance, $\alpha_1$-antitrypsin deficiency in the lung can cause a severe panacinar emphysema (Chapter 12).

### Neuropeptides

Like the vasoactive amines, neuropeptides can initiate inflammatory responses; these are small proteins, such as substance P, that transmit pain signals, regulate vessel tone, and modulate vascular permeability. Nerve fibers that secrete neuropeptides are especially prominent in the lung and gastrointestinal tract.

## SUMMARY

### Major Cell-Derived Mediators of Inflammation

- Vasoactive amines—histamine, serotonin: Their main effects are vasodilation and increased vascular permeability.
- Arachidonic acid metabolites—prostaglandins and leukotrienes: Several forms exist and are involved in vascular reactions, leukocyte chemotaxis, and other reactions of inflammation; they are antagonized by lipoxins.
- Cytokines: These proteins, produced by many cell types, usually act at short range; they mediate multiple effects, mainly in leukocyte recruitment and migration; principal ones in acute inflammation are TNF, IL-1, IL-6, and chemokines.
- ROS: Roles include microbial killing and tissue injury.
- NO: Effects are vasodilation and microbial killing.
- Lysosomal enzymes: Roles include microbial killing and tissue injury.

## Plasma Protein–Derived Mediators

Circulating proteins of three interrelated systems—the complement, kinin, and coagulation systems—are involved in several aspects of the inflammatory reaction.

### Complement

The *complement system* consists of plasma proteins that play an important role in host defense (immunity) and inflammation. Upon activation, different complement proteins coat (opsonize) particles, such as microbes, for phagocytosis and destruction, and contribute to the inflammatory response by increasing vascular permeability and leukocyte chemotaxis. Complement activation ultimately generates a porelike membrane attack complex (MAC) that punches holes in the membranes of invading microbes. Here we summarize the role of the complement system in inflammation.

- Complement components, numbered C1 to C9, are present in plasma in inactive forms, and many of them are activated by proteolysis to acquire their own proteolytic activity, thus setting up an enzymatic cascade.
- The critical step in the generation of biologically active complement products is the activation of the third component, C3 (Fig. 2–18). C3 cleavage occurs by three pathways: (1) the *classical pathway,* triggered by fixation of the first complement component C1 to antigen-antibody complexes; (2) the *alternative pathway,* triggered by bacterial polysaccharides (e.g., endotoxin) and other microbial cell wall components, and involving a distinct set of plasma proteins including properdin and factors B and D; and (3) the *lectin pathway,* in which a plasma lectin binds to mannose residues on microbes and activates an early component of the classical pathway (but in the absence of antibodies).
- All three pathways lead to the formation of a C3 convertase that cleaves C3 to C3a and C3b. C3b deposits on the cell or microbial surface where complement was activated and then binds to the C3 convertase complex to form C5 convertase; this complex cleaves C5 to generate C5a and C5b and initiate the final stages of assembly of C6 to C9.

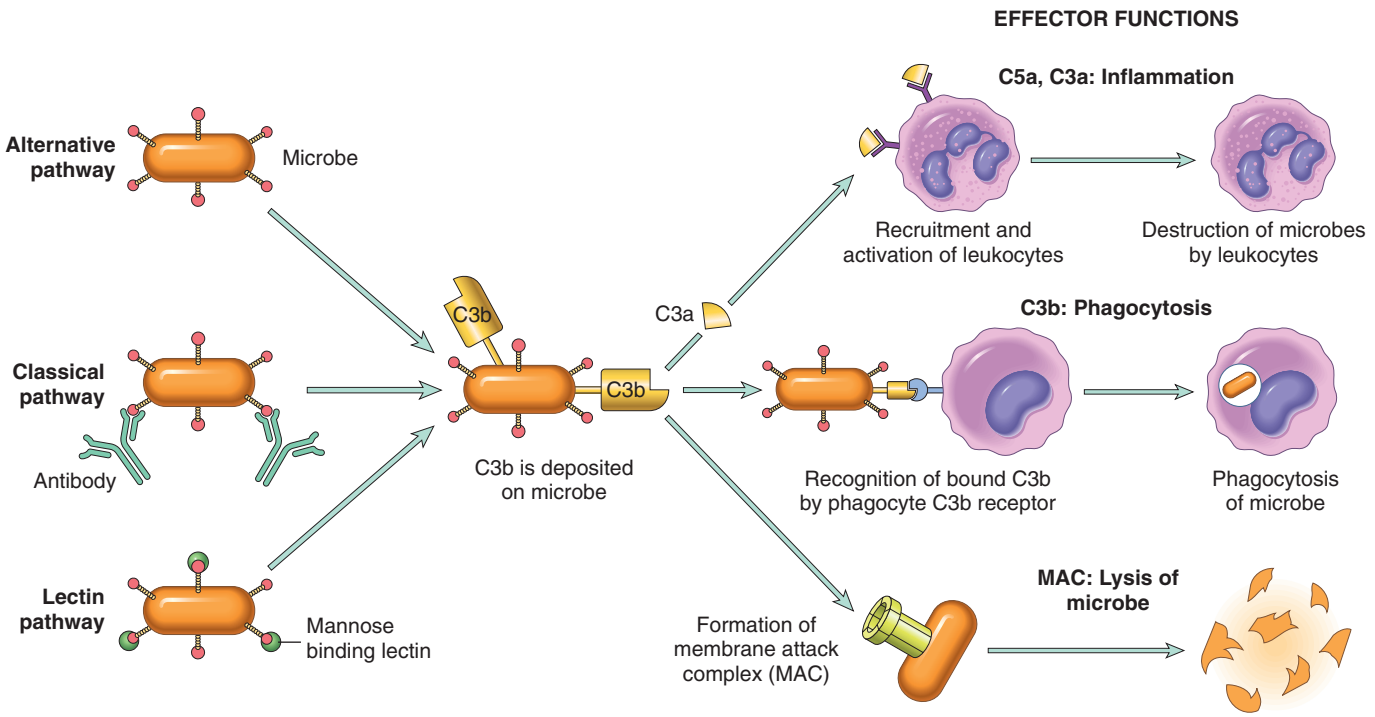


**Figure 2–18** The activation and functions of the complement system. Activation of complement by different pathways leads to cleavage of C3. The functions of the complement system are mediated by breakdown products of C3 and other complement proteins, and by the membrane attack complex (MAC).

The complement-derived factors that are produced along the way contribute to a variety of phenomena in acute inflammation:

- *Vascular effects.* C3a and C5a increase vascular permeability and cause vasodilation by inducing mast cells to release histamine. These complement products are also called anaphylatoxins because their actions mimic those of mast cells, which are the main cellular effectors of the severe allergic reaction called anaphylaxis (Chapter 4). C5a also activates the lipoxygenase pathway of AA metabolism in neutrophils and macrophages, causing release of more inflammatory mediators.
- *Leukocyte activation, adhesion, and chemotaxis.* C5a, and to lesser extent, C3a and C4a, activate leukocytes, increasing their adhesion to endothelium, and is a potent chemotactic agent for neutrophils, monocytes, eosinophils, and basophils.
- *Phagocytosis.* When fixed to a microbial surface, C3b and its inactive proteolytic product iC3b act as opsonins, augmenting phagocytosis by neutrophils and macrophages, which express receptors for these complement products.
- The MAC, which is made up of multiple copies of the final component C9, kills some bacteria (especially thin-walled *Neisseria*) by creating pores that disrupt osmotic balance.

*The activation of complement is tightly controlled by cell-associated and circulating regulatory proteins.* The presence of these inhibitors in host cell membranes protects normal cells from inappropriate damage during protective reactions against microbes. Inherited deficiencies of these regulatory proteins lead to spontaneous complement activation:

- A protein called *C1 inhibitor* blocks activation of C1, and its inherited deficiency causes a disease called hereditary angioedema, in which excessive production of kinins secondary to complement activation results in edema in multiple tissues, including the larynx.
- Another protein called *decay-accelerating factor* (DAF) normally limits the formation of C3 and C5 convertases. In a disease called *paroxysmal nocturnal hemoglobinuria,* there is an acquired deficiency of DAF that results in complement-mediated lysis of red cells (which are more sensitive to lysis than most nucleated cells) (Chapter 11).
- *Factor H* is a plasma protein that also limits convertase formation; its deficiency is associated with a kidney disease called the *hemolytic uremic syndrome* (Chapter 13), as well as spontaneous vascular permeability in *macular degeneration* of the eye.

Even in the presence of regulatory proteins, inappropriate or excessive complement activation (e.g., in antibody-mediated diseases) can overwhelm the regulatory mechanisms; this is why complement activation is responsible for serious tissue injury in a variety of immunologic disorders (Chapter 4).

### Coagulation and Kinin Systems

Some of the molecules activated during blood clotting are capable of triggering multiple aspects of the inflammatory response. *Hageman factor* (also known as *factor XII of the intrinsic coagulation cascade*) (Fig. 2–19) is a protein synthesized by the liver that circulates in an inactive form until it encounters collagen, basement membrane, or activated platelets (e.g., at a site of endothelial injury). Activated Hageman factor (factor XIIa) initiates four systems that may contribute to the inflammatory response: (1) the kinin system, producing vasoactive kinins; (2) the clotting

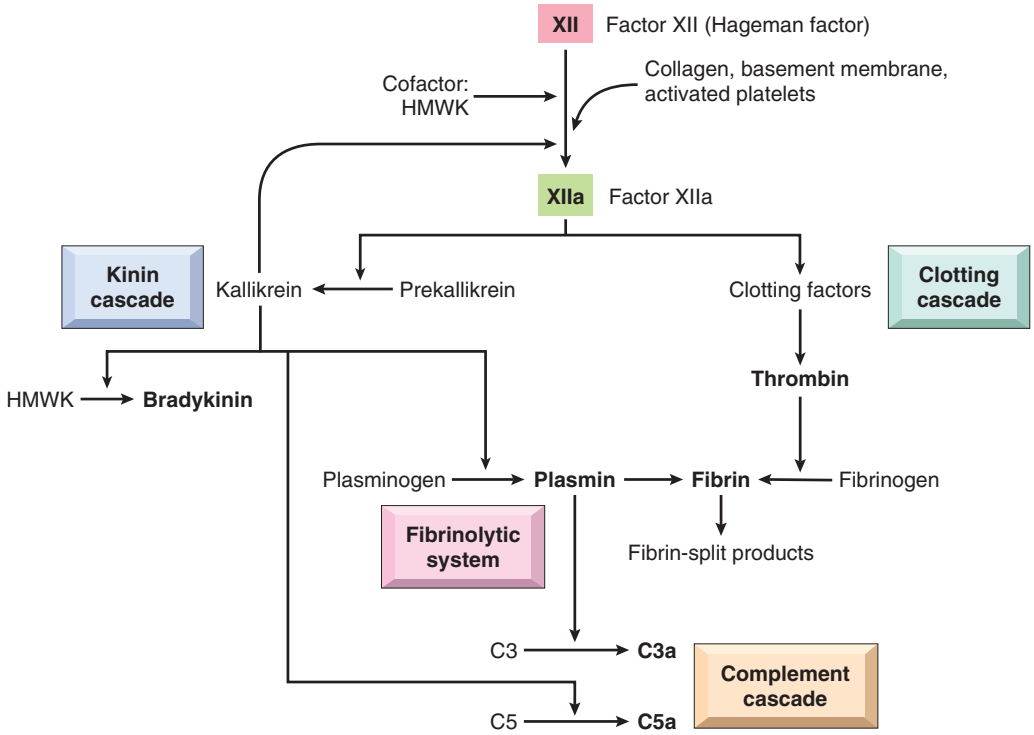


**Figure 2–19** Interrelationships among the four plasma mediator systems triggered by activation of factor XII (Hageman factor). See text for details.

system, inducing the activation of thrombin, fibrinopeptides, and factor X, all with inflammatory properties; (3) the fibrinolytic system, producing plasmin and inactivating thrombin; and (4) the complement system, producing the anaphylatoxins C3a and C5a. These are described below.

- *Kinin system* activation leads ultimately to the formation of *bradykinin* from its circulating precursor, high-molecular-weight kininogen (HMWK) (Fig. 2–19). Like histamine, bradykinin causes increased vascular permeability, arteriolar dilation, and bronchial smooth muscle contraction. It also causes pain when injected into the skin. The actions of bradykinin are short-lived because it is rapidly degraded by kininases present in plasma and tissues. Of note, *kallikrein*, an intermediate in the kinin cascade with chemotactic activity, also is a potent activator of Hageman factor and thus constitutes another link between the kinin and clotting systems.
- In the *clotting system* (Chapter 3), the proteolytic cascade leads to activation of thrombin, which then cleaves circulating soluble fibrinogen to generate an insoluble *fibrin clot. Factor Xa,* an intermediate in the clotting cascade, causes increased vascular permeability and leukocyte emigration. Thrombin participates in inflammation by binding to protease-activated receptors that are expressed on platelets, endothelial cells, and many other cell types. Binding of thrombin to these receptors on endothelial cells leads to their activation and enhanced leukocyte adhesion. In addition, thrombin generates *fibrinopeptides* (during fibrinogen cleavage) that increase vascular permeability and are chemotactic for leukocytes. Thrombin also cleaves C5 to generate C5a, thus linking coagulation with complement activation.
- As a rule, whenever clotting is initiated (e.g., by activated Hageman factor), the *fibrinolytic system* is also activated concurrently. This mechanism serves to limit clotting by cleaving fibrin, thereby solubilizing the fibrin clot (Chapter 3). *Plasminogen activator* (released from endothelium, leukocytes, and other tissues) and *kallikrein* cleave *plasminogen,* a plasma protein bound up in the evolving fibrin clot. The resulting product, plasmin, is a multifunctional protease that cleaves fibrin and is therefore important in lysing clots. However, fibrinolysis also participates in multiple steps in the vascular phenomena of inflammation. For example, fibrin degradation products increase vascular permeability, and plasmin cleaves the C3 complement protein, resulting in production of C3a and vasodilation and increased vascular permeability. Plasmin can also activate Hageman factor, thereby amplifying the entire set of responses.

As is evident from the preceding discussion, many molecules are involved in different aspects of the inflammatory reaction, and these molecules often interact with, amplify, and antagonize one another. From this almost bewildering potpourri of chemical mediators, it is possible to identify the major contributors to various components of acute inflammation (Table 2–7). The relative contributions of individual mediators to inflammatory reactions to different stimuli have yet to be fully elucidated. Such knowledge would have obvious therapeutic implications since it might allow one to "custom design" antagonists for various inflammatory diseases.

**Table 2–7** Role of Mediators in Different Reactions of Inflammation

| Inflammatory Component | Mediators |
|---|---|
| Vasodilation | Prostaglandins<br>Nitric oxide<br>Histamine |
| Increased vascular permeability | Histamine and serotonin<br>C3a and C5a (by liberating vasoactive amines from mast cells, other cells)<br>Bradykinin<br>Leukotrienes $C_4$, $D_4$, $E_4$<br>PAF<br>Substance P |
| Chemotaxis, leukocyte recruitment and activation | TNF, IL-1<br>Chemokines<br>C3a, C5a<br>Leukotriene $B_4$<br>Bacterial products (e.g., *N*-formyl methyl peptides) |
| Fever | IL-1, TNF<br>Prostaglandins |
| Pain | Prostaglandins<br>Bradykinin |
| Tissue damage | Lysosomal enzymes of leukocytes<br>Reactive oxygen species<br>Nitric oxide |

IL-1, interleukin-1; PAF, platelet-activating factor; TNF, tumor necrosis factor.

## SUMMARY

### Plasma Protein–Derived Mediators of Inflammation

- Complement proteins: Activation of the complement system by microbes or antibodies leads to the generation of multiple breakdown products, which are responsible for leukocyte chemotaxis, opsonization and phagocytosis of microbes and other particles, and cell killing.
- Coagulation proteins: Activated factor XII triggers the clotting, kinin, and complement cascades and activates the fibrinolytic system.
- Kinins: Produced by proteolytic cleavage of precursors, this group mediates vascular reaction and pain.

## Anti-inflammatory Mechanisms

Inflammatory reactions subside because many of the mediators are short-lived and are destroyed by degradative *enzymes*. In addition, there are several mechanisms that counteract inflammatory mediators and function to limit or terminate the inflammatory response. Some of these, such as lipoxins, and complement regulatory proteins, have been mentioned earlier. Activated macrophages and other cells secrete a cytokine, IL-10, whose major function is to down-regulate the responses of activated macrophages, thus providing a negative feedback loop. In a rare inherited disease in which IL-10 receptors are mutated, affected patients develop severe colitis in infancy. Other anti-inflammatory cytokines include TGF-β, which is also a mediator of fibrosis in tissue repair after inflammation. Cells also express a number of intracellular proteins, such as tyrosine phosphatases, that inhibit pro-inflammatory

signals triggered by receptors that recognize microbes and cytokines.

## CHRONIC INFLAMMATION

*Chronic inflammation is inflammation of prolonged duration (weeks to years) in which continuing inflammation, tissue injury, and healing, often by fibrosis, proceed simultaneously.* In contrast with acute inflammation, which is distinguished by vascular changes, edema, and a predominantly neutrophilic infiltrate, chronic inflammation is characterized by a different set of reactions (Fig. 2–20; see also Table 2–1):

- *Infiltration with mononuclear cells,* including macrophages, lymphocytes, and plasma cells
- *Tissue destruction,* largely induced by the products of the inflammatory cells
- *Repair,* involving new vessel proliferation (angiogenesis) and fibrosis

Acute inflammation may progress to chronic inflammation if the acute response cannot be resolved, either because of the persistence of the injurious agent or because of interference with the normal process of healing. For example, a peptic ulcer of the duodenum initially shows acute inflammation followed by the beginning stages of resolution. However, recurrent bouts of duodenal epithelial injury interrupt this process, resulting in a lesion characterized by both acute and chronic inflammation (Chapter 14). Alternatively, some forms of injury (e.g., immunologic reactions, some viral infections) engender a chronic inflammatory response from the outset.

Chronic inflammation may arise in the following settings:

- *Persistent infections* by microbes that are difficult to eradicate. These include *Mycobacterium tuberculosis, Treponema pallidum* (the causative organism of syphilis), and certain viruses and fungi, all of which tend to establish persistent infections and elicit a T lymphocyte–mediated immune response called *delayed-type hypersensitivity* (Chapter 4).
- *Immune-mediated inflammatory diseases (hypersensitivity diseases).* Diseases that are caused by excessive and inappropriate activation of the immune system are increasingly recognized as being important health problems (Chapter 4). Under certain conditions, immune reactions develop against the affected person's own tissues, leading to *autoimmune diseases.* In such diseases, autoantigens evoke a self-perpetuating immune reaction that results in tissue damage and persistent inflammation. Autoimmunity plays an important role in several common and debilitating chronic inflammatory diseases, such as rheumatoid arthritis, inflammatory bowel disease, and psoriasis. Immune responses against common environmental substances are the cause of *allergic diseases,* such as bronchial asthma. Immune-mediated diseases may show morphologic patterns of mixed acute and chronic inflammation because they are characterized by repeated bouts of inflammation. Since, in most cases, the eliciting antigens cannot be eliminated, these disorders tend to be chronic and intractable.
- *Prolonged exposure to potentially toxic agents.* Examples are nondegradable exogenous materials such as inhaled particulate silica, which can induce a chronic inflammatory response in the lungs (silicosis, Chapter 12), and endogenous agents such as cholesterol crystals, which may contribute to atherosclerosis (Chapter 9).
- Mild forms of chronic inflammation may be important in the pathogenesis of many diseases that are not conventionally thought of as inflammatory disorders. Such diseases include neurodegenerative disorders such as Alzheimer disease, atherosclerosis, metabolic syndrome and the associated type 2 diabetes, and some forms of cancer in which inflammatory reactions promote tumor development. As mentioned earlier in the chapter, in many of these conditions the inflammation may be triggered by recognition of the initiating stimuli by the inflammasome. The role of inflammation in these conditions is discussed in the relevant chapters.

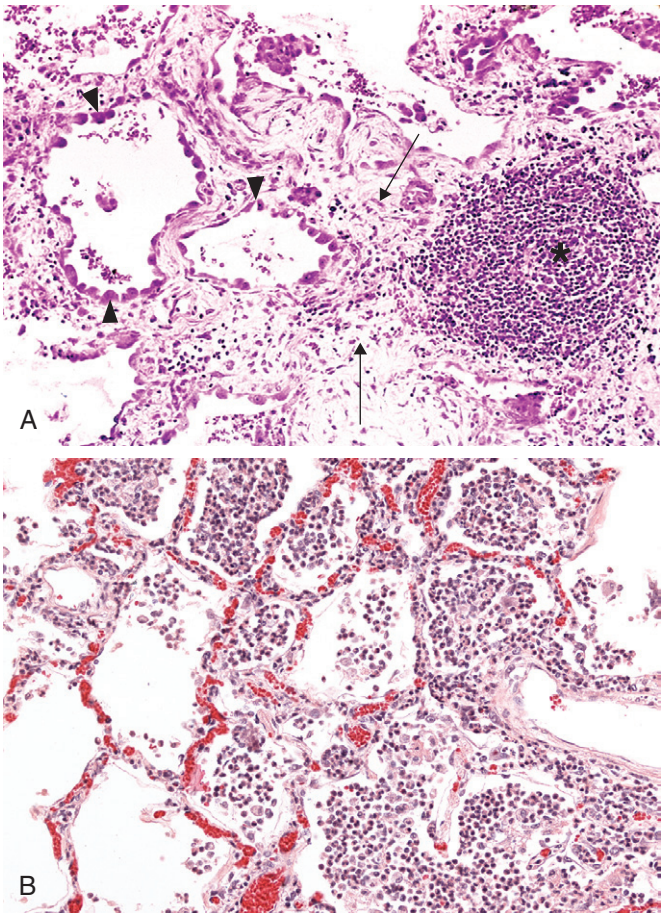


**Figure 2–20 A,** Chronic inflammation in the lung, showing the characteristic histologic features: collection of chronic inflammatory cells (*asterisk*); destruction of parenchyma, in which normal alveoli are replaced by spaces lined by cuboidal epithelium (*arrowheads*); and replacement by connective tissue, resulting in fibrosis (*arrows*). **B,** By contrast, in acute inflammation of the lung (acute bronchopneumonia), neutrophils fill the alveolar spaces and blood vessels are congested.

### Chronic Inflammatory Cells and Mediators

The combination of prolonged and repeated inflammation, tissue destruction and fibrosis that characterizes chronic inflammation involves complex interactions between

several cell populations and their secreted mediators. Understanding the pathogenesis of chronic inflammatory reactions requires an appreciation of these cells and their biologic responses and functions.

### *Macrophages*

*Macrophages,* the dominant cells of chronic inflammation, are tissue cells derived from circulating blood monocytes after their emigration from the bloodstream. Macrophages are normally diffusely scattered in most connective tissues and are also found in organs such as the liver (where they are called Kupffer cells), spleen and lymph nodes (where they are called sinus histiocytes), central nervous system (microglial cells), and lungs (alveolar macrophages). Together these cells constitute the so-called *mononuclear phagocyte system,* also known by the older name of reticuloendothelial system. In all tissues, macrophages act as filters for particulate matter, microbes, and senescent cells, as well as the effector cells that eliminate microbes in cellular and humoral immune responses (Chapter 4).

Monocytes arise from precursors in the bone marrow and circulate in the blood for only about a day. Under the influence of adhesion molecules and chemokines, they migrate to a site of injury within 24 to 48 hours after the onset of acute inflammation, as described earlier. When monocytes reach the extravascular tissue, they undergo transformation into macrophages, which are somewhat larger and have a longer lifespan and a greater capacity for phagocytosis than do blood monocytes.

Tissue macrophages are activated by diverse stimuli to perform a range of functions. Two major pathways of macrophage activation, *classical* and *alternative,* have been described (Fig. 2–21):

- *Classical macrophage activation* is induced by microbial products such as endotoxin, by T cell–derived signals, importantly the cytokine IFN-γ, and by foreign substances including crystals and particulate matter. Classically activated macrophages produce lysosomal enzymes, NO, and ROS, all of which enhance their ability to kill ingested organisms, and secrete cytokines that stimulate inflammation. These macrophages are important in host defense against ingested microbes and in many chronic inflammatory reactions.
- *Alternative macrophage activation* is induced by cytokines other than IFN-γ, such as IL-4 and IL-13, produced by T lymphocytes and other cells, including mast cells and eosinophils. Alternatively activated macrophages are not actively microbicidal; instead, their principal role is in tissue repair. They secrete growth factors that promote angiogenesis, activate fibroblasts and stimulate collagen synthesis. It may be that in response to most injurious stimuli, macrophages are initially activated by the classical pathway, designed to destroy the offending agents, and this is followed by alternative activation, which initiates tissue repair. However, such a precise sequence is not well documented in most inflammatory reactions.

Macrophages have several critical roles in host defense and the inflammatory response.

- Macrophages, like the other type of phagocyte, the neutrophils, *ingest and eliminate microbes and dead tissues.* Because macrophages respond to activating signals from T lymphocytes, they are the most important phagocytes in the cell-mediated arm of adaptive immune responses (Chapter 4).
- Macrophages *initiate the process of tissue repair* and are involved in scar formation and fibrosis.
- Macrophages *secrete mediators of inflammation*, such as cytokines (TNF, IL-1, chemokines, and others) and eicosanoids. These cells are therefore central to the initiation and propagation of all inflammatory reactions.
- Macrophages *display antigens to T lymphocytes and respond to signals from T cells,* thus setting up a feedback loop that

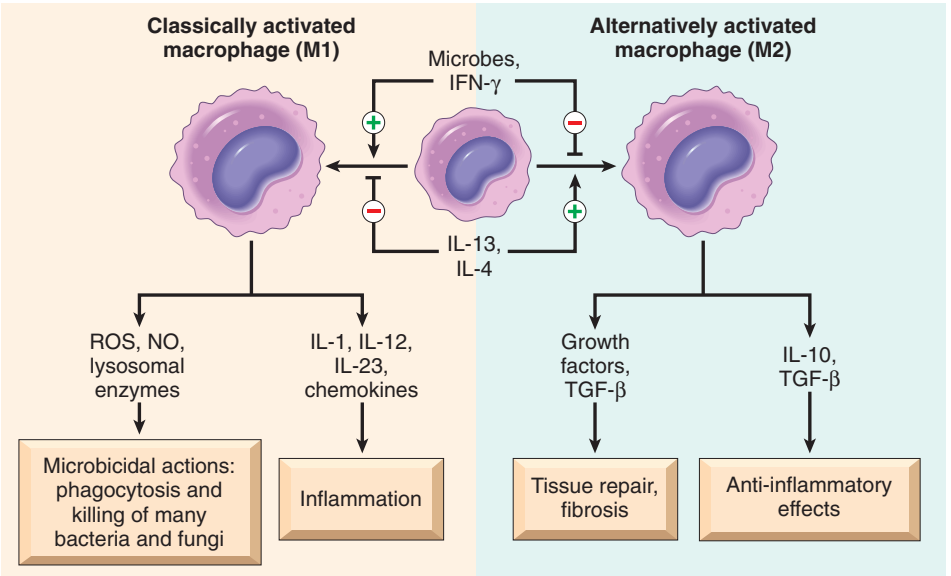


**Figure 2–21** Pathways of macrophage activation. Different stimuli activate monocytes/macrophages to develop into functionally distinct populations. Classically activated macrophages are induced by microbial products and cytokines, particularly IFN-γ, and are microbicidal and involved in potentially harmful inflammation. Alternatively activated macrophages are induced by IL-4 and IL-13, produced by $T_H2$ cells (a helper T cell subset) and other leukocytes, and are important in tissue repair and fibrosis. IFN-γ, interferon-γ; IL-4, IL-13, interkeukin-4, -13.

is essential for defense against many microbes by cell-mediated immune responses. The same bidirectional interactions are central to the development of chronic inflammatory diseases. The roles of cytokines in these interactions are discussed later.

After the initiating stimulus is eliminated and the inflammatory reaction abates, macrophages eventually die or wander off into lymphatics. In chronic inflammatory sites, however, macrophage accumulation persists, because of continued recruitment from the blood and local proliferation. IFN-γ can also induce macrophages to fuse into large, multinucleate giant cells.

### *Lymphocytes*

*Lymphocytes* are mobilized in the setting of any specific immune stimulus (i.e., infections) as well as non–immune-mediated inflammation (e.g., due to ischemic necrosis or trauma), and are the major drivers of inflammation in many autoimmune and other chronic inflammatory diseases. The activation of T and B lymphocytes is part of the adaptive immune response in infections and immunologic diseases (Chapter 4). Both classes of lymphocytes migrate into inflammatory sites using some of the same adhesion molecule pairs and chemokines that recruit other leukocytes. In the tissues, B lymphocytes may develop into *plasma cells,* which secrete antibodies, and CD4+ T lymphocytes are activated to secrete cytokines.

*By virtue of cytokine secretion, CD4+ T lymphocytes promote inflammation and influence the nature of the inflammatory reaction*. There are three subsets of CD4+ helper T cells that secrete different sets of cytokines and elicit different types of inflammation:

- $T_H1$ cells produce the cytokine IFN-γ, which activates macrophages in the classical pathway.
- $T_H2$ cells secrete IL-4, IL-5, and IL-13, which recruit and activate eosinophils and are responsible for the alternative pathway of macrophage activation.
- $T_H17$ cells secrete IL-17 and other cytokines that induce the secretion of chemokines responsible for recruiting neutrophils and monocytes into the reaction.

Both $T_H1$ and $T_H17$ cells are involved in defense against many types of bacteria and viruses and in autoimmune diseases. $T_H2$ cells are important in defense against helminthic parasites and in allergic inflammation. These T cell subsets and their functions are described in more detail in Chapter 4.

Lymphocytes and macrophages interact in a bidirectional way, and these interactions play an important role in propagating chronic inflammation (Fig. 2–22). Macrophages display antigens to T cells, express membrane molecules (called costimulators), and produce cytokines (IL-12 and others) that stimulate T cell responses (Chapter 4). Activated T lymphocytes, in turn, produce cytokines, described earlier, which recruit and activate macrophages and thus promote more antigen presentation and cytokine secretion. The result is a cycle of cellular reactions that fuel and sustain chronic inflammation. In some strong and prolonged inflammatory reactions, the accumulation of lymphocytes, antigen-presenting cells, and plasma cells may assume the morphologic features of lymphoid organs, and akin to lymph nodes, may even contain well-formed germinal centers. This pattern of lymphoid organogenesis is often seen in the synovium of patients with long-standing rheumatoid arthritis and the thyroid of patients with autoimmune thyroiditis.

### *Other Cells*

*Eosinophils* are characteristically found in inflammatory sites around parasitic infections and as part of immune reactions mediated by IgE, typically associated with allergies. Their recruitment is driven by adhesion molecules similar to those used by neutrophils, and by specific chemokines (e.g., eotaxin) derived from leukocytes and epithelial cells. Eosinophil granules contain major basic protein, a highly charged cationic protein that is toxic to parasites but also causes epithelial cell necrosis.

*Mast cells* are sentinel cells widely distributed in connective tissues throughout the body, and they can participate in both acute and chronic inflammatory responses. In atopic persons (those prone to allergic reactions), mast cells are "armed" with IgE antibody specific for certain

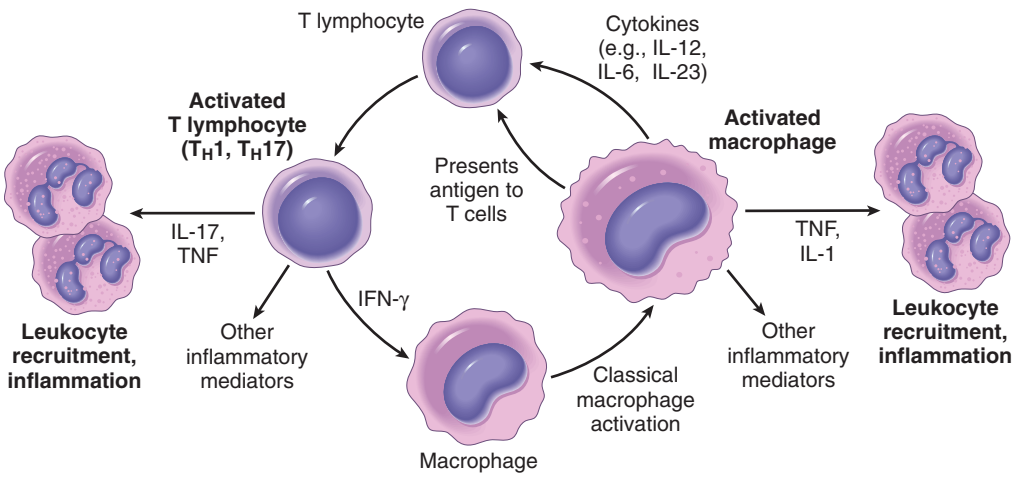


**Figure 2–22** Macrophage–lymphocyte interactions in chronic inflammation. Activated lymphocytes and macrophages stimulate each other, and both cell types release inflammatory mediators that affect other cells. IFN-γ, interferon-γ; IL-1, interleukin-1; TNF, tumor necrosis factor.

environmental antigens. When these antigens are subsequently encountered, the IgE-coated mast cells are triggered to release histamines and AA metabolites that elicit the early vascular changes of acute inflammation. IgE-armed mast cells are central players in allergic reactions, including anaphylactic shock (Chapter 4). Mast cells can also elaborate cytokines such as TNF and chemokines and may play a beneficial role in combating some infections.

An important final point: *Although the presence of neutrophils is the hallmark of acute inflammation, many forms of chronic inflammation may continue to show extensive neutrophilic infiltrates,* as a result of either persistent microbes or necrotic cells, or mediators elaborated by macrophages. Such inflammatory lesions are sometimes called "acute on chronic"—for example, in inflammation of bones (osteomyelitis).

## Granulomatous Inflammation

Granulomatous inflammation is a distinctive pattern of chronic inflammation characterized by aggregates of activated macrophages with scattered lymphocytes. Granulomas are characteristic of certain specific pathologic states; consequently, recognition of the granulomatous pattern is important because of the limited number of conditions (some life-threatening) that cause it (Table 2–8). Granulomas can form under three settings:

- With persistent T-cell responses to certain microbes (such as *Mycobacterium tuberculosis, T. pallidum,* or fungi), in which T cell–derived cytokines are responsible for chronic macrophage activation. *Tuberculosis is the prototype of a granulomatous disease caused by infection and should always be excluded as the cause when granulomas are identified.*
- Granulomas may also develop in some immune-mediated inflammatory diseases, notably Crohn disease, which is one type of inflammatory bowel disease and an important cause of granulomatous inflammation in the United States.
- They are also seen in a disease of unknown etiology called sarcoidosis, and they develop in response to relatively inert foreign bodies (e.g., suture or splinter), forming so-called *foreign body granulomas.*

The formation of a granuloma effectively "walls off" the offending agent and is therefore a useful defense mechanism. However, granuloma formation does not always lead to eradication of the causal agent, which is frequently resistant to killing or degradation, and granulomatous inflammation with subsequent fibrosis may even be the major cause of organ dysfunction in some diseases, such as tuberculosis.

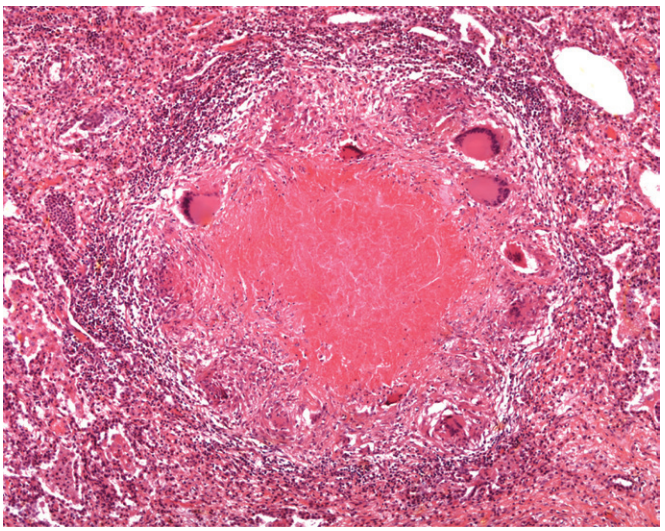

**Figure 2–23** A typical granuloma resulting from infection with *Mycobacterium tuberculosis* showing central area of caseous necrosis, activated epithelioid macrophages, giant cells, and a peripheral accumulation of lymphocytes.

### MORPHOLOGY

In the usual H&E preparations (Fig. 2–23), some of the activated macrophages in granulomas have pink, granular cytoplasm with indistinct cell boundaries; these are called **epithelioid cells** because of their resemblance to epithelia. Typically, the aggregates of epithelioid macrophages are surrounded by a collar of lymphocytes. Older granulomas may have a rim of fibroblasts and connective tissue. Frequently, but not invariably, multinucleate **giant cells** 40 to 50 μm in diameter are found in granulomas. Such cells consist of a large mass of cytoplasm and many nuclei, and they derive from the fusion of multiple activated macrophages. In granulomas

**Table 2–8** Examples of Diseases with Granulomatous Inflammation

| Disease | Cause | Tissue Reaction |
|---|---|---|
| Tuberculosis | *Mycobacterium tuberculosis* | Caseating granuloma (tubercle): focus of activated macrophages (epithelioid cells), rimmed by fibroblasts, lymphocytes, histiocytes, occasional Langhans giant cells; central necrosis with amorphous granular debris; acid-fast bacilli |
| Leprosy | *Mycobacterium leprae* | Acid-fast bacilli in macrophages; noncaseating granulomas |
| Syphilis | *Treponema pallidum* | Gumma: microscopic to grossly visible lesion, enclosing wall of histiocytes; plasma cell infiltrate; central cells are necrotic without loss of cellular outline |
| Cat-scratch disease | Gram-negative bacillus | Rounded or stellate granuloma containing central granular debris and neutrophils; giant cells uncommon |
| Sarcoidosis | Unknown etiology | Noncaseating granulomas with abundant activated macrophages |
| Crohn disease | Immune reaction against intestinal bacteria, self antigens | Occasional noncaseating granulomas in the wall of the intestine, with dense chronic inflammatory infiltrate |

associated with certain infectious organisms (most classically the tubercle bacillus), a combination of hypoxia and free radical injury leads to a central zone of necrosis. On gross examination, this has a granular, cheesy appearance and is therefore called **caseous necrosis** (Chapters 1 and 13). On microscopic examination, this necrotic material appears as eosinophilic amorphous, structureless, granular debris, with complete loss of cellular details. The granulomas associated with Crohn disease, sarcoidosis, and foreign body reactions tend to not have necrotic centers and are said to be "non-caseating." Healing of granulomas is accompanied by fibrosis that may be quite extensive.

## SUMMARY

### Features of Chronic Inflammation

- Prolonged host response to persistent stimulus
- Caused by microbes that resist elimination, immune responses against self and environmental antigens, and some toxic substances (e.g., silica); underlies many important diseases
- Characterized by persistent inflammation, tissue injury, attempted repair by scarring, and immune response
- Cellular infiltrate consisting of activated macrophages, lymphocytes, and plasma cells, often with prominent fibrosis
- Mediated by cytokines produced by macrophages and lymphocytes (notably T lymphocytes), with a tendency to an amplified and prolonged inflammatory response owing to bidirectional interactions between these cells

# SYSTEMIC EFFECTS OF INFLAMMATION

Anyone who has suffered a severe bout of viral illness (such as influenza) has experienced the systemic effects of inflammation, collectively called the *acute-phase reaction,* or the systemic inflammatory response syndrome. *The cytokines TNF, IL-1, and IL-6 are the most important mediators of the acute-phase reaction.* These cytokines are produced by leukocytes (and other cell types) in response to infection or in immune reactions and are released systemically. TNF and IL-1 have similar biologic actions, although these may differ in subtle ways (Fig. 2–17). IL-6 stimulates the hepatic synthesis of a number of plasma proteins, described further on.

The acute-phase response consists of several clinical and pathologic changes.

- *Fever,* characterized by an elevation of body temperature, is one of the most prominent manifestations of the acute-phase response. Fever is produced in response to substances called pyrogens that act by stimulating prostaglandin synthesis in the vascular and perivascular cells of the hypothalamus. Bacterial products, such as lipopolysaccharide (LPS) (called *exogenous pyrogens*), stimulate leukocytes to release cytokines such as IL-1 and TNF (called *endogenous pyrogens*), which increase the levels of cyclooxygenases that convert AA into prostaglandins. In the hypothalamus the prostaglandins, especially $PGE_2$, stimulate the production of neurotransmitters, which function to reset the temperature set point at a higher level. NSAIDs, including aspirin, reduce fever by inhibiting cyclooxygenase and thus blocking prostaglandin synthesis. Although fever was recognized as a sign of infection hundreds of years ago, it is still not clear what the purpose of this reaction may be. An elevated body temperature has been shown to help amphibians ward off microbial infections, and it is assumed that fever does the same for mammals, although the mechanism is unknown.
- *Elevated plasma levels of acute-phase proteins.* These plasma proteins are mostly synthesized in the liver, and in the setting of acute inflammation, their concentrations may increase several hundred-fold. Three of the best known of these proteins are C-reactive protein (CRP), fibrinogen, and serum amyloid A (SAA) protein. Synthesis of these molecules by hepatocytes is stimulated by cytokines, especially IL-6. Many acute-phase proteins, such as CRP and SAA, bind to microbial cell walls, and they may act as opsonins and fix complement, thus promoting the elimination of the microbes. Fibrinogen binds to erythrocytes and causes them to form stacks (rouleaux) that sediment more rapidly at unit gravity than individual erythrocytes. This is the basis for measuring the erythrocyte sedimentation rate (ESR) as a simple test for the systemic inflammatory response, caused by any number of stimuli, including LPS. Serial measurements of ESR and CRP are used to assess therapeutic responses in patients with inflammatory disorders such as rheumatoid arthritis. Elevated serum levels of CRP are now used as a marker for increased risk of myocardial infarction or stroke in patients with atherosclerotic vascular disease. It is believed that inflammation is involved in the development of atherosclerosis (Chapter 9), and increased CRP is a measure of inflammation.
- *Leukocytosis* is a common feature of inflammatory reactions, especially those induced by bacterial infection (see Table 11–6, Chapter 11). The leukocyte count usually climbs to 15,000 to 20,000 cells/mL, but in some extraordinary cases it may reach 40,000 to 100,000 cells/mL. These extreme elevations are referred to as *leukemoid reactions* because they are similar to those seen in leukemia. The leukocytosis occurs initially because of accelerated release of cells (under the influence of cytokines, including TNF and IL-1) from the bone marrow postmitotic reserve pool. Both mature and immature neutrophils may be seen in the blood; the presence of circulating immature cells is referred to as a "shift to the left." Prolonged infection also stimulates production of colony-stimulating factors (CSFs), which increase the bone marrow output of leukocytes, thus compensating for the consumption of these cells in the inflammatory reaction. Most bacterial infections induce an increase in the blood neutrophil count, called neutrophilia. Viral infections, such as infectious mononucleosis, mumps, and German measles, are associated with increased numbers of lymphocytes (lymphocytosis). Bronchial asthma, hay fever, and parasite infestations all involve an increase in the absolute number of eosinophils, creating an

eosinophilia. Certain infections (typhoid fever and infections caused by some viruses, rickettsiae, and certain protozoa) are paradoxically associated with a decreased number of circulating white cells (leukopenia), likely because of cytokine-induced sequestration of lymphocytes in lymph nodes.

- Other manifestations of the acute-phase response include increased heart rate and blood pressure; decreased sweating, mainly as a result of redirection of blood flow from cutaneous to deep vascular beds, to minimize heat loss through the skin; and rigors (shivering), chills (perception of being cold as the hypothalamus resets the body temperature), anorexia, somnolence, and malaise, probably secondary to the actions of cytokines on brain cells.
- In severe bacterial infections (sepsis), the large amounts of bacterial products in the blood or extravascular tissue stimulate the production of several cytokines, notably TNF, as well as IL-12 and IL-1. TNF can cause disseminated intravascular coagulation (DIC), metabolic disturbances including acidosis, and hypotensive shock. This clinical triad is described as *septic shock*; it is discussed in more detail in Chapter 3.

## SUMMARY

### Systemic Effects of Inflammation

- Fever: cytokines (TNF, IL-1) stimulate production of prostaglandins in hypothalamus
- Production of acute-phase proteins: C-reactive protein, others; synthesis stimulated by cytokines (IL-6, others) acting on liver cells
- Leukocytosis: cytokines (CSFs) stimulate production of leukocytes from precursors in the bone marrow
- In some severe infections, septic shock: fall in blood pressure, disseminated intravascular coagulation, metabolic abnormalities; induced by high levels of TNF

Even before the inflammatory reaction ends, the body begins the process of healing the damage and restoring normal structure and function. This process is called repair, and it involves the proliferation and differentiation of several cell types and the deposition of connective tissue. Defects in tissue repair have serious consequences. Conversely, excessive connective tissue deposition (fibrosis) is also a cause of significant abnormalities. Therefore, the mechanisms and regulation of the repair process are of great physiologic and pathologic importance.

## OVERVIEW OF TISSUE REPAIR

Critical to the survival of an organism is the ability to repair the damage caused by toxic insults and inflammation. The inflammatory response to microbes and injured tissues not only serves to eliminate these dangers but also sets into motion the process of repair. Repair, sometimes called

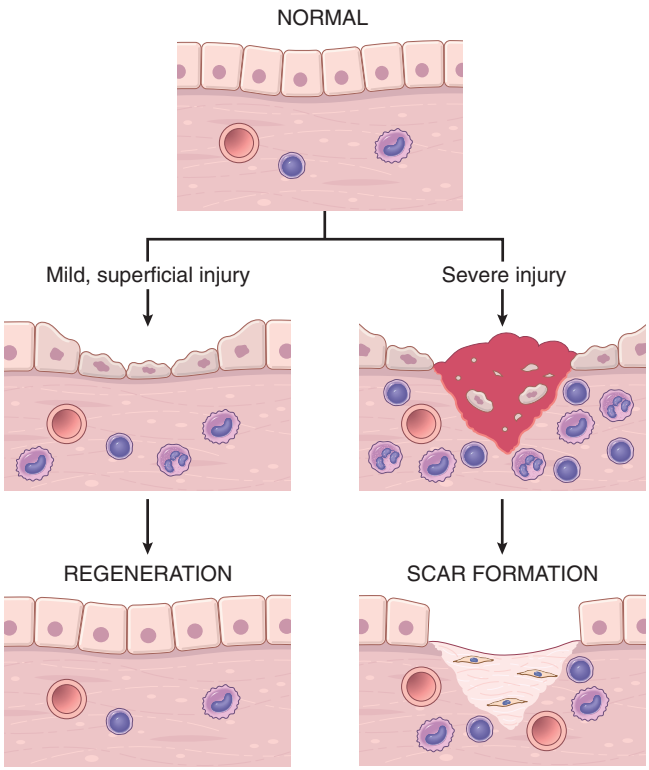


**Figure 2–24** Mechanisms of tissue repair: regeneration and scar formation. After mild injury, which damages the epithelium but not the underlying tissue, resolution occurs by regeneration, but after more severe injury with damage to the connective tissue, repair is by scar formation.

healing, refers to the restoration of tissue architecture and function after an injury. It occurs by two types of reactions: regeneration of the injured tissue and scar formation by the deposition of connective tissue (Fig. 2–24).

- *Regeneration.* Some tissues are able to replace the damaged cells and essentially return to a normal state; this process is called regeneration. Regeneration occurs by proliferation of residual (uninjured) cells that retain the capacity to divide, and by replacement from tissue stem cells. It is the typical response to injury in the rapidly dividing epithelia of the skin and intestines, and some parenchymal organs, notably the liver.
- *Scar formation.* If the injured tissues are incapable of regeneration, or if the supporting structures of the tissue are severely damaged, repair occurs by the laying down of connective (fibrous) tissue, a process that results in scar formation. Although the fibrous scar cannot perform the function of lost parenchymal cells, it provides enough structural stability that the injured tissue is usually able to function. The term *fibrosis* is most often used to describe the extensive deposition of collagen that occurs in the lungs, liver, kidney, and other organs as a consequence of chronic inflammation, or in the myocardium after extensive ischemic necrosis (infarction). If fibrosis develops in a tissue space occupied by an inflammatory exudate, it is called organization (as in organizing pneumonia affecting the lung).

After many common types of injury, both regeneration and scar formation contribute in varying degrees to the

ultimate repair. Both processes involve the proliferation of various cells and close interactions between cells and the ECM. The next section discusses the principles of cellular proliferation, the roles of growth factors in the proliferation of different cell types involved in repair, and the roles of stem cells in tissue homeostasis. This is followed by a summary of some important properties of the ECM and how it is involved in repair. These sections lay the foundation for a consideration of the salient features of regeneration and healing by scar formation, concluding with a description of cutaneous wound healing and fibrosis (scarring) in parenchymal organs as illustrations of the repair process.

## CELL AND TISSUE REGENERATION

The regeneration of injured cells and tissues involves cell proliferation, which is driven by growth factors and is critically dependent on the integrity of the extracellular matrix. Before describing examples of repair by regeneration, we discuss the general principles of cell proliferation and the functions of the ECM in this process.

### The Control of Cell Proliferation

Several cell types proliferate during tissue repair. These include the remnants of the injured tissue (which attempt to restore normal structure), vascular endothelial cells (to create new vessels that provide the nutrients needed for the repair process), and fibroblasts (the source of the fibrous tissue that forms the scar to fill defects that cannot be corrected by regeneration). The proliferation of these cell types is driven by proteins called *growth factors.* The production of polypeptide growth factors and the ability of cells to divide in response to these factors are important determinants of the adequacy of the repair process.

The normal size of cell populations is determined by a balance among cell proliferation, cell death by apoptosis, and emergence of new differentiated cells from stem cells (Fig. 2–25). The key processes in the proliferation of cells are DNA replication and mitosis. The sequence of events that control these two processes is known as the *cell cycle*, described in detail in Chapter 5 in the context of cancer. At this stage, it is sufficient to note that nondividing cells are in cell cycle arrest in the $G_1$ phase or have exited the cycle and are in the $G_0$ phase. Growth factors stimulate cells to transition from $G_0$ into the $G_1$ phase and beyond into DNA synthesis (S), $G_2$, and mitosis (M) phases. Progression is regulated by cyclins, whose activity is controlled by cyclin-dependent kinases. Once cells enter the S phase, their DNA is replicated and they progress through $G_2$ and mitosis.

### Proliferative Capacities of Tissues

The ability of tissues to repair themselves is critically influenced by their intrinsic proliferative capacity. On the basis of this criterion, the tissues of the body are divided into three groups.

- *Labile (continuously dividing) tissues.* Cells of these tissues are continuously being lost and replaced by maturation from stem cells and by proliferation of mature cells. Labile cells include hematopoietic cells in the bone marrow and the majority of surface epithelia, such as the stratified squamous surfaces of the skin, oral cavity, vagina, and cervix; the cuboidal epithelia of the ducts draining exocrine organs (e.g., salivary glands, pancreas, biliary tract); the columnar epithelium of the gastrointestinal tract, uterus, and fallopian tubes; and the transitional epithelium of the urinary tract. These tissues can readily regenerate after injury as long as the pool of stem cells is preserved.
- *Stable tissues.* Cells of these tissues are quiescent and have only minimal replicative activity in their normal state. However, these cells are capable of proliferating in response to injury or loss of tissue mass. Stable cells constitute the parenchyma of most solid tissues, such as liver, kidney, and pancreas. They also include endothelial cells, fibroblasts, and smooth muscle cells; the proliferation of these cells is particularly important in wound healing. With the exception of liver, stable tissues have a limited capacity to regenerate after injury.
- *Permanent tissues.* The cells of these tissues are considered to be terminally differentiated and nonproliferative in postnatal life. Most neurons and cardiac muscle cells belong to this category. Thus, injury to brain or heart is irreversible and results in a scar, because neurons and cardiac myocytes cannot regenerate. Limited stem cell replication and differentiation occur in some areas of the adult brain, and there is some evidence that cardiac stem

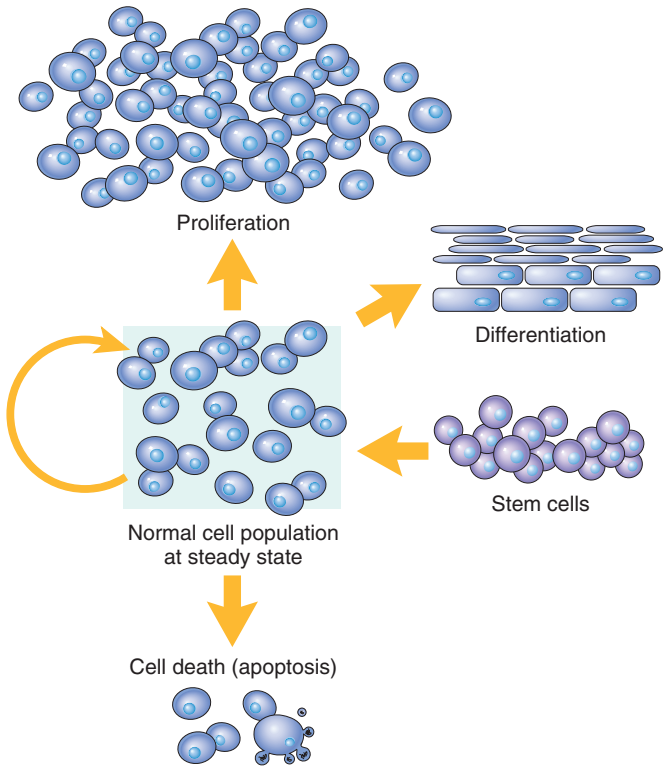


**Figure 2–25** Mechanisms regulating cell populations. Cell numbers can be altered by increased or decreased rates of stem cell input, cell death by apoptosis, or changes in the rates of proliferation or differentiation. *(Modified from McCarthy NJ, et al: Apoptosis in the development of the immune system: growth factors, clonal selection and bcl-2. Cancer Metastasis Rev 11:157, 1992.)*

cells may proliferate after myocardial necrosis. Nevertheless, whatever proliferative capacity may exist in these tissues, it is insufficient to produce tissue regeneration after injury. Skeletal muscle is usually classified as a permanent tissue, but satellite cells attached to the endomysial sheath provide some regenerative capacity for this tissue. In permanent tissues, repair is typically dominated by scar formation.

With the exception of tissues composed primarily of nondividing permanent cells (e.g., cardiac muscle, nerve), most mature tissues contain variable proportions of three cell types: continuously dividing cells, quiescent cells that can return to the cell cycle, and cells that have lost replicative ability.

## Stem Cells

In most dividing tissues the mature cells are terminally differentiated and short-lived. As mature cells die, the tissue is replenished by the differentiation of cells generated from stem cells. Thus, in these tissues there is a homeostatic equilibrium between the replication, self-renewal, and differentiation of stem cells and the death of the mature, fully differentiated cells. Such relationships are particularly evident in the continuously dividing epithelium of the skin and the gastrointestinal tract, in which stem cells live near the basal layer of the epithelium, and cells differentiate as they migrate to the upper layers of the epithelium before they die and are shed from the surface.

*Stem cells are characterized by two important properties: self-renewal capacity and asymmetric replication.* Asymmetric replication means that when a stem cell divides, one daughter cell enters a differentiation pathway and gives rise to mature cells, while the other remains an undifferentiated stem cell that retains its self-renewal capacity. Self-renewal enables stem cells to maintain a functional population of precursors for long periods of time. Although the scientific literature is replete with descriptions of various types of stem cells, fundamentally there are two kinds:

- *Embryonic stem cells (ES cells)* are the most undifferentiated stem cells. They are present in the inner cell mass of the blastocyst and have extensive cell renewal capacity. Hence they can be maintained in culture for over a year without differentiating. Under appropriate culture conditions, ES cells can be induced to form specialized cells of all three germ cell layers, including neurons, cardiac muscle, liver cells, and pancreatic islet cells.
- *Adult stem cells,* also called tissue stem cells, are less undifferentiated than ES cells and are found among differentiated cells within an organ or tissue. Although, like ES cells, they also have self-renewal capacity, this property is much more limited. In addition, their lineage potential (ability to give rise to specialized cells) is restricted to some or all of the differentiated cells of the tissue or organ in which they are found.

Whereas the normal function of ES cells is to give rise to all cells of the body, adult stem cells are involved in tissue homeostasis. They maintain the compartment size both in tissues with high turnover, such as skin, bone marrow, and gut epithelium, and in those with low cell turnover, such as heart and blood vessels. Although there is much interest in isolation and infusion of tissue stem cells for replenishment of specialized cells in organs such as the heart (after a myocardial infarct) and brain (after a stroke), tissue stem cells are rare and very difficult to isolate to purity. Furthermore, they occur in specialized microenvironments within the organ called *stem cell niches*. Apparently, signals from other cells in such niches keep the stem cells quiescent and undifferentiated. Stem cell niches have been identified in many organs. In the brain, neural stem cells occur in the subventricular zone and dentate gyrus; in the skin, tissue stem cells are found in the bulge region of the hair follicle; and in the cornea, they are found at the limbus.

Perhaps the most extensively studied tissue stem cells are hematopoietic stem cells found in the bone marrow. Although rare, they can be purified to virtual purity based on cell surface markers. Hematopoietic stem cells can be isolated from bone marrow as well as from the peripheral blood after mobilization by administration of certain cytokines such as granulocyte colony-stimulating factor (G-CSF). As is well known, they can give rise to all blood cell lineages and continuously replenish the formed elements of the blood as these are consumed in the periphery. In clinical practice, marrow stem cells are used for treatment of diseases such as leukemia and lymphomas (Chapter 11). In addition to hematopoietic stem cells, the bone marrow also contains a somewhat distinctive population of tissue stem cells, often called *mesenchymal stem cells*. These cells can give rise to a variety of mesenchymal cells, such as chondroblasts, osteoblasts, and myoblasts. Hence, there is great interest in their therapeutic potential.

The ability to identify and isolate stem cells has given rise to the new field of *regenerative medicine,* which has as its main goal the repopulation of damaged organs by using differentiated progeny of ES cells or adult stem cells. Since ES cells have extensive self-renewal capacity and can give rise to all cell lineages, they often are considered ideal for developing specialized cells for therapeutic purposes. However, since ES cells are derived from blastocysts (typically produced from in vitro fertilization), their progeny carry histocompatibility molecules (human leukocyte antigen [HLA] in people) (Chapter 4) of the donors of the egg and sperm. Thus, they are likely to evoke immunologically mediated rejection by the host, just as organs transplanted from genetically disparate hosts do. Hence, much effort has gone into producing cells with the potential of ES cells from patient tissues. To accomplish this goal, the expressed genes in ES cells and differentiated cells have been compared and a handful of genes that are critical for the "stem-cell-ness" of ES cells have been identified. Introduction of such genes into fully differentiated cells, such as fibroblasts or skin epithelial cells, leads, quite remarkably, to reprogramming of the somatic cell nucleus, such that the cells acquire many of the properties of ES cells. These cells are called *induced pluripotent stem cells (iPS cells)* (Fig. 2–26). Since iPS cells can be derived from each patient, their differentiated progeny should engraft successfully and restore or replace damaged or deficient cells in the patient—for example, insulin-secreting β cells in a patient with diabetes. Although iPS cells hold considerable promise, their clinical usefulness remains to be proved.

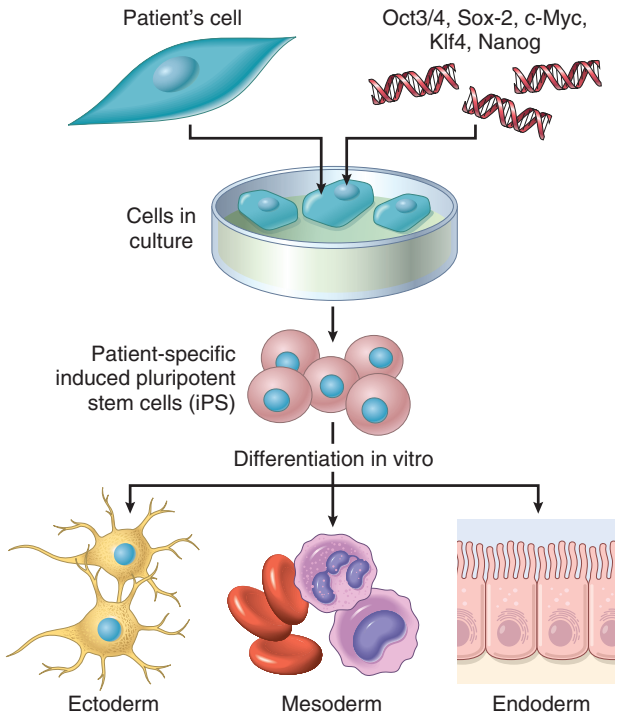


**Figure 2–26** The production of induced pluripotent stem cells (iPS cells). Genes that confer stem cell properties are introduced into a patient's differentiated cells, giving rise to stem cells, which can be induced to differentiate into various lineages.

## SUMMARY

### Cell Proliferation, the Cell Cycle, and Stem Cells

- Regeneration of tissues is driven by proliferation of uninjured (residual) cells and replacement from stem cells.
- Cell proliferation occurs when quiescent cells enter the cell cycle. The cell cycle is tightly regulated by stimulators and inhibitors and contains intrinsic checkpoint controls to prevent replication of abnormal cells.
- Tissues are divided into labile, stable, and permanent, according to the proliferative capacity of their cells.
- Continuously dividing tissues (labile tissues) contain mature cells that are capable of dividing and stem cells that differentiate to replenish lost cells.
- Stem cells from embryos (ES cells) are pluripotent; adult tissues, particularly the bone marrow, contain adult stem cells capable of generating multiple cell lineages.
- Induced pluripotent stem cells (iPS cells) are derived by introducing into mature cells genes that are characteristic of ES cells. iPS cells acquire many characteristics of stem cells.

## Growth Factors

*Most growth factors are proteins that stimulate the survival and proliferation of particular cells, and may also promote migration, differentiation, and other cellular responses.* They induce cell proliferation by binding to specific receptors and affecting the expression of genes whose products typically have several functions: They promote entry of cells into the cell cycle, they relieve blocks on cell cycle progression (thus promoting replication), they prevent apoptosis, and they enhance the synthesis of cellular proteins in preparation for mitosis. A major activity of growth factors is to stimulate the function of growth control genes, many of which are called *proto-oncogenes* because mutations in them lead to unrestrained cell proliferation characteristic of cancer (oncogenesis) (Chapter 5).

There is a huge (and ever-increasing) list of known growth factors. In the following discussion, rather than attempting an exhaustive cataloguing, we highlight only selected molecules that contribute to tissue repair (Table 2–9). Many of the growth factors that are involved in repair are produced by macrophages and lymphocytes that are recruited to the site of injury or are activated at this site, as part of the inflammatory process. Other growth factors are produced by parenchymal cells or stromal (connective tissue) cells in response to cell injury. We start the discussion by describing general principles of growth factor actions. We return to the roles of individual growth factors in the repair process later in the chapter.

### *Signaling Mechanisms of Growth Factor Receptors*

Most growth factors function by binding to specific cell-surface receptors and triggering biochemical signals in cells. The major intracellular signaling pathways induced by growth factor receptors are similar to those of many other cellular receptors that recognize extracellular ligands. In general, these signals lead to the stimulation or repression of gene expression. Signaling may occur directly in the same cell that produces the factor (autocrine signaling), between adjacent cells (paracrine signaling), or over greater distances (endocrine signaling).

Receptor proteins are generally located on the cell surface, but they may be intracellular; in the latter case, the ligands must be sufficiently hydrophobic to enter the cell (e.g., vitamin D, or steroid and thyroid hormones). On the basis of their major signaling transduction pathways, plasma membrane receptors fall into three main types, listed in Table 2–10.

- *Receptors with intrinsic kinase activity.* Binding of ligand to the extracellular portion of the receptor causes dimerization and subsequent phosphorylation of the receptor subunits. Once phosphorylated, the receptors can bind and activate other intracellular proteins (e.g., RAS, phosphatidylinositol 3[PI3]-kinase, phospholipase Cγ [PLC-γ]) and stimulate downstream signals that lead to cell proliferation, or induction of various transcriptional programs.
- *G protein–coupled receptors.* These receptors contain seven-transmembrane α-helix segments and are also known as seven-transmembrane receptors. After ligand binding, the receptors associate with intracellular guanosine triphosphate (GTP)-binding proteins (G proteins) that contain guanosine diphosphate (GDP). Binding of the G proteins causes the exchange of GDP with GTP, resulting in activation of the proteins. Among the several signaling pathways activated through G protein–coupled receptors are those involving cyclic AMP (cAMP), and the generation of inositol 1,4,5-triphosphate ($IP_3$), which releases calcium from the endoplasmic

**Table 2–9** Growth Factors Involved in Regeneration and Repair

| Growth Factor | Sources | Functions |
|---|---|---|
| Epidermal growth factor (EGF) | Activated macrophages, salivary glands, keratinocytes, and many other cells | Mitogenic for keratinocytes and fibroblasts; stimulates keratinocyte migration; stimulates formation of granulation tissue |
| Transforming growth factor-α (TGF-α) | Activated macrophages, keratinocytes, many other cell types | Stimulates proliferation of hepatocytes and many other epithelial cells |
| Hepatocyte growth factor (HGF) (scatter factor) | Fibroblasts, stromal cells in the liver, endothelial cells | Enhances proliferation of hepatocytes and other epithelial cells; increases cell motility |
| Vascular endothelial growth factor (VEGF) | Mesenchymal cells | Stimulates proliferation of endothelial cells; increases vascular permeability |
| Platelet-derived growth factor (PDGF) | Platelets, macrophages, endothelial cells, smooth muscle cells, keratinocytes | Chemotactic for neutrophils, macrophages, fibroblasts, and smooth muscle cells; activates and stimulates proliferation of fibroblasts, endothelial, and other cells; stimulates ECM protein synthesis |
| Fibroblast growth factors (FGFs), including acidic (FGF-1) and basic (FGF-2) | Macrophages, mast cells, endothelial cells, many other cell types | Chemotactic and mitogenic for fibroblasts; stimulates angiogenesis and ECM protein synthesis |
| Transforming growth factor-β (TGF-β) | Platelets, T lymphocytes, macrophages, endothelial cells, keratinocytes, smooth muscle cells, fibroblasts | Chemotactic for leukocytes and fibroblasts; stimulates ECM protein synthesis; suppresses acute inflammation |
| Keratinocyte growth factor (KGF) (i.e., FGF-7) | Fibroblasts | Stimulates keratinocyte migration, proliferation, and differentiation |

ECM, extracellular membrane.

reticulum. Receptors in this category constitute the largest family of plasma membrane receptors (more than 1500 members have been identified).

- *Receptors without intrinsic enzymatic activity.* These are usually monomeric transmembrane molecules with an extracellular ligand-binding domain; ligand interaction induces an intracellular conformational change that allows association with intracellular protein kinases called Janus kinases (JAKs). Phosphorylation of JAKs activates cytoplasmic transcription factors called STATs (signal transducers and activators of transcription), which shuttle into the nucleus and induce transcription of target genes.

## SUMMARY

### Growth Factors, Receptors, and Signal Transduction

- Polypeptide growth factors act in autocrine, paracrine, or endocrine manner.
- Growth factors are produced transiently in response to an external stimulus and act by binding to cellular receptors. Different classes of growth factor receptors include receptors with intrinsic kinase activity, G protein–coupled receptors and receptors without intrinsic kinase activity.
- Growth factors such as epidermal growth factor (EGF) and hepatocyte growth factor (HGF) bind to receptors with intrinsic kinase activity, triggering a cascade of phosphorylating events through MAP kinases, which culminate in transcription factor activation and DNA replication.
- G protein–coupled receptors produce multiple effects via the cAMP and $Ca^{2+}$ pathways. Chemokines utilize such receptors.
- Cytokines generally bind to receptors without kinase activity; such receptors interact with cytoplasmic transcription factors that move into the nucleus.
- Most growth factors have multiple effects, such as cell migration, differentiation, stimulation of angiogenesis, and fibrogenesis, in addition to cell proliferation.

**Table 2–10** Principal Signaling Pathways Used by Cell Surface Receptors

| Receptor Class | Ligands | Signaling Mechanism(s) |
|---|---|---|
| Receptors with intrinsic tyrosine kinase activity | EGF, VEGF, FGF, HGF | Ligand binding to one chain of the receptor activates tyrosine kinase on the other chain, resulting in activation of multiple downstream signaling pathways (RAS-MAP kinase, PI-3 kinase, PLC-γ) and activation of various transcription factors. |
| G protein–coupled seven-transmembrane receptors (GPCRs) | Multiple inflammatory mediators, hormones, all chemokines | Ligand binding induces switch from GDP-bound inactive form of associated G protein to GTP-bound active form; activates cAMP; $Ca^{2+}$ influx leading to increased cell motility; multiple other effects. |
| Receptors without intrinsic enzymatic activity | Many cytokines including interferons, growth hormone, CSFs, EPO | Ligand binding recruits kinases (e.g., Janus kinases [JAKs]) that phosphorylate and activate transcription factors (e.g., signal transducers and activators of transcription [STATs]). |

cAMP, cyclic adenosine monophosphate; CSFs, colony-stimulating factors; EGF, epidermal growth factor; EPO, epopoietin; FGF, fibroblast growth factor; GDP, guanosine diphosphate; GTP, guanosine triphosphate; HGF, hepatocyte growth factor; PI3, phosphatidylinositol-3; PLC-γ, phospholipase Cγ; MAP, microtubule-associated protein; VEGF, vascular endothelial growth factor.

## Role of the Extracellular Matrix in Tissue Repair

Tissue repair depends not only on growth factor activity but also on interactions between cells and ECM components. The ECM is a complex of several proteins that assembles into a network that surrounds cells and constitutes a significant proportion of any tissue. *ECM sequesters water, providing turgor to soft tissues, and minerals, giving rigidity to bone. It also regulates the proliferation, movement, and differentiation of the cells living within it, by supplying a substrate for cell adhesion and migration and serving as a reservoir for growth factors.* The ECM is constantly being remodeled; its synthesis and degradation accompany morphogenesis, wound healing, chronic fibrosis, and tumor invasion and metastasis.

ECM occurs in two basic forms: interstitial matrix and basement membrane (Fig. 2–27).

- *Interstitial matrix:* This form of ECM is present in the spaces between cells in connective tissue, and between epithelium and supportive vascular and smooth muscle structures. It is synthesized by mesenchymal cells (e.g., fibroblasts) and tends to form a three-dimensional, amorphous gel. Its major constituents are fibrillar and nonfibrillar collagens, as well as fibronectin, elastin, proteoglycans, hyaluronate, and other elements (described later).
- *Basement membrane:* The seemingly random array of interstitial matrix in connective tissues becomes highly organized around epithelial cells, endothelial cells, and smooth muscle cells, forming the specialized basement membrane. The basement membrane lies beneath the epithelium and is synthesized by overlying epithelium and underlying mesenchymal cells; it tends to form a platelike "chicken wire" mesh. Its major constituents are amorphous nonfibrillar type IV collagen and laminin (see later).

### *Components of the Extracellular Matrix*

There are three basic components of ECM: (1) fibrous structural proteins such as collagens and elastins, which confer tensile strength and recoil; (2) water-hydrated gels such as proteoglycans and hyaluronan, which permit resilience and lubrication; and (3) adhesive glycoproteins that connect the matrix elements to one another and to cells (Fig. 2–27).

#### Collagen

The collagens are composed of three separate polypeptide chains braided into a ropelike triple helix. Approximately 30 collagen types have been identified, some of which are unique to specific cells and tissues. Some collagen types (e.g., types I, II, III, and V) form fibrils by virtue of lateral cross-linking of the triple helices. The fibrillar collagens form a major proportion of the connective tissue in healing wounds and particularly in scars. The tensile strength of the fibrillar collagens derives from their cross-linking, which is the result of covalent bonds catalyzed by the enzyme lysyl-oxidase. This process is dependent on vitamin C; therefore, individuals with vitamin C deficiency have skeletal deformities, bleed easily because of weak vascular wall basement membrane, and suffer from poor wound healing. Genetic defects in these collagens cause diseases such as osteogenesis imperfecta and Ehlers-Danlos syndrome. Other collagens are nonfibrillar and may form basement membrane (type IV) or be components of other structures such as intervertebral disks (type IX) or dermal–epidermal junctions (type VII).

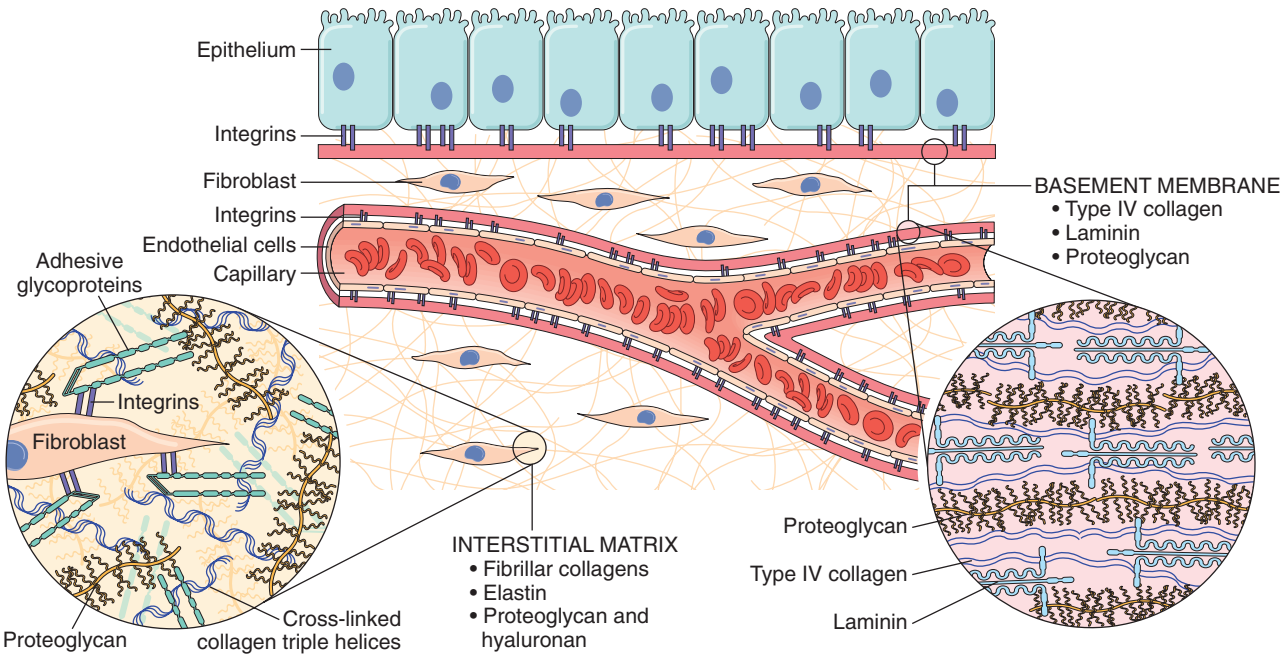


**Figure 2–27** The major components of the extracellular matrix (ECM), including collagens, proteoglycans, and adhesive glycoproteins. Note that although there is some overlap in their constituents, basement membrane and interstitial ECM differ in general composition and architecture. Both epithelial and mesenchymal cells (e.g., fibroblasts) interact with ECM through integrins. For simplification, many ECM components have been left out (e.g., elastin, fibrillin, hyaluronan, syndecan).

### Elastin

The ability of tissues to recoil and return to a baseline structure after physical stress is conferred by elastic tissue. This is especially important in the walls of large vessels (which must accommodate recurrent pulsatile flow), as well as in the uterus, skin, and ligaments. Morphologically, elastic fibers consist of a central core of elastin surrounded by a meshlike network of fibrillin glycoprotein. Defects in fibrillin synthesis lead to skeletal abnormalities and weakened aortic walls (as in Marfan syndrome, discussed in Chapter 6).

### Proteoglycans and Hyaluronan

Proteoglycans form highly hydrated compressible gels conferring resilience and lubrication (such as in the cartilage in joints). They consist of long polysaccharides, called glycosaminoglycans or mucopolysaccharides (examples are dermatan sulfate and heparan sulfate), linked to a protein backbone. Hyaluronan (also called hyaluronic acid), a huge mucopolysaccharide without a protein core, is also an important constituent of the ECM that binds water, and forms a viscous, gelatin-like matrix. Besides providing compressibility to tissues, proteoglycans also serve as reservoirs for growth factors secreted into the ECM (e.g., fibroblast growth factor [FGF], HGF). Some proteoglycans are integral cell membrane proteins that have roles in cell proliferation, migration, and adhesion—for example, by binding growth factors and chemokines and providing high local concentrations of these mediators.

### Adhesive Glycoproteins and Adhesion Receptors

Adhesive glycoproteins and adhesion receptors are structurally diverse molecules involved in cell-to-cell adhesion, the linkage of cells to the ECM, and binding between ECM components. The adhesive glycoproteins include fibronectin (a major component of the interstitial ECM) and laminin (a major constituent of basement membrane); they are described here as prototypical of the overall group. The adhesion receptors, also known as cell adhesion molecules (CAMs), are grouped into four families—immunoglobulins, cadherins, selectins, and integrins—of which only the integrins are discussed here.

- *Fibronectin* is a large (450-kDa) disulfide-linked heterodimer synthesized by a variety of cells, including fibroblasts, monocytes, and endothelium that exists in tissue and plasma forms. Fibronectins have specific domains that bind to a wide spectrum of ECM components (e.g., collagen, fibrin, heparin, proteoglycans) and can also attach to cell integrins via a tripeptide arginine–glycine–aspartic acid (abbreviated *RGD*) motif. Tissue fibronectin forms fibrillar aggregates at wound healing sites; plasma fibronectin binds to fibrin within the blood clot that forms in a wound, providing the substratum for ECM deposition and re-epithelialization.
- *Laminin* is the most abundant glycoprotein in basement membrane. It is an 820-kDa cross-shaped heterotrimer that connects cells to underlying ECM components such as type IV collagen and heparan sulfate. Besides mediating attachment to basement membrane, laminin can also modulate cell proliferation, differentiation, and motility.
- *Integrins* are a family of transmembrane heterodimeric glycoprotein chains that were introduced in the context of leukocyte adhesion to endothelium. They are also the main cellular receptors for ECM components, such as fibronectins and laminins. We have already discussed some of the integrins as leukocyte surface molecules that mediate firm adhesion and transmigration across endothelium at sites of inflammation, and we shall meet them again when we discuss platelet aggregation in Chapter 3. Integrins are present in the plasma membrane of most cells, with the exception of red blood cells. They bind to many ECM components through RGD motifs, initiating signaling cascades that can affect cell locomotion, proliferation, and differentiation. Their intracellular domains link to actin filaments, thereby affecting cell shape and mobility.

## *Functions of the Extracellular Matrix*

The ECM is much more than a space filler around cells. Its various functions include

- *Mechanical support* for cell anchorage and cell migration, and maintenance of cell polarity
- *Control of cell proliferation* by binding and displaying growth factors and by signaling through cellular receptors of the integrin family. The type of ECM proteins can affect the degree of differentiation of the cells in the tissue, again acting largely through cell surface integrins.
- *Scaffolding for tissue renewal.* Because maintenance of normal tissue structure requires a basement membrane or stromal scaffold, the integrity of the basement membrane or the stroma of parenchymal cells is critical for the organized regeneration of tissues. Thus, although labile and stable cells are capable of regeneration, disruption of the ECM results in a failure of the tissues to regenerate and repair by scar formation (Fig. 2–24).
- *Establishment of tissue microenvironments.* Basement membrane acts as a boundary between epithelium and underlying connective tissue and also forms part of the filtration apparatus in the kidney.

## SUMMARY

### Extracellular Matrix and Tissue Repair

- The ECM consists of the *interstitial matrix* between cells, made up of collagens and several glycoproteins, and *basement membranes* underlying epithelia and surrounding vessels, made up of nonfibrillar collagen and laminin.
- The ECM serves several important functions:
  - It provides mechanical support to tissues; this is the role of collagens and elastin.
  - It acts as a substrate for cell growth and the formation of tissue microenvironments.
  - It regulates cell proliferation and differentiation; proteoglycans bind growth factors and display them at high concentration, and fibronectin and laminin stimulate cells through cellular integrin receptors.
- An intact ECM is required for tissue regeneration, and if the ECM is damaged, repair can be accomplished only by scar formation.

Having described the basic components of tissue repair, we now proceed to a discussion of repair by regeneration and by scar formation.

## Role of Regeneration in Tissue Repair

The importance of regeneration in the replacement of injured tissues varies in different types of tissues and with the severity of injury.

- In labile tissues, such as the epithelia of the intestinal tract and skin, injured cells are rapidly replaced by proliferation of residual cells and differentiation of tissue stem cells provided the underlying basement membrane is intact. The growth factors involved in these processes are not defined. Loss of blood cells is corrected by proliferation of hematopoietic progenitors in the bone marrow and other tissues, driven by CSFs, which are produced in response to the reduced numbers of blood cells.
- Tissue regeneration can occur in parenchymal organs with stable cell populations, but with the exception of the liver, this is usually a limited process. Pancreas, adrenal, thyroid, and lung have some regenerative capacity. The surgical removal of a kidney elicits in the contralateral kidney a compensatory response that consists of both hypertrophy and hyperplasia of proximal duct cells. The mechanisms underlying this response are not understood.
- The regenerative response of the liver that occurs after surgical removal of hepatic tissue is remarkable and unique among all organs. As much as 40% to 60% of the liver may be removed in a procedure called living-donor transplantation, in which a portion of the liver is resected from a normal person and transplanted into a recipient with end-stage liver disease (Fig. 2–28), or after partial hepatectomy performed for tumor removal. In both situations, the removal of tissue triggers a proliferative response of the remaining hepatocytes (which are normally quiescent), and the subsequent replication of hepatic nonparenchymal cells. In experimental systems, hepatocyte replication after partial hepatectomy is initiated by cytokines (e.g., TNF, IL-6) that prepare the cells for replication by stimulating the transition from $G_0$ to $G_1$ in the cell cycle. Progression through the cell cycle is dependent on the activity of growth factors such as HGF (produced by fibroblasts, endothelial cells, and liver nonparenchymal cells) and the EGF family of factors, which includes transforming growth factor-α (TGF-α) (produced by many cell types).

A point worthy of emphasis is that *extensive regeneration or compensatory hyperplasia can occur only if the residual connective tissue framework is structurally intact, as after partial surgical resection. By contrast, if the entire tissue is damaged by infection or inflammation, regeneration is incomplete and is accompanied by scarring*. For example, extensive destruction of the liver with collapse of the reticulin framework, as occurs in a liver abscess, leads to scar formation even though the remaining liver cells have the capacity to regenerate.

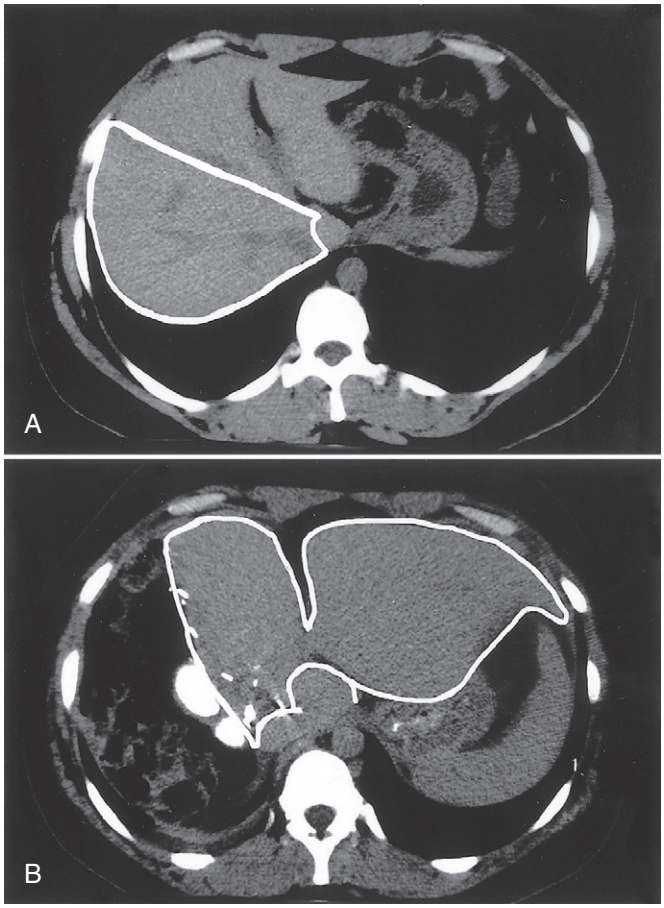


**Figure 2–28** Regeneration of the liver. Computed tomography scans show a donor liver in living-donor liver transplantation. **A,** The donor liver before the operation. Note the right lobe (*outline*), which will be resected and used as a transplant. **B,** Scan of the same liver 1 week after resection of the right lobe; note the enlargement of the left lobe (*outline*) without regrowth of the right lobe.
*(Courtesy of R. Troisi, MD, Ghent University, Flanders, Belgium.)*

# SCAR FORMATION

As discussed earlier, if tissue injury is severe or chronic and results in damage to parenchymal cells and epithelia as well as the connective tissue, or if nondividing cells are injured, repair cannot be accomplished by regeneration alone. Under these conditions, repair occurs by replacement of the nonregenerated cells with connective tissue, leading to the formation of a scar, or by a combination of regeneration of some cells and scar formation.

## Steps in Scar Formation

Repair by connective tissue deposition consists of sequential processes that follow the inflammatory response (Fig. 2–29):

- Formation of new blood vessels (angiogenesis)
- Migration and proliferation of fibroblasts and deposition of connective tissue, which, together with abundant

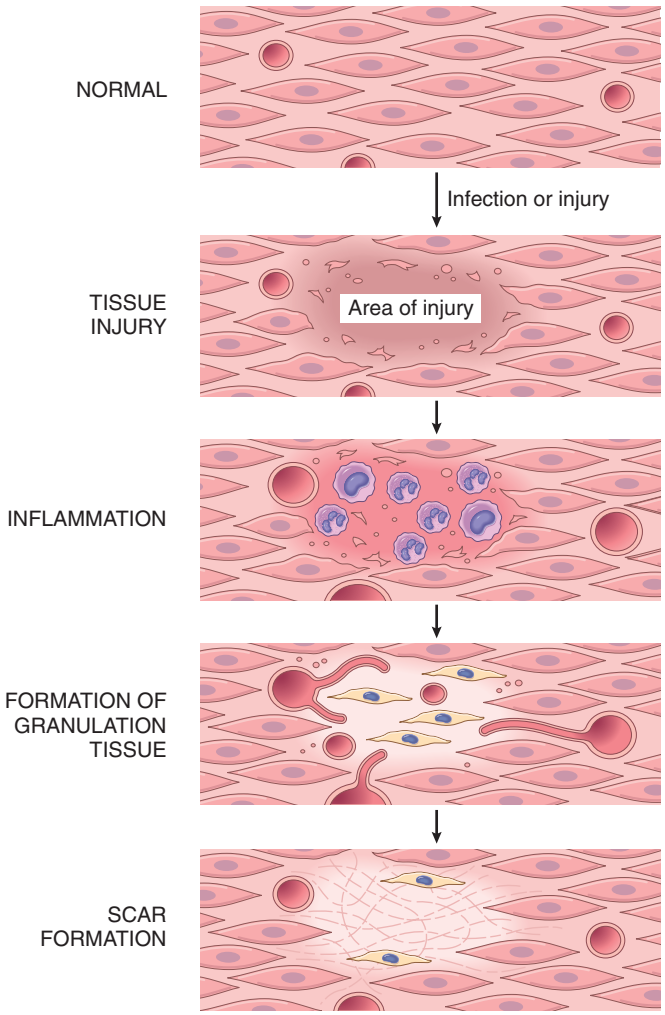


**Figure 2–29** Steps in repair by scar formation. Injury to a tissue that has limited regenerative capacity first induces inflammation, which clears dead cells and microbes, if any. This is followed by formation of vascularized granulation tissue and then deposition of ECM to form the scar. ECM, extracellular matrix.

vessels and interspersed leukocytes, has a pink, granular appearance and hence is called *granulation tissue*
- Maturation and reorganization of the fibrous tissue (remodeling) to produce the stable fibrous scar

Repair begins within 24 hours of injury by the emigration of fibroblasts and the induction of fibroblast and endothelial cell proliferation. By 3 to 5 days, the specialized granulation tissue that is characteristic of healing is apparent. The term granulation tissue derives from the gross appearance, such as that beneath the scab of a skin wound. Its histologic appearance is characterized by proliferation of fibroblasts and new thin-walled, delicate capillaries (angiogenesis) in a loose ECM, often with admixed inflammatory cells, mainly macrophages (Fig. 2–30, *A*). Granulation tissue progressively accumulates more fibroblasts, which lay down collagen, eventually resulting in the formation of a scar (Fig. 2–30, *B*). Scars remodel over time. We next describe each of the steps in this process.

## Angiogenesis

*Angiogenesis is the process of new blood vessel development from existing vessels, primarily venules.* It is critical in healing at sites of injury, in the development of collateral circulations at sites of ischemia, and in allowing tumors to increase in size beyond the constraints of their original blood supply. Much work has been done to understand the mechanisms underlying angiogenesis, and therapies to either augment the process (e.g., to improve blood flow to a heart ravaged by coronary atherosclerosis) or inhibit it (e.g., to frustrate tumor growth or block pathologic vessel growth such as in diabetic retinopathy) are being developed.

Angiogenesis involves sprouting of new vessels from existing ones and consists of the following steps (Fig. 2–31):

- Vasodilation occurring in response to NO and increased permeability induced by VEGF
- Separation of pericytes from the abluminal surface
- Migration of endothelial cells toward the area of tissue injury

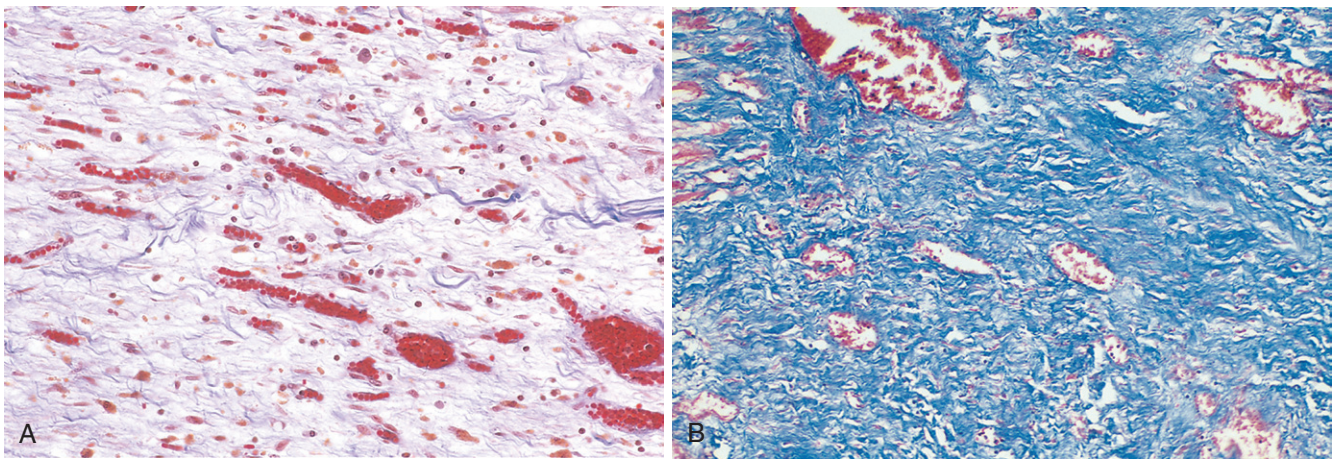


**Figure 2–30 A,** Granulation tissue showing numerous blood vessels, edema, and a loose ECM containing occasional inflammatory cells. Collagen is stained blue by the trichrome stain; minimal mature collagen can be seen at this point. **B,** Trichrome stain of mature scar, showing dense collagen with only scattered vascular channels. ECM, extracellular matrix.

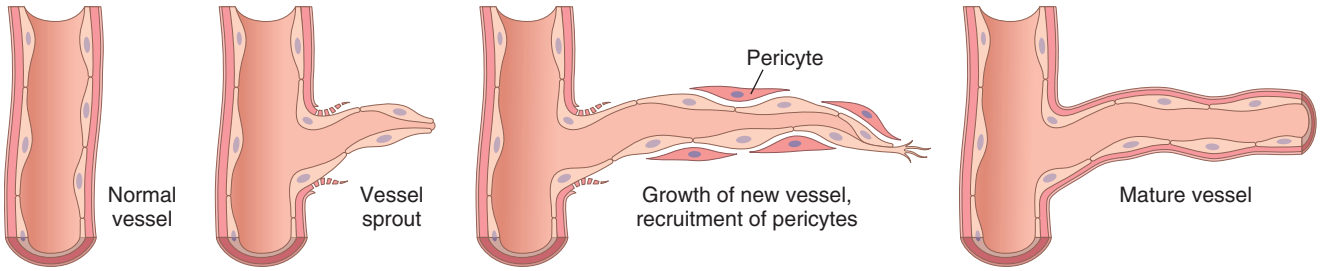


**Figure 2–31** Mechanism of angiogenesis. In tissue repair, angiogenesis occurs mainly by growth factor–driven outgrowth of residual endothelium, sprouting of new vessels, and recruitment of pericytes to form new vessels.

- Proliferation of endothelial cells just behind the leading front of migrating cells
- Remodeling into capillary tubes
- Recruitment of periendothelial cells (pericytes for small capillaries and smooth muscle cells for larger vessels) to form the mature vessel
- Suppression of endothelial proliferation and migration and deposition of the basement membrane

The process of angiogenesis involves a variety of growth factors, cell–cell interactions, interactions with ECM proteins, and tissue enzymes.

### Growth Factors Involved in Angiogenesis

Several growth factors contribute to angiogenesis; the most important are VEGF and basic fibroblast growth factor (FGF-2).

- The *VEGF family of growth factors* includes VEGF-A, -B, -C, -D, and -E and placental growth factor (PlGF). VEGF-A is generally referred to as VEGF and is the major inducer of angiogenesis after injury and in tumors; VEGF-B and PlGF are involved in vessel development in the embryo; and VEGF-C and -D stimulate both lymphangiogenesis and angiogenesis. VEGFs are expressed in most adult tissues, with the highest expression in epithelial cells adjacent to fenestrated epithelium (e.g., podocytes in the kidney, pigment epithelium in the retina). They bind to a family of tyrosine kinase receptors (VEGFR-1, -2, and -3). The most important of these receptors for angiogenesis is VEGFR-2, which is expressed by VEGF target cells, especially endothelial cells. Of the many inducers of VEGF, hypoxia is the most important; others are platelet-derived growth factor (PDGF), TGF-α, and TGF-β.

  VEGF stimulates both migration and proliferation of endothelial cells, thus initiating the process of capillary sprouting in angiogenesis. It promotes vasodilation by stimulating the production of NO, and contributes to the formation of the vascular lumen. Antibodies against VEGF are approved for the treatment of some tumors that depend on angiogenesis for their spread and growth. These antibodies are also used in the treatment of "wet" (neovascular) age-related macular degeneration, a major cause of visual impairment in adults older than 50 years of age, and is in clinical trials for the treatment of the angiogenesis associated with retinopathy of prematurity and the leaky vessels that lead to diabetic macular edema.
- The *FGF family of growth factors* has more than 20 members; the best characterized are FGF-1 (acidic FGF) and FGF-2 (basic FGF). These growth factors are produced by many cell types and bind to a family of plasma membrane receptors that have tyrosine kinase activity. Released FGF can bind to heparan sulfate and be stored in the ECM. FGF-2 participates in angiogenesis mostly by stimulating the proliferation of endothelial cells. It also promotes the migration of macrophages and fibroblasts to the damaged area, and stimulates epithelial cell migration to cover epidermal wounds.
- *Angiopoietins Ang1 and Ang2* are growth factors that play a role in angiogenesis and the structural maturation of new vessels. Newly formed vessels need to be stabilized by the recruitment of pericytes and smooth muscle cells and by the deposition of connective tissue. Ang1 interacts with a tyrosine kinase receptor on endothelial cells called Tie2. The growth factors PDGF and TGF-β also participate in the stabilization process—PDGF recruits smooth muscle cells and TGF-β suppresses endothelial proliferation and migration, and enhances the production of ECM proteins.

The growth of blood vessels during embryonic development is called *vasculogenesis.* In vasculogenesis, vessels are formed de novo by the coalescence of endothelial precursors called angioblasts. Angioblasts are derived from hemangioblasts, which also provide the precursors of the hematopoietic system. In addition, there are endothelial progenitors in the adult that are derived from bone marrow stem cells and circulate. The contribution of these cells to angiogenesis in adults is not definitely established.

ECM proteins participate in the process of vessel sprouting in angiogenesis, largely through interactions with integrin receptors in endothelial cells and by providing the scaffold for vessel growth. Enzymes in the ECM, notably the matrix metalloproteinases (MMPs), degrade the ECM to permit remodeling and extension of the vascular tube. Newly formed vessels are leaky because of incomplete interendothelial junctions and because VEGF increases vascular permeability. This leakiness explains why granulation tissue is often edematous and accounts in part for the edema that may persist in healing wounds long after the acute inflammatory response has resolved. Furthermore, it leads to high intratumoral pressure and is the basis for the edema that is so problematic in ocular angiogenesis in pathologic processes such as wet macular degeneration.

## Activation of Fibroblasts and Deposition of Connective Tissue

*The laying down of connective tissue in the scar occurs in two steps: (1) migration and proliferation of fibroblasts into the site of injury and (2) deposition of ECM proteins produced by these cells.* The recruitment and activation of fibroblasts to synthesize connective tissue proteins are driven by many growth factors, including PDGF, FGF-2 (described earlier), and TGF-β. The major source of these factors is inflammatory cells, particularly macrophages, which are present at sites of injury and in granulation tissue. Sites of inflammation are also rich in mast cells, and in the appropriate chemotactic milieu, lymphocytes may be present as well. Each of these cell types can secrete cytokines and growth factors that contribute to fibroblast proliferation and activation.

As healing progresses, the number of proliferating fibroblasts and new vessels decreases; however, the fibroblasts progressively assume a more synthetic phenotype, so there is increased deposition of ECM. Collagen synthesis, in particular, is critical to the development of strength in a healing wound site. As described later, collagen synthesis by fibroblasts begins early in wound healing (days 3 to 5) and continues for several weeks, depending on the size of the wound. Net collagen accumulation, however, depends not only on increased synthesis but also on diminished collagen degradation (discussed later). Ultimately, the granulation tissue evolves into a scar composed of largely inactive, spindle-shaped fibroblasts, dense collagen, fragments of elastic tissue, and other ECM components (Fig. 2–30, *B*). As the scar matures, there is progressive vascular regression, which eventually transforms the highly vascularized granulation tissue into a pale, largely avascular scar.

### Growth Factors Involved in ECM Deposition and Scar Formation

Many growth factors are involved in these processes, including TGF-β, PDGF, and FGF. Because FGF also is involved in angiogenesis, it was described earlier. Here we briefly describe the major properties of TGF-β and PDGF.

- *Transforming growth factor-β (TGF-β)* belongs to a family of homologous polypeptides (TGF-β1, -β2, and -β3) that includes other cytokines such as bone morphogenetic proteins. The TGF-β1 isoform is widely distributed and is usually referred to as TGF-β. The active factor binds to two cell surface receptors with serine-threonine kinase activity, triggering the phosphorylation of transcription factors called Smads. TGF-β has many and often opposite effects, depending on the cell type and the metabolic state of the tissue. In the context of inflammation and repair, TGF-β has two main functions:
  - TGF-β stimulates the production of collagen, fibronectin, and proteoglycans, and it inhibits collagen degradation by both decreasing proteinase activity and increasing the activity of tissue inhibitors of proteinases known as TIMPs (discussed later on). TGF-β is involved not only in scar formation after injury but also in the development of fibrosis in lung, liver, and kidneys that follows chronic inflammation.
  - TGF-β is an anti-inflammatory cytokine that serves to limit and terminate inflammatory responses. It does so by inhibiting lymphocyte proliferation and the activity of other leukocytes. Mice lacking TGF-β exhibit widespread inflammation and abundant lymphocyte proliferation.
- *Platelet-derived growth factor (PDGF)* belongs to a family of closely related proteins, each consisting of two chains, designated A and B. There are five main PDGF isoforms, of which the BB isoform is the prototype; it is often referred to simply as PDGF. PDGFs bind to receptors designated as PDGFRα and PDGFRβ. PDGF is stored in platelets and released on platelet activation and is also produced by endothelial cells, activated macrophages, smooth muscle cells, and many tumor cells. PDGF causes migration and proliferation of fibroblasts and smooth muscle cells and may contribute to the migration of macrophages.
- *Cytokines* (discussed earlier as mediators of inflammation, and in Chapter 4 in the context of immune responses) may also function as growth factors and participate in ECM deposition and scar formation. IL-1 and IL-13, for example, act on fibroblasts to stimulate collagen synthesis, and can also enhance the proliferation and migration of fibroblasts.

## Remodeling of Connective Tissue

After its synthesis and deposition, the connective tissue in the scar continues to be modified and remodeled. Thus, the outcome of the repair process is a balance between synthesis and degradation of ECM proteins. We have already discussed the cells and factors that regulate ECM synthesis. *The degradation of collagens and other ECM components is accomplished by a family of matrix metalloproteinases (MMPs),* which are dependent on zinc ions for their activity. MMPs should be distinguished from neutrophil elastase, cathepsin G, plasmin, and other serine proteinases that can also degrade ECM but are not metalloenzymes. MMPs include interstitial collagenases, which cleave fibrillar collagen (MMP-1, -2, and -3); gelatinases (MMP-2 and -9), which degrade amorphous collagen and fibronectin; and stromelysins (MMP-3, -10, and -11), which degrade a variety of ECM constituents, including proteoglycans, laminin, fibronectin, and amorphous collagen.

MMPs are produced by a variety of cell types (fibroblasts, macrophages, neutrophils, synovial cells, and some epithelial cells), and their synthesis and secretion are regulated by growth factors, cytokines, and other agents. The activity of the MMPs is tightly controlled. They are produced as inactive precursors (zymogens) that must be first activated; this is accomplished by proteases (e.g., plasmin) likely to be present only at sites of injury. In addition, activated MMPs can be rapidly inhibited by specific tissue inhibitors of metalloproteinases (TIMPs), produced by most mesenchymal cells. Thus, during scarring, MMPs are activated to remodel the deposited ECM, and then their activity is shut down by the TIMPs.

## SUMMARY

### Repair by Scar Formation

- Tissues can be repaired by regeneration with complete restoration of form and function, or by replacement with connective tissue and scar formation.
- Repair by connective tissue deposition involves angiogenesis, migration and proliferation of fibroblasts, collagen synthesis, and connective tissue remodeling.
- Repair by connective tissue starts with the formation of granulation tissue and culminates in the laying down of fibrous tissue.
- Multiple growth factors stimulate the proliferation of the cell types involved in repair.
- TGF-β is a potent fibrogenic agent; ECM deposition depends on the balance among fibrogenic agents, the metalloproteinases (MMPs) that digest ECM, and the TIMPs.

## FACTORS THAT INFLUENCE TISSUE REPAIR

Tissue repair may be altered by a variety of influences, frequently reducing the quality or adequacy of the reparative process. Variables that modify healing may be extrinsic (e.g., infection) or intrinsic to the injured tissue. Particularly important are infections and diabetes.

- *Infection* is clinically the most important cause of delay in healing; it prolongs inflammation and potentially increases the local tissue injury.
- *Nutrition* has profound effects on repair; protein deficiency, for example, and especially vitamin C deficiency inhibit collagen synthesis and retard healing.
- *Glucocorticoids* (steroids) have well-documented anti-inflammatory effects, and their administration may result in weakness of the scar because of inhibition of TGF-β production and diminished fibrosis. In some instances, however, the anti-inflammatory effects of glucocorticoids are desirable. For example, in corneal infections, glucocorticoids are sometimes prescribed (along with antibiotics) to reduce the likelihood of opacity that may result from collagen deposition.
- *Mechanical variables* such as increased local pressure or torsion may cause wounds to pull apart, or dehisce.
- *Poor perfusion,* due either to arteriosclerosis and diabetes or to obstructed venous drainage (e.g., in varicose veins), also impairs healing.
- *Foreign bodies* such as fragments of steel, glass, or even bone impede healing.
- The type and extent of tissue injury affects the subsequent repair. Complete restoration can occur only in tissues composed of stable and labile cells; injury to tissues composed of permanent cells must inevitably result in scarring, as in healing of a myocardial infarct.
- The *location of the injury* and the character of the tissue in which the injury occurs are also important. For example, inflammation arising in tissue spaces (e.g., pleural, peritoneal, or synovial cavities) develops extensive exudates. Subsequent repair may occur by digestion of the exudate, initiated by the proteolytic enzymes of leukocytes and resorption of the liquefied exudate. This is called resolution, and generally, in the absence of cellular necrosis, normal tissue architecture is restored. In the setting of larger accumulations, however, the exudate undergoes organization: Granulation tissue grows into the exudate, and a fibrous scar ultimately forms.
- *Aberrations of cell growth* and ECM production may occur even in what begins as normal wound healing. For example, the accumulation of exuberant amounts of collagen can give rise to prominent, raised scars known as *keloids* (Fig. 2–32). There appears to be a heritable predisposition to keloid formation, and the condition is more common in African-Americans. Healing wounds may also generate exuberant granulation tissue that protrudes above the level of the surrounding skin and hinders re-epithelialization. Such tissue is called "proud

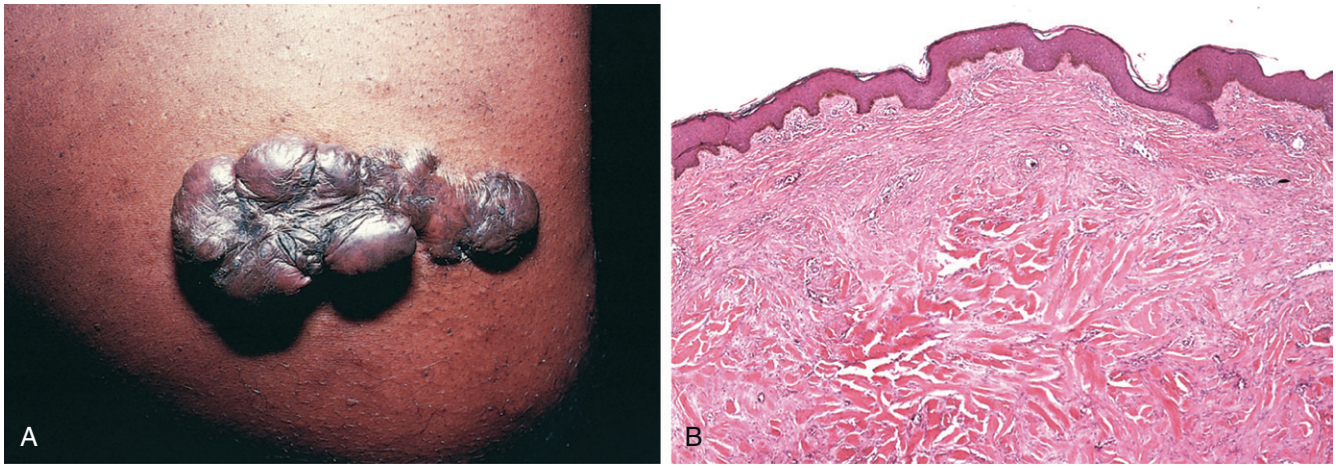


**Figure 2–32** Keloid. **A,** Excess collagen deposition in the skin forming a raised scar known as a keloid. **B,** Thick connective tissue deposition in the dermis.

*(A, From Murphy GF, Herzberg AJ: Atlas of Dermatology. Philadelphia, WB Saunders, 1996. B, Courtesy of Z. Argenyi, MD, University of Washington, Seattle, Washington.)*

flesh" in old medical parlance, and restoration of epithelial continuity requires cautery or surgical resection of the granulation tissue.

## SELECTED CLINICAL EXAMPLES OF TISSUE REPAIR AND FIBROSIS

Thus far we have discussed the general principles and mechanisms of repair by regeneration and scarring. In this section we describe two clinically significant types of repair—the healing of skin wounds (cutaneous wound healing) and fibrosis in injured parenchymal organs.

### Healing of Skin Wounds

Cutaneous wound healing is a process that involves both epithelial regeneration and the formation of connective tissue scar and is thus illustrative of the general principles that apply to healing in all tissues.

Depending on the nature and size of the wound, the healing of skin wounds is said to occur by first or second intention.

#### *Healing by First Intention*

One of the simplest examples of wound repair is the healing of a clean, uninfected surgical incision approximated by surgical sutures (Fig. 2–33). This is referred to as primary

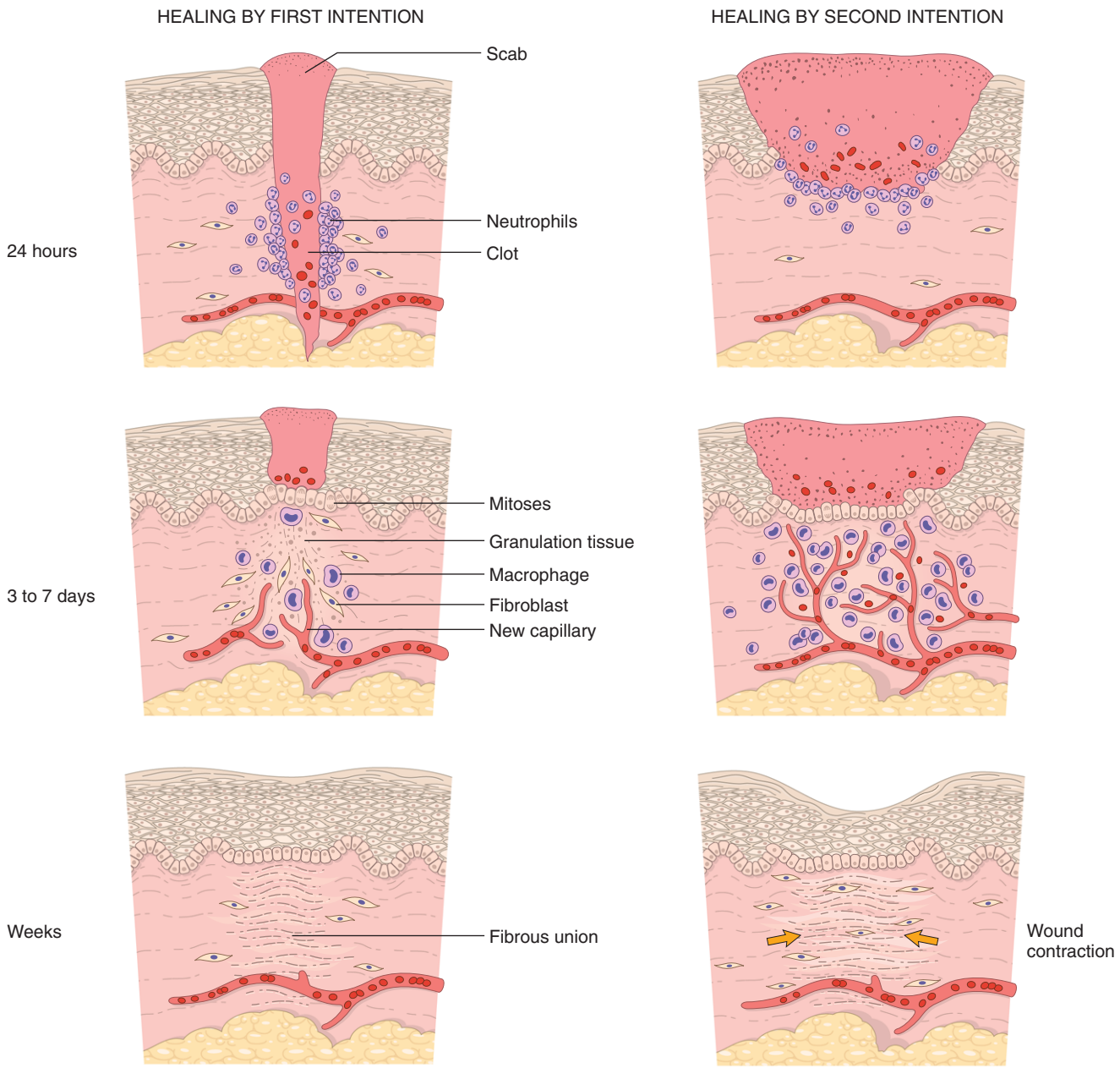


**Figure 2–33** Steps in wound healing by first intention (*left*) and second intention (*right*). In the latter case, note the large amount of granulation tissue and wound contraction.

union, or healing by first intention. The incision causes only focal disruption of epithelial basement membrane continuity and death of relatively few epithelial and connective tissue cells. As a result, *epithelial regeneration is the principal mechanism of repair*. A small scar is formed, but there is minimal wound contraction. The narrow incisional space first fills with fibrin-clotted blood, which then is rapidly invaded by granulation tissue and covered by new epithelium. The steps in the process are well defined:

- Within 24 hours, neutrophils are seen at the incision margin, migrating toward the fibrin clot. Basal cells at the cut edge of the epidermis begin to show increased mitotic activity. Within 24 to 48 hours, epithelial cells from both edges have begun to migrate and proliferate along the dermis, depositing basement membrane components as they progress. The cells meet in the midline beneath the surface scab, yielding a thin but continuous epithelial layer.
- By day 3, neutrophils have been largely replaced by macrophages, and granulation tissue progressively invades the incision space. Collagen fibers are now evident at the incision margins, but these are vertically oriented and do not bridge the incision. Epithelial cell proliferation continues, yielding a thickened epidermal covering layer.
- By day 5, neovascularization reaches its peak as granulation tissue fills the incisional space. Collagen fibrils become more abundant and begin to bridge the incision. The epidermis recovers its normal thickness as differentiation of surface cells yields a mature epidermal architecture with surface keratinization.
- During the second week, there is continued collagen accumulation and fibroblast proliferation. The leukocyte infiltrate, edema, and increased vascularity are substantially diminished. The long process of "blanching" begins, accomplished by increasing collagen deposition within the incisional scar and the regression of vascular channels.
- By the end of the first month, the scar consists of a cellular connective tissue, largely devoid of inflammatory cells, covered by an essentially normal epidermis. However, the dermal appendages destroyed in the line of the incision are permanently lost. The tensile strength of the wound increases with time, as described later.

### *Healing by Second Intention*

When cell or tissue loss is more extensive, such as in large wounds, at sites of abscess formation, ulceration, and ischemic necrosis (infarction) in parenchymal organs, the repair process is more complex and involves a combination of regeneration and scarring. In second intention healing of skin wounds, also known as healing by secondary union (Fig. 2–34; see also Fig. 2–33), the inflammatory reaction is

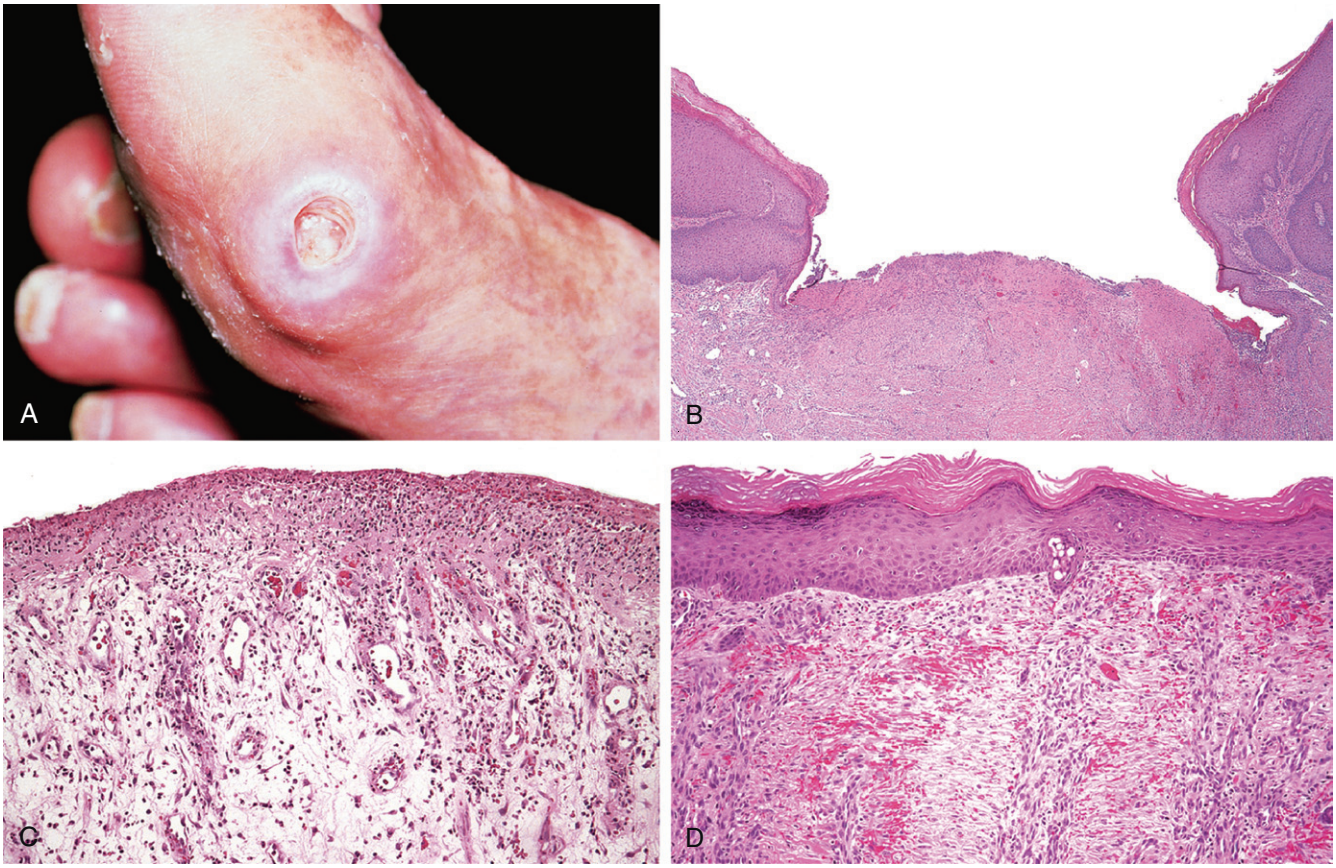


**Figure 2–34** Healing of skin ulcers. **A,** Pressure ulcer of the skin, commonly found in diabetic patients. **B,** A skin ulcer with a large gap between the edges of the lesion. **C,** A thin layer of epidermal re-epithelialization, and extensive granulation tissue formation in the dermis. **D,** Continuing re-epithelialization of the epidermis and wound contraction.
*(Courtesy of Z. Argenyi, MD, University of Washington, Seattle, Wash.)*

more intense, and there is development of abundant granulation tissue, with accumulation of ECM and formation of a large scar, followed by wound contraction mediated by the action of myofibroblasts.

Secondary healing differs from primary healing in several respects:

- A larger clot or scab rich in fibrin and fibronectin forms at the surface of the wound.
- Inflammation is more intense because large tissue defects have a greater volume of necrotic debris, exudate, and fibrin that must be removed. Consequently, large defects have a greater potential for secondary, inflammation-mediated, injury.
- Larger defects require a greater volume of granulation tissue to fill in the gaps and provide the underlying framework for the regrowth of tissue epithelium. A greater volume of granulation tissue generally results in a greater mass of scar tissue.
- Secondary healing involves wound contraction. Within 6 weeks, for example, large skin defects may be reduced to 5% to 10% of their original size, largely by contraction. This process has been ascribed to the presence of myofibroblasts, which are modified fibroblasts exhibiting many of the ultrastructural and functional features of contractile smooth muscle cells.

### *Wound Strength*

Carefully sutured wounds have approximately 70% of the strength of normal skin, largely because of the placement of sutures. When sutures are removed, usually at 1 week, wound strength is approximately 10% of that of unwounded skin, but this increases rapidly over the next 4 weeks. The recovery of tensile strength results from collagen synthesis exceeding degradation during the first 2 months, and from structural modifications of collagen (e.g., cross-linking, increased fiber size) when synthesis declines at later times. Wound strength reaches approximately 70% to 80% of normal by 3 months and usually does not improve substantially beyond that point.

## Fibrosis in Parenchymal Organs

Deposition of collagen is part of normal wound healing. The term *fibrosis* is used to denote the excessive deposition of collagen and other ECM components in a tissue. As already mentioned, the terms *scar* and *fibrosis* are used interchangeably, but *fibrosis* most often refers to the deposition of collagen in chronic diseases.

The basic mechanisms of fibrosis are the same as those of scar formation during tissue repair. However, tissue repair typically occurs after a short-lived injurious stimulus and follows an orderly sequence of steps, whereas fibrosis is induced by persistent injurious stimuli such as infections, immunologic reactions, and other types of tissue injury. The fibrosis seen in chronic diseases such as pulmonary fibrosis is often responsible for organ dysfunction and even organ failure.

## SUMMARY

### Cutaneous Wound Healing and Pathologic Aspects of Repair

- Cutaneous wounds can heal by primary union (first intention) or secondary union (second intention); secondary healing involves more extensive scarring and wound contraction.
- Wound healing can be altered by many conditions, particularly infection and diabetes; the type, volume, and location of the injury are also important factors in healing.
- Excessive production of ECM can cause keloids in the skin.
- Persistent stimulation of collagen synthesis in chronic inflammatory diseases leads to fibrosis of the tissue.

## BIBLIOGRAPHY


Bradley JR: TNF-mediated inflammatory disease. J Pathol 214:149, 2008. *[An overview of the biology of TNF and the clinical utility of TNF antagonists.]*

Carlson BM: Some principles of regeneration in mammalian systems. Anat Rec 287:4, 2005. *[A thoughtful review of the evolutionary aspects and general mechanisms of limb and organ regeneration.]*

Carmeliet P: Angiogenesis in life, disease and medicine. Nature 438:932, 2005. *[A review of the main aspects of normal and abnormal angiogenesis.]*

Charo IF, Ransohoff RM: The many roles of chemokines and chemokine receptors in inflammation. N Engl J Med 354:610, 2006. *[An overview of the functions of chemokines in inflammation.]*

Fausto N: Liver regeneration and repair: hepatocytes, progenitor cells and stem cells. Hepatology 39:1477, 2004. *[A review of the cellular and molecular mechanisms of liver regeneration.]*

Gabay C, Lamacchia C, Palmer G: IL-1 pathways in inflammation and human diseases. Nat Rev Rheumatol 6:232, 2010. *[An excellent review of the biology of IL-1 and the therapeutic targeting of this cytokine in inflammatory diseases.]*

Gurtner GC, Werner S, Barrandon Y, Longaker MT: Wound repair and regeneration. Nature 453:314, 2008. *[An excellent review of the principles of tissue regeneration and repair.]*

Hynes RO: Integrins: bidirectional, allosteric signaling machines. Cell 110:673, 2002. *[An excellent review of the molecular mechanisms of integrin signaling, linking ECM components to intracellular signal transduction pathways.]*

Jiang D, Liang J, Noble PW: Hyaluronans in tissue injury and repair. Annu Rev Cell Dev Biol 23:435, 2007. *[A discussion of the role of a major family of ECM proteins in tissue repair.]*

Khanapure SP, Garvey DS, Janero DR, et al: Eicosanoids in inflammation: biosynthesis, pharmacology, and therapeutic frontiers. Curr Top Med Chem 7:311, 2007. *[A summary of the properties of this important class of inflammatory mediators.]*

Lentsch AB, Ward PA: Regulation of inflammatory vascular damage. J Pathol 190:343, 2000. *[Discussion of the mechanisms of endothelial damage and increased vascular permeability.]*

Ley K, Laudanna C, Cybulsky MI, Nourshargh S: Getting to the site of inflammation: the leukocyte adhesion cascade updated. Nat Rev Immunol 7:678, 2007. *[A modern discussion of leukocyte recruitment to sites of inflammation.]*

Martin P, Leibovich SJ: Inflammatory cells during wound repair: the good, the bad, and the ugly. Trends Cell Biol 15:599, 2005. *[Good review on the multiple roles of inflammatory cells in repair.]*

Masters SL, Simon A, Aksentijevich I, Kastner DL: Horror autoinflammaticus: the molecular pathophysiology of autoinflammatory disease. Annu Rev Immunol 27:621, 2009. *[An excellent discussion of autoinflammatory syndromes caused by gain-of-function mutations in components of the inflammasome.]*

McAnulty RJ: Fibroblasts and myofibroblasts: their source, function, and role in disease. Int J Biochem Cell Biol 39:666, 2007. *[A discussion*

*of the two major types of stroma cells and their roles on tissue repair and fibrosis.]*

Muller WA: Mechanisms of leukocyte transendothelial migration. Annu Rev Pathol 6:323, 2011. *[A thoughtful review of the mechanisms by which leukocytes traverse the endothelium.]*

Nagy JA, Dvorak AM, Dvorak HF: VEGF-A and the induction of pathological angiogenesis. Annu Rev Pathol 2:251, 2007. *[A review of the VEGF family of growth factors and their role in angiogenesis in cancer, inflammation, and various disease states.]*

Nathan C, Ding A: Nonresolving inflammation. Cell 140:871, 2010. *[A discussion of the abnormalities that lead to chronic inflammation.]*

Page-McCaw A, Ewald AJ, Werb Z: Matrix metalloproteinases and the regulation of tissue remodelling. Nat Rev Mol Cell Biol 8:221, 2007. *[A review of the function of matrix modifying enzymes in tissue repair.]*

Papayannapoulos V, Zychlinsky A: NETs: a new strategy for using old weapons. Trends Immunol 30:513, 2009. *[A review of a newly discovered mechanism by which neutrophils destroy microbes.]*

Ricklin D, Hajishengallis G, Yang K, Lambris JD: Complement: a key system for immune surveillance and homeostasis. Nat Immunol 11:785, 2010. *[A current overview of the activation and functions of the complement system and its role in disease.]*

Rock KL, Kono H: The inflammatory response to cell death. Annu Rev Pathol 3:99, 2008. *[An excellent discussion of how the immune system recognizes necrotic cells.]*

Schultz GS, Wysocki A: Interactions between extracellular matrix and growth factors in wound healing. Wound Repair Regen 17:153, 2009. *[A discussion of the regulation of growth factors by the ECM.]*

Schroder K, Tschopp J: The inflammasomes. Cell 140:821, 2010. *[An excellent review of the cellular machinery that recognizes products of dead cells, many foreign and abnormal substances, and some microbes.]*

Segal AW: How neutrophils kill microbes. Annu Rev Immunol 23:197, 2005. *[An excellent discussion of the microbicidal mechanisms of neutrophils.]*

Stappenbeck TS, Miyoshi H: The role of stromal stem cells in tissue regeneration and wound repair. Science 324:1666, 2009. *[An excellent review of the role of tissue stem cells in repair.]*

Stearns-Kurosawa DJ, Osuchowski MF, Valentine C, et al: The pathogenesis of sepsis. Annu Rev Pathol 6:19, 2011. *[A discussion of the current concepts of pathogenic mechanisms in sepsis and septic shock.]*

Takeuchi O, Akira S: Pattern recognition receptors and inflammation. Cell 140:805, 2010. *[An excellent overview of Toll-like receptors and other pattern recognition receptor families, and their roles in host defense and inflammation.]*

Wynn TA: Cellular and molecular mechanisms of fibrosis. J Pathol 214:199, 2008. *[An overview of the cellular mechanisms of fibrosis, with an emphasis on the role of the immune system in fibrotic reactions to chronic infections.]*

Yamanaka S, Blau HM: Nuclear reprogramming to a pluripotent state by three approaches. Nature 465:704, 2010. *[A review of the exciting technology for generating iPS cells for regenerative medicine.]*

This page intentionally left blank

See Targeted Therapy available online at
studentconsult.com

CHAPTER 3

# Hemodynamic Disorders, Thromboembolism, and Shock

CHAPTER CONTENTS

**Hyperemia and Congestion** 75
**Edema** 76
**Hemorrhage** 78
**Hemostasis and Thrombosis** 79
Normal Hemostasis 79
Thrombosis 86
Disseminated Intravascular Coagulation 90
**Embolism** 90
Pulmonary Thromboembolism 90
Systemic Thromboembolism 91
**Infarction** 92
**Shock** 94
Pathogenesis of Septic Shock 94
Stages of Shock 96

The health of cells and tissues depends on the circulation of blood, which delivers oxygen and nutrients and removes wastes generated by cellular metabolism. Under normal conditions, as blood passes through capillary beds, proteins in the plasma are retained within the vasculature and there is little net movement of water and electrolytes into the tissues. This balance is often disturbed by pathologic conditions that alter endothelial function, increase vascular pressure, or decrease plasma protein content, all of which promote *edema*—accumulation of fluid resulting from a net outward movement of water into extravascular spaces. Depending on its severity and location, edema may have minimal or profound effects. In the lower extremities, it may only make one's shoes feel snugger after a long sedentary day; in the lungs, however, edema fluid can fill alveoli, causing life-threatening hypoxia.

Our blood vessels are frequently subject to trauma of varying degrees. *Hemostasis* is the process of blood clotting that prevents excessive bleeding after blood vessel damage. Inadequate hemostasis may result in *hemorrhage,* which can compromise regional tissue perfusion and, if massive and rapid, may lead to *hypotension, shock,* and death. Conversely, inappropriate clotting (*thrombosis*) or migration of clots (*embolism*) can obstruct blood vessels, potentially causing ischemic cell death (*infarction*). Indeed, *thromboembolism* lies at the heart of three major causes of morbidity and death in developed countries: myocardial infarction, pulmonary embolism, and cerebrovascular accident (stroke).

## HYPEREMIA AND CONGESTION

*Hyperemia and congestion both refer to an increase in blood volume within a tissue* but they have different underlying mechanisms. *Hyperemia is an active process* resulting from arteriolar dilation and increased blood inflow, as occurs at sites of inflammation or in exercising skeletal muscle. Hyperemic tissues are redder than normal because of engorgement with oxygenated blood. *Congestion is a passive process* resulting from impaired outflow of venous blood from a tissue. It can occur systemically, as in cardiac failure, or locally as a consequence of an isolated venous obstruction. Congested tissues have an abnormal blue-red color (*cyanosis*) that stems from the accumulation of deoxygenated hemoglobin in the affected area. In long-standing *chronic congestion,* inadequate tissue perfusion and persistent hypoxia may lead to parenchymal cell death and secondary tissue fibrosis, and the elevated intravascular pressures may cause edema or sometimes rupture capillaries, producing focal hemorrhages.

### MORPHOLOGY

Cut surfaces of hyperemic or congested tissues feel wet and typically ooze blood. On microscopic examination, **acute pulmonary congestion** is marked by blood-engorged alveolar capillaries and variable degrees of alveolar septal edema and intra-alveolar hemorrhage. In **chronic pulmonary congestion,** the septa become thickened and fibrotic, and the alveolar spaces contain numerous macrophages laden with hemosiderin ("heart failure cells") derived from phagocytosed red cells. In **acute hepatic congestion,** the central vein and sinusoids are distended with blood, and there may even be central hepatocyte dropout due to necrosis. The periportal hepatocytes, better oxygenated because of their proximity to hepatic arterioles, experience less severe hypoxia and may develop only reversible fatty change. In **chronic passive congestion of the liver,** the central regions of the hepatic lobules, viewed on gross examination, are red-brown and slightly depressed (owing to cell loss) and are accentuated against the surrounding zones of uncongested tan, sometimes fatty, liver **(nutmeg liver)** (Fig. 3–1, *A*). Microscopic findings include centrilobular hepatocyte

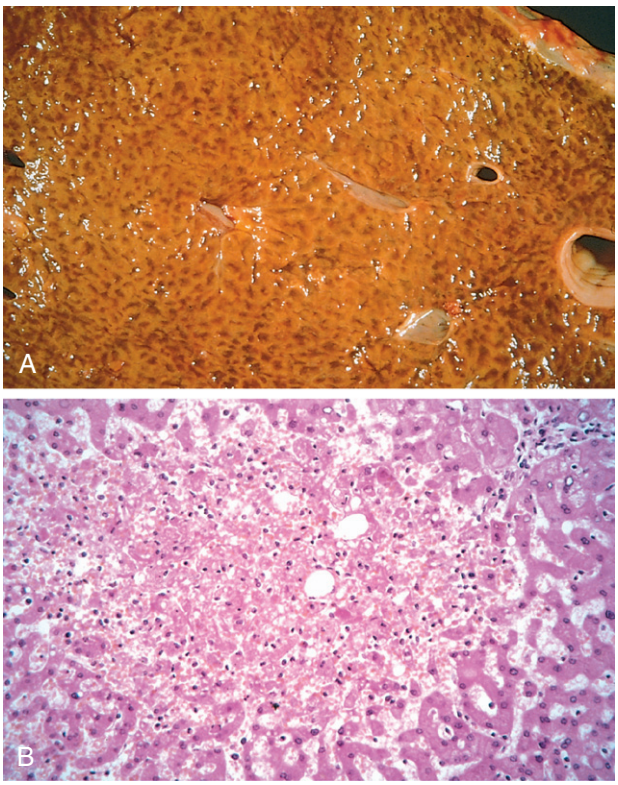


**Figure 3–1** Liver with chronic passive congestion and hemorrhagic necrosis. **A,** In this autopsy specimen, central areas are red and slightly depressed compared with the surrounding tan viable parenchyma, creating "nutmeg liver" (so called because it resembles the cut surface of a nutmeg). **B,** Microscopic preparation shows centrilobular hepatic necrosis with hemorrhage and scattered inflammatory cells.
*(Courtesy of Dr. James Crawford.)*

necrosis, hemorrhage, and hemosiderin-laden macrophages (Fig. 3–1, *B*). In long-standing, severe hepatic congestion (most commonly associated with heart failure), hepatic fibrosis ("cardiac cirrhosis") can develop. Because the central portion of the hepatic lobule is the last to receive blood, centrilobular necrosis also can occur in any setting of reduced hepatic blood flow (including shock from any cause); there need not be previous hepatic congestion.

## EDEMA

Approximately 60% of lean body weight is water, two thirds of which is intracellular. Most of the remaining water is found in extracellular compartments in the form of interstitial fluid; only 5% of the body's water is in blood plasma. As noted earlier, *edema* is an accumulation of interstitial fluid within tissues. Extravascular fluid can also collect in body cavities such as the pleural cavity (*hydrothorax*), the pericardial cavity (*hydropericardium*), or the peritoneal cavity (*hydroperitoneum*, or *ascites*). *Anasarca* is severe, generalized edema marked by profound swelling of subcutaneous tissues and accumulation of fluid in body cavities.

**Table 3–1** Pathophysiologic Causes of Edema

| |
|---|
| **Increased Hydrostatic Pressure** |
| Impaired Venous Return |
| Congestive heart failure |
| Constrictive pericarditis |
| Ascites (liver cirrhosis) |
| Venous obstruction or compression |
| Thrombosis |
| External pressure (e.g., mass) |
| Lower extremity inactivity with prolonged dependency |
| Arteriolar Dilation |
| Heat |
| Neurohumoral dysregulation |
| **Reduced Plasma Osmotic Pressure (Hypoproteinemia)** |
| Protein-losing glomerulopathies (nephrotic syndrome) |
| Liver cirrhosis (ascites) |
| Malnutrition |
| Protein-losing gastroenteropathy |
| **Lymphatic Obstruction** |
| Inflammatory |
| Neoplastic |
| Postsurgical |
| Postirradiation |
| **Sodium Retention** |
| Excessive salt intake with renal insufficiency |
| Increased tubular reabsorption of sodium |
| Renal hypoperfusion |
| Increased renin-angiotensin-aldosterone secretion |
| **Inflammation** |
| Acute inflammation |
| Chronic inflammation |
| Angiogenesis |

Data from Leaf A, Cotran RS: *Renal Pathophysiology*, 3rd ed. New York, Oxford University Press, 1985, p 146.

Table 3–1 lists the major causes of edema. The mechanisms of inflammatory edema are largely related to increased vascular permeability and are discussed in Chapter 2; the *noninflammatory causes* are detailed in the following discussion.

Fluid movement between the vascular and interstitial spaces is governed mainly by two opposing forces—the *vascular hydrostatic pressure* and the *colloid osmotic pressure* produced by plasma proteins. Normally, the outflow of fluid produced by hydrostatic pressure at the arteriolar end of the microcirculation is neatly balanced by inflow due to the slightly elevated osmotic pressure at the venular end; hence there is only a small net outflow of fluid into the interstitial space, which is drained by lymphatic vessels. Either increased hydrostatic pressure or diminished colloid osmotic pressure causes increased movement of water into the interstitium (Fig. 3–2). This in turn increases the tissue hydrostatic pressure, and eventually a new equilibrium is achieved. Excess edema fluid is removed by lymphatic drainage and returned to the bloodstream by way of the thoracic duct (Fig. 3–2).

The edema fluid that accumulates owing to increased hydrostatic pressure or reduced intravascular colloid typically is a protein-poor *transudate*; it has a specific gravity less than 1.012. By contrast, because of increased vascular permeability, inflammatory edema fluid is a protein-rich

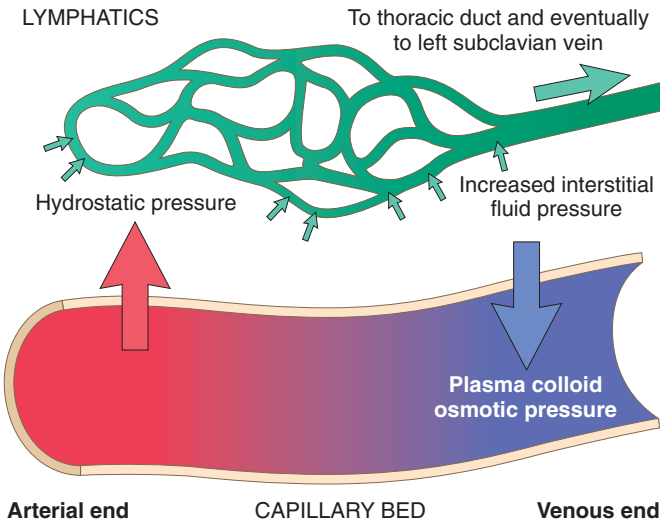


**Figure 3–2** Factors influencing fluid movement across capillary walls. Capillary hydrostatic and osmotic forces are normally balanced so there is little net movement of fluid into the interstitium. However, *increased* hydrostatic pressure or *diminished* plasma osmotic pressure leads to extravascular fluid accumulation (edema). Tissue lymphatics drain much of the excess fluid back to the circulation by way of the thoracic duct; however, if the capacity for lymphatic drainage is exceeded, tissue edema results.

*exudate* with a specific gravity usually greater than 1.020 (see Chapter 2). We will now discuss the various causes of edema.

### *Increased Hydrostatic Pressure*

*Local* increases in intravascular pressure can result from impaired venous return—for example, a deep venous thrombosis in the lower extremity can cause edema restricted to the distal portion of the affected leg. *Generalized* increases in venous pressure, with resultant systemic edema, occur most commonly in *congestive heart failure* (Chapter 10). Several factors increase venous hydrostatic pressure in patients with congestive heart failure (Fig. 3–3). The reduced cardiac output leads to hypoperfusion of the kidneys, triggering the renin-angiotensin-aldosterone axis and inducing sodium and water retention (*secondary hyperaldosteronism*). In patients with normal heart function, this adaptation increases cardiac filling and cardiac output, thereby improving renal perfusion. However, the failing heart often cannot increase its cardiac output in response to the compensatory increases in blood volume. Instead, a vicious circle of fluid retention, increased venous hydrostatic pressures, and worsening edema ensues. Unless cardiac output is restored or renal water retention is reduced (e.g., by salt restriction or treatment with diuretics or aldosterone antagonists) this downward spiral continues. Because secondary hyperaldosteronism is a common feature of generalized edema, salt restriction, diuretics, and aldosterone antagonists also are of value in the management of generalized edema resulting from other causes.

### *Reduced Plasma Osmotic Pressure*

Under normal circumstances albumin accounts for almost half of the total plasma protein. Therefore conditions in which albumin is either lost from the circulation or synthesized in inadequate amounts are common causes of reduced plasma osmotic pressure. In *nephrotic syndrome* (Chapter 13), damaged glomerular capillaries become leaky, leading to the loss of albumin (and other plasma proteins) in the urine and the development of generalized edema. Reduced albumin synthesis occurs in the setting of severe liver disease (e.g., *cirrhosis*) (Chapter 15) and protein malnutrition (Chapter 7). Regardless of cause, low albumin levels lead in a stepwise fashion to edema, reduced intravascular volume, renal hypoperfusion, and secondary hyperaldosteronism. Unfortunately, increased salt and water retention by the kidney not only fails to correct the plasma volume deficit but also exacerbates the edema, since the primary defect—low serum protein—persists.

### *Lymphatic Obstruction*

Impaired lymphatic drainage and consequent *lymphedema* usually result from a localized obstruction caused by an inflammatory or neoplastic condition. For example, the parasitic infection *filariasis* can cause massive edema of the lower extremity and external genitalia (so-called *elephantiasis*) by engendering inguinal lymphatic and lymph node fibrosis. Infiltration and obstruction of superficial lymphatics by breast cancer may cause edema of the overlying skin; the characteristic finely pitted appearance of the skin of the affected breast is called *peau d'orange* (orange peel). Lymphedema also may occur as a complication of therapy. One relatively common setting for this clinical entity is in women with breast cancer who undergo axillary lymph node resection and/or irradiation, both of which can disrupt and obstruct lymphatic drainage, resulting in severe lymphedema of the arm.

### *Sodium and Water Retention*

Excessive retention of salt (and its obligate associated water) can lead to edema by increasing hydrostatic pressure (due to expansion of the intravascular volume) and

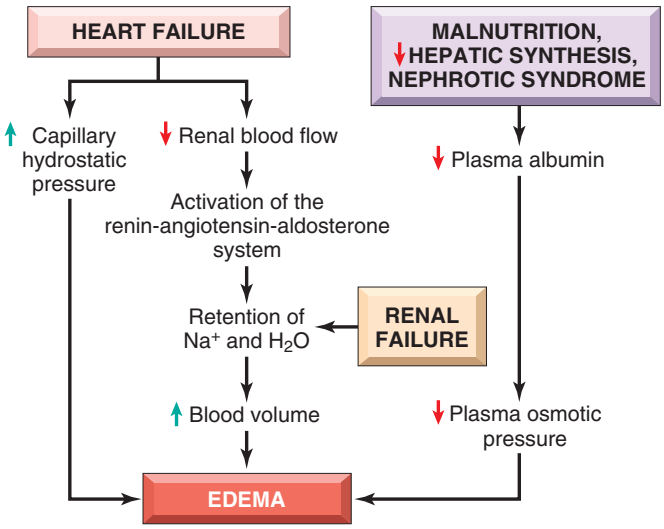


**Figure 3–3** Pathways leading to systemic edema due to heart failure, renal failure, or reduced plasma osmotic pressure.

reducing plasma osmotic pressure. Excessive salt and water retention are seen in a wide variety of diseases that compromise renal function, including *poststreptococcal glomerulonephritis* and *acute renal failure* (Chapter 13).

## MORPHOLOGY

Edema is easily recognized on gross inspection; microscopic examination shows clearing and separation of the extracellular matrix elements. Although any tissue can be involved, edema most commonly is encountered in subcutaneous tissues, lungs, and brain.

**Subcutaneous edema** can be diffuse but usually accumulates preferentially in parts of the body positioned the greatest distance below the heart where hydrostatic pressures are highest. Thus, edema typically is most pronounced in the legs with standing and the sacrum with recumbency, a relationship termed **dependent edema.** Finger pressure over edematous subcutaneous tissue displaces the interstitial fluid, leaving a finger-shaped depression; this appearance is called **pitting edema.** Edema due to **renal dysfunction** or **nephrotic syndrome** often manifests first in loose connective tissues (e.g., the eyelids, causing **periorbital edema**). With **pulmonary edema**, the lungs often are two to three times their normal weight, and sectioning reveals frothy, sometimes blood-tinged fluid consisting of a mixture of air, edema fluid, and extravasated red cells. **Brain edema** can be localized (e.g., due to abscess or tumor) or generalized, depending on the nature and extent of the pathologic process or injury. With generalized edema, the sulci are narrowed while the gyri are swollen and flattened against the skull.

### Clinical Correlation

The effects of edema vary, ranging from merely annoying to rapidly fatal. Subcutaneous edema is important to recognize primarily because it signals potential underlying cardiac or renal disease; however, when significant, it also can impair wound healing or the clearance of infections. Pulmonary edema is a common clinical problem that most frequently is seen in the setting of left ventricular failure but also may occur in renal failure, acute respiratory distress syndrome (Chapter 11), and inflammatory and infectious disorders of the lung. It can cause death by interfering with normal ventilatory function; besides impeding oxygen diffusion, alveolar edema fluid also creates a favorable environment for infections. Brain edema is life-threatening; if the swelling is severe, the brain can *herniate* (extrude) through the foramen magnum. With increased intracranial pressure, the brain stem vascular supply can be compressed. Either condition can cause death by injuring the medullary centers (Chapter 22).

## SUMMARY

### Edema

- Edema is the result of the movement of fluid from the vasculature into the interstitial spaces; the fluid may be protein-poor (*transudate*) or protein-rich (*exudate*).
- Edema may be caused by:
  - increased hydrostatic pressure (e.g., heart failure)
  - increased vascular permeability (e.g., inflammation)
  - decreased colloid osmotic pressure, due to reduced plasma albumin
    - decreased synthesis (e.g., liver disease, protein malnutrition)
    - increased loss (e.g., nephrotic syndrome)
  - lymphatic obstruction (e.g., inflammation or neoplasia).
  - sodium retention (e.g., renal failure)

# HEMORRHAGE

*Hemorrhage,* defined as the extravasation of blood from vessels, occurs in a variety of settings. As described earlier, capillary bleeding can occur in chronically congested tissues. The risk of hemorrhage (often after a seemingly insignificant injury) is increased in a wide variety of clinical disorders collectively called *hemorrhagic diatheses.* Trauma, atherosclerosis, or inflammatory or neoplastic erosion of a vessel wall also may lead to hemorrhage, which may be extensive if the affected vessel is a large vein or artery.

Hemorrhage may be manifested by different appearances and clinical consequences.

- Hemorrhage may be external or accumulate within a tissue as a *hematoma,* which ranges in significance from trivial (e.g., a bruise) to fatal (e.g., a massive retroperitoneal hematoma resulting from rupture of a dissecting aortic aneurysm) (Chapter 9).

  Large bleeds into body cavities are given various names according to location—*hemothorax, hemopericardium, hemoperitoneum,* or *hemarthrosis* (in joints). Extensive hemorrhages can occasionally result in jaundice from the massive breakdown of red cells and hemoglobin.
- *Petechiae* are minute (1 to 2 mm in diameter) hemorrhages into skin, mucous membranes, or serosal surfaces (Fig. 3–4, *A*); causes include low platelet counts *(thrombocytopenia),* defective platelet function, and loss of vascular wall support, as in vitamin C deficiency (Chapter 7).
- *Purpura* are slightly larger (3 to 5 mm) hemorrhages. Purpura can result from the same disorders that cause petechiae, as well as trauma, vascular inflammation (*vasculitis*), and increased vascular fragility.
- *Ecchymoses* are larger (1 to 2 cm) subcutaneous hematomas (colloquially called *bruises*). Extravasated red cells are phagocytosed and degraded by macrophages; the characteristic color changes of a bruise are due to the enzymatic conversion of hemoglobin (red-blue color) to bilirubin (blue-green color) and eventually hemosiderin (golden-brown).

The clinical significance of any particular hemorrhage depends on the volume of blood lost and the rate of bleeding. Rapid loss of up to 20% of the blood volume, or slow losses of even larger amounts, may have little impact in healthy adults; greater losses, however, can cause *hemorrhagic (hypovolemic) shock* (discussed later). The site of hemorrhage also is important; bleeding that would be trivial in

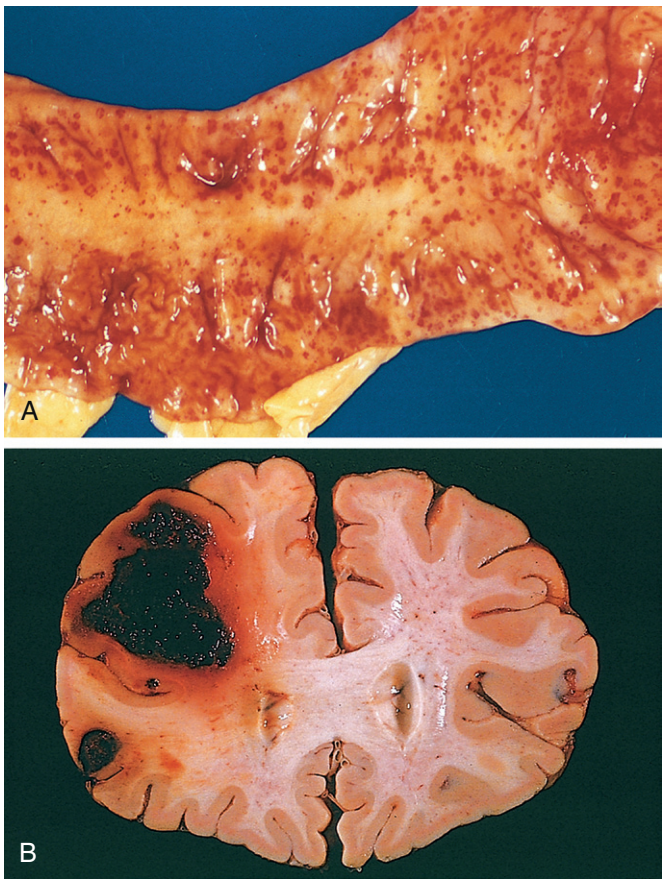


**Figure 3–4 A,** Punctate petechial hemorrhages of the colonic mucosa, a consequence of thrombocytopenia. **B,** Fatal intracerebral hemorrhage.

the subcutaneous tissues can cause death if located in the brain (Fig. 3–4, *B*). Finally, chronic or recurrent external blood loss (e.g., due to peptic ulcer or menstrual bleeding) frequently culminates in iron deficiency anemia as a consequence of loss of iron in hemoglobin. By contrast, iron is efficiently recycled from phagocytosed red cells, so internal bleeding (e.g., a hematoma) does not lead to iron deficiency.

# HEMOSTASIS AND THROMBOSIS

*Normal hemostasis* comprises a series of regulated processes that maintain blood in a fluid, clot-free state in normal vessels while rapidly forming a localized *hemostatic plug* at the site of vascular injury. The pathologic counterpart of hemostasis is *thrombosis,* the formation of blood clot (*thrombus*) within intact vessels. Both hemostasis and thrombosis involve three elements: the *vascular wall, platelets,* and the *coagulation cascade.* The discussion here begins with normal hemostasis and its regulation.

## Normal Hemostasis

The main steps in the process of hemostasis and its regulation are summarized below and shown in Figure 3–5.

- Vascular injury causes transient *arteriolar vasoconstriction* through reflex neurogenic mechanisms, augmented by local secretion of *endothelin* (a potent endothelium-derived vasoconstrictor) (Fig. 3–5, *A*). This effect is fleeting, however, and bleeding would quickly resume if not for the activation of platelets and coagulation factors.
- *Endothelial injury* exposes highly thrombogenic subendothelial extracellular matrix (ECM), facilitating *platelet adherence, activation, and aggregation*. The formation of the initial platelet plug is called *primary hemostasis* (Fig. 3–5, *B*).
- Endothelial injury also exposes *tissue factor* (also known as *factor III* or *thromboplastin*), a membrane-bound procoagulant glycoprotein synthesized by endothelial cells. Exposed tissue factor, acting in conjunction with factor VII (see later), is the major in vivo trigger of the coagulation cascade and its activation eventually culminates in the *activation of thrombin*, which has several roles in regulating coagulation.
- *Activated thrombin* promotes the formation of an insoluble *fibrin* clot by cleaving fibrinogen; thrombin also is a potent activator of additional platelets, which serve to reinforce the hemostatic plug. This sequence, termed secondary hemostasis, results in the formation of a stable clot capable of preventing further hemorrhage (Fig. 3–5, *C*).
- As bleeding is controlled, counterregulatory mechanisms (e.g., factors that produce fibrinolysis, such as *tissue-type plasminogen activator*) are set into motion to ensure that clot formation is limited to the site of injury (Fig. 3–5, *D*).

Discussed next in greater detail are the roles of endothelium, platelets, and the coagulation cascade.

### *Endothelium*

*Endothelial cells are central regulators of hemostasis*; the balance between the anti- and prothrombotic activities of endothelium determines whether thrombus formation, propagation, or dissolution occurs. Normal endothelial cells express a variety of *anticoagulant* factors that inhibit platelet aggregation and coagulation and promote fibrinolysis; after injury or activation, however, this balance shifts, and endothelial cells acquire numerous *procoagulant* activities (Fig. 3–6). Besides trauma, endothelium can be activated by microbial pathogens, hemodynamic forces, and a number of pro-inflammatory mediators (Chapter 2).

#### Antithrombotic Properties of Normal Endothelium

***Inhibitory Effects on Platelets.*** Intact endothelium prevents platelets (and plasma coagulation factors) from engaging the highly thrombogenic subendothelial ECM. Nonactivated platelets do not adhere to normal endothelium; even with activated platelets, prostacyclin (i.e., prostaglandin $I_2$ [$PGI_2$]) and nitric oxide produced by endothelium impede their adhesion. Both mediators also are potent vasodilators and inhibitors of platelet aggregation; their synthesis by endothelial cells is stimulated by a number of factors (e.g., thrombin, cytokines) produced during coagulation. Endothelial cells also produce adenosine diphosphatase, which degrades adenosine diphosphate (ADP) and further inhibits platelet aggregation (see later).

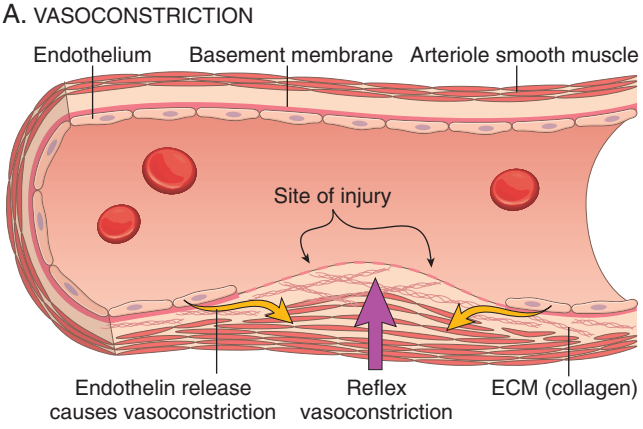


**Figure 3–5** Normal hemostasis. **A,** After vascular injury, local neurohumoral factors induce a transient vasoconstriction. **B,** Platelets bind via glycoprotein 1b (Gplb) receptors to von Willebrand factor (vWF) on exposed extracellular matrix (ECM) and are activated, undergoing a shape change and granule release. Released adenosine diphosphate (ADP) and thromboxane $A_2$ ($TxA_2$) induce additional platelet aggregation through binding of platelet GpIIb-IIIa receptors to fibrinogen. This platelet aggregate fills the vascular defect, forming the *primary hemostatic plug.* **C,** Local activation of the coagulation cascade (involving tissue factor and platelet phospholipids) results in fibrin polymerization, "cementing" the platelets into a definitive *secondary hemostatic plug* that is larger and more stable than the primary plug and contains entrapped red cells and leukocytes. **D,** Counterregulatory mechanisms, such as release of t-PA (tissue plasminogen activator, a fibrinolytic product) and thrombomodulin (interfering with the coagulation cascade), limit the hemostatic process to the site of injury.

***Inhibitory Effects on Coagulation Factors.*** These actions are mediated by factors expressed on endothelial surfaces, particularly heparin-like molecules, thrombomodulin, and tissue factor pathway inhibitor (Fig. 3–6). *The heparin-like molecules* act indirectly: They are cofactors that greatly enhance the inactivation of thrombin (and other coagulation factors) by the plasma protein *antithrombin III. Thrombomodulin* also acts indirectly: It binds to thrombin, thereby modifying the substrate specificity of thrombin, so that instead of cleaving fibrinogen, it instead cleaves and activates protein C, an anticoagulant. Activated protein C inhibits clotting by cleaving and inactivating two procoagulants, factor Va and factor VIIIa; it requires a cofactor, protein S, which is also synthesized by endothelial cells. Finally, tissue factor pathway inhibitor (TFPI) directly inhibits tissue factor–factor VIIa complex and factor Xa.

***Fibrinolysis.*** Endothelial cells synthesize *tissue-type plasminogen activator*, a protease that cleaves plasminogen to plasmin; plasmin, in turn, cleaves fibrin to degrade thrombi.

### Prothrombotic Properties of Injured or Activated Endothelium

***Activation of Platelets.*** Endothelial injury brings platelets into contact with the subendothelial ECM, which includes among its constituents *von Willebrand factor (vWF)*, a large multimeric protein that is synthesized by EC. vWF is held fast to the ECM through interactions with collagen and also binds tightly to Gp1b, a glycoprotein found on the surface of platelets. These interactions allow vWF to act as a sort of molecular glue that binds platelets tightly to denuded vessel walls (Fig. 3–7).

***Activation of Clotting Factors.*** In response to cytokines (e.g., tumor necrosis factor [TNF] or interleukin-1 [IL-1]) or certain bacterial products including endotoxin, endothelial cells produce *tissue factor,* the major in vivo activator of coagulation, and downregulate the expression of thrombomodulin. Activated endothelial cells also bind coagulation factors IXa and Xa (see further on), which augments the catalytic activities of these factors.

***Antifibrinolytic Effects.*** Activated endothelial cells secrete *plasminogen activator inhibitors (PAIs),* which limit fibrinolysis and thereby favor thrombosis.

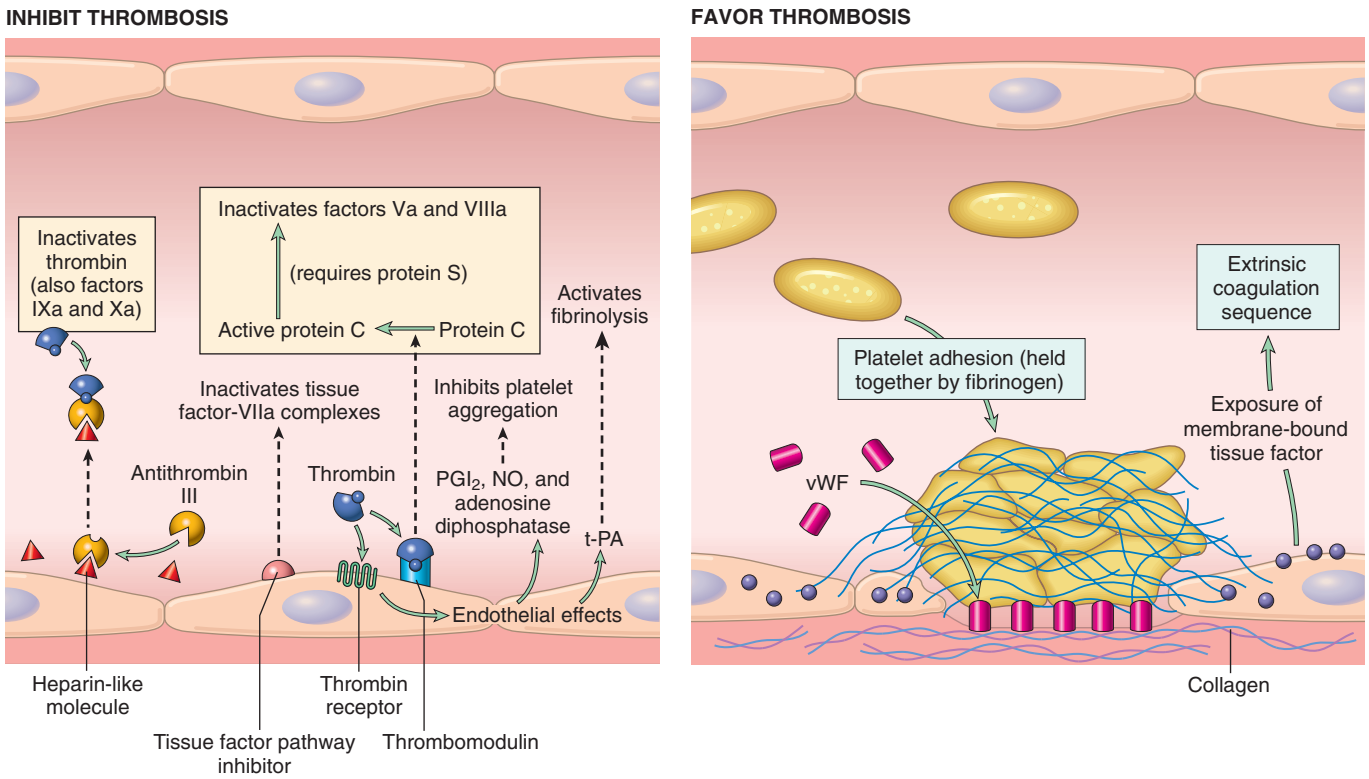


**Figure 3–6** Anticoagulant properties of normal endothelium *(left)* and procoagulant properties of injured or activated endothelium *(right)*. NO, nitric oxide; $PGI_2$, prostaglandin $I_2$ (prostacyclin); t-PA, tissue plasminogen activator; vWF, von Willebrand factor. Thrombin receptors are also called protease-activated receptors (PARs).

## SUMMARY

### Endothelial Cells and Coagulation

- Intact, normal endothelial cells help to maintain blood flow by inhibiting the activation of platelets and coagulation factors.
- Endothelial cells stimulated by injury or inflammatory cytokines upregulate expression of procoagulant factors (e.g., tissue factor) that promote clotting, and downregulate expression of anticoagulant factors.
- Loss of endothelial integrity exposes subendothelial vWF and basement membrane collagen, stimulating platelet adhesion, platelet activation, and clot formation.

### *Platelets*

Platelets are anucleate cell fragments shed into the bloodstream by marrow megakaryocytes. They play a critical role in normal hemostasis by forming a hemostatic plug that seals vascular defects, and by providing a surface that recruits and concentrates activated coagulation factors. Platelet function depends on several integrin family glycoprotein receptors, a contractile cytoskeleton, and two types of cytoplasmic granules:

- α *granules,* which express the adhesion molecule P-selectin on their membranes (Chapter 2) and contain

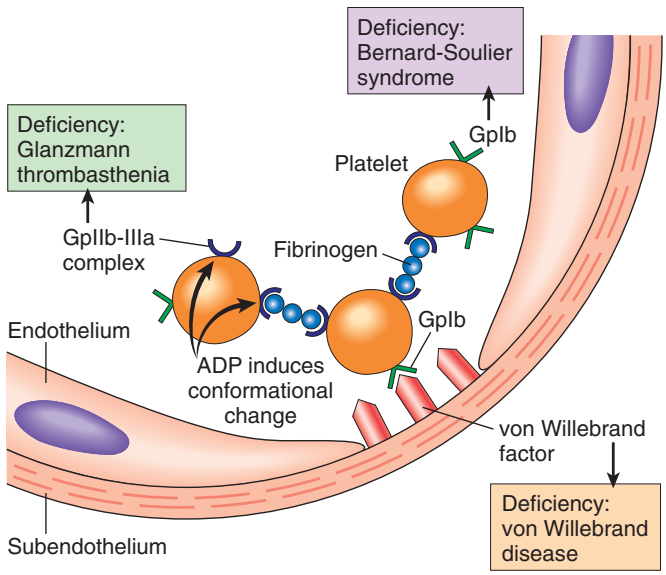


**Figure 3–7** Platelet adhesion and aggregation. Von Willebrand factor functions as an *adhesion* bridge between subendothelial collagen and the glycoprotein Ib (GpIb) platelet receptor. Platelet *aggregation* is accomplished by fibrinogen binding to platelet GpIIb-IIIa receptors on different platelets. Congenital deficiencies in the various receptors or bridging molecules lead to the diseases indicated in the *colored boxes*. ADP, adenosine diphosphate.

fibrinogen, fibronectin, factors V and VIII, platelet factor-4 (a heparin-binding chemokine), platelet-derived growth factor (PDGF), and transforming growth factor-β (TGF-β)
- *Dense bodies* (δ granules), which contain adenine nucleotides (ADP and ATP), ionized calcium, histamine, serotonin, and epinephrine

After vascular injury, platelets encounter ECM constituents (collagen is most important) and adhesive glycoproteins such as vWF. This sets in motion a series of events that lead to (1) platelet adhesion, (2) platelet activation, and (3) platelet aggregation (Fig. 3–5, *B*).

### Platelet Adhesion

Platelet adhesion initiates clot formation and depends on vWF and platelet glycoprotein Gp1b. Under shear stress (e.g., in flowing blood), vWF undergoes a conformational change, assuming an extended shape that allows it to bind simultaneously to collagen in the ECM and to platelet Gp1b (Fig. 3–7). The importance of this adhesive interaction is highlighted by genetic deficiencies of vWF and Gp1b, both of which result in bleeding disorders—von Willebrand disease (Chapter 11) and Bernard-Soulier disease (a rare condition), respectively.

### Platelet Activation

Platelet adhesion leads to an irreversible shape change and secretion (release reaction) of both granule types—a process termed *platelet activation.* Calcium and ADP released from δ granules are especially important in subsequent events, since calcium is required by several coagulation factors and ADP is a potent activator of resting platelets. Activated platelets also synthesize thromboxane $A_2$ ($TxA_2$) (Chapter 2), a prostaglandin that activates additional nearby platelets and that also has an important role in platelet aggregation (described below). During activation, platelets undergo a dramatic change in shape from smooth discs to spheres with numerous long, spiky membrane extensions, as well as more subtle changes in the make-up of their plasma membranes. The shape changes enhance subsequent aggregation and increase the surface area available for interaction with coagulation factors. The subtle membrane changes include an increase in the surface expression of negatively charged *phospholipids,* which provide binding sites for both calcium and coagulation factors, and a conformation change in platelet GpIIb/IIIa that permits it to bind fibrinogen.

### Platelet Aggregation

Platelet aggregation follows platelet adhesion and activation, and is stimulated by some of the same factors that induce platelet activation, such as $TxA_2$. Aggregation is promoted by bridging interactions between fibrinogen and GpIIb/IIIa receptors on adjacent platelets (Fig. 3–7). The importance of this interaction is emphasized by a rare inherited deficiency of GpIIb/IIIa (Glanzmann thrombasthenia), which is associated with bleeding and an inability of platelets to aggregate. Recognition of the central role of GpIIb-IIIa receptors in platelet aggregation has stimulated the development of antithrombotic agents that inhibit GpIIb-IIIa function.

Concurrent activation of the coagulation cascade generates thrombin, which stabilizes the platelet plug through two mechanisms:
- Thrombin activates a platelet surface receptor (protease-activated receptor [PAR]), which in concert with ADP and $TxA_2$ further enhances platelet aggregation. *Platelet contraction* follows, creating an irreversibly fused mass of platelets that constitutes the definitive *secondary hemostatic plug.*
- Thrombin converts fibrinogen to *fibrin* (discussed shortly) within the vicinity of the plug, cementing the platelet plug in place.

Red cells and leukocytes are also found in hemostatic plugs. Leukocytes adhere to platelets by means of P-selectin and to endothelium by various adhesion molecules (Chapter 2); they contribute to the inflammatory response that accompanies thrombosis. Thrombin also promotes inflammation by stimulating neutrophil and monocyte adhesion (described later) and by generating chemotactic *fibrin split products* during fibrinogen cleavage.

### Platelet-Endothelial Interactions

The interplay of platelets and endothelium has a profound impact on clot formation. For example, prostaglandin $PGI_2$ (synthesized by normal endothelium) is a vasodilator and inhibits platelet aggregation, whereas $TxA_2$ (synthesized by activated platelets, as discussed above) is a potent vasoconstrictor. The balance between the opposing effects of $PGI_2$ and $TxA_2$ varies: In normal vessels, $PGI_2$ effects dominate and platelet aggregation is prevented, whereas endothelial injury decreases $PGI_2$ production and promotes platelet aggregation and $TxA_2$ production. The clinical utility of aspirin (an irreversible cyclooxygenase inhibitor) in lowering the risk of coronary thrombosis resides in its ability to permanently block $TxA_2$ production by platelets, which have no capacity for protein synthesis. Although endothelial $PGI_2$ production is also inhibited by aspirin, endothelial cells can resynthesize cyclooxygenase, thereby overcoming the blockade. In a manner similar to that for $PGI_2$, endothelium-derived nitric oxide also acts as a vasodilator and inhibitor of platelet aggregation (Fig. 3–6).

## SUMMARY

### Platelet Adhesion, Activation, and Aggregation

- Endothelial injury exposes the underlying basement membrane ECM; platelets adhere to the ECM primarily through binding of platelet GpIb receptors to vWF.
- Adhesion leads to platelet activation, an event associated with secretion of platelet granule contents, including calcium (a cofactor for several coagulation proteins) and ADP (a mediator of further platelet activation); dramatic changes in shape and membrane composition; and activation of GpIIb/IIIa receptors.
- The GpIIb/IIIa receptors on activated platelets form bridging crosslinks with fibrinogen, leading to platelet aggregation.
- Concomitant activation of thrombin promotes fibrin deposition, cementing the platelet plug in place.

### *Coagulation Cascade*

The coagulation cascade constitutes the third arm of the hemostatic system. The pathways are schematically presented in Figure 3–8; only general principles are discussed here.

The coagulation cascade is a successive series of amplifying enzymatic reactions. At each step in the process, a proenzyme is proteolyzed to become an active enzyme, which in turn proteolyzes the next proenzyme in the series, eventually leading to the activation of thrombin and the formation of fibrin. *Thrombin has a key role,* as it acts at numerous points in the cascade (highlighted in Fig. 3–8). Thrombin proteolyzes *fibrinogen* into *fibrin* monomers that polymerize into an insoluble gel; this gel encases platelets and other circulating cells in the definitive secondary hemostatic plug. Fibrin polymers are stabilized by the cross-linking activity of factor XIIIa, which also is activated by thrombin.

Each reaction in the pathway depends on the assembly of a complex composed of an *enzyme* (an activated coagulation factor), a *substrate* (a proenzyme form of the next coagulation factor in the series), and a *cofactor* (a reaction accelerator). These components typically are assembled on a *phospholipid surface* (provided by endothelial cells or platelets) and are held together by interactions that depend on *calcium ions* (explaining why blood clotting is prevented

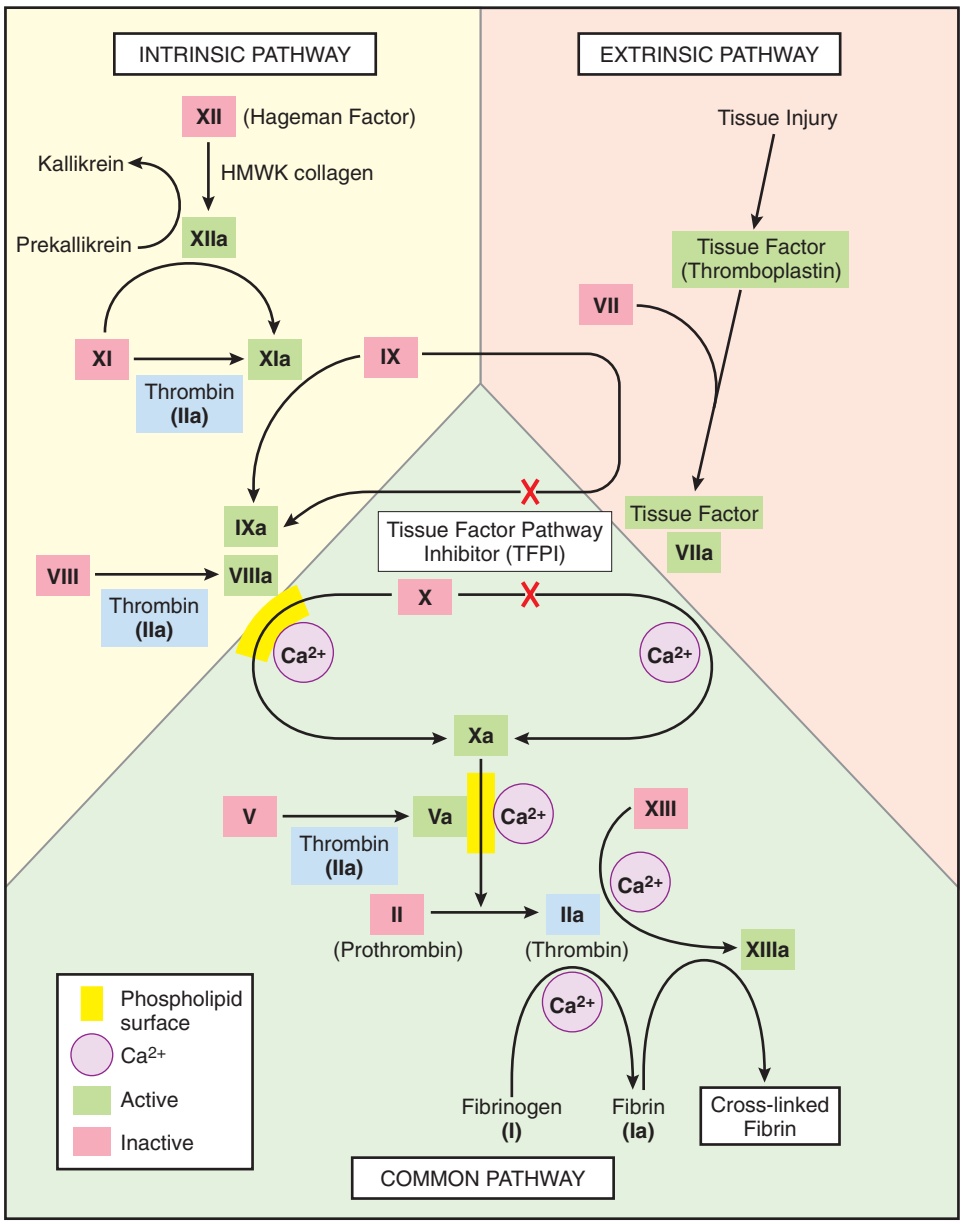


**Figure 3–8** The coagulation cascade. Factor IX can be activated by either factor XIa or factor VIIa: In laboratory tests, activation is predominantly dependent on factor XIa, whereas in vivo, factor VIIa appears to be the predominant activator of factor IX. Factors in *red boxes* represent inactive molecules; activated factors, indicated with a lowercase *a*, are in *green boxes*. Note that thrombin (factor IIa) (in *light blue boxes*) contributes to coagulation through multiple positive feedback loops. The *red X's* denote points at which tissue factor pathway inhibitor (TFPI) inhibits activation of factor X and factor IX by factor VIIa. HMWK, high-molecular-weight kininogen; PL, phospholipid.

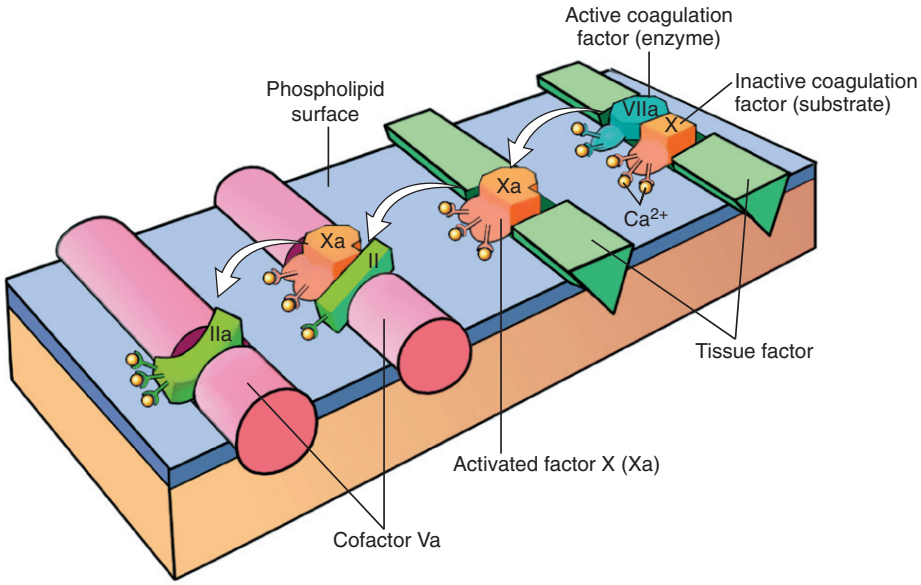


**Figure 3–9** Sequential conversion of factor X to factor Xa by way of the extrinsic pathway, followed by conversion of factor II (prothrombin) to factor IIa (thrombin). The initial reaction complex consists of a protease (factor VIIa), a substrate (factor X), and a reaction accelerator (tissue factor) assembled on a platelet phospholipid surface. Calcium ions hold the assembled components together and are essential for the reaction. Activated factor Xa then becomes the protease component of the next complex in the cascade, converting prothrombin to thrombin (factor IIa) in the presence of a different reaction accelerator, factor Va.

by calcium chelators). As shown in Figure 3–9, the sequential cascade of activation can be likened to a "dance" of complexes, with coagulation factors being passed successively from one partner to the next. Parenthetically, the ability of coagulation factors II, VII, IX, and X to bind to calcium requires that additional γ-carboxyl groups be enzymatically appended to certain glutamic acid residues on these proteins. This reaction requires vitamin K as a cofactor and is antagonized by drugs such as *coumadin,* which is widely used as an anticoagulant.

Blood coagulation traditionally is divided into *extrinsic* and *intrinsic* pathways, converging at the activation of factor X (Fig. 3–8). The extrinsic pathway was so designated because it required the addition of an exogenous trigger (originally provided by tissue extracts); the intrinsic pathway only required exposing factor XII (Hageman factor) to a negatively charged surface (even glass suffices). However, this division is largely an artifact of in vitro testing; there are, in fact, several interconnections between the two pathways. The extrinsic pathway is the most physiologically relevant pathway for coagulation occurring after vascular damage; it is activated by *tissue factor,* a membrane-bound glycoprotein expressed at sites of injury.

Clinical labs assess the function of the two arms of the pathway using two standard assays.

- *Prothrombin time* (PT) screens for the activity of the proteins in the extrinsic pathway (factors VII, X, II, V, and fibrinogen). The PT is performed by adding phospholipids and tissue factor to a patient's citrated plasma (sodium citrate chelates calcium and prevents spontaneous clotting), followed by calcium, and the time to fibrin clot formation (usually 11 to 13 seconds) is recorded. Because factor VII is the vitamin K–dependent coagulation factor with the shortest half-life (roughly 7 hours), the PT is used to guide treatment of patients with vitamin K antagonists (e.g., coumadin).
- *Partial thromboplastin time* (PTT) screens for the activity of the proteins in the intrinsic pathway (factors XII, XI, IX, VIII, X, V, II, and fibrinogen). The PTT is performed by adding a negatively charged activator of factor XII (e.g., ground glass) and phospholipids to a patient's citrated plasma, followed by calcium, and recording the time required for clot formation (usually 28 to 35 seconds). The PTT is sensitive to the anticoagulant effects of heparin and is therefore used to monitor its efficacy.

Once thrombin is formed, it not only catalyzes the final steps in the coagulation cascade, but also exerts a wide variety of effects on the local vasculature and inflammatory milieu; it even actively participates in limiting the extent of the hemostatic process (Fig. 3–10). Most of these thrombin-mediated effects occur through *protease-activated receptors (PARs),* which belong to a family of seven-transmembrane-spanning proteins. PARs are present on a variety of cell types, including platelets, endothelium, monocytes, and T lymphocytes. Thrombin activates PARs by clipping their extracellular domains, causing a conformational change that activates associated G proteins. Thus, PAR activation is a catalytic process, explaining the impressive potency of thrombin in eliciting PAR-dependent effects, such as enhancing the adhesive properties of leukocytes.

Once activated, the coagulation cascade must be tightly restricted to the site of injury to prevent inappropriate and potentially dangerous clotting elsewhere in the vascular tree. Besides restricting factor activation to sites of exposed phospholipids, clotting also is controlled by three general categories of natural anticoagulants:

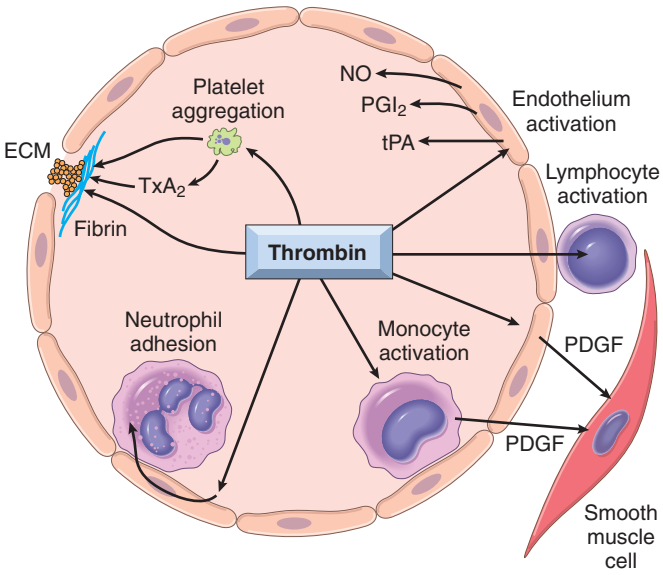


**Figure 3–10** Role of thrombin in hemostasis and cellular activation. Thrombin generates fibrin by cleaving fibrinogen, activates factor XIII (which is responsible for cross-linking fibrin into an insoluble clot), and also activates several other coagulation factors, thereby amplifying the coagulation cascade (Fig. 3–8). Through protease-activated receptors (PARs), thrombin activates (1) platelet aggregation and $TxA_2$ secretion; (2) endothelium, which responds by generating leukocyte adhesion molecules and a variety of fibrinolytic (t-PA), vasoactive (NO, $PGI_2$), or cytokine (PDGF) mediators; and (3) leukocytes, increasing their adhesion to activated endothelium. ECM, extracellular matrix; NO, nitric oxide; PDGF, platelet-derived growth factor; $PGI_2$, prostaglandin $I_2$ (prostacyclin); $TxA_2$, thromboxane $A_2$; t-PA, tissue type plasminogen activator. See Figure 3–6 for anticoagulant activities mediated by thrombin via thrombomodulin.

*(Courtesy of permission from Shaun Coughlin, MD, PhD, Cardiovascular Research Institute, University of California at San Francisco, San Francisco, California.)*

- *Antithrombins* (e.g., antithrombin III) inhibit the activity of thrombin and other serine proteases, namely factors IXa, Xa, XIa, and XIIa. Antithrombin III is activated by binding to heparin-like molecules on endothelial cells—hence the clinical utility of heparin administration to limit thrombosis (Fig. 3–6).
- *Protein C and protein S* are two vitamin K–dependent proteins that act in a complex to proteolytically inactivate cofactors Va and VIIIa. Protein C activation by thrombomodulin was described earlier; protein S is a cofactor for protein C activity (Fig. 3–6).
- *Tissue factor pathway inhibitor (TFPI)* is a protein secreted by endothelium (and other cell types) that inactivates factor Xa and tissue factor–factor VIIa complexes (Fig. 3–8).

Clotting also sets into motion a *fibrinolytic cascade* that moderates the ultimate size of the clot. Fibrinolysis is largely carried out by *plasmin,* which breaks down fibrin and interferes with its polymerization (Fig. 3–11). The resulting *fibrin split products* (*FSPs* or *fibrin degradation products*) also can act as weak anticoagulants. Elevated levels of FSPs (most notably fibrin-derived *D-dimers*) can be used for diagnosing abnormal thrombotic states including disseminated intravascular coagulation (DIC) (Chapter 11), deep venous thrombosis, or pulmonary thromboembolism (described in detail later).

Plasmin is generated by proteolysis of *plasminogen,* an inactive plasma precursor, either by factor XII or by plasminogen activators (Fig. 3–11). The most important of the plasminogen activators is *tissue-type plasminogen activator (t-PA);* t-PA is synthesized principally by endothelial cells and is most active when attached to fibrin. The affinity for fibrin largely confines t-PA fibrinolytic activity to sites of recent thrombosis. *Urokinase-like plasminogen activator* (*u-PA*) is another plasminogen activator present in plasma and in various tissues; it can activate plasmin in the fluid phase. In addition, plasminogen can be cleaved to its active form by the bacterial product *streptokinase,* which is used clinically to lyse clots in some forms of thrombotic disease. As with any potent regulatory component, the activity of plasmin is tightly restricted. To prevent excess plasmin from lysing thrombi indiscriminately throughout the body, free plasmin rapidly complexes with circulating $\alpha_2$-antiplasmin and is inactivated (Fig. 3–11).

Endothelial cells further modulate the coagulation–anticoagulation balance by releasing *plasminogen activator inhibitors (PAIs);* these block fibrinolysis and confer an overall procoagulation effect (Fig. 3–11). PAI production

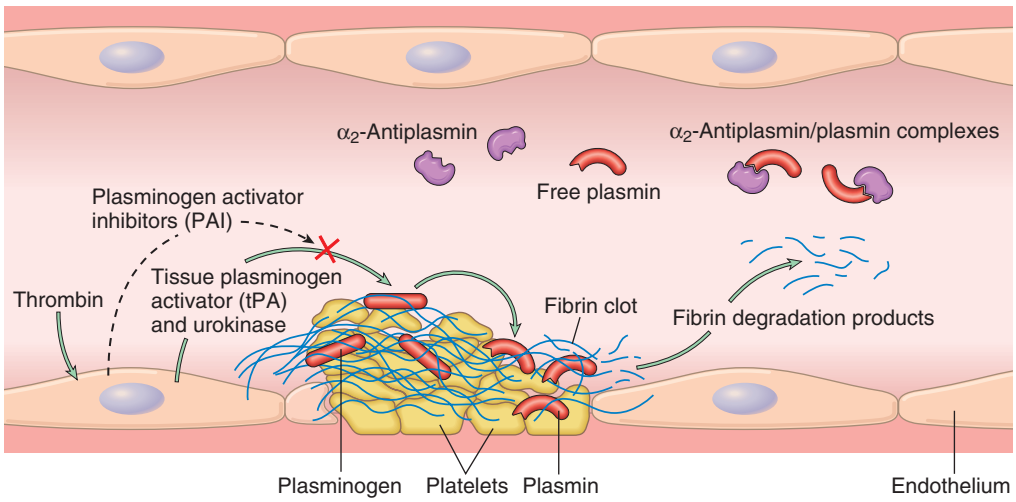


**Figure 3–11** The fibrinolytic system, illustrating various plasminogen activators and inhibitors (see text).

is increased by inflammatory cytokines (in particular interferon-γ) and probably contributes to the intravascular thrombosis that accompanies severe inflammation.

## SUMMARY

### Coagulation Factors

- Coagulation occurs via the sequential enzymatic conversion of a cascade of circulating and locally synthesized proteins.
- Tissue factor elaborated at sites of injury is the most important initiator of the coagulation cascade in vivo.
- At the final stage of coagulation, thrombin converts fibrinogen into insoluble fibrin that contributes to formation of the definitive hemostatic plug.
- Coagulation normally is restricted to sites of vascular injury by
  - limiting enzymatic activation to phospholipid surfaces provided by activated platelets or endothelium
  - natural anticoagulants elaborated at sites of endothelial injury or during activation of the coagulation cascade
  - expression of thrombomodulin on normal endothelial cells, which binds thrombin and converts it into an anticoagulant
  - activation of fibrinolytic pathways (e.g., by association of tissue plasminogen activator with fibrin)

## Thrombosis

Having reviewed the process of normal hemostasis, we now turn to the three primary *abnormalities that lead to thrombus formation (called Virchow's triad)*: (1) endothelial injury, (2) stasis or turbulent blood flow, and (3) hypercoagulability of the blood (Fig. 3–12).

### *Endothelial Injury*

Endothelial injury is an important cause of thrombosis, particularly in the heart and the arteries, where high flow rates might otherwise impede clotting by preventing platelet adhesion or diluting coagulation factors. Examples of thrombosis related to endothelial damage are the formation of thrombi in the cardiac chambers after myocardial infarction, over ulcerated plaques in atherosclerotic arteries, or at sites of traumatic or inflammatory vascular injury (*vasculitis*). Overt loss of endothelium exposes subendothelial ECM (leading to platelet adhesion), releases tissue factor, and reduces local production of $PGI_2$ and plasminogen activators. Of note, however, *endothelium need not be denuded or physically disrupted to contribute to the development of thrombosis; any perturbation in the dynamic balance of the prothrombotic and antithrombotic effects of endothelium can influence clotting locally.* Thus, dysfunctional endothelium elaborates greater amounts of procoagulant factors (e.g., platelet adhesion molecules, tissue factor, PAI) and synthesizes lesser amounts of anticoagulant molecules (e.g., thrombomodulin, $PGI_2$, t-PA). Endothelial dysfunction can be induced by a variety of insults, including hypertension, turbulent blood flow, bacterial products, radiation injury, metabolic abnormalities such as homocystinuria and hypercholesterolemia, and toxins absorbed from cigarette smoke.

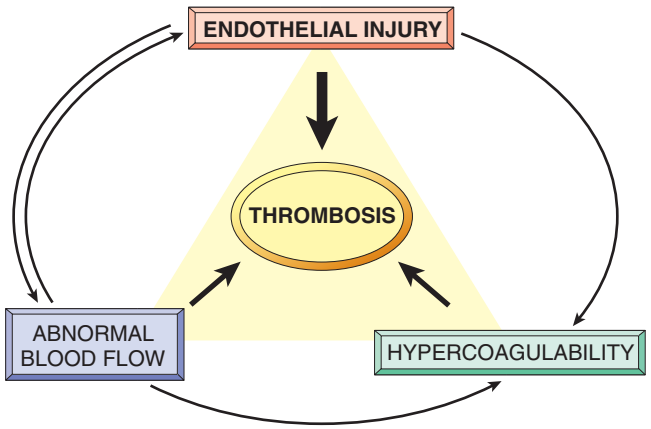


**Figure 3–12** Virchow's triad in thrombosis. Endothelial integrity is the most important factor. Abnormalities of procoagulants or anticoagulants can tip the balance in favor of thrombosis. Abnormal blood flow (stasis or turbulence) can lead to hypercoagulability directly and also indirectly through endothelial dysfunction.

### *Abnormal Blood Flow*

*Turbulence* contributes to arterial and cardiac thrombosis by causing endothelial injury or dysfunction, as well as by forming countercurrents and local pockets of stasis. *Stasis* is a major factor in the development of venous thrombi. Under conditions of normal *laminar* blood flow, platelets (and other blood cells) are found mainly in the center of the vessel lumen, separated from the endothelium by a slower-moving layer of plasma. By contrast, stasis and turbulent (chaotic) blood flow have the following deleterious effects:

- Both promote endothelial cell activation and enhanced procoagulant activity, in part through flow-induced changes in endothelial gene expression.
- Stasis allows platelets and leukocytes to come into contact with the endothelium when the flow is sluggish.
- Stasis also slows the washout of activated clotting factors and impedes the inflow of clotting factor inhibitors.

Turbulent and static blood flow contribute to thrombosis in a number of clinical settings. Ulcerated atherosclerotic plaques not only expose subendothelial ECM but also cause turbulence. Abnormal aortic and arterial dilations called *aneurysms* create local stasis and consequently a fertile site for thrombosis (Chapter 9). Acute myocardial infarction results in focally noncontractile myocardium. Ventricular remodeling after more remote infarction can lead to aneurysm formation. In both cases, cardiac mural thrombi are more easily formed due to the local blood stasis (Chapter 10). Mitral valve stenosis (e.g., after rheumatic heart disease) results in left atrial dilation. In conjunction with atrial fibrillation, a dilated atrium is a site of profound stasis and a prime location for the development of thrombi. *Hyperviscosity syndromes* (such as *polycythemia*) (Chapter 11) increase resistance to flow and cause small vessel stasis; the deformed red cells in sickle cell anemia (Chapter 11) cause vascular occlusions, and the resultant stasis also predisposes to thrombosis.

### *Hypercoagulability*

Hypercoagulability contributes infrequently to arterial or intracardiac thrombosis but is an important underlying risk factor for venous thrombosis. It is loosely defined as any alteration of the coagulation pathways that predisposes affected persons to thrombosis, and can be divided into primary (genetic) and secondary (acquired) disorders (Table 3–2).

*Primary (inherited) hypercoagulability* most often is caused by mutations in the factor V and prothrombin genes:

- Approximately 2% to 15% of whites carry a specific factor V mutation (called the Leiden mutation, after the Dutch city where it was first described). The mutation alters an amino acid residue in factor V and renders it resistant to protein C. Thus, an important antithrombotic counter-regulatory mechanism is lost. Heterozygotes carry a 5-fold increased risk for venous thrombosis, with homozygotes having a 50-fold increased risk.
- A single-nucleotide substitution (G to A) in the 3′-untranslated region of the prothrombin gene is a fairly common allele (found in 1% to 2% of the general population). This variant results in increased prothrombin transcription and is associated with a nearly threefold increased risk for venous thromboses.

**Table 3–2** Hypercoagulable States

| |
|---|
| **Primary (Genetic)** |
| Common (>1% of the Population) |
| Factor V mutation (G1691A mutation; factor V Leiden) |
| Prothrombin mutation (G20210A variant) |
| 5,10-Methylene tetrahydrofolate reductase (homozygous C677T mutation) |
| Increased levels of factor VIII, IX, or XI or fibrinogen |
| Rare |
| Antithrombin III deficiency |
| Protein C deficiency |
| Protein S deficiency |
| Very Rare |
| Fibrinolysis defects |
| Homozygous homocystinuria (deficiency of cystathione β-synthetase) |
| **Secondary (Acquired)** |
| High Risk for Thrombosis |
| Prolonged bed rest or immobilization |
| Myocardial infarction |
| Atrial fibrillation |
| Tissue injury (surgery, fracture, burn) |
| Cancer |
| Prosthetic cardiac valves |
| Disseminated intravascular coagulation |
| Heparin-induced thrombocytopenia |
| Antiphospholipid antibody syndrome |
| Lower Risk for Thrombosis |
| Cardiomyopathy |
| Nephrotic syndrome |
| Hyperestrogenic states (pregnancy and postpartum) |
| Oral contraceptive use |
| Sickle cell anemia |
| Smoking |

- Less common primary hypercoagulable states include inherited deficiencies of anticoagulants such as antithrombin III, protein C, or protein S; affected patients typically present with venous thrombosis and recurrent thromboembolism in adolescence or early adult life. Congenitally elevated levels of homocysteine contribute to arterial and venous thromboses (and indeed to the development of atherosclerosis) (Chapter 9).

Although the risk of thrombosis is only mildly increased in heterozygous carriers of factor V Leiden and the prothrombin gene variant, these genetic factors carry added significance for two reasons. First, both abnormal alleles are sufficiently frequent that homozygous and compound heterozygous persons are not uncommon, and these individuals are at much higher risk for thrombosis. More importantly, heterozygous individuals are at higher risk for venous thrombosis in the setting of other acquired risk factors, such as pregnancy, prolonged bed rest, and lengthy airplane flights. Consequently, *inherited causes of hypercoagulability should be considered in young patients (<50 years of age), even when other acquired risk factors are present*.

*Secondary (acquired) hypercoagulability* is seen in many settings (Table 3–2). In some situations (e.g., cardiac failure or trauma), stasis or vascular injury may be the most important factor. The hypercoagulability associated with oral contraceptive use and the hyperestrogenic state of pregnancy may be related to increased hepatic synthesis of coagulation factors and reduced synthesis of antithrombin III. In disseminated cancers, release of procoagulant tumor products (e.g., mucin from adenocarcinoma) predisposes to thrombosis. The hypercoagulability seen with advancing age has been attributed to increased platelet aggregation and reduced release of $PGI_2$ from endothelium. Smoking and obesity promote hypercoagulability by unknown mechanisms.

Among the acquired thrombophilic states, two are particularly important clinical problems and deserve special mention:

- *Heparin-induced thrombocytopenic (HIT) syndrome.* This syndrome occurs in up to 5% of patients treated with *unfractionated* heparin (for therapeutic anticoagulation). It is marked by the development of autoantibodies that bind complexes of heparin and platelet membrane protein (platelet factor-4) (Chapter 11). Although the mechanism is unclear, it appears that these antibodies may also bind similar complexes present on platelet and endothelial surfaces, resulting in platelet activation, aggregation, and consumption (hence *thrombocytopenia*), as well as causing endothelial cell injury. The overall result is a *prothrombotic state,* even in the face of heparin administration and low platelet counts. Newer low-molecular-weight *fractionated* heparin preparations induce autoantibodies less frequently but can still cause thrombosis if antibodies have already formed.
- *Antiphospholipid antibody syndrome.* This syndrome has protean manifestations, including recurrent thrombosis, repeated miscarriages, cardiac valve vegetations, and thrombocytopenia; it is associated with autoantibodies directed against anionic phospholipids (e.g., cardiolipin) or—more accurately—plasma protein antigens that are unveiled by binding to such phospholipids (e.g., prothrombin). In vivo, these antibodies induce a

*hypercoagulable state,* perhaps by inducing endothelial injury, by activating platelets or complement directly, or by interacting with the catalytic domains of certain coagulation factors. In vitro (in the absence of platelets and endothelium), however, the antibodies interfere with phospholipid complex assembly, thereby inhibiting coagulation (hence the designation *lupus anticoagulant*). In patients with anticardiolipin antibodies, serologic testing for syphilis will yield a false-positive result, because the antigen in the standard assays is embedded in cardiolipin.

Patients with antiphospholipid antibody syndrome fall into two categories. Many have *secondary antiphospholipid syndrome* due to a well-defined autoimmune disease, such as systemic lupus erythematosus (Chapter 4). The remainder of these patients exhibit only the manifestations of a hypercoagulable state without evidence of another autoimmune disorder (*primary antiphospholipid syndrome*). Although antiphospholipid antibodies are associated with thrombotic diatheses, they also occur in 5% to 15% of apparently normal persons; the implication is that their presence may be necessary but not sufficient to cause full-blown antiphospholipid antibody syndrome.

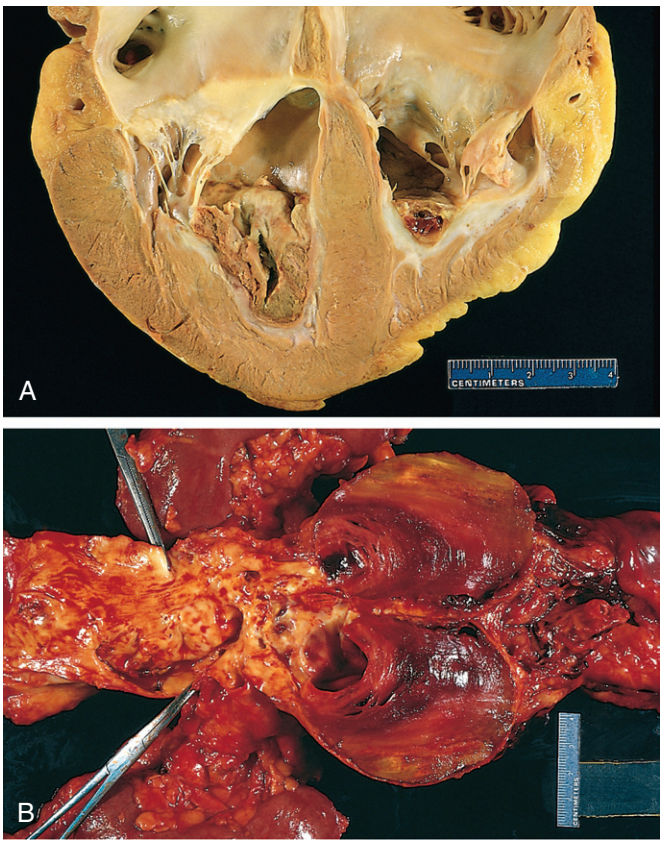


**Figure 3–13** Mural thrombi. **A,** Thrombus in the left and right ventricular apices, overlying white fibrous scar. **B,** Laminated thrombus in a dilated abdominal aortic aneurysm. Numerous friable mural thrombi are also superimposed on advanced atherosclerotic lesions of the more proximal aorta (*left side of photograph*).

## MORPHOLOGY

Thrombi can develop anywhere in the cardiovascular system. Arterial or cardiac thrombi typically arise at sites of endothelial injury or turbulence; venous thrombi characteristically occur at sites of stasis. Thrombi are focally attached to the underlying vascular surface and tend to propagate **toward** the heart; thus, arterial thrombi grow in a retrograde direction from the point of attachment, while venous thrombi extend in the direction of blood flow. The propagating portion of a thrombus tends to be poorly attached and therefore prone to fragmentation and migration through the blood as an **embolus.**

Thrombi can have grossly (and microscopically) apparent laminations called **lines of Zahn;** these represent pale platelet and fibrin layers alternating with darker red cell–rich layers. Such lines are significant in that they are only found in thrombi that form in flowing blood; their presence can therefore usually distinguish antemortem thrombosis from the bland nonlaminated clots that form in the postmortem state. Although thrombi formed in the "low-flow" venous system superficially resemble postmortem clots, careful evaluation generally reveals ill-defined laminations.

Thrombi occurring in heart chambers or in the aortic lumen are designated **mural thrombi.** Abnormal myocardial contraction (arrhythmias, dilated cardiomyopathy, or myocardial infarction) or endomyocardial injury (myocarditis, catheter trauma) promote cardiac mural thrombi (Fig. 3–13, *A*), while ulcerated atherosclerotic plaques and aneurysmal dilation promote aortic thrombosis (Fig. 3-13, *B*).

**Arterial thrombi** are typically relatively rich in platelets, as the processes underlying their development (e.g., endothelial injury) lead to platelet activation. Although usually superimposed on a ruptured atherosclerotic plaque, other vascular injuries (vasculitis, trauma) can also be causal. **Venous thrombi (phlebothrombosis)** frequently propagate some distance toward the heart, forming a long cast within the vessel lumen that is prone to give rise to emboli. An increase in the activity of coagulation factors is involved in the genesis of most venous thrombi, with platelet activation playing a secondary role. Because these thrombi form in the sluggish venous circulation, they tend to contain more enmeshed red cells, leading to the moniker **red,** or **stasis, thrombi.** The veins of the lower extremities are most commonly affected (90% of venous thromboses); however, venous thrombi also can occur in the upper extremities, periprostatic plexus, or ovarian and periuterine veins, and under special circumstances may be found in the dural sinuses, portal vein, or hepatic vein.

At autopsy, **postmortem clots** can sometimes be mistaken for venous thrombi. However, the former are gelatinous and due to red cell settling have a dark red dependent portion and a yellow "chicken fat" upper portion; they also are usually not attached to the underlying vessel wall. By contrast, red thrombi typically are firm, focally attached to vessel walls, and contain gray strands of deposited fibrin.

Thrombi on heart valves are called **vegetations.** Bacterial or fungal blood-borne infections can cause valve damage, leading to the development of large thrombotic masses **(infective endocarditis)** (Chapter 10). Sterile vegetations also can develop on noninfected valves in hypercoagulable

states—the lesions of so-called **nonbacterial thrombotic endocarditis** (Chapter 10). Less commonly, sterile, **verrucous endocarditis (Libman-Sacks endocarditis)** can occur in the setting of systemic lupus erythematosus (Chapter 4).

### *Fate of the Thrombus*

If a patient survives an initial thrombotic event, over the ensuing days to weeks the thrombus evolves through some combination of the following four processes:

- *Propagation.* The thrombus enlarges through the accretion of additional platelets and fibrin, increasing the odds of vascular occlusion or embolization.
- *Embolization.* Part or all of the thrombus is dislodged and transported elsewhere in the vasculature.
- *Dissolution.* If a thrombus is newly formed, activation of fibrinolytic factors may lead to its rapid shrinkage and complete dissolution. With older thrombi, extensive fibrin polymerization renders the thrombus substantially more resistant to plasmin-induced proteolysis, and lysis is ineffectual. This acquisition of resistance to lysis has clinical significance, as therapeutic administration of fibrinolytic agents (e.g., t-PA in the setting of acute coronary thrombosis) generally is not effective unless given within a few hours of thrombus formation.
- *Organization and recanalization.* Older thrombi become *organized* by the ingrowth of endothelial cells, smooth muscle cells, and fibroblasts into the fibrin-rich thrombus (Fig. 3–14). In time, capillary channels are formed that—to a limited extent—create conduits along the length of the thrombus, thereby reestablishing the continuity of the original lumen. Further recanalization can sometimes convert a thrombus into a vascularized mass of connective tissue that is eventually incorporated into the wall of the remodeled vessel. Occasionally, instead of organizing, the center of a thrombus undergoes enzymatic digestion, presumably because of the release of lysosomal enzymes from entrapped leukocytes. If bacterial seeding occurs, the contents of degraded thrombi serve as an ideal culture medium, and the resulting infection may weaken the vessel wall, leading to formation of a *mycotic aneurysm* (Chapter 9).

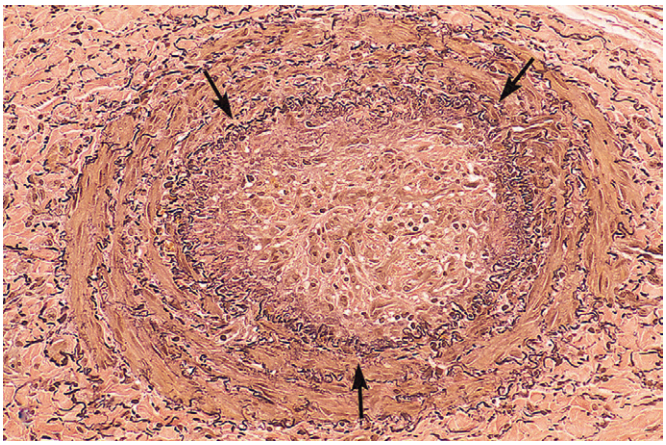

**Figure 3–14** Low-power view of a thrombosed artery stained for elastic tissue. The original lumen is delineated by the internal elastic lamina *(arrows)* and is totally filled with organized thrombus.

### Clinical Correlation

Thrombi are significant because *they cause obstruction of arteries and veins and may give rise to emboli.* Which effect is of greatest clinical importance depends on the site of thrombosis. Thus, while venous thrombi can cause congestion and edema in vascular beds distal to an obstruction, they are most worrisome because of their potential to embolize to the lungs and cause death. Conversely, while arterial thrombi can embolize and cause tissue infarction, their tendency to obstruct vessels (e.g., in coronary and cerebral vessels) is considerably more important.

***Venous Thrombosis (Phlebothrombosis).*** Most venous thrombi occur in either the superficial or the deep veins of the leg. Superficial venous thrombi usually arise in the saphenous system, particularly in the setting of varicosities; these rarely embolize but can be painful and can cause local congestion and swelling from impaired venous outflow, predisposing the overlying skin to development of infections and *varicose ulcers.* Deep venous thromboses ("DVTs") in the *larger leg veins at or above the knee joint* (e.g., popliteal, femoral, and iliac veins) are more serious because they are prone to embolize. Although such DVTs may cause local pain and edema, the venous obstruction often is circumvented by collateral channels. Consequently, DVTs are entirely asymptomatic in *approximately 50% of patients* and are recognized only after they have embolized to the lungs.

Lower-extremity DVTs are associated with stasis and hypercoagulable states, as described earlier (Table 3–2); thus, common predisposing factors include congestive heart failure, bed rest and immobilization; the latter two factors reduce the milking action of leg muscles and thus slow venous return. Trauma, surgery, and burns not only immobilize a patient but are also associated with vascular injury, procoagulant release, increased hepatic synthesis of coagulation factors, and reduced t-PA production. Many factors contribute to the thrombotic diathesis of pregnancy; besides the potential for amniotic fluid infusion into the circulation at the time of delivery, pressure produced by the enlarging fetus and uterus can produce stasis in the veins of the legs, and late pregnancy and the postpartum period are associated with hypercoagulability. Tumor-associated procoagulant release is largely responsible for the increased risk of thromboembolic phenomena seen in disseminated cancers, which is sometimes referred to as *migratory thrombophlebitis* due to its tendency to transiently involve several different venous beds, or as *Trousseau syndrome,* for Armand Trousseau, who both described the disorder and suffered from it. Regardless of the specific clinical setting, the risk of DVT is increased in persons over age 50.

While the many conditions that predispose to thrombosis are well recognized, the phenomenon remains unpredictable. It occurs at a distressingly high frequency in otherwise healthy and ambulatory people without apparent provocation or underlying abnormality. Equally important is that asymptomatic thrombosis (and presumably subsequent resolution) occurs considerably more frequently than is generally appreciated.

## SUMMARY

### Thrombosis

- Thrombus development usually is related to one or more components of Virchow's triad:
  - endothelial injury (e.g., by toxins, hypertension, inflammation, or metabolic products)
  - abnormal blood flow, stasis or turbulence (e.g., due to aneurysms, atherosclerotic plaque)
  - hypercoagulability: either primary (e.g., factor V Leiden, increased prothrombin synthesis, antithrombin III deficiency) or secondary (e.g., bed rest, tissue damage, malignancy)
- Thrombi may propagate, resolve, become organized, or embolize.
- Thrombosis causes tissue injury by local vascular occlusion or by distal embolization.

### Disseminated Intravascular Coagulation

Disseminated intravascular coagulation (DIC) is the sudden or insidious onset of widespread thrombosis within the microcirculation. It may be seen in disorders ranging from obstetric complications to advanced malignancy. The thrombi are generally microscopic in size, yet so numerous as to often cause circulatory insufficiency, particularly in the brain, lungs, heart, and kidneys. To complicate matters, the widespread microvascular thrombosis consumes platelets and coagulation proteins (hence the synonym *consumption coagulopathy*), and at the same time, fibrinolytic mechanisms are activated. Thus, an initially thrombotic disorder can evolve into a bleeding catastrophe. A point worthy of emphasis is that *DIC is not a primary disease but rather a potential complication of numerous conditions associated with widespread activation of thrombin*. It is discussed in greater detail along with other bleeding diatheses in Chapter 11.

## EMBOLISM

*An embolus is an intravascular solid, liquid, or gaseous mass that is carried by the blood to a site distant from its point of origin.* The vast majority of emboli derive from a dislodged thrombus—hence the term *thromboembolism.* Less common types of emboli include fat droplets, bubbles of air or nitrogen, atherosclerotic debris (*cholesterol emboli*), tumor fragments, bits of bone marrow, and amniotic fluid. Inevitably, emboli lodge in vessels too small to permit further passage, resulting in partial or complete vascular occlusion; depending on the site of origin, emboli can lodge anywhere in the vascular tree. The primary consequence of systemic embolization is ischemic necrosis (*infarction*) of downstream tissues, while embolization in the pulmonary circulation leads to hypoxia, hypotension, and right-sided heart failure.

### Pulmonary Thromboembolism

The incidence of pulmonary embolism is 2 to 4 per 1000 hospitalized patients. Although the rate of fatal pulmonary embolus (PE) has declined from 6% to 2% over the last quarter-century, pulmonary embolism still causes about 200,000 deaths per year in the United States. In greater than 95% of cases, venous emboli originate from thrombi within deep leg veins proximal to the popliteal fossa; embolization from lower leg thrombi is uncommon.

Fragmented thrombi from DVTs are carried through progressively larger channels and usually pass through the right side of the heart before arresting in the pulmonary vasculature. Depending on size, a PE can occlude the main pulmonary artery, lodge at the bifurcation of the right and left pulmonary arteries (*saddle embolus*), or pass into the smaller, branching arterioles (Fig. 3–15). Frequently, multiple emboli occur, either sequentially or as a shower of smaller emboli from a single large thrombus; *a patient who has had one pulmonary embolus is at increased risk for having more.* Rarely, an embolus passes through an atrial or ventricular defect and enters the systemic circulation (*paradoxical embolism*). A more complete discussion of PE is found in Chapter 12; the major clinical and pathologic features are the following:

- Most pulmonary emboli (60% to 80%) are small and clinically silent. With time, they undergo organization and become incorporated into the vascular wall; in some cases, organization of thromboemboli leaves behind bridging fibrous *webs.*
- At the other end of the spectrum, a large embolus that blocks a major pulmonary artery can cause sudden death.
- Embolic obstruction of medium-sized arteries and subsequent rupture of capillaries rendered anoxic can cause pulmonary hemorrhage. Such embolization does not usually cause pulmonary infarction since the area also receives blood through an intact bronchial circulation (dual circulation). However, a similar embolus in the setting of left-sided cardiac failure (and diminished bronchial artery perfusion) can lead to a pulmonary infarct.
- Embolism to small end-arteriolar pulmonary branches usually causes infarction.
- Multiple emboli occurring over time can cause pulmonary hypertension and right ventricular failure (cor pulmonale).

**Figure 3–15** Embolus derived from a lower-extremity deep venous thrombus lodged in a pulmonary artery branch.

## Systemic Thromboembolism

Most systemic emboli (80%) arise from intracardiac mural thrombi; two thirds are associated with left ventricular infarcts and another 25% with dilated left atria (e.g., secondary to mitral valve disease). The remainder originate from aortic aneurysms, thrombi overlying ulcerated atherosclerotic plaques, fragmented valvular vegetations (Chapter 10), or the venous system (*paradoxical emboli*); 10% to 15% of systemic emboli are of unknown origin.

By contrast with venous emboli, which lodge primarily in the lung, arterial emboli can travel virtually anywhere; their final resting place understandably depends on their point of origin and the relative flow rates of blood to the downstream tissues. Common arteriolar *embolization sites* include the lower extremities (75%) and central nervous system (10%); intestines, kidneys, and spleen are less common targets. The consequences of embolization depend on the caliber of the occluded vessel, the collateral supply, and the affected tissue's vulnerability to anoxia; arterial emboli often lodge in end arteries and cause infarction.

### *Fat Embolism*

Soft tissue crush injury or rupture of marrow vascular sinusoids (long bone fracture) releases microscopic fat globules into the circulation. Fat and marrow emboli are common incidental findings after vigorous cardiopulmonary resuscitation but probably are of little clinical consequence. Similarly, although fat and marrow embolism occurs in some 90% of individuals with severe skeletal injuries (Fig. 3–16, *A*), less than 10% show any clinical findings. However, a minority of patients develop a symptomatic *fat embolism syndrome* characterized by *pulmonary insufficiency, neurologic symptoms, anemia, thrombocytopenia, and a diffuse petechial rash, which is fatal in 10% of cases*. Clinical signs and symptoms appear 1 to 3 days after injury as the sudden onset of tachypnea, dyspnea, tachycardia, irritability, and restlessness, which can progress rapidly to delirium or coma.

The pathogenesis of fat emboli syndrome involves both mechanical obstruction and biochemical injury. Fat microemboli occlude pulmonary and cerebral microvasculature, both directly and by triggering platelet aggregation. This deleterious effect is exacerbated by fatty acid release from lipid globules, which causes local toxic endothelial injury. Platelet activation and granulocyte recruitment (with free radical, protease, and eicosanoid release) (Chapter 2) complete the vascular assault. Because lipids are dissolved by the solvents used during tissue-processing, microscopic demonstration of fat microglobules (i.e., in the absence of accompanying marrow elements) requires specialized techniques (frozen sections and fat stains).

### *Amniotic Fluid Embolism*

Amniotic fluid embolism is an uncommon, grave complication of labor and the immediate postpartum period (1 in 40,000 deliveries). The mortality rate approaches 80%, making it the most common cause of maternal death in the developed world; it accounts for 10% of maternal deaths in the United States, while 85% of survivors suffer some form of permanent neurologic deficit. Onset is characterized by sudden severe dyspnea, cyanosis, and hypotensive shock, followed by seizures and coma. If the patient survives the initial crisis, pulmonary edema typically develops, along with (in about half the patients) disseminated intravascular coagulation secondary to release of thrombogenic substances from amniotic fluid.

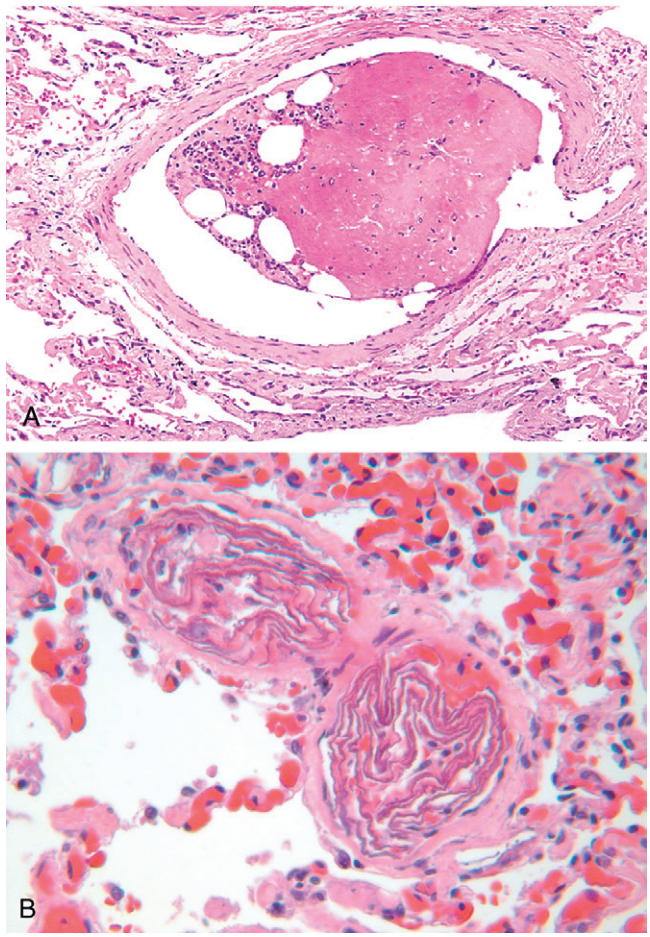


**Figure 3–16** Unusual types of emboli. **A,** Bone marrow embolus. The embolus is composed of hematopoietic marrow and marrow fat cells (*clear spaces*) attached to a thrombus. **B,** Amniotic fluid emboli. Two small pulmonary arterioles are packed with laminated swirls of fetal squamous cells. The surrounding lung is edematous and congested.
*(Courtesy of Dr. Beth Schwartz, Baltimore, Maryland.)*

The underlying cause is entry of amniotic fluid (and its contents) into the maternal circulation via tears in the placental membranes and/or uterine vein rupture. Histologic analysis reveals squamous cells shed from fetal skin, lanugo hair, fat from vernix caseosa, and mucin derived from the fetal respiratory or gastrointestinal tracts in the maternal pulmonary microcirculation (Fig. 13-16, *B*). Other findings include marked pulmonary edema, diffuse alveolar damage (Chapter 12), and systemic fibrin thrombi generated by disseminated intravascular coagulation.

### *Air Embolism*

Gas bubbles within the circulation can coalesce and obstruct vascular flow and cause distal ischemic injury. Thus, a small volume of air trapped in a coronary artery during bypass surgery or introduced into the cerebral arterial circulation by neurosurgery performed in an upright "sitting position" can occlude flow, with dire consequences. Small

venous gas emboli generally have no deleterious effects, but sufficient air can enter the pulmonary circulation inadvertently during obstetric procedures or as a consequence of a chest wall injury to cause hypoxia, and very large venous emboli may arrest in the heart and cause death.

A particular form of gas embolism called *decompression sickness* is caused by sudden changes in atmospheric pressure. Thus, scuba divers, underwater construction workers, and persons in unpressurized aircraft who undergo rapid ascent are at risk. When air is breathed at high pressure (e.g., during a deep sea dive), increased amounts of gas (particularly nitrogen) become dissolved in the blood and tissues. If the diver then ascends (depressurizes) too rapidly, the nitrogen expands in the tissues and bubbles out of solution in the blood to form gas emboli, which cause tissue ischemia. Rapid formation of gas bubbles within skeletal muscles and supporting tissues in and about joints is responsible for the painful condition called "the bends" (so named in the 1880s because the afflicted person arches the back in a manner reminiscent of a then-popular women's fashion pose called the *Grecian bend*). Gas bubbles in the pulmonary vasculature cause edema, hemorrhages, and focal atelectasis or emphysema, leading to respiratory distress, the so-called *chokes.* A more chronic form of decompression sickness is called *caisson disease* (named for pressurized underwater vessels used during bridge construction) in which recurrent or persistent gas emboli in the bones lead to multifocal ischemic necrosis; the heads of the femurs, tibiae, and humeri are most commonly affected.

Acute decompression sickness is treated by placing affected persons in a high-pressure chamber, to force the gas back into solution. Subsequent slow decompression permits gradual gas resorption and exhalation so that obstructive bubbles do not re-form.

## SUMMARY

### Embolism

- An embolus is a solid, liquid, or gaseous mass carried by the blood to a site distant from its origin; most are dislodged thrombi.
- Pulmonary emboli derive primarily from lower-extremity deep vein thrombi; their effects depend mainly on the size of the embolus and the location in which it lodges. Consequences may include right-sided heart failure, pulmonary hemorrhage, pulmonary infarction, or sudden death.
- Systemic emboli derive primarily from cardiac mural or valvular thrombi, aortic aneurysms, or atherosclerotic plaques; whether an embolus causes tissue infarction depends on the site of embolization and the presence or absence of collateral circulation.

# INFARCTION

*An infarct is an area of ischemic necrosis caused by occlusion of the vascular supply to the affected tissue*; the process by which such lesions form termed *infarction,* is a common and extremely important cause of clinical illness. Roughly 40% of all deaths in the United States are a consequence of cardiovascular disease, with most of these deaths stemming from myocardial or cerebral infarction. Pulmonary infarction is a common clinical complication, bowel infarction often is fatal, and ischemic necrosis of distal extremities (*gangrene*) causes substantial morbidity in the diabetic population.

*Arterial thrombosis or arterial embolism underlies the vast majority of infarctions.* Less common causes of arterial obstruction include vasospasm, expansion of an atheroma secondary to intraplaque hemorrhage, and extrinsic compression of a vessel, such as by tumor, a dissecting aortic aneurysm, or edema within a confined space (e.g., in *anterior tibial compartment syndrome*). Other uncommon causes of tissue infarction include vessel twisting (e.g., in testicular torsion or bowel volvulus), traumatic vascular rupture, and entrapment in a hernia sac. Although venous thrombosis can cause infarction, the more common outcome is simply congestion; typically, bypass channels rapidly open to provide sufficient outflow to restore the arterial inflow. Infarcts caused by venous thrombosis thus usually occur only in organs with a single efferent vein (e.g., testis or ovary).

## MORPHOLOGY

Infarcts are classified on the basis of their color (reflecting the amount of hemorrhage) and the presence or absence of microbial infection. Thus, infarcts may be either **red (hemorrhagic)** or **white (anemic)** and may be either **septic** or **bland.**

**Red infarcts** (Fig. 3–17, *A*) occur (1) with venous occlusions (such as in ovarian torsion); (2) in loose tissues (e.g., lung) where blood can collect in infarcted zones; (3) in tissues with **dual circulations** such as lung and small intestine, where partial, inadequate perfusion by collateral arterial supplies is typical; (4) in previously congested tissues (as a consequence of sluggish venous outflow); and (5) when flow is reestablished after infarction has occurred (e.g., after angioplasty of an arterial obstruction).

**White infarcts** occur with arterial occlusions in solid organs with end-arterial circulations (e.g., heart, spleen, and kidney), and where tissue density limits the seepage of blood from adjoining patent vascular beds (Fig. 3–17, *B*). Infarcts tend to be wedge-shaped, with the occluded vessel at the apex and the organ periphery forming the base (Fig. 3–17); when the base is a serosal surface, there is often an overlying fibrinous exudate. Lateral margins may be irregular, reflecting flow from adjacent vessels. The margins of acute infarcts typically are indistinct and slightly hemorrhagic; with time, the edges become better defined by a narrow rim of hyperemia attributable to inflammation.

Infarcts resulting from arterial occlusions in organs without a dual circulation typically become progressively paler and sharply defined with time (Fig. 3–17, *B*). By comparison, hemorrhagic infarcts are the rule in the lung and other spongy organs (Fig. 3–17, *A*). Extravasated red cells in hemorrhagic infarcts are phagocytosed by macrophages, and the heme iron is converted to intracellular hemosiderin. Small amounts

**Figure 3–17** Red and white infarcts. **A,** Hemorrhagic, roughly wedge-shaped pulmonary infarct (red infarct). **B,** Sharply demarcated pale infarct in the spleen (white infarct).

do not impart any appreciable color to the tissue, but extensive hemorrhages leave a firm, brown residuum.

In most tissues, the main histologic finding associated with infarcts is **ischemic coagulative necrosis** (Chapter 1). An inflammatory response begins to develop along the margins of infarcts within a few hours and usually is well defined within 1 to 2 days. Eventually, inflammation is followed by repair, beginning in the preserved margins (Chapter 2). In some tissues, parenchymal regeneration can occur at the periphery of the infarct, where the underlying stromal architecture has been spared. Most infarcts, however, are ultimately replaced by scar (Fig. 3–18). The brain is an exception to these generalizations: Ischemic tissue injury in the central nervous system results in **liquefactive necrosis** (Chapter 1).

Septic infarctions occur when infected cardiac valve vegetations embolize, or when microbes seed necrotic tissue. In these cases the infarct is converted into an **abscess,** with a correspondingly greater inflammatory response (Chapter 2).

**Figure 3–18** Remote kidney infarct, now replaced by a large fibrotic scar.

***Factors That Influence Infarct Development.*** The effects of vascular occlusion range from inconsequential to tissue necrosis leading to organ dysfunction and sometimes death. The range of outcomes is influenced by (1) the anatomy of the vascular supply; (2) the time over which the occlusion develops; (3) the intrinsic vulnerability of the affected tissue to ischemic injury; and (4) the blood oxygen content.

- *Anatomy of the vascular supply.* The presence or absence of an alternative blood supply is the most important factor in determining whether occlusion of an individual vessel causes damage. The dual supply of the lung by the pulmonary and bronchial arteries means that obstruction of the pulmonary arterioles does not cause lung infarction unless the bronchial circulation also is compromised. Similarly, the liver, which receives blood from the hepatic artery and the portal vein, and the hand and forearm, with its parallel radial and ulnar arterial supply, are resistant to infarction. By contrast, the kidney and the spleen both have end-arterial circulations, and arterial obstruction generally leads to infarction in these tissues.
- *Rate of occlusion.* Slowly developing occlusions are less likely to cause infarction because they allow time for the development of collateral blood supplies. For example, small interarteriolar anastomoses, which normally carry minimal blood flow, interconnect the three major coronary arteries. If one coronary artery is slowly occluded (e.g., by encroaching atherosclerotic plaque), flow in this *collateral circulation* may increase sufficiently to prevent infarction—even if the original artery becomes completely occluded.
- *Tissue vulnerability to ischemia.* Neurons undergo irreversible damage when deprived of their blood supply for only 3 to 4 minutes. Myocardial cells, although hardier than neurons, still die after only 20 to 30 minutes of ischemia. By contrast, fibroblasts within myocardium remain viable after many hours of ischemia.
- *Hypoxemia.* Understandably, abnormally low blood $O_2$ content (regardless of cause) increases both the likelihood and extent of infarction.

## SUMMARY

### Infarction

- Infarcts are areas of ischemic necrosis most commonly caused by arterial occlusion (typically due to thrombosis or embolization); venous outflow obstruction is a less frequent cause.
- Infarcts caused by venous occlusion or occurring in spongy tissues typically are hemorrhagic (red); those caused by arterial occlusion in compact tissues typically are pale (white).
- Whether or not vascular occlusion causes tissue infarction is influenced by collateral blood supplies, the rate at which an obstruction develops, intrinsic tissue susceptibility to ischemic injury, and blood oxygenation.

# SHOCK

Shock is the final common pathway for several potentially lethal events, including exsanguination, extensive trauma or burns, myocardial infarction, pulmonary embolism, and sepsis. Regardless of cause, *shock is characterized by systemic hypoperfusion of tissues; it can be caused by diminished cardiac output or by reduced effective circulating blood volume.* The consequences are *impaired tissue perfusion and cellular hypoxia.* Although shock initially is reversible, prolonged shock eventually leads to irreversible tissue injury that often proves fatal.

The most common forms of shock can be grouped into three pathogenic categories (Table 3–3):

- *Cardiogenic shock* results from low cardiac output due to myocardial pump failure. It may be caused by myocardial damage (infarction), ventricular arrhythmias, extrinsic compression (cardiac tamponade) (Chapter 10), or outflow obstruction (e.g., pulmonary embolism).
- *Hypovolemic shock* results from low cardiac output due to loss of blood or plasma volume (e.g., due to hemorrhage or fluid loss from severe burns).
- *Septic shock* results from arterial vasodilation and venous blood pooling that stems from the systemic immune response to microbial infection. Its complex pathogenesis is discussed in greater detail next.

Less commonly, shock can result from loss of vascular tone associated with anesthesia or secondary to a spinal cord injury (*neurogenic shock*). *Anaphylactic shock* results from systemic vasodilation and increased vascular permeability that is triggered by an immunoglobulin E–mediated hypersensitivity reaction (Chapter 4).

## Pathogenesis of Septic Shock

Despite medical advances over the past several decades, septic shock remains a daunting clinical problem. Septic shock kills 20% of its victims, accounts for over 200,000 deaths annually in the United States, and is the number one cause of mortality in intensive care units. The incidence is rising, ironically, in part because of improved life support for critically ill patients, as well as an increase in invasive procedures and the growing numbers of immunocompromised patients (due to chemotherapy, immunosuppression, or HIV infection).

In septic shock, systemic arterial and venous dilation leads to tissue hypoperfusion, even though cardiac output is preserved or even initially increased. The decreased vascular tone is accompanied by widespread endothelial cell activation, often triggering a hypercoagulable state manifesting as disseminated intravascular coagulation. In addition, septic shock is associated with perturbations of metabolism that directly suppress cell and tissue function. *The net effect of these abnormalities is hypoperfusion and dysfunction of multiple organs.*

At present, gram-positive bacteria constitute the most common cause of septic shock, followed by gram-negative organisms and fungi. Although it was for a time thought that infections had to be disseminated to cause septic shock, infections localized to a specific tissue can trigger sepsis, even without detectable spread to the bloodstream. The ability of diverse flora to precipitate septic shock is consistent with the idea that several different microbial constituents can initiate the process. Most notably, macrophages, neutrophils, dendritic cells, endothelial cells, as well as soluble components of the innate immune system (e.g., complement) recognize and are activated by a variety of substances derived from microorganisms. Once activated, these cells and soluble factors initiate a number of inflammatory responses that interact in a complex, incompletely understood fashion to produce septic shock (Fig. 3–19). As an aside, a similar widespread inflammatory

**Table 3–3** Three Major Types of Shock

| Type of Shock | Clinical Examples | Principal Pathogenic Mechanisms |
|---|---|---|
| Cardiogenic | Myocardial infarction<br>Ventricular rupture<br>Arrhythmia<br>Cardiac tamponade<br>Pulmonary embolism | Failure of myocardial pump resulting from intrinsic myocardial damage, extrinsic pressure, or obstruction to outflow |
| Hypovolemic | Hemorrhage<br>Fluid loss (e.g., vomiting, diarrhea, burns, trauma) | Inadequate blood or plasma volume |
| Septic | Overwhelming microbial infections<br>Endotoxic shock<br>Gram-positive septicemia<br>Fungal sepsis<br>Superantigens (e.g., toxic shock syndrome) | Peripheral vasodilation and pooling of blood; endothelial activation/injury; leukocyte-induced damage; disseminated intravascular coagulation; activation of cytokine cascades |

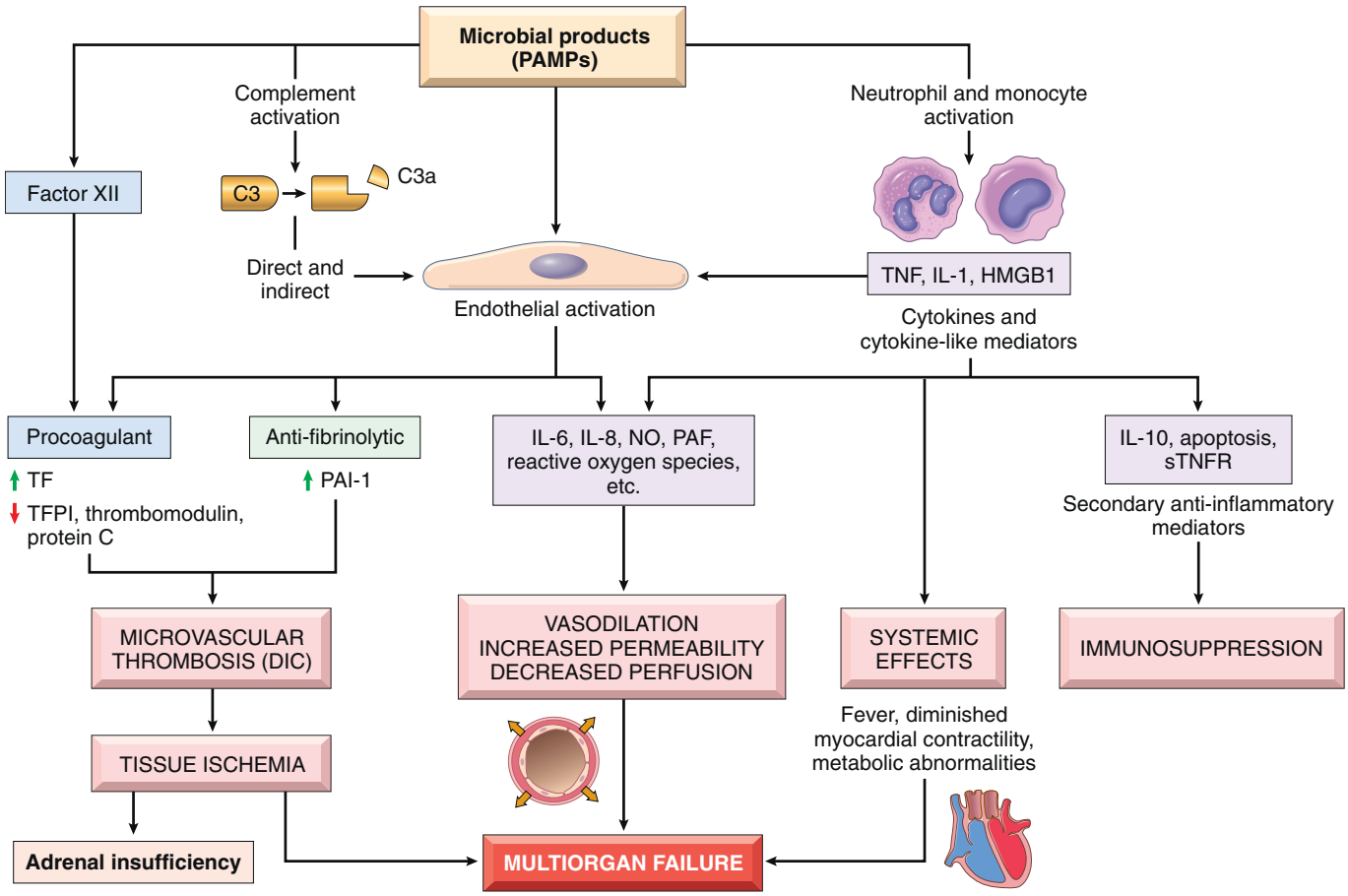


**Figure 3–19** Major pathogenic pathways in septic shock. Microbial products activate endothelial cells and cellular and humoral elements of the innate immune system, initiating a cascade of events that lead to end-stage multiorgan failure. Additional details are given in the text. DIC, disseminated intravascular coagulation; HMGB1, high-mobility group box 1 protein; NO, nitric oxide; PAF, platelet-activating factor; PAI-1, plasminogen activator inhibitor-1; PAMP, pathogen-associated molecular pattern; STNFR, soluble tumor necrosis factor receptor; TF, tissue factor; TFPI, tissue factor pathway inhibitor.

response—the so-called *systemic inflammatory response syndrome (SIRS)*—can also be triggered in the absence of any apparent underlying infection; causes include extensive trauma or burns, pancreatitis, and diffuse ischemia.

Factors contributing to the pathophysiology of septic shock include the following:

- *Inflammatory mediators.* Cells of the innate immune system express receptors (e.g., Toll-like receptors [TLRs]) (Chapter 2) that recognize a host of microbe-derived substances containing so-called *pathogen-associated molecular patterns* (PAMPs). *Activation of pathogen recognition receptors by PAMPs triggers the innate immune responses that drive sepsis*. Upon activation, the inflammatory cells produce TNF and IL-1 (and other cytokines), plus cytokine-like mediators such as high-mobility group box 1 (HMGB1). Reactive oxygen species and lipid mediators such as prostaglandins and platelet-activating factor (PAF) also are elaborated (Chapter 2). These effector molecules activate endothelial cells, resulting in expression of adhesion molecules, a procoagulant phenotype, and secondary waves of cytokine production. The *complement cascade* also is activated by microbial components, both directly and through the proteolytic activity of plasmin (Chapter 2), resulting in the production of anaphylotoxins (C3a, C5a), chemotaxic fragments (C5a), and opsonins (C3b), all of which can contribute to the pro-inflammatory state.
- *Endothelial cell activation and injury.* Endothelial activation by microbial constituents or inflammatory cell mediators has three major sequelae: (1) thrombosis; (2) increased vascular permeability; and (3) vasodilation.

  *The derangement in coagulation is sufficient to produce the formidable complication of disseminated intravascular coagulation in up to half of septic patients.* Sepsis alters the expression of many factors ultimately favoring coagulation. Pro-inflammatory cytokines result in increased tissue factor production, while at the same time dampening fibrinolysis by increasing PAI expression. The production of other endothelial anticoagulant factors, such as tissue factor pathway inhibitor, thrombomodulin, and protein C, is also diminished. The procoagulant tendency is further enhanced by decreased blood flow within small vessels, which produces stasis and diminishes the washout of activated coagulation factors. Acting in concert, these effects promote the systemic deposition of fibrin-rich thrombi in small vessels, thus exacerbating tissue hypoperfusion. In full-blown disseminated intravascular coagulation, there

is also *consumption* of clotting factors and platelets, leading to concomitant bleeding and hemorrhage (Chapter 11).

*The pro-inflammatory state associated with sepsis leads to widespread vascular leakage and tissue edema, with deleterious effects on both nutrient delivery and waste removal.* It appears that inflammatory cytokines loosen endothelial cell tight junctions by causing the adhesion molecule VE-cadherin to be displaced from the junctions. The altered junctions become leaky, resulting in the accumulation of protein-rich exudates and edema throughout the body.

Expression of vasoactive inflammatory mediators (e.g., C3a, C5a, PAF), together with increased NO production, leads to systemic relaxation of vascular smooth muscle, producing hypotension and further reductions in tissue perfusion.

- *Metabolic abnormalities.* Septic patients exhibit insulin resistance and hyperglycemia. Cytokines such as TNF and IL-1, stress-induced hormones (such as glucagon, growth hormone, and glucocorticoid), and catecholamines all drive gluconeogenesis. At the same time, the pro-inflammatory cytokines suppress insulin release while simultaneously promoting insulin resistance in skeletal muscle and other tissues. Hyperglycemia suppresses neutrophil function—thereby decreasing bactericidal activity—and causes increased adhesion molecule expression on endothelial cells. Although sepsis initially is associated with a surge in glucocorticoid production, this increase is frequently followed by adrenal insufficiency and a relative glucocorticoid deficit. This effect may stem from depression of the synthetic capacity of adrenal glands or frank adrenal necrosis due to disseminated intravascular coagulation (*Waterhouse-Friderichsen syndrome*) (Chapter 19).
- *Immune suppression.* The hyperinflammatory state initiated by sepsis can paradoxically lead to a state of immunosuppression. Proposed mechanisms include production of anti-inflammatory mediators (e.g., soluble TNF receptor and IL-1 receptor antagonist), and widespread apoptosis of lymphocytes in the spleen and lymph nodes, the cause of which is uncertain. It is still debated whether immunosuppressive mediators are deleterious or protective in sepsis.
- *Organ dysfunction.* Systemic hypotension, increased vascular permeability, tissue edema, and small vessel thrombosis all decrease the delivery of oxygen and nutrients to the tissues and contribute to organ dysfunction. High levels of cytokines and secondary mediators can reduce myocardial contractility, thereby blunting cardiac output; increased vascular permeability and endothelial injury in the pulmonary circulation lead to the *acute respiratory distress syndrome* (ARDS) (Chapter 13). Ultimately, these factors conspire to cause multiorgan failure, particularly of the kidneys, liver, lungs, and heart, culminating in death.

Outcomes in patients with septic shock are difficult to predict; in general those with widespread infections and comorbid diseases have the highest mortality rates, but even young healthy individuals with virulent infections (e.g., meningococcal sepsis) can succumb within hours.

In view of the multiplicity of factors and the complexity of the interactions that underlie sepsis, it is perhaps not surprising that most attempts to intervene therapeutically with inhibitors of specific mediators have been of very modest benefit at best. The standard of care remains treatment with appropriate antibiotics, intensive insulin therapy for hyperglycemia, fluid resuscitation to maintain systemic pressures, and "physiologic doses" of corticosteroids to correct relative adrenal insufficiency. Some promising results have been observed in models of sepsis with treatments directed at restoring endothelial cell integrity.

An additional group of secreted bacterial proteins called *superantigens* also cause a syndrome similar to septic shock (e.g., *toxic shock syndrome*). Superantigens are polyclonal T-lymphocyte activators that induce T cells to release high levels of cytokines, which in turn results in a variety of clinical manifestations, ranging from a diffuse rash to vasodilation, hypotension, and death.

## Stages of Shock

Shock is a progressive disorder that leads to death if the underlying problems are not corrected. The exact mechanisms of sepsis-related death are still unclear; aside from increased lymphocyte and enterocyte apoptosis, cellular necrosis is minimal. Death typically follows the failure of multiple organs, which usually offer no morphological clues to explain their dysfunction. For hypovolemic and cardiogenic shock, however, the pathways leading to a patient's demise are reasonably well understood. Unless the insult is massive and rapidly lethal (e.g., exsanguination from a ruptured aortic aneurysm), shock tends to evolve through three general (albeit somewhat artificial) stages. These stages have been documented most clearly in hypovolemic shock but are common to other forms as well:

- An initial *nonprogressive stage,* during which reflex compensatory mechanisms are activated and vital organ perfusion is maintained
- A *progressive stage,* characterized by tissue hypoperfusion and onset of worsening circulatory and metabolic derangement, including acidosis
- An *irreversible stage,* in which cellular and tissue injury is so severe that even if the hemodynamic defects are corrected, survival is not possible

In the early nonprogressive phase of shock, various *neurohumoral mechanisms* help maintain cardiac output and blood pressure. These mechanisms include baroreceptor reflexes, release of catecholamines and antidiuretic hormone, activation of the renin-angiotensin-aldersterone axis, and generalized sympathetic stimulation. The net effect is *tachycardia, peripheral vasoconstriction,* and *renal fluid conservation*; cutaneous vasoconstriction causes the characteristic "shocky" skin coolness and pallor (notably, septic shock can initially cause cutaneous *vasodilation,* so the patient may present with *warm, flushed skin*). Coronary and cerebral vessels are less sensitive to sympathetic signals and maintain relatively normal caliber, blood flow, and oxygen delivery. Thus, blood is shunted away from the skin to the vital organs such as the heart and the brain.

If the underlying causes are not corrected, shock passes imperceptibly to the progressive phase, which as noted is

characterized by widespread tissue hypoxia. In the setting of persistent oxygen deficit, intracellular aerobic respiration is replaced by anaerobic glycolysis with excessive production of lactic acid. The resultant metabolic *lactic acidosis lowers the tissue pH, which blunts the vasomotor response*; arterioles dilate, and blood begins to pool in the microcirculation. Peripheral pooling not only worsens the cardiac output but also puts endothelial cells at risk for the development of anoxic injury with subsequent DIC. With widespread tissue hypoxia, vital organs are affected and begin to fail.

In the absence of appropriate intervention, the process eventually enters an irreversible stage. Widespread cell injury is reflected in lysosomal enzyme leakage, further aggravating the shock state. Myocardial contractile function worsens, in part because of increased nitric oxide synthesis. The ischemic bowel may allow intestinal flora to enter the circulation, and thus bacteremic shock may be superimposed. Commonly, further progression to renal failure occurs as a consequence of ischemic injury of the kidney (Chapter 13), and despite the best therapeutic interventions, the downward spiral frequently culminates in death.

## MORPHOLOGY

The cellular and tissue effects of shock are essentially those of hypoxic injury (Chapter 1) and are caused by a combination of **hypoperfusion and microvascular thrombosis.** Although any organ can be affected, brain, heart, kidneys, adrenals, and gastrointestinal tract are most commonly involved. **Fibrin thrombi** can form in any tissue but typically are most readily visualized in kidney glomeruli. **Adrenal cortical cell lipid depletion** is akin to that seen in all forms of stress and reflects increased utilization of stored lipids for steroid synthesis. While the lungs are resistant to hypoxic injury in hypovolemic shock occurring after hemorrhage, sepsis or trauma can precipitate diffuse alveolar damage (Chapter 12), leading to so-called **shock lung.** Except for neuronal and cardiomyocyte loss, affected tissues can recover completely if the patient survives.

### Clinical Course

The clinical manifestations of shock depend on the precipitating insult. In hypovolemic and cardiogenic shock, patients exhibit hypotension, a weak rapid pulse, tachypnea, and cool, clammy, cyanotic skin. As already noted, in septic shock, the skin may be warm and flushed owing to peripheral vasodilation. The primary threat to life is the underlying initiating event (e.g., myocardial infarction, severe hemorrhage, bacterial infection). However, the cardiac, cerebral, and pulmonary changes rapidly aggravate the situation. If patients survive the initial period, worsening renal function can provoke a phase dominated by progressive oliguria, acidosis, and electrolyte imbalances.

Prognosis varies with the origin of shock and its duration. Thus, more than 90% of young, otherwise healthy patients with hypovolemic shock survive with appropriate management; by comparison, septic or cardiogenic shock is associated with substantially worse outcomes, even with state-of-the-art care.

## SUMMARY

### Shock

- Shock is defined as a state of systemic tissue hypoperfusion due to reduced cardiac output and/or reduced effective circulating blood volume.
- The major types of shock are cardiogenic (e.g., myocardial infarction), hypovolemic (e.g., blood loss), and septic (e.g., infections).
- Shock of any form can lead to hypoxic tissue injury if not corrected.
- Septic shock is caused by the host response to bacterial or fungal infections; it is characterized by endothelial cell activation, vasodilation, edema, disseminated intravascular coagulation, and metabolic derangements.

## BIBLIOGRAPHY


Akhtar S: Fat embolism. Anesthesiol Clin 27:533, 2009. *[Recent overview of the pathogenesis and clinical issues in fat embolism syndrome.]*

Coppola A, Tufano A, Cerbone AM, Di Minno G: Inherited thrombophilia: implications for prevention and treatment of venous thromboembolism. Semin Thromb Hemost 35:683, 2009. *[Review of the genetic underpinnings of hypercoagulable states in a volume of the journal devoted to various aspects of thrombophilia.]*

Crawley J et al: The central role of thrombin in hemostasis. J Thromb Haemost 5 (Suppl 1):95, 2007. *[Review of the various pathways impacted by thrombin activation.]*

Crawley J, Lane D: The haemostatic role of tissue factor pathway inhibitor. Arterioscler Thromb Vasc Biol 28:233, 2008. *[Summary of the physiologic roles of TFPI.]*

Cushman M: Epidemiology and risk factors for venous thrombosis. Semin Hematol 44:62, 2007. *[Overview of the risk factors and pathophysiology of venous clotting.]*

Dahlback B: Blood coagulation and its regulation by anticoagulant pathways: genetic pathogenesis of bleeding and thrombotic diseases. J Intern Med 257:209, 2005. *[Although slightly older, this is a good one-stop review on normal and abnormal hemostasis.]*

Esmon CT, Esmon NL: The link between vascular features and thrombosis. Annu Rev Physiol 2011. *[Up-to-date review of the interactions of endothelium, blood flow, and hemostasis/thrombosis.]*

Goldhaber SZ: Advanced treatment strategies for acute pulmonary embolism, including thrombolysis and embolectomy. J Thromb Haemost 7(Suppl 1):322, 2009. *[Up-to-date guide to the recognition and therapy of pulmonary embolism.]*

Holy EW, Tanner FC: Tissue factor in cardiovascular disease pathophysiology and pharmacological intervention. Adv Pharmacol 59:259, 2010. *[Comprehensive review of the roles of tissue factor in hemostasis and potential pathways to be exploited in preventing pathologic thrombosis.]*

Hong MS, Amanullah AM: Heparin-induced thrombocytopenia: a practical review. Rev Cardiovasc Med 11:13, 2010. *[As characterized by the title, a good, practical review of the mechanisms and therapies for heparin-induced thrombocytopenia.]*

Hotchkiss R, Karl I: The pathophysiology and treatment of sepsis. N Engl J Med 348:138, 2003. *[Although an older paper, this is extremely well-written, and lays a solid pathogenic foundation for the pathways underlying sepsis.]*

Jennings LK: Mechanisms of platelet activation: need for new strategies to protect against platelet-mediated atherothrombosis. Thromb Haemost 102:248, 2009. *[Excellent and current review of the roles played by platelets in thrombosis and inflammation, as well as possible targets for therapeutic intervention.]*

Kwaan HC, Samama MM: The significance of endothelial heterogeneity in thrombosis and hemostasis. Semin Thromb Hemost 36:286, 2010. *[Review with newer data regarding the influence of endothelium on hemostasis and thrombosis.]*

Mackman N, Tilley RE, Key NS: Role of the extrinsic pathway of blood coagulation in hemostasis and thrombosis. Arterioscler Thromb Vasc Biol 27:1687, 2007. *[Good general overview of fundamental pathways in coagulation.]*

Montagnana M, Franchi M, Danese E, et al: Disseminated intravascular coagulation in obstetric and gynecologic disorders. Semin Thromb Hemost 36:404, 2010. *[Review of the mechanisms of DIC, and a good discussion of the pathophysiology of amniotic fluid embolism.]*

Munford RS: Severe sepsis and septic shock: the role of gram-negative bacteremia. Annu Rev Pathol 1:467, 2006. *[An interesting and provocative view regarding the pathogenesis of septic shock.]*

Osinbowale O, Ali L, Chi YW: Venous thromboembolism: a clinical review. Postgrad Med 122:54, 2010. *[Good review at a medical student/house officer level.]*

Stearns-Kurosawa DJ, Osuchowski MF, Valentine C, et al: The pathogenesis of sepsis. Ann Rev Pathol Mech Dis 6:19, 2011. *[Good update on some of the newer approaches to understanding and therapeutically targeting sepsis.]*

Rijken DC, Lijnen HR: New insights into the molecular mechanisms of the fibrinolytic system. J Thromb Haemost 7:4, 2009. *[Excellent review of fibrinolytic pathways.]*

Ruiz-Irastorza G, Crowther M, Branch W, Khamashta MA: Antiphospholipid syndrome. Lancet 376:1498, 2010. *[Good summary of the anti-phospholipid syndrome with emphasis on diagnosis and therapeutics.]*

Wu KK, Matijevic-Aleksic N: Molecular aspects of thrombosis and antithrombotic drugs. Crit Rev Clin Lab Sci 42:249, 2005. *[Lengthy, thorough overview of the mechanisms of thrombus formation with emphasis on targets for therapeutic intervention.]*

Zwicker J, Furie BC, Furie B: Cancer-associated thrombosis. Crit Rev Oncol Hematol 62:126, 2007. *[Thorough review of the mechanisms underlying the hypercoagulable state of malignancy.]*

See Targeted Therapy available online at studentconsult.com

CHAPTER 4

# Diseases of the Immune System

CHAPTER CONTENTS


**Innate and Adaptive Immunity 99**
**Cells and Tissues of the Immune System 100**
Lymphocytes 100
Antigen-Presenting Cells 104
Effector Cells 104
Lymphoid Tissues 104
**Overview of Normal Immune Responses 105**
The Early Innate Immune Response to Microbes 105
The Capture and Display of Microbial Antigens 105
Cell-Mediated Immunity: Activation of T Lymphocytes and Elimination of Cell-Associated Microbes 105
Humoral Immunity: Activation of B Lymphocytes and Elimination of Extracellular Microbes 108
Decline of Immune Responses and Immunologic Memory 109
**Hypersensitivity Reactions: Mechanisms of Immune-Mediated Injury 109**
Causes of Hypersensitivity Reactions 109
Types of Hypersensitivity Reactions 110
Immediate (Type I) Hypersensitivity 111
Antibody-Mediated Diseases (Type II Hypersensitivity) 114
Immune Complex Diseases (Type III Hypersensitivity) 115
T Cell–Mediated (Type IV) Hypersensitivity 117
**Autoimmune Diseases 120**
Immunologic Tolerance 121
Mechanisms of Autoimmunity 122
Systemic Lupus Erythematosus 125
Rheumatoid Arthritis 131
Sjögren Syndrome 131
Systemic Sclerosis (Scleroderma) 132
Inflammatory Myopathies 135
Mixed Connective Tissue Disease 135
Polyarteritis Nodosa and Other Vasculitides 135
IgG4-Related Disease 135
**Rejection of Transplants 135**
Immune Recognition of Allografts 135
Effector Mechanisms of Graft Rejection 137
Methods of Improving Graft Survival 138
Transplantation of Hematopoietic Stem Cells 139
**Immune Deficiency Diseases 139**
Primary (Congenital) Immune Deficiencies 139
Secondary (Acquired) Immune Deficiencies 143
Acquired Immunodeficiency Syndrome (AIDS) 143
**Amyloidosis 153**
Classification of Amyloidosis 154


*Immunity* refers to protection against infections, and the immune system is the collection of cells and molecules that are responsible for defending the body against the countless pathogenic microbes in the environment. Deficiencies in immune defenses result in an increased susceptibility to infections, which can be life-threatening if the deficits are not corrected. On the other hand, the immune system is itself capable of causing great harm and is the root cause of some of the most vexing and intractable diseases of the modern world. Thus, diseases of immunity range from those caused by "too little" to those caused by "too much or inappropriate" immune activity.

This chapter starts with a brief review of some of the basic concepts of lymphocyte biology and normal immune responses, which establishes a foundation for the subsequent discussions of diseases caused by excessive or inappropriate immune responses, rejection of organ transplants and immune deficiency disorders. The chapter concludes with a discussion of amyloidosis, a disease characterized by the abnormal extracellular deposition of certain proteins (some of which are produced in the setting of immune responses).

## INNATE AND ADAPTIVE IMMUNITY

Defense against microbes consists of two types of reactions (Fig. 4–1). *Innate immunity* (also called natural, or native, immunity) is mediated by cells and proteins that are always present and poised to fight against microbes, being called into action immediately in response to infection. The major components of innate immunity are epithelial barriers of the skin, gastrointestinal tract, and respiratory tract, which prevent microbe entry; phagocytic leukocytes (neutrophils and macrophages); a specialized cell type called the natural killer (NK) cell; and several circulating plasma proteins, the most important of which are the proteins of the complement system.

The innate immune response is able to prevent and control many infections. However, many pathogenic microbes have evolved to overcome the early defenses, and protection against these infections requires the more specialized and powerful mechanisms of *adaptive immunity* (also called acquired, or specific, immunity). Adaptive immunity is normally silent and responds (or "adapts") to

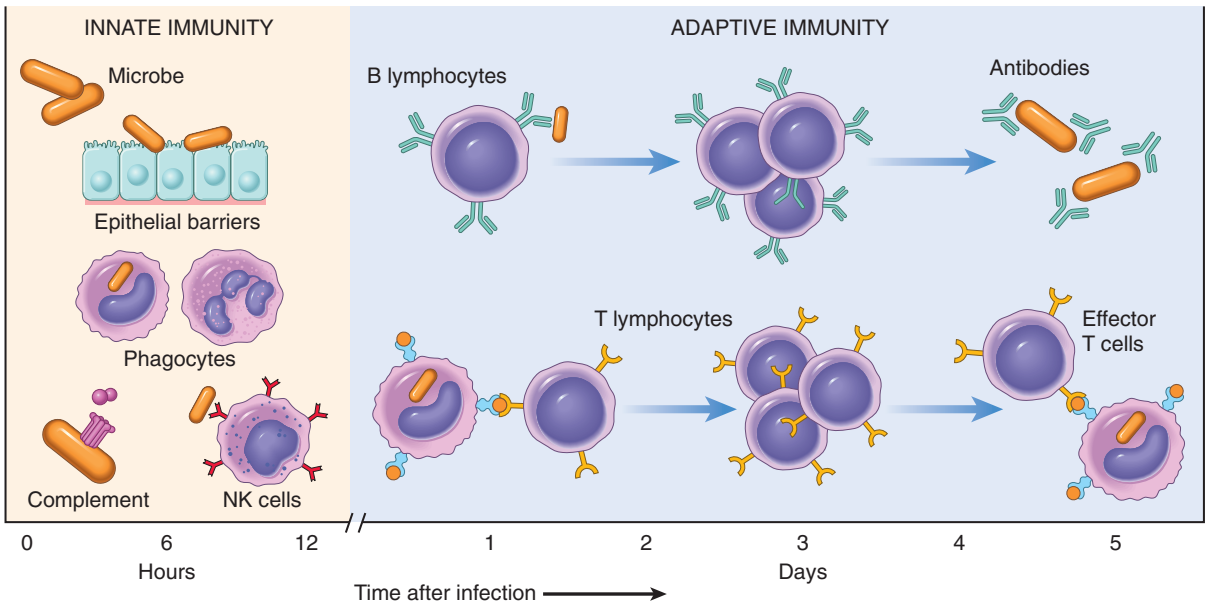


**Figure 4–1** The principal mechanisms of innate immunity and adaptive immunity. NK, natural killer.

the presence of infectious microbes by becoming active, expanding, and generating potent mechanisms for neutralizing and eliminating the microbes. *The components of the adaptive immune system are lymphocytes and their products.* By convention, the terms "immune system" and "immune response" refer to adaptive immunity.

*There are two types of adaptive immune responses: humoral immunity, mediated by soluble proteins called antibodies that are produced by B lymphocytes (also called B cells), and cell-mediated (or cellular) immunity, mediated by T lymphocytes (also called T cells).* Antibodies provide protection against extracellular microbes in the blood, mucosal secretions, and tissues. T lymphocytes are important in defense against intracellular microbes. They work by either directly killing infected cells (accomplished by cytotoxic T lymphocytes) or by activating phagocytes to kill ingested microbes, via the production of soluble protein mediators called cytokines (made by helper T cells). The main properties and functions of the cells of the immune system are described in the next section.

When the immune system is inappropriately triggered or not properly controlled, the same mechanisms that are involved in host defense cause tissue injury and disease. The reaction of the cells of innate and adaptive immunity may be manifested as *inflammation.* As discussed in Chapter 2, inflammation is a beneficial process, but it is also the basis for many human diseases. Presented later in this chapter is an overview of the ways in which the adaptive immune response triggers pathologic inflammatory reactions.

## CELLS AND TISSUES OF THE IMMUNE SYSTEM

*The cells of the immune system consist of lymphocytes, which recognize antigens and mount adaptive immune responses; specialized antigen-presenting cells (APCs), which capture and display microbial and other antigens to the lymphocytes; and various effector cells, whose function is to eliminate microbes and other antigens.* Two remarkable features of the immune system are the specialization of the cells to perform diverse functions, and the precise control mechanisms that permit useful responses when needed and prevent potentially harmful ones.

### Lymphocytes

Lymphocytes are present in the circulation and in various lymphoid organs. Although all lymphocytes appear morphologically identical, there are actually several functionally and phenotypically distinct lymphocyte populations. Lymphocytes develop from precursors in the generative lymphoid organs; T lymphocytes are so called because they mature in the thymus, whereas B lymphocytes mature in the bone marrow. Each T or B lymphocyte expresses receptors for a single antigen, and the total population of lymphocytes (numbering about $10^{12}$ in humans) is capable of recognizing tens or hundreds of millions of antigens. This enormous diversity of antigen recognition is generated by the somatic rearrangement of antigen receptor genes during lymphocyte maturation, and variations that are introduced during the joining of different gene segments to form antigen receptors. These antigen receptors are rearranged and expressed in lymphocytes but not in any other cell. Therefore, the demonstration of antigen receptor gene rearrangements by molecular methods (e.g., polymerase chain reaction [PCR] assay) is a definitive marker of T or B lymphocytes. Because each lymphocyte has a unique DNA rearrangement (and hence a unique antigen receptor), molecular analysis of the rearrangements in cell populations can distinguish polyclonal (non-neoplastic) lymphocyte proliferations from monoclonal (neoplastic) expansions. Such analyses are used in the diagnosis of lymphoid malignancies (Chapter 11).

### *T Lymphocytes*

*Thymus-derived, or T, lymphocytes are the effector cells of cellular immunity and the "helper cells" for antibody responses to protein antigens.* T cells constitute 60% to 70% of the lymphocytes in peripheral blood and are the major lymphocyte population in splenic periarteriolar sheaths and lymph node interfollicular zones. T cells do not detect free or circulating antigens. Instead, the vast majority (greater than 95%) of T cells recognize only peptide fragments of protein antigens bound to proteins of the major histocompatibility complex (MHC). The MHC was discovered on the basis of studies of graft rejection and acceptance (tissue, or "histo," compatibility). It is now known that *the normal function of MHC molecules is to display peptides for recognition by T lymphocytes.* By forcing T cells to see MHC-bound peptides on cell surfaces the system ensures that T cells can recognize antigens displayed by other cells. T cells function by interacting with other cells—either to kill infected cells or to activate phagocytes or B lymphocytes that have ingested protein antigens. In each person, T cells recognize only peptides displayed by that person's MHC molecules, which, of course, are the only MHC molecules that the T cells normally encounter. This phenomenon is called MHC restriction. Peptide antigens presented by self MHC molecules are recognized by the T cell receptor (TCR), which is a heterodimer composed of disulfide-linked α and β protein chains (Fig. 4–2, *A*); each chain has a variable region that participates in binding a particular peptide antigen and a constant region that interacts with associated signaling molecules.

TCRs are noncovalently linked to a cluster of five invariant polypeptide chains, the γ, δ, and ε proteins of the CD3 molecular complex and two ζ chains (Fig. 4–2, *A*). The CD3 proteins and ζ chains do not themselves bind antigens; instead, they are attached to the TCR and deliver intracellular biochemical signals after TCR recognition of antigen. In addition to these signaling proteins, T cells express a number of other invariant molecules that serve diverse functions. CD4 and CD8 are expressed on distinct T cell subsets and serve as coreceptors for T cell activation. During antigen recognition, CD4 molecules on T cells bind to invariant portions of class II MHC molecules (see later) on selected APCs; in an analogous fashion, CD8 binds to class I MHC molecules. CD4 is expressed on 50%–60% of mature T cells, whereas CD8 is expressed on about 40% of T cells. The CD4- and CD8-expressing T cells—called CD4+ and CD8+ cells, respectively—perform different but overlapping functions. CD4+ T cells are "helper" T cells because they secrete soluble molecules (cytokines) that help B cells to produce antibodies (the origin of the name "helper" cells) and also help macrophages to destroy phagocytosed microbes. The central role of CD4+ helper cells in immunity is highlighted by the severe compromise that results from the destruction of this subset by human immunodeficiency

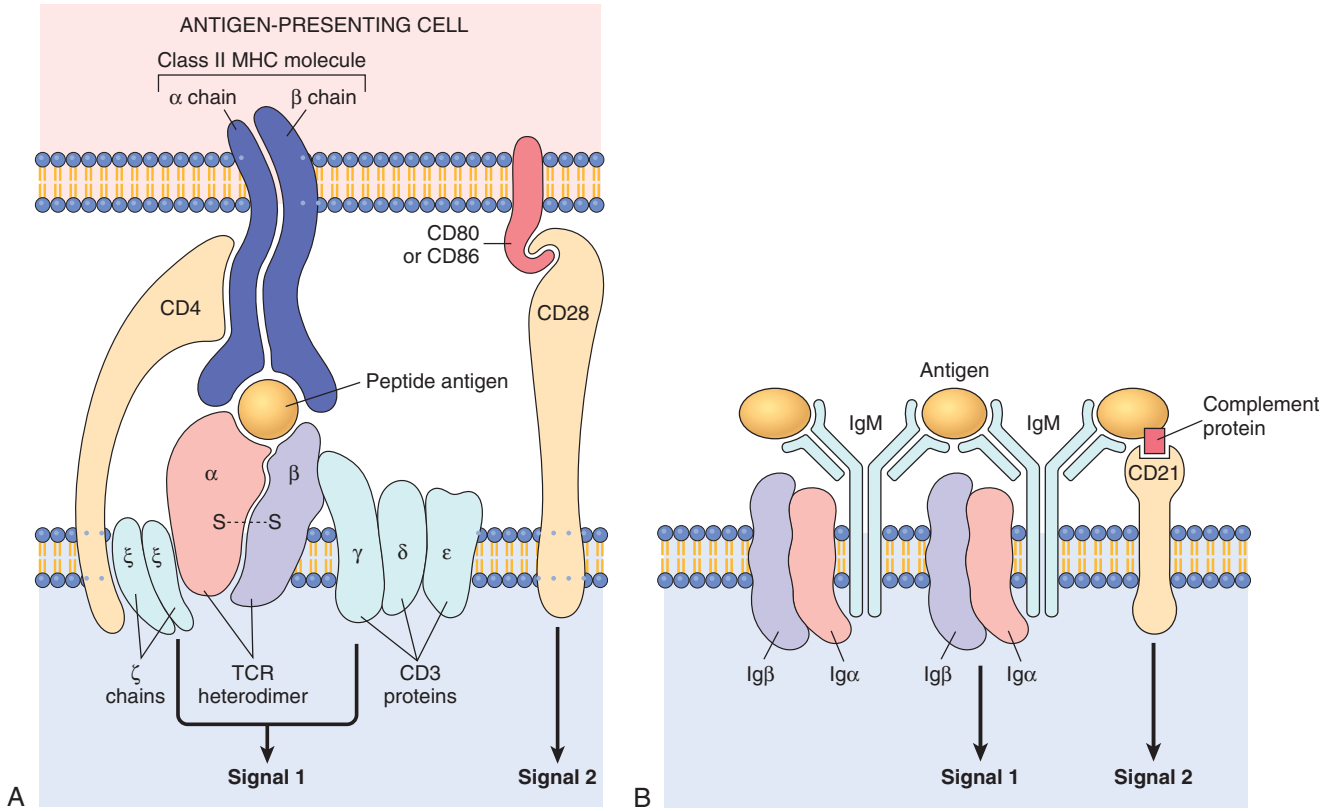


**Figure 4–2** Lymphocyte antigen receptors. **A,** The T cell receptor (TCR) complex and other molecules involved in T cell activation. The TCRα and TCRβ chains recognize antigen (in the form of peptide–MHC complexes expressed on antigen-presenting cells), and the linked CD3 complex initiates activating signals. CD4 and CD28 are also involved in T cell activation. (Note that some T cells express CD8 and not CD4; these molecules serve analogous roles.) **B,** The B cell receptor complex is composed of membrane IgM (or IgD, *not shown*) and the associated signaling proteins Igα and Igβ. CD21 is a receptor for a complement component that promotes B cell activation. Ig, immunoglobulin; MHC, major histocompatibilty complex.

virus (HIV) infection. CD8+ T cells can also secrete cytokines, but they play a more important role in directly killing virus-infected or tumor cells, and hence are called "cytotoxic" T lymphocytes (CTLs). Other important invariant proteins on T cells include CD28, which functions as the receptor for molecules that are induced on APCs by microbes (and are called costimulators), and various adhesion molecules that strengthen the bond between the T cells and APCs and control the migration of the T cells to different tissues.

In a minority of peripheral blood T cells and in many of the T cells associated with mucosal surfaces (e.g., lung, gastrointestinal tract), the TCRs are heterodimers of γ and δ chains, which are similar but not identical to the α and β chains of most TCRs. Such γδ T cells, which do not express CD4 or CD8, recognize nonprotein molecules (e.g., bacterial lipoglycans), but their functional roles are not well understood. Another small population of T cells expresses markers of T cells and NK cells. These so-called NKT cells recognize microbial glycolipids, and may play a role in defense against some infections. The antigen receptors of NKT cells are much less diverse than the receptors of "conventional" T cells, suggesting that the former recognize conserved microbial structures.

Another population of T cells that functions to suppress immune responses is that of regulatory T lymphocytes. This cell type is described later, in the context of tolerance of self antigens.

### *Major Histocompatibility Complex Molecules: The Peptide Display System of Adaptive Immunity*

Because MHC molecules are fundamental to T cell recognition of antigens, and because genetic variations in MHC molecules are associated with immunologic diseases, it is important to review the structure and function of these molecules. The human MHC, known as the human leukocyte antigen (HLA) complex, consists of a cluster of genes on chromosome 6 (Fig. 4–3). The HLA system is highly polymorphic; that is, there are several alternative forms (alleles) of a gene at each locus (estimated to number about 3500 for all HLA genes and about 1100 for HLA-B alleles alone). Such diversity provides a system whereby a vast range of peptides can be displayed by MHC molecules for recognition by T cells. As we shall see, this polymorphism also constitutes a formidable barrier to organ transplantation.

On the basis of their chemical structure, tissue distribution, and function, MHC gene products fall into two main categories:

- *Class I MHC* molecules are encoded by three closely linked loci, designated HLA-A, HLA-B, and HLA-C (Fig. 4–3). Each of these molecules is a heterodimer, consisting of a polymorphic 44-kDa α chain noncovalently associated with an invariant 12-kDa $\beta_2$-microglobulin polypeptide (encoded by a separate gene on chromosome 15). The extracellular portion of the α chain

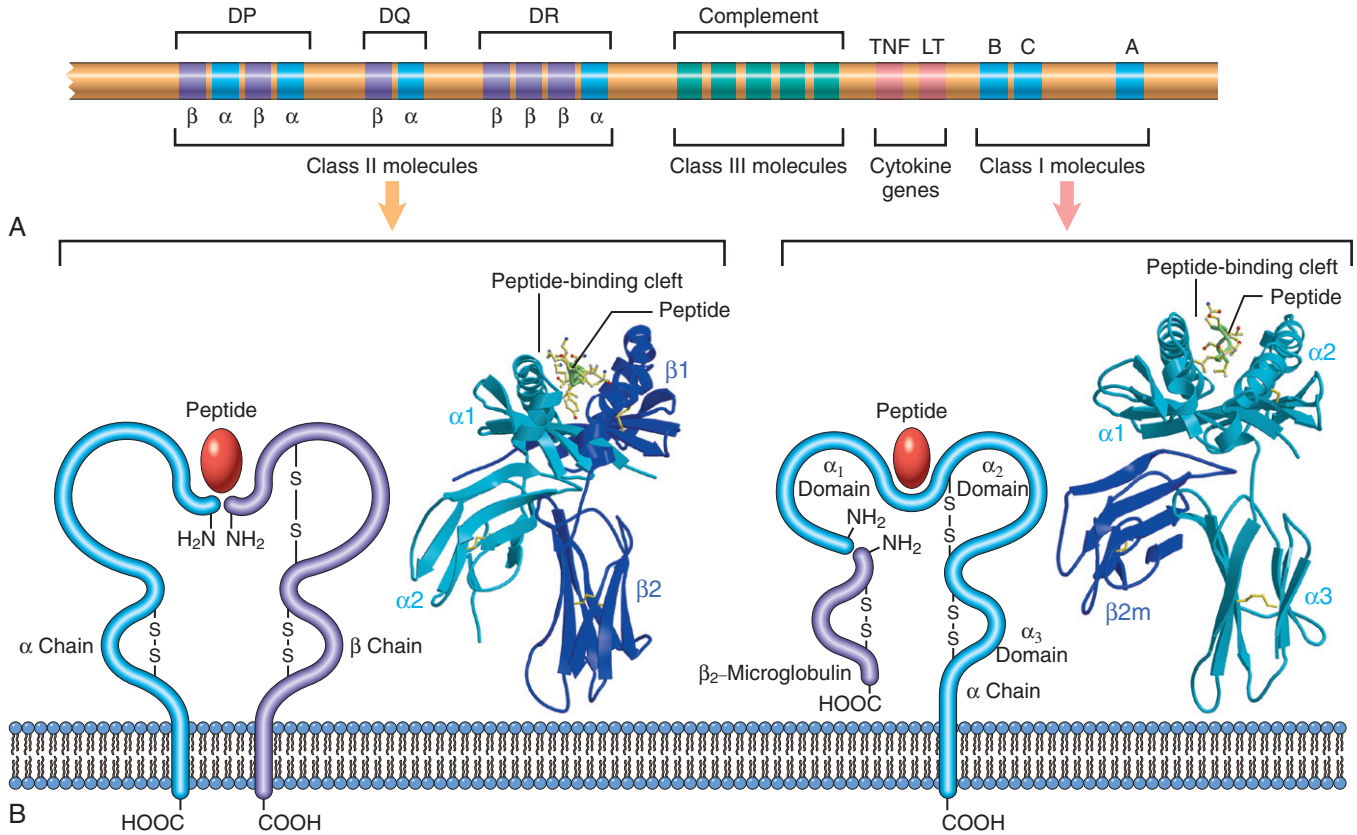


**Figure 4–3** The human leukocyte antigen (HLA) complex and the structure of HLA molecules. **A,** The location of genes in the HLA complex. The sizes and distances between genes are not to scale. The class II region also contains genes that encode several proteins involved in antigen processing (not shown). **B,** Schematic diagrams and crystal structures of class I and class II HLA molecules. LT, lymphotoxin; TNF, tumor necrosis factor.
*(Crystal structures are courtesy of Dr. P. Bjorkman, California Institute of Technology, Pasadena, California.)*

contains a cleft where the polymorphic residues are located and where foreign peptides bind to MHC molecules for presentation to T cells, and a conserved region that binds CD8, ensuring that only CD8+ T cells can respond to peptides displayed by class I molecules. In general, class I MHC molecules bind and display peptides derived from proteins synthesized in the cytoplasm of the cell (e.g., viral antigens). Because class I MHC molecules are present on all nucleated cells, all virus-infected cells can be detected and eliminated by CD8+ CTLs.

- *Class II MHC* molecules are encoded by genes in the HLA-D region, which contains at least three subregions: DP, DQ, and DR. Class II MHC molecules are heterodimers of noncovalently linked polymorphic α and β subunits (Fig. 4–3). The extracellular portion of the class II MHC heterodimer contains a cleft for the binding of antigenic peptides and a region that binds CD4. Class II MHC expression is restricted to a few types of cells, mainly APCs (notably, dendritic cells [DCs]), macrophages, and B cells. In general, class II MHC molecules bind to peptides derived from proteins synthesized outside the cell (e.g., those derived from extracellular bacteria) and ingested into the cell. This property allows CD4+ T cells to recognize the presence of extracellular pathogens and to orchestrate a protective response.
- Several other proteins are encoded in the MHC locus, some of which have been called "class III molecules." These include complement components (C2, C3, and Bf) and the cytokines tumor necrosis factor (TNF) and lymphotoxin. These molecules do not form a part of the peptide display system and are not discussed further.

Each person inherits one HLA allele from each parent; typically, then, two different molecules are expressed for every HLA locus. Cells of a heterozygous person can therefore express six different class I HLA molecules: three of maternal origin and three of paternal origin. Similarly, a given individual expresses maternal and paternal alleles of the class II MHC loci; because some HLA-D α and β chains can mix and match with each other, each class II–expressing cell can have as many as 20 different class II MHC molecules. Different MHC alleles bind to different peptide fragments; *the expression of many different MHC molecules allows each cell to present a wide array of peptide antigens*.

As a result of the polymorphism at the major HLA loci in the population, a virtually infinite number of combinations of molecules exist, and each person expresses a unique MHC antigenic profile on his or her cells. The combination of HLA alleles for each person is called the HLA haplotype. The implications of HLA polymorphism are obvious in the context of transplantation—because each person has HLA alleles that differ to some extent from every other person's, grafts from virtually any donor will evoke immune responses in the recipient and be rejected (except, of course, for identical twins). In fact, HLA molecules were discovered in the course of early attempts at tissue transplantation. HLA molecules of the graft evoke both humoral and cell-mediated responses, eventually leading to graft destruction (as discussed later in this chapter). This ability of MHC molecules to trigger immune responses is the reason these molecules are often called "antigens." It is believed that the polymorphism of MHC genes arose to enable display of and response to any conceivable microbial peptide encountered in the environment.

The role of the MHC in T cell stimulation also has important implications for the genetic control of immune responses. The ability of any given MHC allele to bind the peptide antigens generated from a particular pathogen will determine whether a specific person's T cells can actually "see" and respond to that pathogen. The inheritance of particular alleles influences both protective and harmful immune responses. For example, if the antigen is ragweed pollen and the response is an allergic reaction, inheritance of some HLA genes may make individuals susceptible to "hay fever," the colloquial name for ragweed allergy. On the other hand, responsiveness to a viral antigen, determined by inheritance of certain HLA alleles, may be beneficial for the host.

Finally, *many autoimmune diseases are associated with particular HLA alleles*. We return to a discussion of HLA associations with diseases when we consider autoimmunity.

### B Lymphocytes

*Bone marrow–derived B lymphocytes are the cells that produce antibodies and are thus the effector cells of humoral immunity.* B cells make up 10% to 20% of the circulating peripheral lymphocyte population. They also are present in bone marrow and in the follicles of peripheral lymphoid tissues (lymph nodes, spleen, tonsils, and other mucosal tissues).

B cells recognize antigen by means of membrane-bound antibody of the immunoglobulin M (IgM) class, expressed on the surface together with signaling molecules to form the B cell receptor (BCR) complex (Fig. 4–2, *B*). Whereas T cells can recognize only MHC-associated peptides, B cells can recognize and respond to many more chemical structures, including soluble or cell-associated proteins, lipids, polysaccharides, nucleic acids, and small chemicals; furthermore, B cells (and antibodies) recognize native (properly folded) forms of these antigens. As with TCRs, each antibody has a unique antigen specificity. The diversity of antibodies is generated during somatic rearrangements of immunoglobulin genes. B cells express several invariant molecules that are responsible for signal transduction and for activation of the cells (Fig. 4–2, *B*). Some are the signaling molecules attached to the BCR; another example is CD21 (also known as the type 2 complement receptor, or CR2), which recognizes a complement breakdown product that frequently is deposited on microbes and promotes B cell responses to microbial antigens. Interestingly, the ubiquitous Epstein-Barr virus has cleverly evolved to use CD21 as a receptor for binding to B cells and infecting them.

After stimulation, B cells differentiate into *plasma cells,* which secrete large amounts of antibodies, the mediators of humoral immunity. There are five classes, or isotypes, of immunoglobulins: IgG, IgM, and IgA constitute more than 95% of circulating antibodies. IgA is the major isotype in mucosal secretions; IgE is present in the circulation at very low concentrations and also is found attached to the surfaces of tissue mast cells; and IgD is expressed on the surfaces of B cells but is not secreted. As discussed later, each isotype has characteristic abilities to activate

complement or recruit inflammatory cells and thus plays a different role in host defense and disease states.

### *Natural Killer Cells*

Natural killer (NK) cells are lymphocytes that arise from the common lymphoid progenitor that gives rise to T and B lymphocytes. However, NK cells are cells of innate immunity and do not express highly variable and clonally distributed receptors for antigens. Therefore, *they do not have specificities as diverse as do T cells or B cells*. NK cells have two types of receptors—inhibitory and activating. The inhibitory receptors recognize self class I MHC molecules, which are expressed on all healthy cells, whereas the activating receptors recognize molecules that are expressed or upregulated on stressed or infected cells or cells with DNA damage. Normally, the effects of the inhibitory receptors dominate over those of the activating receptors, thereby preventing activation of the NK cells. Infections (especially viral infections) and stress are associated with reduced expression of class I MHC molecules, thus releasing the NK cells from inhibition. At the same time, there is increased engagement of the activating receptors. The net result is that the NK cells are activated and the infected or stressed cells are killed and eliminated.

## Antigen-Presenting Cells

The immune system contains several cell types that are specialized to capture microbial antigens and display these to lymphocytes. Foremost among these APCs are dendritic cells (DCs), the major cells for displaying protein antigens to naive T cells to initiate immune responses. Several other cell types present antigens to different lymphocytes at various stages of immune responses.

### *Dendritic Cells*

Cells with dendritic morphology (i.e., with fine dendritic cytoplasmic processes) occur as two functionally distinct types. *Dendritic cells (DCs)*, sometimes called interdigitating DCs, express high levels of class II MHC and T cell costimulatory molecules and function to capture and present antigens to T cells. DCs reside in and under epithelia, where they are strategically located to capture entering microbes; an example is the Langerhans cell of the epidermis. DCs also are present in the T cell zones of lymphoid tissues, where they present antigens to T cells circulating through these tissues, and in the interstitium of many nonlymphoid organs, such as the heart and lungs, where they are poised to capture the antigens of any invading microbes. One subset of DCs is called *plasmacytoid DCs* because of their resemblance to plasma cells. These cells are present in the blood and lymphoid organs, and are major sources of the antiviral cytokine type I interferon, produced in response to many viruses.

The second type of cells with dendritic morphology are *follicular dendritic cells (FDCs)*. These cells are located in the germinal centers of lymphoid follicles in the spleen and lymph nodes. FDCs bear receptors for the Fc tails of IgG molecules and for complement proteins and hence efficiently trap antigens bound to antibodies and complement. These cells display antigens to activated B lymphocytes in lymphoid follicles and promote secondary antibody responses, but are not involved in capturing antigens for display to T cells.

### *Other Antigen-Presenting Cells*

Macrophages ingest microbes and other particulate antigens and display peptides for recognition by T lymphocytes. These T cells in turn activate the macrophages to kill the microbes, the central reaction of cell-mediated immunity. B cells present peptides to helper T cells and receive signals that stimulate antibody responses to protein antigens.

## Effector Cells

Many different types of leukocytes perform the ultimate task of the immune response, which is to eliminate infections. NK cells are front-line effector cells in that they can rapidly react against "stressed" cells. Antibody-secreting plasma cells are the effector cells of humoral immunity. T lymphocytes, both CD4+ helper T cells and CD8+ CTLs, are effector cells of cell-mediated immunity. These lymphocytes often function in host defense together with other cells. Macrophages, as described in Chapter 2, bind microbes that are coated with antibodies or complement and then phagocytose and destroy these microbes, thus serving as effector cells of humoral immunity. Macrophages also respond to signals from helper T cells, which improves their ability to destroy phagocytosed microbes, thus serving as effector cells of cellular immunity. T lymphocytes secrete cytokines that recruit and activate other leukocytes, such as neutrophils and eosinophils, and together these cell types function in defense against various pathogens.

## Lymphoid Tissues

The lymphoid tissues of the body are divided into generative (primary) organs, where lymphocytes express antigen receptors and mature, and peripheral (secondary) lymphoid organs, where adaptive immune responses develop. The generative organs are the thymus and bone marrow, and the peripheral organs are the lymph nodes, spleen, and mucosal and cutaneous lymphoid tissues. Mature lymphocytes recirculate through the peripheral organs, hunting for microbial antigens that they can respond to. An important characteristic of these organs is that T and B lymphocytes are anatomically organized in a manner that facilitates the adaptive immune response, a process that is described later.

## SUMMARY

### Cells and Tissues of the Immune System

- Lymphocytes are the mediators of adaptive immunity and the only cells that produce specific and diverse receptors for antigens.
- T (thymus-derived) lymphocytes express TCRs that recognize peptide antigens displayed by MHC molecules on the surface of APCs.

- B (bone marrow–derived) lymphocytes express membrane-bound antibodies that recognize a wide variety of antigens. B cells are activated to become plasma cells, which secrete antibodies.
- NK cells kill cells that are infected by some microbes or are stressed and damaged beyond repair. NK cells express inhibitory receptors that recognize MHC molecules that are normally expressed on healthy cells, and are thus prevented from killing normal cells.
- APCs capture microbes and other antigens, transport them to lymphoid organs, and display them for recognition by lymphocytes. The most efficient APCs are DCs, which are located in epithelia and most tissues.
- The cells of the immune system are organized in tissues. Some of these tissues are the sites of mature lymphocyte production (the generative lymphoid organs, the bone marrow and thymus), while others are the sites of immune responses (the peripheral lymphoid organs, including lymph nodes, spleen, and mucosal lymphoid tissues).

# OVERVIEW OF NORMAL IMMUNE RESPONSES

The previous section described the major components of the immune system. This section summarizes the key features of normal immune responses. This overview will serve as a foundation for the subsequent discussions of diseases caused by deficient or uncontrolled immune responses.

## The Early Innate Immune Response to Microbes

The principal barriers between hosts and their environment are the epithelia of the skin and the gastrointestinal and respiratory tracts. Infectious microbes usually enter through these routes and attempt to colonize the hosts. The mechanisms of innate immunity operate at every step in a microbe's attempt to invade. At the site of entry, epithelia serve as physical barriers to infections and eliminate microbes through production of peptide antibiotics and the actions of intraepithelial lymphocytes. If microbes are able to survive and traverse these epithelia, they encounter phagocytes, including neutrophils, which are rapidly recruited from the blood into tissues, and macrophages, which live in tissues under epithelia. The function of these phagocytic cells is to ingest microbes and destroy them by producing microbicidal substances. In response to recognition of microbes, phagocytes, DCs, and many other cell types secrete proteins called cytokines (described later), which promote inflammation and microbial killing and enhance protective immune responses. Cells use several receptors to sense microbes; foremost among these are the Toll-like receptors (TLRs), so named because of homology with the *Drosophila* Toll protein, that recognize bacterial and viral components (Chapter 2). NK cells kill virus-infected cells and produce the macrophage-activating cytokine IFN-γ. If the microbes enter the blood, many plasma proteins, including the proteins of the complement system, recognize the microbes and are activated, and their products kill microbes and coat (opsonize) the microbes for phagocytosis. In addition to combating infections, innate immune responses stimulate subsequent adaptive immunity, providing signals that are essential for initiating the responses of antigen-specific T and B lymphocytes.

## The Capture and Display of Microbial Antigens

Microbes that enter through epithelia, along with their protein antigens, are captured by DCs that are resident in and under these epithelia. Antigen-bearing DCs then migrate to draining lymph nodes (Fig. 4–4). Protein antigens are proteolytically digested in the APCs to generate peptides that are displayed on the surface of the APCs bound to MHC molecules. Antigens in different cellular compartments are presented by different MHC molecules and are recognized by different subsets of T cells. Antigens that are ingested from the extracellular environment are processed in endosomal and lysosomal vesicles and then are displayed bound to class II MHC molecules. Because CD4 binds to class II MHC molecules, CD4+ helper T cells recognize class II–associated peptides. By contrast, antigens in the cytoplasm are displayed by class I MHC molecules and are recognized by CD8+ cytotoxic T cells, because CD8 binds to class I MHC. This segregation of different antigens is key to the specialized functions of CD4+ and CD8+ T cells; as we discuss below, the two classes of T cells are designed to combat microbes that are located in different cellular compartments. Protein antigens, as well as polysaccharides and other nonprotein antigens, can also be recognized directly by B lymphocytes in the lymphoid follicles of the peripheral lymphoid organs.

Before being recognized by B and T cells, the microbe elicits an innate immune response. This response activates APCs to express costimulatory molecules and secrete cytokines that stimulate the proliferation and differentiation of T lymphocytes. The principal costimulators for T cells are the B7 molecules (CD80 and CD86) that are expressed on APCs and recognized by the CD28 receptor on naive T cells. The innate immune response to some microbes and polysaccharides also results in the activation of complement, generating cleavage products that enhance the proliferation and differentiation of B lymphocytes. Thus, antigen (signal 1 in Fig. 4–2) and molecules produced during innate immune responses (signal 2 in Fig. 4–2) function cooperatively to activate antigen-specific lymphocytes. The requirement for microbe-triggered signal 2 ensures that the adaptive immune response is induced by microbes and not by harmless substances.

## Cell-Mediated Immunity: Activation of T Lymphocytes and Elimination of Cell-Associated Microbes

Naive T lymphocytes are activated by antigen and costimulators in peripheral lymphoid organs, and proliferate and differentiate into effector cells, most of which migrate to any site where the antigen (microbe) is present (Fig. 4–4). Upon activation, T lymphocytes secrete soluble proteins called *cytokines,* which function as growth and

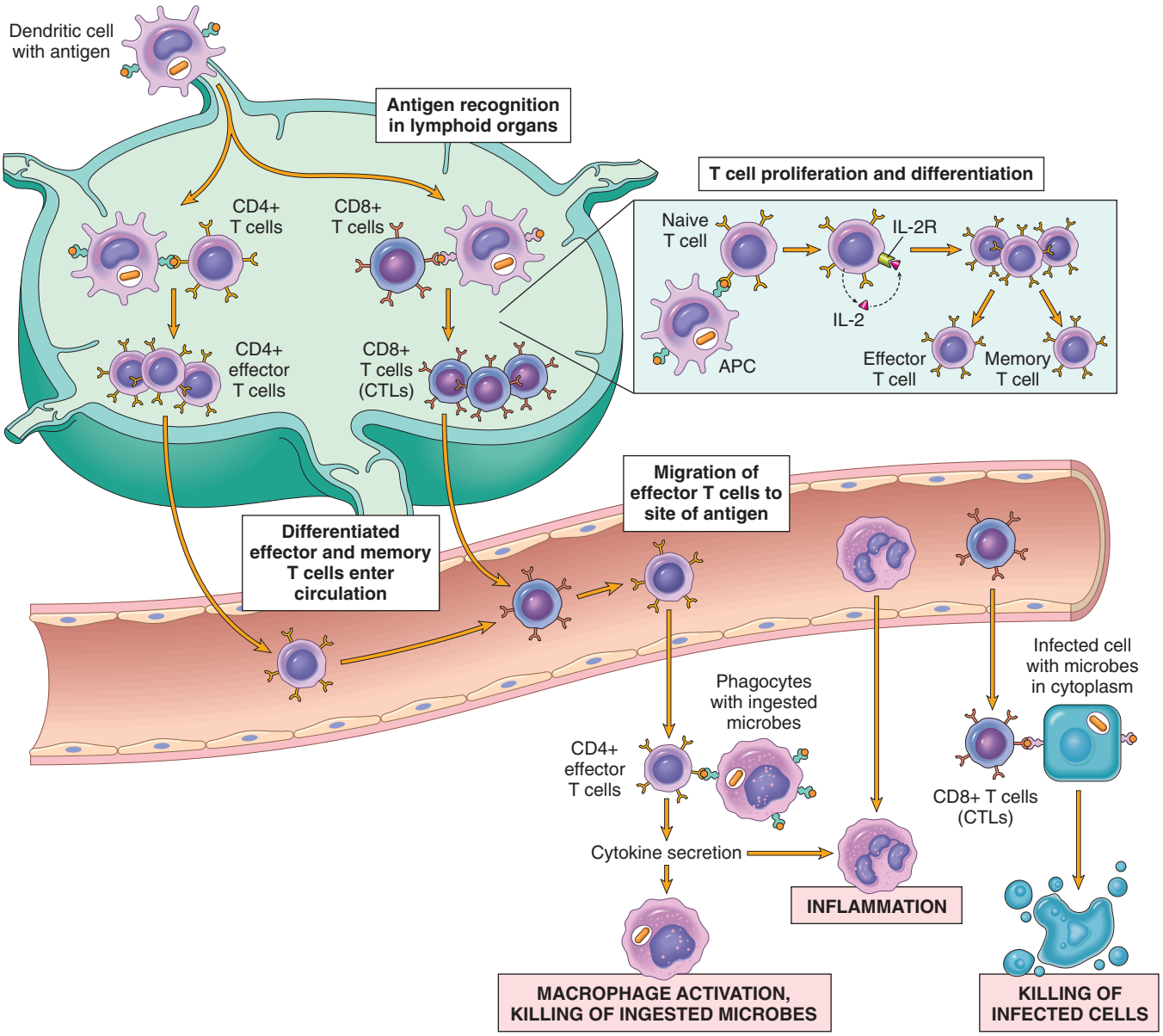


**Figure 4–4** Cell-mediated immunity. Naive T cells recognize MHC-associated peptide antigens displayed on dendritic cells in lymph nodes. The T cells are activated to proliferate (under the influence of the cytokine IL-2) and to differentiate into effector and memory cells, which migrate to sites of infection and serve various functions in cell-mediated immunity. Effector CD4+ T cells of the $T_H1$ subset recognize the antigens of microbes ingested by phagocytes and activate the phagocytes to kill the microbes; $T_H17$ effector cells enhance leukocyte recruitment and stimulate inflammation; $T_H2$ cells activate eosinophils. CD8+ CTLs kill infected cells harboring microbes in the cytoplasm. Some activated T cells differentiate into long-lived memory cells. APC, antigen-presenting cell; CTLs, cytotoxic T lymphocytes.

differentiation factors for lymphocytes and other cells, and mediate communications between leukocytes. Because of the important roles of cytokines in both beneficial immune responses and in inflammatory diseases, it is important to understand their properties and actions.

### *Cytokines: Messenger Molecules of the Immune System*

Cytokines are polypeptide products of many cell types (but principally activated lymphocytes and macrophages) that function as mediators of inflammation and immune responses. They were introduced in Chapter 2 in the context of inflammation; here we review their general properties and focus on those cytokines specifically involved in immunity.

Although different cytokines have diverse actions and functions, they all share some common features. Cytokines are synthesized and secreted in response to external stimuli, which may be microbial products, antigen recognition, or other cytokines. Their secretion typically is transient and is controlled by transcription and post-translational mechanisms. The actions of cytokines may be *autocrine* (on the cell that produces the cytokine), *paracrine* (on adjacent cells), and, less commonly, *endocrine* (at a distance from the site

of production) (Chapter 2). The effects of cytokines tend to be pleiotropic (one cytokine can have diverse biologic activities, often on many cell types) and redundant (multiple cytokines may have the same activity). Molecularly defined cytokines are called interleukins, referring to their ability to mediate communications between leukocytes.

Cytokines may be grouped into several classes on the basis of their biologic activities and functions.

- *Cytokines involved in innate immunity and inflammation,* the earliest host response to microbes and dead cells. The major cytokines in this group are TNF and interleukin-1 (IL-1) and a group of chemoattractant cytokines called chemokines. IL-12, IFN-γ, IL-6, IL-23, and several other cytokines also participate in the early innate immune response. Major sources of these cytokines are activated macrophages and DCs, as well as endothelial cells, lymphocytes, mast cells, and other cell types. These were described in Chapter 2.
- *Cytokines that regulate lymphocyte responses and effector functions in adaptive immunity.* Different cytokines are involved in the proliferation and differentiation of lymphocytes (e.g., IL-2, IL-4), and in the activation of various effector cells (e.g., IFN-γ, which activates macrophages; IL-5, which activates eosinophils). The major sources of these cytokines are CD4+ helper T lymphocytes stimulated by antigens and costimulators. These cytokines are key participants in the induction and effector phases of adaptive cell-mediated immune responses (see later).
- *Cytokines that stimulate hematopoiesis.* Many of these are called colony-stimulating factors. They function to increase the output of leukocytes from the bone marrow and to thus replenish leukocytes that are consumed during immune and inflammatory reactions.

### *Effector Functions of T Lymphocytes*

One of the earliest responses of CD4+ helper T cells is secretion of the cytokine IL-2 and expression of high-affinity receptors for IL-2. IL-2 is a growth factor that acts on these T lymphocytes and stimulates their proliferation, leading to an increase in the number of antigen-specific lymphocytes. Some of the progeny of the expanded pool of T cells differentiate into effector cells that can secrete different sets of cytokines and thus perform different functions. *The best-defined subsets of CD4+ helper cells are the $T_H1$, $T_H2$, and $T_H17$ subsets* (Fig. 4–5). $T_H1$ cells produce the cytokine IFN-γ, which activates macrophages and stimulates B cells to produce antibodies that activate complement and coat microbes for phagocytosis. $T_H2$ cells produce IL-4, which stimulates B cells to differentiate into IgE-secreting plasma cells; IL-5, which activates eosinophils; and IL-13, which activates mucosal epithelial cells to secrete mucus and expel microbes, and activates macrophages to secrete growth factors important for tissue repair. $T_H17$ cells produce the cytokine IL-17, which recruits neutrophils and thus promotes inflammation; $T_H17$ cells play an important role in some T cell–mediated inflammatory disorders. These effector cells migrate to sites of infection and accompanying tissue damage. When the differentiated effectors again encounter cell-associated microbes, they are activated to perform the functions that are responsible for elimination of the microbes. The key mediators of the functions of helper T cells are various cytokines and the surface molecule called CD40 ligand (CD40L), which binds to its receptor, CD40, on B cells and macrophages. Differentiated CD4+ effector T cells of the $T_H1$ subset recognize microbial peptides on macrophages that have ingested the microbes. The T cells express CD40L, which engages CD40 on the macrophages, and the T cells secrete the cytokine IFN-γ,

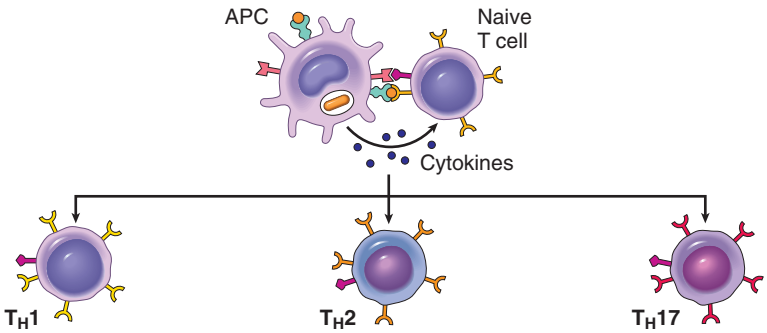


| | $T_H1$ | $T_H2$ | $T_H17$ |
|---|---|---|---|
| **Cytokines produced** | IFN-γ | IL-4, IL-5, IL-13 | IL-17, IL-22, chemokines |
| **Cytokines that induce this subset** | IFN-γ, IL-12 | IL-4 | TGF-β, IL-6, IL-1, IL-23 |
| **Immunologic reactions triggered** | Macrophage activation, stimulation of IgG antibody production | Stimulation of IgE production, activation of mast cells and eosinophils | Recruitment of neutrophils, monocytes |
| **Host defense against** | Intracellular microbes | Helminthic parasites | Extracellular bacteria, fungi |
| **Role in disease** | Immune-mediated chronic inflammatory diseases (often autoimmune) | Allergies | Immune-mediated chronic inflammatory diseases (often autoimmune) |

**Figure 4–5** Subsets of CD4+ effector T cells. In response to stimuli (mainly cytokines) present at the time of antigen recognition, naive CD4+ helper T cells may differentiate into populations of effector cells that produce distinct sets of cytokines and perform different functions. The types of immune reactions elicited by each subset, and its role in host defense and immunological diseases, are summarized. Two other populations of CD4+ T cells, regulatory cells and follicular helper cells, are not shown.

which is a potent macrophage activator. The combination of CD40- and IFN-γ–mediated activation results in the induction of potent microbicidal substances in the macrophages, including reactive oxygen species and nitric oxide, leading to the destruction of ingested microbes. $T_H2$ cells elicit cellular defense reactions that are dominated by eosinophils and not macrophages. As discussed later, CD4+ helper T cells also stimulate B cell responses by CD40L and cytokines. Some CD4+ T cells remain in the lymphoid organs in which they were activated and then migrate into follicles, where they stimulate antibody responses; these cells are called follicular helper T cells.

Activated CD8+ lymphocytes differentiate into CTLs, which kill cells harboring microbes in the cytoplasm. These microbes may be viruses that infect many cell types, or bacteria that are ingested by macrophages but have learned to escape from phagocytic vesicles into the cytoplasm (where they are inaccessible to the killing machinery of phagocytes, which is largely confined to vesicles). By destroying the infected cells, CTLs eliminate the reservoirs of infection.

## Humoral Immunity: Activation of B Lymphocytes and Elimination of Extracellular Microbes

Upon activation, B lymphocytes proliferate and then differentiate into plasma cells that secrete different classes of antibodies with distinct functions (Fig. 4–6). There are two major mechanisms of B cell activation.

- *T cell–independent.* Many polysaccharide and lipid antigens have multiple identical antigenic determinants (epitopes) that are able to engage several antigen receptor molecules on each B cell and initiate the process of B cell activation.
- *T cell–dependent.* Typical globular protein antigens are not able to bind to many antigen receptors, and the full response of B cells to protein antigens requires help from CD4+ T cells. B cells also can act as APCs—they ingest protein antigens, degrade them, and display peptides bound to class II MHC molecules for recognition by helper T cells. The helper T cells express CD40L and secrete cytokines, which work together to activate the B cells.

Some of the progeny of the expanded B cell clones differentiate into antibody-secreting *plasma cells.* Each plasma cell secretes antibodies that have the same specificity as the cell surface antibodies (B cell receptors) that first recognized the antigen. Polysaccharides and lipids stimulate secretion mainly of IgM antibody. Protein antigens, by virtue of CD40L- and cytokine-mediated helper T cell actions, induce the production of antibodies of different classes (IgG, IgA, IgE). This production of functionally different antibodies, all with the same specificity, is called heavy-chain class (isotype) switching; it provides plasticity in the antibody response, allowing antibodies to serve many functions. Helper T cells also stimulate the production of antibodies with higher and higher affinity for the antigen. This process, called affinity maturation, improves the quality of the humoral immune response.

The humoral immune response combats microbes in numerous ways (Fig. 4–6).

- Antibodies bind to microbes and prevent them from infecting cells, thereby "neutralizing" the microbes.

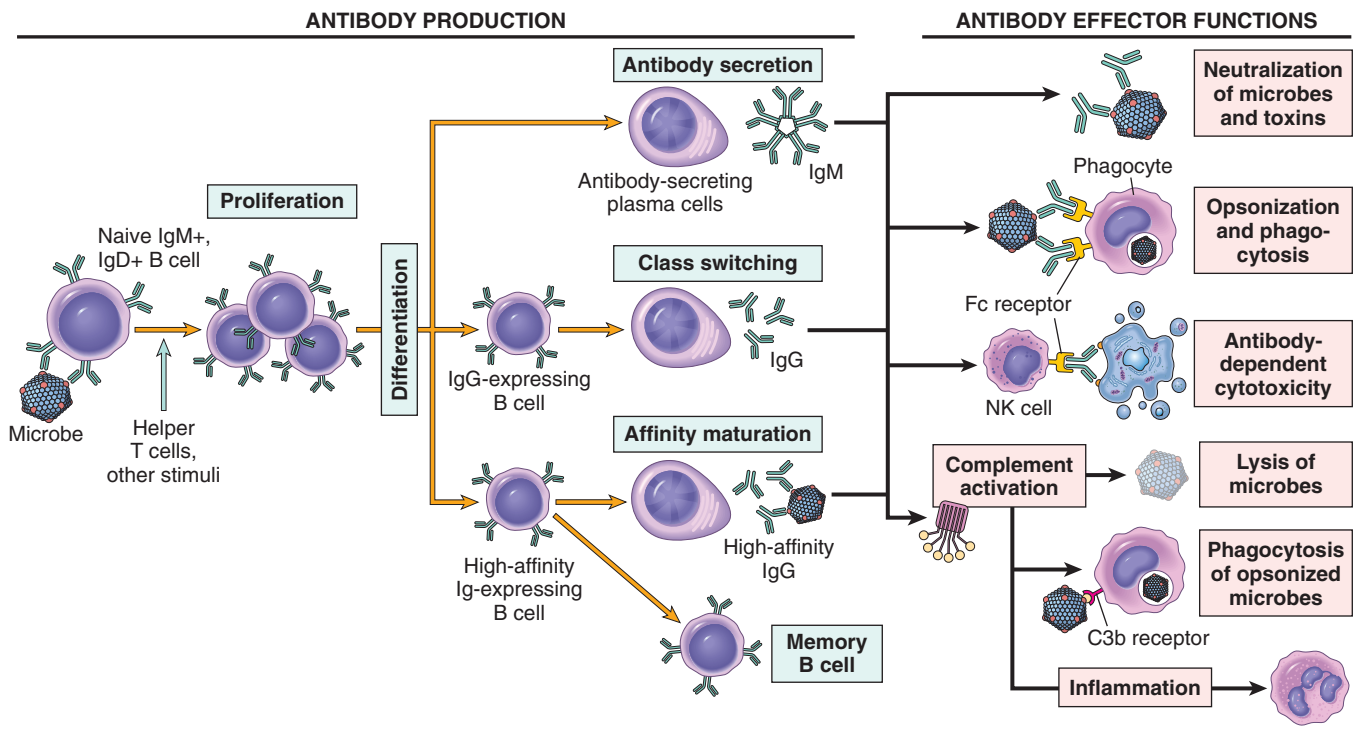


**Figure 4–6** Humoral immunity. Naive B lymphocytes recognize antigens, and under the influence of helper T cells and other stimuli (not shown), the B cells are activated to proliferate and to differentiate into antibody-secreting plasma cells. Some of the activated B cells undergo heavy chain class switching and affinity maturation, and some become long-lived memory cells. Antibodies of different heavy chain isotypes (classes) perform different effector functions, shown on the right.

- IgG antibodies coat ("opsonize") microbes and target them for phagocytosis, since phagocytes (neutrophils and macrophages) express receptors for the Fc tails of IgG molecules.
- IgG and IgM activate the complement system by the classical pathway, and complement products promote phagocytosis and destruction of microbes. Production of most opsonizing and complement-fixing IgG antibodies is stimulated by IFN-γ, typically produced by $T_H1$ helper cells, which respond to many bacteria and viruses, and IgG antibodies are important mechanisms of defense against these microbes.
- IgA is secreted in mucosal tissues and neutralizes microbes in the lumens of the respiratory and gastrointestinal tracts (and other mucosal tissues).
- IgG is actively transported across the placenta and protects the newborn until the immune system becomes mature. This is called *passive immunity*.
- IgE coats helminthic parasites and functions with mast cells and eosinophils to kill them. As mentioned earlier, $T_H2$ helper cells secrete cytokines that stimulate the production of IgE and activate eosinophils, and thus the response to helminths is orchestrated by $T_H2$ cells.

Circulating IgG antibodies have half-lives of about 3 weeks, which is much longer than the half-lives of most blood proteins, as a consequence of special mechanisms for recycling IgG and reducing its catabolism. Some antibody-secreting plasma cells migrate to the bone marrow and live for years, continuing to produce low levels of antibodies.

### Decline of Immune Responses and Immunologic Memory

A majority of effector lymphocytes induced by an infectious pathogen die by apoptosis after the microbe is eliminated, thus returning the immune system to its basal resting state. This return to a stable or steady state, called homeostasis, occurs because microbes provide essential stimuli for lymphocyte survival and activation, and effector cells are short-lived. Therefore, as the stimuli are eliminated, the activated lymphocytes are no longer kept alive.

The initial activation of lymphocytes also generates long-lived *memory cells*, which may survive for years after the infection. Memory cells are an expanded pool of antigen-specific lymphocytes (more numerous than the naive cells specific for any antigen that are present before encounter with that antigen), and memory cells respond faster and more effectively against the antigen than do naive cells. This is why the generation of memory cells is an important goal of vaccination.

This brief discussion of the normal immune response sets the stage for a consideration of the situations in which immune responses become abnormal, and of how these abnormalities lead to tissue injury and disease.

#### SUMMARY

##### Overview of Normal Immune Responses

- The physiologic function of the immune system is defense against infectious microbes.
- The early reaction to microbes is mediated by the mechanisms of innate immunity, which are ready to respond to microbes. These mechanisms include epithelial barriers, phagocytes, NK cells, and plasma proteins (e.g., of the complement system). The reaction of innate immunity is often manifested as inflammation.
- The defense reactions of adaptive immunity develop slowly, but are more potent and specialized.
- Microbes and other foreign antigens are captured by DCs and transported to lymph nodes, where the antigens are recognized by naive lymphocytes. The lymphocytes are activated to proliferate and differentiate into effector and memory cells.
- Cell-mediated immunity is the reaction of T lymphocytes, designed to combat cell-associated microbes (e.g., phagocytosed microbes and microbes in the cytoplasm of infected cells). Humoral immunity is mediated by antibodies and is effective against extracellular microbes (in the circulation and mucosal lumens).
- CD4+ helper T cells help B cells to make antibodies, activate macrophages to destroy ingested microbes, stimulate recruitment of leukocytes, and regulate all immune responses to protein antigens. The functions of CD4+ T cells are mediated by secreted proteins called cytokines. CD8+ CTLs kill cells that express antigens in the cytoplasm that are seen as foreign (e.g., virus-infected and tumor cells).
- Antibodies secreted by plasma cells neutralize microbes and block their infectivity, and promote the phagocytosis and destruction of pathogens. Antibodies also confer passive immunity to neonates.

## HYPERSENSITIVITY REACTIONS: MECHANISMS OF IMMUNE-MEDIATED INJURY

Immune responses that normally are protective are also capable of causing tissue injury. Injurious immune reactions are grouped under *hypersensitivity*, and the resulting diseases are called hypersensitivity diseases. This term originated from the idea that persons who mount immune responses against an antigen are "sensitized" to that antigen, so pathologic or excessive reactions represent manifestations of a "hypersensitive" state. Normally, an exquisite system of checks and balances optimizes the eradication of infecting organisms without serious injury to host tissues. However, immune responses may be inadequately controlled or inappropriately targeted to host tissues, and in such situations, the normally beneficial response is the cause of disease. In this section we describe the causes and general mechanisms of hypersensitivity diseases and then discuss specific situations in which the immune response is responsible for the disease.

### Causes of Hypersensitivity Reactions

Pathologic immune responses may be directed against different types of antigens and may result from various underlying abnormalities.

- *Autoimmunity: reactions against self antigens.* Normally, the immune system does not react against self-generated antigens. This phenomenon is called self tolerance, implying that the body "tolerates" its own antigens. On occasion, self-tolerance fails, resulting in reactions against the body's own cells and tissues; collectively, such reactions constitute autoimmunity. The diseases caused by autoimmunity are referred to as autoimmune diseases. We shall return to the mechanisms of self-tolerance and autoimmunity later in this chapter.
- *Reactions against microbes.* There are many types of reactions against microbial antigens that may cause disease. In some cases, the reaction appears to be excessive or the microbial antigen is unusually persistent. If antibodies are produced against such antigens, the antibodies may bind to the microbial antigens to produce immune complexes, which deposit in tissues and trigger inflammation; this is the underlying mechanism of poststreptococcal glomerulonephritis (Chapter 13). T cell responses against persistent microbes may give rise to severe inflammation, sometimes with the formation of granulomas (Chapter 2); this is the cause of tissue injury in tuberculosis and other infections. Rarely, antibodies or T cells reactive with a microbe cross-react with a host tissue; such cross-reactivity is believed to be the basis for rheumatic heart disease (Chapter 10). In some instances, the disease-causing immune response may be entirely normal, but in the process of eradicating the infection, host tissues are injured. In viral hepatitis, the virus that infects liver cells is not cytopathic, but it is recognized as foreign by the immune system. Cytotoxic T cells try to eliminate infected cells, and this normal immune response damages liver cells.
- *Reactions against environmental antigens.* Most healthy people do not react strongly against common environmental substances (e.g., pollens, animal danders, or dust mites), but almost 20% of the population are "allergic" to these substances. These individuals are genetically predisposed to make unusual immune responses to a variety of noninfectious, and otherwise harmless, antigens to which all persons are exposed but against which only some react.

In all of these conditions, tissue injury is caused by the same mechanisms that normally function to eliminate infectious pathogens—namely, antibodies, effector T lymphocytes, and various other effector cells. The problem in these diseases is that the response is triggered and maintained inappropriately. Because the stimuli for these abnormal immune responses are difficult or impossible to eliminate (e.g., self antigens, persistent microbes, or environmental antigens), and the immune system has many intrinsic positive feedback loops (amplification mechanisms), once a pathologic immune response starts it is difficult to control or terminate it. Therefore, these hypersensitivity diseases tend to be chronic and debilitating, and are therapeutic challenges. Since inflammation, typically chronic inflammation, is a major component of the pathology of these disorders, they are sometimes grouped under the rubric *immune-mediated inflammatory diseases.*

## Types of Hypersensitivity Reactions

*Hypersensitivity reactions are traditionally subdivided into four types based on the principal immune mechanism responsible for injury*; three are variations on antibody-mediated injury, whereas the fourth is T cell–mediated (Table 4–1). The rationale for this classification is that the mechanism of immune injury is often a good predictor of the clinical manifestations and may even help to guide the therapy. However, this classification of immune-mediated diseases is not perfect, because several immune reactions may coexist in one disease.

- *Immediate (type I) hypersensitivity,* often called *allergy,* results from the activation of the $T_H2$ subset of CD4+ helper T cells by environmental antigens, leading to the production of IgE antibodies, which become attached to mast cells. When these IgE molecules bind the antigen (allergen), the mast cells are triggered to release mediators that transiently affect vascular permeability and

**Table 4–1** Mechanisms of Hypersensitivity Reactions

| Type | Immune Mechanisms | Histopathologic Lesions | Prototypical Disorders |
|---|---|---|---|
| Immediate (type I) hypersensitivity | Production of IgE antibody → immediate release of vasoactive amines and other mediators from mast cells; later recruitment of inflammatory cells | Vascular dilation, edema, smooth muscle contraction, mucus production, tissue injury, inflammation | Anaphylaxis; allergies; bronchial asthma (atopic forms) |
| Antibody-mediated (type II) hypersensitivity | Production of IgG, IgM → binds to antigen on target cell or tissue → phagocytosis or lysis of target cell by activated complement or Fc receptors; recruitment of leukocytes | Phagocytosis and lysis of cells; inflammation; in some diseases, functional derangements without cell or tissue injury | Autoimmune hemolytic anemia; Goodpasture syndrome |
| Immune complex–mediated (type III) hypersensitivity | Deposition of antigen–antibody complexes → complement activation → recruitment of leukocytes by complement products and Fc receptors → release of enzymes and other toxic molecules | Inflammation, necrotizing vasculitis (fibrinoid necrosis) | Systemic lupus erythematosus; some forms of glomerulonephritis; serum sickness; Arthus reaction |
| Cell-mediated (type IV) hypersensitivity | Activated T lymphocytes → (1) release of cytokines, inflammation and macrophage activation; (2) T cell–mediated cytotoxicity | Perivascular cellular infiltrates; edema; granuloma formation; cell destruction | Contact dermatitis; multiple sclerosis; type 1 diabetes; tuberculosis |

IgE, IgG, IgM, immunoglobulins E, G, M.

induce smooth muscle contraction in various organs, and that also may stimulate more prolonged inflammation (the late-phase reaction). These diseases are commonly called allergic, or atopic, disorders.

- *Antibody-mediated (type II) hypersensitivity disorders* are caused by antibodies that bind to fixed tissue or cell surface antigens, promoting phagocytosis and destruction of the coated cells or triggering pathologic inflammation in tissues.
- *Immune complex–mediated (type III) hypersensitivity disorders* are caused by antibodies binding to antigens to form complexes that circulate and deposit in vascular beds and stimulate inflammation, typically as a consequence of complement activation. Tissue injury in these diseases is the result of the inflammation.
- *T cell–mediated (type IV) hypersensitivity disorders* are caused mainly by immune responses in which T lymphocytes of the $T_H1$ and $T_H17$ subsets produce cytokines that induce inflammation and activate neutrophils and macrophages, which are responsible for tissue injury. CD8+ CTLs also may contribute to injury by directly killing host cells.

## Immediate (Type I) Hypersensitivity

*Immediate hypersensitivity is a tissue reaction that occurs rapidly (typically within minutes) after the interaction of antigen with IgE antibody that is bound to the surface of mast cells in a sensitized host.* The reaction is initiated by entry of an antigen, which is called an allergen because it triggers allergy. Many allergens are environmental substances that are harmless for most persons on exposure. Some people apparently inherit genes that make them susceptible to allergies. This susceptibility is manifested by the propensity of such persons to mount strong $T_H2$ responses and, subsequently, to produce IgE antibody against the allergens. The IgE is central to the activation of the mast cells and release of mediators that are responsible for the clinical and pathologic manifestations of the reaction. Immediate hypersensitivity may occur as a local reaction that is merely annoying (e.g., seasonal rhinitis, or hay fever), severely debilitating (asthma), or even fatal (anaphylaxis).

### *Sequence of Events in Immediate Hypersensitivity Reactions*

Most hypersensitivity reactions follow the same sequence of cellular responses (Fig. 4–7):

- *Activation of $T_H2$ cells and production of IgE antibody.* Allergens may be introduced by inhalation, ingestion, or injection. Variables that probably contribute to the strong $T_H2$ responses to allergens include the route of entry, dose, and chronicity of antigen exposure, and the genetic makeup of the host. It is not clear if allergenic substances also have unique structural properties that endow them with the ability to elicit $T_H2$ responses. *Immediate hypersensitivity is the prototypical $T_H2$-mediated reaction.* The $T_H2$ cells that are induced secrete several cytokines, including IL-4, IL-5, and IL-13, which are responsible for essentially all the reactions of immediate hypersensitivity. IL-4 stimulates B cells specific for the allergen to undergo heavy-chain class switching to IgE and to secrete this immunoglobulin isotype. IL-5 activates eosinophils that are recruited to the reaction, and IL-13 acts on epithelial cells and stimulates mucus secretion. $T_H2$ cells often are recruited to the site of allergic reactions in response to chemokines that are produced locally; among these chemokines is eotaxin, which also recruits eosinophils to the same site.
- *Sensitization of mast cells by IgE antibody.* Mast cells are derived from precursors in the bone marrow, are widely distributed in tissues, and often reside near blood vessels and nerves and in subepithelial locations. Mast cells

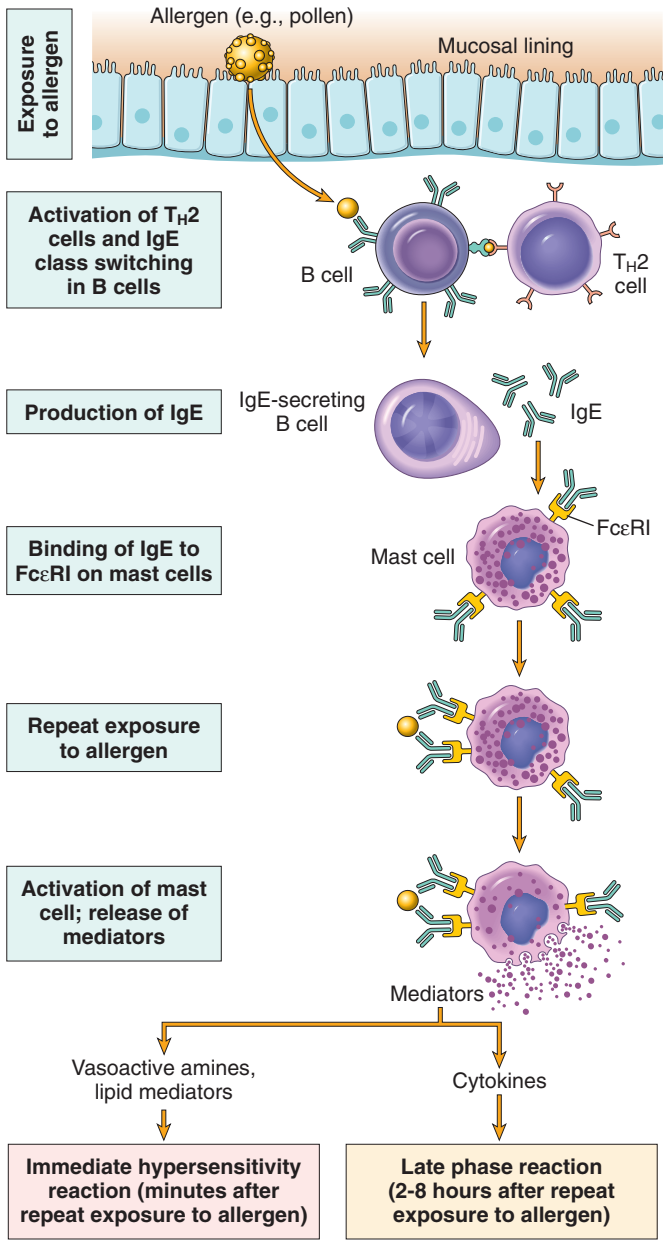


**Figure 4–7** Sequence of events in immediate (type I) hypersensitivity. Immediate hypersensitivity reactions are initiated by the introduction of an allergen, which stimulates $T_H2$ responses and IgE production. IgE binds to Fc receptors (FcεRI) on mast cells, and subsequent exposure to the allergen activates the mast cells to secrete the mediators that are responsible for the pathologic manifestations of immediate hypersensitivity.

express a high-affinity receptor for the Fc portion of the ε heavy chain of IgE, called FcεRI. Even though the serum concentration of IgE is very low (in the range of 1 to 100 μg/mL), the affinity of the mast cell FcεRI receptor is so high that the receptors are always occupied by IgE. These antibody-bearing mast cells are "sensitized" to react if the antigen binds to the antibody molecules. Basophils are the circulating counterparts of mast cells. They also express FcεRI, but their role in most immediate hypersensitivity reactions is not established (since these reactions occur in tissues and not in the circulation). The third cell type that expresses FcεRI is eosinophils, which often are present in these reactions and also have a role in IgE-mediated host defense against helminth infections, described later.

- *Activation of mast cells and release of mediators.* When a person who was sensitized by exposure to an allergen is reexposed to the allergen, it binds to multiple specific IgE molecules on mast cells, usually at or near the site of allergen entry. When these IgE molecules are cross-linked, a series of biochemical signals is triggered in the mast cells. The signals culminate in the secretion of various mediators from the mast cells. Three groups of mediators are the most important in different immediate hypersensitivity reactions (Fig. 4–8):
  - *Vasoactive amines released from granule stores.* The granules of mast cells contain histamine, which is released within seconds or minutes of activation. Histamine causes vasodilation, increased vascular permeability, smooth muscle contraction, and increased secretion of mucus. Other rapidly released mediators include adenosine (which causes bronchoconstriction and inhibits platelet aggregation) and chemotactic factors for neutrophils and eosinophils. Other mast cell granule contents that may be secreted include several neutral proteases (e.g., tryptase), which may damage tissues and also generate kinins and cleave complement components to produce additional chemotactic and inflammatory factors (e.g., C3a) (Chapter 2). The granules also contain acidic proteoglycans (heparin, chondroitin sulfate), the main function of which seems to be as a storage matrix for the amines.
  - *Newly synthesized lipid mediators.* Mast cells synthesize and secrete prostaglandins and leukotrienes, by the same pathways as do other leukocytes (Chapter 2). These lipid mediators have several actions that are important in immediate hypersensitivity reactions. Prostaglandin $D_2$ ($PGD_2$) is the most abundant mediator generated by the cyclooxygenase pathway in mast cells. It causes intense bronchospasm as well as increased mucus secretion. The leukotrienes $LTC_4$ and $LTD_4$ are the most potent vasoactive and spasmogenic agents known; on a molar basis, they are several thousand times more active than histamine in increasing vascular permeability and in causing bronchial smooth muscle contraction. $LTB_4$ is highly chemotactic for neutrophils, eosinophils, and monocytes.
  - *Cytokines.* Activation of mast cells results in the synthesis and secretion of several cytokines that are important for the late-phase reaction. These include TNF and chemokines, which recruit and activate leukocytes (Chapter 2); IL-4 and IL-5, which amplify the $T_H2$-initiated immune reaction; and IL-13, which stimulates epithelial cell mucus secretion.

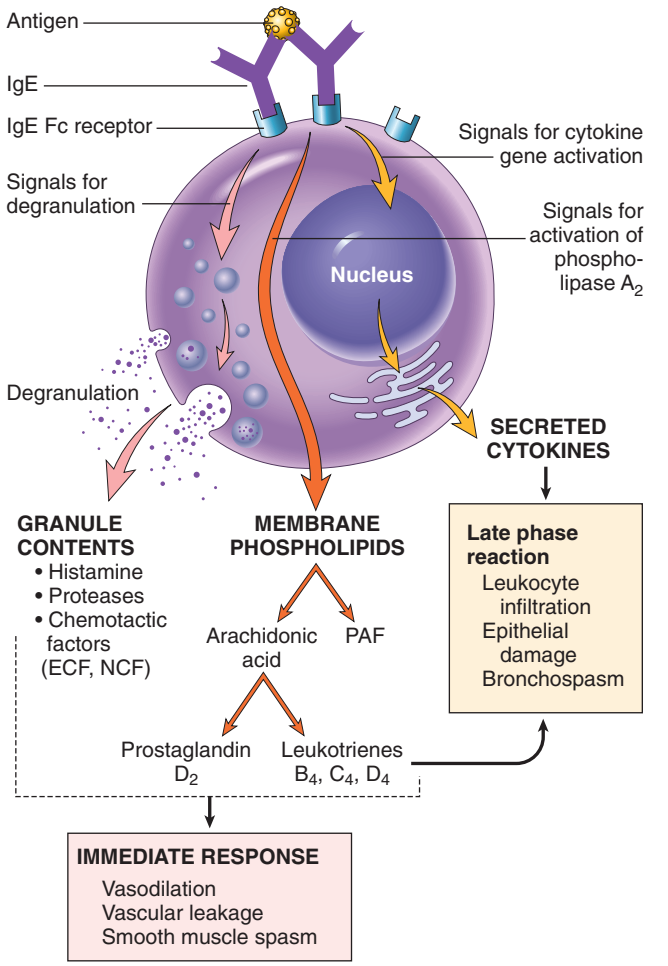


**Figure 4–8** Mast cell mediators. Upon activation, mast cells release various classes of mediators that are responsible for the immediate and late-phase reactions. ECF, eosinophil chemotactic factor; NCF, neutrophil chemotactic factor (neither of these has been biochemically defined); PAF, platelet-activating factor.

In summary, a variety of compounds that act on blood vessels, smooth muscle, and leukocytes mediate type I hypersensitivity reactions (Table 4–2). Some of these compounds are released rapidly from sensitized mast cells and are responsible for the intense immediate reactions associated with conditions such as systemic anaphylaxis. Others, such as cytokines, are responsible for the inflammation seen in late-phase reactions.

Often, the IgE-triggered reaction has two well-defined phases (Fig. 4–9): (1) the *immediate response,* characterized by vasodilation, vascular leakage, and smooth muscle spasm, usually evident within 5 to 30 minutes after exposure to an allergen and subsiding by 60 minutes; and (2) a second, *late-phase reaction* that usually sets in 2 to 8 hours later and may last for several days and is characterized by inflammation as well as tissue destruction, such as mucosal epithelial cell damage. The dominant inflammatory cells in the late-phase reaction are neutrophils, eosinophils, and lymphocytes, especially $T_H2$ cells. Neutrophils are recruited by various chemokines; their roles in inflammation were described in Chapter 2. Eosinophils are recruited by eotaxin

**Table 4–2** Summary of the Action of Mast Cell Mediators in Immediate (Type I) Hypersensitivity

| Action | Mediators |
|---|---|
| Vasodilation, increased vascular permeability | Histamine<br>PAF<br>Leukotrienes $C_4$, $D_4$, $E_4$<br>Neutral proteases that activate complement and kinins<br>Prostaglandin $D_2$ |
| Smooth muscle spasm | Leukotrienes $C_4$, $D_4$, $E_4$<br>Histamine<br>Prostaglandins<br>PAF |
| Cellular infiltration | Cytokines (e.g., chemokines, TNF)<br>Leukotriene $B_4$<br>Eosinophil and neutrophil chemotactic factors (not defined biochemically) |

PAF, platelet-activating factor; TNF, tumor necrosis factor.

and other chemokines released from TNF-activated epithelium and are important effectors of tissue injury in the late-phase response. Eosinophils produce major basic protein and eosinophil cationic protein, which are toxic to epithelial cells, and $LTC_4$ and platelet-activating factor, which promote inflammation. $T_H2$ cells produce cytokines that have multiple actions, as described earlier. These recruited leukocytes can amplify and sustain the inflammatory response even in the absence of continuous allergen exposure. In addition, inflammatory leukocytes are responsible for much of the epithelial cell injury in immediate hypersensitivity. Because inflammation is a major component of many allergic diseases, notably asthma and atopic dermatitis, therapy usually includes anti-inflammatory drugs such as corticosteroids.

### *Clinical and Pathologic Manifestations*

An immediate hypersensitivity reaction may occur as a systemic disorder or as a local reaction. The nature of the reaction is often determined by the route of antigen exposure. Systemic exposure to protein antigens (e.g., in bee venom) or drugs (e.g., penicillin) may result in systemic anaphylaxis. Within minutes of the exposure in a sensitized host, itching, urticaria (hives), and skin erythema appear, followed in short order by profound respiratory difficulty caused by pulmonary bronchoconstriction and accentuated by hypersecretion of mucus. Laryngeal edema may exacerbate matters by causing upper airway obstruction. In addition, the musculature of the entire gastrointestinal tract may be affected, with resultant vomiting, abdominal cramps, and diarrhea. Without immediate intervention, there may be systemic vasodilation with a fall in blood pressure (anaphylactic shock), and the patient may progress to circulatory collapse and death within minutes.

Local reactions generally occur when the antigen is confined to a particular site, such as skin (contact, causing urticaria), gastrointestinal tract (ingestion, causing diarrhea), or lung (inhalation, causing bronchoconstriction). The common forms of skin and food allergies, hay fever, and certain forms of asthma are examples of localized allergic reactions. However, ingestion or inhalation of allergens also can trigger systemic reactions.

Susceptibility to localized type I reactions has a strong genetic component, and the term *atopy* is used to imply familial predisposition to such localized reactions. Patients who suffer from nasobronchial allergy (including hay fever and some forms of asthma) often have a family history of similar conditions. Genes that are implicated in susceptibility to asthma and other atopic disorders include those encoding HLA molecules (which may confer immune responsiveness to particular allergens), cytokines (which may control $T_H2$ responses), a component of the FcεRI, and ADAM33, a metalloproteinase that may be involved in tissue remodeling in the airways.

The reactions of immediate hypersensitivity clearly did not evolve solely to cause human discomfort and disease. The immune response dependent on $T_H2$ cells and IgE—in particular, the late-phase inflammatory reaction—plays an important protective role in combating parasitic infections.

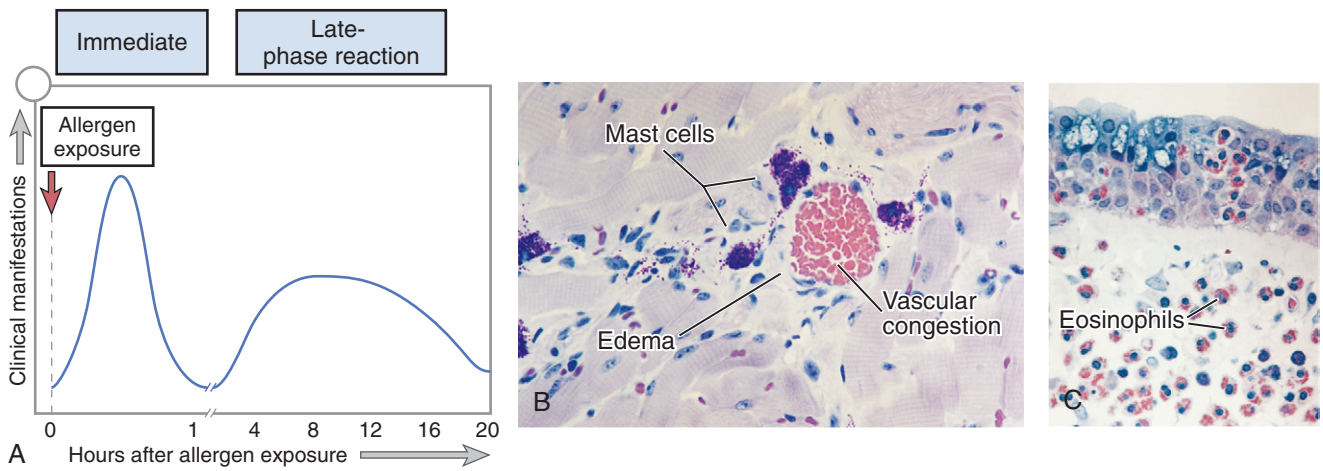


**Figure 4–9** Immediate hypersensitivity. **A,** Kinetics of the immediate and late-phase reactions. The immediate vascular and smooth muscle reaction to allergen develops within minutes after challenge (allergen exposure in a previously sensitized person), and the late-phase reaction develops 2 to 24 hours later. **B–C,** Morphology: The immediate reaction **(B)** is characterized by vasodilation, congestion, and edema, and the late-phase reaction **(C)** is characterized by an inflammatory infiltrate rich in eosinophils, neutrophils, and T cells.

*(B and C, Courtesy of Dr. Daniel Friend, Department of Pathology, Brigham and Women's Hospital, Boston, Massachusetts.)*

IgE antibodies are produced in response to many helminthic infections, and their physiologic function is to target helminths for destruction by eosinophils and mast cells. Mast cells also are involved in defense against bacterial infections. And snake aficionados will be relieved to hear that their mast cells may protect them from some snake venoms by releasing granule proteases that degrade the toxins. Why these beneficial responses are inappropriately activated by harmless environmental antigens, giving rise to allergies, remains a puzzle.

## SUMMARY

### Immediate (Type I) Hypersensitivity

- Also called allergic reactions, or allergies
- Induced by environmental antigens (allergens) that stimulate strong $T_H2$ responses and IgE production in genetically susceptible individuals
- IgE coats mast cells by binding to Fcε receptors; reexposure to the allergen leads to cross-linking of the IgE and FcεRI, activation of mast cells, and release of mediators.
- Principal mediators are histamine, proteases, and other granule contents; prostaglandins and leukotrienes; and cytokines.
- Mediators are responsible for the immediate vascular and smooth muscle reactions and the late-phase reaction (inflammation).
- The clinical manifestations may be local or systemic, and range from mildly annoying rhinitis to fatal anaphylaxis.

## Antibody-Mediated Diseases (Type II Hypersensitivity)

*Antibody-mediated (type II) hypersensitivity disorders are caused by antibodies directed against target antigens on the surface of cells or other tissue components.* The antigens may be normal molecules intrinsic to cell membranes or in the extracellular matrix, or they may be adsorbed exogenous antigens (e.g., a drug metabolite). Antibody-mediated abnormalities are the underlying cause of many human diseases; examples of these are listed in Table 4–3. In all of these disorders, the tissue damage or functional abnormalities result from a limited number of mechanisms.

### *Mechanisms of Antibody-Mediated Diseases*

Antibodies cause disease by targeting cells for phagocytosis, by activating the complement system, and by interfering with normal cellular functions (Fig. 4–10). The antibodies that are responsible typically are high-affinity antibodies capable of activating complement and binding to the Fc receptors of phagocytes.

- *Opsonization and phagocytosis.* When circulating cells, such as erythrocytes or platelets, are coated (opsonized) with autoantibodies, with or without complement proteins, the cells become targets for phagocytosis by neutrophils and macrophages (Fig. 4–10, *A*). These phagocytes express receptors for the Fc tails of IgG antibodies and for breakdown products of the C3 complement protein, and use these receptors to bind and ingest opsonized particles. Opsonized cells are usually eliminated in the spleen, and this is why splenectomy is of

**Table 4–3** Examples of Antibody-Mediated Diseases (Type II Hypersensitivity)

| Disease | Target Antigen | Mechanisms of Disease | Clinicopathologic Manifestations |
|---|---|---|---|
| Autoimmune hemolytic anemia | Red cell membrane proteins (Rh blood group antigens, I antigen) | Opsonization and phagocytosis of erythrocytes | Hemolysis, anemia |
| Autoimmune thrombocytopenic purpura | Platelet membrane proteins (GpIIb/IIIa integrin) | Opsonization and phagocytosis of platelets | Bleeding |
| Pemphigus vulgaris | Proteins in intercellular junctions of epidermal cells (epidermal desmoglein) | Antibody-mediated activation of proteases, disruption of intercellular adhesions | Skin vesicles (bullae) |
| Vasculitis caused by ANCA | Neutrophil granule proteins, presumably released from activated neutrophils | Neutrophil degranulation and inflammation | Vasculitis |
| Goodpasture syndrome | Noncollagenous protein (NC1) in basement membranes of kidney glomeruli and lung alveoli | Complement- and Fc receptor–mediated inflammation | Nephritis, lung hemorrhage |
| Acute rheumatic fever | Streptococcal cell wall antigen; antibody cross-reacts with myocardial antigen | Inflammation, macrophage activation | Myocarditis |
| Myasthenia gravis | Acetylcholine receptor | Antibody inhibits acetylcholine binding, downmodulates receptors | Muscle weakness, paralysis |
| Graves disease (hyperthyroidism) | TSH receptor | Antibody-mediated stimulation of TSH receptors | Hyperthyroidism |
| Insulin-resistant diabetes | Insulin receptor | Antibody inhibits binding of insulin | Hyperglycemia, ketoacidosis |
| Pernicious anemia | Intrinsic factor of gastric parietal cells | Neutralization of intrinsic factor, decreased absorption of vitamin $B_{12}$ | Abnormal myelopoiesis, anemia |

ANCA, antineutrophil cytoplasmic antibodies; TSH, thyroid-stimulating hormone.

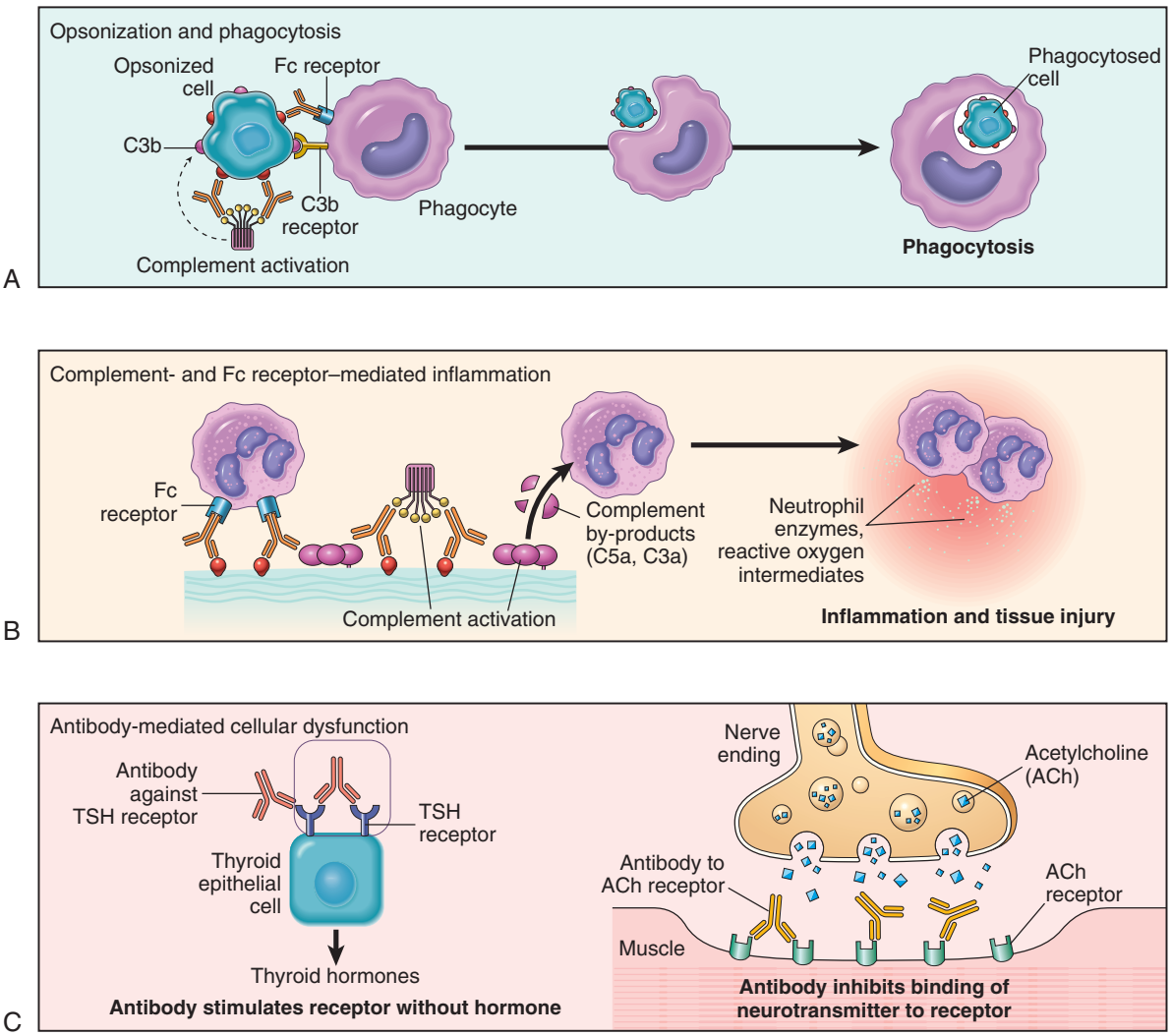


**Figure 4–10** Mechanisms of antibody-mediated injury. **A,** Opsonization of cells by antibodies and complement components, and ingestion of opsonized cells by phagocytes. **B,** Inflammation induced by antibody binding to Fc receptors of leukocytes and by complement breakdown products. **C,** Antireceptor antibodies disturb the normal function of receptors. In these examples, antibodies against the thyroid-stimulating hormone (TSH) receptor activate thyroid cells in Graves disease, and acetylcholine (ACh) receptor antibodies impair neuromuscular transmission in myasthenia gravis.

clinical benefit in autoimmune thrombocytopenia and some forms of autoimmune hemolytic anemia.

- *Inflammation.* Antibodies bound to cellular or tissue antigens activate the complement system by the "classical" pathway (Fig. 4–10, *B*). Products of complement activation serve several functions (see Fig. 2–18, Chapter 2), one of which is to recruit neutrophils and monocytes, triggering inflammation in tissues. Leukocytes may also be activated by engagement of Fc receptors, which recognize the bound antibodies. This mechanism of injury is exemplified by Goodpasture syndrome and pemphigus vulgaris.
- *Antibody-mediated cellular dysfunction.* In some cases, antibodies directed against cell surface receptors impair or dysregulate cellular function without causing cell injury or inflammation (Fig. 4–10, *C*). In myasthenia gravis, antibodies against acetylcholine receptors in the motor end plates of skeletal muscles inhibit neuromuscular transmission, with resultant muscle weakness. Antibodies can also stimulate cellular responses excessively. In Graves disease, antibodies against the thyroid-stimulating hormone receptor stimulate thyroid epithelial cells to secrete thyroid hormones, resulting in hyperthyroidism. Antibodies against hormones and other essential proteins can neutralize and block the actions of these molecules, causing functional derangements.

## Immune Complex Diseases (Type III Hypersensitivity)

*Antigen–antibody (immune) complexes that are formed in the circulation may deposit in blood vessels, leading to complement activation and acute inflammation.* The antigens in these complexes may be exogenous antigens, such as microbial proteins, or endogenous antigens, such as nucleoproteins. The mere formation of immune complexes does not equate with hypersensitivity disease; small amounts of antigen–antibody complexes may be produced during normal

**Table 4–4** Examples of Immune Complex–Mediated Diseases

| Disease | Antigen Involved | Clinicopathologic Manifestations |
|---|---|---|
| Systemic lupus erythematosus | Nuclear antigens | Nephritis, skin lesions, arthritis, others |
| Poststreptococcal glomerulonephritis | Streptococcal cell wall antigen(s); may be "planted" in glomerular basement membrane | Nephritis |
| Polyarteritis nodosa | Hepatitis B virus antigens in some cases | Systemic vasculitis |
| Reactive arthritis | Bacterial antigens (e.g., *Yersinia*) | Acute arthritis |
| Serum sickness | Various proteins (e.g., foreign serum protein such as horse antithymocyte globulin) | Arthritis, vasculitis, nephritis |
| Arthus reaction (experimental) | Various foreign proteins | Cutaneous vasculitis |

immune responses and are usually phagocytosed and destroyed. It is only when these complexes are produced in large amounts, persist, and are deposited in tissues that they are pathogenic. Pathogenic immune complexes may form in the circulation and subsequently deposit in blood vessels, or the complexes may form at sites where antigen has been planted (in situ immune complexes). Immune complex–mediated injury is systemic when complexes are formed in the circulation and are deposited in several organs, or it may be localized to particular organs (e.g., kidneys, joints, or skin) if the complexes are formed and deposited in a specific site. The mechanism of tissue injury is the same regardless of the pattern of distribution; however, the sequence of events and the conditions leading to the formation of systemic and local immune complexes are different and are considered separately in the following descriptions. Immune complex diseases are some of the most common immunologic diseases (Table 4–4).

### *Systemic Immune Complex Disease*

The pathogenesis of systemic immune complex disease can be divided into three phases: (1) formation of antigen–antibody complexes in the circulation and (2) deposition of the immune complexes in various tissues, thereby initiating (3) an inflammatory reaction in various sites throughout the body (Fig. 4–11).

*Acute serum sickness* is the prototype of a systemic immune complex disease. It was first described in humans when large amounts of foreign serum were administered for passive immunization (e.g., in persons receiving horse serum containing antidiphtheria antibody); it is now seen only rarely (e.g., in patients injected with rabbit or horse antithymocyte globulin for treatment of aplastic anemia or graft rejection, or patients with snakebite given anti-venom antibody made in animals). Although serum sickness is no longer common, the study of its pathogenesis sheds light on the mechanisms of human immune complex diseases. Approximately 5 days after the foreign protein is injected, specific antibodies are produced; these react with the antigen still present in the circulation to form antigen–antibody complexes. The complexes deposit in blood vessels in various tissue beds, triggering the subsequent injurious inflammatory reaction.

Several *variables determine whether immune complex formation leads to tissue deposition and disease*. Perhaps foremost among these factors is the size of the complexes. Very large complexes or complexes with many free IgG Fc regions (typically formed in antibody excess) are rapidly removed from the circulation by macrophages in the spleen and liver

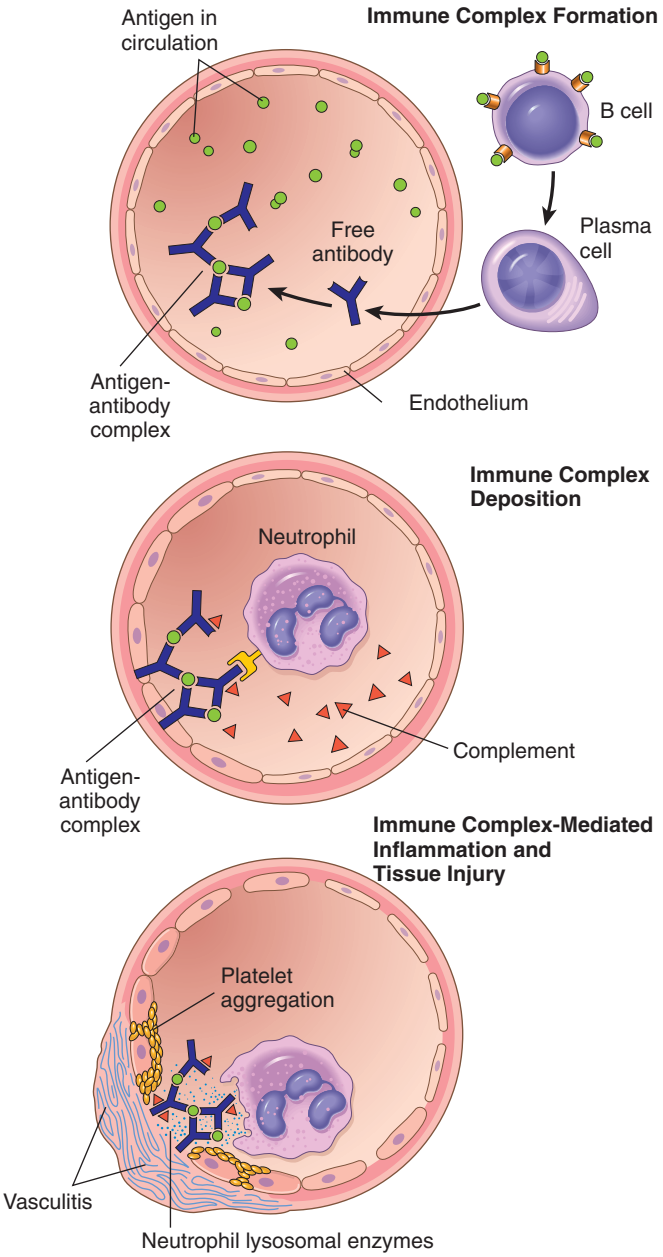


**Figure 4–11** Immune complex disease: The sequential phases in the induction of systemic immune complex–mediated diseases (type III hypersensitivity).

and are therefore usually harmless. The most pathogenic complexes are formed during antigen excess and are small or intermediate in size and are cleared less effectively by phagocytes and therefore circulate longer. In addition, the charge of the complex, the valency of the antigen, the avidity of the antibody, and the hemodynamics of a given vascular bed all influence the tendency to develop disease. The favored sites of deposition are kidneys, joints, and small blood vessels in many tissues. Localization in the kidney and joints is explained in part by the high hemodynamic pressures associated with the filtration function of the glomerulus and the synovium. For complexes to leave the circulation and deposit within or outside the vessel wall, an increase in vascular permeability also must occur. This is probably triggered when immune complexes bind to leukocytes and mast cells by means of Fc and C3b receptors and stimulate release of mediators that increase vascular permeability.

Once complexes are deposited in the tissue, the third phase, the *inflammatory reaction*, ensues. During this phase (approximately 10 days after antigen administration), clinical features such as fever, urticaria, arthralgias, lymph node enlargement, and proteinuria appear. Wherever immune complexes deposit, characteristic tissue damage occurs. The immune complexes activate the complement system, leading to the release of biologically active fragments such as the anaphylatoxins (C3a and C5a), which increase vascular permeability and are chemotactic for neutrophils and monocytes (Chapter 2). The complexes also bind to Fcγ receptors on neutrophils and monocytes, activating these cells. Attempted phagocytosis of immune complexes by the leukocytes results in the secretion of a variety of additional pro-inflammatory substances, including prostaglandins, vasodilator peptides, and chemotactic substances, as well as lysosomal enzymes capable of digesting basement membrane, collagen, elastin, and cartilage, and reactive-oxygen species that damage tissues. Immune complexes can also cause platelet aggregation and activate Hageman factor; both of these reactions augment the inflammatory process and initiate formation of microthrombi, which contribute to the tissue injury by producing local ischemia (Fig. 4–11). The resultant pathologic lesion is termed *vasculitis* if it occurs in blood vessels, *glomerulonephritis* if it occurs in renal glomeruli, *arthritis* if it occurs in the joints, and so on.

Predictably, the antibody classes that induce such lesions are complement-fixing antibodies (i.e., IgG and IgM) and antibodies that bind to phagocyte Fc receptors (IgG). During the active phase of the disease, consumption of complement may result in decreased serum complement levels. The role of complement- and Fc receptor–dependent inflammation in the pathogenesis of the tissue injury is supported by the observation that experimental depletion of serum complement levels or knockout of Fc receptors in mice greatly reduces the severity of lesions, as does depletion of neutrophils.

### MORPHOLOGY

The morphologic appearance of immune complex injury is dominated by acute **necrotizing vasculitis,** microthrombi, and superimposed ischemic necrosis accompanied by acute inflammation of the affected organs. The necrotic vessel wall takes on a smudgy eosinophilic appearance called **fibrinoid necrosis,** caused by protein deposition (see Fig. 1–13, Chapter 1). Immune complexes can be visualized in the tissues, usually in the vascular wall (examples of such deposits in the kidney in lupus are shown in Fig. 4–18, *E*). In due course, the lesions tend to resolve, especially when they were brought about by a single exposure to antigen (e.g., in acute serum sickness or acute poststreptococcal glomerulonephritis) (Chapter 13). However, chronic immune complex disease develops when there is persistent antigenemia or repeated exposure to an antigen. This occurs in some human diseases, such as systemic lupus erythematosus (SLE). Most often, even though the morphologic changes and other findings strongly implicate immune complex disease, the inciting antigens are unknown.

#### *Local Immune Complex Disease*

A model of local immune complex diseases is the *Arthus reaction,* in which an area of tissue necrosis appears as a result of acute immune complex vasculitis. The reaction is produced experimentally by injecting an antigen into the skin of a previously immunized animal (i.e., pre-formed antibodies against the antigen are already present in the circulation). Because of the initial antibody excess, immune complexes are formed as the antigen diffuses into the vascular wall; these are precipitated at the site of injection and trigger the same inflammatory reaction and histologic appearance as in systemic immune complex disease. Arthus lesions evolve over a few hours and reach a peak 4 to 10 hours after injection, when the injection site develops visible edema with severe hemorrhage, occasionally followed by ulceration.

### SUMMARY

#### Pathogenesis of Diseases Caused by Antibodies and Immune Complexes

- Antibodies can coat (opsonize) cells, with or without complement proteins, and target these cells for phagocytosis by macrophages, which express receptors for the Fc tails of IgG molecules and for complement proteins. The result is depletion of the opsonized cells.
- Antibodies and immune complexes may deposit in tissues or blood vessels, and elicit an acute inflammatory reaction by activating complement, with release of breakdown products, or by engaging Fc receptors of leukocytes. The inflammatory reaction causes tissue injury.
- Antibodies can bind to cell surface receptors or essential molecules, and cause functional derangements (either inhibition or unregulated activation) without cell injury.

## T Cell–Mediated (Type IV) Hypersensitivity

*Several autoimmune disorders, as well as pathologic reactions to environmental chemicals and persistent microbes, are now known to be caused by T cells* (Table 4–5). The occurrence and significance of T lymphocyte–mediated tissue injury

**Table 4–5** T Cell–Mediated Diseases*

| Disease | Specificity of Pathogenic T Cells | Principal Mechanisms of Tissue Injury | Clinicopathologic Manifestations |
|---|---|---|---|
| Rheumatoid arthritis | Collagen?; citrullinated self proteins? | Inflammation mediated by $T_H17$ (and $T_H1$?) cytokines; role of antibodies and immune complexes? | Chronic arthritis with inflammation, destruction of articular cartilage and bone |
| Multiple sclerosis | Protein antigens in myelin (e.g., myelin basic protein) | Inflammation mediated by $T_H1$ and $T_H17$ cytokines, myelin destruction by activated macrophages | Demyelination in CNS with perivascular inflammation; paralysis, ocular lesions |
| Type I diabetes mellitus | Antigens of pancreatic islet β cells (insulin, glutamic acid decarboxylase, others) | T cell–mediated inflammation, destruction of islet cells by CTLs | Insulitis (chronic inflammation in islets), destruction of β cells; diabetes |
| Hashimoto thyroiditis | Thyroglobulin, other thyroid proteins | Inflammation, CTL-mediated killing of thyroid epithelial cells | Hypothyroidism |
| Inflammatory bowel disease | Enteric bacteria; self antigens? | Inflammation mediated mainly by $T_H17$ cytokines | Chronic intestinal inflammation, ulceration, obstruction |
| Autoimmune myocarditis | Myosin heavy chain protein | CTL-mediated killing of myocardial cells; inflammation mediated by $T_H1$ cytokines | Cardiomyopathy |
| Contact sensitivity | Various environmental chemicals (e.g., urushiol from poison ivy or poison oak) | Inflammation mediated by $T_H1$ (and $T_H17$?) cytokines | Epidermal necrosis, dermal inflammation with skin rash and blisters |

*Examples of human T cell–mediated diseases are listed. In many cases, the specificity of the T cells and the mechanisms of tissue injury are inferred on the basis of similarity to experimental animal models of the diseases.
CNS, central nervous system; CTL, cytotoxic T lymphocyte.

have been increasingly appreciated as the methods for detecting and purifying T cells from patients' circulation and lesions have improved. This group of diseases is of great clinical interest because many of the new, rationally designed biologic therapies for immune-mediated inflammatory diseases have been developed to target abnormal T cell reactions. Two types of T cell reactions are capable of causing tissue injury and disease: (1) cytokine-mediated inflammation, in which the cytokines are produced mainly by CD4+ T cells, and (2) direct cell cytotoxicity, mediated by CD8+ T cells (Fig. 4–12). In inflammation, exemplified by the delayed-type hypersensitivity (DTH) reaction, CD4+ T cells of the $T_H1$ and $T_H17$ subsets secrete cytokines, which recruit and activate other cells, especially macrophages, and these are the major effector cells of injury. In cell-mediated cytotoxicity, cytotoxic CD8+ T cells are responsible for tissue damage.

### *Inflammatory Reactions Elicited by CD4+ T Cells*

The sequence of events in T cell–mediated inflammatory reactions begins with the first exposure to antigen and is essentially the same as the reactions of cell-mediated immunity (Fig. 4–4). Naive CD4+ T lymphocytes recognize peptide antigens of self or microbial proteins in association with class II MHC molecules on the surface of DCs (or macrophages) that have processed the antigens. If the DCs produce IL-12, the naive T cells differentiate into effector cells of the $T_H1$ type. The cytokine IFN-γ, made by NK cells and by the $T_H1$ cells themselves, further promotes $T_H1$ differentiation, providing a powerful positive feedback loop. If the APCs produce IL-1, IL-6, or IL-23 instead of IL-12, the CD4+ cells develop into $T_H17$ effectors. On subsequent exposure to the antigen, the previously generated effector cells are recruited to the site of antigen exposure and are activated by the antigen presented by local APCs. The $T_H1$ cells secrete IFN-γ, which is the most potent macrophage-activating cytokine known. Activated macrophages have increased phagocytic and microbicidal activity. Activated macrophages also express more class II MHC molecules and costimulators, leading to augmented antigen presentation capacity, and the cells secrete more IL-12, thus stimulating more $T_H1$ responses. Upon activation by antigen, $T_H17$ effector cells secrete IL-17 and several other cytokines, which promote the recruitment of neutrophils (and monocytes) and thus induce inflammation. Because the cytokines produced by the T cells enhance leukocyte recruitment and activation, these inflammatory reactions become chronic unless the offending agent is eliminated or the cycle is interrupted therapeutically. In fact, inflammation occurs as an early response to microbes and dead cells (Chapter 2), but it is greatly increased and prolonged when T cells are involved.

Delayed-type hypersensitivity (DTH), described next, is an illustrative model of T cell–mediated inflammation and tissue injury. The same reactions are the underlying basis for several diseases. *Contact dermatitis* is an example of tissue injury resulting from T cell–mediated inflammation. It is evoked by contact with pentadecylcatechol (also known as urushiol, the active component of poison ivy and poison oak, which probably becomes antigenic by binding to a host protein). On reexposure of a previously exposed person to the plants, sensitized $T_H1$ CD4+ cells accumulate in the dermis and migrate toward the antigen within the epidermis. Here they release cytokines that damage keratinocytes, causing separation of these cells and formation of an intraepidermal vesicle, and inflammation manifested as a vesicular dermatitis. It has long been thought that several *systemic diseases,* such as type 1 diabetes and multiple sclerosis, are caused by $T_H1$ and $T_H17$ reactions against self antigens, and Crohn disease may be caused by uncontrolled reactions involving the same T cells but directed against intestinal bacteria. T cell–mediated inflammation also plays a role in the rejection of transplants, described later in the chapter.

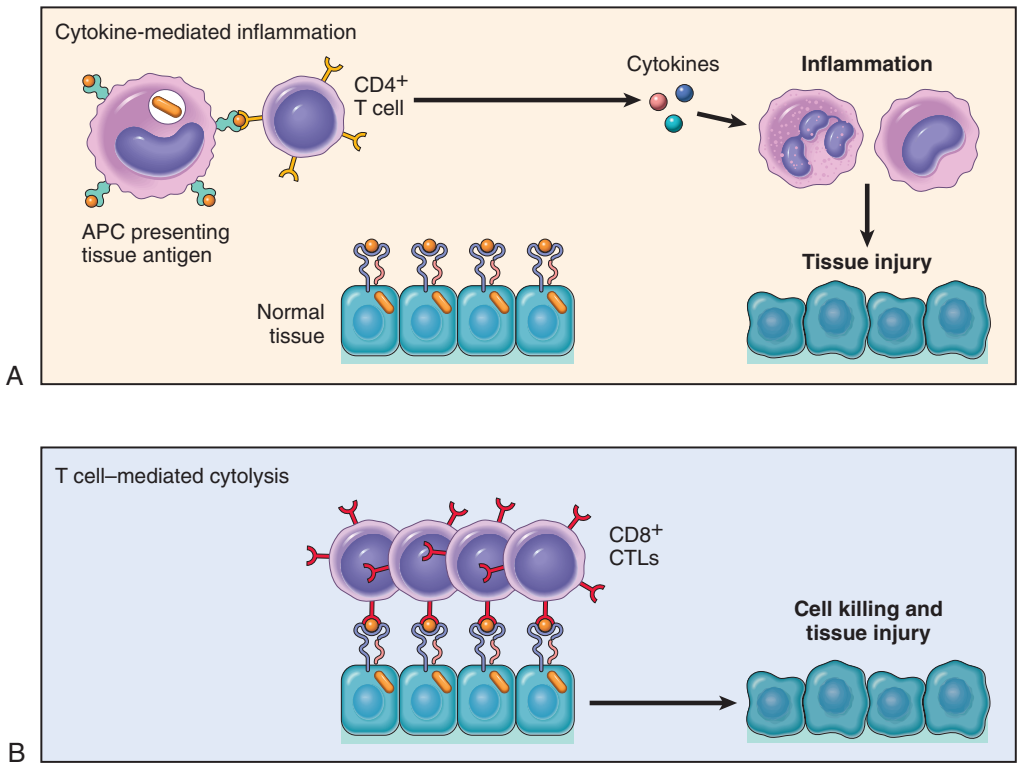


**Figure 4–12** Mechanisms of T cell–mediated (type IV) hypersensitivity reactions. **A,** In cytokine-mediated inflammatory reactions, CD4+ T cells respond to tissue antigens by secreting cytokines that stimulate inflammation and activate phagocytes, leading to tissue injury. **B,** In some diseases, CD8+ CTLs directly kill tissue cells. APC, antigen-presenting cell; CTLs, cytotoxic T lymphocytes.

### Delayed-Type Hypersensitivity

DTH is a T cell–mediated reaction that develops in response to antigen challenge in a previously sensitized individual. In contrast with immediate hypersensitivity, the DTH reaction is delayed for 12 to 48 hours, which is the time it takes for effector T cells to be recruited to the site of antigen challenge and to be activated to secrete cytokines. The classic example of DTH is the tuberculin reaction, elicited by challenge with a protein extract of *M. tuberculosis* (tuberculin) in a person who has previously been exposed to the tubercle bacillus. Between 8 and 12 hours after intracutaneous injection of tuberculin, a local area of erythema and induration appears, reaching a peak (typically 1 to 2 cm in diameter) in 24 to 72 hours and thereafter slowly subsiding. On histologic examination, the DTH reaction is characterized by perivascular accumulation ("cuffing") of CD4+ helper T cells and macrophages (Fig. 4–13). Local secretion of cytokines by these cells leads to increased microvascular permeability, giving rise to dermal edema and fibrin deposition; the latter is the main cause of the tissue induration in these responses. DTH reactions are mediated primarily by $T_H1$ cells; the contribution of $T_H17$ cells is unclear. The tuberculin response is used to screen populations for people who have had previous exposure to tuberculosis and therefore have circulating memory T cells specific for mycobacterial proteins. Notably, immunosuppression or loss of CD4+ T cells (e.g., resulting from HIV infection) may lead to a negative tuberculin response even in the presence of a severe infection.

Prolonged DTH reactions against persistent microbes or other stimuli may result in a special morphologic pattern of reaction called *granulomatous inflammation.* The initial perivascular CD4+ T cell infiltrate is progressively replaced by macrophages over a period of 2 to 3 weeks. These accumulated macrophages typically exhibit morphologic evidence of activation; that is, they become large, flat, and eosinophilic, and are called epithelioid cells. The epithelioid cells occasionally fuse under the influence of cytokines (e.g., IFN-γ) to form multinucleate giant cells. A microscopic aggregate of epithelioid cells, typically surrounded by a collar of lymphocytes, is called a granuloma (Fig. 4–14, *A*). The process is essentially a chronic form of $T_H1$-mediated inflammation and macrophage activation (Fig. 4–14, *B*). Older granulomas develop an enclosing rim of fibroblasts and connective tissue. Recognition of a granuloma is of diagnostic importance because of the limited number of conditions that can cause it (Chapter 2).

### *T Cell–Mediated Cytotoxicity*

In this form of T cell–mediated tissue injury, CD8+ CTLs kill antigen-bearing target cells. As discussed earlier, class I MHC molecules bind to intracellular peptide antigens and present the peptides to CD8+ T lymphocytes, stimulating the differentiation of these T cells into effector cells called CTLs. CTLs play a critical role in resistance to virus infections and some tumors. The principal mechanism of killing by CTLs is dependent on the perforin–granzyme system. Perforin and granzymes are stored in the granules of CTLs and are rapidly released when CTLs engage their targets (cells bearing the appropriate class I MHC–bound peptides). Perforin binds to the plasma membrane of the

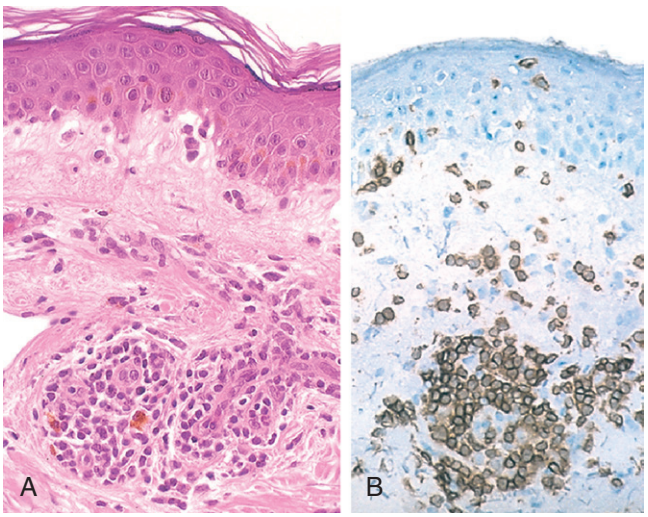


**Figure 4–13** Delayed-type hypersensitivity reaction in the skin. **A,** Perivascular accumulation ("cuffing") of mononuclear inflammatory cells (lymphocytes and macrophages), with associated dermal edema and fibrin deposition. **B,** Immunoperoxidase staining reveals a predominantly perivascular cellular infiltrate that marks positively with anti-CD4 antibodies.

*(B, Courtesy of Dr. Louis Picker, Department of Pathology, Oregon Health & Science University, Portland, Oregon.)*

target cells and promotes the entry of granzymes, which are proteases that specifically cleave and thereby activate cellular caspases. These enzymes induce apoptotic death of the target cells (Chapter 1). CTLs play an important role in the rejection of solid-organ transplants and may contribute to many immunologic diseases, such as type 1 diabetes (in which insulin-producing β cells in pancreatic islets are destroyed by an autoimmune T cell reaction). CD8+ T cells may also secrete IFN-γ and contribute to cytokine-mediated inflammation, but less so than CD4+ cells.

## SUMMARY

### Mechanisms of T Cell–Mediated Hypersensitivity Reactions

- Cytokine-mediated inflammation: CD4+ T cells are activated by exposure to a protein antigen and differentiate into $T_H1$ and $T_H17$ effector cells. Subsequent exposure to the antigen results in the secretion of cytokines. IFN-γ activates macrophages to produce substances that cause tissue damage and promote fibrosis, and IL-17 and other cytokines recruit leukocytes, thus promoting inflammation.
- T cell–mediated cytotoxicity: CD8+ CTLs specific for an antigen recognize cells expressing the target antigen and kill these cells. CD8+ T cells also secrete IFN-γ.

With the basic mechanisms of pathologic immune reactions as background, we now proceed to a consideration of two categories of reactions that are of great clinical importance: autoimmunity and transplant rejection.

## AUTOIMMUNE DISEASES

Immune reactions to self antigens (i.e., autoimmunity) are the underlying cause of numerous human diseases. Autoimmune diseases currently are estimated to affect 2% to 5% of the population in developed countries, and appear to be increasing in incidence. The evidence that these diseases are indeed the result of autoimmune reactions is more persuasive for some than for others. For instance, in many of these disorders, multiple high-affinity autoantibodies have

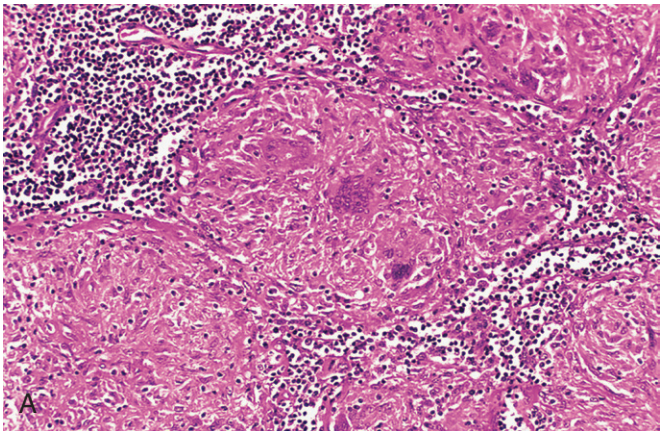


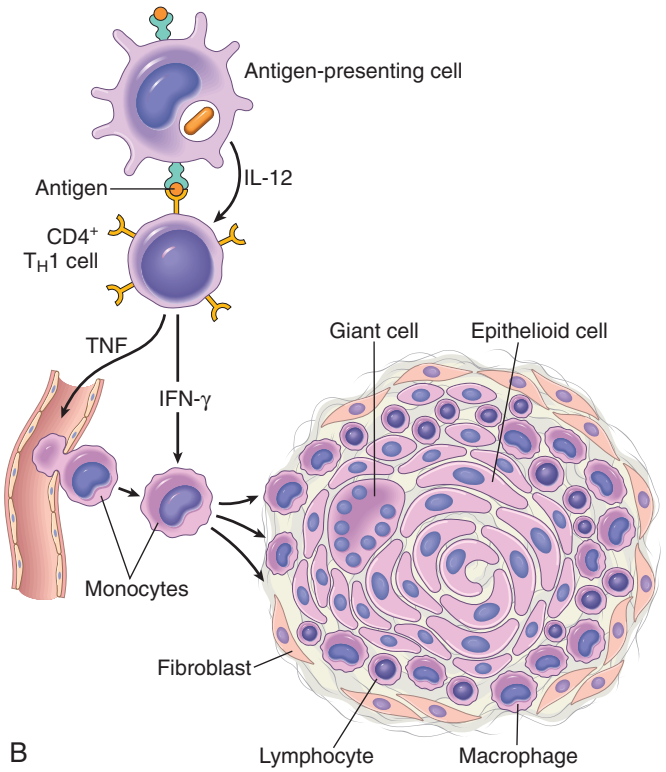


**Figure 4–14** Granulomatous inflammation. **A,** A section of a lymph node shows several granulomas, each made up of an aggregate of epithelioid cells and surrounded by lymphocytes. The granuloma in the center shows several multinucleate giant cells. **B,** The events that give rise to the formation of granulomas in type IV hypersensitivity reactions. Note the role played by T cell–derived cytokines.

*(A, Courtesy of Dr. Trace Worrell, Department of Pathology, University of Texas Southwestern Medical School, Dallas, Texas.)*

**Table 4–6** Autoimmune Diseases

| Organ-Specific | Systemic |
|---|---|
| **Diseases Mediated by Antibodies** | |
| Autoimmune hemolytic anemia | Systemic lupus erythematosus |
| Autoimmune thrombocytopenia | |
| Autoimmune atrophic gastritis of pernicious anemia | |
| Myasthenia gravis | |
| Graves disease | |
| Goodpasture syndrome | |
| **Diseases Mediated by T Cells*** | |
| Type I diabetes mellitus | Rheumatoid arthritis |
| Multiple sclerosis | Systemic sclerosis (scleroderma) |
| Hashimoto thyroiditis | Sjögren syndrome |
| Crohn disease | |
| **Diseases Postulated to Be of Autoimmune Origin†** | |
| Primary biliary cirrhosis | Polyarteritis nodosa |
| Autoimmune (chronic active) hepatitis | Inflammatory myopathies |

*A role for T cells has been demonstrated in these disorders, but antibodies also may be involved in tissue injury.
†An autoimmune basis for these disorders is suspected, but the supporting evidence is not strong.

been identified, and in some cases these antibodies are known to cause pathologic abnormalities (Table 4–6). Similarly, with improving technology, there is growing evidence for the activation of pathogenic self-reactive T cells in some of these diseases. In addition, experimental models have proved very informative, providing circumstantial evidence supporting an autoimmune etiology. Nevertheless, it is fair to say that for many disorders traditionally classified as autoimmune, this etiologic origin is suspected but not proved.

Presumed autoimmune diseases range from those in which specific immune responses are directed against one particular organ or cell type and result in localized tissue damage, to multisystem diseases characterized by lesions in many organs and associated with multiple autoantibodies or T cell–mediated reactions against numerous self antigens. In many of the systemic diseases that are caused by immune complexes and autoantibodies, the lesions affect principally the connective tissue and blood vessels of the various organs involved. Therefore, these diseases are often referred to as "collagen vascular" or "connective tissue" disorders, even though the immunologic reactions are not specifically directed against constituents of connective tissue or blood vessels.

Normal persons are unresponsive (tolerant) to their own (self) antigens, and autoimmunity results from a failure of self-tolerance. Therefore, understanding the pathogenesis of autoimmunity requires familiarity with the mechanisms of normal immunologic tolerance.

## Immunologic Tolerance

*Immunologic tolerance is unresponsiveness to an antigen that is induced by exposure of specific lymphocytes to that antigen.* Self-tolerance refers to a lack of immune responsiveness to one's own tissue antigens. Billions of different antigen receptors are randomly generated in developing T and B lymphocytes, and it is not surprising that during this process, receptors are produced that can recognize self antigens. Since these antigens cannot all be concealed from the immune system, there must be means of eliminating or controlling self-reactive lymphocytes. Several mechanisms work in concert to select against self-reactivity and to thus prevent immune reactions against the body's own antigens. These mechanisms are broadly divided into two groups: central tolerance and peripheral tolerance (Fig. 4–15).

*Central tolerance.* The principal mechanism of central tolerance is the antigen-induced deletion (death) of self-reactive T and B lymphocytes during their maturation in central (generative) lymphoid organs (i.e., in the thymus for T cells and in the bone marrow for B cells). In the thymus, many autologous (self) protein antigens are processed and presented by thymic APCs in association with self MHC. Any immature T cell that encounters such a self antigen undergoes apoptosis (a process called deletion, or negative selection), and the T cells that complete their maturation are thereby depleted of self-reactive cells (Fig. 4–15). An exciting advance has been the identification of putative transcription factors that induce the expression of peripheral tissue antigens in the thymus, thus making the thymus an immunologic mirror of self. One such factor is called the autoimmune regulator (AIRE); mutations in the *AIRE* gene are responsible for an autoimmune polyendocrine syndrome in which T cells specific for multiple self antigens escape deletion (presumably because these self antigens are not expressed in the thymus), and attack tissues expressing the self antigens. Some T cells that encounter self antigens in the thymus are not killed but differentiate into regulatory T cells, as described later.

Immature B cells that recognize self antigens with high affinity in the bone marrow also may die by apoptosis. Some self-reactive B cells may not be deleted but may undergo a second round of rearrangement of antigen receptor genes and then express new receptors that are no longer self-reactive (a process called "receptor editing").

Unfortunately, the process of deletion of self-reactive lymphocytes is not perfect. Many self antigens may not be present in the thymus, so T cells bearing receptors for such autoantigens can escape into the periphery. There is similar "slippage" in the B cell system as well, and B cells that bear receptors for a variety of self antigens, including thyroglobulin, collagen, and DNA, can be found in healthy persons.

*Peripheral tolerance.* Self-reactive T cells that escape negative selection in the thymus can potentially wreak havoc unless they are deleted or effectively muzzled. Several mechanisms in the peripheral tissues that silence such potentially autoreactive T cells have been identified (Fig. 4–15):

- *Anergy*: This term refers to functional inactivation (rather than death) of lymphocytes induced by encounter with antigens under certain conditions. As described previously, activation of T cells requires two signals: recognition of peptide antigen in association with self MHC molecules on APCs, and a set of second costimulatory

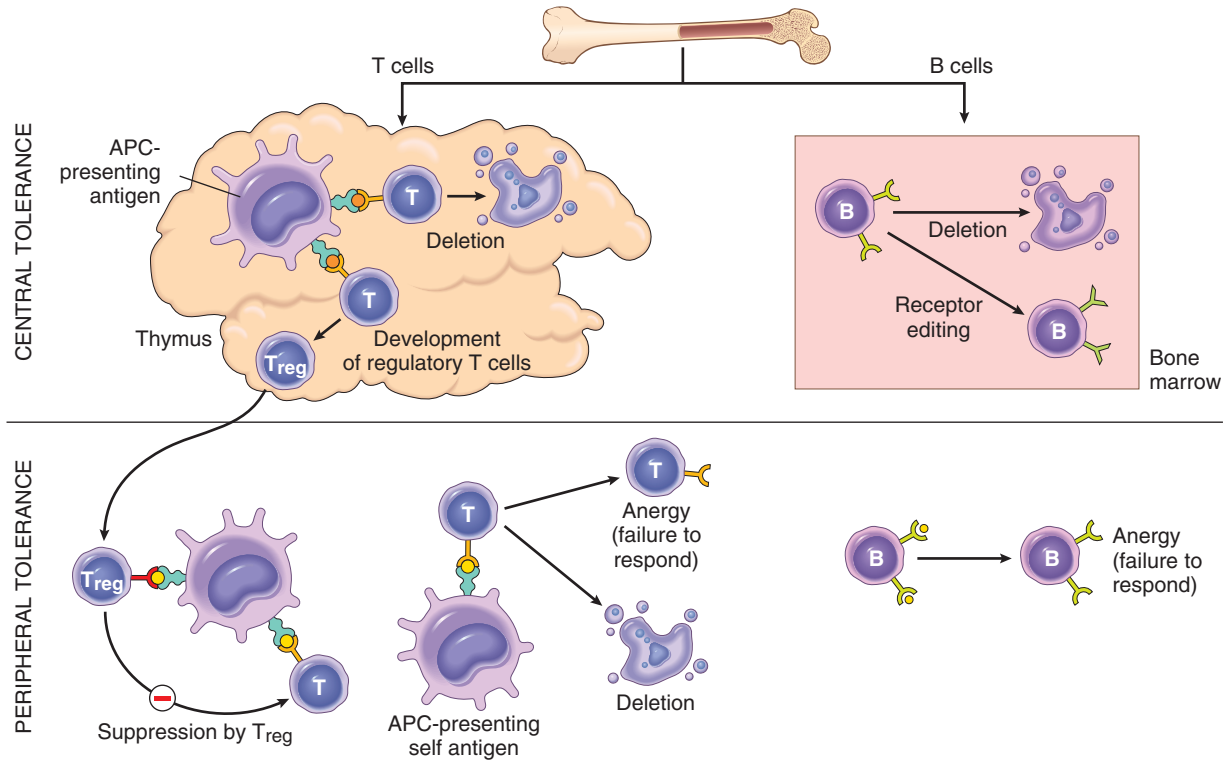


**Figure 4–15** Immunologic self-tolerance: The principal mechanisms of central and peripheral self-tolerance in T and B cells.

signals (e.g., through B7 molecules) provided by the APCs. If the second costimulatory signals are not delivered, or if an inhibitory receptor on the T cell (rather than the costimulatory receptor) is engaged when the cell encounters self antigen, the T cell becomes anergic and cannot respond to the antigen (Fig. 4–15). Because costimulatory molecules are not strongly expressed on most normal tissues, the encounter between autoreactive T cells and self antigens in tissues may result in anergy. B cells can also become anergic if they encounter antigen in the absence of specific helper T cells.

- *Suppression by regulatory T cells*: The responses of T lymphocytes to self antigens may be actively suppressed by regulatory T cells. The best-defined populations of regulatory T cells express CD25, one of the chains of the receptor for IL-2, and require IL-2 for their generation and survival. These cells also express a unique transcription factor called FoxP3. This protein is necessary for the development of regulatory cells, and mutations in the *FOXP3* gene are responsible for a systemic autoimmune disease called IPEX (immune dysregulation, polyendocrinopathy, enteropathy, X-linked syndrome), which is associated with deficiency of regulatory T cells. Several mechanisms have been proposed to explain how regulatory T cells control immune responses, including secretion of immunosuppressive cytokines (e.g., IL-10, transforming growth factor-β [TGF-β]), which can dampen a variety of T cell responses, and competitive blocking of B7 molecules on APCs.
- *Activation-induced cell death*: Another mechanism of peripheral tolerance involves apoptosis of mature lymphocytes as a result of self-antigen recognition. One mechanism of apoptosis involves the death receptor Fas (a member of the TNF receptor family), which can be engaged by its ligand coexpressed on the same or neighboring cells. The same pathway is important for the deletion of self-reactive B cells by Fas ligand expressed on T cells. The importance of this pathway of self-tolerance is illustrated by the discovery that mutations in the *FAS* gene are responsible for an autoimmune disease called the autoimmune lymphoproliferative syndrome (ALPS), characterized by lymphadenopathy and multiple autoantibodies including anti-DNA. Defects in Fas and Fas ligand are also the cause of similar autoimmune diseases in mice. The mitochondrial pathway of apoptosis, which does not depend on death receptors, may also be involved in the elimination of self-reactive lymphocytes.

## Mechanisms of Autoimmunity

Proceeding from the foregoing summary of the principal mechanisms of self-tolerance, we can ask how these mechanisms might break down to give rise to pathologic autoimmunity. Unfortunately, there are no simple answers to this question, and the underlying causes of most human autoimmune diseases remain to be determined. As mentioned earlier, certain mutations can compromise one or another pathway of self-tolerance and cause pathologic autoimmunity. Study of these single-gene mutations is extremely informative, and such research helps to establish the biologic significance of the various pathways of self-tolerance. The diseases caused by such mutations are rare, however, and most autoimmune diseases cannot be explained by defects in single genes.

It is believed that *the breakdown of self-tolerance and development of autoimmunity result from a combination of inherited susceptibility genes, which influence lymphocyte tolerance, and environmental factors, such as infections or tissue injury, that alter the display of self antigens* (Fig. 4–16).

### *Genetic Factors in Autoimmunity*

There is abundant evidence that susceptibility genes play an important role in the development of autoimmune diseases.

- Autoimmune diseases have a tendency to run in families, and there is a greater incidence of the same disease in monozygotic than in dizygotic twins.
- Several autoimmune diseases are linked with the HLA locus, especially class II alleles (HLA-DR, -DQ). The frequency of a disease in a person with a particular HLA allele, compared with that in people who do not inherit that allele, is called the *odds ratio* or *relative risk* (Table 4–7). The relative risk ranges from 3 or 4 for rheumatoid arthritis (RA) and HLA-DR4 to 100 or more for ankylosing spondylitis and HLA-B27. However, how MHC genes influence the development of autoimmunity is still not clear, especially because MHC molecules do not distinguish between self and foreign peptide antigens. It is also worthy of note that most people with a susceptibility-related MHC allele never develop any disease, and, conversely, people without the relevant MHC gene can develop the disease. Expression of a particular MHC gene is therefore but one variable that can contribute to autoimmunity.
- Genome-wide association studies and linkage studies in families are revealing many genetic polymorphisms that are associated with different autoimmune diseases (Table 4–8). Some of these polymorphisms seem to be associated with several diseases, suggesting that the genes involved influence general mechanisms of self-tolerance and immune regulation. Others are disease-specific and may influence end-organ sensitivity or display of particular self antigens. There is great interest in elucidating how these genes contribute to autoimmunity, and many plausible hypotheses have been proposed (Table 4–8), but the actual role of these genes in the development of particular autoimmune diseases is not established.

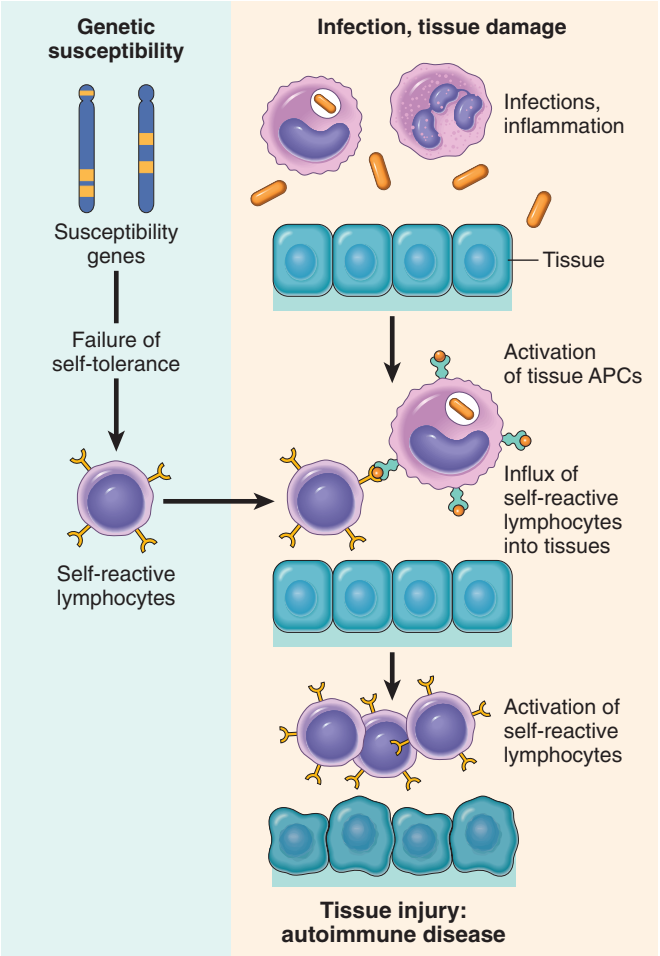


**Figure 4–16** Pathogenesis of autoimmunity. Autoimmunity arises from the inheritance of susceptibility genes that may interfere with self-tolerance, in association with environmental triggers (infection, tissue injury, inflammation) that alter the display of self antigens, promote lymphocyte entry into tissues, and enhance the activation of self-reactive lymphocytes.

### *Role of Infections and Tissue Injury*

A variety of microbes, including bacteria, mycoplasmas, and viruses, have been implicated as triggers for autoimmunity. Microbes may induce autoimmune reactions by several mechanisms:

**Table 4–7** Association of Human Leukocyte Antigen (HLA) Alleles with Autoimmune Diseases

| Disease | HLA Allele | Odds Ratio* |
|---|---|---|
| Rheumatoid arthritis (anti-CCP Ab–positive)† | DRB1 | 4–12 |
| Type 1 diabetes | DRB1*0301-DQA1*0501-DQB1*0201 haplotype | 4 |
| | DRB1*0401- DQA1*0301-DQB1*0302 haplotype | 8 |
| | DRB1*0301/0401 haplotype heterozygotes | 35 |
| Multiple sclerosis | DRB1*1501 | 3 |
| Systemic lupus erythematosus | DRB1*0301 | 2 |
| | DRB1*1501 | 1.3 |
| Ankylosing spondylitis | B*27 (mainly B*2705 and B*2702) | 100–200 |
| Celiac disease | DQA1*0501-DQB1*0201 haplotype | 7 |

*The *odds ratio* (also called *relative risk*) is the approximate value of the increased risk of the disease associated with the inheritance of particular HLA alleles. The data are from European-derived populations.
†Anti-CCP Ab, antibodies directed against cyclic citrullinated peptides. Data are from patients who tested positive for these antibodies in serum.
Table courtesy of Dr. Michelle Fernando, Imperial College London.

**Table 4–8** Selected Non–Human Leukocyte Antigen (HLA) Genes Associated with Autoimmune Diseases

| Putative Gene Involved* | Diseases | Postulated Function of Encoded Protein and Role of Mutation/Polymorphism in Disease |
|---|---|---|
| **Genes Involved in Immune Regulation** | | |
| *PTPN22* | RA, T1D, IBD | Protein tyrosine phosphatase, may affect signaling in lymphocytes and may alter negative selection or activation of self-reactive T cells |
| *IL23R* | IBD, PS, AS | Receptor for the $T_H17$-inducing cytokine IL-23; may alter differentiation of CD4+ T cells into pathogenic $T_H17$ effector cells |
| *CTLA4* | T1D, RA | Inhibits T cell responses by terminating activation and promoting activity of regulatory T cells; may interfere with self-tolerance |
| *IL2RA* | MS, T1D | α chain of the receptor for IL-2, which is a growth and survival factor for activated and regulatory T cells; may affect development of effector cells and/or regulation of immune responses |
| **Genes Involved in Immune Responses to Microbes** | | |
| *NOD2* | IBD | Cytoplasmic sensor of bacteria expressed in Paneth and other intestinal epithelial cells; may control resistance to gut commensal bacteria |
| *ATG16* | IBD | Involved in autophagy; possible role in defense against microbes and maintenance of epithelial barrier function |
| *IRF5, IFIH1* | SLE | Role in production of type I IFN, involved in the pathogenesis of SLE (see text) |

*The probable linkage of these genes with various autoimmune diseases has been defined by genome-wide association studies (GWAS) and other methods for studying disease-associated polymorphisms.
AS, ankylosing spondylitis; IBD, inflammatory bowel disease; IFN, interferon; MS, multiple sclerosis; PS, psoriasis; RA, rheumatoid arthritis; SLE, systemic lupus erythematosus; T1D, type 1 diabetes.
Adapted from Zenewicz L, Abraham C, Flavell RA, Cho J: Unraveling the genetics of autoimmunity. Cell 140:791, 2010.

- *Viruses and other microbes may share cross-reacting epitopes with self antigens,* such that responses may be induced by the microbe but may attack self tissues. This phenomenon is called molecular mimicry. It is the probable cause of a few diseases, the best example being rheumatic heart disease, in which an immune response against streptococci cross-reacts with cardiac antigens. It is not known if more subtle mimicry plays a role in other autoimmune diseases.
- *Microbial infections with resultant tissue necrosis and inflammation can cause upregulation of costimulatory molecules on APCs in the tissue,* thus favoring a breakdown of T cell anergy and subsequent T cell activation.

There is no lack of possible mechanisms to explain how infectious agents might participate in the pathogenesis of autoimmunity. At present, however, no evidence is available that clearly implicates any microbe in the causation of human autoimmune diseases. Adding to the complexity are recent suggestions (based largely on epidemiologic data) that infections may paradoxically protect affected persons from some autoimmune diseases, notably type 1 diabetes and multiple sclerosis. The possible mechanisms underlying this effect are not understood.

*The display of tissue antigens may be altered by a variety of environmental insults,* not only infections. As discussed later, ultraviolet (UV) radiation causes cell death and may lead to the exposure of nuclear antigens, which elicit pathologic immune responses in lupus; this mechanism is the proposed explanation for the association of lupus flares with exposure to sunlight. Smoking is a risk factor for RA, perhaps because it leads to chemical modification of self antigens. Local tissue injury for any reason may lead to the release of self antigens and autoimmune responses.

Finally, there is a strong gender bias of autoimmunity, with many of these diseases being more common in women than in men. The underlying mechanisms are still not well understood, and may include the effects of hormones and other factors.

An autoimmune response may itself promote further autoimmune attack. Tissue injury caused by an autoimmune response or any other cause may lead to exposure of self antigen epitopes that were previously concealed but are now presented to T cells in an immunogenic form. The activation of such autoreactive T cells is called "epitope spreading," because the immune response "spreads" to epitopes that were not recognized initially. This is one of the mechanisms that may contribute to the chronicity of autoimmune diseases.

## SUMMARY

### Immunologic Tolerance and Autoimmunity

- *Tolerance* (unresponsiveness) to self antigens is a fundamental property of the immune system, and breakdown of tolerance is the basis of autoimmune diseases.
- *Central tolerance*: Immature lymphocytes that recognize self antigens in the central (generative) lymphoid organs are killed by apoptosis; in the B cell lineage, some of the self-reactive lymphocytes switch to new antigen receptors that are not self-reactive.
- *Peripheral tolerance*: Mature lymphocytes that recognize self antigens in peripheral tissues become functionally inactive (anergic), or are suppressed by regulatory T lymphocytes, or die by apoptosis.
- The *factors that lead to a failure of self-tolerance and the development of autoimmunity* include (1) inheritance of susceptibility genes that may disrupt different tolerance pathways and (2) infections and tissue alterations that may expose self-antigens and activate APCs and lymphocytes in the tissues.

Having discussed the general principles of tolerance and autoimmunity, we proceed to a discussion of some of the most common and important autoimmune diseases. Although each disease is discussed separately, considerable overlap is apparent in their clinical, serologic, and morphologic features. Only the systemic autoimmune diseases are covered in this chapter; the autoimmune diseases that affect single organ systems are more appropriately discussed in the chapters that deal with the relevant organs.

## Systemic Lupus Erythematosus

Systemic lupus erythematosus (SLE) is a multisystem autoimmune disease of protean manifestations and variable clinical behavior. Clinically, it is an unpredictable, remitting and relapsing disease of acute or insidious onset that may involve virtually any organ in the body; however, it affects principally the skin, kidneys, serosal membranes, joints, and heart. Immunologically, the disease is associated with an enormous array of autoantibodies, classically including antinuclear antibodies (ANAs). The clinical presentation of SLE is so variable, with so many overlapping features with those of other autoimmune diseases (RA, polymyositis, and others), that it has been necessary to develop diagnostic criteria for SLE (Table 4–9). The diagnosis is established by demonstration of four or more of the criteria during any interval of observation.

Incidence and prevalence estimates of SLE vary among racial and ethnic groups; some studies estimate the prevalence to be as high as 0.2% in certain groups. As with many autoimmune diseases, there is a strong (approximately 9:1) female preponderance, and the disease affects 1 in 700 women of childbearing age. SLE is more common and severe in black Americans, affecting 1 in 245 women in that group. Onset typically is in the second or third decade of life, but it may manifest at any age, including early childhood.

### PATHOGENESIS

The fundamental defect in SLE is a failure to maintain self-tolerance, leading to the production of a large number of autoantibodies that can damage tissues either directly or in the form of immune complex deposits. As in other autoimmune diseases, the pathogenesis of SLE involves a combination of genetic and environmental factors. Recent studies have revealed interesting clues about the pathogenesis of this enigmatic disorder (Fig. 4–17).

**Genetic Factors.** Many lines of evidence support a genetic predisposition to SLE.

- **Familial association.** Family members have an increased risk for the development of SLE, and up to 20% of clinically unaffected first-degree relatives may have autoantibodies. There is a high rate of concordance in

**Table 4–9** 1997 Revised Criteria for Classification of Systemic Lupus Erythematosus*

| Criterion | Definition |
|---|---|
| 1. Malar rash | Fixed erythema, flat or raised, over the malar eminences, tending to spare the nasolabial folds |
| 2. Discoid rash | Erythematous raised patches with adherent keratotic scaling and follicular plugging; atrophic scarring may occur in older lesions |
| 3. Photosensitivity | Rash occurring as an unusual reaction to sunlight, reported in patient history or as physician observation |
| 4. Oral ulcers | Oral or nasopharyngeal ulceration, usually painless, observed by a physician |
| 5. Arthritis | Nonerosive arthritis involving two or more peripheral joints, characterized by tenderness, swelling, or effusion |
| 6. Serositis | Pleuritis—convincing history of pleuritic pain or rub heard by a physician or evidence of pleural effusion *or*<br>Pericarditis—documented by electrocardiogram or rub or evidence of pericardial effusion |
| 7. Renal disorder | Persistent proteinuria >0.5 g/dL or >3+ if quantitation not performed *or*<br>Cellular casts—may be red blood cell, hemoglobin, granular, tubular, or mixed |
| 8. Neurologic disorder | Seizures—in the absence of offending drugs or known metabolic derangements, (e.g., uremia, ketoacidosis, or electrolyte imbalance) *or*<br>Psychosis—in the absence of offending drugs or known metabolic derangements, (e.g., uremia, ketoacidosis, or electrolyte imbalance) |
| 9. Hematologic disorder | Hemolytic anemia—with reticulocytosis *or*<br>Leukopenia—$<4.0 \times 10^9$/L ($4000/mm^3$) total on two or more occasions *or*<br>Lymphopenia—$<1.5 \times 10^9$/L ($1500/mm^3$) on two or more occasions *or*<br>Thrombocytopenia—$<100 \times 10^9$/L ($100 \times 10^3/mm^3$) in the absence of offending drugs |
| 10. Immunologic disorder | Anti-DNA antibody to native DNA in abnormal titer or<br>Anti-Sm—presence of antibody to Sm nuclear antigen or<br>Positive finding of antiphospholipid antibodies based on (1) an abnormal serum level of IgG or IgM anticardiolipin antibodies, (2) a positive test for lupus anticoagulant using a standard test, or (3) a false-positive serologic test for syphilis known to be positive for at least 6 months and confirmed by negative *Treponema pallidum* immobilization or fluorescent treponemal antibody absorption test |
| 11. Antinuclear antibody | An abnormal titer of antinuclear antibody by immunofluorescence or an equivalent assay at any point in time and in the absence of drugs known to be associated with drug-induced lupus syndrome |

*The proposed classification is based on 11 criteria. For the purpose of identifying patients in clinical studies, a person is said to have systemic lupus erythematosus if any 4 or more of the 11 criteria are present, serially or simultaneously, during any period of observation.

From Tan EM, Cohen AS, Fries JF, et al: The revised criteria for the classification of systemic lupus erythematosus. Arthritis Rheum 25:1271, 1982; and Hochberg MC: Updating the American College of Rheumatology revised criteria for the classification of systemic lupus erythematosus. Arthritis Rheum 40:1725, 1997.

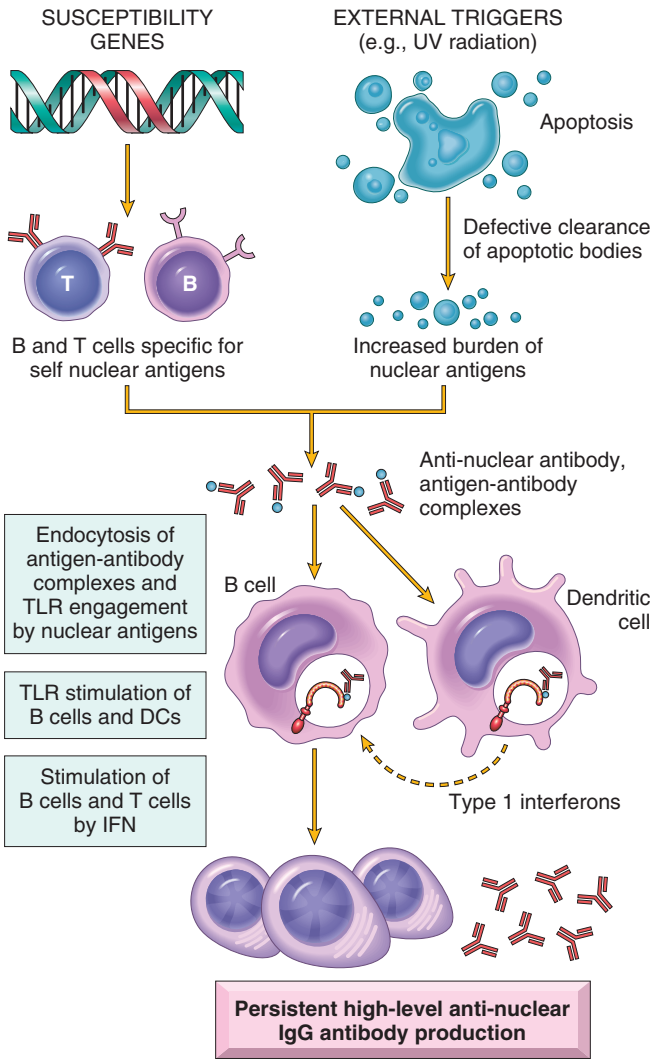


**Figure 4–17** Model for the pathogenesis of systemic lupus erythematosus. Genetic susceptibility and exposure result in failure of self-tolerance and persistence of nuclear antigens. Autoantibodies serve to internalize nuclear components, which engage TLRs and stimulate IFN production. IFN may stimulate B and T cell responses to the nuclear antigens. IFN, interferon; IgG, immunoglobulin G; MHC, major histocompatibility complex; TLRs, Toll-like receptors; UV, ultraviolet.

monozygotic twins (25%) versus dizygotic twins (1% to 3%).

- **HLA association.** The odds ratio (relative risk) for persons with HLA-DR2 or HLA-DR3 is 2 to 3, and if both haplotypes are present, the risk is about 5.
- **Other genes.** Genetic deficiencies of classical pathway complement proteins, especially C1q, C2, or C4, are seen in about 10% of patients with SLE. The complement deficiencies may result in defective clearance of immune complexes and apoptotic cells, and failure of B cell tolerance. A polymorphism in the inhibitory Fc receptor, FcγRIIb, has been described in some patients; this may contribute to inadequate control of B cell activation. Many other genes have been detected by genome-wide association studies, but the role of each of these is not established and their contribution to the development of the disease remains unclear.

**Environmental Factors.** There are many indications that environmental factors are involved in the pathogenesis of SLE.

- **Ultraviolet (UV) radiation** (sun exposure) exacerbates the lesions of SLE. A postulated mechanism of this effect is that UV radiation causes apoptosis of host cells, leading to an increased burden of nuclear fragments and inflammatory responses to the products of dead cells.
- **Cigarette smoking** has been shown to be associated with the development of SLE. Although the mechanism of this is unknown, smoking tobacco may modulate the production of autoantibodies.
- **Sex hormones** had been thought to exert an important influence on the development of disease, because SLE is 10 times more common in women during reproductive years than in men of similar ages but only 2 to 3 times more common in women during childhood or after the age of 65. However, treatment of women with oral contraceptives containing high doses of estrogen and progesterone did not influence the frequency or severity of disease flares, suggesting that factors other than hormones may account for the increased risk of this disease in women.
- **Drugs** such as procainamide and hydralazine can induce an SLE-like disease, although typically glomerulonephritis does not develop. These drugs cause demethylation of DNA, which could influence the expression of a variety of genes involved in the development of autoimmunity, or the ability of DNA to activate host cells.

**Immunologic Abnormalities in SLE.** Studies have implicated several components of the innate and adaptive immune system in the pathogenesis of SLE.

- **Type I interferons.** Blood cells show a striking molecular signature that indicates exposure to interferon-α (IFN-α), a type I interferon that is produced mainly by plasmacytoid DCs. Some studies have shown that such cells from patients with SLE also produce abnormally large amounts of IFN-α.
- **TLR signals.** Studies in animal models have shown that TLRs that recognize DNA and RNA, notably the DNA-recognizing TLR9 and the RNA-recognizing TLR7, produce signals that activate B cells specific for self nuclear antigens.
- **Failure of B cell tolerance.** Studies with B cells from patients with SLE suggest the presence of defects in both central and peripheral tolerance, resulting in a higher frequency of autoreactive B cells than that typical for healthy people.

Based on these clues, a model for the pathogenesis of SLE has been proposed (Fig. 4–17). According to this model, UV irradiation and other environmental insults lead to the apoptosis of cells. Inadequate clearance of the nuclei of these cells, in part because of defects in clearance mechanisms such as complement proteins and receptors, results in a large burden of nuclear antigens. Polymorphisms in various genes, which are susceptibility genes for lupus, lead to defective ability to maintain self-tolerance in B and T lymphocytes, because of which self-reactive lymphocytes remain functional. The self-reactive B cells are stimulated by the self nuclear antigens, and antibodies are produced against the antigens. Complexes of the antigens and antibodies bind to

Fc receptors on B cells and DCs and may be internalized. The nucleic acid components engage TLRs and stimulate B cells to produce autoantibodies and activate DCs, particularly plasmacytoid DCs, to produce IFN-α, which further enhances the immune response and causes more apoptosis. The net result is a cycle of antigen release and immune activation resulting in the production of high-affinity autoantibodies.

### *Spectrum of Autoantibodies in SLE*

Antibodies have been identified against a host of nuclear and cytoplasmic components of the cell that are specific to neither organs nor species. Another group of antibodies is directed against surface antigens of blood cells, while yet another is reactive with proteins in complex with phospholipids (antiphospholipid antibodies) (Chapter 3).

- *Antinuclear antibodies*. ANAs are directed against several nuclear antigens and can be grouped into four categories: (1) antibodies to DNA, (2) antibodies to histones, (3) antibodies to nonhistone proteins bound to RNA, and (4) antibodies to nucleolar antigens. Table 4–10 lists several autoantibodies, including ANAs, and their association with SLE as well as with other autoimmune diseases, to be discussed later. The most widely used method of detecting ANAs is the indirect immunofluorescence assay (IFA), which screens for autoantibodies that bind to a variety of nuclear antigens, including DNA, RNA, and proteins. Four staining patterns are seen with IFA: homogeneous or diffuse, rim or peripheral, speckled, and nucleolar. While each pattern can be suggestive of the presence of specific autoantibodies, the strength of these associations is limited and should not be relied on. *ANA testing by IFA is extremely sensitive, as more than 95% of patients with SLE will test positive, but the test's specificity is quite limited, because patients with other autoimmune diseases, chronic infections, and cancer will test positive as well*. Furthermore, ANAs are seen in approximately 5% to 15% of healthy people, and the incidence increases with age. Recently, the IFA has been replaced in many clinical laboratories by multiplex flow cytometry immunoassays that can simultaneously test for multiple specific autoantibodies, but these assays may lack the sensitivity of the IFA. *Antibodies to double-stranded DNA (dsDNA) and the so-called Smith (Sm) antigen can be detected by ELISA or multiplex flow methods and are specific for SLE.*
- *Other autoantibodies*. Antibodies against blood cells, including red cells, platelets, and lymphocytes, are found in many patients. Antiphospholipid antibodies are present in 40% to 50% of patients with lupus and react with a wide variety of proteins in complex with phospholipids. Some bind to cardiolipin antigen, used in serologic tests for syphilis, so patients with lupus may have a false-positive test result for syphilis. Antiphospholipid antibodies contribute to coagulation abnormalities, which are described below.

### *Mechanisms of Tissue Injury*

Regardless of the exact sequence by which autoantibodies are formed, they are likely to be the mediators of tissue injury, probably through multiple mechanisms.

- *Most organ damage in SLE is caused by immune complex deposition.* Skin and kidney biopsies from patients with SLE typically demonstrate diffuse and heavy granular deposits of complement and immunoglobulin. Autoantibodies complexed with DNA can be detected as well. These deposits of immune complexes had been thought to cause tissue damage by activating the classical complement pathway (type III hypersensitivity); 75% of patients will have reduced serum levels of C3 and C4 at the time of SLE flares, presumably because complement is being activated and consumed faster than it can be produced. However, people and rodents deficient in C1q are not protected from SLE and actually can spontaneously develop SLE, raising the possibility that

**Table 4–10** Selected Autoantibodies Associated with Presumed Autoimmune Diseases

| Autoantibody (Specificity) | Major Disease Association(s) | Likely Role(s) in Disease |
|---|---|---|
| Anti-dsDNA (double-stranded DNA) | SLE* | Formation of immune complexes |
| Anti-Sm (ribonuclear core protein, Sm antigen) | SLE* | Formation of immune complexes |
| Anti-RNP U1 (ribonuclear protein) | SLE, mixed connective tissue disease | Formation of immune complexes |
| Anti–SS-A (Ro), anti–SS-B (La) (ribonucleoproteins) | Sjögren syndrome, SLE | Role in Sjögren syndrome not known |
| Anti–Scl-70 (DNA topoisomerase I) | Systemic sclerosis* | Unknown |
| Anti-histones (histone proteins) | SLE | Formation of immune complexes |
| Anti-centromere (centromere proteins) | Limited scleroderma, systemic sclerosis* | Unknown |
| Antiphospholipid (phospholipid–protein complexes involved in blood coagulation) | Antiphospholipid syndrome, SLE | Thrombotic episodes |
| Anti-Jo1 (histidyl tRNA ligase) | Inflammatory myopathies* | Unknown |
| Anti-mitochondrial | Primary biliary cirrhosis* | Unknown |
| Anti-eTg (transglutaminase) | Dermatitis herpetiformis | Unknown |
| Anti–neutrophil cytoplasmic antibody (ANCA) (proteins in neutrophil cytoplasm) | Various vasculitides* | Formation of immune complexes? |
| | | Neutrophil degranulation? |
| Anti–smooth muscle | Chronic autoimmune hepatitis | Unknown |

Each antibody specificity is detected in 30% to 90% of patients with a particular disease. Asterisks indicate high correlation between the antibody specificity and the disease.
SLE, systemic lupus erythematosus.

complement-independent mechanisms may also contribute to tissue damage.

- *Autoantibodies of different specificities contribute to the pathology and clinical manifestations of SLE* (type II hypersensitivity). *Autoantibodies against red cells, white cells, and platelets* opsonize these cells and lead to their phagocytosis, resulting in cytopenias. *Autoantibodies against various phospholipids* lead to increased thrombosis in patients, with varied clinical consequences, including recurrent spontaneous abortion and thrombotic episodes. These disorders are part of the *antiphospholipid syndrome*. Paradoxically, these antibodies interfere with clotting tests and are actually called "lupus anticoagulants." Autoantibodies are also produced against clotting factors such as thrombin, and these too may contribute to clotting disorders. *Autoantibodies against central nervous system receptors for various neurotransmitters* have been implicated in the neuropsychiatric complications of the disease.
- There is no evidence that ANAs can permeate intact cells. However, if cell nuclei are exposed, the ANAs can bind to them. In tissues, nuclei of damaged cells react with ANAs, lose their chromatin pattern, and become homogeneous, to produce so-called *LE bodies* or *hematoxylin bodies*. An in vitro correlate of this is the *LE cell,* a neutrophil or macrophage that has engulfed the denatured nucleus of another injured cell. When blood is withdrawn and agitated, a number of leukocytes are sufficiently damaged to expose their nuclei to ANAs, with secondary complement activation; these antibody- and complement-opsonized nuclei are then readily phagocytosed. Although the LE cell test is positive in as many as 70% of patients with SLE, it is now largely of historical interest.

## MORPHOLOGY

SLE is a systemic disease with protean manifestations (Table 4–9). The morphologic changes in SLE are therefore extremely variable and depend on the nature of the autoantibodies, the tissue in which immune complexes deposit, and the course and duration of disease. The most characteristic morphologic changes result from the deposition of immune complexes in a variety of tissues.

**Blood Vessels.** An **acute necrotizing vasculitis** affecting small arteries and arterioles may be present in any tissue. The arteritis is characterized by necrosis and by fibrinoid deposits within vessel walls containing antibody, DNA, complement fragments, and fibrinogen; a transmural and perivascular leukocytic infiltrate is also frequently present. In chronic stages, vessels show fibrous thickening with luminal narrowing.

**Kidneys. Kidney involvement is one of the most important clinical features of SLE,** with renal failure being the most common cause of death. The focus here is on glomerular pathology, although interstitial and tubular lesions are also seen in SLE.

The pathogenesis of all forms of **glomerulonephritis** in SLE involves deposition of DNA–anti-DNA complexes within the glomeruli. These evoke an inflammatory response that may cause proliferation of the endothelial, mesangial, and/or epithelial cells and, in severe cases, necrosis of the glomeruli. Although the kidney appears normal by light microscopy in 25% to 30% of cases, almost all cases of SLE show some renal abnormality if examined by immunofluorescence and electron microscopy. According to the current International Society of Nephrology/Renal Pathology Society morphologic classification, there are six patterns of glomerular disease in SLE (none of which is specific to the disease): **class I,** minimal mesangial lupus nephritis; **class II,** mesangial proliferative lupus nephritis; **class III,** focal lupus nephritis; **class IV,** diffuse lupus nephritis; **class V,** membranous lupus nephritis; and **class VI,** advanced sclerosing lupus nephritis.

- **Minimal mesangial lupus nephritis (class I)** is rarely encountered in renal biopsies. Immune complexes are present in the mesangium, but there are no concomitant structural alterations detectable by light microscopy.
- **Mesangial proliferative lupus nephritis (class II)** is seen in 10% to 25% of cases and is associated with mild clinical symptoms. Immune complexes deposit in the mesangium, with a mild to moderate increase in the mesangial matrix and cellularity.
- **Focal lupus nephritis (class III)** is seen in 20% to 35% of cases. Lesions are visualized in fewer than half the glomeruli, and they may be segmentally or globally distributed within each glomerulus. Active lesions are characterized by swelling and proliferation of endothelial and mesangial cells, infiltration by neutrophils, and/or fibrinoid deposits with capillary thrombi (Fig. 4–18, *A*). The clinical presentation may range from only mild microscopic hematuria and proteinuria to a more active urinary sediment with red blood cell casts and acute, severe renal insufficiency.
- **Diffuse lupus nephritis (class IV)** is the most serious form of renal lesions in SLE and is also the most commonly encountered in renal biopsies, occurring in 35% to 60% of patients. It is distinguished from focal lupus nephritis (class III) by involvement of half or more of glomeruli. Most of the glomeruli show endothelial and mesangial proliferation, leading to diffuse hypercellularity of these structures (Fig. 4–18, *B*) and producing in some cases epithelial crescents that fill Bowman's space. When extensive, subendothelial immune complexes create a circumferential thickening of the capillary wall, resembling rigid "wire loops" on routine light microscopy (Fig. 4–18, *C*). Electron microscopy reveals prominent electron-dense subendothelial immune complexes (between endothelium and basement membrane) (Fig. 4–18, *D*), but immune complexes are also usually present in other parts of the capillary wall and in the mesangium. Immune complexes can be visualized by staining with fluorescent antibodies directed against immunoglobulins or complement, resulting in a granular fluorescent staining pattern (Fig. 4–18, *E*). In due course, glomerular injury may give rise to scarring (glomerulosclerosis). Most affected patients have hematuria with moderate to severe proteinuria, hypertension, and renal insufficiency.
- **Membranous lupus nephritis (class V)** occurs in 10% to 15% of cases and is the designation for glomerular disease characterized by widespread thickening of the capillary wall due to deposition of subepithelial immune complexes. Membranous glomerulonephritis associated

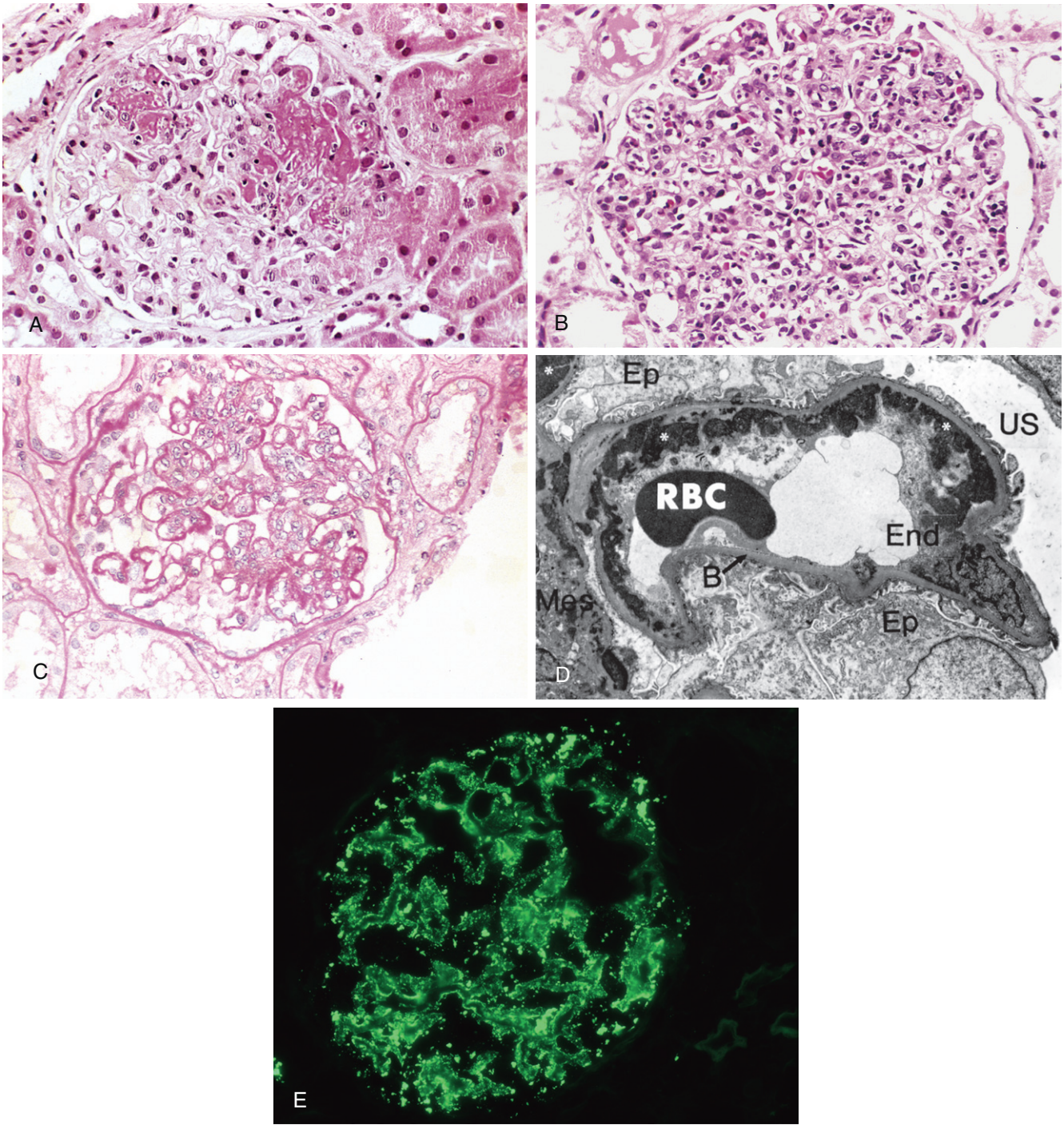


**Figure 4–18** Lupus nephritis. **A,** Focal lupus nephritis, with two necrotizing lesions in a glomerulus (segmental distribution) (H&E stain). **B,** Diffuse lupus nephritis. Note the marked global increase in cellularity throughout the glomerulus (H&E stain). **C,** Lupus nephritis showing a glomerulus with several "wire loop" lesions representing extensive subendothelial deposits of immune complexes (periodic acid Schiff stain). **D,** Electron micrograph of a renal glomerular capillary loop from a patient with SLE nephritis. Confluent subendothelial dense deposits correspond to "wire loops" seen by light microscopy. **E,** Deposition of IgG antibody in a granular pattern, detected by immunofluorescence. B, basement membrane; End, endothelium; Ep, epithelial cell with foot processes; Mes, mesangium; RBC, red blood cell in capillary lumen; US, urinary space; *, electron-dense deposits in subendothelial location.

*(A–C, courtesy of Dr. Helmut Rennke, Department of Pathology, Brigham and Women's Hospital, Boston, Massachusetts. D, Courtesy of Dr. Edwin Eigenbrodt, Department of Pathology, University of Texas Southwestern Medical School, Dallas. E, Courtesy of Dr. Jean Olson, Department of Pathology, University of California, San Francisco, California.)*

with SLE is very similar to that encountered in idiopathic membranous nephropathy (Chapter 13). Thickening of capillary walls is caused by increased deposition of basement membrane–like material, as well as accumulation of immune complexes. Patients with this histologic change almost always have severe proteinuria with overt nephrotic syndrome (Chapter 13).

- **Advanced sclerosing lupus nephritis (class VI)** is characterized by **complete sclerosis** of greater than 90% of glomeruli and corresponds to clinical end stage renal disease.

**Skin.** The **skin** is involved in a majority of patients; a characteristic erythematous or maculopapular eruption over the malar eminences and bridge of the nose ("butterfly pattern") is observed in approximately half of the cases. Exposure to sunlight (UV light) exacerbates the erythema (so-called **photosensitivity**), and a similar rash may be present elsewhere on the extremities and trunk, frequently in sun-exposed areas. Histopathologic findings include liquefactive degeneration of the basal layer of the epidermis, edema at the dermoepidermal junction, and mononuclear infiltrates around blood vessels and skin appendages (Fig. 4–19, *A*). Immunofluorescence microscopy reveals deposition of immunoglobulin and complement at the dermoepidermal junction (Fig. 4–19, *B*); similar immunoglobulin and complement deposits may also be present in apparently uninvolved skin.

**Joints.** Joint involvement is frequent but usually is not associated with striking anatomic changes or with joint deformity. When present, it consists of swelling and a nonspecific mononuclear cell infiltration in the synovial membranes. Erosion of the membranes and destruction of articular cartilage, such as in RA, are exceedingly rare.

**CNS. Central nervous system (CNS) involvement** also is very common, with focal neurologic deficits and/or neuropsychiatric symptoms. CNS disease often is ascribed to vascular lesions causing ischemia or multifocal cerebral microinfarcts. Small vessel angiopathy with noninflammatory intimal proliferation is the most frequent pathological lesion; frank vasculitis is uncommon. The angiopathy may result from thrombosis caused by antiphospholipid antibodies. Premature atherosclerosis occurs and may contribute to CNS ischemia. Another postulated mechanism for CNS disease is injury from antineuronal antibodies with consequent neurologic dysfunction, but this hypothesis remains unproved.

**Other Organs.** The **spleen** may be moderately enlarged. Capsular fibrous thickening is common, as is follicular hyperplasia with numerous plasma cells in the red pulp. Central penicilliary arteries characteristically show thickening and perivascular fibrosis, producing **onion-skin lesions**.

Pericardium and pleura, in particular, are **serosal membranes** that show a variety of inflammatory changes in SLE ranging (in the acute phase) from serous effusions to fibrinous exudates that may progress to fibrous opacification in the chronic stage.

**Involvement of the heart** is manifested primarily in the form of pericarditis. Myocarditis, in the form of a nonspecific mononuclear cell infiltrate, and valvular lesions, called

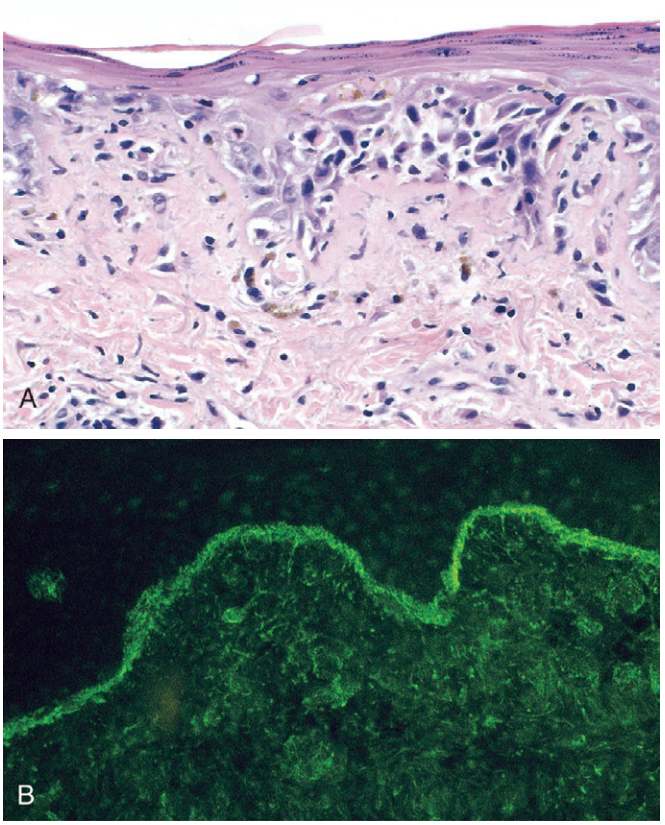


**Figure 4–19** Systemic lupus erythematosus involving the skin. **A,** An H&E-stained section shows liquefactive degeneration of the basal layer of the epidermis and edema at the dermoepidermal junction. **B,** An immunofluorescence micrograph stained for IgG reveals deposits of immunoglobulin along the dermoepidermal junction. H&E, hematoxylin–eosin; IgG, immunoglobulin G.

*(A, Courtesy of Dr. Jag Bhawan, Boston University School of Medicine, Boston, Massachusetts. B, Courtesy of Dr. Richard Sontheimer, Department of Dermatology, University of Texas Southwestern Medical School, Dallas, Texas.)*

**Libman-Sacks endocarditis,** also occur but are less common in the current era of aggressive corticosteroid therapy. This **nonbacterial verrucous endocarditis** takes the form of irregular, 1- to 3-mm warty deposits, seen as distinctive lesions on either surface of the leaflets (i.e., on the surface exposed to the forward flow of the blood or on the underside of the leaflet) (see Chapter 10). An increasing number of patients also show clinical and anatomic manifestations of coronary artery disease. The basis of accelerated atherosclerosis is not fully understood, but the process seems to be multifactorial; certainly, immune complexes can deposit in the coronary vasculature, leading to endothelial damage by that pathway. Moreover, glucocorticoid treatment causes alterations in lipid metabolism, and renal disease (common in SLE) causes hypertension; both of these are risk factors for atherosclerosis (Chapter 9).

Many **other organs and tissues** may be involved. The changes consist essentially of acute vasculitis of the small vessels, foci of mononuclear infiltrations, and fibrinoid deposits. In addition, **lungs** may reveal interstitial fibrosis, along with pleural inflammation; the **liver** shows nonspecific inflammation of the portal tracts.

### Clinical Manifestations

SLE is a multisystem disease that is highly variable in clinical presentation. Typically, the patient is a young woman with some, but rarely all, of the following features: a butterfly rash over the face, fever, pain and swelling in one or more peripheral joints (hands and wrists, knees, feet, ankles, elbows, shoulders), pleuritic chest pain, and photosensitivity. In many patients, however, the presentation of SLE is subtle and puzzling, taking forms such as a febrile illness of unknown origin, abnormal urinary findings, or joint disease masquerading as RA or rheumatic fever. ANAs are found in virtually 100% of patients, but an important point is that ANAs are not specific (Table 4–10). A variety of clinical findings may point toward renal involvement, including hematuria, red cell casts, proteinuria, and in some cases the classic nephrotic syndrome (Chapter 13). Laboratory evidence of some hematologic derangement is common, and in some patients anemia or thrombocytopenia may be the presenting manifestation as well as the dominant clinical problem. In still others, neuropsychiatric manifestations, including psychosis or convulsions, or coronary artery disease may be prominent clinical problems. Patients with SLE are also prone to infections, presumably because of their underlying immune dysfunction and treatment with immunosuppressive drugs. Recent strategies include B cell depletion with anti-CD20 antibody (Rituximab) and by blocking growth factors. The course of the disease is variable and unpredictable. Rare acute cases progress to death within weeks to months. More often, with appropriate therapy, the disease is characterized by flareups and remissions spanning a period of years or even decades. During acute flareups, increased deposition of immune complexes and the accompanying complement activation are thought to result in hypocomplementemia. Disease exacerbations usually are treated with corticosteroids or other immunosuppressive drugs. Even without therapy, in some patients the disease may run a benign course with only skin manifestations and mild hematuria for years. The outcome has improved significantly, and a 5-year survival can be expected in approximately 95% of patients. *The most common causes of death are renal failure, intercurrent infections, and cardiovascular disease.* The incidence of cancer also is increased, particularly B cell lymphomas, an association common to diseases marked by B cell hyperstimulation (e.g., Sjögren syndrome, discussed below). Patients treated with steroids and immunosuppressive drugs incur the usual risks associated with such therapy.

## SUMMARY

### Systemic Lupus Erythematosus

- SLE is a systemic autoimmune disease caused by autoantibodies produced against numerous self-antigens and the formation of immune complexes.
- The major autoantibodies, and the ones responsible for the formation of circulating immune complexes, are directed against nuclear antigens. Other autoantibodies react with erythrocytes, platelets, and various complexes of phospholipids with proteins.
- Disease manifestations include nephritis, skin lesions and arthritis (caused by the deposition of immune complexes), and hematologic and neurologic abnormalities.
- The underlying cause of the breakdown in self-tolerance in SLE is unknown; it may include excess or persistence of nuclear antigens, multiple inherited susceptibility genes, and environmental triggers (e.g., UV irradiation, which results in cellular apoptosis and release of nuclear proteins).

## Rheumatoid Arthritis

Rheumatoid arthritis (RA) is a systemic, chronic inflammatory disease affecting many tissues but principally attacking the joints to produce a nonsuppurative proliferative synovitis that frequently progresses to destroy articular cartilage and underlying bone with resulting disabling arthritis. Because the principal lesions affect the joints and bones, this disease, as well as the juvenile form and other inflammatory diseases of joints, is discussed in Chapter 20.

## Sjögren Syndrome

Sjögren syndrome is a clinicopathologic entity characterized by dry eyes (*keratoconjunctivitis sicca*) and dry mouth (*xerostomia*), resulting from immune-mediated destruction of the lacrimal and salivary glands. It occurs as an isolated disorder (primary form), also known as the *sicca syndrome,* or more often in association with another autoimmune disease (secondary form). Among the associated disorders, RA is the most common, but some patients have SLE, polymyositis, systemic sclerosis, vasculitis, or thyroiditis.

## PATHOGENESIS

Several lines of evidence suggest that Sjögren syndrome is an autoimmune disease caused by CD4+ T cell reactions against unknown antigens in the ductal epithelial cells of the exocrine glands. There is also systemic B cell hyperactivity, as evidenced by the presence of ANAs and rheumatoid factor (RF) (even in the absence of associated RA). Most patients with primary Sjögren syndrome have autoantibodies to the ribonucleoprotein (RNP) antigens SS-A (Ro) and SS-B (La); note that these antibodies are also present in some SLE patients and are therefore not diagnostic for Sjögren syndrome (Table 4–10). Although patients with high-titer anti-SS-A antibodies are more likely to have systemic (extraglandular) manifestations, there is no evidence that the autoantibodies cause primary tissue injury. A viral trigger also has been suggested, but no causative virus has been identified conclusively. Genetic variables play a role in the pathogenesis of Sjögren syndrome. As with SLE, inheritance of certain class II MHC alleles predisposes to the development of specific RNP autoantibodies.

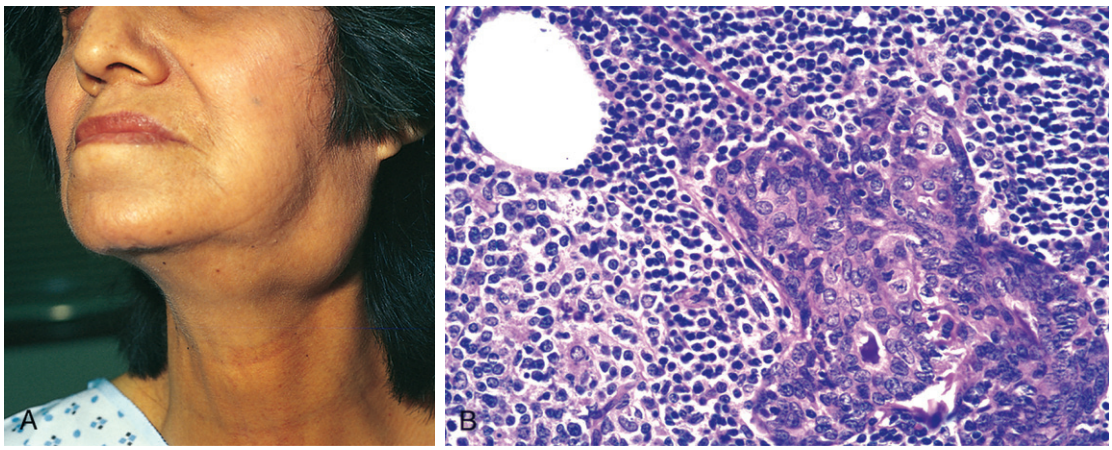


**Figure 4–20** Sjögren syndrome. **A,** Enlargement of the salivary gland. **B,** Histopathologic findings include intense lymphocytic and plasma cell infiltration with ductal epithelial hyperplasia.

*(A, Courtesy of Dr. Richard Sontheimer, Department of Dermatology, University of Texas Southwestern Medical School, Dallas, Texas. B, Courtesy of Dr. Dennis Burns, Department of Pathology, University of Texas Southwestern Medical School, Dallas, Texas.)*

## MORPHOLOGY

Lacrimal and salivary glands are the primary targets, but other secretory glands, including those in the nasopharynx, upper airway, and vagina, also may be involved. Histologic examination shows an intense lymphocyte (primarily activated CD4+ T cells) and plasma cell infiltrate, occasionally forming lymphoid follicles with germinal centers. There is associated destruction of the native architecture (Fig. 4–20).

Lacrimal gland destruction results in a lack of tears, leading to drying of the corneal epithelium, with subsequent inflammation, erosion, and ulceration **(keratoconjunctivitis).** Similar changes may occur in the oral mucosa as a result of loss of salivary gland output, giving rise to mucosal atrophy, with inflammatory fissuring and ulceration **(xerostomia).** Dryness and crusting of the nose may lead to ulcerations and even perforation of the nasal septum. When the respiratory passages are involved, secondary laryngitis, bronchitis, and pneumonitis may appear. Approximately 25% of the patients (especially those with anti-SS-A antibodies) acquire extraglandular disease involving the CNS, skin, kidneys, and muscles. Renal lesions take the form of mild interstitial nephritis associated with tubular transport defects; unlike in SLE, glomerulonephritis is rare.

### Clinical Course

Approximately 90% of Sjögren syndrome cases occur in women between the ages of 35 and 45 years. Patients present with dry mouth, lack of tears, and the resultant complications described above. Salivary glands are often enlarged as a result of lymphocytic infiltrates (Fig. 4–20). Extraglandular manifestations include synovitis, pulmonary fibrosis, and peripheral neuropathy. About 60% of Sjögren patients have another accompanying autoimmune disorder such as RA. Notably, there is a 40-fold increased risk for developing a non-Hodgkin B cell lymphoma, arising in the setting of the initial robust polyclonal B cell proliferation. These so-called marginal zone lymphomas are discussed in Chapter 11.

## SUMMARY

### Sjögren Syndrome

- Sjögren syndrome is an inflammatory disease that affects primarily the salivary and lacrimal glands, causing dryness of the mouth and eyes.
- The disease is believed to be caused by an autoimmune T cell reaction against one or more unknown self antigens expressed in these glands, or immune reactions against the antigens of a virus that infects the tissues.

## Systemic Sclerosis (Scleroderma)

*Systemic sclerosis (SS) is an immunologic disorder characterized by excessive fibrosis in multiple tissues, obliterative vascular disease, and evidence of autoimmunity, mainly the production of multiple autoantibodies.* It is commonly called scleroderma because the skin is a major target, but this disorder is better labeled "systemic" because lesions are present throughout the body. Cutaneous involvement is the usual presenting manifestation and eventually appears in approximately 95% of cases, but it is the visceral involvement—of the gastrointestinal tract, lungs, kidneys, heart, and skeletal muscles—that is responsible for most of the related morbidity and mortality.

SS can be classified into two groups on the basis of its clinical course:

- *Diffuse scleroderma,* characterized by initial widespread skin involvement, with rapid progression and early visceral involvement
- *Limited scleroderma,* with relatively mild skin involvement, often confined to the fingers and face. Involvement of the viscera occurs late, so the disease in these patients generally has a fairly benign course. This clinical presentation is also called the CREST syndrome because of its frequent features of calcinosis, Raynaud phenomenon, esophageal dysmotility, sclerodactyly, and telangiectasia.

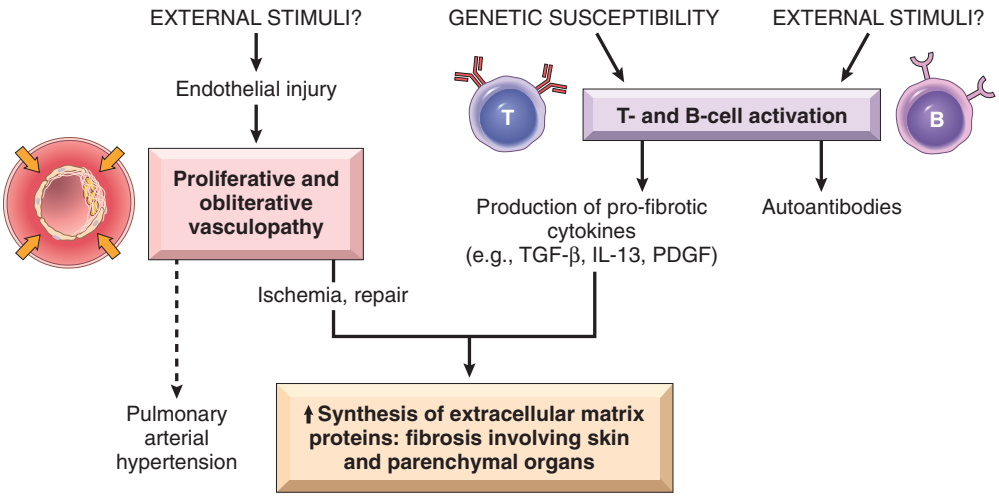


**Figure 4–21** A model for the pathogenesis of systemic sclerosis. Unknown external stimuli cause vascular abnormalities and immune activation in genetically susceptible individuals, and both contribute to the excessive fibrosis.

## PATHOGENESIS

The cause of the disease is not known, but genetic and environmental factors probably contribute. A postulated sequence of events is the following (Fig. 4–21).

- **Injury to endothelial cells** of small arteries by unknown mechanisms leads to endothelial activation, increased expression of adhesion molecules, and migration of activated T cells into the perivascular tissues. The local T cell reaction may cause further activation and injury to endothelial cells.
- **T cells** respond to some self antigen and produce cytokines. It has been suggested that the dominant T cells are $T_H2$ cells, and their cytokines induce alternative macrophage activation and collagen deposition. The activated T cells and macrophages produce **cytokines that activate fibroblasts and stimulate collagen production,** resulting in fibrosis. These cytokines include TGF-β, IL-13, platelet-derived growth factor (PDGF), and others.
- Repeated bouts of endothelial damage followed by platelet aggregation lead to **endothelial proliferation and intimal fibrosis,** which, together with periadventitial fibrosis, narrow the small vessels, with eventual **ischemic injury.** The subsequent repair reaction may lead to more fibrosis, thus setting up a self-perpetuating cycle.
- **B cell activation** also occurs, as indicated by the presence of hypergammaglobulinemia and ANAs. Although there is no evidence that humoral immunity plays a significant role in the pathogenesis of SS, two of the ANAs are virtually unique to this disease and are therefore useful in diagnosis (Table 4–10). One of these, directed **against DNA topoisomerase I** (anti-Scl 70), is highly specific; it is present in as many as 70% of patients with diffuse scleroderma (and in less than 1% of patients with other connective tissue diseases) and is a marker for the development of more aggressive disease with pulmonary fibrosis and peripheral vascular changes. The other ANA is an **anticentromere antibody,** found in as many as 90% of patients with limited scleroderma (i.e., the CREST syndrome); it indicates a relatively benign course.

## MORPHOLOGY

Virtually any organ may be affected in SS, but the most prominent changes are found in the skin, musculoskeletal system, gastrointestinal tract, lungs, kidneys, and heart.

**Skin.** The vast majority of patients have diffuse, sclerotic atrophy of the skin, usually beginning in the fingers and distal regions of the upper extremities and extending proximally to involve the upper arms, shoulders, neck, and face. In the early stages, affected skin areas are somewhat edematous and have a doughy consistency. Histopathologic findings include edema and perivascular infiltrates containing CD4+ T cells. Capillaries and small arteries (as large as 500 μm in diameter) may show thickening of the basal lamina, endothelial cell damage, and partial occlusion. With progression, the edematous phase is replaced by progressive fibrosis of the dermis, which becomes tightly bound to the subcutaneous structures. There is marked increase of compact collagen in the dermis along with thinning of the epidermis, atrophy of the dermal appendages, and hyaline thickening of the walls of dermal arterioles and capillaries (Fig. 4–22, *A, B*). Focal and sometimes diffuse subcutaneous calcifications may develop, especially in patients with the CREST syndrome. In advanced stages, the fingers take on a tapered, clawlike appearance with limitation of motion in the joints (Fig. 4–22, *C*), and the face becomes a drawn mask. Loss of blood supply may lead to cutaneous ulcerations and to atrophic changes in the terminal phalanges, including autoamputation.

**Gastrointestinal Tract.** The gastrointestinal tract is affected in approximately 90% of patients. Progressive atrophy and collagenous fibrous replacement of the muscularis may develop at any level of the gut but are most severe in the esophagus, with the lower two thirds often demonstrating an inflexibility not unlike that typical of a rubber hose. The associated dysfunction of the lower esophageal sphincter gives rise to gastroesophageal reflux and its complications, including Barrett metaplasia (Chapter 14) and strictures. The mucosa is thinned and may be ulcerated, and there is excessive collagenization of the lamina propria and submucosa.

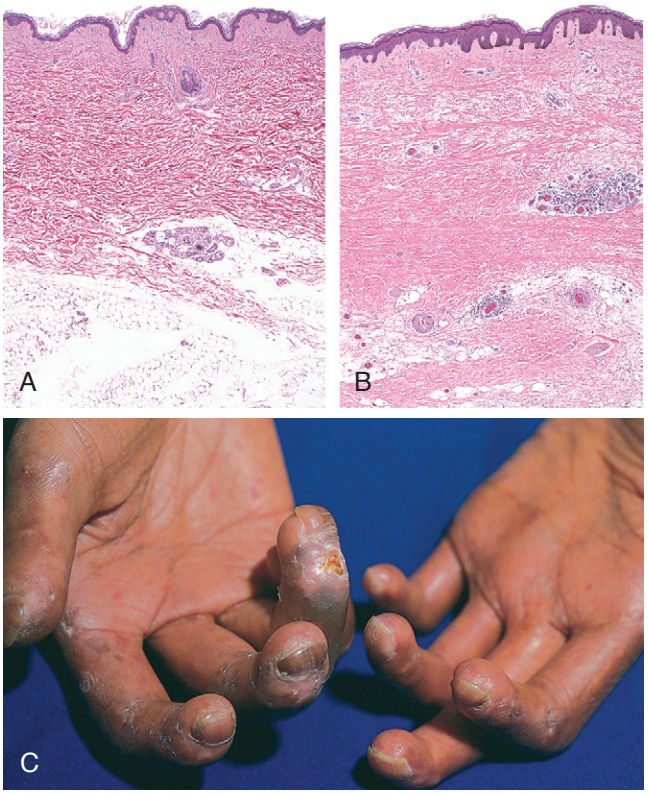


**Figure 4–22** Systemic sclerosis. **A,** Normal skin. **B,** Extensive deposition of dense collagen in the dermis. **C,** The extensive subcutaneous fibrosis has virtually immobilized the fingers, creating a clawlike flexion deformity. Loss of blood supply has led to cutaneous ulcerations.
*(A–C, Courtesy of Dr. Richard Sontheimer, Department of Dermatology, University of Texas Southwestern Medical School, Dallas, Texas.)*

Loss of villi and microvilli in the small bowel is the anatomic basis for the malabsorption syndrome sometimes encountered in affected patients.

**Musculoskeletal System.** Synovial hyperplasia and inflammation are common in the early stages; fibrosis later ensues. Although these changes are reminiscent of RA, joint destruction is not common in SS. In a small subset of patients (approximately 10%), inflammatory myositis indistinguishable from polymyositis may develop.

**Lungs.** The lungs are affected in more than 50% of patients; lung involvement may manifest as pulmonary hypertension and/or interstitial fibrosis. Pulmonary vasospasm from pulmonary vascular endothelial dysfunction is considered important in the pathogenesis of pulmonary hypertension. Pulmonary fibrosis, when present, is indistinguishable from that seen in idiopathic pulmonary fibrosis (Chapter 12).

**Kidneys.** Renal abnormalities occur in two thirds of patients with SS, most typically associated with thickening of the vessel walls of interlobular arteries (150 to 500 μm in diameter). These show intimal cell proliferation with deposition of various glycoproteins and acid mucopolysaccharides. Although similar to the changes seen in malignant hypertension, the alterations in SS are restricted to vessels 150 to 500 μm in diameter and are not always associated with hypertension. Hypertension does occur in 30% of the patients and, in 20% of those patients, takes an ominously malignant course (malignant hypertension). In hypertensive patients, vascular alterations are more pronounced and are often associated with fibrinoid necrosis involving the arterioles together with thrombosis and infarction. Such patients often die of renal failure, accounting for about half of the deaths attributable to SS. There are no specific glomerular changes.

**Heart.** Patchy myocardial fibrosis, along with thickening of intramyocardial arterioles, occurs in one-third of the patients; this is putatively caused by microvascular injury and resultant ischemia (so-called cardiac Raynaud). Because of the changes in the lung, right ventricular hypertrophy and failure (cor pulmonale) are frequent.

### Clinical Course

SS affects women three times more often than men, with a peak incidence in the 50- to 60-year age group. There is a substantial overlap in presentation between SS and RA, SLE, and dermatomyositis (see later); *the distinctive feature of SS is the striking cutaneous involvement*. Almost all patients exhibit Raynaud phenomenon, a vascular disorder characterized by reversible vasospasm of the arteries. Typically the hands turn white on exposure to cold, reflecting vasospasm, followed by change to blue as ischemia and cyanosis supervene. Finally, the color changes to red as reactive vasodilation occurs. Progressive collagen deposition in the skin leads to atrophy of the hands, with increasing stiffness and eventually complete immobilization of the joints. Difficulty in swallowing results from esophageal fibrosis and resultant hypomotility. Eventually, destruction of the esophageal wall leads to atony and dilation. Malabsorption may appear if the submucosal and muscular atrophy and fibrosis involve the small intestine. Dyspnea and chronic cough reflect the pulmonary changes; with advanced lung involvement, *secondary pulmonary hypertension* may develop, leading to right-sided cardiac failure. Renal functional impairment secondary to both the advance of SS and the concomitant malignant hypertension is frequently marked.

The clinical course for diffuse SS is difficult to predict. In most patients the disease pursues a steady, slow, downhill course over the span of many years, although in the absence of renal involvement, life span may be normal. The overall 10-year survival rate ranges from 35% to 70%. The chances of survival are significantly better for patients with localized scleroderma than for those with the usual diffuse progressive disease. Limited scleroderma, or CREST syndrome, frequently has Raynaud phenomenon as its presenting feature. It is associated with limited skin involvement confined to the fingers and face, and these two features may be present for decades before the appearance of visceral lesions.

## SUMMARY

### Systemic Sclerosis

- SS (commonly called scleroderma) is characterized by progressive fibrosis involving the skin, gastrointestinal tract, and other tissues.

- Fibrosis may be the result of activation of fibroblasts by cytokines produced by T cells, but what triggers T cell responses is unknown.
- Endothelial injury and microvascular disease are commonly present in the lesions of SS, causing chronic ischemia, but the pathogenesis of vascular injury is not known.

### Inflammatory Myopathies

Inflammatory myopathies make up a heterogeneous group of rare disorders characterized by immune-mediated muscle injury and inflammation. Based on the clinical, morphologic, and immunologic features, three disorders—polymyositis, dermatomyositis, and inclusion body myositis—have been described. These are discussed in Chapter 21.

### Mixed Connective Tissue Disease

The term *mixed connective tissue disease* refers to a spectrum of pathologic processes in patients who present with clinical features suggestive of SLE, polymyositis, or SS; they also have high titers of antibodies to an RNP antigen called U1RNP. Two other features of mixed connective tissue disease are the paucity of renal disease and an extremely good response to corticosteroids, both of which suggest a favorable long-term prognosis.

Mixed connective tissue disease may manifest as arthritis, swelling of the hands, Raynaud phenomenon, esophageal dysmotility, myositis, leukopenia and anemia, fever, lymphadenopathy, and/or hypergammaglobulinemia. Because of these overlapping features, it is not entirely clear whether mixed connective tissue disease constitutes a distinct clinical entity or if such disorders represent heterogeneous subsets of SLE, systemic sclerosis, and polymyositis; most authorities do not consider it to be a specific entity.

### Polyarteritis Nodosa and Other Vasculitides

Polyarteritis nodosa belongs to a group of diseases characterized by necrotizing inflammation of the walls of blood vessels, most likely caused by deposition of immune complexes. The general term *noninfectious necrotizing vasculitis* differentiates these conditions from those attributable to direct vessel infection (e.g., an abscess) and serves to emphasize that any type of vessel may be involved—arteries, arterioles, veins, or capillaries. A detailed classification and description of vasculitides are presented in Chapter 9.

### IgG4-Related Disease

IgG4-related disease (IgG4-RD) is a newly recognized fibroinflammatory condition characterized by a tendency to form tumor-like lesions in several organs. The disorder is often, but not always, associated with elevated serum IgG4 concentrations. However, increased numbers of IgG4-producing plasma cells (or an increased IgG4 to total IgG ratio) in tissue are a sine qua non of this disorder. Although recognized only recently when extra-pancreatic manifestations were identified in patients with autoimmune pancreatitis, IgG4-RD has now been described in virtually every organ system: the biliary tree, salivary glands, periorbital tissues, kidneys, lungs, lymph nodes, meninges, aorta, breast, prostate, thyroid, pericardium, and skin. The histopathologic features bear striking similarities across organs, regardless of the site of disease. These include a mixed infiltrate of lymphoid cells (T cells, B cells, plasma cells), storiform fibrosis, obliterative phlebitis, and mild to moderate tissue eosinophilia. B cells are typically organized in germinal centers but the T cells—the predominant cell type—are distributed diffusely throughout the lesion. The ratio of IgG4 to IgG-bearing plasma cells (determined by semiquantitative immunohistochemistry) is typically equal to or greater than 50%.

Many medical conditions long viewed as confined to single organs are part of the IgG4-RD spectrum. These include Mikulicz syndrome (enlargement and fibrosis of salivary and lacrimal glands), Riedel thyroiditis, idiopathic retroperitoneal fibrosis, autoimmune pancreatitis, and inflammatory pseudotumors of the orbit, lungs, and kidneys, to name a few.

The role of IgG4 in the pathogenesis of this condition is not fully understood. However, the key role of B cells is supported by initial studies in which depletion of B cells by anti–B cell reagents such as Rituximab provided clinical benefit. It is unclear if the disease is truly autoimmune in nature, and no target autoantigens have been identified.

## REJECTION OF TRANSPLANTS

The major barrier to transplantation of organs from one individual to another of the same species (called allografts) is immunologic rejection of the transplanted tissue. Rejection is a complex phenomenon involving both cell- and antibody-mediated reactions that destroy the graft. The key to successful transplantation has been the development of therapies that prevent or minimize rejection. Discussed next is how grafts are recognized as foreign and how they are rejected.

### Immune Recognition of Allografts

*Rejection of allografts is a response mainly to MHC molecules,* which are so polymorphic that most individuals in an outbred population differ in at least some of the MHC molecules they express (except, of course, for identical twins). There are two main mechanisms by which the host immune system recognizes and responds to the MHC molecules on the graft (Fig. 4–23):

- *Direct recognition.* Host T cells directly recognize the allogeneic (foreign) MHC molecules that are expressed on graft cells. Direct recognition of foreign MHC seems to violate the rule of MHC restriction, which states that in every individual, all of the T cells are educated to recognize foreign antigens displayed by only that individual's MHC molecules. It is postulated that allogeneic MHC molecules (with any bound peptides) structurally mimic

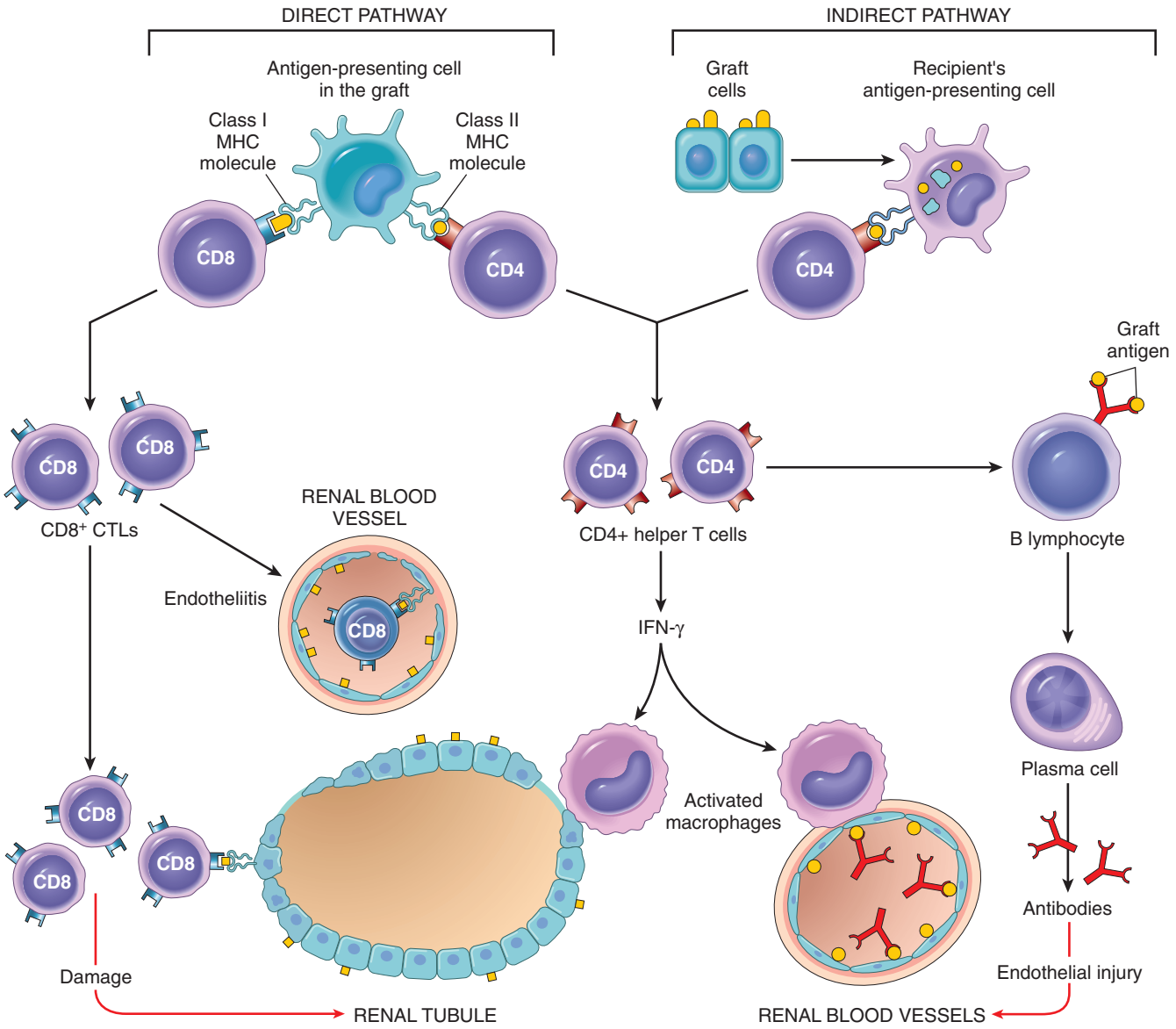


**Figure 4–23** Recognition and rejection of allografts. In the direct pathway, donor class I and class II MHC antigens on antigen-presenting cells (APCs) in the graft (along with costimulators, *not shown*) are recognized by host CD8+ cytotoxic T cells and CD4+ helper T cells, respectively. CD4+ cells proliferate and produce cytokines (e.g., IFN-γ), which induce tissue damage by a local delayed-type hypersensitivity reaction. CD8+ T cells responding to graft antigens differentiate into CTLs that kill graft cells. In the indirect pathway, graft antigens are displayed by host APCs and activate CD4+ T cells, which damage the graft by a local delayed-type hypersensitivity reaction and stimulate B lymphocytes to produce antibodies. IFN-γ, interferon-γ; MHC, major histocompatibility complex.

self MHC and foreign peptide, and so direct recognition of the allogeneic MHC is essentially an immunologic cross-reaction. Because DCs in the graft express high levels of MHC as well as costimulatory molecules, they are believed to be the major culprits contributing to direct recognition. The most important consequence of direct recognition is the activation of host CD8+ T cells that recognize class I MHC (HLA-A, -B) molecules in the graft. These T cells differentiate into CTLs, which kill the cells in the graft. Host CD4+ helper T cells may be triggered into proliferation and cytokine production by recognition of donor class II MHC (HLA-D) molecules and drive an inflammatory response.

- *Indirect recognition.* In this pathway, host CD4+ T cells recognize donor MHC molecules after these molecules are picked up, processed, and presented by the host's own APCs. This sequence is similar to the physiologic processing and presentation of other foreign (e.g., microbial) antigens. The activated CD4+ T cells then recognize APCs displaying graft antigens and secrete cytokines that induce inflammation and damage the graft. The indirect pathway is also involved in the production of antibodies against graft alloantigens; if these antigens are proteins, they are picked up by host B cells, and peptides are presented to helper T cells, which then stimulate antibody responses.

## Effector Mechanisms of Graft Rejection

Both T cells and antibodies reactive with the graft are involved in the rejection of most solid-organ allografts (Fig. 4–23).

### *T Cell–Mediated Rejection*

CTLs kill cells in the grafted tissue, causing parenchymal and endothelial cell death (the latter resulting in thrombosis and graft ischemia). Cytokine-secreting CD4+ T cells trigger inflammatory reactions resembling DTH in the tissues and blood vessels, with local accumulation of mononuclear cells (lymphocytes and macrophages). Activated microphages can injure graft cells and vasculature. The microvascular injury also results in tissue ischemia, which contributes to graft destruction.

### *Antibody-Mediated Rejection*

Although T cells are of paramount importance in allograft rejection, antibodies also mediate some forms of rejection. Alloantibodies directed against graft MHC molecules and other alloantigens bind to the graft endothelium and cause vascular injury through complement activation and recruitment of leukocytes. Superimposed on the resulting endothelial damage and dysfunction is thrombosis, adding further ischemic insult to the injury.

*Hyperacute rejection* is a special form of rejection occurring if *pre-formed anti-donor antibodies* are present in the circulation of the host before transplantation. This may happen in multiparous women who have anti-HLA antibodies against paternal antigens encountered during pregnancy, or in individuals exposed to foreign HLA (on platelets or leukocytes) from previous blood transfusions. Obviously, such antibodies also may be present in a patient who has previously rejected an organ transplant. Subsequent transplantation in such patients will result in immediate rejection (within minutes to hours) because the circulating antibodies rapidly bind to the endothelium of the grafted organ, with resultant complement activation and vascular thrombosis. With the current practice of screening potential recipients for pre-formed anti-HLA antibodies and cross-matching (testing recipients for the presence of antibodies directed against the donor's lymphocytes), hyperacute rejection occurs in less than 0.4% of transplant recipients.

### MORPHOLOGY

On the basis of the time course and morphology of rejection reactions, they have been classified as hyperacute, acute, and chronic (Fig. 4–24). This classification is helpful for understanding the mechanism of rejection, because each pattern is caused by a different type of dominant immunologic reaction. The morphology of these patterns is described in the context of renal transplants; however, similar changes are encountered in other vascularized organ transplants.

#### ***Hyperacute Rejection***

Hyperacute rejection occurs within minutes to a few hours after transplantation in a presensitized host and typically is recognized by the surgeon just after the vascular anastomosis is completed. In contrast with a nonrejecting kidney graft, which regains a normal pink color and tissue turgor and promptly excretes urine, a hyperacutely rejecting kidney rapidly becomes cyanotic, mottled, and flaccid and may excrete only a few drops of bloody fluid. The histologic picture is characterized by widespread acute arteritis and arteriolitis, vessel thrombosis, and ischemic necrosis, all resulting from the binding of preformed antibodies to graft endothelium. Virtually all arterioles and arteries exhibit characteristic acute fibrinoid necrosis of their walls, with narrowing or complete occlusion of the lumens by precipitated fibrin and cellular debris (Fig. 4–24, *A*).

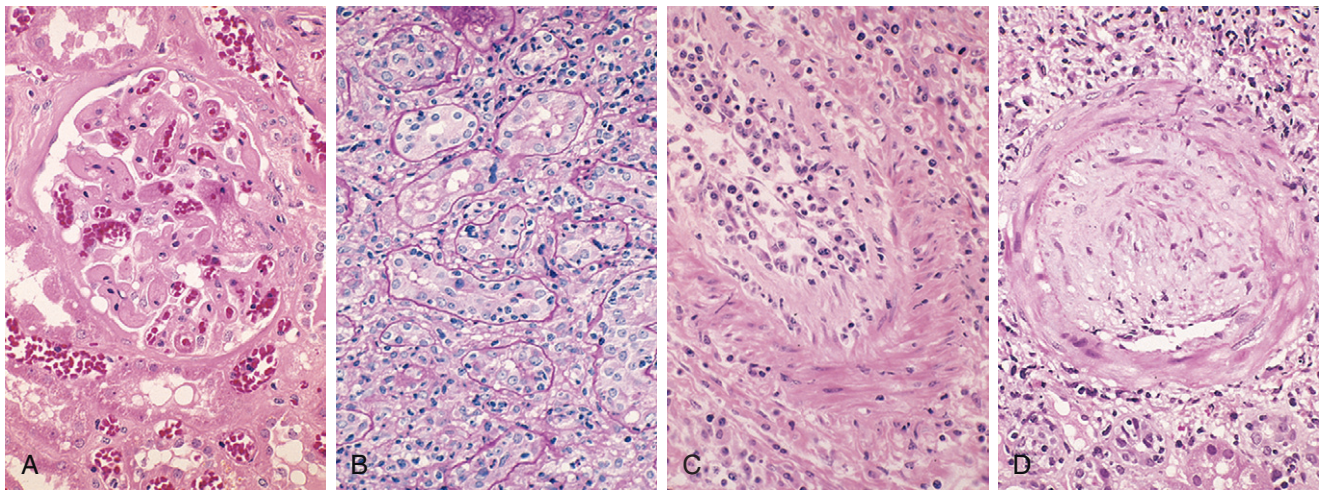


**Figure 4–24** Morphologic patterns of graft rejection. **A,** Hyperacute rejection of a kidney allograft associated with endothelial damage and thrombi in a glomerulus. **B,** Acute cellular rejection of a kidney allograft with inflammatory cells in the interstitium and between epithelial cells of the tubules. **C,** Acute humoral rejection of a kidney allograft (rejection vasculitis) with inflammatory cells and proliferating smooth muscle cells in the intima. **D,** Chronic rejection in a kidney allograft with graft arteriosclerosis. The arterial lumen is replaced by an accumulation of smooth muscle cells and connective tissue in the intima.

*(A–D, Courtesy of Dr. Helmut Rennke, Department of Pathology, Brigham and Women's Hospital and Harvard Medical School, Boston, Massachusetts.)*

### *Acute Rejection*

Acute rejection may occur within days to weeks of transplantation in a nonimmunosuppressed host or may appear months or even years later, even in the presence of adequate immunosuppression. Acute rejection is caused by both cellular and humoral immune mechanisms, and in any one patient, one or the other may predominate, or both may be present. On histologic examination, cellular rejection is marked by an interstitial mononuclear cell infiltrate with associated edema and parenchymal injury, whereas humoral rejection is associated with vasculitis.

**Acute cellular rejection** most commonly is seen within the first months after transplantation and typically is accompanied by clinical signs of renal failure. Histologic examination usually shows extensive interstitial CD4+ and CD8+ T cell infiltration with edema and mild interstitial hemorrhage (Fig. 4–24, *B*). Glomerular and peritubular capillaries contain large numbers of mononuclear cells, which also may invade the tubules, leading to focal tubular necrosis. In addition to tubular injury, CD8+ T cells also may injure the endothelium, causing an endothelitis. Cyclosporine (a widely used immunosuppressive agent) is also nephrotoxic and induces so-called arteriolar hyaline deposits. Renal biopsy is used to distinguish rejection from drug toxicity. Accurate recognition of cellular rejection is important, because patients typically respond promptly to increased immunosuppressive therapy.

**Acute humoral rejection** (rejection vasculitis) caused by antidonor antibodies also may participate in acute graft rejection. The histologic lesions may take the form of necrotizing vasculitis with endothelial cell necrosis; neutrophilic infiltration; deposition of antibody, complement, and fibrin; and thrombosis. Such lesions may be associated with ischemic necrosis of the renal parenchyma. Somewhat older subacute lesions are characterized by marked thickening of the intima by proliferating fibroblasts, myocytes, and foamy macrophages (Fig. 4–24, *C*). The resultant narrowing of the arterioles may cause infarction or renal cortical atrophy. The proliferative vascular lesions mimic arteriosclerotic thickening and are believed to be caused by cytokines that stimulate proliferation of vascular smooth muscle cells. Local deposition of complement breakdown products (specifically C4d) is used to detect antibody-mediated rejection of kidney allografts.

### *Chronic Rejection*

Patients present with chronic rejection late after transplantation (months to years) with a progressive rise in serum creatinine levels (an index of renal function) over a period of 4 to 6 months. Chronic rejection is dominated by vascular changes, interstitial fibrosis, and loss of renal parenchyma; there are typically only mild or no ongoing cellular parenchymal infiltrates. The vascular changes occur predominantly in the arteries and arterioles, which exhibit intimal smooth muscle cell proliferation and extracellular matrix synthesis (Fig. 4–24, *D*). These lesions ultimately compromise vascular perfusion and result in renal ischemia manifested by loss or hyalinization of glomeruli, interstitial fibrosis, and tubular atrophy. The vascular lesion may be caused by cytokines released by activated T cells that act on the cells of the vascular wall, and it may be the end stage of the proliferative arteritis described earlier.

## SUMMARY

### Recognition and Rejection of Organ Transplants (Allografts)

- The graft rejection response is initiated mainly by host T cells that recognize the foreign HLA antigens of the graft, either directly (on APCs in the graft) or indirectly (after uptake and presentation by host APCs).
- Types and mechanisms of rejection comprise the following:
  - *Hyperacute rejection*: Pre-formed antidonor antibodies bind to graft endothelium immediately after transplantation, leading to thrombosis, ischemic damage, and rapid graft failure.
  - *Acute cellular rejection*: T cells destroy graft parenchyma (and vessels) by cytotoxicity and inflammatory reactions.
  - *Acute humoral rejection*: Antibodies damage graft vasculature.
  - *Chronic rejection*: Dominated by arteriosclerosis, this type is probably caused by T cell reaction and secretion of cytokines that induce proliferation of vascular smooth muscle cells, associated with parenchymal fibrosis.

## Methods of Improving Graft Survival

Because HLA molecules are the major targets in transplant rejection, better matching of the donor and the recipient improves graft survival. The benefits of HLA matching are most dramatic for living related donor kidney transplants, and survival improves with increasing number of loci matched. However, as drugs for immunosuppression have improved, HLA matching is not even attempted in some situations, such as heart, lung, liver, and islet transplantation; in such instances, the recipient often needs a transplant urgently and other considerations, such as anatomic (size) compatibility, are of greater practical importance.

Immunosuppression of the recipient is a practical necessity in all organ transplantation except in the case of identical twins. At present, drugs such as cyclosporine, the related FK506, mofetil mycophenolate (MMF), rapamycin, azathioprine, corticosteroids, antilymphocyte globulin, and monoclonal antibodies (e.g., monoclonal anti-CD3) are used. Cyclosporine and FK506 suppress T cell–mediated immunity by inhibiting transcription of cytokine genes, in particular, the gene for IL-2. Although immunosuppression has made transplantation of many organs feasible, there is still a price to be paid. Global immunosuppression results in increased susceptibility to opportunistic fungal, viral, and other infections. These patients are also at increased risk for developing Epstein-Barr virus (EBV)–induced lymphomas, human papillomavirus–induced squamous cell carcinomas, and Kaposi sarcoma. To circumvent the untoward effects of immunosuppression, much effort is devoted to trying to induce donor-specific tolerance in host T cells. One strategy being pursued is to prevent host T cells from receiving costimulatory signals from donor DCs during the initial phase of sensitization. This can be accomplished by administration of agents to interrupt the interaction between the B7 molecules on the DCs of the graft with the CD28 receptors on host T cells.

This will interrupt the second signal for T cell activation and either induce apoptosis or render the T cells functionally unresponsive. The improvement in immunosuppressive therapy has led to improving survival of grafts and acute rejection is becoming less of a concern, especially for kidney and heart grafts. Chronic rejection remains a serious problem, however, especially because it responds much less effectively than does acute rejection to available immunosuppressive agents.

### Transplantation of Hematopoietic Stem Cells

Hematopoietic stem cell (HSC) transplantation is used as therapy for hematopoietic and some nonhematopoietic malignancies, aplastic anemias, and certain inherited disorders, particularly immune deficiency states and severe forms of thalassemia. HSCs historically were obtained solely from donor bone marrow, but are now increasingly harvested from the peripheral blood after mobilization by administration of hematopoietic growth factors, or from the umbilical cord blood of newborns, a readily available rich source of HSCs. The recipient receives chemotherapy and/or irradiation to destroy malignant cells (e.g., in leukemia) and to create a graft bed; then, HSCs are infused into the peripheral blood, from which they home to their bone marrow niches. Rejection of allogeneic HSC transplants seems to be mediated by some combination of host T cells and NK cells that are resistant to radiation therapy and chemotherapy. Two major problems complicate this form of transplantation: graft-versus-host disease and immune deficiency.

***Graft-Versus-Host Disease (GVHD).*** This occurs when immunologically competent T cells (or their precursors) are transplanted into recipients who are immunologically compromised. Although GVHD happens most commonly in the setting of allogeneic HSC transplantation (usually involving minor histocompatibility mismatches between donor and recipient), it also may occur after transplantation of solid organs rich in lymphoid cells (e.g., the liver) or after transfusion of nonirradiated blood. On receiving allogeneic HSCs, an immunologically compromised host cannot reject the graft, but T cells present in the donor graft perceive the recipient's tissue as "foreign" and react against it. This results in the activation of both CD4+ and CD8+ T cells, ultimately causing inflammation and killing host cells.

- *Acute GVHD* (occurring days to weeks after transplantation) causes epithelial cell necrosis in three principal target organs: liver, skin, and gut. Destruction of small bile ducts gives rise to jaundice, and mucosal ulceration of the gut results in bloody diarrhea. Cutaneous involvement is manifested by a generalized rash.
- *Chronic GVHD* may follow the acute syndrome or may occur insidiously. The patients develop skin lesions resembling those of SS (discussed earlier) and manifestations mimicking other autoimmune disorders.

GVHD is a potentially lethal complication that can be minimized but not eliminated by HLA matching. As another potential solution, donor T cells can be depleted before marrow transplant. This protocol has proved to be a mixed blessing: The risk of GVHD is reduced, but the incidence of graft failure and (in those with the disease) the recurrence of leukemia increase. It seems that the multifunctional T cells not only mediate GVHD but also are required for the efficient engraftment of the transplanted HSCs and elimination of leukemia cells (so-called graft-versus-leukemia effect).

***Immune Deficiencies.*** These are often of prolonged duration in recipients of HSC transplants. Among the many reasons for this impairment is the slow reconstitution of the recipient's adaptive immune system, which is destroyed or suppressed to allow the graft to take and requires many months to recover. During this vulnerable period, recipients are susceptible to a variety of infections, mostly viral, such as cytomegalovirus (CMV) and EBV infections.

## IMMUNE DEFICIENCY DISEASES

Immune deficiency diseases may be caused by inherited defects affecting immune system development, or they may result from secondary effects of other diseases (e.g., infection, malnutrition, aging, immunosuppression, autoimmunity, or chemotherapy). *Clinically, patients with immune deficiency present with increased susceptibility to infections as well as to certain forms of cancer.* The type of infections in a given patient depends largely on the component of the immune system that is affected. Patients with defects in immunoglobulin, complement, or phagocytic cells typically suffer from recurrent infections with pyogenic bacteria, whereas those with defects in cell-mediated immunity are prone to infections caused by viruses, fungi, and intracellular bacteria. Discussed next are some of the more important primary (congenital) immune deficiencies, followed by a detailed description of the acquired immunodeficiency syndrome (AIDS), the most devastating example of secondary (acquired) immune deficiency.

### Primary (Congenital) Immune Deficiencies

Primary immune deficiency states are fortunately rare, but their study has nevertheless contributed greatly to the current understanding of the development and function of the immune system. Most primary immune deficiency diseases are genetically determined and affect either adaptive immunity (i.e., humoral or cellular) or innate host defense mechanisms, including complement proteins and cells such as phagocytes and NK cells. Defects in adaptive immunity are often subclassified on the basis of the primary component involved (i.e., B cells or T cells, or both); however, because of the interactions between T and B lymphocytes, these distinctions are not clear-cut. For instance, T cell defects frequently lead to impaired antibody synthesis, and hence isolated deficiencies of T cells may be indistinguishable from combined deficiencies of T and B cells. Most primary immune deficiencies come to attention early in life (between the ages of 6 months and 2 years), usually because the affected infants are susceptible to recurrent infections. One of the most impressive accomplishments of modern molecular biology has been the identification of the genetic basis for many primary immune deficiencies (Fig. 4–25), laying the foundation for future gene replacement therapy.

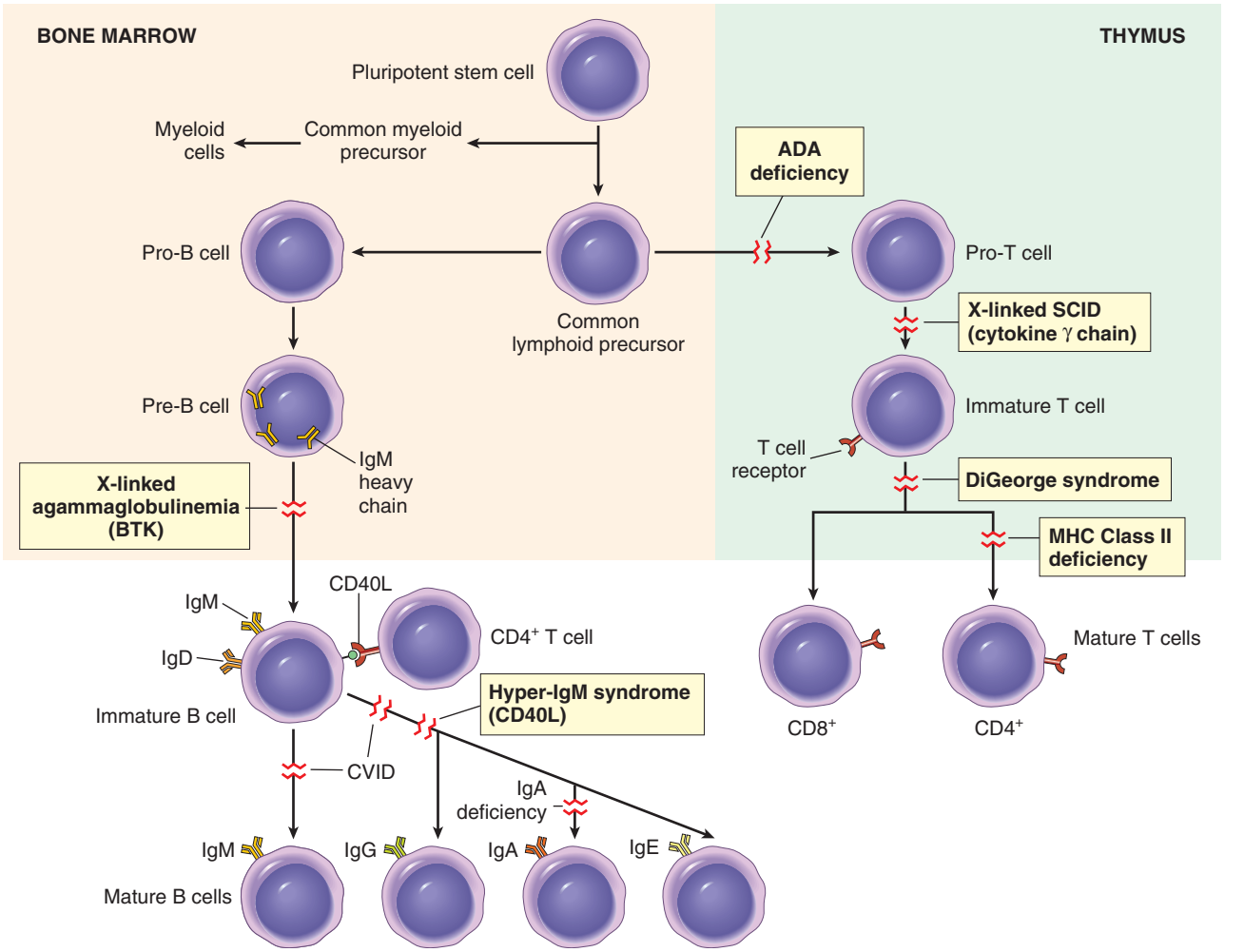


**Figure 4–25** Primary immune deficiency diseases. Shown are the principal pathways of lymphocyte development and the blocks in these pathways in selected primary immune deficiency diseases. The affected genes are indicated in *parentheses* for some of the disorders. ADA, adenosine deaminase; CD40L, CD40 ligand (also known as CD154); CVID, common variable immunodeficiency; SCID, severe combined immunodeficiency.

### *X-Linked Agammaglobulinemia: Bruton Disease*

*X-linked agammaglobulinemia (XLA), or Bruton disease, is characterized by the failure of pre-B cells to differentiate into B cells and, as the name implies, there is a resultant absence of antibodies (gamma globulin) in the blood.* It occurs at a frequency of about 1 in 100,000 male infants. During normal B cell maturation, immunoglobulin heavy chain genes are rearranged first, followed by light chain rearrangement. At each stage, signals are received from the expressed components of the antigen receptor that drive maturation to the next stage; these signals act as quality controls, to ensure that the correct receptor proteins are being produced. In XLA, B cell maturation stops after the initial heavy chain gene rearrangement because of mutations in a tyrosine kinase that is associated with the pre-B cell receptor and is involved in pre-B cell signal transduction. This kinase is called Bruton tyrosine kinase (BTK). When it is nonfunctional, the pre-B cell receptor cannot signal the cells to proceed along the maturation pathway. As a result, immunoglobulin light chains are not produced, and the complete immunoglobulin molecule containing heavy and light chains cannot be assembled and transported to the cell membrane, although free heavy chains can be found in the cytoplasm. Because the *BTK* gene is on the X chromosome, the disorder is seen in males.

Classically, this disease is characterized by the following:

- Absent or markedly decreased numbers of B cells in the circulation, with depressed serum levels of all classes of immunoglobulins. The numbers of pre-B cells in the bone marrow may be normal or reduced.
- Underdeveloped or rudimentary germinal centers in peripheral lymphoid tissues, including lymph nodes, Peyer patches, the appendix, and tonsils
- Absence of plasma cells throughout the body
- Normal T cell–mediated responses

XLA does not become apparent until the affected infant attains the age of approximately 6 months, when the transplacental supply of maternal antibodies is depleted. In most cases, recurrent bacterial infections such as acute and chronic pharyngitis, sinusitis, otitis media, bronchitis, and pneumonia suggest an underlying immune defect. The causal organisms typically are those bacterial pathogens that are cleared by antibody-mediated opsonization and phagocytosis (e.g., *Haemophilus influenzae, Streptococcus*

*pneumoniae,* and *Staphylococcus aureus*). Because antibodies are important for neutralizing viruses, patients with XLA also are susceptible to certain viral infections, especially those caused by enteroviruses. Similarly, *Giardia lamblia,* an intestinal protozoan usually neutralized by secreted IgA, cannot be efficiently cleared and causes persistent infections. Fortunately, replacement therapy with intravenous immunoglobulin (IVIG) from pooled human serum allows most patients to adequately combat bacterial infections. Patients with XLA clear some viral, fungal, and protozoal infections, because their T cell–mediated immunity is intact. For unclear reasons, autoimmune diseases (such as RA and dermatomyositis) occur in as many as 20% of patients with this disease.

### *Common Variable Immunodeficiency*

Common variable immunodeficiency is an umbrella term for a heterogeneous group of disorders characterized by hypogammaglobulinemia, impaired antibody responses to infection (or vaccination), and increased susceptibility to infections. The clinical manifestations are superficially similar to those of XLA, but in common variable immunodeficiency, males and females are affected equally and the onset of symptoms is much later, in the second or third decade of life. The diagnosis usually is one of exclusion (after other causes of immune deficiency are ruled out). The estimated prevalence of the disease is about 1 in 50,000. Although most patients have normal numbers of mature B cells, plasma cells are absent, suggesting a block in antigen-stimulated B cell differentiation. The defective antibody production has been variably attributed to intrinsic B cell defects, deficient T cell help, or excessive T cell suppressive activity. Paradoxically, these patients are prone to develop a variety of autoimmune disorders (hemolytic anemia, pernicious anemia), as well as lymphoid tumors. The underlying mechanism of the antibody deficiency is variable (hence the name). Some patients with this disease have mutations in B cell receptors for certain growth factors, or in molecules involved in T cell–B cell interactions. However, the genetic basis of most cases of the disease is not known.

### *Isolated IgA Deficiency*

The most common of all the primary immune deficiency diseases, IgA deficiency affects about 1 in 700 whites. As noted previously, IgA is the major immunoglobulin in mucosal secretions and is thus involved in defending the airways and the gastrointestinal tract. Although most people with this condition are asymptomatic, weakened mucosal defenses predispose patients to recurrent sinopulmonary infections and diarrhea. There is also a significant (but unexplained) association with autoimmune diseases. The pathogenesis of IgA deficiency seems to involve a block in the terminal differentiation of IgA-secreting B cells to plasma cells; IgM and IgG subclasses of antibodies are present in normal or even supranormal levels. The molecular basis for this defect is not understood.

### *Hyper-IgM Syndrome*

In a normal immune response to protein antigen, IgM antibodies are produced first, followed by the sequential elaboration of IgG, IgA, and IgE antibodies. As discussed earlier in this chapter, the orderly appearance of different antibody types is called heavy-chain class (isotype) switching and is important for generating classes of antibody that can effectively activate complement and/or opsonize bacterial pathogens. The ability of IgM-producing B cells to turn on the transcription of genes that encode other immunoglobulin isotypes depends on certain cytokines, as well as on contact-mediated signals from CD4+ helper T cells. The contact-dependent signals are provided by interaction between CD40 molecules on B cells and CD40L (also known as CD154), expressed on activated helper T cells. *Patients with the hyper-IgM syndrome produce normal (or even supranormal) levels of IgM antibodies to antigens but lack the ability to produce the IgG, IgA, and IgE isotypes*; the underlying defect is an inability of T cells to induce B cell isotype switching. The most common genetic abnormality is mutation of the gene encoding CD40L. This gene is located on the X chromosome; consequently, *in approximately 70% of the cases, hyper-IgM syndrome is X-linked*. In the remaining patients, the mutations affect CD40 or other molecules involved in class switching, notably an enzyme called activation-induced deaminase. In addition to defective class switching, in those with CD40 or CD40L mutations there is also often a defect in the production of high-affinity antibodies, because the same mechanism is responsible for affinity maturation of the antibody response.

Although the disease is diagnosed and named because of the antibody abnormality, in patients with CD40 or CD40L mutations there is also a defect in cell-mediated immunity because the CD40–CD40L interaction is critical for helper T cell–mediated activation of macrophages, the central reaction of cell-mediated immunity. Male patients with the X-linked form of hyper-IgM syndrome present with recurrent pyogenic infections owing to low levels of opsonizing IgG antibodies. These patients also are susceptible to infections with a variety of intracellular pathogens that normally are combated by cell-mediated immunity, including *Pneumocystis jiroveci* (formerly called *Pneumocystis carinii*).

### *Thymic Hypoplasia: DiGeorge Syndrome*

DiGeorge syndrome results from a congenital defect in thymic development with deficient T cell maturation. T cells are absent in the lymph nodes, spleen, and peripheral blood, and infants with this defect are extremely vulnerable to viral, fungal, and protozoal infections. Patients are also susceptible to infection with intracellular bacteria, because of defective T cell–mediated immunity. B cells and serum immunoglobulins are generally unaffected.

The disorder is a consequence of a developmental malformation affecting the third and fourth pharyngeal pouches, structures that give rise to the thymus, parathyroid glands, and portions of the face and aortic arch. Thus, in addition to the thymic and T cell defects, there may be parathyroid gland hypoplasia, resulting in hypocalcemic tetany, as well as additional midline developmental abnormalities. In 90% of cases of DiGeorge syndrome there is a deletion affecting chromosomal region 22q11, as discussed in Chapter 6. Transplantation of thymic tissue has successfully treated some affected infants. In patients with partial defects, immunity may improve spontaneously with age.

### *Severe Combined Immunodeficiency*

Severe combined immunodeficiency (SCID) represents a constellation of genetically distinct syndromes with the common feature of defects in both humoral and cell-mediated immune responses. Affected infants are susceptible to severe recurrent infections by a wide array of pathogens, including bacteria, viruses, fungi, and protozoans, and opportunistic infections by *Candida, Pneumocystis,* CMV, and *Pseudomonas*. These pathogens cause serious (and occasionally lethal) disease. The prevalence of the disease is approximately 1 in 65,000 to 1 in 100,000, and the frequency is 20 to 30 times higher in some Native American populations.

Despite the common clinical features, the underlying defects in individual patients are quite diverse. Some forms of SCID are caused by a single defect affecting both T and B cells, and others may result from a primary T cell deficit with secondary impairment of humoral immunity. *Approximately half of the cases are X-linked; these are caused by mutations in the gene encoding the common γ chain* shared by the receptors for the cytokines IL-2, IL-4, IL-7, IL-9, and IL-15. Of these cytokines, IL-7 is the most important in this disease because it is the growth factor responsible for stimulating the survival and expansion of immature B and T cell precursors in the generative lymphoid organs. Another 40% to 50% of SCID cases are inherited in an autosomal recessive fashion, with approximately half of these caused by *mutations in adenosine deaminase (ADA)*, an enzyme involved in purine metabolism. ADA deficiency results in accumulation of adenosine and deoxyadenosine triphosphate metabolites, which inhibit DNA synthesis and are toxic to lymphocytes. The other autosomal recessive cases of SCID are attributed to defects in another purine metabolic pathway, primary failure of class II MHC expression, or mutations in genes encoding the recombinase responsible for the rearrangement of lymphocyte antigen-receptor genes.

In the two most common forms of SCID (cytokine receptor common γ chain mutation and ADA deficiency), the thymus is hypoplastic. Lymph nodes and lymphoid tissues (e.g., in the tonsils, gut, and appendix) are atrophic and lack germinal centers as well as paracortical T cells. Affected patients may have marked lymphopenia, with both T and B cell deficiency; others may have increased numbers of immature T cells and/or large numbers of B cells that are nonfunctional as a consequence of a lack of T cell help. Patients with SCID are currently treated by bone marrow transplantation. X-SCID is the first disease in which gene therapy has been used to successfully replace the mutated gene, but the approach is being reevaluated because some of the treated patients have developed T cell leukemias, presumably because the introduced gene was inserted close to a cellular oncogene.

### *Defects in Lymphocyte Activation*

Rare patients with mutations in genes required for T cell activation have been identified that manifest with defective cell-mediated immunity or a phenotype resembling SCID. One of the interesting ones is a mutation in a transcription factor that is required for the $T_H17$ response. The resulting disease manifestations include fungal (and occasionally bacterial) skin infections and chronic mucocutaneous candidiasis. By contrast, mutations in genes involved in $T_H1$ responses result in susceptibility to infections with atypical mycobacteria. These observations emphasize the importance of $T_H17$ cells for defense against fungal infections and of $T_H1$ cells for combating intracellular bacterial infections. Mutations in genes encoding calcium channel proteins, and other components of T cell signaling, also have been described.

### *Immune Deficiency with Thrombocytopenia and Eczema: Wiskott-Aldrich Syndrome*

Wiskott-Aldrich syndrome is an X-linked recessive disease *characterized by thrombocytopenia, eczema, and a marked vulnerability to recurrent infection*, ending in early death; the only treatment is bone marrow transplantation. This is a curious syndrome in that the clinical presentation and immunologic deficits are difficult to explain on the basis of the known underlying genetic defect. The thymus is initially normal, but there is progressive age-related depletion of T lymphocytes in the peripheral blood and lymph nodes, with concurrent loss of cellular immunity. Additionally, patients do not make effective antibody responses to polysaccharide antigens, and are therefore particularly susceptible to infections with encapsulated, pyogenic bacteria. Affected patients also are prone to the development of malignant lymphomas. The responsible gene encodes a protein (Wiskott-Aldrich syndrome protein) that links several membrane receptors to the cytoskeleton. Although the mechanism is not known, a defect in this protein could result in abnormal cellular morphology (including platelet shape changes) or defective cytoskeleton-dependent activation signals in lymphocytes and other leukocytes, with abnormal cell–cell adhesions and leukocyte migration.

### *Genetic Deficiencies of Components of Innate Immunity*

Several genetic defects have been shown to affect molecules or cells that are important in the early innate immune response to microbes.

#### Complement Proteins

As discussed earlier in this chapter and in Chapter 2, complement components play important roles in inflammatory and immunologic responses. Consequently, hereditary deficiency of C3 (critical for both the classical and alternative pathways) results in an increased susceptibility to infection with pyogenic bacteria. Inherited deficiencies of C1q, C2, and C4 do not make affected persons susceptible to infections, but they do increase the risk of immune complex–mediated disease (e.g., SLE), possibly by impairing the clearance of apoptotic cells or of antigen–antibody complexes from the circulation. Deficiencies of the late components of the classical complement pathway (C5 to C9) result in recurrent infections by Neisseria (gonococci, meningococci) but not by other microbes because Neisseria have thin cell walls and are especially susceptible to lysis by the membrane attack complex, the product of the late steps of complement activation. Lack of the regulatory protein C1 inhibitor allows unfettered C1 activation, with the generation of downstream vasoactive complement mediators; the result is hereditary angioedema, characterized by recurrent episodes of localized edema affecting the skin and/or mucous membranes.

### Phagocytes

Several congenital defects in phagocytes are known. These include defects in the phagocyte oxidase (NADPH oxidase) enzyme, the cause of chronic granulomatous disease, and defects in integrins and selectin ligands, causing the leukocyte adhesion deficiencies. These disorders were described in Chapter 2.

### Other Genetic Disorders of Innate Immunity

Mutations in TLRs and their signaling pathways are quite rare, but study of the associated disorders has been informative. One of the surprises that has emerged from these diseases is that the immune deficiency typically is very restricted. For instance, patients with mutations affecting TLR3, which recognizes viral RNA, develop recurrent herpes simplex encephalitis, and those with mutations affecting MyD88, the signaling protein downstream of many TLRs, are susceptible to bacterial infections, especially severe pneumococcal lung disease, but neither suffers from multiple disseminated infections.

## SUMMARY

### Primary (Congenital) Immune Deficiency Diseases

- Caused by mutations in genes involved in lymphocyte maturation or function, or in innate immunity
- Some of the common disorders:
  - *XLA*: failure of B cell maturation, absence of antibodies; caused by mutations in BTK, which encodes a tyrosine kinase required for maturation signals from the pre-B cell and B cell receptors
  - *Common variable immunodeficiency*: defects in antibody production; cause unknown in most cases
  - *Selective IgA deficiency*: failure of IgA production; cause unknown
  - *X-SCID*: failure of T cell and B cell maturation; mutation in the common γ chain of a cytokine receptor, leading to failure of IL-7 signaling and defective lymphopoiesis
  - *Autosomal SCID*: failure of T cell development, secondary defect in antibody responses; approximately 50% of cases caused by mutation in the gene encoding ADA, leading to accumulation of toxic metabolites during lymphocyte maturation and proliferation
  - *X-linked hyper-IgM syndrome*: failure to produce isotype-switched high-affinity antibodies (IgG, IgA, IgE); mutation in gene encoding CD40L
- Clinical presentation: increased susceptibility to infections in early life

## Secondary (Acquired) Immune Deficiencies

Immune deficiencies secondary to other diseases or therapies are much more common than the primary (inherited) disorders. Secondary immune deficiencies may be encountered in patients with malnutrition, infection, cancer, renal disease, or sarcoidosis. However, the most common cause of immune deficiency is therapy-induced suppression of the bone marrow or of lymphocyte function.

Discussed next is perhaps the most important secondary immune deficiency disease, AIDS, which has become one of the great scourges of humankind.

## Acquired Immunodeficiency Syndrome (AIDS)

AIDS is a retroviral disease caused by the human immunodeficiency virus (HIV). It is characterized by infection and depletion of CD4+ T lymphocytes, and by profound immunosuppression leading to opportunistic infections, secondary neoplasms, and neurologic manifestations. Although AIDS was first described in the United States, it has now been reported in virtually every country in the world. At the end of 2009, more than 33 million people were living with HIV infection and AIDS, of which approximately 70% were in Africa and 20% in Asia; there were almost 2 million cases diagnosed and almost 2 million died of the disease that year, with a total of more than 22 million deaths since the epidemic was recognized in 1981. Although the largest number of infections is in Africa, the most rapid increases in HIV infection in the past decade have occurred in Southeast Asian countries, including Thailand, India, and Indonesia. The statistics are only slightly better in the Western world; for example, approximately 1 million U.S. citizens are infected (roughly 1 in 300). Moreover, more Americans (more than 500,000) have died of AIDS than died in both world wars combined. AIDS-related death rates continue to decline from their 1995 peak.

Because of the combined work of many scientists and clinicians, there has been an explosion of new knowledge about this modern plague. So rapid is the pace of research on the biology of HIV that any text covering the topic will probably be out of date by the time it goes to press. Nevertheless, presented next is a summary of the currently available information on HIV epidemiology, etiology, pathogenesis, and clinical features.

### *Epidemiology*

Epidemiologic studies in the United States have identified five groups at risk for developing AIDS, and these are similar in other countries, except as noted in the following list. *Transmission of HIV occurs under conditions that facilitate the exchange of blood or body fluids that contain the virus or virus-infected cells.* Thus, the major routes of HIV infection are sexual contact, parenteral inoculation, and passage of the virus from infected mothers to their newborns. In about 10% of cases, the risk factors are unknown or not reported. The case distribution data cited are for the United States.

- Men who have sex with men constitute the largest group of infected persons, accounting for 48% of reported cases in the period 2001 to 2004 and 56% of infected men (approximately 4% of whom also inject drugs). However, transmission of AIDS in this category is declining, with less than 50% of new cases attributable to male homosexual contact.
- Heterosexual contacts of members of other high-risk groups constituted about 34% of infections from 2001 to 2004. In Africa and Asia, this is by far the largest group of patients with new infections, and a majority of new cases are in women infected by male partners.

- Intravenous drug abusers with no history of homosexual behavior compose the next largest group, representing about 17% of all patients.
- Recipients of blood and blood components (but not hemophiliacs) who received transfusions of HIV-infected whole blood or components (e.g., platelets, plasma) account for about 1% of patients.
- Hemophiliacs, especially those who received large amounts of factor VIII or IX concentrates before 1985, make up less than 1% of all cases.
- The epidemiology of HIV infection and AIDS is quite different in children (diagnosed when younger than 13 years of age). About 1% of all AIDS cases occur in this population, and the vast majority (about 90%) result from vertical transmission of virus from infected mother to the fetus or newborn.

***Sexual Transmission.*** Sexual transmission is by far the major mode of infection worldwide, accounting for more than 75% of all cases of HIV transmission. Although most sexually transmitted cases in the United States are still due to male-with-male sexual contacts, the vast majority of sexually transmitted HIV infections globally are due to heterosexual activity. Even in the United States, the rate of increase of heterosexual transmission has outpaced transmission by other means; such spread accounts for the dramatic increase in HIV infection in female sex partners of male intravenous drug abusers.

The virus is present in semen, both extracellularly and within mononuclear inflammatory cells, and it enters the recipient's body through lacerations or abrasions in mucosa. Viral transmission to newborns can occur either by direct entry of virus or infected cells into blood vessels breached through traumatic injury or by uptake into mucosal DCs. Clearly, all forms of sexual transmission are aided and abetted by the concomitant presence of other sexually transmitted diseases that cause genital ulcerations, including syphilis, chancroid, and herpes simplex virus infections. Gonorrhea and chlamydial infection also are cofactors for HIV transmission, primarily by increasing the seminal fluid content of inflammatory cells (presumably carrying HIV). In addition to male-to-male and male-to-female transmission, HIV is present in the vaginal and cervical cells of infected women and can also be spread from females to males, albeit about eight times less efficiently.

***Parenteral Transmission.*** Parenteral transmission of HIV is well documented in three different groups: intravenous drug abusers (the largest group), hemophiliacs receiving factor VIII or IX concentrates, and random recipients of blood transfusion. Among intravenous drug abusers, transmission occurs through shared needles, syringes, or other paraphernalia contaminated with HIV-containing blood.

Transmission of HIV by transfusion of blood or blood products such as lyophilized factor VIII concentrates has been virtually eliminated since 1985. Four public health measures are responsible: screening of donated blood and plasma for antibody to HIV, screening for HIV-associated p24 antigen (detectable before the development of antibodies), heat treatment of clotting factor concentrates, and screening of donors on the basis of history. With all of these measures, it is estimated currently that one in 1.5 million blood donations are HIV infected, and that 20 HIV-positive blood components derived from 11 infectious donations are released each year that could potentially infect recipients. With the advent of nucleic acid testing, this already small risk is expected to show further decline.

***Mother-to-Infant Transmission.*** As noted earlier, mother-to-infant vertical transmission is the major cause of pediatric AIDS. Three routes are involved: in utero, by transplacental spread; intrapartum, during delivery; and by ingestion of HIV-contaminated breast milk. Of these, the transplacental and intrapartum routes account for most cases. Vertical transmission rates worldwide vary, ranging from 25% to 35%, with a 15% to 25% rate reported in the United States; higher rates of infection occur with high maternal viral load and/or the presence of chorioamnionitis, presumably by increasing placental accumulation of inflammatory cells.

Because of the dismal outcome for AIDS, the lay public is justifiably concerned about the spread of HIV infection outside recognized high-risk groups. Many of these anxieties can be laid to rest, because extensive studies indicate that HIV infection cannot be transmitted by casual personal contact in the home, workplace, or school, and no convincing evidence for spread by insect bites has been obtained. There is an extremely small but confirmed risk of transmission of HIV infection to health care workers. Seroconversion has been documented after accidental needlestick injury or exposure of nonintact skin to infected blood in laboratory accidents, with a rate of about 0.3% per accidental exposure. By comparison, the rate of seroconversion after accidental exposure to hepatitis B–infected blood is about 6% to 30%.

### *Etiology and Pathogenesis*

AIDS is caused by HIV, a human retrovirus belonging to the lentivirus family (which also includes feline immunodeficiency virus, simian immunodeficiency virus, visna virus of sheep, and the equine infectious anemia virus). Two genetically different but antigenically related forms of HIV, called HIV-1 and HIV-2, have been isolated from patients with AIDS. HIV-1 is the more common type associated with AIDS in the United States, Europe, and Central Africa, whereas HIV-2 causes a similar disease principally in West Africa. Specific tests for HIV-2 are now available, and blood collected for transfusion also is routinely screened for HIV-2 seropositivity. The ensuing discussion relates primarily to HIV-1 and diseases caused by it, but it is generally applicable to HIV-2 as well.

#### Structure of HIV

Like most retroviruses, the HIV-1 virion is spherical and contains an electron-dense, cone-shaped core surrounded by a lipid envelope derived from the host cell membrane (Fig. 4–26). The virus core contains (1) major capsid protein p24, (2) nucleocapsid protein p7/p9, (3) two copies of genomic RNA, and (4) three viral enzymes—protease, reverse transcriptase, and integrase. The p24 protein is the most readily detected viral antigen and is therefore the target for the antibodies used to diagnose HIV infection in blood screening. The viral core is surrounded by a matrix protein called p17, lying beneath the virion envelope. The viral envelope itself is studded with two viral

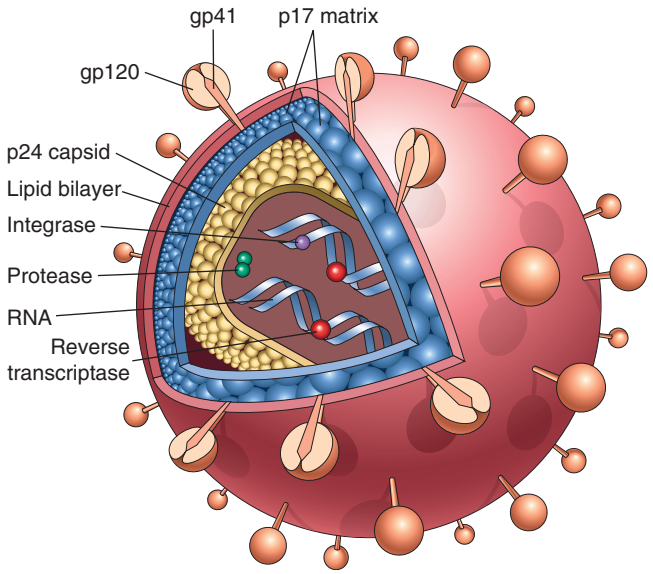


**Figure 4–26** The structure of human immunodeficiency virus (HIV). The HIV-1 virion. The viral particle is covered by a lipid bilayer derived from the host cell and studded with viral glycoproteins gp41 and gp120.

glycoproteins (gp120 and gp41), critical for HIV infection of cells. The HIV-1 proviral genome contains the gag, pol, and env genes, which code for various viral proteins. The products of the gag and pol genes are translated initially into large precursor proteins that must be cleaved by the viral protease to yield the mature proteins. The highly effective anti-HIV-1 protease inhibitor drugs prevent viral assembly by inhibiting the formation of mature viral proteins.

In addition to these three standard retroviral genes, HIV contains several other genes (given three-letter names such as tat, rev, vif, nef, vpr, and vpu) that regulate the synthesis and assembly of infectious viral particles. The product of the tat (transactivator) gene, for example, is critical for virus replication, causing a 1000-fold increase in the transcription of viral genes. The nef protein activates intracellular kinase activity (affecting T cell activation, viral replication, and viral infectivity) and reduces surface expression of CD4 and MHC molecules on infected cells. The progression of HIV infection in vivo is dependent on nef; strains of simian immunodeficiency virus with mutated nef genes cause AIDS in monkeys at a markedly decreased rate, and humans infected with a nef-defective HIV-1 strain display low viral burden, with AIDS onset at a substantially slower pace than for nonmutant strains. The products of various regulatory genes are important for HIV pathogenicity, and therapeutic approaches are being developed to block their actions.

Nucleic acid sequencing of different viral isolates reveals considerable variability in many parts of the HIV genome. This high variability is due to the relatively low fidelity of the viral polymerase, with estimates of one mistake for each $10^5$ replicated nucleotides. Most sequence variants cluster in parts of the genome encoding the envelope glycoproteins. Because the immune response against HIV-1 is targeted against its envelope, such extreme variability in antigen structure poses a formidable barrier to vaccine development.

On the basis of genomic analyses, HIV-1 can be divided into two groups, designated M (major) and O (outlier). Group M viruses, the more common form worldwide, are further divided into subtypes, or clades, designated A through J. The clades differ in their geographic distribution, with B being the most common form in Western Europe and the United States and E being the most common in Thailand. Beyond molecular homologies, the clades also show differences in modes of transmission. Thus, E clade is spread predominantly by heterosexual contact (male-to-female), presumably because of its ability to infect vaginal subepithelial DCs. By contrast, B clade virus grows poorly in DCs and may be transmitted by monocytes and lymphocytes.

### Life Cycle of HIV

The two major targets of HIV infection are the immune system and the CNS. The life cycle of the virus is best understood in terms of its interactions with the immune system.

*The entry of HIV into cells requires the CD4 molecule, which acts as a high-affinity receptor for the virus* (Fig. 4–27). This requirement explains the tropism of the virus for CD4+ T cells and its ability to infect other CD4+ cells, particularly macrophages and DCs. However, binding to CD4 is not sufficient for infection; *the HIV envelope gp120 must also bind to other cell surface molecules (coreceptors) to facilitate cell entry*. Two cell surface chemokine receptors, CCR5 and CXCR4, serve this role. HIV envelope gp120 (noncovalently attached to transmembrane gp41) binds initially to CD4 molecules (Fig. 4–27). This binding leads to a conformational change that exposes a new recognition site on gp120 for the coreceptors CXCR4 (mostly on T cells) or CCR5 (mostly on macrophages). The gp41 then undergoes a conformational change that allows it to insert into the target membrane, and this process facilitates fusion of the virus with the cell. After fusion, the virus core containing the HIV genome enters the cytoplasm of the cell.

The coreceptors are critical components of the HIV infection process, and their discovery resolved some previously unexplained observations regarding HIV tropism. It had been known that HIV strains could be classified according to their relative ability to infect macrophages and/or CD4+ T cells. Macrophage-tropic (R5 virus) strains infect both monocytes/macrophages and freshly isolated peripheral blood T cells, whereas T cell–tropic (X4 virus) strains infect only activated T cell lines. This selectivity is now explained by selective coreceptor usage. R5 strains use CCR5 as their coreceptor, and, because CCR5 is expressed on both monocytes and T cells, these cells are susceptible to infection by R5 strains. Conversely, X4 strains bind to CXCR4, which is expressed on T cell lines (and not on monocytes/macrophages), so that only activated T cells are susceptible. Of interest, approximately 90% of HIV infections initially are transmitted by R5 strains. Over the course of infection, however, X4 viruses gradually accumulate; these are especially virulent and are responsible for T cell depletion in the final, rapid phase of disease progression. It is thought that during the course of HIV infection, R5 strains evolve into X4 strains, as a result of mutations in genes that encode gp120. Persons with defective CCR5 receptors (of U.S. whites, 20% are heterozygous and 1% are homozygous for the mutant CCR5) are relatively resistant to developing

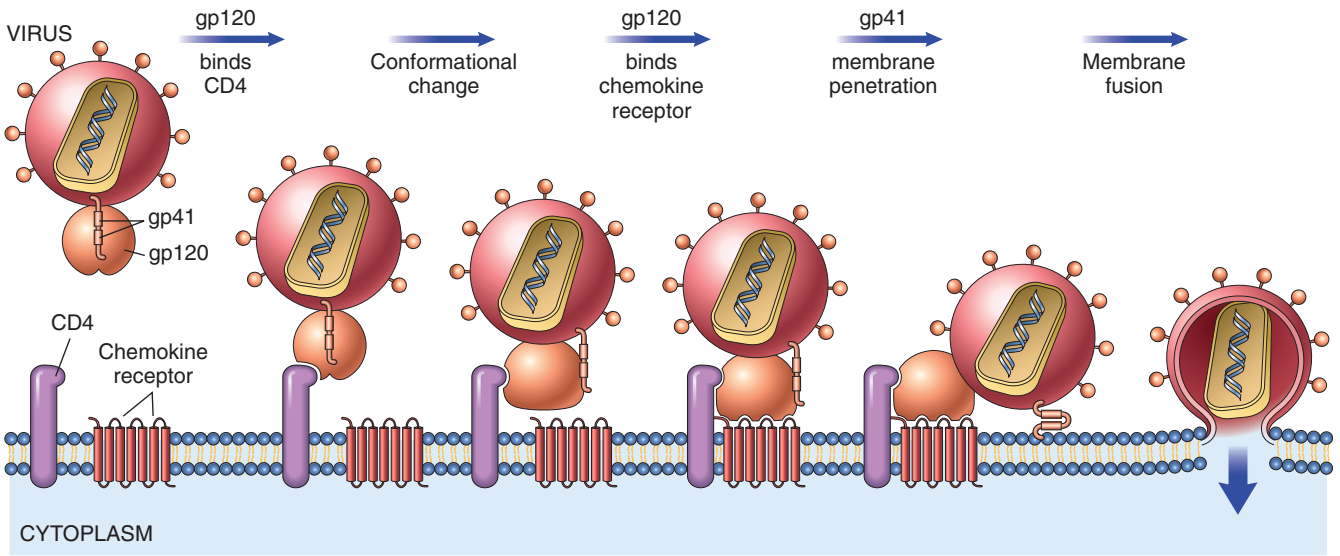


**Figure 4–27** Molecular basis of entry of human immunodeficiency virus (HIV) into host cells. Interactions with CD4 and a chemokine receptor ("coreceptor").
*(Adapted by permission from Macmillan Publishers Ltd, from Wain-Hobson S: HIV. One on one meets two. Nature 384:117, copyright 1996.)*

AIDS, despite repeated HIV exposure in vivo. Because of the significance of HIV–coreceptor interaction in the pathogenesis of AIDS, preventing this interaction may be of significant therapeutic value.

Once internalized, the viral genome undergoes reverse transcription, leading to formation of complementary DNA (cDNA). In quiescent T cells, HIV proviral cDNA may remain in the cytoplasm in a linear episomal form. However, in dividing T cells, the cDNA enters the nucleus and becomes integrated into the host genome. After integration, the provirus may remain nontranscribed for months or years, and the infection becomes latent; alternatively, proviral DNA may be transcribed to form complete viral particles that bud from the cell membrane. Such productive infections, associated with extensive viral budding, lead to cell death. It is important to note that although HIV-1 can infect resting T cells, the initiation of proviral DNA transcription (and hence productive infection) occurs only when the infected cell is activated by exposure to antigens or cytokines. Thus, in a cruel twist, physiologic responses to infections and other stimuli promote the death of HIV-infected T cells.

### Progression of HIV Infection

*HIV disease begins with acute infection, which is only partly controlled by the host immune response, and advances to chronic progressive infection of peripheral lymphoid tissues* (Fig. 4–28). The first cell types to be infected may be memory CD4+ T cells (which express CCR5) in mucosal lymphoid tissues. Because the mucosal tissues are the largest reservoir of T cells in the body and a major site of residence of memory T cells, the death of these cells results in considerable depletion of lymphocytes.

*The transition from the acute phase to a chronic phase of infection is characterized by dissemination of the virus, viremia, and the development of host immune responses.* DCs in epithelia at sites of virus entry capture the virus and then migrate into the lymph nodes. Once in lymphoid tissues, DCs may pass HIV on to CD4+ T cells through direct cell–cell contact. Within days after the first exposure to HIV, viral replication can be detected in the lymph nodes. This replication leads to viremia, during which high numbers of HIV particles are present in the patient's blood, accompanied by an acute HIV syndrome that includes a variety of nonspecific signs and symptoms typical of many viral diseases. The virus disseminates throughout the body and infects helper T cells, macrophages, and DCs in peripheral lymphoid tissues. As the infection spreads, the immune system mounts both humoral and cell-mediated immune responses directed at viral antigens. These immune responses partially control the infection and viral production, and such control is reflected by a drop in viremia to low but detectable levels by about 12 weeks after the primary exposure.

*In the next, chronic phase of the disease, lymph nodes and the spleen are sites of continuous HIV replication and cell destruction* (Fig. 4–28). During this period of the disease, the immune system remains competent at handling most infections with opportunistic microbes, and few or no clinical manifestations of the HIV infection are present. Therefore, this phase of HIV disease is called the *clinical latency period*. Although a majority of peripheral blood T cells do not harbor the virus, destruction of CD4+ T cells within lymphoid tissues steadily progresses during the latent period, and the number of circulating blood CD4+ T cells steadily declines. More than 90% of the body's approximately $10^{12}$ T cells are normally found in lymphoid tissues, and it is estimated that HIV destroys up to 1 to $2 \times 10^9$ CD4+ T cells every day. Early in the course of the disease, the body may continue to make new CD4+ T cells, so CD4+ T cells can be replaced almost as quickly as they are destroyed. At this stage, up to 10% of CD4+ T cells in lymphoid organs may be infected, but the number of circulating CD4+ T cells that are infected at any one time may be less than 0.1% of the total CD4+ T cells in a given case. Eventually, over a period of years, the continuous cycle of virus infection and T cell

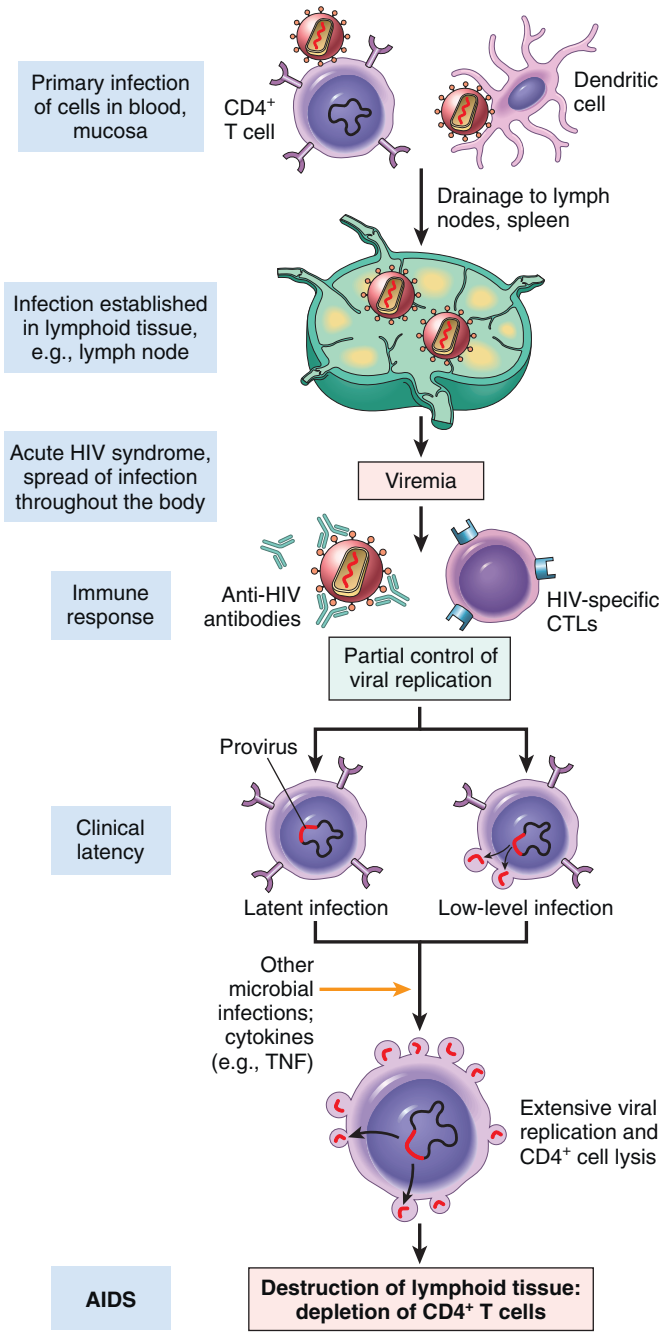


**Figure 4–28** Pathogenesis of human immunodeficiency virus (HIV) infection. Initially, HIV infects T cells and macrophages directly or is carried to these cells by Langerhans cells. Viral replication in the regional lymph nodes leads to viremia and widespread seeding of lymphoid tissue. The viremia is controlled by the host immune response (not shown), and the patient then enters a phase of clinical latency. During this phase, viral replication in both T cells and macrophages continues unabated, but there is some immune containment of virus (not illustrated). There continues a gradual erosion of CD4+ cells by productive infection (or other mechanisms, not shown). Ultimately, CD4+ cell numbers decline and the patient develops clinical symptoms of full-blown AIDS. Macrophages are also parasitized by the virus early; they are not lysed by HIV and they transport the virus to tissues, particularly the brain.

death leads to a steady decline in the number of CD4+ T cells in the lymphoid tissues and the circulation.

In addition to T cell depletion, abnormalities have been described in many components of the immune system, summarized in Table 4–11. Discussed next are the major defects in immune cells during the course of HIV infection.

### Mechanisms of T Cell Depletion in HIV Infection

*The major mechanism of loss of CD4+ T cells is lytic HIV infection of the cells, and cell death during viral replication and production of virions* (Fig. 4–29). Like other cytopathic viruses, HIV disrupts cellular functions sufficiently to cause death of infected cells. In addition to direct cell lysis, other mechanisms may cause T cell loss:

- Loss of immature precursors of CD4+ T cells, either by direct infection of thymic progenitor cells or by infection of accessory cells that secrete cytokines essential for CD4+ T cell maturation. The result is decreased production of mature CD4+ T cells.
- Chronic activation of uninfected cells by HIV antigens or by other concurrent infectious microbes may lead to apoptosis of the T cells. Because of this "activation-induced death" of uninfected cells, the numbers of T cells that die may be much greater than the number of HIV-infected cells.
- Infection of various cells in lymphoid tissues may disrupt the normal architecture, leading to impaired immune responses.
- Fusion of infected and uninfected cells causes formation of syncytia (giant cells). In tissue culture, the gp120 expressed on productively infected cells binds to CD4

**Table 4–11** Major Abnormalities of Immune Function in AIDS

| |
|---|
| **Lymphopenia** |
| Predominantly caused by selective loss of the CD4+ helper T cell subset; reduced CD4+/CD8+ ratio |
| **Decreased T Cell Function in vivo** |
| Preferential loss of activated and memory T cells<br>Decreased delayed-type hypersensitivity<br>Susceptibility to opportunistic infections<br>Susceptibility to neoplasms |
| **Altered T Cell Function in vitro** |
| Decreased proliferative response to mitogens, alloantigens, and soluble antigens<br>Decreased cytotoxicity<br>Decreased helper function for B cell antibody production<br>Decreased interleukin-2 and interferon-γ production |
| **Polyclonal B Cell Activation** |
| Hypergammaglobulinemia and circulating immune complexes<br>Inability to mount de novo antibody response to a new antigen<br>Poor responses to normal signals for B cell activation in vitro |
| **Altered Monocyte or Macrophage Functions** |
| Decreased chemotaxis and phagocytosis<br>Decreased HLA class II antigen expression<br>Diminished capacity to present antigen to T cells<br>Increased spontaneous secretion of interleukin-1, tumor necrosis factor, interleukin-6 |

HLA, human leukocyte antigen.

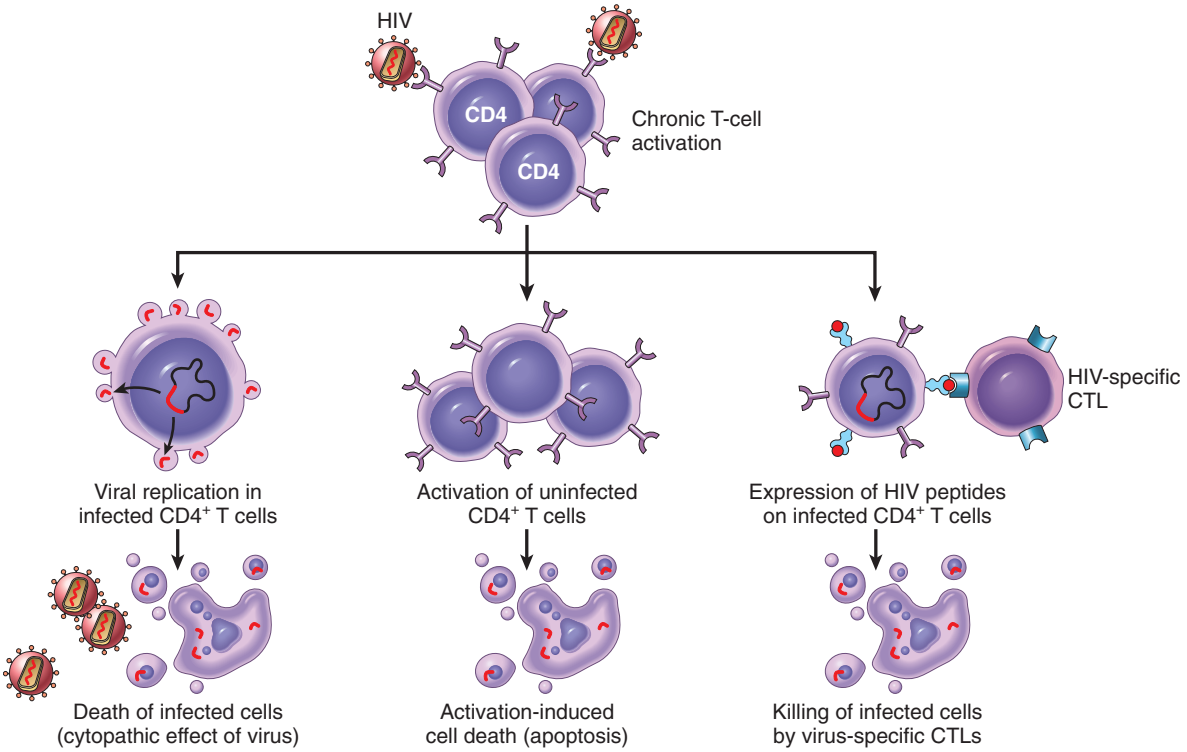


**Figure 4–29** Mechanisms of CD4+ T cell loss in human immunodeficiency virus (HIV) infection. Some of the principal known and postulated mechanisms of T cell depletion after HIV infection are shown.

molecules on uninfected T cells, followed by cell fusion, ballooning, and death within a few hours. This property of syncytia formation is confined to the X4 strain of HIV.

- Uninfected CD4+ T cells may bind soluble gp120 to the CD4 molecule, leading to aberrant signaling and apoptosis.
- Infected CD4+ T cells may be killed by HIV-specific CD8+ CTLs.

The loss of CD4+ cells leads to an inversion of the CD4+/CD8+ ratio in the peripheral blood. Thus, while the normal CD4+/CD8+ ratio is 1 to 2, patients with AIDS have a ratio of 0.5 or less. Such inversion is a common finding in AIDS, but it also may occur in other viral infections and is therefore not diagnostic.

Although marked reduction in CD4+ T cells is a hallmark of AIDS and can account for much of the immune deficiency late in the course of HIV infection, there is also compelling evidence for qualitative defects in T cell function that can be detected even in asymptomatic HIV-infected persons. Such defects include reduced antigen-induced T cell proliferation, impaired $T_H1$ cytokine production, and abnormal intracellular signaling. There is also a selective loss of memory CD4+ T cells early in the course of the disease, possibly related to the abundance of these cells in mucosal tissues and higher level of CCR5 expression in this T cell subset.

Low-level chronic or latent infection of T cells (and macrophages) is an important feature of HIV infection. Although only rare CD4+ T cells express infectious virus early in the course of infection, up to 10% of lymph node T cells can be demonstrated to actually harbor the HIV genome. It is widely believed that integrated provirus, without virus production (latent infection), can persist within cells for months or years. Even with highly active antiretroviral therapy (which can eliminate most of the virus in the blood), latent virus lurks in lymph node CD4+ cells (as many as 0.05% of resting, long-lived CD4+ T cells are infected). Completion of the viral life cycle in latently infected cells requires cell activation. Thus, if latently infected CD4+ cells are activated by environmental antigens, an unfortunate consequence is increased HIV proviral DNA transcription. This increased transcription leads to virion production and, in the case of T cells, also results in cell lysis. In addition, TNF, IL-1, and IL-6 produced by activated macrophages during normal immune responses can also lead to increased HIV gene transcription (Fig. 4–28). Thus, it seems that HIV thrives when the host macrophages and T cells are physiologically activated (e.g., through intercurrent infection by other microbial agents). The life styles of most HIV-infected patients in the United States place them at increased risk for recurrent exposure to other sexually transmitted diseases; in Africa, socioeconomic conditions probably impose a higher burden of chronic microbial infections. It is easy to understand how patients with AIDS enter a vicious circle of T cell destruction; infections to which these patients are prone because of diminished helper T cell function lead to increased production of pro-inflammatory cytokines, which in turn stimulate more HIV production, followed by infection and loss of additional CD4+ T cells.

### Monocytes/Macrophages in HIV Infection

In addition to infection of CD4+ T cells, infection of monocytes and macrophages is also important in the pathogenesis of HIV disease. Similar to T cells, most of the

HIV-infected macrophages are found in the tissues and not in peripheral blood. As many as 10% to 50% of macrophages in certain tissues, such as brain and lungs, may be infected. Several additional aspects of macrophage HIV infection warrant emphasis:

- Although cell division is required for integration and subsequent replication of most retroviruses, HIV-1 can infect and multiply in terminally differentiated nondividing macrophages, a property conferred by the HIV-1 vpr gene.
- Infected macrophages bud relatively small amounts of virus from the cell surface but contain large numbers of virus particles located in intracellular vesicles.
- In contrast with CD4+ T cells, macrophages are quite resistant to the cytopathic effects of HIV and can, therefore, harbor the virus for long periods.
- In more than 90% of cases, HIV infection is transmitted by R5 strains. The more virulent X4 strains that evolve later in the course of HIV infection are inefficient in transmitting HIV to monocytes. This suggests that the initial infection of macrophages (or DCs) is critical for HIV transmission.

Thus, in all likelihood, macrophages are the gatekeepers of HIV infection. Besides providing a portal for initial transmission, monocytes and macrophages are viral reservoirs and factories, whose output remains largely protected from host defenses. Circulating monocytes also provide a vehicle for HIV transport to various parts of the body, particularly the nervous system. In late stages of HIV infection, when the CD4+ T cell numbers are massively depleted, macrophages remain a major site of continued viral replication. Although the number of HIV-infected monocytes in the circulation is low, their functional deficits (e.g., impaired microbicidal activity, decreased chemotaxis, abnormal cytokine production, diminished antigen presentation capacity) have important bearing on host defenses.

### DCs in HIV Infection

In addition to macrophages, two types of DCs also are important targets for the initiation and maintenance of HIV infection: mucosal and follicular DCs. As discussed earlier, mucosal DCs capture the virus and transport it to regional lymph nodes, where CD4+ T cells are infected. Follicular DCs in the germinal centers of lymph nodes are important reservoirs of HIV. Although some follicular DCs are infected by HIV, most virus particles are found on the surface of their dendritic processes, including those bound to Fc receptors through HIV–anti-HIV antibody complexes. The antibody-coated virions localized to follicular DCs retain the ability to infect CD4+ T cells. HIV infection of macrophages and DCs also may impair the functions of these cell populations, with secondary effects on T cell responsiveness.

### B Cells and Other Lymphocytes in HIV Infection

Although much attention has been focused on T cells and macrophages, patients with AIDS also display profound abnormalities of B cell function. Paradoxically, these patients have hypergammaglobulinemia and circulating immune complexes as a result of polyclonal B cell activation. This may result from multiple factors, including infection with CMV or EBV, both of which are polyclonal B cell activators. The HIV gp41 itself can promote B cell growth and differentiation, and HIV-infected macrophages produce increased amounts of IL-6, which enhances B cell proliferation. Despite the presence of spontaneously activated B cells, patients with AIDS are unable to mount antibody responses to newly encountered antigens. Not only is this attributable to deficient T cell help, but antibody responses against T cell–independent antigens are also suppressed, suggesting additional B cell defects. Impaired humoral immunity renders these patients susceptible to encapsulated bacteria (e.g., *S. pneumoniae, H. influenzae*) that require antibodies for effective opsonization and clearance.

CD4+ T cells play a pivotal role in regulating the immune response: they produce a plethora of cytokines, chemotactic factors, and hematopoietic growth factors (e.g., granulocyte-macrophage colony-stimulating factor). Therefore, loss of this "master cell" has ripple effects on virtually every other cell of the immune system, as summarized in Table 4–11.

### Pathogenesis of CNS Involvement

The pathogenesis of the neurologic manifestations in AIDS deserves special mention because, in addition to the lymphoid system, the nervous system is a major target of HIV infection. Macrophages and cells belonging to the monocyte–macrophage lineage (microglial cells) are the predominant cell types in the brain that are infected with HIV. The virus is most likely carried into the brain by infected monocytes (thus, brain HIV isolates are almost exclusively of the R5 type). The mechanism of HIV-induced damage of the brain, however, remains obscure. Because neurons are not infected by HIV, and the extent of neuropathologic changes is often less than might be expected from the severity of neurologic symptoms, most experts believe that the neurologic deficit is caused indirectly by viral products and soluble factors (e.g., cytokines such as TNF) produced by macrophages and microglial cells. In addition, injury from nitric oxide induced in neuronal cells by gp41 and direct damage of neurons by soluble HIV gp120 have been postulated.

## SUMMARY

### Human Immunodeficiency Virus Life Cycle and the Pathogenesis of AIDS

- Virus entry into cells: requires CD4 and co-receptors, which are receptors for chemokines; involves binding of viral gp120 and fusion with the cell mediated by viral gp41 protein; main cellular targets: CD4+ helper T cells, macrophages, DCs
- Viral replication: integration of provirus genome into host cell DNA; triggering of viral gene expression by stimuli that activate infected cells (e.g., infectious microbes, cytokines produced during normal immune responses)
- Progression of infection: acute infection of mucosal T cells and DCs; viremia with dissemination of virus; latent infection of cells in lymphoid tissue; continuing viral replication and progressive loss of CD4+ T cells

- Mechanisms of immune deficiency:
  - Loss of CD4+ T cells: T cell death during viral replication and budding (similar to other cytopathic infections); apoptosis occurring as a result of chronic stimulation; decreased thymic output; functional defects
  - Defective macrophage and DC functions
  - Destruction of architecture of lymphoid tissues (late)

### *Natural History and Clinical Course*

The clinical course of HIV infection can best be understood in terms of an interplay between HIV and the immune system. Three phases reflecting the dynamics of virus–host interaction can be recognized: (1) an early acute phase, (2) a middle chronic phase, and (3) a final crisis phase (Fig. 4–30).

- The *acute phase* represents the initial response of an immunocompetent adult to HIV infection. Clinically, this phase typically manifests as a self-limited illness that develops in 50% to 70% of affected persons 3 to 6 weeks after infection; it is characterized by nonspecific symptoms including sore throat, myalgia, fever, rash, and sometimes aseptic meningitis. This phase is also characterized by high levels of virus production, viremia, and widespread seeding of the peripheral lymphoid tissues, typically with a modest reduction in CD4+ T cells. Soon, however, a virus-specific immune response develops, evidenced by seroconversion (usually within 3 to 17 weeks of exposure) and by the development of virus-specific CD8+ CTLs. As viremia abates, CD4+ T cells return to nearly normal numbers. However, the reduction in plasma virus does not signal the end of viral replication, which continues within CD4+ T cells and macrophages in the tissues (particularly lymphoid organs).
- The middle, *chronic phase* represents a stage of relative containment of the virus. The immune system is largely intact at this point, but there is continued HIV replication that may last for several years. Patients either are asymptomatic or develop persistent lymphadenopathy, and "minor" opportunistic infections such as thrush (*Candida*) or herpes zoster. During this phase, viral replication in the lymphoid tissues continues unabated; thus, there is no true microbiologic latency in HIV infection. The extensive viral turnover is associated with continued loss of CD4+ cells, but a large proportion of the CD4+ cells is replenished and the decline of CD4+ cells in the peripheral blood is modest. After an extended and variable period, the number of CD4+ cells begins to decline, the proportion of the surviving CD4+ cells infected with HIV increases, and host defenses begin to wane. Persistent lymphadenopathy with significant constitutional symptoms (fever, rash, fatigue) reflects the onset of immune system decompensation, escalation of viral replication, and the onset of the "crisis" phase.
- The final, *crisis phase* is characterized by a catastrophic breakdown of host defenses, a marked increase in viremia, and clinical disease. Typically, patients present with fever of more than 1 month's duration, fatigue, weight loss, and diarrhea; the CD4+ cell count is reduced below 500 cells/μL. After a variable interval, serious opportunistic infections, secondary neoplasms, and/or neurologic manifestations (so-called AIDS-defining conditions) emerge, and the patient is said to have full-blown AIDS. Even if the usual AIDS-defining conditions are not present, Centers for Disease Control and

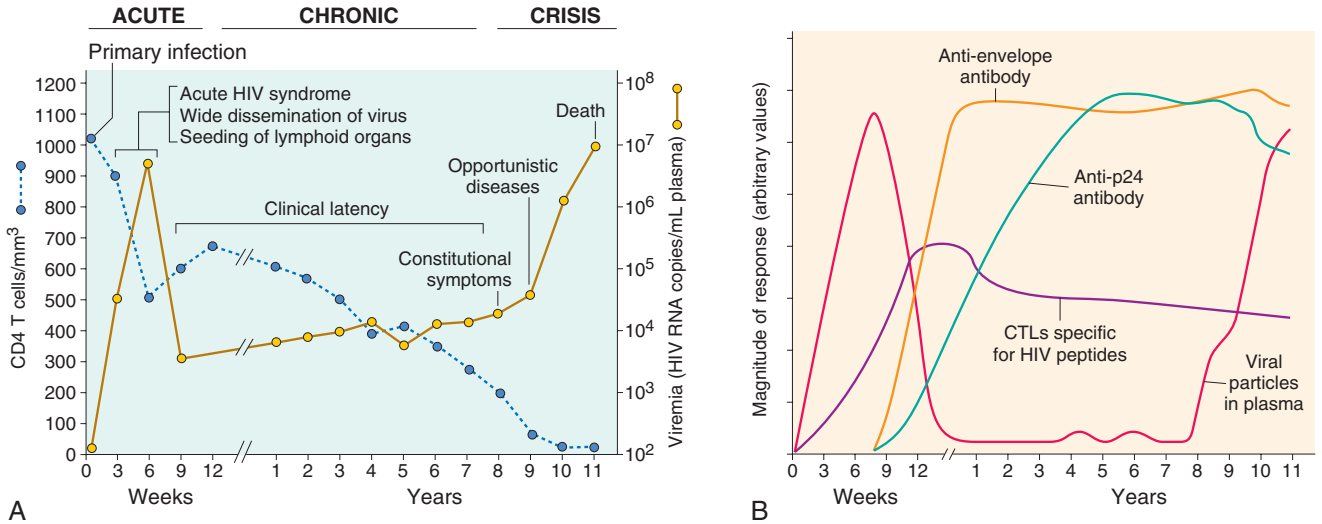


**Figure 4–30** Clinical and immune response to human immunodeficiency virus (HIV) infection. **A,** Clinical course. The early period after primary infection is characterized by dissemination of virus, development of an immune response to HIV, and often an acute viral syndrome. During the period of clinical latency, viral replication continues, and the CD4+ T cell count gradually decreases until it reaches a critical level below which there is a substantial risk of AIDS-associated diseases. **B,** Immune response to HIV infection. A cytotoxic T lymphocyte (CTL) response to HIV is detectable by 2 to 3 weeks after the initial infection and peaks by 9 to 12 weeks. Marked expansion of virus-specific CD8+ T cell clones occurs during this time, and up to 10% of a patient's CTLs may be HIV-specific at 12 weeks. The humoral immune response to HIV peaks at about 12 weeks.

*(A, Redrawn from Fauci AS, Lane HC: Human immunodeficiency virus disease: AIDS and related conditions. In Fauci AS, Braunwald E, Isselbacher KJ, et al [eds]: Harrison's Principles of Internal Medicine, 14th ed. New York, McGraw-Hill, 1997, p 1791.)*

Prevention (CDC) guidelines define any HIV-infected person with CD4+ counts of 200 cells/μL or less as having AIDS.

In the absence of treatment, most patients with HIV infection develop AIDS after a chronic phase lasting 7 to 10 years. Exceptions to this time frame are seen in so-called rapid progressors and long-term nonprogressors. In rapid progressors, the middle, chronic phase is telescoped to 2 to 3 years after primary infection. Nonprogressors (less than 5% of infected persons) are defined as HIV-infected patients who remain asymptomatic for 10 years or more, with stable CD4+ counts and low levels of plasma viremia; notably, AIDS eventually develops in a majority of these patients, albeit after a much-prolonged clinical latency. Despite much study, the reason for nonprogression is not known.

Because the loss of immune containment is associated with declining numbers of CD4+ T cells, the CDC classification of HIV infection stratifies patients into three categories on the basis of CD4+ T cell counts: more than 500 cells/μL, between 200 and 500 cells/μL, and less than 200 cells/μL. Patients in the first group are generally asymptomatic; counts below 500 cells/μL are associated with early symptoms, and a decline of CD4+ T cell levels below 200 cells/μL is associated with severe immunosuppression. For clinical management, CD4+ cell counts are an important adjunct to HIV viral load measurements. The significance of these two measurements, however, is slightly different: Whereas CD4+ cell counts indicate the status of the patient's disease at the time of measurement, the viral load provides information about the direction in which the disease is progressing.

Although this summary of the clinical course is true for untreated or refractory cases, recently developed antiretroviral therapy has changed the course of the disease and greatly reduced the incidence of severe opportunistic infections (such as *Pneumocystis* pneumonia) and tumors (such as Kaposi sarcoma). The available therapy does not eliminate all of the virus, however, and the disease can recur if treatment is stopped. Also not known is whether drug-resistant viral strains will become widespread.

### Clinical Features

The clinical manifestations of HIV infection range from a mild acute illness to severe disease. Because the salient clinical features of the acute, early and chronic, middle phases of HIV infection were described earlier, only the clinical manifestations of the terminal phase, full-blown AIDS, are summarized here.

In the United States the typical adult patient with AIDS presents with fever, weight loss, diarrhea, generalized lymphadenopathy, multiple opportunistic infections, neurologic disease, and (in many cases) secondary neoplasms. The infections and neoplasms listed in Table 4–12 are included in the surveillance definition of AIDS.

***Opportunistic Infections.*** Opportunistic infections have accounted for approximately 80% of deaths among patients with AIDS. Their spectrum is constantly changing, and their incidence is decreasing markedly as a result of more effective antiretroviral therapy. A brief summary of selected opportunistic infections is provided here.

Pneumonia caused by the opportunistic fungus *P. jiroveci* (representing reactivation of a previous latent infection) is the presenting feature in many cases, although its incidence is declining as a result of effective prophylactic regimens. The risk of developing this infection is extremely high in individuals with fewer than 200 CD4+ T cells/μL. Many patients present with an opportunistic infection other than *P. jiroveci* pneumonia (Table 4–12). Among the most common are recurrent mucosal candidiasis, disseminated CMV infection (particularly enteritis and retinitis), severe ulcerating oral and perianal herpes simplex, and disseminated infection with M. tuberculosis and atypical mycobacteria (*Mycobacterium avium-intracellulare*). The AIDS epidemic has caused a resurgence of active tuberculosis in the United States. Although in most cases it represents reactivation, the frequency of new infections is also increasing. Whereas M. tuberculosis manifests itself early in the course of AIDS, infections with atypical mycobacteria are seen late in the course of HIV disease, usually occurring in patients with fewer than 100 CD4+ cells/μL. Toxoplasmosis is the most common secondary infection of the CNS. Cryptococcal meningitis also is quite frequent. Persistent diarrhea, which is common in patients with AIDS, often is caused by *Cryptosporidium* or *Isospora belli* infections, but bacterial pathogens such as *Salmonella* and *Shigella* also may be involved. Because of depressed humoral immunity, patients with AIDS are susceptible to infections with *S. pneumoniae* and *H. influenzae.*

***Neoplasms.*** Patients with AIDS have a high incidence of certain tumors, particularly Kaposi sarcoma, non-Hodgkin lymphomas, and cervical cancer in women. The common feature of all of these diverse neoplasms is that the tumor cells in each are typically infected by an oncogenic virus. The basis of the increased risk of virus-associated

**Table 4–12** AIDS-Defining Opportunistic Infections and Neoplasms Found in Patients with Human Immunodeficiency Virus (HIV) infection

| Infections |
|---|
| *Protozoal and Helminthic Infections* |
| Cryptosporidiosis or isosporidiosis (enteritis) |
| Pneumocystosis (pneumonia or disseminated infection) |
| Toxoplasmosis (pneumonia or CNS infection) |
| *Fungal Infections* |
| Candidiasis (esophageal, tracheal, or pulmonary) |
| Cryptococcosis (CNS infection) |
| Coccidioidomycosis (disseminated) |
| Histoplasmosis (disseminated) |
| *Bacterial Infections* |
| Mycobacteriosis ("atypical," e.g., *Mycobacterium avium-intracellulare*, disseminated or extrapulmonary; *Mycobacterium tuberculosis*, pulmonary or extrapulmonary) |
| Nocardiosis (pneumonia, meningitis, disseminated) |
| *Salmonella* infections, disseminated |
| *Viral Infections* |
| Cytomegalovirus (pulmonary, intestinal, retinitis, or CNS infections) |
| Herpes simplex virus (localized or disseminated infection) |
| Varicella-zoster virus (localized or disseminated infection) |
| Progressive multifocal leukoencephalopathy |
| **Neoplasms** |
| Kaposi sarcoma |
| Primary lymphoma of brain |
| Invasive cancer of uterine cervix |

CNS, central nervous system.

malignancy is multifactorial, but defective T cell immunity is believed to be the predominant contributor.

*Kaposi sarcoma,* a vascular tumor that is otherwise rare in the United States (Chapter 9), was once the most common neoplasm in AIDS patients but its incidence has decreased significantly with anti-retroviral therapy. The tumor is far more common among homosexual or bisexual males than in intravenous drug abusers or patients belonging to other risk groups. The lesions can arise early, before the immune system is compromised, or in advanced stages of HIV infection. Unlike the lesions in sporadic cases of Kaposi sarcoma, those that occur in patients with AIDS are multicentric and tend to be more aggressive; they can affect the skin, mucous membranes, gastrointestinal tract, lymph nodes, and lungs. The lesions contain spindle cells that share features with endothelial cells and smooth muscle cells and are believed to be lymphatic endothelial cells or mesenchymal cells that can form vascular channels. In different patients, the lesions are monoclonal or oligoclonal or even polyclonal, an unusual feature shared by other proliferations driven by oncogenic viruses, such as certain EBV-related B cell proliferations.

Kaposi sarcoma is caused by a herpesvirus called Kaposi sarcoma herpesvirus (KSHV), or human herpesvirus-8 (HHV-8). The mechanisms by which the virus causes the vascular proliferation are uncertain. One hypothesis is that KSHV infects lymphatic endothelial or other cells, and in concert with cytokines produced by HIV-infected immune cells, stimulates proliferation of the endothelial cells. The KSHV genome contains homologues of several human oncogenes and cytokines that may contribute to the growth and survival of the proliferating vessels.

*B cell non-Hodgkin lymphomas* constitute the second most common type of AIDS-associated tumors. These tumors are highly aggressive, occur most frequently in severely immunosuppressed patients, and involve many extranodal sites. The brain is the most common extranodal site in late-stage HIV infection, and hence primary lymphoma of the brain is considered an AIDS-defining condition. Close to 100% of these brain lymphomas are EBV-related. In comparison only 30% to 40% of lymphomas occuring earlier in the course of HIV infection are EBV-related, emphasizing the contribution of other factors, such as chronic B cell hyperstimulation, to lymphoma risk in HIV-infected individuals. Another, less common AIDS-related lymphoma is primary effusion lymphoma, which grows exclusively in body cavities, manifesting as pleural, peritoneal, or pericardial effusions. This rare tumor is always associated with KSHV, and in many cases the tumor cells are co-infected with both KSHV and EBV.

The incidence of *cervical carcinoma* also is increased in patients with AIDS. This correlation is attributable to the high prevalence of human papillomavirus infection among patients with AIDS, whose immune systems are compromised. This virus is believed to be intimately associated with squamous cell carcinoma of the cervix and its precursor lesions, cervical dysplasia and carcinoma in situ (Chapter 18). Hence, gynecologic examination should be part of the routine evaluation in HIV-infected women.

In general, the incidence of the classical "AIDS-defining cancers"—Kaposi sarcoma, EBV-associated tumors, and cervical cancer—has decreased significantly with the use of antiretroviral therapy, but the relative incidence of other tumors considered "non–AIDS-defining cancers" is actually increasing. This latter group includes liver cancer, anal cancer, and Hodgkin lymphoma, all of which are types of tumors associated with various viral infections.

***CNS Involvement.*** Involvement of the CNS is a common and important manifestation of AIDS. At autopsy, 90% of patients are found to have some form of neurologic involvement, and 40% to 60% have clinically evident neurologic dysfunction. Significantly, in some patients neurologic manifestations may be the sole or earliest presenting feature of HIV infection. In addition to opportunistic infections and neoplasms, several virally determined neuropathologic changes occur. These include an aseptic meningitis occurring at the time of seroconversion, vacuolar myelopathy, peripheral neuropathies, and (most commonly) a progressive encephalopathy clinically designated the AIDS dementia complex (Chapter 22).

## MORPHOLOGY

The anatomic changes in the tissues (with the exception of lesions in the brain) are neither specific nor diagnostic. In general, the pathologic features of AIDS are those of widespread opportunistic infections, Kaposi sarcoma, and lymphoma. Most of these lesions are discussed elsewhere, because they also occur in patients who do not have HIV infection. To appreciate the distinctive nature of lesions in the CNS, they are discussed in the context of other disorders affecting the brain (Chapter 22). Here the focus is on changes in the lymphoid organs.

Biopsy specimens from enlarged lymph nodes in the early stages of HIV infection reveal a **marked follicular hyperplasia** (Chapter 11). The medulla contains abundant **plasma cells**. These changes, affecting primarily the B cell areas of the node, are the morphologic counterparts of the polyclonal B cell activation and hypergammaglobulinemia seen in AIDS patients. In addition to changes in the follicles, the sinuses show increased cellularity, due primarily to increased numbers of macrophages but also contributed to by B cell lymphoblasts and plasma cells. HIV particles can be demonstrated within the germinal centers, concentrated on the villous processes of the follicular DCs. Viral DNA also can be detected in macrophages and CD4+ T cells.

With disease progression, the frenzy of B cell proliferation gives way to a pattern of severe follicular involution and generalized lymphocyte depletion. The organized network of follicular DCs is disrupted, and the follicles may even become hyalinized. These "burnt-out" lymph nodes are atrophic and small and may harbor numerous opportunistic pathogens. Because of profound immunosuppression, the inflammatory response to infections both in the lymph nodes and at extranodal sites may be sparse or atypical. For example, with severe immunosuppression, mycobacteria do not evoke granuloma formation, because CD4+ T cells are lacking. In the empty-looking lymph nodes and in other organs, the presence of infectious agents may not be readily apparent without the application of special stains. As might be expected, lymphoid depletion is not confined to the nodes; in the later stages of AIDS, the spleen and thymus also appear to be "wastelands."

Non-Hodgkin lymphomas, often involving extranodal sites such as the brain are primarily aggressive B cell neoplasms (Chapter 11).

Since the emergence of AIDS in 1981, the concerted efforts of epidemiologists, immunologists, and molecular biologists have resulted in spectacular advances in our understanding of this disorder. Despite all this progress, however, the prognosis of patients with AIDS remains guarded. Although the mortality rate has declined as a result of the use of potent combinations of antiretroviral drugs, all treated patients still carry viral DNA in their lymphoid tissues. Can there be a cure with persistent virus? Despite the considerable effort that has been mounted to develop a vaccine, many hurdles remain to be crossed before vaccine-based prophylaxis or treatment becomes a reality. Molecular analyses have revealed an alarming degree of variation in viral isolates from different patients, rendering vaccine development even more difficult. A further complication to this task is that the nature of the protective immune response is not yet fully understood. Consequently, at present, prevention and effective public health measures, combined with antiretroviral therapy, are the mainstays in the fight against AIDS.

## AMYLOIDOSIS

Amyloidosis is a condition associated with a number of inherited and inflammatory disorders in which extracellular deposits of fibrillar proteins are responsible for tissue damage and functional compromise. These abnormal fibrils are produced by the aggregation of misfolded proteins (which are soluble in their normal folded configuration) or protein fragments. The fibrillar deposits bind a wide variety of proteoglycans and glycosaminoglycans, including heparan sulfate and dermatan sulfate, and plasma proteins, notably serum amyloid P component (SAP). The presence of abundant charged sugar groups in these adsorbed proteins gives the deposits staining characteristics that were thought to resemble starch (amylose). Therefore, the deposits were called "amyloid," a name that is firmly entrenched despite the realization that the deposits are unrelated to starch.

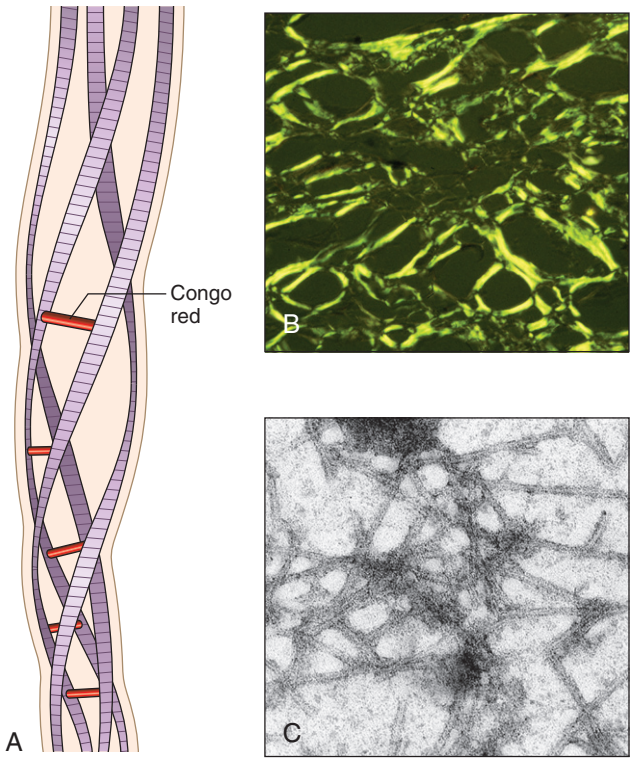


**Figure 4–31** Structure of amyloid. **A,** Schematic diagram of an amyloid fiber showing fibrils (four are shown; as many as six may be present) wound around one another with regularly spaced binding of the Congo red dye. **B,** Congo red staining shows an apple-green birefringence under polarized light, a diagnostic feature of amyloid. **C,** Electron micrograph of 7.4- to 10-nm amyloid fibrils.

*(Reproduced from Merlini G, Bellotti V: Molecular mechanisms of amyloidosis. N Engl J Med 349:583–596, 2003. Copyright 2003 Massachusetts Medical Society. All rights reserved.)*

### PATHOGENESIS OF AMYLOID DEPOSITION

**Amyloidosis is fundamentally a disorder of protein misfolding.** Amyloid is not a structurally homogeneous protein, although it always has the same morphologic appearance. In fact, more than 20 (at last count, 23) different proteins can aggregate to form fibrils with the appearance of amyloid. Regardless of their derivation, all amyloid deposits are composed of nonbranching fibrils, 7.5 to 10 nm in diameter, each formed of β-sheet polypeptide chains that are wound together (Fig. 4–31). The dye Congo red binds to these fibrils and produces a red–green dichroism (birefringence), which is commonly used to identify amyloid deposits in tissues.

Amyloidosis results from abnormal folding of proteins, which are deposited as fibrils in extracellular tissues and disrupt normal function. Normally, misfolded proteins are degraded intracellularly in proteasomes, or extracellularly by macrophages. It appears that in amyloidosis, these quality control mechanisms fail, allowing the misfolded protein to accumulate outside cells. Misfolded proteins often are unstable and self-associate, ultimately leading to the formation of oligomers and fibrils that are deposited in tissues. The diverse conditions that are associated with amyloidosis all are likely to result in excessive production of proteins that are prone to misfolding (Fig. 4–32). The proteins that form amyloid fall into two general categories: (1) normal proteins that have an inherent tendency to fold improperly, associate to form fibrils, and do so when they are produced in increased amounts and (2) mutant proteins that are prone to misfolding and subsequent aggregation. Of the many biochemically distinct forms of amyloid proteins that have been identified, three are most common:

- The **AL (amyloid light chain) protein** is produced by plasma cells and is made up of complete immunoglobulin light chains, the amino-terminal fragments of light chains, or both. For unknown reasons, only a few types of immunoglobulin light chains are prone to forming aggregates. As expected, the deposition of amyloid fibril protein of the AL type is associated with some form of monoclonal B cell proliferation. Defective degradation has also been invoked as the basis for fibril formation, and perhaps particular light chains are resistant to complete proteolysis. However, there are no sequence motifs peculiar to the immunoglobulin light chains found in amyloid deposits.
- The **AA (amyloid-associated) fibril** is a unique nonimmunoglobulin protein derived from a larger (12-kDa)

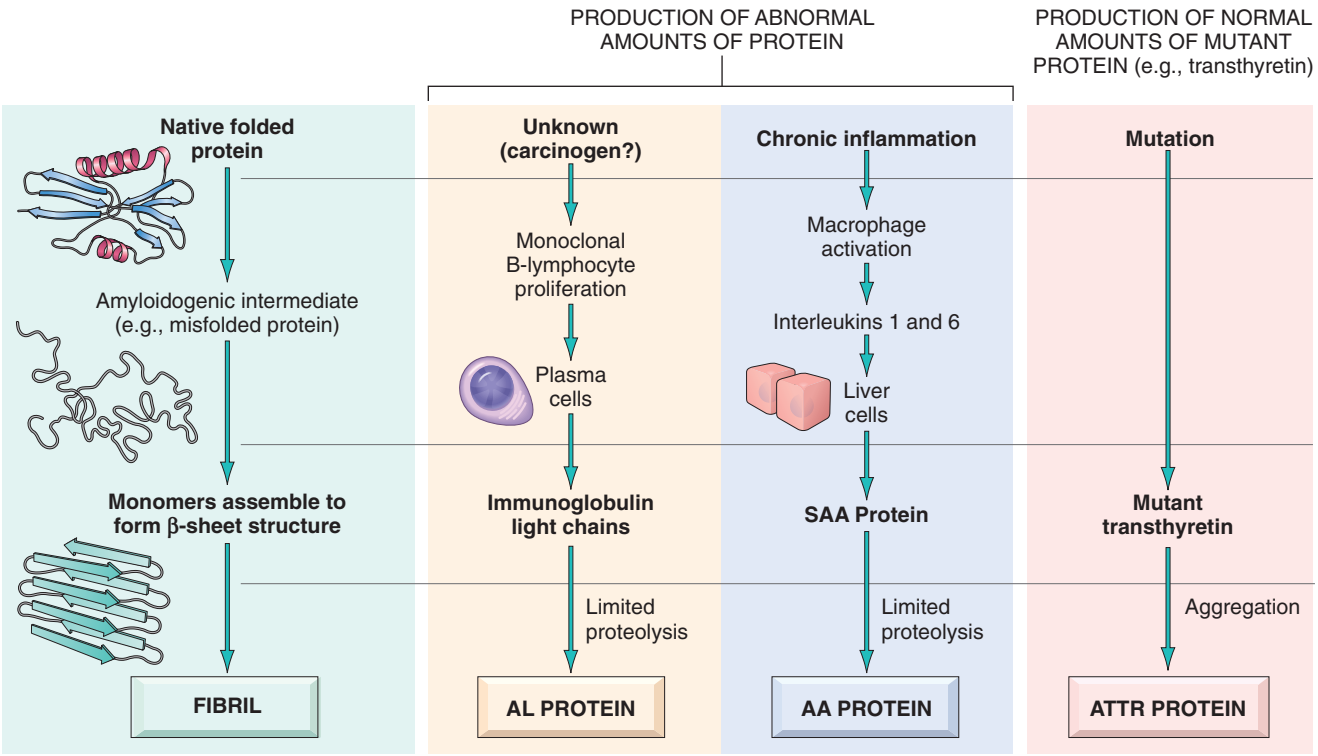


**Figure 4–32** Pathogenesis of amyloidosis. The proposed mechanisms underlying deposition of the major forms of amyloid fibrils.

serum precursor called SAA (serum amyloid-associated) protein that is synthesized in the liver. SAA is synthesized by liver cells under the influence of cytokines such as IL-6 and IL-1 that are produced during inflammation; thus, long-standing inflammation leads to elevated SAA levels, and ultimately the AA form of amyloid deposits. However, increased production of SAA by itself is not sufficient for the deposition of amyloid. Elevation of serum SAA levels is common to inflammatory states but in most instances does not lead to amyloidosis. There are two possible explanations for this. According to one view, SAA normally is degraded to soluble end products by the action of monocyte-derived enzymes. Conceivably, people who develop amyloidosis have an enzyme defect that results in incomplete breakdown of SAA, thus generating insoluble AA molecules. Alternatively, a genetically determined structural abnormality in the SAA molecule itself renders it resistant to degradation by macrophages.

- **Aβ amyloid** is found in the cerebral lesions of Alzheimer disease. Aβ is a 4-kDa peptide that constitutes the core of cerebral plaques and the amyloid deposits in cerebral blood vessels in this disease. The Aβ protein is derived from a much larger transmembrane glycoprotein called amyloid precursor protein (APP) (Chapter 22).

Several other proteins have been found in amyloid deposits in a variety of clinical settings:

- **Transthyretin** (TTR) is a normal serum protein that binds and transports thyroxine and retinol, hence the name. Mutations in the gene encoding TTR may alter its structure, making the protein prone to misfolding and aggregation, and resistant to proteolysis. This leads to the formation of aggregates that deposit as amyloid. The resultant diseases are called familial amyloid polyneuropathies. TTR is also deposited in the heart of aged persons (senile systemic amyloidosis); in such cases the protein is structurally normal, but it accumulates at high concentrations. Some cases of familial amyloidosis are associated with deposits of mutant lysozyme.
- **$\beta_2$-Microglobulin,** a component of MHC class I molecules and a normal serum protein, has been identified as the amyloid fibril subunit (Aβ2m) in amyloidosis that complicates the course of patients on long-term hemodialysis. Aβ2m fibers are structurally similar to normal β2m protein. This protein is present in high concentrations in the serum of patients with renal disease and is retained in the circulation because it is not efficiently filtered through dialysis membranes. In some series, as many as 60% to 80% of patients on long-term dialysis developed amyloid deposits in the synovium, joints, and tendon sheaths.
- Amyloid deposits derived from diverse precursors such as hormones (procalcitonin) and keratin also have been reported.

## Classification of Amyloidosis

Because a given biochemical form of amyloid (e.g., AA) may be associated with amyloid deposition in diverse clinical settings, a combined biochemical and clinical classification is followed for this discussion (Table 4–13). Amyloid may be systemic (generalized), involving several organ systems, or it may be localized, when deposits are limited to a single organ, such as the heart. On clinical grounds, the systemic, or generalized, pattern is subclassified into *primary amyloidosis* when associated with a monoclonal

**Table 4–13** Classification of Amyloidosis

| Clinicopathologic Category | Associated Disease(s) | Major Fibril Protein | Chemically Related Precursor Protein |
|---|---|---|---|
| **Systemic (Generalized) Amyloidosis** | | | |
| Immunocyte dyscrasias with amyloidosis (primary amyloidosis) | Multiple myeloma and other monoclonal plasma cell proliferations | AL | Immunoglobulin light chains, chiefly λ type |
| Reactive systemic amyloidosis (secondary amyloidosis) | Chronic inflammatory conditions | AA | SAA |
| Hemodialysis-associated amyloidosis | Chronic renal failure | $A\beta_2m$ | $\beta_2$-Microglobulin |
| **Hereditary Amyloidosis** | | | |
| Familial Mediterranean fever | | AA | SAA |
| Familial amyloidotic neuropathies (several types) | | ATTR | Transthyretin |
| Systemic senile amyloidosis | | ATTR | Transthyretin |
| **Localized Amyloidosis** | | | |
| Senile cerebral | Alzheimer disease | Aβ | APP |
| Endocrine | | | |
| Medullary carcinoma of thyroid | | A Cal | Calcitonin |
| Islets of Langerhans | Type 2 diabetes | AIAPP | Islet amyloid peptide |
| Isolated atrial amyloidosis | | AANF | Atrial natriuretic factor |

plasma cell proliferation and *secondary amyloidosis* when it occurs as a complication of an underlying chronic inflammatory or tissue destructive process. Hereditary or familial amyloidosis constitutes a separate, albeit heterogeneous group, with several distinctive patterns of organ involvement.

### *Primary Amyloidosis: Immunocyte Dyscrasias with Amyloidosis*

Amyloid in this category usually is systemic in distribution and is of the AL type. With approximately 3000 new cases each year in the United States, this is the most common form of amyloidosis. In some of these cases, there is a readily identifiable monoclonal plasma cell proliferation; best defined is the occurrence of systemic amyloidosis in 5% to 15% of patients with multiple myeloma, a plasma cell tumor characterized by multiple osteolytic lesions throughout the skeletal system (Chapter 11). The malignant plasma cells characteristically synthesize abnormal amounts of a single specific immunoglobulin (monoclonal gammopathy), producing an M (myeloma) protein spike on serum electrophoresis. In addition to the synthesis of whole immunoglobulin molecules, plasma cells also may synthesize and secrete either the λ or κ light chain, also known as Bence Jones proteins. By virtue of their small molecular size, these proteins frequently are also excreted in the urine. Almost all patients with myeloma who develop amyloidosis have Bence Jones proteins in the serum or urine, or both. However, amyloidosis develops in only 6% to 15% of patients with myeloma who have free light chains. Clearly, the presence of Bence Jones proteins, although necessary, is by itself not sufficient to produce amyloidosis. Other variables, such as the type of light chain produced and its catabolism, contribute to the "amyloidogenic potential" and influence the deposition of Bence Jones proteins.

The great majority of patients with AL amyloid do not have classic multiple myeloma or any other overt B cell neoplasm; such cases are nevertheless classified as primary amyloidosis because their clinical features derive from the effects of amyloid deposition without any other associated disease. In virtually all such cases, patients have a modest increase in the number of plasma cells in the bone marrow, and monoclonal immunoglobulins or free light chains can be found in the serum or urine. Clearly, these patients have an underlying monoclonal plasma cell proliferation in which production of an abnormal protein, rather than production of tumor masses, is the predominant manifestation.

### *Reactive Systemic Amyloidosis*

The amyloid deposits in this pattern are systemic in distribution and are composed of AA protein. This category was previously referred to as secondary amyloidosis, because it is *secondary to an associated inflammatory condition.* In fact, the feature common to most cases of reactive systemic amyloidosis is chronic inflammation. Classically, tuberculosis, bronchiectasis, and chronic osteomyelitis were the most common causes; with the advent of effective antimicrobial therapies, reactive systemic amyloidosis is seen most frequently in the setting of chronic inflammation caused by autoimmune states (e.g., RA, ankylosing spondylitis, inflammatory bowel disease). Patients with RA are particularly prone to develop amyloidosis, with amyloid deposition seen in as many as 3% of RA cases. Chronic skin infections caused by "skin-popping" of narcotics are also associated with amyloid deposition. Finally, reactive systemic amyloidosis may also occur in association with tumors not derived from immune cells, the two most common being renal cell carcinoma and Hodgkin lymphoma.

### *Familial (Hereditary) Amyloidosis*

A variety of familial forms of amyloidosis have been described; most are rare and occur in limited geographic areas. The best-characterized is an autosomal recessive condition called familial Mediterranean fever. This is a febrile disorder characterized by attacks of fever

accompanied by inflammation of serosal surfaces, including peritoneum, pleura, and synovial membrane. This disorder is encountered largely in persons of Armenian, Sephardic Jewish, and Arabic origins. It is associated with widespread tissue involvement indistinguishable from reactive systemic amyloidosis. The amyloid fibril proteins are made up of AA proteins, suggesting that this form of amyloidosis is related to the recurrent bouts of inflammation that characterize this disease. The gene for familial Mediterranean fever is called *pyrin* and encodes a protein that is a component of the inflammasome (Chapter 2). Patients have gain-of-function mutations in *pyrin* that result in constitutive overproduction of the pro-inflammatory cytokine IL-1 and persistent inflammation.

In contrast with familial Mediterranean fever, a group of autosomal dominant familial disorders is characterized by deposition of amyloid predominantly in the peripheral and autonomic nerves. These familial amyloidotic polyneuropathies have been described in kindreds in different parts of the world—for example, in Portugal, Japan, Sweden, and the United States. As mentioned previously, the fibrils in these familial polyneuropathies are made up of mutant forms of transthyretin (ATTRs).

### *Localized Amyloidosis*

Sometimes deposition of amyloid is limited to a single organ or tissue without involvement of any other site in the body. The deposits may produce grossly detectable nodular masses or be evident only on microscopic examination. Nodular (tumor-forming) deposits of amyloid are most often encountered in the lung, larynx, skin, urinary bladder, tongue, and the region about the eye. Frequently, there are infiltrates of lymphocytes and plasma cells in the periphery of these amyloid masses, raising the question of whether the mononuclear infiltrate is a response to the deposition of amyloid or instead is responsible for it. At least in some cases, the amyloid consists of AL protein and may therefore represent a localized form of plasma cell–derived amyloid.

### *Endocrine Amyloid*

Microscopic deposits of localized amyloid may be found in certain endocrine tumors, such as medullary carcinoma of the thyroid gland, islet tumors of the pancreas, pheochromocytomas, and undifferentiated carcinomas of the stomach, as well as in the islets of Langerhans in patients with type 2 diabetes mellitus. In these settings, the amyloidogenic proteins seem to be derived either from polypeptide hormones (medullary carcinoma) or from unique proteins (e.g., islet amyloid polypeptide).

### *Amyloid of Aging*

Several well-documented forms of amyloid deposition occur with aging. Senile systemic amyloidosis refers to the systemic deposition of amyloid in elderly persons (usually in their 70s and 80s). Because of the dominant involvement and related dysfunction of the heart (typically manifesting as a restrictive cardiomyopathy and arrhythmias), this form also is called *senile cardiac amyloidosis*. The amyloid in this form is composed of normal transthyretin. In addition, another form typically affecting only the heart results from the deposition of a mutant form of TTR. Approximately 4% of the black population in the United States are carriers of the mutant allele, and cardiomyopathy has been identified in both homozygous and heterozygous patients.

## MORPHOLOGY

There are no consistent or distinctive patterns of organ or tissue distribution of amyloid deposits in any of the categories cited. Nonetheless, a few generalizations can be made. In amyloidosis secondary to chronic inflammatory disorders, kidneys, liver, spleen, lymph nodes, adrenals, and thyroid, as well as many other tissues, typically are affected. Although primary (AL) amyloidosis cannot reliably be distinguished from the secondary form by its organ distribution, it more often involves the heart, gastrointestinal tract, respiratory tract, peripheral nerves, skin, and tongue. However, the same organs affected by reactive systemic amyloidosis (secondary amyloidosis), including kidneys, liver, and spleen, also may contain deposits in the immunocyte-associated form of the disease. The localization of amyloid deposits in the hereditary syndromes is varied. In familial Mediterranean fever, the amyloidosis may be widespread, involving the kidneys, blood vessels, spleen, respiratory tract, and (rarely) liver. The localization of amyloid in the remaining hereditary syndromes can be inferred from the designation of these entities.

Whatever the clinical disorder, the amyloidosis may or may not be apparent grossly. Often small amounts are not recognized until the surface of the cut organ is painted with iodine and sulfuric acid. This yields mahogany brown staining of the amyloid deposits. When amyloid accumulates in larger amounts, the organ frequently is enlarged and the tissue typically appears gray with a waxy, firm consistency. **On histologic examination, the amyloid deposition is always extracellular and begins between cells,** often closely adjacent to basement membranes. As the amyloid accumulates, it encroaches on the cells, in time surrounding and destroying them. In the AL form, perivascular and vascular localizations are common.

The histologic diagnosis of amyloid is based almost entirely on its staining characteristics. The most commonly used staining technique uses the dye Congo red, which under ordinary light imparts a pink or red color to amyloid deposits. Under polarized light the Congo red–stained amyloid shows so-called apple-green birefringence (Fig. 4–33). This reaction is shared by all forms of amyloid and is caused by the crossed β-pleated configuration of amyloid fibrils. Confirmation can be obtained by electron microscopy, which reveals amorphous nonoriented thin fibrils. AA, AL, and ATTR types of amyloid also can be distinguished from one another by specific immunohistochemical staining.

Because the pattern of organ involvement in different clinical forms of amyloidosis is variable, each of the major organ involvements is described separately.

**Kidney.** Amyloidosis of the kidney is the most common and most serious feature of the disease. Grossly, the kidney may appear unchanged, or it may be abnormally large, pale, gray, and firm; in long-standing cases, the kidney may be reduced in size. Microscopically, the **amyloid deposits are found principally in the glomeruli,** but they also are present in the interstitial peritubular tissue as well as in the walls of the blood vessels. The glomerulus first develops focal deposits

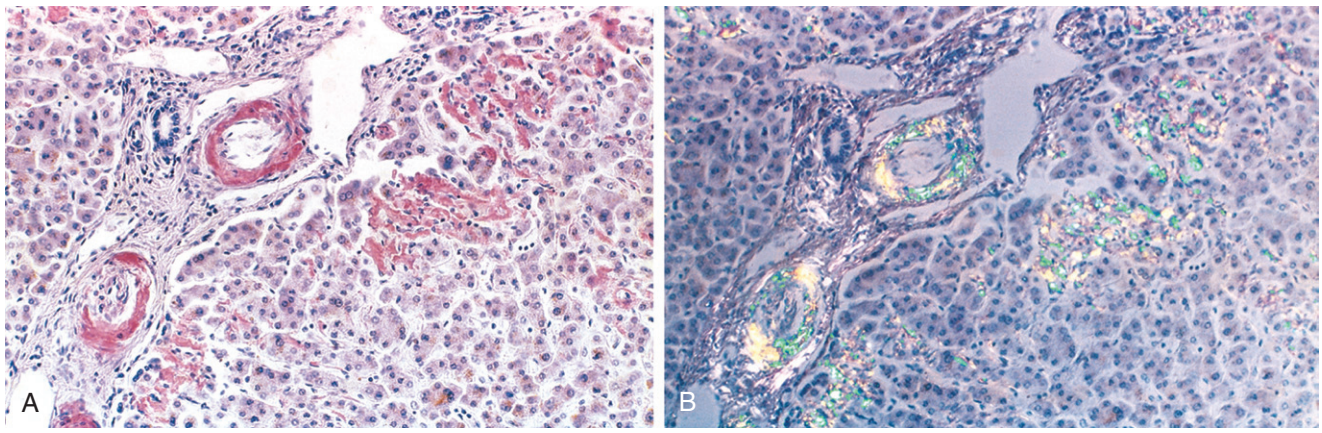


**Figure 4–33** Amyloidosis: hepatic involvement. **A,** Staining of a section of the liver with Congo red reveals pink-red deposits of amyloid in the walls of blood vessels and along sinusoids. **B,** Note the yellow-green birefringence of the deposits when observed under the polarizing microscope.
*(Courtesy of Dr. Trace Worrell and Sandy Hinton, Department of Pathology, University of Texas Southwestern Medical School, Dallas, Texas.)*

within the mesangial matrix and diffuse or nodular thickenings of the basement membranes of the capillary loops. With progression, the deposition encroaches on the capillary lumina and eventually leads to total obliteration of the vascular tuft (Fig. 4–34, *A*). The interstitial peritubular deposits frequently are associated with the appearance of amorphous pink casts within the tubular lumens, presumably of a proteinaceous nature. Amyloid deposits may develop in the walls of blood vessels of all sizes, often causing marked vascular narrowing.

**Spleen.** Amyloidosis of the spleen often causes moderate or even marked enlargement (200 to 800 gm). For obscure reasons, either of two patterns may develop. The deposits may be virtually limited to the splenic follicles, producing tapioca-like granules on gross examination ("sago spleen"), or the amyloidosis may principally involve the splenic sinuses, eventually extending to the splenic pulp, with formation of large, sheetlike deposits ("lardaceous spleen"). In both patterns, the spleen is firm in consistency. The presence of blood in splenic sinuses usually imparts a reddish color to the waxy, friable deposits.

**Liver.** Amyloidosis of the liver may cause massive enlargement (as much as 9000 gm). In such advanced cases, the liver is extremely pale, grayish, and waxy on both the external surface and the cut section. Histologic analysis shows that **amyloid deposits first appear in the space of Disse** and then progressively enlarge to encroach on the adjacent hepatic parenchyma and sinusoids (Fig. 4–33). The trapped liver cells undergo compression atrophy and are eventually replaced by sheets of amyloid; remarkably, normal liver function may be preserved even in the setting of severe involvement.

**Heart.** Amyloidosis of the heart may occur either as isolated organ involvement or as part of a systemic distribution. When accompanied by systemic involvement, it is usually of the AL form. The isolated form (senile amyloidosis) usually is confined to older persons. The deposits may not be evident on gross examination, or they may cause minimal to moderate cardiac enlargement. The most characteristic gross findings are gray-pink, dewdrop-like subendocardial elevations, particularly evident in the atrial chambers. On histologic examination, deposits typically are found throughout the myocardium, beginning **between myocardial fibers** and eventually causing their pressure atrophy (Fig. 4–34, *B*).

**Other Organs.** Amyloidosis of other organs generally is encountered in systemic disease. The adrenals, thyroid, and

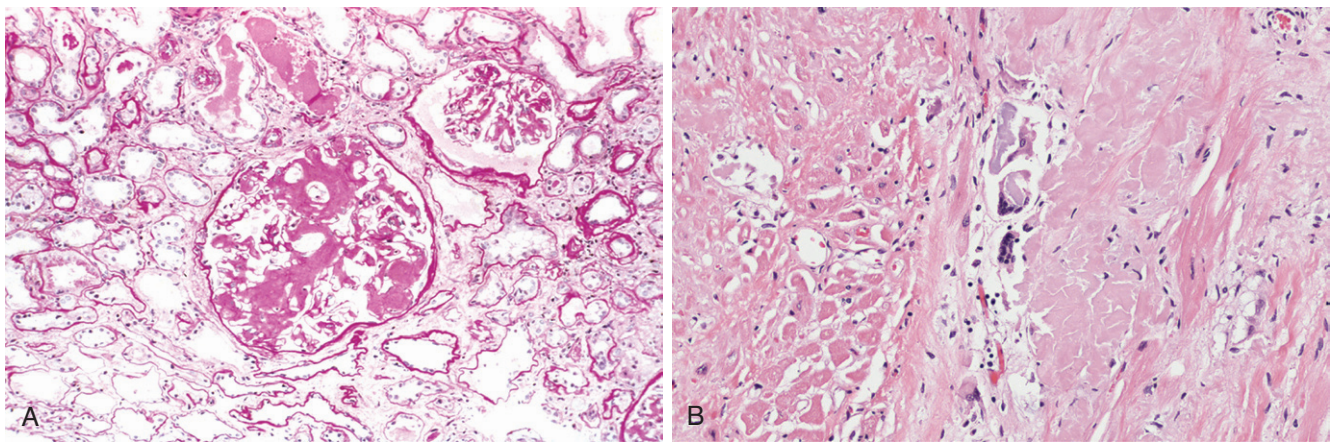


**Figure 4–34** Amyloidosis: renal and cardiac involvement. **A,** Amyloidosis of the kidney. The glomerular architecture is almost totally obliterated by the massive accumulation of amyloid. **B,** Cardiac amyloidosis. The atrophic myocardial fibers are separated by structureless, pink-staining amyloid.

pituitary are common sites of involvement. In such cases as well, the amyloid deposition begins in relation to stromal and endothelial cells and progressively encroaches on the parenchymal cells. Surprisingly large amounts of amyloid may be present in any of these endocrine glands without apparent disturbance of function. In the gastrointestinal tract, a relatively favored site for deposition, amyloid may be found at all levels, sometimes producing tumorous masses that must be distinguished from neoplasms. Nodular depositions in the tongue may produce **macroglossia.** On the basis of the frequent involvement of the gastrointestinal tract in systemic cases, gingival, intestinal, and rectal biopsies serve in the diagnosis of suspected cases. Deposition of $\beta_2$-microglobulin amyloid in patients receiving long-term dialysis occurs most commonly in the **carpal ligaments of the wrist,** resulting in compression of the median nerve (leading to carpal tunnel syndrome).

### *Clinical Course*

Amyloidosis may be an unsuspected finding at autopsy in a patient who has no apparent related clinical manifestations, or it may be responsible for serious clinical dysfunction and even death. The clinical course depends on the particular sites or organs affected and the severity of the involvement. Nonspecific complaints such as weakness, fatigue, and weight loss are the most common presenting manifestations. Later in the course, amyloidosis tends to manifest in one of several ways: by renal disease, hepatomegaly, splenomegaly, or cardiac abnormalities. Renal involvement giving rise to severe proteinuria (nephrotic syndrome) (Chapter 13) often is the major cause of symptoms in reactive systemic amyloidosis. Progression of the renal disease may lead to renal failure, which is an important cause of death in amyloidosis. The hepatosplenomegaly rarely causes significant clinical dysfunction, but it may be the presenting finding. Cardiac amyloidosis may manifest as conduction disturbances or as restrictive cardiomyopathy (Chapter 10). Cardiac arrhythmias are an important cause of death in cardiac amyloidosis. In one large series, 40% of the patients with AL amyloid died of cardiac disease.

The diagnosis of amyloidosis may be suspected from the clinical signs and symptoms and from some of the findings mentioned; however, more specific tests must often be done for definitive diagnosis. Biopsy and subsequent Congo red staining is the most important tool in the diagnosis of amyloidosis. In general, biopsy is taken from the organ suspected to be involved. For example, renal biopsy is useful in the presence of urinary abnormalities. Rectal and gingival biopsy specimens contain amyloid in as many as 75% of cases with generalized amyloidosis. Examination of abdominal fat aspirates stained with Congo red is a simple, low-risk method. In suspected cases of AL amyloidosis, serum and urinary protein electrophoresis and immunoelectrophoresis should be performed. Bone marrow examination in such cases usually shows plasmacytosis, even if skeletal lesions of multiple myeloma are not present. Proteomic analysis of affected tissue is now being widely used for detection of small amounts of amyloid (from fat aspirates) and for definitive identification of the type of amyloid.

The outlook for patients with generalized amyloidosis is poor, with the mean survival time after diagnosis ranging from 1 to 3 years. In AA amyloidosis, the prognosis depends to some extent on the control of the underlying condition. Patients with myeloma-associated amyloidosis have a poorer prognosis, although they may respond to cytotoxic drugs used to treat the underlying disorder. Resorption of amyloid after treatment of the associated condition has been reported, but this is a rare occurrence.

## SUMMARY

### Amyloidosis

- Amyloidosis is a disorder characterized by the extracellular deposits of misfolded proteins that aggregate to form insoluble fibrils.
- The deposition of these proteins may result from excessive production of proteins that are prone to misfolding and aggregation; mutations that produce proteins that cannot fold properly and tend to aggregate; or defective or incomplete proteolytic degradation of extracellular proteins.
- Amyloidosis may be localized or systemic. It is seen in association with a variety of primary disorders, including monoclonal plasma cell proliferations (in which the amyloid deposits consist of immunoglobulin light chains); chronic inflammatory diseases such as RA (deposits of amyloid A protein, derived from an acute-phase protein produced in inflammation); Alzheimer disease (amyloid B protein); familial conditions in which the amyloid deposits consist of mutants of normal proteins (e.g., transthyretin in familial amyloid polyneuropathies); amyloidosis associated with dialysis (deposits of $\beta_2$-microglobulin, whose clearance is defective).
- Amyloid deposits cause tissue injury and impair normal function by causing pressure on cells and tissues. They do not evoke an inflammatory response.

## BIBLIOGRAPHY

Banchereau J, Pascual V: Type I interferon in systemic lupus erythematosus and other autoimmune diseases. Immunity 25:383, 2006. *[A review of the recently discovered role of interferons in SLE and other autoimmune diseases, and the potential for targeting this family of cytokines for therapy.]*

Campbell DJ, Koch MA: Phenotypic and functional specialization of FoxP3+ regulatory T cells. Nat Rev Immunol 11:119, 2011. *[A current review of the properties and functions of regulatory T cells.]*

Chervonsky A: Influence of microbial environment on autoimmunity. Nat Immunol 11:28, 2010. *[A summary of the role of microbes and other environmental factors in the development of autoimmunity.]*

Cunningham-Rundles C, Ponda PP: Molecular defects in T- and B-cell primary immunodeficiency diseases. Nat Rev Immunol 5:880, 2006. *[Excellent, up-to-date review of primary immunodeficiencies.]*

Davidson A, Diamond B: Autoimmune diseases. N Engl J Med 345:340, 2001. *[A readable overview of the etiology, pathogenesis, and therapy for autoimmune diseases.]*

Douek DC, Roederer M, Koup RA: Emerging concepts in the immunopathogenesis of AIDS. Annu Rev Med 60:471, 2009. *[A balanced discussion of the pathogenesis of AIDS, and the still unresolved issues.]*

Fairhurst AM, Wandstrat AE, Wakeland EK: Systemic lupus erythematosus: multiple immunological phenotypes in a complex genetic disease. Adv Immunol 92:1, 2006. *[A comprehensive review of the*

*genetics of SLE in humans and animal models, and the pathogenic mechanisms deduced from identification of susceptibility genes.]*

Fischer A: Human primary immunodeficiency diseases. Immunity 28:835, 2008. *[An excellent summary of primary immunodeficiencies affecting the innate and adaptive immune systems.]*

Galli SJ: The development of allergic inflammation. Nature 454:445, 2008. *[An excellent review of the mechanisms of inflammation in allergic diseases.]*

Gonzalez-Scarano F, Martin-Garcia J: The neuropathogenesis of AIDS. Nat Rev Immunol 5:69, 2005. *[A discussion of the pathogenesis of HIV-associated dementia.]*

Goodnow CC: Multistep pathogenesis of autoimmune disease. Cell 130:25, 2007. *[An excellent discussion of the checkpoints that prevent autoimmunity and why these might fail.]*

Jancar S, Sanchez Crespo M: Immune complex–mediated tissue injury: a multistep paradigm. Trends Immunol 26:48, 2005. *[A summary of the mechanisms of immune complex–mediated tissue injury.]*

Katsumoto TR, Whitfield ML, Connolly MK: The pathogenesis of systemic sclerosis. Annu Rev Pathol 6:509, 2011. *[An excellent review of the pathogenesis of systemic sclerosis, and the many unanswered questions.]*

Kay AB: Allergy and allergic diseases. First of two parts. N Engl J Med 344:30, 2001. *[Excellent two-part review of the mechanisms and manifestations of immediate hypersensitivity.]*

Kyewski B, Klein L: A central role for central tolerance. Annu Rev Immunol 24:571, 2006. *[A discussion of the mechanisms of central tolerance, with a focus on T cells.]*

Merlini G, Bellotti V: Molecular mechanisms of amyloidosis. N Engl J Med 349:583, 2003. *[Good review of the general pathogenic mechanisms in various forms of systemic amyloidosis.]*

Mitchell RN: Graft vascular disease: immune response meets the vessel wall. Annu Rev Pathol 4:19, 2009. *[A review of the mechanisms that lead to vascular disease in chronic graft rejection.]*

Moir S, Chun TW, Fauci AS: Pathogenic mechanisms of HIV disease. Annu Rev Pathol 6:223, 2011. *[A discussion of current concepts of the mechanisms by which HIV causes immunodeficiency.]*

Mueller DL: Mechanisms maintaining peripheral tolerance. Nat Immunol 11:21, 2010. *[A discussion of the mechanisms of peripheral tolerance, with an emphasis on T cells.]*

Nankivell BJ, Alexander SI: Rejection of the kidney allograft. N Engl J Med 363:1451, 2010. *[Good review of the mechanisms of recognition and rejection of allografts and the development of new strategies for treating rejection.]*

Notarangelo LD: Primary immunodeficiencies. J Allergy Clin Immunol 125:S182, 2010. *[An update on congenital immunodeficiencies and their molecular basis.]*

O'Shea JJ, Paul WE: Mechanisms underlying lineage commitment and plasticity of helper CD4+ T cells. Science 327:1098, 2010. *[An excellent review of the development and functions of helper T cell subsets, and the uncertainties in the field.]*

Palmer MT, Weaver CT: Autoimmunity: increasing suspects in the CD4+ T cell lineage. Nat Immunol 11:36, 2010. *[A thoughtful discussion of the central role of CD4+ T cells in the pathogenesis of autoimmune diseases.]*

Pepys MB: Amyloidosis. Annu Rev Med 57:223, 2006. *[An excellent review of the pathogenesis, clinical features and therapeutic approaches in amyloidosis.]*

Rahman A, Isenberg DA: Systemic lupus erythematosus. New Engl J Med 358:929, 2008. *[An excellent review of the pathogenesis and genetics of SLE.]*

Sakaguchi S, Miyara M, Costantino CM, Hafler DA: FOXP3+ regulatory T cells in the human immune system. Nat Rev Immunol 10:490, 2010. *[An excellent discussion of the properties and role of regulatory T cells in humans.]*

Sakaguchi S, Yamaguchi T, Nomura T, Ono M: Regulatory T cells and immune tolerance. Cell 133:775, 2008. *[An excellent review of the properties and functions of regulatory T cells.]*

Stone J, Zen Y, Deshpande V: IgG4-related disease. New Engl J Med, in press, 2011. *[A comprehensive discussion of the features and likely pathogenesis of this recently recognized entity.]*

Vercelli D: Discovering susceptibility genes for asthma and allergy. Nat Rev Immunol 8:169, 2008. *[A summary of the known susceptibility genes for asthma and other allergic diseases.]*

Voulgarelis M, Tzioufas AG: Pathogenetic mechanisms in the initiation and perpetuation of Sjögren's syndrome. Nat Rev Rheumatol 6:529, 2010. *[A good discussion of what is known and not known about the pathogenesis of Sjögren's syndrome.]*

Zenewicz L, Abraham C, Flavell RA, Cho J: Unraveling the genetics of autoimmunity. Cell 140:791, 2010. *[An update on susceptibility genes for autoimmune diseases, how these are identified, and their significance.]*

This page intentionally left blank

See Targeted Therapy available online at studentconsult.com

CHAPTER 5

# Neoplasia

CHAPTER CONTENTS

**Nomenclature 162**
Benign Tumors 162
Malignant Tumors 162
**Characteristics of Benign and Malignant Neoplasms 164**
Differentiation and Anaplasia 164
Rate of Growth 166
Local Invasion 167
Metastasis 168
**Epidemiology 169**
Cancer Incidence 170
Geographic and Environmental Variables 170
Age 171
Heredity 171
Acquired Preneoplastic Lesions 172
**Carcinogenesis: The Molecular Basis of Cancer 173**
**Genetic Lesions in Cancer 173**
Karyotypic Changes in Tumors 173
MicroRNAs and Cancer 175
Epigenetic Modifications and Cancer 175
**Carcinogenesis: A Multistep Process 177**
**Hallmarks of Cancer 178**
Self-Sufficiency in Growth Signals 178
Insensitivity to Growth Inhibitory Signals 182
Evasion of Cell Death 189
Limitless Replicative Potential 190
Development of Sustained Angiogenesis 191
Ability to Invade and Metastasize 192
Reprogramming Energy Metabolism 195
Evasion of the Immune System 196
Genomic Instability as an Enabler of Malignancy 196
Tumor-Promoting Inflammation as Enabler of Malignancy 197
Multistep Carcinogenesis and Cancer Progression 198
**Etiology of Cancer: Carcinogenic Agents 198**
Chemical Carcinogens 199
Radiation Carcinogenesis 200
Viral and Microbial Oncogenesis 201
**Host Defense Against Tumors: Tumor Immunity 204**
Tumor Antigens 204
Antitumor Effector Mechanisms 206
Immune Surveillance and Immune Evasion by Tumors 207
**Clinical Aspects of Neoplasia 207**
Effects of Tumor on Host 207
Grading and Staging of Cancer 208
Laboratory Diagnosis of Cancer 210

Cancer is the second leading cause of death in the United States; only cardiovascular diseases exact a higher toll. Even more agonizing than the associated mortality is the emotional and physical suffering inflicted by neoplasms. Patients and the public often ask, "When will there be a cure for cancer?" The answer to this simple question is difficult, because cancer is not one disease but many disorders that share a profound growth dysregulation. Some cancers, such as Hodgkin lymphomas, are highly curable, whereas others, such as cancer of the pancreas, are virtually always fatal. The only hope for controlling cancer lies in learning more about its pathogenesis, and great strides have been made in understanding the molecular basis of cancer. This chapter deals with the basic biology of neoplasia—the nature of benign and malignant neoplasms and the molecular basis of neoplastic transformation. The host response to tumors and the clinical features of neoplasia also are discussed. Before we discuss the features of cancer cells and the mechanisms of carcinogenesis, it is useful to summarize the fundamental and shared characteristics of cancers:

- *Cancer is a genetic disorder* caused by DNA mutations that are (for the most part) acquired spontaneously or induced by environmental insults. In addition, cancers frequently show epigenetic changes, such as focal increases in DNA methylation and alterations in histone modifications, which may themselves stem from acquired mutations in genes that regulate such modifications. These genetic and epigenetic changes alter the expression or function of key genes that regulate fundamental cellular processes, such as growth, survival, and senescence.
- *These genetic alterations are heritable, being passed to daughter cells upon cell division*. As a result, *cells harboring these alterations are subject to darwinian selection* (survival of the fittest, arguably the most important scientific concept yet conceived), with cells bearing mutations that provide them with growth or survival advantages outcompeting their neighbors and thus coming to dominate the population. Darwinian selection also plays a role in the progression and recurrence of cancers, as discussed in more detail later. Because the selective advantages are conferred on a single cell that ultimately gives rise to the tumor, all tumors are *clonal* (i.e., the progeny of one cell).
- *Accumulation of mutations gives rise to a set of properties that have been called hallmarks of cancer*. These include (1) self-sufficiency in growth signals whereby the growth of cancers becomes autonomous and is unregulated by physiologic cues; (2) lack of response to growth inhibitory signals that control non-neoplastic cellular

proliferations such as hyperplasias; (3) evasion of cell death, allowing cancer cells to survive under conditions that induce apoptosis in normal cells; (4) limitless replicative potential, thus making cancer cells immortal; (5) development of angiogenesis to sustain the growth of cancer cells; (6) ability to invade local tissues and spread to distant sites; (7) reprogramming of metabolic pathways—specifically, a switch to aerobic glycolysis even when there is abundant oxygen; and (8) ability to evade the immune system. The genetic alterations that give rise to these hallmarks of cancers are sustained and enabled by the development of genomic instability, adding fuel to the fire. The molecular underpinnings of these hallmarks are discussed in detail in a later section.

Understanding the cellular and molecular abnormalities in cancer cells is leading to a revolution in the treatment of cancer founded on basic research, and is one of the emerging triumphs of biomedical science.

## NOMENCLATURE

*Neoplasia* literally means "new growth." Neoplastic cells are said to be *transformed* because they continue to replicate, apparently oblivious to the regulatory influences that control normal cell growth. Neoplasms therefore enjoy a certain degree of autonomy and tend to increase in size regardless of their local environment. Their autonomy is by no means complete, however. Some neoplasms require endocrine support, and such dependencies sometimes can be exploited therapeutically. All neoplasms depend on the host for their nutrition and blood supply.

In common medical usage, a neoplasm often is referred to as a *tumor,* and the study of tumors is called *oncology* (from *oncos,* "tumor," and *logos,* "study of"). Among tumors, the division of neoplasms into benign and malignant categories is based on a judgment of a tumor's potential clinical behavior.

- A tumor is said to be *benign* when its microscopic and gross characteristics are considered to be relatively innocent, implying that it will remain localized and is amenable to local surgical removal; the patient generally survives. Of note, however, benign tumors can produce more than localized lumps, and sometimes they are responsible for serious disease.
- Malignant tumors are collectively referred to as *cancers,* derived from the Latin word for "crab"—that is, they adhere to any part that they seize in an obstinate manner, similar to a crab's behavior. *Malignant,* as applied to a neoplasm, implies that the lesion can invade and destroy adjacent structures and spread to distant sites (metastasize) to cause death. Not all cancers pursue so deadly a course. The most aggressive are also some of the most curable, but the designation *malignant* constitutes a red flag.

All tumors, benign and malignant, have two basic components: (1) the *parenchyma,* made up of transformed or neoplastic cells, and (2) the supporting, host-derived, nonneoplastic *stroma,* made up of connective tissue, blood vessels, and host-derived inflammatory cells. The parenchyma of the neoplasm largely determines its biologic behavior, and it is this component from which the tumor derives its name. The stroma is crucial to the growth of the neoplasm, since it carries the blood supply and provides support for the growth of parenchymal cells. Although the biologic behavior of tumors largely reflects the behavior of the parenchymal cells, there has been a growing realization that stromal cells and neoplastic cells carry on a two-way conversation that influences the growth of the tumor.

### Benign Tumors

In general, benign tumors are designated by attaching the suffix *-oma* to the cell type from which the tumor arises. A benign tumor arising in fibrous tissue is a *fibroma*; a benign cartilaginous tumor is a *chondroma.* The nomenclature of benign epithelial tumors is more complex. They are classified sometimes on the basis of their microscopic pattern and sometimes on the basis of their macroscopic pattern. Others are classified by their cells of origin.

For instance, the term *adenoma* is generally applied to benign epithelial neoplasms producing gland patterns and to neoplasms derived from glands but not necessarily exhibiting glandular patterns. A benign epithelial neoplasm arising from renal tubule cells and growing in glandlike patterns is termed an adenoma, as is a mass of benign epithelial cells that produces no glandular patterns but has its origin in the adrenal cortex. *Papillomas* are benign epithelial neoplasms, growing on any surface, that produce microscopic or macroscopic finger-like fronds. A *polyp* is a mass that projects above a mucosal surface, as in the gut, to form a macroscopically visible structure (Fig. 5–1). Although this term commonly is used for benign tumors, some malignant tumors also may grow as polyps, whereas other polyps (such as nasal polyps) are not neoplastic but inflammatory in origin. *Cystadenomas* are hollow cystic masses that typically arise in the ovary.

### Malignant Tumors

The nomenclature of malignant tumors essentially follows that of benign tumors, with certain additions and exceptions.

- Malignant neoplasms arising in "solid" mesenchymal tissues or its derivatives are called *sarcomas*, whereas those arising from the mesenchymal cells of the blood are called leukemias or lymphomas. Sarcomas are designated by the cell type of which they are composed, which is presumably their cell of origin. Thus, a cancer of fibrous tissue origin is a *fibro*sarcoma, and a malignant neoplasm composed of chondrocytes is a *chondro*sarcoma.
- While the epithelia of the body are derived from all three germ cell layers, malignant neoplasms of epithelial cells are called *carcinomas* regardless of the tissue of origin. Thus, a malignant neoplasm arising in the renal tubular epithelium (mesoderm) is a carcinoma, as are the cancers arising in the skin (ectoderm) and lining epithelium of the gut (endoderm). Furthermore, mesoderm may give rise to carcinomas (epithelial), sarcomas (mesenchymal), and hematolymphoid tumors (leukemias and lymphomas).
- Carcinomas are subdivided further. Carcinomas that grow in a glandular pattern are called *adenocarcinomas,*

**Figure 5–1** Colonic polyp. This glandular tumor (adenoma) is seen projecting into the colonic lumen. The polyp is attached to the mucosa by a distinct stalk.

and those that produce squamous cells are called *squamous cell carcinomas.* Sometimes the tissue or organ of origin can be identified, as in the designation of renal cell adenocarcinoma. Sometimes the tumor shows little or no differentiation and must be called *poorly differentiated or undifferentiated carcinoma.*

The transformed cells in a neoplasm, whether benign or malignant, often resemble each other, as though all had been derived from a single progenitor, consistent with the monoclonal origin of tumors. In some unusual instances, however, the tumor cells undergo *divergent differentiation,* creating so-called *mixed tumors.* The best example is mixed tumor of salivary gland. These tumors have obvious epithelial components dispersed throughout a fibromyxoid stroma, sometimes harboring islands of cartilage or bone (Fig. 5–2). All of these diverse elements are thought to derive from epithelial cells or myoepithelial cells, or both, and the preferred designation for these neoplasms is *pleomorphic adenoma.* Fibroadenoma of the female breast is another common mixed tumor. This benign tumor contains a mixture of proliferating ductal elements (adenoma) embedded in a loose fibrous tissue (fibroma). Although only the fibrous component is neoplastic, the term *fibroadenoma* remains in common usage.

*Teratoma* is a special type of mixed tumor that contains recognizable mature or immature cells or tissues representative of more than one germ cell layer and sometimes all three. Teratomas originate from totipotential germ cells such as those normally present in the ovary and testis and sometimes abnormally present in sequestered midline embryonic rests. Germ cells have the capacity to differentiate into any of the cell types found in the adult body; not surprisingly, therefore, they may give rise to neoplasms that mimic, in helter-skelter fashion, bits of bone, epithelium, muscle, fat, nerve, and other tissues.

The specific names of the more common forms of neoplasms are presented in Table 5–1. Some glaring inconsistencies may be noted. For example, the terms *lymphoma, mesothelioma, melanoma,* and *seminoma* are used for malignant neoplasms. Unfortunately for students, these exceptions are firmly entrenched in medical terminology.

There are other instances of confusing terminology:

- *Hamartoma* is a mass of disorganized tissue indigenous to the particular site. Histopathologic examination may show a mass of mature but disorganized hepatic cells, blood vessels, and possibly bile ducts within the liver, or a nodule in the lung containing islands of cartilage, bronchi, and blood vessels. Hamartomas have traditionally been considered developmental malformations, but some genetic studies have shown the presence of acquired translocations, suggesting a neoplastic origin.
- *Choristoma* is a congenital anomaly consisting of a heterotopic rest of cells. For example, a small nodule of well-developed and normally organized pancreatic tissue may be found in the submucosa of the stomach, duodenum, or small intestine. This heterotopic rest may be replete with islets of Langerhans and exocrine glands. The designation *-oma,* connoting a neoplasm, imparts to the heterotopic rest a gravity far beyond its usual trivial significance.

Although the terminology of neoplasms is regrettably not simple, a firm grasp of the nomenclature is important because it is the language by which the nature and significance of tumors are categorized.

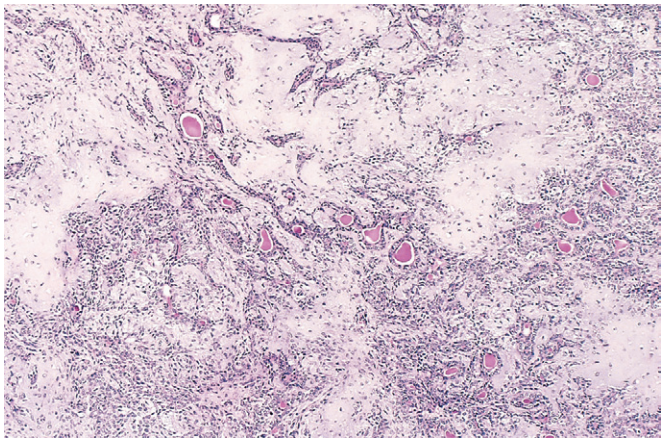

**Figure 5–2** Mixed tumor of the parotid gland contains epithelial cells forming ducts and myxoid stroma that resembles cartilage.
*(Courtesy of Dr. Trace Worrell, Department of Pathology, University of Texas Southwestern Medical School, Dallas, Texas.)*

**Table 5–1** Nomenclature of Tumors

| Tissue of Origin | Benign | Malignant |
|---|---|---|
| **Composed of One Parenchymal Cell Type** | | |
| Connective tissue and derivatives | Fibroma | Fibrosarcoma |
| | Lipoma | Liposarcoma |
| | Chondroma | Chondrosarcoma |
| | Osteoma | Osteogenic sarcoma |
| Endothelial and related tissues | | |
| Blood vessels | Hemangioma | Angiosarcoma |
| Lymph vessels | Lymphangioma | Lymphangiosarcoma |
| Mesothelium | | Mesothelioma |
| Brain coverings | Meningioma | Invasive meningioma |
| Blood cells and related cells | | |
| Hematopoietic cells | | Leukemias |
| Lymphoid tissue | | Lymphomas |
| Muscle | | |
| Smooth | Leiomyoma | Leiomyosarcoma |
| Striated | Rhabdomyoma | Rhabdomyosarcoma |
| Tumors of epithelial origin | | |
| Stratified squamous | Squamous cell papilloma | Squamous cell or epidermoid carcinoma |
| Basal cells of skin or adnexa | | Basal cell carcinoma |
| Epithelial lining of glands or ducts | Adenoma | Adenocarcinoma |
| | Papilloma | Papillary carcinomas |
| | Cystadenoma | Cystadenocarcinoma |
| Respiratory passages | Bronchial adenoma | Bronchogenic carcinoma |
| Renal epithelium | Renal tubular adenoma | Renal cell carcinoma |
| Liver cells | Liver cell adenoma | Hepatocellular carcinoma |
| Urinary tract epithelium (transitional) | Urothelial papilloma | Urothelial carcinoma |
| Placental epithelium | Hydatidiform mole | Choriocarcinoma |
| Testicular epithelium (germ cells) | | Seminoma |
| | | Embryonal carcinoma |
| Tumors of melanocytes | Nevus | Malignant melanoma |
| **More Than One Neoplastic Cell Type—Mixed Tumors, Usually Derived from One Germ Cell Layer** | | |
| Salivary glands | Pleomorphic adenoma (mixed tumor of salivary gland) | Malignant mixed tumor of salivary gland |
| Renal anlage | | Wilms tumor |
| **More Than One Neoplastic Cell Type Derived from More Than One Germ Cell Layer—Teratogenous** | | |
| Totipotential cells in gonads or in embryonic rests | Mature teratoma, dermoid cyst | Immature teratoma, teratocarcinoma |

# CHARACTERISTICS OF BENIGN AND MALIGNANT NEOPLASMS

Nothing is more important to the patient with a tumor than being told: "It is benign." In general, benign tumors appear to be genetically "simple," harboring fewer mutations than cancers, and genetically stable, changing little in genotype over time. The latter feature probably explains why benign tumors such as lipomas and leiomyomas transform to malignancies rarely, if at all. In practice, the determination of benign versus malignant is made with remarkable accuracy using long-established clinical and anatomic criteria, but some neoplasms defy easy characterization. Certain features may indicate innocence, and others may indicate malignancy. Such problems are not the rule, however, and *there are four fundamental features by which benign and malignant tumors can be distinguished: differentiation and anaplasia, rate of growth, local invasion, and metastasis.*

## Differentiation and Anaplasia

Differentiation and anaplasia are characteristics seen only in the parenchymal cells that constitute the transformed elements of neoplasms. The differentiation of parenchymal tumor cells refers to the extent to which they resemble their normal forebears morphologically and functionally.

- Benign neoplasms are composed of well-differentiated cells that closely resemble their normal counterparts. A lipoma is made up of mature fat cells laden with cytoplasmic lipid vacuoles, and a chondroma is made up of mature cartilage cells that synthesize their usual cartilaginous matrix—evidence of morphologic and functional differentiation. In well-differentiated benign tumors, mitoses are usually rare and are of normal configuration.
- Malignant neoplasms are characterized by a wide range of parenchymal cell differentiation, from surprisingly well differentiated (Fig. 5–3) to completely

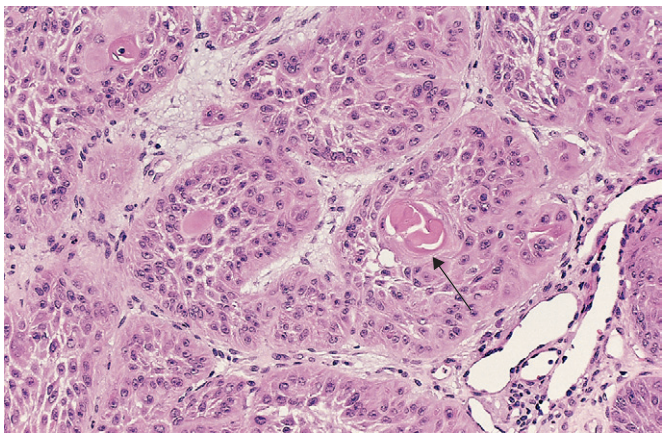

**Figure 5–3** Well-differentiated squamous cell carcinoma of the skin. The tumor cells are strikingly similar to normal squamous epithelial cells, with intercellular bridges and nests of keratin *(arrow)*.
*(Courtesy of Dr. Trace Worrell, Department of Pathology, University of Texas Southwestern Medical School, Dallas, Texas.)*

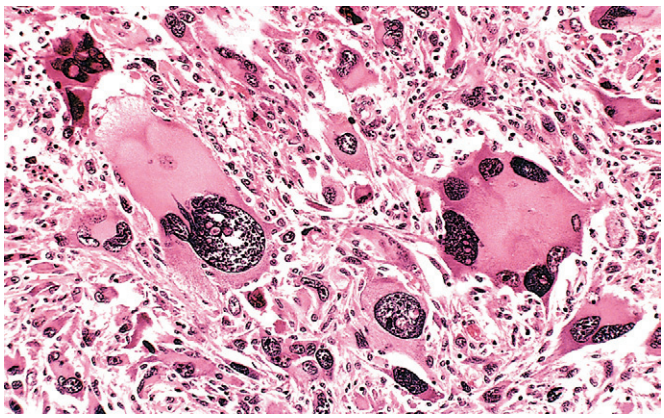

**Figure 5–4** Anaplastic tumor of the skeletal muscle (rhabdomyosarcoma). Note the marked cellular and nuclear pleomorphism, hyperchromatic nuclei, and tumor giant cells.
*(Courtesy of Dr. Trace Worrell, Department of Pathology, University of Texas Southwestern Medical School, Dallas, Texas.)*

undifferentiated. For example, well-differentiated adenocarcinomas of the thyroid may contain normal-appearing follicles. Such tumors sometimes may be difficult to distinguish from benign proliferations. Between the two extremes lie tumors loosely referred to as *moderately well differentiated.* The stroma carrying the blood supply is crucial to the growth of tumors but does not aid in the separation of benign from malignant ones. The amount of stromal connective tissue does determine, however, the consistency of a neoplasm. Certain cancers induce a dense, abundant fibrous stroma (desmoplasia), making them hard, so-called scirrhous tumors.

- Malignant neoplasms that are composed of undifferentiated cells are said to be *anaplastic.* Lack of differentiation, or anaplasia, is considered a hallmark of malignancy. The term *anaplasia* literally means "backward formation"—implying dedifferentiation, or loss of the structural and functional differentiation of normal cells. It is now known, however, that at least some cancers arise from stem cells in tissues; in these tumors, failure of differentiation, rather than dedifferentiation of specialized cells, accounts for their undifferentiated appearance. Recent studies also indicate that in some cases, dedifferentiation of apparently mature cells does occur during carcinogenesis. Anaplastic cells display marked *pleomorphism* (i.e., variation in size and shape) (Fig. 5–4). Often the *nuclei are extremely hyperchromatic* (dark-staining) and large resulting in an increased nuclear-to-cytoplasmic ratio that may approach 1:1 instead of the normal 1:4 or 1:6. *Giant cells* that are considerably larger than their neighbors may be formed and possess either one enormous nucleus or several nuclei. *Anaplastic nuclei are variable and bizarre in size and shape.* The chromatin is coarse and clumped, and nucleoli may be of astounding size. More important, *mitoses often are numerous and distinctly atypical*; anarchic multiple spindles may produce tripolar or quadripolar mitotic figures (Fig. 5–5). Also, anaplastic cells usually fail to develop recognizable patterns of orientation to one another (i.e., they lose normal polarity). They may grow in sheets, with total loss of communal structures, such as glands or stratified squamous architecture.

The more differentiated the tumor cell, the more completely it retains the functional capabilities of its normal counterparts. Benign neoplasms and even well-differentiated cancers of endocrine glands frequently elaborate the hormones characteristic of their origin. Well-differentiated squamous cell carcinomas produce keratin (Fig. 5–3), just as well-differentiated hepatocellular carcinomas secrete bile. In other instances, unanticipated functions emerge. Some cancers may elaborate fetal proteins not produced by comparable cells in the adult. Cancers of nonendocrine origin may produce so-called ectopic hormones. For example, certain lung carcinomas may produce adrenocorticotropic hormone (ACTH), parathyroid hormone–like hormone, insulin, glucagon, and others. More is said about these phenomena later. Despite exceptions, *the more rapidly growing and the more anaplastic a tumor, the less likely it is to have specialized functional activity.*

Of relevance in the discussion of differentiation and anaplasia is *dysplasia,* referring to disorderly but non-neoplastic

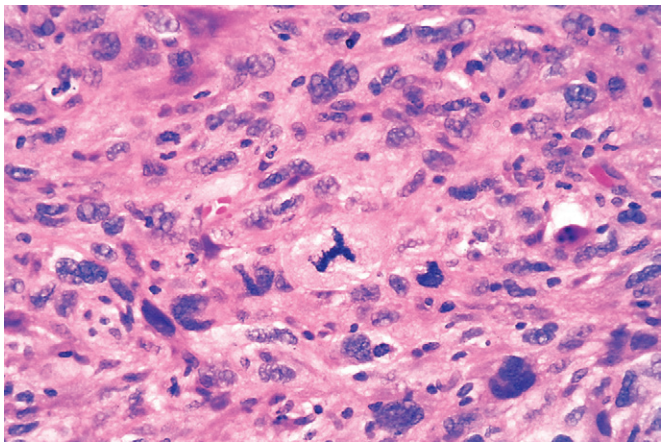

**Figure 5–5** High-power detail view of anaplastic tumor cells shows cellular and nuclear variation in size and shape. The prominent cell in the center field has an abnormal tripolar spindle.

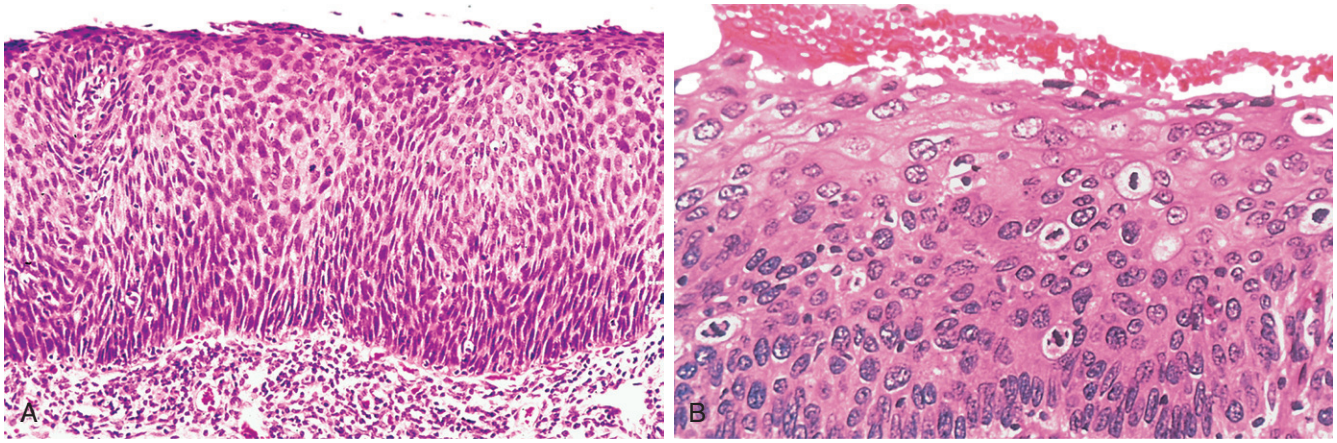


**Figure 5–6** Carcinoma in situ. **A,** Low-power view shows that the entire thickness of the epithelium is replaced by atypical dysplastic cells. There is no orderly differentiation of squamous cells. The basement membrane is intact, and there is no tumor in the subepithelial stroma. **B,** High-power view of another region shows failure of normal differentiation, marked nuclear and cellular pleomorphism, and numerous mitotic figures extending toward the surface. The intact basement membrane (*below*) is not seen in this section.

proliferation. Dysplasia is encountered principally in epithelial lesions. It is a *loss in the uniformity of individual cells and in their architectural orientation.* Dysplastic cells exhibit considerable pleomorphism and often possess hyperchromatic nuclei that are abnormally large for the size of the cell. Mitotic figures are more abundant than usual and frequently appear in abnormal locations within the epithelium. In dysplastic stratified squamous epithelium, mitoses are not confined to the basal layers, where they normally occur, but may be seen at all levels and even in surface cells. There is considerable architectural anarchy. For example, the usual progressive maturation of tall cells in the basal layer to flattened squames on the surface may be lost and replaced by a disordered scrambling of dark basal-appearing cells (Fig. 5–6). When dysplastic changes are marked and involve the entire thickness of the epithelium, the lesion is referred to as *carcinoma in situ,* a preinvasive stage of cancer (Chapter 18). Although dysplastic changes often are found adjacent to foci of malignant transformation, and long-term studies of cigarette smokers show that epithelial dysplasia almost invariably antedates the appearance of cancer, *the term dysplasia is not synonymous with cancer; mild to moderate dysplasias that do not involve the entire thickness of the epithelium sometimes regress completely, particularly if inciting causes are removed.*

## Rate of Growth

Most benign tumors grow slowly, and most cancers grow much faster, eventually spreading locally and to distant sites (metastasizing) and causing death. There are many exceptions to this generalization, however, and some benign tumors grow more rapidly than some cancers. For example, the rate of growth of leiomyomas (benign smooth muscle tumors) of the uterus is influenced by the circulating levels of estrogens. They may increase rapidly in size during pregnancy and then cease growing, becoming largely fibrocalcific, after menopause. Other influences, such as adequacy of blood supply or pressure constraints, also may affect the growth rate of benign tumors. Adenomas of the pituitary gland locked into the sella turcica have been observed to shrink suddenly. Presumably, they undergo a wave of necrosis as progressive enlargement compresses their blood supply. Despite these caveats and the variation in growth rate from one neoplasm to another, it generally is true that most benign tumors increase in size slowly over the span of months to years.

*The rate of growth of malignant tumors usually correlates inversely with their level of differentiation.* In other words, poorly differentiated tumors tend to grow more rapidly than do well-differentiated tumors. However, there is wide variation in the rate of growth. Some grow slowly for years and then enter a phase of rapid growth, signifying the emergence of an aggressive subclone of transformed cells. Others grow relatively slowly and steadily; in exceptional instances, growth may come almost to a standstill. Even more exceptionally, some primary tumors (particularly choriocarcinomas) may become totally necrotic, leaving only secondary metastatic implants. Despite these rarities, most cancers progressively enlarge over time, some slowly, others rapidly, but the notion that they "emerge out of the blue" is not true. Many lines of experimental and clinical evidence document that most if not all cancers take years and sometimes decades to evolve into clinically overt lesions. This is true even of "acute" childhood leukemias, which often initiate during fetal development yet manifest as full-blown cancers years later. Rapidly growing malignant tumors often contain central areas of ischemic necrosis, because the tumor blood supply, derived from the host, fails to keep pace with the oxygen needs of the expanding mass of cells.

### *Cancer Stem Cells and Lineages*

The continued growth and maintenance of many tissues that contain short-lived cells, such as the formed elements of the blood and the epithelial cells of the gastrointestinal tract and skin, require a resident population of tissue stem cells that are long-lived and capable of self-renewal. Tissue stem cells are rare and exist in a niche created by support cells, which produce paracrine factors that sustain the stem cells. As described in Chapter 2, tissue stem cells divide asymmetrically to produce two types of daughter

cells—those with limited proliferative potential, which undergo terminal differentiation to form particular tissues, and those that retain stem cell potential. Cancers are immortal and have limitless proliferative capacity, indicating that like normal tissues, they also must contain cells with "stemlike" properties.

The cancer stem cell hypothesis posits that, in analogy with normal tissues, only a special subset of cells within tumors has the capacity for self-renewal. The concept of cancer stem cells has several important implications. Most notably, if cancer stem cells are essential for tumor persistence, it follows that these cells must be eliminated to cure the affected patient. It is hypothesized that, like normal stem cells, cancer stem cells are resistant to conventional therapies, because of their low rate of cell division and the expression of factors, such as multiple drug resistance-1 (MDR-1), that counteract the effects of chemotherapeutic drugs. Thus, the limited success of current therapies could be explained by their failure to kill the malignant stem cells that lie at the root of cancer. Cancer stem cells could arise from normal tissue stem cells or from more differentiated cells that, as part of the transformation process, acquire the property of self-renewal. Studies of certain leukemias (Chapter 11) suggest that both possibilities occur, in that chronic myelogenous leukemia originates from the malignant counterpart of a normal hematopoietic stem cell, whereas certain acute myeloid (myelogenous) leukemias are derived from more differentiated myeloid precursors that acquire an abnormal capacity for self-renewal. The identification of "leukemia stem cells" has spurred the search for cancer stem cells in solid tumors.

## Local Invasion

A benign neoplasm remains localized at its site of origin. It does not have the capacity to infiltrate, invade, or metastasize to distant sites, as do malignant neoplasms. For example, as adenomas slowly expand, most develop an enclosing fibrous capsule that separates them from the host tissue. This capsule probably is derived from the stroma of the host tissue as the parenchymal cells atrophy under the pressure of the expanding tumor. The stroma of the tumor itself also may contribute to the capsule (Figs. 5–7 and 5–8). Of note, however, *not all benign neoplasms are encapsulated.* For example, the leiomyoma of the uterus is discretely demarcated from the surrounding smooth muscle by a zone of compressed and attenuated normal myometrium, but there is no well-developed capsule. Nonetheless, a well-defined cleavage plane exists around these lesions. A few benign tumors are neither encapsulated nor discretely defined; such lack of demarcation is particularly likely to be seen in some benign vascular neoplasms of the dermis. These exceptions are pointed out only to emphasize that although encapsulation is the rule in benign tumors, the lack of a capsule does not mean that a tumor is malignant.

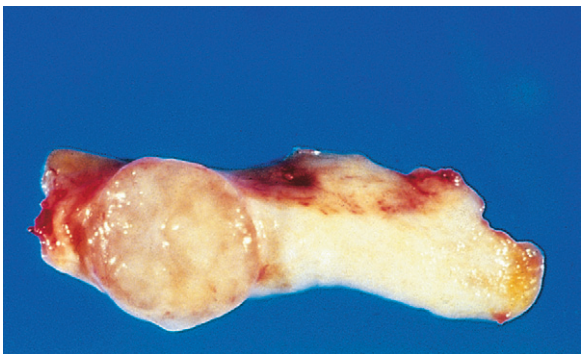

**Figure 5–7** Fibroadenoma of the breast. The tan-colored, encapsulated small tumor is sharply demarcated from the whiter breast tissue.

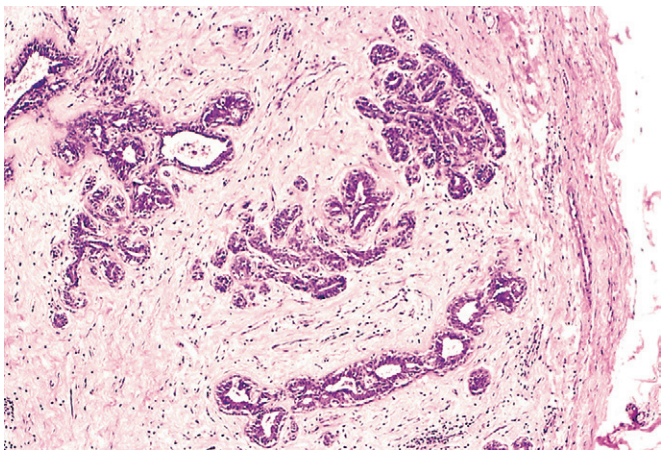

**Figure 5–8** Microscopic view of fibroadenoma of the breast seen in Figure 5–7. The fibrous capsule (*right*) sharply delimits the tumor from the surrounding tissue.
*(Courtesy of Dr. Trace Worrell, Department of Pathology, University of Texas Southwestern Medical School, Dallas, Texas.)*

*Cancers grow by progressive infiltration, invasion, destruction, and penetration of the surrounding tissue* (Figs. 5–9 and 5–10). They do not develop well-defined capsules. There are, however, occasional instances in which a slowly growing malignant tumor deceptively appears to be encased by the stroma of the surrounding host tissue, but microscopic examination usually reveals tiny crablike feet penetrating the margin and infiltrating adjacent structures. The infiltrative mode of growth makes it necessary to remove a wide margin of surrounding normal tissue when surgical excision of a malignant tumor is attempted.

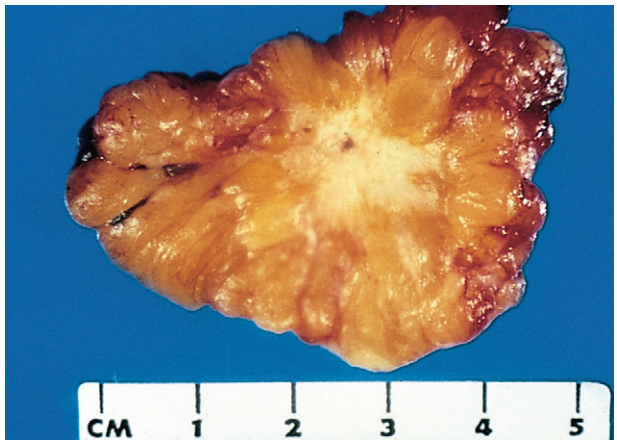


**Figure 5–9** Cut section of invasive ductal carcinoma of the breast. The lesion is retracted, infiltrating the surrounding breast substance, and was stony-hard on palpation.

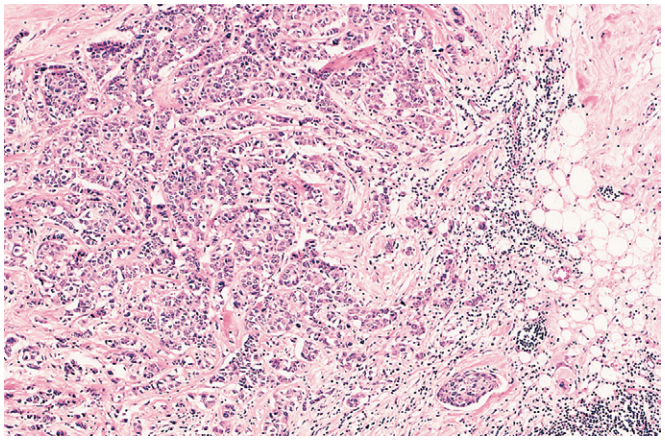

**Figure 5–10** Microscopic view of breast carcinoma seen in Figure 5–9 illustrates the invasion of breast stroma and fat by nests and cords of tumor cells (compare with Fig. 5–8). Note the absence of a well-defined capsule.

*(Courtesy of Dr. Trace Worrell, Department of Pathology, University of Texas Southwestern Medical School, Dallas, Texas.)*

Surgical pathologists carefully examine the margins of resected tumors to ensure that they are devoid of cancer cells (*clean margins*). *Next to the development of metastases, local invasiveness is the most reliable feature that distinguishes malignant from benign tumors.*

## Metastasis

*Metastases* are secondary implants of a tumor that are discontinuous with the primary tumor and located in remote tissues (Fig. 5–11). *More than any other attribute, the property of metastasis identifies a neoplasm as malignant.* Not all cancers have equivalent ability to metastasize, however. At one extreme are basal cell carcinomas of the skin and most primary tumors of the central nervous system, which are highly invasive locally but rarely metastasize. At the other extreme are osteogenic (bone) sarcomas, which usually have metastasized to the lungs at the time of initial discovery.

Approximately 30% of patients with newly diagnosed solid tumors (excluding skin cancers other than melanomas) present with clinically evident metastases. An additional 20% have occult (hidden) metastases at the time of diagnosis.

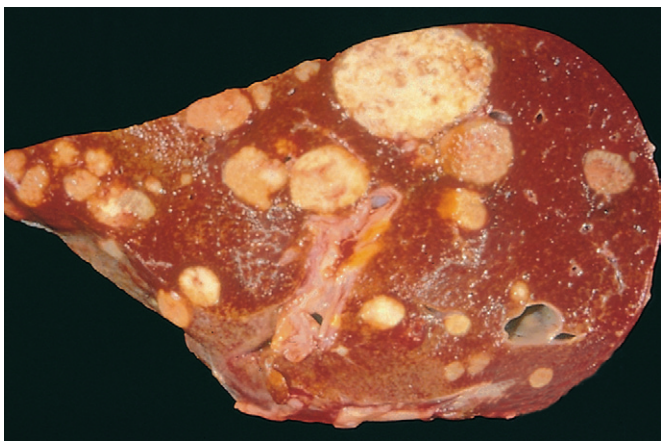

**Figure 5–11** A liver studded with metastatic cancer.

In general, the more anaplastic and the larger the primary neoplasm, the more likely is metastatic spread, but as with most rules, there are exceptions. Extremely small cancers have been known to metastasize; conversely, some large and ominous-looking lesions may not. Dissemination strongly prejudices, and may preclude, the possibility of curing the disease, so obviously, short of prevention of cancer, no achievement would confer greater benefit on patients than the prevention of metastases.

Malignant neoplasms disseminate by one of three pathways: (1) seeding within body cavities, (2) lymphatic spread, or (3) hematogenous spread. *Spread by seeding* occurs when neoplasms invade a natural body cavity. This mode of dissemination is particularly characteristic of cancers of the ovary, which often cover the peritoneal surfaces widely. The implants literally may glaze all peritoneal surfaces and yet not invade the underlying tissues. Here is an instance of the ability to reimplant elsewhere that seems to be separable from the capacity to invade. Neoplasms of the central nervous system, such as a medulloblastoma or ependymoma, may penetrate the cerebral ventricles and be carried by the cerebrospinal fluid to reimplant on the meningeal surfaces, either within the brain or in the spinal cord.

*Lymphatic spread* is more typical of carcinomas, whereas *hematogenous spread* is favored by sarcomas. There are numerous interconnections, however, between the lymphatic and vascular systems, so all forms of cancer may disseminate through either or both systems. The pattern of lymph node involvement depends principally on the site of the primary neoplasm and the natural pathways of local lymphatic drainage. Lung carcinomas arising in the respiratory passages metastasize first to the regional bronchial lymph nodes and then to the tracheobronchial and hilar nodes. Carcinoma of the breast usually arises in the upper outer quadrant and first spreads to the axillary nodes. However, medial breast lesions may drain through the chest wall to the nodes along the internal mammary artery. Thereafter, in both instances, the supraclavicular and infraclavicular nodes may be seeded. In some cases, the cancer cells seem to traverse the lymphatic channels within the immediately proximate nodes to be trapped in subsequent lymph nodes, producing so-called *skip metastases.* The cells may traverse all of the lymph nodes ultimately to reach the vascular compartment by way of the thoracic duct.

A "sentinel lymph node" is the first regional lymph node that receives lymph flow from a primary tumor. It can be identified by injection of blue dyes or radiolabeled tracers near the primary tumor. Biopsy of sentinel lymph nodes allows determination of the extent of spread of tumor and can be used to plan treatment.

Of note, although enlargement of nodes near a primary neoplasm should arouse concern for metastatic spread, it does not always imply cancerous involvement. The necrotic products of the neoplasm and tumor antigens often evoke immunologic responses in the nodes, such as hyperplasia of the follicles (lymphadenitis) and proliferation of macrophages in the subcapsular sinuses (sinus histiocytosis). Thus, histopathologic verification of tumor within an enlarged lymph node is required.

*Hematogenous spread* is the favored pathway for sarcomas, but carcinomas use it as well. As might be expected,

arteries are penetrated less readily than are veins. With venous invasion, the blood-borne cells follow the venous flow draining the site of the neoplasm, with tumor cells often stopping in the first capillary bed they encounter. Since all portal area drainage flows to the liver, and all caval blood flows to the lungs, *the liver and lungs are the most frequently involved secondary sites in hematogenous dissemination.* Cancers arising near the vertebral column often embolize through the paravertebral plexus; this pathway probably is involved in the frequent vertebral metastases of carcinomas of the thyroid and prostate.

Certain carcinomas have a propensity to grow within veins. Renal cell carcinoma often invades the renal vein to grow in a snakelike fashion up the inferior vena cava, sometimes reaching the right side of the heart. Hepatocellular carcinomas often penetrate portal and hepatic radicles to grow within them into the main venous channels. Remarkably, such intravenous growth may not be accompanied by widespread dissemination.

Many observations suggest that the anatomic localization of a neoplasm and its venous drainage cannot wholly explain the systemic distributions of metastases. For example, prostatic carcinoma preferentially spreads to bone, bronchogenic carcinomas tend to involve the adrenals and the brain, and neuroblastomas spread to the liver and bones. Conversely, skeletal muscles, although rich in capillaries, are rarely the site of secondary deposits. The molecular basis of such tissue-specific homing of tumor cells is discussed later on.

Thus, numerous features of tumors (Fig. 5–12), usually permit the differentiation of benign and malignant neoplasms.

## SUMMARY

### Characteristics of Benign and Malignant Tumors

- Benign and malignant tumors can be distinguished from one another based on the degree of differentiation, rate of growth, local invasiveness, and distant spread.
- Benign tumors resemble the tissue of origin and are well differentiated; malignant tumors are poorly or completely undifferentiated (anaplastic).
- Benign tumors are slow-growing, whereas malignant tumors generally grow faster.
- Benign tumors are well circumscribed and have a capsule; malignant tumors are poorly circumscribed and invade the surrounding normal tissues.
- Benign tumors remain localized to the site of origin, whereas malignant tumors are locally invasive and metastasize to distant sites.

## EPIDEMIOLOGY

Because cancer is a disorder of cell growth and behavior, its ultimate cause must be defined at the cellular and molecular levels. Cancer epidemiology can contribute substantially to knowledge about the origin of cancer. The now well-established concept that cigarette smoking is causally associated with lung cancer arose primarily from epidemiologic studies. A comparison of the incidence rates for colon cancer and dietary patterns in the Western world and in Africa led to the recognition that dietary fat and fiber content may figure importantly in the causation of this

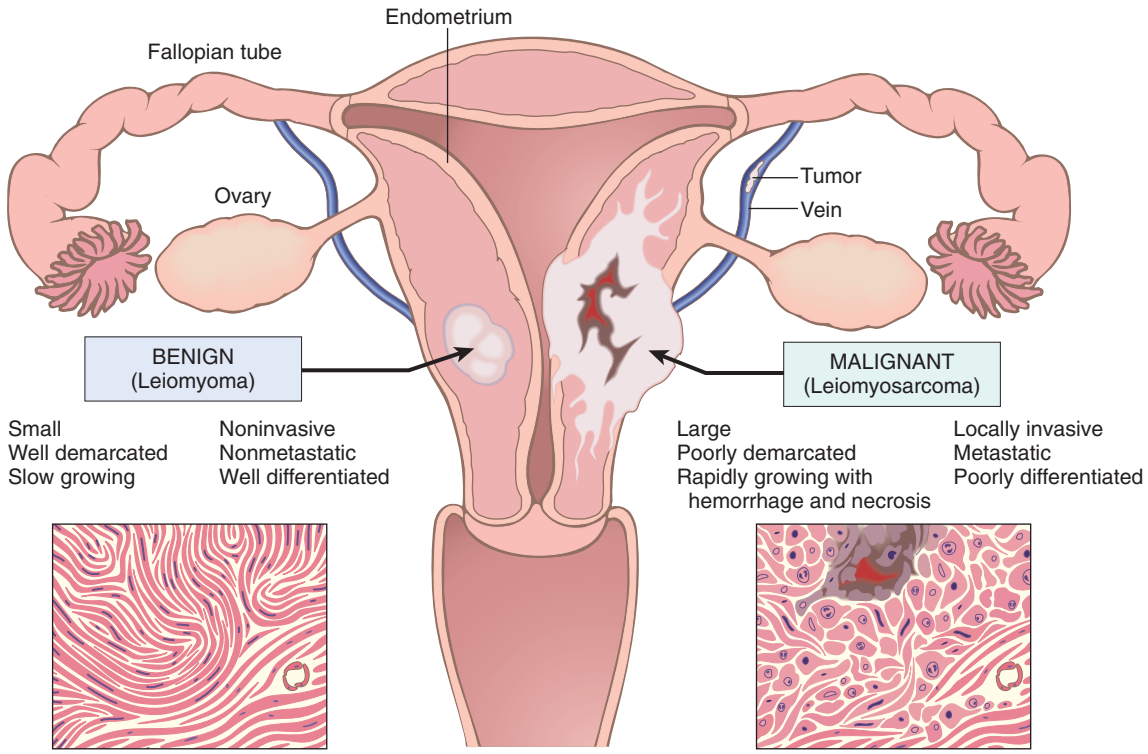


**Figure 5–12** Comparison between a benign tumor of the myometrium (leiomyoma) and a malignant tumor of similar origin (leiomyosarcoma).

cancer. Major insights into the causes of cancer can be obtained by epidemiologic studies that relate particular environmental, racial (possibly hereditary), and cultural influences to the occurrence of specific neoplasms. Certain diseases associated with an increased risk of developing cancer (preneoplastic disorders) also provide clues to the pathogenesis of cancer.

The following discussion first summarizes the overall incidence of cancer to provide insight into the magnitude of the cancer problem and then reviews some issues relating to the patient and environment that influence the predisposition to cancer.

## Cancer Incidence

Some perspective on the likelihood of developing a specific form of cancer can be gained from national incidence and mortality data. Overall, it is estimated that about *1.5 million* new cancer cases occurred in 2011, and 569,000 people died of cancer in the United States that year. Incidence data for the most common forms of cancer, with the major killers identified, are presented in Figure 5–13.

Over several decades, the death rates for many forms of cancer have changed. Particularly notable is the significant increase in the overall cancer death rate among men that was attributable largely to lung cancer, but this has finally begun to drop. By contrast, the overall death rate among women has fallen slightly, mostly as a result of the decline in death rates for cancers of the uterine cervix, stomach, and large bowel. These welcome trends have more than counterbalanced the striking climb in the rate of lung cancer in women, which not long ago was a relatively uncommon form of neoplasia in this sex. The declining death rate from cervical cancer is directly related to widespread use of cytologic smear studies for early detection of this tumor and its precursor lesions. The development of the human papillomavirus (HPV) vaccine may eliminate this cancer altogether in the coming years. The causes of decline in death rates for cancers of the stomach are obscure; however, there have been speculations about decreasing exposure to dietary carcinogens.

## Geographic and Environmental Variables

Although many impressive advances in understanding the molecular pathogenesis of cancer have been made by analyzing hereditary cancers, it is fair to state that environmental factors are the predominant cause of the most common sporadic cancers. This notion is supported by the geographic differences in death rates from specific forms of cancer. For example, death rates from breast cancer are about four to five times higher in the United States and Europe than in Japan. Conversely, the death rate for stomach carcinoma in men and women is about seven times higher in Japan than in the United States. Liver cell carcinoma is relatively infrequent in the United States but is the most lethal cancer among many African populations. Nearly all the evidence indicates that these geographic differences are environmental rather than genetic in origin. Nisei (second-generation Japanese living in the United States) have mortality rates for certain forms of cancer that are intermediate between those in natives of Japan and in Americans who have lived in the United States for many generations. The two rates come closer with each passing generation.

There is no paucity of environmental carcinogens. They lurk in the ambient environment, in the workplace, in food, and in personal practices. They can be as universal as sunlight, can be found particularly in urban settings (e.g., asbestos), or can be limited to a certain occupation (Table 5–2). Certain features of diet have been implicated as possible predisposing influences. Among the possible

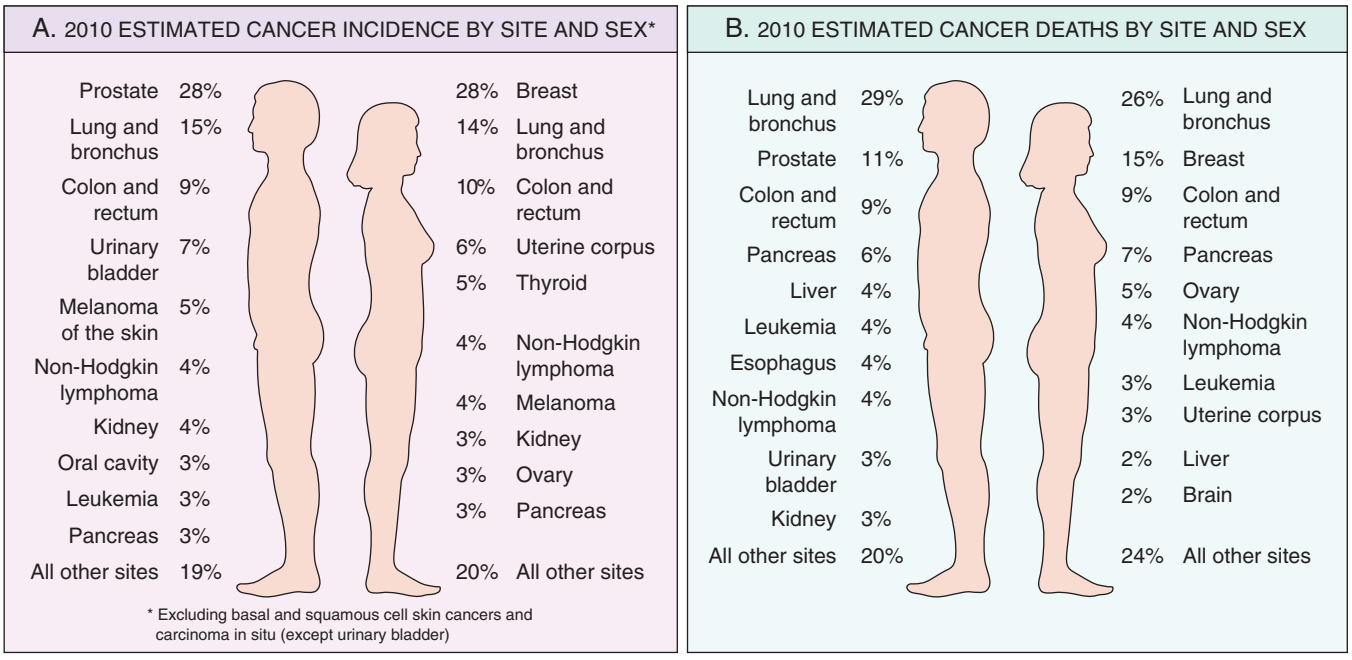


**Figure 5–13** Cancer incidence and mortality by site and sex.
*(Adapted from Jemal A, Siegel R, Xu J, Ward E: Cancer statistics, 2010. CA Cancer J Clin 60:277–300, 2010.)*

**Table 5–2** Occupational Cancers

| Agent/Group of Agents | Human Cancer Site and Type for Which Reasonable Evidence Is Available | Typical Use/Occurrence |
|---|---|---|
| Arsenic and arsenic compounds | Lung, skin, hemangiosarcoma | Byproduct of metal smelting<br>Component of alloys, electrical and semiconductor devices, medications and herbicides, fungicides, and animal dips |
| Asbestos | Lung, mesothelioma; gastrointestinal tract (esophagus, stomach, large intestine) | Formerly used for many applications because of fire, heat, and friction resistance; still found in existing construction as well as fire-resistant textiles, friction materials (e.g., brake linings), underlayment and roofing papers, and floor tiles |
| Benzene | Leukemia | Principal component of light oil<br>Many applications exist in printing and lithography, paint, rubber, dry cleaning, adhesives and coatings, and detergents<br>Formerly widely used as solvent and fumigant |
| Beryllium and beryllium compounds | Lung | Missile fuel and space vehicles<br>Hardener for lightweight compounds metal alloys, particularly in aerospace applications and nuclear reactors |
| Cadmium and cadmium compounds | Prostate | Uses include yellow pigments and phosphors<br>Found in solders<br>Used in batteries and as alloy and in metal platings and coatings |
| Chromium compounds | Lung | Component of metal alloys, paints, pigments, and preservatives |
| Ethylene oxide | Leukemia | Ripening agent for fruits and nuts<br>Used in rocket propellant and chemical synthesis, in fumigants for foodstuffs and textiles, and in sterilants for hospital equipment |
| Nickel compounds | Nose, lung | Nickel plating<br>Component of ferrous alloys, ceramics, and batteries<br>Byproduct of stainless steel arc welding |
| Radon and its decay products | Lung | From decay of minerals containing uranium<br>Can be serious hazard in quarries and mines |
| Vinyl chloride | Angiosarcoma, liver | Refrigerant<br>Monomer for vinyl polymers<br>Adhesive for plastics<br>Formerly used as inert aerosol propellant in pressurized containers |

Modified from Stellman JM, Stellman SD: Cancer and workplace. CA Cancer J Clin 46:70–92, 1996, with permission from Lippincott Williams & Wilkins.

environmental influences, the most distressing in terms of prevention are those incurred in personal practices, notably cigarette smoking and chronic alcohol consumption. The risk of cervical cancer is linked to age at first intercourse and the number of sex partners (pointing to a causal role for venereal transmission of the oncogenic virus HPV). There is no escape: It seems that everything people do to earn a livelihood, to subsist, or to enjoy life turns out to be illegal, immoral, or fattening, or—most disturbing—possibly carcinogenic.

## Age

In general, the frequency of cancer increases with age. Most cancer deaths occur between ages 55 and 75; the rate declines, along with the population base, after age 75. The rising incidence with age may be explained by the accumulation of somatic mutations associated with the emergence of malignant neoplasms (discussed later). The decline in immune competence that accompanies aging also may be a factor.

Cancer causes slightly more than 10% of all deaths among children younger than 15 years (Chapter 5). The major lethal cancers in children are leukemias, tumors of the central nervous system, lymphomas, and soft tissue and bone sarcomas. As discussed later, study of several childhood tumors, such as retinoblastoma, has provided fundamental insights into the pathogenesis of malignant transformation.

## Heredity

The evidence now indicates that for many types of cancer, including the most common forms, there exist not only environmental influences but also hereditary predispositions. Hereditary forms of cancer can be divided into three categories based on their pattern of inheritance (Table 5–3).

### *Autosomal Dominant Cancer Syndromes*

Autosomal dominant cancer syndromes include several well-defined cancers in which inheritance of a single mutant gene greatly increases the risk of developing a tumor. The predisposition to these tumors shows an autosomal dominant pattern of inheritance. Childhood retinoblastoma is the most striking example of this category. Approximately 40% of retinoblastomas are familial. As is discussed later, inherited disabling mutations in a *tumor suppressor gene* are responsible for the development of this tumor in families. Carriers of this gene have a 10,000-fold increased risk of developing retinoblastoma. Unlike those

**Table 5–3** Inherited Predisposition to Cancer

| Gene(s) | Inherited Predisposition |
|---|---|
| **Autosomal Dominant Cancer Syndromes** | |
| *RB* | Retinoblastoma |
| *TP53* | Li-Fraumeni syndrome (various tumors) |
| *p16INK4A* | Melanoma |
| *APC* | Familial adenomatous polyposis/colon cancer |
| *NF1, NF2* | Neurofibromatosis 1 and 2 |
| *BRCA1, BRCA2* | Breast and ovarian tumors |
| *MEN1, RET* | Multiple endocrine neoplasia 1 and 2 |
| *MSH2, MLH1, MSH6* | Hereditary nonpolyposis colon cancer |
| *PATCH* | Nevoid basal cell carcinoma syndrome |
| **Autosomal Recessive Syndromes of Defective DNA Repair** | |
| Xeroderma pigmentosum | |
| Ataxia-telangiectasia | |
| Bloom syndrome | |
| Fanconi anemia | |
| **Familial Cancers of Uncertain Inheritance** | |
| Breast cancer (not linked to *BRCA1* or *BRCA2*) | |
| Ovarian cancer | |
| Pancreatic cancer | |

with sporadic retinoblastoma, patients with familial retinoblastoma develop bilateral tumors, and they also have a greatly increased risk of developing a second cancer, particularly osteosarcoma.

Tumors within this group often are associated with a specific marker phenotype. There may be multiple benign tumors in the affected tissue, as occurs in familial polyposis of the colon and in multiple endocrine neoplasia (see Table 5–3). Sometimes, there are abnormalities in tissue that are not the target of transformation (e.g., Lisch nodules and café-au-lait spots in neurofibromatosis type 1) (Chapter 22).

### *Autosomal Recessive Syndromes of Defective DNA Repair*

A group of rare autosomal recessive disorders is collectively characterized by chromosomal or DNA instability and high rates of certain cancers. One of the best-studied is xeroderma pigmentosum, in which DNA repair is defective. This and other familial disorders of DNA instability are described later.

### *Familial Cancers of Uncertain Inheritance*

Virtually all the common types of cancers that occur sporadically have been reported to occur in familial forms where the pattern of inheritance is unclear. Examples are carcinomas of colon, breast, ovary, and brain. *Features that characterize familial cancers include early age at onset, tumors arising in two or more close relatives of the index case, and sometimes multiple or bilateral tumors.* Familial cancers are not associated with specific marker phenotypes. For example, in contrast with the familial adenomatous polyposis syndrome, familial colonic cancers do not arise in preexisting benign polyps. In general, siblings have a relative risk between 2 and 3. Segregation analysis of large families usually reveals that predisposition to the tumors is dominant, but incomplete penetrance or multifactorial inheritance cannot be easily ruled out.

In summary, no more than 5% to 10% of all human cancers fall into one of the three aforementioned categories. What can be said about the influence of heredity in the large preponderance of malignant tumors? There is emerging evidence that the influence of hereditary factors is subtle and sometimes indirect. The genotype may influence the likelihood of developing environmentally induced cancers. For example, polymorphisms in drug-metabolizing enzymes confer genetic predisposition to lung cancer in people who smoke cigarettes. More strikingly, genome-wide association studies (GWAS) in lung cancer, which sought to identify common genetic variants that increase risk for developing cancer, identified variants in a nicotinic acid receptor as being associated with development of lung cancer. Of interest, these variants were strongly associated with the number of cigarettes smoked, suggesting that they indirectly increase lung cancer risk by enhancing the addictiveness of cigarettes.

## Acquired Preneoplastic Lesions

Just as some hereditary conditions increase the risk of getting certain cancers, so do certain acquired conditions. These are loosely referred to as *preneoplastic lesions* or simply "*precancers*." These designations are unfortunate because they imply inevitability, but in fact, although such lesions increase the likelihood of malignancy, most do not progress to cancer. In many instances, precursor lesions arise in the setting of chronic tissue injury or inflammation, which may increase the likelihood of malignancy by stimulating continuing regenerative proliferation or by exposing cells to byproducts of inflammation, both of which can lead to somatic mutations (discussed later). Indeed, molecular analyses have shown that many precursor lesions possess some of the genetic lesions found in their associated cancers. Clinically, these precursor lesions are important to recognize, because their removal or reversal may prevent the development of a cancer. A brief listing of some of the chief precursor lesions follows:

- Squamous metaplasia and dysplasia of the bronchial mucosa, seen in habitual smokers—a risk factor for lung cancer
- Endometrial hyperplasia and dysplasia, seen in women with unopposed estrogenic stimulation—a risk factor for endometrial carcinoma
- Leukoplakia of the oral cavity, vulva, or penis, which may progress to squamous cell carcinoma
- Villous adenomas of the colon, associated with a high risk of transformation to colorectal carcinoma

In this context it may be asked, "What is the risk of malignant change in a benign neoplasm?"—or, stated differently, "Are benign tumors precancerous?" In general the answer is no, but inevitably there are exceptions, and perhaps it is better to say that each type of benign tumor is associated with a particular level of risk, ranging from high to virtually nonexistent. For example, adenomas of the colon as they enlarge can undergo malignant transformation in 50% of cases; by contrast, malignant change is extremely rare in leiomyomas of the uterus.

## SUMMARY

### Epidemiology of Cancer

- The incidence of cancer varies with age, race, geographic factors, and genetic backgrounds. Cancers are most common at the two extremes of age. The geographic variation results mostly from different environmental exposures.
- Most cancers are sporadic, but some are familial. Predisposition to hereditary cancers may be autosomal dominant or autosomal recessive. The former usually are linked to inheritance of a germ line mutation of cancer suppressor genes, whereas the latter typically are associated with inherited defects in DNA repair.
- Familial cancers tend to be bilateral and arise earlier in life than their sporadic counterparts.
- Some acquired diseases, known as preneoplastic disorders, are known to be associated with an increased risk for development of cancer.

## CARCINOGENESIS: THE MOLECULAR BASIS OF CANCER

It could be argued that the proliferation of literature on the molecular basis of cancer has outpaced the growth of even the most malignant of tumors. Researchers and students alike can easily get lost in the growing forest of information. Accordingly, a review of some fundamental principles is presented as background for more detailed consideration of the genetic basis of cancer.

- As already discussed, *nonlethal genetic damage lies at the heart of carcinogenesis.* Such genetic damage (or mutation) may be acquired by the action of environmental agents, such as chemicals, radiation, or viruses, or it may be inherited in the germ line. The genetic hypothesis of cancer implies that a tumor mass results from the clonal expansion of a single progenitor cell that has incurred genetic damage (i.e., tumors are monoclonal). This expectation has been realized in all tumors that have been systematically analyzed by genomic sequencing.
- *Four classes of normal regulatory genes – growth-promoting proto-oncogenes, growth-inhibiting tumor suppressor genes, genes that regulate programmed cell death (i.e., apoptosis), and genes involved in DNA repair* – are the principal targets of genetic damage. Collectively, the genetic alterations in tumor cells confer growth and survival advantages over normal cells, as will be evident from the discussion that follows.
- *Oncogenes* are genes that induce a transformed phenotype when expressed in cells. A major discovery in cancer was the realization that most oncogenes are mutated or over expressed versions of normal cellular genes, which are called *proto-oncogenes.* Most known oncogenes encode transcription factors, growth regulating proteins, or proteins involved in cell survival and cell–cell and cell–matrix interactions. They are considered dominant because mutation of a single allele can lead to cellular transformation.
- *Tumor suppressor genes* are genes that normally prevent uncontrolled growth and, when mutated or lost from a cell, allow the transformed phenotype to develop. Usually both normal alleles of tumor suppressor genes must be damaged for transformation to occur. However, recent work has clearly shown that, in some cases, loss of a single allele of a tumor suppressor gene can promote transformation (haploinsufficiency).
- Tumor suppressor genes are usefully placed into two general groups, "*governors*" and "*guardians.*" "Governors" are classic tumor suppressor genes, such as *RB*, where mutation of the gene leads to transformation by removing an important brake on cellular proliferation. "Guardian" genes are responsible for sensing genomic damage. Some of these genes initiate and choreograph a complex "damage control response." This response leads to the cessation of proliferation or, if the damage is too great to be repaired, the induction of apoptosis. *TP53,* the so-called "guardian of the genome," is a prototypic tumor suppressor gene of this type. Other guardian genes are directly involved in recognizing and repairing specific kinds of DNA damage; these are the genes that are mutated in the autosomal recessive syndromes of DNA repair. Mutation of *TP53* or other sensors of genomic damage does not directly transform cells, as loss of guardian function has no direct effect on cellular proliferation or apoptosis. Instead, loss of the guardian genes permits and accelerates the acquisition of mutations in oncogenes and tumor suppressor genes that can lead to the development of cancer. This increase in mutation rate is often referred to as a *mutator phenotype.*
- Genes that regulate apoptosis and DNA repair may act like proto-oncogenes (loss of one copy is sufficient) or tumor suppressor genes (loss of both copies).

Several types of alterations can affect cancer-causing genes and lead to cellular transformation, as detailed in a subsequent section. Presented next is a discussion of the varied genetic lesions that underlie mutation of genes in cancer.

## GENETIC LESIONS IN CANCER

The genetic changes that characterize cancer-associated mutations may be subtle (e.g., point mutations or insertions and deletions) or large enough to produce karyotypic changes. Point mutations can either activate or inactivate the resulting protein products. For example, point mutations in proto-oncogenes, such as *RAS* or *EGFR,* frequently result in overactivity of the protein, usually by altering an internal regulatory amino acid and producing a constitutively active protein. However, point mutations in tumor suppressors, such as those affecting *RB* or *TP53* genes, reduce or disable the function of the encoded protein.

### Karyotypic Changes in Tumors

The genetic lesion that activates oncogenes or inactivates tumor suppressor genes may be subtle (as described previously) or large enough to be detected in a karyotype. Some cancers have a virtually normal karyotype, while others are markedly aneuploid, with loss and gain of many entire

chromosomes or chromosomal arms. In certain neoplasms, karyotypic abnormalities are nonrandom and common, or even characteristic of a particular tumor. Specific abnormalities have been identified in most leukemias and lymphomas and in an increasing number of nonhematopoietic tumors. The common types of nonrandom structural abnormalities in tumor cells are (1) balanced translocations, (2) deletions, and (3) cytogenetic manifestations of gene amplification.

### *Balanced Translocations*

Balanced translocations are highly associated with certain malignancies, particularly specific kinds of hematopoietic and mesenchymal neoplasms. Translocations can activate proto-oncogenes in two ways:

- Some translocations result in overexpression of proto-oncogenes by removing them from their normal regulatory elements and placing them under control of an inappropriate, highly active promoter. Two different kinds of B cell lymphoma provide cardinal examples of this mechanism. *In more than 90% of cases of Burkitt lymphoma the cells have a translocation, usually between chromosomes 8 and 14, which leads to overexpression of the MYC gene on chromosome 8 by juxtaposition with immunoglobulin heavy chain gene regulatory elements on chromosome 14. In follicular B cell lymphomas, a reciprocal translocation between chromosomes 14 and 18 leads to overexpression of the anti-apoptotic gene, BCL2, on chromosome 18, also driven by immunoglobulin gene elements.*
- Other oncogenic translocations create fusion genes encoding novel chimeric proteins. Most notable is the Philadelphia (Ph) chromosome in chronic myelogenous leukemia, consisting of a reciprocal and balanced translocation between chromosomes 22 and 9 (Fig. 5–14). As a consequence, the derivative chromosome 22 (the Philadelphia chromosome) appears abbreviated. This cytogenetic change, seen in more than 90% of cases of chronic myelogenous leukemia, is a reliable marker of this disease, and the few Ph chromosome–negative cases show molecular evidence of the *BCR-ABL rearrangement, the crucial consequence of Ph translocation. As discussed later, such changes give rise to the BCR-ABL fusion gene with potent tyrosine kinase activity.*

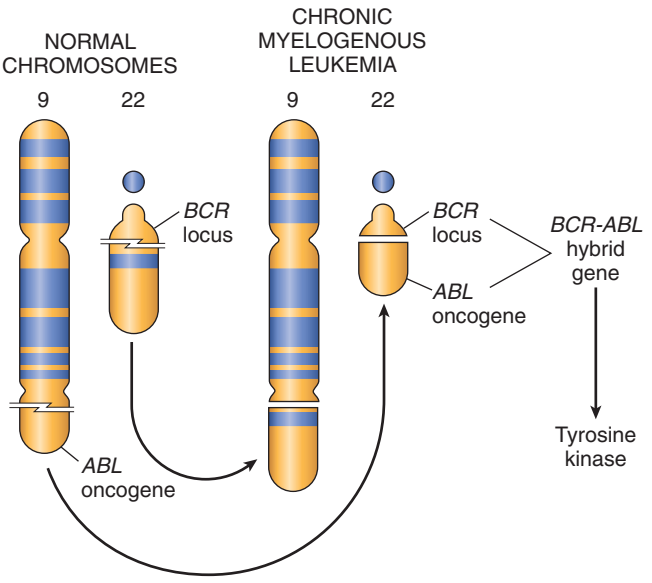


**Figure 5–14** The chromosomal translocation and associated oncogene in chronic myelogenous leukemia.

Lymphoid cells are most commonly the targets of gene rearrangements, which may take the form of translocations, inversions, or interstitial deletions, because these cells purposefully make DNA breaks during the processes of antibody or T cell receptor gene recombination. Two other types of mesenchymal tumors, myeloid neoplasms (acute myeloid leukemias and myeloproliferative disorders) and sarcomas, also frequently possess recurrent translocations, such as the t(11;22)(q24;12) translocation in Ewing sarcoma that results in fusion of the EWS transcription factor with Fli-1. The cause of the DNA breaks that lead to chromosomal translocations in myeloid neoplasms and sarcomas is unknown.

Identification of recurrent chromosomal rearrangements in carcinomas has lagged because of the complexity of the karyotypes of these tumors, but novel molecular techniques are beginning to unravel this tangled skein. As with hematologic malignancies and sarcomas, gene rearrangements in solid tumors can contribute to carcinogenesis either by increasing expression of an oncogene or by generation of a novel fusion gene. For example, various *TMPRSS-ETS* fusion genes found in prostate carcinomas place ETS family transcription factor genes under the control of the TMPRSS promoter, which is activated by androgens. The net effect of these rearrangements is the inappropriate, androgen-dependent expression of ETS family transcription factors. Rearrangements of the *HMGA2* gene found in pleomorphic adenomas and other tumors lead to overexpression of the HMGA2 transcription factor through an unusual mechanism; they replace the 3′ untranslated region of *HMGA2* with that of another gene, thus removing key negative regulatory microRNA binding sites. Although the mechanisms are not yet clear, overexpression of HGMA2 or ETS likely promotes carcinogenesis by altering expression of a number of genes that are the targets of these transcription factors. Another uncommon but clinically important type of rearrangement creates an *EML4-ALK* fusion gene, which is present in roughly 4% of lung carcinomas. The EML4-ALK kinase is constitutively active and upregulates signaling through a several progrowth pathways. As discussed later, lung cancers expressing this fusion protein respond to inhibitors of the ALK kinase.

### *Deletions*

Chromosomal deletions are the second most prevalent karyotypic abnormality in tumor cells. Compared with translocations, deletions large enough to be observed karyotypically are more common in nonhematopoietic solid tumors. At a molecular level, however, deletions are commonly found in hematopoietic tumors as well. Deletion of specific regions of chromosomes may result in the loss of particular tumor suppressor genes. Tumor suppressors generally require inactivation of both alleles in order for them to contribute to carcinogenesis. A common mechanism for this is an inactivating point mutation in one allele, followed by deletion of the other, nonmutated allele.

Such deletions result in loss of heterozygosity (LOH), as formerly heterozygous genetic variants will now only have one allele, and all genetic variants within the deleted region will be detected as homozygous. As discussed later, deletions involving 13q14, the site of the *RB* gene, are associated with retinoblastoma, and deletion of 17p is associated with loss of p53.

### *Gene Amplifications*

Proto-oncogenes may be converted to oncogenes by amplification, with consequent overexpression, of otherwise normal proteins. Such amplification may produce several hundred copies of the proto-oncogene in the tumor cell. The amplified genes can be readily detected by molecular hybridization with appropriate DNA probes. In some cases the amplified genes produce chromosomal changes that can be identified microscopically. Two mutually exclusive patterns are seen: multiple small, extrachromosomal structures called "double minutes" and homogeneously staining regions. The latter derive from the insertion of the amplified genes into new chromosomal locations, which may be distant from the normal location of the involved genes; because regions containing amplified genes lack a normal banding pattern, they appear homogeneous in a G-banded karyotype. The most interesting cases of amplification involve *NMYC* in neuroblastoma and *ERBB2* in breast cancers. *NMYC* is amplified in 25% to 30% of neuroblastomas, and the amplification is associated with poor prognosis (Fig. 5–15). *HER2/NEU* (also known as *ERBB2*) amplification occurs in about 20% of breast cancers, and antibody therapy directed against this receptor has proved effective in this subset of tumors.

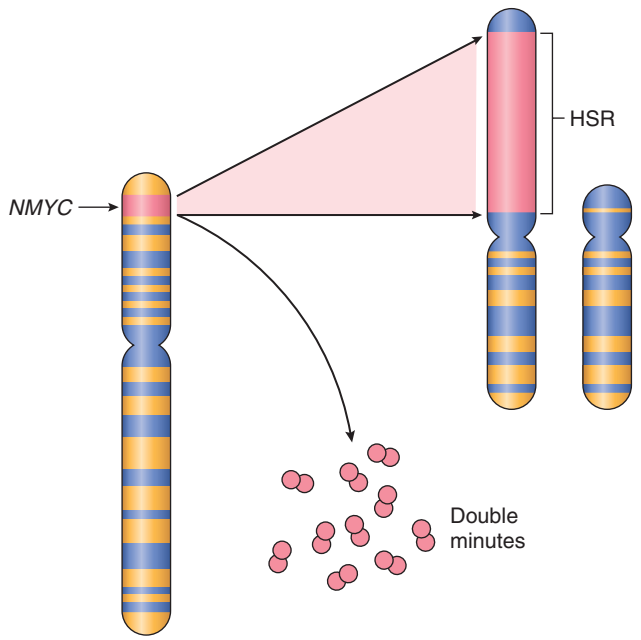


**Figure 5–15** Amplification of the *NMYC* gene in human neuroblastoma. The *NMYC* gene, present normally on chromosome 2p, becomes amplified and is seen either as extrachromosomal double minutes or as a chromosomally integrated homogeneous-staining region (HSR). The integration involves other autosomes, such as 4, 9, or 13.

*(Modified from Brodeur GM, Seeger RC, Sather H, et al: Clinical implications of oncogene activation in human neuroblastomas. Cancer 58:541, 1986. Reprinted by permission of Wiley-Liss, Inc, a subsidiary of John Wiley & Sons, Inc.)*

### *Aneuploidy*

*Aneuploidy* is defined as a number of chromosomes that is not a multiple of the haploid state; for humans that is a chromosome number that is not a multiple of 23. Aneuploidy is remarkably common in cancers, particularly carcinomas, and was proposed as a cause of carcinogenesis over 100 years ago. Aneuploidy frequently results from errors of the mitotic checkpoint, the major cell cycle control mechanism that acts to prevent chromosome missegregation. The mitotic checkpoint prevents aneuploidy by inhibiting the irreversible transition to anaphase until all of the replicated chromosomes have made productive attachments to spindle microtubules. Complete absence of the mitotic checkpoint leads to rapid cell-autonomous lethality as a consequence of massive chromosome missegregation. However, mechanistic data establishing aneuploidy as a cause of carcinogenesis, rather than a consequence, have been difficult to generate.

## MicroRNAs and Cancer

As discussed in Chapter 6, microRNAs (miRNAs) are noncoding, single-stranded RNAs, approximately 22 nucleotides in length, that function as negative regulators of genes. They inhibit gene expression posttranscriptionally by repressing translation or, in some cases, by messenger RNA (mRNA) cleavage. In view of their important function to control cell growth, differentiation, and survival, it is not surprising that accumulating evidence supports a role for miRNAs in carcinogenesis.

As illustrated in Figure 5–16, miRNAs can participate in neoplastic transformation either by increasing the expression of oncogenes or reducing the expression of tumor suppressor genes. If an miRNA inhibits the translation of an oncogene, a reduction in the quantity or function of that miRNA will lead to overproduction of the oncogene product. Conversely, if the target of a miRNA is a tumor suppressor gene, then overactivity of the miRNA can reduce the tumor suppressor protein. Such relationships have already been established by miRNA profiling of several human tumors. For example, downregulation or deletion of certain miRNAs in some leukemias and lymphomas results in increased expression of *BCL2,* the antiapoptotic gene. Thus, by negatively regulating *BCL2,* such miRNAs behave as tumor suppressor genes. Similar miRNA-mediated upregulation of the *RAS* and *MYC* oncogenes also has been detected in lung tumors and in certain B cell leukemias, respectively.

## Epigenetic Modifications and Cancer

*Epigenetics* refers to reversible, heritable changes in gene expression that occur without mutation. Such changes involve posttranslational modifications of histones and DNA methylation, both of which affect gene expression. In normal, differentiated cells, the major portion of the genome is not expressed. These regions of the genome are silenced by DNA methylation and histone modifications. On the other hand, cancer cells are characterized by a global DNA hypomethylation and selective promoter-localized hypermethylation. Indeed, it has become evident

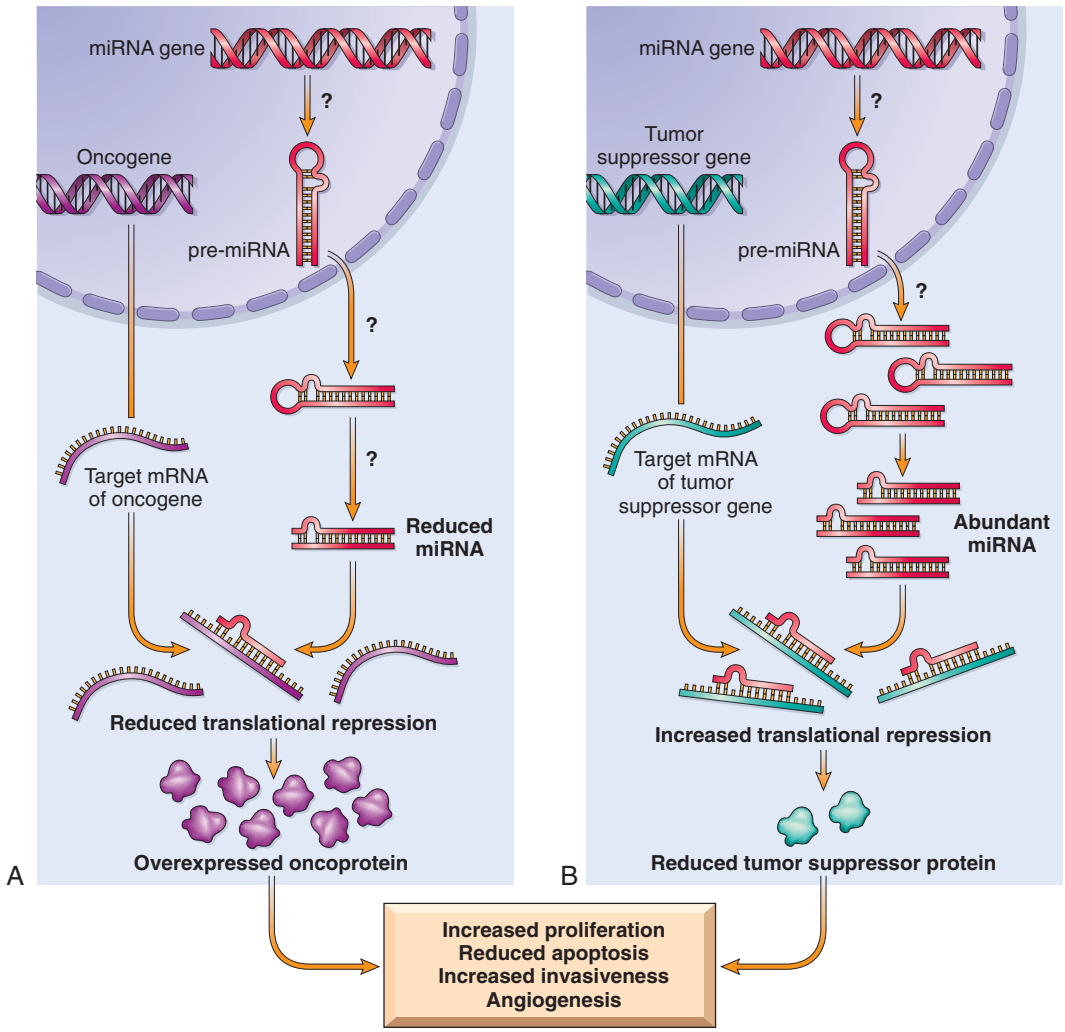


**Figure 5–16** Role of microRNAs (miRNAs) in tumorigenesis. **A,** Reduced activity of an miRNA that inhibits translation of an oncogene gives rise to an excess of oncoproteins. **B,** Overactivity of an miRNA that targets a tumor suppression gene reduces the production of the tumor suppressor protein. Question marks in **A** and **B** are meant to indicate that the mechanisms by which changes in the level or activity of miRNA are not entirely known.

during the past several years that tumor suppressor genes are sometimes silenced by hypermethylation of promoter sequences, rather than by mutation. As discussed later, CDKN2A is a complex locus that encodes two tumor suppressors, p14/ARF and p16/INK4a, produced from two different reading frames; p14/ARF is epigenetically silenced in colon and gastric cancers, while p16/INK4a is silenced in a wide variety of cancers. Since this locus produces two tumor suppressors that affect the p53 and Rb pathways, silencing this locus has the pleasing effect (from the cancer's standpoint) of removing two checkpoints with a single alteration. Genome-wide hypomethylation has been shown to cause chromosomal instability and can induce tumors in mice. Thus, epigenetic changes may influence carcinogenesis in many ways. As an added wrinkle, deep sequencing of cancer genomes has identified mutations in genes that regulate epigenetic modifications in a number of cancers. Thus, certain genetic changes in cancers may be selected for because they lead to alterations of the "epigenome" that favor cancer growth and survival.

The epigenetic state of particular cell types—a feature described as the epigenetic context—also dictates their response to signals that control growth and differentiation. As mentioned earlier, epigenetic modifications regulate gene expression, allowing cells with the same genetic make-up (e.g., a neuron and a keratinocyte) to have completely different appearances and functions. In some instances, the epigenetic state of a cell dramatically affects its response to otherwise identical signals. For example, the gene *NOTCH1* has an oncogenic role in T cell leukemia, yet acts as a tumor suppressor in squamous cell carcinomas. As it turns out, activated *NOTCH1* turns on progrowth genes in the epigenetic context of T cell progenitors (e.g., *MYC*) and tumor suppressor genes (e.g., *p21*) in the epigenetic context of keratinocytes.

## SUMMARY

### Genetic Lesions in Cancer

- Tumor cells may acquire mutations through several means, including point mutations, and nonrandom chromosomal abnormalities that contribute to malignancy; these include

balanced translocations, deletions, and cytogenetic manifestations of gene amplification.

- Balanced translocations contribute to carcinogenesis by overexpression of oncogenes or generation of novel fusion proteins with altered signaling capacity. Deletions frequently affect tumor suppressor genes, whereas gene amplification increases the expression of oncogenes.
- Overexpression of miRNAs can contribute to carcinogenesis by reducing the expression of tumor suppressors, while deletion or loss of expression of miRNAs can lead to overexpression of proto-oncogenes.
- Tumor suppressor genes and DNA repair genes also may be silenced by epigenetic changes, which involve reversible, heritable changes in gene expression that occur not by mutation but by methylation of the promoter.

## CARCINOGENESIS: A MULTISTEP PROCESS

Carcinogenesis is a multistep process resulting from the accumulation of multiple genetic alterations that collectively give rise to the transformed phenotype. Many cancers arise from non-neoplastic precursor lesions, which molecular analyses have shown already possess some of the mutations needed to establish a full-blown cancer. Presumably these mutations provide the cells of the precursor lesion with a selective advantage. Once initiated, cancers continue to undergo darwinian selection.

As discussed earlier, malignant neoplasms have several phenotypic attributes, such as excessive growth, local invasiveness, and the ability to form distant metastases. Furthermore, it is well established that over a period of time, many tumors become more aggressive and acquire greater malignant potential. This phenomenon is referred to as *tumor progression* and is not represented simply by an increase in tumor size. Careful clinical and experimental studies reveal that increasing malignancy often is acquired in an incremental fashion. At the molecular level, tumor progression and associated heterogeneity are most likely to result from multiple mutations that accumulate independently in different cells, generating subclones with different characteristics (Fig. 5–17) such as ability to invade, rate of growth, metastatic ability, karyotype, hormonal responsiveness, and susceptibility to antineoplastic drugs. Some of the mutations may be lethal; others may spur cell growth by affecting proto-oncogenes or cancer suppressor genes. *Thus even though most malignant tumors are monoclonal in origin, by the time they become clinically evident their constituent cells may be extremely heterogeneous.*

During progression, tumor cells are subjected to immune and nonimmune selection pressures. For example, cells that are highly antigenic are destroyed by host defenses, whereas those with reduced growth factor requirements are positively selected. A growing tumor, therefore, tends to be enriched for subclones that "beat the odds" and are adept at survival, growth, invasion, and metastasis. Finally, experience has shown that when tumors recur after chemotherapy, the recurrent tumor is almost always resistant to the drug regimen if it is given again. This acquired resistance, too, is a manifestation of selection, as subclones that by chance bear mutations (or perhaps epigenetic alterations) imparting drug resistance survive and are responsible for tumor regrowth. Thus, *genetic evolution and selection can explain two of the most pernicious properties of cancers: the tendency for cancers to become (1) more aggressive and (2) less responsive to therapy over time.*

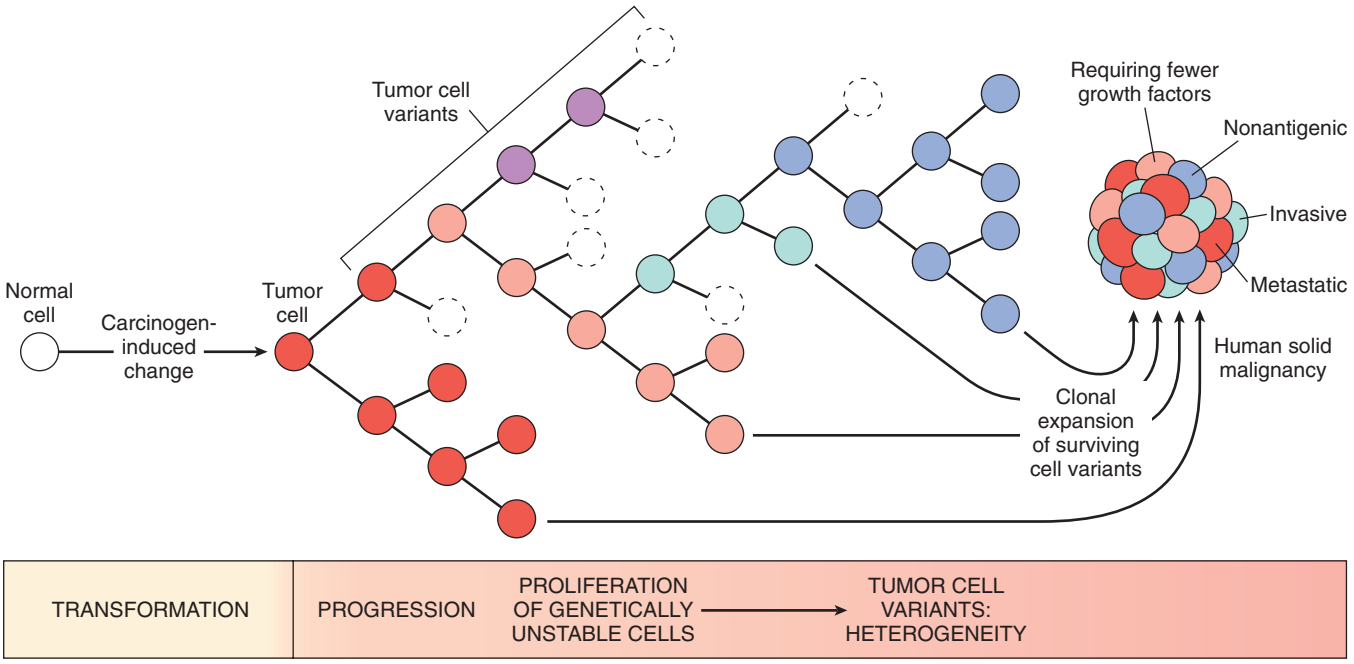


**Figure 5–17** Tumor progression and generation of heterogeneity. New subclones arise from the descendants of the original transformed cell by multiple mutations. With progression, the tumor mass becomes enriched for variants that are more adept at evading host defenses and are likely to be more aggressive.

## HALLMARKS OF CANCER

This overview serves as background for a more detailed consideration of the molecular pathogenesis of cancer and the carcinogenic agents that inflict genetic damage. In the past 30-some years, hundreds of cancer-associated genes have been discovered. Some, such as *TP53,* are commonly mutated; others, such as *ABL,* are affected only in certain leukemias. Each cancer gene has a specific function, the dysregulation of which contributes to the origin or progression of malignancy. It is best, therefore, to consider cancer-related genes in the context of several fundamental changes in cell physiology, the so-called hallmarks of cancer, which together dictate the malignant phenotype. Six of these are illustrated in Figure 5–18:

- Self-sufficiency in growth signals
- Insensitivity to growth inhibitory signals
- Evasion of cell death
- Limitless replicative potential
- Development of sustained angiogenesis
- Ability to invade and metastasize

To this list may be added two *"emerging" hallmarks* of cancer, reprogramming of energy metabolism and evasion of the immune system, and two *enabling characteristics,* genomic instability and tumor-promoting inflammation.

Mutations in genes that regulate some or all of these cellular traits are seen in every cancer; accordingly, these traits form the basis of the following discussion of the molecular origins of cancer. Of note, by convention, gene symbols are *italicized* but their protein products are not (e.g., *RB* gene and Rb protein, *TP53* and p53, *MYC* and MYC).

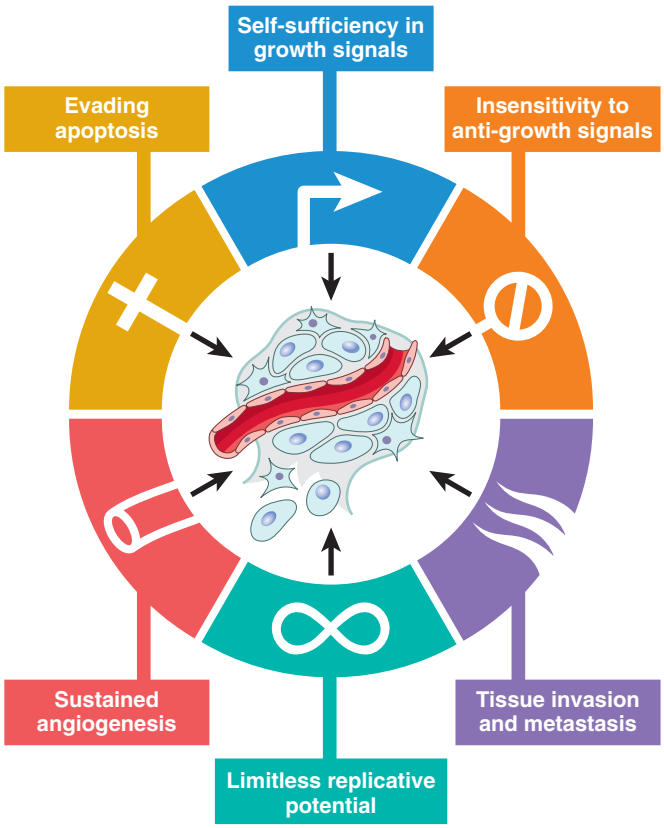


**Figure 5–18** Six hallmarks of cancer. Most cancer cells acquire these properties during their development, typically by mutations in the relevant genes.
*(From Hanahan D, Weinberg RA: The hallmarks of cancer. Cell 100:57, 2000.)*

### Self-Sufficiency in Growth Signals

Cancer cells use a number of strategies to drive their proliferation and become insensitive to normal growth regulators. To appreciate these phenomena, it is helpful to review briefly the sequence of events that characterize normal cell proliferation (introduced in Chapter 2). Under physiologic conditions, cell proliferation can be readily resolved into the following steps:

1. The binding of a growth factor to its specific receptor on the cell membrane
2. Transient and limited activation of the growth factor receptor, which in turn activates several signal-transducing proteins on the inner leaflet of the plasma membrane
3. Transmission of the transduced signal across the cytosol to the nucleus by second messengers or a cascade of signal transduction molecules
4. Induction and activation of nuclear regulatory factors that initiate and regulate DNA transcription
5. Entry and progression of the cell into the cell cycle, resulting ultimately in cell division

The mechanisms that endow cancer cells with the ability to proliferate can be grouped according to their role in the growth factor–induced signal transduction cascade and cell cycle regulation. Indeed, each one of the listed steps is susceptible to corruption in cancer cells.

#### *Growth Factors*

All normal cells require stimulation by growth factors to undergo proliferation. Most soluble growth factors are made by one cell type and act on a neighboring cell to stimulate proliferation (paracrine action). Normally, cells that produce the growth factor do not express the cognate receptor. This specificity prevents the formation of positive feedback loops within the same cell.

- Many cancer cells acquire growth self-sufficiency by acquiring the ability to synthesize the same growth factors to which they are responsive. For example, many glioblastomas secrete platelet-derived growth factor (PDGF) and express the PDGF receptor, and many sarcomas make both transforming growth factor-α (TGF-α) and its receptor. Similar autocrine loops are fairly common in many types of cancer.
- Another mechanism by which cancer cells acquire growth self-sufficiency is by interaction with stroma. In some cases, tumor cells send signals to activate normal cells in the supporting stroma, which in turn produce growth factors that promote tumor growth.

#### *Growth Factor Receptors and Non-Receptor Tyrosine Kinases*

The next group in the sequence of signal transduction is growth factor receptors, and several oncogenes that result from the overexpression or mutation of growth factor

receptors have been identified. Mutant receptor proteins deliver continuous mitogenic signals to cells, even in the absence of the growth factor in the environment. More common than mutations is overexpression of growth factor receptors, which can render cancer cells hyperresponsive to levels of the growth factor that would not normally trigger proliferation. The best-documented examples of overexpression involve the epidermal growth factor (EGF) receptor family. ERBB1, the EGF receptor, is overexpressed in 80% of squamous cell carcinomas of the lung, 50% or more of glioblastomas, and 80% to 100% of epithelial tumors of the head and neck. The gene encoding a related receptor, *HER2/NEU* (*ERBB2*), is amplified in 25% to 30% of breast cancers and adenocarcinomas of the lung, ovary, and salivary glands. These tumors are exquisitely sensitive to the mitogenic effects of small amounts of growth factors, and a high level of HER2/NEU protein in breast cancer cells is a harbinger of poor prognosis. The significance of *HER2/NEU* in the pathogenesis of breast cancers is illustrated dramatically by the clinical benefit derived from blocking the extracellular domain of this receptor with anti-*HER2/NEU* antibodies. Treatment of breast cancer with anti-HER2/NEU antibody is an elegant example of "bench to bedside" medicine.

### *Downstream Signal-Transducing Proteins*

A relatively common mechanism by which cancer cells acquire growth autonomy is mutations in genes that encode various components of the signaling pathways downstream of growth factor receptors. These signaling proteins couple growth factor receptors to their nuclear targets. They receive signals from activated growth factor receptors and transmit them to the nucleus, either through second messengers or through a cascade of phosphorylation and activation of signal transduction molecules. Two important members in this category are *RAS* and *ABL*. Each of these is discussed briefly next.

***RAS Protein.*** *RAS* is the most commonly mutated proto-oncogene in human tumors. Indeed, approximately 30% of all human tumors contain mutated versions of the *RAS* gene, and the frequency is even higher in some specific cancers (e.g., colon and pancreatic adenocarcinomas).

- RAS is a member of a family of small G proteins that bind guanosine nucleotides (guanosine triphosphate [GTP] and guanosine diphosphate [GDP]), similar to the larger trimolecular G proteins.
- Normal RAS proteins flip back and forth between an excited signal-transmitting state and a quiescent state. RAS proteins are inactive when bound to GDP; stimulation of cells by growth factors such as EGF and PDGF leads to exchange of GDP for GTP and subsequent conformational changes that generate active RAS (Fig. 5–19). This excited signal-emitting state is short-lived, however, because the intrinsic guanosine triphosphatase (GTPase) activity of RAS hydrolyzes GTP to GDP, releasing a phosphate group and returning the protein to its quiescent GDP-bound state. The GTPase activity of activated RAS protein is magnified dramatically by a family of GTPase-activating proteins (GAPs), which act as molecular brakes that prevent uncontrolled RAS activation by favoring hydrolysis of GTP to GDP.

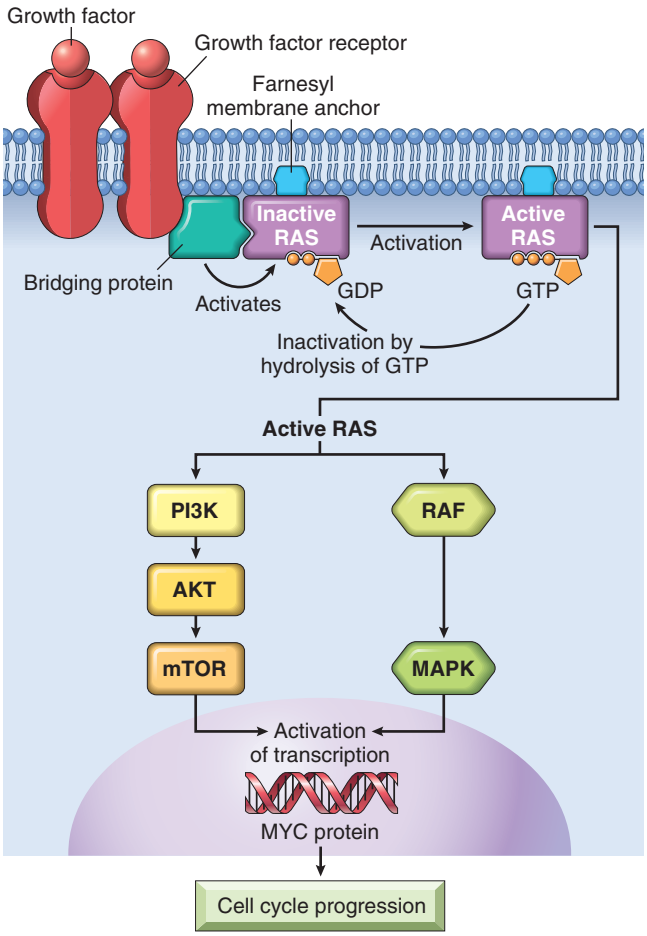


**Figure 5–19** Model for action of *RAS* genes. When a normal cell is stimulated through a growth factor receptor, inactive (GDP-bound) RAS is activated to a GTP-bound state. Activated RAS transduces proliferative signals to the nucleus along two pathways: the so-called RAF/ERK/MAP kinase pathway and the PI3 kinase/AKT pathway. GDP, guanosine diphosphate; GTP, guanosine triphosphate; MAP, mitogen-activated protein; PI3, phosphatidylinositol-3.

- The activated RAS stimulates downstream regulators of proliferation by two distinct pathways that converge on the nucleus and flood it with signals for cell proliferation. While details of the signaling cascades (some of which are illustrated in Fig. 5–19) downstream of RAS are not discussed here, an important point is that mutational activation of these "messengers" to the nucleus can mimic the growth promoting effects of activated RAS. For example, BRAF, which lies in the so-called RAF/ERK/MAP kinase pathway, is mutated in more than 60% of melanomas. Mutations of PI3 kinase in the PI3K/AKT pathway also occur with high frequency in some tumor types. Indeed, it appears that activating mutations of RAS as well as its downstream signaling molecules are very common in a wide variety of tumors.

The RAS protein most commonly is activated by point mutations in amino acid residues that are either within the GTP-binding pocket or in the enzymatic region essential for GTP hydrolysis. Both kinds of mutations interfere with GTP hydrolysis, which is essential to inactivate RAS. RAS is thus trapped in its activated, GTP-bound form, and the

cell is forced into a continuously proliferating state. It follows from this scenario that the consequences of mutations in RAS protein would be mimicked by loss-of-function mutations in the GAPs with a failure to simulate GTP hydrolysis and thereby restrain normal RAS proteins. Indeed, disabling mutation of neurofibromin-1 (NF-1), a GAP, is associated with familial neurofibromatosis type 1 (Chapter 22).

***ABL.*** In addition to *RAS,* several non–receptor-associated tyrosine kinases function as signal transduction molecules. In this group, *ABL* is the most well defined with respect to carcinogenesis.

- The *ABL* proto-oncogene has tyrosine kinase activity that is dampened by internal negative regulatory domains. In chronic myelogenous leukemia and certain acute leukemias, a part of the *ABL* gene is translocated from its normal abode on chromosome 9 to chromosome 22, where it fuses with part of the breakpoint cluster region (*BCR*) gene. The BCR-ABL hybrid protein maintains the tyrosine kinase domain; the BCR domain self-associates, a property that unleashes a constitutive tyrosine kinase activity. Of interest, there is cross-talk between BCR-ABL and RAS pathways, since BCR-ABL protein activates all of the signals that are downstream of RAS.
- The crucial role of *BCR-ABL* in transformation has been confirmed by the dramatic clinical response of patients with chronic myelogenous leukemia to BCR-ABL kinase inhibitors. The prototype of this kind of drug, imatinib mesylate (Gleevec), galvanized interest in design of drugs that target specific molecular lesions found in various cancers (so-called *targeted therapy*). BCR-ABL also is an example of the concept of *oncogene addiction,* wherein a tumor is profoundly dependent on a single signaling molecule. BCR-ABL fusion gene formation is an early, perhaps initiating, event that drives leukemogenesis. Development of leukemia probably requires other collaborating mutations, but the transformed cell continues to depend on BCR-ABL for signals that mediate growth and survival. BCR-ABL signaling can be seen as the central lodgepole around which the structure is built. If the lodgepole is removed by inhibition of the BCR-ABL kinase, the structure collapses. In view of this level of dependency, it is not surprising that acquired resistance of tumors to BCR-ABL inhibitors often is due to the outgrowth of a subclone with a mutation in BCR-ABL that prevents binding of the drug to the BCR-ABL protein.

### *Nuclear Transcription Factors*

Ultimately, all signal transduction pathways enter the nucleus and have an impact on a large bank of responder genes that orchestrate the cell's orderly advance through the mitotic cycle. Indeed, the ultimate consequence of signaling through oncoproteins such as RAS or ABL is inappropriate and continuous stimulation of nuclear transcription factors that drive the expression of growth-promoting genes. Growth autonomy may thus be a consequence of mutations affecting genes that regulate transcription of DNA. A host of oncoproteins, including products of the *MYC, MYB, JUN, FOS,* and *REL* oncogenes, function as transcription factors that regulate the expression of growth-promoting genes, such as cyclins. Of these, the *MYC* gene is involved most commonly in human tumors.

The MYC protein can either activate or repress the transcription of other genes. Those activated by MYC include several growth-promoting genes, including cyclin-dependent kinases (CDKs), whose products drive cells into the cell cycle (discussed next). Genes repressed by MYC include the *CDK* inhibitors (*CDKI*s). Thus, dysregulation of MYC promotes tumorigenesis by increasing expression of genes that promote progression through the cell cycle and repressing genes that slow or prevent progression through the cell cycle. MYC also is a key regulator of intermediate metabolism, upregulating genes that promote aerobic glycolysis (the so-called Warburg effect, described later) and the increased utilization of glutamine, two metabolic changes that are hallmarks of cancer cells. Dysregulation of the *MYC* gene resulting from a t(8;14) translocation occurs in Burkitt lymphoma, a B cell tumor. *MYC* also is amplified in breast, colon, lung, and many other cancers; the related *NMYC* and *LMYC* genes are amplified in neuroblastomas and small cell cancers of lung.

### *Cyclins and Cyclin-Dependent Kinases*

The ultimate outcome of all growth-promoting stimuli is the entry of quiescent cells into the cell cycle. Cancers may become autonomous if the genes that drive the cell cycle become dysregulated by mutations or amplification. Before further consideration of this aspect of carcinogenesis, a brief review of the normal cell cycle is warranted (Fig. 5–20).

#### The Normal Cell Cycle

Cell proliferation is a tightly controlled process that involves a large number of molecules and interrelated pathways. The replication of cells is stimulated by growth factors or by signaling from ECM components through integrins. To achieve DNA replication and division, the cell goes through a tightly controlled sequence of events known as the cell cycle. The cell cycle consists of $G_1$ (presynthetic), S (DNA synthesis), $G_2$ (premitotic), and M (mitotic) phases. Quiescent cells that have not entered the cell cycle are in the $G_0$ state. Each cell cycle phase is dependent on the proper activation and completion of the previous ones and the cycle stops at a place at which an essential gene function is deficient. Because of its central role in maintaining tissue homeostasis and regulating physiologic growth processes such as regeneration and repair, the cell cycle has multiple checkpoints, particularly during emergence from $G_0$ into $G_1$ and the transition from $G_1$ to S phase.

Cells can enter $G_1$ either from $G_0$ (quiescent cells) or after completing mitosis (continuously replicating cells). Quiescent cells must first go through the transition from $G_0$ to $G_1$, the first decision step, which functions as a gateway to the cell cycle. Cells in $G_1$ progress through the cell cycle and reach a critical stage at the $G_1$-S transition, known as a restriction point, a rate-limiting step for replication. On passing this restriction point, normal cells become irreversibly committed to DNA replication. The cell cycle is tightly controlled by activators and inhibitors.

- Progression through the cell cycle, particularly at the $G_1$-S transition, is regulated by proteins called *cyclins,* so

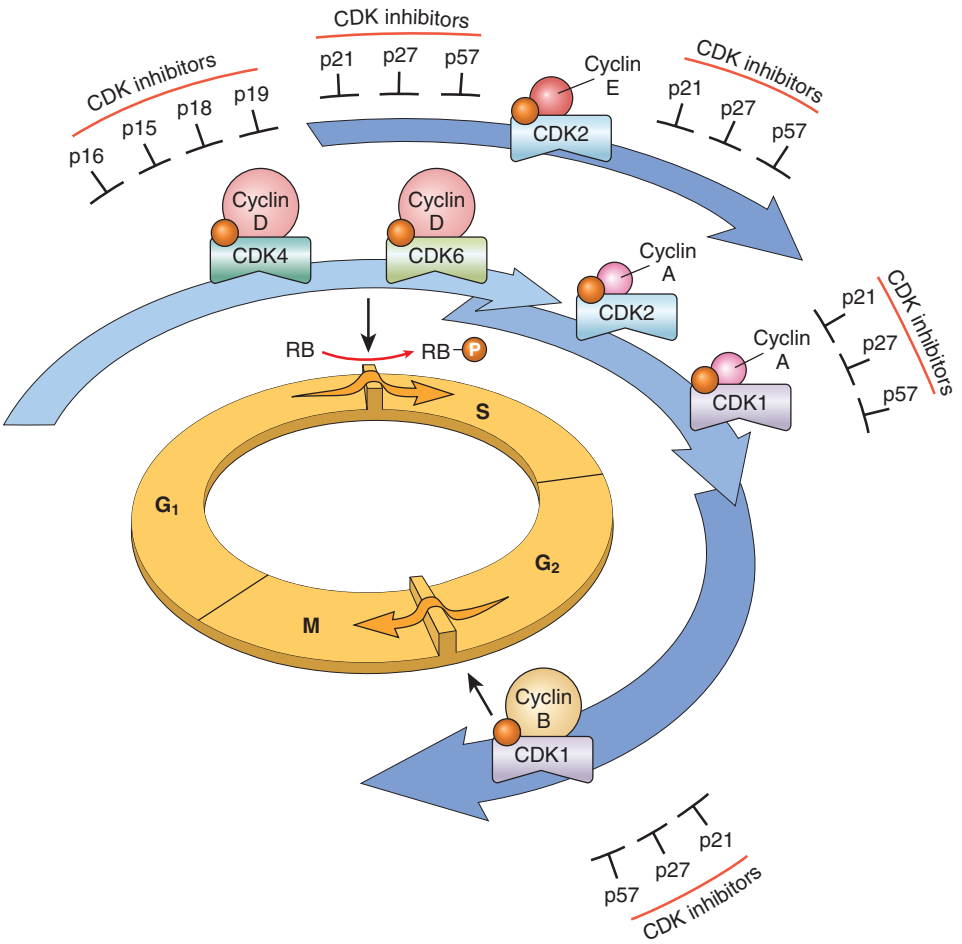


**Figure 5–20** Role of cyclins, cyclin-dependent kinases (CDKs), and CDK inhibitors in regulating the cell cycle. The *shaded arrows* represent the phases of the cell cycle during which specific cyclin–CDK complexes are active. As illustrated, cyclin D–CDK4, cyclin D–CDK6, and cyclin E–CDK2 regulate the $G_1$-to-S transition by phosphorylating the Rb protein (pRb). Cyclin A–CDK2 and cyclin A–CDK1 are active in the S phase. Cyclin B–CDK1 is essential for the $G_2$-to-M transition. Two families of CDK inhibitors can block activity of CDKs and progression through the cell cycle. The so-called INK4 inhibitors, composed of p16, p15, p18, and p19, act on cyclin D–CDK4 and cyclin D–CDK6. The other family of three inhibitors, p21, p27, and p57, can inhibit all CDKs.

called because of the cyclic nature of their production and degradation, and associated enzymes, the *cyclin-dependent kinases* (CDKs). CDKs acquire catalytic activity by binding to and forming complexes with the cyclins. The orderly progression of cells through the various phases of the cell cycle is orchestrated by CDKs, which are activated by binding to the cyclins.

- The CDK–cyclin complexes phosphorylate crucial target proteins that drive the cell through the cell cycle. On completion of this task, cyclin levels decline rapidly. More than 15 cyclins have been identified; cyclins D, E, A, and B appear sequentially during the cell cycle and bind to one or more CDKs. The cell cycle may thus be seen as a relay race in which each leg is regulated by a distinct set of cyclins: As one set of cyclins leaves the track, the next set takes over (Fig. 5–20). Activated CDKs in these complexes drive the cell cycle by phosphorylating proteins that regulate cell cycle transitions. One such protein is the retinoblastoma protein (Rb), discussed later.
- The activity of CDK–cyclin complexes is regulated by CDK inhibitors (CDKIs), which enforce cell cycle checkpoints. Embedded in the cell cycle are surveillance mechanisms that are geared to sensing damage to DNA and chromosomes. These quality control checks are called *checkpoints;* they ensure that cells with damaged DNA or chromosomes do not complete replication. The $G_1$-S checkpoint monitors the integrity of DNA before DNA replication, whereas the $G_2$-M checkpoint checks DNA after replication and monitors whether the cell can safely enter mitosis. When cells sense DNA damage, checkpoint activation delays the cell cycle and triggers DNA repair mechanisms. If DNA damage is too severe to be repaired, the cells are eliminated by apoptosis, or enter a nonreplicative state called senescence, primarily through p53-dependent mechanisms, discussed later on. Mutations in genes regulating these checkpoints allow cells with damaged DNA to divide, producing daughter cells carrying mutations.
- There are several families of CDKIs. One family, composed of three proteins called p21 (CDKN1A), p27 (CDKN1B), and p57 (CDKN1C), inhibits the CDKs broadly, whereas the other family of CDKIs has selective effects on cyclin CDK4 and cyclin CDK6. The four

members of this family—p15 (CDKN2B), p16 (CDKN2A), p18 (CDKN2C), and p19 (CDKN2D)—are sometimes called INK4 (A to D) proteins.

Alterations in Cell Cycle Control Proteins in Cancer Cells

With this background it is easy to appreciate that mutations that dysregulate the activity of cyclins and CDKs would favor cell proliferation. Indeed, all cancers appear to have genetic lesions that disable the $G_1$-S checkpoint, causing cells to continually reenter the S phase. For unclear reasons, particular lesions vary widely in frequency across tumor types.

- Mishaps increasing the expression of cyclin D or CDK4 seem to be a common event in neoplastic transformation. The cyclin D genes are overexpressed in many cancers, including those affecting the breast, esophagus, liver, and a subset of lymphomas and plasma cell tumors. Amplification of the *CDK4* gene occurs in melanomas, sarcomas, and glioblastomas. Mutations affecting cyclins B and E and other CDKs also occur, but they are much less frequent than those affecting cyclin CDK4.
- The CDKIs frequently are disabled by mutation or gene silencing in many human malignancies. Germline mutations of *CDKN2A* are present in 25% of melanoma-prone kindreds. Somatically acquired deletion or inactivation of *CDKN2A* is seen in 75% of pancreatic carcinomas, 40% to 70% of glioblastomas, 50% of esophageal cancers, and 20% of non–small cell lung carcinomas, soft tissue sarcomas, and bladder cancers.

A final consideration of importance in a discussion of growth-promoting signals is that the increased production of oncoproteins does not by itself lead to sustained proliferation of cancer cells. There are two built-in mechanisms, cell senescence and apoptosis, that oppose oncogene-mediated cell growth. As discussed later, genes that regulate these two braking mechanisms must be disabled to allow unopposed action of oncogenes.

## SUMMARY

### Oncogenes That Promote Unregulated Proliferation (Self-Sufficiency in Growth Signals)

*Proto-oncogenes:* normal cellular genes whose products promote cell proliferation

*Oncogenes:* mutant or overexpressed versions of proto-oncogenes that function autonomously without a requirement for normal growth-promoting signals

Oncoproteins promote uncontrolled cell proliferation by several mechanisms:

- Stimulus-independent expression of growth factor and its receptor, setting up an autocrine loop of cell proliferation
  - PDGF–PDGF receptor in brain tumors
- Mutations in genes encoding growth factor receptors or tyrosine kinases leading to constitutive signaling
  - EGF receptor family members, including HER2/NEU (breast, lung, and other tumors)
  - Fusion of ABL tyrosine kinase with BCR protein in certain leukemias generates a hybrid protein with constitutive kinase activity.
- Mutations in genes encoding signaling molecules
  - RAS commonly is mutated in human cancers and normally flips between resting GDP-bound state and active GTP-bound state; mutations block hydrolysis of GTP to GDP, leading to unchecked signaling.
- Overproduction or unregulated activity of transcription factors
  - Translocation of *MYC* in some lymphomas leads to overexpression and unregulated expression of its target genes controlling cell cycling and survival.
- Mutations that activate cyclin genes or inactivate negative regulators of cyclins and cyclin-dependent kinases
  - Complexes of cyclins with CDKs drive the cell cycle by phosphorylating various substrates. CDKs are controlled by inhibitors; mutations in genes encoding cyclins, CDKs, and CDK inhibitors result in uncontrolled cell cycle progression. Such mutations are found in a wide variety of cancers including melanomas, brain, lung, and pancreatic cancer.

## Insensitivity to Growth Inhibitory Signals

Isaac Newton theorized that every action has an equal and opposite reaction. Although Newton was not a cancer biologist, his formulation holds true for cell growth. Whereas oncogenes encode proteins that promote cell growth, the products of tumor suppressor genes apply brakes to cell proliferation. Disruption of such genes renders cells refractory to growth inhibition and mimics the growth-promoting effects of oncogenes. The following discussion describes tumor suppressor genes, their products, and possible mechanisms by which loss of their function contributes to unregulated cell growth.

### RB *Gene: Governor of the Cell Cycle*

It is useful to begin with the retinoblastoma gene (*RB*), the first tumor suppressor gene to be discovered and, as it happens, a prototypical representative. As with many advances in medicine, the discovery of tumor suppressor genes was accomplished by the study of a rare disease—in this case, retinoblastoma, an uncommon childhood tumor. Approximately 60% of retinoblastomas are sporadic, and the remaining ones are familial, the predisposition to develop the tumor being transmitted as an autosomal dominant trait. To account for the sporadic and familial occurrence of an identical tumor, Knudson, in 1974, proposed his now famous *two-hit* hypothesis, which in molecular terms can be stated as follows:

- Two mutations (*hits*) are required to produce retinoblastoma. These involve the *RB* gene, which has been mapped to chromosomal locus 13q14. Both of the normal alleles of the *RB* locus must be inactivated (hence the two hits) for the development of retinoblastoma (Fig. 5–21).
- In familial cases, children inherit one defective copy of the *RB* gene in the germ line; the other copy is normal.

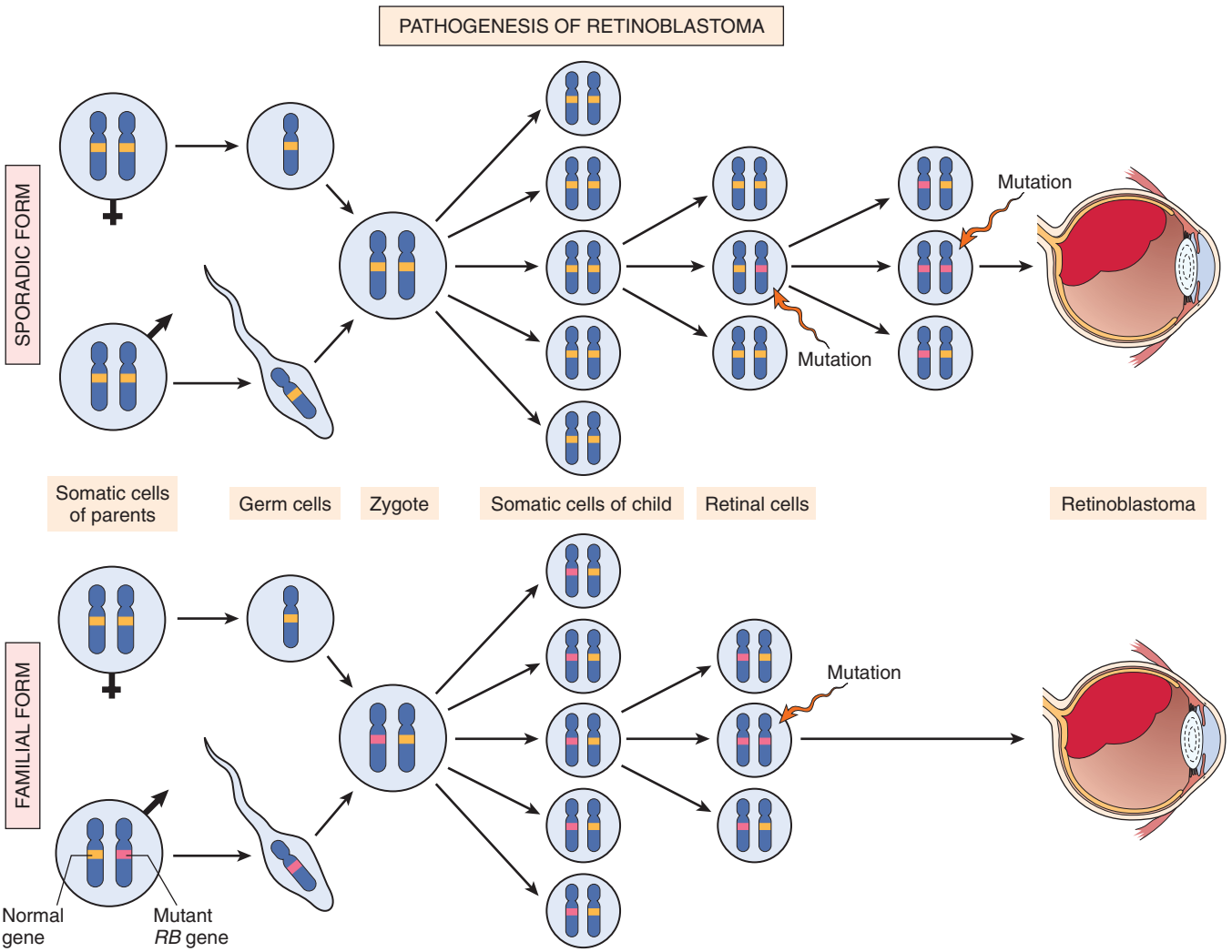


**Figure 5–21** Pathogenesis of retinoblastoma. Two mutations of the *RB* chromosomal locus, on 13q14, lead to neoplastic proliferation of the retinal cells. In the familial form, all somatic cells inherit one mutant *RB* gene from a carrier parent. The second mutation affects the *RB* locus in one of the retinal cells after birth. In the sporadic form, both mutations at the *RB* locus are acquired by the retinal cells after birth.

Retinoblastoma develops when the normal *RB* gene is lost in retinoblasts as a result of somatic mutation. Because in retinoblastoma families only a single somatic mutation is required for expression of the disease, the familial transmission follows an autosomal dominant inheritance pattern.

- In sporadic cases, both normal *RB* alleles are lost by somatic mutation in one of the retinoblasts. The end result is the same: a retinal cell that has lost both of the normal copies of the *RB* gene becomes cancerous.

Although the loss of normal *RB* genes initially was discovered in retinoblastomas, it is now evident that homozygous loss of this gene is a fairly common feature of several tumors, including breast cancer, small cell cancer of the lung, and bladder cancer. Patients with familial retinoblastoma also are at greatly increased risk for development of osteosarcomas and some soft tissue sarcomas.

At this point, some clarification of terminology is in order: A cell heterozygous at the *RB* locus is not neoplastic. Tumors develop when the cell loses its normal *RB* gene copy and thus becomes *homozygous* for the mutant allele.

In principle, antigrowth signals can prevent cell proliferation by several complementary mechanisms. The signal may cause dividing cells to enter $G_0$ (quiescence), where they remain until external cues prod their reentry into the proliferative pool. Alternatively, the cells may enter a postmitotic, differentiated pool and lose replicative potential. Nonreplicative senescence, alluded to earlier, is another escape mechanism from sustained cell growth. And, as a last-ditch effort, the cells may be programmed for death by apoptosis. As we shall see, tumor suppressor genes have all these "tricks" in their toolbox designed to halt wayward cells from becoming malignant.

The subsequent discussion of growth inhibitory mechanisms and their evasion focuses initially on the prototypical tumor suppressor gene, the *RB* gene.

## SUMMARY

### Insensitivity to Growth Inhibitory Signals

- Tumor suppressor genes encode proteins that inhibit cellular proliferation by regulating the cell cycle. Unlike oncogenes, both copies of the gene must be dysfunctional for tumor development to occur.
- In cases with familial predisposition for development of tumors, affected persons inherit one defective (nonfunctional) copy of a tumor suppressor gene and lose the second one through somatic mutation. In sporadic cases, both copies are lost through somatic mutations.

The *RB* gene product is a DNA-binding protein that is expressed in every cell type examined, where it exists in an *active hypophosphorylated state* and an *inactive hyperphosphorylated state*. The importance of Rb lies in its regulation of the $G_1$/S checkpoint, the portal through which cells must pass before DNA replication commences.

As background for an understanding of how tumor suppressors function, it is useful to briefly revisit the cell cycle: In embryos, cell divisions proceed at an amazing clip, with DNA replication beginning immediately after mitosis ends. As development proceeds, however, two gaps are incorporated into the cell cycle: gap 1 ($G_1$) between mitosis (M) and DNA replication (S), and gap 2 ($G_2$) between DNA replication (S) and mitosis (M) (Fig. 5–20). Although each phase of the cell cycle circuitry is monitored carefully, the transition from $G_1$ to S is believed to be an extremely important checkpoint in the cell cycle "clock." Once cells cross the $G_1$ checkpoint they can pause the cell cycle for a time, but they are obligated to complete mitosis. In $G_1$, however, cells can remove themselves entirely from the cell cycle, either temporarily (quiescence, or $G_0$) or permanently (senescence). Indeed, during development, as cells become terminally differentiated, they exit the cell cycle and enter $G_0$. Cells in $G_0$ remain there until external cues, such as mitogenic signaling, push them back into the cell cycle. In $G_1$, therefore, diverse signals are integrated to determine whether the cell should progress through the cell cycle, or exit the cell cycle and differentiate, and Rb is a key hub integrating external mitogenic and differentiation signals to make this decision.

*To appreciate this crucial role of Rb in the cell cycle, it is helpful to review the mechanisms that enforce the $G_1$/S transition.*

- The initiation of DNA replication (S phase) requires the activity of cyclin E/CDK2 complexes, and expression of cyclin E is dependent on the E2F family of transcription factors. Early in $G_1$, Rb is in its hypophosphorylated active form, and it binds to and inhibits the E2F family of transcription factors, preventing transcription of cyclin E. Hypophosphorylated Rb blocks E2F-mediated transcription in at least two ways (Fig. 5–22). First, it sequesters E2F, preventing it from interacting with other transcriptional activators. Second, Rb recruits chromatin remodeling proteins, such as histone deacetylases and histone methyltransferases, which bind to the promoters of E2F-responsive genes such as cyclin E. These enzymes modify chromatin at the promoters to make DNA insensitive to transcription factors.
- This situation is changed on mitogenic signaling. Growth factor signaling leads to cyclin D expression and activation of cyclin D–CDK4/6 complexes. These complexes phosphorylate Rb, inactivating the protein and releasing E2F to induce target genes such as cyclin E. Expression of cyclin E then stimulates DNA replication and progression through the cell cycle. When the cells enter S phase, they are committed to divide without additional growth factor stimulation. During the ensuing M phase, the phosphate groups are removed from Rb by cellular phosphatases, regenerating the hypophosphorylated form of Rb.
- E2F is not the sole target of Rb. The versatile Rb protein binds to a variety of other transcription factors that regulate cell differentiation. For example, Rb stimulates myocyte-, adipocyte-, melanocyte-, and macrophage-specific transcription factors. Thus, the Rb pathway couples control of cell cycle progression at $G_0$-$G_1$ with differentiation, which may explain how differentiation is associated with exit from the cell cycle.

In view of the centrality of Rb to the control of the cell cycle, an interesting question is why *RB* is not mutated in every cancer. In fact, mutations in other genes that control Rb phosphorylation can mimic the effect of *RB* loss; such genes are mutated in many cancers that seem to have normal *RB* genes. For example, mutational activation of CDK4 or overexpression of cyclin D favors cell proliferation by facilitating Rb phosphorylation and inactivation. Indeed, cyclin D is overexpressed in many tumors because of gene amplification or translocation. Mutational inactivation of CDKIs also would drive the cell cycle by unregulated activation of cyclins and CDKs. As mentioned earlier, the *CDKN2A* gene is an extremely common target of deletion or mutational inactivation in human tumors.

*The emerging paradigm is that loss of normal cell cycle control is central to malignant transformation and that at least one of the four key regulators of the cell cycle (CDKN2A, cyclin D, CDK4, Rb) is mutated in most human cancers.* Furthermore, the transforming proteins of several oncogenic human DNA viruses act, in part, by neutralizing the growth inhibitory activities of Rb. For example, the human papillomavirus (HPV) E7 protein binds to the hypophosphorylated form of Rb, preventing it from inhibiting the E2F transcription factors. Thus, Rb is functionally deleted, leading to uncontrolled growth.

## SUMMARY

### *RB* Gene: Governor of the Cell Cycle

- Rb exerts antiproliferative effects by controlling the $G_1$-to-S transition of the cell cycle. In its active form, Rb is hypophosphorylated and binds to E2F transcription factor. This interaction prevents transcription of genes like cyclin E that are needed for DNA replication, and so the cells are arrested in $G_1$.
- Growth factor signaling leads to cyclin D expression, activation of the cyclin D–CDK4/6 complexes, inactivation of Rb by phosphorylation, and thus release of E2F.
- Loss of cell cycle control is fundamental to malignant transformation. Almost all cancers have a disabled $G_1$

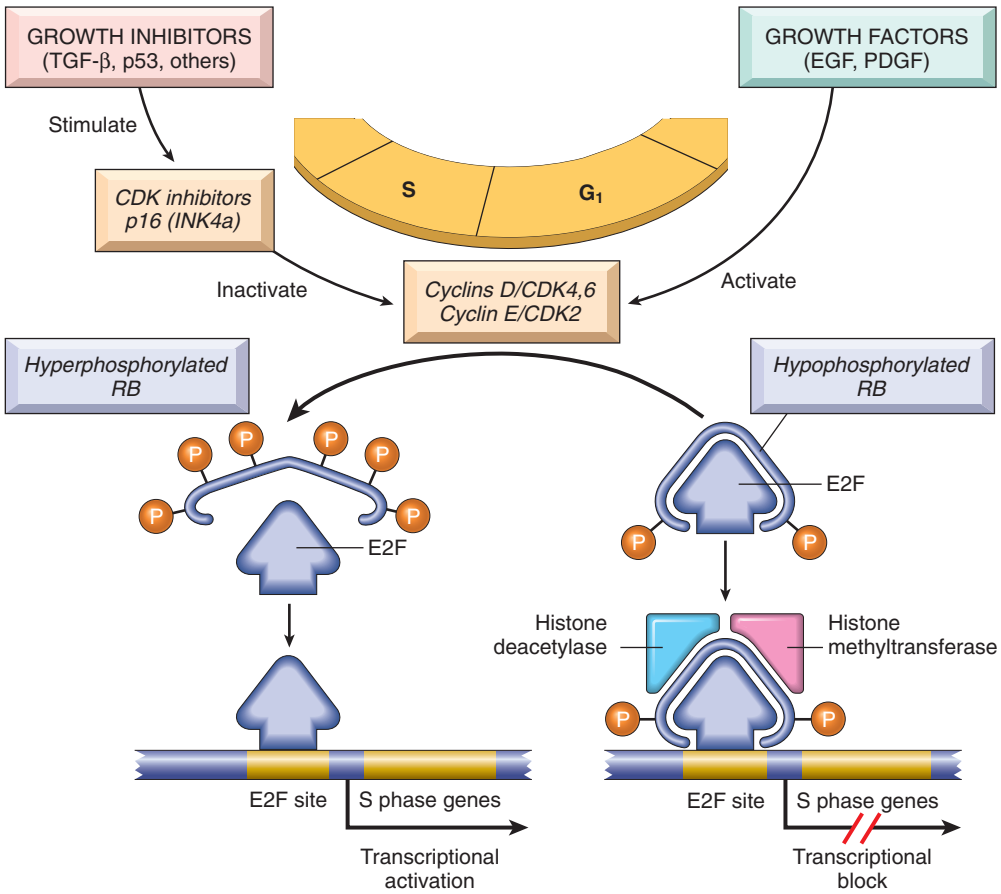


**Figure 5–22** The role of Rb in regulating the $G_1$–S checkpoint of the cell cycle. Hypophosphorylated Rb in complex with the E2F transcription factors binds to DNA, recruits chromatin remodeling factors (histone deacetylases and histone methyltransferases), and inhibits transcription of genes whose products are required for the S phase of the cell cycle. When Rb is phosphorylated by the cyclin D–CDK4, cyclin D–CDK6, and cyclin E–CDK2 complexes, it releases E2F. The latter then activates transcription of S-phase genes. The phosphorylation of Rb is inhibited by CDKIs, because they inactivate cyclin-CDK complexes. Virtually all cancer cells show dysregulation of the $G_1$–S checkpoint as a result of mutation in one of four genes that regulate the phosphorylation of Rb; these genes are *RB*, *CDK4*, *cyclin D*, and *CDKN2A [p16]*. EGF, epidermal growth factor; PDGF, platelet-derived growth factor.

checkpoint due to mutation of either *RB* or genes that affect Rb function, such as cyclin D, CDK4, and CDKIs.

- Many oncogenic DNA viruses, like HPV, encode proteins (e.g., E7) that bind to Rb and render it nonfunctional.

## TP53 *Gene: Guardian of the Genome*

The p53-encoding tumor suppressor gene, *TP53,* is one of the most commonly mutated genes in human cancers. The p53 protein thwarts neoplastic transformation by three interlocking mechanisms: activation of temporary cell cycle arrest (termed quiescence), induction of permanent cell cycle arrest (termed senescence), or triggering of programmed cell death (termed apoptosis). If Rb "senses" external signals, p53 can be viewed as a central monitor of internal stress, directing the stressed cells toward one of these three pathways.

A variety of stresses trigger the p53 response pathways, including anoxia, inappropriate oncoprotein activity (e.g., MYC or RAS), and damage to the integrity of DNA. By managing the DNA damage response, p53 plays a central role in maintaining the integrity of the genome, as described next.

In nonstressed, healthy cells, p53 has a short half-life (20 minutes) because of its association with MDM2, a protein that targets p53 for destruction. When the cell is stressed, for example, by an assault on its DNA, "sensors" that include protein kinases such as ATM (ataxia telangiectasia mutated) are activated. These activated complexes catalyze post-translational modifications in p53 that release it from MDM2 and increase its half-life and enhance its ability to drive the transcription of target genes. Hundreds of genes whose transcription is triggered by p53 have been found. These genes suppress neoplastic transformation by three mechanisms:

- *p53-mediated cell cycle arrest may be considered the primordial response to DNA damage* (Fig. 5–23). It occurs late in the $G_1$ phase and is caused mainly by p53-dependent transcription of the CDKI gene *CDKN1A (p21).* The p21 protein, as described earlier, inhibits cyclin–CDK complexes and prevents phosphorylation of Rb, thereby arresting cells in the $G_1$ phase. Such a pause in cell cycling is welcome, because it gives the cells "breathing time" to repair DNA damage. The p53 protein also

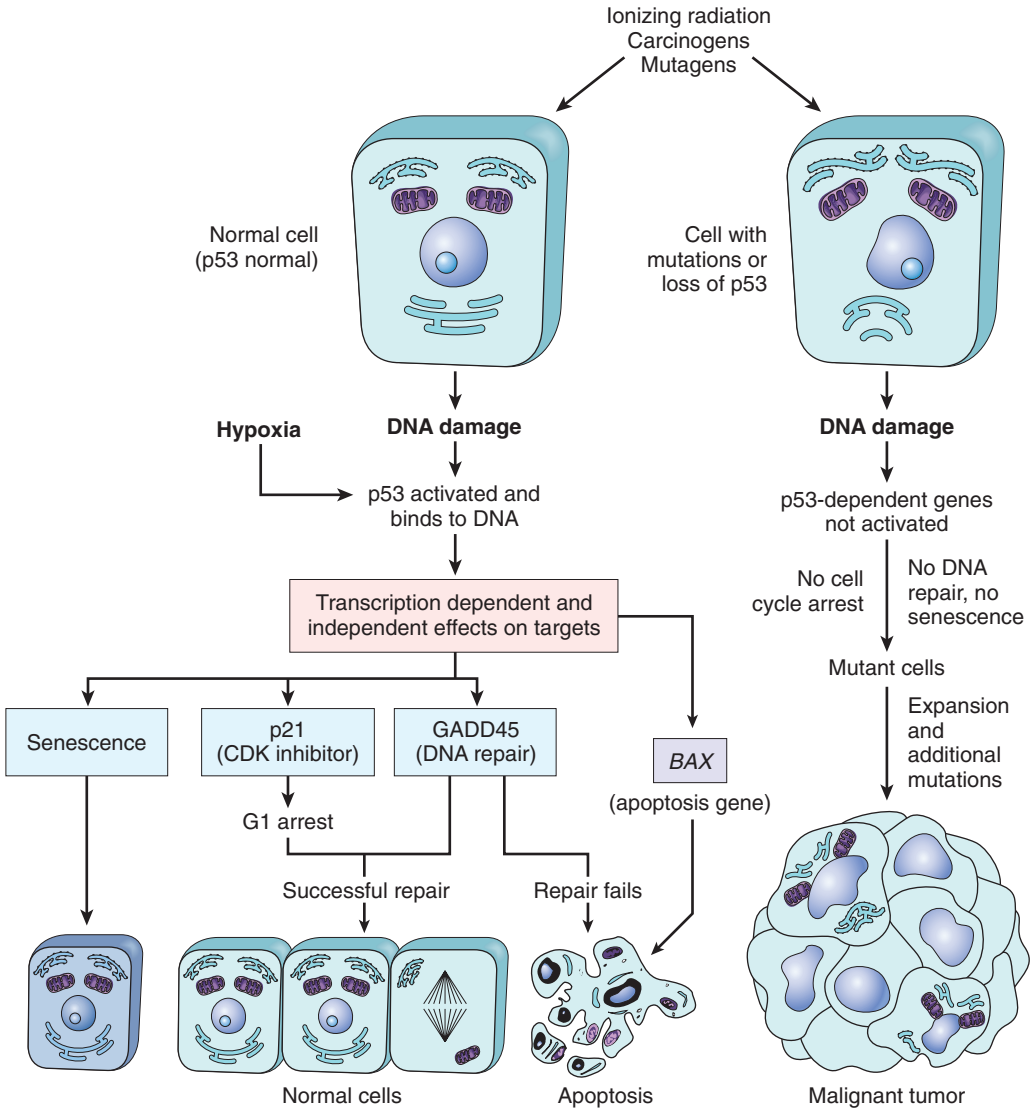


**Figure 5–23** The role of p53 in maintaining the integrity of the genome. Activation of normal p53 by DNA-damaging agents or by hypoxia leads to cell cycle arrest in $G_1$ and induction of DNA repair, by transcriptional upregulation of the cyclin-dependent kinase inhibitor *CDKN1A* (p21) and the *GADD45* genes. Successful repair of DNA allows cells to proceed with the cell cycle; if DNA repair fails, p53 triggers either apoptosis or senescence. In cells with loss or mutations of *TP53*, DNA damage does not induce cell cycle arrest or DNA repair, and genetically damaged cells proliferate, giving rise eventually to malignant neoplasms.

induces expression of DNA damage repair genes. If DNA damage is repaired successfully, p53 upregulates transcription of MDM2, leading to destruction of p53 and relief of the cell cycle block. If the damage cannot be repaired, the cell may enter p53-induced senescence or undergo p53-directed apoptosis.

- *p53-induced senescence is a permanent cell cycle arrest* characterized by specific changes in morphology and gene expression that differentiate it from quiescence or reversible cell cycle arrest. Senescence requires activation of p53 and/or Rb and expression of their mediators, such as the CDKIs. The mechanisms of senescence are unclear but seem to involve global chromatin changes, which drastically and permanently alter gene expression.
- *p53-induced apoptosis of cells with irreversible DNA damage is the ultimate protective mechanism against neoplastic transformation.* It is mediated by several pro-apoptotic genes such as *BAX* and *PUMA* (described later).

Until recently it was thought that these functions of p53 were mediated exclusively by transcriptional activation of genes with antiproliferative, apoptotic, and senescence-inducing functions, as discussed earlier. But the waters were muddied when it was discovered that p53 represses a subset of pro-proliferative and anti-apoptotic genes as well. How could p53, a transcriptional activator, repress gene function? The answer came from the discovery that p53 can transcriptionally activate certain miRNAs (the "small guys with big clubs"). As discussed in Chapter 6, miRNAs can prevent translation of their target genes. The miRNAs activated by p53 can inhibit the translation of pro-proliferative genes such as cyclins and anti-apoptotic genes such as *BCL2*.

*To summarize, p53 is activated by stresses such as DNA damage and assists in DNA repair by causing $G_1$ arrest and inducing DNA repair genes.* A cell with damaged DNA that cannot be repaired is directed by *p53 to either enter senescence or undergo apoptosis* (Fig. 5–25). In view of these activities, *p53 has been rightfully called the "guardian of the genome."* With homozygous loss of the *TP53* gene, DNA damage goes unrepaired, mutations become fixed in dividing cells, and the cell turns onto a one-way street leading to malignant transformation.

Confirming the importance of *TP53* in controlling carcinogenesis, more than 70% of human cancers have a defect in this gene, and the remaining malignant neoplasms have defects in genes upstream or downstream of *TP53.* Biallelic loss of the *TP53* gene is found in virtually every type of cancer, including carcinomas of the lung, colon, and breast—the three leading causes of cancer deaths. In most cases, inactivating mutations affecting both *TP53* alleles are acquired in somatic cells. Less commonly, some patients inherit a mutant *TP53* allele; the resulting disease is called the *Li-Fraumeni syndrome.* As with the *RB* gene, inheritance of one mutant allele predisposes affected persons to develop malignant tumors because only one additional hit is needed to inactivate the second, normal allele. Patients with the Li-Fraumeni syndrome have a 25-fold greater chance of developing a malignant tumor by age 50 compared with the general population. In contrast with tumors developing in patients who inherit a mutant *RB* allele, the spectrum of tumors that develop in patients with the Li-Fraumeni syndrome is varied; the most common types are sarcomas, breast cancer, leukemia, brain tumors, and carcinomas of the adrenal cortex. Compared with persons diagnosed with sporadic tumors, patients with Li-Fraumeni syndrome develop tumors at a younger age and may develop multiple primary tumors.

As with Rb protein, normal p53 also can be rendered nonfunctional by certain DNA viruses. Proteins encoded by oncogenic HPVs, hepatitis B virus (HBV), and possibly Epstein-Barr virus (EBV) can bind to normal p53 and nullify its protective function. Thus, DNA viruses can subvert two of the best-understood tumor suppressors, Rb and p53.

## SUMMARY

### *TP53* Gene: Guardian of the Genome

- The p53 protein is the central monitor of stress in the cell and can be activated by anoxia, inappropriate oncogene signaling, or DNA damage. Activated p53 controls the expression and activity of genes involved in cell cycle arrest, DNA repair, cellular senescence, and apoptosis.
- DNA damage leads to activation of p53 by phosphorylation. Activated p53 drives transcription of *CDKN1A (p21)*, which prevents Rb phosphorylation, thereby causing a $G_1$-S block in the cell cycle. This pause allows the cells to repair DNA damage.
- If DNA damage cannot be repaired, p53 induces cellular senescence or apoptosis.
- Of human tumors, 70% demonstrate biallelic loss of *TP53*. Patients with the rare Li-Fraumeni syndrome inherit one defective copy in the germ line and lose the second one in somatic tissues; such persons develop a variety of tumors.
- As with Rb, p53 can be incapacitated by binding to proteins encoded by oncogenic DNA viruses such as HPV.

### *Transforming Growth Factor-β Pathway*

Although much is known about the circuitry that applies brakes to the cell cycle, the molecules that transmit antiproliferative signals to cells are less well characterized. Best-known is TGF-β, a member of a family of dimeric growth factors that includes bone morphogenetic proteins and activins. In most normal epithelial, endothelial, and hematopoietic cells, TGF-β is a potent inhibitor of proliferation. It regulates cellular processes by binding to a complex composed of TGF-β receptors I and II. Dimerization of the receptor upon ligand binding leads to a cascade of events that result in the transcriptional activation of CDKIs with growth-suppressing activity, as well as repression of growth-promoting genes such as *MYC, CDK2, CDK4,* and those encoding cyclins A and E.

In many forms of cancer, the growth-inhibiting effects of the TGF-β pathways are impaired by mutations affecting TGF-β signaling. These mutations may alter the type II TGF-β receptor or SMAD molecules that serve to transduce antiproliferative signals from the receptor to the nucleus. Mutations affecting the type II receptor are seen in cancers of the colon, stomach, and endometrium. Mutational inactivation of SMAD4, 1 of the 10 proteins known to be involved in TGF-β signaling, is common in pancreatic cancers. *In 100% of pancreatic cancers and 83% of colon cancers, at least one component of the TGF-β pathway is mutated.* In many cancers, however, loss of TGF-β–mediated growth control occurs at a level downstream of the core signaling pathway, for example, loss of p21 and/or persistent expression of MYC. These tumor cells can then use other elements of the TGF-β–induced program, including immune system suppression–evasion or promotion of angiogenesis, to facilitate tumor progression. Thus, TGF-β can function to prevent or promote tumor growth, depending on the state of other genes in the cell. Indeed, in many late-stage tumors, TGF-β signaling activates epithelial-to-mesenchymal transition (EMT), a process that promotes migration, invasion, and metastasis, as described later.

### *Contact Inhibition,* NF2, *and APC*

When nontransformed cells are grown in culture, they proliferate until confluent monolayers are generated; cell–cell contacts formed in these monolayers suppress further cell proliferation. Of importance, "contact inhibition" is abolished in cancer cells, allowing them to pile on top of one another. The mechanisms that govern contact inhibition are only now being discovered. Cell–cell contacts in many tissues are mediated by homodimeric interactions between transmembrane proteins called cadherins. E-cadherin (E for epithelial) mediates cell–cell contact in epithelial layers. How E-cadherin maintains normal contact inhibition is not fully understood. One mechanism that sustains contact inhibition is mediated by the tumor suppressor gene *NF2*. Its product, neurofibromin-2, more commonly called

merlin, facilitates E-cadherin mediated contact inhibition. Homozygous loss of *NF2* is known to cause a form of neural tumors associated with the condition called neurofibromatosis.

There are other mechanisms of E-cadherin regulation as well. One such mechanism is illustrated by the rare hereditary disease *adenomatous polyposis coli* (APC). This disorder is characterized by the development of numerous adenomatous polyps in the colon that have a very high incidence of transformation into colonic cancers. They consistently show loss of a tumor suppressor gene called *APC* (named for the disease). The *APC* gene exerts antiproliferative effects in an unusual manner. It encodes a cytoplasmic protein whose dominant function is to regulate the intracellular levels of β-catenin, a protein with many functions. On the one hand, β-catenin binds to the cytoplasmic portion of E-cadherin; on the other hand, it can translocate to the nucleus and activate cell proliferation. Here the focus is on the latter function of this protein. β-Catenin is an important component of the so-called WNT signaling pathway that regulates cell proliferation (illustrated in Fig. 5–24). WNT is a soluble factor that can induce cellular proliferation. It does so by binding to its receptor and transmitting signals that prevent the degradation of β-catenin, allowing it to translocate to the nucleus, where it acts as a transcriptional activator in conjunction with another molecule, called TcF (Fig. 5–24, *B*). In quiescent cells, which are not exposed to WNT, cytoplasmic β-catenin is degraded by a *destruction complex,* of which APC is an integral part (Fig. 5–24, *A*). With loss of APC (in malignant cells), β-catenin degradation is prevented, and the WNT signaling response is inappropriately activated in the absence of WNT (Fig. 5–24, *C*). This leads to transcription of growth-promoting genes, such as cyclin D1 and *MYC,* as well as transcriptional regulators, such as TWIST and SLUG, that repress E-cadherin expression and thus reduce contact inhibition.

*APC* behaves as a typical tumor suppressor gene. Persons born with one mutant allele typically are found to have hundreds to thousands of adenomatous polyps in the colon by their teens or 20s; these polyps show loss of the other *APC* allele. Almost invariably, one or more polyps undergo malignant transformation, as discussed later. *APC* mutations are seen in 70% to 80% of sporadic colon cancers. Colonic cancers that have normal *APC* genes show activating mutations of β-catenin that render them refractory to the degrading action of APC.

## SUMMARY

### Transforming Growth Factor-β and APC–β-Catenin Pathways

- TGF-β inhibits proliferation of many cell types by activation of growth-inhibiting genes such as CDKIs and suppression of growth-promoting genes such as *MYC* and those encoding cyclins.

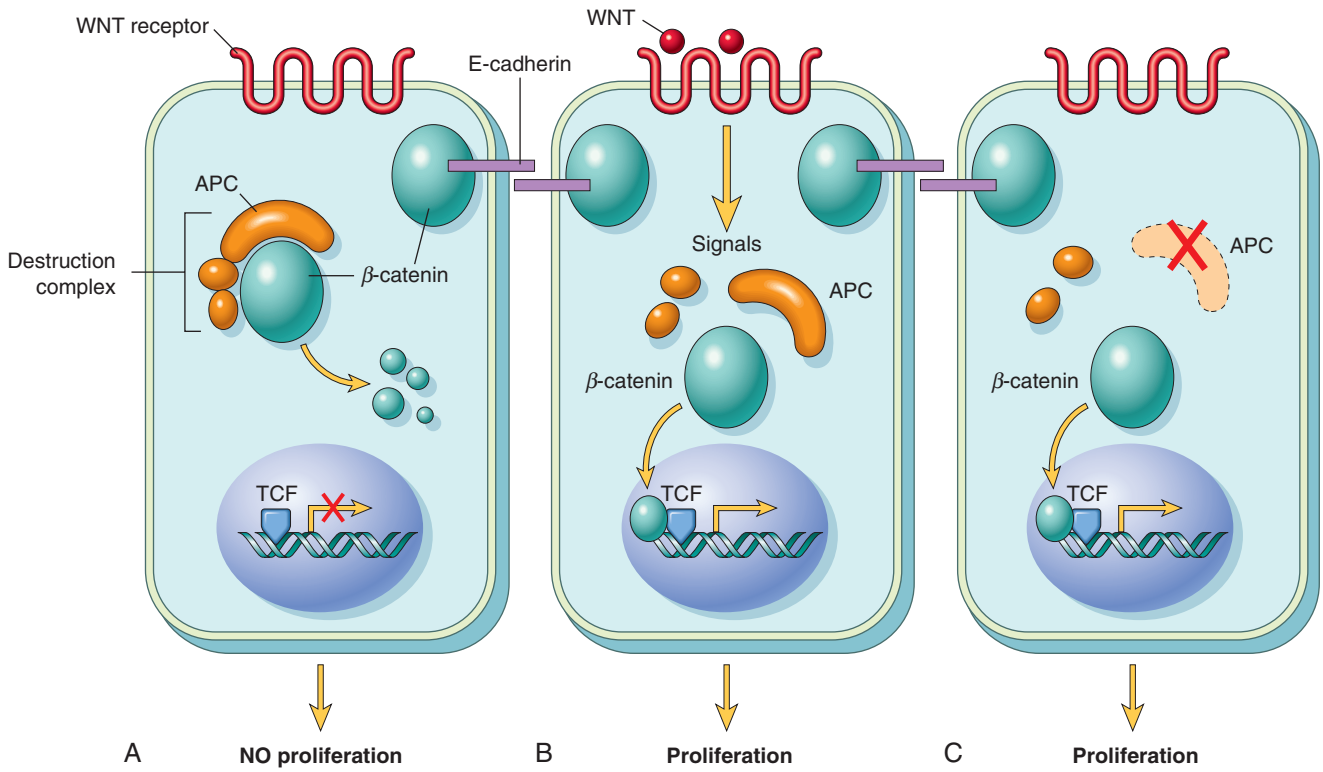


**Figure 5–24 A–C,** The role of APC in regulating the stability and function of β-catenin. APC and β-catenin are components of the WNT signaling pathway. In resting cells (not exposed to WNT), β-catenin forms a macromolecular complex containing the APC protein. This complex leads to the destruction of β-catenin, and intracellular levels of β-catenin are low. When cells are stimulated by secreted WNT molecules, the *destruction complex* is deactivated, β-catenin degradation does not occur, and cytoplasmic levels increase. β-Catenin translocates to the nucleus, where it binds to TCF, a transcription factor that activates several genes involved in the cell cycle. When APC is mutated or absent, the destruction of β-catenin cannot occur. β-Catenin translocates to the nucleus and coactivates genes that promote the cell cycle, and cells behave as if they are under constant stimulation by the WNT pathway.

- TGF-β function is compromised in many tumors by mutations in its receptors (colon, stomach, endometrium) or by mutational inactivation of *SMAD* genes that transduce TGF-β signaling (pancreas).
- E-cadherin maintains contact inhibition, which is lost in malignant cells.
- *APC* gene exerts antiproliferative actions by regulating the destruction of the cytoplasmic protein β-catenin. With a loss of *APC*, β-catenin is not destroyed, and it translocates to the nucleus, where it acts as a growth-promoting transcription factor.
- In familial adenomatous polyposis syndrome, inheritance of a germ line mutation in the *APC* gene and sporadic loss of the sole normal allele causes the development of hundreds of colonic polyps at a young age. Inevitably, one or more of these polyps evolves into a colonic cancer. Somatic loss of both alleles of the *APC* gene is seen in approximately 70% of sporadic colon cancers.

## Evasion of Cell Death

As discussed in Chapter 1, apoptosis, or programmed cell death, refers to an orderly dismantling of cells into component pieces that can then be consumed and disposed of by neighboring cells. *It is now well established that accumulation of neoplastic cells may result not only from activation of growth-promoting oncogenes or inactivation of growth-suppressing tumor suppressor genes but also from mutations in the genes that regulate apoptosis.*

The apoptotic pathway can be divided into upstream regulators and downstream effectors. The regulators are divided into two major pathways, one interpreting extracellular or extrinsic signals and the other interpreting intracellular signals. Stimulation of either pathway results in activation of a normally inactive protease (caspase-8 or caspase-9, respectively), which initiates a proteolytic cascade involving "executioner" caspases that disassemble the cell in orderly fashion. The cellular remains are then efficiently consumed by the cellular neighbors and professional phagocytes, without stimulating inflammation. Figure 5–25 shows, in simplified form, the sequence of events that lead to apoptosis by signaling through death receptors, which are members of the TNF receptor family (extrinsic pathway), and by DNA damage and other stresses (intrinsic pathway).

- The extrinsic (death receptor) pathway is initiated when a TNF receptor, such as CD95 (Fas), is bound to its ligand, CD95L, leading to trimerization of the receptor and its cytoplasmic *death domains,* which attract the intracellular adaptor protein FADD. This protein recruits procaspase-8 to form the death-inducing signaling complex. Procaspase-8 is activated by cleavage into smaller subunits, generating caspase-8. Caspase-8 then activates downstream caspases such as caspase-3, an *executioner caspase* that cleaves DNA and other substrates to cause cell death.
- The intrinsic (mitochondrial) pathway of apoptosis is triggered by a variety of stimuli, including withdrawal of survival factors, stress, and injury. Activation of this pathway leads to permeabilization of the mitochondrial outer membrane and release of molecules, such as cytochrome c, that initiate apoptosis.

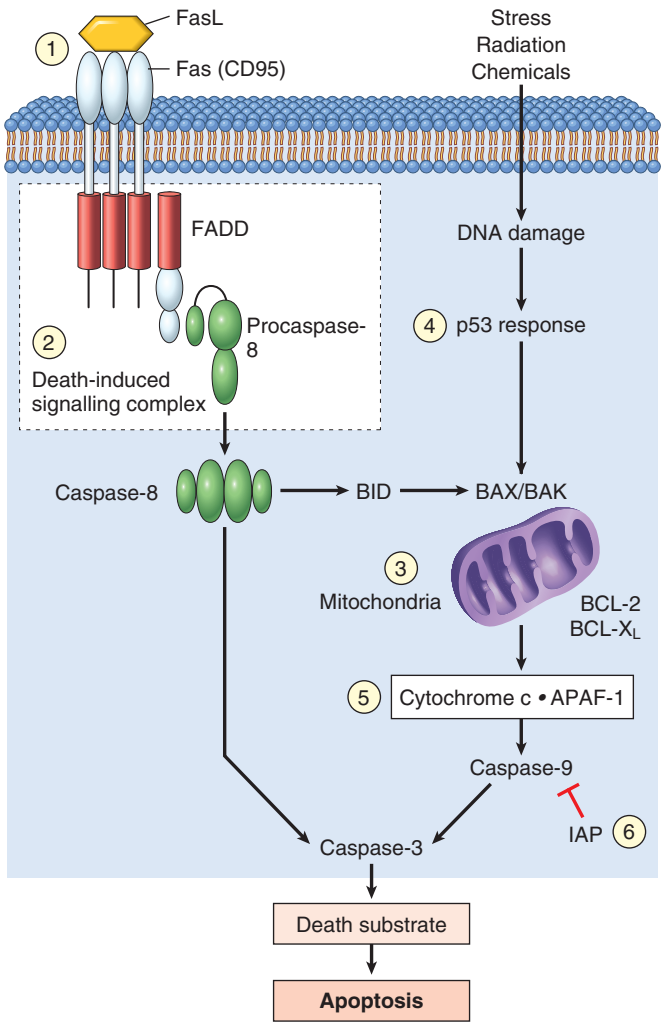


**Figure 5–25** Simplified schema of CD95 receptor–induced and DNA damage–triggered pathways of apoptosis and mechanisms used by tumor cells to evade cell death: *1*, Reduced CD95 level. *2*, Inactivation of death-induced signaling complex by FLICE protein. *3*, Reduced egress of cytochrome c from mitochondrion as a result of upregulation of BCL2. *4*, Reduced levels of pro-apoptotic BAX resulting from loss of p53. *5*, Loss of APAF-1. *6*, Upregulation of inhibitors of apoptosis.

The integrity of the mitochondrial outer membrane is regulated by pro-apoptotic and anti-apoptotic members of the BCL2 family of proteins. The pro-apoptotic proteins BAX and BAK are required for apoptosis and directly promote mitochondrial permeabilization. Their action is inhibited by the anti-apoptotic members of this family exemplified by BCL2 and BCL-$X_L$. A third set of proteins, the so-called BH3-only proteins, which include BAD, BID, and PUMA, regulate the balance between the pro- and anti-apoptotic members of the BCL2 family. The BH3-only proteins promote apoptosis by neutralizing the actions of anti-apoptotic proteins like BCL2 and BCL-$X_L$. When the sum total of all BH3 proteins expressed "overwhelms" the anti-apoptotic BCL2/BCL$X_L$ protein barrier, BAX and BAK are activated and form pores in the mitochondrial membrane. Cytochrome c leaks into the cytosol, where it binds to APAF-1 and

activates caspase-9. Like caspase-8 of the extrinsic pathway, caspase-9 can cleave and activate the executioner caspases. Caspases can be inhibited by a family of proteins called inhibitor of apoptosis proteins (IAPs). Because of the pro-apoptotic effect of BH3 only proteins, efforts are underway to develop BH3 mimetic drugs to promote death of tumor cells.

Within this framework, it is possible to illustrate the multiple sites at which apoptosis is frustrated by cancer cells (Fig. 5–25). Of these candidates, perhaps *best-established is the role of BCL2 in protecting tumor cells from apoptosis.* Approximately 85% of B cell lymphomas of the follicular type (Chapter 11) carry a characteristic t(14;18) (q32;q21) translocation. As noted earlier, 14q32, the chromosomal locus for immunoglobulin heavy-chain genes, also is involved in the pathogenesis of Burkitt lymphoma. Juxtaposition of this transcriptionally active locus with *BCL2* (located at 18q21) causes overexpression of the BCL2 protein. This overabundance in turn increases the BCL2/BCL-$X_L$ buffer, protecting lymphocytes from apoptosis and allowing them to survive for long periods; there is therefore a steady accumulation of B lymphocytes, resulting in lymphadenopathy and marrow infiltration. Because BCL2-overexpressing lymphomas arise in large part through reduced cell death rather than explosive cell proliferation, they tend to be indolent (slow-growing) compared to other lymphomas. In some instances, reduced levels of CD95 may render the tumor cells less susceptible to apoptosis by Fas ligand (FasL). Some tumors have high levels of FLIP, a protein that can bind death-inducing signaling complex and prevent activation of caspase 8.

As mentioned previously, *TP53 is an important pro-apoptotic gene that induces apoptosis in cells that are unable to repair DNA damage.* Similarly, unrestrained action of growth-promoting genes such as *MYC* also leads to apoptosis. Thus, both major oncogenic pathways—inability to repair DNA damage and inappropriate activation of oncogenes—converge on the apoptotic machinery, which, by causing cell death, acts as a major barrier to carcinogenesis.

### *Autophagy*

As described in Chapter 1, autophagy is a key catabolic process that helps balance synthesis, degradation, and recycling of cellular products. During autophagy, cellular organelles, such as ribosomes and mitochondria, are sequestered from the rest of the cell by a membrane (autophagosome) and then fused to a lysosome, where they are degraded and utilized for cellular energy generation. The same process can signal cells to die if they cannot be rescued by the recycling of organelles. It is a tightly regulated process that plays an important role in normal cell function, and can help starving cells shift nutrients from unused cell processes to vital ones. Autophagy, like apoptosis, has regulatory and effector machinery. The effector components consist of proteins that lead to the formation of autophagosomes and direct their contents to lysosomes. Not surprisingly, the regulatory components of autophagy overlap with many of the signaling components that regulate apoptosis. For example, a protein, Beclin-1, required for autophagy, belongs to the BH3 domain containing proteins that regulate apoptosis. When cells sense internal stress (e.g., DNA damage), they may undergo apoptosis or Beclin-1–induced autophagy. Thus, autophagy, by analogy with apoptosis, appears to prevent the growth of tumor cells. Later in tumor growth, however, autophagy may be helpful to tumors. The metabolites generated by autophagy may supply crucial building blocks for growth and survival in the nutrient-poor environments that tumor cells inhabit. Indeed, autophagy may promote tumor survival in unfriendly climates or during therapy. Thus, autophagy may act as either a "friend" or a "foe," depending on other internal and external factors.

## SUMMARY

### Evasion of Apoptosis

- Apoptosis can be initiated through extrinsic or intrinsic pathways.
- Both pathways result in the activation of a proteolytic cascade of caspases that destroys the cell.
- Mitochondrial outer membrane permeabilization is regulated by the balance between pro-apoptotic (e.g., BAX, BAK) and anti-apoptotic molecules (BCL2, BCL-$X_L$). BH-3–only molecules activate apoptosis by tilting the balance in favor of the pro-apoptotic molecules.
- In 85% of follicular B cell lymphomas, the anti-apoptotic gene *BCL2* is activated by the t(14;18) translocation.
- Stress may also induce cells to consume their components in a process called autophagy. Cancer cells may accumulate mutations to avoid autophagy, or may corrupt the process to provide parts for continued growth.

## Limitless Replicative Potential

As discussed previously in the context of cellular aging (Chapter 1), most normal human cells have a capacity of 60 to 70 doublings. Thereafter, the cells lose the capacity to divide and enter senescence. This phenomenon has been ascribed to progressive shortening of *telomeres* at the ends of chromosomes. The consequences of such shortening, when pronounced, are drastic:

- Short telomeres seem to be recognized by the DNA repair machinery as double-stranded DNA breaks, leading to cell cycle arrest and senescence, mediated by *TP53* and *RB*. In cells in which the checkpoints are disabled by *TP53* or *RB* mutations, the nonhomologous end-joining pathway is activated in a last-ditch effort to save the cell, joining the shortened ends of two chromosomes.
- Such an inappropriately activated repair system results in dicentric chromosomes that are pulled apart at anaphase, resulting in new double-stranded DNA breaks. The resulting genomic instability from the repeated bridge–fusion–breakage cycles eventually produces mitotic catastrophe, characterized by massive apoptosis.

*It follows that for tumors to grow indefinitely, as they often do, loss of growth restraints is not enough. Tumor cells also must develop ways to avoid both cellular senescence and mitotic*

*catastrophe* (Fig. 5–26). If during crisis a cell manages to reactivate telomerase, the bridge–fusion–breakage cycles cease, and the cell is able to avoid death. However, during this period of genomic instability that precedes telomerase activation, numerous mutations could accumulate, helping the cell march toward malignancy. Telomerase, active in normal stem cells, normally is absent from, or present at very low levels in, most somatic cells. By contrast, telomere maintenance is seen in virtually all types of cancers. In 85% to 95% of cancers, this is due to upregulation of the enzyme telomerase. A few tumors use other mechanisms, termed alternative lengthening of telomeres, which probably depend on DNA recombination.

Of interest, in a study of the progression from colonic adenoma to colonic adenocarcinoma, early lesions had a high degree of genomic instability with low telomerase expression, whereas malignant lesions had complex karyotypes with high levels of telomerase activity, consistent with a model of telomere-driven tumorigenesis in human cancer. Thus, it appears that in this model, unregulated proliferation in incipient tumors leads to telomere shortening, followed by chromosomal instability and mutation accumulation. If telomerase is then reactivated in these cells, telomeres are extended and these mutations become fixed, contributing to tumor growth. Several other mechanisms of genomic instability are discussed later.

## SUMMARY

### Limitless Replicative Potential

- In normal cells, which lack expression of telomerase, the shortened telomeres generated by cell division eventually activate cell cycle checkpoints, leading to senescence and placing a limit on the number of divisions a cell may undergo.
- In cells that have disabled checkpoints, DNA repair pathways are inappropriately activated by shortened telomeres, leading to massive chromosomal instability and mitotic crisis.
- Tumor cells reactivate telomerase, thus staving off mitotic catastrophe and achieving immortality.

## Development of Sustained Angiogenesis

Even with all the growth advantages, as described previously, tumors cannot enlarge beyond 1 to 2 mm in diameter unless they are vascularized. Like normal tissues, tumors require delivery of oxygen and nutrients and removal of waste products; the 1- to 2-mm zone presumably represents the maximal distance across which oxygen, nutrients, and waste can diffuse from blood vessels. Cancer

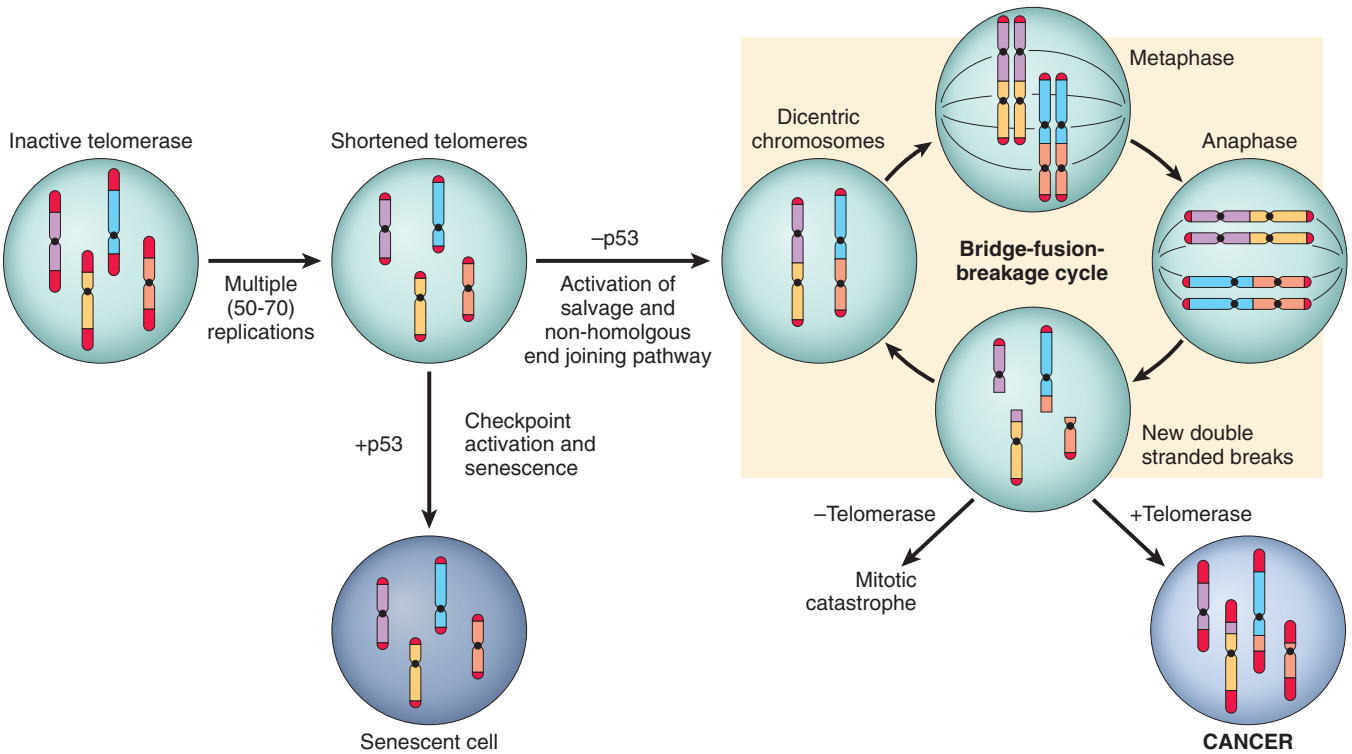


**Figure 5–26** Sequence of events in the development of limitless replicative potential. Replication of somatic cells, which do not express telomerase, leads to shortened telomeres. In the presence of competent checkpoints, cells undergo arrest and enter nonreplicative senescence. In the absence of checkpoints, DNA repair pathways are inappropriately activated, leading to the formation of dicentric chromosomes. At mitosis, the dicentric chromosomes are pulled apart, generating random double-stranded breaks, which then activate DNA repair pathways, leading to the random association of double-stranded ends and the formation, again, of dicentric chromosomes. Cells undergo numerous rounds of this bridge–fusion–breakage cycle, which generates massive chromosomal instability and numerous mutations. If cells fail to reexpress telomerase, they eventually undergo mitotic catastrophe and death. Reexpression of telomerase allows the cells to escape the bridge–fusion–breakage cycle, thus promoting their survival and tumorigenesis.

cells (and large benign tumors) can stimulate neoangiogenesis, during which new vessels sprout from previously existing capillaries, or, in some cases, vasculogenesis, in which endothelial cells are recruited from the bone marrow. Tumor vasculature is abnormal, however. The vessels are leaky and dilated, with a haphazard pattern of connection. Neovascularization has a dual effect on tumor growth: Perfusion supplies needed nutrients and oxygen, and newly formed endothelial cells stimulate the growth of adjacent tumor cells by secreting growth factors, such as insulin-like growth factors, PDGF, and granulocyte-macrophage colony-stimulating factor. Angiogenesis is required not only for continued tumor growth but also for access to the vasculature and hence for metastasis. *Angiogenesis is thus a necessary biologic correlate of neoplasia, both benign and malignant.*

How do growing tumors develop a blood supply? The emerging paradigm is that tumor angiogenesis is controlled by a balance between pro-angiogenic and inhibitory factors.

- The prototypical angiogenesis inducer and inhibitor are vascular endothelial growth factor (VEGF) and thrombospondin-1 (TSP-1), respectively. Early in their growth, most human tumors do not induce angiogenesis. They remain small or in situ for years until the angiogenic switch terminates this stage of vascular quiescence. Normal p53 induces synthesis of TSP-1.
- The molecular basis of the angiogenic switch involves increased production of angiogenic factors and/or loss of angiogenesis inhibitors. These factors may be produced directly by the tumor cells themselves or by inflammatory cells (e.g., macrophages) or other stromal cells associated with the tumors.
- Proteases, elaborated either by the tumor cells directly or from stromal cells in response to the tumor, also are involved in regulating the balance between angiogenic and anti-angiogenic factors. Many proteases can release the angiogenic basic FGF stored in the extracellular matrix (ECM); conversely, three potent angiogenesis inhibitors—angiostatin, endostatin, and vasculostatin—are produced by proteolytic cleavage of plasminogen, collagen, and transthyretin, respectively. TSP-1, on the other hand, is produced by stromal fibroblasts themselves in response to signals from the tumor cells.
- The angiogenic switch is controlled by several physiologic stimuli, such as hypoxia. Relative lack of oxygen stimulates production of a variety of pro-angiogenic cytokines, such as vascular endothelial growth factor (VEGF), through activation of hypoxia-inducible factor-1α (HIF-1α), an oxygen-sensitive transcription factor. HIF-1α is continuously produced, but in normoxic settings the von Hippel–Lindau protein (VHL) binds to HIF-1α, leading to ubiquitination and destruction of HIF-1α.
- In hypoxic conditions, such as in a tumor that has reached a critical size, the lack of oxygen prevents HIF-1α recognition by VHL, and it is not destroyed. HIF-1α translocates to the nucleus and activates transcription of its target genes, such as VEGF. Because of these activities, *VHL* acts as a tumor suppressor gene, and germline mutations of the *VHL* gene are associated with hereditary renal cell cancers, pheochromocytomas, hemangiomas of the central nervous system, retinal angiomas, and renal cysts (*VHL syndrome*).
- VEGF also increases the expression of ligands that activate the Notch signaling pathway, which regulates the branching and density of the new vessels. Because of the crucial role of angiogenesis in tumor growth, much interest is focused on anti-angiogenesis therapy. Indeed, anti-VEGF antibody is now approved for the treatment of several types of cancers.

**SUMMARY**

**Development of Sustained Angiogenesis**

- Vascularization of tumors is essential for their growth and is controlled by the balance between angiogenic and anti-angiogenic factors that are produced by tumor and stromal cells.
- Hypoxia triggers angiogenesis through the actions of HIF-1α on the transcription of the pro-angiogenic factor VEGF. Because of its ability to degrade HIF-1α and thereby prevent angiogenesis, VHL acts as a tumor suppressor. Inheritance of germ line mutations of *VHL* causes VHL syndrome, characterized by the development of a variety of tumors.
- Many other factors regulate angiogenesis; for example, p53 induces synthesis of the angiogenesis inhibitor TSP-1.

## Ability to Invade and Metastasize

The spread of tumors is a complex process involving a series of sequential steps called the invasion–metastasis cascade (Fig. 5–27). These steps consist of local invasion, intravasation into blood and lymph vessels, transit through the vasculature, extravasation from the vessels, formation of micrometastases, and growth of micrometastases into macroscopic tumors. Predictably, this sequence of steps may be interrupted at any stage by either host-related or tumor-related factors. For the purpose of discussion, the metastatic cascade can be subdivided into two phases: (1) invasion of ECM and (2) vascular dissemination and homing of tumor cells.

### *Invasion of Extracellular Matrix (ECM)*

As is well recognized, human tissues are organized into a series of compartments separated from each other by two types of ECM: basement membranes and interstitial connective tissue (Chapter 2). Although organized differently, each type of ECM is composed of collagens, glycoproteins, and proteoglycans. Tumor cells must interact with the ECM at several stages in the metastatic cascade (Fig. 5–27). A carcinoma first must breach the underlying basement membrane, then traverse the interstitial connective tissue, and ultimately gain access to the circulation by penetrating the vascular basement membrane. This cycle is repeated when tumor cell emboli extravasate at a distant site. Thus, to metastasize, a tumor cell must cross several different basement membranes, as well as negotiate its way through at least two interstitial matrices. Invasion of the ECM is an active process that requires four steps (Fig. 5–28):

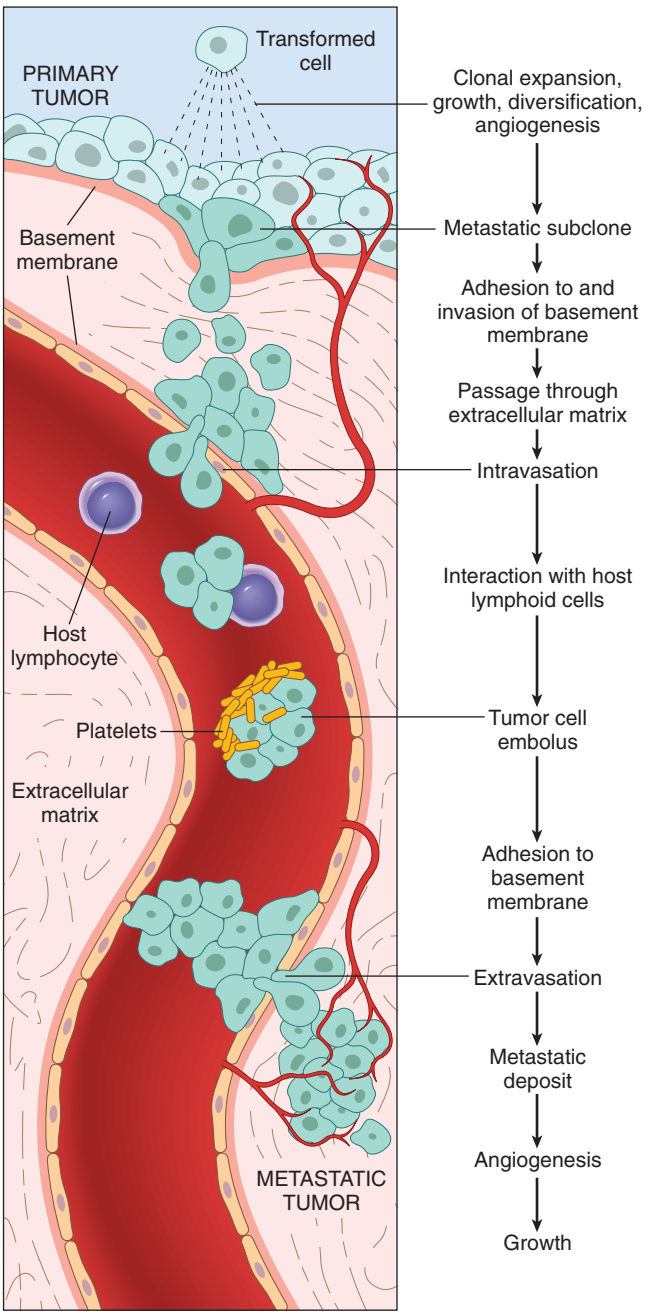


**Figure 5–27** The metastatic cascade: The sequential steps involved in the hematogenous spread of a tumor.

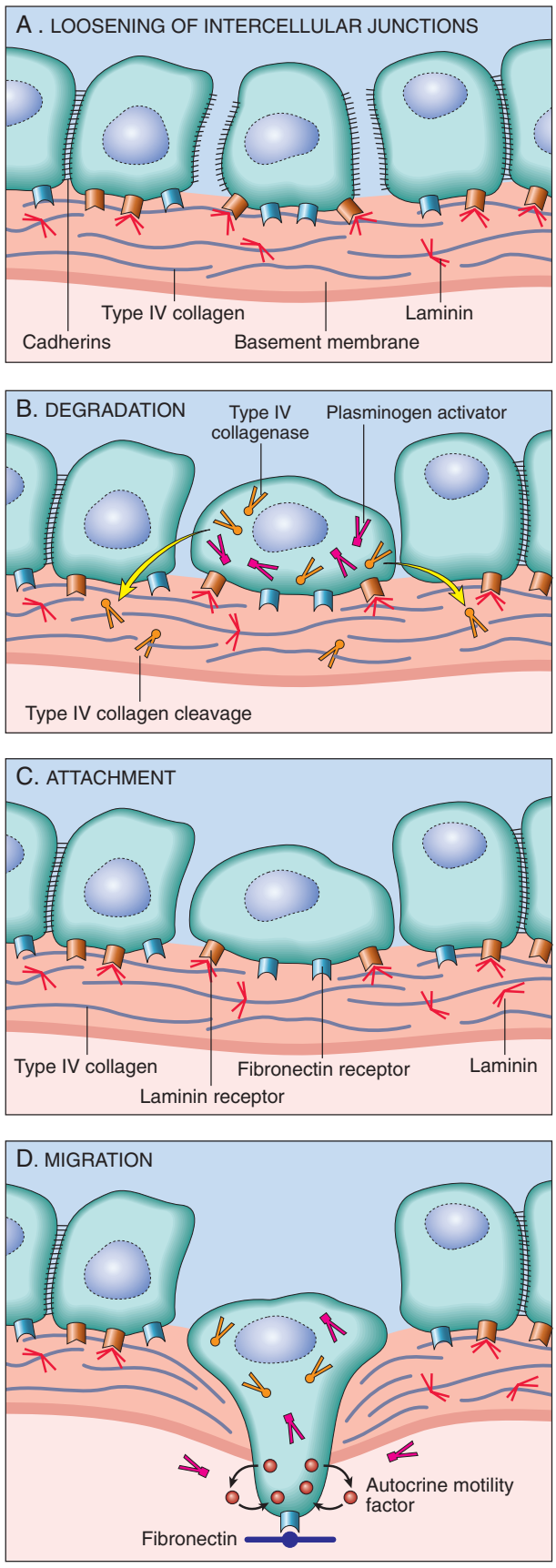


**Figure 5–28 A–D,** Sequence of events in the invasion of epithelial basement membranes by tumor cells. Tumor cells detach from each other because of reduced adhesiveness, then secrete proteolytic enzymes, degrading the basement membrane. Binding to proteolytically generated binding sites and tumor cell migration follow.

- The first step in the metastatic cascade is a *loosening* of tumor cells. As mentioned earlier, E-cadherins act as intercellular glues, and their cytoplasmic portions bind to β-catenin (Fig. 5–24). Adjacent E-cadherin molecules keep the cells together; in addition, as discussed earlier, E-cadherin can transmit antigrowth signals by sequestering β-catenin. *E-cadherin function is lost in almost all epithelial cancers, either by mutational inactivation of E-cadherin genes, by activation of β-catenin genes, or by inappropriate expression of the SNAIL and TWIST transcription factors, which suppress E-cadherin expression.*
- The second step in invasion is local *degradation of the basement membrane and interstitial connective tissue*. Tumor cells may either secrete proteolytic enzymes themselves or induce stromal cells (e.g., fibroblasts and inflammatory cells) to elaborate proteases. Multiple different families of proteases, such as matrix metalloproteinases (MMPs), cathepsin D, and urokinase plasminogen activator, have been implicated in tumor cell invasion. MMPs regulate tumor invasion not only by remodeling insoluble components of the basement membrane and interstitial matrix but also by releasing ECM-sequestered growth factors. Indeed, cleavage products of collagen and proteoglycans also have chemotactic, angiogenic, and growth-promoting effects. For example, MMP-9 is a gelatinase that cleaves type IV collagen of the epithelial and vascular basement membrane and also stimulates release of VEGF from ECM-sequestered pools. Benign tumors of the breast, colon, and stomach show little type IV collagenase activity, whereas their malignant counterparts overexpress this enzyme. Concurrently, the levels of metalloproteinase inhibitors are reduced so that the balance is tilted greatly toward tissue degradation. Indeed, overexpression of MMPs and other proteases has been reported for many tumors.
- The third step in invasion involves *changes in attachment of tumor cells to ECM proteins.* Normal epithelial cells have receptors, such as integrins, for basement membrane laminin and collagens that are polarized at their basal surface; these receptors help to maintain the cells in a resting, differentiated state. Loss of adhesion in normal cells leads to induction of apoptosis, while, not surprisingly, tumor cells are resistant to this form of cell death. Additionally, the matrix itself is modified in ways that promote invasion and metastasis. For example, cleavage of the basement membrane proteins, collagen IV and laminin, by MMP-2 or MMP-9 generates novel sites that bind to receptors on tumor cells and stimulate migration.
- *Locomotion* is the final step of invasion, propelling tumor cells through the degraded basement membranes and zones of matrix proteolysis. Migration is a complex, multistep process that involves many families of receptors and signaling proteins that eventually impinge on the actin cytoskeleton. Such movement seems to be potentiated and directed by tumor cell–derived cytokines, such as autocrine motility factors. In addition, cleavage products of matrix components (e.g., collagen, laminin) and some growth factors (e.g., insulin-like growth factors I and II) have chemotactic activity for tumor cells. Stromal cells also produce paracrine effectors of cell motility, such as hepatocyte growth factor/scatter factor (HGF/SCF), which binds to receptors on tumor cells. Concentrations of HGF/SCF are elevated at the advancing edges of the highly invasive brain tumor glioblastoma multiforme, supporting their role in motility.

More recently, it has become clear that the stromal cells surrounding tumor cells do not merely present a static barrier for tumor cells to traverse but rather constitute a variable environment in which reciprocal signaling between tumor cells and stromal cells may promote or prevent tumorigenesis. Stromal cells that interact with tumors include innate and adaptive immune cells (discussed later), as well as fibroblasts. A variety of studies have demonstrated that tumor-associated fibroblasts exhibit altered expression of genes that encode ECM molecules, proteases, protease inhibitors, and various growth factors. Thus, tumor cells live in a complex and ever-changing milieu composed of ECM, growth factors, fibroblasts, and immune cells, with significant cross-talk among all the components. The most successful tumors may be those that can co-opt and adapt this environment to their own nefarious ends.

### *Vascular Dissemination and Homing of Tumor Cells*

When in the circulation, tumor cells are vulnerable to destruction by host immune cells (discussed later). In the bloodstream, some tumor cells form emboli by aggregating and adhering to circulating leukocytes, particularly platelets; aggregated tumor cells are thus afforded some protection from the antitumor host effector cells. Most tumor cells, however, circulate as single cells. Extravasation of free tumor cells or tumor emboli involves adhesion to the vascular endothelium, followed by egress through the basement membrane into the organ parenchyma by mechanisms similar to those involved in invasion.

The site of extravasation and the organ distribution of metastases generally can be predicted by the location of the primary tumor and its vascular or lymphatic drainage. Many tumors metastasize to the organ that presents the first capillary bed they encounter after entering the circulation. *In many cases, however, the natural pathways of drainage do not readily explain the distribution of metastases.* As pointed out earlier, some tumors (e.g., lung cancers) tend to involve the adrenals quite often but almost never spread to skeletal muscle. Such organ tropism may be related to the following mechanisms:

- Expression of adhesion molecules by tumor cells whose ligands are expressed preferentially on the endothelium of target organs
- Expression of chemokines and their receptors. As discussed in Chapter 2, chemokines participate in directed movement (chemotaxis) of leukocytes, and it seems that cancer cells use similar tricks to home in on specific tissues. Human breast cancer cells express high levels of the chemokine receptors *CXCR4* and *CCR7.* The ligands for these receptors (i.e., chemokines CXCL12 and CCL21) are highly expressed only in those organs to which breast cancer cells metastasize. On the basis of this observation, it is speculated that blockade of chemokine receptors may limit metastases.

- Once they reach a target, the tumor cells must be able to colonize the site. Factors that regulate colonization are not completely understood. However, it is known that after extravasation, tumor cells are dependent on a receptive stroma for growth. Thus, in some cases, the target tissue may be a nonpermissive environment—unfavorable soil, so to speak, for the growth of tumor seedlings. For example, although well vascularized, skeletal muscles are rarely the site of metastases.

Despite their "cleverness" in escaping their sites of origin, tumor cells are quite inefficient in colonizing of distant organs. Millions of tumor cells are shed daily from even small tumors. These cells can be detected in the bloodstream and in small foci in the bone marrow, even in patients in whom gross metastatic lesions never develop. Indeed, the concept of dormancy, referring to the prolonged survival of micrometastases without progression, is well described in melanoma and in breast and prostate cancer.

Although the molecular mechanisms of colonization are just beginning to be unraveled in mouse models, a consistent theme seems to be that tumor cells secrete cytokines, growth factors, and proteases that act on the resident stromal cells, which in turn make the metastatic site habitable for the cancer cell. With a better molecular understanding of the mechanisms of metastasis, the clinician's ability to target them therapeutically will be greatly enhanced. Despite the foregoing considerations, the precise localization of metastases cannot be predicted with any form of cancer. Evidently, many tumors have not read the relevant chapters of the pathology textbooks!

### *Molecular Genetics of Metastasis*

A long-held theory of tumor progression suggests that as tumors grow, individual cells randomly accumulate mutations, creating subclones with distinct combinations of mutations. According to this hypothesis, only a small subpopulation of the tumor cells contains all of the mutations necessary for metastasis. Recent experiments, however, in which gene profiling was performed for primary tumors and for metastatic deposits, have challenged this hypothesis. For example, a subset of breast cancers has a gene expression signature similar to that found in metastases, although no clinical evidence for metastasis is apparent. In these tumors, most if not all cells apparently acquire a predilection for metastatic spread early on, during primary carcinogenesis. Metastasis, according to this view, is not dependent on the stochastic generation of metastatic subclones during tumor progression, but is an intrinsic property of the tumor developed during carcinogenesis. Of note, however, gene expression analyses like those just described would not detect a small subset of metastatic subclones within a large tumor. Perhaps both mechanisms are operative, with aggressive tumors acquiring a metastasis-permissive gene expression pattern early in tumorigenesis that requires some additional random mutations to complete the metastatic phenotype.

An open question in cancer biology is whether there are genes whose principal or sole contribution to tumorigenesis is to control metastases. This question is of more than academic interest, because if altered forms of certain genes promote or suppress the metastatic phenotype, their detection in a primary tumor would have both prognostic and therapeutic implications. Among candidates for such metastasis oncogenes are those encoding SNAIL and TWIST, transcription factors whose primary function is to promote epithelial-to-mesenchymal transition (EMT). In EMT, carcinoma cells downregulate certain epithelial markers (e.g., E-cadherin) and upregulate certain mesenchymal markers (e.g., vimentin, smooth muscle actin). These molecular changes are accompanied by phenotypic alterations such as morphologic change from polygonal epithelioid cell shape to a spindly mesenchymal shape, along with increased production of proteolytic enzymes that promote migration and invasion. These changes are believed to favor the development of a promigratory phenotype that is essential for metastasis. Loss of E-cadherin expression seems to be a key event in EMT, and SNAIL and TWIST are transcriptional repressors that promote EMT by downregulating E-cadherin expression. How expression of these master regulator transcription factors is stimulated in tumors is not clear; however, experimental models suggest that interactions of tumor cells with stromal cells are a key stimulus for this change. Thus, acquisition of a metastatic phenotype may not require a set of mutations but may be an emergent property arising from the interactions of tumor cells and stroma.

## SUMMARY

### Invasion and Metastasis

- Ability to invade tissues, a hallmark of malignancy, occurs in four steps: loosening of cell–cell contacts, degradation of ECM, attachment to novel ECM components, and migration of tumor cells.
- Cell–cell contacts are lost by the inactivation of E-cadherin through a variety of pathways.
- Basement membrane and interstitial matrix degradation is mediated by proteolytic enzymes secreted by tumor cells and stromal cells, such as MMPs and cathepsins.
- Proteolytic enzymes also release growth factors sequestered in the ECM and generate chemotactic and angiogenic fragments from cleavage of ECM glycoproteins.
- The metastatic site of many tumors can be predicted by the location of the primary tumor. Many tumors arrest in the first capillary bed they encounter (lung and liver, most commonly).
- Some tumors show organ tropism, probably due to activation of adhesion or chemokine receptors whose ligands are expressed by endothelial cells at the metastatic site.

## Reprogramming Energy Metabolism

Reprogramming of energy metabolism is so common to tumors that it is now considered a hallmark of cancer. Even in the presence of ample oxygen, cancer cells shift their glucose metabolism away from the oxygen-hungry but efficient mitochondria to glycolysis. This phenomenon, called

the Warburg effect and also known as aerobic glycolysis, has been recognized for many years (indeed, Otto Warburg received the Nobel prize for discovery of the effect that bears his name in 1931) but was largely neglected until recently.

As is well known, aerobic glycolysis is less efficient than mitochondrial oxidative phosphorylation, producing 2 molecules of ATP per molecule of glucose, versus 36. Yet tumors that adopt aerobic glycolysis, such as Burkitt lymphoma, are the most rapidly growing of human cancers. Indeed, in clinical practice, the "glucose hunger" of such tumors is used to visualize tumors by positron emission tomography (PET) scanning, in which the patient is injected with $^{18}$F-fluorodeoxyglucose, a nonmetabolizable derivative of glucose. Most tumors are PET-positive, and rapidly growing ones are markedly so.

Importantly, it is now recognized that rapidly dividing normal cells, such as those in the embryo, also adopt Warburg metabolism, indicating that this mode of metabolism is favored when rapid growth is required. How can this be, given that aerobic glycolysis generates much less ATP per mole of glucose? In addition to doubling its DNA content before division, an actively dividing cell (whether normal or transformed) must also double all of its other components, including membranes, proteins, and organelles. This task requires increased uptake of nutrients, particularly glucose and amino acids. Studies of intermediate metabolism suggest that in rapidly growing cells glucose is the primary source of the carbons that are used for synthesis of lipids (needed for membrane assembly) as well as other metabolites needed for nucleic acid synthesis. This pattern of glucose carbon use is achieved by shunting pyruvate toward biosynthetic pathways at the expense of the oxidative phosphorylation pathway and ATP generation. Thus, the metabolism of cancer can also be viewed from a darwinian perspective; tumor cells that adapt this altered metabolism are able to divide more rapidly and outpace competing tumor cells that do not.

Since aerobic glycolysis continues in tumors in the face of adequate oxygen, it follows that the changes that promote the switch in metabolism must have become hard wired in the tumor cell. It is now becoming clear that oncogenes and tumor suppressors that favor cell growth, such as TP53, PTEN, and Akt (an intermediary in RAS signaling) stimulate glucose uptake by affecting glucose transporter proteins and favor aerobic glycolysis. Indeed the Warburg effect appears to be sufficiently central to the cancer phenotype that drugs that target this pathway are being developed for therapy.

## Evasion of the Immune System

As mentioned at the outset, the ability of tumors to evade destruction by the immune system (like the reprogramming of the energy metabolism) is now considered a hallmark of cancer. Most tumors arise in immunocompetent hosts; accordingly, a likely strategy for success is to trick the immune system in such a way that the tumor fails to be recognized or eliminated despite the fact the affected person's body has an army of cells that are quite capable of thwarting a microbial infection or rejecting an allogeneic organ transplant. Discussion of this hallmark is postponed to a later section, since it is best understood in the context of the nature of tumor antigens and how they might be recognized.

## Genomic Instability as an Enabler of Malignancy

The preceding section identified eight defining features of malignancy and the genetic alterations that are responsible for the phenotypic attributes of cancer cells. How do these mutations arise? Although humans are awash in environmental agents that are mutagenic (e.g., chemicals, radiation, sunlight), cancers are relatively rare outcomes of these encounters. This state of affairs results from the ability of normal cells to repair DNA damage. The importance of DNA repair in maintaining the integrity of the genome is highlighted by several inherited disorders in which genes that encode proteins involved in DNA repair are defective. *Persons born with such inherited defects in DNA repair proteins are at greatly increased risk for the development of cancer.* Typically, genomic instability occurs when both copies of the gene are lost; however, recent work has suggested that at least a subset of these genes may promote cancer in a haploinsufficient manner. Defects in three types of DNA repair systems—mismatch repair, nucleotide excision repair, and recombination repair—are presented next. While these discussions focus on inherited syndromes, a point worthy of emphasis is that sporadic cancers often incur mutations in these genes as well, which in turn enable the accumulation of mutations in other genes whose dysfunction contributes to the hallmarks of cancer.

### *Hereditary Nonpolyposis Colon Cancer Syndrome*

The role of DNA repair genes in predisposition to cancer is illustrated dramatically by hereditary nonpolyposis colon carcinoma (HNPCC) syndrome. This disorder, characterized by familial carcinomas of the colon affecting predominantly the cecum and proximal colon (Chapter 14), results from defects in genes involved in DNA mismatch repair. When a strand of DNA is being repaired, these genes act as "spell checkers." For example, if there is an erroneous pairing of G with T, rather than the normal A with T, the mismatch repair genes correct the defect. Without these "proofreaders," errors accumulate at an increased rate, a so-called mutator phenotype. Mutations in at least four mismatch repair genes have been found to underlie HNPCC (Chapter 14). Each affected person inherits one defective copy of one of several DNA mismatch repair genes and acquires the second hit in colonic epithelial cells. Thus, DNA repair genes affect cell growth only indirectly—by allowing mutations in other genes during the process of normal cell division. A characteristic finding in the genome of patients with mismatch repair defects is microsatellite instability (MSI). Microsatellites are tandem repeats of one to six nucleotides found throughout the genome. In normal people, the length of these microsatellites remains constant. By contrast, in patients with HNPCC, these satellites are unstable and increase or decrease in length. Although HNPCC accounts for only 2% to 4% of all colonic cancers, MSI can be detected in about 15% of sporadic cancers. The growth-regulating genes that are

mutated in HNPCC include those encoding TGF-β receptor type II, BAX, and other oncogenes and tumor suppressor genes.

### *Xeroderma Pigmentosum*

Patients with another inherited disorder, xeroderma pigmentosum, are at increased risk for the development of cancers of sun-exposed skin. The basis for this disorder is defective DNA repair. Ultraviolet (UV) rays in sunlight cause cross-linking of pyrimidine residues, preventing normal DNA replication. Such DNA damage is repaired by the nucleotide excision repair system. Several proteins are involved in nucleotide excision repair, and an inherited loss of any one of these can give rise to xeroderma pigmentosum.

### *Diseases with Defects in DNA Repair by Homologous Recombination*

A group of autosomal recessive disorders comprising Bloom syndrome, ataxia-telangiectasia, and Fanconi anemia is characterized by hypersensitivity to other DNA-damaging agents, such as ionizing radiation (in Bloom syndrome and ataxia-telangiectasia), or to DNA cross-linking agents, such as nitrogen mustard (in Fanconi anemia). Their phenotype is complex and includes, in addition to predisposition to cancer, features such as neural symptoms (in ataxia-telangiectasia), anemia (in Fanconi anemia), and developmental defects (in Bloom syndrome). The gene mutated in ataxia-telangiectasia is *ATM,* which encodes a protein kinase that is important in recognizing DNA damage caused by ionizing radiation and initiating p53 activation.

Evidence for the role of DNA repair genes in the origin of cancer also comes from the study of hereditary breast cancer. Mutations in two genes, *BRCA1* and *BRCA2,* account for 50% of cases of familial breast cancer. In addition to breast cancer, women with *BRCA1* mutations have a substantially higher risk of epithelial ovarian cancers, and men have a slightly higher risk of prostate cancer. Likewise, mutations in the *BRCA2* gene increase the risk of breast cancer in both men and women, as well as cancer of the ovary, prostate, pancreas, bile ducts, stomach, melanocytes, and B lymphocytes. Although the functions of these genes have not been elucidated fully, cells that lack these genes develop chromosomal breaks and severe aneuploidy. Indeed, both genes seem to function, at least in part, in the homologous recombination DNA repair pathway. For example, BRCA1 forms a complex with other proteins in the homologous recombination pathway and also is linked to the ATM kinase pathway. *BRCA2* was identified as one of several genes mutated in Fanconi anemia, and the BRCA2 protein has been shown to bind to RAD51, a protein required for homologous recombination. Similar to other tumor suppressor genes, both copies of *BRCA1* and *BRCA2* must be inactivated for cancer to develop. Although linkage of *BRCA1* and *BRCA2* to familial breast cancers is established, these genes are rarely inactivated in sporadic cases of breast cancer. In this regard, *BRCA1* and *BRCA2* are different from other tumor suppressor genes, such as *APC* and *TP53,* which are inactivated in both familial and sporadic cancers.

### *Cancers Resulting From Mutations Induced by Regulated Genomic Instability: Lymphoid Neoplasms*

A special type of DNA damage plays a central role in the pathogenesis of tumors of B and T lymphocytes. As described earlier, adaptive immunity relies on the ability of B and T cells to diversify their antigen receptor genes. Early B and T cells both express a pair of gene products, RAG1 and RAG2, that carry out V(D)J segment recombination, permitting the assembling of functional antigen receptor genes. In addition, after encountering antigen, mature B cells express a specialized enzyme called activation-induced cytosine deaminase (AID), which catalyzes both immunoglobulin gene class switch recombination and somatic hypermutation. Errors during antigen receptor gene assembly and diversification are responsible for many of the mutations that cause lymphoid neoplasms, described in detail in Chapter 11.

## SUMMARY

### Genomic Instability as Enabler of Malignancy

- Persons with inherited mutations of genes involved in DNA repair systems are at greatly increased risk for the development of cancer.
- Patients with HNPCC syndrome have defects in the mismatch repair system, leading to development of carcinomas of the colon. These patients' genomes show MSI, characterized by changes in length of short tandem repeating sequences throughout the genome.
- Patients with xeroderma pigmentosum have a defect in the nucleotide excision repair pathway and are at increased risk for the development of cancers of the skin exposed to UV light, because of an inability to repair pyrimidine dimers.
- Syndromes involving defects in the homologous recombination DNA repair system constitute a group of disorders—Bloom syndrome, ataxia-telangiectasia, and Fanconi anemia—that are characterized by hypersensitivity to DNA-damaging agents, such as ionizing radiation. *BRCA1* and *BRCA2*, which are mutated in familial breast cancers, are involved in DNA repair.
- Mutations incurred in lymphoid cells expressing gene products that induce genomic instability (RAG1, RAG2, AID) are important causes of lymphoid neoplasms.

## Tumor-Promoting Inflammation as Enabler of Malignancy

Accumulating evidence suggests that inflammation, often thought of as a protective response against tumors, can paradoxically also enable malignancy. This occurs in two different settings:

- *Persistent chronic inflammation in response to microbial infections or as part of an autoimmune reaction*. This is exemplified by the increased risk of cancer in patients affected by a variety of chronic inflammatory diseases of the gastrointestinal tract. These include Barrett esophagus, ulcerative colitis, *H. pylori* gastritis, hepatitis B and C, and chronic pancreatitis. As with any cause of chronic tissue injury, there is a compensatory proliferation of

cells in an attempt to repair the damage. This regenerative process is aided and abetted by a plethora of growth factors, cytokines, chemokines, and other bioactive substances produced by activated immune cells collected at the site. Persistent cell replication and reduced apoptosis under these conditions place the cells at risk of acquiring mutations in one or more of the genes involved in carcinogenesis. In addition, inflammatory cells such as neutrophils can contribute to carcinogenesis by secretion of reactive oxygen species, which in turn can inflict additional DNA damage in rapidly dividing cells.

- *When inflammation occurs in response to tumors.* Pathologists have known for quite some time that many tumors are infiltrated by leukocytes. The degree of inflammation varies, but virtually every tumor contains cells of the adaptive and innate components of the immune system. The conventional wisdom has been that the inflammatory reaction is protective since it represents an attempt by the host to destroy the tumor. Indeed, that may well be the purpose of the inflammatory reaction, but these cells can exert tumor-promoting activity by producing growth factors and inflicting additional DNA damage as described above.

Whatever the precise mechanism, the link between inflammation and cancer has practical implications. For instance, expression of the enzyme cyclooxygenase-2 (COX-2), which brings about the conversion of arachidonic acid into prostaglandins (Chapter 2), is induced by inflammatory stimuli and is increased in colon cancers and other tumors. The use of COX-2 inhibitors for cancer prevention and treatment is an active area of research.

Important clinical considerations emerge from the principles presented in the foregoing discussion of the hallmarks of cancer: These hallmarks provide a road map for the development of new therapeutic agents for the treatment of cancer (Fig. 5–29).

## Multistep Carcinogenesis and Cancer Progression

As described earlier, the acquisition of several fundamental abnormalities is a prerequisite to development of malignancy. It follows, then, that *each cancer must result from accumulation of multiple mutations.* A dramatic example of incremental acquisition of the malignant phenotype is documented by the study of colon carcinoma. These lesions are believed to evolve through a series of morphologically identifiable stages: colon epithelial hyperplasia followed by formation of adenomas that progressively enlarge and ultimately undergo malignant transformation (Chapter 14). The proposed molecular correlates of this adenoma-carcinoma sequence are illustrated in Figure 5–30. According to this scheme, inactivation of the *APC* tumor suppressor gene occurs first, followed by activation of *RAS* and, ultimately, loss of a tumor suppressor gene on 18q and loss of *TP53*. The precise temporal sequence of mutations may be different in different tumors.

# ETIOLOGY OF CANCER: CARCINOGENIC AGENTS

Genetic damage lies at the heart of carcinogenesis. What extrinsic agents can inflict such damage? Three classes of carcinogenic agents have been identified: (1) chemicals, (2) radiant energy, and (3) microbial agents. Chemicals and radiant energy are documented causes of cancer in humans, and oncogenic viruses are involved in the pathogenesis of tumors in several animal models and some human tumors. In the following discussion, each class of agent is considered separately; of note, however, several may act in concert or sequentially to produce the multiple genetic abnormalities characteristic of neoplastic cells.

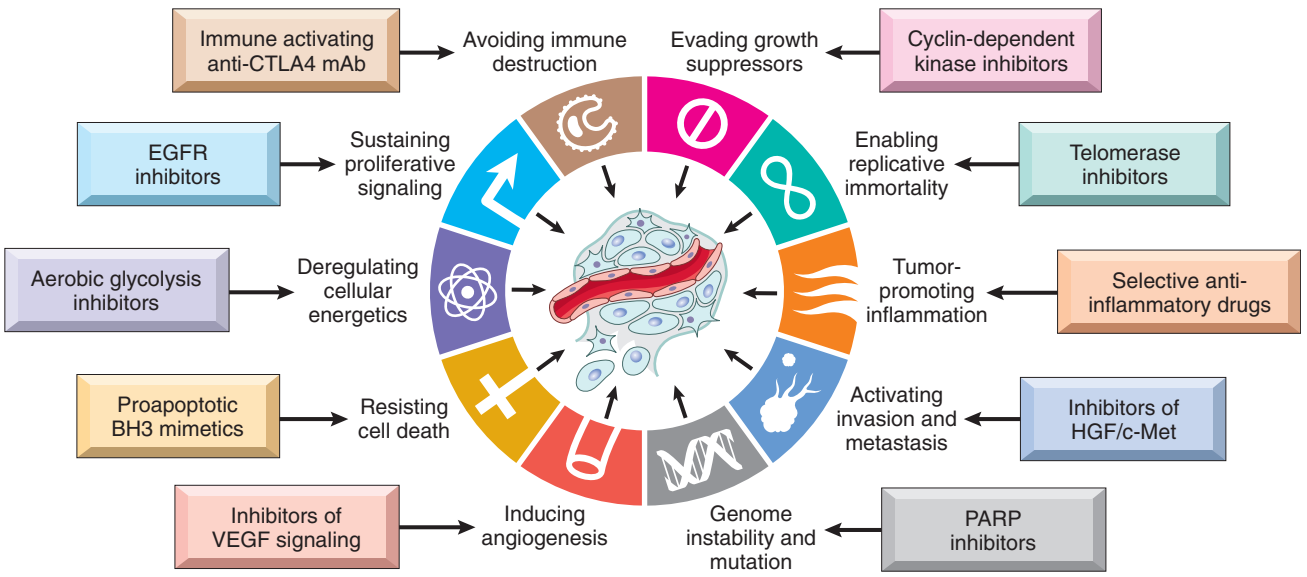


**Figure 5–29** Therapeutic targeting of hallmarks of cancer.
*(From Hanahan D, Weiberg RA: The hallmarks of cancer: the next generation. Cell 144:646, 2011.)*

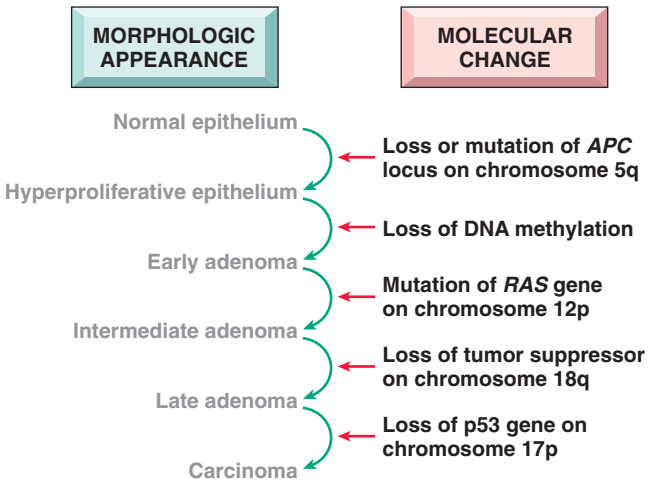


**Figure 5–30** Molecular model for the evolution of colorectal cancers through the adenoma–carcinoma sequence.
*(Data from studies by Fearon ER, Vogelstein B: A genetic model of colorectal carcinogenesis. Cell 61:759, 1990.)*

## Chemical Carcinogens

More than 200 years ago, the London surgeon Sir Percival Pott correctly attributed scrotal skin cancer in chimney sweeps to chronic exposure to soot. On the basis of this observation, the Danish Chimney Sweeps Guild ruled that its members must bathe daily. No public health measure since that time has achieved so much in the control of a form of cancer. Subsequently, hundreds of chemicals have been shown to be carcinogenic in animals.

Some of the major agents are presented in Table 5–4. A few comments on a handful of these are offered next.

### *Direct-Acting Agents*

Direct-acting agents require no metabolic conversion to become carcinogenic. They are in general weak carcinogens but are important because some of them are cancer chemotherapy drugs (e.g., alkylating agents) used in regimens that may cure certain types of cancer (e.g., Hodgkin lymphoma), only to evoke a subsequent, second form of cancer, usually leukemia. This situation is even more tragic when the initial use of such agents has been for nonneoplastic disorders, such as rheumatoid arthritis or Wegener granulomatosis. The associated risk of induced cancer is low, but its existence dictates judicious use of such agents.

### *Indirect-Acting Agents*

The designation *indirect-acting* refers to chemicals that require metabolic conversion to an *ultimate carcinogen*. Some of the most potent indirect chemical carcinogens are polycyclic hydrocarbons, present in fossil fuels. For example, benzo[*a*]pyrene and other carcinogens are formed in the high-temperature combustion of tobacco in cigarette smoking. *These products are implicated in the causation of lung cancer in cigarette smokers.* Polycyclic hydrocarbons also may be produced from animal fats during the process of broiling meats and are present in smoked meats and fish.

**Table 5–4** Major Chemical Carcinogens

| |
|---|
| **Direct-Acting Carcinogens** |
| *Alkylating Agents* |
| β-Propiolactone |
| Dimethyl sulfate |
| Diepoxybutane |
| Anticancer drugs (cyclophosphamide, chlorambucil, nitrosoureas, and others) |
| *Acylating Agents* |
| 1-Acetyl-imidazole |
| Dimethylcarbamyl chloride |
| **Procarcinogens That Require Metabolic Activation** |
| *Polycyclic and Heterocyclic Aromatic Hydrocarbons* |
| Benz(*a*)anthracene |
| Benzo(*a*)pyrene |
| Dibenz(*a*,*h*)anthracene |
| 3-Methylcholanthrene |
| 7, 12-Dimethylbenz(*a*)anthracene |
| *Aromatic Amines, Amides, Azo Dyes* |
| 2-Naphthylamine (β-naphthylamine) |
| Benzidine |
| 2-Acetylaminofluorene |
| Dimethylaminoazobenzene (butter yellow) |
| **Natural Plant and Microbial Products** |
| Aflatoxin $B_1$ |
| Griseofulvin |
| Cycasin |
| Safrole |
| Betel nuts |
| **Others** |
| Nitrosamine and amides |
| Vinyl chloride, nickel, chromium |
| Insecticides, fungicides |
| Polychlorinated biphenyls |

The principal active products in many hydrocarbons are epoxides, which form covalent adducts (addition products) with molecules in the cell, principally DNA, but also with RNA and proteins.

The aromatic amines and azo dyes constitute another class of indirect-acting carcinogens. Before its carcinogenicity was recognized, β-naphthylamine was responsible for a 50-fold increased incidence of bladder cancers in heavily exposed workers in the aniline dye and rubber industries. Many other occupational carcinogens are listed in Table 5–2. Because indirect-acting carcinogens require metabolic activation for their conversion to DNA-damaging agents, much interest is focused on the enzymatic pathways that are involved, such as that mediated by the cytochrome P-450–dependent monooxygenases. The genes that encode these enzymes are polymorphic, and enzyme activity varies among different persons. It is widely believed that the susceptibility to chemical carcinogenesis depends at least in part on the specific allelic form of the enzyme inherited. Thus, it may be possible in the future to assess cancer risk in a given patient by genetic analysis of such enzyme polymorphisms.

A few other agents merit brief mention. Aflatoxin $B_1$ is of interest because it is a naturally occurring agent produced by some strains of *Aspergillus,* a mold that grows on improperly stored grains and nuts. A strong correlation has been found between the dietary level of this food contaminant and the incidence of hepatocellular carcinoma in some parts of Africa and the Far East. Additionally, vinyl chloride, arsenic, nickel, chromium, insecticides, fungicides, and polychlorinated biphenyls are potential carcinogens in the workplace and about the house. Finally, nitrites used as food preservatives have caused concern, since they cause nitrosylation of amines contained in the food. The nitrosamines thus formed are suspected to be carcinogenic.

### *Mechanisms of Action of Chemical Carcinogens*

Because malignant transformation results from mutations, it should come as no surprise that most chemical carcinogens are mutagenic. Indeed, all direct and ultimate carcinogens contain highly reactive electrophile groups that form chemical adducts with DNA, as well as with proteins and RNA. Although any gene may be the target of chemical carcinogens, the commonly mutated oncogenes and tumor suppressors, such as *RAS* and *TP53,* are important targets of chemical carcinogens. Indeed, specific chemical carcinogens, such as aflatoxin $B_1$, produce characteristic mutations in the *TP53* gene, such that detection of the "*signature mutation*" within the *TP53* gene establishes aflatoxin as the causative agent. These associations are proving to be useful tools in epidemiologic studies of chemical carcinogenesis.

Carcinogenicity of some chemicals is augmented by subsequent administration of *promoters* (e.g., phorbol esters, hormones, phenols, certain drugs) that by themselves are nontumorigenic. To be effective, repeated or sustained exposure to the promoter must *follow* the application of the mutagenic chemical, or *initiator.* The initiation-promotion sequence of chemical carcinogenesis raises an important question: Since promoters are not mutagenic, how do they contribute to tumorigenesis? Although the effects of tumor promoters are pleiotropic, *induction of cell proliferation is a sine qua non of tumor promotion.* It seems most likely that while the application of an initiator may cause the mutational activation of an oncogene such as *RAS,* subsequent application of promoters leads to clonal expansion of initiated (mutated) cells. Forced to proliferate, the initiated clone of cells accumulates additional mutations, developing eventually into a malignant tumor. Indeed, the concept that sustained cell proliferation increases the risk of mutagenesis, and hence promotes neoplastic transformation, also is applicable to human carcinogenesis. For example, endometrial hyperplasia (Chapter 18) and increased regenerative activity that accompanies chronic liver cell injury are associated with the development of cancer in these organs. Were it not for the DNA repair mechanisms discussed earlier, the incidence of chemically induced cancers in all likelihood would be much higher. As mentioned previously, the rare hereditary disorders of DNA repair, including xeroderma pigmentosum, are associated with greatly increased risk of cancers induced by UV light and certain chemicals.

## SUMMARY

### Chemical Carcinogens

- Chemical carcinogens have highly reactive electrophile groups that directly damage DNA, leading to mutations and eventually cancer.
- Direct-acting agents do not require metabolic conversion to become carcinogenic, while indirect-acting agents are not active until converted to an ultimate carcinogen by endogenous metabolic pathways. Hence, polymorphisms of endogenous enzymes such as cytochrome P-450 may influence carcinogenesis.
- After exposure of a cell to a mutagen or an initiator, tumorigenesis can be enhanced by exposure to promoters, which stimulate proliferation of the mutated cells.
- Examples of human carcinogens are direct-acting agents (e.g., alkylating agents used for chemotherapy), indirect-acting agents (e.g., benzopyrene, azo dyes, aflatoxin), and promoters or agents that cause hyperplasia of endometrium or regenerative activity in the liver.

## Radiation Carcinogenesis

Radiation, whatever its source (UV rays of sunlight, x-rays, nuclear fission, radionuclides) is an established carcinogen. Unprotected miners of radioactive elements have a 10-fold increased incidence of lung cancers. Follow-up study of survivors of the atomic bombs dropped on Hiroshima and Nagasaki disclosed a markedly increased incidence of leukemia—principally myelogenous leukemias—after an average latent period of about 7 years, as well as increased mortality rates for thyroid, breast, colon, and lung carcinomas. The nuclear power accident at Chernobyl in the former Soviet Union continues to exact its toll in the form of high cancer incidence in the surrounding areas. More recently, it is feared that radiation release from a nuclear power plant in Japan damaged by a massive earthquake and tsunami will result in significantly increased cancer incidence in the surrounding geographic areas.

Therapeutic irradiation of the head and neck can give rise to papillary thyroid cancers years later. The oncogenic properties of ionizing radiation are related to its mutagenic effects; it causes chromosome breakage, translocations, and, less frequently, point mutations. Biologically, double-stranded DNA breaks seem to be the most important form of DNA damage caused by radiation.

The oncogenic effect of UV rays merits special mention because it highlights the importance of DNA repair in carcinogenesis. Natural UV radiation derived from the sun can cause skin cancers (melanomas, squamous cell carcinomas, and basal cell carcinomas). At greatest risk are fair-skinned people who live in locales such as Australia and New Zealand that receive a great deal of sunlight. Nonmelanoma skin cancers are associated with total cumulative exposure to UV radiation, whereas melanomas are associated with intense intermittent exposure—as occurs with sunbathing. UV light has several biologic effects on cells. Of particular relevance to carcinogenesis is the ability to damage DNA by forming pyrimidine dimers.

This type of DNA damage is repaired by the nucleotide excision repair pathway. With extensive exposure to UV light, the repair systems may be overwhelmed, and skin cancer results. As mentioned earlier, patients with the inherited disease *xeroderma pigmentosum* have a defect in the nucleotide excision repair pathway. As expected, there is a greatly increased predisposition to skin cancers in this disorder.

## SUMMARY

### Radiation Carcinogenesis

- Ionizing radiation causes chromosome breakage, translocations, and, less frequently, point mutations, leading to genetic damage and carcinogenesis.
- UV rays induce the formation of pyrimidine dimers within DNA, leading to mutations. Therefore, UV rays can give rise to squamous cell carcinomas and melanomas of the skin.

## Viral and Microbial Oncogenesis

Many DNA and RNA viruses have proved to be oncogenic in animals as disparate as frogs and primates. Despite intense scrutiny, however, only a few viruses have been linked with human cancer. The following discussion focuses on human oncogenic viruses. Also discussed is the emerging role of the bacterium *H. pylori* in gastric cancer.

### *Oncogenic RNA Viruses*

The study of oncogenic retroviruses in animals has provided spectacular insights into the genetic basis of cancer. However, only one retrovirus, the human T cell lymphotropic virus-1 (HTLV-1), has been demonstrated to cause cancer in humans. HTLV-1 is associated with a form of T cell leukemia/lymphoma that is endemic in certain parts of Japan and the Caribbean basin but is found sporadically elsewhere, including the United States. Similar to the human immunodeficiency virus (HIV), HTLV-1 has tropism for CD4+ T cells, and this subset of T cells is the major target for neoplastic transformation. Human infection requires transmission of infected T cells through sexual intercourse, blood products, or breastfeeding. Leukemia develops only in about 3% to 5% of infected persons after a long latent period of 20 to 50 years.

There is little doubt that HTLV-1 infection of T lymphocytes is necessary for leukemogenesis, but the molecular mechanisms of transformation are not clear. The HTLV-1 genome does not contain a viral oncogene, and in contrast with certain animal retroviruses, no consistent integration site next to a cellular oncogene has been discovered. Indeed, the long latency period between initial infection and development of disease suggests a multistep process, during which many oncogenic mutations are accumulated.

The genome of HTLV-1 contains, in addition to the usual retroviral genes, a unique region called *pX*. This region contains several genes, including one called *TAX*. The TAX protein has been shown to be necessary and sufficient for cellular transformation. By interacting with several transcription factors, such as NF-κB, the TAX protein can transactivate the expression of genes that encode cytokines, cytokine receptors, and costimulatory molecules. This inappropriate gene expression leads to autocrine signaling loops and increased activation of promitogenic signaling cascades. Furthermore, TAX can drive progression through the cell cycle by directly binding to and activating cyclins. In addition, TAX can repress the function of several tumor suppressor genes that control the cell cycle, including *CDKN2A/p16* and *TP53*. From these and other observations, the following scenario is emerging (Fig. 5–31): The *TAX* gene turns on several cytokine genes and their receptors (e.g., the interleukins IL-2 and IL-2R and IL-15 and IL-15R), setting up an autocrine system that drives T cell proliferation. Of these cytokines, IL-15 seems to be more important, but much remains to be defined. Additionally, a parallel paracrine pathway is activated by increased production of granulocyte-macrophage colony-stimulating factor, which stimulates neighboring macrophages to produce other T cell mitogens. Initially, the T cell proliferation is polyclonal, because the virus infects many cells, but because of TAX-based inactivation of tumor suppressor genes such as *TP53*, the proliferating T cells are at increased risk for secondary transforming events (mutations), which lead ultimately to the outgrowth of a monoclonal neoplastic T cell population.

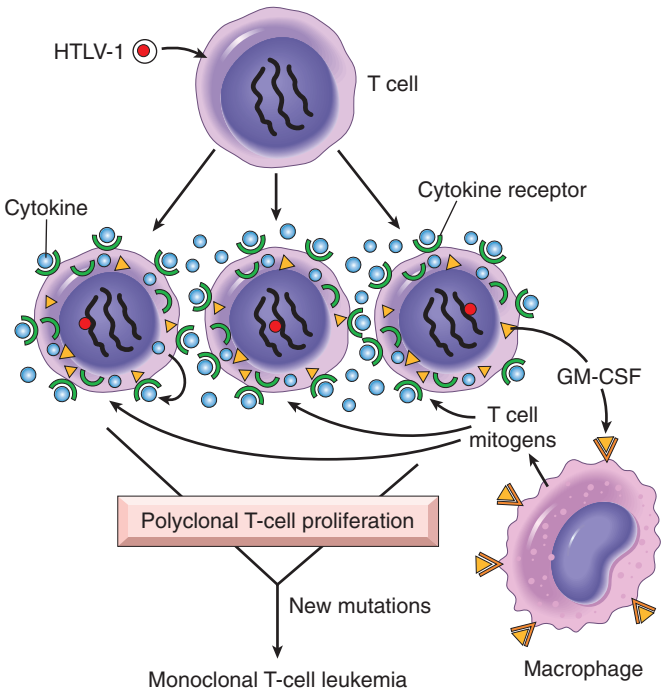


**Figure 5–31** Pathogenesis of human T cell lymphotropic virus (HTLV-1)–induced T cell leukemia/lymphoma. HTLV-1 infects many T cells and initially causes polyclonal proliferation by autocrine and paracrine pathways triggered by the *TAX* gene. Simultaneously, TAX neutralizes growth inhibitory signals by affecting *TP53* and *CDKN2A/p16* genes. Ultimately, a monoclonal T cell leukemia/lymphoma results when one proliferating T cell suffers additional mutations.

## SUMMARY

### Oncogenic RNA Viruses

- HTLV-I causes a T cell leukemia that is endemic in Japan and the Caribbean.
- The HTLV-I genome encodes a viral TAX protein, which turns on genes for cytokines and their receptors in infected T cells. This sets up autocrine and paracrine signaling loops that stimulate T cell proliferation. Although this proliferation initially is polyclonal, the proliferating T cells are at increased risk for secondary mutations that lead to the outgrowth of a monoclonal leukemia.

### *Oncogenic DNA Viruses*

As with RNA viruses, several oncogenic DNA viruses that cause tumors in animals have been identified. Four DNA viruses—HPV, Epstein-Barr virus (EBV), Kaposi sarcoma herpesvirus (KSHV, also called human herpesvirus-8 [HHV-8]), and hepatitis B virus (HBV)—are of special interest because they are strongly associated with human cancer. KSHV and Kaposi sarcoma are discussed in Chapter 4. The others are presented here.

#### Human Papillomavirus

Scores of genetically distinct types of HPV have been identified. Some types (e.g., 1, 2, 4, and 7) cause benign squamous papillomas (warts) in humans (Chapters 18 and 21). Genital warts have low malignant potential and are also associated with low-risk HPVs, predominantly HPV-6 and HPV-11. By contrast, high-risk HPVs (e.g., types 16 and 18) cause several cancers, particularly squamous cell carcinoma of the cervix and anogenital region. In addition, at least 20% of oropharyngeal cancers, particularly those arising in the tonsils, are associated with HPV.

The oncogenic potential of HPV can be related to products of two early viral genes, E6 and E7. Together, they interact with a variety of growth-regulating proteins encoded by proto-oncogenes and tumor suppressor genes. The E7 protein binds to the retinoblastoma protein and releases the E2F transcription factors that normally are sequestered by Rb, promoting progression through the cell cycle. Of interest, E7 protein from high-risk HPV types has a higher affinity for Rb than does E7 from low-risk HPV types. E7 also inactivates the CDKIs CDKN1A/p21 and CDNK1B/p27. The E6 protein has complementary effects. It binds to and mediates the degradation of p53. By analogy with E7, E6 from high-risk HPV types has a higher affinity for p53 than does E6 from low-risk HPV types. Also of interest, in benign warts the HPV genome is maintained in a nonintegrated episomal form, while in cancers the HPV genome is randomly integrated into the host genome. Integration interrupts the viral DNA, resulting in overexpression of the oncoproteins E6 and E7. Furthermore, cells in which the viral genome has integrated show significantly more genomic instability.

To summarize, infection with high-risk HPV types simulates the loss of tumor suppressor genes, activates cyclins, inhibits apoptosis, and combats cellular senescence. Thus, it is evident that many of the hallmarks of cancer discussed earlier are driven by HPV proteins. However, infection with HPV itself is not sufficient for carcinogenesis. For example, when human keratinocytes are transfected with DNA from HPV-16, -18, or -31 in vitro, they are immortalized, but they do not form tumors in experimental animals. Cotransfection with a mutated *RAS* gene results in full malignant transformation. These data strongly suggest that HPV, in all likelihood, acts in concert with other environmental factors (Chapter 18). However, the primacy of HPV infection in the causation of cervical cancer is attested to by the near-complete protection from this cancer by anti-HPV vaccines.

#### Epstein-Barr Virus

EBV was the first virus linked to a human tumor, Burkitt lymphoma. Over the last 40 years, however, EBV has been discovered with the cells of a surprisingly diverse list of tumors, including B cell lymphomas in patients with defective T cell immunity (e.g., those infected with HIV), a subset of Hodgkin lymphoma, nasopharyngeal carcinoma, a subset of T cell lymphomas, gastric carcinomas, NK cell lymphomas, and even, in rare instances, sarcomas, mainly in the immunosuppressed.

Burkitt lymphoma is endemic in certain parts of Africa and is sporadic elsewhere. In endemic areas, tumor cells in virtually all affected patients carry the EBV genome. The molecular basis for B cell proliferations induced by EBV is complex. EBV uses the complement receptor CD21 to attach to and infect B cells. In vitro, such infection leads to polyclonal B cell proliferation and generation of B lymphoblastoid cell lines. One of the EBV-encoded genes, called *LMP1* (latent membrane protein 1) acts as an oncogene, and its expression in transgenic mice induces B cell lymphomas. LMP1 promotes B cell proliferation by activating signaling pathways, such as NF-κB and JAK/STAT, which mimic B cell activation by the B cell surface molecule CD40. Concurrently, LMP1 prevents apoptosis by activating BCL2. Thus, the virus "borrows" a normal B cell activation pathway to promote its own replication by expanding the pool of cells susceptible to infection. Another EBV-encoded protein, EBNA2, transactivates several host genes, including cyclin D and the *src* family of proto-oncogenes. In addition, the EBV genome contains a viral cytokine, vIL-10, that was pirated from the host genome. This viral cytokine can prevent macrophages and monocytes from activating T cells and killing virally infected cells.

In immunologically normal persons, EBV-driven polyclonal B cell proliferation is readily controlled, and the affected patient either remains asymptomatic or experiences a self-limited episode of infectious mononucleosis (Chapter 11). Evasion of the immune system seems to be a key step in EBV-related oncogenesis. In regions of the world in which Burkitt lymphoma is endemic, concomitant (endemic) malaria (or other infections) impairs immune competence, allowing sustained B cell proliferation. Of interest, although *LMP1* is the primary transforming oncogene in the EBV genome, it is not expressed in EBV-associated Burkitt lymphoma, presumably because it also is one of the major viral antigens recognized by the immune system. Infected cells expressing viral antigens such as LMP-1 are kept in check by the immune system. Lymphoma cells may emerge only when translocations activate the *MYC* oncogene, a consistent feature of this tumor. MYC may substitute for LMP1 signaling, allowing the tumor

cells to downregulate LMP1 and evade the immune system. Of note, in nonendemic areas, 80% of tumors are negative for EBV, but virtually all tumors possess *MYC* translocations. This observation suggests that although non-African Burkitt lymphomas are triggered by mechanisms other than EBV, these cancers develop by similar pathways.

In patients with deficient T cell function, including those with HIV and organ transplant recipients, EBV-infected B cells undergo polyclonal expansion, producing lymphoblastoid-like cells. In contrast with Burkitt lymphoma, the B lymphoblasts in immunosuppressed patients do express viral antigens, such as LMP-1, that are recognized by T cells. These potentially lethal proliferations can be subdued if T cell immunity can be restored, as may be achieved by withdrawal of immunosuppressive drugs in transplant recipients.

Nasopharyngeal carcinoma is endemic in southern China and some other locales, and the EBV genome is found in all tumors. LMP-1 is expressed in the carcinoma cells and, as in B cells, activates the NF-κB pathway. Furthermore, LMP1 induces the expression of pro-angiogenic factors such as VEGF, FGF-2, MMP-9, and COX-2, which may contribute to oncogenesis. How EBV enters epithelial cells is unclear, as these cells fail to express the CD21 protein that serves as the EBV receptor in B cells.

## SUMMARY

### Oncogenic DNA Viruses

- HPV is associated with benign warts, as well as cervical cancer.
- The oncogenicity of HPV is related to the expression of two viral oncoproteins, E6 and E7; they bind to Rb and p53, respectively, neutralizing their function.
- E6 and E7 from high-risk strains of HPV (which give rise to cancers) have higher affinity for their targets than do E6 and E7 from low-risk strains of HPV (which give rise to benign warts).
- EBV is implicated in the pathogenesis of Burkitt lymphomas, lymphomas in immunosuppressed patients (HIV infection or organ transplant recipients), some forms of Hodgkin lymphoma, uncommon T cell and NK cell tumors, nasopharyngeal carcinoma, a subset of gastric carcinoma, and rarely sarcomas.
- Certain EBV gene products contribute to oncogenesis by stimulating a normal B cell proliferation pathway. Concomitant compromise of immune competence allows sustained B cell proliferation, leading eventually to development of lymphoma, with occurrence of additional mutations such as t(8;14) leading to activation of the *MYC* gene.

### Hepatitis B and Hepatitis C Viruses

The epidemiologic evidence linking chronic HBV and hepatitis C virus (HCV) infection with hepatocellular carcinoma is strong (Chapter 15). It is estimated that 70% to 85% of hepatocellular carcinomas worldwide are due to infection with HBV or HCV. However, the mode of action of these viruses in tumorigenesis is not fully elucidated. The HBV and HCV genomes do not encode any viral oncoproteins, and although the HBV DNA is integrated within the human genome, there is no consistent pattern of integration in liver cells. Indeed, the oncogenic effects of HBV and HCV are multifactorial, but the dominant effect seems to be immunologically mediated chronic inflammation with hepatocyte death leading to regeneration and genomic damage. Although the immune system generally is thought to be protective, recent work has demonstrated that in the setting of unresolved chronic inflammation, as occurs in viral hepatitis or chronic gastritis caused by *H. pylori* (see further on), the immune response may become maladaptive, promoting tumorigenesis.

As with any cause of hepatocellular injury, chronic viral infection leads to the compensatory proliferation of hepatocytes. This regenerative process is aided and abetted by a plethora of growth factors, cytokines, chemokines, and other bioactive substances produced by activated immune cells that promote cell survival, tissue remodeling, and angiogenesis. The activated immune cells also produce other mediators, such as reactive oxygen species, that are genotoxic and mutagenic. A key molecular step seems to be activation of the nuclear factor-κB (NF-κB) pathway in hepatocytes caused by mediators derived from the activated immune cells. Activation of the NF-κB pathway within hepatocytes blocks apoptosis, allowing the dividing hepatocytes to incur genotoxic stress and to accumulate mutations. Although this seems to be the dominant mechanism in the pathogenesis of virus-induced hepatocellular carcinoma, both HBV and HCV also contain proteins within their genomes that may more directly promote the development of cancer. The HBV genome contains a gene known as *HBx,* and hepatocellular cancers develop in mice transgenic for this gene. *HBx* can directly or indirectly activate a variety of transcription factors and several signal transduction pathways. In addition, viral integration can cause secondary rearrangements of chromosomes, including multiple deletions that may harbor unknown tumor suppressor genes.

Although not a DNA virus, HCV also is strongly linked to the pathogenesis of liver cancer. The molecular mechanisms used by HCV are less well defined than those for HBV. In addition to chronic liver cell injury and compensatory regeneration, components of the HCV genome, such as the HCV core protein, may have a direct effect on tumorigenesis, possibly by activating a variety of growth-promoting signal transduction pathways.

## SUMMARY

### Hepatitis B and Hepatitis C Viruses

- Between 70% and 85% of hepatocellular carcinomas worldwide are due to infection with HBV or HCV.
- The oncogenic effects of HBV and HCV are multifactorial, but the dominant effect seems to be immunologically mediated chronic inflammation, with hepatocellular injury, stimulation of hepatocyte proliferation, and production of reactive oxygen species that can damage DNA.
- The HBx protein of HBV and the HCV core protein can activate a variety of signal transduction pathways that also may contribute to carcinogenesis.

### *Helicobacter pylori*

First incriminated as a cause of peptic ulcers, *H. pylori* now has acquired the dubious distinction of being the first bacterium classified as a carcinogen. Indeed, *H. pylori* infection is implicated in the genesis of both gastric adenocarcinomas and gastric lymphomas.

The scenario for the development of gastric adenocarcinoma is similar to that for HBV- and HCV-induced liver cancer. It involves increased epithelial cell proliferation on a background of chronic inflammation. As in viral hepatitis, the inflammatory milieu contains numerous genotoxic agents, such as reactive oxygen species. The sequence of histopathologic changes consists of initial development of chronic inflammation/gastritis, followed by gastric atrophy, intestinal metaplasia of the lining cells, dysplasia, and cancer. This sequence takes decades to complete and occurs in only 3% of infected patients. Like those of HBV and HCV, the *H. pylori* genome also contains genes directly implicated in oncogenesis. Strains associated with gastric adenocarcinoma have been shown to contain a "pathogenicity island" that contains cytotoxin-associated A gene (*CagA*). Although *H. pylori* is noninvasive, *CagA* is injected into gastric epithelial cells, where it has a variety of effects, including the initiation of a signaling cascade that mimics unregulated growth factor stimulation.

As mentioned previously, *H. pylori* is associated with an increased risk for the development of gastric lymphomas as well. The gastric lymphomas are of B cell origin, and because the transformed B cells grow in a pattern resembling that of normal mucosa-associated lymphoid tissue (MALT), they also have been referred to as MALT lymphomas (Chapter 11). Their molecular pathogenesis is incompletely understood but seems to involve strain-specific *H. pylori* factors, as well as host genetic factors, such as polymorphisms in the promoters of inflammatory cytokines such as IL-1β and tumor necrosis factor (TNF). It is thought that *H. pylori* infection leads to the activation of *H. pylori*–reactive T cells, which in turn cause polyclonal B cell proliferation. In time, a monoclonal B cell tumor emerges in the proliferating B cells, perhaps as a result of accumulation of mutations in growth regulatory genes. In keeping with this model, early in the course of disease, eradication of *H. pylori* "cures" the lymphoma by removing antigenic stimulus for T cells.

## SUMMARY

### *Helicobacter pylori*

- *H. pylori* infection has been implicated in both gastric adenocarcinoma and MALT lymphoma.
- The mechanism of *H. pylori*–induced gastric cancers is multifactorial, including immunologically mediated chronic inflammation, stimulation of gastric cell proliferation, and production of reactive oxygen species that damage DNA. *H. pylori* pathogenicity genes, such as *CagA*, also may contribute by stimulating growth factor pathways.
- It is thought that *H. pylori* infection leads to polyclonal B cell proliferations and that eventually a monoclonal B cell tumor (MALT lymphoma) emerges as a result of accumulation of mutations.

# HOST DEFENSE AGAINST TUMORS: TUMOR IMMUNITY

The idea that tumors are not entirely "self" was conceived by Ehrlich, who proposed that immune-mediated recognition of autologous tumor cells may be a "positive mechanism" capable of eliminating transformed cells. Subsequently, Lewis Thomas and Macfarlane Burnet formalized this concept by coining the term *immune surveillance* to refer to recognition and destruction of newly appearing tumor cells, which are seen as foreign by the host immune system. That cancers occur implies that immune surveillance is imperfect; the escape of some tumors from such policing, however, does not preclude the possibility that others may have been aborted. This section addresses certain questions about tumor immunity: What is the nature of tumor antigens? What host effector systems may recognize tumor cells? Is tumor immunity effective against spontaneous neoplasms?

## Tumor Antigens

Antigens that elicit an immune response have been demonstrated in many experimentally induced tumors and in some human cancers. Initially, they were broadly classified into two categories based on their patterns of expression: *tumor-specific antigens,* which are present only on tumor cells and not on any normal cells, and *tumor-associated antigens,* which are present on tumor cells and also on some normal cells. This classification, however, is imperfect, because many antigens thought to be tumor-specific turned out to be expressed by some normal cells as well. The modern classification of tumor antigens is based on their molecular structure and source.

An important advance in the field of tumor immunology was the development of techniques for identifying tumor antigens that were recognized by cytotoxic T lymphocytes (CTLs), because CTLs are responsible for the major immune defense mechanism against tumors. As described in Chapter 4, CTLs recognize peptides derived from cytoplasmic proteins that are displayed bound to class I major histocompatibility complex (MHC) molecules.

Described next are the main classes of tumor antigens (Fig. 5–32).

### *Products of Mutated Oncogenes and Tumor Suppressor Genes*

Neoplastic transformation, as discussed, results from genetic alterations, some of which may lead to the expression of cell surface antigens that are seen as non-self by the immune system. Antigens in this category are derived from mutant oncoproteins and tumor suppressor proteins. Unique tumor antigens arise from β-catenin, RAS, p53, and CDK4, for which the encoding genes frequently are mutated in tumors. Because the mutant genes are present only in tumors, their peptides are expressed only in tumor cells. Since many tumors may carry the same mutation, such antigens are shared by different tumors. Although CTLs can be induced against such antigens, they do not appear to elicit protective responses in vivo. In some cases, unmutated oncogenes are overexpressed in tumors. The best

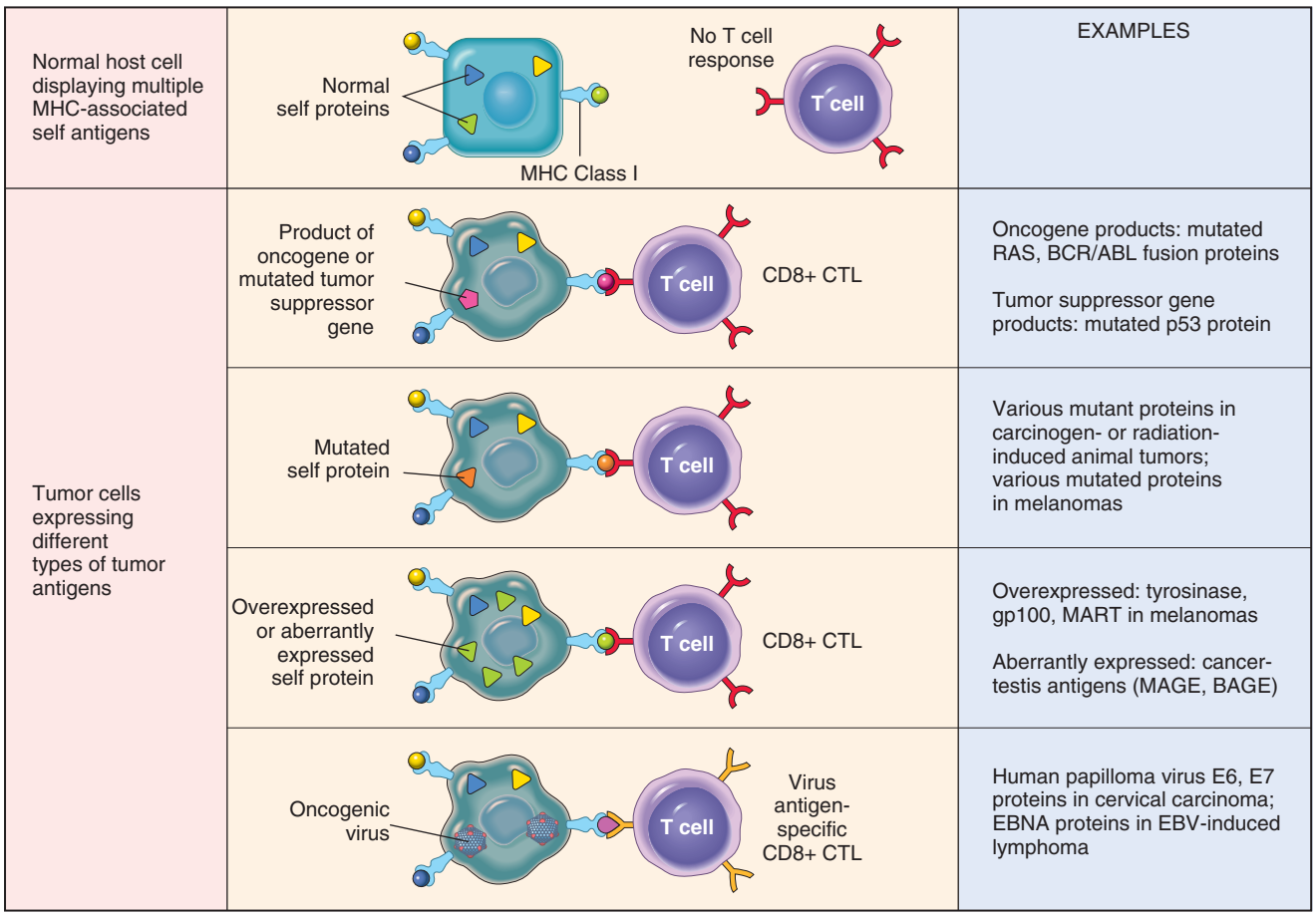


**Figure 5–32** Tumor antigens recognized by CD8+ T cells.
*(Modified from Abbas AK, Lichtman AH: Cellular and Molecular Immunology, 5th ed. Philadelphia, WB Saunders, 2003.)*

example is that of the *HER2/NEU* oncogene, whose product is highly expressed in a subset of breast cancers. Antibodies targeted against Her2/Neu protein are used clinically for the treatment of breast cancers.

### *Products of Other Mutated Genes*

Because of the genetic instability of tumor cells, many genes are mutated in these cells, including genes whose products are not related to the transformed phenotype and have no known function. Products of these mutated genes are potential tumor antigens. These antigens are extremely diverse, because the carcinogens that induce the tumors may randomly mutagenize virtually any host gene. Mutated cellular proteins are found more frequently in chemical carcinogen- or radiation-induced animal tumors than in spontaneous human cancers. They can be targeted by the immune system, since there is no self-tolerance against them.

### *Overexpressed or Aberrantly Expressed Cellular Proteins*

Tumor antigens may be normal cellular proteins that are abnormally expressed in tumor cells and elicit immune responses. In a subset of human melanomas, some tumor antigens are structurally normal proteins that are produced at low levels in normal cells and overexpressed in tumor cells. One such antigen is tyrosinase, an enzyme involved in melanin biosynthesis that is expressed only in normal melanocytes and melanomas. T cells from patients with melanoma recognize peptides derived from tyrosinase, raising the possibility that tyrosinase vaccines may stimulate such responses to melanomas; clinical trials with these vaccines are ongoing. It is somewhat surprising that these patients are able to respond to a normal self-antigen. The probable explanation is that tyrosinase normally is produced in such small amounts and in so few cells that it is not recognized by the immune system and fails to induce tolerance.

Another group, the so-called cancer-testis antigens, are encoded by genes that are silent in all normal adult tissues except the testis, and are deregulated in cancer cells—hence their name. Although the protein is present in the testis, it is not expressed on the cell surface in an antigenic form, because sperm do not express MHC class I molecules. Thus, for all practical purposes, these antigens are tumor-specific. Prototypical of this group is the MAGE (*m*elanoma *a*ntigen *ge*ne) family of genes. Although they are tumor-specific, MAGE antigens are not unique for individual tumors. MAGE-1 is expressed on 37% of melanomas and a variable number of lung, liver, stomach, and esophageal carcinomas. Similar antigens called GAGE, BAGE, and RAGE have been detected in other tumors. Several antigens from this category are now being used in tumor vaccine trials.

### *Tumor Antigens Produced by Oncogenic Viruses*

As discussed earlier, some viruses are associated with cancers. Not surprisingly, these viruses produce proteins that are recognized as foreign by the immune system. The most potent of these antigens are proteins produced by latent DNA viruses; examples in humans are HPV and EBV. There is abundant evidence that CTLs recognize antigens of these viruses and that a competent immune system plays a role in surveillance against virus-induced tumors because of its ability to recognize and kill virus-infected cells. Indeed, vaccines against HPV antigens have been found to be effective in prevention of cervical cancers in girls and young women.

### *Oncofetal Antigens*

Oncofetal antigens or embryonic antigens, such as carcinoembryonic antigen (CEA) and alpha fetoprotein, are expressed during embryogenesis but not in normal adult tissues. Derepression of the genes that encode these antigens causes their reexpression in colon and liver cancers. Antibodies can be raised against these antigens and are useful for detection of oncofetal antigens. Although, as discussed later, they are not entirely tumor-specific, they can serve as serum markers for cancer.

### *Altered Cell Surface Glycolipids and Glycoproteins*

Most human and experimental tumors express higher than normal levels and/or abnormal forms of surface glycoproteins and glycolipids, which may be diagnostic markers and targets for therapy. These altered molecules include gangliosides, blood group antigens, and mucins. Although most of the epitopes recognized by antibodies raised against such antigens are not specifically expressed on tumors, they are present at higher levels on cancer cells than on normal cells. This class of antigens is a target for cancer therapy with specific antibodies.

Several mucins are of special interest and have been the focus of diagnostic and therapeutic studies. These include CA-125 and CA-19-9, expressed on ovarian carcinomas, and MUC-1, expressed on breast carcinomas. Unlike many other types of mucins, MUC-1 is an integral membrane protein that normally is expressed only on the apical surface of breast ductal epithelium, a site that is relatively sequestered from the immune system. In ductal carcinomas of the breast, however, the molecule is expressed in an unpolarized fashion and contains new, tumor-specific carbohydrate and peptide epitopes. These epitopes induce both antibody and T cell responses in cancer patients and are therefore candidates for tumor vaccines.

### *Cell Type–Specific Differentiation Antigens*

Tumors express molecules that normally are present on the cells of origin. These antigens are called *differentiation antigens,* because they are specific for particular lineages or differentiation stages of various cell types. Their importance is as potential targets for immunotherapy and in identifying the tissue of origin of tumors. For example, lymphomas may be diagnosed as B cell–derived tumors by the detection of surface markers characteristic of this lineage, such as CD20. Antibodies against CD20 are used for immunotherapy of certain B cell lymphomas. These differentiation antigens typically are normal self-antigens, so they do not induce immune responses in tumor-bearing hosts.

## Antitumor Effector Mechanisms

Cell-mediated immunity is the dominant antitumor mechanism in vivo. Although antibodies can be made against tumors, there is no evidence that they play a protective role under physiologic conditions. The cellular effectors that mediate immunity are discussed fully in Chapter 4, so they are characterized only briefly here.

### *Cytotoxic T Lymphocytes*

The role of specifically sensitized cytotoxic T lymphocytes (CTLs) in experimentally induced tumors is well established. In humans, they seem to play a protective role, chiefly against virus-associated neoplasms (e.g., EBV-induced Burkitt lymphoma, HPV-induced tumors). The presence of MHC-restricted CD8+ cells that can kill autologous tumor cells within human tumors suggests that the role of T cells in immunity against human tumors may be broader than was previously suspected. In some cases, such CD8+ T cells do not develop spontaneously in vivo but can be generated by immunization with tumor antigen–pulsed dendritic cells.

### *Natural Killer Cells*

NK cells are lymphocytes that are capable of destroying tumor cells without previous sensitization; they may provide the first line of defense against tumor cells. After activation with IL-2, NK cells can lyse a wide range of human tumors, including many that seem to be nonimmunogenic for T cells. T cells and NK cells apparently provide complementary antitumor mechanisms. Tumors that fail to express MHC class I antigens cannot be recognized by T cells, but these tumors may trigger NK cells because the latter are inhibited by recognition of normal autologous class I molecules (Chapter 4). Thus, tumors may downregulate MHC class I molecules to avoid recognition by T cells, which then makes them prime targets for NK cells. The triggering receptors on NK cells are extremely diverse and belong to several gene families. NKG2D proteins expressed on NK cells and some T cells are important activating receptors. They recognize stress-induced antigens that are expressed on tumor cells and on cells that have incurred DNA damage and are at risk for neoplastic transformation.

### *Macrophages*

Classically activated macrophages of the M1 type (Chapter 2) exhibit cytotoxicity against tumor cells in vitro. T cells, NK cells, and macrophages may collaborate in antitumor reactivity, because interferon-γ, a cytokine secreted by T cells and NK cells, is a potent activator of macrophages. Activated macrophages may kill tumors by mechanisms similar to those used to kill microbes (e.g., production of reactive oxygen metabolites) (Chapter 2) or by secretion of tumor necrosis factor (TNF).

### *Humoral Mechanisms*

Although there is no evidence for the protective effects of antitumor antibodies against spontaneous tumors,

administration of monoclonal antibodies against tumor cells can be therapeutically effective. A monoclonal antibody against CD20, a B cell surface antigen, is widely used for treatment of certain non-Hodgkin lymphomas.

### Immune Surveillance and Immune Evasion by Tumors

In view of the host of possible and potential antitumor mechanisms, is there any evidence that they operate in vivo to prevent the emergence of neoplasms? The strongest argument for the existence of immune surveillance is the increased frequency of cancers in immunodeficient hosts. About 5% of persons with congenital immunodeficiencies develop cancers, a rate that is about 200 times reported rates for persons without such immunodeficiencies. By analogy, immunosuppressed transplant recipients and patients with acquired immunodeficiency syndrome have increased numbers of malignancies. Of note, most (but not all) of these neoplasms are lymphomas, often lymphomas of activated B cells. Particularly illustrative is X-linked lymphoproliferative disorder. When affected boys develop an EBV infection, such infection does not take the usual self-limited form of infectious mononucleosis but instead evolves into a fatal form of infectious mononucleosis or, even worse, malignant lymphoma.

Most cancers occur in persons who do not suffer from any overt immunodeficiency. If immune surveillance exists, how do cancers evade the immune system in immunocompetent hosts? Several escape mechanisms have been proposed:

- *Selective outgrowth of antigen-negative variants.* During tumor progression, strongly immunogenic subclones may be eliminated. This notion is supported by experiments in which tumors arising in immunocompromised mice express antigens that are recognized, with consequent elimination of the tumors by the immune system in normal mice, whereas similar tumors arising in immunocompetent mice are nonimmunogenic.
- *Loss or reduced expression of histocompatibility molecules.* Tumor cells may fail to express normal levels of human leukocyte antigen (HLA) class I, escaping attack by CTLs. Such cells, however, may trigger NK cells.
- *Immunosuppression.* Many oncogenic agents (e.g., chemicals, ionizing radiation) suppress host immune responses. Tumors or tumor products also may be immunosuppressive. For example, TGF-β, secreted in large quantities by many tumors, is a potent immunosuppressant. In some cases, the immune response induced by the tumor may inhibit tumor immunity. Several mechanisms of such inhibition have been described. For instance, recognition of tumor cells may lead to engagement of the T cell inhibitory receptor, CTLA-4, or activation of regulatory T cells that suppress immune responses. More insidiously, some tumors express FasL, which can engage Fas on immune cell surfaces and induce the immune cell to enter apoptosis!
- *Antigen masking*. Many tumor cells produce a thicker coat of external glycocalyx molecules, such as sialic acid–containing mucopolysaccharides, than normal cells. This thick coat may block access of immune cells to antigen-presenting molecules, thereby preventing antigen recognition and cell killing.
- *Downregulation of co-stimulatory molecules.* Costimulatory molecules are required to initiate strong T cell responses. Many tumors reduce expression of these costimulatory molecules.

#### SUMMARY

**Immune Surveillance**

- Tumor cells can be recognized by the immune system as non-self and destroyed.
- Antitumor activity is mediated by predominantly cell-mediated mechanisms. Tumor antigens are presented on the cell surface by MHC class I molecules and are recognized by CD8+ CTLs.
- The different classes of tumor antigens include products of mutated proto-oncogenes, tumor suppressor genes, overexpressed or aberrantly expressed proteins, tumor antigens produced by oncogenic viruses, oncofetal antigens, altered glycolipids and glycoproteins, and cell type–specific differentiation antigens.
- Immunosuppressed patients have an increased risk for development of cancer.
- In immunocompetent patients, tumors may avoid the immune system by several mechanisms, including selective outgrowth of antigen-negative variants, loss or reduced expression of histocompatibility antigens, and immunosuppression mediated by secretion of factors (e.g., TGF-β) from the tumor.

## CLINICAL ASPECTS OF NEOPLASIA

The importance of neoplasms ultimately lies in their effects on patients. Although malignant tumors are of course more threatening than benign tumors, morbidity and mortality may be associated with any tumor, even a benign one. Indeed, both malignant and benign tumors may cause problems because of (1) location and impingement on adjacent structures, (2) functional activity such as hormone synthesis or the development of paraneoplastic syndromes, (3) bleeding and infections when the tumor ulcerates through adjacent surfaces, (4) symptoms that result from rupture or infarction, and (5) cachexia or wasting. The following discussion considers the effects of a tumor on the host, the grading and clinical staging of cancer, and the laboratory diagnosis of neoplasms.

### Effects of Tumor on Host

Location is crucial in both benign and malignant tumors. A small (1-cm) pituitary adenoma can compress and destroy the surrounding normal gland, giving rise to hypopituitarism. A 0.5-cm leiomyoma in the wall of the renal artery may encroach on the blood supply, leading to renal ischemia and hypertension. A comparably small carcinoma within the common bile duct may induce fatal biliary tract obstruction.

Hormone production is seen with benign and malignant neoplasms arising in endocrine glands. Adenomas and carcinomas arising in the beta cells of the pancreatic islets of Langerhans can produce hyperinsulinism, sometimes fatal. By analogy, some adenomas and carcinomas of the adrenal cortex elaborate corticosteroids that affect the patient (e.g., aldosterone, which induces sodium retention, hypertension, and hypokalemia). Such hormonal activity is more likely with a well-differentiated benign tumor than with a corresponding carcinoma.

A tumor may ulcerate through a surface, with consequent bleeding or secondary infection. Benign or malignant neoplasms that protrude into the gut lumen may become caught in the peristaltic pull of the gut, causing intussusception (Chapter 14) and intestinal obstruction or infarction.

### *Cancer Cachexia*

Many cancer patients suffer progressive loss of body fat and lean body mass, accompanied by profound weakness, anorexia, and anemia—a condition referred to as *cachexia.* There is some correlation between the size and extent of spread of the cancer and the severity of the cachexia. However, cachexia is not caused by the nutritional demands of the tumor. Although patients with cancer often are anorexic, current evidence indicates that cachexia results from the action of soluble factors such as cytokines produced by the tumor and the host, rather than reduced food intake. In patients with cancer, calorie expenditure remains high, and basal metabolic rate is increased, despite reduced food intake. This is in contrast with the lower metabolic rate that occurs as an adaptive response in starvation. The basis of these metabolic abnormalities is not fully understood. It is suspected that TNF produced by macrophages in response to tumor cells or by the tumor cells themselves mediates cachexia. TNF suppresses appetite and inhibits the action of lipoprotein lipase, inhibiting the release of free fatty acids from lipoproteins. Additionally, a protein-mobilizing factor called proteolysis-inducing factor, which causes breakdown of skeletal muscle proteins by the ubiquitin-proteosome pathway, has been detected in the serum of cancer patients. Other molecules with lipolytic action also have been found. There is no satisfactory treatment for cancer cachexia other than removal of the underlying cause, the tumor.

### *Paraneoplastic Syndromes*

Symptom complexes that occur in patients with cancer and that cannot be readily explained by local or distant spread of the tumor or by the elaboration of hormones not indigenous to the tissue of origin of the tumor are referred to as *paraneoplastic syndromes.* They appear in 10% to 15% of patients with cancer, and their clinical recognition is important for several reasons:

- Such syndromes may represent the earliest manifestation of an occult neoplasm.
- In affected patients, the pathologic changes may be associated with significant clinical illness and may even be lethal.
- The symptom complex may mimic metastatic disease, thereby confounding treatment.

The paraneoplastic syndromes are diverse and are associated with many different tumors (Table 5–5). *The most common such syndromes are hypercalcemia, Cushing syndrome, and nonbacterial thrombotic endocarditis*; the neoplasms most often associated with these and other syndromes are lung and breast cancers and hematologic malignancies. Hypercalcemia in cancer patients is multifactorial, but the most important mechanism is the synthesis of a parathyroid hormone–related protein (PTHrP) by tumor cells. Also implicated are other tumor-derived factors, such as TGF-α, a polypeptide factor that activates osteoclasts, and the active form of vitamin D. Another possible mechanism for hypercalcemia is widespread osteolytic metastatic disease of bone; of note, however, *hypercalcemia resulting from skeletal metastases is not a paraneoplastic syndrome.* Cushing syndrome arising as a paraneoplastic phenomenon usually is related to ectopic production of ACTH or ACTH-like polypeptides by cancer cells, as occurs in small cell cancers of the lung. Sometimes one tumor induces several syndromes concurrently. For example, bronchogenic carcinomas may elaborate products identical to or having the effects of ACTH, antidiuretic hormone, parathyroid hormone, serotonin, human chorionic gonadotropin, and other bioactive substances.

Paraneoplastic syndromes also may manifest as hypercoagulability, leading to venous thrombosis and nonbacterial thrombotic endocarditis (Chapter 10). Other manifestations are clubbing of the fingers and hypertrophic osteoarthropathy in patients with lung carcinomas (Chapter 12). Still others are discussed in the consideration of cancers of the various organs of the body.

## Grading and Staging of Cancer

Methods to quantify the probable clinical aggressiveness of a given neoplasm and its apparent extent and spread in the individual patient are necessary for making an accurate prognosis and for comparing end results of various treatment protocols. For instance, the results of treating extremely small, highly differentiated thyroid adenocarcinomas that are localized to the thyroid gland are likely to be different from those obtained from treating highly anaplastic thyroid cancers that have invaded the neck organs.

The *grading* of a cancer attempts to establish some estimate of its aggressiveness or level of malignancy based on the cytologic differentiation of tumor cells and the number of mitoses within the tumor. The cancer may be classified as grade I, II, III, or IV, in order of increasing anaplasia. Criteria for the individual grades vary with each form of neoplasia and are not detailed here. Difficulties in establishing clear-cut criteria have led in some instances to descriptive characterizations (e.g., "well-differentiated adenocarcinoma with no evidence of vascular or lymphatic invasion" or "highly anaplastic sarcoma with extensive vascular invasion").

*Staging* of cancers is based on the size of the primary lesion, its extent of spread to regional lymph nodes, and the presence or absence of metastases. This assessment usually is based on clinical and radiographic examination (computed tomography and magnetic resonance imaging) and in some cases surgical exploration. Two methods of

**Table 5–5** Paraneoplastic Syndromes

| Clinical Syndrome | Major Forms of Neoplasia | Causal Mechanism(s)/Agent(s) |
|---|---|---|
| **Endocrinopathies** | | |
| Cushing syndrome | Small cell carcinoma of lung<br>Pancreatic carcinoma<br>Neural tumors | ACTH or ACTH-like substance |
| Syndrome of inappropriate antidiuretic hormone secretion | Small cell carcinoma of lung; intracranial neoplasms | Antidiuretic hormone or atrial natriuretic hormones |
| Hypercalcemia | Squamous cell carcinoma of lung<br>Breast carcinoma<br>Renal carcinoma<br>Adult T cell leukemia/lymphoma<br>Ovarian carcinoma | Parathyroid hormone–related protein, TGF-α, TNF, IL-1 |
| Hypoglycemia | Fibrosarcoma<br>Other mesenchymal sarcomas<br>Hepatocellular carcinoma | Insulin or insulin-like substance |
| Carcinoid syndrome | Bronchial adenoma (carcinoid)<br>Pancreatic carcinoma<br>Gastric carcinoma | Serotonin, bradykinin |
| Polycythemia | Renal carcinoma<br>Cerebellar hemangioma<br>Hepatocellular carcinoma | Erythropoietin |
| **Nerve and Muscle Syndrome** | | |
| Myasthenia | Bronchogenic carcinoma, thymoma | Immunologic |
| Disorders of the central and peripheral nervous systems | Breast carcinoma, teratoma | |
| **Dermatologic Disorders** | | |
| Acanthosis nigricans | Gastric carcinoma<br>Lung carcinoma<br>Uterine carcinoma | Immunologic; secretion of epidermal growth factor |
| Dermatomyositis | Bronchogenic and breast carcinoma | Immunologic |
| **Osseous, Articular, and Soft Tissue Changes** | | |
| Hypertrophic osteoarthropathy and clubbing of the fingers | Bronchogenic carcinoma | Unknown |
| **Vascular and Hematologic Changes** | | |
| Venous thrombosis (Trousseau phenomenon) | Pancreatic carcinoma<br>Bronchogenic carcinoma<br>Other cancers | Tumor products (mucins that activate clotting) |
| Nonbacterial thrombotic endocarditis | Advanced cancers | Hypercoagulability |
| Anemia | Thymoma | Immunologic |
| **Others** | | |
| Nephrotic syndrome | Various cancers | Tumor antigens, immune complexes |

ACTH, adrenocorticotropic hormone; IL-1, interleukin-1; TGF-α, transforming growth factor-α; TNF, tumor necrosis factor.

staging are currently in use: the TNM system (*T,* primary tumor; *N,* regional lymph node involvement; *M,* metastases) and the AJC (American Joint Committee) system. In the *TNM system*, T1, T2, T3, and T4 describe the increasing size of the primary lesion; N0, N1, N2, and N3 indicate progressively advancing node involvement; and M0 and M1 reflect the absence and presence, respectively, of distant metastases. In the *AJC method,* the cancers are divided into stages 0 to IV, incorporating the size of primary lesions and the presence of nodal spread and of distant metastases. Examples of the application of these two staging systems are cited in subsequent chapters. Of note, *when compared with grading, staging has proved to be of greater clinical value.*

## SUMMARY

### Clinical Aspects of Tumors

- *Cachexia,* defined as progressive loss of body fat and lean body mass, accompanied by profound weakness, anorexia, and anemia, is caused by release of cytokines by the tumor or host.
- Paraneoplastic syndromes, defined as systemic symptoms that cannot be explained by tumor spread or by hormones appropriate to the tissue, are caused by the ectopic production and secretion of bioactive substances such as ACTH, PTHrP, or TGF-α.

- Grading of tumors is determined by cytologic appearance and is based on the idea that behavior and differentiation are related, with poorly differentiated tumors having more aggressive behavior.
- Staging, determined by surgical exploration or imaging, is based on size, local and regional lymph node spread, and distant metastases. Staging is of greater clinical value than grading.

## Laboratory Diagnosis of Cancer

### *Morphologic Methods*

In most instances, the laboratory diagnosis of cancer is not difficult. The two ends of the benign–malignant spectrum pose no problems; in the middle, however, lies a "no man's land" where the wise tread cautiously. Clinicians tend to underestimate the contributions they make to the diagnosis of a neoplasm. Clinical and radiologic data are invaluable for optimal pathologic diagnosis. Radiation-induced changes in the skin or mucosa can be similar to those of cancer. Sections taken from a healing fracture can mimic an osteosarcoma. The laboratory evaluation of a lesion can be only as good as the specimen submitted for examination. The specimen must be adequate, representative, and properly preserved.

Several sampling approaches are available, including excision or biopsy, fine-needle aspiration, and cytologic smears. When excision of a lesion is not possible, selection of an appropriate site for biopsy of a large mass requires awareness that the margins may not be representative and the center may be largely necrotic. Requesting *frozen section* diagnosis is sometimes desirable, as, for example, in determining the nature of a mass lesion or in evaluating the regional lymph nodes in a patient with cancer for metastasis. This method, in which a sample is quick-frozen and sectioned, permits histologic evaluation within minutes. In experienced, competent hands, frozen section diagnosis is accurate, but there are particular instances in which the better histologic detail provided by the more time-consuming routine methods is needed. In such instances, it is better to wait a few days, despite the drawbacks, than to perform inadequate or unnecessary surgery.

*Fine needle aspiration* of tumors is another approach that is widely used. It involves aspiration of cells from a mass, followed by cytologic examination of the smear. This procedure is used most commonly with readily palpable lesions affecting the breast, thyroid, lymph nodes, and salivary glands. Modern imaging techniques permit extension of the method to deeper structures, such as the liver, pancreas, and pelvic lymph nodes. Use of this diagnostic modality obviates surgery and its attendant risks. Although it entails some difficulties, such as small sample size and sampling errors, in experienced hands it can be reliable, rapid, and useful.

*Cytologic (Papanicolaou) smears* provide another method for the detection of cancer. Historically, this approach has been used widely for discovery of carcinoma of the cervix, often at an in situ stage, but now it is used to investigate many other forms of suspected malignancy, such as endometrial carcinoma, bronchogenic carcinoma, bladder and prostate tumors, and gastric carcinomas; for the identification of tumor cells in abdominal, pleural, joint, and cerebrospinal fluids; and, less commonly, for evaluation of other forms of neoplasia. Neoplastic cells are less cohesive than others and are therefore shed into fluids or secretions (Fig. 5–33). The shed cells are evaluated for features of anaplasia indicative of their origin from a tumor. The gratifying control of cervical cancer is the best testament to the value of the cytologic method.

*Immunocytochemistry* offers a powerful adjunct to routine histologic examination. Detection of cytokeratin by specific monoclonal antibodies labeled with peroxidase points to a diagnosis of undifferentiated carcinoma rather than large cell lymphoma. Similarly, detection of prostate-specific antigen (PSA) in metastatic deposits by immunohistochemical staining allows definitive diagnosis of a primary tumor in the prostate. Immunocytochemical detection of estrogen receptors allows prognostication and directs therapeutic intervention in breast cancers.

*Flow cytometry* is used routinely in the classification of leukemias and lymphomas. In this method, fluorescent antibodies against cell surface molecules and

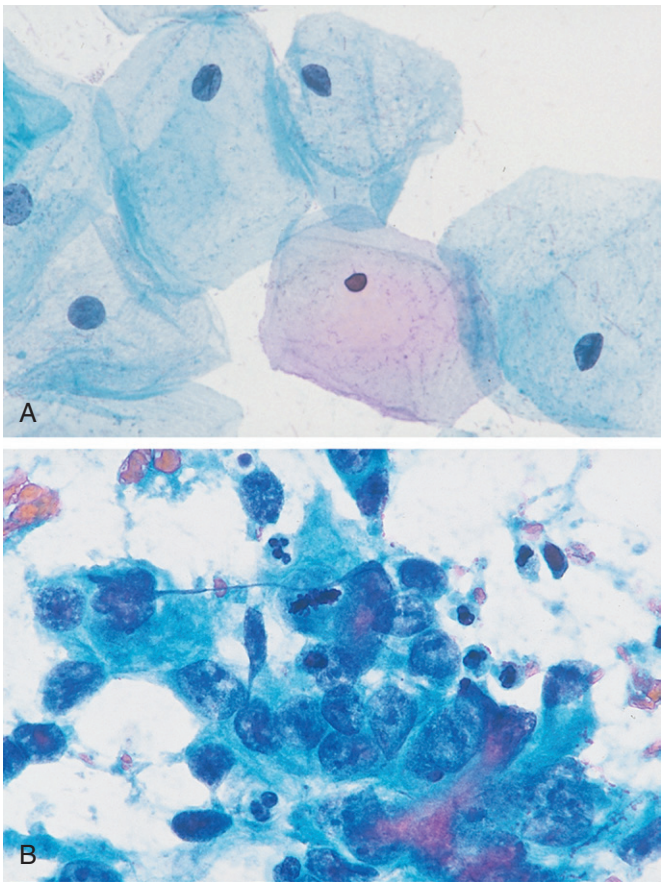


**Figure 5–33 A,** Normal Papanicolaou smear from the uterine cervix. Large, flat cells with small nuclei are typical. **B,** Abnormal smear containing a sheet of malignant cells with large hyperchromatic nuclei. Nuclear pleomorphism is evident, and one cell is in mitosis. A few interspersed neutrophils, much smaller in size and with compact, lobate nuclei, are seen.

*(Courtesy of Dr. Richard M. DeMay, Department of Pathology, University of Chicago, Chicago, Illinois.)*

differentiation antigens are used to obtain the phenotype of malignant cells.

### Tumor Markers

Biochemical assays for tumor-associated enzymes, hormones, and other tumor markers in the blood cannot be utilized for definitive diagnosis of cancer; however, they can be useful screening tests and in some instances have utility in quantitating the response to therapy or detecting disease recurrence. The application of these assays is considered with many of the specific forms of neoplasia discussed in other chapters, so only a few examples suffice here. PSA, used to screen for prostatic adenocarcinoma, may be one of the most frequently and successfully used tumor markers in clinical practice. Prostatic carcinoma can be suspected when elevated levels of PSA are found in the blood. However, PSA screening also highlights problems encountered with use of virtually every tumor marker. Although PSA levels often are elevated in cancer, PSA levels also may be elevated in benign prostatic hyperplasia (Chapter 17). Furthermore, there is no PSA level that ensures that a patient does not have prostate cancer. *Thus, the PSA test suffers from both low sensitivity and low specificity*. PSA assay is extremely valuable, however, for detecting residual disease or recurrence following treatment for prostate cancer. Other tumor markers occasionally used in clinical practice include carcinoembryonic antigen (CEA), which is elaborated by carcinomas of the colon, pancreas, stomach, and breast, and alpha fetoprotein, which is produced by hepatocellular carcinomas, yolk sac remnants in the gonads, and occasionally teratocarcinomas and embryonal cell carcinomas. Unfortunately, like PSA, both of these markers can be produced in a variety of non-neoplastic conditions as well. Thus, CEA and alpha fetoprotein assays lack both specificity and sensitivity required for the early detection of cancers. As with PSA screening, they are still particularly useful in the detection of recurrences after excision. With successful resection of the tumor, these markers disappear from the serum; their reappearance almost always signifies the beginning of the end. CEA is further discussed in Chapter 14 and alpha fetoprotein in Chapter 15.

### Molecular Diagnosis

An increasing number of molecular techniques are being used for the diagnosis of tumors and for predicting their behavior.

- *Diagnosis of malignancy*: Because each T and B cell exhibits unique rearrangement of its antigen receptor genes, polymerase chain reaction (PCR)–based detection of T cell receptor or immunoglobulin genes allows distinction between monoclonal (neoplastic) and polyclonal (reactive) proliferations. Many hematopoietic neoplasms, as well as a few solid tumors, are defined by particular translocations, so the diagnosis can be made by detection of such translocations. For example, fluorescence in situ hybridization (FISH) or PCR analysis (Chapter 6) can be used to detect translocations characteristic of Ewing sarcoma and several leukemias and lymphomas. PCR-based detection of *BCR-ABL* transcripts provides the molecular diagnosis of chronic myeloid leukemia.
- *Prognosis and behavior*: Certain genetic alterations are associated with a poor prognosis, and thus the presence of these alterations determines the patient's subsequent therapy. FISH and PCR methods can be used to detect amplification of oncogenes such as *HER2/NEU* and *NMYC,* which provide prognostic and therapeutic information for breast cancers and neuroblastomas.
- *Detection of minimal residual disease*: Another emerging use of molecular techniques is for detection of minimal residual disease after treatment. For example, detection of *BCR-ABL* transcripts by PCR assay gives a measure of residual disease in patients treated for chronic myeloid leukemia. Recognition that virtually all advanced tumors are associated with both intact circulating tumor cells and products derived from tumors (e.g., tumor DNA) has led to interest in following tumor burden through sensitive blood tests.
- *Diagnosis of hereditary predisposition to cancer*: Germline mutation of several tumor suppressor genes, such as *BRCA1,* increases a patient's risk for development of certain types of cancer. Thus, detection of these mutated alleles may allow the patient and the physician to devise an aggressive screening protocol, as well as an opportunity for prophylactic surgery. In addition, such detection allows genetic counseling of relatives at risk.
- *Therapeutic decision-making*: Therapies that directly target specific mutations are increasingly being developed, and thus detection of such mutations in a tumor can guide the development of targeted therapy, as discussed later. It is now becoming evident that certain targetable mutations may transgress morphologic categories. For example, mutations of the ALK kinase, originally described in a subset of T cell lymphomas, also have been identified in a small percentage of non–small cell carcinomas and neuroblastomas. Clinical trials have shown that lung cancers with ALK mutations respond to ALK inhibitors, whereas other lung cancers do not, leading to recent FDA approval of ALK inhibitors for use in patients with "ALK-mutated" lung cancer. Another recent dramatic example of molecularly "tailored" therapy is seen in melanoma, in which tumors with a valine for glutamate substitution in amino acid 600 (V600E) of the serine/threonine kinase BRAF respond well to BRAF inhibition, whereas melanomas without this mutation show no response. Of some interest, the V600E mutation is also present in a subset of colon cancers, certain thyroid cancers, 100% of hairy cell leukemias, and Langerhans cell histiocytosis (Fig. 5–34). These tumors are morphologically diverse and have distinct cells of origin, but they share identical oncogenic lesions in a common pro-growth pathway.

### Molecular Profiling of Tumors

Molecular profiling of tumors can be done both at the level of mRNA and by nucleotide sequencing. Each of these two is described next.

#### Expression Profiling

This technique allows simultaneous measurements of the expression levels of several thousand genes. The principle of this so-called gene chip technology is illustrated in Figure 5–35 and described briefly here.

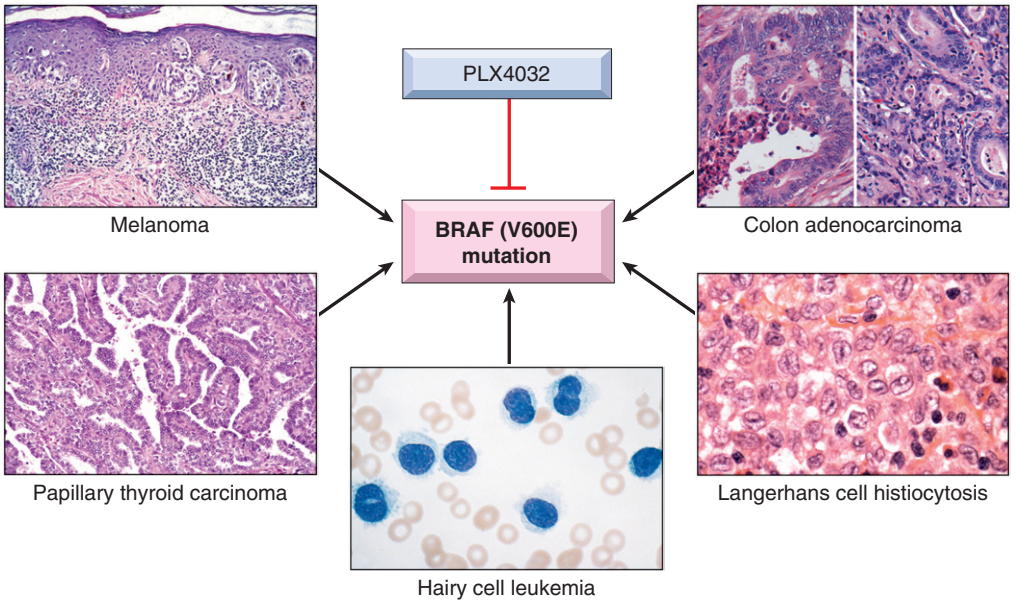


**Figure 5–34** Diverse tumor types that share a common mutation, BRAF (V600E), may be candidates for treatments with the same drug, called PLX4032.

As can be seen, the process begins by extraction of mRNA from any two sources (e.g., normal and malignant, normal and preneoplastic, or two tumors of the same histologic type). Complementary DNA (cDNA) copies of the mRNA are synthesized in vitro with fluorescently labeled nucleotides. The fluorescence-labeled cDNA strands are hybridized to sequence-specific DNA probes linked to a solid support, such as a silicon chip. A 1-$cm^2$ chip can contain thousands of probes arranged in an array of columns and rows. After hybridization, high-resolution laser scanning detects fluorescent signals from each of the spots. The fluorescence intensity of each spot is proportional to the level of expression of the original mRNA used to synthesize the cDNA hybridized to that spot. For each sample, therefore, the expression level of thousands of genes is obtained, and by using bioinformatic tools, the relative levels of gene expression in different samples can be compared. In essence, a molecular profile is generated for each tissue analyzed.

Such analysis has revealed that phenotypically identical large B cell lymphomas (Chapter 11) from different patients are heterogeneous with respect to their gene expression and survival rates. Similar approaches are now being explored in other cancers, such as breast cancers and melanomas.

### Whole Genome Sequencing

*The progression and development of next-generation sequencing technologies promise even more in-depth analysis of tumors.* The advances in such technologies are currently outpacing the famous Moore's law of microprocessors. Sequencing an entire tumor genome, which just a couple of years ago would have taken months and millions of dollars, now takes days and costs a few thousand dollars. Sequences of the entire tumor genomes, when compared with the normal genome from the same patient, can reveal all the somatic alterations present in a tumor.

Recent results from genomic analyses of tumors have revealed that individual tumors can contain from a handful of somatic mutations (certain childhood leukemias) to tens of thousands of mutations, with the highest mutational burden being found in cancers associated with mutagen exposure, such as lung cancer and skin cancer. Among these are two types of mutations: (1) those that subvert normal control of cell proliferation, differentiation, and homeostasis and (2) those that have no effect on cell phenotype. The first set of mutations is referred to as *driver mutations* because they may drive the neoplastic process and hence could be therapeutic targets. The other set of mutations, often much more numerous than driver mutations, most often fall in noncoding regions of the genome or have a neutral effect on growth, not conferring any advantage or disadvantage. Such mutations are called *passenger mutations*. They result from genomic instability of cancer cells and are merely "along for the ride."

In general, driver mutations are recurrent and are present in a substantial percentage of patients with a particular cancer. Thus, for example, *BCR-ABL* fusion genes are present in all cases of chronic myelogenous leukemia, and the fusion protein is an excellent drug target. However, driver mutations may be present in only a subset of tumors of a particular type. For example, approximately 4% of non–small cell lung cancers harbor an *EML4-ALK* tyrosine kinase fusion gene; as already mentioned, in these relatively rare instances, the patient responds well to ALK inhibitors. An additional complication is that some passenger mutations nevertheless have important roles in drug resistance. For example, the mutations in BCR-ABL that confer resistance to imatinib in chronic myelogenous leukemia are present as passenger mutations in rare clones before therapy begins. Because they confer a powerful selective advantage, these mutations are converted from passengers to drivers in the face of drug therapy; it is suspected that the genomic instability of cancer cells sows the seeds of resistance through similar scenarios in many kinds of tumors. Furthermore, in some instances, several distinct and relatively uncommon mutations all converge on the

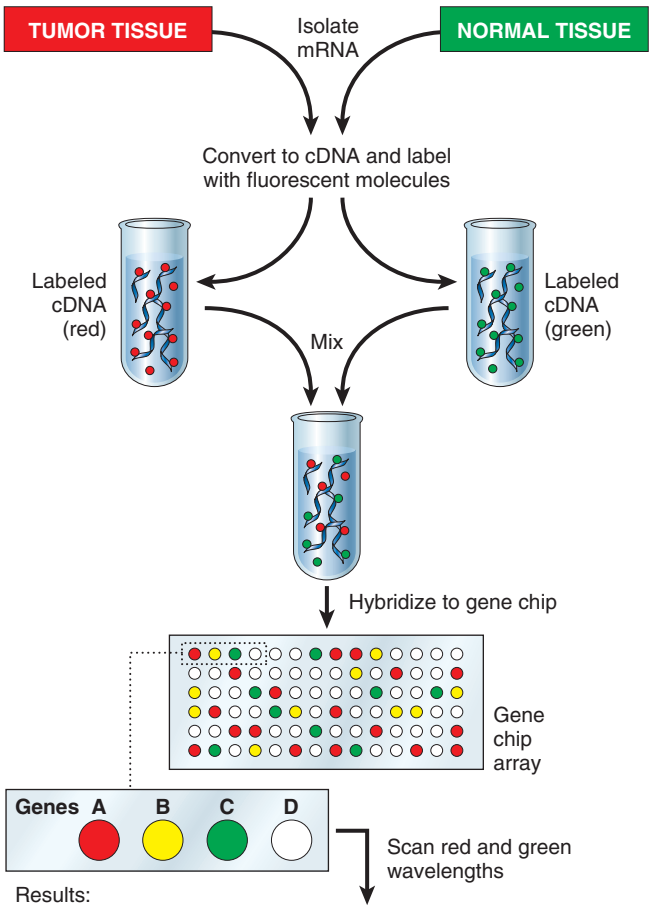


| | Fluorescence intensity Red | Green | Conclusion |
|---|---|---|---|
| Gene A | +++ | + | Upregulated in neoplastic tissue |
| Gene B | ++ | ++ | Unchanged in neoplastic tissue |
| Gene C | + | +++ | Downregulated in neoplastic tissue |
| Gene D | – | – | Not expressed in either tissue |

**Figure 5–35** Complementary DNA (cDNA) microarray analysis. Messenger RNA (mRNA) is extracted from the samples, reverse transcribed to cDNA, and labeled with fluorescent molecules. In the case illustrated, *red* fluorescent molecules were used for normal cDNA, and *green* molecules were used for tumor cDNA. The labeled cDNAs are mixed and applied to a gene chip, which contains thousands of DNA probes representing known genes. The labeled cDNAs hybridize to spots that contain complementary sequences. The hybridization is detected by laser scanning of the chip, and the results are read in units of red or green fluorescence intensity. In the example shown, *spot A* has high red fluorescence, indicating that a greater number of cDNAs from neoplastic cells hybridized to gene A. Thus, gene A seems to be upregulated in tumor cells. *(Courtesy of Dr. Robert Anders, Department of Pathology, University of Chicago, Chicago, Illinois.)*

same pathway (such as resistance to apoptosis) and contribute to the cancer phenotype. It is therefore useful to categorize mutations on the basis of their ability to drive the cells along the "hallmarks of cancer" pathways.

It is hoped that identification of all potentially targetable mutations in each individual tumor will refocus the treatment of tumors from the tissue of origin to the molecular lesion, as drugs that target specific mutations are developed (Fig. 5–36). This approach represents a paradigm shift

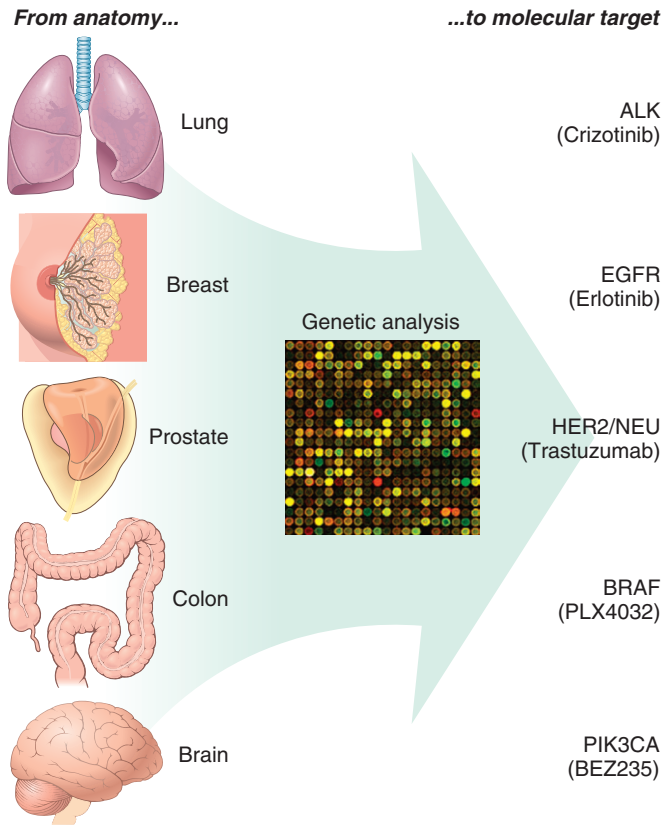


**Figure 5–36** A paradigm shift: Classification of cancer according to therapeutic targets rather than cell of origin and morphology.

in the classification and therapy of tumors. Perhaps in the future the diverse group of tumors that bear a common mutation such as BRAF will be classified as BRAF-omas (Fig. 5–34), rather than individual types based on morphology or cell of origin!

## SUMMARY

### Laboratory Diagnosis of Cancer

- Several sampling approaches exist for the diagnosis of tumors, including excision, biopsy, fine-needle aspiration, and cytologic smears.
- Immunohistochemistry and flow cytometry studies help in the diagnosis and classification of tumors, because distinct protein expression patterns define different entities.
- Proteins released by tumors into the serum, such as PSA, can be used to screen populations for cancer and to monitor for recurrence after treatment.
- Molecular analyses are used to determine diagnosis, prognosis, the detection of minimal residual disease, and the diagnosis of hereditary predisposition to cancer.
- Molecular profiling of tumors by cDNA arrays and sequencing can determine expression of large segments of the genome and catalog all of the mutations in the tumor genome and thus may be useful in molecular stratification of otherwise identical tumors or those of distinct histogenesis that share a mutation for the purpose of treatment and prognostication.

## BIBLIOGRAPHY


Ahmed Z, Bicknell R: Angiogenic signalling pathways. Methods Mol Biol 467:3–24, 2009. *[Discussion of many signaling pathways in angiogenesis.]*

Artandi SE, DePinho RA: Telomeres and telomerase in cancer. Carcinogenesis 31:9–18, 2010. *[Review discussing the importance of telomeres and telomerase.]*

Barrallo-Gimeno A, Nieto MA: The Snail genes as inducers of cell movement and survival: implications in development and cancer. Development 132:3151–3161, 2005. *[Discussion of the genes involved in epithelial-mesenchymal transition in cancer.]*

Berx G, van Roy F: Involvement of members of the cadherin superfamily in cancer. Cold Spring Harb Perspect Biol 1:a003129, 2009. *[Review discussing the role of cadherins and contact inhibition in cancer.]*

Bierie B, Moses HL: Tumour microenvironment: TGFbeta: the molecular Jekyll and Hyde of cancer. Nat Rev Cancer 6:506–520, 2006. *[Review discussing the tumor-suppressive and tumor-promoting effects of TGF-β.]*

Burkhart DL, Sage J: Cellular mechanisms of tumour suppression by the retinoblastoma gene. Nat Rev Cancer 8:671–682, 2008. *[Review of* Rb *function.]*

Ciccia A, Elledge SJ: The DNA damage response: making it safe to play with knives. Mol Cell 40:179–204, 2010. *[Review discussing the DNA damage response.]*

Coghlin C, Murray GI: Current and emerging concepts in tumour metastasis. J Pathol 222:1–15, 2010. *[Discussion of current concepts in metastasis.]*

Collado M, Serrano M: Senescence in tumours: evidence from mice and humans. Nat Rev Cancer 10:51–57, 2010. *[Update on mechanisms of senescence.]*

Feron O: Pyruvate into lactate and back: from the Warburg effect to symbiotic energy fuel exchange in cancer cells. Radiother Oncol 92:329–333, 2009. *[An account of the reemergence and molecular pathways of reprogramming of energy metabolism in cancer.]*

Grivennikov SI, Greten FR, Karin M: Immunity, inflammation, and cancer. Cell 140:883–899, 2010. *[A summary of the links between inflammation and the development of cancer.]*

Hanahan D, Weinberg RA: The hallmarks of cancer (2011): the next generation. Cell 144:646–674, 2011. *[Reexamination of the hallmarks of cancer.]*

Junttila MR, Evan GI: p53—a jack of all trades but master of none. Nat Rev Cancer 9:821–829, 2009. *[Update summarizing p53 function.]*

Kalluri R, Zeisberg M: Fibroblasts in cancer. Nat Rev Cancer 6:392–401, 2006. *[Review discussing the role of stroma in cancer.]*

Mathew R, Karantza-Wadsworth V, White E: Role of autophagy in cancer. Nat Rev Cancer 7:961–967, 2007. *[A discussion of the mechanisms of autophagy.]*

Negrini S, Gorgoulis VG, Halazonetis TD: Genomic instability—an evolving hallmark of cancer. Nat Rev Mol Cell Biol 11:220–228, 2010. *[Review on mechanisms of genomic instability, an enabler of malignancy.]*

Perona R: Cell signalling: growth factors and tyrosine kinase receptors. Clin Transl Oncol 8:77–82, 2006. *[Update on signaling pathways in cancer.]*

Stratton MR, Campbell PJ, Futreal PA: The cancer genome. Nature 458:719–724, 2009. *[Excellent summary of next-generation sequencing technologies and their application to cancer.]*

Willis SN, Adams JM: Life in the balance: how BH3-only proteins induce apoptosis. Curr Opin Cell Biol 17:617–625, 2005. *[A review of the mechanisms of apoptosis.]*

Witsch E, Sela M, Yarden Y: Roles for growth factors in cancer progression. Physiology (Bethesda) 25:85–101, 2010. *[An update on the role of growth factors in cancer.]*

See Targeted Therapy available online at studentconsult.com

CHAPTER 6

# Genetic and Pediatric Diseases

CHAPTER CONTENTS

**GENETIC DISEASES 215**
Nature of Genetic Abnormalities Contributing to Human Disease 216
Mutations in Protein-Coding Genes 216
Alterations in Protein-Coding Genes Other Than Mutations 216
Mendelian Disorders: Diseases Caused by Single-Gene Defects 218
Transmission Patterns of Single-Gene Disorders 219
Diseases Caused by Mutations in Genes Encoding Structural Proteins 220
Diseases Caused by Mutations in Genes Encoding Receptor Proteins or Channels 222
Diseases Caused by Mutations in Genes Encoding Enzyme Proteins 227
Diseases Caused by Mutations in Genes Encoding Proteins That Regulate Cell Growth 233
Complex Multigenic Disorders 234
Cytogenetic Disorders 234
Numeric Abnormalities 235
Structural Abnormalities 235
General Features of Chromosomal Disorders 236
Cytogenetic Disorders Involving Autosomes 237
Cytogenetic Disorders Involving Sex Chromosomes 239
Single-Gene Disorders with Atypical Patterns of Inheritance 241
Triplet Repeat Mutations: Fragile X Syndrome 241
Diseases Caused by Mutations in Mitochondrial Genes 243
Diseases Caused by Alterations of Imprinted Regions: Prader-Willi and Angelman Syndromes 243
**PEDIATRIC DISEASES 245**
Congenital Anomalies 245
Etiology 247
Perinatal Infections 249
Prematurity and Fetal Growth Restriction 249
Respiratory Distress Syndrome of the Newborn 250
Necrotizing Enterocolitis 252
Sudden Infant Death Syndrome 252
Fetal Hydrops 254
Immune Hydrops 254
Nonimmune Hydrops 255
Tumors and Tumor-Like Lesions of Infancy and Childhood 257
Benign Tumors 257
Malignant Tumors 258
Molecular Diagnosis of Mendelian and Complex Disorders 263
Molecular Diagnosis of Copy Number Abnormalities 263
Direct Detection of DNA Mutations by Polymerase Chain Reaction (PCR) Analysis 264
Linkage Analysis and Genome-Wide Association Studies 266
Indications for Genetic Analysis 267

## GENETIC DISEASES

The completion of the human genome project has been a landmark event in the study of human diseases. It has now been established that humans have only about 25,000 protein-coding genes, far fewer than the 100,000 previously estimated and almost half the number in the lowly rice plant (*Oryza sativa*)! The unraveling of this "genetic architecture" promises to unlock secrets of inherited as well as acquired human disease, since ultimately all diseases involve changes in gene structure or expression. Powerful technologies now allow applications of the human gene sequences to the analysis of human diseases. For example, the human genome project cost approximately 3 billion dollars and many years to complete; current high-throughput sequencing technologies can do the same work in a few weeks for less than $10,000. The speed and reduced costs of DNA sequencing are increasingly facilitating the application of "personalized medicine" to the treatment of cancer and other diseases with a genetic component.

Because several pediatric disorders are of genetic origin, developmental and pediatric diseases are discussed along with genetic diseases in this chapter. However, *it must be borne in mind that not all genetic disorders manifest in infancy and childhood, and conversely, many pediatric diseases are not of genetic origin.* To the latter category belong diseases resulting from immaturity of organ systems. In this context it is helpful to clarify three commonly used terms: hereditary, familial, and congenital. *Hereditary* disorders, by definition, are derived from one's parents, are transmitted in the gametes through the generations, and therefore are *familial.* The term *congenital* simply implies "present at birth." Of note, some congenital diseases are not genetic (e.g., congenital syphilis). On the other hand, not all genetic diseases are congenital; the expression of Huntington

disease, for example, begins only after the third or fourth decade of life.

## NATURE OF GENETIC ABNORMALITIES CONTRIBUTING TO HUMAN DISEASE

There are several types of genetic abnormalities that affect the structure and function of proteins, disrupting cellular homeostasis and contributing to disease.

### Mutations in Protein-Coding Genes

As is well recognized, the term *mutation* refers to permanent changes in the DNA. Those that affect germ cells are transmitted to the progeny and may give rise to inherited diseases. Mutations in somatic cells are not transmitted to the progeny but are important in the causation of cancers and some congenital malformations.

Details of specific mutations and their effects are discussed along with the relevant disorders throughout this book. Cited here are some common examples of gene mutations and their effects:

- *Point mutations* result from the substitution of a single nucleotide base by a different base, resulting in the replacement of one amino acid by another in the protein product. The mutation in the β-globin chain of hemoglobin giving rise to sickle cell anemia is an excellent example of a point mutation that alters the meaning of the genetic code. Such mutations are sometimes called *missense mutations.*
- By contrast, certain point mutations may change an amino acid codon to a chain termination codon, or *stop codon.* Such "nonsense" mutations interrupt translation, and in most cases RNAs are rapidly degraded, a phenomenon called nonsense mediated decay, such that little or no protein is formed.
- *Frameshift mutations* occur when the insertion or deletion of one or two base pairs alters the reading frame of the DNA strand.
- *Trinucleotide repeat mutations* belong to a special category, because these mutations are characterized by amplification of a sequence of three nucleotides. Although the specific nucleotide sequence that undergoes amplification varies with different disorders, all affected sequences share the nucleotides guanine (G) and cytosine (C). For example, in fragile X syndrome, prototypical of this category of disorders, there are 200 to 4000 tandem repeats of the sequence CGG within a gene called *FMR1.* In normal populations, the number of repeats is small, averaging 29. The expansions of the trinucleotide sequences prevent normal expression of the *FMR1* gene, thus giving rise to mental retardation. Another distinguishing feature of trinucleotide repeat mutations is that they are dynamic (i.e., the degree of amplification increases during gametogenesis). These features, discussed in greater detail later in this chapter, influence the pattern of inheritance and the phenotypic manifestations of the diseases caused by this class of mutations.

### Alterations in Protein-Coding Genes Other Than Mutations

In addition to alterations in DNA sequence, coding genes also can undergo structural variations, such as copy number changes (amplifications or deletions), or translocations, resulting in aberrant gain or loss of protein function. As with mutations, structural changes may occur in the germline, or be acquired in somatic tissues. In many instances, pathogenic germ line alterations can involve a contiguous portion of a chromosome rather than a single gene, such as in the 22q microdeletion syndrome, discussed later on. With the widespread availability of array technology for assessing genome-wide DNA copy number variation at very high resolution, pathogenic structural alterations have now been discovered in common disorders such as autism. Cancers often contain somatically acquired structural alterations, including amplifications, deletions, and translocations. The so-called Philadelphia chromosome—translocation t(9;22) between the *BCR* and *ABL* genes in chronic myelogenous leukemia (Chapter 11)—is a classic example.

#### *Sequence and Copy Number Variations (Polymorphisms)*

A surprising revelation from the recent progress in genomics is that, on average, any two individuals share greater than 99.5% of their DNA sequences. Thus, the remarkable diversity of humans is encoded in less than 0.5% of our DNA. Though small when compared to the total nucleotide sequences, this 0.5% represents about 15 million base pairs. The two most common forms of DNA variations (polymorphisms) in the human genome are single-nucleotide polymorphisms (SNPs) and copy number variations (CNVs).

- SNPs represent variation at single isolated nucleotide positions and are almost always biallelic (i.e., one of only two choices exist at a given site within the population, such as A or T). Much effort has been devoted to making SNP maps of the human genome. These efforts have identified over 6 million SNPs in the human population, many of which show wide variation in frequency in different populations. SNPs may occur anywhere in the genome—within exons, introns, or intergenic regions—but less than 1% of SNPs occurs in coding regions. These coding sequence variations are important, since they could alter the gene product and predispose to a phenotypic difference or to a disease. Much more commonly, however, the SNP is just a marker that is co-inherited with a disease-associated gene as a result of physical proximity. Another way of expressing this is to say that the SNP and the causative genetic factor are in linkage disequilibrium. There is optimism that groups of SNPs could serve as reliable markers of risk for multigenic complex diseases such as type II diabetes and hypertension, and that by identifying such variants, strategies for disease prevention could be developed (discussed later).
- CNVs are a recently identified form of genetic variation consisting of different numbers of large contiguous stretches of DNA from 1000 base pairs to millions of base pairs. In some instances these loci are, like SNPs, biallelic and simply duplicated or deleted in a subset of

the population. In other instances there are complex rearrangements of genomic material, with multiple alleles in the human population. Current estimates are that CNVs are responsible for between 5 and 24 million base pairs of sequence difference between any two individuals. Approximately 50% of CNVs involve gene-coding sequences; thus, CNVs may underlie a large portion of human phenotypic diversity. There is a significant overrepresentation of certain gene families in regions affected by CNVs; these include genes involved in the immune system and in the nervous system. It is assumed that copy number diversity in such gene families has been subject to strong evolutionary selection, since they would enhance human adaptation to changing environmental factors.

### *Epigenetic Changes*

*Epigenetic* changes are those involving modulation of gene or protein expression in the absence of alterations in DNA sequence (i.e., mutation) or structure of the encoding gene. Epigenetic regulation is of critical importance during development, as well as in homeostasis of fully developed tissues. One central mechanism of epigenetic regulation is by alterations in the methylation of cytosine residues at gene promoters—heavily methylated promoters become inaccessible to RNA polymerase, leading to transcriptional silencing. Promoter methylation and silencing of tumor suppressor genes (Chapter 5) commonly are observed in many human cancers, leading to unchecked cell growth and proliferation. Another major player in epigenetic regulation of transcription involves the family of *histone proteins,* which are components of structures called nucleosomes, around which DNA is coiled. Histone proteins undergo a variety of reversible modifications (e.g., methylation, acetylation) that affect secondary and tertiary DNA structure, and hence, gene transcription. As expected, abnormalities of histone modification are observed in many acquired diseases such as cancer, leading to transcriptional deregulation. Physiologic epigenetic silencing during development is called *imprinting,* and disorders of imprinting are discussed later on.

### *Alterations in Non-Coding RNAs*

It is worth noting that until recently the major focus of gene hunting has been discovery of genes that encode for proteins. Recent studies indicate, however, that a very large number of genes do not encode proteins. Instead, the non-encoded products of these genes—so-called "non-coding RNAs (ncRNAs)"—play important regulatory functions. Although many distinct families of ncRNAs exist, here we will only discuss two examples: small RNA molecules called *microRNAs (miRNAs),* and *long non-coding RNAs (lncRNAs)* (the latter encompasses ncRNAs >200 nucleotides in length). The miRNAs, unlike messenger RNAs, do not encode proteins but instead inhibit the translation of target mRNAs into their corresponding proteins. Posttranscriptional silencing of gene expression by miRNA is preserved in all living forms from plants to humans and is therefore a fundamental mechanism of gene regulation. Because of their profound influence on gene regulation, miRNAs are assuming central importance in efforts to elucidate normal developmental pathways, as well as pathologic conditions, such as cancer. Andrew Fire and Craig Mello were awarded the Nobel prize in physiology or medicine in 2006 for their work on miRNAs.

By current estimates, there are approximately 1000 genes in humans that encode miRNAs. Transcription of miRNA genes produces primary miRNA transcript (pri-miRNA), which is processed within the nucleus to form another structure called pre-miRNA (Fig. 6–1). With the

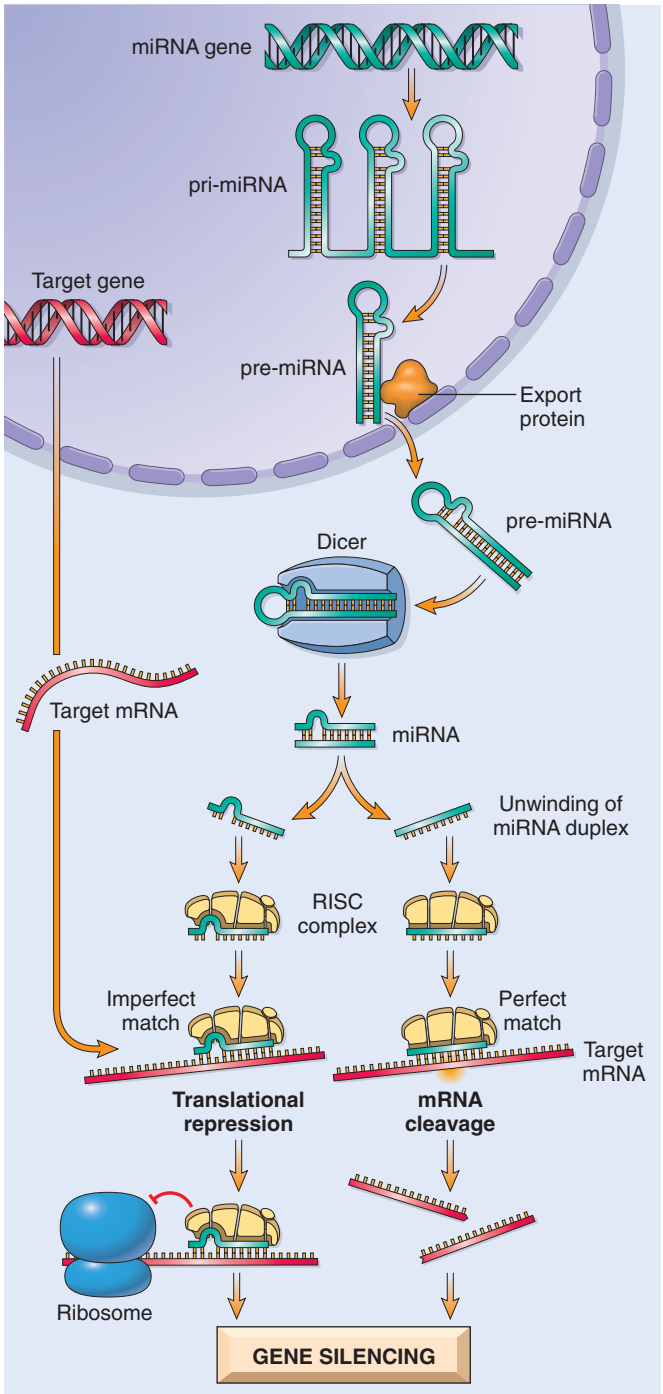


**Figure 6–1** Generation of microRNAs and their mode of action in regulating gene function. pri-miRNA, primary microRNA transcript; pre-miRNA, precursor microRNA; RISC, RNA-induced silencing complex.

help of specific transporter proteins, pre-miRNA is exported to the cytoplasm. Additional "cutting" by an enzyme, appropriately called Dicer, generates mature miRNAs that are about 21 to 30 nucleotides in length (hence the designation *micro-*). At this stage the miRNA is still double-stranded. Next, the miRNA unwinds, and single strands of this duplex are incorporated into a multiprotein complex called RNA-induced silencing complex (RISC). Base pairing between the miRNA strand and its target mRNA directs the RISC to either cause mRNA cleavage or repress its translation. In this way, the gene from which the target mRNA was derived is silenced (at a post-transcriptional state). Given that the numbers of miRNA genes are far fewer than those that encode proteins, it follows that a given miRNA can silence many target genes. All mRNAs contain a so-called seed sequence in their 3′ untranslated region (UTR), which determines the specificity of miRNA binding and gene silencing.

Another species of gene-silencing RNA, called small interfering RNAs (siRNAs), works in a manner quite similar to that of miRNA. Unlike miRNA, however, siRNA precursors are introduced by investigators into the cell. Their processing by Dicer and functioning via RISC are essentially similar to that described for miRNA. Synthetic siRNAs have become powerful tools for studying gene function in the laboratory, and are being developed as possible therapeutic agents to silence specific genes, such as oncogenes, whose products are involved in neoplastic transformation.

Recent studies have elucidated an untapped universe of lncRNAs (by some calculations, the number of lncRNAs may exceed coding mRNAs by ten-fold to twenty-fold), and their putative functions in the human genome might explain why humans are at the apex of the evolutionary pyramid despite the relatively modest number of coding genes. lncRNAs modulate gene expression in many ways; for example, they can bind to regions of chromatin, restricting access of RNA polymerase to the encompassed coding genes within the region. One of the best known examples of lncRNAs is XIST, which is transcribed from the X-chromosome, and plays an essential role in physiologic X chromosome inactivation (see later). XIST itself escapes X inactivation, but forms a repressive "cloak" on the X chromosome from which it is transcribed, resulting in gene silencing. Emerging studies are highlighting the roles of lncRNAs in various human diseases, from atherosclerosis to cancer.

With this brief review of the nature of abnormalities that contribute to the pathogenesis of human diseases, we can turn our attention to the three major categories of genetic disorders: (1) those related to mutant genes of large effect, (2) diseases with complex multigenic inheritance (sometimes known as multifactorial disorders), and (3) those arising from chromosomal aberrations. The first category, sometimes referred to as *mendelian disorders,* includes many uncommon conditions, such as the storage diseases and inborn errors of metabolism, all resulting from single-gene mutations of large effect. Most of these conditions are hereditary and familial. The second category includes some of the most common disorders of humans, such as hypertension and diabetes mellitus. Multifactorial, or complex, inheritance implies that both genetic and environmental influences condition the expression of a phenotypic characteristic or disease. The third category includes disorders that are the consequence of numeric or structural abnormalities in the chromosomes.

To these three well-known categories, it is necessary to add a heterogeneous group of genetic disorders that, like mendelian disorders, involve single genes but do not follow simple mendelian rules of inheritance. These single-gene disorders with nonclassic inheritance patterns include those resulting from triplet repeat mutations, those arising from mutations in mitochondrial DNA, and those in which the transmission is influenced by an epigenetic phenomenon called *genomic imprinting*. Each of these four categories is discussed separately.

## MENDELIAN DISORDERS: DISEASES CAUSED BY SINGLE-GENE DEFECTS

Single-gene defects (mutations) follow the well-known mendelian patterns of inheritance (Tables 6–1 and 6–2). Although individually each is rare, altogether they account for approximately 1% of all adult admissions to hospitals and about 6% to 8% of all pediatric hospital admissions. Listed next are a few important tenets and caveats of relevance in a consideration of mendelian disorders:

- Mutations involving single genes follow one of three patterns of inheritance: autosomal dominant, autosomal recessive, or X-linked.
- A single-gene mutation may lead to many phenotypic effects (*pleiotropy*), and conversely, mutations at several genetic loci may produce the same trait (*genetic heterogeneity*). For example, Marfan syndrome, which results from a basic defect in connective tissue, is associated

**Table 6–1** Estimated Prevalence of Selected Mendelian Disorders Among Liveborn Infants

| Disorder | Estimated Prevalence |
|---|---|
| **Autosomal Dominant Inheritance** | |
| Familial hypercholesterolemia | 1 in 500 |
| Polycystic kidney disease | 1 in 1000 |
| Hereditary spherocytosis | 1 in 5000 (Northern Europe) |
| Marfan syndrome | 1 in 5000 |
| Huntington disease | 1 in 10,000 |
| **Autosomal Recessive Inheritance** | |
| Sickle cell anemia | 1 in 500 (U.S. African Americans)* |
| Cystic fibrosis | 1 in 3200 (U.S. Caucasians) |
| Tay-Sachs disease | 1 in 3500 (U.S. Ashkenazi Jewish; French Canadians) |
| Phenylketonuria | 1 in 10,000 |
| Mucopolysaccharidoses—all types | 1 in 25,000 |
| Glycogen storage diseases—all types | 1 in 50,000 |
| Galactosemia | 1 in 60,000 |
| **X-Linked Inheritance** | |
| Duchenne muscular dystrophy | 1 in 3500 (U.S. males) |
| Hemophilia | 1 in 5000 (U.S. males) |

*The prevalence of heterozygous sickle cell *trait* is 1 in 12 for U.S. African Americans.

**Table 6–2** Biochemical Basis and Inheritance Pattern for Selected Mendelian Disorders

| Disease | Abnormal Protein | Protein Type/Function |
|---|---|---|
| Autosomal Dominant Inheritance | | |
| Familial hypercholesterolemia | Low-density lipoprotein receptor | Receptor transport |
| Marfan syndrome | Fibrillin | Structural support: extracellular matrix |
| Ehlers-Danlos syndrome* | Collagen | Structural support: extracellular matrix |
| Hereditary spherocytosis | Spectrin, ankyrin, or protein 4.1 | Structural support: red blood cell membrane |
| Neurofibromatosis, type 1 | Neurofibromin-1 (NF-1) | Growth regulation |
| Adult polycystic kidney disease | Polycystin-1 (PKD-1) | Cell–cell and cell–matrix interactions |
| Autosomal Recessive Inheritance | | |
| Cystic fibrosis | Cystic fibrosis transmembrane regulator | Ion channel |
| Phenylketonuria | Phenylalanine hydroxylase | Enzyme |
| Tay-Sachs disease | Hexosaminidase | Enzyme |
| Severe combined immunodeficiency | Adenosine deaminase | Enzyme |
| α- and β-Thalassemias† | Hemoglobin | Oxygen transport |
| Sickle cell anemia† | Hemoglobin | Oxygen transport |
| X-linked Recessive Inheritance | | |
| Hemophilia A | Factor VIII | Coagulation |
| Duchenne/Becker muscular dystrophy | Dystrophin | Structural support: cell membrane |
| Fragile X syndrome | FMRP | RNA translation |

*Some variants of Ehlers-Danlos syndrome have an autosomal recessive inheritance pattern.
†Although full-blown symptoms require biallelic mutations, heterozygotes for thalassemia and sickle cell anemia may present with mild clinical disease. Thus, these disorders sometimes are categorized as "autosomal codominant" entities.

with widespread effects involving the skeleton, eye, and cardiovascular system, all of which stem from a mutation in the gene encoding fibrillin, a component of connective tissues. On the other hand, retinitis pigmentosa, an inherited disorder associated with abnormal retinal pigmentation and consequent visual impairment, can be caused by several different types of mutations. Recognition of genetic heterogeneity not only is important in genetic counseling but also facilitates understanding of the pathogenesis of common disorders such as diabetes mellitus (Chapter 19).

- It is now increasingly being recognized that even known "single-gene" diseases are influenced by inheritance at other genetic loci, which are called *modifier* genes. As discussed later in the section on cystic fibrosis, these modifier loci can affect the severity or extent of the disease.
- The use of proactive prenatal genetic screening in high-risk populations (e.g., persons of Ashkenazi Jewish descent) has significantly reduced the incidence (Table 6–1) of certain genetic disorders such as Tay-Sachs disease.

## Transmission Patterns of Single-Gene Disorders

### *Disorders of Autosomal Dominant Inheritance*

Disorders of autosomal dominant inheritance are manifested in the heterozygous state, so at least one parent in an index case usually is affected; both males and females are affected, and both can transmit the condition. When an affected person marries an unaffected one, every child has one chance in two of having the disease. The following features also pertain to autosomal dominant diseases:

- With any autosomal dominant disorder, some patients do not have affected parents. Such patients owe their disorder to new mutations involving either the egg or the sperm from which they were derived. Their siblings are neither affected nor at increased risk for development of the disease.
- Clinical features can be modified by reduced penetrance and variable expressivity. Some persons inherit the mutant gene but are phenotypically normal. This mode of expression is referred to as *reduced penetrance.* The variables that affect penetrance are not clearly understood. In contrast with penetrance, if a trait is consistently associated with a mutant gene but is expressed differently among persons carrying the gene, the phenomenon is called *variable expressivity.* For example, manifestations of neurofibromatosis 1 range from brownish spots on the skin to multiple tumors and skeletal deformities.
- In many conditions, the age at onset is delayed, and symptoms and signs do not appear until adulthood (as in Huntington disease).
- In autosomal dominant disorders, a 50% reduction in the normal gene product is associated with clinical signs and symptoms. Because a 50% loss of enzyme activity can be compensated for, involved genes in autosomal dominant disorders usually do not encode enzyme proteins, but instead fall into two other categories of proteins:
  - Those involved in regulation of complex metabolic pathways, often subject to feedback control (e.g., membrane receptors, transport proteins). An example of this mechanism of inheritance is familial hypercholesterolemia, which results from mutation in the

low-density lipoprotein (LDL) receptor gene (discussed later).
- Key structural proteins, such as collagen and cytoskeletal components of the red cell membrane (e.g., spectrin, abnormalities of which result in hereditary spherocytosis)

The biochemical mechanisms by which a 50% reduction in the levels of such proteins results in an abnormal phenotype are not fully understood. In some cases, especially when the gene encodes one subunit of a multimeric protein, the product of the mutant allele can interfere with the assembly of a functionally normal multimer. For example, the collagen molecule is a trimer in which the three collagen chains are arranged in a helical configuration. Even with a single mutant collagen chain, normal collagen trimers cannot be formed, so there is a marked deficiency of collagen. In this instance the mutant allele is called *dominant negative,* because it impairs the function of a normal allele. This effect is illustrated in some forms of osteogenesis imperfecta (Chapter 20).

### *Disorders of Autosomal Recessive Inheritance*

Disorders of autosomal recessive inheritance make up the largest group of mendelian disorders. They occur when both of the alleles at a given gene locus are mutants; therefore, such disorders are characterized by the following features: (1) The trait does not usually affect the parents, but siblings may show the disease; (2) siblings have one chance in four of being affected (i.e., the recurrence risk is 25% for each birth); and (3) if the mutant gene occurs with a low frequency in the population, there is a strong likelihood that the affected patient (the proband) is the product of a consanguineous marriage.

In contrast with the features of autosomal dominant diseases, the following features generally apply to most autosomal recessive disorders:

- The expression of the defect tends to be more uniform than in autosomal dominant disorders.
- Complete penetrance is common.
- Onset is frequently early in life.
- Although new mutations for recessive disorders do occur, they are rarely detected clinically. Because the affected person is an asymptomatic heterozygote, several generations may pass before the descendants of such a person mate with other heterozygotes and produce affected offspring.
- In many cases, enzyme proteins are affected by the mutation. In heterozygotes, equal amounts of normal and defective enzyme are synthesized. Usually the natural "margin of safety" ensures that cells with half of their complement of the enzyme function normally.

### *X-Linked Disorders*

All sex-linked disorders are X-linked. No Y-linked diseases are known as yet. Save for determinants that dictate male differentiation, the only characteristic that may be located on the Y chromosome is the attribute of hairy ears, which is not altogether devastating. Most X-linked disorders are X-linked *recessive* and are characterized by the following features:

- They are transmitted by heterozygous female carriers only to sons, who of course are hemizygous for the X chromosome.
- Heterozygous females rarely express the full phenotypic change, because they have the paired normal allele; although one of the X chromosomes in females is inactivated (see further on), this process of inactivation is *random,* which typically allows sufficient numbers of cells with the normal expressed allele to emerge.
- An affected male does not transmit the disorder to sons, but all daughters are carriers. Sons of heterozygous women have one chance in two of receiving the mutant gene.

#### SUMMARY

**Transmission Patterns of Single-Gene Disorders**

- Autosomal dominant disorders are characterized by expression in heterozygous state; they affect males and females equally, and both sexes can transmit the disorder.
- Enzyme proteins are not affected in autosomal dominant disorders; instead, receptors and structural proteins are involved.
- Autosomal recessive diseases occur when both copies of a gene are mutated; enzyme proteins are frequently involved. Males and females are affected equally.
- X-linked disorders are transmitted by heterozygous females to their sons, who manifest the disease. Female carriers usually are protected because of random inactivation of one X chromosome.

## Diseases Caused by Mutations in Genes Encoding Structural Proteins

### *Marfan Syndrome*

In Marfan syndrome, a connective tissue disorder of autosomal dominant inheritance, the basic biochemical abnormality is a mutation affecting fibrillin. This glycoprotein, secreted by fibroblasts, is the major component of microfibrils found in the extracellular matrix. Microfibrils serve as scaffolding for the deposition of tropoelastin, an integral component of elastic fibers. Although microfibrils are widely distributed in the body, they are particularly abundant in the aorta, ligaments, and the ciliary zonules that support the ocular lens; these tissues are prominently affected in Marfan syndrome.

Fibrillin is encoded by the *FBN1* gene, which maps to chromosomal locus 15q21. Mutations in the *FBN1* gene are found in all patients with Marfan syndrome. However, molecular diagnosis of Marfan syndrome is not yet feasible, because more than 600 distinct causative mutations in the very large *FBN1* gene have been found. Since heterozygotes have clinical symptoms, it follows that the mutant fibrillin protein must act as a dominant negative by preventing the assembly of normal microfibrils. The prevalence of Marfan syndrome is estimated to be 1 per 5000. Approximately 70% to 85% of cases are familial, and the rest are sporadic, arising from de novo *FBN1* mutations in the germ cells of parents.

While many of the abnormalities in Marfan syndrome can be explained on the basis of structural failure of connective tissues, some, such as overgrowth of bones, are difficult to relate to simple loss of fibrillin. Recent studies indicate that loss of microfibrils gives rise to abnormal and excessive activation of transforming growth factor-β (TGF-β), since normal microfibrils sequester TGF-β, thereby controlling bioavailability of this cytokine. Excessive TGF-β signaling has deleterious effects on vascular smooth muscle development and the integrity of extracellular matrix. In support of this hypothesis, mutations in the TGF-β type II receptor give rise to a related syndrome, called Marfan syndrome type 2 (MFS2). Of note, angiotensin receptor blockers, which inhibit the activity of TGF-β, have been shown to improve aortic and cardiac function in mouse models of Marfan syndrome and currently are being evaluated in clinical trials.

## MORPHOLOGY

**Skeletal abnormalities** are the most obvious feature of Marfan syndrome. Patients have a slender, elongated habitus with abnormally long legs, arms, and fingers (arachnodactyly); a high-arched palate; and hyperextensibility of joints. A variety of spinal deformities, such as severe kyphoscoliosis, may be present. The chest is deformed, exhibiting either pectus excavatum (i.e., deeply depressed sternum) or a pigeon-breast deformity. The most characteristic **ocular change** is bilateral dislocation, or subluxation, of the lens secondary to weakness of its suspensory ligaments **(ectopia lentis).** This abnormality is so uncommon in persons who do not have this genetic disease that the finding of bilateral ectopia lentis should raise the diagnostic possibility of Marfan syndrome. Most serious, however, is the involvement of the **cardiovascular system.** Fragmentation of the elastic fibers in the tunica media of the aorta predisposes affected patients to aneurysmal dilation and aortic dissection (Chapter 9). These changes, called **cystic medionecrosis,** are not specific for Marfan syndrome. Similar lesions occur in hypertension and with aging. Loss of medial support causes dilation of the aortic valve ring, giving rise to aortic incompetence. The cardiac valves, especially the mitral valve, may be excessively distensible and regurgitant **(floppy valve syndrome),** giving rise to mitral valve prolapse and congestive cardiac failure (Chapter 10). Death from aortic rupture may occur at any age, and aortic rupture is in fact the most common cause of death. Less commonly, cardiac failure is the terminal event.

Although the lesions described are typical of Marfan syndrome, they are not seen in all cases. There is much variation in clinical expression, and some patients may exhibit predominantly cardiovascular lesions with minimal skeletal and ocular changes. The variable expressivity is believed to be related to different allelic mutations in the *FBN1* gene.

### *Ehlers-Danlos Syndromes*

Ehlers-Danlos syndromes (EDSs) are a group of diseases characterized by defects in collagen synthesis or structure. All are single-gene disorders, but the mode of inheritance encompasses both autosomal dominant and recessive patterns. There are approximately 30 distinct types of collagen; all have characteristic tissue distributions and are the products of different genes. To some extent, the clinical heterogeneity of EDS can be explained by mutations in different collagen genes.

At least six clinical and genetic variants of EDS are recognized. Because defective collagen is the basis for these disorders, certain clinical features are common to all variants.

As might be expected, tissues rich in collagen, such as skin, ligaments, and joints, frequently are involved in most variants of EDS. Because the abnormal collagen fibers lack adequate tensile strength, the *skin is hyperextensible and joints are hypermobile.* These features permit grotesque contortions, such as bending the thumb backward to touch the forearm and bending the knee upward to create almost a right angle. Indeed, it is believed that most contortionists have one of the EDSs; however, a predisposition to joint dislocation is one of the prices paid for this virtuosity. *The skin is extraordinarily stretchable, extremely fragile,* and *vulnerable to trauma.* Minor injuries produce gaping defects, and surgical repair or any surgical intervention is accomplished only with great difficulty because of the lack of normal tensile strength. The basic defect in connective tissue may lead to serious internal complications, including rupture of the colon and large arteries (vascular EDS); ocular fragility, with rupture of the cornea and retinal detachment (kyphoscoliotic EDS); and diaphragmatic hernias (classical EDS), among others.

The molecular bases for three of the more common variants are as follows:

- *Deficiency of the enzyme lysyl hydroxylase.* Decreased hydroxylation of lysyl residues in types I and III collagen interferes with the formation of cross-links among collagen molecules. As might be expected, this variant (kyphoscoliotic EDS), resulting from an enzyme deficiency, is inherited as an autosomal recessive disorder.
- *Deficient synthesis of type III collagen resulting from mutations affecting the COL3A1* gene. This variant, the vascular type, is inherited as an autosomal dominant disorder and is characterized by weakness of tissues rich in type III collagen (e.g., blood vessels, bowel wall), predisposing them to rupture.
- *Deficient synthesis of type V collagen* due to mutations in *COL5A1* and *COL5A2* is inherited as an autosomal dominant disorder and results in classical EDS.

## SUMMARY

### Marfan Syndrome

- Marfan syndrome is caused by a mutation in the *FBN1* gene encoding fibrillin, which is required for structural integrity of connective tissues.
- The major tissues affected are the skeleton, eyes, and cardiovascular system.
- Clinical features may include tall stature, long fingers, bilateral subluxation of lens, mitral valve prolapse, aortic aneurysm, and aortic dissection.
- Clinical trials with drugs that inhibit TGF-β signaling such as angiotensin receptor blockers are ongoing, as these have been shown to improve aortic and cardiac function in mouse models.

**Ehlers-Danlos Syndromes**

- There are six variants of Ehlers-Danlos syndromes, all characterized by defects in collagen synthesis or assembly. Each of the variants is caused by a distinct mutation.
- Clinical features may include fragile, hyperextensible skin vulnerable to trauma, hypermobile joints, and ruptures involving colon, cornea, or large arteries. Wound healing is poor.

## Diseases Caused by Mutations in Genes Encoding Receptor Proteins or Channels

### *Familial Hypercholesterolemia*

Familial hypercholesterolemia is among the most common mendelian disorders; the frequency of the heterozygous condition is 1 in 500 in the general population. It is caused by a mutation in the *LDLR* gene that encodes the receptor for low-density lipoprotein (LDL), the form in which 70% of total plasma cholesterol is transported. A brief review of the synthesis and transport of cholesterol follows.

***Normal Cholesterol Metabolism.*** Cholesterol may be derived from the diet or from endogenous synthesis. Dietary triglycerides and cholesterol are incorporated into chylomicrons in the intestinal mucosa, which drain by way of the gut lymphatics into the blood. These chylomicrons are hydrolyzed by an endothelial lipoprotein lipase in the capillaries of muscle and fat. The chylomicron remnants, rich in cholesterol, are then delivered to the liver. Some of the cholesterol enters the metabolic pool (to be described), and some is excreted as free cholesterol or bile acids into the biliary tract. The endogenous synthesis of cholesterol and LDL begins in the liver (Fig. 6–2). The first step in the synthesis of LDL is the secretion of triglyceride-rich very-low-density lipoprotein (VLDL) by the liver into the blood. In the capillaries of adipose tissue and muscle, the VLDL particle undergoes lipolysis and is converted to intermediate-density lipoprotein (IDL). In comparison with VLDL, the content of triglyceride is reduced and that of cholesteryl esters enriched in intermediate-density lipoprotein (IDL), but IDL retains on its surface two of the three VLDL-associated apolipoproteins B-100 and E. Further metabolism of IDL occurs along two pathways: Most of the IDL particles are directly taken up by the liver through the LDL receptor described later; others are converted to cholesterol-rich LDL by a further loss of triglycerides and apolipoprotein E. In the liver cells, IDL is recycled to generate VLDL.

Two thirds of the resultant LDL particles are metabolized by the LDL receptor pathway, and the rest is metabolized by a receptor for oxidized LDL (scavenger receptor), to be described later. The LDL receptor binds to apolipoproteins B-100 and E and thus is involved in the transport of both LDL and IDL. *Although the LDL receptors are widely distributed, approximately 75% are located on hepatocytes, so the liver plays an extremely important role in LDL metabolism.* The first step in the receptor-mediated transport of LDL involves binding to the cell surface receptor, followed by endocytotic internalization inside so-called "clathrin-coated pits" (Fig. 6–3). Within the cell, the endocytic vesicles fuse with the lysosomes, and the LDL molecule is enzymatically degraded, resulting ultimately in the release of free cholesterol into the cytoplasm. *The cholesterol not only is used by the cell for membrane synthesis but also takes part in intracellular cholesterol homeostasis by a sophisticated system of feedback control*:

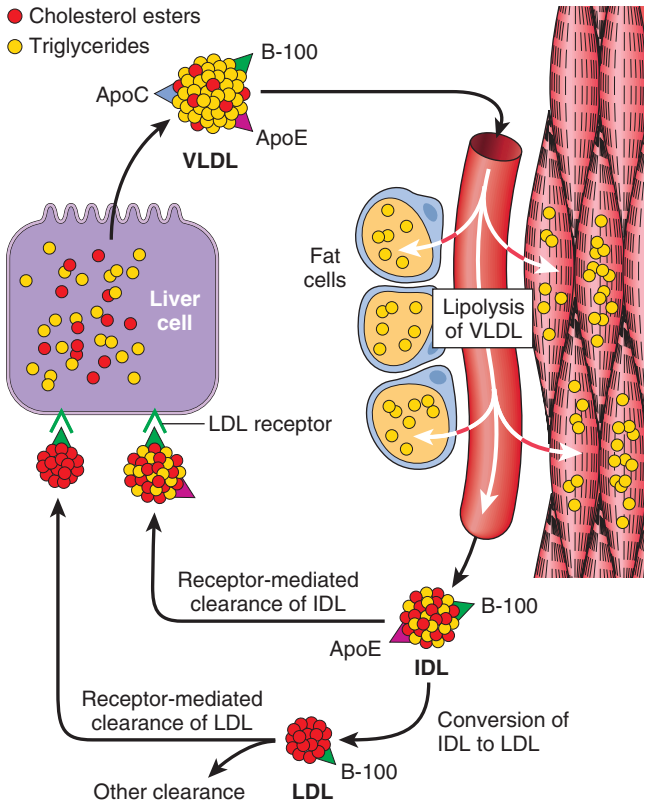


**Figure 6–2** Low-density lipoprotein (LDL) metabolism and the role of the liver in its synthesis and clearance. Lipolysis of very-low-density lipoprotein (VLDL) by lipoprotein lipase in the capillaries releases triglycerides, which are then stored in fat cells and used as a source of energy in skeletal muscles. IDL (intermediate-density lipoprotein) remains in the blood and is taken up by the liver.

- It suppresses cholesterol synthesis by inhibiting the activity of the enzyme 3-hydroxy-3-methylglutaryl–coenzyme A reductase (HMG-CoA reductase), which is the rate-limiting enzyme in the synthetic pathway.
- It stimulates the formation of cholesterol esters for storage of excess cholesterol.
- It downregulates the synthesis of cell surface LDL receptors, thus protecting cells from excessive accumulation of cholesterol.

The transport of LDL by the scavenger receptors, alluded to earlier, seems to take place in cells of the mononuclear-phagocyte system and possibly in other cells as well. Monocytes and macrophages have receptors for chemically modified (e.g., acetylated or oxidized) LDLs. The amount catabolized by this "scavenger receptor" pathway is directly related to the plasma cholesterol level.

**PATHOGENESIS OF FAMILIAL HYPERCHOLESTEROLEMIA**

In familial hypercholesterolemia, mutations in the LDL receptor protein impair the intracellular transport and catabolism

of LDL, resulting in accumulation of LDL cholesterol in the plasma. In addition, the absence of LDL receptors on liver cells also impairs the transport of IDL into the liver, so a greater proportion of plasma IDL is converted into LDL. Thus, patients with familial hypercholesterolemia develop excessive levels of serum cholesterol as a result of the combined effects of reduced catabolism and excessive biosynthesis (Fig. 6–2). In the presence of such hypercholesterolemia, there is a marked increase of cholesterol traffic into the monocyte-macrophages and vascular walls mediated by the scavenger receptor. This accounts for the appearance of skin xanthomas and premature atherosclerosis.

Familial hypercholesterolemia is an autosomal dominant disease. Heterozygotes have a two- to three-fold elevation of plasma cholesterol levels, whereas homozygotes may have in excess of a five-fold elevation. Although their cholesterol levels are elevated from birth, heterozygotes remain asymptomatic until adult life, when they develop cholesterol deposits (xanthomas) along tendon sheaths and premature atherosclerosis resulting in coronary artery disease. Homozygotes are much more severely affected, developing cutaneous xanthomas in childhood and often dying of myocardial infarction before the age of 20 years.

Analysis of the cloned LDL receptor gene has revealed that more than 900 different mutations can give rise to familial hypercholesterolemia. These can be divided into five categories. Class I mutations are uncommon, and they are associated with complete loss of receptor synthesis. With class II mutations, the most prevalent form, the receptor protein is synthesized, but its transport from the endoplasmic reticulum to the Golgi apparatus is impaired due to defects in protein folding. Class III mutations produce receptors that are transported to the cell surface but fail to bind LDL normally. Class IV mutations give rise to receptors that fail to internalize within clathrin pits after binding to LDL, while class V mutations encode receptors that can bind LDL and are internalized but are trapped in endosomes because dissociation of receptor and bound LDL does not occur.

The discovery of the critical role of LDL receptors in cholesterol homeostasis has led to the rational design of the statin family of drugs that are now widely used to lower plasma cholesterol. They inhibit the activity of HMG-CoA reductase and thus promote greater synthesis of LDL receptor (Fig. 6–3).

## SUMMARY

### Familial Hypercholesterolemia

- Familial hypercholesterolemia is an autosomal dominant disorder caused by mutations in the gene encoding the LDL receptor.
- Patients develop hypercholesterolemia as a consequence of impaired transport of LDL into the cells.
- In heterozygotes, elevated serum cholesterol greatly increases the risk of atherosclerosis and resultant coronary artery disease; homozygotes have an even greater increase in serum cholesterol and a higher frequency of ischemic heart disease. Cholesterol also deposits along tendon sheaths to produce xanthomas.

### *Cystic Fibrosis*

With an incidence of 1 in 3200 live births in the United States, *cystic fibrosis (CF) is the most common lethal genetic disease that affects white populations.* It is uncommon among Asians (1 in 31,000 live births) and African Americans (1 in 15,000 live births). CF follows simple *autosomal recessive* transmission, and does not affect heterozygote carriers. There is, however, a bewildering compendium of phenotypic variation that results from diverse mutations in the CF-associated gene, the tissue-specific effects of loss of this gene's function, and the influence of newly recognized disease modifiers. It is, fundamentally, a *disorder of epithelial transport affecting fluid secretion in exocrine glands and the epithelial lining of the respiratory, gastrointestinal, and reproductive tracts.* Indeed, abnormally viscid mucous secretions that block the airways and the pancreatic ducts are responsible for the two most important clinical manifestations: recurrent and chronic pulmonary infections and pancreatic insufficiency. In addition, although the exocrine sweat glands are structurally normal (and remain so throughout the course of this disease), *a high level of sodium chloride in the sweat is a consistent and characteristic biochemical abnormality in CF.*

## PATHOGENESIS

The primary defect in CF is abnormal function of an epithelial chloride channel protein encoded by the CF transmembrane conductance regulator (*CFTR*) gene at chromosomal locus 7q31.2. The changes in mucus are considered secondary to the disturbance in transport of chloride ions. In normal epithelia, the transport of chloride ions across the cell membrane occurs through transmembrane proteins, such as CFTR, that form chloride channels. Mutations in the *CFTR* gene render the epithelial membranes relatively impermeable to chloride ions (Fig. 6–4). However, the impact of this defect on transport function is tissue-specific. The major function of the CFTR protein in the sweat gland ducts is to reabsorb luminal chloride ions and augment sodium reabsorption through the epithelial sodium channel (ENaC). Therefore, in the sweat ducts, loss of CFTR function leads to decreased reabsorption of sodium chloride and production of hypertonic ("salty") sweat (Fig. 6–4, *top*). In contrast with that in the sweat glands, CFTR in the respiratory and intestinal epithelium forms one of the most important avenues for active luminal secretion of chloride. At these sites, *CFTR* mutations result in loss or reduction of chloride secretion into the lumen (Fig. 6–4, *bottom*). Active luminal sodium absorption through ENaCs also is increased, and both of these ion changes increase passive water reabsorption from the lumen, lowering the water content of the surface fluid layer coating mucosal cells. Thus, unlike the sweat ducts, there is no difference in the salt concentration of the surface fluid layer coating the respiratory and intestinal mucosal cells in normal persons and in those with CF. Instead, the pathogenesis of respiratory and intestinal complications in CF seems to stem from an isotonic but low-volume surface fluid layer. In the lungs, this dehydration leads to defective mucociliary action and the accumulation of concentrated, viscid secretions that obstruct the air passages and predispose to recurrent pulmonary infections.

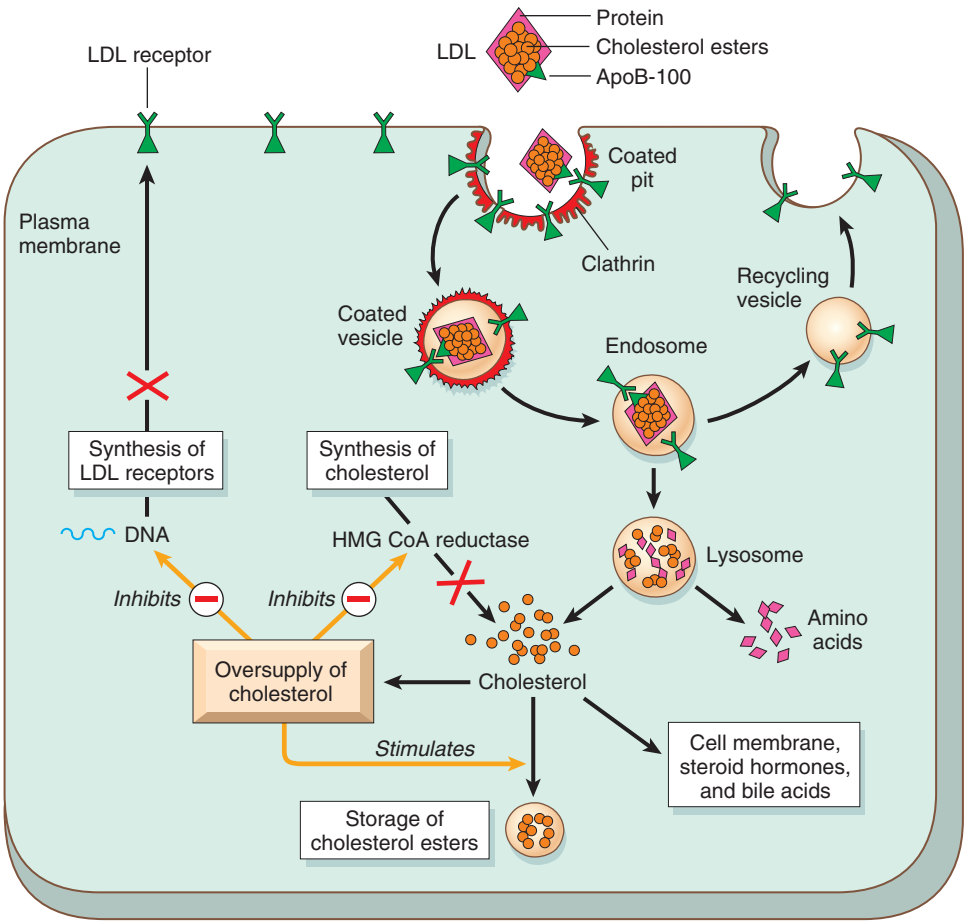


**Figure 6–3** The LDL receptor pathway and regulation of cholesterol metabolism. The *yellow arrows* show three regulatory functions of free intracellular cholesterol: (1) suppression of cholesterol synthesis by inhibition of HMG-CoA reductase, (2) stimulating the storage of excess cholesterol as esters, and (3) inhibition of synthesis of LDL receptors. HMG-CoA reductase, 3-hydroxy-3-methylglutaryl–coenzyme A reductase; LDL, low-density lipoprotein.

Since the *CFTR* gene was cloned in 1989, more than 1300 disease-causing mutations have been identified. They can be classified as severe or mild, depending on the clinical phenotype: **Severe** mutations are associated with complete loss of CFTR protein function, whereas **mild** mutations allow some residual function. The most common severe *CFTR* mutation is a deletion of three nucleotides coding for phenylalanine at amino acid position 508 (Δ*F508*). This causes misfolding and total loss of the CFTR. Worldwide, Δ*F508* mutation is found in approximately 70% of patients with CF. Since CF is an autosomal recessive disease, affected persons harbor mutations on both alleles. As discussed later, the combination of mutations on the two alleles influences the overall phenotype, as well as organ-specific manifestations. Although CF remains one of the best-known examples of the "one gene–one disease" axiom, there is increasing evidence that other genes modify the frequency and severity of organ-specific manifestations. One example of a candidate genetic modifier is **mannose-binding lectin,** a key effector of innate immunity involved in phagocytosis of microorganisms. In the setting of CF, polymorphisms in one or both mannose-binding lectin alleles that produce lower circulating levels of the protein are associated with a three-fold higher risk of end-stage lung disease, due to chronic bacterial infections.

## MORPHOLOGY

The anatomic changes are highly variable and depend on which glands are affected and on the severity of this involvement. **Pancreatic abnormalities** are present in 85% to 90% of patients with CF. In the milder cases, there may be only accumulations of mucus in the small ducts, with some dilation of the exocrine glands. In more advanced cases, usually seen in older children or adolescents, the ducts are totally plugged, causing atrophy of the exocrine glands and progressive fibrosis (Fig. 6–5). The total loss of pancreatic exocrine secretion impairs fat absorption, so avitaminosis A may contribute to squamous metaplasia of the lining epithelium of the ducts in the pancreas, which are already injured by the inspissated mucus secretions. Thick viscid plugs of mucus also may be found in the small intestine of infants. Sometimes these cause small bowel obstruction, known as **meconium ileus.**

The **pulmonary changes** are the most serious complications of this disease (Fig. 6–6). These changes stem from obstruction and infection of the air passages secondary to the viscous mucus secretions of the submucosal glands of the respiratory tree. The bronchioles often are distended with thick mucus, associated with marked hyperplasia and

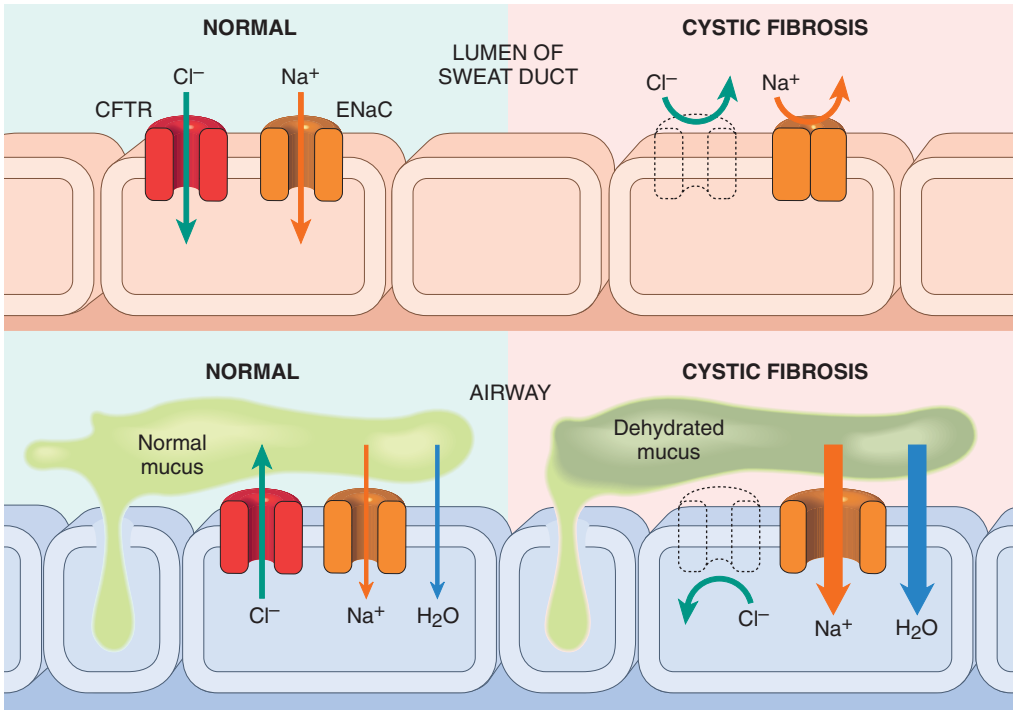


**Figure 6–4 Top,** In cystic fibrosis (CF), a chloride channel defect in the sweat duct causes increased chloride and sodium concentration in sweat. **Bottom,** Patients with CF have decreased chloride secretion and increased sodium and water reabsorption in the airways, leading to dehydration of the mucus layer coating epithelial cells, defective mucociliary action, and mucous plugging. CFTR, cystic fibrosis transmembrane conductance regulator; ENaC, epithelial sodium channel responsible for intracellular sodium conduction.

hypertrophy of the mucus-secreting cells. Superimposed infections give rise to severe chronic bronchitis and bronchiectasis. Development of lung abscesses is common. *Staphylococcus aureus, Haemophilus influenzae,* and *Pseudomonas aeruginosa* are the three most common organisms responsible for lung infections. Even more sinister is the increasing frequency of infection with another pseudomonad, *Burkholderia cepacia.* This opportunistic bacterium is particularly hardy, and infection with this organism has been associated with fulminant illness ("cepacia syndrome"). The **liver**

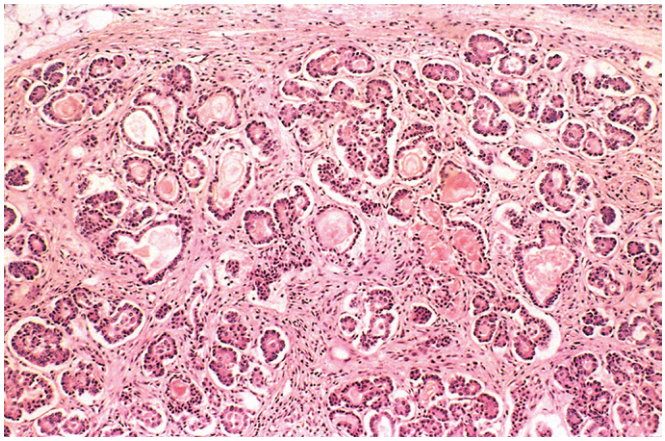

**Figure 6–5** Mild to moderate changes of cystic fibrosis in the pancreas. The ducts are dilated and plugged with eosinophilic mucin, and the parenchymal glands are atrophic and replaced by fibrous tissue.

**Figure 6–6** Lungs of a patient who died of cystic fibrosis. Extensive mucous plugging and dilation of the tracheobronchial tree are apparent. The pulmonary parenchyma is consolidated by a combination of both secretions and pneumonia; the *greenish* discoloration is the product of *Pseudomonas* infections.

*(Courtesy of Dr. Eduardo Yunis, Children's Hospital of Pittsburgh, Pittsburgh, Pennsylvania.)*

**involvement** follows the same basic pattern. Bile canaliculi are plugged by mucinous material, accompanied by ductular proliferation and portal inflammation. Hepatic **steatosis** is a common finding in liver biopsies. Over time, **cirrhosis** develops, resulting in diffuse hepatic nodularity. Such severe hepatic involvement is encountered in less than 10% of patients. **Azoospermia and infertility** are found in 95% of the affected males who survive to adulthood; **bilateral absence of the vas deferens** is a frequent finding in these patients. In some males, this may be the only feature suggesting an underlying *CFTR* mutation.

## Clinical Course

In few childhood diseases are clinical manifestations as protean as those of CF (Table 6–3). The signs and symptoms are extremely varied and range from mild to severe, from presence at birth to onset years later, and from confinement to one organ system to involvement of many. Approximately 5% to 10% of the cases come to clinical attention at birth or soon after because of an attack of *meconium ileus. Exocrine pancreatic insufficiency* occurs in a majority (85% to 90%) of patients with CF and is associated with "severe" *CFTR* mutations on *both* alleles (e.g., Δ*F508/*Δ*F508*), whereas 10% to 15% of patients with one "severe" and one "mild" *CFTR* mutation, or two "mild" *CFTR* mutations, retain sufficient pancreatic exocrine function that enzyme supplementation is not required—the *pancreas-sufficient* phenotype. Pancreatic insufficiency is associated with malabsorption of protein and fat and increased fecal loss. Manifestations of malabsorption (e.g., large, foul-smelling stools; abdominal distention; poor weight gain) appear during the first year of life. The faulty fat absorption may induce deficiency states of the fat-soluble vitamins, resulting in manifestations of avitaminosis A, D, or K. Hypoproteinemia may be severe enough to cause generalized edema. Persistent diarrhea may result in rectal prolapse in as many as 10% of children with CF. The pancreas-sufficient phenotype usually is not associated with other gastrointestinal complications, and in general, these patients demonstrate excellent growth and development. *"Idiopathic" chronic pancreatitis* occurs in a subset of patients with pancreas-sufficient CF and is associated with recurring episodes of abdominal pain with life-threatening complications.

Cardiorespiratory complications, such as chronic cough, persistent lung infections, obstructive pulmonary disease, and cor pulmonale, constitute the most common cause of death (accounting for approximately 80% of fatalities) in patients who receive follow-up care in most CF centers in the United States. By 18 years of age, 80% of patients with classic CF harbor *P. aeruginosa,* and 3.5% harbor *B. cepacia.* With the indiscriminate use of antibiotic prophylaxis against *Staphylococcus,* there has been an unfortunate resurgence of resistant strains of *Pseudomonas* in many patients. *Recurrent sinonasal polyps* can occur in as many as 10% to 25% of patients with CF; accordingly, children who present with such polyps should be tested for abnormalities of sweat chloride. Significant *liver disease* occurs late in the natural history of CF and is foreshadowed by pulmonary and pancreatic involvement; with increasing life expectancy, liver disease is now the third most common cause of death in patients with CF (after cardiopulmonary and transplant-related complication).

In most cases, the diagnosis of CF is based on persistently elevated sweat electrolyte concentrations (often the mother makes the diagnosis because her infant "tastes salty"), characteristic clinical findings (sinopulmonary disease and gastrointestinal manifestations), or a family history. Sequencing the *CFTR* gene is, of course, the standard modality for diagnosis of CF. Therefore, in patients with clinical findings or family history (or both) suggestive of this disorder, genetic analysis may be warranted. Advances in management of CF have meant that more patients are now surviving to adulthood; the median life

**Table 6–3** Clinical Features and Diagnostic Criteria for Cystic Fibrosis

| Clinical Features of Cystic Fibrosis |
|---|
| 1. Chronic sinopulmonary disease manifested by |
| a. Persistent colonization/infection with typical cystic fibrosis pathogens, including *Staphylococcus aureus,* nontypable *Haemophilus influenzae,* mucoid and nonmucoid *Pseudomonas aeruginosa, Burkholderia cepacia* |
| b. Chronic cough and sputum production |
| c. Persistent chest radiograph abnormalities (e.g., bronchiectasis, atelectasis, infiltrates, hyperinflation) |
| d. Airway obstruction manifested by wheezing and air trapping |
| e. Nasal polyps; radiographic or computed tomographic abnormalities of paranasal sinuses |
| f. Digital clubbing |
| 2. Gastrointestinal and nutritional abnormalities, including |
| a. Intestinal: meconium ileus, distal intestinal obstruction syndrome, rectal prolapse |
| b. Pancreatic: pancreatic insufficiency, recurrent acute pancreatitis, chronic pancreatitis |
| c. Hepatic: chronic hepatic disease manifested by clinical or histologic evidence of focal biliary cirrhosis, or multilobular cirrhosis, prolonged neonatal jaundice |
| d. Nutritional: failure to thrive (protein–calorie malnutrition), hypoproteinemia, edema, complications secondary to fat-soluble vitamin deficiency |
| 3. Salt loss syndromes: acute salt depletion, chronic metabolic alkalosis |
| 4. Male urogenital abnormalities resulting in obstructive azoospermia (congenital bilateral absence of vas deferens) |
| **Criteria for Diagnosis of Cystic Fibrosis** |
| One or more characteristic phenotypic features, OR a history of cystic fibrosis in a sibling, OR a positive newborn screening test result |
| AND |
| An increased sweat chloride concentration on two or more occasions, OR identification of two cystic fibrosis mutations, OR demonstration of abnormal epithelial nasal ion transport |

Adapted with permission from Rosenstein BJ, Cutting GR: The diagnosis of cystic fibrosis: a consensus statement. J Pediatr 132:589, 1998.

expectancy is now 36 years and continues to increase. Clinical trials with gene therapy in humans are still in their early stages but provide a source of encouragement for millions of patients with CF worldwide.

## SUMMARY

### Cystic Fibrosis

- CF is an autosomal recessive disease caused by mutations in the *CFTR* gene encoding the CF transmembrane regulator.
- The principal defect is of chloride ion transport, resulting in high salt concentrations in sweat and in viscous luminal secretions in respiratory and gastrointestinal tracts.
- *CFTR* mutations can be severe (Δ*F508*), resulting in multisystem disease, or mild, with limited disease extent and severity.
- Cardiopulmonary complications constitute the most common cause of death; pulmonary infections, especially with resistant pseudomonads, are frequent. Bronchiectasis and right-sided heart failure are long-term sequelae.
- Pancreatic insufficiency is extremely common; infertility caused by congenital bilateral absence of vas deferens is a characteristic finding in adult patients with CF.
- Liver disease, including cirrhosis, is increasing in frequency due to improved survival.

## Diseases Caused by Mutations in Genes Encoding Enzyme Proteins

### *Phenylketonuria*

There are several variants of phenylketonuria (PKU), an inborn error of metabolism that affects 1 in 10,000 live-born white infants. The most common form, referred to as *classic phenylketonuria*, is quite common in persons of Scandinavian descent and is distinctly uncommon in African American and Jewish populations.

Homozygotes with this autosomal recessive disorder classically have a severe lack of the enzyme phenylalanine hydroxylase (PAH), leading to hyperphenylalaninemia and PKU. Affected infants are normal at birth but within a few weeks exhibit a rising plasma phenylalanine level, which in some way impairs brain development. Usually, by 6 months of life, *severe mental retardation* becomes all too evident; less than 4% of untreated phenylketonuric children have intelligence quotients (IQs) greater than 50 or 60. About one third of these children are never able to walk, and two thirds cannot talk. *Seizures,* other neurologic abnormalities, *decreased pigmentation of hair and skin,* and *eczema* often accompany the *mental retardation* in untreated children. Hyperphenylalaninemia and the resultant mental retardation can be avoided by restriction of phenylalanine intake early in life. Hence, several screening procedures are routinely performed to detect PKU in the immediate postnatal period.

Many female patients with PKU who receive dietary treatment beginning early in life reach child-bearing age and are clinically normal. Most of them have marked hyperphenylalaninemia, because dietary treatment is discontinued after they reach adulthood. Between 75% and 90% of children born to such women are mentally retarded and microcephalic, and 15% have congenital heart disease, even though the infants themselves are heterozygotes. This syndrome, termed *maternal PKU,* results from the teratogenic effects of phenylalanine or its metabolites that cross the placenta and affect specific fetal organs during development. The presence and severity of the fetal anomalies directly correlate with the maternal phenylalanine level, so *it is imperative that maternal dietary restriction of phenylalanine be initiated before conception and continued throughout pregnancy.*

The biochemical abnormality in PKU is an inability to convert phenylalanine into tyrosine. In normal children, less than 50% of the dietary intake of phenylalanine is necessary for protein synthesis. The remainder is converted to tyrosine by the phenylalanine hydroxylase system (Fig. 6–7). When phenylalanine metabolism is blocked because of a lack of PAH enzyme, minor shunt pathways come into play, yielding several intermediates that are excreted in large amounts in the urine and in the sweat. These impart a *strong musty or mousy odor* to affected infants. It is believed that excess phenylalanine or its metabolites contribute to the brain damage in PKU. Concomitant lack of tyrosine (Fig. 6–7), a precursor of melanin, is responsible for the light color of hair and skin.

At the molecular level, approximately 500 mutant alleles of the *PAH* gene have been identified, only some of which cause a severe deficiency of the enzyme. Infants with mutations resulting in a lack of PAH activity present with the classic features of PKU, while those with approximately 6% residual activity present with milder disease. Moreover,

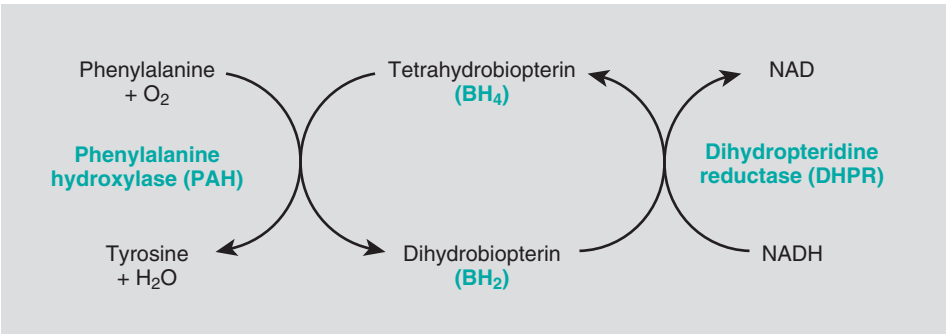


**Figure 6–7** The phenylalanine hydroxylase system. NADH, nicotinamide adenine dinucleotide, reduced form.

some mutations result in only modest elevations of blood phenylalanine levels without associated neurologic damage. This latter condition, referred to as *benign hyperphenylalaninemia,* is important to recognize, because affected persons may well have positive screening tests but do not acquire the stigmata of PKU. Because of the numerous disease-causing alleles of the phenylalanine hydroxylase gene, molecular diagnosis is not feasible, and measurement of serum phenylalanine levels is necessary to differentiate benign hyperphenylalaninemia from PKU; the levels in the latter disorder typically are five times (or more) higher than normal. Once a biochemical diagnosis is established, the specific mutation causing PKU can be determined. With this information, carrier testing of at-risk family members can be performed.

While 98% of cases of PKU are attributable to mutations in PAH, approximately 2% arise from abnormalities in synthesis or recycling of the cofactor *tetrahydrobiopterin* (Fig. 6–7). *Clinical recognition of these variant forms of PKU is important to establish a prognosis, because the patients cannot be treated by dietary restriction of phenylalanine.*

### *Galactosemia*

Galactosemia is an autosomal recessive disorder of galactose metabolism that affects 1 in 60,000 live-born infants. Normally, lactase splits lactose, the major carbohydrate of mammalian milk, into glucose and galactose in the intestinal microvilli. Galactose is then converted to glucose in several steps, in one of which the enzyme galactose-1-phosphate uridyltransferase (GALT) is required. Lack of this enzyme, due to homozygous mutations in the encoding gene *GALT*, is responsible for galactosemia. As a result of this transferase deficiency, galactose-1-phosphate and other metabolites, including galactitol, accumulate in many tissues, including the liver, spleen, lens of the eye, kidney, and cerebral cortex.

The liver, eyes, and brain bear the brunt of the damage. The early-onset hepatomegaly is due largely to fatty change, but in time widespread scarring that closely resembles the cirrhosis of alcohol abuse may supervene (Chapter 15). Opacification of the lens (cataract) develops, probably because the lens absorbs water and swells as galactitol, produced by alternative metabolic pathways, accumulates and increases its tonicity. Nonspecific alterations appear in the central nervous system (CNS), including loss of nerve cells, gliosis, and edema. There is still no clear understanding of the mechanism of injury to the liver and brain.

Almost from birth, affected infants fail to thrive. *Vomiting and diarrhea* appear within a few days of milk ingestion. *Jaundice* and *hepatomegaly* usually become evident during the first week of life. Accumulation of galactose and galactose-1-phosphate in the kidney impairs amino acid transport, resulting in aminoaciduria. Fulminant *Escherichia coli* septicemia occurs with increased frequency. The diagnosis of galactosemia can be suspected from demonstration in the urine of a reducing sugar other than glucose, but tests that directly identify the deficiency of the transferase in leukocytes and red cells are more reliable. Antenatal diagnosis is possible by assay of GALT activity in cultured amniotic fluid cells or determination of galactitol level in amniotic fluid supernatant.

*Many of the clinical and morphologic changes of galactosemia can be prevented or ameliorated by early removal of galactose from the diet for at least the first 2 years of life.* Control instituted soon after birth prevents the cataracts and liver damage and permits almost normal development. Even with dietary restrictions, however, it is now established that older patients frequently are affected by a speech disorder and gonadal failure (especially premature ovarian failure) and, less commonly, by an ataxic condition.

## SUMMARY

### Phenylketonuria

- PKU is a disorder of autosomal recessive inheritance caused by a lack of the enzyme phenylalanine hydroxylase and consequent inability to metabolize phenylalanine.
- Clinical features of untreated PKU may include severe mental retardation, seizures, and decreased pigmentation of skin, which can be avoided by restricting the intake of phenylalanine in the diet.
- Female patients with PKU who discontinue dietary treatment can give birth to children with malformations and neurologic impairment resulting from transplacental passage of phenylalanine metabolites.

### Galactosemia

- Galactosemia is caused by an inherited lack of the GALT enzyme, leading to accumulation of galactose-1-phosphate and its metabolites in tissues.
- Clinical features may include jaundice, liver damage, cataracts, neural damage, vomiting and diarrhea, and *E. coli* sepsis. Dietary restriction of galactose can prevent at least some of the more severe complications.

### *Lysosomal Storage Diseases*

Lysosomes, the digestive system of the cells, contain a variety of hydrolytic enzymes that are involved in the breakdown of complex substrates, such as sphingolipids and mucopolysaccharides, into soluble end products. These large molecules may be derived from the turnover of intracellular organelles that enter the lysosomes by autophagy, or they may be acquired from outside the cell by phagocytosis. With an inherited lack of a lysosomal enzyme, catabolism of its substrate remains incomplete, leading to accumulation of the partially degraded insoluble metabolites within the lysosomes (Fig. 6–8). Approximately 40 lysosomal storage diseases have been identified, each resulting from the functional absence of a specific lysosomal enzyme or proteins involved in their function. Traditionally, lysosomal storage disorders are divided into broad categories based on the biochemical nature of the substrates and the accumulated metabolites, but a more mechanistic classification is based on the underlying molecular defect (Table 6–4). Within each group are several entities, each resulting from the deficiency of a specific enzyme. Despite this complexity, certain features are common to most diseases in this group:

- Autosomal recessive transmission
- Patient population consisting of infants and young children

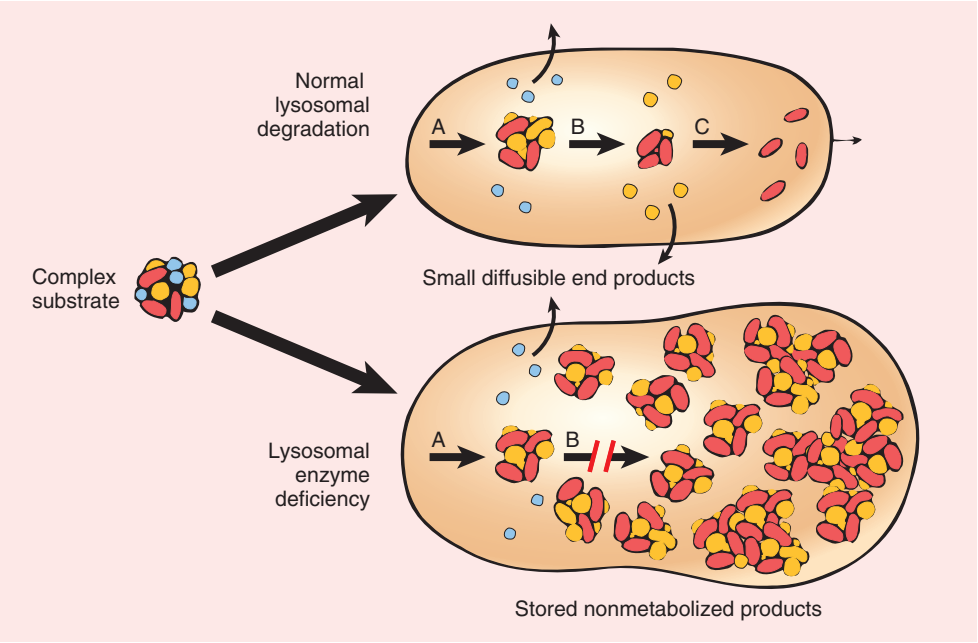


**Figure 6–8** Pathogenesis of lysosomal storage diseases. In this example, a complex substrate is normally degraded by a series of lysosomal enzymes (*A*, *B*, and *C*) into soluble end products. If there is a deficiency or malfunction of one of the enzymes (e.g., *B*), catabolism is incomplete, and insoluble intermediates accumulate in the lysosomes.

- Storage of insoluble intermediates in the mononuclear phagocyte system, giving rise to hepatosplenomegaly
- Frequent CNS involvement with associated neuronal damage
- Cellular dysfunctions, caused not only by storage of undigested material but also by a cascade of secondary events triggered, for example, by macrophage activation and release of cytokines

Fortunately for the potential victims of the diseases, most of these conditions are very rare, and their detailed description is better relegated to specialized texts and reviews. Only a few of the more common conditions are considered here. Type II glycogen storage disease (Pompe disease), also a lysosomal disorder, is discussed later in the chapter.

### Tay-Sachs Disease ($G_{M2}$ Gangliosidosis: Deficiency in Hexosaminidase β Subunit)

Gangliosidoses are characterized by accumulation of gangliosides, principally in the brain, as a result of a deficiency of a catabolic lysosomal enzyme. Depending on the ganglioside involved, these disorders are subclassified into $G_{M1}$ and $G_{M2}$ categories. Tay-Sachs disease, by far the most common of all gangliosidoses, is characterized by a mutation in and consequent deficiency of the β subunit of the

**Table 6–4** Lysosomal Storage Disorders

| Disease Category | Disease | Deficiency |
|---|---|---|
| Primary lysosomal hydrolase defect | Gaucher disease | Glucocerebrosidase |
| | $G_{M1}$ gangliosidosis | $G_{M1}$-β-galactosidase |
| | Tay-Sachs disease | Hexosaminidase, α subunit |
| | Sandhoff disease | Hexosaminidase, β subunit |
| | Fabry disease | α-Galactosidase A |
| | Krabbe disease | Galactosylceramidase |
| | Niemann-Pick disease types A and B | Sphingomyelinase |
| Posttranslational processing defect of lysosomal enzymes | Mucosulfatidosis (juvenile sulfatidosis) | Multiple sulfatases |
| Inefficient targeting of synthesized hydrolase to the lysosome | Mucolipidosis types II and III alpha/beta | *N*-acetyl glucosamine-1-phosphotransferase |
| Defect in lysosomal enzyme protection | Galactosialidosis | Protective protein cathepsin A (β-galactosidase and neuraminidase) |
| Defect in soluble nonenzymatic lysosomal proteins | $G_{M2}$ activator protein deficiency, variant AB | $G_{M2}$ activator protein |
| | Sphingolipid activator protein deficiency | Sphingolipid activator protein |
| Transmembrane (nonenzymatic) protein deficiency | Niemann-Pick disease type C (NPC) | *NPC1* and *NPC2* |
| | Salla disease (free sialic acid storage) | Sialin |

Data from Jeyakumar M, Dwek RA, Butters TD, Platt FM: Storage solutions: treating lysosomal disorders of the brain. Nat Rev Neurosci 6:1, 2005.

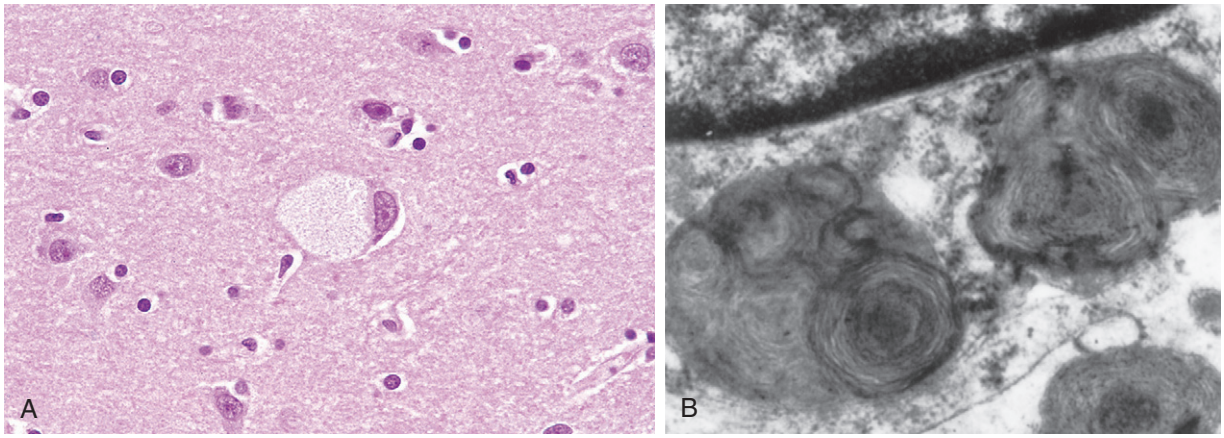


**Figure 6–9** Ganglion cells in Tay-Sachs disease. **A,** Under the light microscope, a large neuron has obvious lipid vacuolation. **B,** A portion of a neuron under the electron microscope shows prominent lysosomes with whorled configurations. Part of the nucleus is shown above.
*(A, Courtesy of Dr. Arthur Weinberg, Department of Pathology, University of Texas Southwestern Medical Center, Dallas, Texas. B, Courtesy of Dr. Joe Rutledge, Children's Regional Medical Center, Seattle, Washington.)*

enzyme hexosaminidase A, which is necessary for the degradation of $G_{M2}$. More than 100 mutations have been described; most affect protein folding or intracellular transport. The brain is principally affected, because it is most involved in ganglioside metabolism. *The storage of $G_{M2}$* occurs within neurons, axon cylinders of nerves, and glial cells throughout the CNS. Affected cells appear swollen and sometimes foamy (Fig. 6–9, *A*). Electron microscopy reveals whorled configurations within lysosomes composed of onion-skin layers of membranes (Fig. 6–9, *B*). These pathologic changes are found throughout the CNS (including the spinal cord), peripheral nerves, and autonomic nervous system. The retina usually is involved as well, where the pallor produced by swollen ganglion cells in the peripheral retina results in a contrasting "cherry red" spot in the relatively unaffected central macula.

The molecular basis for neuronal injury is not fully understood. Because in many cases the mutant protein is misfolded, it induces the so-called "unfolded protein" response (Chapter 1). If such misfolded proteins are not stabilized by chaperones, they trigger apoptosis. These findings have spurred clinical trials of *molecular chaperone therapy* for this and similar lysosomal storage diseases. Such therapy involves use of small molecules that increase chaperone synthesis or reduce degradation of misfolded proteins by the proteosomes.

In the most common acute infantile variant of Tay-Sachs disease, infants appear normal at birth, but motor weakness begins at 3 to 6 months of age, followed by neurologic impairment, onset of blindness, and progressively more severe neurologic dysfunctions. Death occurs within 2 or 3 years. Tay-Sachs disease, like other lipidoses, is most common among Ashkenazi Jews, among whom the frequency of heterozygous carriers is estimated to be 1 in 30. Heterozygote carriers can be reliably detected by estimation of the level of hexosaminidase in the serum or by DNA analysis.

### Niemann-Pick Disease Types A and B

Type A and type B Niemann-Pick disease are related entities characterized by a primary deficiency of acid sphingomyelinase and the resultant accumulation of sphingomyelin. In type A, characterized by a severe deficiency of sphingomyelinase, the breakdown of sphingomyelin into ceramide and phosphorylcholine is impaired, and excess sphingomyelin accumulates in all phagocytic cells and in the neurons. The macrophages become stuffed with droplets or particles of the complex lipid, imparting a fine vacuolation or foaminess to the cytoplasm (Fig. 6–10). Electron microscopy confirms that the vacuoles are engorged secondary lysosomes that often contain membranous cytoplasmic bodies resembling concentric lamellated myelin figures, sometimes called "zebra" bodies. Because of their high content of phagocytic cells, *the organs most severely affected are the spleen, liver, bone marrow, lymph nodes, and lungs.* The splenic enlargement may be striking. In addition, the entire CNS, including the spinal cord and ganglia, is involved in this tragic, inexorable process. The affected neurons are enlarged and vacuolated as a result of the storage of lipids. This variant manifests itself in infancy with *massive visceromegaly and severe neurologic deterioration.*

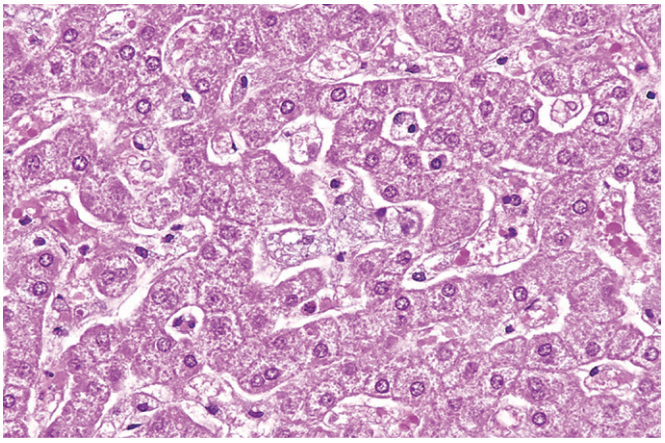

**Figure 6–10** Niemann-Pick disease in liver. The hepatocytes and Kupffer cells have a foamy, vacuolated appearance resulting from deposition of lipids.
*(Courtesy of Dr. Arthur Weinberg, Department of Pathology, University of Texas Southwestern Medical Center, Dallas, Texas.)*

Death usually occurs within the first 3 years of life. By comparison, patients with the type B variant have organomegaly but no neurologic manifestations. Estimation of sphingomyelinase activity in the leukocytes or cultured fibroblasts can be used for diagnosis of suspected cases, as well as for detection of carriers. Antenatal diagnosis is possible by enzyme assays or DNA probe analysis.

### Niemann-Pick Disease Type C

Although previously considered to be related to type A and type B Niemann-Pick disease, type C (NPC) is quite distinct at the biochemical and molecular levels and is more common than types A and B combined. Mutations in two related genes, *NPC1* and *NPC2,* can give rise to the disorder, with *NPC1* being responsible for a majority of cases. Unlike most other lysosomal storage diseases, NPC is due to a primary defect in lipid transport. Affected cells accumulate cholesterol as well as gangliosides such as $G_{M1}$ and $G_{M2}$. Both NPC1 and NPC2 are involved in the transport of free cholesterol from the lysosomes to the cytoplasm. NPC is clinically heterogeneous: The most common form manifests in childhood and is marked by ataxia, vertical supranuclear gaze palsy, dystonia, dysarthria, and psychomotor regression.

### Gaucher Disease

Gaucher disease results from mutation in the gene that encodes glucocerebrosidase. There are three autosomal recessive variants of Gaucher disease resulting from distinct allelic mutations. Common to all is variably deficient activity of a glucocerebrosidase that normally cleaves the glucose residue from ceramide. This deficit leads to an accumulation of glucocerebroside, an intermediate in glycolipid metabolism, in the mononuclear phagocytic cells and their transformation into so-called Gaucher cells. Normally the glycolipids derived from the breakdown of senescent blood cells are sequentially degraded by the phagocytic cells of the body particularly in the liver, spleen, and bone marrow. In Gaucher disease, the degradation stops at the level of glucocerebrosides, which accumulate in the phagocytes. These phagocytes—the Gaucher cells—become enlarged, with some reaching a diameter as great as 100 μm, because of the accumulation of distended lysosomes, and acquire a pathognomonic cytoplasmic appearance characterized as "wrinkled tissue paper" (Fig. 6–11). No distinct vacuolation is present. It is evident now that Gaucher disease is caused not just by the burden of storage material but also by activation of the macrophages. High levels of macrophage-derived cytokines, such as interleukins (IL-1, IL-6) and tumor necrosis factor (TNF), are found in affected tissues.

One variant, type I, also called the *chronic nonneuronopathic form,* accounts for 99% of cases of Gaucher disease. It is characterized by clinical or radiographic bone involvement (osteopenia, focal lytic lesions, and osteonecrosis) in 70% to 100% of cases. Additional features are hepatosplenomegaly and the absence of CNS involvement. The spleen often enlarges to massive proportions, filling the entire abdomen. Gaucher cells are found in the liver, spleen, lymph nodes, and bone marrow. Marrow replacement and cortical erosion may produce radiographically visible skeletal lesions, as well as a reduction in the formed elements of blood. Bone changes are believed to be caused by the aforementioned macrophage-derived cytokines. Type I is most common in Ashkenazi Jews; unlike other variants, it is compatible with long life. Types II and III variants are characterized by neurologic signs and symptoms. In type II, these manifestations appear during infancy (*acute infantile neuronopathic form*) and are more severe, whereas in type III, they emerge later and are milder (*chronic neuronopathic form*). Although the liver and spleen also are involved, the clinical features in types II and III are dominated by neurologic disturbances, including convulsions and progressive mental deterioration. The level of glucocerebrosides in leukocytes or cultured fibroblasts is helpful in diagnosis and in the detection of heterozygote carriers.

Current therapy is aimed at lifelong enzyme replacement by infusion of recombinant glucocerebrosidase. A newer form of therapy involves reducing the substrate (glucocerebroside) by oral administration of drugs that inhibit glucocerebroside synthase. Since glucosylceramide is reduced, its accumulation also is reduced. Recent clinical trials in humans have shown considerable promise for this

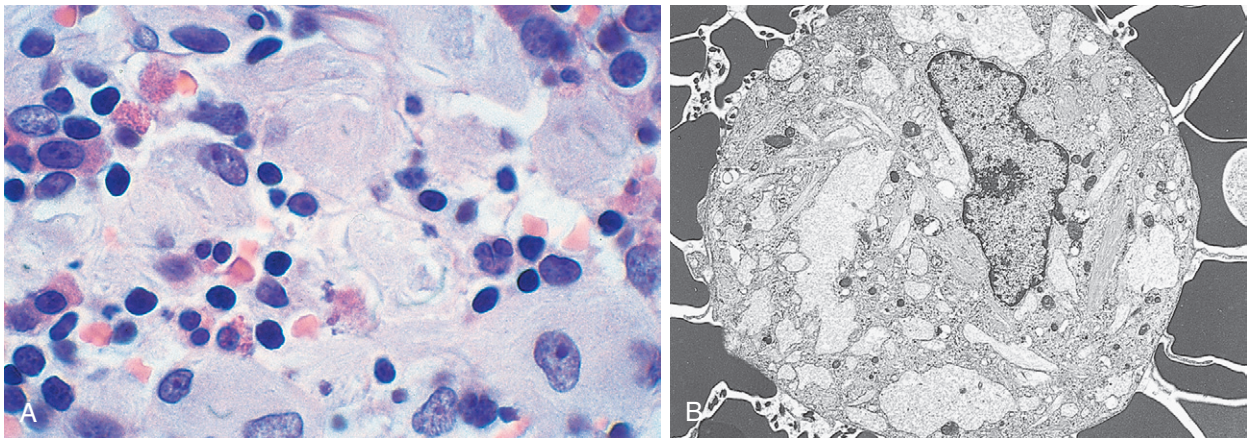


**Figure 6–11** Gaucher disease involving the bone marrow. **A,** Gaucher cells with abundant lipid-laden granular cytoplasm. **B,** Electron micrograph of Gaucher cells with elongated distended lysosomes.
*(Courtesy of Dr. Matthew Fries, Department of Pathology, University of Texas Southwestern Medical Center, Dallas, Texas.)*

modality of therapy, with decrease in splenomegaly and improvements in skeletal disease. On the horizon is glucocerebrosidase gene therapy involving infusion of autologous hematopoietic stem cells transfected with the normal gene.

### Mucopolysaccharidoses

Mucopolysaccharidoses (MPSs) are characterized by defective degradation (and therefore excessive storage) of mucopolysaccharides in various tissues. Recall that mucopolysaccharides form a part of ground substance and are synthesized by connective tissue fibroblasts. Most of the mucopolysaccharide is secreted into the ground substance, but a certain fraction is degraded within lysosomes. Multiple enzymes are involved in this catabolic pathway; it is the lack of these enzymes that leads to accumulation of mucopolysaccharides within the lysosomes. Several clinical variants of MPS, classified numerically from MPS I to MPS VII, have been described, each resulting from the deficiency of one specific enzyme. The mucopolysaccharides that accumulate within the tissues include dermatan sulfate, heparan sulfate, keratan sulfate, and (in some cases) chondroitin sulfate.

*Hepatosplenomegaly, skeletal deformities, lesions of heart valves, and subendothelial arterial deposits, particularly in the coronary arteries, and lesions in the brain, are common threads that run through all of the MPSs.* In many of the more protracted syndromes, coronary subendothelial lesions lead to myocardial ischemia. *Thus, myocardial infarction and cardiac decompensation are important causes of death.* Most cases are associated with *coarse facial features, clouding of the cornea, joint stiffness, and mental retardation.* Urinary excretion of the accumulated mucopolysaccharides often is increased. With all of these disorders except one, the mode of inheritance is autosomal recessive; the exception, Hunter syndrome, is an X-linked recessive disease. Of the seven recognized variants, only two well-characterized syndromes are discussed briefly here.

MPS type I, also known as *Hurler syndrome,* is caused by a deficiency of α-L-iduronidase. In Hurler syndrome, affected children have a life expectancy of 6 to 10 years, and death is often due to cardiac complications. Accumulation of dermatan sulfate and heparan sulfate is seen in cells of the mononuclear phagocyte system, in fibroblasts, and within endothelium and smooth muscle cells of the vascular wall. The affected cells are swollen and have clear cytoplasm, resulting from the accumulation of material positive for periodic acid–Schiff staining within engorged, vacuolated lysosomes. Lysosomal inclusions also are found in neurons, accounting for the mental retardation.

The other well-characterized variant, MPS type II or *Hunter syndrome,* differs from Hurler syndrome in its mode of inheritance (X-linked), the absence of corneal clouding, and often its milder clinical course. As in Hurler syndrome, the accumulated mucopolysaccharides in Hunter syndrome are heparan sulfate and dermatan sulfate, but this results from a deficiency of L-iduronate sulfatase. Despite the difference in enzyme deficiency, an accumulation of identical substrates occurs because breakdown of heparan sulfate and dermatan sulfate requires both α-L-iduronidase and the sulfatase; if either one is missing, further degradation is blocked.

## SUMMARY

### Lysosomal Storage Diseases

- *Tay-Sachs disease* is caused by an inability to metabolize $G_{M2}$ gangliosides due to lack of the β subunit of lysosomal hexosaminidase. $G_{M2}$ gangliosides accumulate in the CNS and cause severe mental retardation, blindness, motor weakness, and death by 2 to 3 years of age.
- *Niemann-Pick disease types A and B* are caused by a deficiency of sphingomyelinase. In the more severe, type A variant, accumulation of sphingomyelin in the nervous system results in neuronal damage. Lipid also is stored in phagocytes within the liver, spleen, bone marrow, and lymph nodes, causing their enlargement. In type B, neuronal damage is not present.
- *Niemann-Pick disease type C* is caused by a defect in cholesterol transport and resultant accumulation of cholesterol and gangliosides in the nervous system. Affected children exhibit ataxia, dysarthria, and psychomotor regression.
- *Gaucher disease* results from lack of the lysosomal enzyme glucocerebrosidase and accumulation of glucocerebroside in mononuclear phagocytic cells. In the most common, type I variant, affected phagocytes become enlarged (Gaucher cells) and accumulate in liver, spleen, and bone marrow, causing hepatosplenomegaly and bone erosion. Types II and III are characterized by variable neuronal involvement.
- *Mucopolysaccharidoses* result from accumulation of mucopolysaccharides in many tissues including liver, spleen, heart, blood vessels, brain, cornea, and joints. Affected patients in all forms have coarse facial features. Manifestations of Hurler syndrome include corneal clouding, coronary arterial and valvular deposits, and death in childhood. Hunter syndrome is associated with a milder clinical course.

### *Glycogen Storage Diseases (Glycogenoses)*

An inherited deficiency of any one of the enzymes involved in glycogen synthesis or degradation can result in excessive accumulation of glycogen or some abnormal form of glycogen in various tissues. The type of glycogen stored, its intracellular location, and the tissue distribution of the affected cells vary depending on the specific enzyme deficiency. Regardless of the tissue or cells affected, the glycogen most often is stored within the cytoplasm, or sometimes within nuclei. One variant, Pompe disease, is a form of lysosomal storage disease, because the missing enzyme is localized to lysosomes. Most glycogenoses are inherited as autosomal recessive diseases, as is common with "missing enzyme" syndromes.

Approximately a dozen forms of glycogenoses have been described in association with specific enzyme deficiencies. On the basis of pathophysiologic findings, they can be grouped into three categories (Table 6–5):

- *Hepatic type.* Liver contains several enzymes that synthesize glycogen for storage and also break it down into free glucose. Hence, a deficiency of the hepatic enzymes involved in glycogen metabolism is associated with two major clinical effects: *enlargement of the liver due to storage*

**Table 6–5** Principal Subgroups of Glycogenoses

| Clinicopathologic Category | Specific Type | Enzyme Deficiency | Morphologic Changes | Clinical Features |
|---|---|---|---|---|
| Hepatic type | Hepatorenal (von Gierke disease, type I) | Glucose-6-phosphatase | *Hepatomegaly*: intracytoplasmic accumulations of glycogen and small amounts of lipid; intranuclear glycogen<br>*Renomegaly*: intracytoplasmic accumulations of glycogen in cortical tubular epithelial cells | In untreated patients, failure to thrive, stunted growth, hepatomegaly, and renomegaly<br>Hypoglycemia due to failure of glucose mobilization, often leading to convulsions<br>Hyperlipidemia and hyperuricemia resulting from deranged glucose metabolism; many patients develop gout and skin xanthomas<br>Bleeding tendency due to platelet dysfunction<br>With treatment (providing continuous source of glucose), most patients survive and develop late complications (e.g., hepatic adenomas) |
| Myopathic type | McArdle syndrome (type V) | Muscle phosphorylase | *Skeletal muscle only*: accumulations of glycogen predominant in subsarcolemmal location | Painful cramps associated with strenuous exercise<br>Myoglobinuria occurs in 50% of cases<br>Onset in adulthood (>20 yr)<br>Muscular exercise fails to raise lactate level in venous blood<br>Compatible with normal longevity |
| Miscellaneous type | Generalized glycogenosis (Pompe disease, type II) | Lysosomal glucosidase (acid maltase) | *Mild hepatomegaly*: ballooning of lysosomes with glycogen creating lacy cytoplasmic pattern<br>*Cardiomegaly*: glycogen within sarcoplasm as well as membrane-bound<br>*Skeletal muscle*: similar to heart (see above under cardiomegaly) | Massive cardiomegaly, muscle hypotonia, and cardiorespiratory failure before age 2<br>Milder adult form with only skeletal muscle involvement manifests with chronic myopathy. |

*of glycogen* and *hypoglycemia due to a failure of glucose production* (Fig. 6–12). *Von Gierke* disease (type I glycogenosis), resulting from a lack of glucose-6-phosphatase, is the most important example of the hepatic form of glycogenosis (Table 6–5).

- *Myopathic type.* In striated muscle, glycogen is an important source of energy. Not surprisingly, most forms of glycogen storage disease affect muscles. When enzymes that are involved in glycolysis are deficient, glycogen storage occurs in muscles and there is an associated muscle weakness due to impaired energy production. Typically, *the myopathic forms of glycogen storage diseases are marked by muscle cramps after exercise, myoglobinuria, and failure of exercise to induce an elevation in blood lactate levels because of a block in glycolysis.* McArdle disease (type V glycogenosis), resulting from a deficiency of muscle phosphorylase, is the prototype of myopathic glycogenoses.
- Type II glycogenosis (*Pompe disease*) is caused by a deficiency of lysosomal acid maltase and so is associated with deposition of glycogen in virtually every organ, but cardiomegaly is most prominent. Most affected patients die within 2 years of onset of cardiorespiratory failure. Therapy with the missing enzyme (glucosidase) can reverse cardiac muscle damage and modestly increase longevity.

### SUMMARY

#### Glycogen Storage Diseases

- Inherited deficiency of enzymes involved in glycogen metabolism can result in storage of normal or abnormal forms of glycogen, predominantly in liver or muscles or in all tissues.
- In the *hepatic form* (von Gierke disease), liver cells store glycogen because of a lack of hepatic glucose-6-phosphatase. There are several *myopathic forms*, including McArdle disease, in which muscle phosphorylase lack gives rise to storage in skeletal muscles and cramps after exercise. In *Pompe disease* there is lack of lysosomal acid maltase, and all organs are affected, but heart involvement is predominant.

## Diseases Caused by Mutations in Genes Encoding Proteins That Regulate Cell Growth

As detailed in Chapter 5, two classes of genes, proto-oncogenes and tumor suppressor genes, regulate normal cell growth and differentiation. Mutations affecting these genes, most often in somatic cells, are involved in the

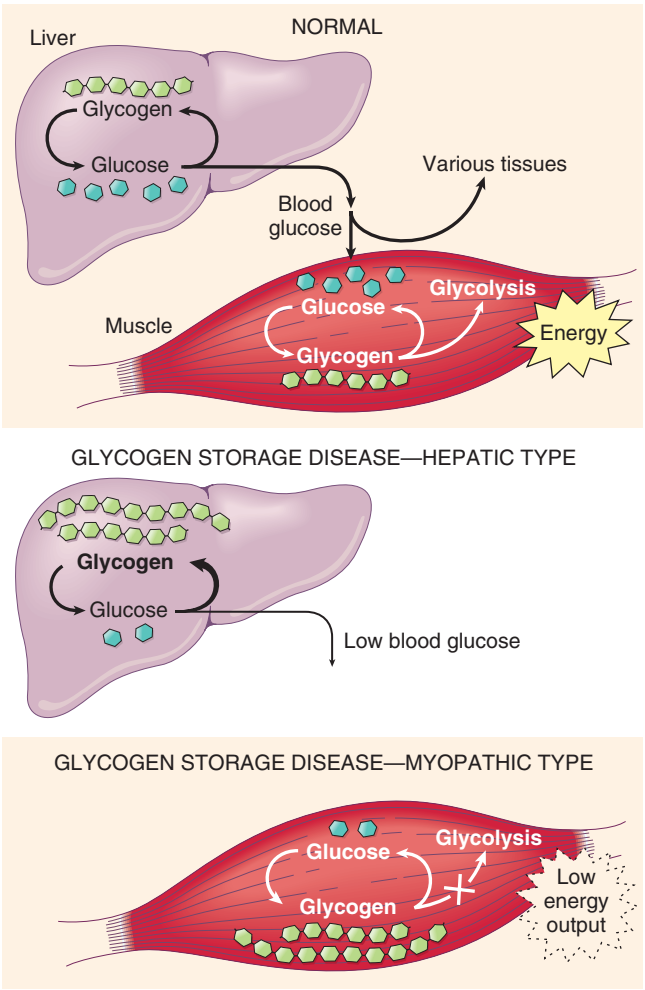


**Figure 6–12 Top,** A simplified scheme of normal glycogen metabolism in the liver and skeletal muscles. **Middle,** The effects of an inherited deficiency of hepatic enzymes involved in glycogen metabolism. **Bottom,** The consequences of a genetic deficiency in the enzymes that metabolize glycogen in skeletal muscles.

pathogenesis of tumors. In approximately 5% to 10% of all cancers, however, mutations affecting certain tumor suppressor genes are present in all cells of the body, including germ cells and hence can be transmitted to the offspring. These mutant genes predispose the offspring to hereditary tumors, a topic discussed in greater detail in Chapter 5.

## COMPLEX MULTIGENIC DISORDERS

Complex multigenic disorders—so-called multifactorial or polygenic disorders—are caused by interactions between variant forms of genes and environmental factors. A genetic variant that has at least two alleles and occurs in at least 1% of the population is called a *polymorphism.* According to the common disease–common variant hypothesis, complex multigenic disorders occur when many polymorphisms, each with a modest effect and low penetrance, are co-inherited. Two additional important facts have emerged from studies of common complex disorders such as type 1 diabetes:

- While complex disorders result from the collective inheritance of many polymorphisms, different polymorphisms vary in significance. For example, of the 20 to 30 genes implicated in type 1 diabetes, 6 or 7 are most important, and a few HLA alleles contribute more than 50% of the risk (Chapter 19).
- Some polymorphisms are common to multiple diseases of the same type, while others are disease-specific. This observation is well illustrated in immune-mediated inflammatory diseases (Chapter 4).

Several normal phenotypic characteristics are governed by multigenic inheritance, such as hair color, eye color, skin color, height, and intelligence. These characteristics (also known as *quantitative trait loci* [QTLs]) show a continuous variation within, as well as across, all population groups. Environmental influences, however, significantly modify the phenotypic expression of complex traits. For example, type 2 diabetes mellitus has many of the features of a complex multigenic disorder. It is well recognized clinically that affected persons often first exhibit clinical manifestations of this disease after weight gain. Thus, obesity as well as other environmental influences, unmasks the diabetic genetic trait. Assigning a disease to this mode of inheritance must be done with caution. Such attribution depends on many factors but first on familial clustering and the exclusion of mendelian and chromosomal modes of transmission. A range of levels of severity of a disease is suggestive of a complex multigenic disorder, but as pointed out earlier, variable expressivity and reduced penetrance of single mutant genes also may account for this phenomenon. Because of these problems, sometimes it is difficult to distinguish between mendelian and multifactorial disorders.

## CYTOGENETIC DISORDERS

Chromosomal abnormalities occur much more frequently than is generally appreciated. It is estimated that approximately 1 in 200 newborn infants has some form of chromosomal abnormality. The figure is much higher in fetuses that do not survive to term. It is estimated that in 50% of first-trimester spontaneous abortions, the fetus has a chromosomal abnormality. Cytogenetic disorders may result from alterations in the number or structure of chromosomes and may affect autosomes or sex chromosomes.

Before embarking on a discussion of chromosomal aberrations, it is appropriate to review karyotyping as the basic tool of the cytogeneticist. A *karyotype* is a photographic representation of a stained metaphase spread in which the chromosomes are arranged in order of decreasing length. A variety of techniques for staining chromosomes have been developed. With the widely used Giemsa stain (G banding) technique, each chromosome set can be seen to possess a distinctive pattern of alternating light and dark bands of variable widths (Fig. 6–13). The use of banding techniques allows identification of each chromosome, and can detect and localize structural abnormalities large enough to produce changes in banding pattern (described later).

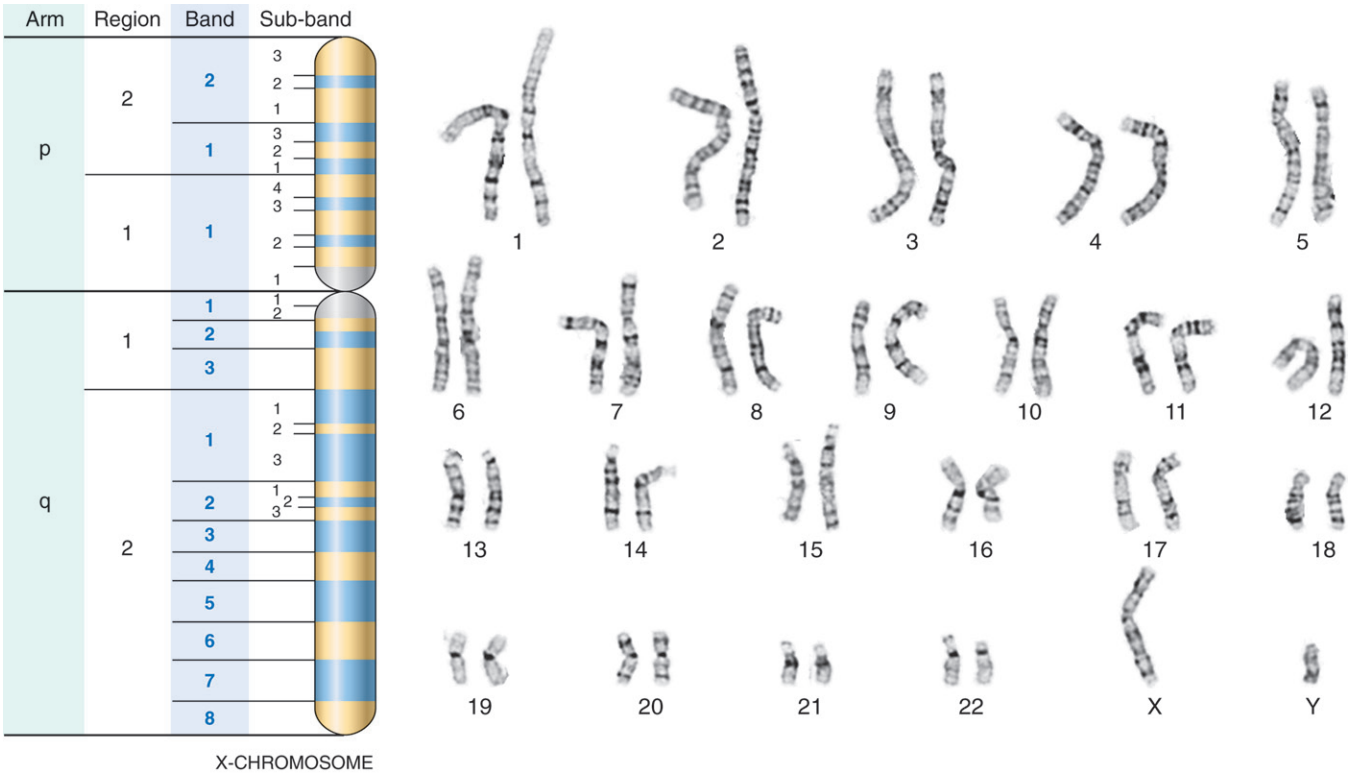


**Figure 6–13** G-banded karyotype from a normal male (46,XY). Also shown is the banding pattern of the X-chromosome with nomenclature of arms, regions, bands, and sub-bands.

*(Karyotype courtesy of Dr. Stuart Schwartz, Department of Pathology, University of Chicago, Chicago, Illinois.)*

## Numeric Abnormalities

In humans, the normal chromosome count is 46 (i.e., $2n = 46$). Any exact multiple of the haploid number ($n$) is called *euploid.* Chromosome numbers such as $3n$ and $4n$ are called *polyploid.* Polyploidy generally results in a spontaneous abortion. Any number that is not an exact multiple of $n$ is called *aneuploid.* The chief cause of aneuploidy is nondisjunction of a homologous pair of chromosomes at the first meiotic division or a failure of sister chromatids to separate during the second meiotic division. The latter also may occur during mitosis in somatic cells, leading to the production of two aneuploid cells. Failure of pairing of homologous chromosomes followed by random assortment (anaphase lag) can also lead to aneuploidy. When nondisjunction occurs at the time of meiosis, the gametes formed have either an extra chromosome ($n + 1$) or one less chromosome ($n - 1$). Fertilization of such gametes by normal gametes would result in two types of zygotes: trisomic, with an extra chromosome ($2n + 1$), or monosomic ($2n - 1$). Monosomy involving an autosome is incompatible with life, whereas trisomies of certain autosomes and monosomy involving sex chromosomes are compatible with life. These, as we shall see, are associated with variable degrees of phenotypic abnormality. *Mosaicism* is a term used to describe the presence of two or more populations of cells with different complements of chromosomes in the same individual. In the context of chromosome numbers, postzygotic mitotic nondisjunction would result in the production of a trisomic and a monosomic daughter cell; the descendants of these cells would then produce a mosaic. As discussed later, mosaicism affecting sex chromosomes is common, whereas autosomal mosaicism is not.

## Structural Abnormalities

Structural changes in the chromosomes usually result from chromosomal breakage followed by loss or rearrangement of material. Such changes usually are designated using a cytogenetic shorthand in which *p* (French, *petit*) denotes the short arm of a chromosome, and *q,* the long arm. Each arm is then divided into numbered regions (1, 2, 3, and so on) from centromere outward, and within each region the bands are numerically ordered (Fig. 6–13). Thus, 2q34 indicates chromosome 2, long arm, region 3, band 4. The patterns of chromosomal rearrangement after breakage (Fig. 6–14) are as follows:

- *Translocation* implies transfer of a part of one chromosome to another chromosome. The process is usually reciprocal (i.e., fragments are exchanged between two chromosomes). In genetic shorthand, translocations are indicated by *t* followed by the involved chromosomes in numeric order—for example, 46,XX,t(2;5)(q31;p14). This notation would indicate a reciprocal translocation involving the long arm (q) of chromosome 2 at region 3, band 1, and the short arm of chromosome 5, region 1, band 4. When the entire broken fragments are exchanged, the resulting balanced reciprocal translocation (Fig. 6–14) is not harmful to the carrier, who has the normal number of chromosomes and the full complement of genetic material. However, during gametogenesis,

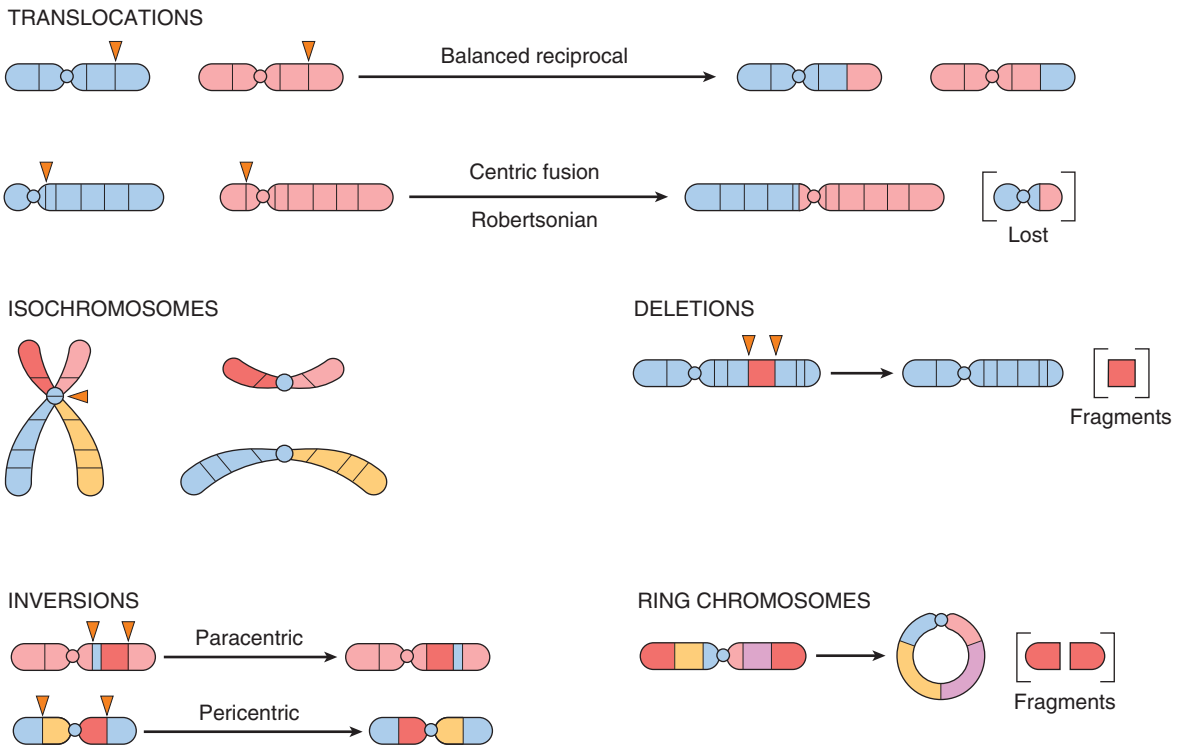


**Figure 6–14** Types of chromosomal rearrangements.

abnormal (unbalanced) gametes are formed, resulting in abnormal zygotes. A special pattern of translocation involving two acrocentric chromosomes is called *centric fusion type,* or *robertsonian,* translocation. The breaks typically occur close to the centromere, affecting the short arms of both chromosomes. Transfer of the segments leads to one very large chromosome and one extremely small one (Fig. 6–14). The short fragments are lost, and the carrier has 45 chromosomes. Because the short arms of all acrocentric chromosomes carry highly redundant genes (e.g., ribosomal RNA genes), such loss is compatible with survival. However, difficulties arise during gametogenesis, resulting in the formation of unbalanced gametes that could lead to abnormal offspring.

- *Isochromosomes* result when the centromere divides horizontally rather than vertically. One of the two arms of the chromosome is then lost, and the remaining arm is duplicated, resulting in a chromosome with two short arms only or two long arms only. The most common isochromosome present in live births involves the long arm of the X chromosome and is designated *i(Xq)*. When fertilization occurs by a gamete that contains a normal X chromosome, the result is monosomy for genes on Xp and trisomy for genes on Xq.
- *Deletion* involves loss of a portion of a chromosome. A single break may delete a terminal segment. Two interstitial breaks, with reunion of the proximal and distal segments, may result in loss of an intermediate segment. The isolated fragment, which lacks a centromere, almost never survives, and thus many genes are lost.
- *Inversions* occur when there are two interstitial breaks in a chromosome, and the segment reunites after a complete turnaround.
- A *ring chromosome* is a variant of a deletion. After loss of segments from each end of the chromosome, the arms unite to form a ring.

## General Features of Chromosomal Disorders

- Chromosomal disorders may be associated with absence (deletion, monosomy), excess (trisomy), or abnormal rearrangements (translocations) of chromosomes.
- In general, loss of chromosomal material produces more severe defects than does gain of chromosomal material.
- Excess chromosomal material may result from a complete chromosome (as in trisomy) or from part of a chromosome (as in robertsonian translocation).
- Imbalances of sex chromosomes (excess or loss) are tolerated much better than are similar imbalances of autosomes.
- Sex chromosomal disorders often produce subtle abnormalities, sometimes not detected at birth. Infertility, a common manifestation, cannot be diagnosed until adolescence.
- In most cases, chromosomal disorders result from de novo changes (i.e., parents are normal, and risk of recurrence in siblings is low). An uncommon but important exception to this principle is exhibited by the translocation form of Down syndrome (described later).

Some specific examples of diseases involving changes in the karyotype are presented next.

## Cytogenetic Disorders Involving Autosomes

Three autosomal trisomies (21, 18, and 13) and one deletion syndrome (cri du chat syndrome), which results from partial deletion of the short arm of chromosome 5, were the first chromosomal abnormalities identified. More recently, several additional trisomies and deletion syndromes (such as that affecting 22q) have been described. Most of these disorders are quite uncommon, but their clinical features should permit ready recognition (Fig. 6–15).

Only trisomy 21 and 22q11.2 deletion occur with sufficient frequency to merit further consideration.

### *Trisomy 21 (Down Syndrome)*

Down syndrome is the most common of the chromosomal disorders. About 95% of affected persons have trisomy 21, so their chromosome count is 47. As mentioned earlier, the most common cause of trisomy, and therefore of Down syndrome, is *meiotic nondisjunction.* The parents of such children have a normal karyotype and are normal in all respects. *Maternal age has a strong influence* on the incidence of Down syndrome. It occurs in 1 in 1550 live births in women younger than 20 years, in contrast with 1 in 25 live births in women older than 45 years. The correlation with maternal age suggests that in most cases the meiotic nondisjunction of chromosome 21 occurs in the ovum. Indeed, in 95% of cases the extra chromosome is of maternal origin. The reason for the increased susceptibility of the ovum to nondisjunction is not fully understood. No effect of paternal age has been found in those cases in which the extra chromosome is derived from the father.

In about 4% of all patients with trisomy 21, the extra chromosomal material is present not as an extra chromosome but as a translocation of the long arm of chromosome 21 to chromosome 22 or 14. Such cases frequently (but not always) are familial, and the translocated chromosome is inherited from one of the parents, who typically is a carrier of a robertsonian translocation. Approximately 1% of patients with trisomy 21 are mosaics, usually having a mixture of 46- and 47-chromosome cells. These cases result from mitotic nondisjunction of chromosome 21 during an early stage of embryogenesis. Clinical manifestations in such cases are variable and milder, depending on the proportion of abnormal cells.

The diagnostic clinical features of this condition—flat facial profile, oblique palpebral fissures, and epicanthic folds (Fig. 6–15) —are usually readily evident, even at birth. Down syndrome is a leading cause of severe mental retardation; approximately 80% of those afflicted have an IQ of 25 to 50. Ironically, these severely disadvantaged children may have a gentle, shy manner and may be more easily directed than their more fortunate normal siblings. Of interest, some mosaics with Down syndrome have mild phenotypic changes and often even have normal or near-normal intelligence. In addition to the phenotypic abnormalities and the mental retardation already noted, some other clinical features are worthy of mention:

- Approximately 40% of the patients have congenital heart disease, most commonly defects of the endocardial cushion, including atrial septal defects, atrioventricular valve malformations, and ventricular septal defects (Chapter 10). Cardiac problems are responsible for a majority of the deaths in infancy and early childhood. Several other congenital malformations, including atresias of the esophagus and small bowel, also are common.
- Children with trisomy 21 have a 10- to 20-fold increased risk of developing acute leukemia. Both acute lymphoblastic leukemias and acute myeloid leukemias occur (Chapter 11).
- Virtually all patients with trisomy 21 older than age 40 develop neuropathologic changes characteristic of Alzheimer disease, a degenerative disorder of the brain (Chapter 22).
- Patients with Down syndrome demonstrate abnormal immune responses that predispose them to serious infections, particularly of the lungs, and to thyroid autoimmunity (Chapter 19). Although several abnormalities, affecting mainly T cell functions, have been reported, the basis for the immunologic disturbances is not clear.

Despite all of these problems, improved medical care has increased the longevity of persons with trisomy 21. Currently the median age at death is 47 years (up from 25 years in 1983). Although the karyotype of Down syndrome has been known for decades, the molecular basis for this disease remains elusive. Data from the human genome project indicate that chromosome 21 carries about 500 annotated genes, including approximately 170 that are conserved protein-coding genes and 5 miRNAs. It is unclear whether the phenotype of Down syndrome arises as a consequence of increased gene dosage of protein coding genes on chromosome 21 itself or of the effects of deregulated miRNA expression on target genes located on other chromosomes (as described previously, miRNAs act through inhibition of target gene expression). Two chromosome 21 candidate genes, *DYRK1A,* which codes for a serine-threonine kinase, and *RCAN1* (*r*egulator of *ca*lci*n*eurin *1*), which codes for a protein that inhibits a critical cellular phosphatase enzyme called calcineurin, have emerged as the "top culprits" in the pathogenesis of Down syndrome.

### *22q11.2 Deletion Syndrome*

The 22q11.2 deletion syndrome encompasses a spectrum of disorders that result from a small interstitial deletion of band 11 on the long arm of chromosome 22. The clinical features of this deletion syndrome include congenital heart disease affecting the outflow tracts, abnormalities of the palate, facial dysmorphism, developmental delay, thymic hypoplasia with impaired T cell immunity (Chapter 4), and parathyroid hypoplasia resulting in hypocalcemia (Chapter 19). Previously, these clinical features were believed to represent two different disorders: *DiGeorge syndrome* and *velocardiofacial syndrome.* However, it is now known that both are caused by 22q11.2 deletion. Variations in the size and position of the deletion are thought to be responsible for the differing clinical manifestations. When T cell immunodeficiency and hypocalcemia are the dominant features, the patients are said to have *DiGeorge syndrome,* whereas patients with the so-called *velocardiofacial syndrome* have mild immunodeficiency but pronounced dysmorphology

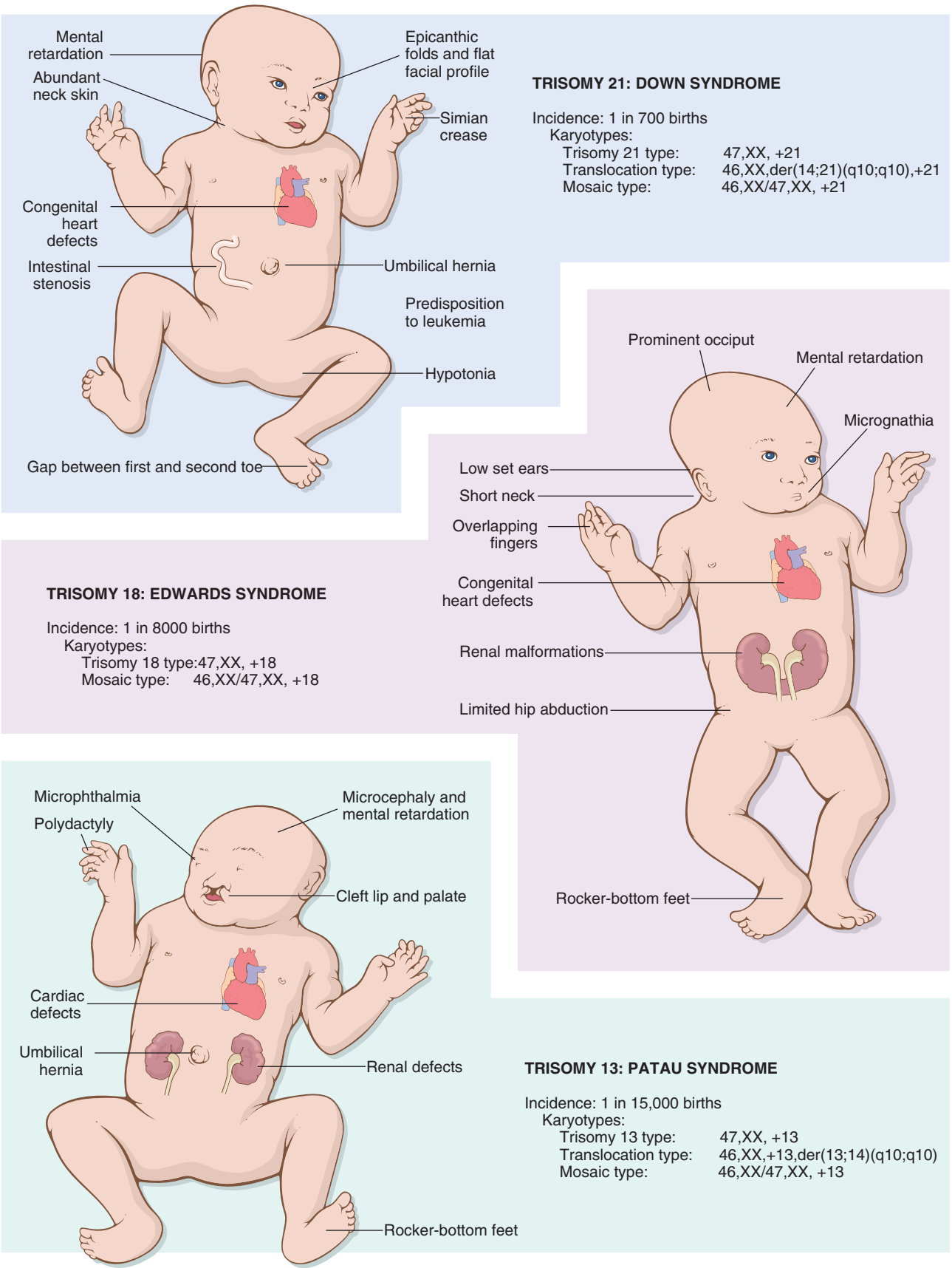


**Figure 6–15** Clinical features and karyotypes of the three most common autosomal trisomies.

and cardiac defects. In addition to these malformations, patients with 22q11.2 deletion are at *particularly high risk for psychoses such as schizophrenia and bipolar disorder.* The molecular basis for this syndrome is not fully understood. The affected region of chromosome 11 encodes many genes. Among these, a transcription factor gene called *TBX1* is suspected to be responsible, since its loss seems to correlate with the occurrence of DiGeorge syndrome.

The diagnosis of this condition may be suspected on clinical grounds but can be established only by detection of the deletion by fluorescence in situ hybridization (FISH) (Fig. 6–37, *B*).

## SUMMARY

### Cytogenetic Disorders Involving Autosomes

- *Down syndrome* is associated with an extra copy of genes on chromosome 21, most commonly due to trisomy 21 and less frequently from translocation of extra chromosomal material from chromosome 21 to other chromosomes or from mosaicism.
- Patients with Down syndrome have severe mental retardation, flat facial profile, epicanthic folds, cardiac malformations, higher risk of leukemia and infections, and premature development of Alzheimer disease.
- Deletion of genes at chromosomal locus 22q11.2 gives rise to malformations affecting the face, heart, thymus, and parathyroids. The resulting disorders are recognized as (1) *DiGeorge syndrome* (thymic hypoplasia with diminished T cell immunity and parathyroid hypoplasia with hypocalcemia) and (2) *velocardiofacial syndrome* (congenital heart disease involving outflow tracts, facial dysmorphism, and developmental delay).

## Cytogenetic Disorders Involving Sex Chromosomes

A number of abnormal karyotypes involving the sex chromosomes, ranging from 45,X to 49,XXXXY, are compatible with life. Indeed, phenotypically normal males with two and even three Y chromosomes have been identified. Such extreme karyotypic deviations are not encountered with the autosomes. In large part, this latitude relates to two factors: (1) lyonization of X chromosomes and (2) the small amount of genetic information carried by the Y chromosome. The consideration of lyonization must begin with Mary Lyon, who in 1962 proposed that in females, only one X chromosome is genetically active. X inactivation occurs early in fetal life, about 16 days after conception: Either the paternal or the maternal X chromosome is randomly inactivated in each of the primitive cells representing the developing embryo. Once inactivated, the same X chromosome remains genetically neutralized in all of the progeny of these cells. Moreover, all but one X chromosome is inactivated, and so a 48,XXXX female has only one active X chromosome. This phenomenon explains why normal females do not have a double dose (compared with males) of phenotypic attributes encoded on the X chromosome. The Lyon hypothesis also explains why normal females are in reality mosaics, containing two cell populations: one with an active maternal X, the other with an active paternal X.

Although essentially accurate, the Lyon hypothesis subsequently has been somewhat modified. Most important, the initial presumption that all of the genes on the inactive X are "switched off" has been revised as more recent studies suggest that 21% of genes on Xp, and a smaller number (3%) on Xq, escape X inactivation. This possibility has implications for monosomic X chromosome disorders, or Turner syndrome, as discussed later on.

Extra Y chromosomes are readily tolerated because the only information known to be carried on the Y chromosome seems to relate to male differentiation. Of note, whatever the number of X chromosomes, the presence of a Y invariably dictates the male phenotype. The gene for male differentiation (*SRY,* sex-determining region of Y chromosome) is located on the short arm of the Y.

Described briefly next are two disorders, Klinefelter syndrome and Turner syndrome, that result from aberrations of sex chromosomes.

### *Klinefelter Syndrome*

*Klinefelter syndrome is best defined as male hypogonadism that develops when there are at least two X chromosomes and one or more Y chromosomes.* Most affected patients have a 47,XXY karyotype. This karyotype results from nondisjunction of sex chromosomes during meiosis. The extra X chromosome may be of either maternal or paternal origin. Advanced maternal age and a history of irradiation in either parent may contribute to the meiotic error resulting in this condition. Approximately 15% of the patients show mosaic patterns, including 46,XY/47,XXY, 47,XXY/48,XXXY, and variations on this theme. The presence of a 46,XY line in mosaics usually is associated with a milder clinical condition.

Klinefelter syndrome is associated with a wide range of clinical manifestations. In some persons it may be expressed only as hypogonadism, but most patients have a distinctive body habitus with an *increase in length between the soles and the pubic bone,* which creates the appearance of an elongated body. Also characteristic is eunuchoid body habitus. *Reduced facial, body, and pubic hair* and *gynecomastia* also are frequently seen. The testes are markedly reduced in size, sometimes to only 2 cm in greatest dimension. In keeping with the *testicular atrophy,* the serum testosterone levels are lower than normal, and urinary gonadotropin levels are elevated.

*Klinefelter syndrome is the most common cause of hypogonadism in males.* Only rarely are patients fertile, and presumably such persons are mosaics with a large proportion of 46,XY cells. The sterility is due to impaired spermatogenesis, sometimes to the extent of total azoospermia. Histologic examination reveals hyalinization of tubules, which appear as ghostlike structures on tissue section. By contrast, Leydig cells are prominent, as a result of either hyperplasia or an apparent increase related to loss of tubules. Although Klinefelter syndrome may be associated with mental retardation, the degree of intellectual impairment typically is mild, and in some cases, no deficit is detectable. The reduction in intelligence is correlated with the number of extra X chromosomes. Klinefelter syndrome is associated with a higher frequency of several disorders, including breast cancer (seen 20 times more commonly than in

normal males), extragonadal germ cell tumors, and autoimmune diseases such as systemic lupus erythematosus.

### *Turner Syndrome*

Turner syndrome, characterized by primary hypogonadism in phenotypic females, results from partial or complete monosomy of the short arm of the X chromosome. With routine cytogenetic methods, the entire X chromosome is found to be missing in 57% of patients, resulting in a 45,X karyotype. These patients are the most severely affected, and the diagnosis often can be made at birth or early in childhood. Typical clinical features associated with 45,X Turner syndrome include significant growth retardation, leading to abnormally short stature (below the third percentile); swelling of the nape of the neck due to distended lymphatic channels (in infancy) that is seen as webbing of the neck in older children; low posterior hairline; cubitus valgus (an increase in the carrying angle of the arms); shieldlike chest with widely spaced nipples; high-arched palate; lymphedema of the hands and feet; and a variety of congenital malformations such as horseshoe kidney, bicuspid aortic valve, and coarctation of the aorta (Fig. 6–16). Cardiovascular abnormalities are the most common cause of death in childhood. In adolescence, affected girls fail to develop normal secondary sex characteristics; the genitalia remain infantile, breast development is minimal, and little pubic hair appears. Most patients have primary amenorrhea, and morphologic examination reveals transformation of the ovaries into white streaks of fibrous stroma devoid of follicles. The mental status of these patients usually is normal, but subtle defects in nonverbal, visual-spatial information processing have been noted. Curiously, hypothyroidism caused by autoantibodies occurs, especially in women with isochromosome Xp. As many as 50% of these patients develop clinical hypothyroidism. In adult patients, *a combination of short stature and primary amenorrhea should prompt strong suspicion for Turner syndrome.* The diagnosis is established by karyotyping.

Approximately 43% of patients with Turner syndrome either are mosaics (one of the cell lines being 45,X) or have structural abnormalities of the X chromosome. The most common is deletion of the short arm, resulting in the formation of an isochromosome of the long arm, 46,X,i(X)(q10). The net effect of the associated structural abnormalities is to produce partial monosomy of the X chromosome. Combinations of deletions and mosaicism are reported. It is important to appreciate the karyotypic heterogeneity associated with Turner syndrome because it is responsible for significant variations in the phenotype. In contrast with the patients with monosomy X, *those who are mosaics or have deletion variants may have an almost normal appearance and may present only with primary amenorrhea.*

The molecular pathogenesis of Turner syndrome is not completely understood, but studies have begun to shed some light. As mentioned earlier, both X chromosomes are active during oogenesis and are essential for normal development of the ovaries. During normal fetal development, ovaries contain as many as 7 million oocytes. The oocytes gradually disappear so that by menarche their numbers have dwindled to a mere 400,000, and when menopause occurs fewer than 10,000 remain. In Turner syndrome, fetal ovaries develop normally early in embryogenesis, but the absence of the second X chromosome leads to an accelerated loss of oocytes, which is complete by age 2 years. In a sense, therefore, "menopause occurs before menarche," and the ovaries are reduced to atrophic fibrous strands, devoid of ova and follicles (*streak ovaries*). Because patients with Turner syndrome also have other (nongonadal) abnormalities, it follows that some genes for normal growth and development of somatic tissues also must reside on the X chromosome. Among the genes involved in the Turner phenotype is the short stature homeobox (*SHOX*) gene at Xp22.33. *This is one of the genes that remain active in both X chromosomes* and is unique in having an active homologue on the short arm of the Y chromosome. Thus, both normal males and females have two copies of this gene. One copy of *SHOX* gives rise to short stature. Indeed, deletions of the *SHOX* gene are noted in 2% to 5% of otherwise normal children with short stature. Whereas one copy of *SHOX* can explain growth deficit in Turner syndrome, it cannot explain other important clinical

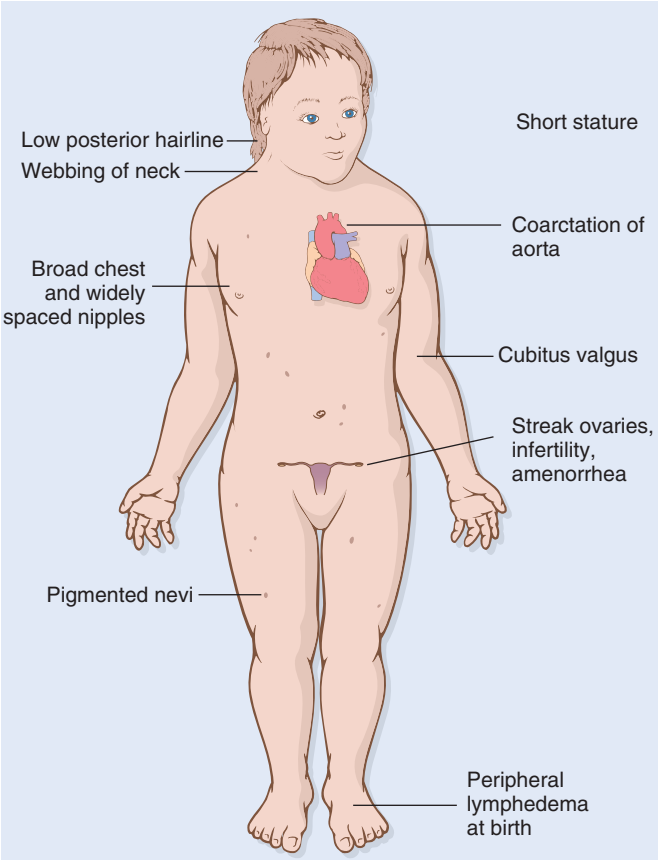


**Figure 6–16** Clinical features and karyotypes of Turner syndrome.

features such as cardiac malformations and endocrine abnormalities. Clearly, several other genes located on the X chromosome also are involved.

## SUMMARY

### Cytogenetic Disorders Involving Sex Chromosomes

- In females, one X chromosome, maternal or paternal, is randomly inactivated during development (Lyon hypothesis).
- In *Klinefelter syndrome*, there are two or more X chromosomes with one Y chromosome as a result of nondisjunction of sex chromosomes. Patients have testicular atrophy, sterility, reduced body hair, gynecomastia, and eunuchoid body habitus. It is the most common cause of male sterility.
- In *Turner syndrome*, there is partial or complete monosomy of genes on the short arm of the X chromosome, most commonly due to absence of one X chromosome (45,X) and less commonly from mosaicism, or from deletions involving the short arm of the X chromosome. Short stature, webbing of the neck, cubitus valgus, cardiovascular malformations, amenorrhea, lack of secondary sex characteristics, and fibrotic ovaries are typical clinical features.

# SINGLE-GENE DISORDERS WITH ATYPICAL PATTERNS OF INHERITANCE

Three groups of diseases resulting from mutations affecting single genes do not follow the mendelian rules of inheritance:

- Diseases caused by triplet repeat mutations
- Diseases caused by mutations in mitochondrial genes
- Diseases associated with alteration of imprinted regions of the genome

## Triplet Repeat Mutations: Fragile X Syndrome

Fragile X syndrome is the prototype of diseases in which the causative mutation occurs in a long repeating sequence of three nucleotides. Other examples of diseases associated with trinucleotide repeat mutations are Huntington disease and myotonic dystrophy. About 40 diseases are now known to be caused by this type of mutation, and all disorders discovered so far are associated with neurodegenerative changes. In each of these conditions, *amplification of specific sets of three nucleotides within the gene disrupts its function.* Certain unique features of trinucleotide repeat mutations, described later, are responsible for the atypical pattern of inheritance of the associated diseases.

Fragile X syndrome results from a mutation in the *FMR1* gene, which maps to Xq27.3. The syndrome gets its name from the karyotypic appearance of the X chromosome in the original method of diagnosis: Culturing patient cells in a folate-deficient medium typically revealed a *discontinuity of staining or constriction in the long arm of the X chromosome.* This method has now been supplanted by DNA-based analysis of triplet repeat size as discussed later. With a frequency of 1 in 1550 for affected males and 1 in 8000 for affected females, *fragile X syndrome is the second most common genetic cause of mental retardation, after Down syndrome.* Clinically affected males have moderate to severe mental retardation. The characteristic physical phenotype includes a long face with a large mandible, large everted ears, and large testicles (*macroorchidism*). Although characteristic of fragile X syndrome, these abnormalities are not always present or may be quite subtle. The only distinctive physical abnormality that can be detected in at least 90% of postpubertal males with fragile X syndrome is macroorchidism.

As with all X-linked diseases, fragile X syndrome predominantly affects males. Analysis of several pedigrees, however, reveals some patterns of transmission not typically associated with other X-linked recessive disorders (Fig. 6–17). These include the following:

- *Carrier males*: Approximately 20% of males who, by pedigree analysis and by molecular tests, are known to carry a fragile X mutation are clinically and cytogenetically normal. Because carrier males transmit the trait through all their daughters (phenotypically normal) to affected grandchildren, they are called *normal transmitting males.*
- *Affected females*: From 30% to 50% of carrier females are affected (i.e., mentally retarded), a number much higher than that for other X-linked recessive disorders.
- *Anticipation*: This term refers to the phenomenon whereby clinical features of fragile X syndrome worsen with each successive generation, as if the mutation becomes increasingly deleterious as it is transmitted from a man to his grandsons and great-grandsons.

These unusual features have been related to the dynamic nature of the mutation. In the normal population, the number of repeats of the sequence CGG in the *FMR1* gene is small, averaging around 29, whereas affected persons have 200 to 4000 repeats. These so-called full mutations are believed to arise through an intermediate stage of *premutations* characterized by 52 to 200 CGG repeats. Carrier males and females have premutations. During oogenesis (but not spermatogenesis), the premutations can be converted to full mutations by further amplification of the CGG repeats, which can then be transmitted to both the sons and the daughters of the carrier female. These observations provide an explanation for why some carrier males are unaffected (they have premutations), and certain carrier females are affected (they inherit full mutations). Recent studies indicate that premutations are not so benign after all. *Approximately 30% of females carrying the premutation have premature ovarian failure (before the age of 40 years), and about one third of premutation-carrying males exhibit a progressive neurodegenerative syndrome starting in their sixth decade.* This syndrome, referred to as fragile X–associated tremor-ataxia, is characterized by intention tremors and cerebellar ataxia and may progress to parkinsonism. It is clear, however, that the abnormalities in permutation carriers are milder and occur later in life.

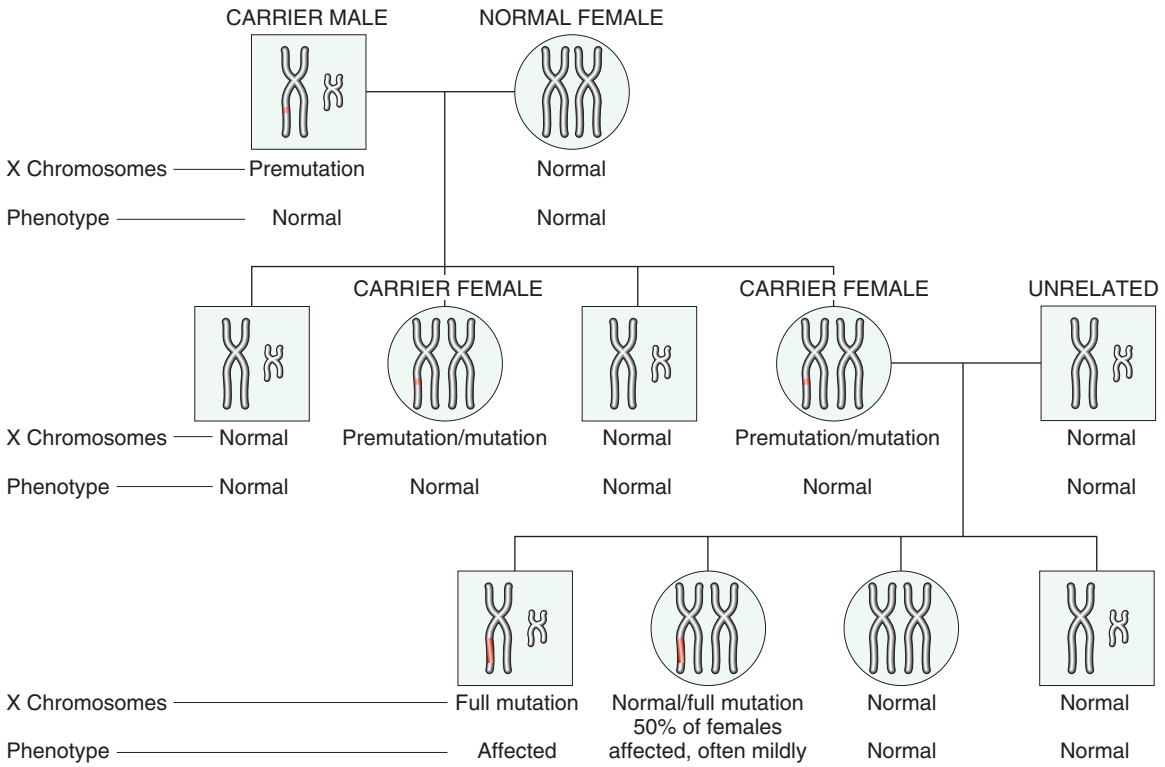


**Figure 6–17** Fragile X pedigree. X and Y chromosomes are shown. Note that in the first generation, all sons are normal and all females are carriers. During oogenesis in the carrier female, premutation expands to full mutation; hence, in the next generation, all males who inherit the X with full mutation are affected. However, only 50% of females who inherit the full mutation are affected, and often only mildly.
*(Based on an original sketch courtesy of Dr. Nancy Schneider, Department of Pathology, University of Texas Southwestern Medical School, Dallas, Texas.)*

## PATHOGENESIS

The molecular basis for fragile X syndrome is beginning to be understood and relates to silencing of the product of the *FMR1* gene, familial mental retardation protein (FMRP). The normal *FMR1* gene contains CGG repeats in its 5′ untranslated region. When the number of trinucleotide repeats in the *FMR1* gene exceeds approximately 230, the DNA of the entire 5′ region of the gene becomes abnormally methylated. Methylation also extends upstream into the promoter region of the gene, resulting in transcriptional suppression of *FMR1*. The resulting absence of FMRP is believed to cause the phenotypic changes. FMRP is widely expressed in normal tissues, but higher levels are found in the brain and the testis. Current evidence suggests that FMRP is an RNA-binding protein that is transported from the cytoplasm to the nucleus, where it binds specific mRNAs and transports them to the axons and dendrites (Fig. 6–18). It is in the synapses that FMRP–mRNA complexes perform critical roles in regulating the translation of specific mRNAs. The absence of this finely coordinated "shuttle" function seems to underlie the causation of fragile X syndrome.

As noted, in addition to fragile X syndrome, many other neurodegenerative diseases related to trinucleotide repeat expansions are recognized. Some general principles follow:

- In all cases, gene functions are altered by an expansion of the repeats, but the precise threshold at which

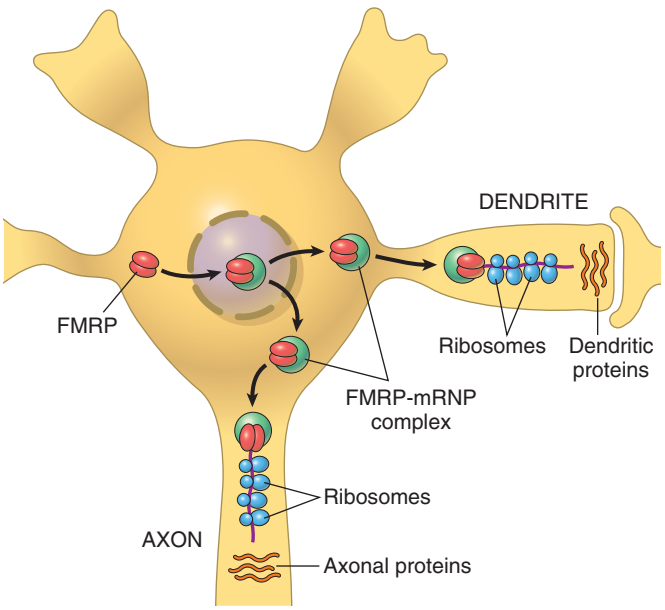


**Figure 6–18** A model for the action of familial mental retardation protein (FMRP) in neurons. FMRP plays a critical role in regulating the translation of axonal proteins from bound RNAs. These locally produced proteins, in turn, play diverse roles in the microenvironment of the synapse.
*(Adapted from Hin P, Warren ST: New insights into fragile X syndrome: from molecules to neurobehavior. Trends Biochem Sci 28:152, 2003.)*

premutations are converted to full mutations differs with each disorder.
- While the expansion in fragile X syndrome occurs during oogenesis, in other disorders such as Huntington disease, premutations are converted to full mutations during spermatogenesis.
- The expansion may involve any part of the gene, and the range of possibilities can be divided into two broad categories: those that affect untranslated regions (as in fragile X syndrome) or coding regions (as in Huntington disease) (Fig. 6–19). When mutations affect noncoding regions, there is "loss of function," since protein synthesis is suppressed (e.g., FMRP). By contrast, mutations involving translated parts of the gene give rise to misfolded proteins that interfere with function of normal proteins (e.g., Huntington disease). Many of these so-called toxic gain-of-function mutations involve CAG repeats that encode polyglutamine tracts, and the resultant diseases are sometimes referred to as "polyglutamine diseases," affecting primarily the nervous system. Accumulation of misfolded proteins in aggregates within the cytoplasm is a common feature of such diseases.

## SUMMARY

### Fragile X Syndrome

- Pathologic amplification of trinucleotide repeats causes loss-of-function (fragile X syndrome) or gain-of-function mutations (Huntington disease). Most such mutations produce neurodegenerative disorders.
- Fragile X syndrome results from loss of *FMR1* gene function and is characterized by mental retardation, macroorchidism, and abnormal facial features.
- In the normal population, there are about 29 CGG repeats in the *FMR1* gene. The genomes of carrier males and females contain premutations with 52 to 200 CGG repeats that can expand to 4000 repeats (full mutations) during oogenesis. When full mutations are transmitted to progeny, fragile X syndrome occurs.

## Diseases Caused by Mutations in Mitochondrial Genes

Mitochondria contain several genes that encode enzymes involved in oxidative phosphorylation. Inheritance of mitochondrial DNA differs from that of nuclear DNA in that the former is associated with *maternal inheritance*. The reason for this peculiarity is that ova contain mitochondria within their abundant cytoplasm, whereas spermatozoa contain few, if any, mitochondria. The mitochondrial DNA complement of the zygote is therefore derived entirely from the ovum. Thus, only mothers transmit mitochondrial genes to all of their offspring, both male and female; however, daughters but not sons transmit the DNA further to their progeny.

Diseases caused by mutations in mitochondrial genes are rare. Because mitochondrial DNA encodes enzymes involved in oxidative phosphorylation, diseases caused by mutations in such genes affect organs most dependent on oxidative phosphorylation (skeletal muscle, heart, brain). Leber hereditary optic neuropathy is the prototypical disorder in this group. This neurodegenerative disease manifests itself as progressive bilateral loss of central vision that leads in due course to blindness.

## Diseases Caused by Alterations of Imprinted Regions: Prader-Willi and Angelman Syndromes

All humans inherit two copies of each gene (except, of course, the sex chromosome genes in males), carried on homologous maternal and paternal chromosomes. It was long assumed that there was no difference between normal homologous genes derived from the mother and those from the father. Indeed, this is true for many genes. It has now been established, however, that functional differences exist between the paternal and the maternal copies of some genes. These differences arise from an epigenetic process called *genomic imprinting*, whereby certain genes are differentially "inactivated" during paternal and maternal gametogenesis. Thus, *maternal imprinting* refers to transcriptional silencing of the maternal allele, whereas *paternal imprinting* implies that the paternal allele is inactivated. At the molecular level, imprinting is associated with methylation of the gene promoter, as well as related events such as

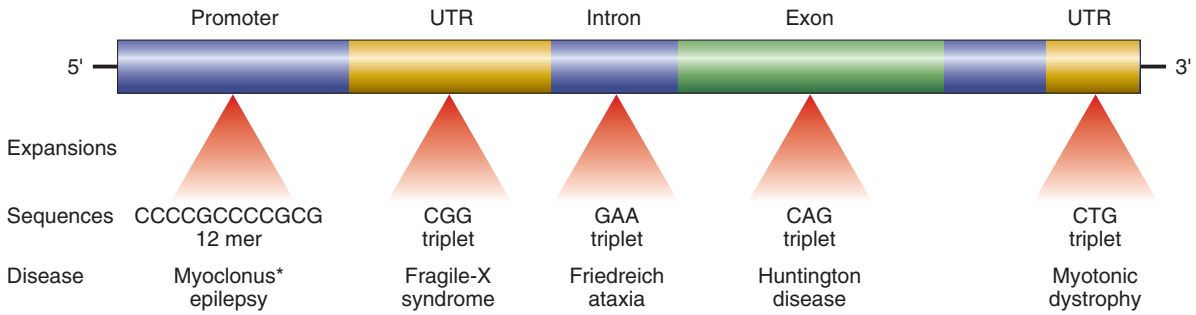


**Figure 6–19** Sites of expansion and the affected sequence in selected diseases caused by nucleotide repeat mutations. UTR, untranslated region. *Though not strictly a trinucleotide-repeat disease, progressive myoclonus epilepsy is caused, like others in this group, by a heritable DNA expansion. The expanded segment is in the promoter region of the gene.

modification of DNA-binding histone proteins, the sum total effect of which is to silence the gene. Imprinting occurs in ovum or sperm and is then stably transmitted to all somatic cells derived from the zygote.

Genomic imprinting is best illustrated by considering two uncommon genetic disorders: Prader-Willi syndrome and Angelman syndrome.

*Prader-Willi syndrome* is characterized by mental retardation, short stature, hypotonia, obesity, small hands and feet, and hypogonadism. In 60% to 75% of cases, an interstitial deletion of band q12 in the long arm of chromosome 15—del(15)(q11;q13)—can be detected. In many patients without a detectable cytogenetic abnormality, FISH analysis reveals smaller deletions within the same region. *It is striking that in all cases, the deletion affects the paternally derived chromosome 15.* In contrast with Prader-Willi syndrome, patients with the phenotypically distinct *Angelman syndrome* are born with a deletion of the same chromosomal region derived from their mothers. Patients with Angelman syndrome also are mentally retarded, but in addition they present with ataxic gait, seizures, and inappropriate laughter. Because of the laughter and ataxia, this syndrome has been called the *happy puppet syndrome.* A comparison of these two syndromes clearly demonstrates the "parent-of-origin" effects on gene function. If all the paternal and maternal genes contained within chromosome 15 were expressed in an identical fashion, clinical features resulting from these deletions would be expected to be identical regardless of the parental origin of chromosome 15.

The molecular basis of these two syndromes can be understood in the context of imprinting (Fig. 6–20). A set of genes on the maternal chromosome at 15q12 is imprinted (and hence silenced), so the only functional alleles are provided by the paternal chromosome. When these are lost as a result of a deletion (in the paternal chromosome), the patient develops Prader-Willi syndrome. Conversely, a distinct gene that also maps to the same region of chromosome 15 is imprinted on the paternal chromosome. Only the maternally derived allele of the gene normally is active. Deletion of this maternal gene on chromosome 15 gives rise to the Angelman syndrome. Molecular studies of cytogenetically normal patients with Prader-Willi syndrome have revealed that in some cases, both of the structurally normal copies of chromosome 15 are derived from the mother. *Inheritance of both chromosomes of a pair from one parent is called uniparental disomy.* The net effect is the same (i.e., the patient does not have a functional set of genes from the [nonimprinted] paternal chromosome 15).

*Angelman syndrome,* as might be expected, also can result from uniparental disomy of parental chromosome 15. The Angelman syndrome gene (imprinted on the paternal chromosome) is now known to encode a ligase that has a role in the ubiquitin-proteasome proteolytic pathway (Chapter 1). This gene, called, somewhat laboriously, *UBE3A,* is expressed primarily from the maternal allele in specific regions of the normal brain. In Angelman syndrome, *UBE3A* is not expressed in these areas of the brain—hence the neurologic manifestations.

Prader-Willi syndrome, unlike Angelman syndrome, probably is caused by the loss of function of several genes located on chromosome 15 between q11 and q13. These genes are still being fully characterized.

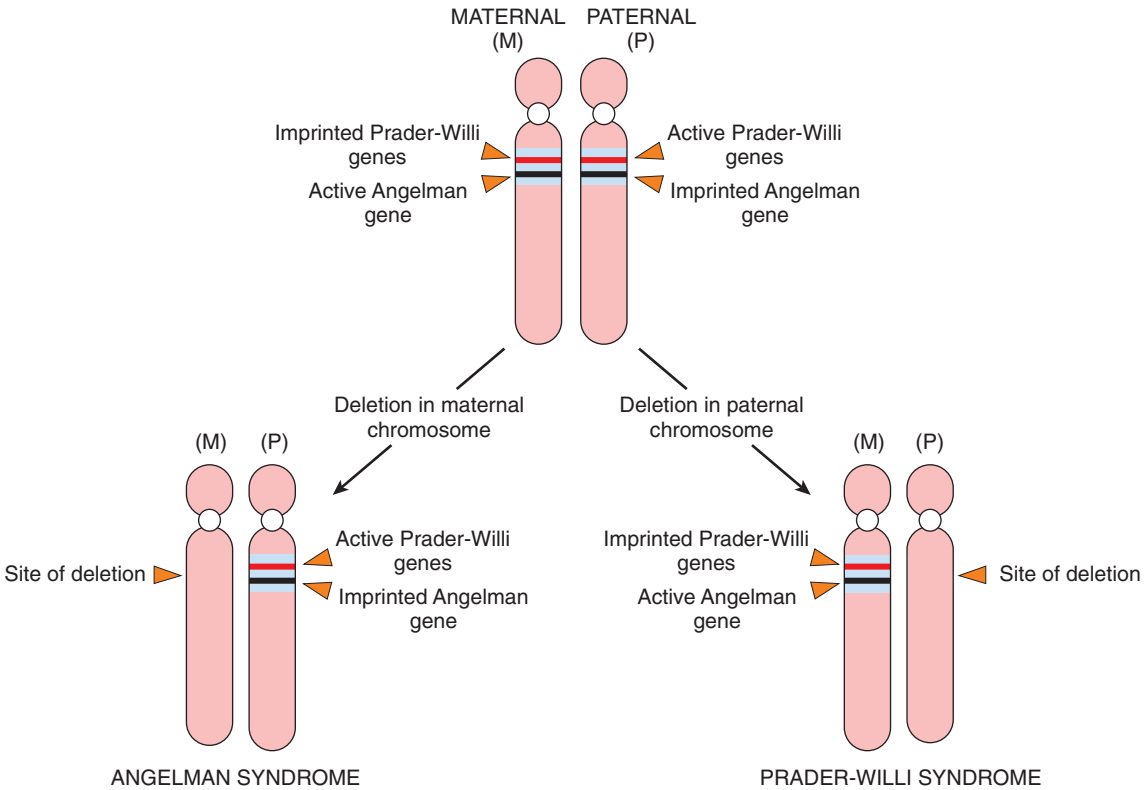


**Figure 6–20** Genetics of Angelman and Prader-Willi syndromes.

## SUMMARY

### Genomic Imprinting

- Imprinting involves transcriptional silencing of the paternal or maternal copies of certain genes during gametogenesis. For such genes only one functional copy exists in the individual. Loss of the functional allele (not imprinted) by deletions gives rise to diseases.
- *Prader-Willi syndrome* results from deletion of paternal chromosomal region 15q12 and is characterized by mental retardation, short stature, hypotonia, obesity, and hypogonadism.
- *Angelman syndrome* results from deletion of maternal chromosomal region 15q12 and is characterized by mental retardation, ataxia, seizures, and inappropriate laughter.

# PEDIATRIC DISEASES

As mentioned earlier and illustrated by several examples, many diseases of infancy and childhood are of genetic origin. Others, although not genetic, either are unique to children or take distinctive forms in this patient population and thus merit the designation *pediatric diseases*. During each stage of development, infants and children are prey to a somewhat different group of diseases (Table 6–6). Clearly, diseases of infancy (i.e., the first year of life) pose the highest risk of death. During this phase, the neonatal period (the first 4 weeks of life) is unquestionably the most hazardous time.

Once the infant survives the first year of life, the outlook brightens considerably. However, it is sobering to note that between 1 year and 14 years of age, injuries resulting from accidents are the leading cause of death. Not all conditions listed in Table 6–6 are described in this chapter; only a select few that are most common are considered here. Although general principles of neoplastic disease and specific tumors are discussed elsewhere, a few tumors of children are described, to highlight the differences between pediatric and adult neoplasms.

## CONGENITAL ANOMALIES

Congenital anomalies are structural defects that are present at birth, although some, such as cardiac defects and renal anomalies, may not become clinically apparent until years later. As will be evident from the ensuing discussion, the term *congenital* does not imply or exclude a genetic basis for birth defects. It is estimated that about 120,000 babies are born with a birth defect each year in the United States, an incidence of 1 in 33. As indicated in Table 6–6, congenital anomalies constitute an important cause of infant mortality. Moreover, they continue to be a significant cause of illness, disability, and death throughout the early years of life.

Before consideration of the etiology and pathogenesis of congenital anomalies, it is essential to define some of the terms used to describe errors in morphogenesis.

- *Malformations* represent primary errors of morphogenesis. In other words, there is an *intrinsically abnormal developmental process.* Malformations usually are

**Table 6–6** Causes of Death by Age

| Cause* | Rate† |
|---|---|
| **Under 1 Year** | **677.3** |
| Congenital malformations, deformations, and chromosomal anomalies | |
| Disorders related to short gestation and low birth weight | |
| Sudden infant death syndrome (SIDS) | |
| Newborn affected by maternal complications of pregnancy | |
| Newborn affected by complications of placenta, cord, and membranes | |
| Respiratory distress syndrome of newborn | |
| Accidents (unintentional injuries) | |
| Bacterial sepsis of newborn | |
| Neonatal hemorrhage | |
| Diseases of the circulatory system | |
| **1–4 Years** | **28.2** |
| Accidents (unintentional injuries) | |
| Congenital malformations, deformations, and chromosomal abnormalities | |
| Assault (homicide) | |
| **1–4 Years—cont'd** | **28.2** |
| Malignant neoplasms | |
| Diseases of the heart‡ | |
| **5–9 Years** | **13.6** |
| Accidents (unintentional injuries) | |
| Malignant neoplasms | |
| Congenital malformations, deformations, and chromosomal abnormalities | |
| Assault (homicide) | |
| Diseases of the heart | |
| **10–14 Years** | **16.7** |
| Accidents (unintentional injuries) | |
| Malignant neoplasms | |
| Assault (homicide) | |
| Intentional self-harm (suicide) | |
| Congenital malformations, deformations, and chromosomal abnormalities | |

Data from Heron MP, Sutton PD, Xu J, et al: Annual Summary of Vital Statistics: 2007. Pediatrics 125:4, 2010.
*Causes are listed in decreasing order of frequency. All causes and rates are final 2007 statistics.
†Rates are expressed per 100,000 population from all causes within each age group.
‡Excludes congenital heart disease.

**Figure 6–21** Human malformations can range in severity from the incidental to the lethal. **A,** *Polydactyly* (one or more extra digits) and *syndactyly* (fusion of digits), have little functional consequence when they occur in isolation. **B,** Similarly, *cleft lip*, with or without associated *cleft palate*, is compatible with life when it occurs as an isolated anomaly; in this case, however, the child had an underlying *malformation syndrome* (trisomy 13) and expired because of severe cardiac defects. **C,** Stillbirth representing a severe and essentially lethal malformation, in which the midface structures are fused or ill-formed; in almost all cases, this degree of external dysmorphogenesis is associated with severe internal anomalies such as maldevelopment of the brain and cardiac defects.

*(A and C, Courtesy of Dr. Reade Quinton, Department of Pathology, University of Texas Southwestern Medical Center, Dallas, Texas. B, Courtesy of Dr. Beverly Rogers, Department of Pathology, University of Texas Southwestern Medical Center, Dallas, Texas.)*

multifactorial, rather than the result of a single gene or chromosomal defect. They may manifest in any of several patterns. In some presentations, such as congenital heart diseases, single body systems may be involved, whereas in others, multiple malformations involving many organs and tissues may coexist (Fig. 6–21).

- *Disruptions* result from secondary destruction of an organ or body region that was previously normal in development; thus, in contrast with malformations, disruptions arise from an *extrinsic disturbance in morphogenesis. Amniotic bands,* denoting rupture of amnion with resultant formation of "bands" that encircle, compress, or attach to parts of the developing fetus, constitute the classic example of a disruption (Fig. 6–22). A variety of environmental agents may cause disruptions (see below). Disruptions are not heritable, of course, and thus are not associated with risk of recurrence in subsequent pregnancies.
- *Deformations,* like disruptions, also represent an *extrinsic disturbance of development* rather than an intrinsic error of morphogenesis. Deformations are common problems, affecting approximately 2% of newborn infants to various degrees. Fundamental to the pathogenesis of deformations is localized or generalized compression of the growing fetus by abnormal biomechanical forces, leading eventually to a variety of structural abnormalities. The most common cause of such deformations is uterine constraint. Between weeks 35 and 38 of gestation, rapid increase in the size of the fetus outpaces the growth of the uterus, and the relative amount of amniotic fluid (which normally acts as a cushion) also decreases. Thus, even the normal fetus is subjected to some degree of uterine constraint. However, several variables increase the likelihood of excessive compression of the fetus, including maternal conditions such as first pregnancy, small uterus, malformed (bicornuate) uterus, and leiomyomas. Causes relating to the fetus, such as presence of multiple fetuses, oligohydramnios, and abnormal fetal presentation, also may be involved.
- *Sequence* refers to multiple congenital anomalies that result from *secondary effects of a single localized aberration in organogenesis.* The initiating event may be a malformation, deformation, or disruption. An excellent example is the oligohydramnios (or Potter) sequence (Fig. 6–23, *A*). Oligohydramnios, denoting decreased amniotic fluid, may be caused by a variety of unrelated maternal, placental, or fetal abnormalities. Chronic leakage of amniotic fluid due to rupture of the amnion, uteroplacental insufficiency resulting from maternal hypertension or severe toxemia, and renal agenesis in the fetus

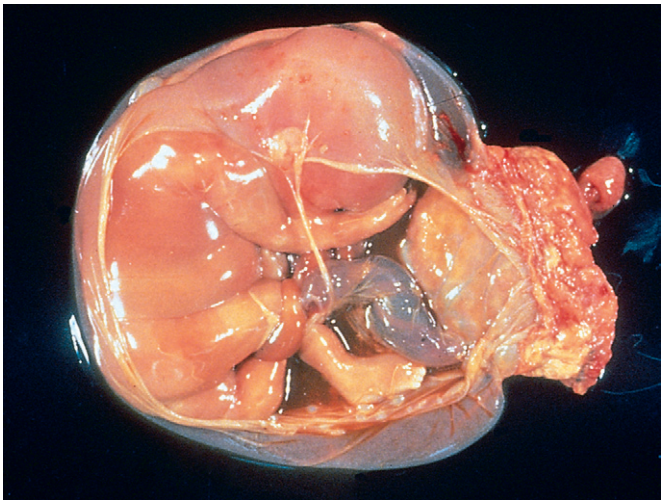

**Figure 6–22** Disruptions occur in a developing organ because of an extrinsic abnormality that interferes with normal morphogenesis. *Amniotic bands* are a frequent cause of disruptions. In the gross specimen shown, the placenta is at the *right of the diagram*, and the band of amnion extends from the *top portion of the amniotic sac* to encircle the leg of the fetus.

*(Courtesy of Dr. Theonia Boyd, Children's Hospital of Boston, Boston, Massachusetts.)*

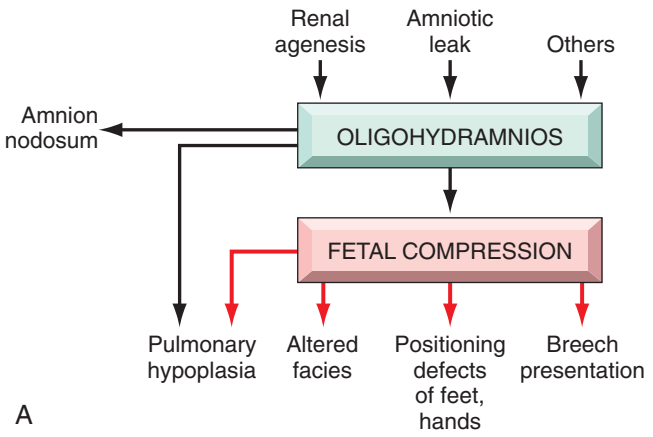


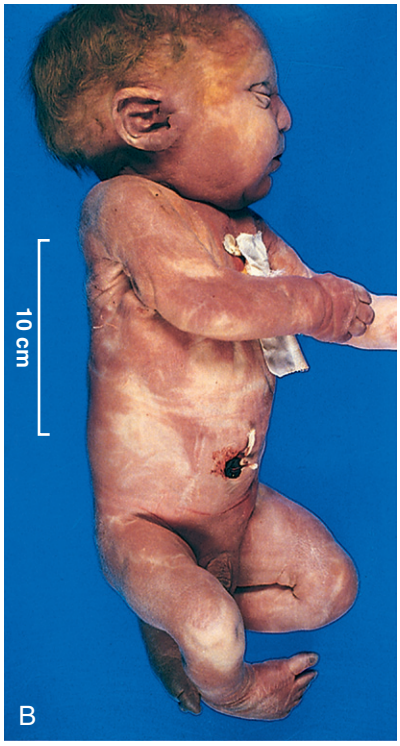


**Figure 6–23** **A,** Pathogenesis of the oligohydramnios (Potter) sequence. **B,** Infant with oligohydramnios (Potter) sequence. Note flattened facial features and deformed foot (talipes equinovarus).

(because fetal urine is a major constituent of amniotic fluid) all are potential causes of oligohydramnios. The fetal compression associated with significant oligohydramnios in turn results in a classic phenotype in the newborn infant, including flattened facies and positional abnormalities of the hands and feet (Fig. 6–23, *B*). The hips may be dislocated. Growth of the chest wall and the contained lungs also is compromised, sometimes to such an extent that survival is not possible. If the embryologic connection between these defects and the initiating event is not recognized, a sequence may be mistaken for a malformation syndrome.

- *Malformation syndrome* refers to the presence of several defects that cannot be explained on the basis of a single localizing initiating error in morphogenesis. Syndromes most often arise from a single causative condition (e.g., viral infection or a specific chromosomal abnormality) that simultaneously affects several tissues.
- In addition to these global definitions, some general terms are applied to organ-specific malformations: *Agenesis* refers to the complete absence of an organ or its anlage, whereas *aplasia* and *hypoplasia* indicate incomplete development and underdevelopment, respectively, of an organ. *Atresia* describes the absence of an opening, usually of a hollow visceral organ or duct such as intestines and bile ducts.

## Etiology

Known causes of errors in human malformations can be grouped into three major categories: *genetic, environmental,* and *multifactorial* (Table 6–7). *The cause has not been identified for almost half of the reported cases.*

*Genetic causes* of malformations include all of the previously discussed mechanisms of genetic disease. Virtually all chromosomal syndromes are associated with congenital malformations. Examples are Down syndrome and other trisomies, Turner syndrome, and Klinefelter syndrome. Most chromosomal disorders arise during gametogenesis and hence are not familial. Single-gene mutations, characterized by mendelian inheritance, may underlie major malformations. For example, holoprosencephaly is the most common developmental defect of the forebrain and midface in humans (see Chapter 22); the Hedgehog signaling

**Table 6–7** Causes of Congenital Malformations in Humans

| Cause | Frequency of Malformations* (%) |
|---|---|
| **Genetic** | |
| Chromosomal aberrations | 10–15 |
| Mendelian inheritance | 2–10 |
| **Environmental** | |
| Maternal/placental infections<br>Rubella<br>Toxoplasmosis<br>Syphilis<br>Cytomegalovirus infection<br>Human immunodeficiency virus infection | 2–3 |
| Maternal disease states<br>Diabetes<br>Phenylketonuria<br>Endocrinopathies | 6–8 |
| Drugs and chemicals<br>Alcohol<br>Folic acid antagonists<br>Androgens<br>Phenytoin<br>Thalidomide<br>Warfarin<br>13-*Cis*-retinoic acid<br>Others | ~1 |
| Irradiation | ~1 |
| **Multifactorial** | 20–25 |
| **Unknown** | 40–60 |

Data from Stevenson RE, Hall JG, Goodman RM (eds): Human Malformations and Related Anomalies. New York, Oxford University Press, 1993, p 115.
*Live births.

pathway plays a critical role in the morphogenesis of these structures, and loss-of-function mutations of individual components within this pathway are reported in families with a history of recurrent holoprosencephaly.

*Environmental influences,* such as viral infections, drugs, and radiation to which the mother was exposed during pregnancy, may cause fetal malformations (the appellation of "malformation" is used loosely in this context, since technically, these anomalies represent *disruptions*). Among the viral infections listed in Table 6–7, rubella was a major scourge of the 19th and early 20th centuries. Fortunately, maternal rubella and the resultant *rubella embryopathy* have been virtually eliminated in developed countries as a result of vaccination. A variety of drugs and chemicals have been suspected to be teratogenic, but perhaps less than 1% of congenital malformations are caused by these agents. The list includes thalidomide, alcohol, anticonvulsants, warfarin (oral anticoagulant), and 13-*cis*-retinoic acid, which is used in the treatment of severe acne. For example, *thalidomide,* once used as a tranquilizer in Europe and currently used for treatment of certain cancers, causes an extremely high incidence (50% to 80%) of limb malformations. *Alcohol,* perhaps the most widely used agent today, is an important environmental teratogen. Affected infants show prenatal and postnatal growth retardation, facial anomalies (microcephaly, short palpebral fissures, maxillary hypoplasia), and psychomotor disturbances. These features in combination are designated the *fetal alcohol syndrome.* While cigarette smoke–derived nicotine has not been convincingly demonstrated to be a teratogen, there is a high incidence of spontaneous abortions, premature labor, and placental abnormalities among pregnant smokers; babies born to mothers who smoke often have a low birth weight and may be prone to the sudden infant death syndrome (SIDS). *In light of these findings, it is best to avoid nicotine exposure altogether during pregnancy.* Among maternal conditions listed in Table 6–7, *diabetes mellitus* is a common entity, and despite advances in antenatal obstetric monitoring and glucose control, the incidence of major malformations in infants of diabetic mothers stands between 6% and 10% in most reported series. Maternal hyperglycemia–induced fetal hyperinsulinemia results in fetal macrosomia (organomegaly and increased body fat and muscle mass); cardiac anomalies, neural tube defects, and other CNS malformations are some of the major anomalies seen in *diabetic embryopathy.*

*Multifactorial inheritance,* which implies the interaction of environmental influences with two or more genes of small effect, is the most common genetic cause of congenital malformations. Included in this category are some relatively common malformations such as cleft lip and palate and neural tube defects. The importance of environmental contributions to multifactorial inheritance is underscored by the dramatic reduction in the incidence of neural tube defects by periconceptional intake of folic acid in the diet. The recurrence risks and mode of transmission of multifactorial disorders are described earlier in this chapter.

## PATHOGENESIS

The pathogenesis of congenital anomalies is complex and still poorly understood, but two general principles of developmental pathology are relevant regardless of the etiologic agent:

1. **The timing of the prenatal teratogenic insult has an important impact on the occurrence and the type of anomaly produced.** The intrauterine development of humans can be divided into two phases: (1) the embryonic period, occupying the first 9 weeks of pregnancy, and (2) the fetal period, terminating at birth.
   - In the **early embryonic period** (first 3 weeks after fertilization), an injurious agent damages either enough cells to cause death and abortion or only a few cells, presumably allowing the embryo to recover without developing defects. **Between the third and the ninth weeks, the embryo is extremely susceptible to teratogenesis,** and the peak sensitivity during this period occurs between the fourth and the fifth weeks. During this period organs are being crafted out of the germ cell layers.
   - The **fetal period** that follows organogenesis is marked chiefly by the further growth and maturation of the organs, with greatly reduced susceptibility to teratogenic agents. Instead, the fetus is susceptible to growth retardation or injury to already formed organs. It is therefore possible for a given agent to produce different anomalies if exposure occurs at different times of gestation.
2. The complex interplay between environmental teratogens and intrinsic genetic defects is exemplified by the fact that features of dysmorphogenesis caused by environmental insults often can be recapitulated by genetic defects in the pathways targeted by these teratogens. Some representative examples follow:
   - **Cyclopamine** is a plant teratogen. Pregnant sheep who feed on plants containing cyclopamine give birth to lambs that have severe craniofacial abnormalities including holoprosencephaly and **cyclopia** (single fused eye—hence the origin of the moniker cyclopamine). This compound is a potent inhibitor of Hedgehog signaling in the embryo, and as stated previously, mutations of Hedgehog genes are present in subsets of fetuses with holoprosencephaly.
   - **Valproic acid** is an antiepileptic and a recognized teratogen. Valproic acid disrupts expression of a family of highly conserved developmentally critical transcription factors known as **homeobox (HOX)** proteins. In vertebrates, HOX proteins have been implicated in the patterning of limbs, vertebrae, and craniofacial structures. Not surprisingly, mutations in HOX family genes are responsible for congenital anomalies that mimic features observed in **valproic acid embryopathy.**
   - The vitamin A (retinol) derivative **all-trans-retinoic acid** is essential for normal development and differentiation, and its **absence** during embryogenesis results in a constellation of malformations affecting multiple organ systems, including the eyes, genitourinary system, cardiovascular system, diaphragm, and lungs (see Chapter 7 for vitamin A deficiency in the postnatal period). Conversely, **excessive exposure to retinoic acid also is teratogenic.** Infants born to mothers treated with retinoic acid for severe acne have a predictable phenotype **(retinoic acid embryopathy),** including CNS, cardiac, and craniofacial defects,

such as **cleft lip and cleft palate.** The last entity may stem from retinoic acid–mediated deregulation of components of the transforming growth factor-β (TGF-β) signaling pathway, which is involved in palatogenesis. Mice with knockout of the *Tgfb3* gene uniformly develop cleft palate, once again underscoring the functional relationship between teratogenic exposure and signaling pathways in the causation of congenital anomalies.

## SUMMARY

### Congenital Anomalies

- Congenital anomalies result from intrinsic abnormalities (malformations) as well as extrinsic disturbances (deformations, disruptions).
- Congenital anomalies can result from genetic (chromosomal abnormalities, gene mutations), environmental (infections, drugs, alcohol), and multifactorial causes.
- The timing of the in utero insult has profound influence on the extent of congenital anomalies, with earlier events usually demonstrating greater impact.
- The interplay between genetic and environmental causes of anomalies is demonstrated by the fact that teratogens often target signaling pathways in which mutations have been reported as a cause for the same anomalies.

## PERINATAL INFECTIONS

Infections of the fetus and neonate may be acquired transcervically (ascending infections) or transplacentally (hematologic infections).

- *Transcervical, or ascending, infections* involve spread of infection from the cervicovaginal canal and may be acquired in utero or during birth. Most bacterial infections (e.g., α-hemolytic streptococcal infection) and a few viral infections (e.g., herpes simplex) are acquired in this manner. In general, the fetus acquires the infection by "inhaling" infected amniotic fluid into the lungs or by passing through an infected birth canal during delivery. Fetal infection usually is associated with inflammation of the placental membranes (chorioamnionitis) and inflammation of the umbilical cord (funisitis). This mode of spread is typical for pneumonia and, in severe cases, sepsis and meningitis.
- *Transplacental infections* gain access to the fetal bloodstream by crossing the placenta via the chorionic villi, and may occur at any time during gestation or occasionally, as may be the case with hepatitis B and human immunodeficiency virus, at the time of delivery via maternal-to-fetal transfusion. Most parasitic (e.g., toxoplasma, malaria) and viral infections and a few bacterial infections (i.e., from *Listeria* and *Treponema*) demonstrate this mode of hematogenous transmission. The clinical manifestations of these infections are highly variable, depending largely on the gestational timing and the microorganism involved. The most important transplacental infections can be conveniently remembered by the acronym *TORCH.* The elements of the TORCH complex are *Toxoplasma* (T), rubella virus (R), cytomegalovirus (C), herpesvirus (H), and any of a number of other (O) microbes such as *Treponema pallidum.* These agents are grouped together because they may evoke similar clinical and pathologic manifestations. TORCH infections occurring early in gestation may cause chronic sequelae in the child, including growth restriction, mental retardation, cataracts, and congenital cardiac anomalies, whereas infections later in pregnancy result primarily in tissue injury accompanied by inflammation (encephalitis, chorioretinitis, hepatosplenomegaly, pneumonia, and myocarditis).

## PREMATURITY AND FETAL GROWTH RESTRICTION

*Prematurity is the second most common cause of neonatal mortality (second only to congenital anomalies), and is defined by a gestational age less than 37 weeks.* As might be expected, infants born before completion of gestation also weigh less than normal (below 2500 gm). The major risk factors for prematurity include premature rupture of membranes; intrauterine infection leading to inflammation of the placental membranes (chorioamnionitis); structural abnormalities of the uterus, cervix, and placenta; and multiple gestation (e.g., twin pregnancy). It is well established that children born before completion of the full period of gestation demonstrate higher morbidity and mortality rates than those reported for full-term infants. The immaturity of organ systems in preterm infants makes them especially vulnerable to several important complications:

- Respiratory distress syndrome (RDS), also called hyaline membrane disease
- Necrotizing enterocolitis (NEC)
- Sepsis
- Intraventricular and germinal matrix hemorrhage (Chapter 22)
- Long-term sequelae, including developmental delay

Although birth weight is low in preterm infants, it usually is appropriate once adjusted for gestational age. By contrast, as many as one third of infants who weigh less than 2500 gm are born at term and are therefore undergrown rather than immature. These small-for-gestational-age (SGA) infants suffer from fetal growth restriction. Fetal growth restriction may result from fetal, maternal, or placental abnormalities, although in many cases the specific cause is unknown.

- *Fetal factors*: This category consists of conditions that intrinsically reduce growth potential of the fetus despite an adequate supply of nutrients from the mother. Prominent among such fetal conditions are *chromosomal disorders, congenital anomalies,* and *congenital infections.* Chromosomal abnormalities may be detected in as many as 17% of fetuses evaluated for fetal growth restriction and in as many as 66% of fetuses with documented ultrasonographic malformations. *Fetal infection* should be considered in all growth-restricted neonates, with the TORCH group of infections (see earlier) being a common cause. When the causation is intrinsic to the fetus,

growth retardation is *symmetric* (i.e., affects all organ systems equally).

- *Placental factors*: Placental causes include any factor that compromises the uteroplacental supply line. This may result from placenta previa (low implantation of the placenta), placental abruption (separation of placenta from the decidua by a retroplacental clot), or placental infarction. With placental (and maternal) causes of growth restriction, the growth retardation is *asymmetric* (i.e., the brain is spared relative to visceral organs such as the liver).
- *Maternal factors*: This category comprises by far the most common causes of the growth deficit in SGA infants. Important examples are vascular diseases such as preeclampsia ("toxemia of pregnancy") (Chapter 18) and chronic hypertension. The list of other maternal conditions associated with fetal growth restriction is long, but some of the avoidable influences are maternal narcotic abuse, alcohol intake, and heavy cigarette smoking (as noted previously, many of these same causes also are involved in the pathogenesis of congenital anomalies). Drugs causing fetal growth restriction in similar fashion include teratogens, such as the commonly administered anticonvulsant phenytoin (Dilantin), as well as nonteratogenic agents. Maternal malnutrition (in particular, prolonged hypoglycemia) also may affect fetal growth, but the association between growth restriction in infants and the nutritional status of the mother is complex.

Not only is the growth-restricted infant handicapped in the perinatal period, but the deficits also persist into childhood and adult life. Affected persons are thus more likely to have cerebral dysfunction, learning disabilities, and sensory (i.e., visual and hearing) impairment.

## RESPIRATORY DISTRESS SYNDROME OF THE NEWBORN

There are many causes of respiratory distress in the newborn, including excessive sedation of the mother, fetal head injury during delivery, aspiration of blood or amniotic fluid, and intrauterine hypoxia secondary to compression from coiling of the umbilical cord about the neck. The most common cause, however, is *respiratory distress syndrome (RDS), also known as hyaline membrane disease* because of the formation of "membranes" in the peripheral air spaces observed in infants who succumb to this condition. An estimated 24,000 cases of RDS are reported annually in the United States, and improvements in management of this condition have sharply decreased deaths due to respiratory insufficiency from as many as 5000 per year a decade ago to less than 900 cases yearly.

### PATHOGENESIS

**RDS is basically a disease of premature infants.** It occurs in about 60% of infants born at less than 28 weeks of gestation, 30% of those born between 28 to 34 weeks' gestation, and less than 5% of those born after 34 weeks' gestation. There are also strong though not invariable associations with **male gender, maternal diabetes,** and delivery by **cesarean section.**

The fundamental defect in RDS is the inability of the immature lung to synthesize sufficient surfactant. Surfactant is a complex of surface-active phospholipids, principally dipalmitoylphosphatidylcholine (lecithin) and at least two groups of **surfactant-associated proteins.** The importance of surfactant-associated proteins in normal lung function can be gauged by the occurrence of severe respiratory failure in neonates with congenital deficiency of surfactant caused by mutations in the corresponding genes. Surfactant is synthesized by type II pneumocytes and, with the healthy newborn's first breath, rapidly coats the surface of alveoli, reducing surface tension and thus decreasing the pressure required to keep alveoli open. In a lung deficient in surfactant, alveoli tend to collapse, and a relatively greater inspiratory effort is required with each breath to open the alveoli. The infant rapidly tires from breathing, and generalized atelectasis sets in. The resulting hypoxia sets into motion a sequence of events that lead to epithelial and endothelial damage and eventually to the formation of hyaline membranes (Fig. 6–24). As discussed later, this classical picture of surfactant deficiency is greatly modified by surfactant treatment.

**Surfactant synthesis is regulated by hormones.** Corticosteroids stimulate the formation of surfactant lipids

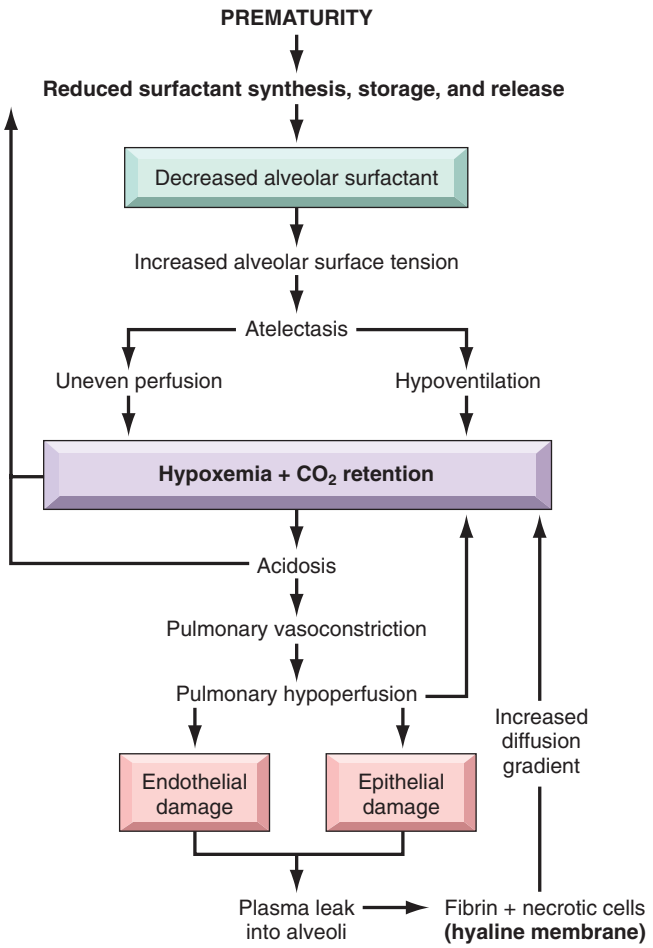


**Figure 6–24** Pathophysiology of respiratory distress syndrome (see text).

and associated proteins. Therefore, conditions associated with intrauterine stress and fetal growth restriction that increase corticosteroid release lower the risk of developing RDS. Surfactant synthesis can be suppressed by the compensatory high blood levels of insulin in infants of diabetic mothers, which counteracts the effects of steroids. This may explain, in part, why infants of diabetic mothers are at higher risk for developing RDS. Labor is known to increase surfactant synthesis; accordingly, cesarean section performed before the onset of labor may be associated with increased risk for RDS.

## MORPHOLOGY

The lungs in infants with RDS are of normal size but are heavy and relatively airless. They have a mottled purple color, and on microscopic examination the tissue appears solid, with poorly developed, generally collapsed (atelectatic) alveoli. If the infant dies within the first several hours of life, only necrotic cellular debris will be present in the terminal bronchioles and alveolar ducts. Later in the course, characteristic **eosinophilic hyaline membranes** line the respiratory bronchioles, alveolar ducts, and random alveoli (Fig. 6–25). These "membranes" contain necrotic epithelial cells admixed with extravasated plasma proteins. There is a remarkable paucity of neutrophilic inflammatory reaction associated with these membranes. The lesions of hyaline membrane disease are never seen in stillborn infants or in live-born infants who die within a few hours of birth. If the infant dies after several days, evidence of reparative changes, including proliferation of type II pneumocytes and interstitial fibrosis, is seen.

### Clinical Features

The classic clinical presentation before the era of treatment with exogenous surfactant was described earlier. Currently, the actual clinical course and prognosis for neonatal RDS vary, depending on the maturity and birth weight of the infant and the promptness of institution of therapy. A major thrust in the control of RDS focuses on prevention, either by delaying labor until the fetal lung reaches maturity or by inducing maturation of the lung in the fetus at risk. Critical to these objectives is the ability to assess fetal lung maturity accurately. Because pulmonary secretions are discharged into the amniotic fluid, analysis of amniotic fluid phospholipids provides a good estimate of the level of surfactant in the alveolar lining. Prophylactic administration of exogenous surfactant at birth to extremely premature infants (born before a gestational age of 28 weeks) has been shown to be very beneficial, such that it is now uncommon for infants to die of acute RDS.

In uncomplicated cases, recovery begins to occur within 3 or 4 days. In affected infants, oxygen is required. Use of high concentrations of ventilator-administered oxygen for prolonged periods, however, is associated with two well-known complications: *retrolental fibroplasia* (also called *retinopathy of prematurity*) in the eyes and *bronchopulmonary dysplasia* (BPD):

- Retinopathy of prematurity has a two-phase pathogenesis. During the *hyperoxic* phase of RDS therapy (phase I), expression of the pro-angiogenic vascular endothelial growth factor (VEGF) is markedly decreased, causing endothelial cell apoptosis; VEGF levels rebound after return to relatively hypoxic room air ventilation (phase II), inducing retinal vessel proliferation (*neovascularization*) characteristic of the lesions in the retina.
- *The major abnormality in BPD is a striking decrease in alveolar septation* (manifested as large, simplified alveolar structures) and a dysmorphic capillary configuration. Thus, the current view is that BPD is caused by a potentially reversible impairment in the development of alveolar septation at the so-called saccular stage. Multiple factors—hyperoxemia, hyperventilation, prematurity, inflammatory cytokines, and vascular maldevelopment—contribute to BPD and probably act additively or synergistically to promote injury. The levels of a variety of pro-inflammatory cytokines (TNF and the interleukins IL-1β, IL-6, and IL-8) are increased in the alveoli of infants in whom BPD subsequently develops, suggesting a role for these cytokines in arresting pulmonary development.

Fortunately, both complications are now significantly less common as a result of gentler ventilation techniques, antenatal glucocorticoid therapy, and prophylactic surfactant treatments.

Infants who recover from RDS also are at increased risk for developing a variety of other complications associated with preterm birth; most important among these are *patent ductus arteriosus, intraventricular hemorrhage,* and *necrotizing enterocolitis* (NEC). Thus, although technologic advances help save the lives of many infants with RDS, they also bring to the surface the exquisite fragility of the immature neonate.

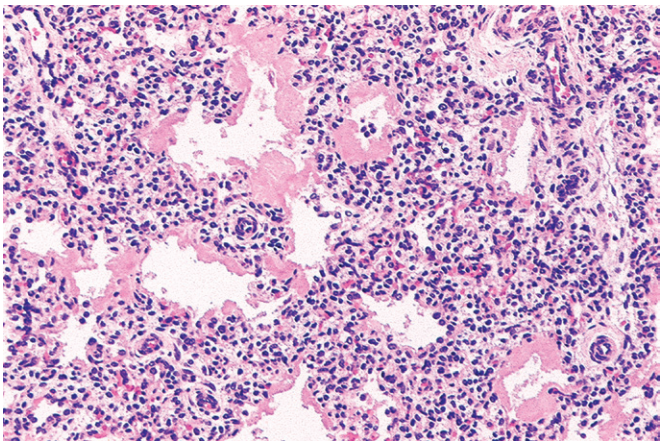

**Figure 6–25** Hyaline membrane disease (hematoxylin-eosin stain). Alternating atelectasis and dilation of the alveoli can be seen. Note the eosinophilic thick hyaline membranes lining the dilated alveoli.

## SUMMARY

### Neonatal Respiratory Distress Syndrome

- Neonatal RDS (hyaline membrane disease) is a disease of prematurity; most cases occur in neonates born before 28 weeks of gestational age.

- The fundamental abnormality in RDS is insufficient pulmonary surfactant, which results in failure of lungs to inflate after birth.
- The characteristic morphologic pattern in RDS is the presence of hyaline membranes (consisting of necrotic epithelial cells and plasma proteins) lining the airways.
- RDS can be ameliorated by prophylactic administration of steroids, surfactant therapy, and by improved ventilation techniques.
- Long-term sequelae associated with RDS therapy include retinopathy of prematurity and BPD; the incidence of both complications has decreased with improvements in management of RDS.

## NECROTIZING ENTEROCOLITIS

Necrotizing enterocolitis (NEC) most commonly occurs in premature infants, with the incidence of the disease being inversely proportional to the gestational age. It occurs in approximately 1 of 10 very-low-birth-weight infants (less than 1500 gm). In addition to *prematurity,* most cases are associated with *enteral feeding,* suggesting that some postnatal insult (such as introduction of bacteria) sets in motion the cascade culminating in tissue destruction. While *infectious agents* are likely to play a role in NEC pathogenesis, no single bacterial pathogen has been linked to the disease. A large number of *inflammatory mediators* have been associated with NEC. One particular mediator, platelet-activating factor (PAF), has been implicated in increasing mucosal permeability by promoting enterocyte apoptosis and compromising intercellular tight junctions, thereby "adding fuel to the fire."

NEC typically involves the terminal ileum, cecum, and right colon, although any part of the small or large intestine may be involved. The involved segment typically is distended, friable, and congested (Fig. 6–26), or it can be frankly gangrenous; intestinal perforation with accompanying peritonitis may be seen. On microscopic examination, mucosal or transmural coagulative necrosis, ulceration, bacterial colonization, and submucosal gas bubbles are all features associated with NEC. Evidence of reparative changes, such as granulation tissue and fibrosis, may be seen shortly after resolution of the acute episode.

The clinical course is fairly typical, with the onset of bloody stools, abdominal distention, and development of circulatory collapse. Abdominal radiographs often demonstrate gas within the intestinal wall (*pneumatosis intestinalis*). When detected early, NEC often can be managed conservatively, but many cases (20% to 60%) require operative intervention including resection of the necrotic segments of bowel. NEC is associated with high perinatal mortality; infants who survive often develop *post-NEC strictures* from fibrosis caused by the healing process.

## SUDDEN INFANT DEATH SYNDROME

Sudden infant death syndrome (SIDS) is a disease of unknown cause. The National Institute of Child Health and Human Development defines *SIDS* as "the sudden death of an infant under 1 year of age which remains unexplained after a thorough case investigation, *including performance of a complete autopsy, examination of the death scene, and review of the clinical history*." An aspect of SIDS that is not stressed in the definition is that the infant usually dies while asleep—hence the lay terms *crib death* and *cot death*. SIDS is the leading cause of death between the ages of 1 month and 1 year in U.S. infants, and the third leading cause of death overall in this age group, after congenital anomalies and diseases of prematurity and low birth weight. In 90% of cases, the infant is younger than 6 months; most are between the ages of 2 and 4 months.

**Figure 6–26** Necrotizing enterocolitis. **A,** At postmortem examination in a severe case, the entire small bowel was markedly distended with a perilously thin wall (usually this appearance implies impending perforation). **B,** The congested portion of the ileum corresponds to areas of hemorrhagic infarction and transmural necrosis seen on microscopy. Submucosal gas bubbles (*pneumatosis intestinalis*) can be seen in several areas (*arrows*).

## PATHOGENESIS

The circumstances surrounding SIDS have been explored in great detail, and the general consensus is that it is a **multifactorial condition,** with a variable mixture of contributing causes in a given case. A proposed "triple-risk" model of SIDS postulates the intersection of three overlapping variables: (1) **a vulnerable infant,** (2) **a critical developmental period in homeostatic control,** and (3) **one or more exogenous stressors.** According to this model, several factors make the infant vulnerable to sudden death during the critical developmental period (i.e., 1 month to 1 year). These vulnerability factors may be specific to the parents or the infant, while the exogenous stressor(s) is attributable to the environment (Table 6–8). Although numerous factors have been proposed to account for a vulnerable infant, **the most compelling hypothesis is that SIDS reflects a delayed development of arousal and cardiorespiratory control.** Regions of the brain stem, particularly the **arcuate nucleus** located in the ventral medullary surface, play a critical role in the body's arousal response to noxious stimuli such as hypercarbia, hypoxia, and thermal stress encountered during sleep. In addition, these areas regulate breathing, heart rate, and body temperature. In certain infants, for as-yet inexplicable reasons, there may be a maldevelopment or delay in maturation of this region, compromising the arousal response to noxious stimuli. Certain polymorphic variants in genes related to **serotonergic signaling** and **autonomic innervation** have been identified at a higher frequency in SIDS babies than in the general population, suggesting that genetic factors may play a role in predisposing the infant to impaired arousal. Among the potential environmental causes, prone sleeping position, sleeping on soft surfaces, and thermal stress are possibly the most important modifiable risk factors for SIDS. The prone position increases the infant's vulnerability to one or more recognized noxious stimuli (hypoxia, hypercarbia, and thermal stress) during sleep. In addition, the prone position also is associated with decreased arousal responsiveness compared with the supine position. Results of studies from Europe, Australia, New Zealand, and the United States showed clearly increased risk for SIDS in infants who sleep in a prone position, prompting the American Academy of Pediatrics to recommend placing **healthy infants on their back** when laying them down to sleep. This "Back to Sleep" campaign has resulted in substantial decreases in SIDS-related deaths since its inception in 1994.

## MORPHOLOGY

Anatomic studies of victims have yielded inconsistent histologic findings. **Multiple petechiae** are the most common finding in the typical SIDS autopsy (in approximately 80% of cases); these usually are present on the thymus, visceral and parietal pleura, and epicardium. On gross examination, the lungs usually are congested, and **vascular engorgement** with or without **pulmonary edema** is demonstrable on microscopic examination in a majority of cases. Sophisticated morphometric studies have revealed quantitative brain stem abnormalities such as **hypoplasia of the arcuate nucleus** or a subtle decrease in brain stem neuronal populations in several cases; these observations are not uniform, however, and use of such studies is not feasible in most "routine" autopsy procedures.

**Table 6–8** Factors Associated with Sudden Infant Death Syndrome (SIDS)

| |
|---|
| **Parental** |
| Young maternal age (younger than 20 years) |
| Maternal smoking during pregnancy |
| Drug abuse in *either* parent—specifically, paternal marijuana and maternal opiate/cocaine use |
| Short intergestational intervals |
| Late or no prenatal care |
| Low socioeconomic group |
| African American and American Indian ethnicity (? socioeconomic factors) |
| **Infant** |
| Brain stem abnormalities associated with defective arousal and cardiorespiratory control |
| Prematurity and/or low birth weight |
| Male sex |
| Product of a multiple birth |
| SIDS in an earlier sibling |
| Antecedent respiratory infections |
| Germline polymorphisms in autonomic nervous system genes |
| **Environment** |
| Prone sleep position |
| Sleeping on a soft surface |
| Hyperthermia |
| Sleeping with parents in first 3 months of life |
| **Postmortem Abnormalities Detected in Cases of Sudden Unexpected Infant Death*** |
| Infections |
| Viral myocarditis |
| Bronchopneumonia |
| Unsuspected congenital anomaly |
| Congenital aortic stenosis |
| Anomalous origin of the left coronary artery from the pulmonary artery |
| Traumatic child abuse |
| Intentional suffocation (filicide) |
| Genetic and metabolic defects |
| Long QT syndrome (*SCN5A* and *KCNQ1* mutations) |
| Fatty acid oxidation disorders (*MCAD*, *LCHAD*, *SCHAD* mutations) |
| Histiocytoid cardiomyopathy (*MTCYB* mutations) |
| Abnormal inflammatory responsiveness (partial deletions in *C4a* and *C4b*) |

*SIDS is not the only cause of sudden unexpected death in infancy; instead, it is a *diagnosis of exclusion.* Therefore, performance of an autopsy may reveal findings that would explain the cause of sudden unexpected death. These cases should *not,* strictly speaking, be designated SIDS.
C4, complement component 4; KCNQ1, potassium voltage-gated channel; LCHAD, long-chain 3-hydroxyacyl coenzyme A dehydrogenase; MCAD, medium-chain acyl coenzyme A dehydrogenase; MTCYB, mitochondrial cytochrome *b*; SCHAD, short-chain 3-hydroxyacyl coenzyme A dehydrogenase; SCN5A, sodium channel, voltage-gated.

Of note, SIDS is not the only cause of sudden unexpected death in infancy. In fact, SIDS is a diagnosis of exclusion, requiring careful examination of the death scene and a complete postmortem examination. The latter can reveal an unsuspected cause of sudden death in as many as 20% or more of babies presumed to have died of SIDS (Table 6–8). Infections (e.g., viral myocarditis or bronchopneumonia) are the most common causes of sudden "unexpected" death, followed by an unsuspected congenital anomaly. As a result of advancements in molecular diagnostics, several genetic causes of sudden "unexpected" infant death have emerged. For example, fatty acid oxidation disorders,

characterized by defects in mitochondrial fatty acid oxidative enzymes, may be responsible for as many as 5% of sudden deaths in infancy; of these, a deficiency in medium-chain acyl-coenzyme A dehydrogenase is the most common. Retrospective analyses in cases of sudden infant death originally designated SIDS also have revealed mutations of cardiac sodium and potassium channels, which result in a form of cardiac arrhythmia characterized by prolonged QT intervals; these cases account for no more than 1% of SIDS deaths. SIDS in an earlier sibling is associated with a five-fold relative risk of recurrence; traumatic child abuse must be carefully excluded under these circumstances.

## SUMMARY

### Sudden Infant Death Syndrome

- SIDS is a disorder of *unknown cause*, defined as the sudden death of an infant younger than 1 year of age that remains unexplained after a thorough case investigation including performance of an autopsy. Most SIDS deaths occur between the ages of 2 and 4 months.
- The most likely basis for SIDS is a delayed development in arousal reflexes and cardiorespiratory control.
- Numerous risk factors have been proposed, of which the prone sleeping position is best recognized—hence the success of the "Back to Sleep" program in reducing the incidence of SIDS.

**Table 6–9** Major Causes of Fetal Hydrops*

| |
|---|
| **Cardiovascular** |
| Malformations |
| Tachyarrhythmia |
| High-output failure |
| **Chromosomal** |
| Turner syndrome |
| Trisomy 21, trisomy 18 |
| **Thoracic** |
| Cystic adenomatoid malformation |
| Diaphragmatic hernia |
| **Fetal Anemia** |
| Homozygous α-thalassemia |
| Parvovirus B19 |
| Immune hydrops (Rh and ABO) |
| **Twin Gestation** |
| Twin-to-twin transfusion |
| **Infection (excluding parvovirus)** |
| Cytomegalovirus infection |
| Syphilis |
| Toxoplasmosis |
| **Genitourinary tract malformations** |
| **Tumors** |
| **Genetic/metabolic disorder** |

*The cause of fetal hydrops may be "idiopathic" in as many as 20% of cases.
Modified from Machin GA: Hydrops, cystic hygroma, hydrothorax, pericardial effusions, and fetal ascites. In Gilbert-Barnes E (ed): Potter's pathology of fetus and infant. St. Louis, Mosby, 1997.

# FETAL HYDROPS

*Fetal hydrops* refers to the accumulation of edema fluid in the fetus during intrauterine growth. The causes of fetal hydrops are manifold; the most important are listed in Table 6–9. In the past, hemolytic anemia caused by Rh blood group incompatibility between mother and fetus (immune hydrops) was the most common cause, but with the successful prophylaxis of this disorder during pregnancy, causes of nonimmune hydrops have emerged as the principal culprits. Notably, the intrauterine fluid accumulation can be quite variable, ranging in degree from progressive, generalized edema of the fetus (*hydrops fetalis*), a usually lethal condition, to more localized and less marked edematous processes, such as isolated pleural and peritoneal effusions or postnuchal fluid collections (*cystic hygroma*), that often are compatible with life (Fig. 6–27). The mechanism of immune hydrops is discussed first, followed by other important causes of fetal hydrops.

## Immune Hydrops

Immune hydrops results from an antibody-induced *hemolytic disease in the newborn* that is caused by blood group incompatibility between mother and fetus. Such an incompatibility occurs only when the fetus inherits red cell antigenic determinants from the father that are foreign to the mother. The most common antigens to result in clinically significant hemolysis are the Rh and ABO blood group antigens. Of the numerous antigens included in the Rh system, only the D antigen is a major cause of Rh incompatibility. Fetal red cells may reach the maternal circulation during the last trimester of pregnancy, when the cytotrophoblast is no longer present as a barrier, or during childbirth itself (fetomaternal bleed). The mother then becomes sensitized to the foreign antigen and produces antibodies that can freely traverse the placenta to the fetus, in which they cause red cell destruction. With initiation of immune hemolysis, progressive anemia in the fetus leads to tissue ischemia, intrauterine cardiac failure, and peripheral pooling of fluid (edema). As discussed later, cardiac failure may be the final pathway by which edema occurs in many cases of nonimmune hydrops as well.

Several factors influence the immune response to Rh-positive fetal red cells that reach the maternal circulation:

- Concurrent ABO incompatibility protects the mother against Rh immunization, because the fetal red cells are promptly coated by isohemagglutinins (pre-formed anti-A or anti-B antibodies) and removed from the maternal circulation.
- The antibody response depends on the dose of immunizing antigen, so hemolytic disease develops only when the mother has experienced a significant transplacental bleed (more than 1 mL of Rh-positive red cells).
- The isotype of the antibody is important, because immunoglobulin G (IgG) (but not IgM) antibodies can cross the placenta. The initial exposure to Rh antigen evokes the formation of IgM antibodies, *so Rh disease is very uncommon with the first pregnancy.* Subsequent exposure

**Figure 6–27** Hydrops fetalis. **A,** Generalized accumulation of fluid in the fetus. **B,** Fluid accumulation particularly prominent in the soft tissues of the neck. This condition has been termed *cystic hygroma.* Cystic hygromas are characteristically seen with, but not limited to, constitutional chromosomal anomalies such as 45,X karyotypes.

*(Courtesy of Dr. Beverly Rogers, Department of Pathology, University of Texas Southwestern Medical Center, Dallas, Texas.)*

during the second or third pregnancy generally leads to a brisk IgG antibody response.

*Appreciation of the role of previous sensitization in the pathogenesis of Rh-hemolytic disease of the newborn has led to its therapeutic control.* Currently, Rh-negative mothers are given anti-D globulin soon after the delivery of an Rh-positive baby. The anti-D antibodies mask the antigenic sites on the fetal red cells that may have leaked into the maternal circulation during childbirth, thus preventing long-lasting sensitization to Rh antigens.

As a result of the remarkable success achieved in prevention of Rh hemolysis, fetomaternal ABO incompatibility currently is the most common cause of immune hemolytic disease of the newborn. Although ABO incompatibility occurs in approximately 20% to 25% of pregnancies, hemolysis develops in only a small fraction of infants born subsequently, and in general the disease is much milder than Rh incompatibility. ABO hemolytic disease occurs almost exclusively in infants of blood group A or B who are born to mothers of blood group O. The normal anti-A and anti-B isohemagglutinins in group O mothers usually are of the IgM type and therefore do not cross the placenta. However, for reasons not well understood, certain group O women possess IgG antibodies directed against group A or B antigens (or both) even without previous sensitization. Therefore, the firstborn may be affected. Fortunately, even with transplacentally acquired antibodies, lysis of the infant's red cells is minimal. There is no effective method of preventing hemolytic disease resulting from ABO incompatibility.

## Nonimmune Hydrops

The major causes of nonimmune hydrops include those disorders associated with *cardiovascular defects, chromosomal anomalies,* and *fetal anemia.* Both structural cardiovascular defects and functional abnormalities (i.e., arrhythmias) may result in intrauterine cardiac failure and hydrops. Among the chromosomal anomalies, 45,X karyotype (Turner syndrome) and trisomies 21 and 18 are associated with fetal hydrops; the basis for this disorder usually is the presence of underlying structural cardiac anomalies, although in Turner syndrome there may be an abnormality of lymphatic drainage from the neck leading to postnuchal fluid accumulation (resulting in *cystic hygromas*). Fetal anemias due to causes other than Rh or ABO incompatibility also may result in hydrops. In fact, in some parts of the world (e.g., Southeast Asia), severe fetal anemia caused by homozygous α-thalassemia probably is the most common cause of fetal hydrops. Transplacental infection by parvovirus B19 is increasingly recognized as an important cause of fetal hydrops. The virus gains entry into erythroid precursors (normoblasts), where it replicates. The ensuing cellular injury leads to the death of the normoblasts and aplastic anemia. Parvoviral intranuclear inclusions can be seen within circulating and marrow erythroid precursors (Fig. 6–28). The basis for fetal hydrops in fetal anemia of both immune and nonimmune cause is tissue ischemia with secondary myocardial dysfunction and circulatory failure. Additionally, secondary liver failure may occur, with loss of synthetic function contributing to

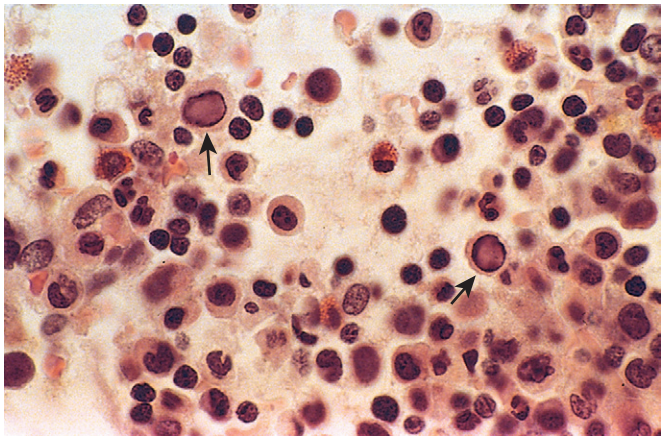

**Figure 6–28** Bone marrow from an infant infected with parvovirus B19. The *arrows* point to two erythroid precursors with large homogeneous intranuclear inclusions and a surrounding peripheral rim of residual chromatin.

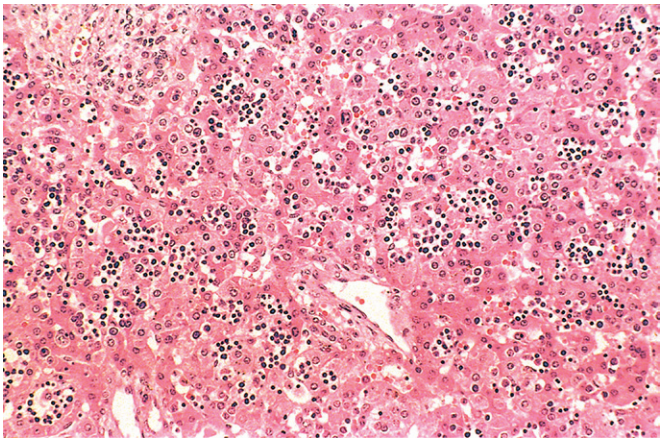

**Figure 6–29** Numerous islands of extramedullary hematopoiesis *(small blue cells)* are scattered among mature hepatocytes in this histologic preparation from an infant with nonimmune hydrops fetalis.

hypoalbuminemia, reduced plasma osmotic pressure, and edema.

## MORPHOLOGY

The anatomic findings in fetuses with intrauterine fluid accumulation vary with both the severity of the disease and the underlying etiologic disorder. As previously noted, **hydrops fetalis** represents the most severe and generalized manifestation (Fig. 6–27), and lesser degrees of edema such as isolated pleural, peritoneal, or postnuchal fluid collections can occur. Accordingly, infants may be stillborn, die within the first few days, or recover completely. The presence of dysmorphic features suggests underlying constitutional chromosomal abnormalities; postmortem examination may reveal a cardiac anomaly. In hydrops associated with fetal anemia, both fetus and placenta are characteristically pale; in most cases, the liver and spleen are enlarged as a consequence of **cardiac failure** and congestion. Additionally, the bone marrow shows compensatory hyperplasia of erythroid precursors (parvovirus-associated aplastic anemia being a notable exception), and **extramedullary hematopoiesis** is present in the liver, the spleen, and possibly other tissues such as the kidneys, the lungs, the lymph nodes, and even the heart. The increased hematopoietic activity accounts for the presence in the peripheral circulation of large numbers of normoblasts, and even more immature erythroblasts (**erythroblastosis fetalis**) (Fig. 6–29).

The presence of hemolysis in Rh or ABO incompatibility is associated with the added complication of increased circulating bilirubin from the red cell breakdown. The CNS may be damaged when hyperbilirubinemia is marked (usually above 20 mg/dL in full-term infants, but often less in premature infants). The circulating unconjugated bilirubin is taken up by the brain tissue, on which it apparently exerts a toxic effect. The basal ganglia and brain stem are particularly prone to deposition of bilirubin pigment, which imparts a characteristic yellow hue to the parenchyma (**kernicterus**) (Fig. 6–30).

### Clinical Course

Early recognition of intrauterine fluid accumulation is imperative, since even severe cases can sometimes be salvaged with currently available therapy. Fetal hydrops that results from Rh incompatibility may be more or less accurately predicted, because severity correlates well with rapidly rising Rh antibody titers in the mother during pregnancy. Amniotic fluid obtained by amniocentesis may show high levels of bilirubin. The human anti-globulin test (Coombs test) (Chapter 11) using fetal cord blood yields a positive result if the red cells have been coated by maternal antibody. Antenatal exchange transfusion is an effective form of therapy. Postnatally, phototherapy is helpful, because visible light converts bilirubin to readily excreted

**Figure 6–30** Kernicterus. Severe hyperbilirubinemia in the neonatal period—for example, secondary to immune hydrolysis—results in deposition of bilirubin pigment (*arrows*) in the brain parenchyma. This occurs because the blood–brain barrier is less well developed in the neonatal period than it is in adulthood. Infants who survive develop long-term neurologic sequelae.

dipyrroles. As already discussed, in an overwhelming majority of cases, administration of anti-D globulins to the mother can prevent the occurrence of immune hydrops in subsequent pregnancies. Group ABO hemolytic disease is more difficult to predict but is readily anticipated by awareness of the blood incompatibility between mother and father and by hemoglobin and bilirubin determinations in the vulnerable newborn infant. In fatal cases of fetal hydrops, a thorough postmortem examination is imperative to determine the cause and to exclude a potentially recurring cause such as a chromosomal abnormality.

### SUMMARY

#### Fetal Hydrops

- Fetal hydrops refers to the accumulation of edema fluid in the fetus during intrauterine growth.
- The degree of fluid accumulation is variable, from generalized hydrops fetalis to localized cystic hygromas.
- The most common causes of fetal hydrops are *nonimmune* (chromosomal abnormalities, cardiovascular defects, and fetal anemia), while immune hydrops has become less frequent as a result of Rh antibody prophylaxis.
- Erythroblastosis fetalis (due to circulating immature erythroid precursors) is a characteristic finding of fetal anemia-associated hydrops.
- Hemolysis-induced hyperbilirubinemia can result in kernicterus in the basal ganglia and brain stem, particularly in premature infants.

## TUMORS AND TUMOR-LIKE LESIONS OF INFANCY AND CHILDHOOD

Malignant neoplasms constitute the second most common cause of death in children between the ages of 4 and 14 years; only accidents exact a higher toll. Benign tumors are even more common than cancers.

It is difficult to segregate, on morphologic grounds, true tumors from tumor-like lesions in the infant and child. In this context, two special categories of tumor-like lesions should be recognized:

- *Heterotopia* or *choristoma* refers to microscopically normal cells or tissues that are present in abnormal locations. Examples are a pancreatic tissue "rest" found in the wall of the stomach or small intestine and a small mass of adrenal cells found in the kidney, lungs, ovaries, or elsewhere. Heterotopic rests usually are of little clinical significance, but on the basis of their appearance they can be confused with neoplasms.
- *Hamartoma* refers to an excessive but focal overgrowth of cells and tissues native to the organ in which it occurs. Although the cellular elements are mature and identical to those found in the remainder of the organ, they do not reproduce the normal architecture of the surrounding tissue. Hamartomas can be thought of as the linkage between malformations and neoplasms. The line of demarcation between a hamartoma and a benign neoplasm frequently is tenuous and is variously interpreted. Hemangiomas, lymphangiomas, rhabdomyomas of the heart, and adenomas of the liver are considered by some researchers to be hamartomas and by others to be true neoplasms.

### Benign Tumors

Virtually any tumor may be encountered in the pediatric age group, but three—hemangiomas, lymphangiomas, and sacrococcygeal teratomas—deserve special mention here because they occur commonly in childhood.

*Hemangiomas* are the most common tumors of infancy. Both cavernous and capillary hemangiomas may be encountered (Chapter 9), although the latter often are more cellular than in adults and thus may be deceptively worrisome-appearing. In children, most hemangiomas are located in the skin, particularly on the face and scalp, where they produce flat to elevated, irregular, red-blue masses; the flat, larger lesions are referred to as *port wine stains*. Hemangiomas may enlarge as the child gets older, but in many instances they spontaneously regress (Fig. 6–31). The vast majority of superficial hemangiomas have no more than a cosmetic significance; rarely, they may be the manifestation of a hereditary disorder associated with disease within internal organs, such as the von

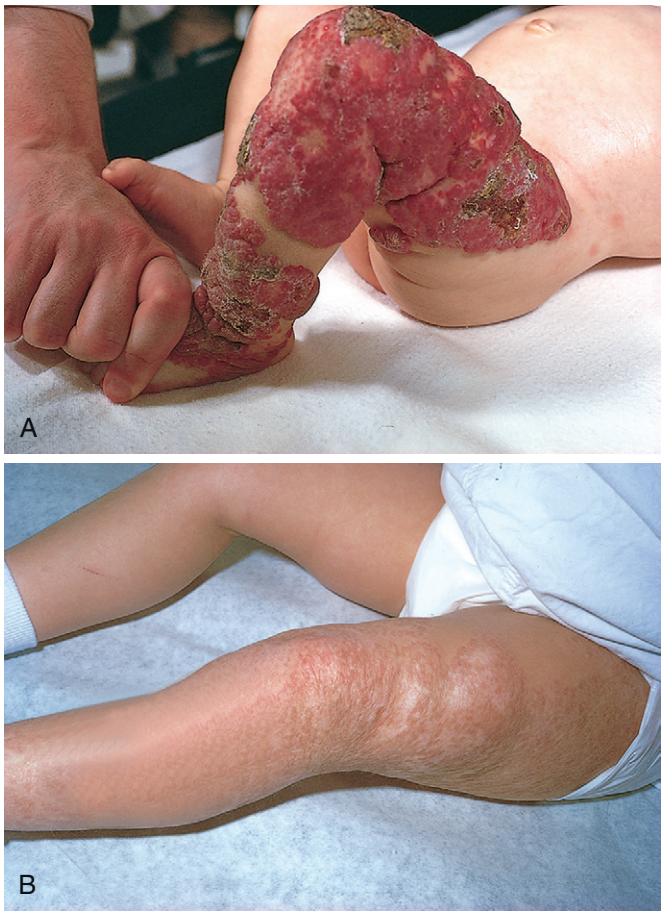


**Figure 6–31** Congenital capillary hemangioma at birth (**A**) and at 2 years of age (**B**) after the lesion had undergone spontaneous regression.
*(Courtesy of Dr. Eduardo Yunis, Children's Hospital of Pittsburgh, Pittsburgh, Pennsylvania.)*

Hippel-Lindau and Sturge-Weber syndromes (Chapter 9). A subset of CNS cavernous hemangiomas can occur in the familial setting; affected families harbor mutations in one of three *cerebral cavernous malformation* (CCM) genes.

*Lymphangiomas* represent the lymphatic counterpart of hemangiomas. Microscopic examination shows cystic and cavernous spaces lined by endothelial cells and surrounded by lymphoid aggregates; the spaces usually contain pale fluid. They may occur on the skin but, more important, also are encountered in the deeper regions of the neck, axilla, mediastinum, and retroperitoneum. Although histologically benign, they tend to increase in size after birth and may encroach on mediastinal structures or nerve trunks in axilla.

*Sacrococcygeal teratomas* are the most common germ cell tumors of childhood, accounting for 40% or more of cases (Fig. 6–32). In view of the overlap in the mechanisms underlying teratogenesis and oncogenesis, it is interesting that approximately 10% of sacrococcygeal teratomas are associated with congenital anomalies, primarily defects of the hindgut and cloacal region and other midline defects (e.g., meningocele, spina bifida) not believed to result from local effects of the tumor. Approximately 75% of these tumors are histologically mature with a benign course, and about 12% are unmistakably malignant and lethal (Chapter 17). The remainder are designated *immature teratomas,* and their malignant potential correlates with the amount of immature tissue elements present. Most of the benign teratomas are encountered in younger infants (4 months of age or younger), whereas children with malignant lesions tend to be somewhat older.

## Malignant Tumors

The organ systems involved most commonly by malignant neoplasms in infancy and childhood are the hematopoietic system, neural tissue, and soft tissues (Table 6–10). This distribution is in sharp contrast with that in adults, in whom tumors of the lung, heart, prostate, and colon are the most common forms. Malignant tumors of infancy and childhood differ biologically and histologically from those in adults. The main differences are as follows:

- Relatively frequent demonstration of a close relationship between abnormal development (teratogenesis) and tumor induction (oncogenesis)
- Prevalence of constitutional genetic abnormalities or syndromes that predispose to cancer
- Tendency of fetal and neonatal malignancies to spontaneously regress or undergo "differentiation" into mature elements
- Improved survival or cure of many childhood tumors, so that more attention is now being paid to minimizing the adverse delayed effects of chemotherapy and radiotherapy in survivors, including the development of second malignancies

**Figure 6–32** Sacrococcygeal teratoma. Note the size of the lesion compared with that of the infant.

**Table 6–10** Common Malignant Neoplasms of Infancy and Childhood

| 0–4 Years of Age | 5–9 Years of Age | 10–14 Years of Age |
|---|---|---|
| Leukemia | Leukemia | Hepatocellular carcinoma |
| Retinoblastoma | Retinoblastoma | Soft tissue sarcoma |
| Neuroblastoma | Neuroblastoma | Osteogenic sarcoma |
| Wilms tumor | Hepatocellular carcinoma | Thyroid carcinoma |
| Hepatoblastoma | Soft tissue sarcoma | Hodgkin disease |
| Soft tissue sarcoma (especially rhabdomyosarcoma) | Ewing tumor | |
| Teratomas | CNS tumors | |
| CNS tumors | Lymphoma | |

CNS, central nervous system.

Many malignant pediatric neoplasms are histologically unique. In general, they tend to have a primitive (*embryonal*) rather than pleomorphic-anaplastic microscopic appearance, and frequently they exhibit features of organogenesis specific to the site of tumor origin. Because of their primitive histologic appearance, many childhood tumors have been collectively referred to as *small, round, blue cell tumors*. These are characterized by sheets of cells with small, round nuclei. The tumors in this category include neuroblastoma, lymphoma, rhabdomyosarcoma, Ewing sarcoma (peripheral neuroectodermal tumor), and some cases of Wilms tumor. Sufficient distinctive features usually are present to permit definitive diagnosis on the basis of histologic examination alone, but when necessary, clinical and radiographic findings, combined with ancillary studies (e.g., chromosome analysis, immunoperoxidase stains, electron microscopy) are used. Three common tumors—neuroblastoma, retinoblastoma, and Wilms tumor—are described here to highlight the differences between pediatric tumors and those in adults.

### *Neuroblastoma*

The term *neuroblastic* includes tumors of the sympathetic ganglia and adrenal medulla that are derived from primordial neural crest cells populating these sites; neuroblastoma is the most important member of this family. It is the second most common solid malignancy of childhood after brain tumors, accounting for 7% to 10% of all pediatric neoplasms, and as many as 50% of malignancies diagnosed in infancy. Neuroblastomas demonstrate several unique features in their natural history, including *spontaneous*

*regression* and *spontaneous or therapy-induced maturation*. Most occur sporadically, but 1% to 2% are familial, with autosomal dominant transmission, and in such cases the neoplasms may involve both of the adrenals or multiple primary autonomic sites. Germ line mutations in the *anaplastic lymphoma kinase* gene (*ALK*) recently have been identified as a major cause of familial predisposition to neuroblastoma. Somatic gain-of-function *ALK* mutations also are observed in a subset of sporadic neuroblastomas. It is envisioned that tumors harboring *ALK* mutations in either the germline or somatic setting will be amenable to treatment using drugs that target the activity of this kinase.

## MORPHOLOGY

In childhood, about 40% of neuroblastomas arise in the **adrenal medulla.** The remainder occur anywhere along the sympathetic chain, with the most common locations being the paravertebral region of the abdomen (25%) and posterior mediastinum (15%). Macroscopically, neuroblastomas range in size from minute nodules (the in situ lesions) to large masses weighing more than 1 kg. In situ neuroblastomas are reported to be 40 times more frequent than overt tumors. The great preponderance of these silent lesions spontaneously regress, leaving only a focus of fibrosis or calcification in the adult. Some neuroblastomas are sharply demarcated with a fibrous pseudocapsule, but others are far more infiltrative and invade surrounding structures, including the kidneys, renal vein, and vena cava, and envelop the aorta. On transection, they are composed of soft, gray-tan, brainlike tissue. Larger tumors have areas of necrosis, cystic softening, and hemorrhage.

Histologically, classic neuroblastomas are composed of small, primitive-appearing cells with dark nuclei, scant cytoplasm, and poorly defined cell borders growing in solid sheets (Fig. 6–33, *A*). Mitotic activity, nuclear breakdown ("karyorrhexis"), and pleomorphism may be prominent. The background often demonstrates a faintly eosinophilic fibrillary material (neuropil) that corresponds to neuritic processes of the primitive neuroblasts. Typically, so-called **Homer-Wright pseudo-rosettes** can be found in which the tumor cells are concentrically arranged about a central space filled with neuropil (the absence of an actual central lumen garners the designation "pseudo-"). Other helpful features include immunochemical detection of **neuron-specific enolase** and demonstration on ultrastructural studies of small, membrane-bound, cytoplasmic catecholamine-containing secretory granules.

Some neoplasms show signs of **maturation**, either spontaneous or therapy-induced. Larger cells having more abundant cytoplasm with large vesicular nuclei and a prominent nucleolus, representing **ganglion cells** in various stages of maturation, may be found in tumors admixed with primitive neuroblasts **(ganglioneuroblastoma).** Even better-differentiated lesions contain many more large cells resembling mature ganglion cells in the absence of residual neuroblasts; such neoplasms merit the designation **ganglioneuroma** (Fig. 6–33, *B*). Maturation of neuroblasts into ganglion cells usually is accompanied by the appearance of Schwann cells. In fact, the presence of a "schwannian stroma" composed of organized fascicles of neuritic processes, mature **Schwann cells,** and fibroblasts is a histologic prerequisite for the designation of ganglioneuroblastoma and ganglioneuroma; ganglion cells in and of themselves do not fulfill the criteria for maturation.

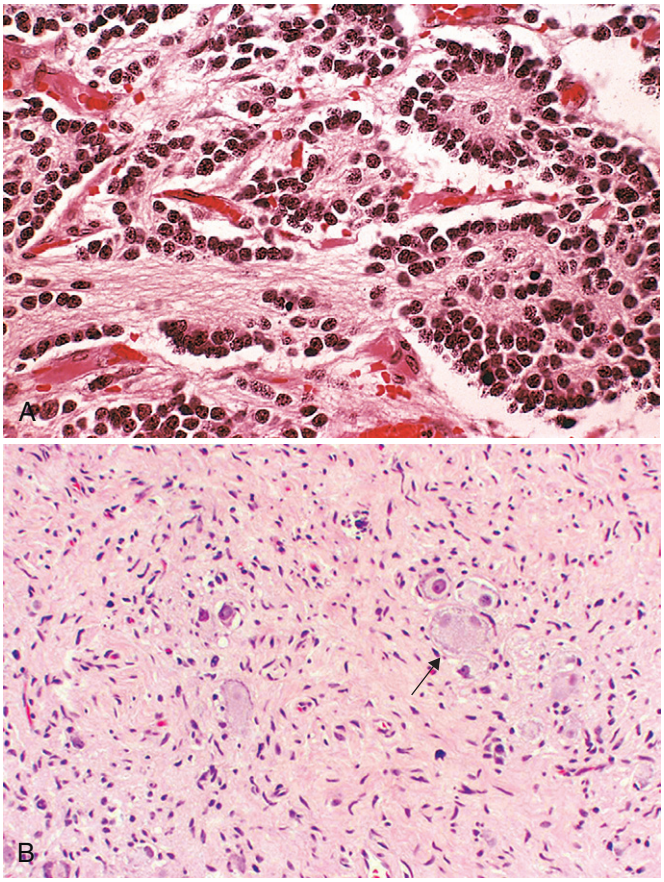


**Figure 6–33 A,** Neuroblastoma. This tumor is composed of small cells embedded in a finely fibrillar matrix (neuropil). A Homer-Wright pseudorosette (tumor cells arranged concentrically around a central core of neuropil) is seen in the upper right corner. **B,** Ganglioneuromas, arising from spontaneous or therapy-induced maturation of neuroblastomas, are characterized by clusters of large cells with vesicular nuclei and abundant eosinophilic cytoplasm (*arrow*), representing neoplastic ganglion cells. Spindle-shaped Schwann cells are present in the background stroma.

### Clinical Course and Prognosis

*Many factors influence prognosis, but the most important are the stage of the tumor and the age of the patient.*

- Staging of neuroblastomas (Table 6–11) assumes great importance in establishing a prognosis. Special note should be taken of stage 4S (S means special), because the outlook for these patients is excellent, despite the spread of disease. As noted in Table 6–11, the primary tumor would be classified as stage 1 or 2 but for the presence of metastases, which are limited to liver, skin, and bone marrow, without bone involvement. Infants with 4S tumors have an excellent prognosis with minimal therapy, and it is not uncommon for the primary or metastatic tumors to undergo spontaneous regression. The biologic basis for this welcome behavior is not clear.

**Table 6–11** Staging of Neuroblastomas

| | |
|---|---|
| Stage 1 | Localized tumor completely excised, with or without microscopic residual disease; representative ipsilateral nonadherent lymph nodes negative for tumor (nodes adherent to the primary tumor may be positive for tumor) |
| Stage 2A | Localized tumor resected incompletely grossly; representative ipsilateral nonadherent lymph nodes negative for tumor microscopically |
| Stage 2B | Localized tumor with or without complete gross excision, ipsilateral nonadherent lymph nodes positive for tumor; enlarged contralateral lymph nodes, which are negative for tumor microscopically |
| Stage 3 | Unresectable unilateral tumor infiltrating across the midline with or without regional lymph node involvement; or localized unilateral tumor with contralateral regional lymph node involvement |
| Stage 4 | Any primary tumor with dissemination to distant lymph nodes, bone, bone marrow, liver, skin, and/or other organs (*except as defined for stage 4S*) |
| Stage 4S* | Localized primary tumor (as defined for stage 1, 2A, or 2B) with dissemination limited to skin, liver, and/or bone marrow (<10% of nucleated cells are constituted by neoplastic cells; >10% involvement of bone marrow is considered as stage 4); *stage 4S limited to infants younger than 1 year of age* |

*S, special.
Adapted from Brodeur GM, Pritchard J, Berthold F, et al: Revisions of the international neuroblastoma diagnosis, staging, and response to treatment. J Clin Oncol 11:1466, 1993.

- *Age is the other important determinant of outcome,* and the outlook for children younger than 18 months is much more favorable than for older children at a comparable stage of disease. Most neoplasms diagnosed in children during the first 18 months of life are stage 1 or 2, or stage 4S ("low" risk category in Table 6–11), while neoplasms in older children fall into the "intermediate" or "high" risk category.
- *Morphology* is an independent prognostic variable in neuroblastic tumors; evidence of schwannian stroma and gangliocytic differentiation is indicative of a favorable histologic pattern.
- *Amplification of the NMYC oncogene* in neuroblastomas is a molecular event that has profound impact on prognosis. *NMYC* amplification is present in about 25% to 30% of primary tumors, most in advanced-stage disease; the greater the number of copies, the worse the prognosis. *NMYC amplification is currently the most important genetic abnormality used in risk stratification of neuroblastic tumors and automatically renders a tumor as "high" risk, irrespective of stage or age.*
- Deletion of the distal short arm of chromosome 1, gain of the distal long arm of chromosome 17, and overexpression of telomerase all are adverse prognostic factors, while expression of TrkA, a high-affinity receptor for nerve growth factor that is indicative of differentiation toward sympathetic ganglia lineage, is associated with favorable prognosis.

Children younger than 2 years with neuroblastomas generally present with protuberant abdomen resulting from an abdominal mass, fever, and weight loss. In older children the neuroblastomas may remain unnoticed until metastases cause hepatomegaly, ascites, and bone pain. Neuroblastomas may metastasize widely through the hematogenous and lymphatic systems, particularly to liver, lungs, bones, and the bone marrow. In neonates, disseminated neuroblastomas may manifest with multiple cutaneous metastases associated with deep blue discoloration to the skin (earning the rather unfortunate moniker of "blueberry muffin baby"). As already noted, many variables can influence the prognosis of neuroblastomas, but as a rule of thumb, stage and age are the paramount determinants. Tumors of all stages diagnosed in the first 18 months of life, as well as low-stage tumors in older children, have a favorable prognosis, while high-stage tumors diagnosed in children younger than 18 months of age have the poorest outcome. About 90% of neuroblastomas, regardless of location, produce catecholamines (similar to the catecholamines associated with pheochromocytomas), which constitutes an important diagnostic feature (i.e., elevated blood levels of catecholamines and elevated urine levels of catecholamine metabolites such as vanillylmandelic acid [VMA] and homovanillic acid [HVA]). Despite the elaboration of catecholamines, hypertension is much less frequent with these neoplasms than with pheochromocytomas (Chapter 19).

## SUMMARY

### Neuroblastoma

- Neuroblastomas and related tumors arise from neural crest–derived cells in the sympathetic ganglia and adrenal medulla.
- Neuroblastomas are undifferentiated, whereas ganglioneuroblastomas and ganglioneuromas demonstrate evidence of differentiation (schwannian stroma and ganglion cells). Homer-Wright pseudo-rosettes are characteristic of neuroblastomas.
- Age, stage, and *NMYC* amplification are the most important prognostic features; children younger than 18 months usually have a better prognosis than older children, while children with higher-stage tumors or *NMYC* amplification fare worse.
- Neuroblastomas secrete catecholamines, whose metabolites (VMA/HVA) can be used for screening patients.

### *Retinoblastoma*

Retinoblastoma is the most common primary intraocular malignancy of children. The molecular genetics of retinoblastoma has been discussed previously (Chapter 5). Approximately 40% of the tumors are associated with a germline mutation in the *RB1* gene and are therefore heritable. The remaining 60% of the tumors develop sporadically, and these have somatic *RB1* gene mutations. Although the name *retinoblastoma* might suggest origin from a primitive retinal cell that is capable of differentiation into both glial and neuronal cells, it is now clear that the cell of origin of retinoblastoma is neuronal. As noted earlier, in approximately 40% of cases, retinoblastoma occurs in persons who inherit a germ line mutation of one *RB* allele. *Familial cases typically are associated with development of multiple tumors that are bilateral,* although they may be unifocal and unilateral.

All of the sporadic, nonheritable tumors are unilateral and unifocal. Patients with familial retinoblastoma also are at increased risk for the development of osteosarcoma and other soft tissue tumors.

## MORPHOLOGY

Retinoblastomas tend to be nodular masses, usually in the posterior retina, often with satellite seedings (Fig. 6–34, *A*). On light microscopic examination, undifferentiated areas of these tumors are found to be composed of small, round cells with large hyperchromatic nuclei and scant cytoplasm, resembling undifferentiated retinoblasts.

Differentiated structures are found within many retinoblastomas, the most characteristic of these being **Flexner-Wintersteiner rosettes** (Fig. 6–34, *B*). These structures consist of clusters of cuboidal or short columnar cells arranged around a central lumen (in contrast with the **pseudo-rosettes** of neuroblastoma, which lack a central lumen). The nuclei are displaced away from the lumen, which by light microscopy appears to have a limiting membrane resembling the external limiting membrane of the retina.

Tumor cells may disseminate beyond the eye through the optic nerve or subarachnoid space. The most common sites of distant metastases are the CNS, skull, distal bones, and lymph nodes.

### Clinical Features

The median age at presentation is 2 years, although the tumor may be present at birth. The presenting findings include poor vision, strabismus, a whitish hue to the pupil ("cat's eye reflex"), and pain and tenderness in the eye. Untreated, the tumors usually are fatal, but after early treatment with enucleation, chemotherapy, and radiotherapy, survival is the rule. As noted earlier, some tumors spontaneously regress, and patients with familial retinoblastoma are at increased risk for the development of osteosarcoma and other soft tissue tumors.

### *Wilms Tumor*

Wilms tumor, or *nephroblastoma,* is the most common primary tumor of the kidney in children. Most cases occur in children between 2 and 5 years of age. This tumor illustrates several important concepts of childhood tumors: the relationship between congenital malformation and increased risk of tumors, the histologic similarity between tumor and developing organ, and finally, the remarkable success in the treatment of childhood tumors. Each of these concepts is evident in the following discussion.

Three groups of congenital malformations are associated with an increased risk for development of Wilms tumor. Of patients with the *WAGR syndrome* (i.e., Wilms tumor, aniridia, genital abnormalities, and mental retardation), approximately one in three will go on to develop this tumor. Another group of patients, those with the so-called *Denys-Drash syndrome* (DDS), also have an extremely high risk (approximately 90%) for the development of Wilms tumor. This syndrome is characterized by gonadal dysgenesis and renal abnormalities. Both of these conditions are associated with abnormalities of the Wilms tumor 1 gene (*WT1*), located on 11p13. The nature of genetic aberration differs, however: Patients with WAGR syndrome demonstrate loss of genetic material (i.e., deletions) of *WT1,* and persons with DDS harbor a dominant negative inactivating mutation in a critical region of the gene. (A dominant negative mutation interferes with the function of the remaining wild-type allele.) The *WT1* gene is critical to normal renal and gonadal development; it is not surprising, therefore, that constitutional inactivation of one copy of this gene results in genitourinary abnormalities in humans. A third group of patients, those with the *Beckwith-Wiedemann syndrome* (BWS), also are at increased risk for the development of Wilms tumor. These patients exhibit enlargement of individual body organs (e.g., tongue, kidneys, or liver) or

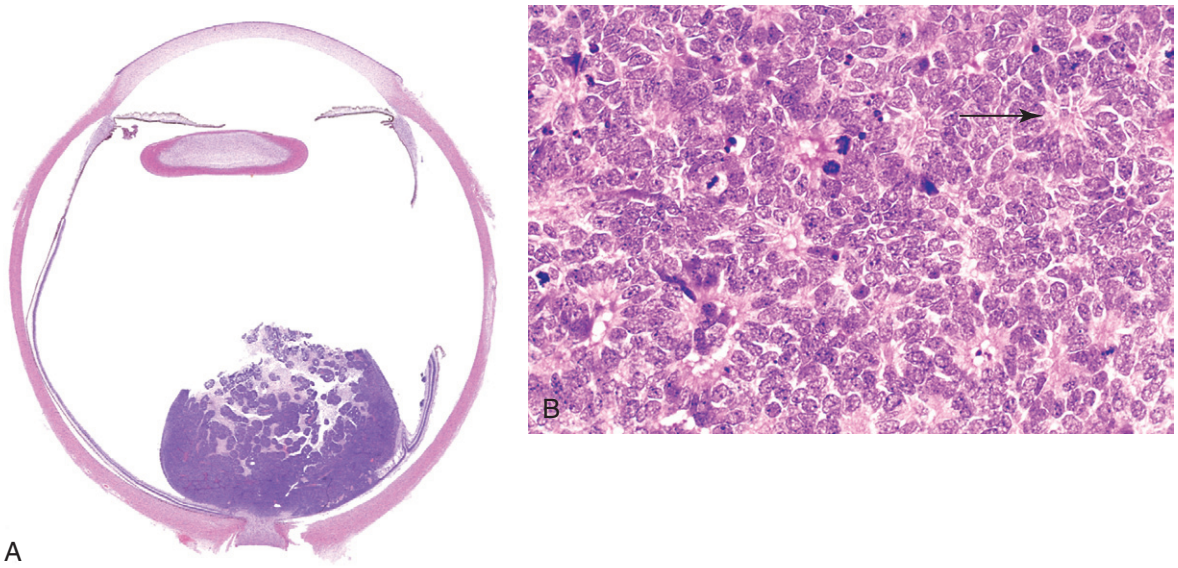


**Figure 6–34** Retinoblastoma. **A,** Poorly cohesive tumor in retina is seen abutting the optic nerve. **B,** Higher-power view showing Flexner-Wintersteiner rosettes (*arrow*) and numerous mitotic figures.

entire body segments (hemihypertrophy); enlargement of adrenal cortical cells (adrenal cytomegaly) is a characteristic microscopic feature. *BWS is an example of a disorder of genomic imprinting* (see earlier). The genetic locus that is involved in these patients is in band p15.5 of chromosome 11 distal to the *WT1* locus. Although this locus is called "WT2" for the second Wilms tumor locus, the gene involved has not been identified. This region contains at least 10 genes that normally are expressed from only *one* of the two parental alleles, with transcriptional silencing of the other parental homologue by *methylation of the promoter region,* located upstream of the transcription start site. Of all candidate "WT2" genes, imprinting abnormalities of insulin-like growth factor-2 (*IGF2*) have the strongest relationship to tumor predisposition in persons with BWS. *IGF2* normally is expressed solely from the *paternal allele,* while the maternal allele is imprinted (i.e., silenced) by methylation. In some Wilms tumors, *loss of imprinting* (i.e., reexpression of *IGF2* by the maternal allele) can be demonstrated, leading to overexpression of the IGF2 protein, which is postulated to result in both organ enlargement and tumorigenesis. Thus, these associations suggest that in some cases, congenital malformations and tumors represent related manifestations of genetic lesions affecting a single gene or closely linked genes. In addition to Wilms tumors, patients with BWS also are at increased risk for the development of hepatoblastoma, adrenocortical tumors, rhabdomyosarcomas, and pancreatic tumors. Recently, gain-of-function mutations of the gene encoding β-catenin (Chapter 5) have been demonstrated in approximately 10% of sporadic Wilms tumors.

## MORPHOLOGY

As seen on gross examination, Wilms tumor typically is a large, solitary, well-circumscribed mass, although 10% are either bilateral or multicentric at the time of diagnosis. On cut section, the tumor is soft, homogeneous, and tan to gray, with occasional foci of hemorrhage, cystic degeneration, and necrosis (Fig. 6–35).

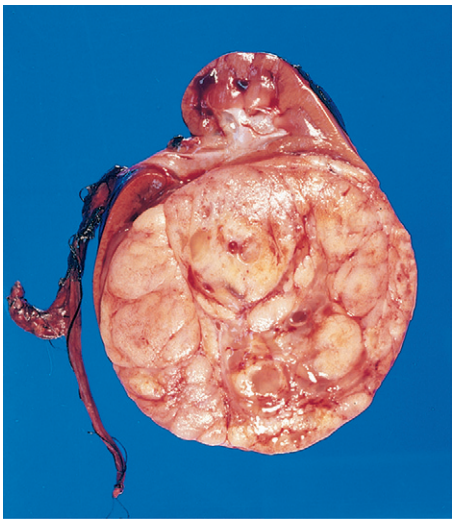

**Figure 6–35** Wilms tumor in the lower pole of the kidney with the characteristic tan to gray color and well-circumscribed margins.

On microscopic examination, Wilms tumors are characterized by recognizable attempts to recapitulate different stages of nephrogenesis. The classic **triphasic combination** of blastemal, stromal, and epithelial cell types is observed in most lesions, although the percentage of each component is variable (Fig. 6–36, *A*). Sheets of small blue cells, with few distinctive features, characterize the blastemal component. Epithelial "differentiation" usually takes the form of **abortive tubules or glomeruli.** Stromal cells are usually fibrocytic or myxoid in nature, although skeletal muscle "differentiation" is not uncommon. Rarely, other heterologous elements are identified, including squamous or mucinous epithelium, smooth muscle, adipose tissue, cartilage, and osteoid and neurogenic tissue. Approximately 5% of tumors contain foci of **anaplasia** (cells with large, hyperchromatic, pleomorphic nuclei and abnormal mitoses) (Fig. 6–36, *B*). The presence of anaplasia correlates with the presence of acquired *TP53* mutations, and the emergence of resistance to chemotherapy. The pattern of distribution of anaplastic cells within the primary tumor (focal versus diffuse) has important implications for prognosis (see further on).

**Nephrogenic rests** are putative precursor lesions of Wilms tumors and are sometimes present in the renal parenchyma adjacent to the tumor. Nephrogenic rests have a spectrum of histologic appearances, from expansile masses that resemble Wilms tumors (hyperplastic rests) to sclerotic rests consisting predominantly of fibrous tissue with occasional admixed immature tubules or glomeruli. It is important to document the presence of nephrogenic rests in the resected specimen, since these patients are at an increased risk for the development of Wilms tumors in the **contralateral** kidney.

### Clinical Course

Patients' complaints usually are referable to the tumor's enormous size. Commonly, there is a readily palpable abdominal mass, which may extend across the midline and down into the pelvis. Less often, the patient presents with fever and abdominal pain, with hematuria or, occasionally, with intestinal obstruction as a result of pressure from the tumor. The prognosis for Wilms tumor generally is very good, and excellent results are obtained with a combination of nephrectomy and chemotherapy. Anaplasia is a harbinger of adverse prognosis, but careful analyses by the National Wilms' Tumor Study group in the United States have shown that as long as the anaplasia is *focal* and confined within the resected nephrectomy specimen, the outcome is no different from that for tumors without evidence of anaplasia. By contrast, Wilms tumors with *diffuse anaplasia,* especially those exhibiting extrarenal spread, have the least favorable outcome, underscoring the need for correctly identifying this histologic pattern.

## SUMMARY

### Wilms Tumor

- Wilms tumor is the most common renal neoplasm of childhood.
- Patients with three syndromes are at increased risk for Wilms tumors: Denys-Drash, Beckwith-Wiedemann, and

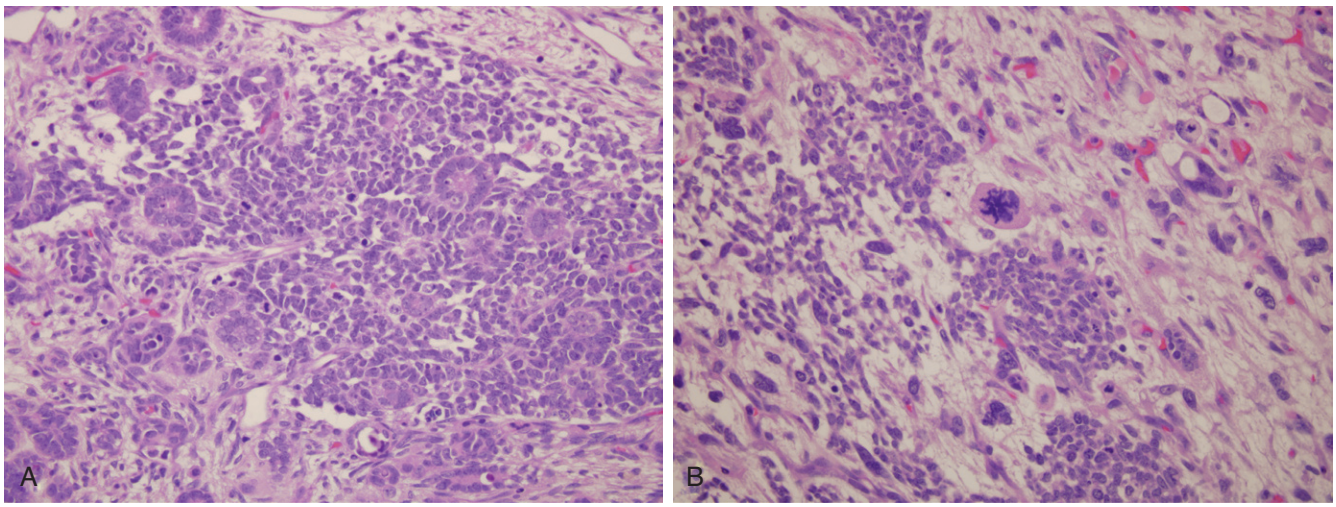


**Figure 6–36 A,** Wilms tumor with tightly packed blue cells consistent with the blastemal component and interspersed primitive tubules, representing the epithelial component. Although multiple mitotic figures are seen, none are atypical in this field. **B**, Focal anaplasia was present in other areas within this Wilms tumor, characterized by cells with hyperchromatic, pleomorphic nuclei and abnormal mitoses.

Wilms tumor, aniridia, genital abnormalities, and mental retardation syndrome.

- Wilms tumor, aniridia, genital abnormalities, and mental retardation syndrome and Denys-Drash syndrome are associated with *WT1* inactivation, while Beckwith-Wiedemann arises through imprinting abnormalities at the *WT2* locus, principally involving the *IGF2* gene.
- The morphologic components of Wilms tumor include blastema (small, round blue cells) and epithelial and stromal elements.
- Nephrogenic rests are precursor lesions of Wilms tumors.

## MOLECULAR DIAGNOSIS OF MENDELIAN AND COMPLEX DISORDERS

In the past decade, few disciplines within pathology have seen a surge in both "supply" and "demand" comparable with that observed for molecular diagnostics. In the era predating the ready availability of molecular diagnostic assays, rendering the diagnosis of a genetic disorder depended on the identification of abnormal gene products (e.g., mutant hemoglobin or abnormal metabolites) or their clinical effects, such as mental retardation (e.g., in PKU). The nascent field of molecular diagnostics emerged in the latter half of the 20th century, with the application of low-throughput approaches such as conventional karyotyping for recognition of cytogenetic disorders (e.g., Down syndrome) and DNA-based assays such as Southern blotting for the diagnosis of Huntington disease. Several factors have since enabled the rapid expansion of molecular diagnostics from the esoteric realm to an almost ubiquitous presence in both academic and commercial pathology laboratories (with current estimates for the "worldwide market" running into tens of billions of dollars). These factors include (1) the sequencing of the human genome and the deposition of these data in publicly available databases; (2) the availability of numerous "off the shelf" polymerase chain reaction (PCR) kits tailor-made for the identification of specific genetic disorders; (3) the availability of high-resolution microarrays ("gene chips") that can interrogate both DNA and RNA on a genome-wide scale using a single platform; and finally, (4) the emergence of automated and extremely high-throughput, next-generation ("NextGen") sequencing technologies. The last two advances have been especially useful in the context of new research to elucidate the genetic basis for both mendelian and complex disorders. While a detailed discussion of molecular diagnostics is beyond the scope of this book, some of the better-known approaches are highlighted in the ensuing paragraphs. One important caveat at this juncture is that irrespective of the technique used, the genetic aberration being queried can be either in the germ line (i.e., present in each and every cell of the affected person, as with the *CFTR* mutation in a patient with CF) or somatic (i.e., restricted to specific tissue types or lesions, as with the *NMYC* amplification in neuroblastoma cells). This consideration will determine the nature of the sample (e.g., peripheral blood lymphocytes [PBLs], saliva, tumor tissue) used for the assay.

### Molecular Diagnosis of Copy Number Abnormalities

As already discussed in this chapter, various diseases may occur as a result of copy number abnormalities, at the level of either the entire chromosome (trisomy 21), chromosomal segments (22q11 deletion syndrome), or submicroscopic *intragenic* deletions (WAGR syndrome). Karyotype analysis of chromosomes by G banding remains the classic approach for identifying changes at the chromosomal level; however, as might be expected, the resolution with this technique is fairly low. In order to identify subchromosomal alterations, both focused analysis of chromosomal regions by FISH and global genomic approaches such as comparative genomic hybridization (CGH) have become popular.

### *Fluorescence in Situ Hybridization (FISH)*

FISH utilizes DNA probes that recognize sequences specific to chromosomal regions of greater than 100 kilobases in size, which defines the limit of resolution with this technique for identifying chromosomal changes. Such probes are labeled with fluorescent dyes and applied to metaphase spreads or interphase nuclei. The probe hybridizes to its complementary sequence on the chromosome and thus labels the specific chromosomal region that can then be visualized under a fluorescence microscope. The ability of FISH to circumvent the need for dividing cells is invaluable when a rapid diagnosis is warranted (e.g., in a critically ill infant suspected of having an underlying genetic disorder). Such analysis can be performed on prenatal samples (e.g., cells obtained by amniocentesis, chorionic villus biopsy, or umbilical cord blood), peripheral blood lymphocytes, and even archival tissue sections. FISH has been used for detection of numeric abnormalities of chromosomes (aneuploidy) (Fig. 6–37, *A*); for the demonstration of subtle microdeletions (Fig. 6–37, *B*) or complex translocations not detectable by routine karyotyping; for analysis of gene amplification (e.g., *NMYC* amplification in neuroblastomas); and for mapping newly isolated genes of interest to their chromosomal loci.

### *Array-Based Genomic Hybridization*

It is obvious from the preceding discussion that FISH requires previous knowledge of the one or few specific chromosomal regions suspected of being altered in the test sample. However, chromosomal abnormalities may also be detected without previous knowledge of what these aberrations may be, using a global strategy known as array-based CGH. Here the test DNA and a reference (normal) DNA are labeled with two different fluorescent dyes (most commonly, Cy5 and Cy3, which fluoresce red and green, respectively). The differentially labeled samples are then hybridized to an array of segments of genomic DNA "spotted" on a solid matrix, usually a glass slide (Fig. 6–38, *A*). These segments of DNA are representations of the human genome at regularly spaced intervals, and cover all 22 autosomes and the sex chromosome (Fig. 6–38, *A*). Amplifications and deletions in the test sample produce an increase or decrease in signal relative to the normal DNA that can be detected down to a 10-kilobase (kb) resolution (Fig. 6–38, *B*). Newer generations of microarrays using single-nucleotide polymorphisms (SNPs) (see further on) provide even higher resolution (with more than 1 million SNPs from the human genome on a single microarray!) and are currently being used to uncover copy number abnormalities in a variety of diseases, from cancer to autism.

## Direct Detection of DNA Mutations by Polymerase Chain Reaction (PCR) Analysis

PCR analysis, which involves exponential amplification of DNA, is now widely used in molecular diagnosis. If RNA is used as the substrate, it is first reverse-transcribed to obtain cDNA and then amplified by PCR. This method involving reverse transcription (RT) often is abbreviated as RT-PCR. One prerequisite for direct detection is that the sequence of the normal gene must be known. To detect the mutant gene, two primers that bind to the 3′ and 5′ ends of the normal sequence are designed. By utilizing appropriate DNA polymerases and thermal cycling, the target DNA is greatly amplified, producing millions of copies of the DNA sequence between the two primer sites. The subsequent identification of an abnormal sequence can then be performed in several ways:

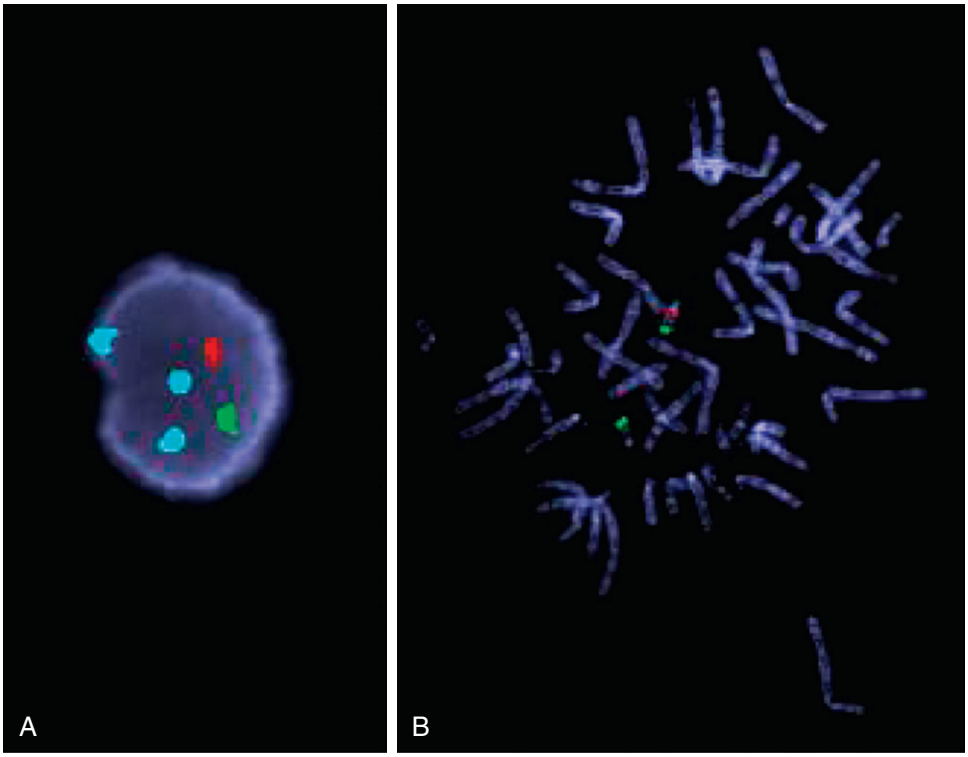


**Figure 6–37** Fluorescence in situ hybridization (FISH). **A,** Interphase nucleus from a male patient with suspected trisomy 18. Three different fluorescent probes have been used in a "FISH cocktail"; the green probe hybridizes to the X chromosome centromere (one copy), the red probe to the Y chromosome centromere (one copy), and the aqua probe to the chromosome 18 centromere (three copies). **B,** A metaphase spread in which two fluorescent probes have been used, one hybridizing to chromosome region 22q13 (*green*) and the other hybridizing to chromosome region 22q11.2 (*red*). There are two 22q13 signals. One of the two chromosomes does not stain with the probe for 22q11.2, indicating a microdeletion in this region. This abnormality gives rise to the 22q11.2 deletion syndrome (DiGeorge syndrome).

*(Courtesy of Dr. Nancy R. Schneider and Jeff Doolittle, Cytogenetics Laboratory, University of Texas Southwestern Medical Center, Dallas, Texas.)*

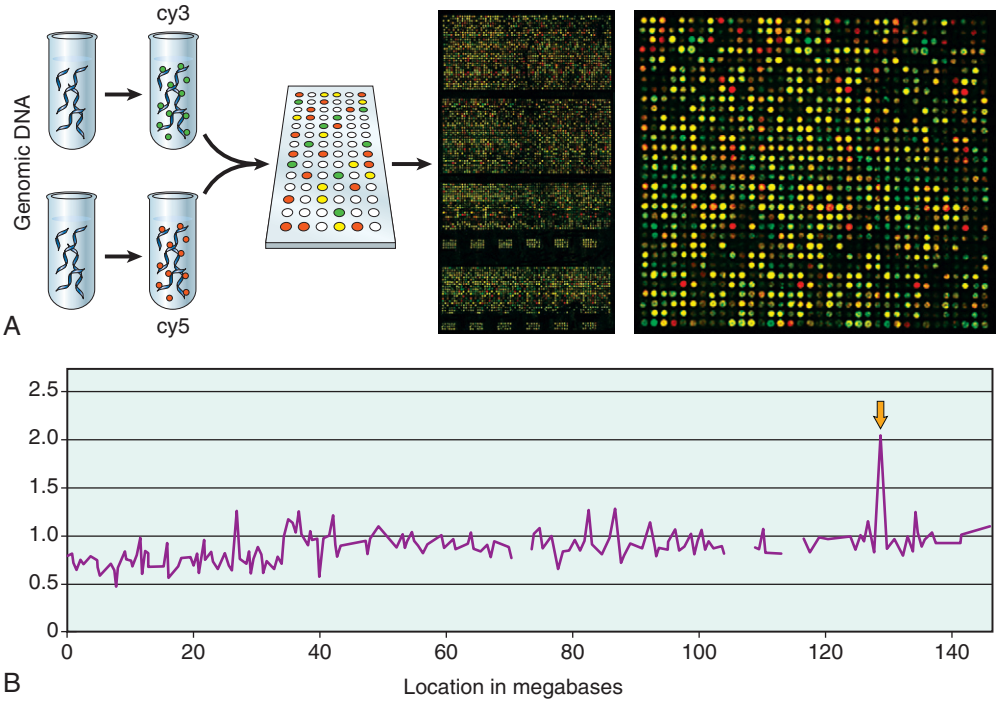


**Figure 6–38** Array comparative genomic hybridization (CGH) is performed by hybridization of fluorescently labeled test DNA and control DNA on a slide that contains thousands of probes corresponding to defined chromosomal regions across the human genome. The resolution with most currently available array CGH technology is on the order of approximately 10 kb. **A,** Higher-power view of the array demonstrates copy number aberrations in the test Cy5-labeled sample (*red*), including regions of amplification (spots with excess of *red signal*) and deletion (spots with excess of *green signal*); *yellow* spots correspond to regions of normal (diploid) copy number. **B,** The hybridization signals are digitized, resulting in a virtual karyotype of the genome of the "test" sample. In the illustrated example, array CGH of a cancer cell line identifies an amplification on the distal long arm of chromosome 8, which corresponds to increased copy number of the oncogene *MYC*.

*(A, From Snijders AM, Nowak N, Segraves R, et al: Assembly of microarrays for genome-wide measurement of DNA copy number. Nat Genet 29:263, 2001; Web Figure A. Copyright 2001. Reprinted by permission from Macmillan Publishers Ltd.)*

- The DNA can be sequenced to obtain a readout of the order of nucleotides, and by comparison with a normal (wild-type) sequence, mutations can be identified. Most DNA sequencing machines are automated and use a fluorescent dye–based version of a sequencing technology originally named after its inventor, Frederick Sanger. More recently, gene chips (microarrays) also have become available that can be used for sequencing genes or portions of genes. Short sequences of DNA (oligonucleotides) that are complementary to the wild-type sequence and to known mutations are "tiled" adjacent to each other on the gene chip, and the DNA sample to be tested is hybridized to the array (Fig. 6–39). Before hybridization, the sample is labeled with fluorescent dyes. The hybridization (and, consequently, the fluorescent signal emitted) will be strongest at the oligonucleotide that is complementary to the wild-type sequence if no mutations are present, while the presence of a mutation will cause hybridization to occur at the complementary mutant oligonucleotide. Computerized algorithms can then rapidly "decode" the DNA sequence for hundreds of thousands of base pairs of sequence from the fluorescent hybridization pattern on the chip, to identify potential mutations.
- Another approach for identifying mutations at a specific nucleotide position (say, a codon 12 mutation in the *KRAS* oncogene that converts glycine [GGT] to aspartic acid [GAT]) would be to add fluorescently labeled nucleotides C and T to the PCR mixture, which are complementary to either the wild-type (G) or mutant (A) sequence, respectively. Since these two nucleotides are labeled with different fluorophores, the fluorescence emitted by the resulting PCR product can be of one or another color, depending on whether a C or a T becomes incorporated in the process of primer extension (Fig. 6–40). The advantage of this allele-specific extension strategy is that it can detect the presence of mutant DNA even in heterogeneous mixtures of normal and abnormal cells (for example, in clinical specimens obtained from patients suspected of harboring a malignancy). Many variations on this theme have been developed and are being currently used for mutation detection in the laboratory and clinical settings.
- In this context, one would be remiss not to mention next-generation ("NextGen") sequencing technologies, so named because the Sanger sequencing mentioned earlier is now considered "first generation." The availability of NextGen sequencing technology has the potential to alter molecular diagnostics radically, by the sheer volume of sequencing data (more than 1 giga–base pairs or 1,000,000,000 base pairs of DNA per day!) at relatively cheap costs. The entire human genome has a little over 3 gigabases, so true "whole genome sequencing" can be performed several times over in a matter of days. In contrast with Sanger sequencing, NextGen sequencing technologies utilize platforms where sequencing of

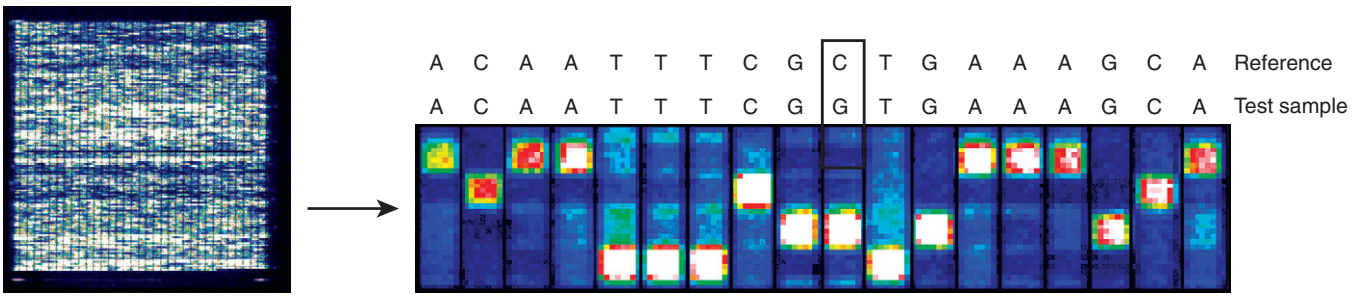


**Figure 6–39** Microarray-based DNA sequencing. *Left panel*, A low-power digitized scan of a "gene chip" that is no larger than a nickel in size but is capable of sequencing thousands of base pairs of DNA. High-throughput microarrays have been used for sequencing whole organisms (such as viruses), organelles (such as the mitochondria), and entire human chromosomes. *Right panel*, A high-resolution view of the gene chip illustrates hybridization patterns corresponding to a stretch of DNA sequence. Typically, a computerized algorithm is available that can convert the individual hybridization patterns across the entire chip into actual sequence data within a matter of minutes ("conventional" sequencing technologies would require days to weeks for such analysis). Here, the sequence on top is the reference (wild-type) sequence, while the lower one corresponds to the test sample sequence. As shown, the computerized algorithm has identified a C→G mutation in the test sample.
*(Adapted from Maitra A, Cohen Y, Gillespie SE, et al: The Human MitoChip: a high-throughput sequencing microarray for mitochondrial mutation detection. Genome Res 14:812, 2004.)*

multiple fragments of the human genome (DNA or cDNA) can occur in parallel ("massively parallel sequencing"), significantly enhancing its speed (Fig. 6–41). Fluorescently labeled nucleotides are incorporated complementary to the template DNA strands, which are immobilized on a solid phase, with one nucleotide added per template per cycle. The cycles are repeated until a sufficient length of "read" is generated that can then be mapped back to the human genome using sophisticated bioinformatics. Deep sequencing is now being utilized to sequence somatic mutations in some of the most common tumor types, while germline sequencing has started identifying the hitherto unknown genetic basis of rare mendelian disorders.

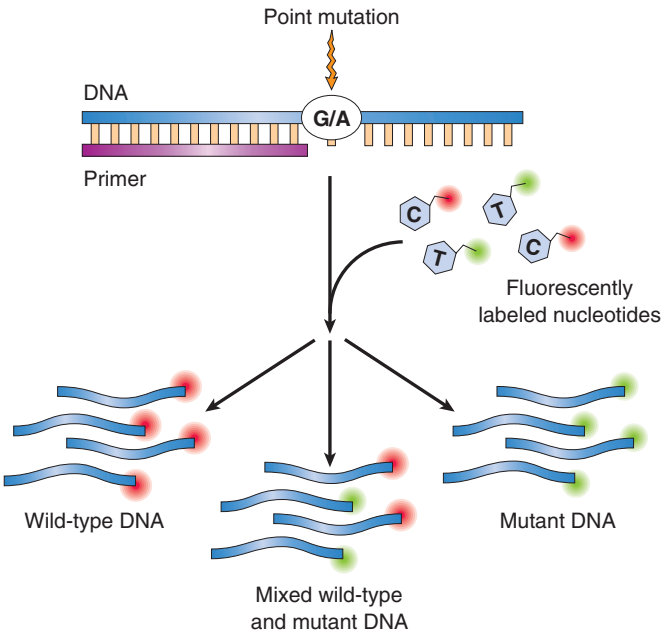


**Figure 6–40** Allele-specific polymerase chain reaction (PCR) analysis for mutation detection in a heterogeneous sample containing an admixture of normal and mutant DNA. Nucleotides complementary to the mutant and wild-type nucleotides at the queried base position are labeled with different fluorophores such that incorporation into the resulting PCR product yields fluorescent signals of variable intensity in accordance with the ratio of mutant to wild-type DNA present.

## Linkage Analysis and Genome-Wide Association Studies

Direct diagnosis of mutations is possible only if the gene responsible for a genetic disorder is known and its sequence has been identified. In several diseases that have a genetic basis, including some common disorders, direct genetic diagnosis is not possible, either because the causal gene has not been identified or because the disease is multifactorial (polygenic) and no single gene is involved. In such cases, two types of analyses can be performed for unbiased identification of disease-associated gene(s): linkage analysis and genome-wide association studies (GWASs). In both instances, surrogate markers in the genome, also known as marker loci, must be used to localize the chromosomal regions of interest, based on their linkage to one or more putative disease-causing genes. The marker loci utilized are naturally occurring variations in DNA sequences known as *polymorphisms*. The most common DNA polymorphisms—SNPs—occur at a frequency of approximately one nucleotide in every 1000–base pair stretch and are found throughout the genome (e.g., in exons and introns and in regulatory sequences). SNPs serve both as a physical landmark within the genome and as a genetic marker whose transmission can be followed from parent to child.

Two technologic breakthroughs have enabled the application of SNPs to high-throughput "gene hunting": *First* is the completion of the so-called HapMap project, which has provided *linkage disequilibrium* patterns in three major ethnoracial groups, based on genome-wide SNP mapping. The entire human genome can now be divided into blocks known as "haplotypes," which contain varying numbers of contiguous SNPs on the same chromosome that are in linkage disequilibrium and hence inherited together as a cluster. As a result, rather than querying every single SNP in the human genome, comparable information about shared DNA can be obtained simply by looking for shared haplotypes, using single or a small number of SNPs that

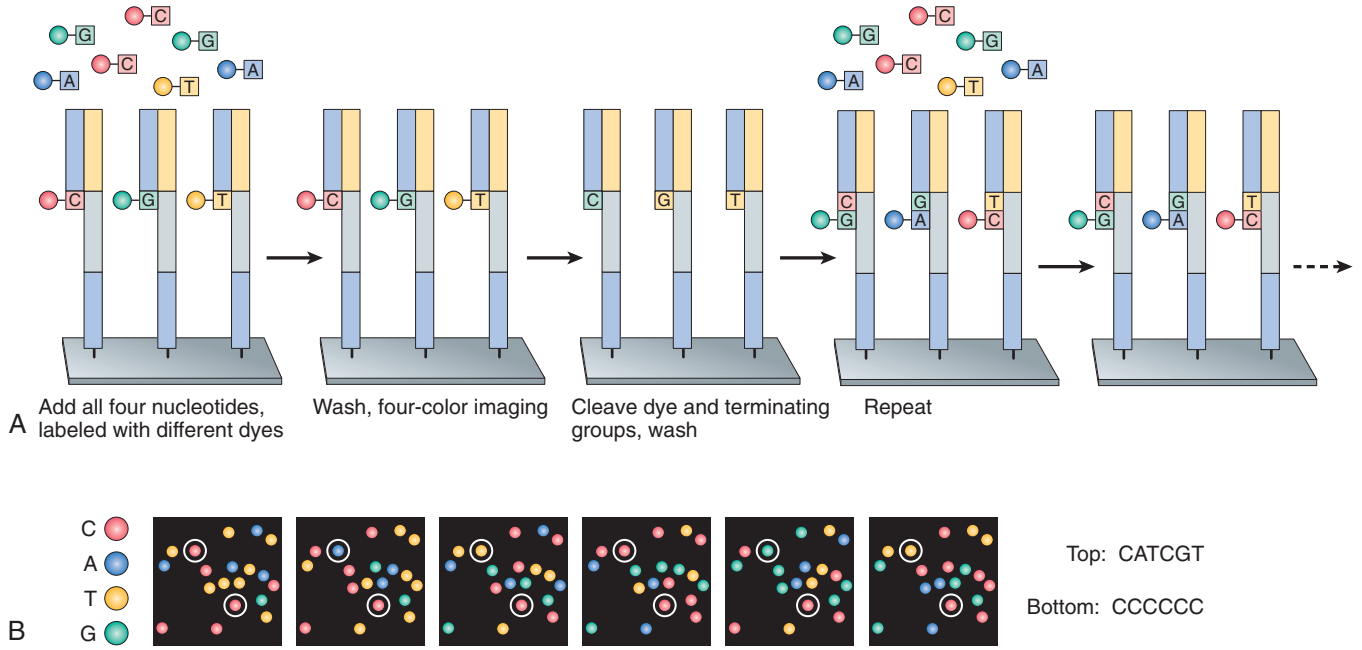


**Figure 6–41** Principle of next-generation sequencing. Several alternative approaches currently are available for "NextGen" sequencing, and one of the more commonly used platforms is illustrated. **A,** Short fragments of genomic DNA ("template") between 100 and 500 base pairs in length are immobilized on a solid phase platform such as a glass slide, using universal capture primers that are complementary to adapters that have previously been added to ends of the template fragments. The addition of fluorescently labeled complementary nucleotides, one per template DNA per cycle, occurs in a "massively parallel" fashion, at millions of templates immobilized on the solid phase at the same time. A four-color imaging camera captures the fluorescence emanating from each template location (corresponding to the specific incorporated nucleotide), following which the fluorescent dye is cleaved and washed away, and the entire cycle is repeated. **B,** Powerful computational programs can decipher the images to generate sequences complementary to the template DNA at the end of one "run," and these sequences are then mapped back to the reference genomic sequence, in order to identify alterations.

*(Reproduced with permission from Metzker M: Sequencing technologies—the next generation. Nat Rev Genet 11:31–46, 2010, © Nature Publishing Group.)*

"tag" or identify a specific haplotype. *Second*, it is now possible to simultaneously genotype hundreds of thousands to a million SNPs at one time, in a cost-effective way, using high-density SNP chip technology.

- *Linkage analysis* deals with assessing shared marker loci (i.e., SNPs) in family members exhibiting the disease or trait of interest, with the assumption that SNPs in linkage disequilibrium with the disease allele are transmitted through pedigrees. With time it becomes possible to define a "disease haplotype" based on a panel of SNPs, all of which cosegregate with the putative disease allele. Eventually, linkage analysis facilitates localization and cloning of the disease allele. Linkage analysis is most useful in mendelian disorders that are related to one gene with profound effects and high penetrance.
- It is now established that some of the most common human diseases, such as hypertension, diabetes, mental disorders, and asthma, have a polygenic basis, with multiple genetic loci contributing small independent effects, resulting in a disease phenotype. Conventional linkage analyses lack the statistical power to detect such genetic variants. In *GWASs,* large cohorts of patients with and without a disease (rather than families) are examined across the entire genome for variant SNPs that are overrepresented in persons with the disease. This identifies regions of the genome that contain a variant gene or genes that confer disease susceptibility. The causal variant within the region is then provisionally identified using a "candidate gene" approach, in which genes are selected on the basis of how tightly they are associated with the disease and whether their biologic function seems likely to be involved in the disease under study. In addition to polygenic diseases, GWASs also have led to the identification of genetic loci that modulate common quantitative traits in humans, such as height, body mass, hair and eye color, and bone density.

## Indications for Genetic Analysis

The preceding discussion described some of the many techniques available today for the diagnosis of genetic diseases. For judicious application of these methods, it is important to recognize which persons require genetic testing. In general, genetic testing can be divided into prenatal and postnatal analysis. It may involve conventional cytogenetics, FISH, molecular diagnostics, or a combination of these techniques.

*Prenatal genetic analysis* should be offered to all patients who are at risk of having cytogenetically abnormal progeny. It can be performed on cells obtained by amniocentesis, on chorionic villus biopsy material, or on umbilical cord blood. Some important indications are the following:

- Advanced maternal age (beyond 34 years), which is associated with greater risk of trisomies
- Confirmed carrier status for a balanced reciprocal translocation, Robertsonian translocation, or inversion (in

such cases, the gametes may be unbalanced, so the progeny would be at risk for chromosomal disorders)
- A chromosomal abnormality affecting a previous child
- Determination of fetal sex when the patient or partner is a confirmed carrier of an X-linked genetic disorder

*Postnatal genetic analysis* usually is performed on peripheral blood lymphocytes. Indications are as follows:
- Multiple congenital anomalies
- Unexplained mental retardation and/or developmental delay
- Suspected aneuploidy (e.g., features of Down syndrome)
- Suspected unbalanced autosome (e.g., Prader-Willi syndrome)
- Suspected sex chromosome abnormality (e.g., Turner syndrome)
- Suspected fragile X syndrome
- Infertility (to rule out sex chromosome abnormality)
- Multiple spontaneous abortions (to rule out the parents as carriers of balanced translocation; both partners should be evaluated)

In the context of these and other clinical applications, an important point is that we are currently living in a breathtaking era of so-called genomic medicine. Future years will foretell how the advances in elucidation of the genetic basis of human disease will affect its diagnosis, prevention, and therapy.

## BIBLIOGRAPHY


Bassell GJ, Waren ST: Fragile X syndrome: loss of local mRNA regulation alters synaptic development and function. Neuron 60:201, 2008. *[An update on the molecular pathogenesis of fragile X syndrome, particularly as it relates to the consequences of loss in* FMRP *function.]*

Bojesen A, Gravholt CH: Klinefelter syndrome in clinical practice. Nat Clin Prac Urol 4:192, 2007. *[A clinically oriented review of this entity.]*

Butler MG: Genomic imprinting disorders in humans: a mini-review. J Assist Reprod Genet 26:477, 2009. *[A succinct and excellent overview on the genetic bases of imprinting disorders, including the two discussed in this chapter.]*

Collaco JM, Cutting GR: Update on gene modifiers in cystic fibrosis. Curr Opin Pulm Med 14:559, 2008. *[A review from one of the world experts on cystic fibrosis on the role of genetic modifiers besides the CFTR gene that influence phenotype.]*

Croce CM: Causes and consequences of microRNA dysregulation in cancer. Nat Rev Genet 10:704, 2009. *[A comprehensive review from the pioneer who discovered the first example of microRNA dysregulation in human cancer.]*

Farrell PM, Rosenstein BJ, White TB, et al: Guidelines for diagnosis of cystic fibrosis in newborns through older adults: Cystic Fibrosis Foundation consensus report. J Pediatr 153:S4-S14, 2008. *[An excellent consensus statement from an expert group addressing the protean manifestations of cystic fibrosis, and genotype-phenotype correlations.]*

Feinberg AP: Epigenetics at the epicenter of modern medicine. JAMA 299:1345, 2008. *[An outstanding review from the world expert on imprinting, highlighting the role of epigenetic abnormalities in the pathogenesis of cancers and other human diseases.]*

Hartl FU, Bracher A, Hayer-Hartl M: Molecular chaperones in protein folding and proteostasis. Nature 475:324, 2011. *[An excellent review of protein misfolding and chaperone therapy.]*

Janoueix-Lerosey I, Schleiermacher G, Delattre O: Molecular pathogenesis of peripheral neuroblastic tumors. Oncogene 29:1566, 2010.

Judge DP, Dietz HC: Therapy of Marfan syndrome. Annu Rev Med 59:43, 2008. *[An outstanding review authored by one of the world's foremost experts on the pathogenesis of Marfan syndrome, focused on "druggable" targets that are undergoing clinical evaluation, mainly for prevention of cardiac and aortic complications.]*

Kinney HC, Thach BT: The sudden infant death syndrome. N Engl J Med 361:795, 2009. *[A succinct review on SIDS authored by the group that described some of the key neuropathological findings and neurotransmitter abnormalities in this phenomenon.]*

Kobrynski LJ, Sullivan KE: Velocardiofacial syndrome, DiGeorge syndrome: the chromosome 22q11.2 deletion syndromes. Lancet 370:1443, 2007. *[A well-written review on the 22q11.2 microdeletion syndromes, including clinical features, diagnosis, and management.]*

Ku CS, Loy EY, Pawitan Y, Chia KS: The pursuit of genome-wide association studies: where are we now? J Hum Genet 55:195, 2010. *[A five-year "audit" on the status of GWASs and how these have influenced our understanding of complex disorders.]*

Lin PW, Nasr TR, Stoll BJ: Necrotizing enterocolitis: recent scientific advances in pathophysiology and prevention. Semin Perinatol 32:70, 2008. *[A well-written review on the current understanding of the molecular pathogenesis of NEC, and avenues for prevention.]*

Loscalzo ML: Turner syndrome. Pediatr Rev 29:219, 2008. *[A well-rounded review that covers both the basics of genetics as well as clinical aspects of Turner syndrome.]*

Metzker M: Sequencing technologies—the next generation. Nat Rev Genet 11:31, 2010. *[An update on the currently available next generation sequencing platforms and the applications thereof.]*

Patterson D: Molecular genetic analysis of Down syndrome. Hum Genet 126:195, 2009. *[An in-depth review of the molecular pathogenesis of Down syndrome.]*

Staretz-Chacham O, Lang TC, LaMarca ME, et al: Lysosomal storage disorders in the newborn. Pediatrics 123:1191, 2009. *[An excellent discussion of this class of rare disorders, with a particular emphasis on those presenting in the newborn period.]*

Sweetser DA, Grabowski EF: Pediatric malignancies: retinoblastoma and Wilms tumor. In Chung DC, Haber DA (eds): Principles of Clinical Cancer Genetics: A Handbook from the Massachusetts General Hospital. Springer, New York, 2010, pp 163–180. *[A well-written book chapter that summarizes the clinical features, molecular pathogenesis, and management of these two solid tumors of childhood.]*

Wheeler DA, Srinivasan M, Egholm M, et al: The complete genome of an individual by massively parallel DNA sequencing. Nature 452:872, 2008. *[Landmark paper describing the first complete sequencing of a human genome—that of the codiscoverer of the DNA double helix structure and Nobel laureate, James D. Watson, using next-generation sequencing.]*

Winter J, Jung S, Keller S, et al: Many roads to maturity: microRNA biogenesis pathways and their regulation. Nat Cell Biol 11:228, 2009. *[An outstanding review on how miRNA is synthesized and processed, and emerging knowledge on how this complex process is regulated—not for the faint of heart!]*

See Targeted Therapy available online at
studentconsult.com

CHAPTER 7

# Environmental and Nutritional Diseases

CHAPTER CONTENTS

**Health Effects of Climate Change 269**
**Toxicity of Chemical and Physical Agents 271**
**Environmental Pollution 272**
Air Pollution 272
Metals as Environmental Pollutants 273
Industrial and Agricultural Exposures 276
**Effects of Tobacco 277**
**Effects of Alcohol 280**
**Injury by Therapeutic Drugs and Drugs of Abuse 282**
Injury by Therapeutic Drugs: Adverse Drug Reactions 282
Injury by Nontherapeutic Agents (Drug Abuse) 284
**Injury by Physical Agents 287**
Mechanical Trauma 287
Thermal Injury 288
Electrical Injury 289
Injury Produced by Ionizing Radiation 289
**Nutritional Diseases 293**
Malnutrition 293
Protein-Energy Malnutrition 294
Anorexia Nervosa and Bulimia 295
Vitamin Deficiencies 296
Obesity 302
Diet and Systemic Diseases 306
Diet and Cancer 306

Many diseases are caused or influenced by environmental factors. Broadly defined, the term *environment* encompasses the various outdoor, indoor, and occupational settings in which humans live and work. In each of these settings, the air people breathe, the food and water they consume, and the toxic agents they are exposed to are major determinants of health. Other environmental factors pertain to the individual ("personal environment") and include tobacco use, alcohol ingestion, therapeutic and "recreational" drug consumption, diet, and the like. Factors in the personal environment generally have a larger effect on human health than that of the ambient environment, but new threats related to global warming (described later on) may change this equation.

The term *environmental disease* refers to disorders caused by exposure to chemical or physical agents in the ambient, workplace, and personal environments, including diseases of nutritional origin. Environmental diseases are surprisingly common. The International Labor Organization has estimated that work-related injuries and illnesses kill 1.1 million people per year globally—more deaths than are caused by road accidents and wars combined. Most of these work-related problems are caused by illnesses rather than accidents. The burden of disease in the general population created by nonoccupational exposures to toxic agents is much more difficult to estimate, mostly because of the diversity of agents and the difficulties in measuring the dose and duration of exposures. Whatever the precise numbers, environmental diseases are major causes of disability and suffering and constitute a heavy financial burden, particularly in developing countries.

Environmental diseases are sometimes the consequence of major disasters, such as the methyl mercury contamination of Minamata Bay in Japan in the 1960s, the leakage of methyl isocyanate gas in Bhopal, India, in 1984, the Chernobyl nuclear accident in 1986, and the intentional contamination of Tokyo subways by the organophosphate pesticide sarin in 1995. Fortunately, these are unusual and infrequent occurrences. Less dramatic, but much more common, are diseases and injury produced by chronic exposure to relatively low levels of contaminants. Several agencies in the United States set permissible levels of exposure to known environmental hazards (e.g., the maximum level of carbon monoxide [CO] in air that is noninjurious or the level of radiation exposure that is harmless or "safe"). But a host of factors, including complex interactions between pollutants producing multiplicative effects, as well as the age, genetic predisposition, and different tissue sensitivities of exposed persons, create wide variations in individual sensitivity. Nevertheless, such "safe" levels are useful for comparative studies of the effects of harmful agents between populations, and for estimating disease risk in heavily exposed persons. From this brief overview of the nature and magnitude of the problem, we turn to a consideration of mechanisms of toxicity and then some of the more important environmental hazards.

## HEALTH EFFECTS OF CLIMATE CHANGE

Temperature measurements show that the earth has warmed at an accelerating pace over the last 50 years, perhaps at a rate greater than in any period during the preceding 1000 years. Since 1960 the global average temperature has increased by 0.6°C, with the greatest increases seen over land areas between 40°N and 70°N. These changes have been accompanied by the rapid loss of glacial and sea ice, leading to predictions that the glaciers of

Glacier National Park in Montana and Mt. Kilimanjaro in Kenya will disappear by the year 2025, and that the Arctic Ocean will be completely ice-free in summer by no later than the year 2040.

Although politicians quibble, among scientists there is a general acceptance that climate change is, at least in part, man-made. The culprit is the rising atmospheric level of greenhouse gases, particularly carbon dioxide ($CO_2$) released through the burning of fossil fuels (Fig. 7–1, *A*), as well as ozone (an important air pollutant, discussed later) and methane. These gases, along with water vapor, produce the so-called greenhouse effect by absorbing energy radiated from Earth's surface that otherwise would be lost into space. The annual average level of atmospheric $CO_2$ (about 387 ppm) in 2009 was higher than at any point in approximately 650,000 years and, without changes in human behavior, is expected to increase to 500 to 1200 ppm by the end of this century—levels not experienced for tens of millions of years. This increase stems not only from increased $CO_2$ production but also from deforestation and the attendant decrease in carbon fixation by plants. Depending on which computer model is used, increased levels of greenhouse gases are projected to cause the global temperature to rise by 2°C to 5°C by the year 2100 (Fig. 7–1, *B*). Part of the uncertainty about the extent of the temperature increase stems from questions about the degree to which positive-feedback loops will exacerbate factors driving the process. Examples of such self-reinforcing loops are increases in heat absorption due to loss of reflective ice and snow; increases in water vapor due to greater evaporation from rivers, lakes, and oceans; large releases of $CO_2$ and methane from organic matter in thawing Arctic "permafrost" and submarine methane hydrates; and decreased sequestration of $CO_2$ in oceans due to reduced growth of organisms, such as diatoms, that serve as carbon sinks.

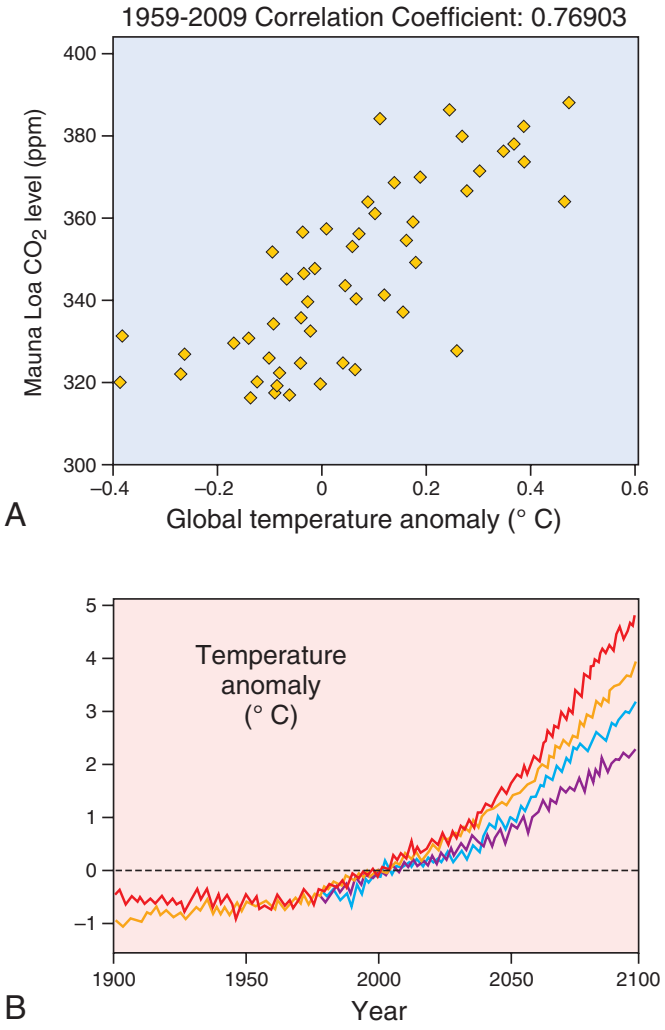


**Figure 7–1** Climate change, past and future. **A,** Correlation of $CO_2$ levels measured at the Mauna Loa Observatory in Hawaii with average global temperature trends over the past 50 years. "Global temperature" in any given year was deduced at the Hadley Center (United Kingdom) from measurements taken at over 3000 weather stations located around the globe. **B,** Predicted temperature increases during the 21st century. Different computer models plot anticipated rises in global temperatures of 2°C to 5°C by the year 2100.

*(A, Courtesy of Dr. Richard Aster, Department of Earth and Environmental Science, New Mexico Institute of Mining and Technology, Socorro, New Mexico.)*

The health consequences of climate change will depend on its extent and rapidity, the severity of the ensuing consequences, and humankind's ability to mitigate the damaging effects. Even in the best-case scenario, however, climate change is expected to have a serious negative impact on human health by increasing the incidence of a number of diseases, including

- Cardiovascular, cerebrovascular, and respiratory diseases, all of which will be exacerbated by heat waves and air pollution.
- Gastroenteritis, cholera, and other food- and water-borne infectious diseases, caused by contamination as a consequence of floods and disruption of clean water supplies and sewage treatment, after heavy rains and other environmental disasters
- Vector-borne infectious diseases, such as malaria and dengue fever, due to changes in vector number and geographic distribution related to increased temperatures, crop failures and more extreme weather variation (e.g., more frequent and severe El Niño events)
- Malnutrition, caused by changes in local climate that disrupt crop production. Such changes are anticipated to be most severe in tropical locations, in which average temperatures may already be near or above crop tolerance levels; it is estimated that by 2080, agricultural productivity may decline by 10% to 25% in some developing countries as a consequence of climate change.

Beyond these disease-specific effects, it is estimated that melting of glacial ice, particularly in Greenland and other parts of the Northern Hemisphere, combined with the thermal expansion of warming oceans, will raise sea levels by 2 to 6 feet by 2100. Approximately 10% of the world's population—roughly 600 million people—live in low-lying areas that are at risk for flooding even if the rise in ocean levels is at the low end of these estimates. The resulting displacement of people will disrupt lives and commerce, creating conditions ripe for political unrest, war, and poverty, the "vectors" of malnutrition, sickness, and death.

Both developed and developing countries will suffer the consequences of climate change, but the burden will be greatest in developing countries, which are least culpable for increases in greenhouse gases to date. This picture is changing rapidly, however, owing to the growth of the economies of India and China, which has recently surpassed the United States to become the largest producer of

$CO_2$ in the world. The urgent challenge is to develop new renewable energy resources that stem the production of greenhouse gases. Without immediate action, climate change stands to become the preeminent global cause of environmental disease in the 21st century and beyond.

## TOXICITY OF CHEMICAL AND PHYSICAL AGENTS

*Toxicology* is defined as the science of poisons. It studies the distribution, effects, and mechanisms of action of toxic agents. More broadly, it also includes the study of the effects of physical agents such as radiation and heat. Approximately 4 billion pounds of toxic chemicals, including 72 million pounds of known carcinogens, are produced each year in the United States. In general, however, little is known about the potential health effects of chemicals. Of the approximately 100,000 chemicals in use in the United States, less than 1% have been tested experimentally for health effects. In Europe the number of available chemicals is less than one-half that in the United States, but many of these chemicals are released into the environment as industrial products or discharged as human and animal wastes.

We now consider some basic principles regarding the toxicity of exogenous chemicals and drugs.

- The *definition of a poison* is not straightforward. It is basically a quantitative concept strictly dependent on *dosage*. The quote from Paracelsus in the 16th century that "all substances are poisons; the right dosage differentiates a poison from a remedy" is perhaps even more valid today, in view of the proliferation of therapeutic drugs with potentially harmful effects.
- *Xenobiotics* are exogenous chemicals in the environment that may be absorbed by the body through inhalation, ingestion, or skin contact (Fig. 7–2).
- Chemicals may be excreted in urine or feces or eliminated in expired air, or they may accumulate in bone, fat, brain, or other tissues.
- Chemicals may act at the site of entry, or they may be transported to other sites. Some agents are not modified upon entry in the body, but most solvents and drugs are metabolized to form water-soluble products (*detoxification*) or are *activated to form toxic metabolites.*
- Most solvents and drugs are lipophilic, which facilitates their transport in the blood by lipoproteins and penetration through lipid components of cell membranes.
- The reactions that metabolize xenobiotics into nontoxic products, or activate xenobiotics to generate toxic compounds (Fig. 7–3; see also Fig. 7–2), occur in two phases. In *phase I* reactions, chemicals can undergo hydrolysis, oxidation, or reduction. Products of phase I reactions often are metabolized into water-soluble compounds through *phase II* reactions of glucuronidation, sulfation, methylation, and conjugation with glutathione (GSH). Water-soluble compounds are readily excreted.
- The most important cellular enzyme system involved in phase I reactions is the *cytochrome P-450* system, located primarily in the endoplasmic reticulum (ER) of the liver but also present in skin, lungs, and gastrointestinal (GI) mucosa and in practically every organ. The system catalyzes reactions that either *detoxify xenobiotics or activate xenobiotics into active compounds that cause cellular injury.* Both types of reactions may produce, as a byproduct, *reactive oxygen species (ROS),* which can cause cellular damage (discussed in Chapter 1). Examples of metabolic activation of chemicals through the P-450 system are the conversion of carbon tetrachloride to the toxic trichloromethyl free radical and the generation of a DNA-binding metabolite from benzo[*a*]pyrene (BaP), a carcinogen present in cigarette smoke. The cytochrome P-450 system also participates in the metabolism of a large number of common therapeutic drugs such as acetaminophen, barbiturates, and anticonvulsants, and in alcohol metabolism (discussed later).
- P-450 enzymes vary widely in activity among different people, owing to both *polymorphisms* in the genes

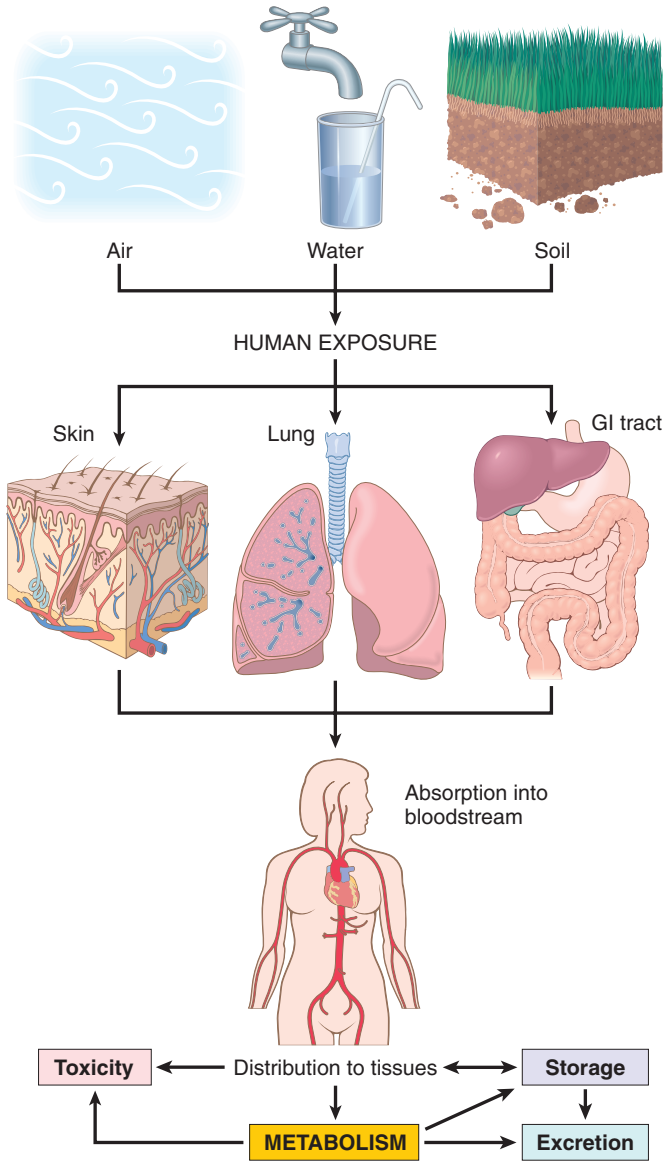


**Figure 7–2** Human exposure to pollutants. Pollutants contained in air, water, and soil are absorbed through the lungs, gastrointestinal tract, and skin. In the body, they may act at the site of absorption, but they generally are transported through the bloodstream to various organs, where they may be stored or metabolized. Metabolism of xenobiotics may result in the formation of water-soluble compounds, which are excreted, or in activation of the agent, creating a toxic metabolite.

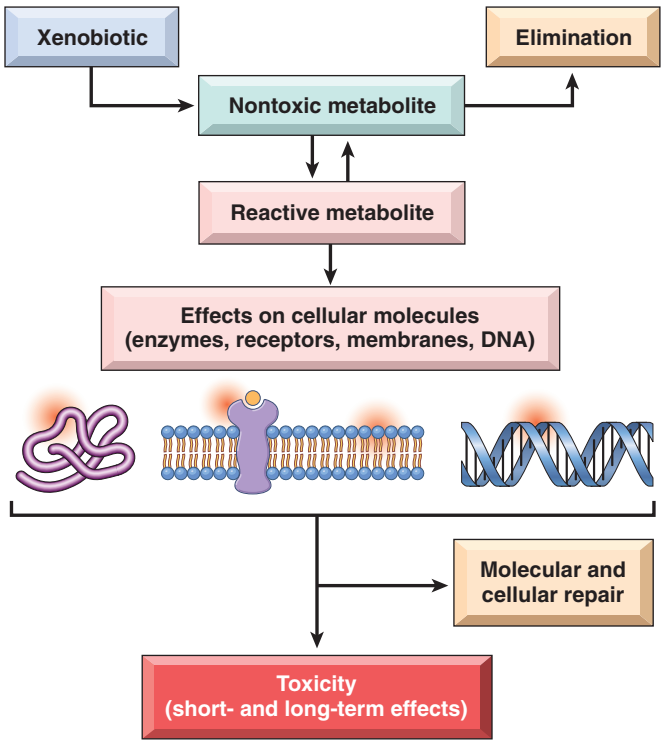


**Figure 7–3** Xenobiotic metabolism. Xenobiotics can be metabolized to nontoxic metabolites and eliminated from the body (detoxification). However, their metabolism also may result in activation of the chemical, leading to formation of a reactive metabolite that is toxic to cellular components. If repair is not effective, short- and long-term effects develop.

*(Modified from Hodgson E:* A Textbook of Modern Toxicology, *3rd ed, and Fig. 1–1. Hoboken, NJ, John Wiley & Sons, 2004.)*

encoding the enzymes and interactions with drugs that are metabolized through the system. The activity of the enzymes also may be decreased by fasting or starvation, and increased by alcohol consumption and smoking.

# ENVIRONMENTAL POLLUTION

## Air Pollution

The life-giving air that we breathe is also often laden with many potential causes of disease. Airborne microorganisms have long been major causes of morbidity and death. More widespread are the chemical and particulate pollutants found in the air, both in so-called "developed" and "underdeveloped" countries. Specific hazards have been recognized for both outdoor and indoor air.

### *Outdoor Air Pollution*

The ambient air in industrialized nations is contaminated with an unsavory mixture of gaseous and particulate pollutants, more heavily in cities and in proximity to heavy industry. In the United States, the Environmental Protection Agency (EPA) monitors and sets allowable upper limits for six pollutants: sulfur dioxide, CO, ozone, nitrogen dioxide, lead, and particulate matter. Together, some of these agents produce the well-known smog that sometimes stifles large cities such as Cairo, Los Angeles, Houston, Mexico City, and São Paulo. It may seem that air pollution is a modern phenomenon. This is not the case; Seneca wrote in AD 61 that he felt an alteration of his disposition as soon as he left the "pestilential vapors, soot, and heavy air of Rome." The first environmental control law was proclaimed by Edward I in 1306 and was straightforward in its simplicity: "Whoever should be found guilty of burning coal shall suffer the loss of his head." What has changed in modern times is the nature and sources of air pollutants, and the types of regulations that control their emission. It could be argued that modern man has lost his head to drown himself in pollution!

The lungs bear the brunt of the adverse consequences of air pollution, but air pollutants can affect many organ systems (as with the effects of lead poisoning and CO, discussed later). Except for some comments on smoking later in this chapter, pollutant-caused lung diseases are discussed in Chapter 12. Discussed here are the major health effects of ozone, sulfur dioxide, particulates, and CO (Table 7–1).

*Ozone* is one of the most pervasive air pollutants, with levels in many cities exceeding EPA standards. It is a gas formed by sunlight-driven reactions involving nitrogen oxides, which are released mostly by automobile exhaust. Together with oxides and fine particulate matter, ozone forms the familiar *smog* (from smoke and fog). Its toxicity

**Table 7–1** Health Effects of Outdoor Air Pollutants

| Pollutant | Populations at Risk | Effect(s) |
|---|---|---|
| Ozone | Healthy adults and children | Decreased lung function<br>Increased airway reactivity<br>Lung inflammation |
| | Athletes, outdoor workers | Decreased exercise capacity |
| | Asthmatics | Increased hospitalizations |
| Nitrogen dioxide | Healthy adults<br>Asthmatics<br>Children | Increased airway reactivity<br>Decreased lung function<br>Increased respiratory infections |
| Sulfur dioxide | Healthy adults | Increased respiratory symptoms |
| | Patients with chronic lung disease | Increased mortality |
| | Asthmatics | Increased hospitalization<br>Decreased lung function |
| Acid aerosols | Healthy adults | Altered mucociliary clearance |
| | Children | Increased respiratory infections |
| | Asthmatics | Decreased lung function<br>Increased hospitalizations |
| Particulates | Children | Increased respiratory infections<br>Decreased lung function |
| | Patients with chronic lung or heart disease | Excess mortality |
| | Asthmatics | Increased attacks |

Data from Health effects of outdoor air pollution. Part 2. Committee of the Environmental and Occupational Health Assembly of the American Thoracic Society. *Am J Respir Crit Care Med* 153:477, 1996.

stems from its participation in chemical reactions that generate free radicals, which injure the lining cells of the respiratory tract and the alveoli. Low levels of ozone may be tolerated by healthy persons but are detrimental to lung function, especially in those with asthma or emphysema, and when present along with particulate pollution. Unfortunately, pollutants rarely occur singly but combine to create a veritable "witches' brew."

*Sulfur dioxide, particles, and acid aerosols* are emitted by coal- and oil-fired power plants and industrial processes burning these fuels. Of these, particles (although not well characterized chemically or physically) appear to be the main cause of morbidity and death. Particles less than 10 μm in diameter are particularly harmful, since when inhaled they are carried by the airstream all the way to the alveoli. Here, they are phagocytosed by macrophages and neutrophils, causing the release of mediators and inciting an inflammatory reaction. By contrast, larger particles are removed in the nose or are trapped by the mucociliary "escalator" and as a result are less dangerous.

*Carbon monoxide (CO)* is a nonirritating, colorless, tasteless, odorless gas. It is produced by the incomplete oxidation of carbonaceous materials. Its sources include automotive engines, industries using fossil fuels, home oil burners, and cigarette smoke. The low levels often found in ambient air may contribute to impaired respiratory function but usually are not life-threatening. However, persons working in confined environments with high exposure to fumes, such as tunnel and underground garage workers, may develop chronic poisoning. CO is included here as an air pollutant, but it also is an important cause of accidental and suicidal death. In a small, closed garage, exhaust from a running car engine can induce lethal coma within 5 minutes. CO is a systemic asphyxiant that kills by binding to hemoglobin and preventing oxygen transport. Hemoglobin has a 200-fold greater affinity for CO than for $O_2$. The resultant compound, carboxyhemoglobin, is incapable of carrying oxygen. Hypoxia leads to central nervous system (CNS) depression, which develops so insidiously that victims may not be aware of their plight and indeed may be unable to help themselves. Systemic hypoxia appears when the hemoglobin is 20% to 30% saturated with CO, and unconsciousness and death are probable with 60% to 70% saturation.

### MORPHOLOGY

**Chronic poisoning** by CO develops because carboxyhemoglobin, once formed, is remarkably stable. As a result, with low-level persistent exposure to CO, carboxyhemoglobin may accumulate to a life-threatening concentration in the blood. The slowly developing hypoxia can insidiously evoke widespread ischemic changes in the brain; these changes are particularly marked in the basal ganglia and lenticular nuclei. With cessation of exposure to CO, the patient usually recovers, but there may be permanent neurologic damage. The diagnosis of CO poisoning is based on detection of high levels of carboxyhemoglobin in the blood.

**Acute poisoning** by CO generally is a consequence of accidental exposure or suicide attempt. In light-skinned people, it is marked by a characteristic **generalized cherry-red color of the skin and mucous membranes,** a color imparted by carboxyhemoglobin. If death occurs rapidly, morphologic changes may not be present; with longer survival, the brain may be slightly edematous and exhibit punctate hemorrhages and hypoxia-induced neuronal changes. These changes are not specific; they simply imply systemic hypoxia. In victims who survive CO poisoning, complete recovery is possible; however, sometimes impairments of memory, vision, hearing, and speech may remain.

### *Indoor Air Pollution*

As modern homes are increasingly "buttoned up" to exclude the environment, the potential for pollution of the indoor air increases. The commonest pollutant is tobacco smoke (discussed later), but additional offenders are CO, nitrogen dioxide (already mentioned as outdoor pollutants), and asbestos (discussed in Chapter 12). A few comments about some other agents are presented here.

*Wood smoke,* containing various oxides of nitrogen and carbon particulates, is an irritant that predisposes exposed persons to lung infections and may contain carcinogenic polycyclic hydrocarbons. *Radon,* a radioactive gas derived from uranium, is widely present in soil and in homes. Although radon exposure can cause lung cancer in uranium miners (particularly in those who smoke), it does not appear that low-level chronic exposures in the home increase lung cancer risk, at least for nonsmokers. *Bioaerosols* may contain pathogenic microbiologic agents, such as those that can cause Legionnaires' disease, viral pneumonia, and the common cold, as well as allergens derived from pet dander, dust mites, and fungi and molds, which can cause rhinitis, eye irritation, and even asthma.

### SUMMARY

#### Environmental Diseases and Environmental Pollution

- Environmental diseases are conditions caused by exposure to chemical or physical agents in the ambient, workplace, and personal environments.
- Exogenous chemicals known as xenobiotics enter the body through inhalation, ingestion, and skin contact, and can either be eliminated or accumulate in fat, bone, brain, and other tissues.
- Xenobiotics can be converted into nontoxic products, or activated to generate toxic compounds, through a two-phase reaction process that involves the cytochrome P-450 system.
- The most common air pollutants are ozone (which in combination with oxides and particulate matter forms smog), sulfur dioxide, acid aerosols, and particles less than 10 μm in diameter.
- Carbon monoxide is an air pollutant and important cause of death from accidents and suicide; it binds hemoglobin with high affinity, leading to systemic asphyxiation associated with CNS depression.

## Metals as Environmental Pollutants

Lead, mercury, arsenic, and cadmium, the heavy metals most commonly associated with harmful effects in human populations, are considered here.

### *Lead*

Lead exposure occurs through contaminated air and food. For most of the 20th century the major sources of lead in the environment were house paints and gasoline. Although the use of lead-based paints and leaded gas has greatly diminished, many sources of lead persist in the environment, such as mines, foundries, batteries, and spray paints, all of which constitute occupational hazards. However, *flaking lead paint* in older houses and soil contamination pose the major hazards for youngsters. Indeed, a single 1-$cm^2$ chip of old leaded paint (pre-1977) contains about 175 µg of lead; this amount, if consumed each day over time, will rapidly produce toxic lead levels. According to a 2008 report from the Environmental Protection Agency (EPA), 0.9% of American children had blood lead levels in excess of 10 µg/dL (the maximum allowable level). This percentage represents a decrease from 4.4% in the early 1990s. However, blood levels of lead in children living in homes containing lead-based paint or lead-contaminated dust generally exceed the maximum allowed levels. Children absorb more than 50% of lead from food, while adults absorb approximately 15%. A more permeable blood–brain barrier in children creates a high susceptibility to brain damage. The main clinical features of lead poisoning are shown in Figure 7–4.

Most of the absorbed lead (80% to 85%) is taken up into bone and developing teeth; lead competes with calcium, binds phosphates, and has a half-life in bone of 20 to 30 years. About 5% to 10% of the absorbed lead remains in the blood, and the remainder is distributed throughout soft tissues. *Excess lead causes neurologic effects in adults and children; peripheral neuropathies* predominate in adults, while central effects are more common in children. The effects of chronic lead exposure in children include a lower intellectual capacity manifested by low intelligence quotient (IQ), behavioral problems such as hyperactivity, and poor organizational skills. Lead-induced peripheral neuropathies in adults generally remit with elimination of exposure, but both peripheral and CNS abnormalities in children usually are irreversible. *Excess lead interferes with the normal remodeling of calcified cartilage* and primary bone trabeculae in the epiphyses in children, causing increased bone density detected as radiodense "lead lines" (Fig. 7–5). Lead lines of a different sort also may occur in the gums, where excess lead stimulates hyperpigmentation. Lead inhibits the healing of fractures by increasing chondrogenesis and delaying cartilage mineralization. Excretion of lead occurs by way of the kidneys, and acute exposures may cause damage to proximal tubules.

Lead has a high affinity for sulfhydryl groups and interferes with two enzymes involved in heme synthesis, aminolevulinic acid dehydratase and delta ferrochelatase. Iron incorporation into heme is impaired, leading to *anemia.* Lead also inhibits sodium- and potassium-dependent ATPases in cell membranes, an effect that may increase the fragility of red cells, causing *hemolysis.* The diagnosis of lead poisoning requires constant vigilance. It may be suspected on the basis of neurologic changes in children or unexplained anemia with basophilic stippling in red cells. Elevated blood lead and red cell free protoporphyrin levels (greater than 50 µg/dL) or, alternatively, zinc-protoporphyrin levels, are required for definitive diagnosis. In milder cases of lead exposure, anemia may be the only obvious abnormality.

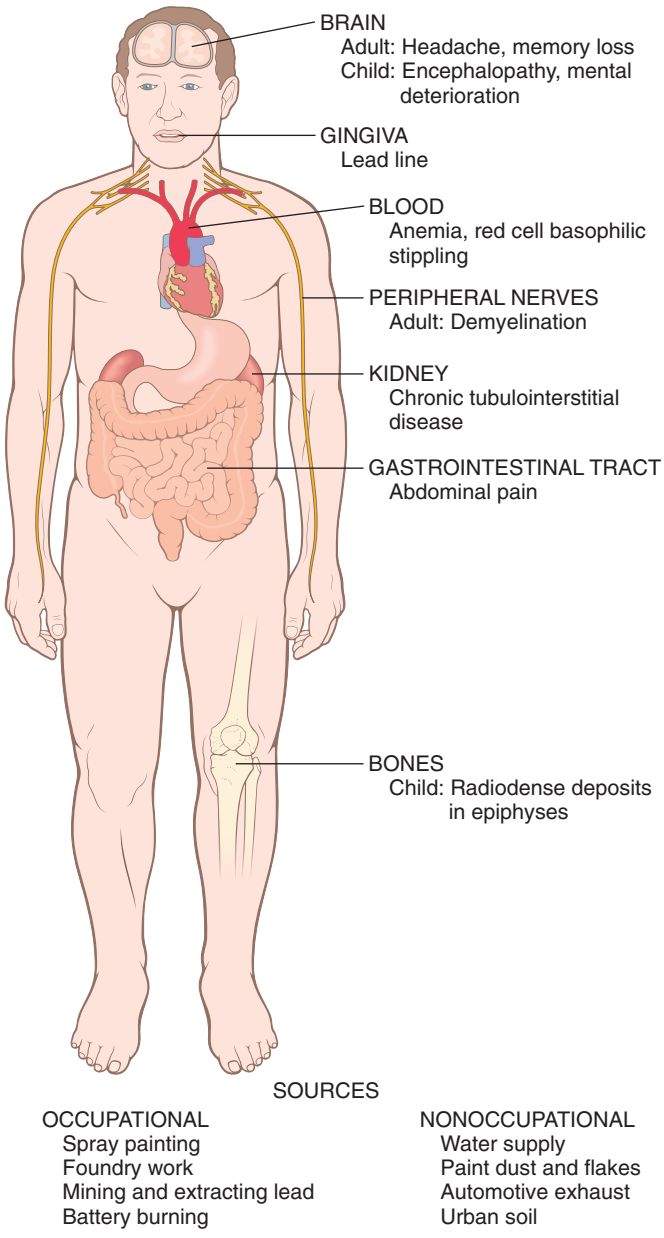


**Figure 7–4** Pathologic features of lead poisoning.

## MORPHOLOGY

The major anatomic targets of lead toxicity are the blood, bone marrow, nervous system, GI tract, and kidneys (Fig. 7–4).

**Blood changes** are one of the earliest signs of lead accumulation and are characteristic, consisting of a microcytic, hypochromic anemia associated with a distinctive punctate **basophilic stippling** of red cells. These changes in the blood stem from the inhibition of heme synthesis in marrow erythroid progenitors. Another consequence of this

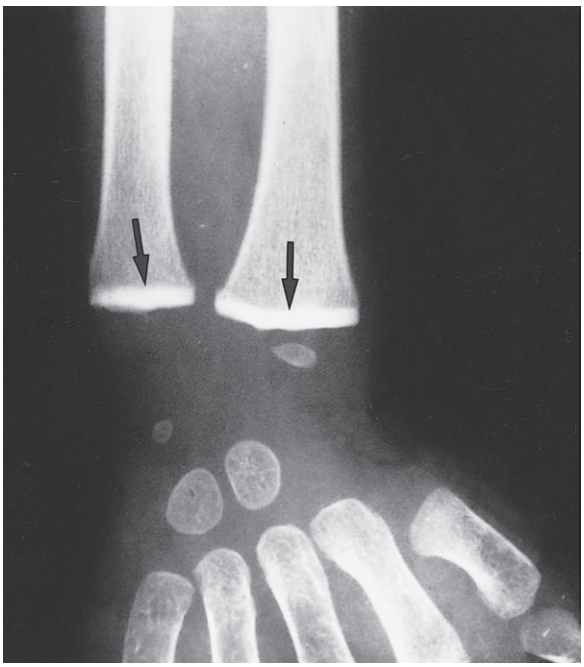

**Figure 7–5** Lead poisoning. Impaired remodeling of calcified cartilage in the epiphyses (*arrows*) of the wrist has caused a marked increase in their radiodensity, so that they are as radiopaque as the cortical bone.

*(Courtesy of Dr. G.W. Dietz, Department of Radiology, University of Texas Southwestern Medical School, Dallas, Texas.)*

blockade is that zinc-protoporphyrin is formed instead of heme. Thus, elevated blood levels of zinc-protoporphyrin or its product, free red cell protoporphyrin, are important indicators of lead poisoning.

**Brain damage** is prone to occur in children. It may be subtle, producing mild dysfunction, or it may be massive and lethal. In young children, sensory, motor, intellectual, and psychologic impairments have been described, including reduced IQ, learning disabilities, retarded psychomotor development, and, in more severe cases, blindness, psychoses, seizures, and coma. Lead toxicity in the mother may be the cause of impairment of prenatal brain development. The anatomic changes underlying the more subtle functional deficits are ill defined, but some of the defects may be permanent. At the more severe end of the spectrum are brain edema, demyelination of the cerebral and cerebellar white matter, and necrosis of cortical neurons accompanied by diffuse astrocytic proliferation. In adults, the CNS is less often affected, but frequently a **peripheral demyelinating neuropathy** appears, typically involving motor neurons innervating the most commonly used muscles. Thus, the extensor muscles of the wrist and fingers are often the first to be affected, followed by paralysis of the peroneal muscles (**wristdrop** and **footdrop**).

The **GI tract** also is a locus for major clinical manifestations. Lead "colic" is characterized by extremely severe, poorly localized abdominal pain.

The **kidneys** may develop proximal tubular damage with intranuclear lead inclusions. Chronic renal damage leads eventually to interstitial fibrosis and possibly renal failure and findings suggestive of gout ("saturnine gout"). Other features of lead poisoning are shown in Figure 7–4.

### *Mercury*

Humans have used mercury in many ways throughout history, including as a pigment in cave paintings, a cosmetic, a remedy for syphilis, and a component of diuretics. Poisoning from inhalation of mercury vapors has long been recognized and is associated with tremor, gingivitis, and bizarre behavior, such as that of the "Mad Hatter" in Lewis Carroll's *Alice in Wonderland* (mercury formerly was used in hat-making).

Today, the main sources of exposure to mercury are contaminated fish and dental amalgams, which release mercury vapors. In some areas of the world, mercury used in gold mining has contaminated rivers and streams. Inorganic mercury from the natural degassing of the earth's crust or from industrial contamination is converted to organic compounds such as methyl mercury by bacteria. Methyl mercury enters the food chain, and in carnivorous fish such as swordfish, shark, and bluefish, mercury levels may be a million times higher than in the surrounding water. The consumption of contaminated fish from the release of methyl mercury in Minamata Bay and the Agano River in Japan, and the consumption of bread containing grain treated with a methyl mercury–based fungicide in Iraq, caused widespread morbidity and many deaths.

The medical disorders associated with the Minamata episode became known as "*Minamata disease*" and include cerebral palsy, deafness, blindness, and major CNS defects in children exposed in utero. *The developing brain is extremely sensitive to methyl mercury*; for this reason, the Centers for Disease Control and Prevention (CDC) in the United States has recommended that pregnant women avoid the consumption of fish known to contain mercury. There has been much publicity about a possible relationship between thimerosal (a compound that contains ethyl mercury, used until recently as a preservative in some vaccines) and the development of autism, but several large studies have failed to detect any association.

### *Arsenic*

Arsenic was the favorite poison in Renaissance Italy, and this application had some skilled practitioners among the Borgias and Medicis. Deliberate poisoning by arsenic is exceedingly rare today, but exposure to arsenic is an important health problem in many areas of the world. Arsenic is found naturally in soil and water and is used in wood preservatives, herbicides, and other agricultural products. It may be released into the environment by the mining and smelting industries. Large concentrations of inorganic arsenic are present in ground water in countries such as Bangladesh, Chile, and China. As many as 20 million people in Bangladesh drink water contaminated by arsenic, constituting one of the largest environmental cancer risks yet identified.

The most toxic forms of arsenic are the trivalent compounds arsenic trioxide, sodium arsenite, and arsenic trichloride. If ingested in large quantities, arsenic causes acute toxicity manifesting as severe gastrointestinal, cardiovascular, and central nervous system disturbances, often progressing to death. These effects may be attributed to the interference with mitochondrial oxidative

phosphorylation. Chronic exposure to arsenic causes hyperpigmentation and hyperkeratosis of the skin, which may be followed by the development of basal and squamous cell carcinomas (but not melanomas). Arsenic-induced skin tumors differ from those induced by sunlight by appearing on palms and soles, and by occurring as multiple lesions. Arsenic exposure also is associated with an increased risk of lung carcinoma. The mechanisms of arsenic carcinogenesis in skin and lung are uncertain.

### *Cadmium*

In contrast with the metals already discussed, cadmium is a relatively modern toxic agent. It is used mainly in nickel-cadmium batteries, which generally are disposed of as household waste. It can contaminate soil and plants directly or through fertilizers and irrigation water. Food is the most important source of exposure for the general population. Excessive cadmium intake can lead to obstructive lung disease and renal toxicity, initially as tubular damage that may progress to end-stage renal disease. Cadmium exposure can also cause skeletal abnormalities associated with calcium loss. Cadmium-contaminated water used to irrigate rice fields in Japan caused a disease in postmenopausal women known as "itai-itai" (ouch-ouch), a combination of osteoporosis and osteomalacia associated with renal disease. A recent survey showed that 5% of persons aged 20 years and older in the U.S. population have urinary cadmium levels that, according to research data, may produce subtle kidney injury and increased calcium loss.

## SUMMARY

### Toxic Effects of Heavy Metals

- Lead, mercury, arsenic, and cadmium are the heavy metals most commonly associated with toxic effects in humans.
- Children absorb more ingested lead than adults; the main source of exposure for children is lead-containing paint.
- Excess lead causes CNS defects in children and peripheral neuropathy in adults. Excess lead competes with calcium in bones and interferes with the remodeling of cartilage; it also causes anemia.
- The major source of exposure to mercury is contaminated fish. The developing brain is highly sensitive to methyl mercury, which accumulates in the brain and blocks ion channels.
- Exposure of the fetus to high levels of mercury in utero may lead to Minamata disease, characterized by cerebral palsy, deafness, and blindness.
- Arsenic is naturally found in soil and water and is a component of some wood preservatives and herbicides. Excess arsenic interferes with mitochondrial oxidative phosphorylation and causes toxic effects in the GI tract, CNS, and cardiovascular system; long-term exposure causes skin lesions and carcinomas.
- Cadmium from nickel-cadmium batteries and chemical fertilizers can contaminate soil. Excess cadmium causes obstructive lung disease and kidney damage.

## Industrial and Agricultural Exposures

More than 10 million occupational injuries occur annually in the United States, and approximately 65,000 people die as a consequence of occupational injuries and illnesses. Industrial exposures to toxic agents are as varied as the industries themselves. They range from merely annoying irritations of respiratory airways by formaldehyde or ammonia fumes to fatal lung cancers arising from exposure to asbestos, arsenic, or uranium mining. Human diseases associated with occupational exposures are listed in Table 7–2. In addition to the toxic metals (which have already been discussed), other important agents that contribute to environmental diseases include the following:

- *Organic solvents* are widely used in huge quantities worldwide. Some, such as *chloroform* and *carbon tetrachloride,* are found in degreasing and dry cleaning agents and paint removers. Acute exposure to high levels of vapors from these agents can cause dizziness and confusion, leading to CNS depression and even coma. Lower levels have toxicity for the liver and kidneys. Occupational exposure of rubber workers to *benzene* and *1,3-butadiene* increases the risk of leukemia. Benzene is oxidized to an epoxide through hepatic CYP2E1, a component of the P-450 enzyme system already mentioned. The epoxide and other metabolites disrupt progenitor cell differentiation in the bone marrow, causing marrow aplasia and acute myeloid leukemia.
- *Polycyclic hydrocarbons* may be released during the combustion of coal and gas, particularly at the high temperatures used in steel foundries, and also are present in tar and soot. (Pott identified soot as the cause of scrotal cancers in chimney sweeps in 1775, as mentioned in Chapter 5.) Polycyclic hydrocarbons are among the most potent carcinogens, and industrial exposures have been implicated in the causation of lung and bladder cancer.
- *Organochlorines* (and halogenated organic compounds in general) are synthetic products that resist degradation and are lipophilic. Important organochlorines used as pesticides are *DDT (dichlorodiphenyltrichloroethane) and its metabolites* and agents such as lindane, aldrin, and dieldrin. Nonpesticide organochlorines include *polychlorinated biphenyls (PCBs) and dioxin* (*TCDD* [2,3,7,8-tetrachlorodibenzo-*p*-dioxin]). DDT was banned in the United States in 1973, but more than half of the population have detectable serum levels of *p,p'*-DDE, a long-lasting DDT metabolite, including those born after the ban on DDT went into effect. PCB and TCDD also are present in the blood of most of the U.S. population. Acute DDT poisoning in humans causes neurologic toxicity. *Most organochlorines are endocrine disruptors* and have antiestrogenic or antiandrogenic activity in laboratory animals, but long-term health effects in humans have not been firmly established.
- *Dioxins and PCBs* can cause skin disorders such as folliculitis and acneiform dermatosis known as *chloracne,* which consists of acne, cyst formation, hyperpigmentation, and hyperkeratosis, generally around the face and behind the ears. It can be accompanied by abnormalities in the liver and CNS. Because PCBs induce the P-450 enzyme system, workers exposed to these substances may show altered drug metabolism. Environmental

**Table 7–2** Human Diseases Associated With Occupational Exposures

| Organ/System | Effect(s) | Toxicant(s) |
|---|---|---|
| Cardiovascular system | Heart disease | Carbon monoxide, lead, solvents, cobalt, cadmium |
| Respiratory system | Nasal cancer | Isopropyl alcohol, wood dust |
| | Lung cancer | Radon, asbestos, silica, bis(chloromethyl)ether, nickel, arsenic, chromium, mustard gas |
| | Chronic obstructive lung disease | Grain dust, coal dust, cadmium |
| | Hypersensitivity | Beryllium, isocyanates |
| | Irritation | Ammonia, sulfur oxides, formaldehyde |
| | Fibrosis | Silica, asbestos, cobalt |
| Nervous system | Peripheral neuropathies | Solvents, acrylamide, methyl chloride, mercury, lead, arsenic, DDT |
| | Ataxic gait | Chlordane, toluene, acrylamide, mercury |
| | Central nervous system depression | Alcohols, ketones, aldehydes, solvents |
| | Cataracts | Ultraviolet radiation |
| Urinary system | Toxicity | Mercury, lead, glycol ethers, solvents |
| | Bladder cancer | Naphthylamines, 4-aminobiphenyl, benzidine, rubber products |
| Reproductive system | Male infertility | Lead, phthalate plasticizers |
| | Female infertility | Cadmium, lead |
| | Teratogenesis | Mercury, polychlorinated biphenyls |
| Hematopoietic system | Leukemia | Benzene, radon, uranium |
| Skin | Folliculitis and acneiform dermatosis | Polychlorinated biphenyls, dioxins, herbicides |
| | Cancer | Ultraviolet radiation |
| Gastrointestinal tract | Liver angiosarcoma | Vinyl chloride |

DDT, dichlorodiphenyltrichloroethane.
Data from Leigh JP, Markowitz SB, Fahs M, et al: Occupational injury and illness in the United States. Estimates of costs, morbidity, and mortality. *Arch Intern Med* 157:1557, 1997; Mitchell FL: Hazardous waste. In Rom WN (ed): *Environmental and Occupational Medicine,* 2nd ed. Boston, Little, Brown, 1992, p 1275; and Levi PE: Classes of toxic chemicals. In Hodgson E, Levi PE (eds): *A Textbook of Modern Toxicology.* Stamford, CT, Appleton & Lange, 1997, p 229.

disasters in Japan and China in the late 1960s caused by the consumption of rice oil contaminated by PCBs during its production poisoned about 2000 people in each episode. The primary manifestations of the disease (*yusho* in Japan, *yu-cheng* in China) were chloracne and hyperpigmentation of the skin and nails.

- *Bisphenol A* (BPA) is used in the synthesis of polycarbonate food and water containers and of epoxy resins that line almost all food bottles and cans; as a result, exposure to BPA is virtually ubiquitous in humans. BPA has long been known as a potential endocrine disruptor. Several large retrospective studies have linked elevated urinary BPA levels to heart disease in adult populations. In addition, infants who drink from BPA-containing containers may be particularly susceptible to its endocrine effects. In 2010, Canada was the first country to list BPA as a toxic substance, and the largest makers of baby bottles and "sippy" cups have stopped using BPA in the manufacturing process. The extent of the human health risks associated with BPA remains uncertain, however, and requires further study.
- Exposure to *vinyl chloride,* used in the synthesis of polyvinyl resins, was found to cause angiosarcoma of the liver, a rare type of liver tumor.
- Inhalation of *mineral dusts* causes chronic, non-neoplastic lung diseases called *pneumoconioses.* This group of disorders includes diseases induced by organic and inorganic particulates as well as chemical fume- and vapor-induced non-neoplastic lung diseases. The most common pneumoconioses are caused by exposures to mineral dust: *coal dust* (in mining of hard coal), *silica* (in sandblasting and stone cutting), *asbestos* (in mining, fabrication, and insulation work), and *beryllium* (in mining and fabrication). Exposure to these agents nearly always occurs in the workplace. The increased risk of cancer as a result of asbestos exposure, however, extends to family members of asbestos workers and to other persons exposed outside the workplace. Pneumoconioses and their pathogenesis are discussed in Chapter 12.

## EFFECTS OF TOBACCO

Tobacco is the most common exogenous cause of human cancers, being responsible for 90% of lung cancers. The main culprit is cigarette smoking, but smokeless tobacco in its various forms (snuff, chewing tobacco) also is harmful to health and is an important cause of oral cancer. Not only does the use of tobacco products create personal risk, but passive tobacco inhalation from the environment ("second-hand smoke") can cause lung cancer in nonsmokers. Cigarette smoking causes, worldwide, more than 4 million deaths annually, mostly from cardiovascular disease, various types of cancers, and chronic respiratory problems. It is expected that there will be 8 million tobacco-related deaths yearly by 2020, the major increase occurring in developing countries. Of people alive today, an estimated 500 million will die from tobacco-related illnesses. In the United States alone, tobacco is responsible for more than 400,000 deaths per year, one third of these attributable to lung cancer.

*Smoking is the most preventable cause of human death.* It reduces overall survival in a dose-dependent fashion. While 80% of nonsmokers are alive at age 70, only about 50% of smokers survive to this age (Fig. 7–6). *Cessation of smoking greatly reduces the risk of death from lung cancer,* and it even has an effect, albeit reduced, on people who stop smoking at age 60. During the period 1998 to 2007 in the

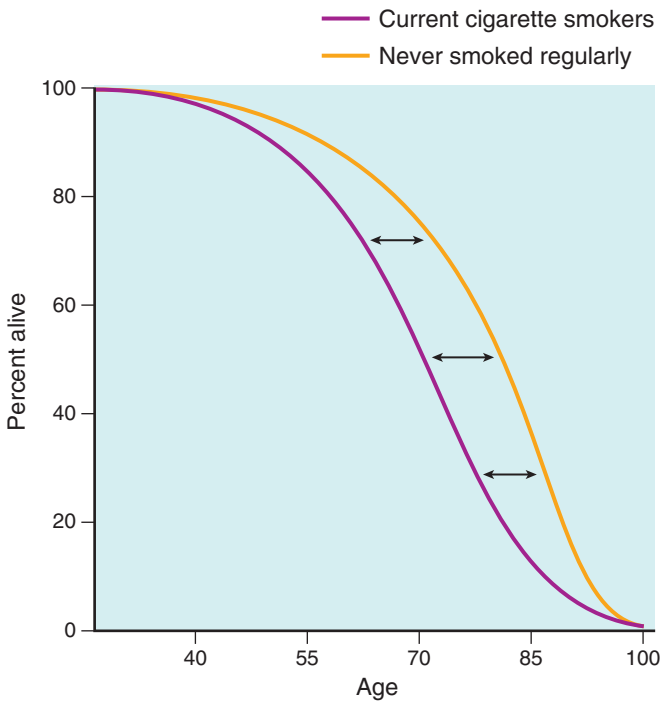


**Figure 7–6** The effects of smoking on survival. The study compared age-specific death rates for current cigarette smokers with that of individuals who never smoke regularly (British Doctors Study). The difference in survival, measured at age 75, between smokers and nonsmokers is 7.5 years.

*(Modified from Stewart BW, Kleihues P [eds]:* World Cancer Report. *Lyon, IARC Press, 2003.)*

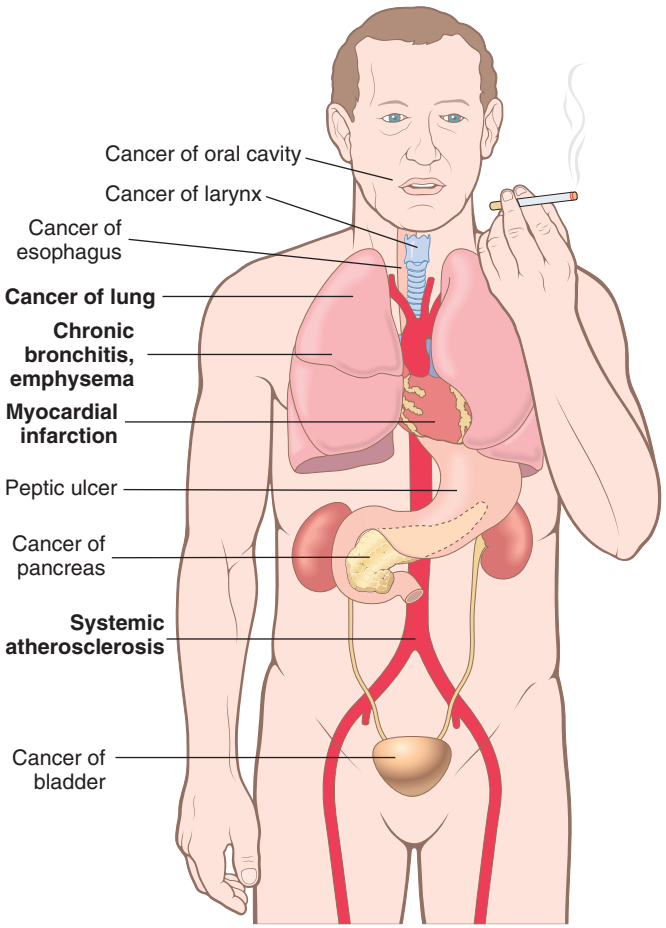


**Figure 7–7** Adverse effects of smoking. The more common are in **boldface.**

United States, the incidence of smoking declined modestly, but approximately 20% of adults remained smokers. More disturbing, smoking in the world's most populous country, China, is becoming the rule rather than the exception. It is estimated that more than 1 million people in China die each year of smoking-related diseases.

Discussed next are some of the agents contained in tobacco and diseases associated with tobacco consumption. Adverse effects of smoking in various organ systems are shown in Figure 7–7.

The number of potentially noxious chemicals in tobacco smoke is vast; Table 7–3 presents only a partial list and includes the type of injury produced by these agents. *Nicotine,* an alkaloid present in tobacco leaves, is not a direct cause of tobacco-related diseases, but it is highly addictive. Nicotine binds to receptors in the brain and, through the release of catecholamines, is responsible for the acute effects of smoking, such as increased heart rate and blood pressure, and increased cardiac contractility and output.

The *most common diseases caused by cigarette smoking involve the lung and include emphysema, chronic bronchitis, and lung cancer,* all discussed in Chapter 12. The mechanisms responsible for some tobacco-induced diseases are outlined next.

- Agents in smoke have a direct irritant effect on the tracheobronchial mucosa, producing *inflammation and increased mucus production (bronchitis).* Cigarette smoke also causes the recruitment of leukocytes to the lung, increasing local elastase production and subsequent injury to lung tissue that leads to *emphysema.*
- *Components of cigarette smoke, particularly polycyclic hydrocarbons and nitrosamines* (Table 7–4)*, are potent carcinogens in animals and probably are involved in the causation of lung carcinomas in humans* (see Chapter 12). The risk of developing lung cancer is related to the intensity of exposure, frequently expressed in terms of "pack years" (e.g., one pack daily for 20 years equals 20 pack years) or in cigarettes smoked per day (Fig. 7–8). Moreover, smoking multiplies the risk of disease associated with

**Table 7–3** Effects of Selected Tobacco Smoke Constituents

| Substance | Effect(s) |
|---|---|
| Tar | Carcinogenesis |
| Polycyclic aromatic hydrocarbons | Carcinogenesis |
| Nicotine | Ganglionic stimulation and depression, tumor promotion |
| Phenol | Tumor promotion; mucosal irritation |
| Benzopyrene | Carcinogenesis |
| Carbon monoxide | Impaired oxygen transport and utilization |
| Formaldehyde | Toxicity to cilia; mucosal irritation |
| Oxides of nitrogen | Toxicity to cilia; mucosal irritation |
| Nitrosamine | Carcinogenesis |

**Table 7–4** Organ-Specific Carcinogens in Tobacco Smoke

| Organ | Carcinogen(s) |
|---|---|
| Lung, larynx | Polycyclic aromatic hydrocarbons<br>4-(Methylnitrosoamino)-1-(3-pyridyl)-1-butanone (NNK)<br>$^{210}$Polonium |
| Esophagus | *N*′-Nitrosonornicotine (NNN) |
| Pancreas | NNK (?) |
| Bladder | 4-Aminobiphenyl, 2-naphthylamine |
| Oral cavity: smoking | Polycyclic aromatic hydrocarbons, NNK, NNN |
| Oral cavity: snuff | NNK, NNN, $^{210}$polonium |

Data from Szczesny LB, Holbrook JH: Cigarette smoking. In Rom WH (ed): *Environmental and Occupational Medicine,* 2nd ed. Boston, Little, Brown, 1992, p 1211.

other carcinogens; well-recognized examples are the 10-fold higher incidence of lung carcinomas in asbestos workers and uranium miners who smoke than that in those who do not, and the interaction between tobacco consumption and alcohol in the risk for oral cancers as described later on.

- *Atherosclerosis and its major complication, myocardial infarction, are strongly linked to cigarette smoking.* The causal mechanisms probably relate to several factors, including increased platelet aggregation, decreased myocardial oxygen supply (because of lung disease coupled with hypoxia related to CO in cigarette smoke) accompanied by increased oxygen demand, and a decreased threshold for ventricular fibrillation. Almost one third of all heart attacks are associated with cigarette smoking. Smoking has a multiplicative effect on risk when combined with hypertension and hypercholesterolemia.
- In addition to lung cancers, *tobacco smoke contributes to the development of cancers of the oral cavity, esophagus, pancreas, and bladder.* Table 7–4 lists organ-specific carcinogens contained in tobacco smoke.
- The combination of tobacco (chewed or smoked) and alcohol consumption has multiplicative effects on the risks of oral, laryngeal, and esophageal cancers. An example of the carcinogenic interaction of these all too common vices is shown below for laryngeal cancer (Fig. 7–9).
- *Maternal smoking increases the risk of spontaneous abortions and preterm births* and results in intrauterine growth retardation (Chapter 6); however, birth weights of infants born to mothers who stopped smoking before pregnancy are normal.
- Exposure to *environmental tobacco smoke (passive smoke inhalation)* is also associated with detrimental effects. It is estimated that the relative risk of lung cancer in nonsmokers exposed to environmental smoke is about 1.3 times that in nonsmokers who are not exposed to smoke. In the United States, approximately 3000 lung cancer deaths in nonsmokers over the age of 35 years can be attributed each year to environmental tobacco smoke. Even more striking is the increased risk of coronary atherosclerosis and fatal myocardial infarction. Studies report that every year, 30,000 to 60,000 cardiac deaths in the United States are associated with passive exposure to smoke. Children living in a household with an adult who smokes have an increased frequency of respiratory illnesses and asthma. Passive smoke inhalation in nonsmokers can be estimated by measuring the blood levels of *cotinine,* a metabolite of nicotine. In the United States, median cotinine levels in nonsmokers have decreased by more than 60% during the last 15 years due to adoption of non-smoking policies in public places. However, passive exposure to tobacco smoke in the home remains a major public health concern, particularly for children. It is clear that the transient pleasure a puff may give comes with a heavy long-term price.

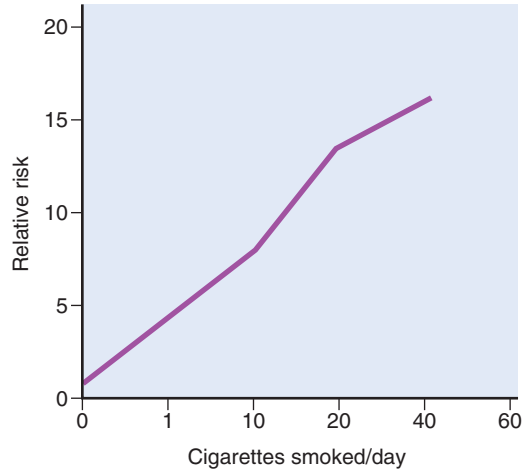


**Figure 7–8** The risk of lung cancer is determined by the number of cigarettes smoked.
*(Data from Stewart BW, Kleihues P [eds]:* World Cancer Report. *Lyon, IARC Press, 2003.)*

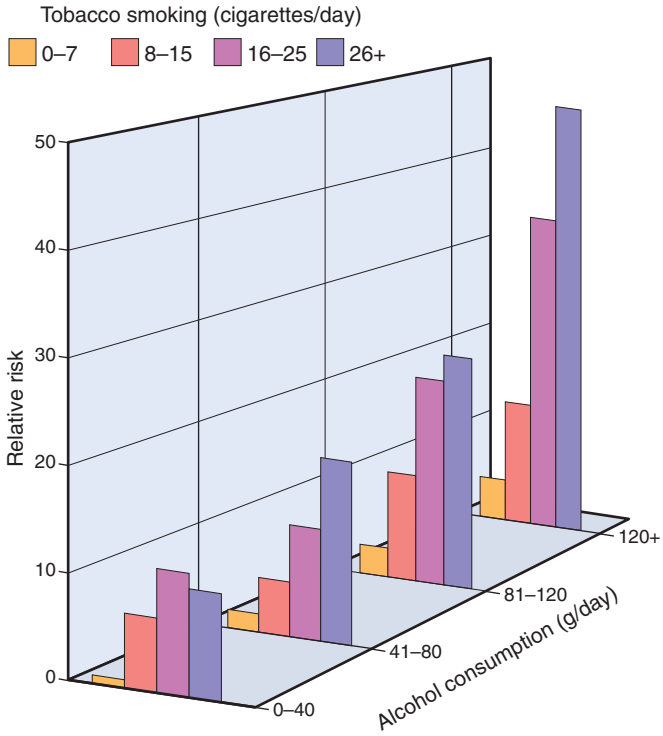


**Figure 7–9** Multiplicative increase in the risk of laryngeal cancer from the interaction between cigarette smoking and alcohol consumption.
*(Data from Stewart BW, Kleihues P [eds]:* World Cancer Report. *Lyon, IARC Press, 2003.)*

## SUMMARY

### Health Effects of Tobacco

- Smoking is the most preventable cause of human death.
- Tobacco smoke contains more than 2000 compounds. Among these are nicotine, which is responsible for tobacco addiction and strong carcinogens—mainly, polycyclic aromatic hydrocarbons, nitrosamines, and aromatic amines.
- Approximately 90% of lung cancers occur in smokers. Smoking is also associated with an increased risk of cancers of the oral cavity, larynx, esophagus, stomach, bladder, and kidney, as well as some forms of leukemia. Cessation of smoking reduces the risk of lung cancer.
- Smokeless tobacco use is an important cause of oral cancers. Tobacco consumption interacts with alcohol in multiplying the risk of oral, laryngeal, and esophageal cancer and increases the risk of lung cancers from occupational exposures to asbestos, uranium, and other agents.
- Tobacco consumption is an important risk factor for development of atherosclerosis and myocardial infarction, peripheral vascular disease, and cerebrovascular disease. In the lungs, in addition to cancer, it predisposes to emphysema, chronic bronchitis, and chronic obstructive disease.
- Maternal smoking increases the risk of abortion, premature birth, and intrauterine growth retardation.

## EFFECTS OF ALCOHOL

Ethanol is consumed, at least partly, for its mood-altering properties, but when used in moderation its effects are socially acceptable and not injurious. When excessive amounts are used, alcohol can cause marked physical and psychologic damage. Here we describe the lesions that are directly associated with the abuse of alcohol.

Despite all the attention given to illegal drugs, alcohol abuse is a more widespread hazard and claims many more lives. Fifty percent of adults in the Western world drink alcohol, and approximately 5% to 10% have chronic alcoholism. It is estimated that *there are more than 10 million chronic alcoholics in the United States and that alcohol consumption is responsible for more than 100,000 deaths annually.* Almost 50% of these deaths result from accidents caused by drunken driving and alcohol-related homicides and suicides, and about 25% are a consequence of cirrhosis of the liver.

After consumption, ethanol is absorbed unaltered in the stomach and small intestine and then distributes to all of the tissues and fluids of the body in direct proportion to the blood level. Less than 10% is excreted unchanged in the urine, sweat, and breath. The amount exhaled is proportional to the blood level and forms the basis for the breath test used by law enforcement agencies. A concentration of 80 mg/dL in the blood constitutes the legal definition of drunk driving in most states. For an average individual, this alcohol concentration may be reached after consumption of about eight bottles of beer (6 to 16 g of alcohol per bottle), 12 ounces of wine (9 to 18 g of alcohol per glass), or 6 ounces of whiskey (about 11 g of alcohol per ounce). Drowsiness occurs at 200 mg/dL, stupor at 300 mg/dL, and coma, with possible respiratory arrest, at higher levels. The rate of metabolism affects the blood alcohol level. Persons with chronic alcoholism can tolerate levels as high as 700 mg/dL, due in part to accelerated ethanol metabolism caused by a 5- to 10-fold increase in induction of the hepatic cytochrome P-450 system, discussed next.

Most of the alcohol in the blood is metabolized to acetaldehyde in the liver by three enzyme systems: alcohol dehydrogenase, cytochrome P-450 isoenzymes, and catalase (Fig. 7–10). Of these, *the main enzyme involved in alcohol metabolism is alcohol dehydrogenase,* located in the cytosol of hepatocytes. At high blood alcohol levels, however, the microsomal ethanol-oxidizing system also has an important role. This system involves cytochrome P-450 enzymes, particularly the CYP2E1 isoform, located in the smooth ER. Induction of P-450 enzymes by alcohol explains the increased susceptibility of alcoholics to other compounds metabolized by the same enzyme system, which include drugs (acetaminophen, cocaine), anesthetics, carcinogens, and industrial solvents. Of note, however, when alcohol is present in the blood at high concentrations, it competes with other CYP2E1 substrates and may delay the catabolism of other drugs, thereby potentiating their effects. Catalase is of minor importance, being responsible for only about 5% of alcohol metabolism. Acetaldehyde produced by these systems is in turn converted by acetaldehyde dehydrogenase to acetate, which is utilized in the mitochondrial respiratory chain.

Several toxic effects result from ethanol metabolism. Listed here are only the most important of these:

- *Alcohol oxidation by alcohol dehydrogenase causes a decrease in nicotinamide adenine dinucleotide* ($NAD^+$) and an increase in NADH (the reduced form of $NAD^+$). $NAD^+$ is required for fatty acid oxidation in the liver. Its deficiency is a main cause of *fat accumulation* in the liver of alcoholics. The increase in the NADH/$NAD^+$ ratio in alcoholics also causes lactic acidosis.
- Acetaldehyde has many toxic effects and may be responsible for some of the acute effects of alcohol. Acetaldehyde metabolism differs between populations because of genetic variation. Most notably, about 50% of Asians express a defective form of acetaldehyde dehydrogenase. After ingesting alcohol, such persons experience flushing, tachycardia, and hyperventilation owing to the accumulation of acetaldehyde.
- *Metabolism of ethanol in the liver by CYP2E1 produces reactive oxygen species and causes lipid peroxidation of cell membranes.* Nevertheless, the precise mechanisms that account for alcohol-induced cellular injury have not been well defined.
- Alcohol may cause the release of endotoxin (lipopolysaccharide), a product of gram-negative bacteria, from the intestinal flora. Endotoxin stimulates the release of tumor necrosis factor (TNF) and other cytokines from circulating macrophages and from Kupffer cells in the liver, causing cell injury.

The adverse effects of ethanol abuse can be categorized as acute or chronic. *Acute alcoholism* exerts its effects mainly on the CNS but also may induce reversible hepatic and gastric injuries. Even with moderate intake of alcohol,

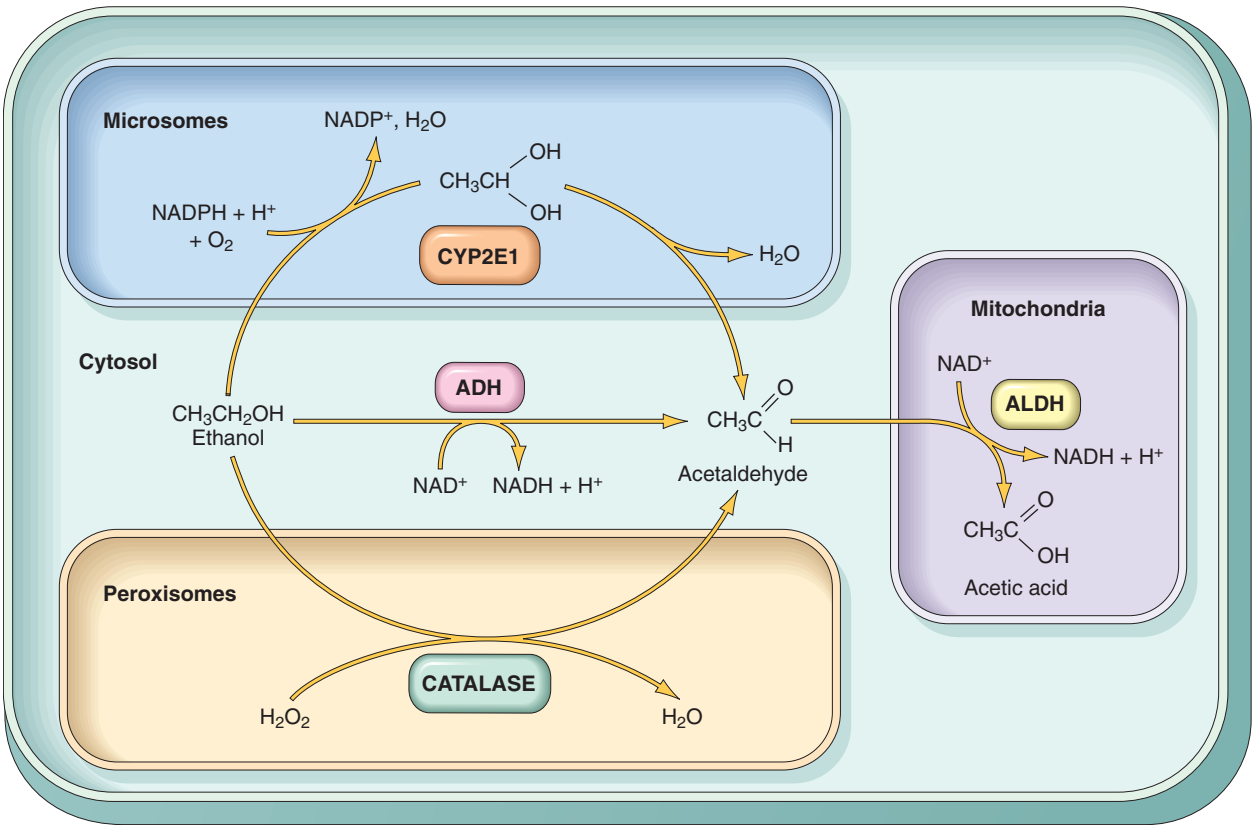


**Figure 7–10** Metabolism of ethanol: oxidation of ethanol to acetaldehyde by three different routes, and the generation of acetic acid. Note that oxidation by alcohol dehydrogenase (ADH) takes place in the cytosol; the cytochrome P-450 system and its CYP2E1 isoform are located in the ER (microsomes), and catalase is located in peroxisomes. Oxidation of acetaldehyde by aldehyde dehydrogenase (ALDH) occurs in mitochondria. *(Data from Parkinson A: Biotransformation of xenobiotics. In Klassen CD [ed]: Casarett and Doull's Toxicology:* The Basic Science of Poisons, *6th ed. New York, McGraw-Hill, 2001, p 133.)*

multiple fat droplets accumulate in the cytoplasm of hepatocytes (*fatty change* or *hepatic steatosis*). Gastric damage occurs in the form of acute *gastritis and ulceration*. In the CNS, alcohol is a depressant, first affecting subcortical structures that modulate cerebral cortical activity. Consequently there is stimulation and disordered cortical, motor, and intellectual behavior. At progressively higher blood levels, cortical neurons and then lower medullary centers are depressed, including those that regulate respiration. Respiratory arrest may follow.

*Chronic alcoholism* affects not only the liver and stomach but virtually all other organs and tissues as well. Chronic alcoholics suffer significant morbidity and have a shortened life span, related principally to damage to the liver, GI tract, CNS, cardiovascular system, and pancreas.

- The *liver* is the main site of chronic injury. In addition to fatty change, mentioned earlier, chronic alcoholism causes alcoholic hepatitis and cirrhosis (described in Chapter 15). Cirrhosis is associated with portal hypertension and an increased risk of hepatocellular carcinoma.
- In the *GI tract,* chronic alcoholism can cause massive bleeding from gastritis, gastric ulcer, or esophageal varices (associated with cirrhosis), which may prove fatal.
- Thiamine deficiency is common in chronic alcoholic patients; the principal lesions resulting from this deficiency are *peripheral neuropathies* and the *Wernicke-Korsakoff syndrome* (see Table 7–9 and Chapter 22). Cerebral atrophy, cerebellar degeneration, and optic neuropathy may also occur.
- Alcohol has diverse effects on the cardiovascular system. Injury to the myocardium may produce dilated congestive cardiomyopathy (*alcoholic cardiomyopathy*), discussed in Chapter 10. Moderate amounts of alcohol (one drink per day) have been reported to increase serum levels of high-density lipoproteins (HDLs) and inhibit platelet aggregation, thus protecting against coronary heart disease. However, heavy consumption, with attendant liver injury, results in decreased levels of HDL, increasing the likelihood of coronary heart disease. Chronic alcoholism also is associated with an increased incidence of hypertension.
- Excess alcohol intake increases the risk of *acute and chronic pancreatitis* (Chapter 16).
- The use of ethanol during pregnancy—reportedly even in low amounts—can cause *fetal alcohol syndrome.* It consists of microcephaly, growth retardation and facial abnormalities in the newborn and reduction in mental functions in older children. It is difficult to establish the amount of alcohol consumption that can cause fetal alcohol syndrome, but consumption during the first trimester of pregnancy is particularly harmful.
- Chronic alcohol consumption is associated with an *increased incidence of cancers* of the oral cavity, esophagus,

liver, and, possibly, breast in females. The mechanisms of the carcinogenic effect are uncertain.
- Ethanol is a substantial source of energy, but is often consumed at the expense of food (empty calories). Chronic alcoholism is thus associated with malnutrition and deficiencies, particularly of the B vitamins.

## SUMMARY

### Alcohol—Metabolism and Health Effects

- Acute alcohol abuse causes drowsiness at blood levels of approximately 200 mg/dL. Stupor and coma develop at higher levels.
- Alcohol is oxidized to acetaldehyde in the liver by alcohol dehydrogenase, by the cytochrome P-450 system, and by catalase, which is of minor importance. Acetaldehyde is converted to acetate in mitochondria and utilized in the respiratory chain.
- Alcohol oxidation by alcohol dehydrogenase depletes NAD, leading to accumulation of fat in the liver and metabolic acidosis.
- The main effects of chronic alcoholism are fatty liver, alcoholic hepatitis, and cirrhosis, which leads to portal hypertension and increases the risk for development of hepatocellular carcinoma.
- Chronic alcoholism can cause bleeding from gastritis and gastric ulcers, peripheral neuropathy associated with thiamine deficiency, and alcoholic cardiomyopathy and increases the risk for development of acute and chronic pancreatitis.
- Chronic alcoholism is a major risk factor for cancers of the oral cavity, larynx, and esophagus. The risk is greatly increased by concurrent smoking or use of smokeless tobacco.

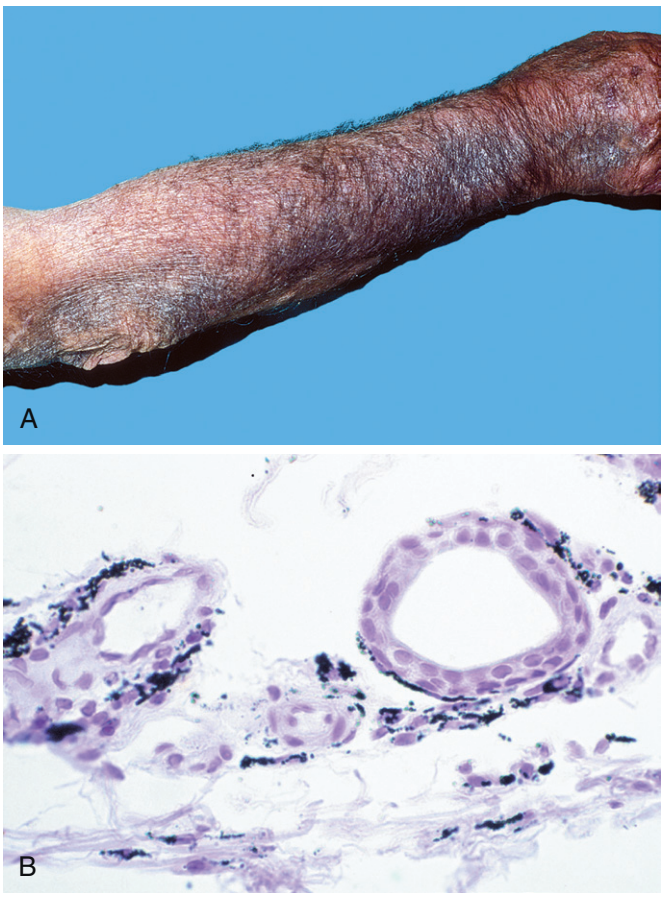


**Figure 7–11** Adverse reaction to minocycline, a long-acting tetracycline derivative. **A,** Diffuse blue-gray pigmentation of the forearm, secondary to minocycline administration. **B,** Deposition of drug metabolite/iron/melanin pigment particles in the dermis.
*(A and B, Courtesy of Dr. Zsolt Argenyi, Department of Pathology, University of Washington, Seattle, Washington.)*

# INJURY BY THERAPEUTIC DRUGS AND DRUGS OF ABUSE

## Injury by Therapeutic Drugs: Adverse Drug Reactions

Adverse drug reactions (ADRs) are untoward effects of drugs that are given in conventional therapeutic settings. These reactions are extremely common in the practice of medicine and are believed to affect 7% to 8% of patients admitted to a hospital. About 10% of such reactions prove fatal. Table 7–5 lists common pathologic findings in ADRs and the drugs most frequently involved. As can be seen, many of the drugs involved in ADRs, such as the antineoplastic agents, are highly potent, and the ADR is a calculated risk for the dosage assumed to achieve the maximum therapeutic effect. Commonly used drugs such as long-acting tetracyclines, which are used to treat diverse conditions, including acne, may produce localized or systemic reactions (Fig. 7–11). Because they are widely used, estrogens and oral contraceptives (OCs) are discussed next in more detail. In addition, acetaminophen and aspirin, which are nonprescription drugs but are important causes of accidental or intentional overdose, merit special comment.

### *Exogenous Estrogens and Oral Contraceptives*

***Exogenous Estrogens.*** Estrogen therapy, once used primarily for distressing menopausal symptoms (e.g., hot flashes), has been widely used in postmenopausal women, with or without added progestins, to prevent or slow the progression of osteoporosis (Chapter 20) and to reduce the likelihood of myocardial infarction. Such therapy is referred to as *hormone replacement therapy* (HRT). In view of the fact that endogenous hyperestrinism increases the risk of endometrial carcinoma and, probably, breast carcinoma, from the outset there has been understandable concern about the use of HRT. The main focus of controversy is the potential benefit of HRT as protection against ischemic myocardial disease. *Recent data have confirmed the adverse effects of HRT on endometrial and breast cancers but do not support the view that HRT offers protection against ischemic heart disease.* Here is a summary of the main adverse effects of HRT.

- Results from randomized control trials show that *HRT with estrogen alone increases the risk of endometrial cancer.*

**Table 7–5** Some Common Adverse Drug Reactions and Their Agents

| Reaction | Major Offenders |
|---|---|
| Blood Dyscrasias* | |
| Granulocytopenia, aplastic anemia, pancytopenia | Antineoplastic agents, immunosuppressives, and chloramphenicol |
| Hemolytic anemia, thrombocytopenia | Penicillin, methyldopa, quinidine |
| Cutaneous | |
| Urticaria, macules, papules, vesicles, petechiae, exfoliative dermatitis, fixed drug eruptions, abnormal pigmentation | Antineoplastic agents, sulfonamides, hydantoins, some antibiotics, and many other agents |
| Cardiac | |
| Arrhythmias | Theophylline, hydantoins |
| Cardiomyopathy | Doxorubicin, daunorubicin |
| Renal | |
| Glomerulonephritis | Penicillamine |
| Acute tubular necrosis | Aminoglycoside antibiotics, cyclosporine, amphotericin B |
| Tubulointerstitial disease with papillary necrosis | Phenacetin, salicylates |
| Pulmonary | |
| Asthma | Salicylates |
| Acute pneumonitis | Nitrofurantoin |
| Interstitial fibrosis | Busulfan, nitrofurantoin, bleomycin |
| Hepatic | |
| Fatty change | Tetracycline |
| Diffuse hepatocellular damage | Halothane, isoniazid, acetaminophen |
| Cholestasis | Chlorpromazine, estrogens, contraceptive agents |
| Systemic | |
| Anaphylaxis | Penicillin |
| Lupus erythematosus syndrome (drug-induced lupus) | Hydralazine, procainamide |
| Central Nervous System | |
| Tinnitus and dizziness | Salicylates |
| Acute dystonic reactions and parkinsonian syndrome | Phenothiazine antipsychotics |
| Respiratory depression | Sedatives |

*Feature in almost half of all drug-related deaths.

Unopposed estrogen therapy increases the risk of *endometrial carcinoma* 3- to 6-fold after 5 years of use and more than 10-fold after 10 years, but the risk is drastically reduced or eliminated when progestins are added to the therapeutic regimen. On the other hand, long-term HRT with estrogens and progestins is associated with an increased risk of *breast cancer.* Of note, these findings led to a decrease in HRT prescriptions from 16 million in 2001 to 6 million in 2006, a drop that was accompanied by an apparent decrease in the number of newly diagnosed breast cancers. It is sobering to note that at 3 years of follow-up after cessation of estrogen-progestin HRT, women receiving these hormones continued to develop breast cancer at an increased rate.

- HRT with estrogen, with or without progestins, increases the risk of *thromboembolism,* including deep vein thrombosis, pulmonary embolism, and stroke, by several-fold. The increase is more pronounced during the first 2 years of treatment and in association with other risk factors such as immobilization or factor V or prothrombin mutations.
- Estrogens and progestins increase blood levels of high-density lipoprotein and decrease levels of low-density lipoprotein. On the basis of retrospective epidemiologic data, it was thought that HRT would be beneficial in protecting against atherosclerosis and ischemic heart disease. However, large well-controlled prospective studies did not demonstrate a protective effect of HRT against myocardial infarction.

***Oral Contraceptives.*** Although OCs have been used for over 35 years, disagreement continues about their safety and adverse effects. They nearly always contain a synthetic estradiol and a variable amount of a progestin ("combination OCs"), but a few preparations contain only progestins. Currently prescribed OCs contain a smaller amount of estrogens (less than 50 μg/day) and clearly have fewer side effects than those reported for earlier formulations. Hence, the results of epidemiologic studies must be interpreted in the context of the dosage. Nevertheless, there is reasonable evidence to support the following conclusions:

- *Breast carcinoma*: The prevailing opinion is that OCs *do not* cause an increase in breast cancer risk.
- *Endometrial cancer and ovarian cancers*: OCs have a protective effect against these tumors.

- *Cervical cancer*: OCs may increase risk of cervical carcinomas in women infected with human papillomavirus, although it is unclear whether the increased risk results from sexual activity.
- *Thromboembolism*: Most studies indicate that OCs, including the newer low-dose (less than 50 μg of estrogen) preparations, are associated with a three- to six-fold increased risk of venous thrombosis and pulmonary thromboembolism resulting from increased hepatic synthesis of coagulation factors. This risk may be even higher with newer "third-generation" OCs that contain synthetic progestins, particularly in women who are carriers of the factor V Leiden mutation. To put this complication into context, however, the risk of thromboembolism associated with OC use is two to six times lower than the risk of thromboembolism associated with pregnancy.
- *Cardiovascular disease*: There is considerable uncertainty about the risk of atherosclerosis and myocardial infarction in users of OCs. It seems that OCs do not increase the risk of coronary artery disease in women younger than 30 years or in older women who are nonsmokers, but the risk does approximately double in women older than 35 years who smoke.
- *Hepatic adenoma*: There is a well-defined association between the use of OCs and this rare benign hepatic tumor, especially in older women who have used OCs for prolonged periods. The tumor appears as a large, solitary, and well-encapsulated mass.

Obviously, the pros and cons of OCs must be viewed in the context of their wide applicability and acceptance as a form of contraception that protects against unwanted pregnancies.

### *Acetaminophen*

At therapeutic doses, acetaminophen, a widely used nonprescription analgesic and antipyretic, is mostly conjugated in the liver with glucuronide or sulfate. About 5% or less is metabolized to NAPQI (*N*-acetyl-*p*-benzoquinoneimine) through the hepatic P-450 system. With very large doses, however, *NAPQI accumulates, leading to centrilobular hepatic necrosis.* The mechanisms of injury produced by NAPQI include (1) covalent binding to hepatic proteins and (2) depletion of reduced glutathione (GSH). The depletion of GSH makes the hepatocytes more susceptible to cell death caused by reactive oxygen species. The window between the usual therapeutic dose (0.5 g) and the toxic dose (15 to 25 g) is large, and the drug ordinarily is very safe. Nevertheless, accidental overdoses occur in children, and suicide attempts using acetaminophen are not uncommon, particularly in the United Kingdom. Toxicity begins with nausea, vomiting, diarrhea, and sometimes shock, followed in a few days by appearance of jaundice. Overdoses of acetaminophen can be treated in early stages by administration of *N*-acetylcysteine, which restores GSH. With serious overdoses, liver failure ensues, and centrilobular necrosis may extend to involve entire lobules; patients often require liver transplantation for survival. Some patients also show evidence of concurrent renal damage.

### *Aspirin (Acetylsalicylic Acid)*

Aspirin overdose may result from accidental ingestion in young children or suicide attempts in adults. The major untoward consequences are metabolic, with few morphologic changes. At first, *respiratory alkalosis develops, followed by a metabolic acidosis* that often proves fatal. Fatal doses may be as little as 2 to 4 gm in children and 10 to 30 gm in adults, but survival has been reported after doses five times larger.

*Chronic aspirin toxicity* (salicylism) may develop in persons who take 3 gm or more daily (the dose used to treat chronic inflammatory conditions). Chronic salicylism is manifested by *headache, dizziness, ringing in the ears (tinnitus), difficulty in hearing, mental confusion, drowsiness, nausea, vomiting, and diarrhea.* The CNS changes may progress to convulsions and coma. The morphologic consequences of chronic salicylism are varied. Most often, there is an acute erosive gastritis (Chapter 14), which may produce overt or covert GI bleeding and lead to gastric ulceration. A bleeding tendency may appear concurrently with chronic toxicity, because aspirin irreversibly inhibits platelet cyclooxygenase and blocks the ability to make thromboxane $A_2$, an activator of platelet aggregation. Petechial hemorrhages may appear in the skin and internal viscera, and bleeding from gastric ulcerations may be exaggerated.

Proprietary analgesic mixtures of aspirin and phenacetin or its active metabolite, acetaminophen, when taken over several years, can cause tubulointerstitial nephritis with renal papillary necrosis. This clinical entity is referred to as *analgesic nephropathy* (Chapter 13).

## Injury by Nontherapeutic Toxic Agents (Drug Abuse)

Drug abuse generally involves the use of mind-altering substances beyond therapeutic or social norms. Drug addiction and overdose are serious public health problems. Common drugs of abuse are listed in Table 7–6. Considered here are cocaine, heroin, and marijuana, with a brief mention of a few other drugs.

### *Cocaine*

In 2008, the National Survey on Drug Use and Health estimated that there were 1.9 million users of cocaine in the United States, of which approximately 15% to 20% were users of "crack" cocaine. Use is highest among adults 18 to 25 years of age, of whom 1.5% reported taking cocaine within the past month. Extracted from the leaves of the coca plant, cocaine usually is prepared as a water-soluble powder, cocaine hydrochloride, but when sold on the street it is liberally diluted with talcum powder, lactose, or other look-alikes. Crystallization of the pure alkaloid from cocaine hydrochloride yields nuggets of crack (so called because of the popping sound it makes when heated). The pharmacologic actions of cocaine and crack are identical, but crack is far more potent. Both forms can be snorted, smoked after mixing with tobacco, ingested, or injected subcutaneously or intravenously.

Cocaine produces a sense of intense euphoria and mental alertness, making it one of the most addictive of all drugs.

**Table 7–6** Common Drugs of Abuse

| Class | Molecular Target | Examples |
|---|---|---|
| Opioid narcotics | Mu opioid receptor (agonist) | Heroin, hydromorphone (Dilaudid)<br>Oxycodone<br>Methadone (Dolophine) |
| Sedative-hypnotics | $GABA_A$ receptor (agonist) | Barbiturates<br>Ethanol<br>Methaqualone ("Quaalude")<br>Glutethimide (Doriden)<br>Ethchlorvynol (Placidyl) |
| Psychomotor stimulants | Dopamine transporter (antagonist)<br>Serotonin receptors (toxicity) | Cocaine<br>Amphetamine<br>3,4-methylenedioxymethamphetamine (MDMA) (i.e., "ecstasy") |
| Phencyclidine-like drugs | NMDA glutamate receptor channel (antagonist) | Phencyclidine (PCP) (i.e., "angel dust")<br>Ketamine |
| Cannabinoids | CB1 cannabinoid receptors (agonist) | Marijuana<br>Hashish |
| Nicotine | Nicotine acetylcholine receptor (agonist) | Tobacco products |
| Hallucinogens | Serotonin $5\text{-}HT_2$ receptors (agonist) | Lysergic acid diethylamide (LSD)<br>Mescaline<br>Psilocybin |

CB1, cannabinoid receptor type 1; GABA, γ-aminobutyric acid; $5\text{-}HT_2$, 5-hydroxytryptamine; NMDA, *N*-methyl-D-aspartate; PCP, 1-(1-phenylcyclohexyl)piperidine.
Data from Hyman SE: A 28-year-old man addicted to cocaine. *JAMA* 286:2586, 2001.

Experimental animals will press a lever more than 1000 times and forgo food and drink to obtain the drug. In cocaine users, although physical dependence seems not to occur, the psychologic dependence is profound. Intense cravings are particularly severe in the first several months after abstinence and can recur for years. Acute overdose produces seizures, cardiac arrhythmias, and respiratory arrest. Following are the important manifestations of cocaine toxicity:

- *Cardiovascular effects.* The most serious physical effects of cocaine relate to its acute action on the cardiovascular system. Cocaine is a sympathomimetic agent (Fig. 7–12), both in the CNS, where it blocks the reuptake of dopamine, and at adrenergic nerve endings, where it blocks the reuptake of both epinephrine and norepinephrine while stimulating the presynaptic release of norepinephrine. The net effect is the accumulation of these neurotransmitters in synapses and excessive stimulation, manifested by *tachycardia, hypertension,* and *peripheral vasoconstriction.* Cocaine also induces *myocardial ischemia,* the basis for which is multifactorial. It causes *coronary artery vasoconstriction* and promotes thrombus formation by facilitating platelet aggregation. Cigarette smoking potentiates cocaine-induced coronary vasospasm. Thus, by increasing myocardial oxygen demand by its sympathomimetic action and, at the same time, reducing coronary blood flow, cocaine often triggers myocardial ischemia, which may lead to myocardial infarction. Cocaine also can precipitate *lethal arrhythmias* by enhanced sympathetic activity as well as by disrupting normal ion ($K^+$, $Ca^{2+}$, $Na^+$) transport in the myocardium. These toxic effects are not necessarily dose-related, and a fatal event may occur in a first-time user with what is a typical mood-altering dose.
- *CNS effects.* The most common CNS findings are hyperpyrexia (thought to be caused by aberrations of the dopaminergic pathways that control body temperature) and seizures.
- *Effects on the fetus.* In pregnant women, cocaine may cause decreased blood flow to the placenta, resulting in fetal hypoxia and spontaneous abortion. Neurologic development may be impaired in the fetuses of pregnant women who are chronic drug users.
- *Chronic cocaine use.* Chronic use may cause (1) perforation of the nasal septum in snorters, (2) decrease in lung diffusing capacity in users who inhale the smoke, and (3) the development of dilated cardiomyopathy.

### Heroin

Heroin is an addictive opioid derived from the poppy plant and is closely related to morphine. Its effects are even more harmful than those of cocaine. Nevertheless, it is estimated that almost 4 million people in the United States have used heroin at least once, and that in 2008 more than 400,000 people used the drug at some time during the year. As sold on the street, it is cut (diluted) with an agent (often talc or quinine); thus, the size of the dose not only is variable but also usually is unknown to the buyer. Heroin along with any contaminating substances usually is self-administered intravenously or subcutaneously. Effects are varied and include euphoria, hallucinations, somnolence, and sedation. Heroin has a wide range of adverse physical effects that can be categorized etiologically according to (1) the pharmacologic action of the agent, (2) reactions to the cutting agents or contaminants, (3) hypersensitivity reactions to the drug or its adulterants, and (4) diseases contracted through sharing of needles. Some of the most important adverse effects of heroin are the following:

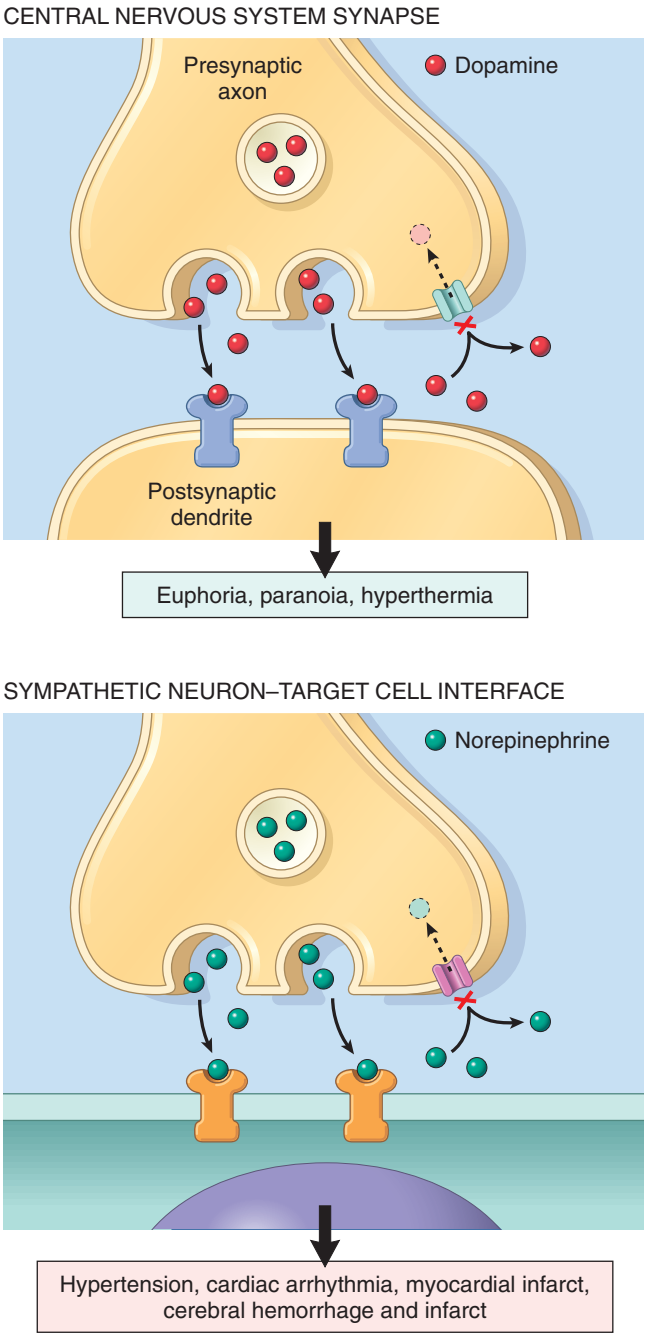


**Figure 7–12** The effect of cocaine on neurotransmission. The drug inhibits reuptake of the neurotransmitters dopamine and norepinephrine in the central and peripheral nervous systems.

- *Sudden death.* Sudden death, usually related to overdose, is an ever-present risk, because drug purity generally is unknown and may range from 2% to 90%. The yearly incidence of sudden death among chronic users in the United States is estimated to be between 1% and 3%. Sudden death sometimes is due to loss of tolerance for the drug, such as after a period of incarceration. The mechanisms of death include profound respiratory depression, arrhythmia and cardiac arrest, and pulmonary edema.
- *Pulmonary disease.* Pulmonary complications include edema, septic embolism, lung abscess, opportunistic infections, and foreign body granulomas from talc and other adulterants. Although granulomas occur principally in the lung, they also are sometimes found in the spleen, liver, and lymph nodes that drain the upper extremities. Examination under polarized light often highlights trapped talc crystals, sometimes enclosed within foreign body giant cells.
- *Infections.* Infectious complications are common. The sites most commonly affected are the skin and subcutaneous tissue, heart valves, liver, and lungs. In a series of addicted patients admitted to the hospital, more than 10% had endocarditis, which often takes a distinctive form involving right-sided heart valves, particularly the tricuspid. Most cases are caused by *Staphylococcus aureus,* but fungi and a multitude of other organisms have also been implicated. Viral hepatitis is the most common infection among addicts and is acquired by the sharing of dirty needles. In the United States, this practice has also led to a very high incidence of human immunodeficiency virus (HIV) infection in intravenous drug abusers.
- *Skin lesions.* Cutaneous lesions probably are the most frequent telltale sign of heroin addiction. Acute changes include abscesses, cellulitis, and ulcerations due to subcutaneous injections. Scarring at injection sites, hyperpigmentation over commonly used veins, and thrombosed veins are the usual sequelae of repeated intravenous inoculations.
- *Renal problems.* Kidney disease is a relatively common hazard. The two forms most frequently encountered are amyloidosis (generally secondary to skin infections) and focal glomerulosclerosis; both induce heavy proteinuria and the nephrotic syndrome.

### *Marijuana*

Marijuana, or "pot," is the most widely used illegal drug. As of 2008, it was estimated that over 100 million people in the United States had used marijuana during their lifetimes, with more than 15 million people (6.1% of the population) admitting use during the previous month. It is made from the leaves of the *Cannabis sativa* plant, which contain the psychoactive substance $\Delta^9$-tetrahydrocannabinol (THC). When marijuana is smoked, about 5% to 10% of the THC content is absorbed. Despite numerous studies, whether the drug has persistent adverse physical and functional effects remains unresolved. Some of the untoward anecdotal effects may be allergic or idiosyncratic reactions or are possibly related to contaminants in the preparations, rather than to marijuana's pharmacologic effects. On the other hand, beneficial effects of THC include its capacity to decrease intraocular pressure in glaucoma and to combat intractable nausea secondary to cancer chemotherapy.

The functional and organic CNS consequences of marijuana have received great scrutiny. Marijuana use is well recognized to distort sensory perception and impair motor coordination, but these acute effects generally clear in 4 to 5 hours. With continued use, these changes may progress to cognitive and psychomotor impairments, such as inability to judge time, speed, and distance. Among adolescents, such impairment often leads to automobile accidents.

Marijuana increases the heart rate and sometimes blood pressure, and it may cause angina in a person with coronary artery disease.

The lungs are affected by chronic marijuana smoking; laryngitis, pharyngitis, bronchitis, cough, hoarseness, and asthma-like symptoms all have been described, along with mild but significant airway obstruction. Smoking a marijuana cigarette, compared with a tobacco cigarette, is associated with a three-fold increase in the amount of tar inhaled and retained in the lungs, as a consequence of deeper inhalation and longer breath holding.

### *Other Illicit Drugs*

The variety of drugs that have been tried by those seeking "new experiences" (highs, lows, "out-of-body experiences") defies belief. These drugs include various stimulants, depressants, analgesics, and hallucinogens. Among these are PCP (1-(1-phenylcyclohexyl) piperidine), or phenylcyclidine, and ketamine (related anesthetic agents); lysergic acid diethylamide (LSD), the most potent hallucinogen known; "ecstasy" (3,4-methylenedioxymethamphetamine [MDMA]); and oxycodone (an opiate). Not much is known about the long-time deleterious effects of any of these agents. Acutely, LSD has unpredictable effects on mood, affect, and thought, sometimes leading to bizarre and dangerous behaviors. Chronic use of ecstasy may deplete the CNS of serotonin, potentially leading to sleep disorders, depression, anxiety, and aggressive behavior.

## SUMMARY

### Drug Injury

- Drug injury may be caused by therapeutic drugs (adverse drug reactions) or non-therapeutic agents (drug abuse).
- Antineoplastic agents, long-acting tetracyclines and other antibiotics, HRT preparations and OCs, acetaminophen, and aspirin are the drugs most frequently involved.
- HRT increases the risk of endometrial and breast cancers and thromboembolism but does not appear to protect against ischemic heart disease. OCs have a protective effect against endometrial and ovarian cancers but increase the risk of thromboembolism and hepatic adenomas.
- Overdose of acetaminophen may cause centrilobular liver necrosis, leading to liver failure. Early treatment with agents that restore GSH levels may limit toxicity. Aspirin blocks the production of thromboxane $A_2$, which may produce gastric ulceration and bleeding.
- The common drugs of abuse include sedative-hypnotics (barbiturates, ethanol), psychomotor stimulants (cocaine, amphetamine, ecstasy), opioid narcotics (heroin, methadone, oxycodone), hallucinogens (LSD, mescaline), and cannabinoids (marijuana, hashish).

# INJURY BY PHYSICAL AGENTS

Injury induced by physical agents is divided into the following categories: mechanical trauma, thermal injury, electrical injury, and injury produced by ionizing radiation. Each type is considered separately.

## Mechanical Trauma

Mechanical forces may inflict a variety of forms of damage. The type of injury depends on the shape of the colliding object, the amount of energy discharged at impact, and the tissues or organs that bear the impact. Bone and head injuries result in unique damage and are discussed elsewhere (Chapter 22). All soft tissues react similarly to mechanical forces, and the patterns of injury can be divided into abrasions, contusions, lacerations, incised wounds, and puncture wounds (Fig. 7–13).

## MORPHOLOGY

An **abrasion** is a wound produced by scraping or rubbing the skin surface, damaging the superficial layer. Typical skin abrasions remove only the epidermal layer. A **contusion,** or bruise, is a wound usually produced by a blunt trauma and is

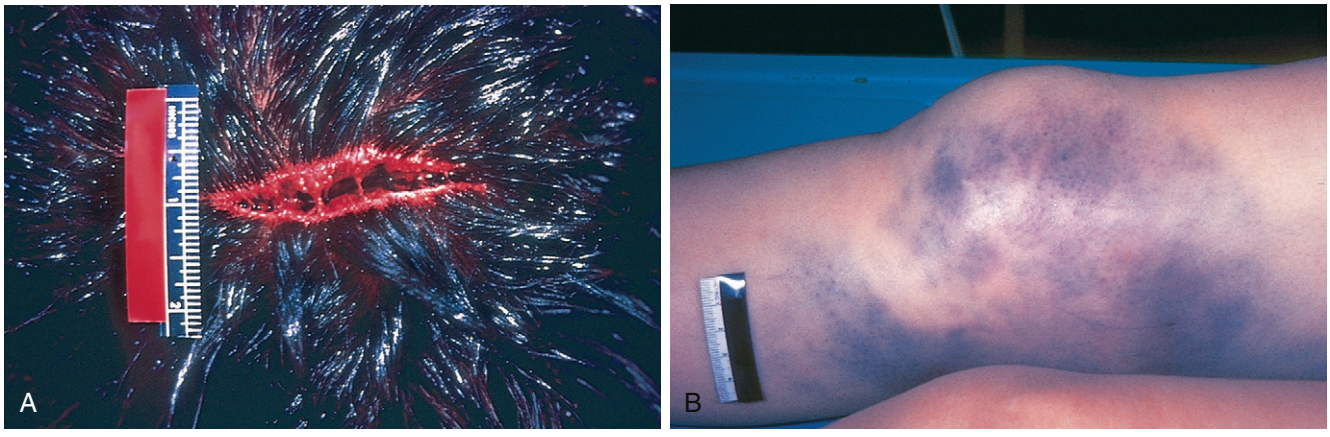


**Figure 7–13 A,** Laceration of the scalp: The bridging strands of fibrous tissues are evident. **B,** Contusion resulting from blunt trauma. The skin is intact, but hemorrhage of subcutaneous vessels has produced extensive discoloration.

*(A, B, From the teaching collection of the Department of Pathology, University of Texas Southwestern Medical School, Dallas, Texas.)*

characterized by damage to vessel and extravasation of blood into tissues. A **laceration** is a tear or disruptive stretching of tissue caused by the application of force by a blunt object. In contrast with an incision, most lacerations have intact bridging blood vessels and jagged, irregular edges. An **incised wound** is one inflicted by a sharp instrument. The bridging blood vessels are severed. A **puncture wound** is typically caused by a long, narrow instrument and is termed **penetrating** when the instrument pierces the tissue and perforating when it traverses a tissue to also create an exit wound. Gunshot wounds are special forms of puncture wounds that demonstrate distinctive features important to the forensic pathologist. For example, a wound from a bullet fired at close range leaves powder burns, whereas one fired from more than 4 or 5 feet away does not.

One of the most common causes of mechanical injury is **vehicular accident.** Injuries typically sustained result from (1) hitting a part of the interior of the vehicle or being hit by objects that enter the passenger compartment during the crash, such as engine parts; (2) being thrown from the vehicle; or (3) being trapped in a burning vehicle. The pattern of injury relates to whether one or all three of these mechanisms are operative. For example, in a head-on collision, a common pattern of injury sustained by a driver who is not wearing a seat belt includes trauma to the head (windshield impact), chest (steering column impact), and knees (dashboard impact). Common chest injuries stemming from such accidents include sternal and rib fractures, heart contusions, aortic lacerations, and (less commonly) lacerations of the spleen and liver. Thus, in caring for an automobile injury victim, it is essential to recognize that internal wounds often accompany superficial abrasions, contusions, and lacerations. Indeed, in many cases, external evidence of serious internal damage is completely absent.

## Thermal Injury

Both excess heat and excess cold are important causes of injury. Burns are all too common and are discussed first; a brief discussion of hyperthermia and hypothermia follows.

### *Thermal Burns*

In the United States, burns cause 5000 deaths per year and result in the hospitalization of more than 10 times that many persons. Many victims are children, in whom the cause of injury often is scalding by hot liquids. Fortunately, since the 1970s marked decreases have been seen in both mortality rates and the length of hospitalizations. These improvements have been achieved through better understanding of the systemic effects of massive burns and discovery of better ways to prevent wound infection and facilitate the healing of skin surfaces.

The clinical severity of burns depends on the following important variables:

- Depth
- Percentage of body surface involved
- Whether internal injuries from inhalation of hot and toxic fumes are present
- Promptness and efficacy of therapy, especially fluid and electrolyte management and prevention or control of wound infections

A *full-thickness* burn produces total destruction of the epidermis and dermis, including the dermal appendages that harbor cells needed for epithelial regeneration. Both third- and fourth-degree burns are in this category. In *partial-thickness* burns, at least the deeper portions of the dermal appendages are spared. Partial-thickness burns include first-degree burns (epithelial involvement only) and second-degree burns (involving both epidermis and superficial dermis).

### MORPHOLOGY

On gross inspection, **full-thickness burns** are white or charred, dry, and anesthetic (as a result of destruction of nerve endings), whereas **partial-thickness burns,** depending on the depth, are pink or mottled, blistered and painful. Histologic examination of devitalized tissue reveals coagulative necrosis adjacent to vital tissue, which quickly accumulates inflammatory cells and marked exudation.

Despite continuous improvement in therapy, any burn exceeding 50% of the total body surface, whether superficial or deep, is grave and potentially fatal. With burns of more than 20% of the body surface, there is a rapid shift of body fluids into the interstitial compartments, both at the burn site and systemically, which can result in **hypovolemic shock** (Chapter 3). Because protein from the blood is lost into interstitial tissue, generalized edema, including **pulmonary edema,** may become severe.

Another important consideration is the degree of injury to the airways and lungs. **Inhalation injury** is frequent in persons trapped in burning buildings and may result from the direct effect of heat on the mouth, nose, and upper airways or from the inhalation of heated air and gases in the smoke. Water-soluble gases, such as chlorine, sulfur oxides, and ammonia, may react with water to form acids or alkalis, particularly in the upper airways, resulting in inflammation and swelling, which may lead to partial or complete airway obstruction. Lipid-soluble gases, such as nitrous oxide and products of burning plastics, are more likely to reach deeper airways, producing pneumonitis. Unlike in shock, which develops within hours, pulmonary manifestations may not develop for 24 to 48 hours.

**Organ system failure** resulting from **sepsis** continues to be the leading cause of death in burned patients. The burn site is ideal for growth of microorganisms; the serum and debris provide nutrients, and the burn injury compromises blood flow, blocking effective inflammatory responses. The most common offender is the opportunist *Pseudomonas aeruginosa,* but antibiotic-resistant strains of other common hospital-acquired bacteria, such as *S. aureus,* and fungi, particularly *Candida* spp., also may be involved. Furthermore, cellular and humoral defenses against infections are compromised, and both lymphocyte and phagocyte functions are impaired. Direct bacteremic spread and release of toxic substances such as endotoxin from the local site have dire consequences. **Pneumonia** or **septic shock** accompanied by **renal failure** and/or the acute respiratory distress

syndrome (ARDS) (Chapter 12) are the most common serious sequelae.

Another very important pathophysiologic effect of burns is the development of a hypermetabolic state, with excess heat loss and an increased need for nutritional support. It is estimated that when more than 40% of the body surface is burned, the resting metabolic rate may approach twice normal.

### *Hyperthermia*

Prolonged exposure to elevated ambient temperatures can result in heat cramps, heat exhaustion, or heat stroke.

- *Heat cramps* result from loss of electrolytes through sweating. Cramping of voluntary muscles, usually in association with vigorous exercise, is the hallmark sign. Heat-dissipating mechanisms are able to maintain normal core body temperature.
- *Heat exhaustion* is probably the most common hyperthermic syndrome. Its onset is sudden, with prostration and collapse, and it results from a failure of the cardiovascular system to compensate for hypovolemia, secondary to water depletion. After a period of collapse, which is usually brief, equilibrium is spontaneously reestablished.
- *Heat stroke* is associated with high ambient temperatures and high humidity. Thermoregulatory mechanisms fail, sweating ceases, and core body temperature rises. In the clinical setting, a rectal temperature of 106°F or higher is considered a grave prognostic sign, and the mortality rate for such patients exceeds 50%. The underlying mechanism is marked generalized peripheral vasodilation with peripheral pooling of blood and a decreased effective circulating blood volume. Necrosis of the muscles and myocardium may occur. Arrhythmias, disseminated intravascular coagulation, and other systemic effects are common. Elderly people, persons with cardiovascular disease, and otherwise healthy people undergoing physical stress (such as young athletes and military recruits) are prime candidates for heat stroke.
- *Malignant hyperthermia,* although similar sounding, is not caused by exposure to high temperature. It is a genetic condition resulting from mutations in genes such as RYR1 that control calcium levels in skeletal muscle cells. In affected individuals, exposure to certain anesthetics during surgery may trigger a rapid rise in calcium levels in skeletal muscle, which in turn leads to muscle rigidity and increased heat production. The resulting hyperthermia has a mortality rate of approximately 80% if untreated, but this falls to less than 5% if the condition is recognized and muscle relaxants are given promptly.

### *Hypothermia*

Prolonged exposure to low ambient temperature leads to hypothermia. The condition is seen all too frequently in homeless alcoholics, in whom wet or inadequate clothing and dilation of superficial blood vessels occurring as a result of the ingestion of alcohol hasten the lowering of body temperature. At about 90°F, loss of consciousness occurs, followed by bradycardia and atrial fibrillation at lower core temperatures.

Chilling or freezing of cells and tissues causes injury by two mechanisms:

- *Direct effects* probably are mediated by physical disruptions within cells and high salt concentrations incident to the crystallization of the intra- and extracellular water.
- *Indirect effects* are the result of circulatory changes, which vary depending on the rate and the duration of the temperature drop. Slowly developing, prolonged chilling may induce vasoconstriction and increased permeability, leading to edema. Such changes are typical of "trench foot." Atrophy and fibrosis may follow. Alternatively, with sudden sharp drops in temperature, the vasoconstriction and increased viscosity of the blood in the local area may cause ischemic injury and degenerative changes in peripheral nerves. In this situation, the vascular injury and increased permeability with exudation only become evident with rewarming. If the period of ischemia is prolonged, hypoxic changes and infarction of the affected tissues (e.g., gangrene of toes or feet) may result.

## Electrical Injury

Electrical injuries, which may be fatal, can arise from low-voltage currents (i.e., in the home and workplace) or from high-voltage currents carried in power lines or by lightning. Injuries are of two types: (1) burns and (2) ventricular fibrillation or cardiac and respiratory center failure resulting from disruption of normal electrical impulses. The type of injury and the severity and extent of burning depend on the amperage of the electric current and its path within the body.

Voltage in the household and the workplace (120 or 220 V) is high enough that with low resistance at the site of contact (as when the skin is wet), sufficient current can pass through the body to cause serious injury, including ventricular fibrillation. If current flow continues long enough, it generates enough heat to produce burns at the site of entry and exit as well as in internal organs. An important characteristic of alternating current, the type available in most homes, is that it induces tetanic muscle spasm, so that when a live wire or switch is grasped, irreversible clutching is likely to occur, prolonging the period of current flow. This results in a greater likelihood of extensive electrical burns and, in some cases, spasm of the chest wall muscles, producing death from asphyxia. Currents generated from high-voltage sources cause similar damage; however, because of the large current flows generated, these injuries are more likely to produce paralysis of medullary centers and extensive burns. Lightning is a classic cause of high-voltage electrical injury.

## Injury Produced by Ionizing Radiation

*Radiation* is energy that travels in the form of waves or high-speed particles. Radiation has a wide range of energies that span the electromagnetic spectrum; it can be divided into nonionizing and ionizing radiation. The energy of nonionizing radiation, such as ultraviolet (UV)

and infrared light, microwaves, and sound waves, can move atoms in a molecule or cause them to vibrate but is not sufficient to displace electrons from atoms. By contrast, *ionizing radiation has sufficient energy to remove tightly bound electrons.* Collision of these free electrons with other atoms releases additional electrons, in a reaction cascade referred to as *ionization.* The main sources of ionizing radiation are (1) *x-rays* and *gamma rays,* which are electromagnetic waves of very high frequencies, and (2) high-energy neutrons, *alpha particles* (composed of two protons and two neutrons), and *beta particles,* which are essentially electrons. About 18% of the total dose of ionizing radiation received by the U.S. population is related to health care, originating for the most part in use of medical devices and radioisotopes.

Ionizing radiation is indispensable in medical practice, but this application constitutes a two-edged sword. Radiation in this form is used in the treatment of cancer, in diagnostic imaging, and as therapeutic or diagnostic radioisotopes. However, it also is *mutagenic, carcinogenic, and teratogenic*. The following terms are used to express exposure, absorption, and dose of ionizing radiation:

- *Curie* (Ci) represents the disintegrations per second of a spontaneously disintegrating radionuclide (radioisotope). One Ci is equal to $3.7 \times 10^{10}$ disintegrations per second.
- *Gray* (Gy) is a unit that expresses the energy absorbed by a target tissue. It corresponds to the absorption of $10^4$ ergs per gram of tissue. A centigray (cGy), which is the absorption of 100 ergs per gram of tissue, is equivalent to the exposure of tissue to 100 rads (R) ("*r*adiation *a*bsorbed *d*ose"). The cGy nomenclature has now replaced the rad in medical parlance.
- *Sievert* (Sv) is a unit of equivalent dose that depends on the biologic rather than the physical effects of radiation (it replaced a unit called the rem). For the same absorbed dose, various types of radiation differ in the extent of damage they produce. The equivalent dose controls for this variation and provides a uniform measuring unit. *The equivalent dose (expressed in sieverts) corresponds to the absorbed dose (expressed in grays) multiplied by the relative biologic effectiveness of the radiation.* The relative biologic effectiveness depends on the type of radiation, the type and volume of the exposed tissue, and the duration of the exposure, as well as other biologic factors (discussed next). The effective dose of x-rays, computed tomography (CT), and other imaging and nuclear medicine procedures are commonly expressed in millisieverts (mSv).

In addition to the physical properties of the radiation, its biologic effects depend heavily on the following variables:

- *Rate of delivery.* The rate of delivery significantly modifies the biologic effect. Although the effect of radiant energy is cumulative, delivery in divided doses may allow cells to repair some of the damage in the intervals. Thus, fractional doses of radiant energy have a cumulative effect only to the extent that repair during the intervals is incomplete. Radiotherapy of tumors exploits the capability of normal cells to repair themselves and recover more rapidly than tumor cells.
- *Field size.* The size of the field exposed to radiation has a great influence on its consequences. The body can sustain relatively high doses of radiation when they are delivered to small, carefully shielded fields, whereas smaller doses delivered to larger fields may be lethal.
- *Cell proliferation.* Because ionizing radiation damages DNA, rapidly dividing cells are more vulnerable to injury than are quiescent cells. Except at extremely high doses that impair DNA transcription, DNA damage is compatible with survival in nondividing cells, such as neurons and muscle cells. However, in dividing cells, chromosome abnormalities and other types of mutations are recognized by cell cycle checkpoint mechanisms, which lead to growth arrest and apoptosis. Understandably, therefore, *tissues with a high rate of cell turnover, such as gonads, bone marrow, lymphoid tissue, and the mucosa of the GI tract, are extremely vulnerable to radiation,* and the injury is manifested early after exposure.
- *Hypoxia.* The production of reactive oxygen species by the radiolysis of water is the most important mechanism of DNA damage by ionizing radiation. Tissue hypoxia, such as may exist in the center of rapidly growing poorly vascularized tumors, may thus reduce the extent of damage and the effectiveness of radiotherapy directed against tumors.
- *Vascular damage.* Damage to endothelial cells, which are moderately sensitive to radiation, may cause narrowing or occlusion of blood vessels, leading to impaired healing, fibrosis, and chronic ischemic atrophy. These changes may appear months or years after exposure. Despite the low sensitivity of brain cells to radiation, vascular damage after irradiation can lead to late manifestations of radiation injury in this tissue.

### DNA Damage and Carcinogenesis

The most important cellular target of ionizing radiation is DNA. Damage to DNA caused by ionizing radiation that is not precisely repaired leads to mutations, which can manifest years or decades later as cancer. Ionizing radiation can cause many types of damage in DNA, including base damage, single- and double-strand breaks, and cross-links between DNA and protein (Fig. 7–14). In surviving cells, simple defects may be reparable by various enzyme repair systems contained in mammalian cells (see Chapter 5). These repair systems are linked to cell cycle regulation through proteins such as ATM (ataxia-telangiectasia mutated) that initiate signal transduction after the damage, and p53, which can transiently slow down the cell cycle to allow for DNA repair or trigger apoptosis of cells that are irreparable. However, double-strand breaks may persist without repair, or the repair of lesions may be imprecise (error-prone), creating mutations. If cell cycle checkpoints are not functioning (for instance, because of a mutation in *P53*), cells with abnormal and unstable genomes survive and may expand as abnormal clones to eventually form tumors.

### Fibrosis

A common consequence of cancer radiotherapy is the development of fibrosis in the irradiated field (Fig. 7–15). Fibrosis may occur weeks or months after irradiation,

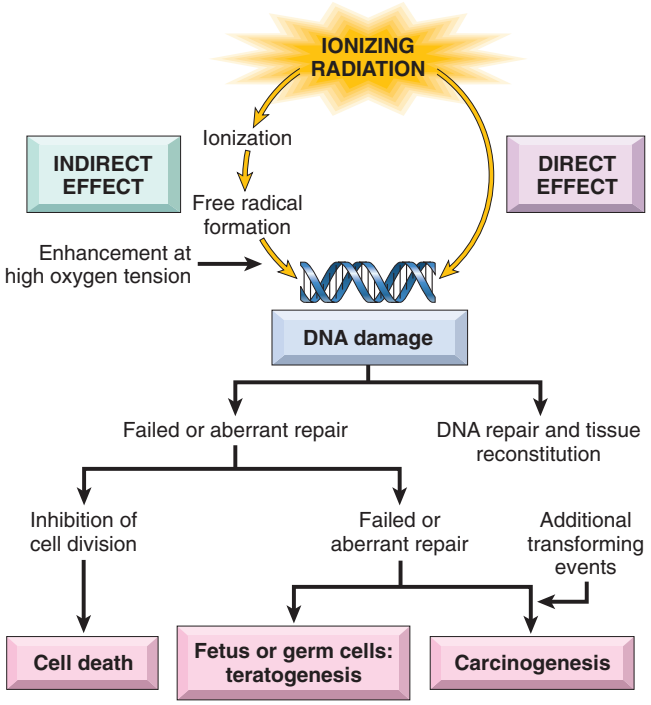


**Figure 7–14** Effects of ionizing radiation on DNA and their consequences. The effects on DNA can be direct or, most important, indirect, through free radical formation.

leading to the replacement of dead parenchymal cells by connective tissue and the formation of scars and adhesions (see Chapter 2). As already mentioned, ionizing radiation causes vascular damage and consequent tissue ischemia. Vascular damage, the killing of tissue stem cells by ionizing radiation, and the release of cytokines and chemokines that promote an inflammatory reaction and fibroblast activation are the main contributors to the development of radiation-induced fibrosis.

## MORPHOLOGY

Cells surviving radiant energy damage show a wide range of structural **changes in chromosomes,** including deletions, breaks, translocations, and fragmentation. The mitotic spindle often becomes disorderly, and polyploidy and aneuploidy may be encountered. **Nuclear swelling** and condensation and clumping of chromatin may appear; breaks in the nuclear membrane also may be noted. **Apoptosis** may occur. Cells with abnormal nuclear morphology may be produced and persist for years, including giant cells with pleomorphic nuclei or more than one nucleus. At extremely high dose levels of radiant energy, features that foretell impending cell death, such as nuclear pyknosis, appear quickly.

In addition to affecting DNA and nuclei, radiant energy may induce a variety of **cytoplasmic changes,** including cytoplasmic swelling, mitochondrial distortion, and degeneration of the ER. Plasma membrane breaks and focal defects may appear. The histologic constellation of cellular pleomorphism, giant cell formation, changes in nuclei, and mitotic figures creates a more than passing similarity between radiation-injured cells and cancer cells, a problem that plagues the pathologist when evaluating post-irradiation tissues for the possible persistence of tumor cells.

At the light microscopic level, vascular changes and interstitial fibrosis are prominent in irradiated tissues (Fig. 7–15). During the immediate post-irradiation period, vessels may show only dilation. Later, or with higher doses, a variety of degenerative changes appear, including endothelial cell swelling and vacuolation, or even dissolution with total necrosis of the walls of small vessels such as capillaries and venules.

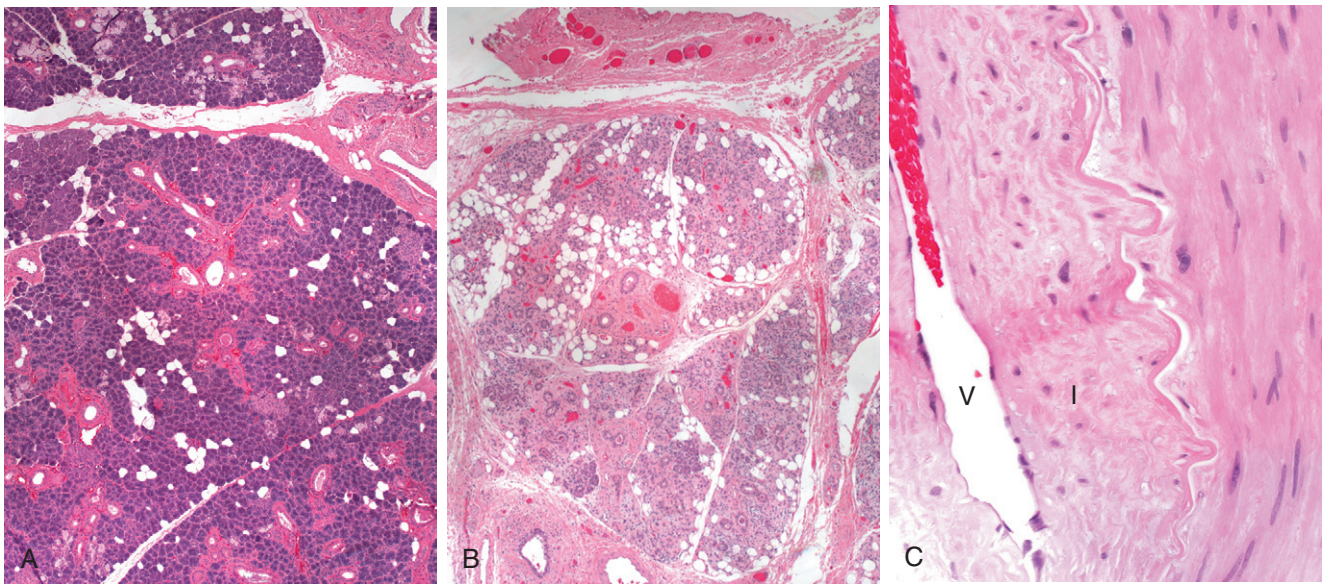


**Figure 7–15** Vascular changes and fibrosis of salivary glands produced by radiation therapy of the neck region. **A,** Normal salivary gland; **B,** fibrosis caused by radiation; **C,** fibrosis and vascular changes consisting of fibrointimal thickening and arteriolar sclerosis. V, vessel lumen; I, thickened intima.

*(A–C, Courtesy of Dr. Melissa Upton, Department of Pathology, University of Washington, Seattle, Washington.)*

Affected vessels may rupture or undergo thrombosis. Still later, endothelial cell proliferation and collagenous hyalinization with thickening of the media layer are seen in irradiated vessels, resulting in marked narrowing or even obliteration of the vascular lumina. At this time, an increase in interstitial collagen in the irradiated field, leading to scarring and contractions, usually becomes evident.

### *Effects on Organ Systems*

Figure 7–16 depicts the main consequences of radiation injury. As already mentioned, *the most sensitive organs and tissues are the gonads, the hematopoietic and lymphoid systems, and the lining of the GI tract.* Estimated threshold doses for the effects of acute exposure to radiation in various organs are shown in Table 7–7. The changes in the hematopoietic and lymphoid systems, along with cancers induced by environmental or occupational exposure to ionizing radiation, are summarized as follows:

- *Hematopoietic and lymphoid systems.* The hematopoietic and lymphoid systems are extremely susceptible to radiation injury and deserve special mention. With high dose levels and large exposure fields, severe lymphopenia may appear within hours of irradiation, along with shrinkage of the lymph nodes and spleen. Radiation directly destroys lymphocytes, both in the circulating blood and in tissues (nodes, spleen, thymus, gut). With sublethal doses of radiation, regeneration from viable progenitors is prompt, leading to restoration of a normal lymphocyte count in the blood within weeks to months. The circulating *granulocyte count* may first rise but begins to fall toward the end of the first week. Levels near zero may be reached during the second week. If the patient survives, recovery of the normal granulocyte count may require 2 to 3 months. *Platelets* are affected as well, with the nadir of the count occurring somewhat later than that for granulocytes; recovery is similarly delayed. *Hematopoietic cells in the bone marrow,* including red cell precursors, also are quite sensitive to radiant energy. Red cells are radioresistant, but red cell progenitors are not; as a result, anemia appears after 2 to 3 weeks and may persist for months.
- *Environmental exposure and cancer development.* Any cell capable of division that has sustained mutations has the potential to become cancerous. Thus, an increased incidence of neoplasms may occur in any organ after exposure to ionizing radiation. The level of radiation required to increase the risk of cancer development is difficult to determine, but there is little doubt that acute or prolonged exposures that result in doses of 100 mSv cause serious consequences, including cancer. This is documented by the increased incidence of leukemias and tumors at various sites (such as thyroid, breast, and lung) in survivors of the atomic bombings of Hiroshima and Nagasaki, the increase in thyroid cancers in survivors of the Chernobyl accident, and the frequent occurrence of "second cancers" in patients, particularly children, treated with radiotherapy for neoplastic

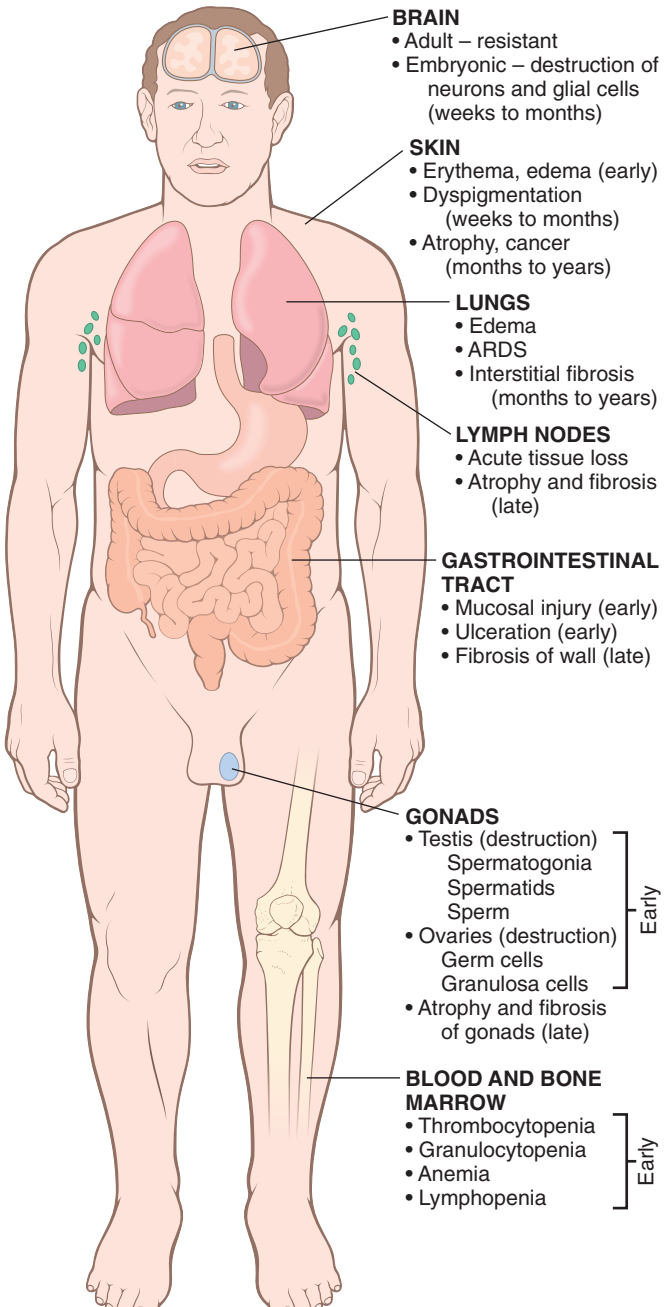


**Figure 7–16** Overview of the major morphologic consequences of radiation injury. Early changes occur in hours to weeks; late changes occur in months to years. ARDS, acute respiratory distress syndrome.

**Table 7–7** Estimated Threshold Doses for Acute Radiation Effects on Specific Organs

| Health Effect | Organ/Structure | Dose (Sv) |
|---|---|---|
| Temporary sterility | Testes | 0.15 |
| Depression of hematopoiesis | Bone marrow | 0.50 |
| Reversible skin effects (e.g., erythema) | Skin | 1.0–2.0 |
| Permanent sterility | Ovaries | 2.5–6.0 |
| Temporary hair loss | Skin | 3.0–5.0 |
| Permanent sterility | Testis | 3.5 |
| Cataract | Lens of eye | 5.0 |

**Table 7–8** Effects of Whole-Body Ionizing Radiation

| | 0–1 Sv | 1–2 Sv | 2–10 Sv | 10–20 Sv | >50 Sv |
|---|---|---|---|---|---|
| Main site of injury | None | Lymphocytes | Bone marrow | Small bowel | Brain |
| Main signs and symptoms | — | Moderate leukopenia | Leukopenia, hemorrhage, epilation, vomiting | Diarrhea, fever, electrolyte imbalance, vomiting | Ataxia, coma, convulsions, vomiting |
| Timing | — | 1 day–1 week | 4–6 weeks | 5–14 days | 1–4 hours |
| Lethality | — | None | Variable (0% to 80%) | 100% | 100% |

disease. It is feared that radiation leaks from the Fukushima nuclear power plant in Japan in the aftermath of the tsunami in 2010 will increase the incidence of cancer in the affected area.

- *Occupational exposure and cancer development. Radon* is a ubiquitous product of the spontaneous decay of uranium. The carcinogenic agents are two radon decay byproducts (polonium-214 and -218, or "radon daughters"), which emit alpha particles and have a short half-life. These particulates are deposited in the lung, and chronic exposure in uranium miners may give rise to lung carcinomas. Risks also are present in those homes in which the levels of radon are very high, comparable to those found in mines. However, there is little or no evidence to suggest that radon may be a contributor to the risk of lung cancer in the average household.

### *Total-Body Irradiation*

Exposure of large areas of the body to even very small doses of radiation may have devastating effects. Dosages below 1 Sv produce minimal or no symptoms. Higher levels of exposure, however, cause health effects known as acute radiation syndromes, which at progressively higher doses involve the hematopoietic system, GI system, and CNS. The syndromes associated with total-body exposure to ionizing radiation are summarized in Table 7–8.

**SUMMARY**

**Radiation Injury**

- Ionizing radiation may injure cells directly or indirectly by generating free radicals from water or molecular oxygen.
- Ionizing radiation damages DNA; therefore, rapidly dividing cells such as germ cells, and those in the bone marrow and GI tract are very sensitive to radiation injury.
- DNA damage that is not adequately repaired may result in mutations that predispose affected cells to neoplastic transformation.
- Ionizing radiation may cause vascular damage and sclerosis, resulting in ischemic necrosis of parenchymal cells and their replacement by fibrous tissue.

## NUTRITIONAL DISEASES

Millions of people in developing nations starve or live on the cruel edge of starvation, while those in the developed world struggle to avoid calories and the attendant obesity or fear that what they eat may contribute to atherosclerosis and hypertension. So both lack of nutrition and overnutrition are major health concerns.

### Malnutrition

A healthy diet provides (1) sufficient energy, in the form of carbohydrates, fats, and proteins, for the body's daily metabolic needs; (2) essential (as well as nonessential) amino acids and fatty acids, used as building blocks for synthesis of structural and functional proteins and lipids; and (3) vitamins and minerals, which function as coenzymes or hormones in vital metabolic pathways or, as in the case of calcium and phosphate, as important structural components. In *primary malnutrition,* one or all of these components are missing from the diet. By contrast, in *secondary, or conditional, malnutrition,* the dietary intake of nutrients is adequate, and malnutrition results from nutrient malabsorption, impaired utilization or storage, excess losses, or increased requirements. The causes of secondary malnutrition can be grouped into three general but overlapping categories: GI diseases, chronic wasting diseases, and acute critical illness.

Malnutrition is widespread and may be gross or subtle. Some common causes of dietary insufficiencies are listed here.

- *Poverty.* Homeless people, elderly persons, and children of the poor often suffer from protein-energy malnutrition (PEM) as well as trace nutrient deficiencies. In poor countries, poverty, together with droughts, crop failure, and livestock deaths, creates the setting for malnourishment of children and adults.
- *Ignorance.* Even the affluent may fail to recognize that infants, adolescents, and pregnant women have increased nutritional needs. Ignorance about the nutritional content of various foods also contributes to malnutrition, as follows: (1) iron deficiency often develops in infants fed exclusively artificial milk diets; (2) polished rice used as the mainstay of a diet may lack adequate amounts of thiamine; and (3) iodine often is lacking from food and water in regions removed from the oceans, unless supplementation is provided.
- *Chronic alcoholism.* Alcoholic persons may sometimes suffer from PEM but are more frequently lacking in several vitamins, especially thiamine, pyridoxine, folate, and vitamin A, as a result of dietary deficiency, defective GI absorption, abnormal nutrient utilization and storage, increased metabolic needs, and an increased rate of loss. A failure to recognize thiamine deficiency in patients with chronic alcoholism may result in irreversible brain damage (e.g., Korsakoff psychosis, discussed in Chapter 22).
- *Acute and chronic illnesses.* The basal metabolic rate becomes accelerated in many illnesses (in patients with extensive burns, it may double), resulting in increased daily requirements for all nutrients. Failure to recognize these nutritional needs may delay recovery. PEM is

often present in patients with metastatic cancers (discussed later).
- *Self-imposed dietary restriction.* Anorexia nervosa, bulimia, and less overt eating disorders affect a large population of persons who are concerned about body image or suffer from an unreasonable fear of cardiovascular disease (anorexia and bulimia are discussed in a separate section in this chapter).
- *Other causes.* Additional causes of malnutrition include GI diseases, acquired and inherited malabsorption syndromes, specific drug therapies (which block uptake or utilization of particular nutrients), and total parenteral nutrition.

The remainder of this section presents a general overview of nutritional disorders. Particular attention is devoted to PEM, anorexia nervosa and bulimia, deficiencies of vitamins and trace minerals, and obesity, with a brief consideration of the relationships of diet to atherosclerosis and cancer. Other nutrients and nutritional issues are discussed in the context of specific diseases throughout the text.

## Protein-Energy Malnutrition

Severe PEM is a serious, often lethal disease. It is common in poor countries, where as many as 25% of children may be affected and where it is a major contributor to the high death rates among the very young. For example, in the drought-prone western African country of Niger, the United Nations estimated in 2009 that 800,000 children younger than 5 years were malnourished, and that malnutrition was the major cause of death in infancy and childhood in this population.

PEM manifests as a range of clinical syndromes, all resulting from a dietary intake of protein and calories that is inadequate to meet the body's needs. The two ends of the spectrum of syndromes are known as *marasmus* and *kwashiorkor.* In considering these conditions, an important point is that from a functional standpoint, there are two protein compartments in the body: the somatic compartment, represented by proteins in skeletal muscles, and the visceral compartment, represented by protein stores in the visceral organs, primarily the liver. These two compartments are regulated differently, as detailed subsequently. The somatic compartment is affected more severely in marasmus and the visceral compartment is depleted more severely in kwashiorkor. Clinical assessment of undernutrition is discussed next, followed by descriptions of the clinical presentations of marasmus and kwashiorkor.

The most common victims of PEM worldwide are children. A child whose weight falls to less than 80% of normal is considered malnourished. The diagnosis of PEM is obvious in its most severe forms. In mild to moderate forms, the usual approach is to compare the body weight for a given height against standard tables; other helpful parameters are fat stores, muscle mass, and serum proteins. With a loss of fat, measured skinfold thickness (which includes skin and subcutaneous tissue) is reduced. If the somatic protein compartment is catabolized, the resultant reduction in muscle mass is reflected by reduced circumference of the midarm. Measurement of levels of serum proteins (albumin, transferrin, and others) provides a measure of the adequacy of the visceral protein compartment.

### *Marasmus*

A child is considered to have *marasmus* when weight level falls to 60% of normal for sex, height, and age (Fig. 7–17, *A*). A marasmic child suffers growth retardation and loss of muscle mass as a result of catabolism and depletion of the somatic protein compartment. This seems to be an adaptive response that provides the body with amino acids as a source of energy. Of interest, the visceral protein compartment, which presumably is more precious and critical for survival, is depleted only marginally, so *serum albumin levels are either normal or only slightly reduced.* In addition to muscle proteins, subcutaneous fat is also mobilized and used as fuel. Leptin (discussed later under "Obesity") production is low, which may stimulate the hypothalamic-pituitary-adrenal axis to produce high levels of cortisol that contribute to lipolysis. With such losses of muscle and subcutaneous fat, the *extremities are emaciated*; by comparison, the head appears too large for the body. Anemia and manifestations of multivitamin deficiencies are present, and there is evidence of *immune deficiency,* particularly of T cell–mediated immunity. Hence, concurrent infections are usually present that impose an additional stress on an already weakened body.

### *Kwashiorkor*

*Kwashiorkor* occurs when protein deprivation is relatively greater than the reduction in total calories (Fig. 7–17, *B*). This is the most common form of PEM seen in African children who have been weaned too early and subsequently fed, almost exclusively, a carbohydrate diet (the name kwashiorkor, from the Ga language in Ghana, describes the illness in a baby that appears after the arrival of another child). The prevalence of kwashiorkor also is high in impoverished countries of Southeast Asia. Less severe forms may occur worldwide in persons with chronic diarrheal states, in which protein is not absorbed, or in those with chronic protein loss (e.g., protein-losing enteropathies, the nephrotic syndrome, or the aftermath of extensive burns). Rare cases of kwashiorkor resulting from fad diets or replacement of milk by rice-based beverages have been reported in the United States.

In kwashiorkor, unlike in marasmus, marked protein deprivation is associated with severe loss of the visceral protein compartment, and the resultant hypoalbuminemia gives rise to *generalized or dependent edema* (Fig. 7–17). The weight of children with severe kwashiorkor typically is 60% to 80% of normal. However, the true loss of weight is masked by the increased fluid retention (edema). In further contrast with marasmus, there is relative sparing of subcutaneous fat and muscle mass. The modest loss of these compartments may also be masked by edema.

Children with kwashiorkor have characteristic *skin lesions* with alternating zones of hyperpigmentation, desquamation, and hypopigmentation, giving a "flaky paint" appearance. *Hair changes* include loss of color or alternating bands of pale and darker color, straightening, fine texture, and loss of firm attachment to the scalp. Other features that distinguish kwashiorkor from marasmus include an enlarged, *fatty liver* (resulting from reduced synthesis of the

**Figure 7–17** Childhood malnutrition. **A,** Marasmus. Note the loss of muscle mass and subcutaneous fat; the head appears to be too large for the emaciated body. **B,** Kwashiorkor. The infant shows generalized edema, seen as ascites and puffiness of the face, hands, and legs.
*(A, From Clinic Barak, Reisebericht Kenya.)*

carrier protein component of lipoproteins) and the development of apathy, listlessness, and loss of appetite. As in marasmus, vitamin deficiencies are likely to be present, as are *defects in immunity* and *secondary infections.* In kwashiorkor, the inflammation caused by infection produces a catabolic state that aggravates the malnutrition. Of note, marasmus and kwashiorkor represent two ends of a spectrum, and considerable overlap exists.

### *Secondary Protein-Energy Malnutrition*

*Secondary PEM* is common in chronically ill or hospitalized patients. A particularly severe form of secondary PEM, called *cachexia,* often develops in patients with advanced cancer (Chapter 5). The wasting is all too apparent and often presages death. Although loss of appetite may partly explain it, cachexia may appear before appetite decreases. The underlying mechanisms are complex, but appear to involve "cachectins" such as *proteolysis-inducing factor,* which are secreted by tumor cells, and cytokines, particularly TNF, which are released as part of the host response to advanced tumors. Both types of factors directly stimulate the degradation of skeletal muscle proteins, and cytokines such as TNF also stimulate fat mobilization from lipid stores.

### MORPHOLOGY

The hallmark anatomic changes in PEM are (1) growth failure, (2) peripheral edema in kwashiorkor, and (3) loss of body fat and atrophy of muscle, more marked in marasmus.

The **liver** in kwashiorkor, but not in marasmus, is enlarged and fatty; superimposed cirrhosis is rare.

In kwashiorkor (rarely in marasmus) the **small bowel** shows a decrease in the mitotic index in the crypts of the glands, associated with mucosal atrophy and loss of villi and microvilli. In such cases concurrent loss of small intestinal enzymes occurs, most often manifested as disaccharidase deficiency. Hence, infants with kwashiorkor are lactate intolerant initially and may not respond well to full-strength, milk-based diets. With treatment, the mucosal changes are reversible.

The **bone marrow** in both kwashiorkor and marasmus may be hypoplastic, mainly as a result of decreased numbers of red cell precursors. How much of this derangement is due to a deficiency of protein and folates and how much to reduced synthesis of transferrin and ceruloplasmin is uncertain. Thus, anemia is usually present, most often hypochromic, microcytic anemia, but a concurrent deficiency of folates may lead to a mixed microcytic-macrocytic anemia.

The **brain** in infants who are born to malnourished mothers and who suffer from PEM during the first 1 or 2 years of life has been reported by some investigators to show cerebral atrophy, a reduced number of neurons, and impaired myelination of white matter.

Many other changes may be present, including (1) thymic and lymphoid atrophy (more marked in kwashiorkor than in marasmus), (2) anatomic alterations induced by intercurrent infections, particularly with endemic helminths and other parasites, and (3) deficiencies of other required nutrients such as iodine and vitamins.

## Anorexia Nervosa and Bulimia

*Anorexia nervosa* is a state of self-induced starvation resulting in marked weight loss; *bulimia* is a condition in which the patient binges on food and then induces vomiting.

Bulimia is more common than anorexia nervosa and carries a better prognosis. It is estimated to occur in 1% to 2% of women and 0.1% of men, with an average age at onset of 20 years. Anorexia nervosa also occurs primarily in previously healthy young women who have acquired an obsession with attaining or maintaining thinness.

The clinical findings in anorexia nervosa generally are similar to those in severe PEM. In addition, effects on the endocrine system are prominent. *Amenorrhea,* resulting from decreased secretion of gonadotropin-releasing hormone (and consequent decreased secretion of luteinizing and follicle-stimulating hormones), is so common that its presence is almost a diagnostic feature. Other common findings, related to decreased thyroid hormone release, include cold intolerance, bradycardia, constipation, and changes in the skin and hair. In addition, dehydration and electrolyte abnormalities are frequent findings. The skin becomes dry and scaly and may be yellow-tinged as a result of excess carotene in the blood. Body hair may be increased but usually is fine and pale (lanugo). Bone density is decreased, most likely because of low estrogen levels, which mimics the postmenopausal acceleration of osteoporosis. As expected with severe PEM, anemia, lymphopenia, and hypoalbuminemia may be present. A major complication of anorexia nervosa is an increased susceptibility to cardiac arrhythmia and sudden death, both due to hypokalemia.

In bulimia, binge eating is the norm. Huge amounts of food, principally carbohydrates, are ingested, only to be followed by induced vomiting. Although menstrual irregularities are common, amenorrhea occurs in less than 50% of bulimic patients, probably because weight and gonadotropin levels are maintained near normal. The major medical complications are related to continual induced vomiting and chronic use of laxatives and diuretics. These include (1) electrolyte imbalances (hypokalemia), which predispose the patient to cardiac arrhythmias; (2) pulmonary aspiration of gastric contents; and (3) esophageal and stomach rupture. Nevertheless, there are no specific signs and symptoms for this syndrome, and the diagnosis must rely on a comprehensive psychologic assessment of the patient.

## Vitamin Deficiencies

Before we summarize the functions of individual vitamins and the consequence of their deficiency, some general comments are in order.

- Thirteen vitamins are necessary for health; four—A, D, E, and K—are fat-soluble and the remainder water-soluble. The distinction between fat- and water-soluble vitamins is important; although the former are more readily stored in the body, they may be poorly absorbed in fat malabsorption disorders, caused by disturbances of digestive functions (discussed in Chapter 14).
- Certain vitamins can be synthesized endogenously—vitamin D from precursor steroids, vitamin K and biotin by the intestinal microflora, and niacin from tryptophan, an essential amino acid. Notwithstanding this endogenous synthesis, a dietary supply of all vitamins is essential for health.
- Deficiency of a single vitamin is uncommon, and single- or multiple-vitamin deficiencies may be submerged in concurrent PEM.

In the following sections, vitamins A, D, and C are presented in some detail because of their wide-ranging functions and the morphologic changes of deficient states. This is followed by a summary in tabular form of the main consequences of deficiencies of the remaining vitamins—E, K, and the B complex—and some essential minerals.

### *Vitamin A*

Vitamin A is a generic name for a group of related fat-soluble compounds that include *retinol, retinal, and retinoic acid,* which have similar biologic activities. Retinol is the chemical name for vitamin A. It is the transport form and, as retinol ester, also the storage form. A widely used term, *retinoids,* refers to both natural and synthetic chemicals that are structurally related to vitamin A but may not necessarily have vitamin A activity. Animal-derived foods such as liver, fish, eggs, milk, and butter are important dietary sources of pre-formed vitamin A. Yellow and leafy green vegetables such as carrots, squash, and spinach supply large amounts of carotenoids, many of which are provitamins that are metabolized to active vitamin A in the body. Carotenoids contribute approximately 30% of the vitamin A in human diets; the most important of these is β-carotene, which is efficiently converted to vitamin A. The recommended dietary allowance for vitamin A is expressed in retinol equivalents, to take into account both pre-formed vitamin A and β-carotene.

As with all fats, the digestion and absorption of carotenes and retinoids require bile and pancreatic enzymes. Retinol (generally ingested as retinol ester) and β-carotene are absorbed through the intestinal wall, where β-carotene is converted to retinol (Fig. 7–18). Retinol is then transported in chylomicrons, where it is taken up into liver cells through the apolipoprotein E receptor. More than 90% of the body's vitamin A reserves are stored in the liver, predominantly in the perisinusoidal stellate (Ito) cells. In healthy persons who consume an adequate diet, these reserves are sufficient to support the body's needs for at least 6 months. Retinol esters stored in the liver can be mobilized; before release, retinol binds to a specific retinol-binding protein (RBP), synthesized in the liver. The uptake of retinol and RBP in peripheral tissues is dependent on cell surface RBP receptors. After uptake by cells, retinol is released, and the RBP is recycled back into the blood. Retinol may be stored in peripheral tissues as retinyl ester or be oxidized to form retinoic acid.

***Function.*** In humans, the best-defined functions of vitamin A are the following:

- Maintaining normal vision in reduced light
- Potentiating the differentiation of specialized epithelial cells, mainly mucus-secreting cells
- Enhancing immunity to infections, particularly in children with measles

In addition, the retinoids, β-carotene, and some related carotenoids can function as photoprotective and antioxidant agents. Retinoids have broad biologic effects, including effects on embryonic development, cellular differentiation and proliferation, and lipid metabolism.

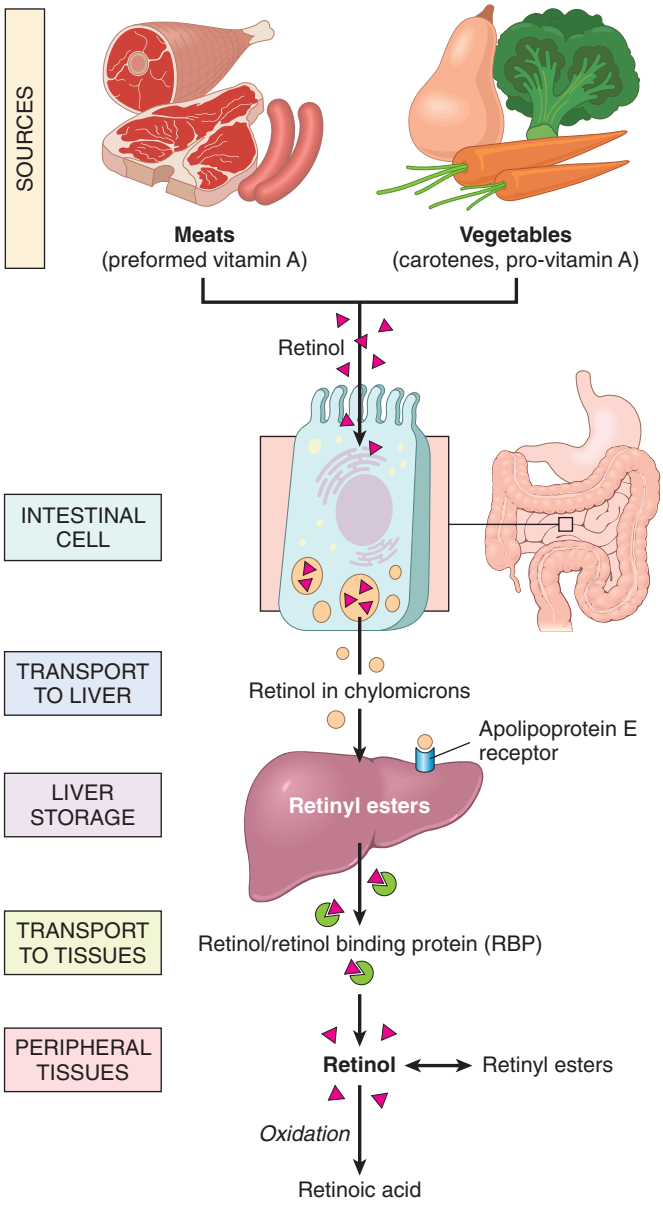


**Figure 7–18** Vitamin A metabolism.

- The *visual process* involves four forms of vitamin A–containing pigments: rhodopsin, the most light-sensitive pigment and therefore important in reduced light, which is located in rod cells; and three iodopsins, each responsive to a specific color in bright light, which are located in cone cells. The synthesis of rhodopsin from retinol involves (1) oxidation to all-*trans*-retinal, (2) isomerization to 11-*cis*-retinal, and (3) interaction with opsin to form rhodopsin. A photon of light causes the isomerization of 11-*cis*-retinal to all-*trans*-retinal, and a sequence of configuration changes in rhodopsin, which produce a visual signal. In the process, a nerve impulse is generated (by changes in membrane potential) and transmitted by means of neurons from the retina to the brain. During dark adaptation, some of the all-*trans*-retinal is reconverted to 11-*cis*-retinal, but most is reduced to retinol and lost to the retina, explaining the need for continuous supply of retinol.
- Vitamin A and retinoids play an important role in the orderly *differentiation of mucus-secreting epithelium.* When a deficiency state exists, the epithelium undergoes squamous metaplasia and differentiation to a keratinizing epithelium. All-*trans*–retinoic acid (ATRA), a potent acid derivative of vitamin A, exerts its effects by binding to retinoic acid receptors (RARs), which regulate the differentiation of myeloid cells. This coupling is the basis for the remarkable ability of ATRA to induce remission of acute promyelocytic leukemia (APML). In this leukemia, a t(15:17) translocation (Chapter 11) results in the fusion of a truncated *RARA* gene on chromosome 17 with the *PML* gene on chromosome 15. The fusion gene encodes an abnormal RAR that blocks the expression of genes that are required for myeloid cell differentiation. Pharmacologic doses of ATRA overcome the block, causing the malignant promyelocytes to differentiate into neutrophils and die. When combined with other conventional chemotherapeutic agents or arsenic salts, ATRA therapy is often curative in APML. Retinoic acid, it should be noted, has no effect on vision.
- Vitamin A plays a role in host *resistance to infections.* Vitamin A supplementation can reduce morbidity and mortality rates for some forms of diarrhea. Similarly, supplementation in preschool children with measles, particularly those who are malnourished, can reduce mortality and complications of the disease, including eye damage and blindness.

  The effects of vitamin A on infections probably derive in part from its ability to stimulate the immune system through unclear mechanisms. Infections may reduce the bioavailability of vitamin A, possibly by inducing the acute phase response, which appears to inhibit RBP synthesis in the liver. The drop in hepatic RBP causes a decrease in circulating retinol, which reduces the tissue availability of vitamin A. The beneficial effect of vitamin A in diarrheal diseases may be related to the maintenance and restoration of the integrity of the epithelium of the gut.

***Deficiency States.*** Vitamin A deficiency occurs worldwide as a consequence of either poor nutrition or fat malabsorption. In children, stores of vitamin A are depleted by infections, and the absorption of the vitamin is poor in newborn infants. In adults, vitamin A deficiency, in conjunction with depletion of other fat-soluble vitamins, may develop in conjunction with malabsorption syndromes, such as celiac disease, Crohn disease, and colitis. Bariatric surgery and continuous use of mineral oil laxatives also may lead to deficiency. The multiple effects of vitamin A deficiency are discussed next.

- As was already discussed, vitamin A is a component of rhodopsin and other visual pigments. Not surprisingly, one of the earliest manifestations of vitamin A deficiency is impaired vision, particularly in reduced light (*night blindness*).
- Other effects of vitamin A deficiency are related to the role of vitamin A in maintaining the differentiation of epithelial cells (Fig. 7–19). Persistent deficiency gives rise to a series of changes involving epithelial metaplasia and keratization. The most devastating changes occur in the eyes and result in the clinical entity referred to as *xerophthalmia* (dry eye). First, there is dryness of

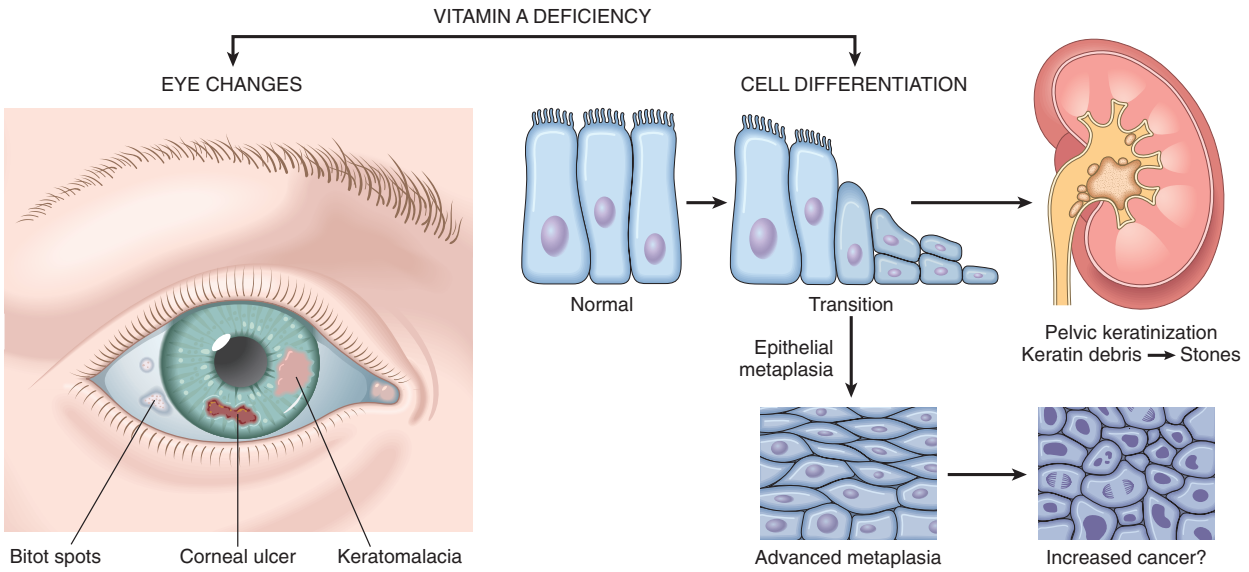


**Figure 7–19** Vitamin A deficiency: major consequences in the eye and in the production of keratinizing metaplasia of specialized epithelial surfaces, and its possible role in epithelial metaplasia. Not depicted are night blindness and immune deficiency.

the conjunctiva (xerosis conjunctivae) as the normal lachrymal and mucus-secreting epithelium is replaced by keratinized epithelium. This is followed by a buildup of keratin debris in small opaque plaques (*Bitot spots*) and, eventually, the erosion of the roughened corneal surface, leading to softening and destruction of the cornea (*keratomalacia*) and total blindness.

- Vitamin A deficiency also leads to replacement of the epithelium lining the upper respiratory passage and urinary tract by keratinizing squamous cells (*squamous metaplasia*). Loss of the mucociliary epithelium of the airways predisposes affected patients to pulmonary infections, and desquamation of keratin debris in the urinary tract predisposes to renal and bladder stones. Hyperplasia and *hyperkeratinization of the epidermis* with plugging of the ducts of the adnexal glands may produce follicular or papular dermatosis.
- Another serious consequence of lack of vitamin A is immune deficiency. This impairment of immunity leads to higher mortality rates from common infections such as measles, pneumonia, and infectious diarrhea. In parts of the world with high prevalence of vitamin A deficiency, dietary supplements reduce mortality rates for infectious disorders by 20% to 30%.

***Vitamin A Toxicity.*** Both short- and long-term excesses of vitamin A may produce toxic manifestations—a point of concern because of the megadoses being touted by certain sellers of supplements. The consequences of acute hypervitaminosis A were first described in 1597 by Gerrit de Veer, a ship's carpenter stranded in the Arctic, who recounted in his diary the serious symptoms that he and other crew members developed after eating polar bear liver. With this cautionary tale in mind, the adventurous eater should note that acute vitamin A toxicity also has been described in persons who ingested the livers of whales, sharks, and even tuna!

The signs and symptoms of acute toxicity include headache, dizziness, vomiting, stupor, and blurred vision—all of which may be confused with those of a brain tumor. Chronic toxicity is associated with weight loss, anorexia, nausea, vomiting, and bone and joint pain. Retinoic acid stimulates osteoclast production and activity, which lead to increased bone resorption and consequent high risk of fractures. Although synthetic retinoids used for the treatment of acne are not associated with these complications, their use in pregnancy must be avoided because of the well-established teratogenic effect of retinoids.

### *Vitamin D*

The major function of the fat-soluble vitamin D is the maintenance of normal plasma levels of calcium and phosphorus. In this capacity, it is required for the prevention of bone diseases known as *rickets* (in children whose epiphyses have not already closed), *osteomalacia* (in adults), and hypocalcemic tetany. With respect to tetany, vitamin D maintains the correct concentration of ionized calcium in the extracellular fluid compartment. When deficiency develops, the drop in ionized calcium in the extracellular fluid results in continuous excitation of muscle (tetany). Our attention here is focused on the function of vitamin D in the regulation of serum calcium levels.

***Metabolism.*** The major source of vitamin D for humans is its endogenous synthesis in the skin by photochemical conversion of a precursor, 7-dehydrocholesterol, powered by the energy of solar or artificial UV light. Irradiation of this compound forms *cholecalciferol,* known as vitamin $D_3$; in the following discussion, for the sake of simplicity, the term *vitamin D* is used to refer to this compound.

Under usual conditions of sun exposure, approximately 90% of the vitamin D needed is endogenously derived from 7-dehydrocholesterol present in the skin. However, blacks may have a lower level of vitamin D production in the skin because of melanin pigmentation (perhaps a small price to pay for protection against UV-induced cancers). The small remainder comes from dietary sources, such as deep sea fish, plants, and grains. In plant sources, vitamin D is present in a precursor form, ergosterol, that is converted to vitamin D in the body.

The metabolism of vitamin D can be outlined as follows (Fig. 7–20):

1. Absorption of vitamin D along with other fats in the gut or synthesis from precursors in the skin
2. Binding to plasma $\alpha_1$-globulin (vitamin D–binding protein) and transport to liver
3. Conversion to 25-hydroxyvitamin D (25-OH-D) by 25-hydroxylase in the liver
4. Conversion of 25-OH-D to 1,25-dihydroxyvitamin D [1,25-$(OH)_2$-D] (biologically the most active form of vitamin D) by $\alpha_1$-hydroxylase in the kidney

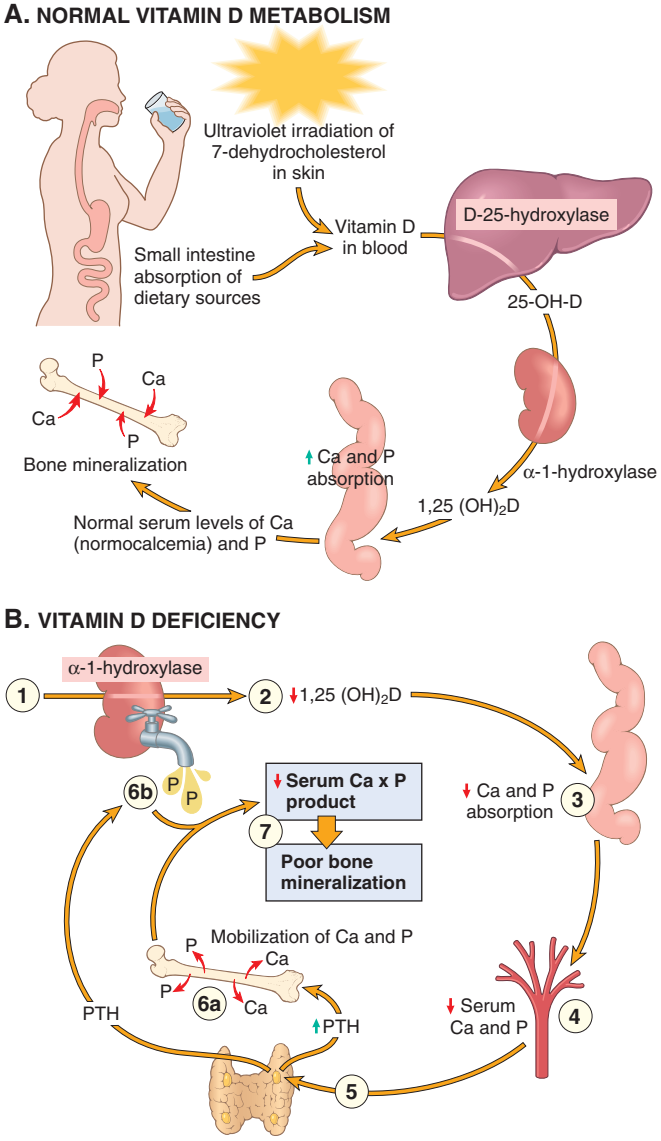


**Figure 7–20** **A,** Normal vitamin D metabolism. **B,** Vitamin D deficiency. There is inadequate substrate for the renal hydroxylase (*1*), yielding a deficiency of 1,25-$(OH)_2$D (2), and deficient absorption of calcium and phosphorus from the gut (*3*), with consequent depressed serum levels of both (*4*). The hypocalcemia activates the parathyroid glands (*5*), causing mobilization of calcium and phosphorus from bone (*6a*). Simultaneously, parathyroid hormone (PTH) induces wasting of phosphate in the urine (*6b*) and calcium retention. Consequently, the serum levels of calcium are normal or nearly normal, but the phosphate is low; hence, mineralization is impaired (*7*).

Renal production of 1,25-$(OH)_2$-D is regulated by three mechanisms:

- *Hypocalcemia stimulates secretion of parathyroid hormone (PTH),* which in turn augments the conversion of 25-OH-D to 1,25-$(OH)_2$-D by activating $\alpha_1$-hydroxylase.
- *Hypophosphatemia directly activates $\alpha_1$-hydroxylase,* thereby increasing the formation of 1,25$(OH)_2$-D.
- In a feedback loop, increased levels of 1,25-$(OH)_2$-D downregulate the synthesis of this metabolite by inhibiting the action of $\alpha_1$-hydroxylase (decreases in 1,25-$(OH)_2$-D have the opposite effect).

***Functions.*** Like retinoids and steroid hormones, 1,25-$(OH)_2$-D acts by binding to a high-affinity nuclear receptor that in turn binds to regulatory DNA sequences, thereby inducing transcription of specific target genes. The receptors for 1,25-$(OH)_2$-D are present in most nucleated cells of the body, and they transduce signals that result in various biologic activities, beyond those involved in calcium and phosphorus homeostasis. Nevertheless, the best-understood functions of vitamin D relate to the maintenance of normal plasma levels of calcium and phosphorus, through action on the intestines, bones, and kidneys (Fig. 7–20).

The active form of vitamin D:

- *Stimulates intestinal absorption of calcium* through upregulation of calcium transport, in enterocytes
- *Stimulates calcium resorption in renal distal tubules.*
- *Collaborates with PTH to regulate blood calcium.* This occurs in part through upregulation of RANK ligand on osteoblasts, which in turn activates RANK receptors on osteoclast precursors. RANK activation produces signals that increase osteoclast differentiation and bone resorptive activities (Chapter 20).
- *Promotes the mineralization of bone.* Vitamin D is needed for the mineralization of osteoid matrix and epiphyseal cartilage during the formation of flat and long bones. It stimulates osteoblasts to synthesize the calcium-binding protein osteocalcin, which promotes calcium deposition.

Of note, effects of vitamin D on bone depend on the plasma levels of calcium: On the one hand, in hypocalcemic states 1,25-$(OH)_2$-D together with PTH increases the resorption of calcium and phosphorus from bone to support blood levels. On the other hand, in normocalcemic states vitamin D also is required for calcium deposition in epiphyseal cartilage and osteoid matrix.

### Deficiency States

*Rickets* in growing children and *osteomalacia* in adults are skeletal diseases with worldwide distribution. They may result from diets deficient in calcium and vitamin D, but probably more important is limited exposure to sunlight (for instance, in heavily veiled women; children born to mothers who have frequent pregnancies followed by lactation, which leads to vitamin D deficiency; and inhabitants of northern climates with scant sunlight). Other, less common causes of rickets and osteomalacia include renal disorders causing decreased synthesis of 1,25-$(OH)_2$-D or phosphate depletion, and malabsorption disorders. Although rickets and osteomalacia rarely occur outside high-risk groups, milder forms of vitamin D deficiency (also called vitamin D insufficiency) leading to bone loss

and hip fractures are common among elderly persons. Studies also suggest that vitamin D may be important for preventing demineralization of bones. It appears that certain genetically determined variants of the vitamin D receptor are associated with an accelerated loss of bone minerals with aging and certain familial forms of osteoporosis (Chapter 20).

Whatever the basis, a deficiency of vitamin D tends to cause hypocalcemia. This in turn stimulates PTH production, which (1) activates renal $\alpha_1$-hydroxylase, increasing the amount of active vitamin D and calcium absorption; (2) mobilizes calcium from bone; (3) decreases renal calcium excretion; and (4) increases renal excretion of phosphate. Thus, the serum level of calcium is restored to near normal, but hypophosphatemia persists, so mineralization of bone is impaired or there is high bone turnover.

An understanding of the morphologic changes in rickets and *osteomalacia* is facilitated by a brief summary of normal bone development and maintenance. The development of flat bones in the skeleton involves intramembranous ossification, while the formation of long tubular bones proceeds by endochondral ossification. With intramembranous bone formation, mesenchymal cells differentiate directly into osteoblasts, which synthesize the collagenous osteoid matrix on which calcium is deposited. By contrast, with endochondral ossification, growing cartilage at the epiphyseal plates is provisionally mineralized and then progressively resorbed and replaced by osteoid matrix, which undergoes mineralization to create bone (Fig. 7–21, *A*).

## MORPHOLOGY

**The basic derangement in both rickets and osteomalacia is an excess of unmineralized bone matrix.** The changes that occur in the growing bones of children with rickets, however, are complicated by inadequate provisional calcification of epiphyseal cartilage, deranging endochondral bone growth. The following sequence ensues in rickets:

- Overgrowth of epiphyseal cartilage due to inadequate provisional calcification and failure of the cartilage cells to mature and disintegrate
- Persistence of distorted, irregular masses of cartilage, many of which project into the marrow cavity
- Deposition of osteoid matrix on inadequately mineralized cartilaginous remnants
- Disruption of the orderly replacement of cartilage by osteoid matrix, with enlargement and lateral expansion of the osteochondral junction (Fig. 7–21, *B*)
- Abnormal overgrowth of capillaries and fibroblasts in the disorganized zone resulting from microfractures and stresses on the inadequately mineralized, weak, poorly formed bone
- Deformation of the skeleton due to the loss of structural rigidity of the developing bones

The gross skeletal changes depend on the severity of the rachitic process; its duration; and, in particular, the stresses to which individual bones are subjected. During the nonambulatory stage of infancy, the head and chest sustain the greatest stresses. The softened occipital bones may become flattened, and the parietal bones can be buckled inward by pressure; with the release of the pressure, elastic recoil snaps the bones back into their original positions **(craniotabes).** An excess of osteoid produces **frontal bossing** and a squared appearance to the head. Deformation of the chest results from overgrowth of cartilage or osteoid tissue at the costochondral junction, producing the "**rachitic rosary**." The weakened metaphyseal areas of the ribs are subject to the pull of the respiratory muscles, causing them to bend inward and creating anterior protrusion of the sternum **(pigeon breast deformity).** The inward pull at the margin of the diaphragm creates the **Harrison groove,** girdling the

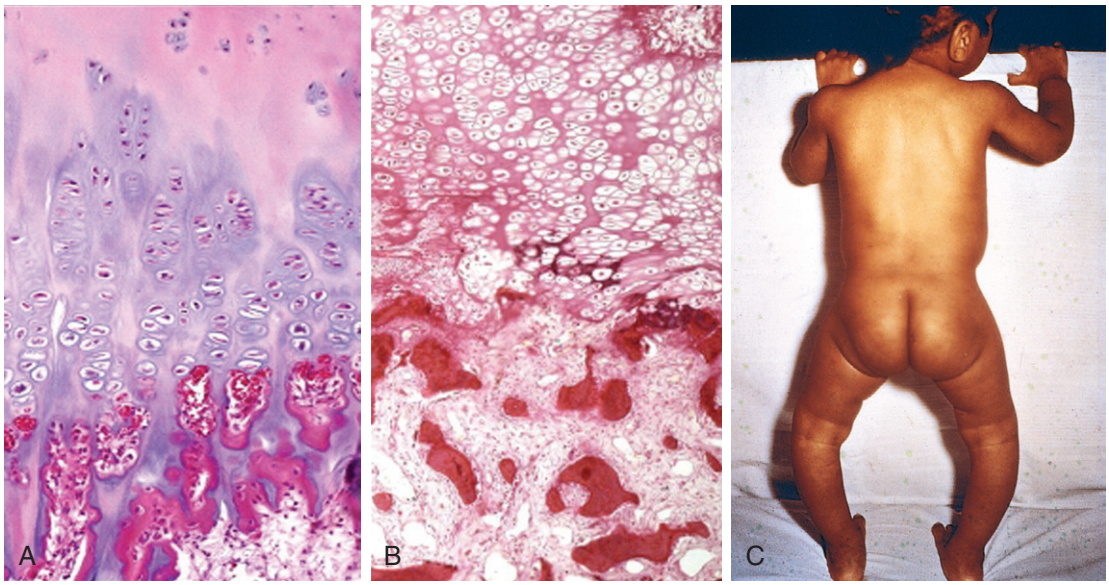


**Figure 7–21** Rickets. **A,** Normal costochondral junction of a young child. Note cartilage palisade formation and orderly transition from cartilage to new bone. **B,** Rachitic costochondral junction in which the palisade of cartilage is absent. Darker trabeculae are well-formed bone; paler trabeculae consist of uncalcified osteoid. **C,** Note bowing of legs as a consequence of the formation of poorly mineralized bone in a child with rickets.
*(B, Courtesy of Dr. Andrew E. Rosenberg, Massachusetts General Hospital, Boston, Massachusetts.)*

thoracic cavity at the lower margin of the rib cage. The pelvis may become deformed. When an ambulating child develops rickets, deformities are likely to affect the spine, pelvis, and long bones (e.g., tibia), causing, most notably, **lumbar lordosis** and **bowing of the legs** (Fig. 7–21, *C*).

In adults, the lack of vitamin D deranges the normal bone remodeling that occurs throughout life. The newly formed osteoid matrix laid down by osteoblasts is inadequately mineralized, producing the excess of persistent osteoid that is characteristic of osteomalacia. Although the contours of the bone are not affected, the bone is weak and vulnerable to gross fractures or microfractures, which are most likely to affect vertebral bodies and femoral necks. On histologic examination, the unmineralized osteoid can be visualized as a thickened layer of matrix (which stains pink in hematoxylin and eosin preparations) arranged about the more basophilic, normally mineralized trabeculae.

***Toxicity.*** Prolonged exposure to normal sunlight does not produce an excess of vitamin D, but megadoses of orally administered vitamin can lead to hypervitaminosis. In children, hypervitaminosis D may take the form of metastatic calcifications of soft tissues such as the kidney; in adults, it causes bone pain and hypercalcemia. As a point of some interest, the toxic potential of this vitamin is so great that in sufficiently large doses it is a potent rodenticide!

### *Vitamin C (Ascorbic Acid)*

A deficiency of water-soluble vitamin C leads to the development of *scurvy,* characterized principally by *bone disease in growing children* and by *hemorrhages and healing defects in both children and adults.* Sailors of the British Royal Navy were nicknamed "limeys" because at the end of the 18th century the Navy began to provide lime and lemon juice to them to prevent scurvy during their long sojourn at sea. It was not until 1932 that ascorbic acid was identified and synthesized. Unlike vitamin D, ascorbic acid is not synthesized endogenously in humans, who therefore are entirely dependent on the diet for this nutrient. Vitamin C is present in milk and some animal products (liver, fish) and is abundant in a variety of fruits and vegetables. All but the most restricted diets provide adequate amounts of vitamin C.

***Function.*** Ascorbic acid acts in a variety of biosynthetic pathways by accelerating hydroxylation and amidation reactions. The most clearly established function of vitamin C is the activation of prolyl and lysyl hydroxylases from inactive precursors, allowing for hydroxylation of procollagen. Inadequately hydroxylated procollagen cannot acquire a stable helical configuration or be adequately cross-linked, so it is poorly secreted from the fibroblasts. Those molecules that are secreted lack tensile strength, are more soluble, and are more vulnerable to enzymatic degradation. Collagen, which normally has the highest content of hydroxyproline, is most affected, particularly in blood vessels, accounting for the predisposition to hemorrhages in scurvy. In addition, a deficiency of vitamin C suppresses the synthesis of collagen polypeptides, independent of effects on proline hydroxylation.

Vitamin C also has antioxidant properties. These include an ability to scavenge free radicals directly and participation in metabolic reactions that regenerate the antioxidant form of vitamin E.

***Deficiency States.*** Consequences of vitamin C deficiency are illustrated in Figure 7–22. Fortunately, because of the abundance of ascorbic acid in foods, scurvy has ceased to be a global problem. It is sometimes encountered even in affluent populations as a secondary deficiency, particularly among elderly persons, people who live alone, and chronic alcoholics—groups often characterized by erratic and inadequate eating patterns. Occasionally, scurvy appears in patients undergoing peritoneal dialysis and hemodialysis and among food faddists.

***Toxicity.*** The popular notion that megadoses of vitamin C protect against the common cold or at least allay the

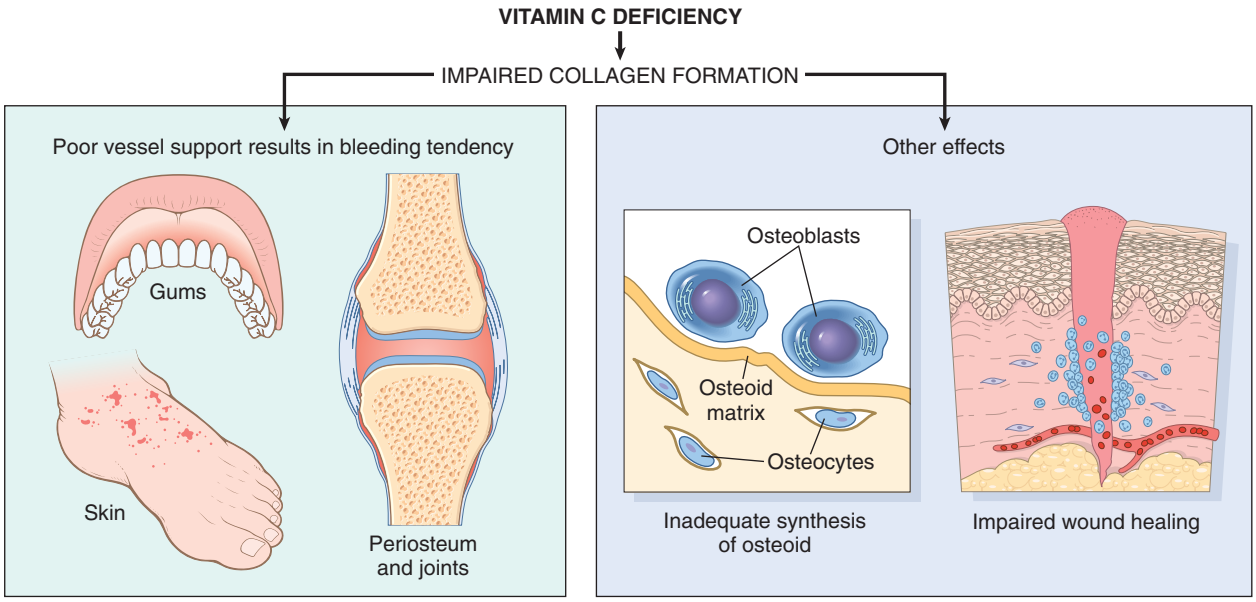


**Figure 7–22** Major consequences of vitamin C deficiency caused by impaired formation of collagen. They include bleeding tendency due to poor vascular support, inadequate formation of osteoid matrix, and impaired wound healing.

symptoms has not been borne out by controlled clinical studies. Such slight relief as may be experienced probably is a result of the mild antihistamine action of ascorbic acid. The large excess of vitamin C is promptly excreted in the urine but may cause uricosuria and increased absorption of iron, with the potential for iron overload.

Other vitamins and some essential minerals are listed and briefly described in Tables 7–9 and 7–10. Folic acid and vitamin $B_{12}$ are discussed in Chapter 11.

## SUMMARY

### Nutritional Diseases

- Primary PEM is a common cause of childhood deaths in poor countries. The two main primary PEM syndromes are marasmus and kwashiorkor. Secondary PEM occurs in the chronically ill and in patients with advanced cancer (as a result of cachexia).
- Kwashiorkor is characterized by hypoalbuminemia, generalized edema, fatty liver, skin changes, and defects in immunity. It is caused by diets low in protein but normal in calories.
- Marasmus is characterized by emaciation resulting from loss of muscle mass and fat with relative preservation of serum albumin. It is caused by diets severely lacking in calories—both protein and nonprotein.
- Anorexia nervosa is self-induced starvation; it is characterized by amenorrhea and multiple manifestations of low thyroid hormone levels. Bulimia is a condition in which food binges alternate with induced vomiting.
- Vitamins A and D are fat-soluble vitamins with a wide range of activities. Vitamin C and members of the vitamin B family are water-soluble (Table 7–9 lists vitamin functions and deficiency syndromes).

## Obesity

In the United States, obesity has reached epidemic proportions. The prevalence of obesity increased from 13% to 34% between 1960 and 2008, and as of 2009, 68% of Americans between 20 and 75 years of age were overweight. Equally alarming, childhood obesity, a strong predictor of obesity in adults, also increased two- to three-fold over the same period. Recent studies suggest that the epidemic of obesity also is rapidly spreading in developing countries such as

**Table 7–9** Vitamins: Major Functions and Deficiency Syndromes

| Vitamin | Functions | Deficiency Syndromes |
|---|---|---|
| Fat-Soluble | | |
| Vitamin A | A component of visual pigment<br>Maintenance of specialized epithelia<br>Maintenance of resistance to infection | Night blindness, xerophthalmia, blindness<br>Squamous metaplasia<br>Vulnerability to infection, particularly measles |
| Vitamin D | Facilitates intestinal absorption of calcium and phosphorus and mineralization of bone | Rickets in children<br>Osteomalacia in adults |
| Vitamin E | Major antioxidant; scavenges free radicals | Spinocerebellar degeneration |
| Vitamin K | Cofactor in hepatic carboxylation of procoagulants—factors II (prothrombin), VII, IX, and X; and protein C and protein S | Bleeding diathesis |
| Water-Soluble | | |
| Vitamin $B_1$ (thiamine) | As pyrophosphate, is coenzyme in decarboxylation reactions | Dry and wet beriberi, Wernicke syndrome, Korsakoff syndrome |
| Vitamin $B_2$ (riboflavin) | Converted to coenzymes flavin mononucleotide and flavin adenine dinucleotide, cofactors for many enzymes in intermediary metabolism | Cheilosis, stomatitis, glossitis, dermatitis, corneal vascularization |
| Niacin | Incorporated into nicotinamide adenine dinucleotide (NAD) and NAD phosphate; involved in a variety of oxidation–reduction (redox) reactions | Pellagra—"three Ds": dementia, dermatitis, diarrhea |
| Vitamin $B_6$ (pyridoxine) | Derivatives serve as coenzymes in many intermediary reactions | Cheilosis, glossitis, dermatitis, peripheral neuropathy |
| Vitamin $B_{12}$ | Required for normal folate metabolism and DNA synthesis<br>Maintenance of myelinization of spinal cord tracts | Combined system disease (megaloblastic anemia and degeneration of posterolateral spinal cord tracts) |
| Vitamin C | Serves in many redox reactions and hydroxylation of collagen | Scurvy |
| Folate | Essential for transfer and use of one-carbon units in DNA synthesis | Megaloblastic anemia, neural tube defects |
| Pantothenic acid | Incorporated in coenzyme A | No nonexperimental syndrome recognized |
| Biotin | Cofactor in carboxylation reactions | No clearly defined clinical syndrome |

**Table 7–10** Selected Trace Elements and Deficiency Syndromes

| Element | Function | Basis of Deficiency | Clinical Features |
|---|---|---|---|
| Zinc | Component of enzymes, principally oxidases | Inadequate supplementation in artificial diets<br>Interference with absorption by other dietary constituents<br>Inborn error of metabolism | Rash around eyes, mouth, nose, and anus called acrodermatitis enteropathica<br>Anorexia and diarrhea<br>Growth retardation in children<br>Depressed mental function<br>Depressed wound healing and immune response<br>Impaired night vision<br>Infertility |
| Iron | Essential component of hemoglobin as well as several iron-containing metalloenzymes | Inadequate diet<br>Chronic blood loss | Hypochromic, microcytic anemia |
| Iodine | Component of thyroid hormone | Inadequate supply in food and water | Goiter and hypothyroidism |
| Copper | Component of cytochrome *c* oxidase, dopamine β-hydroxylase, tyrosinase, lysyl oxidase, and unknown enzyme involved in cross-linking collagen | Inadequate supplementation in artificial diet<br>Interference with absorption | Muscle weakness<br>Neurologic defects<br>Abnormal collagen cross-linking |
| Fluoride | Mechanism unknown | Inadequate supply in soil and water<br>Inadequate supplementation | Dental caries |
| Selenium | Component of glutathione peroxidase<br>Antioxidant with vitamin E | Inadequate amounts in soil and water | Myopathy<br>Cardiomyopathy (Keshan disease) |

India. Globally, the World Health Organization (WHO) estimates that by 2015, 700 million adults will be obese. The causes of this epidemic are complex but undoubtedly are related to societal changes in diet and levels of physical activity. *Obesity is associated with an increased risk of several important diseases (e.g., diabetes, hypertension),* making it a major public health concern. Indeed, in 2009 it was estimated that the health care cost of obesity had risen to $147 billion annually in the United States, a price tag that appears bound to rise as the nation's collective waistline expands.

*Obesity* is defined as a state of increased body weight, due to adipose tissue accumulation, that is of sufficient magnitude to produce adverse health effects. How does one measure fat accumulation? Several high-tech methods have been devised, but for practical purposes the following measures are commonly used:

- Some expression of weight in relation to height, such as the measurement referred to as the *body mass index* (BMI) = (weight in kilograms)/(height in meters)$^2$, or kg/m$^2$
- Skinfold measurements
- Various body circumferences, particularly the waist-to-hip circumference ratio

The BMI is closely correlated with body fat. BMIs in the range 18.5 to 25 kg/m$^2$ are considered normal, while BMIs between 25 and 30 kg/m$^2$ identify the overweight, and BMIs greater than 30 kg/m$^2$, the obese. It is generally agreed that a BMI higher than 30 kg/m$^2$ imparts a health risk. In the following discussion, for the sake of simplicity, the term obesity is applied to both the overweight and the truly obese.

The untoward effects of obesity are related not only to the total body weight but also to the distribution of the stored fat. *Central, or visceral, obesity,* in which fat accumulates in the trunk and in the abdominal cavity (in the mesentery and around viscera), is associated with a much higher risk for several diseases than is excess accumulation of fat in a diffuse distribution in subcutaneous tissue.

The etiology of obesity is complex and incompletely understood. Involved are genetic, environmental, and psychologic factors. However, simply put, obesity is a disorder of energy balance. The two sides of the energy equation, intake and expenditure, are finely regulated by neural and hormonal mechanisms, so that body weight is maintained within a narrow range for many years. Apparently, this fine balance is controlled by an internal set point, or "lipostat," that senses the quantity of energy stores (adipose tissue) and appropriately regulates food intake as well as energy expenditure. In recent years, several "obesity genes" have been identified. As might be expected, they encode the molecular components of the physiologic system that regulates energy balance. A key player in energy homeostasis is the *LEP* gene and its product, *leptin.* This unique member of the cytokine family, secreted by adipocytes, regulates both sides of the energy equation—intake of food and expenditure of energy. As discussed later, *the net effect of leptin is to reduce food intake and enhance the expenditure of energy.*

In a simplified way the neurohumoral mechanisms that regulate energy balance and body weight may be divided into three components (Fig. 7–23):

- *The peripheral or afferent system* generates signals from various sites. Its main components are *leptin and adiponectin* produced by fat cells, *insulin* from the pancreas, *ghrelin* from the stomach, and *peptide YY* from the ileum and colon. Leptin reduces food intake and is discussed in detail further on. Ghrelin secretion stimulates appetite, and it may function as a "meal-initiating" signal. Peptide YY, which is released postprandially by endocrine cells in the ileum and colon, is a satiety signal.
- *The arcuate nucleus in the hypothalamus*, which processes and integrates the peripheral signals and generates new signals that are transmitted by (1) POMC (pro-opiomelanocortin) and CART (cocaine- and amphetamine-regulated transcript) neurons; and (2)

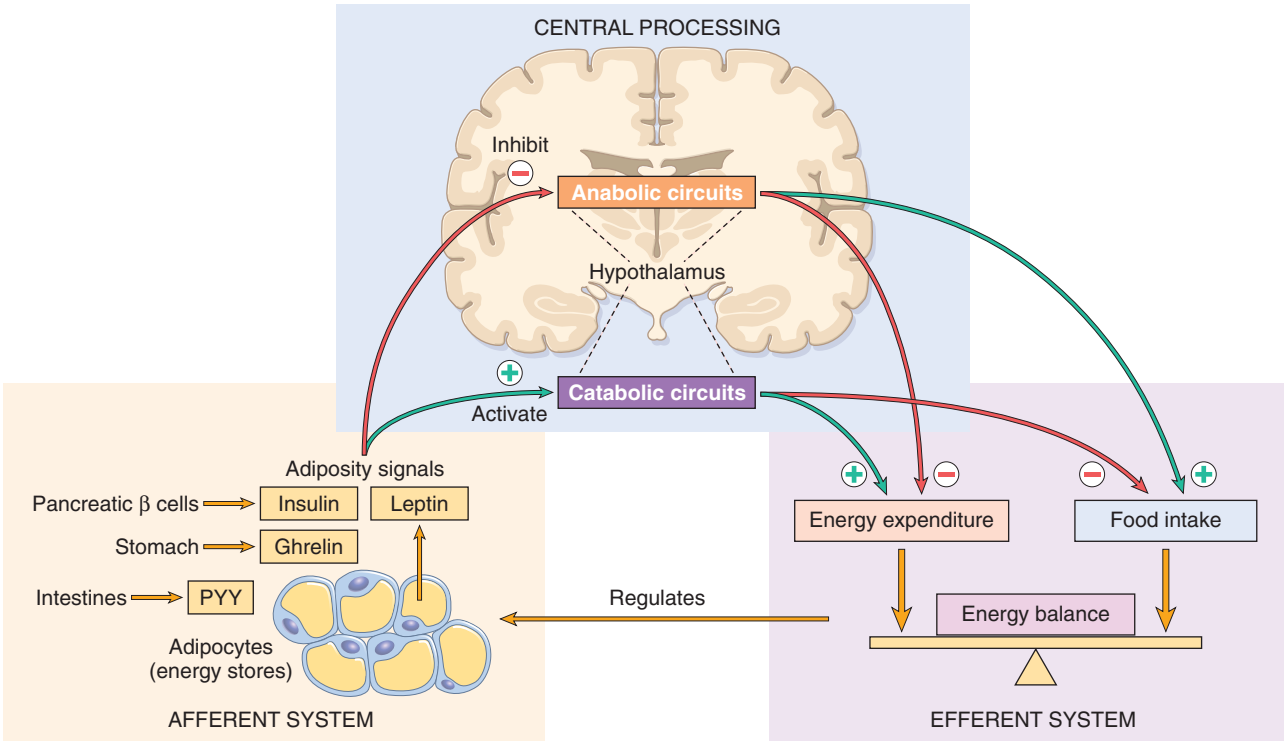


**Figure 7–23** Energy balance regulatory circuitry. When sufficient energy is stored in adipose tissue and the individual is well fed, afferent adiposity signals (insulin, leptin, ghrelin, peptide YY) are delivered to the central neuronal processing units, in the hypothalamus. Here the adiposity signals inhibit anabolic circuits and activate catabolic circuits. The effector arms of these central circuits then influence energy balance by inhibiting food intake and promoting energy expenditure. This in turn reduces the energy stores, and pro-adiposity signals are blunted. Conversely, when energy stores are low, the available anabolic circuits take over, at the expense of catabolic circuits, to generate energy stores in the form of adipose tissue.

NPY (neuropeptide Y) and AgRP (agouti-related peptide) neurons.

- *The efferent system*, which consists of hypothalamic neurons regulated by the arcuate nucleus. POMC/CART neurons activate efferent neurons that enhance energy expenditure and weight loss, while NPY/AgRP neurons activate efferent neurons that promote food intake and weight gain. Signals transmitted by efferent neurons also communicate with forebrain and midbrain centers that control the autonomic nervous system.

Discussed next are three important components of the afferent system that regulate appetite and satiety: leptin, adipose tissue, and gut hormones.

### *Leptin*

Through complex, incompletely understood mechanisms, the *output of leptin is regulated by the adequacy of fat stores.* With abundant adipose tissue, leptin secretion is stimulated, and the hormone travels to the hypothalamus, where it *reduces food intake by stimulating POMC/CART neurons and inhibiting NPY/AgRP neurons.* The opposite sequence of events occurs when there are inadequate stores of body fat: Leptin secretion is diminished and food intake is increased. In persons of stable weight, the activities of these pathways are balanced. Leptin also increases energy expenditure by stimulating physical activity, energy expenditure, and *thermogenesis,* which may be the most important catabolic effects mediated by leptin through the hypothalamus. Thermogenesis seems to be controlled in part by efferent hypothalamic signals that increase the release of norepinephrine from sympathetic nerve endings in adipose tissue. Fat cells express $\beta_3$-adrenergic receptors that, when stimulated by norepinephrine, cause fatty acid hydrolysis and also uncouple energy production from storage.

In rodents and humans, loss-of-function mutations affecting components of the leptin pathway give rise to massive obesity. Mice with mutations that disable the leptin gene or its receptor fail to sense the adequacy of fat stores, so they behave as if they are undernourished, eating ravenously. As in mice, mutations of the leptin gene or receptor in humans, although rare, may cause massive obesity. *More common are mutations in the melanocortin receptor-4 gene (MC4R) gene, found in 4% to 5% of patients with massive obesity.* These monogenic traits underscore the importance of the leptin pathway in the control of body weight, and it is possible that more common types of defects in this pathway will be discovered in the obese. For example, many obese persons have high blood leptin levels, suggesting that leptin resistance is prevalent among humans.

### *Adipose Tissue*

In addition to leptin, adipose tissue produces other mediators, such as adiponectin, cytokines, chemokines, and steroid hormones, which allow adipose tissue to function as a link between lipid metabolism, nutrition, and inflammatory responses. *The total number of adipocytes is established by adolescence* and is higher in people who were obese as children, providing another reason for concern about childhood obesity. Although in adults about 10% of adipocytes turn over annually, the number of adipocytes remains

constant, regardless of individual body mass. Diets fail in part because loss of fat from adipocytes causes leptin levels to fall, stimulating the appetite and diminishing energy expenditure.

### *Gut Hormones*

Gut hormones are rapidly acting initiators and terminators of volitional eating. Prototypical examples are ghrelin and peptide YY (PYY). *Ghrelin* is produced in the stomach and is the only known gut peptide that increases food intake. It probably acts by stimulating the NPY/AgRP neurons in the hypothalamus. Ghrelin levels normally rise before meals and fall 1 to 2 hours afterward, but this drop is attenuated in obese persons. *PYY* is secreted from endocrine cells in the ileum and colon in response to consumption of food. It presumably acts by stimulating POMC/CART neurons in the hypothalamus, thereby decreasing food intake.

### *Clinical Consequences of Obesity*

Obesity, particularly central obesity, is a known *risk factor for a number of conditions, including type 2 diabetes, cardiovascular disease, and cancer.* Central obesity also stands at the center of a cluster of alterations known as the metabolic syndrome, characterized by abnormalities of glucose and lipid metabolism coupled with hypertension and evidence of a systemic pro-inflammatory state. The mechanisms underlying these associations are complex and probably interrelated. The following associations are worthy of note:

- Obesity is associated with *insulin resistance* and hyperinsulinemia, important features of type 2 diabetes (formerly known as non–insulin-dependent diabetes). It has been speculated that excess insulin, in turn, may play a role in the retention of sodium, expansion of blood volume, production of excess norepinephrine, and smooth muscle proliferation that are the hallmarks of hypertension. Whatever the mechanism, *the risk of developing hypertension among previously normotensive persons increases proportionately with weight.*
- Obese persons generally have hypertriglyceridemia and low HDL cholesterol levels, factors that increase the risk of *coronary artery disease.* The association between obesity and heart disease is not straightforward, however, and such linkage as there is relates more to the associated diabetes and hypertension than to weight per se.
- *There is an increased incidence of certain cancers in the overweight,* including cancers of the esophagus, thyroid, colon, and kidney in men and cancers of the esophagus, endometrium, gallbladder, and kidney in women. Overall, obesity is associated with approximately 20% of cancer deaths in women and 14% of deaths in men. The underlying mechanisms are unknown and are likely to be multiple. One suspect is hyperinsulinemia. Insulin increases levels of insulin-like growth factor-1 (IGF-1), which can stimulate the growth and survival of many types of cancer cells by activating its cognate receptor, IGF1R. The association of obesity and endometrial cancer may be indirect: High estrogen levels are associated with an increased risk of endometrial cancer (Chapter 18), and obesity is known to raise estrogen levels. With breast cancer, the data are controversial.
- *Nonalcoholic steatohepatitis* is commonly associated with obesity and type 2 diabetes. This condition, also referred to as nonalcoholic fatty liver disease, can progress to fibrosis and cirrhosis (Chapter 15).
- *Cholelithiasis (gallstones)* is six times more common in obese than in lean subjects. The mechanism is mainly an increase in total body cholesterol, increased cholesterol turnover, and augmented biliary excretion of cholesterol in the bile, which in turn predisposes affected persons to the formation of cholesterol-rich gallstones (Chapter 15).
- *Hypoventilation syndrome* is a constellation of respiratory abnormalities in very obese persons. It has been called the *pickwickian syndrome,* after the fat lad who was constantly falling asleep in Charles Dickens' *The Pickwick Papers.* Hypersomnolence, both at night and during the day, is characteristic and is often associated with apneic pauses during sleep, polycythemia, and eventual right-sided heart failure.
- Marked adiposity is a predisposing factor for the development of degenerative joint disease (*osteoarthritis*). This form of arthritis, which typically appears in older persons, is attributed in large part to the cumulative effects of wear and tear on joints. The greater the body burden of fat, the greater the trauma to joints with passage of time.
- Markers of inflammation, such as C-reactive protein (CRP) and pro-inflammatory cytokines like TNF, are often elevated in obese persons. The basis for the inflammation is uncertain; both a direct pro-inflammatory effect of excess circulating lipids and increased release of cytokines from fat-laden adipocytes have been proposed. Whatever the cause, it is thought that chronic inflammation may contribute to many of the complications of obesity, including insulin resistance, metabolic abnormalities, thrombosis, cardiovascular disease, and cancer.

## SUMMARY

### Obesity

- Obesity is a disorder of energy regulation. It increases the risk for a number of important conditions such as insulin resistance, type 2 diabetes, hypertension, and hypertriglyceridemia, which are associated with the development of coronary artery disease.
- The regulation of energy balance is very complex. It has three main components: (1) afferent signals, provided mostly by insulin, leptin, ghrelin, and peptide YY; (2) the central hypothalamic system, which integrates afferent signals and triggers the efferent signals; and (3) efferent signals, which control energy balance.
- Leptin plays a key role in energy balance. Its output from adipose tissues is regulated by the abundance of fat stores. Leptin binding to its receptors in the hypothalamus reduces food intake by stimulating POMC/CART neurons and inhibiting NPY/AgRP neurons.
- In addition to diabetes and cardiovascular disease, obesity also is associated with increased risk for certain cancers, nonalcoholic fatty liver disease, and gallstones.

## Diet and Systemic Diseases

The problems of under- and overnutrition, as well as specific nutrient deficiencies, have been discussed; however, the composition of the diet, even in the absence of any of these problems, may make a significant contribution to the causation and progression of a number of diseases. A few examples suffice here.

Currently, one of the most important and controversial issues is the contribution of diet to atherogenesis. The central question is whether dietary modification—specifically, reduction in the consumption of foods high in cholesterol and saturated animal fats (e.g., eggs, butter, beef)—can reduce serum cholesterol levels and prevent or retard the development of atherosclerosis (of most importance, coronary heart disease). The average adult in the United States consumes a large amount of fat and cholesterol daily, with a ratio of saturated fatty acids to polyunsaturated fatty acids of about 3:1. Lowering the level of saturates to the level of the polyunsaturates causes a 10% to 15% reduction in serum cholesterol level within a few weeks. Vegetable oils (e.g., corn and safflower oils) and fish oils contain polyunsaturated fatty acids and are good sources of such cholesterol-lowering lipids. Fish oil fatty acids belonging to the omega-3, or *n*-3, family have more double bonds than do the omega-6, or *n*-6, fatty acids found in vegetable oils. One study of Dutch men whose usual daily diet contained 30 gm of fish revealed a substantially lower frequency of death from coronary heart disease than that among comparable control subjects, providing some hope (but no definitive proof) that long-term supplementation of food with omega-3 fatty acids may reduce coronary artery disease.

Other specific effects of diet on disease have been recognized:

- Hypertension is reduced by restricting sodium intake.
- Dietary fiber, or roughage, resulting in increased fecal bulk, is thought by some investigators to have a preventive effect against diverticulosis of the colon.
- Caloric restriction has been convincingly demonstrated to increase life span in experimental animals, including monkeys. The basis for this striking observation is not clear (Chapter 1).
- Even lowly garlic has been touted to protect against heart disease (and also, alas, against kisses—and the devil), although research has yet to prove this effect unequivocally.

## Diet and Cancer

With respect to carcinogenesis, three aspects of the diet are of concern: (1) the content of exogenous carcinogens, (2) the endogenous synthesis of carcinogens from dietary components, and (3) the lack of protective factors.

- An example of an exogenous carcinogen is *aflatoxin*, which is an important factor in the development of hepatocellular carcinomas in parts of Asia and Africa. Exposure to aflatoxin causes a specific mutation (codon 249) in the *P53* gene in tumor cells. The mutation can be used as a molecular signature for aflatoxin exposure in epidemiologic studies. Debate continues about the carcinogenicity of food additives, artificial sweeteners, and contaminating pesticides. Some artificial sweeteners (cyclamates and saccharin) have been implicated in the pathogenesis of bladder cancers, but convincing evidence is lacking.
- The concern about *endogenous* synthesis of carcinogens or promoters from components of the diet relates principally to gastric carcinomas. *Nitrosamines and nitrosamides* are suspected to generate these tumors in humans, as they induce gastric cancer in animals. These compounds are formed in the body from nitrites and amines or amides derived from digested proteins. Sources of nitrites include sodium nitrite, added to foods as a preservative, and nitrates, present in common vegetables, which are reduced in the gut by bacterial flora. There is, then, the potential for endogenous production of carcinogenic agents from dietary components, which might well have an effect on the stomach.
- High animal fat intake combined with low fiber intake has been implicated in the causation of colon cancer. The most convincing explanation for this association is as follows: High fat intake increases the level of bile acids in the gut, which in turn modifies intestinal flora, favoring the growth of microaerophilic bacteria. The bile acids or bile acid metabolites produced by these bacteria might serve as carcinogens or promoters. The protective effect of a high-fiber diet might relate to (1) increased stool bulk and decreased transit time, which decreases the exposure of mucosa to putative offenders, and (2) the capacity of certain fibers to bind carcinogens and thereby protect the mucosa. Attempts to document these theories in clinical and experimental studies have, on the whole, led to contradictory results.
- Vitamins C and E, β-carotenes, and selenium have been assumed to have anticarcinogenic effects because of their antioxidant properties. To date, however, no convincing evidence has emerged to show that these antioxidants act as chemopreventive agents. As already mentioned, retinoic acid promotes epithelial differentiation and is believed to reverse squamous metaplasia.

Thus, despite many tantalizing trends and proclamations by "diet gurus," to date there is no definite proof that diet in general can cause or protect against cancer. Nonetheless, concern persists that carcinogens lurk in things as pleasurable as a juicy steak and rich ice cream.

### BIBLIOGRAPHY

Bellinger DC: Lead. Pediatrics 113:1016, 2004. *[An excellent overview of the subject.]*

Boffetta P, Hecht S, Gray N, et al: Smokeless tobacco and cancer. Lancet Oncol 9:667, 2009. *[A review of cancer risks associated with smokeless tobacco worldwide.]*

Centers for Disease Control and Prevention: Third National Report on Human Exposure to Environmental Chemicals, 2005. *[A very important survey of environmental chemicals, with comments on exposure and health risk trends.]*

Casals-Casas C, Desvergne B: Endocrine disruptors: from endocrine to metabolic disruption. Annu Rev Phys 73:135, 2011. *[An update discussing the scope and possible consequences of human exposure to this class of chemical.]*

Clarkson TW, Magos L, Myers GJ: The toxicology of mercury—current exposures and clinical manifestations. N Engl J Med 349:1731, 2003. *[An excellent overview of the subject.]*

Gregor MF, Hotamisligil GS: Inflammatory mechanisms in obesity. Annu Rev Immunol 29:445, 2011. *[A concise discussion of current views of the pro-inflammatory state associated with obesity.]*

Heiss G, Wallace R, Anderson GL, et al: Health risks and benefits 3 years after stopping randomized treatment with estrogen and progestin. JAMA 299:1036, 2008. *[A paper describing a persistently elevated risk of breast cancer in women 3 years after stopping HRT.]*

Hollick MF: Vitamin D deficiency. N Engl J Med 357:266, 2007. *[A comprehensive review of vitamin D deficiency.]*

Jornayvaz FR, Samuel VT, Shulman GI: The role of muscle insulin resistance in the pathogenesis of atherogenic dyslipidemia and nonalcoholic fatty liver disease associated with the metabolic syndrome. Annu Rev Nutr 30:273, 2010. *[An interesting perspective on the metabolic syndrome focused on the role of insulin resistance in skeletal muscle.]*

Manson JE, Hsia J, Johnson KC, et al: Estrogen plus progestin and the risk of coronary heart disease. N Engl J Med 349:523, 2003. *[A landmark study from the Women's Health Initiative.]*

Pope CA, Ezzati M, Dockery DW: Fine-particulate air pollution and life expectancy in the United States. N Engl J Med 360:376, 2009. *[An interesting paper correlating increases in life expectancy in major U.S. cities with decreases in fine-particulate air pollution.]*

Ravdin PM, Cronin KA, Howlader N, et al: The decrease in breast-cancer incidence in 2003 in the United States. N Engl J Med 356:1670, 2007. *[An important paper documenting the decrease in breast cancer that followed its linkage to HRT.]*

Roberts DL, Dive C, Renehan AG: Biological mechanisms linking obesity and cancer risk: new perspectives. Annu Rev Med 61:301, 2010. *[A discussion of the possible interactions between obesity and cancer risk.]*

Suzuki K, Simpson KA, Minnion JS, et al: The role of gut hormones and the hypothalamus in appetite regulation. Endocr J 57:359, 2010. *[An excellent review of the interplay between the gut and the hypothalamus in regulating food consumption.]*

Tang X-H, Gudas LJ: Retinoids, retinoic acid receptors, and cancer. Annu Rev Pathol 6:345, 2011. *[A review of the role of retinoids in cancer, with a focus on solid tumors.]*

This page intentionally left blank

See Targeted Therapy available online at studentconsult.com

CHAPTER 8

# General Pathology of Infectious Diseases

CHAPTER CONTENTS

General Principles of Microbial Pathogenesis 309
Categories of Infectious Agents 309
Special Techniques for Identifying Infectious Agents 314
New and Emerging Infectious Diseases 314
Agents of Bioterrorism 315
Transmission and Dissemination of Microbes 315
Routes of Entry of Microbes 315
Spread and Dissemination of Microbes Within the Body 317
Release from the Body and Transmission of Microbes 318
How Microorganisms Cause Disease 319
Mechanisms of Viral Injury 319
Mechanisms of Bacterial Injury 320
Injurious Effects of Host Immune Responses 321
Immune Evasion by Microbes 322
Spectrum of Inflammatory Responses to Infection 323

This chapter reviews the general principles of the pathogenesis of infectious disease and describes the characteristic histopathologic changes for different disease categories. Infections that involve specific organs are discussed in other chapters of this book.

## GENERAL PRINCIPLES OF MICROBIAL PATHOGENESIS

Infectious diseases remain an important health problem in the United States and worldwide despite the availability and use of effective vaccines and antibiotics. In the United States, 2 of the top 10 leading causes of death are attributable to infection (pneumonia and septicemia). Infectious diseases are particularly important causes of death among the elderly, people with the acquired immunodeficiency syndrome (AIDS), persons with chronic diseases, and patients receiving immunosuppressive drugs. In developing countries, unsanitary living conditions and malnutrition contribute to a massive burden of infectious diseases that kills more than 10 million people each year. Tragically, the most common victims are children with respiratory and diarrheal infections.

### Categories of Infectious Agents

Infectious agents belong to a wide range of classes and vary greatly in size, ranging from prion protein aggregates of under 20 nm to 10-m tapeworms (Table 8–1).

#### Prions

Prions are composed of abnormal forms of a host protein termed *prion protein* (PrP). These agents cause transmissible spongiform encephalopathies, including kuru (associated with human cannibalism), Creutzfeldt-Jakob disease (CJD), bovine spongiform encephalopathy (BSE) (better known as "mad cow disease"), and variant Creutzfeldt-Jakob disease (vCJD) (probably transmitted to humans through consumption of meat from BSE-infected cattle). PrP is found normally in neurons. Diseases occur when the PrP undergoes a conformational change that confers resistance to proteases. The protease-resistant PrP promotes conversion of the normal protease-sensitive PrP to the abnormal form, explaining the infectious nature of these diseases. Accumulation of abnormal PrP leads to neuronal damage and distinctive spongiform pathologic changes in the brain. Spontaneous and inherited mutations in PrP that make it resistant to proteases have been observed in the sporadic and familial forms of CJD, respectively. CJD can be transmitted from person to person iatrogenically, by surgery, organ transplantation, or blood transfusion. These diseases are discussed in detail in Chapter 22.

#### Viruses

Viruses are obligate intracellular parasites that depend on the host cell's metabolic machinery for their replication. They consist of a nucleic acid genome surrounded by a protein coat (called a capsid) that is sometimes encased in a lipid membrane. Viruses are classified by their nucleic acid genome (DNA or RNA but not both), the shape of the capsid (icosahedral or helical), the presence or absence of

**Table 8–1** Classes of Human Pathogens

| Taxonomic Category | Size | Propagation Site(s) | Example(s) | Disease(s) |
|---|---|---|---|---|
| Prions | <20 nm | Intracellular | Prion protein | Creutzfeldt-Jacob disease |
| Viruses | 20–300 nm | Obligate intracellular | Poliovirus | Poliomyelitis |
| Bacteria | 0.2–15 μm | Obligate intracellular<br>Extracellular<br>Facultative intracellular | *Chlamydia trachomatis*<br>*Streptococcus pneumoniae*<br>*Mycobacterium tuberculosis* | Trachoma, urethritis<br>Pneumonia<br>Tuberculosis |
| Fungi | 2–200 μm | Extracellular<br>Facultative intracellular | *Candida albicans*<br>*Histoplasma capsulatum* | Thrush<br>Histoplasmosis |
| Protozoa | 1–50 μm | Extracellular<br>Facultative intracellular<br>Obligate intracellular | *Trypanosoma gambiense*<br>*Trypanosoma cruzi*<br>*Leishmania donovani* | Sleeping sickness<br>Chagas disease<br>Kala-azar |
| Helminths | 3 mm–10 m | Extracellular<br>Intracellular | *Wuchereria bancrofti*<br>*Trichinella spiralis* | Filariasis<br>Trichinosis |

a lipid envelope, their mode of replication, the preferred cell type for replication (called tropism), or the type of pathology they cause (Table 8–2). Some viral components and particles aggregate within infected cells and form characteristic inclusion bodies, which may be seen with the light microscope and are useful for diagnosis (Fig. 8–1). For example, cytomegalovirus (CMV)-infected cells are enlarged and show a large eosinophilic nuclear inclusion and smaller basophilic cytoplasmic inclusions; herpesviruses form a large nuclear inclusion surrounded by a clear halo; and both smallpox and rabies viruses form characteristic cytoplasmic inclusions. However, many viruses (e.g., poliovirus) do not produce inclusions.

Accounting for a large share of human infections, viruses can cause illnesses in several ways. Many viruses cause transient illnesses (e.g., colds, influenza). Other viruses are not eliminated from the body and persist within cells of the host for years, either continuing to multiply (e.g., chronic infection with hepatitis B virus [HBV]) or surviving in some nonreplicating form (termed *latent infection*) with the potential to be reactivated later. For example, herpes zoster virus, the cause of chickenpox, can enter dorsal root ganglia and establish latency there and later be periodically activated to cause shingles, a painful skin condition. Some viruses are involved in transformation of a host cell into a benign or malignant tumor (e.g., human papillomavirus [HPV]-induced benign warts and cervical carcinoma). Different species of viruses can produce the same clinical picture (e.g., upper respiratory infection); conversely, a single virus can cause different clinical manifestations depending on host age or immune status (e.g., CMV).

**Table 8–2** Selected Human Viral Diseases and Their Pathogens

| Organ System | Pathogen | Disease(s) |
|---|---|---|
| Respiratory | Adenovirus | Upper and lower respiratory tract infections, conjunctivitis |
| | Rhinovirus | Upper respiratory tract infection |
| | Influenza viruses A, B | Influenza |
| | Respiratory syncytial virus | Bronchiolitis, pneumonia |
| Digestive | Mumps virus | Mumps, pancreatitis, orchitis |
| | Rotavirus | Childhood gastroenteritis |
| | Norovirus | Gastroenteritis |
| | Hepatitis A virus | Acute viral hepatitis |
| | Hepatitis B virus | Acute or chronic hepatitis |
| | Hepatitis D virus | *With hepatitis B virus infection*: acute or chronic hepatitis |
| | Hepatitis C virus | Acute or chronic hepatitis |
| | Hepatitis E virus | Acute viral hepatitis |
| Systemic | | |
| With skin eruptions | Measles virus | Measles (rubeola) |
| | Rubella virus | German measles (rubella) |
| | Varicella-zoster virus | Chickenpox, shingles |
| | Herpes simplex virus type 1 | Oral herpes ("cold sore") |
| | Herpes simplex virus type 2 | Genital herpes |
| With hematopoietic disorders | Cytomegalovirus | Cytomegalic inclusion disease |
| | Epstein-Barr virus | Infectious mononucleosis |
| | HIV-1 and HIV-2 | AIDS |
| Skin/genital warts | Papillomavirus | Condyloma; cervical carcinoma |
| Central nervous system | Poliovirus | Poliomyelitis |
| | JC virus | Progressive multifocal leukoencephalopathy (opportunistic) |

AIDS, acquired immunodeficiency syndrome; HIV, human immunodeficiency virus.

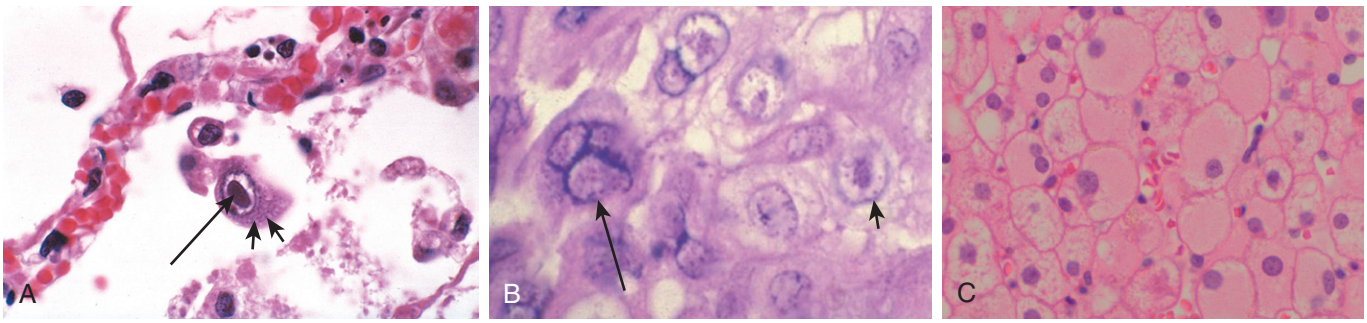


**Figure 8–1** Examples of viral inclusions. **A,** Cytomegalovirus infection in the lung. Infected cells show distinct nuclear (*long arrow*) and ill-defined cytoplasmic (*short arrows*) inclusions. **B,** Varicella-zoster virus infection in the skin. Herpes simplex virus and varicella-zoster virus both cause characteristic cytopathologic changes, including fusion of epithelial cells, which produces multinucleate cells with molding of nuclei to one another (*long arrow*), and eosinophilic haloed nuclear inclusions (*short arrow*). **C,** Hepatitis B viral infection in liver. In chronic infections, infected hepatocytes show diffuse granular ("ground-glass") cytoplasm, reflecting accumulated hepatitis B surface antigen (HBsAg).

### Bacteria

Bacterial infections are common causes of disease (Table 8–3). Bacteria are prokaryotes, meaning that they have a cell membrane but lack membrane-bound nuclei and other membrane-enclosed organelles. Most bacteria are bound by a cell wall consisting of peptidoglycan, a polymer of long sugar chains linked by peptide bridges surrounding the cell membrane. There are two common forms of cell wall structure: a thick wall that retains crystal-violet stain (gram-positive bacteria) and a thin cell wall surrounded by an outer membrane (gram-negative bacteria) (Fig. 8–2). Bacteria are classified by Gram staining (positive or negative), shape (spherical ones are cocci; rod-shaped ones are bacilli) (Fig. 8–3), and need for oxygen (aerobic or anaerobic). Motile bacteria have flagella, which are long helical filaments extending from the cell surface that rotate and move the bacteria. Some bacteria possess pili, another kind of surface projection that can attach bacteria to host cells or extracellular matrix. Bacteria synthesize their own DNA, RNA, and proteins, but they depend on the host for favorable growth conditions. Many bacteria remain extracellular when they grow in the host, while others survive and replicate either outside or inside of host cells (*facultative intracellular* bacteria) and some grow only inside host cells (*obligate intracellular* bacteria).

Normal healthy people can be colonized by as many as $10^{12}$ bacteria on the skin, $10^{10}$ bacteria in the mouth, and $10^{14}$ bacteria in the gastrointestinal tract. Bacteria colonizing the skin include *Staphylococcus epidermidis* and *Propionibacterium acnes,* the cause of acne. Aerobic and anaerobic bacteria in the mouth, particularly *Streptococcus mutans*, contribute to dental plaque, a major cause of tooth decay. There are over 3,000 taxa of bacteria in the normal intestinal flora of an individual human, but only a small subset, mainly anaerobes, account for the great majority.

*Chlamydia* and *Rickettsia* are obligate intracellular bacteria which replicate inside membrane-bound vacuoles in epithelial and endothelial cells, respectively. These bacteria get most or all of their energy source, ATP, from the host cell. *Chlamydia trachomatis* is the most frequent infectious cause of female sterility (by scarring and narrowing of the fallopian tubes) and blindness (by chronic inflammation of the conjunctiva that eventually causes scarring and opacification of the cornea). Rickettsiae injure the endothelial cells in which they grow, causing a hemorrhagic vasculitis, often visible as a rash, but they also may injure the central nervous system (CNS), with potentially fatal outcome, as in Rocky Mountain spotted fever and epidemic typhus. Rickettsiae are transmitted by arthropod vectors, including

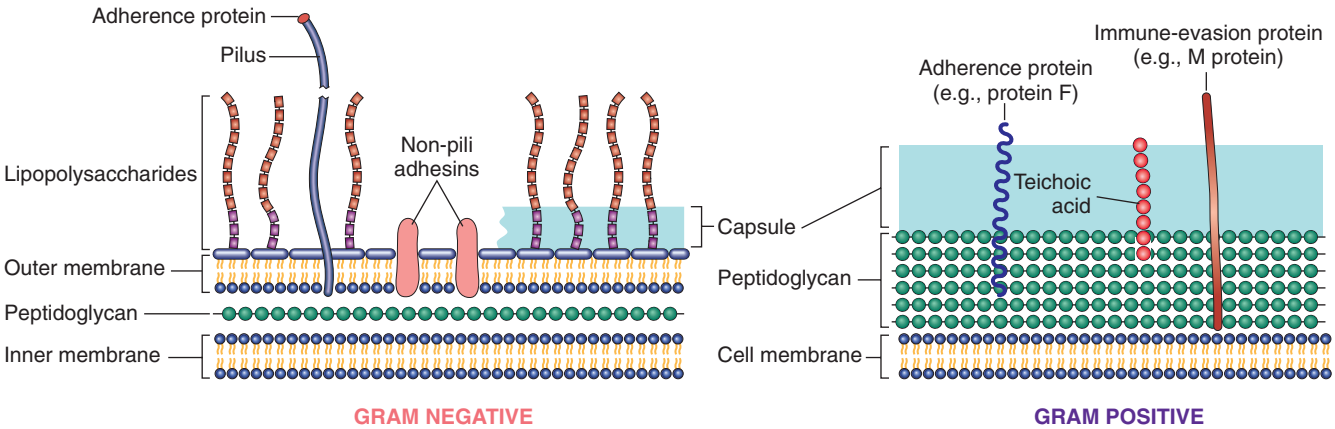


**Figure 8–2** Molecules on the surface of gram-negative and gram-positive bacteria involved in the pathogenesis of infection.

**Table 8–3** Selected Human Bacterial Diseases and Their Pathogens

| Clinical/Microbiologic Category | Species | Frequent Disease Presentation(s) |
|---|---|---|
| Infections by pyogenic cocci | *Staphylococcus aureus, Staphylococcus epidermidis* | Abscess, cellulitis, pneumonia, sepsis |
| | *Streptococcus pyogenes* | Pharyngitis, erysipelas, scarlet fever |
| | *Streptococcus pneumoniae* (pneumococcus) | Lobar pneumonia, meningitis |
| | *Neisseria meningitidis* (meningococcus) | Meningitis |
| | *Neisseria gonorrhoeae* (gonococcus) | Gonorrhea |
| Gram-negative infections | *Escherichia coli,* Klebsiella pneumoniae** | Urinary tract infection, wound infection, abscess, pneumonia, sepsis, shock, endocarditis |
| | *Enterobacter (Aerobacter) aerogenes** | |
| | *Proteus* spp. (*Proteus mirabilis, Proteus morgagni*)* | |
| | *Serratia marcescens,* Pseudomonas* spp. (*Pseudomonas aeruginosa*),* *Bacteroides* spp. (*Bacteroides fragilis*) | |
| | *Legionella* spp. (*Legionella pneumophila*) | Legionnaires disease |
| Contagious childhood bacterial diseases | *Haemophilus influenzae* | Meningitis, upper and lower respiratory tract infections |
| | *Bordetella pertussis* | Whooping cough |
| | *Corynebacterium diphtheriae* | Diphtheria |
| Enteric infections | Enteropathogenic *E. coli, Shigella* spp., *Vibrio cholerae* | Invasive or noninvasive gastroenterocolitis |
| | *Campylobacter jejuni, Campylobacter coli* | |
| | *Yersinia enterocolitica* | |
| | *Salmonella* spp. | |
| | *Salmonella typhi* | Typhoid fever |
| Clostridial infections | *Clostridium tetani* | Tetanus (lockjaw) |
| | *Clostridium botulinum* | Botulism (paralytic food poisoning) |
| | *Clostridium perfringens, Clostridium septicum* | Gas gangrene, necrotizing cellulitis |
| | *Clostridium difficile** | Pseudomembranous colitis |
| Zoonotic bacterial infections | *Bacillus anthracis* | Anthrax |
| | *Yersinia pestis* | Bubonic plague |
| | *Francisella tularensis* | Tularemia |
| | *Brucella melitensis, Brucella suis, Brucella abortus* | Brucellosis (undulant fever) |
| | *Borrelia recurrentis* | Relapsing fever |
| | *Borrelia burgdorferi* | Lyme disease |
| Treponemal infections | *Treponema pallidum* | Syphilis |
| Mycobacterial infections | *Mycobacterium tuberculosis, M. bovis* | Tuberculosis |
| | *Mycobacterium leprae* | Leprosy |
| | *Mycobacterium kansasii,* Mycobacterium avium complex** | Atypical mycobacterial infections |
| Actinomycetal infections | *Nocardia asteroides** | Nocardiosis |
| | *Actinomyces israelii* | Actinomycosis |

*Important opportunistic infections.

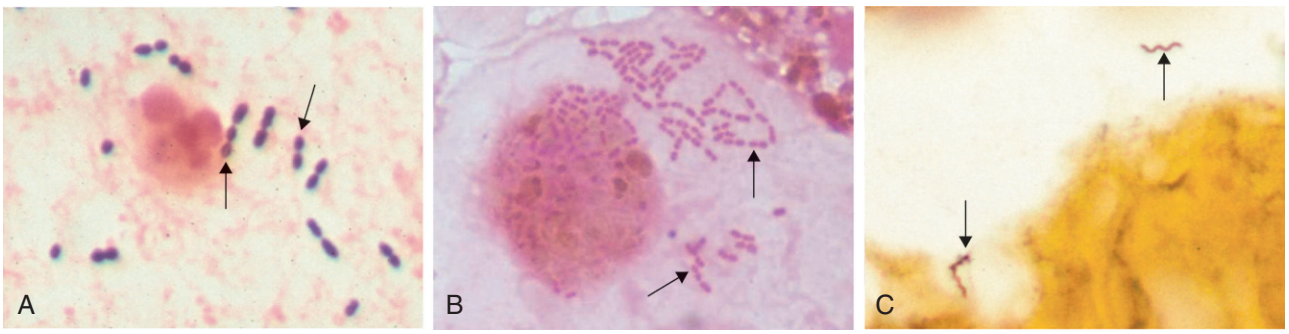


**Figure 8–3** The variety of bacterial morphology. The bacteria are indicated by *arrows*. **A,** Gram stain preparation of sputum from a patient with pneumonia. Gram-positive, elongated cocci in pairs and short chains (*Streptococcus pneumoniae*) and a neutrophil are evident. **B,** Gram stain preparation of a bronchoalveolar lavage specimen showing gram-negative intracellular rods typical of members of Enterobacteriaceae such as *Klebsiella pneumoniae* or *Escherichia coli*. **C,** Silver stain preparation of brain tissue from a patient with Lyme disease meningoencephalitis. Two helical spirochetes (*Borrelia burgdorferi*) are indicated by *arrows*. **A, B,** and **C** are at different magnifications.

*(B, Courtesy of Dr. Karen Krisher, Clinical Microbiology Institute, Wilsonville, Oregon. A and C, Courtesy of Dr. Kenneth Van Horn, Focus Diagnostics, Cypress, California.)*

lice (in epidemic typhus), ticks (in Rocky Mountain spotted fever and ehrlichiosis), and mites (in scrub typhus).

*Mycoplasma* and the related genus *Ureaplasma* are unique among extracellular bacterial pathogens in that they do not have a cell wall. These are the tiniest free-living organisms known (125 to 300 nm).

***Normal Microbiome.*** The intestinal tract and skin normally are colonized by a large number and diversity of bacterial species. Until recently, little was known about these species because most normal flora cannot be cultured. New techniques of microbial identification and speciation relying on ribosomal RNA sequencing have revealed normal microbial flora to be remarkably complex. This veritable ecosystem of microbes and their genes and products that humans live with is called the *microbiome*. In the intestinal tract, the microbiota are responsible not only for absorption of digested foods but also for maintaining the integrity of the epithelium and the normal functioning of the intestinal immune system, and for competitively inhibiting invasion and colonization by potentially pathogenic microbes. Depletion of the microbiome or change in its composition has been implicated in inflammatory bowel disease, the development of allergies, and increased incidence of various systemic autoimmune diseases.

### Fungi

Fungi are eukaryotes that possess thick, chitin-containing cell walls and ergosterol-containing cell membranes. Fungi can grow either as rounded yeast cells or as slender, filamentous hyphae. Hyphae may be septate (with cell walls separating individual cells) or aseptate, which is an important distinguishing characteristic in clinical material. Some of the most important pathogenic fungi exhibit thermal dimorphism; that is, they grow as hyphal forms at room temperature but as yeast forms at body temperature. Fungi may produce sexual spores or, more commonly, asexual spores called *conidia*. The latter are produced on specialized structures or fruiting bodies arising along the hyphal filament.

Fungi may cause superficial or deep infections.

- Superficial infections involve the skin, hair, and nails. Fungal species that cause superficial infections are called *dermatophytes.* Infection of the skin is called *tinea*; thus, *tinea pedis* is "athlete's foot" and *tinea capitis* is scalp ringworm. Certain fungi invade the subcutaneous tissue, causing abscesses or granulomas sometimes called mycetomas.
- Deep fungal infections can spread systemically and invade tissues, destroying vital organs in immunocompromised hosts, but usually resolve or remain latent in otherwise normal hosts.

Fungi are divided into endemic and opportunistic species.

- Endemic fungi are invasive species that are limited to particular geographic regions (e.g., *Coccidioides* in the southwestern United States, *Histoplasma* in the Ohio River Valley).
- By contrast, opportunistic fungi (e.g., *Candida, Aspergillus, Mucor, Cryptococcus*) are ubiquitous organisms that either colonize individuals or are encountered from environmental sources. In immunodeficient individuals, opportunistic fungi give rise to life-threatening invasive infections characterized by tissue necrosis, hemorrhage, and vascular occlusion, with little or no inflammatory response (Fig. 8–4). Patients with AIDS often are infected by the opportunistic fungus *Pneumocystis jiroveci* (previously called *Pneumocystis carinii*).

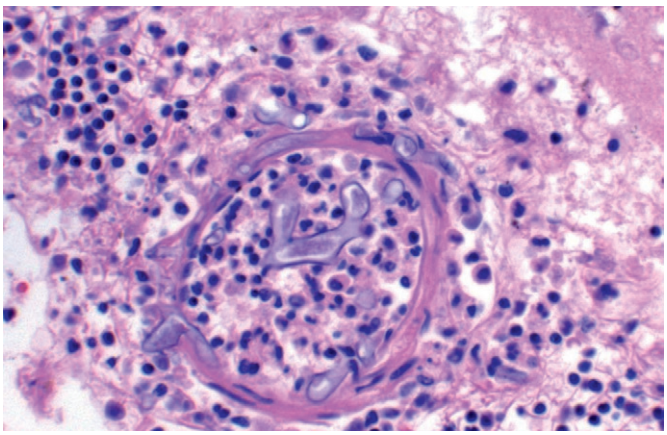

**Figure 8–4** Meningeal blood vessels with angioinvasive *Mucor* species. Note the irregular width and near right-angle branching of the hyphae. *(Courtesy of Dr. Dan Milner, Department of Pathology, Brigham and Women's Hospital, Boston, Massachusetts.)*

### Protozoa

Protozoa are single-celled eukaryotes that are major causes of disease and death in developing countries. Protozoa can replicate intracellularly within a variety of cells (e.g., *Plasmodium* in red cells, *Leishmania* in macrophages) or extracellularly in the urogenital system, intestine, or blood. *Trichomonas vaginalis* organisms are sexually transmitted flagellated protozoal parasites that often colonize the vagina and male urethra. The most prevalent intestinal protozoans, *Entamoeba histolytica* and *Giardia lamblia,* are ingested as nonmotile *cysts* in contaminated food or water and become motile *trophozoites* that attach to intestinal epithelial cells. Bloodborne protozoa (e.g., *Plasmodium*, *Trypanosoma*, *Leishmania*) are transmitted by insect vectors, in which they replicate before being passed to new human hosts. *Toxoplasma gondii* is acquired either through contact with oocyst-shedding kittens or by eating cyst-ridden, undercooked meat.

### Helminths

Parasitic worms are highly differentiated multicellular organisms. Their life cycles are complex; most alternate between sexual reproduction in the definitive host and asexual multiplication in an intermediate host or vector. Thus, depending on the species, humans may harbor adult worms (e.g., *Ascaris lumbricoides*), immature stages (e.g., *Toxocara canis*), or asexual larval forms (e.g., *Echinococcus* spp.). Once adult worms take up residence in humans, they usually do not multiply but they produce eggs or larvae that are usually passed out in stool. Often, the severity of disease is in proportion to the number of infecting organisms. For example, a burden of 10 hookworms is associated with mild or no clinical disease, whereas 1000 hookworms consume enough blood to cause severe anemia. In some helminthic infections, such as schistosomiasis, disease is caused by inflammatory responses to the eggs or larvae, rather than to the adults.

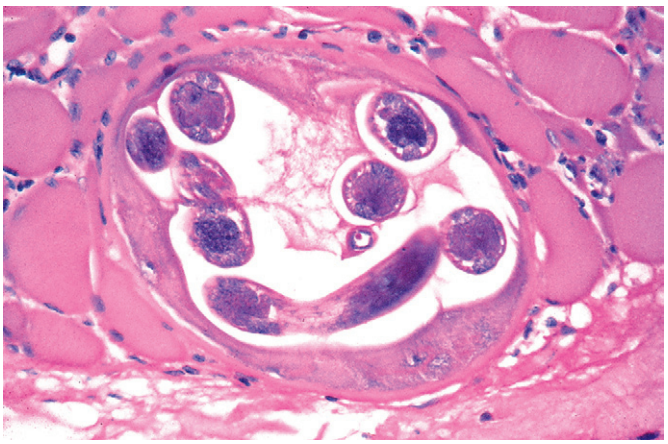

**Figure 8–5** Coiled *Trichinella spiralis* larva within a skeletal muscle cell.

Helminths comprise three groups:

- *Roundworms* (*nematodes*) are circular in cross-section and nonsegmented. Intestinal nematodes include *Ascaris lumbricoides*, *Strongyloides stercoralis*, and hookworms. Nematodes that invade into tissue include the filariae and *Trichinella spiralis* (Fig. 8–5).
- *Tapeworms* (*cestodes*) have a head (scolex) and a ribbon of multiple flat segments (proglottids). They adsorb nutrition through their tegument and do not have a digestive tract. They include the fish, beef, and pork tapeworms, found in the human intestine. The larvae that develop after ingestion of eggs of certain tapeworms can cause cystic disease within tissues (*Echinoccus granulosus* larvae cause *hydatid* cysts; pork tapeworm larvae produce cysts called cysticerci in many organs).
- *Flukes* (*trematodes*) are leaf-shaped flatworms with prominent suckers that are used to attach to the host. They include liver and lung flukes and schistosomes.

### Ectoparasites

Ectoparasites are insects (lice, bedbugs, fleas) or arachnids (mites, ticks, spiders) that attach to and live on or in the skin. Diseases caused directly by arthropods are characterized by itching and excoriations, such as pediculosis caused by lice attached to hairs, or scabies caused by mites burrowing into the stratum corneum. At the site of the bite, mouth parts may be found associated with a mixed infiltrate of lymphocytes, macrophages, and eosinophils. Arthropods also can serve as vectors for other pathogens, such as *Borrelia burgdorferi*, the agent of Lyme disease, which is transmitted by deer ticks.

## SPECIAL TECHNIQUES FOR IDENTIFYING INFECTIOUS AGENTS

Some infectious agents can be seen in hematoxylin and eosin (H&E)–stained sections (e.g., the inclusion bodies formed by CMV and herpes simplex virus (HSV); bacterial clumps, which usually stain blue; *Candida* and *Mucor* among the fungi; most protozoans; all helminths). Many infectious agents, however, are best visualized by special stains that identify organisms on the basis of particular characteristics of their cell wall or coat—Gram, acid-fast, silver, mucicarmine, and Giemsa stains—or after labeling with specific antibodies (Table 8–4). Organisms are usually best visualized at the advancing edge of a lesion rather than at its center, particularly if there is necrosis.

**Table 8–4** Special Techniques for Identifying Infectious Agents

| Technique | Infectious Agent(s) |
|---|---|
| Gram stain | Most bacteria |
| Acid-fast stain | Mycobacteria, nocardiae (modified) |
| Silver stains | Fungi, legionellae, *Pneumocystis* |
| Periodic acid–Schiff | Fungi, amebae |
| Mucicarmine | Cryptococci |
| Giemsa | Leishmaniae, *Plasmodium* |
| Antibodies | All classes |
| Culture | All classes |
| DNA probes | All classes |

Acute infections can be diagnosed serologically by detecting pathogen-specific antibodies in the serum. The presence of specific immunoglobulin M (IgM) antibody shortly after the onset of symptoms is often diagnostic. Alternatively, specific antibody titers can be measured early ("acute") and again at 4 to 6 weeks ("convalescent") after infection; a four-fold rise in titer usually is considered diagnostic. Assays for serum antibodies are very useful for the diagnosis of hepatitis caused by viruses.

Nucleic acid–based tests, collectively called *molecular diagnostics*, are used routinely to detect pathogens. Nucleic acid amplification techniques, such as polymerase chain reaction (PCR) and transcription-mediated amplification, are used for diagnosis of gonorrhea, chlamydial infection, tuberculosis, and herpes encephalitis. Molecular assays are much more sensitive than conventional testing for some pathogens. PCR testing of cerebrospinal fluid (CSF) for HSV encephalitis has a sensitivity of about 80%, whereas viral culture of CSF has a sensitivity of less than 10%. Similarly, nucleic acid tests for genital *Chlamydia* detect 10% to 30% more infections than does conventional *Chlamydia* culture. For other infections, such as gonorrhea, the sensitivity of nucleic acid testing is similar to that of culture. Quantitative nucleic acid amplification tests are used to guide the medical management of infections with human immunodeficiency virus (HIV), HBV and hepatitis C virus (HCV).

## NEW AND EMERGING INFECTIOUS DISEASES

A surprising number of new infectious agents continue to be discovered. The infectious causes of some important diseases were previously unrecognized, because some of the infectious agents are difficult to culture; examples include *Helicobacter pylori* gastritis and peptic ulcer disease, HBV and HCV, and Legionnaires disease (pneumonia). Some infectious agents are relatively new to humans—for example, HIV, which causes AIDS, and *B. burgdorferi*, which causes Lyme disease. Other infections have become much more common because of immunosuppression caused by AIDS or therapy to prevent transplant rejection and for some cancers (e.g., Kaposi sarcoma, *Mycobacterium*

*avium complex, P. jiroveci*). Finally, infectious diseases that are common in one geographic area may be introduced into a new area. For example, West Nile virus has been common in Europe, Asia, and Africa for years but was first described in the United States in 1999.

Several factors contribute to the emergence of infectious diseases:

- Human behavior affects the spread and demographics of infections. AIDS was first recognized in the United States as predominantly a disease of homosexual men and drug abusers, but heterosexual transmission is now more common. In sub-Saharan Africa, the area of the world with the highest number of AIDS cases, it is predominantly a heterosexual disease.
- Changes in the environment occasionally drive rates of infectious diseases. Deforestation of the eastern United States has led to massive increases in deer and mice, which carry the ticks that transmit Lyme disease, babesiosis, and ehrlichiosis. Global warming has also had an impact on the spread of infections. For example, the mosquitoes that carry Dengue fever, which used to be confined to the U.S.-Mexican border, are now found in 28 states.
- Pathogens adapt rapidly to selective pressures exerted by widespread use (and overuse) of antibiotics. Antibiotic resistance has developed and is now common in *Mycobacterium tuberculosis*, *Neisseria gonorrhoeae*, and *Staphylococcus aureus*. Similarly, development of drug-resistant parasites has dramatically increased the morbidity and mortality associated with *Plasmodium falciparum* infection in Asia, Africa, and Latin America.

**Table 8–5** Potential Agents of Bioterrorism

| Category A Diseases and Agents |
|---|
| Anthrax: *Bacillus anthracis* |
| Botulism: *Clostridium botulinum* toxin |
| Plague: *Yersinia pestis* |
| Smallpox: *Variola major* virus |
| Tularemia: *Francisella tularensis* |
| Viral hemorrhagic fevers: filoviruses (e.g., Ebola, Marburg) and arenaviruses (e.g., Lassa, Machupo) |
| **Category B Diseases and Agents** |
| Brucellosis: *Brucella* spp. |
| Epsilon toxin of *Clostridium perfringens* |
| Food safety threats: *Salmonella* spp., *Escherichia coli* O157:H7, *Shigella*, others |
| Glanders: *Burkholderia mallei* |
| Melioidosis: *Burkholderia pseudomallei* |
| Psittacosis: *Chlamydia psittaci* |
| Q fever: *Coxiella burnetii* |
| Ricin toxin from castor beans (*Ricinus communis*) |
| Staphylococcal enterotoxin B |
| Typhus fever: *Rickettsia prowazekii* |
| Viral encephalitis: alphaviruses (e.g., Venezuelan equine encephalitis, Eastern equine encephalitis, Western equine encephalitis) |
| Water safety threats: *Vibrio cholerae*, *Cryptosporidium parvum*, others |
| **Category C Diseases and Agents** |
| Emerging infectious disease threats: Nipah virus, hantavirus, possibly others |

Adapted from Centers for Disease Control and Prevention Information (www.bt.cdc.gov/bioterrorism/2011).

## AGENTS OF BIOTERRORISM

Sadly, the anthrax attacks in the United States in 2001 transformed the theoretical threat of bioterrorism into reality. The Centers for Disease Control and Prevention (CDC) has evaluated the microorganisms that pose the greatest danger as weapons on the basis of the efficiency with which disease can be transmitted, how difficult the microorganisms are to produce and distribute, what can be done to defend against them, and the extent to which they are likely to alarm the public and produce widespread fear. Based on these criteria, the CDC has ranked bioweapons into three categories, designated A, B, and C (Table 8–5).

The agents in the highest-risk category A can be readily disseminated or transmitted from person to person, typically cause diseases that can carry a high mortality rate with potential for major public health impact, may cause pandemics leading to public panic and social disruption, and are likely to require special action for public health preparedness. For example, the smallpox virus is a category A agent because of its high transmissibility, case mortality rates of 30% or greater, and the lack of effective antiviral therapy. Smallpox readily spreads from person to person, mainly through respiratory secretions and by direct contact with virus in skin lesions. After an incubation period of 7 to 17 days, the usual presenting manifestations are high fever, headache, and backache, followed by a rash, which first appears on the mucosa of the mouth and pharynx, face, and forearms and spreads to the trunk and legs. The rash initially is vesicular and later becomes pustular. Because affected persons are contagious during the incubation period, smallpox virus can rapidly spread throughout an unprotected population. Since routine smallpox vaccination ended in the United States in 1972, immunity has waned, leaving the population highly susceptible. Concern that smallpox could be used for bioterrorism has led to reinstitution of vaccination for some medical and military personnel.

Category B agents are moderately easy to disseminate, cause disease associated with moderate morbidity but low mortality, and require specific diagnostic and disease surveillance. Many of these agents can be spread in food or water. Category C agents include emerging pathogens that could be engineered for mass dissemination because of ease of availability, production, and dissemination; the potential for high morbidity and mortality; and great impact on health.

## TRANSMISSION AND DISSEMINATION OF MICROBES

### Routes of Entry of Microbes

Microbes can enter the host through breaches in the skin, inhalation, ingestion, or sexual transmission. The first defenses against infection are intact skin and mucosal surfaces, which provide physical barriers and produce

antimicrobial substances. In general, respiratory, gastrointestinal, or genitourinary tract infections that occur in otherwise healthy persons are caused by relatively virulent microorganisms that are capable of damaging or penetrating intact epithelial barriers. By contrast, most skin infections in healthy persons are caused by less virulent organisms that enter the skin through damaged sites (cuts and burns).

### Skin

The dense, keratinized outer layer of skin is a natural barrier to infection, and the low pH of the skin (less than 5.5) and the presence of fatty acids inhibit growth of microorganisms other than the normal flora. Skin normally is inhabited by bacteria and fungi, including potential opportunists, such as *S. aureus* and *Candida albicans.*

*Most microorganisms penetrate through breaks in the skin*, including superficial pricks (fungal infections), wounds (staphylococci), burns (*Pseudomonas aeruginosa*), and diabetic and pressure-related foot sores (multibacterial infections). Intravenous catheters in hospitalized patients provide portals for local or systemic infection. Needle sticks can expose the recipient to infected blood and transmit HBV, hepatitis C virus (HCV), or HIV. Some pathogens penetrate the skin via an insect or animal bite. Bites by fleas, ticks, mosquitoes, mites, and lice break the skin and transmit arboviruses (causes of yellow fever and encephalitis), bacteria (plague, Lyme disease, Rocky Mountain spotted fever), protozoa (malaria, leishmaniasis), and helminths (filariasis). Animal bites can lead to infections with bacteria or certain viruses, such as rabies. Only a few microorganisms are able to traverse the unbroken skin. For example, *Schistosoma* larvae released from freshwater snails penetrate swimmers' skin by releasing enzymes that dissolve the extracellular matrix. Certain fungi (dermatophytes) can infect intact stratum corneum, hair, and nails.

### Gastrointestinal Tract

Gastrointestinal pathogens are transmitted by food or drink contaminated with fecal material. When hygiene fails, as may occur with natural disasters such as floods and earthquakes, diarrheal disease becomes rampant.

Acidic gastric secretions are important defenses and are lethal for many gastrointestinal pathogens. Healthy volunteers do not become infected by *Vibrio cholerae* unless they are fed $10^{11}$ organisms, but neutralizing the stomach acid reduces the infectious dose by 10,000-fold. By contrast, some ingested agents, such as *Shigella* and *Giardia* cysts, are relatively resistant to gastric acid, so fewer than 100 organisms of each can cause illness.

Other normal defenses within the gastrointestinal tract include (1) the layer of viscous mucus covering the intestinal epithelium, (2) lytic pancreatic enzymes and bile detergents, (3) mucosal antimicrobial peptides called defensins, (4) normal flora, and (5) secreted IgA antibodies. IgA antibodies are made by plasma cells located in mucosa-associated lymphoid tissue (MALT). These lymphoid aggregates are covered by a single layer of specialized epithelial cells called M cells, which are important for transport of antigens to MALT. Numerous gut pathogens use M cells to enter the host from the intestinal lumen, including poliovirus, enteropathic *Escherichia coli, V. cholerae, Salmonella typhi*, and *Shigella flexneri*.

*Infection via the gastrointestinal tract occurs when local defenses are weakened or the organisms develop strategies to overcome these defenses.* Host defenses are weakened by low gastric acidity, by antibiotics that alter the normal bacterial flora (e.g., in pseudomembranous colitis), or when there is stalled peristalsis or mechanical obstruction. Viruses that can enter the body through the intestinal tract (e.g., hepatitis A, rotavirus) are those that lack envelopes, because enveloped viruses are inactivated by bile and digestive enzymes.

*Enteropathogenic bacteria* cause gastrointestinal disease in several ways:

- *S. aureus* can contaminate and grow in food, where it releases powerful enterotoxins that, when ingested, cause food poisoning without any bacterial multiplication in the gut.
- *V. cholerae* and enterotoxigenic *E. coli* bind to the intestinal epithelium and multiply in the overlying mucous layer, where they release exotoxins that cause epithelial cells to secrete large volumes of fluid, resulting in watery diarrhea.
- *Shigella*, *Salmonella*, and *Campylobacter* invade locally and damage the intestinal mucosa and lamina propria, causing ulceration, inflammation, and hemorrhage—changes manifested clinically as dysentery.
- *Salmonella typhi* passes from the damaged mucosa through Peyer's patches and mesenteric lymph nodes and into the bloodstream, resulting in a systemic infection.

*Fungal infection* of the gastrointestinal tract occurs mainly in immunologically compromised persons. *Candida*, part of the normal gastrointestinal flora, shows a predilection for stratified squamous epithelium, causing oral thrush or membranous esophagitis, but also may spread to the stomach, lower gastrointestinal tract, and other organs.

*Intestinal protozoa* are transmitted as cysts, which resist stomach acid. In the gut, cysts convert to motile trophozoites and attach to sugars on the intestinal epithelia through surface lectins. What happens next differs among protozoa. *Giardia lamblia* attaches to the epithelial brush border, whereas cryptosporidia are taken up by enterocytes, in which they form gametes and oocysts. *E. histolytica* kills host cells by contact-mediated cytolysis through a channel-forming pore protein, with consequent ulceration and invasion of the colonic mucosa. *Intestinal helminths* cause disease when they are present in large numbers or by reaching ectopic sites, for example, by obstructing the gut or invading and damaging the bile ducts (*Ascaris lumbricoides*). Hookworms cause iron deficiency anemia by sucking blood from intestinal villi; *Diphyllobothrium*, the fish tapeworm, causes anemia by depriving the host of vitamin $B_{12}$. Finally, larvae of several helminths pass through the gut briefly on their way to another organ; for example, *Trichinella spiralis* larvae preferentially encyst in muscle, and *Echinococcus* larvae grow in the liver or lung.

### Respiratory Tract

A large number of microorganisms, including viruses, bacteria, and fungi, are inhaled daily by every person. In many cases, the microbes are inhaled in dust or aerosol particles.

The distance these particles travel into the respiratory system is inversely proportional to their size. Large particles are trapped in the mucociliary blanket that lines the nose and the upper respiratory tract. Microorganisms trapped in the mucus secreted by goblet cells are transported by ciliary action to the back of the throat, where they are swallowed and cleared. Particles smaller than 5 µm travel directly to the alveoli, where they are phagocytosed by alveolar macrophages or by neutrophils recruited to the lung by cytokines.

*Microorganisms that invade the normal healthy respiratory tract have developed specific mechanisms to overcome mucociliary defenses or to avoid destruction by alveolar macrophages*. Some successful respiratory viruses evade these defenses by attaching to and entering epithelial cells in the lower respiratory tract and pharynx. For example, influenza viruses possess hemagglutinin proteins that project from the surface of the virus and bind to sialic acid on the surface of epithelial cells. This attachment induces the host cell to engulf the virus, leading to viral entry and replication within the host cell.

Certain bacterial respiratory pathogens, including *Haemophilus influenzae*, *Mycoplasma pneumoniae*, and *Bordetella pertussis*, release toxins that impair ciliary activity. Some bacteria lack the ability to overcome the defenses of the healthy lung and can cause respiratory infections only in compromised hosts. *S. pneumoniae* and *S. aureus* can cause pneumonia subsequent to influenza, because the viral infection causes loss of the protective ciliated epithelium. Chronic damage to mucociliary defense mechanisms occurs in smokers and people with cystic fibrosis, while acute injury occurs in intubated patients and in those who aspirate gastric acid.

*Some respiratory pathogens avoid phagocytosis or destruction after phagocytosis. M. tuberculosis*, for example, gains its foothold in alveoli because it escapes killing within the phagolysosomes of macrophages. Opportunistic fungi infect the lungs when cellular immunity is depressed or when leukocytes are reduced in number (e.g., *P. jiroveci* in patients with AIDS, *Aspergillus* spp. after chemotherapy).

### *Urogenital Tract*

*The urinary tract is almost always invaded from the exterior by way of the urethra.* The regular flushing of the urinary tract with urine serves as a defense against invading microorganisms. Urine in the bladder is normally sterile, and successful pathogens (e.g., *N. gonorrhoeae, E. coli*) adhere to the urinary epithelium. Anatomy plays an important role in infection. Women have more than 10 times as many urinary tract infections as in men because the distance between the urinary bladder and skin (i.e., the length of the urethra) is 5 cm in women, in contrast with 20 cm in men. Obstruction of urinary flow or reflux can compromise normal defenses and increase susceptibility to urinary tract infections. Urinary tract infections often spread in retrograde fashion from the bladder to the kidney and cause acute and chronic pyelonephritis.

From puberty until menopause the vagina is protected from pathogens by a low pH resulting from catabolism of glycogen in the normal epithelium by lactobacilli. Antibiotics can kill the lactobacilli, allowing overgrowth of yeast, with resultant vaginal candidiasis.

## Spread and Dissemination of Microbes Within the Body

*Some microorganisms proliferate locally, at the site of initial infection, whereas others penetrate the epithelial barrier and spread to distant sites by way of the lymphatics, the blood, or nerves* (Fig. 8–6). Pathogens that cause superficial infections stay confined to the lumen of hollow viscera (e.g., *Vibrio cholerae*) or adhere to or proliferate exclusively in or on epithelial cells (e.g., papillomaviruses, dermatophytes).

Microbes can spread within the body in several ways:

- Some extracellular bacteria, fungi, and helminths secrete lytic enzymes which destroy tissue and allow direct invasion. For example, *S. aureus* secretes hyaluronidase, which degrades the extracellular matrix between host cells. Invasive microbes initially follow tissue planes of least resistance and drain to regional lymphatics. *S. aureus* may travel from a localized abscess to the draining lymph nodes. This can sometimes lead to bacteremia and spread to deep organs (heart, bone).
- Microorganisms may be spread in the blood or lymph either free in extracellular fluid or within host cells. Some viruses (e.g., poliovirus, HBV), most bacteria and

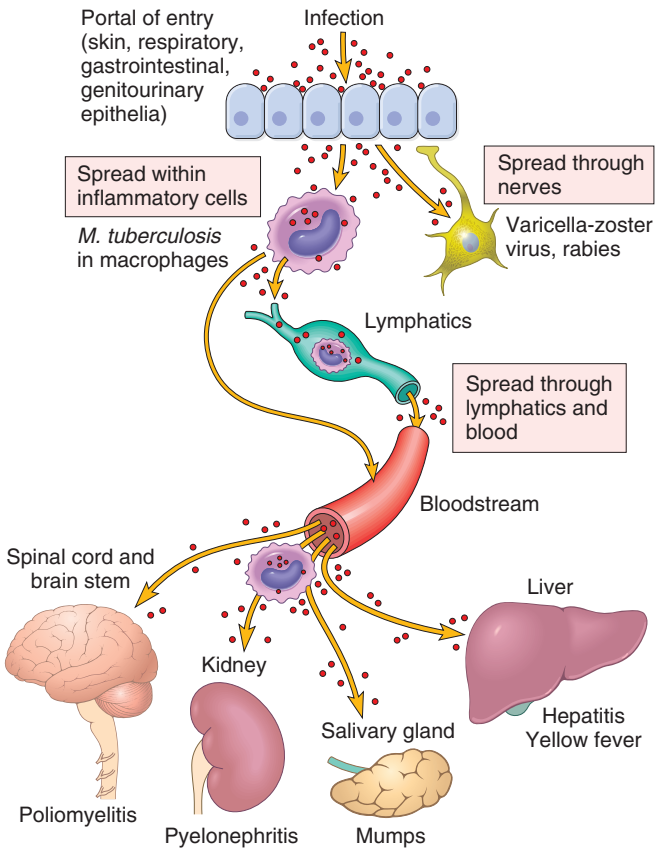


**Figure 8–6** Routes of entry and dissemination of microbes. To enter the body, microbes penetrate epithelial or mucosal barriers. Infection may remain localized at the site of entry or spread to other sites in the body. Most common microbes (selected examples are shown) spread through the lymphatics or bloodstream (either freely or within inflammatory cells). However, certain viruses and bacterial toxins also may travel through nerves.

*(Adapted from Mims CA: The Pathogenesis of Infectious Disease, 4th ed. San Diego, Academic Press, 1996.)*

fungi, some protozoa (e.g., African trypanosomes), and all helminths are transported in blood, free in the plasma. Leukocytes can carry herpesviruses, HIV, mycobacteria, *Leishmania,* and *Toxoplasma.* The parasites *Plasmodium* and *Babesia* are carried within red blood cells.

- Most viruses spread locally from cell to cell by replication and release of infectious virions, but others may propagate from cell to cell by causing fusion of host cells, or by transport within nerves (as with rabies virus and varicella-zoster virus).

Spread of pathogens in the blood can have inconsequential or dire consequences. Infectious foci seeded by blood can be single and large (as with an abscess or tuberculoma) or multiple and tiny (as with miliary tuberculosis or *Candida* microabscesses). Sporadic bloodstream invasion by low-virulence or nonvirulent microbes (e.g., during brushing of teeth) is common but is quickly controlled by normal host defenses. By contrast, disseminated viremia, bacteremia, fungemia, or parasitemia by virulent pathogens is a serious danger and manifests as fever, low blood pressure, and multiple other systemic signs and symptoms of sepsis. Massive bloodstream invasion by bacteria can rapidly lead to fatal sepsis, even in previously healthy persons.

*The major manifestations of infectious disease may appear at sites distant from the point of microbe entry.* For example, varicella-zoster and measles viruses enter through the airways but cause rashes in the skin; poliovirus enters through the intestine but kills motor neurons to cause paralysis. *Schistosoma mansoni* parasites penetrate the skin but eventually localize in blood vessels of the portal system and mesentery, damaging the liver and intestine. *Schistosoma hematobium* localizes to the urinary bladder and causes cystitis. The rabies virus travels from the site of a bite by a rabid animal to the brain by retrograde transport in sensory neurons, where it then causes encephalitis and death.

## Release from the Body and Transmission of Microbes

Transmission depends on the hardiness of the microbe. Some microbes can survive for extended periods in dust, food, or water. Bacterial spores, protozoan cysts, and thick-shelled helminth eggs can survive in a cool and dry environment. Less hardy microorganisms must be quickly passed from person to person, often by direct contact.

For transmission of disease, the mode of exit of a microorganism from the host's body is as important as entry into it. Every fluid or tissue that is normally secreted, excreted, or shed is used by microorganisms to leave the host for transmission to new victims.

- Skin flora, such as *S. aureus,* and pathogens, including the dermatophyte fungi, are shed in the desquamated skin. Some sexually transmitted pathogens are transmitted from genital skin lesions.
- Viruses that replicate in the salivary glands and are spread in saliva include mumps virus, cytomegalovirus, and rabies virus.
- Viruses and bacteria that are part of the normal respiratory flora or cause respiratory tract infections are shed in respiratory secretions during talking, coughing, and sneezing. Most respiratory pathogens, including influenza viruses, spread in large respiratory droplets, which travel no more than 3 feet. A few organisms, including *M. tuberculosis* and varicella-zoster virus, are spread from the respiratory tract by the airborne route in small respiratory droplets or within dust particles, which can travel long distances.
- Organisms shed in stool include many pathogens that replicate in the lumen or epithelium of the gut, such as *Shigella, Giardia lamblia,* and rotavirus. Pathogens that replicate in the liver (hepatitis A virus) or gallbladder (*Salmonella* serotype typhi) enter the intestine in bile and are shed in stool.
- Pathogens which exit the body in the blood are transmitted by invertebrate vectors, medical practices (blood transfusion, reuse of equipment) or sharing of needles by intravenous drug abusers. Bloodborne parasites, including *Plasmodium* spp. and arboviruses, are spread by biting insects.
- Urine is the usual mode of exodus from the human host by only a few organisms, including *Schistosoma haematobium,* which grows in the veins of the bladder and releases eggs that reach the urine.
- Sexually transmitted infections (STIs) infect and spread from the urethra, vagina, cervix, rectum, or oral pharynx. Organisms that cause STIs depend on direct contact for person-to-person spread because these pathogens do not survive in the environment. Transmission of STIs often is by asymptomatic people who do not realize that they are infected. Infection with one STI increases the risk for additional STIs, mainly because the risk factors are the same for all STIs. STIs are described in Chapters 17 and 18.
- Vertical transmission is from mother to fetus or newborn child, and occurs by three main anatomic routes. *Placental-fetal transmission* is most likely to occur when the mother has primary infection with a pathogen during pregnancy. The damage that occurs depends on the developmental stage of the fetus. For example, rubella infection during the first trimester can cause heart malformation, mental retardation, cataracts, or deafness in the infant, while little damage is caused by rubella infection during the third trimester. Vertical transmission also occurs during *passage of the neonate through the birth canal* (e.g., gonococcal or chlamydial conjunctivitis) or *through maternal milk* (e.g., CMV and HBV). Diagnosis of STIs in pregnant women is critical, because vertical transmission of STIs often can be prevented by treatment of the mother or newborn. For example, maternal transmission of HIV is the major cause of AIDS in children; it most often occurs prenatally, during delivery. Antiretroviral treatment of pregnant women with HIV infection and treatment of the newborn can reduce the rate of transmission of HIV to children from 25% to less than 2%.

Microbes also can be transmitted from animal to human (resulting in *zoonotic infections*), either through direct contact or consumption of animal products or indirectly by an invertebrate vector.

## SUMMARY

### Transmission of Microbes

- Transmission of infections can occur by contact (direct and indirect), respiratory droplets, fecal-oral route, sexual transmission, vertical transmission from mother to fetus or newborn, or insect/arthropod vectors.
- A pathogen can establish infection if it possesses virulence factors that overcome normal host defenses or if the host defenses are compromised.
- Host defenses against infection include:
  - *Skin:* tough keratinized barrier, low pH, fatty acids
  - *Respiratory system:* alveolar macrophages and mucociliary clearance by bronchial epithelium, IgA
  - *Gastrointestinal system:* acidic gastric pH, viscous mucus, pancreatic enzymes and bile, defensins, IgA, and normal flora
  - *Urogenital tract:* repeated flushing and acidic environment created by commensal vaginal flora

# HOW MICROORGANISMS CAUSE DISEASE

Infectious agents establish infection and damage tissues by any of three mechanisms:

- They can contact or enter host cells and directly cause cell death.
- They may release toxins that kill cells at a distance, release enzymes that degrade tissue components, or damage blood vessels and cause ischemic necrosis.
- They can induce host immune responses that, although directed against the invader, cause additional tissue damage. Thus, as discussed in Chapters 2 and 4, the defensive responses of the host can be a mixed blessing. They are necessary to overcome the infection but at the same time may directly contribute to tissue damage.

Described next are some of the mechanisms whereby viruses and bacteria damage host tissues.

## Mechanisms of Viral Injury

*Viruses can directly damage host cells by entering them and replicating at the host's expense.* The manifestations of viral infection are largely determined by the tropism of the virus for specific tissues and cell types.

- *A major determinant of tissue tropism is the presence of viral receptors on host cells.* Viruses possess specific cell surface proteins that bind to particular host cell surface proteins. Many viruses use normal cellular receptors of the host to enter cells. For example, HIV glycoprotein gp120 binds to CD4 on T cells and to the chemokine receptors CXCR4 (mainly on T cells) and CCR5 (mainly on macrophages) (Chapter 4). In some cases, host proteases are needed to enable binding of virus to host cells; for instance, a host protease cleaves and activates the influenza virus hemagglutinin.
- The ability of the virus to replicate inside some cells but not in others depends on the presence of cell type–specific transcription factors that recognize viral enhancer and promoter elements. For example, the JC virus, which causes leukoencephalopathy (Chapter 22), replicates specifically in oligodendroglia in the CNS, because the promoter and enhancer DNA sequences regulating viral gene expression are active in glial cells but not in neurons or endothelial cells.
- Physical circumstances, such as chemicals and temperature, contribute to tissue tropism. For example, enteroviruses replicate in the intestine in part because they can resist inactivation by acids, bile, and digestive enzymes. Rhinoviruses infect cells only within the upper respiratory tract because they replicate optimally at the lower temperatures characteristic of this site.

Once viruses are inside host cells, they can damage or kill the cells by a number of mechanisms (Fig. 8–7):

- *Direct cytopathic effects.* Viruses can kill cells by preventing synthesis of critical host macromolecules, by producing degradative enzymes and toxic proteins, or by inducing apoptosis. For example, poliovirus blocks synthesis of host proteins by inactivating cap-binding protein, which is essential for translation of host cell messenger RNAs (mRNAs) but leaves translation of poliovirus mRNAs unaffected. HSV produces proteins that inhibit synthesis of cellular DNA and mRNA and

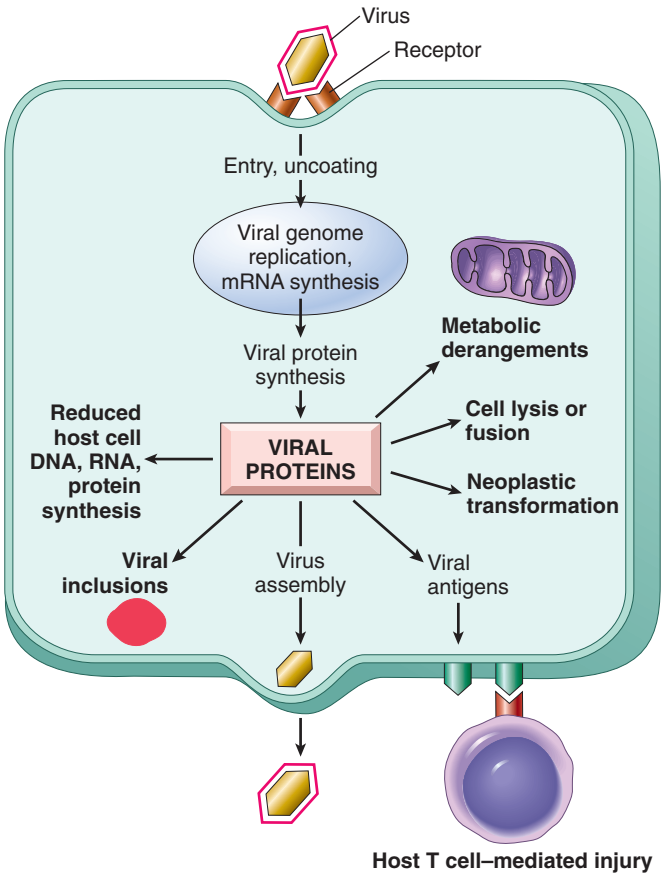


**Figure 8–7** Mechanisms by which viruses cause injury to cells.

other proteins that degrade host DNA. Some viruses can stimulate apoptosis by production of proteins that are proapoptotic (e.g., HIV vpr protein). Viral replication also can trigger apoptosis of host cells by cell-intrinsic mechanisms, such as perturbations of the endoplasmic reticulum during virus assembly, which can activate proteases that mediate apoptosis (caspases).

- *Antiviral immune responses.* Viral proteins on the surface of host cells may be recognized by the immune system, and lymphocytes may attack virus-infected cells. Cytotoxic T lymphocytes (CTLs) are important for defense against viral infections, but CTLs also can be responsible for tissue injury. Acute liver failure during hepatitis B infection may be accelerated by CTL-mediated destruction of infected hepatocytes (a normal response to clear the infection).
- *Transformation of infected cells* into benign or malignant tumor cells. Different oncogenic viruses can stimulate cell growth and survival by a variety of mechanisms, including expression of virus-encoded oncogenes, antiapoptotic strategies, and insertional mutagenesis (in which the insertion of viral DNA into the host genome alters the expression of nearby host genes). The mechanisms of viral transformation are numerous and are discussed in Chapter 5.

## Mechanisms of Bacterial Injury

### Bacterial Virulence

*Bacterial damage to host tissues depends on the ability of the bacteria to adhere to host cells, invade cells and tissues, or deliver toxins.* Pathogenic bacteria have virulence genes that encode proteins conferring these properties. Virulence genes frequently are found grouped together in clusters called *pathogenicity islands*. A small number of virulence genes can determine whether a bacterium is harmful. The *Salmonella* strains that infect humans are so closely related that they are a single species, but a small number of virulence genes determine whether an isolate of *Salmonella* causes life-threatening typhoid fever or self-limited gastroenteritis.

Plasmids and bacteriophages (viruses) are genetic elements that spread between bacteria and can encode virulence factors, including toxins, or enzymes that confer antibiotic resistance. Bacteriophages or plasmids can convert otherwise nonpathogenic bacteria into virulent ones. Exchange of these elements between bacteria can endow the recipient with a survival advantage and/or the capacity to cause disease. Plasmids or transposons encoding antibiotic resistance can convert an antibiotic-susceptible bacterium into a resistant one, making effective therapy difficult.

Populations of bacteria also can act together in ways that alter their virulence.

- Many species of bacteria coordinately regulate gene expression within a large population by *quorum sensing,* in which specific genes, such as virulence genes, are expressed when bacteria reach high concentrations. This in turn may allow bacteria growing in discrete host sites, such as an abscess or consolidated pneumonia, to overcome host defenses. *S. aureus* coordinately regulates virulence factors by secreting *autoinducer peptides.* As the bacteria grow to increasing concentrations, the level of the autoinducer peptide increases, stimulating exotoxin production.
- Communities of bacteria can form *biofilms* in which the organisms live within a viscous layer of extracellular polysaccharides that adhere to host tissues or devices such as intravascular catheters and artificial joints. Biofilms make bacteria inaccessible to immune effector mechanisms and increase their resistance to antimicrobial drugs. Biofilm formation seems to be important in the persistence and relapse of infections such as bacterial endocarditis, artificial joint infections, and respiratory infections in people with cystic fibrosis.

### Bacterial Adherence to Host Cells

Bacterial surface molecules that bind to host cells or extracellular matrix are called *adhesins.* Diverse surface structures are involved in adhesion of various bacteria (Fig. 8–2). *Streptococcus pyogenes* has protein F and teichoic acid projecting from its cell wall that bind to fibronectin on the surface of host cells and in the extracellular matrix. Other bacteria have filamentous proteins called pili on their surfaces. Stalks of pili are structurally conserved, whereas amino acids on the tips of the pili vary and determine the binding specificity of the bacteria. Strains of *E. coli* that cause urinary tract infections uniquely express a specific P pilus, which binds to a gal(α1–4)gal moiety expressed on uroepithelial cells. Pili on *N. gonorrhoeae* bacteria mediate adherence of the bacteria to host cells and also are targets of the host antibody response. Variation in the type of pili expressed is an important mechanism by which *N. gonorrhoeae* escapes the immune response.

### Virulence of Intracellular Bacteria

Facultative intracellular bacteria usually infect epithelial cells (*Shigella* and enteroinvasive *E. coli*), macrophages (*M. tuberculosis, M. leprae*), or both (*S. typhi*). The growth of bacteria in cells may allow them to escape from certain immune effector mechanisms, such as antibodies and complement, or may facilitate spread of the bacteria in the body, as when macrophages carry *M. tuberculosis* from the lung to other sites.

Bacteria have evolved a number of mechanisms for entering host cells. Some bacteria use the host immune response to enter macrophages. Coating of bacteria with antibodies or the complement protein C3b (opsonization) elicits phagocytosis of bacteria by macrophages. Like many bacteria, *M. tuberculosis* activates the alternative complement pathway, resulting in opsonization with C3b and uptake by host macrophages in which the mycobacteria live. Some gram-negative bacteria use a *type III secretion system* to enter epithelial cells. This system consists of needle-like structures projecting from the bacterial surface that bind and form pores in the host cell membrane through which proteins are injected that mediate rearrangement of the cell cytoskeleton and facilitate bacterial entry. Finally, bacteria such as *Listeria monocytogenes* can manipulate the cell cytoskeleton to spread directly from cell to cell, perhaps allowing the bacteria to evade immune defenses.

Intracellular bacteria have different strategies for interacting with the host cell. *Shigella* and *E. coli* inhibit host

protein synthesis, replicate rapidly, and lyse the host cell within hours. Although most bacteria in macrophages are killed when the phagosome fuses with the acidic lysosome to form a phagolysosome, certain bacteria elude this host defense. For example, *M. tuberculosis* blocks fusion of the lysosome with the phagosome, allowing the bacteria to proliferate unchecked within the macrophage. Other bacteria avoid destruction in macrophages by escaping from the phagosome. *L. monocytogenes* produces a pore-forming protein called listeriolysin O and two phospholipases that degrade the phagosome membrane, allowing the bacteria to escape into the cytoplasm.

### *Bacterial Toxins*

Any bacterial substance that contributes to illness can be considered a toxin. Toxins are classified as endotoxins, which are components of the bacterial cell, and exotoxins, which are proteins that are secreted by the bacterium.

*Bacterial endotoxin* is a lipopolysaccharide (LPS) that is a component of the outer membrane of gram-negative bacteria (Fig. 8–2). LPS is composed of a long-chain fatty acid anchor, termed lipid A, connected to a core sugar chain, both of which are very similar in all gram-negative bacteria. Attached to the core sugar is a variable carbohydrate chain (O antigen), which is used diagnostically to serotype strains of bacteria. Lipid A binds to CD14 on the surface of host leukocytes, and the complex then binds to Toll-like receptor 4 (TLR4), a pattern recognition receptor of the innate immune system that transmits signals that promote cell activation and inflammatory responses. Responses to LPS can be both beneficial and harmful to the host. The response is beneficial in that LPS activates protective immunity in several ways, including induction of important cytokines and chemoattractants (chemokines) of the immune system, as well as increased expression of costimulatory molecules, which enhance T lymphocyte activation. However, high levels of LPS play an important role in septic shock, disseminated intravascular coagulation (DIC), and acute respiratory distress syndrome, mainly through induction of excessive levels of cytokines such as TNF (Chapter 4).

*Exotoxins* are secreted proteins that cause cellular injury and disease. They can be classified into broad categories by their mechanism and site of action.

- *Enzymes.* Bacteria secrete a variety of enzymes (proteases, hyaluronidases, coagulases, fibrinolysins) that act on their respective substrates in vitro, but their role in disease is understood in only a few cases. For example, exfoliative toxins are proteases produced by *S. aureus* that cleave proteins known to hold keratinocytes together, causing the epidermis to detach from the deeper skin.
- *Toxins that alter intracellular signaling or regulatory pathways.* Most of these toxins have an active (A) component with enzymatic activity and a binding (B) component that binds cell surface receptors and delivers the A protein into the cell cytoplasm. The effect of these toxins depends on the binding specificity of the B domain and the cellular pathways affected by the A domain. A-B toxins are made by many bacteria including *Bacillus anthracis, V. cholerae,* and *Corynebacterium diphtheriae.* The mechanism of action of the A-B anthrax toxin is well understood (Fig. 8–8). Anthrax toxin has two alternate A components, edema factor (EF) and lethal factor (LF), which enter cells following binding to the B component and mediate different pathologic effects.
- *Superantigens* stimulate very large numbers of T lymphocytes by binding to conserved portions of the T cell receptor, leading to massive T lymphocyte proliferation and cytokine release. The high levels of cytokines lead to capillary leak and consequent shock. Superantigens made by *S. aureus* and *S. pyogenes* cause toxic shock syndrome (TSS).
- *Neurotoxins* produced by *Clostridium botulinum* and *Clostridium tetani* inhibit release of neurotransmitters, resulting in paralysis. These toxins do not kill neurons; instead, the A domains cleave proteins involved in secretion of neurotransmitters at the synaptic junction. Tetanus and botulism can result in death from respiratory failure due to paralysis of the chest and diaphragm muscles.
- Enterotoxins affect the gastrointestinal tract in different ways to cause varied effects, including nausea and vomiting (*S. aureus*), voluminous watery diarrhea (*V. cholerae*), or bloody diarrhea (*C. difficile*).

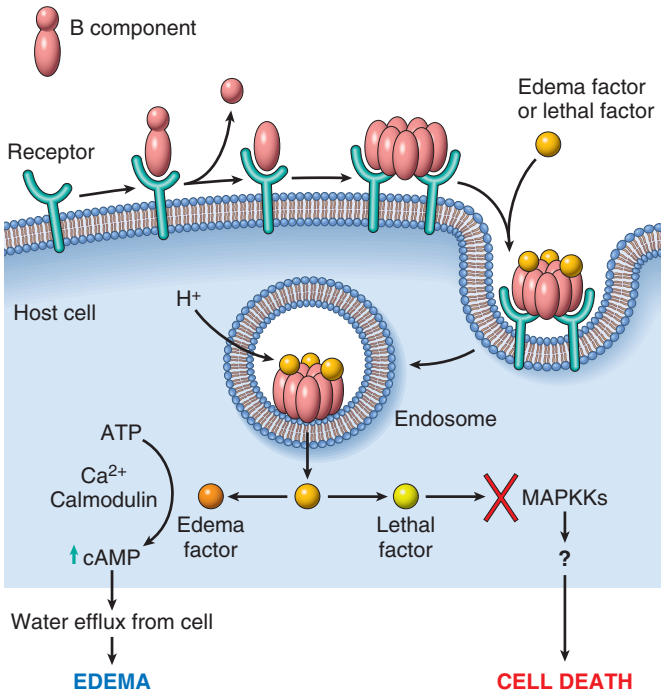


**Figure 8–8** Mechanism of anthrax exotoxin action. The B component, also called "protective antigen," binds a cell-surface protein, is cleaved by a host protease, and forms a heptamer. Three A subunits of edema factor (EF) or lethal factor (LF) bind to the B heptamer, enter the cell, and are released into the cytoplasm. EF binds calcium and calmodulin to form an adenylate cyclase that increases intracellular cAMP, which causes efflux of water and interstitial edema. LF is a protease that destroys mitogen-activated protein kinase kinases (MAPKKs), leading to cell death. cAMP, cyclic adenosine monophosphate.

## Injurious Effects of Host Immune Responses

As mentioned earlier, the host immune response to microbes can sometimes be the cause of tissue injury. The granulomatous inflammatory reaction to *M. tuberculosis* is

a delayed hypersensitivity response that sequesters the bacilli and prevents spread, but also produces tissue damage (caseous necrosis) and fibrosis. Similarly, the liver damage from HBV and HCV infection of hepatocytes is due mainly to the immune response to the infected liver cells and not to cytopathic effects of the virus. The humoral immune response to microbes also can have pathologic consequences. For example, poststreptococcal glomerulonephritis, which can develop after infection with *S. pyogenes,* is caused by antistreptococcal antibodies that bind to streptococcal antigens to form immune complexes, which deposit in renal glomeruli and produce nephritis. Thus, antimicrobial immune responses can have both beneficial and pathologic consequences.

Recent clinical, epidemiologic, and experimental studies suggest that infections may be associated with a wide variety of chronic inflammatory disorders as well as cancer. In some chronic inflammatory diseases, such as inflammatory bowel disease (Chapter 14), an important early event may be compromise of the intestinal epithelial barrier, which enables the entry of both pathogenic and commensal microbes and their interactions with local immune cells, resulting in inflammation. The cycle of inflammation and epithelial injury may be the basis for the disease, with microbes playing the central role. Certain viruses (HBV, HCV) and bacteria (*H. pylori*) that are not known to carry or to activate oncogenes are associated with cancers, presumably because these microbes trigger chronic inflammation with subsequent repair, which provides fertile ground for the development of cancer (Chapter 5).

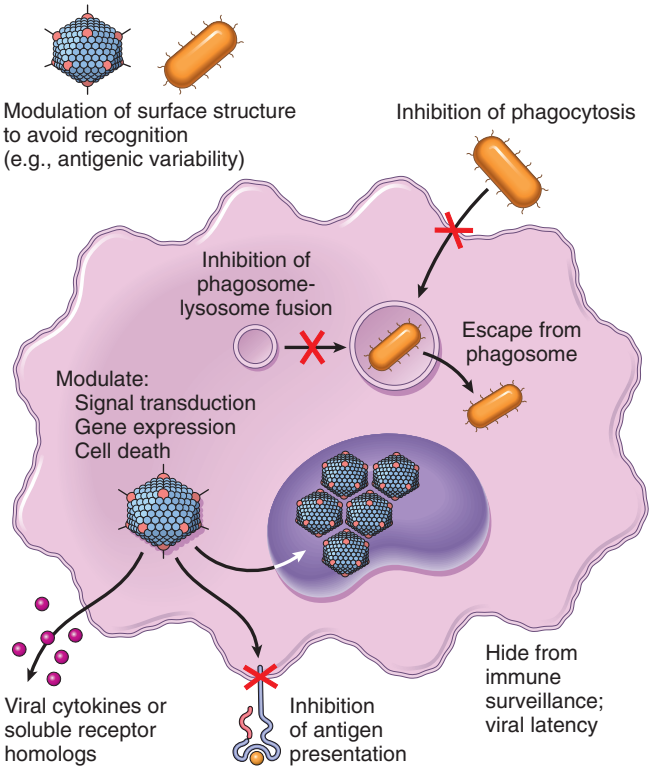


**Figure 8–9** An overview of mechanisms used by viral and bacterial pathogens to evade innate and adaptive immunity.
*(Modified with permission from Finlay B, McFadden G: Anti-immunology: evasion of the host immune system by bacterial and viral pathogens. Cell 124:767–782, 2006.)*

## SUMMARY

### How Microorganisms Cause Disease

- Diseases caused by microbes involve an interplay of microbial virulence and host responses.
  - Infectious agents can cause cell death or dysfunction by directly interacting with the cell.
  - Injury may be due to local or systemic release of bacterial products, including endotoxins (LPS), exotoxins, or superantigens.
  - Pathogens can induce immune responses that cause tissue damage. Absence of an immune response may reduce the damage induced by some infections; conversely, immunocompromise can allow uncontrolled expansion of opportunistic agents or of microorganisms that can directly cause injury.

## IMMUNE EVASION BY MICROBES

Humoral and cellular immune responses that protect the host from most infections are discussed in Chapter 4. Not surprisingly, microorganisms have developed many means to resist and evade the immune system (Fig. 8–9). These mechanisms, which are important determinants of microbial virulence and pathogenicity, include (1) antigenic variation, (2) resistance to innate immune defenses, and (3) impairment of effective T cell antimicrobial responses by specific or nonspecific immunosuppression.

*Some microbes can evade immune responses by varying the antigens they express.* Neutralizing antibodies block the ability of microbes to infect cells and recruit effector mechanisms to kill pathogens. To escape recognition, microbes use many strategies that involve genetic mechanisms for generating antigenic variation. The low fidelity of viral RNA polymerases (in HIV and many respiratory viruses including influenza virus) and reassortment of viral genomes (influenza viruses) create viral antigenic variation (Table 8–6). The spirochete *Borrelia recurrentis* repeatedly switches its surface antigens, and *Borrelia burgdorferi*, the

**Table 8-6** Mechanisms of Antigenic Variation

| Mechanism | Example | |
|---|---|---|
| | Agent(s) | Disease |
| High mutation rate | HIV | AIDS |
| | Influenza virus | Influenza |
| Genetic reassortment | Influenza virus | Influenza |
| | Rotavirus | Diarrhea |
| Genetic rearrangement (e.g., gene recombination, gene conversion, site-specific inversion) | *Borrelia burgdorferi* | Lyme disease |
| | *Neisseria gonorrhoeae* | Gonorrhea |
| | *Trypanosoma* spp. | African sleeping sickness |
| | *Plasmodium* spp. | Malaria |
| Large diversity of serotypes | Rhinoviruses | Colds |
| | *Streptococcus pneumoniae* | Pneumonia<br>Meningitis |

cause of Lyme disease, uses similar mechanisms to vary outer membrane proteins. *Trypanosoma* species have many genes for their major surface antigen, VSG, and can vary the expression of this surface protein. At least 80 different serotypes of *S. pneumoniae*, each with a different capsular polysaccharide, have been recognized.

*Some microbes have devised methods for actively resisting immune defenses.*

- Cationic antimicrobial peptides, including defensins, cathelicidins, and thrombocidins, provide important initial defenses against invading microbes. These peptides bind the bacterial membrane and form pores, killing the bacterium by hypoosmotic lysis. Bacterial pathogens (*Shigella* spp., *S. aureus*) avoid killing by making surface molecules that resist binding of antimicrobial peptides, or that inactivate or downregulate antimicrobial peptides by various mechanisms.
- Phagocytosis and killing of bacteria by polymorphonuclear leukocytes or neutrophils (PMNs) and monocytes constitute a critical host defense against extracellular bacteria. The carbohydrate capsule on the surface of many bacteria that cause pneumonia or meningitis (*S. pneumoniae, N. meningitidis, H. influenzae*) makes them more virulent by preventing phagocytosis of the organisms by neutrophils. Proteins on the surface of bacteria that inhibit phagocytosis include proteins A and M, expressed by *S. aureus* and *S. pyogenes,* respectively. Many bacteria make proteins that kill phagocytes, prevent their migration, or diminish their oxidative burst.
- *Viruses can produce molecules that inhibit innate immunity.* Viruses have developed a large number of strategies to combat interferons (IFNs), which are mediators of early host defense against viruses. Some viruses produce soluble homologues of IFN-α/β or IFN-γ receptors that bind to and inhibit actions of secreted IFNs, or produce proteins that inhibit intracellular JAK/STAT signaling downstream of IFN receptors. Viruses also may inactivate or inhibit double-stranded RNA–dependent protein kinase (PKR), a key mediator of the antiviral effects of IFN. Some viruses encode within their genomes homologues of cytokines, chemokines, or their receptors that act in various ways to inhibit immune responses. Finally, viruses have developed strategies to block apoptosis in the host cell, which may give the viruses time to replicate, persist or transform host cells.
- *Some microbes produce factors that decrease recognition of infected cells by CD4+ helper T cells and CD8+ cytotoxic T cells.* For example, several DNA viruses (e.g., herpesviruses, including HSV, CMV, and EBV) can bind to or alter localization of major histocompatibility complex (MHC) class I proteins, impairing peptide presentation to CD8+ cells. Downregulation of MHC class I molecules might make it likely that virus-infected cells would be targets for NK cells. However, herpesviruses also express MHC class I homologues that act as effective inhibitors of NK cells by engaging inhibitory receptors (Chapter 4). Herpesviruses can target MHC class II molecules for degradation, impairing antigen presentation to CD4+ T helper cells. Viruses also can infect leukocytes to directly compromise their function (e.g., HIV infects CD4+ T cells, macrophages, and dendritic cells).

## SUMMARY

### Immune Evasion by Microbes

After bypassing host tissue barriers, infectious microorganisms must also evade host innate and adaptive immunity mechanisms to successfully proliferate and be transmitted to the next host. Strategies include:

- Antigenic variation
- Inactivating antibodies or complement
- Resisting phagocytosis (e.g., by producing a capsule)
- Suppressing the host adaptive immune response (e.g., by inhibiting MHC expression and antigen presentation)

# SPECTRUM OF INFLAMMATORY RESPONSES TO INFECTION

In contrast with the vast molecular diversity of microbes, the morphologic patterns of tissue responses to microbes are limited, as are the mechanisms directing these responses. Therefore, many pathogens produce similar reaction patterns, and few features are unique to or pathognomonic for a particular microorganism. It is the interaction between the microbe and the host that determines the histologic features of the inflammatory response.

There are five major histologic patterns of tissue reaction in infections: suppurative, mononuclear/granulomatous, cytopathic-cytoproliferative, necrosis, and chronic inflammation/scarring.

### Suppurative (Purulent) Inflammation

This pattern is the reaction to acute tissue damage, characterized by increased vascular permeability and leukocytic infiltration, predominantly of neutrophils (Fig. 8–10). The neutrophils are attracted to the site of infection by release of chemoattractants from the "pyogenic" bacteria and host cells. Neutrophil enzymes cause liquefactive necrosis (Chapter 1).

## MORPHOLOGY

Collections of neutrophils give rise to localized liquefactive necrosis, forming **abscesses.** The necrotic tissue and

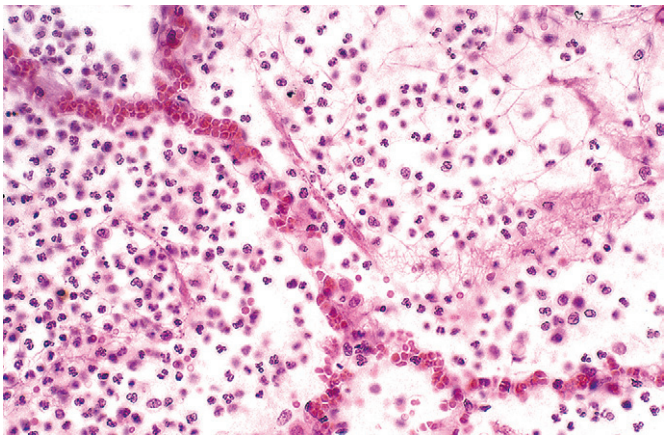

**Figure 8–10** Pneumococcal pneumonia. Note the intra-alveolar polymorphonuclear exudate and intact alveolar septa.

inflammatory cells constitute pus, and bacteria that evoke pus formation are called "pyogenic." Typically, these are extracellular bacteria. The sizes of such lesions can vary from tiny microabscesses formed by bacteria seeding from an infected heart valve, to distended, pus-filled fallopian tubes caused by *N. gonorrhoeae*, to diffuse involvement of the meninges during *H. influenzae* infection, to entire lobes of the lung during pneumonia. The extent to which the lesions are destructive depends on their location and the organism involved. Thus, *S. pneumoniae* usually spares alveolar walls in the lung, and even lobar streptococcal pneumonias typically resolve completely without permanent damage (Fig. 8–10). On the other hand, *S. aureus* and *Klebsiella pneumoniae* destroy alveolar walls and form abscesses that heal with scar formation. Bacterial pharyngitis resolves without sequelae, whereas untreated acute bacterial infection can destroy a joint in a few days.

### Mononuclear and Granulomatous Inflammation

Diffuse, predominantly mononuclear, interstitial infiltrates are a common feature of all chronic inflammatory processes, but development of such changes as an acute process often constitutes a response to viruses, intracellular bacteria, or intracellular parasites. In addition, spirochetes and some helminths provoke chronic mononuclear inflammatory responses.

#### MORPHOLOGY

Which mononuclear cell predominates within the inflammatory lesion depends on the host immune response to the organism. Thus, lymphocytes predominate in HBV infection (Fig. 8–11, *A*), whereas plasma cells are common in the primary and secondary lesions of syphilis (Fig. 8–11, *B*). The presence of these lymphoid cells reflects cell-mediated immune responses against the pathogen or pathogen-infected cells. Granulomatous inflammation is a distinctive form of mononuclear inflammation usually evoked by infectious agents that resist eradication (e.g., *M. tuberculosis, Histoplasma capsulatum,* schistosome eggs) but nevertheless are capable of stimulating strong T cell–mediated immunity. Granulomatous inflammation (Chapter 2) is characterized by accumulation of activated macrophages called "epithelioid" cells, which may fuse to form giant cells. In some cases, there is a central area of caseous necrosis (Fig. 8–11, *C*).

### Cytopathic-Cytoproliferative Reaction

Cytopathic-cytoproliferative reactions usually are produced by viruses. The lesions are characterized by cell necrosis or cellular proliferation, usually with sparse inflammatory cells.

#### MORPHOLOGY

Some viruses replicate within cells and make viral aggregates that are visible as inclusion bodies (e.g., herpesviruses or adenovirus) or induce cells to fuse and form multinucleated cells called polykaryons (e.g., measles virus or herpesviruses) (Fig. 8–1). Focal cell damage in the skin may cause epithelial cells to become detached, forming blisters. Some viruses can cause epithelial cells to proliferate (e.g., venereal warts caused by HPV or the umbilicated papules of molluscum contagiosum caused by poxviruses). Finally, viruses can contribute to the development of malignant neoplasms (Chapter 5).

### Tissue Necrosis

*Clostridium perfringens* and other organisms that secrete powerful toxins can cause such rapid and severe necrosis (gangrenous necrosis) that tissue damage is the dominant feature.

#### MORPHOLOGY

Because few inflammatory cells are present, necrotic lesions resemble infarcts with disruption or loss of basophilic nuclear staining and preservation of cellular outlines. Clostridia often are opportunistic pathogens that are introduced into muscle tissue by penetrating trauma or infection of the bowel in a neutropenic host. Similarly, the parasite *E. histolytica* causes colonic ulcers and liver abscesses characterized by extensive tissue destruction and liquefactive necrosis without a prominent inflammatory infiltrate. By entirely different mechanisms, viruses can cause widespread necrosis of host cells associated with inflammation, as exemplified by destruction of the temporal lobes of the brain by HSV or the liver by HBV.

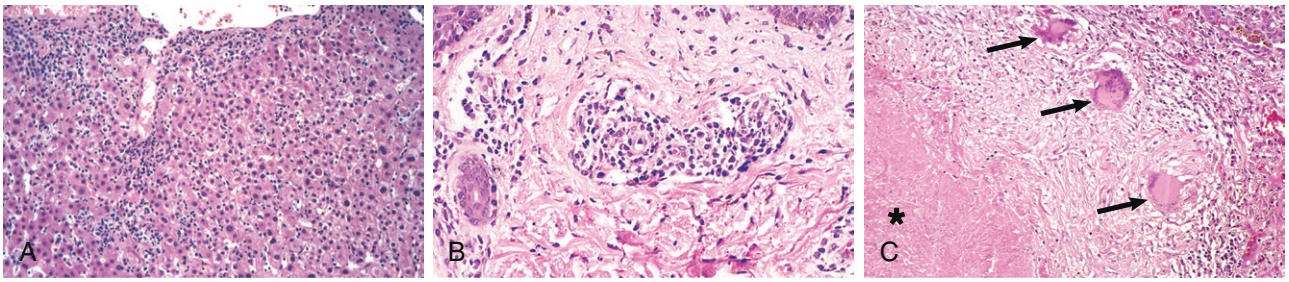


**Figure 8–11** Mononuclear and granulomatous inflammation. **A,** Acute viral hepatitis characterized by a predominantly lymphocytic infiltrate. **B,** Secondary syphilis in the dermis with perivascular lymphoplasmacytic infiltrate and endothelial proliferation. **C,** Granulomatous inflammation in response to tuberculosis. Note the zone of caseation (*asterisk*), which normally forms the center of the granuloma, with a surrounding rim of activated epithelioid macrophages, some of which have fused to form giant cells (*arrows*); this in turn is surrounded by a zone of activated T lymphocytes. This high-magnification view highlights the histologic features; the granulomatous response typically takes the form of a three-dimensional sphere with the offending organism in the central area.

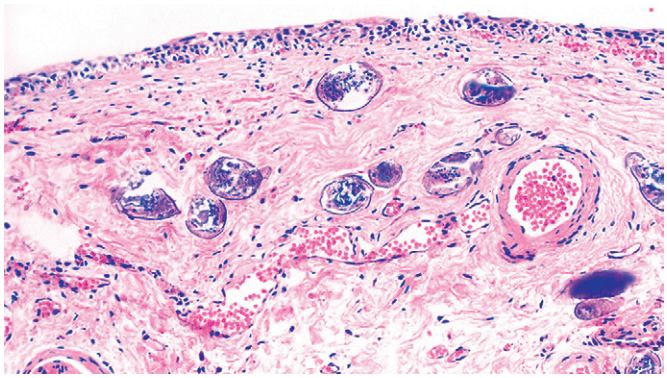

**Figure 8–12** *Schistosoma haematobium* infection of the bladder with numerous calcified eggs and extensive scarring.

### Chronic Inflammation and Scarring

Many infections elicit chronic inflammation, which can either resolve with complete healing or lead to extensive scarring.

#### MORPHOLOGY

Sometimes an exuberant scarring response is the major cause of dysfunction. For example, schistosome eggs cause "pipe-stem" fibrosis of the liver or fibrosis of the bladder wall (Fig. 8–12). *M. tuberculosis* causes constrictive fibrous pericarditis. Chronic HBV infection may cause cirrhosis of the liver, in which dense fibrous septa surround nodules of regenerating hepatocytes.

The patterns of tissue reactions described above are useful guidelines for analyzing microscopic features of infectious processes, but in practice it must be remembered that different types of host reactions often occur at the same time. For example, the lung of a patient with AIDS may be infected with CMV, which causes cytolytic changes, and, at the same time, by *Pneumocystis,* which causes interstitial inflammation. Similar patterns of inflammation also can be seen in tissue responses to physical or chemical agents and in inflammatory conditions of unknown cause (Chapter 2). Finally, in immunocompromised persons, the absence of a host inflammatory response frequently eliminates some of the histologic clues about the potential nature of infecting microorganism(s).

### Infections in People with Immunodeficiencies

Inherited or acquired defects in immunity (Chapter 4) often impair only part of the immune system, rendering the affected persons susceptible to specific types of infections. Patients with antibody deficiency, as in X-linked agammaglobulinemia, contract severe bacterial infections by extracellular bacteria and a few viral infections (rotavirus and enteroviruses). Patients with T cell defects are susceptible to infections with intracellular pathogens, notably viruses and some parasites. Patients with deficiencies in early complement components are particularly susceptible to infections by encapsulated bacteria, such as *S. pneumoniae,* whereas deficiencies of the late components of complement are associated with *Neisseria* infections. Deficiencies in neutrophil function lead to increased infections with *S. aureus,* some gram-negative bacteria, and fungi. People with inherited deficiencies in mediators of innate and adaptive immunity sometimes show strikingly selective susceptibility to specific types of infections. These patterns reveal the essential roles of particular molecules in mediating protective immunity to specific microorganisms. For example, patients with mutations in signaling molecules downstream of several TLRs are prone to pyogenic bacterial diseases, particularly with *S. pneumoniae* infections. Impaired TLR3 responses are associated with childhood HSV encephalitis. Inherited defects in IL-17 immunity (such as mutations in STAT3, a transcription factor needed for $T_H17$ cell generation) are associated with chronic mucocutaneous candidiasis.

Acquired immunodeficiencies have a variety of causes, the most important being infection with HIV, which causes AIDS (Chapter 4). HIV infects and kills CD4+ helper T lymphocytes, leading to profound immunosuppression and a multitude of infections. Other causes of acquired immunodeficiency include infiltrative processes that suppress bone marrow function (e.g., leukemia), immunosuppressive drugs (such as those used to treat certain autoimmune diseases), and hemopoietic stem cell transplantation. Diseases of organ systems other than the immune system also can make patients susceptible to disease due to specific microorganisms. People with cystic fibrosis commonly get respiratory infections caused by *P. aeruginosa.* Lack of splenic function in persons with sickle cell disease makes them susceptible to infection with encapsulated bacteria such as *S. pneumoniae.* Burns destroy skin, removing this barrier to microbes, allowing infection with pathogens such as *P. aeruginosa.* Finally, malnutrition impairs immune defenses.

#### MORPHOLOGY

Patients with antibody, complement, or neutrophil defects may acquire severe local bacterial infections that do not elicit any significant neutrophilic infiltrate. In these patients, the identity of the causative organism may only be inferred by culture or appearance on special stains. Although many viral cytopathic effects (e.g., cell fusion or inclusions) (Fig. 8–1) may still be present, viral infections in immunocompromised hosts may not engender the anticipated mononuclear inflammatory response. In patients with AIDS who have no helper T cells and cannot mount normal cellular responses, organisms that would otherwise cause granulomatous inflammation (e.g., *M. avium complex*) fail to do so (Fig. 8–13).

## SUMMARY

### Patterns of Host Responses to Microbes

- In normal (immunocompetent) persons, the patterns of host responses are fairly stereotypical for different classes of microbes; these response patterns can be used to infer possible causal organisms.

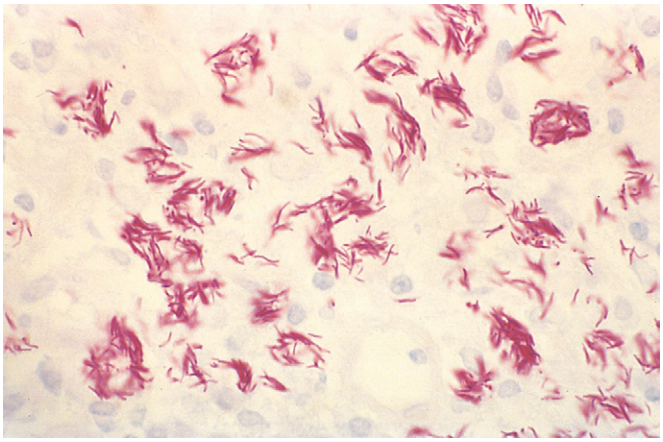

**Figure 8–13** In the absence of appropriate T cell–mediated immunity, granulomatous host response does not occur. *Mycobacterium avium* infection in a patient with AIDS, showing massive intracellular macrophage infection with acid-fast organisms (filamentous and pink in this acid-fast stain preparation). The intracellular bacteria persist and even proliferate within macrophages, because there are inadequate T cells to mount a granulomatous response. AIDS, acquired immunodeficiency syndrome.

- Neutrophil-rich acute suppurative inflammation is typical of infections with many bacteria ("pyogenic" bacteria) and some fungi.
- Mononuclear cell infiltrates are common in many chronic infections and some acute viral infections.
- Granulomatous inflammation is the hallmark of infection with *Mycobacterium tuberculosis* and certain fungi.
- Cytopathic and proliferative lesions are caused by some viruses.
- Chronic inflammation and scarring represent the final common pathway of many infections.

## BIBLIOGRAPHY


Aguzzi A: Prions: protein aggregation and infectious diseases. Physiol Rev 89:1105, 2009.

Coburn B, Sekirov I, Finlay BB: Type III secretion systems and disease. Clin Microbiol Rev 20:535, 2007.

Diacovich L, Gorvel JP: Bacterial manipulation of innate immunity to promote infection. Nat Rev Microbiol 8:117, 2010.

Haldar K, Murphy SC, Milner DA, Taylor TE: Malaria: mechanisms of erythrocytic infection and pathological correlates of severe disease. Annu Rev Pathol 2:217, 2007.

Irie RL: Diagnostic Pathology of Infectious Disease. Philadelphia, Saunders Elsevier, 2010.

Irie Y, Parsek MR: Quorum sensing and microbial biofilms. Curr Top Microbiol Immunol 322:67, 2008.

Lemichez E, Lecuit M, Nassif X, Bourdoulous S: Breaking the wall: targeting of the endothelium by pathogenic bacteria. Nat Rev Microbiol 8:93, 2010.

Lin PL, Flynn JL: Understanding latent tuberculosis: a moving target. J Immunol 185:15, 2010.

Mims CA: The Pathogenesis of Infectious Disease, 5th ed. San Diego, Academic Press, 2001.

O'Connor DH, Chandler FW, Schwartz DA, et al: Pathology of Infectious Diseases. Stamford, CT, Appleton & Lange, 1997.

Palmer GH, Brayton KA: Gene conversion is a convergent strategy for pathogen antigenic variation. Trends Parasitol 23:408, 2007.

Peleg AY, Hooper DC: Hospital-acquired infections due to gram-negative bacteria. N Engl J Med 362:1804, 2010.

Schmidt AC: Response to Dengue fever—the good, the bad and the ugly? N Engl J Med 363:484, 2010.

Segal BH: Aspergillosis. N Engl J Med 360:1870, 2009.

Speck SH, Ganem D: Viral latency and its regulation: lessons from the gamma-herpesviruses. Cell Host Microbe 8:100, 2010.

Writing Committee of the WHO Consultation on Clinical Aspects of Pandemic (H1N1) 2009 Influenza: Clinical aspects of pandemic 2009 influenza A(H1N1) virus infection. N Engl J Med 362:1708, 2010.

Young JA, Collier RJ: Anthrax toxin: receptor binding, internalization, pore formation, and translocation. Annu Rev Biochem 76:243, 2007.

See Targeted Therapy available online at studentconsult.com

CHAPTER 9

# Blood Vessels

CHAPTER CONTENTS

**Structure and Function of Blood Vessels 327**
Vascular Organization 328
Endothelial Cells 329
Vascular Smooth Muscle Cells 330
**Congenital Anomalies 330**
**Blood Pressure Regulation 330**
**Hypertensive Vascular Disease 332**
Epidemiology of Hypertension 332
**Vascular Wall Response to Injury 334**
Intimal Thickening: A Stereotypical Response to Vascular Injury 334
**Arteriosclerosis 335**
**Atherosclerosis 335**
Epidemiology of Atherosclerosis 335
Clinical Consequences of Atherosclerotic Disease 342
**Aneurysms and Dissections 344**
Abdominal Aortic Aneurysm 345
Thoracic Aortic Aneurysm 346
Aortic Dissection 346
**Vasculitis 348**
Noninfectious Vasculitis 348
Infectious Vasculitis 355
**Disorders of Blood Vessel Hyperreactivity 355**
Raynaud Phenomenon 355
Myocardial Vessel Vasospasm 355
**Veins and Lymphatics 356**
Varicose Veins of the Extremities 356
Thrombophlebitis and Phlebothrombosis 356
Superior and Inferior Vena Cava Syndromes 356
Lymphangitis and Lymphedema 356
**Tumors 357**
Benign Tumors and Tumor-like Conditions 357
Intermediate-Grade (Borderline) Tumors 360
Malignant Tumors 361
**Pathology of Vascular Intervention 362**
Endovascular Stenting 362
Vascular Replacement 363

Vascular maladies are of central importance in medicine, as they are responsible for some of the most common and lethal diseases afflicting mankind. Although most clinically significant vascular diseases are caused by arterial lesions, venous disorders also can wreak havoc. Vascular disease develops through two principal mechanisms:

- *Narrowing* or *complete obstruction of* vessel lumina, occurring either progressively (e.g., by atherosclerosis) or acutely (e.g., by thrombosis or embolism)
- *Weakening* of vessel walls, causing dilation and/or rupture

Presented next is an overview of vascular structure and function, as background for the diseases of blood vessels discussed later in the chapter.

## STRUCTURE AND FUNCTION OF BLOOD VESSELS

In essence, all blood vessels consist of a tube with a luminal lining of endothelial cells surrounded by varying amounts of smooth muscle cells and extracellular matrix (ECM). However, the structure of each of these components varies in different parts of the vasculature according to functional needs (Fig. 9–1). To accommodate pulsatile flow and higher blood pressures, arterial walls are thicker than veins and invested with reinforcing layers of smooth muscle cells. As arteries narrow to arterioles, the ratio of wall thickness to lumen diameter increases, to allow more precise regulation of intravascular pressures. Veins, on the other hand, are distensible thin-walled vessels with high capacitance. In keeping with these specializations, certain pathologic lesions characteristically involve particular kinds of vessels. For example, atherosclerosis occurs mainly in larger, muscular arteries, while hypertension affects small arterioles, and specific forms of vasculitis selectively involve vessels of only a certain caliber.

Vessel walls are organized into three concentric layers: *intima, media,* and *adventitia* (see Fig. 9–1). These layers are present in all vessels but are most apparent in larger vessels and particularly arteries. The intima consists of an endothelial cell monolayer on a basement membrane with minimal underlying ECM; it is separated from the media by a dense elastic membrane called the *internal elastic lamina.* The media is composed predominantly of smooth muscle cells and ECM, surrounded by loose connective tissue, nerve fibers, and smaller vessels of the adventitia. An *external elastic lamina* is present in some arteries and defines the transition between media and adventitia. Diffusion of oxygen and nutrients from the lumen is adequate to sustain thin-walled vessels and the innermost smooth muscle cells of all vessels. In large and medium-sized vessels, however, small arterioles within the adventitia

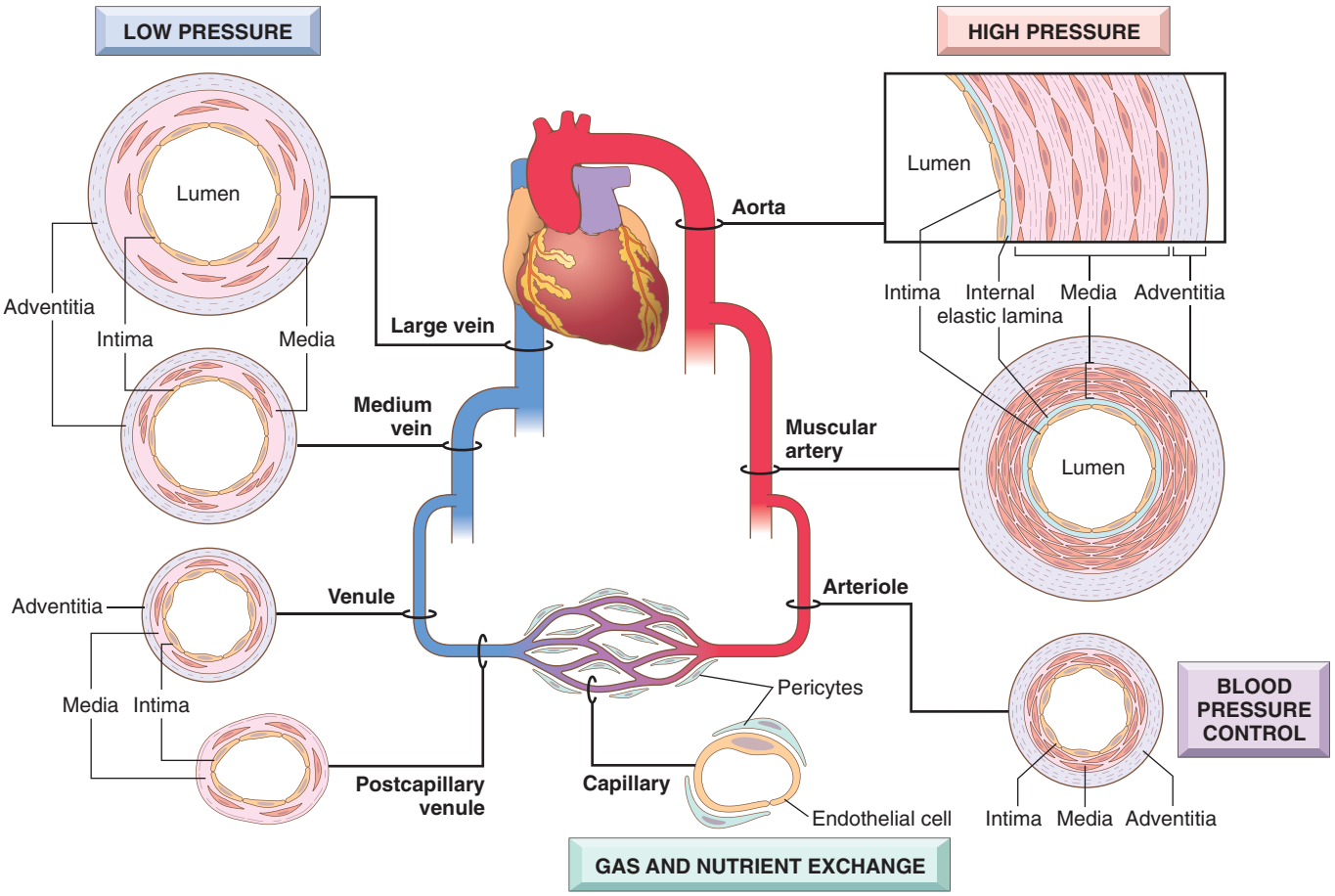


**Figure 9–1** Regional vascular specializations. Although all vessels share the same general constituents, the thickness and composition of the various layers differ as a function of hemodynamic forces and tissue requirements.

(called *vasa vasorum*—literally, "vessels of the vessels") supply the outer half to two thirds of the media.

## Vascular Organization

*Arteries* are divided into three types based on their size and structure:

- *Large elastic arteries* (e.g., aorta, arch vessels, iliac and pulmonary arteries). In these vessels, elastic fibers alternate with smooth muscle cells throughout the media, which expands during systole (storing some of the energy of each cardiac contraction), and recoils during diastole to propel blood distally. With age, the elasticity is lost, and vessels become "stiff pipes" that transmit high arterial pressures to distal organs, or dilated and tortuous (*ectatic*) conduits prone to rupture.
- *Medium-sized muscular arteries* (e.g., coronary and renal arteries). Here, the media is composed primarily of smooth muscle cells, with elastin limited to the internal and external elastic lamina. The medial smooth muscle cells are circularly or spirally arranged around the lumen, and regional blood flow is regulated by smooth muscle cell contraction (*vasoconstriction*) and relaxation (*vasodilation*) controlled by the autonomic nervous system and local metabolic factors (e.g., acidosis).
- *Small arteries* (2 mm or less in diameter) *and arterioles* (20 to 100 μm in diameter) *that lie within the connective tissue of organs.* The media in these vessels is mostly composed of smooth muscle cells. *Arterioles are where blood flow resistance is regulated.* As pressures drop during passage through arterioles, *the velocity of blood flow is sharply reduced, and flow becomes steady rather than pulsatile.* Because the resistance to fluid flow is inversely proportional to the fourth power of the diameter (i.e., halving the diameter increases resistance 16-fold), small changes in arteriolar lumen size have profound effects on blood pressure.

*Capillaries* have lumen diameters that approximate those of red cells (7 to 8 μm). These vessels are lined by endothelial cells and partially surrounded by smooth muscle cell–like cells called *pericytes.* Collectively, capillary beds have a very large total cross-sectional area and a low rate of blood flow. With their thin walls and slow flow, capillaries are ideally suited to the rapid exchange of diffusible substances between blood and tissue. The capillary network of most tissues is necessarily very rich, because diffusion of oxygen and nutrients is not efficient beyond 100 μm; metabolically active tissues (e.g., heart) have the highest capillary density.

*Veins* receive blood from the capillary beds as postcapillary venules, which anastomose to form collecting venules and progressively larger veins. The vascular leakage

(edema) and leukocyte emigration characteristic of inflammation occurs preferentially in postcapillary venules (Chapter 2).

Compared with arteries at the same level of branching, veins have larger diameters, larger lumina, and thinner walls with less distinct layers, all adaptations to the low pressures found on the venous side of the circulation (see Fig. 9–1). Thus, *veins are more prone to dilation, external compression, and penetration by tumors or inflammatory processes.* In veins in which blood flows against gravity (e.g., those of the lower extremities), backflow is prevented by valves. Collectively, the venous system has a huge capacitance and normally contains approximately two thirds of the blood.

*Lymphatics* are thin-walled, endothelium-lined channels that drain fluid (lymph) from the interstitium of tissues, eventually returning it to the blood via the thoracic duct. Lymph also contains mononuclear inflammatory cells and a host of proteins. By delivering interstitial fluid to lymph nodes, lymphatics enable continuous monitoring of peripheral tissues for infection. *These channels can also disseminate disease by transporting microbes or tumor cells to distant sites.*

## Endothelial Cells

Endothelium is a continuous sheet of cells lining the entire vascular tree that regulates many aspects of blood and blood vessel function (Table 9–1). Resting endothelial cells maintain a nonthrombogenic blood-tissue interface (Chapter 3), modulate inflammation (Chapter 2), and affect the growth of other cell types, particularly smooth muscle cells. Endothelial cells influence the vasoreactivity of the underlying smooth muscle cells by producing both relaxing factors (e.g., nitric oxide [NO]) and contracting factors (e.g., endothelin). In most regions, the interendothelial junctions normally are impermeable. However, these junctions open under the influence of hemodynamic stress (e.g., high blood pressure) and/or vasoactive agents (e.g., histamine in inflammation), flooding the adjacent tissues with electrolytes and protein. Vacuolar *transcytosis* also permits the movement of large amounts of solutes across intact endothelium. Endothelial cells also are active participants in the egress of leukocytes during inflammatory cell recruitment (Chapter 2).

Although endothelial cells throughout the vasculature share many attributes, they also show phenotypic variability depending on the anatomic site and adaptations to local environmental cues. Thus, endothelial cell populations from different parts of the vasculature (e.g., large vessels versus capillaries, or arteries versus veins) have distinct transcriptional programs and behaviors. *Fenestrations* (holes) in endothelial cells lining hepatocyte cords or renal glomeruli are specializations that facilitate filtration. Conversely, in the central nervous system, endothelial cells—in conjunction with astrocytes—collaborate to generate an impermeable *blood–brain barrier.*

Maintenance of a "normal," nonthrombogenic endothelial cell lining requires laminar flow, certain growth factors (e.g., vascular endothelial growth factor [VEGF]), and firm adhesion to the underlying basement membrane (Fig. 9–2). Trauma or other injuries that denude vessel walls of endothelial cells understandably tip the scales towards thrombosis and vasoconstriction. However, endothelial cells also respond to various physiologic and pathologic stimuli by modulating their usual (constitutive) functions and by expressing new (inducible) properties—a process called *endothelial activation.*

Inducers of endothelial activation include bacterial products, inflammatory cytokines, hemodynamic stresses

**Table 9–1** Endothelial Cell Properties and Functions

| Property/Function | Mediators/Products |
|---|---|
| Maintenance of permeability barrier | |
| Elaboration of anticoagulant, antithrombotic, fibrinolytic regulators | Prostacyclin<br>Thrombomodulin<br>Heparin-like molecules<br>Plasminogen activator |
| Elaboration of prothrombotic molecules | Von Willebrand factor<br>Tissue factor<br>Plasminogen activator inhibitor |
| Extracellular matrix production | Collagen, proteoglycans |
| Modulation of blood flow and vascular reactivity | *Vasoconstrictors*: endothelin, ACE<br>*Vasodilators*: NO, prostacyclin |
| Regulation of inflammation and immunity | IL-1, IL-6, chemokines<br>Adhesion molecules: VCAM-1, ICAM, E-selectin, P-selectin<br>Histocompatibility antigens |
| Regulation of cell growth | *Growth stimulators*: PDGF, CSF, FGF<br>*Growth inhibitors*: heparin, TGF-β |
| Oxidation of LDL | |

ACE, angiotensin-converting enzyme; CSF, colony-stimulating factor; FGF, fibroblast growth factor; ICAM, intercelluar adhesion molecule; IL, interleukin; LDL, low-density lipoprotein; NO, nitric oxide; PDGF, platelet-derived growth factor; TGF-β, transforming growth factor-β; VCAM, vascular cell adhesion molecule.

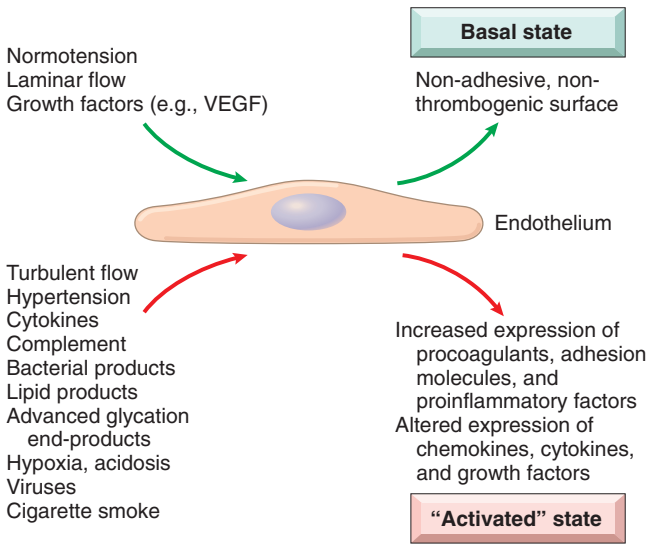


**Figure 9–2** Basal and activated endothelial cell states. Normal blood pressure, laminar flow, and stable growth factor levels promote a basal endothelial cell state that maintains a nonthrombotic surface and appropriate vascular wall smooth muscle tone. Injury or exposure to certain mediators results in *endothelial activation*, a state in which endothelial cells have adhesive, procoagulant surfaces and release factors that lead to smooth muscle contraction and/or proliferation and matrix synthesis.

and lipid products (relevant to atherosclerosis, described later), advanced glycation end products (important in diabetic vascular injury), viruses, complement, and various metabolic insults (e.g., hypoxia) (see Fig. 9–2). Activated endothelial cells undergo shape changes, express adhesion molecules, and produce cytokines, chemokines, growth factors, pro- and anticoagulant factors, and a host of other biologically active products—all presumably intended to respond to the original stimulus. Some of these responses are rapid (occurring within minutes), reversible, and independent of new protein synthesis (e.g., endothelial contraction induced by histamines); others involve alterations in gene and protein expression, and may take days to develop or abate. Exposure of endothelial cells to inducers of activation in high amounts or for sustained periods may result in *endothelial dysfunction,* characterized by impaired endothelium-dependent vasodilation, hypercoagulable states, and increased oxygen free radical production. Dysfunctional endothelium can initiate thrombosis, promote atherosclerosis, or contribute to formation of the vascular lesions of hypertension and diabetes.

### Vascular Smooth Muscle Cells

Smooth muscle cells participate in both normal vascular repair and pathologic processes such as atherosclerosis. When stimulated by various factors, smooth muscle cells can proliferate; upregulate ECM collagen, elastin, and proteoglycan production; and elaborate growth factors and cytokines. Smooth muscle cells also mediate the vasoconstriction or vasodilation that occurs in response to physiologic or pharmacologic stimuli.

The migratory and proliferative activities of smooth muscle cells are regulated by numerous factors. Among the most important pro-growth factors are platelet-derived growth factor (PDGF), endothelin, thrombin, fibroblast growth factors, and inflammatory mediators such as interferon-γ (IFN-γ) and interleukin-1 (IL-1). Factors that maintain smooth muscle cells in a quiescent state include heparan sulfate, NO, and transforming growth factor-α (TGF-α).

## SUMMARY

### Vascular Structure and Function

- All vessels are lined by endothelium; although all endothelial cells share certain homeostatic properties, endothelial cells in specific vascular beds have special features that allow for tissue-specific functions (e.g., fenestrated endothelial cells in renal glomeruli).
- The relative smooth muscle cell and matrix content of vessel walls (e.g., in arteries, veins, and capillaries) vary according to hemodynamic demands (e.g., pressure, pulsatility) and functional requirements.
- Endothelial cell function is tightly regulated in both the basal and activated states. Various physiologic and pathophysiologic stimuli induce endothelial activation and dysfunction that alter the endothelial cell phenotype (e.g., pro- versus anticoagulative, pro- versus anti-inflammatory, nonadhesive versus adhesive).

## CONGENITAL ANOMALIES

Although rarely symptomatic, unusual anatomic variants in the vascular supply can cause complications during surgery, such as when a vessel in an unexpected location is injured. Cardiac surgeons and interventional cardiologists also must be familiar with coronary artery variants. Among the other congenital vascular anomalies, three deserve further mention:

- *Berry aneurysms* are thin-walled arterial outpouchings in cerebral vessels, classically at branch points around the circle of Willis; they occur where the arterial media is congenitally attenuated and can spontaneously rupture causing fatal intracerebral hemorrhage (see Chapter 22).
- *Arteriovenous (AV) fistulas* are abnormal connections between arteries and veins without an intervening capillary bed. They occur most commonly as developmental defects but can also result from rupture of arterial aneurysms into adjacent veins, from penetrating injuries that pierce arteries and veins, or from inflammatory necrosis of adjacent vessels. AV fistulas also are created surgically to provide vascular access for hemodialysis. Extensive AV fistulas can cause high-output cardiac failure by shunting large volumes of blood from the arterial to the venous circulation.
- *Fibromuscular dysplasia* is a focal irregular thickening of the walls of medium-sized and large muscular arteries due to a combination of medial and intimal hyperplasia and fibrosis. It can manifest at any age but occurs most frequently in young women. The focal wall thickening results in luminal stenosis or can be associated with abnormal vessel spasm that reduces vascular flow; *in the renal arteries, it can lead to renovascular hypertension.* Between the focal segments of thickened wall, the artery often also exhibits medial attenuation; vascular outpouchings can develop in these portions of the vessel and sometimes rupture.

## BLOOD PRESSURE REGULATION

Systemic and local blood pressure must be maintained within a narrow range to prevent adverse outcomes. Low blood pressure (*hypotension*) results in inadequate organ perfusion, organ dysfunction, and sometimes tissue death. Conversely, high blood pressure (*hypertension*) causes vessel and end-organ damage and is one of the major risk factors for atherosclerosis (see later on).

Blood pressure is a function of *cardiac output* and *peripheral vascular resistance*, both of which are influenced by multiple genetic and environmental factors (Fig. 9–3). The integration of the various inputs ensures adequate systemic perfusion, despite regional demand differences.

- *Cardiac output* is a function of stroke volume and heart rate. The most important determinant of stroke volume is the filling pressure, which is regulated through sodium homeostasis and its effect on blood volume. Heart rate and myocardial contractility (a second factor affecting stroke volume) are both regulated by the α- and β-adrenergic systems (in addition to their effects on vascular tone).

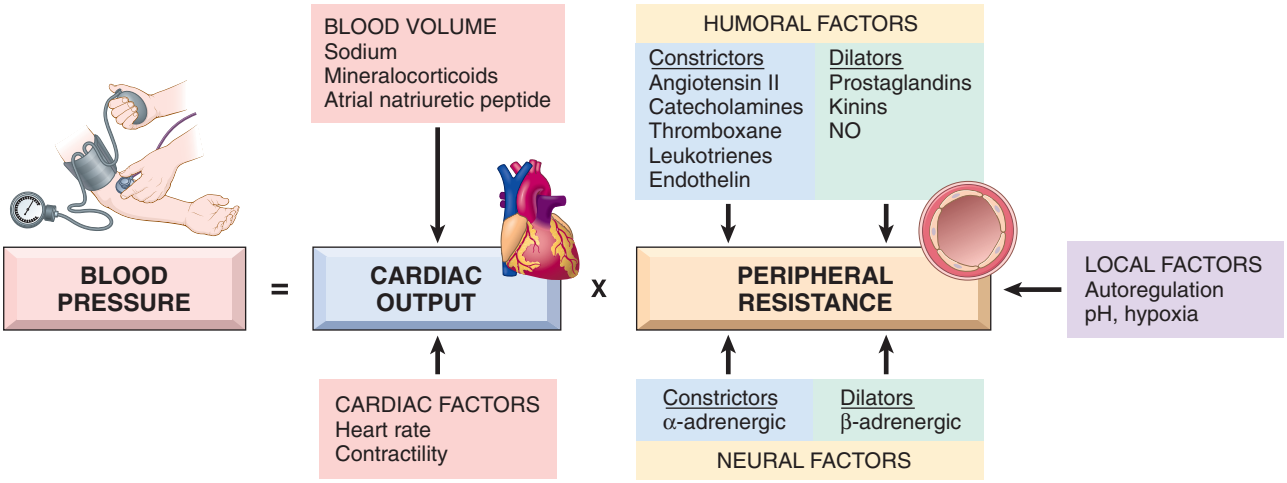


**Figure 9–3** Blood pressure regulation.

- Peripheral resistance is regulated predominantly at the level of the arterioles by neural and hormonal inputs. Vascular tone reflects a balance between vasoconstrictors (including angiotensin II, catecholamines, and endothelin) and vasodilators (including kinins, prostaglandins, and NO). Resistance vessels also exhibit *autoregulation,* whereby increased blood flow induces vasoconstriction to protect tissues against hyperperfusion. Finally, blood pressure is fine-tuned by tissue pH and hypoxia to accommodate local metabolic demands.

Factors released from the kidneys, adrenals, and myocardium interact to influence vascular tone and to regulate blood volume by adjusting sodium balance (Fig. 9–4). The kidneys filter 170 liters of plasma containing 23 moles of salt daily. Thus, with a typical diet containing 100 mEq of sodium, 99.5% of the filtered salt must be reabsorbed to maintain total body sodium levels. About 98% of the filtered sodium is reabsorbed by several constitutively active transporters. Recovery of the remaining 2% of sodium occurs by way of the epithelial sodium channel (ENaC), which is tightly regulated by the renin–angiotensin system; it is this pathway that determines net sodium balance.

Kidneys influence peripheral resistance and sodium excretion/retention primarily through the renin–angiotensin system. The kidneys and heart contain cells that sense changes in blood pressure or blood volume. In response, these cells release several important regulators that act in concert to maintain normal blood pressure, as follows:

- *Renin* is a proteolytic enzyme produced by renal juxtaglomerular cells, myoepithelial cells that surround the glomerular afferent arterioles. Renin is released in response to low blood pressure in afferent arterioles, elevated levels of circulating catecholamines, or low sodium levels in the distal convoluted renal tubules. The latter occurs when the *glomerular filtration rate* falls (e.g., when the cardiac output is low), leading to increased sodium resorption by the proximal tubules and lower sodium levels more distally.
- Renin cleaves *plasma angiotensinogen* to *angiotensin I,* which in turn is converted to *angiotensin II* by angiotensin-converting enzyme (ACE) in the periphery. Angiotensin II raises blood pressure by (1) inducing vascular smooth muscle cell contraction, (2) stimulating aldosterone secretion by the adrenal gland, and (3) increasing tubular sodium resorption.
- The kidney also produces a variety of vascular relaxing substances (including prostaglandins and NO) that presumably counterbalance the vasopressor effects of angiotensin.
- *Adrenal aldosterone* increases blood pressure by its effect on blood volume; aldosterone increases sodium resorption (and thus water) in the distal convoluted tubule while also driving potassium excretion into the urine.
- *Myocardial natriuretic peptides* are released from atrial and ventricular myocardium in response to volume expansion; these inhibit sodium resorption in the distal renal tubules, thus leading to sodium excretion and diuresis. They also induce systemic vasodilation.

## SUMMARY

### Blood Pressure Regulation

- Blood pressure is determined by vascular resistance and cardiac output.
- Vascular resistance is regulated at the level of the arterioles, influenced by neural and hormonal inputs.
- Cardiac output is determined by heart rate and stroke volume, which is strongly influenced by blood volume. Blood volume in turn is regulated mainly by renal sodium excretion or resorption.
- Renin, a major regulator of blood pressure, is secreted by the kidneys in response to decreased blood pressure in afferent arterioles. In turn, renin cleaves angiotensinogen to angiotensin I; subsequent peripheral catabolism produces angiotensin II, which regulates blood pressure by increasing vascular smooth muscle cell tone and by increasing adrenal aldosterone secretion and, consequently, renal sodium resorption.

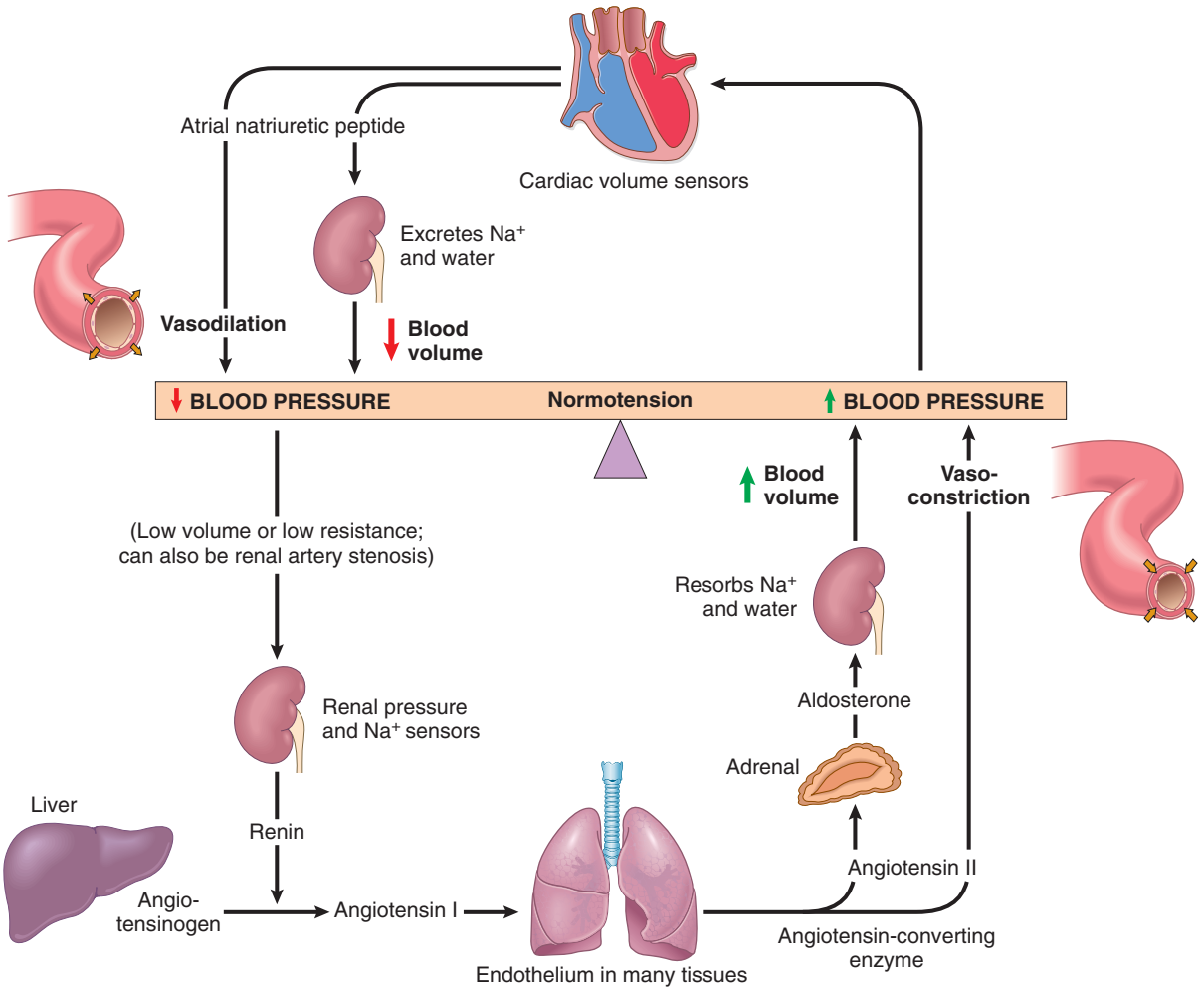


**Figure 9–4** Interplay of renin, angiotensin, aldosterone, and atrial natriuretic peptide in blood pressure regulation (see text).

## HYPERTENSIVE VASCULAR DISEASE

Hypertension is a major health problem in the developed world. Although it occasionally manifests in an acute aggressive form, high blood pressure is much more often asymptomatic for many years. This insidious condition is sometimes referred to as benign hypertension, but it is in fact far from harmless. Besides increasing the risk of stroke and atherosclerotic coronary heart disease, hypertension can lead to cardiac hypertrophy and heart failure (*hypertensive heart disease*), aortic dissection, multi-infarct dementia, and renal failure. While the molecular pathways of blood pressure regulation are reasonably well understood, the mechanisms leading to hypertension in the vast majority of affected persons remain unknown. The accepted wisdom is that such "essential hypertension" results from the interplay of genetic polymorphisms (which individually might be inconsequential) and environmental factors, which conspire to increase blood volume and/or peripheral resistance.

### Epidemiology of Hypertension

Like height and weight, blood pressure is a continuously distributed variable, and the detrimental effects increase continuously as the pressure rises; no rigidly defined threshold reliably predicts who will suffer ill effects. Nevertheless, sustained diastolic pressures greater than 90 mm Hg, or sustained systolic pressures in excess of 140 mm Hg, are associated with an increased risk of atherosclerosis and are therefore used as cutoffs in diagnosing hypertension in clinical practice. By these criteria, some 25% of persons in the general population are hypertensive. As noted however, these values are somewhat arbitrary, and in patients with other cardiovascular risk factors (e.g., diabetes), lower thresholds may be applicable. The prevalence of pathologic effects of high blood pressure increases with age and is also higher in African Americans. Without appropriate treatment, some 50% of hypertensive patients die of ischemic heart disease (IHD) or congestive heart failure, and another third succumb to stroke. Reduction of blood pressure dramatically reduces the incidence and clinical sequelae

(including death) of all forms of hypertension-related disease. Indeed, detection and treatment of asymptomatic hypertension constitute one of the few instances in which "preventive medicine" has a major demonstrated health benefit.

A small percentage of hypertensive patients (approximately 5%) present with a rapidly rising blood pressure that, if untreated, leads to death in within 1 to 2 years. Such *malignant hypertension* usually is severe (i.e., systolic pressures over 200 mm Hg or diastolic pressures over 120 mm Hg) and associated with renal failure and retinal hemorrhages, with or without papilledema. It can arise de novo but most commonly is superimposed on preexisting benign hypertension.

## PATHOGENESIS

Table 9–2 lists the major causes of hypertension, but **most cases (95%) are idiopathic (essential hypertension).** This form is compatible with long life unless a myocardial infarction, stroke, or another complication supervenes. Most of the remaining cases **(secondary hypertension)** are due to primary renal disease, renal artery narrowing **(renovascular hypertension),** or adrenal disorders. Several relatively rare single-gene disorders cause hypertension (and hypotension) by affecting renal sodium resorption. Such disorders include

- **Gene defects in enzymes involved in aldosterone metabolism** (e.g., aldosterone synthase, 11β-hydroxylase, 17α-hydroxylase), leading to increased aldosterone secretion, increased salt and water resorption, and plasma volume expansion
- **Mutations in proteins that affect sodium resorption** (as in Liddle syndrome, which is caused by mutations in ENaC, leading to increased distal tubular resorption of sodium induced by aldosterone)

**Table 9–2** Types and Causes of Hypertension (Systolic and Diastolic)

| |
|---|
| **Essential Hypertension** |
| Accounts for 90% to 95% of all cases |
| **Secondary Hypertension** |
| Renal |
| Acute glomerulonephritis<br>Chronic renal disease<br>Polycystic disease<br>Renal artery stenosis<br>Renal vasculitis<br>Renin-producing tumors |
| Endocrine |
| Adrenocortical hyperfunction (Cushing syndrome, primary aldosteronism, congenital adrenal hyperplasia, licorice ingestion)<br>Exogenous hormones (glucocorticoids, estrogen [including pregnancy-induced and oral contraceptives], sympathomimetics and tyramine-containing foods, monoamine oxidase inhibitors)<br>Pheochromocytoma<br>Acromegaly<br>Hypothyroidism (myxedema)<br>Hyperthyroidism (thyrotoxicosis)<br>Pregnancy-induced (pre-eclampsia) |
| Cardiovascular |
| Coarctation of aorta<br>Polyarteritis nodosa<br>Increased intravascular volume<br>Increased cardiac output<br>Rigidity of the aorta |
| Neurologic |
| Psychogenic<br>Increased intracranial pressure<br>Sleep apnea<br>Acute stress, including surgery |

### Mechanisms of Essential Hypertension

Although the specific triggers are unknown, it appears that both altered renal sodium handling and increased vascular resistance contribute to essential hypertension.

- **Reduced renal sodium excretion** in the presence of normal arterial pressure probably is a key pathogenic feature; indeed, this is a common etiologic factor in most forms of hypertension. Decreased sodium excretion causes an obligatory increase in fluid volume and increased cardiac output, thereby elevating blood pressure (Fig. 9–3). At the new higher blood pressure, the kidneys excrete additional sodium. Thus, a new steady state of sodium excretion is achieved, but at the expense of an elevated blood pressure.
- **Increased vascular resistance may stem from vasoconstriction or structural changes in vessel walls.** These are not necessarily independent factors, as chronic vasoconstriction may result in permanent thickening of the walls of affected vessels.
- **Genetic factors** play an important role in determining blood pressure, as shown by familial clustering of hypertension and by studies of monozygotic and dizygotic twins. Hypertension has been linked to specific angiotensinogen polymorphisms and angiotensin II receptor variants; polymorphisms of the renin-angiotensin system also may contribute to the known racial differences in blood pressure regulation. Susceptibility genes for essential hypertension in the larger population are currently unknown but probably include those that govern renal sodium handling, pressors, and smooth muscle cell growth.
- **Environmental factors,** such as stress, obesity, smoking, physical inactivity, and high levels of salt consumption, modify the impact of genetic determinants. Evidence linking dietary sodium intake with the prevalence of hypertension in different population groups is particularly strong.

## MORPHOLOGY

Hypertension not only accelerates atherogenesis but also causes degenerative changes in the walls of large and medium-sized arteries that can lead to aortic dissection and cerebrovascular hemorrhage. Two forms of small blood vessel disease are hypertension-related: hyaline arteriolosclerosis and hyperplastic arteriolosclerosis (Fig. 9–5).

**Hyaline arteriolosclerosis** is associated with benign hypertension. It is marked by homogeneous, pink hyaline

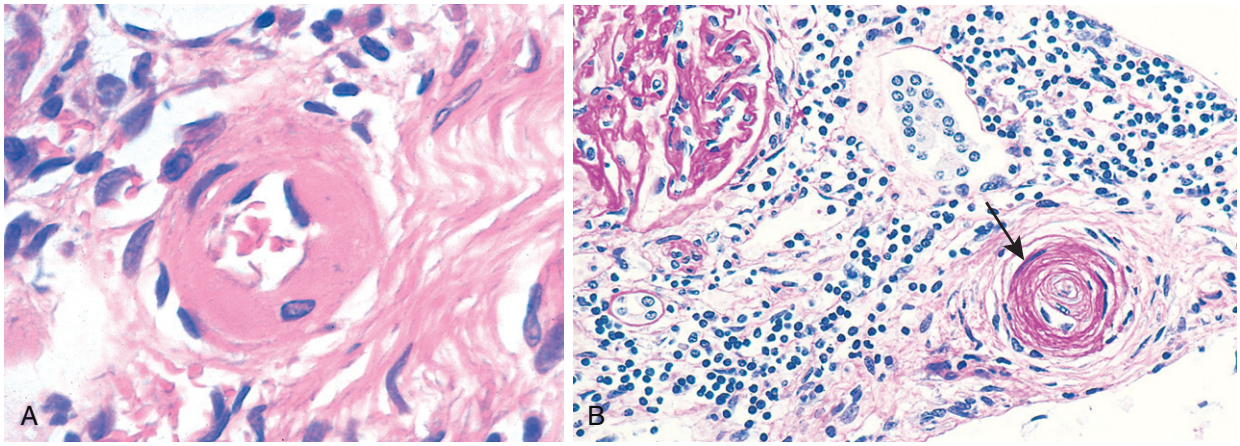


**Figure 9–5** Hypertensive vascular disease. **A,** Hyaline arteriolosclerosis. The arteriolar wall is thickened with the deposition of amorphous proteinaceous material (hyalinized), and the lumen is markedly narrowed. **B,** Hyperplastic arteriolosclerosis ("onion-skinning") (*arrow*) causing luminal obliteration (periodic acid–Schiff stain).

*(Courtesy of Helmut Rennke, MD, Brigham and Women's Hospital, Boston, Massachusetts.)*

thickening of the arteriolar walls, with loss of underlying structural detail, and luminal narrowing (Fig. 9–5, *A*). The lesions stem from leakage of plasma components across injured endothelial cells, into vessel walls and increased ECM production by smooth muscle cells in response to chronic hemodynamic stress. In the kidneys, the arteriolar narrowing caused by hyaline arteriosclerosis leads to diffuse vascular compromise and **nephrosclerosis** (glomerular scarring). Although the vessels of elderly patients (normo- or hypertensive) show the same changes, hyaline arteriolosclerosis is more generalized and severe in patients with hypertension. The same lesions also are common in diabetic microangiopathy; in this disorder, the underlying etiology is hyperglycemia-associated endothelial cell dysfunction.

**Hyperplastic arteriolosclerosis** is more typical of severe hypertension. Vessels exhibit "onionskin," concentric, laminated thickening of arteriolar walls and luminal narrowing (Fig. 9–5, *B*). The laminations consist of smooth muscle cells and thickened, reduplicated basement membrane. In malignant hypertension these changes are accompanied by fibrinoid deposits and vessel wall necrosis **(necrotizing arteriolitis),** which are particularly prominent in the kidney.

## SUMMARY

### Hypertension

- Hypertension is a common disorder affecting 25% of the population; it is a major risk factor for atherosclerosis, congestive heart failure, and renal failure.
- Essential hypertension represents 95% of cases and is a complex, multifactorial disorder, involving both environmental influences and genetic polymorphisms that may influence sodium resorption, aldosterone pathways, and the renin–angiotensin system.
- Hypertension occasionally is caused by single-gene disorders or is secondary to diseases of the kidney, adrenal, or other endocrine organs.

# VASCULAR WALL RESPONSE TO INJURY

Fundamental to a wide variety of vascular disorders is injury to the vessel wall, in particular endothelial cells. Such injurious stimuli may be biochemical, immunologic, or hemodynamic. As the main cellular components of the blood vessel walls, endothelial cells and smooth muscle cells play central roles in vascular pathology. The integrated function of these cells is critical for the vasculature to respond to various stimuli, and its responses can be adaptive or lead to pathologic lesions. Thus, endothelial injury or dysfunction (see earlier discussion) contributes to a host of pathologic processes including thrombosis, atherosclerosis, and hypertensive vascular lesions. Smooth muscle cell proliferation and matrix synthesis can help to repair a damaged vessel wall but also can lead to luminal occlusion.

## Intimal Thickening: A Stereotypical Response to Vascular Injury

*Vascular injury* leading to endothelial cell loss or dysfunction *stimulates smooth muscle cell growth and associated matrix synthesis.* Healing of injured vessels involves the migration of smooth muscle cells or smooth muscle cell precursor cells into the intima. Here these cells proliferate, and synthesize ECM in much the same way that fibroblasts fill in a wound (Fig. 9–6), forming a neointima that typically is covered by an intact endothelial cell layer. This neointimal response occurs with any form of vascular damage or dysfunction, including infection, inflammation, immune injury, physical trauma (e.g., from a balloon catheter or hypertension), or toxic exposure (e.g. oxidized lipids or cigarette smoke). *Thus, intimal thickening is a stereotypical response of the vessel wall to any insult.*

Of note, the phenotype of neointimal smooth muscle cells is distinct from medial smooth muscle cells; neointimal smooth muscle cells lack the capacity to contract like

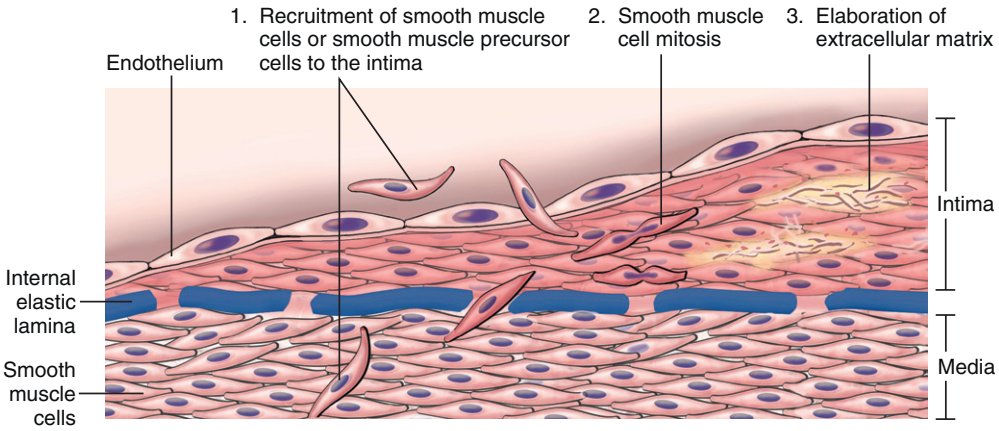


**Figure 9–6** Stereotypical response to vascular injury. Schematic diagram of intimal thickening, emphasizing intimal smooth muscle cell migration and proliferation associated with extracellular matrix synthesis. Intimal smooth muscle cells may derive from the underlying media or may be recruited from circulating precursors; they are depicted in a color different from that of the medial smooth muscle cells, to emphasize their distinct phenotype.

medial smooth muscle cells, but do have the capacity to divide and have a considerably greater synthetic capacity than their medial colleagues. Although neointimal cells were previously thought to arise from dedifferentiated medial smooth muscle cells, increasing evidence suggests that at least a subset is derived from circulating precursor cells. The migratory, proliferative, and synthetic activities of the intimal smooth muscle cells are regulated by growth factors and cytokines produced by platelets, endothelial cells, and macrophages, as well as by activated coagulation and complement factors (as described previously).

With restoration and/or normalization of the endothelial cell layer, intimal smooth muscle cells can return to a nonproliferative state, but not before the healing response produces irreversible intimal thickening. With persistent or recurrent insults, further thickening can occur that leads to the stenosis of small and medium-sized blood vessels (e.g., as in atherosclerosis, discussed later). As a final note, it is also important to recognize that intimal thickening appears to be a part of normal aging. Such age-related intimal change typically is of no consequence, in part because compensatory outward remodeling of the vessel results in little net change in the luminal diameter.

## ARTERIOSCLEROSIS

*Arteriosclerosis* literally means "hardening of the arteries"; it is a generic term reflecting arterial wall thickening and loss of elasticity. Three distinct types are recognized, each with different clinical and pathologic consequences:

- *Arteriolosclerosis* affects small arteries and arterioles and may cause downstream ischemic injury. The two variants, hyaline and hyperplastic arteriolosclerosis, were described above in relation to hypertension.
- *Mönckeberg medial sclerosis* is characterized by the presence of calcific deposits in muscular arteries, typically in persons older than 50. The lesions do not encroach on the vessel lumen and usually are not clinically significant.
- *Atherosclerosis,* from Greek root words for "gruel" and "hardening," is the most frequent and clinically important pattern and is the subject of the next section.

## ATHEROSCLEROSIS

Atherosclerosis is characterized by the presence of intimal lesions called *atheromas* (or *atheromatous* or *atherosclerotic plaques*). Atheromatous plaques are raised lesions composed of soft grumous lipid cores (mainly cholesterol and cholesterol esters, with necrotic debris) covered by fibrous caps (Fig. 9–7). Atherosclerotic plaques can mechanically obstruct vascular lumina and are prone to rupture, resulting in catastrophic vessel thrombosis. Plaques also weaken the underlying media, sometimes leading to aneurysm formation. In the Western world, morbidity and mortality rates for atherosclerosis are higher than for any other disorder, with roughly half of all deaths attributable to this entity. Because coronary artery disease is an important manifestation of atherosclerosis, epidemiologic data related to atherosclerosis mortality typically reflect deaths caused by ischemic heart disease (IHD) (Chapter 10); indeed, myocardial infarction is responsible for almost one fourth of all deaths in the United States.

### Epidemiology of Atherosclerosis

Atherosclerosis is virtually ubiquitous among most developed nations but is much less prevalent in Central and South America, Africa, and parts of Asia. The mortality rate for IHD in the United States is among the highest in the world, approximately five times higher than that in Japan. However, IHD is increasing in Japan, where it is now the second leading cause of death. Furthermore, Japanese emigrants who come to the United States and adopt American life styles and dietary customs acquire the same atherosclerosis risk as for U.S.-born persons, emphasizing the important etiologic role of environmental factors.

The prevalence and severity of atherosclerosis and IHD have been correlated with a number of risk factors in

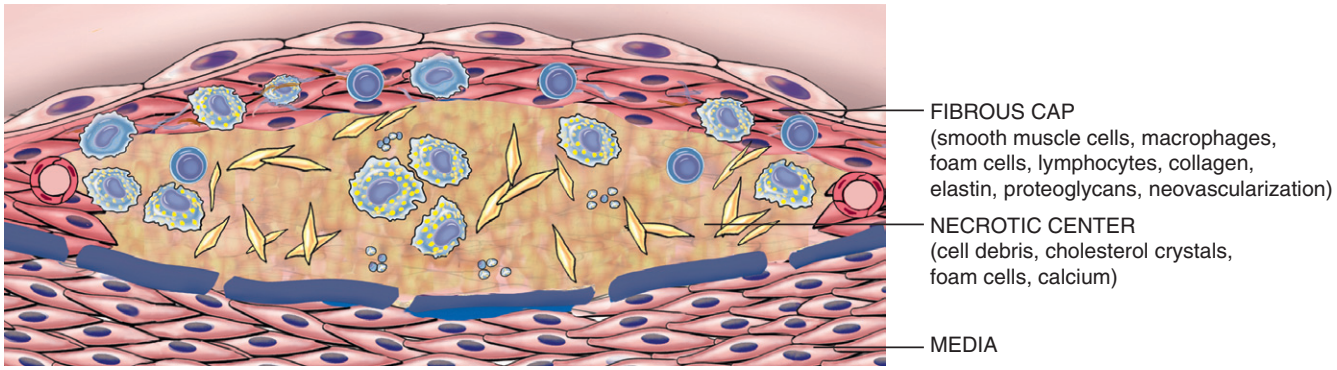


**Figure 9–7** The basic structure of an atheromatous plaque.

several prospective analyses (e.g., the Framingham Heart Study); some of these risk factors are constitutional (and therefore less controllable) but others are acquired or related to modifiable behaviors (Table 9–3). *These risk factors have roughly multiplicative effects.* Thus, two factors increase the risk of myocardial infarction approximately four-fold, and three (i.e., hyperlipidemia, hypertension, and smoking), increase the rate by a factor of 7 (Fig. 9–8).

### *Constitutional Risk Factors*

- *Genetics.* Family history is the most important independent risk factor for atherosclerosis. Certain mendelian disorders are strongly associated with atherosclerosis (e.g., familial hypercholesterolemia) (Chapter 6), but these account for only a small percentage of cases. Most familial risk is related to polygenic traits that go hand-in-hand with atherosclerosis, such as hypertension and diabetes, as well as other genetic polymorphisms.
- *Age.* Atherosclerosis usually remains clinically silent until lesions reach a critical threshold in middle age or later. Thus, the incidence of myocardial infarction increases five-fold between the ages of 40 and 60. Death rates from IHD continue to rise with each successive decade.
- *Gender.* All other factors being equal, premenopausal women are relatively protected against atherosclerosis (and its consequences) compared with age-matched men. Thus, myocardial infarction and other complications of atherosclerosis are uncommon in premenopausal women in the absence of other predisposing factors such as diabetes, hyperlipidemia, or severe hypertension. After menopause, however, the incidence of atherosclerosis-related diseases increases and, in old age, even exceeds that in men. Although a salutary effect of estrogen has long been proposed to explain this gender difference, clinical trials have shown no benefit of hormonal therapy for prevention of vascular disease. Indeed, postmenopausal estrogen replacement appears to *increase* cardiovascular risk. In addition to atherosclerosis, gender also influences other factors that can affect outcome in patients with IHD, such as hemostasis, infarct healing, and myocardial remodeling.

**Table 9–3** Major Risk Factors for Atherosclerosis

| Nonmodifiable (Constitutional) |
|---|
| Genetic abnormalities |
| Family history |
| Increasing age |
| Male gender |
| **Modifiable** |
| Hyperlipidemia |
| Hypertension |
| Cigarette smoking |
| Diabetes |
| Inflammation |

### *Modifiable Major Risk Factors*

- *Hyperlipidemia*—and, more specifically, *hypercholesterolemia*—is a major risk factor for development of atherosclerosis and is sufficient to induce lesions in the absence of other risk factors. The main cholesterol component associated with increased risk is low-density lipoprotein (LDL) cholesterol ("bad cholesterol"); LDL distributes cholesterol to peripheral tissues. By contrast, high-density lipoprotein (HDL) ("good cholesterol") mobilizes cholesterol from developing and existing vascular plaques and transports it to the liver for biliary excretion. Consequently, higher levels of HDL correlate with reduced risk.

  Recognition of these relationships has spurred the development of dietary and pharmacologic interventions that lower total serum cholesterol or LDL, and/or raise serum HDL, as follows:

  - High dietary intake of cholesterol and saturated fats (present in egg yolks, animal fats, and butter, for example) raises plasma cholesterol levels. Conversely, diets low in cholesterol, and/or containing higher ratios of polyunsaturated fats, lower plasma cholesterol levels.
  - Omega-3 fatty acids (abundant in fish oils) are beneficial, whereas (trans)-unsaturated fats produced by artificial hydrogenation of polyunsaturated oils (used in baked goods and margarine) adversely affect cholesterol profiles.
  - Exercise and moderate consumption of ethanol raise HDL levels, whereas obesity and smoking lower them.
  - *Statins* are a widely used class of drugs that lower circulating cholesterol levels by inhibiting

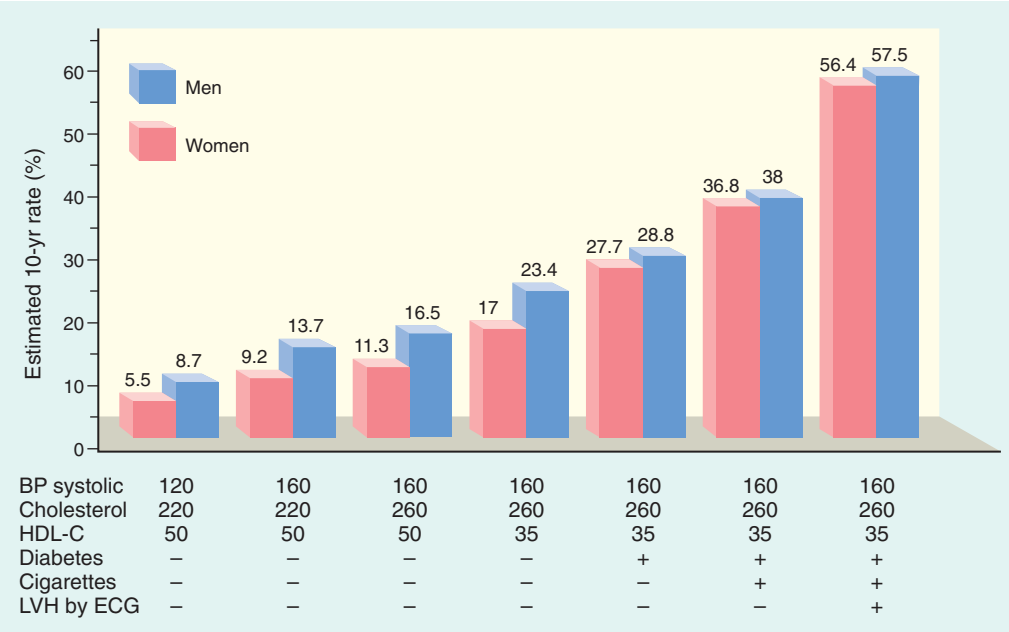


**Figure 9–8** Estimated 10-year risk of coronary artery disease in 55-year-old men and women as a function of established risk factors—hyperlipidemia, hypertension, smoking, and diabetes. BP, blood pressure; ECG, electrocardiogram; HDL-C, high-density lipoprotein cholesterol; LVH, left ventricular hypertrophy.

*(Data from O'Donnell CJ, Kannel WB: Cardiovascular risks of hypertension: lessons from observational studies. J Hypertension 16[Suppl 6]:3, 1998.)*

hydroxymethylglutaryl coenzyme A (HMG-CoA) reductase, the rate-limiting enzyme in hepatic cholesterol biosynthesis.

- *Hypertension* (see earlier discussion) is another major risk factor for development of atherosclerosis. On its own, hypertension can increase the risk of IHD by approximately 60% (see Fig. 9–8). Hypertension also is the major cause of left ventricular hypertrophy (LVH), which also can contribute to myocardial ischemia (see Fig. 9–8).
- *Cigarette smoking* is a well-established risk factor in men and probably accounts for the increasing incidence and severity of atherosclerosis in women. Prolonged (years) smoking of one or more packs of cigarettes a day doubles the rate of IHD-related mortality, while smoking cessation reduces the risk.
- *Diabetes mellitus* is associated with raised circulating cholesterol levels and markedly increases the risk of atherosclerosis. Other factors being equal, the incidence of myocardial infarction is twice as high in diabetics as in nondiabetics. In addition, this disorder is associated with an increased risk of stroke and a 100-fold increase in atherosclerosis-induced gangrene of the lower extremities.

### *Additional Risk Factors*

Roughly 20% of cardiovascular events occur in the absence of identifiable risk factors. For example, in previously healthy women more than 75% of cardiovascular events occur in those with LDL cholesterol levels below 160 mg/dL (a cut-off value generally considered to connote low risk). Other factors that contribute to risk include the following:

- *Inflammation.* Inflammatory cells are present during all stages of atheromatous plaque formation and are intimately linked with plaque progression and rupture (see following discussion). With increasing recognition of the role of inflammation, measures of systemic inflammation have become important in risk stratification. While several systemic markers of inflammation correlate with IHD risk, determination of *C-reactive protein* (CRP) has emerged as one of the simplest and most sensitive.
- *CRP levels.* CRP, a member of *pentraxin* family, is an acute-phase reactant synthesized primarily by the liver in response to a variety of inflammatory cytokines. Locally, CRP secreted by cells within atherosclerotic plaques can activate endothelial cells, increasing adhesiveness and inducing a prothrombotic state. Its clinical importance lies in its value as a circulating biomarker: *CRP levels strongly and independently predict the risk of myocardial infarction, stroke, peripheral arterial disease, and sudden cardiac death, even among apparently healthy persons* (Fig. 9–9). While there is no direct evidence that lowering CRP diminishes cardiovascular risk, it is of interest that CRP is reduced by smoking cessation, weight loss, and exercise. Moreover, statins reduce CRP levels independent of their LDL cholesterol-lowering effects, suggesting a possible anti-inflammatory action of these agents.
- *Hyperhomocysteinemia.* Serum homocysteine levels correlate with coronary atherosclerosis, peripheral vascular disease, stroke, and venous thrombosis. *Homocystinuria*, due to rare inborn errors of metabolism, causes elevated circulating homocysteine (greater than 100 µmol/L) and is associated with early-onset vascular disease. Although low folate and vitamin $B_{12}$ levels can increase

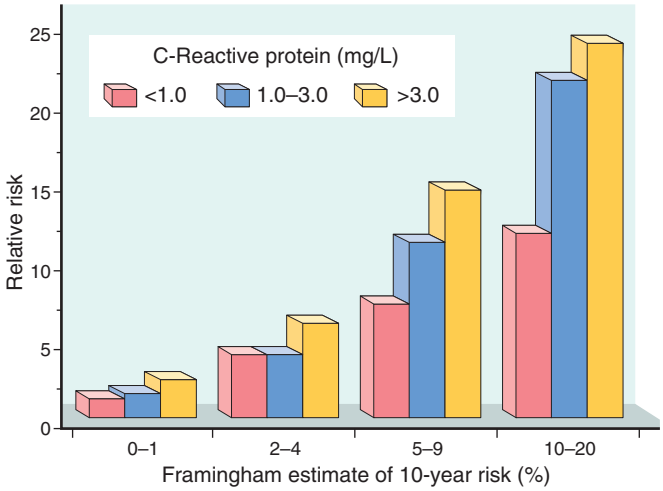


**Figure 9–9** Prognostic value of C-reactive protein (CRP) in coronary artery disease. Relative risk (y-axis) reflects the risk of a cardiovascular event (e.g., myocardial infarction). The x-axis shows the 10-year risk of a cardiovascular event calculated from the traditional risk factors identified in the Framingham Study. In each risk group, CRP levels further stratify the patients.

*(Data from Ridker PM, et al: Comparison of C-reactive protein and low-density lipoprotein cholesterol levels in the prediction of first cardiovascular events. N Engl J Med 347:1557, 2002.)*

homocysteine levels, supplemental vitamin ingestion does not affect the incidence of cardiovascular disease.

- *Metabolic syndrome.* Associated with central obesity (Chapter 7), this clinical entity is characterized by insulin resistance, hypertension, dyslipidemia (elevated LDL and depressed HDL), hypercoagulability, and a proinflammatory state, which may be triggered by cytokines released from adipocytes. The dyslipidemia, hyperglycemia, and hypertension are all cardiac risk factors, while the systemic hypercoagulable and proinflammatory state may contribute to endothelial dysfunction and/or thrombosis.
- *Lipoprotein(a) levels.* Lipoprotein(a) is an LDL-like particle that contains apolipoprotein B-100 linked to apolipoprotein A. Lipoprotein(a) levels are correlated with coronary and cerebrovascular disease risk, independent of total cholesterol or LDL levels.
- *Elevated levels of procoagulants* are potent predictors of risk for major cardiovascular events. Excessive activation of thrombin, which you will recall initiates inflammation through cleavage of protease-activated receptors (PARs) on leukocytes, endothelium, and other cells, may be particularly atherogenic.
- *Other factors* associated with difficult-to-quantify risks include lack of exercise and living a competitive, stressful life style ("type A personality").

## PATHOGENESIS

Historically, there have been two dominant theories regarding atherogenesis; one emphasizing intimal cellular proliferation in response to endothelial injury, and the other focusing on repeated formation and organization of thrombi. The contemporary view of atherogenesis incorporates elements of both theories and also integrates the risk factors previously discussed. Called the **response-to-injury hypothesis,** the model views **atherosclerosis as a chronic inflammatory response of the arterial wall to endothelial injury. Lesion progression involves interaction of modified lipoproteins, monocyte-derived macrophages, T lymphocytes, and the cellular constituents** of the arterial wall (Fig. 9–10). According to this model, atherosclerosis results from the following pathogenic events:

- **Endothelial injury**—and resultant endothelial dysfunction—leading to increased permeability, leukocyte adhesion, and thrombosis
- **Accumulation of lipoproteins** (mainly oxidized LDL and cholesterol crystals) in the vessel wall
- **Platelet adhesion**
- **Monocyte adhesion to the endothelium,** migration into the intima, and differentiation into **macrophages** and **foam cells**
- **Lipid accumulation** within macrophages, which release inflammatory cytokines
- **Smooth muscle cell recruitment due to factors released** from activated platelets, macrophages, and vascular wall cells
- **Smooth muscle cell proliferation and ECM production**

Some details of these steps are presented next.

**Endothelial Injury.** Endothelial cell injury is the cornerstone of the response to injury hypothesis. Endothelial cell loss due to any kind of injury—induced experimentally by mechanical denudation, hemodynamic forces, immune complex deposition, irradiation, or chemicals—results in intimal thickening; in the presence of high-lipid diets, typical atheromas ensue. However, **early human atherosclerotic lesions begin at sites of intact, but dysfunctional, endothelium.** These dysfunctional endothelial cells exhibit increased permeability, enhanced leukocyte adhesion, and altered gene expression, all of which may contribute to the development of atherosclerosis.

Suspected triggers of early atheromatous lesions include hypertension, hyperlipidemia, toxins from cigarette smoke, homocysteine, and even infectious agents. Inflammatory cytokines (e.g., tumor necrosis factor [TNF]) also can stimulate proatherogenic patterns of endothelial cell gene expression. Nevertheless, the two most important causes of endothelial dysfunction are hemodynamic disturbances and hypercholesterolemia.

**Hemodynamic Disturbances.** The importance of hemodynamic factors in atherogenesis is illustrated by the observation that plaques tend to occur at ostia of exiting vessels, at branch points, and along the posterior wall of the abdominal aorta, where there is turbulent blood flow. In vitro studies further demonstrate that nonturbulent laminar flow leads to the induction of endothelial genes whose products *protect* against atherosclerosis. Such "atheroprotective" genes could explain the nonrandom localization of early atherosclerotic lesions.

**Lipids.** Lipids typically are transported in the bloodstream bound to specific apoproteins (forming lipoprotein complexes). **Dyslipoproteinemias** can result from mutations in genes that encode apoproteins or lipoprotein receptors,

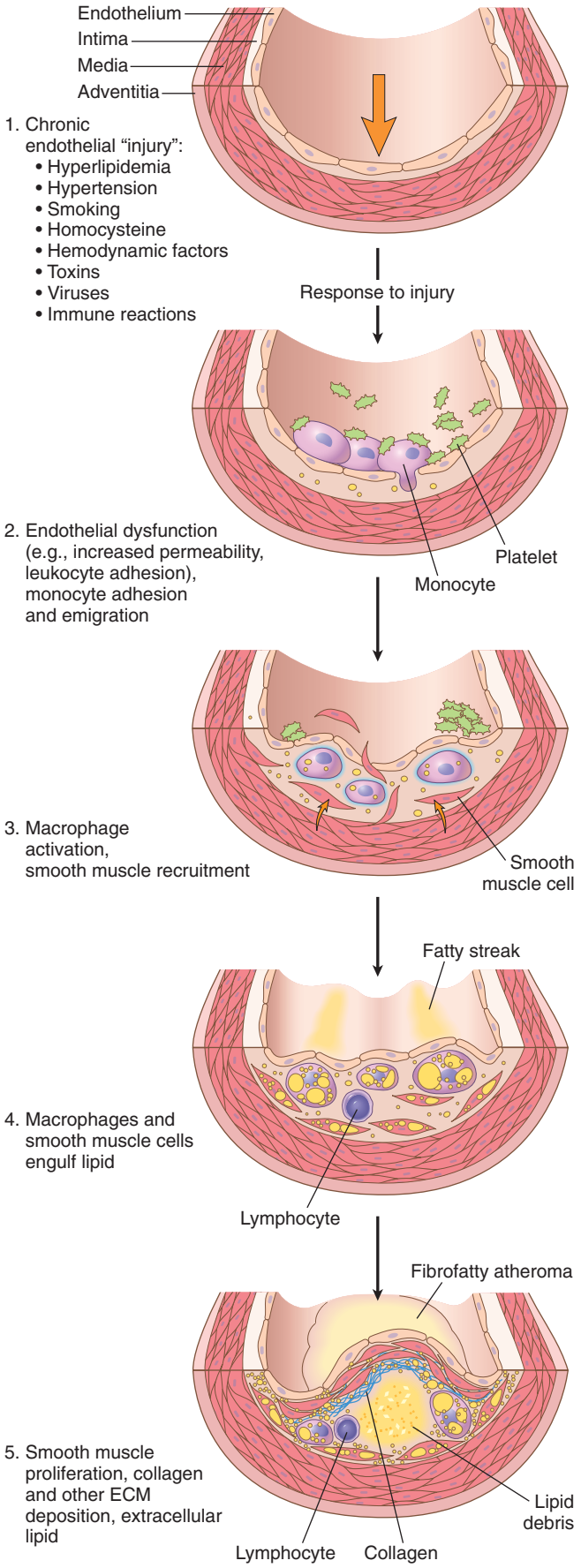


or from disorders that derange lipid metabolism, e.g., nephrotic syndrome, alcoholism, hypothyroidism, or diabetes mellitus. Common lipoprotein abnormalities in the general population (and indeed, present in many myocardial infarction survivors) include (1) increased LDL cholesterol levels, (2) decreased HDL cholesterol levels, and (3) increased levels of lipoprotein(a).

Several lines of evidence implicate hypercholesterolemia in atherogenesis:

- The dominant lipids in atheromatous plaques are cholesterol and cholesterol esters.
- Genetic defects in lipoprotein uptake and metabolism that cause hyperlipoproteinemia are associated with accelerated atherosclerosis. Thus, homozygous familial hypercholesterolemia, caused by defective LDL receptors and inadequate hepatic LDL uptake, can lead to myocardial infarction by age 20.
- Other genetic or acquired disorders (e.g., diabetes mellitus, hypothyroidism) that cause hypercholesterolemia lead to premature atherosclerosis.
- Epidemiologic analyses such as the famous Framingham study demonstrate a significant correlation between the severity of atherosclerosis and the levels of total plasma cholesterol or LDL.
- Lowering serum cholesterol by diet or drugs slows the rate of progression of atherosclerosis, causes regression of some plaques, and reduces the risk of cardiovascular events.

The mechanisms by which dyslipidemia contributes to atherogenesis include the following:

- Chronic hyperlipidemia, particularly hypercholesterolemia, can directly impair endothelial cell function by increasing local oxygen free radical production; among other things, oxygen free radicals accelerate NO decay, damping its vasodilator activity.
- With chronic hyperlipidemia, lipoproteins accumulate within the intima, where they are hypothesized to generate two pathogenic derivatives, **oxidized LDL and cholesterol crystals.** LDL is oxidized through the action of oxygen free radicals generated locally by macrophages or endothelial cells and ingested by macrophages through the **scavenger receptor,** resulting in **foam cell** formation. Oxidized LDL stimulates the local release of growth factors, cytokines, and chemokines, increasing monocyte recruitment, and also is cytotoxic to endothelial cells and smooth muscle cells. More recently, it has been shown that minute extracellular cholesterol crystals found in early atherosclerotic lesions serve as "danger" signals that activate innate immune cells such as monocytes and macrophages.

**Inflammation.** Inflammation contributes to the initiation, progression, and complications of atherosclerotic lesions. Normal vessels do not bind inflammatory cells. Early in atherogenesis, however, dysfunctional endothelial cells express

**Figure 9–10** Response to injury in atherogenesis: **1,** Normal. **2,** Endothelial injury with monocyte and platelet adhesion. **3,** Monocyte and smooth muscle cell migration into the intima, with macrophage activation. **4,** Macrophage and smooth muscle cell uptake of modified lipids and further activation. **5,** Intimal smooth muscle cell proliferation with ECM elaboration, forming a well-developed plaque.

adhesion molecules that promote leukocyte adhesion; vascular cell adhesion molecule-1 (VCAM-1), in particular, binds monocytes and T cells. After these cells adhere to the endothelium, they migrate into the intima under the influence of locally produced chemokines.

- Monocytes differentiate into macrophages and avidly engulf lipoproteins, including oxidized LDL and small cholesterol crystals. Cholesterol crystals appear to be particularly important instigators of inflammation through activation of the inflammasome and subsequent release of IL-1 (Chapter 2). Activated macrophages also produce toxic oxygen species that drive LDL oxidation and elaborate growth factors that stimulate smooth muscle cell proliferation.
- T lymphocytes recruited to the intima interact with the macrophages and also contribute to a state of chronic inflammation. It is not clear whether the T cells are responding to specific antigens (e.g., bacterial or viral antigens, heat-shock proteins [see further on], or modified arterial wall constituents and lipoproteins) or are nonspecifically activated by the local inflammatory milieu. Nevertheless, activated T cells in the growing intimal lesions elaborate inflammatory cytokines (e.g., IFN-γ), which stimulate macrophages, endothelial cells, and smooth muscle cells.
- As a consequence of the chronic inflammatory state, activated leukocytes and vascular wall cells release growth factors that promote smooth muscle cell proliferation and matrix synthesis.

**Infection.** There is circumstantial evidence linking infections to atherosclerosis. Herpesvirus, cytomegalovirus, and *Chlamydia pneumoniae* all have been found in atherosclerotic plaque, and seroepidemiologic studies show increased antibody titers to *Chlamydia pneumoniae* in patients with more severe atherosclerosis. Infections with these organisms, however, are exceedingly common (as is atherosclerosis), making it difficult to draw conclusions about causality. It also is important to recognize that atherosclerosis can be induced in germ-free mice, indicating that there is no obligate role for infection in the disease process.

**Smooth Muscle Proliferation and Matrix Synthesis.** Intimal smooth muscle cell proliferation and ECM deposition lead to conversion of the earliest lesion, a **fatty streak,** into a mature atheroma, thus contributing to the progressive growth of atherosclerotic lesions (Fig. 9–10). Intimal smooth muscle cells can originate from the media or from circulating precursors; regardless of their source, they have a proliferative and synthetic phenotype distinct from that of the underlying medial smooth muscle cells. Several growth factors are implicated in smooth muscle cell proliferation and matrix synthesis, including platelet-derived growth factor (released by locally adherent platelets, macrophages, endothelial cells, and smooth muscle cells), fibroblast growth factor, and TGF-α. The recruited smooth muscle cells synthesize ECM (most notably collagen), which stabilizes atherosclerotic plaques. However, activated inflammatory cells in atheromas also can cause intimal smooth muscle cell apoptosis and breakdown of matrix, leading to the development of **unstable plaques** (see later).

## MORPHOLOGY

**Fatty Streaks.** Fatty streaks begin as minute yellow, flat macules that coalesce into elongated lesions, 1 cm or more in length (Fig. 9–11). They are composed of lipid-filled foamy macrophages but are only minimally raised and do not cause any significant flow disturbance. Fatty streaks can appear in the aortas of infants younger than 1 year of age and are present in virtually all children older than 10 years, regardless of genetic, clinical, or dietary risk factors. The relationship of fatty streaks to atherosclerotic plaques is uncertain; although fatty streaks may evolve into plaques, not all are destined to progress. Nevertheless, it is notable that coronary fatty streaks form during adolescence at the same anatomic sites that are prone to plaques later in life.

**Atherosclerotic Plaque.** The key features of these lesions are intimal thickening and lipid accumulation (Fig. 9–7). Atheromatous plaques are white to yellow raised lesions; they range from 0.3 to 1.5 cm in diameter but can

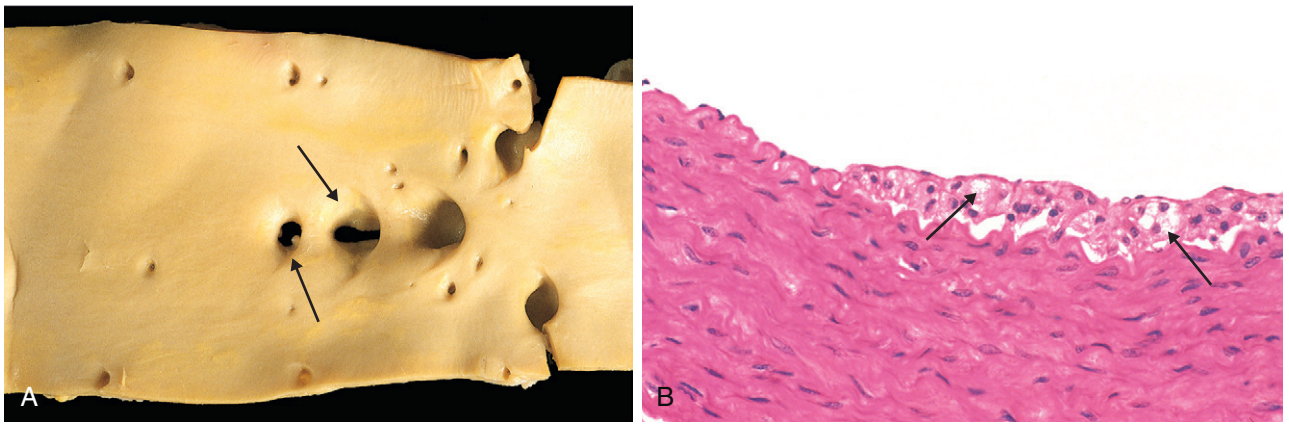


**Figure 9–11** Fatty streaks. **A,** Aorta with fatty streaks (*arrows*), mainly near the ostia of branch vessels. **B,** Fatty streak in an experimental hypercholesterolemic rabbit, demonstrating intimal, macrophage-derived foam cells (*arrow*).
*(B, Courtesy of Myron I. Cybulsky, MD, University of Toronto, Toronto, Ontario, Canada.)*

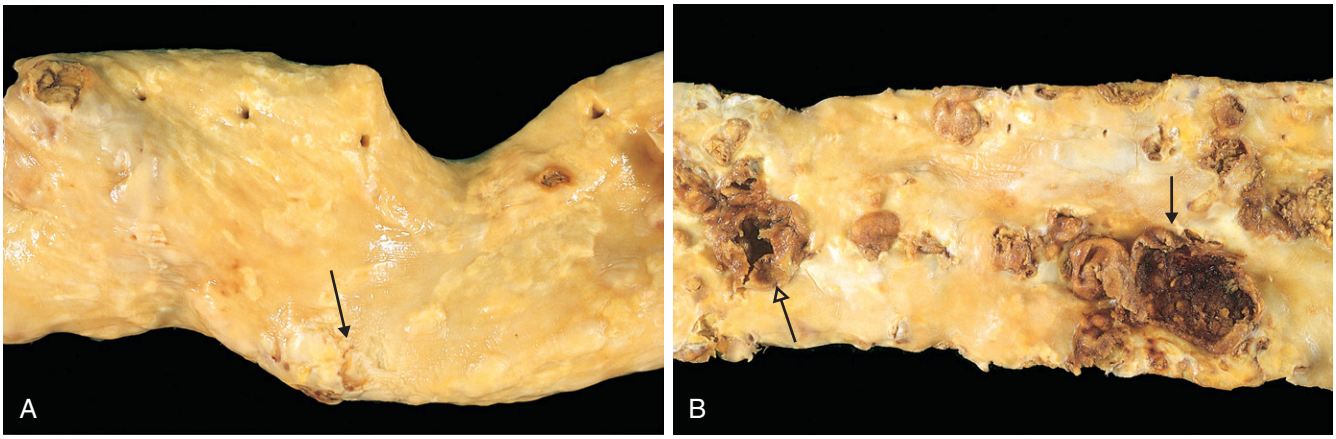


**Figure 9–12** Atherosclerotic lesions. **A,** Aorta with mild atherosclerosis composed of fibrous plaques, one denoted by the *arrow*. **B,** Aorta with severe diffuse complicated lesions, including an ulcerated plaque (*open arrow*), and a lesion with overlying thrombus (*closed arrow*).

coalesce to form larger masses. Thrombus superimposed on ulcerated plaques imparts a red-brown color (Fig. 9–12).

Atherosclerotic plaques are patchy, usually involving only a portion of any given arterial wall; on cross-section, therefore, the lesions appear "eccentric" (Fig. 9–13, *A*). The focal nature of atherosclerotic lesions may be related to the vagaries of vascular hemodynamics. Local flow disturbances, such as turbulence at branch points, make certain parts of a vessel wall especially susceptible to plaque formation.

In descending order, the most extensively involved vessels are the infrarenal abdominal aorta, the coronary arteries, the popliteal arteries, the internal carotid arteries, and the vessels of the circle of Willis. Even in the same patient, atherosclerosis typically is more severe in the abdominal aorta than in the thoracic aorta. Vessels of the upper extremities usually are spared, as are the mesenteric and renal arteries, except at their ostia. Nevertheless, in any individual case, the severity of atherosclerosis in one artery does not predict its severity in another. Moreover, in any given vessel, lesions at various stages often coexist.

**Atherosclerotic plaques have three principal components: (1) cells, including smooth muscle cells, macrophages, and T cells; (2) extracellular matrix, including collagen, elastic fibers, and proteoglycans; and (3) intracellular and extracellular lipid** (Fig. 9–13, *A* and *B*). The proportion and configuration of each component varies from lesion to lesion. Most commonly plaques have a superficial fibrous cap composed of smooth muscle cells and relatively dense collagen. Where the cap meets the vessel wall (the "shoulder") is a more cellular area containing macrophages, T cells, and smooth muscle cells. Deep to the fibrous cap is a necrotic core, containing lipid (primarily cholesterol and cholesterol esters), necrotic debris, lipid-laden macrophages and smooth muscle cells **(foam cells),** fibrin, variably organized thrombus, and other plasma proteins. The extracellular cholesterol frequently takes the forms of

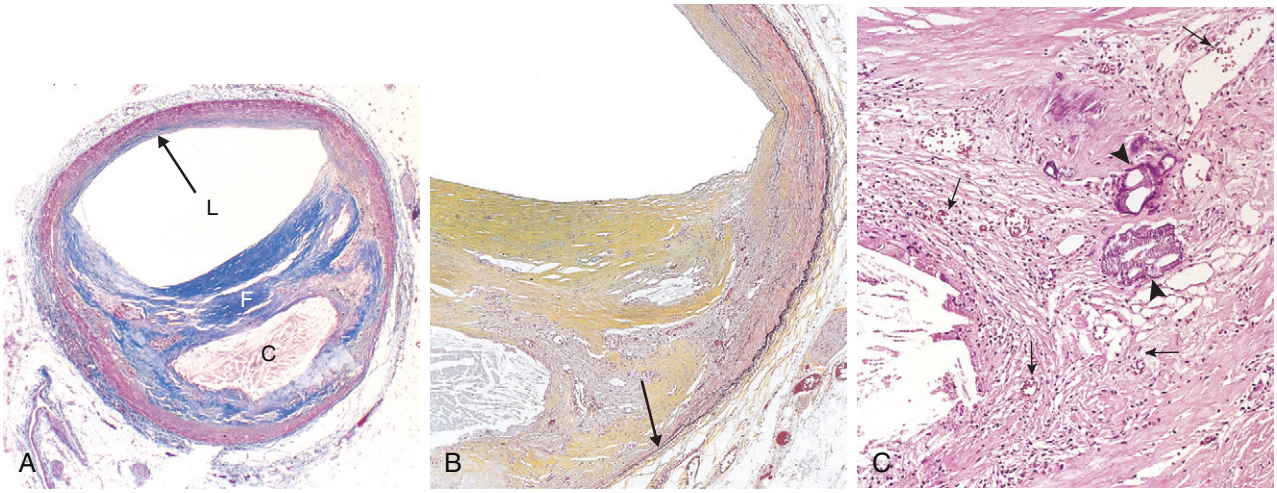


**Figure 9–13** Atherosclerotic plaque in the coronary artery. **A,** Overall architecture demonstrating fibrous cap (F) and a central necrotic (largely lipid) core (C); collagen (*blue*) is stained with Masson trichrome. The lumen (L) is moderately narrowed by this eccentric lesion, which leaves part of the vessel wall unaffected (*arrow*). **B,** Moderate-power view of the plaque shown in **A,** stained for elastin (*black*); the internal and external elastic membranes are attenuated and the media of the artery is thinned under the most advanced plaque (*arrow*). **C,** High-power view of the junction of the fibrous cap and core, showing scattered inflammatory cells, calcification (*arrowheads*), and neovascularization (*small arrows*).

crystalline aggregates that are washed out during routine tissue processing, leaving behind empty "cholesterol clefts." The periphery of the lesions shows **neovascularization** (proliferating small blood vessels) (Fig. 9–13, *C*). The media deep to the plaque may be attenuated and exhibit fibrosis secondary to smooth muscle atrophy and loss. Typical atheromas contain relatively abundant lipid, but some so-called fibrous plaques are composed almost exclusively of smooth muscle cells and fibrous tissue.

Plaques generally continue to change and progressively enlarge through cell death and degeneration, synthesis and degradation of ECM (remodeling), and thrombus organization. Atheromas also often undergo calcification (Fig. 9–10, *C*).

## Clinical Consequences of Atherosclerotic Disease

Large elastic arteries (e.g., aorta, carotid, and iliac arteries) and large and medium-sized muscular arteries (e.g., coronary, renal, and popliteal arteries) are the vessels most commonly involved by atherosclerosis. Accordingly, atherosclerosis is most likely to present with signs and symptoms related to ischemia in the heart, brain, kidneys, and lower extremities. *Myocardial infarction (heart attack), cerebral infarction (stroke), aortic aneurysms, and peripheral vascular disease (gangrene of extremities) are the major clinical consequences of atherosclerosis.*

The natural history, principal morphologic features, and main pathogenic events are schematized in Figure 9–14. The principal pathophysiologic outcomes depend on the size of the affected vessel, the size and stability of the plaques, and the degree to which plaques disrupt the vessel wall:

- Occlusion of smaller vessels can compromise tissue perfusion.
- Plaque rupture can expose atherosclerotic debris, leading to acute (and frequently catastrophic) vascular thrombosis or (with shedding of debris) distal embolization.
- Destruction of the underlying vessel wall can lead to aneurysm formation, with secondary rupture and/or thrombosis.

### *Atherosclerotic Stenosis*

At early stages, remodeling of the media tends to preserve the luminal diameter by increasing the vessel circumference. Owing to limits on remodeling, however, eventually the expanding atheroma may impinge on blood flow. *Critical stenosis* is the tipping point at which chronic occlusion limits flow so severely that tissue demand exceeds supply. In the coronary artery (and other) circulations, this typically occurs at approximately 70% fixed occlusion. At rest, affected patients have adequate cardiac perfusion, but with even modest exertion demand exceeds supply, and chest pain develops because of cardiac ischemia (*stable angina*) (see Chapter 10). The toll of chronic arterial hypoperfusion due to atherosclerosis in various vascular beds includes *bowel ischemia, sudden cardiac death, chronic IHD, ischemic encephalopathy,* and *intermittent claudication* (ischemic leg pain).

### *Acute Plaque Change*

*Plaque erosion or rupture typically triggers thrombosis, leading to partial or complete vascular obstruction and often tissue infarction* (see Fig. 9–14). Plaque changes fall into three general categories:

- *Rupture/fissuring,* exposing highly thrombogenic plaque constituents
- *Erosion/ulceration,* exposing the thrombogenic subendothelial basement membrane to blood
- *Hemorrhage into the atheroma,* expanding its volume

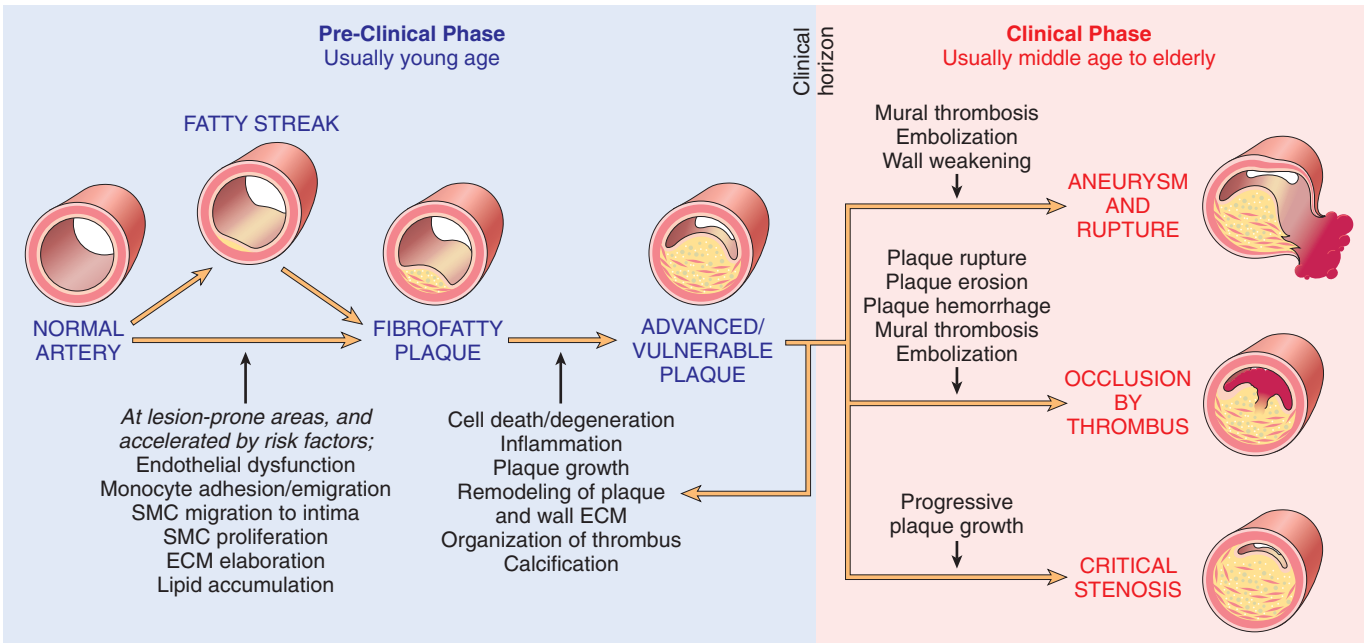


**Figure 9–14** Summary of the natural history, morphologic features, main pathogenic events, and clinical complications of atherosclerosis.

It is now recognized that plaques responsible for myocardial infarctions and other acute coronary syndromes often are asymptomatic *before* the acute event, which superimposes thrombosis on a lesion that previously did not produce significant luminal occlusion. The worrisome conclusion is that large numbers of asymptomatic persons are at risk for a catastrophic coronary event. The causes of acute plaque change are complex and include both intrinsic (e.g., plaque structure and composition) and extrinsic factors (e.g., blood pressure). These factors combine to weaken the integrity of the plaque, making it unable to withstand vascular shear forces.

Certain types of plaques are believed to be at particularly high risk of rupturing. These include plaques that contain large numbers of foam cells and abundant extracellular lipid, plaques that have thin fibrous caps containing few smooth muscle cells, and plaques that contain clusters of inflammatory cells. Plaques at high risk for rupture are referred to as "vulnerable plaques" (Fig. 9–15). The fibrous cap also undergoes continuous remodeling; its mechanical strength and stability is proportional to its collagen content, so the balance of collagen synthesis and degradation affects cap integrity. Collagen in atherosclerotic plaques is synthesized primarily by smooth muscle cells, and loss of smooth muscle cells understandably results in cap weakening. Collagen is degraded by matrix metalloproteinases (MMPs), enzymes elaborated by macrophages within the atheromatous plaque; conversely, tissue inhibitors of metalloproteinases (TIMPs) produced by endothelial cells, smooth muscle cells, and macrophages, all act to dampen MMP activity.

In general, *plaque inflammation increases collagen degradation and reduces collagen synthesis,* thereby destabilizing the mechanical integrity of the cap. Of interest, statins may have a beneficial effect not only by reducing circulating cholesterol levels but also by stabilizing plaques through a reduction in plaque inflammation.

Factors extrinsic to plaques also are important. Thus, adrenergic stimulation (as with intense emotions) can increase systemic blood pressure or induce local vasoconstriction, thereby increasing the mechanical stress on a given plaque. Indeed, one explanation for the pronounced circadian periodicity in the onset of heart attacks (peak incidence between 6 AM and 12 noon) is the adrenergic surge associated with waking and rising, which is sufficient to cause blood pressure spikes and heightened platelet reactivity.

Fortunately, not all plaque ruptures result in occlusive thromboses with catastrophic consequences. In fact, silent plaque disruption and ensuing superficial platelet aggregation and thrombosis probably occur frequently and repeatedly in those with atherosclerosis. Healing of these subclinical plaque disruptions—and their overlying thromboses—is an important mechanism for atheroma enlargement.

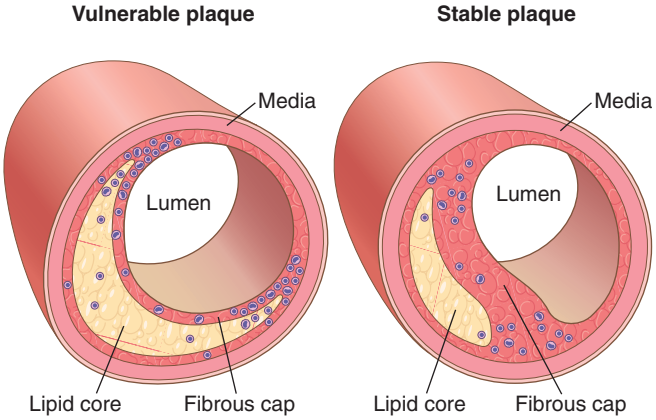


**Figure 9–15** Vulnerable and stable atherosclerotic plaque. Stable plaques have densely collagenized and thickened fibrous caps with minimal inflammation and negligible underlying atheromatous cores, whereas vulnerable plaques have thin fibrous caps, large lipid cores, and increased inflammation.
*(Adapted from Libby P: Circulation 91:2844, 1995.)*

## MORPHOLOGY

Atherosclerotic plaques are susceptible to several clinically important changes:

- **Rupture, ulceration, or erosion** of the luminal surface of atheromatous plaques exposes highly thrombogenic substances and induces **thrombus formation**. Thrombi may partially or completely occlude the lumen, leading to tissue ischemia (e.g., in the heart) (Chapter 10) (Fig. 9–16). If the patient survives, thrombi become organized and incorporated into the growing plaque.
- **Hemorrhage into a plaque.** Rupture of the overlying fibrous cap or of the thin-walled vessels in the areas of neovascularization can cause intra-plaque hemorrhage; the resulting hematoma may cause rapid plaque expansion or plaque rupture.
- **Atheroembolism.** Ruptured plaque can discharge debris into the blood, producing microemboli composed of plaque contents.
- **Aneurysm formation.** Atherosclerosis-induced pressure or ischemic atrophy of the underlying media, with loss of elastic tissue, causes structural weakening that can lead to aneurysmal dilation and rupture.

## SUMMARY

### Atherosclerosis

- Atherosclerosis is an intima-based lesion composed of a fibrous cap and an atheromatous (literally, "gruel-like") core; the constituents of the plaque include smooth muscle cells, ECMs, inflammatory cells, lipids, and necrotic debris.
- Atherogenesis is driven by an interplay of vessel wall injury and inflammation. The multiple risk factors for atherosclerosis all cause endothelial cell dysfunction and influence smooth muscle cell recruitment and stimulation.
- Atherosclerotic plaques develop and grow slowly over decades. Stable plaques can produce symptoms related to chronic ischemia by narrowing vessels, whereas unstable

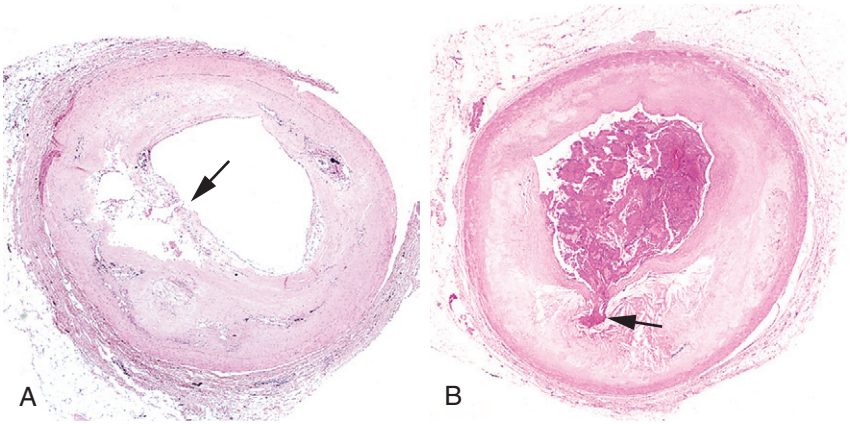


**Figure 9–16** Atherosclerotic plaque rupture. **A,** Plaque rupture without superimposed thrombus, in a patient who died suddenly. **B,** Acute coronary thrombosis superimposed on an atherosclerotic plaque with focal disruption of the fibrous cap, triggering fatal myocardial infarction. In both **A** and **B,** an *arrow* points to the site of plaque rupture.

*(B, Reproduced from Schoen FJ: Interventional and Surgical Cardiovascular Pathology: Clinical Correlations and Basic Principles. Philadelphia, WB Saunders, 1989, p 61.)*

plaques can cause dramatic and potentially fatal ischemic complications related to acute plaque rupture, thrombosis, or embolization.

- Stable plaques tend to have a dense fibrous cap, minimal lipid accumulation, and little inflammation, whereas "vulnerable" unstable plaques have thin caps, large lipid cores, and relatively dense inflammatory infiltrates.

## ANEURYSMS AND DISSECTIONS

*Aneurysms* are *congenital or acquired dilations of blood vessels or the heart* (Fig. 9–17). "True" aneurysms involve all three layers of the artery (intima, media, and adventitia) or the attenuated wall of the heart; these include atherosclerotic and congenital vascular aneurysms, as well as ventricular aneurysms resulting from transmural myocardial infarctions. By comparison, a *false aneurysm* (pseudoaneurysm) results when a wall defect leads to the formation of an extravascular hematoma that communicates with the intravascular space ("pulsating hematoma"). Examples are ventricular ruptures contained by pericardial adhesions and leaks at the junction of a vascular graft with a natural artery. In *arterial dissections,* pressurized blood gains entry to the arterial wall through a surface defect and then pushes apart the underlying layers. Aneurysms and dissections are important causes of stasis and subsequent thrombosis; they also have a propensity to rupture—often with catastrophic results.

Aneurysms can be classified by shape (see Fig. 9–17). *Saccular* aneurysms are discrete outpouchings ranging from 5 to 20 cm in diameter, often with a contained thrombus. *Fusiform* aneurysms are circumferential dilations up to 20 cm in diameter; these most commonly involve the aortic arch, the abdominal aorta, or the iliac arteries.

### PATHOGENESIS

Arteries are dynamic tissues that maintain their integrity through the ongoing synthesis, degradation, and repair of their extracellular matrix. Aneurysms occur when the structure or function of the connective tissue is compromised by any of the following factors:

- **Inadequate or abnormal connective tissue synthesis.** Several rare inherited diseases provide insight into the types of molecular abnormalities that can lead to aneurysm formation. As described previously, TGF-β regulates smooth muscle cell proliferation and matrix

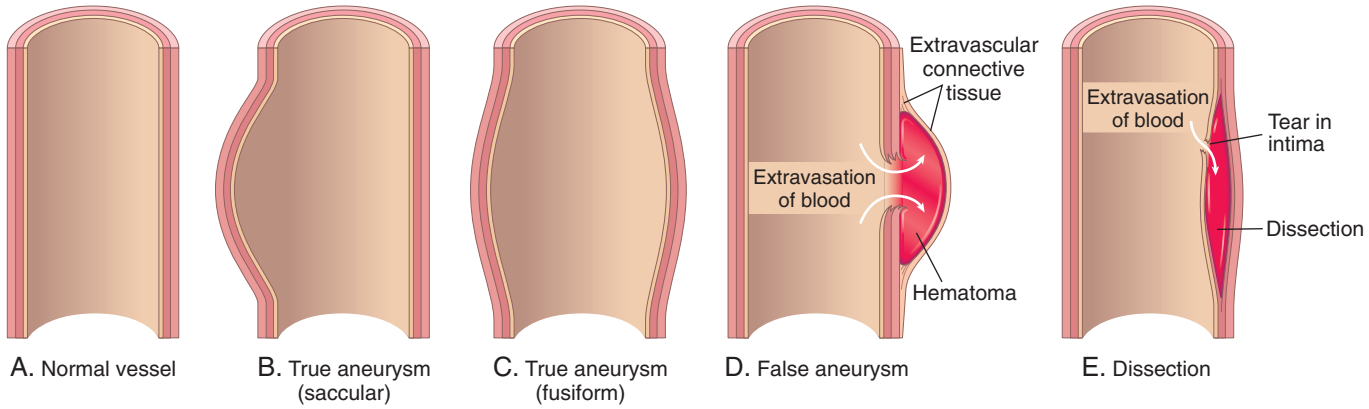


**Figure 9–17** Aneurysms. **A,** Normal vessel. **B,** True aneurysm, saccular type. The wall bulges outward and may be attenuated but is otherwise intact. **C,** True aneurysm, fusiform type. There is circumferential dilation of the vessel. **D,** False aneurysm. The wall is ruptured, creating a collection of blood (hematoma) bounded externally by adherent extravascular tissues. **E,** Dissection. Blood has entered the wall of the vessel and separated (*dissected*) the layers.

synthesis. Thus, mutations in TGF-β receptors or downstream signaling pathways result in defective elastin and collagen synthesis; aneurysms in affected persons often rupture, even when small. In **Marfan syndrome** (Chapter 6), defective synthesis of the scaffolding protein **fibrillin** leads to abnormal sequestration of TGF-β in the aortic wall, with subsequent dilation due to dysregulated signaling and progressive loss of elastic tissue. Defective type III collagen synthesis with aneurysm formation is a hallmark of the type IV **Ehlers-Danlos syndrome** (Chapter 6).

- **Excessive connective tissue degradation.** Increased MMP expression, such as by macrophages in atherosclerotic plaque, can contribute to aneurysm development by degrading arterial ECM in the arterial wall; similarly, decreased TIMP expression can also tip the balance toward net ECM degradation. A genetic predisposition to aneurysm formation in the setting of inflammation may be related to MMP and/or TIMP polymorphisms, or to the nature of the local inflammatory response that drives MMP or TIMP production.
- **Loss of smooth muscle cells or change in the smooth muscle cell synthetic phenotype.** Atherosclerotic thickening of the intima can cause ischemia of the inner media by increasing the diffusion distance from the lumen. Conversely, systemic hypertension can cause luminal narrowing of the aortic vasa vasorum, leading to ischemia of the outer media. Such ischemia results in smooth muscle cell loss as well as aortic "degenerative changes," which include fibrosis (replacing distensible elastic tissue), inadequate ECM synthesis, and accumulation of increasing amounts of amorphous proteoglycans. Histologically, these changes are collectively called **cystic medial degeneration** (Fig. 9–18), although no true cysts are formed. Such changes are nonspecific; they can occur whenever ECM synthesis is defective, including in genetic disorders such as Marfan syndrome and metabolic syndrome such as scurvy.

**The two most important causes of aortic aneurysms are atherosclerosis and hypertension.** Atherosclerosis is the more dominant factor in abdominal aortic aneurysms, while hypertension is associated with ascending aortic aneurysms. Other conditions that weaken vessel walls and lead to aneurysms include trauma, vasculitis (see later), congenital defects, and infections, so-called **mycotic aneurysms.** Mycotic aneurysms result from (1) embolization of a septic embolus, usually as a complication of infective endocarditis; (2) extension of an adjacent suppurative process; or (3) direct infection of an arterial wall by circulating organisms. Tertiary syphilis is a rare cause of aortic aneurysms. A predilection of the spirochetes for the vasa vasorum of the ascending thoracic aorta—and the subsequent immune response to them—results in an **obliterative endarteritis** that compromises blood flow to the media; the ensuing ischemic injury leads to aneurysmal dilation that occasionally also can involve the aortic valve annulus.

## Abdominal Aortic Aneurysm

*Atherosclerotic aneurysms occur most frequently in the abdominal aorta,* but the common iliac arteries, aortic arch, and descending thoracic aorta can also be involved. Abdominal aortic aneurysm (AAA) occurs more frequently in men and in smokers and rarely develops before the age of 50 years. Atherosclerosis is a major cause of AAA, but other factors clearly contribute, since the incidence is less than 5% in men older than 60 despite almost universal abdominal aortic atherosclerosis in that population.

In the majority of cases, AAA results from excess ECM degradation mediated by local inflammatory infiltrates in atherosclerotic arteries and the destructive proteolytic enzymes produced at these sites. Atherosclerotic plaques compromise the diffusion of nutrients and wastes between the vascular lumen and the arterial wall, and also directly compress the underlying media. As a result, the media undergoes degeneration and necrosis, which results in arterial wall thinning. A familial predisposition to AAA, independent of genetic predilection to atherosclerosis or hypertension, may be a factor in some persons; thus, hereditary defects in structural components of the aorta can produce aneurysms (e.g., Marfan syndrome). Of note, the risks of AAA and smoking-related emphysema are

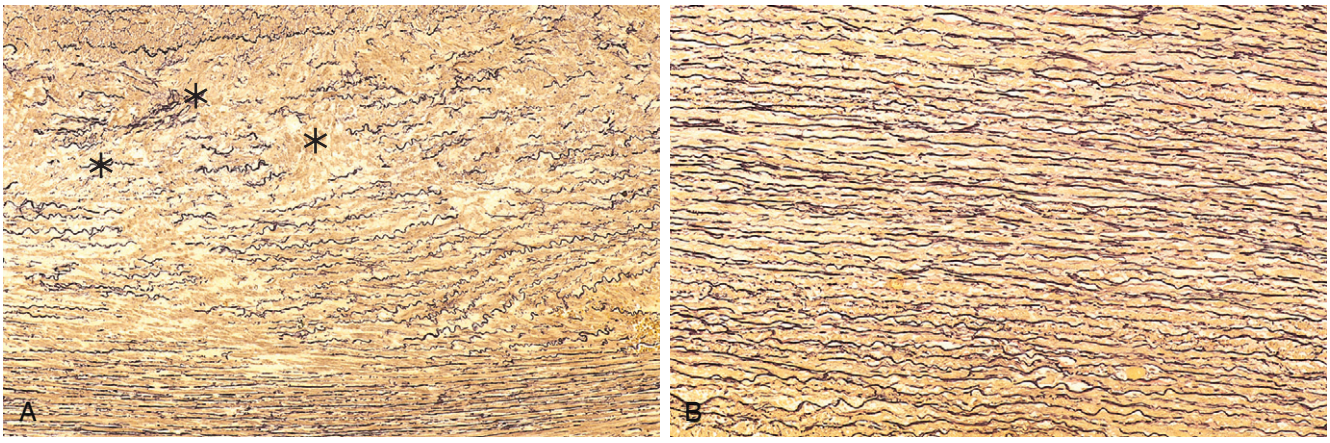


**Figure 9–18** Cystic medial degeneration. **A,** Cross-section of aortic media from a patient with Marfan syndrome, showing marked elastin fragmentation and areas devoid of elastin that resemble cystic spaces (*asterisks*). **B,** Normal media for comparison, showing the regular layered pattern of elastic tissue. In both **A** and **B,** elastin is stained *black*.

associated, suggesting that some affected patients have a systemic dysregulation of ECM degradation.

### MORPHOLOGY

AAAs typically occur between the renal arteries and the aortic bifurcation; they can be saccular or fusiform and up to 15 cm in diameter and 25 cm in length (Fig. 9–19). In the vast majority of cases, extensive atherosclerosis is present, with thinning and focal destruction of the underlying media. The aneurysm sac usually contains bland, laminated, poorly organized mural thrombus, which can fill much of the dilated segment. Not infrequently, AAAs are accompanied by smaller iliac artery aneurysms.

- **Inflammatory AAAs** are a distinct subtype characterized by dense periaortic fibrosis containing abundant lymphoplasmacytic inflammation with many macrophages and giant cells.
- **Mycotic AAAs** occur when circulating microorganisms (as in bacteremia from a *Salmonella* gastroenteritis) seed the aneurysm wall or the associated thrombus; the resulting suppuration accelerates the medial destruction and may lead to rapid dilation and rupture.

#### Clinical Consequences

The clinical consequences of AAA may include

- Obstruction of a vessel branching off the aorta (e.g., the renal, iliac, vertebral, or mesenteric arteries), resulting in distal ischemia of the kidneys, legs, spinal cord, or gastrointestinal tract, respectively
- Embolism from atheroma or mural thrombus
- Impingement on adjacent structures, e.g., compression of a ureter or erosion of vertebrae by the expanding aneurysm
- An abdominal mass (often palpably pulsating) that simulates a tumor
- Rupture into the peritoneal cavity or retroperitoneal tissues, leading to massive, often fatal hemorrhage

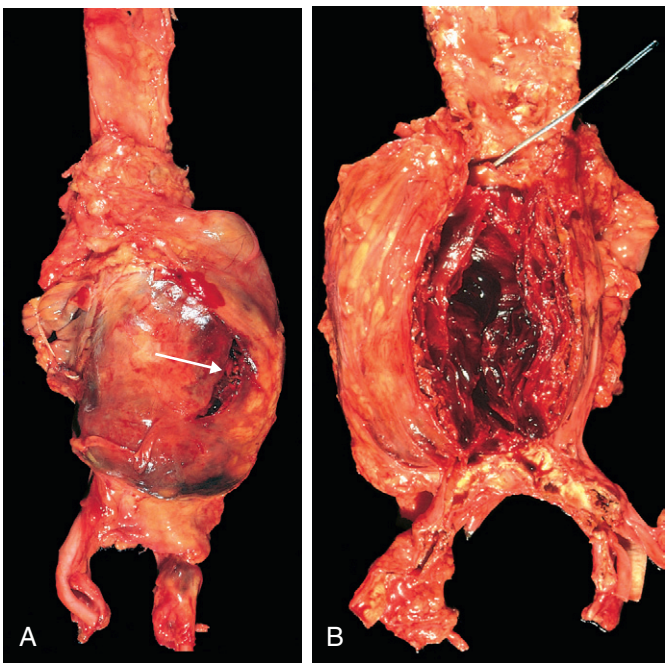


**Figure 9–19** Abdominal aortic aneurysm. **A,** External view of a large aortic aneurysm that ruptured at the site is indicated by the *arrow*. **B,** Opened view, with the location of the rupture tract indicated by a *probe*. The wall of the aneurysm is attenuated, and the lumen is filled by a large, layered thrombus.

The risk of rupture is determined by size. AAAs 4 cm or less in diameter almost never burst, while those between 4 and 5 cm do so at a rate of 1% per year. The risk rises to 11% per year for AAAs 5 to 6 cm in diameter, and to 25% per year for aneurysms greater than 6 cm in diameter. Thus, aneurysms 5 cm in diameter or larger are managed surgically, either by open placement of tubular prosthetic grafts or with endoluminal insertion of stented grafts (expandable wire frames covered by a cloth sleeve). Timely intervention is critical, because the mortality rate for elective procedures is approximately 5%, whereas the rate for emergency surgery after rupture is roughly 50%.

A point worthy of emphasis is that because atherosclerosis is a systemic disease, a patient with AAA also is very likely to have atherosclerosis in other vascular beds and is at a significantly increased risk for IHD and stroke.

## Thoracic Aortic Aneurysm

Thoracic aortic aneurysms most commonly are associated with hypertension and Marfan syndrome, with other disorders caused by mutations in TGF-β signaling pathway components also being increasingly recognized as etiologies. These aneurysms manifest with signs and symptoms referable to (1) encroachment on mediastinal structures (e.g., respiratory or feeding difficulties due to airway or esophageal compression, respectively); (2) persistent cough from irritation of the recurrent laryngeal nerves; (3) pain caused by erosion of bone (i.e., ribs and vertebral bodies); (4) cardiac disease due to valvular insufficiency or narrowing of the coronary ostia; and (5) aortic rupture. Rare patients with syphilitic aneurysms commonly die of heart failure induced by aortic valvular incompetence.

## Aortic Dissection

*Aortic dissection occurs when blood splays apart the laminar planes of the media to form a blood-filled channel within the aortic wall* (Fig. 9–20); this development can be catastrophic if the dissecting blood ruptures through the adventitia and escapes into adjacent spaces. Aortic dissection need not be associated with aortic dilation, and the older term "dissecting aneurysm" should be avoided.

Aortic dissection occurs mainly in two age groups: (1) men aged 40 to 60 with antecedent hypertension (more than 90% of cases); and (2) younger patients with connective tissue abnormalities that affect the aorta (e.g., Marfan syndrome). Dissections also can be iatrogenic (e.g., complicating arterial cannulation during diagnostic catheterization or cardiopulmonary bypass). Rarely, for unknown reasons, pregnant women develop dissection of the aorta or its branches, including the coronary arteries. Dissection

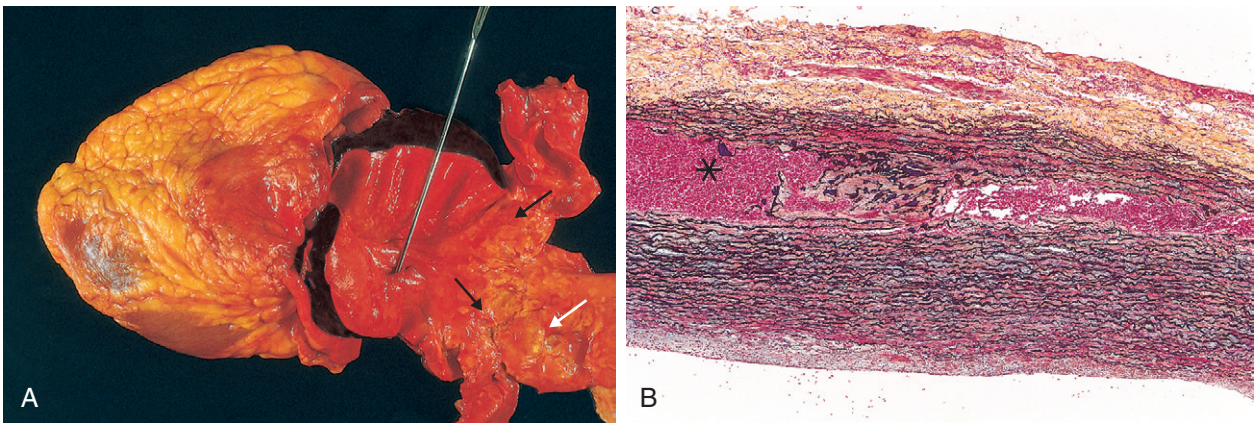


**Figure 9–20** Aortic dissection. **A,** An opened aorta with a proximal dissection originating from a small, oblique intimal tear (identified by the *probe*) associated with an intramural hematoma. Note that the intimal tear occurred in a region largely free of atherosclerotic plaque. The distal edge of the intramural hematoma (*black arrows*) lies at the edge of a large area of atherosclerosis (*white arrow*), which arrested the propagation of the dissection. **B,** Histologic preparation showing the dissection and intramural hematoma (*asterisk*). Aortic elastic layers are black and blood is red in this section, stained with the Movat stain.

is unusual in the presence of substantial atherosclerosis or other causes of medial scarring, presumably because the medial fibrosis inhibits propagation of the dissecting hematoma (see Fig. 9–20).

## PATHOGENESIS

Hypertension is the major risk factor for aortic dissection. Aortas in hypertensive patients show medial hypertrophy of the vasa vasorum associated with degenerative changes in ECM and variable loss of medial smooth muscle cells, suggesting that diminished flow through the vasa vasorum is contributory. Most other dissections are related to heritable or acquired connective tissue disorders that give rise to abnormal aortic ECM, including Marfan syndrome, Ehlers-Danlos syndrome type IV, and defects in copper metabolism.

The trigger for the intimal tear and subsequent intramural hemorrhage is not known in most cases. Nevertheless, once the tear has occurred, blood under systemic pressure dissects through the media along laminar planes. Accordingly, aggressive pressure-reducing therapy may be effective in limiting an evolving dissection. In rare cases, disruption of the vasa vasorum can give rise to an intramural hematoma **without** an intimal tear.

## MORPHOLOGY

In most dissections, the intimal tear marking the point of origin is found in the ascending aorta within 10 cm of the aortic valve (Fig. 9–20, *A*). Such tears usually are transverse or oblique in orientation and 1 to 5 cm long, with sharp, jagged edges. The dissection plane can extend retrograde toward the heart or distally, occasionally as far as the iliac and femoral arteries, and usually lies between the middle and outer thirds of the media (Fig. 9–20, *B*).

External rupture causes massive hemorrhage, or results in cardiac tamponade if it occurs into the pericardial sac. In some (fortunate) instances, the dissecting hematoma reenters the lumen of the aorta through a second distal intimal tear, creating a second vascular channel within the media (so-called double-barreled aorta). Over time, such false channels become endothelialized to give rise to **chronic dissections.**

In most instances, no specific underlying causal pathology is identified in the aortic wall. The most frequent preexisting histologically detectable lesion is the **cystic medial degeneration** described previously; this is characterized by smooth muscle layer dropout and necrosis, elastic tissue fragmentation, and accumulations of amorphous proteoglycan-rich ECM (Fig. 9–18). Inflammation is characteristically absent. Recognizable medial damage appears to be neither a prerequisite for dissection nor a guarantee that dissection is imminent. Occasionally, dissections occur in the setting of rather trivial medial degeneration, while marked degenerative changes frequently are seen at autopsy in persons who exhibited no clinical manifestations in life.

### Clinical Consequences

The clinical manifestations of dissection depend primarily on the portion of the aorta affected; the most serious complications occur with dissections involving the proximal aorta and arch. Thus, aortic dissections generally are classified into two types (Fig. 9–21):

- *Proximal lesions*: *type A dissections*, involving the ascending aorta, with or without involvement of the descending aorta (DeBakey type I or II, respectively)
- *Distal lesions,* usually beginning beyond the subclavian artery: *type B dissections* (DeBakey type III)

The classic clinical symptom of aortic dissection is the sudden onset of excruciating tearing or stabbing pain, usually beginning in the anterior chest, radiating to the back between the scapulae, and moving downward as the dissection progresses. *The most common cause of death is rupture of the dissection into the pericardial, pleural, or peritoneal cavity.* Retrograde dissection into the aortic root also can cause fatal disruption of the aortic valvular apparatus

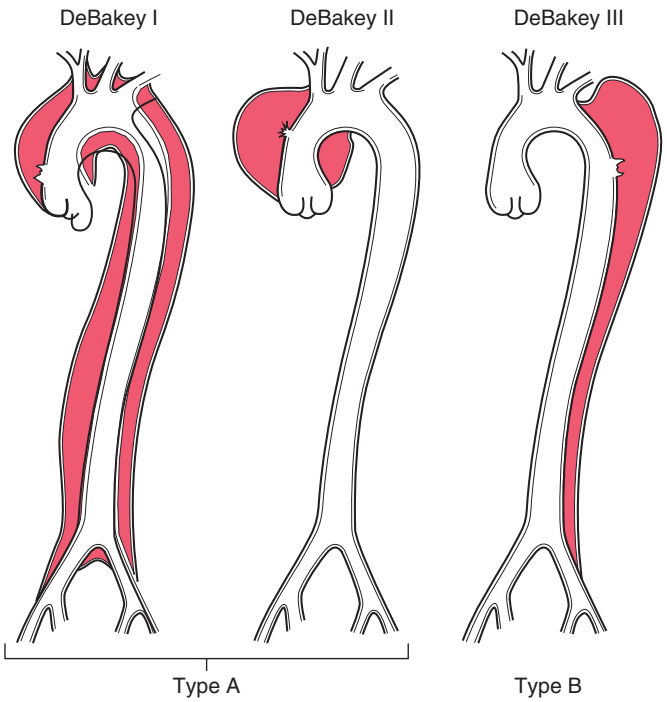


**Figure 9–21** Classification of dissections. Type A (proximal) involves the ascending aorta, either as part of a more extensive dissection (DeBakey type I), or in isolation (DeBakey type II). Type B (distal, or DeBakey type III) dissections arise after the takeoff of the great vessels.

or compression of the coronary arteries. Common clinical presentations with cardiac involvement include tamponade, aortic insufficiency, and myocardial infarction. Other complications are related to extension of the dissection to the great arteries of the neck and the renal, mesenteric, or iliac arteries, any of which may become obstructed. Similarly, compression of spinal arteries can cause transverse myelitis.

In type A dissections, rapid diagnosis and institution of intensive antihypertensive therapy coupled with surgical plication of the aortic intimal tear can save 65% to 85% of the patients. However, the mortality rate approaches 70% in patients who present with hemorrhage or symptoms related to distal ischemia, and the overall 10-year survival rate is only 40% to 60%. Most type B dissections can be managed conservatively; patients have a 75% survival rate whether they are treated with surgery or with antihypertensive medication only.

## SUMMARY

### Aneurysms and Dissections

- Aneurysms are congenital or acquired dilations of the heart or blood vessels that involve the entire wall thickness. Complications are related to rupture, thrombosis, and embolization.
- Dissections occur when blood enters the wall of a vessel and separates the various layers. Complications arise as a result of rupture or obstruction of vessels branching off the aorta.
- Aneurysms and dissections result from structural weakness of the vessel wall caused by loss of smooth muscle cells or insufficient extracellular matrix, which can be a consequence of ischemia, genetic defects, or defective matrix remodeling.

# VASCULITIS

*Vasculitis* is a general term for vessel wall inflammation. The possible clinical manifestations are protean, but largely depend on the specific vascular bed that is affected. Besides findings referable to the involved tissue(s), there are usually also signs and symptoms of systemic inflammation, such as fever, myalgia, arthralgias, and malaise.

Although several forms of vasculitis have a predilection for relatively large vessels (e.g., large or medium-sized muscular arteries), most affect small vessels (arterioles, capillaries, and venules). Some 20 primary forms of vasculitis are recognized, and classification schemes attempt (with varying success) to group them according to vessel size, role of immune complexes, presence of specific autoantibodies, granuloma formation, tissue tropism, and other, poorly defined criteria (Fig. 9–22). As we shall see, there is considerable clinical and pathologic overlap among many of these disorders.

The two most common pathogenic mechanisms of vasculitis are *immune-mediated inflammation* and *direct vascular invasion by infectious pathogens.* Infections also can indirectly precipitate immune-mediated vasculitis (e.g., by generating immune complexes or triggering cross-reactivity). In any given patient, it is critical to distinguish between infectious and immunologic mechanisms because immunosuppressive therapy is appropriate for immune-mediated vasculitis but could exacerbate infectious vasculitis. Physical and chemical injury, including that due to radiation, mechanical trauma, and toxins, also can cause vasculitis.

## Noninfectious Vasculitis

The main immunologic mechanisms underlying noninfectious vasculitis are

- Immune complex deposition
- Antineutrophil cytoplasmic antibodies
- Anti-endothelial cell antibodies
- Autoreactive T cells

***Immune Complex–Associated Vasculitis.*** This form of vasculitis is seen in immunologic disorders such as systemic lupus erythematosus (Chapter 4) that are associated with autoantibody production. The vascular lesions resemble those found in experimental immune complex–mediated disorders, such as the Arthus phenomenon and serum sickness, and in many cases contain readily identifiable antibody and complement. Often, however, this type of vasculitis is a diagnostic challenge. Only rarely is the specific antigen responsible for immune complex formation known. While immune complexes are occasionally detected in the blood, in most instances it is not clear whether the pathogenic antigen-antibody complexes are deposited

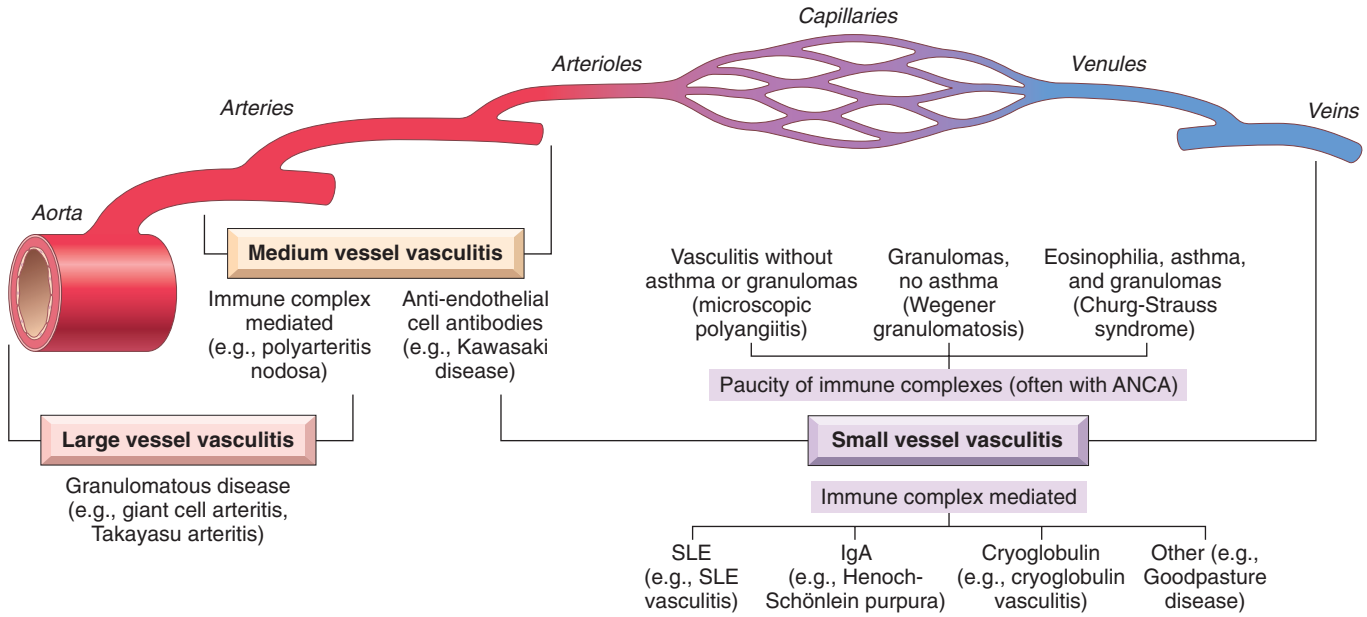


**Figure 9–22** Vascular sites involved in the more common vasculitides and their presumptive etiology. Note the considerable overlap in distributions. ANCA, anti-neutrophil cytoplasmic antibody; SLE, systemic lupus erythematosus.
*(Data from Jennette JC, Falk RJ: Nosology of primary vasculitis. Curr Opin Rheumatol 19:17, 2007.)*

from the circulation or form in situ. In fact, in many suspected cases, even the antigen-antibody deposits are scarce, perhaps because the immune complexes have been degraded by the time of biopsy.

Immune complex deposition is implicated in the following vasculitides:

- *Drug hypersensitivity vasculitis.* In some cases drugs (e.g., penicillin) act as haptens by binding to host proteins; other agents are themselves foreign proteins (e.g., streptokinase). Regardless, antibodies directed against the drug-modified proteins or foreign molecules result in immune complex formation. The clinical manifestations can be mild and self-limiting, or severe and even fatal; skin lesions are most common. It is always important to consider drug hypersensitivity as a cause of vasculitis, since discontinuation of the offending agent usually leads to resolution.
- *Vasculitis secondary to infections.* Antibody to microbial constituents can form immune complexes that circulate and deposit in vascular lesions. In up to 30% of patients with polyarteritis nodosa (see further on), the vasculitis is attributable to immune complexes composed of hepatitis B surface antigen (HBsAg) and anti-HBsAg antibody.

***Anti-Neutrophil Cytoplasmic Antibodies.*** Many patients with vasculitis have circulating antibodies that react with neutrophil cytoplasmic antigens, so-called *anti-neutrophil cytoplasmic antibodies (ANCAs)*. ANCAs are a heterogeneous group of autoantibodies directed against constituents (mainly enzymes) of neutrophil primary granules, monocyte lysosomes, and endothelial cells. ANCAs are very useful diagnostic markers; their titers generally mirror clinical severity, and a rise in titers after periods of quiescence is predictive of disease recurrence. Although a number of ANCAs have been described, two are most important:

- *Antiproteinase-3* (PR3-ANCA), previously called c-ANCA. PR3 is a neutrophil azurophilic granule constituent that shares homology with numerous microbial peptides, possibly explaining the generation of PR3-ANCAs. PR3-ANCAs are associated with Wegener granulomatosis (see below).
- *Anti-myeloperoxidase* (MPO-ANCA), previously called p-ANCA. MPO is a lysosomal granule constituent involved in oxygen free radical generation (Chapter 2). MPO-ANCAs are induced by several therapeutic agents, particularly propylthiouracil. MPO-ANCAs are associated with microscopic polyangiitis and Churg-Strauss syndrome (see later).

The close association between ANCA titers and disease activity suggests a pathogenic role for these antibodies. Of note, ANCAs can directly activate neutrophils, stimulating the release of reactive oxygen species and proteolytic enzymes; in vascular beds, this may lead to endothelial cell injury. While the antigenic targets of ANCA are primarily intracellular (and therefore not usually accessible to circulating antibodies), it is now clear that ANCA antigens (especially PR3) either are constitutively expressed at low levels on the plasma membrane or are translocated to the cell surface in activated and apoptotic leukocytes.

A plausible mechanism for ANCA vasculitis involves the following sequence:

- Drugs or cross-reactive microbial antigens induce ANCA formation; alternatively, leukocyte surface expression or release of PR3 and MPO (in the setting of infections) incites ANCA development in a susceptible host.
- Subsequent infection, endotoxin exposure, or inflammatory stimulus elicits cytokines such as TNF that upregulate the surface expression of PR3 and MPO on neutrophils and other cell types.

- ANCAs bind these cytokine-activated cells, causing further activation of neutrophils.
- ANCA-activated neutrophils cause endothelial cell injury by releasing granule contents and reactive oxygen species.

The ANCA autoantibodies are directed against cellular constituents and do not form circulating immune complexes. The vascular lesions do not typically contain demonstrable antibody and complement; therefore ANCA-associated vasculitides are often described as "pauci-immune." Of interest, ANCAs directed against proteins other than PR3 and MPO are sometimes seen in patients with nonvasculitic inflammatory disorders (e.g., inflammatory bowel disease, sclerosing cholangitis, and rheumatoid arthritis).

***Anti-Endothelial Cell Antibodies.*** Antibodies to endothelial cells, underlie certain vasculitides, such as Kawasaki disease (discussed later).

Presented next is a brief overview of several of the best-characterized vasculitides, with emphasis on the substantial overlap among the different entities. Of note, many cases lack a classic constellation of findings and are difficult to fit into one specific diagnostic category.

### *Giant Cell (Temporal) Arteritis*

*Giant cell (temporal) arteritis is the most common form of vasculitis among the elderly in developed countries. It takes the form of chronic, typically granulomatous, inflammation of large to small size arteries, mainly those supplying the head—especially the temporal arteries.* Vertebral and ophthalmic arteries, as well as the aorta (giant cell aortitis), also can be involved. Because ophthalmic artery involvement can lead to sudden and permanent blindness, affected persons must be diagnosed and treated promptly.

#### PATHOGENESIS

The bulk of evidence suggests the culprit is a T cell–mediated immune response to an as-yet uncharacterized vessel wall antigen. Pro-inflammatory cytokines (especially TNF) and anti-endothelial cell antibodies also contribute. The characteristic granulomatous inflammation, the association with certain MHC class II haplotypes, and the excellent therapeutic response to steroids all are in favor of an immune etiology. The extraordinary predilection for the temporal artery remains unexplained, although one hypothesis is that vessels in various parts of the body develop from distinct anlagen and may, therefore, express unique antigens.

#### MORPHOLOGY

In giant cell arteritis, the pathologic changes are notoriously patchy along the length of affected vessels. Involved arterial segments exhibit nodular intimal thickening (and occasional thromboses) that reduce the lumen diameter and cause distal ischemia. Classic lesions exhibit **granulomatous inflammation** within the inner media centered on the internal elastic membrane; there is an infiltrate of lymphocytes and macrophages, with multinucleate giant cells, and **fragmentation of the internal elastic lamina** (Fig. 9–23). In up to

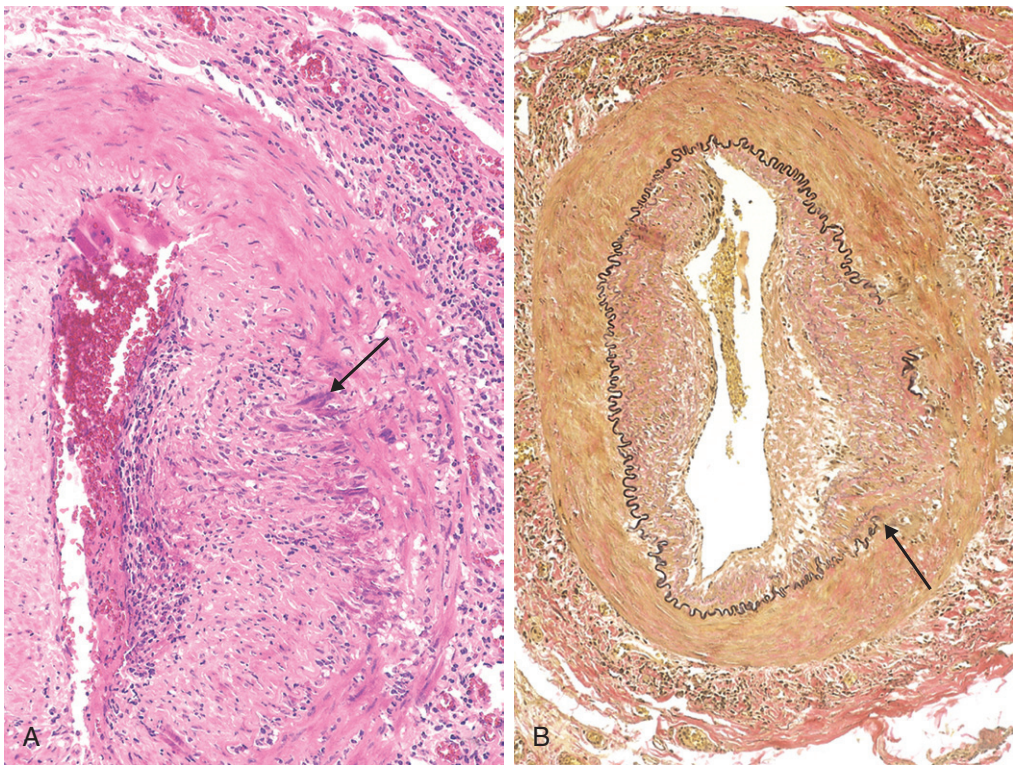


**Figure 9–23** Temporal (giant cell) arteritis. **A,** H&E-stained section of temporal artery showing giant cells near the fragmented internal elastic membrane (*arrow*), along with medial and adventitial inflammation. **B,** Elastic tissue stain demonstrating focal destruction of the internal elastic membrane (*arrow*) and associated medial attenuation and scarring. H&E, hematoxylin-eosin.

25% of cases, granulomas and giant cells are absent, and lesions exhibit only a nonspecific panarteritis with a mixed infiltrate of acute and chronic inflammation. Healing is marked by medial and adventitial fibrosis and intimal thickening. Characteristically, lesions at different stages of development are seen within the same artery.

### Clinical Features of Giant Cell Arteritis

Temporal arteritis is rare before the age of 50. Signs and symptoms may be vague and constitutional—fever, fatigue, weight loss—or take the form of facial pain or headache, most intense along the course of the superficial temporal artery, which is painful to palpation. Ocular symptoms (associated with involvement of the ophthalmic artery) abruptly appear in about 50% of patients; these range from diplopia to complete vision loss. Diagnosis depends on biopsy and histology; however, because involvement in temporal arteritis is patchy a negative biopsy result does not exclude the diagnosis. Corticosteroid or anti-TNF therapies are effective treatments.

## *Takayasu Arteritis*

Takayasu arteritis is a granulomatous vasculitis of medium-sized and larger arteries *characterized principally by ocular disturbances and marked weakening of the pulses in the upper extremities* (hence the alternate name, *pulseless disease*). This disorder manifests with *transmural scarring and thickening of the aorta—particularly the aortic arch and great vessels—with severe luminal narrowing of the major branch vessels* (Fig. 9–24). Aortic lesions share many of the clinical and histologic features of giant cell aortitis. Indeed, the distinction between the two entities is made largely on the basis of a patient's age; those older than 50 years are designated giant cell aortitis, and those younger than 50 years, Takayasu aortitis. Although historically associated with Japanese ethnicity and certain HLA haplotypes, Takayasu aortitis has a global distribution. An autoimmune etiology is likely.

### MORPHOLOGY

**Takayasu arteritis classically affects the aortic arch and arch vessels;** a third of cases also involve the remainder of the aorta and its branches. Occasionally, aortic root involvement causes dilation and aortic valve insufficiency. **Pulmonary arteries are involved in 50% of patients, and renal and coronary arteries also can be affected.** The takeoffs of the great vessels can be markedly narrowed and even obliterated (Fig. 9–24, *A* and *B*), explaining the upper extremity weakness and faint carotid pulses. The histologic picture (Fig. 9–24, *C*) encompasses a spectrum ranging from adventitial mononuclear infiltrates and perivascular cuffing of the vasa vasorum, to intense transmural mononuclear inflammation, to granulomatous inflammation, replete with giant cells and patchy medial necrosis. The inflammation is associated with irregular thickening of the vessel wall, intimal hyperplasia, and adventitial fibrosis.

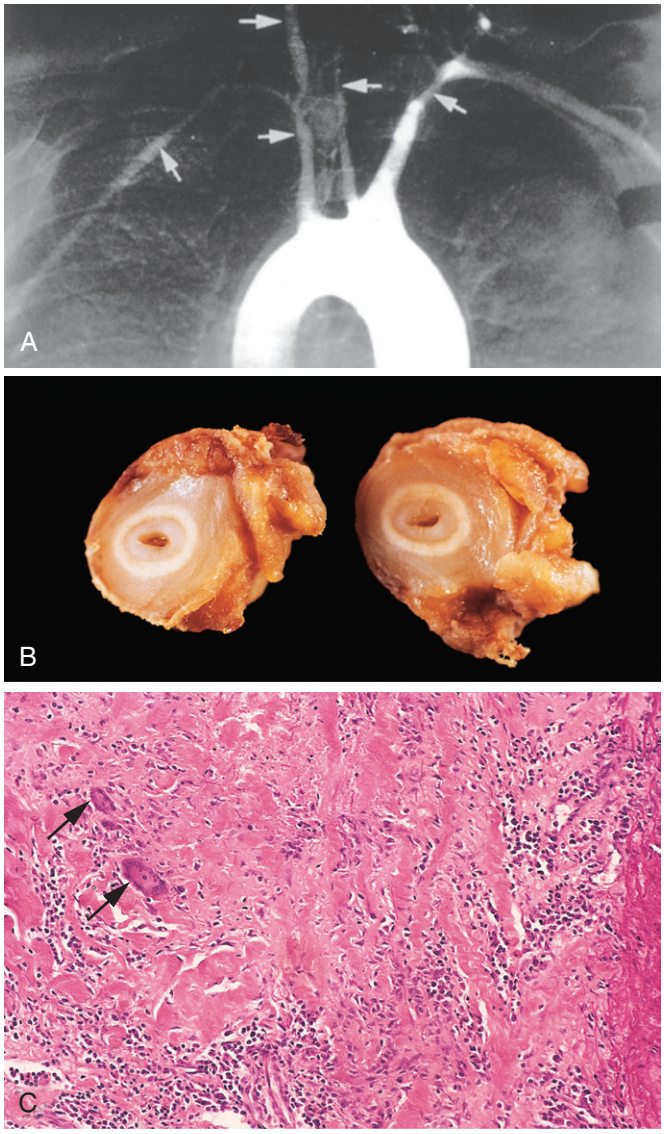


**Figure 9–24** Takayasu arteritis. **A,** Aortic arch angiogram showing reduced flow of contrast material into the great vessels and narrowing of the brachiocephalic, carotid, and subclavian arteries (*arrows*). **B,** Cross-sections of the right carotid artery from the patient shown in **A** demonstrating marked intimal thickening and luminal narrowing. The *white circles* correspond to the original vessel wall; the inner core of tan tissue is the area of intimal hyperplasia. **C,** Histologic appearance in active Takayasu aortitis illustrating destruction and fibrosis of the arterial media associated with mononuclear infiltrates and inflammatory giant cells (*arrows*).

### Clinical Features of Takayasu Aortitis

Initial signs and symptoms usually are nonspecific, including fatigue, weight loss, and fever. With progression, vascular signs and symptoms appear and dominate the clinical picture. These include reduced upper extremity blood pressure and pulse strength; neurologic deficits; and ocular disturbances, including visual field defects, retinal hemorrhages, and total blindness. Distal aorta disease can manifest as leg claudication, and pulmonary artery involvement can cause pulmonary hypertension. Narrowing of the coronary ostia can lead to myocardial infarction, and involvement of the renal arteries causes systemic hypertension in roughly half of the patients. The evolution of the

disease is variable. Some cases rapidly progress, while others become quiescent after 1 to 2 years. In the latter scenario, long-term survival, albeit with visual or neurologic deficits, is possible.

### *Polyarteritis Nodosa*

Polyarteritis nodosa (PAN) is a systemic vasculitis of *small or medium-sized muscular arteries* that typically involves the renal and visceral vessels and spares the pulmonary circulation. There is no association with ANCAs, but a third of the patients have chronic hepatitis B infection, which leads to the formation of immune complexes containing hepatitis B antigens that deposit in affected vessels. The cause is unknown in the remaining cases.

#### MORPHOLOGY

Classic PAN is a **segmental transmural necrotizing inflammation of small to medium-sized arteries,** often with superimposed thrombosis. Kidney, heart, liver, and gastrointestinal tract vessels are affected in descending order of frequency. Lesions usually involve only part of the vessel circumference and have a predilection for branch points. Impaired perfusion may lead to ulcerations, infarcts, ischemic atrophy, or hemorrhages in the distribution of affected vessels. The inflammatory process also weakens the arterial wall, leading to aneurysms and rupture.

In the acute phase, there is transmural mixed inflammatory infiltrate composed of neutrophils and mononuclear cells, frequently accompanied by **fibrinoid necrosis** and luminal thrombosis (Fig. 9–25). Older lesions show fibrous thickening of the vessel wall extending into the adventitia. Characteristically, **all stages of activity** (from early to late) **coexist** in different vessels or even within the same vessel, suggesting ongoing and recurrent pathogenic insults.

#### Clinical Features of PAN

PAN is primarily a disease of young adults but can occur in all age groups. The clinical course may range from acute to chronic but typically is episodic, with long symptom-free intervals. The systemic findings—malaise, fever, and weight loss—are nonspecific, and the vascular involvement is widely scattered, so that the clinical manifestations can be varied and puzzling. A "classic" presentation can involve some combination of rapidly accelerating hypertension due to renal artery involvement; abdominal pain and bloody stools caused by vascular gastrointestinal lesions; diffuse muscular aches and pains; and peripheral neuritis, predominantly affecting motor nerves. Renal involvement often is prominent and constitutes a major cause of death in these patients. Untreated, PAN typically is fatal; however, immunosuppression can yield remission or cure in 90% of the cases.

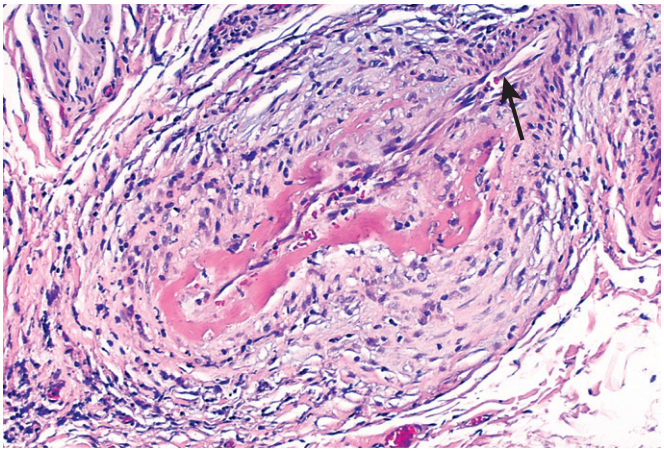

**Figure 9–25** Polyarteritis nodosa, associated with segmental fibrinoid necrosis and thrombotic occlusion of a small artery. Note that part of the vessel (upper right, *arrow*) is uninvolved.

*(Courtesy of Sidney Murphree, MD, Department of Pathology, University of Texas Southwestern Medical School, Dallas, Texas.)*

### *Kawasaki Disease*

Kawasaki disease is an acute, febrile, usually self-limited illness of infancy and childhood (80% of the patients are younger than 4 years of age) associated with an arteritis of mainly large to medium-sized vessels. *Its clinical significance stems from the involvement of coronary arteries.* Coronary arteritis can cause aneurysms that rupture or thrombose, resulting in myocardial infarction. Originally described in Japan, the disease is now recognized in the United States and elsewhere.

In genetically susceptible persons, a variety of infectious agents (mostly viral) have been posited to trigger the disease. The vasculitis may result from a delayed-type hypersensitivity response directed against cross-reactive or newly uncovered vascular antigen(s). Subsequent cytokine production and polyclonal B cell activation result in autoantibodies to endothelial cells and smooth muscle cells that precipitate the vasculitis.

#### MORPHOLOGY

The vasculitis resembles that seen in polyarteritis nodosa. There is a dense transmural inflammatory infiltrate, although the fibrinoid necrosis usually is less prominent than in polyarteritis nodosa. The acute vasculitis typically subsides spontaneously or in response to treatment, but aneurysm formation due to wall damage can supervene. As with other arteritides, healed lesions also can exhibit obstructive intimal thickening. Pathologic changes outside the cardiovascular system are rarely significant.

#### Clinical Features of Kawasaki Disease

Kawasaki disease typically manifests with conjunctival and oral erythema and blistering, edema of the hands and feet, erythema of the palms and soles, a desquamative rash, and cervical lymph node enlargement (hence its other name, *mucocutaneous lymph node syndrome*). Approximately 20% of untreated patients develop cardiovascular sequelae, ranging from asymptomatic coronary arteritis, to coronary artery ectasia, to large coronary artery aneurysms (7 to 8 mm in diameter) with rupture or thrombosis, myocardial infarction, and sudden death. With intravenous immunoglobulin therapy and aspirin, the rate of symptomatic coronary artery disease is reduced to about 4%.

### *Microscopic Polyangiitis*

Microscopic polyangiitis is a *necrotizing vasculitis that generally affects capillaries, as well as small arterioles and venules.* It also is called *hypersensitivity vasculitis* or *leukocytoclastic*

*vasculitis. Unlike in polyarteritis nodosa, all lesions of microscopic polyangiitis tend to be of the same age in any given patient.* The skin, mucous membranes, lungs, brain, heart, gastrointestinal tract, kidneys, and muscle all can be involved; *necrotizing glomerulonephritis* (seen in 90% of patients) *and pulmonary capillaritis are particularly common.* Microscopic angiitis can be a feature of a number of immune disorders, such as Henoch-Schönlein purpura, essential mixed cryoglobulinemia, or the vasculitis associated with connective tissue disorders.

In some cases, antibody responses to antigens such as drugs (e.g., penicillin), microorganisms (e.g., streptococci), heterologous proteins, or tumor proteins have been implicated. These reactions can either lead to immune complex deposition or trigger secondary immune responses (e.g., the development of ANCAs) that are pathogenic. Indeed, most cases are associated with MPO-ANCA. Recruitment and activation of neutrophils within affected vascular beds probably are responsible for the disease manifestations.

### MORPHOLOGY

Microscopic polyangiitis is characterized by **segmental fibrinoid necrosis of the media with focal transmural necrotizing lesions**; granulomatous inflammation is absent. These lesions resemble those of polyarteritis nodosa but spare medium-sized and larger arteries, so that macroscopic infarcts are uncommon. In some areas (typically postcapillary venules), only infiltrating neutrophils that frequently undergo fragmentation are seen, giving rise to the term **leukocytoclastic vasculitis** (Fig. 9–26, *A*). Although immunoglobulins and complement components can be demonstrated in early skin lesions, most lesions are "pauci-immune" (i.e., show little or no antibody).

Clinical Features of Microscopic Polyangiitis

Depending on the vascular bed involved, major features include hemoptysis, hematuria, proteinuria, abdominal pain or bleeding, muscle pain or weakness, and palpable cutaneous purpura. With the exception of patients with widespread renal or CNS involvement, immunosuppression and removal of the offending agent induce durable remissions.

## *Wegener Granulomatosis*

Wegener granulomatosis is a necrotizing vasculitis characterized by a specific triad of findings:

- *Granulomas* of the lung and/or the upper respiratory tract (ear, nose, sinuses, throat)
- *Vasculitis* of small to medium-sized vessels (capillaries, venules, arterioles, and arteries), most prominently in the lungs and upper respiratory tract
- *Glomerulonephritis*

"Limited" forms of disease can be restricted to the respiratory tract. Conversely, a widespread form of the disease can affect eyes, skin, and other organs, notably the heart; clinically, this resembles polyarteritis nodosa with the additional feature of respiratory involvement.

Wegener granulomatosis is likely to be initiated as a cell-mediated hypersensitivity response directed against inhaled infectious or environmental antigens. PR3-ANCAs are present in almost 95% of cases and probably drive the subsequent tissue injury; they also are useful markers of disease activity. After immunosuppressive therapy, ANCA levels fall dramatically, while rising titers are predictive of relapse.

### MORPHOLOGY

Upper respiratory tract lesions range from granulomatous sinusitis to ulcerative lesions of the nose, palate, or pharynx;

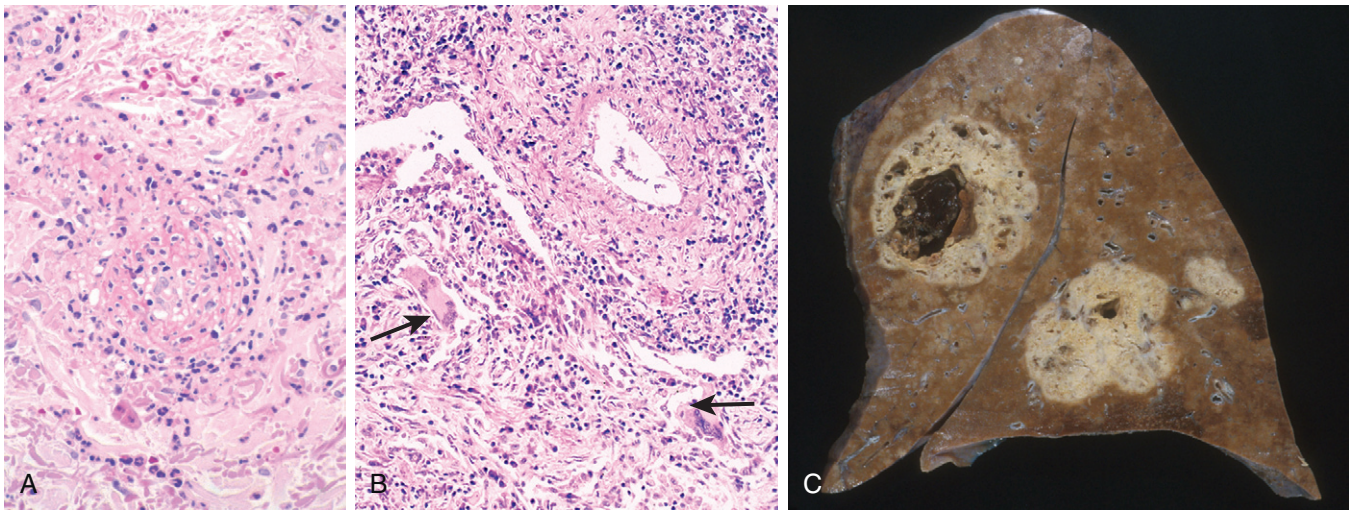


**Figure 9–26** ANCA-associated small vessel vasculitis. **A,** Microscopic polyangiitis (leukocytoclastic vasculitis) with fragmented neutrophils in the thickened vessel wall. **B** and **C,** Wegener granulomatosis. **B,** Vasculitis of a small artery with adjacent granulomatous inflammation including giant cells (*arrows*). **C,** Lung from a patient with Wegener granulomatosis, demonstrating large nodular cavitating lesions.

*(A, Courtesy of Scott Granter, MD, Brigham and Women's Hospital, Boston, Massachusetts. C, Courtesy of Sidney Murphree, MD, Department of Pathology, University of Texas Southwestern Medical School, Dallas, Texas.)*

lung findings also vary, ranging from diffuse parenchymal infiltrates to granulomatous nodules. There is multifocal **necrotizing granulomatous vasculitis with a surrounding fibroblastic proliferation** (see Fig. 9–26, *B*). Multiple granulomata can coalesce to produce radiographically visible nodules with central cavitation (see Fig. 9–26, *B*). Destruction of vessels can lead to hemorrhage and hemoptysis. Lesions can ultimately undergo progressive fibrosis and organization.

The **renal lesions** range from mild, focal glomerular necrosis with thrombosis of isolated glomerular capillary loops **(focal and segmental necrotizing glomerulonephritis)** to more advanced glomerular lesions with diffuse necrosis and parietal cell proliferation forming epithelial crescents **(crescentic glomerulonephritis)** (Chapter 13).

Clinical Features of Wegener Granulomatosis

The typical patient is a 40-year old man, although women and persons of other ages can be affected. Classic presentations include bilateral pneumonitis with nodules and cavitary lesions (95%), chronic sinusitis (90%), mucosal ulcerations of the nasopharynx (75%), and renal disease (80%); patients with low-grade renal involvement may demonstrate only hematuria and proteinuria responsive to therapy, whereas more severe disease can portend rapidly progressive renal failure. Rash, myalgias, articular involvement, neuritis, and fever can also occur. If untreated, the mortality rate at 1 year is 80%. Treatment with steroids, cyclophosphamide, TNF inhibitors and anti–B cell antibodies (Rituximab) has improved this picture considerably. Most patients with Wegener granulomatosis now survive, but remain at high risk for relapses that can ultimately lead to renal failure.

### *Churg-Strauss Syndrome*

*Churg-Strauss syndrome* (also called allergic granulomatosis and angiitis) is a *small vessel necrotizing vasculitis classically associated with asthma, allergic rhinitis, lung infiltrates, peripheral eosinophilia, extravascular necrotizing granulomas, and a striking infiltration of vessels and perivascular tissues by eosinophils.* It is a rare disorder, affecting 1 in 1 million people. Cutaneous involvement (with palpable purpura), gastrointestinal bleeding, and renal disease (primarily as focal and segmental glomerulosclerosis) are the major associations. Cytotoxicity produced by the myocardial eosinophilic infiltrates often leads to cardiomyopathy; cardiac involvement is seen in 60% of patients and is a major cause of morbidity and death.

Churg-Strauss syndrome may stem from "hyperresponsiveness" to some normally innocuous allergic stimulus. MPO-ANCAs are present in a minority of cases, suggesting that the disorder is pathogenically heterogeneous. The vascular lesions differ from those of polyarteritis nodosa or microscopic polyangiitis by virtue of the presence of *granulomas* and *eosinophils*.

### *Thromboangiitis Obliterans (Buerger Disease)*

*Thromboangiitis obliterans (Buerger disease)* is a distinctive disorder that frequently results in severe vascular insufficiency and gangrene of the extremities. It is characterized by focal acute and chronic inflammation of medium-sized and small arteries, especially the tibial and radial arteries, associated with thrombosis; occasionally, secondary extension into adjacent veins and nerves may be seen. Buerger disease occurs almost exclusively in heavy tobacco smokers and usually develops before age 35.

The etiology is unknown. Direct endothelial cell toxicity caused by some component of tobacco is suspected; alternatively, a reactive compound in tobacco may modify vessel wall components and induce an immune response. Indeed, most patients with Buerger disease are hypersensitive to tobacco extracts. A genetic predilection is suggested by an increased prevalence in certain ethnic groups (Israeli, Indian subcontinent, Japanese) and an association with certain HLA haplotypes.

#### MORPHOLOGY

In thromboangiitis obliterans, there is a **sharply segmental acute and chronic transmural vasculitis of medium-sized and small arteries,** predominantly those of the extremities. In early stages, mixed inflammatory infiltrates are accompanied by luminal thrombosis; small **microabscesses,** occasionally rimmed by granulomatous inflammation, also may be present (Fig. 9–27). The inflammation often extends into contiguous veins and nerves (a feature that is rare in other forms of vasculitis). With time, thrombi can organize and recanalize, and eventually the artery and adjacent structures become encased in fibrous tissue.

Clinical Features of Buerger Disease

Early manifestations include cold-induced Raynaud phenomenon, instep foot pain induced by exercise (*instep claudication*), and a superficial nodular phlebitis (venous inflammation). The vascular insufficiency of Buerger disease tends to be accompanied by severe pain—even at rest—undoubtedly from the neural involvement. Chronic extremity ulcerations can develop, progressing over time (occasionally precipitously) to frank gangrene. Smoking

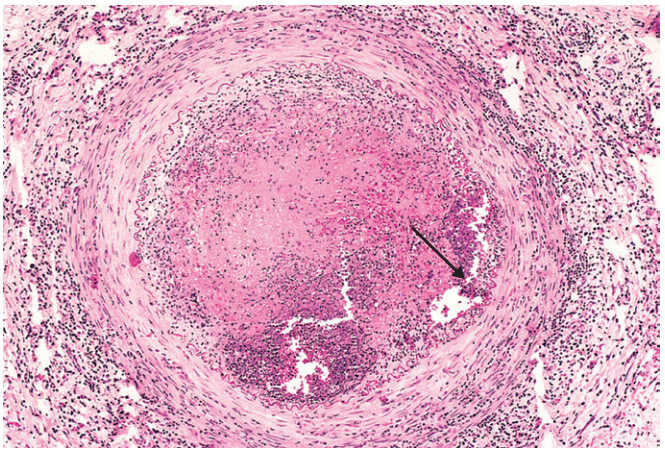

**Figure 9–27** Thromboangiitis obliterans (Buerger disease). The lumen is occluded by thrombus containing abscesses (*arrow*) and the vessel wall is infiltrated with leukocytes.

abstinence in the early stages of the disease often can ameliorate further attacks; however, once established, the vascular lesions do not respond to smoking abstinence.

### *Vasculitis Associated with Other Noninfectious Disorders*

Vasculitis resembling hypersensitivity angiitis or classic PAN can be associated with many other diseases, including malignancies and immunologic disorders such as rheumatoid arthritis, systemic lupus erythematosus, antiphospholipid antibody syndrome, and Henoch-Schönlein purpura. *Rheumatoid vasculitis* can occur in patients with severe, long-standing rheumatoid arthritis; it can cause a clinically significant aortitis but typically affects small and medium-sized arteries, leading to visceral infarction. Linking vasculitis to specific disorders may have important therapeutic implications. For example, although classic immune complex *lupus vasculitis* and antiphospholipid antibody syndrome can share morphologic features, the former requires anti-inflammatory therapy while anticoagulation is indicated in the latter.

## Infectious Vasculitis

Localized arteritis may be caused by the direct invasion of arteries by infectious agents, usually bacteria or fungi, and in particular *Aspergillus* and *Mucor* spp. Vascular invasion can be part of a more general tissue infection (e.g., bacterial pneumonia or adjacent to abscesses), or—less commonly—arise from hematogenous spread of bacteria during septicemia or embolization from infective endocarditis.

Vascular infections can weaken arterial walls and culminate in *mycotic aneurysms* (see earlier), or can induce thrombosis and infarction. Thus, inflammation of vessels in bacterial meningitis can cause thrombosis and infarction, leading ultimately to extension of a subarachnoid infection into the brain parenchyma.

### SUMMARY

#### Vasculitis

- Vasculitis is defined as inflammation of vessel walls; it frequently is associated with systemic manifestations (including fever, malaise, myalgias, and arthralgias) and organ dysfunction that depends on the pattern of vascular involvement.
- Vasculitis can result from infections but more commonly has an immunologic basis such as immune complex deposition, anti-neutrophil antibodies (ANCAs), or anti–endothelial cell antibodies.
- Different forms of vasculitis tend to specifically affect vessels of a particular caliber and location (see Fig. 9–22).

# DISORDERS OF BLOOD VESSEL HYPERREACTIVITY

Several disorders are characterized by inappropriate or exaggerated vasoconstriction of blood vessels.

## Raynaud Phenomenon

*Raynaud phenomenon* results from exaggerated vasoconstriction of arteries and arterioles in the extremities, particularly the fingers and toes, but also sometimes the nose, earlobes, or lips. The restricted blood flow induces paroxysmal pallor or cyanosis; involved digits characteristically show "red-white-and-blue" color changes from most proximal to most distal, reflecting proximal vasodilation, central vasoconstriction, and more distal cyanosis, respectively. Raynaud phenomenon can be a primary entity or may be secondary to other disorders.

*Primary Raynaud phenomenon* (previously called Raynaud disease) is caused by exaggerated central and local vasomotor responses to cold or emotion; it affects 3% to 5% of the general population and has a predilection for young women. Structural changes in the arterial walls are absent except late in the course, when intimal thickening may appear. The course usually is benign, but in chronic cases, atrophy of the skin, subcutaneous tissues, and muscles may occur. Ulceration and ischemic gangrene are rare.

*Secondary Raynaud phenomenon* refers to vascular insufficiency due to arterial disease caused by other entities including systemic lupus erythematosus, scleroderma, Buerger disease, or even atherosclerosis (see later). Indeed, since Raynaud phenomenon may be the first manifestation of such conditions, every patient with Raynaud phenomenon should be evaluated for these secondary causes.

## Myocardial Vessel Vasospasm

Excessive constriction of arteries or arterioles may cause ischemia, and persistent vasospasm can even lead to tissue infarction. In addition to intrinsic hyperreactivity of medial smooth muscle cells, as described earlier for primary Raynaud disease, high levels of vasoactive mediators can precipitate prolonged vascular contraction. Such agents can be endogenous (e.g., epinephrine released by pheochromocytomas) or exogenous (cocaine or phenylephrine). Elevated thyroid hormone causes a similar effect by increasing the sensitivity of vessels to circulating catecholamines, while autoantibodies and T cells in scleroderma (Chapter 4) can cause vascular instability and vasospasm. In some susceptible persons, extreme psychological stress and the attendant release of catecholamines can lead to pathologic vasospasm.

When vasospasm of cardiac arterial or arteriolar beds (so-called *cardiac Raynaud*) is of sufficient duration (20 to 30 minutes), myocardial infarction occurs. Elevated levels of catechols also increase heart rate and myocardial contractility, exacerbating ischemia caused by the vasospasm. The outcome can be sudden cardiac death (probably caused by a fatal arrhythmia) or an ischemic dilated cardiomyopathy—so-called *Takotsubo cardiomyopathy* (also called "broken heart syndrome," because of the association with emotional duress). Histologic findings in acute cases may include microscopic areas of necrosis characterized by myocyte hypercontraction (*contraction band necrosis*) (Chapter 10); in subacute and chronic cases, microscopic foci of granulation tissue and/or scar may be present.

# VEINS AND LYMPHATICS

Varicose veins and phlebothrombosis/thrombophlebitis account for at least 90% of cases of clinically relevant venous disease.

## Varicose Veins of the Extremities

Varicose veins are abnormally dilated tortuous veins produced by chronically increased intraluminal pressures and weakened vessel wall support. The *superficial veins* of the upper and lower leg typically are involved. Up to 20% of men and a third of women develop lower extremity varicose veins. Obesity increases the risk, and the higher incidence in women probably reflects the prolonged elevation in venous pressure caused by compression of the inferior vena cava by the gravid uterus during pregnancy. There is also a familial tendency toward premature varicosities.

### Clinical Features of Varicose Veins

Varicose dilation renders the venous valves incompetent and leads to lower extremity stasis, congestion, edema, pain, and thrombosis. The most disabling sequelae include persistent edema in the extremity and secondary ischemic skin changes, including *stasis dermatitis* and *ulcerations*. The latter can become chronic *varicose ulcers* as a consequence of poor wound healing and superimposed infections. Of note, *embolism from these superficial veins is very rare, in contrast with the relatively frequent emboli that arise from thrombosed deep veins* (Chapter 3).

#### *Varicosities of Other Sites*

Venous dilations in two other sites merit special attention:

- *Esophageal varices.* Liver cirrhosis (less frequently, portal vein obstruction or hepatic vein thrombosis) causes portal vein hypertension (Chapter 15). This in turn leads to the opening of porto-systemic shunts and increased blood flow into veins at the gastro-esophageal junction (forming *esophageal varices*), rectum (forming *hemorrhoids*), and periumbilical veins of the abdominal wall (forming a *caput medusae*). Esophageal varices are most important since they are prone to ruptures that can lead to massive (even fatal) upper gastrointestinal hemorrhage.
- *Hemorrhoids* are varicose dilations of the venous plexus at the anorectal junction that result from prolonged pelvic vascular congestion associated with pregnancy or straining to defecate. Hemorrhoids are a source of bleeding and prone to thrombosis and painful ulceration.

## Thrombophlebitis and Phlebothrombosis

*Thrombosis of deep leg veins accounts for more than 90% of cases of thrombophlebitis and phlebothrombosis*. These two terms are largely interchangeable designations for venous thrombosis and inflammation. Other sites where venous thrombi may form are the periprostatic venous plexus in males and the pelvic venous plexus in females, as well as the large veins in the skull and the dural sinuses (especially in the setting of infection or inflammation). Peritoneal infections, including peritonitis, appendicitis, salpingitis, and pelvic abscesses, as well as certain conditions associated with hypercoagulability (e.g., polycythemia vera) (Chapter 11) can lead to portal vein thrombosis.

In deep venous thrombosis (DVT) of the legs, *prolonged immobilization resulting in venous stasis is the most important risk factor.* This can occur with extended bed rest or even just sitting during long plane or automobile trips. The postoperative state is another independent risk factor for DVT, as are congestive heart failure, pregnancy, oral contraceptive use, and obesity. Inherited defects in coagulation factors (Chapter 3) often predispose affected persons to development of thrombophlebitis. Venous thrombi may result from elaboration of procoagulant factors from malignant tumors (Chapter 5). The resulting hypercoagulable state can manifest as evanescent thromboses in different vascular beds at different times, resulting in so-called *migratory thrombophlebitis* or *Trousseau syndrome.*

Thrombi in the legs tend to produce few, if any, reliable signs or symptoms. When present, local manifestations include distal edema, cyanosis, superficial vein dilation, heat, tenderness, redness, swelling, and pain. In some cases, pain can be elicited by pressure over affected veins, squeezing the calf muscles, or forced dorsiflexion of the foot (*Homan sign*). However, symptoms often are absent, especially in bedridden patients, and *the absence of findings does not exclude DVT.*

*Pulmonary embolism is a common and serious clinical complication of DVT* (Chapter 3), resulting from fragmentation or detachment of the venous thrombus. In many cases, *the first manifestation of thrombophlebitis is a pulmonary embolus.* Depending on the size and number of emboli, the outcome can range from resolution with no symptoms to death.

## Superior and Inferior Vena Cava Syndromes

The *superior vena cava syndrome* usually is caused by neoplasms that compress or invade the superior vena cava, such as bronchogenic carcinoma or mediastinal lymphoma. The resulting obstruction produces a characteristic clinical complex consisting of marked dilation of the veins of the head, neck, and arms associated with cyanosis. Pulmonary vessels also can be compressed, causing respiratory distress.

The *inferior vena cava syndrome* can be caused by neoplasms that compress or invade the inferior vena cava or by a thrombus from the hepatic, renal, or lower extremity veins that propagates upward. Certain neoplasms—particularly hepatocellular carcinoma and renal cell carcinoma—show a striking tendency to grow within veins, and these tumors may ultimately occlude the inferior vena cava. Obstruction of the inferior vena cava induces marked lower extremity edema, distention of the superficial collateral veins of the lower abdomen, and—with renal vein involvement—proteinuria of marked degree.

## Lymphangitis and Lymphedema

Primary disorders of lymphatic vessels are extremely uncommon. Much more commonly, lymphatic vessels are involved by inflammatory, infectious, or malignant processes secondarily.

*Lymphangitis* refers to an acute inflammatory process caused by bacterial seeding of the lymphatic vessels and was discussed in Chapter 2. Clinically, the inflamed lymphatics appear as *red, painful subcutaneous streaks,* usually associated with tender enlargement of draining lymph nodes (*acute lymphadenitis*). If bacteria are not contained within the lymph nodes, they can pass into the venous circulation and cause bacteremia or sepsis.

*Primary lymphedema* can occur as an isolated congenital defect (simple congenital lymphedema) or as the familial *Milroy disease* (*heredofamilial congenital lymphedema*), resulting from agenesis or hypoplasia of lymphatics. *Secondary* or *obstructive lymphedema* stems from the accumulation of interstitial fluid behind an obstructed, previously normal lymphatic; such obstruction can result from various disorders or conditions:

- Tumors involving either the lymphatic channels or the regional lymph nodes
- Surgical procedures that sever lymphatic connections (e.g., axillary lymph nodes in radical mastectomy)
- Postradiation fibrosis
- Filariasis
- Postinflammatory thrombosis and scarring

Regardless of the cause, lymphedema increases the hydrostatic pressure in the lymphatics distal to the obstruction and causes edema. Chronic edema in turn may lead to deposition of ECM and fibrosis, producing *brawny induration* or a *peau d'orange* appearance of the overlying skin. Eventually, inadequate tissue perfusion can lead to skin ulceration. Rupture of dilated lymphatics, typically following obstruction by an infiltrating tumor mass, can lead to milky accumulations of lymph in various spaces designated *chylous ascites* (abdomen), *chylothorax,* and *chylopericardium.*

# TUMORS

Tumors of blood vessels and lymphatics include common and benign hemangiomas, locally aggressive neoplasms that metastasize infrequently, and rare, highly malignant angiosarcomas (Table 9–4). Primary tumors of large vessels (aorta, pulmonary artery, and vena cava) are extremely rare and are mostly sarcomas. Congenital or developmental malformations and non-neoplastic reactive vascular proliferations (e.g., *bacillary angiomatosis*) also can manifest as tumor-like lesions.

Vascular neoplasms can arise from endothelium (e.g., hemangioma, lymphangioma, angiosarcoma) or cells that support or surround blood vessels (e.g., glomus tumor). Although a benign hemangioma usually can be distinguished with ease from an anaplastic high-grade angiosarcoma, on occasion the distinction between benign and malignant can be difficult. General rules of thumb are as follows:

- Benign tumors usually contain obvious vascular channels filled with blood cells or lymph that are lined by a monolayer of normal-appearing endothelial cells.
- Malignant tumors are more cellular, show cytologic atypia, are proliferative, and usually do not form well-organized vessels; confirmation of the endothelial derivation of such proliferations may require immunohistochemical detection of endothelial cell–specific markers, such as CD31 or von Willebrand factor.

**Table 9–4** Classification of Vascular Tumors and Tumor-like Conditions

| |
|---|
| **Benign Neoplasms, Developmental and Acquired Conditions** |
| Hemangioma |
| Capillary hemangioma |
| Cavernous hemangioma |
| Pyogenic granuloma |
| Lymphangioma |
| Simple (capillary) lymphangioma |
| Cavernous lymphangioma (cystic hygroma) |
| Glomus tumor |
| Vascular ectasias |
| Nevus flammeus |
| Spider telangiectasia (arterial spider) |
| Hereditary hemorrhagic telangiectasis (Osler-Weber-Rendu disease) |
| Reactive vascular proliferations |
| Bacillary angiomatosis |
| **Intermediate-Grade Neoplasms** |
| Kaposi sarcoma |
| Hemangioendothelioma |
| **Malignant Neoplasms** |
| Angiosarcoma |

Because these are tumors of dysregulated endothelial cells, the possibility of controlling their growth with inhibitors of blood vessel formation (antiangiogenic factors) is being explored.

## Benign Tumors and Tumor-Like Conditions

### *Vascular Ectasias*

*Ectasia* is a generic term for any local dilation of a structure, while *telangiectasia* is used to describe a permanent dilation of preexisting small vessels (capillaries, venules, and arterioles, usually in the skin or mucous membranes) that forms a discrete red lesion. These lesions can be congenital or acquired and *are not true neoplasms.*

- *Nevus flammeus* (a "birthmark"), the most common form of vascular ectasia, is a light pink to deep purple flat lesion on the head or neck composed of dilated vessels. Most ultimately regress spontaneously.
- The so-called *port wine stain* is a special form of nevus flammeus. These lesions tend to grow during childhood, thicken the skin surface, and do not fade with time. Such lesions occurring in the distribution of the trigeminal nerve are associated with the *Sturge-Weber syndrome* (also called *encephalotrigeminal angiomatosis*). This uncommon congenital disorder is associated with facial port wine nevi, ipsilateral venous angiomas in the cortical leptomeninges, mental retardation, seizures, hemiplegia, and radiopacities of the skull. Thus, *a large facial telangiectasia in a child with mental deficiency may indicate the presence of additional vascular malformations.*
- *Spider telangiectasias* are non-neoplastic vascular lesions with a general shape resembling that of a spider. These lesions manifest as radial, often pulsatile arrays of dilated subcutaneous arteries or arterioles (the "legs" of

the spider) about a central core (the spider's "body") that blanch with pressure. Spider telangiectasias commonly occur on the face, neck, or upper chest and most frequently are associated with hyperestrogenic states (e.g., in pregnant women or patients with cirrhosis).

- *Hereditary hemorrhagic telangiectasia (Osler-Weber-Rendu disease)* is an autosomal dominant disorder caused by mutations in genes that encode components of the TGF-β signaling pathway in endothelial cells. The telangiectasias are malformations composed of dilated capillaries and veins that are present at birth. They are widely distributed over the skin and oral mucous membranes, as well as in the respiratory, gastrointestinal, and urinary tracts. The lesions can spontaneously rupture, causing serious epistaxis (nosebleed), gastrointestinal bleeding, or hematuria.

### *Hemangiomas*

Hemangiomas are very common tumors composed of blood-filled vessels (Fig. 9–28). These lesions constitute 7% of all benign tumors of infancy and childhood; most are present from birth and initially increase in size, but many eventually regress spontaneously. While hemangiomas typically are localized lesions confined to the head and neck, they occasionally may be more extensive (*angiomatosis*) and can arise internally. Nearly one third of these internal lesions are found in the liver. Malignant transformation is rare. Several histologic and clinical variants have been described:

- *Capillary hemangiomas* are the most common type; these occur in the skin, subcutaneous tissues, and mucous membranes of the oral cavities and lips, as well as in the liver, spleen, and kidneys (Fig. 9–28, *A*). Histologically, they are comprised of thin-walled capillaries with scant stroma (Fig. 9–28, *B*).
- *Juvenile hemangiomas* (so-called strawberry hemangiomas) of the newborn skin are extremely common (1 in 200 births) and can be multiple. These grow rapidly for a few months but then fade by the age of 1 to 3 years, with complete regression by age 7 in the vast majority of cases.
- *Pyogenic granulomas* are capillary hemangiomas that manifest as rapidly growing red pedunculated lesions on the skin, gingival, or oral mucosa. Microscopically they resemble exuberant granulation tissue. They bleed easily and are often ulcerated (Fig. 9–28, *C*). Roughly a quarter of the lesions develop after trauma, reaching a size of 1 to 2 cm within a few weeks. Curettage and cautery usually are curative. *Pregnancy tumor* (granuloma gravidarum) is a pyogenic granuloma that occurs infrequently (1% of patients) in the gingiva of pregnant women. These lesions may spontaneously regress (especially after pregnancy) or undergo fibrosis, but occasionally require surgical excision.

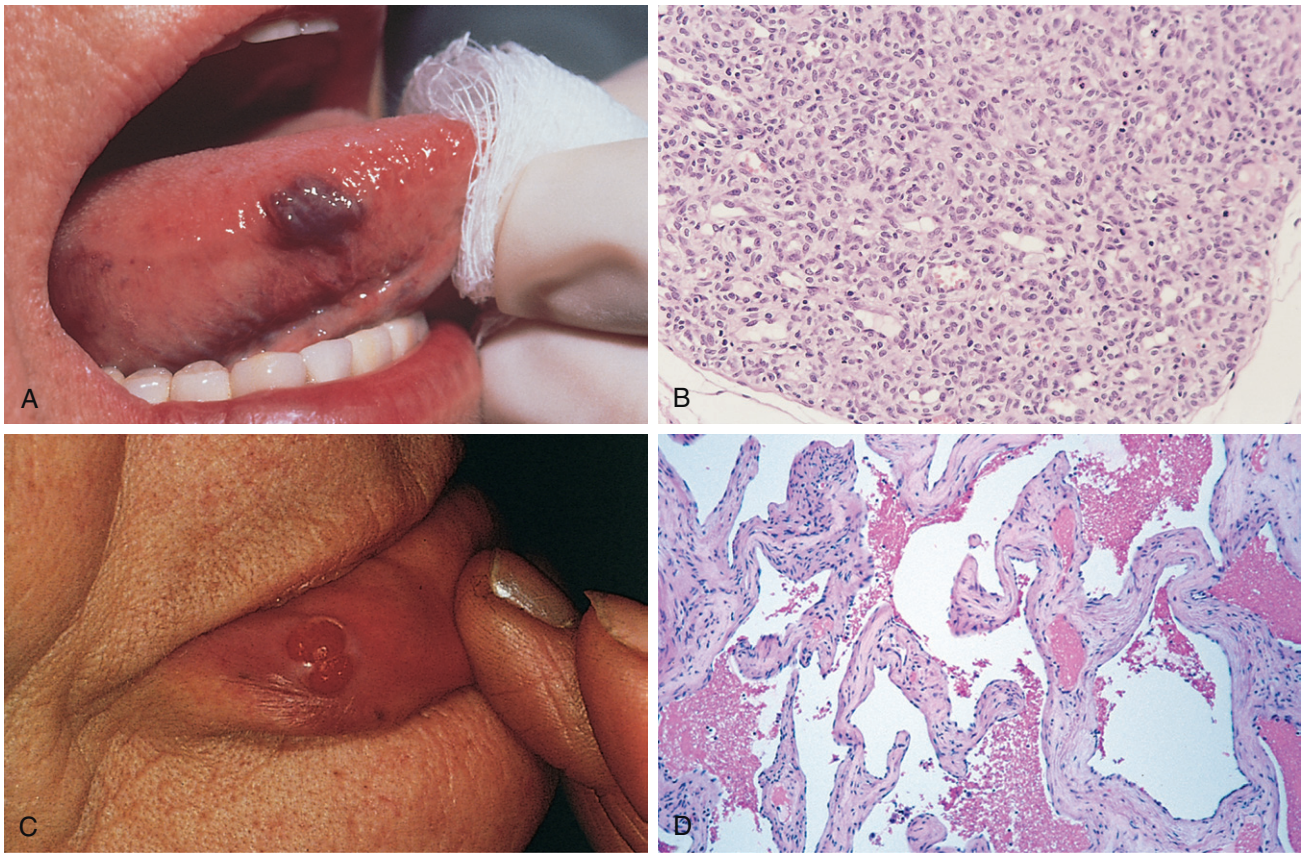


**Figure 9–28** Hemangiomas. **A,** Hemangioma of the tongue. **B,** Histologic appearance in juvenile capillary hemangioma. **C,** Pyogenic granuloma of the lip. **D,** Histologic appearance in cavernous hemangioma.

*(A and D, Courtesy of John Sexton, MD, Beth Israel Hospital, Boston, Massachusetts. B, Courtesy of Christopher D.M. Fletcher, MD, Brigham and Women's Hospital, Boston, Massachusetts. C, Courtesy of Thomas Rogers, MD, University of Texas Southwestern Medical School, Dallas, Texas.)*

- *Cavernous hemangiomas* are composed of large, dilated vascular channels. Compared with capillary hemangiomas, *cavernous hemangiomas* are more infiltrative, frequently involve deep structures, and do not spontaneously regress. On histologic examination, the mass is sharply defined but unencapsulated and is composed of *large, cavernous blood-filled vascular spaces,* separated by connective tissue stroma (see Fig. 9–28, *D*). Intravascular thrombosis with associated dystrophic calcification is common. They may be locally destructive, so surgical excision may be required in some cases. More often the tumors are of little clinical significance, but they can be cosmetically troublesome and are vulnerable to traumatic ulceration and bleeding. Moreover, cavernous hemangiomas detected by imaging studies may be difficult to distinguish from their malignant counterparts. Brain hemangiomas also are problematic, as they can cause symptoms related to compression of adjacent tissue or rupture. Cavernous hemangiomas constitute one component of *von Hippel-Lindau disease* (Chapter 22), in which vascular lesions are commonly found in the cerebellum, brain stem, retina, pancreas, and liver.

### *Lymphangiomas*

Lymphangiomas are the benign lymphatic counterpart of hemangiomas.

- *Simple (capillary) lymphangiomas* are slightly elevated or sometimes pedunculated lesions up to 1 to 2 cm in diameter that occur predominantly in the head, neck, and axillary subcutaneous tissues. Histologically, lymphangiomas are composed of networks of endothelium-lined spaces that can be *distinguished from capillary channels only by the absence of blood cells.*
- *Cavernous lymphangiomas (cystic hygromas)* typically are found in the neck or axilla of children, and more rarely in the retroperitoneum. Cavernous lymphangiomas can be large (up to 15 cm), filling the axilla or producing gross deformities of the neck. Of note, cavernous lymphangiomas of the neck are common in Turner syndrome. These lesions are composed of massively dilated lymphatic spaces lined by endothelial cells and separated by intervening connective tissue stroma containing lymphoid aggregates. The tumor margins are indistinct and unencapsulated, making definitive resection difficult.

### *Glomus Tumors (Glomangiomas)*

*Glomus tumors* are benign, exquisitely painful tumors *arising from specialized smooth muscle cells of glomus bodies,* arteriovenous structures involved in thermoregulation. Although they may superficially resemble cavernous hemangiomas, glomangiomas arise from smooth muscle cells, rather than endothelial cells. They most commonly are found in the distal portion of the digits, especially under the fingernails. Excision is curative.

### *Bacillary Angiomatosis*

*Bacillary angiomatosis* is a vascular proliferation in immunocompromised hosts (e.g., patients with AIDS) caused by opportunistic gram-negative bacilli of the *Bartonella* family. The lesions can involve the skin, bone, brain, and other organs. Two species have been implicated:

- *Bartonella henselae,* whose principal reservoir is the domestic cat; this organism causes *cat-scratch disease* (a necrotizing granulomatous disorder of lymph nodes) in immunocompetent hosts.
- *Bartonella quintana,* which is transmitted by human body lice; this microbe was the cause of "trench fever" in World War I.

Skin lesions are red papules and nodules, or rounded subcutaneous masses. Histologically, there is a proliferation of capillaries lined by prominent epithelioid endothelial cells, which exhibit nuclear atypia and mitoses (Fig. 9–29). Other features include infiltrating neutrophils, nuclear debris, and purplish granular collections of the causative bacteria.

The bacteria induce host tissues to produce hypoxia-inducible factor-1α (HIF-1α), which drives vascular endothelial growth factor (VEGF) production and vascular proliferation. The infections (and lesions) are cured by antibiotic treatment.

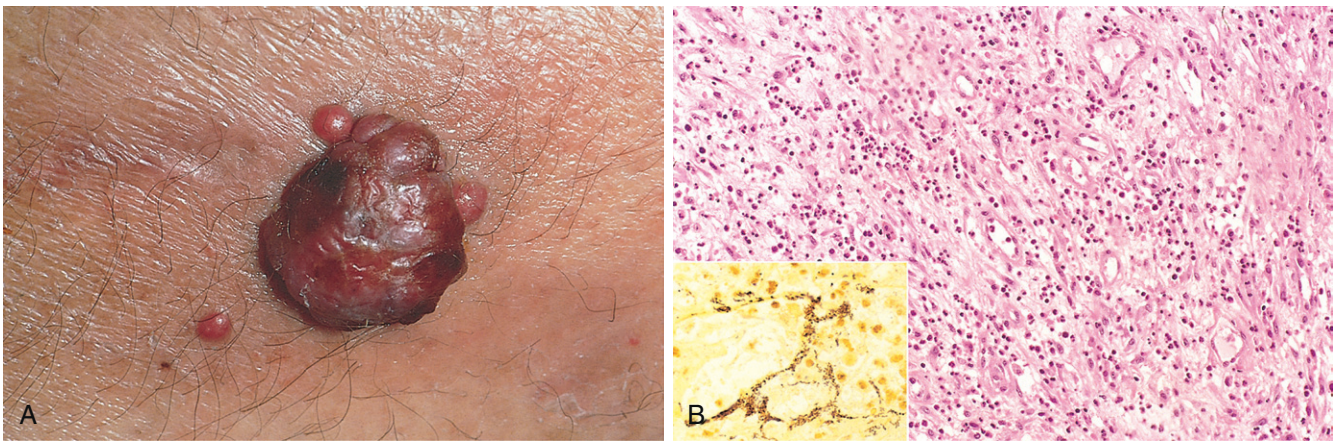


**Figure 9–29** Bacillary angiomatosis. **A,** Characteristic cutaneous lesion. **B,** Histologic features are those of acute inflammation and capillary proliferation. **Inset**, Modified silver (Warthin-Starry) stain demonstrates clusters of tangled bacilli (*black*).

*(A, Courtesy of Richard Johnson, MD, Beth Israel Deaconess Medical Center, Boston, Massachusetts. B and inset, courtesy of Scott Granter, MD, Brigham and Women's Hospital, Boston, Massachusetts.)*

## Intermediate-Grade (Borderline) Tumors

### *Kaposi Sarcoma*

*Kaposi sarcoma (KS) is a vascular neoplasm caused by Kaposi sarcoma herpesvirus* (KSHV, also known as human herpesvirus-8, or HHV-8). Although it occurs in a number of contexts, *it is by far most common in patients with AIDS;* indeed, its presence is used as a criterion for the diagnosis. Four forms of KS, based on population demographics and risks, are recognized:

- *Classic KS* is a disorder of older men of Mediterranean, Middle Eastern, or Eastern European descent (especially Ashkenazic Jews); it is uncommon in the United States. It can be associated with malignancy or altered immunity but is not associated with HIV infection. Classic KS manifests as multiple red-purple skin plaques or nodules, usually on the distal lower extremities; these progressively increase in size and number and spread proximally. Although persistent, the tumors typically are asymptomatic and remain localized to the skin and subcutaneous tissue.
- *Endemic African KS* typically occurs in younger (under age 40) HIV-seronegative persons and can follow an indolent or aggressive course; it involves lymph nodes much more frequently than in the classic variant. In combination with AIDS-associated KS (see later), KS is now the most common tumor in central Africa. A particularly severe form, with prominent lymph node and visceral involvement, occurs in prepubertal children; the prognosis is poor, with an almost 100% mortality rate within 3 years.
- *Transplantation-associated KS* occurs in solid organ transplant recipients in the setting of T cell immunosuppression. The risk of KS is increased 100-fold in transplant recipients, in whom it pursues an aggressive course and often involves lymph nodes, mucosa, and viscera; cutaneous lesions may be absent. Lesions often regress with attenuation of immunosuppression, but at the risk of organ rejection.
- The incidence of KS has fallen more than 80% with the advent of antiretroviral therapy, but it continues to occur in HIV-infected persons with an incidence that is greater than 1000-fold higher than in the general population. *Worldwide, KS is the most common HIV-related malignancy*. AIDS-associated KS often involves lymph nodes and disseminates widely to viscera early in its course. Most patients eventually die of opportunistic infections rather than from KS.

### PATHOGENESIS

**Virtually all KS lesions are infected by KSHV.** Like Epstein-Barr virus, KSHV is a γ-herpesvirus. It is transmitted both through sexual contact and by poorly understood nonsexual routes potentially including oral secretions and cutaneous exposures (of note, the prevalence of endemic African KS is inversely related to the wearing of shoes). KSHV and altered T cell immunity probably are required for KS development; in the elderly, diminished T cell immunity may be related to aging. It also is probable that acquired somatic mutations in the cells of origin contribute to tumor development and progression.

KSHV causes lytic and latent infections in endothelial cells, both of which probably are important in KS pathogenesis. A virally encoded G protein induces VEGF production, stimulating endothelial growth, and cytokines produced by inflammatory cells recruited to sites of lytic infection also create a local proliferative milieu. In latently infected cells, KSHV-encoded proteins disrupt normal cellular proliferation controls (e.g., through synthesis of a viral homologue of cyclin D) and prevent apoptosis by inhibiting p53. Thus, the local inflammatory environment favors cellular proliferation, and latently infected cells have a growth advantage. In its early stages, only a few cells are KSHV-infected, **but with time, virtually all of the proliferating cells carry the virus.**

### MORPHOLOGY

In **classic KS** (and sometimes in other variants), the cutaneous lesions progress through three stages: patch, plaque, and nodule.

- **Patches** are pink, red, or purple macules, typically confined to the distal lower extremities (Fig. 9–30, *A*). Microscopic examination reveals dilated, irregular, and angulated blood vessels lined by endothelial cells and an interspersed infiltrate of chronic inflammatory cells, sometimes containing hemosiderin. These lesions can be difficult to distinguish from granulation tissue.
- With time, lesions spread proximally and become larger, violaceous, **raised plaques** (see Fig. 9–30, *A*) composed of dilated, jagged dermal vascular channels lined and surrounded by plump spindle cells. Other prominent features include extravasated erythrocytes, hemosiderin-laden macrophages, and other mononuclear cells.
- Eventually **nodular,** more overtly neoplastic, lesions appear. These are composed of plump, proliferating spindle cells, mostly located in the dermis or subcutaneous tissues (Fig. 9–30, *B*), often with interspersed slitlike spaces. The spindle cells express both endothelial cell and smooth muscle cell markers and often contain round, pink cytoplasmic globules that represent degenerating red blood cells within phagolysosomes. Hemorrhage and hemosiderin deposition is more pronounced, and mitotic figures are common. The nodular stage often is accompanied by nodal and visceral involvement, particularly in the African and AIDS-associated variants.

#### Clinical Features of KS

The course of disease varies widely according to the clinical setting. Most primary HHV-8 infections are asymptomatic. Classic KS is—at least initially—largely restricted to the surface of the body, and surgical resection usually is adequate for an excellent prognosis. Radiation therapy can be used for multiple lesions in a restricted area, and chemotherapy yields satisfactory results for more disseminated disease, including nodal involvement. In KS associated with immunosuppression, withdrawal of therapy (with or without adjunct chemotherapy or radiotherapy) often is effective. For AIDS-associated KS, HIV antiretroviral therapy generally is beneficial, with or without additional

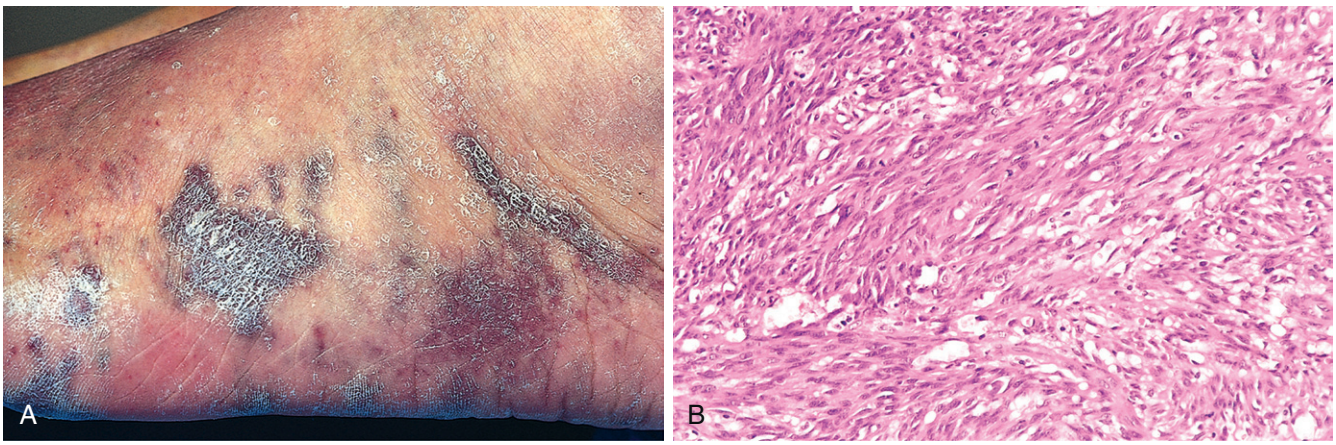


**Figure 9–30** Kaposi sarcoma. **A,** Characteristic coalescent cutaneous red-purple macules and plaques. **B,** Histologic view of the nodular stage, demonstrating sheets of plump, proliferating spindle cells and slitlike vascular spaces.
*(Courtesy of Christopher D.M. Fletcher, MD, Brigham and Women's Hospital, Boston, Massachusetts.)*

therapy. Interferon-γ and angiogenesis inhibitors also have proved somewhat effective.

### *Hemangioendotheliomas*

*Hemangioendotheliomas* comprise a wide spectrum of borderline vascular neoplasms with clinical behaviors *intermediate between those of benign, well-differentiated hemangiomas and aggressively malignant angiosarcomas.*

As an example, *epithelioid hemangioendothelioma* is a vascular tumor of adults arising in association with medium-sized to large veins. The clinical course is highly variable; while excision is curative in a majority of the cases, up to 40% of the tumors recur, and 20% to 30% eventually metastasize; perhaps 15% of patients die of their tumors. The tumor cells are plump and cuboidal and do not form well-defined vascular channels, so that they can be mistaken for metastatic epithelioid tumors or melanomas.

## Malignant Tumors

### *Angiosarcomas*

*Angiosarcomas* are malignant endothelial neoplasms (Fig. 9–31) that range from highly differentiated tumors resembling hemangiomas to wildly anaplastic lesions difficult to distinguish from carcinomas or melanomas. Older adults are more commonly affected. There is no gender bias, and lesions can occur at any site, but most often involve the skin, soft tissue, breast, and liver.

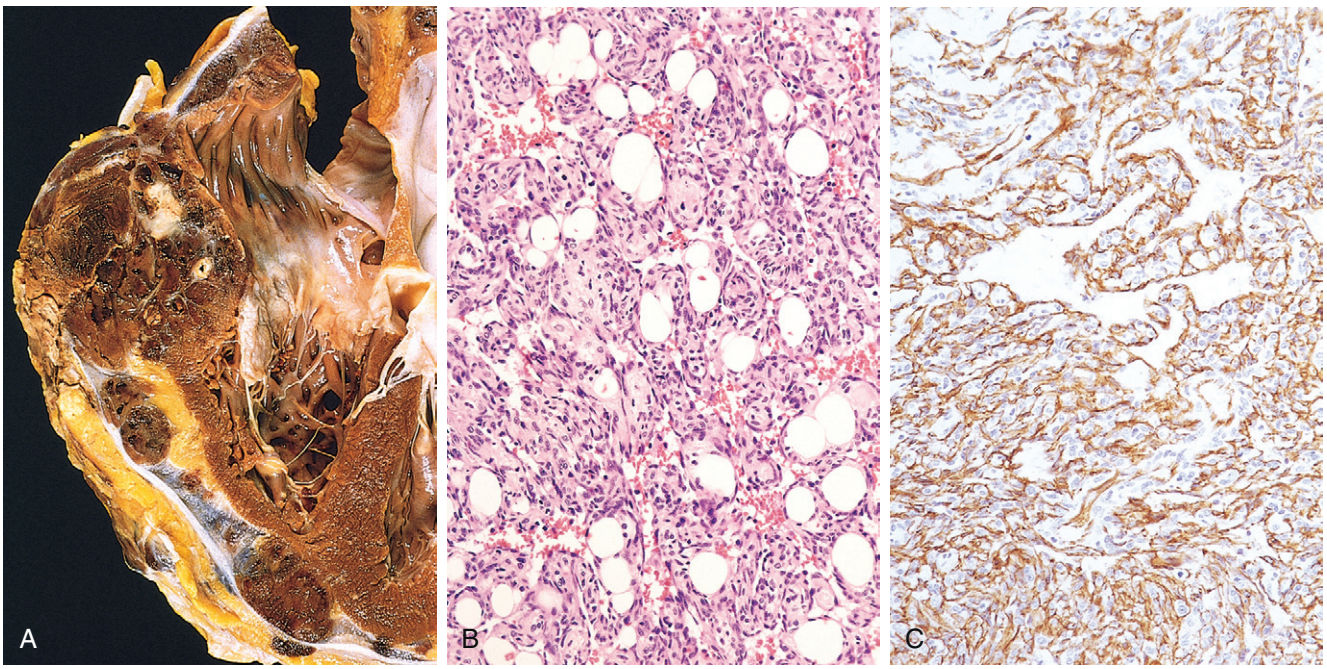


**Figure 9–31** Angiosarcoma. **A,** Angiosarcoma of the right ventricle. **B,** Moderately differentiated angiosarcoma with dense clumps of atypical cells lining distinct vascular lumina. **C,** Immunohistochemical staining of angiosarcoma for the endothelial cell marker CD31.

*Hepatic angiosarcomas* are associated with certain carcinogens, including arsenical pesticides, Thorotrast (a radioactive contrast agent formerly used for radiologic imaging), and polyvinyl chloride (a widely used plastic, and one of the best known examples of human chemical carcinogenesis). A latent period of years between exposure and subsequent tumor development is typical.

Angiosarcomas also can arise in the setting of lymphedema, classically in the ipsilateral upper extremity several years after radical mastectomy (i.e., with lymph node resection) for breast cancer. In such instances, the tumor presumably arises from lymphatic vessels (*lymphangiosarcoma*). Angiosarcomas also can be induced by radiation and rarely are associated with long-term (years) indwelling foreign bodies (e.g., catheters).

### MORPHOLOGY

In the skin, angiosarcomas begin as small, sharply demarcated, asymptomatic red nodules. More advanced lesions are large, fleshy red-tan to gray-white masses (Fig. 9–31, *A*) with margins that blend imperceptibly with surrounding structures. Necrosis and hemorrhage are common.

On microscopic examination, **the extent of differentiation is extremely variable,** ranging from plump atypical endothelial cells that form vascular channels (Fig. 9–31, *B*) to undifferentiated spindle cell tumors without discernible blood vessels. The endothelial cell origin can be demonstrated in the poorly differentiated tumors by staining for the endothelial cell markers CD31 and von Willebrand factor (Fig. 9–31, *C*).

Clinically, angiosarcomas are aggressive tumors that invade locally and metastasize. Current 5-year survival rates are only about 30%.

#### *Hemangiopericytomas*

These tumors derive their name from the cells of origin, the pericytes, myofibroblast-like cells that surround capillaries and venules. Recent studies indicate that tumors of pericytes are exceedingly rare and that most tumors previously assigned to this group have other cellular origins (e.g., fibroblasts). Accordingly, many are now placed in other diagnostic categories, such as solitary fibrous tumor, which often arises on the surface of the pleura.

### SUMMARY

#### Vascular Tumors

- Vascular ectasias are not neoplasms, but rather dilations of existing vessels.
- Vascular neoplasms can derive from either blood vessels or lymphatics, and can be composed of endothelial cells (hemangioma, lymphangioma, angiosarcoma) or other cells of the vascular wall (e.g., glomus tumor)
- Most vascular tumors are benign (e.g., hemangiomas), some have an intermediate, locally aggressive behavior (e.g., Kaposi sarcoma), and others are highly malignant (e.g., angiosarcoma).
- Benign tumors typically form obvious vascular channels lined by normal-appearing endothelial cells. Malignant tumors more often are solid and cellular, exhibit cytologic aytpia, and lack well-defined vessels.

## PATHOLOGY OF VASCULAR INTERVENTION

The morphologic changes that occur in vessels following therapeutic intervention—balloon angioplasty, stenting, or bypass surgery—recapitulate many of the changes that occur in the setting of other forms of vascular injury. Local trauma (due to stenting), vascular thrombosis (after angioplasty), and abnormal mechanical forces (e.g., a saphenous vein inserted into the arterial circulation as a coronary artery bypass graft) all induce the same stereotypical healing responses. Thus, just as with several risk factors for atherosclerosis, interventions that injure the endothelium also tend to induce intimal thickening by recruiting smooth muscle cells and promoting ECM deposition.

### Endovascular Stenting

Arterial stenoses (especially those in coronary and carotid arteries) can be dilated by transiently inflating a balloon catheter to pressures sufficient to rupture the occluding plaque (*balloon angioplasty*); in doing so, a (hopefully) limited *arterial dissection* also is induced. Although most patients experience lessening of clinical signs and symptoms after angioplasty alone, a*brupt reclosure* can occur as a result of compression of the lumen by an extensive circumferential or longitudinal dissection, by vessel wall spasm, or by thrombosis. Thus, greater than 90% of endovascular coronary procedures now involve both angioplasty and concurrent *coronary stent* placement.

Coronary stents are expandable tubes of metallic mesh. They provide a larger and more regular lumen, "tack down" the intimal flaps and dissections that occur during angioplasty, and mechanically limit vascular spasm. Nevertheless, as a consequence of endothelial injury, *thrombosis* is an important immediate post-stenting complication, and patients must receive potent antithrombotic agents (primarily platelet antagonists) to prevent acute catastrophic thrombotic occlusions. The long-term success of angioplasty is limited by the development of *proliferative in-stent restenosis.* This intimal thickening is due to smooth muscle cell ingrowth, proliferation, and matrix synthesis, all driven by the initial vascular wall injury; it results in clinically significant luminal occlusion in 5% to 35% of patients within 6 to 12 months of stenting (Fig. 9–32).

The newest generation of *drug-eluting stents* is designed to avoid this complication by leaching antiproliferative drugs (e.g., paclitaxel, sirolimus) into the adjacent vessel wall to block smooth muscle cell activation. Although the duration of drug elution is short (on the order of days), use of these stents nevertheless reduces the incidence of restenosis at 1 year by 50% to 80%.

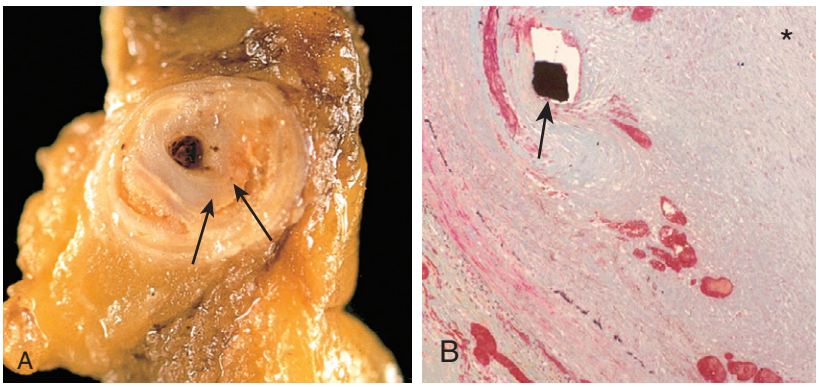


**Figure 9–32** Restenosis after angioplasty and stenting. **A,** Gross view demonstrating residual atherosclerotic plaque (*arrows*) and a new, glistening intimal proliferative lesion. **B,** Histologic view shows a thickened neointima separating and overlying the stent wires (the black diamond indicated by the *arrow*), which encroaches on the lumen (indicated by the *asterisk*).

*(B, Reproduced from Schoen FJ, Edwards WD: Pathology of cardiovascular interventions, including endovascular therapies, revascularization, vascular replacement, cardiac assist/replacement, arrhythmia control, and repaired congenital heart disease. In Silver MD, et al [eds]: Cardiovascular Pathology, 3rd ed. Philadelphia, Churchill Livingstone, 2001.)*

## Vascular Replacement

Synthetic or autologous vascular grafts commonly are used to replace damaged vessels or bypass diseased arteries. Of the synthetic grafts, large-bore (12- to 18-mm-diameter) conduits function well in high-flow locations such as the aorta, while small-diameter artificial grafts (8 mm or less in diameter) generally fail as a result of acute thrombosis or late intimal hyperplasia, primarily at the junction of the graft with the native vasculature.

Consequently, when small-bore vessel replacement is needed (e.g., in the more than 400,000 coronary artery bypass surgeries per year), grafts generally are composed of either autologous saphenous vein (taken from the patient's own leg) or left internal mammary artery (owing to its proximity to the heart). The long-term patency of saphenous vein grafts is only 50% at 10 years. These grafts occlude as a consequence of thrombosis (typically early), intimal thickening (months to years postoperatively), and vein graft atherosclerosis—sometimes with superimposed plaque rupture, thrombus formation, or aneurysms (usually more than 2 to 3 years later). By contrast, more than 90% of internal mammary artery grafts are patent after 10 years.

## BIBLIOGRAPHY


Duewell P, Kono H, Rayner KJ, et al: NLRP3 inflammasomes are required for atherogenesis and activated by cholesterol crystals. Nature 464:1357, 2010. *[A fascinating paper linking cholesterol microcrystals to phagocyte activation, cytokine production, and atherogenesis.]*

Finn AV, Nakano M, Narula J, et al: Concept of vulnerable/unstable plaque. Arterioscler Thromb Vasc Biol 30:1282, 2010. *[Good overview of the evolving concepts regarding plaque stability.]*

Ganem D: KSHV infection and pathogenesis of Kaposi's sarcoma. Annu Rev Pathol 1:273, 2006. *[Excellent scholarly review of the pathologic mechanisms underlying Kaposi sarcoma.]*

Jaffe R, Strauss B: Late and very late thrombosis of drug-eluting stents: evolving concepts and perspectives. J Am Coll Cardiol 50:119, 2007. *[Even-handed discussion of the complications following coronary artery stent placement.]*

Jennette J, Falk R: Nosology of primary vasculitis. Curr Opin Rheumatol 19:10, 2007. *[Classification of vasculitis based on pathogenic pathways and the vessels involved; provides a good organization to a complex and potentially confusing aspect of vascular pathology.]*

Kallenberg C: Antineutrophil cytoplasmic autoantibody-associated small-vessel vasculitis. Curr Opin Rheumatol 19:17, 2007. *[Up-to-date overview of the pathogenesis of ANCA-associated vasculitides.]*

Libby P, Ridker PM, Hansson GK, et al: Inflammation in atherosclerosis: from pathophysiology to practice. J Am Coll Cardiol 54:2129, 2009. *[Excellent overview of the role of inflammation in atherosclerotic disease.]*

Michel JB, Martin-Ventura JL, Egido J, et al: Novel aspects of the pathogenesis of aneurysms of the abdominal aorta in humans. Cardiovasc Res 90:18, 2011. *[Good discussion of the molecular pathways underlying human abdominal aortic aneurysm formation.]*

Packard RR, Lichtman AH, Libby P: Innate and adaptive immunity in atherosclerosis. Semin Immunopathol 31:5, 2009. *[Well-written review concerning the roles of innate and adaptive immune responses in the pathogenesis of atherosclerosis.]*

Penel N, Marréaud S, Robin YM, Hohenberger P: Angiosarcoma: state of the art and perspectives. Crit Rev Oncol Hematol 2010 Nov 3. (Epub ahead of print.) *[Extensive clinical summary of this aggressively malignant vascular tumor.]*

Pober JS, Min W, Bradley JR: Mechanisms of endothelial dysfunction, injury, and death. Annu Rev Pathol Mech Dis 4:71, 2009. *[Well-written and scholarly review of the etiology and outcomes of endothelial injury.]*

Ramirez F, Dietz H: Marfan syndrome: from molecular pathogenesis to clinical treatment. Curr Opin Genet Dev 17:252, 2007. *[Excellent summary of the mechanisms and therapeutic targets in Marfan syndrome.]*

Ridker P: C-reactive protein and the prediction of cardiovascular events among those at intermediate risk: moving an inflammatory hypothesis towards consensus. J Am Coll Cardiol 49:2129, 2007. *[A solid opinion piece regarding the utility of inflammatory markers in providing additional independent information for predicting cardiovascular events.]*

Rocha VZ, Libby P: Obesity, inflammation, and atherosclerosis. Nat Rev Cardiol 6:399, 2009. *[Good review of the interaction of risk factors, including the potential role of the metabolic syndrome in atherosclerotic disease.]*

Sakalihasan N, Limet R, Defawe OD: Abdominal aortic aneurysm. Lancet 365:1577, 2005. *[A good review of diagnosis, treatment, and pathogenesis.]*

Singh M, Mensah GA, Bakris G: Pathogenesis and clinical physiology of hypertension. Cardiol Clin 28:545, 2010. *[Excellent and up-to-date overview of normal blood pressure regulation and the interaction of genetics and environment in the pathophysiology of hypertension.]*

Yasue H, Nakagawa H, Itoh T, et al: Coronary artery spasm—clinical features, diagnosis, pathogenesis, and treatment. J Cardiol 51:2, 2008. *[Good clinical overview of coronary spasm and its sequelae.]*

This page intentionally left blank

See Targeted Therapy available online at
studentconsult.com

CHAPTER

# Heart 10

CHAPTER CONTENTS


**Overview of Heart Disease 365**
**Heart Failure 365**
Left-Sided Heart Failure 367
Right-Sided Heart Failure 368
**Congenital Heart Disease 368**
Left-to-Right Shunts 370
Right-to-Left Shunts 372
Obstructive Lesions 373
**Ischemic Heart Disease 374**
Angina Pectoris 376
Myocardial Infarction 377
Chronic Ischemic Heart Disease 384
Cardiac Stem Cells 385
**Arrhythmias 385**
Sudden Cardiac Death 386
**Hypertensive Heart Disease 386**
Systemic (Left-Sided) Hypertensive Heart Disease 387
Pulmonary Hypertensive Heart Disease—Cor Pulmonale 388
**Valvular Heart Disease 388**
Degenerative Valve Disease 389
Rheumatic Valvular Disease 391
Infective Endocarditis 392
Noninfected Vegetations 394
Carcinoid Heart Disease 395
Prosthetic Cardiac Valves 395
**Cardiomyopathies 396**
Dilated Cardiomyopathy 397
Hypertrophic Cardiomyopathy 400
Restrictive Cardiomyopathy 401
Myocarditis 401
**Pericardial Disease 403**
Pericarditis 403
Pericardial Effusions 404
**Cardiac Tumors 404**
Metastatic Neoplasms 404
**Cardiac Transplantation 405**


The heart is a truly remarkable organ, beating more than 40 million times a year and pumping over 7500 liters of blood a day; in a typical lifespan, the cumulative volume would fill three "supertanker" ships. The cardiovascular system is the first organ system to become fully functional in utero (at approximately 8 weeks of gestation); without a beating heart and vascular supply, further development cannot occur, and fetal demise is inevitable. When the heart fails postnatally, the results are equally catastrophic. Indeed, cardiovascular disease remains the leading contributor to mortality worldwide and accounts for nearly 40% of all U.S. deaths—approximately 1 death every 30 seconds, or 750,000 deaths each year (accounting for 50% greater mortality than for all forms of cancer combined). The annual economic impact of *ischemic heart disease,* the most prevalent form of heart disease, is in excess of $100 billion. Moreover, almost a third of these deaths are "premature," occurring in persons younger than 75 years of age; thus, an additional economic burden is imposed through lost years of productivity.

## OVERVIEW OF HEART DISEASE

Although a host of diseases can affect the cardiovascular system, the pathophysiologic pathways that result in a "broken" heart distill down to six principal mechanisms:

- *Failure of the pump.* In the most common situation, the cardiac muscle contracts weakly and the chambers cannot empty properly—so-called *systolic dysfunction.* In some cases, the muscle cannot relax sufficiently to permit ventricular filling, resulting in *diastolic dysfunction.*
- *Obstruction to flow.* Lesions that prevent valve opening (e.g., calcific aortic valve stenosis) or cause increased ventricular chamber pressures (e.g., systemic hypertension or aortic coarctation) can overwork the myocardium, which has to pump against the obstruction.
- *Regurgitant flow.* Valve lesions that allow backward flow of blood create conditions that add increased volume workload to the affected chambers with each contraction.
- *Shunted flow.* Defects (congenital or acquired) that divert blood inappropriately from one chamber to another, or from one vessel to another, lead to pressure and volume overloads.
- *Disorders of cardiac conduction.* Uncoordinated cardiac impulses or blocked conduction pathways can cause arrhythmias that reduce contraction frequency or diminish effective cardiac output.
- *Rupture of the heart or major vessel.* Loss of circulatory continuity (e.g., gunshot wound through the thoracic aorta) leads to exsanguination, hypotensive shock, and death.

## HEART FAILURE

Heart failure generally is referred to as *congestive heart failure* (CHF). CHF is the common end point for many forms of cardiac disease and typically is a progressive

condition that carries an extremely poor prognosis. In the United States alone, nearly 5 million persons are affected, resulting in more than 1 million hospitalizations and 300,000 deaths each year, with a financial burden in excess of $18 billion. Most cases of heart failure are due to *systolic dysfunction*—inadequate myocardial contractile function, characteristically a consequence of ischemic heart disease or hypertension. Alternatively, CHF also can result from *diastolic dysfunction*—inability of the heart to adequately relax and fill, such as in massive left ventricular hypertrophy, myocardial fibrosis, amyloid deposition, or constrictive pericarditis. Indeed, heart failure in elderly persons, diabetic patients, and women may be more commonly attributable to diastolic dysfunction. Various studies suggest that 40–60% of cases of CHF may be due to diastolic dysfunction. Finally, heart failure also can be caused by valve dysfunction (e.g., due to endocarditis) or can occur in normal hearts suddenly burdened with an abnormal load (e.g., with fluid or pressure overload).

CHF occurs when the heart cannot generate sufficient output to meet the metabolic demands of the tissues—or can only do so at higher-than-normal filling pressures; in a minority of cases, heart failure can be a consequence of greatly increased tissue demands, as in hyperthyroidism, or poor oxygen carrying capacity as in anemia (*high-output failure*). CHF onset can be abrupt, as in the setting of a large myocardial infarct or acute valve dysfunction. In many cases, however, CHF develops gradually and insidiously owing to the cumulative effects of chronic work overload or progressive loss of myocardium.

In CHF, the failing heart can no longer efficiently pump the blood delivered to it by the venous circulation. The result is an increased end-diastolic ventricular volume, leading to increased end-diastolic pressures and, finally, elevated venous pressures. Thus, inadequate cardiac output—called *forward failure*—is almost always accompanied by increased congestion of the venous circulation—that is, *backward failure.* As a consequence, although the root problem in CHF typically is deficient cardiac function, virtually every other organ is eventually affected by some combination of forward and backward failure.

The cardiovascular system attempts to compensate for reduced myocardial contractility or increased hemodynamic burden through several homeostatic mechanisms:

- *The Frank-Starling mechanism.* Increased end-diastolic filling volumes dilate the heart and cause increased cardiac myofiber stretching; these lengthened fibers contract more forcibly, thereby increasing cardiac output. If the dilated ventricle is able to maintain cardiac output by this means, the patient is said to be in *compensated heart failure.* However, ventricular dilation comes at the expense of increased wall tension and amplifies the oxygen requirements of an already-compromised myocardium. With time, the failing muscle is no longer able to propel sufficient blood to meet the needs of the body, and the patient develops *decompensated heart failure.*
- *Activation of neurohumoral systems*:
  - Release of the neurotransmitter norepinephrine by the autonomic nervous system increases heart rate and augments myocardial contractility and vascular resistance.
  - Activation of the renin-angiotensin-aldosterone system spurs water and salt retention (augmenting circulatory volume) and increases vascular tone.
  - Release of atrial natriuretic peptide acts to balance the renin-angiotensin-aldosterone system through diuresis and vascular smooth muscle relaxation.
- *Myocardial structural changes, including augmented muscle mass.* Cardiac myocytes cannot proliferate, yet can adapt to increased workloads by assembling increased numbers of sarcomeres, a change that is accompanied by myocyte enlargement (hypertrophy) (Fig. 10–1).
  - In *pressure overload states* (e.g., hypertension or valvular stenosis), new sarcomeres tend to be added parallel to the long axis of the myocytes, adjacent to existing sarcomeres. The growing muscle fiber diameter thus

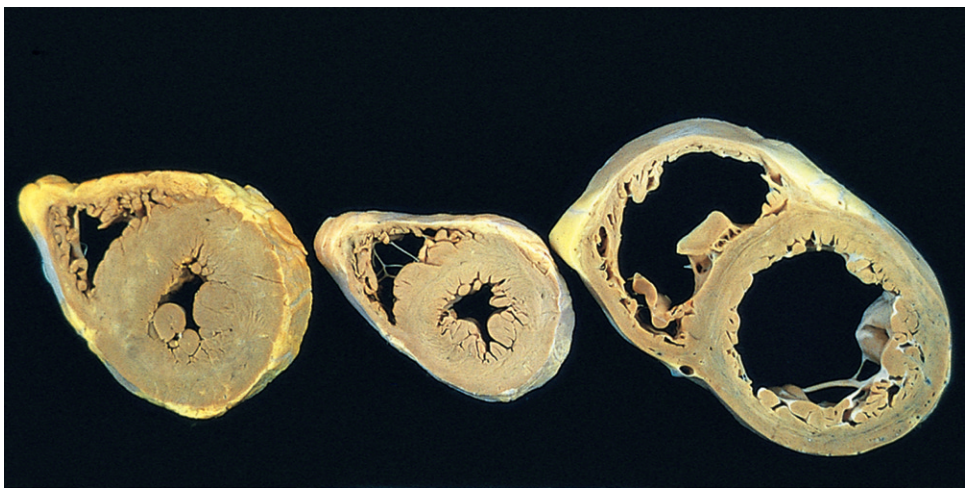

**Figure 10–1** Left ventricular hypertrophy, with and without dilation, viewed in transverse sections. Compared with a normal heart (*center*), the pressure-overloaded heart (*left*) has an increased mass, a thick wall, and a smaller lumen. The volume-overloaded heart (*right*) has an increased mass, larger lumen, and enlarged size, but a normal wall thickness.

*(Reproduced by permission from Edwards WD: Cardiac anatomy and examination of cardiac specimens. In Emmanouilides GC, Allen HD, Riemenschneider TA, Gutgesell HP [eds]: Moss and Adams' Heart Disease in Infants, Children, and Adolescents: Including the Fetus and Young Adults, 5th ed. Philadelphia, Williams & Wilkins, 1995, p 86.)*

results in *concentric hypertrophy*—the ventricular wall thickness increases without an increase in the size of the chamber.

- In *volume overload states* (e.g., valvular regurgitation or shunts), the new sarcomeres are added in series with existing sarcomeres, so that the muscle fiber length increases. Consequently, the ventricle tends to dilate, and the resulting wall thickness can be increased, normal, or decreased; thus, heart weight—rather than wall thickness—is the best measure of hypertrophy in volume-overloaded hearts.

Compensatory hypertrophy comes at a cost to the myocyte. The oxygen requirements of hypertrophic myocardium are amplified owing to increased myocardial cell mass. Because the myocardial capillary bed does not expand in step with the increased myocardial oxygen demands, the myocardium becomes vulnerable to *ischemic* injury. Hypertrophy also typically is associated with altered patterns of gene expression reminiscent of the fetal myocytes, such as changes in the dominant form of myosin heavy chain produced. Altered gene expression may contribute to changes in myocyte function that lead to increases in heart rate and force of contraction, both of which improve cardiac output, but which also lead to higher cardiac oxygen consumption. In the face of ischemia and chronic increases in workload, other untoward changes also eventually supervene, including myocyte apoptosis, cytoskeletal alterations, and increased extracellular matrix (ECM) deposition.

Pathologic compensatory cardiac hypertrophy is correlated with increased mortality; indeed, cardiac hypertrophy is an independent risk factor for sudden cardiac death. By contrast, the volume-loaded hypertrophy induced by regular aerobic exercise (*physiologic hypertrophy*) typically is accompanied by an increase in capillary density, with decreased resting heart rate and blood pressure. These physiologic adaptations reduce overall cardiovascular morbidity and mortality. In comparison, static exercise (e.g., weight lifting) is associated with pressure hypertrophy and may not have the same beneficial effects.

## Left-Sided Heart Failure

Heart failure can affect predominantly the left or the right side of the heart or may involve both sides. The most common causes of left-sided cardiac failure are ischemic heart disease (IHD), systemic hypertension, mitral or aortic valve disease, and primary diseases of the myocardium (e.g., amyloidosis). The morphologic and clinical effects of left-sided CHF stem from diminished systemic perfusion and the elevated back-pressures within the pulmonary circulation.

### MORPHOLOGY

**Heart.** The **gross** cardiac findings depend on the underlying disease process, for example, myocardial infarction or valvular deformities may be present. With the exception of failure due to mitral valve stenosis or restrictive cardiomyopathies (described later), the left ventricle usually is hypertrophied and can be dilated, sometimes massively. Left ventricular dilation can result in mitral insufficiency and left atrial enlargement, which is associated with an increased incidence of atrial fibrillation. The **microscopic** changes in heart failure are nonspecific, consisting primarily of myocyte hypertrophy with interstitial fibrosis of variable severity. Superimposed on this background may be other lesions that contribute to the development of heart failure (e.g., recent or old myocardial infarction).

**Lungs.** Rising pressure in the pulmonary veins is ultimately transmitted back to the capillaries and arteries of the lungs, resulting in congestion and edema as well as pleural effusion due to an increase in hydrostatic pressure in the venules of the visceral pleura. The lungs are heavy and boggy, and microscopically show perivascular and interstitial transudates, alveolar septal edema, and accumulation of edema fluid in the alveolar spaces. In addition, variable numbers of red cells extravasate from the leaky capillaries into alveolar spaces, where they are phagocytosed by macrophages The subsequent breakdown of red cells and hemoglobin leads to the appearance of hemosiderin-laden alveolar macrophages—so-called **heart failure cells**—that reflect previous episodes of pulmonary edema.

### Clinical Features

*Dyspnea* (shortness of breath) on exertion is usually the earliest and most significant symptom of left-sided heart failure; cough also is common as a consequence of fluid transudation into air spaces. As failure progresses, patients experience dyspnea when recumbent (*orthopnea*); this occurs because the supine position increases venous return from the lower extremities and also elevates the diaphragm. Orthopnea typically is relieved by sitting or standing, so patients usually sleep in a semiseated position. *Paroxysmal nocturnal dyspnea* is a particularly dramatic form of breathlessness, awakening patients from sleep with extreme dyspnea bordering on feelings of suffocation.

Other manifestations of left ventricular failure include an enlarged heart (cardiomegaly), tachycardia, a third heart sound ($S_3$), and fine rales at the lung bases, caused by the opening of edematous pulmonary alveoli. With progressive ventricular dilation, the papillary muscles are displaced outwards, causing mitral regurgitation and a systolic murmur. Subsequent chronic dilation of the left atrium can cause *atrial fibrillation,* manifested by an "irregularly irregular" heartbeat. Such uncoordinated, chaotic atrial contractions reduce the ventricular stroke volume and also can cause stasis. The stagnant blood is prone to form thrombi (particularly in the atrial appendage) that can shed emboli and cause strokes and manifestations of infarction in other organs.

Systemically, diminished cardiac output leads to decreased renal perfusion that in turn triggers the renin-angiotension-aldosterone axis, increasing intravascular volume and pressures (Chapter 3). Unfortunately, these compensatory effects exacerbate the pulmonary edema. With further reduction in renal perfusion, *prerenal azotemia* may supervene, with impaired excretion of nitrogenous wastes and increasing metabolic derangement. In severe CHF, diminished cerebral perfusion can manifest as *hypoxic encephalopathy* with irritability, diminished cognition, and restlessness that can progress to stupor and coma.

## Right-Sided Heart Failure

Right heart failure usually is the consequence of left-sided heart failure, since any pressure increase in the pulmonary circulation inevitably produces an increased burden on the right side of the heart. Isolated right-sided heart failure also can occur in a few diseases. The most common of these is severe pulmonary hypertension, resulting in right-sided heart pathology termed *cor pulmonale*. In cor pulmonale, myocardial hypertrophy and dilation generally are confined to the right ventricle and atrium, although bulging of the ventricular septum to the left can cause left ventricular dysfunction. Isolated right-sided failure also can occur in patients with primary pulmonic or tricuspid valve disease, or congenital heart disease, such as with left-to-right shunts causing chronic volume and pressure overloads.

The major morphologic and clinical effects of pure right-sided heart failure differ from those of left-sided heart failure in that engorgement of the systemic and portal venous systems typically is pronounced and pulmonary congestion is minimal.

### MORPHOLOGY

**Liver and Portal System.** The liver usually is increased in size and weight **(congestive hepatomegaly).** A cut section displays prominent **passive congestion,** a pattern referred to as **nutmeg liver** (Chapter 3); congested centrilobular areas are surrounded by peripheral paler, noncongested parenchyma. When left-sided heart failure is also present, severe central hypoxia produces **centrilobular necrosis** in addition to the sinusoidal congestion. With long-standing severe right-sided heart failure, the central areas can become fibrotic, creating so-called **cardiac cirrhosis**.

Right-sided heart failure also leads to elevated pressure in the portal vein and its tributaries **(portal hypertension),** with vascular congestion producing a tense, enlarged spleen **(congestive splenomegaly).** Chronic passive congestion of the bowel wall with edema can be severe enough to interfere with absorption of nutrients and medications.

**Pleural, Pericardial, and Peritoneal Spaces.** Systemic venous congestion due to right heart failure can lead to **transudates (effusions)** in the pleural and pericardial spaces, but usually does not cause pulmonary parenchymal edema. Pleural effusions are most pronounced when there is increase in pulmonary venous as well as systemic venous pressures, as occurs in combined right and left heart failure. When large (e.g., 1 L or more), pleural effusions can cause atelectasis, and, very uncommonly, substantial pericardial effusions (greater than 500 mL) can limit cardiac filling and cause cardiac failure (due to **tamponade**). A combination of hepatic congestion (with or without diminished albumin synthesis) and portal hypertension leads to peritoneal transudates **(ascites)** The effusions into the various body cavities typically are serous, with a low protein content, and lack inflammatory cells.

**Subcutaneous Tissues.** Peripheral edema of dependent portions of the body, especially ankle (pedal) and pretibial edema, is a hallmark of right heart failure. In chronically bedridden patients, the edema may be primarily presacral. In particularly severe cases, generalized massive edema **(anasarca)** may be seen.

Clinical Features

Unlike left-sided heart failure, pure right-sided heart failure typically is associated with very few respiratory symptoms. Instead, the clinical manifestations are related to systemic and portal venous congestion, including hepatic and splenic enlargement, peripheral edema, pleural effusion, and ascites. Venous congestion and hypoxia of the kidneys and brain due to right heart failure can produce deficits comparable to those caused by the hypoperfusion caused by left heart failure.

Of note, in most cases of chronic cardiac decompensation, patients present with *biventricular CHF, encompassing the clinical syndromes of both right-sided and left-sided heart failure.* As congestive heart failure progresses, patients may become frankly cyanotic and acidotic, as a consequence of decreased tissue perfusion resulting from both diminished forward flow and increasing retrograde congestion.

### SUMMARY

#### Heart Failure

- CHF occurs when the heart is unable to provide adequate perfusion to meet the metabolic requirements of peripheral tissues; inadequate cardiac output usually is accompanied by increased congestion of the venous circulation.
- Left-sided heart failure is most commonly secondary to ischemic heart disease, systemic hypertension, mitral or aortic valve disease, or primary diseases of the myocardium; symptoms are mainly a consequence of pulmonary congestion and edema, although systemic hypoperfusion can cause renal and cerebral dysfunction.
- Right-sided heart failure is due most often to left heart failure and, less commonly, to primary pulmonary disorders; signs and symptoms are related chiefly to peripheral edema and visceral congestion.

## CONGENITAL HEART DISEASE

Congenital heart diseases are abnormalities of the heart or great vessels that are present at birth. They account for 20% to 30% of all birth defects and include a broad spectrum of malformations, ranging from severe anomalies incompatible with intrauterine or perinatal survival, to mild lesions that produce only minimal symptoms at birth, or are entirely unrecognized during life. Congenital heart disease affects 6 to 8 of every 1000 liveborn infants, and the incidence is higher in premature infants and in stillborns; roughly 40,000 children are born each year in the United States with clinically significant cardiac malformations, and another 40,000 have subclinical disease. Defects that permit maturation and live birth usually involve only single chambers or regions of the heart. Twelve entities account for 85% of cases of congenital heart disease; their frequencies are shown in Table 10–1.

Thanks to surgical advances, the number of patients surviving with congenital heart disease is increasing rapidly, including over 1 million persons in the United States alone. Although surgery may correct the hemodynamic abnormalities, the repaired heart may not be

**Table 10–1** Frequency of Congenital Cardiac Malformations*

| Malformation | Incidence per 1 Million Live Births | % |
|---|---|---|
| Ventricular septal defect | 4482 | 42 |
| Atrial septal defect | 1043 | 10 |
| Pulmonary stenosis | 836 | 8 |
| Patent ductus arteriosus | 781 | 7 |
| Tetralogy of Fallot | 577 | 5 |
| Coarctation of aorta | 492 | 5 |
| Atrioventricular septal defect | 396 | 4 |
| Aortic stenosis | 388 | 4 |
| Transposition of great arteries | 388 | 4 |
| Truncus arteriosus | 136 | 1 |
| Total anomalous pulmonary venous connection | 120 | 1 |
| Tricuspid atresia | 118 | 1 |
| TOTAL | 9757 | |

*Summary of 44 published studies. Percentages do not add to 100% because of rounding.
Data from Hoffman JI, Kaplan S: The incidence of congenital heart disease. J Am Coll Cardiol 39:1890, 2002.

completely normal, since the myocardial hypertrophy and cardiac remodeling brought about by the congenital defect may be irreversible; in addition, virtually all cardiac surgery results in some degree of myocardial scarring. Such changes lead secondarily to arrhythmias, ischemia, and myocardial dysfunction, which occasionally appear many years after surgical correction.

## PATHOGENESIS

In most instances, congenital heart disease arises from faulty embryogenesis during gestational weeks 3 through 8, when major cardiovascular structures develop; the cause is unknown in almost 90% of cases. Of the known etiologic factors, **environmental** causes, including congenital rubella infection, teratogens, and maternal diabetes, and *genetic* factors are the best characterized. The contribution of specific genetic loci has been demonstrated in familial forms of congenital heart disease and by well-defined associations with certain chromosomal abnormalities (e.g., trisomies 13, 15, 18, and 21, and Turner syndrome).

Cardiac morphogenesis involves **multiple genes** that work together to choreograph a complex series of tightly regulated events. Key steps include commitment of progenitor cells to the myocardial lineage, formation and looping of the heart tube, segmentation and growth of the cardiac chambers, cardiac valve formation, and connection of the great vessels to the heart. Proper orchestration of these remarkable transformations depends on networks of transcription factors and several signaling pathways and molecules, including the Wnt, vascular endothelial growth factor (VEGF), bone morphogenetic protein (BMP), transforming growth factor-β (TGF-β), fibroblast growth factor, and Notch pathways. Also essential for cardiac morphogenesis is the mechanical force imparted by flowing pulsatile blood, which is somehow sensed by the cells of the developing heart and vessels.

Since crafting a normal heart involves many steps, even subtle perturbations can adversely influence the outcome. Most of the known genetic defects are autosomal dominant mutations causing loss (or sometimes gain) of function of a particular factor (Table 10–2). Several mutations involve transcription factors. For example, atrial and ventricular septal defects (ASDs and VSDs, respectively) and/or conduction defects may be caused by transcription factor mutations, such as *TBX5* mutations in the Holt-Oram syndrome and *NKX2.5* or *GATA4* mutations in sporadic, nonsyndromic cases. Other disorders (e.g., Noonan syndrome) are associated with mutations in intracellular signaling cascades that cause constitutive activation. microRNAs, as well as epigenetic changes (e.g., DNA methylation), also are increasingly recognized as important contributors. It is likely that even transient environmental stresses at critical junctures early in pregnancy can cause subtle changes in transcription factor activity, intracellular signaling, or morphogenic gradients that may recapitulate the defects produced by heritable mutations.

**Table 10–2** Selected Examples of Gene Defects Associated With Congenital Heart Disease*

| Disorder | Gene(s) | Gene Product Function |
|---|---|---|
| Nonsyndromic | | |
| ASD or conduction defects | *NKX2.5* | Transcription factor |
| ASD or VSD | *GATA4* | Transcription factor |
| Tetralogy of Fallot | *ZFPM2* or *NKX2.5* | Transcription factors |
| Syndromic† | | |
| Alagille syndrome—pulmonary artery stenosis or tetralogy of Fallot | *JAG1* or *NOTCH2* | Signaling proteins or receptors |
| Char syndrome—PDA | *TFAP2B* | Transcription factor |
| CHARGE syndrome—ASD, VSD, PDA, or hypoplastic right side of the heart | *CHD7* | Helicase-binding protein |
| DiGeorge syndrome—ASD, VSD, or outflow tract obstruction | *TBX1* | Transcription factor |
| Holt-Oram syndrome—ASD, VSD, or conduction defect | *TBX5* | Transcription factor |
| Noonan syndrome—pulmonary valve stenosis, VSD, or hypertrophic cardiomyopathy | *PTPN11, KRAS, SOS1* | Signaling proteins |

*Note that different mutations can cause the same phenotype, and that mutations in some genes can cause multiple phenotypes (e.g., *NKX2.5*). Many of these congenital lesions also can occur sporadically, without specific genetic mutation.
†Only the cardiac manifestations of the syndrome are listed; the other skeletal, facial, neurologic, and visceral changes are not.
ASD, atrial septal defect; CHARGE, posterior coloboma, heart defect, choanal atresia, retardation, genital and ear anomalies; PDA, patent ductus arteriosus; VSD, ventricular septal defect.

### Clinical Features

The various structural anomalies in congenital heart disease can be assigned to three major groups based on their hemodynamic and clinical consequences: (1) malformations causing a *left-to-right shunt*; (2) malformations causing a *right-to-left shunt* (cyanotic congenital heart diseases); and (3) malformations causing *obstruction.*

A *shunt* is an abnormal communication between chambers or blood vessels. Depending on pressure relationships, shunts permit the flow of blood from the left to the right side of the heart (or vice versa).

- With *right-to-left shunt,* a dusky blueness of the skin (*cyanosis*) results because the pulmonary circulation is bypassed and poorly oxygenated blood enters the systemic circulation.
- By contrast, *left-to-right shunts* increase pulmonary blood flow and are not associated (at least initially) with cyanosis. However, they expose the low-pressure, low-resistance pulmonary circulation to increased pressures and volumes; these conditions lead to adaptive changes that increase lung vascular resistance to protect the pulmonary bed, resulting in right ventricular hypertrophy and—eventually—failure. With time, increased pulmonary resistance also can cause shunt reversal (right to left) and late-onset cyanosis.
- Some congenital anomalies *obstruct vascular flow*—by narrowing the chambers, valves, or major blood vessels; a malformation characterized by complete obstruction is called an *atresia.* In some disorders (e.g., tetralogy of Fallot), an obstruction (pulmonary stenosis) can be associated with a shunt (right-to-left, through a VSD).

The altered hemodynamics of congenital heart disease usually lead to chamber dilation or wall hypertrophy. However, some defects result in a reduced muscle mass or chamber size; this is called *hypoplasia* if it occurs before birth and *atrophy* if it develops postnatally.

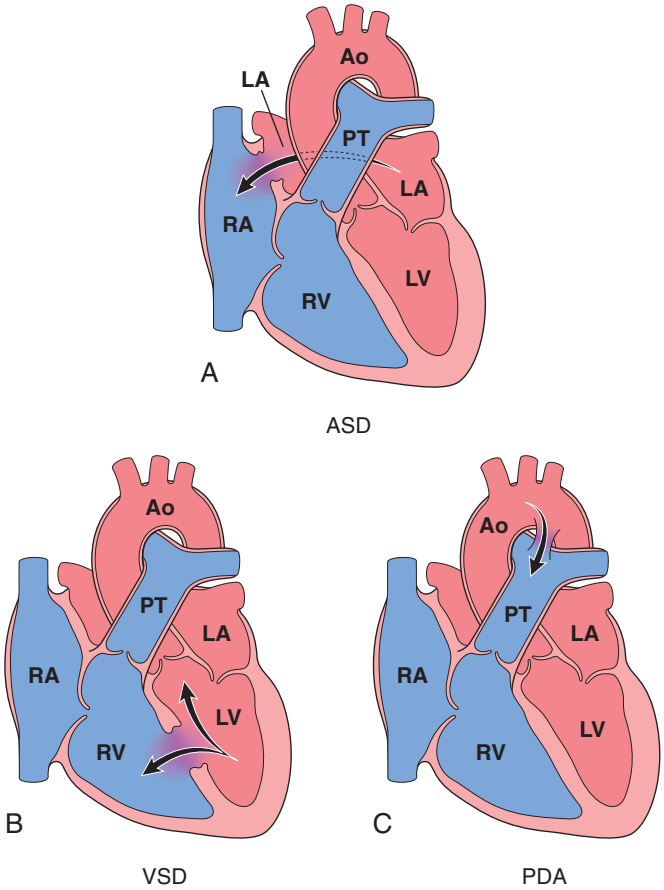


**Figure 10–2** Common congenital left-to-right shunts (*arrows* indicate direction of blood flow). **A,** Atrial septal defect (ASD). **B,** Ventricular septal defect (VSD). **C,** Patent ductus arteriosus (PDA). Ao, aorta; LA, left atrium; LV, left ventricle; PT, pulmonary trunk; RA, right atrium; RV, right ventricle.

## Left-to-Right Shunts

Left-to-right shunts are the most common type of congenital cardiac malformation. They include *atrial septal defects (ASDs)*, *ventricular septal defects (VSDs)*, and *patent ductus arteriosus (PDA)* (Fig. 10–2). ASDs typically increase only right ventricular and pulmonary outflow volumes, while VSDs and PDAs cause both increased pulmonary blood flows and pressures. Manifestations of these shunts range in severity from no symptoms at all to fulminant heart failure.

*Cyanosis is not an early feature* of these defects. However, prolonged left-to-right shunting with volume and pressure overloads eventually causes pulmonary hypertension and secondarily right-sided pressures that exceed those on the left; at that point, reversal of blood flow occurs, with resultant right-to-left shunting, and the development of cyanosis. Such reversal of flow and shunting of unoxygenated blood into the systemic circulation is called *Eisenmenger syndrome. Once significant pulmonary hypertension develops, the structural defects of congenital heart disease are considered irreversible.* This is the rationale for early surgical (or even nonsurgical) intervention.

### *Atrial Septal Defects and Patent Foramen Ovale*

During normal cardiac development patency is maintained between right and left atria by a series of ostia (primum and secundum) that eventually become the *foramen ovale*; this arrangement allows oxygenated blood from the maternal circulation to flow from the right to the left atrium, thereby sustaining fetal development. At later stages of intrauterine development, tissue flaps (*septum primum* and *septum secundum*) grow to occlude the foramen ovale, and in 80% of cases, the higher left-sided pressures in the heart that occur at birth permanently fuse the septa against the foramen ovale. In the remaining 20% of cases, a *patent foramen ovale* results; although the flap is of adequate size to cover the foramen, the unsealed septa can potentially allow transient right-to-left blood flow. Paradoxical embolism, defined as venous emboli (e.g., from deep leg veins) that enter the systemic arterial circulation, may also occur if right-sided atrial pressures increase, such as with pulmonary hypertension or a *Valsalva* maneuver during sneezing or bowel movements.

In contrast to a patent foramen ovale, an ASD is an abnormal *fixed* opening in the atrial septum that allows

unrestricted blood flow between the atrial chambers. A majority (90%) of ASDs are so-called *ostium secundum* defects in which growth of the septum secundum is insufficient to occlude the second ostium.

## MORPHOLOGY

**Ostium secundum ASDs** (90% of ASDs) typically are smooth-walled defects near the foramen ovale, usually without other associated cardiac abnormalities. Hemodynamically significant lesions are accompanied by right atrial and ventricular dilation, right ventricular hypertrophy, and dilation of the pulmonary artery, reflecting the effects of a chronically increased volume load. **Ostium primum ASDs** (accounting for 5% of these defects) occur at the lowest part of the atrial septum and can be associated with mitral and tricuspid valve abnormalities, reflecting the close relationship between development of the septum primum and the endocardial cushions. In more severe cases, additional defects may include a VSD and a **common atrioventricular canal. Sinus venosus ASDs** (accounting for another 5% of the cases) are located high in the atrial septum and often are accompanied by anomalous drainage of the pulmonary veins into the right atrium or superior vena cava.

### Clinical Features

A majority of ASDs are asymptomatic until adulthood. Although VSDs are the most common congenital malformations at birth (Table 10–1), many close spontaneously. Consequently, ASDs—which are less likely to spontaneously close—are the most common defects to be first diagnosed in adults. ASDs initially cause left-to-right shunts, as a consequence of the lower pressures in the pulmonary circulation and the right side of the heart. In general, these defects are well tolerated, especially if they are less than 1 cm in diameter; even larger lesions do not usually produce any symptoms in childhood. Over time, however, chronic volume and pressure overloads can cause pulmonary hypertension. Surgical or intravascular ASD closures are thus performed to reverse the hemodynamic abnormalities and preempt the development of heart failure, paradoxical embolization, and irreversible pulmonary vascular disease. Mortality is low, and postoperative survival is comparable to that for a normal population.

### *Ventricular Septal Defects*

Defects in the ventricular septum allow left-to-right shunting and constitute the most common congenital cardiac anomaly at birth (Table 10–1 and Fig. 10–3). The ventricular septum normally is formed by the fusion of a muscular ridge that grows upward from the apex of the heart to a thinner membranous partition that grows downward from the endocardial cushions. The basal (membranous) region is the last part of the septum to develop and is the site of approximately 90% of VSDs. *Although more common at birth, most VSDs close spontaneously in childhood, so that the overall incidence in adults is lower than that for ASDs.* Only 20% to 30% of VSDs occur in isolation; most are associated with other cardiac malformations.

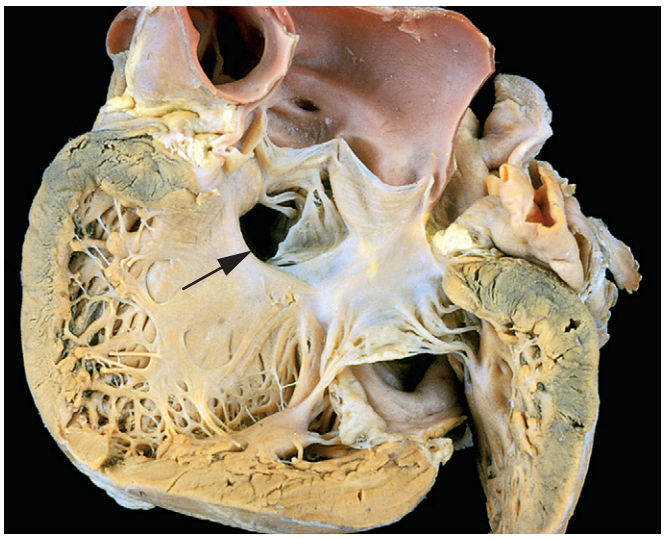

**Figure 10–3** Ventricular septal defect of the membranous type (*arrow*). *(Courtesy of William D. Edwards, MD, Mayo Clinic, Rochester, Minnesota.)*

## MORPHOLOGY

The size and location of VSDs are variable (Fig. 10–3), ranging from minute defects in the membranous septum to large defects involving virtually the entire interventricular wall. In defects associated with a significant left-to-right shunt, the right ventricle is hypertrophied and often dilated. The diameter of the pulmonary artery is increased, owing to the greater volume ejected by the right ventricle. Vascular changes typical of pulmonary hypertension are common (Chapter 12).

### Clinical Features

Small VSDs may be asymptomatic, and roughly half of those in the muscular portion of the septum close spontaneously during infancy or childhood. Larger defects, however, result in chronic severe left-to-right shunting, often complicated by pulmonary hypertension and congestive heart failure. Progressive pulmonary hypertension, with resultant reversal of the shunt and cyanosis, occurs earlier and more frequently with VSDs than with ASDs. Early surgical correction is therefore indicated for such lesions. Small or medium-sized defects that produce jet lesions in the right ventricle—which can cause endothelial damage—also increase the risk for development of infective endocarditis.

### *Patent Ductus Arteriosus*

The *ductus arteriosus* arises from the left pulmonary artery and joins the aorta just distal to the origin of the left subclavian artery. During intrauterine life, it permits blood flow from the pulmonary artery to the aorta, thereby bypassing the unoxygenated lungs. Shortly after birth in healthy term infants, the ductus constricts and is functionally closed after 1 to 2 days; these changes occur in response to increased arterial oxygenation, decreased pulmonary vascular resistance, and declining local levels of

prostaglandin $E_2$. Complete obliteration occurs within the first few months of extrauterine life, leaving only a strand of residual fibrous tissue known as the *ligamentum arteriosum*. Ductal closure often is delayed (or even absent) in infants with hypoxia (related to respiratory distress or heart disease). PDAs account for about 7% of congenital heart lesions (Table 10–1 and Fig. 10–2), and the great majority of these (90%) are isolated defects.

### Clinical Features

PDAs are high-pressure left-to-right shunts that produce harsh, "machinery-like" murmurs. A small PDA generally causes no symptoms, although larger defects eventually can lead to Eisenmenger syndrome with cyanosis and congestive heart failure. The high-pressure shunt also predisposes affected patients to development of infective endocarditis. While there is general agreement that isolated PDAs should be closed as early in life as is feasible, preservation of ductal patency (by administering prostaglandin E) can be lifesaving when a PDA is the only means to sustain systemic or pulmonary blood flow (e.g., in infants with aortic or pulmonic atresia).

## Right-to-Left Shunts

Cardiac malformations associated with right-to-left shunts are distinguished by *early cyanosis.* This occurs because poorly oxygenated blood from the right side of the heart flows directly into the arterial circulation. Two of the most important conditions associated with cyanotic congenital heart disease are *tetralogy of Fallot* and *transposition of the great vessels* (Fig. 10–4). Clinical consequences of severe, systemic cyanosis include clubbing of the tips of the fingers and toes (*hypertrophic osteoarthropathy*), *polycythemia,* and *paradoxical embolization.*

### *Tetralogy of Fallot*

*Tetralogy of Fallot is the most common cause of cyanotic congenital heart disease* and accounts for about 5% of all congenital cardiac malformations (Table 10–1). The four cardinal features are (1) VSD; (2) right ventricular outflow tract obstruction (subpulmonic stenosis); (3) overriding of the VSD by the aorta; and (4) right ventricular hypertrophy (Fig. 10–4, *A*). All of the features of tetralogy of Fallot result from anterosuperior displacement of the infundibular septum leading to abnormal septation between the pulmonary trunk and the aortic root.

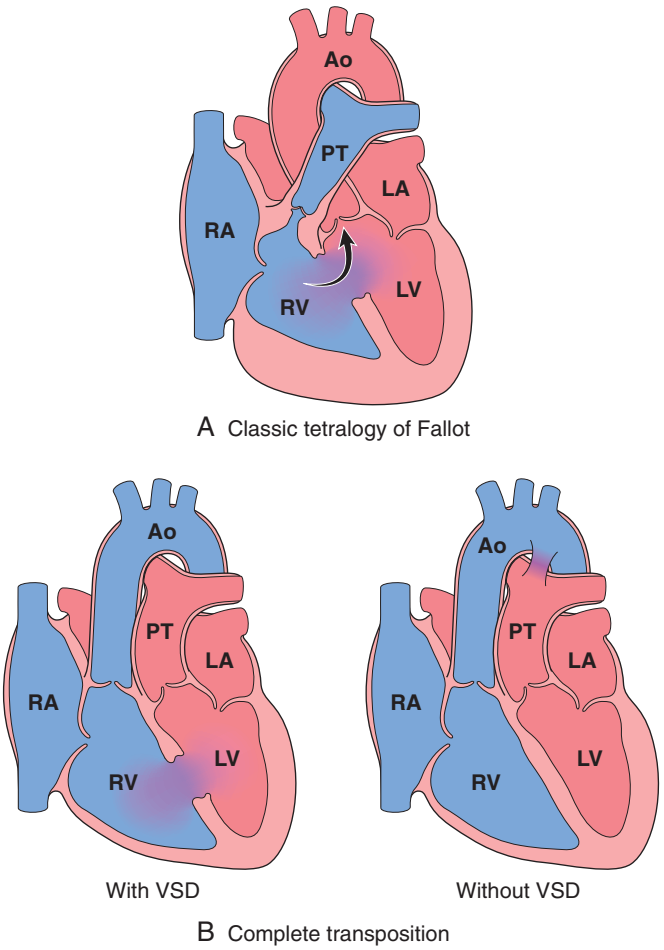


**Figure 10–4** Common congenital right-to-left shunts (cyanotic congenital heart disease). **A,** Tetralogy of Fallot (*arrow* indicates direction of blood flow). **B,** Transposition of the great vessels with and without VSD. Ao, aorta; LA, left atrium; LV, left ventricle; PT, pulmonary trunk; RA, right atrium; RV, right ventricle.

#### MORPHOLOGY

The heart is large and "boot-shaped" as a consequence of right ventricular hypertrophy; the proximal aorta is dilated, while the pulmonary trunk is hypoplastic. The left-sided cardiac chambers are of normal size, while the right ventricular wall is markedly hypertrophied, sometimes even exceeding the thickness of the left ventricle. The VSD usually is large and lies in the vicinity of the membranous portion of the interventricular septum; the aortic valve lies immediately over the VSD **(overriding aorta)** and is the major site of egress for blood flow from both ventricles. The obstruction of the right ventricular outflow most often is due to narrowing of the infundibulum **(subpulmonic stenosis)** but also can be caused by pulmonary valve stenosis or complete atresia of the valve and the proximal pulmonary arteries. In such cases, a persistent PDA or dilated bronchial arteries may be the only route for blood to reach the lungs.

### Clinical Features

The hemodynamic consequences of tetralogy of Fallot are right-to-left shunting, decreased pulmonary blood flow, and increased aortic volumes. *The clinical severity largely depends on the degree of the pulmonary outflow obstruction;* even untreated, some patients can survive into adult life. Thus, if the pulmonic obstruction is mild, the condition resembles an isolated VSD because the high left-sided pressures cause only a left-to-right shunt with no cyanosis. More commonly, more severe degrees of pulmonic stenosis cause early cyanosis. Moreover, as the child grows and the heart increases in size, the pulmonic orifice does not expand proportionately, leading to progressive worsening

of functional stenosis. Fortuitously, the pulmonic outflow stenosis protects the pulmonary vasculature from pressure and volume overloads, so that pulmonary hypertension does not develop, and right ventricular failure is rare. Nevertheless, patients develop the typical sequelae of cyanotic heart disease, such as polycythemia (due to hypoxia) with attendant hyperviscosity and hypertrophic osteoarthropathy; right-to-left shunting also increases the risk for infective endocarditis and systemic embolization. Complete surgical repair is possible with classic tetralogy of Fallot but is more complicated in the setting of pulmonary atresia.

### *Transposition of the Great Arteries*

Transposition of the great arteries is a discordant connection of the ventricles to their vascular outflow. The embryologic defect is an abnormal formation of the truncal and aortopulmonary septa so that the aorta arises from the right ventricle and the pulmonary artery emanates from the left ventricle (Fig. 10–4, *B*). The atrium-to-ventricle connections, however, are normal (concordant), with the right atrium joining the right ventricle and the left atrium emptying into the left ventricle.

The functional outcome is separation of the systemic and pulmonary circulations, a condition incompatible with postnatal life unless a shunt such as a VSD exists for adequate mixing of blood and delivery of oxygenated blood to the aorta. Indeed, VSDs occur in a third of cases and provide stable shunts (Fig. 10–4, *B*). There is marked right ventricular hypertrophy, since that chamber functions as the systemic ventricle; the left ventricle is atrophic, since it pumps only to the low-resistance pulmonary circulation. Some patients with transposition of the great arteries have a patent foramen ovale or PDA that allows oxygenated blood to reach the aorta, but these tend to close; as a result, such infants typically require emergent surgical intervention within the first few days of life.

#### Clinical Features

The dominant manifestation is cyanosis, with the prognosis depending on the magnitude of shunting, the degree of tissue hypoxia, and the ability of the right ventricle to maintain systemic pressures. Without surgery (even with stable shunting), most patients with uncorrected transposition of the great arteries die within the first months of life. However, improved surgical techniques now permit definitive repair and such patients often survive into adulthood.

## Obstructive Lesions

Congenital obstruction to blood flow can occur at the level of the heart valves or more distally within a great vessel. Obstruction can also occur proximal to the valve, as with subpulmonic stenosis in tetralogy of Fallot. Relatively common examples of congenital obstruction are pulmonic valve stenosis, aortic valve stenosis or atresia, and coarctation of the aorta.

### *Aortic Coarctation*

*Coarctation (narrowing, or constriction) of the aorta is a common form of obstructive congenital heart disease* (Table 10–1). Males are affected twice as often as females, although females with Turner syndrome frequently have coarctation. There are two classic forms (Fig. 10–5): (1) an "infantile" form featuring hypoplasia of the aortic arch proximal to a PDA and (2) an "adult" form consisting of a discrete ridgelike infolding of the aorta, adjacent to the ligamentum arteriosum. Coarctation can occur as a solitary defect, but in more than half of the cases it is accompanied by a bicuspid aortic valve. Aortic valve stenosis, ASD, VSD, or mitral regurgitation also can be present.

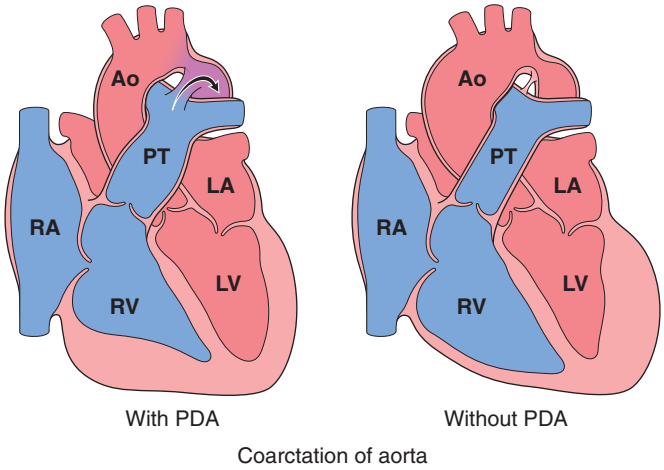


**Figure 10–5** Coarctation of the aorta with ("infantile" or preductal form) and without a patent ductus arteriosus (PDA) ("adult" or postductal form); *arrow* indicates direction of blood flow. Ao, aorta; LA, left atrium; LV, left ventricle; PT, pulmonary trunk; RA, right atrium; RV, right ventricle.

#### MORPHOLOGY

**"Infantile" (preductal) coarctation** is characterized by circumferential narrowing of the aortic segment between the left subclavian artery and the ductus arteriosus; the ductus typically is patent and is the main source of (unoxygenated) blood delivered to the distal aorta. The pulmonary trunk is dilated to accommodate the increased blood flow; because the right side of the heart now perfuses the body distal to the narrowed segment ("coarct"), the right ventricle typically is hypertrophied.

In the more common **"adult" (postductal) coarctation,** the aorta is sharply constricted by a tissue ridge adjacent to the nonpatent ligamentum arteriosum (Fig. 10–6). The constricted segment is made up of smooth muscle and elastic fibers that are continuous with the aortic media. Proximal to the coarctation, the aortic arch and its branch vessels are dilated and the left ventricle is hypertrophied.

#### Clinical Features

Clinical manifestations depend almost entirely on the severity of the narrowing and the patency of the ductus arteriosus.

- *Preductal coarctation with a PDA* usually presents early in life, classically as cyanosis localized to the lower half of the body; without intervention, most affected infants do not survive the neonatal period.

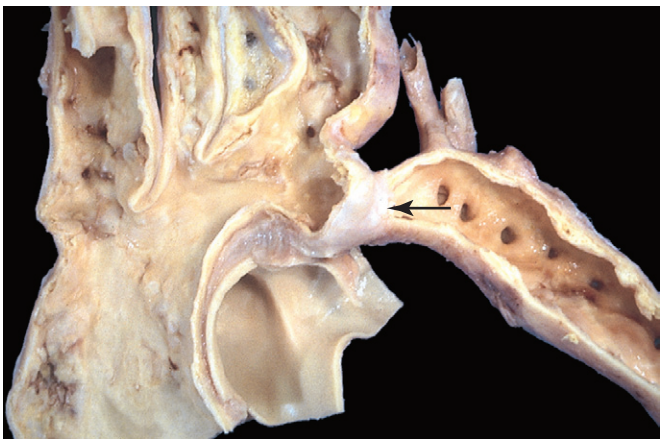

**Figure 10–6** Coarctation of the aorta, postductal type. The coarctation is a segmental narrowing of the aorta (*arrow*). Such lesions typically manifest later in life than preductal coarctations. The dilated ascending aorta and major branch vessels are to the *left* of the coarctation. The lower extremities are perfused predominantly by way of dilated, tortuous collateral channels.

*(Courtesy of Sid Murphree, MD, Department of Pathology, University of Texas Southwestern Medical School, Dallas, Texas.)*

- *Postductal coarctation without a PDA* usually is asymptomatic, and the disease may remain unrecognized well into adult life. Classically, there is upper extremity hypertension paired with weak pulses and relative hypotension in the lower extremities, associated with symptoms of claudication and coldness. Exuberant collateral circulation "around" the coarctation often develops through markedly enlarged intercostal and internal mammary arteries; expansion of the flow through these vessels can lead to radiographically visible "notching" of the ribs.

In most cases, significant coarctations are associated with systolic murmurs and occasionally palpable thrills. Balloon dilation or surgical resection with end-to-end anastomosis (or replacement of the affected aortic segment by a prosthetic graft) yields excellent results.

## SUMMARY

### Congenital Heart Disease

- Congenital heart disease represents defects of cardiac chambers or the great vessels; these either result in shunting of blood between the right and left circulation or cause outflow obstructions. Lesions range from relatively asymptomatic to rapidly fatal. Environmental (toxic or infectious) and genetic causes both contribute.
- Left-to-right shunts are the most common and typically are associated with ASDs, VSDs, or a PDA. These lesions result in chronic right-sided pressure and volume overloads that eventually cause pulmonary hypertension with reversal of flow and right-to-left shunts with cyanosis (*Eisenmenger syndrome*).
- Right-to-left shunts most commonly are caused by tetralogy of Fallot or transposition of the great arteries. These lesions cause early-onset cyanosis and are associated with polycythemia, hypertrophic osteoarthropathy, and paradoxical embolization.
- Obstructive lesions include forms of aortic coarctation; the clinical severity of these lesions depends on the degree of stenosis and the patency of the ductus arteriosus.

## ISCHEMIC HEART DISEASE

Since cardiac myocytes generate energy almost exclusively through mitochondrial oxidative phosphorylation, cardiac function is strictly dependent upon the continuous flow of oxygenated blood through the coronary arteries. Ischemic heart disease (IHD) is a broad term encompassing several closely related syndromes caused by myocardial *ischemia*—an imbalance between cardiac blood supply (perfusion) and myocardial oxygen and nutritional requirements. Despite dramatic improvements in therapy in the past quarter-century, IHD in its various forms remains the leading cause of mortality in the United States and other developed nations, accounting for 7 million deaths worldwide each year.

*In more than 90% of cases, IHD is a consequence of reduced coronary blood flow secondary to obstructive atherosclerotic vascular disease* (Chapter 9). Thus, unless otherwise specified, IHD usually is synonymous with coronary artery disease (CAD). In most cases, the syndromes of IHD are the late manifestations of coronary atherosclerosis that has been gradually building for decades (beginning even in childhood or adolescence).

Less frequently, IHD can result from *increased demand* (e.g., with increased heart rate or hypertension); *diminished blood volume* (e.g., with hypotension or shock); *diminished oxygenation* (e.g., due to pneumonia or CHF); or *diminished oxygen-carrying capacity* (e.g., due to anemia or carbon monoxide poisoning).

The manifestations of IHD are a direct consequence of the insufficient blood supply to the heart. The clinical presentation may include one or more of the following *cardiac syndromes*:

- *Angina pectoris* (literally, "chest pain"): Ischemia induces pain but is insufficient to cause myocyte death. Angina can be *stable* (occurring predictably at certain levels of exertion), can be caused by vessel spasm (*Prinzmetal angina*), or can be *unstable* (occurring with progressively less exertion or even at rest).
- *Acute myocardial infarction* (*MI*): The severity or duration of ischemia is sufficient to cause cardiomyocyte death.
- *Chronic IHD with CHF*: Progressive cardiac decompensation after acute MI, or secondary to accumulated small ischemic insults, eventually precipitates mechanical pump failure.
- *Sudden cardiac death (SCD)*: This can occur as a consequence of tissue damage from MI, but most commonly results from a lethal *arrhythmia* without myocyte necrosis (see later under "Arrhythmias").

The term *acute coronary syndrome* is applied to any of the three catastrophic manifestations of IHD—unstable angina, acute MI, and SCD.

### *Epidemiology*

Nearly a half-million Americans die annually of IHD. As troubling as this toll is, it represents a spectacular advance over previous eras; since peaking in 1963, the mortality related to IHD in the United States has declined by 50%. The improvement can be largely attributed to interventions that have diminished *cardiac risk factors* (behaviors or conditions that promote atherosclerosis) (Chapter 9), in particular smoking cessation programs, hypertension and diabetes treatment, and use of cholesterol-lowering agents. To a lesser extent, *diagnostic and therapeutic advances* have also contributed; these include aspirin prophylaxis, better arrhythmia control, coronary care units, thrombolysis for MI, angioplasty and endovascular stenting, and coronary artery bypass graft surgery. Maintaining this downward trend in mortality will be particularly challenging given the predicted longevity of "baby boomers," as well as the epidemic of obesity that is sweeping the United States and other parts of the world.

## PATHOGENESIS

**IHD is primarily a consequence of inadequate coronary perfusion relative to myocardial demand. This imbalance occurs as a consequence of the combination of preexisting ("fixed") atherosclerotic occlusion of coronary arteries and new, superimposed thrombosis and/or vasospasm.**

Atherosclerotic narrowing can affect any of the coronary arteries—left anterior descending (LAD), left circumflex (LCX), and right coronary artery (RCA)—singly or in any combination. Clinically significant plaques can be located anywhere but tend to occur within the first several centimeters of the LAD and LCX, and along the entire length of the RCA. Sometimes, secondary branches also are involved (i.e., diagonal branches of the LAD, obtuse marginal branches of the LCX, or posterior descending branch of the RCA).

Fixed obstructions that occlude less than 70% of a coronary vessel lumen typically are asymptomatic, even with exertion. In comparison, lesions that occlude more than 70% of a vessel lumen—resulting in so-called **critical stenosis**—generally cause symptoms in the setting of increased demand; with critical stenosis, certain levels of exertion predictably cause chest pain, and the patient is said to have **stable angina.** A fixed stenosis that occludes 90% or more of a vascular lumen can lead to inadequate coronary blood flow with symptoms even at rest—one of the forms of **unstable angina** (see later discussion).

Of importance, if an atherosclerotic lesion progressively occludes a coronary artery at a sufficiently slow rate over years, remodelling of other coronary vessels may provide compensatory blood flow for the area at risk; such **collateral perfusion** can subsequently protect against MI even if the vessel eventually becomes completely occluded. Unfortunately, with acute coronary blockage, there is no time for collateral flow to develop and infarction results.

The following elements contribute to the development and consequences of coronary atherosclerosis:

- **Inflammation** plays an essential role at all stages of atherosclerosis, from inception to plaque rupture (Chapter 9). Atherosclerosis begins with the interaction of endothelial cells and circulating leukocytes, resulting in T cell and macrophage recruitment and activation. These cells drive subsequent smooth muscle cell accumulation and proliferation, with variable amounts of matrix production, all overlying an atheromatous core of lipid, cholesterol, calcification, and necrotic debris. At later stages, destabilization of atherosclerotic plaque occurs through macrophage metalloproteinase secretion.
- **Thrombosis associated with a disrupted plaque often triggers the acute coronary syndromes.** Partial vascular occlusion by a newly formed thrombus on a disrupted atherosclerotic plaque can wax and wane with time and lead to unstable angina or sudden death; alternatively, even partial luminal occlusion by thrombus can compromise blood flow sufficiently to cause a small infarction of the innermost zone of the myocardium **(subendocardial infarct).** Organizing thrombi produce potent activators of smooth muscle proliferation, which can contribute to the growth of atherosclerotic lesions. Mural thrombus in a coronary artery can also embolize; indeed, small emboli can be found in the distal intramyocardial circulation (along with associated microinfarcts) at autopsy of patients who have had unstable angina. In the most serious extreme, completely obstructive thrombus over a disrupted plaque can cause a massive MI.
- **Vasoconstriction** directly compromises lumen diameter; moreover, by increasing local mechanical shear forces, vessel spasm can potentiate plaque disruption. Vasoconstriction in atherosclerotic plaques can be stimulated by (1) circulating adrenergic agonists, (2) locally released platelet contents, (3) imbalance between endothelial cell–relaxing factors (e.g., nitric oxide) and –contracting factors (e.g., endothelin) due to endothelial dysfunction, and (4) mediators released from perivascular inflammatory cells.

**Acute Plaque Change.** Onset of myocardial ischemia depends not only on the extent and severity of fixed atherosclerotic disease but also on dynamic changes in coronary plaque morphology. **In most patients, unstable angina, infarction, and often sudden cardiac death occur because of abrupt plaque change followed by thrombosis**—hence the term **acute coronary syndrome** (Fig. 10–7).

The initiating event typically is sudden disruption of partially occlusive plaque. More than one mechanism of injury may be involved: **Rupture, fissuring, or ulceration** of plaques can expose highly thrombogenic constituents or underlying subendothelial basement membrane, leading to rapid thrombosis. In addition, **hemorrhage into the core of plaques** can expand plaque volume, thereby acutely exacerbating the degree of luminal occlusion.

Factors that trigger acute plaque change are believed to act by increasing the lesion's susceptibility to disruption by mechanical stress. Both **intrinsic** aspects of plaque composition and structure (Chapter 9) and **extrinsic** factors, such as blood pressure and platelet reactivity, may contribute as follows:

- Plaques that contain large atheromatous cores, or have thin overlying fibrous caps are more likely to rupture, and are therefore termed "vulnerable." Fissures frequently occur at the junction of the fibrous cap and the adjacent normal plaque-free arterial segment, where the

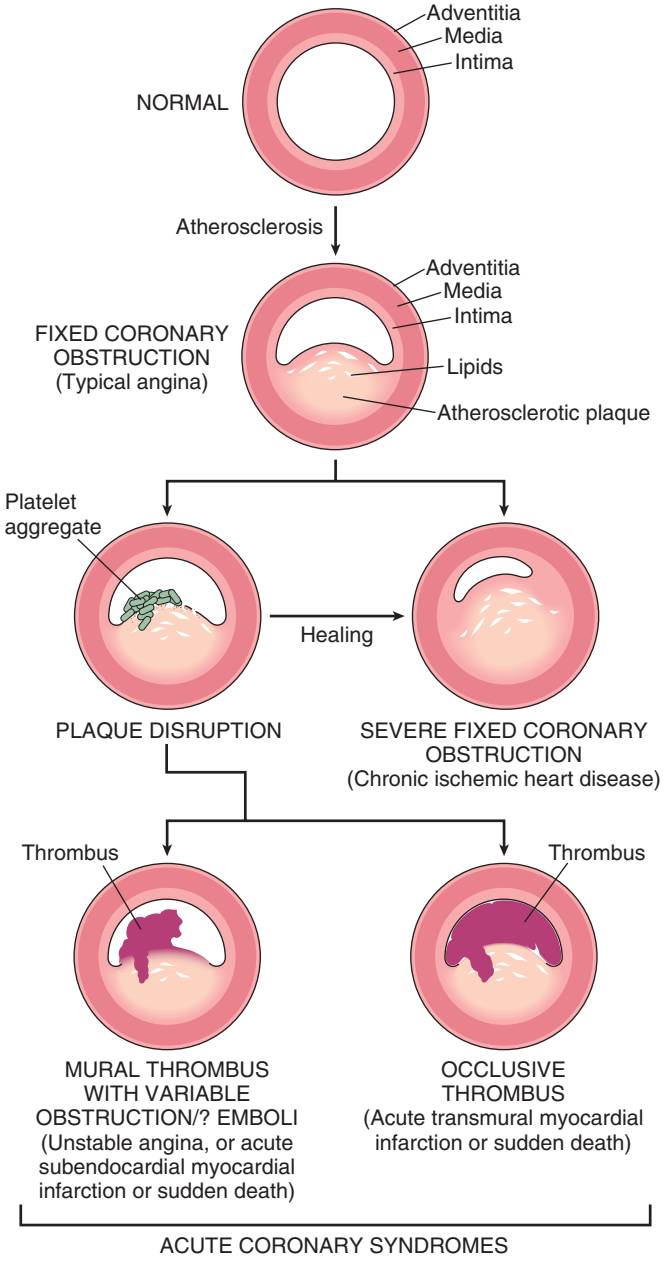


**Figure 10–7** Diagram of sequential progression of coronary artery lesions leading to various acute coronary syndromes.

*(Modified and redrawn from Schoen FJ: Interventional and Surgical Cardiovascular Pathology: Clinical Correlations and Basic Principles. Philadelphia, WB Saunders, 1989, p 63.)*

mechanical stresses are highest and the fibrous cap is thinnest. Fibrous caps also are continuously remodeling; their overall balance of collagen synthesis versus degradation determines mechanical strength and plaque stability. Collagen is produced by smooth muscle cells and degraded by the action of metalloproteases elaborated by macrophages. Consequently, atherosclerotic lesions with a paucity of smooth muscle cells or large numbers of inflammatory cells are more vulnerable to rupture. Of interest, statins (inhibitors of hydroxymethylglutaryl Co-A reductase, a key enzyme in cholesterol synthesis) may be of additional benefit in CAD and IHD by **reducing plaque inflammation and increasing plaque stability,** beyond their cholesterol-lowering effects.

- Influences **extrinsic** to plaque also are important. Adrenergic stimulation can put physical stress on the plaque by causing hypertension or local vasospasm. Indeed, the surge in adrenergic stimulation associated with awakening and rising may underlie the observation that the incidence of acute MI is highest between 6 AM and 12 noon. Intense emotional stress also leads to adrenergic stimulation, explaining the association of natural catastrophes such as earthquakes and floods with secondary waves of MIs in susceptible individuals.

In a majority of cases, the vulnerable "culprit lesion" in patients who suffer an MI was not critically stenotic or even symptomatic before its rupture. As noted previously, anginal symptoms typically occur with fixed lesions exhibiting greater than 70% chronic occlusion. Pathologic and clinical studies show that two thirds of ruptured plaques are 50% stenotic or less before plaque rupture, and 85% exhibit initial stenotic occlusion of 70% or less. Thus, the worrisome conclusion is that a large number of asymptomatic adults are at significant risk for a catastrophic coronary event. At present, it is impossible to predict plaque rupture in any given patient.

Plaque disruption and ensuing nonocclusive thrombosis also are common, repetitive, and often clinically silent complications of atheromas. The healing of such subclinical plaque disruption and overlying thrombosis is an important mechanism by which atherosclerotic lesions progressively enlarge (Fig. 10–7).

## Angina Pectoris

*Angina pectoris is an intermittent chest pain caused by transient, reversible myocardial ischemia.* The pain probably is a consequence of the ischemia-induced release of adenosine, bradykinin, and other molecules that stimulate the autonomic afferents. Three variants are recognized:

- *Typical* or *stable angina* is predictable episodic chest pain associated with particular levels of exertion or some other increased demand (e.g., tachycardia). The pain is classically described as a crushing or squeezing substernal sensation, that can radiate down the left arm or to the left jaw (*referred pain*). The pain usually is relieved by rest (reducing demand) or by drugs such as nitroglycerin, a vasodilator that increases coronary perfusion.
- *Prinzmetal* or *variant angina* occurs at rest and is caused by coronary artery spasm. Although such spasms typically occur on or near existing atherosclerotic plaques, completely normal vessel can be affected. Prinzmetal angina typically responds promptly to vasodilators such as nitroglycerin and calcium channel blockers.
- *Unstable angina* (also called *crescendo angina*) is characterized by increasingly frequent pain, precipitated by progressively less exertion or even occurring at rest. Unstable angina is associated with plaque disruption and superimposed thrombosis, distal embolization of the thrombus, and/or vasospasm; it is often the harbinger of MI, caused by complete vascular occlusion.

## Myocardial Infarction

*Myocardial infarction* (MI), also commonly referred to as "heart attack," is *necrosis of heart muscle resulting from ischemia.* Roughly 1.5 million people per year in the United States suffer an MI; of these, one third die—half before they can get to the hospital. The major underlying cause of IHD is atherosclerosis; while MIs can occur at virtually any age, *the frequency rises progressively with increasing age and with increasing atherosclerotic risk factors* (Chapter 9). Nevertheless, approximately 10% of MIs occur before age 40, and 45% occur before age 65. Blacks and whites are equally affected. Men are at significantly greater risk than women, although the gap progressively narrows with age. In general, women tend to be remarkably protected against MI during their reproductive years. However, menopause—with declining estrogen production—is associated with exacerbation of coronary artery disease and IHD is the most common cause of death in elderly women.

### PATHOGENESIS

**The vast majority of MIs are caused by acute coronary artery thrombosis** (Fig. 10–7). In most instances, disruption of preexisting atherosclerotic plaque serves as the nidus for thrombus generation, vascular occlusion, and subsequent transmural infarction of the downstream myocardium. In 10% of MIs, however, transmural infarction occurs in the absence of occlusive atherosclerotic vascular disease; such infarcts are mostly attributable to coronary artery vasospasm or to embolization from mural thrombi (e.g., in the setting of atrial fibrillation) or valve vegetations. Occasionally, especially with infarcts limited to the innermost (subendocardial) myocardium, thrombi or emboli may be absent. In such cases, severe diffuse coronary atherosclerosis leads to marginal perfusion of the heart. In this setting, a prolonged period of increased demand (e.g., due to tachycardia or hypertension) can lead to ischemic necrosis of the myocardium most distal to the epicardial vessels. Finally, ischemia without detectable atherosclerosis or thromboembolic disease can be caused by disorders of small intramyocardial arterioles, including vasculitis, amyloid deposition, or stasis, as in sickle cell disease.

**Coronary Artery Occlusion.** In a **typical MI,** the following sequence of events takes place:

- An atheromatous plaque is suddenly disrupted by intraplaque hemorrhage or mechanical forces, exposing subendothelial collagen and necrotic plaque contents to the blood.
- Platelets adhere, aggregate, and are activated, releasing thromboxane $A_2$, adenosine diphosphate (ADP), and serotonin—causing further platelet aggregation and vasospasm (Chapter 3).
- Activation of coagulation by exposure of tissue factor and other mechanisms adds to the growing thrombus.
- Within minutes, the thrombus can evolve to completely occlude the coronary artery lumen.

The evidence for this scenario derives from autopsy studies of patients dying of acute MI, as well as imaging studies demonstrating a high frequency of thrombotic occlusion early after MI. Angiography performed within 4 hours of the onset of MI demonstrates coronary thrombosis in almost 90% of cases. When angiography is performed 12 to 24 hours after onset of symptoms, however, evidence of thrombosis is seen in only 60% of patients, **even without intervention.** Thus, at least some occlusions clear spontaneously through lysis of the thrombus or relaxation of spasm. This sequence of events in a typical MI also has therapeutic implications: Early thrombolysis and/or angioplasty can be highly successful in limiting the extent of myocardial necrosis.

**Myocardial Response to Ischemia.** Loss of the myocardial blood supply leads to profound functional, biochemical, and morphologic consequences. Within seconds of vascular obstruction, aerobic glycolysis ceases, leading to a drop in adenosine triphosphate (ATP) and accumulation of potentially noxious metabolites (e.g., lactic acid) in the cardiac myocytes. The **functional** consequence is a rapid loss of contractility, which occurs within a minute or so of the onset of ischemia. Ultrastructural changes (including myofibrillar relaxation, glycogen depletion, cell and mitochondrial swelling) also become rapidly apparent. These early changes are potentially **reversible.** Only severe ischemia lasting at least 20 to 40 minutes causes **irreversible** damage and myocyte death leading to coagulation necrosis (Chapter 1). With longer periods of ischemia, vessel injury ensues, leading to microvascular thrombosis.

Thus, if myocardial blood flow is restored before irreversible injury occurs, cell viability can be preserved; this is the rationale for early diagnosis of MI, and for prompt intervention by thrombolysis or angioplasty to salvage myocardium at risk. As discussed later, however, reperfusion also can have untoward effects. In addition, despite timely reperfusion, in the postischemic state, myocardium remains profoundly dysfunctional for at least several days. This defect is caused by persistent abnormalities in cellular biochemistry that result in a non-contractile state **(stunned myocardium).** Such stunning can be severe enough to produce transient but reversible cardiac failure.

Myocardial ischemia also contributes to arrhythmias, probably by causing **electrical instability (irritability)** of ischemic regions of the heart. Although massive myocardial damage can cause a fatal mechanical failure, sudden cardiac death in the setting of myocardial ischemia most often (in 80% to 90% of cases) is due to ventricular fibrillation caused by myocardial irritability.

Irreversible injury of ischemic myocytes first occurs in the subendocardial zone (Fig. 10–8). This region is especially susceptible to ischemia because it is the last area to receive blood delivered by the epicardial vessels, and also because it is exposed to relatively high intramural pressures, which act to impede the inflow of blood. With more prolonged ischemia, a wavefront of cell death moves through other regions of the myocardium, with the infarct usually achieving its full extent within 3 to 6 hours; in the absence of intervention, the infarct can involve the entire wall thickness **(transmural infarct).** Clinical intercession within this critical window of time can lessen the size of the infarct within the "territory at risk."

**Patterns of Infarction.** The location, size, and morphologic features of an acute myocardial infarct depend on multiple factors:

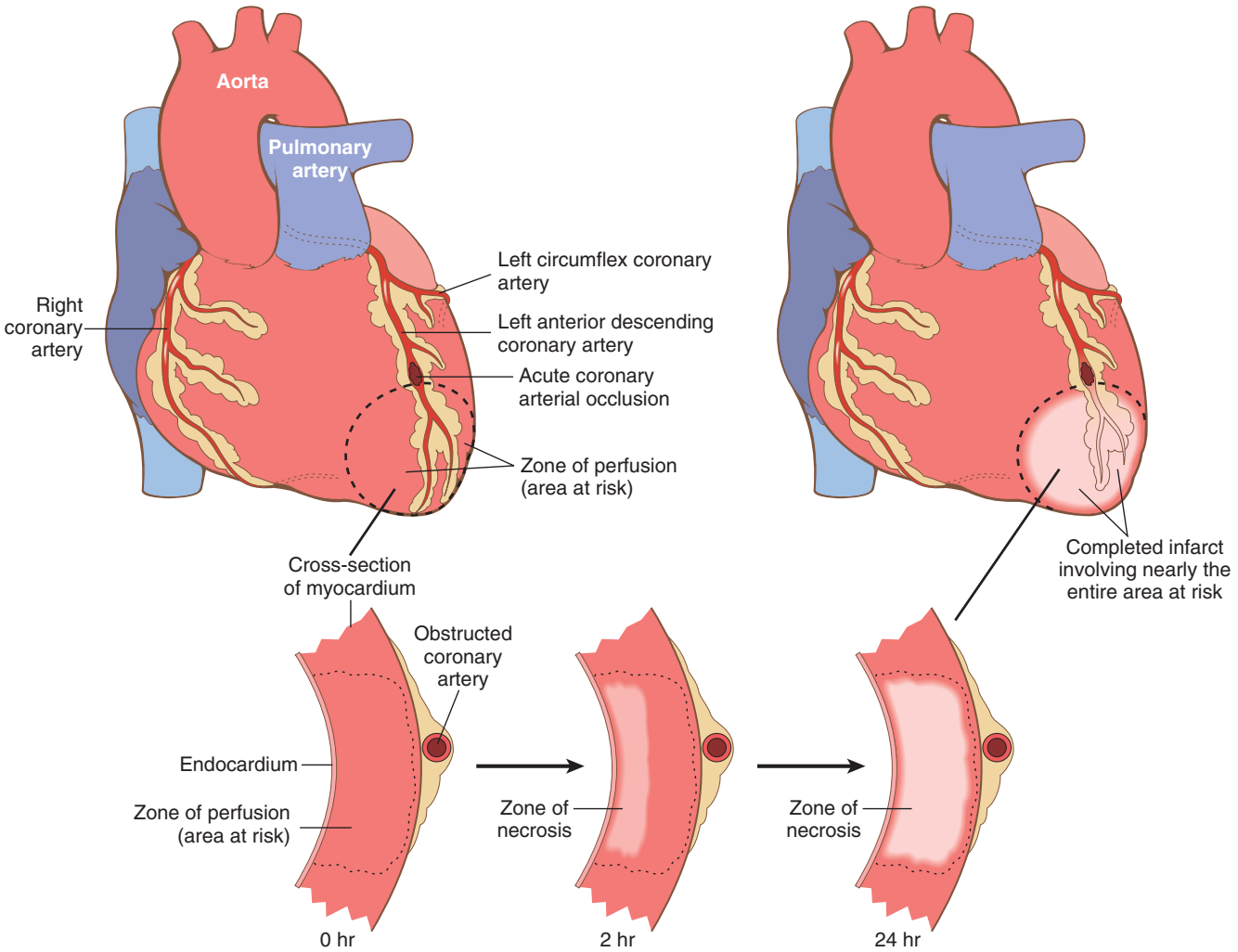


**Figure 10–8** Progression of myocardial necrosis after coronary artery occlusion. A transmural segment of myocardium that is dependent on the occluded vessel for perfusion constitutes the area at risk (*outlined*). Necrosis begins in the subendocardial region in the center of the ischemic zone and with time expands to involve the entire wall thickness. Note that a very narrow zone of myocardium immediately beneath the endocardium is spared from necrosis because it can be oxygenated by diffusion from the ventricle.

- The size and distribution of the involved vessel (Fig. 10–9)
- The rate of development and the duration of the occlusion
- Metabolic demands of the myocardium (affected, for example, by blood pressure and heart rate)
- Extent of collateral supply

Acute occlusion of the proximal left anterior descending (LAD) artery is the cause of 40% to 50% of all MIs and typically results in infarction of the anterior wall of the left ventricle, the anterior two thirds of the ventricular septum, and most of the heart apex; more distal occlusion of the same vessel may affect only the apex. Similarly, acute occlusion of the proximal left circumflex (LCX) artery (seen in 15% to 20% of MIs) will cause necrosis of the lateral left ventricle, and proximal right coronary artery (RCA) occlusion (30% to 40% of MIs) affects much of the right ventricle. The posterior third of the septum and the posterior left ventricle are perfused by the posterior descending artery. The posterior descending artery can arise from either the RCA (in 90% of people) or the LCX. By convention, the coronary artery—either RCA or LCX—that gives rise to the posterior descending artery and thereby perfuses the posterior third of the septum is considered the dominant vessel. Thus, in a **right dominant heart,** occlusion of the RCA can lead to left ventricular ischemic injury, while in a **left dominant heart,** occlusion of the left main coronary artery will generally affect the entire left ventricle and septum. Occasionally coronary occlusions are encountered in the left main coronary artery—a lesion dubbed a "widow maker" because so much myocardial territory is supplied that acute obstructions of the left main coronary artery typically are fatal. Occlusions may also affect secondary branches, such as the diagonal branches of the LAD artery or marginal branches of the LCX artery. By contrast, significant atherosclerosis or thrombosis of penetrating intramyocardial branches of coronary arteries is rare.

Even though the three major coronary arteries are end arteries, these epicardial vessels are interconnected by numerous intercoronary anastomoses **(collateral circulation).** Although these channels normally are closed, gradual

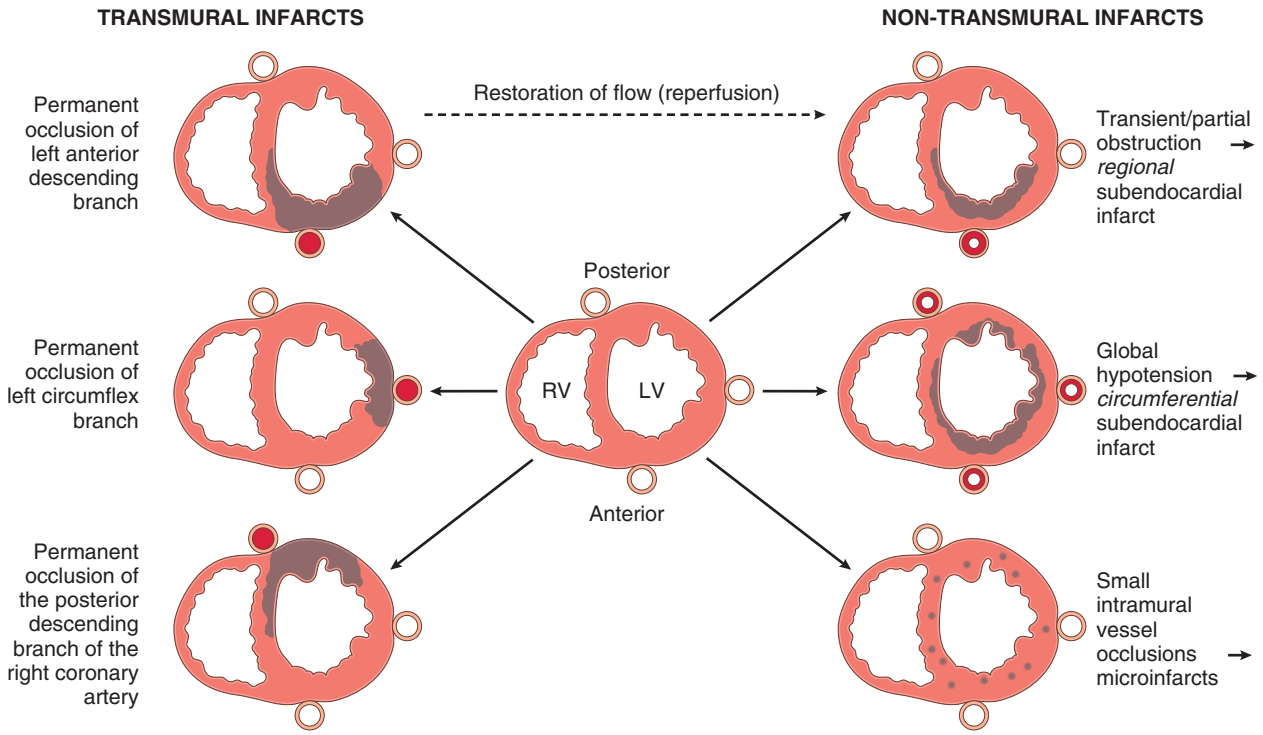


**Figure 10–9** Dependence of myocardial infarction on the location and nature of the diminished perfusion. *Left,* Patterns of transmural infarction resulting from major coronary artery occlusion. Right ventricle may be involved with occlusion of right main coronary artery (not depicted). *Right,* Patterns of infarction resulting from partial or transient occlusion (*top*), global hypotension superimposed on fixed three-vessel disease (*middle*), or occlusion of small intramyocardial vessels (*bottom*).

narrowing of one artery allows blood to flow from high to low pressure areas through the collateral channels. In this manner, gradual collateral dilation can provide adequate perfusion to areas of the myocardium despite occlusion of an epicardial vessel. Based on the size of the involved vessel and the degree of collateral circulation, myocardial infarcts may take one of the following patterns.

- **Transmural infarctions** involve the full thickness of the ventricle and are caused by epicardial vessel occlusion through a combination of chronic atherosclerosis and acute thrombosis; such transmural MIs typically yield ST segment elevations on the electrocardiogram (ECG) and can have a negative Q waves with loss of R wave amplitude. These infarcts are also called ST elevated MIs (STEMIs).
- **Subendocardial infarctions** are MIs limited to the inner third of the myocardium; these infarcts typically do not exhibit ST segment elevations or Q waves on the ECG tracing. As already mentioned, the subendocardial region is most vulnerable to hypoperfusion and hypoxia. Thus, in the setting of severe coronary artery disease, transient decreases in oxygen delivery (as from hypotension, anemia, or pneumonia) or increases in oxygen demand (as with tachycardia or hypertension) can cause subendocardial ischemic injury. This pattern also can occur when an occlusive thrombus lyses before a full-thickness infarction can develop.
- **Microscopic infarcts** occur in the setting of small vessel occlusions and may not show any diagnostic ECG changes. These can occur in the setting of vasculitis, embolization of valve vegetations or mural thrombi, or vessel spasm due to elevated catecholamines—either endogenous (e.g., pheochromocytoma or extreme stress), or exogenous (e.g., cocaine).

## MORPHOLOGY

Nearly all transmural infarcts (involving 50% or more of the ventricle thickness) affect at least a portion of the left ventricle and/or interventricular septum. Roughly 15% to 30% of MIs that involve the posterior or posteroseptal wall also extend into the right ventricle. Isolated right ventricle infarcts occur in only 1% to 3% of cases. Even in transmural infarcts, a narrow rim (approximately 0.1 mm) of viable subendocardial myocardium is preserved by diffusion of oxygen and nutrients from the ventricular lumen.

The gross and microscopic appearance of an MI depends on the age of the injury. Areas of damage progress through a highly characteristic sequence of morphologic changes from coagulative necrosis, to acute and then chronic inflammation, to fibrosis (Table 10–3). Myocardial necrosis proceeds invariably to scar formation without any significant regeneration; studies looking at whether tissue stem cells can be used to

**Table 10–3** Evolution of Morphologic Changes in Myocardial Infarction

| Time Frame | Gross Features | Light Microscopic Findings | Electron Microscopic Findings |
|---|---|---|---|
| Reversible Injury | | | |
| 0–1½ hours | None | None | Relaxation of myofibrils; glycogen loss; mitochondrial swelling |
| Irreversible Injury | | | |
| ½–4 hours | None | Usually none; variable waviness of fibers at border | Sarcolemmal disruption; mitochondrial amorphous densities |
| 4–12 hours | Occasionally dark mottling | Beginning coagulation necrosis; edema; hemorrhage | |
| 12–24 hours | Dark mottling | Ongoing coagulation necrosis; pyknosis of nuclei; hypereosinophilic appearance of myocytes; marginal contraction band necrosis; beginning neutrophilic infiltrate | |
| 1–3 days | Mottling with yellow-tan infarct center | Coagulation necrosis with loss of nuclei and striations; interstitial infiltrate of neutrophils | |
| 3–7 days | Hyperemic border; central yellow-tan softening | Beginning disintegration of dead myofibers, with dying neutrophils; early phagocytosis of dead cells by macrophages at infarct border | |
| 7–10 days | Maximally yellow-tan and soft, with depressed red-tan margins | Well-developed phagocytosis of dead cells; early formation of fibrovascular granulation tissue at margins | |
| 10–14 days | Red-gray depressed infarct borders | Well-established granulation tissue with new blood vessels and collagen deposition | |
| 2–8 weeks | Gray-white scar, progressive from border toward core of infarct | Increased collagen deposition, with decreased cellularity | |
| >2 months | Scarring complete | Dense collagenous scar | |

regenerate functional myocardium are ongoing but have yet to bear fruit.

Recognition of very recent myocardial infarcts can be challenging, particularly when death occurs within a few hours. **Myocardial infarcts less than 12 hours old usually are not grossly apparent.** However, infarcts more than 3 hours old can be visualized by exposing myocardium to vital stains, such as triphenyltetrazolium chloride, a substrate for lactate dehydrogenase. Because this enzyme is depleted in the area of ischemic necrosis (it leaks out of the damaged cells), the infarcted area is unstained (pale), while old scars appear white and glistening (Fig. 10–10). **By 12 to 24 hours after MI, an infarct usually can be grossly identified by a red-blue discoloration caused by stagnated, trapped blood.** Thereafter, infarcts become progressively better delineated as soft, yellow-tan areas; by 10 to 14 days, infarcts are rimmed by hyperemic (highly vascularized) granulation tissue. Over the succeeding weeks, the infarcted tissue evolves to a fibrous scar.

The microscopic appearance also undergoes a characteristic sequence of changes (Table 10–3 and Figure 10–11). Typical features of coagulative necrosis (Chapter 1) become detectable within 4 to 12 hours of infarction. "Wavy fibers" also can be present at the edges of an infarct; these reflect the stretching and buckling of noncontractile dead fibers. Sublethal ischemia can also induce intracellular **myocyte vacuolization;** such myocytes are viable but frequently are poorly contractile.

Necrotic myocardium elicits acute inflammation (typically most prominent 1 to 3 days after MI), followed by a wave of macrophages that remove necrotic myocytes and neutrophil fragments (most pronounced by 5 to 10 days after MI). The infarcted zone is progressively replaced by granulation tissue (most prominent 1 to 2 weeks after MI), which in turn forms the provisional scaffolding upon which dense collagenous scar forms. In most instances, scarring is well advanced by the end of the sixth week, but the efficiency of repair depends on the size of the original lesion. Healing requires the migration of

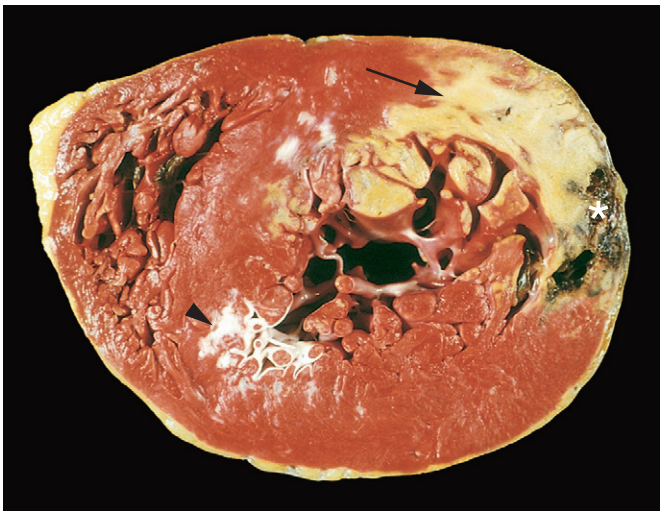

**Figure 10–10** Acute myocardial infarct of the posterolateral left ventricle demonstrated by a lack of triphenyltetrazolium chloride staining in areas of necrosis (*arrow*); the absence of staining is due to enzyme leakage after cell death. Note the anterior scar (*arrowhead*), indicative of remote infarction. The myocardial hemorrhage at the right edge of the infarct (*asterisk*) is due to ventricular rupture, and was the acute cause of death in this patient (specimen is oriented with the posterior wall at the *top*).

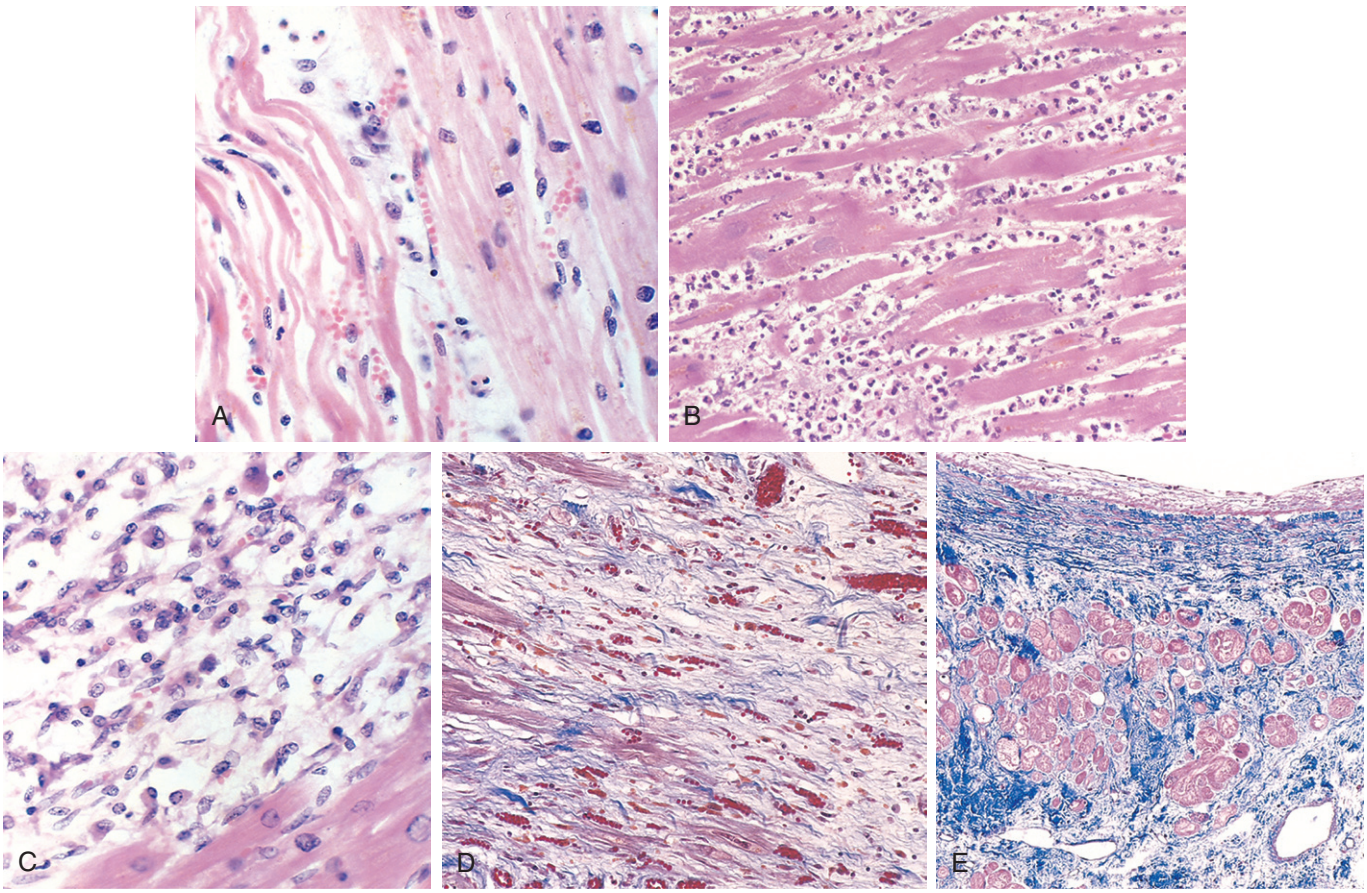


**Figure 10–11** Microscopic features of myocardial infarction and its repair. **A,** One-day-old infarct showing coagulative necrosis and wavy fibers, compared with adjacent normal fibers (at *right*). Necrotic cells are separated by edema fluid. **B,** Dense neutrophilic infiltrate in the area of a 2- to 3-day-old infarct. **C,** Nearly complete removal of necrotic myocytes by phagocytic macrophages (7 to 10 days). **D,** Granulation tissue characterized by loose connective tissue and abundant capillaries. **E,** Healed myocardial infarct consisting of a dense collagenous scar. A few residual cardiac muscle cells are present. **D** and **E** are Masson's trichrome stain, which stains collagen blue.

inflammatory cells and ingrowth of new vessels from the infarct margins. Thus, an MI heals from its borders toward the center, and a large infarct may not heal as fast or as completely as a small one. Once an MI is completely healed, it is impossible to distinguish its age: Whether present for 8 weeks or 10 years, fibrous scars look the same.

### *Infarct Modification by Reperfusion*

The therapeutic goal in acute MI is to salvage the maximal amount of ischemic myocardium; this is accomplished by restoration of tissue perfusion as quickly as possible (hence the adage "time is myocardium"). Such *reperfusion* is achieved by thrombolysis (dissolution of thrombus by tissue plasminogen activator), angioplasty, or coronary arterial bypass graft. Unfortunately, while preservation of viable (but at-risk) heart can improve both short- and long-term outcomes, reperfusion is not an unalloyed blessing. Indeed, restoration of blood flow into ischemic tissues can incite *greater* local damage than might otherwise have occurred—so-called *reperfusion injury.* The factors that contribute to reperfusion injury include: 1) Mitochondrial dysfunction: ischemia alters the mitochondrial membrane permeability, which allows proteins to move into the mitochondria. This leads to swelling and rupture of the outer membrane, releasing mitochondrial contents that promote apoptosis; 2) Myocyte hypercontracture: during periods of ischemia the intracellular levels of calcium are increased as a result of impaired calcium cycling and sarcolemmal damage. After reperfusion the contraction of myofibrils is augmented and uncontrolled, causing cytoskeletal damage and cell death; 3) Free radicals including superoxide anion (•O2), hydrogen peroxide ($H_2O_2$), hypochlorous acid (HOCl), nitric oxide–derived peroxynitrite, and hydroxyl radicals (•OH) are produced within minutes of reperfusion and cause damage to the myocytes by altering membrane proteins and phospholipids; 4) Leukocyte aggregation, which may occlude the microvasculature and contribute to the "no-reflow" phenomenon. Further, leukocytes elaborate proteases and elastases that cause cell death; 5) Platelet and complement activation also contribute to microvascular injury. Complement activation is thought to play a role in the no-reflow phenomenon by injuring the endothelium.

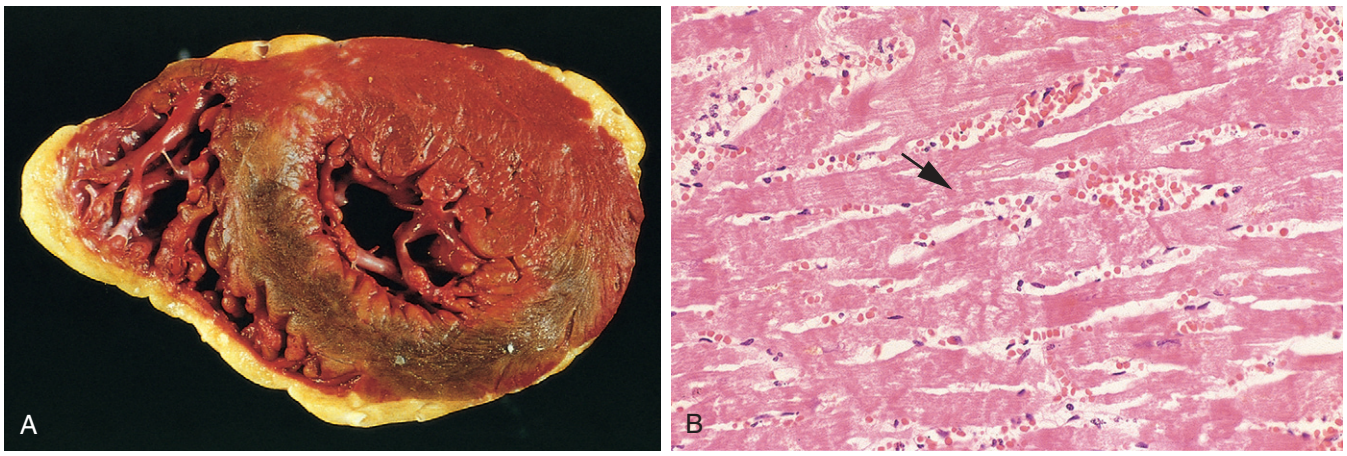


**Figure 10–12** Reperfused myocardial infarction. **A,** The transverse heart slice (stained with triphenyl tetrazolium chloride) exhibits a large anterior wall myocardial infarction that is hemorrhagic because of bleeding from damaged vessels. Posterior wall is at *top*. **B,** Hemorrhage and contraction bands, visible as prominent hypereosinophilic cross-striations spanning myofibers (*arrow*), are seen microscopically.

The typical appearance of reperfused myocardium in the setting of an acute MI is shown in Figure 10–12. Such infarcts typically are hemorrhagic as a consequence of vascular injury and leakiness. Microscopically, irreversibly damaged myocytes subject to reperfusion show *contraction band necrosis*; in this pathologic process, intense eosinophilic bands of hypercontracted sarcomeres are created by an influx of calcium across plasma membranes that enhances actin-myosin interactions. In the absence of ATP, the sarcomeres cannot relax and get stuck in an agonal tetanic state. Thus, while *reperfusion can salvage reversibly injured cells, it also alters the morphology of irreversibly injured cells.*

### Clinical Features

The classic MI is heralded by severe, crushing substernal chest pain (or pressure) that can radiate to the neck, jaw, epigastrium, or left arm. In contrast to angina pectoris, the associated pain typically lasts several minutes to hours, and is not relieved by nitroglycerin or rest. However, in a substantial minority of patients (10% to 15%), MIs have atypical signs and symptoms and may even be entirely asymptomatic. Such "silent" infarcts are particularly common in patients with underlying diabetes mellitus (in which autonomic neuropathies may prevent perception of pain) and in elderly persons.

The pulse generally is rapid and weak, and patients are often diaphoretic and nauseous (particularly with posterior wall MIs). Dyspnea is common, attributable to impaired myocardial contractility and dysfunction of the mitral valve apparatus, with resultant acute pulmonary congestion and edema. With massive MIs (involving more than 40% of the left ventricle), cardiogenic shock develops.

*Electrocardiographic abnormalities* are important for the diagnosis of MI; these include Q waves, ST segment changes, and T wave inversions (the latter two representing abnormalities in myocardial repolarization). Arrhythmias caused by electrical abnormalities in ischemic myocardium and conduction system are common; indeed, sudden cardiac death from a lethal arrhythmia accounts for the vast majority of MI-related deaths occurring before hospitalization.

The *laboratory evaluation* of MI is based on measuring blood levels of macromolecules that leak out of injured myocardial cells through damaged cell membranes (Fig. 10–13); these molecules include myoglobin, cardiac troponins T and I (TnT, TnI), creatine kinase (CK) (specifically the myocardial isoform, CK-MB), and lactate dehydrogenase. Troponins and CK-MB have high specificity and sensitivity for myocardial damage.

- CK-MB remains a valuable marker of myocardial injury, second only to the cardiac-specific troponins (see next entry). Total CK activity is not a reliable marker of cardiac injury since various isoforms of CK are also found in brain, myocardium, and skeletal muscle. However, the CK-MB isoform—principally derived

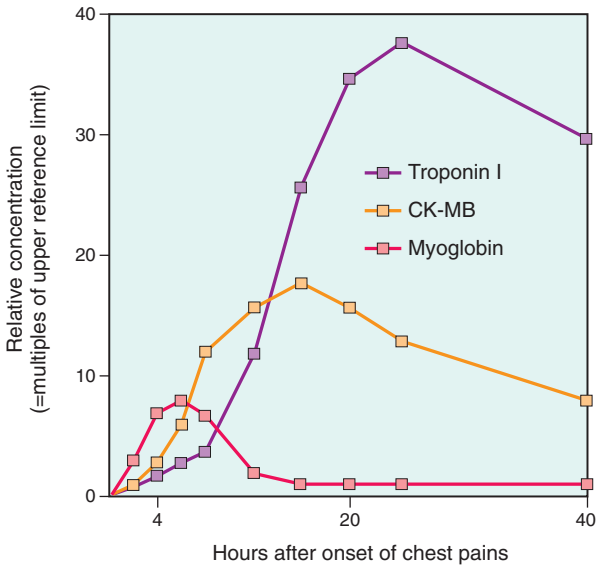


**Figure 10-13** Multiple measurements of troponin I and myocardial form of creatine kinase (CK-MB) at different time points can be used to estimate the size and timing of MIs.

from myocardium, but also present at low levels in skeletal muscle—is the more specific indicator of heart damage. CK-MB activity begins to rise within 2 to 4 hours of MI, peaks at 24 to 48 hours, and returns to normal within approximately 72 hours.

- TnI and TnT normally are not found in the circulation; however, after acute MI, both are detectable within 2 to 4 hours, with levels peaking at 48 hours and remaining elevated for 7 to 10 days. Although cardiac troponin and CK-MB are equally sensitive markers of the early stages of an MI, persistence of elevated troponin levels for approximately 10 days allows the diagnosis of an acute MI long after CK-MB levels have returned to normal. With reperfusion, both troponin and CK-MB levels may peak earlier owing to more rapid washout of the enzyme from the necrotic tissue.

### *Consequences and Complications of Myocardial Infarction*

Extraordinary progress has been made in improving patient outcomes after acute MI; the overall *in-hospital death rate* for MI is approximately 7%. Unfortunately, out-of-hospital mortality is substantially worse: A third of persons with ST elevation MIs (STEMIs) will die, usually of an arrhythmia within an hour of symptom onset, before they receive appropriate medical attention. Such statistics make the rising rate of coronary artery disease in developing countries with scarce hospital facilities all the more worrisome.

Nearly three fourths of patients experience one or more of the following complications after an acute MI (Fig. 10–14):

- *Contractile dysfunction.* In general, MIs affect left ventricular pump function in proportion to the volume of damage. In most cases, there is some degree of left ventricular failure manifested as hypotension, pulmonary congestion, and pulmonary edema. Severe "pump failure" (*cardiogenic shock*) occurs in roughly 10% of patients with transmural MIs and typically is associated with infarcts that damage 40% or more of the left ventricle.
- *Papillary muscle dysfunction.* Although papillary muscles rupture infrequently after MI, they often are dysfunctional and can be poorly contractile as a result of

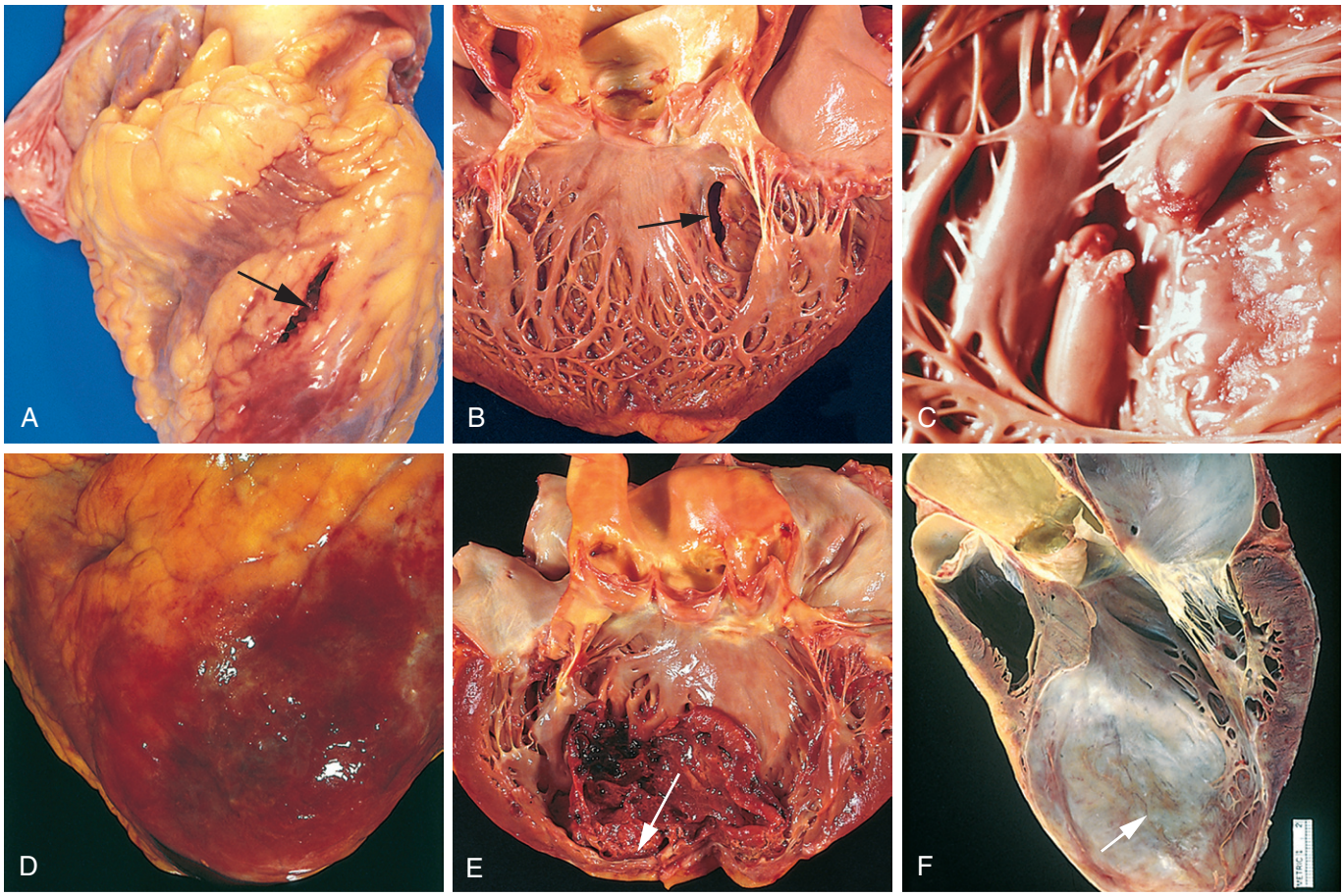


**Figure 10–14** Complications of myocardial infarction. **A–C,** Cardiac rupture. **A,** Anterior free wall myocardial rupture (*arrow*). **B,** Ventricular septal rupture (*arrow*). **C,** Papillary muscle rupture. **D,** Fibrinous pericarditis, with a hemorrhagic, roughened epicardial surface overlying an acute infarct. **E,** Recent expansion of an anteroapical infarct with wall stretching and thinning (*arrow*) and mural thrombus. **F,** Large apical left ventricular aneurysm (*arrow*).

*(A–E, Reproduced by permission from Schoen FJ: Interventional and Surgical Cardiovascular Pathology: Clinical Correlations and Basic Principles. Philadelphia, WB Saunders, 1989; F, Courtesy of William D. Edwards, MD, Mayo Clinic, Rochester, Minnesota.)*

ischemia, leading to postinfarct mitral regurgitation. Much later, papillary muscle fibrosis and shortening or global ventricular dilation also can cause mitral valve insufficiency.

- *Right ventricular infarction.* Although isolated right ventricular infarction occurs in only 1% to 3% of MIs, the right ventricle frequently is injured in association with septal or left ventricular infarction. In either case, right-sided heart failure is a common outcome, leading to venous circulation pooling and systemic hypotension.
- *Myocardial rupture.* Rupture complicates only 1% to 5% of MIs but is frequently fatal when it occurs. Left ventricular free wall rupture is most common, usually resulting in rapidly fatal hemopericardium and cardiac tamponade (Fig. 10–14, *A*). Ventricular septal rupture creates a VSD with left-to-right shunting (Fig. 10–14, *B*), and papillary muscle rupture leads to severe mitral regurgitation (Fig. 10–14, *C*). Rupture occurs most commonly within 3 to 7 days after infarction—the time in the healing process when lysis of myocardial connective tissue is maximal and when much of the infarct has been converted to soft, friable granulation tissue. Risk factors for free wall rupture include age older than 60 years, anterior or lateral wall infarctions, female gender, lack of left ventricular hypertrophy, and first MI (as scarring associated with prior MIs tends to limit the risk of myocardial tearing).
- *Arrhythmias.* MIs lead to *myocardial irritability* and *conduction disturbances that can cause sudden death.* Approximately 90% of patients develop some form of rhythm disturbance, with the incidence being higher in STEMIs *versus* non-STEMIs. MI-associated arrhythmias include heart block of variable degree (including asystole), bradycardia, supraventricular tachyarrhythmias, ventricular premature contractions or ventricular tachycardia, and ventricular fibrillation. The risk of serious arrhythmias (e.g., ventricular fibrillation) is greatest in the first hour and declines thereafter.
- *Pericarditis.* Transmural MIs can elicit a fibrinohemorrhagic pericarditis; this is an epicardial manifestation of the underlying myocardial inflammation (Fig. 10–14, *D*). Heralded by anterior chest pain and a pericardial friction rub, pericarditis typically appears 2 to 3 days after infarction and then gradually resolves over the next few days. Extensive infarcts or severe pericardial inflammation occasionally can lead to large effusions or can organize to form dense adhesions that eventually manifest as a constrictive lesion.
- *Chamber dilation.* Because of the weakening of necrotic muscle, there may be disproportionate stretching, thinning, and dilation of the infarcted region (especially with anteroseptal infarcts).
- *Mural thrombus.* With any infarct, the combination of attenuated myocardial contractility (causing stasis) and endocardial damage (causing a thrombogenic surface) can foster *mural thrombosis* (Fig. 10–14, *E*), eventually leading to left-sided *thromboembolism.*
- *Ventricular aneurysm.* A late complication, aneurysms of the ventricle most commonly result from a large transmural anteroseptal infarct that heals with the formation of a thinned wall of scar tissue (Fig. 10–14, *F*). Although ventricular aneurysms frequently give rise to formation of mural thrombi, arrhythmias, and heart failure, they do not rupture.
- *Progressive late heart failure.* Discussed later on as "chronic IHD."

The risk of developing complications and the prognosis after MI depend on infarct size, site, and type (subendocardial versus transmural infarct). Thus, large transmural infarcts are associated with a higher probability of cardiogenic shock, arrhythmias, and late CHF, and patients with anterior transmural MIs are at greatest risk for free wall rupture, expansion, formation of mural thrombi, and aneurysm formation. By contrast, posterior transmural infarcts are more likely to be complicated by serious conduction blocks, right ventricular involvement, or both; when acute-onset VSDs occur in this area, they are more difficult to manage. Overall, patients with anterior infarcts have a much worse clinical course than those with posterior infarcts. With subendocardial infarcts, thrombi may form on the endocardial surface, but pericarditis, rupture, and aneurysms rarely occur.

In addition to the aforementioned scarring, the remaining viable myocardium attempts to compensate for the loss of contractile mass. Noninfarcted regions undergo hypertrophy and dilation; in combination with the scarring and thinning of the infarcted zones, the changes are collectively termed *ventricular remodeling.* The initial compensatory hypertrophy of noninfarcted myocardium is hemodynamically beneficial. The adaptive effect of remodeling can be overwhelmed, however, and ventricular function may decline in the setting of expansion and ventricular aneurysm formation.

Long-term prognosis after MI depends on many factors, the most important of which are left ventricular function and the severity of atherosclerotic narrowing of vessels perfusing the remaining viable myocardium. The overall mortality rate within the first year is about 30%, including deaths occurring before the patient reaches the hospital. Thereafter, the annual mortality rate is 3% to 4%.

## Chronic Ischemic Heart Disease

Chronic IHD, also called *ischemic cardiomyopathy,* is essentially progressive heart failure secondary to ischemic myocardial damage. In most instances, there is a history of previous MI. In this setting, chronic IHD appears when the compensatory mechanisms (e.g., hypertrophy) of residual viable myocardium begin to fail. In other cases, severe obstructive CAD can cause diffuse myocardial dysfunction without frank infarction.

### MORPHOLOGY

Patients with chronic IHD typically exhibit **left ventricular dilation and hypertrophy,** often with discrete areas of gray-white scarring from previous healed infarcts. Invariably, there is moderate to severe atherosclerosis of the coronary arteries, sometimes with total occlusion. The endocardium generally shows patchy, fibrous thickening, and mural thrombi may be present. Microscopic findings include myocardial hypertrophy, diffuse subendocardial myocyte vacuolization, and fibrosis from previous infarction.

Clinical Features

Severe, progressive heart failure characterizes chronic IHD, occasionally punctuated by new episodes of angina or infarction. Arrhythmias, CHF, and intercurrent MI account for most of the associated morbidity and mortality.

## Cardiac Stem Cells

Because of the serious morbidity associated with IHD, there is much interest in exploring the possibility of using cardiac stem cells to replace the damaged myocardium. Although cardiac regeneration in metazoans (such as newts and zebrafish) is well described, the myocardium of higher-order animals is classically considered a postmitotic cell population without replicative potential. Increasing evidence, however, points to the presence of bone marrow–derived precursors—as well as a small resident stem cell population within the myocardium—capable of repopulating the mammalian heart. These cells are characterized by the expression of a cluster of cell surface markers that allow their isolation and purification. Besides self-renewal, these cardiac stem cells generate all cell lineages seen within the myocardium. Like all other tissue stem cells, they occur in very low frequency. They have a slow intrinsic rate of proliferation, which is greatest in neonates and decreases with age. Of interest, stem cell numbers and progeny increase after myocardial injury or hypertrophy, albeit to a limited extent, since hearts that suffer an MI clearly do not recover any significant function in the necrotic zone. Nevertheless, the potential for stimulating the proliferation of these cells in vivo is tantalizing because it could facilitate recovery of myocardial function after acute MI or chronic IHD. Conversely, ex vivo expansion and subsequent administration of such cells after an MI is another area of vigorous investigation. Unfortunately, results thus far have been less than exciting. Implanted stem cells may show some cardiomyocyte differentiation, but the durability of this benefit has been limited, and they do not contribute significantly to the restoration of contractile force; moreover, aberrant integration into the conducting system of the host heart carries the risk of formation of autonomous arrhythmic foci.

### SUMMARY

#### Ischemic Heart Disease

- In the vast majority of cases, cardiac ischemia is due to coronary artery atherosclerosis; vasospasm, vasculitis, and embolism are less common causes.
- Cardiac ischemia results from a mismatch between coronary supply and myocardial demand and manifests as different, albeit overlapping syndromes:
  - *Angina pectoris* is exertional chest pain due to inadequate perfusion, and is typically due to atherosclerotic disease causing greater than 70% fixed stenosis (so-called critical stenosis).
  - *Unstable angina* results from a small fissure or rupture of atherosclerotic plaque triggering platelet aggregation, vasoconstriction, and formation of a mural thrombus that need not necessarily be occlusive.
  - *Acute myocardial infarction* typically results from acute thrombosis after plaque disruption; a majority occur in plaques that did not previously exhibit critical stenosis.
  - *Sudden cardiac death* usually results from a fatal arrhythmia, typically without significant acute myocardial damage.
  - *Ischemic cardiomyopathy* is progressive heart failure due to ischemic injury, either from previous infarction(s) or chronic ischemia.
- Myocardial ischemia leads to loss of myocyte function within 1 to 2 minutes but causes necrosis only after 20 to 40 minutes. Myocardial infarction is diagnosed on the basis of symptoms, electrocardiographic changes, and measurement of serum CK-MB and troponins. Gross and histologic changes of infarction require hours to days to develop.
- Infarction can be modified by therapeutic intervention (e.g., thrombolysis or stenting), which salvages myocardium at risk but may also induce reperfusion-related injury.
- Complications of infarction include ventricular rupture, papillary muscle rupture, aneurysm formation, mural thrombus, arrhythmia, pericarditis, and CHF.

# ARRHYTHMIAS

As is well known, the heart contains specialized conduction system consisting of excitatory myocytes that regulate the rate and rhythm of cardiac contraction and are essential for normal cardiac function. This system is influenced by direct neural inputs (e.g., vagal stimulation), adrenergic agents (e.g., epinephrine [adrenaline]), hypoxia, and potassium concentrations (i.e., hyperkalemia can block signal transmission altogether). The components of the conduction system include (1) the *sinoatrial (SA) node* pacemaker (located at the junction of the right atrial appendage and superior vena cava), (2) the *atrioventricular (AV) node* (located in the right atrium along the atrial septum), (3) the *bundle of His*, connecting the right atrium to the ventricular septum, and the subsequent divisions into (4) the right and left bundle branches that stimulate their respective ventricles.

Abnormalities in myocardial conduction can be sustained or sporadic (*paroxysmal*). Aberrant rhythms can be initiated anywhere in the conduction system, from the SA node down to the level of an individual myocyte; they are typically designated as originating from the atrium (*supraventricular*) or within the ventricular myocardium. Arrhythmias can manifest as *tachycardia* (fast heart rate), *bradycardia* (slow heart rate), an irregular rhythm with normal ventricular contraction, chaotic depolarization without functional ventricular contraction (*ventricular fibrillation*), or no electrical activity at all (*asystole*). Patients may be unaware of a rhythm disorder or may note a "racing heart" or *palpitations*; loss of adequate cardiac output due to sustained arrhythmia can produce lightheadedness (near syncope), loss of consciousness (*syncope*), or *sudden cardiac death* (see further on).

*Ischemic injury is the most common cause of rhythm disorders,* because of direct damage or due to the dilation of heart chambers with consequent alteration in conduction system firing.

Far less common are inherited causes of arrhythmias. These are caused by mutations in genes that regulate various ion channels that regulate depolarization and repolarization of myocardial cells. Such *channelopathies* are important (but fortunately uncommon) substrates for fatal arrhythmias. They underlie some cases of sudden cardiac death, which is discussed next.

## Sudden Cardiac Death

Sudden cardiac death (SCD) most commonly is defined as sudden death, typically due to sustained ventricular arrhythmias in individuals who have underlying structural heart disease which may or may not have been symptomatic in the past. Some 300,000 to 400,000 persons are victims of SCD each year in the United States alone. Coronary artery disease is the leading cause of death, being responsible for 80% to 90% of cases; unfortunately, SCD often is the first manifestation of IHD. Of interest, autopsy typically shows only chronic severe atherosclerotic disease; acute plaque disruption is found in only 10% to 20% of cases. Healed remote MIs are present in about 40% of the cases.

In younger victims of SCD, other, nonatherosclerotic causes are more common, including:

- Hereditary (channelopathies) or acquired abnormalities of the cardiac conduction system
- Congenital coronary arterial abnormalities
- Mitral valve prolapse
- Myocarditis or sarcoidosis
- Dilated or hypertrophic cardiomyopathy
- Pulmonary hypertension
- Myocardial hypertrophy. Increased cardiac mass is an independent risk factor for SCD; thus, in some young persons who die suddenly, including athletes, hypertensive hypertrophy or unexplained increased cardiac mass is the only pathologic finding.

*The ultimate mechanism of SCD most often is a lethal arrhythmia* (e.g., asystole or ventricular fibrillation). Of note, frank infarction need not occur; 80% to 90% of patients who suffer SCD but are successfully resuscitated do not show any enzymatic or ECG evidence of myocardial necrosis—even if the original cause was IHD! Although ischemic injury (and other pathologic conditions) can directly affect the major components of the conduction system, most cases of fatal arrhythmia are triggered by electrical irritability of myocardium distant from the conduction system.

The relationship of coronary artery disease to the various clinical end points discussed earlier is depicted in Figure 10–15.

The prognosis for patients vulnerable to SCD is markedly improved by medical intervention, particularly by implantation of automatic cardioverter-defibrillators that sense and electrically counteract episodes of ventricular fibrillation.

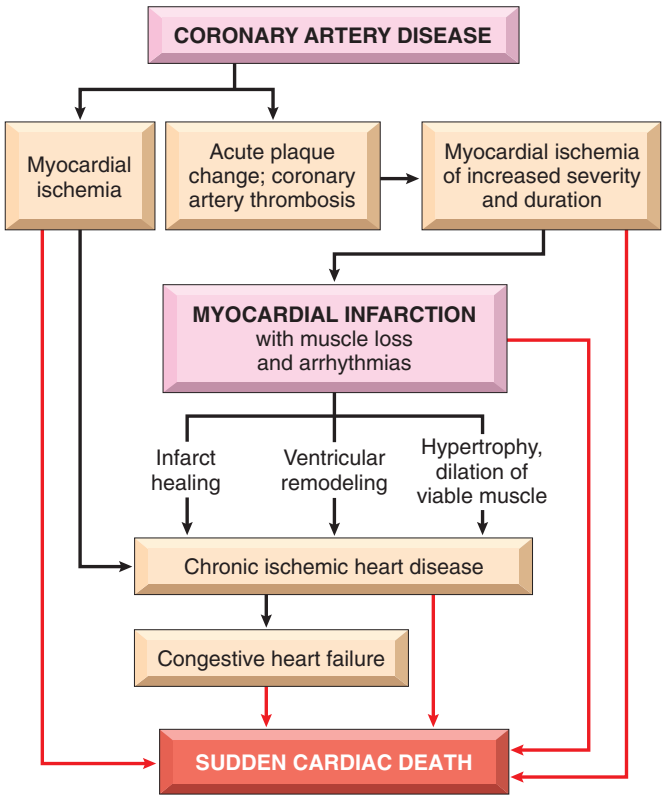


**Figure 10–15** Pathways in the progression of ischemic heart disease showing the relationships among coronary artery disease and its major sequelae.

### SUMMARY

#### Arrhythmias

- Arrhythmias can be caused by ischemic or structural changes in the conduction system or by myocyte electrical instability. In structurally normal hearts, arrhythmias more often are due to mutations in ion channels that cause aberrant repolarization or depolarization.
- SCD most frequently is due to coronary artery disease leading to ischemia. Myocardial irritability typically results from nonlethal ischemia or from preexisting fibrosis from previous myocardial injury. SCD less often is due to acute plaque rupture with thrombosis that induces a rapidly fatal arrhythmia.

# HYPERTENSIVE HEART DISEASE

As discussed in Chapter 9, hypertension is a common disorder associated with considerable morbidity and affecting many organs, including the heart, brain, and kidneys. The comments here will focus specifically on the major cardiac complications of hypertension, which result from pressure overload and ventricular hypertrophy. Myocyte hypertrophy is an adaptive response to pressure overload; there are limits to myocardial adaptive capacity, however, and persistent hypertension eventually can culminate

in dysfunction, cardiac dilation, CHF, and even sudden death. Although hypertensive heart disease most commonly affects the left side of the heart secondary to systemic hypertension, pulmonary hypertension also can cause right-sided hypertensive changes—so-called *cor pulmonale.*

## Systemic (Left-Sided) Hypertensive Heart Disease

The criteria for the diagnosis of systemic hypertensive heart disease are (1) left ventricular hypertrophy in the absence of other cardiovascular pathology (e.g., valvular stenosis), and (2) a history or pathologic evidence of hypertension. The Framingham Heart Study established unequivocally that even mild hypertension (above 140/90 mm Hg), if sufficiently prolonged, induces left ventricular hypertrophy. Roughly 25% of the U.S. population suffers from at least this degree of hypertension.

### MORPHOLOGY

As discussed earlier, systemic hypertension imposes pressure overload on the heart and is associated with gross and microscopic changes somewhat distinct from those caused by volume overload. The essential feature of systemic hypertensive heart disease is **left ventricular hypertrophy,** typically without ventricular dilation until very late in the process (Fig. 10–16, *A*). The heart weight can exceed 500 g (normal, 320 to 360 g), and the left ventricular wall thickness can exceed 2.0 cm (normal, 1.2 to 1.4 cm). With time, the increased left ventricular wall thickness imparts a stiffness that impairs diastolic filling and can result in left atrial dilation. In long-standing systemic hypertensive heart disease leading to congestive failure, the ventricle typically is dilated.

Microscopically, the transverse diameter of myocytes is increased and there is prominent nuclear enlargement and hyperchromasia ("boxcar nuclei"), as well as intercellular fibrosis.

### Clinical Features

Compensated hypertensive heart disease typically is asymptomatic and is suspected only from discovery of elevated blood pressure on routine physical exams, or from ECG or echocardiographic findings of left ventricular hypertrophy. In some patients, the disease comes to attention with the onset of atrial fibrillation (secondary to left atrial enlargement) and/or CHF. The mechanisms by which hypertension leads to heart failure are incompletely understood; presumably the hypertrophic myocytes fail to contract efficiently, possibly due to structural abnormalities in newly assembled sarcomeres and because the vascular supply is inadequate to meet the demands of the increased muscle mass. Depending on the severity and duration of the condition, the underlying cause of hypertension, and the adequacy of therapeutic control, patients can (1) enjoy normal longevity and die of unrelated causes, (2) develop progressive IHD owing to the effects of hypertension in potentiating coronary atherosclerosis, (3) suffer progressive renal damage or cerebrovascular stroke, or (4) experience progressive heart failure. The risk of sudden cardiac death also is increased. Effective hypertension control can prevent or lead to the regression of cardiac hypertrophy and its attendant risks.

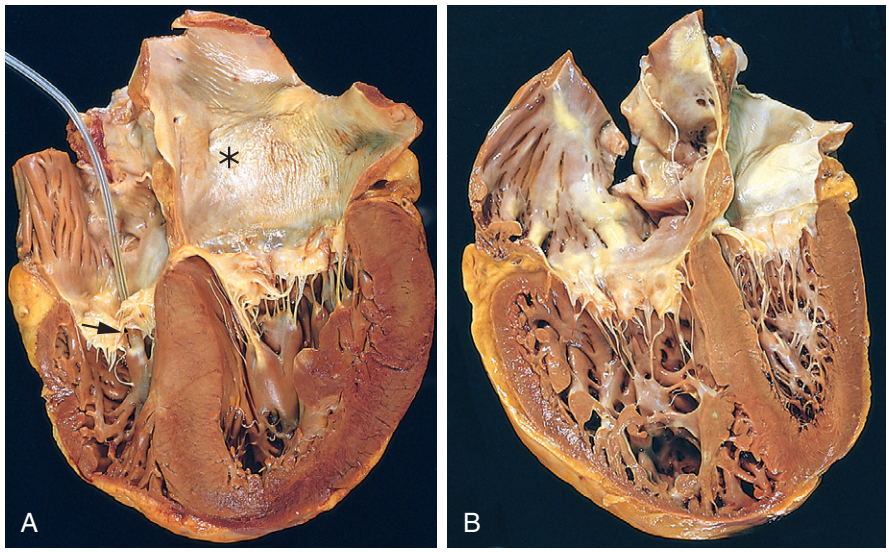


**Figure 10–16** Hypertensive heart disease. **A,** Systemic (left-sided) hypertensive heart disease. There is marked concentric thickening of the left ventricular wall causing reduction in lumen size. The left ventricle and left atrium are on the right in this four-chamber view of the heart. A pacemaker is present incidentally in the right ventricle (*arrow*). Note also the left atrial dilation (*asterisk*) due to stiffening of the left ventricle and impaired diastolic relaxation, leading to atrial volume overload. **B,** Chronic cor pulmonale. The right ventricle (shown on the *left* side of this picture) is markedly dilated and hypertrophied with a thickened free wall and hypertrophied trabeculae. The shape and volume of the left ventricle have been distorted by the enlarged right ventricle.

## Pulmonary Hypertensive Heart Disease—Cor Pulmonale

*Cor pulmonale* consists of right ventricular hypertrophy and dilation—frequently accompanied by right heart failure—caused by *pulmonary hypertension attributable to primary disorders of the lung parenchyma or pulmonary vasculature* (Table 10–4). Right ventricular dilation and hypertrophy caused by left ventricular failure (or by congenital heart disease) is substantially more common but is excluded by this definition.

Cor pulmonale can be acute in onset, as with pulmonary embolism, or can have a slow and insidious onset when due to prolonged pressure overloads in the setting of chronic lung and pulmonary vascular disease (Table 10–4).

### MORPHOLOGY

In **acute cor pulmonale,** the right ventricle usually shows only dilation; if an embolism causes sudden death, the heart may even be of normal size. **Chronic cor pulmonale** is characterized by right ventricular (and often right atrial) hypertrophy. In extreme cases, the thickness of the right ventricular wall may be comparable with or even exceed that of the left ventricle (Fig. 10–16, *B*). When ventricular failure develops, the right ventricle and atrium often are dilated. Because chronic cor pulmonale occurs in the setting of pulmonary hypertension, the pulmonary arteries often contain atheromatous plaques and other lesions, reflecting long-standing pressure elevations.

**Table 10–4** Disorders Predisposing to Cor Pulmonale

| |
|---|
| **Diseases of the Pulmonary Parenchyma** |
| Chronic obstructive pulmonary disease |
| Diffuse pulmonary interstitial fibrosis |
| Pneumoconiosis |
| Cystic fibrosis |
| Bronchiectasis |
| **Diseases of the Pulmonary Vessels** |
| Recurrent pulmonary thromboembolism |
| Primary pulmonary hypertension |
| Extensive pulmonary arteritis (e.g., Wegener granulomatosis) |
| Drug-, toxin-, or radiation-induced vascular obstruction |
| Extensive pulmonary tumor microembolism |
| **Disorders Affecting Chest Movement** |
| Kyphoscoliosis |
| Marked obesity (pickwickian syndrome) |
| Neuromuscular diseases |
| **Disorders Inducing Pulmonary Arterial Constriction** |
| Metabolic acidosis |
| Hypoxemia |
| Obstruction to major airways |
| Idiopathic alveolar hypoventilation |

### SUMMARY

#### Hypertensive Heart Disease

- Hypertensive heart disease can affect either the left ventricle or the right ventricle; in the latter case, the disorder is called cor pulmonale. Elevated pressures induce myocyte hypertrophy and interstitial fibrosis that increases wall thickness and stiffness.
- The chronic pressure overload of systemic hypertension causes left ventricular concentric hypertrophy, often associated with left atrial dilation due to impaired diastolic filling of the ventricle. Persistently elevated pressure overload can cause ventricular failure with dilation.
- Cor pulmonale results from pulmonary hypertension due to primary lung parenchymal or vascular disorders. Hypertrophy of both the right ventricle and the right atrium is characteristic; dilation also may be seen when failure supervenes.

## VALVULAR HEART DISEASE

Valvular disease results in stenosis or insufficiency (regurgitation or incompetence), or both.

- *Stenosis is the failure of a valve to open completely, obstructing forward flow.* Valvular stenosis is almost always due to a primary cuspal abnormality and is virtually always a chronic process (e.g., calcification or valve scarring).
- *Insufficiency results from failure of a valve to close completely, thereby allowing regurgitation (backflow) of blood.* Valvular insufficiency can result from either intrinsic disease of the valve cusps (e.g., endocarditis) or disruption of the supporting structures (e.g., the aorta, mitral annulus, tendinous cords, papillary muscles, or ventricular free wall) without primary cuspal injury. It can appear abruptly, as with chordal rupture, or insidiously as a consequence of leaflet scarring and retraction.

Stenosis or regurgitation can occur alone or together in the same valve. Valvular disease can involve only one valve (the mitral valve being the most common target), or more than one valve. Abnormal flow through diseased valves typically produces abnormal heart sounds called *murmurs*; severe lesions can even be palpated as *thrills.* Depending on the valve involved, murmurs are best heard at different locations on the chest wall; moreover, the nature (regurgitation versus stenosis) and severity of the valvular disease determines the quality and timing of the murmur (e.g., harsh systolic or soft diastolic murmurs).

The outcome of valvular disease depends on the valve involved, the degree of impairment, the tempo of its development, and the effectiveness of compensatory mechanisms. For example, sudden destruction of an aortic valve cusp by infection can cause massive regurgitation and the abrupt onset of cardiac failure. By contrast, rheumatic mitral stenosis usually progresses over years, and its clinical effects can be well tolerated until late in the course.

Valvular abnormalities can be congenital or acquired. By far the most common congenital valvular lesion is a *bicuspid aortic valve,* containing only two functional cusps instead of the normal three; this malformation occurs with

a frequency of 1% to 2% of all live births, and has been associated with a number of mutations including those affecting proteins of the Notch signaling pathway. The two cusps are of unequal size, with the larger cusp exhibiting a midline *raphe* resulting from incomplete cuspal separation (Fig. 10–17, *B*). Bicuspid aortic valves are generally neither stenotic nor incompetent through early life; however, they are more prone to early and progressive degenerative calcification (see further on).

The most important causes of acquired valvular diseases are summarized in Table 10–5; acquired stenoses of the aortic and mitral valves account for approximately two thirds of all valve disease.

## Degenerative Valve Disease

*Degenerative valve disease* is a term used to describe changes that affect the integrity of valvular extracellular matrix (ECM). Degenerative changes include

- *Calcifications,* which can be cuspal (typically in the aortic valve) (Fig. 11–17, *A* and *B*) or annular (in the mitral valve) (Fig. 11–17, *C* and *D*). The mitral annular calcification usually is asymptomatic unless it encroaches on the adjacent conduction system.
- *Decreased numbers of valve fibroblasts and myofibroblasts*

**Table 10–5** Etiology of Acquired Heart Valve Disease

| Mitral Valve Disease | Aortic Valve Disease |
|---|---|
| **Mitral Stenosis** | **Aortic Stenosis** |
| Postinflammatory scarring (rheumatic heart disease) | Postinflammatory scarring (rheumatic heart disease)<br>Senile calcific aortic stenosis<br>Calcification of congenitally deformed valve |
| **Mitral Regurgitation** | **Aortic Regurgitation** |
| Abnormalities of leaflets and commissures<br>Postinflammatory scarring<br>Infective endocarditis<br>Mitral valve prolapse<br>"Fen-phen"–induced valvular fibrosis<br>Abnormalities of tensor apparatus<br>Rupture of papillary muscle<br>Papillary muscle dysfunction (fibrosis)<br>Rupture of chordae tendineae<br>Abnormalities of left ventricular cavity and/or annulus<br>Left ventricular enlargement (myocarditis, dilated cardiomyopathy)<br>Calcification of mitral ring | Intrinsic valvular disease<br>Postinflammatory scarring (rheumatic heart disease)<br>Infective endocarditis<br>Aortic disease<br>Degenerative aortic dilation<br>Syphilitic aortitis<br>Ankylosing spondylitis<br>Rheumatoid arthritis<br>Marfan syndrome |

Fen-phen, fenfluramine-phentermine. Data from Schoen FJ: Surgical pathology of removed natural and prosthetic valves. Hum Pathol 18:558, 1987.

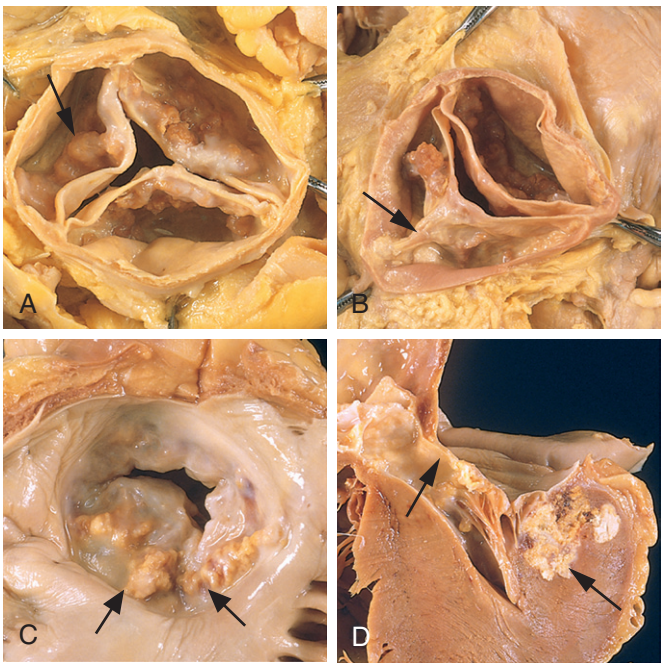


**Figure 10–17** Calcific valvular degeneration. **A,** Calcific aortic stenosis of a previously normal valve (viewed from *above* the valve). Nodular masses of calcium are heaped up within the sinuses of Valsalva (*arrow*). Note that the commissures are not fused, as in rheumatic aortic valve stenosis (Fig. 10–19, *C*). **B,** Calcific aortic stenosis occurring on a congenitally bicuspid valve. One cusp has a partial fusion at its center, called a *raphe* (*arrow*). **C** and **D,** Mitral annular calcification, with calcific nodules within the annulus (attachment margin) of the mitral leaflets (*arrows*). **C,** Left atrial view. **D,** Cut section demonstrating the extension of the calcification into the underlying myocardium. Such involvement of adjacent structures near the interventricular septum can impinge on the conduction system.

- *Alterations in the ECM.* In some cases, changes consist of increased proteoglycan and diminished fibrillar collagen and elastin (*myxomatous degeneration*); in other cases, the valve becomes fibrotic and scarred.
- *Changes in the production of matrix metalloproteinases or their inhibitors*

Degenerative changes in the cardiac valves probably are an inevitable part of the aging process, because of the repetitive mechanical stresses to which valves are subjected—40 million beats per year, with each normal opening and closing requiring substantial valve deformation.

### *Calcific Aortic Stenosis*

Calcific aortic degeneration is the most common cause of aortic stenosis. Although progressive age-associated "wear and tear" has been the pathologic mechanism most often proposed, cuspal fibrosis and calcification are increasingly viewed as the valvular counterparts to age-related arteriosclerosis. Thus, chronic injury due to hyperlipidemia, hypertension, inflammation, and other factors implicated in atherosclerosis probably play a significant role in the pathogenesis. In most cases, calcific degeneration is asymptomatic and is discovered only incidentally by viewing calcifications on a routine chest radiograph or at autopsy. In other patients, valvular sclerosis and/or calcification can be severe enough to cause stenosis, necessitating surgical intervention.

The incidence of calcific aortic stenosis is increasing with the rising average age for the U.S. population. In anatomically normal valves, it typically begins to manifest when patients reach their 70s and 80s; onset with bicuspid aortic valves is at a much earlier age (often 40 to 50 years).

## MORPHOLOGY

The hallmark of calcific aortic stenosis is heaped-up calcified masses on the outflow side of the cusps; these protrude into the sinuses of Valsalva and mechanically impede valve opening (Fig. 10–17, *A* and *B*); commissural fusion (usually a sign of previous inflammation) is not a typical feature of degenerative aortic stenosis, although the cusps may become secondarily fibrosed and thickened. An earlier, hemodynamically inconsequential stage of the calcification process is called aortic valve sclerosis.

### Clinical Features

In severe disease, valve orifices can be compromised by as much as 70% to 80% (from a normal area of approximately 4 $cm^2$ to as little as 0.5 to 1 $cm^2$). Cardiac output is maintained only by virtue of concentric left ventricular hypertrophy, and the chronic outflow obstruction can drive left ventricular pressures to 200 mm Hg or more. The hypertrophied myocardium is prone to ischemia, and angina can develop. Systolic and diastolic dysfunction collude to cause CHF, and cardiac decompensation eventually ensues. The development of angina, CHF, or syncope in aortic stenosis heralds the exhaustion of compensatory cardiac hyperfunction and carries a poor prognosis; without surgical intervention, 50% to 80% of patients die within 2 to 3 years of the onset of symptoms like CHF, angina, and syncope.

### *Myxomatous Mitral Valve*

In *myxomatous degeneration of the mitral valve,* one or both mitral leaflets are "floppy" and *prolapse*—they balloon back into the left atrium during systole. *Mitral valve prolapse* is a primary form of myxomatous mitral degeneration affecting some 0.5% to 2.4% of adults; thus, it is one of the most common forms of valvular heart disease in the Western world. Men and women are equally affected. Secondary myxomatous mitral degeneration can occur in any one of a number of settings where mitral regurgitation is caused by some other entity (e.g., IHD).

## PATHOGENESIS

The basis for **primary** myxomatous degeneration is unknown. Nevertheless, an underlying (possibly systemic) intrinsic defect of connective tissue synthesis or remodeling is likely. Thus, myxomatous degeneration of the mitral valve is a common feature of Marfan syndrome (due to fibrillin-1 mutations) (Chapter 6), and occasionally occurs in other connective tissue disorders. In some patients with primary disease, additional hints of structural abnormalities in the systemic connective tissue, including scoliosis and high-arched palate, may be found. Subtle defects in structural proteins (or the cells that make them) may cause hemodynamically stressed connective tissues rich in microfibrils and elastin (e.g., cardiac valves) to elaborate defective ECM. **Secondary** myxomatous change presumably results from injury to the valve myofibroblasts, imposed by chronically aberrant hemodynamic forces.

## MORPHOLOGY

Myxomatous degeneration of the mitral valve is characterized by ballooning (hooding) of the mitral leaflets (Fig. 10–18). The affected leaflets are enlarged, redundant, thick, and rubbery; the tendinous cords also tend to be elongated, thinned, and occasionally rupture. In those with primary mitral desease, concomitant tricuspid valve involvement is frequent (20% to 40% of cases); less commonly aortic and pulmonic valves can also be affected. On histologic examination, the essential change is thinning of the valve layer known as the **fibrosa** layer of the valve, on which the structural integrity of the leaflet depends, accompanied by expansion of the middle **spongiosa** layer owing to increased deposition of myxomatous (mucoid) material. The same changes occur whether the myxomatous degeneration is due to an intrinsic ECM defect (primary), or is caused by regurgitation secondary to another etiologic process (e.g., ischemic dysfunction).

### Clinical Features

Most patients are asymptomatic, and the valvular abnormality is discovered only incidentally on physical examination. In a minority of cases, patients may complain of palpitations, dyspnea, or atypical chest pain. Auscultation discloses a midsystolic click, caused by abrupt tension on the redundant valve leaflets and chordae tendineae as the valve attempts to close; there may or may not be an associated regurgitant murmur. Although in most instances the natural history and clinical course are benign, approximately 3% of patients develop complications such

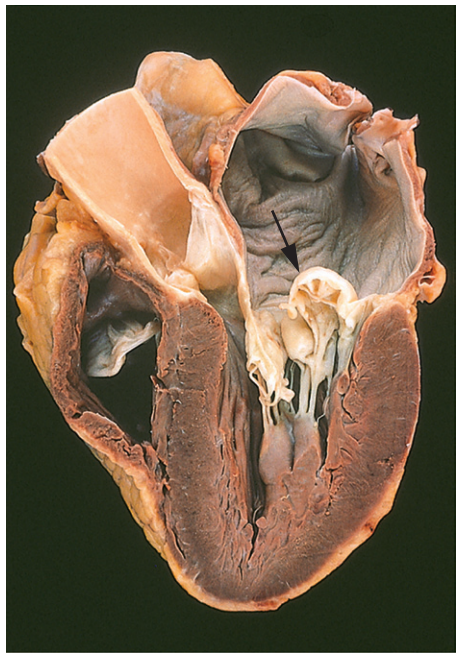

**Figure 10–18** Myxomatous degeneration of the mitral valve. There is prominent hooding with prolapse of the posterior mitral leaflet (*arrow*) into the left atrium; the atrium also is dilated, reflecting long-standing valvular insufficiency and volume overload. The left ventricle is on the *right* in this four-chamber view.
*(Courtesy of William D. Edwards, MD, Mayo Clinic, Rochester, Minnesota.)*

as hemodynamically significant mitral regurgitation and congestive heart failure, particularly if the chordae or valve leaflets rupture. Patients with primary myxomatous degeneration also are at increased risk for the development of infective endocarditis (see later), as well as sudden cardiac death due to ventricular arrhythmias. Stroke or other systemic infarction may rarely occur from embolism of thrombi formed in the left atrium.

## Rheumatic Valvular Disease

Rheumatic fever is an acute, immunologically mediated, multisystem inflammatory disease that occurs after group A β-hemolytic streptococcal infections (usually pharyngitis, but also rarely with infections at other sites such as skin). Rheumatic heart disease is the cardiac manifestation of rheumatic fever. *It is associated with inflammation of all parts of the heart, but valvular inflammation and scarring produces the most important clinical features.*

The valvular disease principally takes the form of deforming fibrotic mitral stenosis; indeed rheumatic heart disease is essentially the *only* cause of acquired mitral stenosis. The incidence of rheumatic fever (and thus rheumatic heart disease) has declined remarkably in many parts of the Western world over the past several decades; this is due to a combination of improved socioeconomic conditions, rapid diagnosis and treatment of streptococcal pharyngitis, and a fortuitous (and unexplained) decline in the virulence of many strains of group A streptococci. Nevertheless, in developing countries and economically depressed urban areas in the United States, rheumatic fever and rheumatic heart disease remain important public health problems.

### PATHOGENESIS

Acute rheumatic fever is a hypersensitivity reaction classically attributed to antibodies directed against group A streptococcal molecules that also are cross-reactive with host antigens (see also Chapter 4). In particular, antibodies against M proteins of certain streptococcal strains bind to proteins in the myocardium and cardiac valves and cause injury through the activation of complement and Fc receptor–bearing cells (including macrophages). CD4+ T cells that recognize streptococcal peptides also can cross-react with host antigens and elicit cytokine-mediated inflammatory responses. The characteristic 2- to 3-week delay in symptom onset after infection is explained by the time needed to generate an immune response; streptococci are completely absent from the lesions. Since only a small minority of infected patients develop rheumatic fever (estimated at 3%), a genetic susceptibility is likely to influence the development of the cross-reactive immune responses. The chronic fibrotic lesions are the predictable consequence of healing and scarring associated with the resolution of the acute inflammation.

### MORPHOLOGY

**Acute rheumatic fever** is characterized by discrete inflammatory foci within a variety of tissues. The myocardial inflammatory lesions—called **Aschoff bodies**—are pathognomonic for rheumatic fever (Fig. 10–19, *B*); these are collections of lymphocytes (primarily T cells), scattered plasma cells, and plump activated macrophages called **Anitschkow cells** occasionally punctuating zones of fibrinoid necrosis. The Anitschkow cells have abundant cytoplasm and central nuclei with chromatin condensed to form a slender, wavy ribbon (so-called caterpillar cells). During acute rheumatic fever, Aschoff bodies can be found in any of the three layers of the heart—pericardium, myocardium, or endocardium (including valves). Hence, rheumatic fever is said to cause **pancarditis,** with the following salient features:

- The pericardium exhibits a fibrinous exudate, which generally resolves without sequelae.
- The myocardial involvement—myocarditis—takes the form of scattered Aschoff bodies within the interstitial connective tissue.
- Valve involvement results in fibrinoid necrosis and fibrin deposition along the lines of closure (Fig. 10–19, *A*) forming 1- to 2-mm vegetations—**verrucae**—that cause little disturbance in cardiac function.

**Chronic rheumatic heart disease** is characterized by organization of the acute inflammation and subsequent scarring. Aschoff bodies are replaced by fibrous scar so that these lesions are rarely seen in chronic rheumatic heart disease. Most characteristically, valve cusps and leaflets become permanently thickened and retracted. Classically, the mitral valves exhibit **leaflet thickening, commissural fusion and shortening, and thickening and fusion of the chordae tendineae** (Fig. 10–19, *C-E*). Fibrous bridging across the valvular commissures and calcification create "fish-mouth" or "buttonhole" stenoses (Fig. 10–19, *C*). Microscopic examination shows neovascularization (grossly evident in Fig. 10–19, *D*) and diffuse fibrosis that obliterates the normal leaflet architecture.

The most important functional consequence of rheumatic heart disease is **valvular stenosis and regurgitation**; stenosis tends to predominate. The mitral valve alone is involved in 70% of cases, with combined mitral and aortic disease in another 25%; the tricuspid valve usually is less frequently (and less severely) involved; and the pulmonic valve almost always escapes injury. With tight mitral stenosis, the left atrium progressively dilates owing to pressure overload, precipitating atrial fibrillation. The combination of dilation and fibrillation is a fertile substrate for thrombosis, and formation of large mural thrombi is common. Long-standing passive venous congestion gives rise to pulmonary vascular and parenchymal changes typical of left-sided heart failure. In time, this leads to right ventricular hypertrophy and failure. With pure mitral stenosis, the left ventricle generally is normal.

### Clinical Features

Acute rheumatic fever occurs most often in children; the principal clinical manifestation is carditis. Nevertheless, about 20% of first attacks occur in adults, with arthritis being the predominant feature. Symptoms in all age groups typically begin 2 to 3 weeks after streptococcal infection, and are heralded by fever and migratory polyarthritis—one large joint after another becomes painful and swollen for a period of days, followed by spontaneous resolution with no residual disability. Although cultures are negative for streptococci at the time of symptom onset, serum titers

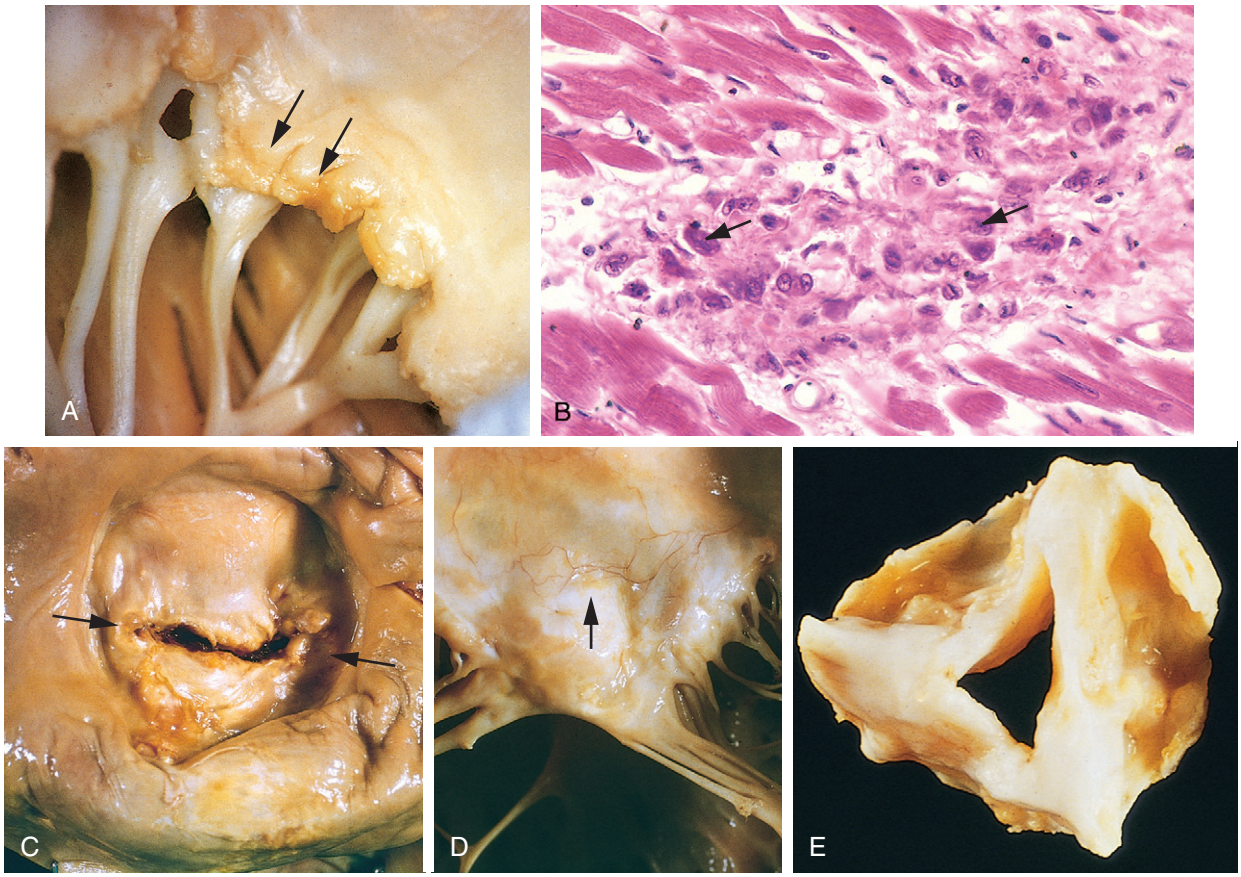


**Figure 10–19** Acute and chronic rheumatic heart disease. **A,** Acute rheumatic mitral valvulitis superimposed on chronic rheumatic heart disease. Small vegetations (verrucae) are visible along the line of closure of the mitral valve leaflet (*arrows*). Previous episodes of rheumatic valvulitis have caused fibrous thickening and fusion of the chordae tendineae. **B,** Microscopic appearance of an Aschoff body in acute rheumatic carditis; there is central necrosis associated with a circumscribed collection of mononuclear inflammatory cells, including some activated macrophages with prominent nucleoli and central wavy (caterpillar) chromatin (*arrows*). **C** and **D,** Mitral stenosis with diffuse fibrous thickening and distortion of the valve leaflets, commissural fusion (*arrows*), and thickening and shortening of the chordae tendineae. There is marked left atrial dilation as seen from above the valve (**C**). **D,** Anterior leaflet of an opened rheumatic mitral valve; note the inflammatory neovascularization (*arrow*). **E,** Surgically removed specimen of rheumatic aortic stenosis, demonstrating thickening and distortion of the cusps with commissural fusion.
*(E, From Schoen FJ, St John-Sutton M: Contemporary issues in the pathology of valvular heart disease. Hum Pathol 18:568, 1967.)*

to one or more streptococcal antigens (e.g., streptolysin O or DNAase) usually are elevated. The clinical signs of carditis include pericardial friction rubs and arrhythmias; myocarditis can be sufficiently aggressive that cardiac dilation ensues, causing functional mitral insufficiency and CHF. Nevertheless, less than 1% of patients die of acute rheumatic fever.

The diagnosis of acute rheumatic fever is made based on serologic evidence of previous streptococcal infection in conjunction with two or more of the so-called *Jones criteria*: (1) carditis; (2) migratory polyarthritis of large joints; (3) subcutaneous nodules; (4) erythema marginatum skin rashes; and (5) Sydenham chorea, a neurologic disorder characterized by involuntary purposeless, rapid movements (also called *St. Vitus dance*). Minor criteria such as fever, arthralgias, ECG changes, or elevated acute phase reactants also can help support the diagnosis.

After an initial attack and the generation of immunologic memory, patients are increasingly vulnerable to disease reactivation with subsequent streptococcal infections. Carditis is likely to worsen with each recurrence, and the damage is cumulative. However, *chronic rheumatic carditis* usually does not manifest itself clinically until years or even decades after the initial episode of rheumatic fever. At that time, the signs and symptoms of valvular disease depend on which cardiac valve(s) are involved. In addition to various cardiac murmurs, cardiac hypertrophy and dilation, and CHF, patients with chronic rheumatic heart disease often have arrhythmias (particularly atrial fibrillation in the setting of mitral stenosis), and thromboembolic complications due to atrial mural thrombi. In addition, scarred and deformed valves are more susceptible to infective endocarditis. The long-term prognosis is highly variable. In some cases, a relentless cycle of valvular deformity ensues, yielding hemodynamic abnormality, which begets further deforming fibrosis. Surgical repair or replacement of diseased valves has greatly improved the outlook for patients with rheumatic heart disease.

## Infective Endocarditis

Infective endocarditis is a serious infection mandating prompt diagnosis and intervention. Microbial invasion of heart valves or mural endocardium—often with

destruction of the underlying cardiac tissues—characteristically results in bulky, friable *vegetations* composed of necrotic debris, thrombus, and organisms. The aorta, aneurysmal sacs, other blood vessels and prosthetic devices also can become infected. Although fungi, rickettsiae (agents of Q fever), and chlamydial species can cause endocarditis, the vast majority of cases are caused by extracellular bacteria.

Infective endocarditis can be classified into *acute* and *subacute* forms, based on the tempo and severity of the clinical course; the distinctions are attributable to the virulence of the responsible microbe and whether underlying cardiac disease is present. Of note, a clear delineation between acute and subacute endocarditis does not always exist, and many cases fall somewhere along the spectrum between the two forms.

- *Acute endocarditis* refers to tumultuous, destructive infections, frequently involving a highly virulent organism attacking a previously normal valve, and capable of causing substantial morbidity and mortality even with appropriate antibiotic therapy and/or surgery.
- *Subacute endocarditis* refers to infections by organisms of low virulence involving a previously abnormal heart, especially scarred or deformed valves. The disease typically appears insidiously and—even untreated—follows a protracted course of weeks to months; most patients recover after appropriate antibiotic therapy.

## PATHOGENESIS

Infective endocarditis can develop on previously normal valves, but cardiac abnormalities predispose to such infections; rheumatic heart disease, mitral valve prolapse, bicuspid aortic valves, and calcific valvular stenosis are all common substrates. Prosthetic heart valves (discussed later) now account for 10% to 20% of all cases of infective endocarditis. Sterile platelet-fibrin deposits at sites of pacemaker lines, indwelling vascular catheters, or damaged endocardium due to jet streams caused by preexisting cardiac disease all can be foci for bacterial seeding with subsequent development of endocarditis. Host factors such as neutropenia, immunodeficiency, malignancy, diabetes mellitus, and alcohol or intravenous drug abuse also increase the risk of infective endocarditis, as well as adversely affecting outcomes.

The causative organisms differ depending on the underlying risk factors. Fifty percent to 60% of cases of endocarditis occurring on damaged or deformed valves are caused by *Streptococcus viridans*, a relatively banal group of normal oral flora. By contrast, the more virulent *S. aureus* (common to skin) can attack deformed **as well as healthy** valves and is responsible for 10% to 20% of cases overall; it also is the major offender in infections occurring in intravenous drug abusers. Additional bacterial agents include enterococci and the so-called HACEK group (*Haemophilus*, *Actinobacillus*, *Cardiobacterium*, *Eikenella*, and *Kingella*), all commensals in the oral cavity. More rarely, gram-negative bacilli and fungi are involved. In about 10% of all cases of endocarditis, no organism is isolated from the blood ("culture-negative" endocarditis) because of previous antibiotic therapy, difficulties in isolating the offending agent, or because deeply embedded organisms within the enlarging vegetation are not released into the blood.

Foremost among the factors predisposing to endocarditis is seeding of the blood with microbes. The mechanism or portal of entry of the agent into the bloodstream may be an obvious infection elsewhere, a dental or surgical procedure that causes a transient bacteremia, injection of contaminated material directly into the bloodstream by intravenous drug users, or an occult source from the gut, oral cavity, or trivial injuries. Recognition of predisposing anatomic substrates and clinical conditions causing bacteremia allows appropriate antibiotic prophylaxis.

## MORPHOLOGY

In both acute and subacute forms of the disease, **friable, bulky, and potentially destructive vegetations** containing fibrin, inflammatory cells, and microorganisms are present on the heart valves (Figs. 10–20 and 10–21). The aortic and mitral valves are the most common sites of infection, although the tricuspid valve is a frequent target in the setting of intravenous drug abuse. Vegetations may be single or multiple and may involve more than one valve; they can sometimes erode into the underlying myocardium to produce an abscess cavity **(ring abscess)** (Fig. 10-21, *B*). Shedding of **emboli** is common because of the friable nature of the vegetations. Since the fragmented vegetations contain large numbers of organisms, abscesses often develop at the sites where emboli lodge, leading to development of **septic infarcts** and **mycotic aneurysms.**

Subacute endocarditis typically elicits less valvular destruction than that associated with acute endocarditis. On microscopic examination, the subacute vegetations of infective endocarditis often have granulation tissue at their bases (suggesting chronicity), promoting development of chronic inflammatory infiltrates, fibrosis, and calcification over time.

### Clinical Features

Fever is the most consistent sign of infective endocarditis. However, in subacute disease (particularly in the elderly), fever may be absent, and the only manifestations may be nonspecific fatigue, weight loss, and a flulike syndrome; splenomegaly also is common in subacute cases. By contrast, acute endocarditis often manifests with a stormy onset including rapidly developing fever, chills, weakness, and lassitude. Murmurs are present in 90% of patients with left-sided lesions; microemboli can give rise to petechia, nail bed (*splinter*) hemorrhages, retinal hemorrhages (*Roth spots*), painless palm or sole erythematous lesions (*Janeway lesions*), or painful fingertip nodules (*Osler nodes*); diagnosis is confirmed by positive blood cultures and echocardiographic findings.

Prognosis depends on the infecting organism and on whether or not complications develop. Complications generally begin within the first weeks after onset of the infectious process and can include glomerulonephritis due to glomerular trapping of antigen-antibody complexes, with hematuria, albuminuria, or renal failure (Chapter 13). A septic pathophysiologic picture, arrhythmias (suggesting

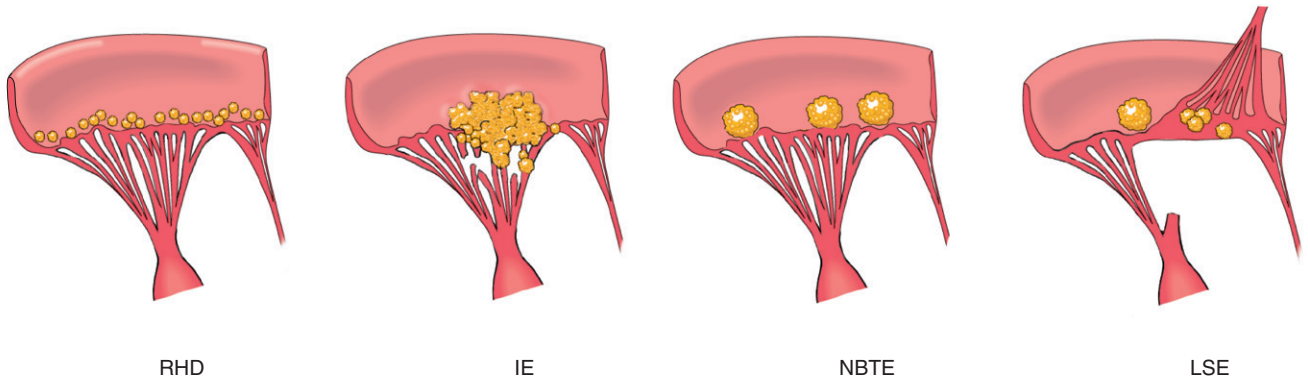


**Figure 10–20** The major forms of vegetative endocarditis. The acute rheumatic fever phase of rheumatic heart disease is marked by the appearance of small, warty, inflammatory vegetations along the lines of valve closure; as the inflammation resolves, substantial scarring can result. Infective endocarditis (IE) is characterized by large, irregular, often destructive masses that can extend from valve leaflets onto adjacent structures (e.g., chordae or myocardium). Nonbacterial thrombotic endocarditis (NBTE) typically manifests with small to medium-sized, bland, nondestructive vegetations at the line of valve closure. Libman-Sacks endocarditis (LSE) is characterized by small to medium-sized inflammatory vegetations that can be attached on either side of valve leaflets; these heal with scarring.

invasion into underlying myocardium), and systemic embolization bode particularly ill for the patient. Left untreated, infective endocarditis generally is fatal. However, with appropriate long-term (6 weeks or more) antibiotic therapy and/or valve replacement, mortality is reduced. For infections involving low-virulence organisms (e.g., *Streptococcus viridans* or *Streptococcus bovis*), the cure rate is 98%, and for enterococci and *Staphylococcus aureus* infections, cure rates range from 60% to 90%; however, with infections due to aerobic gram-negative bacilli or fungi, half of the patients ultimately succumb. The cure rate for endocarditis arising on prosthetic valves is 10% to 15% lower across the board.

## Noninfected Vegetations

### *Nonbacterial Thrombotic Endocarditis*

Nonbacterial thrombotic endocarditis (NBTE) is characterized by the deposition of small (1 to 5 mm in diameter) thrombotic masses composed mainly of fibrin and platelets on cardiac valves. Although NBTE can occur in otherwise healthy persons, a wide variety of diseases associated with general debility or wasting are associated with an increased risk of NBTE—hence the alternate term marantic endocarditis. In contrast with infective endocarditis, the valvular lesions of NBTE are sterile and are nondestructive (Fig. 10–22).

Valvular damage is not a prerequisite for NBTE; indeed, the condition usually is found on *previously normal valves. Rather, hypercoagulable states are the usual precursor to NBTE*; such conditions include chronic disseminated intravascular coagulation, hyperestrogenic states, and those associated with underlying malignancy, particularly mucinous adenocarcinomas. This last association probably relates to the procoagulant effect of circulating mucin and/or tissue factor elaborated by these tumors. Endocardial trauma, such as from an indwelling catheter, also is a well-recognized predisposing condition.

Although the local effect on the valve usually is trivial, NBTE lesions can become clinically significant by giving rise to emboli that can cause infarcts in the brain, heart, and

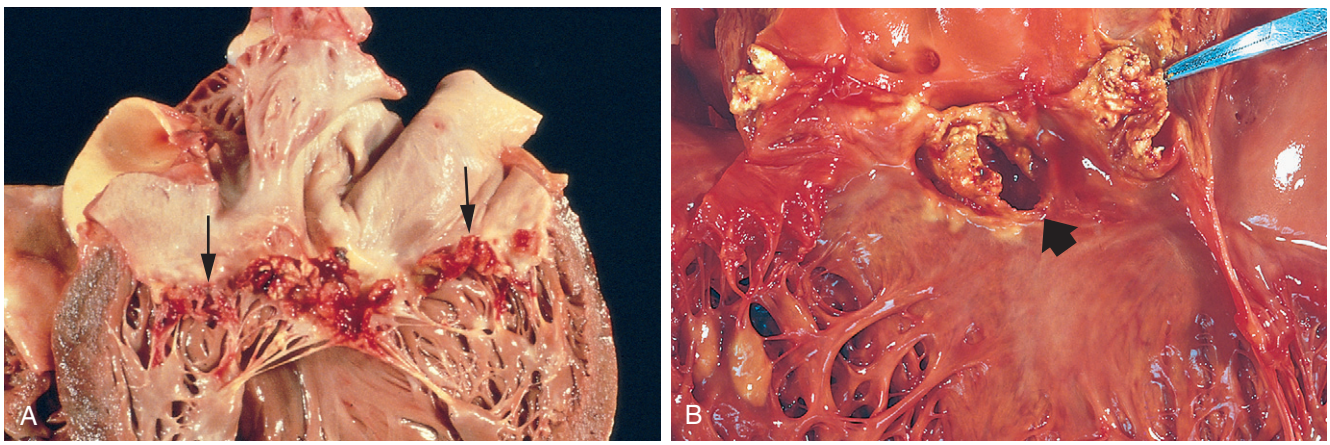


**Figure 10–21** Infective endocarditis. **A,** Subacute endocarditis caused by *Streptococcus viridans* on a previously myxomatous mitral valve. The large, friable vegetations are denoted by *arrows*. **B,** Acute endocarditis caused by *Staphylococcus aureus* on congenitally bicuspid aortic valve with extensive cuspal destruction and ring abscess (*arrow*).

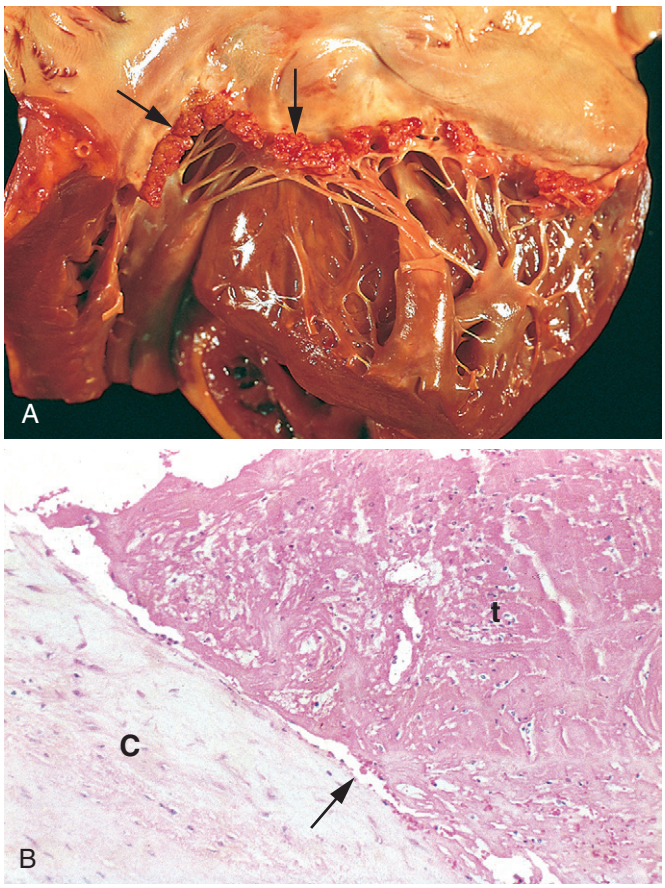


**Figure 10–22** Nonbacterial thrombotic endocarditis (NBTE). **A,** Small thrombotic vegetations along the line of closure of the mitral valve leaflets (*arrows*). **B,** Photomicrograph of NBTE lesion, showing bland thrombus, with virtually no inflammation in the valve cusp (*C*) or the thrombotic deposit (*t*). The thrombus is only loosely attached to the cusp (*arrow*).

other organs. An NBTE lesion also can serve as a potential nidus for bacterial colonization and the consequent development of infective endocarditis.

### *Libman-Sacks Endocarditis*

Libman-Sacks endocarditis is characterized by the presence of sterile vegetations on the valves of patients with systemic lupus erythematosus. The lesions probably develop as a consequence of immune complex deposition and thus exhibit associated inflammation, often with fibrinoid necrosis of the valve substance adjacent to the vegetation; subsequent fibrosis and serious deformity can result in lesions that resemble chronic rheumatic heart disease. These can occur anywhere on the valve surface, on the cords, or even on the atrial or ventricular endocardium (Fig. 10–20). Similar lesions can occur in the setting of *antiphospholipid antibody syndrome* (Chapter 3).

## Carcinoid Heart Disease

The *carcinoid syndrome* results from bioactive compounds such as serotonin released by *carcinoid tumors* (Chapter 14); systemic manifestations include flushing, diarrhea, dermatitis, and bronchoconstriction. *Carcinoid heart disease* refers to the cardiac manifestation caused by the bioactive compounds and occurs in half of the patients in whom the systemic syndrome develops. Cardiac lesions typically do not occur until there is a massive hepatic metastatic burden, since the liver normally catabolizes circulating mediators before they can affect the heart. Classically, endocardium and valves of the right heart are primarily affected since they are the first cardiac tissues bathed by the mediators released by gastrointestinal carcinoid tumors. The left side of the heart is afforded some measure of protection because the pulmonary vascular bed degrades the mediators. However, left-sided heart carcinoid lesions can occur in the setting of atrial or ventricular septal defects and right-to-left flow, or they can arise in association with primary pulmonary carcinoid tumors.

### PATHOGENESIS

The mediators elaborated by carcinoid tumors include serotonin (5-hydroxytryptamine), kallikrein, bradykinin, histamine, prostaglandins, and tachykinins. Although it is not clear which of these is causative, plasma levels of serotonin and urinary excretion of the serotonin metabolite 5-hydroxyindoleacetic acid correlate with the severity of right-sided heart lesions. The valvular plaques in carcinoid syndrome also are similar to lesions that occur with the administration of fenfluramine (an appetite suppressant) or ergot alkaloids (for migraine headaches); of interest, these agents either affect systemic serotonin metabolism or bind to hydroxytryptamine receptors on heart valves.

### MORPHOLOGY

The cardiovascular lesions associated with the carcinoid syndrome are distinctive, glistening white intimal plaquelike thickenings on the endocardial surfaces of the cardiac chambers and valve leaflets (Fig. 10–23). The lesions are composed of smooth muscle cells and sparse collagen fibers embedded in an acid mucopolysaccharide–rich matrix. Underlying structures are intact. With right-sided involvement, typical findings are tricuspid insufficiency and pulmonic stenosis.

## Prosthetic Cardiac Valves

Although prosthetic heart valves are less-than-perfect substitutes for the native tissues, their introduction has radically altered the prognosis for patients with valve disease. Two types of prosthetic valves are currently used, each with its own advantages and disadvantages:

- *Mechanical valves* are now most commonly double tilting disk devices made of pyrolytic carbon. They have excellent durability but require chronic anticoagulation, with the attendant risks of hemorrhage or valve thrombosis, if anticoagulation is inadequate. Mechanical aortic valves can also cause significant red cell hemolysis as a consequence of mechanical shear forces (the so-called Waring blender effect) (Chapter 11).
- *Bioprosthetic valves* are manufactured from glutaraldehyde-fixed porcine or bovine tissues, or cryopreserved human valves. These do not require

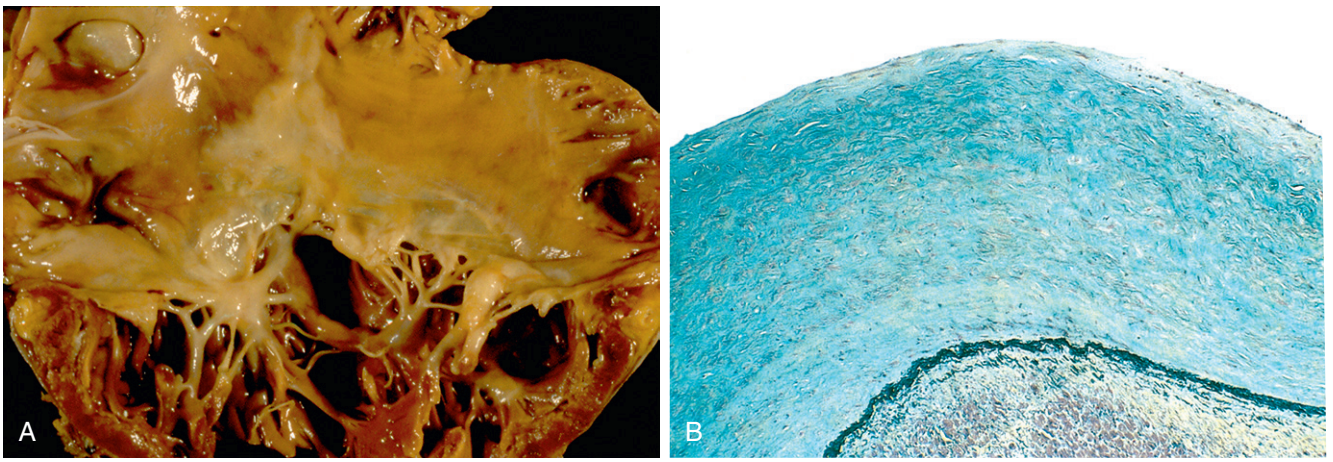


**Figure 10–23** Carcinoid heart disease. **A,** Characteristic endocardial fibrotic lesion "coating" the right ventricle and tricuspid valve, and extending onto the chordae tendineae. **B,** Microscopic appearance of the thickened intima, which contains smooth muscle cells and abundant acid mucopolysaccharides (*blue-green* in this Movat stain, which colors the underlying endocardial elastic tissue *black*).

anticoagulation but are less durable and eventually fail owing to matrix deterioration. Virtually all biologic valve leaflets undergo some degree of stiffening after implantation; the loss of mobility may be sufficient to cause significant stenosis. Calcification of bioprosthetic leaflets is common and can contribute to the stenosis. Bioprosthetic valves also can perforate or tear, resulting in valvular insufficiency.

- All forms of prosthetic valves are susceptible to infection. In mechanical valves, infective endocarditis typically involves the suture line and adjacent perivalvular tissue; the associated tissue changes can cause the valve to detach (*paravalvular leak*). In bioprosthetic valves, the valve leaflets as well as the perivalvular tissues can become infected.

## SUMMARY

### Valvular Heart Disease

- Valve pathology can lead to occlusion (*stenosis*) and/or to regurgitation (*insufficiency*); acquired aortic stenosis and mitral valve stenosis account for approximately two thirds of all valve disease.
- Valve calcification typically results in stenosis; abnormal matrix synthesis and turnover leads to myxomatous degeneration and insufficiency.
- Inflammatory valve diseases cause postinflammatory neovascularization and scarring. Rheumatic heart disease results from antistreptococcal antibodies that cross-react with cardiac tissues; it most commonly affects the mitral valve and is responsible for 99% of cases of acquired mitral stenosis.
- Infective endocarditis can be aggressive and rapidly destroy normal valves (in the acute form), or can be indolent and minimally destructive of previously abnormal valves (in subacute infective endocarditis). Systemic embolization can produce septic infarcts.
- Nonbacterial thrombotic endocarditis occurs on previously normal valves as a result of hypercoagulable states; embolization is an important complication.

## CARDIOMYOPATHIES

Most cardiac muscle diseases are secondary to some other condition, e.g., coronary atherosclerosis, hypertension, or valvular heart disease. However, there are also cardiac diseases attributable to intrinsic myocardial dysfunction. Such diseases are termed *cardiomyopathies* (literally, "heart muscle diseases"); these can be *primary*—that is, principally confined to the myocardium—or *secondary* presenting as the cardiac manifestation of a systemic disorder. Cardiomyopathies are thus a diverse group that includes inflammatory disorders (e.g., myocarditis), immunologic diseases (e.g., sarcoidosis), systemic metabolic disorders (e.g., hemochromatosis), muscular dystrophies, and genetic disorders of myocardial fibers. In many cases, the cardiomyopathy is of unknown etiology and thus is termed *idiopathic*; however, a number of previously "idiopathic" cardiomyopathies have been shown to be the consequence of specific genetic abnormalities in cardiac energy metabolism or in structural and contractile proteins.

Cardiomyopathies can be classified according to a variety of criteria, including the underlying genetic basis of dysfunction; indeed, a number of the arrhythmia-inducing channelopathies that are included in some classifications of cardiomyopathy were alluded to earlier. For purposes of general diagnosis and therapy, however, three time-honored clinical, functional, and pathologic patterns are recognized (Fig. 10–24 and Table 10–6):

- Dilated cardiomyopathy (DCM) (including arrhythmogenic right ventricular cardiomyopathy)
- Hypertrophic cardiomyopathy (HCM)
- Restrictive cardiomyopathy

Another rare form of cardiomyopathy is *left ventricular noncompaction*; it is a congenital disorder characterized by a distinctive "spongy" appearance of the ventricles, associated with CHF and arrhythmias.

Of the three major patterns, DCM is most common (90% of cases), and restrictive cardiomyopathy is the least frequent. Within each pattern, there is a spectrum of clinical severity, and in some cases clinical features overlap among the groups. In addition, each of these patterns can be

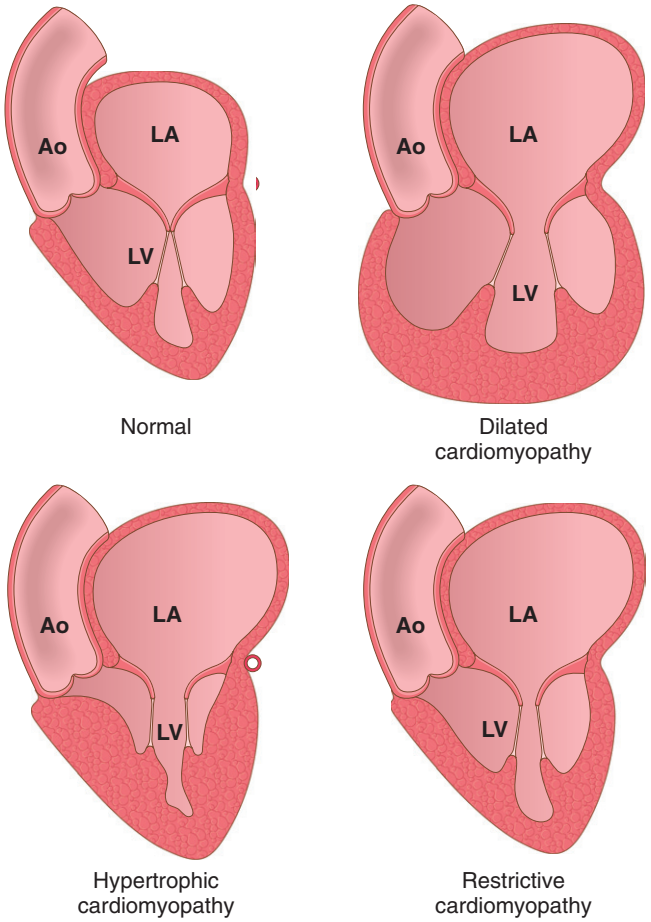


**Figure 10–24** The three major forms of cardiomyopathy. Dilated cardiomyopathy leads primarily to systolic dysfunction, whereas restrictive and hypertrophic cardiomyopathies result in diastolic dysfunction. Note the changes in atrial and/or ventricular dilation and in ventricular wall thickness. Ao, aorta; LA, left atrium; LV, left ventricle.

caused by a specific identifiable cause, or can be idiopathic (Table 10–6).

## Dilated Cardiomyopathy

*Dilated cardiomyopathy* (DCM) is characterized by *progressive cardiac dilation and contractile (systolic) dysfunction,* usually with concurrent hypertrophy; regardless of cause, the clinicopathologic patterns are similar.

### PATHOGENESIS

By the time it is diagnosed, DCM has frequently already progressed to end-stage disease; the heart is dilated and poorly contractile, and at autopsy or cardiac transplant, fails to reveal any specific pathologic features. Nevertheless, genetic and epidemiologic studies suggest that at least five general pathways can lead to end-stage DCM (Fig. 10–25):

- **Genetic causes.** DCM has a hereditary basis in 20% to 50% of cases and over 40 genes are known to be mutated in this form of cardiomyopathy; autosomal dominant inheritance is the predominant pattern, most commonly involving mutations in encoding cytoskeletal proteins, or proteins that link the sarcomere to the cytoskeleton (e.g., α-cardiac actin). X-linked DCM is most frequently associated with **dystrophin** gene mutations affecting the cell membrane protein that physically couples the intracellular cytoskeleton to the ECM; (different types of dystrophin mutations also underlie Duchenne and Becker muscular dystrophies, Chapter 21). Uncommon forms of DCM are caused by mutations of genes in the mitochondrial genome that encode proteins involved in oxidative phosphorylation or fatty acid β-oxidation, presumably leading to defective ATP generation. Other cytoskeletal proteins that are affected in genetic forms of DCM include desmin (the principal intermediate filament protein in cardiac myocytes), and the nuclear lamins A and C. Since contractile myocytes and conduction fibers share a common developmental pathway, congenital conduction abnormalities also can be a feature of inherited forms of DCM.
- **Infection.** The nucleic acid "footprints" of coxsackievirus B and other enteroviruses can occasionally be detected in the myocardium from late-stage DCM patients. Moreover, sequential endomyocardial biopsies have documented instances in which infectious myocarditis progressed to DCM. Consequently, many cases of DCM are attributed to viral infections (discussed later), even though inflammation is absent from the end-stage heart. Simply finding viral transcripts or demonstrating elevated antiviral antibody titers may be sufficient to invoke a myocarditis that was "missed" in its early stages.
- **Alcohol or other toxic exposure.** Alcohol abuse is strongly associated with the development of DCM. Alcohol and its metabolites (especially acetaldehyde) have a direct toxic effect on myocardium. Moreover, chronic alcoholism can be associated with thiamine deficiency, introducing an element of **beriberi** heart disease (Chapter

**Table 10–6** Cardiomyopathies: Functional Patterns, Causes

| Functional Pattern | Left Ventricular Ejection Fraction* | Mechanisms of Heart Failure | Causes | Secondary Myocardial Dysfunction (Mimicking Cardiomyopathy) |
|---|---|---|---|---|
| Dilated | <40% | Impairment of contractility (systolic dysfunction) | Genetic; alcohol; peripartum; myocarditis; hemochromatosis; chronic anemia; doxorubicin (Adriamycin); sarcoidosis; idiopathic | Ischemic heart disease; valvular heart diseases; hypertensive heart disease; congenital heart disease |
| Hypertrophic | 50–80% | Impairment of compliance (diastolic dysfunction) | Genetic; Friedreich ataxia; storage diseases; infants of diabetic mothers | Hypertensive heart disease; aortic stenosis |
| Restrictive | 45–90% | Impairment of compliance (diastolic dysfunction) | Amyloidosis; radiation-induced fibrosis; idiopathic | Pericardial constriction |

*Range of normal values is approximately 50%–65%.

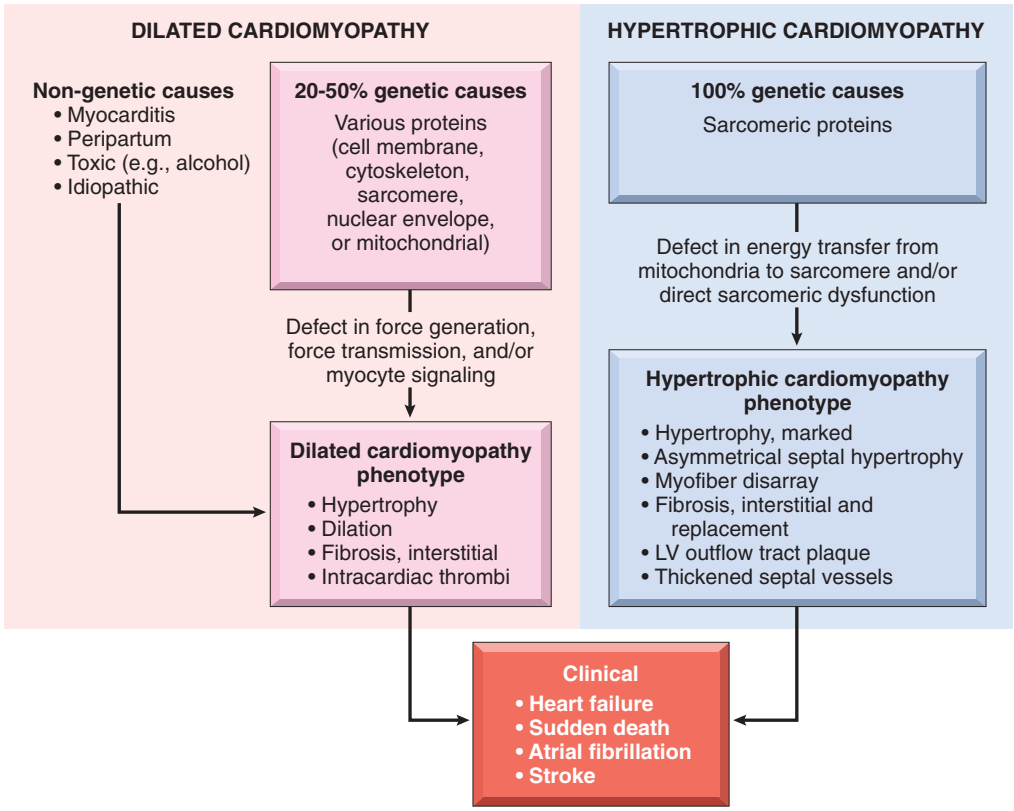


**Figure 10–25** Causes and consequences of dilated and hypertrophic cardiomyopathy. A significant fraction of dilated cardiomyopathies—and virtually all hypertrophic cardiomyopathies—have a genetic origin. Dilated cardiomyopathies can be caused by mutations in cytoskeletal, sarcomeric, nuclear envelope, or mitochondrial proteins; hypertrophic cardiomyopathies typically are caused by sarcomeric protein mutations. Although the two forms of cardiomyopathy differ in cause and morphology, they have common clinical end points. LV, left ventricle.

7). DCM also can develop after exposure to other toxic agents, particularly doxorubicin (Adriamycin), a chemotherapeutic drug, and cobalt.

- **Peripartum cardiomyopathy** occurs late in gestation or several weeks to months postpartum. The etiology is likely to be multifactorial, with contributing factors including pregnancy-associated hypertension, volume overload, nutritional deficiency, metabolic derangements (e.g., gestational diabetes), and/or immunologic responses; recent experiments also suggest that a cleavage product of prolactin (which rises late in pregnancy) can induce myocardial dysfunction. Fortunately, approximately half of these patients spontaneously recover normal function.
- **Iron overload** in the heart can result either from hereditary hemochromatosis (Chapter 15) or from multiple transfusions. DCM is the most common manifestation, and may be attributable to interference with metal-dependent enzyme systems or to injury caused by iron-mediated production of reactive oxygen species.

## MORPHOLOGY

The heart in DCM characteristically is enlarged (up to two to three times the normal weight) and **flabby, with dilation of all chambers** (Fig. 10–26). Because of the wall thinning that accompanies dilation, the ventricular thickness may be less than, equal to, or greater than normal. **Mural thrombi** are often present and may be a source of thromboemboli. By definition, valvular and vascular lesions that can cause cardiac dilation secondarily (e.g., atherosclerotic coronary artery disease) are absent.

**The characteristic histologic abnormalities in DCM are nonspecific, and do not typically point to a specific etiologic entity.** An exception is DCM secondary to iron overload, in which marked accumulation of intramyocardial hemosiderin is demonstrable by staining with Prussian blue.

In general, the severity of morphologic changes in DCM does not necessarily reflect either the degree of dysfunction or the prognosis. Most myocytes exhibit **hypertrophy** with enlarged nuclei, but many are attenuated, stretched, and irregular. There is also variable interstitial and endocardial fibrosis, with scattered areas of replacement fibrosis; the latter mark previous myocyte ischemic necrosis caused by hypoperfusion.

### Clinical Features

DCM can occur at any age but most commonly is diagnosed between the ages of 20 and 50 years. It typically manifests with signs of slowly progressive CHF, including dyspnea, easy fatigability, and poor exertional capacity, although patients can slip precipitously from a compensated to a decompensated state. *The fundamental defect in DCM is ineffective contraction.* Thus, in end-stage DCM, the

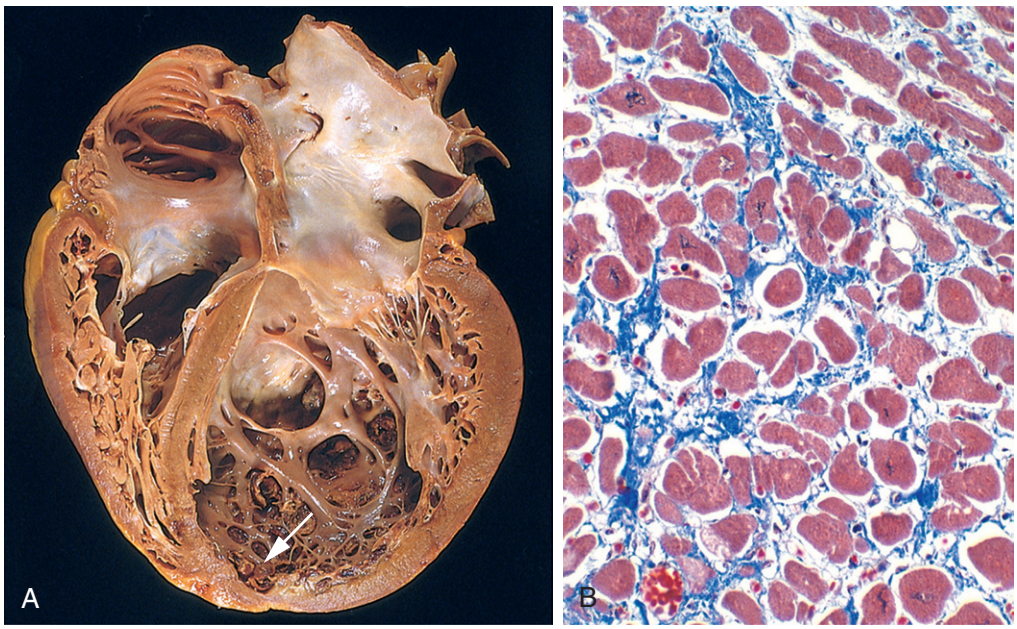


**Figure 10–26** Dilated cardiomyopathy (DCM). **A,** Four-chamber dilation and hypertrophy are evident. A small mural thrombus can be seen at the apex of the left ventricle (*arrow*). **B,** The nonspecific histologic picture in typical DCM, with myocyte hypertrophy and interstitial fibrosis (collagen is blue in this Masson trichrome–stained preparation).

cardiac ejection fraction typically is less than 25% (normal being 50% to 65%). Secondary mitral regurgitation and abnormal cardiac rhythms are common, and embolism from intracardiac (mural) thrombi can occur. Half of the patients die within 2 years, and only 25% survive longer than 5 years; death usually is due to progressive cardiac failure or arrhythmia. Cardiac transplantation is the only definitive treatment. Implantation of long-term ventricular assist devices is being increasingly utilized, however, and in some patients a course of mechanical assistance can produce durable regression of cardiac dysfunction.

### *Arrhythmogenic Right Ventricular Cardiomyopathy*

Arrhythmogenic right ventricular cardiomyopathy (ARVC) is an autosomal dominant disorder of cardiac muscle with variable penetrance; it classically manifests with right-sided heart failure and rhythm disturbances that can cause sudden cardiac death. Morphologically, the right ventricular wall is severely thinned owing to myocyte replacement by massive fatty infiltration and lesser amounts of fibrosis (Fig. 10–27). Many of the mutations involve genes encoding desmosomal junctional proteins at the intercalated disk

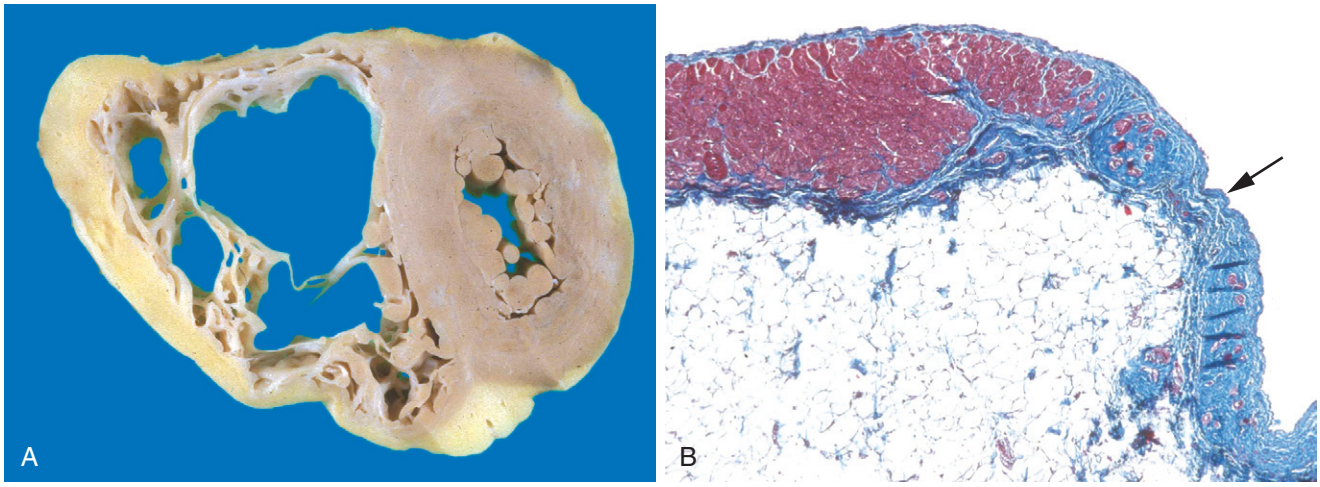


**Figure 10–27** Arrhythmogenic right ventricular cardiomyopathy. **A,** The right ventricle is markedly dilated with focal, almost transmural replacement of the free wall by adipose tissue and fibrosis. The left ventricle has a grossly normal appearance in this heart; it can be involved (albeit to a lesser extent) in some instances. **B,** The right ventricular myocardium *(red)* is focally replaced by fibrous connective tissue (*blue*, *arrow*) and fat (Masson trichrome stain).

(e.g., plakoglobin), as well as proteins that interact with the desmosome (e.g., the intermediate filament desmin).

## Hypertrophic Cardiomyopathy

Hypertrophic cardiomyopathy (HCM) is characterized by *myocardial hypertrophy, defective diastolic filling,* and—in a third of cases—*ventricular outflow obstruction.* The heart is thick-walled, heavy, and hypercontractile, in striking contrast with the flabby, poorly contractile heart in DCM. Systolic function usually is preserved in HCM, but the myocardium does not relax and therefore exhibits primary diastolic dysfunction. HCM needs to be distinguished clinically from disorders causing ventricular stiffness (e.g., amyloid deposition) and ventricular hypertrophy (e.g., aortic stenosis and hypertension).

### PATHOGENESIS

Most cases of HCM are caused by missense mutations in one of several genes encoding proteins that form the contractile apparatus. In most cases, the pattern of transmission is autosomal dominant, with variable expression. Although more than 400 causative mutations in nine different genes have been identified, **HCM is fundamentally a disorder of sarcomeric proteins. Of these, β-myosin heavy chain is most frequently affected,** followed by myosin-binding protein C and troponin T. Mutations in these three genes account for 70% to 80% of all cases of HCM.

The diverse mutations underlying HCM have one unifying feature: they all affect sarcomeric proteins and increase myofilament activation. This results in myocyte hypercontractility with concomitant increase in energy use and net negative energy balance. Some of the genes mutated in HCM are also mutated in DCM (e.g., beta-myosin) but in DCM the (allelic) mutations depress motor function as opposed to gain of function in HCM.

### MORPHOLOGY

HCM is marked by massive myocardial hypertrophy without ventricular dilation (Fig. 10–28, *A*). Classically, there is disproportionate thickening of the ventricular septum relative to the left ventricle free wall (so-called **asymmetric septal hypertrophy**); nevertheless, in about 10% of cases of HCM, concentric hypertrophy is seen. On longitudinal sectioning, the ventricular cavity loses its usual round-to-ovoid shape and is compressed into a "banana-like" configuration. An endocardial plaque in the left ventricular outflow tract and thickening of the anterior mitral leaflet reflect contact of the anterior mitral leaflet with the septum during ventricular systole; these changes correlate with functional left ventricular outflow tract obstruction.

The characteristic histologic features in HCM are marked myocyte hypertrophy, haphazard **myocyte** (and myofiber) **disarray,** and interstitial fibrosis (Fig. 10–28, *B*).

### Clinical Features

Although HCM can present at any age it typically manifests during the postpubertal growth spurt. The clinical symptoms can be best understood in the context of the functional abnormalities. *It is characterized by a massively hypertrophied left ventricle that paradoxically provides a markedly reduced stroke volume.* This condition occurs as a consequence of impaired diastolic filling and overall smaller

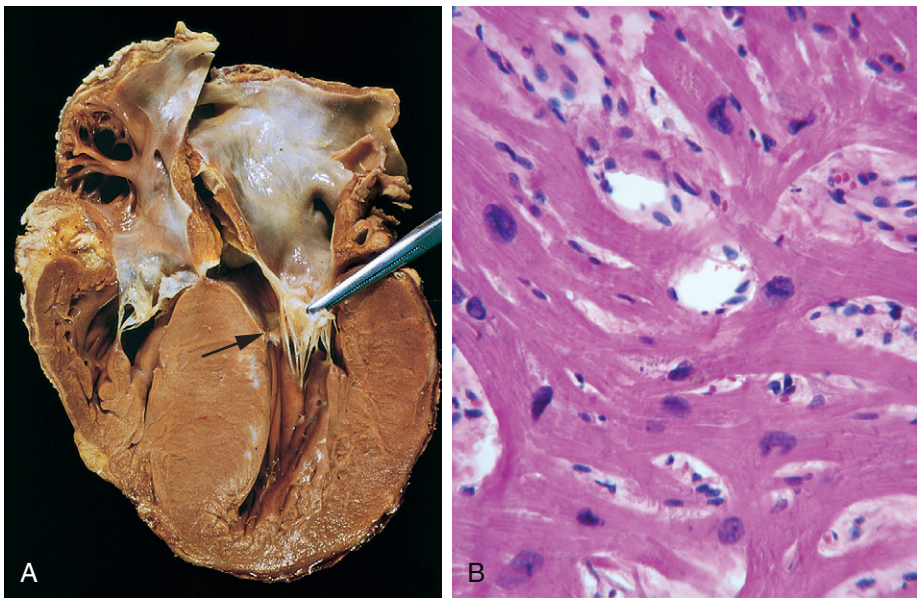


**Figure 10–28** Hypertrophic cardiomyopathy with asymmetric septal hypertrophy. **A,** The septal muscle bulges into the left ventricular outflow tract, giving rise to a "banana-shaped" ventricular lumen, and the left atrium is enlarged. The anterior mitral leaflet has been moved away from the septum to reveal a fibrous endocardial plaque (*arrow*) (see text). **B,** Histologic appearance demonstrating disarray, extreme hypertrophy, and characteristic branching of myocytes, as well as interstitial fibrosis.

chamber size. In addition, roughly 25% of patients have dynamic obstruction to the left ventricular outflow by the anterior leaflet of the mitral valve. Reduced cardiac output and a secondary increase in pulmonary venous pressure cause exertional dyspnea, with a *harsh systolic ejection murmur.* A combination of massive hypertrophy, high left ventricular pressures, and compromised intramural arteries frequently leads to myocardial ischemia (with angina), even in the absence of concomitant CAD. Major clinical problems include atrial and ventricular fibrillations with mural thrombus formation, infective endocarditis of the mitral valve, CHF, and sudden death. Most patients are improved by therapy that promotes ventricular relaxation; partial surgical excision or controlled alcohol-induced infarction of septal muscle also can relieve the outflow tract obstruction. As mentioned earlier, HCM is an important cause of sudden cardiac death. In almost one third of the cases of sudden cardiac death in athletes under the age of 35, the underlying cause is HCM.

## Restrictive Cardiomyopathy

Restrictive cardiomyopathy is characterized by a *primary decrease in ventricular compliance, resulting in impaired ventricular filling during diastole* (simply put, the wall is *stiffer*). Because the contractile (systolic) function of the left ventricle usually is unaffected, the functional state can be confused with constrictive pericarditis or HCM. Restrictive cardiomyopathy can be idiopathic or associated with systemic diseases that also happen to affect the myocardium, for example radiation fibrosis, amyloidosis, sarcoidosis, or products of inborn errors of metabolism.

### MORPHOLOGY

The ventricles are of approximately normal size or only slightly enlarged, the cavities are not dilated, and the myocardium is firm. Biatrial dilation commonly is due to poor ventricular filling and pressure overloads. Microscopic examination reveals variable degrees of interstitial fibrosis. Although gross morphologic findings are similar for restrictive cardiomyopathy of disparate causes, endomyocardial biopsy often can reveal a specific etiologic disorder.

Three forms of restrictive cardiomyopathy merit brief mention:

- *Amyloidosis* is caused by the deposition of extracellular proteins with the predilection for forming insoluble β-pleated sheets (Chapter 4). Cardiac amyloidosis can occur with systemic amyloidosis or can be restricted to the heart, particularly in the case of *senile cardiac amyloidosis.* In the latter instance, deposition of normal (or mutant) forms of transthyretin (a liver-synthesized circulating protein that transports *thy*roxine and *retin*ol) in the hearts of elderly patients results in a restrictive cardiomyopathy. Four percent of African Americans carry a specific mutation of transthyretin that is responsible for a four-fold increased risk of isolated cardiac amyloidosis in that population.
- *Endomyocardial fibrosis* is principally a disease of children and young adults in Africa and other tropical areas; it is characterized by dense diffuse fibrosis of the ventricular endocardium and subendocardium, often involving the tricuspid and mitral valves. The fibrous tissue markedly diminishes the volume and compliance of affected chambers, resulting in a restrictive physiology. Endomyocardial fibrosis has been linked to nutritional deficiencies and/or inflammation related to helminthic infections (e.g., hypereosinophilia); worldwide, it is the most common form of restrictive cardiomyopathy.
- *Loeffler endomyocarditis* also exhibits endocardial fibrosis, typically associated with formation of large mural thrombi, but without geographic predilection. Histologic examination typically shows peripheral hypereosinophilia and eosinophilic tissue infiltrates; release of eosinophil granule contents, especially major basic protein, probably engenders endo- and myocardial necrosis, followed by scarring, layering of the endocardium by thrombus, and finally thrombus organization. Of interest, some patients have an underlying hypereosinophilic myeloproliferative disorder driven by constitutively active platelet derived growth factor receptor (PDGFR) tyrosine kinases (Chapter 11). Treatment of such patients with tyrosine kinase inhibitors can result in hematologic remission and reversal of the endomyocardial lesions.

## Myocarditis

Myocarditis encompasses a diverse group of clinical entities in which *infectious agents and/or inflammatory processes primarily target the myocardium.* It is important to distinguish these conditions from those, such as IHD, in which the inflammatory process is a consequence of some other cause of myocardial injury.

### PATHOGENESIS

In the United States, **viral infections** are the most common cause of myocarditis, with coxsackieviruses A and B and other enteroviruses accounting for a majority of the cases. Cytomegalovirus (CMV), human immunodeficiency virus (HIV), influenza virus, and others are less common pathogens. Offending agents occasionally can be identified by nucleic acid footprints in infected tissues, or by serologic studies showing rising antibody titers. While some viruses cause direct cytolytic injury, in most cases the injury results from an immune response directed against virally infected cells; this is analogous to the damage inflicted by virus-specific T cells on hepatitis virus–infected liver cells (Chapter 15). In some cases viruses trigger a reaction against cross-reacting proteins such as myosin heavy chain.

The **nonviral infectious causes of myocarditis** run the entire gamut of the microbial world. The protozoan *Trypanosoma cruzi* is the agent of Chagas disease. Although uncommon in the northern hemisphere, Chagas disease affects up to half of the population in endemic areas of South America, with myocardial involvement in the vast majority. About 10% of the patients die during an acute attack; others can enter a chronic immune-mediated phase with development of progressive signs of CHF and arrhythmia 10 to 20

years later. *Toxoplasma gondii* (household cats are the most common vector) also can cause myocarditis, particularly in immunocompromised persons. Trichinosis is the most common helminthic disease with associated cardiac involvement.

Myocarditis occurs in approximately 5% of patients with Lyme disease, a systemic illness caused by the bacterial spirochete *Borrelia burgdorferi* (Chapter 8). Lyme myocarditis manifests primarily as self-limited conduction system disease, frequently requiring temporary pacemaker insertion.

**Noninfectious causes of myocarditis** include lesions associated with systemic diseases of immune origin, such as systemic lupus erythematosus and polymyositis. Drug hypersensitivity reactions **(hypersensitivity myocarditis)** also can occur with exposure to any of a wide range of agents; such reactions typically are benign and only in rare circumstances lead to CHF or sudden death.

## MORPHOLOGY

In acute myocarditis, the heart may appear normal or dilated; in advanced stages, the myocardium typically is flabby and often mottled with pale and hemorrhagic areas. Mural thrombi can be present.

Microscopically, active myocarditis is characterized by edema, interstitial inflammatory infiltrates, and myocyte injury (Fig. 10–29). A diffuse lymphocytic infiltrate is most common (Fig. 10–29, *A*), although the inflammatory involvement is often patchy and can be "missed" on endomyocardial biopsy. If the patient survives the acute phase of myocarditis, lesions can resolve without significant sequelae or heal by progressive fibrosis.

In **hypersensitivity myocarditis**, interstitial and perivascular infiltrates are composed of lymphocytes, macrophages, and a high proportion of eosinophils (Fig. 10-29, *B*). **Giant cell myocarditis** is a morphologically distinctive entity characterized by widespread inflammatory cellular infiltrates containing multinucleate giant cells (formed by macrophage fusion). Giant cell myocarditis probably represents the aggressive end of the spectrum of lymphocytic myocarditis, and there is at least focal—and frequently extensive—necrosis (Fig. 10-29, *C*). This variant carries a poor prognosis.

**Chagas myocarditis** is characterized by the parasitization of scattered myofibers by trypanosomes accompanied by an inflammatory infiltrate of neutrophils, lymphocytes, macrophages, and occasional eosinophils (Fig. 10-29, *D*).

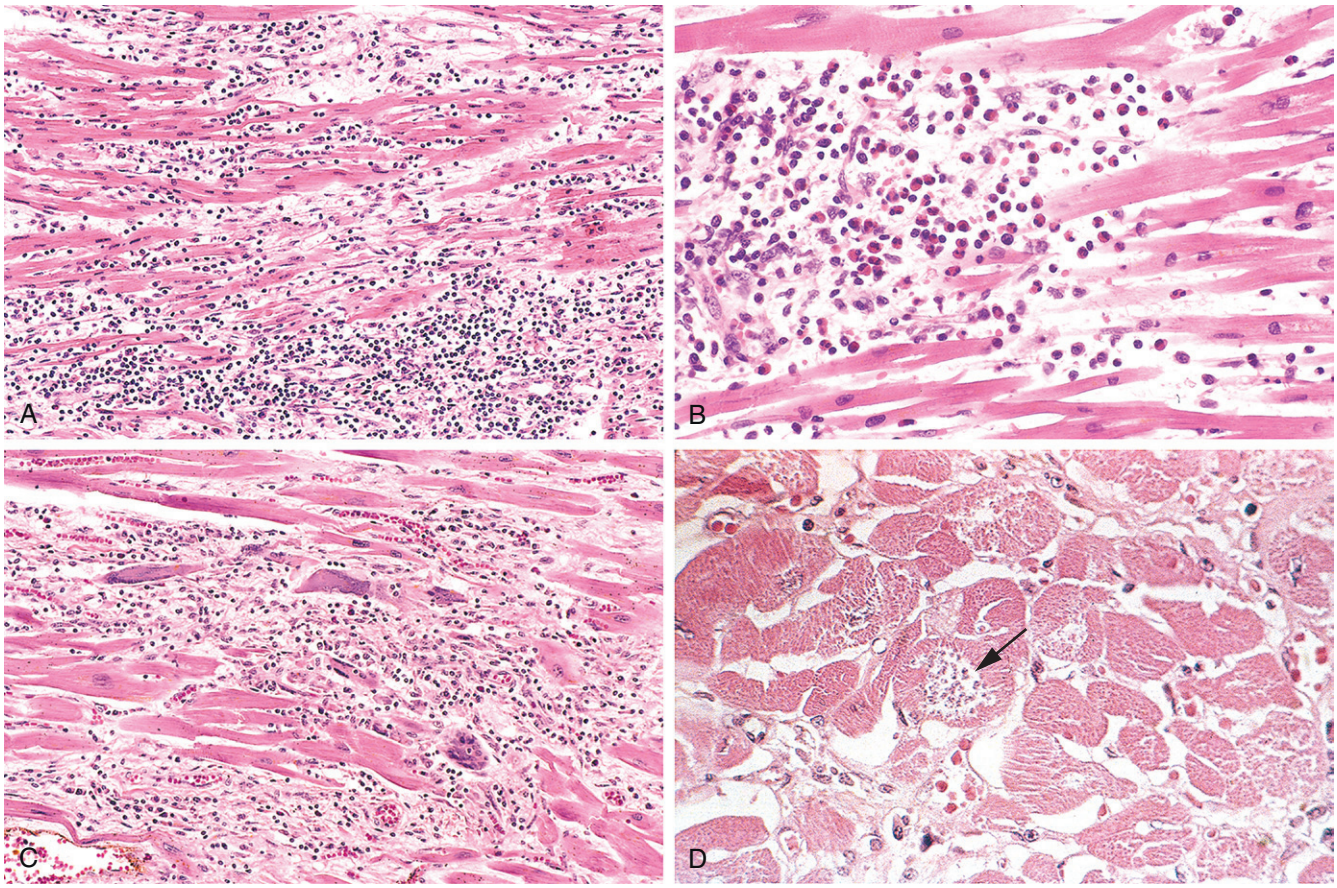


**Figure 10–29** Myocarditis. **A,** Lymphocytic myocarditis, with edema and associated myocyte injury. **B,** Hypersensitivity myocarditis, characterized by perivascular eosinophil-rich inflammatory infiltrates. **C,** Giant cell myocarditis, with lymphocyte and macrophage infiltrates, extensive myocyte damage, and multinucleate giant cells. **D,** Chagas myocarditis. A myofiber distended with trypanosomes (*arrow*) is present, along with mononuclear inflammation and myofiber necrosis.

### Clinical Features

The clinical spectrum of myocarditis is broad; at one end, the disease is asymptomatic, and patients recover without sequelae. At the other extreme is the precipitous onset of heart failure or arrhythmias, occasionally with sudden death. Between these extremes are many levels of involvement associated with a variety of signs and symptoms, including fatigue, dyspnea, palpitations, pain, and fever. The clinical features of myocarditis can mimic those of acute MI. Clinical progression from myocarditis to DCM occasionally is seen.

## SUMMARY

### Cardiomyopathy

- Cardiomyopathy is intrinsic cardiac muscle disease; there may be specific causes, or it may be idiopathic.
- The three general pathophysiologic categories of cardiomyopathy are dilated (accounting for 90% of the cases), hypertrophic, and restrictive (least common).
- DCM results in systolic (contractile) dysfunction. Causes include myocarditis, toxic exposures (e.g., alcohol), and pregnancy. In 20% to 50% of cases, mutations affecting cytoskeletal proteins are responsible.
- HCM results in diastolic (relaxation) dysfunction. Virtually all cases are due to autosomal dominant mutations in the proteins that make up the contractile apparatus, in particular β-myosin heavy chain.
- Restrictive cardiomyopathy results in a stiff, noncompliant myocardium and can be due to depositions (e.g., amyloid), increased interstitial fibrosis (e.g., due to radiation), or to endomyocardial scarring.
- Myocarditis is myocardial damage caused by inflammatory infiltrates secondary to infections or immune reactions. Coxsackieviruses A and B are the most common pathogens in the United States. Clinically, myocarditis can be asymptomatic, give rise to acute heart failure, or evolve to DCM.

# PERICARDIAL DISEASE

Pericardial disorders include effusions and inflammatory conditions, sometimes resulting in fibrous constriction. Isolated pericardial disease is unusual, and pericardial lesions typically are associated with a pathologic process elsewhere in the heart or surrounding structures or are secondary to a systemic disorder.

## Pericarditis

*Primary pericarditis* is uncommon. It most often is due to viral infection (typically with concurrent myocarditis), although bacteria, fungi, or parasites may also be involved. In most cases, pericarditis is secondary to acute MI, cardiac surgery, radiation to the mediastinum, or processes involving other thoracic structures (e.g., pneumonia or pleuritis). *Uremia* is the most common systemic disorder associated with pericarditis. Less common secondary causes include rheumatic fever, systemic lupus erythematosus, and metastatic malignancies. Pericarditis can (1) cause immediate hemodynamic complications if it elicits a large effusion (resulting in cardiac *tamponade*) (see further on), (2) resolve without significant sequelae, or (3) progress to a chronic fibrosing process.

## MORPHOLOGY

In patients with **acute viral pericarditis** or **uremia,** the exudate typically is **fibrinous,** imparting an irregular, shaggy appearance to the pericardial surface (so-called "bread and butter" pericarditis). In **acute bacterial pericarditis,** the exudate is **fibrinopurulent** (suppurative), often with areas of frank pus (Fig. 10–30); tuberculous pericarditis can exhibit areas of caseation. Pericarditis due to malignancy often is associated with an exuberant, shaggy fibrinous exudate and a bloody effusion; metastases can be grossly evident as irregular excrescences or may be grossly inapparent, especially in the case of leukemia. In most cases, acute fibrinous or fibrinopurulent pericarditis resolves without any sequelae. With extensive suppuration or caseation, however, healing can result in fibrosis **(chronic pericarditis).**

**Chronic pericarditis** may be associated with delicate adhesions or dense, fibrotic scars that obliterate the pericardial space. In extreme cases, the heart is so completely encased by dense fibrosis that it cannot expand normally during diastole—resulting in the condition known as **constrictive pericarditis.**

### Clinical Features

Pericarditis classically manifests with atypical chest pain (not related to exertion and worse in recumbency), and a prominent friction rub. When associated with significant

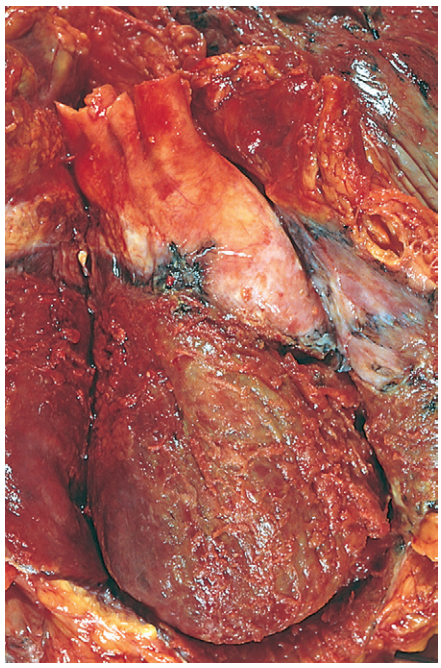

**Figure 10–30** Acute suppurative (purulent, exudative) pericarditis, caused by extension from a pneumonia.

fluid accumulation, acute pericarditis can cause cardiac *tamponade,* with declining cardiac output and consequent shock. Chronic constrictive pericarditis produces a combination of right-sided venous distention and low cardiac output, similar to the clinical picture in restrictive cardiomyopathy.

### Pericardial Effusions

Normally, the pericardial sac contains at most 30 to 50 mL of clear, serous fluid. Serous and/or fibrinous effusions in excess of this amount occur most commonly in the setting of pericardial inflammation. Other types of pericardial effusions and their causes include

- *Serous*: congestive heart failure, hypoalbuminemia of any cause
- *Serosanguineous*: blunt chest trauma, malignancy, ruptured MI or aortic dissection
- *Chylous*: mediastinal lymphatic obstruction

The consequences of pericardial accumulations depend on the volume of fluid and the ability of the parietal pericardium to stretch; the latter depends largely on how fast the effusion accumulates. Thus, slowly accumulating effusions—even as large as 1000 mL—can be well-tolerated. By contrast, rapidly developing collections of as little as 250 mL (e.g., ruptured MI or ruptured aortic dissection) can so restrict diastolic cardiac filling as to produce potentially fatal cardiac tamponade.

## CARDIAC TUMORS

### Metastatic Neoplasms

*Tumor metastases constitute the most common malignancy of the heart;* metastatic cardiac lesions occur in about 5% of patients dying of cancer. Although any malignancy can secondarily involve the heart, certain tumors have a higher predilection for cardiac metastases. In descending order these are lung cancer, lymphoma, breast cancer, leukemia, melanoma, hepatocellular carcinoma, and colon cancer.

#### *Primary Neoplasms*

*Primary cardiac tumors are uncommon*; moreover, most also are (fortunately) benign. The five most common have no malignant potential and account for 80% to 90% of all primary heart tumors. In descending order of frequency, these are myxomas, fibromas, lipomas, papillary fibroelastomas, and rhabdomyomas. Angiosarcomas constitute the most common primary *malignant* tumor of the heart. Only the myxomas and rhabdomyomas merit further mention here.

*Myxomas* are the most common primary tumors of the adult heart (Fig. 10–31). Roughly 90% are atrial, with the left atrium accounting for 80% of those.

*Rhabdomyomas* are the most frequent primary tumors of the heart in infants and children; they frequently are discovered owing to valvular or outflow obstruction. Cardiac rhabdomyomas occur with high frequency in patients with tuberous sclerosis caused by mutations in the *TSC1* or *TSC2* tumor suppressor genes; loss of TSC-1 and -2 activity leads to myocyte overgrowth. Because they often regress spontaneously, rhabdomyomas are best considered to be hamartomas rather than true neoplasms. Like certain other tumors that appear in very young children (e.g., neuroblastoma), rhabdomyomas often regress spontaneously for unknown reasons.

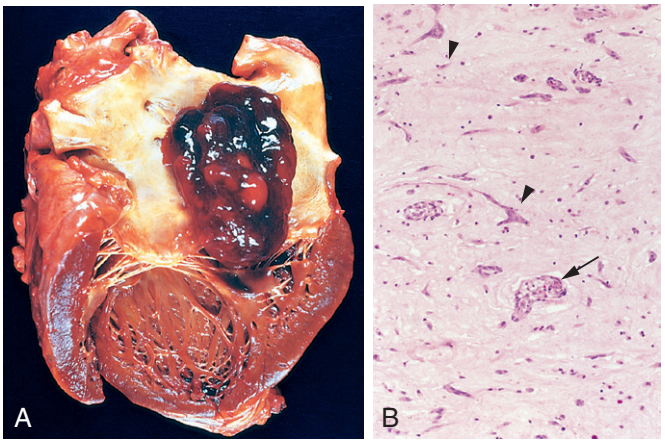


**Figure 10–31** Atrial myxoma. **A,** A large pedunculated lesion arises from the region of the fossa ovalis and extends into the mitral valve orifice. **B,** Abundant amorphous extracellular matrix contains scattered multinucleate myxoma cells (*arrowheads*) in various groupings, including abnormal vascular formations (*arrow*).

#### MORPHOLOGY

Myxomas are almost always single, classically arising in the region of the fossa ovalis (atrial septum). They can be small (less than 1 cm in diameter) to massive (up to 10 cm across), sessile or pedunculated masses (Fig. 10–31, *A*), most often manifesting as soft, translucent, villous lesions with a gelatinous appearance. Pedunculated forms often are sufficiently mobile to swing into the mitral or tricuspid valve during systole, causing intermittent obstruction or exerting a "wrecking ball" effect that damages the valve leaflets.

Histologically, myxomas are composed of stellate, frequently multinucleated myxoma cells (typically with hyperchromatic nuclei), admixed with cells showing endothelial, smooth muscle, and/or fibroblastic differentiation (undifferentiated cells also are present); all of the cell types arise from differentiation of multipotential mesenchymal tumor cells. The cells are embedded in an abundant acid mucopolysaccharide ground substance (Fig. 10–31, *B*). Hemorrhage, poorly organizing thrombus, and mononuclear inflammation also are usually present.

Rhabdomyomas are gray-white masses up to several centimeters in diameter that protrude into the ventricular chambers. Histologic examination shows a mixed population of cells; most characteristic, however, are large, rounded, or polygonal cells containing numerous glycogen-laden vacuoles separated by strands of cytoplasm running from the plasma membrane to the centrally located nucleus, so-called spider cells.

Clinical Features

The major clinical manifestations are due to valvular "ball-valve" obstruction, embolization, or a syndrome of constitutional signs and symptoms including fever and malaise. This syndrome is attributable to tumor elaboration of the cytokine interleukin-6, a major mediator of the acute-phase response. Echocardiography is the diagnostic modality of choice, and surgical resection is almost uniformly curative.

### *Other Cardiac Tumors*

- *Lipomas* are localized, poorly encapsulated masses of adipose tissue; these can be asymptomatic, create ball-valve obstructions (as with myxomas), or produce arrhythmias.
- *Papillary fibroelastomas* usually are only incidentally identified lesions, although they can embolize. Generally located on valves, they form distinctive clusters (up to 1 cm in diameter) of hairlike projections that grossly resemble sea anemones. Histologic examination shows myxoid connective tissue containing abundant mucopolysaccharide matrix and laminated elastic fibers, all surrounded by endothelium.
- *Cardiac angiosarcomas* and other sarcomas are not clinically or morphologically distinctive from their counterparts in other locations and therefore merit no additional comment here.

## CARDIAC TRANSPLANTATION

Although permanent ventricular assist device implantation is increasingly an option for management of end-stage heart disease, cardiac transplantation remains the treatment of choice for patients with intractable heart failure. Without transplantation, medically managed end-stage heart failure carries a 50% 1-year mortality rate, and less than 10% of the patients survive 5 years. Roughly 3000 heart transplantation procedures are performed annually worldwide, mostly for DCM and IHD. Even so, the need far outstrips the number of available organs, and *many* more patients die while on a waiting list (estimated at 50,000 per year) than undergo successful transplantation.

Beyond the issues of supply and demand, the major complications of cardiac transplantation are acute cardiac rejection and allograft arteriopathy (Fig. 10–32). The immunosuppression required for allograft survival also increases the risk of opportunistic infections and certain malignancies (e.g., Epstein-Barr virus–associated lymphoma).

- *Rejection* is suspected clinically in the setting of fever, reduced cardiac ejection fraction, unexplained arrhythmia, or an edematous, thickened ventricular wall on cardiac ultrasound examination. It is diagnosed by endomyocardial biopsy of the transplanted heart. Rejection is characterized by an interstitial lymphocytic inflammation, associated myocyte damage (Fig. 10–32, *A*), and a histologic pattern similar to that seen in viral myocarditis (Fig. 10–29, *A*). In both instances, T cell–mediated killing and local cytokine production compromise cardiac function. Increasingly, antibody-mediated injury also is recognized as an important mechanism in allograft rejection. When myocardial injury is not extensive, the "rejection episode" can be reversed by augmented immunosuppressive therapy. Advanced rejection can be irreversible and fatal.
- *Allograft arteriopathy* is the single most important long-term limitation for cardiac transplantation. It is a condition of late, progressive, diffusely stenosing intimal proliferation in the coronary arteries (Fig. 10–32, *B*), leading to ischemic injury. Within 5 years of transplantation, significant arteriopathy has developed in 50% of patients, and virtually all patients have lesions within 10 years. The pathogenesis of this disorder involves immunologic responses that induce local production of growth factors, which in turn promote intimal smooth muscle cell recruitment and proliferation with ECM synthesis. Allograft arteriopathy is a particularly vexing problem because it can lead to silent MI (transplant recipients have denervated hearts and do not experience angina), progressive CHF, or sudden death.

Despite these problems, the outlook for transplant recipients generally is good, with a 1-year survival rate of 80% and a 5-year survival rate more than 60%.

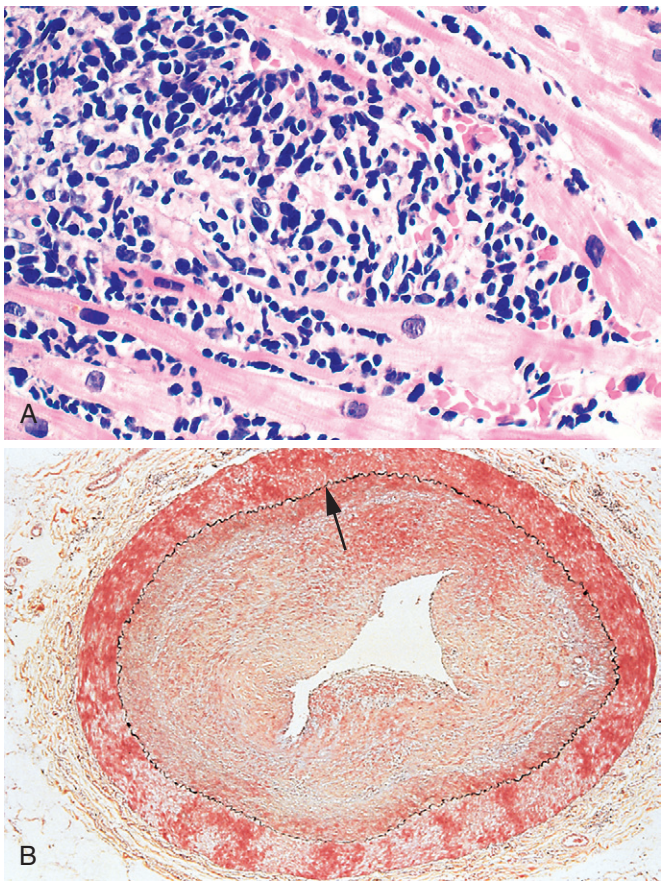


**Figure 10–32** Rejection of cardiac allografts. **A,** Acute cardiac allograft rejection, typified by a lymphocyte infiltrate associated with cardiac myocyte damage. Note the similarity of rejection and viral myocarditis (Fig. 10–29, *A*). **B,** Allograft arteriopathy, with severe concentric intimal thickening producing critical stenosis. The internal elastic lamina (*arrow*) and media are intact. (Movat pentachrome stain.)

*(B, Reproduced by permission from Salomon RN, Hughes CC, Schoen FJ, et al: Human coronary transplantation-associated arteriosclerosis. Evidence for chronic immune reaction to activated graft endothelial cells. Am J Pathol 138:791, 1991.)*

## BIBLIOGRAPHY


Azaouagh A, Churzidse S, Konorza T, Erbel R: Arrhythmogenic right ventricular cardiomyopathy/dysplasia: a review and update. Clin Res Cardiol 100:383, 2011. *[Excellent up-to-date look at this entity and its genetic causes.]*

Bhattacharyya S, Davar J, Dreyfus G, Caplin ME: Carcinoid heart disease. Circulation 116:2860, 2007. *[Good review of the pathophysiology, diagnosis, and treatment of this entity.]*

Brickner ME, Hillis LD, Lange RA: Congenital heart disease in adults. N Engl J Med 342:256, 334, 2000. *[A nice two-part review of congenital cardiac malformations; despite the date, this is still a useful and highly accessible summary of the various conditions.]*

Cannon RO 3rd: Mechanisms, management and future directions for reperfusion injury after acute myocardial infarction. Nat Clin Pract Cardiovasc Med 2:88, 2005. *[Great review of the mechanisms and therapeutic approaches to limiting reperfusion injury after MI.]*

Cerrone M, Priori SG: Genetics of sudden death: focus on inherited channelopathies. Eur Heart J 32:2109, 2011. *[Up-to-date, well-organized description of the known ion channel disorders that cause sudden cardiac death.]*

Cooper LT Jr: Myocarditis. N Engl J Med 360:1526, 2009. *[A nice review of etiology, pathogenesis, and clinical features.]*

Guilherme L, Köhler KF, Kalil J: Rheumatic heart disease: mediation by complex immune events. Adv Clin Chem 53:31, 2011. *[A well-written and scholarly discussion of the pathogenic mechanisms regarding rheumatic heart disease.]*

Hill EE, Herijgers P, Herregods MC, Peetermans WE: Evolving trends in infective endocarditis. Clin Microbiol Infect 12:5, 2006. *[Good, clinically oriented overview of the developments in microorganisms, diagnosis, and therapies for infective endocarditis.]*

Huang JB, Liu YL, Sun PW, et al: Molecular mechanisms of congenital heart disease. Cardiovasc Pathol 19:e183, 2010. *[Comprehensive review of the genes and pathways underlying congenital heart disease.]*

Li C, Xu S, Gotlieb AI: The response to valve injury. A paradigm to understand the pathogenesis of heart valve disease. Cardiovasc Pathol 20:183, 2011. *[Nice overview of pathologic concepts in valvular disease.]*

Libby P, Theroux P: Pathophysiology of coronary artery disease. Circulation 111:3481, 2005. *[A well-written review of the pathways, as well as the diagnostic and therapeutic implications of atherosclerotic coronary disease.]*

MacGrogan D, Nus M, de la Pompa JL: Notch signaling in cardiac development and disease. Curr Top Dev Biol 92:333, 2010. *[A scholarly review of the role of Notch in cardiac development.]*

Mitchell RN: Graft vascular disease: immune response meets the vessel wall. Annu Rev Pathol 4:19, 2009. *[Comprehensive overview of allograft arteriopathy, including animal models, pathogenic mechanisms, clinical diagnosis, and therapy.]*

New SE, Aikawa E: Molecular imaging insights into early inflammatory stages of arterial and aortic valve calcification. Circ Res 108:1381, 2011. *[A good overview of the mechanisms leading to degenerative calcification on valves and vessels.]*

Ovize M, Baxter GF, Di Lisa F, et al: Postconditioning and protection from reperfusion injury: where do we stand? Position paper from the Working Group of Cellular Biology of the Heart of the European Society of Cardiology. Cardiovasc Res 87:406, 2010. *[A good overview of the mechanisms and potential therapeutic interventions for ischemia-reperfusion injury and for ischemic pre-conditioning in limiting infarct size.]*

Rasmussen TL, Raveendran G, Zhang J, Garry DJ: Getting to the heart of myocardial stem cells and cell therapy. Circulation 123:1771, 2011. *[A well-written overview of the challenges and current state of the art regarding stem cell therapies in heart disease.]*

Seidman CE, Seidman JG: Identifying sarcomere gene mutations in hypertrophic cardiomyopathy: a personal history. Circ Res 108:743, 2011. *[A well-written and authoritative overview of the genetics and pathophysiology of hypertrophic cardiomyopathy from one of the leading groups in the world.]*

Sliwa K, Hilfiker-Kleiner D, Petrie MC, et al: Current state of knowledge on aetiology, diagnosis, management, and therapy of peripartum cardiomyopathy: a position statement from the Heart Failure Association of the European Society of Cardiology Working Group on peripartum cardiomyopathy. Eur J Heart Fail 12:767, 2010. *[A definitive overview and position paper.]*

Watkins H, Houman A, Redwood C: Inherited cardiomyopathies. N Engl J Med 364:1643, 2011. *[An excellent review of the molecular basis of cardiomyopathies.]*

Wu JC, Child JS: Common congenital heart disorders in adults. Curr Probl Cardiol 29:641, 2004. *[Exhaustively thorough overview of the congenital heart disorders seen in the adult population, often as a consequence of improved pediatric therapies.]*

Zipes DP, Libby P, Bonow RO, Braunwald E (eds): Braunwald's Heart Disease: A Textbook of Cardiovascular Medicine, 9th ed. Philadelphia, Saunders, 2011. *[An outstanding and authoritative text, with excellent sections on heart failure and atherosclerotic cardiovascular disease.]*

See Targeted Therapy available online at studentconsult.com

CHAPTER 11

# Hematopoietic and Lymphoid Systems

CHAPTER CONTENTS


**RED CELL DISORDERS 408**
Anemia of Blood Loss: Hemorrhage 409
Hemolytic Anemias 409
Hereditary Spherocytosis 410
Sickle Cell Anemia 411
Thalassemia 413
Glucose-6-Phosphate Dehydrogenase Deficiency 416
Paroxysmal Nocturnal Hemoglobinuria 417
Immunohemolytic Anemias 417
Hemolytic Anemias Resulting from Mechanical Trauma to Red Cells 418
Malaria 418
Anemias of Diminished Erythropoiesis 419
Iron Deficiency Anemia 420
Anemia of Chronic Disease 421
Megaloblastic Anemias 422
Aplastic Anemia 424
Myelophthisic Anemia 424
Polycythemia 425
**WHITE CELL DISORDERS 425**
Non-Neoplastic Disorders of White Cells 425
Leukopenia 425
Reactive Leukocytosis 426
Reactive Lymphadenitis 427
Neoplastic Proliferations of White Cells 428
Lymphoid Neoplasms 429
Myeloid Neoplasms 444
Histiocytic Neoplasms 449
**BLEEDING DISORDERS 449**
Disseminated Intravascular Coagulation 450
Thrombocytopenia 452
Immune Thrombocytopenic Purpura 452
Heparin-Induced Thrombocytopenia 453
Thrombotic Microangiopathies: Thrombotic Thrombocytopenic Purpura and Hemolytic Uremic Syndrome 453
Coagulation Disorders 454
Deficiencies of Factor VIII–von Willebrand Factor Complex 454
**DISORDERS THAT AFFECT THE SPLEEN AND THYMUS 456**
Splenomegaly 456
Disorders of the Thymus 456
Thymic Hyperplasia 457
Thymoma 457


The hematopoietic and lymphoid systems are affected by a wide spectrum of diseases. One way to organize these disorders is based on whether they primarily affect red cells, white cells, or the hemostatic system, which includes platelets and clotting factors. The most common *red cell disorders* are those that lead to *anemia,* a state of red cell deficiency. *White cell disorders,* by contrast, are most often associated with excessive proliferation, as a result of malignant transformation. Hemostatic derangements may result in *hemorrhagic diatheses* (bleeding disorders). Finally, splenomegaly, a feature of numerous diseases, is discussed at the end of the chapter, as are tumors of the thymus.

Although these divisions are useful, in reality the production, function, and destruction of red cells, white cells, and components of the hemostatic system are closely linked, and pathogenic derangements primarily affecting one cell type or component of the system often lead to alterations in others. For example, in certain conditions B cells make autoantibodies against components of the red cell membrane. The opsonized red cells are recognized and destroyed by phagocytes in the spleen, which becomes enlarged. The increased red cell destruction causes anemia, which in turn drives a compensatory hyperplasia of red cell progenitors in the bone marrow.

Other levels of interplay and complexity stem from the anatomically dispersed nature of the hematolymphoid system, and the capacity of both normal and malignant white cells to "traffic" between various compartments. Hence, a patient who is diagnosed with lymphoma by lymph node biopsy also may be found to have neoplastic lymphocytes in their bone marrow and blood. The malignant lymphoid cells in the marrow may suppress hematopoiesis, giving rise to low blood cell counts (cytopenias), and the further seeding of tumor cells to the liver and spleen may lead to organomegaly. Thus, in both benign and malignant hematolymphoid disorders, a single underlying abnormality can result in diverse systemic manifestations. Keeping these complexities in mind, we will use the time-honored classification of hematolymphoid disorders based on predominant involvement of red cells, white cells, and the hemostatic system.

# RED CELL DISORDERS

Disorders of red cells can result in anemia or, less commonly, polycythemia (an increase in red cells also known as erythrocytosis). *Anemia* is defined as a reduction in the oxygen-transporting capacity of blood, which usually stems from a decrease in the red cell mass to subnormal levels.

*Anemia can result from bleeding, increased red cell destruction, or decreased red cell production.* These mechanisms serve as one basis for classifying anemias (Table 11–1). In some entities overlap occurs, for example, in thalassemia where reduced red cell production and early destruction give rise to anemia. With the exception of anemias caused by chronic renal failure or chronic inflammation (described later), the decrease in tissue oxygen tension that accompanies anemia triggers increased production of the growth factor erythropoietin from specialized cells in the kidney. This in turn drives a compensatory hyperplasia of erythroid precursors in the bone marrow and, in severe anemias, the appearance of extramedullary hematopoiesis within the secondary hematopoietic organs (the liver, spleen, and lymph nodes). In well-nourished persons who become anemic because of acute bleeding or increased red cell destruction (hemolysis) the compensatory response can increase the production of red cells five- to eight-fold. The rise in marrow output is signaled by the appearance of increased numbers of newly formed red cells (reticulocytes) in the peripheral blood. By contrast, anemias caused by decreased red cell production (aregenerative anemias) are associated with subnormal reticulocyte counts (reticulocytopenia).

**Table 11–1** Classification of Anemia According to Underlying Mechanism

| |
|---|
| **Blood Loss** |
| Acute: trauma |
| Chronic: gastrointestinal tract lesions, gynecologic disturbances |
| **Increased Destruction (Hemolytic Anemias)** |
| Intrinsic (Intracorpuscular) Abnormalities |
| *Hereditary* |
| Membrane abnormalities |
| Membrane skeleton proteins: spherocytosis, elliptocytosis |
| Membrane lipids: abetalipoproteinemia |
| Enzyme deficiencies |
| Enzymes of hexose monophosphate shunt: glucose-6-phosphate dehydrogenase, glutathione synthetase |
| Glycolytic enzymes: pyruvate kinase, hexokinase |
| Disorders of hemoglobin synthesis |
| Structurally abnormal globin synthesis (hemoglobinopathies): sickle cell anemia, unstable hemoglobins |
| Deficient globin synthesis: thalassemia syndromes |
| *Acquired* |
| Membrane defect: paroxysmal nocturnal hemoglobinuria |
| Extrinsic (Extracorpuscular) Abnormalities |
| Antibody-mediated |
| Isohemagglutinins: transfusion reactions, immune hydrops (Rh disease of the newborn) |
| Autoantibodies: idiopathic (primary), drug-associated, systemic lupus erythematosus |
| Mechanical trauma to red cells |
| Microangiopathic hemolytic anemias: thrombotic thrombocytopenic purpura, disseminated intravascular coagulation |
| Defective cardiac valves |
| Infections: malaria |
| **Impaired Red Cell Production** |
| Disturbed proliferation and differentiation of stem cells: aplastic anemia, pure red cell aplasia |
| Disturbed proliferation and maturation of erythroblasts |
| Defective DNA synthesis: deficiency or impaired utilization of vitamin $B_{12}$ and folic acid (megaloblastic anemias) |
| Anemia of renal failure (erythropoietin deficiency) |
| Anemia of chronic disease (iron sequestration, relative erythropoietin deficiency) |
| Anemia of endocrine disorders |
| Defective hemoglobin synthesis |
| Deficient heme synthesis: iron deficiency, sideroblastic anemias |
| Deficient globin synthesis: thalassemias |
| Marrow replacement: primary hematopoietic neoplasms (acute leukemia, myelodysplastic syndromes) |
| Marrow infiltration (myelophthisic anemia): metastatic neoplasms, granulomatous disease |

Anemias also can be classified on the basis of red cell morphology, which often points to particular causes. Specific features that provide etiologic clues include the size, color and shape of the red cells. These features are judged subjectively by visual inspection of peripheral smears and also are expressed quantitatively using the following indices:

- *Mean cell volume* (MCV): the average volume per red cell, expressed in femtoliters (cubic microns)
- *Mean cell hemoglobin* (MCH): the average mass of hemoglobin per red cell, expressed in picograms
- *Mean cell hemoglobin concentration* (MCHC): the average concentration of hemoglobin in a given volume of packed red cells, expressed in grams per deciliter
- *Red cell distribution width* (RDW): the coefficient of variation of red cell volume

Red cell indices are directly measured or automatically calculated by specialized instruments in clinical laboratories. The same instruments also determine the reticulocyte count, a simple measure that distinguishes between hemolytic and aregenerative anemias. Adult reference ranges for these tests are shown in Table 11–2. Depending on the differential diagnosis, a number of other blood tests also may be performed to evaluate anemia, including (1) *iron indices* (serum iron, serum iron-binding capacity, transferrin saturation, and serum ferritin concentrations), which help distinguish among anemias caused by iron deficiency, chronic disease, and thalassemia; (2) *plasma unconjugated bilirubin, haptoglobin, and lactate dehydrogenase levels,* which are abnormal in hemolytic anemias; (3) *serum and red cell folate and vitamin $B_{12}$ concentrations,* which are low in megaloblastic anemias; (4) *hemoglobin electrophoresis,* which is used to detect abnormal hemoglobins; and (5) the *Coombs test,* which is used to detect antibodies or complement on red cells in suspected cases of immunohemolytic anemia. In isolated anemia, tests performed on the peripheral blood usually suffice to establish the cause. By contrast, when anemia occurs along with thrombocytopenia and/or granulocytopenia, it is much more likely to be associated with marrow aplasia or infiltration; in such instances, a marrow examination usually is warranted.

As discussed later, the clinical consequences of anemia are determined by its severity, rapidity of onset, and underlying pathogenic mechanism. If the onset is slow,

**Table 11–2** Adult Reference Ranges for Red Blood Cells*

| | Units | Men | Women |
|---|---|---|---|
| Hemoglobin (Hb) | g/dL | 13.2–16.7 | 11.9–15.0 |
| Hematocrit (Hct) | % | 38–48 | 35–44 |
| Red cell count | $\times 10^6/\mu L$ | 4.2–5.6 | 3.8–5.0 |
| Reticulocyte count | % | 0.5–1.5 | 0.5–1.5 |
| Mean cell volume (MCV) | fL | 81–97 | 81–97 |
| Mean cell Hb (MCH) | pg | 28–34 | 28–34 |
| Mean cell Hb concentration (MCHC) | g/dL | 33–35 | 33–35 |
| Red cell distribution width (RDW) | | 11.5–14.8 | |

*Reference ranges vary among laboratories. The reference ranges for the laboratory providing the result should always be used in interpreting a laboratory test.

the deficit in $O_2$-carrying capacity is partially compensated for by adaptations such as increases in plasma volume, cardiac output, respiratory rate, and levels of red cell 2,3-diphosphoglycerate, a glycolytic pathway intermediate that enhances the release of $O_2$ from hemoglobin. These changes mitigate the effects of mild to moderate anemia in otherwise healthy persons but are less effective in those with compromised pulmonary or cardiac function. *Pallor, fatigue, and lassitude* are common to all forms of anemia. Anemias caused by the premature destruction of red cells (*hemolytic anemias*) are associated with *hyperbilirubinemia, jaundice, and pigment gallstones,* all related to increases in the turnover of hemoglobin. Anemias that stem from *ineffective hematopoiesis* (the premature death of erythroid progenitors in the marrow) are associated with inappropriate increases in iron absorption from the gut, which can lead to iron overload (*secondary hemochromatosis*) with consequent damage to endocrine organs and the heart. If left untreated, *severe congenital anemias* such as β-thalassemia major inevitably result in *growth retardation, skeletal abnormalities, and cachexia.*

## SUMMARY

### Pathology of Anemias

**Causes**
- Blood loss (hemorrhage)
- Increased red cell destruction (hemolysis)
- Decreased red cell production

**Morphology**
- Microcytic (iron deficiency, thalassemia)
- Macrocytic (folate or vitamin $B_{12}$ deficiency)
- Normocytic but with abnormal shapes (hereditary spherocytosis, sickle cell disease)

**Clinical Manifestations**
- *Acute*: shortness of breath, organ failure, shock
- *Chronic*
  - Pallor, fatigue, lassitude
  - With hemolysis: jaundice and gallstones
  - With ineffective erythropoiesis: iron overload, heart and endocrine failure
  - If severe and congenital: growth retardation, bone deformities due to reactive marrow hyperplasia

## ANEMIA OF BLOOD LOSS: HEMORRHAGE

With acute blood loss exceeding 20% of blood volume, the immediate threat is hypovolemic shock rather than anemia. If the patient survives, hemodilution begins at once and achieves its full effect within 2 to 3 days; only then is the full extent of the red cell loss revealed. *The anemia is normocytic and normochromic.* Recovery from blood loss anemia is enhanced by a compensatory rise in the erythropoietin level, which stimulates increased red cell production and reticulocytosis within a period of 5 to 7 days.

With chronic blood loss, iron stores are gradually depleted. Iron is essential for hemoglobin synthesis and erythropoiesis, and its deficiency leads to a chronic anemia of underproduction. Iron deficiency anemia can occur in other clinical settings as well; it is described later along with other anemias caused by decreased red cell production.

## HEMOLYTIC ANEMIAS

Normal red cells have a life span of about 120 days. Anemias caused by accelerated red cell destruction are termed *hemolytic anemias.* Destruction can stem from either intrinsic (intracorpuscular) red cell defects, which are usually inherited, or extrinsic (extracorpuscular) factors, which are usually acquired. Examples of each type of hemolytic anemia are listed in Table 11–1.

Features shared by all uncomplicated hemolytic anemias include (1) a decreased red cell life span, (2) a compensatory increase in erythropoiesis, and (3) the retention of the products of degraded red cells (including iron) by the body. Because the recovered iron is efficiently recycled, red cell regeneration may almost keep pace with the hemolysis. Consequently, *hemolytic anemias are associated with erythroid hyperplasia in the marrow and increased numbers of reticulocytes in the peripheral blood.* In severe hemolytic anemias, extramedullary hematopoiesis may appear in the liver, spleen, and lymph nodes.

Destruction of red cells can occur within the vascular compartment (*intravascular hemolysis*) or within tissue macrophages (*extravascular hemolysis*). Intravascular hemolysis can result from mechanical forces (e.g., turbulence created by a defective heart valve) or biochemical or physical agents that damage the red cell membrane (e.g., fixation of complement, exposure to clostridial toxins, or heat). Regardless of cause, intravascular hemolysis leads to hemoglobinemia, hemoglobinuria, and hemosiderinuria. The conversion of heme to bilirubin can result in unconjugated hyperbilirubinemia and jaundice. Massive intravascular hemolysis sometimes leads to acute tubular necrosis (Chapter 13). *Haptoglobin,* a circulating protein that binds and clears free hemoglobin, is completely depleted from the plasma, which also usually contains high levels of *lactate dehydrogenase* (LDH) as a consequence of its release from hemolyzed red cells.

*Extravascular hemolysis,* the more common mode of red cell destruction, primarily takes place within the spleen and liver. These organs contain large numbers of macrophages, the principal cells responsible for the removal of damaged or immunologically targeted red cells from the

circulation. Because extreme alterations of shape are necessary for red cells to navigate the splenic sinusoids, any reduction in red cell deformability makes this passage difficult and leads to splenic sequestration and phagocytosis. As described later in the chapter, diminished deformability is a major cause of red cell destruction in several hemolytic anemias. Extravascular hemolysis is not associated with hemoglobinemia and hemoglobinuria, but often produces jaundice and, if long-standing, leads to the formation of bilirubin-rich gallstones (pigment stones). *Haptoglobin* is decreased, as some hemoglobin invariably escapes from macrophages into the plasma, and LDH levels also are elevated. In most forms of chronic extravascular hemolysis there is a reactive hyperplasia of mononuclear phagocytes that results in splenomegaly.

We now turn to some of the common hemolytic anemias.

## Hereditary Spherocytosis

This disorder stems from inherited (intrinsic) defects in the red cell membrane that lead to the formation of spherocytes, nondeformable cells that are highly vulnerable to sequestration and destruction in the spleen. Hereditary spherocytosis is usually transmitted as an autosomal dominant trait; a more severe, autosomal recessive form of the disease affects a small minority of patients.

### PATHOGENESIS

Hereditary spherocytosis is caused by **abnormalities in the membrane skeleton,** a network of proteins that underlies lipid bilayer of the red cell (Fig. 11–1). The major membrane skeleton protein is spectrin, a long, flexible heterodimer that self-associates at one end and binds short actin filaments at its other end. These contacts create a two-dimensional meshwork that is linked to the overlying membrane through ankyrin and band 4.2 to the intrinsic membrane protein called band 3, and through band 4.1 to glycophorin.

The mutations in hereditary spherocytosis most frequently involve ankyrin, band 3, and spectrin, but mutations in other components of the skeleton have also been described.

**A shared feature of the pathogenic mutations is that they weaken the vertical interactions between the membrane skeleton and the intrinsic membrane proteins.** This defect somehow destabilizes the lipid bilayer of the red cells, which shed membrane vesicles into the circulation as they age. Little cytoplasm is lost in the process and as a result the surface area to volume ratio decreases progressively over time until the cells become spherical (Fig. 11–1).

The spleen plays a major role in the destruction of spherocytes. Red cells must undergo extreme degrees of deformation to pass through the splenic cords. The floppy discoid shape of normal red cells allows considerable latitude for shape changes. By contrast, spherocytes have limited deformability and are sequestered in the splenic cords, where they are destroyed by the plentiful resident macrophages. **The critical role of the spleen is illustrated by the beneficial effect of splenectomy; although the red cell defect and spherocytes persist, the anemia is corrected.**

### MORPHOLOGY

On smears, **spherocytes are dark red and lack central pallor** (Fig. 11–2). The excessive red cell destruction and resultant anemia lead to a compensatory hyperplasia of red cell progenitors in the marrow and an increase in red cell production marked by reticulocytosis. **Splenomegaly** is more common and prominent in hereditary spherocytosis than in any other form of hemolytic anemia. The splenic weight usually is between 500 and 1000 g. The enlargement results from marked congestion of the splenic cords and increased numbers of tissue macrophages. Phagocytosed red cells are seen within macrophages lining the sinusoids and, in particular, within the cords. In long-standing cases there is prominent systemic hemosiderosis. The other general features of hemolytic anemias also are present, including **cholelithiasis,** which occurs in 40% to 50% of patients with hereditary spherocytosis.

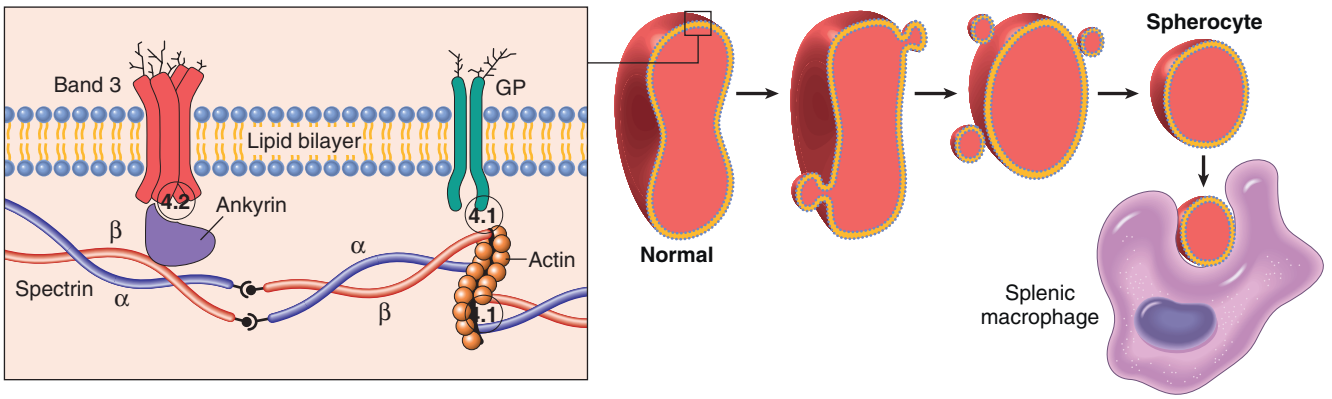


**Figure 11–1** Pathogenesis of hereditary spherocytosis. **Left panel,** Normal organization of the major red cell membrane skeleton proteins. Mutations in α-spectrin, β-spectrin, ankyrin, band 4.2, and band 3 that weaken the association of the membrane skeleton with the overlying plasma membrane cause red cells to shed membrane vesicles and transform into spherocytes (*right panel*). The nondeformable spherocytes are trapped in the splenic cords and phagocytosed by macrophages. GP, glycophorin.

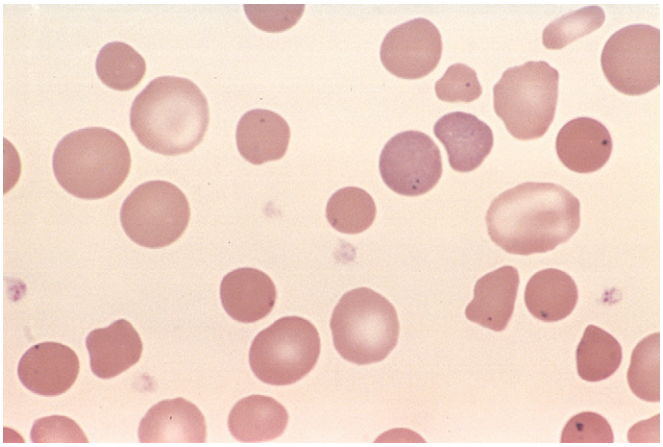

**Figure 11–2** Hereditary spherocytosis—peripheral blood smear. Note the anisocytosis and several hyperchromic spherocytes. Howell-Jolly bodies (small nuclear remnants) are also present in the red cells of this asplenic patient.

*(Courtesy of Dr. Robert W. McKenna, Department of Pathology, University of Texas Southwestern Medical School, Dallas, Texas.)*

### Clinical Features

The characteristic clinical features are *anemia, splenomegaly, and jaundice.* The anemia is highly variable in severity, ranging from subclinical to profound; most commonly it is of moderate degree. Because of their spherical shape, red cells in hereditary spherocytosis have *increased osmotic fragility* when placed in hypotonic salt solutions, a characteristic that can help establish the diagnosis.

The clinical course often is stable but may be punctuated by *aplastic crises.* The most severe crises are triggered by parvovirus B19, which infects and destroys erythroblasts in the bone marrow. Because red cells in hereditary spherocytosis have a shortened life span, a lack of red cell production for even a few days results in a rapid worsening of the anemia. Such episodes are self-limited, but some patients need supportive blood transfusions during the period of red cell aplasia.

There is no specific treatment for hereditary spherocytosis. *Splenectomy* provides relief for symptomatic patients by removing the major site of red cell destruction. The benefits of splenectomy must be weighed against the risk of increased susceptibility to infections, particularly in children. Partial splenectomy is gaining favor, because this approach may produce hematologic improvement while maintaining protection against sepsis.

## Sickle Cell Anemia

The hemoglobinopathies are a group of hereditary disorders caused by inherited mutations that lead to structural abnormalities in hemoglobin. Sickle cell anemia, the prototypical (and most prevalent) hemoglobinopathy, stems from a mutation in the β-globin gene that creates sickle hemoglobin (HbS). Other hemoglobinopathies are infrequent and beyond the scope of this discussion.

Normal hemoglobins are tetramers composed of two pairs of similar chains. On average, the normal adult red cell contains 96% HbA (α2β2), 3% HbA2 (α2δ2), and 1% fetal Hb (HbF, α2γ2). *HbS is produced by the substitution of valine for glutamic acid at the sixth amino acid residue of β-globin.* In homozygotes, all HbA is replaced by HbS, whereas in heterozygotes, only about half is replaced.

### Incidence

*Sickle cell anemia is the most common familial hemolytic anemia in the world.* In parts of Africa where malaria is endemic, the gene frequency approaches 30% as a result of a small but significant protective effect of HbS against *Plasmodium falciparum* malaria. In the United States, approximately 8% of blacks are heterozygous for HbS, and about 1 in 600 have sickle cell anemia.

### PATHOGENESIS

On deoxygenation, HbS molecules form long polymers by means of intermolecular contacts that involve the abnormal valine residue at position 6. These polymers distort the red cell, which assumes an elongated crescentic, or sickle, shape (Fig. 11–3). The sickling of red cells initially is reversible upon reoxygenation. However, the distortion of the membrane that is produced by each sickling episode leads to an influx of calcium, which causes the loss of potassium and water and also damages the membrane skeleton. Over time, this cumulative damage creates **irreversibly sickled cells,** which are rapidly hemolyzed.

Many variables influence the sickling of red cells in vivo. The three most important factors are

- **The presence of hemoglobins other than HbS.** In heterozygotes approximately 40% of Hb is HbS and the remainder is HbA, which interacts only weakly with deoxygenated HbS. Because the presence of HbA greatly retards the polymerization of HbS, the red cells of heterozygotes have little tendency to sickle in vivo. Such persons are said to have **sickle cell trait.** HbC, another mutant β-globin, has a lysine residue instead of the normal glutamic acid residue at position 6. About 2.3% of American blacks are heterozygous carriers of HbC; as a result, about 1 in 1250 newborns are compound heterozygotes for HbC and HbS. Because HbC has a greater tendency to aggregate with HbS than does HbA, HbS/HbC compound heterozygotes have a symptomatic sickling disorder called **HbSC disease.** HbF interacts weakly with HbS, so newborns with sickle cell anemia do not manifest the disease until HbF falls to adult levels, generally around the age of 5 to 6 months.
- **The intracellular concentration of HbS.** The polymerization of deoxygenated HbS is strongly concentration-dependent. Thus, red cell dehydration, which increases the Hb concentration, facilitates sickling. Conversely, the coexistence of α-thalassemia (described later), which decreases the Hb concentration, reduces sickling. The relatively low concentration of HbS also contributes to the absence of sickling in heterozygotes with sickle cell trait.
- **The transit time for red cells through the microvasculature.** The normal transit times of red cells through capillaries are too short for significant polymerization of deoxygenated HbS to occur. Hence, sickling in microvascular beds is confined to areas of the body in which blood flow is sluggish. This is the normal situation

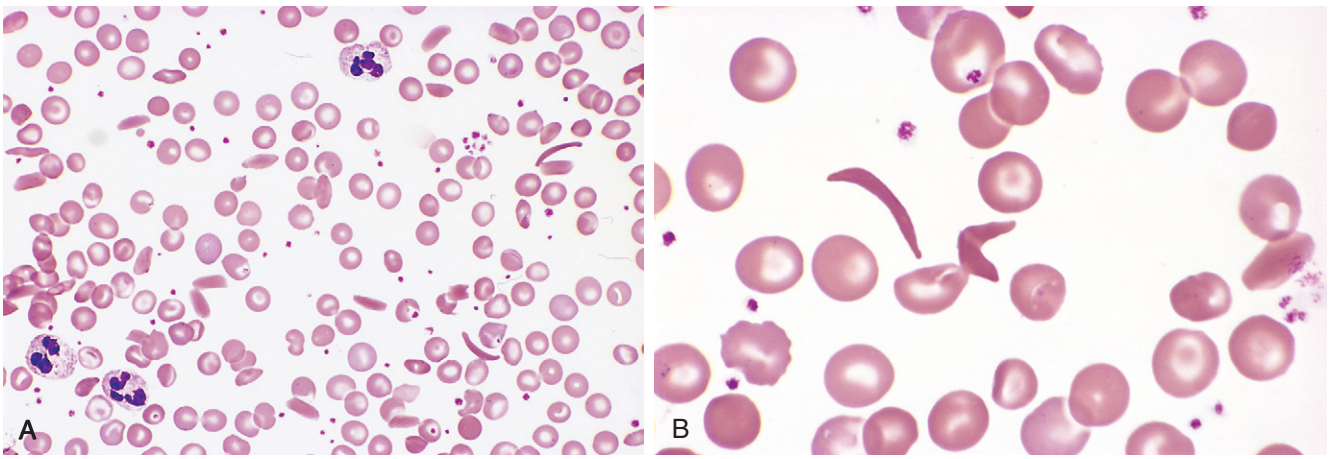


**Figure 11–3** Sickle cell anemia—peripheral blood smear. **A,** Low magnification shows sickle cells, anisocytosis, poikilocytosis, and target cells. **B,** Higher magnification shows an irreversibly sickled cell in the center.
*(Courtesy of Dr. Robert W. McKenna, Department of Pathology, University of Texas Southwestern Medical School, Dallas, Texas.)*

in the spleen and the bone marrow, two tissues prominently affected by sickle cell disease. Sickling also can be triggered in other microvascular beds by acquired factors that retard the passage of red cells. As described previously, inflammation slows the flow of blood by increasing the adhesion of leukocytes and red cells to endothelium and by inducing the exudation of fluid through leaky vessels. In addition, sickle red cells have a greater tendency than normal red cells to adhere to endothelial cells, apparently because repeated bouts of sickling causes membrane damage that make them sticky. These factors conspire to prolong the transit times of sickle red cells, increasing the probability of clinically significant sickling.

**Two major consequences arise from the sickling of red cells** (Fig. 11–4). First, the red cell membrane damage and dehydration caused by repeated episodes of sickling produce a **chronic hemolytic anemia.** The mean life span of red cells in sickle cell anemia is only 20 days (one sixth of normal). Second, red cell sickling produces widespread **microvascular obstructions,** which result in ischemic tissue damage and pain crises. Vaso-occlusion does not correlate with the number of irreversibly sickled cells and therefore appears to result from factors such as infection, inflammation, dehydration, and acidosis that enhance the sickling of reversibly sickled cells.

## MORPHOLOGY

The anatomic alterations in sickle cell anemia stem from (1) the severe chronic hemolytic anemia, (2) the increased breakdown of heme to bilirubin, and (3) microvascular obstructions, which provoke tissue ischemia and infarction. In peripheral smears, elongated, spindled, or boat-shaped irreversibly sickled red cells are evident (Fig. 11–3). Both the anemia and the vascular stasis lead to hypoxia-induced fatty changes in the heart, liver, and renal tubules. There is a compensatory hyperplasia of erythroid progenitors in the marrow. The cellular proliferation in the marrow often causes bone resorption and secondary new bone formation, resulting in prominent cheekbones and changes in the skull resembling a "crewcut" in radiographs. Extramedullary hematopoiesis may appear in the liver and spleen.

In children there is moderate **splenomegaly** (splenic weight up to 500 g) due to red pulp congestion caused by entrapment of sickled red cells. However, the chronic splenic erythrostasis produces hypoxic damage and infarcts, which over time reduce the spleen to a useless nubbin of fibrous

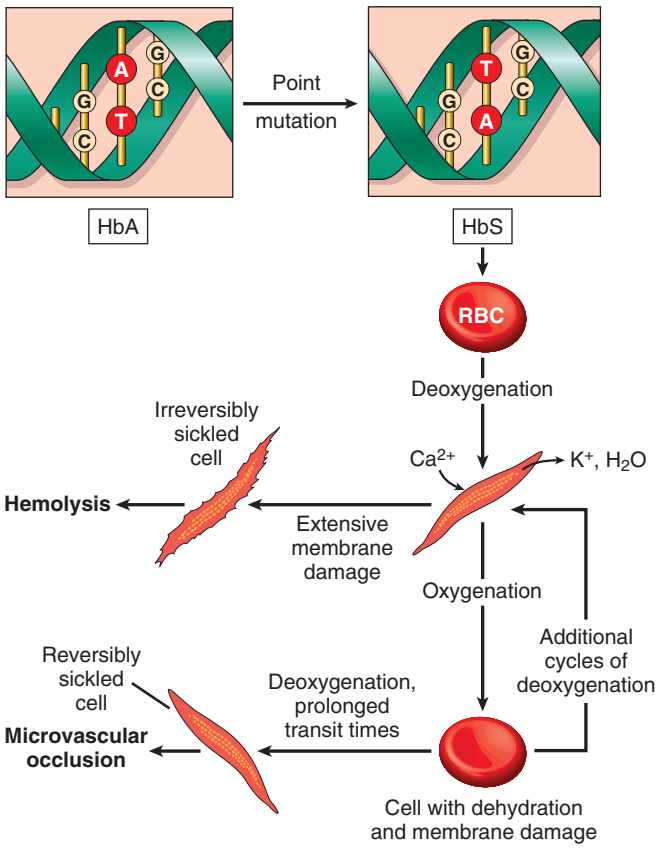


**Figure 11–4** Pathophysiology of sickle cell disease.

tissue. This process, referred to as **autosplenectomy,** is complete by adulthood.

**Vascular congestion, thrombosis, and infarction** can affect any organ, including the bones, liver, kidney, retina, brain, lung, and skin. The bone marrow is particularly prone to ischemia because of its sluggish blood flow and high rate of metabolism. Priapism, another frequent problem, can lead to penile fibrosis and erectile dysfunction. As with the other hemolytic anemias, **hemosiderosis** and **gallstones** are common.

### Clinical Course

Homozygous sickle cell disease usually is asymptomatic until 6 months of age when the shift from HbF to HbS is complete. The anemia is moderate to severe; most patients have hematocrits 18% to 30% (normal range, 36% to 48%). The chronic hemolysis is associated with hyperbilirubinemia and compensatory reticulocytosis. From its onset, the disease runs an unremitting course punctuated by sudden crises. The most serious of these are the *vaso-occlusive,* or *pain, crises.* The vaso-occlusion in these episodes can involve many sites but occurs most commonly in the bone marrow, where it often progresses to infarction.

A feared complication is the *acute chest syndrome,* which can be triggered by pulmonary infections or fat emboli from infarcted marrow. The blood flow in the inflamed, ischemic lung becomes sluggish and "spleenlike," leading to sickling within hypoxemic pulmonary beds. This exacerbates the underlying pulmonary dysfunction, creating a vicious circle of worsening pulmonary and systemic hypoxemia, sickling, and vaso-occlusion. Another major complication is *stroke,* which sometimes occurs in the setting of the acute chest syndrome. Although virtually any organ can be damaged by ischemic injury, *the acute chest syndrome and stroke are the two leading causes of ischemia-related death.*

A second acute event, *aplastic crisis,* is caused by a sudden decrease in red cell production. As in hereditary spherocytosis, this usually is triggered by the infection of erythroblasts by parvovirus B19 and, while severe, is self-limited.

In addition to these crises, patients with sickle cell disease are prone to *infections.* Both children and adults with sickle cell disease are functionally asplenic, making them susceptible to infections caused by encapsulated bacteria, such as pneumococci. In adults the basis for "hyposplenism" is autoinfarction. In the earlier childhood phase of splenic enlargement, congestion caused by trapped sickled red cells apparently interferes with bacterial sequestration and killing; hence, even children with enlarged spleens are at risk for development of fatal septicemia. Patients with sickle cell disease also are predisposed to *Salmonella* osteomyelitis, possibly in part because of poorly understood acquired defects in complement function.

In homozygous sickle cell disease, irreversibly sickled red cells are seen in routine peripheral blood smears. In sickle cell trait, sickling can be induced in vitro by exposing cells to marked hypoxia. The diagnosis is confirmed by electrophoretic demonstration of HbS. Prenatal diagnosis of sickle cell anemia can be performed by analyzing fetal DNA obtained by amniocentesis or biopsy of chorionic villi.

The clinical course is highly variable. As a result of improvements in supportive care, an increasing number of patients are surviving into adulthood and producing offspring. Of particular importance is prophylactic treatment with penicillin to prevent pneumococcal infections. Approximately 50% of patients survive beyond the fifth decade. By contrast, sickle cell trait causes symptoms rarely and only under extreme conditions, such as after vigorous exertion at high altitudes.

A mainstay of therapy is hydroxyurea, a "gentle" inhibitor of DNA synthesis. Hydroxyurea reduces pain crises and lessens the anemia through several beneficial intracorpuscular and extracorpuscular effects, including (1) an increase in red cell levels of HbF; (2) an anti-inflammatory effect due to the inhibition of white cell production; (3) an increase in red cell size, which lowers the mean cell hemoglobin concentration; and (4) its metabolism to NO, a potent vasodilator and inhibitor of platelet aggregation. Encouraging results also have been obtained with allogeneic bone marrow transplantation, which has the potential to be curative.

## Thalassemia

The thalassemias are inherited disorders caused by mutations that decrease the synthesis of α- or β-globin chains. As a result, there is a deficiency of Hb and additional red cell changes due to the relative excess of the unaffected globin chain. The mutations that cause thalassemia are particularly common among populations in Mediterranean, African, and Asian regions in which malaria is endemic. As with HbS, it is hypothesized that globin mutations associated with thalassemia are protective against falciparum malaria.

### PATHOGENESIS

A diverse collection of α-globin and β-globin mutations underlies the thalassemias, which are autosomal codominant conditions. As described previously, adult hemoglobin, or HbA, is a tetramer composed of two α chains and two β chains. The α chains are encoded by two α-globin genes, which lie in tandem on chromosome 11, while the β chains are encoded by a single β-globin gene located on chromosome 16. The clinical features vary widely depending on the specific combination of mutated alleles that are inherited by the patient (Table 11–3), as described next.

#### β-Thalassemia

The mutations associated with β-thalassemia fall into two categories: (1) $\beta^0$, in which no β-globin chains are produced; and (2) $\beta^+$, in which there is reduced (but detectable) β-globin synthesis. Sequencing of β-thalassemia genes has revealed more than 100 different causative mutations, a majority consisting of single-base changes. Persons inheriting one abnormal allele have **β-thalassemia minor** (also known as **β-thalassemia trait**), which is asymptomatic or mildly symptomatic. Most people inheriting any two $\beta^0$ and $\beta^+$ alleles have **β-thalassemia major;** occasionally, persons inheriting two $\beta^+$ alleles have a milder disease termed **β-thalassemia intermedia.** In contrast with α-thalassemias (described

**Table 11–3** Clinical and Genetic Classification of Thalassemias

| Clinical Syndrome | Genotype | Clinical Features | Molecular Genetics |
|---|---|---|---|
| **β-Thalassemias** | | | |
| β-Thalassemia major | Homozygous β-thalassemia ($\beta^0/\beta^0$, $\beta^+/\beta^+$, $\beta^0/\beta^+$) | Severe anemia; regular blood transfusions required | Mainly point mutations that lead to defects in the transcription, splicing, or translation of β-globin mRNA |
| β-Thalassemia intermedia | Variable ($\beta^0/\beta^+$, $\beta^+/\beta^+$, $\beta^0/\beta$, $\beta^+/\beta$) | Severe anemia, but regular blood transfusions not required | |
| β-Thalassemia minor | Heterozygous β-thalassemia ($\beta^0/\beta$, $\beta^+/\beta$) | Asymptomatic with mild or absent anemia; red cell abnormalities seen | |
| **α-Thalassemias** | | | |
| Silent carrier | –/α, α/α | Asymptomatic; no red cell abnormality | Mainly gene deletions |
| α-Thalassemia trait | –/–, α/α (Asian)<br>–/α, –/α (black African, Asian) | Asymptomatic, like β-thalassemia minor | |
| HbH disease | –/–, –/α | Severe; resembles β-thalassemia intermedia | |
| Hydrops fetalis | –/–, –/– | Lethal in utero without transfusions | |

HgH, hemoglobin H; mRNA, messenger ribonucleic acid.

later), **gene deletions rarely underlie β-thalassemias** (Table 11–3).

The mutations responsible for β-thalassemia disrupt β-globin synthesis in several different ways (Fig. 11–5):

- **Mutations leading to aberrant RNA splicing are the most common cause of β-thalassemia.** Some of these mutations disrupt the normal RNA splice junctions; as a result, no mature mRNA is made and there is a complete failure of β-globin production, creating $\beta^0$. Other mutations create new splice junctions in abnormal positions—within an intron, for example. Because the normal splice sites are intact, both normal and abnormal splicing occurs, and some normal β-globin mRNA is made. These alleles are designated $\beta^+$.
- Some mutations lie within the β-globin promoter and lower the rate of β-globin gene transcription. Because some normal β-globin is synthesized, these are $\beta^+$ alleles.
- Other mutations involve the coding regions of the β-globin gene, usually with severe consequences. For example, some single-nucleotide changes create termination ("stop") codons that interrupt the translation of β-globin mRNA and completely prevent the synthesis of β-globin.

**Two mechanisms contribute to the anemia in β-thalassemia.** The reduced synthesis of β-globin leads to inadequate HbA formation and results in the production of poorly hemoglobinized red cells that are pale **(hypochromic)** and small in size **(microcytic).** Even more important is the **imbalance in β-globin and α-globin chain synthesis,** as this creates an excess of unpaired α chains that aggregate into insoluble precipitates, which bind and severely damage the membranes of both red cells and erythroid precursors. A high fraction of the damaged erythroid precursors die by apoptosis (Fig. 11–6), a phenomenon termed **ineffective erythropoiesis,** and the few red cells that are produced have a shortened life span due to **extravascular hemolysis.** Ineffective hematopoiesis has another untoward effect: It is associated with an inappropriate increase in the absorption of dietary iron, which without medical intervention inevitably leads to **iron overload.** The increased iron absorption is caused by inappropriately low levels of hepcidin, which is a negative regulator of iron absorption (see later).

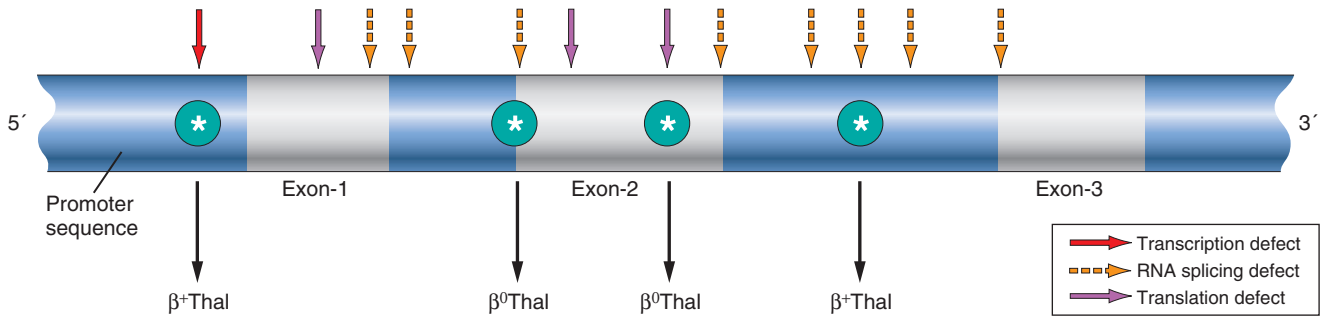


**Figure 11–5** Distribution of β-globin gene mutations associated with β-thalassemia. *Arrows* denote sites at which point mutations giving rise to $\beta^+$ or $\beta^0$ thalassemia have been identified.

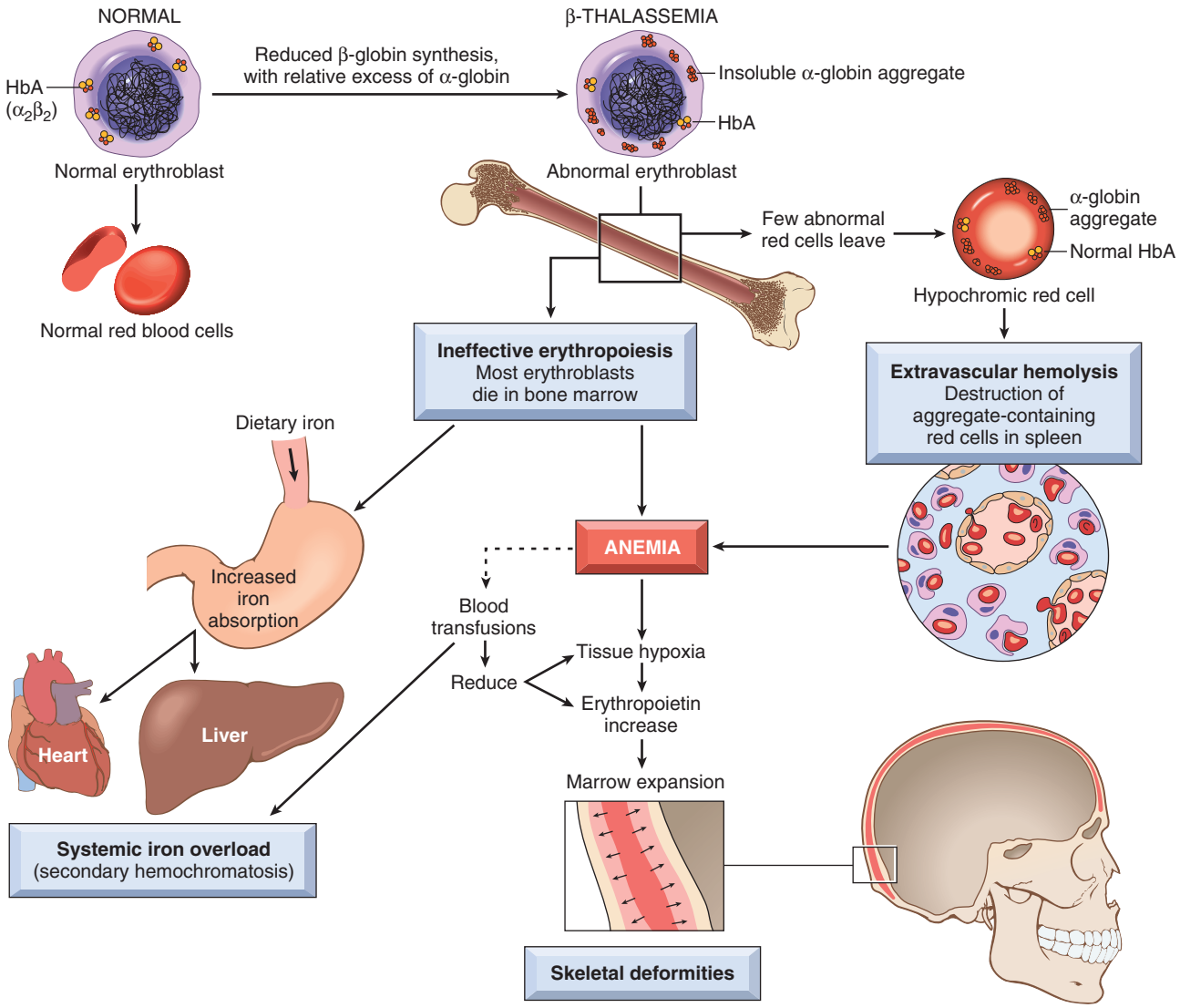


**Figure 11–6** Pathogenesis of β-thalassemia major. Note that aggregates of excess α-globin are not visible on routine blood smears. Blood transfusions constitute a double-edged sword, diminishing the anemia and its attendant complications but also adding to the systemic iron overload.

### α-Thalassemia

Unlike β-thalassemia, **α-thalassemia is caused mainly by deletions involving one or more of the α-globin genes.** The severity of the disease is proportional to the number of α-globin genes that are missing (Table 11–3). For example, the loss of a single α-globin gene produces a silent-carrier state, whereas the deletion of all four α-globin genes is lethal in utero because the red cells have virtually no oxygen-delivering capacity. With loss of three α-globin genes there is a relative excess of β-globin or (early in life) γ-globin chains. Excess β-globin and γ-globin chains form relatively stable β4 and γ4 tetramers known as HbH and Hb Bart, respectively, which cause less membrane damage than the free α-globin chains that are found in β-thalassemia; as a result, ineffective erythropoiesis is less pronounced in α-thalassemia. Unfortunately, both HbH and Hb Bart have an abnormally high affinity for oxygen, which renders them ineffective at delivering oxygen to the tissues.

### MORPHOLOGY

A range of pathologic features are seen, depending on the specific underlying molecular lesion. On one end of the spectrum is β-thalassemia minor and α-thalassemia trait, in which the abnormalities are confined to the peripheral blood. In smears the red cells are small (microcytic) and pale (hypochromic), but regular in shape. Often seen are **target cells,** cells with an increased surface area-to-volume ratio that allows the cytoplasm to collect in a central, dark-red "puddle." On the other end of the spectrum, in β-thalassemia major, peripheral blood smears show marked **microcytosis, hypochromia, poikilocytosis** (variation in cell size), and **anisocytosis** (variation in cell shape). Nucleated red cells (normoblasts) are also seen that reflect the underlying erythropoietic drive. β-Thalassemia intermedia and HbH disease are associated with peripheral smear findings that lie between these two extremes.

The anatomic changes in β-thalassemia major are similar in kind to those seen in other hemolytic anemias but profound in degree. The ineffective erythropoiesis and hemolysis result in a striking hyperplasia of erythroid progenitors, with a shift toward early forms. The expanded erythropoietic marrow may completely fill the intramedullary space of the skeleton, invade the bony cortex, impair bone growth, and produce **skeletal deformities.** Extramedullary hematopoiesis and hyperplasia of mononuclear phagocytes result in prominent **splenomegaly,** hepatomegaly, and lymphadenopathy. The ineffective erythropoietic precursors consume nutrients and produce growth retardation and a degree of **cachexia** reminiscent of that seen in cancer patients. Unless steps are taken to prevent iron overload, over the span of years severe **hemosiderosis** develops (Fig. 11–6). HbH disease and β-thalassemia intermedia are also associated with splenomegaly, erythroid hyperplasia, and growth retardation related to anemia, but these are less severe than in β-thalassemia major.

### Clinical Course

*β-Thalassemia minor and α-thalassemia trait* (caused by deletion of two α-globin genes) are often asymptomatic. There is usually only a mild microcytic hypochromic anemia; generally, these patients have a normal life expectancy. Iron deficiency anemia is associated with a similar red cell appearance and must be excluded by appropriate laboratory tests (described later).

*β-Thalassemia major manifests* postnatally as HbF synthesis diminishes. Affected children suffer from growth retardation that commences in infancy. They are *sustained by repeated blood transfusions,* which improve the anemia and reduce the skeletal deformities associated with excessive erythropoiesis. With transfusions alone, survival into the second or third decade is possible, but systemic iron overload gradually develops owing to inappropriate uptake of iron from the gut and the iron load in transfused red cells. Unless patients are treated aggressively with iron chelators, cardiac dysfunction from *secondary hemochromatosis* inevitably develops and often is fatal in the second or third decade of life. When feasible, bone marrow transplantation at an early age is the treatment of choice. HbH disease (caused by deletion of three α-globin genes) and β-thalassemia intermedia are not as severe as β-thalassemia major, since the imbalance in α- and β-globin chain synthesis is not as great and hematopoiesis is more effective. Anemia is of moderate severity and patients usually do not require transfusions. Thus, the iron overload that is so common in β-thalassemia major is rarely seen.

The diagnosis of β-thalassemia major can be strongly suspected on clinical grounds. *Hb electrophoresis* shows profound reduction or absence of HbA and increased levels of HbF. The HbA2 level may be normal or increased. Similar but less profound changes are noted in patients affected by β-thalassemia intermedia. *Prenatal diagnosis* of β-thalassemia is challenging due to the diversity of causative mutations, but can be made in specialized centers by DNA analysis. In fact, thalassemia was the first disease diagnosed by DNA-based tests, opening the way for the field of molecular diagnostics. The diagnosis of β-thalassemia minor is made by Hb electrophoresis, which typically reveals a reduced level of HbA ($\alpha_2\beta_2$) and an increased level of HbA2 ($\alpha_2\delta_2$). HbH disease can be diagnosed by detection of β4 tetramers by electrophoresis.

## Glucose-6-Phosphate Dehydrogenase Deficiency

Red cells are constantly exposed to both endogenous and exogenous oxidants, which are normally inactivated by reduced glutathione (GSH). Abnormalities affecting the enzymes responsible for the synthesis of GSH leave red cells vulnerable to oxidative injury and lead to hemolytic anemias. By far the most common of these anemias is that caused by glucose-6-phosphate dehydrogenase (G6PD) deficiency. The G6PD gene is on the X chromosome. More than 400 G6PD variants have been identified, but only a few are associated with disease. One of the most important variants is G6PD $A^-$, which is carried by approximately 10% of black males in the United States. G6PD $A^-$ has a normal enzymatic activity but a decreased half-life. Because red cells do not synthesize proteins, older G6PD $A^-$ red cells become progressively deficient in enzyme activity and the reduced form of glutathione. This in turn renders older red cells more sensitive to oxidant stress.

### PATHOGENESIS

**G6PD deficiency produces no symptoms until the patient is exposed to an environmental factor (most commonly infectious agents or drugs) that produces oxidants.** The drugs incriminated include antimalarials (e.g., primaquine), sulfonamides, nitrofurantoin, phenacetin, aspirin (in large doses), and vitamin K derivatives. More commonly, episodes of hemolysis are triggered by **infections,** which induce phagocytes to generate oxidants as part of the normal host response. These oxidants, such as hydrogen peroxide, are normally sopped up by GSH, which is converted to oxidized glutathione in the process. Because regeneration of GSH is impaired in G6PD-deficient cells, oxidants are free to "attack" other red cell components including globin chains, which have sulfhydryl groups that are susceptible to oxidation. Oxidized hemoglobin denatures and precipitates, forming intracellular inclusions called **Heinz bodies,** which can damage the cell membrane sufficiently to cause intravascular hemolysis. Other, less severely damaged cells lose their deformability and suffer further injury when splenic phagocytes attempt to "pluck out" the Heinz bodies, creating so-called **bite cells** (Fig. 11–7). Such cells become trapped upon recirculation to the spleen and are destroyed by phagocytes (extravascular hemolysis).

### Clinical Features

Drug-induced hemolysis is acute and of variable severity. Typically, patients develop hemolysis after a lag of 2 or 3 days. Since G6PD is X-linked, the red cells of affected males are uniformly deficient and vulnerable to oxidant injury. By contrast, random inactivation of one X chromosome in heterozygous females (Chapter 6) creates two populations of red cells, one normal and the other G6PD-deficient. Most carrier females are unaffected except for those with a large proportion of deficient red cells (a chance situation known as *unfavorable lyonization*). In the case of the G6PD

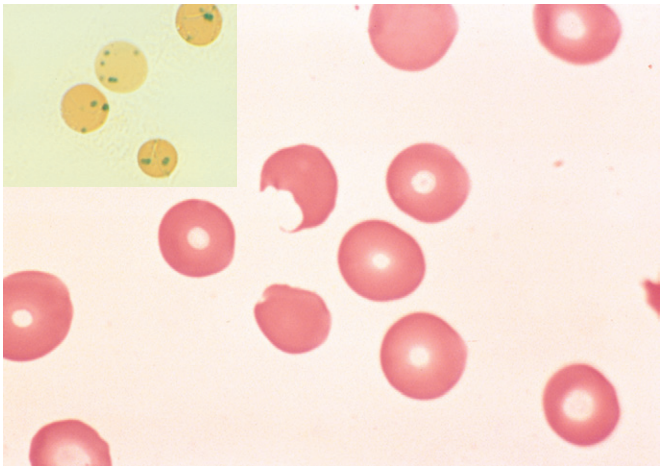

**Figure 11–7** Glucose-6-phosphate dehydrogenase deficiency after oxidant drug exposure—peripheral blood smear. **Inset,** Red cells with precipitates of denatured globin (Heinz bodies) revealed by supravital staining. As the splenic macrophages pluck out these inclusions, "bite cells" like the one in this smear are produced.

*(Courtesy of Dr. Robert W. McKenna, Department of Pathology, University of Texas Southwestern Medical School, Dallas, Texas.)*

$A^-$ variant, it is mainly older red cells that are susceptible to lysis. Since the marrow compensates for the anemia by producing new resistant red cells, the hemolysis abates even if the drug exposure continues. In other variants such as G6PD Mediterranean, found mainly in the Middle East, the enzyme deficiency and the hemolysis that occur on exposure to oxidants are more severe.

## Paroxysmal Nocturnal Hemoglobinuria

Paroxysmal nocturnal hemoglobinuria (PNH) is a rare disorder worthy of mention because it is the only hemolytic anemia that results from an *acquired somatic mutation in myeloid stem cells.*

### PATHOGENESIS

PNH stems from **acquired mutations in gene PIGA,** which is required for the synthesis of phosphatidylinositol glycan (PIG), a membrane anchor that is a component of many proteins. Without the "PIG-tail," these proteins cannot be expressed on the cell surface. The affected proteins include several that limit the activation of complement. As a result, PIGA-deficient precursors give rise to red cells that are **inordinately sensitive to complement-mediated lysis.** Leukocytes are also deficient in these protective proteins, but nucleated cells are generally less sensitive to complement than are red cells, and as a result the red cells take the brunt of the attack. The paroxysmal nocturnal hemolysis that gives the disorder its name occurs because the fixation of complement is enhanced by the slight decrease in blood pH that accompanies sleep (owing to $CO_2$ retention). However, most patients present less dramatically with anemia due to chronic low-level hemolysis. Another complication that is often serious and sometimes fatal is **venous thrombosis.** The etiopathogenesis of the prothrombotic state is somehow also related to the activity of the complement membrane attack complex, as inhibitors of this complex (described below) greatly lessen the incidence of thrombosis.

Because *PIGA* is X-linked, normal cells have only a single active *PIGA* gene, mutation of which is sufficient to give rise to PIGA deficiency. Because all myeloid lineages are affected in PNH, the responsible **mutations must occur in an early myeloid progenitor with self-renewal capacity.** Remarkably, many normal individuals harbor small numbers of bone marrow cells bearing *PIGA* mutations identical to those that cause PNH. It is believed that clinically evident PNH occurs only in rare instances in which the *PIGA* mutant clone has a survival advantage. One setting in which this may be true is in primary bone marrow failure (aplastic anemia), which most often appears to be caused by immune-mediated destruction or suppression of marrow stem cells. It is hypothesized that PIGA-deficient stem cells somehow escape the immune attack and eventually replace the normal marrow elements. Targeted therapy with an antibody that inhibits the C5b–C9 membrane attack complex is effective at diminishing both the hemolysis and the thrombotic complications, but also places patients at high risk for *Neisseria* infections, including meningococcal sepsis.

## Immunohemolytic Anemias

Some individuals develop antibodies that recognize determinants on red cell membranes and cause hemolytic anemia. These antibodies may arise spontaneously or be induced by exogenous agents such as drugs or chemicals. Immunohemolytic anemias are uncommon and classified on the basis of (1) the nature of the antibody and (2) the presence of predisposing conditions (summarized in Table 11–4).

The diagnosis of immunohemolytic anemias depends on the detection of antibodies and/or complement on red cells. This is done with the *direct Coombs antiglobulin test,* in which the patient's red cells are incubated with antibodies against human immunoglobulin or complement. In a positive test result, these antibodies cause the patient's red cells to clump (agglutinate). The *indirect Coombs test,* which assesses the ability of the patient's serum to agglutinate test red cells bearing defined surface determinants, can then be used to characterize the target of the antibody.

### *Warm Antibody Immunohemolytic Anemias*

Warm antibody immunohemolytic anemias are caused by immunoglobulin G (IgG) or, rarely, IgA antibodies that are active at 37°C. More than 60% of cases are idiopathic

**Table 11–4** Classification of Immunohemolytic Anemias

| |
|---|
| **Warm Antibody Type** |
| *Primary* (idiopathic)<br>*Secondary*: B cell neoplasms (e.g., chronic lymphocytic leukemia), autoimmune disorders (e.g., systemic lupus erythematosus), drugs (e.g., α-methyldopa, penicillin, quinidine) |
| **Cold Antibody Type** |
| *Acute: Mycoplasma* infection, infectious mononucleosis<br>*Chronic*: idiopathic, B cell lymphoid neoplasms (e.g., lymphoplasmacytic lymphoma) |

(primary), while another 25% are secondary to an underlying disease affecting the immune system (e.g., systemic lupus erythematosus) or are induced by drugs. *The hemolysis usually results from the opsonization of red cells by the autoantibodies,* which leads to erythrophagocytosis in the spleen and elsewhere. In addition, incomplete consumption ("nibbling") of antibody-coated red cells by macrophages removes membrane. With loss of cell membrane the red cells are transformed into *spherocytes,* which are rapidly destroyed in the spleen, as described earlier for hereditary spherocytosis. The clinical severity of immunohemolytic anemias is quite variable. Most patients have chronic mild anemia with moderate splenomegaly and require no treatment.

The mechanisms of hemolysis induced by drugs are varied and in some instances poorly understood. Drugs such as α-methyldopa induce autoantibodies against intrinsic red cell constituents, in particular Rh blood group antigens. Presumably, the drug somehow alters the immunogenicity of native epitopes and thereby circumvents T cell tolerance (Chapter 4). Other drugs such as penicillin act as haptens, inducing an antibody response by binding covalently to red cell membrane proteins. Sometimes antibodies recognize a drug in the circulation and form immune complexes that are deposited on red cell membranes. Here they may fix complement or act as opsonins, either of which can lead to hemolysis.

### *Cold Antibody Immunohemolytic Anemias*

Cold antibody immunohemolytic anemias usually are caused by low-affinity IgM antibodies that bind to red cell membranes only at temperatures below 30°C, such as occur in distal parts of the body (e.g., ears, hands, and toes) in cold weather. Although bound IgM fixes complement well, the latter steps of the complement fixation cascade occur inefficiently at temperatures lower than 37°C. As a result, most cells with bound IgM pick up some C3b but are not lysed intravascularly. When these cells travel to warmer areas, the weakly bound IgM antibody is released, but the coating of C3b remains. Because C3b is an opsonin (Chapter 2), the cells are phagocytosed by macrophages, mainly in the spleen and liver; hence, the *hemolysis is extravascular*. Binding of pentavalent IgM also cross-links red cells and causes them to clump (agglutinate). *Sludging of blood in capillaries due to agglutination often produces Raynaud phenomenon* in the extremities of affected individuals. Cold agglutinins sometimes also appear transiently during recovery from pneumonia caused by *Mycoplasma* spp. and infectious mononucleosis, producing a mild anemia of little clinical importance. More important chronic forms of cold agglutinin hemolytic anemia occur in association with certain B cell neoplasms or as an idiopathic condition.

## Hemolytic Anemias Resulting from Mechanical Trauma to Red Cells

Abnormal mechanical forces result in red cell hemolysis in a variety of circumstances. *Traumatic hemolysis* can occur incidentally during any activity involving repeated physical blows or their equivalent (e.g., marathon racing, karate chopping, bongo drumming) but is of little clinical importance. More significant mechanical hemolysis is sometimes

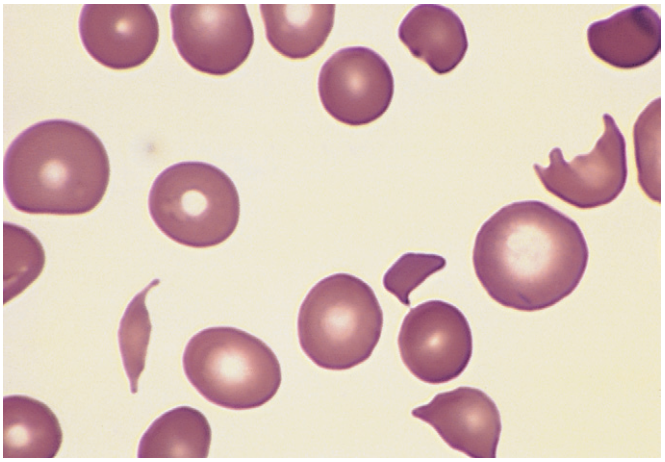

**Figure 11–8** Microangiopathic hemolytic anemia—peripheral blood smear. This specimen from a patient with hemolytic uremic syndrome contains several fragmented red cells.

*(Courtesy of Dr. Robert W. McKenna, Department of Pathology, University of Texas Southwestern Medical School, Dallas, Texas.)*

produced by defective cardiac valve prostheses (the blender effect), which can create sufficiently turbulent blood flow to shear red cells. *Microangiopathic hemolytic anemia* is observed in pathologic states in which small vessels become partially obstructed or narrowed by lesions that predispose passing red cells to mechanical damage. The most frequent of these conditions is disseminated intravascular coagulation (DIC) (see later), in which vessels are narrowed by the intravascular deposition of fibrin. Other causes of microangiopathic hemolytic anemia include malignant hypertension, systemic lupus erythematosus, thrombotic thrombocytopenic purpura, hemolytic uremic syndrome, and disseminated cancer. The morphologic alterations in the injured red cells (*schistocytes*) are striking and quite characteristic; "burr cells," "helmet cells," and "triangle cells" may be seen (Fig. 11–8). While microangiopathic hemolysis is not usually in and of itself a major clinical problem, it often points to a serious underlying condition.

## Malaria

It is estimated that malaria affects 500 million and kills more than 1 million people per year, making it one of the most widespread afflictions of humans. Malaria is endemic in Asia and Africa, but with widespread jet travel cases are now seen all over the world. It is caused by one of four types of protozoa. Of these, the most important is *Plasmodium falciparum*, which causes tertian malaria (falciparum malaria), a serious disorder with a high fatality rate. The other three species of *Plasmodium* that infect humans—*Plasmodium malariae, Plasmodium vivax,* and *Plasmodium ovale*—cause relatively benign disease. All forms are transmitted by the bite of female *Anopheles* mosquitoes, and humans are the only natural reservoir.

### PATHOGENESIS

The life cycle of plasmodia is complex. As mosquitoes feed on human blood, sporozoites are introduced from the saliva

and within a few minutes infect liver cells. Here the parasites multiply rapidly to form a schizont containing thousands of merozoites. After a period of days to several weeks that varies with the *Plasmodium* species, the infected hepatocytes release the merozoites, which quickly infect red cells. Intraerythrocytic parasites either continue asexual reproduction to produce more merozoites or give rise to **gametocytes** capable of infecting the next hungry mosquito. During their asexual reproduction in red cells, each of the four forms of malaria develops into **trophozoites** with a somewhat distinctive appearance. Thus, **the species of malaria that is responsible for an infection can be identified in appropriately stained thick smears of peripheral blood.** The asexual phase is completed when the trophozoites give rise to new merozoites, which escape by lysing the red cells.

### Clinical Features

The distinctive clinical and anatomic features of malaria are related to the following factors:

- Showers of new merozoites are released from the red cells at intervals of approximately 48 hours for *P. vivax, P. ovale,* and *P. falciparum* and 72 hours for *P. malariae.* The episodic shaking, chills, and fever coincide with this release.
- The parasites destroy large numbers of infected red cells, thereby causing a hemolytic anemia.
- A characteristic brown malarial pigment derived from hemoglobin called hematin is released from the ruptured red cells and produces discoloration of the spleen, liver, lymph nodes, and bone marrow.
- Activation of defense mechanisms in the host leads to a marked hyperplasia of mononuclear phagocytes, producing massive splenomegaly and occasional hepatomegaly.

*Fatal falciparum malaria often involves the brain, a complication known as cerebral malaria.* Normally, red cells bear negatively charged surfaces that interact poorly with endothelial cells. Infection of red cells with *P. falciparum* induces the appearance of positively charged surface knobs containing parasite-encoded proteins, which bind to adhesion molecules expressed on activated endothelium. Several endothelial cell adhesion molecules, including intercellular adhesion molecule-1 (ICAM-1), have been proposed to mediate this interaction, which leads to the trapping of red cells in postcapillary venules. In an unfortunate minority of patients, mainly children, this process involves cerebral vessels, which become engorged and occluded. *Cerebral malaria* is rapidly progressive; convulsions, coma, and death usually occur within days to weeks. Fortunately, falciparum malaria usually pursues a chronic course, which may be punctuated at any time by *blackwater fever.* The trigger is obscure for this uncommon complication, which is associated with massive intravascular hemolysis, hemoglobinemia, hemoglobinuria, and jaundice.

With appropriate chemotherapy, the prognosis for patients with most forms of malaria is good; however, treatment of falciparum malaria is becoming more difficult with the emergence of drug-resistant strains. Because of the potentially serious consequences of the disease, early diagnosis and treatment are important. The ultimate solution is an effective vaccine, which is long-sought but still elusive.

## SUMMARY

### Hemolytic Anemias

**Hereditary Spherocytosis**

- Autosomal dominant disorder caused by mutations that affect the red cell membrane skeleton, leading to loss of membrane and eventual conversion of red cells to spherocytes, which are phagocytosed and removed in the spleen
- Manifested by anemia, splenomegaly

**Sickle Cell Anemia**

- Autosomal recessive disorder resulting from a mutation in β-globin that causes deoxygenated hemoglobin to self-associate into long polymers that distort (sickle) the red cell
- Blockage of vessels by sickled cells causes pain crises and tissue infarction, particularly of the marrow and spleen
- Red cell membrane damage caused by repeated bouts of sickling results in a moderate to severe hemolytic anemia

**Thalassemias**

- Autosomal codominant disorders caused by mutations in α- or β-globin that reduce hemoglobin synthesis, resulting in a microcytic, hypochromic anemia. In β-thalassemia, unpaired α-globin chains form aggregates that damage red cell precursors and further impair erythropoiesis.

**Glucose-6-Phosphate Dehydrogenase (G6PD) Deficiency**

- X-linked disorder caused by mutations that destabilize G6PD, making red cells susceptible to oxidant damage

**Immunohemolytic Anemias**

- Caused by antibodies against either normal red cell constituents or antigens modified by haptens (such as drugs)
- Antibody binding results in either red cell opsonization and extravascular hemolysis or (uncommonly) complement fixation and intravascular hemolysis

**Malaria**

- Intracellular red cell parasite that causes chronic hemolysis of variable severity
- Falciparum malaria may be fatal due to the propensity of infected red cells to adhere to small vessels in the brain (cerebral malaria)

# ANEMIAS OF DIMINISHED ERYTHROPOIESIS

The category of anemias involving diminished erythropoiesis includes anemias that are caused by an inadequate dietary supply of nutrients, particularly iron, folic acid, and vitamin $B_{12}$. Other anemias of this type are those associated with bone marrow failure (aplastic anemia), systemic

inflammation (anemia of chronic disease), or bone marrow infiltration by tumor or inflammatory cells (myelophthisic anemia). In this section, some common examples of anemias of these types are discussed individually.

## Iron Deficiency Anemia

About 10% of people living in developed countries and 25% to 50% of those in developing countries are anemic. In both settings, *the most frequent cause of anemia is iron deficiency.* The factors responsible for iron deficiency differ in various populations and are best understood in the context of normal iron metabolism.

The normal total body iron mass is about 2.5 g for women and 3.5 g for men. Approximately 80% of functional body iron is present in hemoglobin, with the remainder being found in myoglobin and iron-containing enzymes (e.g., catalase, cytochromes). The iron storage pool, consisting of hemosiderin and ferritin-bound iron in the liver, spleen, bone marrow, and skeletal muscle, contains on average 15% to 20% of total body iron. Because *serum ferritin* is largely derived from this storage pool, the serum ferritin level is a good measure of iron stores. *Assessment of bone marrow iron* is another reliable but more invasive method for estimating iron stores. Iron is transported in the plasma bound to the protein *transferrin.* In normal persons, transferrin is about 33% saturated with iron, yielding serum iron levels that average 120 µg/dL in men and 100 µg/dL in women. Thus, the normal total iron-binding capacity of serum is 300 to 350 µg/dL.

In keeping with the high prevalence of iron deficiency, evolutionary pressures have yielded metabolic pathways that are strongly biased toward iron retention. There is no regulated pathway for iron excretion, which is limited to the 1 to 2 mg/day that is lost through the shedding of mucosal and skin epithelial cells. *Iron balance is maintained largely by regulating the absorption of dietary iron.* The normal daily Western diet contains 10 to 20 mg of iron. Most of this is found in heme within meat and poultry, with the remainder present as inorganic iron in vegetables. About 20% of heme iron and 1% to 2% of nonheme iron are absorbable; hence, the average Western diet contains sufficient iron to balance fixed daily losses.

Iron is absorbed in the duodenum (Fig. 11–9). Nonheme iron is carried across the apical and basolateral membranes of enterocytes by distinct transporters. After reduction by ferric reductase, ferrous iron ($Fe^{2+}$) is transported across the apical membrane by divalent metal transporter-1 (DMT1). A second transporter, ferroportin, then moves iron from the cytoplasm to the plasma across the basolateral membrane. The newly absorbed iron is next oxidized by hephaestin and ceruloplasmin to ferric iron ($Fe^{3+}$), the form of iron that binds to transferrin. Both DMT1 and ferroportin are widely distributed in the body and are involved in iron transport in other tissues as well. As depicted in Figure 11–9, only a fraction of the iron that enters enterocytes is delivered to transferrin by ferroportin. The remainder is incorporated into cytoplasmic ferritin and lost through the exfoliation of mucosal cells.

When the body is replete with iron, most iron entering duodenal cells is "handed off" to ferritin, whereas transfer to plasma transferrin is enhanced when iron is deficient or erythropoiesis is inefficient. This balance is regulated by hepcidin, a small hepatic peptide that is synthesized and secreted in an iron-dependent fashion. Plasma hepcidin binds ferroportin and induces its internalization and degradation; thus, when hepcidin concentrations are high, ferroportin levels fall and less iron is absorbed. Conversely, when hepcidin levels are low (as occurs in hemochromatosis) (Chapter 15), basolateral transport of iron is increased, eventually leading to systemic iron overload.

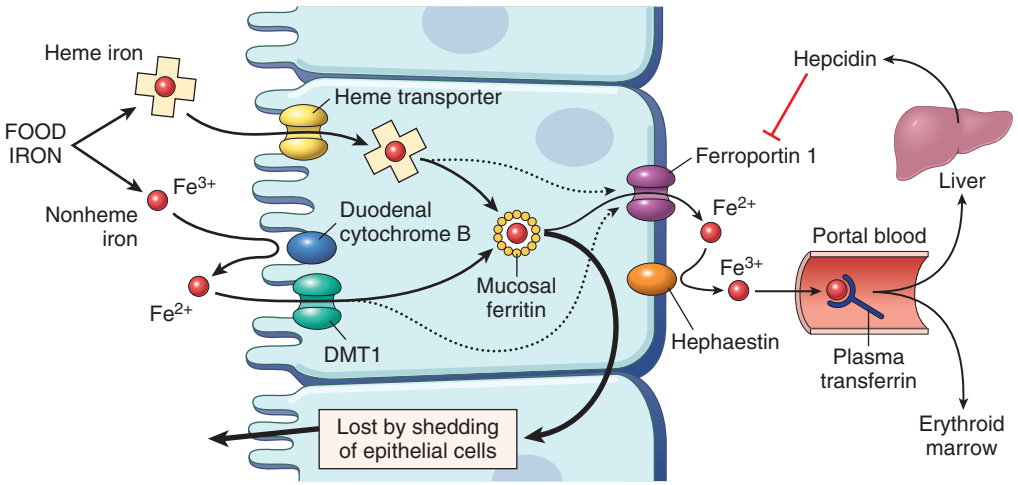


**Figure 11–9** Regulation of iron absorption. Duodenal epithelial cell uptake of heme and nonheme iron discussed in the text is depicted. When the storage sites of the body are replete with iron and erythropoietic activity is normal, plasma hepcidin levels are high. This situation leads to downregulation of ferroportin and trapping of most of the absorbed iron, which is lost when duodenal epithelial cells are shed into the gut. Conversely, when body iron stores decrease or erythropoiesis is stimulated, hepcidin levels fall and ferroportin activity increases, allowing a greater fraction of the absorbed iron to be transferred into plasma transferrin. DMT1, divalent metal transporter-1.

## PATHOGENESIS

Iron deficiency arises in a variety of settings:

- **Chronic blood loss is the most important cause of iron deficiency anemia in the Western world;** the most common sources of bleeding are the gastrointestinal tract (e.g., peptic ulcers, colonic cancer, hemorrhoids) and the female genital tract (e.g., menorrhagia, metrorrhagia, cancers).
- **In the developing world, low intake and poor bioavailability due to predominantly vegetarian diets are the most common causes of iron deficiency.** In the United States, low dietary intake is an infrequent culprit but is sometimes culpable in infants fed exclusively milk, the impoverished, the elderly, and teenagers subsisting predominantly on junk food.
- Increased demands not met by normal dietary intake occur worldwide during pregnancy and infancy.
- Malabsorption can occur with celiac disease or after gastrectomy (Chapter 14).

Regardless of the cause, iron deficiency develops insidiously. Iron stores are depleted first, marked by a decline in serum ferritin and the absence of stainable iron in the bone marrow. These changes are followed by a decrease in serum iron and a rise in the serum transferrin. Ultimately, the capacity to synthesize hemoglobin, myoglobin, and other iron-containing proteins is diminished, leading to microcytic anemia, impaired work and cognitive performance, and even reduced immunocompetence.

### Clinical Features

In most instances, iron deficiency anemia is usually mild and asymptomatic. Nonspecific manifestations, such as weakness, listlessness, and pallor, may be present in severe cases. With long-standing anemia, abnormalities of the fingernails, including thinning, flattening, and "spooning," may appear. A curious but characteristic neurobehavioral complication is *pica,* the compunction to consume nonfoodstuffs such as dirt or clay.

In peripheral smears red cells are *microcytic* and *hypochromic* (Fig. 11–10). *Diagnostic criteria* include anemia, hypochromic and microcytic red cell indices, low serum ferritin and iron levels, low transferrin saturation, increased total iron-binding capacity, and, ultimately, response to iron therapy. For unclear reasons, the platelet count often is elevated. Erythropoietin levels are increased, but the marrow response is blunted by the iron deficiency; thus, marrow cellularity usually is only slightly increased.

Persons often die with iron deficiency anemia, but virtually never of it. An important point is that in well-nourished persons, microcytic hypochromic anemia is not a disease but rather a symptom of some underlying disorder.

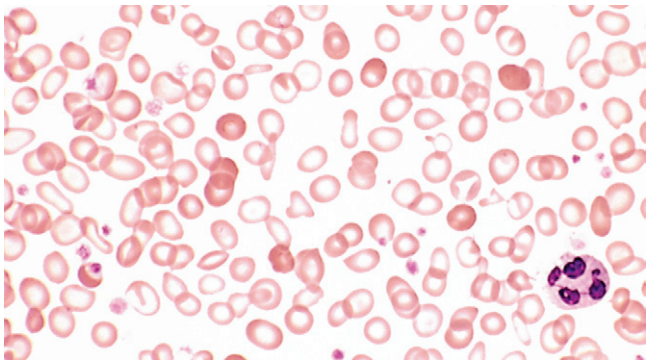

**Figure 11–10** Iron deficiency anemia—peripheral blood smear. Note the increased central pallor of most of the red cells. Scattered, fully hemoglobinized cells, from a recent blood transfusion, stand out in contrast.

*(Courtesy of Dr. Robert W. McKenna, Department of Pathology, University of Texas Southwestern Medical School, Dallas, Texas.)*

## Anemia of Chronic Disease

Anemia associated with chronic disease is the most common form of anemia in hospitalized patients. It superficially resembles the anemia of iron deficiency but arises instead from the suppression of erythropoiesis by systemic inflammation. It occurs in a variety of disorders associated with sustained inflammation, including:

- Chronic microbial infections, such as osteomyelitis, bacterial endocarditis, and lung abscess
- Chronic immune disorders, such as rheumatoid arthritis and regional enteritis
- Neoplasms, such as Hodgkin lymphoma and carcinomas of the lung and breast

## PATHOGENESIS

**The anemia of chronic disease stems from high levels of plasma hepcidin,** which blocks the transfer of iron to erythroid precursors by downregulating ferroportin in macrophages. The elevated hepcidin levels are caused by pro-inflammatory cytokines such as IL-6, which increase hepatic hepcidin synthesis. In addition, chronic inflammation blunts erythropoietin synthesis by the kidney, lowering red cell production by the marrow. The functional advantages of these adaptations in the face of systemic inflammation are unclear; they may serve to inhibit the growth of iron-dependent microorganisms or to augment certain aspects of host immunity.

### Clinical Features

As in anemia of iron deficiency, the serum iron levels usually are low in the anemia of chronic disease, and the red cells may even be slightly hypochromic and microcytic. Unlike iron deficiency anemia, however, *storage iron in the bone marrow is increased, the serum ferritin concentration is elevated, and the total iron-binding capacity is reduced.* Administration of erythropoietin and iron can improve the anemia, but only effective treatment of the underlying condition is curative.

## Megaloblastic Anemias

The two principal causes of megaloblastic anemia are folate deficiency and vitamin $B_{12}$ deficiency. Both vitamins are required for DNA synthesis and the effects of their deficiency on hematopoiesis are essentially identical. However, the causes and consequences of folate and vitamin $B_{12}$ deficiency differ in important ways.

### PATHOGENESIS

The morphologic hallmark of megaloblastic anemia is the presence of megaloblasts, enlarged erythroid precursors that give rise to abnormally large red cells (macrocytes). Granulocyte precursors are also increased in size. Underlying this **cellular gigantism** is a defect in DNA synthesis that impairs nuclear maturation and cell division. Because the synthesis of RNA and cytoplasmic elements proceeds at a normal rate and thus outpaces that of the nucleus, the hematopoietic precursors show **nuclear-cytoplasmic asynchrony.** This maturational derangement contributes to the anemia in several ways. Many megaloblasts are so defective in DNA synthesis that they undergo apoptosis in the marrow (**ineffective hematopoiesis**). Others mature into red cells but do so after fewer cell divisions, further diminishing the output of red cells. Granulocyte and platelet precursors are also affected (although not as severely) and most patients present with pancytopenia (anemia, thrombocytopenia, and granulocytopenia).

### MORPHOLOGY

Certain morphologic features are common to all forms of megaloblastic anemia. The bone marrow is markedly hypercellular and contains numerous megaloblastic erythroid progenitors. **Megaloblasts** are larger than normal erythroid progenitors (normoblasts) and have delicate, finely reticulated nuclear chromatin (indicative of nuclear immaturity) (Fig. 11–11). As megaloblasts differentiate and acquire hemoglobin, the nucleus retains its finely distributed chromatin and fails to undergo the chromatin clumping typical of normoblasts. The granulocytic precursors also demonstrate nuclear-cytoplasmic asynchrony, yielding **giant metamyelocytes.** Megakaryocytes may also be abnormally large and have bizarre multilobed nuclei.

In the peripheral blood the earliest change is the appearance of **hypersegmented neutrophils,** which appear before the onset of anemia. Normal neutrophils have three or four nuclear lobes, but in megaloblastic anemias they often have five or more. The red cells typically include large, **egg-shaped macro-ovalocytes;** the mean cell volume often is greater than 110 fL (normal, 82 to 92 fL). Although macrocytes appear hyperchromic, in reality the mean cell hemoglobin concentration is normal. Large, misshapen platelets also may be seen. Morphologic changes in other systems, especially the gastrointestinal tract, also occur, giving rise to some of the clinical manifestations.

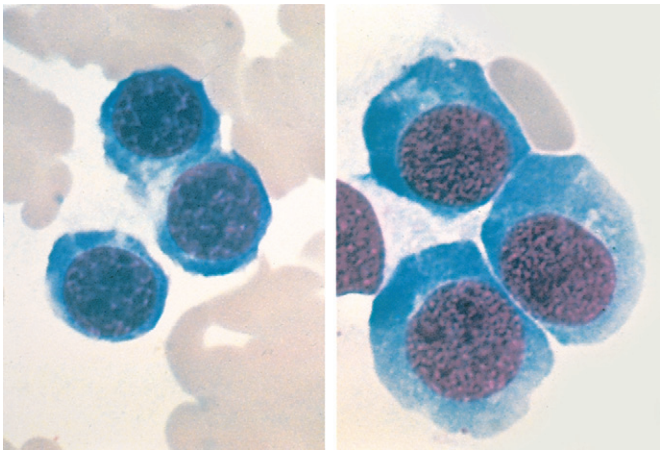

**Figure 11–11** Comparison of normoblasts (*left*) and megaloblasts (*right*)—bone marrow aspirate. Megaloblasts are larger, have relatively immature nuclei with finely reticulated chromatin, and abundant basophilic cytoplasm.

*(Courtesy of Dr. José Hernandez, Department of Pathology, University of Texas Southwestern Medical School, Dallas, Texas.)*

### *Folate (Folic Acid) Deficiency Anemia*

Megaloblastic anemia secondary to folate deficiency is not common, but marginal folate stores occur with surprising frequency even in apparently healthy persons. The risk of clinically significant folate deficiency is high in those with a poor diet (the economically deprived, the indigent, and the elderly) or increased metabolic needs (pregnant women and patients with chronic hemolytic anemias).

Folate is present in nearly all foods but is destroyed by 10 to 15 minutes of cooking. Thus, the best sources are fresh uncooked vegetables and fruits. Food folates are predominantly in polyglutamate form and must be split into monoglutamates for absorption, a conversion that is hampered by concurrent consumption of acidic foods and substances found in beans and other legumes. Phenytoin (dilantin) and a few other drugs also inhibit folate absorption, while others, such as methotrexate, inhibit folate metabolism. The principal site of intestinal absorption is the upper third of the small intestine; thus, malabsorptive disorders that affect this level of the gut, such as celiac disease and tropical sprue, can impair folate uptake.

### PATHOGENESIS

The metabolism and functions of folate are complex. Here, it is sufficient to note that after absorption folate is transported in the blood mainly as a monoglutamate. Within cells it is further metabolized to several derivatives, but its conversion from dihydrofolate to tetrahydrofolate by dihydrofolate reductase is particularly important. **Tetrahydrofolate acts as an acceptor and donor of one-carbon units** in several reactions that are required for the synthesis of **purines and thymidylate,** the building blocks of DNA, and its deficiency accounts for the defect in DNA replication that underlies megaloblastic anemia.

Clinical Features

The onset of the anemia of folate deficiency is insidious, being associated with nonspecific symptoms such as weakness and easy fatigability. The clinical picture may be complicated by the coexistent deficiency of other vitamins, especially in alcoholics. Because the cells lining the gastrointestinal tract, like the hematopoietic system, turn over rapidly, symptoms referable to the alimentary tract, such as sore tongue, are common. *Unlike in vitamin $B_{12}$ deficiency, neurologic abnormalities do not occur.*

The diagnosis of a megaloblastic anemia is readily made from examination of smears of peripheral blood and bone marrow. The anemia of folate deficiency is best distinguished from that of vitamin $B_{12}$ deficiency by measuring serum and red cell folate and vitamin $B_{12}$ levels.

### *Vitamin $B_{12}$ (Cobalamin) Deficiency Anemia (Pernicious Anemia)*

Inadequate levels of vitamin $B_{12}$ (also known as cobalamin) result in a megaloblastic anemia identical to that seen with folate deficiency. However, vitamin $B_{12}$ deficiency can also cause a demyelinating disorder of the peripheral nerves and the spinal cord. There are many causes of vitamin $B_{12}$ deficiency. The term *pernicious anemia,* a relic of days when the cause and therapy of this condition were unknown, applies to vitamin $B_{12}$ deficiency that results from defects involving intrinsic factor. Intrinsic factor plays a critical role in the absorption of vitamin $B_{12}$, a multistep process that proceeds as follows:

1. Peptic digestion releases dietary vitamin $B_{12}$, allowing it to bind a salivary protein called *haptocorrin.*
2. On entering the duodenum, haptocorrin–$B_{12}$ complexes are processed by pancreatic proteases; this releases $B_{12}$, which attaches to *intrinsic factor* secreted from the parietal cells of the gastric fundic mucosa.
3. The intrinsic factor–$B_{12}$ complexes pass to the distal ileum and attach to *cubulin,* a receptor for intrinsic factor, and are taken up into enterocytes.
4. The absorbed vitamin $B_{12}$ is transferred across the basolateral membranes of enterocytes to plasma *transcobalamin,* which delivers vitamin $B_{12}$ to the liver and other cells of the body.

## PATHOGENESIS

**Long-standing malabsorption underlies the vast majority of cases of vitamin $B_{12}$ deficiency.** Vitamin $B_{12}$ is abundant in all food derived from animals, including eggs and dairy products, and is resistant to cooking and boiling. Even bacterial contamination of water and nonanimal foods can provide adequate amounts. As a result, deficiencies due to diet are rare, being confined to strict vegans. Once vitamin $B_{12}$ is absorbed, the body handles it very efficiently. It is stored in the liver, which normally contains reserves sufficient to support bodily needs for 5 to 20 years.

**Pernicious anemia is the most frequent cause of vitamin $B_{12}$ deficiency.** This disease seems to stem from an autoimmune reaction against parietal cells and intrinsic factor itself, which produces gastric mucosal atrophy (Chapter 14). Several associations favor an autoimmune basis:

- Autoantibodies are present in the serum and gastric juice of most patients. Three types of antibodies have been found: **parietal canalicular antibodies,** which bind to the mucosal parietal cells; **blocking antibodies,** which disrupt the binding of vitamin $B_{12}$ to intrinsic factor; and **intrinsic factor–$B_{12}$ complex antibodies,** which prevent the complex from binding to cubulin.
- Pernicious anemia frequently occurs concomitantly with other autoimmune diseases, such as Hashimoto thyroiditis, Addison disease, and type I diabetes mellitus.
- Serum antibodies to intrinsic factor are often present in patients with other autoimmune diseases.

Chronic vitamin $B_{12}$ malabsorption is also seen after gastrectomy (owing to loss of intrinsic factor–producing cells) or ileal resection (owing to loss of intrinsic factor–$B_{12}$ complex–absorbing cells), and in disorders that disrupt the function of the distal ileum (such as Crohn disease, tropical sprue, and Whipple disease). Particularly in older persons, gastric atrophy and achlorhydria may interfere with the production of acid and pepsin, which are needed to release the vitamin $B_{12}$ from its bound form in food.

The metabolic defects responsible for the anemia are intertwined with folate metabolism. Vitamin $B_{12}$ is required for recycling of tetrahydrofolate, the form of folate that is needed for DNA synthesis. In keeping with this relationship, the anemia of vitamin $B_{12}$ deficiency is reversed with administration of folate. By contrast, folate administration does not prevent and may in fact worsen the neurologic symptoms. The main neurologic lesions associated with vitamin $B_{12}$ deficiency are **demyelination of the posterior and lateral columns of the spinal cord,** sometimes beginning in the peripheral nerves. In time, axonal degeneration may supervene. The severity of the neurologic manifestations is not related to the degree of anemia. Indeed, the neurologic disease may occur in the absence of overt megaloblastic anemia.

Clinical Features

The manifestations of vitamin $B_{12}$ deficiency are nonspecific. As with all anemias, findings include pallor, easy fatigability, and, in severe cases, dyspnea and even congestive heart failure. The increased destruction of erythroid progenitors may give rise to mild jaundice. Gastrointestinal signs and symptoms similar to those of folate deficiency are seen. The spinal cord disease begins with symmetric numbness, tingling, and burning in feet or hands, followed by unsteadiness of gait and loss of position sense, particularly in the toes. Although the anemia responds dramatically to parenteral vitamin $B_{12}$, the neurologic manifestations often fail to resolve. As discussed in Chapter 14, patients with pernicious anemia have an increased risk for the development of gastric carcinoma.

The diagnostic features of pernicious anemia include (1) low serum vitamin $B_{12}$ levels, (2) normal or elevated serum folate levels, (3) serum antibodies to intrinsic factor, (4) moderate to severe megaloblastic anemia, (5) leukopenia with hypersegmented granulocytes, and (6) a dramatic reticulocytic response (within 2 to 3 days) to parenteral administration of vitamin $B_{12}$.

## Aplastic Anemia

Aplastic anemia is a disorder in which *multipotent myeloid stem cells are suppressed, leading to bone marrow failure and pancytopenia*. It must be distinguished from pure red cell aplasia, in which only erythroid progenitors are affected and anemia is the only manifestation.

### PATHOGENESIS

In more than half of the cases, aplastic anemia is **idiopathic.** In the remainder, an exposure to a **known myelotoxic agent,** such as a drug or a chemical, can be identified. With some agents, the marrow damage is predictable, dose-related, and reversible. Included in this category are antineoplastic drugs (e.g., alkylating agents, antimetabolites), benzene, and chloramphenicol. In other instances, marrow toxicity occurs as an "idiosyncratic" or hypersensitivity reaction to small doses of known myelotoxic drugs (e.g., chloramphenicol) or to drugs such as sulfonamides, which are not myelotoxic in other persons. Aplastic anemia sometimes arises after certain viral infections, most often community-acquired viral hepatitis. The specific virus responsible is not known; hepatitis viruses A, B, and C are not the culprits. Marrow aplasia develops insidiously several months after recovery from the hepatitis and follows a relentless course.

The pathogenic events leading to marrow failure remain vague, but it seems that **autoreactive T cells** play an important role. This is supported by a variety of experimental data and clinical experience showing that aplastic anemia responds to immunosuppressive therapy aimed at T cells in 70% to 80% of cases. Much less clear are the events that trigger the T cell attack on marrow stem cells; viral antigens, drug-derived haptens, and/or genetic damage may create neoantigens within stem cells that serve as targets for the immune system.

Rare but interesting genetic conditions also are associated with marrow failure. From 5% to 10% of patients with "acquired" aplastic anemia have inherited **defects in telomerase,** which as noted earlier is needed for the maintenance and stability of chromosomes. It is hypothesized that the defect in telomerase leads to premature senescence of hematopoietic stem cells. Of further interest, the bone marrow cells in up to 50% of sporadic cases have unusually short telomeres, possibly as a consequence of as-yet undiscovered defects in telomerase, or of excessive replication of hematopoietic stem cells, which may lead to premature senescence. Some children with Fanconi anemia, an inherited disorder of DNA repair, also develop marrow aplasia.

### MORPHOLOGY

The bone marrow in aplastic anemia is markedly hypocellular, with greater than 90% of the intertrabecular space being occupied by fat. The limited cellularity often consists only of lymphocytes and plasma cells. Anemia may cause fatty change in the liver. Thrombocytopenia and granulocytopenia may result in hemorrhages and bacterial infections, respectively. The requirement for transfusions may eventually lead to hemosiderosis.

### Clinical Course

Aplastic anemia affects persons of all ages and both sexes. The slowly progressive *anemia* causes the insidious development of weakness, pallor, and dyspnea. *Thrombocytopenia* often manifests with petechiae and ecchymoses. *Granulocytopenia* may be manifested by frequent and persistent minor infections or by the sudden onset of chills, fever, and prostration. It is important to separate aplastic anemia from anemias caused by marrow infiltration (myelophthisic anemia), "aleukemic leukemia," and granulomatous diseases, which may have similar clinical presentations but are easily distinguished on examination of the bone marrow. Aplastic anemia does not cause splenomegaly; if it is present, another diagnosis should be sought. Typically, the red cells are normochromic and normocytic or slightly macrocytic. *Reticulocytes are reduced* in number (reticulocytopenia).

The prognosis is unpredictable. Withdrawal of drugs sometimes leads to remission, but this is the exception rather than the rule. The idiopathic form carries a poor prognosis if left untreated. Bone marrow transplantation often is curative, particularly in nontransfused patients younger than 40 years of age. Transfusions sensitize patients to alloantigens, producing a high rate of engraftment failure; thus, they must be minimized in persons eligible for bone marrow transplantation. Successful transplantation requires "conditioning" with high doses of immunosuppressive radiation or chemotherapy, reinforcing the notion that autoimmunity has an important role in the disease. As mentioned earlier, patients who are poor transplantation candidates often benefit from immunosuppressive therapy.

## Myelophthisic Anemia

Myelophthisic anemia is caused by *extensive infiltration of the marrow by tumors or other lesions*. It most commonly is associated with metastatic breast, lung, or prostate cancer. Other tumors, advanced tuberculosis, lipid storage disorders, and osteosclerosis can produce a similar clinical picture. The principal manifestations include anemia and thrombocytopenia; in general, the white cell series is less affected. Characteristically misshapen red cells, some *resembling teardrops,* are seen in the peripheral blood. Immature granulocytic and erythrocytic precursors also may be present (*leukoerythroblastosis*) along with mild leukocytosis. Treatment is directed at the underlying condition.

### SUMMARY

#### Anemias of Diminished Erythropoiesis

**Iron Deficiency Anemia**

- Caused by chronic bleeding or inadequate iron intake; results in insufficient hemoglobin synthesis and hypochromic, microcytic red cells

**Anemia of Chronic Disease**

- Caused by inflammatory cytokines, which increase hepcidin levels and thereby sequester iron in macrophages, and also suppress erythropoietin production

**Megaloblastic Anemia**
- Caused by deficiencies of folate or vitamin $B_{12}$ that lead to inadequate synthesis of thymidine and defective DNA replication
- Results in enlarged abnormal hematopoietic precursors (megaloblasts), ineffective hematopoiesis, macrocytic anemia, and (in most cases) pancytopenia

**Aplastic Anemia**
- Caused by bone marrow failure (hypocellularity) due to diverse causes, including exposures to toxins and radiation, idiosyncratic reactions to drugs and viruses, and inherited defects in telomerase and DNA repair

**Myelophthisic Anemia**
- Caused by replacement of the bone marrow by infiltrative processes such as metastatic carcinoma and granulomatous disease
- Leads to the appearance of early erythroid and granulocytic precursors (leukoerythroblastosis) and teardrop-shaped red cells in the peripheral blood

## POLYCYTHEMIA

Polycythemia, or *erythrocytosis,* denotes an increase in red cells per unit volume of peripheral blood, usually in association with an increase in hemoglobin concentration. Polycythemia may be *absolute* (defined as an increase in total red cell mass) or *relative.* Relative polycythemia results from dehydration, such as occurs with water deprivation, prolonged vomiting, diarrhea, or the excessive use of diuretics. Absolute polycythemia is described as *primary* when the increased red cell mass results from an autonomous proliferation of erythroid progenitors, and *secondary* when the excessive proliferation stems from elevated levels of erythropoietin. Primary polycythemia (polycythemia vera) is a clonal, neoplastic myeloproliferative disorder considered later in this chapter. The increases in erythropoietin that cause secondary forms of absolute polycythemia have a variety of causes (Table 11–5).

**Table 11–5** Pathophysiologic Classification of Polycythemia

| |
|---|
| **Relative** |
| Reduced plasma volume (hemoconcentration) |
| **Absolute** |
| Primary |
| Abnormal proliferation of myeloid stem cells, normal or low erythropoietin levels (polycythemia vera); inherited activating mutations in the erythropoietin receptor (rare) |
| Secondary |
| Increased erythropoietin levels<br>*Adaptive:* lung disease, high-altitude living, cyanotic heart disease<br>*Paraneoplastic:* erythropoietin-secreting tumors (e.g., renal cell carcinoma, hepatomacellular carcinoma, cerebellar hemangioblastoma)<br>*Surreptitious:* endurance athletes |

# WHITE CELL DISORDERS

Disorders of white cells include deficiencies (leukopenias) and proliferations, which may be reactive or neoplastic. Reactive proliferation in response to a primary, often microbial, disease is common. Neoplastic disorders, though less common, are more ominous: They cause approximately 9% of all cancer deaths in adults and a staggering 40% in children younger than 15 years of age.

Presented next are brief descriptions of some non-neoplastic conditions, followed by more detailed considerations of the malignant proliferations of white cells.

## NON-NEOPLASTIC DISORDERS OF WHITE CELLS

### Leukopenia

Leukopenia results most commonly from a decrease in granulocytes, the most numerous circulating white cells. Lymphopenia is much less common; it is associated with rare congenital immunodeficiency diseases, advanced human immunodeficiency virus (HIV) infection, and treatment with high doses of corticosteroids. Only the more common leukopenias of granulocytes are discussed here.

#### *Neutropenia/Agranulocytosis*

A reduction in the number of granulocytes in blood is known as *neutropenia* or, when severe, *agranulocytosis.* Neutropenic persons are susceptible to bacterial and fungal infections, in whom they can be fatal. The risk of infection rises sharply as the neutrophil count falls below 500 cells/μL.

#### PATHOGENESIS

The mechanisms underlying neutropenia can be divided into two broad categories:
- **Decreased granulocyte production.** Clinically important reductions in granulopoiesis are most often caused by marrow failure (as occurs in aplastic anemia), extensive replacement of the marrow by tumor (such as in leukemias), or cancer chemotherapy. Alternatively, some neutropenias are isolated, with only the differentiation of committed granulocytic precursors being affected. The forms of neutropenia are most often caused by certain drugs or, less commonly, by neoplastic proliferations of cytotoxic T cells and natural killer (NK) cells.

- **Increased granulocyte destruction.** This can be encountered with immune-mediated injury (triggered in some cases by drugs) or in overwhelming bacterial, fungal, or rickettsial infections due to increased peripheral utilization. Splenomegaly also can lead to the sequestration and accelerated removal of neutrophils.

## MORPHOLOGY

The alterations in the bone marrow depend on the underlying cause of the neutropenia. **Marrow hypercellularity** is seen when there is excessive neutrophil destruction or ineffective granulopoiesis, such as occurs in megaloblastic anemia. By contrast, **agents such as drugs that cause neutropenia do so by suppressing granulocytopoiesis,** thus decreasing the numbers of granulocytic precursors. Erythropoiesis and megakaryopoiesis can be normal if the responsible agent specifically affects granulocytes, but most myelotoxic drugs reduce marrow elements from all lineages.

### Clinical Features

The initial symptoms often are malaise, chills, and fever, with subsequent marked weakness and fatigability. Infections constitute the major problem. They commonly take the form of ulcerating, necrotizing lesions of the gingiva, floor of the mouth, buccal mucosa, pharynx, or other sites within the oral cavity (agranulocytic angina). Owing to the lack of leukocytes, such lesions often contain large masses or sheets of microorganisms. In addition to removal of the offending drug and control of infection, treatment efforts may also include granulocyte colony-stimulating factor, which stimulates neutrophil production by the bone marrow.

## Reactive Leukocytosis

An increase in the number of white cells in the blood is common in a variety of inflammatory states caused by microbial and nonmicrobial stimuli. Leukocytoses are relatively nonspecific and are classified according to the particular white cell series that is affected (Table 11–6). As discussed later on, in some cases reactive leukocytosis may mimic leukemia. Such *"leukemoid" reactions* must be distinguished from true white cell malignancies. Infectious mononucleosis merits separate consideration because it gives rise to a distinctive syndrome associated with lymphocytosis.

### *Infectious Mononucleosis*

Infectious mononucleosis is an acute, self-limited disease of adolescents and young adults that is caused by Epstein-Barr virus (EBV), a member of the herpesvirus family. The infection is characterized by (1) fever, sore throat, and generalized lymphadenitis and (2) a lymphocytosis of activated, CD8+ T cells. Of note, cytomegalovirus infection induces a similar syndrome that can be differentiated only by serologic methods.

EBV is ubiquitous in all human populations. In the developing world, EBV infection in early childhood is nearly universal. At this age, symptomatic disease is uncommon, and even though infected hosts mount an immune response (described later), more than half continue to shed virus. By contrast, in developed countries with better standards of hygiene, infection usually is delayed until adolescence or young adulthood. For unclear reasons, only about 20% of healthy seropositive persons in developed countries shed the virus, and only about 50% of those who are exposed to the virus acquire the infection.

**Table 11–6** Causes of Leukocytosis

| |
|---|
| **Neutrophilic Leukocytosis** |
| Acute bacterial infections (especially those caused by pyogenic organisms); sterile inflammation caused by, for example, tissue necrosis (myocardial infarction, burns) |
| **Eosinophilic Leukocytosis (Eosinophilia)** |
| Allergic disorders such as asthma, hay fever, allergic skin diseases (e.g., pemphigus, dermatitis herpetiformis); parasitic infestations; drug reactions; certain malignancies (e.g., Hodgkin lymphoma and some non-Hodgkin lymphomas); collagen-vascular disorders and some vasculitides; atheroembolic disease (transient) |
| **Basophilic Leukocytosis (Basophilia)** |
| Rare, often indicative of a myeloproliferative disease (e.g., chronic myelogenous leukemia) |
| **Monocytosis** |
| Chronic infections (e.g., tuberculosis), bacterial endocarditis, rickettsiosis, and malaria; collagen vascular diseases (e.g., systemic lupus erythematosus); and inflammatory bowel diseases (e.g., ulcerative colitis) |
| **Lymphocytosis** |
| Accompanies monocytosis in many disorders associated with chronic immunologic stimulation (e.g., tuberculosis, brucellosis); viral infections (e.g., hepatitis A, cytomegalovirus, Epstein-Barr virus); *Bordetella pertussis* infection |

## PATHOGENESIS

Transmission to a seronegative "kissing cousin" usually involves direct oral contact. It is hypothesized (but has not been proved) that the virus initially infects oropharyngeal epithelial cells and then spreads to underlying lymphoid tissue (tonsils and adenoids), where mature B cells are infected. The infection of B cells takes one of two forms. In a minority of cells, the infection is lytic, leading to viral replication and eventual cell lysis accompanied by the release of virions. In most cells, however, the infection is nonproductive, and the virus persists in latent form as an extrachromosomal episome. **B cells that are latently infected with EBV undergo polyclonal activation and proliferation,** as a result of the action of several EBV proteins (Chapter 5). These cells disseminate in the circulation and secrete antibodies with several specificities, including the well-known heterophil anti-sheep red cell antibodies that are detected in diagnostic tests for mononucleosis. During acute infections, EBV is shed in the saliva; it is not known if the source of these virions is oropharyngeal epithelial cells or B cells.

A normal immune response is extremely important in controlling the proliferation of EBV-infected B cells and the spread of the virus. Early in the course of the infection, IgM

antibodies are formed against viral capsid antigens. Later the serologic response shifts to IgG antibodies, which persist for life. More important in the control of the EBV-positive B cell proliferation are cytotoxic CD8+ T cells and NK cells. **Virus-specific CD8+ T cells appear in the circulation as atypical lymphocytes, a finding that is characteristic of mononucleosis.** In otherwise healthy persons, the fully developed humoral and cellular responses to EBV act as brakes on viral shedding. In most cases, however, a small number of latently infected EBV-positive B cells escape the immune response and persist for the life of the patient. As described later, impaired T cell immunity in the host can have disastrous consequences.

## MORPHOLOGY

The major alterations involve the blood, lymph nodes, spleen, liver, central nervous system, and occasionally other organs. There is peripheral blood **leukocytosis**; the white cell count is usually between 12,000 and 18,000 cells/μL. Typically more than half of these cells are large **atypical lymphocytes,** 12 to 16 μm in diameter, with an oval, indented, or folded nucleus and abundant cytoplasm with a few azurophilic granules (Fig. 11–12). These atypical lymphocytes, which are sufficiently distinctive to suggest the diagnosis, are mainly CD8+ T cells.

**Lymphadenopathy** is common and is most prominent in the posterior cervical, axillary, and groin regions. On histologic examination, the enlarged nodes are flooded by atypical lymphocytes, which occupy the paracortical (T cell) areas. A few cells resembling Reed-Sternberg cells, the hallmark of Hodgkin lymphoma, often are seen. Because of these atypical features, special tests are sometimes needed to distinguish the reactive changes of mononucleosis from lymphoma.

The **spleen** is enlarged in most cases, weighing between 300 and 500 g, and exhibits a heavy infiltration of atypical lymphocytes. As a result of the rapid increase in splenic size and the infiltration of the trabeculae and capsule by the lymphocytes, such spleens are fragile and prone to rupture after even minor trauma.

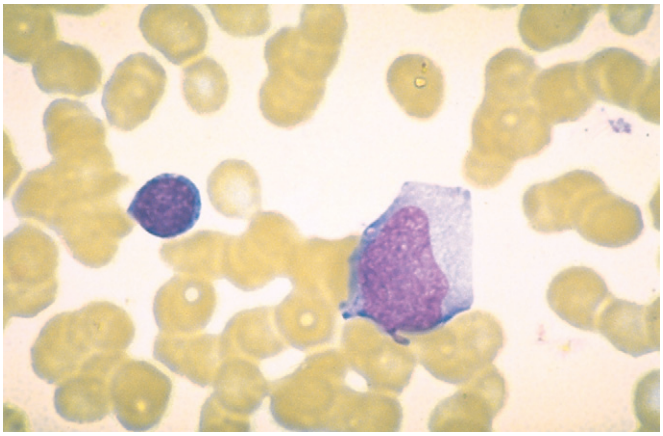

**Figure 11–12** Atypical lymphocytes in infectious mononucleosis—peripheral blood smear. The cell on the *left* is a normal small resting lymphocyte with a compact nucleus and scant cytoplasm. By contrast, the atypical lymphocyte on the *right* has abundant cytoplasm and a large nucleus with dispersed chromatin.

Atypical lymphocytes usually also infiltrate the portal areas and sinusoids of the **liver.** Scattered apoptotic cells or foci of parenchymal necrosis associated with a lymphocytic infiltrate also may be present—a picture that can be difficult to distinguish from that in other forms of viral hepatitis.

### Clinical Features

Although mononucleosis classically manifests with fever, sore throat, lymphadenitis, and the other features mentioned earlier, atypical presentations are not unusual. Sometimes there is little or no fever and only fatigue and lymphadenopathy, raising the specter of lymphoma; fever of unknown origin, unassociated with lymphadenopathy or other localized findings; hepatitis that is difficult to differentiate from one of the hepatotropic viral syndromes (Chapter 15); or a febrile rash resembling rubella. Ultimately, the diagnosis depends on the following findings, in increasing order of specificity: (1) lymphocytosis with the characteristic atypical lymphocytes in the peripheral blood, (2) a positive heterophil reaction (Monospot test), and (3) a rising titer of antibodies specific for EBV antigens (viral capsid antigens, early antigens, or Epstein-Barr nuclear antigen). In most patients, mononucleosis resolves within 4 to 6 weeks, but sometimes the fatigue lasts longer. Occasionally, one or more complications supervene. Perhaps the most common of these is hepatic dysfunction, associated with jaundice, elevated hepatic enzyme levels, disturbed appetite, and, rarely, even liver failure. Other complications involve the nervous system, kidneys, bone marrow, lungs, eyes, heart, and spleen (including fatal splenic rupture).

EBV is a potent transforming virus that plays a role in the pathogenesis of a number of human malignancies, including several types of B cell lymphoma (Chapter 5). A serious complication in those lacking T cell immunity (such as organ and bone marrow transplant recipients and HIV-infected individuals) is unimpeded EBV-driven B cell proliferation. This process can be initiated by an acute infection or the reactivation of a latent B cell infection and generally begins as a polyclonal proliferation that transforms to overt monoclonal B cell lymphoma over time. Reconstitution of immunity (e.g., by cessation of immunosuppressive drugs) is sometimes sufficient to cause complete regression of the B cell proliferation, which is uniformly fatal if left untreated.

The importance of T cells and NK cells in the control of EBV infection is driven home by X-linked lymphoproliferative syndrome, a rare inherited immunodeficiency characterized by an ineffective immune response to EBV. Most affected boys have mutations in the *SH2D1A* gene, which encodes a signaling protein that participates in the activation of T cells and NK cells and in antibody production. In more than 50% of cases, EBV causes an acute overwhelming infection that is usually fatal. Others succumb to lymphoma or infections related to hypogammaglobulinemia, the basis of which is not understood.

## Reactive Lymphadenitis

Infections and nonmicrobial inflammatory stimuli often activate immune cells residing in lymph nodes, which act as defensive barriers. Any immune response against foreign

antigens can lead to lymph node enlargement (lymphadenopathy). The infections causing lymphadenitis are varied and numerous, and may be acute or chronic. In most instances the histologic appearance of the lymph node reaction is nonspecific. A somewhat distinctive form of lymphadenitis that occurs with cat-scratch disease is described separately later.

### *Acute Nonspecific Lymphadenitis*

This form of lymphadenitis may be isolated to a group of nodes draining a local infection, or be generalized, as in systemic infectious and inflammatory conditions.

#### MORPHOLOGY

Inflamed nodes in acute nonspecific lymphadenitis are swollen, gray-red, and engorged. Histologically, there are **large germinal centers** containing numerous mitotic figures. When the cause is a pyogenic organism, a neutrophilic infiltrate is seen around the follicles and within the lymphoid sinuses. With severe infections, the centers of follicles can undergo necrosis, leading to the formation of an abscess.

Affected nodes are tender and may become fluctuant if abscess formation is extensive. The overlying skin is frequently red and may develop draining sinuses. With control of the infection the lymph nodes may revert to a normal "resting" appearance or if damaged undergo scarring.

### *Chronic Nonspecific Lymphadenitis*

Depending on the causative agent, chronic nonspecific lymphadenitis can assume one of three patterns: follicular hyperplasia, paracortical hyperplasia, or sinus histiocytosis.

#### MORPHOLOGY

**Follicular Hyperplasia.** This pattern occurs with infections or inflammatory processes that activate B cells, which migrate into B cell follicles and create the **follicular (or germinal center) reaction.** The reactive follicles contain numerous activated B cells, scattered T cells, and phagocytic macrophages containing nuclear debris (tingible body macrophages), and a meshwork of antigen-presenting follicular dendritic cells. Causes of follicular hyperplasia include **rheumatoid arthritis, toxoplasmosis,** and early **HIV infection.** This form of lymphadenitis can be confused morphologically with follicular lymphoma (discussed later). Findings that favor follicular hyperplasia are (1) the preservation of the lymph node architecture; (2) variation in the shape and size of the germinal centers; (3) the presence of a mixture of germinal center lymphocytes of varying shape and size; and (4) prominent phagocytic and mitotic activity in germinal centers.

**Paracortical Hyperplasia.** This pattern is caused by immune reactions involving the **T cell regions** of the lymph node. When activated, parafollicular T cells transform into large proliferating immunoblasts that can efface the B cell follicles. Paracortical hyperplasia is encountered in **viral infections** (such as EBV), after certain **vaccinations** (e.g., smallpox), and in immune reactions induced by **drugs** (especially phenytoin).

**Sinus Histiocytosis.** This reactive pattern is characterized by distention and prominence of the lymphatic sinusoids, owing to a marked **hypertrophy of lining endothelial cells** and an **infiltrate of macrophages (histiocytes).** It often is encountered in lymph nodes draining cancers and may represent an immune response to the tumor or its products.

### *Cat-Scratch Disease*

Cat-scratch disease is a self-limited lymphadenitis caused by the bacterium *Bartonella henselae.* It is primarily a disease of childhood; 90% of the patients are younger than 18 years of age. It manifests with regional lymphadenopathy, most frequently in the axilla and the neck. The nodal enlargement appears approximately 2 weeks after a feline scratch or, less commonly, after a splinter or thorn injury. An inflammatory nodule, vesicle, or eschar is sometimes visible at the site of the skin injury. In most patients the lymph node enlargement regresses over a period of 2 to 4 months. Encephalitis, osteomyelitis, or thrombocytopenia may develop in rare patients.

#### MORPHOLOGY

The nodal changes in cat-scratch disease are quite characteristic. Initially sarcoid-like granulomas form, but these then undergo central necrosis associated with an infiltrate of neutrophils. These **irregular stellate necrotizing granulomas** are similar in appearance to those seen in a limited number of other infections, such as lymphogranuloma venereum. The microbe is extracellular and can be visualized with silver stains. The diagnosis is based on a history of exposure to cats, the characteristic clinical findings, a positive result on serologic testing for antibodies to *Bartonella*, and the distinctive morphologic changes in the lymph nodes.

## NEOPLASTIC PROLIFERATIONS OF WHITE CELLS

Tumors are the most important disorders of white cells. They can be divided into three broad categories based on the origin of the tumor cells:

- *Lymphoid neoplasms,* which include non-Hodgkin lymphomas (NHLs), Hodgkin lymphomas, lymphocytic leukemias, and plasma cell neoplasms and related disorders. In many instances tumors are composed of cells resembling some normal stage of lymphocyte differentiation, a feature that serves as one of the bases for their classification.
- *Myeloid neoplasms* arise from progenitor cells that give rise to the formed elements of the blood: granulocytes, red cells, and platelets. The myeloid neoplasms fall into three fairly distinct subcategories: *acute myeloid leukemias,* in which immature progenitor cells accumulate in the bone marrow; *myeloproliferative disorders,* in which an inappropriate increase in the production of formed

blood elements leads to elevated blood cell counts; and *myelodysplastic syndromes,* which are characteristically associated with ineffective hematopoiesis and cytopenias.
- *Histiocytic neoplasms* include proliferative lesions of macrophages and dendritic cells. Of special interest is a spectrum of proliferations of Langerhans cells (*Langerhans cell histiocytoses*).

## Lymphoid Neoplasms

The numerous lymphoid neoplasms vary widely in their clinical presentation and behavior, and thus present challenges to students and clinicians alike. Some characteristically manifest as *leukemias,* with involvement of the bone marrow and the peripheral blood. Others tend to manifest as *lymphomas,* tumors that produce masses in lymph nodes or other tissues. *Plasma cell tumors* usually arise within the bones and manifest as discrete masses, causing systemic symptoms related to the production of a complete or partial monoclonal immunoglobulin. While these tendencies are reflected in the names given to these entities, in reality all lymphoid neoplasms have the potential to spread to lymph nodes and various tissues throughout the body, especially the liver, spleen, bone marrow, and peripheral blood. *Because of their overlapping clinical behavior, the various lymphoid neoplasms can be distinguished with certainty only by the morphologic and molecular characteristics of the tumor cells.* Stated another way, for purposes of diagnosis and prognostication, it is most important to focus on what the tumor cell is, not where it resides in the patient.

Two groups of lymphomas are recognized: *Hodgkin lymphomas* and *non-Hodgkin lymphomas.* Although both arise most commonly in lymphoid tissues, Hodgkin lymphoma is set apart by the presence of distinctive neoplastic Reed-Sternberg giant cells (see later), which usually are greatly outnumbered by non-neoplastic inflammatory cells. The biologic behavior and clinical treatment of Hodgkin lymphoma also are different from those of NHLs, making the distinction of practical importance.

Historically, few areas of pathology evoked as much controversy and confusion as the classification of lymphoid neoplasms, which is perhaps inevitable in view of the intrinsic complexity of the immune system, from which they arise. Great progress has been made over the past several decades, however, and an international working group of pathologists, molecular biologists, and clinicians working on behalf of the World Health Organization (WHO) has formulated a widely accepted classification scheme that relies on a combination of morphologic, phenotypic, genotypic, and clinical features. As background for the subsequent discussion of this classification, certain important principles warrant consideration:

- B and T cell tumors often are composed of cells that are arrested at or derived from a specific stage of their normal differentiation (Fig. 11–13). The diagnosis and classification of these tumors rely heavily on tests (either immunohistochemistry or flow cytometry) that detect lineage-specific antigens (e.g., B cell, T cell, and NK cell markers) and markers of maturity. By convention, many such markers are identified by their cluster of differentiation (CD) number.
- The most common lymphomas are derived from germinal center or post–germinal center B cells. This conclusion is drawn from molecular analyses showing that most B cell lymphomas have undergone somatic hypermutation, an event confined to germinal center B cells. Normal germinal center B cells also undergo immunoglobulin class switching, an event that allows B cells to express immunoglobulins other than IgM. Class switching and somatic hypermutation are mistake-prone forms of regulated genomic instability, which places germinal center B cells at high risk for potentially transforming mutations. In fact, many of the recurrent chromosomal translocations found in mature B cell malignancies involve the immunoglobulin loci and appear to stem from "accidents" during attempted diversification of the immunoglobulin genes. In this regard, it is interesting that mature T cells, which are genomically stable, give rise to lymphomas infrequently and only very rarely have chromosomal translocations involving the T cell receptor loci.
- All lymphoid neoplasms are derived from a single transformed cell and are therefore clonal. As described in Chapter 4, differentiating precursor B and T cells rearrange their antigen receptor genes, thereby ensuring that each lymphocyte makes a single, unique antigen receptor. Because antigen receptor gene rearrangement virtually always precedes transformation, the daughter cells derived from a given malignant progenitor share the same antigen receptor gene configuration and synthesize identical antigen receptor proteins (either immunoglobulins or T cell receptors). Thus, analyses of antigen receptor genes and their protein products can be used to differentiate clonal neoplasms from polyclonal, reactive processes.
- Lymphoid neoplasms often disrupt normal immune function. Both immunodeficiency (as evident by increased susceptibility to infection) and autoimmunity may be seen, sometimes in the same patient. Ironically, patients with inherited or acquired immunodeficiency are themselves at high risk for the development of certain lymphoid neoplasms, particularly those associated with EBV infection.
- Although NHLs often manifest at a particular tissue site, sensitive molecular assays usually show the tumor to be widely disseminated at diagnosis. As a result, with few exceptions, only systemic therapies are curative. By contrast, Hodgkin lymphoma often arises at a single site and spreads in a predictable fashion to contiguous lymph node groups. For this reason, early in its course, it is sometimes treated with local therapy alone.

The WHO classification of lymphoid neoplasms considers the morphology, cell of origin (determined by immunophenotyping), clinical features, and genotype (e.g., karyotype, presence of viral genomes) of each entity. It encompasses all lymphoid neoplasms, including leukemias and multiple myeloma, and separates them on the basis of origin into three major categories: (1) tumors of B cells, (2) tumors of T cells and NK cells, and (3) Hodgkin lymphoma.

An updated version of the WHO classification of lymphoid neoplasms is presented in Table 11–7. As is evident, the diagnostic entities are numerous. The focus here is on the following subsets of neoplasms:

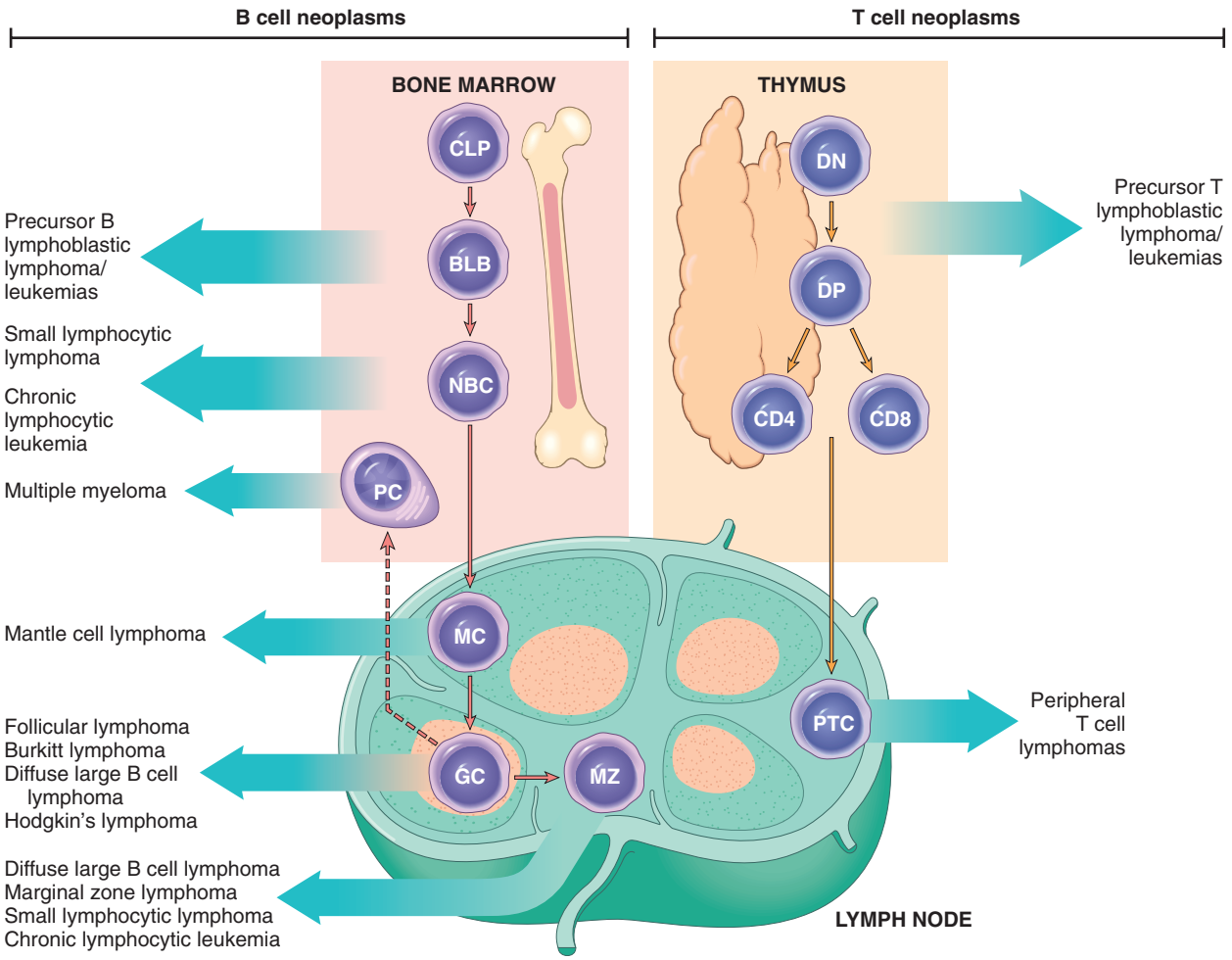


**Figure 11–13** Origin of lymphoid neoplasms. Stages of B and T cell differentiation from which specific lymphoid and tumors emerge are shown. BLB, pre-B lymphoblast; CLP, common lymphoid progenitor; DN, CD4–/CD8– (double-negative) pro-T cell; DP, CD4+/CD8+ (double-positive) pre-T cell; GC, germinal center B cell; MC, mantle zone B cell; MZ, marginal zone B cell; NBC, naive B cell; PC, plasma cell; PTC, peripheral T cell.

- Precursor B and T cell lymphoblastic lymphoma/leukemia—commonly called acute lymphoblastic leukemia (ALL)
- Chronic lymphocytic leukemia/small lymphocytic lymphoma
- Follicular lymphoma
- Mantle cell lymphoma
- Diffuse large B cell lymphomas
- Burkitt lymphoma
- Multiple myeloma and related plasma cell tumors
- Hodgkin lymphoma

Together these neoplasms constitute more than 90% of the lymphoid tumors seen in the United States.

The salient features of the more common lymphoid leukemias, non-Hodgkin lymphomas, and plasma cell tumors are summarized in Table 11–8. Hodgkin lymphomas will be discussed later. Also included in the following discussion are a few of the uncommon entities with distinctive clinicopathologic features.

### *Acute Lymphoblastic Leukemia/Lymphoblastic Lymphoma*

Acute lymphoblastic leukemia (ALL) and lymphoblastic lymphoma are aggressive tumors, composed of immature lymphocytes (lymphoblasts), that occur predominantly in children and young adults. The various lymphoblastic tumors are morphologically indistinguishable, often cause similar signs and symptoms, and are treated similarly. These tumors are therefore considered together here.

Just as B cell precursors normally develop within the bone marrow, pre-B cell tumors usually manifest in the bone marrow and peripheral blood as leukemias. Similarly, pre-T cell tumors commonly manifest as masses involving the thymus, the normal site of early T cell differentiation. However, pre-T cell "lymphomas" often progress rapidly to a leukemic phase, and other pre-T cell tumors seem to involve only the marrow at presentation. Hence, *both pre-B and pre-T cell tumors usually take on the clinical appearance of ALL at some time during their course.* As a group, ALLs constitute 80% of childhood leukemia, peaking in incidence at age 4, with most cases being of pre-B cell origin. The pre-T cell tumors are most common in male patients between 15 and 20 years of age.

**Table 11–7** WHO Classification of Lymphoid Neoplasms*

| |
|---|
| **Precursor B Cell Neoplasms** |
| *Precursor B cell leukemia/lymphoma (B-ALL)* |
| **Peripheral B Cell Neoplasms** |
| *B cell chronic lymphocytic leukemia (CLL)/small lymphocytic lymphoma (SLL)* |
| B cell prolymphocytic leukemia |
| Lymphoplasmacytic lymphoma |
| *Mantle cell lymphoma* |
| *Follicular lymphoma* |
| *Extranodal marginal zone lymphoma* |
| Splenic and nodal marginal zone lymphoma |
| Hairy cell leukemia |
| *Plasmacytoma/plasma cell myeloma* |
| *Diffuse large B cell lymphoma (multiple subtypes)* |
| *Burkitt lymphoma* |
| **Precursor T Cell Neoplasms** |
| *Precursor T cell leukemia/lymphoma (T-ALL)* |
| **Peripheral T/NK Cell Neoplasms** |
| T cell prolymphocytic leukemia |
| T cell granular lymphocytic leukemia |
| *Mycosis fungoides/Sézary syndrome* |
| *Peripheral T cell lymphoma, unspecified* |
| Angioimmunoblastic T cell lymphoma |
| Anaplastic large cell lymphoma |
| Enteropathy-type T cell lymphoma |
| Panniculitis-like T cell lymphoma |
| Hepatosplenic γδ T cell lymphoma |
| Adult T cell lymphoma/leukemia |
| Extranodal NK/T cell lymphoma |
| Aggressive NK cell leukemia |
| **Hodgkin Lymphoma** |
| *Nodular sclerosis* |
| *Mixed cellularity* |
| Lymphocyte-rich |
| Lymphocyte-depletion |
| Lymphocyte predominance, nodular |

*Entries in *italics* are among the most common lymphoid tumors.
NK, natural killer; WHO, World Health Organization.

The pathogenesis, laboratory findings, and clinical features of ALL closely resemble those of acute myeloid leukemia (AML), the other major type of acute leukemia. Because of these similarities, the features common to the acute leukemias are reviewed first, followed by a discussion of those specific to ALL.

## PATHOGENESIS

The principal pathogenic defect in acute leukemia and lymphoblastic lymphoma is a block in differentiation. This "maturation arrest" stems from **acquired mutations in specific transcription factors that regulate the differentiation of immature lymphoid or myeloid progenitors.** Normal B cell, T cell, and myeloid differentiation are regulated by different lineage-specific transcription factors; accordingly, the mutated transcription factor genes found in acute leukemias derived from each of these lineages also are distinct. The most commonly mutated transcription factor genes are *TEL1*, *AML1*, *E2A*, *PAX5*, and *EBF* in ALLs of B cell origin (B-ALLs) and *TAL1* and *NOTCH1* in T cell ALLs (T-ALLs).

Acute leukemias also are associated with complementary acquired mutations that allow the tumor cells to proliferate in a growth factor–independent fashion. In B-ALL, one of the most important mutations of this type is a *BCR-ABL* fusion gene created by a (9;22) translocation (the so-called Philadelphia chromosome, for the city of its discovery). As discussed later on, the same translocation also is found in chronic myelogenous leukemia (CML). The *BCR-ABL* fusion gene encodes a BCR-ABL tyrosine kinase that constitutively activates the same pathways that are normally stimulated by growth factors. Some T-ALLs are associated with a different ABL fusion gene, *NUP214-ABL*, which has functional consequences similar to those of *BCR-ABL*.

**In tumors manifesting as "leukemias," blasts accumulating in the marrow suppress the growth of normal hematopoietic cells** by physical displacement and by other, poorly understood mechanisms. Eventually this suppression produces bone marrow failure, which accounts for the major clinical manifestations. The therapeutic goal, therefore, is to reduce the leukemic clone sufficiently to allow normal hematopoiesis to resume.

### Clinical Features of Acute Leukemias

Acute leukemias have the following characteristics:

- *Abrupt, stormy onset.* Most patients present for medical attention within 3 months of the onset of symptoms.
- *Clinical signs and symptoms related to suppressed marrow function,* including fatigue (due to anemia), fever (reflecting infections resulting from neutropenia), and bleeding (petechiae, ecchymoses, epistaxis, gum bleeding) secondary to thrombocytopenia
- *Bone pain and tenderness,* resulting from marrow expansion and infiltration of the subperiosteum
- *Generalized lymphadenopathy, splenomegaly, and hepatomegaly due to dissemination of the leukemic cells.* These are more pronounced in ALL than in AML.
- *Central nervous system manifestations,* including headache, vomiting, and nerve palsies resulting from meningeal spread. These are more common in children than in adults and in ALL than in AML.

### Laboratory Findings in Acute Leukemias

The diagnosis of acute leukemia rests on the identification of blasts. The peripheral blood sometimes contains no blasts (aleukemic leukemia); in such cases the diagnosis can be established only by marrow examination.

The white cell count is variable; it may be greater than 100,000 cells/μL but in about half of the patients is less than 10,000 cells/μL. Anemia is almost always present, and the platelet count usually is below 100,000/μL. Neutropenia is another common finding.

## MORPHOLOGY

**Because of differing responses to therapy, it is of great practical importance to distinguish ALL from AML.** By definition, in ALL blasts compose more than 25% of the marrow cellularity. In Wright-Giemsa–stained preparations, lymphoblasts have coarse, clumped chromatin, one or

**Table 11–8** Characteristics of the More Common Lymphoid Leukemias, Non-Hodgkin Lymphomas, and Plasma Cell Tumors

| Clinical Entity | Frequency | Salient Morphology | Immunophenotype | Comments |
|---|---|---|---|---|
| Precursor B cell lymphoblastic leukemia/ lymphoma | 85% of childhood acute leukemias | Lymphoblasts with irregular nuclear contours, condensed chromatin, small nucleoli, and scant, agranular cytoplasm | TdT+ immature B cells (CD19+, variable expression of other B cell markers) | Usually manifests as acute leukemia; less common in adults; prognosis is predicted by karyotype |
| Precursor T cell leukemia/ lymphoma | 15% of childhood acute leukemias; 40% of childhood lymphomas | Identical to precursor B cell lymphoblastic leukemia/ lymphoma | TdT+ immature T cells (CD2+, CD7+, variable expression of other T cell markers) | Most common in adolescent males; often manifests as a mediastinal mass associated with *NOTCH1* mutations |
| Small lymphocytic lymphoma/chronic lymphocytic leukemia | 3–4% of adult lymphomas; 30% of all leukemias | Small resting lymphocytes mixed with variable numbers of large activated cells; lymph nodes diffusely effaced | CD5+ B cell expressing surface immunoglobulin | Occurs in older adults; usually involves nodes, marrow, and spleen; most patients have peripheral blood involvement; indolent |
| Follicular lymphoma | 40% of adult lymphomas | Frequent small "cleaved" cells mixed with large cells; growth pattern usually is nodular (follicular) | CD10+, BCL2+ mature B cells that express surface immunoglobulin | Occurs in older adults; usually involves nodes, marrow, and spleen; associated with t(14;18); indolent |
| Mantle cell lymphoma | 3–4% of adult lymphomas | Small to intermediate-sized irregular lymphocytes growing in a diffuse pattern | CD5+ mature B cells that express cyclin D1 and have surface Ig | Occurs mainly in older males; usually involves nodes, marrow, spleen, and GI tract; t(11;14) is characteristic; moderately aggressive |
| Extranodal marginal zone lymphoma | ~5% of adult lymphomas | Malignant B cells home to epithelium, creating "lymphoepithelial lesions" | CD5–, CD10– mature B cells with surface immunoglobulin | Frequently occurs at extranodal sites involved by chronic inflammation; very indolent; may be cured by local excision |
| Diffuse large B cell lymphoma | 40–50% of adult lymphomas | Variable; most resemble large germinal center B cells; diffuse growth pattern | Mature B cells with variable expression of CD10 and surface immunoglobulin | Occurs in all age groups but most common in older adults; often arises at extranodal sites; aggressive |
| Burkitt lymphoma | <1% of lymphomas in the United States | Intermediate-sized round lymphoid cells with several nucleoli; diffuse growth pattern associated with apoptosis produces a "starry sky" appearance | Mature CD10+ B cells expressing surface immunoglobulin | Endemic in Africa, sporadic elsewhere; associated with immunosuppression and EBV (subset of cases); predominantly affects children; often manifests with visceral involvement; highly aggressive |
| Plasmacytoma/plasma cell myeloma | Most common lymphoid neoplasm in older adults | Plasma cells in sheets, sometimes with prominent nucleoli or inclusions containing immunoglobulins | Terminally differentiated plasma cells containing cytoplasmic immunoglobulins | Myeloma manifests as disseminated bone disease, often with destructive lytic lesions; hypercalcemia, renal insufficiency, and bacterial infections are common |
| Mycosis fungoides | Most common cutaneous lymphoid malignancy | In most cases, small lymphoid cells with markedly convoluted nuclei; cells often infiltrate the epidermis (Pautrier microabscesses) | CD4+ mature T cells | Manifests with localized or more generalized skin involvement; generally indolent<br>*Sézary syndrome*: a more aggressive variant characterized by diffuse skin erythema and peripheral blood involvement |
| Peripheral T cell lymphoma, not otherwise specified (NOS) | Most common adult T cell lymphoma | Variable; usually a spectrum of small to large lymphoid cells | Mature T cell phenotype (CD3+) | Probably spans a diverse collection of rare tumors; often disseminated, generally aggressive |

EBV, Epstein-Barr virus; GI, gastrointestinal; TdT, terminal deoxynucleotidyl transferase.

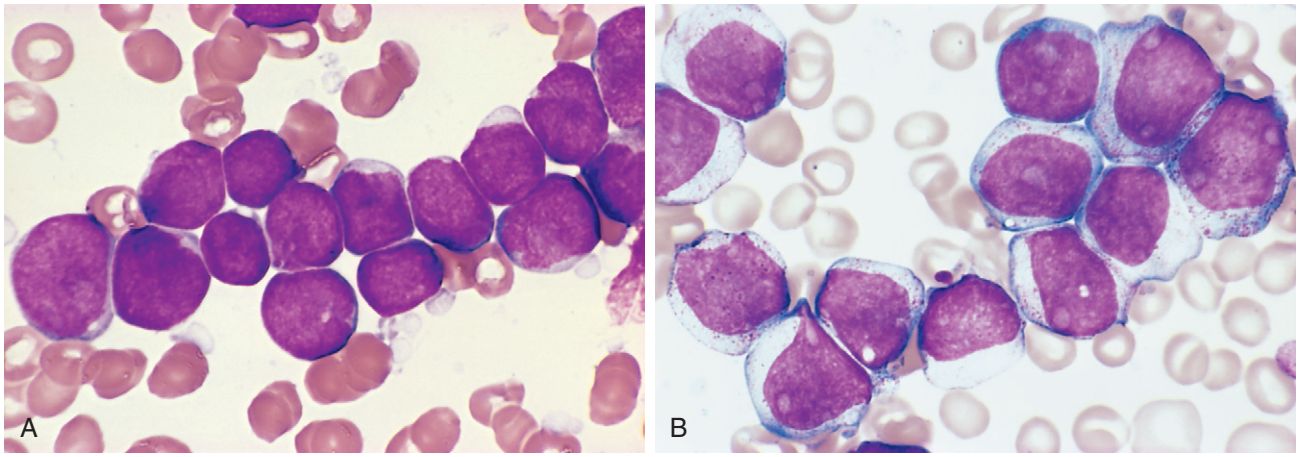


**Figure 11–14** Morphologic comparison of lymphoblasts and myeloblasts. **A,** Lymphoblastic leukemia/lymphoma. Lymphoblasts have condensed nuclear chromatin, small nucleoli, and scant agranular cytoplasm. **B,** Acute myeloid leukemia. Myeloblasts have delicate nuclear chromatin, prominent nucleoli, and fine azurophilic cytoplasmic granules.
*(Courtesy of Dr. Robert W. McKenna, Department of Pathology, University of Texas Southwestern Medical School, Dallas, Texas.)*

two nucleoli, and scant agranular cytoplasm (Fig. 11–14, *A*), whereas myeloblasts have nuclei with finer chromatin and more cytoplasm, which often contains granules (Fig. 11–14, *B*). Lymphoblasts also often contain cytoplasmic glycogen granules that are periodic acid–Schiff–positive, whereas myeloblasts are often peroxidase-positive.

With completion of the foregoing "short course" in acute leukemia, our focus now returns to the ALLs; the AMLs are discussed later.

***Genetic Features.*** Approximately 90% of ALLs have nonrandom karyotypic abnormalities. Most common in childhood pre-B cell tumors are hyperdiploidy (more than 50 chromosomes/cell) and the presence of a cryptic (12;21) translocation involving the *TEL1* and *AML1* genes, while about 25% of adult pre-B cell tumors harbor the (9;22) translocation involving the *ABL* and *BCR* genes. Pre-T cell tumors are associated with diverse chromosomal aberrations, including frequent translocations involving the T cell receptor loci and transcription factor genes such as *TAL1*.

***Immunophenotypic Features.*** Immunophenotyping is very useful in subtyping lymphoblastic tumors and distinguishing them from AML. Terminal deoxynucleotidyl transferase (TdT), an enzyme specifically expressed in pre-B and pre-T cells, is present in more than 95% of cases. Further subtyping of ALL into pre-B and pre-T cell types relies on stains for lineage-specific markers, such as CD19 (B cell) and CD3 (T cell).

### Prognosis

Treatment of childhood ALL is one of the great success stories in oncology. Children 2 to 10 years of age have the best prognosis; with intensive chemotherapy up to 80% are cured. Other groups of patients do less well. Variables correlated with worse outcomes include male gender; age younger than 2 or older than 10 years; a high leukocyte count at diagnosis; and molecular evidence of persistent disease on day 28 of treatment. Age-dependent differences in the frequencies of various karyotypic abnormalities largely explain the relationship of age to outcome. Tumors with "good prognosis" chromosomal aberrations (such as the t[12;21] and hyperdiploidy) are common in the 2- to 10-year age group. By contrast, rearrangements of the gene *MLL* or the presence of a *BCR-ABL* fusion gene, both associated with poor outcomes in B cell tumors, are most common in children younger than 2 years of age and adults, respectively. None of the chromosomal rearrangements found in pre-T cell tumors is predictive of outcome.

## *Chronic Lymphocytic Leukemia/Small Lymphocytic Lymphoma*

Chronic lymphocytic leukemia (CLL) and small lymphocytic lymphoma (SLL) are essentially identical, differing only in the extent of peripheral blood involvement. Somewhat arbitrarily, if the peripheral blood lymphocyte count exceeds 4000 cells/μL, the patient is diagnosed with CLL; if it does not, a diagnosis of SLL is made. Most patients with lymphoid neoplasms fit the diagnostic criteria for CLL, which is the most common leukemia of adults in the Western world. By contrast, SLL constitutes only 4% of NHLs. For unclear reasons, CLL/SLL is much less common in Asia.

### PATHOGENESIS

CLL/SLL is an indolent, slowly growing tumor, suggesting that increased tumor cell survival is more important than tumor cell proliferation in this disease. In line with this idea, the **tumor cells contain high levels of BCL2,** a protein that inhibits apoptosis (Chapters 1 and 5). Unlike in follicular lymphoma (discussed later), the *BCL2* gene is not rearranged. Some evidence suggests that *BCL2* is upregulated in the tumor cells as a consequence of the loss of several regulatory micro-RNAs that are encoded on chromosome 13.

Another important pathogenic aspect of CLL/SLL is **immune dysregulation.** Through unclear mechanisms, the accumulation of CLL/SLL cells suppresses normal B cell function, often resulting in **hypogammaglobulinemia.** Paradoxically, approximately 15% of patients have autoantibodies against their own red cells or platelets. When present, the

autoantibodies are made by nonmalignant bystander B cells, indicating that the tumor cells somehow impair immune tolerance. As time passes the tumor cells tend to displace the normal marrow elements, leading to anemia, neutropenia, and eventual thrombocytopenia.

## MORPHOLOGY

In SLL/CLL, sheets of small lymphocytes and scattered ill-defined foci of larger, actively dividing cells diffusely efface involved lymph nodes (Fig. 11–15, *A*). The predominant cells are small, resting lymphocytes with dark, round nuclei, and scanty cytoplasm (Fig. 11–15, *B*). The foci of mitotically active cells are called **proliferation centers,** which are pathognomonic for CLL/SLL. In addition to the lymph nodes, the bone marrow, spleen, and liver are involved in almost all cases. In most patients there is an absolute **lymphocytosis** featuring small, mature-looking lymphocytes. The circulating tumor cells are fragile and during the preparation of smears frequently are disrupted, producing characteristic **smudge cells.** Variable numbers of larger activated lymphocytes are also usually present in the blood smear.

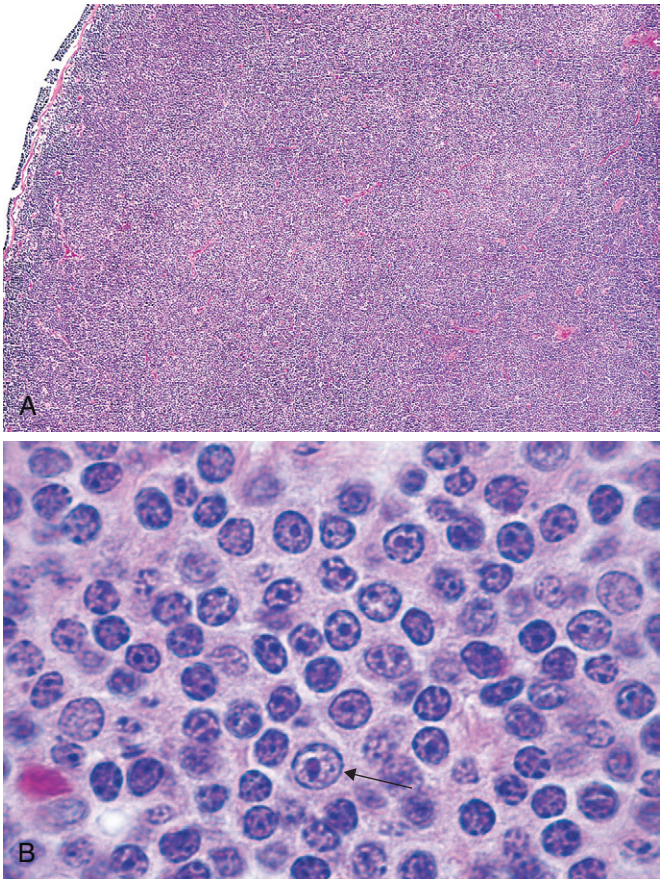


**Figure 11–15** Small lymphocytic lymphoma/chronic lymphocytic leukemia—lymph node. **A,** Low-power view shows diffuse effacement of nodal architecture. **B,** At high power, a majority of the tumor cells have the appearance of small, round lymphocytes. A "prolymphocyte," a larger cell with a centrally placed nucleolus, also is present in this field (*arrow*).

*(A, Courtesy of Dr. José Hernandez, Department of Pathology, University of Texas Southwestern Medical School, Dallas, Texas.)*

***Immunophenotypic and Genetic Features.*** CLL/SLL is a neoplasm of mature B cells expressing the pan-B cell markers CD19, CD20, and CD23 and surface immunoglobulin heavy and light chains. The tumor cells also express CD5. This is a helpful diagnostic clue, since among B cell lymphomas only CLL/SLL and mantle cell lymphoma (discussed later) commonly express CD5. Approximately 50% of tumors have karyotypic abnormalities, the most common of which are trisomy 12 and deletions of chromosomes 11, 13, and 17. "Deep sequencing" of CLL/SLL cell genomes has identified activating mutations in the Notch1 receptor in a subset of cases that predict a worse outcome. Unlike in other B cell neoplasms, chromosomal translocations are rare.

### Clinical Features

When first detected, CLL/SLL is often asymptomatic. The most common clinical signs and symptoms are nonspecific and include easy fatigability, weight loss, and anorexia. Generalized *lymphadenopathy* and *hepatosplenomegaly* are present in 50% to 60% of patients. The leukocyte count may be increased only slightly (in SLL) or may exceed 200,000 cells/μL. *Hypogammaglobulinemia* develops in more than 50% of the patients, usually late in the course, and leads to an increased susceptibility to bacterial infections. Less commonly *autoimmune hemolytic anemia* and *thrombocytopenia* are seen. The course and prognosis are extremely variable. Many patients live more than 10 years after diagnosis and die of unrelated causes. The median survival is 4 to 6 years, however, and as time passes, CLL/SLL tends to transform to more aggressive tumors that resemble either prolymphocytic leukemia or diffuse large B cell lymphoma. Once transformation occurs, the median survival is less than 1 year.

### *Follicular Lymphoma*

This relatively common tumor constitutes 40% of the adult NHLs in the United States. Like CLL/SLL, it occurs much less frequently in Asian populations.

## PATHOGENESIS

As in CLL/SLL, the neoplastic cells characteristically express BCL2, a protein that is absent from normal germinal center B cells. **Greater than 85% of tumors have a characteristic (14;18) translocation** that fuses the *BCL2* gene on chromosome 18 to the *IgH* locus on chromosome 14. This chromosomal rearrangement explains the inappropriate "overexpression" of BCL2 protein in the tumor cells and contributes to tumor cell survival. Whole genome sequencing of follicular lymphomas has identified loss-of-function mutations in several genes encoding histone acetyl transferases in about a third of cases, suggesting that epigenetic changes also contribute to the genesis of these tumors.

## MORPHOLOGY

Lymph nodes usually are effaced by a distinctly **nodular proliferation** (Fig 11–16, *A*). The tumor cells resemble

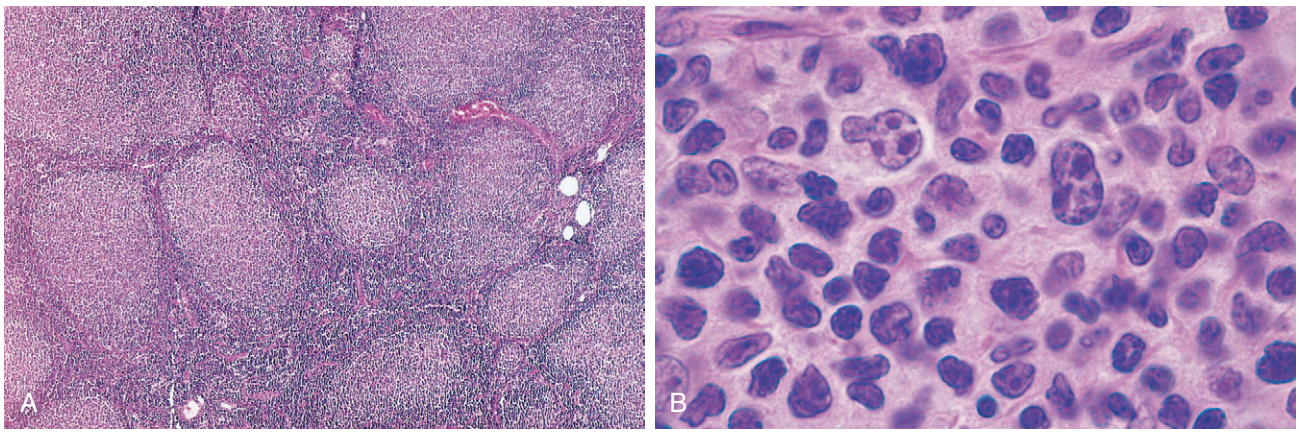


**Figure 11–16** Follicular lymphoma—lymph node. **A,** Nodular aggregates of lymphoma cells are present throughout. **B,** At high magnification, small lymphoid cells with condensed chromatin and irregular or cleaved nuclear outlines (centrocytes) are mixed with a population of larger cells with nucleoli (centroblasts).

*(A, Courtesy of Dr. Robert W. McKenna, Department of Pathology, University of Texas Southwestern Medical School, Dallas, Texas.)*

normal germinal center B cells. Most commonly the predominant neoplastic cells are slightly larger than resting lymphocytes that have angular "cleaved" nuclei with prominent indentations and linear infoldings (Fig. 11–16, *B*). The nuclear chromatin is coarse and condensed, and nucleoli are indistinct. These small, cleaved cells are mixed with variable numbers of larger cells with vesicular chromatin, several nucleoli, and modest amounts of cytoplasm. In most tumors, large cells are a minor component of the overall cellularity, mitoses are infrequent, and single necrotic cells (cells undergoing apoptosis) are not seen. These features help to distinguish follicular lymphoma from follicular hyperplasia, in which mitoses and apoptosis are prominent. Uncommonly, large cells predominate, a histologic pattern that correlates with a more aggressive clinical behavior.

***Immunophenotypic Features.*** These tumors express pan-B cell markers (CD19 and CD20), CD10, and BCL6, a transcription factor required for the generation of germinal center B cells.

### Clinical Features

Follicular lymphoma mainly occurs in adults older than 50 years of age and affects males and females equally. It usually manifests as *painless, generalized lymphadenopathy.* The bone marrow is almost always involved at diagnosis, while visceral disease is uncommon. While the natural history is prolonged (median survival, 7 to 9 years), *follicular lymphoma is not curable,* an unfortunate feature shared with most other relatively indolent lymphoid malignancies. As a result, therapy with cytotoxic drugs and rituximab (anti-CD20 antibody) is reserved for those with bulky, symptomatic disease. In about 40% of patients, follicular lymphoma progresses to diffuse large B cell lymphoma. This transformation is an ominous event, as tumors arising from such conversions are much less curable than de novo diffuse large B cell lymphomas, described later.

## *Mantle Cell Lymphoma*

Mantle cell lymphoma is composed of cells resembling the naive B cells found in the mantle zones of normal lymphoid follicles. It constitutes approximately 4% of all NHLs and occurs mainly in men older than 50 years of age.

### MORPHOLOGY

Mantle cell lymphoma may involve lymph nodes in a diffuse or vaguely nodular pattern. The tumor cells usually are slightly larger than normal lymphocytes and have an irregular nucleus, inconspicuous nucleoli, and scant cytoplasm. Less commonly, the cells are larger and morphologically resemble lymphoblasts. The bone marrow is involved in most cases and the peripheral blood in about 20% of cases. The tumor sometimes arises in the gastrointestinal tract, often manifesting as multifocal submucosal nodules that grossly resemble polyps (lymphomatoid polyposis).

***Immunophenotypic and Genetic Features.*** *Almost all tumors have an (11;14) translocation that fuses the cyclin D1 gene to the IgH locus.* This translocation dysregulates the expression of cyclin D1, a cell cycle regulator (Chapter 5), and is believed to be an important mediator of uncontrolled tumor cell growth. The tumor cells usually coexpress surface IgM and IgD, pan-B cell antigens (CD19 and CD20), and CD5. Mantle cell lymphoma is most readily distinguished from CLL/SLL by the absence of proliferation centers and the presence of cyclin D1 protein.

### Clinical Features

Most patients present with fatigue and lymphadenopathy and are found to have generalized disease involving the bone marrow, spleen, liver, and (often) the gastrointestinal tract. These tumors are moderately aggressive and incurable. The median survival is 3 to 5 years.

### *Diffuse Large B Cell Lymphoma*

Diffuse large B cell lymphoma is the *most common type of lymphoma in adults, accounting for approximately 50% of adult NHLs*. It includes several subtypes that share an aggressive natural history.

#### PATHOGENESIS

**About one third of tumors have rearrangements of the *BCL6* gene, located on 3q27, and an even higher fraction of tumors have activating point mutations in the BCL6 promoter.** Both aberrations result in increased levels of BCL6 protein, an important transcriptional regulator of gene expression in germinal center B cells. Another 30% of tumors have a (14;18) translocation involving the *BCL2* gene that results in overexpression of BCL2 protein. Some of these tumors may represent "transformed" follicular lymphomas. Indeed, like follicular lymphoma, about a third of diffuse large B cell lymphomas have loss-of-function mutations in genes encoding histone acetyl transferases, pointing to a potential role for epigenetic alterations in this tumor.

#### MORPHOLOGY

The neoplastic B cells are large (at least three to four times the size of resting lymphocytes) and vary in appearance from tumor to tumor. In many tumors, cells with round or oval nuclear contours, dispersed chromatin, several distinct nucleoli, and modest amounts of pale cytoplasm predominate (Fig. 11–17). In other tumors, the cells have a round or multilobate vesicular nucleus, one or two prominent centrally placed nucleoli, and abundant pale or basophilic cytoplasm. Occasionally, the tumor cells are highly anaplastic and include tumor giant cells resembling Reed-Sternberg cells, the malignant cells of Hodgkin lymphoma.

***Immunophenotypic Features.*** These mature B cell tumors express pan-B cell antigens, such as CD19 and CD20. Many also express surface IgM and/or IgG. Other antigens (e.g., CD10, BCL2) are variably expressed.

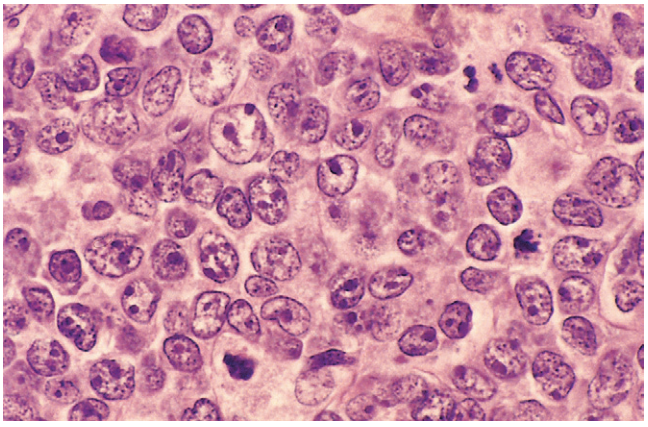

**Figure 11–17** Diffuse large B cell lymphoma—lymph node. The tumor cells have large nuclei with open chromatin and prominent nucleoli.
*(Courtesy of Dr. Robert W. McKenna, Department of Pathology, University of Texas Southwestern Medical School, Dallas, Texas.)*

***Subtypes of Diffuse Large B Cell Lymphoma.*** Several distinctive clinicopathologic subtypes are included in the category of diffuse large B cell lymphoma. *EBV-associated diffuse large B cell lymphomas* arise in the setting of the acquired immunodeficiency syndrome (AIDS), iatrogenic immunosuppression (e.g., in transplant recipients), and the elderly. In the post-transplantation setting, these tumors often begin as EBV-driven polyclonal B cell proliferations that may regress if immune function is restored. Otherwise, transformation to clonal large B cell lymphoma is observed over weeks to months. *Kaposi sarcoma herpesvirus* (KSHV), also called *human herpesvirus type 8* (HHV-8), is associated with rare *primary effusion lymphomas,* which may arise within the pleural cavity, pericardium, or peritoneum. These lymphomas are latently infected with KSHV, which encodes proteins homologous to several known oncoproteins, including cyclin D1, and are confined to immunosuppressed hosts. Of note, KSHV also is associated with Kaposi sarcoma in patients with AIDS (Chapters 4 and 9). *Mediastinal large B cell lymphoma* occurs most often in young women and shows a predilection for spread to abdominal viscera and the central nervous system.

#### Clinical Features

Although the median age at presentation is about 60 years, diffuse large B cell lymphomas can occur at any age; they constitute about 15% of childhood lymphomas. Patients typically present with a rapidly enlarging, often symptomatic mass at one or several sites. *Extranodal presentations are common.* Although the gastrointestinal tract and the brain are among the more frequent extranodal sites, tumors can appear in virtually any organ or tissue. Unlike the more indolent lymphomas (e.g., follicular lymphoma), involvement of the liver, spleen, and bone marrow is not common at diagnosis.

*Without treatment, diffuse large cell B cell lymphomas are aggressive and rapidly fatal.* With intensive combination chemotherapy and anti-CD20 immunotherapy, complete remissions are achieved in 60% to 80% of the patients; of these, approximately 50% remain free of disease and appear to be cured. For those not so fortunate, other aggressive treatments (e.g., high-dose chemotherapy and hematopoietic stem cell transplantation) offer some hope. Microarray-based molecular profiling of these tumors can predict response to current therapies and is being used to identify new, targeted therapy approaches.

### *Burkitt Lymphoma*

Burkitt lymphoma is endemic in parts of Africa and occurs sporadically in other geographic areas, including the United States. Histologically, the African and nonendemic diseases are identical, although there are clinical and virologic differences.

#### PATHOGENESIS

**Burkitt lymphoma is highly associated with translocations involving the *MYC* gene on chromosome 8.** Most translocations fuse *MYC* with the *IgH* gene on chromosome 14, but variant translocations involving the κ and λ light

chain loci on chromosomes 2 and 22, respectively, are also observed. The net result of each is the same—the dysregulation and overexpression of MYC protein. The role of MYC in transformation is discussed in Chapter 5. In most endemic cases and about 20% of sporadic cases, the tumor cells are latently infected with EBV, but the role of EBV in the genesis of this tumor remains uncertain.

## MORPHOLOGY

The tumor cells are intermediate in size and typically have round or oval nuclei and two to five distinct nucleoli (Fig. 11–18). There is a moderate amount of basophilic or amphophilic cytoplasm that often contains small, lipid-filled vacuoles (a feature appreciated only on smears). **Very high rates of proliferation and apoptosis are characteristic,** the latter accounting for the presence of numerous tissue macrophages containing ingested nuclear debris. These benign macrophages often are surrounded by a clear space, creating a **"starry sky" pattern.**

### Immunophenotypic Features

These B cell tumors express surface IgM, the pan-B cell markers CD19 and CD20, and the germinal center B cell markers CD10 and BCL6.

### Clinical Features

Both the endemic and nonendemic sporadic forms affect mainly children and young adults. Burkitt lymphoma accounts for approximately 30% of childhood NHLs in the United States. In both settings, the disease usually arises at extranodal sites. Endemic tumors often manifest as maxillary or mandibular masses, whereas abdominal tumors involving the bowel, retroperitoneum, and ovaries are more common in North America. Leukemic presentations are uncommon but do occur and must be distinguished from ALL, which is treated with different drug regimens. Burkitt lymphoma is among the fastest-growing human neoplasms; however, with very aggressive chemotherapy regimens, a majority of patients can be cured.

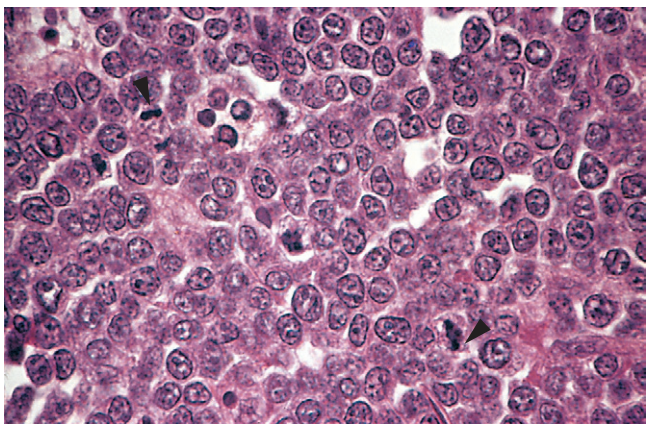

**Figure 11–18** Burkitt lymphoma—lymph node. The tumor cells and their nuclei are fairly uniform, giving a monotonous appearance. Note the high level of mitotic activity (*arrowheads*) and prominent nucleoli. The "starry sky" pattern produced by interspersed, lightly staining, normal macrophages is better appreciated at a lower magnification.

*(Courtesy of Dr. Robert W. McKenna, Department of Pathology, University of Texas Southwestern Medical School, Dallas, Texas.)*

## *Multiple Myeloma and Related Plasma Cell Tumors*

In virtually all cases, multiple myelomas and related plasma cell tumors secrete a single complete or partial immunoglobulin. Because these immunoglobulins can be detected in the serum, these disorders are also referred to as *monoclonal gammopathies,* and the associated immunoglobulin is often referred to as an *M protein.* Although M proteins may be indicative of overt malignancy, they also are found surprisingly often in otherwise normal elderly persons—a condition called monoclonal gammopathy of undetermined significance (MGUS), described later. Collectively, these disorders account for approximately 15% of the deaths that are caused by tumors of white blood cells. They are most common in middle-aged and elderly persons.

The plasma cell neoplasms can be divided into six major variants: (1) multiple myeloma, (2) solitary plasmacytoma, (3) lymphoplasmacytic lymphoma, (4) heavy-chain disease, (5) primary amyloidosis, and (6) MGUS. The focus here is on the most important of these disorders, multiple myeloma and lymphoplasmacytic lymphoma, with a brief discussion of the other disorders.

### Multiple Myeloma

Multiple myeloma is one of the most common lymphoid malignancies; approximately 20,000 new cases are diagnosed in the United States each year. The median age at diagnosis is 70 years of age, and it is more common in males and in people of African origin. *It principally involves the bone marrow and usually is associated with lytic lesions throughout the skeletal system.*

The most frequent M protein produced by myeloma cells is IgG (60%), followed by IgA (20% to 25%); only rarely are IgM, IgD, or IgE M proteins observed. In the remaining 15% to 20% of cases, the plasma cells produce *only* κ or λ light chains. Because of their low molecular weight, free light chains are excreted in the urine, where they are termed Bence Jones proteins. Even more commonly, malignant plasma cells secrete both complete immunoglobulins and free light chains and thus produce both M proteins and Bence Jones proteins. As described later on, the excess light chains have important pathogenic effects.

### Solitary Plasmacytoma

Sometimes plasma tumors manifest as *solitary plasmacytomas* involving the skeleton or the soft tissues. Solitary skeletal plasmacytomas tend to occur in the same locations as does multiple myeloma and usually progress to full-blown multiple myeloma over a period of 5 to 10 years; these tumors probably are best thought of as an early stage of multiple myeloma. Modestly elevated M proteins are present in some cases at diagnosis. By contrast, plasmacytomas that occur in soft tissues (most often the upper respiratory tract) spread infrequently and often are cured by local resection.

## PATHOGENESIS OF MYELOMA

As with most other B cell malignancies, myelomas often have chromosomal translocations involving the *IgH* locus on chromosome 14 and various other genes, including cyclin D1, fibroblast growth factor receptor 3, and cyclin D3 genes. Late in the course, translocations involving *MYC* are sometimes also observed. As might be surmised from this list of genes, **dysregulation of D cyclins is common in multiple myeloma.**

The proliferation of myeloma cells is supported by the cytokine interleukin 6 (IL-6), which is produced by fibroblasts and macrophages in the bone marrow stroma. The characteristic bone resorption results from the secretion of certain cytokines (e.g., IL-1β, tumor necrosis factor, IL-6) by myeloma cells. These cytokines stimulate production of another cytokine called RANK-ligand, which stimulates the differentiation and absorptive activity of osteoclasts (Chapter 20).

**Patients with myeloma are immunosuppressed.** Through uncertain mechanisms, **myeloma cells interfere with the function of normal plasma cells,** leading to defects in antibody production. Thus, although the plasma usually contains increased immunoglobulin owing to the presence of an M protein, the levels of functional antibodies often are profoundly depressed, leaving patients at high risk for bacterial infections.

**Renal dysfunction is a common, serious problem in myeloma.** It stems from several pathologic effects that may occur alone or in combination. Most important are obstructive proteinaceous casts, which often form in the distal convoluted tubules and the collecting ducts. The casts consist mostly of Bence Jones proteins along with variable amounts of complete immunoglobulins, Tamm-Horsfall protein, and albumin. Light chain deposition in the glomeruli or the interstitium, either as amyloid or linear deposits, also may contribute to renal dysfunction. Completing the assault on the kidney is hypercalcemia, which may lead to dehydration and renal stones, and frequent bouts of bacterial pyelonephritis, which stem in part from the hypogammaglobulinemia.

### Monoclonal Gammopathy of Undetermined Significance

*Monoclonal gammopathy of undetermined significance* (MGUS) is the term applied to an asymptomatic monoclonal gammopathy. M proteins are found in the serum of 1% to 3% of otherwise healthy persons older than age 50 years, making this the most common plasma cell proliferation. Despite its name, *it is increasingly apparent that MGUS is a precursor lesion with a tendency to evolve to multiple myeloma.* Among patients with MGUS, a symptomatic plasma cell tumor, most commonly multiple myeloma, develops at a rate of 1% per year. Moreover, the clonal plasma cells in MGUS contain the same chromosomal translocations found in full-blown multiple myeloma. A diagnosis of MGUS should be made only after careful exclusion of other monoclonal gammopathies, particularly multiple myeloma. In general, patients with MGUS have less than 3 g/dL of monoclonal protein in the serum and no Bence Jones proteinuria.

### Lymphoplasmacytic Lymphoma

Lymphoplasmacytic lymphoma is included in the plasma cell neoplasms because the tumor cells secrete an M protein, most commonly IgM, but is otherwise distinct. It is composed of a mixture of B cells ranging from small lymphocytes to plasmacytic lymphocytes to plasma cells. It behaves like an *indolent B cell lymphoma* and commonly involves the lymph nodes, bone marrow, and spleen at presentation. Often the high levels of IgM cause the blood to become viscous, producing a syndrome called *Waldenström macroglobulinemia,* described later on. Other symptoms are related to the infiltration of various tissues, particularly the bone marrow, by tumor cells. The synthesis of immunoglobulin heavy and light chains usually is balanced, so free light chains and Bence Jones proteinuria are not seen. Unlike myeloma, this tumor does not produce lytic bone lesions and is only rarely associated with amyloidosis.

***Heavy-Chain Disease.*** Heavy-chain disease is not a specific entity but represents a group of proliferations in which only heavy chains are produced, most commonly IgA. IgA heavy-chain disease shows a predilection for lymphoid tissues in which IgA normally is produced, such as the small intestine and respiratory tract, and may represent a variant of extranodal marginal zone lymphoma (discussed later). The less common IgG heavy-chain disease often manifests with diffuse lymphadenopathy and hepatosplenomegaly and histologically resembles lymphoplasmacytic lymphoma.

***Primary Amyloidosis.*** As noted earlier (Chapter 4), a monoclonal proliferation of plasma cells that secrete free light chains underlies primary amyloidosis. The amyloid deposits (of AL type) consist of partially degraded light chains.

## MORPHOLOGY

**Multiple myeloma usually manifests with multifocal destructive skeletal lesions, which most commonly involve the vertebral column, ribs, skull, pelvis, femur, clavicle, and scapula.** The lesions generally arise in the medullary cavity, erode cancellous bone, and progressively destroy the cortical bone. This destructive process in turn often leads to **pathologic fractures,** most frequently in the vertebral column or femur. The bone lesions usually appear as **punched-out defects** 1 to 4 cm in diameter (Fig. 11–19, *A*), but in some cases diffuse skeletal demineralization is evident. Microscopic examination of the marrow reveals increased numbers of plasma cells, which usually constitute greater than 30% of the cellularity. Myeloma cells may resemble normal plasma cells but more often show abnormal features such as prominent nucleoli or abnormal cytoplasmic inclusions containing immunoglobulin (Fig. 11–19, *B*). With disease progression, plasma cells may infiltrate the spleen, liver, kidneys, lungs, lymph nodes, and other soft tissue sites. In terminal stages, a leukemic picture may emerge.

Renal involvement **(myeloma nephrosis)** is associated with proteinaceous casts in the distal convoluted tubules and the collecting ducts, consisting mostly of Bence Jones proteins along with variable amounts of complete immunoglobulins, Tamm-Horsfall protein, and albumin. Multinucleate giant cells derived from macrophages usually surround the

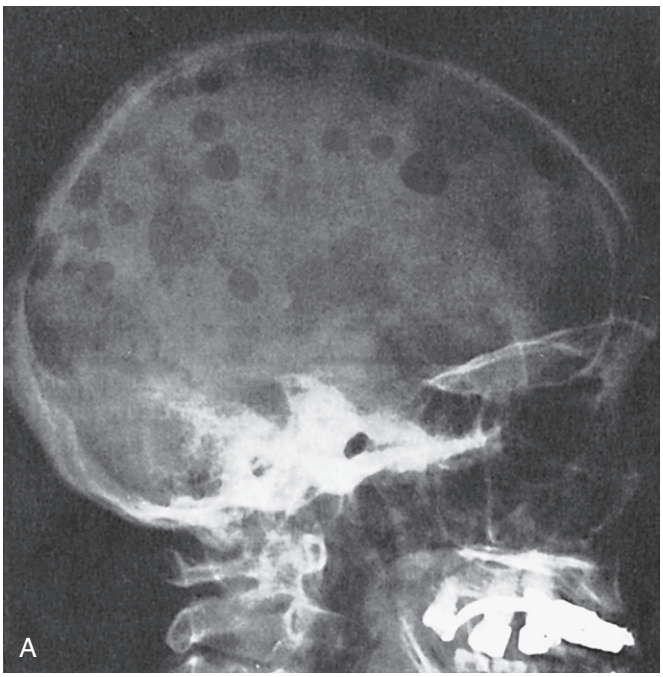


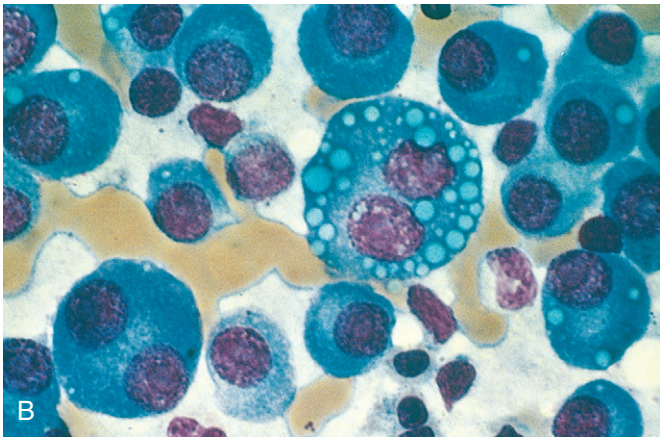


**Figure 11–19** Multiple myeloma. **A,** Radiograph of the skull, lateral view. The sharply punched-out bone defects are most obvious in the calvaria. **B,** Bone marrow aspirate. Normal marrow cells are largely replaced by plasma cells, including atypical forms with multiple nuclei, prominent nucleoli, and cytoplasmic droplets containing immunoglobulin.

casts. **Very often the epithelial cells adjacent to the casts become necrotic or atrophic owing to the toxic effects of Bence Jones proteins.** Other common pathologic processes involving the kidney include **metastatic calcification**, stemming from bone resorption and hypercalcemia; **light chain (AL) amyloidosis**, involving the renal glomeruli and vessel walls; and **bacterial pyelonephritis,** secondary to the increased susceptibility to bacterial infections. Rarely, interstitial infiltrates of neoplastic plasma cells are seen.

**In contrast with multiple myeloma, lymphoplasmacytic lymphoma is not associated with lytic skeletal lesions.** Instead the neoplastic cells diffusely infiltrate the bone marrow, lymph nodes, spleen, and sometimes the liver. Infiltrations of other organs also occur, particularly with disease progression. The cellular infiltrate consists of lymphocytes, plasma cells, and plasmacytic lymphocytes of intermediate differentiation. The remaining forms of plasma cell neoplasms have either already been described (e.g., primary amyloidosis) (Chapter 4) or are too rare to merit further description.

### Clinical Features

The clinical manifestations of plasma cell tumors are varied. They result from the destructive or otherwise damaging effects of tumor cells in various tissues and complications related to the complete or partial immunoglobulins secreted by the tumor cells.

The common clinicopathologic features of multiple myeloma can be summarized as follows:

- *Bone pain,* due to pathologic fractures. Pathologic fractures of vertebrae may lead to spinal cord impingement, an oncologic emergency.
- *Hypercalcemia* stemming from bone resorption leads to neurologic manifestations such as confusion and lethargy and contributes to renal dysfunction.
- *Anemia,* due to marrow replacement by tumor cells as well as suppression of hematopoiesis through uncertain mechanisms
- *Recurrent infections* with bacteria such as *S. aureus, S. pneumoniae,* and *E. coli,* resulting from the marked suppression of normal humoral immunity
- *Renal insufficiency* (in up to 50% of patients), resulting from the deleterious effect of Bence Jones proteins on renal tubular cells, as well as bacterial infections, hypercalcemia, and amyloidosis
- *AL-type amyloidosis* (5% to 10% of patients)
- Symptoms related to hyperviscosity may occur owing to excessive production and aggregation of M proteins but this clinical presentation is much more characteristic of lymphoplasmacytic lymphoma.

Multiple myeloma should be suspected when the characteristic focal, punched-out skeletal defects are present—especially when located in the vertebrae or calvaria. Electrophoresis of the serum and urine is an important diagnostic tool. In 99% of cases, either a monoclonal complete immunoglobulin or a monoclonal free immunoglobulin light chain is present in the serum, the urine, or both. In the few remaining cases, monoclonal free immunoglobulins can usually be detected within the plasma cells; in such cases the lesion is sometimes called nonsecretory myeloma. Examination of the bone marrow is used to confirm the presence of a plasma cell proliferation.

*Lymphoplasmacytic lymphoma* affects older persons; the peak incidence is between the sixth and seventh decades. Most clinical signs and symptoms are caused by secretion of IgM (macroglobulin) from the tumor cells. Because of their size, macroglobulins cause the blood to become viscous, giving rise to a syndrome, known as *Waldenström macroglobulinemia,* which is associated with the following features:

- *Visual impairment,* related to striking tortuosity and distention of retinal veins; retinal hemorrhages and exudates can also contribute to the visual problems

- *Neurologic problems* such as headaches, dizziness, tinnitus, deafness, and stupor, stemming from sluggish blood flow and sludging
- *Bleeding,* related to the formation of complexes between macroglobulins and clotting factors as well as interference with platelet function
- *Cryoglobulinemia,* related to precipitation of macroglobulins at low temperatures and producing symptoms such as Raynaud phenomenon and cold urticaria

Multiple myeloma is a progressive disease, with median survival of around 4 to 6 years. The picture for patients has brightened somewhat with the development of several new therapies, including proteasome inhibitors, which induce plasma cell apoptosis, and thalidomide analogues, which somehow alter the marrow microenvironment in a manner that inhibits myeloma cell growth and survival (recall that thalidomide was removed from the market because of its teratogenic effects in pregnant females). Lymphoplasmacytic lymphoma responds well for a time to relatively gentle chemotherapy regimens and plasmapheresis, which removes the macroglobulins; the median survival time is 4 to 5 years. At present, neither myeloma or lymphoplasmacytic lymphoma is curable.

### *Hodgkin Lymphoma*

Hodgkin lymphoma encompasses a distinctive group of neoplasms that are characterized by the presence of *a tumor giant cell, the Reed-Sternberg cell.* Unlike most NHLs, Hodgkin lymphomas arise in a single lymph node or chain of lymph nodes and typically spread in a stepwise fashion to anatomically contiguous nodes. Although the Hodgkin lymphomas are now understood to be unusual tumors of B cell origin, they are distinguished from the NHLs by their unusual pathologic and clinical features.

***Classification.*** Five subtypes of Hodgkin lymphoma are recognized: (1) nodular sclerosis, (2) mixed cellularity, (3) lymphocyte rich, (4) lymphocyte depletion, and (5) lymphocyte predominance. In the first four subtypes the Reed-Sternberg cells share certain morphologic and immunophenotypic features (described later), leading some researchers to lump together these entities under the rubric "classical Hodgkin lymphoma." The lymphocyte predominance type is set apart by the expression of germinal center B markers by the Reed-Sternberg cells. This subtype and the two most common forms of classical Hodgkin lymphoma, the nodular sclerosis and mixed-cellularity types, are discussed next.

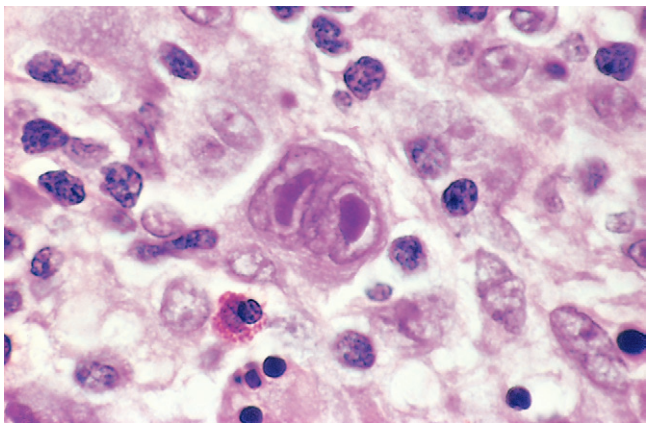

**Figure 11–20** Hodgkin lymphoma—lymph node. A binucleate Reed-Sternberg cell with large, inclusion-like nucleoli and abundant cytoplasm is surrounded by lymphocytes, macrophages, and an eosinophil.
*(Courtesy of Dr. Robert W. McKenna, Department of Pathology, University of Texas Southwestern Medical School, Dallas, Texas.)*

## MORPHOLOGY

**The sine qua non of Hodgkin lymphoma is the Reed-Sternberg (RS) cell** (Fig. 11–20), a very large cell (15 to 45 μm in diameter) with an enormous multilobate nucleus, exceptionally prominent nucleoli and abundant, usually slightly eosinophilic cytoplasm. **Particularly characteristic are cells with two mirror-image nuclei or nuclear lobes, each containing a large (inclusion-like) acidophilic nucleolus surrounded by a clear zone, features that impart an owl-eye appearance.** The nuclear membrane is distinct. Typical RS cells and variants have a characteristic immunophenotype, as they express CD15 and CD30 and fail to express CD45 (common leukocyte antigen), B cell antigens, and T cell antigens. As we shall see, "classic" RS cells are common in the mixed-cellularity subtype, uncommon in the nodular sclerosis subtype, and rare in the lymphocyte-predominance subtype; in these latter two subtypes, other characteristic RS cell variants predominate.

**Nodular sclerosis Hodgkin lymphoma** is the most common form. It is equally frequent in men and in women and has a striking propensity to involve the lower cervical, supraclavicular, and mediastinal lymph nodes. Most patients are adolescents or young adults, and the overall prognosis is excellent. It is characterized morphologically by

- The presence of a particular variant of the RS cell, the lacunar cell (Fig. 11–21). This large cell has a single multilobate nucleus, multiple small nucleoli and abundant, pale-staining cytoplasm. In sections of formalin-fixed tissue, the cytoplasm often is torn away, leaving the nucleus lying in an empty space (a lacune). The immunophenotype of lacunar variants is identical to that of other RS cells found in classical subtypes.

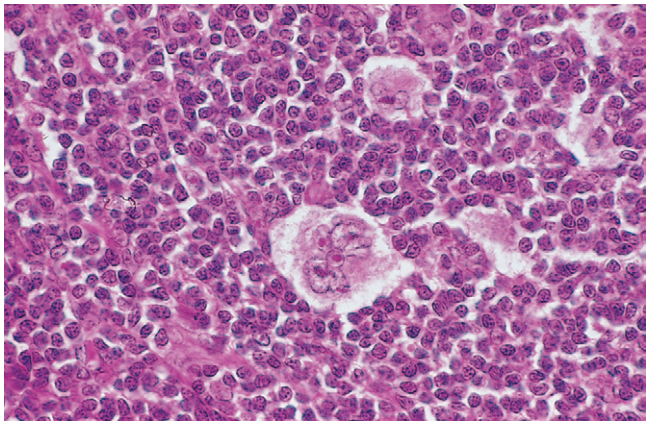

**Figure 11–21** Hodgkin lymphoma, nodular sclerosis type—lymph node. A distinctive "lacunar cell" with a multilobed nucleus containing many small nucleoli is seen lying within a clear space created by retraction of its cytoplasm. It is surrounded by lymphocytes.
*(Courtesy of Dr. Robert W. McKenna, Department of Pathology, University of Texas Southwestern Medical School, Dallas, Texas.)*

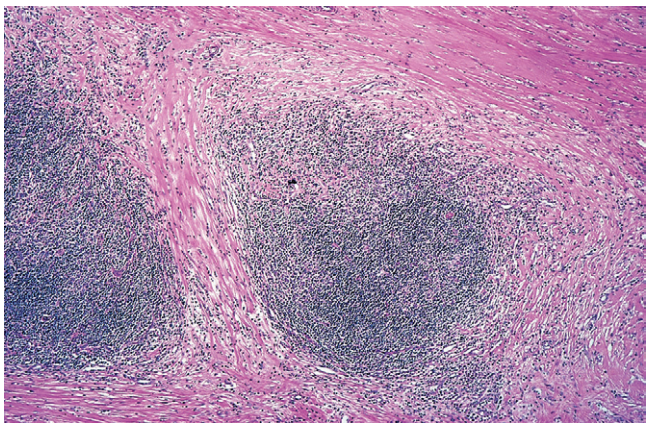

**Figure 11–22** Hodgkin lymphoma, nodular sclerosis type—lymph node. A low-power view shows well-defined bands of pink, acellular collagen that have subdivided the tumor cells into nodules.
*(Courtesy of Dr. Robert W. McKenna, Department of Pathology, University of Texas Southwestern Medical School, Dallas, Texas.)*

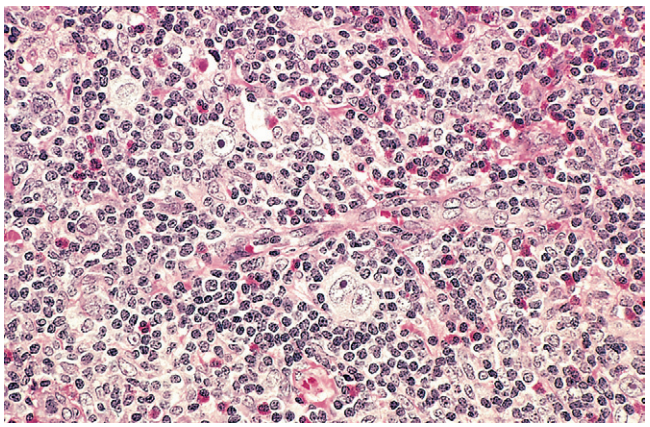

**Figure 11–23** Hodgkin lymphoma, mixed-cellularity type—lymph node. A diagnostic, binucleate Reed-Sternberg cell is surrounded by eosinophils, lymphocytes, and histiocytes.
*(Courtesy of Dr. Robert W. McKenna, Department of Pathology, University of Texas Southwestern Medical School, Dallas, Texas.)*

- The presence of collagen bands that divide involved lymphoid tissue into circumscribed nodules (Fig. 11–22). The fibrosis may be scant or abundant and the cellular infiltrate contains varying proportions of lymphocytes, eosinophils, histiocytes, and lacunar cells.

**Mixed-cellularity Hodgkin lymphoma** is the most common form of Hodgkin lymphoma in patients older than 50 years of age and comprises about 25% of cases overall. There is a male predominance. Classic RS cells are plentiful within a heterogeneous inflammatory infiltrate containing small lymphocytes, eosinophils, plasma cells, and macrophages (Fig. 11–23). This subtype is more likely to be disseminated and to be associated with systemic manifestations than the nodular sclerosis subtype.

**Lymphocyte-Predominance Hodgkin lymphoma.** This subtype, accounting for about 5% of Hodgkin lymphoma, is characterized by the presence of lymphohistiocytic (L&H) variant RS cells that have a delicate multilobed, puffy nucleus resembling popped corn ("popcorn cell"). L&H variants usually are found within large nodules containing mainly small resting B cells admixed with a variable number of macrophages (Fig. 11–24). Other types of reactive cells, such as eosinophils, neutrophils, and plasma cells, are scanty or absent, and typical RS cells are rare. Unlike the Reed-Sternberg variants in "classical" forms of Hodgkin lymphoma, L&H variants express B cell markers (e.g., CD20) and usually fail to express CD15 and CD30. Most patients with this subtype present with isolated cervical or axillary lymphadenopathy, and the prognosis typically is excellent.

**Other Considerations in Histologic Diagnosis.** It is apparent that Hodgkin lymphoma spans a wide range of histologic patterns and that certain forms, with their characteristic fibrosis, eosinophils, neutrophils, and plasma cells, come deceptively close to simulating an inflammatory reactive process. **The histologic diagnosis of Hodgkin lymphoma rests on the definitive identification of RS cells or variants in the appropriate background of reactive cells.** Immunophenotyping plays an important adjunct role in distinguishing Hodgkin lymphoma from reactive conditions and other forms of lymphoma. In all subtypes, involvement of the spleen, liver, bone marrow, and other organs may appear in due course and takes the form of irregular nodules composed of a mixture of RS cells and reactive cells, similar to what is observed in lymph nodes.

## PATHOGENESIS

The origin of RS cells remained mysterious through the 19th and most of the 20th centuries but was finally solved by elegant molecular studies performed on single microdissected RS cells. These showed that every RS cell from any given case possessed the same immunoglobulin gene rearrangements. In addition these studies revealed that the rearranged immunoglobulin genes had undergone somatic hypermutation. As a result, it is now agreed that **Hodgkin lymphoma is a neoplasm arising from germinal center B cells.**

The events that transform these cells and alter their appearance and gene expression programs are still unclear.

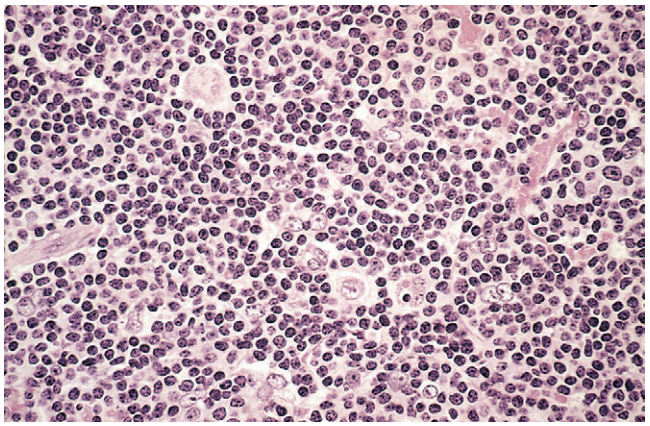

**Figure 11–24** Hodgkin lymphoma, lymphocyte-predominance type—lymph node. Numerous mature-looking lymphocytes surround scattered, large, pale-staining lymphocytic and histiocytic variants ("popcorn" cells).
*(Courtesy of Dr. Robert W. McKenna, Department of Pathology, University of Texas Southwestern Medical School, Dallas, Texas.)*

One clue stems from the involvement of EBV. **EBV is present in the RS cells in as many as 70% of cases of the mixed-cellularity subtype and a smaller fraction of other "classical" forms of Hodgkin lymphoma.** More important, the integration of the EBV genome is identical in all RS cells in a given case, indicating that infection precedes (and therefore may be related to) transformation and clonal expansion. Thus, as in Burkitt lymphoma and B cell lymphomas in immunodeficient patients, EBV infection probably is one of several steps contributing to tumor development, particularly of the mixed-cellularity subtype.

The characteristic non-neoplastic, inflammatory cell infiltrate is generated by a number of cytokines, some secreted by RS cells, including IL-5 (which attracts and activates eosinophils), transforming growth factor-β (a fibrogenic factor), and IL-13 (which may stimulate RS cells through an autocrine mechanism). Conversely, the responding inflammatory cells, rather than being innocent bystanders, produce additional factors such as CD30 ligand that aid the growth and survival of RS cells and contribute further to the tissue reaction.

***Staging and Clinical Features.*** Hodgkin lymphomas, like NHLs, usually manifest as painless lymphadenopathy. Although a definitive distinction from NHL can be made only by examination of a lymph node biopsy, several clinical features favor the diagnosis of Hodgkin lymphoma (Table 11–9). Once the diagnosis is established, *staging is used to guide therapy and determine prognosis* (Table 11–10). Younger patients with the more favorable subtypes tend to present with stage I or II disease and usually are free of systemic manifestations. Patients with advanced disease (stages III and IV) are more likely to have systemic complaints such as fever, weight loss, pruritus, and anemia. Due to the long-term complications of radiotherapy, even patients with stage I disease are now treated with systemic chemotherapy. More advanced disease generally is also treated with chemotherapy, sometimes with involved field radiotherapy at sites of bulky disease. The outlook for patients with Hodgkin lymphoma, even those with advanced disease, is very good. The 5-year survival rate for patients with stage I-A or II-A disease is close to 100%. Even with advanced disease (stage IV-A or IV-B), the overall 5-year disease-free survival rate is around 50%. Among long-term survivors treated with radiotherapy, a much higher risk of certain malignancies, including lung cancer, melanoma, and breast cancer, has been reported. These sobering results have spurred the development of new treatment regimens that minimize the use of radiotherapy and employ less toxic chemotherapeutic agents. Anti-CD30 antibodies have produced excellent responses in patients with disease that has failed conventional therapies and represent a promising "targeted" therapy.

**Table 11–9** Clinical Differences Between Hodgkin and Non-Hodgkin Lymphomas

| Hodgkin Lymphoma | Non-Hodgkin Lymphoma |
|---|---|
| More often localized to a single axial group of nodes (cervical, mediastinal, para-aortic) | More frequent involvement of multiple peripheral nodes |
| Orderly spread by contiguity | Noncontiguous spread |
| Mesenteric nodes and Waldeyer ring rarely involved | Mesenteric nodes and Waldeyer ring commonly involved |
| Extranodal involvement uncommon | Extranodal involvement common |

**Table 11–10** Clinical Staging of Hodgkin and Non-Hodgkin Lymphomas (Ann Arbor Classification)*

| Stage | Distribution of Disease |
|---|---|
| I | Involvement of a single lymph node region (I) or involvement of a single extralymphatic organ or tissue ($I_E$) |
| II | Involvement of two or more lymph node regions on the same side of the diaphragm alone (II) or with involvement of limited contiguous extralymphatic organs or tissue ($II_E$) |
| III | Involvement of lymph node regions on both sides of the diaphragm (III), which may include the spleen ($III_S$), limited contiguous extralymphatic organ or site ($III_E$), or both ($III_{ES}$) |
| IV | Multiple or disseminated foci of involvement of one or more extralymphatic organs or tissues with or without lymphatic involvement |

*All stages are further divided on the basis of the absence (A) or presence (B) of the following systemic symptoms and signs: significant fever, night sweats, unexplained loss of more than 10% of normal body weight.
From Carbone PT, et al: Symposium (Ann Arbor): staging in Hodgkin disease. Cancer Res 31:1707, 1971.

## *Miscellaneous Lymphoid Neoplasms*

Among the many other forms of lymphoid neoplasia in the WHO classification, several with distinctive or clinically important features merit brief discussion.

### Extranodal Marginal Zone Lymphoma

This indolent B cell tumor arises most commonly in epithelial tissues such as the stomach, salivary glands, small and large bowel, lungs, orbit, and breast. Extranodal marginal zone lymphomas tend to develop in the setting of autoimmune disorders (such as Sjögren syndrome and Hashimoto thyroiditis) or chronic infection (such as *H. pylori* gastritis), suggesting that sustained antigenic stimulation contributes to its development. In the case of *H. pylori*–associated gastric marginal zone lymphoma, eradication of the organism with antibiotic therapy often leads to regression of the tumor cells, which depend on cytokines secreted by *H. pylori*–specific T cells for their growth and survival (Chapter 5). When arising at other sites, these lymphomas are often cured by local excision or radiotherapy. Several recurrent cytogenetic abnormalities are recognized, the most common of which is a (11;18) translocation involving the *MALT1* and *IAP2* genes. Of clinical importance, the presence of the t(11;18) is highly predictive of the failure of gastric tumors to respond to antibiotic treatment.

### Hairy Cell Leukemia

Hairy cell leukemia is an uncommon, indolent B cell neoplasm characterized by the presence of leukemic cells with fine, hairlike cytoplasmic projections. The tumor cells express pan-B cell markers (CD19 and CD20), surface immunoglobulin, and CD11c and CD103; the latter two antigens are not present on most other B cell tumors, making them diagnostically useful. Virtually all cases are associated with activating mutations in the serine/threonine kinase BRAF, which is also mutated in diverse other cancers (Chapter 5).

Hairy cell leukemia occurs mainly in older males and its manifestations result from infiltration of bone marrow and spleen. *Splenomegaly,* often massive, is the most

common and sometimes only physical finding. *Pancytopenia,* resulting from marrow infiltration and splenic sequestration, is seen in more than half of cases. Lymph node involvement is seen only rarely. *Leukocytosis is uncommon,* being present in 15% to 20% of patients, but scattered "hairy cells" can be identified in the peripheral blood smear in most cases. The disease is indolent but progressive if untreated; pancytopenia and infections cause the major clinical problems. Unlike most other indolent lymphoid neoplasms, this tumor is extremely sensitive to chemotherapeutic agents, particularly purine nucleosides. Complete durable responses are the rule and the overall prognosis is excellent.

### Mycosis Fungoides and Sézary Syndrome

These tumors of neoplastic CD4+ T cells home to the skin; as a result, they often are referred to as *cutaneous T cell lymphoma.* Mycosis fungoides usually manifests as a nonspecific erythrodermic rash that progresses over time to a plaque phase and then to a tumor phase. Histologically, neoplastic T cells, often with a cerebriform appearance produced by marked infolding of the nuclear membranes, infiltrate the epidermis and upper dermis. With disease progression, both nodal and visceral dissemination appear. Sézary syndrome is a clinical variant characterized by (1) a generalized exfoliative erythroderma and (2) tumor cells (Sézary cells) in the peripheral blood. Circulating tumor cells also are present in as many as 25% of cases of plaque- or tumor-phase mycosis fungoides. Patients diagnosed with early-phase mycosis fungoides often survive for many years, whereas patients with tumor-phase disease, visceral disease, or Sézary syndrome survive on average for 1 to 3 years.

### Adult T Cell Leukemia/Lymphoma

*This is a neoplasm of CD4+ T cells that is caused by a retrovirus, human T cell leukemia virus type 1 (HTLV-1).* HTLV-1 infection is endemic in southern Japan, the Caribbean basin, and West Africa, and occurs sporadically elsewhere, including in the southeastern United States. The pathogenesis of this tumor is discussed in Chapter 5. In addition to lymphoid malignancies, HTLV-1 infection also can cause *transverse myelitis,* a progressive demyelinating disease affecting the central nervous system and the spinal cord.

Adult T cell leukemia/lymphoma commonly is associated with skin lesions, lymphadenopathy, hepatosplenomegaly, hypercalcemia, and variable numbers of malignant lymphocytes in the peripheral blood. In addition to CD4, the leukemic cells express high levels of CD25, the IL-2 receptor α chain. In most cases the tumor is very aggressive and responds poorly to treatment. The median survival time is about 8 months. In 15% to 20% of patients the disease follows a chronic course resembling that of mycosis fungoides.

### Peripheral T Cell Lymphomas

This heterogeneous group of tumors makes up 10% to 15% of adult NHLs. Although several rare distinctive subtypes fall under this heading, most tumors in this group are unclassifiable. In general, these are aggressive tumors that respond poorly to therapy. Moreover, because these are tumors of functional T cells, patients often suffer from symptoms related to tumor-derived inflammatory products, even when the tumor burden is relatively low.

## SUMMARY

### Lymphoid Neoplasms

- Classification is based on cell of origin and stage of differentiation.
- Most common types in children are acute lymphoblastic leukemias/lymphoblastic lymphomas derived from precursor B and T cells.
  - These highly aggressive tumors manifest with signs and symptoms of bone marrow failure, or as rapidly growing masses.
  - Tumor cells contain genetic lesions that block differentiation, leading to the accumulation of immature, nonfunctional blasts.
- Most common types in adults are non-Hodgkin lymphomas derived from germinal center B cells.

**Small Lymphocytic Lymphoma/Chronic Lymphocytic Leukemia**

- This tumor of mature B cells usually manifests with bone marrow and lymph node involvement.
- An indolent course, commonly associated with immune abnormalities, including an increased susceptibility to infection and autoimmune disorders, is typical.

**Follicular Lymphoma**

- Tumor cells recapitulate the growth pattern of normal germinal center B cells; most cases are associated with a (14;18) translocation that results in the overexpression of BCL2.

**Mantle Cell Lymphoma**

- This tumor of mature B cells usually manifests with advanced disease involving lymph nodes, bone marrow, and extranodal sites such as the gut.
- An association with an (11;14) translocation that results in overexpression of cyclin D1, a regulator of cell cycle progression, is recognized.

**Diffuse Large B Cell Lymphoma**

- This heterogeneous group of mature B cell tumors shares a large cell morphology and aggressive clinical behavior and represents the most common type of lymphoma.
- Rearrangements or mutations of *BCL6* gene are recognized associations; one third arise from follicular lymphomas and carry a (14;18) translocation involving *BCL2.*

**Burkitt Lymphoma**

- This very aggressive tumor of mature B cells usually arises at extranodal sites.
- A uniform association with translocations involving the *MYC* proto-oncogene has been established.
- Tumor cells often are latently infected by Epstein-Barr virus (EBV).

**Multiple Myeloma**

- This plasma cell tumor often manifests with multiple lytic bone lesions associated with pathologic fractures and hypercalcemia.
- Neoplastic plasma cells suppress normal humoral immunity and secrete partial immunoglobulins that are nephrotoxic.

**Hodgkin Lymphoma**

- This unusual tumor consists mostly of reactive lymphocytes, macrophages, and stromal cells.
- Malignant Reed-Sternberg cells make up a minor part of the tumor mass.

Table 11–8 lists features of specific entities.

## Myeloid Neoplasms

*Myeloid neoplasms arise from hematopoietic progenitors and typically give rise to clonal proliferations that replace normal bone marrow cells.* There are three broad categories of myeloid neoplasia. In the *acute myeloid leukemias* (AMLs), the neoplastic cells are blocked at an early stage of myeloid cell development. Immature myeloid cells (blasts) accumulate in the marrow and replace normal elements, and frequently circulate in the peripheral blood. In the *myeloproliferative disorders,* the neoplastic clone continues to undergo terminal differentiation but exhibits increased or dysregulated growth. Commonly, these are associated with an increase in one or more of the formed elements (red cells, platelets, and/or granulocytes) in the peripheral blood. In the *myelodysplastic syndromes,* terminal differentiation occurs but in a disordered and ineffective fashion, leading to the appearance of dysplastic marrow precursors and peripheral blood cytopenias.

Although these three categories provide a useful starting point, the divisions between the myeloid neoplasms sometimes blur. Both myelodysplastic syndromes and myeloproliferative disorders often transform to AML, and some neoplasms have features of both myelodysplasia and myeloproliferative disorders. Because all myeloid neoplasms arise from early multipotent progenitors, the close relationship among these disorders is not surprising.

### *Acute Myeloid Leukemia*

AML primarily affects older adults; the median age is 50 years. It is very heterogeneous, as discussed later on. The clinical signs and symptoms closely resemble those produced by ALL and usually are related to the replacement of normal marrow elements by leukemic blasts. Fatigue, pallor, abnormal bleeding, and infections are common in newly diagnosed patients, who typically present within a few weeks of the onset of symptoms. Splenomegaly and lymphadenopathy generally are less prominent than in ALL, but on rare occasions AML mimics a lymphoma by manifesting as a discrete tissue mass (a so-called granulocytic sarcoma). The diagnosis and classification of AML are based on morphologic, histochemical, immunophenotypic, and karyotypic findings. Of these, the karyotype is most predictive of outcome.

### PATHOGENESIS

**Most AMLs harbor mutations in genes encoding transcription factors that are required for normal myeloid cell differentiation.** These mutations interfere with the differentiation of early myeloid cells, leading to the accumulation of myeloid precursors (blasts) in the marrow.

Of particular interest is the (15;17) translocation in acute promyelocytic leukemia, which results in the fusion of the retinoic acid receptor α (*RARA*) gene on chromosome 17 and the *PML* gene on chromosome 15. The chimeric gene produces a PML/RARα fusion protein that blocks myeloid differentiation at the promyelocytic stage, probably in part by inhibiting the function of normal retinoic acid receptors. Remarkably, pharmacologic doses of all-*trans* retinoic acid (ATRA), an analogue of vitamin A (Chapter 7), overcome this block and induce the neoplastic promyelocytes to rapidly differentiate into neutrophils. Because neutrophils die after an average lifespan of 6 hours, ATRA treatment rapidly clears the tumor. The effect is very specific; AMLs without translocations involving *RARA* do not respond to ATRA. More recently, **it has been noted that the combination of ATRA and arsenic trioxide, a salt that induces the degradation of the PML/RARA fusion protein, is even more effective than ATRA alone, producing cures in more than 80% of patients.** This is an important example of a highly effective therapy targeted at a tumor-specific molecular defect.

Other work using transgenic or "knock-in" mice has shown that the mutations in transcription factors found in AML are not sufficient to cause the disease. Some of the other mutations implicated in AML have no effect on differentiation but instead enhance cellular proliferation and survival. One example involves FLT3, a receptor tyrosine kinase that is activated by mutations in a number of AML subtypes, including acute promyelocytic leukemia. Putative collaborating mutations in several other tyrosine kinase genes and in *RAS*, an oncogene that is mutated in diverse forms of cancer, also have been detected.

### MORPHOLOGY

By definition, in AML myeloid blasts or promyelocytes make up more than 20% of the bone marrow cellular component. **Myeloblasts** (precursors of granulocytes) have delicate nuclear chromatin, three to five nucleoli, and fine azurophilic cytoplasmic granules (Fig. 11–14, *B*). **Auer rods,** distinctive red-staining rodlike structures, may be present in myeloblasts or more differentiated cells; they are particularly numerous in acute promyelocytic leukemia (Fig. 11–25). Auer rods are specific for neoplastic myeloblasts and thus a helpful diagnostic clue when present. In other subtypes of AML, monoblasts, erythroblasts, or megakaryoblasts predominate.

***Classification.*** *AMLs are diverse in terms of genetics, cellular lineage, and degree of maturation.* The WHO classification relies on all of these features to divide AML into four categories (Table 11–11): (1) AMLs associated with specific genetic aberrations, which are important because they predict outcome and guide therapy; (2) AMLs with dysplasia, many of which arise from myelodysplastic syndromes; (3) AMLs occurring after genotoxic chemotherapy; and (4) AMLs lacking any of the foregoing features. AMLs in the last category are subclassified on the basis of the predominant line of differentiation that the tumor exhibits.

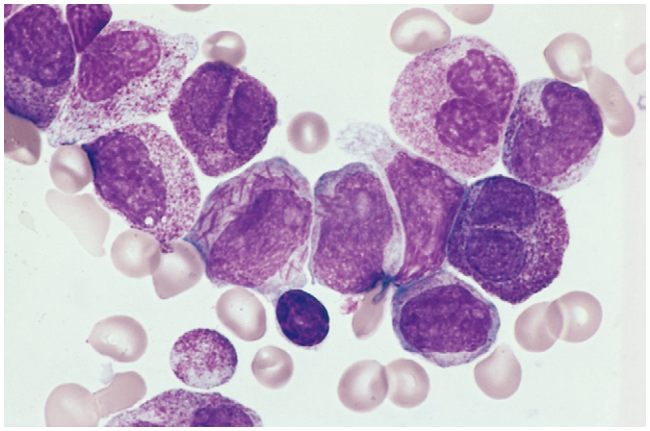

**Figure 11–25** Acute promyelocytic leukemia—bone marrow aspirate. The neoplastic promyelocytes have abnormally coarse and numerous azurophilic granules. Other characteristic findings include the presence of several cells with bilobed nuclei and a cell in the center of the field that contains multiple needle-like Auer rods.

*(Courtesy of Dr. Robert W. McKenna, Department of Pathology, University of Texas Southwestern Medical School, Dallas, Texas.)*

***Immunophenotype.*** The expression of immunologic markers is heterogeneous in AML. Most tumors express some combination of myeloid-associated antigens, such as CD13, CD14, CD15, CD64, or CD117 (cKIT). CD33 is expressed on pluripotent stem cells but is retained on myeloid progenitor cells. Such markers are helpful in distinguishing AML from ALL (as shown in Fig. 11–14) and in identifying AMLs with only minimal differentiation.

***Prognosis.*** AML is a devastating disease. Tumors with "good-risk" karyotypic abnormalities (t[8;21], inv[16]) are associated with a 50% chance of long-term disease-free survival, but the overall survival in all patients is only 15% to 30% with conventional chemotherapy. A bright spot is the improvement in outcomes in acute promyelocytic leukemia brought about by targeted treatment with ATRA and arsenic salts. An increasing number of patients with AML are being treated with more aggressive approaches, such as allogeneic hematopoietic stem cell transplantation.

**Table 11–11** WHO Classification of Acute Myeloid Leukemia (AML)

| Class | Prognosis |
|---|---|
| **I. AML with Recurrent Chromosomal Translocations** | |
| AML with t(8;21)(q22;q22); *CBFA/ETO* fusion gene | Favorable |
| AML with inv(16)(p13;q22); *CBFB/MYH11* fusion gene | Favorable |
| AML with t(15;17)(q22;q21.1); *PML/RARA* fusion gene | Favorable |
| AML with t(11q23;variant); *MLL* fusion genes | Poor |
| AML with mutated *NPM1* | Variable |
| **II. AML with Multilineage Dysplasia** | |
| With previous myelodysplastic syndrome | Very poor |
| Without previous myelodysplastic syndrome | Poor |
| **III. AML, Therapy-Related** | |
| Alkylating agent–related | Very poor |
| Epipodophyllotoxin-related | Very poor |
| **IV. AML, Not Otherwise Classified** | |
| Subclasses defined by extent and type of differentiation (e.g., myelocytic, monocytic) | Intermediate |

NPM1, nucleophosmin 1; WHO, World Health Organization.

### *Myelodysplastic Syndromes*

In myelodysplastic syndromes (MDSs), the bone marrow is partly or wholly replaced by the clonal progeny of a transformed multipotent stem cell that retains the capacity to differentiate into red cells, granulocytes, and platelets, but in a manner that is both ineffective and disordered. As a result, the marrow usually is hypercellular or normocellular, but the peripheral blood shows one or more cytopenias. The abnormal stem cell clone in the bone marrow is genetically unstable and prone to the acquisition of additional mutations and the eventual transformation to AML. Most cases are idiopathic, but some develop after chemotherapy with alkylating agents or exposure to ionizing radiation therapy.

## PATHOGENESIS

The pathogenesis of MDS is poorly understood. Cytogenetic studies reveal clonal abnormalities in up to 70% of cases. Translocations generally are lacking, whereas losses or gains of whole chromosomes or parts thereof are frequent. Some **common karyotypic abnormalities include monosomy 5 or 7; deletions of 5q, 7q, and 20q;** and trisomy 8. Recent work suggests that the critical region deleted on 5q contains genes encoding a ribosomal protein and several microRNAs. Loss of all of these genes appears to contribute to a subtype of MDS called the 5q– syndrome. This syndrome occurs more often in women, is associated with severe anemia and preserved or elevated platelet counts, and often responds to treatment with analogs of thalidomide, which are believed to influence the interaction of hematopoietic progenitors and marrow stromal cells.

## MORPHOLOGY

In MDSs, the marrow is populated by abnormal-appearing hematopoietic precursors. Some of the more common abnormalities include **megaloblastoid erythroid precursors** resembling those seen in the megaloblastic anemias, erythroid forms with iron deposits within their mitochondria **(ringed sideroblasts),** granulocyte precursors with **abnormal granules** or nuclear maturation, and small megakaryocytes with single small nuclei or multiple separate nuclei.

*Although these syndromes often are described as rare, it is now appreciated that MDS is about as common as AML, affecting up to 15,000 patients per year in the United States.* Most persons with MDS are between 50 and 70 years of age. As a result of cytopenias, many suffer from infections, symptoms related to anemia, and hemorrhages. The response to conventional chemotherapy usually is poor, perhaps because MDS arises in a background of stem cell damage. Transformation to AML occurs in 10% to 40%. The prognosis is variable; the median survival time ranges from 9

to 29 months and is worse in patients with increased marrow blasts or cytogenetic abnormalities at the time of diagnosis.

### *Chronic Myeloproliferative Disorders*

Chronic myeloproliferative disorders are marked by the hyperproliferation of neoplastic myeloid progenitors that retain the capacity for terminal differentiation; as a result, there is an increase in one or more formed elements of the peripheral blood. The neoplastic progenitors tend to seed secondary hematopoietic organs (the spleen, liver, and lymph nodes), resulting in hepatosplenomegaly (caused by neoplastic extramedullary hematopoiesis). *A common theme is the association of these disorders with activating mutations in tyrosine kinases, which generate constitutive signals mimicking those that are normally produced in response to hematopoietic growth factors.* This insight provides a satisfying explanation for the observed overproduction of myeloid cells and is important therapeutically because of the availability of tyrosine kinase inhibitors.

Four major diagnostic entities are recognized: chronic myelogenous leukemia (CML), polycythemia vera, primary myelofibrosis, and essential thrombocythemia. CML is separated from the others by its association with a characteristic abnormality, the *BCR-ABL* fusion gene, which produces a constitutively active BCR-ABL tyrosine kinase. The remaining *BCR-ABL*–negative myeloproliferative disorders show considerable clinical and genetic overlap. The most common genetic abnormalities in the "BCR-ABL–negative" myeloproliferative disorders are activating mutations in the tyrosine kinase JAK2, which occur in virtually all cases of polycythemia vera and about 50% of cases of primary myelofibrosis and essential thrombocythemia. Some rare myeloproliferative disorders are associated with activating mutations in other tyrosine kinases, such as platelet-derived growth factor receptor-α and platelet-derived growth factor receptor-β. In addition, all myeloproliferative disorders have variable propensities to transform to a "spent phase" resembling primary myelofibrosis or to a "blast crisis" identical to acute leukemia, both presumably triggered by the acquisition of other somatic mutations. Only CML, polycythemia vera, and primary myelofibrosis are presented here, as essential thrombocythemia and other myeloproliferative disorders are too infrequent to merit discussion.

### Chronic Myelogenous Leukemia

CML principally affects adults between 25 and 60 years of age. The peak incidence is in the fourth and fifth decades of life. About 4500 new cases are diagnosed per year in the United States.

## PATHOGENESIS

**CML is always associated with the presence of a BCR-ABL fusion gene.** In about 95% of cases, the *BCR-ABL* gene is the product of a balanced (9;22) translocation that moves *ABL* from chromosome 9 to a position on chromosome 22 adjacent to *BCR*. In the remaining 5% of cases, a *BCR-ABL* fusion gene is created by cytogenetically cryptic or complex rearrangements involving more than two chromosomes. The *BCR-ABL* fusion gene is present in granulocytic, erythroid, megakaryocytic, and B cell precursors, and in some cases T cell precursors as well, indicating that the tumor arises from a transformed hematopoietic stem cell. Although the Ph chromosome is highly characteristic of CML, it also is present in 25% of adult B cell–ALLs and a small subset of AMLs.

As described in Chapter 5, the *BCR-ABL* gene encodes a fusion protein consisting of portions of BCR and the tyrosine kinase domain of ABL. Normal myeloid progenitors depend on signals generated by growth factors and their receptors for growth and survival. **The growth factor dependence of CML progenitors is greatly decreased by constitutive signals generated by BCR-ABL that mimic the effects of growth factor receptor activation.** Importantly, because BCR-ABL does not inhibit differentiation, the early disease course is marked by excessive hematopoiesis. Although the *BCR-ABL* fusion gene is present in multiple lineages, for unclear reasons the pro-growth effects of BCR-ABL are confined mainly to the granulocyte and megakaryocyte lineages.

## MORPHOLOGY

The peripheral blood findings are highly characteristic. The leukocyte count is elevated, often exceeding 100,000 cells/μL. **The circulating cells are predominantly neutrophils, metamyelocytes, and myelocytes** (Fig. 11–26), but **basophils** and **eosinophils** are also prominent and platelets are usually increased. A small proportion of myeloblasts, usually less than 5%, are often seen in the peripheral blood. The bone marrow is hypercellular owing to increased numbers of granulocytic and megakaryocytic precursors. Myeloblasts usually are only slightly increased. The red pulp of the enlarged spleen resembles bone marrow because of the presence of extensive extramedullary hematopoiesis. This burgeoning proliferation often compromises the local blood supply, leading to splenic infarcts.

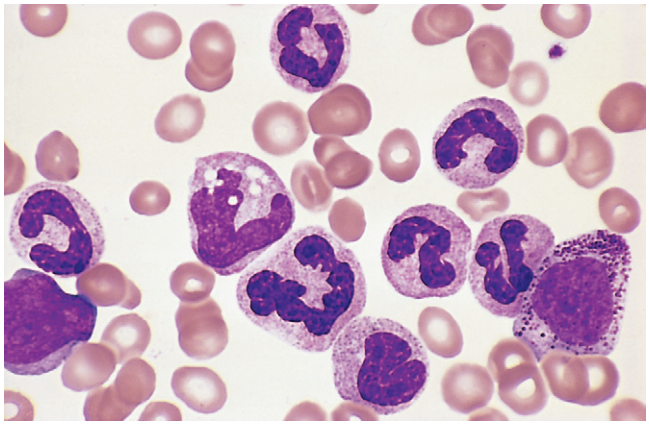

**Figure 11–26** Chronic myelogenous leukemia—peripheral blood smear. Granulocytic forms at various stages of differentiation are present. *(Courtesy of Dr. Robert W. McKenna, Department of Pathology, University of Texas Southwestern Medical School, Dallas, Texas.)*

### Clinical Features

The onset of CML often is insidious, as the initial symptoms usually are nonspecific (e.g., easy fatigability, weakness, weight loss). Sometimes the first symptom is a dragging sensation in the abdomen caused by *splenomegaly.* On occasion it may be necessary to distinguish CML from a "leukemoid reaction," a dramatic elevation of the granulocyte count in response to infection, stress, chronic inflammation, and certain neoplasms. This distinction can be achieved definitively by testing for the presence of the *BCR-ABL* fusion gene, which can be done by karyotyping, fluorescence in situ hybridization, or PCR assay.

The natural history of CML initially is one of slow progression. Even without treatment, the median survival is 3 years. After a variable (and unpredictable) period, approximately half of CML cases enter an accelerated phase marked by increasing anemia and new thrombocytopenia, the appearance of additional cytogenetic abnormalities, and finally transformation into a picture resembling acute leukemia (blast crisis). In the remaining 50% of cases, blast crisis occurs abruptly, without an accelerated phase. Of note, in 30% of cases the blast crisis resembles precursor-B cell ALL, further attesting to the origin of CML from hematopoietic stem cells. In the remaining 70% of cases, the blast crisis resembles AML. Less commonly, CML progresses to a phase of extensive bone marrow fibrosis resembling primary myelofibrosis.

Fortunately for those affected, the natural history of CML has been altered dramatically by the emergence of targeted therapy. Inhibitors of the BCR-ABL tyrosine kinase, such as imatinib and nilotinib, induce complete remission in a high fraction of patients with little associated toxicity. Treatment with tyrosine kinase inhibitors, particularly in patients with early disease, induces sustained remissions and may prevent the appearance of blast crisis by suppressing the proliferative drive that leads to the acquisition of additional mutations. When patients on tyrosine kinase inhibitors relapse, their tumors frequently are found to have acquired mutations in the kinase domain of BCR-ABL that prevent the drugs from binding. In retrospective studies, these mutations have been shown to be present in small numbers of cells at the time of diagnosis. The selective outgrowth of these cells is explained by the powerful antitumor effects of BCR-ABL inhibitors, and indicates that many resistant tumors are still "addicted" to the pro-growth signals created by BCR-ABL. For those with resistant disease, hematopoietic stem cell transplantation is curative in 70% of patients, but carries with it substantial risks, particularly in the aged.

## Polycythemia Vera

Polycythemia vera is characterized by an excessive proliferation of erythroid, granulocytic, and megakaryocytic elements (panmyelosis), but *most clinical signs and symptoms are related to an absolute increase in red cell mass.* Polycythemia vera must be distinguished from relative polycythemia, which results from hemoconcentration. Unlike reactive forms of absolute polycythemia, polycythemia vera is associated with *low levels of serum erythropoietin,* which is a reflection of the growth factor–independent growth of the neoplastic clone. This behavior stems from the presence of activating mutations in JAK2, a tyrosine kinase that acts in the signaling pathways downstream of the erythropoietin receptor and other growth factor receptors. The most common JAK2 mutation, a valine-to-phenylalanine substitution at residue 617, sharply lowers the dependence of hematopoietic cells on growth factors for growth and survival, suggesting that it is an important part of the pathogenesis of the disorder.

### MORPHOLOGY

The major anatomic changes in polycythemia vera stem from increases in blood volume and viscosity brought about by the polycythemia. Plethoric congestion of many tissues is characteristic. The liver is enlarged and often contains small foci of extramedullary hematopoiesis. The spleen usually is slightly enlarged (250 to 300 g) due to vascular congestion. **As a result of the increased viscosity and vascular stasis, thromboses and infarctions are common, particularly in the heart, spleen, and kidneys.** Hemorrhages also occur in about a third of the patients, probably as a result of excessive distention of blood vessels and abnormal platelet function. These most often affect the gastrointestinal tract, oropharynx, or brain. Hemorrhage may occur spontaneously but more often follows some minor trauma or surgical procedure. Platelets produced from the neoplastic clone often are dysfunctional, a derangement that contributes to the elevated risk of thrombosis and bleeding. As in CML, the peripheral blood often shows basophilia.

The bone marrow is hypercellular owing to increased numbers of erythroid, myeloid, and megakaryocytic forms. In addition, some degree of marrow fibrosis is present in 10% of patients at the time of diagnosis. In a subset of patients, this progresses to a spent phase where the marrow is largely replaced by fibroblasts and collagen.

### Clinical Course

Polycythemia vera appears insidiously, usually in late middle age. Patients are plethoric and often somewhat cyanotic. Histamine released from the neoplastic basophils may contribute to *pruritus* and also may account for the increased incidence of *peptic ulceration.* Other complaints are referable to the thrombotic and hemorrhagic tendencies and to hypertension. *Headache, dizziness, gastrointestinal symptoms, hematemesis, and melena* are common. Because of the high rate of cell turnover, symptomatic gout is seen in 5% to 10% of cases, and many more patients have asymptomatic hyperuricemia.

The diagnosis usually is made in the laboratory. *Red cell counts range from 6 to 10 million/μl and the hematocrit is often 60% or greater.* The granulocyte count can be as high as 50,000 cells/μL, and the platelet count is often over 400,000/μL. *Basophilia* is common. The platelets are functionally abnormal in most cases, and giant *platelets* and megakaryocyte fragments are often seen in the blood. About 30% of patients develop *thrombotic complications,* usually affecting the brain or heart. Hepatic vein thrombosis giving rise to the Budd-Chiari syndrome (Chapter 15) is an uncommon but grave complication. Minor *hemorrhages* (e.g., epistaxis and bleeding from gums) are common and life-threatening hemorrhages occur in 5% to 10% of patients. In those receiving no treatment, death occurs from

vascular complications within months; however, the median survival is increased to about 10 years by lowering the red cell count to near normal through repeated phlebotomy.

Unfortunately, prolonged survival has revealed a propensity for polycythemia vera to evolve to a "spent phase" resembling primary myelofibrosis. After an average interval of 10 years, 15% to 20% of cases undergo such a transformation. Owing to the extensive marrow fibrosis, hematopoiesis shifts to the spleen, which enlarges markedly. Transformation to a "blast crisis" identical to AML also occurs but much less frequently than in CML. Inhibitors that target JAK2 are in clinical trials at present.

### Primary Myelofibrosis

In the myeloproliferative disorder known as primary myelofibrosis, a "spent phase" of marrow fibrosis supervenes early in the disease course, often after a brief period of granulocytosis and thrombocytosis. As hematopoiesis shifts from the fibrotic marrow to the spleen, liver, and lymph nodes, extreme splenomegaly and hepatomegaly develop. The extramedullary hematopoiesis at these sites is disordered and inefficient, resulting in anemia and thrombocytopenia. Neutropenia also may occur but tends to be mild.

## PATHOGENESIS

The fibroblasts that lay down the collagen in the marrow are not neoplastic. Instead, the marrow fibrosis is secondary to derangements in the hematopoietic cells. It is believed that **the fibroblast proliferation is stimulated by platelet-derived growth factor and transforming growth factor β released from neoplastic megakaryocytes.** By the time patients come to clinical attention, marrow fibrosis and marked extramedullary hematopoiesis usually are evident. Less commonly, marrow fibrosis is mild at diagnosis and the clinical picture resembles that of other myeloproliferative disorders.

Of pathogenic and possible therapeutic importance, the same JAK2 mutation that is found in polycythemia vera (a valine-to-phenylalanine mutation at amino acid residue 617) is present in around half of cases of primary myelofibrosis (as well as a similar proportion of essential thrombocythemia cases)—a commonality that emphasizes the overlap between these entities. It is not yet known why tumors with the same mutation have such varied clinical pictures.

## MORPHOLOGY

The peripheral blood smear is markedly abnormal (Fig. 11–27). **Red cells often exhibit bizarre shapes (poikilocytes, teardrop cells),** and nucleated erythroid precursors are commonly present along with immature white cells (myelocytes and metamyelocytes), a combination of findings referred to as "leukoerythroblastosis." Abnormally large platelets often are present as well. The **spleen** usually is markedly enlarged, sometimes weighing as much as 4000 g, from the extensive extramedullary hematopoiesis. **Subcapsular splenic infarcts,** often multiple, are commonly present. Within areas of extramedullary hematopoiesis, megakaryocytes usually are numerous and often display bizarre morphologic features. Moderate **hepatomegaly** due to extramedullary hematopoiesis is commonplace. The **lymph nodes** also are involved by extramedullary hematopoiesis, but not to a degree sufficient to cause appreciable enlargement. The **bone marrow** in advanced cases is hypocellular and diffusely fibrotic, while early in the course it may be hypercellular and have only focal areas of fibrosis. Throughout the course, marrow megakaryocytes usually are increased in number and dysplastic.

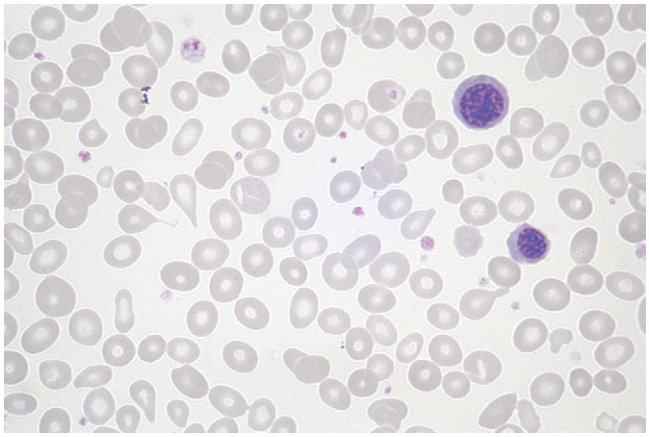

**Figure 11–27** Primary myelofibrosis—peripheral blood smear. Two nucleated erythroid precursors and several teardrop-shaped red cells (dacryocytes) are evident. Immature myeloid cells were present in other fields. An identical histologic picture can be seen in other diseases producing marrow distortion and fibrosis.

### Clinical Course

By the time most patients come to clinical attention, the disease has progressed to the phase of marrow fibrosis. Early stage disease may have features suggestive of CML, but *the Ph chromosome is absent.* Most patients have moderate to severe anemia at the time of diagnosis. The white blood cell count may be normal, reduced, or markedly elevated. Early in the course the platelet count is normal or elevated, but eventually patients develop thrombocytopenia. Because of a high rate of cell turnover, *hyperuricemia and gout* may complicate the picture.

The outcome of this disease is variable, but the median survival time is 4 to 5 years. There is a constant threat of thrombotic and hemorrhagic episodes stemming from platelet abnormalities. Splenic infarctions are common. From 5% to 15% of affected persons develop a blast crisis resembling AML.

## SUMMARY

### Myeloid Neoplasms

Myeloid tumors occur mainly in adults and fall into three major groups:

- **Acute myeloid leukemias (AMLs)**
  - Aggressive tumors comprised of immature myeloid lineage blasts, which replace the marrow and suppress normal hematopoiesis

- Associated with diverse acquired mutations that lead to expression of abnormal transcription factors, which interfere with myeloid differentiation
- **Myeloproliferative disorders**
  - Myeloid tumors in which production of formed myeloid elements is initially increased, leading to high blood counts and extramedullary hematopoiesis
  - Commonly associated with acquired mutations that lead to constitutive activation of tyrosine kinases, which mimic signals from normal growth factors. The most common pathogenic kinases are BCR-ABL (associated with CML) and mutated JAK2 (associated with polycythemia vera and primary myelofibrosis).
  - All can transform to acute leukemia and to a spent phase of marrow fibrosis associated with anemia, thrombocytopenia, and splenomegaly.
- **Myelodysplastic syndromes**
  - Poorly understood myeloid tumors characterized by disordered and ineffective hematopoiesis
  - Manifest with one or more cytopenias and progress in 10% to 40% of cases to AML

## Histiocytic Neoplasms

### *Langerhans Cell Histiocytoses*

The term *histiocytosis* is an "umbrella" designation for a variety of proliferative disorders of dendritic cells or macrophages. Some, such as very rare histiocytic lymphomas, are highly malignant neoplasms. Others, such as most histiocytic proliferations in lymph nodes, are completely benign and reactive. Between these two extremes lie a group of relatively rare tumors comprised of Langerhans cells, the *Langerhans cell histiocytoses*. As described in Chapter 4, Langerhans cells are immature dendritic cells found in the epidermis; similar cells are found in many other organs, and function to capture antigens and display them to T cells.

Langerhans cell proliferations take on different clinical forms, but all are believed to be variations of the same basic disorder. The proliferating Langerhans cells express MHC class II antigens, CD1a, and langerin. Langerin is a transmembrane protein found in *Birbeck granules,* cytoplasmic pentalaminar rodlike tubular structures that in electron micrographs have a characteristic periodicity and sometimes a dilated terminal end ("tennis racket" appearance). Under the light microscope, the proliferating Langerhans cells do not resemble their normal dendritic counterparts. Instead, they have abundant, often vacuolated cytoplasm and vesicular nuclei, an appearance more akin to that of tissue macrophages (called histiocytes by morphologists)—hence the term *Langerhans cell histiocytosis.*

Langerhans cell histiocytoses manifest as three relatively distinctive clinicopathologic entities. *Multisystem Langerhans cell histiocytosis (Letterer-Siwe disease)* usually occurs in children younger than 2 years of age. It typically manifests with multifocal cutaneous lesions that grossly resemble seborrheic skin eruptions and are composed of Langerhans cells. Most affected patients have hepatosplenomegaly, lymphadenopathy, pulmonary lesions, and (later in the course) destructive osteolytic bone lesions. Extensive infiltration of the marrow often leads to pancytopenia and predisposes the patient to recurrent infections such as otitis media and mastoiditis. The disease is rapidly fatal if untreated. With intensive chemotherapy, 50% of patients survive 5 years.

*Unisystem Langerhans cell histiocytosis (eosinophilic granuloma)* may be unifocal or multifocal. It is characterized by expanding, erosive accumulations of Langerhans cells, usually within the medullary cavities of bones or less commonly in the skin, lungs, or stomach. The Langerhans cells are admixed with variable numbers of lymphocytes, plasma cells, neutrophils, and eosinophils, which are usually, but not always, prominent. Virtually any bone in the skeletal system may be involved; the calvaria, ribs, and femur are most commonly affected. Unifocal disease most often involves the skeletal system. It may be asymptomatic or cause pain, tenderness and pathologic fractures. It is an indolent disorder that may heal spontaneously or be cured by local excision or irradiation. Multifocal unisystem disease usually affects children and typically manifests with multiple erosive bony masses that sometimes extend into soft tissues. In about 50% of cases, involvement of the posterior pituitary stalk of the hypothalamus leads to diabetes insipidus. The combination of calvarial bone defects, diabetes insipidus, and exophthalmos is referred to as the *Hand-Schüller-Christian triad.* Many patients experience spontaneous regressions; others are treated effectively with chemotherapy.

*A clue to the pathogenesis of Langerhans cell tumors lies in the discovery that the different clinical forms are frequently associated with an acquired mutation in the serine/threonine kinase BRAF,* a valine to glutamate substitution in residue 600 that leads to hyperactivity of the kinase. This same mutation is found in a variety of other tumors, including hairy cell leukemia, benign nevi, malignant melanoma, papillary thyroid carcinoma, and some colon cancers (Chapter 5). BRAF is a component of the Ras signaling pathway that drives cellular proliferation and survival, effects that likely contribute to the growth of the neoplastic Langerhans cells.

# BLEEDING DISORDERS

Bleeding disorders are characterized clinically by abnormal bleeding, which can appear spontaneously or follow some inciting event (e.g., trauma or surgery). As described in Chapter 3, normal clotting involves the vessel wall, the platelets, and the clotting factors. It follows that abnormalities in any of these components can lead to clinically significant bleeding. A review of the laboratory tests used in the evaluation of patients with a suspected bleeding

disorder, along with the principles involved, is presented next, followed by consideration of specific disorders of coagulation.

The most important tests for investigation of suspected coagulopathies include

- *Prothrombin time* (PT). This test assesses the extrinsic and common coagulation pathways. It measures the time (in seconds) needed for plasma to clot after addition of tissue thromboplastin (e.g., brain extract) and $Ca^{2+}$ ions. A prolonged PT can result from a deficiency of factor V, VII, or X or prothrombin or fibrinogen, or by an acquired inhibitor (typically an antibody) that interferes with the extrinsic pathway.
- *Partial thromboplastin time* (PTT). This test assesses the intrinsic and common coagulation pathways. It measures the time (in seconds) needed for the plasma to clot after the addition of kaolin, cephalin, and $Ca^{2+}$. Kaolin activates the contact-dependent factor XII and cephalin substitutes for platelet phospholipids. Prolongation of PTT can be caused by a deficiency of factor V, VIII, IX, X, XI, or XII or prothrombin or fibrinogen, or by an acquired inhibitor that interferes with the intrinsic pathway.
- *Platelet count.* This is obtained on anticoagulated blood using an electronic particle counter. The reference range is 150,000 to 450,000/μL. Counts outside this range must be confirmed by a visual inspection of a peripheral blood smear.
- *Tests of platelet function.* At present no single test provides an adequate assessment of the complex functions of platelets. Platelet aggregation tests that measure the response of platelets to certain agonists and qualitative and quantitative tests of von Willebrand factor (which you will recall is required for platelet adherence to subvascular collagen) are both commonly used in clinical practice. An older test, the bleeding time, has some value but is time-consuming and difficult to standardize and is therefore performed only rarely. Newer instrument-based assays that provide quantitative measures of platelet function show promise but are not yet available for routine use in the clinic.

Additional, more specialized tests are available that measure the levels of specific clotting factors and fibrin split products, or assess the presence of circulating anticoagulants.

Bleeding disorders may stem from abnormalities of vessels, platelets, or coagulation factors, alone or in combination. Bleeding due to *vascular fragility* is seen with vitamin C deficiency (scurvy) (Chapter 7), systemic amyloidosis (Chapter 4), chronic glucocorticoid use, rare inherited conditions affecting the connective tissues, and a large number of infectious and hypersensitivity vasculitides. These vasculitides include meningococcemia, infective endocarditis, the rickettsial diseases, typhoid, and Henoch-Schönlein purpura. Some of these conditions are discussed in other chapters; others are beyond the scope of this book. Bleeding that results purely from vascular fragility is characterized by the "spontaneous" appearance of petechiae and ecchymoses in the skin and mucous membranes (probably resulting from minor trauma). In most instances laboratory tests of coagulation are normal. *Bleeding also can be triggered by systemic conditions that inflame or damage endothelial cells.* If severe enough, such insults convert the vascular lining to a prothrombotic surface that activates coagulation throughout the circulatory system, a condition known as disseminated intravascular coagulation (DIC) (discussed in the next section). Paradoxically, in DIC, platelets and coagulation factors often are used up faster than they can be replaced, resulting in deficiencies that may lead to severe bleeding (a condition referred to as *consumptive coagulopathy*).

*Deficiencies of platelets* (thrombocytopenia) are an important cause of bleeding. These occur in a variety of clinical settings that are discussed later. Other bleeding disorders stem from *qualitative defects in platelet function.* Such defects may be *acquired,* as in uremia and certain myeloproliferative disorders and after aspirin ingestion; or *inherited,* as in von Willebrand disease and other rare congenital disorders. The clinical signs of inadequate platelet function include easy bruising, nosebleeds, excessive bleeding from minor trauma, and menorrhagia.

*In bleeding disorders stemming from defects in one or more coagulation factors, the PT, PTT, or both are prolonged.* Unlike platelet defects, petechiae and mucosal bleeding are usually absent. Instead, hemorrhages tend to occur in parts of the body that are subject to trauma, such as the joints of the lower extremities. Massive hemorrhage may occur after surgery, dental procedures, or severe trauma. This category includes the hemophilias, an important group of inherited coagulation disorders.

*It is not uncommon for bleeding to occur as a consequence of a mixture of defects.* This is the case in DIC, in which both thrombocytopenia and coagulation factor deficiencies contribute to bleeding, and in von Willebrand disease, a fairly common inherited disorder in which both platelet function and (to a lesser degree) coagulation factor function are abnormal.

With the foregoing overview as background, we now turn to specific bleeding disorders.

## DISSEMINATED INTRAVASCULAR COAGULATION

Disseminated intravascular coagulation (DIC) occurs as a complication of a wide variety of disorders. *DIC is caused by the systemic activation of coagulation and results in the formation of thrombi throughout the microcirculation. As a consequence, platelets and coagulation factors are consumed and, secondarily, fibrinolysis is activated.* Thus, DIC can give rise to either tissue hypoxia and microinfarcts caused by myriad microthrombi or to a bleeding disorder related to pathologic activation of fibrinolysis and the depletion of the elements required for hemostasis (hence the term *consumptive coagulopathy*). This entity probably causes bleeding more commonly than all of the congenital coagulation disorders combined.

### PATHOGENESIS

Before discussing the specific disorders associated with DIC, we will consider in a general way the pathogenic mechanisms

by which intravascular clotting occurs. Reference to earlier comments on normal blood coagulation (Chapter 3) may be helpful at this point. It suffices here to recall that clotting can be initiated by either the extrinsic pathway, which is triggered by the release of tissue factor (tissue thromboplastin); or the intrinsic pathway, which involves the activation of factor XII by surface contact, collagen, or other negatively charged substances. Both pathways lead to the generation of thrombin. Clotting normally is limited by the rapid clearance of activated clotting factors by the macrophages and the liver, endogenous anticoagulants (e.g., protein C), and the concomitant activation of fibrinolysis.

DIC usually is triggered by either (1) the release of tissue factor or thromboplastic substances into the circulation or (2) widespread endothelial cell damage (Fig. 11–28). Thromboplastic substances can be released into the circulation from a variety of sources—for example, the placenta in obstetric complications or certain types of cancer cells, particularly those of acute promyelocytic leukemia and adenocarcinomas. Cancer cells can also provoke coagulation in other ways, such as by releasing proteolytic enzymes and by expressing tissue factor. In gram-negative and gram-positive sepsis (important causes of DIC), endotoxins or exotoxins stimulate the release of tissue factor from monocytes. Activated monocytes also release IL-1 and tumor necrosis factor, both of which stimulate the expression of tissue factor on endothelial cells and simultaneously decrease the expression of thrombomodulin. The latter, you may recall, activates protein C, an anticoagulant (Chapter 3). The net result of these alterations is the enhanced generation of thrombin and the blunting of inhibitory pathways that limit coagulation.

Severe endothelial cell injury can initiate DIC by causing the release of tissue factor and by exposing subendothelial collagen and von Willebrand factor (vWF). However, even subtle forms of endothelial damage can unleash procoagulant activity by stimulating the increased expression of tissue factor on endothelial cell surfaces. Widespread endothelial injury can be produced by the deposition of antigen-antibody complexes (e.g., in systemic lupus erythematosus), by temperature extremes (e.g., after heat stroke or burn injury), or by infections (e.g., due to meningococci or rickettsiae). As discussed in Chapter 3, endothelial injury is an important consequence of endotoxemia, and, not surprisingly, DIC is a frequent complication of gram-negative sepsis.

Disorders associated with DIC are listed in Table 11–12. Of these, DIC is most often associated with sepsis, obstetric complications, malignancy, and major trauma (especially trauma to the brain). The initiating events in these conditions are multiple and often interrelated. For example, in obstetric conditions, tissue factor derived from the placenta, retained dead fetus, or amniotic fluid enters the circulation; however, shock, hypoxia, and acidosis often coexist and can lead to widespread endothelial injury. Trauma to the brain releases fat and phospholipids, which act as contact factors and thereby activate the intrinsic arm of the coagulation cascade.

Whatever the pathogenetic mechanism, DIC has two consequences. First, there is **widespread fibrin deposition within the microcirculation.** The associated obstruction leads to ischemia in the more severely affected or vulnerable organs and hemolysis as red cells are traumatized while passing through vessels narrowed by fibrin thrombi **(microangiopathic hemolytic anemia).** Second, a **bleeding diathesis** results from the depletion of platelets and clotting factors and the secondary release of plasminogen activators. Plasmin cleaves not only fibrin (fibrinolysis) but also factors V and VIII, thereby reducing their concentration further. In addition, fibrinolysis creates fibrin degradation products. These inhibit platelet aggregation, have antithrombin activity, and impair fibrin polymerization, all of which contribute to the hemostatic failure (Fig. 11–28).

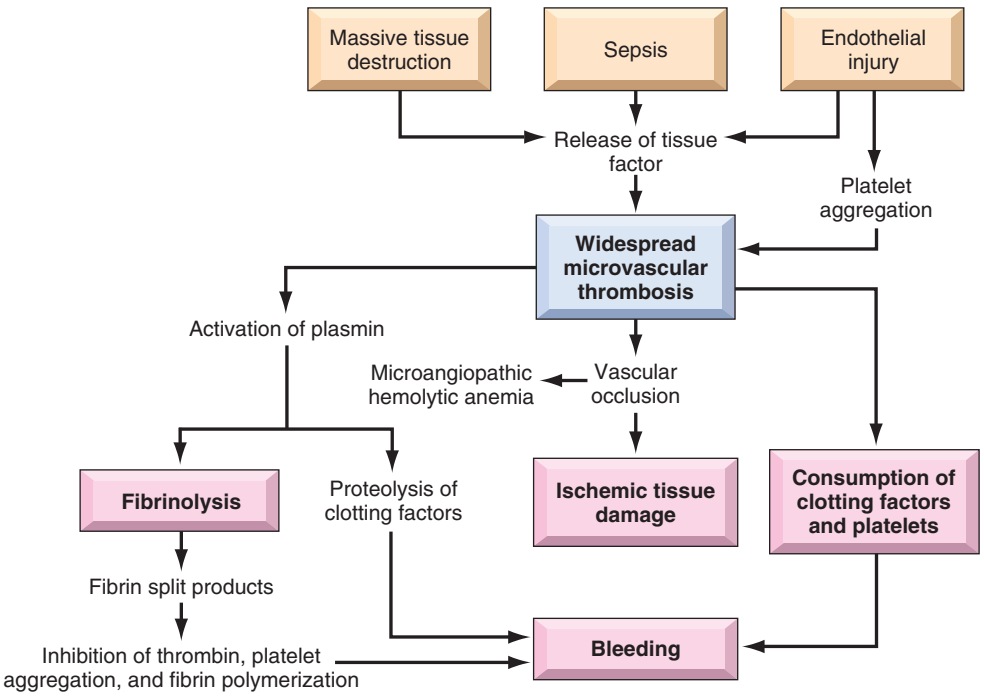


**Figure 11–28** Pathophysiology of disseminated intravascular coagulation.

**Table 11–12** Major Disorders Associated with Disseminated Intravascular Coagulation

| |
|---|
| **Obstetric Complications** |
| Abruptio placentae |
| Retained dead fetus |
| Septic abortion |
| Amniotic fluid embolism |
| Toxemia |
| **Infections** |
| Sepsis (gram-negative and gram-positive) |
| Meningococcemia |
| Rocky Mountain spotted fever |
| Histoplasmosis |
| Aspergillosis |
| Malaria |
| **Neoplasms** |
| Carcinomas of pancreas, prostate, lung, and stomach |
| Acute promyelocytic leukemia |
| **Massive Tissue Injury** |
| Trauma |
| Burns |
| Extensive surgery |
| **Miscellaneous** |
| Acute intravascular hemolysis, snakebite, giant hemangioma, shock, heat stroke, vasculitis, aortic aneurysm, liver disease |

### MORPHOLOGY

In DIC **microthrombi** are most often found in the arterioles and capillaries of the kidneys, adrenals, brain, and heart, but no organ is spared. The glomeruli contain small fibrin thrombi. These may be associated with only a subtle, reactive swelling of the endothelial cells or varying degrees of focal glomerulitis. The microvascular occlusions give rise to small infarcts in the renal cortex. In severe cases the ischemia can destroy the entire cortex and cause bilateral renal cortical necrosis. Involvement of the adrenal glands can produce the **Waterhouse-Friderichsen syndrome** (Chapter 19). Microinfarcts also are commonly encountered in the brain and are often surrounded by microscopic or gross foci of hemorrhage. These can give rise to bizarre neurologic signs. Similar changes are seen in the heart and often in the anterior pituitary. DIC may contribute to the development of **Sheehan postpartum pituitary necrosis** (Chapter 19). Eclampsia (toxemia of pregnancy) is a hypercoagulable state that may be associated with thromboses in the placenta, liver, kidneys, brain, and pituitary (Chapter 18). The bleeding tendency associated with DIC is manifested not only by larger-than-expected hemorrhages near foci of infarction but also by diffuse petechiae and ecchymoses on the skin, serosal linings of the body cavities, epicardium, endocardium, lungs, and mucosal lining of the urinary tract.

### Clinical Course

As might be imagined, depending on the balance between clotting and bleeding tendencies, the range of possible clinical manifestations is enormous. In general, *acute DIC (e.g., that associated with obstetric complications) is dominated by a bleeding diathesis, whereas chronic DIC (e.g., as occurs in those with cancer) tends to manifest with signs and symptoms related to thrombosis.* The abnormal clotting usually is confined to the microcirculation, but large vessels are involved on occasion. The manifestations may be minimal, or there may be shock, with acute renal failure, dyspnea, cyanosis, convulsions, and coma. Most often, attention is called to the presence of DIC by prolonged and copious postpartum bleeding or by the presence of petechiae and ecchymoses on the skin. These may be the only manifestations, or there may be severe hemorrhage into the gut or urinary tract. Laboratory evaluation reveals *thrombocytopenia and prolongation of the PT and the PTT* (from depletion of platelets, clotting factors, and fibrinogen). Fibrin split products are increased in the plasma.

The prognosis varies widely depending on the nature of the underlying disorder and the severity of the intravascular clotting and fibrinolysis. Acute DIC can be life-threatening and must be treated aggressively with anticoagulants such as heparin or the coagulants contained in fresh frozen plasma. Conversely, chronic DIC is sometimes identified unexpectedly by laboratory testing. In either circumstance, definitive treatment must be directed at the underlying cause.

## THROMBOCYTOPENIA

*Isolated thrombocytopenia is associated with a bleeding tendency and normal coagulation tests.* A count less than 150,000 platelets/μL generally is considered to constitute thrombocytopenia. However, only when platelet counts fall to 20,000 to 50,000 platelets/μL is there an increased risk of post-traumatic bleeding, and spontaneous bleeding becomes evident when counts fall below 20,000 platelets/μL. Most bleeding occurs from small, superficial blood vessels and produces petechiae or large ecchymoses in the skin, the mucous membranes of the gastrointestinal and urinary tracts, and other sites. Larger hemorrhages into the central nervous system are a major hazard in those with markedly depressed platelet counts.

The major causes of thrombocytopenia are listed in Table 11–13. Clinically important thrombocytopenia is confined to disorders with reduced production or increased destruction of platelets. When the cause is accelerated destruction of platelets, the bone marrow usually reveals a compensatory increase in the number of megakaryocytes. Hence, bone marrow examination can help to distinguish between the two major categories of thrombocytopenia. Also of note, *thrombocytopenia is one of the most common hematologic manifestations of AIDS.* It can occur early in the course of HIV infection and has a multifactorial basis, including immune complex–mediated platelet destruction, antiplatelet autoantibodies, and HIV-mediated suppression of megakaryocyte development and survival.

### Immune Thrombocytopenic Purpura

Immune thrombocytopenic purpura (ITP) has two clinical subtypes. *Chronic ITP* is a relatively common disorder that tends to affect women between the ages of 20 and 40 years. *Acute ITP* is a self-limited form seen mostly in children after viral infections.

*Antibodies directed against platelet membrane glycoproteins IIb/IIIa or Ib/IX complexes can be detected in roughly 80% of*

**Table 11–13** Causes of Thrombocytopenia

| |
|---|
| **Decreased Production of Platelets** |
| Generalized Bone Marrow Dysfunction |
| Aplastic anemia: congenital and acquired<br>Marrow infiltration: leukemia, disseminated cancer |
| Selective Impairment of Platelet Production |
| Drug-induced: alcohol, thiazides, cytotoxic drugs<br>Infections: measles, HIV infection |
| Ineffective Megakaryopoiesis |
| Megaloblastic anemia<br>Paroxysmal nocturnal hemoglobinuria |
| **Decreased Platelet Survival** |
| Immunologic Destruction |
| Autoimmune: immune thrombocytopenic purpura, systemic lupus erythematosus<br>Isoimmune: post-transfusion and neonatal<br>Drug-associated: quinidine, heparin, sulfa compounds<br>Infections: infectious mononucleosis, HIV infection, cytomegalovirus infection |
| Nonimmunologic Destruction |
| Disseminated intravascular coagulation<br>Thrombotic thrombocytopenic purpura<br>Giant hemangiomas<br>Microangiopathic hemolytic anemias |
| **Sequestration** |
| Hypersplenism |
| **Dilutional** |
| Multiple transfusions (e.g., for massive blood loss) |

HIV, human immunodeficiency virus.

*cases of chronic ITP.* The spleen is an important site of antiplatelet antibody production and the major site of destruction of the IgG-coated platelets. Although splenomegaly is not a feature of uncomplicated chronic ITP, the importance of the spleen in the premature destruction of platelets is proved by the benefits of splenectomy, which normalizes the platelet count and induces a complete remission in more than two thirds of patients. The bone marrow usually contains increased numbers of megakaryocytes, a finding common to all forms of thrombocytopenia caused by accelerated platelet destruction.

The onset of chronic ITP is insidious. Common findings include petechiae, easy bruising, epistaxis, gum bleeding, and hemorrhages after minor trauma. Fortunately, more serious intracerebral or subarachnoid hemorrhages are uncommon. The diagnosis rests on the clinical features, the presence of thrombocytopenia, examination of the marrow, and the exclusion of secondary ITP. Reliable clinical tests for antiplatelet antibodies are not available.

## Heparin-Induced Thrombocytopenia

This special type of drug-induced thrombocytopenia (discussed in more detail in Chapter 3) merits brief mention because of its clinical importance. Moderate to severe thrombocytopenia develops in 3% to 5% of patients after 1 to 2 weeks of treatment with unfractionated heparin. The disorder is caused by IgG antibodies that bind to platelet factor 4 on platelet membranes in a heparin-dependent fashion. Resultant activation of the platelets induces their aggregation, thereby exacerbating the condition that heparin is used to treat—thrombosis. Both venous and arterial thromboses occur, even in the setting of marked thrombocytopenia, and can cause severe morbidity (e.g., loss of limbs) and death. Cessation of heparin therapy breaks the cycle of platelet activation and consumption. The risk of this complication is lowered (but not prevented entirely) by use of low-molecular-weight heparin preparations.

## Thrombotic Microangiopathies: Thrombotic Thrombocytopenic Purpura and Hemolytic Uremic Syndrome

The term *thrombotic microangiopathies* encompasses a spectrum of clinical syndromes that include thrombotic thrombocytopenic purpura (TTP) and hemolytic uremic syndrome (HUS). As originally defined, TTP is associated with the pentad of fever, thrombocytopenia, microangiopathic hemolytic anemia, transient neurologic deficits, and renal failure. HUS also is associated with microangiopathic hemolytic anemia and thrombocytopenia but is distinguished from TTP by the absence of neurologic symptoms, the dominance of acute renal failure, and frequent occurrence in children (Chapter 13). Clinical experience has blurred these distinctions, as many adults with TTP lack one or more of the five criteria, and some patients with HUS have fever and neurologic dysfunction. *Fundamental to both conditions is the widespread formation of platelet-rich thrombi in the microcirculation.* The consumption of platelets leads to thrombocytopenia, and the narrowing of blood vessels by the platelet-rich thrombi results in a microangiopathic hemolytic anemia.

### PATHOGENESIS

For many years the pathogenesis of TTP was enigmatic, although treatment with plasma exchange (initiated in the early 1970s) converted a disease that was almost uniformly fatal to one that is now successfully treated in more than 80% of affected persons. The underlying cause of most cases of TTP has now been elucidated. In brief, **symptomatic patients are deficient in the metalloprotease ADAMTS 13.** This enzyme degrades very-high-molecular-weight multimers of von Willebrand factor (vWF); hence, a deficiency of ADAMTS 13 allows abnormally large vWF multimers to accumulate in plasma. Under some circumstances, these colossal vWF multimers promote the formation of platelet microaggregates throughout the circulation. The superimposition of an endothelial cell injury (caused by some other condition) can further promote microaggregate formation, thus initiating or exacerbating clinically evident TTP.

ADAMTS 13 deficiency can be inherited or acquired, the latter by way of autoantibodies that bind and inhibit the metalloprotease. TTP must be considered in any patient with unexplained thrombocytopenia and microangiopathic hemolytic anemia, as any delay in diagnosis can be fatal.

Although clinically similar to TTP, HUS has a different pathogenesis. Most cases in children and elderly persons are triggered by infectious gastroenteritis caused by *E. coli* strain O157:H7. This organism elaborates a Shiga-like toxin that damages endothelial cells, which initiates platelet activation and aggregation. Affected persons often present with bloody diarrhea, followed a few days later by acute renal failure and microangiopathic anemia. Recovery is possible with supportive care and plasma exchange, but irreversible renal damage and death can occur in more severe cases. About 10% of cases of HUS are caused by inherited mutations or autoantibodies that lead to deficiency of factor H, factor I, or CD46, each of which is a negative regulator of the alternative complement cascade. The absence of these factors leads to uncontrolled complement activation after minor endothelial injury, resulting in thrombosis. HUS also can be seen after other exposures (e.g., to certain drugs or radiation) that damage endothelial cells. Here the prognosis is more guarded, as the underlying conditions that trigger these forms of HUS are often chronic or life-threatening.

Although DIC and the thrombotic microangiopathies share features such as microvascular occlusion and microangiopathic hemolytic anemia, they are pathogenically distinct. Unlike in DIC, in TTP and HUS activation of the coagulation cascade is not of primary importance, so results of laboratory tests of coagulation (such as the PT and the PTT) usually are normal.

## COAGULATION DISORDERS

Coagulation disorders result from either congenital or acquired deficiencies of clotting factors. *Acquired deficiencies are most common* and often involve several factors simultaneously. As discussed in Chapter 7, *vitamin K* is required for the synthesis of prothrombin and clotting factors VII, IX, and X, and its deficiency causes a severe coagulation defect. The liver synthesizes several coagulation factors and also removes many activated coagulation factors from the circulation; thus, *hepatic parenchymal diseases are common causes* of complex hemorrhagic diatheses. As already discussed, DIC also may lead to multiple concomitant factor deficiencies. Rarely, autoantibodies may cause acquired deficiencies limited to a single factor.

*Hereditary deficiencies* of each of the coagulation factors have been identified. Hemophilia A (a deficiency of factor VIII) and hemophilia B (Christmas disease, a deficiency of factor IX) are X-linked traits, whereas most deficiencies are autosomal recessive disorders. Of the inherited deficiencies, only von Willebrand disease, hemophilia A, and hemophilia B are sufficiently common to warrant further consideration.

### Deficiencies of Factor VIII–von Willebrand Factor Complex

Hemophilia A and von Willebrand disease are caused by qualitative or quantitative defects involving the factor VIII–von Willebrand factor (vWF) complex. As background for subsequent discussion of these disorders, it is useful to review the structure and function of these two proteins (Fig. 11–29).

As described earlier, factor VIII is an essential cofactor for factor IX, which activates factor X in the intrinsic coagulation pathway. *Circulating factor VIII binds noncovalently to vWF,* which exists as multimers of up to 20 MDa in weight. These two proteins are encoded by separate genes and are synthesized by different cells. Endothelial cells are the major source of plasma vWF, whereas most factor VIII is synthesized in the liver. vWF is found in the plasma (in association with factor VIII), in platelet granules, in endothelial cells within cytoplasmic vesicles called Weibel-Palade bodies, and in the subendothelium, where it binds to collagen.

When endothelial cells are stripped away by trauma or injury, subendothelial vWF is exposed and binds to platelets, mainly through glycoprotein Ib and to a lesser degree through glycoprotein IIb/IIIa (Fig. 11–29). *The most*

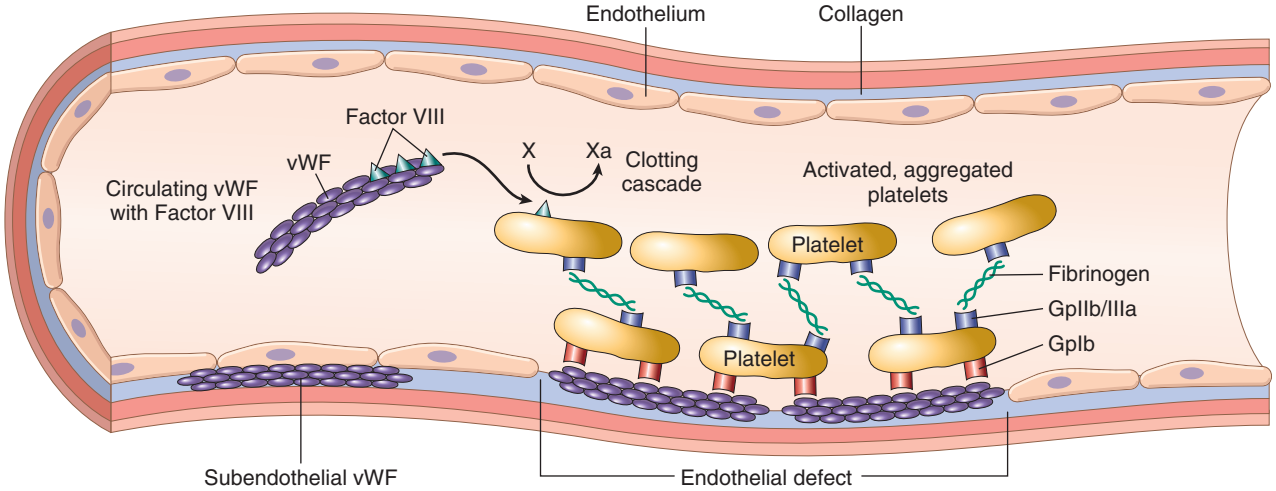


**Figure 11–29** Structure and function of factor VIII–von Willebrand factor (vWF) complex. Factor VIII and vWF circulate as a complex. vWF also is present in the subendothelial matrix of normal blood vessels. Factor VIII takes part in the coagulation cascade by activating factor X by means of factor IX (*not shown*). vWF causes adhesion of platelets to subendothelial collagen, primarily through the glycoprotein Ib (GpIb) platelet receptor.

*important function of vWF is to facilitate the adhesion of platelets to damaged blood vessel walls,* a crucial early event in the formation of a hemostatic plug. Inadequate platelet adhesion is believed to underlie the bleeding tendency in von Willebrand disease. In addition to its role in platelet adhesion, vWF also stabilizes factor VIII; thus, vWF deficiency leads to a secondary deficiency of factor VIII.

The various forms of von Willebrand disease are diagnosed by measuring the quantity, size, and function of vWF. vWF function is assessed using the ristocetin platelet agglutination test. Ristocetin somehow "activates" the bivalent binding of vWF and platelet membrane glycoprotein Ib, creating interplatelet "bridges" that cause platelets to clump (agglutination), an event that can be measured easily. Thus, ristocetin-dependent platelet agglutination serves as a useful bioassay for vWF.

With this background we now turn to the discussion of diseases resulting from deficiencies of factor VIII–vWF complex.

### *von Willebrand Disease*

von Willebrand disease is transmitted as an autosomal dominant disorder. It usually presents as *spontaneous bleeding from mucous membranes, excessive bleeding from wounds, and menorrhagia.* It is underrecognized, as the diagnosis requires sophisticated tests and the clinical manifestations often are quite mild. Actually, this disease is surprisingly prevalent, particularly in persons of European descent. *It is estimated that approximately 1% of people in the United States have von Willebrand disease, making it the most common inherited bleeding disorder.*

People with von Willebrand disease have compound defects in platelet function and coagulation, but in most cases only the platelet defect produces clinical findings. The exceptions are rare patients with homozygous von Willebrand disease, in whom there is a concomitant deficiency of factor VIII severe enough to produce features resembling those of hemophilia (described later on).

*The classic and most common variant of von Willebrand disease (type I) is an autosomal dominant disorder in which the quantity of circulating vWF is reduced.* There is also a measurable but clinically insignificant decrease in factor VIII levels. The other, less common varieties of von Willebrand disease are caused by mutations that produce both qualitative and quantitative defects in vWF. *Type II* is divided into several subtypes *characterized by the selective loss of high-molecular-weight multimers of vWF.* Because these large multimers are the most active form, there is a functional deficiency of vWF. In type IIA, the high-molecular-weight multimers are not synthesized, leading to a true deficiency. In type IIB, abnormal "hyperfunctional" high-molecular-weight multimers are synthesized that are rapidly removed from the circulation. These high-molecular-weight multimers cause spontaneous platelet aggregation (a situation reminiscent of the very-high-molecular-weight multimer aggregates seen in TTP); indeed, some people with type IIB von Willebrand disease have mild chronic thrombocytopenia, presumably due to platelet consumption.

### *Hemophilia A—Factor VIII Deficiency*

*Hemophilia A is the most common hereditary cause of serious bleeding.* It is an X-linked recessive disorder caused by reduced factor VIII activity. It primarily affects males. Much less commonly excessive bleeding occurs in heterozygous females, presumably due to preferential inactivation of the X chromosome carrying the normal factor VIII gene (unfavorable lyonization). *Approximately 30% of cases are caused by new mutations*; in the remainder, there is a positive family history. Severe hemophilia A is observed in people with marked deficiencies of factor VIII (activity levels less than 1% of normal). Milder deficiencies may only become apparent when other predisposing conditions, such as trauma, are also present. The varying degrees of factor VIII deficiency are explained by the existence of many different causative mutations. As in the thalassemias, several types of genetic lesions (e.g., deletions, inversions, splice junction mutations) have been identified. In about 10% of patients, the factor VIII concentration is normal by immunoassay, but the coagulant activity is low because of a mutation in factor VIII that causes a loss of function.

In symptomatic cases there is a tendency toward *easy bruising and massive hemorrhage after trauma or operative procedures.* In addition, "spontaneous" hemorrhages frequently are encountered in tissues that normally are subject to mechanical stress, particularly the joints, where recurrent bleeds (*hemarthroses*) lead to progressive deformities that can be crippling. *Petechiae are characteristically absent.* Specific assays for factor VIII are used to confirm the diagnosis of hemophilia A. Typically, patients with hemophilia A have a prolonged PTT that is corrected by mixing the patient's plasma with normal plasma. Specific factor assays are then used to confirm the deficiency of factor VIII. In approximately 15% of those with severe hemophilia A replacement therapy is complicated by the development of neutralizing antibodies against factor VIII, probably because factor VIII is seen by the immune system as a "foreign" antigen. In these persons, the PTT fails to correct in mixing studies.

Hemophilia A is treated with factor VIII infusions. Historically, factor VIII was prepared from human plasma, carrying with it the risk of transmission of viral diseases. As mentioned in Chapter 4, before 1985 thousands of hemophiliacs received factor VIII preparations contaminated with HIV. Subsequently, many became seropositive and developed AIDS. The availability and widespread use of recombinant factor VIII and more highly purified factor VIII concentrates have now eliminated the infectious risk of factor VIII replacement therapy.

### *Hemophilia B—Factor IX Deficiency*

Severe factor IX deficiency is an X-linked disorder that is indistinguishable clinically from hemophilia A but much less common. The PTT is prolonged. The diagnosis is made using specific assays of factor IX. It is treated by infusion of recombinant factor IX.

## SUMMARY

### Bleeding Disorders

**Disseminated Intravascular Coagulation**
- Syndrome in which systemic activation of the coagulation leads to consumption of coagulation factors and platelets
- Can be dominated by bleeding, vascular occlusion and tissue hypoxemia, or both
- Common triggers: sepsis, major trauma, certain cancers, obstetric complications

**Immune Thrombocytopenic Purpura**
- Caused by autoantibodies against platelet antigens
- May be triggered by drugs, infections, or lymphomas, or may be idiopathic

**Thrombotic Thrombocytopenic Purpura and Hemolytic Uremic Syndrome**
- Both manifest with thrombocytopenia, microangiopathic hemolytic anemia, and renal failure; fever and CNS involvement are more typical of TTP.
- *TTP*: Caused by acquired or inherited deficiencies of ADAMTS 13, a plasma metalloprotease that cleaves very-high-molecular-weight multimers of von Willebrand factor (vWF). Deficiency of ADAMTS 13 results in abnormally large vWF multimers that activate platelets.
- *Hemolytic uremic syndrome*: caused by deficiencies of complement regulatory proteins or agents that damage endothelial cells, such as a Shiga-like toxin elaborated by *E. coli* strain O157:H7. The endothelial injury initiates platelet activation, platelet aggregation, and microvascular thrombosis.

**von Willebrand Disease**
- Autosomal dominant disorder caused by mutations in vWF, a large protein that promotes the adhesion of platelets to subendothelial collagen
- Typically causes a mild to moderate bleeding disorder resembling that associated with thrombocytopenia

**Hemophilia**
- *Hemophilia A*: X-linked disorder caused by mutations in factor VIII. Affected males typically present with severe bleeding into soft tissues and joints and have a PTT.
- *Hemophilia B*: X-linked disorder caused by mutations in coagulation factor IX. It is clinically identical to hemophilia A.

# DISORDERS THAT AFFECT THE SPLEEN AND THYMUS

## SPLENOMEGALY

The spleen is frequently involved in a wide variety of systemic diseases. In virtually all instances, the spleen responds by enlarging (splenomegaly), an alteration that produces a set of stereotypical signs and symptoms. Evaluation of splenic enlargement is aided by recognition of the usual limits of splenomegaly produced by specific disorders. It would be erroneous to attribute an enlarged spleen pushing into the pelvis to vitamin $B_{12}$ deficiency, or to entertain a diagnosis of CML in the absence of splenomegaly. In the following list, disorders are grouped according to the degree of splenomegaly that they characteristically produce:

A. *Massive splenomegaly* (weight more than 1000 g)
- Myeloproliferative disorders (chronic myelogenous leukemia, primary myelofibrosis)
- Chronic lymphocytic leukemia and hairy cell leukemia
- Lymphomas
- Malaria
- Gaucher disease
- Primary tumors of the spleen (rare)

B. *Moderate splenomegaly* (weight 500 to 1000 g)
- Chronic congestive splenomegaly (portal hypertension or splenic vein obstruction)
- Acute leukemias (variable)
- Hereditary spherocytosis
- Thalassemia major
- Autoimmune hemolytic anemia
- Amyloidosis
- Niemann-Pick disease
- Chronic splenitis (especially with infective endocarditis)
- Tuberculosis, sarcoidosis, typhoid
- Metastatic carcinoma or sarcoma

C. *Mild splenomegaly* (weight less than 500 g)
- Acute splenitis
- Acute splenic congestion
- Infectious mononucleosis
- Miscellaneous disorders, including septicemia, systemic lupus erythematosus, and intra-abdominal infections

The microscopic changes associated with these diseases are discussed in the relevant sections of this and other chapters.

A chronically enlarged spleen often removes excessive numbers of one or more of the formed elements of blood, resulting in anemia, leukopenia, or thrombocytopenia. This is referred to as *hypersplenism,* a state that can be associated with many of the diseases listed previously. In addition, platelets are particularly susceptible to sequestration in the interstices of the red pulp; as a result, thrombocytopenia is more prevalent and severe in persons with splenomegaly than is anemia or neutropenia.

## DISORDERS OF THE THYMUS

As is well known, the thymus has a crucial role in T cell differentiation. It is not surprising, therefore, that the thymus can be involved by lymphomas, particularly those of T cell lineage (discussed earlier in this chapter). The

focus here is on the two most frequent (albeit still uncommon) disorders of the thymus: thymic hyperplasia and thymoma.

## Thymic Hyperplasia

Thymic enlargement often is associated with the presence of lymphoid follicles, or germinal centers, within the medulla. These germinal centers contain reactive B cells, which are only present in small numbers in normal thymuses. Thymic follicular hyperplasia is found in most patients with myasthenia gravis and sometimes also occurs in other autoimmune diseases, such as systemic lupus erythematosus and rheumatoid arthritis. The relationship between the thymus and myasthenia gravis is discussed in Chapter 21. Of significance, removal of the hyperplastic thymus is often beneficial early in the disease.

## Thymoma

Thymomas are tumors of thymic epithelial cells. Several classification systems for thymoma based on cytologic and biologic criteria have been proposed. One simple and clinically useful classification is as follows:

- Benign or encapsulated thymoma: cytologically and biologically benign
- Malignant thymoma
  - *Type I*: cytologically benign but infiltrative and locally aggressive
  - *Type II* (thymic carcinoma): cytologically and biologically malignant

### MORPHOLOGY

Macroscopically, thymomas are lobulated, firm, gray-white masses up to 15 to 20 cm in dimension. Most appear encapsulated, but in 20% to 25%, penetration of the capsule and infiltration of perithymic tissues and structures are seen. Microscopically, virtually all thymomas are made up of a mixture of epithelial tumor cells and non-neoplastic thymocytes (immature T cells). In **benign thymomas,** the epithelial cells are spindled or elongated and resemble those that normally populate the medulla. As a result, these are sometimes referred to as **medullary thymomas.** In other tumors, there is an admixture of the plumper, rounder, cortical-type epithelial cells; this pattern is sometimes referred to as a mixed thymoma. The medullary and mixed patterns account for 60% to 70% of all thymomas.

**Malignant thymoma type I** is cytologically bland but locally invasive; it accounts for 20% to 25% of all thymomas. These tumors also occasionally (and unpredictably) metastasize. They are composed of varying proportions of epithelial cells and reactive thymocytes. The epithelial cells usually have abundant cytoplasm and rounded vesicular nuclei, an appearance similar to normal thymic cortical epithelial cells; spindled epithelial cells are sometimes present as well. The epithelial cells often palisade around blood vessels. **The critical distinguishing feature is the penetration of the capsule with the invasion of surrounding structures.**

Malignant thymoma type II is perhaps better thought of as a form of **thymic carcinoma.** These tumors account for about 5% of thymomas. Macroscopically, they usually are fleshy, obviously invasive masses that often metastasize to such sites as the lungs. Microscopically, most resemble **squamous cell carcinoma.** The next most common type is **lymphoepithelioma-like carcinoma,** a tumor composed of anaplastic cortical-type epithelial cells mixed with large numbers of thymocytes. Tumors of this type are more common in Asian populations and sometimes contain the EBV genome.

### Clinical Features

Thymomas are rare. They may arise at any age, but most occur in middle-aged adults. In a large series about 30% were asymptomatic; 30% to 40% produced local manifestations such as cough, dyspnea, and superior vena cava syndrome; and the remainder were associated with a systemic disease, most commonly myasthenia gravis, in which a concomitant thymoma was discovered in 15% to 20% of patients. Removal of the tumor often leads to improvement of the neuromuscular disorder. Additional associations with thymoma include hypogammaglobulinemia, systemic lupus erythematosus, pure red cell aplasia, and nonthymic cancers.

## BIBLIOGRAPHY


### RED CELL DISORDERS

An X, Mohandas N: Disorders of the red cell membrane. Br J Haematol 141:367, 2008. *[An excellent overview of inherited red cell membrane defects.]*

Brodsky RA: Advances in the diagnosis and treatment of paroxysmal nocturnal hemoglobinuria. Blood Rev 22:65, 2008. *[Discussion of the advantages and limitations of treatment of PNH with antibodies that inhibit the C5b–C9 membrane attack complex.]*

Ganz T, Nemeth E: Iron sequestration and the anemia of inflammation. Semin Hematol 46:387, 2009. *[An update focused on how inflammation alters iron metabolism via effects on hepcidin production.]*

Haldar K, Murphy SC, Milner DA, Taylor TE: Malaria: mechanisms of erythrocytic infection and pathological correlates of severe disease. Annu Rev Pathol 2:217, 2007. *[A review of the proposed mechanisms underlying red cell infection by malarial parasites and the events leading to cerebral malaria.]*

Platt OS: Hydroxyurea for the treatment of sickle cell disease. N Engl J Med 358:1362, 2008. *[A review focused on the beneficial effects of hydroxyurea in sickle cell disease.]*

Young NS, Scheinberg P, Calado RT: Aplastic anemia. Curr Opin Hematol 15:162, 2008. *[An updated perspective on the role of the immune system in aplastic anemia.]*

### WHITE CELL DISORDERS

Anderson KC, Carrasco RD: Pathogenesis of myeloma. Annu Rev Pathol 6:249, 2011. *[A review of recent advances in understanding the molecular pathogenesis of multiple myeloma.]*

Jaffe ES, Harris NL, Stein H, Isaacson PG: Classification of lymphoid neoplasms: the microscope as a tool for disease discovery. Blood 112:4384, 2008. *[An overview of the origins and utility of the most recent WHO classification of lymphoid neoplasms.]*

Lenz G, Staudt LM: Aggressive lymphomas. N Engl J Med 362:1417, 2010. *[An excellent brief review of the molecular origins of aggressive B cell lymphomas.]*

Marcucci G, Haferlach T, Dohner H: Molecular genetics of adult acute myeloid leukemia: prognostic and therapeutic implications. J Clin Oncol 29:475, 2011. *[A current view of the clinical role of molecular genetics in AML.]*

Pui CH, Robison LL, Look AT: Acute lymphoblastic leukemia. Lancet 371:1030, 2008. *[A review of the molecular pathogenesis, diagnosis, and treatment of ALL.]*

Schmitz R, Stanelle J, Hansmann ML, Kuppers R: Pathogenesis of classical and lymphocyte-predominant Hodgkin lymphoma. Annu Rev Pathol 4:151, 2009. *[A concise review of Hodgkin lymphoma pathogenesis.]*

Vardiman JW, Thiele J, Arber DA, et al: The 2008 revision of the World Health Organization (WHO) classification of myeloid neoplasms and acute leukemia. Blood 114:937, 2008. *[A report providing the rationale for revision of the the WHO classification of myeloid neoplasms.]*

## BLEEDING DISORDERS

Arepally GM, Ortel TL: Heparin-induced thrombocytopenia. Annu Rev Med 61:77, 2010. *[A discussion of pathogenesis, clinical features, diagnostic criteria, and therapeutic approaches in HIT.]*

De Meyer SF, Deckmyn H, Vanhoorelbeke K: von Willebrand factor to the rescue. Blood 113:5049, 2009. *[An update on the molecular pathogenesis and treatment of vWD.]*

Noris M, Remuzzi G: Atypical hemolytic uremic syndrome. N Engl J Med 361:1676, 2009. *[An article focused on the role of excessive activation of the alternative complement pathway in some forms of HUS.]*

Pawlinski R, Mackman N: Cellular sources of tissue factor in endotoxemia and sepsis. Thromb Res 125(S1):S70, 2010. *[An overview of the role of cellular procoagulants in DIC associated with bacterial infection.]*

Zhou Z, Nguyen TC, Guchhait P, Dong JF: Von Willebrand factor, ADAMTS-13, and thrombotic thrombocytopenia purpura. Semin Thromb Hemost 36:71, 2010. *[A review focused on the role of vWF deregulation and ADAMTS 13 deficiency in TTP.]*

## DISORDERS THAT AFFECT THE SPLEEN AND THYMUS

Choi SS, Kim KD, Chung KY: Prognostic and clinical relevance of the World Health Organization schema for the classification of thymic epithelial tumors: a clinicopathologic study of 108 patients and literature review. Chest 127:755, 2005. *[A large clinicopathologic series that shows that stage is the best predictor of outcome in thymoma.]*

See Targeted Therapy available online at
studentconsult.com

CHAPTER 12

# Lung

CHAPTER CONTENTS


**Atelectasis (Collapse) 460**
**Acute Lung Injury 460**
Acute Respiratory Distress Syndrome 461
**Obstructive Versus Restrictive Pulmonary Diseases 462**
**Obstructive Lung (Airway) Diseases 463**
Emphysema 463
Chronic Bronchitis 467
Asthma 468
Bronchiectasis 470
**Chronic Interstitial (Restrictive, Infiltrative) Lung Diseases 472**
Fibrosing Diseases 472
Granulomatous Diseases 478
Pulmonary Eosinophilia 481
Smoking-Related Interstitial Diseases 481
**Pulmonary Diseases of Vascular Origin 482**
Pulmonary Embolism, Hemorrhage, and Infarction 482
Pulmonary Hypertension 484
Diffuse Alveolar Hemorrhage Syndromes 485
**Pulmonary Infections 486**
Community-Acquired Acute Pneumonias 486
Community-Acquired Atypical Pneumonias 490
Hospital-Acquired Pneumonias 491
Aspiration Pneumonia 492
Lung Abscess 492
Chronic Pneumonias 492
Histoplasmosis, Coccidioidomycosis, and Blastomycosis 499
Pneumonia in the Immunocompromised Host 500
Opportunistic Fungal Infections 502
Pulmonary Disease in Human Immunodeficiency Virus Infection 504
**Lung Tumors 505**
Carcinomas 505
Carcinoid Tumors 510
**Pleural Lesions 511**
Pleural Effusion and Pleuritis 511
Pneumothorax, Hemothorax, and Chylothorax 511
Malignant Mesothelioma 512
**Lesions of the Upper Respiratory Tract 512**
Acute Infections 512
Nasopharyngeal Carcinoma 513
Laryngeal Tumors 513


The major function of the lung is to replenish oxygen and excrete carbon dioxide from blood. Developmentally, the respiratory system is an outgrowth from the ventral wall of the foregut. The midline trachea develops two lateral outpocketings, the lung buds. The right lung bud eventually divides into three main bronchi, and the left into two main bronchi, thus giving rise to three lobes on the right and two on the left. The main bronchi branch dichotomously, giving rise to progressively smaller airways, termed *bronchioles,* which are distinguished from bronchi by the lack of cartilage and submucosal glands within their walls. Additional branching of bronchioles leads to *terminal bronchioles*; the part of the lung distal to the terminal bronchiole is called an *acinus.* Pulmonary acini are composed of *respiratory bronchioles* (emanating from the terminal bronchiole) that proceed into *alveolar ducts,* which immediately branch into *alveolar sacs,* the blind ends of the respiratory passages, whose walls are formed entirely of *alveoli,* the ultimate site of gas exchange. The microscopic structure of the alveolar walls (or alveolar septa) consists of the following components, proceeding from blood to air (Fig. 12–1):

- The capillary endothelium and basement membrane.
- The pulmonary interstitium is composed of fine elastic fibers, small bundles of collagen, a few fibroblast-like cells, smooth muscle cells, mast cells, and rare mononuclear cells. It is most prominent in thicker portions of the alveolar septum.
- Alveolar epithelium contains a continuous layer of two principal cell types: flattened, platelike type I pneumocytes covering 95% of the alveolar surface and rounded type II pneumocytes. The latter synthesize pulmonary surfactant and are the main cell type involved in repair of alveolar epithelium after damage to type I pneumocytes. The alveolar walls are not solid but are perforated by numerous pores of Kohn, which permit passage of air, bacteria, and exudates between adjacent alveoli.
- A few alveolar macrophages usually lie free within the alveolar space. In the adult, these macrophages often contain phagocytosed carbon particles.

There are multiple primary lung diseases that can broadly be divided into those primarily affecting (1) the airways,

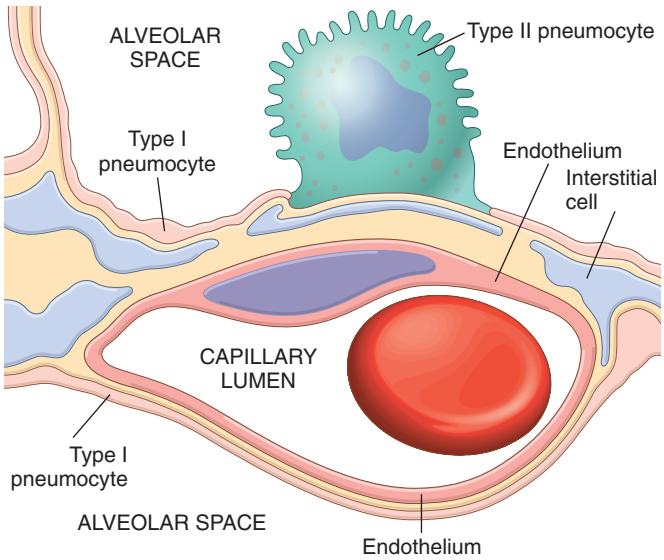


**Figure 12–1** Microscopic structure of the alveolar wall. Note that the basement membrane *(yellow)* is thin on one side and widened where it is continuous with the interstitial space. Portions of interstitial cells are shown.

(2) the interstitium, and (3) the pulmonary vascular system. This division into discrete compartments is, of course, deceptively neat. In reality, disease in one compartment often causes secondary alterations of morphology and function in other areas.

## ATELECTASIS (COLLAPSE)

Atelectasis, also known as collapse, is loss of lung volume caused by *inadequate expansion of air spaces.* It results in shunting of inadequately oxygenated blood from pulmonary arteries into veins, thus giving rise to a ventilation-perfusion imbalance and hypoxia. On the basis of the underlying mechanism or the distribution of alveolar collapse, atelectasis is classified into three forms (Fig. 12–2).

- *Resorption atelectasis.* Resorption atelectasis occurs when an obstruction prevents air from reaching distal airways. The air already present gradually becomes absorbed, and alveolar collapse follows. Depending on the level of airway obstruction, an entire lung, a complete lobe, or one or more segments may be involved. The most common cause of resorption collapse is obstruction of a bronchus by a mucous or mucopurulent plug. This frequently occurs postoperatively but also may complicate bronchial asthma, bronchiectasis, chronic bronchitis, tumor, or foreign body aspiration, particularly in children.
- *Compression atelectasis.* Compression atelectasis (sometimes called *passive* or *relaxation atelectasis*) is usually associated with accumulation of fluid, blood, or air within the pleural cavity, which mechanically collapses the adjacent lung. This is a frequent occurrence with pleural effusion, caused most commonly by congestive heart failure (CHF). Leakage of air into the pleural cavity (pneumothorax) also leads to compression atelectasis. Basal atelectasis resulting from the elevated position of the diaphragm commonly occurs in bedridden patients, in patients with ascites, and during and after surgery.
- *Contraction atelectasis.* Contraction (or *cicatrization*) atelectasis occurs when either local or generalized fibrotic changes in the lung or pleura hamper expansion and increase elastic recoil during expiration.

Atelectasis (except when caused by contraction) is potentially reversible and should be treated promptly to prevent hypoxemia and superimposed infection of the collapsed lung.

## ACUTE LUNG INJURY

The term *acute lung injury* encompasses a spectrum of bilateral pulmonary damage (endothelial and epithelial), which can be initiated by numerous conditions. Clinically, acute lung injury manifests as (1) acute onset of dyspnea, (2) decreased arterial oxygen pressure (hypoxemia), and (3) development of bilateral pulmonary infiltrates on the chest radiograph, all in the absence of clinical evidence of primary left-sided heart failure. Since the pulmonary infiltrates in acute lung injury are usually caused by damage to the alveolar capillary membrane, rather than by left-sided heart failure (Chapter 10), such accumulations constitute

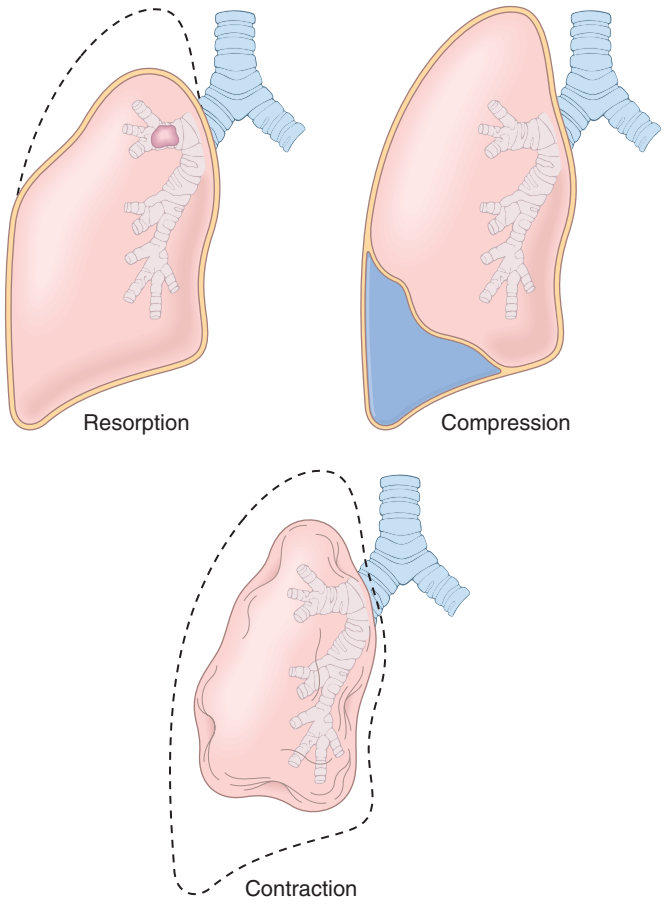


**Figure 12–2** Various forms of acquired atelectasis.

**Table 12–1** Clinical Disorders Associated with the Development of Acute Lung Injury/Acute Respiratory Distress Syndrome

| Direct Lung Injury | Indirect Lung Injury |
|---|---|
| **Common Causes** | |
| Pneumonia | Sepsis |
| Aspiration of gastric contents | Severe trauma with shock |
| **Uncommon Causes** | |
| Pulmonary contusion | Cardiopulmonary bypass |
| Fat embolism | Acute pancreatitis |
| Near-drowning | Drug overdose |
| Inhalational injury | Transfusion of blood products |
| Reperfusion injury after lung transplantation | Uremia |

Modified from Ware LB, Matthay MA: The acute respiratory distress syndrome. N Engl J Med 342:1334, 2000.

an example of *noncardiogenic pulmonary edema.* Acute lung injury can progress to the more severe *acute respiratory distress syndrome,* described next.

## Acute Respiratory Distress Syndrome

Acute respiratory distress syndrome (ARDS) is a clinical syndrome caused by diffuse alveolar capillary and epithelial damage. The usual course is characterized by rapid onset of life-threatening respiratory insufficiency, cyanosis, and severe arterial hypoxemia that is refractory to oxygen therapy and may progress to multisystem organ failure. The histologic manifestation of ARDS in the lungs is known as *diffuse alveolar damage* (DAD). ARDS can occur in a multitude of clinical settings and is associated with either direct injury to the lung or indirect injury in the setting of a systemic process (Table 12–1). It should be recalled that respiratory distress syndrome of the newborn is pathogenetically distinct; it is caused by a primary deficiency of surfactant.

### PATHOGENESIS

The alveolar-capillary membrane is formed by two separate barriers: the microvascular endothelium and the alveolar epithelium. **In ARDS, the integrity of this barrier is compromised by either endothelial or epithelial injury, or, more commonly, both.** The acute consequences of damage to the alveolar capillary membrane include increased vascular permeability and alveolar flooding, loss of diffusion capacity, and widespread surfactant abnormalities caused by damage to type II pneumocytes (Fig. 12–3). Although the cellular and molecular basis of acute lung injury and ARDS remains an area of active investigation, recent work suggests that in ARDS, **lung injury is caused by an imbalance of pro-inflammatory and anti-inflammatory mediators.** As early as 30 minutes after an acute insult, there is increased synthesis of interleukin 8 (IL-8), a potent neutrophil chemotactic and activating agent, by pulmonary macrophages. Release of this and similar mediators, such as IL-1 and tumor necrosis factor (TNF), leads to endothelial activation as well as sequestration and activation of neutrophils in pulmonary capillaries. **Neutrophils are thought to have an important role in the pathogenesis of ARDS.** Histologic examination of lungs early in the disease process shows increased numbers of neutrophils within the vascular space, the interstitium, and the alveoli. Activated neutrophils release a variety of products (e.g., oxidants, proteases, platelet-activating factor, leukotrienes) that cause damage to the alveolar epithelium and endothelium. Combined assault on the endothelium and epithelium perpetuates vascular leakiness and loss of surfactant that render the alveolar unit unable to expand. Of note, the destructive forces unleashed by neutrophils can be counteracted by an array of endogenous antiproteases, antioxidants, and anti-inflammatory cytokines (e.g., IL-10) that are upregulated by pro-inflammatory cytokines. In the end, it is the balance between the destructive and protective factors that determines the degree of tissue injury and clinical severity of ARDS.

### MORPHOLOGY

In the **acute phase of ARDS,** the lungs are dark red, firm, airless, and heavy. Microscopic examination reveals capillary congestion, necrosis of alveolar epithelial cells, interstitial and intra-alveolar edema and hemorrhage, and (particularly with sepsis) collections of neutrophils in capillaries. The most characteristic finding is the presence of **hyaline membranes,** particularly lining the distended alveolar ducts (Fig. 12–4). Such membranes consist of fibrin-rich edema fluid admixed with remnants of necrotic epithelial cells. Overall, the picture is remarkably similar to that seen in respiratory distress syndrome in the newborn (Chapter 6). In the **organizing stage,** vigorous proliferation of type II pneumocytes occurs in an attempt to regenerate the alveolar lining. Resolution is unusual; more commonly, there is organization of the fibrin exudates, with resultant intra-alveolar fibrosis. Marked thickening of the alveolar septa ensues, caused by proliferation of interstitial cells and deposition of collagen.

### Clinical Features

Approximately 85% of patients develop the clinical syndrome of acute lung injury or ARDS within 72 hours of the initiating insult. With improvements in supportive therapy, the mortality rate for the 190,000 ARDS cases occurring yearly has decreased from 60% to 40% in the last decade. Predictors of poor prognosis include advanced age, underlying bacteremia (sepsis), and the development of multisystem (especially cardiac, renal, or hepatic) failure. Should the patient survive the acute stage, diffuse interstitial fibrosis may occur, with continued compromise of respiratory function. However, in most patients who survive the acute insult and are spared the chronic sequelae, normal respiratory function returns within 6 to 12 months.

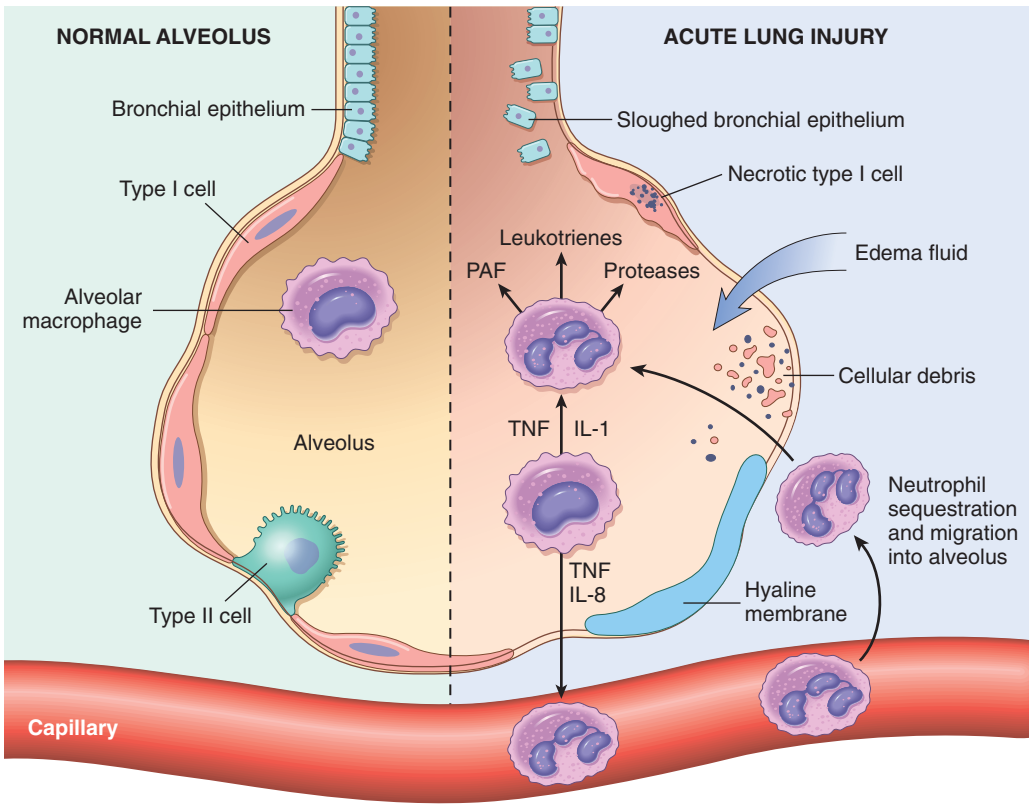


**Figure 12–3** The normal alveolus *(left)*, compared with the injured alveolus in the early phase of acute lung injury and the acute respiratory distress syndrome. Under the influence of proinflammatory cytokines such as interleukins IL-8 and IL-1 and tumor necrosis factor (TNF) (released by macrophages), neutrophils initially undergo sequestration in the pulmonary microvasculature, followed by margination and egress into the alveolar space, where they undergo activation. Activated neutrophils release a variety of factors such as leukotrienes, oxidants, proteases, and platelet-activating factor (PAF), which contribute to local tissue damage, accumulation of edema fluid in the air spaces, surfactant inactivation, and hyaline membrane formation. Subsequently, the release of macrophage-derived fibrogenic cytokines such as transforming growth factor-β (TGF-β) and platelet-derived growth factor (PGDF) stimulate fibroblast growth and collagen deposition associated with the healing phase of injury.
*(Modified from Ware LB: Pathophysiology of acute lung injury and the acute respiratory distress syndrome. Semin Respir Crit Care Med 27:337, 2006.)*

## SUMMARY

### Acute Respiratory Distress Syndrome

- ARDS is a clinical syndrome of progressive respiratory insufficiency caused by diffuse alveolar damage in the setting of sepsis, severe trauma, or diffuse pulmonary infection.
- Neutrophils and their products have a crucial role in the pathogenesis of ARDS by causing endothelial and epithelial injury.
- The characteristic histologic picture is that of alveolar edema, epithelial necrosis, accumulation of neutrophils, and presence of hyaline membranes lining the alveolar ducts.

## OBSTRUCTIVE VERSUS RESTRICTIVE PULMONARY DISEASES

Diffuse pulmonary diseases can be classified into two categories: (1) obstructive (airway) disease, characterized by limitation of airflow, usually resulting from an increase in resistance caused by partial or complete obstruction at any level, and (2) restrictive disease, characterized by reduced expansion of lung parenchyma accompanied by decreased total lung capacity.

*The major diffuse obstructive disorders* are *emphysema, chronic bronchitis, bronchiectasis, and asthma.* In patients with these diseases, forced vital capacity (FVC) is either normal or slightly decreased, while the expiratory flow rate, usually measured as the forced expiratory volume at 1 second ($FEV_1$), is significantly decreased. Thus, *the ratio of FEV to FVC is characteristically decreased.* Expiratory obstruction may result either from anatomic airway narrowing, classically observed in asthma, or from loss of elastic recoil, characteristic of emphysema.

By contrast, in *diffuse restrictive diseases,* FVC is reduced and the expiratory flow rate is normal or reduced proportionately. Hence, *the ratio of FEV to FVC is near normal.* The restrictive defect occurs in two general conditions: (1) *chest wall disorders in the presence of normal lungs* (e.g., with severe obesity, diseases of the pleura, and neuromuscular disorders, such as the Guillain-Barré syndrome [Chapter 21], that affect the respiratory muscles) and (2) *acute or chronic interstitial lung diseases.* The classic *acute* restrictive disease is ARDS, discussed earlier. *Chronic* restrictive diseases

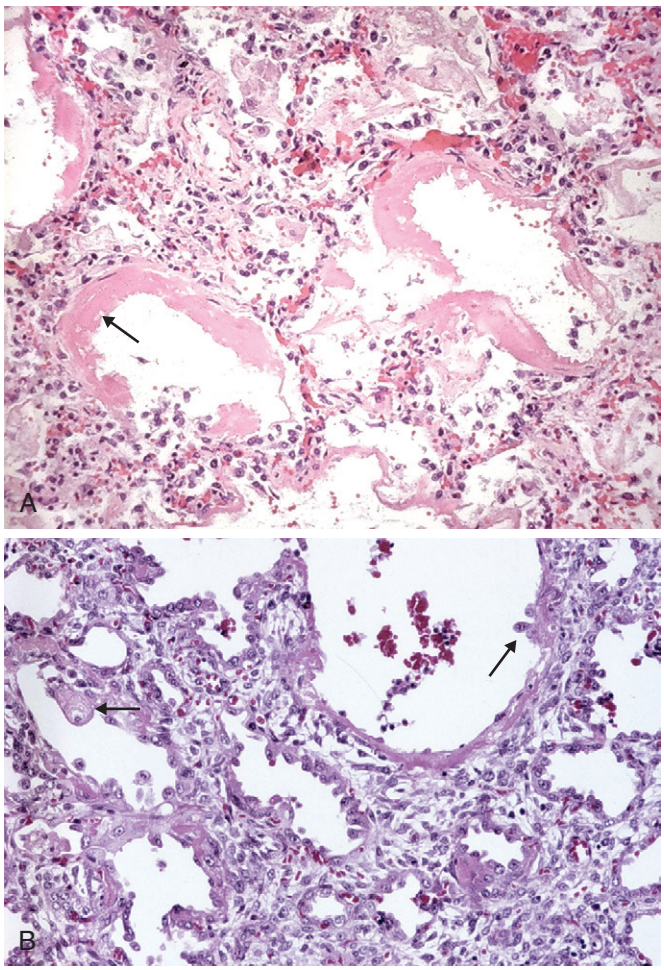


**Figure 12–4 A,** Diffuse alveolar damage in acute lung injury and acute respiratory distress syndrome. Some alveoli are collapsed; others are distended. Many are lined by bright pink hyaline membranes *(arrow)*. **B,** The healing stage is marked by resorption of hyaline membranes with thickening of alveolar septa containing inflammatory cells, fibroblasts, and collagen. Numerous reactive type II pneumocytes also are seen at this stage (*arrows*), associated with regeneration and repair.

(discussed later) include the pneumoconioses, interstitial fibrosis of unknown etiology, and most of the infiltrative conditions (e.g., sarcoidosis).

## OBSTRUCTIVE LUNG (AIRWAY) DISEASES

In their prototypical forms, the four disorders in this group—emphysema, chronic bronchitis, asthma, and bronchiectasis—have distinct clinical and anatomic characteristics (Table 12–2), but overlaps between emphysema, bronchitis, and asthma are common.

At the outset, it should be recognized that *the definition of emphysema is morphologic, whereas chronic bronchitis is defined on the basis of clinical features* such as the presence of chronic and recurrent cough with excessive mucus secretion. Second, the anatomic distribution is partially different; chronic bronchitis initially involves the large airways, whereas emphysema affects the *acinus.* In severe or advanced cases of both, small airway disease (chronic bronchiolitis) is characteristic. Although chronic bronchitis may exist without demonstrable emphysema, and almost pure emphysema may occur (particularly in patients with inherited $\alpha_1$-antitrypsin deficiency) (discussed later), the two diseases usually coexist. This is almost certainly because the major cause—cigarette smoking, especially long-term, heavy tobacco exposure—is common to both disorders. In view of their propensity to coexist, emphysema and chronic bronchitis often are clinically grouped together under the rubric of *chronic obstructive pulmonary disease* (COPD). COPD affects more than 10% of the U.S. adult population and is the fourth leading cause of death in this country. The primarily *irreversible* airflow obstruction of COPD distinguishes it from asthma, which, as described later, is characterized largely by *reversible* airflow obstruction; however, patients with COPD commonly have some degree of reversible obstruction as well (Fig. 12–5).

### Emphysema

Emphysema is characterized by *abnormal permanent enlargement of the air spaces* distal to the terminal bronchioles, accompanied by *destruction of their walls* without significant fibrosis.

**Table 12–2** Disorders Associated with Airflow Obstruction: The Spectrum of Chronic Obstructive Pulmonary Disease

| Clinical Entity | Anatomic Site | Major Pathologic Changes | Etiology | Signs/Symptoms |
|---|---|---|---|---|
| Chronic bronchitis | Bronchus | Mucous gland hypertrophy and hyperplasia, hypersecretion | Tobacco smoke, air pollutants | Cough, sputum production |
| Bronchiectasis | Bronchus | Airway dilation and scarring | Persistent or severe infections | Cough, purulent sputum, fever |
| Asthma | Bronchus | Smooth muscle hypertrophy and hyperplasia, excessive mucus, inflammation | Immunologic or undefined causes | Episodic wheezing, cough, dyspnea |
| Emphysema | Acinus | Air space enlargement, wall destruction | Tobacco smoke | Dyspnea |
| Small airway disease, bronchiolitis* | Bronchiole | Inflammatory scarring, partial obliteration of bronchioles | Tobacco smoke, air pollutants | Cough, dyspnea |

*Can be present in all forms of obstructive lung disease or by itself.

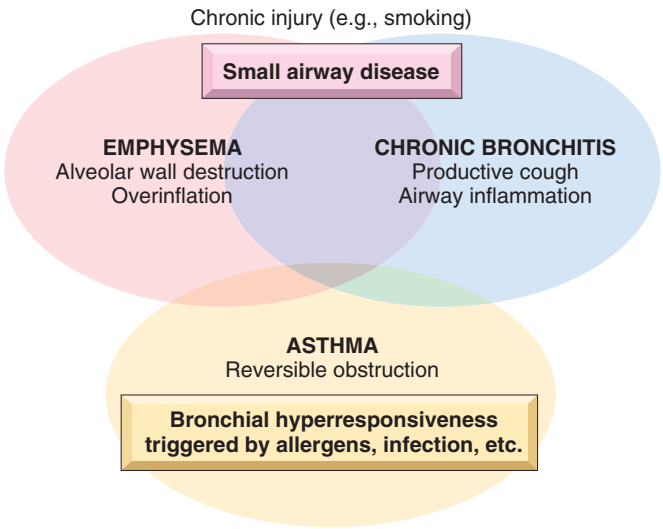


**Figure 12–5** Schematic representation of overlap between chronic obstructive lung diseases.

### *Types of Emphysema*

Emphysema is classified according to its *anatomic distribution* within the *lobule*; as described earlier, the acinus is the structure distal to terminal bronchioles, and a cluster of three to five acini is called a *lobule* (Fig. 12–6, *A*). There are four major types of emphysema: (1) centriacinar, (2) panacinar, (3) distal acinar, and (4) irregular. Only the first two types cause clinically significant airway obstruction, with centriacinar emphysema being about 20 times more common than panacinar disease.

#### Centriacinar (Centrilobular) Emphysema

The distinctive feature of centriacinar (centrilobular) emphysema is the pattern of involvement of the lobules: *The central or proximal parts of the acini, formed by respiratory bronchioles, are affected, while distal alveoli are spared.* Thus, both emphysematous and normal air spaces exist within the same acinus and lobule (Fig. 12–6, *B*). The lesions are more common and severe in the upper lobes, particularly in the apical segments. In severe centriacinar emphysema the distal acinus also becomes involved, and thus, the differentiation from panacinar emphysema becomes difficult. This type of emphysema is most commonly seen as a consequence of cigarette smoking in people who do not have congenital deficiency of $\alpha_1$-antitrypsin.

#### Panacinar (Panlobular) Emphysema

*In panacinar (panlobular) emphysema, the acini are uniformly enlarged,* from the level of the respiratory bronchiole to the terminal blind alveoli (Fig. 12–6, *C*). In contrast with centriacinar emphysema, panacinar emphysema tends to occur more commonly in the lower lung zones and is the type of emphysema that occurs in $\alpha_1$-antitrypsin deficiency.

#### Distal Acinar (Paraseptal) Emphysema

*In distal acinar (paraseptal) emphysema, the proximal portion of the acinus is normal but the distal part is primarily involved.* The emphysema is more striking adjacent to the pleura, along the lobular connective tissue septa, and at the margins of the lobules. It occurs adjacent to areas of fibrosis, scarring, or atelectasis and is usually more severe in the upper half of the lungs. The characteristic finding is the presence of multiple, contiguous, enlarged air spaces ranging in diameter from less than 0.5 mm to more than 2.0 cm, sometimes forming cystic structures that, with progressive enlargement, are referred to as *bullae.* The cause of this type of emphysema is unknown; it is seen most often in cases of spontaneous pneumothorax in young adults.

#### Irregular Emphysema

*Irregular emphysema, so named because the acinus is irregularly involved, is almost invariably associated with scarring,* such as that resulting from healed inflammatory diseases. Although clinically asymptomatic, this may be the most common form of emphysema.

## PATHOGENESIS

Exposure to toxic substances such as tobacco smoke and inhaled pollutants induces ongoing inflammation with accumulation of neutrophils, macrophages and lymphocytes in the lung. Elastases, cytokines (including IL-8) and oxidants are released causing epithelial injury and proteolysis of the extracellular matrix (ECM). Elastin degradation products further increase the inflammation. Unless checked by antielastases

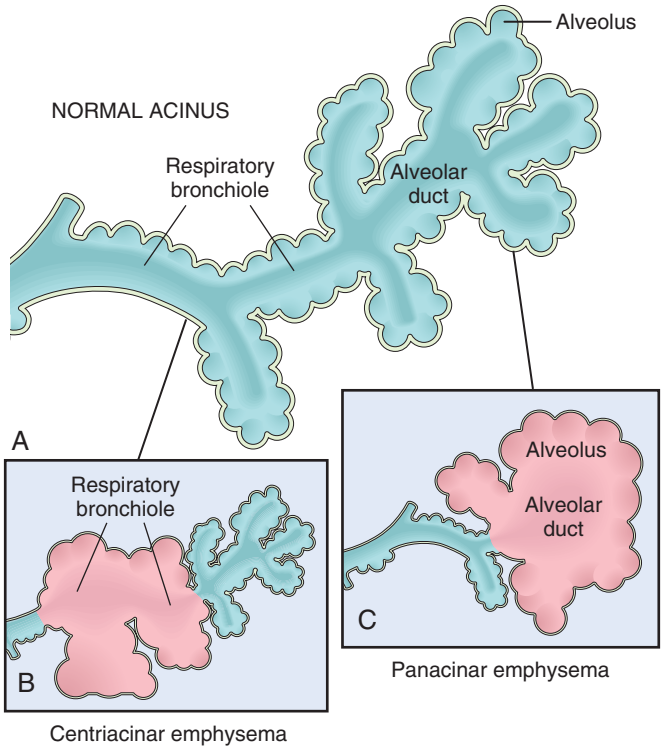


**Figure 12–6** Major patterns of emphysema. **A,** Diagram of normal structure of the acinus, the fundamental unit of the lung. **B,** Centriacinar emphysema with dilation that initially affects the respiratory bronchioles. **C,** Panacinar emphysema with initial distention of all the peripheral structures (i.e., the alveolus and alveolar duct); the disease later extends to affect the respiratory bronchioles.

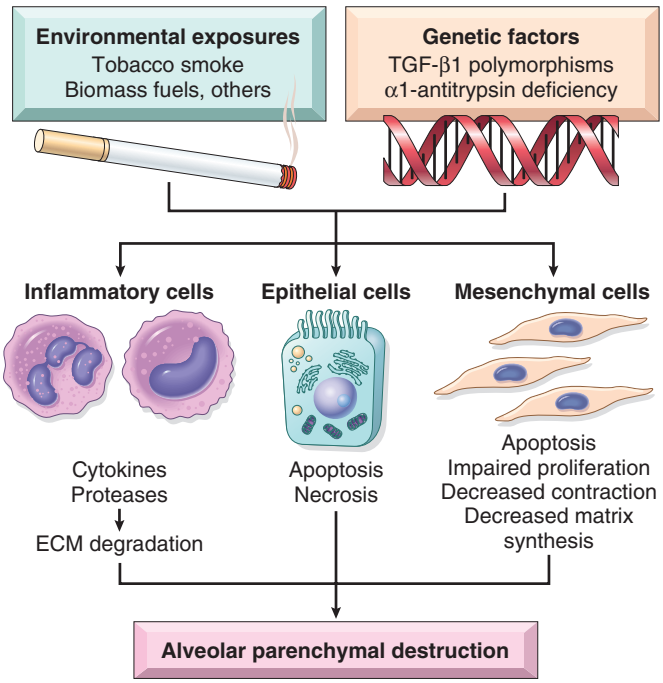


**Figure 12–7** Loss of cellular homeostasis in emphysema pathogenesis. Exposure to inhaled toxins (such as cigarette smoke) leads to epithelial cell death, inflammation, and extracellular matrix proteolysis. In susceptible persons, mesenchymal cell survival and reparative functions are impaired by direct effects of inhaled toxic substances and inflammatory mediators and by the loss of the peri- and extracellular matrix. The result is loss of structural cells of the alveolar wall and the associated matrix components.

*(Reproduced with permission from Horowitz JC, Martinez FJ, Thannickal VJ: Mesenchymal cell fate and phenotypes in the pathogenesis of emphysema. COPD 6:201, 2009.)*

(e.g., $\alpha_1$-antitrypsin) and antioxidants, the cycle of inflammation and ECM proteolysis continues. Indeed, more than 80% of patients with congenital $\alpha_1$-antitrypsin deficiency develop symptomatic panacinar emphysema, which occurs at an earlier age and with greater severity if the affected person smokes.

There is marked individual variation in susceptibility to the development of emphysema/COPD. Multiple genetic factors control the response to injury after smoking. For example, the *TGFB* gene exhibits polymorphisms that influence susceptibility to the development of COPD by regulating the response of mesenchymal cells to injury. For example, with certain polymorphisms, mesenchymal cell response to TGF-β signaling is reduced, which in turn results in inadequate repair of elastin injury caused by inhaled toxins. Matrix metalloproteinases (MMPs), especially MMP-9 and MMP-12, have also been shown to have a pathogenic role in emphysema. MMP-9 gene polymorphisms and higher levels of both MMP-9 and MMP-12 have been found in some emphysema patients. Moreover, MMP-12–deficient mice are protected from cigarette smoke–induced emphysema. Although much remains to be studied, the current understanding of emphysema pathogenesis is summarized in Figure 12–7.

Complex interactions between inflammatory mediators, cell signaling and inappropriate activation of repair mechanisms may result in very different diseases: tissue destruction without fibrosis (emphysema) or interstitial fibrosis (discussed later). Recent data indicate that mesenchymal cell response may be a key factor in determining which of these two processes ensues. In emphysema there is loss of not only epithelial and endothelial cells but also mesenchymal cells, leading to lack of extracellular matrix, the scaffolding upon which epithelial cells would have grown. Thus, **emphysema can be thought of as resulting from insufficient wound repair.** By contrast, patients with fibrosing lung diseases have excessive myofibroblastic or fibroblastic response to injury, leading to unchecked scarring.

## MORPHOLOGY

The diagnosis and classification of emphysema depend largely on the macroscopic appearance of the lung. **Panacinar emphysema,** when the pathologic process is well developed, produces pale, voluminous lungs that often obscure the heart when the anterior chest wall is removed at autopsy. The macroscopic features of **centriacinar emphysema** are less impressive. The lungs are a deeper pink than in panacinar emphysema and less voluminous, unless the disease is well advanced. Generally, in centriacinar emphysema the upper two thirds of the lungs are more severely affected than the lower lungs. Histologic examination reveals **destruction of alveolar walls without fibrosis, leading to enlarged air spaces** (Fig. 12–8). In addition to alveolar loss, the number of alveolar capillaries is diminished. Terminal and respiratory bronchioles may be deformed because of the loss of septa that help tether these structures in the parenchyma. With the **loss of elastic tissue** in the surrounding alveolar septa, radial traction on the small airways is reduced. As a result, they tend to collapse during expiration—an important cause of chronic airflow obstruction in severe emphysema. Bronchiolar inflammation and submucosal fibrosis are consistently present in advanced disease.

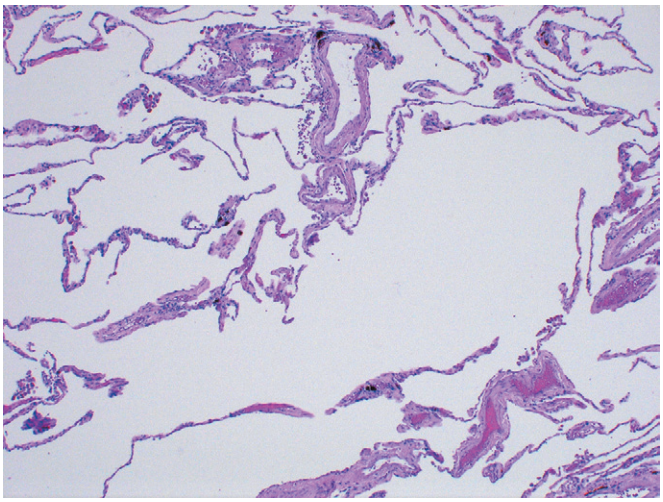

**Figure 12–8** Pulmonary emphysema. There is marked enlargement of air spaces, with destruction of alveolar septa but without fibrosis. Note presence of black anthracotic pigment.

### Clinical Features

*Dyspnea* usually is the first symptom; it begins insidiously but is steadily progressive. In patients with underlying chronic bronchitis or chronic asthmatic bronchitis, cough and wheezing may be the initial complaints. Weight loss is common and may be so severe as to suggest a hidden malignant tumor. Pulmonary function tests reveal reduced $FEV_1$ with normal or near-normal FVC. *Hence, the ratio of $FEV_1$ to FVC is reduced.*

The classic presentation in emphysema with no "bronchitic" component is one in which the patient is barrel-chested and dyspneic, with obviously prolonged expiration, sitting forward in a hunched-over position, attempting to squeeze the air out of the lungs with each expiratory effort. In these patients, air space enlargement is severe and diffusing capacity is low. Dyspnea and hyperventilation are prominent, so that until very late in the disease, gas exchange is adequate and blood gas values are relatively normal. Because of prominent dyspnea and adequate oxygenation of hemoglobin, these patients sometimes are called "pink puffers."

At the other extreme of the clinical presentation in emphysema is a patient who also has pronounced chronic bronchitis and a history of recurrent infections with purulent sputum. Dyspnea usually is less prominent, with diminished respiratory drive, so the patient retains carbon dioxide, becomes hypoxic, and often is cyanotic. For reasons not entirely clear, such patients tend to be obese—hence the designation "blue bloaters." Often they seek medical help after the onset of CHF (cor pulmonale) (Chapter 10) and associated edema.

Most patients with emphysema and COPD, however, fall somewhere between these two classic extremes. In all cases, *secondary pulmonary hypertension develops gradually,* arising from both hypoxia-induced pulmonary vascular spasm and loss of pulmonary capillary surface area from alveolar destruction. Death from emphysema is related to either pulmonary failure, with respiratory acidosis, hypoxia, and coma, or right-sided heart failure (cor pulmonale).

### *Conditions Related to Emphysema*

Several conditions resemble emphysema only superficially but nevertheless are (inappropriately) referred to as such:

- *Compensatory emphysema* is a term used to designate the compensatory dilation of alveoli in response to loss of lung substance elsewhere, such as occurs in residual lung parenchyma after surgical removal of a diseased lung or lobe.
- *Obstructive overinflation* refers to the condition in which the lung expands because air is trapped within it. A common cause is subtotal obstruction by a tumor or foreign object. Obstructive overinflation can be a life-threatening emergency if the affected portion extends sufficiently to compress the remaining normal lung.
- *Bullous emphysema* refers merely to any form of emphysema that produces large subpleural blebs or bullae (spaces greater than 1 cm in diameter in the distended state) (Fig. 12–9). Such blebs represent localized accentuations of one of the four forms of emphysema; most often the blebs are subpleural, and on occasion they may rupture, leading to pneumothorax.
- *Mediastinal (interstitial) emphysema* is the condition resulting when air enters the connective tissue stroma of the lung, mediastinum, and subcutaneous tissue. This may occur spontaneously with a sudden increase in intra-alveolar pressure (as with vomiting or violent coughing) resulting in a tear, with dissection of air into the interstitium. Sometimes it develops in children with whooping cough. It is particularly likely to occur in patients on respirators who have partial bronchiolar obstruction or in persons who suffer a perforating injury (e.g., a fractured rib). When the interstitial air enters the subcutaneous tissue, the patient may literally blow up like a balloon, with marked swelling of the head and neck and crackling crepitation all over the chest. In most instances, the air is resorbed spontaneously after the site of entry is sealed.

## SUMMARY

### Emphysema

- Emphysema is a chronic obstructive airway disease characterized by permanent enlargement of air spaces distal to terminal bronchioles.
- Subtypes include centriacinar (most common; smoking-related), panacinar (seen in $\alpha_1$-antitrypsin deficiency), distal acinar, and irregular.
- Smoking and inhaled pollutants cause ongoing accumulation of inflammatory cells, releasing elastases and oxidants, which destroy the alveolar walls without adequate mesenchymal repair response.
- Most patients with emphysema demonstrate elements of chronic bronchitis concurrently, since cigarette smoking is an underlying risk factor for both; patients with pure emphysema are characterized as "pink puffers."

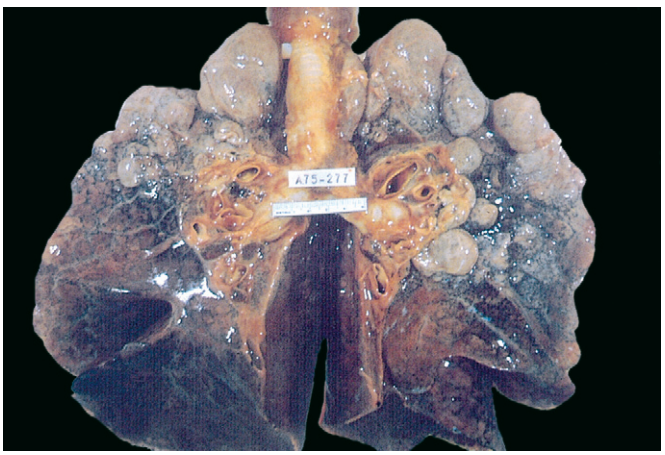


**Figure 12–9** Bullous emphysema with large apical and subpleural bullae. *(From the Teaching Collection of the Department of Pathology, University of Texas Southwestern Medical School, Dallas, Texas.)*

## Chronic Bronchitis

Chronic bronchitis is common among cigarette smokers and urban dwellers in smog-ridden cities; some studies indicate that 20% to 25% of men in the 40- to 65-year-old age group have the disease. The diagnosis of chronic bronchitis is made on clinical grounds: it is defined by the *presence of a persistent productive cough for at least 3 consecutive months in at least 2 consecutive years.* In early stages of the disease, the productive cough raises mucoid sputum, but airflow is not obstructed. Some patients with chronic bronchitis may demonstrate hyperresponsive airways with intermittent bronchospasm and wheezing. A subset of bronchitic patients, especially heavy smokers, develop chronic outflow obstruction, usually with associated emphysema.

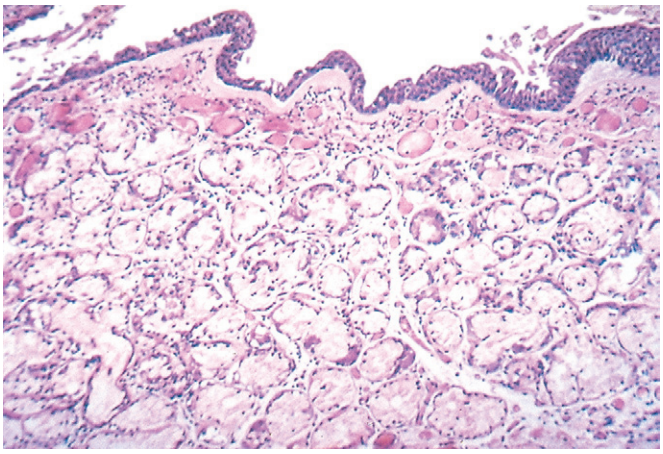

**Figure 12–10** Chronic bronchitis. The lumen of the bronchus is *above*. Note the marked thickening of the mucous gland layer (approximately twice-normal) and squamous metaplasia of lung epithelium.

*(From the Teaching Collection of the Department of Pathology, University of Texas, Southwestern Medical School, Dallas, Texas.)*

### PATHOGENESIS

The distinctive feature of chronic bronchitis is **hypersecretion of mucus,** beginning in the large airways. Although the single most important cause is cigarette smoking, other air pollutants, such as sulfur dioxide and nitrogen dioxide, may contribute. These environmental irritants induce hypertrophy of mucous glands in the trachea and main bronchi, leading to a marked increase in mucin-secreting goblet cells in the surface epithelium of smaller bronchi and bronchioles. In addition, these irritants cause inflammation with infiltration of CD8+ lymphocytes, macrophages, and neutrophils. In contrast with asthma, there are no eosinophils in chronic bronchitis. Whereas the defining feature of chronic bronchitis (mucus hypersecretion) is primarily a reflection of large bronchial involvement, **the morphologic basis of airflow obstruction in chronic bronchitis is more peripheral** and results from (1) **small airway disease,** induced by goblet cell metaplasia with mucous plugging of the bronchiolar lumen, inflammation, and bronchiolar wall fibrosis, and (2) **coexistent emphysema.** In general, while small airway disease (also known as chronic bronchiolitis) is an important component of early and relatively mild airflow obstruction, chronic bronchitis with significant airflow obstruction is almost always complicated by emphysema.

It is postulated that many of the respiratory epithelial effects of environmental irritants (e.g., mucus hypersecretion) are mediated by local release of T cell cytokines such as IL-13. The transcription of the mucin gene *MUC5AC* in bronchial epithelium and the production of neutrophil elastase are increased as a consequence of exposure to tobacco smoke. **Microbial infection** often is present but has a secondary role, chiefly by maintaining the inflammation and exacerbating symptoms.

### MORPHOLOGY

As seen in gross specimens, the mucosal lining of the larger airways usually is **hyperemic and swollen** by edema fluid. It often is covered by a layer of mucinous or mucopurulent **secretions.** The smaller bronchi and bronchioles also may be filled with similar secretions. On histologic examination, the diagnostic feature of chronic bronchitis in the trachea and larger bronchi is **enlargement of the mucus-secreting glands** (Fig. 12–10). The magnitude of the increase in size is assessed by the ratio of the thickness of the submucosal gland layer to that of the bronchial wall (the Reid index—normally 0.4). Inflammatory cells, largely mononuclear but sometimes admixed with neutrophils, are frequently present in variable density in the bronchial mucosa. **Chronic bronchiolitis** (small airway disease), characterized by goblet cell metaplasia, mucous plugging, inflammation, and fibrosis, is also present. In the most severe cases, there may be complete obliteration of the lumen as a consequence of fibrosis (bronchiolitis obliterans). It is the submucosal fibrosis that leads to luminal narrowing and airway obstruction. Changes of emphysema often co-exist.

### Clinical Features

In patients with chronic bronchitis, a prominent cough and the production of sputum may persist indefinitely without ventilatory dysfunction. As alluded to earlier, however, some patients develop significant COPD with outflow obstruction. This clinical syndrome is accompanied by hypercapnia, hypoxemia, and (in severe cases) cyanosis (hence the term "blue bloaters"). Differentiation of this form of COPD from that caused by emphysema can be made in the classic case, but many such patients have both conditions. With progression, chronic bronchitis is complicated by pulmonary hypertension and cardiac failure (Chapter 10). Recurrent infections and respiratory failure are constant threats.

### SUMMARY

#### Chronic Bronchitis

- Chronic bronchitis is defined as persistent productive cough for at least 3 consecutive months in at least 2 consecutive years.
- Cigarette smoking is the most important underlying risk factor; air pollutants also contribute.

- Chronic obstructive component largely results from small airway disease (chronic bronchiolitis) and coexistent emphysema.
- Histologic examination demonstrates enlargement of mucus-secreting glands, goblet cell metaplasia, and bronchiolar wall fibrosis.

## Asthma

Asthma is a chronic inflammatory disorder of the airways that causes recurrent episodes of wheezing, breathlessness, chest tightness, and cough, particularly at night and/or early in the morning. The hallmarks of the disease are *intermittent and reversible airway obstruction, chronic bronchial inflammation with eosinophils, bronchial smooth muscle cell hypertrophy and hyperreactivity, and increased mucus secretion.* Some of the stimuli that trigger attacks in patients would have little or no effect in persons with normal airways. Many cells play a role in the inflammatory response, in particular eosinophils, mast cells, macrophages, lymphocytes, neutrophils, and epithelial cells. Of note, there has been a significant increase in the incidence of asthma in the Western world over the past four decades. This epidemiologic observation has led to the "hygiene hypothesis," according to which the eradication of infections may alter immune homeostasis and promote allergic and other harmful immune responses.

Asthma may be categorized into *atopic* (evidence of allergen sensitization, often in a patient with a history of allergic rhinitis, eczema) and *nonatopic.* In either type, episodes of bronchospasm can be triggered by diverse mechanisms, such as respiratory infections (especially viral), environmental exposure to irritants (e.g., smoke, fumes), cold air, stress, and exercise. There is emerging evidence for differing patterns of inflammation: eosinophilic, neutrophilic, mixed inflammatory, and pauci-granulocytic. These subgroups may differ in etiology, immunopathology, and response to treatment. Asthma also may be classified according to the agents or events that trigger bronchoconstriction.

### PATHOGENESIS

The major etiologic factors of asthma are genetic predisposition to type I hypersensitivity (atopy), acute and chronic airway inflammation, and bronchial hyperresponsiveness to a variety of stimuli. **The inflammation involves many cell types and numerous inflammatory mediators, but the role of type 2 helper T ($T_H2$) cells may be critical to the pathogenesis of asthma.** The classic atopic form of asthma is associated with an excessive $T_H2$ reaction against environmental antigens. Cytokines produced by $T_H2$ cells account for most of the features of asthma—IL-4 stimulates IgE production, IL-5 activates eosinophils, and IL-13 stimulates mucus production and also promotes IgE production by B cells. IgE coats submucosal mast cells, which, on exposure to allergen, release granule contents. This induces two waves of reaction: an early (immediate) phase and a late phase (Fig. 12-11). The early reaction is dominated by bronchoconstriction, increased mucus production and variable vasodilation. Bronchoconstriction is triggered by direct stimulation of subepithelial vagal receptors. The late-phase reaction consists of inflammation, with activation of eosinophils, neutrophils, and T cells. In addition, epithelial cells are activated to produce chemokines that promote recruitment of more $T_H2$ cells and eosinophils (including eotaxin, a potent chemoattractant and activator of eosinophils), as well as other leukocytes, thus amplifying the inflammatory reaction. Repeated bouts of inflammation lead to structural changes in the bronchial wall, collectively referred to as **airway remodeling.** These changes include hypertrophy of bronchial smooth muscle and mucus glands, and increased vascularity and deposition of subepithelial collagen, which may occur as early as several years before initiation of symptoms.

Asthma is a complex genetic disorder in which multiple susceptibility genes interact with environmental factors to initiate the pathologic reaction. There is significant variation in the expression of these genes and in the combinations of polymorphisms that effect the immune response or tissue remodeling. One of the susceptibility loci is on the long arm of chromosome 5 (5q), where several genes involved in regulation of IgE synthesis and mast cell and eosinophil growth and differentiation map. The genes at this locus include *IL13* (genetic polymorphisms linked with susceptibility to the development of atopic asthma), CD14 (single-nucleotide polymorphisms associated with occupational asthma), class II HLA alleles (tendency to produce IgE antibodies), $\beta_2$-adrenergic receptor gene, and IL-4 receptor gene (atopy, total serum IgE level, and asthma). Another important locus is on 20q where ADAM-33 that regulates proliferation of bronchial smooth muscle and fibroblasts is located; this controls airway remodeling. Upregulation of various chitinase enzymes has been shown to be important in $T_H2$ inflammation and severity of asthma; high serum YKL-40 levels (a chitinase family member with no enzymatic activity) correlate with the severity of asthma.

### *Types of Asthma*

#### Atopic Asthma

This is the most common type of asthma, usually beginning in childhood, and is a classic example of *type I IgE–mediated hypersensitivity reaction* (Chapter 4). A positive family history of atopy and/or asthma is common, and asthmatic attacks are often preceded by allergic rhinitis, urticaria, or eczema. The disease is triggered by environmental antigens, such as dusts, pollen, animal dander, and foods. Infections can also trigger atopic asthma. A skin test with the offending antigen results in an immediate wheal-and-flare reaction. Atopic asthma also can be diagnosed based on serum radioallergosorbent tests (RASTs) that identify the presence of IgE specific for a panel of allergens.

#### Non-Atopic Asthma

Patients with nonatopic forms of asthma do not have evidence of allergen sensitization, and skin test results usually are negative. A positive family history of asthma is less common. Respiratory infections due to viruses (e.g., rhinovirus, parainfluenza virus) and inhaled air pollutants (e.g., sulfur dioxide, ozone, nitrogen dioxide) are common triggers. *It is thought that virus-induced inflammation of the*

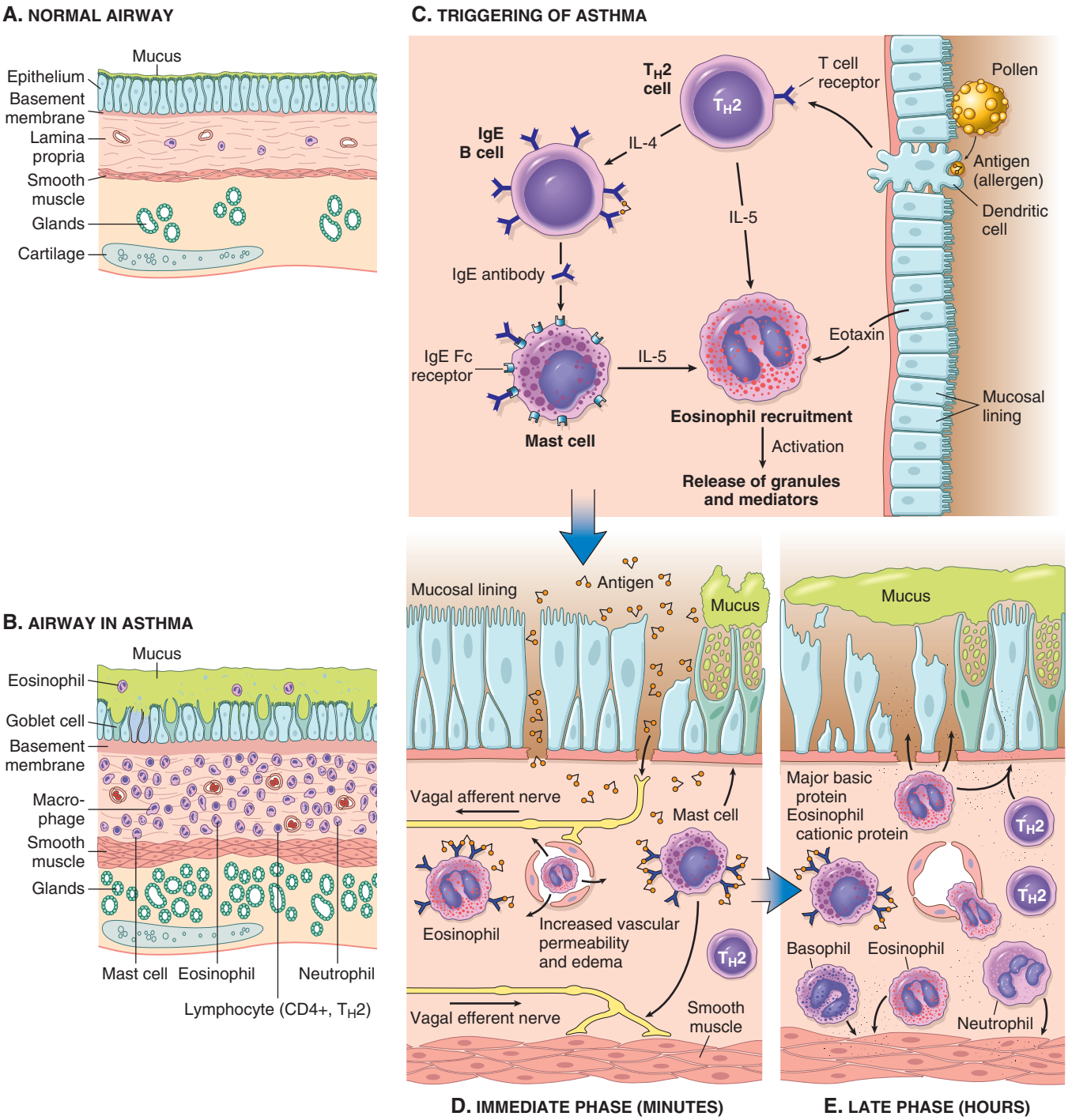


**Figure 12–11** **A** and **B**, Comparison of a normal bronchus with that in a patient with asthma. Note the accumulation of mucus in the bronchial lumen resulting from an increase in the number of mucus-secreting goblet cells in the mucosa and hypertrophy of submucosal glands. In addition, there is intense chronic inflammation due to recruitment of eosinophils, macrophages, and other inflammatory cells. Basement membrane underlying the mucosal epithelium is thickened, and smooth muscle cells exhibit hypertrophy and hyperplasia. **C,** Inhaled allergens (antigens) elicit a $T_H2$-dominated response favoring IgE production and eosinophil recruitment (priming or sensitization). **D,** On reexposure to antigen (Ag), the immediate reaction is triggered by antigen-induced cross-linking of IgE bound to IgE receptors on mast cells in the airways. These cells release preformed mediators. Collectively, either directly or through neuronal reflexes, the mediators induce bronchospasm, increase vascular permeability and mucus production, and recruit additional mediator-releasing cells from the blood. **E,** The arrival of recruited leukocytes (neutrophils, eosinophils, basophils, lymphocytes, and monocytes) signals the initiation of the late phase of asthma and a fresh round of mediator release from leukocytes, endothelium, and epithelial cells. Factors, particularly from eosinophils (e.g., major basic protein, eosinophil cationic protein), also cause damage to the epithelium. IgE, immunoglobulin E.

*respiratory mucosa lowers the threshold of the subepithelial vagal receptors to irritants.* Although the connections are not well understood, the ultimate humoral and cellular mediators of airway obstruction (e.g., eosinophils) are common to both atopic and nonatopic variants of asthma, so they are treated in a similar way.

### Drug-Induced Asthma

Several pharmacologic agents provoke asthma, *aspirin* being the most striking example. Patients with aspirin sensitivity present with recurrent rhinitis and nasal polyps, urticaria, and bronchospasm. The precise mechanism remains unknown, but it is presumed that aspirin inhibits the cyclooxygenase pathway of arachidonic acid metabolism without affecting the lipoxygenase route, thereby shifting the balance of production toward leukotrienes that cause bronchial spasm.

### Occupational Asthma

This form of asthma is stimulated by fumes (epoxy resins, plastics), organic and chemical dusts (wood, cotton, platinum), gases (toluene), and other chemicals. Asthma attacks usually develop after repeated exposure to the inciting antigen(s).

## MORPHOLOGY

The morphologic changes in asthma have been described in persons who die of prolonged severe attacks (status asthmaticus) and in mucosal biopsy specimens of persons challenged with allergens. In gross specimens obtained in fatal cases, the lungs are overdistended because of overinflation, and there may be small areas of atelectasis. The most striking macroscopic finding is occlusion of bronchi and bronchioles by thick, tenacious **mucous plugs.** Histologically, the mucous plugs contain whorls of shed epithelium **(Curschmann spirals).** Numerous eosinophils and **Charcot-Leyden crystals** (collections of crystalloids made up of eosinophil proteins) also are present. Other characteristic morphologic changes in asthma, collectively called "airway remodeling," include (Fig. 12–11, *B*):

- Thickening of airway wall
- Sub-basement membrane fibrosis (Fig. 12–12)
- Increased vascularity in submucosa
- An increase in size of the submucosal glands and goblet cell metaplasia of the airway epithelium
- Hypertrophy and/or hyperplasia of the bronchial muscle (this is the basis for the novel therapy of bronchial thermoplasty, which involves controlled delivery of thermal energy during bronchoscopy; this reduces the mass of smooth muscles which in turn reduces airway hyperresponsiveness)

### Clinical Features

An attack of asthma is characterized by severe dyspnea with wheezing; the chief difficulty lies in expiration. The victim labors to get air into the lungs and then cannot get it out, so that there is progressive hyperinflation of the lungs with air trapped distal to the bronchi, which are constricted and filled with mucus and debris. In the usual case, attacks last from 1 to several hours and subside either spontaneously or with therapy, usually bronchodilators and corticosteroids. Intervals between attacks are characteristically free from overt respiratory difficulties, but persistent, subtle deficits can be detected by spirometry. Occasionally a severe paroxysm occurs that does not respond to therapy and persists for days and even weeks (*status asthmaticus*). The associated hypercapnia, acidosis, and severe hypoxia may be fatal, although in most cases the condition is more disabling than lethal.

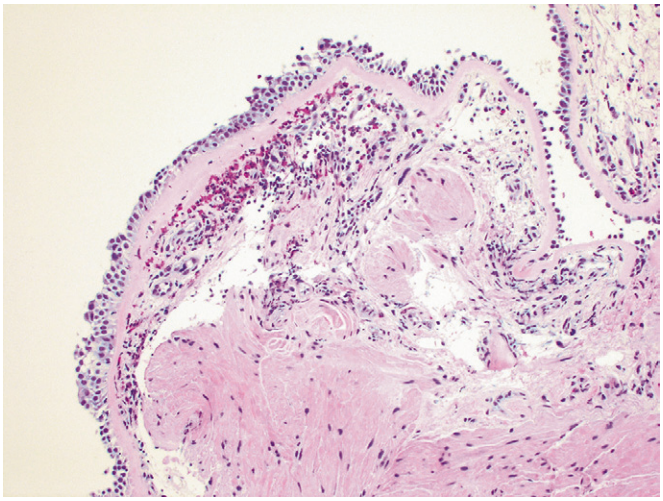

**Figure 12–12** Bronchial biopsy specimen from an asthmatic patient showing sub-basement membrane fibrosis, eosinophilic inflammation, and smooth muscle hyperplasia.

## SUMMARY

### Asthma

- Asthma is characterized by reversible bronchoconstriction caused by airway hyperresponsiveness to a variety of stimuli.
- Atopic asthma is caused by a $T_H2$ and IgE-mediated immunologic reaction to environmental allergens and is characterized by acute-phase (immediate) and late-phase reactions. The $T_H2$ cytokines IL-4, IL-5, and IL-13 are important mediators.
- Triggers for nonatopic asthma are less clear but include viral infections and inhaled air pollutants, which can also trigger atopic asthma.
- *Eosinophils* are key inflammatory cells found in almost all subtypes of asthma; eosinophil products such as major basic protein are responsible for airway damage.
- Airway remodeling (sub-basement membrane thickening and hypertrophy of bronchial glands and smooth muscle) adds an irreversible component to the obstructive disease.

## Bronchiectasis

Bronchiectasis is the permanent dilation of bronchi and bronchioles caused by destruction of the muscle and the supporting elastic tissue, resulting from or associated with

chronic necrotizing infections. It is not a primary disease but rather secondary to persisting infection or obstruction caused by a variety of conditions. Once developed, it gives rise to a characteristic symptom complex dominated by cough and expectoration of copious amounts of purulent sputum. Diagnosis depends on an appropriate history along with radiographic demonstration of bronchial dilation. The conditions that most commonly predispose to bronchiectasis include:

- *Bronchial obstruction.* Common causes are tumors, foreign bodies, and occasionally impaction of mucus. With these conditions, the bronchiectasis is localized to the obstructed lung segment. Bronchiectasis can also complicate atopic asthma and chronic bronchitis.
- Congenital or hereditary conditions—for example:
  - In *cystic fibrosis,* widespread severe bronchiectasis results from obstruction caused by the secretion of abnormally viscid mucus thus predisposing to infections of the bronchial tree. This is an important and serious complication (Chapter 6).
  - In *immunodeficiency states,* particularly immunoglobulin deficiencies, localized or diffuse bronchiectasis is likely to develop because of an increased susceptibility to repeated bacterial infections.
  - *Kartagener syndrome* is a rare autosomal recessive disorder that is frequently associated with bronchiectasis and with sterility in males. In this condition, structural abnormalities of the cilia impair mucociliary clearance in the airways, leading to persistent infections, and reduce the mobility of spermatozoa.
- *Necrotizing,* or *suppurative, pneumonia,* particularly with virulent organisms such as *Staphylococcus aureus* or *Klebsiella* spp., may predispose affected patients to development of bronchiectasis. Posttuberculosis bronchiectasis continues to be a significant cause of morbidity in endemic areas.

## PATHOGENESIS

Two processes are crucial and intertwined in the pathogenesis of bronchiectasis: **obstruction** and **chronic persistent infection.** Either of these may come first. Normal clearance mechanisms are hampered by obstruction, so secondary infection soon follows; conversely, chronic infection over time causes damage to bronchial walls, leading to weakening and dilation. For example, obstruction caused by a primary lung cancer or a foreign body impairs clearance of secretions, providing a favorable substrate for superimposed infection. The resultant inflammatory damage to the bronchial wall and the accumulating exudate further distend the airways, leading to irreversible dilation. Conversely, a persistent necrotizing inflammation in the bronchi or bronchioles may cause obstructive secretions, inflammation throughout the wall (with peribronchial fibrosis and traction on the walls), and eventually the train of events already described.

## MORPHOLOGY

Bronchiectasis usually affects the **lower lobes** bilaterally, particularly those air passages that are most vertical. When caused by tumors or aspiration of foreign bodies the involvement may be sharply localized to a single segment of the lungs. Usually, the most severe involvement is found in the more distal bronchi and bronchioles. The airways may be **dilated** to as much as four times their usual diameter and on gross examination of the lung can be followed almost to the pleural surfaces (Fig. 12–13). By contrast, in normal lungs, the bronchioles cannot be followed by ordinary gross examination beyond a point 2 to 3 cm from the pleural surfaces. The histologic findings vary with the activity and chronicity of the disease. In the full-blown active case, an **intense acute and chronic inflammatory exudate within the walls of the bronchi and bronchioles** and the desquamation of lining epithelium cause extensive areas of ulceration. In the usual case, a **mixed** flora can be cultured from the involved bronchi, including staphylococci, streptococci, pneumococci, enteric organisms, anaerobic and microaerophilic bacteria, and (particularly in children) *Haemophilus influenzae* and *Pseudomonas aeruginosa.* When healing occurs, the lining epithelium may regenerate completely; however, usually so much injury has occurred that abnormal dilation and scarring persist. Fibrosis of the bronchial and bronchiolar walls and **peribronchiolar fibrosis** develop in more chronic cases. In some instances, the necrosis destroys the bronchial or bronchiolar walls resulting in the formation of an abscess cavity within which a fungus ball may develop.

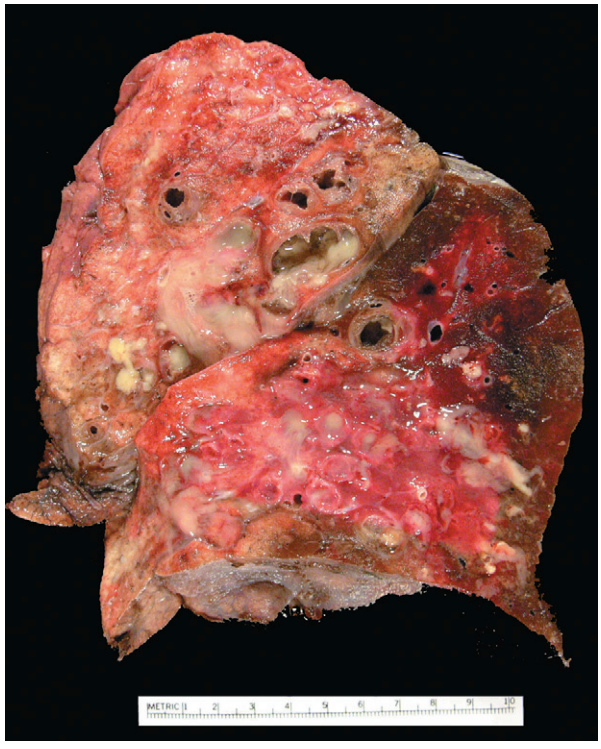

**Figure 12–13** Bronchiectasis in a patient with cystic fibrosis who underwent lung resection for transplantation. Cut surface of lung shows markedly dilated bronchi, filled with purulent mucus, which are seen extending to subpleural regions.

### Clinical Features

The clinical manifestations consist of severe, persistent cough with expectoration of mucopurulent, sometimes fetid, sputum. The sputum may contain flecks of blood; frank hemoptysis can occur. Symptoms often are episodic and are precipitated by upper respiratory tract infections or the introduction of new pathogenic agents. Clubbing of the fingers may develop. In cases of severe, widespread bronchiectasis, significant obstructive ventilatory defects are usual, with hypoxemia, hypercapnia, pulmonary hypertension, and (rarely) cor pulmonale. Metastatic brain abscesses and reactive amyloidosis (Chapter 4) are other, less frequent complications of bronchiectasis.

## CHRONIC INTERSTITIAL (RESTRICTIVE, INFILTRATIVE) LUNG DISEASES

Chronic interstitial diseases are a heterogeneous group of disorders characterized predominantly by bilateral, often patchy, and usually chronic involvement of the pulmonary connective tissue, principally the most peripheral and delicate interstitium in the alveolar walls. The pulmonary interstitium is composed of the basement membrane of the endothelial and epithelial cells (fused in the thinnest portions), collagen fibers, elastic tissue, fibroblasts, a few mast cells, and occasional mononuclear cells (Fig. 12–1). Many of the entities in this group are of unknown cause and pathogenesis; some have an intra-alveolar as well as an interstitial component, and there is frequent overlap in histologic features among the different conditions. Nevertheless, the similarity in clinical signs, symptoms, radiographic alterations, and pathophysiologic changes justifies their consideration as a group. *The hallmark feature of these disorders is reduced compliance (i.e., more pressure is required to expand the lungs because they are stiff), which in turn necessitates increased effort of breathing (dyspnea).* Furthermore, damage to the alveolar epithelium and interstitial vasculature produces abnormalities in the ventilation–perfusion ratio, leading to hypoxia. Chest radiographs show diffuse infiltration by small nodules, irregular lines, or "ground-glass shadows." With progression, patients can develop respiratory failure, often in association with pulmonary hypertension and cor pulmonale (Chapter 10). Advanced forms of these diseases may be difficult to differentiate because they result in scarring and gross destruction of the lung, referred to as end-stage or "honeycomb" lung. Chronic interstitial lung diseases are categorized based on clinicopathologic features and characteristic histology (Table 12–3).

**Table 12–3** Major Categories of Chronic Interstitial Lung Disease

| |
|---|
| **Fibrosing** |
| Usual interstitial pneumonia (idiopathic pulmonary fibrosis) |
| Nonspecific interstitial pneumonia |
| Cryptogenic organizing pneumonia |
| Associated with collagen vascular disease |
| Pneumoconiosis |
| Associated with therapies (drugs, radiation) |
| **Granulomatous** |
| Sarcoidosis |
| Hypersensitivity pneumonia |
| **Eosinophilic** |
| Loeffler syndrome |
| Drug allergy–related |
| Idiopathic chronic eosinophilic pneumonia |
| **Smoking-Related** |
| Desquamative interstitial pneumonia |
| Respiratory bronchiolitis |

### Fibrosing Diseases

#### *Idiopathic Pulmonary Fibrosis*

Idiopathic pulmonary fibrosis (IPF), also known as *cryptogenic fibrosing alveolitis,* refers to a pulmonary disorder of unknown etiology. It is characterized by patchy but progressive bilateral interstitial fibrosis, which in advanced cases results in severe hypoxemia and cyanosis. Males are affected more often than females, and approximately two thirds of patients are older than 60 years of age at presentation. The radiologic and histologic pattern of fibrosis is referred to as *usual interstitial pneumonia* (UIP), which is required for the diagnosis of IPF. Of note, however, similar pathologic changes in the lung may be present in well-defined entities such as asbestosis, the collagen vascular diseases, and a number of other conditions. Therefore, known causes must be ruled out before the appellation of *idiopathic* is used.

#### PATHOGENESIS

The current concept is that IPF is caused by "repeated cycles" of epithelial activation/injury by some unidentified agent (Fig. 12–14). Histopathologic features include inflammation and induction of $T_H2$ type T cell response with eosinophils, mast cells, IL-4, and IL-13 in the lesions. There has been considerable interest in the idea that "alternatively activated macrophages" are dominant in patients with lung fibrosis and may be important in its pathogenesis (Chapter 2). Abnormal epithelial repair at the sites of damage and inflammation gives rise to exuberant fibroblastic or myofibroblastic proliferation, leading to the characteristic fibroblastic foci. Although the mechanisms of abnormal repair are incompletely understood, recent data point to TGF-β1, which is released from injured type I pneumocytes and induces transformation of fibroblasts into myofibroblasts leading to excessive and continuing deposition of collagen and ECM. Some patients with familial IPF have mutations that shorten telomeres (Chapter 1) leading to rapid senescence and apoptosis of pneumocytes. TGF-β1 also downregulates fibroblast caveolin-1, which acts as an endogenous inhibitor of pulmonary fibrosis.

#### MORPHOLOGY

Grossly, the pleural surfaces of the lung have the appearance of cobblestones because of the retraction of scars along the interlobular septa. The cut surface shows fibrosis (firm, rubbery white areas), with lower lobe predominance and a

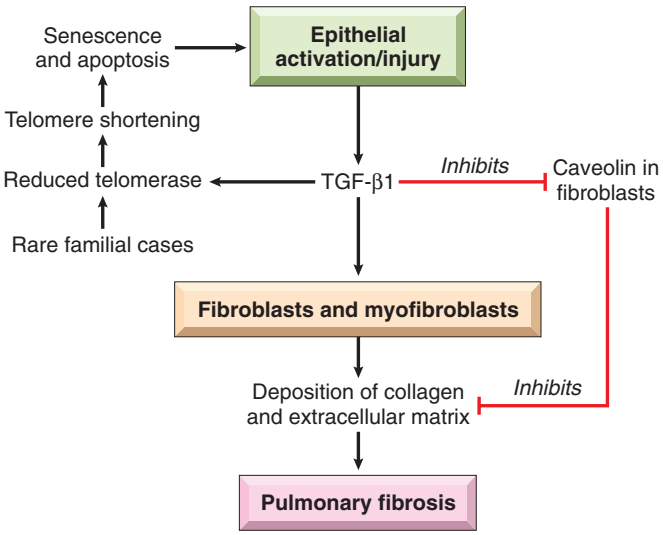


**Figure 12–14** Schematic representation of current understanding of the pathogenesis of idiopathic pulmonary fibrosis.

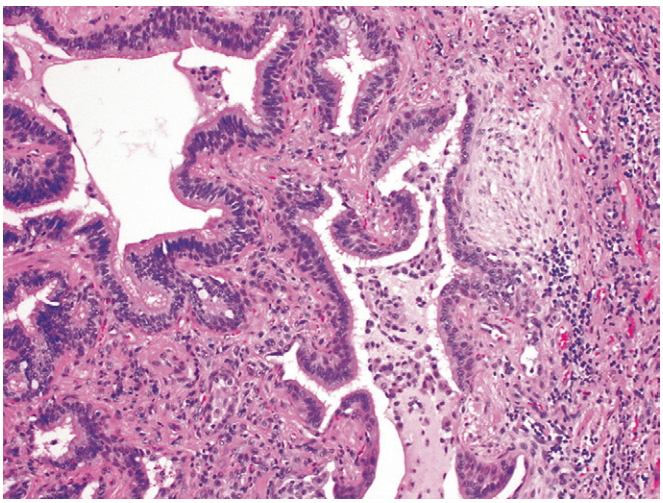

**Figure 12–16** Usual interstitial pneumonia. Fibroblastic focus with fibers running parallel to surface and bluish myxoid extracellular matrix. Honeycombing is present to the *left*.

distinctive distribution in the subpleural regions and along the interlobular septa. The pattern of fibrosis in IPF is referred to as **usual interstitial pneumonia** (UIP). The histologic hallmark of UIP is **patchy interstitial fibrosis,** which varies in intensity (Fig. 12–15) and worsens with time. The earliest lesions demonstrate exuberant fibroblastic proliferation and appear as **fibroblastic foci** (Fig. 12–16). Over time these areas become more collagenous and less cellular. Quite typical is the existence of both early and late lesions **(temporal heterogeneity).** The dense fibrosis causes collapse of alveolar walls and formation of cystic spaces lined by hyperplastic type II pneumocytes or bronchiolar epithelium **(honeycomb fibrosis).** The interstitial inflammation usually is patchy and consists of an alveolar septal infiltrate of mostly lymphocytes and occasional plasma cells, mast cells, and eosinophils. Secondary pulmonary hypertensive changes (intimal fibrosis and medial thickening of pulmonary arteries) are often present.

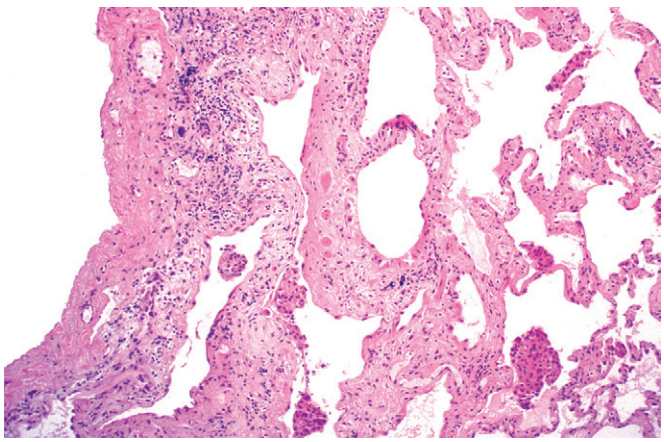

**Figure 12–15** Usual interstitial pneumonia. The fibrosis, which varies in intensity, is more pronounced in the subpleural region.

### Clinical Features

IPF usually manifests insidiously, with the gradual onset of a nonproductive cough and progressive dyspnea. On physical examination, most patients with IPF have characteristic "dry" or "Velcro"-like crackles during inspiration. Cyanosis, cor pulmonale, and peripheral edema may develop in later stages of the disease. The clinical and radiologic findings often are diagnostic; surgical lung biopsy is needed for diagnosis in selected cases. Unfortunately, progression of IPF is relentless despite medical therapy, and the mean survival is 3 years or less. Lung transplantation is the only definitive therapy available.

## *Nonspecific Interstitial Pneumonia*

Nonspecific interstitial pneumonia (NSIP) is a chronic bilateral interstitial lung disease of unknown etiology, which despite its nonspecific name, has distinct clinical, radiologic, and histologic features. It is important to recognize this disease, since it carries a much better prognosis than that for IPF. On the basis of the histologic appearance, NSIP is divided into cellular and fibrosing patterns. The *cellular pattern* features mild-to-moderate chronic interstitial inflammation (lymphocytes and a few plasma cells) in a uniform or patchy distribution. The *fibrosing pattern* consists of diffuse or patchy interstitial fibrosis, *without the temporal heterogeneity characteristic of UIP.* Fibroblastic foci and honeycombing are typically absent in both variants. Patients present with dyspnea and cough of several months' duration. Patients with the cellular pattern have a better outcome than those with the fibrosing pattern and UIP.

## *Cryptogenic Organizing Pneumonia*

*Cryptogenic organizing pneumonia* is synonymous with the previously popular designation *bronchiolitis obliterans organizing pneumonia* ("BOOP"); the former term is now preferred, however, because it emphasizes the unknown etiology of this clinicopathologic entity. Patients present with cough and dyspnea, and chest radiographs demonstrate subpleural or peribronchial patchy areas of air space

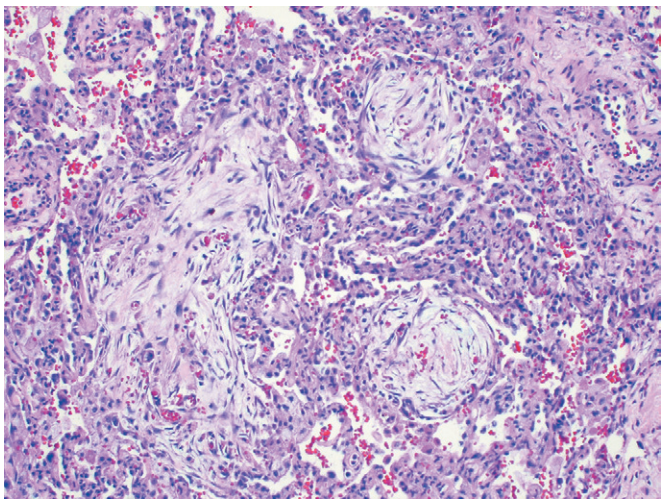

**Figure 12–17** Cryptogenic organizing pneumonia. Some alveolar spaces are filled with balls of fibroblasts (Masson bodies). Although compressed, adjacent alveoli are relatively normal.

consolidation. On histologic examination, cryptogenic organizing pneumonia is characterized by the presence of polypoid plugs of loose organizing connective tissue within alveolar ducts, alveoli, and often bronchioles (Fig. 12–17). The connective tissue is all of the same age, and the underlying lung architecture is normal. Some patients recover spontaneously, but most require treatment with oral steroids for 6 months or longer. Of note, organizing pneumonia with intra-alveolar fibrosis also can be seen as a response to infection (e.g., pneumonia) or inflammatory injury (e.g., collagen vascular disease, transplantation injury) to the lung; in such cases, the etiology obviously is not "cryptogenic," and the outcome is determined by the underlying disease.

### *Pulmonary Involvement in Collagen Vascular Diseases*

Many collagen vascular diseases (e.g., systemic lupus erythematosus, rheumatoid arthritis, systemic sclerosis, dermatomyositis-polymyositis) are associated with pulmonary manifestations. Several histologic variants can be seen, depending on the underlying disorder, with NSIP, UIP pattern (similar to that seen in IPF), vascular sclerosis, organizing pneumonia, and bronchiolitis (small airway disease, with or without fibrosis) being the most common. Pleural involvement (pleuritis, pleural nodules, and pleural effusion) may also be present. Pulmonary involvement in these diseases is usually associated with a poor prognosis, although it is still better than that with IPF.

## SUMMARY

### Chronic Interstitial Lung Diseases

- Diffuse interstitial fibrosis of the lung gives rise to restrictive lung diseases characterized by reduced lung compliance and reduced forced vital capacity (FVC). The ratio of FEV to FVC is normal.
- The diseases that cause diffuse interstitial fibrosis are heterogeneous. The unifying pathogenetic factor is injury to the alveoli with activation of macrophages and release of fibrogenic cytokines such as TGF-β.
- Idiopathic pulmonary fibrosis is prototypic of restrictive lung diseases. It is characterized by patchy interstitial fibrosis, fibroblastic foci, and formation of cystic spaces (honeycomb lung). This histologic pattern is known as *usual interstitial pneumonia* (UIP).

### *Pneumoconioses*

*Pneumoconiosis* is a term originally coined to describe the non-neoplastic lung reaction to inhalation of mineral dusts. The term has been broadened to include diseases induced by organic as well as inorganic particulates, and some experts also regard chemical fume- and vapor-induced non-neoplastic lung diseases as pneumoconioses. The mineral dust pneumoconioses—the three most common of which result from exposure to coal dust, silica, and asbestos—nearly always result from exposure in the workplace. However, the increased risk of cancer as a result of asbestos exposure extends to family members of asbestos workers and to other persons exposed to asbestos outside of the workplace. Table 12–4 indicates the pathologic conditions associated with each mineral dust and the major industries in which the dust exposure is sufficient to produce disease.

## PATHOGENESIS

The reaction of the lung to mineral dusts depends on many variables, including size, shape, solubility, and reactivity of the particles. For example, particles greater than 5 to 10 μm are unlikely to reach distal airways, whereas particles smaller than 0.5 μm move into and out of alveoli, often without substantial deposition and injury. **Particles that are 1 to 5 μm in diameter are the most dangerous, because they get lodged at the bifurcation of the distal airways.** Coal dust is relatively inert, and large amounts must be deposited in the lungs before lung disease is clinically detectable. Silica,

**Table 12–4** Mineral Dust–Induced Lung Disease

| Agent | Disease | Exposure |
|---|---|---|
| Coal dust | Simple coal worker's pneumoconiosis: macules and nodules<br>Complicated coal worker's pneumoconiosis: PMF | Coal mining |
| Silica | Silicosis | Sandblasting, quarrying, mining, stone cutting, foundry work, ceramics |
| Asbestos | Asbestosis, pleural effusions, pleural plaques, or diffuse fibrosis; mesothelioma; carcinoma of the lung and larynx | Mining, milling, and fabrication of ores and materials; installation and removal of insulation |

PMF, progressive massive fibrosis.

asbestos, and beryllium are more reactive than coal dust, resulting in fibrotic reactions at lower concentrations. Most inhaled dust is entrapped in the mucus blanket and rapidly removed from the lung by ciliary movement. However, some of the particles become impacted at alveolar duct bifurcations, where macrophages accumulate and engulf the trapped particulates. **The pulmonary alveolar macrophage is a key cellular element in the initiation and perpetuation of lung injury and fibrosis.** Many particles activate the inflammasome and induce IL-1 production. The more reactive particles trigger the macrophages to release a number of products that mediate an inflammatory response and initiate fibroblast proliferation and collagen deposition. Some of the inhaled particles may reach the lymphatics either by direct drainage or within migrating macrophages and thereby initiate an immune response to components of the particulates and/or to self-proteins that are modified by the particles. This then leads to an amplification and extension of the local reaction. **Tobacco smoking worsens the effects of all inhaled mineral dusts,** more so with asbestos than with any other particle.

### Coal Worker's Pneumoconiosis

Worldwide dust reduction in coal mines has greatly reduced the incidence of coal dust–induced disease. The spectrum of lung findings in coal workers is wide, ranging from *asymptomatic anthracosis,* in which pigment accumulates without a perceptible cellular reaction, to *simple coal worker's pneumoconiosis* (CWP), in which accumulations of macrophages occur with little to no pulmonary dysfunction, to *complicated CWP* or *progressive massive fibrosis* (PMF), in which fibrosis is extensive and lung function is compromised (Table 12–4). Although statistics vary, it seems that less than 10% of cases of simple CWP progress to PMF. Of note PMF is a generic term that applies to a confluent fibrosing reaction in the lung; this can be a complication of any one of the pneumoconioses discussed here.

Although coal is mainly carbon, coal mine dust contains a variety of trace metals, inorganic minerals, and crystalline silica. The ratio of carbon to contaminating chemicals and minerals ("coal rank") increases from bituminous to anthracite coal; in general, anthracite mining has been associated with a higher risk of CWP.

#### MORPHOLOGY

**Pulmonary anthracosis** is the most innocuous coal-induced pulmonary lesion in coal miners and also is commonly seen in all urban dwellers and tobacco smokers. Inhaled carbon pigment is engulfed by alveolar or interstitial macrophages, which then accumulate in the connective tissue along the lymphatics, including the pleural lymphatics, or in lymph nodes.

**Simple CWP** is characterized by **coal macules** and the somewhat larger **coal nodule.** The coal macule consists of dust-laden macrophages; in addition, the nodule contains small amounts of collagen fibers arrayed in a delicate network. Although these lesions are scattered throughout the lung, the upper lobes and upper zones of the lower lobes are more heavily involved. In due course, **centrilobular emphysema** can occur. Functionally significant emphysema is more common in the United Kingdom and Europe, probably because the coal rank is higher than in the United States.

**Complicated CWP (PMF)** occurs on a background of simple CWP by coalescence of coal nodules and generally requires many years to develop. It is characterized by usually multiple, intensely blackened scars larger than 2 cm, sometimes up to 10 cm in greatest diameter. On microscopic examination the lesions are seen to consist of dense collagen and pigment (Fig. 12–18).

#### Clinical Features

CWP is usually a benign disease that produces little decrement in lung function. In those in whom PMF develops, there is increasing pulmonary dysfunction, pulmonary hypertension, and cor pulmonale. Progression from CWP to PMF has been linked to a variety of conditions including coal dust exposure level and total dust burden. Unfortunately, PMF has a tendency to progress even in the absence of further exposure. Once smoking-related risk has been taken into account, there is no increased frequency of lung carcinoma in coal miners, a feature that distinguishes CWP from both silica and asbestos exposures (discussed next).

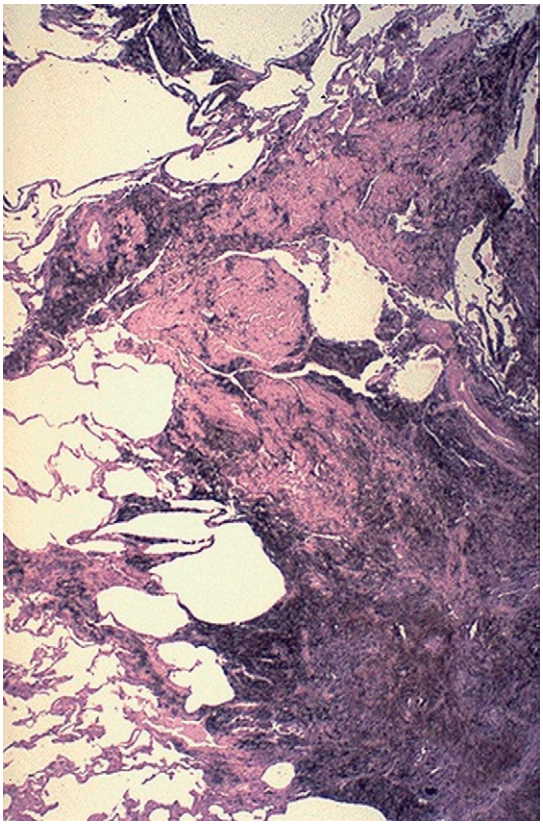

**Figure 12–18** Progressive massive fibrosis in a coal worker. Large amount of black pigment is associated with fibrosis.
*(From Klatt EC: Robbins and Cotran atlas of pathology, ed 2, Elsevier, p. 121.)*

### Silicosis

Silicosis *is currently the most prevalent chronic occupational disease in the world.* It is caused by inhalation of crystalline silica, mostly in occupational settings. Workers in several occupations but especially those involved in sandblasting and hard-rock mining are at particular risk. Silica occurs in both crystalline and amorphous forms, but crystalline forms (including quartz, cristobalite, and tridymite) are by far the most toxic and fibrogenic. Of these, quartz is most commonly implicated in silicosis. After inhalation the particles interact with epithelial cells and macrophages. *Ingested silica particles cause activation and release of mediators by pulmonary macrophages,* including IL-1, TNF, fibronectin, lipid mediators, oxygen-derived free radicals, and fibrogenic cytokines. Especially compelling is the evidence incriminating TNF, since anti-TNF monoclonal antibodies can block lung fibrosis in mice that are given silica intratracheally. *When mixed with other minerals, quartz has been observed to have a reduced fibrogenic effect.* This phenomenon is of practical importance, because quartz in the workplace is rarely pure. Thus, miners of the iron-containing ore hematite may have more quartz in their lungs than some quartz-exposed workers and yet have relatively mild lung disease, because the hematite provides a protective effect.

#### MORPHOLOGY

**Silicotic nodules** are characterized grossly in their early stages by tiny, barely palpable, discrete, pale-to-blackened (if coal dust is also present) nodules in the upper zones of the lungs (Fig. 12–19). Microscopically, the silicotic nodule demonstrates **concentrically arranged hyalinized collagen fibers** surrounding an amorphous center. The "whorled" appearance of the collagen fibers is quite distinctive for silicosis (Fig. 12–20). Examination of the nodules by **polarized microscopy reveals weakly birefringent silica** particles, primarily in the center of the nodules. As the disease progresses, the individual nodules may coalesce into hard, collagenous scars, with eventual progression to PMF. The intervening lung parenchyma may be compressed or overexpanded, and a honeycomb pattern may develop. Fibrotic lesions may also occur in the hilar lymph nodes and pleura. Sometimes, thin sheets of calcification occur in the lymph nodes and are appreciated radiographically as "eggshell" calcification (e.g., calcium surrounding a zone lacking calcification).

### Clinical Features

Silicosis usually is detected on routine chest radiographs obtained in asymptomatic workers. The radiographs typically show a fine nodularity in the upper zones of the lung, but pulmonary function is either normal or only moderately affected. Most patients do not develop shortness of breath until late in the course, after PMF is present. At this time, the disease may be progressive, even if the person is no longer exposed. Many patients with PMF develop pulmonary hypertension and cor pulmonale, as a result of chronic hypoxia-induced vasoconstriction and parenchymal destruction. The disease is slow to kill, but impaired pulmonary function may severely limit activity. *Silicosis is associated with an increased susceptibility to tuberculosis.* It is postulated that silicosis results in a depression of cell-mediated immunity, and crystalline silica may inhibit the ability of pulmonary macrophages to kill phagocytosed mycobacteria. Nodules of silicotuberculosis often contain a central zone of caseation. The relationship between silica and *lung cancer* has been a contentious issue. In 1997, based on evidence from several epidemiologic studies, the International Agency for Research on Cancer concluded that *crystalline silica* from occupational sources is carcinogenic in humans. However, this subject continues to be controversial.

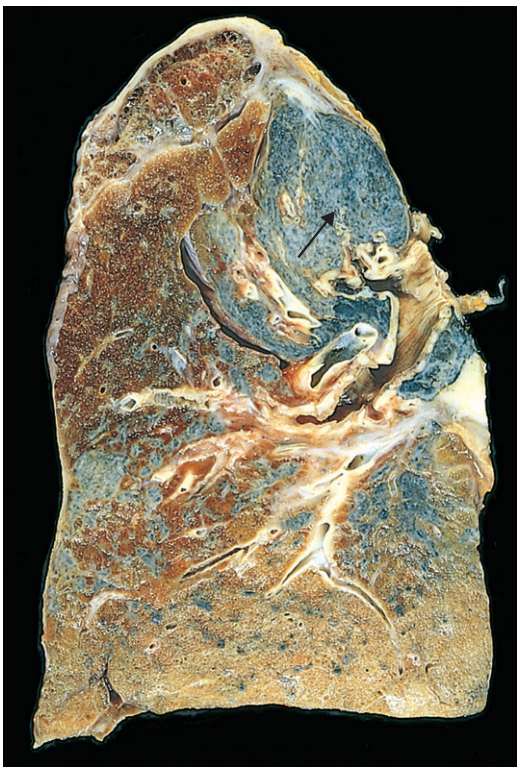

**Figure 12–19** Advanced silicosis seen on transection of lung. Scarring has contracted the upper lobe into a small dark mass (*arrow*). Note the dense pleural thickening.
*(Courtesy of Dr. John Godleski, Brigham and Women's Hospital, Boston, Massachusetts.)*

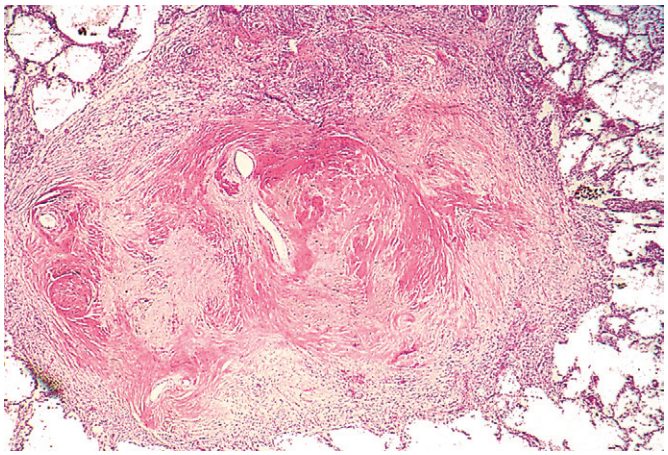

**Figure 12–20** Several coalescent collagenous silicotic nodules.
*(Courtesy of Dr. John Godleski, Brigham and Women's Hospital, Boston, Massachusetts.)*

### Asbestosis and Asbestos-Related Diseases

Asbestos is a family of crystalline hydrated silicates with a fibrous geometry. On the basis of epidemiologic studies, occupational exposure to asbestos is linked to (1) parenchymal interstitial fibrosis (*asbestosis*); (2) localized fibrous plaques or, rarely, diffuse fibrosis in the pleura; (3) pleural effusions; (4) lung carcinomas; (5) malignant pleural and peritoneal mesotheliomas; and (6) laryngeal carcinoma. An increased incidence of asbestos-related cancers in family members of asbestos workers has alerted the general public to the potential hazards of asbestos in the environment.

## PATHOGENESIS

Concentration, size, shape, and solubility of the different forms of asbestos dictate whether inhalation of the material will cause disease. There are two distinct forms of asbestos: **serpentine,** in which the fiber is curly and flexible, and **amphibole,** in which the fiber is straight, stiff, and brittle. Several subtypes of curly and straight asbestos fibers are recognized. The serpentine **chrysotile** accounts for most of the asbestos used in industry. Amphiboles, even though less prevalent, are more pathogenic than the serpentine chrysotile, but both types can produce asbestosis, lung cancer, and mesothelioma. The greater pathogenicity of straight and stiff amphiboles is apparently related to their structure. The serpentine chrysotiles, with their more flexible, curled structure, are likely to become impacted in the upper respiratory passages and removed by the mucociliary elevator. Those that are trapped in the lungs are gradually leached from the tissues, because they are more soluble than amphiboles. The straight, stiff amphiboles, in contrast, align themselves in the airstream and are hence delivered deeper into the lungs, where they may penetrate epithelial cells to reach the interstitium. Despite these differences, both asbestos forms are fibrogenic, and increasing exposure to either is associated with a higher incidence of all asbestos-related diseases. Asbestosis, like other pneumoconioses, causes fibrosis by a process involving interaction of particulates with lung macrophages.

In addition to cellular and fibrotic lung reactions, asbestos probably also functions as both a tumor initiator and a promoter. Some of the oncogenic effects of asbestos on the mesothelium are mediated by reactive free radicals generated by asbestos fibers, which preferentially localize in the distal lung close to the mesothelial layer. However, potentially toxic chemicals adsorbed onto the asbestos fibers undoubtedly contribute to the pathogenicity of the fibers. For example, **the adsorption of carcinogens in tobacco smoke onto asbestos fibers may well be important to the remarkable synergy between tobacco smoking and the development of lung carcinoma in asbestos workers.**

## MORPHOLOGY

**Asbestosis** is marked by diffuse pulmonary interstitial fibrosis. These changes are indistinguishable from UIP, except for the presence of **asbestos bodies,** which are seen as golden brown, fusiform or beaded rods with a translucent center.

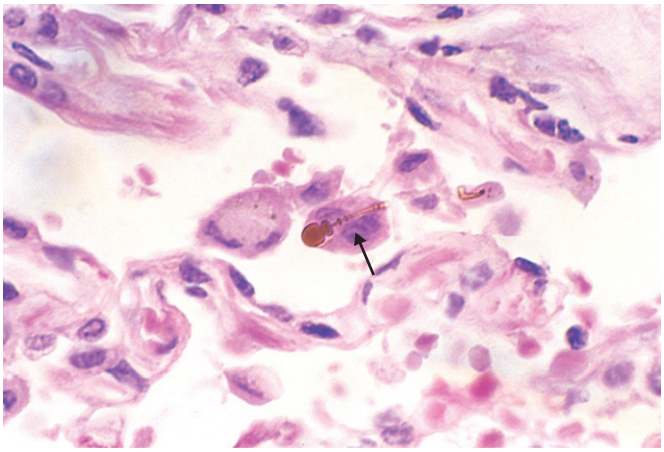

**Figure 12–21** High-power detail of an asbestos body, revealing the typical beading and knobbed ends *(arrow)*.

They consist of asbestos fibers coated with an iron-containing proteinaceous material (Fig. 12–21). Asbestos bodies apparently are formed when macrophages attempt to phagocytose asbestos fibers; the iron is derived from phagocyte ferritin. Asbestos bodies sometimes can be found in the lungs of normal persons, but usually in much lower concentrations and without an accompanying interstitial fibrosis.

In contrast with CWP and silicosis, asbestosis begins in the lower lobes and subpleurally, but the middle and upper lobes of the lungs become affected as fibrosis progresses. Contraction of the fibrous tissue distorts the normal architecture, creating enlarged air spaces enclosed within thick fibrous walls. In this way the affected regions become honeycombed. Simultaneously, fibrosis develops in the visceral pleura, causing adhesions between the lungs and the chest wall. The scarring may trap and narrow pulmonary arteries and arterioles, causing pulmonary hypertension and cor pulmonale.

**Pleural plaques** are the most common manifestation of asbestos exposure and are well-circumscribed plaques of dense collagen (Fig. 12–22), often containing calcium. They develop most frequently on the anterior and posterolateral aspects of the **parietal pleura** and over the domes of the diaphragm. They do not contain asbestos bodies, and only rarely do they occur in persons with no history or evidence of asbestos exposure. Uncommonly, asbestos exposure induces pleural effusion or diffuse pleural fibrosis.

### Clinical Features

The clinical findings in asbestosis are indistinguishable from those of any other chronic interstitial lung disease. Typically, progressively worsening dyspnea appears 10 to 20 years after exposure. The dyspnea is usually accompanied by a cough associated with production of sputum. The disease may remain static or progress to congestive heart failure, cor pulmonale, and death. Pleural plaques are usually asymptomatic and are detected on radiographs as circumscribed densities. *Both lung carcinoma and malignant mesothelioma develop in workers exposed to asbestos.* The risk of lung carcinoma is increased about five-fold for asbestos workers; the relative risk for mesothelioma, normally a very rare tumor (2 to 17 cases per 1 million persons), is more than 1000 times greater. Concomitant cigarette

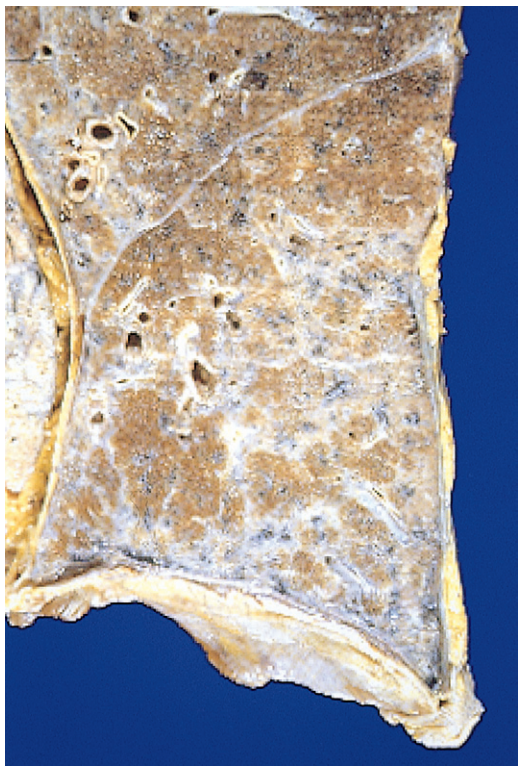

**Figure 12–22** Asbestosis. Markedly thickened visceral pleura covers the lateral and diaphragmatic surface of lung. Note also severe interstitial fibrosis diffusely affecting the lower lobe of the lung.

smoking greatly increases the risk of lung carcinoma but not that of mesothelioma. Lung or pleural cancer associated with asbestos exposure carries a particularly grim prognosis.

## SUMMARY

### Pneumoconioses

- Pneumoconioses encompass a group of chronic fibrosing diseases of the lung resulting from exposure to organic and inorganic particulates, most commonly mineral dust.
- Pulmonary alveolar macrophages play a central role in the pathogenesis of lung injury by promoting inflammation and producing reactive oxygen species and fibrogenic cytokines.
- Coal dust–induced disease varies from *asymptomatic anthracosis*, to *simple coal worker's pneumoconiosis* (coal macules or nodules, and centrilobular emphysema), to progressive massive fibrosis (PMF), manifested by increasing pulmonary dysfunction, pulmonary hypertension, and cor pulmonale.
- Silicosis is the most common pneumoconiosis in the world, and crystalline silica (e.g., quartz) is the usual culprit.
- The manifestations of silicosis can range from asymptomatic silicotic nodules to PMF; persons with silicosis also have an increased susceptibility to tuberculosis. The relationship between silica exposure and subsequent lung cancer is controversial.
- Asbestos fibers come in two forms; the stiff *amphiboles* have a greater fibrogenic and carcinogenic potential than the serpentine *chrysotiles*.
- Asbestos exposure is linked with six disease processes: (1) parenchymal interstitial fibrosis (*asbestosis*); (2) localized fibrous plaques or, rarely, diffuse pleural fibrosis; (3) pleural effusions; (4) lung cancer; (5) malignant pleural and peritoneal mesotheliomas; and (6) laryngeal cancer.
- Cigarette smoking increases the risk of lung cancer in the setting of asbestos exposure; moreover, even family members of workers exposed to asbestos are at increased risk for cancer.

### *Drug- and Radiation-Induced Pulmonary Diseases*

Drugs can cause a variety of both acute and chronic alterations in respiratory structure and function. For example, *bleomycin,* an anticancer agent, causes pneumonitis and interstitial fibrosis, as a result of direct toxicity of the drug and by stimulating the influx of inflammatory cells into the alveoli. Similarly, *amiodarone,* an antiarrhythmic agent, also is associated with risk for pneumonitis and fibrosis. *Radiation pneumonitis* is a well-known complication of therapeutic irradiation of pulmonary and other thoracic tumors. *Acute radiation pneumonitis,* which typically occurs 1 to 6 months after therapy in as many as 20% of the patients, is manifested by fever, dyspnea out of proportion to the volume of irradiated lung, pleural effusion, and development of pulmonary infiltrates corresponding to the area of radiation. These signs and symptoms may resolve with corticosteroid therapy or progress to *chronic radiation pneumonitis,* associated with pulmonary fibrosis.

## Granulomatous Diseases

### *Sarcoidosis*

Although sarcoidosis is considered here as an example of a restrictive lung disease, it is important to note that sarcoidosis is a *multisystem disease of unknown etiology characterized by noncaseating granulomas in many tissues and organs.* Other diseases, including mycobacterial or fungal infections and berylliosis, sometimes also produce noncaseating granulomas; therefore, the histologic *diagnosis of sarcoidosis is one of exclusion.* Although the multisystem involvement of sarcoidosis can manifest in many clinical guises, bilateral hilar lymphadenopathy or lung involvement (or both), visible on chest radiographs, is the major presenting manifestation in most cases. Eye and skin involvement each occurs in about 25% of cases, and either may occasionally be the presenting feature of the disease.

#### Epidemiology

Sarcoidosis occurs throughout the world, affecting both genders and all races and age groups. There are, however, certain interesting epidemiologic trends, including:

- There is a consistent predilection for adults younger than 40 years of age.
- A high incidence has been noted in Danish and Swedish populations, and in the United States among African

Americans (in whom the frequency of involvement is 10 times greater than in whites).
- Sarcoidosis is one of the few pulmonary diseases with a higher prevalence among *nonsmokers.*

## ETIOLOGY AND PATHOGENESIS

Although the etiology of sarcoidosis remains unknown, several lines of evidence suggest that it is a disease of disordered immune regulation in genetically predisposed persons exposed to certain environmental agents. The role of each of these contributory influences is summarized in the following discussion.

Several **immunologic abnormalities** in sarcoidosis suggest the development of a cell-mediated response to an unidentified antigen. The process is driven by CD4+ helper T cells. These abnormalities include:

- Intra-alveolar and interstitial accumulation of CD4+ $T_H1$ cells
- Oligoclonal expansion of T cell subsets as determined by analysis of T cell receptor rearrangement
- Increases in T cell–derived $T_H1$ cytokines such as IL-2 and IFN-γ, resulting in T cell expansion and macrophage activation, respectively
- Increases in several cytokines in the local environment (IL-8, TNF, macrophage inflammatory protein-1α) that favor recruitment of additional T cells and monocytes and contribute to the formation of granulomas
- Anergy to common skin test antigens such as *Candida* or purified protein derivative (PPD), that may result from pulmonary recruitment of CD4+ T cells and consequent peripheral depletion
- Polyclonal hypergammaglobulinemia, another manifestation of $T_H$ cell dysregulation
- The role of genetic factors is suggested by familial and racial clustering of cases and association with certain human leukocyte antigen (HLA) genotypes (e.g., class I HLA-A1 and HLA-B8)

After lung transplantation, sarcoidosis recurs in the new lungs in 75% of patients. Finally, several putative "antigens" have been proposed as the inciting agent for sarcoidosis (e.g., viruses, mycobacteria, *Borrelia,* pollen), but thus far **there is no unequivocal evidence to suggest that sarcoidosis is caused by an infectious agent.**

## MORPHOLOGY

The diagnostic histopathologic feature of sarcoidosis is the **noncaseating epithelioid granuloma,** irrespective of the organ involved (Fig. 12–23). This is a discrete, compact collection of epithelioid cells rimmed by an outer zone of largely CD4+ T cells. The epithelioid cells are derived from macrophages and are characterized by abundant eosinophilic cytoplasm and vesicular nuclei. It is not uncommon to see intermixed multinucleate giant cells formed by fusion of macrophages. A thin layer of laminated fibroblasts is present peripheral to the granuloma; over time, these proliferate and lay down collagen that replaces the entire granuloma with a hyalinized scar. Two other microscopic features are sometimes seen in the granulomas: (1) **Schaumann bodies,** laminated concretions composed of calcium and proteins; and (2) **asteroid bodies,** stellate inclusions enclosed within giant cells. Their presence is not required for diagnosis of sarcoidosis—they also may occur in granulomas of other origins. Rarely, foci of central necrosis may be present in sarcoid granulomas, suggesting an infectious process. Caseation necrosis typical of tuberculosis is absent.

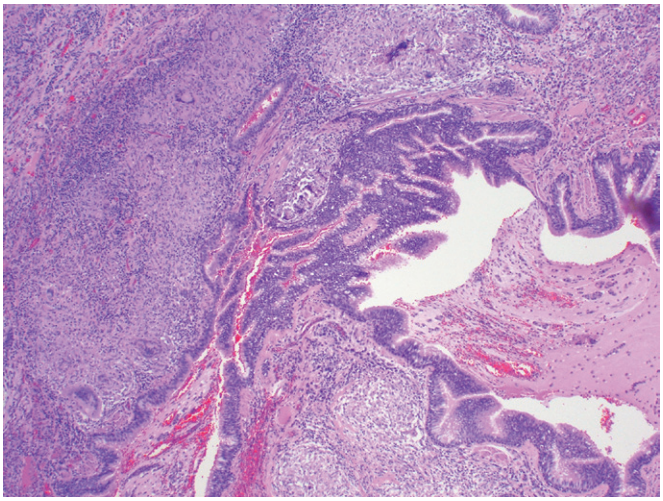

**Figure 12–23** Sarcoid. Characteristic peribronchial noncaseating granulomas with many giant cells.

The **lungs** are involved at some stage of the disease in 90% of patients. The granulomas predominantly involve the interstitium rather than air spaces, with some tendency to localize in the connective tissue around bronchioles and pulmonary venules and in the pleura ("lymphangitic" distribution). The bronchoalveolar lavage fluid contains abundant CD4+ T cells. In 5% to 15% of patients, the granulomas eventually are replaced by **diffuse interstitial fibrosis,** resulting in a so-called honeycomb lung.

Intrathoracic **hilar and paratracheal lymph nodes** are enlarged in 75% to 90% of patients, while a third present with peripheral lymphadenopathy. The nodes are characteristically painless and have a firm, rubbery texture. Unlike in tuberculosis, lymph nodes in sarcoidosis are "nonmatted" (nonadherent) and do not ulcerate.

**Skin lesions** are encountered in approximately 25% of patients. **Erythema nodosum,** the hallmark of acute sarcoidosis, consists of raised, red, tender nodules on the anterior aspects of the legs. Sarcoidal granulomas are uncommon in these lesions. By contrast, discrete painless subcutaneous nodules can also occur in sarcoidosis, and these usually reveal abundant noncaseating granulomas.

**Involvement of the eye and lacrimal glands occurs in about one fifth to one half of patients.** The ocular involvement takes the form of iritis or iridocyclitis and may be unilateral or bilateral. As a consequence, corneal opacities, glaucoma, and (less commonly) total loss of vision may develop. The posterior uveal tract also is affected, with resultant **choroiditis, retinitis,** and **optic nerve involvement.** These ocular lesions are frequently accompanied by inflammation in the lacrimal glands, with suppression of lacrimation **(sicca syndrome). Unilateral or bilateral parotitis with painful enlargement of the parotid glands**

occurs in less than 10% of patients with sarcoidosis; some go on to develop xerostomia (dry mouth). Combined uveoparotid involvement is designated **Mikulicz syndrome.**

**The spleen** may appear unaffected grossly, but in about three fourths of cases, it contains granulomas. In approximately 10%, it becomes clinically enlarged. **The liver** demonstrates microscopic granulomatous lesions, usually in the portal triads, about as often as the spleen, but only about one third of the patients demonstrate hepatomegaly or abnormal liver function. Sarcoid involvement of **bone marrow** is reported in as many as 40% of patients, although it rarely causes severe manifestations. Other findings may include hypercalcemia and hypercalciuria. These changes are not related to bone destruction but rather are caused by increased calcium absorption secondary to production of active vitamin D by the mononuclear phagocytes in the granulomas.

### Clinical Features

In many affected persons the disease is entirely asymptomatic, discovered on routine chest films as bilateral hilar adenopathy or as an incidental finding at autopsy. In others, peripheral lymphadenopathy, cutaneous lesions, eye involvement, splenomegaly, or hepatomegaly may be presenting manifestations. In about two thirds of symptomatic cases, there is gradual appearance of respiratory symptoms (shortness of breath, dry cough, or vague substernal discomfort) or constitutional signs and symptoms (fever, fatigue, weight loss, anorexia, night sweats). Because of the variable and nondiagnostic clinical features, resort is frequently made to lung or lymph node biopsies. *The presence of noncaseating granulomas is suggestive of sarcoidosis, but other identifiable causes of granulomatous inflammation must be excluded.*

Sarcoidosis follows an unpredictable course characterized by either progressive chronicity or periods of activity interspersed with remissions. The remissions may be spontaneous or initiated by steroid therapy and often are permanent. Overall, 65% to 70% of affected persons recover with minimal or no residual manifestations. Another 20% develop permanent lung dysfunction or visual impairment. Of the remaining 10% to 15%, most succumb to progressive pulmonary fibrosis and cor pulmonale.

**SUMMARY**

**Sarcoidosis**

- Sarcoidosis is a multisystem disease of unknown etiology; the diagnostic histopathologic feature is the presence of noncaseating granulomas in various tissues.
- Immunologic abnormalities include high levels of CD4+ T cells in the lung that secrete $T_H1$-dependent cytokines such as IFN-γ and IL-2 locally.
- Clinical manifestations include lymph node enlargement, eye involvement (sicca syndrome [dry eyes], iritis, or iridocyclitis), skin lesions (erythema nodosum, painless subcutaneous nodules), and visceral (liver, skin, marrow) involvement. Lung involvement occurs in 90% of cases, with formation of granulomas and interstitial fibrosis.

## *Hypersensitivity Pneumonitis*

Hypersensitivity pneumonitis is an immunologically mediated inflammatory lung disease that primarily affects the alveoli and is therefore often called *allergic alveolitis.* Most often it is an occupational disease that results from heightened sensitivity to inhaled antigens such as in moldy hay (Table 12–5). Unlike bronchial asthma, in which *bronchi are the focus of immunologically mediated injury, the damage in hypersensitivity pneumonitis occurs at the level of alveoli.* Hence, it manifests as a predominantly restrictive lung disease with decreased diffusion capacity, lung compliance, and total lung volume. The occupational exposures are diverse, but the syndromes share common clinical and pathologic findings and probably have a very similar pathophysiologic basis.

Several lines of evidence suggest that hypersensitivity pneumonitis is an immunologically mediated disease:

- Bronchoalveolar lavage specimens consistently demonstrate increased numbers of T lymphocytes of both CD4+ and CD8+ phenotype.

**Table 12–5** Selected Causes of Hypersensitivity Pneumonitis

| Syndrome | Exposure | Antigens |
|---|---|---|
| Fungal and Bacterial Antigens | | |
| Farmer's lung | Moldy hay | *Micropolyspora faeni* |
| Bagassosis | Moldy pressed sugar cane (bagasse) | Thermophilic actinomycetes |
| Maple bark disease | Moldy maple bark | *Cryptostroma corticale* |
| Humidifier lung | Cool-mist humidifier | Thermophilic actinomycetes, *Aureobasidium pullulans* |
| Malt worker's lung | Moldy barley | *Aspergillus clavatus* |
| Cheese washer's lung | Moldy cheese | *Penicillium casei* |
| Insect Products | | |
| Miller's lung | Dust-contaminated grain | *Sitophilus granarius* (wheat weevil) |
| Animal Products | | |
| Pigeon breeder's lung | Pigeon droppings | Pigeon serum proteins in droppings |
| Chemicals | | |
| Chemical worker's lung | Chemical industry | Trimellitic anhydride, isocyanates |

- Most patients with hypersensitivity pneumonitis have specific precipitating antibodies in their serum, and complement and immunoglobulins have been demonstrated within vessel walls by immunofluorescence, indicating type III hypersensitivity. The presence of noncaseating granulomas in two thirds of patients with this disorder suggests a role for type IV hypersensitivity as well.

In summary, hypersensitivity pneumonitis is an immunologically mediated response to an extrinsic antigen that involves both immune complex and delayed-type hypersensitivity reactions.

### MORPHOLOGY

The histopathologic picture in both acute and chronic forms of hypersensitivity pneumonitis includes patchy mononuclear cell infiltrates in the pulmonary interstitium, with a characteristic peribronchiolar accentuation. Lymphocytes predominate, but plasma cells and epithelioid cells also are present. In acute forms of the disease, variable numbers of neutrophils may also be seen. **Interstitial noncaseating granulomas** are present in more than two thirds of cases, usually in a peribronchiolar location (Fig. 12–24). In advanced chronic cases, diffuse interstitial fibrosis occurs.

#### Clinical Features

Hypersensitivity pneumonitis may manifest either as an *acute reaction,* with fever, cough, dyspnea, and constitutional signs and symptoms arising 4 to 8 hours after exposure, or as a *chronic disease* characterized by insidious onset of cough, dyspnea, malaise, and weight loss. With the acute form of this disease, the diagnosis is usually obvious because of the temporal relationship of symptom onset to exposure to the incriminating antigen. *If antigenic exposure is terminated after acute attacks of the disease,* complete resolution of pulmonary symptoms occurs within days. Failure to remove the inciting agent from the environment eventually results in an irreversible chronic interstitial pulmonary disease.

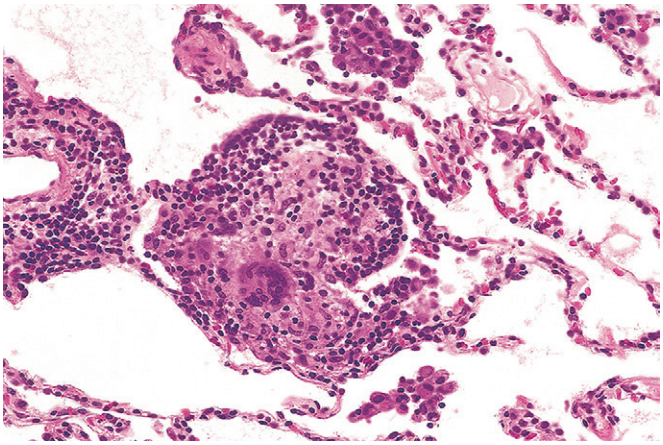

**Figure 12–24** Hypersensitivity pneumonitis, histologic appearance. Loosely formed interstitial granulomas and chronic inflammation are characteristic.

## Pulmonary Eosinophilia

A number of clinical and pathologic pulmonary entities are characterized by an infiltration and activation of eosinophils, the latter by elevated levels of alveolar IL-5. These diverse diseases generally are of immunologic origin, but the etiology is not understood. Pulmonary eosinophilia is divided into the following categories:

- *Acute eosinophilic pneumonia with respiratory failure,* characterized by rapid onset of fever, dyspnea, hypoxia, and diffuse pulmonary infiltrates on chest radiographs. The bronchoalveolar lavage fluid typically contains more than 25% eosinophils. There is prompt response to corticosteroids.
- *Simple pulmonary eosinophilia* (Loeffler syndrome), characterized by transient pulmonary lesions, eosinophilia in the blood, and a benign clinical course. The alveolar septa are thickened by an infiltrate containing eosinophils and occasional giant cells.
- *Tropical eosinophilia,* caused by infection with microfilariae and helminthic parasites
- *Secondary eosinophilia,* seen, for example, in association with asthma, drug allergies, and certain forms of vasculitis
- *Idiopathic chronic eosinophilic pneumonia,* characterized by aggregates of lymphocytes and eosinophils within the septal walls and the alveolar spaces, typically in the periphery of the lung fields, and accompanied by high fever, night sweats, and dyspnea. This is a disease of exclusion, once other causes of pulmonary eosinophilia have been ruled out.

## Smoking-Related Interstitial Diseases

The role of cigarette smoking in causing obstructive pulmonary disease (emphysema and chronic bronchitis) has been discussed. Smoking also is associated with restrictive or interstitial lung diseases. *Desquamative interstitial pneumonia* (DIP) and *respiratory bronchiolitis* are the two related examples of smoking-associated interstitial lung disease. The most striking histologic feature of DIP is the accumulation of large numbers of macrophages with abundant cytoplasm containing dusty-brown pigment (*smoker's macrophages*) in the air spaces (Fig. 12–25). The alveolar septa are thickened by a sparse inflammatory infiltrate (usually lymphocytes), and interstitial fibrosis, when present, is mild. Pulmonary functions usually show a mild restrictive abnormality, and patients with DIP typically have a good prognosis with excellent response to steroid therapy and smoking cessation. Respiratory bronchiolitis is a common histologic lesion found in smokers, characterized by the presence of pigmented intraluminal macrophages akin to those in DIP, but in a "bronchiolocentric" distribution (first- and second-order respiratory bronchioles). Mild peribronchiolar fibrosis also is seen. As with DIP, affected patients present with gradual onset of dyspnea and dry cough, and the symptoms recede with cessation of smoking.

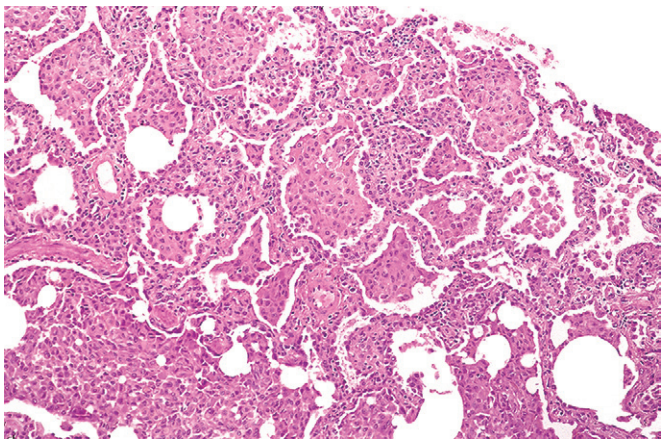

**Figure 12–25** Desquamative interstitial pneumonia. There is accumulation of large numbers of macrophages within the alveolar spaces with only slight fibrous thickening of the alveolar walls.

## PULMONARY DISEASES OF VASCULAR ORIGIN

### Pulmonary Embolism, Hemorrhage, and Infarction

Blood clots that occlude the large pulmonary arteries are almost always embolic in origin. More than 95% of all pulmonary emboli arise from thrombi within the large deep veins of the lower legs, typically originating in the popliteal vein and larger veins above it. Thromboembolism causes approximately 50,000 deaths per year in the United States. Even when not directly fatal, it can complicate the course of other diseases. The true incidence of nonfatal pulmonary embolism is not known. Some cases of embolism undoubtedly occur outside the hospital in ambulatory patients, in whom the emboli are small and clinically silent. Even among hospitalized patients, no more than one third are diagnosed before death. Autopsy data on the incidence of pulmonary embolism vary widely, ranging from 1% in the general hospitalized population, to 30% in persons dying after severe burns, trauma, or fractures.

The influences that predispose the patient to venous thrombosis in the legs are discussed in Chapter 3, but the following risk factors are paramount: (1) prolonged bedrest (particularly with immobilization of the legs); (2) surgery, especially orthopedic surgery, of knee and hip; (3) severe trauma (including burns or multiple fractures); (4) congestive heart failure; (5) in women, the period around parturition or oral contraception using birth control pills with high estrogen content; (6) disseminated cancer; and (7) primary disorders of hypercoagulability (e.g., factor V Leiden) (Chapter 3).

The pathophysiologic consequences of thromboembolism in the lung depend largely on the size of the embolus, which in turn dictates the size of the occluded pulmonary artery, and on the cardiopulmonary status of the patient. There are two important consequences of embolic pulmonary arterial occlusion: (1) an increase in pulmonary artery pressure from blockage of flow and, possibly, vasospasm caused by neurogenic mechanisms and/or release of mediators (e.g., thromboxane $A_2$, serotonin); and (2) ischemia of the downstream pulmonary parenchyma. Thus, occlusion of a *major vessel* results in a sudden increase in pulmonary artery pressure, diminished cardiac output, right-sided heart failure (*acute cor pulmonale*), or even death. Usually hypoxemia also develops, as a result of multiple mechanisms:

- *Perfusion of lung zones that have become atelectatic.* The alveolar collapse occurs in the ischemic areas because of a reduction in surfactant production and because pain associated with embolism leads to reduced movement of the chest wall; in addition, some of the pulmonary blood flow is redirected through areas of the lung that normally are hypoventilated.
- The decrease in cardiac output causes a *widening of the difference in arterial-venous oxygen saturation.*
- *Right-to-left shunting* of blood may occur through a patent foramen ovale, present in 30% of normal persons.
- If *smaller vessels* are occluded, the result is less catastrophic, and the event may even be clinically silent.

Recall that the lungs are oxygenated not only by the pulmonary arteries but also by bronchial arteries and directly from air in the alveoli. Thus, ischemic necrosis (infarction) is the exception rather than the rule, occurring in as few as 10% of patients with thromboemboli. It occurs only if there is compromise in cardiac function or bronchial circulation, or if the region of the lung at risk is underventilated as a result of underlying pulmonary disease.

#### MORPHOLOGY

The morphologic consequences of pulmonary embolism, as noted, depend on the size of the embolic mass and the general state of the circulation. A large embolus may embed in the main pulmonary artery or its major branches or lodge astride the bifurcation as a **saddle embolus** (Fig. 12–26). Death usually follows so suddenly from hypoxia or acute failure of the right side of the heart (acute cor pulmonale) that there is no time for morphologic alterations in the lung. Smaller emboli become impacted in medium-sized and small pulmonary arteries. With adequate circulation and bronchial arterial flow, the vitality of the lung parenchyma is maintained, but alveolar hemorrhage may occur as a result of ischemic damage to the endothelial cells.

With compromised cardiovascular status, as may occur with congestive heart failure, **infarction** results. The more peripheral the embolic occlusion, the higher the risk of infarction. About three fourths of all infarcts affect the lower lobes, and more than half are multiple. Characteristically, they are wedge-shaped, with their base at the pleural surface and the apex pointing toward the hilus of the lung. Pulmonary infarcts typically are hemorrhagic and appear as raised, red-blue areas in the early stages (Fig. 12–27). The adjacent pleural surface often is covered by a fibrinous exudate. If the occluded vessel can be identified, it usually is found near the apex of the infarcted area. The red cells begin to lyse within 48 hours, and the infarct pales, eventually becoming red-brown as hemosiderin is produced. In time, fibrous replacement begins at the margins as a gray-white peripheral zone and eventually converts the infarct into a scar. On histologic examination, the hallmark of fresh infarcts is coagulative necrosis of the lung parenchyma and hemorrhage.

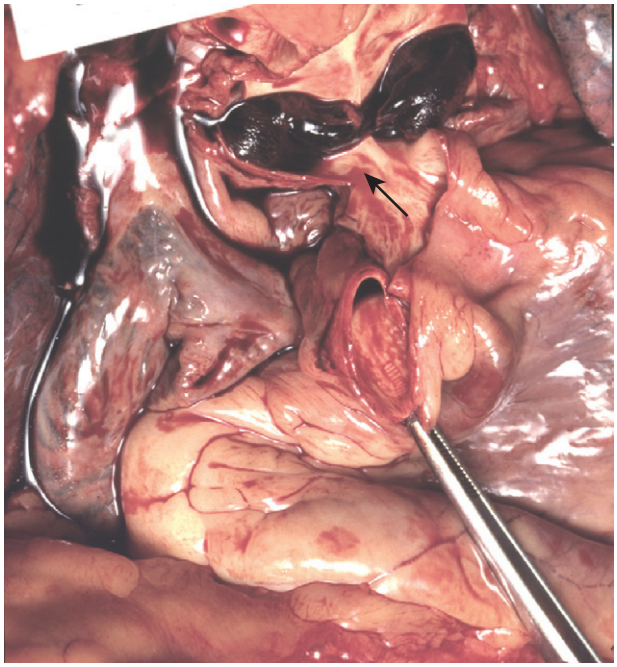

**Figure 12–26** Large saddle embolus from the femoral vein lying astride the main left and right pulmonary arteries.
*(Courtesy of Dr. Linda Margraf, Department of Pathology, University of Texas Southwestern Medical School, Dallas, Texas.)*

### Clinical Features

The clinical consequences of pulmonary thromboembolism are summarized as follows:

- Most pulmonary emboli (60% to 80%) are clinically silent because they are small; the embolic mass is rapidly removed by fibrinolytic activity, and the bronchial circulation sustains the viability of the affected lung parenchyma until this is accomplished.
- In 5% of cases, sudden death, acute right-sided heart failure (acute cor pulmonale), or cardiovascular collapse (shock) may occur typically when more than 60% of the total pulmonary vasculature is obstructed by a large embolus or multiple simultaneous small emboli. Massive pulmonary embolism is one of the few causes of literally instantaneous death, even before the person experiences chest pain or dyspnea.
- Obstruction of relatively small to medium pulmonary branches (10% to 15% of cases) that behave as end arteries causes pulmonary infarction when some element of circulatory insufficiency is present. Typically, persons who sustain such infarction manifest dyspnea.
- In a small but significant subset of patients (accounting for less than 3% of cases), recurrent multiple emboli lead to pulmonary hypertension, chronic right-sided heart strain (chronic cor pulmonale), and, in time, pulmonary vascular sclerosis with progressively worsening dyspnea.

Emboli usually resolve after the initial acute event. They contract, and endogenous fibrinolytic activity may cause total lysis of the thrombus. However, in the presence of an underlying predisposing factor, a small, innocuous embolus may presage a larger one, and *patients who have experienced one pulmonary embolism have a 30% chance of developing a second.* Prophylactic therapy may include anticoagulation, early ambulation for postoperative and postparturient patients, application of elastic stockings, intermittent pneumatic calf compression, and isometric leg exercises for bedridden patients. Patients with pulmonary embolism are given anticoagulation therapy. Patients with massive pulmonary embolism are candidates for thrombolytic therapy.

Nonthrombotic forms of pulmonary embolism include several uncommon but potentially lethal forms, such as air, fat, and amniotic fluid embolism (Chapter 3). Intravenous drug abuse often is associated with foreign body embolism in the pulmonary microvasculature; the presence of magnesium trisilicate (talc) in the intravenous mixture elicits a granulomatous response within the interstitium or pulmonary arteries. Involvement of the interstitium may lead to fibrosis, while the latter leads to pulmonary hypertension. Residual talc crystals can be demonstrated within the granulomas using polarized light. Bone marrow embolism (presence of hematopoietic and fat elements within pulmonary circulation) can occur after massive trauma and in patients with bone infarction secondary to sickle cell anemia.

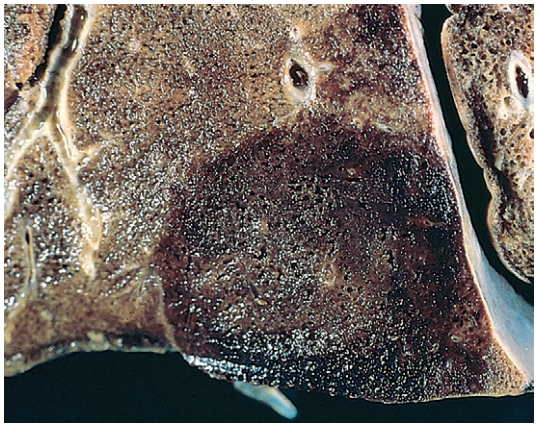

**Figure 12–27** A small, roughly wedge-shaped hemorrhagic pulmonary infarct of recent occurrence.

## SUMMARY

### Pulmonary Embolism

- Almost all large pulmonary artery thrombi are embolic in origin, usually arising from the deep veins of the lower leg.
- Risk factors include prolonged bedrest, leg surgery, severe trauma, CHF, use of oral contraceptives (especially those with high estrogen content), disseminated cancer, and genetic causes of hypercoagulability.
- The vast majority (60% to 80%) of emboli are clinically silent, a minority (5%) cause acute cor pulmonale, shock, or death (typically from large "saddle emboli"), and the remaining cause pulmonary infarction.
- Risk of recurrence is high.

## Pulmonary Hypertension

The pulmonary circulation normally is one of low resistance; pulmonary blood pressures are only about one eighth of systemic pressures. Pulmonary hypertension (when mean pulmonary pressures reach one fourth or more of systemic levels) is most often *secondary* to a decrease in the cross-sectional area of the pulmonary vascular bed, or to increased pulmonary vascular blood flow. The causes of secondary pulmonary hypertension include:

- *Chronic obstructive or interstitial lung disease,* which is accompanied by destruction of lung parenchyma and consequent reduction in alveolar capillaries. This causes increased pulmonary arterial resistance and secondarily, elevated arterial pressure.
- *Recurrent pulmonary emboli.* Presence of these emboli leads to a reduction in the functional cross-sectional area of the pulmonary vascular bed, leading in turn to increased vascular resistance.
- *Antecedent heart disease,* for example, *mitral stenosis,* which increases left atrial pressure, leading to higher pulmonary venous pressures, and ultimately pulmonary arterial hypertension. *Congenital left-to-right shunts* are another cause of secondary pulmonary hypertension.

Uncommonly, pulmonary hypertension exists even though all known causes of increased pulmonary pressure have been excluded; this is referred to as *primary,* or *idiopathic, pulmonary arterial hypertension.* Of these, the vast majority of cases are sporadic, and only 6% are familial with an autosomal dominant mode of inheritance.

### PATHOGENESIS

According to current thinking, **pulmonary endothelial cell and/or vascular smooth muscle dysfunction** is the probable underlying basis for most forms of pulmonary hypertension.

- In states of **secondary pulmonary hypertension,** endothelial cell dysfunction arises as a consequence of the underlying disorder (e.g., shear and mechanical injury due to increased blood flow in left-to-right shunts, or biochemical injury produced by fibrin in recurrent thromboembolism). Endothelial cell dysfunction reduces production of vasodilatory agents (e.g., nitric oxide, prostacyclin) while increasing synthesis of vasoconstrictive mediators like endothelin. In addition, there is production of growth factors and cytokines that induce the migration and replication of vascular smooth muscle and elaboration of extracellular matrix.
- In **primary pulmonary hypertension,** especially in the uncommon **familial form,** the TGF-β signaling pathway has emerged as a key mediator of endothelial and smooth muscle dysfunction. Specifically, germline mutations of **bone morphogenetic protein receptor type 2** (BMPR-2), a cell surface molecule that binds to a variety of TGF-β pathway ligands, have been demonstrated in 50% of familial cases. The *BMPR2* gene product is inhibitory in its effects on proliferation; hence, loss-of-function mutations of this gene result in abnormal vascular endothelial and pulmonary smooth muscle proliferation. The endothelial proliferations in these instances usually are **monoclonal,** reiterating the genetic basis of their origin. However, not all persons with germline mutations of *BMPR2* develop primary pulmonary hypertension, suggesting the existence of **modifier genes** that probably affect penetrance of this particular phenotype.
- Studies on sporadic forms of primary pulmonary hypertension point to a possible role for the **serotonin transporter gene** (*5HTT*). Specifically, pulmonary smooth muscle cells from some patients with primary pulmonary hypertension demonstrate increased proliferation on exposure to serotonin or serum. Genetic polymorphisms of *5HTT* that lead to enhanced expression of the transporter protein on vascular smooth muscle are postulated to cause their proliferation.

### MORPHOLOGY

Vascular alterations in all forms of pulmonary hypertension (primary and secondary) involve the entire arterial tree (Fig. 12–28) and include (1) in the **main elastic arteries,** atheromas similar to those in systemic atherosclerosis; (2) **in medium-sized muscular arteries,** proliferation of myointimal cells and smooth muscle cells, causing thickening of the intima and media with narrowing of the lumina; and (3) in **smaller arteries and arterioles,** thickening, medial hypertrophy, and reduplication of the internal and external elastic membranes. In these vessels, the wall thickness may exceed the diameter of the lumen, which is sometimes narrowed to the point of near-obliteration. Persons with idiopathic pulmonary arterial hypertension have characteristic **plexiform lesions,** in which endothelial proliferation forms multiple lumina within small arteries where they branch from a medium-sized artery.

### Clinical Features

Secondary pulmonary hypertension may develop at any age. The clinical features reflect the underlying disease, usually pulmonary or cardiac, with accentuation of respiratory insufficiency and right-sided heart strain. Primary pulmonary hypertension, on the other hand, is almost always encountered in young adults, more commonly women, and is marked by fatigue, syncope (particularly on exercise), dyspnea on exertion, and sometimes chest pain. Eventually severe respiratory insufficiency and cyanosis develop, and death usually results from right-sided heart failure (decompensated cor pulmonale) within 2 to 5 years of diagnosis. Some amelioration of the respiratory distress can be achieved by vasodilators and antithrombotic agents, and continuous prostacyclin infusions may prolong life (months to years), but without lung transplantation the prognosis is still grim.

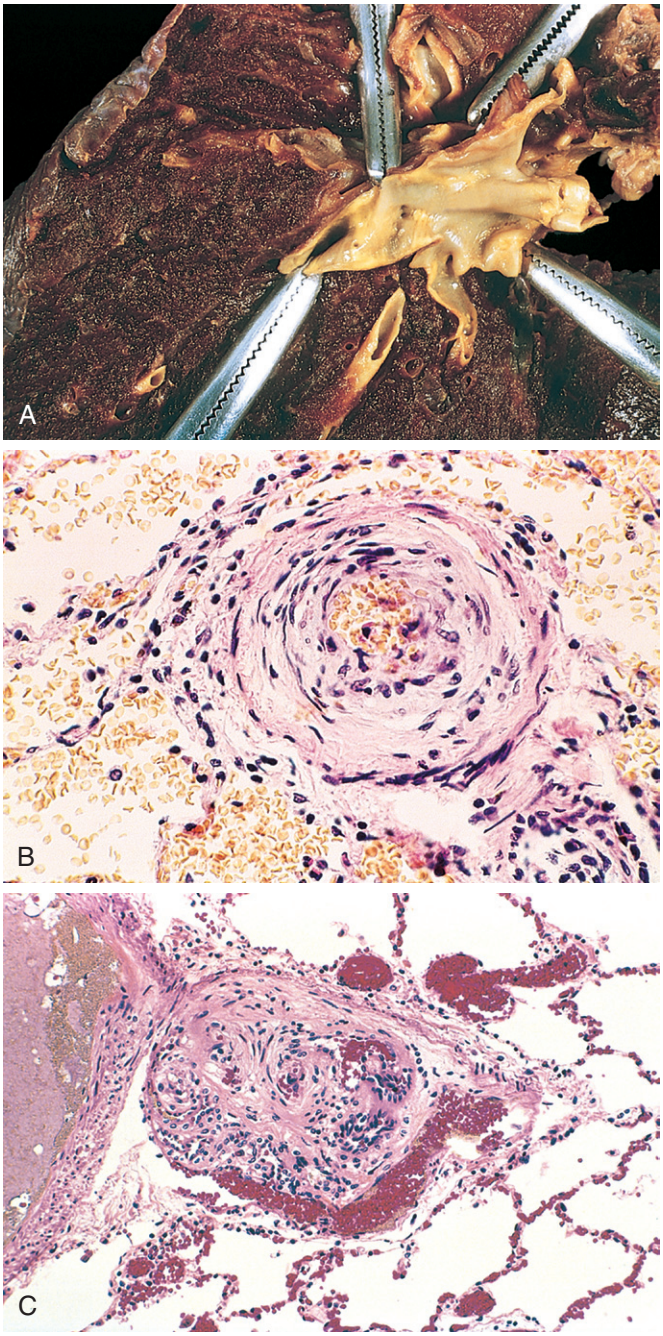


**Figure 12–28** Vascular changes in pulmonary hypertension. **A,** Gross photograph of atheroma, a finding usually limited to large vessels. **B,** Marked medial hypertrophy. **C,** Plexiform lesion characteristic of advanced pulmonary hypertension seen in small arteries.

## Diffuse Alveolar Hemorrhage Syndromes

While there may be several "secondary" causes of pulmonary hemorrhage (necrotizing bacterial pneumonia, passive venous congestion, bleeding diathesis), the diffuse alveolar hemorrhage syndromes constitute a group of "primary" immune-mediated diseases that manifest as the *triad of hemoptysis, anemia, and diffuse pulmonary infiltrates.*

### *Goodpasture Syndrome*

Goodpasture syndrome, the prototype disorder of this group, is an uncommon but intriguing condition characterized by a *proliferative, usually rapidly progressive, glomerulonephritis* (Chapter 13) and *hemorrhagic interstitial pneumonitis.* Both the renal and the pulmonary lesions are caused by antibodies targeted against the noncollagenous domain of the α3 chain of collagen IV. These antibodies can be detected in the serum of more than 90% of persons with Goodpasture syndrome.

#### MORPHOLOGY

The lungs are heavy, with areas of red-brown consolidation, due to **diffuse alveolar hemorrhage.** Microscopic examination demonstrates focal necrosis of alveolar walls associated with intra-alveolar hemorrhages, fibrous thickening of the septa, and hypertrophic type II pneumocytes. Presence of **hemosiderin,** both within macrophages and extracellularly, is characteristic, indicating earlier episode(s) of hemorrhage (Fig. 12–29). The characteristic **linear pattern of immunoglobulin deposition** (usually IgG, sometimes IgA or IgM) that is the hallmark diagnostic finding in renal biopsy specimens (Chapter 13) also may be seen along the alveolar septa.

Plasmapheresis and immunosuppressive therapy have markedly improved the once-dismal prognosis for this disease. Plasma exchange removes offending antibodies, and immunosuppressive drugs inhibit antibody production. With severe renal disease, renal transplantation is eventually required.

### *Idiopathic Pulmonary Hemosiderosis*

Idiopathic pulmonary hemosiderosis is a rare disease of uncertain etiology that has pulmonary manifestations and histologic features similar to those of Goodpasture syndrome, but there is no associated renal disease or circulating anti-basement membrane antibody. Most cases occur in children, although the disease is reported in adults as well, who have a better prognosis. With steroid and immunosuppressive therapy, survival has markedly improved from the historical 2.5 years; thus, an immune-mediated etiology is postulated.

### *Pulmonary Angiitis and Granulomatosis (Wegener Granulomatosis)*

More than 80% of patients with Wegener granulomatosis (WG) develop upper respiratory or pulmonary manifestations at some time in the course of their disease. It is described in Chapter 9. Here we list the salient pulmonary features. The lung lesions are characterized by a combination of necrotizing vasculitis ("angiitis") and parenchymal necrotizing granulomatous inflammation. The manifestations of WG can include both upper respiratory symptoms (chronic sinusitis, epistaxis, nasal perforation) and pulmonary signs and symptoms (cough, hemoptysis, chest pain). PR3-ANCAs are present in close to 95% of cases (Chapter 9).

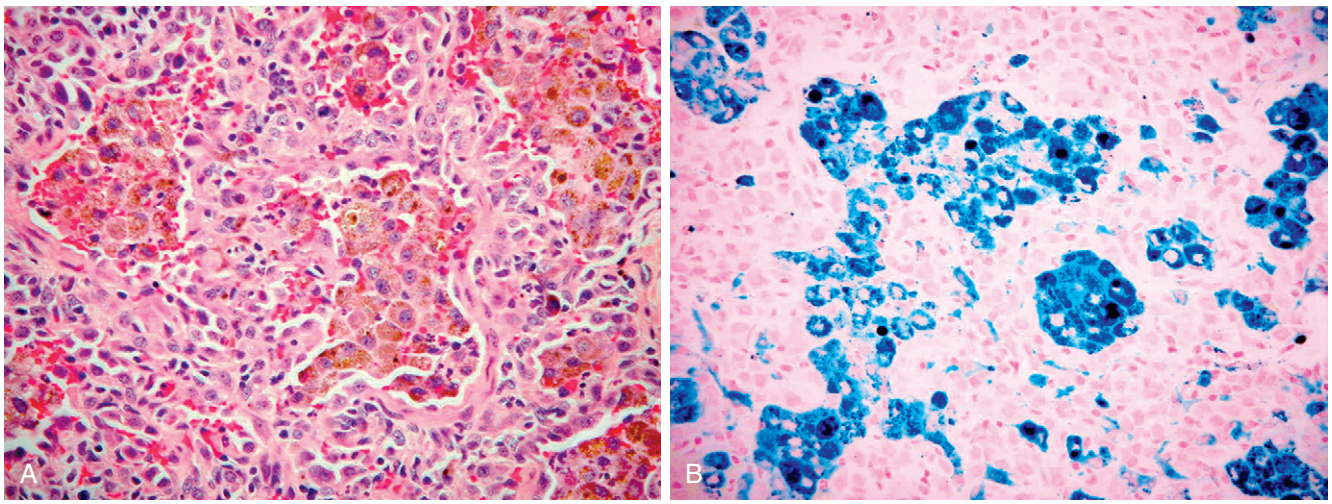

**Figure 12–29 A,** Lung biopsy specimen from a person with a diffuse alveolar hemorrhage syndrome demonstrates large numbers of intra-alveolar hemosiderin-laden macrophages on a background of thickened fibrous septa. **B,** The tissue has been stained with Prussian blue, an iron stain that highlights the abundant intracellular hemosiderin.

*(From the Teaching Collection of the Department of Pathology, Children's Medical Center, Dallas, Texas.)*

## PULMONARY INFECTIONS

Pulmonary infections in the form of pneumonia are responsible for one sixth of all deaths in the United States. This is not surprising because (1) the epithelial surfaces of the lung are constantly exposed to many liters of air containing various levels of microbial contaminants; (2) nasopharyngeal flora are regularly aspirated during sleep, even by healthy persons; and (3) other common lung diseases render the lung parenchyma vulnerable to virulent organisms. The normal lung parenchyma remains sterile because of the efficiency of a number of immune and nonimmune defense mechanisms in the respiratory system, extending from the nasopharynx all the way into the alveolar air spaces (Fig. 12–30).

Despite the multitude of defense mechanisms, "chinks in the armor" do exist, predisposing even healthy persons to infections. Defects in innate immunity (including neutrophil and complement defects) and humoral immunodeficiency typically lead to an increased incidence of infections with pyogenic bacteria. For example, it has been shown that patients with mutations in MyD88, the adaptor protein downstream of many Toll-like receptors (microbial sensors in innate immunity), are extremely susceptible to severe necrotizing pneumococcal infections (and not most other infections). On the other hand, defects in $T_H1$ cell–mediated immunity lead mainly to increased infections with intracellular microbes such as atypical mycobacteria. In addition to inherited anomalies, several aspects of lifestyle interfere with host immune defense mechanisms and facilitate infections. For example, cigarette smoke compromises mucociliary clearance and pulmonary macrophage activity, and alcohol not only impairs cough and epiglottic reflexes, thereby increasing the risk of aspiration, but also interferes with neutrophil mobilization and chemotaxis.

*Pneumonia can be very broadly defined as any infection in the lung.* The clinical presentation may be as an acute, fulminant clinical disease or as a chronic disease with a more protracted course. The histologic spectrum of pneumonia may range from a fibrinopurulent alveolar exudate seen in acute bacterial pneumonias, to mononuclear interstitial infiltrates in viral and other atypical pneumonias, to granulomas and cavitation seen in many of the chronic pneumonias. Acute bacterial pneumonias can manifest as one of two anatomic and radiographic patterns, referred to as *bronchopneumonia* and *lobar pneumonia*. Bronchopneumonia implies a patchy distribution of inflammation that generally involves more than one lobe (Fig. 12–31). This pattern results from an initial infection of the bronchi and bronchioles with extension into the adjacent alveoli. By contrast, in lobar pneumonia the contiguous air spaces of part or all of a lobe are homogeneously filled with an exudate that can be visualized on radiographs as a lobar or segmental consolidation (Fig. 12–31). *Streptococcus pneumoniae* is responsible for more than 90% of lobar pneumonias. The anatomic distinction between lobar pneumonia and bronchopneumonia can often become blurry, because (1) many organisms cause infections that can manifest with either of the two patterns of distribution, and (2) confluent bronchopneumonia can be hard to distinguish radiologically from lobar pneumonia. *Therefore, it is best to classify pneumonias either by the specific etiologic agent or, if no pathogen can be isolated, by the clinical setting in which infection occurs.* The latter approach considerably narrows the list of suspected pathogens for administering empirical antimicrobial therapy. Pneumonia can arise in seven distinct clinical settings, and the implicated pathogens are reasonably specific to each category, as summarized in Table 12–6.

### Community-Acquired Acute Pneumonias

Most community-acquired acute pneumonias are bacterial in origin. Not uncommonly, the infection follows a viral upper respiratory tract infection. The onset usually is abrupt, with high fever, shaking chills, pleuritic chest pain,

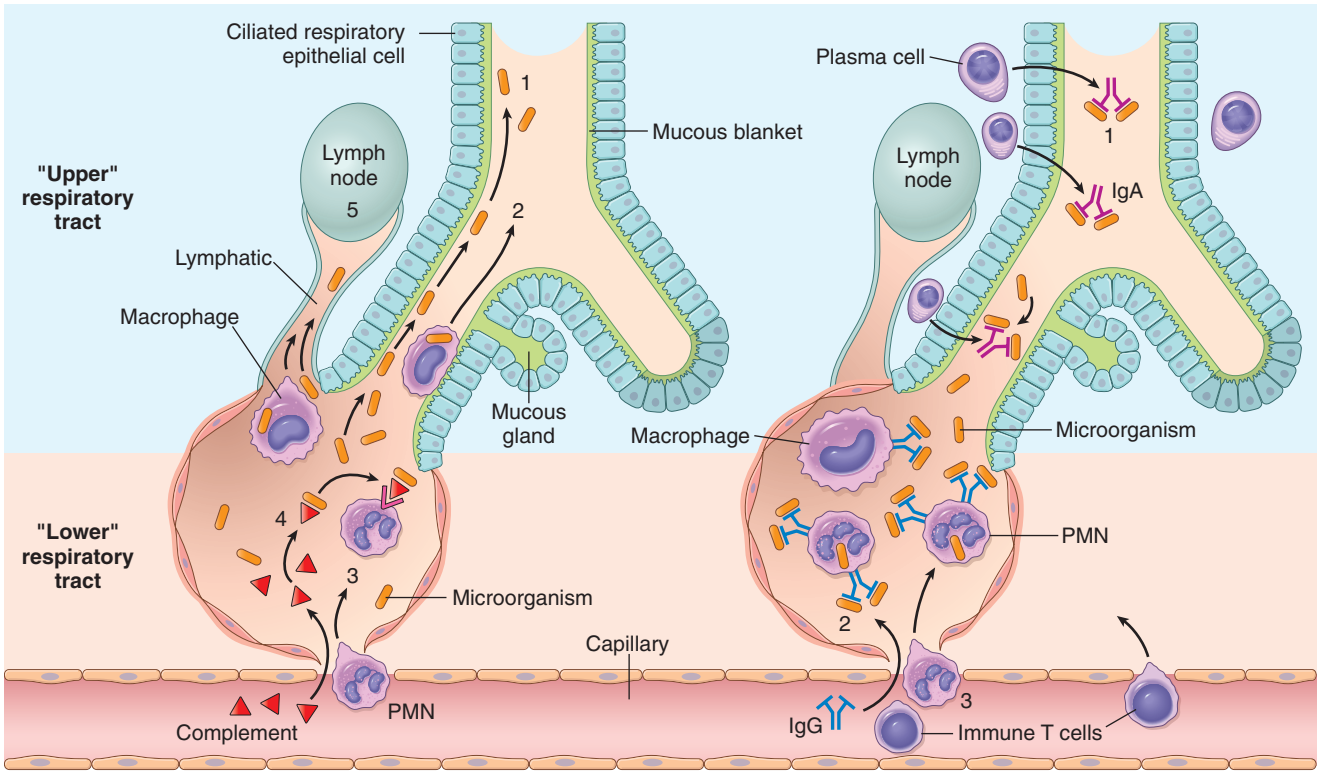


**Figure 12–30** Lung defense mechanisms. **A,** Innate defenses against infection: *1*, In the normal lung, removal of microbial organisms depends on entrapment in the mucous blanket and removal by means of the mucociliary elevator; *2*, phagocytosis by alveolar macrophages that can kill and degrade organisms and remove them from the air spaces by migrating onto the mucociliary elevator; or *3*, phagocytosis and killing by neutrophils recruited by macrophage factors. *4*, Serum complement may enter the alveoli and be activated by the alternative pathway to provide the opsonin C3b, which enhances phagocytosis. *5*, Organisms, including those ingested by phagocytes, may reach the draining lymph nodes to initiate immune responses. **B,** Additional mechanisms operate after development of adaptive immunity. *1*, Secreted IgA can block attachment of the microorganism to epithelium in the upper respiratory tract. *2*, In the lower respiratory tract, serum antibodies (IgM, IgG) are present in the alveolar lining fluid. They activate complement more efficiently by the classic pathway, yielding C3b *(not shown)*. In addition, IgG is opsonic. *3*, The accumulation of immune T cells is important for controlling infections by viruses and other intracellular microorganisms. PMN, polymorphonuclear cell.

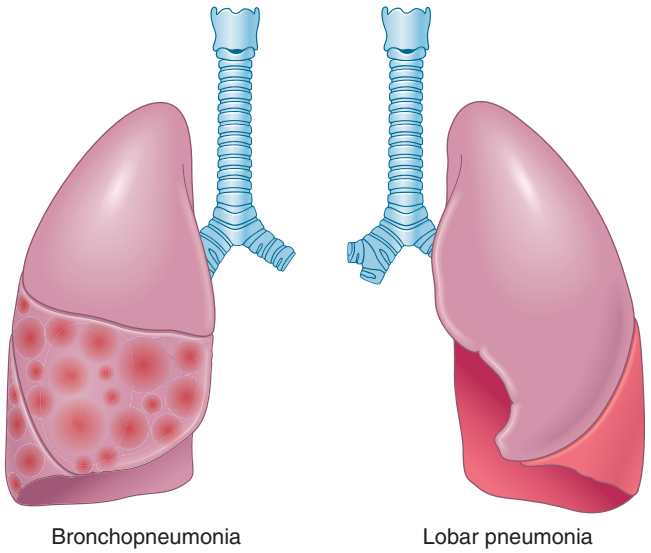


**Figure 12–31** The anatomic distribution of bronchopneumonia and lobar pneumonia.

and a productive mucopurulent cough; occasional patients may have hemoptysis. *S. pneumoniae* (i.e., the pneumococcus) is the most common cause of community-acquired acute pneumonia; hence, pneumococcal pneumonia is discussed as the prototype for this subgroup.

### Streptococcus pneumoniae *Infections*

*Pneumococcal infections occur with increased frequency in three subsets of patients:* (1) those with underlying chronic diseases such as CHF, COPD, or diabetes; (2) those with either congenital or acquired immunoglobulin defects (e.g., with the acquired immune deficiency syndrome [AIDS]); and (3) those with decreased or absent splenic function (e.g., sickle cell disease or after splenectomy). In the last group, such infections are more likely because the spleen contains the largest collection of phagocytes and is therefore the major organ responsible for removing pneumococci from the blood. The spleen is also an important organ for production of antibodies against polysaccharides, which are the dominant protective antibodies against encapsulated bacteria.

**Table 12–6** The Pneumonia Syndromes and Implicated Pathogens

| |
|---|
| **Community-Acquired Acute Pneumonia** |
| *Streptococcus pneumoniae* |
| *Haemophilus influenzae* |
| *Moraxella catarrhalis* |
| *Staphylococcus aureus* |
| *Legionella pneumophila* |
| Enterobacteriaceae *(Klebsiella pneumoniae)* and Pseudomonas spp. |
| **Community-Acquired Atypical Pneumonia** |
| *Mycoplasma pneumoniae* |
| Chlamydia spp.—Chlamydia pneumoniae, Chlamydia psittaci, Chlamydia trachomatis |
| Coxiella burnetii (Q fever) |
| Viruses: respiratory syncytial virus, human metapneumovirus, parainfluenza virus (children); influenza A and B (adults); adenovirus (military recruits) |
| **Nosocomial Pneumonia** |
| Gram-negative rods belonging to Enterobacteriaceae (*Klebsiella* spp., *Serratia marcescens, Escherichia coli*) and *Pseudomonas* spp. |
| *S. aureus* (usually methicillin-resistant) |
| **Aspiration Pneumonia** |
| Anaerobic oral flora (*Bacteroides, Prevotella, Fusobacterium, Peptostreptococcus*), admixed with aerobic bacteria (*S. pneumoniae, S. aureus, H. influenzae,* and *Pseudomonas aeruginosa*) |
| **Chronic Pneumonia** |
| *Nocardia* |
| *Actinomyces* |
| Granulomatous: *Mycobacterium tuberculosis* and atypical mycobacteria, *Histoplasma capsulatum, Coccidioides immitis, Blastomyces dermatitidis* |
| **Necrotizing Pneumonia and Lung Abscess** |
| Anaerobic bacteria (extremely common), with or without mixed aerobic infection |
| *S. aureus, K. pneumoniae, Streptococcus pyogenes,* and type 3 pneumococcus (uncommon) |
| **Pneumonia in the Immunocompromised Host** |
| Cytomegalovirus |
| *Pneumocystis jiroveci* |
| *Mycobacterium avium* complex (MAC) |
| Invasive aspergillosis |
| Invasive candidiasis |
| "Usual" bacterial, viral, and fungal organisms (listed above) |

## MORPHOLOGY

With pneumococcal lung infection, either pattern of pneumonia, lobar or bronchopneumonia, may occur; the latter is much more prevalent at the extremes of age. Regardless of the distribution of the pneumonia, because pneumococcal lung infections usually are acquired by aspiration of pharyngeal flora (20% of adults harbor *S. pneumoniae* in the throat), the lower lobes or the right middle lobe is most frequently involved.

In the era before antibiotics, pneumococcal pneumonia involved entire or almost entire lobes and evolved through four stages: **congestion, red hepatization, gray hepatization,** and **resolution.** Early antibiotic therapy alters or halts this typical progression.

During the first stage, that of **congestion,** the affected lobe(s) is (are) heavy, red, and boggy; histologically, vascular congestion can be seen, with proteinaceous fluid, scattered neutrophils, and many bacteria in the alveoli. Within a few days, the stage of **red hepatization** ensues, in which the lung lobe has a liver-like consistency; the alveolar spaces are packed with neutrophils, red cells, and fibrin (Fig. 12–32, *A*). In the next stage, **gray hepatization,** the lung is dry, gray, and firm, because the red cells are lysed, while the fibrinosuppurative exudate persists within the alveoli (Fig. 12–33; see also Fig. 12–32, *B*). **Resolution** follows in uncomplicated cases, as exudates within the alveoli are enzymatically digested to produce granular, semifluid debris that is resorbed, ingested by macrophages, coughed up, or organized by fibroblasts growing into it (Fig. 12–32, *C*). The pleural reaction (fibrinous or fibrinopurulent **pleuritis**) may similarly resolve or undergo organization, leaving fibrous thickening or permanent adhesions.

In the **bronchopneumonic** pattern, foci of inflammatory consolidation are distributed in patches throughout one or several lobes, most frequently bilateral and basal. Well-developed lesions up to 3 or 4 cm in diameter are slightly elevated and are gray-red to yellow; confluence of these foci may occur in severe cases, producing the appearance of a lobar consolidation. The lung substance immediately surrounding areas of consolidation is usually hyperemic and edematous, but the large intervening areas are generally normal. Pleural involvement is less common than in lobar pneumonia. Histologically, the reaction consists of focal suppurative exudate that fills the bronchi, bronchioles, and adjacent alveolar spaces.

With appropriate therapy, complete restitution of the lung is the rule for both forms of pneumococcal pneumonia, but in occasional cases complications may occur: (1) tissue destruction and necrosis may lead to **abscess** formation; (2) suppurative material may accumulate in the pleural cavity, producing an **empyema;** (3) organization of the intra-alveolar exudate may convert areas of the lung into solid fibrous tissue; and (4) bacteremic dissemination may lead to **meningitis, arthritis,** or **infective endocarditis.** Complications are much more likely with serotype 3 pneumococci.

Examination of gram-stained sputum is an important step in the diagnosis of acute pneumonia. The presence of numerous neutrophils containing the typical gram-positive, lancet-shaped diplococci is good evidence of pneumococcal pneumonia; of note, however, *S. pneumoniae* is a part of the endogenous flora, so false-positive results may be obtained by this method. Isolation of pneumococci from blood cultures is more specific. During early phases of illness, blood cultures may be positive in 20% to 30% of persons with pneumonia. Whenever possible, antibiotic sensitivity should be determined. Commercial pneumococcal vaccines containing capsular polysaccharides from the common serotypes of the bacteria are available, and their proven efficacy mandates their use in persons at risk for pneumococcal infections (see earlier).

### *Pneumonias Caused by Other Important Pathogens*

Other organisms commonly implicated in community-acquired acute pneumonias include the following.

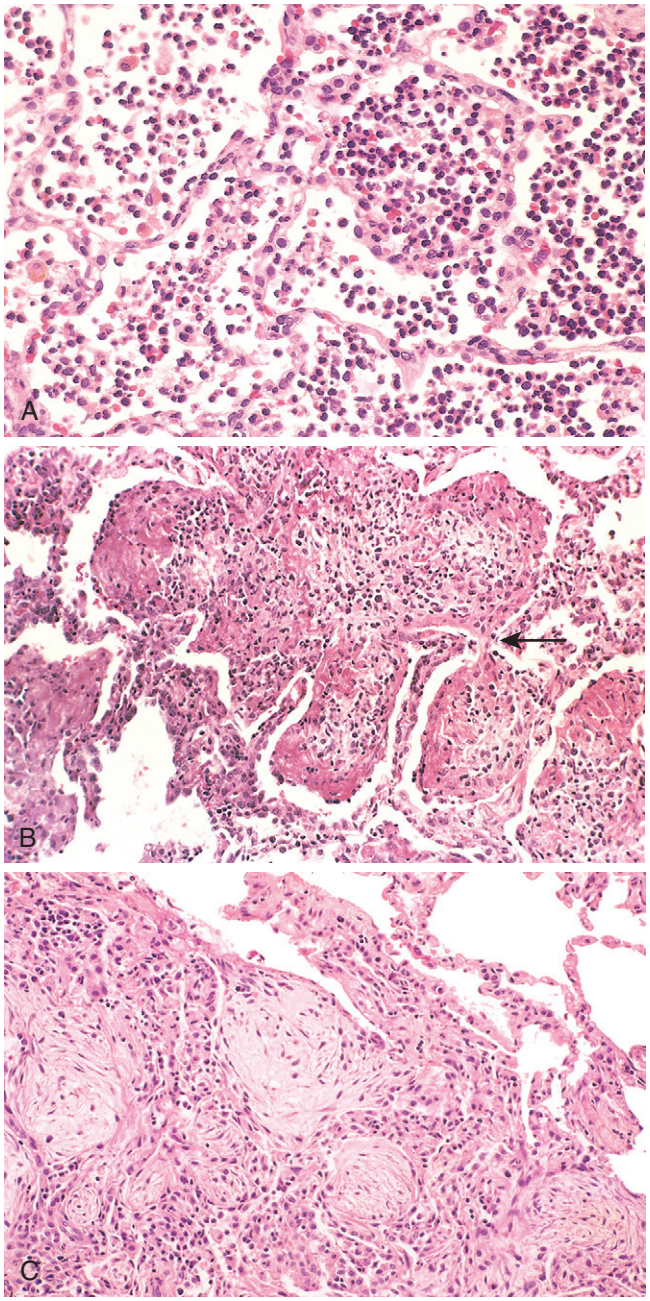


**Figure 12–32 A,** Acute pneumonia. The congested septal capillaries and extensive neutrophil exudation into alveoli correspond to early red hepatization. Fibrin nets have not yet formed. **B,** Early organization of intra-alveolar exudates, seen in areas to be streaming through the pores of Kohn (*arrow*). **C,** Advanced organizing pneumonia, featuring transformation of exudates to fibromyxoid masses richly infiltrated by macrophages and fibroblasts.

*Haemophilus influenzae*

- Both *encapsulated* and *unencapsulated* forms are important causes of community-acquired pneumonias. The former can cause a particularly life-threatening form of pneumonia in children, often after a respiratory viral infection.
- Adults at risk for developing infections include those with chronic pulmonary diseases such as chronic bronchitis, cystic fibrosis, and bronchiectasis. *H. influenzae is the most common bacterial cause of acute exacerbation of COPD.*
- Encapsulated *H. influenzae* type b was formerly an important cause of epiglottitis and suppurative meningitis in children, but vaccination against this organism in infancy has significantly reduced the risk.

*Moraxella catarrhalis*

- *M. catarrhalis* is being increasingly recognized as a cause of bacterial pneumonia, especially in elderly persons.
- It is the second most common bacterial cause of acute exacerbation of COPD in adults.
- Along with *S. pneumoniae* and *H. influenzae, M. catarrhalis* constitutes one of the three most common causes of otitis media (infection of the middle ear) in children.

*Staphylococcus aureus*

- *S. aureus* is an important cause of secondary bacterial pneumonia in children and healthy adults after viral respiratory illnesses (e.g., measles in children and influenza in both children and adults).
- Staphylococcal pneumonia is associated with a high incidence of complications, such as lung abscess and empyema.
- Staphylococcal pneumonia occurring in association with right-sided staphylococcal endocarditis is a serious complication of *intravenous drug abuse.*
- It is also an important cause of nosocomial pneumonia (discussed later).

*Klebsiella pneumoniae*

- *K. pneumoniae* is the most frequent cause of gram-negative bacterial pneumonia.

**Figure 12–33** Gross view of lobar pneumonia with gray hepatization. The lower lobe is uniformly consolidated.

- *Klebsiella*-related pneumonia frequently afflicts debilitated and malnourished persons, particularly *chronic alcoholics.*
- Thick and gelatinous sputum is characteristic, because the organism produces an abundant viscid capsular polysaccharide, which the patient may have difficulty coughing up.

*Pseudomonas aeruginosa*

- Although discussed here with community-acquired pathogens because of its association with infections in cystic fibrosis, *P. aeruginosa* most commonly is seen in nosocomial settings (discussed later).
- *Pseudomonas* pneumonia also is common in persons who are neutropenic, usually secondary to chemotherapy; in victims of extensive burns; and in patients requiring mechanical ventilation.
- *P. aeruginosa* has a propensity to invade blood vessels at the site of infection, with consequent extrapulmonary spread; *Pseudomonas* bacteremia is a fulminant disease, with death often occurring within a matter of days.
- Histologic examination reveals coagulative necrosis of the pulmonary parenchyma with organisms invading the walls of necrotic blood vessels (*Pseudomonas* vasculitis).

*Legionella pneumophila*

- *L. pneumophila* is the agent of Legionnaire disease, an eponym for the epidemic and sporadic forms of pneumonia caused by this organism. Pontiac fever is a related self-limited upper respiratory tract infection caused by *L. pneumophila,* without pneumonic symptoms.
- *L. pneumophila* flourishes in artificial aquatic environments, such as water-cooling towers and within the tubing system of domestic (potable) water supplies. The mode of transmission is thought to be either inhalation of aerosolized organisms or aspiration of contaminated drinking water.
- *Legionella* pneumonia is common in persons with some predisposing condition such as cardiac, renal, immunologic, or hematologic disease. *Organ transplant recipients are particularly susceptible.*
- *Legionella* pneumonia can be quite severe, frequently requiring hospitalization, and immunosuppressed persons may have a fatality rate of 30% to 50%.
- Rapid diagnosis is facilitated by demonstration of *Legionella* antigens in the urine or by a positive fluorescent antibody test on sputum samples; culture remains the standard diagnostic modality. PCR-based tests can be used on bronchial secretions in atypical cases.

## Community-Acquired Atypical Pneumonias

The term *primary atypical pneumonia* initially was applied to an acute febrile respiratory disease characterized by patchy inflammatory changes in the lungs, largely confined to the alveolar septa and pulmonary interstitium. The designation *atypical* denotes the moderate amounts of sputum, absence of physical findings of consolidation, only moderate elevation of white cell count, and lack of alveolar exudates. Atypical pneumonia is caused by a variety of organisms, *Mycoplasma pneumoniae* being the most common. *Mycoplasma* infections are particularly common among children and young adults. They occur sporadically or as local epidemics in closed communities (schools, military camps, prisons). Other etiologic agents are *viruses,* including influenza types A and B, the respiratory syncytial viruses, human metapneumovirus, adenovirus, rhinoviruses, rubeola virus, and varicella virus, and *Chlamydia pneumoniae* and *Coxiella burnetii* (the agent of Q fever) (Table 12–6). Nearly all of these agents can also cause a primarily upper respiratory tract infection ("common cold").

The common pathogenetic mechanism is attachment of the organisms to the respiratory epithelium followed by necrosis of the cells and an inflammatory response. When the process extends to alveoli, there is usually *interstitial* inflammation, but some outpouring of fluid into alveolar spaces may also occur, so that on chest films the changes may mimic those of bacterial pneumonia. Damage to and denudation of the respiratory epithelium inhibits mucociliary clearance and predisposes to secondary bacterial infections. Viral infections of the respiratory tract are well known for this complication. More serious lower respiratory tract infection is more likely to occur in infants, elderly persons, malnourished patients, alcoholics, and immunosuppressed persons. Not surprisingly, viruses and mycoplasmas frequently are involved in outbreaks of infection in hospitals.

### MORPHOLOGY

Regardless of cause, the morphologic patterns in atypical pneumonias are similar. The process may be patchy, or it may involve whole lobes bilaterally or unilaterally. Macroscopically, the affected areas are red-blue, congested, and subcrepitant. On histologic examination, the **inflammatory reaction is largely confined within the walls of the alveoli** (Fig. 12–34). The septa are widened and edematous; they usually contain a mononuclear inflammatory infiltrate of lymphocytes, histiocytes, and, occasionally, plasma cells. In contrast with bacterial pneumonias, alveolar spaces in atypical pneumonias are remarkably free of cellular exudate. In severe cases, however, full-blown diffuse alveolar damage with hyaline membranes may develop. In less severe, uncomplicated cases, subsidence of the disease is followed by reconstitution of the native architecture. Superimposed bacterial infection, as expected, results in a mixed histologic picture.

### Clinical Features

The clinical course of primary atypical pneumonia is extremely varied. It may masquerade as a severe upper respiratory tract infection or "chest cold" that goes undiagnosed, or it may manifest as a fulminant, life-threatening infection in immunocompromised patients. The initial presentation usually is that of an acute, nonspecific febrile illness characterized by fever, headache, and malaise and, later, cough with minimal sputum. Because the edema and exudation are both in a strategic position to cause an alveolocapillary block, there may be *respiratory distress seemingly out of proportion to the physical and radiographic findings.*

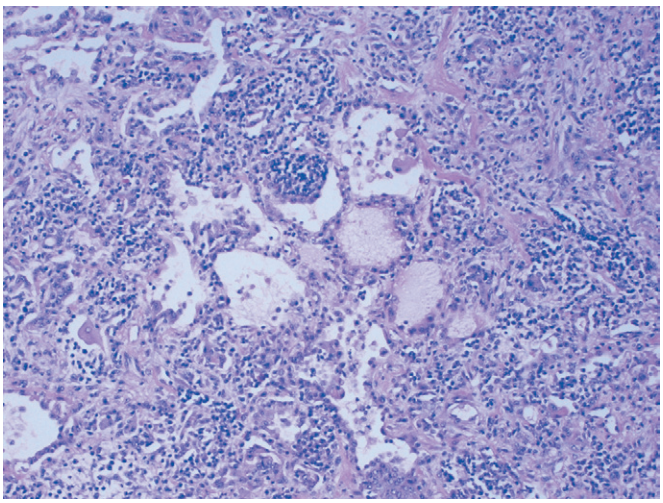

**Figure 12–34** Viral pneumonia. The thickened alveolar walls are infiltrated with lymphocytes and some plasma cells, which are spilling over into alveolar spaces. Note focal alveolar edema in the *center* and early fibrosis at *upper right*.

Identifying the causative agent can be difficult. Tests for *Mycoplasma* antigens and polymerase chain reaction (PCR) testing for *Mycoplasma* DNA are available. As a practical matter, patients with community-acquired pneumonia for which a bacterial agent seems unlikely are treated with a macrolide antibiotic effective against *Mycoplasma* and *Chlamydia pneumoniae,* because these are the most common pathogens producing treatable disease.

### *Influenza Infections*

Perhaps no other communicable disorder causes as much public distress in the developed world as the threat of an influenza epidemic. The influenza virus is a single-stranded RNA virus, bound by a nucleoprotein that determines the virus type—A, B, or C. The spherical surface of the virus is a lipid bilayer containing the viral hemagglutinin and neuraminidase, which determine the subtype (e.g., H1N1, H3N2). Host antibodies to the hemagglutinin and neuraminidase prevent and ameliorate, respectively, future infection with the influenza virus. The type A viruses infect humans, pigs, horses, and birds and are the major cause of *pandemic* and *epidemic* influenza infections. Epidemics of influenza occur through mutations of the hemagglutinin and neuraminidase antigens that allow the virus to escape most host antibodies (*antigenic drift*). Pandemics, which last longer and are more widespread than epidemics, may occur when both the hemagglutinin and neuraminidase are replaced through recombination of RNA segments with those of animal viruses, making all animals susceptible to the new influenza virus (*antigenic shift*). Commercially available influenza vaccines provide reasonable protection against the disease, especially in vulnerable infants and elderly persons. A particular subtype of avian influenza—"bird flu," caused by strain H5N1—has caused massive outbreaks in domesticated poultry in parts of Southeast Asia in the last several years; this strain is particularly dangerous, since it has the potential to "jump" to humans and thereby cause a worldwide influenza pandemic.

### *Influenza Virus Type A/H1N1 Infection*

In March 2009, a novel swine-origin influenza A virus, strain H1N1, was identified, which spread in the United States and worldwide, leading to a pandemic affecting more than half a million patients, with more than 6200 deaths by November 2009.

Most patients have only a self-limiting illness, with viral replication limited to pharynx and tracheobronchial tree. Pneumonia occurs in severe disease. Comorbid conditions such as obesity, heart disease, and COPD are seen in fatal cases. Unlike the usual seasonal influenza in which older patients are more at risk of dying, the H1N1 pandemic killed only a few patients over 60 years of age, suggesting that immunity is achieved with previous exposure. Pathologic findings at autopsy include acute tracheobronchitis, bronchiolitis, diffuse alveolar damage, pulmonary thrombosis, and alveolar hemorrhage. In addition, approximately half have bacterial superinfection.

## SUMMARY

### Acute Pneumonias

- *S. pneumoniae* (the pneumococcus) is the most common cause of community-acquired acute pneumonia, and the distribution of inflammation is usually lobar.
- Morphologically, lobar pneumonias evolve through four stages: congestion, red hepatization, gray hepatization, and resolution.
- Other common causes of acute pneumonias in the community include *H. influenzae* and *M. catarrhalis* (both associated with acute exacerbations of COPD), *S. aureus* (usually secondary to viral respiratory infections), *K. pneumoniae* (observed in patients who are chronic alcoholics), *P. aeruginosa* (seen in persons with cystic fibrosis, in burn victims, and in patients with neutropenia), and *L. pneumophila,* seen particularly in organ transplant recipients.
- In contrast with acute pneumonias, *atypical pneumonias* are characterized by respiratory distress out of proportion to the clinical and radiologic signs, and by inflammation that is predominantly confined to alveolar septa, with generally clear alveoli.
- The most common causes of atypical pneumonias include those caused by *M. pneumoniae*, viruses including influenza viruses types A and B, human metapneumovirus, *C. pneumoniae*, and *C. burnetii* (agent of Q fever).

## Hospital-Acquired Pneumonias

Nosocomial, or hospital-acquired, pneumonias are defined as pulmonary infections acquired in the course of a hospital stay. The specter of nosocomial pneumonia places an immense burden on the burgeoning costs of health care, in addition to the expected adverse impact on illness outcome. Nosocomial infections are common in hospitalized persons with severe underlying disease, those who are immunosuppressed, or those on prolonged antibiotic regimens. Those on mechanical ventilation represent a particularly high-risk group, and infections acquired in this setting

are given the distinctive designation *ventilator-associated pneumonia.* Gram-negative rods (members of Enterobacteriaceae and *Pseudomonas* spp.) and *S. aureus* are the most common isolates; unlike with community-acquired pneumonias, *S. pneumoniae* is not a major pathogen in nosocomial infections.

## Aspiration Pneumonia

Aspiration pneumonia occurs in debilitated patients or those who aspirate gastric contents either while unconscious (e.g., after a stroke) or during repeated vomiting. These patients have abnormal gag and swallowing reflexes that facilitate aspiration. The resultant pneumonia is partly chemical, resulting from the extremely irritating effects of the gastric acid, and partly bacterial. Although it is commonly assumed that anaerobic bacteria predominate, more recent studies implicate aerobes more commonly than anaerobes (Table 12–6). This type of pneumonia is often necrotizing, pursues a fulminant clinical course, and is a frequent cause of death in persons predisposed to aspiration. In those who survive, abscess formation is a common complication. Microaspiration, by contrast, occurs in many people, especially those with gastro-esophageal reflux, and may exacerbate other lung diseases but does not lead to pneumonia.

## Lung Abscess

*Lung abscess* refers to a localized area of suppurative necrosis within the pulmonary parenchyma, resulting in the formation of one or more large cavities. The term *necrotizing pneumonia* has been used to describe a similar process resulting in multiple small cavitations; necrotizing pneumonia often coexists or evolves into lung abscess, making this distinction somewhat arbitrary. The causative organism may be introduced into the lung by any of the following mechanisms:

- *Aspiration of infective material* from carious teeth or infected sinuses or tonsils, particularly likely during oral surgery, anesthesia, coma, or alcoholic intoxication and in debilitated patients with depressed cough reflexes
- *Aspiration of gastric contents,* usually accompanied by infectious organisms from the oropharynx
- *As a complication of necrotizing bacterial pneumonias,* particularly those caused by *S. aureus, Streptococcus pyogenes, K. pneumoniae, Pseudomonas* spp., and, rarely, type 3 pneumococci. Mycotic infections and bronchiectasis may also lead to lung abscesses.
- *Bronchial obstruction,* particularly with bronchogenic carcinoma obstructing a bronchus or bronchiole. Impaired drainage, distal atelectasis, and aspiration of blood and tumor fragments all contribute to the development of abscesses. An abscess may also form within an excavated necrotic portion of a tumor.
- *Septic embolism,* from septic thrombophlebitis or from infective endocarditis of the right side of the heart
- In addition, lung abscesses may result from *hematogenous spread of bacteria* in disseminated pyogenic infection. This occurs most characteristically in staphylococcal bacteremia and often results in multiple lung abscesses.

*Anaerobic bacteria are present in almost all lung abscesses,* sometimes in vast numbers, and they are the exclusive isolates in one third to two thirds of cases. The most frequently encountered anaerobes are commensals normally found in the oral cavity, principally species of *Prevotella, Fusobacterium, Bacteroides, Peptostreptococcus,* and microaerophilic streptococci.

### MORPHOLOGY

Abscesses range in diameter from a few millimeters to large cavities 5 to 6 cm across. The localization and number of abscesses depend on their mode of development. Pulmonary abscesses resulting from aspiration of infective material are much **more common on the right side** (with its more vertical airways) than on the left, and most are single. On the right side, they tend to occur in the posterior segment of the upper lobe and in the apical segments of the lower lobe, because these locations reflect the probable course of aspirated material when the patient is recumbent. Abscesses that develop in the course of pneumonia or bronchiectasis commonly are multiple, basal, and diffusely scattered. Septic emboli and abscesses arising from hematogenous seeding are commonly multiple and may affect any region of the lungs.

As the focus of suppuration enlarges, it almost inevitably ruptures into airways. Thus, the contained exudate may be partially drained, producing an air-fluid level on radiographic examination. Occasionally, abscesses rupture into the pleural cavity and produce bronchopleural fistulas, the consequence of which is **pneumothorax** or **empyema.** Other complications arise from embolization of septic material to the brain, giving rise to meningitis or brain abscess. On histologic examination, as expected with any abscess, the suppurative focus is surrounded by variable amounts of fibrous scarring and mononuclear infiltration (lymphocytes, plasma cells, macrophages), depending on the chronicity of the lesion.

### Clinical Features

The manifestations of a lung abscess are much like those of bronchiectasis and include a prominent cough that usually yields copious amounts of foul-smelling, purulent, or sanguineous sputum; occasionally, hemoptysis occurs. Spiking fever and malaise are common. Clubbing of the fingers, weight loss, and anemia may all occur. Infective abscesses occur in 10% to 15% of patients with bronchogenic carcinoma; thus, when a lung abscess is suspected in an older person, underlying carcinoma must be considered. Secondary amyloidosis (Chapter 4) may develop in chronic cases. Treatment includes antibiotic therapy and, if needed, surgical drainage. Overall, the mortality rate is in the range of 10%.

## Chronic Pneumonias

Chronic pneumonia most often is a localized lesion in an immunocompetent person, with or without regional lymph node involvement. There is typically granulomatous inflammation, which may be due to bacteria (e.g., *M. tuberculosis*) or fungi. In immunocompromised patients,

such as those with debilitating illness, on immunosuppressive regimens, or with human immunodeficiency virus (HIV) infection (see below), systemic dissemination of the causative organism, accompanied by widespread disease, is the usual presentation. Tuberculosis is by far the most important entity within the spectrum of chronic pneumonias; the World Health Organization (WHO) estimates that tuberculosis causes 6% of all deaths worldwide, *making it the most common cause of death resulting from a single infectious agent.*

### *Tuberculosis*

Tuberculosis is a communicable chronic granulomatous disease caused by *Mycobacterium tuberculosis.* It usually involves the lungs but may affect any organ or tissue in the body. Typically, the centers of tubercular granulomas undergo *caseous necrosis.*

#### Epidemiology

Among medically and economically deprived persons throughout the world, tuberculosis remains a leading cause of death. It is estimated that 1.7 billion people are infected worldwide, with 8 to 10 million new cases and 3 million deaths per year. In the Western world, deaths from tuberculosis peaked in 1800 and steadily declined throughout the 1800s and 1900s. However, in 1984 the decline in new cases stopped abruptly, a change that resulted from the increased incidence of tuberculosis in HIV-infected persons. As a consequence of intensive public health surveillance and tuberculosis prophylaxis among immunosuppressed persons, the incidence of tuberculosis in U.S.-born persons has declined since 1992. Currently, it is estimated that about 25,000 new cases with active tuberculosis arise in the United States annually, and nearly 40% of these are in immigrants from countries where tuberculosis is highly prevalent.

Tuberculosis flourishes under conditions of poverty, crowding, and chronic debilitating illness. Similarly, elderly persons, with their weakened defenses, are vulnerable. In the United States, tuberculosis is a disease of the elderly, the urban poor, patients with AIDS, and members of minority communities. African Americans, Native Americans, the Inuit (from Alaska), Hispanics, and immigrants from Southeast Asia have higher attack rates than those typical for other segments of the population. *Certain disease states also increase the risk:* diabetes mellitus, Hodgkin lymphoma, chronic lung disease (particularly silicosis), chronic renal failure, malnutrition, alcoholism, and immunosuppression. In areas of the world where HIV infection is prevalent, *it has become the single most important risk factor for the development of tuberculosis.*

It is important that *infection* be differentiated from *disease.* Infection implies seeding of a focus with organisms, which may or may not cause clinically significant tissue damage (i.e., disease). Although other routes may be involved, most infections are acquired by direct person-to-person transmission of airborne droplets of organisms from an active case to a susceptible host. In most persons, an asymptomatic focus of pulmonary infection appears that is self-limited, although uncommonly, primary tuberculosis may result in the development of fever and pleural effusions. Generally, the only evidence of infection, if any remains, is a tiny, telltale fibrocalcific nodule at the site of the infection. Viable organisms may remain dormant in such loci for decades, and possibly for the life of the host. Such persons are infected but do not have active disease and therefore cannot transmit organisms to others. Yet when their immune defenses are lowered, the infection may reactivate to produce communicable and potentially life-threatening disease.

Infection with *M. tuberculosis* typically leads to the development of delayed hypersensitivity, which can be detected by the tuberculin (Mantoux) test. About 2 to 4 weeks after the infection has begun, intracutaneous injection of 0.1 mL of PPD induces a visible and palpable induration (at least 5 mm in diameter) that peaks in 48 to 72 hours. Sometimes, more PPD is required to elicit the reaction, and unfortunately, in some responders, the standard dose may produce a large, necrotizing lesion. *A positive tuberculin skin test result* signifies cell-mediated hypersensitivity to tubercular antigens. It does not differentiate between infection and disease. A well-recognized limitation of this test is that *false-negative reactions (or skin test anergy) may be produced by certain viral infections, sarcoidosis, malnutrition, Hodgkin lymphoma, immunosuppression, and (notably) overwhelming active tuberculous disease.* False-positive reactions may result from infection by atypical mycobacteria.

About 80% of the population in certain Asian and African countries is tuberculin-positive. In contrast, in 1980, 5% to 10% of the U.S. population was positive, indicating the marked difference in rates of exposure to the tubercle bacillus. In general, 3% to 4% of previously unexposed persons acquire active tuberculosis during the first year after "tuberculin conversion," and no more than 15% do so thereafter. Thus, *only a small fraction of those who contract an infection develop active disease.*

#### Etiology

Mycobacteria are slender rods that are acid-fast (i.e., they have a high content of complex lipids that readily bind the Ziehl-Neelsen [carbol fuchsin] stain and subsequently stubbornly resist decolorization). *M. tuberculosis hominis* is responsible for most cases of tuberculosis; the reservoir of infection typically is found in persons with active pulmonary disease. Transmission usually is direct, by inhalation of airborne organisms in aerosols generated by expectoration or by exposure to contaminated secretions of infected persons. Oropharyngeal and intestinal tuberculosis contracted by drinking milk contaminated with *Mycobacterium bovis* infection is now rare in developed nations, but it is still seen in countries with tuberculous dairy cows and sales of unpasteurized milk. Other mycobacteria, particularly *Mycobacterium avium complex,* are much less virulent than *M. tuberculosis* and rarely cause disease in immunocompetent persons. However, they cause disease in 10% to 30% of patients with AIDS.

## PATHOGENESIS

The pathogenesis of tuberculosis in the previously **unexposed immunocompetent** person is centered on the development of a targeted cell-mediated immunity that confers **resistance** to the organism and results

in development of **tissue hypersensitivity** to tubercular antigens. The pathologic features of tuberculosis, such as caseating granulomas and cavitation, are the result of the destructive tissue hypersensitivity that is part and parcel of the host immune response. Because the effector cells for both processes are the same, the appearance of tissue hypersensitivity also signals the acquisition of immunity to the organism. The sequence of events from inhalation of the infectious inoculum to containment of the primary focus is illustrated in Fig. 12–35, A and B and is outlined next:

- Once a virulent strain of mycobacteria gains entry into the macrophage endosomes (a process mediated by several macrophage receptors, including the macrophage mannose receptor and complement receptors that recognize several components of the mycobacterial cell walls), the organisms are able to inhibit normal microbicidal responses by preventing the fusion of the lysosomes with the phagocytic vacuole. The prevention of phagolysosome formation allows unchecked mycobacterial proliferation. Thus, the earliest phase of primary tuberculosis (in the first 3 weeks) in the nonsensitized patient is characterized by bacillary proliferation within the pulmonary alveolar macrophages and air spaces, with resulting bacteremia and seeding of multiple sites. **Despite the bacteremia, most persons at this stage are asymptomatic or have a mild flu-like illness.**
- The genetic makeup of the patient may influence the course of the disease. In some people with polymorphisms of the **NRAMP1** (**n**atural **r**esistance–**a**ssociated **m**acrophage **p**rotein **1**) gene, the disease may progress from this point without development of an effective immune response. NRAMP1 is a transmembrane ion transport protein found in endosomes and lysosomes that is believed to contribute to microbial killing.
- The development of **cell-mediated immunity** occurs approximately 3 weeks after exposure. Processed mycobacterial antigens reach the draining lymph nodes and are presented to CD4 T cells by dendritic cells and macrophages. Under the influence of macrophage-secreted IL-12, CD4+ T cells of the $T_H1$ subset are generated that are capable of secreting IFN-γ.
- **IFN-γ released by the CD4+ T cells of the $T_H1$ subset is crucial in activating macrophages.** Activated macrophages, in turn, release a variety of mediators and upregulate expression of genes with important downstream effects, including (1) TNF, which is responsible for recruitment of monocytes, which in turn undergo activation and differentiation into the "epithelioid histiocytes"

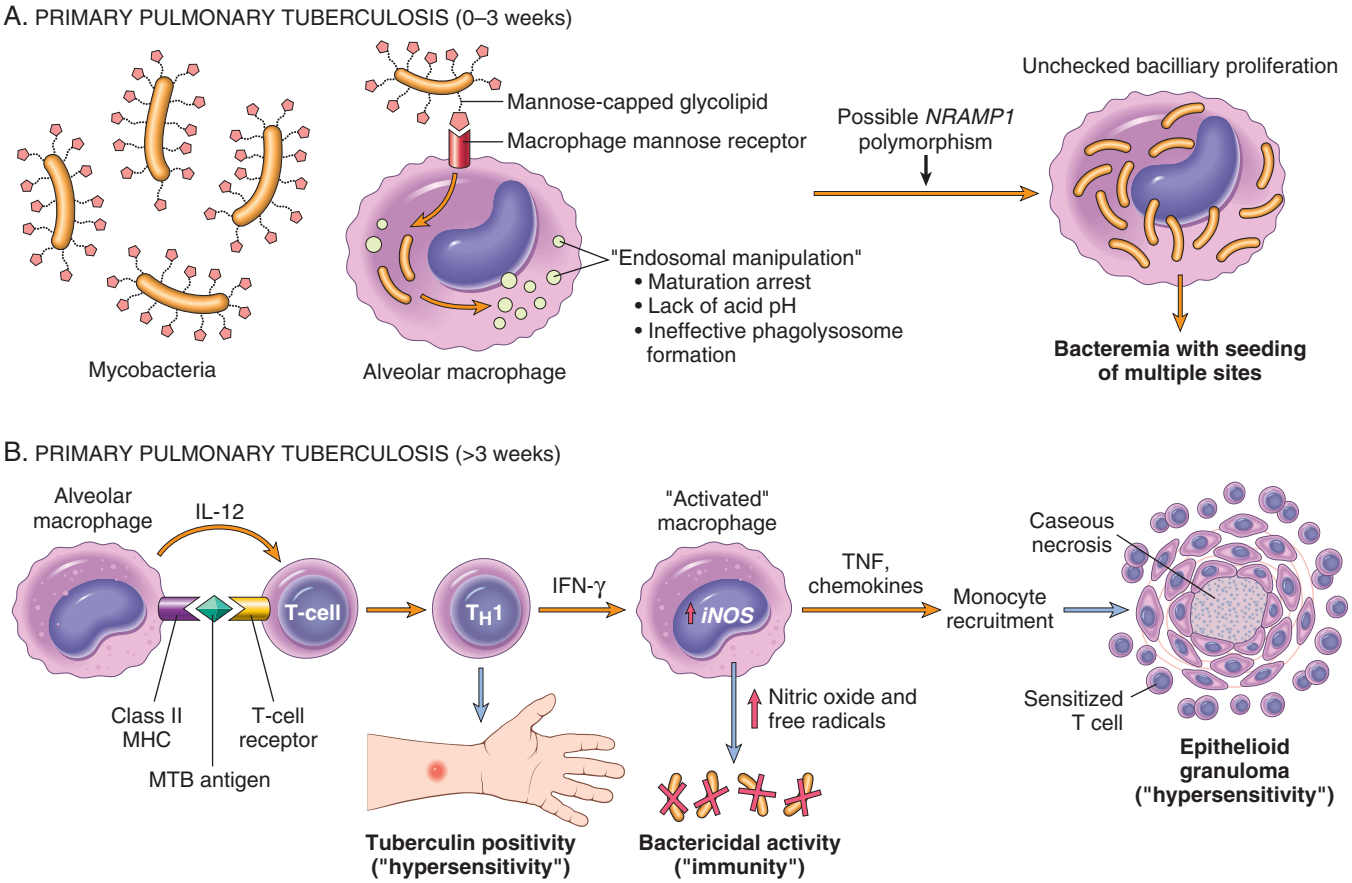


**Figure 12–35** Sequence of events in the natural history of primary pulmonary tuberculosis. This sequence commences with inhalation of virulent strains of *Mycobacterium* and culminates in the development of immunity and delayed hypersensitivity to the organism. **A,** Events occurring in the first 3 weeks after exposure. **B,** Events thereafter. The development of resistance to the organism is accompanied by conversion to a positive result on tuberculin skin testing. Cells and bacteria are not drawn to scale. IFN-γ, interferon γ; iNOS, inducible nitric oxide synthase; MHC, major histocompatibility complex; MTB, *Mycobacterium tuberculosis*; *NRAMP1*, gene encoding natural resistance–associated macrophage protein 1; TNF, tumor necrosis factor.

that characterize the granulomatous response; (2) expression of the **inducible nitric oxide synthase** *(iNOS)* gene, which results in elevated **nitric oxide** levels at the site of infection, with excellent antibacterial activity; and (3) generation of reactive oxygen species, which can have antibacterial activity. You will recall that nitric oxide is a powerful oxidizing agent that results in generation of reactive nitrogen intermediates and other free radicals capable of oxidative destruction of several mycobacterial constituents, from cell wall to DNA.

- Defects in any of the steps of a $T_H1$ response (including IL-12, IFN-γ, TNF, or nitric oxide production) result in poorly formed granulomas, absence of resistance, and disease progression. Persons with inherited mutations in any component of the $T_H1$ pathway are extremely susceptible to infections with mycobacteria.

**In summary, immunity to a tubercular infection is primarily mediated by $T_H1$ cells, which stimulate macrophages to kill bacteria.** This immune response, while largely effective, comes at the cost of hypersensitivity and the accompanying tissue destruction. Reactivation of the infection or reexposure to the bacilli in a previously sensitized host results in rapid mobilization of a defensive reaction but also increased tissue necrosis. Just as hypersensitivity and resistance appear in parallel, so, too, the loss of hypersensitivity (indicated by tuberculin negativity in a tuberculin-positive patient) may be an ominous sign that resistance to the organism has faded.

### Primary Tuberculosis

*Primary tuberculosis is the form of disease that develops in a previously unexposed and therefore unsensitized patient.* Elderly persons and profoundly immunosuppressed patients may lose their sensitivity to the tubercle bacillus, so they may develop primary tuberculosis more than once. About 5% of those newly infected acquire significant disease.

#### MORPHOLOGY

In countries in which bovine tuberculosis and infected milk have largely disappeared, primary tuberculosis almost always begins in the lungs. Typically, the inhaled bacilli implant in the distal air spaces of the lower part of the upper lobe or the upper part of the lower lobe, usually close to the pleura. As sensitization develops, a 1- to 1.5-cm area of gray-white inflammatory consolidation emerges, the **Ghon focus.** In most cases the center of this focus undergoes caseous necrosis. Tubercle bacilli, either free or within phagocytes, travel in lymph drainage to the regional nodes, which also often caseate. **This combination of parenchymal lesion and nodal involvement** is referred to as the Ghon complex (Fig. 12–36). During the first few weeks, there is also lymphatic and hematogenous dissemination to other parts of the body. In approximately 95% of cases, development of cell-mediated immunity controls the infection. Hence, the Ghon complex undergoes progressive fibrosis, often followed by radiologically detectable calcification **(Ranke complex),** and despite seeding of other organs, no lesions develop.

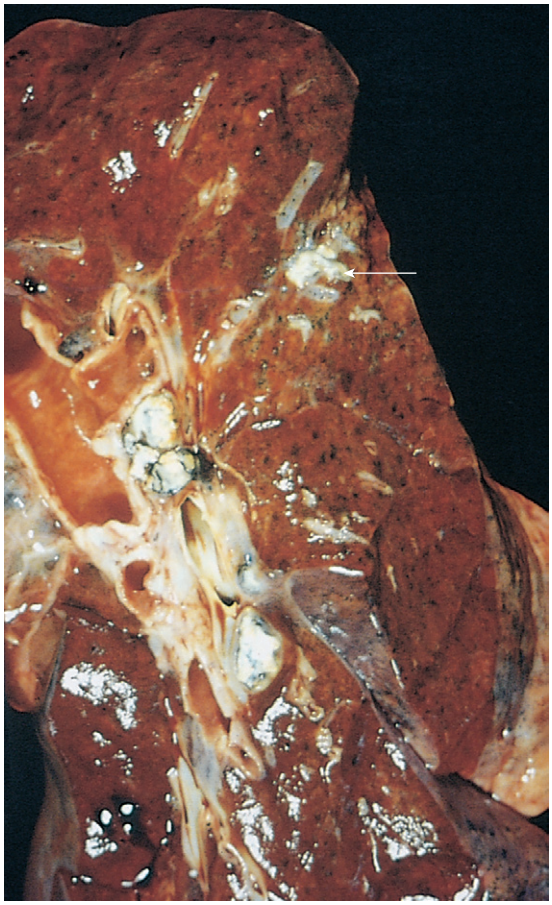

**Figure 12–36** Primary pulmonary tuberculosis, Ghon complex. The gray-white parenchymal focus *(arrow)* is under the pleura in the *lower part* of the upper lobe. Hilar lymph nodes with caseation are seen on the *left.*

On histologic examination, sites of active involvement are marked by a characteristic granulomatous inflammatory reaction that forms both caseating and noncaseating granulomas (Fig. 12–37, *A* to *C*), which consist of epithelioid histiocytes and multinucleate giant cells.

The major consequences of primary tuberculosis are that (1) it induces hypersensitivity and increased resistance; (2) the foci of scarring may harbor viable bacilli for years, perhaps for life, and thus be the nidus for *reactivation* at a later time when host defenses are compromised; and (3) uncommonly, it may lead to *progressive primary tuberculosis.* This complication occurs in patients who are immunocompromised or have nonspecific impairment of host defenses, as characteristic in malnourished children or in elderly persons. Certain racial groups, such as the Inuit, also are more prone to the development of progressive primary tuberculosis. The incidence of progressive primary tuberculosis is particularly high in HIV-positive patients with an advanced degree of immunosuppression (i.e., CD4+ counts below 200 cells/μL). Immunosuppression results in an inability to mount a CD4+ T cell–mediated immunologic reaction that would contain the primary focus; because hypersensitivity and resistance are most often concomitant factors, the lack of a tissue hypersensitivity reaction results

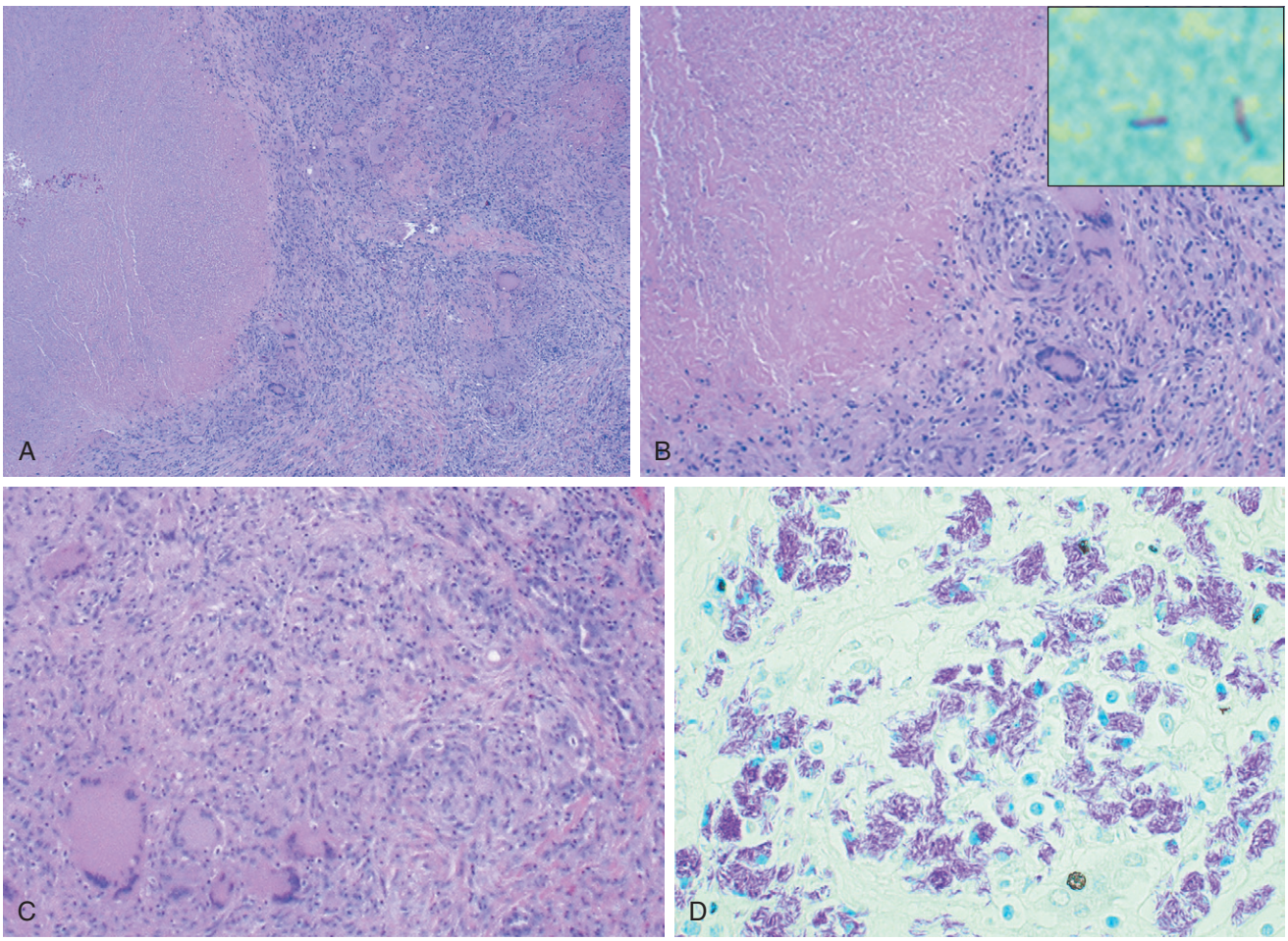


**Figure 12–37** The morphologic spectrum of tuberculosis. **A** and **B,** A characteristic tubercle at low magnification **(A)** and at higher power **(B)** shows central granular caseation surrounded by epithelioid and multinucleate giant cells. This is the usual response seen in persons who have developed cell-mediated immunity to the organism. *Inset:* Acid-fast stain shows rare positive organisms. **C,** Occasionally, even in immunocompetent patients, tubercular granulomas may not show central caseation; hence, irrespective of the presence or absence of caseous necrosis, use of special stains for acid-fast organisms is indicated when granulomas are present. **D,** In this specimen from an immunosuppressed patient, sheets of foamy macrophages packed with mycobacteria are seen (acid-fast stain).

in the absence of the characteristic caseating granulomas (*nonreactive tuberculosis*) (Fig. 12–37, *D*).

### Secondary Tuberculosis (Reactivation Tuberculosis)

*Secondary tuberculosis is the pattern of disease that arises in a previously sensitized host.* It may follow shortly after primary tuberculosis, but more commonly it arises from reactivation of dormant primary lesions many decades after initial infection, particularly when host resistance is weakened. It also may result from exogenous reinfection because of waning of the protection afforded by the primary disease or because of a large inoculum of virulent bacilli. Whatever the source of the organism, only a few patients (less than 5%) with primary disease subsequently develop secondary tuberculosis.

*Secondary pulmonary tuberculosis is classically localized to the apex of one or both upper lobes.* The reason is obscure but may relate to high oxygen tension in the apices. Because of the preexistence of hypersensitivity, the bacilli excite a prompt and marked tissue response that tends to wall off the focus. As a result of this localization, the regional lymph nodes are less prominently involved early in the disease than they are in primary tuberculosis. On the other hand, *cavitation occurs readily in the secondary form,* leading to erosion into and dissemination along airways. Such changes become an important source of infectivity, because the patient now produces sputum containing bacilli.

Secondary tuberculosis should always be an important consideration in HIV-positive patients who present with pulmonary disease. Of note, *although an increased risk of tuberculosis exists at all stages of HIV disease, the manifestations differ depending on the degree of immunosuppression.* For example, patients with less severe immunosuppression (CD4+ counts greater than 300 cells/$mm^3$) present with "usual" secondary tuberculosis (apical disease with cavitation) while those with more advanced immunosuppression (CD4+ counts below 200 cells/$mm^3$) present with a clinical picture that resembles progressive primary tuberculosis (lower and middle lobe consolidation, hilar lymphadenopathy, and noncavitary disease). The extent of immunosuppression also determines the frequency of extrapulmonary involvement, rising from 10% to 15% in mildly immunosuppressed patients to greater than 50% in those with severe immune deficiency.

## MORPHOLOGY

The initial lesion usually is a small focus of consolidation, less than 2 cm in diameter, within 1 to 2 cm of the **apical pleura.** Such foci are sharply circumscribed, firm, gray-white to yellow areas that have a variable amount of central caseation and peripheral fibrosis. In favorable cases, the initial parenchymal focus undergoes progressive fibrous encapsulation, leaving only fibrocalcific scars. Histologically, the active lesions show characteristic coalescent tubercles with central caseation. Although tubercle bacilli can be demonstrated by appropriate methods in early exudative and caseous phases of granuloma formation, it is usually impossible to find them in the late, fibrocalcific stages. Localized, apical, secondary pulmonary tuberculosis may heal with fibrosis either spontaneously or after therapy, or the disease may progress and extend along several different pathways.

**Progressive pulmonary tuberculosis** may ensue. The apical lesion enlarges with expansion of the area of caseation. Erosion into a bronchus evacuates the caseous center, creating a ragged, **irregular cavity lined by caseous material** that is poorly walled off by fibrous tissue (Fig. 12–38). Erosion of blood vessels results in hemoptysis. With adequate treatment, the process may be arrested, although healing by fibrosis often distorts the pulmonary architecture. Irregular cavities, now free of caseation necrosis, may remain or collapse in the surrounding fibrosis. If the treatment is inadequate, or if host defenses are impaired, the infection may spread by direct expansion, by means of dissemination through airways, lymphatic channels, or within the vascular system. **Miliary pulmonary disease** occurs when organisms drain through lymphatics into the lymphatic ducts, which empty into the venous return to the right side of the heart and thence into the pulmonary arteries. Individual lesions are either microscopic or small, visible (2 mm) foci of yellow-white consolidation scattered through the lung parenchyma (the word *miliary* is derived from the resemblance of these foci to millet seeds). With progressive pulmonary tuberculosis, the pleural cavity is invariably involved and serous **pleural effusions, tuberculous empyema,** or **obliterative fibrous pleuritis** may develop.

**Endobronchial, endotracheal,** and **laryngeal tuberculosis** may develop when infective material is spread either through lymphatic channels or from expectorated infectious material. The mucosal lining may be studded with minute granulomatous lesions, sometimes apparent only on microscopic examination.

**Systemic miliary tuberculosis** ensues when the organisms disseminate through the systemic arterial system to almost every organ in the body. Granulomas are the same as in the lung. Miliary tuberculosis is most prominent in the liver, bone marrow, spleen, adrenals, meninges, kidneys, fallopian tubes, and epididymis (Fig. 12–39).

**Isolated-organ tuberculosis** may appear in any one of the organs or tissues seeded hematogenously and may be the presenting manifestation of tuberculosis. Organs typically involved include the meninges (tuberculous meningitis), kidneys (renal tuberculosis), adrenals, bones (osteomyelitis), and fallopian tubes (salpingitis). When the vertebrae are affected, the condition is referred to as Pott disease. Paraspinal "cold" abscesses may track along the tissue planes to present as an abdominal or pelvic mass.

**Lymphadenitis** is the most frequent form of extrapulmonary tuberculosis, usually occurring in the cervical region ("scrofula"). Lymphadenopathy tends to be unifocal, and most patients do not have concurrent extranodal disease. HIV-positive patients, on the other hand, almost always have multifocal disease, systemic symptoms, and either pulmonary or other organ involvement by active tuberculosis.

In years past, **intestinal tuberculosis** contracted by the drinking of contaminated milk was fairly common as a primary focus of tuberculosis. In developed countries today, intestinal tuberculosis is more often a complication of protracted advanced secondary tuberculosis, secondary to the swallowing of coughed-up infective material. Typically, the organisms are trapped in mucosal lymphoid aggregates of the small and large bowel, which then undergo inflammatory enlargement with ulceration of the overlying mucosa, particularly in the ileum.

The many patterns of tuberculosis are depicted in Figure 12–40.

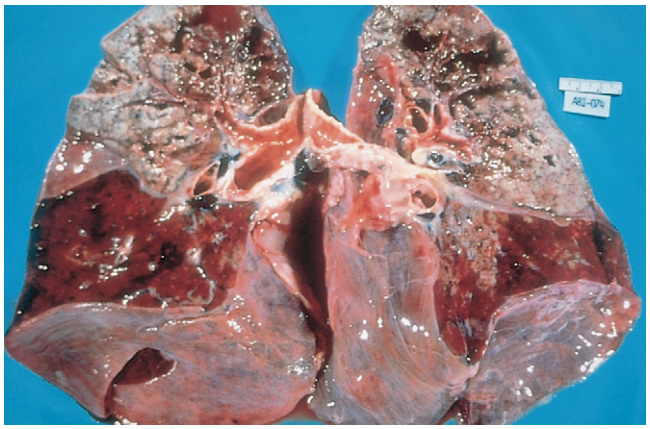

**Figure 12–38** Secondary pulmonary tuberculosis. The upper parts of both lungs are riddled with gray-white areas of caseation and multiple areas of softening and cavitation.

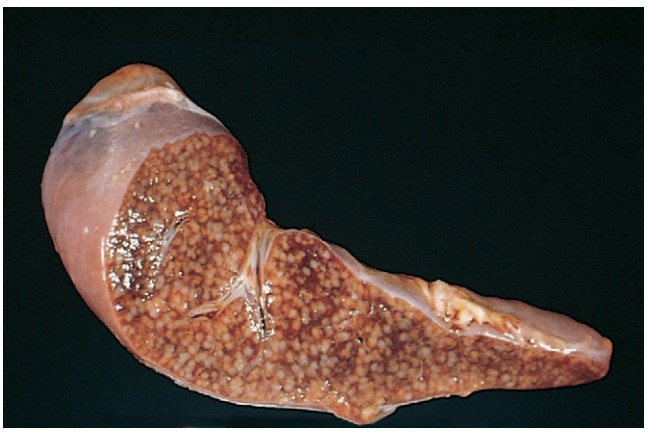

**Figure 12–39** Miliary tuberculosis of the spleen. The cut surface shows numerous gray-white granulomas.

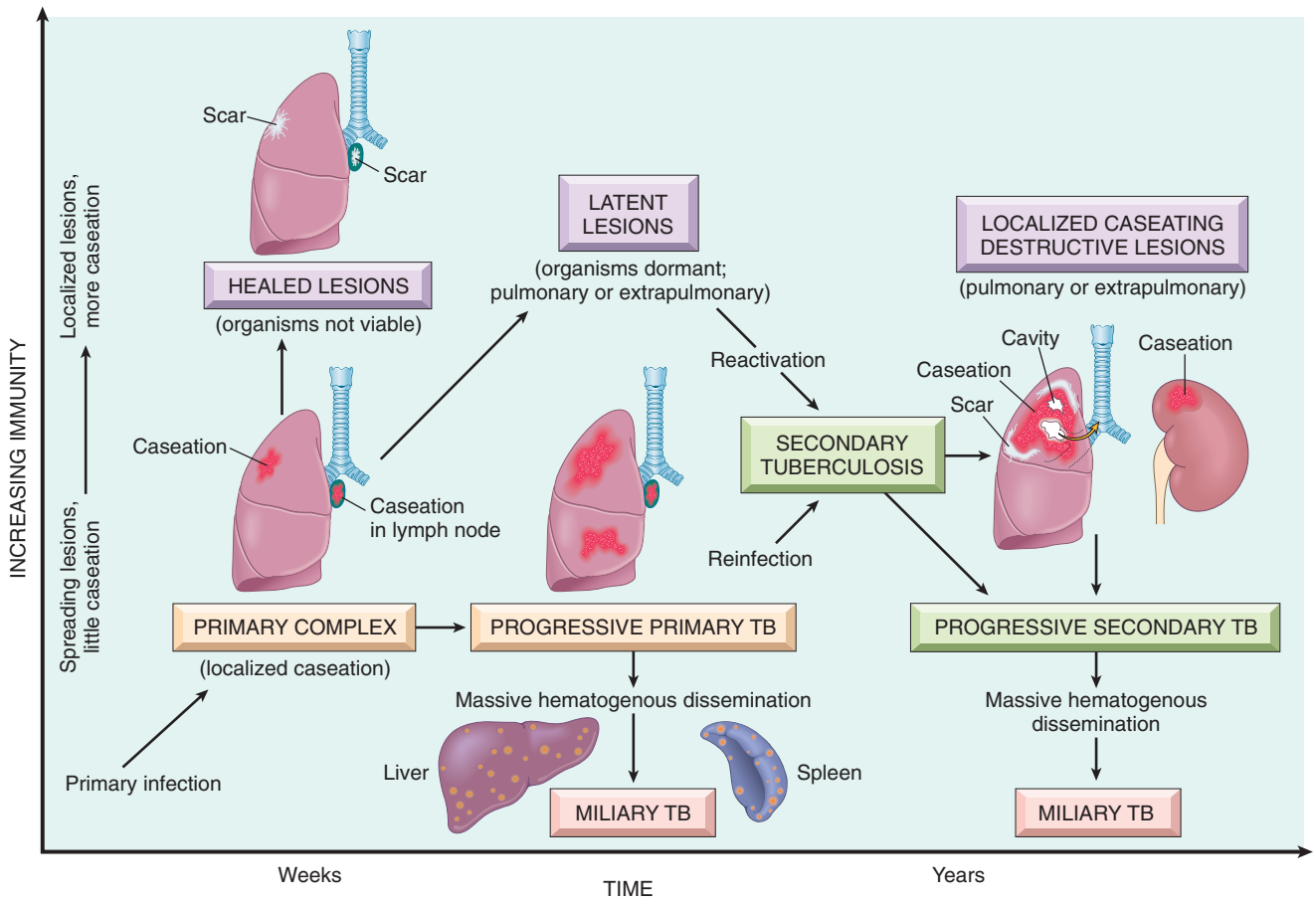


**Figure 12–40** The natural history and spectrum of tuberculosis.
*(Adapted from a sketch provided by Dr. R.K. Kumar, The University of New South Wales, School of Pathology, Sydney, Australia.)*

## Clinical Features

Localized secondary tuberculosis may be asymptomatic. When manifestations appear, they are usually *insidious* in onset, with gradual development of both systemic and localizing symptoms and signs. Systemic manifestations, probably related to the release of cytokines by activated macrophages (e.g., TNF and IL-1), often appear early in the disease course and include malaise, anorexia, weight loss, and fever. Commonly, the *fever is low grade* and remittent (appearing late each afternoon and then subsiding), and *night sweats* occur. With progressive pulmonary involvement, increasing amounts of sputum, at first mucoid and later purulent, appear. When cavitation is present, the sputum contains tubercle bacilli. Some degree of *hemoptysis* is present in about half of all cases of pulmonary tuberculosis. *Pleuritic pain* may result from extension of the infection to the pleural surfaces. Extrapulmonary manifestations of tuberculosis are legion and depend on the organ system involved (for example, tuberculous salpingitis may present as infertility, tuberculous meningitis with headache and neurologic deficits, Pott disease with back pain and paraplegia). The diagnosis of pulmonary disease is based in part on the history and on physical and radiographic findings of *consolidation or cavitation in the apices of the lungs.* Ultimately, however, *tubercle bacilli must be identified.*

The most common methodology for diagnosis of tuberculosis remains demonstration of acid-fast organisms in sputum by acid-fast stains or by use of fluorescent auramine rhodamine. Conventional cultures for mycobacteria require up to 10 weeks, but liquid media–based radiometric assays that detect mycobacterial metabolism are able to provide an answer within 2 weeks. PCR amplification can be performed on positive liquid media, as well as on tissue sections, to identify the mycobacterium. However, culture remains the standard diagnostic modality because it can identify the occasional PCR-negative case and also allows testing of drug susceptibility. Multidrug resistance (MDR), defined as resistance of mycobacteria to two or more of the primary drugs used for treatment of tuberculosis, is now seen more commonly, and the WHO estimates that 50 million people worldwide may be infected with multidrug-resistant tuberculosis.

The prognosis with tuberculosis generally is favorable if infection is localized to the lungs, but it worsens significantly when the disease occurs in aged, debilitated, or immunosuppressed persons, who are at high risk for the development of miliary tuberculosis, and in those with multidrug-resistant tuberculosis. Amyloidosis may develop in persistent cases.

## SUMMARY

### Tuberculosis

- Tuberculosis is a chronic granulomatous disease caused by *M. tuberculosis*, usually affecting the lungs, but virtually any extrapulmonary organ can be involved in isolated infection.
- Initial exposure to mycobacteria results in development of an immune response that confers resistance but also leads to hypersensitivity (as determined by a positive result on the *tuberculin skin test*).
- CD4+ T cells of the $T_H1$ subset have a crucial role in cell-mediated immunity against mycobacteria; mediators of inflammation and bacterial containment include IFN-γ, TNF, and nitric oxide.
- The histopathologic hallmark of host reaction to tuberculosis in immunocompetent persons is the presence of *granulomas*, usually with central caseating necrosis.
- Secondary (reactivation) tuberculosis arises in previously exposed persons when host immune defenses are compromised, and usually manifests as cavitary lesions in the lung apices.
- Both progressive primary tuberculosis and secondary tuberculosis can result in systemic seeding, causing life-threatening forms of disease such as miliary tuberculosis and tuberculous meningitis.
- HIV-seropositive status is a well-known risk factor for development or recrudescence of active tuberculosis.

### *Nontuberculous Mycobacterial Disease*

Nontuberculous mycobacteria most commonly cause chronic but clinically localized pulmonary disease in immunocompetent persons. In the United States, strains implicated most frequently include *Mycobacterium avium-intracellulare* (also called *M. avium* complex), *Mycobacterium kansasii,* and *Mycobacterium abscessus.* It is not uncommon for nontuberculous mycobacterial infection to manifest as upper lobe cavitary disease, mimicking tuberculosis, especially in patients with a long history of smoking or alcohol abuse. Concomitant chronic pulmonary disease (COPD, cystic fibrosis, pneumoconiosis) is often present.

In *immunosuppressed persons* (primarily HIV-seropositive patients), *M. avium* complex infection manifests as disseminated disease, associated with systemic signs and symptoms (fever, night sweats, weight loss). Hepatosplenomegaly and lymphadenopathy, signifying involvement of the mononuclear phagocyte system by the opportunistic pathogen, is common, as are gastrointestinal symptoms such as diarrhea and malabsorption. Pulmonary involvement is often indistinguishable from tuberculosis in patients with AIDS. Disseminated *M. avium* complex infection in patients with AIDS tends to occur late in the clinical course, when CD4+ counts have fallen below 100 cells/μL. Hence, tissue examination usually does not reveal granulomas; instead, foamy histiocytes "stuffed" with atypical mycobacteria typically are seen.

## Histoplasmosis, Coccidioidomycosis, and Blastomycosis

Infections caused by the dimorphic fungi, which include *Histoplasma capsulatum, Coccidioides immitis,* and *Blastomyces dermatitidis,* manifest either with isolated pulmonary involvement, as commonly seen in infected immunocompetent persons, or with disseminated disease in immunocompromised persons. T cell–mediated immune responses are critical for containing the infection, so persons with compromised cell-mediated immunity, such as those with HIV, are more prone to systemic disease. In part because of the overlap in clinical presentations, infectious diseases due to all three dimorphic fungi are considered together in this section.

### Epidemiology

Each of the dimorphic fungi has a typical geographic distribution, as follows:

- *H. capsulatum*: This fungus is endemic in the Ohio and central Mississippi River valleys and along the Appalachian mountains in the southeastern United States. Warm, moist soil, enriched by droppings from bats and birds, provides the ideal medium for the growth of the mycelial form, which produces infectious spores.
- *C. immitis*: This organism is endemic in the southwestern and far western regions of the United States, particularly in California's San Joaquin Valley, where coccidial infection is known as "valley fever."
- *B. dermatitidis*: The endemic area is confined in the United States to areas overlapping with those in which histoplasmosis is found.

## MORPHOLOGY

The yeast forms are fairly distinctive, which helps in the identification of individual fungi in tissue sections:

- *H. capsulatum*: round to oval, small yeast forms measuring 2 to 5 μm in diameter (Fig. 12–41, *A*)
- *C. immitis*: thick-walled, nonbudding spherules, 20 to 60 μm in diameter, often filled with small endospores (Fig. 12–41, *B*)
- *B. dermatitidis*: round to oval and larger than *Histoplasma* (5 to 25 μm in diameter); reproduce by characteristic broad-based budding (Fig. 12–41, *C* and *D*)

### Clinical Features

Clinical manifestations may take the form of (1) *acute (primary) pulmonary infection,* (2) *chronic (granulomatous) pulmonary disease,* or (3) *disseminated miliary disease.* The primary pulmonary nodules, composed of aggregates of macrophages stuffed with organisms, are associated with similar lesions in the regional lymph nodes. These lesions evolve into small granulomas complete with giant cells and may develop central necrosis and later fibrosis and calcification. *The similarity to primary tuberculosis is striking,* and differentiation requires identification of the

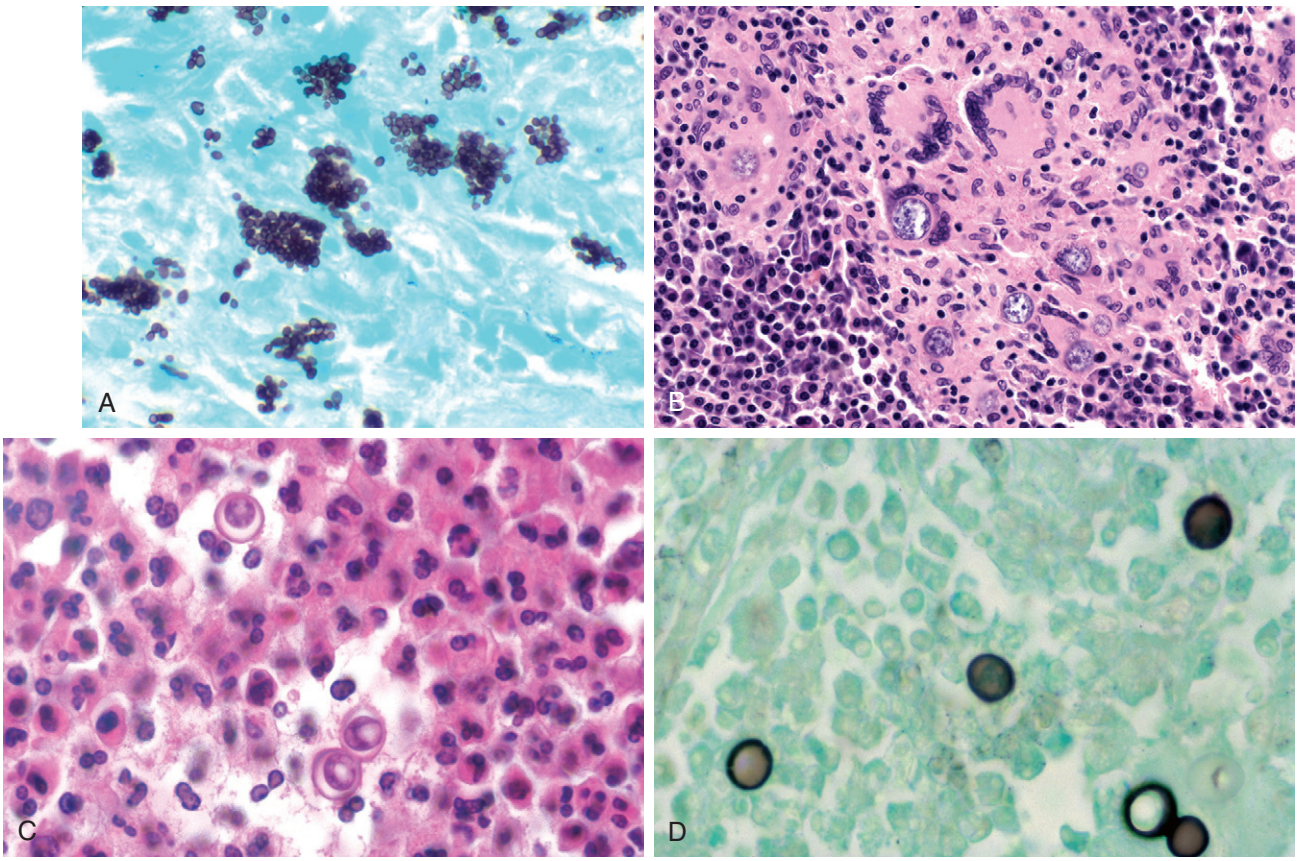


**Figure 12–41 A,** *Histoplasma capsulatum* yeast forms fill phagocytes in a lymph node of a patient with disseminated histoplasmosis (silver stain). **B,** Coccidioidomycosis with intact spherules within multinucleated giant cells. **C,** Blastomycosis, with rounded budding yeasts, larger than neutrophils. Note the characteristic thick wall and nuclei (not seen in other fungi). **D,** Silver stain highlights the broad-based budding seen in *Blastomyces immitis* organisms.

yeast forms (best seen with silver stains). The clinical symptoms and signs resemble those of a "flulike" syndrome, most often self-limited. In the vulnerable host, chronic cavitary pulmonary disease develops, with a predilection for the upper lobe, resembling the secondary form of tuberculosis. It is not uncommon for these fungi to give rise to perihilar mass lesions that resemble bronchogenic carcinoma radiologically. At this stage, manifestations may include cough, hemoptysis, and even dyspnea and chest pain.

In infants or immunocompromised adults, particularly those with HIV infection, disseminated disease (analogous to miliary tuberculosis) may develop. Under these circumstances there are no well-formed granulomas. Instead, focal collections of phagocytes stuffed with yeast forms are seen within cells of the mononuclear phagocyte system, including in the liver, spleen, lymph nodes, lymphoid tissue of the gastrointestinal tract, and bone marrow. The adrenals and meninges may also be involved, and in a minority of cases, ulcers form in the nose and mouth, on the tongue, or in the larynx. Disseminated disease is a hectic, febrile illness marked by hepatosplenomegaly, anemia, leukopenia, and thrombocytopenia. Cutaneous infections with disseminated *Blastomyces* organisms frequently induce striking epithelial hyperplasia, which may be mistaken for squamous cell carcinoma.

## Pneumonia in the Immunocompromised Host

The appearance of a pulmonary infiltrate and signs of infection (e.g., fever) are some of the most common and serious complications in a person in whom the immune and defense systems are suppressed by disease, by immunosuppression for organ transplantation and antitumor therapy, or by irradiation. A wide variety of so-called opportunistic pathogens, many of which rarely cause infection in normal persons, can be the infecting agents with these pneumonias, and often more than one agent is involved. Some of the more common pulmonary pathogens are (1) the bacterial agents *P. aeruginosa*, *Mycobacterium* spp., *L. pneumophila,* and *Listeria monocytogenes*; (2) the viral agents cytomegalovirus and herpesvirus; and (3) the fungal agents *P. jiroveci, Candida* spp., *Aspergillus* spp., and *Cryptococcus neoformans.*

### *Cytomegalovirus Infections*

Cytomegalovirus (CMV), a member of the herpesvirus family, may produce a variety of disease manifestations, depending partly on the age of the infected host but even more on the host's immune status. Cells infected by the virus exhibit gigantism of both the entire cell and its nucleus. Within the nucleus is an enlarged inclusion surrounded by a clear halo ("owl's eye"), which gives the

name to the classic form of symptomatic disease that occurs in neonates—cytomegalic inclusion disease. Although classic cytomegalic inclusion disease involves many organs, CMV infections are discussed here because in immunosuppressed adults, particularly patients with AIDS and recipients of allogeneic bone marrow transplants, CMV pneumonitis is a serious problem.

Transmission of CMV can occur by several mechanisms, depending on the age group affected:

- A fetus can be infected transplacentally from a newly acquired or reactivated infection in the mother (*congenital* CMV infection).
- The virus can be transmitted to the baby through cervical or vaginal secretions at birth, or, later, through breast milk from a mother who has active infection (*perinatal* CMV infection).
- Preschool children, especially in day care centers, can acquire it through saliva. Toddlers thus infected readily transmit the virus to their parents.
- In patients older than 15 years of age, the venereal route is the dominant mode of transmission, but spread also may occur through contact with respiratory secretions and by the fecal-oral route.
- Iatrogenic transmission can occur at any age through organ transplantation or blood transfusions.

### MORPHOLOGY

Histologically, the characteristic enlargement of cells can be appreciated. In the glandular organs, the parenchymal epithelial cells are affected; in the brain, the neurons; in the lungs, the alveolar macrophages and epithelial and endothelial cells; and in the kidneys, the tubular epithelial and glomerular endothelial cells. **Affected cells are strikingly enlarged, often to a diameter of 40 μm, and exhibit cellular and nuclear polymorphism.** Prominent intranuclear basophilic inclusions spanning half the nuclear diameter are usually set off from the nuclear membrane by a clear halo (Fig. 12–42). Within the cytoplasm of these cells, smaller basophilic inclusions may also be seen.

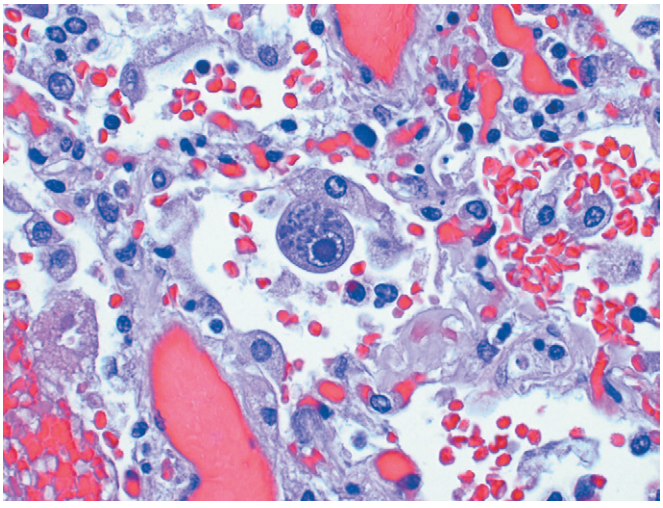

**Figure 12–42** Cytomegalovirus infection of the lung. A typical distinct nuclear and multiple cytoplasmic inclusions are seen in an enlarged cell.

#### Cytomegalovirus Mononucleosis

In healthy young children and adults, the disease is nearly always asymptomatic. In surveys around the world, 50% to 100% of adults demonstrate anti-CMV antibodies in the serum, indicating previous exposure. The most common *clinical manifestation of CMV infection* in immunocompetent hosts beyond the neonatal period is an infectious mononucleosis–like illness, with fever, atypical lymphocytosis, lymphadenopathy, and hepatomegaly accompanied by abnormal liver function test results, suggesting mild hepatitis. Most patients recover from CMV mononucleosis without any sequelae, although excretion of the virus may occur in body fluids for months to years. Irrespective of the presence or absence of symptoms after infection, a person once infected becomes seropositive for life. The virus remains latent within leukocytes, which are the major reservoirs.

#### Cytomegalovirus Infection in Immunosuppressed Persons

Immunosuppression-related CMV infection occurs most commonly in recipients of transplants (such as heart, liver, kidney, lung, or allogeneic stem cell) and in patients with AIDS. This can be either primary infection or reactivation of a latent infection. CMV is the most common opportunistic viral pathogen in AIDS.

In all of these settings, serious, life-threatening disseminated CMV infections primarily affect the lungs (pneumonitis), gastrointestinal tract (colitis), and retina (retinitis); the central nervous system usually is spared. In pneumonitis, an interstitial mononuclear infiltrate with foci of necrosis develops, accompanied by the typical enlarged cells with inclusions, which can progress to ARDS. Intestinal necrosis and ulceration can develop and be extensive, leading to the formation of "pseudomembranes" (Chapter 14) and debilitating diarrhea. CMV retinitis, by far the most common form of opportunistic CMV disease, can occur either alone or in combination with involvement of the lungs and intestinal tract. Diagnosis of CMV infection is made by demonstration of characteristic viral inclusions in tissue sections, successful viral culture, rising antiviral antibody titer, and qualitative or quantitative PCR assay–based detection of CMV DNA. The latter has revolutionized the approach to monitoring patients after transplantation.

### Pneumocystis *Pneumonia*

*P. jiroveci* (formerly known as *P. carinii*), an opportunistic infectious agent formerly considered to be a protozoan, is now classified as a fungus. Serologic evidence indicates that virtually all persons are exposed to *Pneumocystis* during the first few years of life, but in most the infection remains latent. Reactivation with development of clinical disease occurs almost exclusively in persons who are immunocompromised. Indeed, *P. jiroveci* is an extremely common cause of infection in patients with AIDS, and it also may infect severely malnourished infants and immunosuppressed persons (especially after organ transplantation or in persons receiving cytotoxic chemotherapy or corticosteroids). In patients with AIDS, the risk of acquiring *P. jiroveci* infections increases in inverse proportion to the CD4+ count, with counts less than 200 cells/μL having

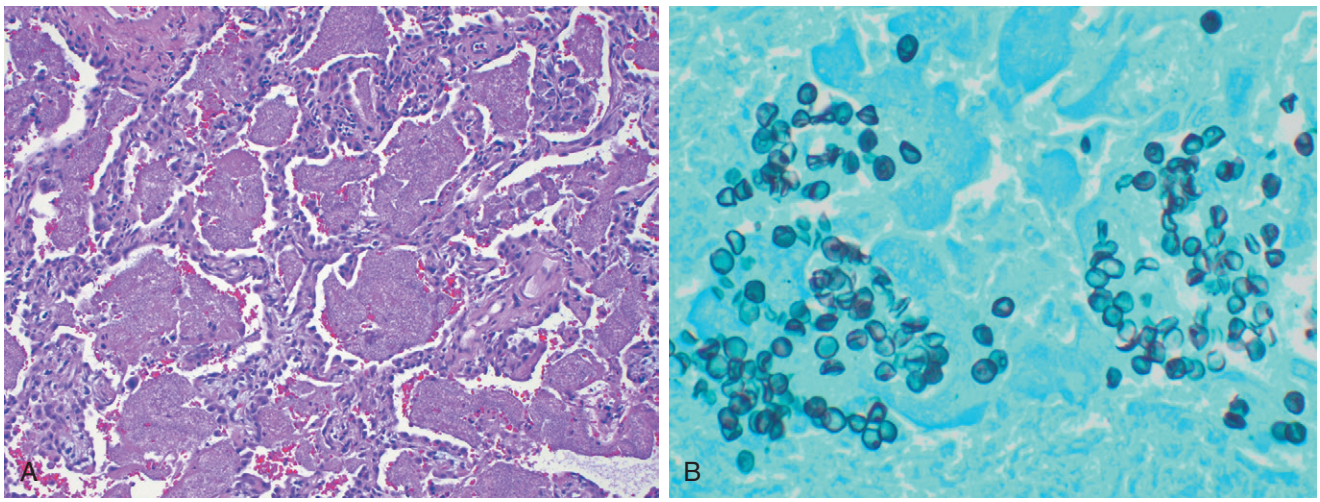


**Figure 12–43** *Pneumocystis* pneumonia. **A,** The alveoli are filled with a characteristic foamy acellular exudate. **B,** Silver stain demonstrates cup-shaped and round cysts within the exudate.

a strong predictive value. *Pneumocystis* infection is largely confined to the lung, where it produces an interstitial pneumonitis.

### MORPHOLOGY

Microscopically, involved areas of the lung demonstrate a characteristic **intra-alveolar foamy, pink-staining exudate** with hematoxylin-eosin (H&E) stain ("cotton candy" exudate) (Fig. 12–43, *A*). The septa are thickened by edema and a minimal mononuclear infiltrate. Special stains are required to visualize the organism. Silver stain of tissue sections reveals **round to cup-shaped cysts** (4 to 10 μm in diameter), often with intracystic bodies but without budding, in the alveolar exudates (Fig. 12–43, *B*).

The diagnosis of *Pneumocystis* pneumonia should be considered in any immunocompromised patient with respiratory symptoms and abnormal findings on the chest radiograph. Fever, dry cough, and dyspnea occur in 90% to 95% of patients, in whom radiographic evidence of bilateral perihilar and basilar infiltrates is typical. Hypoxia is frequent; pulmonary function studies show a restrictive lung defect. The most sensitive and effective method of diagnosis is to identify the organism in induced sputum or bronchoalveolar lavage fluid using immunofluorescence. If treatment is initiated before widespread involvement, the outlook for recovery is good; however, because residual organisms are likely to persist, particularly in patients with AIDS, relapses are common unless the underlying immunodeficiency is corrected or prophylactic therapy is given.

## Opportunistic Fungal Infections

### *Candidiasis*

*Candida albicans* is the most common disease-causing fungus. It is a normal inhabitant of the oral cavity, gastrointestinal tract, and vagina in many people. Even though systemic candidiasis (with associated pneumonia) is a disease that is restricted to immunocompromised patients, the protean manifestations of infections caused by *Candida* spp. are described in this section.

### MORPHOLOGY

In tissue sections, *C. albicans* demonstrates yeastlike forms (blastoconidia), pseudohyphae, and true hyphae (Fig. 12–44, *A*). Pseudohyphae are an important diagnostic clue for *C. albicans* and represent budding yeast cells joined end to end at constrictions, thus simulating true fungal hyphae. The organisms may be visible with routine H&E stains, but a variety of special "fungal" stains (Gomori methenamine-silver, periodic acid–Schiff) commonly are used to better highlight the pathogens.

#### Clinical Features

Candidiasis can involve the mucous membranes, skin, and deep organs (invasive candidiasis).

- The most common presentation with candidiasis is that of a superficial infection on mucosal surfaces of the oral cavity (thrush). Florid proliferation of the fungi creates gray-white, dirty-looking pseudomembranes composed of matted organisms and inflammatory debris. Deep to the surface, there is mucosal hyperemia and inflammation. This form of candidiasis is seen in newborns, debilitated patients, and children receiving oral corticosteroids for asthma, and after a course of broad-spectrum antibiotics that destroy competing normal bacterial flora. The other major risk group includes HIV-positive patients; patients with oral thrush not associated with an obvious underlying condition should be evaluated for HIV infection.
- *Candida* vaginitis is an extremely common form of vaginal infection in women, especially those who are diabetic or pregnant or on oral contraceptive pills.
- *Candida* esophagitis is common in patients with AIDS and in those with hematolymphoid malignancies. These

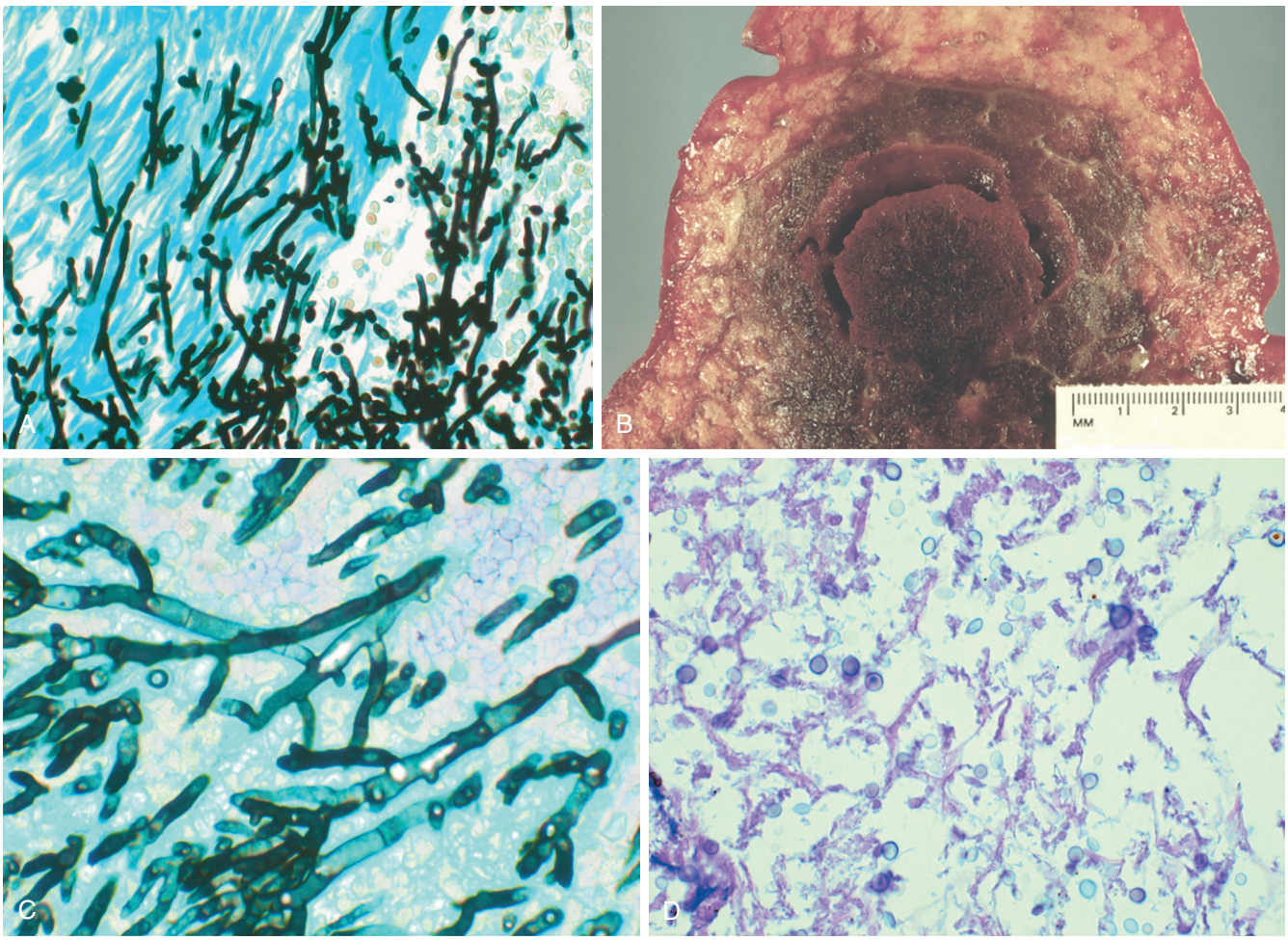


**Figure 12–44** The morphology of fungal infections. **A,** *Candida* organism has pseudohyphae and budding yeasts (silver stain). **B,** Invasive aspergillosis (gross appearance) of the lung in a bone marrow transplant recipient. **C,** Gomori methenamine-silver (GMS) stain shows septate hyphae with acute-angle branching, consistent with *Aspergillus*. **D,** Cryptococcosis of the lung in a patient with AIDS. The organisms are somewhat variable in size.

*(B, Courtesy of Dr. Dominick Cavuoti, Department of Pathology, University of Texas Southwestern Medical School, Dallas, Texas.)*

patients present with dysphagia (painful swallowing) and retrosternal pain; endoscopy demonstrates white plaques and pseudomembranes resembling the changes of oral thrush on the esophageal mucosa.

- Cutaneous candidiasis can manifest in many different forms, including infection of the nail proper (*onychomycosis*), nail folds (*paronychia*), hair follicles (*folliculitis*), moist, intertriginous skin such as armpits or webs of the fingers and toes (*intertrigo*), and penile skin (*balanitis*). *Diaper rash* often is a cutaneous candidal infection seen in the perineum of infants, in the region of contact of wet diapers.
- Chronic mucocutaneous candidiasis is a chronic refractory disease afflicting the mucous membranes, skin, hair, and nails; it is associated with underlying T cell defects. Associated conditions include endocrinopathies (most commonly hypoparathyroidism and Addison disease) and the presence of autoantibodies. Disseminated candidiasis is rare in this disease. A recent finding is that the $T_H17$ subset of CD4+ T cells plays an especially important role in defense against *Candida* and a few other fungi. Patients with mutations affecting $T_H17$ responses are highly susceptible to severe mucocutaneous candidiasis (e.g., "Job syndrome").
- Invasive candidiasis implies blood-borne dissemination of organisms to various tissues or organs. Common patterns include (1) renal abscesses, (2) myocardial abscesses and endocarditis, (3) brain involvement (most commonly meningitis, but parenchymal microabscesses occur), (4) endophthalmitis (virtually any eye structure can be involved), (5) hepatic abscesses, and (6) *Candida* pneumonia, usually manifesting as bilateral nodular infiltrates, resembling *Pneumocystis* pneumonia (see earlier). Patients with acute leukemias who are profoundly neutropenic after chemotherapy are particularly prone to the development of systemic disease. *Candida* endocarditis is the most common fungal endocarditis, usually occurring in patients with prosthetic heart valves or in intravenous drug abusers.

### *Cryptococcosis*

*Cryptococcosis,* caused by *C. neoformans,* rarely occurs in healthy persons. It almost exclusively manifests as an opportunistic infection in immunocompromised hosts,

particularly patients with AIDS or hematolymphoid malignancies.

### MORPHOLOGY

The fungus, a 5- to 10-μm yeast, has a thick, gelatinous capsule and reproduces by budding (Fig. 12–44, *D*). Unlike in *Candida* infections, however, pseudohyphal or true hyphal forms are not seen. **The capsule is invaluable to diagnosis:** (1) In routine H&E stains, the capsule is not directly visible, but often a clear "halo" can be seen surrounding the individual fungi representing the area occupied by the capsule. India ink or periodic acid–Schiff staining effectively highlights the fungus. (2) The capsular polysaccharide antigen is the substrate for the cryptococcal latex agglutination assay, which is positive in more than 95% of patients infected with the organism.

#### Clinical Features

Human cryptococcosis usually manifests as pulmonary, central nervous system, or disseminated disease. Cryptococcus is most likely to be acquired by inhalation from the soil or from bird droppings. The fungus initially localizes in the lungs and then disseminates to other sites, particularly the meninges. Sites of involvement are marked by a variable tissue response, which ranges from florid proliferation of gelatinous organisms with a minimal or absent inflammatory cell infiltrate (in immunodeficient hosts) to a granulomatous reaction (in the more reactive host). In immunosuppressed patients, fungi grow in gelatinous masses within the meninges or expand the perivascular Virchow-Robin spaces, producing the so-called soap-bubble lesions.

### *The Opportunistic Molds*

*Mucormycosis* and *invasive aspergillosis* are uncommon infections almost always limited to immunocompromised hosts, particularly those with hematolymphoid malignancies or profound neutropenia, those undergoing corticosteroid therapy, or allogeneic stem cell transplant recipients.

### MORPHOLOGY

Mucormycosis is caused by the class of fungi known as Zygomycetes. Their hyphae are **nonseptate** and branch at right angles; by contrast, the hyphae of *Aspergillus* organisms are **septate** and branch at more acute angles (Fig. 12–44, *C*). *Rhizopus* and *Mucor* are the two fungi of medical importance within the Zygomycetes class. Both zygomycetes and *Aspergillus* cause a nondistinctive, suppurative, sometimes granulomatous reaction with a **predilection for invading blood vessel walls, causing vascular necrosis and infarction.**

#### Clinical Features

In *rhinocerebral* and *pulmonary mucormycosis,* zygomycetes have a propensity to colonize the nasal cavity or sinuses and then spread by direct extension into the brain, orbit, and other head and neck structures. Patients with diabetic ketoacidosis are most likely to develop a fulminant invasive form of rhinocerebral mucormycosis. Pulmonary disease can be localized (e.g., cavitary lesions) or may manifest radiologically with diffuse "miliary" involvement.

*Invasive aspergillosis* occurs almost exclusively in patients who are immunosuppressed. The fungus preferentially localizes to the lungs, and infection most often manifests as a necrotizing pneumonia (Fig. 12–44, *B*). Systemic dissemination, especially to the brain, is an often fatal complication.

*Allergic bronchopulmonary aspergillosis* occurs in patients with asthma who develop an exacerbation of symptoms caused by a type I hypersensitivity against the fungus growing in the bronchi. Such patients often have circulating IgE antibodies against *Aspergillus* and peripheral eosinophilia.

*Aspergilloma* ("fungus ball") formation occurs by colonization of preexisting pulmonary cavities (e.g., ectatic bronchi or lung cysts, posttuberculosis cavitary lesions) by the fungus. These masses may act as ball valves to occlude the cavity, thereby predisposing the patient to infection and hemoptysis.

## Pulmonary Disease in Human Immunodeficiency Virus Infection

Pulmonary disease continues to be the leading contributor to morbidity and mortality in HIV-infected persons. Although the use of potent antiretroviral agents and effective chemoprophylaxis has markedly decreased incidence and improved outcome, the plethora of entities involved makes diagnosis and treatment a distinct challenge.

- Despite the emphasis on "opportunistic" infections, it should be recognized that bacterial lower respiratory tract infection caused by the "usual" pathogens is one of the most serious pulmonary disorders in HIV infection. The implicated organisms include *S. pneumoniae, S. aureus, H. influenzae,* and gram-negative rods. Bacterial pneumonias in HIV-infected persons are more common, more severe, and more often associated with bacteremia than in those without HIV infection.
- Not all pulmonary infiltrates in HIV-infected persons are infectious. A host of noninfectious diseases, including Kaposi sarcoma (Chapters 4 and 9), pulmonary non-Hodgkin lymphoma (Chapter 11), and primary lung cancer, occur with increased frequency and must be excluded.
- *The CD4+ T cell count often is useful in narrowing the differential diagnosis.* As a rule of thumb, bacterial and tubercular infections are more likely at higher CD4+ counts (more than 200 cells/$mm^3$); *Pneumocystis* pneumonia usually occurs at CD4+ counts below 200 cells/$mm^3$, while CMV and *M. avium* complex infections are uncommon until the very late stages of immunosuppression (CD4+ counts below 50 cells/$mm^3$).

Finally, an important point is that pulmonary disease in HIV-infected persons may result from more than one cause, and that even common pathogens may be responsible for disease with atypical manifestations.

# LUNG TUMORS

Although lungs frequently are the site of metastases from cancers arising in extrathoracic organs, primary lung cancer is also a common disease. Roughly 95% of primary lung tumors are carcinomas; the remaining 5% constitute a miscellaneous group that includes carcinoids, mesenchymal malignancies (e.g., fibrosarcomas, leiomyomas), lymphomas, and a few benign lesions. The most common benign tumor is a spherical, small (3 to 4 cm), discrete "hamartoma" that often shows up as a so-called coin lesion on chest radiographs. It consists mainly of mature cartilage, but this is often admixed with fat, fibrous tissue, and blood vessels in various proportions. Clonal cytogenic abnormalities have been demonstrated, indicating that it is a benign neoplasm, although still commonly referred to as hamartoma.

## Carcinomas

Carcinoma of the lung (also known as "lung cancer") is without doubt the single most important cause of cancer-related deaths in industrialized countries. It has long held this position among males in the United States, accounting for about one third of cancer deaths in men, and has become the leading cause of cancer deaths in women as well. American Cancer Society estimates for 2011 included approximately 221,100 new cases of lung cancer and 156,900 deaths. The incidence among males is gradually decreasing, but it continues to increase among females, with more women dying each year from lung cancer than from breast cancers, since 1987. These statistics undoubtedly reflect the causal relationship of cigarette smoking and lung cancer. The peak incidence of lung cancer is in persons in their 50s and 60s. At diagnosis, more than 50% of patients already have distant metastatic disease, while a fourth have disease in the regional lymph nodes. The prognosis with lung cancer is dismal: The 5-year survival rate for all stages of lung cancer combined is about 16%, a figure that has not changed much over the last 30 years; even with disease localized to the lung, a 5-year survival rate of only 45% is typical.

The four major histologic types of carcinomas of the lung are adenocarcinoma, squamous cell carcinoma, small cell carcinoma, and large cell carcinoma (Table 12–7). In some cases there is a combination of histologic patterns (e.g., small cell carcinoma and adenocarcinoma). Of these, squamous cell and small cell carcinomas show the strongest association with smoking. Possibly because of changes in smoking patterns in the U.S., adenocarcinoma has replaced squamous cell carcinoma as the most common primary lung tumor in recent years. Adenocarcinomas also are by far the most common primary tumors arising in women, in never-smokers, and in persons younger than 45 years.

- Until recently, carcinomas of the lung were classified into two broad groups: small cell lung cancer (SCLC) and non–small cell lung cancer (NSCLC), with the latter including adenocarcinomas and squamous and large cell carcinomas.
- *The key reason for this historical distinction was that virtually all SCLCs have metastasized by the time of diagnosis and hence are not curable by surgery. Therefore, they are best treated by chemotherapy, with or without radiation therapy.* By contrast, NSCLCs were more likely to be resectable and usually responded poorly to chemotherapy; however, now therapies are available that target specific mutated gene products present in the various subtypes of NSCLC, mainly in adenocarcinomas. Thus, NSCLC must be subclassified into histologic and molecular subtypes.

**Table 12–7** Histologic Classification of Malignant Epithelial Lung Tumors

| |
|---|
| Adenocarcinoma* |
| Acinar, papillary, micropapillary, solid, lepidic predominant, mucinous subtypes |
| Squamous cell carcinoma |
| Large cell carcinoma |
| Large cell neuroendocrine carcinoma |
| Small cell carcinoma |
| Combined small cell carcinoma |
| Adenosquamous carcinoma |
| Carcinomas with pleomorphic, sarcomatoid, or sarcomatous elements |
| Spindle cell carcinoma |
| Giant cell carcinoma |
| Carcinoid tumor |
| Typical, atypical |
| Carcinomas of salivary gland type |
| Unclassified carcinoma |

*Adenocarcinoma and squamous cell and large cell carcinoma are collectively referred to as non–small cell lung carcinoma (NSCLC).

## ETIOLOGY AND PATHOGENESIS

Smoking-related carcinomas of the lung arise by a stepwise accumulation of a multitude of genetic abnormalities (estimated to be in the thousands for small cell carcinoma) that result in transformation of benign progenitor cells in the lung into neoplastic cells.

The sequence of molecular changes is not random but follows a predictable sequence that parallels the histologic progression toward cancer. Thus, inactivation of the putative tumor suppressor genes located on the short arm of chromosome 3 (3p) is a very early event, whereas *TP53* mutations or activation of the *KRAS* oncogene occurs relatively late. More important, it seems that certain genetic changes, such as loss of chromosomal material on 3p, can be found even in benign bronchial epithelium of persons with lung cancer, as well as in the respiratory epithelium of smokers **without** lung cancer, suggesting that large areas of the respiratory mucosa are mutagenized after exposure to carcinogens ("field effect"). On this fertile soil, those cells that accumulate additional mutations ultimately develop into cancer.

A subset of adenocarcinomas, particularly those arising in nonsmoking women of Far Eastern origin, harbor activating mutations of the **epidermal growth factor receptor (EGFR).** Of note, these tumors are sensitive to a class of agents that inhibit EGFR signaling, although the response often is short-lived. EGFR and K-RAS mutations (in 30% of adenocarcinomas) are mutually exclusive. Other mutations occurring in 4% to 6% of adenocarcinomas are EML4-ALK tyrosine kinase fusion genes and c-MET tyrosine kinase gene amplifications. These abnormalities, while rare, are important because of their therapeutic implications, as they can be targeted with tyrosine kinase inhibitors. Indeed, the identification of genetic alterations producing overactive EGFR, ALK, and MET has opened up a new era of "personalized" lung cancer therapy, in which the genetics of the tumor guides the selection of drugs.

With regard to carcinogenic influences, there is strong evidence that **cigarette smoking** and, to a much lesser extent, other environmental insults are the main culprits responsible for the genetic changes that give rise to lung cancers.

About 90% of lung cancers occur in active smokers or those who stopped recently. A nearly linear correlation has been recognized between the frequency of lung cancer and pack-years of cigarette smoking. The increased risk becomes 60 times greater among habitual heavy smokers (two packs a day for 20 years) than among nonsmokers. Since only 11% of heavy smokers develop lung cancer, however, other predisposing factors must be operative in the pathogenesis of this deadly disease. For reasons not entirely clear, women have a higher susceptibility to carcinogens in tobacco than men. Although cessation of smoking decreases the risk of developing lung cancer over time, it may never return to baseline levels. In fact, genetic changes that predate lung cancer can persist for many years in the bronchial epithelium of former smokers. Passive smoking (proximity to cigarette smokers) increases the risk of developing lung cancer to approximately twice that of nonsmokers. The smoking of pipes and cigars also increases the risk, but only modestly.

Other influences may act in concert with smoking or may by themselves be responsible for some lung cancers; witness the increased incidence of this form of neoplasia in miners of radioactive ores; asbestos workers; and workers exposed to dusts containing arsenic, chromium, uranium, nickel, vinyl chloride, and mustard gas. Exposure to asbestos increases the risk of lung cancer fivefold in nonsmokers. By contrast, **heavy smokers exposed to asbestos have an approximately 55 times greater risk for development of lung cancer than that for nonsmokers not exposed to asbestos.**

Even though smoking and other environmental influences are paramount in the causation of lung cancer, it is well known that all persons exposed to tobacco smoke do not develop cancer. It is very likely that the mutagenic effect of carcinogens is conditioned by hereditary (genetic) factors. Recall that many chemicals (procarcinogens) require metabolic activation via the P-450 monooxygenase enzyme system for conversion into ultimate carcinogens (Chapter 5). There is evidence that persons with specific genetic polymorphisms involving the P-450 genes have an increased capacity to metabolize procarcinogens derived from cigarette smoke, and thus conceivably incur the greatest risk for development of lung cancer. Similarly, persons whose peripheral blood lymphocytes undergo chromosomal breakages after exposure to tobacco-related carcinogens (mutagen sensitivity genotype) have a greater than 10-fold risk of developing lung cancer over that of control subjects.

The sequential changes leading to cancer have been best documented for squamous cell carcinomas, but they also are present in other histologic subtypes. In essence, there is a linear correlation between the intensity of exposure to cigarette smoke and the appearance of ever more worrisome epithelial changes that begin with rather innocuous basal cell hyperplasia and squamous metaplasia and progress to squamous dysplasia and carcinoma in situ, before culminating in invasive cancer. **Among the major histologic subtypes of lung cancer, squamous and small-cell carcinomas show the strongest association with tobacco exposure.**

## MORPHOLOGY

Carcinomas of the lung begin as small mucosal lesions that typically are firm and gray-white. They may arise as intraluminal masses, invade the bronchial mucosa, or form large bulky masses pushing into adjacent lung parenchyma. Some large masses undergo cavitation secondary to central necrosis or develop focal areas of hemorrhage. Finally, these tumors may extend to the pleura, invade the pleural cavity and chest wall, and spread to adjacent intrathoracic structures. More distant spread can occur by way of the lymphatics or the hematogenous route.

**Squamous cell carcinomas** are more common in men than in women and are closely correlated with a smoking history; they tend to **arise centrally in major bronchi** and eventually spread to local hilar nodes, but they disseminate outside the thorax later than do other histologic types. Large lesions may undergo central necrosis, giving rise to **cavitation.** The preneoplastic lesions that antedate, and usually accompany, invasive squamous cell carcinoma are well characterized. Squamous cell carcinomas often are preceded by the development, over years, of **squamous metaplasia or dysplasia** in the bronchial epithelium, which then transforms to **carcinoma in situ,** a phase that may last for several years (Fig. 12–45). By this time, atypical cells may be identified in cytologic smears of sputum or in bronchial lavage fluids or brushings, although the lesion is asymptomatic and undetectable on radiographs. Eventually, the small neoplasm reaches a symptomatic stage, when a well-defined tumor mass begins to obstruct the lumen of a major bronchus, often producing distal atelectasis and infection. Simultaneously, the lesion invades surrounding pulmonary substance (Fig. 12–46, *A*). On histologic examination, these tumors range from well-differentiated squamous cell neoplasms showing keratin pearls (Fig. 12–46, *B*) and intercellular bridges to poorly differentiated neoplasms exhibiting only minimal residual squamous cell features.

**Adenocarcinomas** may occur as central lesions like the squamous cell variant but usually are more **peripherally located,** many with a central scar. Adenocarcinomas are the most common type of lung cancer in women and nonsmokers. In general, adenocarcinomas grow slowly and form smaller masses than do the other subtypes, but they tend to metastasize widely at an early stage. On histologic examination, they may assume a variety of forms, including **acinar (gland-forming)** (Fig. 12–47, *C*), **papillary, mucinous** (formerly mucinous bronchioloalveolar carcinoma, which often is multifocal and may manifest as pneumonia-like consolidation), and **solid types.** The solid variant often requires demonstration of intracellular mucin production by special stains to establish its adenocarcinomatous lineage.

Although foci of squamous metaplasia and dysplasia may be present in the epithelium proximal to resected adenocarcinomas, these are not the precursor lesions for this tumor. The putative precursor of peripheral adenocarcinomas is thought to be **atypical adenomatous hyperplasia** (AAH) (Fig. 12–47, *A*) which progresses to adenocarcinoma in situ (formerly bronchioloalveolar carcinoma), minimally invasive adenocarcinoma (tumor less than 3 cm and invasive component measuring 5 mm or less), and invasive adenocarcinoma (tumor of any size that has invaded to depths greater than 5 mm). On microscopic examination, AAH is recognized as a

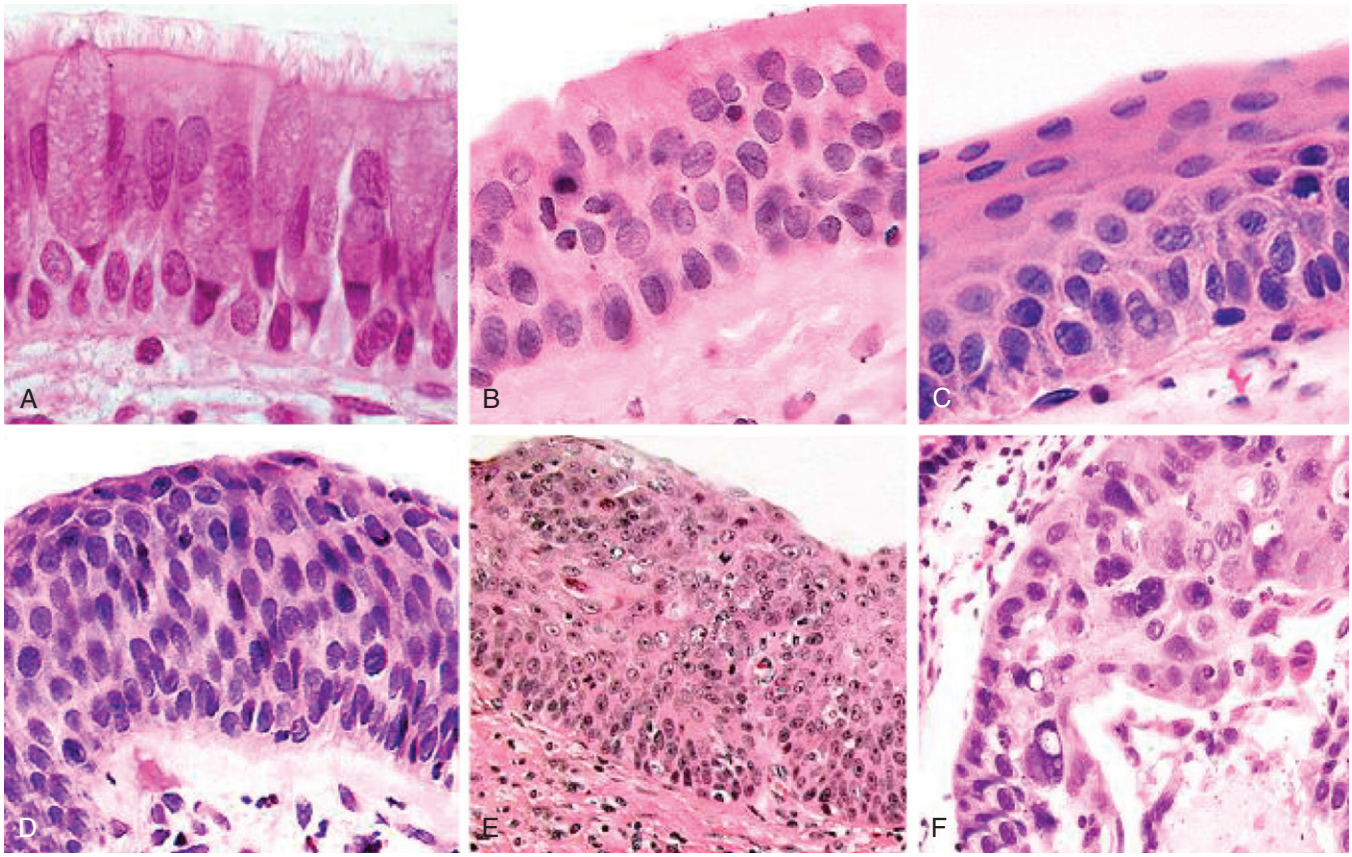


**Figure 12–45** Precursor lesions of squamous cell carcinomas that may antedate the appearance of invasive tumor by years. **A–C,** Some of the earliest (and "mild") changes in smoking-damaged respiratory epithelium include goblet cell hyperplasia (**A**), basal cell (or reserve cell) hyperplasia (**B**), and squamous metaplasia (**C**). **D,** More ominous changes include the appearance of squamous dysplasia, characterized by the presence of disordered squamous epithelium, with loss of nuclear polarity, nuclear hyperchromasia, pleomorphism, and mitotic figures. **E** and **F,** Squamous dysplasia may, in turn, progress through the stages of mild, moderate, and severe dysplasia. Carcinoma in situ (CIS) (**E**) is the stage that immediately precedes invasive squamous carcinoma (**F**). Apart from the lack of basement membrane disruption in CIS, the cytologic features of CIS are similar to those in frank carcinoma. Unless treated, CIS eventually progresses to invasive cancer.

*(A–E, Courtesy of Dr. Adi Gazdar, Department of Pathology, University of Texas Southwestern Medical School, Dallas. F, Reproduced with permission from Travis WD, Colby TV, Corrin B, et al [eds]: World Health Organization Histological Typing of Lung and Pleural Tumours. Heidelberg, Springer, 1999.)*

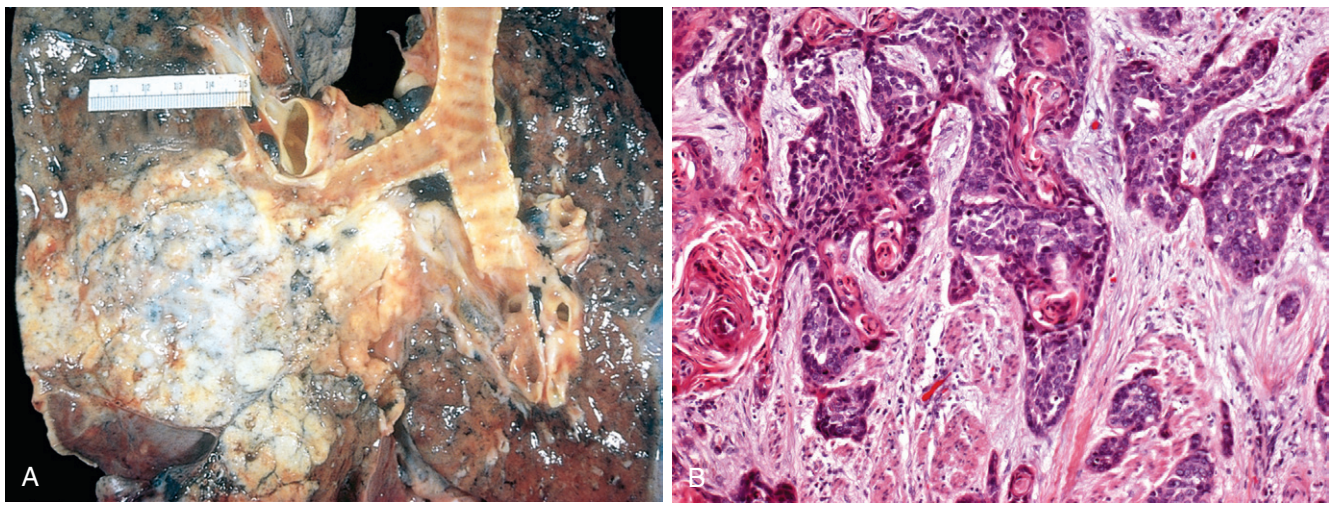


**Figure 12–46** **A**, Squamous cell carcinoma usually begins as a central (hilar) mass and grows contiguously into the peripheral parenchyma as seen here. **B,** Well-differentiated squamous cell carcinoma showing keratinization and pearls.

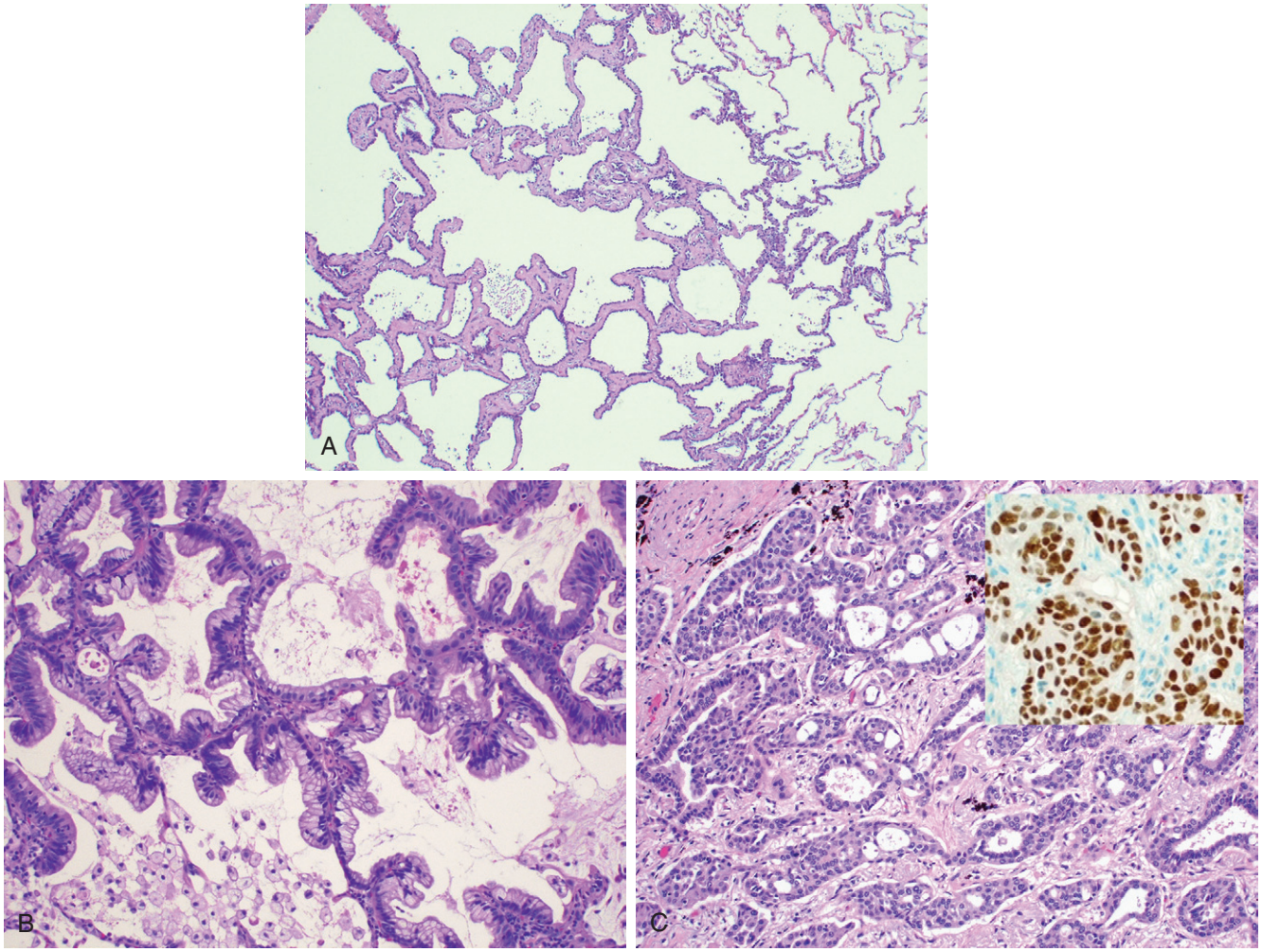


**Figure 12–47** Glandular lesions of the lung. **A,** Atypical adenomatous hyperplasia with cuboidal epithelium and mild interstitial fibrosis. **B,** Adenocarcinoma in situ, mucinous subtype, with characteristic growth along preexisting alveolar septa, without invasion. **C,** Gland-forming adenocarcinoma; inset shows thyroid transcription factor 1 (TTF-1) positivity, which is seen in a majority of pulmonary adenocarcinomas.

well-demarcated focus of epithelial proliferation (with a thickness of 5 mm or less) composed of cuboidal to low-columnar cells, which demonstrate cytologic atypia of variable degree such as nuclear hyperchromasia, pleomorphism, prominent nucleoli, but not to the extent seen in adenocarcinoma. Genetic analyses have shown that lesions of AAH are monoclonal, and they share many of the molecular aberrations associated with adenocarcinomas (e.g., *K-RAS* mutations).

**Adenocarcinoma in situ (AIS), formerly called bronchioloalveolar carcinoma,** often involves peripheral parts of the lung, as a single nodule. **The key features of AIS are diameter of 3 cm or less, growth along preexisting structures, and preservation of alveolar architecture** (Fig. 12–47, *B*). The tumor cells, which may be nonmucinous, mucinous, or mixed, grow in a monolayer along the alveolar septa, which serve as a scaffold (this has been termed a "lepidic" growth pattern, an allusion to the resemblance of neoplastic cells to butterflies sitting on a fence). By definition, AIS does not demonstrate destruction of alveolar architecture or stromal invasion with desmoplasia, features that would merit the diagnosis of frank adenocarcinoma. By analogy to the adenoma–carcinoma sequence in the colon, it is proposed that some invasive adenocarcinomas of the lung may arise through an atypical adenomatous hyperplasia–adenocarcinoma in situ–invasive adenocarcinoma sequence. Studies of lung injury models in mice have now identified a population of multipotent cells at the bronchioloalveolar duct junction, termed bronchioalveolar stem cells (BASCs). After peripheral lung injury, the multipotent BASCs undergo expansion, replenishing the normal cell types (bronchiolar Clara cells and alveolar cells) found in this location, thereby facilitating epithelial regeneration. It is postulated that BASCs incur the initiating oncogenic event (for example, a somatic *K-RAS* mutation) that enables these cells to escape normal "checkpoint" mechanisms and results in pulmonary adenocarcinomas.

**Large cell carcinomas** are undifferentiated malignant epithelial tumors that lack the cytologic features of small cell carcinoma and have no glandular or squamous differentiation. The cells typically have large nuclei, prominent nucleoli, and a moderate amount of cytoplasm. Large cell carcinomas probably represent squamous cell or adenocarcinomas that are so undifferentiated that they can no longer be recognized by means of light microscopy. On ultrastructural examination, however, minimal glandular or squamous differentiation is common.

**Small cell lung carcinomas** (SCLCs) generally appear as pale gray, **centrally located masses** with extension into

the lung parenchyma and early involvement of the hilar and mediastinal nodes. These cancers are composed of tumor cells with a round to fusiform shape, scant cytoplasm, and finely granular chromatin. Mitotic figures frequently are seen (Fig. 12–48). Despite the appellation of **small,** the neoplastic cells are usually twice the size of resting lymphocytes. Necrosis is invariably present and may be extensive. The tumor cells are markedly fragile and often show fragmentation and "crush artifact" in small biopsy specimens. Another feature of small cell carcinomas, best appreciated in cytologic specimens, is nuclear molding resulting from close apposition of tumor cells that have scant cytoplasm. These tumors often express a variety of neuroendocrine markers (Table 12–8) in addition to secreting a host of polypeptide hormones that may result in paraneoplastic syndromes (see below).

**Combined patterns** require no further comment. Of note, however, a significant minority of lung carcinomas reveal more than one line of cellular differentiation, sometimes several (Table 12–7), suggesting that all are derived from a multipotential progenitor cell.

For all of these neoplasms, it is possible to trace involvement of successive chains of nodes about the carina, in the mediastinum, and in the neck (scalene nodes) and clavicular regions and, sooner or later, distant metastases. Involvement of the left supraclavicular node (Virchow node) is particularly characteristic and sometimes calls attention to an occult primary tumor. These cancers, when advanced, often extend into the pleural or pericardial space, leading to inflammation and effusion. They may compress or infiltrate the superior vena cava to cause either venous congestion or the vena caval syndrome (Chapter 9). Apical neoplasms may invade the brachial or cervical sympathetic plexus to cause severe pain in the distribution of the ulnar nerve or to produce Horner syndrome (ipsilateral enophthalmos, ptosis, miosis, and anhidrosis). Such apical neoplasms sometimes are called **Pancoast tumors,** and the combination of clinical findings is known as Pancoast syndrome. Pancoast tumor often is accompanied by destruction of the first and second ribs and sometimes thoracic vertebrae. As with other cancers, tumor-node-metastasis (TNM) categories have been established to indicate the size and spread of the primary neoplasm.

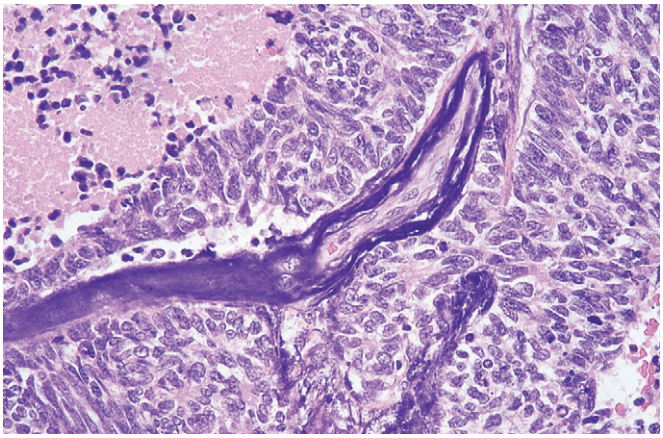

**Figure 12–48** Small cell carcinoma with small deeply basophilic cells and areas of necrosis (*top left*). Note basophilic staining of vascular walls due to encrustation by DNA from necrotic tumor cells (Azzopardi effect).

**Table 12–8** Comparison of Small Cell Lung Carcinoma (SCLC) and Non–Small Cell Lung Carcinoma (NSCLC)

| Feature | SCLC | NSCLC |
|---|---|---|
| Histology | Scant cytoplasm; small, hyperchromatic nuclei with fine chromatin pattern; nucleoli indistinct; diffuse sheets of cells | Abundant cytoplasm; pleomorphic nuclei with coarse chromatin pattern; nucleoli often prominent; glandular or squamous architecture |
| Neuroendocrine markers<br>For example, dense core granules on electron microscopy; expression of chromogranin, neuron-specific enolase, and synaptophysin | Usually present | Usually absent |
| Epithelial markers<br>Epithelial membrane antigen, carcinoembryonic antigen, and cytokeratin intermediate filaments | Present | Present |
| Mucin | Absent | Present in adenocarcinomas |
| Peptide hormone production | Adrenocorticotropic hormone, antidiuretic hormone, gastrin-releasing peptide, calcitonin | Parathyroid hormone–related peptide (PTH-rp) in squamous cell carcinoma |
| Tumor suppressor gene abnormalities | | |
| 3p deletions | >90% | >80% |
| Rb mutations | ~90% | ~20% |
| *p16/CDKN2A* mutations | ~10% | >50% |
| *P53* mutations | >90% | >50% |
| Dominant oncogene abnormalities | | |
| *KRAS* mutations | Rare | ~30% (adenocarcinomas) |
| *EGFR* mutations | Absent | ~20% (adenocarcinomas, nonsmokers, women) |
| ALK rearrangements | Absent | 4%–6% adenocarcinomas, nonsmokers, often have signet ring morphology |
| Response to chemotherapy and radiotherapy | Often complete response but recur invariably | Uncommonly, complete response |

### Clinical Course

Carcinomas of the lung are silent, insidious lesions that in many cases have spread so as to be unresectable before they produce symptoms. In some instances, chronic cough and expectoration call attention to still localized, resectable disease. By the time hoarseness, chest pain, superior vena cava syndrome, pericardial or pleural effusion, or persistent segmental atelectasis or pneumonitis makes its appearance, the prognosis is grim. Too often, the tumor presents with symptoms emanating from metastatic spread to the brain (mental or neurologic changes), liver (hepatomegaly), or bones (pain). Although the adrenals may be nearly obliterated by metastatic disease, adrenal insufficiency (Addison disease) is uncommon, because islands of cortical cells sufficient to maintain adrenal function usually persist.

Overall, NSCLCs carry a better prognosis than SCLCs. When NSCLCs (squamous cell carcinomas or adenocarcinomas) are detected before metastasis or local spread, cure is possible by lobectomy or pneumonectomy. SCLCs, on the other hand, have invariably spread by the time they are first detected, even if the primary tumor appears small and localized. Thus, surgical resection is not a viable treatment. They are very sensitive to chemotherapy but invariably recur. Median survival even with treatment is 1 year.

It is variously estimated that 3% to 10% of all patients with lung cancer develop clinically overt *paraneoplastic syndromes.* These include (1) hypercalcemia caused by secretion of a parathyroid hormone–related peptide (osteolytic lesions may also cause hypercalcemia, but this would not be a paraneoplastic syndrome [Chapter 5]); (2) Cushing syndrome (from increased production of adrenocorticotropic hormone); (3) syndrome of inappropriate secretion of antidiuretic hormone; (4) neuromuscular syndromes, including a myasthenic syndrome, peripheral neuropathy, and polymyositis; (5) clubbing of the fingers and hypertrophic pulmonary osteoarthropathy; and (6) coagulation abnormalities, including migratory thrombophlebitis, nonbacterial endocarditis, and disseminated intravascular coagulation. Secretion of calcitonin and other ectopic hormones also has been documented by assays, but these products usually do not provoke distinctive syndromes. Hypercalcemia most often is encountered with squamous cell neoplasms, the hematologic syndromes with adenocarcinomas. The remaining syndromes are much more common with small cell neoplasms, but exceptions abound.

## SUMMARY

### Carcinomas of the Lung

- The four major histologic subtypes are adenocarcinomas (most common), squamous cell carcinoma, large cell carcinoma, and small cell carcinoma.
- Each of these is clinically and genetically distinct. SCLCs are best treated by chemotherapy, because almost all are metastatic at presentation. The other carcinomas may be curable by surgery if limited to the lung. Combination chemotherapy also is available along with anti-EGFR therapy for those adenocarcinomas with EGFR mutations, and ALK inhibitors for those with ALK mutations.
- Smoking is the most important risk factor for lung cancer; in women and nonsmokers, adenocarcinomas are the most common cancers.
- Precursor lesions include squamous dysplasia (for squamous cancer) and atypical adenomatous hyperplasia and adenocarcinoma in situ (formerly bronchioloalveolar carcinoma) (for some adenocarcinomas).
- Tumors 3 cm or less in diameter characterized by pure growth along preexisting structures (lepidic pattern) without stromal invasion are now called adenocarcinoma in situ.
- Lung cancers, particularly SCLCs, can cause *paraneoplastic syndromes*.

## Carcinoid Tumors

Carcinoid tumors are malignant tumors composed of cells that contain dense-core neurosecretory granules in their cytoplasm and, rarely, may secrete hormonally active polypeptides. They are classified into typical (low-grade) and atypical (intermediate-grade) carcinoids; both are often resectable and curable. They occasionally occur as part of the multiple endocrine neoplasia syndrome (Chapter 19). Bronchial carcinoids occur at an early age (mean 40 years) and represent about 5% of all pulmonary neoplasms.

### MORPHOLOGY

Most carcinoids originate in main bronchi and grow in one of two patterns: (1) an obstructing polypoid, spherical, intraluminal mass (Fig. 12–49, *A*); or (2) a mucosal plaque penetrating the bronchial wall to fan out in the peribronchial tissue—the so-called collar-button lesion. Even these penetrating lesions push into the lung substance along a broad front and are therefore reasonably well demarcated. Peripheral carcinoids are less common. Although 5% to 15% of carcinoids have metastasized to the hilar nodes at presentation, distant metastases are rare. Histologically, **typical carcinoids,** like their counterparts in the intestinal tract, are composed of nests of uniform cells that have regular round nuclei with "salt-and-pepper" chromatin, absent or rare mitoses, and little pleomorphism (Fig. 12–49, *B*). **Atypical carcinoid** tumors display a higher mitotic rate (but less than small or large cell carcinomas) and focal necrosis. The atypical tumors have a higher incidence of lymph node and distant metastasis than typical carcinoids. Unlike typical carcinoids, the atypical subset demonstrates *TP53* mutations in 20% to 40% of cases. **Typical carcinoid, atypical carcinoid, and small cell carcinoma can be considered to represent a continuum of increasing histologic aggressiveness and malignant potential within the spectrum of pulmonary neuroendocrine neoplasms.**

Most carcinoid tumors manifest with signs and symptoms related to their intraluminal growth (i.e., they cause cough, hemoptysis, and recurrent bronchial and pulmonary infections). Peripheral tumors are often asymptomatic, being discovered incidentally on chest radiographs.

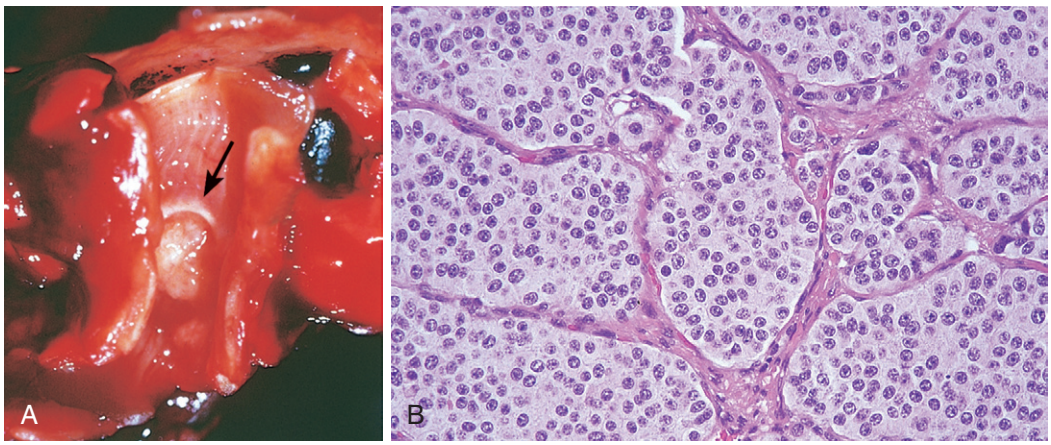


**Figure 12-49** Bronchial carcinoid. **A,** Carcinoid growing as a spherical, pale mass *(arrow)* protruding into the lumen of the bronchus. **B,** Histologic appearance demonstrating small, rounded, uniform nuclei and moderate cytoplasm.
*(Courtesy of Dr. Thomas Krausz, Department of Pathology, University of Chicago Pritzker School of Medicine, Chicago, Illinois.)*

Only rarely do they induce the *carcinoid syndrome,* characterized by intermittent attacks of diarrhea, flushing, and cyanosis. The reported 5- and 10-year survival rates for typical carcinoids are above 85%, while these rates drop to 56% and 35%, respectively, for atypical carcinoids. Only 5% of patients with the most aggressive neuroendocrine lung tumor—SCLC—are alive at 10 years.

## PLEURAL LESIONS

Pathologic involvement of the pleura is, with rare exceptions, a secondary complication of an underlying pulmonary disease. Evidence of secondary infection and pleural adhesions are particularly common findings at autopsy. Important primary disorders are (1) primary intrapleural bacterial infections and (2) a primary neoplasm of the pleura known as *malignant mesothelioma.*

### Pleural Effusion and Pleuritis

In pleural effusion (the presence of fluid in the pleural space) the fluid can be either a transudate or an exudate. When the pleural fluid is a transudate, the condition is termed *hydrothorax.* Hydrothorax from CHF probably is the most common cause of fluid accumulation in the pleural cavity. An exudate, characterized by protein content greater than 2.9gm/dL and, often, inflammatory cells, suggests pleuritis. The four principal causes of *pleural exudate* formation are (1) microbial invasion through either direct extension of a pulmonary infection or blood-borne seeding (*suppurative pleuritis* or *empyema*); (2) cancer (lung carcinoma, metastatic neoplasms to the lung or pleural surface, mesothelioma); (3) pulmonary infarction; and (4) viral pleuritis. Other, less common causes of exudative pleural effusions are systemic lupus erythematosus, rheumatoid arthritis, and uremia, as well as previous thoracic surgery. Malignant effusions characteristically are large and frequently bloody (*hemorrhagic pleuritis*). Cytologic examination may reveal malignant and inflammatory cells.

Whatever the cause, transudates and serous exudates usually are resorbed without residual effects if the inciting cause is controlled or remits. By contrast, fibrinous, hemorrhagic, and suppurative exudates may lead to fibrous organization, yielding adhesions or fibrous pleural thickening, and sometimes minimal to massive calcifications.

### Pneumothorax, Hemothorax, and Chylothorax

*Pneumothorax* refers to presence of air or other gas in the pleural sac. It may occur in young, apparently healthy adults, usually men without any known pulmonary disease (simple or spontaneous pneumothorax), or as a result of some thoracic or lung disorder (secondary pneumothorax), such as emphysema or a fractured rib. Secondary pneumothorax is the consequence of rupture of any pulmonary lesion situated close to the pleural surface that allows inspired air to gain access to the pleural cavity. Such pulmonary lesions include emphysema, lung abscess, tuberculosis, carcinoma, and many other, less common processes. Mechanical ventilatory support with high pressure also may trigger secondary pneumothorax.

There are several possible complications of pneumothorax. A ball-valve leak may create a tension pneumothorax that shifts the mediastinum. Compromise of the pulmonary circulation may follow and may even be fatal. If the leak seals and the lung is not reexpanded within a few weeks (either spontaneously or through medical or surgical intervention), so much scarring may occur that it can never be fully reexpanded. In these cases, serous fluid collects in the pleural cavity, creating hydropneumothorax. With prolonged collapse, the lung becomes vulnerable to infection, as does the pleural cavity when communication between it and the lung persists. Empyema is thus an important complication of pneumothorax (pyopneumothorax).

*Hemothorax,* the collection of whole blood (in contrast with bloody effusion) in the pleural cavity, is a complication of a ruptured intrathoracic aortic aneurysm that is almost always fatal. With hemothorax, in contrast with bloody pleural effusions, the blood clots within the pleural cavity.

*Chylothorax* is a pleural collection of a milky lymphatic fluid containing microglobules of lipid. The total volume

of fluid may not be large, but chylothorax is always significant because it implies obstruction of the major lymph ducts, usually by an intrathoracic cancer (e.g., a primary or secondary mediastinal neoplasm, such as a lymphoma).

### Malignant Mesothelioma

Malignant mesothelioma is a rare cancer of mesothelial cells, usually arising in the parietal or visceral pleura, although it also occurs, much less commonly, in the peritoneum and pericardium. It has assumed great importance because it is related to occupational exposure to asbestos in the air. Approximately 50% of persons with this cancer have a history of exposure to asbestos. Those who work directly with asbestos (shipyard workers, miners, insulators) are at greatest risk, but malignant mesotheliomas have appeared in persons whose only exposure was living in proximity to an asbestos factory or being a relative of an asbestos worker. The latent period for developing malignant mesothelioma is long, often 25 to 40 years after initial asbestos exposure, suggesting that multiple somatic genetic events are required for neoplastic conversion of a mesothelial cell. As stated earlier, *the combination of cigarette smoking and asbestos exposure greatly increases the risk of lung carcinoma, but it does not increase the risk of developing malignant mesothelioma.*

#### MORPHOLOGY

Malignant mesotheliomas are often preceded by extensive **pleural fibrosis and plaque formation,** readily seen on computed tomography scans. These tumors begin in a localized area and over time spread widely, either by contiguous growth or by diffusely seeding the pleural surfaces. At autopsy, the affected lung **typically is ensheathed by a yellow-white, firm, sometimes gelatinous layer of tumor** that obliterates the pleural space (Fig. 12–50). Distant metastases are rare. The neoplasm may directly invade the thoracic wall or the subpleural lung tissue. Normal mesothelial cells are biphasic, giving rise to pleural lining cells as well as the underlying fibrous tissue. Therefore, histologically, mesotheliomas conform to one of three patterns: (1) **epithelial,** in which cuboidal cells line tubular and microcystic spaces, into which small papillary buds project; this is the most common pattern and also the one most likely to be confused with a pulmonary adenocarcinoma; (2) **sarcomatous,** in which spindled and sometimes fibroblastic-appearing cells grow in nondistinctive sheets; and (3) **biphasic,** having both sarcomatous and epithelial areas.

Asbestos is not removed or metabolized from the lung, so the fibers remain in the body for life. Thus, the lifetime risk after exposure does not diminish over time (unlike with smoking, in which the risk decreases after cessation). It has been hypothesized that asbestos fibers preferentially gather near the mesothelial cell layer, where they generate reactive oxygen species, which cause DNA damage with potentially oncogenic mutations. Somatic mutations of two tumor suppressor genes (*p16/CDKN2A,* at chromosomal locus 9p21, and *NF2,* at chromosomal locus 22q12) have been observed in malignant mesotheliomas.

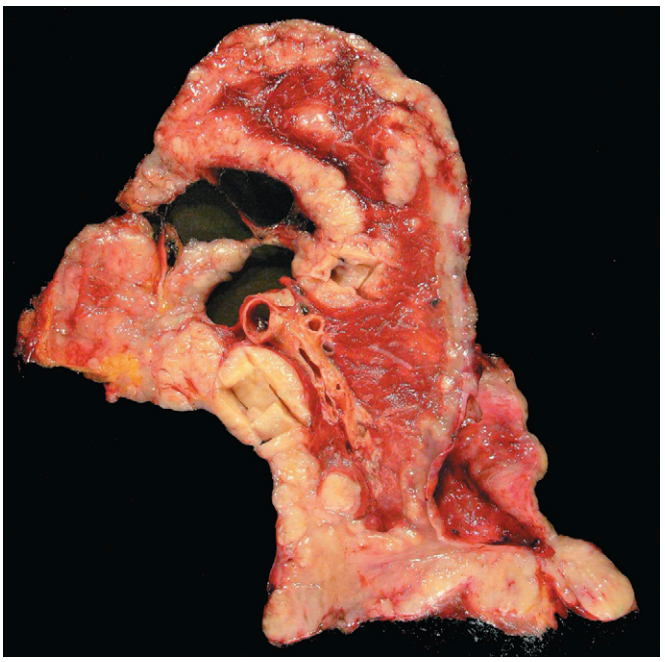

**Figure 12–50** Malignant mesothelioma. Note the thick, firm, white pleural tumor that ensheathes this bisected lung.

## LESIONS OF THE UPPER RESPIRATORY TRACT

### Acute Infections

Acute infections of the upper respiratory tract are among the most common afflictions of humans, most frequently manifesting as the "common cold." The clinical features are well known: nasal congestion accompanied by watery discharge; sneezing; scratchy, dry sore throat; and a slight increase in temperature that is more pronounced in young children. The most common pathogens are rhinoviruses, but coronaviruses, respiratory syncytial viruses, parainfluenza and influenza viruses, adenoviruses, enteroviruses, and sometimes even group A β-hemolytic streptococci have been implicated. In a significant number of cases (around 40%) the cause cannot be determined; perhaps new viruses will be discovered. Most of these infections occur in the fall and winter and are self-limiting (usually lasting for a week or less). In a minority of cases, colds may be complicated by the development of bacterial otitis media or sinusitis.

In addition to the common cold, infections of the upper respiratory tract may produce signs and symptoms localized to the pharynx, epiglottis, or larynx. *Acute pharyngitis,* manifesting as a sore throat, may be caused by a host of agents. Mild pharyngitis with minimal physical findings frequently accompanies a cold and is the most common form of pharyngitis. More severe forms with tonsillitis, associated with marked hyperemia and exudates, occur with β-hemolytic streptococcal and adenovirus infections. Streptococcal tonsillitis is important to recognize and treat early, because of the associated potential for development of peritonsillar abscesses ("quinsy") or for progression to poststreptococcal glomerulonephritis and acute rheumatic

fever. Coxsackievirus A infection may produce pharyngeal vesicles and ulcers (herpangina). Infectious mononucleosis, caused by Epstein-Barr virus (EBV), is an important cause of pharyngitis and bears the moniker of "kissing disease"—reflecting the common mode of transmission in previously nonexposed persons.

Acute *bacterial epiglottitis* is a syndrome predominantly affecting young children who have an infection of the epiglottis caused by *H. influenzae,* in which pain and airway obstruction are the major findings. The onset is abrupt. Failure to appreciate the need to maintain an open airway for a child with this condition can have fatal consequences. The advent of vaccination against *H. influenzae* has greatly decreased the incidence of this disease.

*Acute laryngitis* can result from inhalation of irritants or may be caused by allergic reactions. It may also be caused by the agents that produce the common cold and usually involve the pharynx and nasal passages as well as the larynx. Brief mention should be made of two uncommon but important forms of laryngitis: *tuberculous* and *diphtheritic.* The former is almost always a consequence of protracted active tuberculosis, during which infected sputum is coughed up. Diphtheritic laryngitis has fortunately become uncommon because of the widespread immunization of young children against diphtheria toxin. After it is inhaled, *Corynebacterium diphtheriae* implants on the mucosa of the upper airways, where it elaborates a powerful exotoxin that causes necrosis of the mucosal epithelium, accompanied by a dense fibrinopurulent exudate, to create the classic superficial, dirty-gray pseudomembrane of diphtheria. The major hazards of this infection are sloughing and aspiration of the pseudomembrane (causing obstruction of major airways) and absorption of bacterial exotoxins (producing myocarditis, peripheral neuropathy, or other tissue injury).

In children, parainfluenza virus is the most common cause of laryngotracheobronchitis, more commonly known as *croup,* but other agents such as respiratory syncytial virus also may precipitate this condition. Although self-limited, croup may cause frightening inspiratory stridor and harsh, persistent cough. In occasional cases, the laryngeal inflammatory reaction may narrow the airway sufficiently to result in respiratory failure. Viral infections in the upper respiratory tract predispose the patient to secondary bacterial infection, particularly by staphylococci, streptococci, and *H. influenzae.*

## Nasopharyngeal Carcinoma

Nasopharyngeal carcinoma is a rare neoplasm that merits comment because of (1) the strong epidemiologic links to EBV and (2) the high frequency of this form of cancer among the Chinese, which raises the possibility of viral oncogenesis on a background of genetic susceptibility. It is thought that EBV infects the host by first replicating in the nasopharyngeal epithelium and then infecting nearby tonsillar B lymphocytes. In some persons this leads to transformation of the epithelial cells. Unlike the case with Burkitt lymphoma (Chapter 11), another EBV-associated tumor, the EBV genome is found in virtually all nasopharyngeal carcinomas, including those that occur outside the endemic areas in Asia.

The three histologic variants are keratinizing squamous cell carcinoma, nonkeratinizing squamous cell carcinoma, and undifferentiated carcinoma; the last-mentioned is the most common and the one most closely linked with EBV. The undifferentiated neoplasm is characterized by large epithelial cells with indistinct cell borders (reflecting "syncytial" growth) and prominent eosinophilic nucleoli. As described in Chapter 11, in infectious mononucleosis, EBV directly infects B lymphocytes, after which a marked proliferation of reactive T lymphocytes causes atypical lymphocytosis, seen in the peripheral blood, and enlarged lymph nodes. Similarly, in nasopharyngeal carcinomas, a striking influx of mature lymphocytes often can be seen. These neoplasms are therefore referred to as "lymphoepitheliomas"—a misnomer, because the lymphocytes are not part of the neoplastic process, nor are the tumors benign. The presence of large neoplastic cells in a background of reactive lymphocytes may give rise to an appearance similar to that in non-Hodgkin lymphomas, and immunohistochemical stains may be required to prove the epithelial nature of the malignant cells. Nasopharyngeal carcinomas invade locally, spread to cervical lymph nodes, and then metastasize to distant sites. They tend to be radiosensitive, and 5-year survival rates of 50% are reported even for patients with advanced cancers.

## Laryngeal Tumors

A variety of non-neoplastic, benign, and malignant neoplasms of epithelial and mesenchymal origin may arise in the larynx, but only vocal cord nodules, papillomas, and squamous cell carcinomas are sufficiently common to merit comment. In all of these conditions, the most common presenting feature is hoarseness.

### *Nonmalignant Lesions*

*Vocal cord nodules* ("polyps") are smooth, hemispherical protrusions (usually less than 0.5 cm in diameter) located, most often, on the true vocal cords. The nodules are composed of fibrous tissue and covered by stratified squamous mucosa that usually is intact but can be ulcerated from contact trauma with the other vocal cord. These lesions occur chiefly in heavy smokers or singers (singer's nodes), suggesting that they are the result of chronic irritation or abuse.

*Laryngeal papilloma* or *squamous papilloma* of the larynx is a benign neoplasm, usually located on the true vocal cords, that forms a soft, raspberry-like excrescence rarely more than 1 cm in diameter. Histologically, it consists of multiple, slender, finger-like projections supported by central fibrovascular cores and covered by an orderly, typical, stratified squamous epithelium. When the papilloma is on the free edge of the vocal cord, trauma may lead to ulceration that can be accompanied by hemoptysis.

Papillomas usually are single in adults but often are multiple in children, in whom the condition is referred to as *recurrent respiratory papillomatosis* (RRP), since they typically tend to recur after excision. These lesions are caused by human papillomavirus (HPV) types 6 and 11, do not become malignant, and often spontaneously regress at puberty. Cancerous transformation is rare. The most likely cause for their occurrence in children is vertical

transmission from an infected mother during delivery. Therefore, the recent availability of an HPV vaccine that can protect women of reproductive age against infection with types 6 and 11 provides an opportunity for prevention of RRP in children.

### *Carcinoma of the Larynx*

Carcinoma of the larynx represents only 2% of all cancers. It most commonly occurs after age 40 years and is more common in men than in women (with a gender ratio of 7:1). Environmental influences are very important in its causation; nearly all cases occur in smokers, and alcohol and asbestos exposure may also play roles. Human papillomavirus sequences have been detected in about 15% of tumors, which tend to have a better prognosis than other carcinomas.

About 95% of laryngeal cancers are typical squamous cell carcinomas. Rarely, adenocarcinomas are seen, presumably arising from mucous glands. The tumor develops directly on the vocal cords (glottic tumors) in 60% to 75% of cases, but it may arise above the cords (supraglottic; 25% to 40%) or below the cords (subglottic; less than 5%). Squamous cell carcinomas of the larynx begin as in situ lesions that later appear as pearly gray, wrinkled plaques on the mucosal surface, ultimately ulcerating and fungating (Fig. 12–51). The glottic tumors are usually keratinizing, well- to moderately differentiated squamous cell carcinomas, although nonkeratinizing, poorly differentiated carcinomas may also be seen. As expected with lesions arising from recurrent exposure to environmental carcinogens, adjacent mucosa may demonstrate squamous cell hyperplasia with foci of dysplasia, or even carcinoma in situ.

Carcinoma of the larynx manifests itself clinically with persistent hoarseness. The location of the tumor within the larynx has a significant bearing on prognosis. For example, about 90% of glottic tumors are confined to the larynx at diagnosis. First, as a result of interference with vocal cord mobility, they develop symptoms early in the course of disease; second, the glottic region has a sparse lymphatic supply, and spread beyond the larynx is uncommon. By contrast, the supraglottic larynx is rich in lymphatic spaces, and nearly a third of these tumors metastasize to regional (cervical) lymph nodes. The subglottic tumors tend to remain clinically quiescent, usually manifesting as advanced disease. With surgery, radiation therapy, or combination treatment, many patients can be cured, but about one third die of the disease. The usual cause of death is infection of the distal respiratory passages or widespread metastases and cachexia.

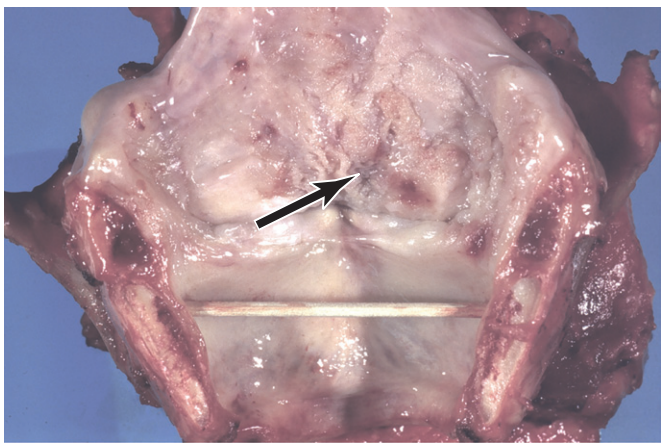

**Figure 12–51** Laryngeal squamous cell carcinoma *(arrow)* arising in a supraglottic location (above the true vocal cord).

## ACKNOWLEDGMENT

The contributions of Anirban Maitra, MD, to this chapter are gratefully acknowledged.

## BIBLIOGRAPHY

American Thoracic Society; European Respiratory Society: International Multidisciplinary Consensus Classification of the Idiopathic Interstitial Pneumonias. This joint statement of the American Thoracic Society (ATS) and the European Respiratory Society (ERS) was adopted by the ATS board of directors, June 2001 and by the ERS Executive Committee, June 2001. Am J Respir Crit Care Med 165:277, 2002. *[The authoritative classification of interstitial pneumonias from the two major trans-Atlantic pulmonary societies.]*

Baughman RP, Lower EE, du Bois RM: Sarcoidosis. Lancet 361:1111, 2003. *[A good review of this subject, including evidence on the role of genetic polymorphisms that determine susceptibility to sarcoidosis, and treatment options.]*

Beasley MB: Smoking-related small airway disease—a review and update. Adv Anat Pathol 17:270, 2010. *[Review of histologic findings and pathogenesis of small airway disease in smoking-related diseases.]*

Collard HR, King TE Jr: Demystifying idiopathic interstitial pneumonia. Arch Intern Med 163:17, 2003. *[A review on the histopathologic and clinical features distinguishing interstitial pneumonias from other causes of pulmonary fibrosis, with particular emphasis on idiopathic pulmonary fibrosis and the importance of recognizing this pattern.]*

Cosio MG, Saetta M, Agusti A: Immunologic aspects of chronic obstructive pulmonary disease. N Engl J Med 360:2445, 2009. *[An excellent review of mechanisms leading to COPD.]*

Davies D, Wicks J, Powell RM, et al: Airway remodeling in asthma: new insights. J Allergy Clin Immunol 111:215, 2003. *[A review on the structural changes involved in asthma pathogenesis, and the role of candidate gene polymorphisms that may confer potential susceptibility to airway remodeling and asthma.]*

Eramo A, Haas TL, De Maria R: Lung cancer stem cells: tools and targets to fight lung cancer. Oncogene 29:4625, 2010. *[Review of what is currently known about lung cancer stem cells and their diagnostic, prognostic, and therapeutic implications.]*

Frieden TR, Sterling TR, Munsiff SS, et al: Tuberculosis. Lancet 362:887, 2003. *[A clinical review on global trends in tuberculosis, emergence of multidrug resistance, and measures for primary prevention of this disease from a public health perspective.]*

Hogg JC, Timens W: The pathology of chronic obstructive pulmonary disease. Annu Rev Pathol 4:435, 2009. *[A comprehensive review on the pathogenesis of COPD, stressing the roles of inflammation, tissue repair and remodeling, and small airway disease in COPD.]*

Horowitz JC, Martinez FJ, Thannickal VJ: Mesenchymal cell fate and phenotypes in the pathogenesis of emphysema. COPD 6:201, 2009. *[An excellent discussion of the emerging evidence supporting that genetic factors, inflammation and environmental factors, including cigarette smoke itself, collectively contribute to the pathogenesis of emphysema.]*

Jones KD: An update on lung cancer staging. Adv Anat Pathol 17:33, 2010. *[Review of the tumor-node-metastasis (TNM) criteria for lung cancer staging.]*

King PT: The pathophysiology of bronchiectasis. Int J Chron Obstruct Pulmon Dis 4:411, 2009. *[A review of the pathology, associated conditions, and microbiology of bronchiectasis.]*

Meyers DA: Genetics of asthma and allergy: what have we learned? J Allergy Clin Immunol 126:439, 2010. *[An update on genetic approaches to understanding the susceptibility and severity of asthma and allergy.]*

Noguchi M: Stepwise progression of pulmonary adenocarcinoma—clinical and molecular implications. Cancer Metastasis Rev 29:15, 2010. *[Correlates the progression of adenocarcinoma with molecular changes.]*

Rabinovitch M: Pathobiology of pulmonary hypertension. Annu Rev Pathol 2:369, 2007. *[Current concepts in the causation of pulmonary hypertension.]*

Rimal B, Greenberg AK, Rom WN: Basic pathogenetic mechanisms in silicosis: current understanding. Curr Opin Pulm Med 11:169; 2005. *[A review on how silica exposure leads to pulmonary disease, including discussions on the controversy surrounding the potential carcinogenic role of this mineral dust.]*

Runo J, Loyd J: Primary pulmonary hypertension. Lancet 361:1533, 2003. *[A comprehensive review on the genetics, pathophysiology, clinical manifestations, and treatment options for this entity.]*

Sekido Y, Fong KM, Minna JD: Molecular genetics of lung cancer. Annu Rev Med 54:73, 2003. *[An outstanding review on the molecular abnormalities underlying lung cancers, particularly those differentiating SCLCs from NSCLCs.]*

Simonneau G, Robbins IM, Beghetti M, et al: Updated clinical classification of pulmonary hypertension. J Am Coll Cardiol 30:54, 2009. *[This is a clinical classification based on pathophysiologic mechanisms, clinical presentation, and therapeutic approaches.]*

Stewart S, Rassi D: Advances in the understanding and classification of pulmonary hypertension. Histopathology 54:104, 2009. *[Describes recent advances in genetic and molecular mechanisms and histopathologic findings in pulmonary hypertension.]*

Travis WD, Brambilla E, Noguchi M, et al: International Association for the Study of Lung Cancer/American Thoracic Society/European Respiratory Society international multidisciplinary classification of lung adenocarcinoma. J Thorac Oncol 6:244, 2011. *[New classification of adenocarcinoma that incorporates clinical, radiologic, histologic, molecular, and prognostic features.]*

Tsushima K, King LS, Aggarwal NR, et al: Acute lung injury review. Intern Med 48:621, 2009. *[Includes definition, incidence, outcome, pathogenesis, and therapy of acute lung injury/acute respiratory distress syndrome.]*

Varella-Garcia M: Chromosomal and genomic changes in lung cancer. Cell Adh Migr 4:1, 2010. *[Comprehensive review of recurrent genomic changes affecting cell growth and differentiation and apoptotic pathways in lung cancer and their application to targeted therapy.]*

Walter MJ, Holtzmann MJ: A centennial history of research on asthma pathogenesis. Am J Respir Cell Mol Biol 32:483, 2005. *[An excellent summary paper describing important milestones in 100 years of research on the pathogenesis of asthma.]*

Ware LB: Pathophysiology of acute lung injury and the acute respiratory distress syndrome. Semin Respir Crit Care Med 27:337, 2006. *[An excellent discussion of the pathogenesis of ARDS.]*

This page intentionally left blank

See Targeted Therapy available online at
studentconsult.com

CHAPTER 13

# Kidney and Its Collecting System

CHAPTER CONTENTS

**Clinical Manifestations of Renal Diseases 517**
**Glomerular Diseases 518**
Mechanisms of Glomerular Injury and Disease 519
The Nephrotic Syndrome 523
The Nephritic Syndrome 529
Rapidly Progressive Glomerulonephritis 531
**Diseases Affecting Tubules and Interstitium 533**
Tubulointerstitial Nephritis 533
Acute Tubular Injury 537
**Diseases Involving Blood Vessels 538**
Arterionephrosclerosis 539
Malignant Hypertension 539
Thrombotic Microangiopathies 540
**Chronic Kidney Disease 541**
**Cystic Diseases of the Kidney 542**
Simple Cysts 542
Autosomal Dominant (Adult) Polycystic Kidney Disease 542
Autosomal Recessive (Childhood) Polycystic Kidney Disease 544
Medullary Diseases with Cysts 544
**Urinary Outflow Obstruction 545**
Renal Stones 545
Hydronephrosis 545
**Tumors 547**
Tumors of the Kidney 547

The kidney is a structurally complex organ that has evolved to carry out a number of important functions: excretion of the waste products of metabolism, regulation of body water and salt, maintenance of acid balance, and secretion of a variety of hormones and prostaglandins. Diseases of the kidney are as complex as its structure, but their study is facilitated by dividing them into those that affect its four components: glomeruli, tubules, interstitium, and blood vessels. This traditional approach is useful because the early manifestations of diseases that affect each of these components tend to be distinctive. Furthermore, some structures seem to be more vulnerable to specific forms of renal injury; for example, glomerular diseases are often immunologically mediated, whereas tubular and interstitial disorders are more likely to be caused by toxic or infectious agents. However, some disorders affect more than one structure, and functional interdependence of structures in the kidney means that damage to one component almost always secondarily affects the others. Thus, severe glomerular damage impairs the flow through the peritubular vascular system; conversely, tubular destruction, by increasing intraglomerular pressure and inducing cytokines and chemokines, may induce glomerular sclerosis. Whatever the origin, there is a tendency for chronic renal disease ultimately to damage all four components of the kidney, culminating in *end-stage kidney disease.* For these reasons, the early signs and symptoms of renal disease are particularly important in discerning the initiating cause of the disease, and therefore are referred to in the discussion of individual diseases. The functional reserve of the kidney is large, and much damage may occur before renal dysfunction becomes evident.

## CLINICAL MANIFESTATIONS OF RENAL DISEASES

The clinical manifestations of renal disease can be grouped into reasonably well-defined syndromes. Some are peculiar to glomerular diseases and others are shared by several renal disorders. Before we list the syndromes, a few terms must be defined.

*Azotemia* is an elevation of blood urea nitrogen and creatinine levels and usually reflects a decreased glomerular filtration rate (GFR). GFR may be decreased as a consequence of intrinsic renal disease or extrarenal causes. *Prerenal azotemia* is encountered when there is hypoperfusion of the kidneys, which decreases GFR *in the absence of parenchymal damage. Postrenal azotemia* results when urine flow is obstructed below the level of the kidney. Relief of the obstruction is followed by correction of the azotemia.

When azotemia gives rise to clinical manifestations and systemic biochemical abnormalities, it is termed *uremia.* Uremia is characterized not only by failure of renal excretory function but also by a host of metabolic and endocrine alterations incident to renal damage. There is, in addition, secondary gastrointestinal (e.g., uremic gastroenteritis); neuromuscular (e.g., peripheral neuropathy); and cardiovascular (e.g., uremic fibrinous pericarditis) involvement.

We now turn to a brief description of the major renal syndromes:

- *Nephritic syndrome* results from glomerular injury and is dominated by the acute onset of usually grossly visible hematuria (red blood cells and red cell casts in urine), proteinuria of mild to moderate degree, azotemia,

edema, and hypertension; it is the classic presentation of acute poststreptococcal glomerulonephritis.
- *Nephrotic syndrome* is a glomerular syndrome characterized by heavy proteinuria (excretion of greater than 3.5 g of protein/day in adults), hypoalbuminemia, severe edema, hyperlipidemia, and lipiduria (lipid in the urine).
- *Asymptomatic hematuria* or non-nephrotic *proteinuria,* or a combination of these two, is usually a manifestation of subtle or mild glomerular abnormalities.
- *Rapidly progressive glomerulonephritis* is associated with severe glomerular injury and results in loss of renal function in a few days or weeks. It is manifested by microscopic hematuria, dysmorphic red blood cells and red cell casts in the urine sediment, and mild to moderate proteinuria.
- *Acute kidney injury* is dominated by oliguria or anuria (no urine flow), and recent onset of azotemia. It can result from glomerular injury (such as rapidly progessive glomerulonephritis), interstitial injury, vascular injury (such as thrombotic microangiopathy), or acute tubular injury.
- *Chronic kidney disease,* characterized by prolonged symptoms and signs of uremia, is the result of progressive scarring in the kidney from any cause and may culminate in end-stage kidney disease, requiring dialysis or transplantation.
- *Urinary tract infection* is characterized by bacteriuria and pyuria (bacteria and leukocytes in the urine). The infection may be symptomatic or asymptomatic, and it may affect the kidney (*pyelonephritis*) or the bladder (*cystitis*) only.
- *Nephrolithiasis* (renal stones) is manifested by renal colic, hematuria (without red cell casts), and recurrent stone formation.

In addition to these renal syndromes, *urinary tract obstruction* and *renal tumors* also commonly present with signs and symptoms related to renal dysfunction and are discussed later.

## GLOMERULAR DISEASES

Disorders affecting the glomerulus encompass a clinically important category of renal disease. The glomerulus consists of an anastomosing network of capillaries invested by two layers of epithelium. The visceral epithelium (composed of podocytes) is an intrinsic part of the capillary wall, whereas the parietal epithelium lines Bowman space (urinary space), the cavity in which plasma ultrafiltrate first collects. The glomerular capillary wall is the filtration unit and consists of the following structures (Figs. 13–1 and 13–2):

- A thin layer of fenestrated *endothelial cells,* each fenestra being 70 to 100 nm in diameter.
- A *glomerular basement membrane* (GBM) with a thick, electron-dense central layer, the *lamina densa,* and thinner, electron-lucent peripheral layers, the *lamina rara interna* and *lamina rara externa.* The GBM consists of collagen (mostly type IV), laminin, polyanionic proteoglycans, fibronectin, and several other glycoproteins.
- *Podocytes,* which are structurally complex cells that possess interdigitating processes embedded in and adherent to the lamina rara externa of the basement membrane. Adjacent *foot processes* are separated by 20- to 30-nm-wide *filtration slits,* which are bridged by a thin slit diaphragm composed in large part of nephrin (see further on).
- The glomerular tuft is supported by *mesangial cells* lying between the capillaries. Basement membrane–like mesangial matrix forms a meshwork through which the mesangial cells are scattered. These cells, of mesenchymal origin, are contractile and are capable of proliferation, of laying down collagen and other matrix components, and of secreting a number of biologically active mediators.

Normally, the glomerular filtration system is extraordinarily permeable to water and small solutes and almost completely impermeable to molecules of the size and molecular charge of albumin (a 70,000-kDa protein). This selective permeability, called glomerular barrier function, discriminates among protein molecules according to their size (the larger, the less permeable), their charge (the more cationic, the more permeable), and their configuration. The characteristics of the normal barrier depend on the complex structure of the capillary wall, the integrity of the GBM, and the many anionic molecules present within the wall, including the acidic proteoglycans of the GBM and the sialoglycoproteins of epithelial and endothelial cell coats. *The podocyte is also crucial to the maintenance of glomerular barrier function*. Podocyte slit diaphragms are important diffusion barriers for plasma proteins, and podocytes are also largely responsible for synthesis of GBM components.

In the past few years, much has been learned about the molecular architecture of the glomerular filtration barrier. *Nephrin,* a transmembrane glycoprotein, is the major component of the slit diaphragms between adjacent foot processes. Nephrin molecules from adjacent foot processes bind to each other through disulfide bridges at the center of the slit diaphragm. The intracellular part of nephrin interacts with several cytoskeletal and signaling proteins (Fig. 13–1). Nephrin and its associated proteins, including *podocin,* have a crucial role in maintaining the selective permeability of the glomerular filtration barrier. This role is dramatically illustrated by rare hereditary diseases in which mutations of nephrin or its partner proteins are associated with abnormal leakage into the urine of plasma proteins, giving rise to the nephrotic syndrome (discussed later). This observation suggests that acquired defects in the function or structure of slit diaphragms constitute an important mechanism of proteinuria, the hallmark of the nephrotic syndrome.

Glomeruli may be injured by diverse mechanisms and in the course of a number of systemic diseases (Table 13–1). Immunologically mediated diseases such as systemic lupus erythematosus, vascular disorders such as hypertension and hemolytic uremic syndrome, metabolic diseases such as diabetes mellitus, and some purely hereditary conditions such as Alport syndrome often affect the glomerulus. These are termed *secondary glomerular diseases* to differentiate them from those in which the kidney is the only or predominant organ involved. The latter constitute

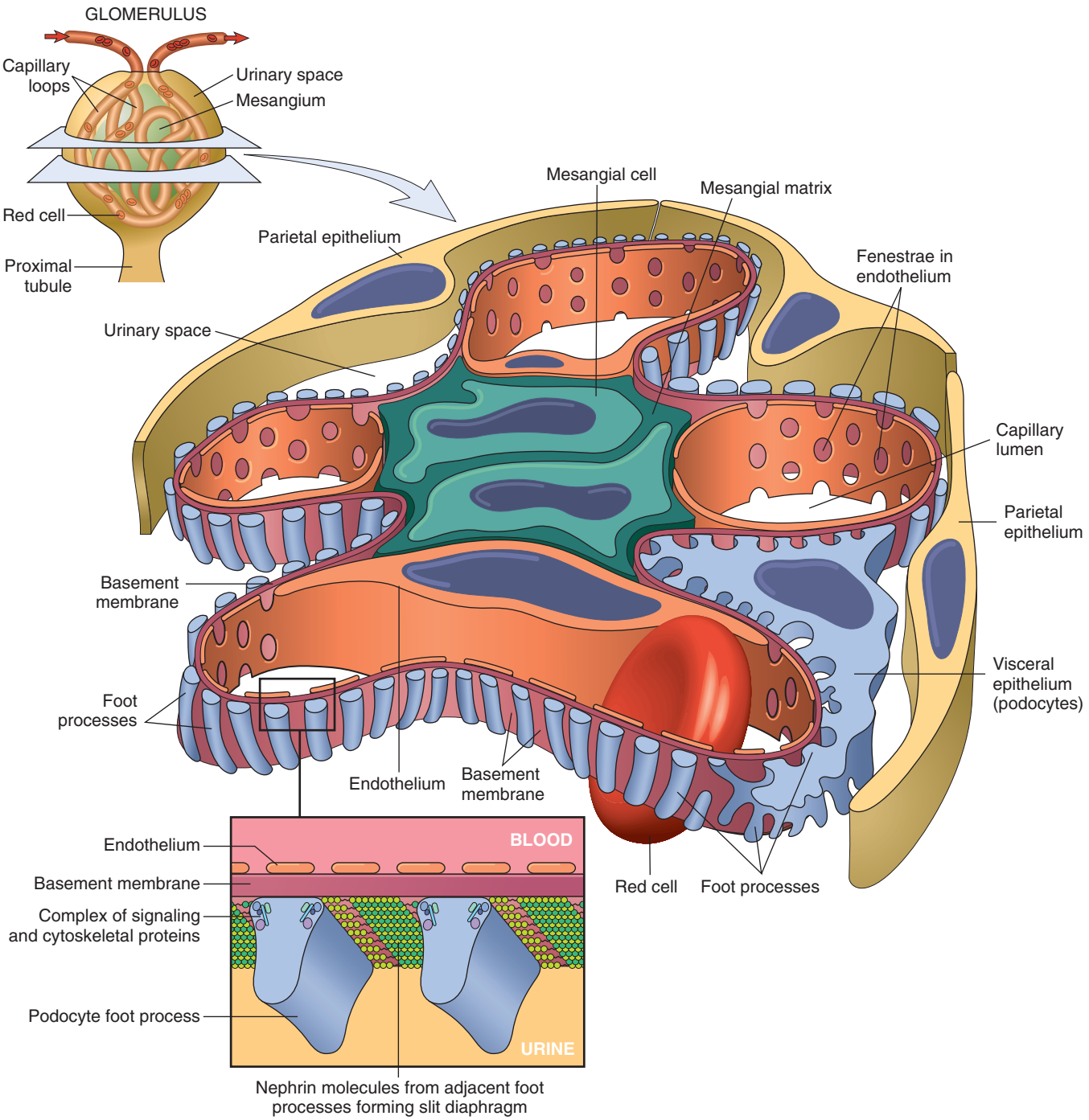


**Figure 13–1** Schematic diagram of a lobe of a normal glomerulus.

the various types of *primary glomerular diseases,* which are discussed later in this section. The glomerular alterations in systemic diseases are discussed elsewhere.

## Mechanisms of Glomerular Injury and Disease

Although little is known about the etiologic agents or triggering events, it is clear that immune mechanisms underlie most types of primary glomerular diseases and many of the secondary glomerular diseases. Under experimental conditions, glomerulonephritis (GN) can be readily induced by antibodies, and deposits of immunoglobulins, often with various components of complement, are found frequently in patients with GN. Cell-mediated immune mechanisms may also play a role in certain glomerular diseases.

Two forms of antibody-associated injury have been established: (1) injury resulting from deposition of soluble circulating antigen-antibody complexes in the glomerulus and (2) injury by antibodies reacting in situ within the glomerulus, either with insoluble fixed (intrinsic)

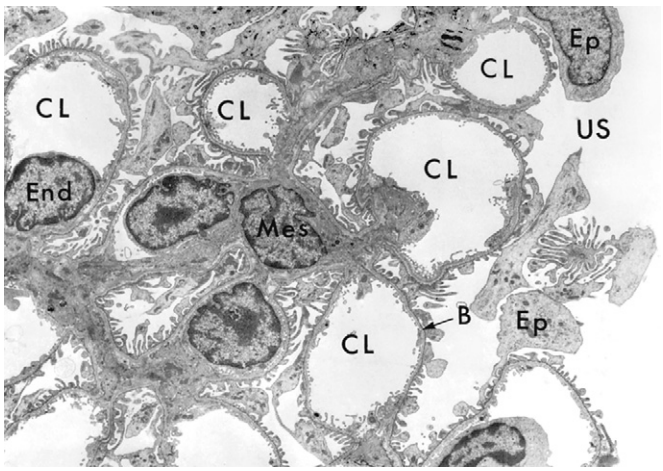


**Figure 13–2** Low-power electron micrograph of rat glomerulus. B, basement membrane; CL, capillary lumen; End, endothelium; Ep, visceral epithelial cells (podocytes) with foot processes; Mes, mesangium; US, urinary space.

glomerular antigens or with molecules planted within the glomerulus (Fig. 13–3). In addition, antibodies directed against glomerular cell components may cause glomerular injury. These pathways are not mutually exclusive, and in humans all may contribute to injury.

### *Glomerulonephritis Caused by Circulating Immune Complexes*

The pathogenesis of immune complex diseases is discussed in detail in Chapter 4. Presented here is a brief review of the salient features that relate to glomerular injury in GN.

With circulating immune complex–mediated disease, the glomerulus may be considered an "innocent bystander" because it does not incite the reaction. The antigen is not of glomerular origin. It may be endogenous, as in the GN associated with systemic lupus erythematosus, or it may be exogenous, as is probable in the GN that follows certain bacterial (streptococcal), viral (hepatitis B), parasitic (*Plasmodium falciparum* malaria), and spirochetal (*Treponema pallidum*) infections. Often the inciting antigen is unknown, as in most cases of membranoproliferative GN (MPGN).

Whatever the antigen may be, *antigen–antibody complexes* are formed in situ or in the circulation and are then trapped in the glomeruli, where they *produce injury, in large part through the activation of complement and the recruitment of leukocytes*. Injury also may occur through the engagement of Fc receptors on leukocytes independent of complement activation, as cross-linking of Fc receptors by IgG antibodies also results in leukocyte activation and degranulation. Regardless of the mechanism, the glomerular lesions usually consist of leukocytic infiltration (exudation) into glomeruli and variable proliferation of endothelial, mesangial, and parietal epithelial cells. Electron microscopy reveals the immune complexes as electron-dense deposits or clumps that lie at one of three sites: in the mesangium, between the endothelial cells and the GBM (subendothelial deposits), or between the outer surface of the GBM and the podocytes (subepithelial deposits). Deposits may be located at more than one site in a given case. The presence of immunoglobulins and complement in these deposits can be demonstrated by immunofluorescence microscopy (Fig. 13–4, *A*). *The pattern and location of immune complex deposition are helpful in distinguishing among various types of GN.*

Once deposited in the kidney, immune complexes may eventually be degraded or phagocytosed, mostly by infiltrating leukocytes and mesangial cells, and the inflammatory changes may then subside. Such a course occurs when the exposure to the inciting antigen is short-lived and limited, as in most cases of poststreptococcal or acute infection-related GN. However, if exposure to antigen is sustained over time, repeated cycles of immune complex formation, deposition, and injury may occur, leading to chronic GN. In some cases the source of chronic antigenic exposure is clear, such as in hepatitis B virus infection and self nuclear antigens in systemic lupus erythematosus. In other cases, however, the antigen is unknown. Circulating immune complex deposition as a mechanism of injury is well studied in animal models but is uncommonly identified in human disease.

**Table 13–1** Glomerular Diseases

| |
|---|
| **Primary Glomerular Diseases** |
| Minimal-change disease |
| Focal segmental glomerulosclerosis |
| Membranous nephropathy |
| Acute postinfectious GN |
| Membranoproliferative GN |
| IgA nephropathy |
| **Glomerulopathies Secondary to Systemic Diseases** |
| Lupus nephritis (systemic lupus erythematosus) |
| Diabetic nephropathy |
| Amyloidosis |
| GN secondary to multiple myeloma |
| Goodpasture syndrome |
| Microscopic polyangiitis |
| Wegener granulomatosis |
| Henoch-Schönlein purpura |
| Bacterial endocarditis–related GN |
| Thrombotic microangiopathy |
| **Hereditary Disorders** |
| Alport syndrome |
| Fabry disease |
| Podocyte/slit-diaphragm protein mutations |

GN, glomerulonephritis; IgA, immunoglobulin A.

### *Glomerulonephritis Caused by In Situ Immune Complexes*

*Antibody deposition in the glomerulus is a major pathway of glomerular injury.* As noted, antibodies in this form of injury react directly with fixed or planted antigens in the glomerulus. Immune reactions in situ, trapping of circulating complexes, interactions between these two events, and local hemodynamic and structural determinants in the glomerulus all contribute to the morphologic and functional alterations in GN. Antibodies also may react in situ with previously "planted" nonglomerular antigens, which may localize in the kidney by interacting with various intrinsic components of the glomerulus. Planted antigens include nucleosomal complexes (in patients with systemic lupus erythematosus); bacterial products, such as endostroptosin, a protein expressed by group A streptococci; large aggregated proteins (e.g., aggregated

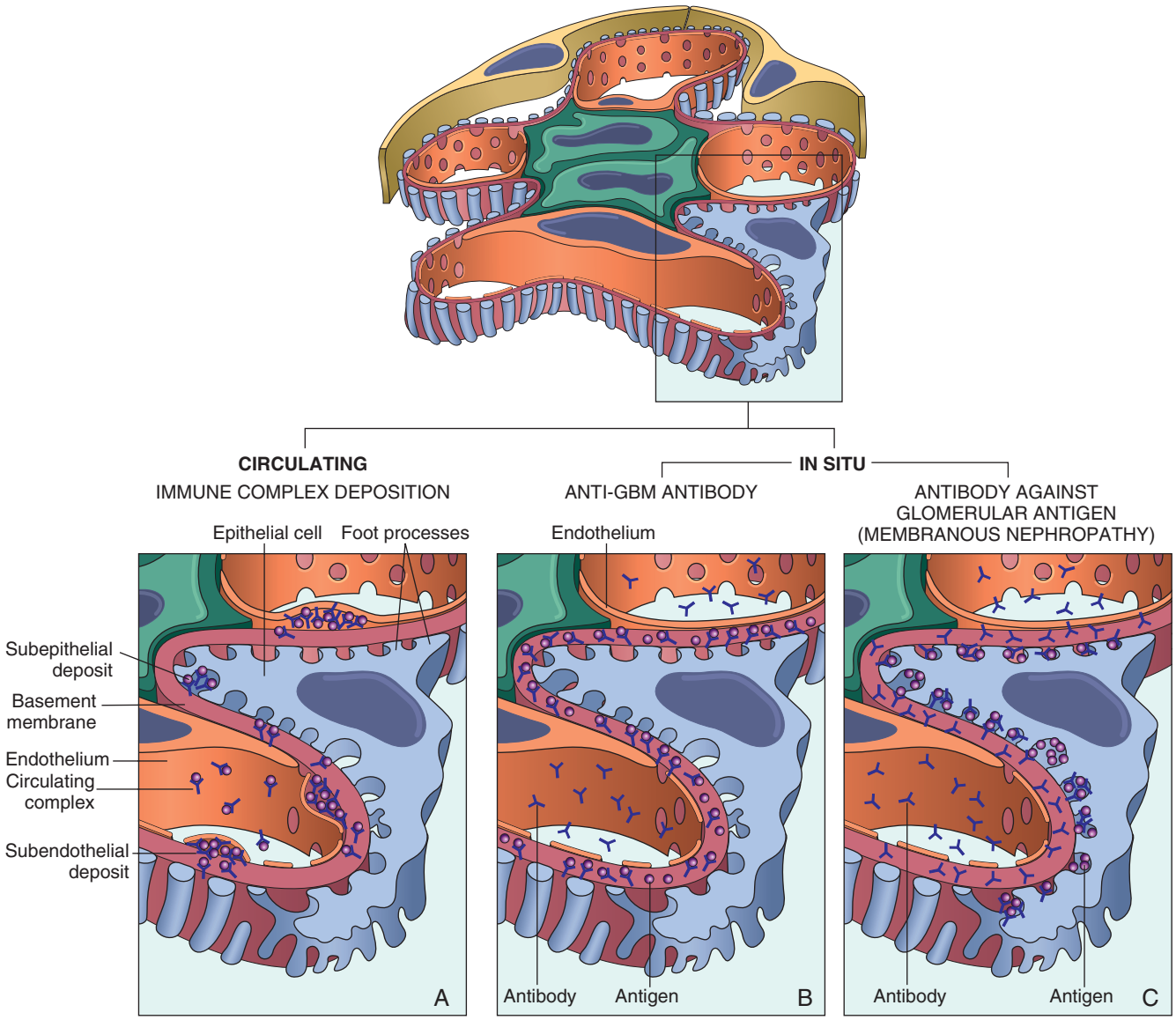


**Figure 13–3** Antibody-mediated glomerular injury. Injury can result either from the deposition of circulating immune complexes or from formation of complexes in situ. **A,** Deposition of circulating immune complexes gives a granular immunofluorescence pattern. **B,** Anti-glomerular basement membrane (anti-GBM) antibody glomerulonephritis is characterized by a linear immunofluorescence pattern. **C,** Antibodies against some glomerular components deposit in a granular pattern.

immunoglobulin G [IgG]), which tend to deposit in the mesangium; and immune complexes themselves, because they contain reactive sites for further interactions with free antibody, free antigen, or complement. Most of these planted antigens induce a granular pattern of immunoglobulin deposition as seen by immunofluorescence microscopy.

The following factors affect glomerular localization of antigen, antibody, or immune complexes: the molecular charge and size of the reactants; glomerular hemodynamics; mesangial function; and the integrity of the charge-selective glomerular barrier. The localization of antigen, antibody, or immune complexes in turn determines the glomerular injury response. Studies in experimental models have shown that complexes deposited in the endothelium or subendothelium elicit an inflammatory reaction in the glomerulus with infiltration of leukocytes and exuberant proliferation of glomerular resident cells. By contrast, antibodies directed to the subepithelial region of glomerular capillaries are largely noninflammatory and elicit lesions similar to those of Heymann nephritis or membranous nephropathy (discussed later).

### *Anti-Glomerular Basement Membrane Antibody–Mediated Glomerulonephritis*

The best-characterized disease in this group is classic anti-GBM antibody–mediated crescentic GN (Fig. 13–3, *B*). In this type of injury, antibodies are directed against fixed antigens in the GBM. It has its experimental counterpart in the nephritis of rodents called *nephrotoxic serum nephritis.* This is produced by injecting rats with anti-GBM antibodies produced by immunization of rabbits or other species with rat kidney. *Antibody–mediated GN in humans results*

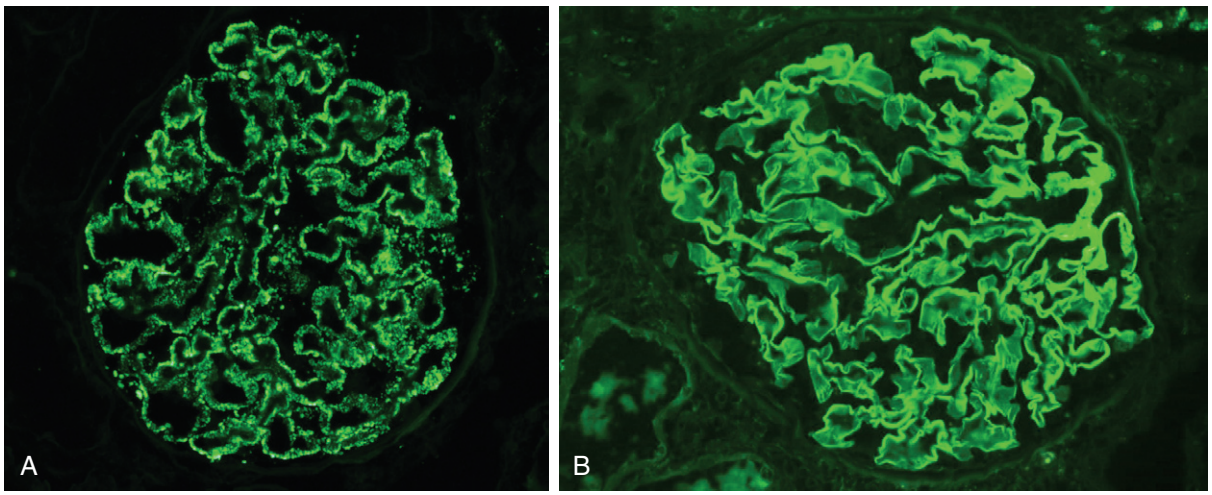


**Figure 13–4** Two patterns of deposition of immune complexes as seen by immunofluorescence microscopy. **A,** Granular, characteristic of circulating and in situ immune complex deposition. **B,** Linear, characteristic of classic anti-glomerular basement membrane (anti-GBM) antibody glomerulonephritis.
*(A, Courtesy of Dr. J. Kowalewska, Department of Pathology, University of Washington, Seattle, Washington.)*

*from the formation of autoantibodies directed against the GBM.* Deposition of these antibodies creates a *linear pattern* of staining when the bound antibodies are visualized with immunofluorescence microscopy, in contrast with the granular pattern described for other forms of immune complex–mediated nephritis (Fig. 13–4, *B*). This distinction is useful in the diagnosis of glomerular disease. A conformational change in the α3 chain of the type IV collagen of the GBM appears to be key in inciting autoimmunity. Sometimes the anti-GBM antibodies cross-react with basement membranes of lung alveoli, resulting in simultaneous lung and kidney lesions (*Goodpasture syndrome*). Although anti-GBM antibody–mediated GN accounts for less than 1% of human GN cases, the resulting disease can be very serious. Many instances of anti-GBM antibody–mediated crescentic GN are characterized by very severe glomerular damage with necrosis and crescents and the development of the clinical syndrome of rapidly progressive GN (see below).

### *Mediators of Immune Injury*

Once immune reactants are localized in the glomerulus, how does glomerular damage ensue? A major pathway of antibody-initiated injury involves complement activation and recruitment of leukocytes (Fig. 13–5). Activation of complement via the classical pathway leads to the generation of chemotactic agents (mainly C5a) for neutrophils and monocytes. Neutrophils release proteases, which cause GBM degradation; oxygen-derived free radicals, which cause cell damage; and arachidonic acid metabolites, which contribute to reduction in GFR. This mechanism applies only to some types of GN, however, because many types show few neutrophils in the damaged glomeruli. In these cases neutrophil-independent but complement-dependent injury may occur, possibly caused by the C5b-C9 membrane attack complex, which is formed on the GBM and may induce sublytic epithelial cell injury and stimulate the secretion of various inflammatory mediators from

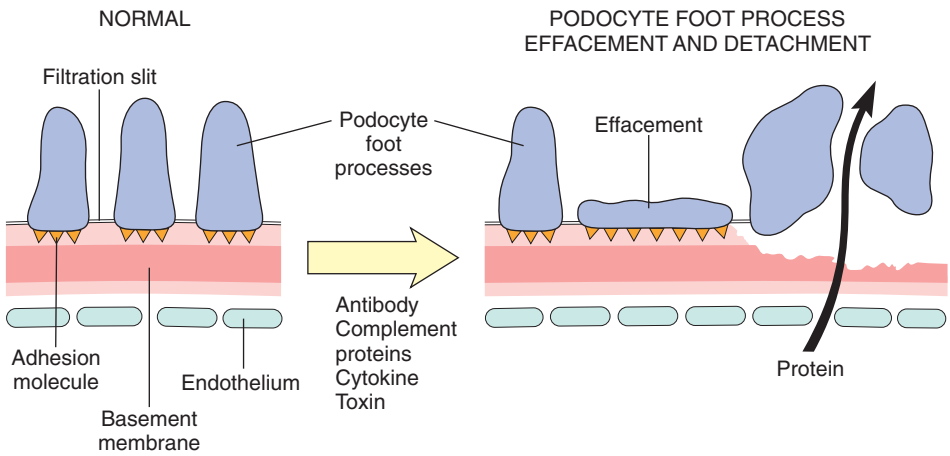


**Figure 13–5** Podocyte injury. The postulated sequence may be initiated by antibodies to podocyte antigens, toxins, cytokines, or other factors. The common features are podocyte injury leading to foot process effacement and variable degrees of podocyte detachment, and degradation of the basement membrane. These defects permit plasma proteins to be lost into the urinary space.

mesangial and epithelial cells. The alternative and mannose-binding lectin pathways of complement can be activated by cell injury or apoptosis, also leading to glomerular injury (Fig. 13–5).

Antibodies against glomerular cell antigens also may directly damage glomerular cells or slit diaphragms. Such antibodies are suspected of being involved in certain disorders in which immune complexes are not found. Other mediators of glomerular damage include the following:

- *Monocytes and macrophages,* which infiltrate the glomerulus in antibody- and cell-mediated reactions and, when activated, release diverse mediators
- Sensitized T cells, formed during the course of a cell-mediated immune reaction, can cause experimental glomerular injury. In some forms of experimental GN, the disease can be induced by transfer of sensitized T cells. T cell–mediated injury may account for the instances of GN in which either there are no deposits of antibodies or immune complexes or the deposits do not correlate with the severity of damage. However, it has been difficult to establish a causal role for T cells or cell-mediated immune responses in human GN.
- *Platelets,* which aggregate in the glomerulus during immune-mediated injury and release prostaglandins and growth factors
- *Resident glomerular cells* (epithelial, mesangial, and endothelial), which can be stimulated to secrete mediators such as cytokines (interleukin-1), arachidonic acid metabolites, growth factors, nitric oxide, and endothelin
- *Thrombin,* produced as a consequence of intraglomerular thrombosis, which causes leukocyte infiltration and glomerular cell proliferation by triggering protease-activated receptors (PARs)

In essence, virtually all of the mediators described in the discussion of inflammation in Chapter 2 may contribute to glomerular injury.

### *Other Mechanisms of Glomerular Injury*

Other mechanisms contribute to glomerular damage in certain primary renal disorders. Two that deserve special mention due to their importance are podocyte injury and nephron loss.

#### Podocyte Injury

Podocyte injury can be induced by antibodies to podocyte antigens; by toxins, as in an experimental model of proteinuria induced by the ribosome poison puromycin; conceivably by certain cytokines; or by still poorly characterized circulating factors, as in some cases of focal segmental glomerulosclerosis (see later). Podocyte injury is reflected by morphologic changes, which include effacement of foot processes, vacuolization, and retraction and detachment of cells from the GBM, and clinically by proteinuria. In most forms of glomerular injury, loss of normal slit diaphragms is key in the development of proteinuria (Fig. 13–5). Functional abnormalities of the slit diaphragm also may result from mutations in its structural components, such as nephrin and the associated podocin. Such mutations cause rare hereditary forms of the nephrotic syndrome.

#### Nephron Loss

Once renal disease, glomerular or otherwise, destroys sufficient nephrons to reduce the GFR to 30% to 50% of normal, progression to end-stage kidney disease proceeds inexorably at varying rates. Affected persons have proteinuria, and their kidneys show widespread *glomerulosclerosis.* Such progressive sclerosis may be initiated, at least in part, by the adaptive changes that occur in the remaining glomeruli not destroyed by the initial disease. These remaining glomeruli undergo hypertrophy to maintain renal function. This hypertrophy is associated with hemodynamic changes, including increases in single-nephron GFR, blood flow, and transcapillary pressure (capillary hypertension). These alterations ultimately become "maladaptive" and lead to further endothelial and podocyte injury, increased glomerular permeability to proteins, and accumulation of proteins and lipids in the mesangial matrix. This is followed by capillary obliteration, increased deposition of mesangial matrix and plasma proteins, and ultimately by segmental (affecting a portion) or global (complete) sclerosis of glomeruli. The latter results in further reductions in nephron mass and a vicious circle of progressive glomerulosclerosis.

## SUMMARY

### Glomerular Injury

- Antibody-mediated immune injury is an important mechanism of glomerular damage, mainly by way of complement- and leukocyte-mediated pathways. Antibodies also may be directly cytotoxic to cells in the glomerulus.
- The most common forms of antibody-mediated GN are caused by the formation of immune complexes, whether occurring in situ or by deposition of circulating immune complexes. These immune complexes may contain exogenous (e.g. microbial) circulating antigens or endogenous antigens (e.g. in membranous nephropathy). Immune complexes show a granular pattern of deposition.
- Autoantibodies against components of the GBM are the cause of anti-GBM-antibody–mediated disease, often associated with severe injury. The pattern of antibody deposition is linear.
- Immune complexes and antibodies cause injury by complement activation and leukocyte recruitment, with release of various mediators, and sometimes by direct podocyte damage.

We now turn to a consideration of specific types of GN and the glomerular syndromes they produce.

## The Nephrotic Syndrome

The nephrotic syndrome refers to a clinical complex that includes

- *Massive proteinuria,* with daily protein loss in the urine of 3.5 g or more in adults
- *Hypoalbuminemia,* with plasma albumin levels less than 3 g/dL

- *Generalized edema,* the most obvious clinical manifestation
- *Hyperlipidemia and lipiduria.*

The nephrotic syndrome has diverse causes that share a common pathophysiology (Table 13–2). In all there is a derangement in the capillary walls of the glomeruli that results in increased permeability to plasma proteins. Any increased permeability resulting from either structural or physicochemical alterations in the GBM allows protein to escape from the plasma into the glomerular filtrate. With long-standing or extremely heavy proteinuria, serum albumin is decreased, resulting in hypoalbuminemia and a drop in plasma colloid osmotic pressure. As discussed in Chapter 3, the resulting decrease in intravascular volume and renal blood flow triggers increased release of renin from renal juxtaglomerular cells. Renin in turn stimulates the angiotensin-aldosterone axis, which promotes the retention of salt and water by the kidney. This tendency is exacerbated by reductions in the cardiac secretion of natriuretic factors. In the face of continuing proteinuria, these alterations further aggravate the edema and if unchecked may lead to the development of generalized edema (termed *anasarca*). At the onset, there is little or no azotemia, hematuria, or hypertension.

The genesis of the hyperlipidemia is more obscure. Presumably, hypoalbuminemia triggers increased synthesis of lipoproteins in the liver or massive proteinuria causes loss of an inhibitor of their synthesis. There is also abnormal transport of circulating lipid particles and impairment of peripheral breakdown of lipoproteins. The lipiduria, in turn, reflects the increased permeability of the GBM to lipoproteins.

**Table 13–2** Causes of Nephrotic Syndrome

| Cause | Prevalence (%)* | |
|---|---|---|
| | Children | Adults |
| **Primary Glomerular Disease** | | |
| Membranous nephropathy | 5 | 30 |
| Minimal-change disease | 65 | 10 |
| Focal segmental glomerulosclerosis | 10 | 35 |
| Membranoproliferative glomerulonephritis | 10 | 10 |
| IgA nephropathy and others | 10 | 15 |
| **Systemic Diseases with Renal Manifestations** | | |
| Diabetes mellitus | | |
| Amyloidosis | | |
| Systemic lupus erythematosus | | |
| Ingestion of drugs (gold, penicillamine, "street heroin") | | |
| Infections (malaria, syphilis, hepatitis B, HIV infection) | | |
| Malignancy (carcinoma, melanoma) | | |
| Miscellaneous (bee sting allergy, hereditary nephritis) | | |

*Approximate prevalence of primary disease is 95% of the cases in children, 60% in adults. Approximate prevalence of systemic disease is 5% of the cases in children, 40% in adults.
HIV, human immunodeficiency virus.

The relative frequencies of the several causes of the nephrotic syndrome vary according to age (Table 13–2). In children 1 to 7 years of age, for example, the nephrotic syndrome is almost always caused by a lesion primary to the kidney, whereas among adults it often is due to renal manifestations of a systemic disease. The most frequent systemic causes of the nephrotic syndrome in adults are diabetes, amyloidosis, and systemic lupus erythematosus. The renal lesions produced by these disorders are described in Chapter 4. The most important of the primary glomerular lesions that characteristically lead to the nephrotic syndrome are focal and segmental glomerulosclerosis and minimal-change disease. The latter is more important in children; the former, in adults. Two other primary lesions, membranous nephropathy and membranoproliferative glomerulonephritis, also commonly produce the nephrotic syndrome. These four lesions are discussed individually next.

### *Minimal-Change Disease*

Minimal-change disease, a relatively benign disorder, is the most frequent cause of the nephrotic syndrome in children. Characteristically, the *glomeruli have a normal appearance by light microscopy but show diffuse effacement of podocyte foot processes when viewed with the electron microscope*. Although it may develop at any age, this condition is most common between the ages of 1 and 7 years.

The pathogenesis of proteinuria in minimal-change disease remains to be elucidated. On the basis of some experimental studies, the proteinuria has been attributed to a circulating, possibly T cell–derived, factor that causes podocyte damage and effacement of foot processes. Neither the nature of such a putative factor nor a causal role of T cells, however, is established in the human disease.

#### MORPHOLOGY

Under the light microscope, the glomeruli appear normal, thus giving rise to the name "minimal-change disease" (Fig. 13–6, *A*). The cells of the proximal convoluted tubules often are heavily laden with protein droplets and lipids, but this feature is secondary to tubular reabsorption of the lipoproteins passing through the diseased glomeruli. Even under the electron microscope, the GBM appears normal. The only obvious glomerular abnormality is the **uniform and diffuse effacement of the foot processes of the podocytes** (Fig. 13–6, *B*). The cytoplasm of the podocytes thus appears flattened over the external aspect of the GBM, obliterating the network of arcades between the podocytes and the GBM. There are also epithelial cell vacuolization, microvillus formation, and occasional focal detachments, suggesting some form of podocyte injury. With reversal of the changes in the podocytes (e.g., in response to corticosteroids), the proteinuria remits.

#### Clinical Course

The disease manifests with the insidious development of the nephrotic syndrome in an otherwise healthy child. There is no hypertension, and renal function is preserved in most of these patients. The protein loss usually is

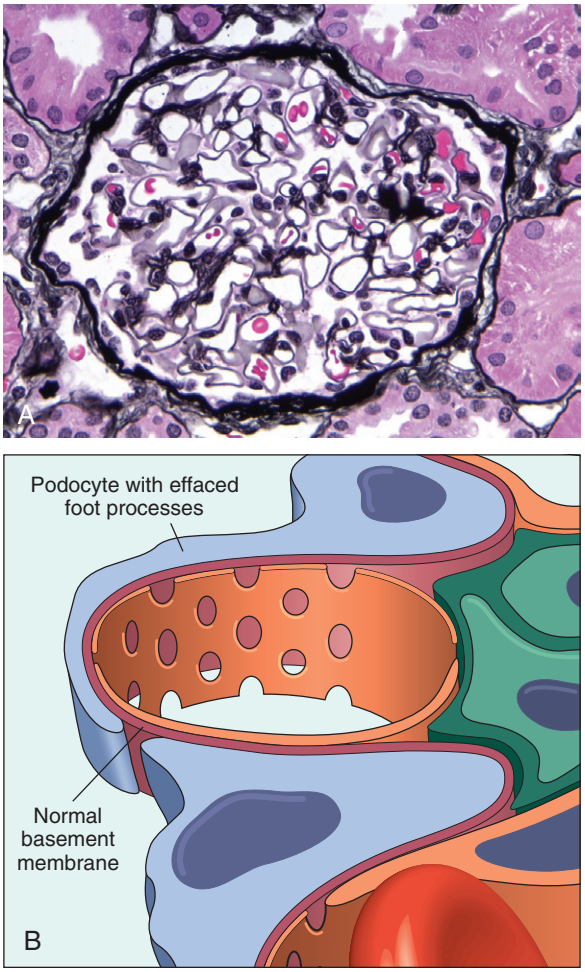


**Figure 13–6** Minimal-change disease. **A,** Under the light microscope the silver methenamine–stained glomerulus appears normal, with a delicate basement membrane. **B,** Schematic diagram illustrating diffuse effacement of foot processes of podocytes with no immune deposits.

confined to the smaller plasma proteins, chiefly albumin (selective proteinuria). The prognosis for children with this disorder is good. *More than 90% of children respond to a short course of corticosteroid therapy;* however, proteinuria recurs in more than two thirds of the initial responders, some of whom become steroid-dependent. Less than 5% develop chronic kidney disease after 25 years, and it is likely that most persons in this subgroup had nephrotic syndrome caused by focal and segmental glomerulosclerosis not detected by biopsy. Because of its responsiveness to therapy in children, minimal-change disease must be differentiated from other causes of the nephrotic syndrome in nonresponders. Adults with this disease also respond to steroid therapy, but the response is slower and relapses are more common.

### *Focal Segmental Glomerulosclerosis*

Focal segmental glomerulosclerosis (FSGS) is characterized histologically by sclerosis affecting some but not all glomeruli (*focal involvement*) and involving only segments of each affected glomerulus (*segmental involvement*). This histologic picture often is associated with the nephrotic syndrome. FSGS may be primary (idiopathic) or secondary to one of the following conditions:

- In association with other conditions, such as HIV infection (HIV nephropathy) or heroin abuse (heroin nephropathy)
- As a secondary event in other forms of GN (e.g., IgA nephropathy)
- As a maladaptation to nephron loss (as described earlier)
- In inherited or congenital forms. Autosomal dominant forms are associated with mutations in cytoskeletal proteins and podocin, both of which are required for the integrity of podocytes. In addition, a sequence variant in the apolipoprotein L1 gene (*APOL1*) on chromosome 22 appears to be strongly associated with an increased risk of FSGS and renal failure in individuals of African descent.

Primary FSGS accounts for approximately 20% to 30% of all cases of the nephrotic syndrome. It is an increasingly common cause of nephrotic syndrome in adults and remains a frequent cause in children.

#### PATHOGENESIS

The pathogenesis of primary FSGS is unknown. Some investigators have suggested that FSGS and minimal-change disease are part of a continuum and that minimal-change disease may transform into FSGS. Others believe them to be distinct clinicopathologic entities from the outset. In any case, **injury to the podocytes is thought to represent the initiating event of primary FSGS.** As with minimal-change disease, permeability-increasing factors produced by lymphocytes have been proposed. The deposition of hyaline masses in the glomeruli represents the entrapment of plasma proteins and lipids in foci of injury where sclerosis develops. IgM and complement proteins commonly seen in the lesion are also believed to result from nonspecific entrapment in damaged glomeruli. The recurrence of proteinuria and subsequent FSGS in a renal transplant in some patients who had FSGS, sometimes within 24 hours of transplantation, supports the idea that a circulating mediator is the cause of the podocyte damage in some cases.

#### MORPHOLOGY

In FSGS, the disease first affects only some of the glomeruli (hence the term ***focal***) and, in the case of primary FSGS, initially only the juxtamedullary glomeruli. With progression, eventually all levels of the cortex are affected. On histologic examination, FSGS is characterized by lesions occurring in some tufts within a glomerulus and sparing of the others (hence the term ***segmental***). Thus, the involvement is both focal and segmental (Fig. 13–7). The affected glomeruli exhibit **increased mesangial matrix, obliterated capillary lumina, and deposition of hyaline masses (hyalinosis) and lipid droplets.** In affected glomeruli, immunofluorescence microscopy often reveals nonspecific trapping of immunoglobulins, usually IgM, and complement

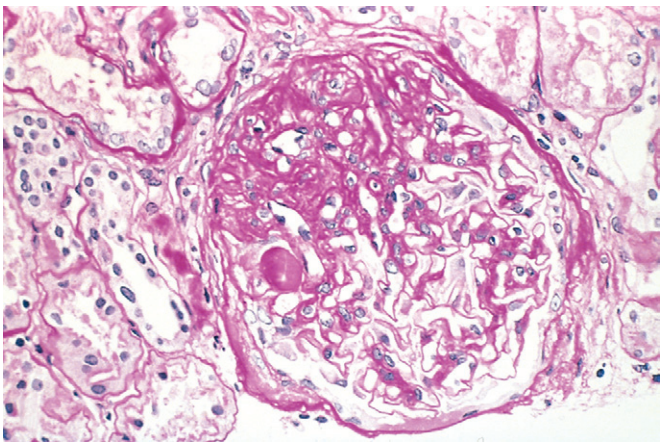

**Figure 13–7** High-power view of focal and segmental glomerulosclerosis (periodic acid–Schiff stain), seen as a mass of scarred, obliterated capillary lumens with accumulations of matrix material that has replaced a portion of the glomerulus.
*(Courtesy of Dr. H. Rennke, Department of Pathology, Brigham and Women's Hospital, Boston, Massachusetts.)*

in the areas of hyalinosis. On electron microscopy, the podocytes exhibit **effacement of foot processes,** as in minimal-change disease.

In time, progression of the disease leads to global sclerosis of the glomeruli with pronounced tubular atrophy and interstitial fibrosis. This advanced picture is difficult to differentiate from other forms of chronic glomerular disease, described later on.

A morphologic variant called **collapsing glomerulopathy** is being increasingly reported. It is characterized by collapse of the glomerular tuft and podocyte hyperplasia. This is a more severe manifestation of FSGS that may be idiopathic or associated with HIV infection, drug-induced toxicities, and some microvascular injuries. It carries a particularly poor prognosis.

Clinical Course

*In children it is important to distinguish FSGS as a cause of the nephrotic syndrome from minimal-change disease,* because the clinical courses are markedly different. The incidence of hematuria and hypertension is higher in persons with FSGS than in those with minimal-change disease; the FSGS-associated proteinuria is nonselective; and in general the response to corticosteroid therapy is poor. At least 50% of patients with FSGS develop end-stage kidney disease within 10 years of diagnosis. Adults typically fare even less well than children.

### *Membranous Nephropathy*

Membranous nephropathy is a slowly progressive disease, most common between 30 and 60 years of age. *It is characterized morphologically by the presence of subepithelial immunoglobulin-containing deposits along the GBM.* Early in the disease, the glomeruli may appear normal by light microscopy, but well-developed cases show *diffuse thickening of the capillary wall.*

In about 85% of cases, membranous nephropathy is caused by autoantibodies that cross-react with antigens expressed by podocytes. In the remainder (secondary membranous nephropathy), it occurs secondary to other disorders, including

- Infections (chronic hepatitis B, syphilis, schistosomiasis, malaria)
- Malignant tumors, particularly carcinoma of the lung and colon and melanoma
- Systemic lupus erythematosus and other autoimmune conditions
- Exposure to inorganic salts (gold, mercury)
- Drugs (penicillamine, captopril, nonsteroidal anti-inflammatory agents)

#### PATHOGENESIS

**Membranous nephropathy is a form of chronic immune complex glomerulonephritis** induced by antibodies reacting in situ to endogenous or planted glomerular antigens. An endogenous podocyte antigen, the phospholipase $A_2$ receptor, is the antigen that is most often recognized by the causative autoantibodies.

The experimental model of membranous nephropathy is Heymann nephritis, which is induced in animals by immunization with renal tubular brush border proteins that also are present on podocytes. The antibodies that are produced react with an antigen located in the glomerular capillary wall, resulting in granular deposits **(in situ immune complex formation)** and proteinuria without severe inflammation.

A puzzling aspect of the disease is how antigen-antibody complexes cause capillary damage despite the absence of inflammatory cells. The likely answer is by activating complement, which is uniformly present in the lesions of membranous nephropathy. It is hypothesized that complement activation leads to assembly of the C5b-C9 membrane attack complex, which damages mesangial cells and podocytes directly, setting in motion events that cause the loss of slit filter integrity and proteinuria.

#### MORPHOLOGY

Histologically, the main feature in membranous nephropathy is **diffuse thickening of the capillary wall** (Fig. 13–8, *A*). Electron microscopy reveals that this thickening is caused in part by **subepithelial deposits,** which nestle against the GBM and are separated from each other by small, spikelike protrusions of GBM matrix that form in reaction to the deposits **(spike and dome pattern)** (Fig. 13–8, *B*). As the disease progresses, these spikes close over the deposits, incorporating them into the GBM. In addition, as in other causes of nephrotic syndrome, the podocytes show **effacement of foot processes.** Later in the disease, the incorporated deposits may be broken down and eventually disappear, leaving cavities within the GBM. Continued deposition of basement membrane matrix leads to progressive thickening of basement membranes. With further progression, the glomeruli can become sclerosed. Immunofluorescence microscopy shows typical **granular deposits** of immunoglobulins and complement along the GBM (Fig. 13–4, *A*).

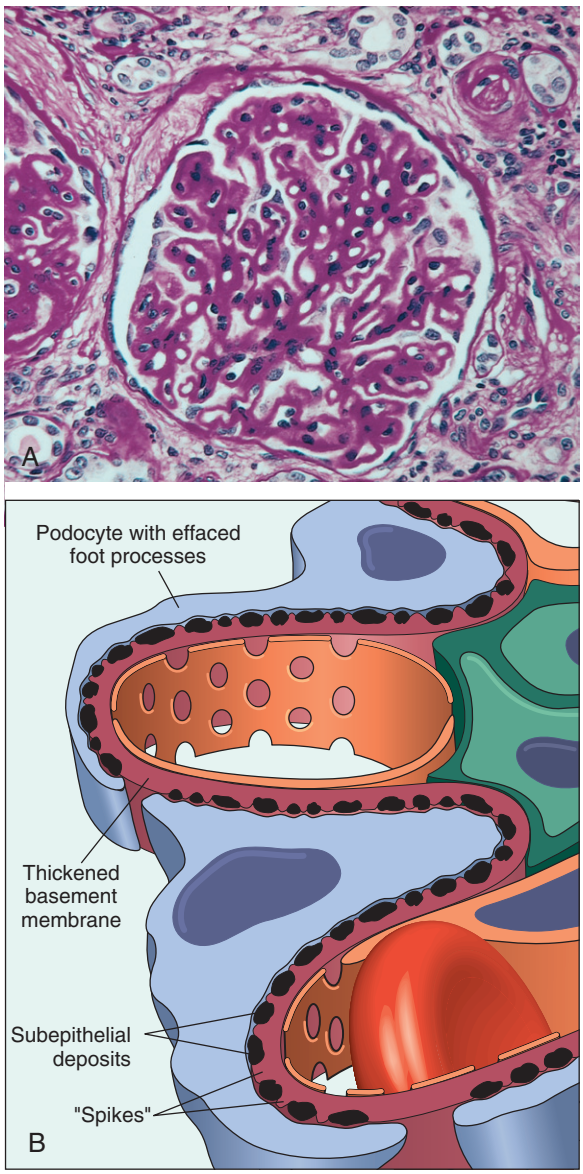


**Figure 13–8** Membranous nephropathy. **A,** Diffuse thickening of the glomerular basement membrane (periodic acid–Schiff stain). **B,** Schematic diagram illustrating subepithelial deposits, effacement of foot processes, and the presence of *spikes* of basement membrane material between the immune deposits.

### Clinical Course

Most cases of membranous nephropathy present as full-blown nephrotic syndrome, usually without antecedent illness; other individuals may have lesser degrees of proteinuria. In contrast with minimal-change disease, the proteinuria is nonselective, with urinary loss of globulins as well as smaller albumin molecules, and does not usually respond to corticosteroid therapy. Secondary causes of membranous nephropathy should be ruled out. Membranous nephropathy follows a notoriously variable and often indolent course. Overall, although proteinuria persists in greater than 60% of patients with membranous nephropathy, only about 40% suffer progressive disease terminating in renal failure after 2 to 20 years. An additional 10% to 30% have a more benign course with partial or complete remission of proteinuria.

## *Membranoproliferative Glomerulonephritis and Dense Deposit Disease*

Membranoproliferative GN (MPGN) is manifested histologically by alterations in the GBM and mesangium and by proliferation of glomerular cells. It accounts for 5% to 10% of cases of idiopathic nephrotic syndrome in children and adults. Some patients present only with hematuria or proteinuria in the non-nephrotic range; others exhibit a combined nephrotic–nephritic picture. Two major types of MPGN (I and II) have traditionally been recognized on the basis of distinct ultrastructural, immunofluorescence, microscopic, and pathogenic findings, but these are now recognized to be separate entities, termed MPGN type I and dense deposit disease (formerly MPGN type II). Of the two types of disease, MPGN type I is far more common (about 80% of cases).

### PATHOGENESIS

Different pathogenic mechanisms are involved in the development of MPGN and dense deposit disease.

- **Some cases of type I MPGN may be caused by circulating immune complexes,** akin to chronic serum sickness, or may be due to a planted antigen with subsequent *in situ* immune complex formation. In either case, the inciting antigen is not known. Type I MPGN also occurs in association with hepatitis B and C antigenemia, systemic lupus erythematosus, infected atrioventricular shunts, and extrarenal infections with persistent or episodic antigenemia.
- The pathogenesis of **dense deposit disease** is less clear. **The fundamental abnormality in dense deposit disease appears to be excessive complement activation.** Some patients have an autoantibody against C3 convertase, called **C3 nephritic factor,** which is believed to stabilize the enzyme and lead to uncontrolled cleavage of C3 and activation of the alternative complement pathway. Mutations in the gene encoding the complement regulatory protein **factor H** or autoantibodies to factor H have been described in some patients. These abnormalities result in excessive complement activation. Hypocomplementemia, more marked in dense deposit disease, is produced in part by excessive consumption of C3 and in part by reduced synthesis of C3 by the liver. It is still not clear how the complement abnormality induces the glomerular changes.

### MORPHOLOGY

By light microscopy, type I MPGN and many cases of dense deposit disease are similar. The glomeruli are large, with an accentuated **lobular appearance,** and show **proliferation of mesangial and endothelial cells** as well as infiltrating leukocytes (Fig. 13–9, *A*). The **GBM is thickened,** and the glomerular capillary wall often shows a double contour, or "tram track," appearance, especially evident with use of silver or periodic acid–Schiff (PAS) stains. This "**splitting**" **of the GBM** is due to extension of processes of mesangial and inflammatory cells into the peripheral capillary loops and deposition of mesangial matrix (Fig. 13–9, *B*).

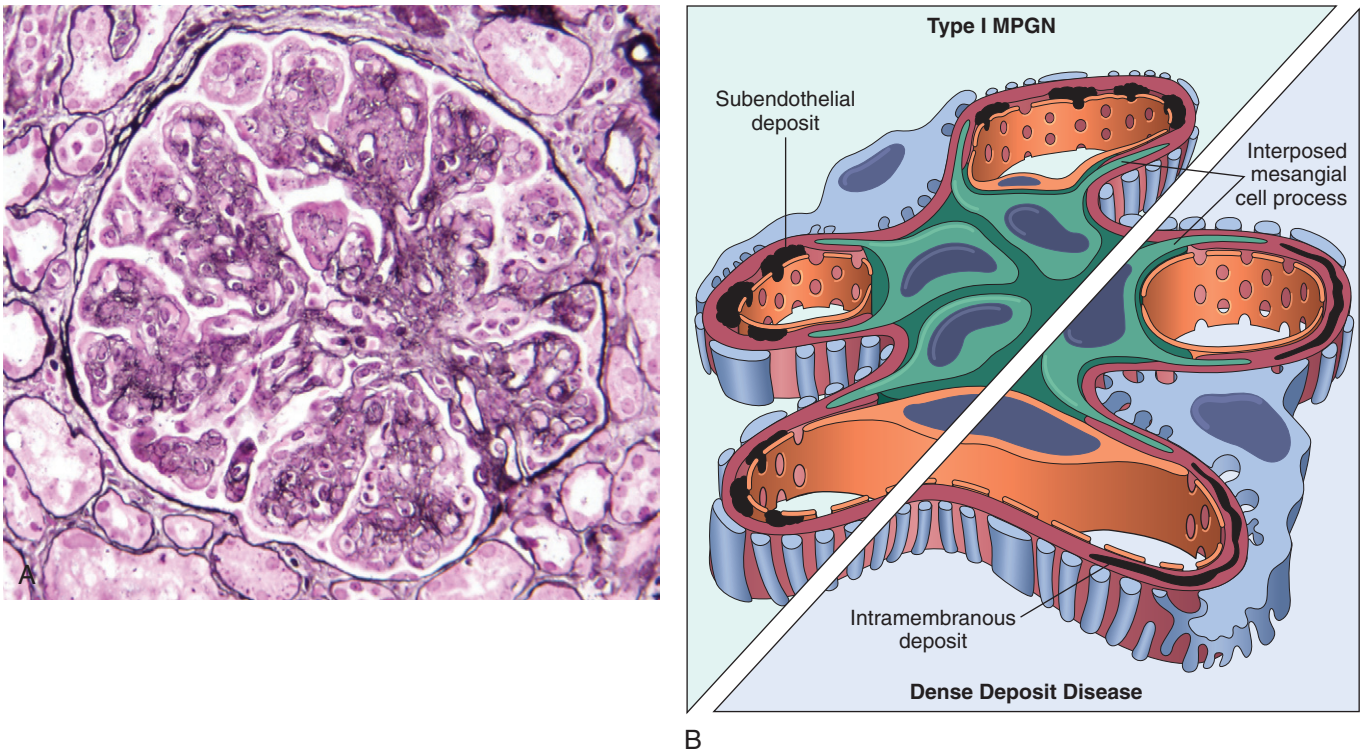


**Figure 13–9 A,** Membranoproliferative glomerulonephritis (MPGN), showing mesangial cell proliferation, basement membrane thickening, leukocyte infiltration, and accentuation of lobular architecture. **B,** Schematic representation of patterns in the two types of MPGN. In type I there are subendothelial deposits; in type II, now called dense deposit disease, intramembranous characteristically dense deposits are seen. In both types, mesangial interposition gives the appearance of split basement membranes when viewed by light microscopy.

**Type I MPGN** is characterized by discrete **subendothelial electron-dense deposits** (Fig. 13–9, *B*). By immunofluorescence microscopy, C3 is deposited in an irregular granular pattern, and IgG and early complement components (C1q and C4) often are also present, indicative of an immune complex pathogenesis.

By contrast, in the aptly named **dense deposit disease** the lamina densa and the subendothelial space of the GBM are transformed into an irregular, ribbon-like, extremely electron-dense structure, resulting from the deposition of material of unknown composition. C3 is present in irregular chunky and segmental linear foci in the basement membranes and in the mesangium. IgG and the early components of the classical complement pathway (C1q and C4) are usually absent.

### Clinical Course

The principal mode of presentation (in approximately 50% of cases) is the nephrotic syndrome, although MPGN or dense deposit disease may begin as acute nephritis or mild proteinuria. The prognosis of MPGN type I generally is poor. In one study, none of the 60 patients followed for 1 to 20 years showed complete remission. Forty percent progressed to end-stage renal failure, 30% had variable degrees of renal insufficiency, and the remaining 30% had persistent nephrotic syndrome without renal failure. Dense deposit disease carries an even worse prognosis, and it tends to recur more frequently in renal transplant recipients. MPGN type I may occur in association with other disorders (*secondary MPGN*), such as systemic lupus erythematosus, hepatitis B and C, chronic liver disease, and chronic bacterial infections. Indeed, many so-called idiopathic cases are believed to be associated with hepatitis C and related cryoglobulinemia.

## SUMMARY

### The Nephrotic Syndrome

- The nephrotic syndrome is characterized by proteinuria, which results in hypoalbuminemia and edema.
- Podocyte injury is an underlying mechanism of proteinuria, and may be the result of nonimmune causes (as in minimal-change disease and FSGS) or immune mechanisms (as in membranous nephropathy).
- *Minimal-change disease* is the most frequent cause of nephrotic syndrome in children; it is manifested by proteinuria and effacement of glomerular foot processes without antibody deposits; the pathogenesis is unknown; the disease responds well to steroid therapy.
- *FSGS* may be primary (podocyte injury by unknown mechanisms) or secondary (e.g., as a consequence of previous glomerulonephritis, hypertension, or infection such as with HIV); glomeruli show focal and segmental obliteration of capillary lumina, and loss of foot processes; the disease often is resistant to therapy and may progress to end-stage renal disease.

- *Membranous nephropathy* is caused by an autoimmune response, most often directed against the phospholipase $A_2$ receptor on podocytes; it is characterized by granular subepithelial deposits of antibodies with GBM thickening and loss of foot processes but little or no inflammation; the disease often is resistant to steroid therapy.
- MPGN and dense deposit disease are now recognized to be distinct entities. MPGN is caused by immune complex deposition; dense deposit disease is a consequence of complement dysregulation. Both may present with nephrotic and/or nephritic features.

## The Nephritic Syndrome

The nephritic syndrome is a clinical complex, usually of acute onset, characterized by (1) *hematuria* with dysmorphic red cells and red cell casts in the urine; (2) some degree of *oliguria and azotemia;* and (3) *hypertension.*

Although proteinuria and even edema also may be present, these usually are not as severe as in the nephrotic syndrome. The lesions that cause the nephritic syndrome have in common proliferation of the cells within the glomeruli, often accompanied by an inflammatory leukocytic infiltrate. This inflammatory reaction severely injures the capillary walls, permitting blood to pass into the urine and inducing hemodynamic changes that lead to a reduction in the GFR. The reduced GFR is manifested clinically by oliguria, fluid retention, and azotemia. Hypertension probably is a result of both the fluid retention and some augmented renin release from the ischemic kidneys.

The acute nephritic syndrome may be produced by systemic disorders such as systemic lupus erythematosus, or it may be secondary to primary glomerular disease. The latter is exemplified by acute postinfectious GN.

### *Acute Postinfectious (Poststreptococcal) Glomerulonephritis*

*Acute postinfectious GN, one of the more frequently occurring glomerular disorders, is caused by glomerular deposition of immune complexes resulting in proliferation of and damage to glomerular cells and infiltration of leukocytes, especially neutrophils.* The inciting antigen may be exogenous or endogenous. The prototypic exogenous pattern is seen in poststreptococcal GN. Infections by organisms other than streptococci may also be associated with postinfectious GN. These include certain pneumococcal and staphylococcal infections as well as several common viral diseases such as mumps, measles, chickenpox, and hepatitis B and C. Endogenous antigens, as occur in systemic lupus erythematosus, also may cause a proliferative GN but more commonly result in a membranous nephropathy (see earlier) lacking the neutrophil infiltrates that are characteristic of postinfectious GN.

The classic case of poststreptococcal GN develops in a child 1 to 4 weeks after they recover from a group A streptococcal infection. Only certain "nephritogenic" strains of β-hemolytic streptococci evoke glomerular disease. In most cases, the initial infection is localized to the pharynx or skin.

#### PATHOGENESIS

**Poststreptococcal GN is an immune complex disease** in which tissue injury is primarily caused by complement activation by the classical pathway. Typical features of immune complex disease, such as hypocomplementemia and granular deposits of IgG and complement on the GBM, are seen. The relevant antigens probably are streptococcal proteins. Specific antigens implicated in pathogenesis include streptococcal exotoxin B (Spe B) and streptococcal GAPDH. Both activate the alternative complement pathway and have affinity for glomerular proteins and plasmin. It is not clear if immune complexes are formed mainly in the circulation or in situ (the latter by binding of antibodies to bacterial antigens "planted" in the GBM).

#### MORPHOLOGY

By light microscopy, the most characteristic change in postinfectious GN is **increased cellularity** of the glomerular tufts that affects nearly all glomeruli—hence the term **diffuse** (Fig. 13–10, *A*). The increased cellularity is caused both by proliferation and swelling of endothelial and mesangial cells and by infiltrating neutrophils and monocytes. Sometimes there is necrosis of the capillary walls. In a few cases, "crescents" (described later) may be observed within the urinary space, formed in response to the severe inflammatory injury. Electron microscopy shows deposited immune complexes arrayed as subendothelial, intramembranous, or, most often, **subepithelial "humps"** nestled against the GBM (Fig. 13–10, *B*). Mesangial deposits also are occasionally present. Immunofluorescence studies reveal scattered **granular deposits of IgG and complement** within the capillary walls and some mesangial areas, corresponding to the deposits visualized by electron microscopy. These deposits usually are cleared over a period of about 2 months.

#### Clinical Course

The onset of the kidney disease tends to be abrupt, heralded by malaise, a slight fever, nausea, and the nephritic syndrome. In the usual case, oliguria, azotemia, and hypertension are only mild to moderate. Characteristically, there is gross hematuria, the urine appearing smoky brown rather than bright red. Some degree of proteinuria is a constant feature of the disease, and as mentioned earlier it occasionally may be severe enough to produce the nephrotic syndrome. Serum complement levels are low during the active phase of the disease, and serum anti–streptolysin O antibody titers are elevated in poststreptococcal cases.

Recovery occurs in most children in epidemic cases. Some children develop rapidly progressive GN owing to severe injury with formation of crescents, or chronic renal disease from secondary scarring. The prognosis in sporadic cases is less clear. In adults, 15% to 50% of affected persons develop end-stage renal disease over the ensuing few years or 1 to 2 decades, depending on the clinical and histologic severity. By contrast, in children, the prevalence of chronicity after sporadic cases of acute postinfectious GN is much lower.

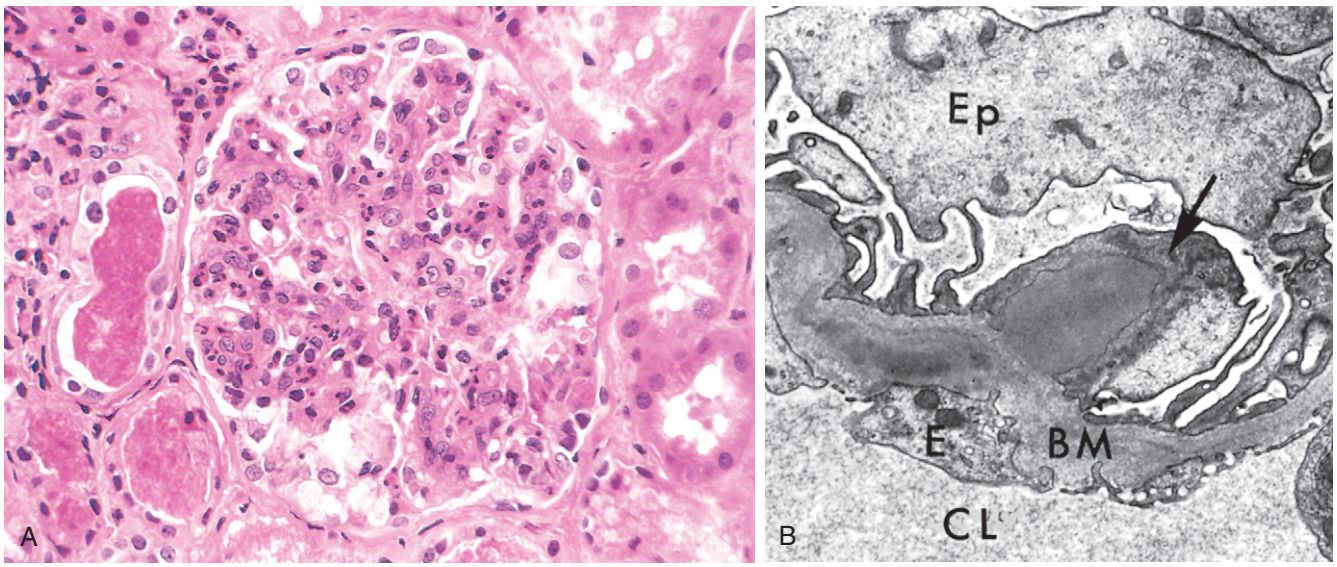


**Figure 13–10** Poststreptococcal glomerulonephritis. **A,** Glomerular hypercellularity is caused by intracapillary leukocytes and proliferation of intrinsic glomerular cells. Note the red cell casts in the tubules. **B,** Typical electron-dense subepithelial "hump" (*arrow*) and intramembranous deposits. BM, basement membrane; CL, capillary lumen; E, endothelial cell; Ep, visceral epithelial cells (podocytes).

### *IgA Nephropathy*

This condition usually affects children and young adults and begins as an episode of gross hematuria that occurs within 1 or 2 days of a nonspecific upper respiratory tract infection. Typically, the hematuria lasts several days and then subsides, only to recur every few months. It may be associated with local pain. *IgA nephropathy is one of the most common causes of recurrent microscopic or gross hematuria and is the most common glomerular disease revealed by renal biopsy worldwide.*

*The hallmark of the disease is the deposition of IgA in the mesangium.* Some workers have considered IgA nephropathy to be a localized variant of *Henoch-Schönlein purpura,* also characterized by IgA deposition in the mesangium. In contrast with IgA nephropathy, which is purely a renal disorder, Henoch-Schönlein purpura is a systemic syndrome involving the skin (purpuric rash), gastrointestinal tract (abdominal pain), joints (arthritis), and kidneys.

## PATHOGENESIS

Accumulating evidence suggests that IgA nephropathy is associated with an abnormality in IgA production and clearance, as well as antibodies against abnormally glycosylated IgA. IgA, the main immunoglobulin in mucosal secretions, is increased in 50% of patients with IgA nephropathy owing to increased production of the IgA1 subtype by plasma cells in the bone marrow. In addition, circulating IgA-containing immune complexes are present in some cases. A genetic influence is suggested by the occurrence of this condition in families and in HLA–identical siblings, and by the increased frequency of certain HLA and complement genotypes in some populations. Studies also suggest an abnormality in glycosylation of the IgA1 immunoglobulin that reduces plasma clearance and favors deposition in the mesangium. This abnormal IgA1 may also elicit glycan-specific IgG antibodies. The prominent mesangial deposition of IgA may stem from entrapment of IgA immune complexes, and the absence of C1q and C4 in glomeruli points to activation of the alternative complement pathway. Taken together, these clues suggest that in genetically susceptible individuals, respiratory or gastrointestinal exposure to microbial or other antigens (e.g., viruses, bacteria, food proteins) may lead to increased IgA synthesis, some of which is abnormally glycosylated, and deposition of IgA and IgA-containing immune complexes in the mesangium, where they activate the alternative complement pathway and initiate glomerular injury. In support of this scenario, IgA nephropathy occurs with increased frequency in individuals with celiac disease, in whom intestinal mucosal defects are seen, and in liver disease, in which there is defective hepatobiliary clearance of IgA complexes **(secondary IgA nephropathy).**

## MORPHOLOGY

Histologically, the lesions in IgA nephropathy vary considerably. The glomeruli may be normal or may show mesangial widening and segmental inflammation confined to some glomeruli (focal proliferative GN); diffuse mesangial proliferation (mesangioproliferative GN); or (rarely) overt crescentic GN. The characteristic immunofluorescence picture is of **mesangial deposition of IgA,** often with C3 and properdin and smaller amounts of IgG or IgM (Fig. 13–11). Early components of the classical complement pathway usually are absent. Electron microscopy confirms the presence of electron-dense deposits in the mesangium. The deposits may extend to the subendothelial area of adjacent capillary walls in a minority of cases, usually those with focal proliferation. Biopsy findings may help predict whether progression or response to intervention is likely.

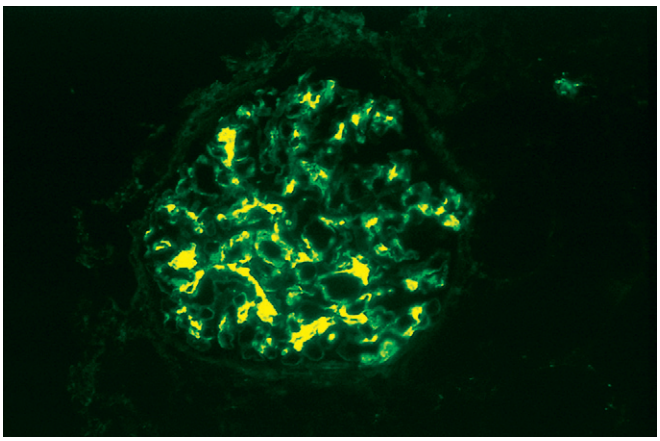

**Figure 13–11** IgA nephropathy. Characteristic immunofluorescence deposition of IgA, principally in mesangial regions, is evident. IgA, immunoglobulin A.

### Clinical Course

The disease most often affects children and young adults. More than half of those with IgA nephropathy present with gross hematuria after an infection of the respiratory or, less commonly, gastrointestinal or urinary tract; 30% to 40% have only microscopic hematuria, with or without proteinuria, and 5% to 10% develop a typical acute nephritic syndrome. The hematuria typically lasts for several days and then subsides, only to return every few months. The subsequent course is highly variable. Many patients maintain normal renal function for decades. Slow progression to chronic renal failure occurs in 25% to 50% of cases over a period of 20 years. Renal biopsy findings may help identify those with worse prognosis, as indicated by diffuse mesangial proliferation, segmental sclerosis, endocapillary proliferation, or tubulointerstitial fibrosis.

### *Hereditary Nephritis*

Hereditary nephritis refers to a group of hereditary glomerular diseases caused by *mutations in genes encoding GBM proteins*. The best-studied entity is *Alport syndrome*, in which nephritis is accompanied by nerve deafness and various eye disorders, including lens dislocation, posterior cataracts, and corneal dystrophy.

## PATHOGENESIS

The GBM is composed largely of type IV collagen, which is made up of heterotrimers of α3, α4, and α5 type IV collagen. This form of type IV collagen is crucial for normal function of the lens, cochlea, and glomerulus. Mutation of any one of the α chains results in defective heterotrimer assembly and, consequently, the disease manifestations of Alport syndrome.

## MORPHOLOGY

On histologic examination, glomeruli in hereditary nephritis appear unremarkable until late in the course, when secondary sclerosis may occur. In some kidneys, interstitial cells take on a foamy appearance as a result of accumulation of neutral fats and mucopolysaccharides **(foam cells)** as a reaction to marked proteinuria. With progression, increasing glomerulosclerosis, vascular sclerosis, tubular atrophy, and interstitial fibrosis are typical changes. Under the electron microscope, the **basement membrane of glomeruli is thin** and attenuated early in the course. Late in the course, the GBM develops irregular foci of thickening or attenuation with pronounced splitting and lamination of the lamina densa, yielding a **"basketweave"** appearance.

### Clinical Course

The inheritance is heterogeneous, being most commonly X-linked as a result of mutation of the gene encoding α5 type IV collagen. Males therefore tend to be affected more frequently and more severely than females and are more likely to develop renal failure. Rarely, inheritance is autosomal recessive or dominant, linked to defects in the genes that encode α3 or α4 type IV collagen. Persons with hereditary nephritis present at age 5 to 20 years with gross or microscopic hematuria and proteinuria, and overt renal failure occurs between 20 and 50 years of age.

Female carriers of X-linked Alport syndrome or carriers of either gender of the autosomal forms usually present with persistent hematuria, which most often is asymptomatic and is associated with a benign clinical course. In these patients, biopsy specimens show only thinning of the GBM.

## SUMMARY

### The Nephritic Syndrome

- The nephritic syndrome is characterized by hematuria, oliguria with azotemia, proteinuria, and hypertension.
- The most common cause is immunologically mediated glomerular injury; lesions are characterized by proliferative changes and leukocyte infiltration.
- *Acute postinfectious glomerulonephritis* typically occurs after streptococcal infection in children and young adults but may occur following infection with many other organisms; it is caused by deposition of immune complexes, mainly in the subepithelial spaces, with abundant neutrophils and proliferation of glomerular cells. Most affected children recover; the prognosis is worse in adults.
- *IgA nephropathy*, characterized by mesangial deposits of IgA-containing immune complexes, is the most common cause of the nephritic syndrome worldwide; it is also a common cause of recurrent hematuria; it commonly affects children and young adults and has a variable course.
- *Hereditary nephritis* (*Alport syndrome*) is caused by mutations in genes encoding GBM collagen; it manifests as hematuria and slowly progressing proteinuria and declining renal function; glomeruli appear normal by light microscopy until late in the disease course.

## Rapidly Progressive Glomerulonephritis

Rapidly progressive glomerulonephritis (RPGN) is a clinical syndrome and not a specific etiologic form of GN. It is characterized by progressive loss of renal function,

laboratory findings typical of the nephritic syndrome, and often severe oliguria. If untreated, it leads to death from renal failure within a period of weeks to months. *The characteristic histologic finding associated with RPGN is the presence of crescents* (crescentic GN).

## PATHOGENESIS

Crescentic GN may be caused by a number of different diseases, some restricted to the kidney and others systemic. Although no single mechanism can explain all cases, there is little doubt that in most cases the glomerular injury is immunologically mediated. The diseases causing crescentic GN may be associated with a known disorder or it may be idiopathic. When the cause can be identified, about 12% of the patients have anti-GBM antibody–mediated crescentic GN with or without lung involvement; 44% have immune complex GN with crescents; and the remaining 44% have pauci-immune crescentic GN. All have severe glomerular injury.

### *Anti-Glomerular Basement Membrane Antibody–Mediated Crescentic Glomerulonephritis*

*Anti-GBM antibody–mediated crescentic GN* is characterized by linear deposits of IgG and, in many cases, C3 on the GBM, as described earlier. In some patients, the anti-GBM antibodies also bind to pulmonary alveolar capillary basement membranes to produce the clinical picture of pulmonary hemorrhages associated with renal failure. These patients are said to have *Goodpasture syndrome,* to distinguish their condition from so-called idiopathic cases, in which renal involvement occurs in the absence of pulmonary disease. Anti-GBM antibodies are present in the serum and are helpful in diagnosis. It is important to recognize anti-GBM antibody–mediated crescentic GN, because affected persons benefit from plasmapheresis, which removes pathogenic antibodies from the circulation.

## MORPHOLOGY

The kidneys are enlarged and pale, often with **petechial hemorrhages** on the cortical surfaces. Glomeruli show segmental necrosis and GBM breaks, with resulting proliferation of the parietal epithelial cells in response to the exudation of plasma proteins and the deposition of fibrin in Bowman's space. These distinctive lesions of proliferation are called **crescents** owing to their shape as they fill Bowman's space. Crescents are formed both by proliferation of parietal cells and by migration of monocytes/macrophages into Bowman's space (Fig. 13–12). Smaller numbers of other types of leukocytes also may be present. The uninvolved portion of the glomerulus shows no proliferation. Immunofluorescence studies characteristically show strong staining of linear IgG and C3 deposits along the GBM (Fig. 13–4, *B*). These antibodies typically recognize type IV collagen. Because of the diffuse distribution of type IV collagen in the glomerulus, the density of antibody : antigen complexes is not high enough for them to be seen by electron microscopy. Electron microscopy may show distinct ruptures in the GBM. The crescents eventually obliterate Bowman's space and compress the glomeruli. In time, crescents may undergo scarring, and glomerulosclerosis develops.

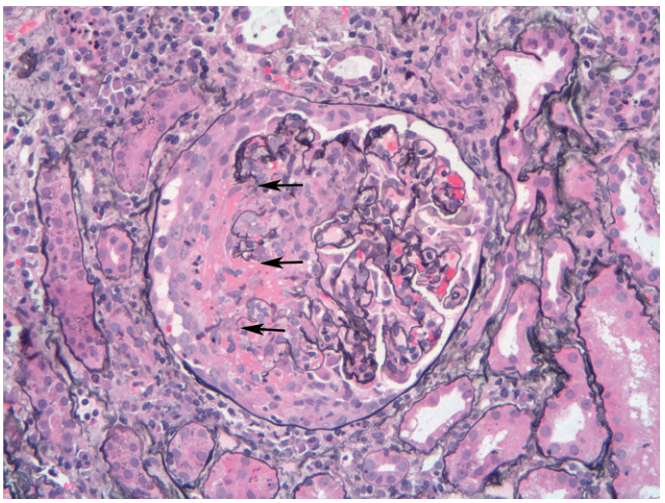

**Figure 13–12** Crescentic glomerulonephritis (GN) (Jones silver methenamine stain). Note the areas of necrosis with rupture of capillary loops (*arrows*) and destruction of normal glomerular structures, and the adjacent crescent-shaped mass of proliferating cells and leukocytes filling the urinary space. The segmental distribution of the necrotizing and crescentic GN is typical of ANCA (antineutrophil cytoplasmic antibody)-associated crescentic GN.

### *Immune Complex–Mediated Crescentic Glomerulonephritis*

Crescents can be a complication of any of the immune complex nephritides, including poststreptococcal GN, systemic lupus erythematosus, IgA nephropathy, and Henoch-Schönlein purpura. In some cases, immune complexes can be demonstrated but the underlying cause is undetermined. A consistent finding in this form of GN of any cause is the characteristic granular ("lumpy bumpy") pattern of staining of the GBM and/or mesangium for immunoglobulin and/or complement on immunofluorescence studies. This disorder usually does not respond to plasmapheresis.

## MORPHOLOGY

There is severe injury in the form of **segmental necrosis** and GBM breaks with resultant crescent formation, as described earlier. However, in contrast with crescentic GN associated with anti-GBM antibodies, segments of glomeruli without necrosis show evidence of the underlying immune complex GN (e.g., diffuse proliferation and leukocyte exudation in postinfectious GN or systemic lupus erythematosus; mesangial proliferation in IgA nephropathy or Henoch-Schönlein purpura). Immunofluorescence shows the characteristic **granular pattern** of immune complex disease, and electron microscopy demonstrates discrete deposits.

### *Pauci-Immune Crescentic Glomerulonephritis*

*Pauci-immune type crescentic GN* is defined by the lack of anti-GBM antibodies or of significant immune complex deposition detectable by immunofluorescence and electron microscopy. Antineutrophil cytoplasmic antibodies (ANCA) typically are found in the serum, which, as described in Chapter 9, have an etiopathogenic role in

some vasculitides. In some instances, therefore, crescentic GN is a component of a systemic vasculitis such as microscopic polyangiitis or Wegener granulomatosis. In many cases, however, pauci-immune crescentic GN is limited to the kidney and is thus called idiopathic.

### MORPHOLOGY

Glomeruli show **segmental necrosis** and GBM breaks with resulting crescent formation (see earlier). Uninvolved segments of glomeruli appear normal without proliferation or prominent inflammatory cell influx. In contrast with anti-GBM antibody disease, however, results of immunofluorescence studies for immunoglobulin and complement are negative or nearly so, and no deposits are detectable by electron microscopy.

#### Clinical Course

The onset of RPGN is much like that of the nephritic syndrome, except that the oliguria and azotemia are more pronounced. Proteinuria sometimes approaching nephrotic range may occur. Some affected persons become anuric and require long-term dialysis or transplantation. The prognosis can be roughly related to the fraction of involved glomeruli: Patients in whom crescents are present in less than 80% of the glomeruli have a better prognosis than those in whom the percentages of crescents are higher. Plasma exchange is of benefit in those with anti-GBM antibody GN and Goodpasture disease, as well as in some patients with ANCA-related pauci-immune crescentic GN.

### SUMMARY

#### Rapidly Progressive Glomerulonephritis

- RPGN is a clinical entity with features of the nephritic syndrome and rapid loss of renal function.
- RPGN is commonly associated with severe glomerular injury with necrosis and GBM breaks and subsequent proliferation of parietal epithelium (crescents).
- RPGN may be immune-mediated, as when autoantibodies to the GBM develop in anti-GBM antibody disease or when it arises consequent to immune complex deposition; it also can be pauci-immune, associated with antineutrophil cytoplasmic antibodies.

## DISEASES AFFECTING TUBULES AND INTERSTITIUM

Most forms of tubular injury also involve the interstitium, so the two are discussed together. Presented under this heading are diseases characterized by (1) inflammatory involvement of the tubules and interstitium (interstitial nephritis) or (2) ischemic or toxic tubular injury, leading to the morphologic appearance of *acute tubular injury* and the clinical syndrome of *acute kidney injury.*

### Tubulointerstitial Nephritis

Tubulointerstitial nephritis (TIN) refers to a group of inflammatory diseases of the kidneys that primarily involve the interstitium and tubules. The glomeruli may be spared altogether or affected only late in the course. In most cases of TIN caused by bacterial infection, the renal pelvis is prominently involved—hence the more descriptive term *pyelonephritis* (from *pyelo,* "pelvis"). The term *interstitial nephritis* generally is reserved for cases of TIN that are nonbacterial in origin. These include tubular injury resulting from drugs, metabolic disorders such as hypokalemia, physical injury such as irradiation, viral infections, and immune reactions. On the basis of clinical features and the character of the inflammatory exudate, TIN, regardless of the etiologic agent, can be divided into acute and chronic categories. Discussed next is acute pyelonephritis, which is always of bacterial origin, followed by consideration of other, nonbacterial forms of interstitial nephritis.

#### *Acute Pyelonephritis*

*Acute pyelonephritis, a common suppurative inflammation of the kidney and the renal pelvis, is caused by bacterial infection.* It is an important manifestation of urinary tract infection (UTI), which can involve the lower (cystitis, prostatitis, urethritis) or upper (pyelonephritis) urinary tract, or both. As we shall see, the great majority of cases of pyelonephritis are associated with infection of the lower urinary tract. Such infection, however, may remain localized without extending to involve the kidney. UTIs constitute an extremely common clinical problem.

### PATHOGENESIS

**The principal causative organisms in acute pyelonephritis are the enteric gram-negative rods.** *Escherichia coli* is by far the most common one. Other important organisms are *Proteus*, *Klebsiella*, *Enterobacter*, and *Pseudomonas;* these usually are associated with recurrent infections, especially in persons who undergo urinary tract manipulations or have congenital or acquired anomalies of the lower urinary tract (see later). Staphylococci and *Streptococcus faecalis* also may cause pyelonephritis, but they are uncommon pathogens in this setting.

Bacteria can reach the kidneys from the lower urinary tract (ascending infection) or through the bloodstream (hematogenous infection) (Fig. 13–13). **Ascending infection from the lower urinary tract is the most important and common route by which the bacteria reach the kidney.** Adhesion of bacteria to mucosal surfaces is followed by colonization of the distal urethra (and the introitus in females). Genetically determined properties of both the urothelium and the bacterial pathogens may facilitate adhesion to the urothelial lining by bacterial fimbriae (proteins that attach to receptors on the surface of urothelial cells), conferring susceptibility to infection. The organisms then reach the bladder, by expansive growth of the colonies and by moving against the flow of urine. This may occur during urethral instrumentation, including catheterization and cystoscopy. Although **hematogenous spread** is the far less

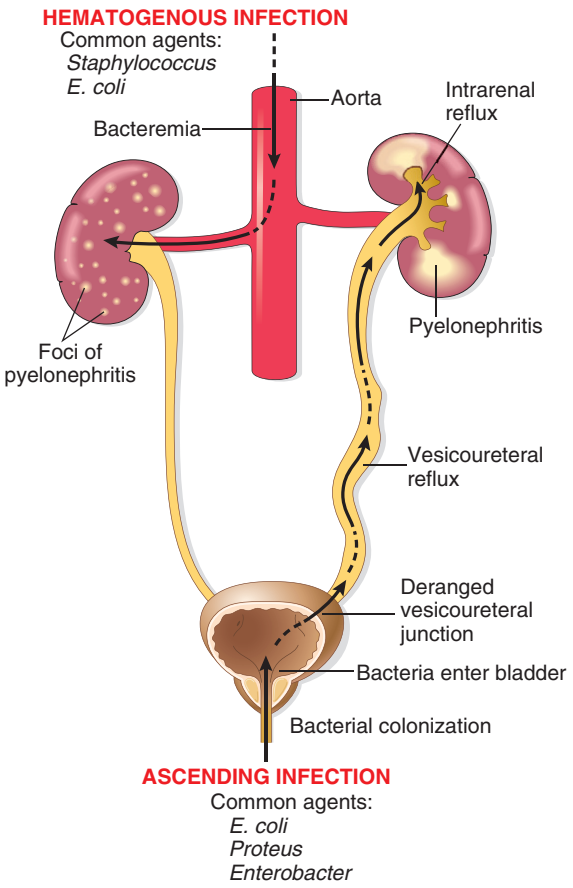


**Figure 13–13** Pathways of renal infection. Hematogenous infection results from bacteremic spread. More common is ascending infection, which results from a combination of urinary bladder infection, vesicoureteral reflux, and intrarenal reflux.

common of the two, acute pyelonephritis may result from seeding of the kidneys by bacteria in the course of septicemia or infective endocarditis.

In the absence of instrumentation, UTI most commonly affects females. Because of the close proximity of the female urethra to the rectum, colonization by enteric bacteria is favored. Furthermore, the short urethra, and trauma to the urethra during sexual intercourse, facilitate the entry of bacteria into the urinary bladder. Ordinarily, bladder urine is sterile, as a result of the antimicrobial properties of the bladder mucosa and the flushing mechanism associated with periodic voiding of urine. With outflow obstruction or bladder dysfunction, however, the natural defense mechanisms of the bladder are overwhelmed, setting the stage for UTI. In the presence of stasis, bacteria introduced into the bladder can multiply undisturbed, without being flushed out or destroyed by the bladder wall. From the contaminated bladder urine, the bacteria ascend along the ureters to infect the renal pelvis and parenchyma. Accordingly, UTI is particularly frequent among patients with urinary tract obstruction, as may occur with benign prostatic hyperplasia and uterine prolapse. UTI frequency also is increased in diabetes because of the increased susceptibility to infection and neurogenic bladder dysfunction, which in turn predisposes to stasis.

Incompetence of the vesicoureteral orifice, resulting in **vesicoureteral reflux** (VUR), is an important cause of ascending infection. The reflux allows bacteria to ascend the ureter into the pelvis. VUR is present in 20% to 40% of young children with UTI, usually as a consequence of a congenital defect that results in incompetence of the ureterovesical valve. VUR also can be acquired in persons with a flaccid bladder resulting from spinal cord injury or with neurogenic bladder dysfunction secondary to diabetes. VUR results in residual urine after voiding in the urinary tract, which favors bacterial growth. Furthermore, VUR affords a ready mechanism by which the infected bladder urine can be propelled up to the renal pelvis and farther into the renal parenchyma through open ducts at the tips of the papillae **(intrarenal reflux).**

## MORPHOLOGY

One or both kidneys may be involved. The affected kidney may be normal in size or enlarged. **Characteristically, discrete, yellowish, raised abscesses are grossly apparent on the renal surface** (Fig. 13–14). They may be widely scattered or limited to one region of the kidney, or they may coalesce to form a single large area of suppuration.

The characteristic histologic feature of acute pyelonephritis is liquefactive necrosis with abscess formation within the renal parenchyma. In the early stages pus formation (suppuration) is limited to the interstitial tissue, but later abscesses rupture into tubules. Large masses of intratubular neutrophils frequently extend within involved nephrons into the collecting ducts, giving rise to the characteristic white cell casts found in the urine. Typically, the glomeruli are not affected.

When obstruction is prominent, the pus may not drain and then fills the renal pelvis, calyces, and ureter, producing pyonephrosis.

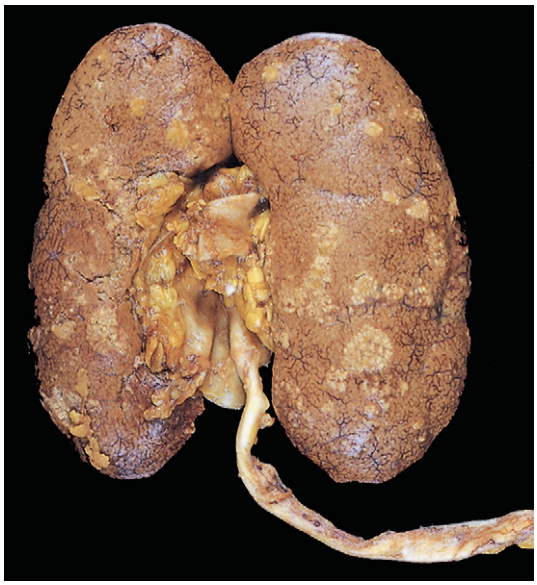

**Figure 13–14** Acute pyelonephritis. The cortical surface is studded with focal pale abscesses, more numerous in the upper pole and middle region of the kidney; the lower pole is relatively unaffected. Between the abscesses there is dark congestion of the renal surface.

A second (and fortunately infrequent) form of pyelonephritis is necrosis of the renal papillae, known as **papillary necrosis.** There are three predisposing conditions for this: diabetes, urinary tract obstruction, and analgesic abuse. This lesion consists of a combination of ischemic and suppurative necrosis of the tips of the renal pyramids (renal papillae). The pathognomonic gross feature of papillary necrosis is sharply defined gray-white to yellow necrosis of the apical two thirds of the pyramids. One papilla or several or all papillae may be affected. Microscopically, the papillary tips show characteristic coagulative necrosis, with surrounding neutrophilic infiltrate.

When the bladder is involved in a UTI, as is often the case, **acute** or **chronic cystitis** results. In long-standing cases associated with obstruction, the bladder may be grossly hypertrophic, with trabeculation of its walls, or it may be thinned and markedly distended from retention of urine.

### Clinical Course

Acute pyelonephritis often is associated with predisposing conditions, as described previously in the discussion of pathogenetic mechanisms. These factors include

- *Urinary obstruction,* either congenital or acquired
- *Instrumentation* of the urinary tract, most commonly catheterization
- *Vesicoureteral reflux*
- *Pregnancy*—4% to 6% of pregnant women develop bacteriuria sometime during pregnancy, and 20% to 40% of these eventually develop symptomatic urinary infection if not treated.
- *Female gender and patient age.* After the first year of life (an age by which congenital anomalies in males commonly become evident) and up to approximate age 40 years, infections are much more frequent in females. With increasing age, the incidence in males rises as a result of the development of prostatic hyperplasia, which causes urinary outflow obstruction.
- *Preexisting renal lesions,* causing intrarenal scarring and obstruction
- *Diabetes mellitus,* in which common predisposing factors are infection and bladder dysfunction
- *Immunosuppression and immunodeficiency*

The onset of uncomplicated acute pyelonephritis usually is sudden, with pain at the costovertebral angle and systemic evidence of infection, such as chills, fever, and malaise, and localizing urinary tract signs of dysuria, frequency, and urgency. The urine appears turgid due to the contained pus (pyuria). Even without antibiotic treatment, the disease tends to be benign and self-limited. The symptomatic phase of the disease typically lasts no longer than a week, although bacteriuria may persist much longer. The disease usually is unilateral, and affected persons thus do not develop renal failure because they still have one unaffected kidney. In cases in which predisposing factors are present, the disease may become recurrent or chronic, particularly when involvement is bilateral. The development of papillary necrosis is associated with a much poorer prognosis.

## *Chronic Pyelonephritis and Reflux Nephropathy*

*Chronic pyelonephritis* is defined here as a morphologic entity in which predominantly interstitial inflammation and scarring of the renal parenchyma are associated with grossly visible scarring and deformity of the pelvicalyceal system. Chronic pyelonephritis is an important cause of chronic renal failure. It can be divided into two forms: chronic obstructive pyelonephritis and chronic reflux–associated pyelonephritis.

### Chronic Obstructive Pyelonephritis

As noted, obstruction predisposes the kidney to infection. Recurrent infections superimposed on diffuse or localized obstructive lesions lead to recurrent bouts of renal inflammation and scarring, which eventually cause chronic pyelonephritis. The disease can be bilateral, as with congenital anomalies of the urethra (e.g., posterior urethral valves), resulting in fatal renal insufficiency unless the anomaly is corrected, or unilateral, such as occurs with calculi and unilateral obstructive lesions of the ureter.

### Chronic Reflux–Associated Pyelonephritis (Reflux Nephropathy)

This is the more common form of chronic pyelonephritic scarring and results from superimposition of a UTI on congenital vesicoureteral reflux and intrarenal reflux. Reflux may be unilateral or bilateral; thus, the resultant renal damage either may cause scarring and atrophy of one kidney or may involve both, potentially leading to chronic renal insufficiency.

### MORPHOLOGY

One or both kidneys may be involved, either diffusely or in patches. Even when involvement is bilateral, the kidneys are not equally damaged and therefore are not equally contracted. This **uneven scarring** is useful in differentiating chronic pyelonephritis from the more symmetrically contracted kidneys associated with vascular sclerosis (often referred to as "benign nephrosclerosis") and chronic GN. The hallmark of chronic pyelonephritis is **scarring involving the pelvis or calyces,** or both, leading to papillary blunting and marked **calyceal deformities** (Fig. 13–15).

The microscopic changes are largely nonspecific, and similar alterations may be seen with other chronic tubulointerstitial disorders such as analgesic nephropathy. The parenchyma shows the following features:

- Uneven interstitial fibrosis and an inflammatory infiltrate of lymphocytes, plasma cells, and occasionally neutrophils
- Dilation or contraction of tubules, with atrophy of the lining epithelium. Many of the dilated tubules contain pink to blue, glassy-appearing PAS-positive casts, known as colloid casts, that suggest the appearance of thyroid tissue—hence the descriptive term thyroidization. Often, neutrophils are seen within tubules.
- Chronic inflammatory cell infiltration and fibrosis involving the calyceal mucosa and wall
- Arteriolosclerosis caused by the frequently associated hypertension
- Glomerulosclerosis that usually develops as a secondary process caused by nephron loss (a maladaptation discussed earlier).

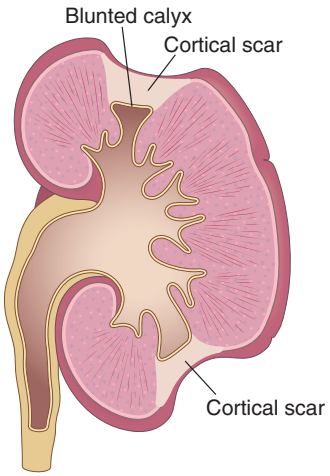


**Figure 13–15** Typical coarse scars of chronic pyelonephritis associated with vesicoureteral reflux. The scars are usually located at the upper or lower poles of the kidney and are associated with underlying blunted calyces.

### Clinical Course

Many persons with chronic pyelonephritis come to medical attention relatively late in the course of the disease, because of the gradual onset of renal insufficiency or because signs of kidney disease are noticed on routine laboratory tests. In other cases, the renal disease is heralded by the development of hypertension. The radiologic image is characteristic: The affected kidney is asymmetrically contracted, with some degree of blunting and deformity of the calyceal system (caliectasis). The presence or absence of significant bacteriuria is not particularly helpful diagnostically; its absence certainly should not rule out chronic pyelonephritis. If the disease is bilateral and progressive, tubular dysfunction occurs with loss of concentrating ability, manifested by polyuria and nocturia.

As noted earlier, some persons with chronic pyelonephritis or reflux nephropathy ultimately develop secondary glomerulosclerosis, associated with proteinuria; eventually, these injuries all contribute to progressive chronic kidney disease.

## *Drug-Induced Interstitial Nephritis*

In this era of widespread antibiotic and analgesic use, drugs have emerged as an important cause of renal injury. Acute drug-induced tubulointerstitial nephritis (TIN) occurs as an adverse reaction to any of an increasing number of drugs. Acute drug-induced TIN is associated most frequently with synthetic penicillins (methicillin, ampicillin), other synthetic antibiotics (rifampin), diuretics (thiazides), nonsteroidal anti-inflammatory agents, and numerous other drugs (phenindione, cimetidine).

### PATHOGENESIS

Many features of the disease suggest an immune mechanism. Clinical evidence of hypersensitivity includes latent period, eosinophilia and rash, the idiosyncratic nature of the drug reaction (i.e., the lack of dose dependency), and the recurrence of hypersensitivity after reexposure to the same drug or others that are similar in structure. Serum IgE levels are increased in some persons, suggesting type I hypersensitivity. In other cases the nature of the inflammatory infiltrate (discussed below) and the presence of positive skin tests to drugs suggest a T cell–mediated (type IV) hypersensitivity reaction.

The most likely sequence of pathogenic events is as follows: The drugs act as haptens that, during secretion by tubules, covalently bind to some cytoplasmic or extracellular component of tubular cells and become immunogenic. The resultant tubulointerstitial injury is then caused by IgE- and cell-mediated immune reactions to tubular cells or their basement membranes.

### MORPHOLOGY

The abnormalities in acute drug-induced nephritis are in the interstitium, which shows pronounced edema and infiltration by mononuclear cells, principally lymphocytes and macrophages (Fig. 13–16). Eosinophils and neutrophils may be present, often in large numbers. With some drugs (e.g., methicillin, thiazides, rifampin), interstitial non-necrotizing granulomas with giant cells may be seen. The glomeruli are normal except in some cases caused by nonsteroidal anti-inflammatory agents, in which the hypersensitivity reaction also leads to podocyte foot process effacement and the nephrotic syndrome.

### Clinical Course

The disease begins about 15 days (range, 2 to 40 days) after exposure to the drug and is characterized by *fever, eosinophilia* (which may be transient), *a rash* (in about 25% of persons), and *renal abnormalities.* Urinary findings include hematuria, minimal or no proteinuria, and leukocyturia (sometimes including eosinophils). A rising serum creatinine or acute kidney injury with oliguria develops in about 50% of cases, particularly in older patients. Clinical recognition of drug-induced kidney injury is imperative, because withdrawal of the offending drug is followed by recovery,

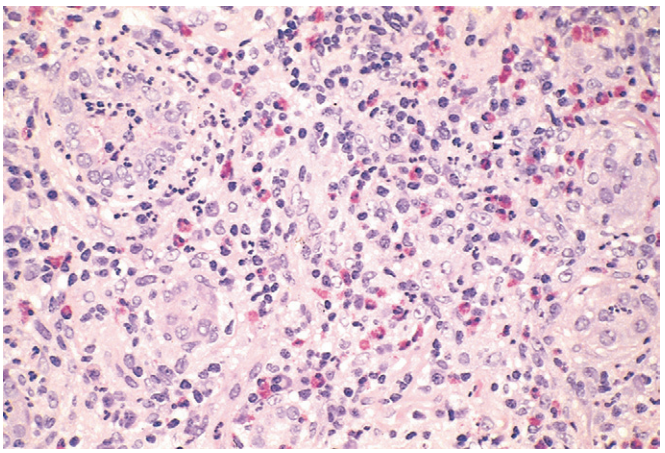

**Figure 13–16** Drug-induced interstitial nephritis, with prominent eosinophilic and mononuclear infiltrate.

*(Courtesy of Dr. H. Rennke, Department of Pathology, Brigham and Women's Hospital, Boston, Massachusetts.)*

although it may take several months for renal function to return to normal.

## SUMMARY

### Tubulointerstitial Nephritis

- TIN consists of inflammatory disease primarily involving the renal tubules and interstitium.
- *Acute pyelonephritis* is a bacterial infection caused either by ascending infection as a result of reflux, obstruction, or other abnormality of the urinary tract, or by hematogenous spread of bacteria; characterized by abscess formation in the kidneys, sometimes with papillary necrosis.
- *Chronic pyelonephritis* usually is associated with urinary obstruction or reflux; results in scarring of the involved kidney, and gradual renal insufficiency.
- *Drug-induced interstitial nephritis* is an IgE- and T cell–mediated immune reaction to a drug; characterized by interstitial inflammation, often with abundant eosinophils, and edema.

## Acute Tubular Injury

Acute tubular injury (ATI) is a clinicopathologic entity characterized morphologically by damaged tubular epithelial cells and clinically by acute decline of renal function, with granular casts and tubular cells observed in the urine. *This constellation of changes, termed acute kidney injury, manifests clinically as decreased GFR.* When ATI is caused by acute kidney injury, there may be oliguria (defined as urine output of less than 400 mL/day). Other causes of acute kidney injury include (1) severe glomerular diseases manifesting clinically as RPGN; (2) acute tubular injury caused by diffuse renal vascular diseases, such as microscopic polyangiitis and thrombotic microangiopathies; and (3) acute drug-induced allergic interstitial nephritis, which often is not associated with tubular injury. These other disorders involving acute kidney injury are discussed elsewhere in this chapter.

ATI arises in a variety of clinical settings, so it occurs relatively frequently. Most of these clinical conditions, ranging from severe trauma to acute pancreatitis to septicemia, have in common a period of inadequate blood flow to all or regions of peripheral organs such as the kidney, sometimes in the setting of marked hypotension and shock. The pattern of ATI associated with generalized or localized reduction in blood flow is called *ischemic ATI.* Mismatched blood transfusions and other hemolytic crises, as well as myoglobinuria, also produce a clinical picture resembling that in ischemic ATI. A second pattern, called *nephrotoxic ATI,* is caused by a variety of poisons, including heavy metals (e.g., mercury); organic solvents (e.g., carbon tetrachloride); and a multitude of drugs such as gentamicin and other antibiotics, and radiographic contrast agents. ATI is often reversible, and proper recognition and management can mean the difference between full recovery and death.

## PATHOGENESIS

The decisive events in both ischemic and nephrotoxic ATI are believed to be

- Tubular injury. Tubular epithelial cells are particularly sensitive to anoxia and are also vulnerable to toxins (Fig. 13–17). Several factors predispose the tubules to toxic injury, including elevated intracellular concentrations of various molecules that are resorbed or secreted across the proximal tubule, as well as exposure to high concentrations of luminal solutes that are concentrated by the resorption of water from the glomerular filtrate.
- Persistent and severe disturbances in blood flow resulting in diminished oxygen and substrate delivery to tubular

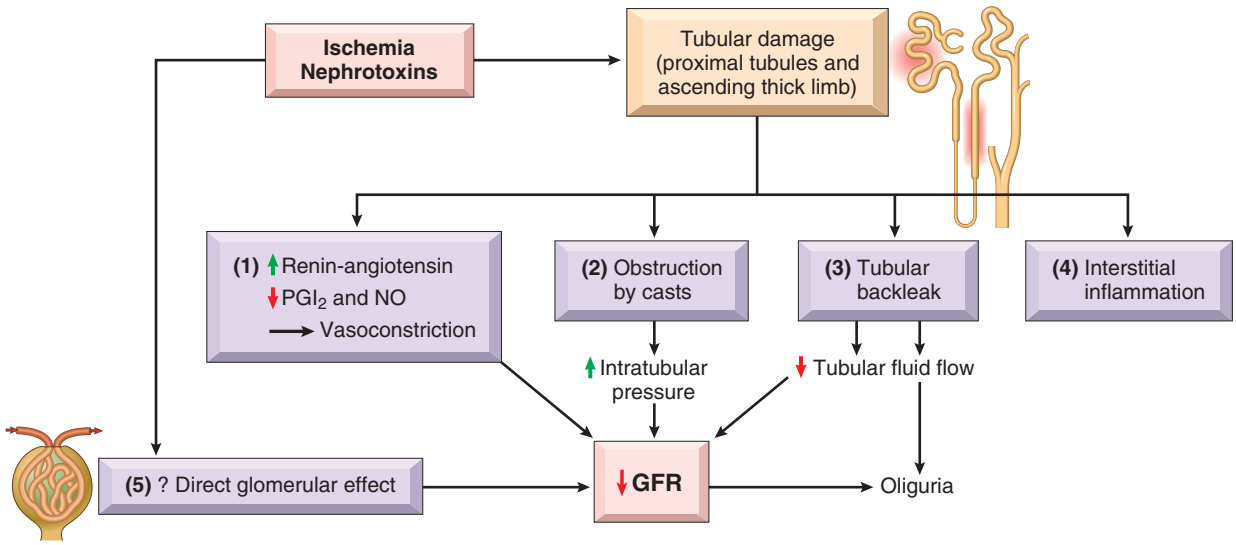


**Figure 13–17** Pathophysiologic mechanisms of acute kidney injury. Various injuries can directly damage tubules, which in turn decreases GFR by multiple mechanisms and also promotes vasoconstriction. Some injuries that cause tubular injury also directly decrease GFR by decreasing renal blood flow. NO, nitric oxide; $PGI_2$, prostaglandin $I_2$ (prostacyclin).
*(Modified from Lameire N, et al: JASN 12:S20-S32, 2001.)*

cells. Ischemia causes numerous structural alterations in epithelial cells. **Loss of cell polarity** is an early reversible event. It leads to the redistribution of membrane proteins (e.g., $Na^+$,$K^+$-ATPase) from the basolateral to the luminal surface of tubular cells, resulting in decreased sodium reabsorption by proximal tubules and hence increased sodium delivery to distal tubules. The latter, through a tubuloglomerular feedback system, contributes to preglomerular arteriolar vasoconstriction. Redistribution or alteration of integrins that anchor tubular cells results in their detachment from the basement membranes and their shedding into the urine. If sufficient tubular debris builds up it can block the outflow of urine (obstruction by casts), increasing intratubular pressure and thereby decreasing the GFR. Additionally, fluid from the damaged tubules may leak into the interstitium (backleak), resulting in increased interstitial pressure and collapse of the tubules. Ischemic tubular cells also express chemokines, cytokines, and adhesion molecules such as P-selectin that recruit leukocytes and can participate in tissue injury (interstitial inflammation).

Ischemic renal injury also is characterized by severe hemodynamic alterations that cause reduced GFR. The major one is intrarenal **vasoconstriction,** which results in both reduced glomerular plasma flow and reduced oxygen delivery to the tubules in the outer medulla (thick ascending limb and straight segment of the proximal tubule) (Fig. 13–17). Although a number of vasoconstrictor pathways have been implicated in this phenomenon (e.g., renin-angiotensin, thromboxane $A_2$, sympathetic nerve activity), the current opinion is that vasoconstriction is mediated by **sublethal endothelial injury,** leading to increased release of the endothelial vasoconstrictor **endothelin** and decreased production of vasodilatory **nitric oxide and prostaglandins.** Finally, some evidence points to a direct effect of ischemia or toxins on the glomerulus, causing a reduced effective glomerular filtration surface.

In addition to vasoconstriction, the pathogenesis of ATI may involve apoptosis and necrosis of tubular cells. Dead cells may elicit an inflammatory reaction (Chapter 2) that exacerbates the tubular injury and functional derangements.

## MORPHOLOGY

**Ischemic ATI** is characterized by lesions in the straight portions of the proximal tubule and the ascending thick limbs, but no segment of the proximal or distal tubules is spared. There is often a variety of **tubular injuries,** including attenuation of proximal tubular brush borders, blebbing and sloughing of brush borders, vacuolization of cells, and detachment of tubular cells from their underlying basement membranes with sloughing of cells into the urine. A striking additional finding is the presence of proteinaceous casts in the distal tubules and collecting ducts, which consist of Tamm-Horsfall protein (normally secreted by tubular epithelium) along with hemoglobin and other plasma proteins. When crush injuries have produced ATI, the casts also contain myoglobin. The interstitium usually shows generalized edema along with a mild inflammatory infiltrate consisting of polymorphonuclear leukocytes, lymphocytes, and plasma cells. The histologic picture in **toxic ATI** is basically similar, with some differences. Overt necrosis is most prominent in the proximal tubule, and the tubular basement membranes generally are spared.

If the patient survives for a week, epithelial regeneration becomes apparent in the form of a low cuboidal epithelial covering and mitotic activity in the surviving tubular epithelial cells. Acute kidney injury with underlying acute tubular injury as its cause may result in fibrosis rather than repair if the proximal tubular cells are arrested at $G_2$/M stage of the cell cycle after injury, as this arrest amplifies profibrotic mediators.

### Clinical Course

The clinical course of ischemic ATI initially is dominated by the inciting medical, surgical or obstetric event. Affected patients often present with manifestations of acute kidney injury, including *oliguria and decreased GFR*. Not all patients may manifest oliguria; some will have anuria, while in others, particularly if the injury is milder, the ATI may be nonoliguric. During acute kidney injury, the clinical picture is dominated by electrolyte abnormalities, acidosis and the signs and symptoms of uremia and fluid overload. Depending upon the severity and nature of the underlying injury and comorbid conditions, the prognosis varies. In the absence of careful supportive treatment or dialysis, patients may die. When the cause of acute kidney injury is ATI, repair and tubular regeneration lead to gradual clinical improvement. With supportive care, patients who do not die from the underlying precipitating problem have a good chance of recovering renal function unless kidney disease was present at the time of the acute insult. In those with preexisting kidney disease complete recovery is less certain, and progression over time to end-stage renal disease is unfortunately too frequent.

## SUMMARY

### Acute Tubular Injury

- ATI is the most common cause of acute kidney injury; its clinical manifestations are electrolyte abnormalities, acidosis, uremia, and signs of fluid overload, often with oliguria.
- ATI results from ischemic or toxic injury to renal tubules, and is associated with intrarenal vasoconstriction resulting in reduced GFR and diminished delivery of oxygen and nutrients to tubular epithelial cells.
- ATI is characterized morphologically by injury or necrosis of segments of the tubules (typically the proximal tubules), proteinaceous casts in distal tubules, and interstitial edema.

# DISEASES INVOLVING BLOOD VESSELS

Nearly all diseases of the kidney involve the renal blood vessels secondarily. Systemic vascular diseases, such as various forms of vasculitis, also involve renal blood vessels,

and often the effects on the kidney are clinically important (Chapter 9). The kidney is intimately involved in the pathogenesis of both essential and secondary hypertension. This section covers the renal lesions associated with benign and malignant hypertension.

## Arterionephrosclerosis

*Arterionephrosclerosis is the term used for the thickening and sclerosis of arterial walls and the renal changes associated with benign hypertension.* The characteristic morphologic alterations involve small arterioles and are called *hyaline arteriolosclerosis*. Some degree of arterionephrosclerosis, albeit mild, is present at autopsy in many persons older than 60 years of age. The frequency and severity of the lesions are increased at any age when hypertension is present.

### PATHOGENESIS

Of note, many renal diseases cause hypertension, which in turn is associated with arterionephrosclerosis. Thus, this renal lesion often is superimposed on other primary kidney diseases. Similar changes in arteries and arterioles are seen in individuals with chronic thrombotic microangiopathies. Whether hypertension causes the arterionephrosclerosis, or a subtle primary microvascular renal injury causes the hypertension, which in turn accelerates the sclerosis, is unknown. Recent studies implicate mutation in the apolipoprotein L1 gene (the same gene implicated in increased risk for FSGS) as tightly linked to the high incidence of arterionephrosclerosis observed in African Americans. The mechanisms of increased risk of kidney disease are unknown, but this mutation confers protection against trypanosomal disease, so its prevalence may have been influenced by natural selection.

### MORPHOLOGY

Grossly, the kidneys are **symmetrically atrophic,** each weighing 110 to 130 g. Typically the renal surface shows diffuse, fine granularity that resembles grain leather. Microscopically, the basic anatomic change is hyaline thickening of the walls of the small arteries and arterioles, known as **hyaline arteriolosclerosis.** This appears as a homogeneous, pink hyaline thickening, at the expense of the vessel lumina, with loss of underlying cellular detail (Fig. 13–18). The narrowing of the lumen results in markedly decreased blood flow through the affected vessels, with consequent ischemia in the organ served. All structures of the kidney show ischemic atrophy. In advanced cases of arterionephrosclerosis, the glomerular tufts may become sclerosed. Diffuse tubular atrophy and interstitial fibrosis are present. Often there is a scant interstitial lymphocytic infiltrate. The larger blood vessels (interlobar and arcuate arteries) show reduplication of internal elastic lamina along with fibrous thickening of the media **(fibroelastic hyperplasia)** and the subintima.

#### Clinical Course

This renal lesion alone rarely causes severe damage to the kidney except in persons with genetic susceptibility, such as African Americans, in whom it may lead to uremia and death. However, all patients with this lesion usually show some functional impairment, such as loss of concentrating ability or a variably diminished GFR. A mild degree of proteinuria is a frequent finding.

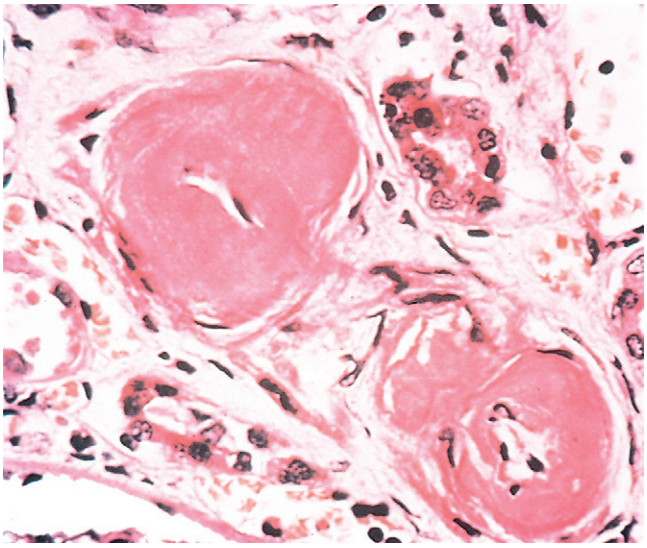

**Figure 13–18** Benign nephrosclerosis. High-power view of two arterioles with hyaline deposition, marked thickening of the walls, and a narrowed lumen.

*(Courtesy of Dr. M. A. Venkatachalam, Department of Pathology, University of Texas Health Sciences Center, San Antonio, Texas.)*

## Malignant Hypertension

Malignant hypertension, defined as blood pressure usually greater than 200/120 mm Hg, is far less common in the United States than so-called "benign" hypertension and occurs in only about 5% of persons with elevated blood pressure. It may arise de novo (i.e., without preexisting hypertension), or it may appear suddenly in a person who had mild hypertension. The prevalence of malignant hypertension is higher in less developed countries.

### PATHOGENESIS

The basis for this turn for the worse in hypertensive subjects is unclear, but the following sequence is suggested: The initial event seems to be some form of vascular damage to the kidneys. This most commonly results from long-standing hypertension, with eventual injury to the arteriolar walls. The result is increased permeability of the small vessels to fibrinogen and other plasma proteins, endothelial injury, and platelet deposition. This leads to the appearance of **fibrinoid necrosis** of arterioles and small arteries and intravascular thrombosis. Mitogenic factors from platelets (e.g., platelet-derived growth factor) and plasma cause intimal hyperplasia of vessels, resulting in the **hyperplastic arteriolosclerosis** typical of organizing injury of malignant hypertension and of morphologically similar thrombotic microangiopathies (see later) and further narrowing of the lumina. The kidneys become markedly ischemic. With severe involvement of the renal afferent arterioles, the renin-angiotensin system receives

a powerful stimulus. This then sets up a self-perpetuating cycle in which angiotensin II causes intrarenal vasoconstriction and the attendant renal ischemia perpetuates renin secretion. Aldosterone levels also are elevated, and the resultant salt retention exacerbates the elevation of blood pressure.

## MORPHOLOGY

The kidney may be essentially normal in size or slightly shrunken, depending on the duration and severity of the hypertensive disease. Small, **pinpoint petechial hemorrhages** may appear on the cortical surface from rupture of arterioles or glomerular capillaries, giving the kidney a peculiar, **flea-bitten appearance.**

The microscopic changes reflect the pathogenetic events described earlier. Damage to the small vessels is manifested as **fibrinoid necrosis** of the arterioles (Fig. 13–19, *A*). The vessel walls show a homogeneous, granular eosinophilic appearance masking underlying detail. In the interlobular arteries and larger arterioles, proliferation of intimal cells after acute injury produces an onion-skin appearance (Fig. 13–19, *B*). This name is derived from the concentric arrangement of cells whose origin is believed to be intimal smooth muscle, although this issue has not been finally settled. This lesion, called **hyperplastic arteriolosclerosis,** causes marked narrowing of arterioles and small arteries, to the point of total obliteration. Necrosis also may involve glomeruli, with microthrombi within the glomeruli as well as necrotic arterioles. Similar lesions are seen in persons with acute thrombotic microangiopathies (described later), and in patients with scleroderma in renal crisis.

### Clinical Course

The full-blown syndrome of malignant hypertension is characterized by papilledema, encephalopathy, cardiovascular abnormalities, and renal failure. Most often, the early symptoms are related to *increased intracranial pressure* and include headache, nausea, vomiting, and visual impairment, particularly the development of scotomas, or "spots" before the eyes. At the onset of rapidly mounting blood pressure there is marked proteinuria and microscopic, or sometimes macroscopic, hematuria but no significant alteration in renal function. Soon, however, *acute kidney injury develops.* The syndrome represents a true medical emergency that requires prompt and aggressive antihypertensive therapy before irreversible renal lesions develop. About 50% of patients survive at least 5 years, and further progress is still being made. Ninety percent of deaths are caused by uremia and the other 10% by cerebral hemorrhage or cardiac failure.

## Thrombotic Microangiopathies

As described in Chapter 11, the term *thrombotic microangiopathy* refers to lesions seen in various clinical syndromes characterized morphologically by *widespread thrombosis in the microcirculation* and clinically by *microangiopathic hemolytic anemia, thrombocytopenia,* and, in certain instances, *renal failure.* Common causes of thrombotic microangiopathy include

- Childhood hemolytic uremic syndrome (HUS)
- Various forms of adult HUS
- Thrombotic thrombocytopenic purpura (TTP)
- Various drugs
- Malignant hypertension or scleroderma

## PATHOGENESIS

The major pathogenetic factors in the thrombotic microangiopathies are endothelial activation (the dominant abnormality in HUS) and platelet activation and aggregation (which is dominant in TTP). Both may be caused by a number of external insults and inherited mutations, and together they lead to excessive small vessel thrombosis, the hallmark of these diseases.

- **Childhood HUS** is the best-characterized of the renal syndromes associated with thrombotic microangiopathy. As many as 75% of cases follow intestinal infection with Shiga toxin–producing *E. coli*, such as occurs in epidemics

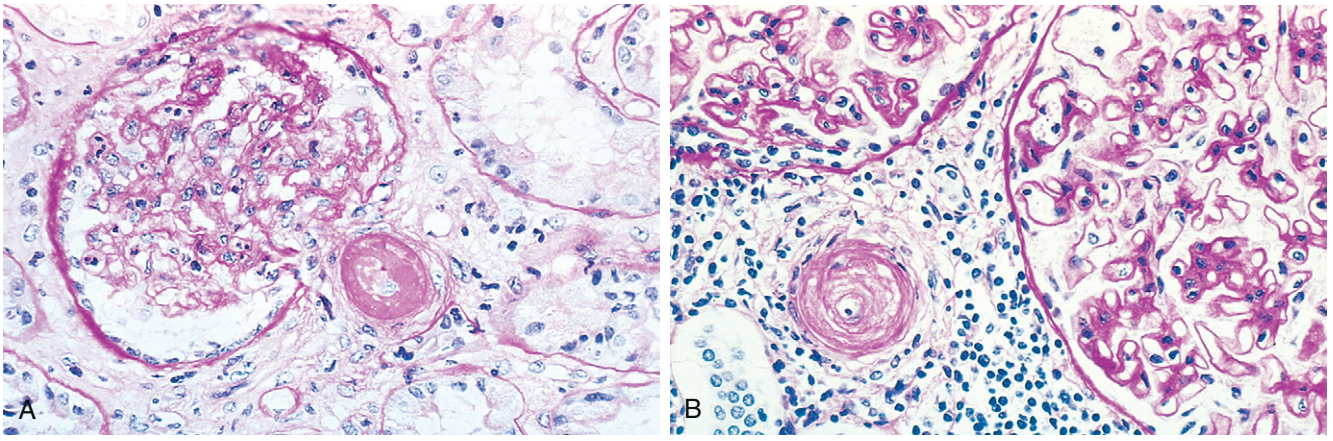


**Figure 13–19** Malignant hypertension. **A,** Fibrinoid necrosis of afferent arteriole (periodic acid–Schiff stain). **B,** Hyperplastic arteriolosclerosis (onion-skin lesion).
*(Courtesy of Dr. H. Rennke, Department of Pathology, Brigham and Women's Hospital, Boston, Massachusetts.)*

caused by ingestion of infected ground meat (e.g., in hamburgers) and infections with *Shigella dysenteriae* type I. The pathogenesis of this syndrome is related to the effects of Shiga toxin, which is carried by neutrophils in the circulation. Renal glomerular endothelial cells are targets because the cells express the membrane receptor for the toxin. The toxin has multiple effects on the endothelium, including increased adhesion of leukocytes, increased endothelin production, and loss of endothelial nitric oxide (both favoring vasoconstriction), and (in the presence of cytokines, such as tumor necrosis factor) endothelial damage. The toxin also gains entry to the cells and directly causes cell death. The resultant endothelial damage leads to thrombosis, which is most prominent in glomerular capillaries, afferent arterioles, and interlobular arteries, as well as vasoconstriction, resulting in the characteristic thrombotic microangiopathy.

Approximately 10% of the cases of HUS in children are not preceded by diarrhea caused by Shiga toxin–producing bacteria. In a subset of these patients, mutational inactivation of complement regulatory proteins (e.g., factor H) allows uncontrolled complement activation after minor vascular injuries. These conditions promote the formation of thrombi.

- **Adult HUS.** In typical (epidemic, classic, diarrhea-positive) HUS, the trigger for endothelial injury and activation usually is a Shiga-like toxin, while in inherited forms of atypical HUS, the cause of endothelial injury appears to be excessive, inappropriate activation of complement. Many other forms of exposures and conditions, including drug toxicities, can occasionally precipitate a HUS-like picture, presumably also by injuring the endothelium.
- **TTP** often is caused by an acquired defect in proteolytic cleavage of von Willebrand factor (vWF) multimers due to autoantibodies, or more rarely, an inherited defect as seen in familial TTP (Chapter 11). Pathogenic autoantibodies, whether arising in a context of autoimmunity or drug-induced, typically are directed against ADAMTS 13 (a disintegrin and metalloprotease with thrombospondin-like motifs), a plasma protease that cleaves vWF multimers into smaller sizes. Autoantibody binding to ADAMTS 13 results in loss of function and increased levels of large vWF multimers in the circulation, which in turn can activate platelets spontaneously, leading to platelet aggregation and thrombosis. Genetic defects in ADAMTS 13 lead to a similar pattern of disease.

### MORPHOLOGY

In childhood HUS, there are lesions of classic **thrombotic microangiopathy** with fibrin thrombi predominantly involving glomeruli, and extending into arterioles and larger arteries in severe cases. Cortical necrosis may be present. Morphologic changes in glomeruli resulting from endothelial injury include widening of the subendothelial space in glomerular capillaries, duplication or splitting of GBMs, and lysis of mesangial cells with mesangial disintegration. Chronically, scarring of glomeruli may develop.

Clinical Course

Typically, childhood HUS is characterized by the sudden onset, usually after a gastrointestinal or flulike prodromal episode, of bleeding manifestations (especially hematemesis and melena), severe oliguria, hematuria, microangiopathic hemolytic anemia, and (in some persons) prominent neurologic changes. *This disease is one of the main causes of acute kidney injury in children.* If the acute kidney injury is managed properly with dialysis, most patients recover in a matter of weeks. The long-term prognosis (over 15 to 25 years), however, is not uniformly favorable, because in about 25% of these children, renal insufficiency eventually develops as a consequence of the secondary scarring. Although HUS and TTP have some overlapping clinical features, such as microangiopathic hemolytic anemia and thrombocytopenia, TTP more often has dominant involvement of the central nervous system and the kidneys are less commonly involved compared to HUS.

### SUMMARY

#### Vascular Diseases of the Kidney

- *Arterionephrosclerosis*: Progressive, chronic renal damage associated with hypertension. Characteristic features are hyaline arteriolosclerosis and narrowing of vascular lumina with resultant cortical atrophy.
- *Malignant hypertension*: Acute kidney injury associated with severe elevation of blood pressure. Arteries and arterioles show fibrinoid necrosis and hyperplasia of smooth muscle cells; petechial hemorrhages on the cortical surface.
- *Thrombotic microangiopathies*: Disorders characterized by fibrin thrombi in glomeruli and small vessels resulting in acute kidney injury. Childhood HUS is usually caused by endothelial injury by an *E. coli* toxin; TTP is often caused by defects in von Willebrand factor leading to excessive thrombosis, with platelet consumption.

## CHRONIC KIDNEY DISEASE

Chronic kidney disease is the result of progressive scarring resulting from any type of kidney disease. Alterations in the function of remaining initially intact nephrons are ultimately maladaptive and cause further scarring. This eventually results in an end-stage kidney where glomeruli, tubules, interstitium and vessels are sclerosed, regardless of the primary site of injury. Unless the disorder is treated with dialysis or transplantation, death from uremia results.

### MORPHOLOGY

Classically, the kidneys are **symmetrically contracted,** and their surfaces are red-brown and **diffusely granular** when the underlying disorder affects blood vessels or glomeruli. Kidneys damaged by chronic pyelonephritis are typically unevenly involved and have deep scars. Microscopically, the feature common to all cases is advanced scarring of the glomeruli, sometimes to the point of complete sclerosis (Fig. 13–20). This **obliteration of the glomeruli** is the end point of many diseases, and it is impossible to ascertain from

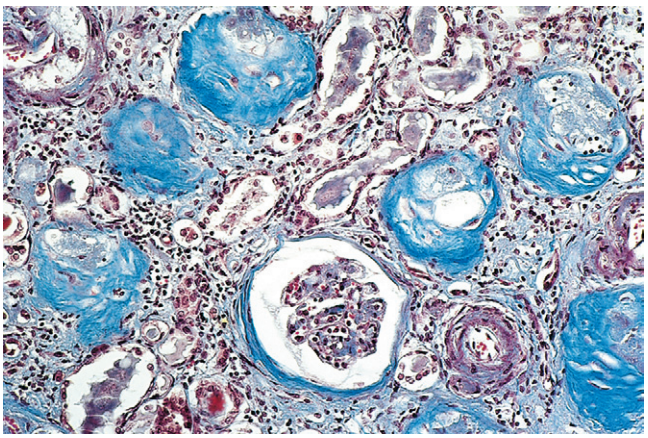

**Figure 13–20** Chronic glomerulonephritis. A Masson trichrome preparation shows complete replacement of virtually all glomeruli by blue-staining collagen.
*(Courtesy of Dr. M.A. Venkatachalam, Department of Pathology, University of Texas Health Sciences Center, San Antonio, Texas.)*

such kidneys the nature of the initial lesion. There is also marked **interstitial fibrosis,** associated with atrophy and dropout of many of the tubules in the cortex, and diminution and loss of portions of the peritubular capillary network. The small and medium-sized arteries frequently are thick-walled, with narrowed lumina, secondary to hypertension. Lymphocytic (and, rarely, plasma cell) infiltrates are present in the fibrotic interstitial tissue. As damage to all structures progresses, it may become difficult to ascertain whether the primary lesion was glomerular, vascular, tubular, or interstitial. Such markedly damaged kidneys have been designated **end-stage kidneys.**

### Clinical Course

Chronic kidney disease may sometimes develop insidiously and be discovered only late in its course, after the onset of renal insufficiency. Frequently, renal disease is first detected with the discovery of proteinuria, hypertension, or azotemia on routine medical examination. Disease-specific findings may precede development of chronic kidney disease. In patients with glomerular disease resulting in nephrotic syndrome, as the glomeruli undergo sclerotic changes, the avenue for protein loss is progressively closed, and the nephrotic syndrome thus becomes less severe with more advanced disease. Some degree of proteinuria, however, is present in almost all cases. Hypertension is very common, and its effects may dominate the clinical picture. Although microscopic hematuria is usually present, grossly bloody urine is infrequent at this late stage.

Without treatment, the prognosis is poor; relentless progression to uremia and death is the rule. The rate of progression is extremely variable.

## CYSTIC DISEASES OF THE KIDNEY

Cystic diseases of the kidney are a heterogeneous group comprising hereditary, developmental, and acquired disorders. These diseases are important for several reasons:

- They are reasonably common and often present diagnostic problems for clinicians, radiologists, and pathologists.
- Some forms, such as adult polycystic disease, constitute major causes of chronic renal failure.
- Simple cysts can occasionally be confused with malignant tumors.

*An emerging theme in the pathophysiology of the hereditary cystic diseases is that the underlying defect is in the cilia–centrosome complex of tubular epithelial cells.* Such defects may interfere with fluid absorption or cellular maturation, resulting in cyst formation. A brief overview of simple cysts, the most common form, is presented next, followed by a more detailed discussion of polycystic kidney disease.

### Simple Cysts

Simple cysts are generally innocuous lesions that occur as multiple or single cystic spaces of variable size. Commonly, they are 1 to 5 cm in diameter; translucent; lined by a gray, glistening, smooth membrane; and filled with clear fluid. On microscopic examination, these membranes are seen to be composed of a single layer of cuboidal or flattened cuboidal epithelium, which in many instances may be completely atrophic. The cysts usually are confined to the cortex. Rarely, massive cysts as large as 10 cm in diameter are encountered.

Simple cysts constitute a common postmortem finding that has no clinical significance. The main importance of cysts lies in their differentiation from kidney tumors, when they are discovered either incidentally or during evaluation of hemorrhage and pain. Radiographic studies show that in contrast with renal tumors, renal cysts have smooth contours, are almost always avascular, and produce fluid rather than solid tissue signals on ultrasonography.

*Dialysis-associated acquired cysts* occur in the kidneys of patients with end-stage kidney disease who have undergone prolonged dialysis. They are present in both the cortex and the medulla and may bleed, causing hematuria. Occasionally, renal adenomas or even papillary adenocarcinomas arise in the walls of these cysts.

### Autosomal Dominant (Adult) Polycystic Kidney Disease

Adult polycystic kidney disease is characterized by multiple expanding cysts affecting both kidneys that ultimately destroy the intervening parenchyma. It is seen in approximately 1 in 500 to 1000 persons and accounts for 10% of cases of chronic kidney disease. This disease is genetically heterogeneous. It can be caused by inheritance of one of at least two autosomal dominant genes of very high penetrance. In 85% to 90% of families, *PKD1,* on the short arm of chromosome 16, is the defective gene. This gene encodes a large (460-kDa) and complex cell membrane–associated protein, called polycystin-1.

#### PATHOGENESIS

The polycystin molecule is mainly extracellular and has regions of homology with proteins involved in cell–cell or

cell–matrix adhesion (e.g., domains that bind collagen, laminin, and fibronectin). It also has several other domains including those that can bind receptor tyrosine phosphatases. The polycystins have been localized to the primary cilium of tubular cells, like the nephrocystins linked to medullary cystic disease that are discussed later on, giving rise to the concept of renal cystic diseases as a type of **ciliopathy.** Cilia are hairlike organelles that project into the lumina from the apical surface of tubular cells, where they serve as mechanosensors of fluid flow. Current evidence suggests that polycystin mutations produce defects in mechanosensing. This in turn alters downstream signaling events involving calcium influx, leading to dysregulation of cell polarity, proliferation, and cell-cell and cell-matrix adhesion. It is interesting to note that whereas germline mutations of the *PKD1* gene are present in all renal tubular cells of affected persons, cysts develop in only some tubules. This is most likely due to loss of both alleles of *PKD1*. Thus, as with tumor suppressor genes, a second "somatic hit" is required for expression of the disease. The *PKD2* gene, implicated in 10% to 15% of cases, resides on chromosome 4 and encodes **polycystin 2,** a smaller, 110-kD protein. Polycystin 2 is thought to function as a calcium-permeable membrane channel, and is also expressed in cilia. Although structurally distinct, polycystins 1 and 2 are believed to act together by forming heterodimers. Thus, mutation in either gene gives rise to essentially the same phenotype, although patients with *PKD2* mutations have a slower rate of disease progression as compared with patients with *PKD1* mutations.

## MORPHOLOGY

In autosomal dominant adult polycystic kidney disease, the kidney may reach enormous size, and weights of up to 4 kg for each kidney have been recorded. These **very large kidneys** are readily palpable abdominally as masses extending into the pelvis. On gross examination the kidney seems to be composed solely of a mass of cysts of various sizes up to 3 or 4 cm in diameter with no intervening parenchyma. The cysts are filled with fluid, which may be clear, turbid, or hemorrhagic (Fig. 13–21).

Cysts may arise at any level of the nephron, from tubules to collecting ducts, and therefore they have a variable, often atrophic, lining. Occasionally, Bowman's capsules are involved in the cyst formation, and in these cases glomerular tufts may be seen within the cystic space. The pressure of the expanding cysts leads to ischemic atrophy of the intervening renal substance. Some normal parenchyma may be dispersed among the cysts. Evidence of superimposed hypertension or infection is common. Asymptomatic liver cysts occur in one third of the patients.

### Clinical Course

Polycystic kidney disease in adults usually *does not produce symptoms until the fourth decade of life,* by which time the kidneys are quite large, although small cysts start to develop in adolescence. The most common presenting complaint is *flank pain* or a heavy, dragging sensation. Acute distention of a cyst, either by intracystic hemorrhage or by obstruction, may cause excruciating pain. Sometimes attention is first drawn to the lesion on palpation of an abdominal mass. *Intermittent gross hematuria* commonly occurs. The most important complications, because of their deleterious effect on already marginal renal function, are *hypertension and urinary infection.* Hypertension of variable severity develops in about 75% of persons with this disorder. Saccular aneurysms of the circle of Willis (Chapter 22) are present in 10% to 30% of patients and are associated with a high incidence of subarachnoid hemorrhage.

Although the disease is ultimately fatal, the outlook is generally better than with most chronic kidney diseases. The condition tends to be relatively stable and progresses

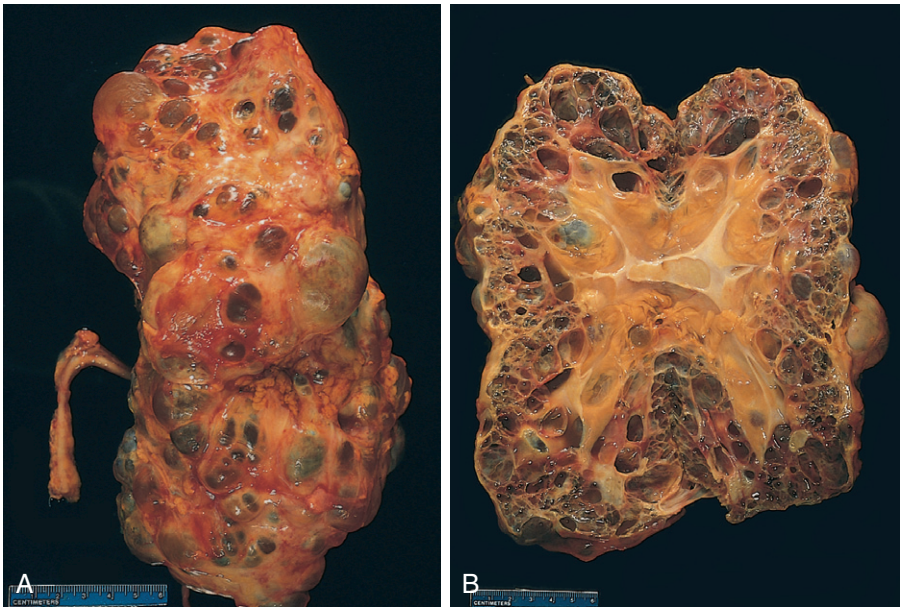


**Figure 13–21** Autosomal dominant adult polycystic kidney, viewed from the external surface (**A**) and bisected (**B**). The kidney is markedly enlarged (centimeter rule is shown for scale), with numerous dilated cysts.

very slowly. End-stage kidney disease occurs at about age 50, but there is wide variation in the course of this disorder, and nearly normal life spans are reported. Patients in whom the disease progresses to renal failure are treated by renal transplantation. Death usually results from uremia or hypertensive complications.

## Autosomal Recessive (Childhood) Polycystic Kidney Disease

The childhood form of polycystic kidney disease is a rare autosomal recessive disorder that is genetically distinct from adult polycystic kidney disease. It occurs in approximately 1 in 20,000 live births. Perinatal, neonatal, infantile, and juvenile subcategories have been defined, depending on age at presentation and the presence of associated hepatic lesions. All types result from mutations in the *PKHD1* gene, coding for a putative membrane receptor protein called *fibrocystin,* localized to the short arm of chromosome 6 (6p). Fibrocystin is found in cilia in tubular epithelial cells, but its function remains unknown.

### MORPHOLOGY

In autosomal recessive polycystic kidney disease, **numerous small cysts** in the cortex and medulla give the kidney a spongelike appearance. Dilated, elongated channels at right angles to the cortical surface completely replace the medulla and cortex. The cysts have a uniform lining of cuboidal cells, reflecting their origin from the collecting tubules. The disease is invariably bilateral. In almost all cases, findings include multiple epithelium-lined **cysts in the liver** and proliferation of portal bile ducts.

### Clinical Course

Perinatal and neonatal forms are most common; serious manifestations usually are present at birth, and young infants may die quickly from hepatic or renal failure. Patients who survive infancy develop liver cirrhosis (congenital hepatic fibrosis).

## Medullary Diseases with Cysts

There are two major types of cystic disease affecting the medulla: *medullary sponge kidney,* a relatively common and usually innocuous condition, occasionally associated with nephrolithiasis, which will not be discussed further, and *nephronophthisis-medullary cystic disease complex,* which is almost always associated with renal dysfunction.

Nephronophthisis–medullary cystic disease complex is an under-appreciated cause of chronic kidney disease that usually begins in childhood. Four variants of this disease complex are recognized on the basis of the timing of onset: infantile, juvenile, and adolescent nephronophthisis and medullary cystic disease developing later in adult life. The juvenile form is the most common. Approximately 15% to 20% of children with juvenile nephronophthisis have extrarenal manifestations, which most often appear as retinal abnormalities, including retinitis pigmentosa, and even early-onset blindness in the most severe form. Other abnormalities found in some persons include oculomotor apraxia, mental retardation, cerebellar malformations, and liver fibrosis. In aggregate, the various forms of nephronophthisis are now thought to be the most common genetic cause of end-stage renal disease in children and young adults.

At least nine gene loci (NHP1-NHP9) have been identified for the autosomal recessive forms of the nephronophthisis complex. The majority of these genes encode proteins that are components of epithelial cilia, as is the case with other types of polycystic disease. Two autosomal forms cause disease in adults; these are far less common.

### MORPHOLOGY

Pathologic features of medullary cystic disease include **small contracted kidneys.** Numerous small cysts lined by flattened or cuboidal epithelium are present, typically at the corticomedullary junction. Other pathologic changes are nonspecific, but most notably they include a chronic tubulointerstitial nephritis with tubular atrophy and thickened tubular basement membranes and progressive interstitial fibrosis.

### Clinical Course

The initial manifestations are usually polyuria and polydipsia, a consequence of diminished tubular function. Progression to end-stage kidney disease ensues over a 5- to 10-year period. The disease is difficult to diagnose, since there are no serologic markers and the cysts may be too small to be seen with radiologic imaging. Adding to this difficulty, cysts may not be apparent on renal biopsy if the corticomedullary junction is not well sampled. A positive family history and unexplained chronic renal failure in young patients should lead to suspicion of nephronophthisis.

### SUMMARY

#### Cystic Diseases

- *Adult polycystic kidney disease* is a disease of autosomal dominant inheritance caused by mutations in the genes encoding polycystin-1 or -2. It accounts for about 10% of cases of chronic renal failure; kidneys may be very large and contain many cysts.
- *Autosomal recessive (childhood) polycystic kidney disease* is caused by mutations in the gene encoding fibrocystin. It is less common than the adult form and strongly associated with liver abnormalities; kidneys contain numerous small cysts.
- *Nephronophthisis–medullary cystic disease complex* is being increasingly recognized as a cause of chronic kidney disease in children and young adults. Of autosomal recessive inheritance, it is associated with mutations in several genes that encode epithelial cell proteins called nephrocystins that may be involved in ciliary function; kidneys are contracted and contain multiple small cysts.

# URINARY OUTFLOW OBSTRUCTION

## Renal Stones

*Urolithiasis* is calculus formation at any level in the urinary collecting system, but most often the calculi arise in the kidney. They occur frequently, and it is estimated that by the age of 70 years, 11% of men and 5.6% of women in the United States will have experienced a symptomatic kidney stone. Symptomatic urolithiasis is more common in men than in women. A familial tendency toward stone formation has long been recognized.

### PATHOGENESIS

There are three major types of stones.

- About 80% of renal stones are composed of either calcium oxalate or calcium oxalate mixed with calcium phosphate.
- Ten percent are composed of magnesium ammonium phosphate.
- Six percent to 9% are either uric acid or cystine stones.

In all cases, an organic matrix of mucoprotein is present that makes up about 2.5% of the stone by weight (Table 13–3).

The cause of stone formation is often obscure, particularly in the case of calcium-containing stones. Probably involved is a confluence of predisposing conditions, including the concentration of the solute, changes in urine pH, and bacterial infections. The **most important cause is increased urinary concentration of the stone's constituents, so that it exceeds their solubility in urine (supersaturation).** As shown in Table 13–3, 50% of patients who develop **calcium stones** have hypercalciuria that is not associated with hypercalcemia. Most in this group absorb calcium from the gut in excessive amounts **(absorptive hypercalciuria)** and promptly excrete it in the urine, and some have a primary renal defect of calcium reabsorption **(renal hypercalciuria).**

The causes of the other types of renal stones are better understood. **Magnesium ammonium phosphate (struvite) stones** almost always occur in persons with a persistently alkaline urine resulting from UTIs. In particular, infections with urea-splitting bacteria, such as *Proteus vulgaris* and staphylococci, predispose individuals to urolithiasis. Moreover, bacteria may serve as particulate nidi for the formation of any kind of stone. In avitaminosis A, desquamated cells from the metaplastic epithelium of the collecting system act as nidi.

Gout and diseases involving rapid cell turnover, such as the leukemias, lead to high uric acid levels in the urine and the possibility of **uric acid stones.** About half of people with uric acid stones, however, have neither hyperuricemia nor increased urine urate but demonstrate an unexplained tendency to excrete a persistently acid urine (with a pH less than 5.5). This low pH favors uric acid stone formation—in contrast with the high pH that favors formation of stones containing calcium phosphate. **Cystine stones** are almost invariably associated with a genetically determined defect in the renal transport of certain amino acids, including cystine. Like uric acid stones, cystine stones are more likely to form when the urine is relatively acidic.

Urolithiasis also may result from the lack of substances that normally inhibit mineral precipitation. Inhibitors of crystal formation in urine include Tamm-Horsfall protein, osteopontin, pyrophosphate, mucopolysaccharides, diphosphonates, and a glycoprotein called nephrocalcin, but no deficiency of any of these substances has been consistently demonstrated in persons with urolithiasis.

**Table 13–3** Prevalence of Various Types of Renal Stones

| Stone | Distribution (%) |
|---|---|
| Calcium oxalate and/or calcium phosphate | 80 |
| Idiopathic hypercalciuria (50%) | |
| Hypercalcemia and hypercalciuria (10%) | |
| Hyperoxaluria (5%) | |
| Enteric (4.5%) | |
| Primary (0.5%) | |
| Hyperuricosuria (20%) | |
| No known metabolic abnormality (15% to 20%) | |
| Struvite ($Mg, NH_3, PO_4$) | 10 |
| Renal infection | |
| Uric acid | 6–7 |
| Associated with hyperuricemia | |
| Associated with hyperuricosuria | |
| Idiopathic (50% of uric acid stones) | |
| Cystine | 1–2 |
| Others or unknown | ±1–2 |

### MORPHOLOGY

Stones are unilateral in about 80% of patients. Common sites of formation are renal pelves and calyces and the bladder. Often, many stones are found in one kidney. They tend to be small (average diameter, 2 to 3 mm) and may be smooth or jagged. Occasionally, progressive accretion of salts leads to the development of branching structures known as **staghorn calculi,** which create a cast of the renal pelvis and calyceal system. These massive stones usually are composed of magnesium ammonium phosphate.

### Clinical Course

Stones may be present without producing either symptoms or significant renal damage. This is particularly true with large stones lodged in the renal pelvis. Smaller stones may pass into the ureter, where they may lodge, producing a typical intense pain known as *renal or ureteral colic,* characterized by paroxysms of flank pain radiating toward the groin. Often at this time there is *gross hematuria.* The clinical significance of stones lies in their capacity to obstruct urine flow or to produce sufficient trauma to cause ulceration and bleeding. In either case, they *predispose the sufferer to bacterial infection.* Fortunately, in most cases the diagnosis is readily made radiologically.

## Hydronephrosis

Hydronephrosis refers to dilation of the renal pelvis and calyces, with accompanying atrophy of the parenchyma, caused by obstruction to the outflow of urine. The

obstruction may be sudden or insidious, and it may occur at any level of the urinary tract, from the urethra to the renal pelvis. The most common causes are categorized as follows:

- *Congenital*: atresia of the urethra, valve formations in either ureter or urethra, aberrant renal artery compressing the ureter, renal ptosis with torsion, or kinking of the ureter
- *Acquired*
  - *Foreign bodies*: calculi, sloughed necrotic papillae
  - *Proliferative lesions*: benign prostatic hyperplasia, carcinoma of the prostate, bladder tumors (papilloma and carcinoma), contiguous malignant disease (retroperitoneal lymphoma, carcinoma of the cervix or uterus)
  - *Inflammation*: prostatitis, ureteritis, urethritis, retroperitoneal fibrosis
  - *Neurogenic*: spinal cord damage with paralysis of the bladder
  - *Normal pregnancy*: mild and reversible

Bilateral hydronephrosis occurs only when the obstruction is below the level of the ureters. If blockage is at the ureters or above, the lesion is unilateral. Sometimes obstruction is complete, allowing no urine to pass; usually it is only partial.

## PATHOGENESIS

Even with complete obstruction, glomerular filtration persists for some time, and the filtrate subsequently diffuses back into the renal interstitium and perirenal spaces, whence it ultimately returns to the lymphatic and venous systems. Because of the continued filtration, the **affected calyces and pelvis become dilated,** often markedly so. The unusually high pressure thus generated in the renal pelvis, as well as that transmitted back through the collecting ducts, causes compression of the renal vasculature. Both arterial insufficiency and venous stasis result, although the latter probably is more important. The most severe effects are seen in the papillae, because they are subjected to the greatest increases in pressure. Accordingly, **the initial functional disturbances are largely tubular, manifested primarily by impaired concentrating ability.** Only later does glomerular filtration begin to diminish. Experimental studies indicate that serious irreversible damage occurs in about 3 weeks with complete obstruction, and in 3 months with incomplete obstruction. In addition to functional changes, the obstruction also triggers an interstitial inflammatory reaction, leading eventually to interstitial fibrosis.

## MORPHOLOGY

**Bilateral** hydronephrosis (as well as unilateral hydronephrosis when the other kidney is already damaged or absent) leads to renal failure, and the onset of uremia tends to abort the natural course of the lesion. By contrast, **unilateral** involvement is associated with the full range of morphologic changes, which vary with the degree and speed of obstruction. With subtotal or intermittent obstruction, the kidney may be massively enlarged (lengths in the range of 20 cm), and the organ may consist almost entirely of the greatly distended pelvicalyceal system. The renal parenchyma itself is compressed and atrophied, with obliteration of the papillae and flattening of the pyramids (Fig. 13–22). On the other hand, when obstruction is sudden and complete, glomerular filtration is compromised relatively early, and as a consequence, renal function may cease while dilation is still comparatively slight. Depending on the level of the obstruction, one or both ureters may be dilated **(hydroureter).**

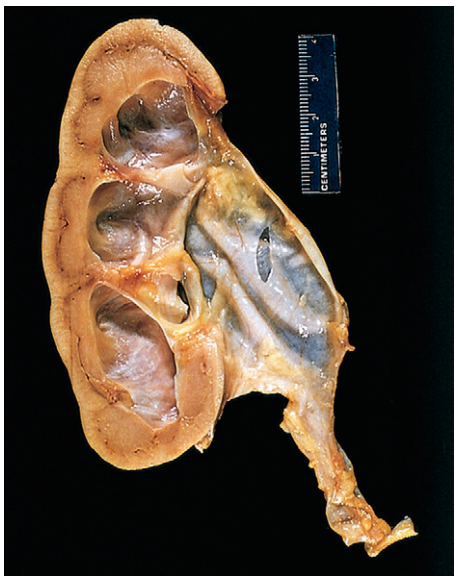


**Figure 13–22** Hydronephrosis of the kidney, with marked dilation of the pelvis and calyces and thinning of renal parenchyma.

On microscopic examination the early lesions show tubular dilation, followed by atrophy and fibrous replacement of the tubular epithelium with relative sparing of the glomeruli. Eventually, in severe cases the glomeruli also become atrophic and disappear, converting the entire kidney into a thin shell of fibrous tissue. With sudden and complete obstruction, there may be coagulative necrosis of the renal papillae, similar to the changes of papillary necrosis. In uncomplicated cases the accompanying inflammatory reaction is minimal. Superimposed pyelonephritis, however, is common.

### Clinical Course

*Bilateral* complete obstruction produces anuria, which is soon brought to medical attention. When the obstruction is below the bladder, the dominant symptoms are those of bladder distention. Paradoxically, incomplete bilateral obstruction causes polyuria rather than oliguria, as a result of defects in tubular concentrating mechanisms, and this may obscure the true nature of the disturbance. Unfortunately, *unilateral* hydronephrosis may remain completely silent for long periods unless the other kidney is for some reason not functioning. Often the enlarged kidney is discovered on routine physical examination. Sometimes the basic cause of the hydronephrosis, such as renal calculi or an obstructing tumor, produces symptoms that indirectly draw attention to the hydronephrosis. Removal of

obstruction within a few weeks usually permits full return of function; however, with time the changes become irreversible.

# TUMORS

Many types of benign and malignant tumors occur in the urinary tract. In general, benign tumors such as small (less than 0.5 cm in diameter) cortical papillary adenomas, which are found in 40% of adults, have no clinical significance. The most common malignant tumor of the kidney is renal cell carcinoma, followed in frequency by nephroblastoma (Wilms tumor) and by primary tumors of the calyces and pelvis. Other types of renal cancer are rare and need not be discussed here. *Tumors of the lower urinary tract are about twice as common as renal cell carcinomas.* They are described at the end of this section.

## Tumors of the Kidney

### *Oncocytoma*

Oncocytoma, a benign tumor that arises from the intercalated cells of collecting ducts, represents about 10% of renal tumors. These tumors are associated with genetic changes—loss of chromosomes 1, 14, and Y—that distinguish them from other renal neoplasms. Oncocytomas are histologically characterized by a plethora of mitochondria, providing the basis for their tan color and their finely granular eosinophilic cytoplasm that is seen histologically. A central stellate scar, which is another feature of oncocytomas, provides a characteristic appearance on imaging studies. Owing to their large size and clinical and radiologic similarity to some renal cell carcinomas, however, they are removed by nephrectomy, both to prevent such complications as spontaneous hemorrhage and to make a definitive diagnosis.

### *Renal Cell Carcinoma*

Renal cell carcinomas are derived from the renal tubular epithelium and hence they are located predominantly in the cortex. These tumors represent 80% to 85% of all primary malignant tumors of the kidney and 2% to 3% of all cancers in adults. These data translate into about 58,000 cases per year in the United States; 40% of patients die of the disease. Carcinomas of the kidney are most common from the sixth to seventh decades, and men are affected about twice as commonly as women. The risk of developing these tumors is higher in smokers, hypertensive or obese patients, and those who have had occupational exposure to cadmium. The risk of developing renal cell cancer is increased 30-fold in persons who acquire polycystic disease as a complication of chronic dialysis. The role of genetic factors in the causation of these cancers is discussed later on.

Renal cell cancers are classified on the basis of morphology and growth patterns. However, recent advances in the understanding of the genetic basis of renal carcinomas have led to a new classification that takes into account the molecular origins of these tumors. The three most common forms, discussed next, are clear cell carcinoma, papillary renal cell carcinoma, and chromophobe renal carcinoma.

#### Clear Cell Carcinomas

Clear cell carcinomas are the most common type, accounting for 65% of renal cell cancers. Histologically, they are composed of cells with clear cytoplasm. Although most are sporadic, they also occur in familial forms or in association with von Hippel-Lindau (VHL) disease. It is the study of VHL disease that has provided molecular insights into the causation of clear cell carcinomas. VHL disease is inherited as an autosomal dominant trait and is characterized by predisposition to a variety of neoplasms, but particularly to hemangioblastomas of the cerebellum and retina. Hundreds of bilateral renal cysts and bilateral, often multiple, clear cell carcinomas develop in 40% to 60% of affected persons. Those with VHL syndrome inherit a germline mutation of the *VHL* gene on chromosomal band 3p25 and lose the second allele by somatic mutation. Thus, the loss of both copies of this tumor suppressor gene is a key step in the development of clear cell carcinoma. The *VHL* gene is also involved in the majority of sporadic clear cell carcinomas. Cytogenetic abnormalities giving rise to loss of chromosomal segment 3p14 to 3p26 are often seen in sporadic renal cell cancers. This region harbors the *VHL* gene (3p25.3). The second, nondeleted allele is inactivated by a somatic mutation or hypermethylation in 60% of sporadic cases. Thus, homozygous loss of the *VHL* gene seems to be the common underlying molecular abnormality in both sporadic and familial forms of clear cell carcinomas. The VHL protein causes the degradation of hypoxia-induced factors (HIFs), and in the absence of VHL, HIFs are stabilized. HIFs are transcription factors that contribute to carcinogenesis by stimulating the expression of vascular endothelial growth factor (VEGF), an important angiogenic factor, as well as a number of other genes that drive tumor cell growth (Chapter 5). An uncommon familial form of clear cell carcinoma unrelated to VHL disease also is associated with cytogenetic abnormalities involving the short arm of chromosome 3 (3p). In addition, recent deep sequencing of clear cell carcinoma genomes has revealed frequent loss-of-function mutations in *SETD2, JARID1C,* and *UTX,* all of which encode proteins that regulate histone methylation, suggesting that changes in the "epigenome" have a central role in the genesis of this subtype of renal carcinoma.

#### Papillary Renal Cell Carcinomas

Papillary renal cell carcinomas account for 10% to 15% of all renal cancers. As the name indicates, they show a papillary growth pattern. These tumors are frequently multifocal and bilateral and appear as early-stage tumors. Like clear cell carcinomas, they occur in familial and sporadic forms, but unlike these tumors, papillary renal cancers are not associated with abnormalities of chromosome 3. The culprit in most cases of hereditary papillary renal cell cancers is the *MET* proto-oncogene, located on chromosomal sub-band 7q31. The *MET* gene is a tyrosine kinase receptor for the growth factor called hepatocyte growth factor. The increased dosage of the *MET* gene due to duplications of chromosome 7 seems to spur abnormal growth in the proximal tubular epithelial cell precursors of papillary carcinomas. In familial cases, genetic analysis shows activating mutations of *MET* in the germline, along with increased gene dosage in the cancers. Activating mutations of the *MET* gene also are found in a subset of

patients with sporadic forms of papillary renal cell carcinoma.

### Chromophobe Renal Carcinomas

Chromophobe renal carcinomas are the least common, representing 5% of all renal cell carcinomas. They arise from intercalated cells of collecting ducts. Their name derives from the observation that the tumor cells stain more darkly (i.e., they are less clear) than cells in clear cell carcinomas. These tumors are unique in having multiple losses of entire chromosomes, including chromosomes 1, 2, 6, 10, 13, 17, and 21. Thus, they show extreme hypodiploidy. Because of multiple losses, the "critical hit" has not been determined. In general, chromophobe renal cancers have a good prognosis.

## MORPHOLOGY

**Clear cell cancers** (the most common form of these renal carcinomas) usually are solitary and large when symptomatic (spherical masses 3 to 15 cm in diameter), but high-resolution radiographic techniques for investigation of unrelated problems sometimes detect smaller lesions incidentally. They may arise anywhere in the cortex. The cut surface of clear cell renal cell carcinomas is **yellow to orange to gray-white, with prominent areas of cystic softening or of hemorrhage,** either fresh or old (Fig. 13–23). The margins of the tumor are well defined. However, at times small processes project into the surrounding parenchyma and small satellite nodules are found, providing clear evidence of the aggressiveness of these lesions. As the tumor enlarges, it may fungate through the walls of the collecting system, extending through the calyces and pelvis as far as the ureter. Even more frequently, the **tumor invades the renal vein** and grows as a solid column within this vessel, sometimes extending in serpentine fashion as far as the inferior vena cava and even into the right side of the heart. Occasionally, direct invasion into the perinephric fat and adrenal gland may be seen.

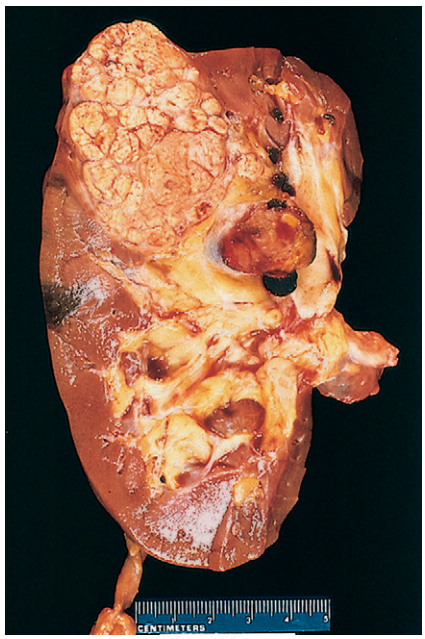


**Figure 13–23** Renal cell carcinoma: Representative cross-section showing yellowish, spherical neoplasm in one pole of the kidney. Note the tumor in the dilated, thrombosed renal vein.

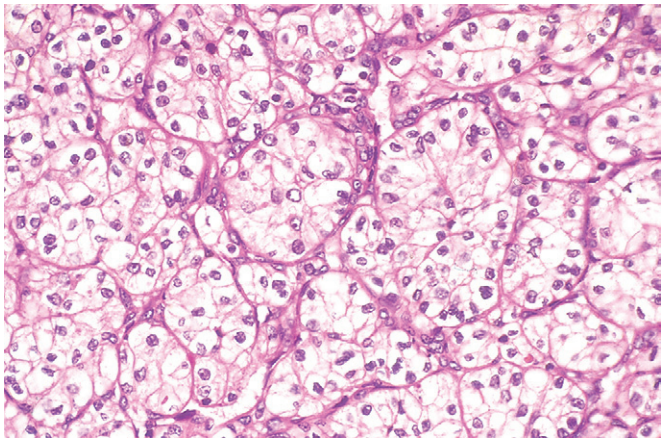

**Figure 13–24** High-power detail of the clear cell pattern of renal cell carcinoma.

Depending on the amounts of lipid and glycogen present, **the tumor cells of clear cell renal cell carcinoma may appear almost vacuolated or may be solid.** The classic vacuolated (lipid-laden), or clear cells are demarcated only by their cell membranes. The nuclei are usually small and round (Fig. 13–24). At the other extreme are granular cells, resembling the tubular epithelium, which have small, round, regular nuclei enclosed within granular pink cytoplasm. Some tumors are highly anaplastic, with numerous mitotic figures and markedly enlarged, hyperchromatic, pleomorphic nuclei. Between the extremes of clear cells and solid, granular cells, all intergradations may be found. The cellular arrangement, too, varies widely. The cells may form abortive tubules or may cluster in cords or disorganized masses. The stroma is usually scant but highly vascularized.

**Papillary renal cell carcinomas** exhibit various degrees of papilla formation with fibrovascular cores. They tend to be bilateral and multiple. They also may show gross evidence of necrosis, hemorrhage, and cystic degeneration, but they are less vibrantly orange-yellow because of their lower lipid content. The cells may have clear or, more commonly, pink cytoplasm. **Chromophobe-type renal cell carcinoma** tends to be grossly tan-brown. The cells usually have clear, flocculent cytoplasm with very prominent, distinct cell membranes. The nuclei are surrounded by halos of clear cytoplasm. Ultrastructurally, large numbers of characteristic macrovesicles are seen.

### Clinical Course

Renal cell carcinomas have several peculiar clinical characteristics that create especially difficult and challenging diagnostic problems. The signs and symptoms vary, but the *most frequent presenting manifestation is hematuria, occurring in more than 50% of cases.* Macroscopic hematuria tends to be intermittent and fleeting, superimposed on a steady microscopic hematuria. Less commonly the tumor may declare itself simply by virtue of its size, when it has grown large enough to produce flank pain and a *palpable mass*. Because of the widespread use of imaging studies for

unrelated conditions, even smaller tumors are detected. Extra-renal effects are *fever* and *polycythemia*, which, because they are nonspecific, may be misinterpreted for some time before their association with the renal tumor is appreciated. Polycythemia affects 5% to 10% of persons with this disease. It results from elaboration of erythropoietin by the cancer cells. Uncommonly, these tumors produce other hormone-like substances, resulting in hypercalcemia, hypertension, Cushing syndrome, or feminization or masculinization. These, as noted in Chapter 5, are *paraneoplastic syndromes*. In many patients, the primary tumor remains silent and is discovered only after its metastases have produced symptoms. The prevalent locations for metastases are the lungs and the bones. It must be apparent that renal cell carcinoma manifests in many ways, some quite devious, *but the triad of painless hematuria, a palpable abdominal mass, and dull flank pain is characteristic.*

## SUMMARY

### Renal Cell Carcinoma

Renal cell carcinomas account for 2% to 3% of all cancers in adults and are classified into three types:

- *Clear cell carcinomas* are the most common and are associated with homozygous loss of the VHL tumor suppressor protein; tumors frequently invade the renal vein.
- *Papillary renal cell carcinomas* frequently are associated with increased expression and activating mutations of the *MET* oncogene; they tend to be bilateral and multiple and show variable papilla formation.
- *Chromophobe renal cell carcinomas* are less common; tumor cells are not as clear as in the other renal cell carcinomas.

### *Wilms Tumor*

Although Wilms tumor occurs infrequently in adults, it is the third most common organ cancer in children younger than 10 years of age. These tumors contain a variety of cell and tissue components, all derived from the mesoderm. Wilms tumor, like retinoblastoma, may arise sporadically or be familial, with the susceptibility to tumorigenesis inherited as an autosomal dominant trait. This tumor is discussed in greater detail in Chapter 6 along with other tumors of childhood.

Tumors and other lesions of the lower urinary tract (ureters, bladder, and urethra) are described in Chapter 17.

## BIBLIOGRAPHY


Barratt J, Feehally J: IgA nephropathy. J Am Soc Nephrol 16:2088, 2005. *[A comprehensive update on the pathogenesis, clinical manifestations, and treatment of this disease.]*

Beck LH Jr, Bonegio RG, Lambeau G, et al: M-type phospholipase $A_2$ receptor as target antigen in idiopathic membranous nephropathy. N Engl J Med 361:11, 2009. *[A landmark study describing the discovery of the antigen in idiopathic membranous nephropathy.]*

D'Agati VD: The spectrum of focal segmental glomerulosclerosis: new insights. Curr Opin Nephrol Hypertens 17:271, 2008. *[A comprehensive review of mechanisms contributing to various forms of FSGS.]*

Genovese G, Friedman DJ, Ross MD, et al: Association of trypanolytic ApoL1 variants with kidney disease in African Americans. Science 329:841, 2010. *[A landmark study of natural selection, linking a genetic variant of apolipoprotein L1 in African Americans to protection against sleeping sickness, and risk for kidney disease.]*

Guay-Woodford LM: Renal cystic diseases: diverse phenotypes converge on the cilium/centrosome complex. Pediatr Nephrol 21:1369, 2006. *[An excellent review on the pathophysiology of renal cystic diseases, with emphasis on the role of ciliary dysfunction in tubular epithelial cells.]*

Gubler MC: Inherited diseases of the glomerular basement membrane. Nat Clin Pract Nephrol 4:24, 2008. *[A superb review of the pathophysiology, clinical presentations and diagnostic testing strategies for Alport syndrome, thin basement membrane disease, and other types of hereditary nephritis.]*

Harris PC: 2008 Homer W. Smith Award: Insights into the pathogenesis of polycystic kidney disease from gene discovery. J Am Soc Nephrol 20:1188, 2009. *[A review of the discovery of the major genes leading to polycystic kidney disease, along with their phenotypic manifestations.]*

Knowles MA: Molecular subtypes of bladder cancer: Jekyll and Hyde or chalk and cheese. Carcinogenesis 27:371, 2006. *[Comprehensive review of molecular changes in different types of bladder cancer.]*

Lionaki S, Jennette JC, Falk RJ: Anti-neutrophil cytoplasmic (ANCA) and anti-glomerular basement membrane (GBM) autoantibodies in necrotizing and crescentic glomerulonephritis. Semin Immunopathol 29:459, 2007. *[A good summary of mechanisms of injury and clinical manifestations in ANCA and anti-GBM antibody–mediated disease.]*

Mathieson PW: Minimal change nephropathy and focal segmental glomerulosclerosis. Semin Immunopathol 29:415, 2007. *[An excellent overview of new insights into the pathogenesis and diagnosis of MCD versus FSGS.]*

Miller O, Hemphill RR: Urinary tract infection and pyelonephritis. Emerg Med Clin North Am 19:655, 2001. *[An excellent review of acute urinary tract infections.]*

Murray PT, Devarajan P, Levey AS, et al: A framework and key research questions in AKI diagnosis and staging in different environments. Clin J Am Soc Nephrol 3:864, 2008. *[An excellent review outlining recent advances in early diagnosis and consequences of acute kidney injury.]*

Nsar SH, Markowitz GS, Stokes MB, et al: Acute postinfectious glomerulonephritis in modern era: experience with 86 adults and review of the literature. Medicine 87:21, 2008. *[A contemporary review of postinfectious glomerulonephritis with an emphasis on clinicopathologic correlations and epidemiologic associations.]*

Ronco P, Debiec H: Membranous glomerulopathy: the evolving story. Curr Opin Nephrol Hypertens 19:254, 2010. *[An excellent review of recent insights into the etiology of membranous nephropathy.]*

Schrier RW, Wang W, Poole B, et al: Acute renal failure: definitions, diagnosis, pathogenesis, and therapy. J Clin Invest 114:5, 2004. *[An insightful review covering all aspects of acute renal failure.]*

Tryggvason K, Patrakka J, Wartiovaava J: Hereditary proteinuria syndromes and mechanisms of proteinuria. N Engl J Med 354:1387, 2006. *[An excellent review of the pathophysiology of defects in glomerular permeability.]*

Tsai HM: The molecular biology of thrombotic microangiopathy. Kidney Int 70:16, 2006. *[An excellent review of the pathogenesis of HUS and TTP.]*

Wilson PD, Goilav B: Cystic disease of the kidney. Annu Rev Pathol 2:341, 2007. *[Pathobiology of a common condition affecting the kidney.]*

Worcester EM, Coe FL: Calcium kidney stones. N Engl J Med 363:954, 2010. *[A comprehensive review of the pathophysiology and management of the most common types of kidney stones.]*

This page intentionally left blank

See Targeted Therapy available online at studentconsult.com

CHAPTER 14

# Oral Cavity and Gastrointestinal Tract

CHAPTER CONTENTS


**ORAL CAVITY 551**
Oral Inflammatory Lesions 552
Aphthous Ulcers (Canker Sores) 552
Herpes Simplex Virus Infections 552
Oral Candidiasis (Thrush) 552
Proliferative and Neoplastic Lesions of the Oral Cavity 552
Fibrous Proliferative Lesions 552
Leukoplakia and Erythroplakia 553
Squamous Cell Carcinoma 554
Diseases of Salivary Glands 555
Xerostomia 555
Sialadenitis 555
Neoplasms 555
Odontogenic Cysts and Tumors 557
**ESOPHAGUS 558**
Obstructive and Vascular Diseases 558
Mechanical Obstruction 558
Functional Obstruction 558
Ectopia 558
Esophageal Varices 559
Esophagitis 559
Lacerations 559
Chemical and Infectious Esophagitis 560
Reflux Esophagitis 560
Eosinophilic Esophagitis 561
Barrett Esophagus 561
Esophageal Tumors 562
Adenocarcinoma 562
Squamous Cell Carcinoma 563
**STOMACH 564**
Inflammatory Disease of the Stomach 564
Acute Gastritis 564
Acute Peptic Ulceration 565
Chronic Gastritis 566
Peptic Ulcer Disease 568
Neoplastic Disease of the Stomach 569
Gastric Polyps 569
Gastric Adenocarcinoma 570
Lymphoma 571
Carcinoid Tumor 571
Gastrointestinal Stromal Tumor 572
**SMALL AND LARGE INTESTINES 573**
Intestinal Obstruction 573
Hirschsprung Disease 573
Abdominal Hernia 574
Vascular Disorders of Bowel 574
Ischemic Bowel Disease 574
Hemorrhoids 576
Diarrheal Disease 576
Malabsorptive Diarrhea 576
Infectious Enterocolitis 580
Inflammatory Intestinal Disease 586
Sigmoid Diverticulitis 586
Inflammatory Bowel Disease 587
Colonic Polyps and Neoplastic Disease 592
Inflammatory Polyps 592
Hamartomatous Polyps 592
Hyperplastic Polyps 593
Adenomas 593
Familial Syndromes 595
Adenocarcinoma 596
**APPENDIX 600**
Acute Appendicitis 600
Tumors of the Appendix 601


The gastrointestinal tract is a hollow tube consisting of the esophagus, stomach, small intestine, colon, rectum, and anus. Each region has unique, complementary, and highly integrated functions that together serve to regulate the intake, processing, and absorption of ingested nutrients and the disposal of waste products. The intestines also are the principal site at which the immune system interfaces with a diverse array of antigens present in food and gut microbes. Thus, it is not surprising that the small intestine and colon frequently are involved by infectious and inflammatory processes. Finally, the colon is the most common site of gastrointestinal neoplasia in Western populations. In this chapter we discuss the diseases that affect each section of the gastrointestinal tract. Disorders that typically involve more than one segment, such as Crohn disease, are considered with the most frequently involved region.

## ORAL CAVITY

Pathologic conditions of the oral cavity can be broadly divided into diseases affecting the oral mucosa, salivary glands, and jaws. Discussed next are the more common conditions affecting these sites. Although common, disorders affecting the teeth and supporting structures are not considered here. Reference should be made to specialized texts. Odontogenic cysts and tumors (benign and malignant), which are derived from the epithelial and/or

mesenchymal tissues associated with tooth development, also are discussed briefly.

## ORAL INFLAMMATORY LESIONS

### Aphthous Ulcers (Canker Sores)

These common superficial mucosal ulcerations affect up to 40% of the population. They are more common in the first two decades of life, extremely painful, and recurrent. Although the cause of aphthous ulcers is not known, they do tend to be more prevalent within some families and may be associated with celiac disease, inflammatory bowel disease (IBD), and Behçet disease. Lesions can be solitary or multiple; typically, they are shallow, hyperemic ulcerations covered by a thin exudate and rimmed by a narrow zone of erythema (Fig. 14–1). In most cases they resolve spontaneously in 7 to 10 days but can recur.

### Herpes Simplex Virus Infections

Most orofacial herpetic infections are caused by herpes simplex virus type 1 (HSV-1), with the remainder being caused by HSV-2 (genital herpes). With changing sexual practices, oral HSV-2 is increasingly common. Primary infections typically occur in children between 2 and 4 years of age and are often asymptomatic. However, in 10% to 20% of cases the primary infection manifests as *acute herpetic gingivostomatitis,* with abrupt onset of vesicles and ulcerations throughout the oral cavity. Most adults harbor latent HSV-1, and the virus can be reactivated, resulting in a so-called "cold sore" or *recurrent herpetic stomatitis*. Factors associated with HSV reactivation include trauma, allergies, exposure to ultraviolet light, upper respiratory tract infections, pregnancy, menstruation, immunosuppression, and exposure to extremes of temperature. These recurrent lesions, which occur at the site of primary inoculation or in adjacent mucosa innervated by the same ganglion, typically appear as groups of small (1 to 3 mm) vesicles. The lips (herpes labialis), nasal orifices, buccal mucosa, gingiva, and hard palate are the most common locations. Although lesions typically resolve within 7 to 10 days, they can persist in immunocompromised patients, who may require systemic antiviral therapy. Morphologically, the lesions resemble those seen in esophageal herpes (see Fig. 14–8) and genital herpes (Chapter 17). The infected cells become ballooned and have large eosinophilic intranuclear inclusions. Adjacent cells commonly fuse to form large multinucleated polykaryons.

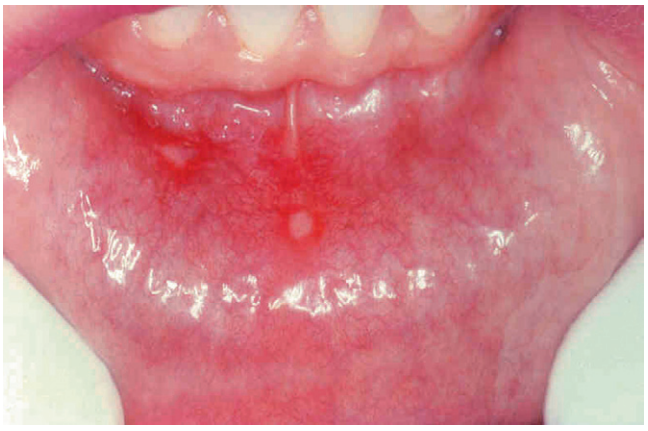

**Figure 14–1** Aphthous ulcer. Single ulceration with an erythematous halo surrounding a yellowish fibrinopurulent membrane.

### Oral Candidiasis (Thrush)

Candidiasis is the most common fungal infection of the oral cavity. *Candida albicans* is a normal component of the oral flora and only produces disease under unusual circumstances. Modifying factors include:

- Immunosuppression
- The strain of *C. albicans*
- The composition of the oral microbial flora (microbiota)

Broad-spectrum antibiotics that alter the normal microbiota can also promote oral candidiasis. The three major clinical forms of oral candidiasis are pseudomembranous, erythematous, and hyperplastic. The pseudomembranous form is most common and is known as *thrush*. This condition is characterized by a superficial, curdlike, gray to white inflammatory membrane composed of matted organisms enmeshed in a fibrinosuppurative exudate that can be readily scraped off to reveal an underlying erythematous base. In mildly immunosuppressed or debilitated individuals, such as diabetics, the infection usually remains superficial, but can spread to deep sites in association with more severe immunosuppression, including that seen in organ or hematopoietic stem cell transplant recipients, as well as patients with neutropenia, chemotherapy-induced immunosuppression, or AIDS.

#### SUMMARY

##### Oral Inflammatory Lesions

- *Aphthous ulcers* are painful superficial ulcers of unknown etiology that may be associated with systemic diseases.
- *Herpes simplex virus* causes a self-limited infection that presents with vesicles (cold sores, fever blisters) that rupture and heal, without scarring, and often leave latent virus in nerve ganglia. Reactivation can occur.
- *Oral candidiasis* may occur when the oral microbiota is altered (e.g., after antibiotic use). Invasive disease may occur in immunosuppressed individuals.

## PROLIFERATIVE AND NEOPLASTIC LESIONS OF THE ORAL CAVITY

### Fibrous Proliferative Lesions

*Fibromas* (Fig. 14–2, *A*) are submucosal nodular fibrous tissue masses that are formed when chronic irritation results in reactive connective tissue hyperplasia. They

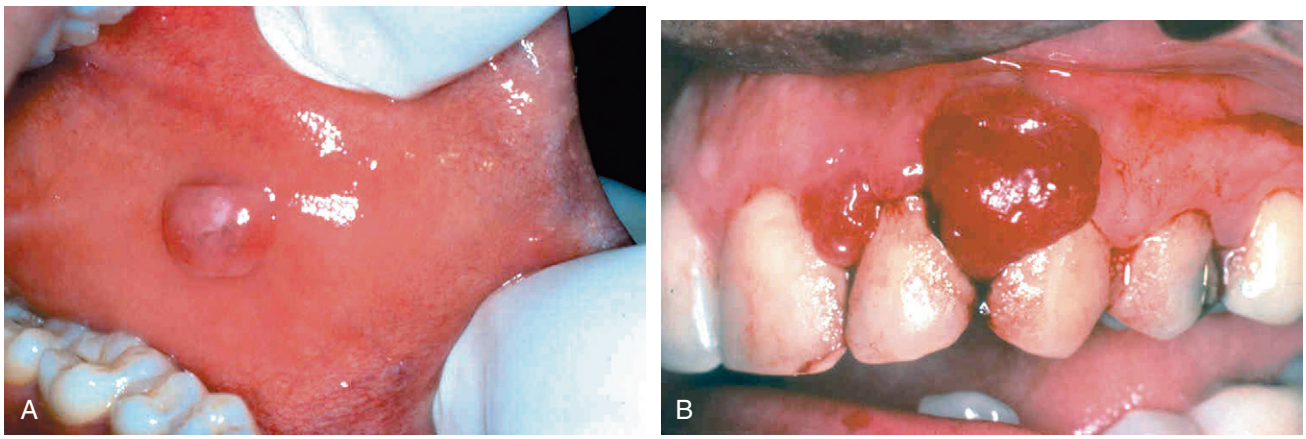


**Figure 14–2** Fibrous proliferations. **A,** Fibroma. Smooth pink exophytic nodule on the buccal mucosa. **B,** Pyogenic granuloma. Erythematous hemorrhagic exophytic mass arising from the gingival mucosa.

occur most often on the buccal mucosa along the bite line and are thought to be reactions to chronic irritation. Treatment is complete surgical excision and removal of the source of irritation.

*Pyogenic granulomas* (Fig. 14–2, *B*) are pedunculated masses usually found on the gingiva of children, young adults, and pregnant women. These lesions are richly vascular and typically are ulcerated, which gives them a red to purple color. In some cases, growth can be rapid and raise fear of a malignant neoplasm. However, histologic examination demonstrates a dense proliferation of immature vessels similar to that seen in granulation tissue. Pyogenic granulomas can regress, mature into dense fibrous masses, or develop into a peripheral ossifying fibroma. Complete surgical excision is definitive treatment.

## Leukoplakia and Erythroplakia

*Leukoplakia* is defined by the World Health Organization as "a white patch or plaque that cannot be scraped off and cannot be characterized clinically or pathologically as any other disease." This clinical term is reserved for lesions that arise in the oral cavity in the absence of any known etiologic factor (Fig. 14–3, *A*). Accordingly, white patches caused by obvious irritation or entities such as lichen planus and candidiasis are not considered leukoplakia. Approximately 3% of the world's population has leukoplakic lesions, of which 5% to 25% are premalignant and may progress to squamous cell carcinoma. *Thus, until proved otherwise by means of histologic evaluation, all leukoplakias must be considered precancerous.* A related but less common lesion, *erythroplakia,* is a red, velvety, possibly eroded area that is flat or slightly depressed relative to the surrounding mucosa. Erythroplakia is associated with a much greater risk of malignant transformation than leukoplakia. While leukoplakia and erythroplakia may be seen in adults at any age, they typically affect persons between the ages of 40 and 70 years, with a 2:1 male preponderance. *Although the etiology is multifactorial, tobacco use (cigarettes, pipes, cigars, and chewing tobacco) is the most common risk factor for leukoplakia and erythroplakia.*

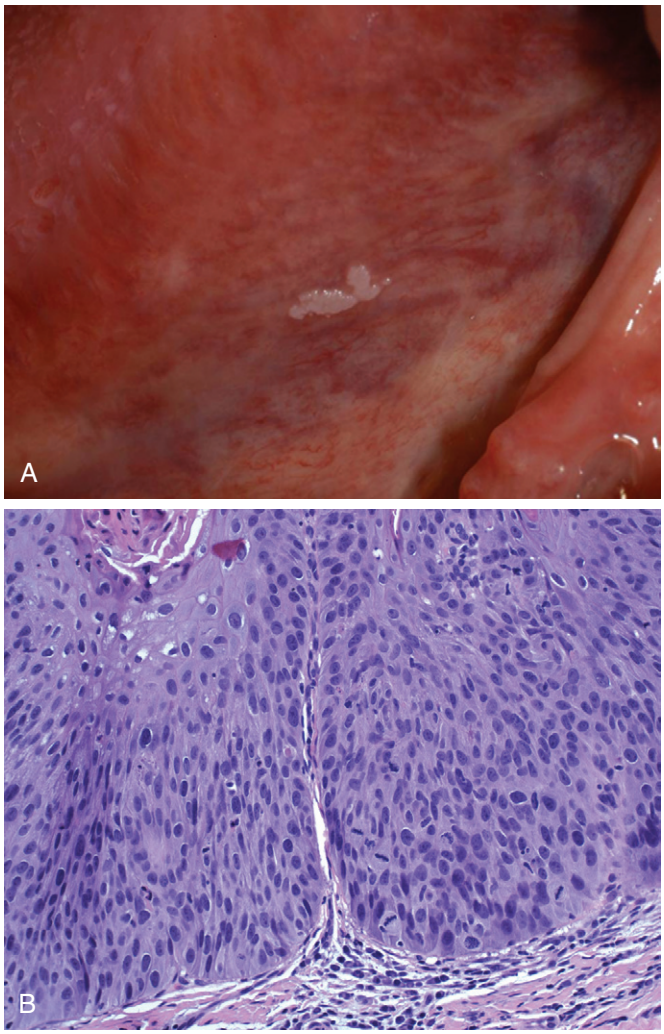


**Figure 14–3** Leukoplakia. **A,** Clinical appearance of leukoplakia is highly variable. In this example, the lesion is smooth with well-demarcated borders and minimal elevation. **B,** Histologic appearance of leukoplakia showing dysplasia, characterized by nuclear and cellular pleomorphism and loss of normal maturation.

### MORPHOLOGY

**Leukoplakia** includes a spectrum of histologic features ranging from **hyperkeratosis** overlying a thickened, acanthotic, but orderly mucosal lesions with marked **dysplasia** that sometimes merges with **carcinoma in situ** (Fig. 14–3, *B*). The most severe dysplastic changes are associated with erythroplakia, and more than 50% of these cases undergo malignant transformation. With increasing dysplasia and anaplasia, a subjacent inflammatory cell infiltrate of lymphocytes and macrophages is often present.

## Squamous Cell Carcinoma

Approximately 95% of cancers of the oral cavity are squamous cell carcinomas, with the remainder largely consisting of adenocarcinomas of salivary glands, as discussed later. This aggressive epithelial malignancy is the sixth most common neoplasm in the world today. Despite numerous advances in treatment, the overall long-term survival rate has been less than 50% for the past 50 years. This dismal outlook is due to several factors, most notably the fact that oral cancer often is diagnosed at an advanced stage.

Multiple primary tumors may be present at initial diagnosis but more often are detected later, at an estimated rate of 3% to 7% per year; patients who survive 5 years after diagnosis of the initial tumor have up to a 35% chance of developing at least one new primary tumor within that interval. The development of these secondary tumors can be particularly devastating for persons whose initial lesions were small. Thus, despite a 5-year survival rate greater than 50% for patients with small tumors, these patients often die of second primary tumors. Therefore, surveillance and early detection of new premalignant lesions are critical for the long-term survival of patients with oral squamous cell carcinoma.

The elevated risk of additional primary tumors in these patients has led to the concept of "field cancerization." This hypothesis suggests that multiple primary tumors develop independently as a result of years of chronic mucosal exposure to carcinogens such as alcohol or tobacco (described next).

### PATHOGENESIS

Squamous cancers of the oropharynx arise through two distinct pathogenic pathways. One group of tumors in the oral cavity occurs mainly in persons who are chronic alcohol and tobacco (both smoked and chewed) users. Deep sequencing of these cancers has revealed frequent mutations that bear a molecular signature consistent with exposure to carcinogens in tobacco. These mutations frequently involve *TP53* and genes that regulate the differentiation of squamous cells, such as *p63* and *NOTCH1*. The second group of tumors tends to occur in the tonsillar crypts or the base of the tongue and harbor oncogenic variants of human papillomavirus (HPV), particularly HPV-16. These tumors carry far fewer mutations than those associated with tobacco exposure and often overexpress p16, a cyclin-dependent kinase inhibitor. It is predicted that the incidence of HPV-associated oropharyngeal squamous cell carcinoma will surpass that of cervical cancer in the next decade, in part because the anatomic sites of origin—tonsillar crypts, base of tongue, and oropharynx—are not readily accessible or amenable to cytologic screening (unlike the cervix). Notably, the **prognosis for patients with HPV-positive tumors is better than for those with HPV-negative tumors.** The HPV vaccine, which is protective against cervical cancer, offers hope to limit the increasing frequency of HPV-associated oropharyngeal squamous cell carcinoma.

In India and southeast Asia, chewing of betel quid and paan are important predisposing factors. Betel quid is a "witch's brew" containing araca nut, slaked lime, and tobacco, all wrapped in betel nut leaf. It is likely that these tumors arise by a pathway similar to that characterized for tobacco use–associated tumors in the West.

### MORPHOLOGY

Squamous cell carcinoma may arise anywhere in the oral cavity. However, **the most common locations are the ventral surface of the tongue, floor of the mouth, lower lip, soft palate, and gingiva** (Fig. 14–4, *A*). In early stages, these cancers can appear as raised, firm, pearly plaques or as irregular, roughened, or verrucous mucosal thickenings. Either pattern may be superimposed on a background of a leukoplakia or erythroplakia. As these lesions enlarge, they typically form ulcerated and protruding masses that have irregular and indurated or rolled borders. Histopathologic analysis has shown that **squamous cell carcinoma develops from dysplastic precursor lesions.** Histologic patterns **range from well-differentiated keratinizing neoplasms** (Fig. 14–4, *B*) **to anaplastic, sometimes sarcomatoid tumors.** However, the degree of histologic differentiation, as determined by the relative degree of keratinization, does not necessarily correlate with biologic behavior. Typically, oral squamous cell carcinoma infiltrates locally before it metastasizes. The cervical lymph nodes are the most common sites of regional metastasis; frequent sites of distant metastases include the mediastinal lymph nodes, lungs, and liver.

### SUMMARY

#### Lesions of the Oral Cavity

- *Fibromas* and *pyogenic granulomas* are common reactive lesions of the oral mucosa.
- *Leukoplakias* are mucosal plaques that may undergo malignant transformation.
- The risk of malignant transformation is greater in *erythroplakia* (relative to leukoplakia).
- A majority of oral cavity cancers are *squamous cell carcinomas*.
- Oral squamous cell carcinomas are classically linked to tobacco and alcohol use, but the incidence of HPV-associated lesions is rising.

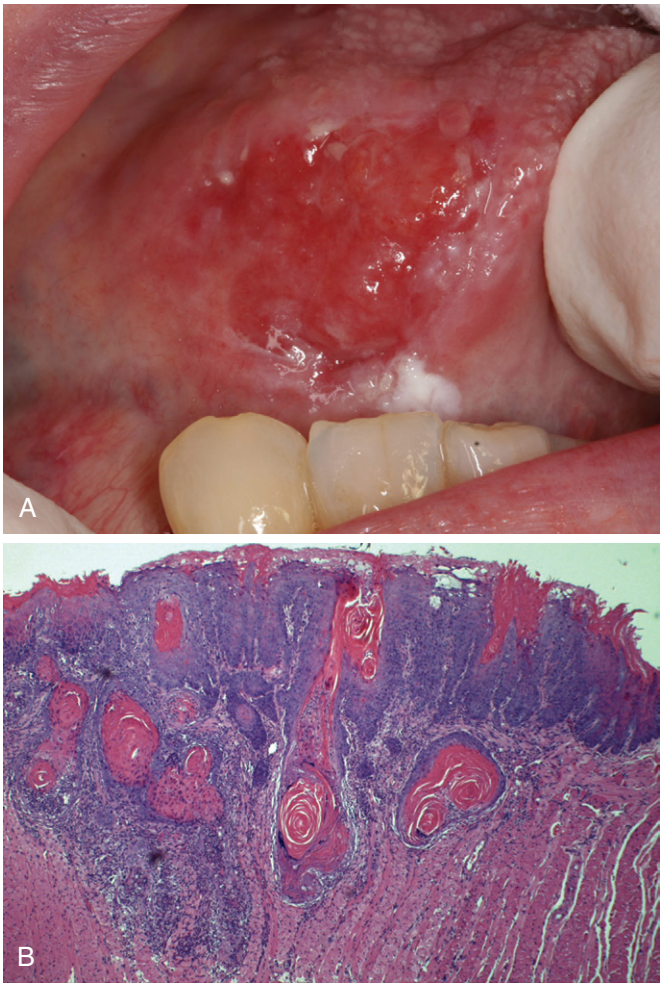


**Figure 14–4** Oral squamous cell carcinoma. **A,** Clinical appearance demonstrating ulceration and induration of the oral mucosa. **B,** Histologic appearance demonstrating numerous nests and islands of malignant keratinocytes invading the underlying connective tissue stroma.

## DISEASES OF SALIVARY GLANDS

There are three major salivary glands—parotid, submandibular, and sublingual—as well as innumerable minor salivary glands distributed throughout the oral mucosa. Inflammatory or neoplastic disease may develop within any of these.

### Xerostomia

Xerostomia is defined as a *dry mouth* resulting from a decrease in the production of saliva. Its incidence varies among populations, but has been reported in more than 20% of individuals above the age of 70 years. It is a major feature of the autoimmune disorder Sjögren syndrome, in which it usually is accompanied by dry eyes (Chapter 4). A lack of salivary secretions is also a major complication of radiation therapy. However, xerostomia is most frequently observed as a result of many commonly prescribed classes of medications including anticholinergic, antidepressant/antipsychotic, diuretic, antihypertensive, sedative, muscle relaxant, analgesic, and antihistaminic agents. The oral cavity may merely reveal dry mucosa and/or atrophy of the papillae of the tongue, with fissuring and ulcerations, or, in Sjögren syndrome, concomitant inflammatory enlargement of the salivary glands. Complications of xerostomia include increased rates of dental caries and candidiasis, as well as difficulty in swallowing and speaking.

### Sialadenitis

Sialadenitis, or inflammation of the salivary glands, may be induced by trauma, viral or bacterial infection, or autoimmune disease. The most common form of *viral sialadenitis is mumps,* which may produce enlargement of all salivary glands but predominantly involves the parotids. The mumps virus is a paramyxovirus related to the influenza and parainfluenza viruses. Mumps produces interstitial inflammation marked by a mononuclear inflammatory infiltrate. While mumps in children is most often a self-limited benign condition, in adults it can cause pancreatitis or orchitis; the latter sometimes causes sterility.

The *mucocele* is the most common inflammatory lesion of the salivary glands, and results from either blockage or rupture of a salivary gland duct, with consequent leakage of saliva into the surrounding connective tissue stroma. Mucocele occurs most often in toddlers, young adults, and the aged, and typically manifests as a fluctuant swelling of the lower lip that may change in size, particularly in association with meals (Fig. 14–5, *A*). Histologic examination demonstrates a cystlike space lined by inflammatory granulation tissue or fibrous connective tissue that is filled with mucin and inflammatory cells, particularly macrophages (Fig. 14–5, *B*). Complete excision of the cyst and the minor salivary gland lobule constitutes definitive treatment.

*Bacterial sialadenitis* is a common infection that most often involves the major salivary glands, particularly the submandibular glands. The most frequent pathogens are *Staphylococcus aureus* and *Streptococcus viridans.* Duct obstruction by stones (*sialolithiasis*) is a common antecedent to infection; it may also be induced by impacted food debris or by edema consequent to injury. Dehydration and decreased secretory function also may predispose to bacterial invasion and sometimes are associated with long-term phenothiazine therapy, which suppresses salivary secretion. Systemic dehydration, with decreased salivary secretions, may predispose to suppurative bacterial parotitis in elderly patients following major thoracic or abdominal surgery. This obstructive process and bacterial invasion lead to a nonspecific inflammation of the affected glands that may be largely interstitial or, when induced by staphylococcal or other pyogens, may be associated with overt suppurative necrosis and abscess formation.

Autoimmune sialadenitis, also called Sjögren syndrome, is discussed in Chapter 4.

### Neoplasms

Despite their relatively simple morphology, the salivary glands give rise to at least 30 histologically distinct tumors. As indicated in Table 14–1, a small number of these neoplasms account for more than 90% of tumors. Overall,

salivary gland tumors are relatively uncommon and represent less than 2% of all human tumors. Approximately 65% to 80% arise within the parotid, 10% in the submandibular gland, and the remainder in the minor salivary glands, including the sublingual glands. Approximately 15% to 30% of tumors in the parotid glands are malignant. By contrast, approximately 40% of submandibular, 50% of minor salivary gland, and 70% to 90% of sublingual tumors are cancerous. *Thus, the likelihood that a salivary gland tumor is malignant is inversely proportional, roughly, to the size of the gland.*

Salivary gland tumors usually occur in adults, with a slight female predominance, but about 5% occur in children younger than 16 years of age. Whatever the histologic pattern, parotid gland neoplasms produce swelling in front of and below the ear. In general, when they are first diagnosed, both benign and malignant lesions are usually 4 to 6 cm in diameter and are mobile on palpation except in the case of neglected malignant tumors. Benign tumors may be present for months to several years before coming to clinical attention, while cancers more often come to attention promptly, probably because of their more rapid growth. However, there are no reliable criteria to differentiate benign from malignant lesions on clinical grounds, and histopathologic evaluation is essential.

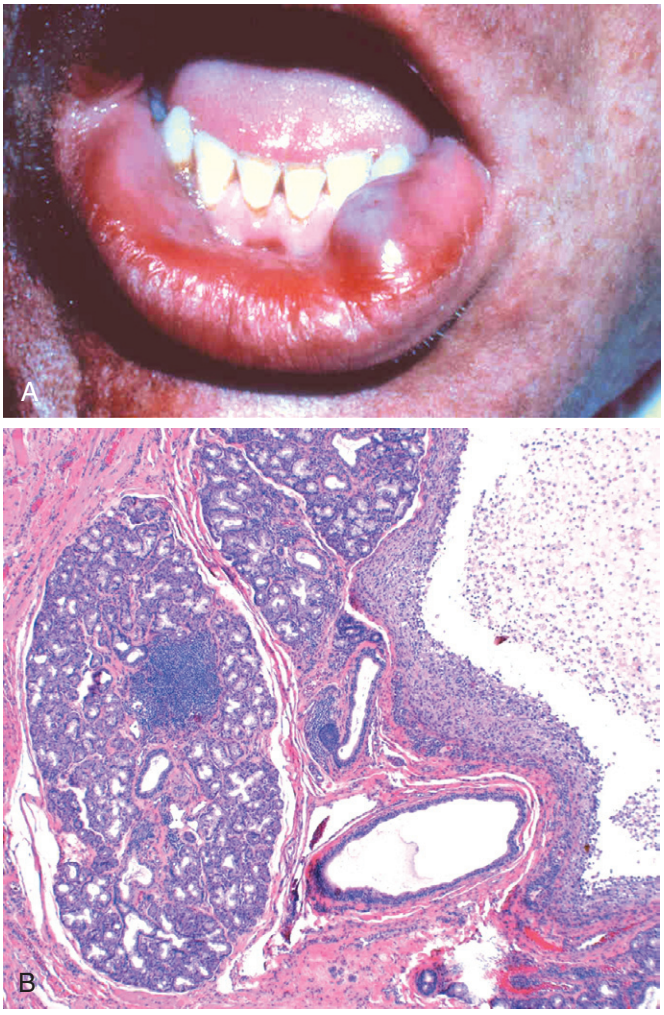


**Figure 14–5** Mucocele. **A,** Fluctuant fluid-filled lesion on the lower lip subsequent to trauma. **B,** Cystlike cavity *(right)* filled with mucinous material and lined by organizing granulation tissue.

**Table 14–1** Histopathologic Classification and Prevalence of the Most Common Benign and Malignant Salivary Gland Tumors

| Benign | Malignant |
|---|---|
| Pleomorphic adenoma (50%) | Mucoepidermoid carcinoma (15%) |
| Warthin tumor (5%) | Acinic cell carcinoma (6%) |
| Oncocytoma (2%) | Adenocarcinoma NOS (6%) |
| Cystadenoma (2%) | Adenoid cystic carcinoma (4%) |
| Basal cell adenoma (2%) | Malignant mixed tumor (3%) |

NOS, not otherwise specified.
Data from Ellis GL, Auclair PL, Gnepp DR: Surgical Pathology of the Salivary Glands, Vol 25: Major Problems in Pathology, Philadelphia, WB Saunders, 1991.

### *Pleomorphic Adenoma*

Pleomorphic adenomas present as painless, slow-growing, mobile discrete masses. They represent about *60% of tumors in the parotid,* are less common in the submandibular glands, and are relatively rare in the minor salivary glands. Pleomorphic adenomas are benign tumors that consist of a mixture of ductal (epithelial) and myoepithelial cells, so they exhibit both epithelial and mesenchymal differentiation. Epithelial elements are dispersed throughout the matrix, which may contain variable mixtures of myxoid, hyaline, chondroid (cartilaginous), and even osseous tissue. In some pleomorphic adenomas, the epithelial elements predominate; in others, they are present only in widely dispersed foci. This histologic diversity has given rise to the alternative, albeit less preferred name *mixed tumor.* The tumors consistently overexpress the transcription factor PLAG1, often because of chromosomal rearrangements involving the *PLAG1* gene, but how PLAG1 contributes to tumor development is unknown.

Pleomorphic adenomas recur if incompletely excised: Recurrence rates approach 25% after simple enucleation of the tumor, but are only 4% after wider resection. In both settings, recurrence stems from a failure to recognize minute extensions of tumor into surrounding soft tissues.

Carcinoma arising in a pleomorphic adenoma is referred to variously as a *carcinoma ex pleomorphic adenoma* or *malignant mixed tumor.* The incidence of malignant transformation increases with time from 2% of tumors present for less than 5 years to almost 10% for those present for more than 15 years. The cancer usually takes the form of an adenocarcinoma or undifferentiated carcinoma. Unfortunately, these are among the most aggressive malignant neoplasms of salivary glands, with mortality rates of 30% to 50% at 5 years.

#### MORPHOLOGY

Pleomorphic adenomas typically manifest as rounded, well-demarcated masses rarely exceeding 6 cm in the greatest dimension. Although they are encapsulated, in some locations (particularly the palate), the capsule is not fully developed, and expansile growth produces protrusions into the surrounding tissues. The cut surface is gray-white and typically contains myxoid and blue translucent chondroid (cartilage-like) areas. **The most striking histologic feature is their characteristic heterogeneity.** Epithelial

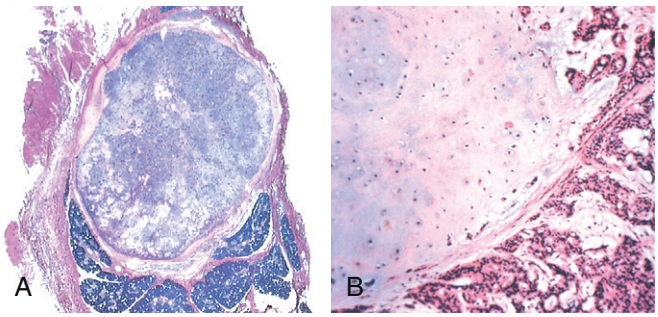


**Figure 14–6** Pleomorphic adenoma. **A,** Low-power view showing a well-demarcated tumor with adjacent normal salivary gland parenchyma. **B,** High-power view showing epithelial cells as well as myoepithelial cells within chondroid matrix material.

elements resembling ductal or myoepithelial cells are arranged in **ducts, acini, irregular tubules, strands, or even sheets.** These typically are dispersed within a **mesenchyme-like background of loose myxoid tissue** containing **islands of chondroid** and, rarely, foci of bone (Fig. 14–6). Sometimes the epithelial cells form well-developed ducts lined by cuboidal to columnar cells with an underlying layer of deeply chromatic, small myoepithelial cells. In other instances there may be strands or sheets of myoepithelial cells. Islands of well-differentiated squamous epithelium also may be present. In most cases, no epithelial dysplasia or mitotic activity is evident. No difference in biologic behavior has been observed between the tumors composed largely of epithelial elements and those composed largely of mesenchymal elements.

### *Mucoepidermoid Carcinoma*

Mucoepidermoid carcinomas are composed of variable mixtures of squamous cells, mucus-secreting cells, and intermediate cells. These neoplasms represent about 15% of all salivary gland tumors, and while they occur mainly (60% to 70%) in the parotids, they account for a large fraction of salivary gland neoplasms in the other glands, particularly the minor salivary glands. Overall, mucoepidermoid carcinoma is the most common form of primary *malignant* tumor of the salivary glands. It is commonly associated with chromosome rearrangements involving *MAML2,* a gene that encodes a signaling protein in the Notch pathway.

#### MORPHOLOGY

Mucoepidermoid carcinomas can grow as large as 8 cm in diameter and, although they are apparently circumscribed, they lack well-defined capsules and often are infiltrative. The cut surface is pale gray to white and frequently demonstrates small, mucinous cysts. On histologic examination, these tumors contain **cords, sheets, or cysts lined by squamous, mucous, or intermediate cells.** The latter is a hybrid cell type with both squamous features and mucus-filled vacuoles, which are most easily detected with mucin stains. Cytologically, tumor cells may be benign-appearing or highly anaplastic and unmistakably malignant. On this basis, mucoepidermoid carcinomas are subclassified as low-, intermediate-, or high-grade.

Clinical course and prognosis depend on histologic grade. Low-grade tumors may invade locally and recur in about 15% of cases but metastasize only rarely and afford a 5-year survival rate over 90%. By contrast, high-grade neoplasms and, to a lesser extent, intermediate-grade tumors are invasive and difficult to excise. As a result, they recur in 25% to 30% of cases, and about 30% metastasize to distant sites. The 5-year survival rate is only 50%.

#### SUMMARY

**Diseases of Salivary Glands**

- *Sialadenitis* (inflammation of the salivary glands) can be caused by trauma, infection (such as mumps), or an autoimmune reaction.
- *Pleomorphic adenoma* is a slow-growing neoplasm composed of a heterogeneous mixture of epithelial and mesenchymal cells.
- *Mucoepidermoid carcinoma* is a malignant neoplasm of variable biologic aggressiveness that is composed of a mixture of squamous and mucous cells.

## ODONTOGENIC CYSTS AND TUMORS

In contrast with other skeletal sites, epithelium-lined cysts are common in the jaws. A majority of these cysts are derived from remnants of odontogenic epithelium. In general, these cysts are subclassified as either inflammatory or developmental. Only the most common of these lesions are considered here.

The *dentigerous cyst* originates around the crown of an unerupted tooth and is thought to be the result of a degeneration of the dental follicle (primordial tissue that makes the enamel surface of teeth). On radiographic evaluation, these unilocular lesions most often are associated with impacted third molar (wisdom) teeth. They are lined by a thin, stratified squamous epithelium that typically is associated with a dense chronic inflammatory infiltrate within the underlying connective tissue. Complete removal is curative.

Odontogenic keratocysts can occur at any age but are most frequent in persons between 10 and 40 years of age, have a male predominance, and typically are located within the posterior mandible. Differentiation of the *odontogenic keratocyst* from other odontogenic cysts is important because it is locally aggressive and has a high recurrence rate. On radiographic evaluation, odontogenic keratocysts are seen as well-defined unilocular or multilocular radiolucencies. On histologic examination, the cyst lining consists of a thin layer of parakeratinized or orthokeratinized stratified squamous epithelium with a prominent basal cell layer and a corrugated luminal epithelial surface. Treatment requires aggressive and complete removal; recurrence rates of up to 60% are associated with inadequate resection. Multiple odontogenic keratocysts may occur, particularly in patients with the nevoid basal cell carcinoma syndrome (Gorlin syndrome).

In contrast with the developmental cysts just described, the *periapical cyst* has an inflammatory etiology. These

extremely common lesions occur at the tooth apex as a result of long-standing pulpitis, which may be caused by advanced caries or trauma. Necrosis of the pulpal tissue, which can traverse the length of the root and exit the apex of the tooth into the surrounding alveolar bone, can lead to a periapical abscess. Over time, granulation tissue (with or without an epithelial lining) may develop. These are often designated *periapical granuloma.* Although the lesion does not show true granulomatous inflammation, old terminology, like bad habits, is difficult to shed. Periapical inflammatory lesions persist as a result of bacteria or other offensive agents in the area. Successful treatment, therefore, necessitates the complete removal of the offending material followed by restoration or extraction of the tooth.

*Odontogenic tumors* are a complex group of lesions with diverse histologic appearances and clinical behaviors. Some are true neoplasms, either benign or malignant, while others are thought to be hamartomatous. Odontogenic tumors are derived from odontogenic epithelium, ectomesenchyme, or both. The two most common and clinically significant tumors are ameloblastoma and odontoma.

*Ameloblastoma*s arise from odontogenic epithelium and do not demonstrate chondroid or osseous differentiation. These typically cystic lesions are slow-growing and, despite being locally invasive, have an indolent course.

*Odontoma*, the most common type of odontogenic tumor, arises from epithelium but shows extensive deposition of enamel and dentin. Odontomas are cured by local excision.

### SUMMARY

#### Odontogenic Cysts and Tumors

- The jaws are a common site of epithelium-lined cysts derived from odontogenic remnants.
- The *odontogenic keratocyst* is locally aggressive, with a high recurrence rate.
- The *periapical cyst* is a reactive, inflammatory lesion associated with caries or dental trauma.
- The most common *odontogenic tumors* are *ameloblastoma* and *odontoma.*

# ESOPHAGUS

The esophagus develops from the cranial portion of the foregut. It is a hollow, highly distensible muscular tube that extends from the epiglottis to the gastroesophageal junction, located just above the diaphragm. Acquired diseases of the esophagus run the gamut from lethal cancers to "heartburn," with clinical manifestations ranging from chronic and incapacitating disease to mere annoyance.

## OBSTRUCTIVE AND VASCULAR DISEASES

### Mechanical Obstruction

Atresia, fistulas, and duplications may occur in any part of the gastrointestinal tract. When they involve the esophagus, they are discovered shortly after birth, usually because of regurgitation during feeding, and must be corrected promptly. Absence, or *agenesis,* of the esophagus is extremely rare. *Atresia,* in which a thin, noncanalized cord replaces a segment of esophagus, is more common. Atresia occurs most commonly at or near the tracheal bifurcation and usually is associated with a *fistula* connecting the upper or lower esophageal pouches to a bronchus or the trachea. This abnormal connection can result in aspiration, suffocation, pneumonia, or severe fluid and electrolyte imbalances.

Passage of food can be impeded by esophageal *stenosis.* The narrowing generally is caused by fibrous thickening of the submucosa, atrophy of the muscularis propria, and secondary epithelial damage. *Stenosis most often is due to inflammation and scarring, which may be caused by chronic gastroesophageal reflux, irradiation, or caustic injury.* Stenosis-associated dysphagia usually is progressive; difficulty eating solids typically occurs long before problems with liquids.

### Functional Obstruction

Efficient delivery of food and fluids to the stomach requires a coordinated wave of peristaltic contractions. Esophageal dysmotility interferes with this process and can take several forms, all of which are characterized by discoordinated contraction or spasm of the muscularis. Because it increases esophageal wall stress, spasm also can cause small *diverticula* to form.

Increased *lower esophageal sphincter* (LES) tone can result from impaired smooth muscle relaxation with consequent functional esophageal obstruction. *Achalasia is characterized by the triad of incomplete LES relaxation, increased LES tone, and esophageal aperistalsis.* Primary achalasia is caused by failure of distal esophageal inhibitory neurons and is, by definition, idiopathic. Degenerative changes in neural innervation, either intrinsic to the esophagus or within the extraesophageal vagus nerve or the dorsal motor nucleus of the vagus, also may occur. Secondary achalasia may arise in Chagas disease, in which *Trypanosoma cruzi* infection causes destruction of the myenteric plexus, failure of LES relaxation, and esophageal dilatation. Duodenal, colonic, and ureteric myenteric plexuses also can be affected in Chagas disease. Achalasia-like disease may be caused by diabetic autonomic neuropathy; infiltrative disorders such as malignancy, amyloidosis, or sarcoidosis; and lesions of dorsal motor nuclei, which may be produced by polio or surgical ablation.

### Ectopia

Ectopic tissues (*developmental rests*) are common in the gastrointestinal tract. The most frequent site of *ectopic gastric mucosa* is the upper third of the esophagus, where it is referred to as an *inlet patch.* Although the presence of such tissue generally is asymptomatic, acid released by gastric

mucosa within the esophagus can result in dysphagia, esophagitis, Barrett esophagus, or, rarely, adenocarcinoma. *Gastric heterotopia,* small patches of ectopic gastric mucosa in the small bowel or colon, may manifest with occult blood loss secondary to peptic ulceration of adjacent mucosa.

### Esophageal Varices

Instead of returning directly to the heart, venous blood from the gastrointestinal tract is delivered to the liver via the portal vein before reaching the inferior vena cava. This circulatory pattern is responsible for the *first-pass effect,* in which drugs and other materials absorbed in the intestines are processed by the liver before entering the systemic circulation. Diseases that impede this flow cause portal hypertension, which can lead to the development of esophageal varices, an important cause of esophageal bleeding.

#### PATHOGENESIS

One of the few sites where the splanchnic and systemic venous circulations can communicate is the esophagus. Thus, portal hypertension induces development of collateral channels that allow portal blood to shunt into the caval system. However, these collateral veins enlarge the subepithelial and submucosal venous plexi within the distal esophagus. These vessels, termed **varices,** develop in 90% of cirrhotic patients, most commonly in association with alcoholic liver disease. Worldwide, hepatic schistosomiasis is the second most common cause of varices. A more detailed consideration of portal hypertension is given in Chapter 15.

#### MORPHOLOGY

Varices can be detected by angiography (Fig. 14–7, *A*) and appear as tortuous dilated veins lying primarily within the submucosa of the distal esophagus and proximal stomach. Varices may not be obvious on gross inspection of surgical or postmortem specimens, because they collapse in the absence of blood flow (Fig. 14–7, *B*). The overlying mucosa can be intact (Fig. 14–7, *C*) but is ulcerated and necrotic if rupture has occurred.

#### Clinical Features

Varices often are asymptomatic, but their rupture can lead to massive hematemesis and death. Variceal rupture therefore constitutes a medical emergency. Despite intervention, as many as half of the patients die from the first bleeding episode, either as a direct consequence of hemorrhage or due to hepatic coma triggered by the protein load that results from intraluminal bleeding and hypovolemic shock. Among those who survive, additional episodes of hemorrhage, each potentially fatal, occur in more than 50% of cases. As a result, greater than half of the deaths associated with advanced cirrhosis result from variceal rupture.

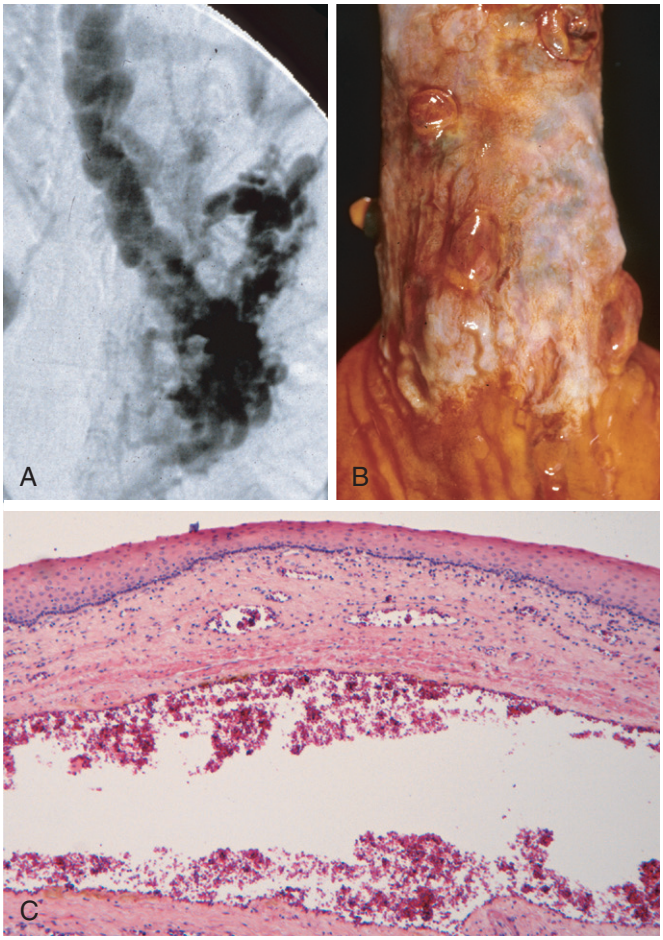


**Figure 14–7** Esophageal varices. **A,** Angiogram showing several tortuous esophageal varices. Although the angiogram is striking, endoscopy is more commonly used to identify varices. **B,** Collapsed varices are present in this postmortem specimen corresponding to the angiogram in **A.** The polypoid areas are sites of variceal hemorrhage that were ligated with bands. **C,** Dilated varices beneath intact squamous mucosa.

## ESOPHAGITIS

### Lacerations

The most common esophageal lacerations are *Mallory-Weiss tears,* which are often associated with severe retching or vomiting, as may occur with acute alcohol intoxication. Normally, a reflex relaxation of the gastroesophageal musculature precedes the antiperistaltic contractile wave associated with vomiting. This relaxation is thought to fail during prolonged vomiting, with the result that refluxing gastric contents overwhelm the gastric inlet and cause the esophageal wall to stretch and tear. Patients often present with hematemesis.

The roughly linear lacerations of *Mallory-Weiss syndrome* are longitudinally oriented, range in length from millimeters to several centimeters, and usually cross the gastroesophageal junction. These tears are superficial and do not generally require surgical intervention; healing tends to be rapid and complete. By contrast, *Boerhaave syndrome,* characterized by transmural esophageal tears and mediastinitis, occurs rarely and is a catastrophic event. The factors

giving rise to this syndrome are similar to those for Mallory-Weiss tears, but more severe.

## Chemical and Infectious Esophagitis

The stratified squamous mucosa of the esophagus may be damaged by a variety of irritants including alcohol, corrosive acids or alkalis, excessively hot fluids, and heavy smoking. Medicinal pills may lodge and dissolve in the esophagus, rather than passing into the stomach intact, resulting in a condition termed *pill-induced esophagitis.* Esophagitis due to chemical injury generally causes only self-limited pain, particularly *odynophagia* (pain with swallowing). Hemorrhage, stricture, or perforation may occur in severe cases. Iatrogenic esophageal injury may be caused by cytotoxic *chemotherapy, radiation therapy,* or *graft-versus-host disease.* The morphologic changes are nonspecific with ulceration and accumulation of neutrophils. Irradiation causes blood vessel thickening adding some element of ischemic injury.

Infectious esophagitis may occur in otherwise healthy persons but is most frequent in those who are debilitated or immunosuppressed. In these patients, esophageal infection by *herpes simplex viruses, cytomegalovirus* (CMV), or *fungal organisms* is common. Among fungi, *Candida* is the most common pathogen, although *mucormycosis* and *aspergillosis* may also occur. The esophagus may also be involved in desquamative skin diseases such as *bullous pemphigoid* and *epidermolysis bullosa* and, rarely, *Crohn disease.*

Infection by fungi or bacteria can be primary or complicate a preexisting ulcer. Nonpathogenic oral bacteria frequently are found in ulcer beds, while pathogenic organisms, which account for about 10% of infectious esophagitis cases, may invade the lamina propria and cause necrosis of overlying mucosa. Candidiasis, in its most advanced form, is characterized by adherent, gray-white pseudomembranes composed of densely matted fungal hyphae and inflammatory cells covering the esophageal mucosa.

The endoscopic appearance often provides a clue to the identity of the infectious agent in viral esophagitis. Herpesviruses typically cause punched-out ulcers (Fig. 14–8, *A*), and histopathologic analysis demonstrates nuclear viral inclusions within a rim of degenerating epithelial cells at the ulcer edge (Fig. 14–8, *B*). By contrast, CMV causes shallower ulcerations and characteristic nuclear and cytoplasmic inclusions within capillary endothelium and stromal cells (Fig. 14–8, *C*). Immunohistochemical staining for viral antigens can be used as an ancillary diagnostic tool.

## Reflux Esophagitis

The stratified squamous epithelium of the esophagus is resistant to abrasion from foods but is sensitive to acid. The submucosal glands of the proximal and distal esophagus contribute to mucosal protection by secreting mucin and bicarbonate. More important, constant LES tone prevents reflux of acidic gastric contents, which are under positive pressure. Reflux of gastric contents into the lower esophagus is the most frequent cause of esophagitis and the most common outpatient gastrointestinal diagnosis in the United States. The associated clinical condition is termed *gastroesophageal reflux disease* (GERD).

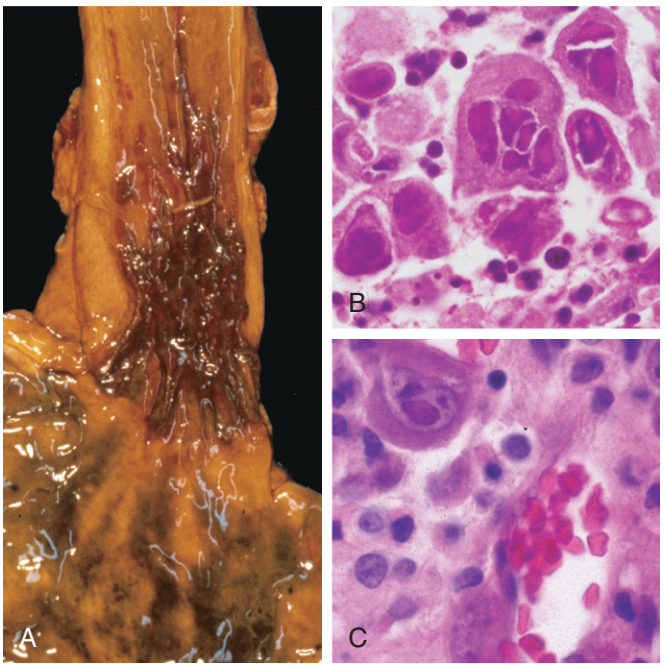


**Figure 14–8** Viral esophagitis. **A,** Postmortem specimen with multiple herpetic ulcers in the distal esophagus. **B,** Multinucleate squamous cells containing herpesvirus nuclear inclusions. **C,** Cytomegalovirus-infected endothelial cells with nuclear and cytoplasmic inclusions.

### PATHOGENESIS

Reflux of gastric juices is central to the development of mucosal injury in GERD. In severe cases, duodenal bile reflux may exacerbate the damage. Conditions that decrease LES tone or increase abdominal pressure contribute to GERD and include alcohol and tobacco use, obesity, central nervous system depressants, pregnancy, hiatal hernia (discussed later), delayed gastric emptying, and increased gastric volume. In many cases, no definitive cause is identified.

### MORPHOLOGY

Simple **hyperemia,** evident to the endoscopist as redness, may be the only alteration. In mild GERD the mucosal histology is often unremarkable. With more significant disease, **eosinophils** are recruited into the squamous mucosa, followed by neutrophils, which usually are associated with more severe injury (Fig. 14–9, *A*). **Basal zone hyperplasia** exceeding 20% of the total epithelial thickness and elongation of lamina propria papillae, such that they extend into the upper third of the epithelium, also may be present.

#### Clinical Features

GERD is most common in adults older than 40 years of age but also occurs in infants and children. The most frequently reported symptoms are heartburn, dysphagia, and, less often, noticeable regurgitation of sour-tasting gastric contents. Rarely, chronic GERD is punctuated by attacks of

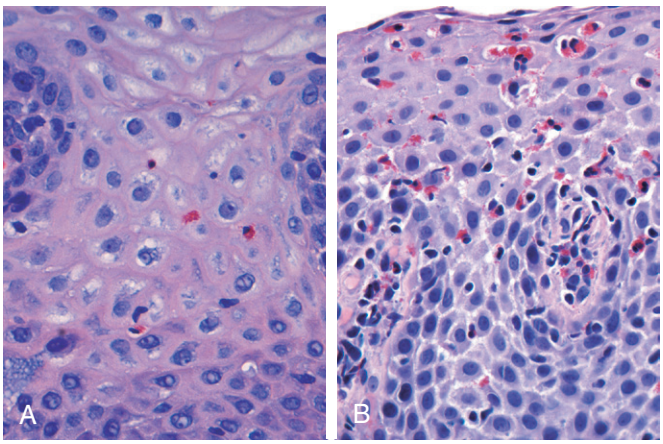


**Figure 14–9** Esophagitis. **A,** Reflux esophagitis with scattered intraepithelial eosinophils. **B,** Eosinophilic esophagitis with numerous intraepithelial eosinophils.

severe chest pain that may be mistaken for heart disease. Treatment with proton pump inhibitors reduces gastric acidity and typically provides symptomatic relief. While the severity of symptoms is not closely related to the degree of histologic damage, the latter tends to increase with disease duration. Complications of reflux esophagitis include esophageal ulceration, hematemesis, melena, stricture development, and Barrett esophagus.

*Hiatal hernia* is characterized by separation of the diaphragmatic crura and protrusion of the stomach into the thorax through the resulting gap. Congenital hiatal hernias are recognized in infants and children, but many are acquired in later life. Hiatal hernia is asymptomatic in more than 90% of adult cases. Thus, symptoms, which are similar to GERD, are often associated with other causes of LES incompetence.

## Eosinophilic Esophagitis

The incidence of eosinophilic esophagitis is increasing markedly. Symptoms include food impaction and dysphagia in adults and feeding intolerance or GERD-like symptoms in children. The cardinal histologic feature is epithelial infiltration by large numbers of eosinophils, particularly superficially (Fig. 14–9, *B*) and at sites far from the gastroesophageal junction. Their abundance can help to differentiate eosinophilic esophagitis from GERD, Crohn disease, and other causes of esophagitis. Certain clinical characteristics, particularly failure of high-dose proton pump inhibitor treatment and the absence of acid reflux, are also typical. A majority of persons with eosinophilic esophagitis are atopic, and many have atopic dermatitis, allergic rhinitis, asthma, or modest peripheral eosinophilia. Treatments include dietary restrictions to prevent exposure to food allergens, such as cow milk and soy products, and topical or systemic corticosteroids.

## Barrett Esophagus

*Barrett esophagus* is a complication of chronic GERD that is characterized by *intestinal metaplasia within the esophageal squamous mucosa*. The incidence of Barrett esophagus is rising; it is estimated to occur in as many as 10% of persons with symptomatic GERD. White males are affected most often and typically present between 40 and 60 years of age. The greatest concern in Barrett esophagus is that *it confers an increased risk of esophageal adenocarcinoma*. Molecular studies suggest that Barrett epithelium may be more similar to adenocarcinoma than to normal esophageal epithelium, consistent with the view that Barrett esophagus is a premalignant condition. In keeping with this, epithelial *dysplasia*, considered to be a preinvasive lesion, develops in 0.2% to 1.0% of persons with Barrett esophagus each year; its incidence increases with duration of symptoms and increasing patient age. Although the vast majority of esophageal adenocarcinomas are associated with Barrett esophagus, it should be noted that most persons with Barrett esophagus do not develop esophageal cancer.

### MORPHOLOGY

Barrett esophagus is recognized endoscopically as tongues or patches of red, velvety mucosa extending upward from the gastroesophageal junction. This metaplastic mucosa alternates with residual smooth, pale squamous (esophageal) mucosa proximally and interfaces with light-brown columnar (gastric) mucosa distally (Fig. 14–10, *A* and *B*). High-resolution endoscopes have increased the sensitivity of Barrett esophagus detection.

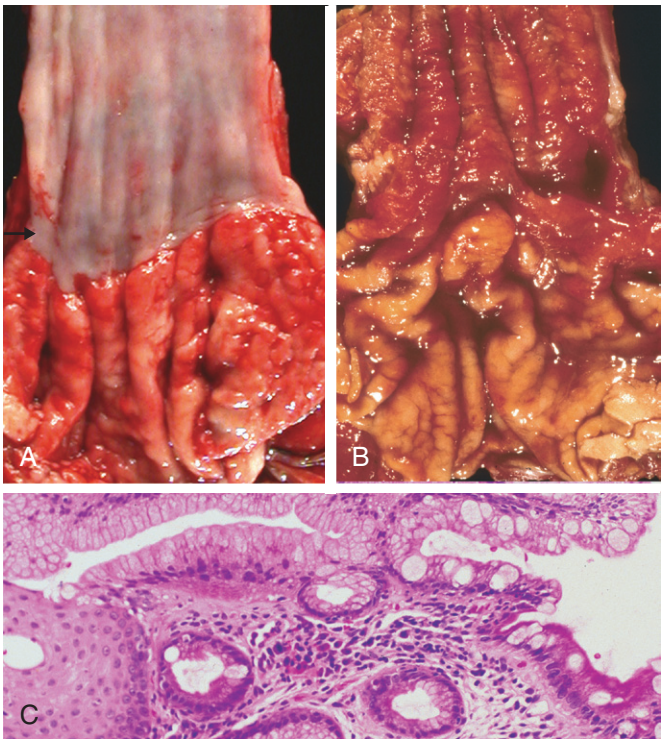


**Figure 14–10** Barrett esophagus. **A,** Normal gastroesophageal junction. **B,** Barrett esophagus. Note the small islands of paler squamous mucosa within the Barrett mucosa. **C,** Histologic appearance of the gastroesophageal junction in Barrett esophagus. Note the transition between esophageal squamous mucosa (*left*) and metaplastic mucosa containing goblet cells (*right*).

Most authors require both endoscopic evidence of abnormal mucosa above the gastroesophageal junction and histologically documented gastric or intestinal metaplasia for diagnosis of Barrett esophagus. **Goblet cells**, which have distinct mucous vacuoles that stain pale blue by H&E and impart the shape of a wine goblet to the remaining cytoplasm, define intestinal metaplasia and are a feature of Barrett esophagus (Fig. 14–10, *C*). Dysplasia is classified as low-grade or high-grade on the basis of morphologic criteria. Intramucosal carcinoma is characterized by invasion of neoplastic epithelial cells into the lamina propria.

### Clinical Features

Diagnosis of Barrett esophagus requires endoscopy and biopsy, usually prompted by GERD symptoms. The best course of management is a matter of debate. While many investigators agree that periodic endoscopy with biopsy, for detection of dysplasia, is reasonable, uncertainties about the frequency with which dysplasia occurs and whether it can regress spontaneously complicate clinical decision making. By contrast, intramucosal carcinoma requires therapeutic intervention. Treatment options include surgical resection (*esophagectomy*), and newer modalities such as photodynamic therapy, laser ablation, and endoscopic mucosectomy. Multifocal high-grade dysplasia, which carries a significant risk of progression to intramucosal or invasive carcinoma, may be treated in a fashion similar to intramucosal carcinoma.

## ESOPHAGEAL TUMORS

Two morphologic variants account for a majority of esophageal cancers: adenocarcinoma and squamous cell carcinoma. Worldwide, squamous cell carcinoma is more common, but in the United States and other Western countries adenocarcinoma is on the rise. Other rare tumors occur but are not discussed here.

### Adenocarcinoma

Esophageal adenocarcinoma typically arises in a background of Barrett esophagus and long-standing GERD. Risk of adenocarcinoma is greater in patients with documented dysplasia and is further increased by tobacco use, obesity, and previous radiation therapy. Conversely, reduced adenocarcinoma risk is associated with diets rich in fresh fruits and vegetables.

Esophageal adenocarcinoma occurs most frequently in whites and shows a strong gender bias, being seven times more common in men than in women. However, the incidence varies by a factor of 60 worldwide, with rates being highest in developed Western countries, including the United States, the United Kingdom, Canada, Australia, and the Netherlands, and lowest in Korea, Thailand, Japan, and Ecuador. In countries where esophageal adenocarcinoma is more common, the incidence has increased markedly since 1970, more rapidly than for almost any other cancer. As a result, esophageal adenocarcinoma, which represented less than 5% of esophageal cancers before 1970, now accounts for half of all esophageal cancers in the United States.

#### PATHOGENESIS

Molecular studies suggest that the progression of Barrett esophagus to adenocarcinoma occurs over an extended period through the stepwise acquisition of genetic and epigenetic changes. This model is supported by the observation that epithelial clones identified in nondysplastic Barrett metaplasia persist and accumulate mutations during progression to dysplasia and invasive carcinoma. Chromosomal abnormalities and *TP53* mutation are often present at early stages of esophageal adenocarcinoma. Additional genetic changes and inflammation also are thought to contribute to neoplastic progression.

#### MORPHOLOGY

Esophageal adenocarcinoma usually occurs in the distal third of the esophagus and may invade the adjacent gastric cardia (Fig. 14–11, *A*). While early lesions may appear as flat or raised patches in otherwise intact mucosa, tumors may form large exophytic masses, infiltrate diffusely, or ulcerate and invade deeply. On microscopic examination, Barrett esophagus frequently is present adjacent to the tumor. Tumors typically produce mucin and form glands (Fig. 14–11, *B*).

### Clinical Features

Although esophageal adenocarcinomas are occasionally discovered during evaluation of GERD or surveillance of Barrett esophagus, they more commonly manifest with

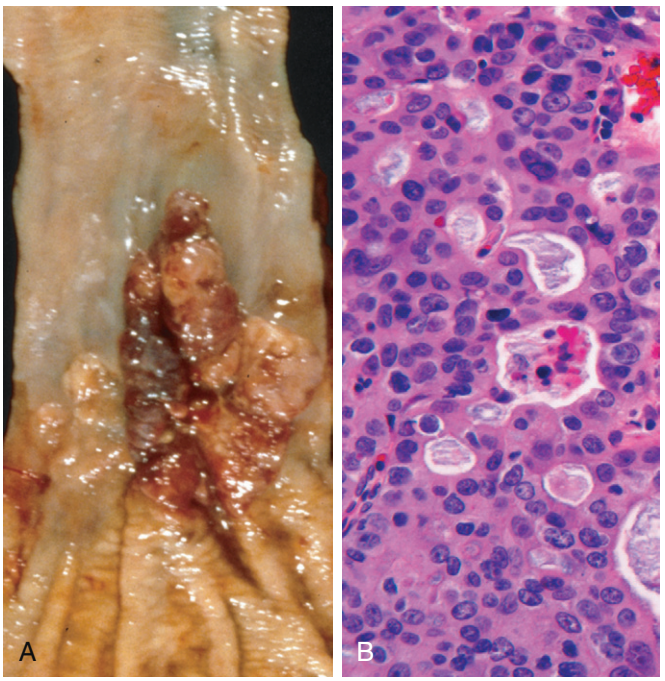


**Figure 14–11** Esophageal adenocarcinoma. **A,** Adenocarcinoma usually occurs distally and, as in this case, often involves the gastric cardia. **B,** Esophageal adenocarcinoma growing as back-to-back glands.

pain or difficulty in swallowing, progressive weight loss, chest pain, or vomiting. By the time symptoms and signs appear, the tumor usually has spread to submucosal lymphatic vessels. As a result of the advanced stage at diagnosis, the overall 5-year survival rate is less than 25%. By contrast, 5-year survival approximates 80% in the few patients with adenocarcinoma limited to the mucosa or submucosa.

## Squamous Cell Carcinoma

In the United States, esophageal squamous cell carcinoma typically occurs in adults older than 45 years of age and affects males four times more frequently than females. Risk factors include alcohol and tobacco use, poverty, caustic esophageal injury, achalasia, Plummer-Vinson syndrome, frequent consumption of very hot beverages, and previous radiation therapy to the mediastinum. It is nearly 6 times more common in African Americans than in whites—a striking risk disparity that cannot be accounted for by differences in rates of alcohol and tobacco use. The incidence of esophageal squamous cell carcinoma can vary by more than 100-fold between and within countries, being more common in rural and underdeveloped areas. The countries with highest incidences are Iran, central China, Hong Kong, Argentina, Brazil, and South Africa.

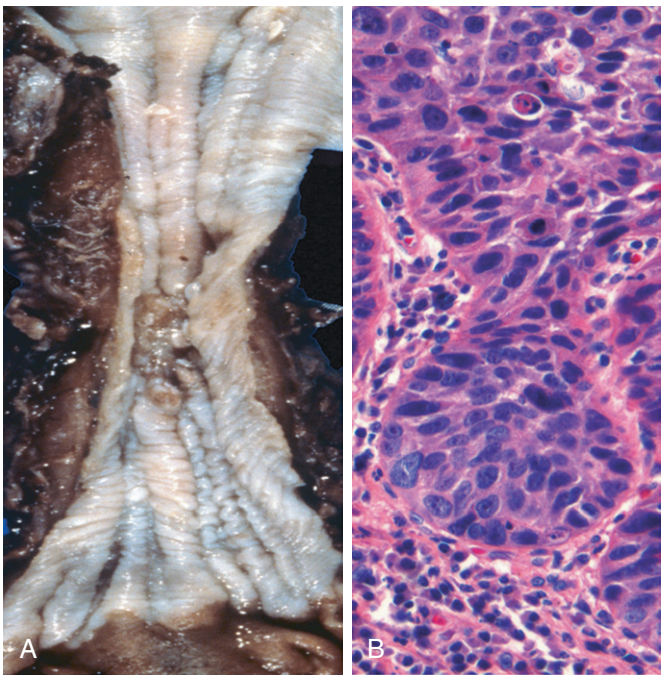


**Figure 14–12** Esophageal squamous cell carcinoma. **A,** Squamous cell carcinoma most frequently is found in the midesophagus, where it commonly causes strictures. **B,** Squamous cell carcinoma composed of nests of malignant cells that partially recapitulate the stratified organization of squamous epithelium.

### PATHOGENESIS

A majority of esophageal squamous cell carcinomas in Europe and the United States are at least partially attributable to the use of alcohol and tobacco, the effects of which synergize to increase risk. However, esophageal squamous cell carcinoma also is common in some regions where alcohol and tobacco use is uncommon. Thus, nutritional deficiencies, as well as polycyclic hydrocarbons, nitrosamines, and other mutagenic compounds, such as those found in fungus-contaminated foods, have been considered as possible risk factors. HPV infection also has been implicated in esophageal squamous cell carcinoma in high-risk but not in low-risk regions. The molecular pathogenesis of esophageal squamous cell carcinoma remains incompletely defined.

### MORPHOLOGY

In contrast to the distal location of most adenocarcinomas, half of squamous cell carcinomas occur in the middle third of the esophagus (Fig. 14–12, *A*). Squamous cell carcinoma begins as an in situ lesion in the form of **squamous dysplasia.** Early lesions appear as small, gray-white plaquelike thickenings. Over months to years they grow into tumor masses that may be polypoid and protrude into and obstruct the lumen. Other tumors are either ulcerated or diffusely infiltrative lesions that spread within the esophageal wall, where they cause thickening, rigidity, and luminal narrowing. These cancers may invade surrounding structures including the respiratory tree, causing pneumonia; the aorta, causing catastrophic exsanguination; or the mediastinum and pericardium.

Most squamous cell carcinomas are moderately to well differentiated (Fig. 14–12, *B*). Less common histologic variants include verrucous squamous cell carcinoma, spindle cell carcinoma, and basaloid squamous cell carcinoma. Regardless of histologic type, symptomatic tumors are generally very large at diagnosis and have already invaded the esophageal wall. The rich submucosal lymphatic network promotes circumferential and longitudinal spread, and intramural tumor nodules may be present several centimeters away from the principal mass. The sites of lymph node metastases vary with tumor location: Cancers in the upper third of the esophagus favor cervical lymph nodes; those in the middle third favor mediastinal, paratracheal, and tracheobronchial nodes; and those in the lower third spread to gastric and celiac nodes.

### Clinical Features

Clinical manifestations of squamous cell carcinoma of the esophagus begin insidiously and include dysphagia, odynophagia (pain on swallowing), and obstruction. As with other forms of esophageal obstruction, patients may unwittingly adjust to the progressively increasing obstruction by altering their diet from solid to liquid foods. Extreme weight loss and debilitation result from both impaired nutrition and effects of the tumor itself. Hemorrhage and sepsis may accompany tumor ulceration. Occasionally, the first symptoms are caused by aspiration of food through a tracheoesophageal fistula.

Increased use of endoscopic screening has led to earlier detection of esophageal squamous cell carcinoma. The

timing is critical, because 5-year survival rates are 75% for patients with superficial esophageal carcinoma but much lower for patients with more advanced tumors. Lymph node metastases, which are common, are associated with poor prognosis. The overall 5-year survival rate remains a dismal 9%.

### SUMMARY

#### Diseases of the Esophagus

- *Esophageal obstruction* may occur as a result of mechanical or functional anomalies. Mechanical causes include developmental defects, fibrotic strictures, and tumors.
- *Achalasia,* characterized by incomplete LES relaxation, increased LES tone, and esophageal aperistalsis, is a common form of *functional esophageal obstruction.*
- *Esophagitis* can result from chemical or infectious mucosal injury. Infections are most frequent in immunocompromised persons.
- The most common cause of esophagitis is *gastroesophageal reflux disease* (GERD), which must be differentiated from *eosinophilic esophagitis.*
- *Barrett esophagus,* which may develop in patients with chronic GERD, is associated with increased risk of esophageal adenocarcinoma.
- *Esophageal squamous cell carcinoma* is associated with alcohol and tobacco use, poverty, caustic esophageal injury, achalasia, tylosis, and Plummer-Vinson syndrome.

## STOMACH

Disorders of the stomach are a frequent cause of clinical disease, with inflammatory and neoplastic lesions being particularly common. In the United States, symptoms related to gastric acid account for nearly one third of all health care spending on gastrointestinal disease. In addition, despite a decreasing incidence in certain locales, including the United States, gastric cancer remains a leading cause of death worldwide.

The stomach is divided into four major anatomic regions: the cardia, fundus, body, and antrum. The cardia is lined mainly by mucin-secreting *foveolar cells* that form shallow glands. The antral glands are similar but also contain endocrine cells, such as *G cells,* that release gastrin to stimulate luminal acid secretion by *parietal cells* within the gastric fundus and body. The well-developed glands of the body and fundus also contain *chief cells* that produce and secrete digestive enzymes such as pepsin.

## INFLAMMATORY DISEASE OF THE STOMACH

### Acute Gastritis

Acute gastritis is a transient mucosal inflammatory process that may be asymptomatic or cause variable degrees of epigastric pain, nausea, and vomiting. In more severe cases there may be mucosal erosion, ulceration, hemorrhage, hematemesis, melena, or, rarely, massive blood loss.

### PATHOGENESIS

The gastric lumen is strongly acidic, with a pH close to one—more than a million times more acidic than the blood. This harsh environment contributes to digestion but also has the potential to damage the mucosa. Multiple mechanisms have evolved to protect the gastric mucosa (Fig. 14–13). Mucin secreted by surface **foveolar cells** forms a thin layer of mucus that prevents large food particles from directly touching the epithelium. The mucus layer also promotes formation of an "unstirred" layer of fluid over the epithelium that protects the mucosa and has a neutral pH as a result of bicarbonate ion secretion by surface epithelial cells. Finally, the rich vascular supply to the gastric mucosa delivers oxygen, bicarbonate, and nutrients while washing away acid that has back-diffused into the lamina propria. Acute or chronic gastritis can occur after disruption of any of these protective mechanisms. For example, reduced mucin synthesis in elderly persons is suggested to be one factor that explains their increased susceptibility to gastritis. Nonsteroidal anti-inflammatory drugs (NSAIDs) may interfere with cytoprotection normally provided by prostaglandins or reduce bicarbonate secretion, both of which increase the susceptibility of the gastric mucosa to injury. Ingestion of harsh chemicals, particularly acids or bases, either accidentally or as a suicide attempt, also results in severe gastric injury, predominantly as a consequence of direct damage to mucosal epithelial and stromal cells. Direct cellular injury also is implicated in gastritis due to excessive alcohol consumption, NSAIDs, radiation therapy, and chemotherapy.

### MORPHOLOGY

On histologic examination, mild acute gastritis may be difficult to recognize, since the lamina propria shows only moderate edema and slight vascular congestion. The **surface epithelium is intact,** although scattered neutrophils may be present. Lamina propria lymphocytes and plasma cells are not prominent. The presence of neutrophils above the basement membrane—specifically, in direct contact with epithelial cells—is abnormal in all parts of the gastrointestinal tract and signifies **active inflammation.** With more severe mucosal damage, *erosion,* or loss of the superficial epithelium, may occur, leading to formation of mucosal neutrophilic infiltrates and purulent exudates. Hemorrhage also may occur, manifesting as dark puncta in an otherwise hyperemic mucosa. Concurrent presence of erosion and hemorrhage is termed **acute erosive hemorrhagic gastritis.**

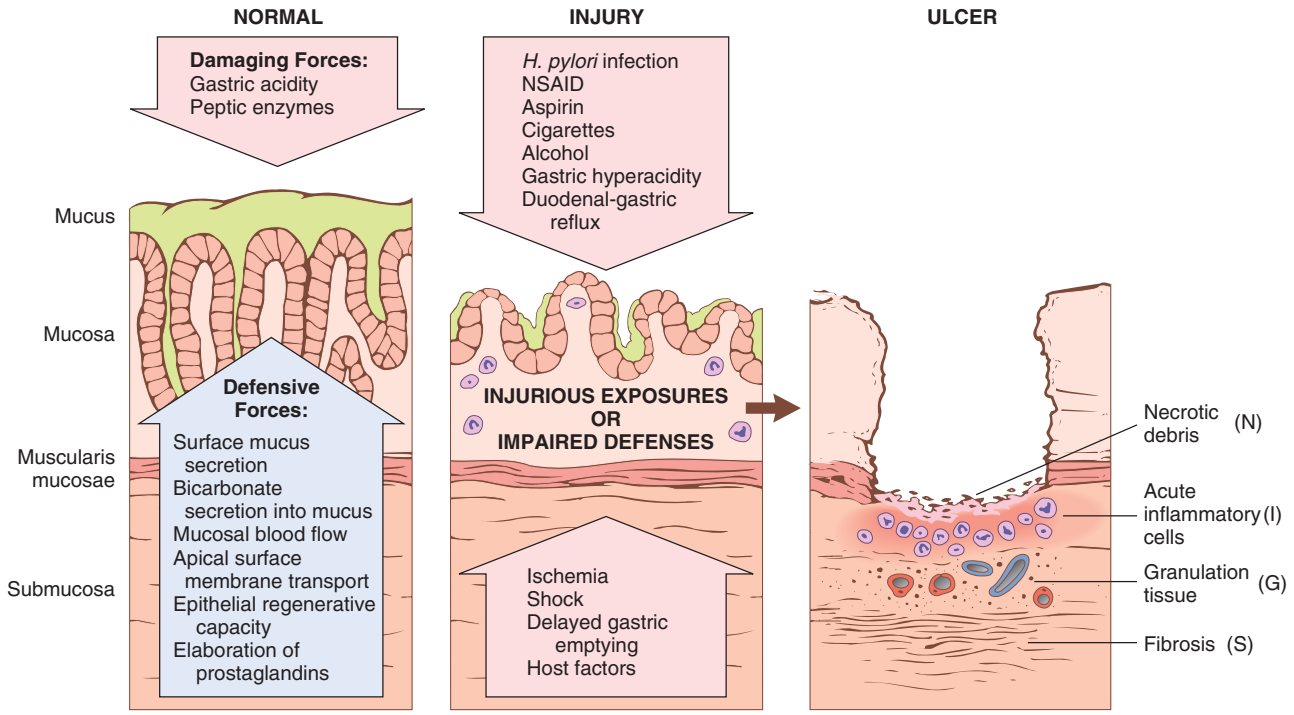


**Figure 14–13** Mechanisms of gastric injury and protection. This diagram illustrates the progression from more mild forms of injury to ulceration that may occur with acute or chronic gastritis. Ulcers include layers of necrotic debris *(N)*, inflammation *(I)*, and granulation tissue *(G)*; a fibrotic scar *(S)*, which develops over time, is present only in chronic lesions.

## Acute Peptic Ulceration

Focal, acute peptic injury is a well-known complication of therapy with NSAIDs as well as severe physiologic stress. Such lesions include

- *Stress ulcers,* most commonly affecting critically ill patients with shock, sepsis, or severe trauma
- *Curling ulcers,* occurring in the proximal duodenum and associated with severe burns or trauma
- *Cushing ulcers,* arising in the stomach, duodenum, or esophagus of persons with intracranial disease, have a high incidence of perforation

### PATHOGENESIS

The pathogenesis of acute ulceration is complex and incompletely understood. NSAID-induced ulcers are caused by direct chemical irritation as well as cyclooxygenase inhibition, which prevents prostaglandin synthesis. This eliminates the protective effects of prostaglandins, which include enhanced bicarbonate secretion and increased vascular perfusion. Lesions associated with intracranial injury are thought to be caused by direct stimulation of vagal nuclei, which causes gastric acid hypersecretion. Systemic acidosis, a frequent finding in critically ill patients, also may contribute to mucosal injury by lowering the intracellular pH of mucosal cells. Hypoxia and reduced blood flow caused by stress-induced splanchnic vasoconstriction also contribute to acute ulcer pathogenesis.

### MORPHOLOGY

Lesions described as acute gastric ulcers range in depth from shallow erosions caused by superficial epithelial damage to deeper lesions that penetrate the mucosa. Acute ulcers are rounded and typically are less than 1 cm in diameter. The ulcer base frequently is stained brown to black by acid-digested extravasated red cells, in some cases associated with transmural inflammation and local serositis. While these lesions may occur singly, more often multiple ulcers are present within the stomach and duodenum. Acute stress ulcers are sharply demarcated, with essentially normal adjacent mucosa, although there may be suffusion of blood into the mucosa and submucosa and some inflammatory reaction. The scarring and thickening of blood vessels that characterize chronic peptic ulcers are absent. Healing with complete reepithelialization occurs days or weeks after the injurious factors are removed.

### Clinical Features

Symptoms of gastric ulcers include nausea, vomiting, and coffee-ground hematemesis. Bleeding from superficial gastric erosions or ulcers that may require transfusion develops in 1% to 4% of these patients. Other complications, including perforation, can also occur. Proton pump inhibitors, or the less frequently used histamine $H_2$ receptor antagonists, may blunt the impact of stress ulceration, but the most important determinant of outcome is the severity of the underlying condition.

## Chronic Gastritis

The symptoms and signs associated with chronic gastritis typically are less severe but more persistent than those of acute gastritis. Nausea and upper abdominal discomfort may occur, sometimes with vomiting, but hematemesis is uncommon. *The most common cause of chronic gastritis is infection with the bacillus* Helicobacter pylori. *Autoimmune gastritis,* the most common cause of *atrophic gastritis,* represents less than 10% of cases of chronic gastritis and is the most common form of chronic gastritis in patients without *H. pylori* infection. Less common causes include radiation injury and chronic bile reflux.

### Helicobacter pylori *Gastritis*

The discovery of the association of *H. pylori* with peptic ulcer disease revolutionized the understanding of chronic gastritis. These spiral-shaped or curved bacilli are present in gastric biopsy specimens from almost all patients with duodenal ulcers and a majority of those with gastric ulcers or chronic gastritis. Acute *H. pylori* infection does not produce sufficient symptoms to require medical attention in most cases; rather the chronic gastritis ultimately causes the afflicted person to seek treatment. *H. pylori* organisms are present in 90% of patients with chronic gastritis affecting the antrum. In addition, the increased acid secretion that occurs in *H. pylori* gastritis may result in peptic ulcer disease of the stomach or duodenum; *H. pylori* infection also confers increased risk of gastric cancer.

#### Epidemiology

In the United States, *H. pylori* infection is associated with poverty, household crowding, limited education, African American or Mexican American ethnicity, residence in areas with poor sanitation, and birth outside of the United States. Colonization rates exceed 70% in some groups and range from less than 10% to more than 80% worldwide. In high-prevalence areas, infection often is acquired in childhood and then persists for decades. Thus, the incidence of *H. pylori* infection correlates most closely with sanitation and hygiene during an individual's childhood.

## PATHOGENESIS

*H. pylori* infection most often manifests as a **predominantly antral gastritis with high acid production, despite hypogastrinemia.** The risk of duodenal ulcer is increased in these patients, and in most cases, gastritis is limited to the antrum.

*H. pylori* organisms have adapted to the ecologic niche provided by gastric mucus. Although *H. pylori* may invade the gastric mucosa, the contribution of invasion to disease pathogenesis is not known. Four features are linked to *H. pylori* virulence:

- **Flagella,** which allow the bacteria to be motile in viscous mucus
- **Urease,** which generates ammonia from endogenous urea, thereby elevating local gastric pH around the organisms and protecting the bacteria from the acidic pH of the stomach
- **Adhesins,** which enhance bacterial adherence to surface foveolar cells
- **Toxins,** such as that encoded by cytotoxin-associated gene A (*CagA*), that may be involved in ulcer or cancer development by poorly defined mechanisms

These factors allow *H. pylori* to create an imbalance between gastroduodenal mucosal defenses and damaging forces that overcome those defenses. Over time, chronic antral *H. pylori* gastritis may progress to **pangastritis,** resulting in **multifocal atrophic gastritis,** reduced acid secretion, intestinal metaplasia, and increased risk of gastric adenocarcinoma in a subset of patients. The underlying mechanisms contributing to this progression are not clear, but interactions between the host immune system and the bacterium seem to be critical.

## MORPHOLOGY

Gastric biopsy specimens generally demonstrate *H. pylori* in infected persons (Fig. 14–14, *A*). The organism is concentrated within the superficial mucus overlying epithelial cells in

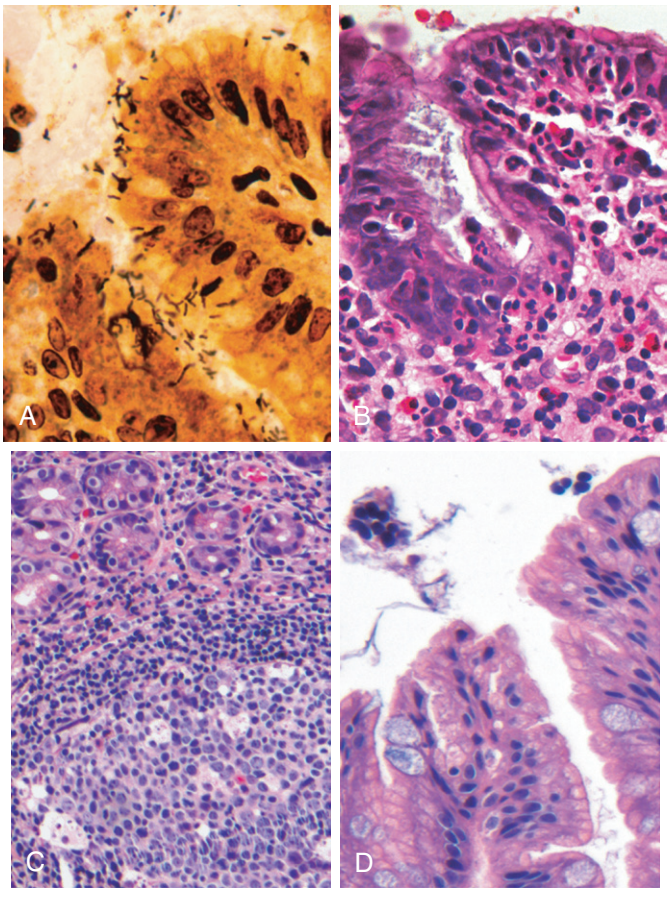


**Figure 14–14** Chronic gastritis. **A,** Spiral-shaped *Helicobacter pylori* bacilli are highlighted in this Warthin-Starry silver stain. Organisms are abundant within surface mucus. **B,** Intraepithelial and lamina propria neutrophils are prominent. **C,** Lymphoid aggregates with germinal centers and abundant subepithelial plasma cells within the superficial lamina propria are characteristic of *H. pylori* gastritis. **D,** Intestinal metaplasia, recognizable as the presence of goblet cells admixed with gastric foveolar epithelium, can develop and is a risk factor for development of gastric adenocarcinoma.

the surface and neck regions. The inflammatory reaction includes a variable number of neutrophils within the lamina propria, including some that cross the basement membrane to assume an intraepithelial location (Fig. 14–14, *B*) and accumulate in the lumen of gastric pits to create pit abscesses. The superficial lamina propria includes large numbers of plasma cells, often in clusters or sheets, as well as increased numbers of lymphocytes and macrophages. When intense, inflammatory infiltrates may create thickened rugal folds, mimicking infiltrative lesions. Lymphoid aggregates, some with germinal centers, frequently are present (Fig. 14–14, *C*) and represent an induced form of **mucosa-associated lymphoid tissue** (MALT) that has the potential to transform into lymphoma. **Intestinal metaplasia,** characterized by the presence of goblet cells and columnar absorptive cells (Fig. 14–14, *D*), also may be present and is associated with increased risk of gastric adenocarcinoma. *H. pylori* shows tropism for gastric foveolar epitheleum and generally is not found in areas of intestinal metaplasia, acid-producing mucosa of the gastric body, or duodenal epithelium. Thus, an antral biopsy is preferred for evaluation of *H. pylori* gastritis.

Clinical Features

In addition to histologic identification of the organism, several diagnostic tests have been developed including a noninvasive serologic test for anti–*H. pylori* antibodies, fecal bacterial detection, and the urea breath test based on the generation of ammonia by bacterial urease. Gastric biopsy specimens also can be analyzed by the rapid urease test, bacterial culture, or polymerase chain reaction (PCR) assay for bacterial DNA. Effective treatments include combinations of antibiotics and proton pump inhibitors. Patients with *H. pylori* gastritis usually improve after treatment, although relapses can follow incomplete eradication or reinfection.

### *Autoimmune Gastritis*

*Autoimmune gastritis* accounts for less than 10% of cases of chronic gastritis. In contrast with that caused by *H. pylori,* autoimmune gastritis typically spares the antrum and induces *hypergastrinemia* (Table 14–2). Autoimmune gastritis is characterized by

- Antibodies to parietal cells and intrinsic factor that can be detected in serum and gastric secretions
- Reduced serum pepsinogen I levels
- Antral endocrine cell hyperplasia
- Vitamin $B_{12}$ deficiency
- Defective gastric acid secretion (*achlorhydria*)

## PATHOGENESIS

Autoimmune gastritis is associated with loss of parietal cells, which secrete acid and intrinsic factor. Deficient acid production stimulates gastrin release, resulting in hypergastrinemia and hyperplasia of antral gastrin-producing G cells. Lack of intrinsic factor disables ileal vitamin $B_{12}$ absorption, leading to $B_{12}$ deficiency and megaloblastic anemia **(pernicious anemia);** reduced serum concentration of pepsinogen I reflects chief cell loss. Although *H. pylori* can cause hypochlorhydria, it is not associated with achlorhydria or pernicious anemia, because the parietal and chief cell damage is not as severe as in autoimmune gastritis.

## MORPHOLOGY

Autoimmune gastritis is characterized by diffuse **damage of the oxyntic** (acid-producing) **mucosa** within the body and fundus. Damage to the antrum and cardia typically is absent or mild. With **diffuse atrophy,** the oxyntic mucosa of the body and fundus appears markedly thinned, and rugal folds are lost. Neutrophils may be present, but the inflammatory infiltrate more commonly is composed of lymphocytes, macrophages, and plasma cells; in contrast with ***H. pylori* gastritis,** the inflammatory reaction most often is deep and centered on the gastric glands. **Parietal and chief cell loss** can be extensive, and **intestinal metaplasia** may develop.

Clinical Features

Antibodies to parietal cells and intrinsic factor are present early in disease, but pernicious anemia develops in only a minority of patients. The median age at diagnosis is 60 years, and there is a slight female predominance. Autoimmune gastritis often is associated with other autoimmune diseases but is not linked to specific human leukocyte antigen (HLA) alleles.

**Table 14–2** Characteristics of *Helicobacter pylori*–Associated and Autoimmune Gastritis

| Feature | Location | |
|---|---|---|
| | *H. pylori*–Associated: Antrum | Autoimmune: Body |
| Inflammatory infiltrate | Neutrophils, subepithelial plasma cells | Lymphocytes, macrophages |
| Acid production | Increased to slightly decreased | Decreased |
| Gastrin | Normal to decreased | Increased |
| Other lesions | Hyperplastic/inflammatory polyps | Neuroendocrine hyperplasia |
| Serology | Antibodies to *H. pylori* | Antibodies to parietal cells ($H^+$,$K^+$-ATPase, intrinsic factor) |
| Sequelae | Peptic ulcer, adenocarcinoma, lymphoma | Atrophy, pernicious anemia, adenocarcinoma, carcinoid tumor |
| Associations | Low socioeconomic status, poverty, residence in rural areas | Autoimmune disease; thyroiditis, diabetes mellitus, Graves disease |

## Peptic Ulcer Disease

*Peptic ulcer disease* (PUD) most often is associated with *H. pylori* infection or NSAID use. In the US, the latter is becoming the most common cause of gastric ulcers as *H. pylori* infection rates fall and low-dose aspirin use in the aging population increases. PUD may occur in any portion of the gastrointestinal tract exposed to acidic gastric juices but is most common in the gastric antrum and first portion of the duodenum. PUD also may occur in the esophagus as a result of GERD or acid secretion by ectopic gastric mucosa, and in the small intestine secondary to gastric heteropia within a Meckel diverticulum.

### Epidemiology

PUD is common and is a frequent cause of physician visits worldwide. It leads to treatment of over 3 million people, 190,000 hospitalizations, and 5000 deaths in the United States each year. The lifetime risk of developing an ulcer is approximately 10% for males and 4% for females.

### PATHOGENESIS

*H. pylori* infection and NSAID use are the primary underlying causes of PUD. **The imbalances of mucosal defenses and damaging forces that cause chronic gastritis (Fig. 14–13) are also responsible for PUD.** Thus, PUD generally develops on a background of chronic gastritis. Although more than 70% of PUD cases are associated with *H. pylori* infection, only 5% to 10% of *H. pylori*–infected persons develop ulcers. It is probable that host factors as well as variation among *H. pylori* strains determine the clinical outcomes.

Gastric hyperacidity is fundamental to the pathogenesis of PUD. The acidity that drives PUD may be caused by *H. pylori* infection, parietal cell hyperplasia, excessive secretory responses, or impaired inhibition of stimulatory mechanisms such as gastrin release. For example, **Zollinger-Ellison syndrome,** characterized by multiple peptic ulcerations in the stomach, duodenum, and even jejunum, is caused by uncontrolled release of gastrin by a tumor and the resulting massive acid production. Cofactors in peptic ulcerogenesis include chronic NSAID use, as noted; cigarette smoking, which impairs mucosal blood flow and healing; and high-dose corticosteroids, which suppress prostaglandin synthesis and impair healing. Peptic ulcers are more frequent in persons with alcoholic cirrhosis, chronic obstructive pulmonary disease, chronic renal failure, and hyperparathyroidism. In the latter two conditions, hypercalcemia stimulates gastrin production and therefore increases acid secretion. Finally, psychologic stress may increase gastric acid production and exacerbate PUD.

### MORPHOLOGY

Peptic ulcers are four times more common in the proximal duodenum than in the stomach. Duodenal ulcers usually occur within a few centimeters of the pyloric valve and involve the anterior duodenal wall. Gastric peptic ulcers are predominantly located near the interface of the body and antrum.

Peptic ulcers are solitary in more than 80% of patients. Lesions less than 0.3 cm in diameter tend to be shallow, whereas those over 0.6 cm are likely to be deeper. The classic peptic ulcer is a round to oval, **sharply punched-out defect** (Fig. 14–15, *A*). The base of peptic ulcers is smooth and clean as a result of peptic digestion of exudate and on histologic examination is composed of richly vascular granulation tissue (Fig. 14–15, *B*). Ongoing bleeding within the ulcer base may cause life-threatening hemorrhage. **Perforation** is a complication that demands emergent surgical intervention.

### Clinical Features

Peptic ulcers are chronic, recurring lesions that occur most often in middle-aged to older adults without obvious precipitating conditions, other than chronic gastritis. A majority of peptic ulcers come to clinical attention after patient complaints of *epigastric burning or aching pain,* although a significant fraction manifest with complications such as *iron deficiency anemia, frank hemorrhage,* or *perforation.* The pain tends to occur 1 to 3 hours after meals during the day, is worse at night, and is relieved by alkali or food. Nausea,

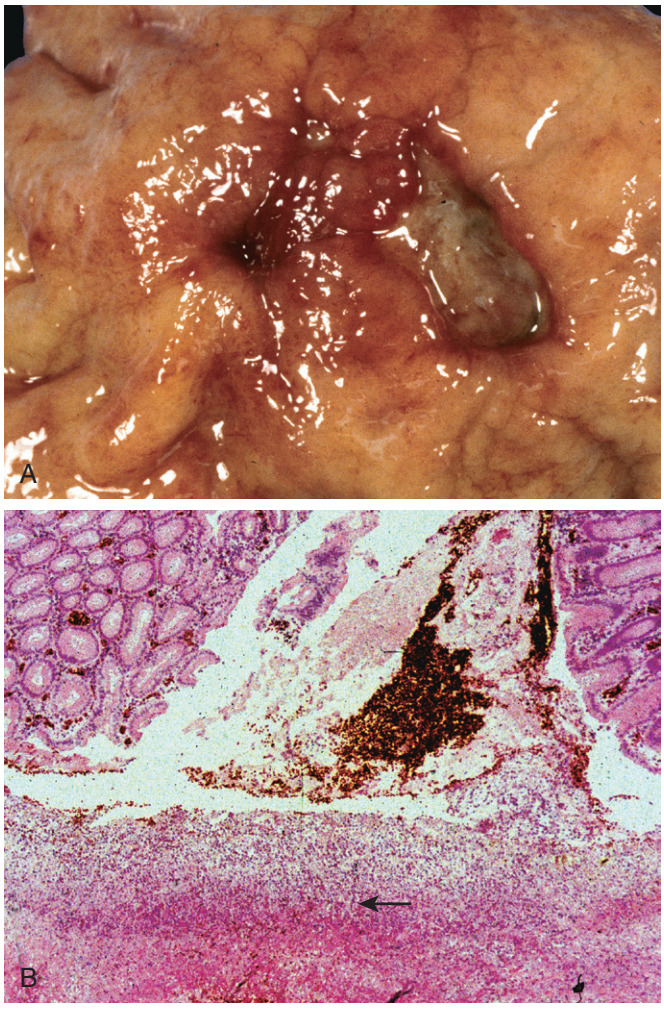


**Figure 14–15** Acute gastric perforation in a patient presenting with free air under the diaphragm. **A,** Mucosal defect with clean edges. **B,** The necrotic ulcer base *(arrow)* is composed of granulation tissue.

vomiting, bloating, and belching may be present. Healing may occur with or without therapy, but the tendency to develop ulcers later remains.

A variety of surgical approaches formerly were used to treat PUD, but current therapies are aimed at *H. pylori* eradication with antibiotics and neutralization of gastric acid, usually through use of proton pump inhibitors. These efforts have markedly reduced the need for surgical management, which is reserved primarily for treatment of bleeding or perforated ulcers. PUD causes much more morbidity than mortality.

## SUMMARY

### Acute and Chronic Gastritis

- The spectrum of *acute gastritis* ranges from asymptomatic disease to mild epigastric pain, nausea, and vomiting. Causative factors include any agent or disease that interferes with gastric mucosal protection. Acute gastritis can progress to *acute gastric ulceration.*
- The most common cause of chronic gastritis is *H. pylori infection*; most remaining cases are caused by *autoimmune gastritis*.
- *H. pylori* gastritis typically affects the antrum and is associated with increased gastric acid production. The induced mucosa-associated lymphoid tissue (MALT) can transform into lymphoma.
- *Autoimmune gastritis* causes atrophy of the gastric body oxyntic glands, which results in decreased gastric acid production, antral G cell hyperplasia, achlorhydria, and vitamin $B_{12}$ deficiency. Anti-parietal cell and anti–intrinsic factor antibodies typically are present.
- *Intestinal metaplasia* develops in both forms of chronic gastritis and is a risk factor for development of gastric adenocarcinoma.
- Peptic ulcer disease can be caused by *H. pylori* chronic gastritis and the resultant hyperchlorhydria or NSAID use. Ulcers can develop in the stomach or duodenum and usually heal after suppression of gastric acid production and, if present, eradication of the *H. pylori.*

# NEOPLASTIC DISEASE OF THE STOMACH

## Gastric Polyps

*Polyps,* nodules or masses that project above the level of the surrounding mucosa, are identified in up to 5% of upper gastrointestinal tract endoscopies. Polyps may develop as a result of epithelial or stromal cell hyperplasia, inflammation, ectopia, or neoplasia. Although many different types of polyps can occur in the stomach, only hyperplastic and inflammatory polyps, fundic gland polyps, and adenomas are considered here.

### *Inflammatory and Hyperplastic Polyps*

Approximately 75% of all gastric polyps are *inflammatory* or *hyperplastic polyps.* They most commonly affect persons between 50 and 60 years of age, usually arising in a background of chronic gastritis that initiates the injury and reactive hyperplasia that cause polyp growth. If associated with *H. pylori* gastritis, polyps may regress after bacterial eradication.

#### MORPHOLOGY

In the stomach, inflammatory and hyperplastic polyps are essentially the same entity, with the distinction based solely on the degree of inflammation. The polyps frequently are multiple and characteristically are ovoid in shape, less than 1 cm in diameter, and covered by a smooth surface. On microscopic examination, polyps have irregular, cystically dilated, and elongated foveolar glands. The lamina propria typically is edematous with variable degrees of acute and chronic inflammation, and surface erosions may be present.

The frequency with which **dysplasia,** a precancerous in situ lesion, develops in inflammatory or hyperplastic polyps correlates with size; there is a significant increase in risk in polyps larger than 1.5 cm.

### *Fundic Gland Polyps*

*Fundic gland polyps* occur sporadically and in persons with familial adenomatous polyposis (FAP) but do not have neoplastic potential. They are, however, worth mentioning here because their incidence has increased markedly as a result of the use of proton pump inhibitors. This likely results from increased gastrin secretion, in response to reduced acidity, and glandular hyperplasia driven by gastrin. Fundic gland polyps may be asymptomatic or associated with nausea, vomiting, or epigastric pain. These well-circumscribed polyps occur in the gastric body and fundus, often are multiple, and are composed of cystically dilated, irregular glands lined by flattened parietal and chief cells.

### *Gastric Adenoma*

Gastric adenomas represent as many as 10% of all gastric polyps. Their incidence increases with age and varies among different populations in parallel with that of gastric adenocarcinoma. Patients usually are between 50 and 60 years of age, and males are affected three times more often than females. Similar to other forms of gastric dysplasia, adenomas almost always occur on a background of chronic gastritis with atrophy and intestinal metaplasia. The risk for development of adenocarcinoma in gastric adenomas is related to the size of the lesion and is particularly elevated with lesions greater than 2 cm in diameter. Overall, carcinoma may be present in up to 30% of gastric adenomas.

#### MORPHOLOGY

Gastric adenomas are most commonly located in the antrum and typically are composed of intestinal-type columnar epithelium. By definition, all gastrointestinal adenomas exhibit epithelial dysplasia, which can be classified as low- or high-grade. Both grades may include enlargement, elongation, and hyperchromasia of epithelial cell nuclei, epithelial crowding, and pseudostratification. High-grade dysplasia is characterized by more severe cytologic atypia and irregular architecture, including glandular budding and gland-within-gland, or cribriform, structures.

## Gastric Adenocarcinoma

Adenocarcinoma is the most common malignancy of the stomach, comprising more than 90% of all gastric cancers. Early symptoms resemble those of chronic gastritis, including dyspepsia, dysphagia, and nausea. As a result, in low-incidence regions such as the United States, the cancer is often at advanced stages when clinical manifestations such as weight loss, anorexia, altered bowel habits, anemia, and hemorrhage trigger diagnostic evaluation.

### Epidemiology

Gastric cancer rates vary markedly with geography. The incidence is up to 20 times higher in Japan, Chile, Costa Rica, and Eastern Europe than in North America, northern Europe, Africa, and Southeast Asia. Mass endoscopic screening programs can be successful in regions of high incidence, such as Japan, where 35% of newly detected cases are *early gastric cancer,* or tumors limited to the mucosa and submucosa. Unfortunately, mass screening programs are not cost-effective in regions in which the incidence is low, and less than 20% of cases are detected at an early stage in North America and northern Europe.

Gastric cancer is more common in lower socioeconomic groups and in persons with *multifocal mucosal atrophy and intestinal metaplasia.* PUD does not impart an increased risk of gastric cancer, but patients who have had *partial gastrectomies* for PUD have a slightly higher risk of developing cancer in the residual gastric stump as a result of hypochlorhydria, bile reflux, and chronic gastritis.

In the United States, *gastric cancer rates dropped by more than 85% during the 20th century.* Similar declines have been reported in many other Western countries, reflecting the importance of environmental and dietary factors. Despite this decrease in overall gastric adenocarcinoma incidence, *cancer of the gastric cardia is on the rise.* This trend probably is related to increased rates of Barrett esophagus and may reflect the growing prevalence of chronic GERD and obesity.

### PATHOGENESIS

Gastric cancers are genetically heterogeneous but certain molecular alterations are common. We will consider these first to be followed by the role of *H. pylori*–induced chronic inflammation and the association of a subset of gastric cancers with EBV infection.

- **Mutations:** While the majority of gastric cancers are not hereditary, mutations identified in familial gastric cancer have provided important insights into mechanisms of carcinogenesis in sporadic cases. Germline mutations in *CDH1*, which encodes E-cadherin, a protein that contributes to epithelial intercellular adhesion, are associated with familial gastric cancers, usually of the diffuse type. Mutations in *CDH1* are present in about 50% of diffuse gastric tumors, while E-cadherin expression is drastically decreased in the rest, often by methylation of the *CDH1* promoter. **Thus, the loss of E-cadherin function seems to be a key step in the development of diffuse gastric cancer.**

  In contrast to *CDH1*, patients with familial adenomatous polyposis (FAP) who have germline mutations in **adenomatous polyposis coli (*APC*) genes** have an increased risk of intestinal-type gastric cancer. Sporadic intestinal-type gastric cancer is associated with several genetic abnormalities including acquired mutations of β-catenin, a protein that binds to both E-cadherin and APC protein; microsatellite instability; and hypermethylation of genes including *TGFβRII, BAX, IGFRII,* and *p16/INK4a*. *TP53* mutations are present in a majority of sporadic gastric cancers of both histologic types.
- ***H. pylori:*** Chronic gastritis, most commonly due to *H. pylori* infection, promotes the development and progression of cancers that may be induced by diverse genetic alterations (Chapter 5). As is the case with many forms of chronic inflammation, *H. pylori*–induced chronic gastritis is associated with increased production of proinflammatory proteins, such as interleukin-1β (IL-1β) and tumor necrosis factor (TNF). It is therefore not surprising that polymorphisms associated with enhanced production of these cytokines confer increased risk of chronic gastritis-associated intestinal-type gastric cancer in those with coexisting *H. pylori* infection.
- **EBV:** While *H. pylori* is most commonly associated with gastric cancer, approximately 10% of gastric adenocarcinomas are associated with Epstein-Barr virus (EBV) infection. Although the precise role of EBV in the development of gastric adenocarcinomas remains to be defined, it is notable that EBV episomes in these tumors frequently are clonal, suggesting that infection preceded neoplastic transformation. Further, *TP53* mutations are uncommon in the EBV-positive gastric tumors, suggesting that the molecular pathogenesis of these cancers is distinct from that of other gastric adenocarcinomas. Morphologically, EBV-positive tumors tend to occur in the proximal stomach and most commonly have a diffuse morphology with a marked lymphocytic infiltrate.

### MORPHOLOGY

Gastric adenocarcinomas are classified according to their location in the stomach as well as gross and histologic morphology. The **Lauren classification** that separates gastric cancers into **intestinal** and **diffuse** types correlates with distinct patterns of molecular alterations, as discussed above. Intestinal-type cancers tend to be bulky (Fig. 14–16, *A*) and are composed of glandular structures similar to esophageal and colonic adenocarcinoma. Intestinal-type adenocarcinomas typically grow along broad cohesive fronts to form either an exophytic mass or an ulcerated tumor. The neoplastic cells often contain apical mucin vacuoles, and abundant mucin may be present in gland lumina.

Diffuse gastric cancers display an infiltrative growth pattern (Fig. 14–16, *B*) and are composed of discohesive cells with large mucin vacuoles that expand the cytoplasm and push the nucleus to the periphery, creating a **signet ring cell** morphology (Fig. 14–16, *C*). These cells permeate the mucosa and stomach wall individually or in small clusters. A mass may be difficult to appreciate in diffuse gastric cancer, but these infiltrative tumors often evoke a **desmoplastic** reaction that stiffens the gastric wall and may cause diffuse rugal flattening and a rigid, thickened wall that imparts a "leather bottle" appearance termed **linitis plastica.**

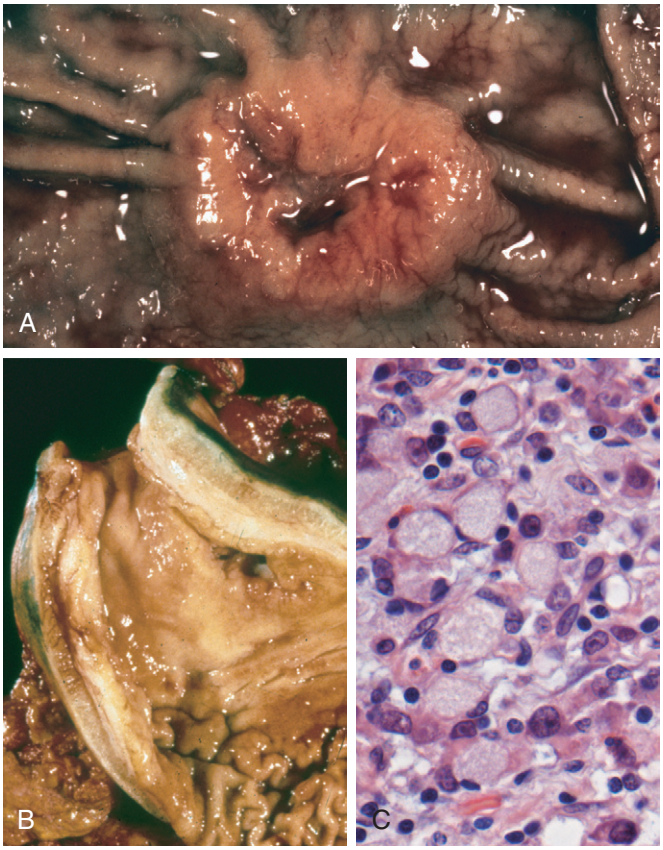


**Figure 14–16** Gastric adenocarcinoma. **A,** Intestinal-type adenocarcinoma consisting of an elevated mass with heaped-up borders and central ulceration. Compare with the peptic ulcer in Figure 14-15, A. **B,** Linitis plastica. The gastric wall is markedly thickened, and rugal folds are partially lost. **C,** Signet ring cells with large cytoplasmic mucin vacuoles and peripherally displaced, crescent-shaped nuclei.

### Clinical Features

Intestinal-type gastric cancer predominates in high-risk areas and develops from precursor lesions including flat dysplasia and adenomas. The mean age at presentation is 55 years, and the male-to-female ratio is 2:1. By contrast, the incidence of diffuse gastric cancer is relatively uniform across countries, there are no identified precursor lesions, and the disease occurs at similar frequencies in males and females. Of note, *the remarkable decrease in gastric cancer incidence applies only to the intestinal type,* which is most closely associated with atrophic gastritis and intestinal metaplasia. As a result, the incidences of intestinal and diffuse types of gastric cancers are now similar in some regions.

*The depth of invasion and the extent of nodal and distant metastasis at the time of diagnosis remain the most powerful prognostic indicators for gastric cancer.* Local invasion into the duodenum, pancreas, and retroperitoneum also is characteristic. When possible, surgical resection remains the preferred treatment for gastric adenocarcinoma. After surgical resection, the 5-year survival rate for early gastric cancer can exceed 90%, even if lymph node metastases are present. By contrast, the 5-year survival rate for advanced gastric cancer remains below 20%, in large part because current chemotherapy regimens are minimally effective. Because of the advanced stage at which most gastric cancers are discovered in the United States, the overall 5-year survival is less than 30%.

## Lymphoma

Although extranodal lymphomas can arise in virtually any tissue, they do so most commonly in the gastrointestinal tract, particularly the stomach. In allogeneic hematopoietic stem cell and organ transplant recipients, the bowel also is the most frequent site for Epstein-Barr virus–positive B cell lymphoproliferations. Nearly 5% of all gastric malignancies are primary lymphomas, the most common of which are indolent extranodal marginal zone B cell lymphomas. In the gut, these tumors often are referred to as lymphomas of *mucosa-associated lymphoid tissue* (MALT), or *MALTomas.* This entity and the second most common primary lymphoma of the gut, diffuse large B cell lymphoma, are discussed in Chapter 11.

## Carcinoid Tumor

Carcinoid tumors arise from neuroendocrine organs (e.g., the endocrine pancreas) and neuroendocrine-differentiated gastrointestinal epithelia (e.g., G-cells). A majority are found in the gastrointestinal tract, and more than 40% occur in the small intestine. The tracheobronchial tree and lungs are the next most commonly involved sites. Gastric carcinoids may be associated with endocrine cell hyperplasia, chronic atrophic gastritis, and Zollinger-Ellison syndrome. These tumors were called "carcinoid" because they are slower growing than carcinomas. The most current WHO classification describes these as low- or intermediate grade neuroendocrine tumors. The grade is based on mitotic activity and the fraction of cells immunohistochemcially positive for Ki67, a mitotic marker. However, it is important to recognize that site within the GI tract and extent of local invasion are also important prognostic indicators (see later). High-grade neuroendocrine tumors, termed *neuroendocrine carcinoma*, frequently display necrosis and, in the GI tract, are most common in the jejunum.

### MORPHOLOGY

Carcinoid tumors are intramural or submucosal masses that create small polypoid lesions (Fig. 14–17, *A*). The tumors are yellow or tan in appearance and elicit an intense desmoplastic reaction that may cause kinking of the bowel and obstruction. On histologic examination, carcinoid tumors are composed of islands, trabeculae, strands, glands, or sheets of uniform cells with scant, pink granular cytoplasm and a round to oval stippled nucleus (Fig. 14–17, *B*).

### Clinical Features

The peak incidence of carcinoid tumors is in the sixth decade, but they may appear at any age. Symptoms are determined by the hormones produced. For example, the *carcinoid syndrome* is caused by vasoactive substances secreted by the tumor that cause cutaneous flushing, sweating, bronchospasm, colicky abdominal pain, diarrhea, and right-sided cardiac valvular fibrosis. When tumors are

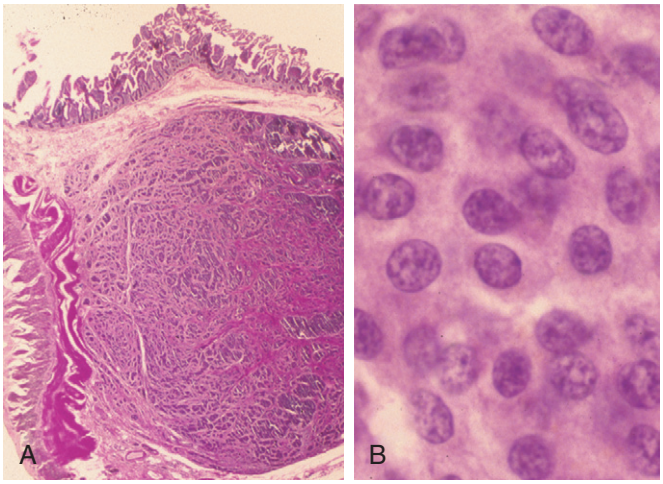


**Figure 14–17** Gastrointestinal carcinoid tumor (neuroendocrine tumor). **A,** Carcinoid tumors often form a submucosal nodule composed of tumor cells embedded in dense fibrous tissue. **B,** High magnification shows the bland cytology that typifies carcinoid tumors. The chromatin texture, with fine and coarse clumps, frequently assumes a "salt and pepper" pattern. Despite their innocuous appearance, carcinoids can be aggressive.

confined to the intestine, the vasoactive substances released are metabolized to inactive forms by the liver—a "first-pass" effect similar to that seen with oral drugs. Thus, carcinoid syndrome occurs in less than 10% of patients and is *strongly associated with metastatic disease.*

*The most important prognostic factor for gastrointestinal carcinoid tumors is location:*

- *Foregut carcinoid tumors,* those found within the stomach, duodenum proximal to the ligament of Treitz, and esophagus, rarely metastasize and generally are cured by resection. Although rare, duodenal gastrin-producing carcinoid tumors, *gastrinomas,* have been associated with proton pump inhibitor therapy.
- *Midgut carcinoid tumors* that arise in the jejunum and ileum often are multiple and tend to be aggressive. In these tumors, greater depth of local invasion, increased size, and presence of necrosis and mitosis are associated with poor outcome.
- *Hindgut carcinoids* arising in the appendix and colorectum typically are discovered incidentally. Those in the appendix occur at any age and are almost uniformly benign. Rectal carcinoid tumors tend to produce polypeptide hormones and may manifest with abdominal pain and weight loss; they only occasionally metastasize.

## Gastrointestinal Stromal Tumor

A wide variety of mesenchymal neoplasms may arise in the stomach. Many are named according to the cell type they most resemble; for example, smooth muscle tumors are called *leiomyomas* or *leiomyosarcomas,* nerve sheath tumors are termed *schwannomas,* and those resembling glomus bodies in the nail beds and at other sites are termed *glomus tumors.* These tumors are all rare and are not discussed here. *Gastrointestinal stromal tumor (GIST)* is the most common mesenchymal tumor of the abdomen, and more than half of these tumors occur in the stomach.

### Epidemiology

Overall, GISTs are slightly more common in males. The peak incidence of gastric GIST is around 60 years of age, with less than 10% occurring in persons younger than 40 years of age.

### PATHOGENESIS

Approximately **75% to 80% of all GISTs have oncogenic, gain-of-function mutations of the gene encoding the tyrosine kinase c-KIT,** which is the receptor for stem cell factor. Another 8% of GISTs have mutations that activate a related tyrosine kinase, platelet-derived growth factor receptor A (PDGFRA); thus activating mutations in tyrosine kinases are found in virtually all GISTs. However, either mutation is sufficient for tumorigenesis, and *c-KIT* and *PDGFRA* mutations are almost never found in a single tumor. GISTs appear to arise from, or share a common stem cell with, the interstitial cells of Cajal, which express c-KIT, are located in the muscularis propria, and serve as pacemaker cells for gut peristalsis.

### MORPHOLOGY

Primary gastric GISTs usually form a solitary, well-circumscribed, fleshy, submucosal mass. Metastases may form multiple small serosal nodules or fewer large nodules in the liver; spread outside of the abdomen is uncommon. GISTs can be composed of thin, elongated **spindle cells** or plumper **epithelioid cells.** The most useful diagnostic marker is c-KIT, consistent with the relationship between GISTs and interstitial cells of Cajal, which is immunohistochemically detectable in 95% of these tumors.

### Clinical Features

Symptoms of GISTs at presentation may be related to mass effects or mucosal ulceration. Complete surgical resection is the primary treatment for localized gastric GIST. The prognosis correlates with tumor size, mitotic index, and location, *with gastric GISTs being somewhat less aggressive than those arising in the small intestine.* Recurrence or metastasis is rare for gastric GISTs less than 5 cm across but common for mitotically active tumors larger than 10 cm. Patients with unresectable, recurrent, or metastatic disease often respond to *imatinib,* an inhibitor of the tyrosine kinase activity of c-KIT and PDGFRA that is also effective in suppressing BCR-ABL kinase activity in chronic myelogenous leukemia (Chapter 11). Unfortunately, GISTs eventually become resistant to imatinib, and other kinase inhibitors are now being evaluated in imatinib-resistant disease.

### SUMMARY

#### Gastric Polyps and Tumors

- *Inflammatory and hyperplastic gastric polyps* are reactive lesions associated with chronic gastritis. Risk of dysplasia increases with polyp size.

- *Gastric adenomas* develop in a background of chronic gastritis and are particularly associated with intestinal metaplasia and mucosal (glandular) atrophy. Adenocarcinoma frequently arises in gastric adenomas, which therefore require complete excision and surveillance to detect recurrence.
- Gastric adenocarcinoma incidence varies markedly with geography and also is more common in lower socioeconomic groups.
- Gastric adenocarcinomas are classified according to location and gross and histologic morphology. Those with an *intestinal* histologic pattern tend to form bulky tumors and may be ulcerated, whereas those composed of *signet ring cells* typically display a diffuse infiltrative growth pattern that may thicken the gastric wall (*linitis plastica*) without forming a discrete mass.
- *H. pylori* infection is the most common etiologic agent for gastric adenocarcinoma, but other associations, including chronic atrophic gastritis and EBV infection, suggest several pathways of neoplastic transformation are operative.
- *Primary gastric lymphomas* most often are derived from the mucosa-associated lymphoid tissue whose development is induced by chronic gastritis.
- *Carcinoid tumors* arise from the diffuse components of the endocrine system, and are most common in the gastrointestinal tract, particularly the small intestine. The single most important prognostic factor is location: Tumors of the small intestine tend to be most aggressive, while those of the appendix are almost always benign.
- *Gastrointestinal stromal tumor* (GIST) is the most common mesenchymal tumor of the abdomen, occurs most often in the stomach; it arises from benign pacemaker cells, also known as the interstitial cells of Cajal. A majority of tumors have activating mutations in either the c-KIT or the PDGFRA tyrosine kinases and respond to kinase inhibitors.

# SMALL AND LARGE INTESTINES

The small intestine and colon account for most of the length of the gastrointestinal tract and are the sites of a wide variety of diseases, many of which affect nutrient and water transport. Perturbation of these processes can cause malabsorption and diarrhea. The intestines are also the principal site where the immune system interfaces with a diverse array of antigens present in food and gut microbes. Indeed, intestinal bacteria outnumber eukaryotic cells in the human body by ten-fold. Thus, it is not surprising that the small intestine and colon frequently are involved by infectious and inflammatory processes. Finally, the colon is the most common site of gastrointestinal neoplasia in Western populations.

## INTESTINAL OBSTRUCTION

Obstruction of the gastrointestinal tract may occur at any level, but the small intestine is most often involved because of its relatively narrow lumen. Collectively, *hernias, intestinal adhesions, intussusception,* and *volvulus* account for 80% of mechanical obstructions (Fig. 14–18), while tumors and infarction account for most of the remainder. The clinical manifestations of intestinal obstruction include abdominal pain and distention, vomiting, and constipation. Surgical intervention usually is required in cases involving mechanical obstruction or severe infarction.

### Hirschsprung Disease

*Hirschsprung disease* occurs in approximately 1 of 5000 live births and stems from a congenital defect in colonic innervation. It may be isolated or occur in combination with other developmental abnormalities. It is more common in males but tends to be more severe in females. Siblings of patients have an increased risk of Hirschsprung disease.

Patients typically present as neonates with failure to pass meconium in the immediate postnatal period followed by obstructive constipation. The major threats to life

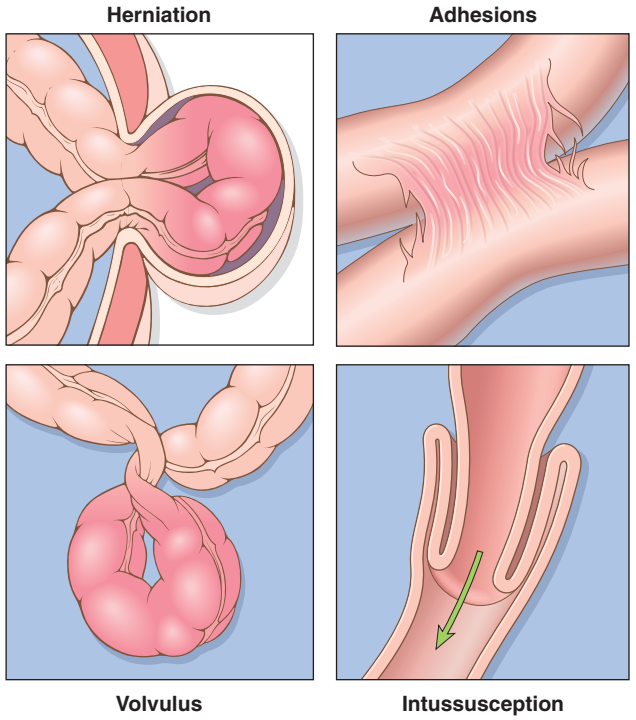


**Figure 14–18** Intestinal obstruction. The four major mechanical causes of intestinal obstruction are (1) herniation of a segment in the umbilical or inguinal regions, (2) adhesion between loops of intestine, (3) volvulus, and (4) intussusception.

are enterocolitis, fluid and electrolyte disturbances, perforation, and peritonitis. Surgical resection of the aganglionic segment with anastomosis of the normal colon to the rectum is effective, although it may take years for patients to attain normal bowel function and continence.

### PATHOGENESIS

The enteric neuronal plexus develops from neural crest cells that migrate into the bowel wall during embryogenesis. Hirschsprung disease, also known as **congenital aganglionic megacolon,** results when the normal migration of neural crest cells from cecum to rectum is disrupted. This produces a distal intestinal segment that lacks both the Meissner submucosal plexus and the Auerbach myenteric plexus ("aganglionosis"). Coordinated peristaltic contractions are absent and the subsequent functional obstruction results in dilation proximal to the affected segment. While the mechanisms underlying this defective neural crest cell migration are unknown, **heterozygous loss-of-function mutations in the receptor tyrosine kinase RET account for a majority of familial cases** and approximately 15% of sporadic cases. However, mutations also occur in other genes, only some of which have been identified, and modifying genes or environmental factors also play a role.

### MORPHOLOGY

Hirschsprung disease always affects the rectum, but the length of the additional involved segments varies. Most cases are limited to the rectum and sigmoid colon, but severe disease can involve the entire colon. The aganglionic region may have a grossly normal or contracted appearance, while the normally innervated proximal colon may undergo progressive dilation as a result of the distal obstruction (Fig. 14–19). Diagnosis of Hirschsprung disease requires demonstrating the absence of ganglion cells in the affected segment.

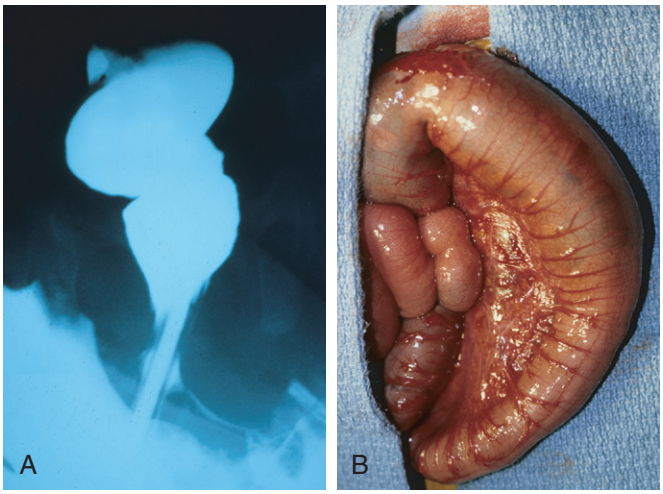


**Figure 14–19** Hirschsprung disease. **A,** Preoperative barium enema study showing constricted rectum (*bottom of the image*) and dilated sigmoid colon. Ganglion cells were absent in the rectum, but present in the sigmoid colon. **B,** Corresponding intraoperative appearance of the dilated sigmoid colon.
*(Courtesy of Dr. Aliya Husain, The University of Chicago, Chicago, Illinois.)*

## Abdominal Hernia

Any weakness or defect in the wall of the peritoneal cavity may permit protrusion of a serosa-lined pouch of peritoneum called a *hernia sac.* Acquired hernias most commonly occur anteriorly, through the inguinal and femoral canals or umbilicus, or at sites of surgical scars. These are of concern because of visceral protrusion (*external herniation*). This is particularly true of inguinal hernias, which tend to have narrow orifices and large sacs. Small bowel loops are herniated most often, but portions of omentum or large bowel also protrude, and any of these may become entrapped. Pressure at the neck of the pouch may impair venous drainage, leading to stasis and edema. These changes increase the bulk of the herniated loop, leading to permanent entrapment, or *incarceration,* and over time, arterial and venous compromise, or *strangulation,* can result in infarction.

### SUMMARY

#### Intestinal Obstruction

- *Hirschsprung disease* is the result of defective neural crest cell migration from cecum to rectum. It gives rise to functional obstruction.
- *Abdominal herniation* may occur through any weakness or defect in the wall of the peritoneal cavity, including inguinal and femoral canals, umbilicus, and sites of surgical scarring.

# VASCULAR DISORDERS OF BOWEL

The greater portion of the gastrointestinal tract is supplied by the celiac, superior mesenteric, and inferior mesenteric arteries. As they approach the intestinal wall, the superior and inferior mesenteric arteries fan out to form the mesenteric arcades. Interconnections between arcades, as well as collateral supplies from the proximal celiac and distal pudendal and iliac circulations, make it possible for the small intestine and colon to tolerate slowly progressive loss of the blood supply from one artery. By contrast, acute compromise of any major vessel can lead to infarction of several meters of intestine.

## Ischemic Bowel Disease

Ischemic damage to the bowel wall can range from *mucosal infarction,* extending no deeper than the muscularis mucosa; to *mural infarction* of mucosa and submucosa; to *transmural infarction* involving all three layers of the wall. While mucosal or mural infarctions often are secondary to acute or chronic *hypoperfusion,* transmural infarction is generally caused by acute vascular obstruction. Important causes of acute arterial obstruction include severe *atherosclerosis* (which is often prominent at the origin of mesenteric vessels), *aortic aneurysm, hypercoagulable states, oral contraceptive use,* and *embolization of cardiac vegetations or aortic atheromas.* Intestinal hypoperfusion can also be associated with *cardiac failure, shock, dehydration,* or *vasoconstrictive drugs.* Systemic *vasculitides,* such as polyarteritis nodosum, Henoch-Schönlein purpura, or Wegener granulomatosis,

also may damage intestinal arteries. Mesenteric venous thrombosis can also lead to ischemic disease, but is uncommon. Other causes include invasive neoplasms, cirrhosis, portal hypertension, trauma, or abdominal masses that compress the portal drainage.

## PATHOGENESIS

Intestinal responses to ischemia occur in two phases. The initial hypoxic injury occurs at the onset of vascular compromise and, although some damage occurs, intestinal epithelial cells are relatively resistant to transient hypoxia. The second phase, reperfusion injury, is initiated by restoration of the blood supply and associated with the greatest damage. In severe cases multiorgan failure may occur. While the underlying mechanisms of reperfusion injury are incompletely understood, they involve free radical production, neutrophil infiltration, and release of inflammatory mediators, such as complement proteins and cytokines (Chapter 10). **The severity of vascular compromise, time frame during which it develops, and vessels affected are the major variables that determine severity of ischemic bowel disease.** Two aspects of intestinal vascular anatomy also contribute to the distribution of ischemic damage:

- Intestinal segments at the end of their respective arterial supplies are particularly susceptible to ischemia. These **watershed zones** include the splenic flexure, where the superior and inferior mesenteric arterial circulations terminate, and, to a lesser extent, the sigmoid colon and rectum where inferior mesenteric, pudendal, and iliac arterial circulations end. Generalized hypotension or hypoxemia can therefore cause localized injury, and ischemic disease should be considered in the differential diagnosis for focal colitis of the splenic flexure or rectosigmoid colon.
- Intestinal capillaries run alongside the glands, from crypt to surface, before making a hairpin turn at the surface to empty into the postcapillary venules. This configuration allows oxygenated blood to supply crypts but leaves the surface epithelium vulnerable to ischemic injury. This anatomy protects the crypts, which contain the epithelial stem cells that are necessary to repopulate the surface. Thus, surface epithelial atrophy, or even necrosis with consequent sloughing, with normal or hyperproliferative crypts constitutes a morphologic signature of ischemic intestinal disease.

## MORPHOLOGY

Despite the increased susceptibility of watershed zones, **mucosal and mural infarction** may involve any level of the gut from stomach to anus. Disease frequently is segmental and patchy in distribution, and the mucosa is hemorrhagic and often ulcerated. The bowel wall is thickened by edema that may involve the mucosa or extend into the submucosa and muscularis propria. With severe disease, pathologic changes include extensive mucosal and submucosal hemorrhage and necrosis, but serosal hemorrhage and serositis generally are absent. Damage is more pronounced in acute arterial thrombosis and **transmural infarction.** Blood-tinged mucus or blood accumulates within the lumen. Coagulative necrosis of the muscularis propria occurs within 1 to 4 days and may be associated with purulent serositis and perforation.

In **mesenteric venous thrombosis,** arterial blood continues to flow for a time, resulting in a less abrupt transition from affected to normal bowel. However, propagation of the thrombus may lead to secondary involvement of the splanchnic bed. The ultimate result is similar to that produced by acute arterial obstruction, because impaired venous drainage eventually prevents entry of oxygenated arterial blood.

Microscopic examination of ischemic intestine demonstrates **atrophy or sloughing of surface epithelium** (Fig. 14–20, *A*). By contrast, crypts may be hyperproliferative. Inflammatory infiltrates initially are absent in acute ischemia, but neutrophils are recruited within hours of reperfusion. Chronic ischemia is accompanied by fibrous scarring of the lamina propria (Fig. 14–20, *B*) and, uncommonly, stricture formation. In acute phases of ischemic damage, bacterial superinfection and enterotoxin release may induce pseudomembrane formation that can resemble *Clostridium difficile*–associated pseudomembranous colitis (discussed later).

### Clinical Features

Ischemic bowel disease tends to occur in older persons with coexisting cardiac or vascular disease. Acute transmural infarction typically manifests with sudden, severe abdominal pain and tenderness, sometimes accompanied by nausea, vomiting, bloody diarrhea, or grossly melanotic stool. This presentation may progress to shock and vascular collapse within hours as a result of blood loss. Peristaltic sounds diminish or disappear, and muscular spasm creates boardlike rigidity of the abdominal wall. Because these physical signs overlap with those of other abdominal emergencies, including acute appendicitis, perforated ulcer, and acute cholecystitis, the diagnosis of intestinal infarction may be delayed or missed, with disastrous consequences. As the mucosal barrier breaks down, bacteria enter the circulation and sepsis can develop; the mortality rate may exceed 50%.

The overall progression of ischemic enteritis depends on the underlying cause and severity of injury:

- *Mucosal and mural infarctions* by themselves may not be fatal. However, these may progress to more extensive,

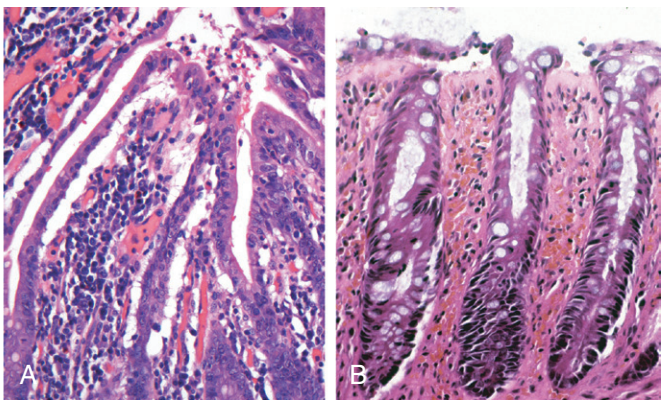


**Figure 14–20** Ischemia. **A,** Characteristic attenuated and partially detached villous epithelium in acute jejunal ischemia. Note the hyperchromatic nuclei of proliferating crypt cells. **B,** Chronic colonic ischemia with atrophic surface epithelium and fibrotic lamina propria.

transmural infarction if the vascular supply is not restored by correction of the insult or, in chronic disease, by development of adequate collateral supplies.

- *Chronic ischemia* may masquerade as inflammatory bowel disease, with episodes of bloody diarrhea interspersed with periods of healing.
- *CMV infection* causes ischemic gastrointestinal disease as a consequence of the viral tropism for and infection of endothelial cells. CMV infection can be a complication of immunosuppressive therapy (Chapter 8).
- *Radiation enterocolitis* occurs when the gastrointestinal tract is irradiated. In addition to epithelial damage, radiation-induced vascular injury may be significant and produce changes that are similar to ischemic disease. In addition to clinical history, the presence of bizarre "radiation fibroblasts" within the stroma may provide an important clue to the etiology. Acute radiation enteritis manifests as anorexia, abdominal cramps, and a malabsorptive diarrhea, while chronic radiation enteritis or colitis often is more indolent and may present as an inflammatory colitis.
- *Necrotizing enterocolitis* is an acute disorder of the small and large intestines that can result in transmural necrosis. It is the most common acquired gastrointestinal emergency of neonates, particularly those who are premature or of low birth weight, and occurs most often when oral feeding is initiated (Chapter 6). Ischemic injury generally is considered to contribute to its pathogenesis.
- *Angiodysplasia* is characterized by malformed submucosal and mucosal blood vessels. It occurs *most often in the cecum or right colon,* and usually presents after the sixth decade of life. Although the prevalence of angiodysplasia is less than 1% in the adult population, *it accounts for 20% of major episodes of lower intestinal bleeding; intestinal hemorrhage may be chronic and intermittent or acute and massive.* The pathogenesis is unknown.

## Hemorrhoids

*Hemorrhoids* affect about 5% of the general population. Simply put, hemorrhoids are dilated anal and perianal collateral vessels that connect the portal and caval venous systems to relieve elevated venous pressure within the hemorrhoid plexus. Thus, although hemorrhoids are both more common and less serious than esophageal varices, the pathogenesis of these lesions is similar. Common factors that predispose to hemorrhoids are constipation and associated straining, which increase intra-abdominal and venous pressures, venous stasis of pregnancy, and portal hypertension.

### MORPHOLOGY

Collateral vessels within the inferior hemorrhoidal plexus are located below the anorectal line and are termed **external hemorrhoids,** while those that result from dilation of the superior hemorrhoidal plexus within the distal rectum are referred to as **internal hemorrhoids.** On histologic examination, hemorrhoids consist of thin-walled, dilated, submucosal vessels that protrude beneath the anal or rectal mucosa. In their exposed position, they are subject to trauma and tend to become inflamed, thrombosed, and, in the course of time, recanalized. Superficial ulceration may occur.

### Clinical Features

Hemorrhoids often manifest with pain and rectal bleeding, particularly bright red blood seen on toilet tissue. Except in pregnant women, hemorrhoids are rarely encountered in persons younger than 30 years of age. Hemorrhoids also may develop as a result of portal hypertension, where the implications are more ominous. Hemorrhoidal bleeding generally is not a medical emergency; treatment options include sclerotherapy, rubber band ligation, and infrared coagulation. In severe cases, hemorrhoids may be removed surgically by *hemorrhoidectomy.*

### SUMMARY

#### Vascular Disorders of Bowel

- Intestinal ischemia can occur as a result of either *arterial or venous obstruction.*
- *Ischemic bowel disease* resulting from hypoperfusion is most common at the splenic flexure, sigmoid colon, and rectum; these are *watershed zones* where two arterial circulations terminate.
- *Systemic vasculitides and infectious diseases* (e.g., CMV infection) can cause vascular disease that is not confined to the gastrointestinal tract.
- *Angiodysplasia* is a common cause of major lower gastrointestinal bleeding in the elderly.
- *Hemorrhoids* are collateral vessels that form to allow resolution of venous hypertension.

# DIARRHEAL DISEASE

## Malabsorptive Diarrhea

Diarrhea is a common symptom of many intestinal diseases, including those due to infection, inflammation, ischemia, malabsorption, and nutritional deficiency. This section focuses primarily on *malabsorption,* which manifests most commonly as *chronic diarrhea* and is characterized by defective absorption of fats, fat- and water-soluble vitamins, proteins, carbohydrates, electrolytes and minerals, and water. Other disorders associated with *secretory* and *exudative* types of diarrhea (e.g., cholera and inflammatory bowel disease, respectively) are addressed in separate sections.

Chronic malabsorption causes weight loss, anorexia, abdominal distention, borborygmi, and muscle wasting. A hallmark of malabsorption is *steatorrhea,* characterized by excessive fecal fat and bulky, frothy, greasy, yellow or clay-colored stools. *The chronic malabsorptive disorders most commonly encountered in the United States are pancreatic insufficiency, celiac disease, and Crohn disease.* Intestinal graft-versus-host disease is an important cause of both

malabsorption and diarrhea after allogeneic hematopoietic stem cell transplantation. Environmental enteropathy (previously known as tropical sprue) is pervasive in some communities within developing countries.

*Diarrhea* is defined as an increase in stool mass, frequency, or fluidity, typically to volumes greater than 200 mL per day. In severe cases stool volume can exceed 14 L per day and, without fluid resuscitation, result in death. Painful, bloody, small-volume diarrhea is known as *dysentery.* Diarrhea can be classified into four major categories:

- *Secretory diarrhea* is characterized by isotonic stool and persists during fasting.
- *Osmotic diarrhea,* such as that occurring with lactase deficiency, is due to osmotic forces exerted by unabsorbed luminal solutes. The diarrheal fluid is more than 50 mOsm more concentrated than plasma, and the condition abates with fasting.
- *Malabsorptive diarrhea* caused by inadequate nutrient absorption is associated with steatorrhea and is relieved by fasting.
- *Exudative diarrhea* is due to inflammatory disease and characterized by purulent, bloody stools that continue during fasting.

Malabsorption results from disturbance in at least one of the four phases of nutrient absorption: (1) *intraluminal digestion,* in which proteins, carbohydrates, and fats are broken down into absorbable forms; (2) *terminal digestion,* which involves the hydrolysis of carbohydrates and peptides by disaccharidases and peptidases, respectively, in the brush border of the small intestinal mucosa; (3) *transepithelial transport,* in which nutrients, fluid, and electrolytes are transported across and processed within the small intestinal epithelium; and (4) *lymphatic transport* of absorbed lipids.

In many malabsorptive disorders, a defect in one of these processes predominates, but more than one usually contributes (Table 14–3). As a result, malabsorption syndromes resemble each other more than they differ. Symptoms and signs include *diarrhea* (from nutrient malabsorption and excessive intestinal secretion), *flatus, abdominal pain,* and *weight loss.* Inadequate absorption of vitamins and minerals can result in anemia and mucositis due to pyridoxine, folate, or vitamin $B_{12}$ deficiency; bleeding due to vitamin K deficiency; osteopenia and tetany due to calcium, magnesium, or vitamin D deficiency; or neuropathy due to vitamin A or $B_{12}$ deficiency. A variety of endocrine and skin disturbances also may occur.

### Cystic Fibrosis

Cystic fibrosis is discussed in greater detail elsewhere (Chapter 6). Only the malabsorption associated with cystic fibrosis is considered here. Owing to the absence of the epithelial cystic fibrosis transmembrane conductance regulator (CFTR), persons with cystic fibrosis have defects in intestinal and pancreatic ductal chloride ion secretion. This abnormality leads to interference with bicarbonate, sodium, and water secretion, ultimately resulting in defective luminal hydration. This failure of hydration can result in meconium ileus, which is present in up to 10% of newborns with cystic fibrosis. In the pancreas, intraductal concretions can begin to form in utero. This leads to obstruction, low-grade chronic autodigestion of the pancreas, and eventual *exocrine pancreatic insufficiency in more than 80% of patients.* The result is failure of the intraluminal phase of nutrient absorption, which can be effectively treated in most patients with oral enzyme supplementation.

### Celiac Disease

*Celiac disease,* also known as *celiac sprue* or *gluten-sensitive enteropathy,* is an immune-mediated enteropathy triggered by the ingestion of gluten-containing cereals, such as wheat, rye, or barley, in genetically predisposed persons. In countries whose populations consist predominantly of white people of European ancestry, celiac disease is a common disorder, with an estimated prevalence of 0.5%

**Table 14–3** Defects in Malabsorptive and Diarrheal Disease

| Disease | Intraluminal Digestion | Terminal Digestion | Transepithelial Transport | Lymphatic Transport |
|---|---|---|---|---|
| Celiac disease | | + | + | |
| Tropical sprue | | + | + | |
| Chronic pancreatitis | + | | | |
| Cystic fibrosis | + | | | |
| Primary bile acid malabsorption | + | | + | |
| Carcinoid syndrome | | | + | |
| Autoimmune enteropathy | | + | + | |
| Disaccharidase deficiency | | + | | |
| Whipple disease | | | | + |
| Abetalipoproteinemia | | | + | |
| Viral gastroenteritis | | + | + | |
| Bacterial gastroenteritis | | + | + | |
| Parasitic gastroenteritis | | + | + | |
| Inflammatory bowel disease | + | + | + | |

+ indicates that the process is abnormal in the disease indicated. Other processes are not affected.

to 1%. The primary treatment for celiac disease is a *gluten-free diet.* Despite the challenges of adhering to such a diet, it does result in symptomatic improvement for most patients.

## PATHOGENESIS

Celiac disease is an intestinal immune reaction to gluten, the major storage protein of wheat and similar grains. Gluten is digested by luminal and brush border enzymes into amino acids and peptides, including a 33–amino acid gliadin peptide that is resistant to degradation by gastric, pancreatic, and small intestinal proteases (Fig. 14–21). Gliadin is deamidated by tissue transglutaminase and is then able to interact with HLA-DQ2 or HLA-DQ8 on antigen-presenting cells and be presented to CD4+ T cells. These T cells produce cytokines that are likely to contribute to the tissue damage and characteristic mucosal histopathology. A characteristic B cell response follows: this includes production of anti-tissue transglutaminase, anti-deamidated gliadin, and, perhaps as a result of cross-reactive epitopes, anti-endomysial antibodies, which are diagnostically useful (see below). However, whether these antibodies contribute to celiac disease pathogenesis or are merely markers remains controversial. In addition to CD4+ cells, there is accumulation of CD8+ cells that are not specific for gliadin. These CD8+ cells may play an ancillary role in causing tissue damage. It is thought that deamidated gliadin peptides induce epithelial cells to produce the cytokine IL-15, which in turn triggers activation and proliferation of CD8+ intraepithelial lymphocytes that can express the MIC-A receptor NKG2D. These lymphocytes become cytotoxic and kill enterocytes that have been induced by various stressors to express surface MIC-A, an HLA class I–like protein that is recognized by NKG2D and, possibly, other epithelial proteins. The damage caused by these immune mechanisms may increase the movement of gliadin peptides across the epithelium, which are deamidated by tissue transglutaminase, thus perpetuating the cycle of disease.

While nearly all people eat grain and are exposed to gluten and gliadin, most do not develop celiac disease. Thus, host factors determine whether disease develops. Among these, HLA proteins seem to be critical, since almost all people with celiac disease carry the class II HLA-DQ2 or HLA-DQ8 alleles. However, the HLA locus accounts for less than half of the genetic component of celiac disease. Other genetic contributors are not fully defined. There is also an association of celiac disease with other immune diseases including type 1 diabetes, thyroiditis, and Sjögren syndrome.

## MORPHOLOGY

Biopsy specimens from the second portion of the duodenum or proximal jejunum, which are exposed to the highest concentrations of dietary gluten, generally are diagnostic in celiac disease. The histopathologic picture is characterized by increased numbers of intraepithelial CD8+ T lymphocytes, with **intraepithelial lymphocytosis, crypt hyperplasia, and villous atrophy** (Fig. 14–22). This loss of mucosal and brush border surface area probably accounts for the malabsorption. In addition, increased rates of epithelial turnover, reflected in increased crypt mitotic activity, may limit the ability of absorptive enterocytes to fully differentiate and contribute to defects in terminal digestion and transepithelial transport. Other features of fully developed celiac disease include increased numbers of plasma cells, mast cells, and eosinophils, especially within the upper part of the lamina propria. With increased serologic screening and early detection of disease-associated antibodies, it is now appreciated that an increase in the number of intraepithelial lymphocytes,

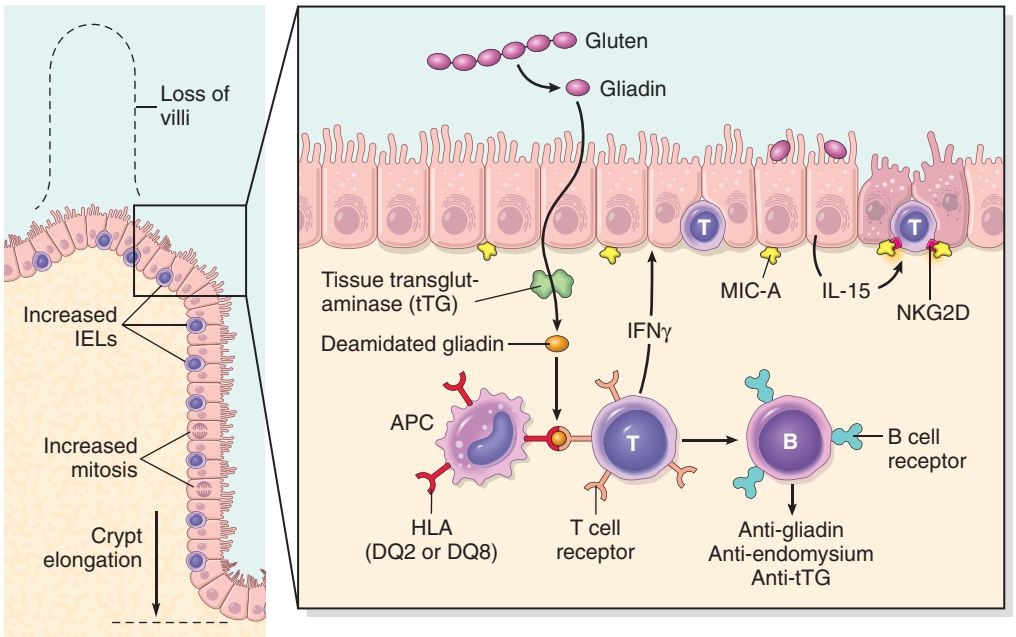


**Figure 14–21** *Left panel,* The morphologic alterations that may be present in celiac disease, including villous atrophy, increased numbers of intraepithelial lymphocytes (IELs), and epithelial proliferation with crypt elongation. *Right panel,* A model for the pathogenesis of celiac disease. Note that both innate and adaptive immune mechanisms are involved in the tissue responses to gliadin.

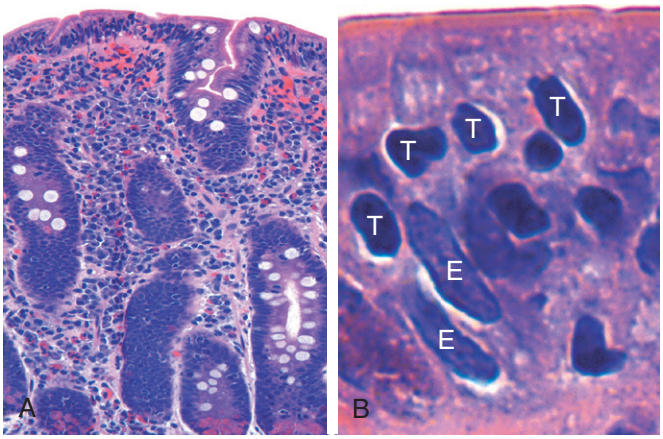


**Figure 14–22** Celiac disease. **A,** Advanced cases of celiac disease show complete loss of villi, or total villous atrophy. Note the dense plasma cell infiltrates in the lamina propria. **B,** Infiltration of the surface epithelium by T lymphocytes, which can be recognized by their densely stained nuclei (labeled *T*). Compare with elongated, pale-staining epithelial nuclei (labeled *E*).

particularly within the villus, is a marker of mild forms of celiac disease. Intraepithelial lymphocytosis and villous atrophy are not specific for celiac disease, however, and can be a feature of other disorders, including viral enteritis. The combination of histologic and serologic findings is most specific for diagnosis of celiac disease.

### Clinical Features

In adults, celiac disease manifests most commonly between the ages of 30 and 60. However, many cases escape clinical attention for extended periods because of atypical presentations. Some patients have *silent* celiac disease, defined as positive serology and villous atrophy without symptoms, or *latent* celiac disease, in which positive serology is not accompanied by villous atrophy. Symptomatic adult celiac disease is often associated with anemia (due to iron deficiency and, less commonly, $B_{12}$ and folate deficiency), diarrhea, bloating, and fatigue.

Pediatric celiac disease, which affects male and female children equally, may manifest with *classic symptoms,* typically between the ages of 6 and 24 months (after introduction of gluten to the diet) with irritability, abdominal distention, anorexia, diarrhea, failure to thrive, weight loss, or muscle wasting. Children with *nonclassic symptoms* tend to present at older ages with complaints of abdominal pain, nausea, vomiting, bloating, or constipation. A characteristic pruritic, blistering skin lesion, *dermatitis herpetiformis,* also is present in as many as 10% of patients, and the incidence of *lymphocytic gastritis* and *lymphocytic colitis* also is increased.

Noninvasive serologic tests generally are performed before biopsy. The most sensitive tests are the presence of IgA antibodies to tissue transglutaminase or IgA or IgG antibodies to deamidated gliadin. Antiendomysial antibodies are highly specific but less sensitive than other antibodies. The absence of HLA-DQ2 or HLA-DQ8 is useful for its high negative predictive value, but the presence of these common alleles is not helpful in confirming the diagnosis.

Patients with celiac disease exhibit a higher than normal rate of malignancy. The most common celiac disease–associated cancer is *enteropathy-associated T cell lymphoma,* an aggressive tumor of intraepithelial T lymphocytes. *Small intestinal adenocarcinoma* also is more frequent in persons with celiac disease. Thus, when symptoms such as abdominal pain, diarrhea, and weight loss develop despite a strict gluten-free diet, cancer or *refractory sprue,* in which the response to a gluten-free diet is lost, must be considered. It is, however, important to recognize that failure to adhere to a gluten-free diet is the most common cause of recurrent symptoms, and that most people with celiac disease do well with dietary restrictions and die of unrelated causes.

### *Environmental (Tropical) Enteropathy*

The term *environmental enteropathy* refers to a syndrome of stunted growth and impaired intestinal function that is common in developing countries, including many parts of sub-Saharan Africa, such as Gambia; aboriginal populations within northern Australia; and some groups within South America and Asia, such as residents of impoverished communities within Brazil, Guatemala, India, and Pakistan. The impact of environmental enteropathy, which was previously called *tropical enteropathy* or *tropical sprue,* cannot be overstated, as it is estimated to affect over 150 million children worldwide. Although malnutrition must contribute to the pathogenesis of this disorder, also referred to as *tropical enteropathy,* neither supplementary feeding nor vitamin and mineral supplementation are able to fully reverse the syndrome. Repeated bouts of diarrhea suffered within the first 2 or 3 years of life are most closely linked to environmental enteropathy. Many pathogens are endemic in these communities, but no single infectious agent has been linked to these diarrheal episodes. Intestinal biopsy specimens have been examined in only a small number of cases, and reported histologic features are more similar to those of severe celiac disease than to those of infectious enteritis. One hypothesis is that recurrent diarrhea establishes a cycle of mucosal injury, malnutrition, infection, and inflammation. However, this has not been established in part because accepted diagnostic criteria for environmental enteropathy are lacking, as the entity has been defined primarily by epidemiologic assessment of physical and cognitive growth and development.

### *Lactase (Disaccharidase) Deficiency*

The disaccharidases, including lactase, are located in the apical brush border membrane of the villous absorptive epithelial cells. Because the defect is biochemical, biopsies are generally unremarkable. Lactase deficiency is of two types:

- *Congenital lactase deficiency* is an autosomal recessive disorder caused by a mutation in the gene encoding lactase. The disease is rare and manifests as explosive diarrhea with watery, frothy stools and abdominal distention after milk ingestion. Symptoms abate when exposure to milk and milk products is terminated, thus removing the osmotically active but unabsorbable lactose from the lumen.
- *Acquired lactase deficiency* is caused by downregulation of lactase gene expression and is particularly common among Native Americans, African Americans, and

Chinese populations. Downregulation of lactase occurs in the gut after childhood, perhaps reflecting the fact that, before farming of dairy animals, lactase was unnecessary after children stopped drinking mother's milk. Onset of acquired lactase deficiency is sometimes associated with enteric viral or bacterial infections.

### *Abetalipoproteinemia*

*Abetalipoproteinemia* is an autosomal recessive disease characterized by an inability to secrete triglyceride-rich lipoproteins. Although it is rare, it is included here as an example of a transepithelial transport defect that leads to malabsorption. Mutation in the *microsomal triglyceride transfer protein* renders enterocytes unable to export lipoproteins and free fatty acids. As a result, monoglycerides and triglycerides accumulate within the epithelial cells. Lipid vacuoles in small intestinal epithelial cells are evident by light microscopy and can be highlighted by special stains, such as oil red O, particularly after a fatty meal. Abetalipoproteinemia manifests in infancy, and the clinical picture is dominated by failure to thrive, diarrhea, and steatorrhea. Failure to absorb essential fatty acids leads to deficiencies of fat-soluble vitamins, and lipid defects in plasma membranes often produce acanthocytic red cells (spur cells) in peripheral blood smears.

### *Irritable Bowel Syndrome*

*Irritable bowel syndrome* (IBS) is characterized by chronic and relapsing abdominal pain, bloating, and changes in bowel habits including diarrhea and constipation. The pathogenesis is poorly defined but involves psychologic stressors, diet, and abnormal gastrointestinal motility. Despite very real symptoms, no gross or microscopic abnormalities are found in most IBS patients. Thus, the diagnosis depends on clinical symptoms. IBS typically manifests between 20 and 40 years of age, and there is a significant female predominance. Variability in diagnostic criteria makes it difficult to establish the incidence, but *reported prevalence rates in developed countries typically are between 5% and 10%*. In patients with diarrhea, microscopic colitis, celiac disease, giardiasis, lactose intolerance, small bowel bacterial overgrowth, bile salt malabsorption, colon cancer, and inflammatory bowel disease must be excluded (although IBS is common in patients with inflammatory bowel disease). The prognosis for IBS is most closely related to symptom duration, with longer duration correlating with reduced likelihood of improvement.

### *Microscopic Colitis*

*Microscopic colitis* encompasses two entities, *collagenous colitis* and *lymphocytic colitis*. Both of these idiopathic diseases manifest with chronic, nonbloody, watery diarrhea without weight loss. Findings on radiologic and endoscopic studies typically are normal. Collagenous colitis, which occurs primarily in middle-aged and older women, is characterized by the presence of a dense subepithelial collagen layer, increased numbers of intraepithelial lymphocytes, and a mixed inflammatory infiltrate within the lamina propria. Lymphocytic colitis is histologically similar, but the subepithelial collagen layer is of normal thickness and the increase in intraepithelial lymphocytes may be greater, frequently exceeding one T lymphocyte per five colonocytes. Lymphocytic colitis is associated with celiac and autoimmune diseases, including thyroiditis, arthritis, and autoimmune or lymphocytic gastritis.

### *Graft-Versus-Host Disease*

Graft-versus-host disease occurs after allogeneic hematopoietic stem cell transplantation. The small bowel and colon are involved in most cases. Although graft-versus-host disease is secondary to the targeting of antigens on the recipient's epithelial cells by donor T cells, the lymphocytic infiltrate in the lamina propria is typically sparse. Epithelial apoptosis, particularly of crypt cells, is the most common histologic finding. Intestinal graft-versus-host disease often manifests as a watery diarrhea.

## SUMMARY

### Malabsorptive Diarrhea

- Diarrhea can be characterized as *secretory*, *osmotic*, *malabsorptive*, or *exudative*.
- The malabsorption associated with cystic fibrosis is the result of *pancreatic insufficiency* (i.e., inadequate pancreatic digestive enzymes) and *deficient luminal breakdown* of nutrients.
- *Celiac disease* is an immune-mediated enteropathy triggered by the ingestion of gluten-containing grains. The malabsorptive diarrhea in celiac disease is due to *loss of brush border surface area* and, possibly, deficient enterocyte maturation as a result of immune-mediated epithelial damage.
- *Lactase deficiency* causes an *osmotic diarrhea* owing to the inability to break down or absorb lactose.
- *Irritable bowel syndrome* (IBS) is characterized by chronic, relapsing abdominal pain, bloating, and changes in bowel habits. The pathogenesis is poorly defined.
- The two forms of microscopic colitis, *collagenous colitis* and *lymphocytic colitis*, both cause chronic watery diarrhea. The intestines are grossly normal, and the diseases are identified by their characteristic histologic features.

## Infectious Enterocolitis

Enterocolitis can manifest with a broad range of signs and symptoms including diarrhea, abdominal pain, urgency, perianal discomfort, incontinence, and hemorrhage. This global problem is responsible for more than 12,000 deaths per day among children in developing countries and half of all deaths before age 5 worldwide. Bacterial infections, such as enterotoxigenic *Escherichia coli*, frequently are responsible, but the most common pathogens vary with age, nutrition, and host immune status, as well as environmental influences (Table 14–4). For example, epidemics of cholera are common in areas with poor sanitation, as a result of inadequate public health measures, or as a consequence of natural disasters (e.g., the Haiti earthquake of 2010) or war. Pediatric infectious diarrhea, which may result in severe dehydration and metabolic acidosis, commonly is caused by enteric viruses. A summary of the epidemiology and clinical features of selected causes of bacterial enterocolitis is presented in

**Table 14–4** Features of Bacterial Enterocolitides

| Infection Type | Geography | Reservoir | Transmission | Epidemiology | Affected GI Sites | Symptoms | Complications |
|---|---|---|---|---|---|---|---|
| Cholera | India, Africa | Shellfish | Fecal-oral, water | Sporadic, endemic, epidemic | Small intestine | Severe watery diarrhea | Dehydration, electrolyte imbalances |
| *Campylobacter* spp. | Developed countries | Chickens, sheep, pigs, cattle | Poultry, milk, other foods | Sporadic; children, travelers | Colon | Watery or bloody diarrhea | Arthritis, Guillain-Barré syndrome |
| Shigellosis | Developing countries | Humans | Fecal-oral, food, water | Children | Left colon, ileum | Bloody diarrhea | Reactive arthritis hemolytic-uremic syndrome |
| Salmonellosis | Worldwide | Poultry, farm animals, reptiles | Meat, poultry, eggs, milk | Children, elderly | Colon and small intestine | Watery or bloody diarrhea | Sepsis |
| Enteric (typhoid) fever | India, Mexico, Philippines | Humans | Fecal-oral, water | Children. adolescents, travelers | Small intestine | Bloody diarrhea, fever | Chronic infection, carrier state, encephalopathy, myocarditis |
| *Yersinia* spp. | Northern and central Europe | Pigs | Pork, milk, water | Clustered cases | Ileum, appendix, right colon | Abdominal pain, fever, diarrhea | Autoimmune, e.g., reactive arthritis |
| *Escherichia coli* | | | | | | | |
| Enterotoxigenic (ETEC) | Developing countries | Unknown | Food, fecal-oral | Infants, adolescents, travelers | Small intestine | Severe watery diarrhea | Dehydration, electrolyte imbalances |
| Enterohemorrhagic (EHEC) | Worldwide | Widespread, includes cattle | Beef, milk, produce | Sporadic and epidemic | Colon | Bloody diarrhea | Hemolytic-uremic syndrome |
| Enteroinvasive (EIEC) | Developing countries | Unknown | Cheese, other foods, water | Young children | Colon | Bloody diarrhea | Unknown |
| Enteroaggregative (EAEC) | Worldwide | Unknown | Unknown | Children, adults, travelers | Colon | Nonbloody diarrhea, afebrile | Poorly defined |
| Pseudomembranous colitis (*C. difficile*) | Worldwide | Humans, hospitals | Antibiotics allow emergence | Immunosuppressed, antibiotic-treated | Colon | Watery diarrhea, fever | Relapse, toxic megacolon |
| Whipple disease | Rural > urban | Unknown | Unknown | Rare | Small intestine | Malabsorption | Arthritis, CNS disease |
| Mycobacterial infection | Worldwide | Unknown | Unknown | Immunosuppressed | Small intestine | Malabsorption, diarrhea, fever | Pneumonia, infection at other sites |

CNS, central nervous system; GI, gastrointestinal.

Table 14–4. Representative bacterial, viral, and parasitic enterocolitides are discussed below.

### *Cholera*

*Vibrio cholerae* organisms are comma-shaped, gram-negative bacteria that cause cholera, a disease that has been endemic in the Ganges Valley of India and Bangladesh for all of recorded history. *V. cholerae* is transmitted primarily by contaminated drinking water. However, it also can be present in food and causes rare cases of seafood-associated disease. There is a marked seasonal variation in most climates due to rapid growth of *Vibrio* bacteria at warm temperatures; the only animal reservoirs are shellfish and plankton. Relatively few *V. cholerae* serotypes are pathogenic, but other species of *Vibrio* also can cause disease.

#### PATHOGENESIS

Despite the severe diarrhea, *Vibrio* organisms are noninvasive and remain within the intestinal lumen. Flagellar proteins, which are involved in motility and attachment, are necessary for efficient bacterial colonization, and a secreted metalloproteinase that also has hemagglutinin activity is important for bacterial detachment and shedding in the stool. However, it is the **preformed enterotoxin,** cholera toxin, which causes disease. The toxin, which is composed of five B subunits that direct endocytosis and a single active A subunit, is delivered to the endoplasmic reticulum by **retrograde transport.** A fragment of the A subunit is transported from the endoplasmic reticulum lumen into the cytosol, where it interacts with cytosolic ADP ribosylation factors to ribosylate and activate the G protein $G_{s\alpha}$. This stimulates adenylate cyclase and the resulting increases in intracellular cyclic adenosine monophosphate (cAMP) open the cystic fibrosis transmembrane conductance regulator (CFTR), which releases chloride ions into the lumen. Sodium and bicarbonate absorption are also reduced. Accumulation of these ions creates an osmotic gradient that draws water into the lumen, leading to massive **secretory diarrhea.** Remarkably, mucosal biopsy specimens show only minimal morphologic alterations.

#### Clinical Features

Most exposed persons are asymptomatic or suffer only mild diarrhea. Those with severe disease have an abrupt onset of watery diarrhea and vomiting after an incubation period of 1 to 5 days. The rate of diarrheal stool production may reach 1 L per hour, leading to dehydration, hypotension, electrolyte imbalances, muscular cramping, anuria, shock, loss of consciousness, and death. Most deaths occur within the first 24 hours after presentation. Although the mortality rate for severe cholera is 50% to 70% without treatment, fluid replacement can save more than 99% of patients.

### Campylobacter *Enterocolitis*

*Campylobacter jejuni* is the most common bacterial enteric pathogen in developed countries and is an important cause of traveler's diarrhea. Most infections are associated with ingestion of improperly cooked chicken, but outbreaks also can be caused by unpasteurized milk or contaminated water.

#### PATHOGENESIS

The pathogenesis of *Campylobacter* infection remains poorly defined, but four major virulence properties contribute: motility, adherence, toxin production, and invasion. Flagella allow *Campylobacter* to be motile. This facilitates adherence and colonization, which are also necessary for mucosal invasion. Cytotoxins that cause epithelial damage and a cholera toxin–like enterotoxin are also released by some *C. jejuni* isolates. **Dysentery** generally is associated with invasion and only occurs with a small minority of *Campylobacter* strains. **Enteric fever** occurs when bacteria proliferate within the lamina propria and mesenteric lymph nodes.

*Campylobacter* infection can result in reactive arthritis, primarily in patients with HLA-B27. Other extraintestinal complications, including erythema nodosum and Guillain-Barré syndrome, a flaccid paralysis caused by autoimmune-induced inflammation of peripheral nerves, are not HLA-linked. Fortunately, Guillain-Barré syndrome develops in 0.1% or less of persons infected with *Campylobacter.*

#### MORPHOLOGY

***Campylobacter, Shigella, Salmonella,*** and many other bacterial infections, including ***Yersinia*** and ***E. coli,*** all induce a similar histopathology, termed **acute self-limited colitis,** and these pathogens cannot be reliably distinguished by tissue biopsy. Thus, specific diagnosis is primarily by stool culture. The histology of acute self-limited colitis includes prominent lamina propria and intraepithelial neutrophil infiltrates (Fig. 14–23, *A*); **cryptitis** (neutrophil infiltration of the crypts) and **crypt abscesses** (crypts with accumulations of luminal neutrophils) also may be present. The preservation of crypt architecture in most cases of acute self-limited colitis is helpful in distinguishing these infections from inflammatory bowel disease (Fig. 14–23, *B*).

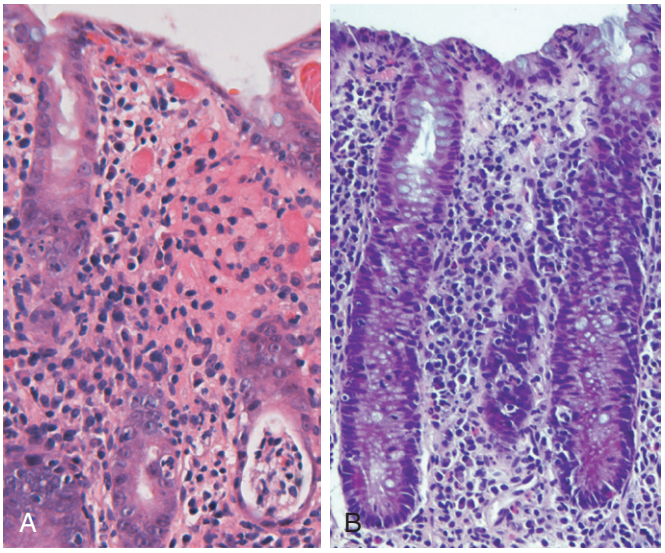


**Figure 14–23** Bacterial enterocolitis. **A,** *Campylobacter jejuni* infection produces acute, self-limited colitis. Neutrophils can be seen within surface and crypt epithelium and a crypt abscess is present at the *lower right.* **B,** Enteroinvasive *Escherichia coli* infection is similar to other acute, self-limited colitides. Note the maintenance of normal crypt architecture and spacing, despite abundant intraepithelial neutrophils.

### Clinical Features

Ingestion of as few as 500 *C. jejuni* organisms can cause disease after an incubation period of up to 8 days. Watery diarrhea, either acute or with onset after an influenza-like prodrome, is the primary manifestation, and dysentery develops in 15% to 50% of patients. Patients may shed bacteria for 1 month or more after clinical resolution. The disease is self limited and therefore antibiotic therapy generally is not required. Diagnosis is primarily by stool culture since the histologic changes are not specific for *Campylobacter* colitis.

## *Shigellosis*

*Shigella* organisms are gram-negative bacilli that are unencapsulated, nonmotile, facultative anaerobes. Although humans are the only known reservoir, *Shigella* remains one of the most common causes of bloody diarrhea. It is estimated that 165 million cases occur worldwide each year. Shigellae are highly transmissible by the fecal-oral route or through ingestion of contaminated water and food; the *infective dose is fewer than 100 organisms* and each gram of stool contains as many as $10^9$ organisms during acute phases of the disease.

In the United States and Europe, children in day care centers, migrant workers, travelers to developing countries, and residents of nursing homes are most commonly affected. Most *Shigella*-associated infections and deaths occur in children younger than 5 years of age; in countries in which *Shigella* is endemic, it is responsible for approximately 10% of all cases of pediatric diarrheal disease and as many as 75% of diarrheal deaths.

### PATHOGENESIS

*Shigella* organisms are resistant to the harsh acidic environment of the stomach, which partially explains the very low infective dose. Once in the intestine, organisms are taken up by M (microfold) epithelial cells, which are specialized for sampling and uptake of luminal antigens. After intracellular proliferation, the bacteria escape into the lamina propria. These bacteria then infect small intestinal and colonic epithelial cells through the basolateral membranes, which express bacterial receptors. Alternatively, luminal shigellae can directly modulate epithelial tight junctions to expose basolateral bacterial receptors. The latter is partly mediated by virulence proteins, some of which are directly injected into the host cytoplasm by a type III secretion system. Some *Shigella dysenteriae* serotypes also release the Shiga toxin Stx, which inhibits eukaryotic protein synthesis and causes host cell death.

### MORPHOLOGY

*Shigella* infections are most prominent in the left colon, but the ileum may also be involved, perhaps reflecting the abundance of M cells in the epithelium overlying the Peyer's patches. The histologic appearance in early cases is similar to that in other acute self-limited colitides. In more severe cases, the mucosa is hemorrhagic and ulcerated, and pseudomembranes may be present. Perhaps because of the tropism for M cells, aphthous-appearing ulcers similar to those seen in Crohn disease also may occur. The potential for confusion with chronic inflammatory bowel disease is substantial, particularly if there is distortion of crypt architecture. Confirmation of *Shigella* infection requires stool culture.

### Clinical Features

After an incubation period of 1 to 7 days, *Shigella* causes self-limited disease characterized by about 6 days of diarrhea, fever, and abdominal pain. The initially watery diarrhea progresses to a dysenteric phase in approximately 50% of patients, and constitutional symptoms can persist for as long as 1 month. A subacute presentation also can develop in a minority of adults. Antibiotic treatment shortens the clinical course and reduces the duration over which organisms are shed in the stool, but antidiarrheal medications are contraindicated because they can prolong symptoms by delaying bacterial clearance.

Complications of *Shigella* infection are uncommon and include *reactive arthritis,* a triad of sterile arthritis, urethritis, and conjunctivitis that preferentially affects HLA-B27–positive men between 20 and 40 years of age. Hemolytic uremic syndrome, which typically is associated with *enterohemorrhagic Escherichia coli* (EHEC), also may occur after infection with shigellae that secrete Shiga toxin.

## Escherichia coli

*Escherichia coli* are gram-negative bacilli that colonize the healthy GI tract; most are nonpathogenic, but a subset cause human disease. The latter are classified according to morphology, mechanism of pathogenesis, and in vitro behavior (Table 14–4). Here we summarize their pathogenic mechanisms:

- **Enterotoxigenic *E. coli* (ETEC) organisms** are the principal cause of traveler's diarrhea, and are spread by the fecal-oral route. They express a heat labile toxin (LT) that is similar to cholera toxin and a heat-stable toxin (ST) that increases intracellular cGMP with effects similar to the cAMP elevations caused by LT.
- **Enterohemorrhagic *E. coli* (EHEC) organisms** are categorized as O157:H7 and non-O157:H7 serotypes. Outbreaks of *E. coli* O157:H7 in developed countries have been associated with the consumption of inadequately cooked ground beef, milk, and vegetables. Both O157:H7 and non-O157:H7 serotypes produce Shiga-like toxins and can cause dysentery. They can also give rise to hemolytic-uremic syndrome (Chapter 13).
- **Enteroinvasive *E. coli* (EIEC) organisms** resemble *Shigella* bacteriologically but do not produce toxins. They invade the gut epithelial cells and produce a bloody diarrhea.
- **Enteroaggregative *E. coli* (EAEC) organisms** attach to enterocytes by adherence fimbriae. Although they produce LT and Shiga-like toxins, histologic damage is minimal.

## *Salmonellosis*

*Salmonella* species, which are members of the Enterobacteriaceae family of gram-negative bacilli, are divided into

*Salmonella typhi,* the causative agent of typhoid fever (discussed in the next section) and nontyphoid *Salmonella* strains that cause gastroenteritis. Nontyphoid *Salmonella* infection usually is due to *Salmonella enteritidis*; more than 1 million cases occur each year in the United States, which result in 2000 deaths; the prevalence is even greater in many other countries. Infection is most common in young children and elderly persons, with peak incidence in summer and fall. Transmission usually is through contaminated food, particularly raw or undercooked meat, poultry, eggs, and milk.

## PATHOGENESIS

Very few viable *Salmonella* organisms are necessary to cause infection, and the absence of gastric acid, as in persons with atrophic gastritis or those on acid-suppressive therapy, further reduces the required inoculum. Salmonellae possess **virulence genes that encode a type III secretion system** capable of transferring bacterial proteins into M cells and enterocytes. The transferred proteins activate host cell Rho GTPases, thereby triggering actin rearrangement and bacterial uptake into phagosomes where the bacteria can grow. Salmonellae also secrete a molecule that induces epithelial release of a chemoattractant eicosanoid that draws neutrophils into the lumen and potentiates mucosal damage. Stool cultures are essential for diagnosis.

### *Typhoid Fever*

Typhoid fever, also referred to as enteric fever, is caused by *Salmonella typhi* and *Salmonella paratyphi*. It affects up to 30 million individuals worldwide each year. Infection by *S. typhi* is more common in endemic areas, where children and adolescents are most often affected. By contrast, *S. paratyphi* predominates in travelers and those living in developed countries. Humans are the sole reservoir for *S. typhi* and *S. paratyphi* and transmission occurs from person to person or via contaminated food or water. Gallbladder colonization may be associated with gallstones and a chronic carrier state. Acute infection is associated with anorexia, abdominal pain, bloating, nausea, vomiting, and bloody diarrhea followed by a short asymptomatic phase that gives way to bacteremia and fever with flu-like symptoms. It is during this phase that detection of organisms by blood culture may prompt antibiotic treatment and prevent further disease progression. Without such treatment, the febrile phase is followed by up to 2 weeks of sustained high fevers with abdominal tenderness that may mimic appendicitis. *Rose spots*, small erythematous maculopapular lesions, are seen on the chest and abdomen. Systemic dissemination may cause *extraintestinal complications* including encephalopathy, meningitis, seizures, endocarditis, myocarditis, pneumonia, and cholecystitis. Patients with sickle cell disease are particularly susceptible to *Salmonella* osteomyelitis.

Like *S. enteritidis*, *S. typhi* and *S. paratyphi* are taken up by M cells and then engulfed by mononuclear cells in the underlying lymphoid tissue. Thus, infection causes Peyer's patches in the terminal ileum to enlarge into plateau-like elevations up to 8 cm in diameter. Mucosal shedding creates oval ulcers oriented along the long axis of the ileum. However, unlike *S. enteritidis*, *S. typhi* and *S. paratyphi* can disseminate via lymphatic and blood vessels. This causes reactive hyperplasia of draining lymph nodes, in which bacteria-containing phagocytes accumulate. In addition, the spleen is enlarged and soft with pale red pulp, obliterated follicular markings, and prominent phagocyte hyperplasia. Randomly scattered small foci of parenchymal necrosis with macrophage aggregates, termed *typhoid nodules*, are also present in the liver, bone marrow, and lymph nodes.

### *Pseudomembranous Colitis*

Pseudomembranous colitis, generally caused by *Clostridium difficile,* is also known as antibiotic-associated colitis or antibiotic-associated diarrhea. The latter terms apply to diarrhea developing during or after a course of antibiotic therapy and may be due to *C. difficile* as well as *Salmonella, C. perfringens* type A, or *S. aureus.* However, the latter two organisms produce enterotoxins and are common agents of food poisoning. They do not cause pseudomembranes. Disruption of the normal colonic microbiota by antibiotics allows *C. difficile* overgrowth. Toxins released by *C. difficile* cause the ribosylation of small GTPases, such as Rho, and lead to disruption of the epithelial cytoskeleton, tight junction barrier loss, cytokine release, and apoptosis.

## MORPHOLOGY

Fully developed *C. difficile*–associated colitis is accompanied by formation of **pseudomembranes** (Fig. 14–24, *A*), made up of an adherent layer of inflammatory cells and debris at sites of colonic mucosal injury. The surface epithelium is denuded, and the superficial lamina propria contains a dense infiltrate of neutrophils and occasional fibrin thrombi within capillaries. Damaged crypts are distended by a mucopurulent exudate that "erupts" to the surface in a fashion reminiscent of a volcano (Fig. 14–24, *B*).

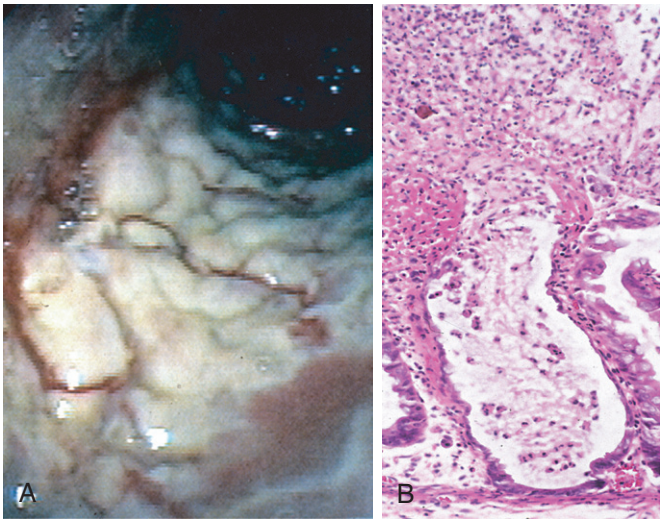


**Figure 14–24** *Clostridium difficile* colitis. **A,** The colon is coated by tan pseudomembranes composed of neutrophils, dead epithelial cells, and inflammatory debris (endoscopic view). **B,** Typical pattern of neutrophils emanating from a crypt is reminiscent of a volcanic eruption.

Clinical Features

In addition to antibiotic exposure, risk factors for *C. difficile*–associated colitis include advanced age, hospitalization, and immunosuppression. The organism is particularly prevalent in hospitals; as many as 20% of hospitalized adults are colonized with *C. difficile* (a rate 10 times higher than in the general population), but most colonized patients are free of disease. Persons with *C. difficile*–associated colitis present with fever, leukocytosis, abdominal pain, cramps, hypoalbuminemia, watery diarrhea, and dehydration. Fecal leukocytes and occult blood may be present, but grossly bloody diarrhea is rare. Diagnosis of *C. difficile*–associated colitis usually is accomplished by detection of *C. difficile* toxin, rather than culture, and is supported by the characteristic histopathologic findings. Regimens of metronidazole or vancomycin are generally effective treatments, but antibiotic-resistant and hypervirulent *C. difficile* strains are increasingly common, and the infection may recur in at-risk patients.

### *Norovirus*

Norovirus, previously known as Norwalk-like virus, is a common agent of nonbacterial infectious gastroenteritis. Norovirus causes approximately half of all gastroenteritis outbreaks worldwide and is a common cause of sporadic gastroenteritis in developed countries. Local outbreaks usually are related to contaminated food or water, but person-to-person transmission underlies most sporadic cases. Infections spread easily within schools, hospitals, and nursing homes and, most recently, on cruise ships. After a short incubation period, affected persons develop nausea, vomiting, watery diarrhea, and abdominal pain. Biopsy morphology is nonspecific. The disease is self-limited.

### *Rotavirus*

The encapsulated rotavirus infects 140 million people and causes 1 million deaths each year, making rotavirus *the most common cause of severe childhood diarrhea and diarrhea-related deaths worldwide.* Children between 6 and 24 months of age are most vulnerable. Protection in the first 6 months of life is probably due to the presence of antibodies to rotavirus in breast milk, while protection beyond 2 years is due to immunity that develops after the first infection. Outbreaks in hospitals and day care centers are common, and infection spreads easily; the estimated minimal infective inoculum is only 10 viral particles. *Rotavirus selectively infects and destroys mature (absorptive) enterocytes in the small intestine, and the villus surface is repopulated by immature secretory cells.* This change in functional capacity results in loss of absorptive function and net secretion of water and electrolytes that is compounded by an osmotic diarrhea from incompletely absorbed nutrients. Like norovirus, rotavirus produces clinically apparent infection after a short incubation period, manifested by vomiting and watery diarrhea for several days. Vaccines are now available, and their use is beginning to change the epidemiology of rotavirus infection. For unknown reasons, oral rotavirus vaccines have been less effective in developing countries where they are most needed.

### *Parasitic Disease*

Although viruses and bacteria are the predominant enteric pathogens in the United States, parasitic disease and protozoal infections affect over half of the world's population on a chronic or recurrent basis. The small intestine can harbor as many as 20 species of parasites, including nematodes, such as the roundworms *Ascaris* and *Strongyloides*; hookworms and pinworms; cestodes, including flatworms and tapeworms; trematodes, or flukes; and protozoa.

- *Ascaris lumbricoides.* This nematode infects more than 1 billion people worldwide as a result of human fecal-oral contamination. Ingested eggs hatch in the intestine and larvae penetrate the intestinal mucosa. From here the larvae migrate via the splanchnic circulation to the liver, creating hepatic abscesses, and then through the systemic circulation to the lung, where they can cause *Ascaris* pneumonitis. In the latter case, larvae migrate up the trachea, are swallowed, and arrive again in the intestine to mature into adult worms.
- *Strongyloides.* The larvae of *Strongyloides* live in fecally contaminated ground soil and can penetrate unbroken skin. They migrate through the lungs to the trachea from where they are swallowed and then mature into adult worms in the intestines. Unlike other intestinal worms, which require an ovum or larval stage outside the human, the eggs of *Strongyloides* can hatch within the intestine and release larvae that penetrate the mucosa, creating a vicious cycle referred to as autoinfection. Hence, *Strongyloides* infection can persist for life, and immunosuppressed individuals can develop overwhelming infections.
- *Necator americanus* and *Ancylostoma duodenale.* These hookworms infect 1 billion people worldwide and cause significant morbidity. Infection is initiated by larval penetration through the skin. After further development in the lungs, the larvae migrate up the trachea and are swallowed. Once in the duodenum, the larvae mature and the adult worms attach to the mucosa, suck blood, and reproduce. Hookworms are the leading cause of iron deficiency anemia in the developing world.
- *Giardia lamblia.* This flagellated protozoan, also referred to as *Giardia duodenalis* or *Giardia intestinalis*, is responsible for the *most common pathogenic parasitic infection in humans* and is spread by fecally contaminated water or food. Infection may occur after ingestion of as few as 10 cysts. Because cysts are resistant to chlorine, *Giardia* organisms are endemic in unfiltered public and rural water supplies. In the acid environment of the stomach excystation occurs and trophozoites are released. Secretory IgA and mucosal IL-6 responses are important for clearance of *Giardia* infections, and immunosuppressed, agammaglobulinemic, or malnourished persons often are severely affected. *Giardia* evade immune clearance through continuous modification of the major surface antigen, variant surface protein, and can persist for months or years while causing intermittent symptoms. *Giardia* infection decreases the expression of brush border enzymes, including lactase, and causes microvillous damage and apoptosis of small intestinal epithelial cells. *Giardia* trophozoites are noninvasive and can be identified in duodenal biopsy specimens by their

characteristic pear shape. Giardiasis is clinically characterized by acute or chronic diarrhea and can result in malabsorption.

## SUMMARY

### Infectious Enterocolitis

- *Vibrio cholerae* secretes a pre-formed toxin that causes massive chloride secretion. Water follows the resulting osmotic gradient, leading to *secretory diarrhea.*
- *Campylobacter jejuni* is the most common bacterial enteric pathogen in developed countries and also causes traveler's diarrhea. Most isolates are noninvasive. *Salmonella* and *Shigella* spp. are invasive and associated with exudative bloody diarrhea (dysentery). *Salmonella* infection is a common cause of food poisoning. *S. typhi* can cause systemic disease (typhoid fever).
- Pseudomembranous colitis is often triggered by antibiotic therapy that disrupts the normal microbiota and allows *C. difficile* to colonize and grow. The organism releases toxins that disrupt epithelial function. The associated inflammatory response includes characteristic volcano-like eruptions of neutrophils from colonic crypts that spread to form mucopurulent pseudomembranes.
- *Rotavirus* is the most common cause of severe childhood diarrhea and diarrheal mortality worldwide. The diarrhea is secondary to loss of mature enterocytes, resulting in malabsorption as well as secretion.
- *Parasitic* and *protozoal* infections affect over half of the world's population on a chronic or recurrent basis.

# INFLAMMATORY INTESTINAL DISEASE

## Sigmoid Diverticulitis

In general, diverticular disease refers to acquired pseudodiverticular outpouchings of the colonic mucosa and submucosa. Such *colonic diverticula* are rare in persons younger than 30 years of age, but the prevalence approaches 50% in Western adult populations beyond the age of 60. Diverticula generally are multiple, and the condition is referred to as *diverticulosis.* This disease is much less common in Japan and nonindustrialized countries, probably because of dietary differences.

### PATHOGENESIS

Colonic diverticula tend to develop under conditions of elevated intraluminal pressure in the sigmoid colon. This is facilitated by the unique structure of the colonic muscularis propria, where nerves, arterial vasa recta, and their connective tissue sheaths penetrate the inner circular muscle coat to create discontinuities in the muscle wall. In other parts of the intestine, these gaps are reinforced by the external longitudinal layer of the muscularis propria, but in the colon, this muscle layer is discontinuous, being gathered into the three bands termed **taeniae coli.** High luminal pressures may be generated by exaggerated peristaltic contractions, with spasmodic sequestration of bowel segments that may be exacerbated by diets low in fiber, which reduce stool bulk.

### MORPHOLOGY

Anatomically, colonic diverticula are small, flask-like outpouchings, usually 0.5 to 1 cm in diameter, that occur in a regular distribution in between the taeniae coli (Fig. 14–25, *A*). They are most common in the sigmoid colon, but other regions of the colon may be affected in severe cases. Because diverticula are compressible, easily emptied of fecal contents, and often surrounded by the fat-containing **epiploic appendices** on the surface of the colon, they may be missed on casual inspection. Colonic diverticula have a thin wall composed of a flattened or atrophic mucosa, compressed submucosa, and attenuated muscularis propria—often, this last component is totally absent (Fig. 14–30, *B* and *C*). Hypertrophy of the circular layer of the muscularis propria in the affected bowel segment is common. Obstruction of diverticula leads to inflammatory changes, producing **diverticulitis** and peridiverticulitis. Because the wall of the diverticulum is supported only by the muscularis mucosa and a thin layer of subserosal adipose tissue, inflammation and increased pressure within an obstructed diverticulum can lead to **perforation.** With or without perforation, recurrent diverticulitis may cause segmental colitis, fibrotic thickening in and around the colonic wall, or stricture formation. Perforation can lead to formation of pericolonic abscesses, development of sinus tracts, and, occasionally, peritonitis.

#### Clinical Features

Most persons with diverticular disease remain asymptomatic throughout their lives. About 20% of those affected develop complaints including intermittent cramping, continuous lower abdominal discomfort, constipation, and

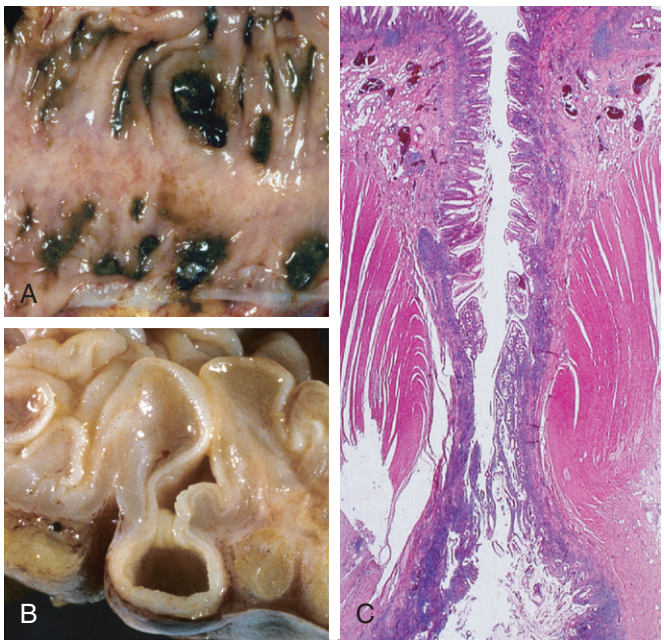


**Figure 14–25** Sigmoid diverticular disease. **A,** Stool-filled diverticula are regularly arranged. **B,** Cross-section showing the outpouching of mucosa beneath the muscularis propria. **C,** Low-power photomicrograph of a sigmoid diverticulum showing protrusion of the mucosa and submucosa through the muscularis propria.

diarrhea. Longitudinal studies have shown that while diverticula can regress early in their development they often become more numerous and larger over time. Whether a high-fiber diet prevents such progression or protects against diverticulitis is unclear. Even when diverticulitis occurs, it most often resolves spontaneously or after antibiotic treatment, and relatively few patients require surgical intervention.

## SUMMARY

### Sigmoid Diverticulitis

- *Diverticular disease* of the sigmoid colon is common in Western populations over the age of 60. Contributing etiologic factors include low-fiber diets, colonic spasm, and the unique anatomy of the colon. Inflammation of diverticula, *diverticulitis*, affects a minority of persons with *diverticulosis* but can cause perforation in its most severe form.

## Inflammatory Bowel Disease

*Inflammatory bowel disease* (IBD) is a chronic condition resulting from inappropriate mucosal immune activation. IBD encompasses two major entities, *Crohn disease* and *ulcerative colitis*. The distinction between ulcerative colitis and Crohn disease is based, in large part, on the distribution of affected sites and the morphologic expression of disease at those sites (Fig. 14–26; Table 14–5). *Ulcerative colitis is limited to the colon and rectum and extends only into the mucosa and submucosa.* By contrast, *Crohn disease, which also has been referred to as regional enteritis (because of frequent ileal involvement), may involve any area of the gastrointestinal tract and frequently is transmural.*

**Table 14–5** Features That Differ Between Crohn Disease and Ulcerative Colitis

| Feature | Crohn Disease | Ulcerative Colitis |
|---|---|---|
| **Macroscopic** | | |
| Bowel region affected | Ileum ± colon | Colon only |
| Rectal involvement | Sometimes | Always |
| Distribution | Skip lesions | Diffuse |
| Stricture | Yes | Rare |
| Bowel wall appearance | Thick | Thin |
| Inflammation | Transmural | Limited to mucosa and submucosa |
| Pseudopolyps | Moderate | Marked |
| Ulcers | Deep, knifelike | Superficial, broad-based |
| Lymphoid reaction | Marked | Moderate |
| Fibrosis | Marked | Mild to none |
| Serositis | Marked | No |
| Granulomas | Yes (~35%) | No |
| Fistulas/sinuses | Yes | No |
| **Clinical** | | |
| Perianal fistula | Yes (in colonic disease) | No |
| Fat/vitamin malabsorption | Yes | No |
| Malignant potential | With colonic involvement | Yes |
| Recurrence after surgery | Common | No |
| Toxic megacolon | No | Yes |

NOTE: Not all features may be present in a single case.

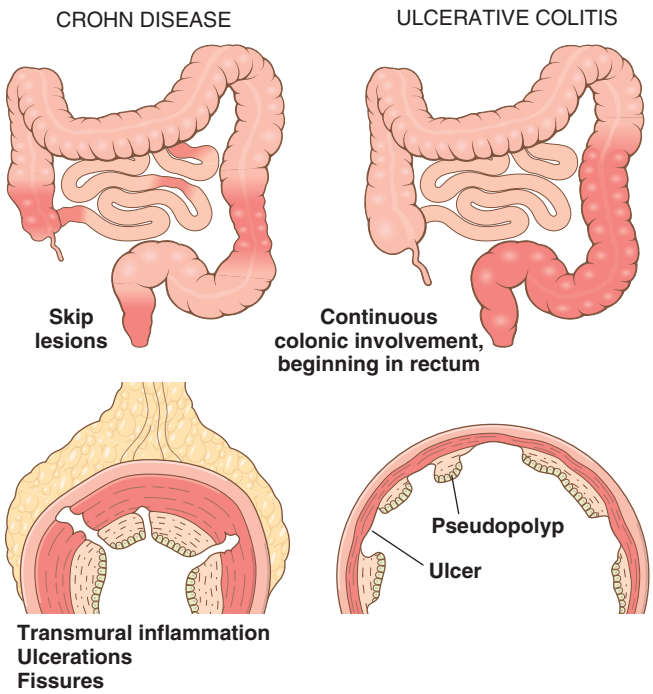


**Figure 14–26** Distribution of lesions in inflammatory bowel disease. The distinction between Crohn disease and ulcerative colitis is based primarily on morphology.

### Epidemiology

Both Crohn disease and ulcerative colitis are more common in females and frequently present during adolescence or in young adults. In Western industrialized nations, IBD is most common among whites and, in the United States, occurs 3 to 5 times more often among eastern European (Ashkenazi) Jews. This predilection is at least partly due to genetic factors, as discussed next under "Pathogenesis." The geographic distribution of IBD is highly variable, but it is most prevalent in North America, northern Europe, and Australia. IBD incidence worldwide is on the rise and is becoming more common in regions in which the prevalence was historically low. The *hygiene hypothesis* suggests that these changes in incidence are related to improved food storage conditions and decreased food contamination. Specifically, it proposes that a reduced frequency of enteric infections due to improved hygiene has resulted in inadequate development of regulatory processes that limit mucosal immune responses early in life. As a result, exposure of susceptible individuals to normally innocuous microbes later in life triggers inappropriate immune responses that may be self-sustaining due to loss of intestinal epithelial barrier function. Although many details are

lacking, some data, including some from animal models and the observation in humans that an episode of acute infectious gastroenteritis increases the risk of developing IBD, are consistent with the hygiene hypothesis.

## PATHOGENESIS

The cause(s) of IBD remains uncertain. However, **most investigators believe that IBD results from a combination of errant host interactions with intestinal microbiota, intestinal epithelial dysfunction, and aberrant mucosal immune responses.** This view is supported by epidemiologic, genetic, and clinical studies as well as data from laboratory models of IBD (Fig. 14–27).

- **Genetics.** Risk of disease is increased when there is an affected family member, and in Crohn disease, the concordance rate for monozygotic twins is approximately 50%. By contrast, concordance of monozygotic twins for ulcerative colitis is only 16%, suggesting that genetic factors are less dominant in this form of IBD.

  Molecular linkage analyses of affected families have identified *NOD2* (nucleotide oligomerization binding domain 2) as a susceptibility gene in Crohn disease. *NOD2* encodes a protein that binds to intracellular bacterial peptidoglycans and subsequently activates NF-κB. It has been postulated that disease-associated *NOD2* variants are less effective at recognizing and combating luminal microbes, which are then able to enter the lamina propria and trigger inflammatory reactions. Other data suggest that *NOD2* may regulate immune responses to prevent excessive activation by luminal microbes. Whatever the mechanism by which *NOD2* polymorphisms contribute to the pathogenesis of Crohn disease, it should be recognized that disease develops in less than 10% of persons carrying *NOD2* mutations, and *NOD2* mutations are uncommon in African and Asian patients with Crohn disease.

  In recent years, genome-wide association studies (GWAS) that assess single-nucleotide polymorphisms have been used to broaden the search for IBD-associated genes. The number of genes identified by GWAS is increasing rapidly (already numbering more than 30), but along with *NOD2*, two Crohn disease–related genes of particular interest are *ATG16L1* (autophagy-related 16–like-1), a part of the autophagosome pathway that is critical to host cell responses to intracellular bacteria, and *IRGM* (immunity-related GTPase M), which also is involved in autophagy and clearance of intracellular bacteria. *NOD2, ATG16L1,* and *IRGM* are expressed in multiple cell types, and their precise roles in the pathogenesis of Crohn disease have yet to be defined. Like *NOD2,* however, *ATG16L1* and *IRGM* are related to recognition and response to intracellular pathogens, supporting the hypothesis that inappropriate immune reactions to luminal bacteria are important in pathogenesis of IBD. None of these genes are associated with ulcerative colitis.
- **Mucosal immune responses.** Although the mechanisms by which mucosal immunity contributes to the pathogenesis of ulcerative colitis and Crohn disease are still being deciphered, immunosuppressive and immunomodulatory agents remain mainstays of IBD therapy. Polarization of helper T cells to the $T_H1$ type is well recognized in Crohn disease, and emerging data suggest that $T_H17$ T cells also contribute to disease pathogenesis. Consistent with this, certain polymorphisms of the IL-23 receptor confer protection from Crohn disease and ulcerative colitis (IL-23 is involved in the development and maintenance of $T_H17$ cells). The protection afforded by IL-23 receptor polymorphisms, together with the recognized effectiveness of anti-TNF therapy in some patients with ulcerative colitis, seems to support roles for $T_H1$ and $T_H17$ cells.

  Some data suggest that the pathogenic immune response in ulcerative colitis includes a significant $T_H2$ component. For example, mucosal IL-13 production is increased in ulcerative colitis, and, to a lesser degree, Crohn disease. However, the pathogenic role of $T_H2$ cells in IBD pathogenesis remains controversial. Polymorphisms of the *IL-10* gene as well as *IL-10R,* the IL10 receptor gene, have been linked to ulcerative colitis but not Crohn disease, further emphasizing the importance of immunoregulatory signals in IBD pathogenesis.

  Overall, it is likely that some combination of derangements that activate mucosal immunity and suppress immunoregulation contribute to the development of both ulcerative colitis and Crohn disease. The relative roles of the innate and adaptive arms of the immune system are the subject of ongoing intense scrutiny.
- **Epithelial defects.** A variety of epithelial defects have been described in Crohn disease, ulcerative colitis, or both. For example, defects in intestinal epithelial tight junction barrier function are present in patients with Crohn disease and a subset of their healthy first-degree relatives. This barrier dysfunction cosegregates with specific disease-associated *NOD2* polymorphisms, and experimental models demonstrate that barrier dysfunction can activate

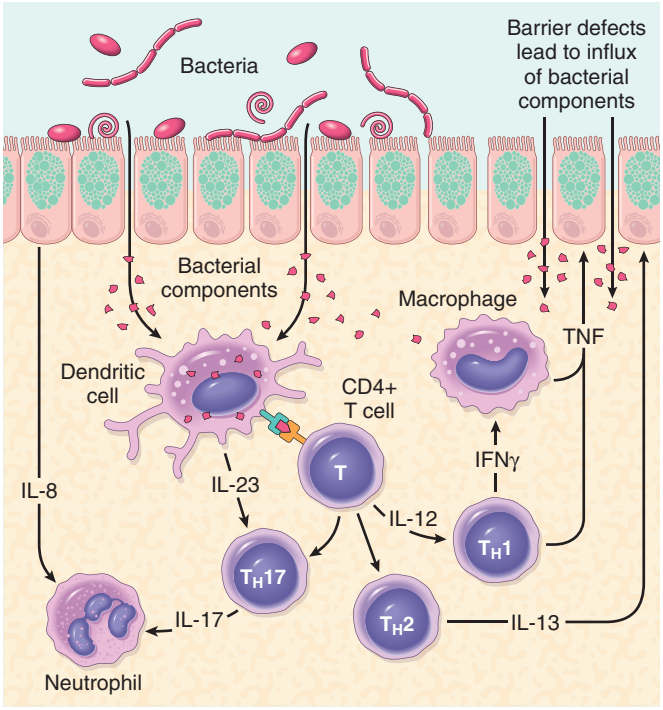


**Figure 14–27** A model of pathogenesis of inflammatory bowel disease (IBD). Aspects of both Crohn disease and ulcerative colitis are shown.

innate and adaptive mucosal immunity and sensitize subjects to disease. Interestingly, the Paneth cell granules, which contain antimicrobial peptides that can affect composition of the luminal microbiota, are abnormal in patients with Crohn disease carrying *ATG16L1* mutations, thus providing one potential mechanism where a defective feedback loop between the epithelium and microbiota could contribute to disease pathogenesis.

- **Microbiota.** The quantity of microbial organisms in the gastrointestinal lumen is enormous, amounting to as many as $10^{12}$ organisms/mL of fecal material in the colon (50% of fecal mass). This abundance means that, on a per cell level, we are only about 10% human. There is significant inter-individual variation in the composition of this microbial population, which is modified by diet and disease. Despite a growing body of data that suggest that intestinal microbiota contribute to IBD pathogenesis, their precise role remains to be defined. In keeping with this, some antibiotics, such as metronidazole, can be helpful in maintenance of remission in Crohn disease. Ongoing studies suggest that ill-defined mixtures containing probiotic, or beneficial, bacteria also may combat disease in experimental models, as well as in some patients with IBD, although the mechanisms responsible are not well understood.

One model that unifies the roles of intestinal microbiota, epithelial function, and mucosal immunity suggests a cycle by which transepithelial flux of luminal bacterial components activates innate and adaptive immune responses. In a genetically susceptible host, the subsequent release of TNF and other immune-mediated signals direct epithelia to increase tight junction permeability, which further increases the flux of luminal material. These events may establish a self-amplifying cycle in which a stimulus at any site may be sufficient to initiate IBD. Although this model is helpful in advancing the current understanding of IBD pathogenesis, a variety of factors are associated with disease for unknown reasons. For example, a single episode of appendicitis is associated with reduced risk of developing ulcerative colitis. Tobacco use also modifies the risk of IBD. Somewhat surprisingly, the risk of Crohn disease is increased by smoking, whereas that of ulcerative colitis is reduced.

### *Crohn Disease*

Crohn disease, also known as regional enteritis, may occur in any area of the gastrointestinal tract.

#### MORPHOLOGY

The most common sites involved by Crohn disease at presentation are the **terminal ileum, ileocecal valve,** and **cecum.** Disease is limited to the small intestine alone in about 40% of cases; the small intestine and the colon both are involved in 30% of patients; and the remainder of cases are characterized by colonic involvement only. The presence of multiple, separate, sharply delineated areas of disease, resulting in **skip lesions,** is characteristic of Crohn disease and may help in differentiation from ulcerative colitis. Strictures are common (Fig. 14–28, *A*).

The earliest lesion, the **aphthous ulcer,** may progress, and multiple lesions often coalesce into elongated, serpentine ulcers oriented along the axis of the bowel. Edema and loss of normal mucosal folds are common. Sparing of interspersed mucosa results in a coarsely textured, **cobblestone** appearance in which diseased tissue is depressed below the level of normal mucosa (Fig. 14–28, *B*). **Fissures** frequently develop between mucosal folds and may extend deeply to become sites of perforation or fistula tracts. The intestinal wall is thickened as a consequence of transmural edema, inflammation, submucosal fibrosis, and hypertrophy of the muscularis propria, all of which contribute to stricture formation. In cases with extensive transmural disease, mesenteric fat frequently extends around the serosal surface **(creeping fat)** (Fig. 14–28, *C*).

The microscopic features of active Crohn disease include abundant neutrophils that infiltrate and damage crypt epithelium. Clusters of neutrophils within a crypt are referred to as a **crypt abscess** and often are associated with crypt destruction. Ulceration is common in Crohn disease, and there may be an abrupt transition between ulcerated and normal mucosa. Repeated cycles of crypt destruction and regeneration lead to **distortion of mucosal architecture;** the normally straight and parallel crypts take on bizarre branching shapes and unusual orientations to one another (Fig. 14–29,

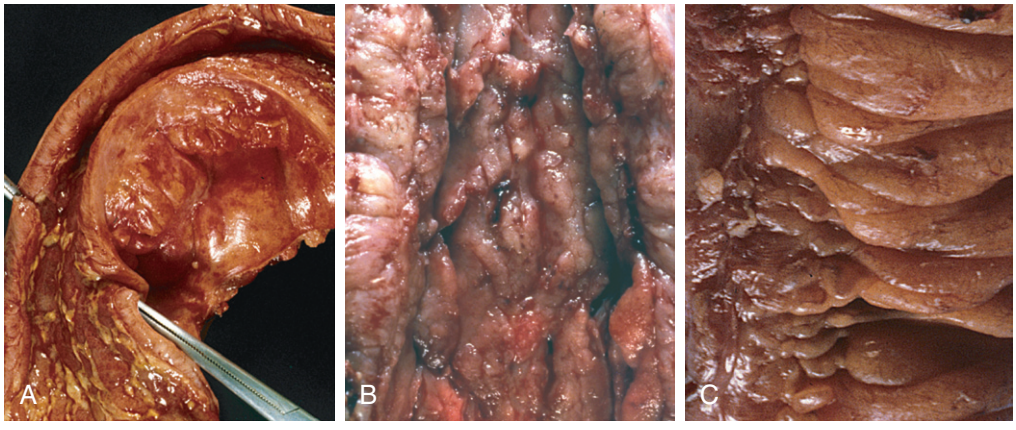


**Figure 14–28** Gross pathology of Crohn disease. **A,** Small intestinal stricture. **B,** Linear mucosal ulcers and thickened intestinal wall. **C,** Creeping fat.

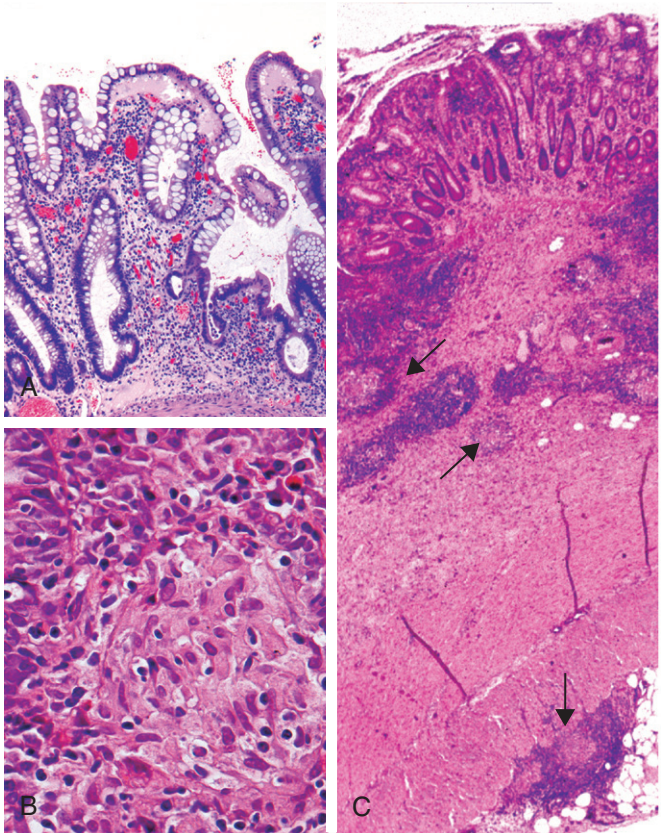


**Figure 14–29** Microscopic pathology of Crohn disease. **A,** Haphazard crypt organization results from repeated injury and regeneration. **B,** Noncaseating granuloma. **C,** Transmural Crohn disease with submucosal and serosal granulomas (*arrows*).

*A*). Epithelial metaplasia, another consequence of chronic relapsing injury, often takes the form of gastric antral-appearing glands (pseudopyloric metaplasia). **Paneth cell metaplasia** also may occur in the left colon, where Paneth cells normally are absent. These architectural and metaplastic changes may persist even when active inflammation has resolved. Mucosal atrophy, with loss of crypts, may result after years of disease. **Noncaseating granulomas** (Fig. 14–29, *B*), a hallmark of Crohn disease, are found in approximately 35% of cases and may arise in areas of active disease or uninvolved regions in any layer of the intestinal wall (Fig. 14–29, *C*). Granulomas also may be found in mesenteric lymph nodes. Cutaneous granulomas form nodules that are referred to (misleadingly) as **metastatic Crohn disease. The absence of granulomas does not preclude a diagnosis of Crohn disease.**

### Clinical Features

The clinical manifestations of Crohn disease are extremely variable. *In most patients, disease begins with intermittent attacks of relatively mild diarrhea, fever, and abdominal pain.* Approximately 20% of patients present acutely with right lower quadrant pain, fever, and bloody diarrhea that may mimic acute appendicitis or bowel perforation. Periods of active disease typically are interrupted by asymptomatic intervals that last for weeks to many months. Disease reactivation can be associated with a variety of external triggers, including physical or emotional stress, specific dietary items, and cigarette smoking.

Iron deficiency anemia may develop in persons with colonic disease, while extensive small bowel disease may result in serum protein loss and hypoalbuminemia, generalized nutrient malabsorption, or malabsorption of vitamin $B_{12}$ and bile salts. Fibrosing strictures, particularly of the terminal ileum, are common and require surgical resection. Disease often recurs at the site of anastomosis, and as many as 40% of patients require additional resections within 10 years. Fistulas develop between loops of bowel and may also involve the urinary bladder, vagina, and abdominal or perianal skin. Perforations and peritoneal abscesses are common.

Extraintestinal manifestations of Crohn disease include uveitis, migratory polyarthritis, sacroiliitis, ankylosing spondylitis, erythema nodosum, and clubbing of the fingertips, any of which may develop before intestinal disease is recognized. Pericholangitis and primary sclerosing cholangitis also occur in Crohn disease but are more common in ulcerative colitis. As discussed later on, risk of colonic adenocarcinoma is increased in patients with long-standing colonic Crohn disease.

## *Ulcerative Colitis*

Ulcerative colitis is closely related to Crohn disease. However, ulcerative colitis is limited to the colon and rectum. Some extraintestinal manifestations of ulcerative colitis overlap with those of Crohn disease, including migratory polyarthritis, sacroiliitis, ankylosing spondylitis, uveitis, skin lesions, pericholangitis, and primary sclerosing cholangitis.

### MORPHOLOGY

Ulcerative colitis always involves the rectum and extends proximally in a continuous fashion to involve part or all of the colon. Skip lesions are not seen (although focal appendiceal or cecal inflammation occasionally may be present). Disease of the entire colon is termed **pancolitis** (Fig. 14–30, *A*). Disease limited to the rectum or rectosigmoid may be referred to descriptively as **ulcerative proctitis** or **ulcerative proctosigmoiditis.** The small intestine is normal, although mild mucosal inflammation of the distal ileum, **backwash ileitis,** may be present in severe cases of pancolitis.

On gross evaluation, involved colonic mucosa may be slightly red and granular-appearing or exhibit extensive **broad-based ulcers.** The transition between diseased and uninvolved colon can be abrupt (Fig. 14–30, *B*). Ulcers are aligned along the long axis of the colon but typically do not replicate the serpentine ulcers of Crohn disease. Isolated islands of regenerating mucosa often bulge into the lumen to create small elevations, termed **pseudopolyps.** Chronic disease may lead to **mucosal atrophy** and a flat, smooth mucosal surface lacking normal folds. Unlike in Crohn disease, **mural thickening is absent, the serosal surface is normal, and strictures do not occur.** However, inflammation and inflammatory mediators can damage the muscularis propria and disturb neuromuscular function leading to

colonic dilation and **toxic megacolon,** which carries a significant risk of perforation.

Histologic features of mucosal disease in ulcerative colitis are similar to those in colonic Crohn disease and include inflammatory infiltrates, crypt abscesses, crypt distortion, and epithelial metaplasia. However, **skip lesions are absent and inflammation generally is limited to the mucosa and superficial submucosa** (Fig. 14–30, *C*). In severe cases, mucosal damage may be accompanied by ulcers that extend more deeply into the submucosa, but the muscularis propria is rarely involved. Submucosal fibrosis, mucosal atrophy, and distorted mucosal architecture remain as residua of healed disease, but the histologic pattern also may revert to near normal after prolonged remission. **Granulomas are not present.**

### Clinical Features

Ulcerative colitis is a relapsing disorder characterized by attacks of bloody diarrhea with expulsion of stringy, mucoid material and lower abdominal pain and cramps that are temporarily relieved by defecation. These symptoms may persist for days, weeks, or months before they subside, and occasionally the initial attack may be severe enough to constitute a medical or surgical emergency. More than half of the patients have mild disease, and almost all experience at least one relapse during a 10-year period. Colectomy cures intestinal disease, but extraintestinal manifestations may persist.

The factors that trigger ulcerative colitis are not known, but as noted previously, infectious enteritis precedes disease onset in some cases. In other cases the first attack is preceded by psychologic stress, which also may be linked to relapse during remission. The initial onset of symptoms also has been reported to occur shortly after smoking cessation in some patients, and smoking may partially relieve symptoms. Unfortunately, studies of nicotine as a therapeutic agent have been disappointing.

### *Indeterminate Colitis*

Histopathologic and clinical overlap between ulcerative colitis and Crohn disease is common, and it is not possible to make a distinction in up to 10% of patients with IBD. In such cases, termed *indeterminate colitis,* the small bowel is not involved, and the continuous pattern of colonic disease typically would indicate ulcerative colitis. However, patchy disease, fissures, a family history of Crohn disease, perianal lesions, onset after initiation of cigarette smoking, or findings that are not typical of ulcerative colitis may create uncertainty. Because of extensive overlap in medical management of ulcerative colitis and Crohn disease, patients carrying a diagnosis of indeterminate colitis can be treated effectively. Nevertheless, it is preferable, when possible, to definitively categorize patients, because evolving medical therapies and surgical management differ for ulcerative colitis and for Crohn disease.

### *Colitis-Associated Neoplasia*

*One of the most feared long-term complications of ulcerative colitis and colonic Crohn disease is the development of neoplasia.* This process begins as dysplasia, which, just as in Barrett esophagus and chronic gastritis, is a step along the road to full-blown carcinoma. The risk of dysplasia is related to several factors:

- Risk increases sharply 8 to 10 years after disease initiation.
- Patients with pancolitis are at greater risk than those with only left-sided disease.
- Greater frequency and severity of active inflammation (characterized by the presence of neutrophils) may increase risk. This is another example of the enabling effect of inflammation on carcinogenesis (Chapter 5).

To facilitate early detection of neoplasia, patients typically are enrolled in surveillance programs approximately 8 years after diagnosis of IBD. The primary exception to this approach is in patients with primary sclerosing cholangitis,

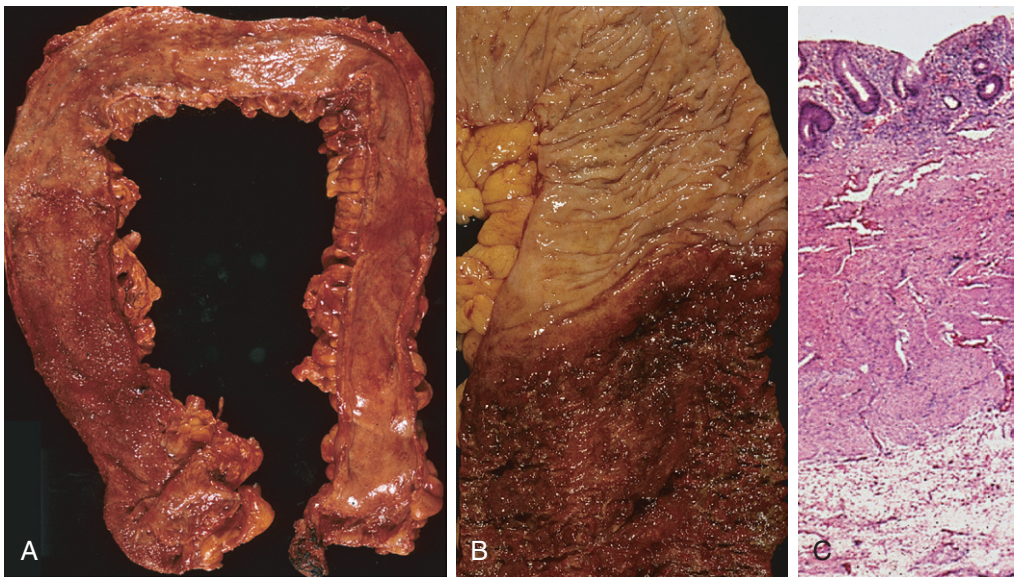


**Figure 14–30** Pathology of ulcerative colitis. **A,** Total colectomy with pancolitis showing active disease, with red, granular mucosa in the cecum (*left*) and smooth, atrophic mucosa distally (*right*). **B,** Sharp demarcation between active ulcerative colitis (*bottom*) and normal (*top*). **C,** This full-thickness histologic section shows that disease is limited to the mucosa. Compare with Figure 14–28, C.

who are at markedly greater risk for development of dysplasia and generally are enrolled for surveillance at the time of diagnosis. Surveillance requires regular and extensive mucosal biopsy, making it a costly practice. In many cases, dysplasia occurs in flat areas of mucosa that are not recognized as abnormal on gross evaluation. Thus, advanced endoscopic imaging techniques are beginning to be used experimentally to increase sensitivity of detection in normal-looking tissue.

IBD-associated dysplasia is classified histologically as low-grade or high-grade. High-grade dysplasia can be associated with invasive carcinoma at the same site or elsewhere in the colon and therefore often prompts colectomy, particularly when the changes are multifocal. Low-grade dysplasia may be treated with colectomy or monitored closely, depending on a variety of clinical factors. Colonic adenomas (discussed later on) also occur in patients with IBD, and in some cases these may be difficult to differentiate from a polypoid focus of IBD-associated dysplasia.

### SUMMARY

#### Inflammatory Bowel Disease

- Inflammatory bowel disease (IBD) is an umbrella term for Crohn disease and ulcerative colitis.
- Crohn disease most commonly affects the terminal ileum and cecum, but any site within the gastrointestinal tract can be involved; skip lesions and noncaseating granulomas are common.
- Ulcerative colitis is limited to the colon, is continuous from the rectum, and ranges in extent from only rectal disease to pancolitis; neither skip lesions nor granulomas are present.
- Both Crohn disease and ulcerative colitis can have extraintestinal manifestations.
- The risk of colonic epithelial dysplasia and adenocarcinoma is increased in patients who have had IBD for more than 8 to 10 years.

## COLONIC POLYPS AND NEOPLASTIC DISEASE

Polyps are most common in the colon but may occur in the esophagus, stomach, or small intestine. Those without stalks are referred to as *sessile.* As sessile polyps enlarge, proliferation of cells adjacent to the polyp and the effects of traction on the luminal protrusion, may combine to create a stalk. Polyps with stalks are termed *pedunculated.* In general, intestinal polyps can be classified as non-neoplastic or neoplastic. The most common neoplastic polyp is the adenoma, which has the potential to progress to cancer. Non-neoplastic colonic polyps can be further classified as inflammatory, hamartomatous, or hyperplastic.

### Inflammatory Polyps

The polyp that forms as part of the *solitary rectal ulcer syndrome* is an example of the purely inflammatory lesion. Patients present with the clinical triad of rectal bleeding, mucus discharge, and an inflammatory lesion of the anterior rectal wall. The underlying cause is impaired relaxation of the anorectal sphincter, creating a sharp angle at the anterior rectal shelf. This leads to recurrent abrasion and ulceration of the overlying rectal mucosa. Chronic cycles of injury and healing produce a polypoid mass made up of inflamed and reactive mucosal tissue.

### Hamartomatous Polyps

Hamartomatous polyps occur sporadically and as components of various genetically determined or acquired syndromes (Table 14–6). As described previously, hamartomas are disorganized, tumor-like growths composed of mature cell types normally present at the site at which the polyp develops. Hamartomatous polyposis syndromes are rare, but they are important to recognize because of associated intestinal and extraintestinal manifestations and the need to screen family members.

#### *Juvenile Polyps*

*Juvenile polyps* are the most common type of hamartomatous polyp. They may be *sporadic or syndromic.* In adults, the sporadic form sometimes is also referred to as an *inflammatory polyp,* particularly when dense inflammatory infiltrates are present. The vast majority of juvenile polyps occur in children younger than 5 years of age. *Juvenile polyps characteristically are located in the rectum,* and most manifest with rectal bleeding. In some cases, prolapse occurs and the polyp protrudes through the anal sphincter. Sporadic juvenile polyps are usually solitary but in persons with the autosomal dominant syndrome of juvenile polyposis the number varies from 3 to as many as 100. Colectomy may be required to limit the hemorrhage associated with polyp ulceration in juvenile polyposis. Dysplasia occurs in a small proportion of (mostly syndrome-associated) juvenile polyps, and the juvenile polyposis syndrome is associated with increased risk for the development of colonic adenocarcinoma.

### MORPHOLOGY

Individual sporadic and syndromic juvenile polyps often are indistinguishable. They typically are pedunculated, smooth-surfaced, reddish lesions that are less than 3 cm in diameter and display characteristic cystic spaces on cut sections. Microscopic examination shows the spaces to be dilated glands filled with mucin and inflammatory debris (Fig. 14–31, *A*). Some data suggest that mucosal hyperplasia is the initiating event in polyp development, and this mechanism is consistent with the discovery that mutations in pathways that regulate cellular growth, such as transforming growth factor-β (TGF-β) signaling, are associated with autosomal dominant juvenile polyposis.

#### *Peutz-Jeghers Syndrome*

Peutz-Jeghers syndrome is a rare autosomal dominant disorder defined by the presence of multiple gastrointestinal

**Table 14–6** Gastrointestinal (GI) Polyposis Syndromes

| Syndrome | Mean Age at Presentation (years) | Mutated Gene(s) | GI Lesions | Selected Extragastrointestinal Manifestations |
|---|---|---|---|---|
| Peutz-Jeghers syndrome | 10–15 | *LKB1/STK11* | Arborizing polyps—small intestine > colon > stomach; colonic adenocarcinoma | Mucocutaneous pigmentation; increased risk of thyroid, breast, lung, pancreas, gonadal, and bladder cancers |
| Juvenile polyposis | <5 | *SMAD4, BMPR1A* | Juvenile polyps; increased risk of gastric, small intestinal, colonic, and pancreatic adenocarcinoma | Pulmonary arteriovenous malformations, digital clubbing |
| Cowden syndrome, Bannayan-Ruvalcaba-Riley syndrome | <15 | *PTEN* | Hamartomatous polyps, lipomas, ganglioneuromas, inflammatory polyps; increased risk of colon cancer | Benign skin tumors, benign and malignant thyroid and breast lesions |
| Cronkhite-Canada syndrome | >50 | Nonhereditary | Hamartomatous colon polyps, crypt dilatation and edema in nonpolypoid mucosa | Nail atrophy, hair loss, abnormal skin pigmentation, cachexia, anemia |
| Tuberous sclerosis | Infancy to adulthood | *TSC1, TSC2* | Hamartomatous polyps (rectal) | Facial angiofibroma, cortical tubers, renal angiomyolipoma |
| Familial adenomatous polyposis (FAP) | | | | |
| Classic FAP | 10–15 | *APC, MUTYH* | Multiple adenomas | Congenital RPE hypertrophy |
| Attenuated FAP | 40–50 | *APC, MUTYH* | Multiple adenomas | |
| Gardner syndrome | 10–15 | *APC, MUTYH* | Multiple adenomas | Osteomas, desmoids, skin cysts |
| Turcot syndrome | 10–15 | *APC, MUTYH* | Multiple adenomas | CNS tumors, medulloblastoma |

CNS, central nervous system; RPE, retinal pigment epithelium.

hamartomatous polyps and mucocutaneous hyperpigmentation that carries an increased risk of several malignancies, including cancers of the colon, pancreas, breast, lung, ovaries, uterus, and testes, as well as other unusual neoplasms. Germ line heterozygous loss-of-function mutations in the gene *LKB1/STK11* are present in approximately half of the patients with the familial form of Peutz-Jeghers syndrome, as well as a subset of patients with the sporadic form. Intestinal polyps are most common in the small intestine, although they may also occur in the stomach and colon and, rarely, in the bladder and lungs. On gross evaluation, the polyps are large and pedunculated with a lobulated contour. Histologic examination demonstrates a characteristic arborizing network of connective tissue, smooth muscle, lamina propria, and glands lined by normal-appearing intestinal epithelium (Fig. 14–31, *B*).

## Hyperplastic Polyps

Colonic hyperplastic polyps are common epithelial proliferations that typically are discovered in the sixth and seventh decades of life. The pathogenesis of hyperplastic polyps is incompletely understood, but formation of these lesions is thought to result from decreased epithelial cell turnover and delayed shedding of surface epithelial cells, leading to a "pileup" of goblet cells.

Although these lesions have no malignant potential, they must be distinguished from sessile serrated adenomas, histologically similar lesions that have malignant potential, as described later.

### MORPHOLOGY

Hyperplastic polyps are most commonly found in the left colon and typically are less than 5 mm in diameter. They are smooth, nodular protrusions of the mucosa, often on the crests of mucosal folds. They may occur singly but more frequently are multiple, particularly in the sigmoid colon and rectum. Histologically, hyperplastic polyps are composed of mature goblet and absorptive cells. The delayed shedding of these cells leads to crowding that creates the serrated surface architecture that is the morphologic hallmark of these lesions (Fig. 14–32).

## Adenomas

Any neoplastic mass lesion in the gastrointestinal tract may produce a mucosal protrusion, or polyp. The most common and clinically important neoplastic polyps are *colonic adenomas, benign polyps that give rise to a majority of colorectal adenocarcinomas*. Most adenomas, however, do not progress to adenocarcinoma.

*Colorectal adenomas are characterized by the presence of epithelial dysplasia.* These growths range from small, often pedunculated polyps to large sessile lesions. There is no gender predilection, and they are present in nearly 50% of adults living in the Western world beginning age 50. Because these polyps are precursors to colorectal cancer, current recommendations are that all adults in the United States undergo surveillance colonoscopy starting at age 50. Because persons with a family history are at risk for

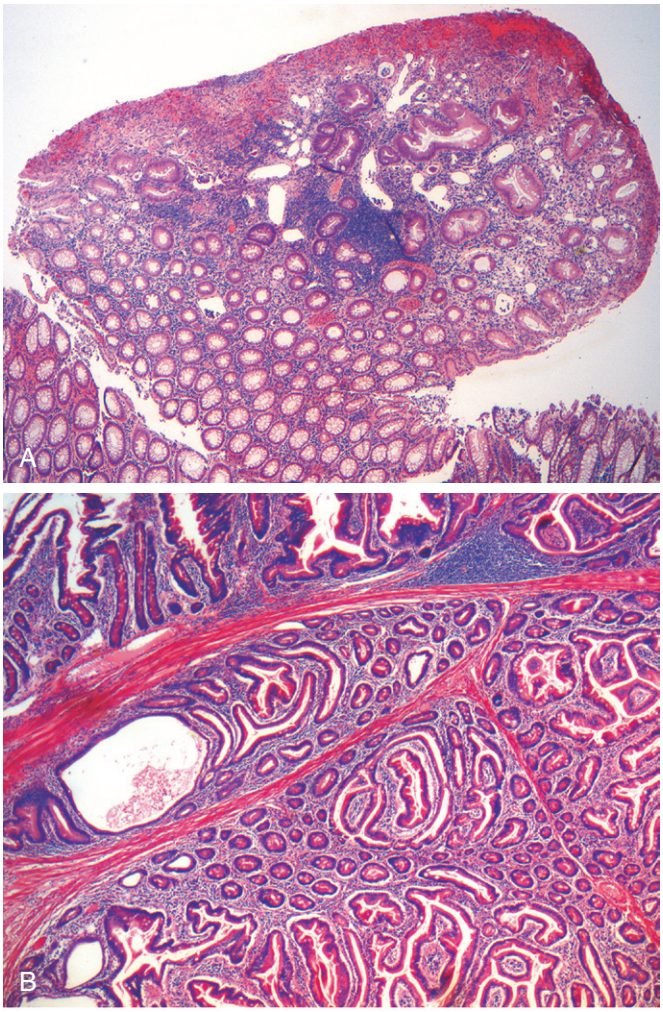


**Figure 14–31** Hamartomatous polyps. **A,** Juvenile polyp. Note the surface erosion and cystically dilated crypts filled with mucus, neutrophils, and debris. **B,** Peutz-Jeghers polyp. Complex glandular architecture and bundles of smooth muscle help to distinguish Peutz-Jeghers polyps from juvenile polyps.

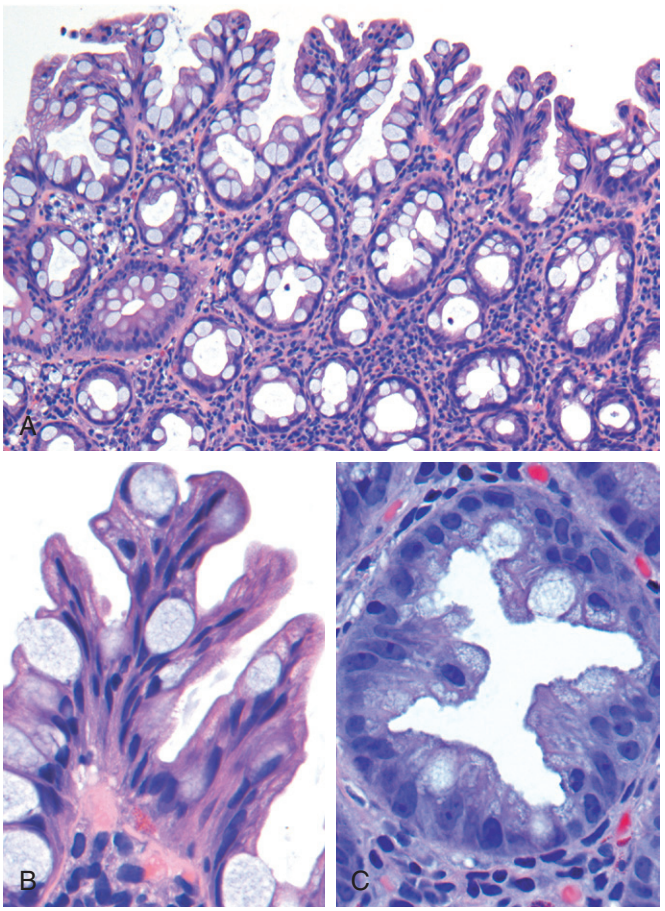


**Figure 14–32** Hyperplastic polyp. **A,** Polyp surface with irregular tufting of epithelial cells. **B,** Tufting results from epithelial overcrowding. **C,** Epithelial crowding produces a serrated architecture when glands are cut in cross-section.

developing colon cancer earlier in life, they typically are screened at least 10 years before the youngest age at which a relative was diagnosed. While adenomas are less common in Asia, their frequency has risen (in parallel with an increasing incidence of colorectal adenocarcinoma) as Western diets and lifestyles become more common.

## MORPHOLOGY

Typical adenomas range from 0.3 to 10 cm in diameter and can be **pedunculated** (Fig. 14–33, *A*) or **sessile,** with the surface of both types having a texture resembling velvet (Fig. 14–33, *B*) or a raspberry, due to the abnormal epithelial growth pattern. Histologically, the cytologic hallmark of **epithelial dysplasia** (Fig. 14–34, *C*) is nuclear hyperchromasia, elongation, and stratification. These changes are most easily appreciated at the surface of the adenoma, because the epithelium fails to mature as cells migrate out of the crypt. Pedunculated adenomas have slender fibromuscular stalks (Fig. 14–33, *C*) containing prominent blood vessels derived from the submucosa. The stalk usually is covered by non-neoplastic epithelium, but dysplastic epithelium is sometimes present.

Adenomas can be classified as **tubular, tubulovillous, or villous** on the basis of their architecture. These categories, however, have little clinical significance in isolation. Tubular adenomas tend to be small, pedunculated polyps composed of small, rounded or tubular glands (Fig. 14–34, *A*). By contrast, villous adenomas, which often are larger and sessile, are covered by slender villi (Fig. 14–34, *B*). Tubulovillous adenomas have a mixture of tubular and villous elements. Although foci of invasion are more frequent in villous adenomas than in tubular adenomas, villous architecture alone does not increase cancer risk when polyp size is considered.

The histologic features of **sessile serrated adenomas** overlap with those of hyperplastic polyps and the typical cytologic features of dysplasia are lacking (Fig. 14–34, *D*). However, these lesions, which are most common in the right colon, have a malignant potential similar to that of traditional adenomas. The most useful histologic feature that distinguishes sessile serrated adenomas and hyperplastic polyps is the presence of serrated architecture throughout the full length of the glands, including the crypt base, associated with crypt dilation and lateral growth, in the former (Fig. 14–34,

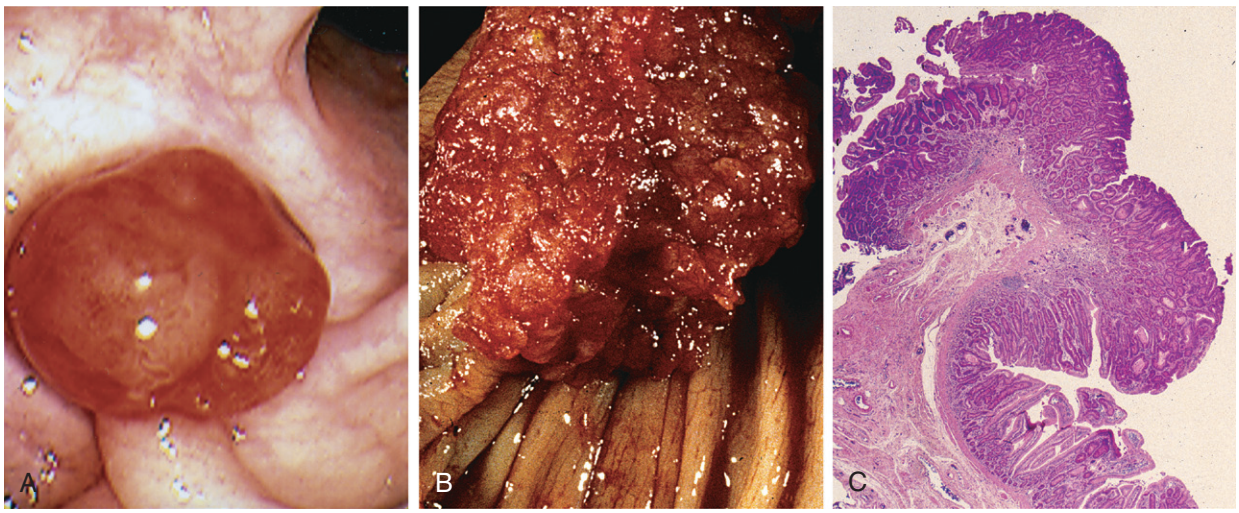


**Figure 14–33** Colonic adenomas. **A,** Pedunculated adenoma (endoscopic view). **B,** Adenoma with a velvety surface. **C,** Low-magnification photomicrograph of a pedunculated tubular adenoma.

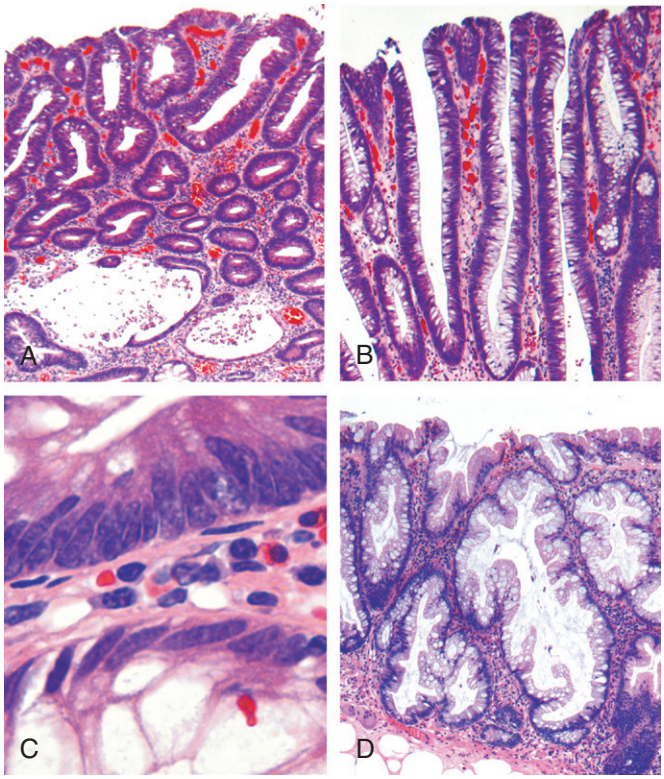


**Figure 14–34** Histologic appearance of colonic adenomas. **A,** Tubular adenoma with a smooth surface and rounded glands. In this case, crypt dilation and rupture, with associated reactive inflammation, can be seen at the bottom of the field. **B,** Villous adenoma with long, slender projections that are reminiscent of small intestinal villi. **C,** Dysplastic epithelial cells (*top*) with an increased nuclear-to-cytoplasmic ratio, hyperchromatic and elongated nuclei, and nuclear pseudostratification. Compare with the nondysplastic epithelium below. **D,** Sessile serrated adenoma lined by goblet cells without typical cytologic features of dysplasia. This lesion is distinguished from a hyperplastic polyp by involvement of the crypts. Compare with the hyperplastic polyp in Figure 14–32.

*D*). By contrast, serrated architecture typically is confined to the surface of hyperplastic polyps.

Although most colorectal adenomas are benign lesions, a small proportion may harbor invasive cancer at the time of detection. **Size is the most important characteristic that correlates with risk of malignancy.** For example, while cancer is extremely rare in adenomas less than 1 cm in diameter, some studies suggest that nearly 40% of lesions larger than 4 cm in diameter contain foci of cancer. In addition to size, high-grade dysplasia is a risk factor for cancer in an individual polyp (but not other polyps in the same patient).

## Familial Syndromes

Several syndromes associated with colonic polyps and increased rates of colon cancer have been described. The genetic basis of these disorders has been established and has greatly enhanced the current understanding of sporadic colon cancer (Table 14–7).

### *Familial Adenomatous Polyps*

Familial adenomatous polyposis (FAP) is an autosomal dominant disorder marked by the appearance of numerous colorectal adenomas by the teenage years. It is caused by mutations of the *adenomatous polyposis coli* gene (*APC*). *A count of at least 100 polyps is necessary for a diagnosis* of classic FAP, and as many as several thousand may be present (Fig. 14–35). Except for their remarkable numbers, these growths are *morphologically indistinguishable from sporadic adenomas*. Colorectal adenocarcinoma develops in 100% of patients with untreated FAP, often before age 30. As a result, prophylactic colectomy is standard therapy for persons carrying *APC* mutations. However, patients remain at risk for *extraintestinal manifestations,* including neoplasia at other sites. Specific *APC* mutations are also associated with the development of other manifestations of FAP and explain variants such as Gardner syndrome and Turcot syndrome. In addition to intestinal polyps, clinical features of *Gardner syndrome*, a variant of FAP, may include osteomas of

**Table 14–7** Common Patterns of Sporadic and Familial Colorectal Neoplasia

| Etiology | Molecular Defect | Target Gene(s) | Transmission | Predominant Site(s) | Histology |
|---|---|---|---|---|---|
| Familial adenomatous polyposis (70% of FAP) | APC/WNT pathway | *APC* | Autosomal dominant | None | Tubular, villous; typical adenocarcinoma |
| Familial adenomatous polyposis (<10% of FAP) | DNA mismatch repair | *MUTYH* | None, recessive | None | Sessile serrated adenoma; mucinous adenocarcinoma |
| Hereditary nonpolyposis colorectal cancer | DNA mismatch repair | *MSH2, MLH1* | Autosomal dominant | Right side | Sessile serrated adenoma; mucinous adenocarcinoma |
| Sporadic colon cancer (80%) | APC/WNT pathway | *APC* | None | Left side | Tubular, villous; typical adenocarcinoma |
| Sporadic colon cancer (10% to 15%) | DNA mismatch repair | *MSH2, MLH1* | None | Right side | Sessile serrated adenoma; mucinous adenocarcinoma |

mandible, skull, and long bones; epidermal cysts; desmoid and thyroid tumors; and dental abnormalities, including unerupted and supernumerary teeth. *Turcot syndrome* is rarer and is characterized by intestinal adenomas and tumors of the central nervous system. Two thirds of patients with Turcot syndrome have *APC* gene mutations and develop medulloblastomas. The remaining one third have mutations in one of several genes involved in DNA repair and develop glioblastomas. Some patients who have FAP without *APC* loss have mutations of the base excision repair gene *MUTYH*. The role of these genes in tumor development is discussed below.

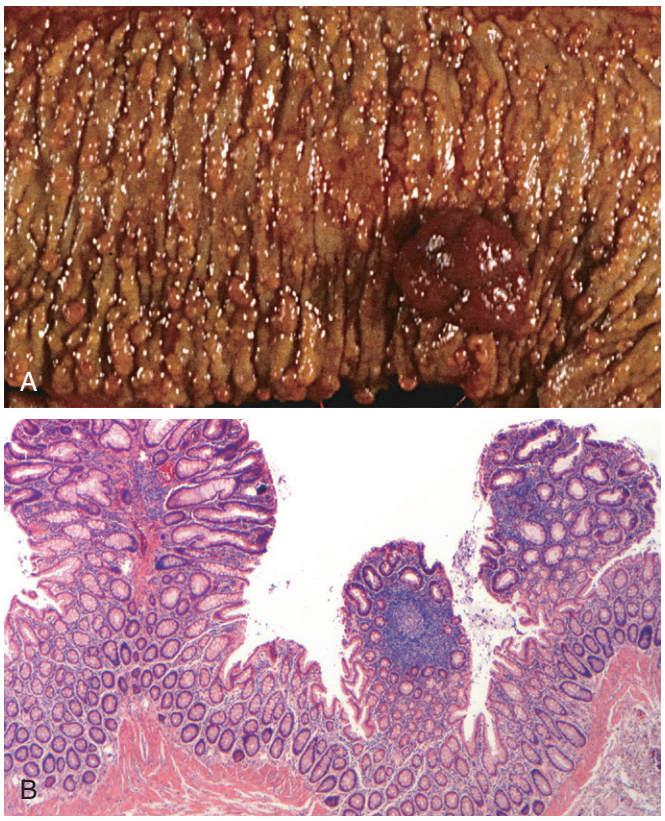


**Figure 14–35** Familial adenomatous polyposis. **A,** Hundreds of small colonic polyps are present along with a dominant polyp (*right*). **B,** Three tubular adenomas are present in this single microscopic field.

### *Hereditary Nonpolyposis Colorectal Cancer*

*Hereditary nonpolyposis colorectal cancer* (HNPCC), also known as Lynch syndrome, originally was described as familial clustering of cancers at several sites including the colorectum, endometrium, stomach, ovary, ureters, brain, small bowel, hepatobiliary tract, and skin. Colon cancers in patients with HNPCC tend to occur at *younger ages* than for sporadic colon cancers and often are located in the *right colon* (Table 14–7).

Just as identification of *APC* mutations in FAP has provided molecular insights into the pathogenesis of a majority of sporadic colon cancers, dissection of the defects in HNPCC has shed light on the mechanisms responsible for most of the remaining sporadic cases. HNPCC is caused by inherited germline mutations in genes that encode proteins responsible for the detection, excision, and repair of errors that occur during DNA replication. At least five such mismatch repair genes have been recognized, but a majority of HNPCC cases involve either *MSH2* or *MLH1.* Patients with HNPCC inherit one mutated DNA repair gene and one normal allele. When the second copy is lost through mutation or epigenetic silencing, defects in mismatch repair lead to the accumulation of mutations at rates up to 1000 times higher than normal, mostly in regions containing short repeating DNA sequences referred to as microsatellite DNA. The human genome contains approximately 50,000 to 100,000 microsatellites, which are prone to undergo expansion during DNA replication and represent the most frequent sites of mutations in HNPCC. The consequences of mismatch repair defects and the resulting *microsatellite instability* are discussed next in the context of colonic adenocarcinoma.

## Adenocarcinoma

Adenocarcinoma of the colon is the most common malignancy of the gastrointestinal tract and is a major contributor to morbidity and mortality worldwide. By contrast, the small intestine, which accounts for 75% of the overall length of the gastrointestinal tract, is an uncommon site for benign and malignant tumors. Among malignant small intestinal tumors, adenocarcinomas and carcinoid tumors have roughly equal rates of occurrence, followed by lymphomas and sarcomas.

### Epidemiology

Each year in the United States there are more than 130,000 new cases and 55,000 deaths from colorectal adenocarcinoma. This represents nearly 15% of all cancer-related deaths, second only to lung cancer. Colorectal cancer incidence peaks at 60 to 70 years of age, and less than 20% of cases occur before age 50. Males are affected slightly more often than females. Colorectal carcinoma is most prevalent in the United States, Canada, Australia, New Zealand, Denmark, Sweden, and other developed countries. The incidence of this cancer is as much as 30-fold lower in India, South America, and Africa. In Japan, where incidence was previously very low, rates have now risen to intermediate levels (similar to those in the United Kingdom), presumably as a result of changes in lifestyle and diet.

The dietary factors most closely associated with increased colorectal cancer rates are low intake of unabsorbable vegetable fiber and high intake of refined carbohydrates and fat.

In addition to dietary modification, pharmacologic chemoprevention has become an area of great interest. Several epidemiologic studies suggest that aspirin or other NSAIDs have a protective effect. This is consistent with studies showing that some NSAIDs cause polyp regression in patients with FAP in whom the rectum was left in place after colectomy. It is suspected that this effect is mediated by inhibition of the enzyme cyclooxygenase-2 (COX-2), which is highly expressed in 90% of colorectal carcinomas and 40% to 90% of adenomas and is known to promote epithelial proliferation, particularly in response to injury.

## PATHOGENESIS

Studies of colorectal carcinogenesis have provided fundamental insights into the general mechanisms of cancer evolution. The combination of molecular events that lead to colonic adenocarcinoma is heterogeneous and includes genetic and epigenetic abnormalities. At least two distinct genetic pathways APC/β-catenin pathway, have been described. In simplest terms, these are the disturbances of which lead to increased WNT signaling, and the microsatellite instability pathway, which is associated with defects in DNA mismatch repair (see Table 14–7). Both pathways involve the stepwise accumulation of multiple mutations, but the genes involved and the mechanisms by which the mutations accumulate differ. Epigenetic events, the most common of which is methylation-induced gene silencing, may enhance progression along both pathways.

- The **APC/β-catenin pathway.** The classic **adenoma-carcinoma sequence,** which accounts for as much as 80% of sporadic colon tumors, typically involves mutation of the *APC* tumor suppressor early in the neoplastic process (Fig. 14–36). Both copies of the *APC* gene must be functionally inactivated, either by mutation or epigenetic events, for adenomas to develop. **APC is a key negative regulator of β-catenin, a component of the WNT signaling pathway** (Chapter 5). The APC protein normally binds to and promotes degradation of β-catenin. With loss of APC function, β-catenin accumulates and translocates to the nucleus, where it activates the transcription of genes, such as those encoding MYC and cyclin D1, which promote proliferation. This is followed by additional mutations, including activating mutations in *KRAS*, which also promote growth and prevent apoptosis. The conclusion that mutation of *KRAS* is a late event is supported by the observation that mutations are present in fewer than 10% of adenomas less than 1 cm in diameter, in 50% of adenomas greater than 1 cm in diameter, and in 50% of invasive adenocarcinomas. Neoplastic progression also is associated with mutations in other

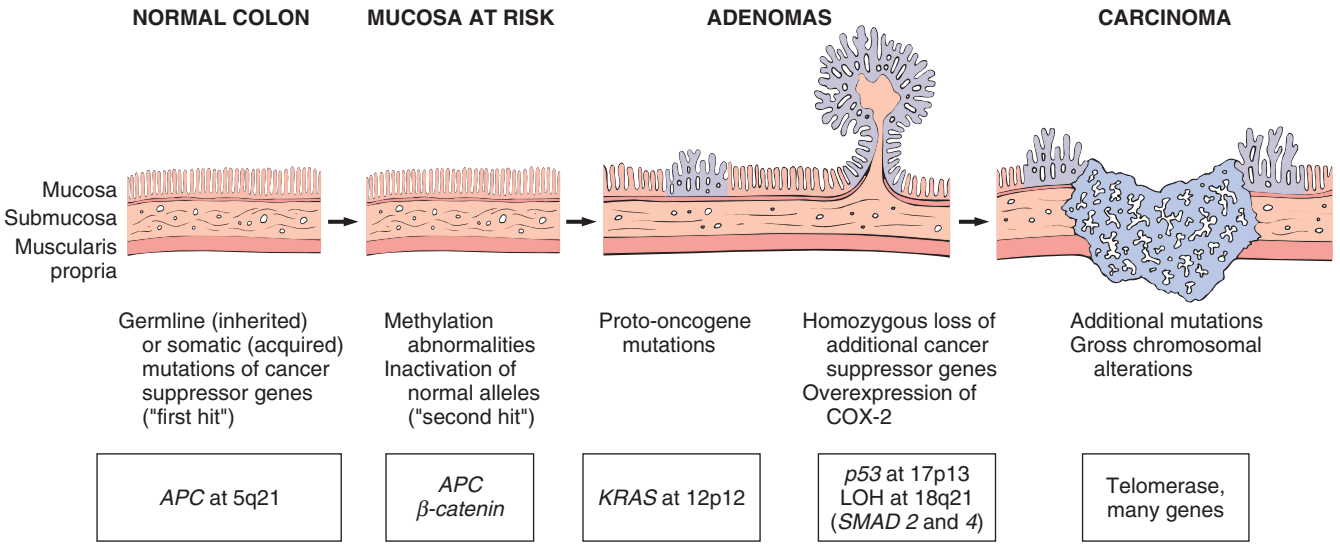


**Figure 14–36** Morphologic and molecular changes in the adenoma-carcinoma sequence. It is postulated that loss of one normal copy of the tumor suppressor gene *APC* occurs early. Persons may be born with one mutant allele, making them extremely prone to the development of colon cancer, or inactivation of *APC* may occur later in life. This is the "first hit" according to Knudson's hypothesis. The loss of the intact copy of *APC* follows ("second hit"). Other mutations involving *KRAS*, *SMAD2*, and *SMAD4*, and the tumor suppressor gene *TP53*, lead to the emergence of carcinoma, in which additional mutations occur. Although there may be a preferred temporal sequence for these changes, it is the aggregate effect of the mutations, rather than their order of occurrence, that appears most critical.

tumor suppressor genes such as those encoding SMAD2 and SMAD4, which are effectors of TGF-β signaling. Because TGF-β signaling normally inhibits the cell cycle, loss of these genes may allow unrestrained cell growth. The tumor suppressor gene *TP53* is mutated in 70% to 80% of colon cancers but is uncommonly affected in adenomas, suggesting that *TP53* mutations also occur at late stages of tumor progression. "Loss of function" of *TP53* and other tumor suppressor genes often is caused by chromosomal deletions, highlighting chromosomal instability as a hallmark of the APC/β-catenin pathway. Alternatively, tumor suppressor genes may be silenced by methylation of CpG islands, a 5′ region of some genes that frequently includes the promoter and transcriptional start site. Expression of telomerase also increases as lesions become more advanced.

- **The microsatellite instability pathway.** In patients with DNA mismatch repair deficiency (due to loss of mismatch repair genes, as discussed earlier) mutations accumulate in microsatellite repeats, a condition referred to as **microsatellite instability.** These mutations generally are silent, because microsatellites typically are located in noncoding regions, but other microsatellite sequences are located in the coding or promoter regions of genes involved in regulation of cell growth, such as those encoding the type II TGF-β receptor and the pro-apoptotic protein BAX (Fig. 14–37). Because TGF-β inhibits colonic epithelial cell proliferation, type II TGF-β receptor mutants can contribute to uncontrolled cell growth, while loss of *BAX* may enhance the survival of genetically abnormal clones. Mutations in the oncogene *BRAF* and silencing of distinct groups of genes due to CpG island hypermethylation also are common in cancers that develop through DNA mismatch repair defects. By contrast, *KRAS* and *TP53* typically are not mutated. Thus, the combination of microsatellite instability, *BRAF* mutation, and methylation of specific targets, such as *MLH1*, is the signature of this pathway of carcinogenesis.

## MORPHOLOGY

Overall, adenocarcinomas are distributed approximately equally over the entire length of the colon. **Tumors in the proximal colon often grow as polypoid, exophytic masses** that extend along one wall of the large-caliber cecum and ascending colon; these tumors rarely cause obstruction. By contrast, **carcinomas in the distal colon tend to be annular lesions that produce "napkin ring"** constrictions and luminal narrowing (Fig. 14–38), sometimes to the point of obstruction. Both forms grow into the bowel wall over time and may be palpable as firm masses. The general microscopic characteristics of right- and left-sided colonic adenocarcinomas are similar. Most tumors are composed of tall columnar cells that resemble dysplastic epithelium found in adenomas (Fig. 14–39, *A*). The invasive component of these tumors elicits a strong stromal desmoplastic response, which is responsible for their characteristic firm consistency. Some poorly differentiated tumors form few glands (Fig. 14–39, *B*). Others may produce abundant mucin that accumulates within the intestinal wall, and these carry a poor prognosis. Tumors also may be composed of signet ring cells that are similar to those in gastric cancer (Fig. 14–39, *C*).

### Clinical Features

The availability of endoscopic screening combined with the recognition that most carcinomas arise within adenomas presents a unique opportunity for cancer prevention. Unfortunately, colorectal cancers develop insidiously and may therefore go undetected for long periods. Cecal and other *right-sided colon cancers* most often are called to clinical attention by the appearance of *fatigue and weakness due to iron deficiency anemia.* Thus, it is a clinical maxim that the underlying cause of iron deficiency anemia in an older man or postmenopausal woman is gastrointestinal cancer until proven otherwise. *Left-sided colorectal adenocarcinomas* may produce *occult bleeding, changes in bowel habits, or cramping* left lower quadrant discomfort.

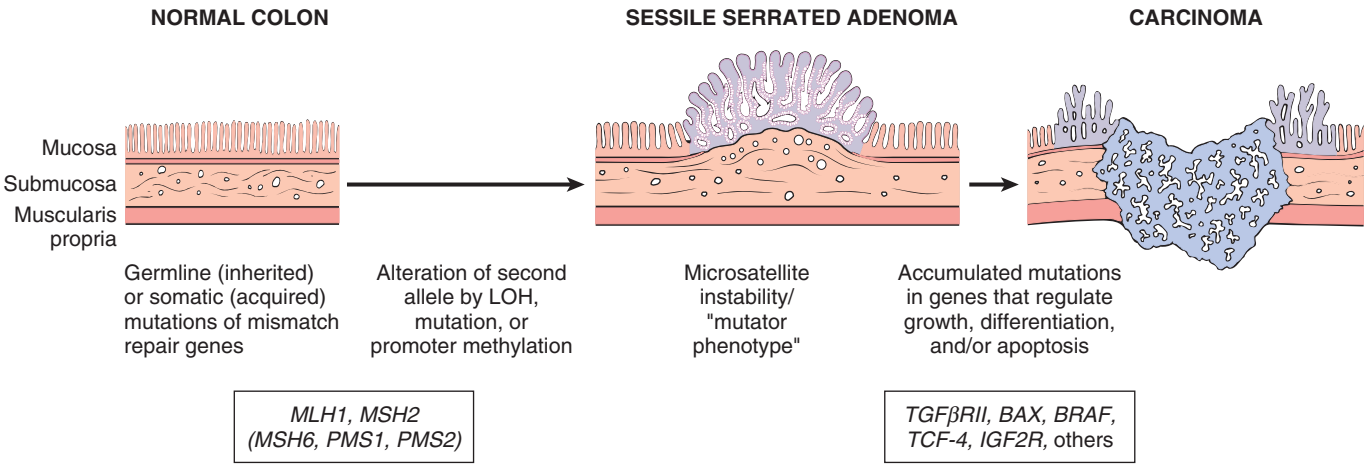


**Figure 14–37** Morphologic and molecular changes in the mismatch repair pathway of colon carcinogenesis. Defects in mismatch repair genes result in microsatellite instability and permit accumulation of mutations in numerous genes. If these mutations affect genes involved in cell survival and proliferation, cancer may develop. LOH, loss of heterozygosity.

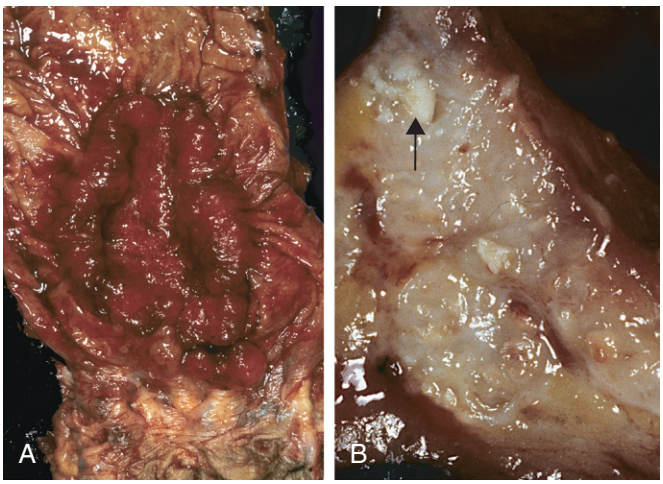


**Figure 14–38** Colorectal carcinoma. **A,** Circumferential, ulcerated rectal cancer. Note the anal mucosa at the bottom of the image. **B,** Cancer of the sigmoid colon that has invaded through the muscularis propria and is present within subserosal adipose tissue (*left*). Areas of chalky necrosis are present within the colon wall (*arrow*).

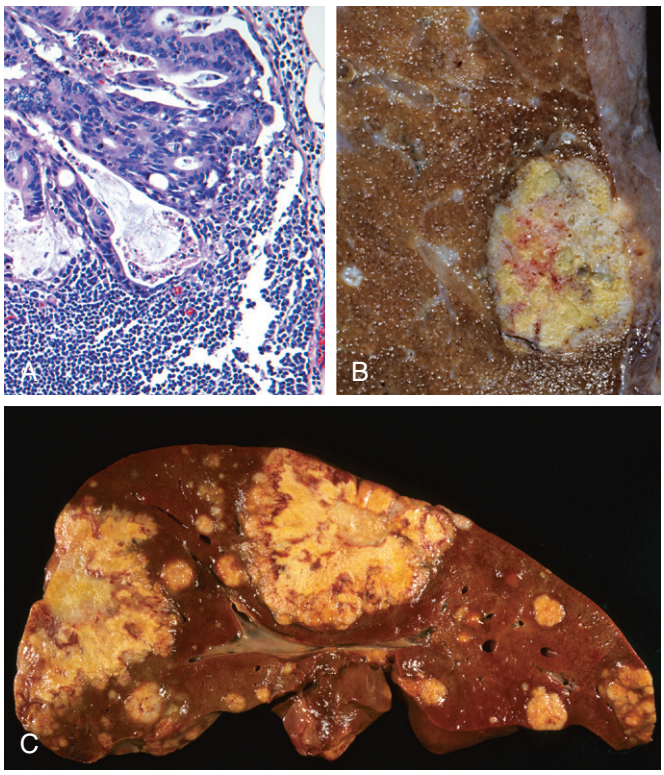


**Figure 14–40** Metastatic colorectal carcinoma. **A,** Lymph node metastasis. Note the glandular structures within the subcapsular sinus. **B,** Solitary subpleural nodule of colorectal carcinoma metastatic to the lung. **C,** Liver containing two large and many smaller metastases. Note the central necrosis within metastases.

Although poorly differentiated and mucinous histologic patterns are associated with poor prognosis, *the two most important prognostic factors are depth of invasion and the presence or absence of lymph node metastases.* Invasion into the muscularis propria imparts significantly reduced survival that is decreased further by the presence of lymph node metastases (Fig. 14–40, *A*). These factors were originally recognized by Dukes and Kirklin and form the core of the TNM (tumor-node-metastasis) classification (Table 14–8) and staging system (Table 14–9) from the American Joint Committee on Cancer. Regardless of stage, however, some patients with small numbers of metastases do well for years after resection of distant tumor nodules. This observation once again emphasizes the clinical and molecular heterogeneity of colorectal carcinomas. Metastases may involve regional lymph nodes, lungs (Fig. 14–40, *B*), and bones, but because of the portal drainage, the liver is the most common site of metastatic lesions (Fig. 14–40, *C*). The rectum does not drain by way of the portal circulation, and metastases from carcinomas of the anal region often circumvent the liver.

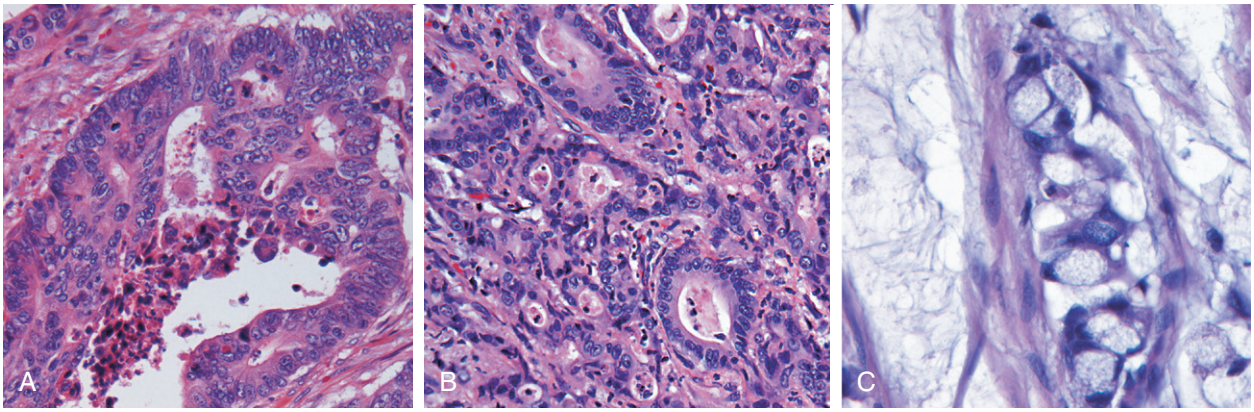


**Figure 14–39** Histologic appearance of colorectal carcinoma. **A,** Well-differentiated adenocarcinoma. Note the elongated, hyperchromatic nuclei. Necrotic debris, present in the gland lumen, is typical. **B,** Poorly differentiated adenocarcinoma forms a few glands but is largely composed of infiltrating nests of tumor cells. **C,** Mucinous adenocarcinoma with signet ring cells and extracellular mucin pools.

**Table 14–8** AJCC Tumor-Node-Metastasis (TNM) Classification of Colorectal Carcinoma

| Designation | Description |
|---|---|
| **Tumor** | |
| Tis | In situ dysplasia or intramucosal carcinoma |
| T1 | Tumor invades submucosa |
| T2 | Tumor invades into, but not through, muscularis propria |
| T3 | Tumor invades through muscularis propria |
| T4 | Tumor invades adjacent organs or visceral peritoneum |
| **Regional Lymph Nodes** | |
| NX | Lymph nodes cannot be assessed |
| N0 | No regional lymph node metastasis |
| N1 | Metastasis in one to three regional lymph nodes |
| N2 | Metastasis in four or more regional lymph nodes |
| **Distant Metastasis** | |
| MX | Distant metastasis cannot be assessed |
| M0 | No distant metastasis |
| M1 | Distant metastasis or seeding of abdominal organs |

AJCC, American Joint Committee on Cancer.

**Table 14–9** AJCC Colorectal Cancer Staging and Survival

| Stage* | Tumor-Node-Metastasis (TNM) Criteria | | | 5-Year Survival (%) |
|---|---|---|---|---|
| | T | N | M | |
| I | T1, T2 | N0 | M0 | 74 |
| II | | | | |
| IIA | T3 | N0 | M0 | 67 |
| IIB | T4 | N0 | M0 | 59 |
| III | | | | |
| IIIA | T1, T2 | N1 | M0 | 73 |
| IIIB | T3, T4 | N1 | M0 | 46 |
| IIIC | Any T | N2 | M0 | 28 |
| IV | Any T | Any N | M1 | 6 |

*Colorectal cancer staging is based on the TNM classification (Table 14–8). For example, a T3 tumor without nodal or distant metastases is classified as stage IIA and is associated with a 5-year survival rate of 67%.
AJCC, American Joint Committee on Cancer.

## SUMMARY

### Colonic Polyps, Adenomas, and Adenocarcinomas

- *Intestinal polyps* can be classified as non-neoplastic or neoplastic. The non-neoplastic polyps can be further defined as inflammatory, hamartomatous, or hyperplastic.
- *Inflammatory polyps* form as a result of chronic cycles of injury and healing.
- *Hamartomatous polyps* occur sporadically or as a part of genetic diseases. In the latter case, they often are associated with increased risk of malignancy.
- Hyperplastic polyps are benign epithelial proliferations most commonly found in the left colon and rectum. They are not reactive in origin, in contrast with gastric hyperplastic polyps; have no malignant potential; and must be distinguished from *sessile serrated adenomas*.
- Benign epithelial neoplastic polyps of the intestines are termed *adenomas*. The hallmark feature of these lesions, which are the precursors of colonic adenocarcinomas, is cytologic dysplasia.
- In contrast with traditional adenomas, *sessile serrated adenomas* lack cytologic dysplasia and share morphologic features with hyperplastic polyps.
- *Familial adenomatous polyposis* (FAP) and *hereditary nonpolyposis colorectal cancer* (HNPCC) are the most common forms of familial colon cancer. FAP is caused by *APC* mutations, and patients typically have over 100 adenomas and develop colon cancer before the age of 30.
- HNPCC is caused by mutations in DNA mismatch repair genes. Patients with HNPCC have far fewer polyps and develop cancer at an older age than that typical for patients with FAP but at a younger age than in patients with sporadic colon cancer.
- FAP and HNPCC are examples of two distinct pathways of neoplastic transformation, both of which contribute to sporadic colon cancer.
- The vast majority of colonic cancers are adenocarcinomas. The two most important prognostic factors are *depth of invasion* and the presence or absence of *lymph node metastases*.

# APPENDIX

The appendix is a normal true diverticulum of the cecum. Like any diverticulum, it is prone to acute and chronic inflammation, and acute appendicitis is a relatively common entity. Other lesions, including tumors, can also occur in the appendix but are far less common.

## ACUTE APPENDICITIS

Acute appendicitis is most common in adolescents and young adults but may occur in any age group. The lifetime risk for appendicitis is 7%; males are affected slightly more often than females. Despite the prevalence of acute appendicitis, the diagnosis can be difficult to confirm preoperatively, and the condition may be confused with mesenteric lymphadenitis (often secondary to unrecognized *Yersinia* infection or viral enterocolitis), acute salpingitis, ectopic pregnancy, mittelschmerz (pain associated with ovulation), and Meckel diverticulitis.

### PATHOGENESIS

Acute appendicitis is thought to be initiated by progressive increases in intraluminal pressure that compromises venous outflow. In 50% to 80% of cases, acute appendicitis is associated with overt luminal obstruction, usually by a small, stone-like mass of stool, or **fecalith,** or, less commonly, a gallstone,

tumor, or mass of worms. Ischemic injury and stasis of luminal contents, which favor bacterial proliferation, trigger inflammatory responses including tissue edema and neutrophilic infiltration of the lumen, muscular wall, and periappendiceal soft tissues.

## MORPHOLOGY

In early acute appendicitis, subserosal vessels are congested, and a modest perivascular neutrophilic infiltrate is present within all layers of the wall. The inflammatory reaction transforms the normal glistening serosa into a dull, granular-appearing, erythematous surface. Although mucosal neutrophils and focal superficial ulceration often are present, these findings are not specific, and diagnosis of acute appendicitis requires neutrophilic infiltration of the muscularis propria. In more severe cases, focal abscesses may form within the wall **(acute suppurative appendicitis),** and these may even progress to large areas of hemorrhagic ulceration and gangrenous necrosis that extend to the serosa, creating **acute gangrenous appendicitis,** which often is followed by rupture and suppurative peritonitis.

### Clinical Features

Typically, early acute appendicitis produces periumbilical pain that ultimately localizes to the right lower quadrant, followed by nausea, vomiting, low-grade fever, and a mildly elevated peripheral white cell count. A classic physical finding is *McBurney's sign,* deep tenderness noted at a location two thirds of the distance from the umbilicus to the right anterior superior iliac spine (McBurney's point). These signs and symptoms often are absent, however, creating difficulty in clinical diagnosis.

# TUMORS OF THE APPENDIX

The most common tumor of the appendix is the *carcinoid.* It usually is discovered incidentally at the time of surgery or on examination of a resected appendix. This neoplasm most frequently involves the distal tip of the appendix, where it produces a solid bulbous swelling up to 2 to 3 cm in diameter. Although intramural and transmural extension may be evident, nodal metastases are very infrequent, and distant spread is exceptionally rare. Conventional *adenomas* or *non–mucin-producing adenocarcinomas* also occur in the appendix and may cause obstruction and enlargement that mimics the changes of acute appendicitis. *Mucocele,* a dilated appendix filled with mucin, may simply stem from an obstructed appendix containing inspissated mucin or may be a consequence of *mucinous cystadenoma* or *mucinous cystadenocarcinoma.* In the latter instance, invasion through the appendiceal wall can lead to intraperitoneal seeding and spread. In women, the resulting peritoneal implants may be mistaken for mucinous ovarian tumors. In the most advanced cases, the abdomen fills with tenacious, semisolid mucin, a condition called *pseudomyxoma peritonei.* This disseminated intraperitoneal disease may be held in check for years by repeated debulking but in most instances is ultimately fatal.

## SUMMARY

### Appendix

- *Acute appendicitis* is most common in children and adolescents. It is thought to be initiated by increased intraluminal pressure consequent to obstruction of the appendiceal lumen, which compromises venous outflow.
- The most common tumor of the appendix is the *carcinoid.*
- The clinical presentation with *appendiceal adenocarcinoma* can be indistinguishable from that with acute appendicitis.

## BIBLIOGRAPHY


### ORAL CAVITY

Hennessey PT, Westra WH, Califano JA: Human papillomavirus and head and neck squamous cell carcinoma: recent evidence and clinical implications. J Dent Res 88:300, 2009. *[Discussion of head and neck cancers associated with HPV.]*

Leemans CR, Braakhuis BJ, Brakenhoff RH: The molecular biology of head and neck cancer. Nat Rev Cancer 11:9, 2011. *[An up to date discussion of the molecular biology of head and neck cancer.]*

Leivo I: Insights into a complex group of neoplastic disease: advances in histopathologic classification and molecular pathology of salivary gland cancer. Acta Oncol 45:662, 2006. *[A good review of the histologic spectrum of salivary gland tumors.]*

### ESOPHAGUS

Liacouras CA, Furuta GT, Hirano I, et al: Eosinophilic esophagitis: updated consensus recommendations for children and adults. J Allergy Clin Immunol 128:3, 2011. *[The most current diagnostic definition of and therapeutic recommendations for eosinophilic esophagitis.]*

Sharma P: Clinical practice. Barrett's esophagus. N Engl J Med 361:2548, 2009. *[A comprehensive discussion of Barrett esophagus.]*

### INFLAMMATORY DISEASE OF THE STOMACH

Malfertheiner P, Chan FK, McColl KE: Peptic ulcer disease. Lancet 374:1449, 2009. *[Summary of current understanding of peptic ulcer disease.]*

Mills JC, Shivdasani RA: Gastric epithelial stem cells. Gastroenterology 140:412, 2011. *[A good discussion of cell lineages and differentiation pathways in the gastric epithelium.]*

Polk DB, Peek RM, Jr: *Helicobacter pylori:* gastric cancer and beyond. Nat Rev Cancer 10:403, 2010. *[A good review of* H. pylori *and mechanisms by which it is linked to gastric cancer.]*

### NEOPLASTIC DISEASE OF THE STOMACH

Murphy G, Pfeiffer R, Camargo MC, Rabkin CS: Meta-analysis shows that prevalence of Epstein-Barr virus-positive gastric cancer differs based on sex and anatomic location. Gastroenterology 137:824, 2009. *[A meta-analysis of over 15,000 gastric cancer cases tested for EBV RNA.]*

Polk DB, Peek RM Jr: *Helicobacter pylori:* gastric cancer and beyond. Nat Rev Cancer 10:403, 2010. *[A good review of* H. pylori *and mechanisms by which it is linked to gastric cancer.]*

Sagaert X, Van Cutsem E, De Hertogh G, et al: Gastric MALT lymphoma: a model of chronic inflammation-induced tumor development. Nat Rev Gastroenterol Hepatol 7:336, 2010. *[A discussion of gastric MALT lymphoma pathogenesis.]*

### INTESTINAL OBSTRUCTION

Kapur RP: Practical pathology and genetics of Hirschsprung's disease. Semin Pediatr Surg 18:212, 2009. *[A review of Hirschsprung disease etiology and diagnosis.]*

Muysoms FE, Miserez M, Berrevoet F, et al: Classification of primary and incisional abdominal wall hernias. Hernia 13:407, 2009. *[An explanation of abdominal hernia classification.]*

## VASCULAR DISORDERS

Barnert J, Messmann H: Diagnosis and management of lower gastrointestinal bleeding. Nat Rev Gastroenterol Hepatol 6:637, 2009. *[A good discussion of clinical approaches to lower GI bleeding.]*
Colgan SP, Taylor CT: Hypoxia: an alarm signal during intestinal inflammation. Nat Rev Gastroenterol Hepatol 7:281, 2010. *[A review of signaling events activated by intestinal hypoxia.]*
Sneider EB, Maykel JA: Diagnosis and management of symptomatic hemorrhoids. Surg Clin North Am 90:17, 2010. *[A clinically oriented review of hemorrhoids.]*

## MALABSORPTIVE DIARRHEA

Khan S, Chang L: Diagnosis and management of IBS. Nat Rev Gastroenterol Hepatol 7:565, 2010. *[A recent review of IBS.]*
Moore SR, Lima NL, Soares AM, et al: Prolonged episodes of acute diarrhea reduce growth and increase risk of persistent diarrhea in children. Gastroenterology 139:1156, 2010. *[A detailed study of environmental enteropathy.]*
Pardi DS, Kelly CP: Microscopic colitis. Gastroenterology 140:1155, 2011. *[A review of collagenous and lymphocytic colitis.]*
Schuppan D, Junker Y, Barisani D: Celiac disease: from pathogenesis to novel therapies. Gastroenterology 137:1912, 2009. *[A recent review of celiac disease.]*
Suchy FJ, Brannon PM, Carpenter TO, et al: National Institutes of Health Consensus Development Conference: lactose intolerance and health. Ann Intern Med 152:792, 2010. *[A consensus conference on lactose intolerance.]*

## INFECTIOUS ENTEROCOLITIS

Barton Behravesh C, Mody RK, Jungk J, et al: 2008 outbreak of *Salmonella* Saintpaul infections associated with raw produce. N Engl J Med 364:918, 2011. *[Analysis of a* Salmonella *epidemic.]*
John TJ, Dandona L, Sharma VP, Kakkar M: Continuing challenge of infectious diseases in India. Lancet 377:252, 2011. *[Review of enteric infections in India.]*
Kirkpatrick BD, Tribble DR: Update on human *Campylobacter jejuni* infections. Curr Opin Gastroenterol 27:1, 2011. *[Recent verview of* Campylobacter *gastroenteritis.]*
Kuehne SA, Cartman ST, Heap JT, et al: The role of toxin A and toxin B in *Clostridium difficile* infection. Nature 467:711, 2010. *[A detailed analysis of toxin function in* C. difficile *pathogenesis.]*
Navaneethan U, Giannella RA: Infectious colitis. Curr Opin Gastroenterol 27:66, 2011. *[Good overview of infectious colitis.]*
Prince Christopher RH, David KV, John SM, Sankarapandian V: Antibiotic therapy for *Shigella* dysentery. Cochrane Database Syst Rev 1:CD006784, 2010. *[A meta-analysis of antibiotic effectiveness in dysentery.]*
van Lieshout L, Verweij JJ: Newer diagnostic approaches to intestinal protozoa. Curr Opin Infect Dis 23:488, 2010. *[Recent review of evolving diagnostic tools.]*

## SIGMOID DIVERTICULITIS

Eglinton T, Nguyen T, Raniga S, et al: Patterns of recurrence in patients with acute diverticulitis. Br J Surg 97:952, 2010. *[Evaluation of outcome following acute episodes of diverticulitis.]*
Hall J, Hammerich K, Roberts P: New paradigms in the management of diverticular disease. Curr Probl Surg 47:680, 2010. *[A recent review of approaches to diverticulosis and diverticulitis management.]*

## INFLAMMATORY BOWEL DISEASE

Abraham C, Cho JH: Inflammatory bowel disease. N Engl J Med 361:2066, 2009. *[A complete review of IBD mechanisms and genomics.]*
Glocker EO, Kotlarz D, Boztug K, et al: Inflammatory bowel disease and mutations affecting the interleukin-10 receptor. N Engl J Med 361:2033, 2009. *[Identification of IL-10 receptor mutations in a subset of ulcerative colitis patients.]*
Goel GA, Kandiel A, Achkar JP, Lashner B: Molecular pathways underlying IBD-associated colorectal neoplasia: therapeutic implications. Am J Gastroenterol 106:719, 2011. *[A good review of colitis-associated cancer.]*
Kaser A, Zeissig S, Blumberg RS: Inflammatory bowel disease. Annu Rev Immunol 28:573, 2010. *[A review of immune mechanisms in IBD.]*
Marchiando AM, Graham WV, Turner JR: Epithelial barriers in homeostasis and disease. Annu Rev Pathol 5:119, 2010. *[A review of intestinal epithelial barrier function and its implications in IBD and other disorders.]*
Molodecky NA, Panaccione R, Ghosh S, et al: Challenges associated with identifying the environmental determinants of the inflammatory bowel diseases. Inflamm Bowel Dis 17:1792, 2011. *[A good discussion of environmental IBD triggers.]*
Turner JR: Intestinal mucosal barrier function in health and disease. Nat Rev Immunol 9:799, 2009. *[An analysis of epithelial-immune interactions in gastrointestinal disease.]*

## COLONIC POLYPS AND NEOPLASTIC DISEASE

Beggs AD, Latchford AR, Vasen HF, et al: Peutz-Jeghers syndrome: a systematic review and recommendations for management. Gut 59:975, 2010. *[A review of Peutz-Jeghers disease etiology and management.]*
Boland CR, Goel A: Microsatellite instability in colorectal cancer. Gastroenterology 138:2073, 2010. *[A discussion of the microsatellite instability pathway of colon cancer.]*
Hardwick JC, Kodach LL, Offerhaus GJ, van den Brink GR: Bone morphogenetic protein signalling in colorectal cancer. Nat Rev Cancer 8:806, 2008. *[A good review of signaling pathways in colon cancer.]*
Jasperson KW, Tuohy TM, Neklason DW, Burt RW: Hereditary and familial colon cancer. Gastroenterology 138:2044, 2010. *[A comprehensive review of colon cancer syndromes.]*
Jass JR: Colorectal polyposes: from phenotype to diagnosis. Pathol Res Pract 204:431, 2008. *[A morphology-focused review of polyposis syndromes.]*
Noffsinger AE: Serrated polyps and colorectal cancer: new pathway to malignancy. Annu Rev Pathol 4:343, 2009. *[A detailed review of sessile serrated adenomas and the mechanisms by which they develop and progress.]*
Pino MS, Chung DC: The chromosomal instability pathway in colon cancer. Gastroenterology 138:2059, 2010. *[A review of colon cancer genetics.]*

## APPENDIX

Cartwright SL, Knudson MP: Evaluation of acute abdominal pain in adults. Am Fam Physician 77:971, 2008. *[A clinically oriented approach to the acute abdomen.]*
Deschamps L, Couvelard A: Endocrine tumors of the appendix: a pathologic review. Arch Pathol Lab Med 134:871, 2010. *[A pathology-focused review of appendiceal carcinoid tumors.]*
Tang LH: Epithelial neoplasms of the appendix. Arch Pathol Lab Med 134:1612, 2010. *[A review of appendiceal cancers.]*

See Targeted Therapy available online at studentconsult.com

CHAPTER 15

# Liver, Gallbladder, and Biliary Tract

CHAPTER CONTENTS


**THE LIVER 603**
Clinical Syndromes 604
Hepatic Failure 604
Jaundice and Cholestasis 605
Hepatic Encephalopathy 606
Cirrhosis 607
Portal Hypertension 608
Portosystemic Shunt 609
Drug- or Toxin-Induced Liver Disease 610
Acute and Chronic Hepatitis 611
Viral Hepatitis 614
Other Viral Infections of the Liver 620
Autoimmune Hepatitis 620
Drug/Toxin-Mediated Injury Mimicking Hepatitis 621
Alcoholic and Nonalcoholic Fatty Liver Disease 621
Alcoholic Liver Disease 623
Nonalcoholic Fatty Liver Disease (NAFLD) 625
Drug/Toxin-Mediated Injury with Steatosis 625
Cholestatic Liver Diseases 626
Neonatal Cholestasis 626
Cholestasis of Sepsis 626
Primary Biliary Cirrhosis 627
Primary Sclerosing Cholangitis 628
Drug/Toxin-Induced Cholestasis 629
Inherited Metabolic Diseases 629
Hemochromatosis 629
Wilson Disease 630
$\alpha_1$-Antitrypsin Deficiency 631
Circulatory Disorders 632
Impaired Blood Flow into the Liver 632
Impaired Blood Flow Through the Liver 633
Hepatic Vein Outflow Obstruction 634
Other Inflammatory and Infectious Diseases 635
Liver Abscesses 635
Granulomatous Disease 635
Tumors and Hepatic Nodules 635
Benign Tumors 635
Precursor Lesions of Hepatocellular Carcinoma 636
Hepatocellular Carcinomas 637
**DISORDERS OF THE GALLBLADDER AND THE EXTRAHEPATIC BILIARY TRACT 639**
Gallbladder Diseases 639
Cholelithiasis (Gallstones) 639
Cholecystitis 641
Disorders of Extrahepatic Bile Ducts 642
Choledocholithiasis and Cholangitis 642
Secondary Biliary Cirrhosis 642
Biliary Atresia 642
Tumors 643
Carcinoma of the Gallbladder 643
Cholangiocarcinomas 643


## THE LIVER

The liver and its companion biliary tree and gallbladder are considered together because of their anatomic proximity and interrelated functions and the overlapping features of some diseases that affect these organs. This chapter focuses primarily on the liver, because it has by far the greater role in normal physiology and is the site of a wide variety of diseases.

Residing at the crossroads between the digestive tract and the rest of the body, the liver has the enormous task of maintaining the body's metabolic homeostasis. This task includes the processing of dietary amino acids, carbohydrates, lipids, and vitamins; synthesis of serum proteins; and detoxification and excretion into bile of endogenous waste products and xenobiotics. Thus, it is not surprising that the liver is vulnerable to a wide variety of metabolic, toxic, microbial, and circulatory insults. In some instances the disease process is primary to the liver. In others the hepatic involvement is secondary, often to some of the most common diseases in humans, such as heart failure, diabetes, and extrahepatic infections.

The liver has enormous functional reserve, and regeneration occurs in all but the most fulminant of hepatic diseases. Surgical removal of 60% of the liver in a normal person is followed by minimal and transient hepatic impairment, with restoration of most of its mass by regeneration within 4 to 6 weeks. In persons who have sustained massive hepatic necrosis, almost perfect restoration may occur if the patient can survive the metabolic insult of liver failure. The functional reserve and the regenerative capacity of the liver mask to some extent the clinical impact of early liver damage. However, with progression of diffuse disease or disruption of the circulation or bile flow, the consequences of deranged liver function become severe and even life-threatening.


*Contributions of Drs. Jim Crawford and Nelson Fausto to this chapter in earlier editions are gratefully acknowledged.*

**Table 15–1** Clinical Consequences of Liver Disease

| |
|---|
| **Characteristic Signs of Severe Hepatic Dysfunction** |
| Jaundice and cholestasis |
| Hypoalbuminemia |
| Hyperammonemia |
| Hypoglycemia |
| Palmar erythema |
| Spider angiomas |
| Hypogonadism |
| Gynecomastia |
| Weight loss |
| Muscle wasting |
| **Portal Hypertension Associated with Cirrhosis** |
| Ascites with or without spontaneous bacterial peritonitis |
| Splenomegaly |
| Esophageal varices |
| Hemorrhoids |
| Caput medusae—abdominal skin |
| **Complications of Hepatic Failure** |
| Coagulopathy |
| Hepatic encephalopathy |
| Hepatorenal syndrome |
| Portopulmonary hypertension |
| Hepatopulmonary syndrome |

# CLINICAL SYNDROMES

The major clinical syndromes of liver disease are hepatic failure, cirrhosis, portal hypertension, and cholestasis. These conditions have characteristic clinical manifestations (Table 15–1), and a battery of laboratory tests for their evaluation (Table 15–2), with liver biopsy representing the gold standard for diagnosis.

**Table 15–2** Laboratory Evaluation of Liver Disease

| Test Category | Serum Measurement* |
|---|---|
| Hepatocyte integrity | Cytosolic hepatocellular enzymes†<br>*Serum aspartate aminotransferase* (AST)<br>*Serum alanine aminotransferase* (ALT)<br>*Serum lactate dehydrogenase* (LDH) |
| Biliary excretory function | Substances secreted in bile†<br>*Serum bilirubin*<br>*Total:* unconjugated plus conjugated<br>*Direct:* conjugated only<br>*Delta:* covalently linked to albumin<br>Urine bilirubin<br>Serum bile acids<br>Plasma membrane enzymes† (from damage to bile canaliculi)<br>*Serum alkaline phosphatase*<br>*Serum γ-glutamyl transpeptidase*<br>Serum 5′-nucleotidase |
| Hepatocyte function | Proteins secreted into the blood<br>*Serum albumin*‡<br>*Prothrombin time*† (factors V, VII, X, prothrombin, fibrinogen)<br>Hepatocyte metabolism<br>Serum ammonia†<br>Aminopyrine breath test (hepatic demethylation)<br>Galactose elimination (intravenous injection) |

*The most commonly performed tests are in *italics*.
†An elevation indicates liver disease.
‡A decrease indicates liver disease.

## Hepatic Failure

The most severe clinical consequence of liver disease is hepatic failure. It generally develops as the end point of progressive damage to the liver, either through insidious piecemeal destruction of hepatocytes or by repetitive waves of symptomatic parenchymal damage. Less commonly, hepatic failure is the result of sudden, massive destruction. Whatever the sequence, 80% to 90% of hepatic function must be lost before hepatic failure ensues. In many cases, the balance is tipped toward decompensation by intercurrent conditions or events that place demands on the liver. These include systemic infections, electrolyte disturbances, major surgery, heart failure, and gastrointestinal bleeding.

The patterns of injury that cause liver failure fall into three categories:

- *Acute liver failure with massive hepatic necrosis.* Most often caused by *drugs* or *viral hepatitis*, acute liver failure denotes clinical hepatic insufficiency that progresses from onset of symptoms to hepatic encephalopathy within 2 to 3 weeks. A course extending as long as 3 months is called subacute failure. *The histologic correlate of acute liver failure is massive hepatic necrosis,* whatever the underlying cause. It is an uncommon but life-threatening condition that often necessitates liver transplantation.
- *Chronic liver disease.* This is the most common route to hepatic failure and is the end point of relentless chronic liver damage. While all structural components of the liver are involved in end-stage chronic liver disease, the processes that initiate and drive chronic damage to the liver can usually be classified as either primarily hepatocytic (or *parenchymal*), biliary, or vascular. Regardless of the initiating factors, chronic damage to the liver often ends in cirrhosis, as described later.
- *Hepatic dysfunction without overt necrosis.* Less commonly than the forms described above, hepatocytes may be viable but unable to perform their normal metabolic function. Settings where this is seen most often are mitochondrial injury in Reye syndrome, acute fatty liver of pregnancy, and some drug- or toxin-mediated injuries.

### Clinical Features

The clinical manifestations of hepatic failure from chronic liver disease are much the same regardless of the cause of the disease. *Jaundice* is an almost invariable finding. Impaired hepatic synthesis and secretion of albumin lead to *hypoalbuminemia,* which predisposes to peripheral edema. *Hyperammonemia* is attributable to defective hepatic urea cycle function. Signs and symptoms of chronic disease include *palmar erythema* (a reflection of local vasodilatation) and *spider angiomas* of the skin. Each angioma is a central, pulsating, dilated arteriole from which small vessels radiate. There may also be impaired estrogen metabolism and consequent hyperestrogenemia, which leads to *hypogonadism* and *gynecomastia* in men. Acute liver failure may manifest as jaundice or encephalopathy, but notably absent on physical examination are the other stigmata of chronic liver disease.

Hepatic failure is life-threatening for several reasons. The accumulation of toxic metabolites may have

widespread effects and patients are highly susceptible to failure of multiple organ systems. Thus, respiratory failure with pneumonia and sepsis can give rise to renal failure and thus claim the lives of many individuals with hepatic failure. A *coagulopathy* develops, attributable to impaired hepatic synthesis of blood clotting factors. The resultant bleeding tendency may lead to massive gastrointestinal hemorrhage as well as bleeding elsewhere. Intestinal absorption of blood places a metabolic load on the liver that worsens the severity of hepatic failure.

The outlook with full-blown hepatic failure is particularly grave for persons with chronic liver disease. A rapid downhill course is usual, with death occurring within weeks to a few months in about 80% of cases. About 40% of patients with acute liver failure may recover spontaneously. Liver transplantation in acute or chronic liver failure can be curative, however. Conditions contributing to the extraordinary morbidity and eventual mortality associated with severe liver disease are discussed next.

## Jaundice and Cholestasis

Jaundice results from the retention of bile. Hepatic bile formation serves two major functions. First, bile constitutes the primary pathway for the elimination of bilirubin, excess cholesterol, and xenobiotics that are insufficiently water-soluble to be excreted in the urine. Second, secreted bile salts and phospholipid molecules promote emulsification of dietary fat in the lumen of the gut. Bile formation is a complex process and is readily disrupted by a variety of hepatic insults. Thus, *jaundice,* a yellow discoloration of skin and sclerae (*icterus*), occurs when systemic retention of bilirubin produces serum levels above 2.0 mg/dL (the normal level in adults is below 1.2 mg/dL). *Cholestasis* is defined as systemic retention of not only bilirubin but also other solutes eliminated in bile (particularly bile salts and cholesterol).

### *Bilirubin and Bile Acids*

Bilirubin is the end product of heme degradation (Fig. 15–1). Most of the daily production (0.2 to 0.3 g) is derived from breakdown of senescent red cells within mononuclear phagocytes, with the remainder derived primarily from the turnover of hepatic hemoproteins. Excessive destruction of erythroid progenitors in the bone marrow due to intramedullary apoptosis (ineffective erythropoiesis) is an important cause of jaundice in hematologic disorders (Chapter 11). Whatever the source, heme oxygenase oxidizes heme to biliverdin, which is then reduced to bilirubin by biliverdin reductase. Bilirubin thus formed outside the liver in cells of the mononuclear phagocyte system (including the spleen) is released and bound to serum albumin. Hepatocellular processing of bilirubin involves the following sequence:

1. Carrier-mediated uptake at the sinusoidal membrane
2. Cytosolic protein binding and delivery to the endoplasmic reticulum
3. Conjugation with one or two molecules of glucuronic acid by bilirubin uridine diphosphate–glucuronosyltransferase
4. Excretion of the water-soluble, nontoxic bilirubin glucuronides into bile. Most bilirubin glucuronides are deconjugated by gut bacterial β-glucuronidases and degraded to colorless urobilinogens. The urobilinogens and the residue of intact pigment are largely excreted in feces. Approximately 20% of the urobilinogens are reabsorbed in the ileum and colon, returned to the liver, and promptly reexcreted into bile. Conjugated and unconjugated bile acids also are reabsorbed in the ileum and returned to the liver by the *enterohepatic circulation.*

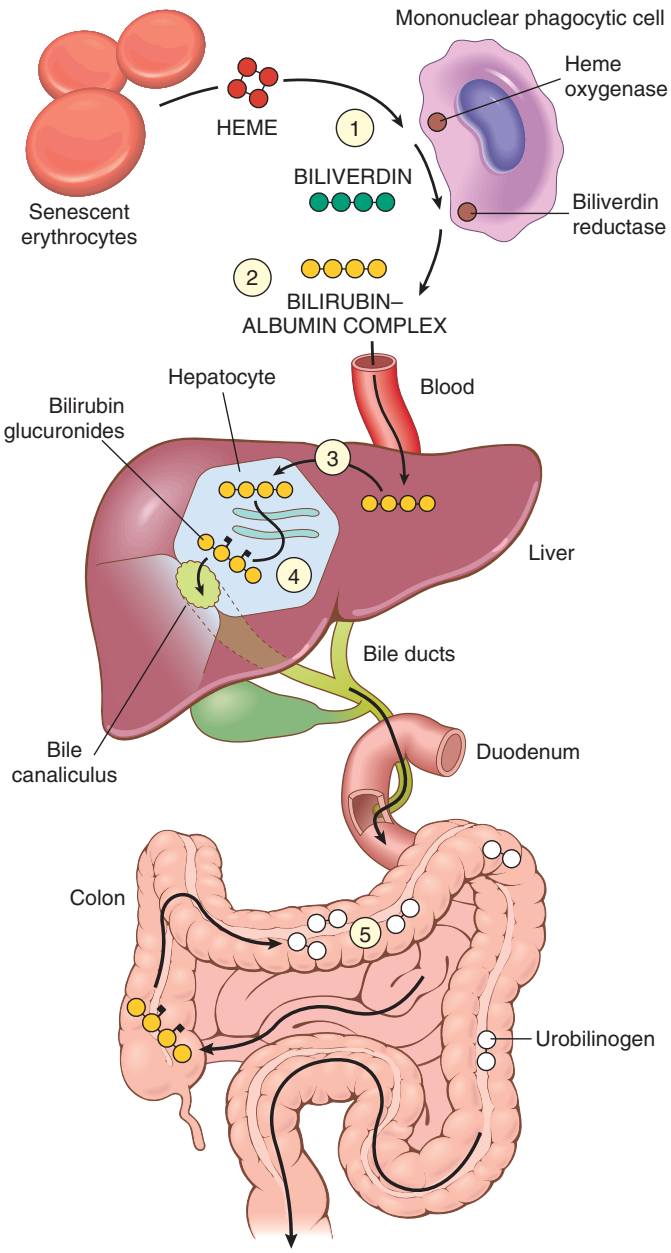


**Figure 15–1** Bilirubin metabolism and elimination. *1*, Normal bilirubin production (0.2 to 0.3 g/day) is derived primarily from the breakdown of senescent circulating red cells, with a minor contribution from degradation of tissue heme-containing proteins. *2*, Extrahepatic bilirubin is bound to serum albumin and delivered to the liver. *3* and *4*, Hepatocellular uptake (*3*) and glucuronidation (*4*) by glucuronosyltransferase in the hepatocytes generate bilirubin monoglucuronides and diglucuronides, which are water-soluble and readily excreted into bile. *5*, Gut bacteria deconjugate the bilirubin and degrade it to colorless urobilinogens. The urobilinogens and the residue of intact pigments are excreted in the feces, with some reabsorption and reexcretion into bile.

## PATHOGENESIS

In the normal adult, the rate of systemic bilirubin production is equal to the rates of hepatic uptake, conjugation, and biliary excretion. Jaundice occurs when the equilibrium between bilirubin production and clearance is disrupted; the major responsible disorders are listed in Table 15–3. More than one mechanism may operate to cause jaundice, especially in hepatitis, when both unconjugated and conjugated bilirubin may be produced in excess. In severe disease, bilirubin levels may reach 30 to 40 mg/dL.

Of these various causes of jaundice, the most common are hepatitis, obstruction to the flow of bile (discussed later in this chapter), and hemolytic anemia (Chapter 11). Because the hepatic machinery for conjugating and excreting bilirubin does not fully mature until about 2 weeks of age, almost every newborn develops transient and mild unconjugated hyperbilirubinemia, termed **neonatal jaundice** or physiologic jaundice of the newborn.

Jaundice also may result from inborn errors of metabolism, including

- **Gilbert syndrome,** a relatively common (7% of the population), benign, somewhat heterogeneous inherited condition manifesting as mild, fluctuating unconjugated hyperbilirubinemia. The primary cause is decreased hepatic levels of glucuronosyltransferase attributed to a mutation in the encoding gene; polymorphisms in the gene may play a role in the variable expression of this disease. **The hyperbilirubinemia is not associated with any morbidity.**
- **Dubin-Johnson syndrome** results from an autosomal recessive defect in the transport protein responsible for hepatocellular excretion of bilirubin glucuronides across the canalicular membrane. Affected persons exhibit conjugated hyperbilirubinemia. Other than having a darkly pigmented liver (from polymerized epinephrine metabolites, not bilirubin) and hepatomegaly, patients are otherwise without functional problems.

**Table 15–3** Main Causes of Jaundice

| |
|---|
| **Predominantly Unconjugated Hyperbilirubinemia** |
| Excess Production of Bilirubin |
| Hemolytic anemias<br>Resorption of blood from internal hemorrhage (e.g., alimentary tract bleeding, hematomas)<br>Ineffective erythropoiesis syndromes (e.g., pernicious anemia, thalassemia) |
| Reduced Hepatic Uptake |
| Drug interference with membrane carrier systems<br>Diffuse hepatocellular disease (e.g., viral or drug-induced hepatitis, cirrhosis) |
| Impaired Bilirubin Conjugation |
| Physiologic jaundice of the newborn |
| **Predominantly Conjugated Hyperbilirubinemia** |
| Decreased Hepatocellular Excretion |
| Deficiency in canalicular membrane transporters<br>Drug-induced canalicular membrane dysfunction (e.g., oral contraceptives, cyclosporine)<br>Hepatocellular damage or toxicity (e.g., viral or drug-induced hepatitis, total parenteral nutrition, systemic infection) |
| Impaired Intra- or Extrahepatic Bile Flow |
| Inflammatory destruction of intrahepatic bile ducts (e.g., primary biliary cirrhosis, primary sclerosing cholangitis, graft-versus-host disease, liver transplantation); gall stones, carcinoma of the pancreas |

Cholestasis, which results from impaired bile flow due to hepatocellular dysfunction or intrahepatic or extrahepatic biliary obstruction, also may manifest as jaundice. However, sometimes *pruritus* is the presenting symptom, the pathogenesis of which remains obscure. *Skin xanthomas* (focal accumulations of cholesterol) sometimes appear, the result of hyperlipidemia and impaired excretion of cholesterol. A *characteristic laboratory finding is elevated serum alkaline phosphatase,* an enzyme present in bile duct epithelium and in the canalicular membrane of hepatocytes. A different alkaline phosphatase isozyme normally is expressed in many other tissues such as bone, and so hepatic origin must be verified. Reduced bile flow also causes intestinal malabsorption including inadequate absorption of the fat-soluble vitamins A, D, and K.

Extrahepatic biliary obstruction frequently is amenable to surgical correction. By contrast, cholestasis caused by diseases of the intrahepatic biliary tree or hepatocellular secretory failure (collectively termed *intrahepatic cholestasis*) cannot be treated surgically (short of transplantation), and the patient's condition may be worsened by an operative procedure. Thus, *there is some urgency in identifying the cause of jaundice and cholestasis.*

## SUMMARY

### Jaundice and Cholestasis

- Jaundice occurs when retention of bilirubin leads to serum levels above 2.0 mg/dL.
- Hepatitis and intra- or extrahepatic obstruction of bile flow are the most common causes of jaundice involving the accumulation of conjugated bilirubin.
- Hemolytic anemias are the most common cause of jaundice involving the accumulation of unconjugated bilirubin.
- Cholestasis is the impairment of bile flow resulting in the retention of bilirubin, bile acids, and cholesterol.
- Serum alkaline phosphatase usually is elevated in cholestatic conditions.

## Hepatic Encephalopathy

Hepatic encephalopathy may develop rapidly in acute liver failure or insidiously with gradually evolving chronic liver failure from cirrhosis. In either setting, patients with hepatic encephalopathy show a spectrum of brain dysfunction ranging from subtle behavioral abnormalities to

marked confusion and stupor, to deep coma and death. These changes may progress over hours or days as, for example, in fulminant hepatic failure or gradually in a person with marginal hepatic function from chronic liver disease. Associated fluctuating neurologic signs include rigidity, hyperreflexia, nonspecific electroencephalographic changes, and, rarely, seizures. Particularly characteristic is *asterixis* (also called flapping tremor), which is a pattern of nonrhythmic, rapid extension-flexion movements of the head and extremities, best seen when the arms are held in extension with dorsiflexed wrists.

In most instances there are only minor morphologic changes in the brain, such as edema and an astrocytic reaction. Two factors seem to be important in the genesis of this disorder:

- Severe loss of hepatocellular function
- Shunting of blood from portal to systemic circulation around the chronically diseased liver

In the acute setting, an elevation in blood ammonia, which impairs neuronal function and promotes generalized brain edema, seems to be key. In the chronic setting, deranged neurotransmitter production, particularly in monoaminergic, opioidergic, γ-aminobutyric acid (GABA)-ergic, and endocannabanoid systems, leads to neuronal dysfunction.

## Cirrhosis

Cirrhosis is among the top 10 causes of death in the Western world. Its major causes include chronic viral infections, alcoholic or nonalcoholic steatohepatitis (NASH), autoimmune diseases affecting hepatocytes and/or bile ducts, and iron overload. *Cirrhosis* is defined as a *diffuse process characterized by fibrosis and the conversion of normal liver architecture into structurally abnormal nodules.* Its main characteristics by definition are not focal but rather involve most (if not all) of the diseased liver and include

- *Fibrous septa* in the form of delicate bands or broad scars around multiple adjacent lobules. Long-standing fibrosis generally is irreversible so long as disease persists or if disease-associated vascular shunts are widespread, although regression is possible if the underlying cause of liver disease is reversed.
- *Parenchymal nodules,* ranging in size from very small (less than 3 mm in diameter—micronodules) to large (over 1 cm—macronodules), encircled by these fibrous bands. Hepatocytes in these nodules derive from two sources: (1) preexistent, long-lived hepatocytes that, by the time cirrhosis is established, display features of replicative senescence; and (2) newly formed hepatocytes capable of replication that are derived from stem/progenitor cells found adjacent to the canals of Hering and small bile ductules—the hepatobiliary stem cell niche. These stem/progenitor cells also give rise to the *ductular reactions* found at the periphery of most cirrhotic nodules, where parenchyma meets stromal scar, and are accompanied by proliferating endothelial cells, myofibroblasts, and inflammatory cells.

There is no satisfactory classification of cirrhosis save for specification of the presumed underlying etiology. After all known causes have been excluded, about 10% of cases remain, referred to as cryptogenic cirrhosis, although in recent years most of these are recognized as probable "burned-out" NASH. General principles are presented next; the distinguishing features of each form of cirrhosis are discussed subsequently in the relevant disease overview.

### PATHOGENESIS

**Three processes are central to the pathogenesis of cirrhosis: death of hepatocytes, extracellular matrix deposition, and vascular reorganization.**

Changes in the connective tissue and extracellular matrix (ECM) are common to all forms of cirrhosis. In the normal liver, ECM consisting of interstitial collagens (fibril-forming collagen types I, III, V, and XI) is present only in the liver capsule, in portal tracts, and around central veins. The hepatocytes have no true basement membrane; instead, a delicate framework containing type IV collagen and other proteins lies in the space between sinusoidal endothelial cells and hepatocytes (the space of Disse). By contrast, in cirrhosis, types I and III collagen and other ECM components are deposited in the space of Disse (Fig. 15–2).

The major source of excess collagen in cirrhosis are the perisinusoidal stellate cells (formerly known as Ito cells), which lie in the space of Disse. Although they normally function as storage cells for vitamin A, during the development of fibrosis they activate and transform into myofibroblasts. The stimuli for the activation of stellate cells and production of collagen are believed to include reactive oxygen species, growth factors, and cytokines such as tumor necrosis factor (TNF), interleukin-1 (IL-1), and lymphotoxins, which can be produced by damaged hepatocytes or by stimulated Kupffer cells and sinusoidal endothelial cells. Activated stellate cells themselves produce growth factors, cytokines, and chemokines that cause their further proliferation and collagen synthesis—in particular, transforming growth factor-β (TGF-β). Portal fibroblasts probably also participate in some forms of cirrhosis. During the course of chronic liver disease, fibrosis is a dynamic process that involves the synthesis, deposition, and resorption of ECM components, modulated by changing balances between metalloproteases and tissue inhibitors of metalloproteases (Chapter 2). Thus, even in late-stage disease, if the disease process is halted or eliminated, significant remodeling and even restoration of liver function **(cirrhotic regression)** is possible.

Vascular injuries and changes also play significant roles in remodeling of the liver into a cirrhotic state. Inflammation and thrombosis of portal veins, hepatic arteries, and/or central veins may lead to alternating zones of parenchymal hypoperfusion, with resulting parenchymal atrophy, and hyperperfusion, with overcompensating regeneration. The major vascular lesions that contribute to defects in liver function are loss of sinusoidal endothelial cell fenestrations (Fig. 15–2) and the development of portal vein–hepatic vein and hepatic artery–portal vein vascular shunts. While normal sinusoids have fenestrated endothelial cells that allow free exchange of solutes between plasma and hepatocytes, loss of fenestrations and increased basement membrane

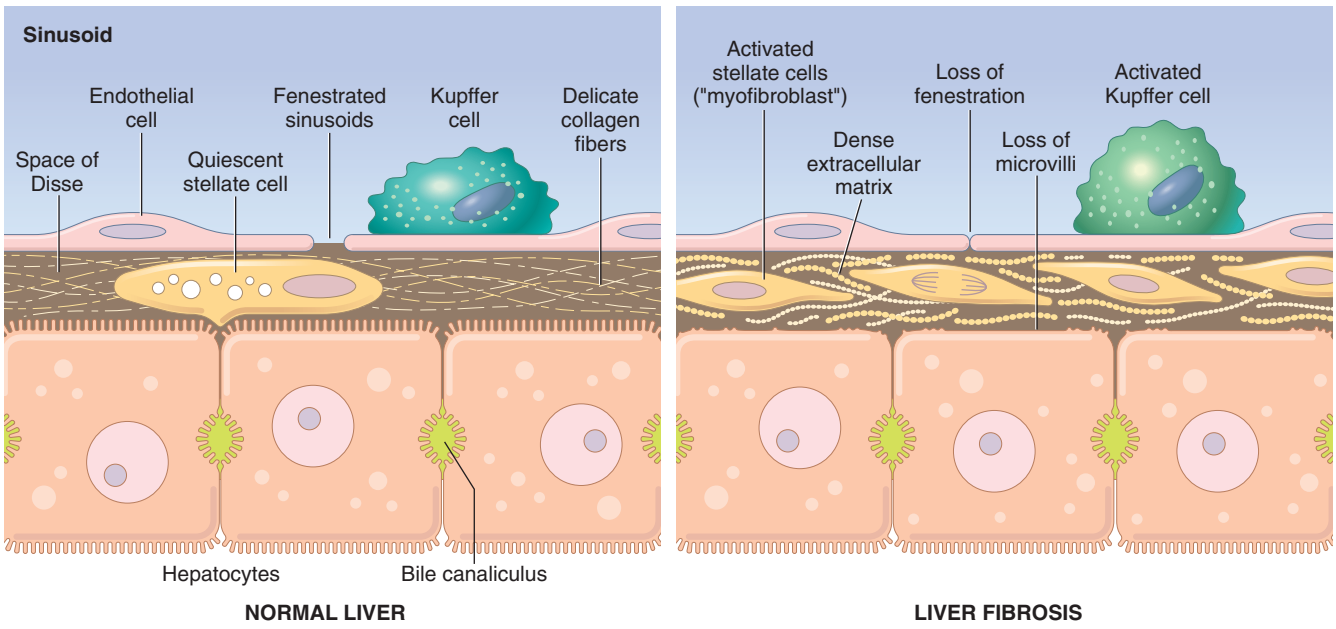


**Figure 15–2** Liver fibrosis. In the normal liver, the perisinusoidal space (space of Disse) contains a delicate framework of extracellular matrix components. In liver fibrosis, stellate cells are activated to produce a dense layer of matrix material that is deposited in the perisinusoidal space. Collagen deposition blocks the endothelial fenestrations and prevents the free exchange of materials from the blood. Kupffer cells also are activated and produce cytokines that are involved in fibrosis. Note that this illustration is not to scale; the space of Disse is actually much narrower than shown.

formation convert thin-walled sinusoids into higher pressure, fast-flowing vascular channels without such solute exchange. In particular, the movement of proteins (e.g., albumin, clotting factors, lipoproteins) between hepatocytes and the plasma is markedly impaired. These functional changes are aggravated by the loss of microvilli from the hepatocyte surface, further diminishing its transport capacity. Vascular shunts mentioned earlier lead to abnormal vascular pressures in the liver and contribute to hepatic dysfunction and portal hypertension, described later.

The causes of liver cell injury that give rise to cirrhosis are varied and depend on the etiology (viral, alcoholic, drugs). As described earlier, the normal liver cells are replaced by parenchymal nodules derived from long-lived surviving hepatocytes and new cells generated from stem cells. The regenerating liver cells form spherical nodules confined by fibrous septa.

## SUMMARY

### Cirrhosis

- The three main characteristics of cirrhosis are (1) involvement of most or all of the liver, (2) bridging fibrous septa, and (3) parenchymal nodules containing a mix of senescent and replicating (often stem/progenitor cell-derived) hepatocytes.
- Cirrhosis usually is an end-stage process that may have multiple causes. The most frequent are chronic hepatitis B and C and alcoholic and nonalcoholic steatohepatitis. Less frequent causes are autoimmune and biliary diseases and metabolic conditions such as hemochromatosis.
- The main complications of cirrhosis are related to decreased liver function, portal hypertension, and increased risk for development of hepatocellular carcinoma.

### Clinical Features

All forms of cirrhosis may be clinically silent. When symptoms appear, they typically are nonspecific and include anorexia, weight loss, weakness, and, in advanced disease, frank debilitation. Incipient or overt hepatic failure may develop, usually precipitated by imposition of a metabolic load on the liver, as from systemic infection or a gastrointestinal hemorrhage. Most cases of ultimately fatal cirrhosis involve one of the following mechanisms:

- Progressive liver failure
- A complication related to portal hypertension
- The development of hepatocellular carcinoma

## Portal Hypertension

Increased resistance to portal blood flow may develop from prehepatic, intrahepatic, and posthepatic causes (described later). *The dominant intrahepatic cause is cirrhosis, accounting for most cases of portal hypertension.* Far less frequent are instances of *noncirrhotic portal hypertension*, such as from schistosomiasis, massive fatty change, diffuse granulomatous diseases (e.g., sarcoidosis, miliary tuberculosis), and diseases affecting the portal microcirculation, exemplified by *nodular regenerative hyperplasia.*

Portal hypertension in cirrhosis results from increased resistance to portal flow at the level of the sinusoids and

compression of central veins by perivenular fibrosis and expanded parenchymal nodules. Anastomoses between the arterial and portal systems in the fibrous bands also contribute to portal hypertension by imposing arterial pressure on the normally low-pressure portal venous system. Another major factor in the causation of portal hypertension is an increase in portal venous blood flow resulting from a hyperdynamic circulation. This is caused by arterial vasodilation in the splanchnic circulation, resulting primarily from increased production of nitric oxide (NO) in the vascular bed. This occurs in response to reduced clearance of bacterial DNA absorbed from the gut that bypasses the Kupffer cells due to intrahepatic shunting of blood from portal to systemic circulation. Bacterial DNA causes increased production of NO. The major clinical consequences are discussed next (Fig. 15–3).

### *Ascites*

*Ascites* refers to the collection of excess fluid in the peritoneal cavity. It usually becomes clinically detectable when at least 500 mL have accumulated, but many liters may collect, causing massive abdominal distention. Ascites generally is a serous fluid containing as much as 3 g/dL of protein (largely albumin). More importantly, the serum to ascites albumin gradient is ≥1.1 g/dL. The fluid may contain a scant number of mesothelial cells and mononuclear leukocytes. Influx of neutrophils suggests secondary infection, whereas presence of red cells points to possible disseminated intraabdominal cancer. With long-standing ascites, seepage of peritoneal fluid through transdiaphragmatic lymphatics may produce hydrothorax, more often on the right side.

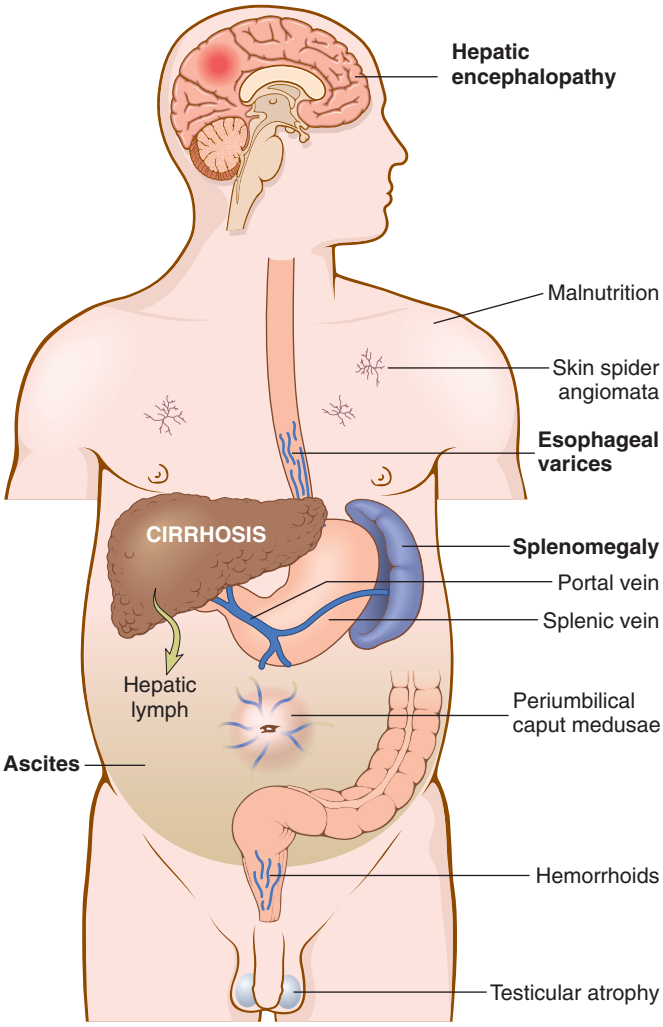


**Figure 15–3** Some clinical consequences of portal hypertension in the setting of cirrhosis. The most important manifestations are in **bold** type.

## PATHOGENESIS

The pathogenesis of ascites is complex, involving one or more of the following mechanisms:

- Increased movement of intravascular fluid into the extravascular space of Disse, caused by sinusoidal hypertension and hypoalbuminemia.
- Leakage of fluid from the hepatic interstitium into the peritoneal cavity. Normal thoracic duct lymph flow is 800 to 1000 mL/day. With cirrhosis, hepatic lymphatic flow may approach 20 L/day, exceeding thoracic duct capacity. Hepatic lymph is rich in proteins and low in triglycerides, as reflected in the protein-rich ascitic fluid.
- Renal retention of sodium and water due to secondary hyperaldosteronism (Chapter 3), despite a total body sodium mass greater than normal.

## Portosystemic Shunt

With the rise in portal venous pressure, shunts develop wherever the systemic and portal circulations share capillary beds. Principal sites are veins around and within the rectum (manifest as hemorrhoids), the cardioesophageal junction (producing esophagogastric varices), the retroperitoneum, and the falciform ligament of the liver (involving periumbilical and abdominal wall collaterals). Although hemorrhoidal bleeding may occur, it is rarely massive or life-threatening. Much more important are the *esophagogastric varices* that appear in about 65% of persons with advanced cirrhosis of the liver, causing massive hematemesis and death in some instances (Chapter 14). Rarely, abdominal wall collaterals appear as dilated subcutaneous veins extending outward from the umbilicus (*caput medusae*).

### *Splenomegaly*

Long-standing congestion may cause congestive splenomegaly. The degree of enlargement varies widely (usually 1000 g or less) and is not necessarily correlated with other features of portal hypertension. Massive splenomegaly may secondarily induce a variety of hematologic abnormalities attributable to hypersplenism (Chapter 11).

### *Hepatorenal Syndrome*

Hepatorenal syndrome generally appears only with severe liver disease and is marked by the development of renal failure without primary abnormalities of the kidneys themselves. Excluded by this definition are concomitant toxic damage to both the liver and the kidney, as may occur in carbon tetrachloride and mushroom poisoning and the copper toxicity of Wilson disease. Also excluded are instances of advanced hepatic failure in which circulatory collapse leads to acute tubular necrosis and renal failure. Kidney function promptly improves if hepatic failure is reversed. Although the exact cause is unknown, evidence points to splanchnic vasodilatation and systemic vasoconstriction, leading to a severe reduction in renal blood flow, particularly to the cortex.

The syndrome is heralded by a drop in urine output and rising blood urea nitrogen and creatinine values. The ability to concentrate urine is retained, producing a hyperosmolar urine devoid of proteins and abnormal sediment that is surprisingly low in sodium (unlike renal tubular necrosis). Renal dialysis or other treatments are at best bridges to the only cure, liver transplantation; however, transplantation recipients with hepatorenal syndrome have a high mortality in the months after the operation.

### *Portopulmonary Hypertension and Hepatopulmonary Syndrome*

Pulmonary dysfunction in chronic liver disease is common and may be life-threatening. Causes of liver injury also may damage the lungs (e.g., $\alpha_1$-antitrypsin deficiency leading to both cirrhosis and emphysema). Ascites, pressing upward on the diaphragm, and pleural effusions associated with portal hypertension can compromise lung capacity. Finally, changes in pulmonary blood flow occurring secondary to hepatic failure may lead to *portopulmonary hypertension* or *hepatopulmonary syndrome*.

Portopulmonary hypertension is defined as pulmonary arterial hypertension associated with liver disease or portal hypertension. Although the mechanisms underlying this condition remain obscure, they seem to involve portal hypertension of any cause (cirrhotic or non-cirrhotic) and excessive pulmonary vasoconstriction and vascular remodeling, which eventually lead to right-sided heart failure; *the most common clinical manifestations are dyspnea on exertion* and clubbing of the fingers, followed by palpitations and chest pain.

Hepatopulmonary syndrome is associated with abnormal intrapulmonary vascular dilatation in combination with increased pulmonary blood flow. Shunting of blood through such dilatations leads to ventilation-perfusion mismatch and reduced oxygen diffusion, thus giving rise to *severe arterial hypoxemia with dyspnea and cyanosis*. Oxygen supplementation can alleviate these problems early on, though the most severe intrapulmonary vascular dilatation or formation of arteriovenous malformations causes right-to-left shunting that is only partially correctable. Platypnea (easier breathing while lying down as compared to when sitting or standing) and orthodeoxia (fall of arterial blood oxygen with upright posture) are pathognomonic of hepatopulmonary syndrome.

Selected patients with portopulmonary hypertension experience some degree of reversal of disturbed pulmonary function with liver transplantation.

## DRUG- OR TOXIN-INDUCED LIVER DISEASE

As the major drug metabolizing and detoxifying organ in the body, the liver is subject to injury from an enormous array of therapeutic and environmental chemicals. Injury may result from direct toxicity, through hepatic conversion of a xenobiotic to an active toxin, or by immune mechanisms, such as by a drug or a metabolite acting as a hapten to convert a cellular protein into an immunogen.

A diagnosis of drug- or toxin-induced liver disease may be made on the basis of a temporal association of liver damage with drug or toxin exposure and, it is hoped, recovery on removal of the compound(s), combined with exclusion of other potential causes. *Exposure to a toxin or therapeutic agent should always be included in the differential diagnosis of any form of liver disease.* By far the most important agent that produces toxic liver injury is alcohol; its characteristic histologic (but not clinical) features are shared with nonalcoholic fatty liver disease (NAFLD) and therefore it is discussed in that section.

Drug-induced liver disease is a common condition that may manifest as a mild reaction or, much more seriously, as acute liver failure or chronic liver disease. A large number of drugs and chemicals can produce liver injury (Table 15–4). It is important to keep in mind that compounds other than those normally thought of as drugs or medicines may be to blame; often careful, persistent history taking will uncover exposure to other potential toxins such as herbal remedies, dietary supplements, topical applications (e.g., ointments, perfumes, shampoo), and environmental exposures (e.g., cleaning solvents, pesticides, fertilizers).

Principles of drug and toxic injury are discussed in Chapter 7. Here it suffices to note that drug reactions may be classified as *predictable* or *unpredictable* (idiosyncratic). Predictable drug or toxin reactions affect all people in a dose-dependent fashion. Unpredictable reactions depend on individual host variations, particularly the propensity to mount an immune response to drug-related antigen or the rate at which the agent is metabolized. Both classes of injury may be immediate or take weeks to months to develop.

A classic predictable hepatotoxin is acetaminophen, now the most common cause of acute liver failure necessitating transplantation in the United States. The toxic agent is not acetaminophen itself but rather toxic metabolites produced by the cytochrome P-450 system in acinus zone 3 hepatocytes (Fig. 15–4). As these cells die, the zone 2 hepatocytes take over this metabolic function, in turn becoming injured. In severe overdoses the zone of injury extends to the periportal hepatocytes, resulting in fulminant hepatic failure (Fig. 15–5, *A* and *B*). While intentional suicidal overdoses are common, so are accidental overdoses. This is because the cytotoxicity is dependent on the activity of the cytochrome P-450 system, which may be

**Table 15–4** Different Forms of Drug- or Toxin-Induced Hepatic Injury

| Pattern of Injury | Morphologic Findings | Examples of Associated Agents |
|---|---|---|
| Cholestatic | Bland hepatocellular cholestasis, without inflammation | Contraceptive and anabolic steroids; estrogen replacement therapy |
| Cholestatic hepatitis | Cholestasis with lobular inflammation and necrosis; may show bile duct destruction | Numerous antibiotics; phenothiazines |
| Hepatocellular necrosis | Spotty hepatocyte necrosis<br>Submassive necrosis, zone 3<br>Massive necrosis | Methyldopa, phenytoin<br>Acetaminophen, halothane<br>Isoniazid, phenytoin |
| Steatosis | Macrovesicular | Ethanol, methotrexate, corticosteroids, total parenteral nutrition |
| Steatohepatitis | Microvesicular, Mallory bodies | Amiodarone, ethanol |
| Fibrosis and cirrhosis | Periportal and pericellular fibrosis | Methotrexate, isoniazid, enalapril |
| Granulomas | Noncaseating epithelioid granulomas | Sulfonamides, numerous other agents |
| Vascular lesions | Sinusoidal obstruction syndrome (venoocclusive disease): obliteration of central veins<br>Budd-Chiari syndrome<br>Sinusoidal dilatation<br>Peliosis hepatis: blood-filled cavities, not lined by endothelial cells | High-dose chemotherapy, bush teas<br>Oral contraceptives<br>Oral contraceptives, numerous other agents<br>Anabolic steroids, tamoxifen |
| Neoplasms | Hepatic adenoma<br>Hepatocellular carcinoma<br>Cholangiocarcinoma<br>Angiosarcoma | Oral contraceptives, anabolic steroids<br>Thorotrast<br>Thorotrast<br>Thorotrast, vinyl chloride |

From Washington K: Metabolic and toxic conditions of the liver. In Iacobuzio-Donahue CA, Montgomery EA (eds): Gastrointestinal and Liver Pathology. Philadelphia, Churchill Livingstone, 2005.

upregulated by other agents taken in combination with acetaminophen, such as alcohol (beware acetaminophen as a hangover prophylactic) or codeine in acetaminophen compound tablets.

Examples of drugs that can cause idiosyncratic reactions are chlorpromazine (an agent that causes cholestasis in individuals who metabolize it slowly), halothane (which can cause a fatal immune-mediated hepatitis in some persons exposed to this anesthetic on several occasions), and other drugs such as sulfonamides, α-methyldopa, and allopurinol. Often, idiosyncratic drug or toxin reactions involve a variable combination of direct cytotoxicity and immune-mediated hepatocyte or bile duct destruction. Examples of hepatotoxins are given in each disease-specific category described later.

## SUMMARY

### Drug- or Toxin-Induced Liver Disease

- Drug- and toxin-induced liver disease may be predictable (intrinsic) or unpredictable (idiosyncratic).
- Predictable hepatotoxins affect most individuals in a dose-dependent fashion.
- Unpredictable hepatotoxins affect rare persons in an idiosyncratic way, often involving a combination of direct cytotoxicity and immune-mediated injury.
- Every pattern of liver injury can be caused by some toxin or drug; therefore, exposures involving these agents must always be considered in the differential diagnosis.
- In addition to prescription and over-the-counter medications, herbal remedies, dietary supplements, topical applications, and environmental exposures may be responsible for hepatotoxicity.

# ACUTE AND CHRONIC HEPATITIS

The terminology of acute and chronic hepatitis can be confusing, since the term *hepatitis* is applied to a number of different diseases and different forms of liver injury. For example, *hepatitis* is a descriptor for specific histopathologic patterns of hepatocyte injury associated with inflammation and, when chronic, with scarring. Acute and chronic forms of hepatitis are distinguished in part by duration and in part by the pattern of cell injury. Viral hepatitides are also classified on the basis of the causative hepatotropic virus such as hepatitis types A, B, C, D, and E. Because all forms of hepatitis, including those due to the hepatitis viruses as well as autoimmune and drug- and toxin-induced hepatitides, share the same patterns of injury, the general descriptions are presented first, followed by clinicopathologic correlations specific to each cause.

## MORPHOLOGY

On gross inspection, liver involved by mild acute hepatitis appears normal or slightly mottled. At the other end of the spectrum, in massive hepatic necrosis the liver may shrink to 500 to 700 g and become transformed into a limp, red organ covered by a wrinkled, baggy capsule. The distribution of liver destruction is extremely capricious: **The entire liver may be involved, or only patchy areas affected.** On sectioning (Fig. 15–5, *A*), necrotic areas have a muddy-red, mushy appearance with blotchy bile staining.

If patients survive for more than a week, surviving hepatocytes begin to regenerate (Chapter 2). If the parenchymal framework is preserved, regeneration is orderly and liver architecture is restored. With more massive destruction,

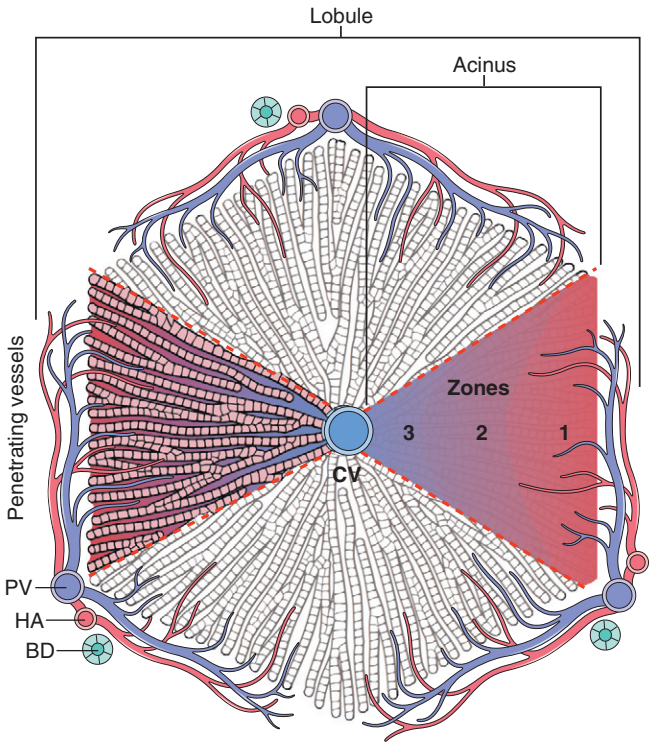


**Figure 15–4** Microscopic architecture of the liver parenchyma. Both a lobule and an acinus are represented. The idealized classic lobule is represented as hexagonal centered on a central vein (CV), also known as terminal hepatic venule, and has portal tracts at three of its apices. The portal tracts contain branches of the portal vein (PV), hepatic artery (HA), and the bile duct (BD) system. Regions of the lobule generally are referred to as *periportal, midzonal,* and *centrilobular,* according to their proximity to portal spaces and central vein. Another useful way to subdivide the liver architecture is to use the blood supply as a point of reference. Using this approach, triangular acini can be recognized. Acini have at their base branches of portal vessels that penetrate the parenchyma ("penetrating vessels"). On the basis of the distance from the blood supply, the acinus is divided into zones 1 (closest to blood source), 2, and 3 (farthest from blood source).

regeneration is disorderly, yielding nodular masses of liver cells separated by granulation tissue and, eventually, scar, particularly in patients with a protracted course of submassive necrosis.

The gross appearance of the liver in chronic hepatitis may be normal or include grossly evident focal scarring or, as cirrhosis develops, may feature widespread nodularity surrounded by extensive scarring.

The general microscopic features of acute and chronic hepatitis of all causes are listed in Table 15–5. Unlike most other organ systems in which the distinction between acute and chronic inflammation depends on the predominant type of inflammatory cell—neutrophilic in acute injury, mononuclear in chronic phases—mononuclear infiltrates predominate in all phases of most hepatitic diseases because they all invoke T cell–mediated immunity. Thus, **the distinction between acute and chronic hepatitis is based on the pattern of cell injury and severity of inflammation, with acute hepatitis often showing less inflammation and more hepatocyte death than chronic hepatitis.**

Both hepatocyte injury and inflammation, while related, can be highly variable depending on etiology and host factors. The hepatocyte injury takes two forms. The first is swelling **(ballooning degeneration),** producing cells with empty-appearing pale cytoplasm that subsequently rupture and undergo **necrosis (cytolysis).** The necrotic cells appear to have **dropped out,** leaving collapsing sinusoidal collagen reticulin framework behind; scavenger macrophages mark sites of dropout. The second pattern of cell death is **apoptosis,** in which hepatocytes shrink, become intensely eosinophilic, and have fragmented nuclei; effector T cells may be present in the immediate vicinity. When located in the parenchyma away from portal tracts, these features are called **lobular hepatitis** (Fig. 15–6).

In severe cases, confluent necrosis of hepatocytes is seen around central veins (Fig. 15–5, *B*). In these areas there may be cellular debris, collapsed reticulin fibers, congestion/hemorrhage, and variable inflammation. With increasing severity, **central-portal bridging necrosis** develops, followed by, even worse, **parenchymal collapse.** When the injury is overwhelming, massive hepatic necrosis and fulminant liver failure ensue. In occasional cases, the injury is not

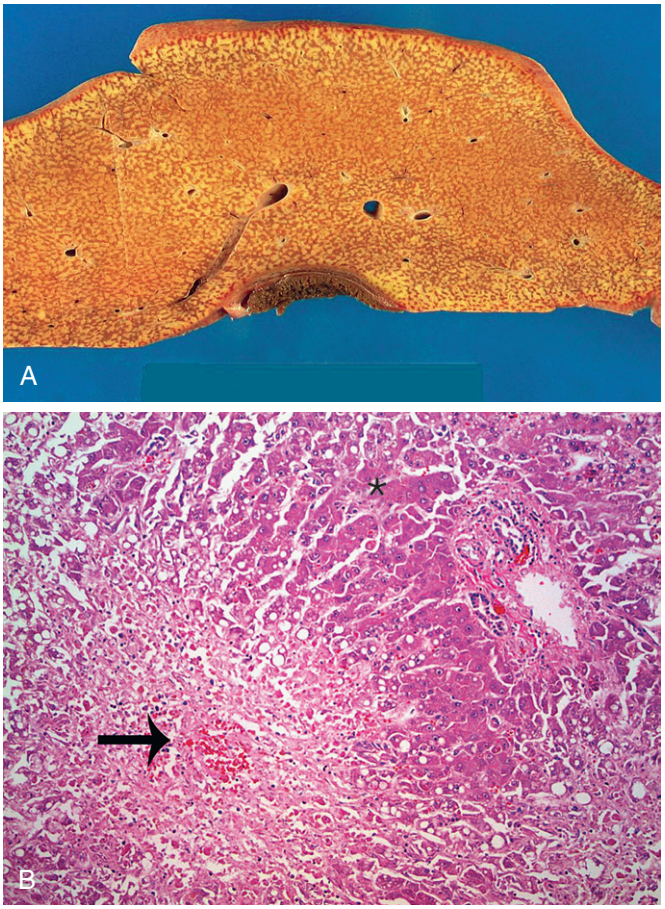


**Figure 15–5 A,** Massive necrosis, cut section of liver. The liver is small (700 g), bile-stained, soft, and congested. **B,** Hepatocellular necrosis caused by acetaminophen overdose. Confluent necrosis is seen in the perivenular region (zone 3) (*large arrow*). There is little inflammation. The residual normal tissue is indicated by the *asterisk*.
*(Courtesy of Dr. Matthew Yeh, University of Washington, Seattle, Washington.)*

**Table 15–5** Main Morphologic Features of Acute and Chronic Viral Hepatitis

| |
|---|
| **Acute Hepatitis** |
| *Gross Changes* |
| Enlarged, reddened liver; greenish if cholestatic |
| *Parenchymal Changes (Microscopic)* |
| Hepatocyte injury: swelling (ballooning degeneration)<br>Cholestasis: canalicular bile plugs<br>HCV: mild fatty change of hepatocytes<br>Hepatocyte necrosis: isolated cells or clusters<br>Cytolysis (rupture) or apoptosis (shrinkage)<br>*If severe*: bridging necrosis (portal-portal, central-central, portal-central)<br>Lobular disarray: loss of normal architecture<br>Regenerative changes: hepatocyte proliferation<br>Sinusoidal cell reactive changes<br>Accumulation of phagocytosed cellular debris in Kupffer cells<br>Influx of mononuclear cells into sinusoids<br>Portal tracts<br>Inflammation: predominantly mononuclear<br>Inflammatory spillover into adjacent parenchyma, with hepatocyte necrosis |
| **Chronic Hepatitis** |
| Changes shared with acute hepatitis<br>Hepatocyte injury, necrosis, apoptosis, and regeneration<br>Sinusoidal cell reactive changes<br>Portal tracts<br>Inflammation<br>Confined to portal tracts, *or*<br>Spillover into adjacent parenchyma, with necrosis of hepatocytes ("interface hepatitis"), *or*<br>Bridging inflammation and necrosis<br>Fibrosis<br>Portal deposition, *or*<br>Portal and periportal deposition, *or*<br>Formation of bridging fibrous septa<br>HBV: ground-glass hepatocytes (accumulation of HBsAg)<br>HCV: bile duct epithelial cell proliferation, lymphoid aggregate formation |

HBsAg, hepatitis B surface antigen; HBV, hepatitis B virus; HCV, hepatitis C virus.

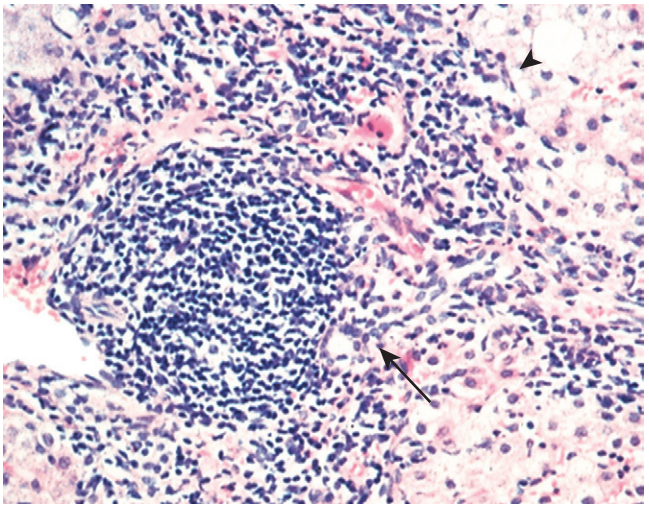

**Figure 15–7** Chronic hepatitis showing portal tract expansion by a dense infiltrate of mononuclear cells (*arrow*) and interface hepatitis with spillover of inflammation into the parenchyma (*arrowhead*). The prominent lymphoid infiltrate is typical of the cause of disease in this biopsy: chronic hepatitis C.

severe enough to cause death (or necessitate transplantation), and the liver survives, although with abundant scarring that replaces areas of confluent necrosis. In such cases, some patients rapidly develop **posthepatitic cirrhosis.**

Portal inflammation in acute hepatitis is minimal or absent; dense **mononuclear portal infiltrates** of variable prominence are the defining lesion of **chronic hepatitis** (Fig. 15–7). There is often **interface hepatitis** as well, distinguished from lobular hepatitis by its location at the interface between hepatocellular parenchyma and portal stroma (or scars, when present). The hallmark of severe chronic liver damage is scarring. At first, only portal tracts exhibit fibrosis, but in some patients, with time, **fibrous septa**—bands of dense scar—will extend between portal tracts. In the most severe cases, continued scarring and nodule formation leads to the development of **cirrhosis** (Fig 15–8).

Clinical assessment of chronic hepatitis often requires liver biopsy in addition to clinical and serologic data. Liver biopsy is helpful in confirming the clinical diagnosis, excluding common concomitant conditions (e.g., fatty liver disease, hemochromatosis), assessing histologic features associated

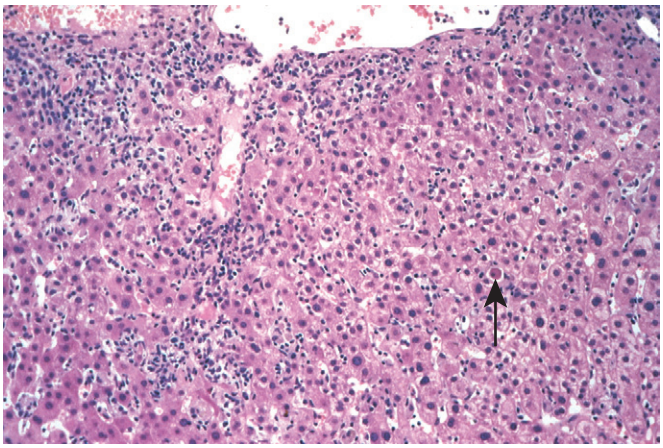

**Figure 15–6** Acute viral hepatitis showing disruption of lobular architecture, inflammatory cells in sinusoids, and apoptotic cells (*arrow*).

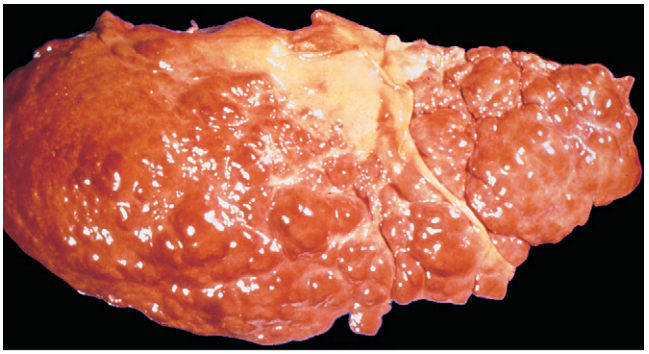

**Figure 15–8** Cirrhosis resulting from chronic viral hepatitis. Note the irregular nodularity of the liver surface.

with an increased risk of malignancy (e.g., small and large cell change, described later), **grading the extent of hepatocyte injury and inflammation, and staging the progression of scarring.** Such grading and staging are useful for assessing prognosis and therapeutic options.

## Viral Hepatitis

Viral hepatitis is caused mainly by hepatitis viruses A (HAV), B (HBV), C (HCV), D (HDV), and E (HEV). These viruses and their infections have distinct features, which are summarized in Table 15–6.

### *Hepatitis A Virus*

Hepatitis A usually is a benign, self-limited disease with an incubation period of 2 to 6 weeks (average 28 days). HAV does not cause chronic hepatitis or a carrier state. Rarely there is fulminant hepatitis; fatalities occur at a rate of only 0.1%. HAV occurs throughout the world and is endemic in countries with poor hygiene and sanitation, so that most natives of such countries have detectable antibodies to HAV by the age of 10 years. Epidemics are not unusual. The disease tends to be mild or asymptomatic in children, with severe HAV infections occurring mainly in adults.

HAV is spread by ingestion of contaminated water and foods and is shed in the stool for 2 to 3 weeks before and 1 week after the onset of jaundice. HAV is not shed in any significant quantities in saliva, urine, or semen. Close personal contact with an infected person during the period of fecal shedding, with fecal-oral contamination, accounts for most cases and explains the outbreaks in institutional settings such as schools and nurseries. *Because HAV viremia is transient, blood-borne transmission of HAV occurs only rarely; therefore, donated blood is not routinely screened for this virus.* Waterborne epidemics may occur in developing countries where people live in overcrowded, unsanitary conditions. Among developed countries, sporadic infections may be contracted by the consumption of raw or steamed shellfish (oysters, mussels, clams), which concentrate the virus from seawater contaminated with human sewage.

HAV is a small, nonenveloped, single-stranded RNA picornavirus. It reaches the liver from the intestinal tract after ingestion, replicates in hepatocytes, and is shed in the bile and feces. The virus itself does not seem to be toxic to hepatocytes, and hence the liver injury seems to result from T cell–mediated damage of infected hepatocytes. As depicted in Figure 15–9, immunoglobulin M (IgM) antibodies against HAV appear in blood at the onset of symptoms. Detection of anti-HAV IgM antibody is the best diagnostic marker for the disease; IgG antibody persists beyond convalescence and is the primary defense against reinfection. In the United States, the prevalence of seropositivity increases gradually with age, reaching 40% by the age of 50 years.

Measures for the prevention and management of hepatitis A include (1) hygienic practices focused on the disposal of human wastes and personal hygiene; (2) passive immunization with immune serum globulin for persons at high risk for infection (very young, very old, or immunocompromised) after exposure to the virus; and (3) administration of inactivated-virus vaccine given either before exposure (e.g., before travel to endemic areas) or very early after exposure.

### *Hepatitis B Virus*

HBV can produce various clinical syndromes:

- Acute hepatitis with recovery and clearance of the virus
- Fulminant hepatitis with massive liver necrosis
- Nonprogressive chronic hepatitis
- Progressive chronic disease sometimes ending in cirrhosis
- An asymptomatic carrier state

**Table 15–6** The Hepatitis Viruses

| Virus | Hepatitis A | Hepatitis B | Hepatitis C | Hepatitis D | Hepatitis E |
|---|---|---|---|---|---|
| Type of virus | ssRNA | Partially dsDNA | ssRNA | Circular defective ssRNA | ssRNA |
| Viral family | Hepatovirus; related to picornavirus | Hepadnavirus | Flaviridae | Subviral particle in Deltaviridae family | Hepevirus |
| Route of transmission | Fecal-oral (contaminated food or water) | Parenteral, sexual contact, perinatal | Parenteral; intranasal cocaine use is a risk factor | Parenteral | Fecal-oral |
| Incubation period | 2–6 weeks | 4–26 weeks | 2–26 weeks | Same as for HBV | 2–8 weeks |
| Frequency of chronic liver disease | Never | 10% | ~80% | 5% (coinfection); ≤70% for superinfection | Never |
| Laboratory diagnosis | Detection of serum IgM antibodies | Detection of HBsAg or antibody to HBcAg | PCR assay for HCV RNA; 3rd-generation ELISA for antibody detection | Detection of IgM and IgG antibodies; HDV RNA serum; HDAg in liver | PCR assay for HEV RNA; detection of serum IgM and IgG antibodies |

dsDNA, double-stranded DNA; ELISA, enzyme-linked immunosorbent assay; HBcAg, hepatitis B core antigen; HBsAg, hepatitis B surface antigen; HBV, hepatitis B virus; HCV, hepatitis C virus; HDAg, hepatitis D antigen; HDV, hepatitis D virus; HEV, hepatitis E virus; IgG, IgM, immunoglobulins G and M; PCR, polymerase chain reaction; ssRNA, single-stranded RNA.
From Washington K: Inflammatory and infectious diseases of the liver. In Iacobuzio-Donahue CA, Montgomery EA (eds): Gastrointestinal and Liver Pathology. Philadelphia, Churchill Livingstone, 2005.

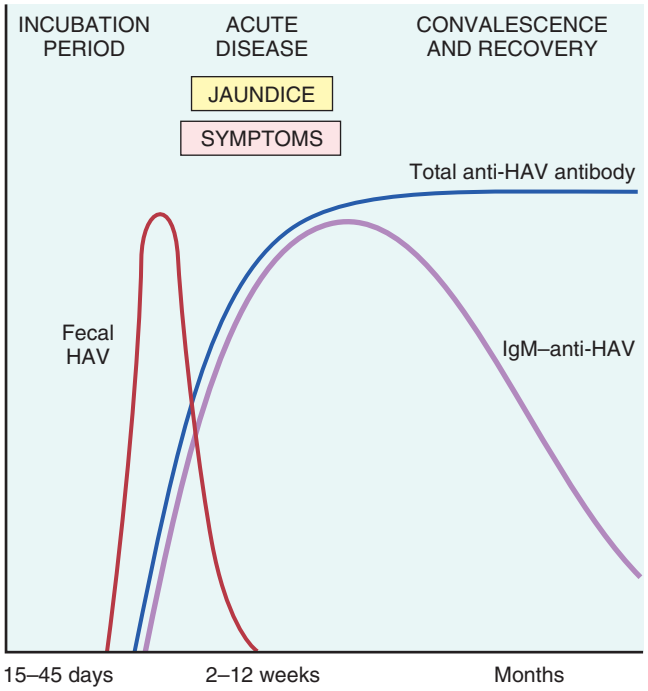


**Figure 15–9** The sequence of serologic markers in acute hepatitis A infection. HAV, hepatitis A virus. There are no routinely available tests for IgG anti-HAV; therefore the presence of this antibody is inferred from the difference between total and IgM-HAV.

HBV-induced chronic liver disease is an important precursor for the development of hepatocellular carcinoma. Figure 15–10 depicts the approximate frequencies of these outcomes.

***Epidemiology and Transmission.*** Globally, liver disease caused by HBV is an enormous problem, with an estimated 400 million people who are carriers of the virus. It is estimated that HBV will infect more than 2 billion people alive today at some point in their lives. About 80% of all chronic carriers live in Asia and the Western Pacific Rim region, where the prevalence of chronic hepatitis B is more than 10%. In the United States there are approximately 185,000 new infections per year. HBV is found in the blood during the last stages of a prolonged incubation period (4 to 26 weeks) and during active episodes of acute and chronic hepatitis. It also is present in all physiologic and pathologic body fluids, with the exception of stool. HBV is a hardy virus and can withstand extremes of temperature and humidity. Thus, whereas blood and body fluids are the primary vehicles of transmission, virus also may be spread by contact with body secretions such as semen, saliva, sweat, tears, breast milk, and pathologic effusions. In endemic regions, vertical transmission from mother to child during birth constitutes the main mode of transmission. In areas of low prevalence, horizontal transmission via transfusion, blood products, dialysis, needlestick accidents among health care workers, sharing of needles in intravenous drug use, and sexual transmission (homosexual or heterosexual) constitute the primary mechanisms for HBV infection. In one third of patients, the source of infection is unknown. Most HBV infections in adults are cleared, but vertical transmission produces a high rate of persistent infection since infants cannot readily clear the infection. Chronically infected persons are at significantly increased risk for development of hepatocellular carcinoma, explaining the high rate of that malignancy in Asia and Pacific Rim nations.

***HBV Structure and Genome.*** HBV is a member of the Hepadnaviridae, a group of DNA-containing viruses that cause hepatitis in many animal species. HBV replication does not involve the integration of the virus in the DNA of the host cell, but integrated HBV frequently is found in cells. The integrated viruses generally have large deletions and rearrangements and usually become inactive. The genome of HBV is a partially double-stranded circular DNA molecule of 3200 nucleotides that encodes

- The precore/core region of a nucleocapsid "core" protein, the *hepatitis B core antigen (HBcAg)*, and a precore

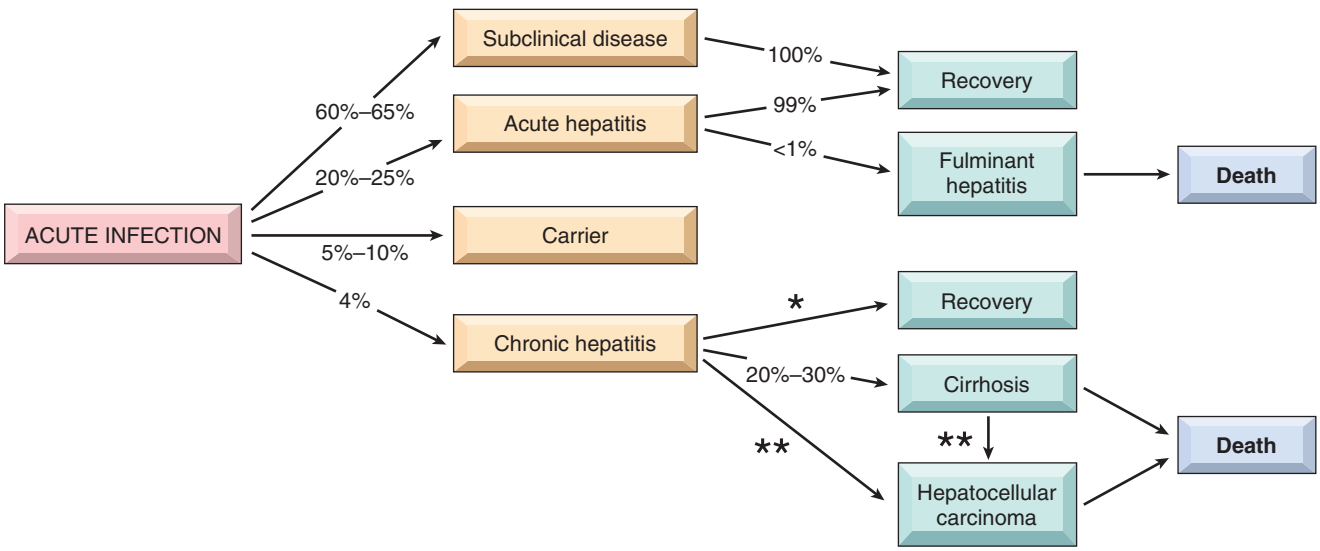


**Figure 15–10** The potential outcomes with hepatitis B infection in adults, with their approximate annual frequencies in the United States. *Estimated rate of recovery from chronic hepatitis is 0.5% to 1% per year. **The risk of hepatocellular carcinoma is 0.02% per year for chronic hepatitis B and 2.5% per year when cirrhosis has developed.

protein designated hepatitis Be antigen (HBeAg). HBcAg is retained in the infected hepatocyte; HBeAg is secreted into blood and is essential for the establishment of persistent infection.

- Envelope glycoprotein, the *hepatitis B surface antigen (HBsAg),* which may be produced and secreted into the blood in massive amounts. Blood HBsAg is immunogenic.
- A *DNA polymerase* with an error-prone reverse transcriptase activity that generates mutations in the genomes of replicating virus at a high rate.
- *HBV-X* protein, which acts as a transcriptional transactivator for many viral and host genes through interaction with various transcription factors. HBV-X is required for viral infectivity and may have a role in the development of hepatocellular carcinoma by regulating p53 degradation and expression (Chapter 6).

### Clinical Course

After exposure to the virus, there is a long, asymptomatic incubation period, which may be followed by acute disease (described later) lasting many weeks to months. The natural course of acute disease can be tracked using serum markers (Fig. 15–11):

- HBsAg appears before the onset of symptoms, peaks during overt disease, and then declines to undetectable levels in 3 to 6 months.
- Anti-HBs antibody does not rise until the acute disease is over and usually is not detectable for a few weeks to several months after the disappearance of HBsAg. Anti-HBs may persist for life, conferring immunity; this is the basis for current vaccination strategies using noninfectious HBsAg.
- HBeAg, HBV-DNA, and DNA polymerase appear in serum soon after HBsAg, and all signify active viral replication. Persistence of HBeAg is an important indicator of continued viral replication, infectivity, and probable progression to chronic hepatitis. The appearance of anti-HBe antibodies implies that an acute infection has peaked and is on the wane.
- IgM anti-HBc becomes detectable in serum shortly before the onset of symptoms, concurrent with elevation of serum aminotransferase levels (indicative of hepatocyte destruction). Over a period of months the IgM anti-HBc antibody is replaced by IgG anti-HBc. As in the case of anti-HAV, there is no specific assay for IgG anti-HBc, but its presence is inferred from decline of IgM anti-HBc in the face of rising levels of total anti-HBc.

Occasionally, mutated strains of HBV emerge that do not produce HBeAg, but are replication-competent and express HBcAg (more than 30% in the Mediterranean, up to 20% in the United States). In patients infected with such mutated strains, the HBeAg may be low or undetectable despite the presence of HBV viral load. A second ominous development is the emergence of viruses that are resistant to vaccine-induced immunity. For instance, replacement of arginine at amino acid 145 of HBsAg with glycine significantly alters recognition of HBsAg by anti-HBsAg antibodies.

Innate immunity protects the host during the initial phases of the infection, and a strong response by virus-specific CD4+ and CD8+ interferon γ–producing cells is associated with the resolution of acute infection. Current evidence suggests that HBV does not cause direct hepatocyte injury, and hepatocyte damage results from killing of the virus-infected cells by CD8+ cytotoxic T cells.

Hepatitis B can largely be prevented by vaccination and by the screening of donor blood, organs, and tissues. The vaccine is prepared from purified HBsAg produced in yeast. Vaccination induces a protective anti-HBs antibody response in 95% of infants, children, and adolescents. Universal vaccination has been a notable success in countries such as Taiwan and Gambia but unfortunately has not been adopted worldwide.

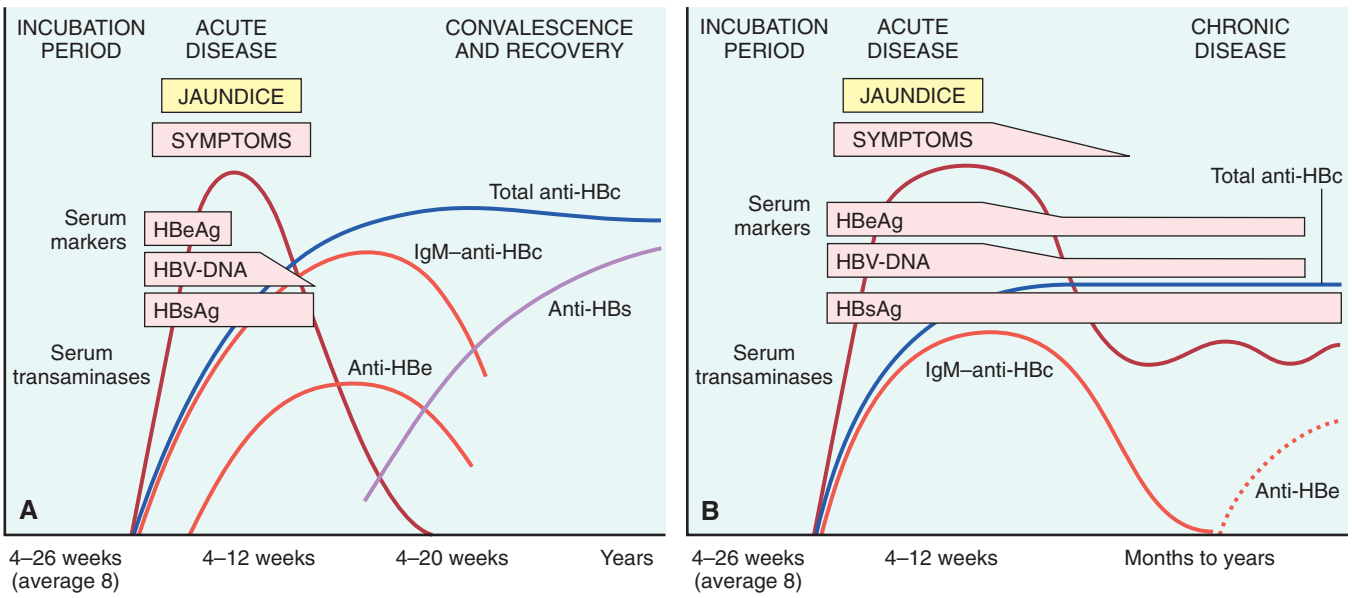


**Figure 15–11** The sequence of serologic markers in acute hepatitis B infection. **A,** Resolution of active infection. **B,** Progression to chronic infection. See text for abbreviations.

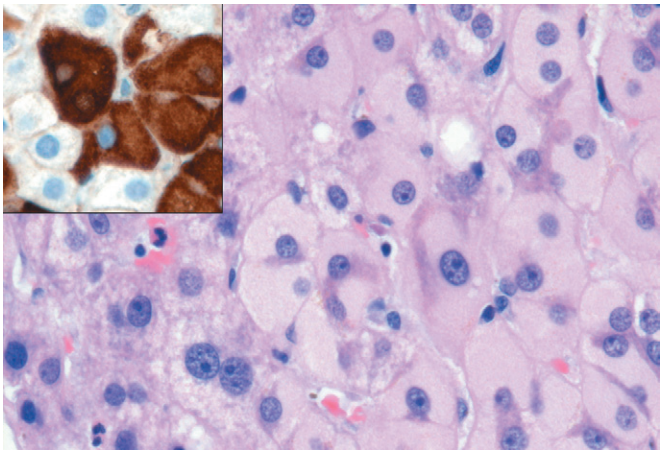

**Figure 15-12** Ground-glass hepatocytes in chronic hepatitis B, caused by accumulation of HBsAg in cytoplasm, have large, pale, finely granular, pink cytoplasmic inclusions on hematoxylin-eosin staining; immunostaining (*inset*) confirms that the endoplasmic reticulum is ballooned with surface antigen (*brown*). HBsAg, hepatitis B surface antigen.

## MORPHOLOGY

Microscopically, hepatitis B can produce all of the histologic features of acute and chronic hepatitis described earlier, but some liver biopsy specimens also display a particular morphologic feature that is nearly diagnostic, the **ground glass cell** (Fig. 15–12). In chronic HBV infection, some hepatocytes may have viral genomes integrated into the host genome. If, by chance, the surface antigen gene integrates into a host genomic site adjacent to an active promoter, then the cell is converted into a factory for surface antigen production. Usually in such cells full viral replication does not take place. Since surface antigen can only exit the cell as part of intact viral particles, the antigen just accumulates in these cells, creating a large cytoplasmic inclusion consisting of endoplasmic reticulum stuffed with surface antigen that has a fine, smoothly granular appearance similar to that of ground glass.

### *Hepatitis C Virus*

***Epidemiology and Transmission.*** HCV also is a major cause of liver disease. The worldwide carrier rate is estimated at 175 million persons (a 3% prevalence rate, ranging widely from 0.1% to 12%, depending on the country). Persistent chronic infection exists in 3 to 4 million persons in the United States, where the number of newly acquired HCV infections per year dropped from 180,000 in the mid-1980s to about 19,000 in 2006. This welcome change resulted from the marked reduction in transfusion-associated hepatitis C (as a result of screening procedures) and a decline of infections in intravenous drug abusers (related to practices motivated by fear of human immunodeficiency virus infection). However, the death rate from HCV will continue to climb for 20 to 25 years, because of the decades-long lag time between acute infection and liver failure. *The major route of transmission is through blood inoculation, with intravenous drug use accounting for at least 60% of cases in the United States.* Transmission by blood products is now fortunately rare, accounting for only 4% of all acute HCV infections. Occupational exposure among health care workers accounts for another 4% of cases. The rates of sexual transmission and vertical transmission are low. Infections of unknown origin account for 9% to 27% of cases. *HCV infection has a much higher rate than HBV of progression* to *chronic disease and eventual cirrhosis* (Fig. 15–13). In fact, hepatitis C is the condition that most frequently necessitates liver transplantation in the United States.

***Viral Structure and Genome.*** HCV is a positive-sense single-stranded RNA virus belonging to the family Flaviviridae. It contains highly conserved 5′- and 3′-terminal regions that flank a single open reading frame of nearly 9500 nucleotides that encode structural and nonstructural proteins. HCV is subclassified into six genotypes, based on the genetic sequence. Moreover, because of the poor fidelity of RNA replication, an infected person may carry many HCV variants, called *quasispecies.* The relationships between quasispecies and disease progression are being investigated, but it seems that high multiplicity of quasispecies is associated with worse prognosis. In addition, this variability seriously hampers efforts to develop an HCV vaccine.

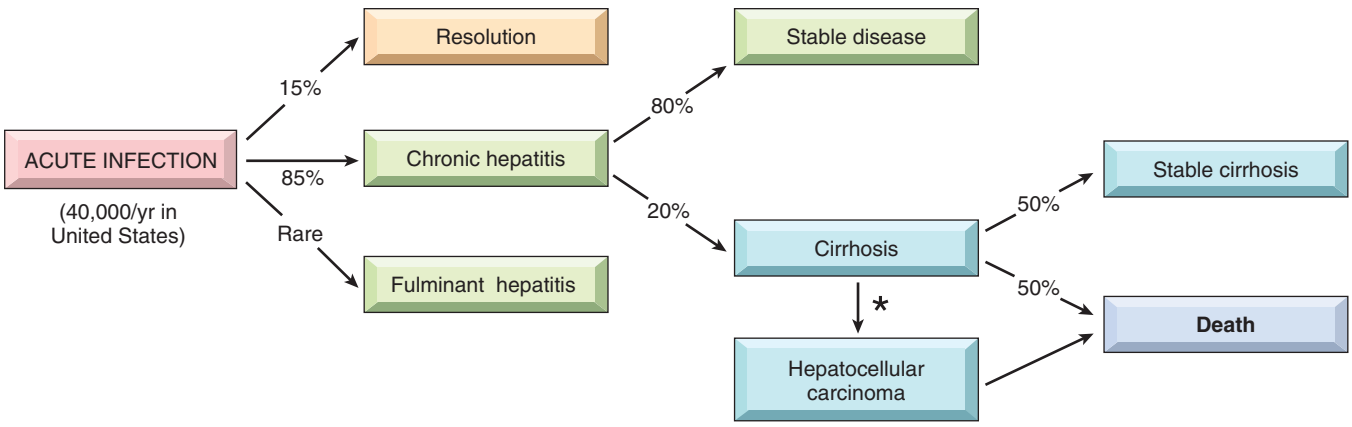


**Figure 15–13** The potential outcomes of hepatitis C infection in adults, with their approximate annual frequencies in the United States. The population estimates are for newly detected infection; because of the decades-long lag time for progression from acute infection to cirrhosis, the actual annual death rate from hepatitis C is about 10,000 per year and exceeded 22,000 deaths per year by 2008. *The risk of hepatocellular carcinoma is 1% to 4% per year.

### Clinical Course

The incubation period for hepatitis C ranges from 2 to 26 weeks, with a mean of 6 to 12 weeks. *Acute hepatitis C is asymptomatic in 75% of affected persons and is easily missed.* Thus, not much is known about this phase of the disease. HCV RNA can be detected in blood within days to 8 weeks depending on the inoculum size. Elevations of serum aminotransferases occur in 2 to 12 weeks. Although neutralizing anti-HCV antibodies develop within weeks to a few months, they *do not confer effective immunity* (Fig. 15–14). Strong immune responses involving CD4+ and CD8+ cells are associated with self-limited HCV infections, but it is not known why only a minority of persons are capable of clearing HCV infection.

In persistent infection, circulating HCV-RNA is detectable, and aminotransferases show episodic elevations, or continuous elevation with fluctuating levels. In a small percentage of affected persons, aminotransferase levels are normal even though abnormal liver histology persists. Increased enzyme activity may occur in the absence of clinical symptoms, presumably reflecting recurrent bouts of hepatocyte necrosis. *Persistent infection is the hallmark of HCV infection, occurring in 80% to 85% of patients with subclinical or asymptomatic acute infection* (Fig. 15–13). Cirrhosis develops in 20% of persistently infected persons: It can be present at the time of diagnosis or may take up to 20 years to develop. Alternatively, patients may have documented chronic HCV infection for decades, without progressing to cirrhosis. Fulminant hepatitis is rare. *Hepatitis C confers a significantly increased risk for hepatocellular carcinoma.*

### MORPHOLOGY

Microscopically, chronic hepatitis C displays the typical features of chronic hepatitis described above, but has some distinctive, common associated findings: (1) **fatty change,** resulting either from altered lipid metabolism in infected hepatocytes, or insulin resistance and the so-called metabolic syndrome (described later); (2) **lymphoid infiltrates** in portal tracts, sometimes with fully formed lymphoid follicles (Fig. 15–7); and (3) **bile duct injury,** which may be related to direct infection of cholangiocytes by the virus.

### *Hepatitis D Virus*

Also called *delta hepatitis virus,* HDV is a unique RNA virus that is replication-defective, causing infection only when it is encapsulated by HBsAg. Thus, *although taxonomically distinct from HBV, HDV is absolutely dependent on HBV coinfection for multiplication.* Delta hepatitis arises in two settings: (1) acute coinfection after exposure to serum containing both HDV and HBV and (2) superinfection of a chronic carrier of HBV with a new inoculum of HDV. In coinfections, HBV infection must first be established before HBsAg is made in sufficient amounts for production of HDV virions. Most coinfected persons clear the viruses and recover completely. By contrast, in most superinfected persons there is an acceleration of hepatitis, progressing to more severe chronic hepatitis 4 to 7 weeks later.

Infection by HDV is worldwide, with prevalence rates ranging from 8% among HBsAg carriers in southern Italy to as high as 40% in Africa and the Middle East. Surprisingly, HDV infection is uncommon in Southeast Asia and China, areas in which HBV infection is endemic. Periodic epidemic outbreaks have occurred in subtropical areas of Peru, Colombia, and Venezuela. In the United States, HDV infection is largely restricted to drug addicts and persons receiving multiple transfusions (e.g., hemophiliacs), who have prevalence rates of 1% to 10%.

HDV RNA and the HDV antigen (HDV Ag) are detectable in the blood and liver just before and in the early days of acute symptomatic disease. *IgM anti-HDV antibody is the most reliable indicator of recent HDV exposure,* as it is present at high titers only transiently in the immediate post-infection period. Acute coinfection by HDV and HBV

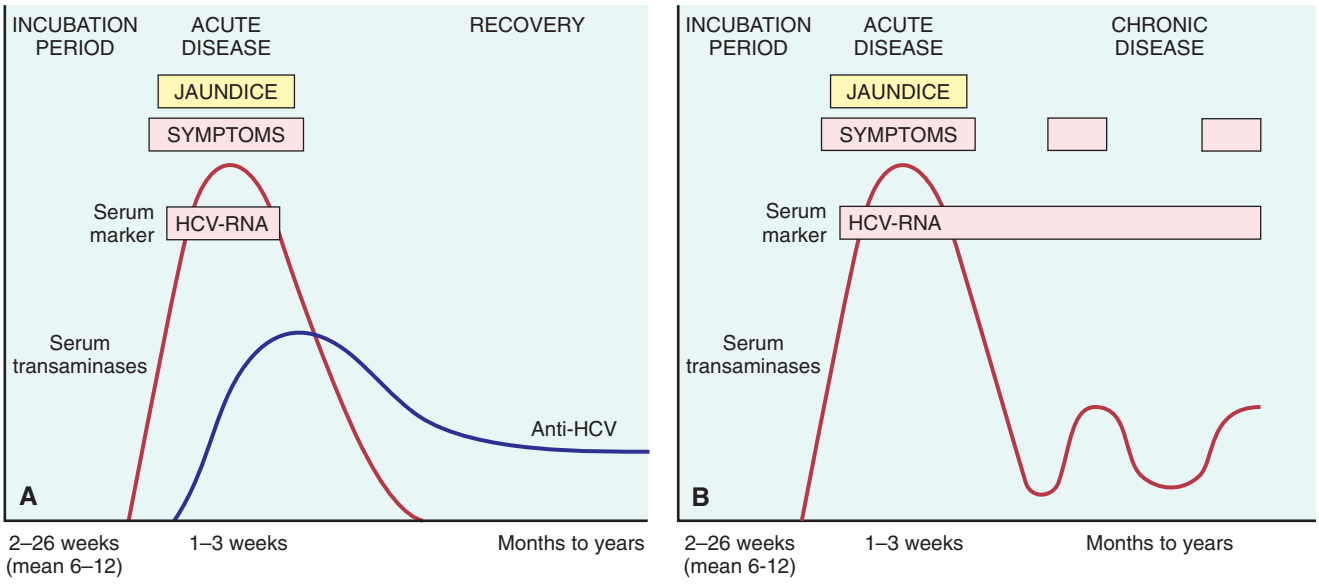


**Figure 15–14** Sequence of serologic markers for hepatitis C. **A,** Acute infection with resolution. **B,** Progression to chronic infection. See text for abbreviations.

is best indicated by detection of IgM against both HDV Ag and HBcAg (denoting new infection with HBV). With chronic delta hepatitis arising from HDV superinfection, HBsAg is present in serum, and anti-HDV antibodies (IgM and IgG) persist in low titer for months or longer.

### *Hepatitis E Virus*

HEV hepatitis is an enterically transmitted, waterborne infection occurring primarily beyond the years of infancy. HEV is endemic in India where it is caused by fecal contamination of drinking water. Prevalence rates of anti-HEV IgG antibodies approach 40% in the Indian population. Epidemics have been reported from Asia, sub-Saharan Africa, and Mexico. Sporadic infection seems to be uncommon; it is seen mainly in travelers and accounts for more than 50% of cases of sporadic acute viral hepatitis in India. *In most cases, the disease is self-limited; HEV is not associated with chronic liver disease or persistent viremia. A characteristic feature of the infection is the high mortality rate among pregnant women, approaching 20%.* The average incubation period after exposure is 6 weeks (range, 2 to 8 weeks).

HEV is a nonenveloped, single-stranded RNA hepevirus. A specific antigen, HEV Ag, can be identified in the cytoplasm of hepatocytes during active infection. Virus can be detected in stools, and anti-HEV IgG and IgM antibodies are detectable in serum.

### *Clinical Features and Outcomes for Viral Hepatitis*

A number of clinical syndromes may develop after exposure to hepatitis viruses:

- *Asymptomatic acute infection*: serologic evidence only
- *Acute hepatitis*: anicteric or icteric
- *Fulminant hepatitis*: submassive to massive hepatic necrosis with acute liver failure
- *Chronic hepatitis*: with or without progression to cirrhosis
- *Chronic carrier state*: asymptomatic without apparent disease

Not all of the hepatotropic viruses provoke each of these clinical syndromes (Table 15–6). As already mentioned, viral persistence and development of chronic disease are much more common after HCV infection than for HBV infection. *Because other infectious or noninfectious causes, particularly drugs and toxins, can lead to essentially identical syndromes, serologic studies are critical for the diagnosis of viral hepatitis and identification of virus types.*

Presented next are brief summaries of clinical outcomes with viral hepatitis.

***Asymptomatic Infection.*** Not surprisingly, patients with asymptomatic infection are identified only incidentally on the basis of minimally elevated serum aminotransferases or after the fact by the presence of antiviral antibodies.

***Acute Viral Hepatitis.*** Any one of the hepatotropic viruses can cause acute viral hepatitis. Acute infections are easily detected for HBV infections but are only rarely diagnosed for HCV. Although the following description is based mostly on HBV infections, *acute viral hepatitis, whatever the agent, can be divided into four phases:* (1) *incubation period,* (2) *symptomatic preicteric phase,* (3) *symptomatic icteric phase (with jaundice and scleral icterus),* and (4) *convalescence.*

Peak infectivity, attributed to the presence of circulating infectious viral particles, occurs during the last asymptomatic days of the incubation period and the early days of acute symptoms. The preicteric phase is marked by nonspecific, constitutional symptoms. Malaise is followed in a few days by general fatigability, nausea, and loss of appetite. Weight loss, low-grade fever, headaches, muscle and joint aches, vomiting, and diarrhea are inconstant symptoms. About 10% of patients with acute hepatitis B develop a serum sickness–like syndrome consisting of fever, rash, and arthralgias, attributed to circulating immune complexes. The hepatitis-related origin of all of these symptoms is suggested by elevated serum aminotransferase levels. Physical examination reveals a mildly enlarged, tender liver. In some patients the nonspecific symptoms are more severe, with higher fever, shaking chills, and headache, sometimes accompanied by right upper quadrant pain and tender liver enlargement. Surprisingly, as jaundice appears and these patients enter the icteric phase, other symptoms abate. The jaundice is caused predominantly by conjugated hyperbilirubinemia, which produces dark-colored urine. With hepatocellular damage and consequent defect in bilirubin conjugation, unconjugated hyperbilirubinemia also can occur. The stools may become light-colored, and the retention of bile salts may cause pruritus. An icteric phase is usual in adults (but not children) infected with HAV, present in about half of the cases involving HBV, and absent in most cases of HCV infection. In a few weeks to perhaps several months, the jaundice and most of the other systemic symptoms clear as convalescence begins.

***Fulminant Hepatitis.*** In a very small proportion of patients with acute hepatitis A, B, D, or E, acute liver failure may result from massive hepatic necrosis. (With the exception of immunosuppressed individuals, HCV almost never causes acute liver failure). Cases with a more protracted course of several weeks or months usually are referred to as "subacute hepatic necrosis"; the liver shows both massive necrosis and regenerative hyperplasia. As discussed later, drugs and chemicals also may cause massive hepatic necrosis.

***Chronic Hepatitis.*** *Chronic hepatitis* is defined by the presence of symptomatic, biochemical, or serologic evidence of continuing or relapsing hepatic disease for more than 6 months, with histologically documented inflammation and necrosis. Although the hepatitis viruses are responsible for most cases, there are many causes of chronic hepatitis (described later), such as autoimmunity, drugs and toxins, Wilson disease, and $\alpha_1$-antitrypsin (AAT) deficiency.

Etiology rather than the histologic pattern is the most important determinant of the probability of developing progressive chronic hepatitis. In particular, HCV is notorious for causing a chronic hepatitis evolving to cirrhosis (Fig. 15–13), regardless of histologic features at the time of initial evaluation.

The clinical features of chronic hepatitis are highly variable and are not predictive of outcome. In some patients, the only signs of chronic disease are persistent elevations of serum aminotransferase levels. The most common overt symptoms are fatigue and, less commonly, malaise, loss of appetite, and bouts of mild jaundice. Physical findings are few, the most common being spider angiomas, palmar erythema, mild hepatomegaly, and hepatic tenderness.

Laboratory studies may reveal prolongation of the prothrombin time and, in some instances, hypergammaglobulinemia, hyperbilirubinemia, and mildly elevated alkaline phosphatase levels. Occasionally in cases of HBV and HCV infection, circulating antibody-antigen complexes produce immune-complex disease in the form of vasculitis (subcutaneous or visceral) (Chapter 9) and glomerulonephritis (Chapter 13). Cryoglobulinemia is found in as many as 50% of patients with hepatitis C.

The clinical course is highly variable. Persons with hepatitis C may experience spontaneous remission or may have indolent disease without progression for years. Conversely, some patients have rapidly progressive disease and develop cirrhosis within a few years. The major causes of death in patients with chronic hepatitis relate to cirrhosis—namely, liver failure, hepatic encephalopathy, massive hematemesis from esophageal varices, and hepatocellular carcinoma.

***The Carrier State.*** A *carrier* is an asymptomatic person who harbors and therefore can transmit an organism. With hepatotropic viruses, carriers are those who

- Harbor one of the viruses but are free of symptoms or of significant histologic hepatitis on liver biopsy
- Have liver damage evident on biopsy (e.g., only mild necroinflammatory activity and scarring that remains in the early, noncirrhotic stages) but are essentially free of symptoms or disability

Both types of carriers constitute reservoirs of infection. HBV infection early in life, particularly through vertical transmission during childbirth, produces a carrier state 90% to 95% of the time. By contrast, only 1% to 10% of HBV infections acquired in adulthood yield a carrier state. Persons with impaired immunity are particularly likely to become carriers. The situation is less clear with HDV, although there is a well-defined low risk of posttransfusion hepatitis D, indicative of a carrier state in conjunction with HBV infection. From 0.2% to 0.6% of the general U.S. population is estimated to carry HCV.

## Other Viral Infections of the Liver

- *Epstein-Barr virus (EBV) infection* may cause a mild hepatitis during the acute phase of infectious mononucleosis.
- *Cytomegalovirus infection,* particularly in the newborn or immunocompromised, can cause the typical cytomegalic changes of that virus in almost any cell of the liver, including hepatocytes, cholangiocytes, and endothelial cells.
- *Herpes simplex* may infect hepatocytes in newborns or the immunosuppressed, leading to the appearance of the characteristic cytopathic changes and hepatic necrosis.
- *Yellow fever,* which has been a major and serious cause of hepatitis in tropical countries, causes hepatocyte apoptosis, which can be extensive. The apoptotic hepatocytes are intensely eosinophilic and are referred to as *Councilman bodies* after the pathologist who first described them. Infrequently, in children and immunosuppressed persons, hepatitis may be caused by rubella virus, adenovirus, or enterovirus infections.

### SUMMARY

#### Viral Hepatitis

- In the alphabet of hepatotropic viruses, some easy mnemonic devices may be useful:
  - The vowels (hepatitis A and E) never cause chronic hepatitis, only acute hepatitis.
  - Only the consonants (hepatitis B, C, D) have the potential to cause chronic disease (C for consonant and for chronic).
  - Hepatitis B can be transmitted by blood, birthing, and "bonking" (as they say in the United Kingdom).
  - Hepatitis C is the single virus that is more often chronic than not (almost never detected acutely; 85% or more of patients develop chronic hepatitis, 20% of whom will develop cirrhosis).
  - Hepatitis D, the delta agent, is a defective virus, requiring hepatitis B coinfection for its own capacity to infect and replicate.
  - Hepatitis E is endemic in equatorial regions and frequently epidemic.
- The inflammatory cells in both acute and chronic viral hepatitis are mainly T cells; it is the pattern of injury that is different, not the nature of the infiltrate.
- Biopsy assessment in chronic viral hepatitis is most important for grading and staging of disease, which are used to decide whether a patient undergoes often arduous antiviral treatments.
- Patients with long-standing HBV or HCV infections are at increased risk for the development of hepatocellular carcinomas, even in the absence of established cirrhosis.

## Autoimmune Hepatitis

Autoimmune hepatitis is a chronic disorder associated with histologic features that may be indistinguishable from chronic viral hepatitis. This disease may run an indolent or a severe course and typically responds dramatically to immunosuppressive therapy. Salient features include

- Female predominance (70%)
- Absence of serologic evidence of viral infection
- Elevated serum IgG (levels greater than 2.5 g/dL)
- High titers of autoantibodies in 80% of cases
- The presence of other forms of autoimmune diseases, seen in up to 60% of patients, including rheumatoid arthritis, thyroiditis, Sjögren syndrome, and ulcerative colitis

Autoimmune hepatitis can be divided into subtypes on the basis of the autoantibodies produced, but the relevance of this classification to clinical management is unclear. Most patients are found to have circulating antinuclear antibodies, anti–smooth muscle antibodies, liver/kidney microsomal antibody, and/or anti–soluble liver/pancreas antigen. These antibodies can be detected by immunofluorescence or enzyme-linked immunosorbent assays. The main effectors of cell damage in autoimmune hepatitis are believed to be CD4+ helper cells. Autoimmune hepatitis may manifest as mild to severe chronic hepatitis. Response to immunosuppressive therapy usually is

dramatic, although a full remission of disease is unusual. The overall risk of cirrhosis, the main cause of death, is 5%.

### MORPHOLOGY

Although autoimmune hepatitis shares patterns of injury with acute or chronic viral hepatitis, the time course of histologic progression differs. In viral hepatitis, fibrosis typically follows years or decades of slowly accumulating parenchymal injury, whereas in autoimmune hepatitis, there appears to be an early phase of severe cell injury and inflammation followed by rapid scarring. Of interest, and for unclear reasons, this early wave of hepatocyte damage and necrosis usually is subclinical. Clinical evolution correlates with a limited number of histologic patterns:

- Very severe hepatocyte injury associated with widespread **confluent necrosis**
- Marked inflammation concurrent with advanced scarring
- **Burned-out cirrhosis,** associated with little ongoing cell injury or inflammation. This last category was once the most common finding at diagnosis, but heightened clinical awareness of autoimmune hepatitis specifically has led to increasingly earlier diagnosis. Of note, the mononuclear infiltrate in autoimmune hepatitis frequently has **abundant plasma cells.**

## Drug/Toxin-Mediated Injury Mimicking Hepatitis

Many drugs have effects that can mimic the features of acute or chronic viral or autoimmune hepatitis.

- As already described, *acetaminophen toxicity* is one of the leading causes of acute failure leading to liver transplantation. The histologic features may be indistinguishable from those of fulminant acute hepatitis A or hepatitis B.
- *Isoniazid* is an example of an idiosyncratic hepatotoxin that can cause a chronic hepatitis precisely mimicking chronic viral hepatitis that may or may not resolve on removal of the instigating agent.
- Other drugs (e.g., minocyclin and nitrofurantoin) or toxins can induce an autoimmune hepatitis with all of the clinical and histologic features typical of that disease: autoantibodies, elevated IgG, and plasma cell–rich hepatic infiltrates. Such cases sometimes respond to treatment with immunosuppression but occasionally do not, progressing to cirrhosis despite withdrawal of the inciting agent.

# ALCOHOLIC AND NONALCOHOLIC FATTY LIVER DISEASE

Alcohol is a well-known cause of fatty liver disease in adults, and can manifest histologically as steatosis, steatohepatitis, and cirrhosis. In recent years it has become evident that another entity, the so-called nonalcoholic fatty liver disease (NAFLD), can mimic the entire spectrum of hepatic changes typically associated with alcohol abuse. NAFLD (described in more detail later) is associated with insulin resistance, obesity, diabetes mellitus, hypertension, and dyslipidemias, collectively called the metabolic syndrome. Since the morphologic changes of alcoholic and nonalcoholic fatty liver disease are indistinguishable, they are described together, followed by the distinctive clinical features of each of the entities.

### MORPHOLOGY

Three categories of liver alterations are observed in fatty liver disease. They can be present in any combination: steatosis (fatty change), hepatitis (alcoholic or steatohepatitis), and fibrosis.

**Hepatocellular Steatosis.** Hepatocellular fat accumulation typically begins in centrilobular hepatocytes. The lipid droplets range from small (microvesicular) to large (macrovesicular), the largest filling and expanding the cell and displacing the nucleus. As steatosis becomes more extensive, the lipid accumulation spreads outward from the central vein to hepatocytes in the midlobule and then the periportal regions (Fig. 15–15). Macroscopically, the fatty liver with widespread steatosis is large (weighing 4 to 6 kg or more), soft, yellow, and greasy.

**Steatohepatitis.** These changes typically are more pronounced with alcohol use than in NAFLD, but can be seen with variable degrees of prominence in fatty liver disease of any cause:

- **Hepatocyte ballooning.** Single or scattered foci of cells undergo swelling and necrosis; as with steatosis, these features are most prominent in the centrilobular regions.
- **Mallory-Denk bodies.** These consist of tangled skeins of intermediate filaments (including ubiquitinated keratins 8 and 18) and are visible as eosinophilic cytoplasmic inclusions in degenerating hepatocytes (Fig. 15–16).
- **Neutrophil infiltration.** Predominantly neutrophilic infiltration may permeate the lobule and accumulate around degenerating hepatocytes, particularly those containing Mallory-Denk bodies. Lymphocytes and macrophages also may be seen in portal tracts or parenchyma (Fig. 15–16, *A* and *B*).

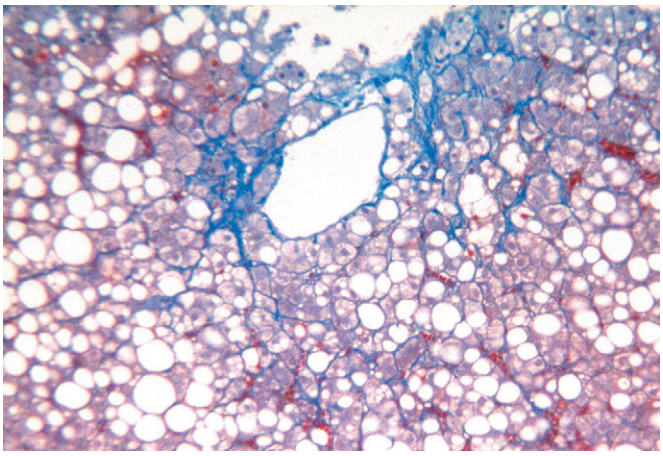

**Figure 15–15** Fatty liver disease. Macrovesicular steatosis is most prominent around the central vein and extends outward to the portal tracts with increasing severity. The intracytoplasmic fat is seen as clear vacuoles. Some fibrosis (stained *blue*) is present in a characteristic perisinusoidal "chicken wire fence" pattern. (Masson trichrome stain.)
*(Courtesy of Dr. Elizabeth Brunt, Washington University in St. Louis, St. Louis, Missouri.)*

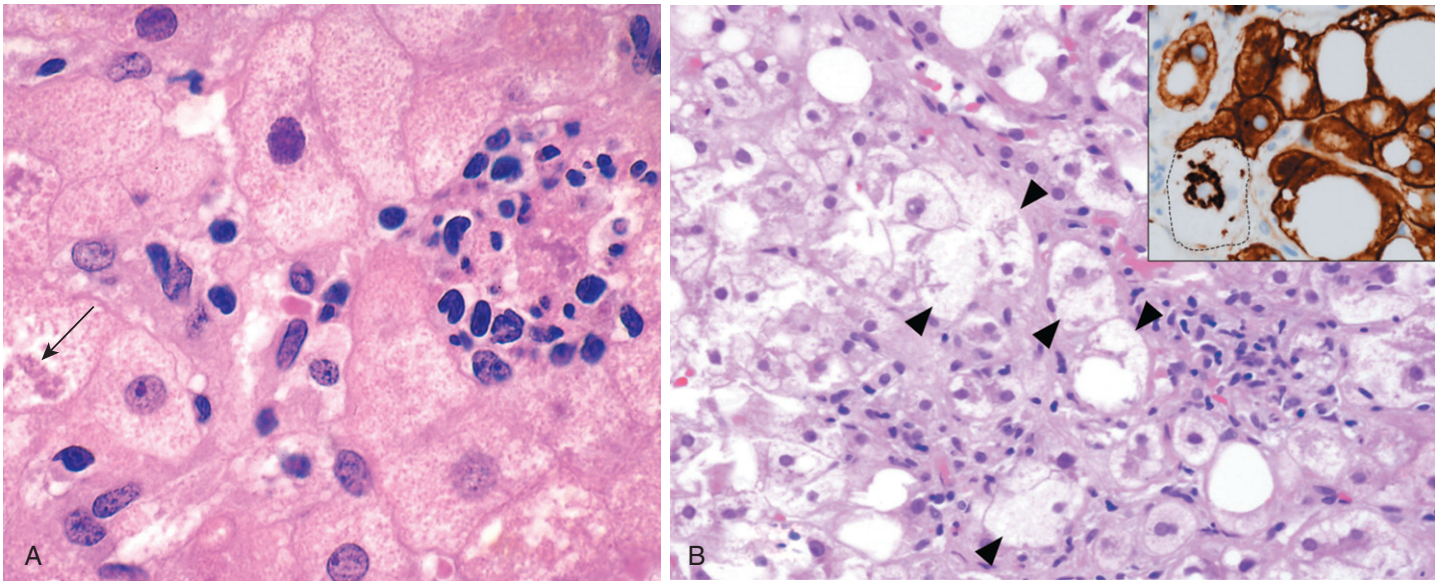


**Figure 15-16 A,** Alcoholic hepatitis with clustered inflammatory cells marking the site of a necrotic hepatocyte. A Mallory-Denk body is present in another hepatocyte (*arrow*). **B,** Steatohepatitis with many ballooned hepatocytes (*arrowheads*) containing prominent Mallory-Denk bodies; clusters of inflammatory cells are also seen; *inset* shows immunostaining for keratins 8 and 18 (*brown*), with most hepatocytes, including those with fat vacuoles, showing normal cytoplasmic staining, but in the ballooned cell (*dotted line*), the keratins are collapsed into the Mallory-Denk body, leaving the cytoplasm "empty."

*(Courtesy of Dr. Elizabeth Brunt, Washington University in St. Louis, St. Louis, Missouri.)*

**Steatohepatitis with fibrosis.** Fatty liver disease of all kinds has a distinctive pattern of scarring. Like the other changes, fibrosis appears first in the centrilobular region as **central vein sclerosis.** Perisinusoidal scar appears next in the space of Disse of the centrilobular region and then spreads outward, encircling individual or small clusters of hepatocytes in a **chicken wire fence pattern** (Fig. 15–15). These tendrils of fibrosis eventually link to portal tracts and then begin to condense to create **central-portal fibrous septa.** As these become more prominent, the liver takes on a nodular, cirrhotic appearance. Because in most cases of fatty liver disease the underlying cause persists, the continual subdivision of established nodules by new, perisinusoidal scarring leads to a classic **micronodular** or **Laennec cirrhosis.** Early in the course, the liver is yellow-tan, fatty, and enlarged. However, with persistent damage, over the course of years the liver is transformed into a brown, shrunken, nonfatty organ composed of cirrhotic nodules that are usually less than 0.3 cm in diameter—smaller than is typical for most chronic viral hepatitis (Fig. 15–17). The end-stage cirrhotic liver may enter into a "burned-out" phase devoid of fatty change and other typical features (Fig. 15–18). A majority of cases of **cryptogenic cirrhosis,** without clear etiology, are now recognized as "burned-out" NASH.

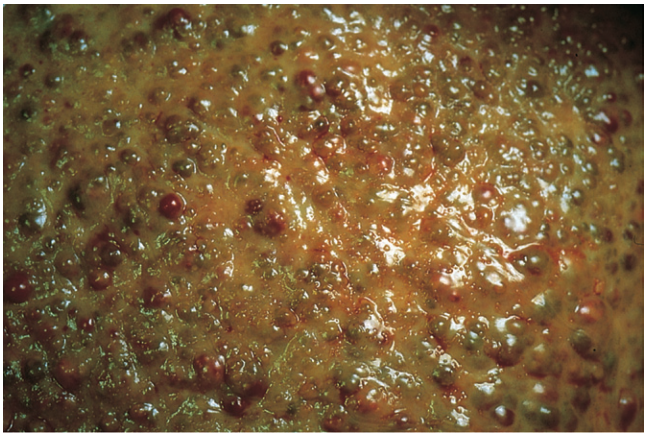

**Figure 15–17** Alcoholic cirrhosis. The characteristic diffuse nodularity of the surface is induced by the underlying fibrous scarring. The average nodule size is 3 mm in this close-up view. The *greenish* tint is caused by bile stasis.

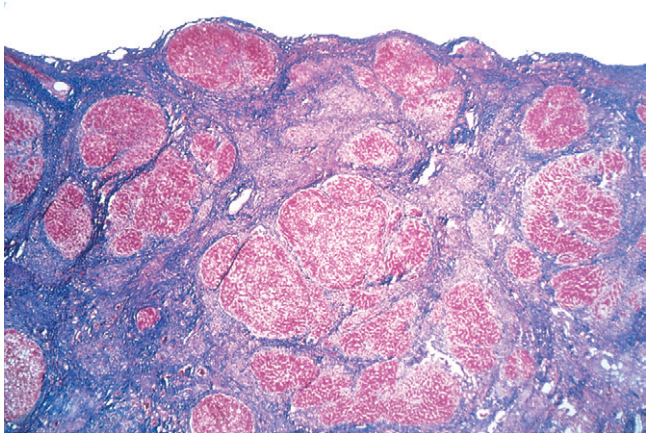

**Figure 15–18** Steatohepatitis leading to cirrhosis. Small nodules are entrapped in *blue*-staining fibrous tissue; fatty accumulation is no longer seen in this "burned-out" stage. (Masson trichrome stain.)

## Alcoholic Liver Disease

Excessive ethanol consumption causes more than 60% of chronic liver disease in Western countries and accounts for 40% to 50% of deaths due to cirrhosis. The following statistics attest to the magnitude of the problem in the United States:

- More than 10 million Americans are alcoholics.
- Alcohol abuse is the fifth leading cause of death, being responsible for 80,000 to 85,000 deaths annually. Of these deaths, 20,000 are attributable directly to end-stage cirrhosis; another 10,000 to 12,000 are the result of automobile accidents.
- From 25% to 30% of hospitalized patients have problems related to alcohol abuse.

Chronic alcohol consumption has many adverse effects (Chapter 7). Among the most important are the distinctive, overlapping forms of alcohol-related fatty liver disease already described: (1) hepatic steatosis, (2) alcoholic hepatitis, and (3) fibrosis and cirrhosis, collectively referred to as *alcoholic liver disease* (Fig. 15–19).

From 90% to 100% of heavy drinkers develop fatty liver (i.e., hepatic steatosis), and of those, 10% to 35% develop alcoholic hepatitis, whereas only 8% to 20% of chronic alcoholics develop cirrhosis. Steatosis, alcoholic hepatitis, and fibrosis may develop independently, so they do not necessarily represent a continuum of changes. Hepatocellular carcinoma arises in 10% to 20% of patients with alcoholic cirrhosis.

### PATHOGENESIS

Short-term ingestion of as much as 80 g of ethanol per day (5–6 beers or 8–9 ounces of 80-proof liquor) generally produces mild, reversible hepatic changes, such as fatty liver. Chronic intake of 40 to 80 g/day is considered a borderline risk factor for severe injury. For reasons that may relate to decreased gastric metabolism of ethanol and differences in body composition, women are more susceptible than men to hepatic injury. It seems that how often and what one drinks may affect the risk of liver disease development. For example, binge drinking causes more liver injury than that associated with steady, lower level consumption. Individual, possibly genetic risk factors must exist, but no reliable markers of susceptibility are known. In the absence of a clear understanding of the factors that influence liver damage, no **safe** upper limit for alcohol consumption can be proposed.

The metabolism of ethanol by the alcohol dehydrogenase and microsomal ethanol-oxidizing system is discussed in Chapter 7. As mentioned, the induction of cytochrome P-450 by chronic alcohol use leads to augmented transformation of other drugs to toxic metabolites. In particular, this effect can accelerate the metabolism of acetaminophen into highly toxic metabolites and increase the risk of liver injury even with therapeutic doses. Discussed next are the detrimental effects of alcohol and its byproducts on hepatocellular function.

**Hepatocellular steatosis** results from several mechanisms: (1) shunting of substrates away from catabolism and

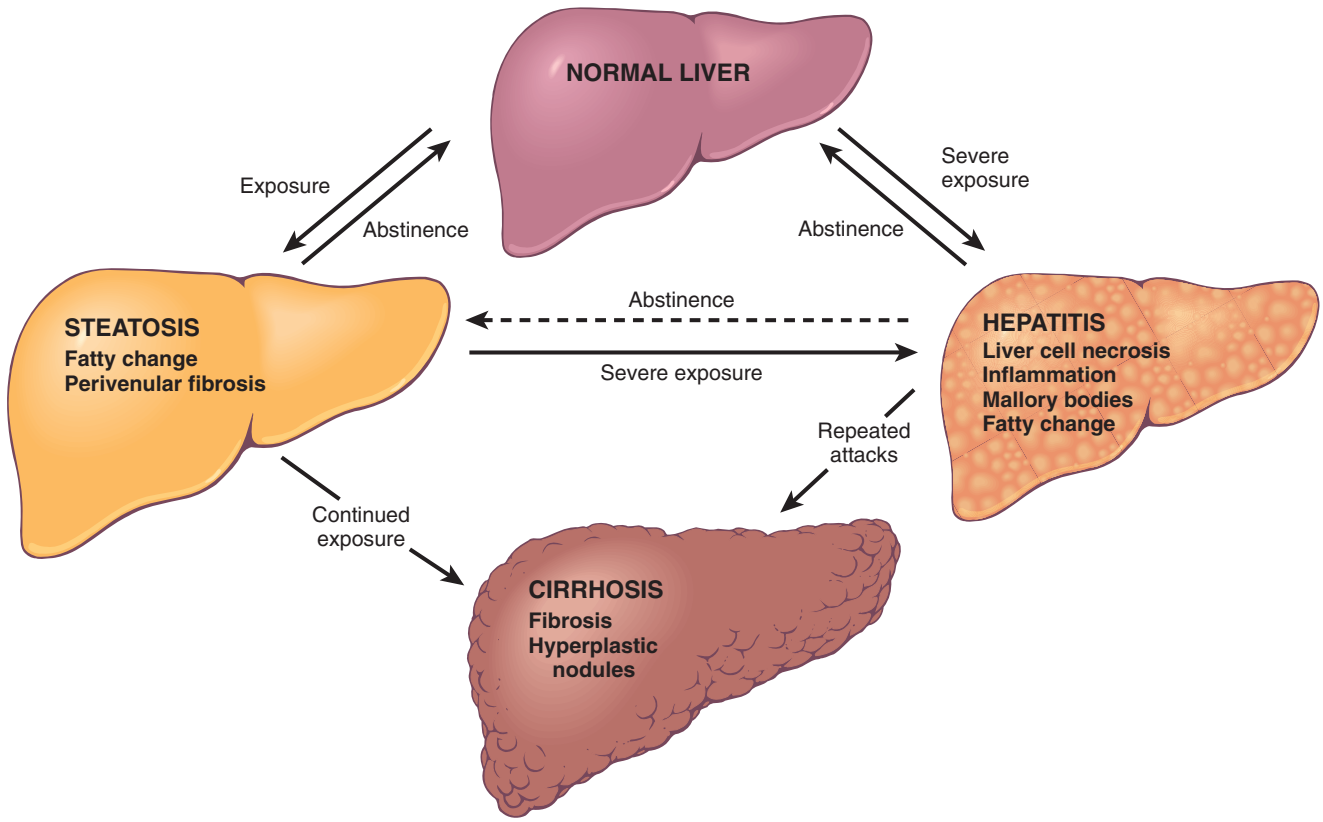


**Figure 15–19** Alcoholic liver disease. The interrelationships among hepatic steatosis, alcoholic hepatitis, and alcoholic cirrhosis are shown, along with a depiction of key morphologic features at the microscopic level. As stated in the text, it should be noted that steatosis, alcoholic hepatitis, and cirrhosis may also develop independently and not along a continuum.

toward lipid biosynthesis, because of the generation of excess reduced nicotinamide-adenine dinucleotide resulting from metabolism of ethanol by alcohol dehydrogenase and acetaldehyde dehydrogenase; (2) impaired assembly and secretion of lipoproteins; and (3) increased peripheral catabolism of fat.

The causes of **alcoholic hepatitis** are uncertain, but it may stem from one or more of the following toxic by products of ethanol and its metabolites:

- **Acetaldehyde** (a major metabolite of ethanol) induces lipid peroxidation and acetaldehyde-protein adduct formation, which may disrupt cytoskeleton and membrane function.
- **Alcohol** directly affects cytoskeleton organization (as illustrated by Mallory-Denk bodies), mitochondrial function, and membrane fluidity.
- **Reactive oxygen species** generated during oxidation of ethanol by the microsomal ethanol oxidizing system react with and damage membranes and proteins. Reactive oxygen species also are produced by neutrophils, which infiltrate areas of hepatocyte necrosis.
- **Cytokine-mediated inflammation** and cell injury is a major feature of alcoholic hepatitis and alcoholic liver disease in general. TNF is considered to be the main effector of injury; IL-1, IL-6, and IL-8 may also contribute. The main stimuli for the production of cytokines in alcoholic liver disease are the reactive oxygen species, mentioned earlier, and microbial products (e.g., endotoxin) derived from gut bacteria.

Because generation of acetaldehyde and free radicals is maximal in the centrilobular region, this region is most susceptible to toxic injury. Pericellular fibrosis and sinusoidal fibrosis develop in this area of the lobule. Concurrent viral hepatitis, particularly hepatitis C, is a major accelerator of liver disease in alcoholics. The prevalence of hepatitis C among persons with alcoholic disease is about 30% (and vice versa).

For unknown reasons, **cirrhosis** develops in only a small fraction of chronic alcoholics. With complete abstinence, some regression of scar can be seen in all cases, and the micronodular liver transforms, with regeneration, into a macronodular cirrhotic organ; rarely, there is regression of cirrhosis altogether.

### Clinical Features

*Hepatic steatosis* may be innocuous or give rise to hepatomegaly with mild elevations of serum bilirubin and alkaline phosphatase. Severe hepatic compromise is unusual. Alcohol withdrawal and the provision of an adequate diet are sufficient treatment.

It is estimated that 15 to 20 years of excessive drinking are necessary to develop *alcoholic cirrhosis,* but *alcoholic hepatitis* can occur after just weeks or months of consistent use. The onset is typically acute and often follows a bout of particularly heavy drinking. Symptoms and laboratory abnormalities may range from minimal to severe. Most patients present with malaise, anorexia, weight loss, upper abdominal discomfort, tender hepatomegaly, and fever. Typical laboratory findings include hyperbilirubinemia, elevated alkaline phosphatase, and neutrophilic leukocytosis. Serum alanine aminotransferase and aspartate aminotransferase are elevated but usually remain below 500 U/mL. The outlook is unpredictable; each bout of hepatitis carries about a 10% to 20% risk of death. With repeated bouts, cirrhosis appears in about one third of patients within a few years; alcoholic hepatitis also may be superimposed on cirrhosis.

The manifestations of alcoholic cirrhosis are similar to those of other forms of cirrhosis, presented earlier. Commonly, the first signs of cirrhosis relate to complications of portal hypertension. The stigmata of cirrhosis (e.g., an abdomen grossly distended with ascites, wasted extremities, caput medusae) may be the presenting features. Alternatively, a patient may first present with life-threatening variceal hemorrhage or hepatic encephalopathy. In other cases, insidious onset of malaise, weakness, weight loss, and loss of appetite precede the appearance of jaundice, ascites, and peripheral edema. Laboratory findings reflect the developing hepatic disease, with elevated serum aminotransferase, hyperbilirubinemia, variable elevation of alkaline phosphatase, hypoproteinemia (globulins, albumin, and clotting factors), and anemia. Finally, cirrhosis may be clinically silent, discovered only at autopsy or when stress such as infection or trauma tips the balance toward hepatic insufficiency. In chronic alcoholics, alcohol may become a major caloric source in the diet, displacing other nutrients and leading to malnutrition and vitamin deficiencies (e.g., thiamine, vitamin $B_{12}$). Compounding these effects is impaired digestive function, primarily related to chronic gastric and intestinal mucosal damage and pancreatitis.

The long-term outlook for alcoholic patients with liver disease is variable. The most important aspect of treatment is abstinence from alcohol. The 5-year survival rate approaches 90% in abstainers who are free of jaundice, ascites, or hematemesis but drops to 50% to 60% in persons who continue to imbibe. Among those with end-stage alcoholic liver disease, the immediate causes of death are

- Hepatic failure
- Massive gastrointestinal hemorrhage
- Intercurrent infection (to which affected persons are predisposed)
- Hepatorenal syndrome
- Hepatocellular carcinoma in 3% to 6% of cases

## SUMMARY

### Alcoholic Liver Disease

- Alcoholic liver disease has three main manifestations: hepatic steatosis, alcoholic hepatitis, and cirrhosis, which may occur alone or in combination.
- Consumption of 50 to 60 g/day of alcohol is considered to be the threshold for the development of alcoholic liver disease.
- Cirrhosis typically develops after 10 to 15 years of drinking or more, but only occurs in a small proportion of chronic alcoholics; alcoholic cirrhosis has the same morphologic and clinical features as cirrhosis caused by viral hepatitis.
- The multiple pathologic effects of alcohol include changes in lipid metabolism, decreased export of lipoproteins, and cell injury caused by reactive oxygen species and cytokines.

## Nonalcoholic Fatty Liver Disease (NAFLD)

NAFLD is a common condition in which fatty liver disease develops in persons who do not drink alcohol. The liver can show any of the three types of changes described earlier (steatosis, steatohepatitis, and cirrhosis). The term nonalcoholic steatohepatitis (NASH) is used to describe overt clinical features of liver injury, such as elevated transaminases and histologic features of hepatitis already described. NAFLD is consistently associated with insulin resistance and the metabolic syndrome (described below). Other commonly associated abnormalities are:

- Type 2 diabetes (or family history of the condition)
- Obesity, primarily central obesity (body mass index greater than 30 $kg/m^2$ in whites and greater than 25 $kg/m^2$ in Asians)
- Dyslipidemia (hypertriglyceridemia, low high-density lipoprotein cholesterol, high low-density lipoprotein cholesterol)
- Hypertension

### PATHOGENESIS

Metabolic syndrome is defined as having at least two of the following: obesity, insulin resistance, dyslipidemia, and hypertension. In patients with metabolic syndrome, the presence of type 2 diabetes and obesity is the best predictor of severe fibrosis and disease progression. Insulin resistance results in the accumulation of triglycerides in hepatocytes by at least three mechanisms:

- Impaired oxidation of fatty acids
- Increased synthesis and uptake of fatty acids
- Decreased hepatic secretion of very-low-density lipoprotein cholesterol

Fat-laden hepatocytes are highly sensitive to lipid peroxidation products generated by oxidative stress, which can damage mitochondrial and plasma membranes, causing apoptosis. Either as a consequence of oxidative stress or through release from visceral adipose tissue, levels of TNF, IL-6, and of the MCP-1 chemokine increase, contributing to liver damage and inflammation. Important roles are emerging for adiponectin and leptin in regulating these processes as well.

NAFLD is the most common cause of incidental elevation of serum transaminases. Most persons with steatosis are asymptomatic; patients with active steatohepatitis or fibrosis may also be asymptomatic, but some may have fatigue, malaise, right upper quadrant discomfort, or more severe symptoms of chronic liver disease. Liver biopsy is required for diagnosis. Fortunately, the frequency of progression from steatosis to active steatohepatitis and then from active steatohepatitis to cirrhosis seems to be low. Nevertheless, NAFLD is considered to be a significant contributor to the pathogenesis of "cryptogenic" cirrhosis.

Because they share common features, the incidence of coronary artery disease is increased in patients with NAFLD. Current therapy of NAFLD is directed toward obesity reduction and decrease in insulin resistance. Clinical trials of pioglitazone, a stimulator of the transcription factor PPAR-γ, which modulates the expression of insulin-sensitive genes, in nondiabetic patients with biopsy-proven steatohepatitis demonstrated a significant benefit as evidenced by reversal of NAFLD histologic changes. Lifestyle modifications (diet and exercise) appear to be the most effective form of treatment.

Pediatric NAFLD is becoming an increasing problem as metabolic syndrome and NAFLD approach epidemic proportions. *In children, the appearance of the histologic injuries is somewhat different: Inflammation and scarring tend to be more prominent in the portal tracts and periportal regions, and mononuclear infiltrates rather than neutrophilic infiltrates predominate.*

### SUMMARY

#### Nonalcoholic Fatty Liver Disease

- Nonalcoholic fatty liver disease (NAFLD) is associated with the metabolic syndrome, obesity, type 2 diabetes, and dyslipidemia and/or hypertension.
- NAFLD may show all the changes associated with alcoholic liver disease: steatosis, steatohepatitis (NASH), and cirrhosis, although the features of steatohepatitis (such as hepatocyte ballooning, Mallory-Denk bodies, and neutrophilic infiltration) often are less prominent than they are in alcohol-related injury.
- Pediatric NAFLD is increasingly being recognized as the obesity epidemic spreads to pediatric age groups, although its histologic pattern differs somewhat from that seen in adults.

## Drug/Toxin-Mediated Injury with Steatosis

Steatosis has a wide array of causes, including alcohol abuse, total parenteral nutrition, amiodarone, and methotrexate. A special category meriting emphasis involves mitochondrial injury leading to diffuse, hepatocellular *microvesicular steatosis,* usually associated with severe and potentially fatal acute liver dysfunction. The classic example is *Reye syndrome,* a rare disease that primarily affects children younger than 4 years of age who have a viral illness. The onset is heralded by pernicious vomiting and accompanied by irritability or lethargy and hepatomegaly. Serum bilirubin, ammonia, and aminotransferase levels are essentially normal at presentation. Although most patients recover, about 25% progress to coma, accompanied by elevations in the serum levels of bilirubin, aminotransferases, and particularly ammonia. Death occurs from progressive neurologic deterioration or liver failure. Survivors of more serious illness may be left with permanent neurologic impairments.

Reye syndrome has been associated with aspirin administration during viral illnesses; while there is no definitive evidence that salicylates play a causal role in this disorder, as a precaution aspirin is contraindicated in children and teenagers with febrile illnesses. Agents that are known to cause similar mitochondrial dysfunction include tetracycline and valproate, as well as toxins in unripe ackee fruit, popular in Jamaica. Highly active antiretroviral therapy (HAART) regimens used for HIV disease also may cause the same histologic injuries, but, for unclear reasons, these patients are spared significant morbidity.

### MORPHOLOGY

The key pathologic finding is **hepatocellular microvesicular steatosis.** Electron microscopy of hepatocellular mitochondria reveals pleomorphic enlargement and electron lucency of the matrices, with disruption of cristae and loss of dense bodies. Specifically with Reye syndrome, **cerebral edema** usually is present. Astrocytes are swollen and mitochondrial changes similar to those seen in the liver may develop. Inflammation is notably absent, as is any evidence of viral infection. **Skeletal muscles, kidneys,** and **heart** also may reveal microvesicular fatty change and mitochondrial alterations, although these changes are more subtle than those in the liver.

## CHOLESTATIC LIVER DISEASES

Cholestatic liver diseases include entities that lead to primary hepatocellular dysfunction (e.g. neonatal cholestasis, drug cholestasis, sepsis) or to bile duct injuries, including some that are mechanical (e.g., obstruction of large ducts by stones or tumor) or inflammatory (such as autoimmune diseases). To be clear, however, bile duct diseases cannot be neatly divided into intrahepatic or extrahepatic, because diseases may affect both intra- and extrahepatic segments, and exclusively extrahepatic biliary disorders may still cause secondary changes within the liver. We will first discuss the important cholestatic liver diseases, a heterogeneous group of disorders that have as their hallmark clinical signs and symptoms of cholestasis; biliary obstruction is considered under diseases of the extrahepatic biliary tree.

### Neonatal Cholestasis

As mentioned earlier, mild transient elevations in serum unconjugated bilirubin are common in normal newborns. Prolonged conjugated hyperbilirubinemia that lasts beyond the first 14 days of life is termed *neonatal cholestasis*. The major causes are extrahepatic biliary atresia, discussed later, and a variety of other disorders collectively referred to as *neonatal hepatitis.* Neonatal hepatitis is not a specific entity, nor are the disorders necessarily inflammatory. Instead, the finding of *neonatal cholestasis* should evoke a diligent search for recognizable toxic, metabolic, and infectious liver diseases. With greater awareness of etiology and better diagnostic tools, *idiopathic neonatal hepatitis* constitutes only 10% to 15% of cases of neonatal hepatitis.

Clinical presentation of infants with any form of neonatal cholestasis is fairly typical, with jaundice, dark urine, light or acholic stools, and hepatomegaly. Variable degrees of hepatic synthetic defects, such as hypoprothrombinemia, may be present. Differentiation between the two most common causes of neonatal cholestasis—extrahepatic atresia and idiopathic hepatitis—assumes great importance, because definitive treatment of biliary atresia requires surgical intervention, whereas surgery may adversely affect the clinical course in a child with idiopathic neonatal hepatitis. Fortunately, discrimination between these diseases can be made in about 90% of cases using clinical data and liver biopsy.

### Cholestasis of Sepsis

Sepsis may affect the liver in many ways. These include direct effects of intrahepatic bacterial infection (e.g., abscess formation or bacterial cholangitis) and ischemia caused by septic shock (particularly when the liver is cirrhotic) or in response to circulating microbial products. The latter is most likely to lead to the cholestasis of sepsis, particularly when the systemic infection is due to gram-negative organisms.

The most common alteration is *canalicular cholestasis,* with bile plugs within predominantly centrilobular canaliculi (Fig. 15–20, *A*). Histologic findings include prominent activated Kupffer cells and mild portal inflammation, but hepatocyte necrosis is scant or absent. *Ductular cholestasis* is a more ominous finding, wherein canals of Hering and

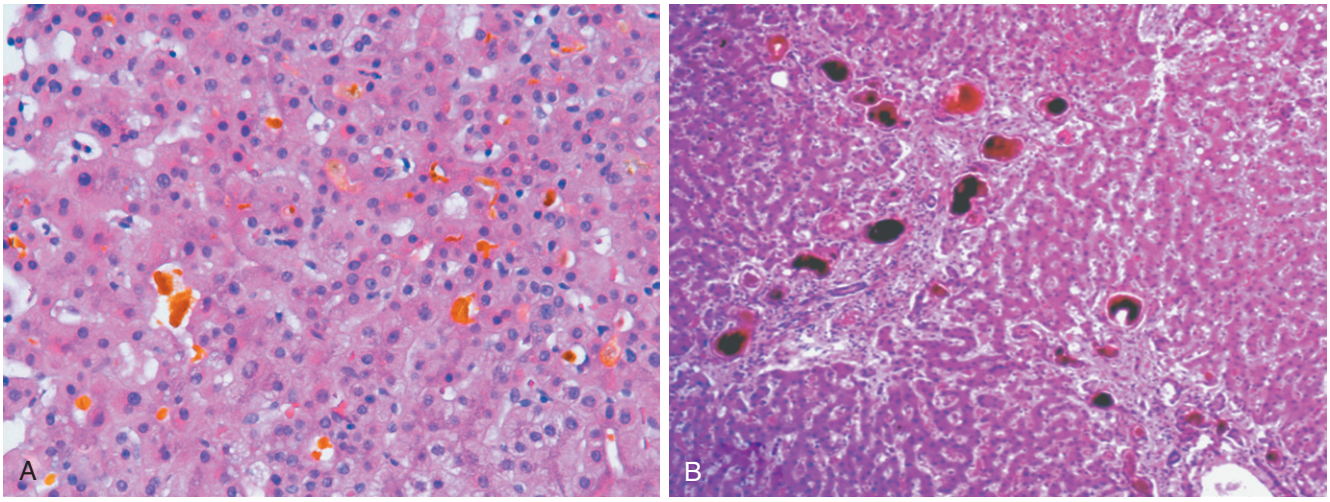


**Figure 15–20 A,** Cholestasis of sepsis. Prominent bile plugs are present in dilated canaliculi in the centrilobular region. **B,** Ductular cholestasis. Large, dark bile concretions within markedly dilated canals of Hering and ductules at the portal-parenchymal interface. This feature, indicative of current or impending severe sepsis, is related to endotoxemia.
*(B, Courtesy of Dr. Jay Lefkowitch, Columbia University, New York.)*

**Table 15–7** Main Features of Primary Biliary Cirrhosis and Primary Sclerosing Cholangitis

| Parameter | Primary Biliary Cirrhosis | Primary Sclerosing Cholangitis |
|---|---|---|
| Age | Median age 50 years (30–70) | Median age 30 years |
| Gender | 90% female | 70% male |
| Clinical course | Progressive | Unpredictable but progressive |
| Associated conditions | Sjögren syndrome (70%)<br>Scleroderma (5%)<br>Thyroid disease (20%) | Inflammatory bowel disease (70%)<br>Pancreatitis (≤25%)<br>Idiopathic fibrosing diseases (retroperitoneal fibrosis) |
| Serology | 95% AMA-positive<br>20% ANA-positive<br>40% ANCA-positive | 0–5% AMA-positive (low titer)<br>6% ANA-positive<br>65% ANCA-positive |
| Radiology | Normal | Strictures and beading of large bile ducts; pruning of smaller ducts |
| Duct lesion | Florid duct lesions and loss of small ducts only | Inflammatory destruction of extrahepatic and large intrahepatic ducts; fibrotic obliteration of medium and small intrahepatic ducts |

AMA, antimitochondrial antibody; ANA, antinuclear antibody; ANCA, antineutrophil cytoplasmic antibody.

bile ductules at the interface of portal tracts and parenchyma become dilated and contain prominent bile plugs (Fig. 15–20, *B*). This change, which is not a typical feature of biliary obstruction, often accompanies or even precedes the development of septic shock.

## Primary Biliary Cirrhosis

Primary biliary cirrhosis (PBC) is a chronic, progressive, and sometimes fatal cholestatic liver disease characterized by destruction of intrahepatic bile ducts, portal inflammation and scarring, and the development of cirrhosis and liver failure over years to decades (Table 15–7). *The cardinal feature of PBC is a nonsuppurative destruction of small and medium-sized intrahepatic bile ducts.* PBC is primarily a disease of middle-aged women, with peak incidence between the ages of 40 and 50 years. The name is a bit of a misnomer, because end-stage PBC is not always cirrhotic. Some patients may die or undergo transplantation because of severe portal hypertension in the absence of fully established cirrhosis, although others, usually displaying severe intractable cholestasis, are fully cirrhotic.

### PATHOGENESIS

More than 90% of persons with PBC demonstrate high titers of autoantibodies directed against several mitochondrial acid dehydrogenases. It is still unclear why the immune response is focused on these enzymes and why intrahepatic bile ducts are the targets of the immune attack. Recent evidence suggests that exposure to certain xenobiotics may modify mitochondrial proteins, providing one possible trigger for the immune response.

### Clinical Course

The onset of PBC is insidious, but the disease often comes to attention while the patient is still asymptomatic through discovery of an elevated serum alkaline phosphatase in routine laboratory tests. The diagnosis is usually made by demonstration of antimitochondrial antibodies and typical biopsy findings. Patients often present with pruritus and usually prove to have advanced disease.

Untreated patients progress to hepatic decompensation associated with portal hypertension, with variceal bleeding and hepatic encephalopathy, over a period of 2 or more decades. However, *early treatment with oral ursodeoxycholic acid dramatically improves the disease course, greatly slowing progression. Its mechanisms of action remain unclear, although they appear to include inhibition of apoptosis of biliary epithelium and inhibition of immune responses.* Hyperbilirubinemia is a late feature and usually signifies incipient hepatic decompensation. Associated extrahepatic conditions include the Sjögren syndrome of dry eyes and dry mouth, scleroderma, thyroiditis, rheumatoid arthritis, Raynaud phenomenon, and celiac disease.

### MORPHOLOGY

The morphology of PBC is most revealing in the precirrhotic stage. Interlobular bile ducts are actively destroyed by lymphocytic or plasmacytic inflammation with or without granulomas (the **florid duct lesion**) (Fig. 15–21). Some biopsy specimens, however, do not have active destructive lesions and show only portal tracts lacking bile ducts. Portal tracts upstream from the damaged bile ducts show bile ductular proliferation, and inflammation and necrosis of the adjacent periportal parenchyma. This leads to the development of

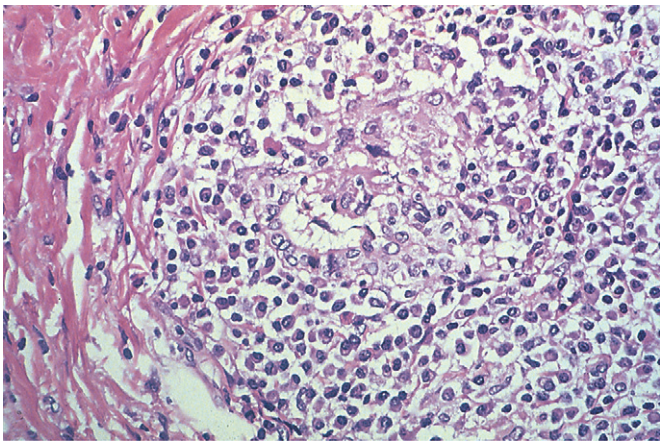

**Figure 15–21** Primary biliary cirrhosis. A portal tract is markedly expanded by an infiltrate of lymphocytes and plasma cells. Note the granulomatous reaction to a bile duct undergoing destruction (florid duct lesion).

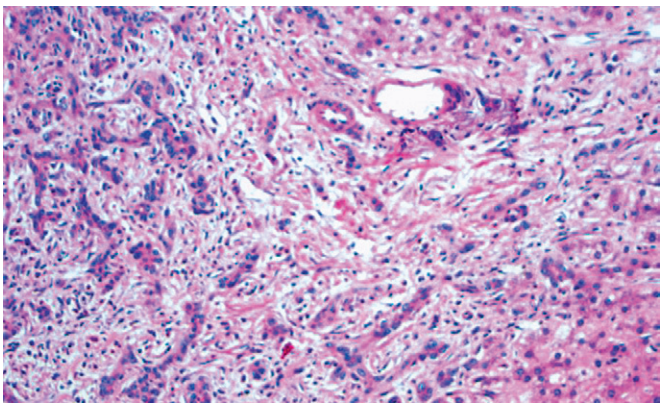

**Figure 15–22** An example of ductular reaction in a fibrotic septum. *(Courtesy of Dr. Matthew Yeh, University of Washington, Seattle, Washington.)*

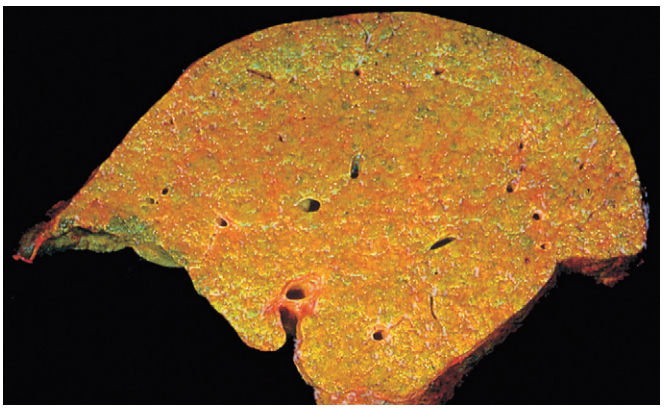

**Figure 15–23** Primary biliary cirrhosis, end stage. This sagittal section demonstrates liver enlargement, nodularity indicative of cirrhosis, and green discoloration due to cholestasis.

portal-portal septal fibrosis (Fig. 15–22). Mild interface and lobular hepatitis also may be present. The features sometimes overlap with those of autoimmune hepatitis; this overlap syndrome is diagnosed only when the hepatitic component is very prominent and there are serologic findings typical for autoimmune hepatitis.

Two paths to end-stage liver disease are recognized, both taking years or decades to evolve. Some patients develop prominent portal hypertension; on histologic examination these livers may display widespread nodularity without the surrounding scar tissue seen in cirrhosis—a feature called **nodular regenerative hyperplasia.** Such livers often are larger than normal and may show a vague nodularity that differs from the obvious nodules of cirrhosis. Why these hepatocytic changes occur in a disease that appears to be primarily biliary in nature is not understood.

Other patients follow a classical path with increasingly widespread duct loss leading to cirrhosis and profound cholestasis. The bile accumulation in such **chronic cholestasis** is not centrilobular, as in drug-induced or sepsis-associated cholestatic syndromes, but is periportal/periseptal and associated with **feathery degeneration** marked by ballooned, bile-stained hepatocytes, often with prominent Mallory-Denk bodies. These cells, while morphologically similar to those seen in alcoholic hepatitis, differ by their periportal rather than centrilobular location. Such end-stage livers show cirrhosis and vivid green discoloration, matching the patient's general icteric state (Fig. 15–23). Because there is little hepatocyte loss, the regenerative nodular hyperplasia often leads to hepatomegaly early in the disease course, a point of distinction from the shrunken livers of chronic hepatitis or alcoholism.

## Primary Sclerosing Cholangitis

Primary sclerosing cholangitis (PSC) is a chronic cholestatic disorder, characterized by progressive fibrosis and destruction of extrahepatic and intrahepatic bile ducts of all sizes (Table 15–7). Because the changes in the ducts are patchy, cholangiography, performed endoscopically or with the aid of magnetic resonance imaging (MRI), shows a characteristic *beading* in the affected segments of the biliary tree due to narrow strictures alternating with normal sized or dilated ducts. PSC commonly is seen in association with inflammatory bowel disease (Chapter 15), particularly ulcerative colitis, which coexists in approximately 70% of affected patients. Conversely, the prevalence of PSC among persons with ulcerative colitis is about 4%. The disorder tends to occur in the third through fifth decades of life, most often after development of inflammatory bowel disease. Males are affected more often than females, in a ratio of 2:1.

The cause of PSC is unknown. The association with ulcerative colitis, linkage with certain *HLA-DR* alleles, and presence of antinuclear cytoplasmic antibodies with a perinuclear localization (Chapter 10) in 80% of cases all suggest that this is an immunologically mediated disease.

### MORPHOLOGY

The characteristic features of PSC are different in the extrahepatic and large intrahepatic ducts than in the smaller ducts. The largest ducts have chronic inflammation with superimposed acute inflammation, very similar to the mucosal lesions of ulcerative colitis. These inflamed areas lead to narrowing of the larger ducts either because edema and inflammation narrows the lumen or because of subsequent scarring. The smaller ducts, however, often have little in the way of inflammation and show a striking **circumferential fibrosis** often referred to as **onion skinning** around an increasingly atrophic duct lumen (Fig. 15–24). Eventually the lumen disappears altogether, leaving just a dense button of scar tissue, the virtually diagnostic **tombstone scar.** Because the likelihood of sampling such smaller duct lesions on a random needle biopsy is minuscule, diagnosis depends not on biopsy but on radiologic imaging of the extrahepatic and largest intrahepatic ducts.

In response to duct loss, as in PBC, bile ductular proliferation, portal-portal septal fibrosis, and cirrhosis follow. The end-stage liver is therefore usually cirrhotic and green. **Biliary intraepithelial neoplasia** may appear and be a harbinger of **cholangiocarcinoma,** a fatal complication seen in a minority of patients.

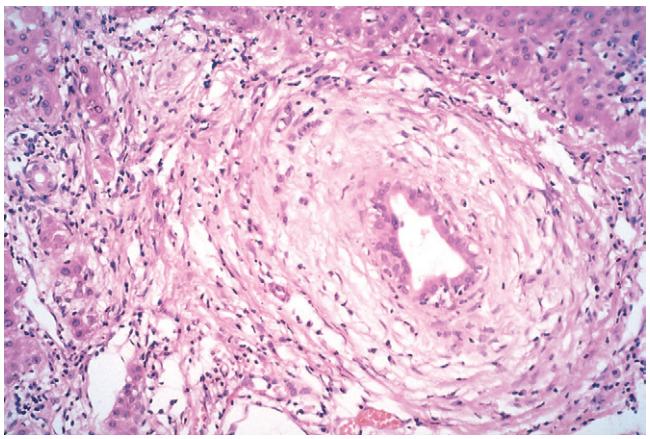

**Figure 15–24** Primary sclerosing cholangitis. A bile duct undergoing degeneration is entrapped in a dense, "onion-skin" concentric scar.

### Clinical Course

Asymptomatic patients may come to attention due to persistently elevated levels of serum alkaline phosphatase. Other patients present acutely with symptoms related to acute cholangitis—infection complicating previously asymptomatic biliary strictures—such as fever, right upper quadrant tenderness, and sometimes acute jaundice. Patients who present at later stages may have progressive fatigue, pruritus, and chronic jaundice. PSC generally has a protracted course over many years. Cholangiocarcinoma develops in 10% to 15% of patients with PSC, with a median time from diagnosis to malignant transformation of 5 years.

## Drug/Toxin-Induced Cholestasis

Cholestasis is a common feature of drug- or toxin-induced hepatic injury and may be seen alone or in combination with hepatitic features. When hepatocyte injury is minimal it is referred to as *bland* cholestasis, which is characterized by canalicular bile plugs and/or mid-centrilobular hepatocyte swelling and cytoplasmic bile pigment accumulation. *Cholestatic hepatitis,* in which features of cholestasis (elevated serum bilirubin and alkaline phosphatase, canalicular and hepatocellular cholestasis) and of hepatitis (elevated serum transaminases, lobular and interface hepatitis) coexist, is a particularly telling indication of drug- or toxin-induced injury. Common or well-known causes of such injury include C17 alkylated anabolic or contraceptive steroids, total parenteral nutrition, and antibiotics. Mimics of PBC and PSC, associated with not only cholestasis but actual loss of bile ducts, include liver injuries caused by chlorpromazine, amitryptyline, and organic arsenicals.

# INHERITED METABOLIC DISEASES

Although there are a relatively large number of inherited metabolic liver diseases, in this section only some common and selected conditions are discussed: hemochromatosis, Wilson disease, and AAT deficiency.

## Hemochromatosis

*Hereditary hemochromatosis* refers to genetic disorders characterized by excessive accumulation of body iron, most of which is deposited in the liver, pancreas, and heart. *At least four genetic variants of hereditary hemochromatosis are recognized. The most common form is an autosomal recessive disease of adult onset caused by mutations in the HFE gene.* Acquired forms of iron accumulation from known sources of excess iron are called *secondary iron overload.* Among the most important are multiple transfusions, ineffective erythropoiesis (as in β-thalassemia and myelodysplastic syndromes), and increased iron intake.

As discussed in Chapter 11, the total body iron pool ranges from 2 to 6 gm in normal adults; about 0.5 gm is stored in the liver, 98% of which is in hepatocytes. In hereditary hemochromatosis, iron accumulates over the lifetime of the affected person from excessive intestinal absorption. Total iron accumulation may exceed 50 gm, over one third of which is found in the liver. *Fully developed cases show (1) cirrhosis (seen in all patients), (2) diabetes mellitus (in 75% to 80% of patients), and (3) skin pigmentation (in 75% to 80%).*

### PATHOGENESIS

The total body content of iron is tightly regulated, such that the limited daily losses of iron are matched by gastrointestinal absorption since there is no excretory pathway for excess absorbed iron. **In hereditary hemochromatosis there is a defect in the regulation of intestinal absorption of dietary iron, leading to net iron accumulation of 0.5 to 1.0 g/year.** The hereditary hemochromatosis gene, responsible for the most common form of this disorder, is called *HFE*. It is located on the short arm of chromosome 6. It encodes a protein that is similar in structure to MHC class I proteins. The role of HFE in regulating iron uptake is complex and not fully understood. Expression of the mutated HFE protein on small intestinal enterocytes leads to inappropriately upregulated absorption of iron and its binding **to transferrin,** the major iron carrying molecule in blood. But HFE is not the whole story, and its interactions with other proteins, particularly **hepcidin,** produced by the liver, form a web of iron metabolic control networks that are only recently becoming elucidated.

It appears that *HFE* and the other genes involved in less common forms of hereditary hemochromatosis all regulate the levels of hepcidin, the iron hormone produced by the liver. Hepcidin normally down-regulates the efflux of iron from the intestines and macrophages into the plasma and inhibits iron absorption. When hepcidin levels are reduced there is increased iron absorption. Mice in whom the hepcidin gene is deleted develop iron overload resembling hemochromatosis, and mice that overexpress hepcidin develop severe iron deficiency, thus establishing the central role of hepcidin in regulating iron absorption. As might be expected, hepcidin levels are reduced in all currently known genetic forms of hemochromatosis, including the most common form caused by mutations in the HFE gene. The interconnections between the functions of these various genes and hepcidin synthesis are still being elucidated.

Hereditary hemochromatosis manifests typically after 20 gm of storage iron has accumulated. Regardless of source, excessive iron seems to be directly toxic to tissues by the following mechanisms:

- Lipid peroxidation by iron-catalyzed free radical reactions
- Stimulation of collagen formation
- Direct interactions of iron with DNA

## MORPHOLOGY

The morphologic changes in hereditary hemochromatosis are all responses to the **deposition of hemosiderin** in the following organs (in decreasing order of severity): liver, pancreas, myocardium, pituitary, adrenal, thyroid and parathyroid glands, joints, and skin. In the liver, iron becomes evident first as golden-yellow hemosiderin granules in the cytoplasm of periportal hepatocytes, which stain blue with the Prussian blue stain (Fig. 15–25). With increasing iron load, there is progressive involvement of the rest of the lobule, along with bile duct epithelium and Kupffer cells. Iron is a direct hepatotoxin, and inflammation is characteristically absent. At this stage, the liver typically is slightly larger than normal, dense, and chocolate brown. Fibrous septa develop slowly, linking portal tracts to each other and leading ultimately to **cirrhosis** in an intensely pigmented (very dark brown to black) liver.

In normal persons the iron content of unfixed liver tissue is less than 1000 μg/g dry weight. Adult patients with clinically evident iron overload of hereditary hemochromatosis exhibit greater than 10,000 μg/g dry weight of iron; hepatic iron concentrations in excess of 22,000 μg/g dry weight are associated with the development of fibrosis and cirrhosis.

The **pancreas** becomes intensely pigmented, acquires diffuse interstitial fibrosis, and may show some parenchymal atrophy. Hemosiderin is found in the acinar and the islet cells and sometimes in the interstitial fibrous stroma. The **heart** often is enlarged, with hemosiderin granules within the myocardial fibers. The pigmentation may induce a striking brown coloration of the myocardium. A delicate interstitial fibrosis may appear. Although **skin** pigmentation is partially attributable to hemosiderin deposition in dermal macrophages and fibroblasts, most of the coloration results from increased epidermal melanin production. The combination of these pigments renders the skin slate-gray. With hemosiderin deposition in the **joint synovial linings,** an acute synovitis may develop. There is also excessive deposition of calcium pyrophosphate, which damages the articular cartilage and sometimes produces disabling polyarthritis, referred to as pseudogout. The **testes** may be small and atrophic but usually are not discolored.

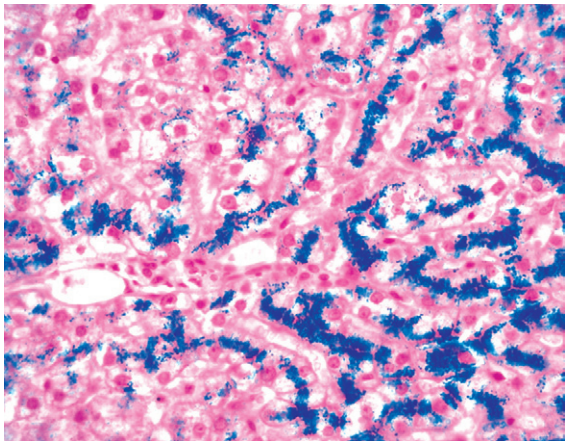

**Figure 15–25** Hereditary hemochromatosis. In this Prussian blue–stained histologic section, hepatocellular iron appears *blue*. The parenchymal architecture is normal.

### Clinical Features

Males predominate (in a ratio of 5 to 7:1), with slightly earlier clinical presentation, partly because physiologic iron loss (with menstruation or pregnancy) retards iron accumulation in women. In the most common forms, caused by *HFE* mutations, symptoms usually first appear in the fifth and sixth decades of life in men and later in women. With population screening it has become clear that even homozygous carriers of the most common *HFE* mutation (C282Y) have variable penetrance, so that disease progression is unpredictable.

The principal manifestations include hepatomegaly, skin pigmentation (particularly in sun-exposed areas), deranged glucose homeostasis or frank diabetes mellitus from destruction of pancreatic islets, cardiac dysfunction (arrhythmias, cardiomyopathy), and atypical arthritis. In some patients the presenting complaint is loss of libido and impotence. *The classic clinical triad of cirrhosis with hepatomegaly, skin pigmentation, and diabetes mellitus* may not develop until late in the course of the disease. Death may result from cirrhosis, hepatocellular carcinoma, or cardiac disease. Treatment of iron overload does not remove the risk for development of hepatocellular carcinoma, because of the cumulative, irreversible oxidative damage to DNA produced by iron. The risk for hepatocellular carcinoma development in patients with hemochromatosis is 200 times higher than in normal populations.

Fortunately, hereditary hemochromatosis can be diagnosed long before irreversible tissue damage has occurred. Screening involves demonstration of very high levels of serum iron and ferritin, exclusion of secondary causes of iron overload, and liver biopsy if indicated. Also important is screening of relatives of probands for the causative mutations. The natural course of the disease can be substantially altered by a variety of interventions, mainly phlebotomy and the use of iron chelators to decrease total body iron. Patients diagnosed in the subclinical, precirrhotic stage and treated by regular phlebotomy have a normal life expectancy. Heterozygotes may show a mild increase in iron absorption and accumulation.

## Wilson Disease

This autosomal recessive disorder is marked by the accumulation of toxic levels of copper in many tissues and organs, principally the liver, brain, and eye. The cause is loss-of-function mutations in the *ATP7B* gene, more than 300 of which have been identified. This gene, located on chromosome 13, encodes an ATPase metal ion transporter that localizes to the Golgi region of hepatocytes. About

1 in 100 people are asymptomatic carriers, and the incidence of the disease is approximately 1 per 30,000 population; thus, it is much less common than hereditary hemochromatosis.

## PATHOGENESIS

Normal copper physiology involves the following sequence:

1. Absorption of ingested copper (2 to 5 mg/day)
2. Plasma transport in complex with albumin
3. Hepatocellular uptake, followed by binding to an $\alpha_2$-globulin (apoceruloplasmin) to form ceruloplasmin
4. Secretion of ceruloplasmin-bound copper into plasma, where it accounts for 90% to 95% of plasma copper
5. Hepatic uptake of desialylated, senescent ceruloplasmin from the plasma, followed by lysosomal degradation and secretion of free copper into bile

In Wilson disease, the initial steps of copper absorption and transport to the liver are normal. However, without ATP7B activity, copper cannot be passed on to apoceruloplasmin and therefore cannot be excreted into bile, the **primary route for copper elimination from the body.** Copper thus accumulates progressively in hepatocytes, apparently causing toxic injury by a three-step mechanism: (1) promoting the formation of free radicals, (2) binding to sulfhydryl groups of cellular proteins, and (3) displacing other metals in hepatic metalloenzymes.

Usually by the age of 5 years, copper begins to escape from the overloaded, damaged hepatocytes into the circulation. Free copper generates oxidants that can lead to red cell hemolysis. It also is deposited in many other tissues, such as the brain, cornea, kidneys, bones, joints, and parathyroid glands, where it also produces damage through the same mechanisms that injure hepatocytes. Concomitantly, urinary excretion of copper increases markedly.

## MORPHOLOGY

The liver often bears the brunt of injury in Wilson disease, with protean hepatic changes ranging from relatively minor to massive damage and mimicking many other diseases. Thus, Wilson disease may mimic **fatty liver disease,** with mild to moderate steatosis, steatohepatitis, and even similar patterns of scarring. Patterns of **acute hepatitis** and **chronic hepatitis** simulate those of viral hepatitis. The acute hepatitis–like injury, in its most severe form, may manifest as fulminant hepatic failure. The chronic hepatitis–like picture may coexist with features of fatty liver disease, including the mononuclear infiltrates and lobular-interface hepatitis of the former, with the steatosis, hepatocyte ballooning, and Mallory-Denk bodies of the latter. With progression of chronic hepatitis, **cirrhosis** develops. Excess copper deposition can often be demonstrated by special stains (e.g., rhodanine stain for copper, orcein stain for copper-associated protein). Because copper also accumulates in chronic obstructive cholestasis, and because histologic analysis cannot reliably distinguish Wilson disease from other causes of liver disease, demonstration of hepatic copper content in excess of 250 μg/g dry weight is most helpful for making a diagnosis.

In the **brain,** toxic injury primarily affects the basal ganglia, particularly the putamen, which demonstrates atrophy and even cavitation. Nearly all patients with neurologic involvement develop **eye lesions** called **Kayser-Fleischer rings** (green to brown deposits of copper in Descemet membrane in the limbus of the cornea)—hence the alternative designation of this condition as hepatolenticular degeneration.

### Clinical Features

The age at onset and the clinical presentation of Wilson disease are extremely variable, but the disorder rarely manifests before the age of 6 years or in elderly persons. The most common presentation is acute or chronic liver disease. Neuropsychiatric manifestations, including mild behavioral changes, frank psychosis, or a Parkinson disease–like syndrome, are the initial features in most of the remaining cases. Unlike nearly all other forms of cirrhosis, hepatocellular carcinoma is quite uncommon in Wilson disease. Demonstration of Kayser-Fleischer rings or of markedly elevated hepatic copper levels in a person with low serum ceruloplasmin strongly favors the diagnosis. Early recognition and long-term therapy with copper chelators (such as D-penicillamine) and zinc salts (which lower copper uptake from the gut) have dramatically altered the usual progressive downhill course.

## $\alpha_1$-Antitrypsin Deficiency

$\alpha_1$-Antitrypsin (AAT) deficiency is an autosomal recessive disorder marked by abnormally low serum levels of this protease inhibitor. The major function of AAT is the inhibition of proteases, particularly neutrophil elastase released at sites of inflammation. AAT deficiency leads to pulmonary emphysema, because a relative lack of this protein permits the unrestrained activity of tissue-destructive proteases (Chapter 12). Hepatic disease results from retention of mutant AAT in the liver.

## PATHOGENESIS

AAT is a small (394–amino acid) plasma glycoprotein synthesized predominantly by hepatocytes. The *AAT* gene, located on human chromosome 14, is very polymorphic, and at least 75 forms have been identified. Most allelic variants produce normal or mildly reduced levels of serum AAT. However, homozygotes for the Z allele (*PiZZ* genotype) have circulating AAT levels that are only 10% of normal levels. *AAT* alleles are autosomal codominant, and consequently *PiMZ* heterozygotes have intermediate plasma levels of AAT. The PiZ polypeptide contains a single amino acid substitution that results in misfolding of the nascent polypeptide in the hepatocyte endoplasmic reticulum. Because the mutant protein cannot be secreted by the hepatocyte, it accumulates in the endoplasmic reticulum and triggers the so-called unfolded protein response, which can lead to induction of apoptosis (Chapter 1). Curiously, all persons with the *PiZZ* genotype accumulate AAT in the liver, but only 8% to 20% develop significant liver damage. This manifestation may be related to a genetic tendency in which susceptible persons are less able to degrade accumulated AAT protein within hepatocytes.

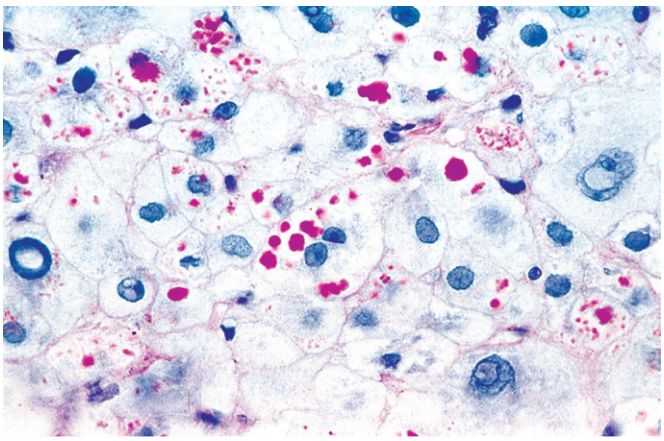

**Figure 15–26** $\alpha_1$-Antitrypsin deficiency. Periodic acid–Schiff stained histologic section of liver, highlighting the characteristic magenta cytoplasmic granules.
*(Courtesy of Dr. I. Wanless, Toronto General Hospital, Toronto, Ontario, Canada.)*

## MORPHOLOGY

Hepatocytes in AAT deficiency contain round to oval **cytoplasmic globules** composed of retained AAT, a glycoprotein that is strongly positive in a periodic acid–Schiff stain (Fig. 15–26). By electron microscopy they lie within smooth, and sometimes rough, endoplasmic reticulum. Hepatic injury associated with PiZZ homozygosity may range from marked **cholestasis** with **hepatocyte necrosis** in newborns, to **childhood cirrhosis,** to a smoldering chronic hepatitis or cirrhosis that becomes apparent only late in life.

### Clinical Course

Of all newborns with AAT deficiency, 10% to 20% exhibit cholestasis. In older children, adolescents, and adults, presenting symptoms may be related to chronic hepatitis, cirrhosis, or pulmonary disease. The disease may remain silent until cirrhosis appears in middle to later life. Hepatocellular carcinoma develops in 2% to 3% of adults with *PiZZ* genotype, usually but not always in the setting of cirrhosis. The treatment and cure for the severe hepatic disease are orthotopic liver transplantation.

## SUMMARY

### Inherited Metabolic Diseases

- Hemochromatosis is characterized by accumulation of iron in liver, pancreas, heart, pituitary gland, joints and other tissues. It is usually caused by mutations in the *HFE* gene, which encodes a protein that influences intestinal iron uptake.
- Wilson disease is the result of accumulation of copper in the liver, brain, and eyes; it is caused by a mutation in the metal ion transporter *ATP7B*.
- $\alpha_1$-Antitrypsin (AAT) deficiency in persons of *PiZZ* genotype causes pulmonary emphysema (due to increased elastase activity) and liver injury (caused by the accumulation of misfolded AAT).

# CIRCULATORY DISORDERS

In view of the enormous flow of blood through the liver, it is not surprising that circulatory disturbances have considerable impact on the liver. These disorders can be grouped according to whether blood flow into, through, or from the liver is impaired (Fig. 15–27).

## Impaired Blood Flow into the Liver

### *Hepatic Artery Inflow*

*Liver infarcts* are rare, thanks to the double blood supply to the liver. Interruption of the main hepatic artery does not always produce ischemic necrosis of the organ, because retrograde arterial flow through accessory vessels and the portal venous supply may sustain the liver parenchyma. The one exception is hepatic artery thrombosis in the transplanted liver, which generally leads to loss of the organ. Thrombosis or compression of an intrahepatic branch of the hepatic artery by polyarteritis nodosa (Chapter 9), embolism, neoplasia, or sepsis may result in a localized parenchymal infarct.

### *Portal Vein Obstruction and Thrombosis*

Extrahepatic blockage of the portal vein may be slow in developing and well tolerated or may be a catastrophic and potentially lethal event; most cases fall somewhere in between. Occlusion of the portal vein or its major branches typically produces abdominal pain and, in most instances, ascites and other manifestations of portal hypertension like esophageal varices prone to rupture. Acute impairment of visceral blood flow leads to profound congestion and bowel infarction. Extrahepatic portal vein obstruction may arise from the following:

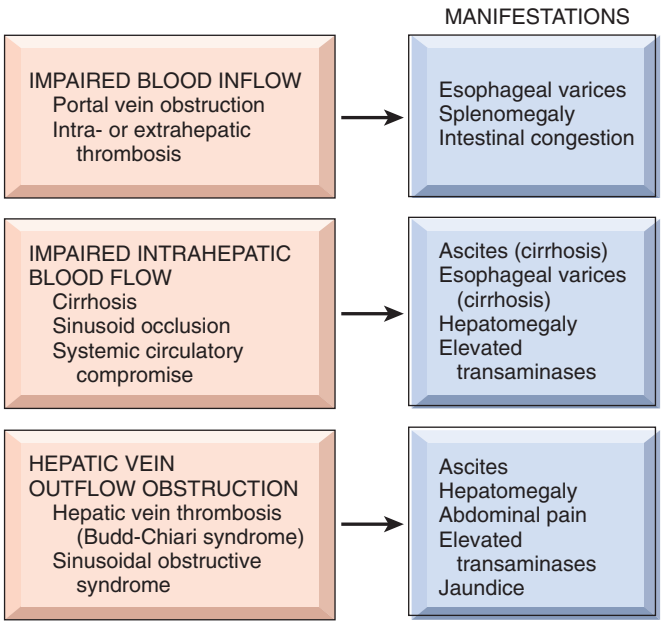


**Figure 15–27** Hepatic circulatory disorders. The forms and clinical manifestations of compromised blood flow are contrasted.

- Peritoneal sepsis (e.g., acute diverticulitis or appendicitis leading to pylephlebitis in the splanchnic circulation)
- Pancreatitis initiating splenic vein thrombosis that propagates into the portal vein
- Thrombogenic diseases and postsurgical thromboses
- Vascular invasion by primary or secondary cancer in the liver that progressively occludes portal inflow to the liver (extensions of hepatocellular carcinoma can even occlude the main portal vein)
- Banti syndrome, in which subclinical thrombosis of the portal vein (as from neonatal omphalitis or umbilical vein catheterization) produces a fibrotic, partially recanalized vascular channel presenting as splenomegaly or esophageal varices years after the occlusive event
- Cirrhosis, although not an extrahepatic cause of obstruction, reduces the flow of blood in the portal veins and hence provides a substratum for extrahepatic portal vein thrombosis.

Intrahepatic thrombosis of a portal vein radicle, when acute, does not cause ischemic infarction but instead results in a sharply demarcated area of red-blue discoloration (so-called *infarct of Zahn*). There is no necrosis; the only morphologic changes are hepatocellular atrophy and marked congestion of distended sinusoids. *Hepatoportal sclerosis* is a chronic, usually idiopathic (perhaps autoimmune), generally bland condition of progressive portal tract sclerosis leading to impaired portal vein inflow. Identified causes include myeloproliferative disorders associated with hypercoagulability, peritonitis, or exposure to arsenicals.

## Impaired Blood Flow Through the Liver

The most common intrahepatic cause of portal blood flow obstruction is cirrhosis, as described earlier. In addition, physical occlusion of the sinusoids occurs in a small but important group of diseases. In sickle cell disease, the hepatic sinusoids may become obstructed by sickled red cells, leading to panlobular parenchymal necrosis. *Disseminated intravascular coagulation* may cause occlusion of sinusoids. This blockage usually is inconsequential except in eclampsia, in which periportal sinusoidal occlusion and parenchymal necrosis may occur. Subsequent suffusion of blood under the capsule may precipitate a fatal intra-abdominal hemorrhage.

### *Passive Congestion and Centrilobular Necrosis*

Passive congestion and centrilobular necrosis are hepatic manifestations of systemic circulatory disorders that constitute a morphologic continuum. Right-sided cardiac decompensation leads to passive congestion of the liver and, if persistent, can cause centrilobular necrosis and perivenular fibrosis in the areas of necrosis. In most instances, the only clinical evidence of centrilobular necrosis is a small elevation in serum aminotransferase levels, although some patients have hyperbilirubinemia and elevated alkaline phosphatase.

#### MORPHOLOGY

In right-sided cardiac failure, the liver is slightly enlarged, tense, and cyanotic, with rounded edges. Microscopic examination reveals **congestion of centrilobular sinusoids.** Over time, centrilobular hepatocytes become atrophic, resulting in markedly attenuated liver cell cords. An uncommon complication of sustained, chronic, severe congestive heart failure is so-called **cardiac sclerosis.** The pattern of liver fibrosis is distinctive, inasmuch as it is mostly centrilobular. Rarely bridging fibrous septa and cirrhosis develop.

Left-sided cardiac failure or shock may lead to hepatic hypoperfusion and hypoxia. In this instance, the two areas most dependent on arterial flow (receiving little in the way of portal vein nutrients)—namely, centrilobular hepatocytes and bile ducts—undergo ischemic necrosis. The combination of left-sided hypoperfusion and right-sided retrograde congestion acts synergistically to generate a distinctive lesion, centrilobular hemorrhagic necrosis (Fig. 15–28). The liver takes on a variegated mottled appearance, reflecting hemorrhage and necrosis in the centrilobular regions, alternating with pale midzonal areas, known traditionally as the **nutmeg liver** because of its similarity to the cut surface of a nutmeg.

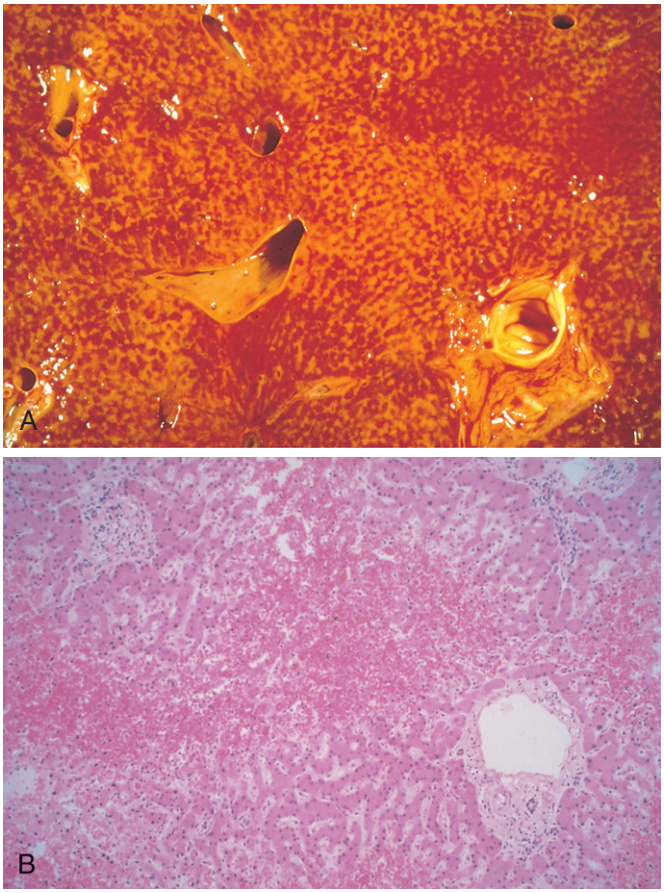


**Figure 15–28** Centrilobular hemorrhagic necrosis (nutmeg liver). **A,** The cut liver section, in which major blood vessels are visible, is notable for a variegated mottled red appearance, representing hemorrhage in the centrilobular regions of the parenchyma. **B,** On microscopic examination, the centrilobular region is suffused with red blood cells, and hepatocytes are not readily visible. Portal tracts and the periportal parenchyma are intact.

## Hepatic Vein Outflow Obstruction

### *Hepatic Vein Thrombosis (Budd-Chiari Syndrome)*

The Budd-Chiari syndrome results from the *thrombosis one or more major hepatic veins* and is characterized by hepatomegaly, ascites, and abdominal pain. Hepatic vein thrombosis is associated with myeloproliferative disorders (especially polycythemia vera), pregnancy, the postpartum state, the use of oral contraceptives, paroxysmal nocturnal hemoglobinuria, and intra-abdominal cancers, particularly hepatocellular carcinoma. All of these conditions produce thrombotic tendencies or, in the case of liver cancers, sluggish blood flow. Some cases are caused by mechanical obstruction to blood outflow, as by a massive intrahepatic abscess or parasitic cyst, or by obstruction of the inferior vena cava at the level of the hepatic veins by thrombus or tumor. About 10% of cases are idiopathic.

#### MORPHOLOGY

With acutely developing thrombosis of the major hepatic veins or inferior vena cava, the liver is swollen and red-purple, with a tense capsule (Fig. 15–29). On microscopic examination, severe centrilobular congestion and necrosis are apparent in affected hepatic parenchyma. In instances in which the thrombosis develops more slowly, centrilobular fibrosis is seen. The major veins may contain completely or incompletely occlusive fresh thrombi or, in chronic cases, organized adherent thrombi.

Mortality attributable to untreated acute Budd-Chiari syndrome is high. Prompt surgical creation of a portosystemic venous shunt permits reverse flow through the portal vein and improves the prognosis considerably; direct dilation of caval obstruction may be possible during angiography. The chronic form of the syndrome is far less grave, and more than two thirds of the patients are alive after 5 years.

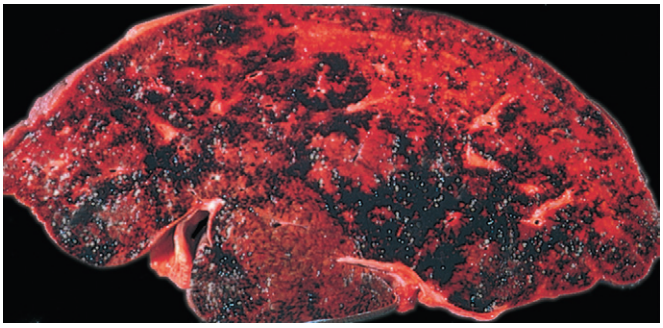

**Figure 15–29** Budd-Chiari syndrome. Thrombosis of the major hepatic veins has caused profound hepatic congestion.

### *Sinusoidal Obstruction Syndrome*

Originally described in Jamaican drinkers of "bush tea" containing pyrrolizidine alkaloid, *sinusoidal obstruction syndrome* formerly was known as *venoocclusive disease*. The new designation more specifically indicates that the condition is caused by toxic injury to sinusoidal endothelium. Damaged endothelial cells slough, leading to formation of thrombi that block sinusoidal flow. Endothelial damage allows red cells to spill into the space of Disse, and also causes proliferation of stellate cells and fibrosis of terminal branches of the hepatic vein (Fig. 15–30). Sinusoidal obstruction syndrome now occurs primarily in the first 20 to 30 days after bone marrow transplantation, affecting 20% of recipients. The sinusoidal injury is believed to be caused by chemotherapeutic agents such as cyclophosphamide, actinomycin D, and mithramycin, and by total body radiation, used in pre- or posttransplantation regimens. The clinical presentation resembles the Budd-Chiari syndrome and varies, ranging from mild to severe. Severe sinusoidal obstruction syndrome that does not resolve after 3 months of treatment can be fatal.

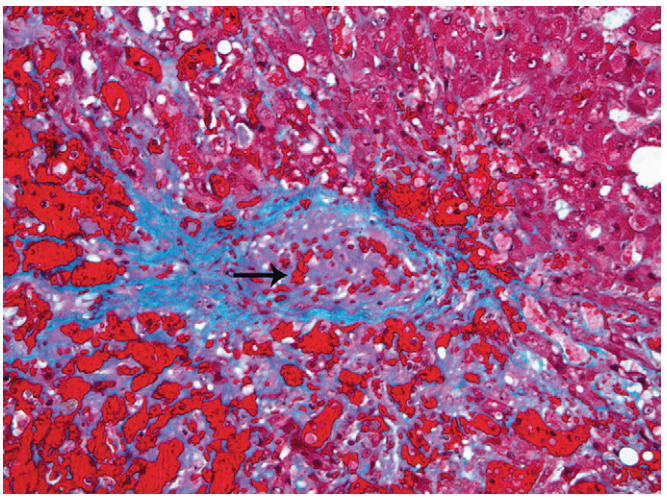

**Figure 15–30** Sinusoidal obstruction syndrome (formerly known as venoocclusive disease). A central vein is occluded by cells and newly formed collagen (*arrow*). There is also fibrosis in the sinusoidal spaces. Fibrous tissue is stained *blue* by the Masson trichrome stain.
*(Courtesy of Dr. Matthew Yeh, University of Washington, Seattle, Washington.)*

#### SUMMARY

##### Circulatory Disorders

- Circulatory disorders of the liver can be caused by impaired blood inflow, defects in intrahepatic blood flow, and obstruction of blood outflow.
- Portal vein obstruction by intra- or extrahepatic thrombosis may cause portal hypertension, esophageal varices, and ascites.
- The most common cause of impaired intrahepatic blood flow is cirrhosis.
- Conditions of obstruction of blood outflow include hepatic vein thrombosis (Budd-Chiari syndrome) and sinusoidal obstruction syndrome, previously known as venoocclusive disease.

# OTHER INFLAMMATORY AND INFECTIOUS DISEASES

## Liver Abscesses

In developing countries liver abscesses are common; most result from parasitic infections, such as amebic and (less commonly) other protozoal and helminthic organisms. In developed countries parasitic liver abscesses are more rare. In the Western world, bacterial abscesses are more common, representing a complication of an infection elsewhere. The organisms reach the liver through one of the following pathways:

- Ascending infection in the biliary tract (ascending cholangitis)
- Vascular seeding, either portal or arterial, predominantly from the gastrointestinal tract
- Direct invasion of the liver from a nearby source
- A penetrating injury

Debilitating disease with immune deficiency is a common setting—for example, extreme old age, immunosuppression, or cancer chemotherapy with marrow failure.

Pyogenic (bacterial) hepatic abscesses may occur as solitary or multiple lesions, ranging in size from millimeters to massive lesions many centimeters in diameter. Many pathogens can cause pyogenic liver abscess and often more than one organism is involved. The most common bacterial agents are *E. coli, Klebsiella pneumoniiae*, *Proteus* spp., pseudomonas, and *Streptococcus milleri.* Increasingly *Candida* spp. are also being isolated. Because of the polymicrobial nature of the abscesses, identification of the organisms is important. Gross and microscopic features are those of any pyogenic abscess: liquefactive necrosis with abundant neutrophils.

Liver abscesses are associated with fever and, in many instances, with right upper quadrant pain and tender hepatomegaly. Jaundice may result if there is biliary obstruction. Antibiotic therapy along with percutaneous or surgical drainage is often necessary. If the treatment is delayed, particularly in persons with serious coexistent disease, the mortality rate with large liver abscesses ranges from 30% to 90%. With early recognition and appropriate management, as many as 90% of patients may survive.

## Granulomatous Disease

Granulomas are common in the liver, being present in as many as 10% of liver biopsy specimens. They may reflect systemic disease or be specific to the liver. Granulomatous disease may be classified into four etiologic categories:

- "See the cause," in which infectious agents can be visualized with special stains, such as fungal or acid-fast organisms
- "Know the cause," in which organisms are not seen but a previous diagnosis (e.g., known tuberculosis, systemic sarcoidosis, duct destructive lesions in known primary biliary cirrhosis) explains the lesions
- "Suspect the cause," in which the appearance of the granulomas or clinicopathologic correlation points to a likely underlying disorder, such as caseous necrosis, strongly suggestive of infection, or eosinophilia, which points to parasites or drug- or toxin-induced injury
- "Don't know the cause," accounting for approximately 10% of hepatic granulomas, most of which are incidental findings of no clinical import

Because of their infiltrative nature, granulomatous diseases of the liver give rise to intrahepatic cholestasis with elevations of alkaline phosphatase and γ-glutamyl transpeptidase.

# TUMORS AND HEPATIC NODULES

The liver and lungs share the dubious distinction of being the visceral organs most often involved by metastatic cancers. Indeed, *the most common hepatic neoplasms are metastatic carcinomas,* with colon, lung, and breast heading the list of the primary sites. *Primary hepatic malignancies* are almost all *hepatocellular carcinomas,* which show a dramatic geographic variation in incidence throughout the world, as discussed later. Two other types of primary liver cancers, hepatoblastoma (a childhood hepatocellular tumor) and angiosarcoma (a tumor of blood vessels associated with exposure to vinyl chloride and arsenic), are too rare to merit further discussion here.

Hepatic masses come to attention for a variety of reasons. They may generate epigastric fullness and discomfort or be detected by routine physical examination. Radiographic studies for other indications may pick up incidental liver masses.

## Benign Tumors

The most common benign lesions of the liver are *cavernous hemangiomas,* which are identical to those occurring in other parts of the body (Chapter 9). These well-circumscribed lesions consist of endothelial cell–lined vascular channels and intervening stroma. They appear as discrete red-blue, soft nodules, usually less than 2 cm in diameter, often directly beneath the capsule. Their chief clinical significance lies in the importance of not mistaking them for metastatic tumors; blind percutaneous needle biopsy may cause severe intra-abdominal bleeding.

*Von Meyenburg complexes* are another quite common benign finding in the liver. These are presumed to be congenital bile duct hamartomas and are usually isolated or present in small numbers. They are composed of bile duct–like structures separated by bland, densely collagenized stroma. These lesions have no malignant potential, but when multiple may indicate the presence of *fibropolycystic disease of the liver,* which may occur in association with certain forms of polycystic kidney disease (Chapter 13).

### *Focal Nodular Hyperplasia*

*Focal nodular hyperplasia* (FNH) is found most often in otherwise normal livers. It is a localized, well-demarcated, but poorly encapsulated lesion, consisting of hyperplastic hepatocyte nodules with a central, stellate fibrous scar. It is not a true neoplasm but rather represents a response to abnormal vascular flow through a congenital or acquired vascular anomaly that gives rise to alternating areas of

parenchymal regeneration and atrophy. FNH may range in size from 1 cm to many centimeters across. It usually is an incidental finding, most commonly in women of reproductive age, in whom it may grow in response to estrogens, including those found in contraceptive pills. These lesions carry no risk for malignancy but may cause symptoms by pressing on the liver capsule.

### *Hepatic Adenoma*

Hepatic adenoma is a benign hepatocellular neoplasm that usually occurs in women of child-bearing age who have used oral contraceptive pills, and it may regress on discontinuance of hormone use. These lesions usually are well-demarcated but unencapsulated tumors that may be pale, yellow-tan, or bile-stained and up to 30 cm in diameter (Fig. 15–31). On histologic examination, hepatic adenomas are composed of sheets and cords of cells that may resemble normal hepatocytes or have minimal variation in cell and nuclear size. Portal tracts are absent; instead, prominent arterial vessels and draining veins are distributed throughout. Liver cell adenomas are significant for three reasons: (1) when they manifest as an intrahepatic mass, they may be mistaken for the more ominous hepatocellular carcinoma; (2) subcapsular adenomas are at risk for rupture, particularly during pregnancy (under estrogenic stimulation), causing life-threatening intraabdominal hemorrhage; and (3) although malignant transformation is unusual, adenomas harboring β-catenin mutations carry a risk of developing into hepatocellular carcinoma.

Molecular studies now classify these lesions into three somewhat discrete types:

- 35% to 40% of adenomas have biallelic inactivation through somatic (90%) or germline (10%) mutations of either the *HNF1A* gene (encoding a hepatocyte transcription factor) or the *CYP1B1* gene (encoding cytochrome P-450). These adenomas are most common in women, sometimes associated with oral contraceptive use, and are often yellow from marked steatosis. They carry little risk for malignant transformation.
- 10% to 15% of adenomas have activating mutations of β-catenin. These have a high risk for malignant transformation, are most common in men and may be related to anabolic steroid use and possibly nonalcoholic fatty liver disease.
- More than 50% of adenomas are *inflammatory,* being associated with increased expression of acute phase reactant proteins such as serum amyloid A and C-reactive protein in the tumor and sometimes in the serum. About 10% of these tumors also have activating mutations of β-catenin and may undergo malignant transformation. This type is most common in women and is often associated with obesity and fatty liver disease. Morphologically, this subgroup may be identical to FNH, and the distinction may be made by demonstrating an inflammatory phenotype (such as by expression of serum amyloid A protein, SAA).

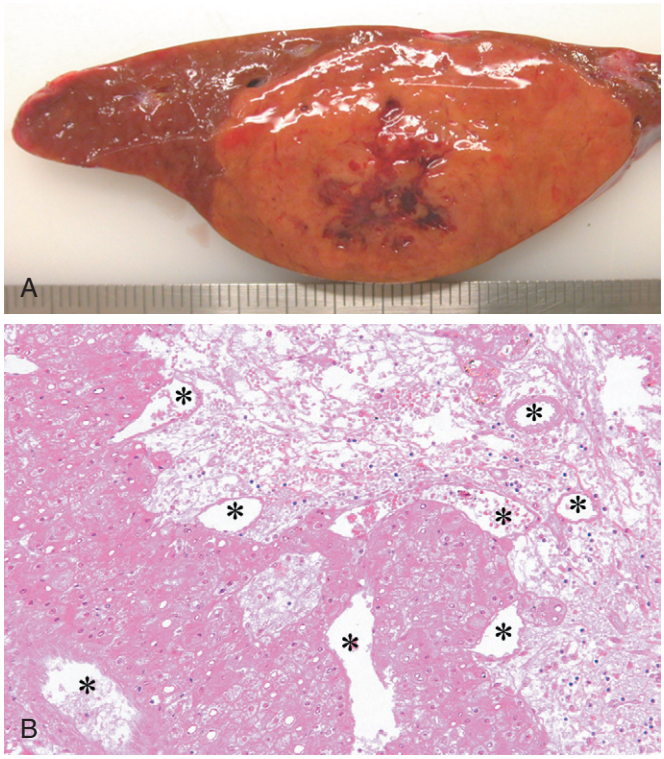


**Figure 15–31** Hepatic adenoma. **A,** Surgically resected specimen showing a discrete mass underneath the liver capsule with hemorrhagic necrosis (*dark red areas*). **B,** Photomicrograph showing adenoma, with cords of normal-appearing hepatocytes, absence of portal tracts, and prominent neovascularization (*asterisks*). A large zone of infarcted tumor is present.
*(A, Courtesy of Dr. Paulette Bioulac-Sage, University of Bordeaux, Bordeaux, France.)*

## Precursor Lesions of Hepatocellular Carcinoma

While hepatocellular adenomas sometimes can be premalignant, they represent a rare pathway to hepatocellular malignancy. Far more common precursors are cellular changes and nodular lesions that are found in the setting of chronic liver disease, particularly chronic viral hepatitis, alcoholic liver disease, and metabolic diseases such as AAT deficiency and hereditary hemochromatosis. Usually they are found in late-stage disease, in particular when cirrhosis is already established. However, while it has often been said that cirrhosis itself is premalignant, this is imprecise: The processes that lead to cirrhosis and to malignant transformation usually take years to decades and run parallel to each other, rather than in sequence.

### *Cellular Dysplasia*

Two forms of hepatocellular dysplasia are recognized, both of which are most common in the setting of chronic viral hepatitis. *Large cell change* consists of scattered hepatocytes, usually in periportal or periseptal regions, that are larger than normal hepatocytes and have pleomorphic, often multiple nuclei (Fig. 15–32, *A*). Although morphologically atypical, these cells are not believed to be on the pathway to malignant transformation but rather are considered a marker of molecular changes stemming from chronic injury that predispose other morphologically normal hepatocytes to undergo malignant transformation. *Small cell change* is characterized by smaller-than-normal hepatocytes with normal-sized, often hyperchromatic, oval or angulated nuclei. Small cell change may appear anywhere in the

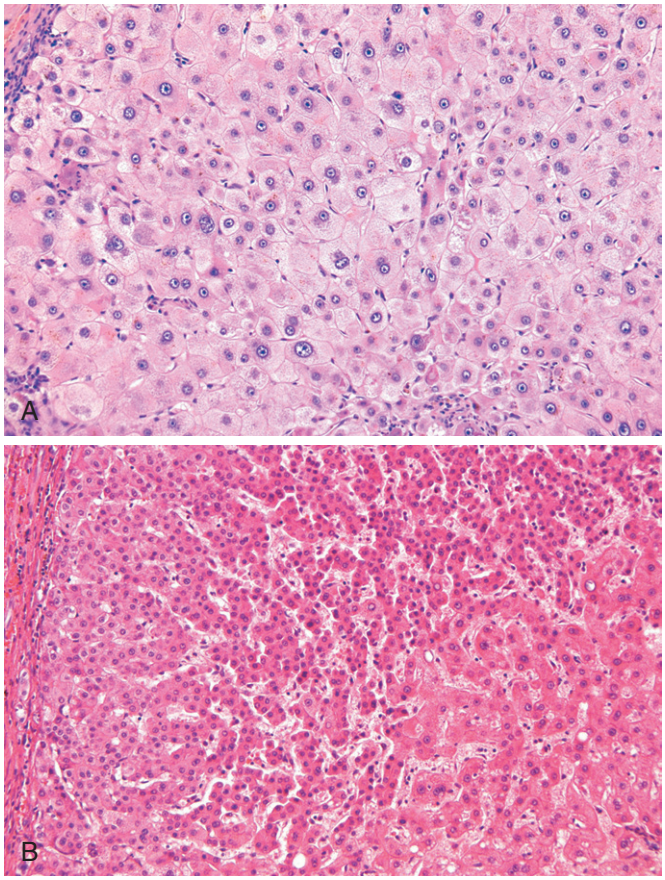


**Figure 15–32 A,** Large cell change. Very large hepatocytes with very large, often atypical nuclei are scattered among normal-size hepatocytes with round, typical nuclei. **B,** Small cell change (SCC). Normal-appearing hepatocytes are in the *lower right corner.* SCC is indicated by smaller than normal hepatocytes with thickened liver cell plates, and high nuclear : cytoplasmic ratio.
*(A and B, Courtesy of Dr. Young Nyun Park, Yonsei Medical College, Seoul, South Korea.)*

hepatic lobule, often with formation of vaguely nodular clusters. This form of dysplasia is considered to be directly premalignant (Fig. 15–32, *B*).

### *Dysplastic Nodules*

Dysplastic nodules probably represent the major pathway to hepatocellular carcinoma in chronic liver disease. In cirrhotic livers, dysplastic nodules are distinguished by their larger size: Most cirrhotic nodules range from 0.3 to 0.8 cm, but dysplastic nodules often are 1 to 2 cm across (Fig. 15–33, *A*). These are neoplastic growths that encompass many adjacent hepatic lobules, without displacing all of the portal tracts. These lesions are at high risk for malignant transformation and in fact sometimes contain overtly malignant subnodules (Fig. 15–33, *B*).

## Hepatocellular Carcinomas

### Epidemiology

Worldwide, hepatocellular carcinoma, HCC (also known erroneously as hepatoma) accounts for approximately 5.4% of all cancers, but its incidence varies widely in different parts of the world. More than 85% of cases occur in countries with high rates of chronic HBV infection. The highest incidences of HCC are found in Asian countries (southeast China, Korea, Taiwan) and sub-Saharan African countries in which HBV is transmitted vertically, and, as already discussed, the carrier state starts in infancy. Moreover, many of these populations are exposed to aflatoxin, which when combined with HBV infection increases the risk of hepatocellular carcinoma dramatically over that in noninfected, nonexposed populations; depending on the study, the estimated increase in HCC ranges from 23-fold to 216-fold.The peak incidence of hepatocellular carcinoma in these areas is between 20 and 40 years of age, and in almost 50% of cases, the tumor appears in the absence of cirrhosis. In Western countries the incidence of hepatocellular carcinoma is rapidly increasing, largely owing to the

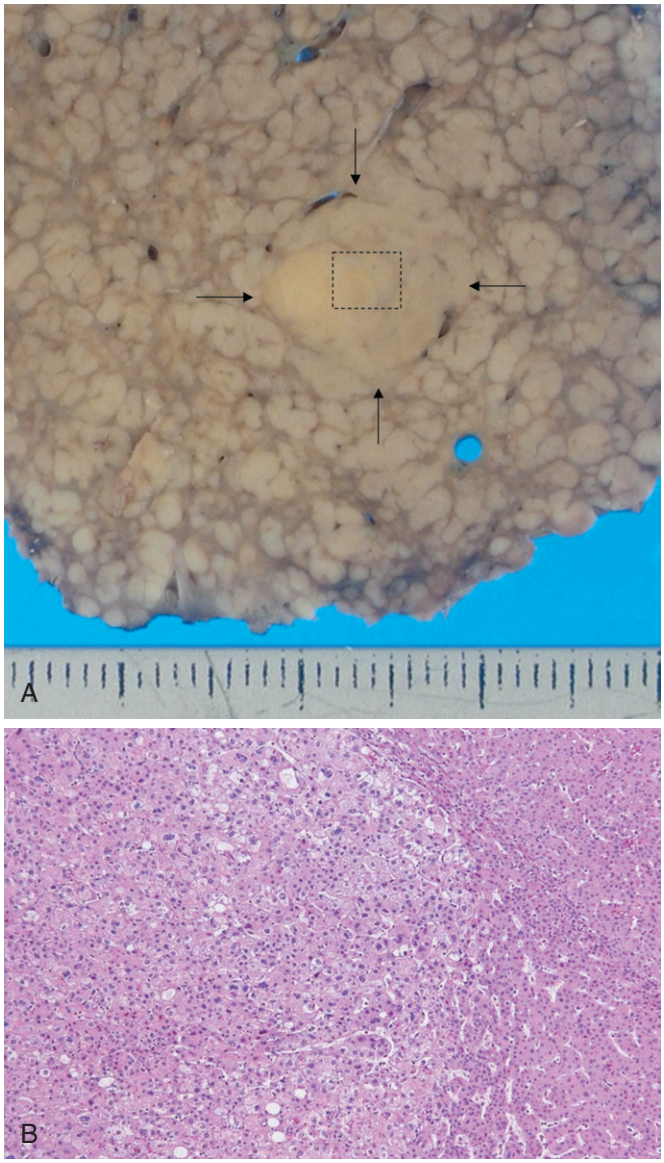


**Figure 15–33 A,** Hepatitis C–related cirrhosis with a distinctively large nodule (*arrows*). Nodule-in-nodule growth in this dysplastic nodule suggests a high grade lesion. **B,** Histologically the region within the box in **A** shows a well-differentiated hepatocellular carcinoma (HCC) (*right side*) and a subnodule of moderately differentiated HCC within it (*center, left*).
*(A and B, Courtesy of Dr. Masamichi Kojiro, Kurume University, Kurume, Japan.)*

hepatitis C epidemic. It tripled in the United States in recent decades, but it is still 8-fold to 30-fold lower than the incidence in some Asian countries. In Western populations, hepatocellular carcinoma rarely manifests before the age of 60, and in almost 90% of cases, tumors develop in the setting of cirrhosis. There is a pronounced male preponderance throughout the world, about 3:1 in low-incidence areas and as high as 8:1 in high-incidence areas.

## PATHOGENESIS

Several general factors relevant to the pathogenesis of HCC are discussed in Chapter 5. Only a few points merit emphasis here.

- Three major etiologic associations have been established: infection with HBV or HCV, alcoholic cirrhosis, and aflatoxin exposure. In the U.S., NAFLD is increasingly becoming an important risk factor for hepatocellular cancer. Other associated conditions include hemochromatosis, $\alpha_1$-antitrypsin deficiency, and tyrosinemia.
- Many variables, including age, gender, chemicals, viruses, hormones, alcohol, and nutrition, interact in the development of HCC. For example, the disease most likely to give rise to this tumor is hereditary tyrosinemia, a rare disorder in which almost 40% of patients develop this tumor.
- In many parts of the world, including Japan and Central Europe, chronic HCV infection is the most important risk factor in the development of liver cancer.
- In certain regions of the world, such as China and southern Africa, especially Mozambique, where HBV is endemic, high-level exposure to dietary aflatoxins derived from the fungus *Aspergillus flavus* is common. These carcinogenic toxins are found in "moldy" grains and peanuts. Aflatoxin can bind covalently with cellular DNA, resulting in mutations in genes such as *TP53*.

Despite the detailed knowledge about the etiologic agents of HCC, the pathogenesis of the tumor is still uncertain. **In most cases, it develops from small-cell, high-grade dysplastic nodules in cirrhotic livers.** In keeping with this, these nodules may be monoclonal and may contain chromosomal aberrations similar to those seen in HCCs. The cell of origin of HCC has been the subject of considerable debate. It seems that **the tumors may arise from both mature hepatocytes and progenitor cells (known as ductular cells or oval cells).** Distinguishing high-grade dysplastic nodules from early HCC is difficult even in biopsies, because there are no molecular markers specific for these stages. An important criterion is nodule vascularization, visualized by imaging, which is almost always a clear indication of malignancy.

**An almost universal feature of hepatocellular carcinoma is the presence of structural and numeric chromosomal abnormalities indicative of genomic instability.** The precise origin of genomic instability in this tumor is not known, but several factors seem to be most important:

- Inflammation and regeneration, seen in all forms of chronic hepatitis, are believed to be main contributors to acquired mutations in genomic DNA.
- Acquired mutations in specific oncogenes (such as *β-catenin*) and tumor suppressors (such as *TP53*) contribute to dysregulated growth and further increases in genomic instability.
- Acquired defects in DNA repair, particularly those in repair systems for double-stranded DNA breaks, also perpetuate DNA damage and may cause chromosomal defects.

Neither HBV nor HCV contains oncogenes. The already mentioned *HBV-X* gene may have some oncogenic potential (Chapter 5). The tumorigenic capacity of these viruses probably relates primarily to their capacity to cause chronic inflammation and increased cell turnover.

## MORPHOLOGY

HCC may appear grossly as (1) a **unifocal,** usually massive tumor; (2) a **multifocal tumor** made of nodules of variable size; or (3) a **diffusely infiltrative** cancer, permeating widely and sometimes involving the entire liver, blending imperceptibly into the cirrhotic background. Particularly in the latter two patterns, it may be difficult to radiologically distinguish regenerative cirrhotic nodules from neoplasms of similar size. Discrete tumor masses usually are yellow-white, punctuated sometimes by bile staining and areas of hemorrhage or necrosis. **HCC has a strong propensity for vascular invasion.** Extensive intrahepatic metastases are characteristic, and occasionally snakelike masses of tumor invade the portal vein (with occlusion of the portal circulation) or inferior vena cava, extending even into the right side of the heart.

On histologic examination, HCCs range from well-differentiated lesions that reproduce hepatocytes arranged in cords, trabeculae or glandular patterns (Fig. 15–34), to poorly differentiated lesions, often composed of large, multinucleate anaplastic giant cells. **In the better-differentiated variants, globules of bile may be found within the cytoplasm of cells and in pseudocanaliculi** between cells. Acidophilic hyaline inclusions within the cytoplasm may be present, resembling Mallory bodies. There is little stroma in most hepatocellular carcinomas, explaining their soft consistency.

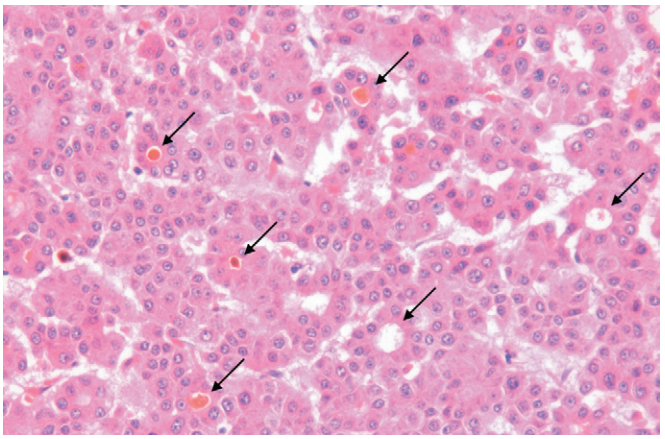

**Figure 15–34** Well-differentiated hepatocellular carcinoma has distortions of normal structures: Liver cell plates are markedly widened, and frequent "pseudoacinar" structures (*arrows*)—abnormal bile canaliculi—often contain bile.

A distinctive clinicopathologic variant of HCC is the **fibrolamellar carcinoma.** It occurs in young male and female adults (20 to 40 years of age) with equal incidence and has no association with cirrhosis or other risk factors. It usually consists of a single tumor with fibrous bands coursing through it, superficially resembling focal nodular hyperplasia. The fibrolamellar variant has a better prognosis than that of the other, more common variants.

Clinical Features

Although HCC may manifest with silent hepatomegaly, it is more often encountered in persons with symptomatic cirrhosis of the liver. In these persons, *a rapid increase in liver size, sudden worsening of ascites, or the appearance of bloody ascites, fever, and pain call attention to the development of a tumor.* There are no good serologic screening tests for hepatocellular carcinoma. The most commonly used marker is serum alpha-fetoprotein level, but it rises only with advanced tumors and only in 50% of patients. Furthermore, false-positive results are obtained in yolk-sac tumors, and many non-neoplastic conditions such as cirrhosis, chronic hepatitis, normal pregnancy, and massive liver necrosis. Hence the test is neither specific nor sensitive. *Radiologic screening of patients with cirrhosis at 6-month intervals, looking for dysplastic nodules or early, small hepatocellular carcinomas, is the current clinical frontier.*

The overall prognosis with advanced HCC is grim. Resection or ablation may be curative for a single small lesion (most often those with the uncommon fibrolamellar variant), but does not prevent de novo emergence of new HCCs in a chronically diseased liver. Transplantation can be curative, however. Without resection, median survival is 7 months. Recent clinical trials have shown that treatment with sorafenib, a broad-spectrum tyrosine kinase inhibitor, provides some benefit to those with advanced disease. In some countries such as Taiwan, HBV immunization programs have lowered the incidence of HCC substantially, proving that preventive measures can alleviate the terrible toll taken by this disease in endemic regions.

### SUMMARY

#### Liver Tumors

- The most common malignant tumors of the liver are metastatic carcinomas, most often from colon, lung, and breast.
- The main primary malignancy is hepatocellular carcinoma. It is common in regions of Asia and Africa, and its incidence is increasing in the United States.
- The main etiologic agents for hepatocellular carcinoma are hepatitis B and C, alcoholic cirrhosis, hemochromatosis, and, more rarely, tyrosinemia and $\alpha_1$-antitrypsin (AAT) deficiency.
- In the Western population, about 90% of hepatocellular carcinomas develop in cirrhotic livers; in Asia, almost 50% of cases develop in noncirrhotic livers.
- The chronic inflammation and cellular regeneration associated with viral hepatitis may be predisposing factors for the development of carcinomas.
- Hepatocellular carcinomas may be unifocal or multifocal, tend to invade blood vessels, and recapitulate normal liver architecture to varying degrees.

# DISORDERS OF THE GALLBLADDER AND THE EXTRAHEPATIC BILIARY TRACT

Disorders of the gallbladder and biliary tract affect a large proportion of the world's population. *Cholelithiasis* (*gallstones*) accounts for more than 95% of these diseases. About 2% of the United States federal health budget is spent on cholelithiasis and its complications. In this section, gallbladder diseases (cholelithiasis and cholecystitis) are discussed first, followed by consideration of some disorders of the extrahepatic bile ducts. It should be kept in mind that lesions of the extrahepatic biliary tract may extend to intrahepatic bile ducts, and that tumors of the biliary tract (cholangiocarcinomas, described later) may have intra- or extrahepatic locations.

## GALLBLADDER DISEASES

### Cholelithiasis (Gallstones)

Gallstones afflict 10% to 20% of adults residing in Western countries in the Northern Hemisphere, 20% to 40% in Latin American countries, and only 3% to 4% in Asian countries. In the United States, about 1 million new cases of gallstones are diagnosed annually, and two thirds of persons so affected undergo surgery, with retrieval of as much as 25 to 50 million tons of stones! There are two main types of gallstones: *cholesterol stones,* containing crystalline cholesterol monohydrate (80% of stones in the West), and *pigment stones,* made of bilirubin calcium salts.

### PATHOGENESIS

Bile formation is the only significant pathway for elimination of excess cholesterol from the body, either as free cholesterol or as bile salts. Cholesterol is rendered water-soluble by aggregation with bile salts and lecithins. When cholesterol concentrations exceed the solubilizing capacity of bile (supersaturation), cholesterol can no longer remain dispersed and crystallizes out of solution. Cholesterol gallstone formation is enhanced by **hypomobility of the gallbladder** (stasis), which promotes nucleation, and by **mucus hypersecretion,** with consequent trapping of the crystals, thereby enhancing their aggregation into stones.

Formation of pigment stones is more likely in the presence of unconjugated bilirubin in the biliary tree, as occurs in

**Table 15–8** Risk Factors for Gallstones

| |
|---|
| **Cholesterol Stones** |
| Demography: Northern Europeans, North and South Americans, Native Americans, Mexican Americans |
| Advancing age |
| Female sex hormones |
| Female gender |
| Oral contraceptives |
| Pregnancy |
| Obesity and insulin resistance |
| Rapid weight reduction |
| Gallbladder stasis |
| Inborn disorders of bile acid metabolism |
| Dyslipidemia syndromes |
| **Pigment Stones** |
| Demography: Asian more than Western, rural more than urban |
| Chronic hemolysis (e.g., sickle cell anemia, hereditary spherocytosis) |
| Biliary infection |
| Gastrointestinal disorders: ileal disease (e.g., Crohn disease), ileal resection or bypass, cystic fibrosis with pancreatic insufficiency |

hemolytic anemias and infections of the biliary tract. The precipitates are primarily insoluble calcium bilirubinate salts.

The major risk factors for gallstones are listed in Table 15–8. Up to 80% of people with gallstones, however, have no identifiable risk factors other than age and gender. Some elaboration on these risk factors follows:

- **Age and gender.** The prevalence of gallstones increases throughout life. In the United States, less than 5% to 6% of the population younger than age 40 has stones, in contrast with 25% to 30% of those older than 80 years. The prevalence in women of all ages is about twice as high as in men.
- **Ethnic and geographic.** Cholesterol gallstone prevalence approaches 50% to 75% in certain Native American populations—the Pima, Hopi, and Navajos—whereas pigment stones are rare; the prevalence seems to be related to biliary cholesterol hypersecretion.
- **Heredity.** In addition to ethnicity, a positive family history imparts increased risk, as do a variety of inborn errors of metabolism such as those associated with impaired bile salt synthesis and secretion.
- **Environment.** Estrogenic influences, including oral contraceptives and pregnancy, increase hepatic cholesterol uptake and synthesis, leading to excess biliary secretion of cholesterol. Obesity, rapid weight loss, and treatment with the hypocholesterolemic agent clofibrate also are strongly associated with increased biliary cholesterol secretion.
- **Acquired disorders.** Any condition in which gallbladder motility is reduced predisposes to gallstones, such as pregnancy, rapid weight loss, and spinal cord injury. In most cases, however, gallbladder hypomotility is present without obvious cause.

## MORPHOLOGY

**Cholesterol stones** arise exclusively in the gallbladder and consist of 50% to 100% cholesterol. **Pure cholesterol stones** are pale yellow; increasing proportions of calcium carbonate, phosphates, and bilirubin impart gray-white to black discoloration (Fig. 15–35). They are ovoid and firm; they can occur singly, but most often there are several, with faceted surfaces resulting from their apposition. **Most cholesterol stones are radiolucent, although as many as 20% may have sufficient calcium carbonate to be radiopaque.**

**Figure 15–35** Cholesterol gallstones. Mechanical manipulation during laparoscopic cholecystectomy has caused fragmentation of several cholesterol gallstones, revealing interiors that are pigmented because of entrapped bile pigments. The gallbladder mucosa is reddened and irregular as a result of coexistent acute and chronic cholecystitis.

**Pigment stones** may arise anywhere in the biliary tree and are classified into black and brown stones. In general, black pigment stones are found in sterile gallbladder bile, while brown stones are found in infected intrahepatic or extrahepatic ducts. The stones contain calcium salts of unconjugated bilirubin and lesser amounts of other calcium salts, mucin glycoproteins, and cholesterol. Black stones are usually small in size, fragile to the touch, and numerous (Fig. 15–36). Brown stones tend to be single or few in number and to have a soft, greasy, soaplike consistency that results from the presence of retained fatty acid salts released by the action of bacterial phospholipases on biliary lecithins. Because of calcium carbonates and phosphates, **50% to 75% of black stones are radiopaque.** Brown stones, which contain calcium soaps, are radiolucent.

**Figure 15–36** Pigmented gallstones. Several faceted black gallstones are present in this otherwise unremarkable gallbladder removed from a patient who had a mechanical mitral valve prosthesis, leading to chronic intravascular hemolysis.

### Clinical Features

70% to 80% of individuals with gallstones remain asymptomatic throughout life, with the risk of symptoms diminishing over time. In the unfortunate minority, however, the symptoms are striking. There is usually pain, often excruciating, which typically localizes to the right upper quadrant or epigastric region and can be constant or, less commonly, spasmodic. Such "biliary" pain is caused by gallbladder or biliary tree obstruction, or by inflammation of the gallbladder itself. More severe complications include empyema, perforation, fistulas, inflammation of the biliary tree, and obstructive cholestasis or pancreatitis. The larger the calculi, the less likely they are to enter the cystic or common ducts to produce obstruction; it is the very small stones, or "gravel," that are more dangerous. Occasionally a large stone may erode directly into an adjacent loop of small bowel, generating intestinal obstruction (*gallstone ileus*).

## Cholecystitis

Inflammation of the gallbladder may be acute, chronic, or acute superimposed on chronic, and almost always occurs in association with gallstones. In the United States, cholecystitis is one of the most common indications for abdominal surgery. Its epidemiologic distribution closely parallels that of gallstones.

### MORPHOLOGY

In **acute cholecystitis,** the gallbladder usually is enlarged and tense, and it assumes a bright red or blotchy, violaceous color, the latter imparted by subserosal hemorrhages. The serosa frequently is covered by a fibrinous, or in severe cases, fibrinopurulent exudate. In 90% of cases, stones are present, often obstructing the neck of the gallbladder or the cystic duct. The gallbladder lumen is filled with cloudy or turbid bile that may contain fibrin, blood, and frank pus. When the contained exudate is mostly pus, the condition is referred to as **empyema of the gallbladder.** In mild cases the gallbladder wall is thickened, edematous, and hyperemic. In more severe cases the gallbladder is transformed into a green-black necrotic organ—a condition termed **gangrenous cholecystitis.** On histologic examination, the inflammatory reactions are not distinctive and consist of the usual patterns of acute inflammation (i.e., edema, leukocytic infiltration, vascular congestion, frank abscess formation, or gangrenous necrosis).

The morphologic changes in **chronic cholecystitis** are extremely variable and sometimes subtle. The mere presence of stones within the gallbladder, even in the absence of acute inflammation, often is taken as sufficient justification for the diagnosis. The gallbladder may be contracted, of normal size, or enlarged. Mucosal ulcerations are infrequent; the submucosa and subserosa often are thickened from fibrosis. In the absence of superimposed acute cholecystitis, mural lymphocytes are the only signs of inflammation.

### *Acute Calculous Cholecystitis*

Acute inflammation of a gallbladder that contains stones is termed *acute calculous cholecystitis* and is precipitated by obstruction of the gallbladder neck or cystic duct. *It is the most common major complication of gallstones and the most common reason for emergency cholecystectomy.* Manifestations of obstruction may appear with remarkable suddenness and constitute a surgical emergency. In some cases, however, symptoms may be mild and resolve without medical intervention.

Acute calculous cholecystitis is initially the result of chemical irritation and inflammation of the gallbladder wall in the setting of obstruction to bile outflow. The action of phospholipases derived from the mucosa hydrolyzes biliary lecithin to lysolecithin, which is toxic to the mucosa. The normally protective glycoprotein mucous layer is disrupted, exposing the mucosal epithelium to the direct detergent action of bile salts. Prostaglandins released within the wall of the distended gallbladder contribute to mucosal and mural inflammation. Distention and increased intraluminal pressure also may compromise blood flow to the mucosa. These events occur in the absence of bacterial infection; only later may bacterial contamination develop.

### *Acute Acalculous Cholecystitis*

Between 5% and 12% of gallbladders removed for acute cholecystitis contain no gallstones. Most cases occur in seriously ill patients. Some of the most common predisposing insults are

- Major, nonbiliary surgery
- Severe trauma (e.g., from motor vehicle crashes)
- Severe burns
- Sepsis

Other contributing factors include dehydration, gallbladder stasis and sludging, vascular compromise, and, ultimately, bacterial contamination.

### *Chronic Cholecystitis*

Chronic cholecystitis may be the sequel to repeated bouts of acute cholecystitis, but in most instances it develops without any history of acute attacks. Like acute cholecystitis it is almost always associated with gallstones. However, gallstones do not seem to have a direct role in the initiation of inflammation or the development of pain, because chronic acalculous cholecystitis causes symptoms and morphologic alterations similar to those seen in the calculous form. Rather, supersaturation of bile predisposes the patient to both chronic inflammation and, in most instances, stone formation. Microorganisms, usually *E. coli* and enterococci, can be cultured from the bile in only about one third of cases. Unlike acute calculous cholecystitis, stone obstruction of gallbladder outflow in chronic cholecystitis is not a requisite. Most gallbladders removed at elective surgery for gallstones show features of chronic cholecystitis, making it likely that biliary symptoms emerge after long-term coexistence of gallstones and low-grade inflammation.

### Clinical Features

*Acute calculous cholecystitis* presents with biliary pain that lasts for more than 6 hours. The pain is severe, usually steady, upper abdominal in location, and often radiates to the right shoulder. Fever, nausea, leukocytosis, and prostration are classic; the presence of conjugated

hyperbilirubinemia suggests obstruction of the common bile duct. The right subcostal region is markedly tender and rigid as a result of spasm of the abdominal muscles; occasionally a tender, distended gallbladder can be palpated. Mild attacks usually subside spontaneously over 1 to 10 days; however, recurrence is common. Approximately 25% of symptomatic patients are sufficiently ill to require surgical intervention.

Symptoms arising from *acute acalculous cholecystitis* usually are obscured by the generally severe clinical condition of the patient. The diagnosis therefore rests on keeping this possibility in mind.

*Chronic cholecystitis* does not have the striking manifestations of the acute forms and is usually characterized by recurrent attacks of steady epigastric or right upper quadrant pain. Nausea, vomiting, and intolerance for fatty foods are frequent accompaniments.

The diagnosis of acute cholecystitis usually is based on the detection of gallstones by ultrasonography, typically accompanied by evidence of a thickened gallbladder wall. Chronic cholecystitis, on the other hand, is a pathologic diagnosis based on the examination of the resected gallbladder. Attention to this disorder is important because of the potential for the following serious complications:

- Bacterial superinfection with cholangitis or sepsis
- Gallbladder perforation and local abscess formation
- Gallbladder rupture with diffuse peritonitis
- Biliary enteric (cholecystenteric) fistula, with drainage of bile into adjacent organs, entry of air and bacteria into the biliary tree, and potentially gallstone-induced intestinal obstruction (ileus)
- Aggravation of preexisting medical illness, with cardiac, pulmonary, renal, or liver decompensation

# DISORDERS OF EXTRAHEPATIC BILE DUCTS

## Choledocholithiasis and Cholangitis

Choledocholithiasis and cholangitis are considered together because these conditions frequently go hand in hand. *Choledocholithiasis* is the presence of stones within the biliary tree. In Western nations, almost all stones are derived from the gallbladder; in Asia, there is a much higher incidence of primary ductal and intrahepatic, usually pigmented, stone formation. Choledocholithiasis may not immediately obstruct major bile ducts; asymptomatic stones are found in about 10% of patients at the time of surgical cholecystectomy. Symptoms may develop because of (1) biliary obstruction, (2) cholangitis, (3) hepatic abscess, (4) chronic liver disease with secondary biliary cirrhosis, or (5) acute calculous cholecystitis.

*Cholangitis* is the term used for acute inflammation of the wall of bile ducts, almost always caused by bacterial infection of the normally sterile lumen. It can result from any lesion obstructing bile flow, most commonly choledocholithiasis, and also from surgery involving the biliary tree. Other causes include tumors, indwelling stents or catheters, acute pancreatitis, and benign strictures. Bacteria most likely enter the biliary tract through the sphincter of Oddi, rather than by the hematogenous route. *Ascending cholangitis* refers to the propensity of bacteria, once within the biliary tree, to infect intrahepatic biliary ducts. The usual pathogens are *E. coli, Klebsiella, Enterococci, Clostridium,* and *Bacteroides*. Two or more organisms are found in half of the cases. In some world populations, parasitic cholangitis is a significant problem. Causative organisms include *Fasciola hepatica* or schistosomiasis in Latin America and the Near East, *Clonorchis sinensis* or *Opisthorchis viverrini* in the Far East, and cryptosporidiosis in persons with acquired immunodeficiency syndrome.

Bacterial cholangitis usually produces fever, chills, abdominal pain, and jaundice. The most severe form of cholangitis is suppurative cholangitis, in which purulent bile fills and distends bile ducts, with an attendant risk of liver abscess formation. Because sepsis rather than cholestasis is the predominant risk in cholangitic patients, prompt diagnosis and intervention are imperative.

## Secondary Biliary Cirrhosis

Prolonged obstruction of the extrahepatic biliary tree results in profound damage to the liver itself. The most common cause of obstruction is extrahepatic cholelithiasis. Other obstructive conditions include biliary atresia (discussed later on), malignancies of the biliary tree and head of the pancreas, and strictures resulting from previous surgical procedures. The initial morphologic features of cholestasis were described earlier and are entirely reversible with correction of the obstruction. However, secondary inflammation resulting from biliary obstruction initiates periportal fibrogenesis, which eventually leads to scarring and nodule formation, generating secondary biliary cirrhosis.

## Biliary Atresia

Biliary atresia is a major cause of neonatal cholestasis, accounting for one third of the cases of cholestasis in infants and occurring in approximately 1 in 10,000 live births. *Biliary atresia is defined as a complete obstruction of bile flow caused by destruction or absence of all or part of the extrahepatic bile ducts.* It is the most frequent cause of death from liver disease in early childhood and accounts for more than half of the referrals of children for liver transplantation.

The salient features of biliary atresia include

- Inflammation and fibrosing stricture of the hepatic or common bile ducts
- Inflammation of major intrahepatic bile ducts, with progressive destruction of the intrahepatic biliary tree
- Florid features of biliary obstruction on liver biopsy (i.e., ductular reaction, portal tract edema and fibrosis, and parenchymal cholestasis)
- Periportal fibrosis and cirrhosis within 3 to 6 months of birth

### Clinical Course

Infants with biliary atresia present with neonatal cholestasis; there is a slight female predominance. Affected infants have normal birth weights and postnatal weight gain. Stools become acholic as the disease evolves. Laboratory

findings do not distinguish between biliary atresia and intrahepatic cholestasis, but a liver biopsy provides evidence of bile duct obstruction in 90% of cases of biliary atresia. Liver transplantation is the definitive treatment. Without surgical intervention, death usually occurs within 2 years of birth.

## SUMMARY

### Diseases of the Gallbladder and Extrahepatic Bile Ducts

- Gallbladder diseases include cholelithiasis and acute and chronic cholecystitis.
- Gallstone formation is a common condition in Western countries. The great majority of the gallstones are cholesterol stones. Pigmented stones containing bilirubin and calcium are most common in Asian countries.
- Risk factors for the development of cholesterol stones are advancing age, female gender, estrogen use, obesity, and heredity.
- Cholecystitis almost always occurs in association with cholelithiasis, although in about 10% of cases it occurs in the absence of gallstones.
- Acute calculous cholecystitis is the most common reason for emergency cholecystectomy.
- Obstructive lesions of the extrahepatic bile ducts in adults can give rise to ascending infection (cholangitis) and secondary biliary cirrhosis.
- Infants born with congenital biliary atresia present with neonatal cholestasis and require liver transplantation for cure.

# TUMORS

## Carcinoma of the Gallbladder

Although uncommon, carcinoma of the gallbladder is the most frequent malignant tumor of the biliary tract. It is 2 to 6 times more common in women and occurs most frequently in the seventh decade of life. Carcinoma of the gallbladder is more frequent in the populations of Mexico and Chile, presumably due to the higher incidence of gallstone disease in these regions. In the United States the incidence is highest in Hispanics and Native Americans. Only rarely is it discovered at a resectable stage, and the mean 5-year survival rate is a dismal 5%. Gallstones are present in 60% to 90% of cases. In Asia, where pyogenic and parasitic diseases of the biliary tree are more common, gallstones are less important. Presumably, gallbladders containing stones or infectious agents develop cancer as a result of recurrent trauma and chronic inflammation. The role of carcinogenic derivatives of bile acids is unclear.

### MORPHOLOGY

Cancers of the gallbladder may exhibit **exophytic** or **infiltrating** growth patterns. The infiltrating pattern is more common and usually appears as a poorly defined area of diffuse thickening and induration of the gallbladder wall that may cover several square centimeters or involve the entire gallbladder. These tumors are scirrhous and very firm. The exophytic pattern grows into the lumen as an irregular, cauliflower-like mass but at the same time also invades the underlying wall (Fig. 15–37). **Most are adenocarcinomas,** which may be papillary or poorly differentiated. About 5% are squamous cell carcinomas or demonstrate adenosquamous differentiation, and rare neuroendocrine tumors also occur. By the time gallbladder cancers are discovered, most have invaded the liver or have spread to the bile ducts or to the portal hepatic lymph nodes.

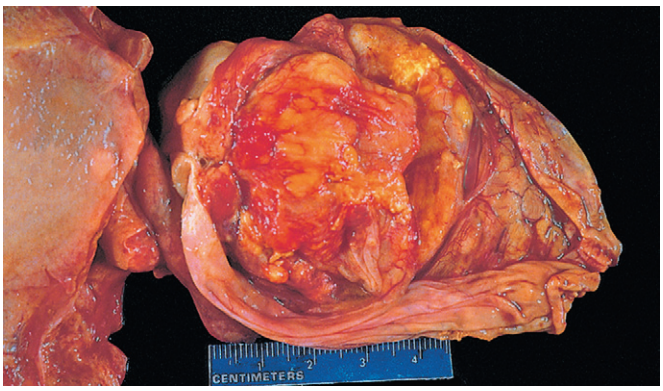


**Figure 15–37** Adenocarcinoma of the gallbladder. The opened gallbladder contains a large, exophytic tumor that virtually fills the lumen.

#### Clinical Features

Preoperative diagnosis of carcinoma of the gallbladder is the exception, being reported in less than 20% of patients. Onset of symptoms is insidious, and presenting manifestations typically are indistinguishable from those associated with cholelithiasis: abdominal pain, jaundice, anorexia, and nausea and vomiting. The fortunate person develops early obstruction and acute cholecystitis or undergoes cholecystectomy for coexistent symptomatic gallstones before the tumor spreads to other sites.

## Cholangiocarcinomas

Cholangiocarcinomas are adenocarcinomas that arise from cholangiocytes lining the intrahepatic and extrahepatic biliary ducts. Extrahepatic cholangiocarcinomas constitute approximately two thirds of these tumors and may develop at the hilum (known as Klatskin tumors) or more distally in the biliary tree. Cholangiocarcinomas occur mostly in persons of 50 to 70 years of age. Because both intra- and extrahepatic cholangiocarcinomas generally are asymptomatic until they reach an advanced stage, the prognosis is poor, and most patients have unresectable tumors. Risk factors include primary sclerosing cholangitis, fibropolycystic diseases of the biliary tree, and infestation by *Clonorchis sinensis* or *Opisthorchis viverrini.*

All risk factors for cholangiocarcinomas cause chronic cholestasis and inflammation, which presumably promote the occurrence of somatic mutations in cholangiocytes.

Several consistent genetic changes have been noted in these tumors, including activating mutations in the *KRAS* and *BRAF* oncogenes and loss-of-function mutations in the *TP53* tumor suppressor gene.

## MORPHOLOGY

**Cholangiocarcinomas** are typical adenocarcinomas with more or less well-formed glands often accompanied by abundant fibrous stroma (desmoplasia) yielding a firm, gritty consistency (Fig. 15–38). Bile pigment and hyaline inclusions are absent from the tumor cells, while intracellular mucin may be prominent.

Because partial or complete obstruction of bile ducts rapidly leads to jaundice, extrahepatic biliary tumors tend to be relatively small at the time of diagnosis, whereas intrahepatic tumors may cause symptoms only when much of the liver is replaced by tumor. Cholangiocarcinomas may spread to extrahepatic sites such as regional lymph nodes, lungs, bones, and adrenal glands. Invasion along peribiliary nerves is another route of spread to the abdomen. Cholangiocarcinoma has a greater propensity for extrahepatic spread than does hepatocellular carcinoma.

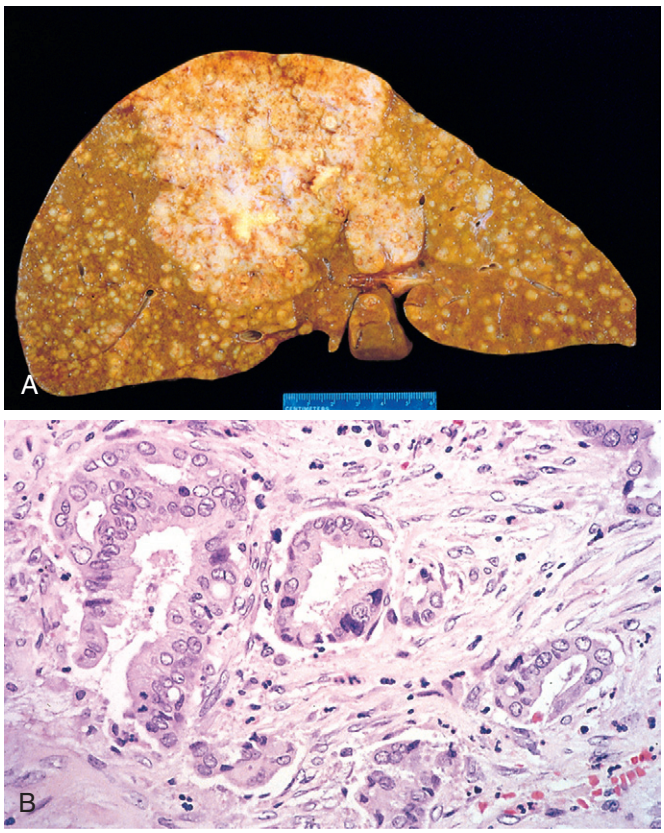


**Figure 15–38** Cholangiocarcinoma. **A,** Massive neoplasm in the right lobe and widespread intrahepatic metastases. **B,** Tumor cells forming glandular structures surrounded by dense sclerotic stroma.

### Clinical Features

*Intrahepatic* cholangiocarcinoma may be manifested by the presence of a liver mass and nonspecific signs and symptoms such as weight loss, pain, anorexia, and ascites. Symptoms and signs arising from *extrahepatic* cholangiocarcinomas (jaundice, acholic stools, nausea and vomiting, and weight loss) result from biliary obstruction. Commonly associated findings include elevated serum levels of alkaline phosphatase and aminotransferases. Surgical resection is the only treatment available, but in a large majority of cases is not curative. Transplantation is contraindicated. Mean survival times range from 6 to 18 months, regardless of whether aggressive resection or palliative surgery is performed.

## BIBLIOGRAPHY

Beier JI, Arteel GE, McClain CJ: Advances in alcoholic liver disease. Curr Gastroenterol Rep 13:56, 2011.

Bernal W, Auzinger G, Dhawan A, et al: Acute liver failure. Lancet 376:190, 2010.

Bioulac-Sage P, Balabaud C, Zucman-Rossi J: Focal nodular hyperplasia, hepatocellular adenomas: past, present, future. Gastroenterol Clin Biol 34:355, 2010. *[From the pioneers of the new, molecular diagnostics of benign liver tumors.]*

Brunt EM: Pathology of nonalcoholic fatty liver disease. Nat Rev Gastroenterol Hepatol 7:195, 2010. *[As authoritative as one can be on the topic.]*

Chun LJ, Tong MJ, Busuttil RW, et al: Acetaminophen hepatotoxicity and acute liver failure. J Clin Gastroenterol 43:342, 2009. *[About the most common cause of acute liver failure leading to transplantation.]*

Czaja AJ, Manns MP: Advances in the diagnosis, pathogenesis, and management of autoimmune hepatitis. Gastroenterology 139:58, 2010.

Friedman SL: Mechanisms of hepatic fibrogenesis. Gastroenterology 134:1655, 2008. *[As authoritative as one can be on the topic.]*

Gatto M, Alvaro D: New insights on cholangiocarcinoma. World J Gastrointest Oncol 2:136, 2010.

Gouw ASW, Clouston AD, Theise ND: Ductular reactions in human livers: diversity at the interface. Hepatology 54:1853, 2011. *[A review of ductular reactions, the stem cell response of human livers in all liver diseases, that are related to mechanisms of regeneration, fibrogenesis and neoplasia.]*

Hirschfield GM, Heathcote EJ, Gershwin ME: Pathogenesis of cholestatic liver disease and therapeutic approaches. Gastroenterology 139:1481, 2010.

International Consensus Group for Hepatocellular Neoplasia: Pathologic diagnosis of early hepatocellular carcinoma. Hepatology 49:658, 2009. *[A good example of how change comes to medicine, individual efforts combining, over years, to achieve a new consensus.]*

Joyce MA, Tyrrell DL: The cell biology of hepatitis C virus. Microbes Infect 12:263, 2010.

Lai M, Liaw YF: Chronic hepatitis B: past, present, and future. Clin Liver Dis 14:531, 2010.

Lagana SM, Moreira RK, Lefkowitch JH: Hepatic granulomas: pathogenesis and differential diagnosis. Clin Liver Dis 14:605, 2010.

Paumgartner G: Biliary physiology and disease: reflections of a physician-scientist. Hepatology 51:1095, 2010. *[How bench top work comes to exert an impact on clinical medicine, sometimes, slowly, over decades.]*

Perrault M, Pécheur EI: The hepatitis C virus and its hepatic environment: a toxic but finely tuned partnership. Biochem J 423:303, 2009.

Pietrangelo A: Hereditary hemochromatosis: pathogenesis, diagnosis, and treatment. Gastroenterology 139:393, 2010.

Poupon R: Primary biliary cirrhosis: a 2010 update. J Hepatol 52:745, 2010.

Schilsky ML: Wilson disease: current status and the future. Biochimie 91:1278, 2009.

See Targeted Therapy available online at studentconsult.com

CHAPTER 16

# Pancreas

CHAPTER CONTENTS


**Congenital Anomalies 646**
Agenesis 646
Pancreas Divisum 646
Annular Pancreas 646
Ectopic Pancreas 646
Congenital Cysts 646
**Pancreatitis 646**
Acute Pancreatitis 646
Chronic Pancreatitis 649
**Pancreatic Neoplasms 651**
Cystic Neoplasms 651
Pancreatic Carcinoma 652


The pancreas has critical endocrine functions, and the exocrine portion of the pancreas is a major source of potent enzymes that are essential for digestion. Diseases affecting the pancreas can be the source of significant morbidity and mortality. Unfortunately, despite its physiologic importance, the retroperitoneal location of the pancreas and the generally vague nature of signs and symptoms associated with its injury or dysfunction allow many pancreatic diseases to progress undiagnosed for extended periods of time; thus, recognition of pancreatic disorders often requires a high degree of suspicion.

The pancreas is a transversely oriented retroperitoneal organ extending from the so-called C loop of the duodenum to the hilum of the spleen. Although the pancreas does not have well-defined anatomic subdivisions, adjacent vessels and ligaments serve to demarcate the organ into a head, body, and tail.

The pancreas gets its name from the Greek *pankreas,* meaning "all flesh," and is a complex lobulated organ with distinct endocrine and exocrine elements. The endocrine portion constitutes only 1% to 2% of the pancreas and is composed of about 1 million cell clusters, the islets of Langerhans; these cells secrete insulin, glucagon, and somatostatin. The most significant disorders of the *endocrine pancreas* are diabetes mellitus and neoplasms; these are described in detail in Chapter 19 and are not discussed further here.

The *exocrine pancreas* is composed of *acinar cells* that produce the digestive enzymes, and the ductules and ducts that convey them to the duodenum. The acinar cells are responsible for the synthesis of digestive enzymes, which are mostly made as inactive pro-enzymes that are stored in *zymogen granules.* When acinar cells are stimulated to secrete, the granules fuse with the apical plasma membrane and release their contents into the central acinar lumen. These secretions are transported to the duodenum through a series of anastomosing ducts.

The epithelial cells lining the ducts also are active participants in pancreatic secretion: The cuboidal cells lining the smaller ductules secrete bicarbonate-rich fluid, while the columnar cells lining the larger ducts produce mucin. The epithelial cells of the larger ducts also express the *cystic fibrosis transmembrane conductance regulator* (CFTR); aberrant function of this membrane protein affects the viscosity of the pancreatic secretions and has a fundamental role in the pathophysiology of pancreatic disease in persons with cystic fibrosis (Chapter 6).

As described later, autodigestion of the pancreas (e.g., in pancreatitis) can be a catastrophic event. A number of "fail-safe" mechanisms have evolved to minimize the risk of occurrence of this phenomenon:

- A majority of pancreatic enzymes are synthesized as inactive proenzymes and sequestered in membrane-bound zymogen granules, as mentioned above.
- Activation of proenzymes requires conversion of trypsinogen to trypsin by duodenal enteropeptidase (also called enterokinase).
- Trypsin inhibitors (e.g., SPINK1, also known as pancreatic secretory trypsin inhibitor) also are secreted by acinar and ductal cells.
- Trypsin cleaves and inactivates itself, a negative feedback mechanism that normally puts a limit on local levels of activated trypsin.
- Acinar cells are remarkably resistant to the action of activated enzymes such as trypsin, chymotrypsin, and phospholipase $A_2$.

Diseases of the exocrine pancreas include cystic fibrosis, congenital anomalies, acute and chronic pancreatitis, and neoplasms. Cystic fibrosis is discussed in detail in Chapter 6; the other pathologic processes are discussed in the remainder of this chapter.


*The contributions of those who authored this chapter in previous editions of this book are gratefully acknowledged.*

# CONGENITAL ANOMALIES

Pancreatic development is a complex process involving fusion of dorsal and ventral primordia; subtle deviations in this process frequently give rise to congenital variations in pancreatic anatomy. While most of these do not cause disease per se, variants (especially in ductal anatomy) can present challenges to the endoscopist and the surgeon. For example, failure to recognize idiosyncratic anatomy could result in inadvertent severing of a pancreatic duct during surgery, resulting in pancreatitis.

## Agenesis

Very rarely, the pancreas may be totally absent, a condition usually (but not invariably) associated with additional severe malformations that are incompatible with life. *Pancreatic duodenal homeobox 1* is a homeodomain transcription factor critical for normal pancreatic development, and mutations of the *PDX1* gene, located on chromosomal locus 13q12.1, have been associated with pancreatic agenesis.

## Pancreas Divisum

*Pancreas divisum* is the most common clinically significant congenital pancreatic anomaly, with an incidence of 3% to 10% in autopsy series. It occurs when the duct systems of the fetal pancreatic primordia fail to fuse. As a result, the main pancreatic duct drains only a small portion of the head of the gland, while the bulk of the pancreas (from the dorsal pancreatic primordium) drains through the minor sphincter, which has a narrow opening. As a result of this defect in drainage, persons with pancreas divisum have elevated intraductal pressures throughout most of the pancreas and are at increased risk for chronic pancreatitis.

## Annular Pancreas

*Annular pancreas* is a relatively uncommon variant of pancreatic fusion in which a ring of pancreatic tissue completely encircles the duodenum. It can manifest with signs and symptoms of duodenal obstruction such as gastric distention and vomiting.

## Ectopic Pancreas

Aberrantly situated, or *ectopic,* pancreatic tissue occurs in about 2% of the population; favored sites are the stomach and duodenum, followed by the jejunum, Meckel diverticulum, and ileum. These embryologic rests typically are small (ranging from millimeters to centimeters in diameter) and are located in the submucosa; they are composed of normal pancreatic acini with occasional islets. Though usually incidental and asymptomatic, ectopic pancreas can cause pain from localized inflammation, or—rarely—can cause mucosal bleeding. Approximately 2% of pancreatic neuroendocrine tumors (Chapter 19) arise in ectopic pancreatic tissue.

## Congenital Cysts

*Congenital cysts* probably result from anomalous development of the pancreatic ducts. In *polycystic disease,* the kidneys, liver, and pancreas can all contain cysts (Chapter 13). Congenital cysts generally are unilocular and range from microscopic to 5 cm in diameter. They are lined by either uniform cuboidal or flattened epithelium and are enclosed in a thin, fibrous capsule. These benign cysts contain clear serous fluid—an important point of distinction from pancreatic cystic neoplasms, which often are mucinous (see further on).

# PANCREATITIS

Inflammatory disorders of the pancreas range in severity from mild, self-limited disease to life-threatening, widely destructive process, and are accordingly associated with deficits that may be trivial and transient or serious and permanent. In *acute pancreatitis,* function can return to normal if the underlying cause of inflammation is removed. By contrast, *chronic pancreatitis* is defined by irreversible destruction of exocrine pancreatic parenchyma.

## Acute Pancreatitis

Acute pancreatitis is a reversible inflammatory disorder that varies in severity, ranging from focal edema and fat necrosis to widespread hemorrhagic parenchymal necrosis. Acute pancreatitis is relatively common, with an annual incidence of 10 to 20 per 100,000 people in the Western world. *Approximately 80% of cases are attributable to either biliary tract disease or alcoholism* (Table 16–1). Roughly 5% of patients with gallstones develop acute pancreatitis, and gallstones are implicated in 35% to 60% of cases overall.

**Table 16–1** Etiologic Factors in Acute Pancreatitis

| |
|---|
| **Metabolic** |
| Alcoholism* |
| Hyperlipoproteinemia |
| Hypercalcemia |
| Drugs (e.g., azathioprine) |
| **Genetic** |
| Mutations in the cationic trypsinogen (*PRSS1*) and trypsin inhibitor (*SPINK1*) genes |
| **Mechanical** |
| Gallstones* |
| Trauma |
| Iatrogenic injury |
| Perioperative injury |
| Endoscopic procedures with dye injection |
| **Vascular** |
| Shock |
| Atheroembolism |
| Polyarteritis nodosa |
| **Infectious** |
| Mumps |
| Coxsackievirus |

*Most common causes in the United States.

Excessive alcohol intake has been reported as a cause of acute pancreatitis at variable rates, from 65% of cases in the United States to 5% or less in the United Kingdom.

Other causes of acute pancreatitis include

- Non–gallstone-related obstruction of the pancreatic ducts (e.g., due to periampullary neoplasms such as pancreatic cancer, pancreas divisum, biliary "sludge," or parasites, particularly *Ascaris lumbricoides* and *Clonorchis sinensis*)
- Medications including anticonvulsants, cancer chemotherapeutic agents, thiazide diuretics, estrogens, and more than 85 others in clinical use
- Infections with mumps virus or coxsackievirus
- Metabolic disorders, including hypertriglyceridemia, hyperparathyroidism, and other hypercalcemic states
- Ischemia due to vascular thrombosis, embolism, vasculitis, or shock
- Trauma, both blunt force and iatrogenic during surgery or endoscopy
- Inherited mutations in genes encoding pancreatic enzymes or their inhibitors (e.g., *SPINK1*). For example, *hereditary pancreatitis* is an autosomal dominant disease with 80% penetrance that is characterized by recurrent attacks of severe pancreatitis, usually beginning in childhood. It is caused by mutations in the gene *PRSS1*, which encodes trypsinogen, the proenzyme of pancreatic trypsin. The pathogenic mutations alter the site through which trypsin cleaves and inactivates itself, abrogating an important negative feedback mechanism. This defect leads not only to the hyperactivation of trypsin, but also to the hyperactivation of many other digestive enzymes that require trypsin cleavage for their activation. As a result of this unbridled protease activity, the pancreas is prone to autodigestion and injury.

Of note, 10% to 20% of cases of acute pancreatitis have no identifiable cause (*idiopathic pancreatitis*), although a growing body of evidence suggests that many may have an underlying genetic basis.

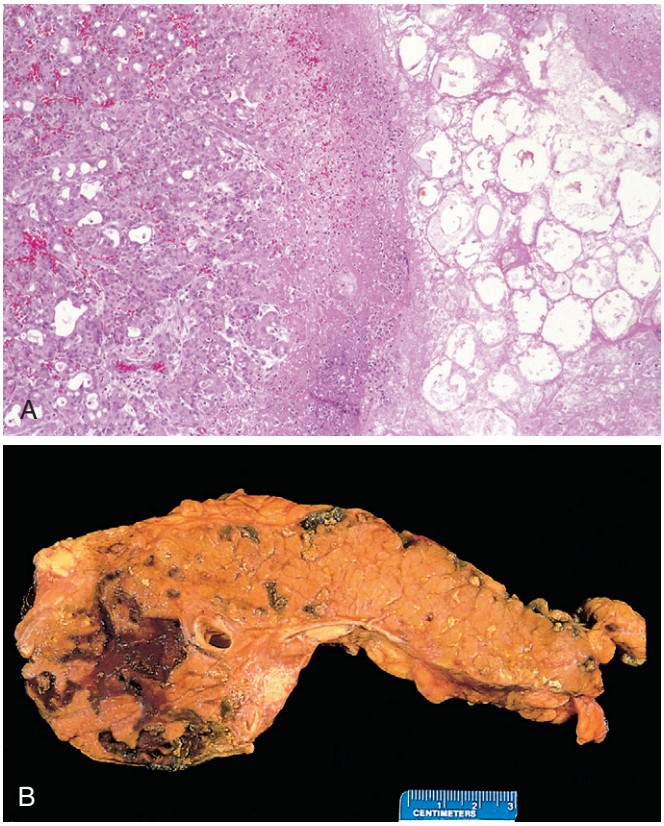


**Figure 16–1** Acute pancreatitis. **A,** The microscopic field shows a region of fat necrosis (*right*) and focal pancreatic parenchymal necrosis (*center*). **B,** The pancreas has been sectioned longitudinally to reveal dark areas of hemorrhage in the pancreatic substance and a focal area of pale fat necrosis in the peripancreatic fat (*upper left*).

## MORPHOLOGY

The basic alterations in acute pancreatitis are **(1) microvascular leakage causing edema, (2) necrosis of fat by lipases, (3) an acute inflammatory reaction, (4) proteolytic destruction of pancreatic parenchyma, and (5) destruction of blood vessels leading to interstitial hemorrhage.**

In milder forms, histologic alterations include interstitial edema and focal areas of fat necrosis in the pancreatic substance and peripancreatic fat (Fig. 16–1, *A*). Fat necrosis results from enzymatic destruction of fat cells; the released fatty acids combine with calcium to form insoluble salts that precipitate in situ.

In more severe forms, such as **acute necrotizing pancreatitis,** necrosis of pancreatic tissue affects acinar and ductal tissues as well as the islets of Langerhans; vascular damage causes hemorrhage into the parenchyma of the pancreas. Macroscopically, the pancreas exhibits red-black hemorrhagic areas interspersed with foci of yellow-white, chalky fat necrosis (Fig. 16–1, *B*). Fat necrosis also can occur in extrapancreatic fat, including the omentum and bowel mesentery, and even outside the abdominal cavity (e.g., in subcutaneous fat). In most cases the peritoneum contains a serous, slightly turbid, brown-tinged fluid with globules of fat (derived from enzymatically digested adipose tissue). In the most severe form, **hemorrhagic pancreatitis,** extensive parenchymal necrosis is accompanied by diffuse hemorrhage within the substance of the gland.

## PATHOGENESIS

The histologic changes seen in acute pancreatitis strongly suggest **autodigestion of the pancreatic substance by inappropriately activated pancreatic enzymes.** As described previously, the zymogen forms of pancreatic enzymes must be enzymatically cleaved to be activated; trypsin is central in this process, so **activation of trypsin is a critical triggering event in acute pancreatitis.** If trypsin is inappropriately generated from its proenzyme trypsinogen, it can activate itself as well as other proenzymes (e.g., phospholipases and elastases) that can then take part in the process of autodigestion. Trypsin also converts prekallikrein to its activated form, thus sparking the kinin system, and, by activation of factor XII (Hageman factor), also sets in motion the clotting and complement systems (Chapter 2).

Three pathways can incite the initial enzyme activation that may lead to acute pancreatitis (Fig. 16–2):

- **Pancreatic duct obstruction.** Impaction of a gallstone or biliary sludge, or extrinsic compression of the ductal system by a mass blocks ductal flow, increases intraductal pressure, and allows accumulation of an enzyme-rich interstitial fluid. Since lipase is secreted in an active form, local fat necrosis may result. Injured tissues, periacinar myofibroblasts, and leukocytes then release pro-inflammatory cytokines that promote local inflammation and interstitial edema through a leaky microvasculature. Edema further compromises local blood flow, causing vascular insufficiency and ischemic injury to acinar cells.
- **Primary acinar cell injury.** This pathogenic mechanism comes into play in acute pancreatitis caused by ischemia, viral infections (e.g., mumps), drugs, and direct trauma to the pancreas.
- **Defective intracellular transport of proenzymes within acinar cells.** In normal acinar cells, digestive enzymes intended for zymogen granules (and eventually extracellular release) and hydrolytic enzymes destined for lysosomes are transported in discrete pathways after synthesis in the endoplasmic reticulum. However, at least in some animal models of metabolic injury, pancreatic proenzymes and lysosomal hydrolases become packaged together. This results in proenzyme activation, lysosomal rupture (action of phospholipases), and local release of activated enzymes. The role of this mechanism in human acute pancreatitis is not clear.

**Alcohol consumption may cause pancreatitis by several mechanisms.** Alcohol transiently increases pancreatic exocrine secretion and contraction of the sphincter of Oddi (the muscle regulating the tone at the ampulla of Vater). Alcohol also has direct toxic effects on acinar cells, including induction of oxidative stress in acinar cells, which leads to membrane damage (see below). Finally, chronic alcohol ingestion results in the secretion of protein-rich pancreatic fluid, which leads to the deposition of inspissated protein plugs and obstruction of small pancreatic ducts.

### Clinical Features

*Abdominal pain* is the cardinal manifestation of acute pancreatitis. Its severity varies from mild and uncomfortable to severe and incapacitating. Suspected acute pancreatitis is diagnosed primarily by the presence of elevated plasma

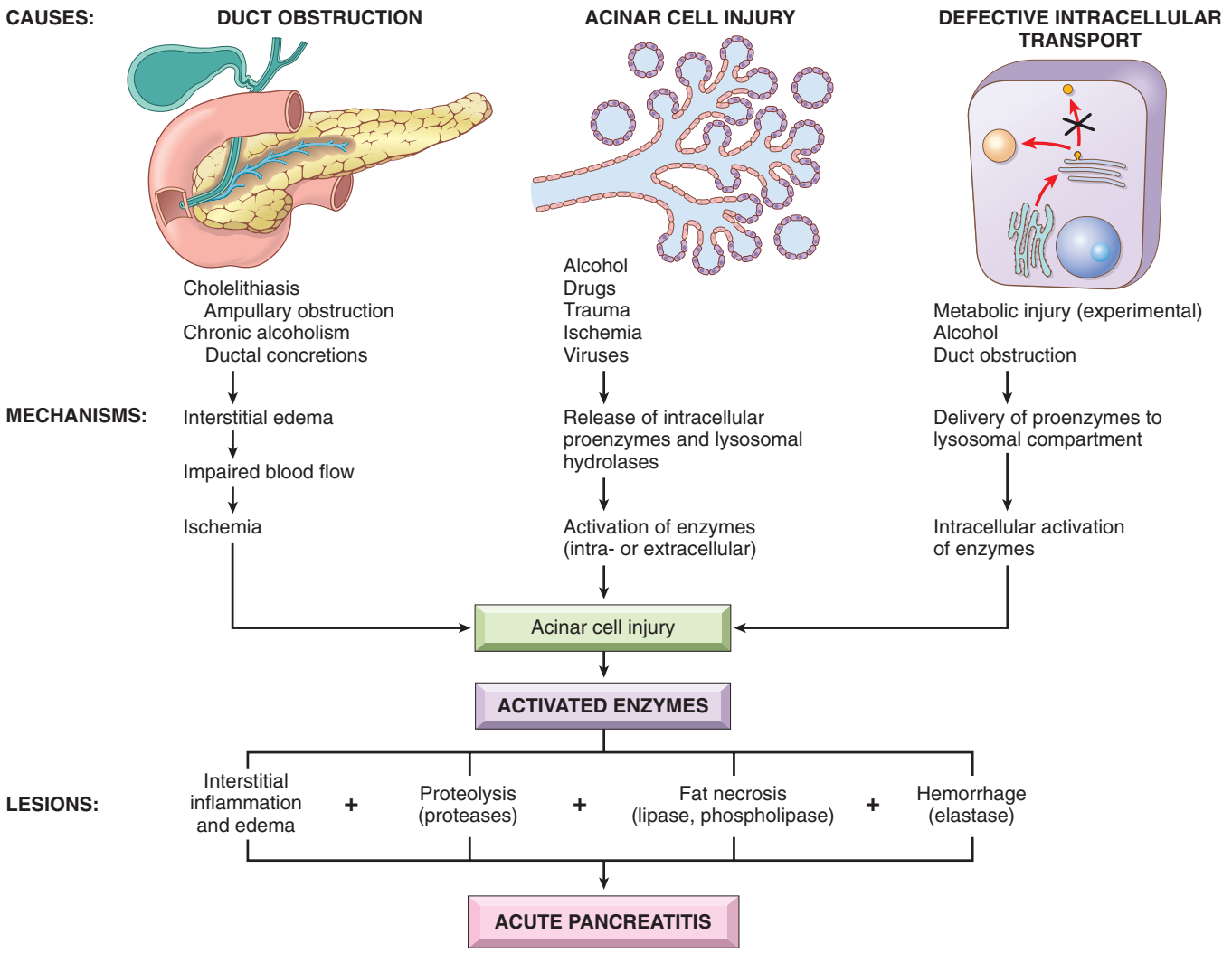


**Figure 16–2** Proposed pathogenesis of acute pancreatitis.

levels of amylase and lipase and the exclusion of other causes of abdominal pain. In 80% of cases acute pancreatitis is mild and self limiting; the remaining 20% develop severe disease.

*Full-blown acute pancreatitis constitutes a medical emergency of the first magnitude.* Affected persons usually experience the sudden calamitous onset of an "acute abdomen" with pain, abdominal guarding, and the ominous absence of bowel sounds. Characteristically, the pain is constant and intense and often is referred to the upper back; it must be differentiated from pain of other causes such as perforated peptic ulcer, biliary colic, acute cholecystitis with rupture, and occlusion of mesenteric vessels with infarction of the bowel.

The manifestations of severe acute pancreatitis are attributable to systemic release of digestive enzymes and explosive activation of the inflammatory response. The initial clinical evaluation may reveal leukocytosis, disseminated intravascular coagulation (Chapter 11), acute respiratory distress syndrome (due to alveolar capillary injury) (Chapter 12), and diffuse fat necrosis. Peripheral vascular collapse (shock) can rapidly ensue as a result of increased microvascular permeability and resultant hypovolemia, compounded by endotoxemia (from breakdown of the barriers between gastrointestinal flora and the bloodstream), and renal failure due to acute tubular necrosis (Chapter 13).

*Laboratory findings* include markedly elevated serum amylase during the first 24 hours, followed (within 72 to 96 hours) by rising serum lipase levels. Hypocalcemia can result from precipitation of calcium in areas of fat necrosis; if persistent, it is a poor prognostic sign. The enlarged inflamed pancreas can be visualized by computed tomography (CT) or magnetic resonance imaging (MRI).

The crux of the management of acute pancreatitis is supportive therapy (e.g., maintaining blood pressure and alleviating pain) and "resting" the pancreas by total restriction of food and fluids. In 40% to 60% of cases of acute necrotizing pancreatitis, the necrotic debris becomes infected, usually by gram-negative organisms from the alimentary tract, further complicating the clinical course. Although most persons with acute pancreatitis eventually recover, some 5% die from shock during the first week of illness; acute respiratory distress syndrome and acute renal failure are ominous complications. In surviving patients, sequelae include sterile or infected *pancreatic "abscesses"* or *pancreatic pseudocysts.*

### *Pancreatic Pseudocysts*

A common sequela of acute pancreatitis (and in particular, alcoholic pancreatitis) is a *pancreatic pseudocyst.* Liquefied areas of necrotic pancreatic tissue become walled off by fibrous tissue to form a cystic space, lacking an epithelial lining (hence the designation *pseudo*). The cyst contents are rich in pancreatic enzymes, and a laboratory assessment of the cyst aspirate can be diagnostic. Pseudocysts account for approximately 75% of all pancreatic cysts. While many pseudocysts spontaneously resolve, they can become secondarily infected, and larger pseudocysts can compress or even perforate into adjacent structures.

#### MORPHOLOGY

Pseudocysts usually are solitary; they commonly are attached to the surface of the gland and involve peripancreatic tissues such as the lesser omental sac or the retroperitoneum between the stomach and transverse colon or liver (Fig. 16–3, *A*). They can range in diameter from 2 cm to 30 cm. Since pseudocysts form by walling off areas of hemorrhagic fat necrosis, they typically are composed of necrotic debris encased by fibrous walls of granulation tissue lacking an epithelial lining (Fig. 16–3, *B*).

## Chronic Pancreatitis

Chronic pancreatitis is characterized by long-standing inflammation, fibrosis, and destruction of the exocrine pancreas; in its late stages, the endocrine parenchyma also is lost. Although chronic pancreatitis can result from recurrent bouts of acute pancreatitis, *the chief distinction between acute and chronic pancreatitis is the irreversible impairment in pancreatic function in the latter.* The prevalence of chronic pancreatitis is difficult to determine but probably ranges between 0.04% and 5% of the U.S. population. By far *the most common cause of chronic pancreatitis is long-term alcohol abuse*; middle-aged men constitute the bulk of patients in

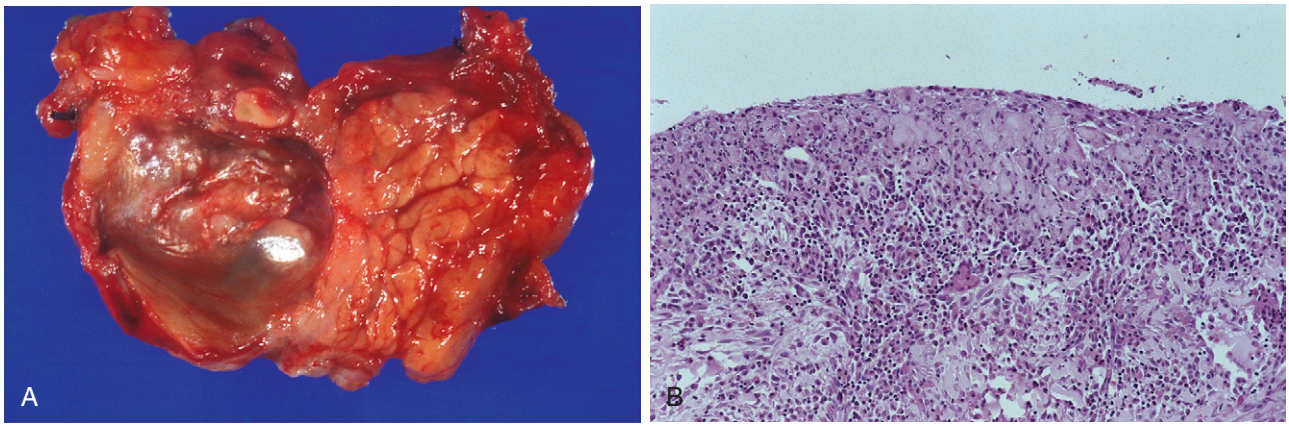


**Figure 16–3** Pancreatic pseudocyst. **A,** Cross-section revealing a poorly defined cyst with a necrotic brownish wall. **B,** Histologically, the cyst lacks a true epithelial lining and instead is lined by fibrin and granulation tissue, with typical changes of chronic inflammation.

this etiologic group. Less common causes of chronic pancreatitis include

- Long-standing pancreatic duct *obstruction* (e.g., by pseudocysts, calculi, neoplasms, or pancreas divisum)
- *Tropical pancreatitis,* a poorly characterized heterogeneous disorder seen in Africa and Asia, with a subset of cases having a genetic basis
- *Hereditary pancreatitis* due to mutations in the pancreatic trypsinogen gene (*PRRS1*) (see Table 16–1 earlier), or the *SPINK1* gene encoding a trypsin inhibitor
- *Chronic pancreatitis associated with CFTR mutations.* As discussed in detail in Chapter 6, cystic fibrosis is caused by mutations in the *CFTR* gene; the CFTR protein also is expressed in pancreatic ductal epithelium, and *CFTR* mutations decrease bicarbonate secretion and increase the viscosity of the secretions, thereby promoting protein plugging.

As many as 40% of persons with chronic pancreatitis have no recognizable predisposing factors. As with acute pancreatitis, however, a growing number of these "idiopathic" cases are associated with inherited mutations in genes important for normal pancreatic exocrine function. For example, genetic testing reveals that 25% to 30% of patients with "idiopathic" pancreatitis harbor germline mutations in the *CFTR* gene, albeit distinct from the ones that lead to classic multisystem cystic fibrosis (Chapter 6).

## MORPHOLOGY

Chronic pancreatitis is characterized by **parenchymal fibrosis, reduced number and size of acini, and variable dilation of the pancreatic ducts;** there is a relative sparing of the islets of Langerhans (Fig. 16–4, *A*). **Acinar loss** is a constant feature, usually with a chronic inflammatory infiltrate around remaining lobules and ducts. The ductal epithelium may be atrophied or hyperplastic or exhibit squamous metaplasia, and ductal concretions may be noted (Fig. 16–4, *B*). The remaining islets of Langerhans become embedded in the sclerotic tissue and may fuse and appear enlarged; eventually they also disappear. On gross evaluation, the gland is hard, sometimes with extremely dilated ducts and visible calcified concretions.

Autoimmune pancreatitis (AIP) is a distinct form of chronic pancreatitis that is characterized by one of two morphologic patterns: (1) striking infiltration of the pancreas by lymphoplasmacytic cells, many of which are positive for IgG4, accompanied by a "swirling" fibrosis and venulitis **(lymphoplasmacytic sclerosing pancreatitis),** or (2) a duct-centric mixed infiltrate composed of neutrophils, lymphocytes and plasma cells, often obliterating the ductal epithelium **(idiopathic duct centric pancreatitis).** IgG4-related autoimmune pancreatitis is a multisystem disease and may be one manifestation of IgG4-associated fibrosing disorders (Chapter 4). Recognition of autoimmune pancreatitis in both its forms is important, because it can mimic pancreatic cancer and also because it responds to steroid therapy.

## PATHOGENESIS

Although the pathogenesis of chronic pancreatitis is not well defined, several hypotheses are proposed:

- **Ductal obstruction by concretions.** Many of the inciting agents in chronic pancreatitis (e.g., alcohol) increase the protein concentration of pancreatic secretions, and these proteins can form ductal plugs.
- **Toxic-metabolic.** Toxins, including alcohol and its metabolites, can exert a direct toxic effect on acinar cells, leading to lipid accumulation, acinar cell loss, and eventually parenchymal fibrosis.
- **Oxidative stress.** Alcohol-induced oxidative stress may generate free radicals in acinar cells, leading to membrane damage (Chapter 1), and subsequent expression of chemokines like interleukin-8 (IL-8), which recruits mononuclear inflammatory cells. Oxidative stress also promotes the fusion of lysosomes and zymogen granules with resulting acinar cell necrosis, inflammation, and fibrosis.

In contrast with acute pancreatitis, a variety of profibrogenic cytokines, such as transforming growth factor-β (TGF-β), connective tissue growth factor, and platelet-derived growth factor, are secreted in chronic pancreatitis. These cytokines induce the activation and proliferation of periacinar myofibroblasts ("pancreatic stellate cells"), which deposit collagen and are instrumental in the pathogenesis of fibrosis.

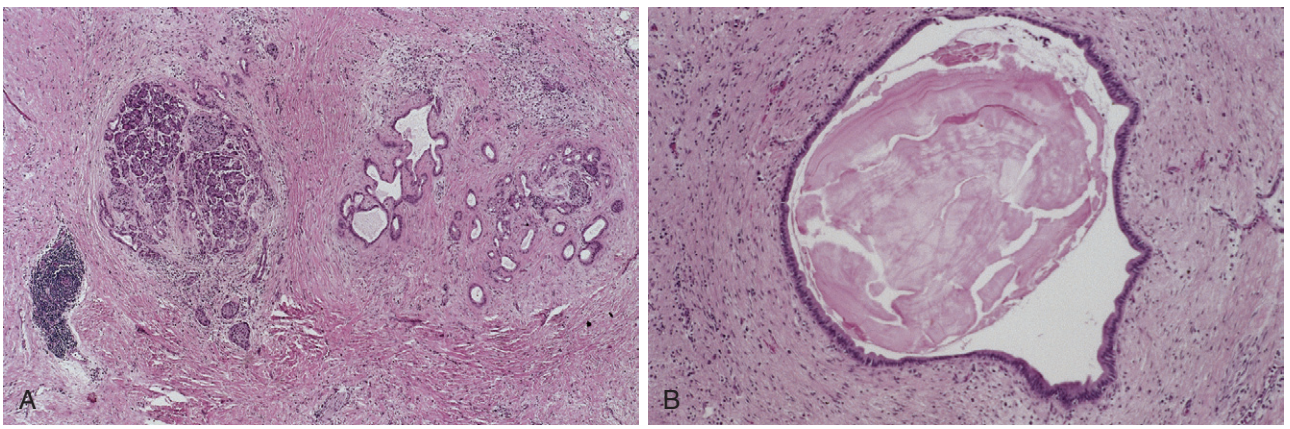


**Figure 16–4** Chronic pancreatitis. **A,** Extensive fibrosis and atrophy has left only residual islets (*left*) and ducts (*right*), with a sprinkling of chronic inflammatory cells and acinar tissue. **B,** A higher-power view demonstrating dilated ducts with inspissated eosinophilic concretions in a patient with alcoholic chronic pancreatitis.

### Clinical Features

Chronic pancreatitis manifests in several different ways. It may announce itself with repeated bouts of jaundice, vague indigestion, or persistent or recurrent abdominal and back pain, or it may be entirely silent until pancreatic insufficiency and diabetes mellitus develop (the latter as a consequence of islet destruction). Attacks can be precipitated by alcohol abuse, overeating (increases demand on pancreatic secretions), or opiates or other drugs that increase the muscle tone of the sphincter of Oddi.

*The diagnosis of chronic pancreatitis requires a high degree of clinical suspicion.* During an attack of abdominal pain, there may be mild fever and modest elevations of serum amylase. In end-stage disease, however, acinar destruction may be so advanced that enzyme elevations are absent. Gallstone-induced obstruction may manifest as jaundice or elevated levels of serum alkaline phosphatase. A very helpful finding is visualization of calcifications within the pancreas by CT or ultrasonography. Weight loss and hypoalbuminemic edema from malabsorption caused by pancreatic exocrine insufficiency also can point to the disease.

Although chronic pancreatitis is usually not acutely life-threatening, the long-term outlook is poor, with a 50% mortality rate over 20 to 25 years. Severe *pancreatic exocrine insufficiency* and chronic malabsorption may develop, as can *diabetes mellitus.* In other patients, *severe chronic pain* may dominate the clinical picture. *Pancreatic pseudocysts* (described earlier) develop in about 10% of patients. Persons with hereditary pancreatitis have a 40% lifetime risk of developing pancreatic cancer. The degree to which other forms of chronic pancreatitis contribute to cancer development is unclear.

#### SUMMARY

**Pancreatitis**

- *Acute pancreatitis* is characterized by inflammation and reversible parenchymal damage that ranges from focal edema and fat necrosis to widespread parenchymal necrosis and hemorrhage; the clinical presentation varies widely, from mild abdominal pain to rapidly fatal vascular collapse.
- *Chronic pancreatitis* is characterized by irreversible parenchymal damage and scar formation; clinical presentations include chronic malabsorption (due to pancreatic exocrine insufficiency) and diabetes mellitus (due to islet cell loss).
- Both entities share similar pathogenic mechanisms, and indeed recurrent acute pancreatitis can result in chronic pancreatitis. *Ductal obstruction* and *long-term alcohol abuse* are the most common causes in both forms. Inappropriate activation of pancreatic digestive enzymes (due to mutations in genes encoding trypsinogen or trypsin inhibitors) and primary acinar injury (due to toxins, infections, ischemia, or trauma) also cause pancreatitis.

## PANCREATIC NEOPLASMS

Pancreatic exocrine neoplasms can be cystic or solid. Some tumors are benign, while others are among the most lethal of all malignancies.

### Cystic Neoplasms

Only 5% to 15% of all pancreatic cysts are neoplastic; these constitute less than 5% of all pancreatic neoplasms. Some of these are entirely benign (e.g., serous cystadenoma); others, such as mucinous cystic neoplasms, can be benign or malignant.

#### *Serous Cystadenomas*

*Serous cystadenomas* account for approximately 25% of all pancreatic cystic neoplasms; they are composed of glycogen-rich cuboidal cells surrounding small cysts containing clear, straw-colored fluid (Fig. 16–5). The tumors typically manifest in the seventh decade of life with nonspecific symptoms such as abdominal pain; the female-to-male ratio is 2:1. These tumors are almost uniformly benign, and surgical resection is curative in the vast majority of patients. Most serous cystadenomas carry somatic mutations of the von Hippel-Lindau (*VHL*) tumor suppressor gene, the product of which binds to hypoxia-inducible factor 1 alpha (HIF1alpha) and results in its degradation (Chapter 5).

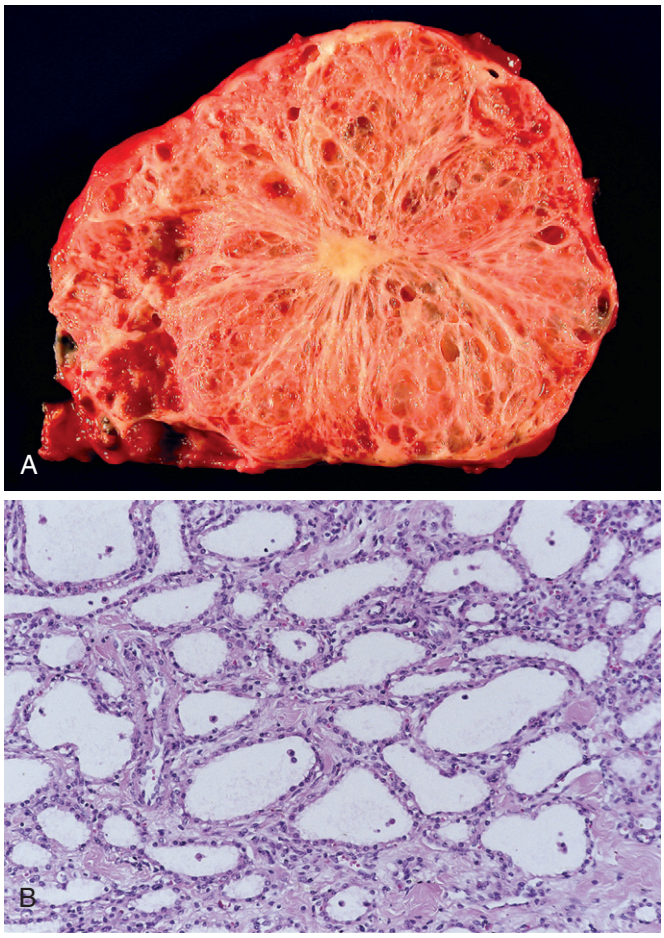


**Figure 16–5** Serous cystadenoma. **A,** Cross-section through a serous cystadenoma. Only a thin rim of normal pancreatic parenchyma remains. The cysts are relatively small and contain clear, straw-colored fluid. **B,** The cysts are lined by cuboidal epithelium without atypia.

### *Mucinous Cystic Neoplasms*

*Close to 95% of mucinous cystic neoplasms* arise in women, usually in the body or tail of the pancreas, and manifest as painless, slow-growing masses. The cystic spaces are filled with thick, tenacious mucin, and the cysts are lined by a columnar mucinous epithelium with an associated densely cellular stroma resembling that of the ovary (Fig. 16–6). Based on the degree of cytologic and architectural atypia in the lining epithelium, noninvasive mucinous cystic neoplasms are classified as harboring *low-grade, moderate,* or *severe* dysplasia. Up to one third of these cysts can be associated with an invasive adenocarcinoma. Distal pancreatectomy for noninvasive cysts typically is curative, even in the setting of severe dysplasia.

### *Intraductal Papillary Mucinous Neoplasms*

*Intraductal papillary mucinous neoplasms* (IPMNs) are mucin-producing intraductal neoplasms. In contrast with mucinous cystic neoplasms, IPMNs occur more frequently in men than in women and more frequently involve the head of the pancreas. IPMNs arise in the main pancreatic ducts, or one of its major branch ducts, and lack the cellular stroma seen in mucinous cystic neoplasms (Fig. 16–7). As with mucinous cystic neoplasms, the epithelia of noninvasive IPMNs harbor various grades of dysplasia, and a subset of lesions is associated with an invasive adenocarcinoma component. Notably, up to two thirds of IPMNs harbor oncogenic mutations of *GNAS* on chromosome 20q13, which encodes the alpha subunit of a stimulatory G-protein, $G_s$ (Chapter 19). Constitutive activation of this G-protein is predicted to result in an intracellular cascade that promotes cell proliferation.

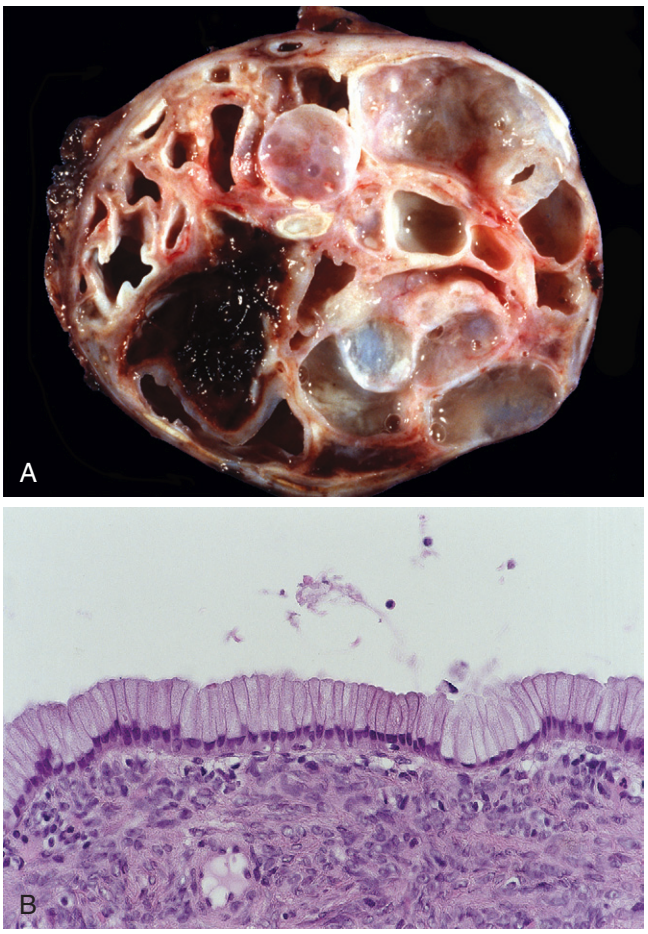


**Figure 16–6** Mucinous cystic neoplasm. **A,** Cross-section through a mucinous multiloculated cyst in the tail of the pancreas. The cysts are large and filled with tenacious mucin. **B,** The cysts are lined by columnar mucinous epithelium, with a densely cellular "ovarian" stroma.

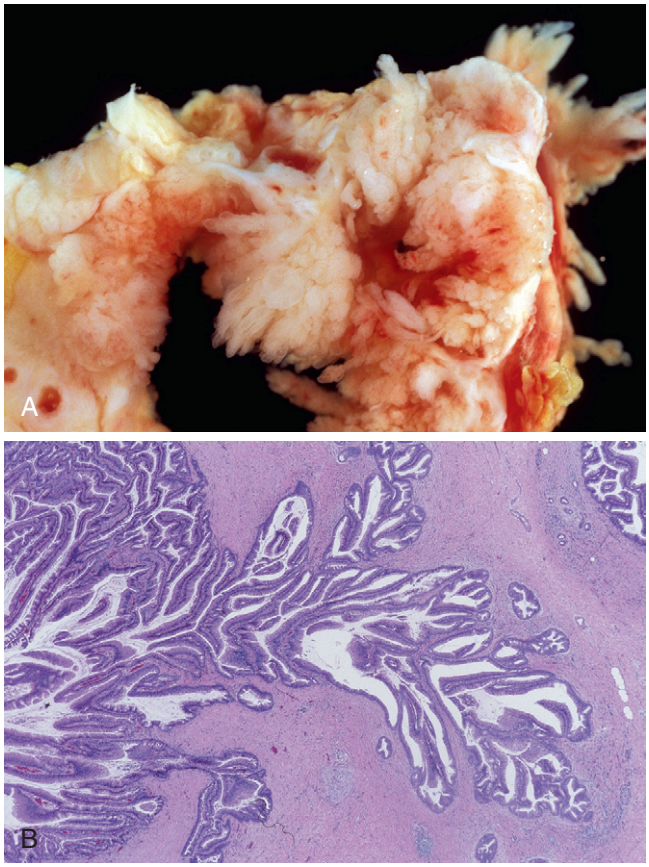


**Figure 16–7** Intraductal papillary mucinous neoplasm. **A,** Cross-section through the head of the pancreas showing a prominent papillary neoplasm distending the main pancreatic duct. **B,** The papillary mucinous neoplasm involved the main pancreatic duct (*left*) and is extending down into the smaller ducts and ductules (*right*).

## Pancreatic Carcinoma

Infiltrating ductal adenocarcinoma of the pancreas (more commonly referred to as "pancreatic cancer") is the fourth leading cause of cancer death in the United States, preceded only by lung, colon, and breast cancers. Although it is substantially less common than the other three malignancies, pancreatic carcinoma is near the top of the list of killers because it carries one of the highest mortality rates. Over 44,000 Americans were diagnosed with pancreatic cancer in 2010, and virtually all will die of it; the 5-year survival rate is dismal—less than 5%. Sadly, Ralph Steinman, one of the 2011 Nobel Laureates in physiology or medicine died of pancreatic cancer, three days before the announcement of his award.

## PATHOGENESIS

Like all cancers, pancreatic cancer arises as a consequence of inherited and acquired mutations in cancer-associated genes. In a pattern analogous to that seen in the multistep progression of colon cancer (Chapter 5), there is a progressive accumulation of genetic changes in pancreatic epithelium as it proceeds from non-neoplastic, to noninvasive precursor lesions, to invasive carcinoma (Fig. 16–8). While both intraductal papillary mucinous neoplasms and mucinous cystic neoplasms can progress to invasive adenocarcinoma and are thus considered bona fide precursors of cancer (as noted earlier), the most common antecedent lesions of pancreatic cancer arise in small ducts and ductules, and are called **pancreatic intraepithelial neoplasias (PanINs).** Evidence in favor of the precursor relationship of PanINs to frank malignancy includes the fact that these microscopic lesions often are found adjacent to infiltrating carcinomas and the two share a number of genetic alterations. Moreover, the epithelial cells in PanINs show dramatic telomere shortening, potentially predisposing these lesions to accumulating additional chromosomal abnormalities on their way to becoming invasive carcinoma.

The recent sequencing of the pancreatic cancer genome has confirmed that four genes are most commonly affected by somatic mutations in this neoplasm: *KRAS, CDKNA2A/p16, SMAD4,* and *TP53*:

- *KRAS* is the most frequently altered oncogene in pancreatic cancer; it is activated by a point mutation in 80% to 90% of cases. These mutations impair the intrinsic GTPase activity of the Kras protein so that it is constitutively active. In turn, Kras activates a number of intracellular signaling pathways ("Kras effectors") that promote carcinogenesis (Chapter 5).
- The *p16 (CDKN2A)* gene is the most frequently inactivated tumor suppressor gene in pancreatic cancer, being turned off in 95% of cases. The p16 protein has a critical role in cell cycle control; inactivation removes an important checkpoint.
- The *SMAD4* tumor suppressor gene is inactivated in 55% of pancreatic cancers and only rarely in other tumors; it codes for a protein that plays an important role in signal transduction downstream of the transforming growth factor-β receptor.
- Inactivation of the *TP53* tumor suppressor gene occurs in 50% to 70% of pancreatic cancers. Its gene product, p53, acts both to enforce cell cycle checkpoints and as an inducer of apoptosis or senescence (Chapter 5).
- Mutations of *VHL* or *GNAS,* found in aforementioned pancreatic cysts, have not been described in ductal adenocarcinomas, and provide a likely basis for the widely different histopathology and natural history of these lesions.

What causes these molecular changes is unknown. Pancreatic cancer is primarily a disease of the elderly population, with 80% of cases occurring between the ages of 60 and 80. The strongest environmental influence is **smoking,** which doubles the risk. Chronic pancreatitis and diabetes mellitus are also both associated with an increased risk of pancreatic cancer. It is difficult to sort out whether chronic pancreatitis is the cause of pancreatic cancer or an effect of the disease, since small pancreatic cancers can block the pancreatic duct and thereby produce chronic pancreatitis. On the other hand, as discussed in Chapter 5, chronic inflammation is now considered an enabler of malignancy. Likewise, the basis of the association of diabetes mellitus with pancreatic cancer is also unclear, since diabetes can occur as a consequence of pancreatic cancer, and in fact, new-onset diabetes in an elderly patient may be the first sign of this malignancy. Familial clustering of pancreatic cancer has been reported, and a growing number of inherited genetic defects are now recognized that increase pancreatic cancer risk. For example, germline mutations of the familial breast/ovarian cancer gene *BRCA2* are seen in approximately 10% of cases arising in persons of Ashkenazi Jewish heritage.

## MORPHOLOGY

Approximately 60% of pancreatic cancers arise in the head of the gland, 15% in the body, and 5% in the tail; in the remaining 20%, the neoplasm diffusely involves the entire

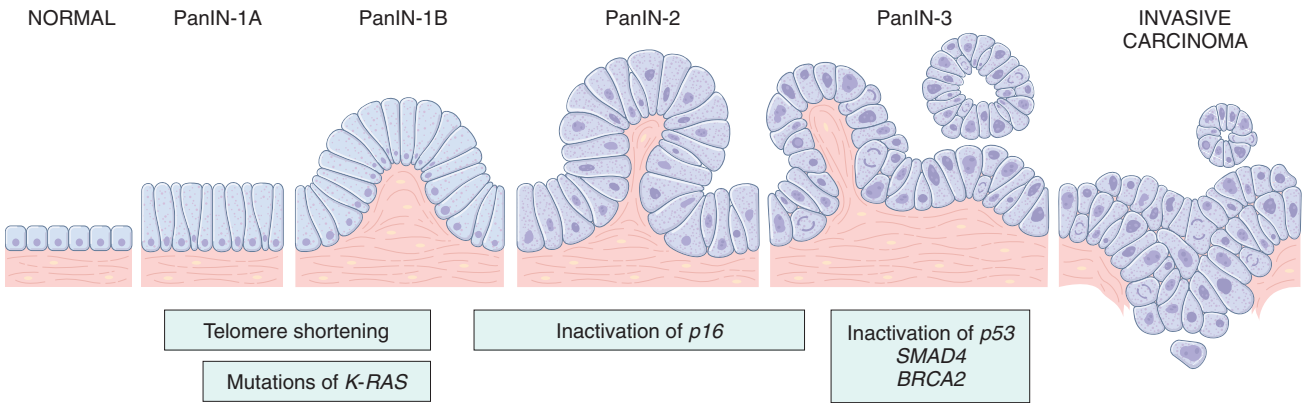


**Figure 16–8** Progression model for the development of pancreatic cancer. It is postulated that telomere shortening and mutations of the oncogene *K-RAS* occur at early stages, inactivation of the *p16* tumor suppressor gene occurs at intermediate stages, and the inactivation of the *TP53, SMAD4,* and *BRCA2* tumor suppressor genes occurs at late stages. Note that while there is a general temporal sequence of changes, the accumulation of multiple mutations is more important than their occurrence in a specific order. PanIN, pancreatic intraepithelial neoplasm. The numbers following the labels on the top refer to stages in the development of PanINs.

*(Modified from Maitra A, Hruban RH: Pancreatic cancer. Annu Rev Pathol Mech Dis 3:157, 2008.)*

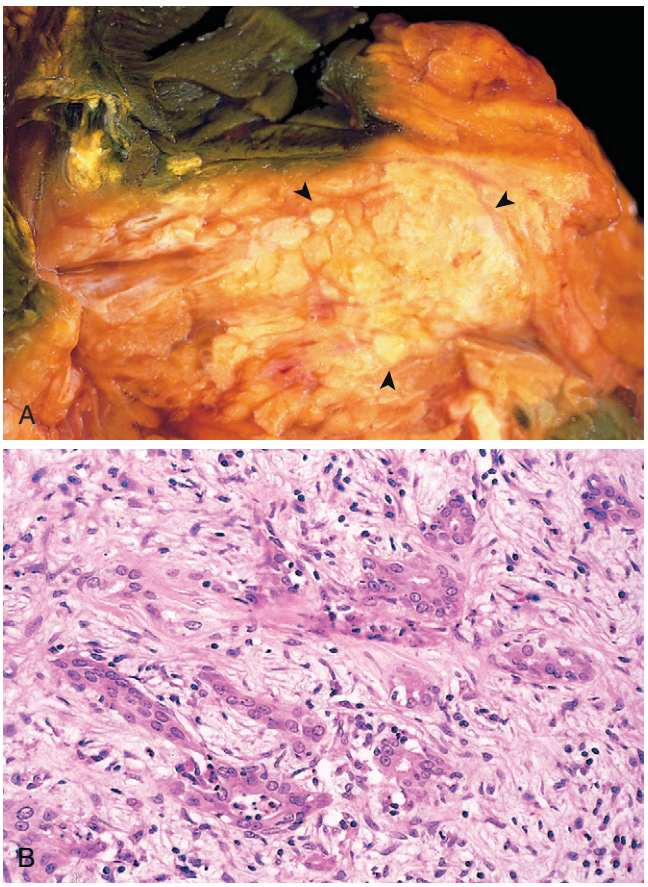


**Figure 16–9** Carcinoma of the pancreas. **A,** A cross-section through the head of the pancreas and adjacent common bile duct showing both an ill-defined mass in the pancreatic substance (*arrowheads*) and the green discoloration of the duct resulting from total obstruction of bile flow. **B,** Poorly formed glands are present in a densely fibrotic (desmoplastic) stroma within the pancreatic substance.

organ. Carcinomas of the pancreas usually are hard, gray-white, stellate, poorly defined masses (Fig. 16–9, *A*).

The vast majority of carcinomas are **ductal adenocarcinomas,** recapitulating to some degree the normal duct epithelium by forming glands and secreting mucin. Two features are characteristic of pancreatic cancer: It is highly invasive (even "early" invasive pancreatic cancers invade peripancreatic tissues extensively), and it elicits an intense non-neoplastic host reaction composed of fibroblasts, lymphocytes, and extracellular matrix **(desmoplastic response).**

**Most carcinomas of the head of the pancreas obstruct the distal common bile duct** as it courses through the head of the pancreas. In 50% of such cases, there is marked distention of the biliary tree, and patients typically exhibit jaundice. In marked contrast, **carcinomas of the body and tail of the pancreas do not impinge on the biliary tract and hence remain silent for some time. They may be quite large and widely disseminated by the time they are discovered.** Pancreatic cancers often extend through the retroperitoneal space, entrapping adjacent nerves (thus, accounting for the pain), and occasionally invade the spleen, adrenals, vertebral column, transverse colon, and stomach. Peripancreatic, gastric, mesenteric, omental, and portahepatic lymph nodes frequently are involved, and the liver often is enlarged as a consequence of metastatic deposits. Distant metastases may occur, principally to the lungs and bones.

On microscopic examination, pancreatic carcinoma usually is a moderately to poorly differentiated adenocarcinoma forming abortive tubular structures or cell clusters and exhibiting an aggressive, deeply infiltrative growth pattern (Fig. 16–9, *B*). Dense stromal fibrosis accompanies tumor invasion, and there is a proclivity for perineural invasion within and beyond the organ. Lymphatic invasion also is commonly seen.

Less common variants of pancreatic cancer include **adenosquamous carcinomas** with focal squamous differentiation in addition to glandular differentiation; and **undifferentiated carcinomas with osteoclast-like giant cells** of monocytic lineage intermixed within the neoplasm.

### Clinical Features

*Carcinomas of the pancreas typically remain silent until their extension impinges on some other structure.* Pain usually is the first symptom, but by that point these cancers are often beyond cure. *Obstructive jaundice* can be associated with carcinoma in the head of the pancreas, but it rarely draws attention to the cancer soon enough for timely intervention. Weight loss, anorexia, and generalized malaise and weakness are manifestations of advanced disease. *Migratory thrombophlebitis* (*Trousseau syndrome*) occurs in about 10% of patients and is attributable to the elaboration of platelet-aggregating factors and pro-coagulants from the tumor or its necrotic products (Chapter 3).

The clinical course of pancreatic carcinoma is rapidly progressive and distressingly brief. Less than 20% of pancreatic cancers are resectable at the time of diagnosis. It has long been recognized that there is a profound need for biomarkers capable of detecting early, potentially curable, pancreatic cancers. Although serum levels of many enzymes and antigens (e.g., carcinoembryonic and CA19-9 antigens) are elevated, these markers are neither specific nor sensitive enough to be useful for screening. Several imaging techniques, such as endoscopic ultrasonography and high-resolution CT scans, are helpful for investigation in cases of suspected cancer but are not useful as screening tests.

## SUMMARY

### Pancreatic Neoplasms

- Pancreatic cancer probably arises from noninvasive precursor lesions (most commonly, PanINs), developing by progressive accumulation of characteristic mutations of oncogenes (e.g., *KRAS*) and tumor suppressor genes (e.g., *CDKN2A/p16, TP53,* and *SMAD4*).
- Typically, these neoplasms are ductal adenocarcinomas that produce an intense desmoplastic response.
- Most pancreatic cancers are diagnosed at an advanced stage, accounting for the high mortality rate.
- Obstructive jaundice is a feature of carcinoma of the head of the pancreas; many patients also experience debilitating pain.

## BIBLIOGRAPHY


Chen JM, Ferec C: Chronic pancreatitis: genetics and pathogenesis. Annu Rev Genomics Hum Genet 10:63, 2009. *[A comprehensive review on the basic science aspects of chronic pancreatitis, including genetic causes.]*

DiMagno MJ, DiMagno EP: Chronic pancreatitis. Curr Opin Gastroenterol 25:454, 2009. *[A clinically oriented review on the natural history and management of chronic pancreatitis.]*

Hidalgo M: Pancreatic cancer. N Engl J Med 362:1605, 2010. *[An outstanding clinically oriented update on pancreatic cancer, including newly emerging molecular targets for therapy.]*

Matthaei H, et al: Cystic precursors to invasive pancreatic cancer. Nat Rev Gastroenterol Hepatol 8:141, 2011. *[A comprehensive review on pancreatic cysts and their clinical relevance.]*

Sand J, Nordback I: Acute pancreatitis: risk of recurrence and late consequences of the disease. Nat Rev Gastroenterol Hepatol 6:470, 2009. *[An outstanding review on the late complications of acute pancreatitis, such as pseudocysts, and the progression to chronic pancreatic insufficiency.]*

Sugumar A, Chari ST: Autoimmune pancreatitis. J Gastroenterol Hepatol 26:1368, 2011. *[An excellent update on this newly emerging form of chronic pancreatitis, including a discussion of the major subtypes.]*

Vincent A, Herman J, Schulick R, et al: Pancreatic cancer. Lancet 378:607, 2011. *[A state of the art clinical and pathologic review on pancreatic cancer.]*

Yadav D, Whitcomb DC: The role of alcohol and smoking in pancreatitis. Nat Rev Gastroenterol Hepatol 7:131, 2010. *[An excellent review on the pathogenesis of pancreatitis in the setting of alcohol and nicotine exposure, including the contribution of genetic susceptibility.]*

This page intentionally left blank

See Targeted Therapy available online at
studentconsult.com

CHAPTER 17

# Male Genital System and Lower Urinary Tract

CHAPTER CONTENTS

**Penis 657**
Malformations 657
Inflammatory Lesions 657
Neoplasms 657
**Scrotum, Testis, and Epididymis 658**
Cryptorchidism and Testicular Atrophy 658
Inflammatory Lesions 659
Vascular Disturbances 659
Testicular Neoplasms 659
**Prostate 663**
Prostatitis 663
Benign Prostatic Hyperplasia (Nodular Hyperplasia) 664
Carcinoma of the Prostate 665
**Ureter, Bladder, and Urethra 668**
Ureter 668
Urinary Bladder 668
**Sexually Transmitted Diseases 671**
Syphilis 671
Gonorrhea 674
Nongonococcal Urethritis and Cervicitis 676
Lymphogranuloma Venereum 676
Chancroid (Soft Chancre) 677
Granuloma Inguinale 677
Trichomoniasis 677
Genital Herpes Simplex 678
Human Papillomavirus Infection 678

## PENIS

### Malformations

The most common malformations of the penis include abnormalities in the location of the distal urethral orifice, termed *hypospadias* and *epispadias*. In *hypospadias,* the more common of the two conditions, the abnormal opening of the urethra is on the ventral aspect of the penis anywhere along the shaft. This anomalous urethral orifice is sometimes constricted, resulting in urinary tract obstruction and an increased risk for urinary tract infections. The abnormality occurs in 1 in 300 live male births and may be associated with other congenital anomalies, such as inguinal hernia and undescended testis. In *epispadias,* the abnormal urethral orifice is on the dorsal aspect of the penis.

### Inflammatory Lesions

*Balanitis* and *balanoposthitis* refer to local inflammation of the glans penis and of the overlying prepuce, respectively. Among the more common agents are *Candida albicans,* anaerobic bacteria, *Gardnerella,* and pyogenic bacteria. Most cases occur as a consequence of poor local hygiene in uncircumcised males, with accumulations of desquamated epithelial cells, sweat, and debris, termed *smegma,* acting as a local irritant. *Phimosis* represents a condition in which the prepuce cannot be retracted easily over the glans penis. Although phimosis may occur as a congenital anomaly, most cases are acquired from scarring of the prepuce secondary to previous episodes of balanoposthitis.

### Neoplasms

More than 95% of penile neoplasms arise on squamous epithelium. In the United States, squamous cell carcinomas of the penis are relatively uncommon, accounting for about 0.4% of all cancers in males. In developing countries, however, penile carcinoma occurs at much higher rates. Most cases occur in uncircumcised patients older than 40 years of age. Several factors have been implicated in the pathogenesis of squamous cell carcinoma of the penis, including poor hygiene (with resultant exposure to potential carcinogens in smegma), smoking, and infection with human papillomavirus (HPV), particularly types 16 and 18.

*Squamous cell carcinoma in situ* of the penis (*Bowen disease*) occurs in older uncircumcised males and appears grossly as a solitary plaque on the shaft of the penis. Histologic examination reveals morphologically malignant cells throughout the epidermis with no invasion of the underlying stroma (Fig. 17–1). It gives rise to infiltrating squamous cell carcinoma in approximately 10% of patients.

*Invasive squamous cell carcinoma* of the penis appears as a gray, crusted, papular lesion, most commonly on the glans penis or prepuce. In many cases, infiltration of the underlying connective tissue produces an indurated, ulcerated lesion with irregular margins (Fig. 17–2). Histologically, it is a typical keratinizing squamous cell carcinoma. The prognosis is related to the stage of the tumor. With localized lesions, the 5-year survival rate is 66%, whereas metastasis to inguinal lymph nodes carries a grim 27% 5-year survival rate. *Verrucous carcinoma* is a variant of squamous cell carcinoma characterized by a papillary

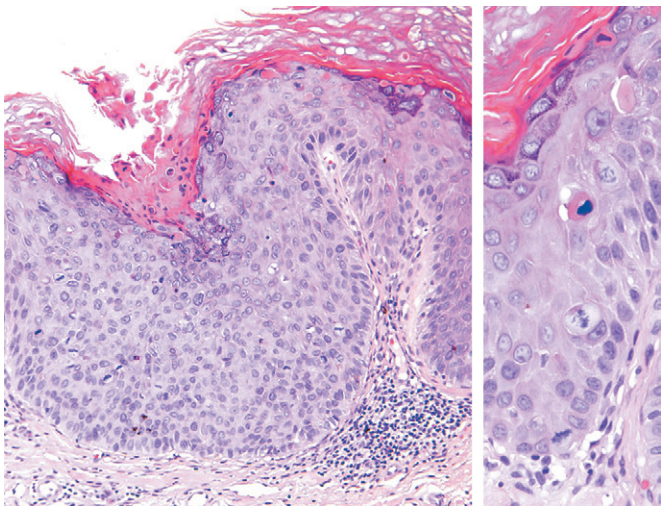

**Figure 17–1** Carcinoma in situ (Bowen disease) of the penis. The epithelium above the intact basement membrane shows delayed maturation and disorganization *(left)*. Higher magnification *(right)* shows several mitotic figures, some above the basal layer, a dyskeratotic cell, and nuclear pleomorphism.

architecture, virtually no cytologic atypia, and rounded, pushing deep margins. Verrucous carcinomas are locally invasive but do not metastasize.

## SUMMARY

### Lesions of the Penis

- Squamous cell carcinoma and its precursor lesions are the most important penile lesions. Many are associated with HPV infection.
- Squamous cell carcinoma occurs on the glans or shaft of the penis as an ulcerated infiltrative lesion that may spread to inguinal nodes and infrequently to distant sites. Most cases occur in uncircumcised males.
- Other important penile disorders include congenital abnormalities involving the position of the urethra (epispadias, hypospadias) and inflammatory disorders (balanitis, phimosis).

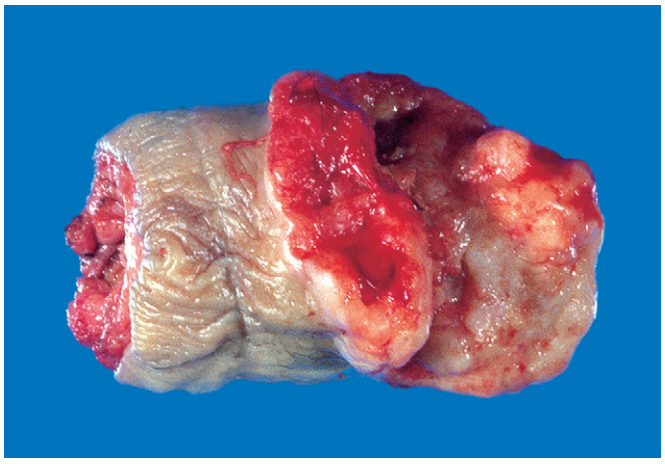

**Figure 17–2** Carcinoma of the penis. The glans penis is deformed by an ulcerated, infiltrative mass.

# SCROTUM, TESTIS, AND EPIDIDYMIS

The skin of the scrotum may be affected by several inflammatory processes, including local fungal infections and systemic dermatoses. Neoplasms of the scrotal sac are unusual. *Squamous cell carcinoma,* the most common of these, is of historical interest in that it represents the first human malignancy associated with environmental influences, dating from Sir Percival Pott's observation of a high incidence of the disease in chimney sweeps. The subsequent edict by the Chimney Sweeps Guild that its members must bathe daily remains one of the most successful public health measures for cancer prevention. Several disorders unrelated to the testes and epididymis may also present as scrotal enlargement. *Hydrocele,* the most common cause of scrotal enlargement, is caused by an accumulation of serous fluid within the tunica vaginalis. It may arise in response to neighboring infections or tumors, or it may be idiopathic. It is readily distinguished from collections of pus, lymph, and blood by allowing a beam of light to pass through (transluminescence). Accumulation of blood or lymphatic fluid within the tunica vaginalis, termed *hematoceles* and *chyloceles,* respectively, also may cause testicular enlargement. In extreme cases of lymphatic obstruction, caused, for example, by filariasis, the scrotum and the lower extremities may enlarge to grotesque sizes—a condition termed *elephantiasis.*

## Cryptorchidism and Testicular Atrophy

Cryptorchidism represents a *failure of testicular descent* into the scrotum. Normally, the testes descend from the abdominal cavity into the pelvis by the third month of gestation and then through the inguinal canals into the scrotum during the last 2 months of intrauterine life. The diagnosis of cryptorchidism is only established with certainty after the age of 1 year, particularly in premature infants, because testicular descent into the scrotum is not always complete at birth. By 1 year of age, cryptorchidism affects 1% of the male population. The condition is bilateral in approximately 10% of affected patients. In the vast majority of cases, the cause of the cryptorchidism is unknown. Because undescended testes become atrophic, bilateral cryptorchidism causes sterility. However, even unilateral cryptorchidism may be associated with atrophy of the contralateral descended gonad and therefore may also lead to sterility. In addition to infertility, failure of descent is associated with a 3- to 5-fold increased risk of *testicular cancer.* Patients with unilateral cryptorchidism are also at increased risk for the development of cancer in the contralateral, normally descended testis, suggesting that some intrinsic abnormality, rather than simple failure of descent, is responsible for the increased cancer risk. Surgical placement of the undescended testis into the scrotum (orchiopexy) before puberty decreases the likelihood of testicular atrophy and reduces but does not eliminate the risk of cancer and infertility.

The cryptorchid testis may be of normal size early in life, but some degree of atrophy usually is present by the onset of puberty. Microscopic evidence of tubular atrophy is evident by the age of 5 to 6 years, and hyalinization is present by the time of puberty. Foci of *intratubular germ cell neoplasia* (discussed later), may be present in cryptorchid

testes and are likely precursors of subsequent germ cell tumors. Atrophic changes similar to those in cryptorchid testes may be caused by several other insults, including chronic ischemia, trauma, irradiation, and antineoplastic chemotherapy, as well as conditions associated with chronically elevated estrogen levels (e.g., cirrhosis). Intratubular germ cell neoplasia is not a feature of these conditions, however.

## SUMMARY

### Cryptorchidism

- Cryptorchidism refers to incomplete descent of the testis from the abdomen to the scrotum and is present in about 1% of 1-year-old male infants.
- Bilateral or, in some cases, even unilateral cryptorchidism is associated with tubular atrophy and sterility.
- The cryptorchid testis carries a 3- to 5-fold higher risk for testicular cancer, which arises from foci of intratubular germ cell neoplasia within the atrophic tubules. Orchiopexy reduces the risk of sterility and cancer.

## Inflammatory Lesions

Inflammatory lesions of the testis are more common in the epididymis than in the testis proper. Some of the more important inflammatory disorders are sexually transmitted and are discussed later in the chapter. Other causes of testicular inflammation include nonspecific epididymitis and orchitis, mumps, and tuberculosis. *Nonspecific epididymitis* and *orchitis* usually begin as a primary urinary tract infection that then spreads to the testis through the vas deferens or the lymphatics of the spermatic cord. The involved testis typically is swollen and tender, and histologic examination reveals a predominantly neutrophilic inflammatory infiltrate. Orchitis complicates *mumps infection* in roughly 20% of infected adult males but rarely occurs in children. Affected testes are edematous and congested, and contain a predominantly lymphoplasmacytic inflammatory infiltrate. Severe mumps orchitis may lead to extensive necrosis, loss of seminiferous epithelium, tubular atrophy, fibrosis, and sterility. Several conditions, including infections and autoimmune injury, may elicit granulomatous inflammation in the testis. Of these, *tuberculosis* is the most common. Testicular tuberculosis generally begins as an epididymitis, with secondary involvement of the testis. Histologically, there is granulomatous inflammation and caseous necrosis identical to that seen in active tuberculosis in other sites.

## Vascular Disturbances

*Torsion,* or twisting of the spermatic cord, typically results in obstruction of testicular venous drainage while leaving the thick-walled and more resilient arteries patent, so that intense vascular engorgement and venous infarction follow unless the torsion is relieved. There are two types of testicular torsion. *Neonatal torsion* occurs either in utero or shortly after birth. It lacks any associated anatomic defect to account for its occurrence. *Adult torsion* typically is seen in adolescence and manifests with sudden onset of testicular pain. In contrast with neonatal torsion, adult torsion results from a bilateral anatomic defect whereby the testis has increased mobility, giving rise to the so-called bell clapper abnormality. It often occurs without any inciting injury; sudden pain heralding the torsion may even awaken the patient from sleep.

Torsion constitutes one of the few urologic emergencies. If the testis is explored surgically and the cord can be manually untwisted within approximately 6 hours, there is a good chance that the testis will remain viable. To prevent the catastrophic occurrence of torsion in the contralateral testis, the unaffected testis typically is surgically fixed within the scrotum (orchiopexy).

## Testicular Neoplasms

Testicular neoplasms occur in roughly 6 per 100,000 males. In the 15- to 34-year-old age group, when these neoplasms peak in incidence, they are the most common tumors of men. Tumors of the testis are a heterogeneous group of neoplasms that include germ cell tumors and sex cord–stromal tumors. *In postpubertal males, 95% of testicular tumors arise from germ cells, and all are malignant.* By contrast, neoplasms derived from Sertoli or Leydig cells (sex cord–stromal tumors) are uncommon and usually benign. The focus of the remainder of this discussion is on testicular germ cell tumors.

The cause of testicular neoplasms remains unknown. Testicular tumors are more common in whites than in blacks, and the incidence has increased in white populations over recent decades. As noted previously, *cryptorchidism is associated with a three- to five-fold increase in the risk of cancer* in the undescended testis, as well as an increased risk of cancer in the contralateral descended testis. A history of cryptorchidism is present in approximately 10% of cases of testicular cancer. Intersex syndromes, including androgen insensitivity syndrome and gonadal dysgenesis, also are associated with an increased frequency of testicular cancer. Family history is important, because brothers of males with germ cell tumors have an 8- to 10-fold increased risk over that of the population at large, presumably owing to inherited risk factors. The development of cancer in one testis is associated with a markedly increased risk of neoplasia in the contralateral testis. An isochromosome of the short arm of chromosome 12, i(12p), is found in virtually all germ cell tumors, regardless of their histologic type. The gene(s) that are dysregulated by this chromosomal abnormality, as well as the other mutations that contribute to the molecular pathogenesis of germ cell tumors, are an area of ongoing research.

Most testicular tumors in postpubertal males arise from the in situ lesion *intratubular germ cell neoplasia.* This lesion is present in conditions associated with a high risk of developing germ cell tumors (e.g., cryptorchidism, dysgenetic gonads). These in situ lesions can be found in grossly "normal" testicular tissue adjacent to germ cell tumors in virtually all cases.

Testicular germ cell tumors are subclassified into seminomas and nonseminomatous germ cell tumors (Table 17–1). Seminomas, sometimes referred to as "classic" seminomas to distinguish them from the less common spermatocytic seminoma (discussed further on), account for about 50% of testicular germ cell neoplasms. They are

**Table 17–1** Summary of Testicular Tumors

| Tumor | Peak Patient Age (yr) | Morphology | Tumor Marker(s) |
|---|---|---|---|
| Seminoma | 40–50 | Sheets of uniform polygonal cells with cleared cytoplasm; lymphocytes in the stroma | 10% of patients have elevated hCG |
| Embryonal carcinoma | 20–30 | Poorly differentiated, pleomorphic cells in cords, sheets, or papillary formation; most contain some yolk sac and choriocarcinoma cells | Negative (pure embryonal carcinoma) |
| Yolk sac tumor | 3 | Poorly differentiated endothelium-like, cuboidal, or columnar cells | 90% of patients have elevated AFP |
| Choriocarcinoma | 20–30 | Cytotrophoblast and syncytiotrophoblast without villus formation | 100% of patients have elevated hCG |
| Teratoma | All ages | Tissues from all three germ cell layers with varying degrees of differentiation | Negative (pure teratoma) |
| Mixed tumor | 15–30 | Variable, depending on mixture; commonly teratoma and embryonal carcinoma | 90% of patients have elevated hCG and AFP |

AFP, alpha fetoprotein; hCG, human chorionic gonadotropin.

histologically identical to ovarian dysgerminomas and to germinomas occurring in the central nervous system and other extragonadal sites.

## MORPHOLOGY

The histologic appearances of germ cell tumors may be **pure** (i.e., composed of a single histologic type) or **mixed** (seen in 40% of cases). **Seminomas** are soft, well-demarcated, gray-white tumors that bulge from the cut surface of the affected testis (Fig. 17–3). Large tumors may contain foci of coagulation necrosis, usually without hemorrhage. Microscopically, seminomas are composed of **large, uniform cells with distinct cell borders, clear, glycogen-rich cytoplasm, and round nuclei with conspicuous nucleoli** (Fig. 17–4). The cells often are arrayed in small lobules with intervening fibrous septa. A lymphocytic infiltrate usually is present and may, on occasion, overshadow the neoplastic cells. Seminomas may also be accompanied by an ill-defined granulomatous reaction. In approximately 15% of cases, syncytiotrophoblasts are present that are the source of the minimally elevated serum hCG concentrations encountered in some males with pure seminoma. Their presence has no bearing on prognosis.

Although related by name to seminoma, **spermatocytic seminoma** is a distinct clinical and histologic entity. This is an uncommon tumor. It occurs in much older individuals than other testicular tumors; affected patients generally are older than 65 years of age. In contrast with classic seminomas, spermatocytic seminomas lack lymphocytic infiltrates, granulomas, and syncytiotrophoblasts; are not admixed with other germ cell tumor histologies; are not associated with intratubular germ cell neoplasia; and do not metastasize. The tumor usually comprises polygonal cells of variable size that are arranged in nodules or sheets.

**Embryonal carcinomas** are ill-defined, invasive masses containing foci of hemorrhage and necrosis (Fig. 17–5). The primary lesions may be small, even in patients with systemic metastases. The tumor cells are **large and primitive-looking, with basophilic cytoplasm, indistinct cell borders, and large nuclei with prominent nucleoli.** The neoplastic cells may be arrayed in undifferentiated, solid sheets or may contain primitive glandular structures and irregular papillae (Fig. 17–6). In most cases, cells characteristic of other germ cell tumors (e.g., yolk sac tumor, teratoma, choriocarcinoma) are admixed with the embryonal areas. Pure embryonal carcinomas account for only 2% to 3% of all testicular germ cell tumors.

**Figure 17–3** Seminoma of the testis appearing as a well-circumscribed, pale, fleshy, homogeneous mass.

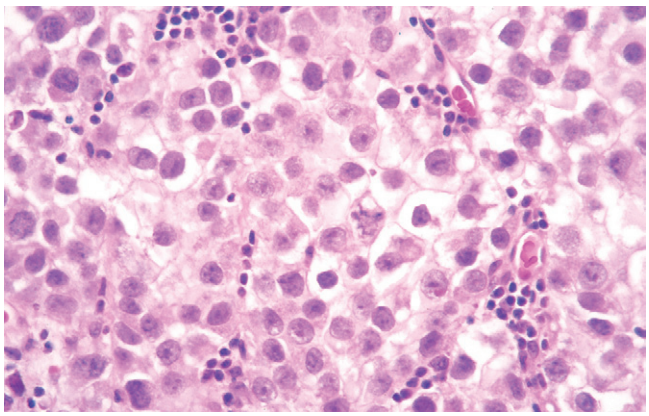

**Figure 17–4** Seminoma of the testis. Microscopic examination reveals large cells with distinct cell borders, pale nuclei, prominent nucleoli, and a sparse lymphocytic infiltrate.

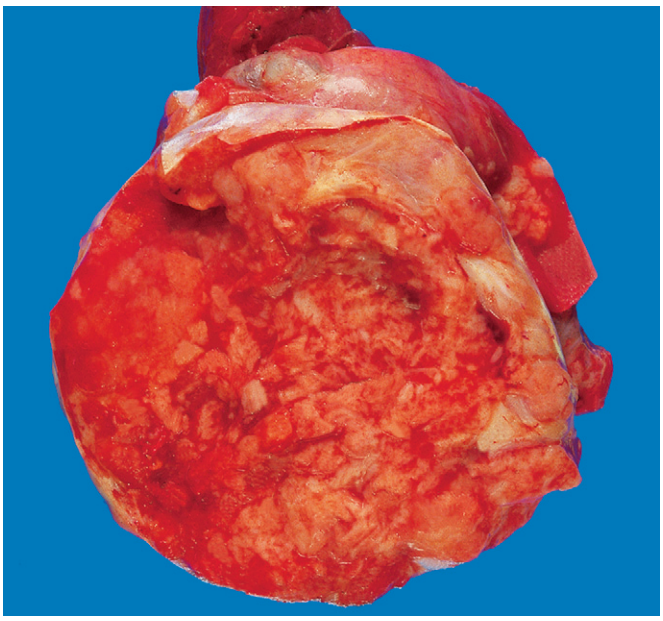

**Figure 17–5** Embryonal carcinoma. In contrast with the seminoma illustrated in Figure 17–3, this tumor is a hemorrhagic mass.

**Yolk sac tumors** are the most common primary testicular neoplasm in children younger than 3 years of age; in this age group it has a very good prognosis. In adults, yolk sac tumors most often are seen admixed with embryonal carcinoma. On gross inspection, these tumors often are large and may be well demarcated. Histologic examination discloses low cuboidal to columnar epithelial cells forming microcysts, lacelike (reticular) patterns, sheets, glands, and papillae (Fig. 17–7). A distinctive feature is the presence of structures resembling primitive glomeruli, the so-called **Schiller-Duvall** bodies. Tumors often have eosinophilic hyaline globules in which $\alpha_1$-antitrypsin and alpha fetoprotein (AFP) can be demonstrated by immunohistochemical techniques. As mentioned later, AFP can also be detected in the serum.

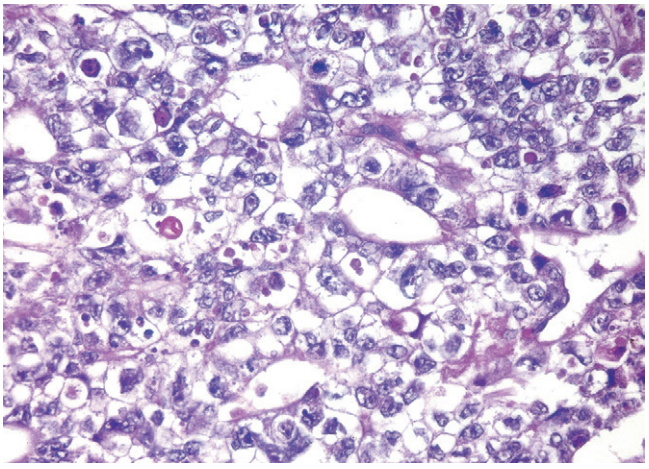

**Figure 17–6** Embryonal carcinoma. Note the sheets of undifferentiated cells and primitive gland-like structures. The nuclei are large and hyperchromatic.

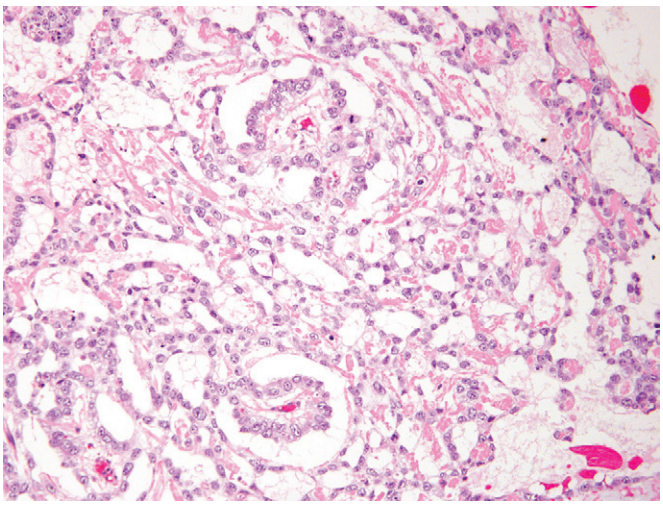

**Figure 17–7** Yolk sac tumor demonstrating areas of loosely textured, microcystic tissue and papillary structures resembling a developing glomerulus (Schiller-Duval bodies).

**Choriocarcinomas** are tumors in which the pluripotential neoplastic germ cells differentiate along **trophoblastic** lines. Grossly, the primary tumors often are small, nonpalpable lesions, even those with extensive systemic metastases. Microscopic examination reveals that choriocarcinomas are composed of sheets of small cuboidal cells irregularly intermingled with or capped by large, eosinophilic syncytial cells containing multiple dark, pleomorphic nuclei; these represent **cytotrophoblastic** and **syncytiotrophoblastic** differentiation, respectively (Fig. 17–8). HCG within syncytiotrophoblasts can be identified by immunohistochemical staining and is elevated in the serum.

**Teratomas** are tumors in which the neoplastic germ cells differentiate along somatic cell lines. These tumors form firm masses that on cut surface often contain cysts and recognizable areas of cartilage. They may occur at any age from infancy to adult life. Pure forms of teratoma are fairly common in infants and children, being second in frequency only to yolk

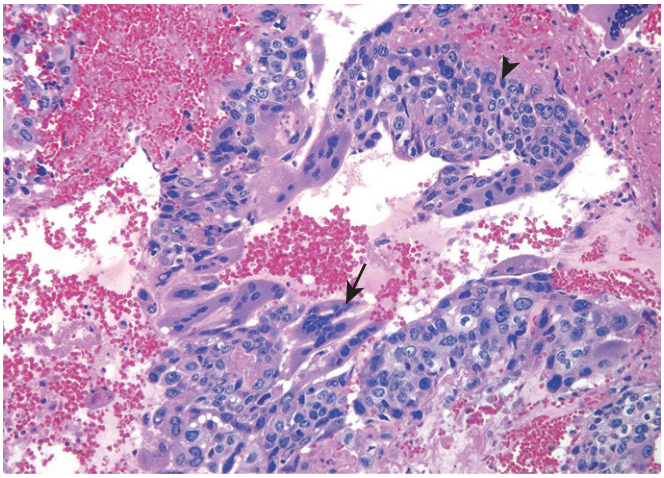

**Figure 17–8** Choriocarcinoma. Both cytotrophoblastic cells with central nuclei (*arrowhead, upper right*) and syncytiotrophoblastic cells with multiple dark nuclei embedded in eosinophilic cytoplasm (*arrow, middle*) are present. Hemorrhage and necrosis are prominent.

sac tumors. In adults, pure teratomas are rare, constituting 2% to 3% of germ cell tumors, and as with embryonal carcinomas, most are seen in combination with other histologic types. Teratomas are composed of a heterogeneous, helter-skelter collection of differentiated cells or organoid structures, such as neural tissue, muscle bundles, islands of cartilage, clusters of squamous epithelium, structures reminiscent of thyroid gland, bronchial epithelium, and bits of intestinal wall or brain substance, all embedded in a fibrous or myxoid stroma (Fig. 17–9). Elements may be mature (resembling various tissues within the adult) or immature (sharing histologic features with fetal or embryonal tissues). In prepubertal males, teratomas are typically benign, whereas teratomas in postpubertal males are malignant, being capable of metastasis regardless of whether they are composed of mature or immature elements.

Dermoid cysts and epidermoid cysts, common in the ovary (Chapter 18), are rare in the testis. These tumors should not be considered teratomas since they are uniformly benign regardless of the patient's age.

Rarely, non–germ cell tumors may arise in teratoma—a phenomenon referred to as "teratoma with malignant transformation." These neoplasms may take the form of a focus of squamous cell carcinoma, mucin-secreting adenocarcinoma, or sarcoma. The importance of non–germ cell malignancies arising in a teratoma is that when the non–germ cell component spreads outside of the testis it does not respond to chemotherapy; thus, the only hope for cure resides in the local resectability of the metastases.

### Clinical Features

Patients with testicular germ cell neoplasms present most frequently with a *painless testicular mass* that (unlike enlargements caused by hydroceles) is non-translucent. Biopsy of a testicular neoplasm is associated with a risk of tumor spillage, which would necessitate excision of the scrotal skin in addition to orchiectomy. Consequently, the standard management of a solid testicular mass is radical orchiectomy, based on the presumption of malignancy. Some tumors, especially nonseminomatous germ cell neoplasms, may have metastasized widely by the time of diagnosis in the absence of a palpable testicular lesion.

Seminomas and nonseminomatous tumors differ in their behavior and clinical course. *Seminomas often remain confined to the testis* for long intervals and may reach considerable size before diagnosis. Metastases most commonly are encountered in the iliac and paraaortic lymph nodes, particularly in the upper lumbar region. Hematogenous metastases occur late in the course of the disease.

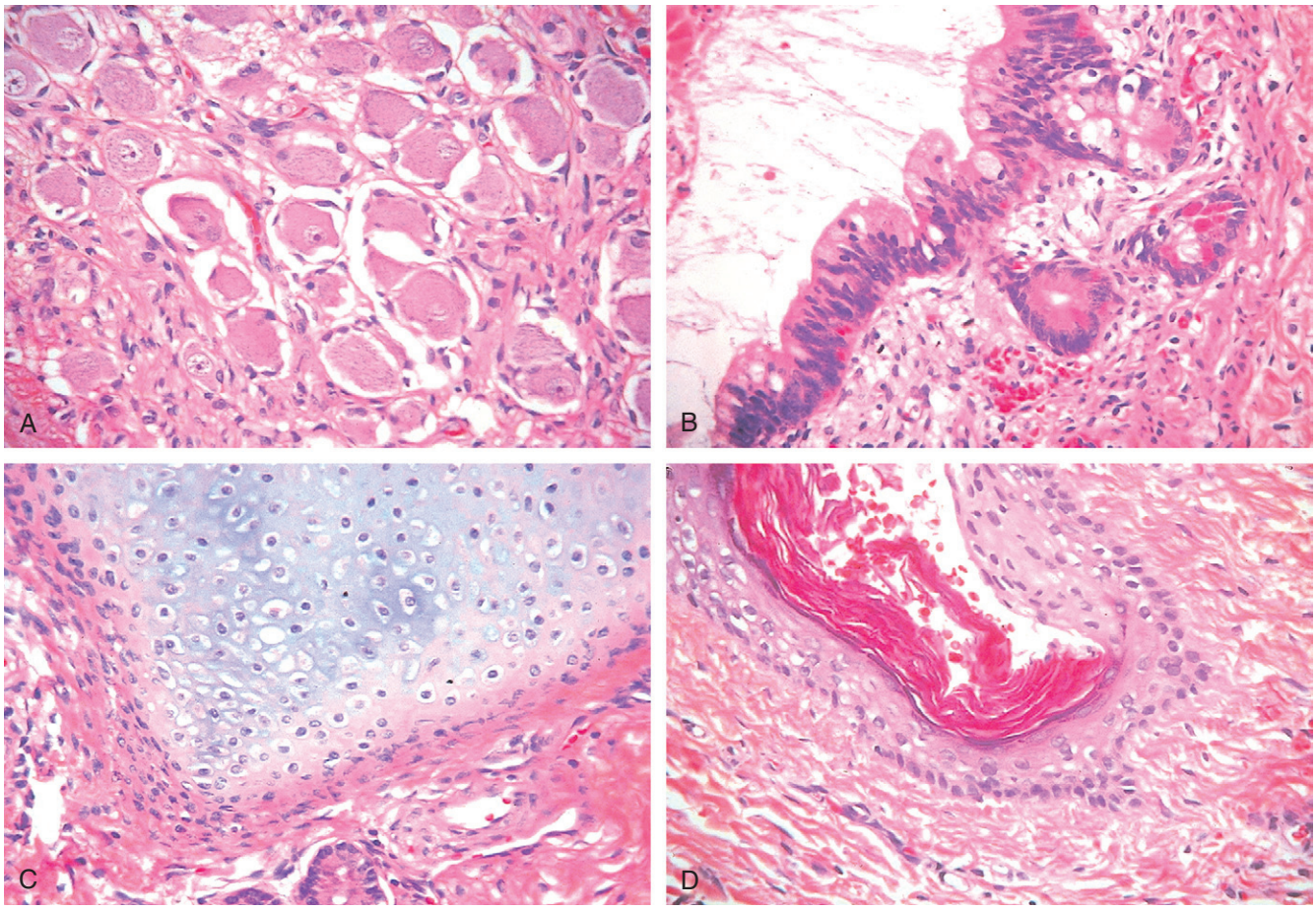


**Figure 17–9** Teratoma. Testicular teratomas contain mature cells from endodermal, mesodermal, and ectodermal lines. **A–D,** Four different fields from the same tumor specimen contain neural (ectodermal) **(A),** glandular (endodermal) **(B),** cartilaginous (mesodermal) **(C),** and squamous epithelial **(D)** elements.

By contrast, *nonseminomatous germ cell neoplasms tend to metastasize earlier,* by lymphatic as well as hematogenous routes. Hematogenous metastases are most common in the liver and lungs. Metastatic lesions may be identical to the primary testicular tumor or may contain elements of other germ cell tumors.

Assay of *tumor markers* secreted by germ cell tumors is important in two ways; these markers (summarized in Table 17–1 along with some salient clinical and morphologic features) are helpful diagnostically, but have an even more valuable role in following the response of tumors to therapy after the diagnosis is established. Human chorionic gonadotropin (hCG) is always elevated in patients with choriocarcinoma and, as noted, can be minimally elevated in persons with other germ cell tumors containing syncytiotrophoblastic cells without cytotrophoblasts. Increased alpha fetoprotein (AFP) in the setting of a testicular neoplasm indicates a yolk sac tumor component. The levels of lactate dehydrogenase (LDH) correlate with the tumor burden.

The treatment of testicular germ cell neoplasms is a remarkable cancer therapy success story. Although roughly 8000 new cases of testicular cancer occur in the United States yearly, fewer than 400 men are expected to die of the disease. In fact, after being treated for widely metastatic testicular cancer, Lance Armstrong won the grueling Tour de France bicycle race a record seven times! Seminoma, which is extremely radiosensitive and tends to remain localized for long periods, has the best prognosis. More than 95% of patients with early-stage disease can be cured. Among nonseminomatous germ cell tumors, the histologic subtype does not influence the prognosis significantly, and hence these are treated as a group. Approximately 90% of the patients achieve complete remission with aggressive chemotherapy, and most are cured. Pure choriocarcinoma carries a dismal prognosis. However, when it is a minor component of a mixed germ cell tumor, the prognosis is not so adversely affected. With all testicular tumors, recurrences, typically in the form of distant metastases, usually occur within the first 2 years after treatment.

## SUMMARY

### Testicular Tumors

- Testicular tumors are the most common cause of painless testicular enlargement. They occur with increased frequency in association with undescended testis and with testicular dysgenesis.
- Germ cells are the source of 95% of testicular tumors, and the remainder arise from Sertoli or Leydig cells. Germ cell tumors may be composed of a single histologic pattern (60% of cases) or mixed patterns (40%).
- The most common "pure" histologic patterns of germ cell tumors are seminoma, embryonal carcinoma, yolk sac tumors, choriocarcinoma, and teratoma. Mixed tumors contain more than one element, most commonly embryonal carcinoma, teratoma, and yolk sac tumor.
- Clinically, testicular germ cell tumors can be divided into two groups: seminomas and nonseminomatous tumors. Seminomas remain confined to the testis for a long time and spread mainly to paraaortic nodes—distant spread is rare. Nonseminomatous tumors tend to spread earlier, by both lymphatics and blood vessels.
- HCG is produced by syncytiotrophoblasts and is always elevated in patients with choriocarcinomas and those with seminomas containing syncytiotrophoblasts. AFP is elevated when there is a yolk sac tumor component.

# PROSTATE

The prostate can be divided into several biologically distinct regions, the most important of which are the peripheral and transition zones (Fig. 17–10). The types of proliferative lesions are different in each region. For example, most *hyperplastic lesions* arise in the inner transition zone, while most *carcinomas* (70% to 80%) arise in the peripheral zones. The normal prostate contains glands with two cell layers, a flat basal cell layer and an overlying columnar secretory cell layer. Surrounding prostatic stroma contains a mixture of smooth muscle and fibrous tissue. It is involved by infectious, inflammatory, hyperplastic, and neoplastic disorders, of which prostate cancer is by far the most important clinically.

## Prostatitis

Prostatitis is divided into four categories: (1) *acute bacterial prostatitis* (2% to 5% of cases), caused by the same

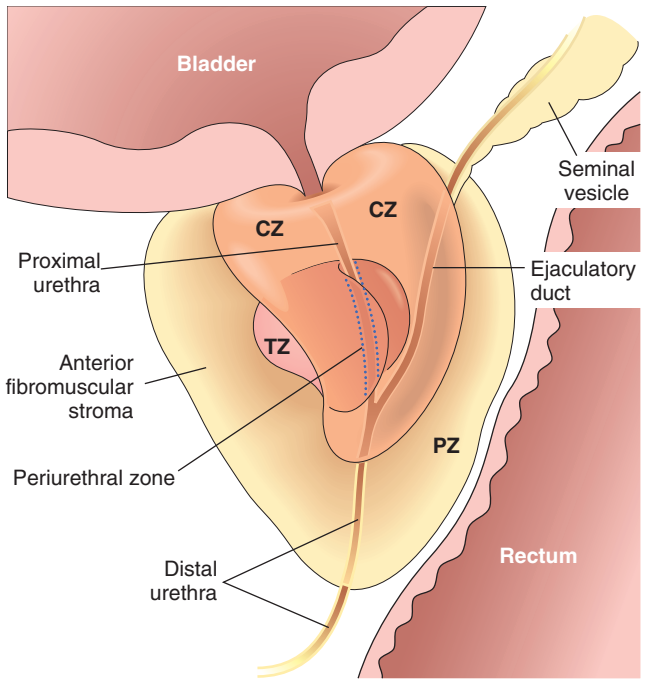


**Figure 17–10** Adult prostate. The normal prostate contains several distinct regions, including a central zone (CZ), a peripheral zone (PZ), a transitional zone (TZ), and a periurethral zone. Most carcinomas arise from the peripheral glands of the organ and often are palpable during digital examination of the rectum. Nodular hyperplasia, by contrast, arises from more centrally situated glands and is more likely than carcinoma to produce urinary obstruction early in its course.

organisms associated with other acute urinary tract infections; (2) *chronic bacterial prostatitis* (2% to 5% of cases), also caused by common uropathogens; (3) *chronic nonbacterial prostatitis, or chronic pelvic pain syndrome* (90% to 95% of cases), in which no uropathogen is identified despite the presence of local symptoms; and (4) *asymptomatic inflammatory prostatitis* (incidence unknown), associated with incidental identification of leukocytes in prostatic secretions without uropathogens.

The prostate is usually not biopsied in men with symptoms of acute or chronic prostatitis, since the findings are usually non-specific and are not helpful in managing patients. The exception is in patients with granulomatous prostatitis, in which a specific etiology may be established. In the United States, the most common cause is instillation of bacille Calmette-Guérin (BCG) within the bladder for treatment of superficial bladder cancer. BCG is an attenuated tuberculosis strain that produces a histologic picture in the prostate indistinguishable from tuberculosis. Disseminated prostatic tuberculosis is rare in the Western world. Fungal granulomatous prostatitis is typically seen only in immunocompromised hosts. Nonspecific granulomatous prostatitis is relatively common and represents a reaction to secretions from ruptured prostatic ducts and acini. Postsurgical prostatic granulomas also may be seen.

### Clinical Features

Clinically, *acute bacterial prostatitis* is associated with fever, chills, and dysuria; it may be complicated by sepsis. On rectal examination, the prostate is exquisitely tender and boggy. *Chronic bacterial prostatitis* usually is associated with recurrent urinary tract infections bracketed by asymptomatic periods. Presenting manifestations may include with low back pain, dysuria, and perineal and suprapubic discomfort. Both acute and chronic bacterial prostatitis are treated with antibiotics. The diagnosis of *chronic nonbacterial prostatitis* (chronic pelvic pain syndrome) is difficult. It requires completion of the NIH Chronic Prostatitis Symptom Index survey by the patient, digital rectal examination, urinalysis, and sequential collection of urine and prostatic fluid specimens, before, during, and after prostatic massage. This technique of collecting samples prevents contamination from the bladder and urethra and is used to document prostatic inflammation (by presence of leukocytes) in the absence of infection. There are no proven therapies for chronic pelvic pain syndrome.

## SUMMARY

### Prostatitis

- Bacterial prostatitis may be acute or chronic; the responsible organism usually is *E. coli* or another gram-negative rod.
- Chronic nonbacterial prostatitis (also known as chronic pelvic pain syndrome), despite sharing symptomatology with chronic bacterial prostatitis, is of unknown etiology and does not respond to antibiotics.
- Granulomatous prostatitis has a multifactorial etiology, with both infectious and noninfectious elements.

## Benign Prostatic Hyperplasia (Nodular Hyperplasia)

*Benign prostatic hyperplasia* (BPH) is an extremely common abnormality. It is present in a significant number of men by the age of 40, and its frequency rises progressively with age, reaching 90% by the eighth decade of life. BPH is characterized by proliferation of both stromal and epithelial elements, with resultant enlargement of the gland and, in some cases, urinary obstruction. Although the cause of BPH remains incompletely understood, it is clear that *excessive androgen-dependent growth of stromal and glandular elements has a central role.* BPH does not occur in males castrated before the onset of puberty or in men with genetic diseases that block androgen activity. Dihydrotestosterone (DHT), the ultimate mediator of prostatic growth, is synthesized in the prostate from circulating testosterone by the action of the enzyme 5α-reductase, type 2. DHT binds to nuclear androgen receptors, which regulate the expression of genes that support the growth and survival of prostatic epithelium and stromal cells. Although testosterone can also bind to androgen receptors and stimulate growth, DHT is 10 times more potent. Clinical symptoms of lower urinary tract obstruction caused by prostatic enlargement may also be exacerbated by contraction of prostatic smooth muscle mediated by $\alpha_1$-adrenergic receptors.

## MORPHOLOGY

BPH virtually always occurs in the inner, transitional zone of the prostate. The affected prostate is enlarged, typically weighing between 60 and 100 g, and contains many well-circumscribed nodules that bulge from the cut surface (Fig. 17–11). The nodules may appear solid or contain cystic spaces, the latter corresponding to dilated glandular elements. The urethra is usually compressed by the hyperplastic nodules, often to a narrow slit. In some cases, hyperplastic glandular and stromal elements lying just under the epithelium of the proximal prostatic urethra may project into the bladder lumen as a pedunculated mass, producing a ball-valve type of urethral obstruction.

Microscopically the hyperplastic nodules are composed of variable proportions of proliferating glandular elements and fibromuscular stroma. The hyperplastic glands are lined by tall, columnar epithelial cells and a peripheral layer of flattened basal cells (Fig. 17–12). The glandular lumina often contain inspissated, proteinaceous secretory material known as **corpora amylacea.**

### Clinical Features

Clinical manifestations of prostatic hyperplasia occur in only about 10% of men with pathologic evidence of BPH. Because BPH preferentially involves the inner portions of the prostate, the most common manifestations are related to *lower urinary tract obstruction*, often in the form of difficulty in starting the stream of urine (hesitancy) and intermittent interruption of the urinary stream while voiding. These symptoms frequently are accompanied by urinary urgency, frequency, and nocturia, all indicative of bladder irritation. Similar symptoms also may arise from urethral stricture or as a consequence of impaired bladder detrusor

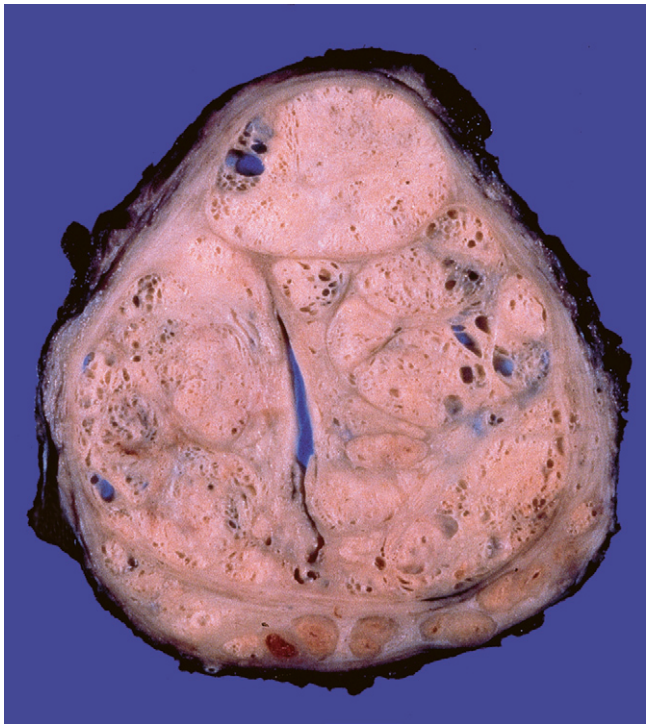

**Figure 17–11** Nodular prostatic hyperplasia. Well-defined nodules compress the urethra into a slitlike lumen.

muscle contractility in both men and women. The presence of residual urine in the bladder due to chronic obstruction increases the risk of urinary tract infections. In some affected men, BPH leads to complete urinary obstruction, with resultant painful distention of the bladder and, in the absence of appropriate treatment, hydronephrosis (Chapter 13). Initial treatment is pharmacologic, using targeted therapeutic agents that inhibit DHT formation (Finestride) or that relax smooth muscle by blocking alpha adrenergic blockers (Flomax). Various surgical techniques are reserved for severely symptomatic cases recalcitrant to medical therapy.

## SUMMARY

### Benign Prostatic Hyperplasia

- BPH is characterized by proliferation of benign stromal and glandular elements. DHT, an androgen derived from testosterone, is the major hormonal stimulus for proliferation.
- BPH most commonly affects the inner periuretheral zone of the prostate, producing nodules that compress the prostatic urethra. On microscopic examination, the nodules exhibit variable proportions of stroma and glands. Hyperplastic glands are lined by two cell layers: an inner columnar layer and an outer layer composed of flattened basal cells.
- Clinical symptoms and signs are reported by 10% of affected patients and include hesitancy, urgency, nocturia, and poor urinary stream. Chronic obstruction predisposes to recurrent urinary tract infections. Acute urinary obstruction may occur.

## Carcinoma of the Prostate

Adenocarcinoma of the prostate occurs mainly in men older than 50 years of age. It is the most common form of cancer in men, accounting for 25% of cancer in men in the United States in 2009. However, prostate cancer causes only 9% of cancer deaths in the United States, less than that for cancers of the lung and equal to that for colorectal cancer. Furthermore, over the past several decades, there has been a significant drop in prostate cancer mortality.

This relatively favorable outcome is related in part to increased detection of the disease through screening (described later), but how effective screening is at saving lives is controversial. This seeming paradox is related to wide variation in the natural history of prostate cancer, from aggressive and rapidly fatal to indolent disease of no clinical significance. Indeed, prostate carcinoma commonly is found incidentally at autopsy in men dying of other

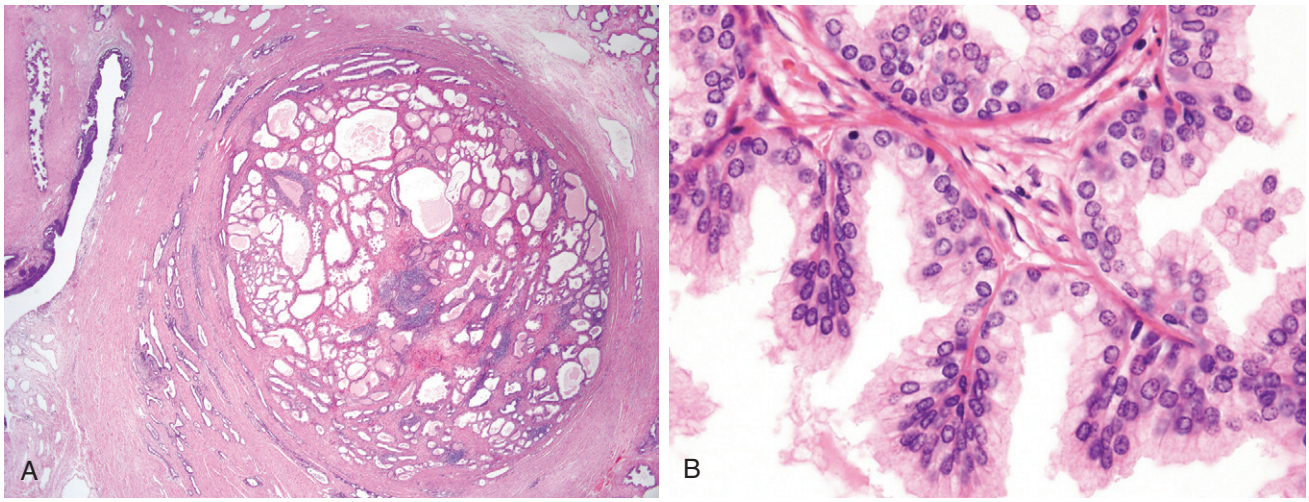


**Figure 17–12** Nodular hyperplasia of the prostate. **A,** Low-power photomicrograph demonstrates a well-demarcated nodule at the *right* of the field, with a portion of urethra seen to the *left*. In other cases of nodular hyperplasia, the nodularity is caused predominantly by stromal, rather than glandular, proliferation. **B,** Higher-power photomicrograph demonstrates the morphology of the hyperplastic glands, which are large, with papillary infolding.

causes, and many more men die with prostate cancer than of prostate cancer. It is not currently possible to identify the tumors that will be "bad actors" with certainty; thus, while some men are no doubt saved by early detection and treatment of their prostate cancers, it is equally certain that others are being "cured" of clinically inconsequential tumors.

## PATHOGENESIS

Clinical and experimental observations suggest that androgens, heredity, environmental factors, and acquired somatic mutations have roles in the pathogenesis of prostate cancer.

- **Androgens** are of central importance. Cancer of the prostate does not develop in males castrated before puberty, indicating that androgens somehow provide the "soil," the cellular context, within which prostate cancer develops. This dependence on androgens extends to established cancers, which often regress for a time in response to surgical or chemical castration. Notably, **tumors resistant to anti-androgen therapy often acquire mutations that permit androgen receptors to activate the expression of their target genes even in the absence of the hormones**. Thus, tumors that recur in the face of anti-androgen therapies still depend on gene products regulated by androgen receptors for their growth and survival. However, while prostate cancer, like normal prostate, is dependent on androgens for its survival, there is no evidence that androgens initiate carcinogenesis.
- **Heredity** also contributes, as there is an increased risk among first-degree relatives of patients with prostate cancer. Incidence of prostatic cancer is uncommon in Asians and highest among blacks and is also high in Scandinavian countries. Genome-wide association studies have identified a number of genetic variants that are associated with increased risk, including a variant near the *MYC* oncogene on chromosome 8q24 that appears to account for some of the increased incidence of prostate cancer in males of African descent. Similarly, in white American men, the development of prostate cancer has been linked to a susceptibility locus on chromosome 1q24-q25.
- **Environment** also plays a role, as evidenced by the fact that in Japanese immigrants to the United States the incidence of the disease rises (although not to the level seen in native-born Americans). Also, as the diet in Asia becomes more Westernized, the incidence of clinical prostate cancer in this region of the world appears to be increasing. However, the relationship between specific dietary components and prostate cancer risk is unclear.
- **Acquired somatic mutations,** as in other cancers, are the actual drivers of cellular transformation. One important class of somatic mutations is gene rearrangements that create fusion genes consisting of the androgen-regulated promoter of the *TMPRSS2* gene and the coding sequence of ETS family transcription factors (the most common being ERG). ***TMPRSS2-ETS* fusion genes** occur in approximately 40% to 50% of prostate cancers; it is possible that unregulated increased expression of ETS transcription factors interfere with prostatic epithelial cell differentiation. Other mutations commonly lead to activation of the oncogenic PI3K/AKT signaling pathway; of these, the most common are **mutations that inactivate the tumor suppressor gene *PTEN*,** which acts as a brake on PI3K activity.

## MORPHOLOGY

Most carcinomas detected clinically are not visible grossly. More advanced lesions appear as firm, gray-white lesions with ill-defined margins that infiltrate the adjacent gland (Fig. 17–13).

On histologic examination, most lesions are moderately differentiated adenocarcinomas that produce well-defined glands. The glands typically are smaller than benign glands and are lined by a single uniform layer of cuboidal or low columnar epithelium, lacking the basal cell layer seen in benign glands. In further contrast with benign glands, malignant glands are crowded together and characteristically lack branching and papillary infolding. The cytoplasm of the tumor cells ranges from pale-clear (as in benign glands) to a distinctive amphophilic (dark purple) appearance. Nuclei are enlarged and often contain one or more prominent nucleoli (Fig. 17–14). Some variation in nuclear size and shape is usual, but in general, pleomorphism is not marked. Mitotic figures are uncommon. With increasing grade, irregular or ragged glandular structures, cribriform glands, sheets of cells, or infiltrating individual cells are present. In approximately 80% of cases, prostatic tissue removed for carcinoma also harbors presumptive precursor lesions, referred to as high-grade prostatic intraepithelial neoplasia (HGPIN).

Prostate cancer is graded by the Gleason system, created in 1967 and updated in 2005. According to this system, prostate cancers are stratified into five grades on the basis of glandular patterns of differentiation. Grade 1 represents the most well-differentiated tumors and grade 5 tumors show no glandular differentiation. Since most tumors contain more than one pattern, a primary grade is assigned to the dominant pattern and a secondary grade to the next most frequent pattern. The two numerical grades are then added to obtain

**Figure 17–13** Adenocarcinoma of the prostate. Carcinomatous tissue is seen on the posterior aspect (*lower left*). Note the solid whiter tissue of cancer, in contrast with the spongy appearance of the benign peripheral zone on the contralateral side.

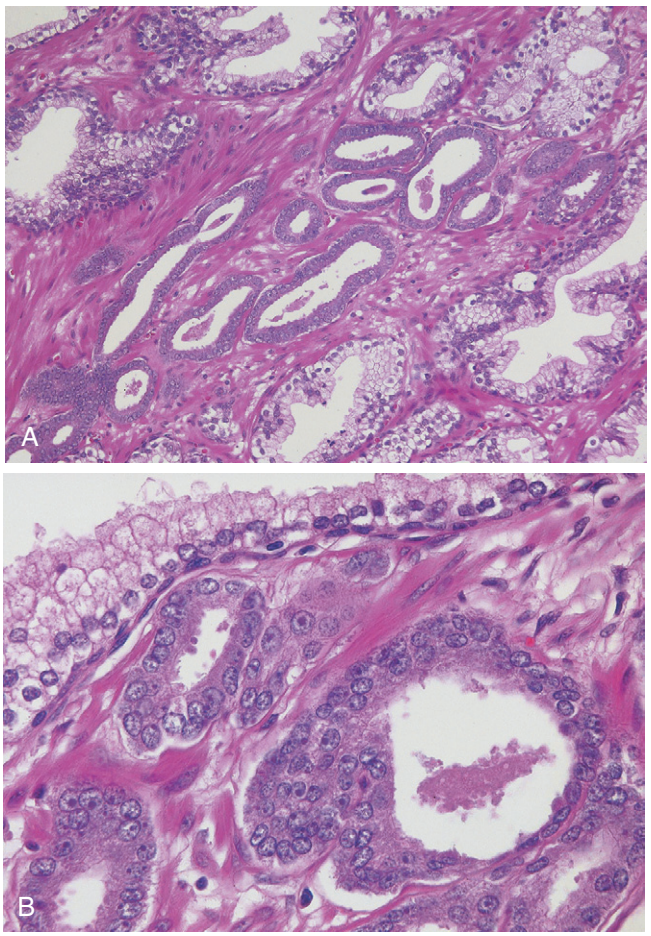


**Figure 17–14 A,** Adenocarcinoma of the prostate demonstrating small glands crowded in between larger benign glands. **B,** Higher magnification shows several small malignant glands with enlarged nuclei, prominent nucleoli, and dark cytoplasm, as compared with the larger, benign gland (*top*).

a combined Gleason score. Tumors with only one pattern are treated as if their primary and secondary grades are the same, and, hence, the number is doubled. Thus the most differentiated tumors have a Gleason score of 2 (1 + 1) and the least differentiated tumors merit a score of 10 (5 + 5).

### Clinical Features

A minority of carcinomas are discovered unexpectedly during histologic examination of prostate tissue removed by transurethral resection for BPH. Some *70% to 80% of prostate cancers arise in the outer (peripheral) glands* and hence may be palpable as irregular hard nodules on digital rectal examination. However, most prostate cancers are small, nonpalpable, asymptomatic lesions discovered on needle biopsy performed to investigate an elevated serum prostate-specific antigen (PSA) level (discussed later). Because of the peripheral location, prostate cancer is less likely than BPH to cause urethral obstruction in its initial stages. Locally advanced cancers often infiltrate the seminal vesicles and periurethral zones of the prostate and may invade the adjacent soft tissues, the wall of the urinary bladder, or (less commonly) the rectum. Bone metastases, particularly to the axial skeleton, are frequent late in the disease and typically cause osteoblastic (bone-producing) lesions that can be detected on *radionuclide bone scans.* The poor sensitivity and specificity of prostate imaging studies limit their diagnostic utility for the detection of early prostate cancer.

The PSA assay is the most important test used in the diagnosis and management of prostate cancer but, as will be discussed, suffers from a number of limitations. PSA is a product of prostatic epithelium and is normally secreted in the semen. It is a serine protease whose function is to cleave and liquefy the seminal coagulum formed after ejaculation. *In most laboratories, a serum PSA level of 4 ng/mL is the cutoff between normal and abnormal, although some guidelines designate values above 2.5 ng/mL as abnormal.* Although PSA screening can detect prostate cancers early in their course, many prostate cancers are slow-growing and clinically insignificant, requiring no treatment. In addition, prostate cancer treatments often cause significant complications, particularly erectile dysfunction and incontinence.

*One limitation of PSA is that while it is organ-specific, it is not cancer-specific.* BPH, prostatitis, prostatic infarcts, instrumentation of the prostate, and ejaculation also increase serum PSA levels. *Conversely, 20 to 40% of patients with organ-confined prostate cancer have a PSA value of 4.0 ng/mL or less.* In recognition of these problems, several refinements in the estimation and interpretation of PSA values have been proposed that aim to enhance the specificity and sensitivity of the test. One approach is to correct the PSA for estimated prostate size, to account for elevations in PSA that are associated with enlarged prostates (e.g., those involved by BPH). A second is to use a sliding scale that takes the rise in PSA that occurs with age into account. A third is to focus on changes in PSA levels in serial measurements over time. Men with prostate cancer demonstrate an increased rate of rise in PSA as compared with men who do not have prostate cancer. A significant rise in serum PSA levels, even if the PSA is within the "normal" range, should prompt a workup. Finally, PSA present in the serum is mostly bound to plasma proteins but also includes a minor free fraction. The *percentage of free PSA (the ratio of free PSA to total PSA) is lower in men with prostate cancer than in men with benign prostatic diseases.*

Once cancer is diagnosed, *serial measurements of PSA are of great value in assessing the response to therapy.* For example, a rising PSA level after radical prostatectomy or radiotherapy for localized disease is indicative of recurrent or disseminated disease.

The most common treatments for clinically localized prostate cancer are radical prostatectomy and radiotherapy. The prognosis after radical prostatectomy is based on the pathologic stage, margin status, and Gleason grade. The Gleason grade, clinical stage, and serum PSA values are important predictors of outcome after radiotherapy. Because many prostate cancers follow an indolent course, active surveillance ("watchful waiting") is an appropriate approach for older men, patients with significant comorbidity, or even some younger men with low serum PSA values and small, low-grade cancers. Advanced metastatic carcinoma is treated by androgen deprivation, effected either by orchiectomy or by administration of synthetic agonists of luteinizing hormone–releasing hormone (LHRH), which in effect achieve a pharmacologic

orchiectomy. Although antiandrogen therapy induces remissions, androgen-independent clones eventually emerge, leading to rapid disease progression and death. As mentioned earlier, these mutant clones continue to express many genes that in normal prostate are androgen-dependent.

### SUMMARY

#### Carcinoma of the Prostate

- Carcinoma of the prostate is a common cancer of older men between 65 and 75 years of age. Aggressive, clinical significant disease is more common in American blacks than in whites, while clinically insignificant occult lesions appear to occur at equal frequencies in these two races.
- Prostate carcinomas range from indolent lesions that will never cause patient harm to aggressive fatal tumors.
- The most common acquired mutations in prostatic carcinomas are *TPRSS2-ETS* fusion genes and mutations that activate the PI3K/AKT signaling pathway.
- Carcinomas of the prostate arise most commonly in the outer, peripheral gland and may be palpable by rectal examination, although currently many are nonpalpable.
- Microscopically, they are adenocarcinomas with variable differentiation. Neoplastic glands are lined by a single layer of cells.
- Grading of prostate cancer by the Gleason system correlates with pathologic stage and prognosis.
- Most localized cancers are clinically silent and are detected by routine monitoring of PSA concentrations in older men. Bone metastases, often osteoblastic, typify advanced prostate cancer.
- Serum PSA measurement is a useful but imperfect cancer screening test, with significant rates of false-negative and false-positive results. Evaluation of PSA concentrations after treatment has great value in monitoring progressive or recurrent disease.

## URETER, BLADDER, AND URETHRA

The renal pelves, ureters, bladder, and urethra are lined by urothelium. Beneath the mucosa are the lamina propria and, deeper yet, the muscularis propria (detrusor muscle), which makes up the bladder wall.

### Ureter

*Ureteropelvic junction (UPJ) obstruction,* a congenital disorder, results in hydronephrosis. It usually manifests in infancy or childhood, much more commonly in boys. It is the most frequent cause of hydronephrosis in infants and children (Chapter 13).

Primary *malignant tumors* of the ureter follow patterns similar to those arising in the renal pelvis, calyces, and bladder, and a majority are urothelial carcinomas.

*Retroperitoneal fibrosis* is an uncommon cause of ureteral narrowing or obstruction characterized by a *fibrous proliferative inflammatory process encasing the retroperitoneal structures and causing hydronephrosis.* The disorder occurs in middle to old age. At least a proportion of these cases are related to the newly described entity in which elevations of serum IgG4 are associated with fibroinflammatory lesions that are rich in IgG4-secreting plasma cells (Chapter 4). The affected sites include the pancreas, retroperitoneum, and salivary glands, to mention a few. Other cases are associated with drug exposures (ergot derivatives, adrenergic blockers), or malignant disease (lymphomas, urinary tract carcinomas). The majority of cases, however, have no obvious cause and are considered primary, or idiopathic (Ormond disease).

### Urinary Bladder

#### *Non-neoplastic Conditions*

A bladder or vesical *diverticulum* consists of a pouchlike evagination of the bladder wall. Diverticula may be congenital but more commonly are acquired lesions that arise as a consequence of persistent urethral obstruction caused, for example, by benign prostatic hyperplasia. Although most diverticula are small and asymptomatic, they sometimes lead to urinary stasis and predispose to infection.

Cystitis takes many forms. Most cases stem from nonspecific acute or chronic inflammation of the bladder. The common etiologic agents of *bacterial cystitis* are coliform bacteria. Patients receiving *cytotoxic antitumor drugs,* such as cyclophosphamide, sometimes develop *hemorrhagic cystitis.* Adenovirus infection also causes a hemorrhagic cystitis. Several distinct variants of cystitis are defined by either morphologic appearance or causation.

- *Interstitial cystitis* (i.e., chronic pelvic pain syndrome) is a *persistent, painful form of chronic cystitis occurring most frequently in women.* It is characterized by intermittent, often severe suprapubic pain, urinary frequency, urgency, hematuria and dysuria without evidence of bacterial infection, and cystoscopic findings of fissures and punctate hemorrhages (glomerulations) in the bladder mucosa. The histologic findings are nonspecific. Late in the course, transmural fibrosis may ensue, leading to a contracted bladder.
- *Malakoplakia* most commonly occurs in the bladder and results from defects in phagocytic or degradative function of macrophages, such that phagosomes become overloaded with undigested bacterial products. The macrophages have abundant granular cytoplasm filled with phagosomes stuffed with particulate and membranous bacterial debris. In addition, laminated mineralized concretions resulting from deposition of calcium in enlarged lysosomes, known as *Michaelis-Gutmann bodies,* typically are present within the macrophages.
- *Polypoid cystitis* is an inflammatory condition resulting from irritation to the bladder mucosa in which the urothelium is thrown into broad bulbous polypoid projections as a result of marked submucosal edema. Polypoid cystitis may be confused with papillary urothelial carcinoma both clinically and histologically.

Various metaplastic lesions may occur in the bladder. Nests of urothelium (*Brunn nests*) may grow downward into the lamina propria, and their central epithelial cells may variously differentiate into a cuboidal or columnar epithelium lining (*cystitis glandularis*); cystic spaces filled

with clear fluid lined by flattened urothelium (*cystitis cystica*); or goblet cells resembling intestinal mucosa (*intestinal or colonic metaplasia*). As a response to injury, the urothelium often undergoes *squamous metaplasia,* which must be differentiated from normal glycogenated squamous epithelium, commonly found at the trigone in women.

### *Neoplasms*

Bladder cancer accounts for approximately 7% of cancers and 3% of cancer deaths in the United States. The vast majority of bladder cancers (90%) are urothelial carcinomas. Carcinoma of the bladder is more common in men than in women, in industrialized than in developing nations, and in urban than in rural dwellers. About 80% of patients are between the ages of 50 and 80 years. Squamous cell carcinomas represent about 3% to 7% of bladder cancers in the United States but are much more common in countries where urinary schistosomiasis is endemic. They typically show extensive keratinization and are nearly always associated with chronic bladder irritation and infection. Adenocarcinomas of the bladder are rare and are histologically identical to adenocarcinomas seen in the gastrointestinal tract. Some arise from urachal remnants in the dome of the bladder or in association with extensive intestinal metaplasia.

## PATHOGENESIS

Bladder cancer, with rare exceptions, is not familial. Some of the most common factors implicated in the causation of urothelial carcinoma include **cigarette smoking, various occupational carcinogens,** and *Schistosoma haematobium* infections in areas where it is endemic, such as Egypt. Cancers occurring in the setting of schistosoma infections arise in a background of chronic inflammation, which you will recall is linked to a number of different cancers (Chapter 5). A model for bladder carcinogenesis has been proposed in which the tumor is **initiated by deletions of tumor-suppressor** genes on 9p and 9q, leading to formation of superficial papillary tumors, a few of which may then acquire *TP53* mutations and progress to invasion. A second pathway, possibly initiated by *TP53* mutations, leads first to carcinoma in situ and then, with loss of chromosome 9, progresses to invasion. The underlying genetic alterations in superficial tumors include fibroblast growth factor receptor 3 (FGFR3) mutations and activation of the Ras pathway (indeed, bladder cancer was one of the first human neoplasms found to have activating mutations in the *Ras* oncogene), whereas less common muscle invasive tumors often have loss-of-function mutations involving *TP53* and *RB*, the retinoblastoma tumor suppressor gene.

## MORPHOLOGY

Two distinct precursor lesions to invasive urothelial carcinoma are recognized (Fig. 17–15). The most common is a noninvasive papillary tumor (Fig. 17–16). The other precursor is carcinoma in situ (CIS), described below. In about half of the patients with invasive bladder cancer, no precursor lesion is found; in such cases, it is presumed that the precursor lesion was overgrown by the high-grade invasive component.

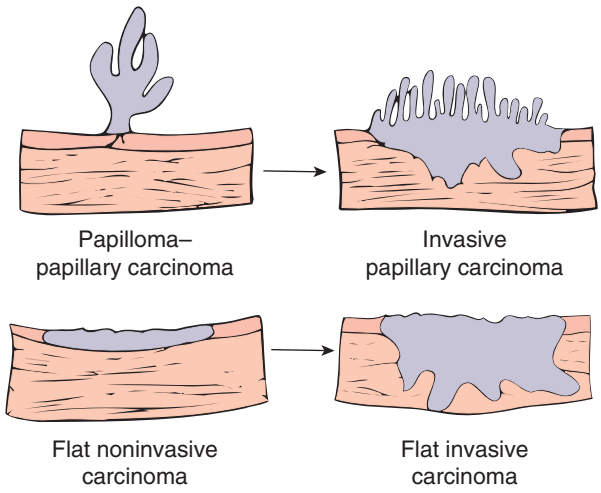


**Figure 17–15** Precursor lesions of invasive urothelial carcinoma.

Noninvasive papillary urothelial neoplasms demonstrate a range of atypia and are graded to reflect their biologic behavior (Table 17–2). The most common grading system classifies tumors as follows: (1) **papilloma**; (2) **papillary urothelial neoplasm of low malignant potential (PUNLMP)**; (3) **low-grade papillary urothelial carcinoma**; and (4) **high-grade papillary urothelial carcinoma** (Fig. 17–17). These exophytic papillary neoplasms are to be distinguished from **inverted urothelial papilloma,** which is entirely benign and not associated with an increased risk for subsequent carcinoma.

CIS is defined by the presence of cytologically malignant cells within a flat urothelium (Fig. 17–18). Like high-grade papillary urothelial carcinoma, CIS tumor cells lack cohesiveness. This leads to the shedding of malignant cells into the urine, where they can be detected by cytology. CIS

**Figure 17–16** Cystoscopic appearance of a papillary urothelial tumor, resembling coral, within the bladder.

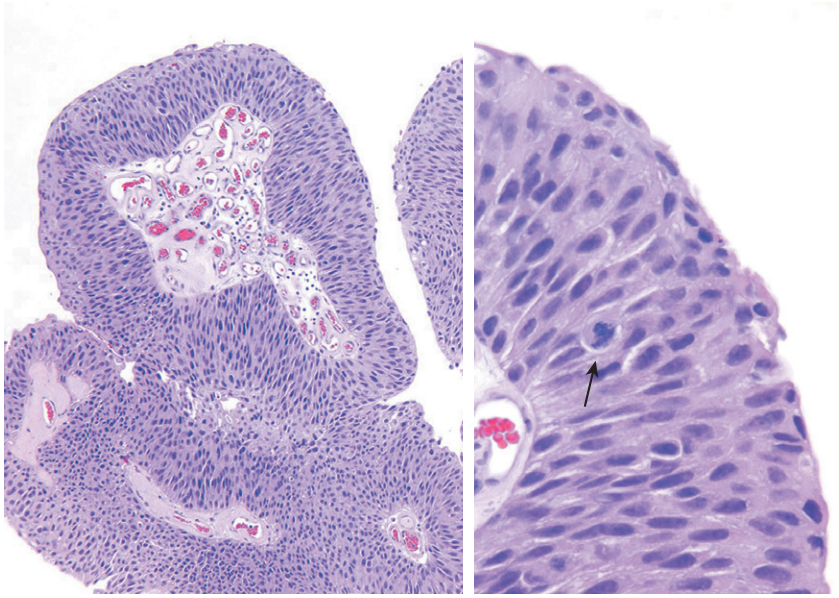

**Figure 17–17** Noninvasive low-grade papillary urothelial carcinoma. Higher magnification (*right*) shows slightly irregular nuclei with scattered mitotic figures (*arrow*).

commonly is multifocal and sometimes involves most of the bladder surface or extends into the ureters and urethra. Without treatment, 50% to 75% of CIS cases progress to muscle-invasive cancer.

**Invasive urothelial cancer** associated with papillary urothelial cancer (usually of high grade) or CIS may superficially invade the lamina propria or extend more deeply into underlying muscle. Underestimation of the extent of invasion in biopsy specimens is a significant problem. **The extent of invasion and spread (staging) at the time of initial diagnosis is the most important prognostic factor.** Almost all infiltrating urothelial carcinomas are of high grade.

### Clinical Features

Bladder tumors most commonly present with *painless hematuria.* Patients with urothelial tumors, whatever their grade, have a tendency to develop new tumors after excision, and recurrences may exhibit a higher grade. The risk of recurrence is related to several factors, including tumor size, stage, grade, multifocality, mitotic index, and associated dysplasia and/or CIS in the surrounding mucosa. Most recurrent tumors arise at sites different than that of the original lesion, yet share the same clonal abnormalities as those of the initial tumor; thus, these are true recurrences that stem from shedding and implantation of the original tumor cells at new sites. Whereas high-grade papillary urothelial carcinomas frequently are associated with either concurrent or subsequent invasive urothelial carcinoma, lower-grade papillary urothelial neoplasms often recur but infrequently invade (Table 17–2).

The treatment for bladder cancer depends on tumor grade and stage and on whether the lesion is flat or papillary. For small localized papillary tumors that are not high-grade, the initial transurethral resection is both diagnostic and therapeutically sufficient. Patients with tumors that are at high risk for recurrence or progression typically receive topical immunotherapy consisting of intravesical instillation of an attenuated strain of the tuberculosis bacillus called bacille Calmette-Guérin (BCG). BCG elicits a typical granulomatous reaction, and in doing so also triggers an effective local antitumor immune response. Patients are

**Table 17–2** Noninvasive Papillary Urothelial Neoplasms

| Neoplasm | Recurrences | Coexistent Invasion | Progression | Death |
|---|---|---|---|---|
| Papilloma | Rare | None | Rare* | None |
| PUNLMP | 30% | None | 2% | None |
| LGUC | 45% | <10% | 8–10% | 2–3% |
| HGUC | 45% | Up to 80% | 30% | 20% |

HGUC, high-grade papillary urothelial carcinoma; LGUC, low-grade papillary urothelial carcinoma; PUNLMP, papillary urothelial neoplasia of uncertain malignant potential.
*Rare cases of progression have occurred in immunocompromised patients.

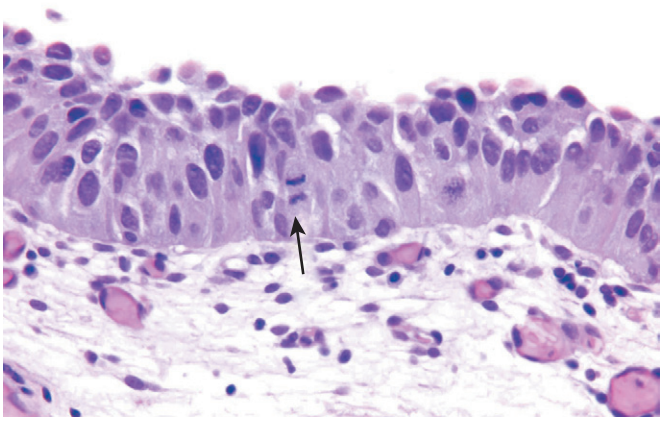

**Figure 17–18** Carcinoma in situ (CIS) with enlarged hyperchromatic nuclei and a mitotic figure (*arrow*).

closely monitored for tumor recurrence with periodic cystoscopy and urine cytologic studies for the rest of their lives. Radical cystectomy typically is reserved for (1) tumor invading the muscularis propria; (2) CIS or high-grade papillary cancer refractory to BCG; and (3) CIS extending into the prostatic urethra and down the prostatic ducts, where BCG cannot contact the neoplastic cells. Advanced bladder cancer is treated using chemotherapy, which can palliate but is not curative.

## SEXUALLY TRANSMITTED DISEASES

Sexually transmitted diseases (STDs) have complicated human existence for centuries. Globally, approximately 15 million new cases of STD occur every year; of these, 4 million affect 15- to 19-year-olds, and 6 million affect 20- to 24-year-olds. Of the 10 leading infectious diseases that require notification of the Centers for Disease Control and Prevention (CDC) in the United States, five—chlamydial infection, gonorrhea, acquired immunodeficiency syndrome (AIDS), syphilis, and hepatitis B—are STDs (Table 17–3). In the United States, the two most common STDs are genital herpes and genital HPV infection, but these do not require CDC notification. Several of these entities, such as human immunodeficiency virus (HIV) infection, HPV infection, hepatitis B, and infection with *E. histolytica,* are discussed in other chapters.

### Syphilis

Syphilis, or lues, is a chronic venereal infection caused by the spirochete *Treponema pallidum.* First recognized in epidemic form in 16th-century Europe as the Great Pox, syphilis is an endemic infection in all parts of the world. In the United States, approximately 6000 cases are reported every year, but this number has been rising since 2000. For example, primary and secondary syphilis among females 10 years of age and older rose from 0.8 per 100,000 in 2004 to 1.5 per 100,000 in 2009. A strong racial disparity is evident: African Americans are affected 30 times more often than whites.

*T. pallidum* is a fastidious organism whose only natural host is man. The usual source of infection is contact with a cutaneous or mucosal lesion in a sexual partner in the early (primary or secondary) stages of syphilis. The organism is transmitted from such lesions during sexual activity through minute breaks in the skin or mucous membranes of the uninfected partner. In congenital cases, *T. pallidum* is

**Table 17–3** Classification of Important Sexually Transmitted Diseases

| Pathogen | Associated Disease(s)—Distribution by Gender | | |
|---|---|---|---|
| | Males | Both | Females |
| **Viruses** | | | |
| Herpes simplex virus | | Primary and recurrent herpes, neonatal herpes | |
| Hepatitis B virus | | Hepatitis | |
| Human papillomavirus | Cancer of penis (some cases) | Condyloma acuminatum | Cervical dysplasia and cancer, vulvar cancer |
| Human immunodeficiency virus | | Acquired immunodeficiency syndrome | |
| **Chlamydiae** | | | |
| *Chlamydia trachomatis* | Urethritis, epididymitis, proctitis | Lymphogranuloma venereum | Urethral syndrome, cervicitis, bartholinitis, salpingitis, and sequelae |
| **Mycoplasmas** | | | |
| *Ureaplasma urealyticum* | Urethritis | | Cervicitis |
| **Bacteria** | | | |
| *Neisseria gonorrhoeae* | Epididymitis, prostatitis, urethral stricture | Urethritis, proctitis, pharyngitis, disseminated gonococcal infection | Cervicitis, endometritis, bartholinitis, salpingitis and sequelae (infertility, ectopic pregnancy, recurrent salpingitis) |
| *Treponema pallidum* | | Syphilis | |
| *Haemophilus ducreyi* | | Chancroid | |
| *Calymmatobacterium granulomatis* | | Granuloma inguinale (donovanosis) | |
| *Shigella* spp. | Enterocolitis* | | |
| *Campylobacter* spp. | Enterocolitis* | | |
| **Protozoa** | | | |
| *Trichomonas vaginalis* | Urethritis, balanitis | Vaginitis | |
| *Entamoeba histolytica* | Amebiasis* | | |
| *Giardia lamblia* | Giardiasis* | | |

*Most important in populations of men who have sex with men.
Data updated from Krieger JN: Biology of sexually transmitted diseases. Urol Clin North Am 11:15, 1984.

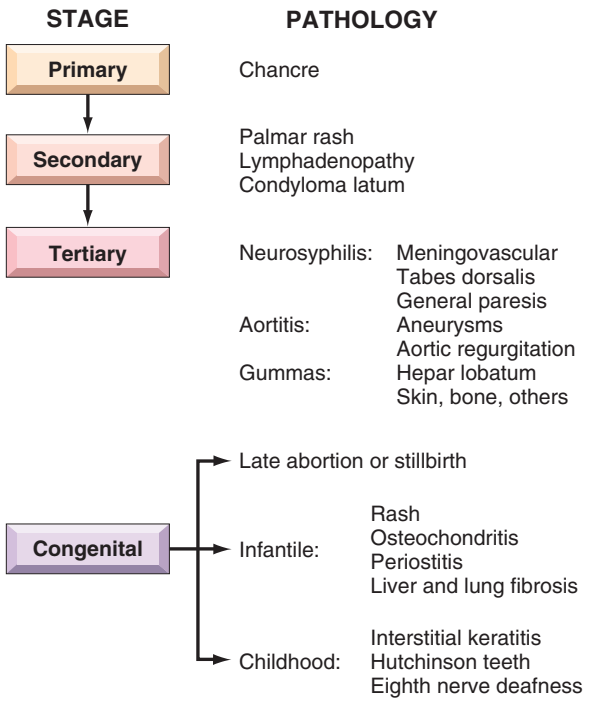


**Figure 17–19** Protean manifestations of syphilis.

transmitted across the placenta from mother to fetus, particularly during the early stages of maternal infection.

Once introduced into the body, the organisms rapidly disseminate to distant sites through lymphatics and the blood, even before the appearance of lesions at the primary inoculation site. This widespread dissemination accounts for the protean manifestations of the disease (Fig. 17–19), which can be divided into primary, secondary, and tertiary stages in adults. Between 9 and 90 days (mean, 21 days) after infection, a primary lesion, termed a *chancre,* appears at the point of spirochete entry. Systemic dissemination of organisms continues during this period, while the host mounts an immune response. Two types of antibodies are formed: antibodies that cross-react with host constituents (nontreponemal antibodies) and antibodies to specific treponemal antigens. This humoral response, however, fails to eradicate the organisms.

The chancre of *primary syphilis* resolves spontaneously over a period of 4 to 6 weeks and is followed in approximately 25% of untreated patients by the development of *secondary syphilis.* The manifestations of secondary syphilis, discussed in greater detail later on, include generalized lymphadenopathy and variable mucocutaneous lesions. *The mucocutaneous lesions of both primary and secondary syphilis are teeming with spirochetes and are highly infectious.* Like the chancre, the lesions of secondary syphilis resolve without any specific antimicrobial therapy, at which point patients are said to be in *early latent phase syphilis.* The U.S. Public Health Service restricts the definition of early latent syphilis to the 1-year period after infection. Mucocutaneous lesions may recur during this phase of the disease.

Patients with untreated syphilis next enter an asymptomatic, *late latent* phase of the illness. In about one third of cases, new symptoms develop over the next 5 to 20 years. This late symptomatic phase, or *tertiary syphilis,* is marked by the development of lesions in the cardiovascular system, central nervous system, or, less frequently, other organs. Spirochetes are much more difficult to demonstrate during the later stages of disease, and patients are accordingly much less likely to be infectious than are those in the primary or secondary stage of disease. Syphilis is common in HIV-infected patients. Like all other ulcerative genital diseases, syphilis promotes the transmission of HIV, and HIV stimulates the progression of syphilis.

## MORPHOLOGY

The pathognomonic microscopic lesion of syphilis is a **proliferative endarteritis** with an accompanying **inflammatory infiltrate rich in plasma cells.** Endarteritis has a central role in tissue injury at all sites involved by syphilis, but its pathogenesis is not understood; there is no evidence that the spirochetes cause any damage to host tissues directly. Instead, it is thought that the host immune response is responsible for the endothelial cell activation and proliferation that is the hallmark of the endarteritis, which eventually leads to perivascular fibrosis and luminal narrowing. Spirochetes are readily demonstrable in histologic sections of early lesions with the use of standard silver stains (e.g., Warthin-Starry stains). Large areas of parenchymal damage in tertiary syphilis result in the formation of a **gumma,** an irregular, firm mass of necrotic tissue surrounded by resilient connective tissue. On microscopic examination, the gumma contains a central zone of coagulative necrosis surrounded by a mixed inflammatory infiltrate composed of lymphocytes, plasma cells, activated macrophages (epithelioid cells), occasional giant cells, and a peripheral zone of dense fibrous tissue.

### *Primary Syphilis*

The chancre of syphilis is characteristically indurated and has been referred to as a "hard chancre," to distinguish it from the "soft chancre" of chancroid caused by *Haemophilus ducreyi* (discussed later). The primary chancre in males usually is on the penis. In females, multiple chancres may be present, usually in the vagina or on the uterine cervix. The chancre begins as a small, firm papule, which gradually enlarges to produce a painless ulcer with well-defined, indurated margins and a "clean," moist base (Fig. 17–20). Regional lymph nodes often are slightly enlarged and firm but painless. Histologic examination of the ulcer reveals the usual lymphocytic and plasmacytic inflammatory infiltrate and proliferative vascular changes, as described previously. Even without therapy, the primary chancre resolves over a period of several weeks to form a subtle scar.

### *Secondary Syphilis*

Within approximately 2 months of resolution of the chancre, the lesions of secondary syphilis appear. The manifestations of secondary syphilis are varied but typically include a combination of *generalized lymph node enlargement* and a variety of *mucocutaneous lesions.* Skin lesions usually are symmetrically distributed and may be maculopapular, scaly, or pustular. *Involvement of the palms of the hands and soles of the feet is common.* In moist skin areas, such as the

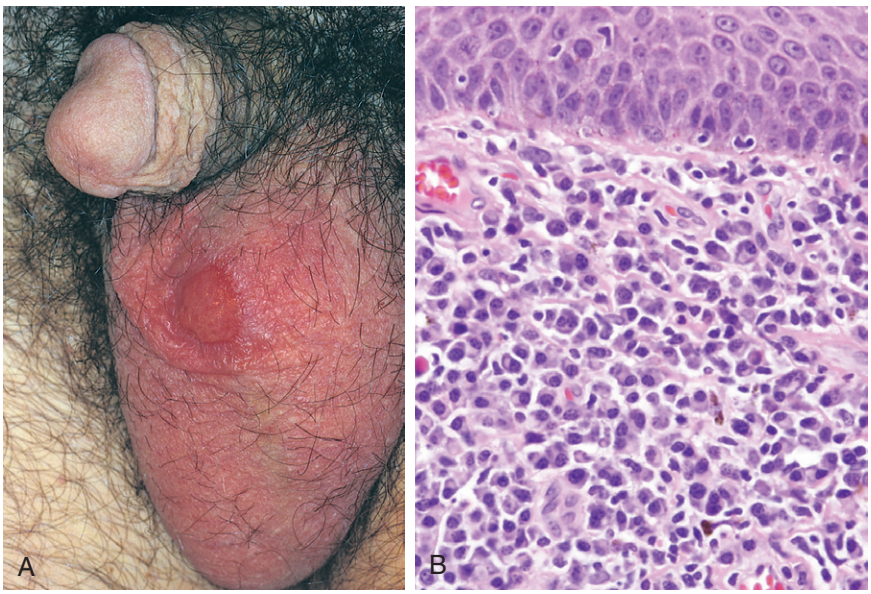


**Figure 17–20 A,** Syphilitic chancre of the scrotum. Such lesions typically are painless despite the presence of ulceration, and they heal spontaneously. **B,** Histologic features of the chancre include a diffuse plasma cell infiltrate beneath squamous epithelium of skin.

anogenital region, inner thighs, and axillae, broad-based, elevated lesions termed *condylomata lata* may appear (not to be confused with condyloma acuminata caused by HPV (Chapters 18 and 23). Superficial mucosal lesions resembling condylomata lata can occur anywhere but are particularly common in the oral cavity and pharynx and on the external genitalia.

Histologic examination of mucocutaneous lesions during the secondary phase of the disease reveals the characteristic *proliferative endarteritis,* accompanied by a *lymphoplasmacytic inflammatory infiltrate.* Spirochetes are present and often abundant within these mucocutaneous lesions; they are therefore contagious. Lymph node enlargement is most common in the neck and inguinal areas. Histologic examination of enlarged nodes demonstrates hyperplasia of germinal centers accompanied by increased numbers of plasma cells or, less commonly, granulomas or neutrophils.

Less common manifestations of secondary syphilis include hepatitis, renal disease, eye disease (iritis), and gastrointestinal abnormalities. The mucocutaneous lesions of secondary syphilis resolve over several weeks, at which point the disease enters its early latent phase, which lasts approximately 1 year. Lesions may recur at any time during this latent period, and these lesions are also highly infectious.

### *Tertiary Syphilis*

Tertiary syphilis develops in approximately one third of untreated patients, usually after a latent period of 5 years or more. Complications related to this phase of syphilis are divided into three major categories, cardiovascular syphilis, neurosyphilis, and so-called benign tertiary syphilis, which may occur singly or in combination. Cardiovascular syphilis takes the form of *syphilitic aortitis* and accounts for more than 80% of cases of tertiary disease; it is much more common in men than in women. The morphologic and clinical features of syphilitic aortitis are discussed in greater detail in Chapter 9. *Neurosyphilis* accounts for 10% of cases of tertiary syphilis overall but occurs at increased frequency in those with concomitant HIV infection; it is discussed in detail in Chapter 22. "Benign" tertiary syphilis is an uncommon form marked by the development of gummas in various sites. Emergence of these lesions probably is related to the development of delayed hypersensitivity. *Gummas occur most commonly in bone, skin, and the mucous membranes of the upper airway and mouth,* but any organ may be affected. *Spirochetes are rarely demonstrable within gummas.* Once common, gummas have become exceedingly rare thanks to the development of effective antibiotics such as penicillin. They are reported now mostly in patients with AIDS.

### *Congenital Syphilis*

*T. pallidum* may be transmitted across the placenta from an infected mother to the fetus at any time during pregnancy. *The likelihood of transmission is greatest during the early (primary and secondary) stages of disease, when spirochetes are most numerous.* Because the manifestations of maternal disease may be subtle, routine serologic testing for syphilis is mandatory in all pregnancies. The stigmata of congenital syphilis typically do not develop until after the fourth month of pregnancy. In the absence of treatment, as many as 40% of infected infants die in utero, typically after the fourth month. The incidence of congenital syphilis increased 23% in the United States from 2003 to 2008.

Manifestations of *congenital syphilis* include stillbirth, infantile syphilis, and late (tardive) congenital syphilis. Among infants who are stillborn, the most common manifestations are *hepatomegaly, bone abnormalities, pancreatic fibrosis,* and *pneumonitis.* The liver often shows extramedullary hematopoiesis and portal tract inflammation. Changes in the bones include inflammation and disruption of the osteochondral junction in long bones and, on occasion, bone resorption and fibrosis of the flat bones of the skull. The lungs may be firm and pale as a result of the presence of inflammatory cells and fibrosis in the alveolar septa (pneumonia alba). Spirochetes are readily demonstrable in tissue sections. In cases of congenital syphilis, the placenta is enlarged, pale, and edematous. Microscopy reveals

proliferative endarteritis involving the fetal vessels, a mononuclear inflammatory reaction (villitis), and villous immaturity.

*Infantile syphilis* refers to congenital syphilis in liveborn infants that is clinically manifest at birth or within the first few months of life. Affected infants present with chronic rhinitis (snuffles) and mucocutaneous lesions similar to those seen in secondary syphilis in adults. Visceral and skeletal changes resembling those seen in stillborn infants also may be present.

*Late, or tardive, congenital syphilis* refers to cases of untreated congenital syphilis of more than 2 years' duration. Classic manifestations include the Hutchinson triad: notched central incisors, interstitial keratitis with blindness, and deafness from eighth cranial nerve injury. Other changes include a so-called saber shin deformity caused by chronic inflammation of the periosteum of the tibia, deformed molar teeth ("mulberry molars"), chronic meningitis, chorioretinitis, and gummas of the nasal bone and cartilage with a resultant "saddlenose" deformity.

### *Serologic Tests for Syphilis*

Although polymerase chain reaction (PCR)–based testing for syphilis has been developed, serology remains the mainstay of diagnosis. Serologic tests for syphilis include nontreponemal antibody tests and antitreponemal antibody tests. Nontreponemal tests measure antibody to cardiolipin, an antigen that is present in both host tissues and the treponemal cell wall. These antibodies are detected by the rapid plasma reagin (RPR) and Venereal Disease Research Laboratory (VDRL) tests. Nontreponemal antibody tests are usually positive by 4 to 6 weeks of infection and are strongly positive in the secondary phase of infection. *However, nontreponemal antibody test results may revert to negative during the tertiary phase* or, conversely, may on occasion be persistently positive in some patients after successful treatment. Two additional points regarding nontreponemal antibody tests deserve emphasis:

- *Nontreponemal antibody test results often are negative during the early stages of disease,* even in the presence of a primary chancre. Hence, during this period, direct visualization of the spirochetes by darkfield or immunofluorescence microscopy may be the only way to confirm the diagnosis.
- *As many as 15% of positive VDRL test results are unrelated to syphilis.* These false-positive results, which may be acute (transient) or chronic (persistent), increase in frequency with age and are associated with a variety of conditions, including the antiphospholipid antibody syndrome (Chapter 3).

Treponemal antibody tests also become positive within 4 to 6 weeks after an infection, but, unlike those for nontreponemal antibody tests, they usually remain positive indefinitely, even after successful treatment. *These tests give strongly positive results in virtually all cases of secondary syphilis.* They are not recommended as screening tests, however, because they remain positive after treatment and have a high false-positive test rate (approximately 2%) in the general population.

Serologic response may be delayed, exaggerated (false-positive results), or absent in patients with syphilis and coexistent HIV infection. In most cases, however, these tests remain useful in the diagnosis and management of syphilis in patients with AIDS.

## SUMMARY

### Syphilis

- Syphilis is caused by *T. pallidum* and has three stages. In primary syphilis a painless lesion called chancre develops on the external genitalia along with regional lymph node enlargement. Secondary syphilis manifests with generalized lymphadenopathy and mucocutaneous lesions that may be maculopapular or take the form of flat raised lesions called condylomata lata. Tertiary syphilis may cause proximal aortitis and aortic insufficiency; may involve the brain, meninges, and the spinal cord; or may cause focal granulomatous lesions called gummas in multiple organs.
- Congenital syphilis is caused by maternal transmission of the spirochetes, mostly during primary and secondary stages of disease in the mother. It may lead to stillbirth or cause widespread tissue injury in liver, spleen, lung, bones, and pancreas.
- On histologic examination, most syphilitic lesions demonstrate proliferative endarteritis and a plasma cell–rich inflammatory infiltrate. Gummas have a central area of necrosis surrounded by lymphoplasmacytic infiltrates and epithelioid cells.
- The diagnostic mainstay is serologic testing. Nontreponemal antibody tests (VDRL and RPR) are usually positive in early disease, but may be negative in advanced disease. Treponeme-specific antibody test results become positive later and remain positive indefinitely. Treponemes can also be identified by microscopic examination of primary and secondary lesions.

## Gonorrhea

Gonorrhea is a sexually transmitted infection of the lower genitourinary tract caused by *Neisseria gonorrhoeae.* Gonorrhea is second only to chlamydial infection of the genitourinary tract (discussed later) among reportable communicable diseases in the United States. With an estimated 650,000 cases each year in the United States, it remains a major public health problem. The gravity of gonococcal infections has increased with the emergence of strains of *N. gonorrhoeae* that are resistant to multiple antibiotics.

Humans are the only natural reservoir for *N. gonorrhoeae.* The organism is highly fastidious, and spread of infection requires direct contact with the mucosa of an infected person, usually during sexual activity. The bacteria initially attach to mucosal epithelium, particularly of the columnar or transitional type, using a variety of membrane-associated adhesion molecules and structures termed *pili* (Chapter 8). Such attachment prevents the organism from being unceremoniously flushed away by body fluids such as urine or endocervical mucus. The organism then penetrates through the epithelial cells to invade the deeper tissues of the host.

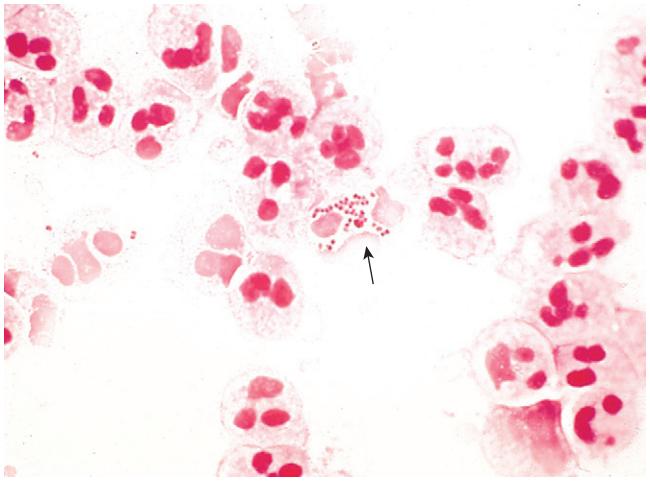

**Figure 17–21** *Neisseria gonorrhoeae.* Gram stain of urethral discharge demonstrates characteristic gram-negative, intracellular diplococci (*arrow*).

*(Courtesy of Dr. Rita Gander, Department of Pathology, University of Texas Southwestern Medical School, Dallas, Texas.)*

## MORPHOLOGY

***N. gonorrhoeae*** provokes an intense, suppurative inflammatory reaction. In males this manifests most often as a **purulent urethral discharge,** associated with an edematous, congested urethral meatus. Gram-negative diplococci, many within the cytoplasm of neutrophils, are readily identified in Gram stains of the purulent exudate (Fig. 17–21). Ascending infection may result in the development of **acute prostatitis, epididymitis** (Fig. 17–22), or **orchitis.** Abscesses may complicate severe cases. Urethral and endocervical exudates tend to be less conspicuous in females, although acute inflammation of adjacent structures, such as the Bartholin glands, is fairly common. Ascending infection involving the uterus, fallopian tubes, and ovaries results in **acute salpingitis,** sometimes complicated by tuboovarian abscesses. The acute inflammatory process is followed by the development of granulation tissue and scarring, with resultant strictures and other permanent deformities of the involved structures, giving rise to **pelvic inflammatory disease** (Chapter 18).

**Figure 17–22** Acute epididymitis caused by gonococcal infection. The epididymis is involved by an abscess. Normal testis is seen on the *right.*

### Clinical Features

In most infected males, gonorrhea is manifested by the presence of *dysuria, urinary frequency, and a mucopurulent urethral exudate* within 2 to 7 days of the time of initial infection. Treatment with appropriate antimicrobial therapy results in eradication of the organism and prompt resolution of symptoms. Untreated infections may ascend to involve the prostate, seminal vesicles, epididymis, and testis. Neglected cases may be complicated by chronic urethral stricture and, in more advanced cases, by permanent sterility. Untreated men also may become chronic carriers of *N. gonorrhoeae.*

Among female patients, acute infections acquired by vaginal intercourse may be asymptomatic or associated with *dysuria, lower pelvic pain, and vaginal discharge.* Untreated cases may be complicated by ascending infection, leading to acute inflammation of the fallopian tubes (salpingitis) and ovaries. Scarring of the fallopian tubes may occur, with resultant infertility and an increased risk of ectopic pregnancy. Gonococcal infection of the upper genital tract may spread to the peritoneal cavity, where the exudate may extend up the right paracolic gutter to the dome of the liver, resulting in gonococcal perihepatitis. Depending on sexual practices, other sites of primary infection in both males and females include the oropharynx and the anorectal area, with resultant acute pharyngitis and proctitis, respectively.

*Disseminated infection* is much less common than local infection, occurring in 0.5% to 3% of cases of gonorrhea. It is more common in females than in males. Manifestations include, most commonly, tenosynovitis, arthritis, and pustular or hemorrhagic skin lesions. Endocarditis and meningitis are rare presentations. Strains that cause disseminated infection usually are resistant to the lytic action of complement, but rare patients with inherited complement deficiencies are susceptible to systemic spread regardless of the infecting strain.

*Gonococcal infection may be transmitted to infants* during passage through the birth canal. The affected neonate may develop purulent infection of the eyes (ophthalmia neonatorum), an important cause of blindness in the past. The routine application of antibiotic ointment to the eyes of newborns has markedly reduced this disorder.

Both culture and a variety of tests that detect organism-specific nucleic acids can be used to diagnose gonococcal infections. The advantage of culture is that it permits determination of antibiotic sensitivity. Nucleic acid–based tests are more rapid and somewhat more sensitive than culture, and are being used increasingly.

## SUMMARY

### Gonorrhea

- Gonorrhea is a common STD affecting the genitourinary tract. Control of dissemination requires an effective complement-mediated immune response.
- In males there is a severe, symptomatic urethritis that can spread to the prostate, epididymis, and testis. In females the initial lesions on the cervix and urethra are less prominent than corresponding lesions in males, but ascending infection to fallopian tubes and ovaries can cause scarring and deformity with resultant sterility.
- Pregnant women can transmit gonorrhea to newborns during passage through the birth canal.
- Diagnosis can be made by culture of the exudates as well as by nucleic acid amplification techniques.

## Nongonococcal Urethritis and Cervicitis

Nongonococcal urethritis (NGU) and cervicitis are the most common forms of STD. A variety of organisms has been implicated in the pathogenesis of NGU and cervicitis, including *C. trachomatis, Trichomonas vaginalis, U. urealyticum,* and *Mycoplasma genitalium. Most cases are apparently caused by C. trachomatis, and this organism is believed to be the most common bacterial cause of STD in the United States. U. urealyticum* is the next most common cause of NGU. Gonorrhea infection frequently is accompanied by chlamydial infection.

*C. trachomatis* is a small gram-negative bacterium that is an obligate intracellular pathogen. It exists in two forms. The infectious form, the *elementary body,* is capable of at least limited survival in the extracellular environment. The elementary body is taken up by host cells, primarily through a process of receptor-mediated endocytosis. Once inside the cell, the elementary body differentiates into a metabolically active form, termed the *reticulate body.* Using energy sources from the host cell, the reticulate body replicates and ultimately forms new elementary bodies capable of infecting additional cells. They preferentially infect columnar epithelial cells.

*C. trachomatis* infections may be associated with a wide range of clinical features that are virtually indistinguishable from those caused by *N. gonorrhoeae.* Thus, patients may develop epididymitis, prostatitis, pelvic inflammatory disease, pharyngitis, conjunctivitis, perihepatic inflammation, and, among persons engaging in anal sex, proctitis. *C. trachomatis* also causes lymphogranuloma venereum (LGV), discussed in the next section.

The morphologic and clinical features of chlamydial infection, with the exception of lymphogranuloma venereum, are virtually identical to those of gonorrhea. The primary infection is characterized by a *mucopurulent discharge containing a predominance of neutrophils.* Organisms are not visible in Gram-stained sections. In contrast with the gonococcus, *C. trachomatis* cannot be isolated with the use of conventional culture media. The diagnosis is best made by nucleic acid amplification tests on voided urine. Although culture can be done from genital swabs, it is not possible from urine. Molecular tests also are more sensitive than culture. Another important manifestation of chlamydial infection is *reactive arthritis* (formerly known as Reiter syndrome), predominantly in patients who are HLA-B27–positive. This condition typically manifests as a combination of urethritis, conjunctivitis, arthritis, and generalized mucocutaneous lesions.

## SUMMARY

### Nongonococcal Urethritis and Cervicitis

- NGU and cervicitis are the most common forms of STD. A majority of the cases are caused by *C. trachomatis,* and the rest by *T. vaginalis, U. urealyticum,* and *M. genitalium.*
- *C. trachomatis* is a gram-negative intracellular bacterium that causes a disease that is clinically indistinguishable from gonorrhea in both men and in women. Diagnosis requires detection of the bacteria by molecular methods. Culture from genital swabs is possible but requires special methods.
- In patients who are HLA-B27–positive, *C. trachomatis* infection can cause reactive arthritis along with conjunctivitis, and generalized mucocutaneous lesions.

## Lymphogranuloma Venereum

Lymphogranuloma venereum (LGV) is a chronic, ulcerative disease caused by certain strains of *C. trachomatis,* which are distinct from those causing the more common NGU or cervicitis discussed earlier. It is a sporadic disease in the United States and western Europe but is endemic in parts of Asia, Africa, the Caribbean region, and South America. As in the case of granuloma inguinale (discussed later), sporadic cases of LGV are seen most often among persons with multiple sexual partners.

## MORPHOLOGY

LGV may present as nonspecific urethritis, papular or ulcerative lesions involving the lower genitalia, tender inguinal and/or femoral lymphadenopathy that typically is unilateral, or proctocolitis. The lesions contain a **mixed granulomatous and neutrophilic inflammatory response;** variable numbers of chlamydial inclusions may be seen in the cytoplasm of epithelial cells or inflammatory cells with special staining methods. Regional lymphadenopathy is common, usually appearing within 30 days of the time of infection. Lymph node involvement is characterized by a granulomatous inflammatory reaction associated with irregularly shaped foci of necrosis and neutrophilic infiltration **(stellate abscesses).** With time, the inflammatory reaction gives rise to extensive fibrosis that can cause local lymphatic obstruction and strictures, producing **lymphedema.** Rectal strictures also occur, particularly in women. In active lesions, the diagnosis of LGV may be made by demonstration of the organism in biopsy sections or smears of exudate. In more chronic cases, the diagnosis rests on the demonstration of antibodies to the appropriate chlamydial serotypes in the patient's serum. Nucleic acid amplification tests have also been developed.

## Chancroid (Soft Chancre)

Chancroid, sometimes called the "third" venereal disease (after syphilis and gonorrhea), is an acute, ulcerative infection caused by *Haemophilus ducreyi,* a small, gram-negative coccobacillus. The disease is most common in tropical and subtropical areas and is more prevalent in lower socioeconomic groups, particularly among men who have regular contact with prostitutes. *Chancroid is one of the most common causes of genital ulcers in Africa and Southeast Asia,* where it serves as an important cofactor in the transmission of HIV infection. Chancroid probably is underdiagnosed in the United States, because most STD clinics do not have facilities for isolating *H. ducreyi* and PCR-based tests are not widely available.

### MORPHOLOGY

At 4 to 7 days after inoculation, a tender, **erythematous papule** develops on the external genitalia. In male patients, the primary lesion is usually on the penis; in female patients, most lesions occur in the vagina or periurethral area. Over the course of several days the surface of the primary lesion erodes to produce an **irregular ulcer,** which is more likely to be painful in males than in females. In contrast with the primary chancre of syphilis, the ulcer of chancroid is not indurated, and multiple lesions may be present. The base of the ulcer is covered by shaggy, yellow-gray exudate. The regional **lymph nodes,** particularly in the inguinal region, become enlarged and tender in about 50% of cases within 1 to 2 weeks of the primary inoculation. In untreated cases, the inflamed and enlarged nodes (buboes) may erode the overlying skin to produce chronic, draining ulcers.

On microscopic examination, the ulcer of chancroid contains a superficial zone of neutrophilic debris and fibrin, with an underlying zone of granulation tissue containing areas of necrosis and thrombosed vessels. A dense, lymphoplasmacytic inflammatory infiltrate is present beneath the layer of granulation tissue. Coccobacillary organisms sometimes are demonstrable in Gram- or silver-stained preparations, but they often are obscured by the mixed bacterial growth frequently present at the ulcer base. A definitive diagnosis of chancroid requires the identification of *H. ducreyi* on special culture media that are not widely available from commercial sources; even when such media are used, sensitivity is less than 80%. Therefore, the diagnosis often is based on clinical grounds alone.

## Granuloma Inguinale

Granuloma inguinale is a chronic inflammatory disease caused by *Calymmatobacterium granulomatis,* a minute, encapsulated coccobacillus related to the *Klebsiella* genus. This disease is uncommon in the United States and western Europe but is endemic in rural areas in certain tropical and subtropical regions. When it occurs in urban settings, transmission of *C. granulomatis* typically is associated with a history of multiple sexual partners. Untreated cases are characterized by extensive scarring, often associated with lymphatic obstruction and lymphedema (elephantiasis) of the external genitalia. Culture of the organism is difficult, and PCR-based assays are not widely available.

### MORPHOLOGY

Granuloma inguinale begins as a raised, papular lesion involving the moist, stratified squamous epithelium of the genitalia. The lesion eventually undergoes ulceration, accompanied by the development of abundant granulation tissue, which takes the form of a protuberant, soft, painless mass. As the lesion enlarges, its borders become raised and indurated. Disfiguring scars may develop in untreated cases, sometimes associated with formation of urethral, vulvar, or anal strictures. Regional lymph nodes typically are spared or show only nonspecific reactive changes, in contrast with chancroid.

Microscopic examination of active lesions reveals marked epithelial hyperplasia at the borders of the ulcer, sometimes mimicking carcinoma **(pseudoepitheliomatous hyperplasia).** A mixture of neutrophils and mononuclear inflammatory cells is present at the base of the ulcer and beneath the surrounding epithelium. The organisms are demonstrable in Giemsa-stained smears of the exudate as minute coccobacilli within vacuoles in macrophages (Donovan bodies). Silver stains (e.g., the Warthin-Starry stain) also may be used to demonstrate the organism.

### SUMMARY

#### Lymphogranuloma Venereum, Chancroid, and Granuloma Inguinale

- LGV is caused by *C. trachomatis* serotypes that are distinct from those that cause NGU. LGV is associated with urethritis, ulcerative genital lesions, lymphadenopathy, and involvement of the rectum. The lesions show both acute and chronic inflammation; they progress to fibrosis, with consequent lymphedema and formation of rectal strictures.
- *H. ducreyi* infection causes an acute painful ulcerative genital infection called *chancroid.* Inguinal node involvement occurs in many cases and leads to their enlargement and ulceration. Ulcers show a superficial area of acute inflammation and necrosis, with an underlying zone of granulation tissue and mononuclear infiltrate. Diagnosis is possible by culture of the organism.
- *Granuloma inguinale* is a chronic fibrosing STD caused by *C. granulomatis.* The initial papular lesion on the genitalia expands and ulcerates, with formation of urethral, vulvar, or anal strictures in some cases. Microscopic examination reveals granulation tissue and intense epithelial hyperplasia that can mimic the histologic pattern in squamous cell carcinoma. Organisms are visible as small intracellular coccobacilli within vacuolated macrophages (Donovan bodies).

## Trichomoniasis

*T. vaginalis* is a sexually transmitted protozoan that is a frequent cause of vaginitis. The trophozoite form adheres to the mucosa, where it causes superficial lesions. In females, *T. vaginalis* infection often is associated with loss

of acid-producing Döderlein bacilli. It may be asymptomatic or be associated with pruritus and a profuse, frothy, yellow vaginal discharge. Urethral colonization may cause urinary frequency and dysuria. *T. vaginalis* infection typically is asymptomatic in males but in some cases may manifest as NGU. The organism usually is demonstrable in smears of vaginal scrapings.

## Genital Herpes Simplex

Genital herpes infection, or herpes genitalis, is a common STD that affects an estimated 50 million people in the United States. Although both herpes simplex virus 1 (HSV-1) and HSV-2 can cause anogenital or oral infections, most cases of anogenital herpes are caused by HSV-2. However, *recent years have seen a rise in the number of genital infections caused by HSV-1, in part due to the increasing practice of oral sex.* Genital HSV infection may occur in any sexually active population. As with other STDs, the risk of infection is directly related to the number of sexual contacts. Up to 95% of HIV-positive men who have sex with men are seropositive for HSV-1 and/or HSV-2. HSV is transmitted when the virus comes into contact with a mucosal surface or broken skin of a susceptible host. Such transmission requires direct contact with an infected person, because the virus is readily inactivated at room temperature, particularly if dried.

### MORPHOLOGY

The initial lesions of genital HSV infection are **painful, erythematous vesicles** on the mucosa or skin of the lower genitalia and adjacent extragenital sites. The anorectal area is a particularly common site of primary infection among men who have sex with men. Histologic changes include the presence of **intraepithelial vesicles** accompanied by necrotic cellular debris, neutrophils, and cells harboring characteristic intranuclear viral inclusions. The classic **Cowdry type A inclusion** appears as a light purple, homogeneous intranuclear structure surrounded by a clear halo. Infected cells commonly fuse to form multinucleate syncytia. The inclusions readily stain with antibodies to HSV, permitting a rapid, specific diagnosis of HSV infection in histologic sections or smears. Immunohistochemical tests have largely replaced detection of HSV infection by cytologic examination, which is less sensitive and prone to false-positive results.

### Clinical Features

As mentioned earlier, both HSV-1 and HSV-2 can cause genital or oral infection, and both can produce primary or recurrent mucocutaneous lesions that are clinically indistinguishable. The manifestations of HSV infection vary considerably, depending on whether the infection is primary or recurrent. Primary infection with HSV-2 often is mildly symptomatic. In persons experiencing their first episode, locally painful vesicular lesions are often accompanied by dysuria, urethral discharge, local lymph node enlargement and tenderness, and systemic manifestations, such as fever, muscle aches, and headache. HSV is actively shed during this period and continues to be shed until the mucosal lesions have completely healed. Signs and symptoms may last for several weeks during the primary phase of disease. Recurrences are much more common with HSV-1 than with HSV-2 and typically are milder and of shorter duration than in the primary episode. As with primary infection, HSV is shed while active lesions are present.

In immunocompetent adults, herpes genitalis generally is not life-threatening. However, HSV does pose a major threat to immunosuppressed patients, in whom fatal, disseminated disease may develop. Also life-threatening is *neonatal herpes infection,* which occurs in about half of infants delivered vaginally of mothers suffering from either primary or recurrent genital HSV infection. The viral infection is acquired during passage through the birth canal. Its incidence has risen in parallel with the rise in genital HSV infection. *The manifestations of neonatal herpes, which typically develop during the second week of life, include rash, encephalitis, pneumonitis, and hepatic necrosis.* Approximately 60% of affected infants die of the disease, with significant morbidity occurring in about half of the survivors. The laboratory diagnosis of genital herpes relies on viral culture. Of note, however, the sensitivity of culture is low, especially for recurrent lesions, and declines rapidly as lesions begin to heal. Molecular diagnostic tests also are available but are used mostly in diagnosis of extragenital herpes, particularly with central nervous system infections.

## Human Papillomavirus Infection

HPV causes a number of squamous proliferations in the genital tract, including condyloma acuminatum, as well as several precancerous lesions that commonly undergo transformation to carcinomas; these most commonly involve the cervix (Chapter 18), but also occur in the penis, vulva, and oropharyngeal tonsils. *Condylomata acuminata,* also known as venereal warts, are caused by HPV types 6 and 11. These lesions occur on the penis as well as on the female genitalia. They should not be confused with the condylomata lata of secondary syphilis. Genital HPV infection may be transmitted to neonates during vaginal delivery. Recurrent and potentially life-threatening papillomas of the upper respiratory tract may develop subsequently in affected infants.

### MORPHOLOGY

In males, condylomata acuminata usually occur on the coronal sulcus or inner surface of the prepuce, where they range in size from small, sessile lesions to large, papillary proliferations measuring several centimeters in diameter. In females, they commonly occur on the vulva. Examples of the microscopic appearance of these lesions are presented in Chapter 18.

### SUMMARY

#### Herpes Simplex Virus and Human Papillomavirus Infections

- HSV-2 and, less commonly, HSV-1 can cause genital infections. Initial (primary) infection causes painful, erythematous, intraepithelial vesicles on the mucosa and skin of external genitalia, along with regional lymph node

enlargement. Recurrent lesions are more common with HSV-1 than with HSV-2 infection, and in general are less painful and less extensive than primary lesions.

- On histologic examination the vesicles of HSV infection contain necrotic cells and fused multinucleate giant cells with intranuclear inclusions (Cowdry type A) that stain with antibodies to the virus.
- Neonatal herpes can be life-threatening and occurs in children born to mothers with genital herpes. Affected infants have generalized herpes, often associated with encephalitis and consequent high mortality.
- HPV causes many proliferative lesions of the genital mucosa, including condyloma acuminatum, precancerous lesions, and invasive cancers.

## BIBLIOGRAPHY


Bahrami A, Ro JY, Ayala AG: An overview of testicular germ cell tumors. Arch Pathol Lab Med 131:1267, 2007.

Bleeker MC, Heideman DA, Snijders PJ, et al: Penile cancer: epidemiology, pathogenesis, and prevention. World J Urol 27:141, 2009. *[A systematic review of the literature evaluating penile carcinogenesis, risk factors, and molecular mechanisms involved.]*

Bushman W: Etiology, epidemiology, and natural history of benign prostatic hyperplasia. Urol Clin N Am 36:403, 2009.

Centers for Disease Control and Prevention, Workowski KA, Berman SM: Sexually transmitted diseases treatment guidelines, 2006. MMWR Recomm Rep 55:1, 2006. *[An excellent updated review along with treatment recommendations.]*

Clark PE: Bladder cancer. Curr Opin Oncol 19:241, 2007. *[Reviews the diagnosis and management of both more superficial and advanced bladder cancer.]*

Donovan B: Sexually transmitted infections other than HIV. Lancet 363:545, 2004. *[A clinical review of STDs.]*

Epstein JI: An update of the Gleason grading system. J Urol 183:433, 2010.

Gori S, Porrozzi S, Roila F, et al: Germ cell tumours of the testis. Crit Rev Oncol Hematol 53:141, 2005. *[An informative review of the predisposing factors, clinical features, and treatment of testicular neoplasms.]*

Hsing AW, Chokkalingam AP: Prostate cancer epidemiology. Front Biosci 11:1388, 2006.

Loeb SA, Catalona WJ: Prostate-specific antigen in clinical practice. Cancer Lett 249:30, 2007. *[An excellent summary of clinical use of PSA.]*

Le BV, Schaeffer AJ: Genitourinary pain syndromes, prostatitis and lower urinary tract symptoms. Urol Clin North Am 36:527, 2009. *[A recent review of the etiology, diagnosis, symptoms, and treatment of prostatitis and interstitial cystitis along with pelvic pain syndromes.]*

Lee PK, Wilkins KB: Condyloma and other infections including human immunodeficiency virus. Surg Clin North Am 90:99, 2010.

Makorov DV, Loeb S, Getzenberg RH, Partin AW: Biomarkers for prostate cancer. Annu Rev Med 60:139, 2009. *[A review covering PSA and possible new prostate cancer biomarkers that are under evaluation.]*

Mitra AP, Cole RJ: Molecular pathogenesis and diagnostics of bladder cancer. Annu Rev Pathol 4:251, 2008.

Nelson WG, De Marzo AM, Yegnasubramanian S: Epigenetic alterations in human prostate cancers. Endocrinology 150:3991, 2009.

Patel AK, Chapple CR: Medical management of lower urinary tract symptoms in men: current treatment and future approaches. Nat Clin Pract Urol 5:211, 2008. *[This article also clarifies the terminology used to evaluate men with lower urinary tract symptoms.]*

Rapley EA, Nathanson KL: Predisposition alleles for testicular germ cell tumour. Curr Opin Genes Dev 20:225, 2010. *[An update on inherited risk factors in germ cell tumors.]*

Shand RL, Gelmann EP: Molecular biology of prostate-cancer pathogenesis. Curr Opin Urol 16:123, 2006.

Sulak PJ: Sexually transmitted diseases. Semin Reprod Med 21:399, 2003. *[An exhaustive review of STDs.]*

This page intentionally left blank

See Targeted Therapy available online at studentconsult.com

CHAPTER 18

# Female Genital System and Breast

CHAPTER CONTENTS

**VULVA 681**
Vulvitis 681
Non-neoplastic Epithelial Disorders 682
Lichen Sclerosus 682
Lichen Simplex Chronicus 682
Tumors 683
Condylomas 683
Carcinoma of the Vulva 683
Extramammary Paget Disease 683
**VAGINA 684**
Vaginitis 684
Malignant Neoplasms 684
Squamous Cell Carcinoma 684
Clear Cell Adenocarcinoma 685
Sarcoma Botryoides 685
**CERVIX 685**
Cervicitis 685
Neoplasia of the Cervix 685
Invasive Carcinoma of the Cervix 687
Endocervical Polyp 689
**BODY OF UTERUS 689**
Endometritis 689
Adenomyosis 689
Endometriosis 689
Abnormal Uterine Bleeding 690
Proliferative Lesions of the Endometrium and Myometrium 691
Endometrial Hyperplasia 691
Endometrial Carcinoma 692
Endometrial Polyps 693
Leiomyoma 693
Leiomyosarcoma 694
**FALLOPIAN TUBES 695**
**OVARIES 695**
Follicle and Luteal Cysts 695
Polycystic Ovarian Disease 695
Tumors of the Ovary 696
Surface Epithelial Tumors 696
Serous Tumors 697
Mucinous Tumors 697
Endometrioid Tumors 698
Brenner Tumor 698
Other Ovarian Tumors 698
Teratomas 698
**DISEASES OF PREGNANCY 700**
Placental Inflammations and Infections 701
Ectopic Pregnancy 701
Gestational Trophoblastic Disease 701
Hydatidiform Mole: Complete and Partial 701
Invasive Mole 702
Gestational Choriocarcinoma 703
Placental Site Trophoblastic Tumor 703
Preeclampsia/Eclampsia (Toxemia of Pregnancy) 703
**BREAST 704**
Fibrocystic Changes 705
Nonproliferative Changes 705
Proliferative Change 705
Relationship of Fibrocystic Changes to Breast Carcinoma 706
Inflammatory Processes 707
Tumors of the Breast 707
Fibroadenoma 707
Phyllodes Tumor 707
Intraductal Papilloma 708
Carcinoma 708
Lesions of the Male Breast 714
Gynecomastia 714
Carcinoma 714

## VULVA

The *vulva* is the external female genitalia and includes the moist hair-bearing skin and mucosa in that region. Disorders of the vulva most frequently are inflammatory, rendering them more uncomfortable than serious. Malignant tumors of the vulva, although life-threatening, are rare.

### VULVITIS

One of the most common causes of vulvitis is reactive inflammation in response to an exogenous stimulus, whether an irritant (contact irritant dermatitis) or an allergen (contact allergic dermatitis). Scratching-induced trauma secondary to associated intense "itching" (pruritus) often exacerbates the primary condition.

Contact irritant eczymatous dermatitis manifests as well-defined erythematous weeping and crusting papules and plaques (Chapter 23) and may be a reaction to urine, soaps, detergents, antiseptics, deodorants, or alcohol. Allergic dermatitis has a similar clinical appearance and may result from allergy to perfumes; additives in creams, lotions, and soaps; chemical treatments on clothing; and other antigens.

Vulvitis also may be caused by infections, which in this setting often are sexually transmitted (Chapter 17). The most important of these infectious agents in North America are human papillomavirus (HPV), the causative agent of condyloma acuminatum and vulvar intraepithelial neoplasia (VIN) (discussed later); herpes simplex virus (HSV-1 or -2), the agent of genital herpes with its characteristic

*The contributions of Drs. Susan Lester (Diseases of Breast) and Anthony Montag (Diseases of Female Genital System) are gratefully acknowledged.*

vesicular eruption; *N. gonorrhoeae*, a cause of suppurative infection of the vulvovaginal glands; *Treponema pallidum,* the syphilis pathogen, in association with the primary chancre at a vulvar site of inoculation; and *Candida,* also a potential cause of vulvitis.

An important complication of vulvitis is obstruction of the excretory ducts of Bartholin glands. This blockage may result in painful dilation of the glands (a Bartholin cyst) and abscess formation.

## NON-NEOPLASTIC EPITHELIAL DISORDERS

The epithelium of the vulvar mucosa may undergo both atrophic thinning and hyperplastic thickening, often in the form of lichen sclerosus and lichen simplex chronicus, respectively.

### Lichen Sclerosus

Lichen sclerosus is characterized by thinning of the epidermis, disappearance of rete pegs, hydropic degeneration of the basal cells, dermal fibrosis, and a scant perivascular, mononuclear inflammatory cell infiltrate (Fig. 18–1). It appears as smooth, white plaques (termed *leukoplakia*) or papules that in time may extend and coalesce. When the entire vulva is affected, the labia become somewhat atrophic and stiffened, and the vaginal orifice is constricted. Lichen sclerosus occurs in all age groups but most commonly affects postmenopausal women. The pathogenesis is uncertain, but the presence of activated T cells in the subepithelial inflammatory infiltrate and the increased frequency of autoimmune disorders in affected women suggest an autoimmune etiology. Lichen sclerosus is benign; however, a small percentage of women (1% to 5%) with symptomatic lichen sclerosus develop squamous cell carcinoma of the vulva.

### Lichen Simplex Chronicus

Lichen simplex chronicus is marked by epithelial thickening (particularly of the stratum granulosum) and hyperkeratosis. Increased mitotic activity is seen in the basal and suprabasal layers; however, there is no epithelial atypia (Fig. 18–1). Leukocytic infiltration of the dermis is sometimes pronounced. These nonspecific changes are a consequence of chronic irritation, often caused by pruritus related to an underlying inflammatory dermatosis. Lichen simplex chronicus appears as an area of leukoplakia. With isolated lesions, no increased predisposition to cancer has been found, but lichen simplex chronicus often is present at the margins of established vulvar cancer, raising the possibility of an association with neoplastic disease.

Lichen sclerosus and lichen simplex chronicus may coexist in different areas of the body in the same person, and both lesions may take the form of leukoplakia. Similar white patches or plaques also are seen in a variety of other benign dermatoses, such as psoriasis and lichen planus (Chapter 23), as well as in malignant lesions of the vulva, such as squamous cell carcinoma in situ and invasive squamous cell carcinoma. Thus, biopsy and microscopic examination are needed to differentiate these clinically similar-appearing lesions.

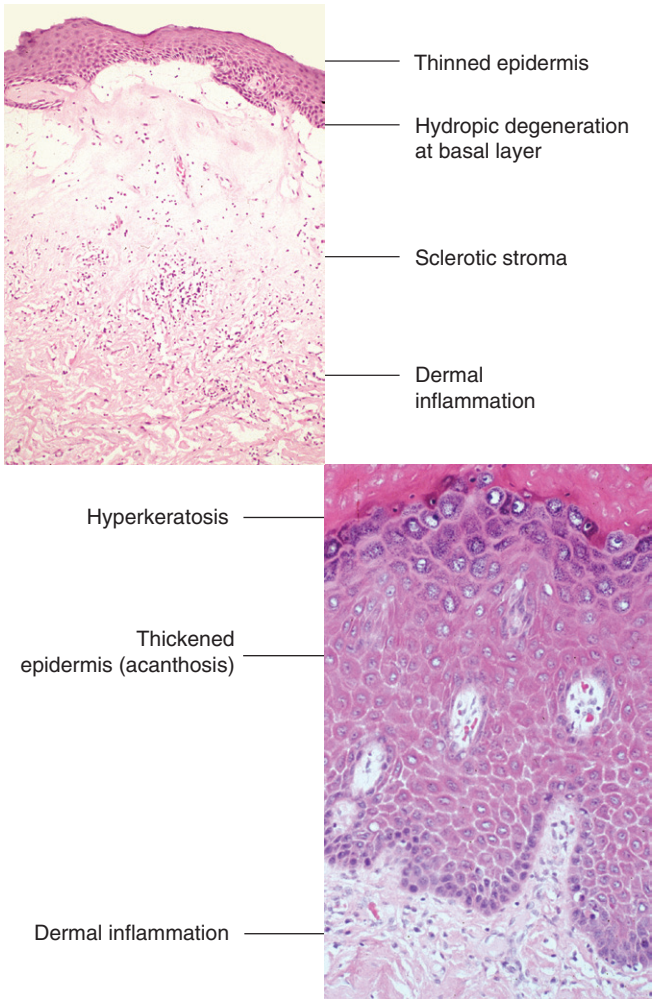


**Figure 18–1** *Upper panel*, Lichen sclerosus. *Lower panel*, Lichen simplex chronicus. The main features of the lesions are labeled.

### SUMMARY

#### Non-neoplastic Epithelial Disorders

- Lichen sclerosus is characterized by atrophic epithelium, usually with dermal fibrosis.
- Lichen sclerosus carries a slightly increased risk for development of squamous cell carcinoma.
- Lichen simplex chronicus is characterized by thickened epithelium (hyperplasia), usually with an inflammatory infiltrate.
- The lesions of lichen sclerosus and lichen simplex chronicus must be biopsied to definitively distinguish them from other causes of leukoplakia, such as squamous cell carcinoma of the vulva.

# TUMORS

## Condylomas

*Condyloma* is the name given to any warty lesion of the vulva. Most such lesions can be assigned to one of two distinctive forms. *Condylomata lata,* not commonly seen today, are flat, moist, minimally elevated lesions that occur in secondary syphilis (Chapter 17). The more common *condylomata acuminata* may be papillary and distinctly elevated or somewhat flat and rugose. They can occur anywhere on the anogenital surface, sometimes as single but more often as multiple lesions. When located on the vulva, they range from a few millimeters to many centimeters in diameter and are red-pink to pink-brown (Fig. 18–2). On histologic examination, the characteristic cellular feature is koilocytosis, a cytopathic change characterized by perinuclear cytoplasmic vacuolization and wrinkled nuclear contours that is a hallmark of HPV infection (Fig. 18–2; see also Chapter 17). Indeed, condylomata acuminata are strongly associated with HPV subtypes 6 and 11. HPV can be transmitted venereally, and identical lesions occur in men on the penis and around the anus. HPV 6 and 11 infections carry a low risk of malignant transformation, and hence, vulvar condylomas do not commonly progress to cancer.

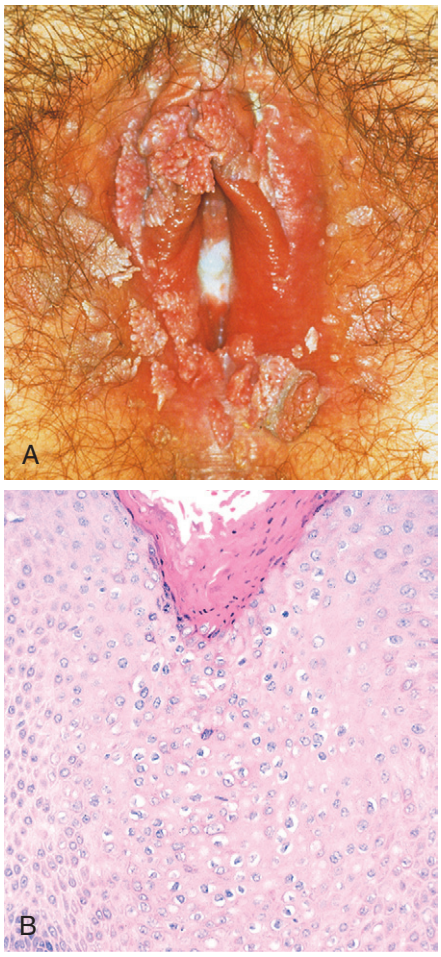


**Figure 18–2 A,** Numerous condylomas of the vulva. **B,** Histopathologic features of condyloma acuminatum include acanthosis, hyperkeratosis, and cytoplasmic vacuolation (koilocytosis, *center*).
*(A, Courtesy of Dr. Alex Ferenczy, McGill University, Montreal, Quebec, Canada.)*

## Carcinoma of the Vulva

Carcinoma of the vulva represents about 3% of all female genital tract cancers, occurring mostly in women older than age 60. Approximately 90% of carcinomas are squamous cell carcinomas; the other tumors are mainly adenocarcinomas or basal cell carcinomas.

There appear to be two distinct forms of vulvar squamous cell carcinoma. The less common form is related to high-risk HPV strains (especially HPV subtypes 16 and 18) and occurs in middle-aged women, particularly cigarette smokers. In this form, the onset of carcinoma often is preceded by precancerous changes in the epithelium termed *vulvar intraepithelial neoplasia* (VIN). VIN progresses in most patients to greater degrees of atypia and eventually undergoes transformation to carcinoma in situ; however, progression to invasive carcinoma is not inevitable and often occurs after many years. Environmental factors such as cigarette smoking and immunodeficiency appear to increase the risk of such progression.

A second form of vulvar carcinoma occurs in older women. It is not associated with HPV but often is preceded by years of reactive epithelial changes, principally lichen sclerosus. The overlying epithelium frequently lacks the typical cytologic changes of VIN, but it may display subtle atypia of the basal layer and basal keratinization. Invasive tumors of this form tend to be well differentiated and highly keratinizing.

### MORPHOLOGY

VIN and early vulvar carcinomas manifest as areas of **leukoplakia** in the form of whitish patches of epithelial thickening. In about one fourth of the cases, the lesions are pigmented owing to the presence of melanin. Over time, these areas are transformed into overt **exophytic** or ulcerative **endophytic tumors.** HPV-positive tumors often are multifocal and warty and tend to be poorly differentiated **squamous cell carcinomas,** whereas HPV-negative tumors usually are unifocal and typically manifest as well-differentiated keratinizing squamous cell carcinomas.

Both forms of vulvar carcinoma tend to remain confined to their site of origin for a few years but ultimately invade and spread, usually first to regional nodes. The risk of metastasis correlates with the size of the tumor and the depth of invasion. Women with tumors less than 2 cm in diameter have about a 90% 5-year survival rate after radical excision, whereas only 20% of those with advanced-stage lesions survive for 10 years.

## Extramammary Paget Disease

Paget disease is an intraepidermal proliferation of malignant epithelial cells that can occur in the skin of the vulva or nipple of the breast. However, unlike in the breast, where Paget disease is virtually always associated with an

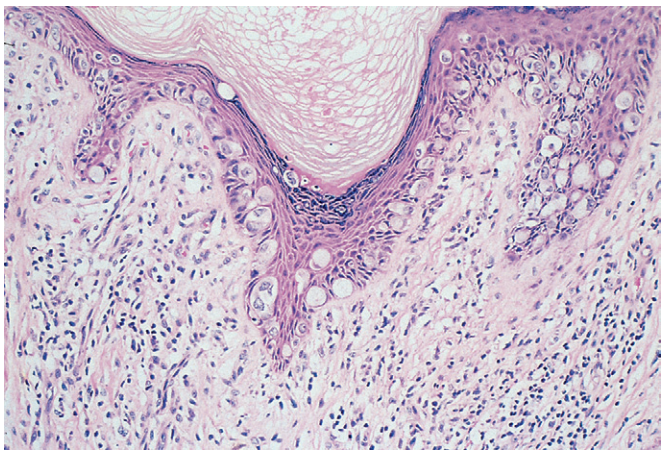

**Figure 18–3** Paget disease of the vulva, with large tumor cells with abundant clear cytoplasm scattered throughout the epidermis.

underlying carcinoma, a majority of cases of vulvar (extramammary) Paget disease have no demonstrable underlying tumor. Instead, vulvar Paget cells most commonly appear to arise from epidermal progenitor cells. Only occasionally, Paget disease in this location is accompanied by a subepithelial or submucosal tumor arising in an adnexal structure, typically sweat glands.

Paget disease manifests as a red, scaly, crusted plaque that may mimic the appearance of an inflammatory dermatitis. On histologic examination, large epithelioid cells with abundant pale, finely granular cytoplasm and occasional cytoplasmic vacuoles infiltrate the epidermis, singly and in groups (Fig. 18–3). The presence of mucin, as detected by periodic acid–Schiff (PAS) staining, is useful in distinguishing Paget disease from vulvar melanoma, which lacks mucin.

Intraepidermal Paget disease may persist for years or even decades without evidence of invasion. However, when there is an associated tumor involving skin appendages, the Paget cells may invade locally, and ultimately metastasize. Once metastasis occurs, the prognosis is poor.

### SUMMARY

#### Squamous Cell Carcinoma of the Vulva

- HPV-related vulvar squamous cell carcinomas usually are poorly differentiated lesions and sometimes are multifocal. They often evolve from vulvar intraepithelial neoplasia (VIN).
- Non–HPV-related vulvar squamous cell carcinomas occur in older women, usually are well differentiated and unifocal, and often are associated with lichen sclerosus or other inflammatory conditions.

#### Paget Disease of the Vulva

- Vulvar Paget disease is characterized by a red, scaly plaque caused by proliferation of malignant epithelial cells within the epidermis; usually, there is no underlying carcinoma, unlike Paget disease of nipple.
- Positive staining for PAS distinguishes Paget disease cells from melanoma.

## VAGINA

In adult fernales, the vagina is seldom a site of primary disease. More often, it is involved secondarily by cancer or infections arising in adjacent organs (e.g., cervix, vulva, bladder, rectum).

Congenital anomalies of the vagina fortunately are uncommon and include entities such as total absence of the vagina, a septate or double vagina (usually associated with a septate cervix and, sometimes, septate uterus), and congenital, lateral Gartner duct cysts arising from persistent wolffian duct rests.

### VAGINITIS

Vaginitis is a relatively common condition that is usually transient and of no clinical consequence. It is associated with production of a vaginal discharge (leukorrhea). A large variety of organisms have been implicated, including bacteria, fungi, and parasites. Many are normal commensals that become pathogenic only in the setting of diabetes, systemic antibiotic therapy (which causes disruption of normal microbial flora), immunodeficiency, pregnancy, or recent abortion. In adults, primary gonorrheal infection of the vagina is uncommon. The only other organisms worthy of mention, because they are frequent offenders, are *Candida albicans* and *Trichomonas vaginalis.* Candidal (monilial) vaginitis is characterized by a curdy white discharge. This organism is part of the normal vaginal flora in about 5% of women, so the appearance of symptomatic infection almost always involves one of the predisposing influences cited above or superinfection by a new, more aggressive strain. *T. vaginalis* produces a watery, copious gray-green discharge in which parasites can be identified by microscopy. *Trichomonas* also can be identified in about 10% of asymptomatic women; thus, active infection usually stems from sexual transmission of a new strain.

### MALIGNANT NEOPLASMS

#### Squamous Cell Carcinoma

Squamous cell carcinoma of the vagina is an extremely uncommon cancer that usually occurs in women older than 60 years of age in the setting of risk factors similar to those associated with carcinoma of the cervix (discussed later). Vaginal intraepithelial neoplasia is a precursor lesion that is nearly always associated with HPV infection. Invasive squamous cell carcinoma of the vagina is associated with the presence of HPV DNA in more than half of the cases, presumably derived from HPV-positive VIN.

### Clear Cell Adenocarcinoma

In 1970, clear cell adenocarcinoma, a very rare tumor, was identified in a cluster of young women whose mothers took diethylstilbestrol during pregnancy to prevent threatened abortion. Follow-up studies determined that the incidence of this tumor in persons exposed to diethylstilbestrol in utero was low (less than 1 per 1000, albeit about 40 times greater than in the unexposed population). However, since this agent was in wide use at the time it appears to be associated with a persistently elevated risk of cancer in those exposed. In about one third of exposed women, small glandular or microcystic inclusions appear in the vaginal mucosa. These benign lesions are seen as red, granular-appearing foci that on histologic examination are lined by mucus-secreting or ciliated columnar cells. This clinical condition is called *vaginal adenosis*, and it is from such precursor lesions that clear cell adenocarcinoma arises.

### Sarcoma Botryoides

Sarcoma botryoides (embryonal rhabdomyosarcoma) is a rare form of primary vaginal cancer that manifests as soft polypoid masses. It usually is encountered in infants and children younger than 5 years of age. It also may occur in other sites, such as the urinary bladder and bile ducts. These lesions are described in further detail in Chapter 20.

## CERVIX

Most cervical lesions are relatively banal inflammations (cervicitis), but the cervix also is the site of one of the most common cancers in women worldwide.

## CERVICITIS

Inflammatory conditions of the cervix are extremely common and are associated with a purulent vaginal discharge. Cervicitis can be subclassified as infectious or noninfectious, although differentiation is difficult owing to the presence of normal vaginal flora including incidental vaginal aerobes and anaerobes, streptococci, staphylococci, enterococci, and *Escherichia coli*.

Much more important are *Chlamydia trachomatis, Ureaplasma urealyticum, T. vaginalis, Candida* spp., *Neisseria gonorrhoeae,* HSV-2 (the agent of herpes genitalis), and certain types of HPV, all of which are often sexually transmitted. *C. trachomatis* is by far the most common of these pathogens, accounting for as many as 40% of cases of cervicitis encountered in sexually transmitted disease (STD) clinics. Although less common, herpetic infections are noteworthy because maternal-infant transmission during childbirth may result in serious, sometimes fatal systemic herpetic infection in the newborn.

### MORPHOLOGY

Nonspecific cervicitis may be either **acute** or **chronic.** The relatively uncommon **acute form** is limited to women in the postpartum period and usually is caused by staphylococci or streptococci. Chronic cervicitis consists of inflammation and epithelial regeneration, some degree of which is common in all women of reproductive age. The cervical epithelium may show hyperplasia and reactive changes in both squamous and columnar mucosae. Eventually, the columnar epithelium undergoes squamous metaplasia.

Cervicitis commonly comes to attention on routine examination or because of leukorrhea. Culture of the discharge must be interpreted cautiously, because (as mentioned previously) commensal organisms are virtually always present. Only the identification of known pathogens is helpful.

## NEOPLASIA OF THE CERVIX

*Most tumors of the cervix are of epithelial origin and are caused by oncogenic strains of human papillomavirus (HPV).* During development, the columnar, mucus-secreting epithelium of the endocervix is joined to the squamous epithelial covering of the exocervix at the cervical os. With the onset of puberty, the squamocolumnar junction undergoes eversion, causing columnar epithelium to become visible on the exocervix. The exposed columnar cells, however, eventually undergo squamous metaplasia, forming a region called the *transformation zone* (Fig. 18–4).

### PATHOGENESIS

HPV, the causative agent of cervical neoplasia, has a tropism for the immature squamous cells of the transformation zone. Most HPV infections are transient and are eliminated within months by an acute and chronic inflammatory response. A subset of infections persists, however, and some of these progress to cervical intraepithelial neoplasia (CIN), a

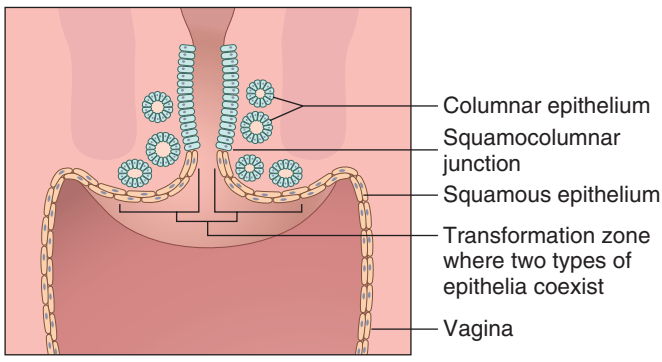


**Figure 18–4** Development of the cervical transformation zone.

precursor lesion from which most invasive cervical carcinomas develop.

HPV is detectable by molecular methods in nearly all cases of CIN and cervical carcinoma. Important risk factors for the development of CIN and invasive carcinoma thus are directly related to HPV exposure and include

- Early age at first intercourse
- Multiple sexual partners
- Male partner with multiple previous sexual partners
- Persistent infection by high-risk strains of papillomavirus

Although HPV infection occurs in the most immature squamous cells of the basal layer, replication of HPV DNA takes place in more differentiated overlying squamous cells. Squamous cells at this stage of maturation do not normally replicate DNA, but HPV-infected squamous cells do, as a consequence of expression of two potent oncoproteins encoded in the HPV genome called E6 and E7. The E6 and E7 proteins bind and inactivate two critical tumor suppressors, p53 and Rb, respectively (Chapter 5), and in doing so promote growth and increased susceptibility to additional mutations that may eventually lead to carcinogenesis.

Recognized serotypes of HPV can be classified as high-risk or low-risk types based on their propensity to induce carcinogenesis. High-risk HPV infection is the most important risk factor for the development of CIN and carcinoma. Two high-risk HPV strains, types 16 and 18, account for approximately 70% of cases of CIN and cervical carcinoma. In general, infections with high-risk HPV serotypes are more likely to persist, which is a risk factor for progression to carcinoma. These HPV subtypes also show a propensity to integrate into the host cell genome, an event that is linked to progression. Low-risk HPV strains (e.g., types 6 and 11), on the other hand, are associated with development of condylomas of the lower genital tract (Fig. 18–5) and do not integrate into the host genome, remaining instead as free episomal viral DNA. Despite the strong association of HPV infection with cancer of the cervix, HPV is not sufficient to drive the neoplastic process. As mentioned below, several HPV-infected high-grade precursor lesions do not progress to invasive cancer. The progression of cervical dysplasias to cervical cancers has been attributed to diverse factors such as immune and hormonal status, or co-infection with other sexually transmitted agents. More recently, somatically acquired mutations in the tumor suppressor gene *LKB1* were identified in more than 20% of cervical cancers. *LKB1* was first identified as the gene mutated in Peutz-Jeghers syndrome, an autosomal dominant condition characterized by hamartomatous polyps of the GI tract (Chapter 14) and a significantly elevated risk of epithelial malignancies at a variety of anatomic sites including the cervix. *LKB1* is also frequently inactivated in lung cancer. The LKB1 protein is a serine-threonine kinase that phosphorylates and activates AMPK, a metabolic sensor. AMPK in turn regulates cell growth through the mTOR complex.

## Cervical Intraepithelial Neoplasia (CIN)

HPV-related carcinogenesis begins with the precancerous epithelial change termed CIN, which usually precedes the development of an overt cancer by many years, sometimes decades. In keeping with this idea, CIN peaks in incidence at about 30 years of age, whereas invasive carcinoma peaks at about 45 years of age.

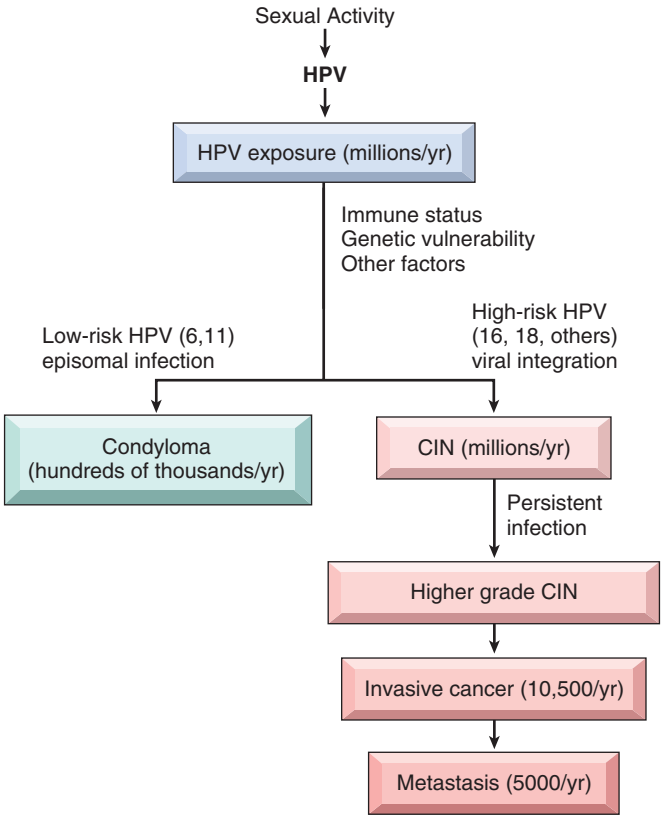


**Figure 18–5** Possible consequences of human papillomavirus (HPV) infection. Progression is associated with integration of virus and acquisition of additional mutations as discussed in the text. CIN, cervical intraepithelial neoplasia.

CIN usually starts as low-grade dysplasia (CIN I) and progresses to moderate (CIN II) and then severe dysplasia (CIN III) over time; exceptions have been reported, however, and some patients already have CIN III when the condition is first diagnosed. Generally speaking, the higher the grade of CIN, the greater the likelihood of progression; of note, however, in many cases, even high-grade lesions fail to progress to cancer and may even regress. Because decisions about patient management are two-tiered (i.e., observation versus surgical treatment), this three-tiered grading system has recently been simplified to a two-tiered system, with CIN I renamed **low-grade squamous intraepithelial lesion** (LSIL) and CIN II and CIN III combined into one category referred to as **high-grade squamous intraepithelial lesion** (HSIL). As shown in Table 18–1, the decision to treat HSIL and to observe LSIL is based on differences in the natural histories of these two groups of lesions.

**Table 18–1** Natural History of Squamous Intraepithelial Lesions (SILs)

| Lesion | Regress | Persist | Progress |
|---|---|---|---|
| LSIL (CIN I) | 60% | 30% | 10% (to HSIL) |
| HSIL (CIN II, III) | 30% | 60% | 10% (to carcinoma)* |

LSIL, low-grade SIL; HSIL, high-grade SIL.
*Progression within 10 years.

Cervical precancerous lesions are associated with abnormalities in cytologic preparations (Pap smears) that can be detected long before any abnormality is visible on gross inspection. Early detection of dysplastic changes is the rationale for the Papanicolaou (Pap) test, in which cells are scraped from the transformation zone and examined microscopically. To date, the Pap smear remains the most successful cancer screening test ever developed. In the United States, Pap screening has dramatically lowered the incidence of invasive cervical tumors to about 12,000 cases annually with a mortality of about 4000 per year; in fact, cervical cancer no longer ranks among the top 10 causes of cancer deaths in U.S. women. Paradoxically, the incidence of CIN has increased to its present level of more than 50,000 cases annually. Increased detection has certainly contributed to this.

The recently introduced quadrivalent HPV vaccine for types 6, 11, 16, and 18 is very effective in preventing HPV infections, which is expected to greatly lower the frequency of genital warts and cervical cancers associated with these HPV serotypes. Despite its efficacy, the vaccine does not supplant the need for routine cervical cancer screening—many at-risk women are already infected, and the vaccine protects against only some of the many oncogenic HPV serotypes.

### MORPHOLOGY

Figure 18–6 illustrates the three stages of CIN. **CIN I** is characterized by dyplastic changes in the lower third of the squamous epithelium and koilocytotic change in the superficial layers of the epithelium. In **CIN II,** dysplasia extends to the middle third of the epithelium and takes the form of delayed keratinocyte maturation. It also is associated with some variation in cell and nuclear size, heterogeneity of nuclear chromatin, and presence of mitoses above the basal layer extending into the middle third of the epithelium. The superficial layer of cells shows some differentiation and occasionally demonstrates the koilocytotic changes described. The next stage, **CIN III,** is marked by almost complete loss of maturation, even greater variation in cell and nuclear size, chromatin heterogeneity, disorderly orientation of the cells, and normal or abnormal mitoses; these changes affect virtually all layers of the epithelium. Koilocytotic change usually is absent. These histologic features correlate with the cytologic appearances shown in Figure 18–7. As mentioned previously, for clinical purposes CIN is divided into LSIL (CIN I) and HSIL (CIN II and CIN III).

CIN is asymptomatic and comes to clinical attention through an abnormal Pap smear result. These cases are followed up by colposcopy, during which acetic acid is used to highlight the location of lesions and the areas to be biopsied. Women with biopsy-documented LSIL are managed conservatively with careful observation, whereas HSILs are treated with surgical excision (cone biopsy). Follow-up smears and clinical examination are mandated for life in patients with HSIL, as these women remain at risk for HPV-associated cervical, vulvar, and vaginal cancers.

## Invasive Carcinoma of the Cervix

The most common cervical carcinomas are squamous cell carcinomas (75%), followed by adenocarcinomas and mixed adenosquamous carcinomas (20%) and small cell neuroendocrine carcinomas (less than 5%). All of these types of carcinomas are caused by HPV. Of interest, the relative proportion of adenocarcinomas has been increasing in recent decades owing to the decreasing incidence of invasive squamous carcinoma and suboptimal detection of glandular lesions by Pap smear.

Squamous cell carcinoma has a peak incidence at the age of about 45 years, some 10 to 15 years after detection of precursor CIN. As already discussed, progression of CIN to invasive carcinoma is variable and unpredictable and requires HPV infection as well as mutations in genes such as *LKB*. Risk factors for progression include cigarette smoking and human immunodeficiency virus

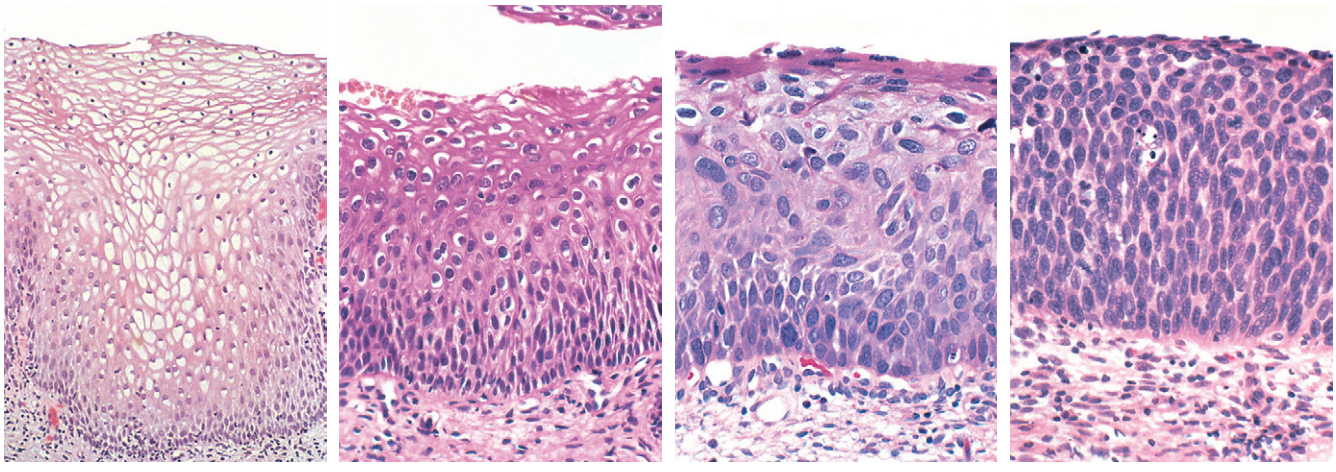


**Figure 18–6** Spectrum of cervical intraepithelial neoplasia (CIN), with normal squamous epithelium for comparison: CIN I with koilocytotic atypia; CIN II with progressive atypia in all layers of the epithelium; and CIN III (carcinoma in situ) with diffuse atypia and loss of maturation.

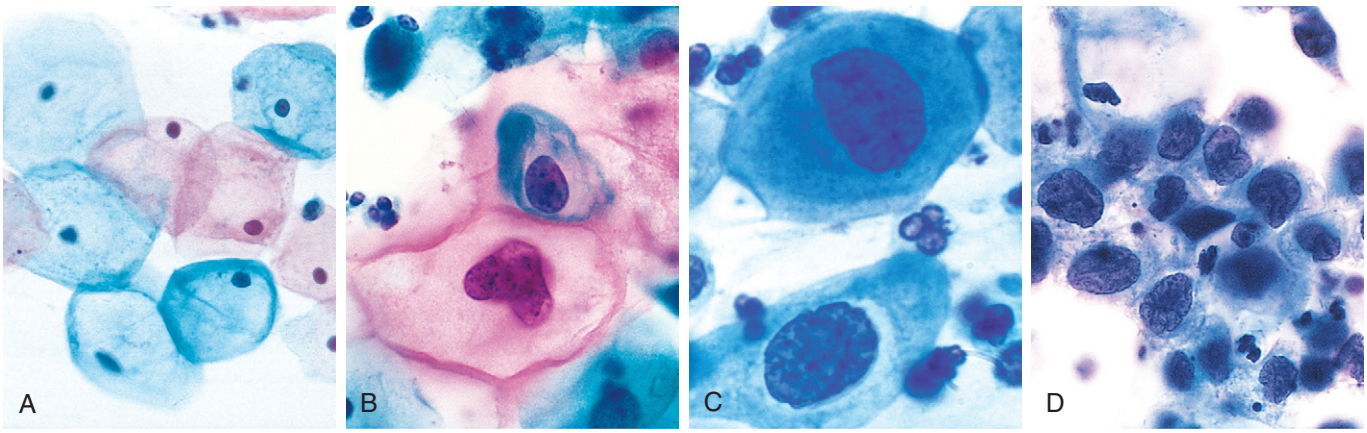


**Figure 18–7** Cytologic features of cervical intraepithelial neoplasia (CIN) in a Papanicolaou smear. Superficial squamous cells may stain either red or blue. **A,** Normal exfoliated superficial squamous epithelial cells. **B,** CIN I—low-grade squamous intraepithelial lesion (LSIL). **C** and **D,** CIN II and CIN III, respectively—both high-grade squamous intraepithelial lesions (HSILs). Note the reduction in cytoplasm and the increase in the nucleus-to-cytoplasm ratio as the grade of the lesion increases. This observation reflects the progressive loss of cellular differentiation on the surface of the cervical lesions from which these cells are exfoliated (Figure 18–6).
*(Courtesy of Dr. Edmund S. Cibas, Brigham and Women's Hospital, Boston, Massachusetts.)*

(HIV) infection, the latter finding suggesting that immune surveillance has a role in holding CIN in check. Although risk factors may help stratify patients who are likely to progress from CIN to carcinoma, the only reliable way to monitor the disease course is with frequent physical examinations coupled with biopsy of suspicious lesions.

## MORPHOLOGY

Invasive carcinomas of the cervix develop in the **transformation zone** and range from microscopic foci of stromal invasion to grossly conspicuous exophytic tumors (Fig. 18–8). Tumors encircling the cervix and penetrating into the underlying stroma produce a **barrel cervix,** which can be identified by direct palpation. Extension into the parametrial soft tissues can affix the uterus to the surrounding pelvic structures. The likelihood of spread to pelvic lymph nodes correlates with the depth of tumor invasion and the presence of tumor cells in vascular spaces. The risk of metastasis increases from less than 1% for tumors under 3 mm in depth to over 10% once invasion exceeds 3 mm. With the exception of unusual tumors exhibiting neuroendocrine differentiation, which are uniformly aggressive in their behavior, cervical carcinomas are graded based on their degree of squamous differentiation.

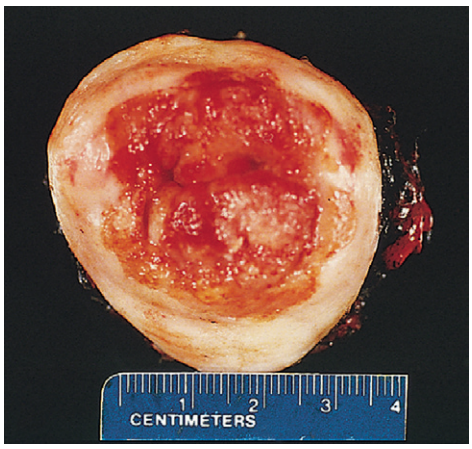


**Figure 18–8** Cervical os with surrounding, invasive, exophytic cervical carcinoma.

### Clinical Course

Invasive cervical cancer most often is seen in women who have never had a Pap smear or who have not been screened for many years. In such cases, cervical cancer often is symptomatic, with patients coming to medical attention for unexpected vaginal bleeding, leukorrhea, painful coitus (dyspareunia), or dysuria. Treatment is surgical by hysterectomy and lymph node dissection; small microinvasive carcinomas may be treated with cone biopsy. Mortality is most strongly related to tumor stage and, in the case of neuroendocrine carcinomas, to cell type. Most patients with advanced disease die as a result of local invasion rather than distant metastasis. In particular, renal failure stemming from obstruction of the urinary bladder and ureters is a common cause of death.

## SUMMARY

### Cervical Neoplasia

- Risk factors for cervical carcinoma are related to HPV exposure, such as early age at first intercourse, multiple sexual partners, and other factors including cigarette smoking and immunodeficiency.
- Nearly all cervical carcinomas are caused by HPV infections, particularly high-risk HPV types 16, 18, 31, and 33; the HPV vaccine is effective in preventing infection due to HPV types 16 and 18.
- HPV expresses E6 and E7 proteins that inactivate the p53 and Rb tumor suppressors, respectively, resulting in increased cell proliferation and suppression of DNA

damage–induced apoptosis. Loss of *LKB1* gene is also involved.
- In high-grade cervical dysplasias (CIN II and III), HPV is incorporated into the genome of the host cell.
- Not all HPV infections progress to CIN III or to invasive carcinoma. The time course from infection to invasive disease is usually 10 years or more. In general, the risk of progression is proportional to the degree of dysplasia.
- The Pap smear is a highly effective screening tool for the detection of cervical dysplasia and carcinoma and has significantly reduced the incidence of cervical carcinoma.

### Endocervical Polyp

Endocervical polyps are benign polypoid masses seen protruding from the endocervical mucosa (sometimes through the exocervix). They can be as large as a few centimeters, are soft and yielding to palpation, and have a smooth, glistening surface with underlying cystically dilated spaces filled with mucinous secretions. The surface epithelium and lining of the underlying cysts are composed of the same mucus-secreting columnar cells that line the endocervical canal. The stroma is edematous and may contain scattered mononuclear cells. Superimposed chronic inflammation may lead to squamous metaplasia of the overlying epithelium and ulcerations. These lesions may bleed, thereby arousing concern, but they have no malignant potential.

## BODY OF UTERUS

The uterine corpus is composed of endometrial mucosa and the underlying smooth muscle myometrium. The more frequent and significant disorders of the uterus are considered here.

## ENDOMETRITIS

Inflammation of the endometrium is classified as acute or chronic depending on whether a neutrophilic or a lymphoplasmacytic response predominates, respectively. The diagnosis of chronic endometritis generally requires the presence of plasma cells, as lymphocytes normally are seen in the endometrium.

Endometritis often is a consequence of pelvic inflammatory disease and is frequently due to *N. gonorrhoeae* or *C. trachomatis.* Histologic examination reveals a neutrophilic infiltrate in the superficial endometrium and glands coexisting with a stromal lymphoplasmacytic infiltrate. Prominent lymphoid follicles are more commonly seen in chlamydial infection. Tuberculosis causes granulomatous endometritis, frequently with associated tuberculous salpingitis and peritonitis. Although seen in the United States mainly in immunocompromised persons, tuberculous endometritis is common in countries where tuberculosis is endemic and should be included in the differential diagnosis for pelvic inflammatory disease in women who have recently emigrated from endemic areas.

Endometritis also may be due to retained products of conception, subsequent to miscarriage or delivery, or to presence of a foreign body such as an intrauterine device. Retained tissue or foreign bodies act as a nidus for ascending infection by vaginal or intestinal tract flora. Removal of the offending tissue or foreign body typically results in resolution.

Clinically, all forms of endometritis may manifest with fever, abdominal pain, and menstrual abnormalities. In addition, there is an increased risk of infertility and ectopic pregnancy as a consequence of damage and scarring of the fallopian tubes.

## ADENOMYOSIS

*Adenomyosis* refers to the growth of the basal layer of the endometrium down into the myometrium. Nests of endometrial stroma, glands, or both, are found deep in the myometrium interposed between the muscle bundles. The aberrant presence of endometrial tissue induces reactive hypertrophy of the myometrium, resulting in an enlarged, globular uterus, often with a thickened uterine wall. Because the glands in adenomyosis derive from the stratum basalis of the endometrium, they do not undergo cyclic bleeding. Nevertheless, marked adenomyosis may produce menorrhagia, dysmenorrhea, and pelvic pain before the onset of menstruation.

## ENDOMETRIOSIS

*Endometriosis* is defined by the presence of endometrial glands and stroma in a location outside the endomyometrium. It occurs in as many as 10% of women in their reproductive years and in nearly half of women with infertility. It frequently is multifocal and often involves pelvic structures (ovaries, pouch of Douglas, uterine ligaments, tubes, and rectovaginal septum). Less frequently, distant areas of the peritoneal cavity or periumbilical tissues are involved. Uncommonly, distant sites such as lymph nodes, lungs, and even heart, skeletal muscle, or bone are affected.

Three hypotheses have been put forth to explain the origin of these dispersed lesions (Fig. 18–9). The *regurgitation theory,* which is currently favored, proposes that menstrual backflow through the fallopian tubes leads to implantation. The *metaplastic theory*, on the other hand, posits endometrial differentiation of coelomic epithelium (from which endometrium originates) as the source. These two theories cannot, however, explain lesions in the lymph nodes, skeletal muscle, or lungs. Hence, the *vascular* or *lymphatic dissemination theory* has been invoked to explain

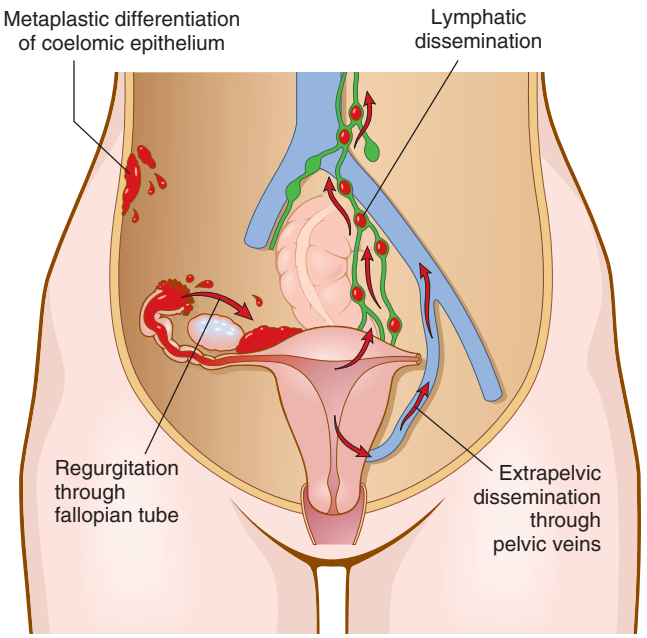


**Figure 18–9** Proposed origins of endometriosis.

extrapelvic or intranodal implants. Conceivably, all pathways could be valid in individual instances.

Recent studies suggest that the *endometriotic tissue is not just misplaced but is also abnormal.* As compared to normal endometrium, endometriotic tissue exhibits increased levels of inflammatory mediators, particularly prostaglandin E2, and increased estrogen production due to high aromatase activity of stromal cells. These changes enhance the survival and persistence of the endometriotic tissue within a foreign location (a key feature in the pathogenesis of endometriosis) and help to explain the beneficial effects of COX-2 inhibitors and aromatase inhibitors in the treatment of endometriosis.

## MORPHOLOGY

In contrast with adenomyosis, **endometriosis** almost always contains **functioning endometrium,** which undergoes cyclic bleeding. Because blood collects in these aberrant foci, they usually appear grossly as red-brown nodules or implants. They range in size from microscopic to 1 to 2 cm in diameter and lie on or just under the affected serosal surface. Often, individual lesions coalesce to form larger masses. When the ovaries are involved, the lesions may form large, blood-filled cysts that turn brown **(chocolate cysts)** as the blood ages (Fig. 18–10). With seepage and organization of the blood, widespread fibrosis occurs, leading to adhesions among pelvic structures, sealing of the tubal fimbriated ends, and distortion of the oviducts and ovaries. The histologic diagnosis at all sites depends on finding two of the following three features within the lesions: endometrial glands, endometrial stroma, and hemosiderin pigment.

### Clinical Features

The clinical manifestations of endometriosis depend on the distribution of the lesions. Extensive scarring of the oviducts and ovaries often produces discomfort in the lower abdominal quadrants and eventual sterility. Rectal wall involvement may produce pain on defecation, while involvement of the uterine or bladder serosa can cause dyspareunia (painful intercourse) and dysuria, respectively. Almost all cases feature severe dysmenorrhea and pelvic pain resulting from intrapelvic bleeding and periuterine adhesions.



**Figure 18–10** Ovarian endometriosis. Sectioning of ovary reveals a large endometriotic cyst with degenerated blood ("chocolate cyst").

## ABNORMAL UTERINE BLEEDING

Women commonly seek medical attention for some type of abnormal uterine bleeding such as *menorrhagia* (profuse or prolonged bleeding at the time of the period), *metrorrhagia* (irregular bleeding between the periods), or postmenopausal bleeding. Common causes include endometrial polyps, leiomyomas, endometrial hyperplasia, endometrial carcinoma, and endometritis.

The probable cause of uterine bleeding in any given case depends somewhat on the age of the patient (Table 18–2). Abnormal bleeding from the uterus in the absence of an organic uterine lesion is called *dysfunctional uterine bleeding.* The various causes of abnormal uterine bleeding, both dysfunctional and that which is secondary to an organic lesion, can be segregated into four groups:

**Table 18–2** Causes of Abnormal Uterine Bleeding by Age Group

| Age Group | Cause(s) |
|---|---|
| Prepuberty | Precocious puberty (hypothalamic, pituitary, or ovarian origin) |
| Adolescence | Anovulatory cycle |
| Reproductive age | Complications of pregnancy (abortion, trophoblastic disease, ectopic pregnancy)<br>Proliferations (leiomyoma, adenomyosis, polyps, endometrial hyperplasia, carcinoma)<br>Anovulatory cycle<br>Ovulatory dysfunctional bleeding (e.g., inadequate luteal phase) |
| Perimenopause | Anovulatory cycle<br>Irregular shedding<br>Proliferations (carcinoma, hyperplasia, polyps) |
| Postmenopause | Proliferations (carcinoma, hyperplasia, polyps)<br>Endometrial atrophy |

- *Failure of ovulation.* Anovulatory cycles are very common at both ends of reproductive life, due to (1) hypothalamic-pituitary axis, adrenal, or thyroid dysfunction; (2) functional ovarian lesions producing excess estrogen; (3) malnutrition, obesity, or debilitating disease; and (4) severe physical or emotional stress. Regardless of the cause, ovulatory failure results in an excess of estrogen relative to progesterone. Thus, the endometrium goes through a proliferative phase that is not followed by the normal secretory phase. The endometrial glands may develop mild cystic changes or appear disorderly (Fig. 18–11, *A*), while the endometrial stroma, which requires progesterone for growth, may be scarce. This combination of abnormalities makes the endometrium prone to breakdown and abnormal bleeding.
- *Inadequate luteal phase.* The corpus luteum may fail to mature normally or may regress prematurely leading to a relative lack of progesterone. The endometrium under these circumstances fails to show the expected secretory changes.
- *Contraceptive-induced bleeding.* Older oral contraceptives containing synthetic estrogens and progestin induced a variety of endometrial responses, including a lush, decidua-like stroma and inactive, nonsecretory glands. The pills in current use no longer cause these abnormalities.
- *Endomyometrial disorders,* including chronic endometritis, endometrial polyps, and submucosal leiomyomas

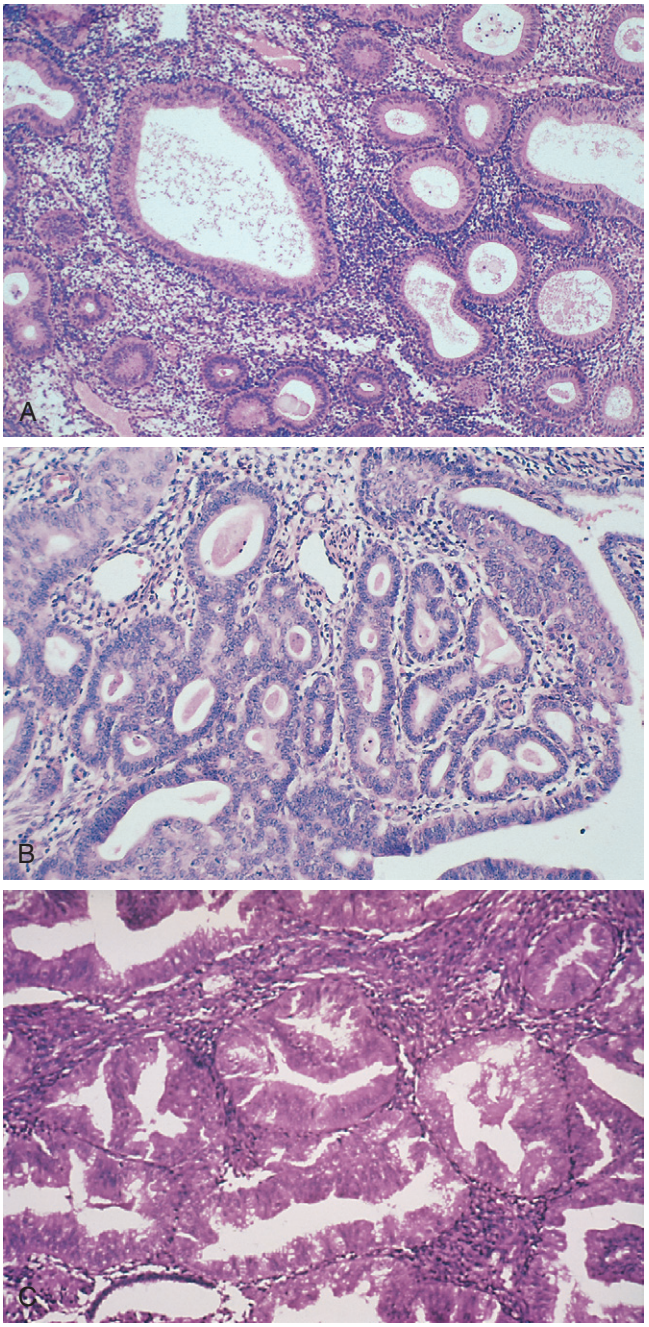


**Figure 18–11** Endometrial hyperplasia. **A,** Anovulatory or "disordered" endometrium containing dilated glands. **B,** Complex hyperplasia without atypia, characterized by nests of closely packed glands. **C,** Complex hyperplasia with atypia, seen as glandular crowding and cellular atypia.

### SUMMARY

#### Non-neoplastic Disorders of Endometrium

- Endometriosis refers to endometrial glands and stroma located outside the uterus and may involve the pelvic or abdominal peritoneum. Rarely, distant sites like the lymph nodes and the lungs also are involved.
- The ectopic endometrium in endometriosis undergoes cyclic bleeding, and the condition is a common cause of dysmenorrhea and pelvic pain.
- Adenomyosis refers to growth of endometrium into the myometrium with uterine enlargement. Unlike with endometriosis, there is no cyclic bleeding.

## PROLIFERATIVE LESIONS OF THE ENDOMETRIUM AND MYOMETRIUM

The most common proliferative lesions of the uterine corpus are endometrial hyperplasia, endometrial carcinomas, endometrial polyps, and smooth muscle tumors. All tend to produce abnormal uterine bleeding as their earliest manifestation.

### Endometrial Hyperplasia

An excess of estrogen relative to progestin, if sufficiently prolonged or marked, can induce exaggerated endometrial proliferation (hyperplasia), which is an important precursor of endometrial carcinoma. Potential causes of estrogen excess include failure of ovulation (such as is seen in perimenopause), prolonged administration of estrogenic steroids without counterbalancing progestin, and estrogen-producing ovarian lesions (such as polycystic ovary disease and granulosa-theca cell tumors of the ovary). A common cause of estrogen excess is obesity, as adipose tissue converts steroid precursors into estrogens.

The severity of hyperplasia is correlated with the level and duration of estrogen excess, and is classified based on architectural crowding (simple versus complex) and the

presence or absence of cytologic atypia (Fig. 18–11, *B* and *C*). The risk of developing carcinoma is related to the presence of cellular atypia. Complex hyperplasia without cellular atypia carries a low risk (less than 5%) for progression to endometrial carcinoma, while complex hyperplasia with cellular atypia is associated with a much higher risk (20% to 50%). When hyperplasia with atypia is discovered, it must be carefully evaluated for the presence of cancer and must be monitored by serial endometrial biopsies.

In time, the hyperplasia may proliferate autonomously, no longer requiring estrogen, and eventually may give rise to carcinoma. In a significant number of cases, the hyperplasia is associated with inactivating mutations in the *PTEN* tumor suppressor gene, an important brake on signaling through the PI-3-kinase/AKT signaling pathway. Acquisition of *PTEN* mutations is believed to be one of several key steps in the transformation of hyperplasias to endometrial carcinomas, which also often harbor *PTEN* mutations.

## Endometrial Carcinoma

In the United States and many other Western countries, endometrial carcinoma is the most frequent cancer occurring in the female genital tract. It generally appears between the ages of 55 and 65 years and is uncommon before age 40. Endometrial carcinomas comprise two distinct kinds of cancer: *endometrioid* and *serous carcinoma of the endometrium*. These two types are histologically and pathogenetically distinct. Endometrioid cancers arise in association with estrogen excess and endometrial hyperplasia in perimenopausal women, whereas serous cancers arise in the setting of endometrial atrophy in older postmenopausal women.

### PATHOGENESIS

The endometrioid type accounts for 80% of cases of endometrial carcinomas. These tumors are designated **endometrioid** because of their histologic similarity to normal endometrial glands. Risk factors for this type of carcinoma include (1) obesity, (2) diabetes, (3) hypertension, (4) infertility, and (5) exposure to unopposed estrogen. Many of these risk factors result in increased estrogenic stimulation of the endometrium and are associated with endometrial hyperplasia. In fact, it is well recognized that prolonged estrogen replacement therapy and estrogen-secreting ovarian tumors increase the risk of endometrioid type of endometrial carcinoma. Additionally, breast carcinoma (which also is estrogen-dependent) occurs in women with endometrial cancer (and vice versa) more frequently than by chance alone. **Mutations in mismatch repair genes and the tumor suppressor gene PTEN are early events in the stepwise development of endometrioid carcinoma.** Women with germline mutations in *PTEN* (Cowden syndrome) are at high risk for this cancer. *TP53* mutations occur but are relatively uncommon and are believed to be late events in the genesis of this tumor type.

The **serous type** of endometrial carcinoma is much less common, accounting for roughly 15% of tumors. Nearly all cases have mutations in the *TP53* tumor suppressor gene, whereas mutations in DNA mismatch repair genes and *PTEN* are rare.

### MORPHOLOGY

**Endometrioid carcinomas** closely resemble normal endometrium and may be exophytic or infiltrative (Fig. 18–12, *A* and *B*). They include a range of histologic types, including those showing mucinous, tubal (ciliated), and squamous (occasionally adenosquamous) differentiation. Tumors originate in the mucosa and may infiltrate the myometrium and enter vascular spaces. They may also metastasize to regional lymph nodes. Endometrioid carcinomas are graded I to III, based on the degree of differentiation. **Serous carcinomas,** on the other hand, form small tufts and papillae, rather than the glands seen in endometrioid carcinoma, and exhibit much greater cytologic atypia. They behave aggressively and thus are by definition high-grade. Immunohistochemistry often reveals high levels of p53 in serous carcinoma (Fig. 18–12, *C* and *D*), a finding that correlates with the presence of *TP53* mutations (mutant p53 accumulates and hence is more easily detected by staining).

### Clinical Course

Endometrial carcinomas usually manifest with leukorrhea and irregular bleeding, often in postmenopausal women. With progression, the uterus enlarges and may become affixed to surrounding structures as the cancer infiltrates surrounding tissues. These tumors usually are slow to metastasize, but if left untreated, eventually disseminate to regional nodes and more distant sites. With therapy, the 5-year survival rate for early-stage carcinoma is 90%, but survival drops precipitously in higher-stage tumors. The prognosis with serous carcinomas is strongly dependent on operative staging and cytologic screening of peritoneal washings; the latter is imperative, because very small or superficial serous tumors may nonetheless spread by way of the fallopian tube to the peritoneal cavity.

### SUMMARY

#### Endometrial Hyperplasia and Endometrial Carcinoma

- Endometrial hyperplasia results from excess endogenous or exogenous estrogen.
- Risk factors for developing endometrial hyperplasia include anovulatory cycles, polycystic ovary syndrome, estrogen-producing ovarian tumor, obesity, and estrogen therapy without counterbalancing progestin.
- The severity of hyperplasia is graded on the basis of architectural (simple versus complex) and cytologic (normal versus atypical) criteria. The risk of developing carcinoma is predominantly related to cytologic atypia.
- On the basis of clinical and molecular data, two major types of endometrial carcinoma are recognized:
  - *Endometrioid carcinoma* is associated with estrogen excess and endometrial hyperplasia. Early molecular changes include inactivation of DNA mismatch repair genes and the *PTEN* gene.
  - *Serous carcinoma* of the endometrium arises in older women and usually is associated with endometrial atrophy. Mutations in the *TP53* gene are an early event.

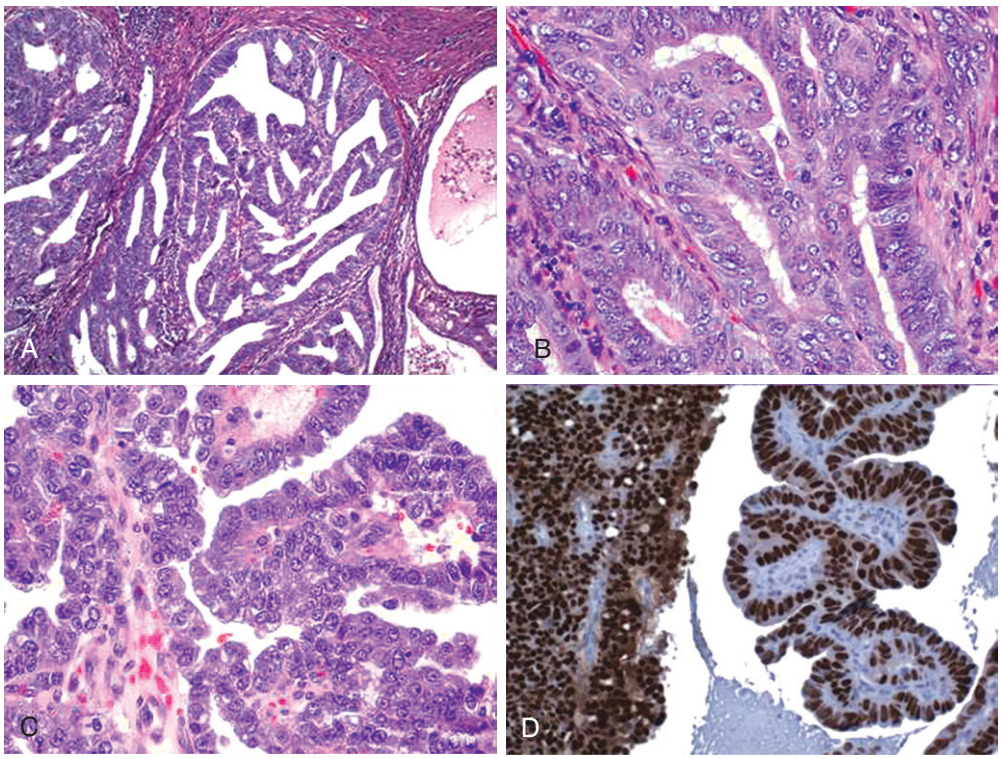


**Figure 18–12** Endometrial carcinoma. **A,** Endometrioid type, infiltrating myometrium and growing in a cribriform pattern. **B,** Higher magnification reveals loss of polarity and nuclear atypia. **C,** Serous carcinoma of the endometrium, with papilla formation and marked cytologic atypia. **D,** Immunohistochemical staining reveals accumulation of p53, a finding associated with *TP53* mutation.

- Stage is the major determinant of survival in both types. Serous tumors tend to manifest more frequently with extrauterine extension and therefore have a worse prognosis than endometrioid carcinomas.

## Endometrial Polyps

These sessile, usually hemispheric lesions range from 0.5 to 3 cm in diameter. Larger polyps may project from the endometrial mucosa into the uterine cavity. On histologic examination, they are composed of endometrium resembling the basalis, frequently with small muscular arteries. Some glands have a normal endometrial architecture, but more often they are cystically dilated. The stromal cells are monoclonal, often with a rearrangement of chromosomal region 6p21, and thus constitute the neoplastic component of the polyp.

Although endometrial polyps may occur at any age, they most commonly are detected around the time of menopause. Their clinical significance lies in abnormal uterine bleeding and, more important, in the risk (however rare) of giving rise to a cancer.

## Leiomyoma

Benign tumors that arise from the smooth muscle cells in the myometrium are properly termed *leiomyomas.* Because of their firmness, however, they often are referred to clinically as *fibroids.* Leiomyomas are the most common benign tumor in females, affecting 30% to 50% of women of reproductive age, and are considerably more frequent in blacks than in whites. These tumors are monoclonal and are associated with several different recurrent chromosomal abnormalities, including rearrangements of chromosomes 6 and 12 that also are found in a variety of other benign neoplasms, such as endometrial polyps and lipomas. Estrogens and possibly oral contraceptives stimulate the growth of leiomyomas; conversely, these tumors shrink postmenopausally.

### MORPHOLOGY

Leiomyomas are typically **sharply circumscribed,** firm gray-white masses with a characteristic **whorled cut surface.** They may occur singly, but more often **multiple tumors** are scattered within the uterus, ranging from small nodules to large tumors (Fig. 18–13) that may dwarf the uterus. Some are embedded within the myometrium (intramural), whereas others may lie directly beneath the endometrium (submucosal) or directly beneath the serosa (subserosal). In the latter location, tumors may extend out on attenuated stalks and even become attached to surrounding organs, from which they may develop a blood supply (**parasitic** leiomyomas). On histologic examination, the tumors are characterized by **bundles of smooth muscle cells** mimicking the appearance of normal myometrium. Foci of fibrosis, calcification, and degenerative softening may be present.

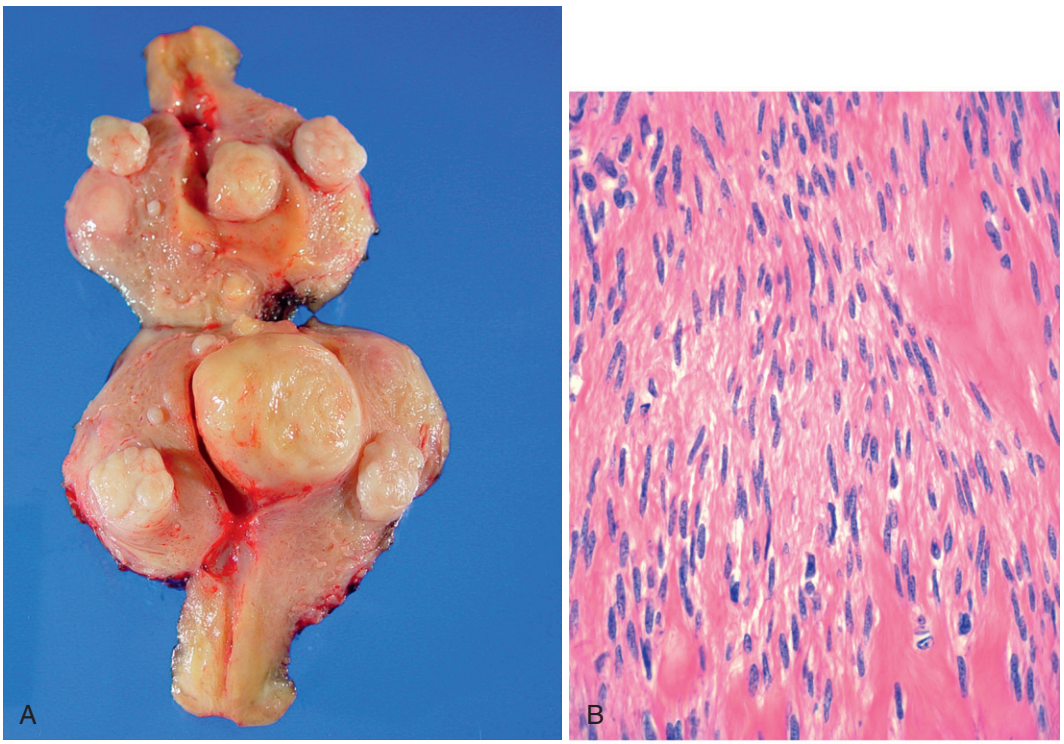


**Figure 18–13** Uterine leiomyomas. **A,** The uterus is opened to reveal multiple submucosal, myometrial, and subserosal gray-white tumors, each with a characteristic whorled appearance on cut section **B.** Microscopic appearance of leiomyoma reveals bundles of normal-looking smooth muscle cells.

*Leiomyomas* of the uterus often are asymptomatic, being discovered incidentally on routine pelvic examination. The most frequent presenting sign is menorrhagia, with or without metrorrhagia. Large leiomyomas may be palpated by the affected woman or may produce a dragging sensation. Leiomyomas almost never transform into sarcomas, and the presence of multiple lesions does not increase the risk of malignancy.

## Leiomyosarcoma

*Leiomyosarcomas* arise de novo from the mesenchymal cells of the myometrium, not from preexisting leiomyomas. They are almost always solitary and most often occur in postmenopausal women, in contradistinction to leiomyomas, which frequently are multiple and usually arise premenopausally.

### MORPHOLOGY

Leiomyosarcomas typically take the form of **soft, hemorrhagic, necrotic masses.** The histologic appearance varies widely, from tumors that closely resemble leiomyoma to wildly anaplastic neoplasms. Those well-differentiated tumors that lie at the interface between leiomyoma and leiomyosarcoma are sometimes designated smooth muscle tumors of uncertain malignant potential; in such cases, only time will tell if the tumor's behavior is benign or malignant. The diagnostic features of overt leiomyosarcoma include **tumor necrosis, cytologic atypia, and mitotic activity.** Since increased mitotic activity is sometimes seen in benign smooth muscle tumors, particularly in young women, an assessment of all three features is necessary to make a diagnosis of malignancy.

Recurrence after removal is common with these cancers, and many metastasize, typically to the lungs, yielding a 5-year survival rate of about 40%. The outlook with anaplastic tumors is less favorable than with well-differentiated tumors.

### SUMMARY

#### Uterine Smooth Muscle Neoplasms

- Benign smooth muscle tumors, called leiomyomas, are common and frequently multiple; they may manifest with menorrhagia or as a pelvic mass or may be detected as a cause of infertility.
- Malignant smooth muscle tumors, called leiomyosarcomas, arise de novo, not from leiomyomas.
- Criteria of malignancy include necrosis, cytologic atypia, and mitotic activity.

# FALLOPIAN TUBES

The most common disorder of the fallopian tubes is inflammation (salpingitis), almost invariably occurring as a component of pelvic inflammatory disease. Less common abnormalities are ectopic (tubal) pregnancy, endometriosis, and, rarely, primary tumors.

*Inflammations of the tube* are almost always microbial in origin. With the declining incidence of gonorrhea, nongonococcal organisms, such as *Chlamydia, Mycoplasma hominis,* coliforms, and (in the postpartum setting) streptococci and staphylococci, are now the major offenders. The morphologic changes produced by gonococci are similar to those in the male genital tract (Chapter 17). Nongonococcal infections can penetrate the wall of the tubes, giving rise to blood-borne infections, with seeding of the meninges, joint spaces, and sometimes even the heart valves. Tuberculous salpingitis is far less common and is almost always encountered in combination with tuberculous endometritis. All forms of salpingitis may produce fever, lower abdominal or pelvic pain, and pelvic masses, which are the result of distention of the tubes with either exudate or inflammatory debris (Fig. 18–14). Adherence of the inflamed tube to the ovary and adjacent ligamentous tissues may result in a *tuboovarian abscess,* referred to as a tuboovarian complex when infection subsides. Even more serious are adhesions of the tubal plicae, which are associated with increased risk of tubal ectopic pregnancy (discussed later). Damage to or obstruction of the tubal lumina may produce permanent sterility.

*Primary adenocarcinomas* of the fallopian tubes may be of serous or endometrioid histologic type. Although less common than ovarian tumors, serous fallopian tube carcinomas seem to be increased in women with *BRCA* mutations. In studies of prophylactic oophorectomies in such women, 10% had occult foci of malignancy, equally divided between the ovary and the fallopian tube, where they usually occurred in the fimbria. This has led to the suggestion that sporadic "ovarian" serous carcinomas (discussed later) may also originate in the fallopian tube, an idea that remains controversial. Because the fallopian tube provides access to the peritoneal cavity, fallopian tube carcinomas frequently involve the omentum and peritoneal cavity at presentation.

## SUMMARY

### Fallopian Tube Disease

- Salpingitis is usually a component of pelvic inflammatory disease; it results in scarring of the fallopian tube lining, increasing the risk of tubal ectopic pregnancy.
- Fallopian tube carcinomas usually manifest at an advanced stage, with involvement of the peritoneal cavity.

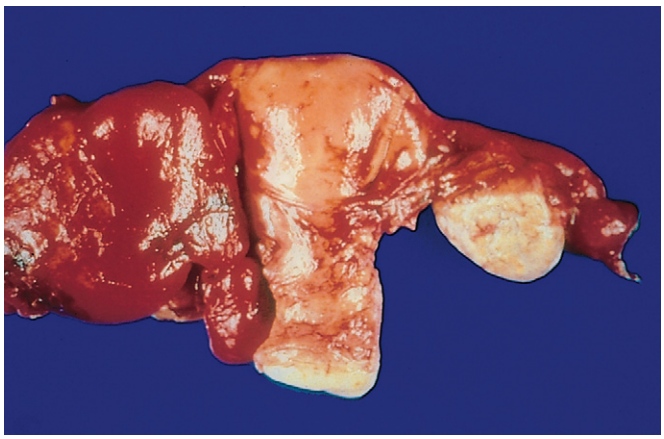

**Figure 18–14** Pelvic inflammatory disease, bilateral and asymmetric. The tube and ovary to the left of the uterus is totally obscured by a hemorrhagic inflammatory mass. The tube is adherent to the adjacent ovary on the other side.

# OVARIES

## FOLLICLE AND LUTEAL CYSTS

Follicle and luteal cysts in the ovaries are so commonplace that they may be considered variants of normal physiology. These innocuous lesions originate from unruptured graafian follicles or from follicles that have ruptured and then become immediately sealed. Such cysts often are multiple and develop subjacent to the serosal covering of the ovary. They typically are small (1 to 1.5 cm in diameter) and are filled with clear serous fluid. Occasionally, they become sufficiently large (4 to 5 cm) to produce palpable masses and pelvic pain. When small, they are lined by granulosa lining cells or luteal cells, but as fluid accumulates, pressure may cause atrophy of these cells. Sometimes these cysts rupture, producing intraperitoneal bleeding and peritoneal symptoms (acute abdomen).

## POLYCYSTIC OVARIAN DISEASE

*Polycystic ovarian disease* (formerly called *Stein-Leventhal syndrome*) is a disorder in which multiple cystic follicles in the ovaries produce excess androgens and estrogens. It usually comes to attention after menarche in teenage girls or young adults who present with oligomenorrhea, hirsutism, infertility, and sometimes obesity.

The ovaries are usually twice the normal size, gray-white with a smooth outer cortex, and studded with subcortical cysts 0.5 to 1.5 cm in diameter. Histologic examination reveals a thickened, fibrotic ovarian capsule overlying innumerable cystic follicles lined by granulosa cells with a hyperplastic luteinized theca interna. There is a conspicuous absence of corpora lutea in the ovary.

In most patients, the principal biochemical abnormalities are excessive production of androgens, high concentrations of luteinizing hormone, and low concentrations of follicle-stimulating hormone. The origins of these changes are poorly understood, but it is proposed that the ovaries elaborate excess androgens, which are converted to estrogenic hormones in peripheral fatty depots, which inhibit the secretion of follicle-stimulating hormone by the pituitary through the hypothalamus.

## TUMORS OF THE OVARY

With more than 20,000 new cases diagnosed annually, ovarian cancer is the eighth most common cancer in U.S. women. It also is the fifth leading contributor to cancer mortality in women, with an estimated 14,000 deaths in 2010. Tumors of the ovary are amazingly varied. This diversity is attributable to the presence of three cell types in the normal ovary: the multipotent surface (coelomic) epithelium, the totipotent germ cells, and the sex cord–stromal cells, each of which gives rise to a number of different tumors (Fig. 18–15).

Neoplasms of surface epithelial origin account for the great majority of primary ovarian tumors and, in their malignant forms, account for almost 90% of ovarian cancers. Germ cell and sex cord–stromal cell tumors are much less frequent; although they constitute 20% to 30% of ovarian tumors, they are collectively responsible for less than 10% of malignant tumors of the ovary.

### Surface Epithelial Tumors

The vast majority of ovarian neoplasms is derived from the coelomic epithelium that covers the surface of the ovary. With repeated ovulation and scarring, surface epithelium becomes entrapped in the cortex of the ovary, forming small epithelial cysts. These can become metaplastic or undergo neoplastic transformation to give rise to a number of different epithelial tumors. Benign lesions usually are cystic (cystadenoma) and may have an accompanying stromal component (cystadenofibroma). Malignant tumors may also be cystic (cystadenocarcinoma) or solid (carcinoma). Some ovarian epithelial tumors fall into an intermediate, borderline category currently referred to as *tumors of low malignant potential*. These are best considered low-grade cancers with limited invasive potential and understandably carry a better prognosis than that for overtly malignant ovarian carcinomas.

Important risk factors for ovarian cancer include nulliparity, family history, and germline mutations in certain tumor suppressor genes. There is a higher incidence of carcinoma in unmarried women and married women with low parity. Of interest, prolonged use of oral contraceptives

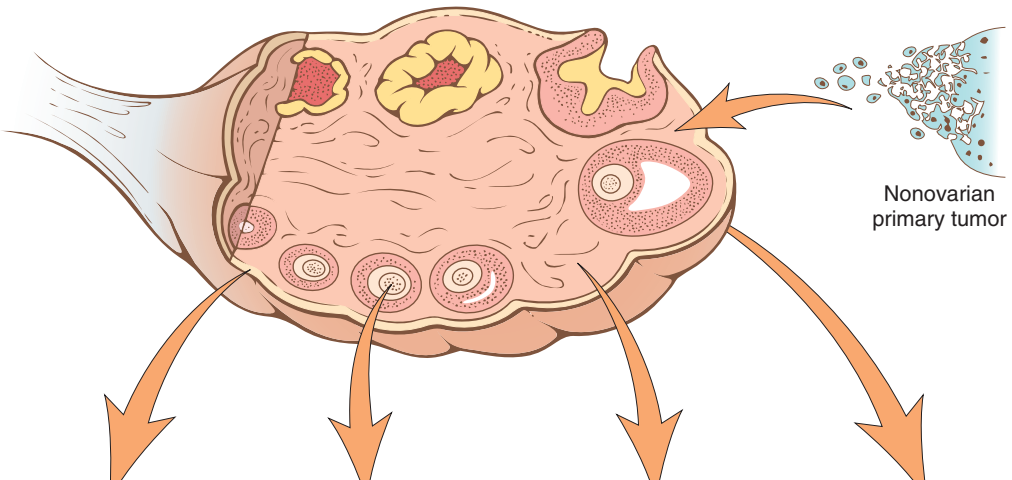


| ORIGIN | SURFACE EPITHELIAL CELLS (Surface epithelial–stromal cell tumors) | GERM CELL | SEX CORD–STROMA | METASTASIS TO OVARIES |
|---|---|---|---|---|
| Overall frequency | 65%–70% | 15%–20% | 5%–10% | 5% |
| Proportion of malignant ovarian tumors | 90% | 3%–5% | 2%–3% | 5% |
| Age group affected | 20+ years | 0–25+ years | All ages | Variable |
| Types | • Serous tumor<br>• Mucinous tumor<br>• Endometrioid tumor<br>• Clear cell tumor<br>• Brenner tumor<br>• Cystadenofibroma | • Teratoma<br>• Dysgerminoma<br>• Endodermal sinus tumor<br>• Choriocarcinoma | • Fibroma<br>• Granulosa-theca cell tumor<br>• Sertoli-Leydig cell tumor | |

**Figure 18–15** Derivation, frequency, and age distribution for various ovarian neoplasms.

somewhat reduces the risk. Around 5% to 10% of ovarian cancers are familial, and most of these are associated with mutations in *BRCA1* and *BRCA2* tumor suppressor genes. As will be discussed later, mutations in *BRCA1* and *BRCA2* are also associated with hereditary breast cancer. The average lifetime risk for ovarian cancer approximates 30% in *BRCA1* carriers; the risk in *BRCA2* carriers is somewhat lower. In contrast with familial ovarian cancer, mutations in *BRCA1* and *BRCA2* are found in only 8% to 10% of sporadic ovarian cancers, which appear to arise through alternative molecular mechanisms.

## Serous Tumors

Serous tumors are the most common of the ovarian epithelial tumors. About 60% are benign, 15% are of low malignant potential, and 25% are malignant. Benign lesions are usually encountered in patients between 30 and 40 years of age, and malignant serous tumors are more commonly seen between 45 and 65 years of age. Taken together, borderline and malignant serous tumors are the most common ovarian malignancies, accounting for about 60% of all ovarian cancers.

Emerging evidence indicates that there are two types of serous carcinomas: low-grade and high-grade. The former arise from benign or borderline lesions and progress slowly in a stepwise manner to become invasive carcinoma. These low-grade tumors are associated with *KRAS*, *BRAF*, or *ERBB2* mutations. The high-grade serous tumors develop rapidly. As already mentioned, at least some of these high-grade lesions develop from tubal intraepithelial carcinoma, rather than ovarian coelomic epithelium. Recent "deep sequencing" of high-grade serous carcinomas has confirmed that 96% of tumors have mutations in *TP53*. Mutations affecting the Notch signaling pathway and FOXM1, a transcription factor previously implicated in the pathogenesis of ovarian carcinoma, were also detected in a sizable minority of tumors.

### MORPHOLOGY

Most serous tumors are large, spherical to ovoid, cystic structures up to 30 to 40 cm in diameter. **About 25% of the benign tumors are bilateral.** In the benign tumors, the serosal covering is smooth and glistening. By contrast, the surface of the cystadenocarcinoma has nodular irregularities representing areas in which the tumor has penetrated into the serosa. On cut section, small cystic tumors may have a single cavity, but larger ones frequently are divided by multiple septa into multiloculated masses. The cystic spaces usually are filled with a clear serous fluid. Protruding into the cystic cavities are papillary projections, which are more prominent in malignant tumors (Fig. 18–16).

On histologic examination, benign tumors contain a single layer of **tall columnar epithelial cells** that line the cyst or cysts. The cells often are ciliated. **Psammoma bodies** (concentrically laminated calcified concretions) are common in the tips of papillae. When frank carcinoma develops, anaplasia of the lining cells appears, as does invasion of the stroma. In carcinoma, papillary formations are complex and multilayered, and nests or undifferentiated sheets of malignant cells invade the axial fibrous tissue. Between clearly benign and obviously malignant forms lie **tumors of low malignant potential,** which exhibit less cytologic atypia and, typically, little or no stromal invasion. Tumors of low malignant potential may seed the peritoneum, but fortunately the tumor implants usually are "noninvasive." In general, malignant serous tumors spread to regional lymph nodes, including periaortic lymph nodes; distant lymphatic and hematogenous metastases are infrequent.

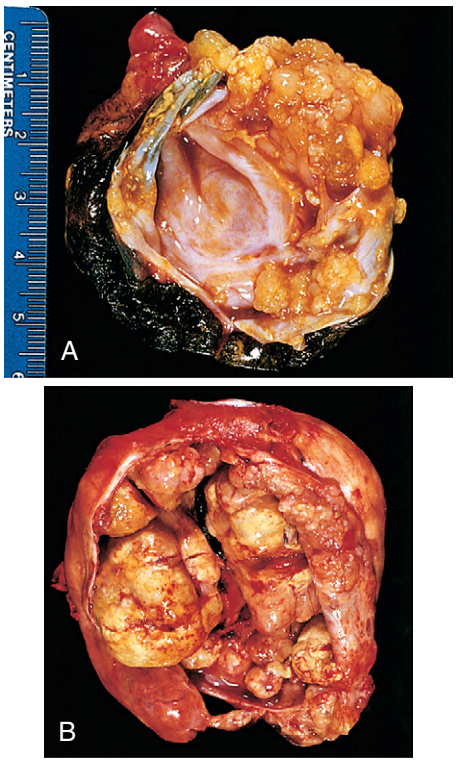


**Figure 18–16** Ovarian serous tumors. **A,** Borderline serous cystadenoma opened to display a cyst cavity lined by delicate papillary tumor growths. **B,** Cystadenocarcinoma. The cyst is opened to reveal a large, bulky tumor mass.
*(Courtesy of Dr. Christopher Crum, Brigham and Women's Hospital, Boston, Massachusetts.)*

The prognosis for patients with invasive serous cystadenocarcinoma is poor, even after surgery, irradiation, and chemotherapy, and depends heavily on the disease stage at diagnosis. If the tumor appears confined to the ovary, frank carcinomas have a 5-year survival rate of about 70%, whereas tumors of low malignant potential are associated with nearly 100% survival. With cancers that have penetrated the capsule, the 10-year survival rate is less than 15%.

## Mucinous Tumors

Mucinous tumors are, in most respects, similar to serous tumors, the essential difference being that the neoplastic epithelium consists of mucin-secreting cells. These tumors occur in women in the same age range as for those with serous tumors but are considerably less likely to be malignant. Overall, only 10% of mucinous tumors are malignant; another 10% are of low malignant potential, and 80% are benign.

### MORPHOLOGY

On gross examination, mucinous tumors produce cystic masses that may be indistinguishable from serous tumors except by the mucinous nature of the cystic contents. However, **they are more likely to be larger and multicystic** (Fig. 18–17, *A*)**. Serosal penetration and solid areas of growth are suggestive of malignancy.** On histologic examination, the cysts are lined by mucin-producing epithelial cells (Fig. 18–17, *B*). Malignant tumors are characterized by the presence of architectural complexity, including solid areas of growth, cellular stratification, cytologic atypia, and stromal invasion.

Compared with serous tumors, mucinous tumors are much less likely to be bilateral. This feature is sometimes useful in differentiating mucinous tumors of the ovary from metastatic mucinous adenocarcinoma from a gastrointestinal tract primary (the so-called **Krukenberg tumor**), which more often produces bilateral ovarian masses.

Ruptured ovarian mucinous tumors may seed the peritoneum; however, these deposits typically are transient and fail to establish long-term growth in the peritoneum. Implantation of mucinous tumor cells in the peritoneum with production of copious amounts of mucin is called **pseudomyxoma peritonei;** in most cases, this disorder is caused by metastasis from the gastrointestinal tract, primarily the appendix (Chapter 14).

The prognosis of mucinous cystadenocarcinoma is somewhat better than with its serous counterpart, although stage rather than histologic type (serous versus mucinous) is the major determinant of outcome.

### Endometrioid Tumors

These tumors may be solid or cystic; they sometimes develop in association with endometriosis. On microscopic examination, they are distinguished by the formation of tubular glands, similar to those of the endometrium, within the lining of cystic spaces. Although benign and borderline forms exist, endometrioid tumors usually are malignant. They are bilateral in about 30% of cases, and 15% to 30% of women with these ovarian tumors have a concomitant endometrial carcinoma. Similar to endometrioid-type carcinoma of the endometrium, endometrioid carcinomas of the ovary have mutations in the *PTEN* tumor suppressor gene.

### Brenner Tumor

The Brenner tumor is an uncommon, solid, usually unilateral ovarian tumor consisting of abundant stroma containing nests of transitional-type epithelium resembling that of the urinary tract. Occasionally, the nests are cystic and are lined by columnar mucus-secreting cells. Brenner tumors generally are smoothly encapsulated and gray-white on cut section, ranging from a few centimeters to 20 cm in diameter. These tumors may arise from the surface epithelium or from urogenital epithelium trapped within the germinal ridge. Although most are benign, both malignant and borderline tumors have been described.

## OTHER OVARIAN TUMORS

Many other types of tumors of germ cell and sex cord–stromal origin also arise in the ovary, but only the teratomas of germ cell origin are sufficiently common to merit description. Table 18–3 presents some salient features of other neoplasms of germ cell and sex cord origin.

### Teratomas

Teratomas constitute 15% to 20% of ovarian tumors. A distressing feature of these germ cell tumors is their predilection to arise in the first 2 decades of life; to make matters worse, the younger the person, the greater the likelihood of malignancy. More than 90% of these germ cell neoplasms, however, are benign mature cystic teratomas; the immature, malignant variant is rare.

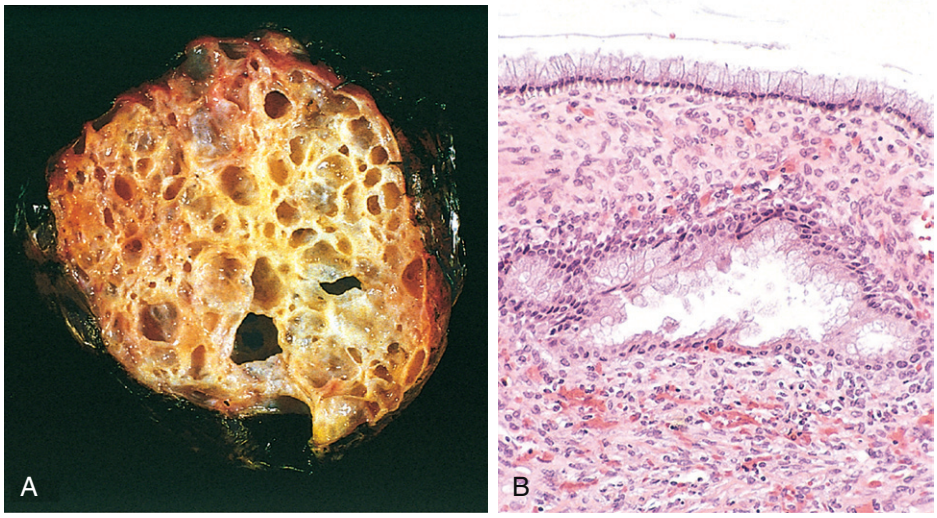


**Figure 18–17** Ovarian mucinous cystadenoma. **A,** Mucinous cystadenoma with multicystic appearance and delicate septa. Note the presence of glistening mucin within the cysts. **B,** Columnar cell lining of mucinous cystadenoma.

**Table 18–3** Salient Features of Ovarian Germ Cell and Sex Cord Neoplasms

| Neoplasm | Peak Incidence | Usual Location | Morphologic Features | Behavior |
|---|---|---|---|---|
| **Germ Cell Origin** | | | | |
| Dysgerminoma | Second to third decade of life<br>Occur with gonadal dysgenesis | Unilateral in 80–90% | Counterpart of testicular seminoma<br>Solid large to small gray masses<br>Sheets or cords of large clear cells separated by scant fibrous strands<br>Stroma may contain lymphocytes and occasional granulomas | All malignant but only one third aggressive and spread; all radiosensitive; 80% cure rate |
| Choriocarcinoma | First 3 decades of life | Unilateral | Identical to placental tumor<br>Often small, hemorrhagic focus with two types of epithelium: cytotrophoblast and syncytiotrophoblast | Metastasizes early and widely.<br>Primary focus may degenerate, leaving only metastases<br>In contrast with gestational tumors, ovarian primaries are resistant to chemotherapy |
| **Sex Cord Tumors** | | | | |
| Granulosa-theca cell | Most postmenopausal, but may occur at any age | Unilateral | May be tiny or large, gray to yellow (with cystic spaces)<br>Composed of mixture of cuboidal granulosa cells in cords, sheets, or strands and spindled or plump lipid-laden theca cells<br>Granulosa elements may recapitulate ovarian follicle as Call-Exner bodies | May elaborate large amounts of estrogen (from thecal elements) and so may promote endometrial or breast carcinoma<br>Granulosa element may be malignant (5% to 25%) |
| Thecoma-fibroma | Any age | Unilateral | Solid gray fibrous cells to yellow (lipid-laden) plump thecal cells | Most hormonally inactive<br>A few elaborate estrogens<br>About 40%, for obscure reasons, produce ascites and hydrothorax (Meigs syndrome)<br>Rarely malignant |
| Sertoli-Leydig cell | All ages | Unilateral | Usually small, gray to yellow-brown, and solid<br>Recapitulates development of testis with tubules or cords and plump pink Sertoli cells | Many masculinizing or defeminizing<br>Rarely malignant |
| **Metastases to Ovary** | | | | |
| | Older ages | Mostly bilateral | Usually solid gray-white masses as large as 20 cm in diameter<br>Anaplastic tumor cells, cords, glands, dispersed through fibrous background<br>Cells may be "signet ring" mucin-secreting | Primaries are gastrointestinal tract (Krukenberg tumors), breast, and lung |

### *Benign (Mature) Cystic Teratomas*

Almost all benign (mature) cystic teratomas are marked by the presence of mature tissues derived from all three germ cell layers: ectoderm, endoderm, and mesoderm. Usually these tumors contain cysts lined by epidermis replete with adnexal appendages—hence the common designation *dermoid cysts*. Most are discovered in young women as ovarian masses or are found incidentally on abdominal radiographs or scans because they contain foci of calcification produced by tooth-like structures contained within the tumor. About 90% are unilateral, with the right side more commonly affected. Rarely do these cystic masses exceed 10 cm in diameter. On cut section, they often are filled with sebaceous secretion and matted hair that, when removed, reveal a hair-bearing epidermal lining (Fig. 18–18). Sometimes there is a nodular projection from which teeth protrude. Occasionally, foci of bone and cartilage, nests of bronchial or gastrointestinal epithelium, and other tissues also are present.

For unknown reasons, these neoplasms sometimes produce infertility and are prone to undergo torsion (in 10% to 15% of cases), which constitutes an acute surgical emergency. A rare, but fascinating, paraneoplastic complication is limbic encephalitis, which may develop in women with teratomas containing mature neural tissue and often remits with tumor resection. In about 1% of cases, malignant transformation, usually to a squamous cell carcinoma, is seen.

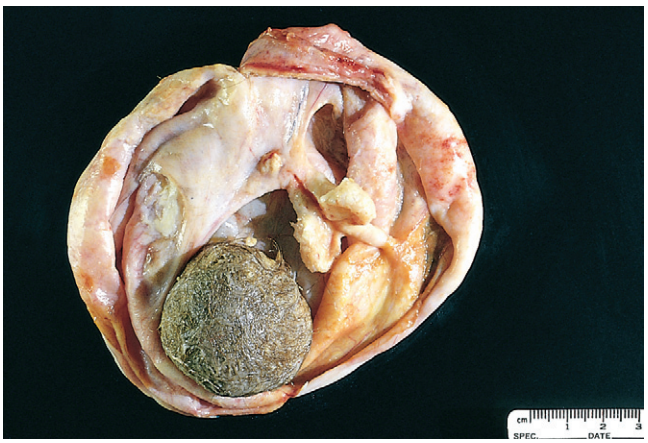

**Figure 18–18** Mature cystic teratoma (dermoid cyst) of the ovary. A ball of hair (*bottom*) and a mixture of tissues are evident.
*(Courtesy of Dr. Christopher Crum, Brigham and Women's Hospital, Boston, Massachusetts.)*

### *Immature Malignant Teratomas*

Malignant (immature) teratomas are found early in life, the mean age at clinical detection being 18 years. They differ strikingly from benign mature teratomas insofar as they often are bulky, predominantly solid on cut section, and punctuated by areas of necrosis; uncommonly, cystic foci are present that contain sebaceous secretion, hair, and other features similar to those of mature teratomas. On microscopic examination, the distinguishing feature is presence of immature elements or minimally differentiated cartilage, bone, muscle, nerve, or other tissues. Particularly ominous are foci of neuroepithelial differentiation, in view of the propensity of such foci to be aggressive and metastasize widely. Immature teratomas are both graded and staged in an effort to predict their behavior. Grade I, stage I tumors often can be cured with appropriate therapy, whereas those of higher grade and stage are associated with a more guarded outlook.

### *Specialized Teratomas*

A rare subtype of teratoma is composed entirely of specialized tissue. The most common example is struma ovarii, which is composed entirely of mature thyroid tissue that may actually produce hyperthyroidism. These tumors appear as small, solid, unilateral brown ovarian masses. Other specialized teratomas may take the form of ovarian carcinoid, which in rare instances produces carcinoid syndrome.

### Clinical Correlations

With all ovarian neoplasms, management poses a formidable clinical challenge, because symptoms or signs usually appear only when tumors are well advanced. The clinical presentation is remarkably similar, except with functioning neoplasms that exert hormonal effects. Ovarian tumors of surface epithelial origin usually are asymptomatic until they become large enough to cause local pressure symptoms (e.g., pain, gastrointestinal complaints, urinary frequency). Indeed, about 30% of all ovarian neoplasms are discovered incidentally on routine gynecologic examination. Larger masses, particularly the common epithelial tumors, may cause an increase in abdominal girth. Smaller masses, particularly dermoid cysts, sometimes twist on their pedicles (torsion), producing severe abdominal pain that mimics an acute abdomen. Metastatic seeding of malignant serous tumors often causes ascites, whereas functioning ovarian tumors often come to attention because of the endocrinopathies they produce.

Unfortunately, treatment of ovarian tumors remains unsatisfactory; only a modest increase in survival has been achieved since the mid-1970s. Screening methods that detect early tumors are badly needed, but those evaluated to date are of limited value. One such marker, the protein CA-125, is elevated in the sera of 75% to 90% of women with epithelial ovarian cancer. However, CA-125 is undetectable in up to 50% of women with cancer limited to the ovary; conversely, it often is elevated in a variety of benign conditions and nonovarian cancers. Hence, its usefulness as a screening test in asymptomatic postmenopausal women is limited. Currently, CA-125 measurements are of greatest value in monitoring response to therapy.

## SUMMARY

### Ovarian Tumors

- Tumors may arise from epithelium, sex cord–stromal cells, or germ cells.
- Epithelial tumors are the most common malignant ovarian tumors and are more common in women older than 40 years of age.
- The major types of epithelial tumors are serous, mucinous, and endometrioid. Each has a benign, malignant, and borderline (low malignant potential) counterpart.
- Sex cord–stromal tumors may display differentiation toward granulosa, Sertoli, Leydig, or ovarian stromal cell type. Depending on differentiation, they may produce estrogens or androgens.
- Germ cell tumors (mostly cystic teratomas) are the most common ovarian tumor in young women; a majority are benign.
- Germ cell tumors may differentiate toward oogonia (dysgerminoma), primitive embryonal tissue (embryonal), yolk sac (endodermal sinus tumor), placental tissue (choriocarcinoma), or multiple fetal tissues (teratoma).

# DISEASES OF PREGNANCY

Diseases of pregnancy and pathologic conditions of the placenta are important contributors to morbidity and mortality for both mother and child. Discussed in this section are a limited number of disorders in which knowledge of the morphologic lesions contributes to an understanding of clinical disease.

## PLACENTAL INFLAMMATIONS AND INFECTIONS

Infections may reach the placenta by either of two paths: (1) ascension through the birth canal or (2) hematogenous (transplacental) spread.

*Ascending infections* are by far the more common; in most instances, they are bacterial and are associated with premature rupture of the fetal membranes. On microscopic examination, the chorioamnion shows neutrophilic infiltration associated with edema and congestion (acute chorioamnionitis). With extension beyond the membranes, the infection may involve the umbilical cord and placental villi, resulting in acute vasculitis of the cord (funisitis). Ascending infections are caused by *Mycoplasma, Candida,* and the numerous bacteria of the vaginal flora.

Uncommonly, placental infections may arise by *hematogenous spread* of bacteria and other organisms; on histologic examination, placental villi are the most frequently affected structures (villitis). Syphilis, tuberculosis, listeriosis, toxoplasmosis, and various viruses (rubella, cytomegalovirus, herpes simplex virus) all can cause placental villitis. Transplacental infections can affect the fetus and give rise to the so-called TORCH (*t*oxoplasmosis, *o*ther infections, *r*ubella, *c*ytomegalovirus infection, *h*erpes) complex (Chapter 6).

## ECTOPIC PREGNANCY

Ectopic pregnancy is defined as implantation of a fertilized ovum in any site other than the uterus. As many as 1% of pregnancies are ectopic. In more than 90% of these cases, implantation occurs in the oviducts (tubal pregnancy); other sites include the ovaries and the abdominal cavity. Any factor that retards passage of the ovum through the oviducts predisposes to ectopic pregnancy. In about half of the cases, slowed passage is attributable to chronic inflammation and scarring in the oviduct; intrauterine tumors and endometriosis may also hamper passage of the ovum. In the other 50% of tubal pregnancies, no anatomic cause is evident. Ovarian pregnancies probably result from rare instances in which the ovum is fertilized just as the follicle ruptures. Gestation within the abdominal cavity occurs when the fertilized egg drops out of the fimbriated end of the oviduct and implants on the peritoneum.

### MORPHOLOGY

In all sites, early development of ectopic pregnancies proceeds normally, with formation of placental tissue, the amniotic sac, and decidual changes. With tubal pregnancies, the invading placenta eventually burrows through the wall of the oviduct, causing **intratubal hematoma (hematosalpinx), intraperitoneal hemorrhage,** or both. The tube is usually distended by freshly clotted blood containing bits of gray placental tissue and fetal parts. The histologic diagnosis depends on visualization of placental villi or, rarely, of the embryo.

Until rupture occurs, an ectopic pregnancy may be indistinguishable from a normal pregnancy, with cessation of menstruation and elevation of serum and urinary placental hormones. Under the influence of these hormones, the endometrium (in approximately 50% of cases) undergoes the characteristic hypersecretory and decidual changes of pregnancy. The absence of elevated gonadotropin levels does not exclude the diagnosis, however, because poor attachment and necrosis of the ectopic placenta are common. Rupture of an ectopic pregnancy may be catastrophic, with the sudden onset of intense abdominal pain and signs of an acute abdomen, often followed by shock. Prompt surgical intervention is necessary.

### SUMMARY

#### Ectopic Pregnancy

- Ectopic pregnancy is defined as implantation of the fertilized ovum outside of the uterine corpus. Approximately 1% of pregnancies implant ectopically; the most common site is the fallopian tube.
- Chronic salpingitis with scarring is a major risk factor for tubal ectopic pregnancy.
- Rupture of an ectopic pregnancy is a medical emergency that, if left untreated, may result in exsanguination and death.

## GESTATIONAL TROPHOBLASTIC DISEASE

Gestational trophoblastic tumors have been divided on histopathologic grounds into three overlapping morphologic categories: *hydatidiform mole, invasive mole,* and *choriocarcinoma.* These demonstrate a range of aggressiveness from benign hydatidiform moles to highly malignant choriocarcinomas. All elaborate human chorionic gonadotropin (hCG), which can be detected in the blood and urine at levels considerably higher than those found during normal pregnancy. In addition to aiding diagnosis, the rise or fall of hormone levels in the blood or urine can be used to monitor treatment efficacy. Clinicians prefer the umbrella term *gestational trophoblastic disease* because the response to therapy, as judged by the hormone levels, is significantly more important than pathologic subtyping of lesions. However, the genetics, pathology, and natural history of these disorders are sufficiently distinct to merit discussion of each.

### Hydatidiform Mole: Complete and Partial

The typical hydatidiform mole is a voluminous mass of swollen, sometimes cystically dilated, chorionic villi, appearing grossly as grapelike structures. The swollen villi are covered by varying amounts of normal to highly atypical chorionic epithelium. There are two distinctive subtypes of hydatidiform moles: *complete* and *partial.* Complete hydatidiform moles are not compatible with embryogenesis and never contain fetal parts. All of the chorionic villi are abnormal, and the chorionic epithelial cells are diploid (46,XX or, uncommonly, 46,XY). The partial hydatidiform mole is compatible with early embryo formation

**Table 18–4** Features of Complete and Partial Hydatidiform Mole

| Feature | Complete Mole | Partial Mole |
|---|---|---|
| Karyotype | 46,XX (46,XY) | Triploid (69,XXY) |
| Villous edema | All villi | Some villi |
| Trophoblast proliferation | Diffuse; circumferential | Focal; slight |
| Serum hCG | Elevated | Less elevated |
| Tissue hCG | ++++ | + |
| Risk of subsequent choriocarcinoma | 2% | Rare |

hCG, human chorionic gonadotropin.

and therefore may contain fetal parts, has some normal chorionic villi, and is almost always triploid (e.g., 69,XXY) (Table 18–4). Both types result from abnormal fertilization. In a complete mole the entire genetic content is supplied by two spermatozoa (or a diploid sperm), yielding diploid cells containing only paternal chromosomes, whereas in a partial mole a normal egg is fertilized by two spermatozoa (or a diploid sperm), resulting in a triploid karyotype with a preponderance of paternal genes.

The incidence of complete hydatidiform mole is about 1 to 1.5 per 2000 pregnancies in the United States and other Western countries. For unknown reasons, the incidence is much higher in Asian countries. Moles are most common before the age of 20 years and after the age of 40, and a history of the condition increases the risk for molar disease in subsequent pregnancies. Although molar disease formerly was discovered at 12 to 14 weeks of pregnancy during investigation for a gestation that was "too large for dates," early monitoring of pregnancies by ultrasound has lowered the gestational age at detection. In both complete and partial moles, elevation of hCG in the maternal blood and absence of fetal heart sounds are typical.

### MORPHOLOGY

The uterus may be of normal size in early moles, but in more advanced cases the uterine cavity is expanded by a delicate, friable mass of thin-walled, translucent cystic structures (Fig. 18–19). Fetal parts are rarely seen in complete moles but are common in partial moles. On microscopic examination, the **complete mole** shows hydropic swelling of poorly vascularized chorionic villi with a loose, myxomatous, edematous stroma. The chorionic epithelium almost always shows some degree of proliferation of both cytotrophoblasts and syncytiotrophoblasts (Fig. 18–20). Histologic grading to predict the clinical outcome of moles has been supplanted by careful monitoring of hCG levels. In **partial moles,** villous edema involves only some of the villi, and the trophoblastic proliferation is focal and slight. The villi of partial moles have a characteristic irregular, scalloped margin. In most cases of partial mole, some fetal cells are present, ranging from fetal red blood cells in placental villi to, in rare cases, a fully formed fetus.

Overall, 80% to 90% of moles do not recur after thorough curettage; 10% of complete moles are invasive. No more than 2% to 3% give rise to choriocarcinoma.

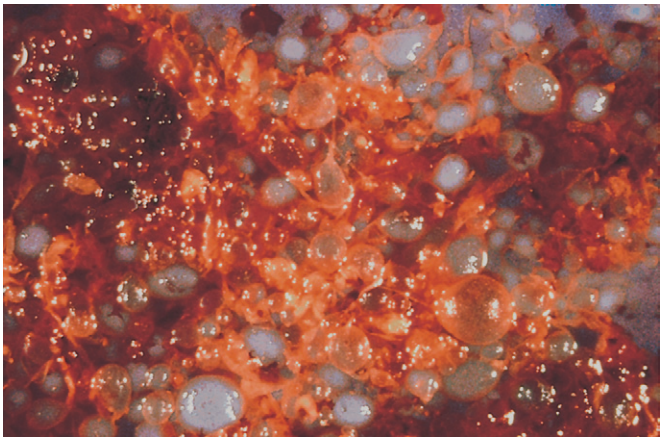

**Figure 18–19** Complete hydatidiform mole, consisting of numerous swollen (hydropic) villi.

## Invasive Mole

Invasive moles are complete moles that are more invasive locally but do not have the aggressive metastatic potential of a choriocarcinoma. An invasive mole retains hydropic villi, which penetrate the uterine wall deeply, possibly causing rupture and sometimes life-threatening hemorrhage. On microscopic examination, the epithelium of the villi shows atypical changes, with proliferation of both trophoblastic and syncytial components.

Although the marked invasiveness of this lesion makes removal technically difficult, metastases do not occur. Hydropic villi may embolize to distant organs, such as lungs or brain, but these emboli do not constitute true metastases and may indeed regress spontaneously. Because of deeper invasion into the myometrium, an invasive mole is difficult to remove completely by curettage, so if serum β-hCG remains elevated, further treatment is

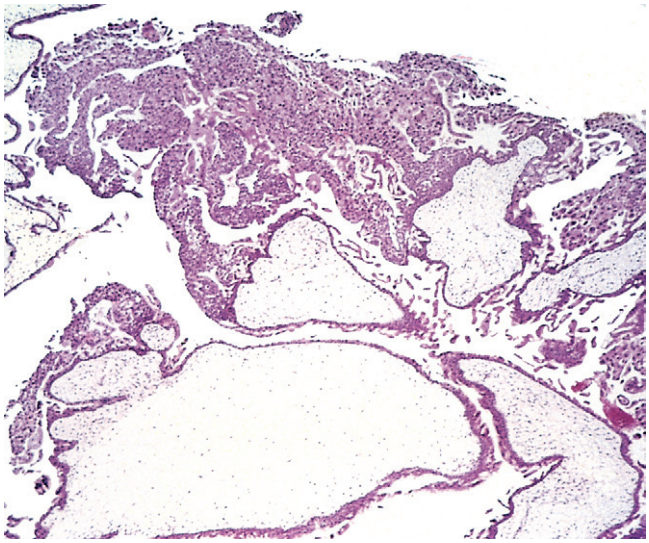

**Figure 18–20** Complete hydatidiform mole. In this microscopic image, distended hydropic villi (*below*) and proliferation of the chorionic epithelium (*above*) are evident.

*(Courtesy of Dr. Kyle Molberg, Department of Pathology, University of Texas Southwestern Medical School, Dallas, Texas.)*

required. Fortunately, in most cases cure is possible with chemotherapy.

## Gestational Choriocarcinoma

Choriocarcinoma, a very aggressive malignant tumor, arises either from gestational chorionic epithelium or, less frequently, from totipotential cells within the gonads (as a germ cell tumor). These tumors are rare in the Western Hemisphere; in the United States, they occur in about 1 per 30,000 pregnancies but are much more common in Asian and African countries, reaching a frequency of 1 in 2000 pregnancies. Approximately 50% of choriocarcinomas arise from complete hydatidiform moles; about 25% arise after an abortion; the remainder manifest after what had been a normal pregnancy. Stated in another way, the more abnormal the conception, the greater the risk of developing gestational choriocarcinoma. In most cases, choriocarcinoma manifests with a bloody, brownish discharge accompanied by a rising titer of β-hCG in blood and urine, in the absence of marked uterine enlargement, such as would be anticipated with a mole. In general, the β-hCG titers are much higher than those associated with a mole.

### MORPHOLOGY

Choriocarcinomas usually appear as hemorrhagic, necrotic uterine masses. Sometimes the necrosis is so extensive that little viable tumor remains. Indeed, the primary lesion may "self-destruct," and only the metastases tell the story. Very early, the tumor insinuates itself into the myometrium and into vessels. **In contrast with hydatidiform moles and invasive moles, chorionic villi are not formed; instead, the tumor is composed of anaplastic cuboidal cytotrophoblasts and syncytiotrophoblasts** (Fig. 18–21).

By the time most choriocarcinomas are discovered, widespread vascular spread usually has occurred to the lungs (50%), vagina (30% to 40%), brain, liver, or kidneys. Lymphatic invasion is uncommon.

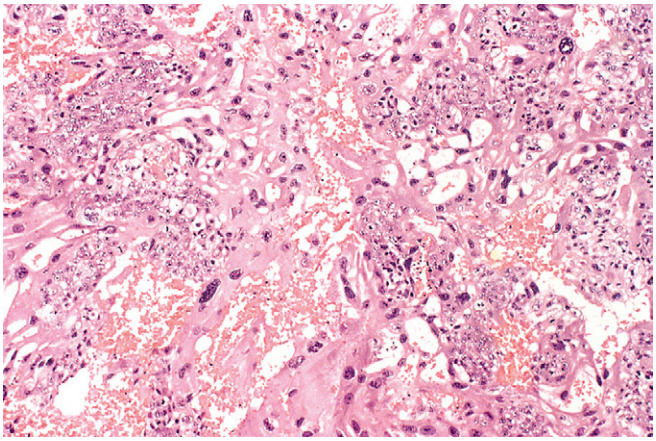

**Figure 18–21** Choriocarcinoma. This field contains both neoplastic cytotrophoblasts and multinucleate syncytiotrophoblasts.
*(Courtesy of Dr. David R. Genest, Brigham and Women's Hospital, Boston, Massachusetts.)*

Despite the extremely aggressive nature of placental choriocarcinoma, these tumors are remarkably sensitive to chemotherapy. Nearly 100% of affected patients are cured, even those with metastases at distant sites such as the lungs. By contrast, response to chemotherapy with choriocarcinomas that arise in the gonads (ovary or testis) is relatively poor. This striking difference in prognosis may be related to the presence of paternal antigens on placental choriocarcinomas that are lacking in gonadal lesions. Conceivably, a maternal immune response against the foreign (paternal) antigens helps clear the tumor by acting as an adjunct to chemotherapy.

## Placental Site Trophoblastic Tumor

Placental site trophoblastic tumors are derived from the placental site or intermediate trophoblast. These uncommon diploid tumors, often XX in karyotype, typically arise a few months after pregnancy. Because intermediate trophoblasts do not produce hCG in large amounts, hCG concentrations are only slightly elevated. More typically, these tumors produce human placental lactogen. An indolent clinical course is typical, with a generally favorable outcome if the tumor is confined to the endomyometrium. Of note, however, placental site trophoblastic tumors are not as sensitive to chemotherapy as are other trophoblastic tumors, and the prognosis is poor when spread has occurred beyond the uterus.

### SUMMARY

#### Gestational Trophoblastic Disease

- Molar disease is due to an abnormal contribution of paternal chromosomes in the gestation.
- Partial moles are triploid and have two sets of paternal chromosomes. They typically are accompanied by fetal tissue. There is a low rate of persistent disease.
- Complete moles are diploid, and all chromosomes are paternal. No embryonic or fetal tissues are associated with complete mole.
- Among complete moles, 10% to 15% are associated with persistent disease that usually takes the form of an invasive mole. Only 2% of complete moles progress to choriocarcinoma.
- Gestational choriocarcinoma is a highly invasive and frequently metastatic tumor that, in contrast with ovarian choriocarcinoma, is responsive to chemotherapy and curable in most cases.
- Placental site trophoblastic tumor is an indolent and usually early-stage tumor of intermediate trophoblast that produces human placental lactogen and does not respond well to chemotherapy.

# PREECLAMPSIA/ECLAMPSIA (TOXEMIA OF PREGNANCY)

The development of hypertension, accompanied by proteinuria and edema in the third trimester of pregnancy, is referred to as *preeclampsia*. This syndrome occurs in 5% to

10% of pregnancies, particularly with first pregnancies in women older than age 35 years. In those severely affected, seizures may occur, and the symptom complex is then termed *eclampsia.* By long-existing precedent, preeclampsia and eclampsia are still sometimes referred to as *toxemia of pregnancy.* No blood-borne toxin has ever been identified, and this historically sanctified term is a misnomer. Recognition and early treatment of preeclampsia have now made eclampsia, particularly fatal eclampsia, rare.

The exact triggering events initiating these syndromes are unknown, but a common feature underlying all cases is *insufficient maternal blood flow to the placenta secondary to inadequate remodeling of the spiral arteries of the uteroplacental vascular bed.* In normal pregnancy, the musculoelastic walls of the spiral arteries are invaded by trophoblasts, permitting them to dilate into wide vascular sinusoids. In preeclampsia and eclampsia, this vascular remodeling is impaired, the musculoelastic walls are retained, and the channels remain narrow. Decreased uteroplacental blood flow appears to result in placental hypoxia, placental dysfunction, and a shift to a systemic antiangiogenic state. Specifically, both increases in the circulating antiangiogenic factors soluble Flt1 (sFlt1) and soluble endoglin (sEng) and reductions in the level of proangiogenic factors, such as VEGF and PIGF, have been noted. These disturbances are hypothesized to result in *endothelial cell dysfunction, vascular hyperreactivity, and end-organ microangiopathy.* While the exact basis of preeclampsia remains to be further defined, several serious consequences have been associated with this condition:

- *Placental infarction,* stemming from the chronic hypoperfusion
- *Hypertension,* due to reduced endothelial production of the vasodilators prostacyclin (i.e., prostaglandin $I_2$) and prostaglandin $E_2$, and to increased production of the vasoconstrictor thromboxane $A_2$
- *Hypercoagulability,* due to endothelial dysfunction and release of tissue factor from the placenta
- *End-organ failure,* most notably of the kidney and the liver, which occurs in patients with full-blown eclampsia. Approximately 10% of the patients with severe preeclampsia develop the so-called HELLP syndrome, characterized by hemolysis, elevated liver enzymes, and low platelets.

### MORPHOLOGY

The morphologic changes of preeclampsia and eclampsia are variable and correlate to some degree with the severity of the disorder. **Placental abnormalities** include:

- **Infarcts,** which can be a feature of normal pregnancy, but are much more numerous with severe preeclampsia or eclampsia
- **Retroplacental hemorrhages**
- **Premature maturation of placental villi** associated with villous edema, hypovascularity, and increased production of syncytial epithelial knots
- **Fibrinoid necrosis** and focal accumulation of lipid-containing macrophages (acute atherosis) of decidual vessels

#### Clinical Features

Preeclampsia presents insidiously during weeks 24 and 25 of gestation, with edema, proteinuria, and rising blood pressure. Should the condition evolve into eclampsia, renal function is impaired, blood pressure rises further, and convulsions may occur. Prompt therapy early in the course aborts the associated organ changes, with all abnormalities resolving promptly after delivery or cesarean section.

### SUMMARY

#### Preeclampsia/Eclampsia

- Preeclampsia is due to abnormalities in maternal and placental blood flow, with resultant placental ischemia and infarction and abnormalities in production of vasodilators.
- Preeclampsia is characterized by edema, proteinuria, and hypertension in the second and third trimesters of pregnancy.
- Eclampsia is characterized, in addition, by seizures. It can be fatal when accompanied by multiorgan damage.

## BREAST

Lesions of the female breast are much more common than lesions of the male breast and usually take the form of palpable, sometimes painful nodules or masses. Fortunately, most are innocent, but as is well known, breast cancer is the most common cancer in women (excluding neoplasia of the skin) and is second only to lung cancer as a cause of cancer-related death. Hence, it is not uncommon for women to seek evaluation of even slightly suspicious *lumps* in the breast (Fig. 18–22).

We start our discussion of diseases of the breast with benign non-neoplastic lesions. Before considering the extremely common fibrocystic changes, several relatively minor lesions warrant brief mention. *Supernumerary nipples or breast tissue* may be found anywhere along the

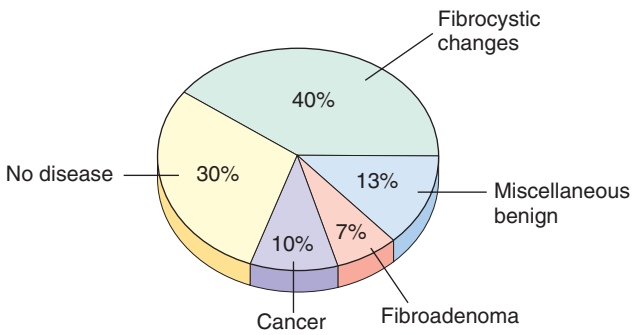


**Figure 18–22** Histopathologic findings in a series of women seeking evaluation of breast "lumps."

embryonic ridge (milk line). Besides being curiosities, these congenital anomalies are subject to the same diseases that affect the normal breast. *Congenital inversion of the nipple* is of clinical significance because similar changes may be produced by an underlying cancer. *Galactocele* arises during lactation from cystic dilation of an obstructed duct. Besides being painful "lumps," these cysts may rupture, inciting a local inflammatory reaction, with production of an indurated focus falsely suggestive of malignancy.

## FIBROCYSTIC CHANGES

The designation *fibrocystic* is applied to a miscellany of changes in the female breast that consist predominantly of cyst formation and fibrosis. In the past, these lesions were called *fibrocystic disease.* However, since most of these changes have little clinical significance beyond the need to distinguish them from cancer, the term *fibrocystic change* is preferred.

Overall, fibrocystic changes are the most common breast abnormality seen in premenopausal women. The changes tend to arise during reproductive age and are most likely a consequence of the *cyclic breast changes that occur normally in the menstrual cycle.* Estrogenic therapy and oral contraceptives do not seem to increase the incidence of these alterations, and oral contraceptives may, in fact, *decrease* the risk.

Fibrocystic changes can be subdivided into nonproliferative and proliferative patterns, as described next.

### Nonproliferative Changes

#### *Cysts and Fibrosis*

Nonproliferative changes are the most common type of fibrocystic lesions, characterized by an increase in fibrous stroma associated with dilation of ducts and formation of variably sized cysts.

#### MORPHOLOGY

A single, large cyst may form within one breast, but changes usually are multifocal and often bilateral. The involved areas appear as ill-defined, diffusely increased densities and discrete nodularities on mammography. The cysts range from less than 1 cm and up to 5 cm in diameter. Unopened, they are brown to blue **(blue dome cysts)** and are filled with watery, turbid fluid (Fig. 18–23). The secretions within the cysts may calcify, producing microcalcifications on mammograms. Histologic examination reveals an epithelial lining that in larger cysts may be flattened or even totally atrophic (Fig. 18–24). Frequently, the lining cells are large and polygonal with abundant granular, eosinophilic cytoplasm and small, round, deeply chromatic nuclei. Such morphology is called **apocrine metaplasia** and virtually always is benign.

The stroma surrounding all types of cysts usually consists of compressed fibrous tissue that has lost the delicate, myxomatous appearance of normal breast stroma. A stromal lymphocytic infiltrate is common in this and all other variants of fibrocystic change.

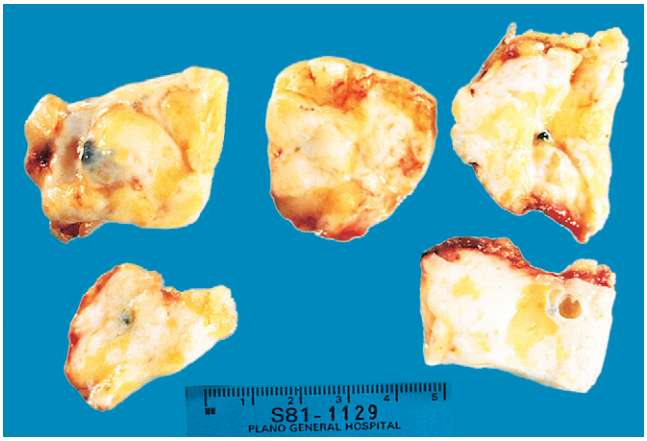


**Figure 18–23** Fibrocystic change seen in breast biopsy specimens. The scattered, poorly demarcated white areas represent foci of fibrosis. In the specimen at the *lower right*, a transected empty cyst is evident; in the two specimens on the *left*, unopened blue dome cysts are seen.
*(Courtesy of Dr. Kyle Molberg, Department of Pathology, University of Texas Southwestern Medical School, Dallas, Texas.)*

### Proliferative Change

#### *Epithelial Hyperplasia*

Normal ducts and lobules of the breast are lined by two layers of cells—a layer of luminal cells overlying a second layer of myoepithelial cells. *Epithelial hyperplasia* is recognized by the presence of more than two cell layers. The spectrum of epithelial hyperplasia ranges from mild and orderly to atypical hyperplasias with features that resemble those of in situ carcinoma.

#### MORPHOLOGY

The gross appearance of epithelial hyperplasia is not distinctive and is dominated by coexisting fibrous or cystic changes. Histologic examination shows an almost infinite spectrum of proliferative alterations. The ducts, ductules, or lobules may be filled with orderly cuboidal cells within which small gland

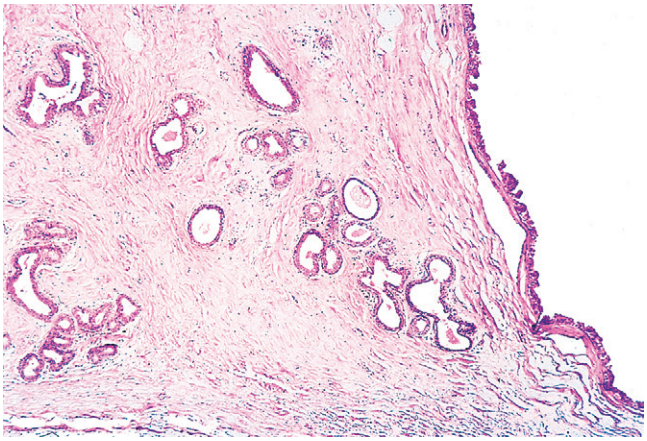

**Figure 18–24** Fibrocystic change of the nonproliferative type in a breast biopsy specimen. Visible in this field are dilated ducts, producing microcysts and, at *right*, the wall of a large cyst lined with epithelial cells.
*(Courtesy of Dr. Kyle Molberg, Department of Pathology, University of Texas Southwestern Medical School, Dallas, Texas.)*

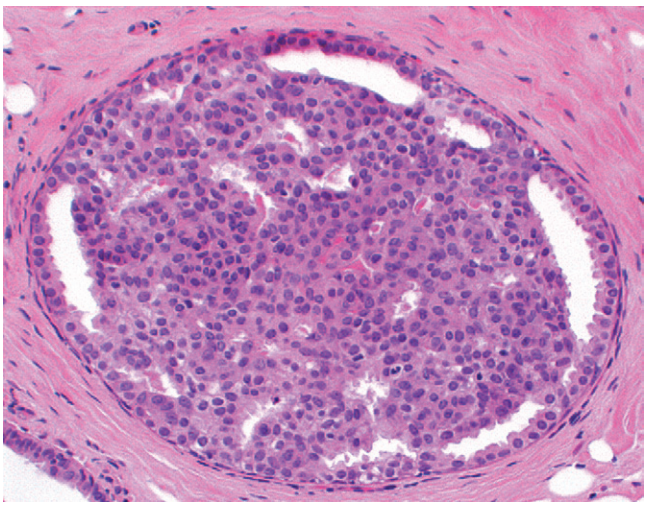

**Figure 18–25** Epithelial hyperplasia in a breast biopsy specimen. The duct lumen is filled with a heterogeneous population of cells of differing morphology. Irregular slitlike fenestrations are prominent at the periphery.

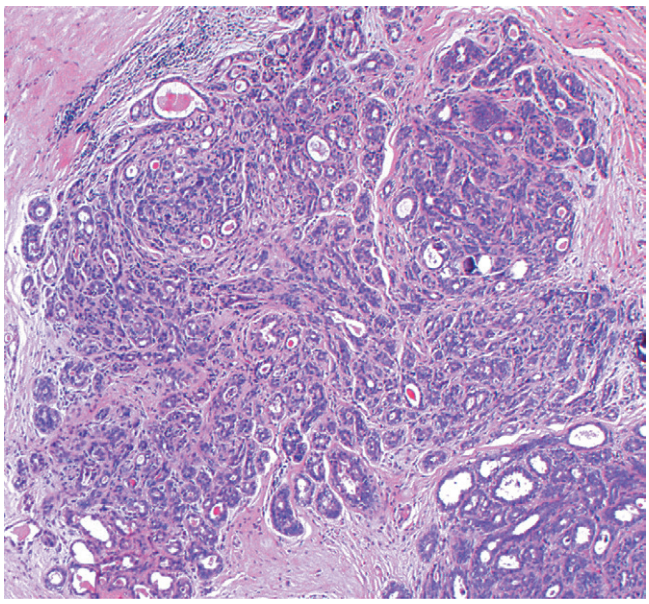

**Figure 18–26** Sclerosing adenosis, breast biopsy. The involved terminal duct lobular unit is enlarged, and the acini are compressed and distorted by surrounding dense stroma. Unlike in breast carcinoma, the acini are arranged in a swirling pattern, and the outer border is well circumscribed.

patterns (called **fenestrations**) can be discerned (Fig. 18–25). Sometimes, the proliferating epithelium projects as multiple small papillary excrescences into the ductal lumen **(ductal papillomatosis).** The degree of hyperplasia, judged in part by the number of layers of intraductal epithelium, can be mild, moderate, or marked. Occasionally, hyperplasia produces microcalcifications on mammography, raising concern for cancer.

In some instances the hyperplastic cells have features bearing some resemblance to ductal carcinoma in situ (described later). Such hyperplasia is called **atypical ductal hyperplasia. Atypical lobular hyperplasia** is used to describe hyperplasias that exhibit changes that approach but do not meet diagnostic criteria for lobular carcinoma in situ. Both atypical ductal and lobular hyperplasia are associated with an increased risk of invasive carcinoma.

### *Sclerosing Adenosis*

The type of fibrocystic change termed *sclerosing adenosis* is less common than cysts and hyperplasia but is significant because its clinical and morphologic features may mimic those of carcinoma. These lesions contain marked intralobular fibrosis and proliferation of small ductules and acini.

#### MORPHOLOGY

Grossly, the lesion has a hard, rubbery consistency, similar to that of breast cancer. Histologic examination shows a characteristic **proliferation of luminal spaces (adenosis) lined by epithelial cells and myoepithelial cells,** yielding masses of small glands within a fibrous stroma (Fig. 18–26). Aggregated glands may be virtually back to back, with single or multiple layers of cells in contact with one another. Marked stromal fibrosis, which may compress and distort the proliferating epithelium, is always associated with the adenosis—hence the designation **sclerosing adenosis.** This overgrowth of fibrous tissue may completely compress the lumina of the acini and ducts, so that they appear as solid cords of cells—a pattern that is difficult to distinguish histologically from invasive ductal carcinoma. The presence of double layers of epithelium and the identification of myoepithelial elements are helpful in arriving at the correct diagnosis.

## Relationship of Fibrocystic Changes to Breast Carcinoma

Certain clinical features of fibrocystic change tend to distinguish it from cancer, but the only certain way of making this distinction is through biopsy and histologic examination. Although fibrocystic changes are benign, some features may confer an increased risk for development of cancer:

- *Minimal or no increased risk of breast carcinoma*: fibrosis, cystic changes, apocrine metaplasia, mild hyperplasia
- *Slightly increased risk* (1.5- to 2-fold): moderate to florid hyperplasia (without atypia), ductal papillomatosis, sclerosing adenosis
- *Significantly increased risk* (5-fold): atypical hyperplasia, whether ductular or lobular

Proliferative fibrocystic changes usually are bilateral and multifocal and are associated with increased risk of subsequent carcinoma in both breasts.

## SUMMARY

### Fibrocystic Changes

- Fibrocystic changes may be classified as nonproliferative (cystic) or proliferative.
- Proliferative lesions include epithelial proliferations of ducts and lobules (with or without features of atypia) and adenosis (proliferation of terminal ducts), sometimes associated with fibrosis (sclerosing adenosis).
- Atypical hyperplasia (whether ductal or lobular) is associated with a five-fold increase in the risk of developing carcinoma.

## INFLAMMATORY PROCESSES

Inflammatory processes involving the breast are uncommon and are usually associated with pain and tenderness in the affected areas. Included in this category are several forms of mastitis and traumatic fat necrosis, none of which increase the risk of cancer.

Acute mastitis develops when bacteria, usually *Staphylococcus aureus,* gain access to the breast tissue through the ducts. The vast majority of cases arise during the early weeks of nursing, when the skin of the nipple is vulnerable to the development of fissures. Clinically, staphylococcal infections induce typical acute inflammatory changes, which can progress to form single or multiple abscesses.

*Mammary duct ectasia (plasma cell mastitis)* is a nonbacterial chronic inflammation of the breast associated with inspissation of breast secretions in the main excretory ducts. Ductal dilation and eventual rupture leads to reactive changes in the surrounding tissue that may present as a poorly defined periareolar mass with nipple retraction, mimicking the changes caused by some cancers. It is an uncommon condition usually encountered in parous women between 40 and 60 years of age.

### MORPHOLOGY

Usually the inflammatory changes are confined to an area drained by one or more of the major excretory ducts of the nipple. On histologic examination, the ducts are filled with granular debris, sometimes containing leukocytes and lipid-laden macrophages. The lining epithelium generally is destroyed. **The most distinguishing features consist of a prominent lymphoplasmacytic infiltrate and occasional granulomas in the periductal stroma.**

*Fat necrosis* is an uncommon, innocuous lesion that is significant only because it often produces a mass. Most women with this condition report some antecedent trauma to the breast.

### MORPHOLOGY

During the early stage of traumatic fat necrosis, the lesion is small, often tender, rarely more than 2 cm in diameter, and sharply localized. It consists of a central focus of necrotic fat cells surrounded by neutrophils and lipid-laden macrophages, sometimes with giant cells. This lesion later becomes enclosed by fibrous tissue and mononuclear leukocytes and eventually is replaced by scar tissue or a cyst consisting of necrotic debris. Calcifications may develop in either the scar or the cyst wall.

## TUMORS OF THE BREAST

Tumors are the most important lesions of the female breast. Although they may arise from connective tissue or epithelial structures, it is the latter that give rise to the common breast neoplasms.

### Fibroadenoma

Fibroadenoma is by far the most common benign neoplasm of the female breast. It is a biphasic tumor composed of fibroblastic stroma and epithelium-lined glands; however, only the stromal cells are clonal and truly neoplastic. Fibroadenomas typically appear in young women with a peak incidence in the third decade of life. They usually manifest as solitary, discrete, mobile masses. An absolute or relative increase in estrogen is thought to contribute to their development. In addition, fibroadenomas may enlarge late in the menstrual cycle and during pregnancy; after menopause, they may regress and calcify.

### MORPHOLOGY

The fibroadenomas form discrete masses, 1 cm to 10 cm in diameter and of firm consistency (Fig. 18–27). A cut section shows a uniform tan-white color, punctuated by softer yellow-pink specks representing the glandular areas. Histologic examination shows a loose fibroblastic stroma containing ductlike, epithelium-lined spaces of various shapes and sizes. As in normal breast tissue, these glandular spaces are lined by luminal and myoepithelial cells with a well-defined, intact basement membrane.

### Phyllodes Tumor

Like fibroadenomas, phyllodes tumors are biphasic, being composed of neoplastic stromal cells and epithelium-lined glands. However, the stromal element of these tumors is more cellular and abundant, often forming epithelium-lined leaflike projections (*phyllodes* is Greek for "leaflike"). These tumors are much less common than fibroadenomas and arise de novo, not from preexisting fibroadenomas. In the past, they had the tongue-tangling name *cystosarcoma phyllodes*—an unfortunate term because these tumors usually are benign. Ominous changes suggesting malignancy include increased stromal cellularity, anaplasia, high mitotic activity, rapid increase in size, and infiltrative margins. Fortunately, most phyllodes tumors remain localized and are cured by excision; malignant lesions may recur, but they also tend to remain localized. Only 15% of all cases are fully malignant, metastasizing to distant sites.

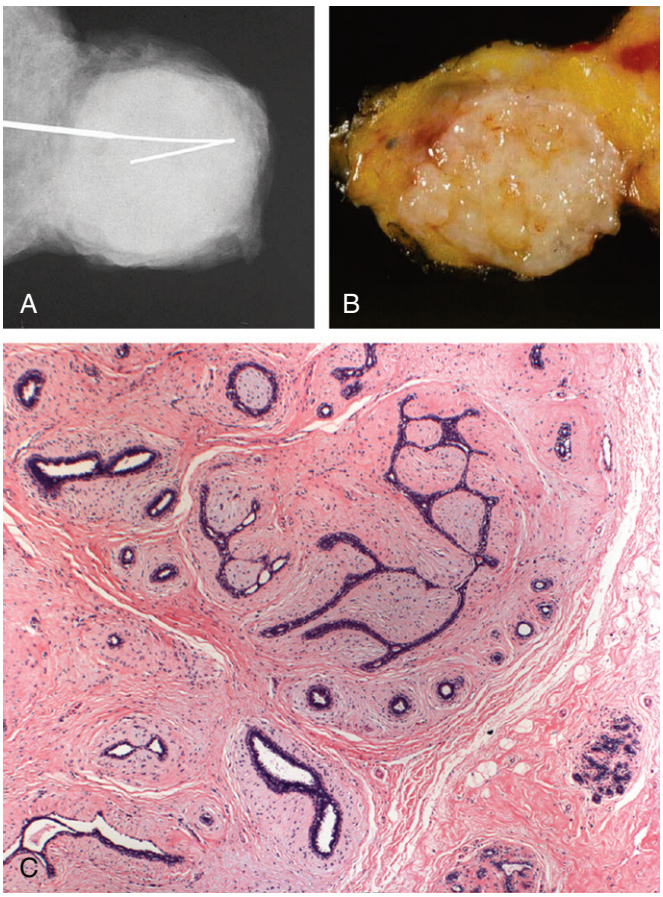


**Figure 18–27** Fibroadenoma. **A,** The radiograph shows a characteristic well-circumscribed mass. **B,** In this gross specimen, a rubbery well-circumscribed mass is clearly demarcated from the surrounding adipose tissue. **C,** In this micrograph, the proliferation of intralobular stroma can be seen to compress the entrapped glands, creating a "pushing" border that is sharply delineated from the surrounding normal tissue.

## Intraductal Papilloma

Intraductal papilloma is a benign neoplastic papillary growth. It is most often seen in premenopausal women. These lesions typically are solitary and found within the principal lactiferous ducts or sinuses. The clinical presentation may include

- Serous or bloody nipple discharge
- The presence of a *small subareolar tumor* a few millimeters in diameter
- *Nipple retraction,* in rare instances

### MORPHOLOGY

The tumors usually are solitary and less than 1 cm in diameter, consisting of delicate, branching growths within a dilated duct. On histologic examination, they are composed of multiple papillae, each having a connective tissue core covered by epithelial cells that are double-layered, with an outer luminal layer overlying a myoepithelial layer. The presence of a double-layered epithelium helps to distinguish intraductal papilloma from intraductal papillary carcinoma, which can present with clinical features similar to benign papilloma.

## Carcinoma

In 2010, more than 200,000 invasive breast cancers were diagnosed in women in the United States, and around 40,000 women died of this disease, making this scourge second only to lung cancer as a cause of cancer-related death in women. The lifetime risk of developing breast cancer is 1 in 8 for women in the United States. During the past 3 decades, the mortality rate among those diagnosed with breast cancer has dropped from 30% to 20%, mostly as a result of improved screening and treatment.

### *Epidemiology and Risk Factors*

A large number of risk factors for breast cancer have been identified. Table 18–5 divides these into well-established and less well-established groups and indicates, when possible, the relative risk posed by each. Some of the more important risk factors are summarized next.

***Age.*** Risk steadily increases throughout life, especially after menopause, peaking at roughly 80 years of age; 75% of women with breast cancer are older than 50 years of age, and only 5% are younger than 40.

***Geographic Variations.*** Surprising differences in the incidence and mortality rates of breast cancer have been reported for various countries. The risk for development of this disease is significantly higher in North America and northern Europe than in Asia and Africa. For example, the incidence and mortality rates are five times higher in the

**Table 18–5** Breast Cancer Risk Factors

| Factor | Relative Risk |
|---|---|
| **Well-Established Factors** | |
| Geography | Varies in different areas |
| Age | Increases after age 30 |
| Family history | |
| First-degree relative with breast cancer | 1.2–3.0 |
| Premenopausal | 3.1 |
| Premenopausal and bilateral | 8.5–9.0 |
| Postmenopausal | 1.5 |
| Postmenopausal and bilateral | 4.0–5.4 |
| Menstrual history | |
| Age at menarche <12 years | 1.3 |
| Age at menopause >55 years | 1.5–2.0 |
| Pregnancy | |
| First live birth from ages 25 to 29 years | 1.5 |
| First live birth after age 30 years | 1.9 |
| First live birth after age 35 years | 2.0–3.0 |
| Nulliparous | 3.0 |
| Benign breast disease | |
| Proliferative disease without atypia | 1.6 |
| Proliferative disease with atypical hyperplasia | >2.0 |
| Lobular carcinoma in situ | 6.9–12.0 |
| **Other Possible Factors** | |
| Exogenous estrogens | |
| Oral contraceptives | |
| Obesity | |
| High-fat diet | |
| Alcohol consumption | |
| Cigarette smoking | |

Data from Bilimoria MM, Morrow M: The women at increased risk for breast cancer: evaluation and management strategies. CA Cancer J Clin 46:263, 1995.

United States than in Japan. These differences seem to be environmental rather than genetic in origin, because migrants from low-incidence to high-incidence areas tend to acquire the rates of their adoptive countries, and vice versa. Diet, reproductive patterns, and nursing habits are thought to be involved.

***Race/Ethnicity.*** The highest rate of breast cancer is in non-Hispanic white women. However, Hispanic and African American women tend to develop cancer at a younger age and are more likely to develop aggressive tumors that present at an advanced stage. Such disparities between ethnicities are an area of intense study and currently are thought to be due to a combination of genetic differences and social factors, such as lifestyle choices and access to health care.

***Other Risk Factors.*** *Prolonged exposure to exogenous estrogens* postmenopausally, as occurs with hormone replacement therapy, has been proved to be useful for the prevention of osteoporosis. However, according to recent studies, relatively short-term use of combined estrogen plus progestin hormone therapy is associated with an increased risk of breast cancer, diagnosis at a more advanced stage of breast cancer, and higher incidence of abnormal mammograms. Because the 2002 Women's Health Initiative report suggested greater harm than benefit of combined estrogen plus a progestin, a precipitous decline has occurred in estrogen and progestin use, along with a serious reevaluation of perimenopausal hormone therapy.

*Oral contraceptives* have not been shown to affect the risk of breast cancer, even in women who have taken the pill for a long time or in women with a family history of breast cancer.

*Ionizing radiation* to the chest increases the risk of breast cancer. The magnitude of the risk depends on the radiation dose, the time since exposure, and age. Only women in whom irradiation occurred before age 30, during breast development, seem to be affected. For example, breast cancer develops in 20% to 30% of women who underwent irradiation for Hodgkin lymphoma in their teens and 20s, but the risk for women treated later in life is not elevated. Of import, the low doses of radiation associated with mammographic screening have no significant effect on the incidence of breast cancer.

*Many other, less well-established risk factors,* such as obesity, alcohol consumption, and a diet high in fat, have been implicated in the development of breast cancer by analysis of population studies. The risk associated with obesity probably is due to exposure of the breast to estrogen produced by adipose tissue.

## PATHOGENESIS

The causes of breast cancer remain incompletely understood. However, three sets of influences seem to be important: (1) genetic changes, (2) hormonal influences, and (3) environmental variables.

**Genetic Changes.** As with all cancers, mutations affecting proto-oncogenes and tumor suppressor genes in breast epithelium underlie oncogenesis. Among the best-characterized is **overexpression of the *HER2/NEU* proto-oncogene,** which undergoes amplification in up to 30% of invasive breast cancers. This gene is a member of the epidermal growth factor receptor family, and its overexpression is associated with a poor prognosis. **Amplification of *RAS* and *MYC* genes also has been reported in some human breast cancers.** Mutations of the well-known tumor suppressor genes *RB* and *TP53* also may be present. A large number of genes including the estrogen receptor gene may be inactivated by promoter hypermethylation. Undoubtedly, the transformation process involves multiple acquired genetic alterations, which can occur in various combinations, thereby giving rise to different subtypes of breast cancer. **Gene expression profiling can separate breast cancer into four molecular subtypes:** (1) luminal A (estrogen receptor–positive, *HER2/NEU*-negative); (2) luminal B (estrogen receptor–positive, *HER2/NEU* overexpressing); (3) *HER2/NEU* positive (*HER2/NEU* over expressing, estrogen receptor–negative); and (4) basal-like (estrogen receptor–negative and *HER2/NEU*-negative). These subtypes are associated with different outcomes and, in some instances, different therapies.

Approximately 10% of breast cancers are related to specific inherited mutations. Women who carry a breast cancer susceptibility gene are more likely to have bilateral cancer, to have other familial forms of cancer (e.g., ovarian cancer), to have a positive family history (i.e., multiple first-degree relatives affected before menopause), to develop breast cancer before menopause, and to belong to certain ethnic groups (e.g., people of Ashkenazi Jewish descent). **Roughly one third of women with hereditary breast cancer have mutations in *BRCA1* (at chromosomal locus 17q21.3) or *BRCA2* (located on chromosomal band 13q12-13).** These genes encode large, complex proteins that do not exhibit close homology to each other or other proteins. Although the molecular basis for their strong association with breast cancer risk is still being elucidated, both BRCA1 and BRCA2 are believed to function in a common DNA repair pathway (Chapter 5).

Genetically, *BRCA1* and *BRCA2* are classic tumor suppressor genes, in that cancer arises only when both alleles are inactivated or defective—the first genetic lesion caused by a germline mutation and the second by a subsequent somatic mutation. Genetic testing is available, but its utility is complicated by the existence of hundreds of different mutant alleles, only some of which confer cancer susceptibility. The degree of penetrance, age at cancer onset, and susceptibility to other types of cancers differ among the specific mutations. Most carriers, however, develop breast cancer by the age of 70 years, as compared with only 7% of women who do not carry a mutation. The role of these genes in nonhereditary sporadic breast cancer is less clear, as mutations affecting *BRCA1* and *BRCA2* are infrequent in sporadic tumors. Less common genetic diseases associated with breast cancer are the Li-Fraumeni syndrome (caused by germline mutations in *TP53*) (Chapter 5), Cowden syndrome (caused by germline mutations in *PTEN*—mentioned earlier under endometrial carcinoma) (see also Chapter 14), and the ataxia-telangiectasia gene carriers (Chapter 5).

**Hormonal Influences.** Endogenous estrogen excess, or more accurately, hormonal imbalance, clearly has a significant role. Many of the risk factors mentioned (long duration of

reproductive life, nulliparity, and late age at birth of first child) involve increased exposure to estrogen unopposed by progesterone (Table 18–5). Functioning ovarian tumors that elaborate estrogens are associated with breast cancer in postmenopausal women. Estrogens stimulate the production of growth factors, such as transforming growth factor-α, platelet-derived growth factor, and fibroblast growth factor and others, which may promote tumor development through paracrine and autocrine mechanisms.

**Environmental Variables.** Environmental influences are suggested by the variable incidence of breast cancer in genetically homogeneous groups and the geographic differences in prevalence, as discussed earlier.

## MORPHOLOGY

The most common location of tumors within the breast is in the upper outer quadrant (50%), followed by the central portion (20%). About 4% of women with breast cancer have bilateral primary tumors or sequential lesions in the same breast.

Breast cancers are classified according to whether they have or have not penetrated the limiting basement membrane: Those that remain within this boundary are termed in situ carcinomas, and those that have spread beyond it are designated invasive or infiltrating carcinomas. In this classification, the main forms of breast carcinoma are as follows:

A. Noninvasive
   1. Ductal carcinoma in situ (DCIS)
   2. Lobular carcinoma in situ (LCIS)
B. Invasive (infiltrating)
   1. Invasive ductal carcinoma ("not otherwise specified"), the most common subtype of invasive carcinoma
   2. Invasive lobular carcinoma
   3. Medullary carcinoma
   4. Colloid carcinoma (mucinous carcinoma)
   5. Tubular carcinoma
   6. Other types

### *Noninvasive (in situ) Carcinoma*

There are two types of noninvasive breast carcinoma: DCIS and LCIS. Morphologic studies have shown that both types usually arise from cells in the terminal duct lobular unit. DCIS tends to fill and distort ductlike spaces. By contrast, LCIS usually expands but does not alter the acini of lobules. Both are confined by a basement membrane and do not invade into stroma or lymphovascular channels.

**DCIS** has a wide variety of histologic appearances. Architectural patterns often are mixed and include solid, comedo, cribriform, papillary, micropapillary, and "clinging" types. Necrosis may be present in any of these types. Nuclear appearance tends to be uniform in a given case and ranges from bland and monotonous (low nuclear grade) to pleomorphic (high nuclear grade). The **comedo** subtype is distinctive and is characterized by cells with high-grade nuclei with extensive central necrosis (Fig. 18–28). The name derives from the toothpaste-like necrotic tissue that extrudes from transected ducts on application of gentle pressure. **Calcifications frequently are associated with DCIS,** originating as either calcified necrotic debris or calcified secretory material. The proportion of breast cancers that are diagnosed at the DCIS stage is only 5% in unscreened populations but up to 40% in screened populations, largely because of the ability of mammography to detect calcifications. DCIS only rarely manifests as a palpable or radiologically detectable mass. The prognosis with DCIS is excellent, with greater than 97% long-term survival after simple mastectomy. In some women, distant metastases develop without local recurrence; these patients usually are found to have extensive high-nuclear-grade DCIS, probably with small, undetected areas of invasion. At least one third of women with small areas of untreated DCIS of low nuclear grade will eventually develop invasive carcinoma. When invasive cancer does develop, it usually is in the same breast and quadrant as the earlier DCIS. Current treatment strategies attempt to eradicate the DCIS by surgery and irradiation. Treatment with antiestrogenic agents such as tamoxifen and aromatase also may decrease the risk of recurrence.

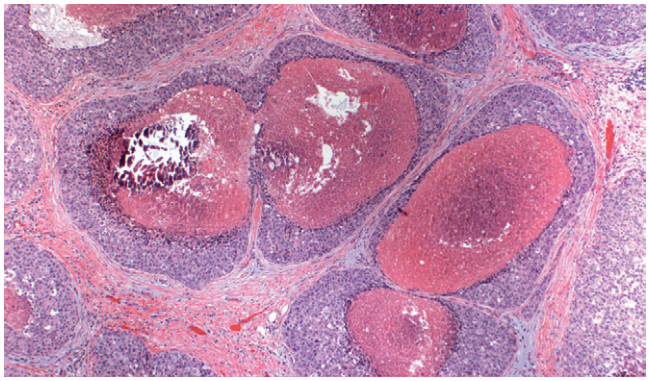

**Figure 18–28** Comedo ductal carcinoma in situ (DCIS). Several adjacent ducts are filled by tumor associated with large central zones of necrosis and calcified debris. This type of DCIS most frequently is detected as radiologic calcifications.

**Paget disease of the nipple** is caused by the extension of DCIS up the lactiferous ducts and into the contiguous skin of the nipple, producing a unilateral crusting exudate over the nipple and areolar skin. In almost all cases, an underlying carcinoma is present, and approximately 50% of the time this carcinoma is invasive. Prognosis is based on the underlying carcinoma and is not affected by the presence of Paget disease.

**LCIS** has a uniform appearance. The cells are monomorphic with bland, round nuclei and occur in loosely cohesive clusters within the lobules (Fig. 18–29). Intracellular mucin vacuoles (sometimes forming signet ring cells) are common. LCIS is virtually always an incidental finding, because unlike DCIS, it is only rarely associated with calcifications. Therefore, the incidence of LCIS has remained unchanged in mammographically screened populations. Approximately one third of women with LCIS will eventually develop invasive carcinoma. Unlike with DCIS, **subsequent invasive carcinomas may arise in either breast.** Most of these cancers are invasive lobular carcinomas; however, invasive ductal carcinomas also arise from LCIS. Thus, **LCIS is both a marker of an increased risk of carcinoma in both breasts and a direct precursor of some cancers.** Current treatment involves either chemoprevention with tamoxifen along with close clinical and radiologic follow-up evaluation or, less commonly, bilateral prophylactic mastectomy.

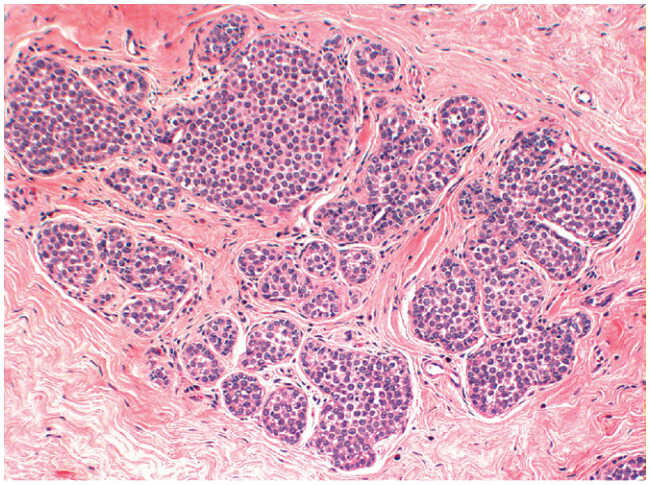

**Figure 18–29** Lobular carcinoma in situ. A monomorphic population of small, rounded, loosely cohesive cells fills and expands the acini of a lobule. The underlying lobular architecture is intact.

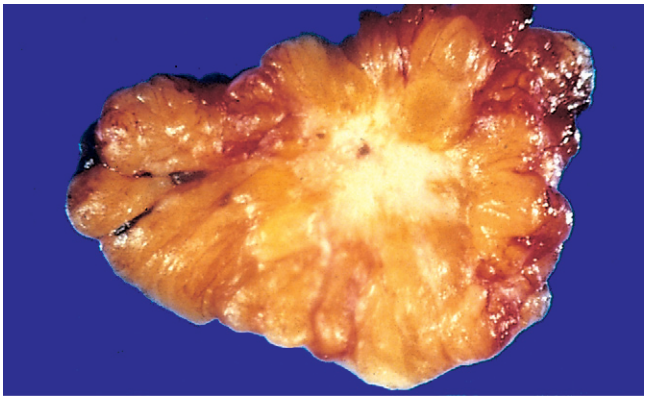

**Figure 18–30** Invasive ductal carcinoma is evident in this breast biopsy specimen. The hard, fibrotic lesion infiltrates the surrounding tissue, causing retraction.

***Invasive (Infiltrating) Carcinoma***

The distinctive histologic patterns of the subtypes of invasive carcinoma are described first, followed by the gross features common to all.

**Invasive ductal carcinoma** is a term used for all carcinomas that cannot be subclassified into one of the specialized types described below**.** A majority (70% to 80%) of cancers fall into this group. This type of cancer usually is associated with DCIS and, rarely, LCIS. Most ductal carcinomas produce a desmoplastic response, which replaces normal breast fat (resulting in a mammographic density) and forms a hard, palpable mass (Fig. 18–30). The microscopic appearance is quite heterogeneous, ranging from tumors with well-developed tubule formation and low-grade nuclei to tumors consisting of sheets of anaplastic cells (Fig. 18–31). The tumor margins typically are irregular. Invasion of lymphovascular spaces may be seen. About two thirds express estrogen or progesterone receptors, and about one third overexpress HER2/NEU.

**Invasive lobular carcinoma** consists of cells morphologically identical to the cells of LCIS. Two thirds of the cases are associated with adjacent LCIS. The cells invade individually into stroma and are often aligned in "single-file" strands or chains. This growth pattern correlates with the presence of mutations that abrogate the function of E-cadherin, a surface protein that contributes to the cohesion of normal breast epithelial cells. Although most manifest as palpable masses or mammographic densities, a significant subgroup may exhibit a diffusely invasive pattern without a desmoplastic response and may be clinically occult. Lobular carcinomas have a unique pattern of metastases among breast cancers;

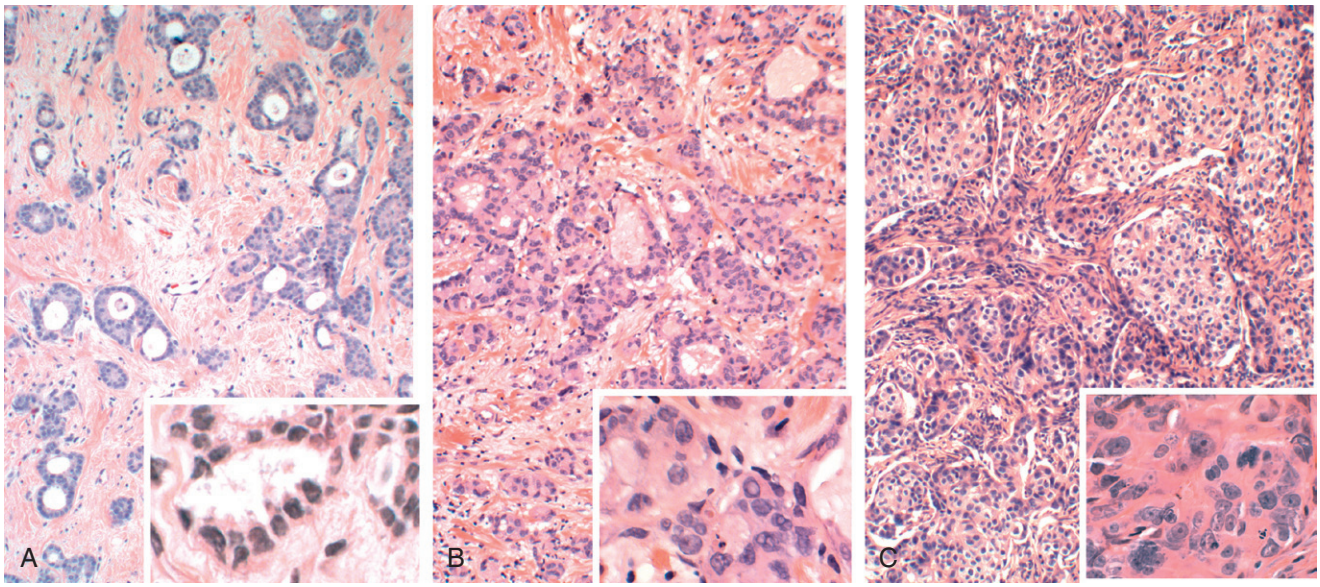


**Figure 18–31** Invasive breast carcinomas of no special type (*insets* show each tumor at higher magnification). **A,** Well-differentiated carcinoma consists of tubular or cribriform glands containing cells with small monomorphic nuclei within a desmoplastic response. **B,** Moderately differentiated carcinoma demonstrates less tubule formation and more solid nests of cells with pleomorphic nuclei. **C,** Poorly differentiated carcinoma infiltrates as ragged sheets of pleomorphic cells containing numerous mitotic figures and areas of tumor necrosis.

they more frequently spread to cerebrospinal fluid, serosal surfaces, gastrointestinal tract, ovary, uterus, and bone marrow. Lobular carcinomas also are more frequently multicentric and bilateral (in 10% to 20% of cases). Almost all of these carcinomas express hormone receptors, whereas HER2/NEU overexpression is rare. These tumors comprise fewer than 20% of all breast carcinomas.

**Inflammatory carcinoma** is defined by the clinical presentation of an enlarged, swollen, erythematous breast, usually without a palpable mass. The underlying carcinoma is generally poorly differentiated and diffusely infiltrative. Characteristically, carcinoma involves dermal lymphatic spaces. The resultant blockage of these channels leads to edema, resulting in the characteristic "inflamed" clinical appearance; true inflammation is minimal to absent. Many of these tumors metastasize to distant sites; the overall 5-year survival is under 50%, and understandably even lower in those with metastatic disease at diagnosis.

**Medullary carcinoma** is a rare subtype of carcinoma, accounting for less than 1% of breast cancers. These cancers consist of sheets of large anaplastic cells with well-circumscribed, "pushing" borders (Fig. 18–32, *A*). Clinically, they can be mistaken for fibroadenomas. There is invariably a pronounced lymphoplasmacytic infiltrate. DCIS usually is absent or minimal. Medullary carcinomas occur with increased frequency in women with *BRCA1* mutations, although most women with medullary carcinoma are not carriers. These carcinomas uniformly lack the estrogen and progesterone receptors and do not overexpress HER2/NEU (a combination that often is referred to as **triple-negative**).

**Colloid (mucinous) carcinoma** also is a rare subtype. The tumor cells produce abundant quantities of extracellular mucin, which dissects into the surrounding stroma (Fig. 18–32, *B*). Like medullary carcinomas, they often present as well-circumscribed masses and can be mistaken for fibroadenomas. On gross evaluation, the tumors usually are soft and gelatinous. Most express hormone receptors but do not overexpress HER2/NEU.

**Tubular carcinomas** rarely present as palpable masses but account for 10% of invasive carcinomas smaller than 1 cm found with mammographic screening. They usually are detected as irregular mammographic densities. On microscopic examination, the carcinomas consist of well-formed tubules with low-grade nuclei. Lymph node metastases are rare, and prognosis is excellent. Virtually all tubular carcinomas express hormone receptors and do not show HER2/NEU overexpression.

#### *Common Features of Invasive Cancers*

In all forms of breast cancer, local disease progression leads to similar physical findings. Invasive cancers tend to become adherent and fixed to the pectoral muscles or deep fascia of the chest wall and the overlying skin, with consequent retraction or dimpling of the skin or nipple. The latter is an important sign because it may be the first indication of malignancy. Involvement of the lymphatic pathways may result in localized lymphedema. In such cases, the skin becomes thickened around exaggerated hair follicles, giving an appearance known as peau d'orange ("orange peel").

### Clinical Course

Breast cancer often is discovered by the patient or her physician as a deceptively discrete, solitary, painless, and movable mass. At the time of clinical detection, the carcinoma typically is 2 to 3 cm in size, and involvement of the regional lymph nodes (most often axillary) is already present in about 50% of patients. With mammographic screening, carcinomas frequently are detected even before they become palpable. The average invasive carcinoma found by mammographic screening is around 1 cm in size, and only 15% of these have produced nodal metastases. In addition, DCIS often is detected before the development of invasive carcinoma during screening. As women age, fibrous breast tissue is replaced by fat, and screening becomes more sensitive as a result of the increased radiolucency of the breast and the increased incidence of malignancy. The current controversy over the best time to begin mammographic screening arises from efforts to balance the benefits of early cancer detection in some women with the

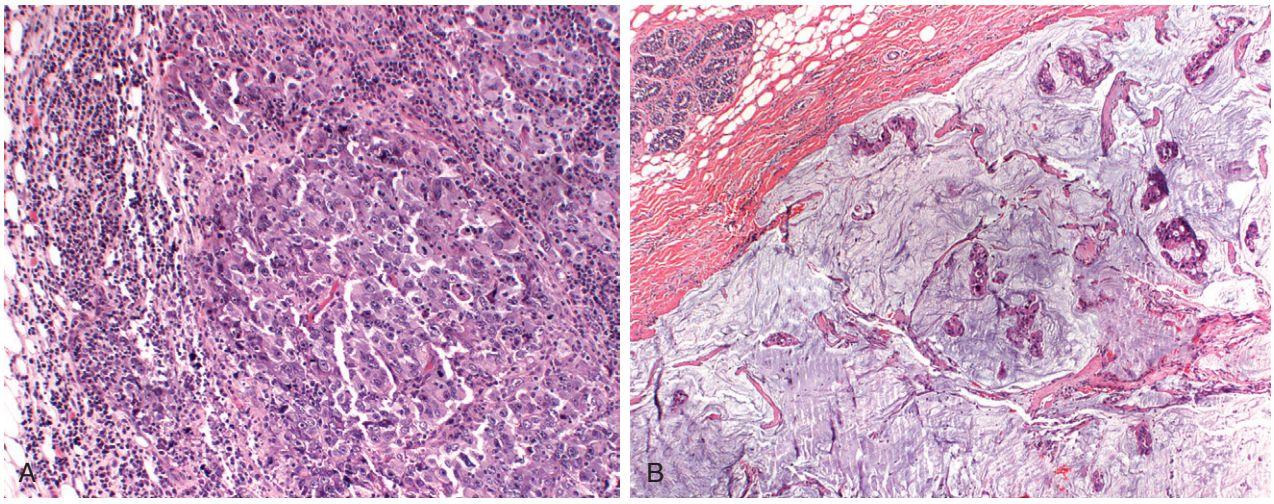


**Figure 18–32** Special types of breast carcinoma. **A,** Medullary carcinoma. The highly pleomorphic tumor cells grow in cohesive sheets and are associated with a prominent reactive infiltrate of lymphocytes and plasma cells. **B,** Mucinous (colloid) carcinoma. The tumor cells are present in small clusters within large pools of mucin. Note the characteristic well-circumscribed border, which mimics the appearance of benign masses.

risks of radiation exposure and the morbidity and expense associated with clinical workup of benign breast lesions (false positives). Magnetic resonance imaging is being studied as an adjunct to mammographic screening in high-risk, young patients with dense breasts that are difficult to image by mammography.

Breast cancer spread occurs through lymphatic and hematogenous channels. Outer quadrant and centrally located lesions typically spread first to the axillary nodes. Those in the medial inner quadrants often travel first to lymph nodes along the internal mammary arteries. More distant dissemination eventually ensues, and can involve virtually any organ or tissue in the body. Favored locations are the lungs, skeleton, liver, adrenals, and (less commonly) brain, but no site is exempt. *Metastases may come to clinical attention many years after apparent therapeutic control of the primary lesion, sometimes as long as 15 years later.* Nevertheless, with each passing year without disease recurrence, the likelihood of cure increases.

Prognosis of breast cancers is influenced by the following variables the first three of which are components of the tumor-node-metastasis (TNM) staging classification:

- *Tumor invasion and size.* In situ carcinomas carry an excellent prognosis (5-year survival rate greater than 90%), as do invasive carcinomas less than 2 cm in size (5-year survival rate of 87%).
- *Extent of lymph node involvement.* With no axillary node involvement, the 5-year survival rate is close to 80%. Survival is inversely related to the number of involved lymph nodes and is less than 50% with 16 or more involved nodes. Sentinel node biopsy is currently the mainstay for staging the axilla. This procedure identifies the primary lymph node(s) that drain the breast parenchyma using dye or a radioactive tracer (or sometimes both). Once identified, sentinel nodes are removed and examined microscopically. A sentinel lymph node that is free from carcinoma (a "negative node") is highly predictive of absence of metastatic carcinoma in the remaining lymph nodes. A "positive node," on the other hand, is an indication for a complete axillary dissection, which is used to stage the patient's disease.
- *Distant metastases.* Patients who develop hematogenous spread are rarely curable, although chemotherapy may prolong survival (the 5-year survival rate is approximately 15%).
- *Histologic grade.* The most common grading system for breast cancer evaluates tubule formation, nuclear grade, and mitotic rate. Well-differentiated carcinomas are associated with a significantly better prognosis than poorly differentiated carcinomas. Moderately differentiated carcinomas initially have a good prognosis, but survival at 20 years approaches that for poorly differentiated carcinomas.
- *The histologic type of carcinoma.* All specialized types of breast carcinoma (tubular, medullary, and mucinous) are associated with a somewhat better prognosis than carcinomas of no special type (*ductal carcinomas*). A major exception is inflammatory carcinoma, which has a poor prognosis.
- *The presence or absence of estrogen or progesterone receptors.* The presence of hormone receptors confers a slightly better prognosis. However, the practical reason for determining their presence is to predict the response to therapy. The highest rate of response (approximately 80%) to antiestrogen therapy (oophorectomy or tamoxifen) is seen in women whose tumor cells express both estrogen and progesterone receptors. Lower rates of response (25% to 45%) are seen if only estrogen receptor is present. If both are absent, very few patients (less than 10%) respond.
- *Overexpression of HER2/NEU.* Overexpression of this membrane-bound protein is almost always caused by gene amplification and can be determined by immunohistochemistry (which assesses protein levels) or by fluorescence in situ hybridization (which assesses the gene copy number). Overexpression is associated with a poorer prognosis. However, the clinical importance of evaluating HER2/NEU lies in predicting response to trastuzumab (Herceptin), a monoclonal antibody that binds and inhibits the function of HER2/NEU. This remains one of the best-characterized examples of an effective therapy directed against a tumor-specific molecular lesion.

Why some cancers recur after postoperative therapy while others do not remains a mystery. As mentioned earlier, gene expression profiling of breast cancers on microarrays (gene chips) (Chapter 5) has defined several molecular classes of breast cancer and also has been used to develop commercial tests that may predict the response of an individual patient's tumor to chemotherapy. At present there is insufficient data on the prognostic value of such tests.

## SUMMARY

### Breast Carcinoma

- The lifetime risk of developing breast cancer for an American woman is 1 in 8.
- A majority (75%) of breast cancers are diagnosed after the age of 50.
- Risk of developing breast cancer is related to estrogen exposure, genetic factors, long duration between menarche and menopause, atypical proliferative lesions, and family history of breast cancer in a first-degree relative, particularly if the disease was multifocal or in a premenopausal woman.
- About 10% of all breast cancers are caused by inherited mutations; *BRCA1* and *BRCA2* genes account for one third of the cases associated with single-gene mutations.
- Ductal carcinoma in situ (DCIS) is a precursor to invasive ductal carcinoma and typically is found on mammographic examination as calcifications. When carcinoma develops in a woman with a previous diagnosis of DCIS, it usually is an invasive ductal carcinoma in the same breast.
- Lobular carcinoma in situ (LCIS) frequently is an incidental finding and usually is not associated with calcifications. When carcinoma develops in a woman with a previous diagnosis of LCIS, it may occur in the affected or unaffected breast and usually is invasive lobular carcinoma but may be invasive ductal carcinoma.

- The natural history of breast carcinoma is long, with metastases sometimes appearing decades after the initial diagnosis.
- Prognosis is most dependent on tumor size, lymph node involvement, distant metastasis at presentation, tumor grade, and histologic type.
- Estrogen and progesterone receptor status and expression of HER2/NEU are used primarily to determine response to treatment. Estrogen receptor–expressing tumors are more likely to respond to tamoxifen. HER2/NEU-overexpressing tumors often are treated with trastuzumab.

## LESIONS OF THE MALE BREAST

The rudimentary male breast is relatively free of pathologic involvement. Only two disorders occur with sufficient frequency to be considered here: *gynecomastia* and *carcinoma.*

### Gynecomastia

As in females, male breasts are subject to hormonal influences, but they are considerably less sensitive in this regard than female breasts. Nonetheless, enlargement of the male breast, or gynecomastia, may occur in response to absolute or relative estrogen excesses. The most important cause of hyperestrinism in the male is cirrhosis and the consequent inability of the liver to metabolize estrogens. Other causes include Klinefelter syndrome, anabolic steroids, and some pharmacologic agents. Physiologic gynecomastia often occurs in puberty and in extreme old age.

The morphologic features of gynecomastia include an increase in connective tissue and epithelial hyperplasia of the ducts; lobule formation is rare. Clinically, a button-like, subareolar swelling develops, usually in both breasts but occasionally in only one.

### Carcinoma

Breast cancer is rare in men, with an incidence less than 1% of that reported for women. It typically is diagnosed in advanced age. Because of the scant amount of breast tissue in men, the tumor rapidly infiltrates the overlying skin and underlying thoracic wall. Both morphologically and biologically, these tumors resemble the invasive carcinomas seen in women. Unfortunately, almost half have spread to regional nodes or more distant sites by the time they are discovered.

## BIBLIOGRAPHY


Amant F: Endometrial cancer. Lancet 366:491, 2005. *[A comprehensive review of the subject.]*

Bulun SE: Mechanism of disease: endometriosis. New Engl J Med 360:268, 2009. *[Excellent review of the molecular basis of endometriosis.]*

Burstein HJ, Polyak K, Wong JS, et al: Ductal carcinoma in situ of the breast. N Engl J Med 350:1430, 2004. *[An excellent clinical-pathologic and molecular genetics discussion.]*

Cannistra S: Cancer of ovary. N Engl J Med 351:2519, 2004. *[A comprehensive review.]*

Christos S: Gene-expression signatures in breast cancer. N Engl J Med 360:790, 2009. *[A review of the molecular classification of breast cancer and its significance.]*

DiCristofano A, Ellenson LH: Endometrial carcinoma. Annu Rev Pathol 2:57, 2007. *[A comprehensive discussion of pathogenesis.]*

Ehrmann DA: Polycystic ovary syndrome. N Engl J Med 352:1223, 2004. *[A detailed review.]*

Fox H, Wells M: Recent advances in the pathology of the vulva. Histopathology 42:209, 2003. *[A short update on vulvar pathology.]*

Herrington CS: Recent advances in molecular gynaecological pathology. Histopathology 55:243, 2009. *[A review of molecular genetics of cervical, ovarian, and endometrial neoplasia.]*

Kathleen RC: Ovarian cancer. Annu Rev Pathol Mech Dis 4:287, 2009. *[A good review on the subject with discussion of molecular genetics.]*

Moody CA: Human papillomavirus oncoproteins: pathways to transformation. Nat Rev Cancer 10:550, 2010. *[A review of current opinion on cervical carcinogenesis.]*

Santen RJ, Mansel R: Benign breast disorders. N Engl J Med 353:275, 2005. *[A good review of benign breast lesions and risk of cancer.]*

Seckl MJ, Sebire NJ, Berkowitz RS: Gestational trophoblastic disease. Lancet 376:717, 2010. *[A review of gestation trophoblastic including discussion regarding management.]*

Wilkinson N, Rollason TP: Recent advances in the pathology of smooth muscle tumours of the uterus. Histopathology 39:331, 2001. *[A good introduction to smooth muscle tumors.]*

Wingo SN, Gallardo TD, Akbay EA, et al: Somatic LKB1 mutations promote cervical cancer progression. PLos One 4:e5137, 2009. *[A paper describing the role of LKB1 gene in cancer of the cervix.]*

Wooster R, Weber BL: Breast and ovarian cancer. N Engl J Med 348:2339, 2003. *[Discussion of genetics of breast and ovarian cancer.]*

Yager JD, Davidson NE: Estrogen carcinogenesis in breast cancer. N Engl J Med 354:273, 2006. *[Role of estrogens including those used in hormonal replacement therapy in breast cancer.]*

See Targeted Therapy available online at studentconsult.com

CHAPTER 19

# Endocrine System

CHAPTER CONTENTS

**PITUITARY 716**
Hyperpituitarism and Pituitary Adenomas 717
Prolactinomas 719
Growth Hormone–Producing (Somatotroph Cell) Adenomas 719
Adrenocorticotropic Hormone–Producing (Corticotroph Cell) Adenomas 719
Other Anterior Pituitary Neoplasms 720
Hypopituitarism 720
Posterior Pituitary Syndromes 721
**THYROID 721**
Hyperthyroidism 722
Hypothyroidism 723
Thyroiditis 724
Chronic Lymphocytic (Hashimoto) Thyroiditis 724
Subacute Granulomatous (de Quervain) Thyroiditis 725
Subacute Lymphocytic Thyroiditis 726
Other Forms of Thyroiditis 726
Graves Disease 726
Diffuse and Multinodular Goiter 728
Neoplasms of the Thyroid 728
Adenomas 729
Carcinomas 730
**PARATHYROID GLANDS 735**
Hyperparathyroidism 735
Primary Hyperparathyroidism 736
Secondary Hyperparathyroidism 738
Hypoparathyroidism 738
**ENDOCRINE PANCREAS 739**
Diabetes Mellitus 739
Diagnosis 739
Classification 739
Normal Insulin Physiology and Glucose Homeostasis 739
Insulin Resistance 741
Beta Cell Dysfunction 743
Monogenic Forms of Diabetes 743
Complications of Diabetes 743
Pancreatic Neuroendocrine Tumors 751
Insulinomas 751
Gastrinomas 752
**ADRENAL CORTEX 752**
Adrenocortical Hyperfunction (Hyperadrenalism) 752
Hypercortisolism and Cushing Syndrome 752
Hyperaldosteronism 755
Adrenogenital Syndromes 756
Adrenal Insufficiency 757
Acute Adrenocortical Insufficiency 757
Chronic Adrenocortical Insufficiency: Addison Disease 757
Secondary Adrenocortical Insufficiency 758
Adrenocortical Neoplasms 759
**ADRENAL MEDULLA 760**
Tumors of the Adrenal Medulla 760
Pheochromocytoma 760
Neuroblastoma and Other Neuronal Neoplasms 761
**MULTIPLE ENDOCRINE NEOPLASIA SYNDROMES 761**
Multiple Endocrine Neoplasia Type 1 761
Multiple Endocrine Neoplasia Type 2 762

The endocrine system is a highly integrated and widely distributed group of organs that orchestrate a state of metabolic equilibrium, or homeostasis, among the various tissues of the body. Signaling by extracellular secreted molecules can be classified as one of three types—autocrine, paracrine, or endocrine—according to the distance over which the signal acts (Chapter 2). In *endocrine* signaling, the secreted molecules, which frequently are called *hormones,* act on target cells distant from their site of synthesis. An endocrine hormone typically is carried by the blood from its site of release to its target. Increased activity of the target tissue often downregulates the activity of the gland that secretes the stimulating hormone, a process known as *feedback inhibition.*

Hormones can be classified into several broad categories, based on the nature of their receptors:

- *Hormones that trigger biochemical signals upon interacting with cell surface receptors*: This large class of compounds is composed of two groups: (1) peptide hormones, such as *growth hormone* and *insulin,* and (2) small molecules, such as *epinephrine.* Binding of these hormones to cell surface receptors leads to an increase in intracellular molecules, termed *second messengers,* such as cyclic adenosine monophosphate (cAMP); production of mediators from membrane phospholipids (e.g., inositol 1,4,5-trisphosphate); and shifts in intracellular levels of ionized calcium. Elevated levels of one or more of these compounds can change proliferation, differentiation, survival, and functional activity of cells, mainly by regulating the expression of specific genes.
- *Hormones that diffuse across the plasma membrane and interact with intracellular receptors*: Many lipid-soluble hormones pass through the plasma membrane by diffusion to interact with receptors in the cytosol or the nucleus. The resulting hormone-receptor complexes bind specifically to promoter and enhancer elements in DNA,

thereby affecting the expression of specific target genes. Hormones of this type include the *steroids* (e.g., estrogen, progesterone, glucocorticoids), the *retinoids* (vitamin A), and *thyroxine.*

Several processes may disturb the normal activity of the endocrine system, including impaired synthesis or release of hormones, abnormal interactions between hormones and their target tissues, and abnormal responses of target organs to their hormones. Endocrine diseases can be generally classified as (1) diseases of *underproduction or overproduction* of hormones, with associated biochemical and clinical consequences, or (2) diseases associated with the development of *mass lesions,* which may be nonfunctional or may be associated with overproduction or underproduction of hormones.

With the exception of mass lesions, study of endocrine diseases relies heavily on biochemical measurements of the levels of hormones, their regulators, and other metabolites.

## PITUITARY

The pituitary gland is a small, bean-shaped structure that lies at the base of the brain within the confines of the sella turcica. It is intimately related to the hypothalamus, with which it is connected by both a *stalk,* composed of axons extending from the hypothalamus, and a rich venous plexus constituting a portal circulation. Along with the hypothalamus, the pituitary has a central role in the regulation of most of the other endocrine glands. The pituitary is composed of two morphologically and functionally distinct components: the anterior lobe (adenohypophysis) and the posterior lobe (neurohypophysis). Diseases of the pituitary, accordingly, can be divided into those that primarily affect the anterior lobe and those that primarily affect the posterior lobe.

The *anterior pituitary,* or *adenohypophysis,* is composed of epithelial cells derived embryologically from the developing oral cavity. In routine histologic sections, a colorful array of cells containing basophilic cytoplasm, eosinophilic cytoplasm, or poorly staining (*chromophobic*) cytoplasm is present (Fig. 19–1). Detailed studies using electron microscopy and immunocytochemical techniques have demonstrated that the staining properties of these cells are related to the presence of various trophic polypeptide hormones within their cytoplasm. The release of trophic hormones is in turn under the control of factors produced in the hypothalamus; while most hypothalamic factors are stimulatory and promote pituitary hormone release, others (e.g., somatostatin and dopamine) are inhibitory in their effects (Fig. 19–2). Rarely, signs and symptoms of pituitary disease may be caused by excess or lack of the hypothalamic factors, rather than by a primary pituitary abnormality.

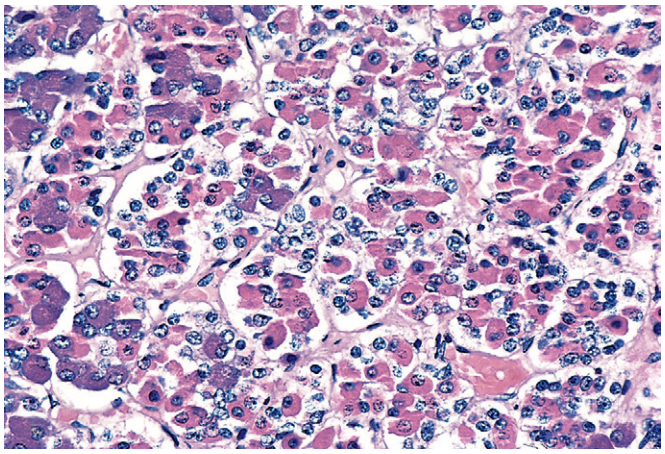

**Figure 19–1** Normal architecture of the anterior pituitary. The gland is populated by several distinct cell types containing a variety of stimulating (trophic) hormones. Each of the hormones has different staining characteristics, resulting in a mixture of cell types in routine histologic preparations. Note also the presence of a fine reticulin network.

Symptoms and signs of pituitary disease can be grouped as follows:

- *Hyperpituitarism*-related effects: Hyperpituitarism arises from excessive secretion of trophic hormones. It most often results from an *anterior pituitary adenoma* but also may be caused by other pituitary and extrapituitary lesions, as described subsequently. The symptoms and signs of hyperpituitarism are discussed in the context of individual tumors, later in the chapter.
- *Hypopituitarism*-related effects: Hypopituitarism is caused by deficiency of trophic hormones and results from a variety of destructive processes, including *ischemic injury, surgery or radiation,* and *inflammatory reactions.* In addition, *nonfunctional pituitary adenomas* may encroach upon and destroy adjacent normal anterior pituitary parenchyma, causing hypopituitarism.
- *Local mass effects*: Among the earliest changes referable to mass effect are *radiographic abnormalities of the sella turcica,* including sellar expansion, bony erosion, and disruption of the diaphragma sellae. Because of the close proximity of the optic nerves and chiasm to the sella, expanding pituitary lesions often compress decussating fibers in the optic chiasm. This altered neuroanatomy gives rise to *visual field abnormalities,* classically in the form of defects in the lateral (temporal) visual fields—a so-called *bitemporal hemianopsia.* As in the case of any expanding intracranial mass, pituitary adenomas may produce signs and symptoms of *elevated intracranial pressure,* including headache, nausea, and vomiting. Pituitary adenomas that extend beyond the sella turcica into the base of the brain (invasive pituitary adenoma) produce *seizures* or *obstructive hydrocephalus*; involvement of cranial nerves can result in *cranial nerve palsy.* On occasion, acute hemorrhage into an adenoma is associated with clinical evidence of rapid enlargement of the lesion and depression of consciousness, a situation appropriately termed *pituitary apoplexy.* Acute pituitary apoplexy constitutes a neurosurgical emergency, because it may be rapidly fatal.

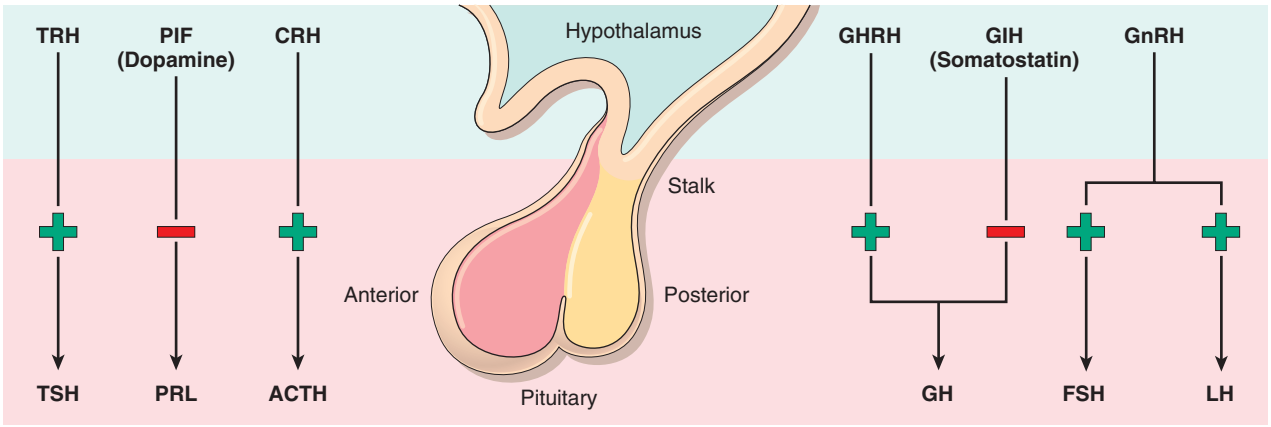


**Figure 19–2** The adenohypophysis (anterior pituitary) releases six hormones: adrenocorticotropic hormone (ACTH), or corticotropin; follicle-stimulating hormone (FSH); growth hormone (GH), or somatotropin; luteinizing hormone (LH); prolactin (PRL); and thyroid-stimulating hormone (TSH), or thyrotropin. These hormones are in turn under the control of various stimulatory and inhibitory hypothalamic releasing factors. The *stimulatory* releasing factors are corticotropin-releasing hormone (CRH), growth hormone–releasing hormone (GHRH), gonadotropin-releasing hormone (GnRH), and thyrotropin-releasing hormone (TRH). The *inhibitory* hypothalamic factors are growth hormone inhibitory hormone (GIH), or somatostatin, and prolactin inhibitory factor (PIF), which is the same as dopamine.

## HYPERPITUITARISM AND PITUITARY ADENOMAS

*The most common cause of hyperpituitarism is an adenoma arising in the anterior lobe.* Other, less common, causes include hyperplasia and carcinomas of the anterior pituitary, secretion of hormones by some extrapituitary tumors, and certain hypothalamic disorders. Some salient features of pituitary adenomas are as follows:

- *Pituitary adenomas are classified on the basis of hormone(s) produced by the neoplastic cells, which are detected by immunohistochemical stains performed on tissue sections* (Table 19–1).
- Pituitary adenomas can be *functional* (i.e., associated with hormone excess and clinical manifestations thereof) or *nonfunctioning* (i.e., demonstration of hormone production at the tissue level only, without clinical manifestations of hormone excess). Both functional and nonfunctioning pituitary adenomas usually are composed of a single cell type and produce a single predominant hormone, but there are some exceptions. Some pituitary adenomas can secrete two different hormones (growth hormone and prolactin being the most common combination); rarely, pituitary adenomas are plurihormonal. At the other end of the spectrum, pituitary adenomas also may be truly "*hormone negative,*" as indicated by absence of immunohistochemical reactivity or ultrastructural evidence of hormone production.
- Most pituitary adenomas occur as sporadic (i.e., nonfamilial) lesions. In about 5% of cases, however, adenomas occur as a result of an inherited predisposition (see later).
- Pituitary adenomas are designated, somewhat arbitrarily, as *microadenomas* if they are less than 1 cm in diameter and *macroadenomas* if they exceed 1 cm in diameter.
- Nonfunctioning and hormone-negative adenomas are likely to come to clinical attention at a later stage and are, therefore, more likely to be macroadenomas than

**Table 19–1** Classification of Pituitary Adenomas

| Pituitary Cell Type | Hormone | Tumor Type | Associated Syndrome* |
|---|---|---|---|
| Corticotroph | ACTH and other POMC-derived peptides | Densely granulated<br>Sparsely granulated | Cushing syndrome<br>Nelson syndrome |
| Somatotroph | GH | Densely granulated<br>Sparsely granulated | Gigantism (children)<br>Acromegaly (adults) |
| Lactotroph | Prolactin | Densely granulated<br>Sparsely granulated | Galactorrhea and amenorrhea (in females)<br>Sexual dysfunction, infertility |
| Mammosomatotroph | Prolactin, GH | Mammosomatotroph | Combined features of GH and prolactin excess |
| Thyrotroph | TSH | Thyrotroph | Hyperthyroidism |
| Gonadotroph | FSH, LH | Gonadotroph, "null cell," oncocytic adenomas | Hypogonadism, mass effects and hypopituitarism |

ACTH, adrenocorticotropic hormone; FSH, follicle-stimulating hormone; GH, growth hormone; LH, luteinizing hormone; POMC, pro-opiomelanocortin; TSH, thyroid-stimulating hormone.
*Nonfunctioning adenomas in each category typically manifest with *mass effects* and often with *hypopituitarism*.
Data from Ezzat S, Asa SL: Mechanisms of disease: the pathogenesis of pituitary tumors. Nat Clin Pract Endocrinol Metab 2:220–230, 2006.

are lesions associated with endocrine abnormalities. In addition, nonfunctioning adenomas may cause *hypo*pituitarism as they encroach on and destroy adjacent anterior pituitary parenchyma.

## PATHOGENESIS

With recent advances in molecular techniques, substantial insight has been gained into the **genetic abnormalities associated with pituitary adenomas:**

- Guanine nucleotide–binding protein (G protein) mutations are the best-characterized molecular abnormalities in these neoplasms. G proteins have a critical role in signal transduction, transmitting signals from **cell surface receptors** (e.g., growth hormone–releasing hormone receptor) to **intracellular effectors** (e.g., adenyl cyclase), which then generate **second messengers** (e.g., cAMP). $G_s$ is a stimulatory G protein that has a pivotal role in signal transduction in several endocrine organs, including the pituitary. $G_s$ exists as an inactive protein, with guanosine diphosphate (GDP) bound to the guanine nucleotide–binding site of the alpha subunit of $G_s$, encoded by the *GNAS1* gene. On triggering of the hormone receptor, GDP dissociates, and guanosine triphosphate (GTP) binds to $G_s\alpha$, activating the G protein. GTP-bound $G_s\alpha$ directly interacts with and activates its effectors (such as adenyl cyclase), with a resultant increase in intracellular cAMP. The cAMP acts as a potent mitogenic stimulus for a variety of endocrine cell types, promoting cellular proliferation and hormone synthesis and secretion. The activation of $G_s\alpha$ and the resultant generation of cAMP are **transient** because of an intrinsic GTPase activity in the $\alpha$-subunit, which hydrolyzes GTP into GDP. **A mutation in the $\alpha$-subunit that interferes with its intrinsic GTPase activity therefore results in constitutive activation of $G_s\alpha$, persistent generation of cAMP, and unchecked cellular proliferation.** Approximately 40% of growth hormone–secreting somatotroph cell adenomas and a minority of adrenocorticotropic hormone (ACTH)–secreting corticotroph cell adenomas bear *GNAS1* mutations.
- As stated previously, approximately 5% of pituitary adenomas arise as a consequence of an inherited predisposition. **Four genes have been identified thus far as a cause of familial pituitary adenomas: *MEN1*, *CDKN1B*, *PRKAR1A*, and *AIP*.** Germline inactivating mutations of the *MEN1* gene are responsible for multiple endocrine neoplasia syndrome type 1 (MEN-1) (discussed in detail later on). The product of the *CDKN1B* gene is the cell cycle checkpoint regulator p27 or KIP1; germline mutations of *CDKN1B* are responsible for a subset of patients with a "MEN-1 like" syndrome who lack *MEN1* abnormalities. The gene encoding the **aryl hydrocarbon receptor–interacting protein (AIP)** is a recently described pituitary adenoma predisposition gene, and patients with *AIP* germline mutations often develop GH-secreting adenomas at a younger age (before 35 years) than that typical for sporadic GH adenoma patients.
- Mutations of *TP53* in pituitary adenomas are associated with a propensity for aggressive behavior, such as invasion and recurrence.

## MORPHOLOGY

The usual pituitary adenoma is a well-circumscribed, soft lesion that may, in the case of smaller tumors, be confined by the sella turcica. Larger lesions may compress the optic chiasm and adjacent structures (Fig. 19–3), erode the sella turcica and anterior clinoid processes, and extend locally into the cavernous and sphenoidal sinuses. In as many as 30% of cases, the adenomas are nonencapsulated and infiltrate adjacent bone, dura, and (uncommonly) brain. Foci of hemorrhage and/or necrosis are common in larger adenomas.

Pituitary adenomas are composed of relatively uniform, polygonal cells arrayed in sheets, cords, or papillae. Supporting connective tissue, or reticulin, is sparse, accounting for the soft, gelatinous consistency of many of these tumors. The nuclei of the neoplastic cells may be uniform or pleomorphic. Mitotic activity usually is scanty. The cytoplasm of the constituent cells may be acidophilic, basophilic, or chromophobic, depending on the type and amount of secretory product within the cell, but it is fairly uniform throughout the neoplasm. **This cellular monomorphism and the absence of a significant reticulin network distinguish pituitary adenomas from non-neoplastic anterior pituitary parenchyma** (Fig. 19–4). The functional status of the adenoma cannot be reliably predicted from its histologic appearance. Adenomas that harbor *TP53* mutations often demonstrate brisk mitotic activity and higher proliferation rates and are designated **atypical adenomas** to reinforce their potential for aggressive behavior.

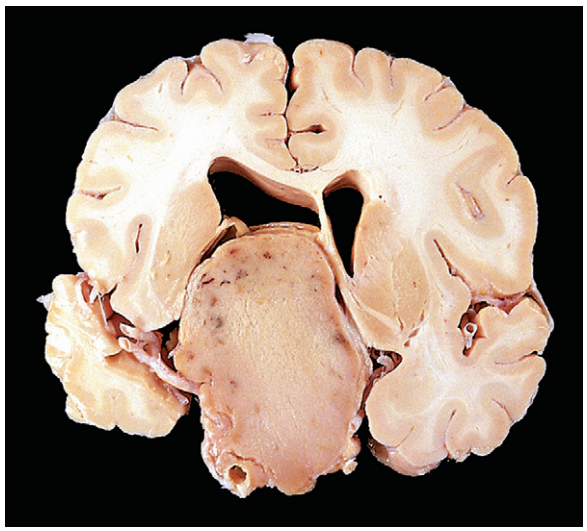

**Figure 19–3** Pituitary adenoma. This massive, nonfunctioning adenoma has grown far beyond the confines of the sella turcica and has distorted the overlying brain. Nonfunctioning adenomas tend to be larger at the time of diagnosis than those that secrete a hormone.

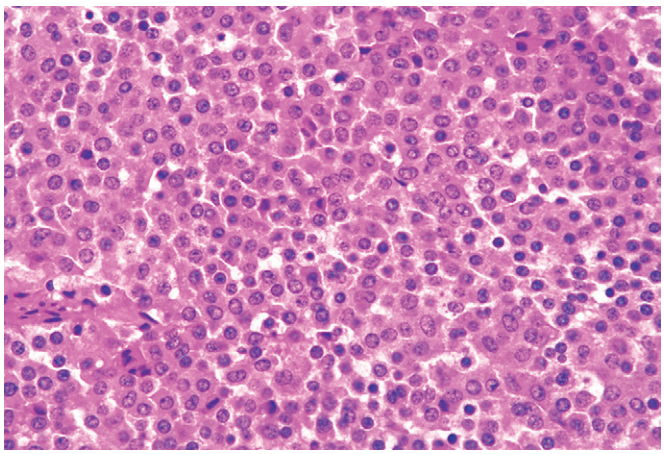

**Figure 19–4** Pituitary adenoma. The monomorphism of these cells contrasts markedly with the admixture of cells seen in the normal anterior pituitary in Figure 19–1. Note also the absence of reticulin network.

## SUMMARY

### Hyperpituitarism

- The most common cause of hyperpituitarism is an anterior lobe pituitary adenoma.
- Pituitary adenomas can be macroadenomas (greater than 1 cm in diameter) or microadenomas (less than 1 cm across), and on clinical evaluation, they can be functional or nonfunctioning.
- Macroadenomas may potentially lead to mass effects, including visual disturbances.
- Functioning adenomas are associated with distinct endocrine signs and symptoms.
- Mutation of the *GNAS1* gene, which results in constitutive activation of a stimulatory G protein, is one of the more common genetic alterations.
- The two distinctive morphologic features of most adenomas are their cellular monomorphism and absence of a reticulin network.

## Prolactinomas

*Prolactinomas are the most common type of hyperfunctioning pituitary adenoma.* They range in size from small microadenomas to large, expansile tumors associated with considerable mass effect. Prolactin is demonstrable within the cytoplasm of the neoplastic cells by immunohistochemical techniques.

*Hyperprolactinemia* causes amenorrhea, galactorrhea, loss of libido, and infertility. Because many of the manifestations of hyperprolactinemia (e.g., amenorrhea) are more obvious in premenopausal women than in men or postmenopausal women, prolactinomas usually are diagnosed at an earlier stage in women of reproductive age than in other persons so affected. By contrast, hormonal manifestations may be quite subtle in men and older women, in whom the tumor may reach considerable size before coming to clinical attention. Hyperprolactinemia may be caused by conditions or factors other than prolactin-secreting pituitary adenomas, including pregnancy, high-dose estrogen therapy, renal failure, hypothyroidism, hypothalamic lesions, and dopamine-inhibiting drugs (e.g., reserpine). In addition, any mass in the suprasellar compartment may disturb the normal inhibitory influence of hypothalamus on prolactin secretion, resulting in hyperprolactinemia—a mechanism known as the *stalk effect.* Thus, *mild* elevations of serum prolactin (less than 200 μg/L) in a patient with a pituitary adenoma do not necessarily indicate a prolactin-secreting neoplasm.

## Growth Hormone–Producing (Somatotroph Cell) Adenomas

Growth hormone–producing neoplasms (somatotroph cell adenomas), including those that produce a mixture of growth hormone and other hormones (e.g., prolactin), constitute the second most common type of functional pituitary adenoma. Because the clinical manifestations of excessive growth hormone may be subtle, somatotroph cell adenomas may be quite large by the time they come to clinical attention. On microscopic examination, growth hormone–producing adenomas are composed of densely or sparsely granulated cells, and immunohistochemical staining demonstrates growth hormone within the cytoplasm of the neoplastic cells. Small amounts of immunoreactive prolactin often are present as well.

*Persistent hypersecretion of growth hormone stimulates the hepatic secretion of insulin-like growth factor I (somatomedin C), which causes many of the clinical manifestations.* If a growth hormone–secreting adenoma occurs before the epiphyses close, as is the case in prepubertal children, excessive levels of growth hormone result in *gigantism.* This condition is characterized by a generalized increase in body size, with disproportionately long arms and legs. If elevated levels of growth hormone persist, or develop after closure of the epiphyses, affected persons develop *acromegaly,* in which growth is most conspicuous in soft tissues, skin, and viscera and in the bones of the face, hands, and feet. Enlargement of the jaw results in its protrusion (prognathism), with broadening of the lower face and separation of the teeth. The hands and feet are enlarged, with broad, sausage-like fingers. In clinical practice, the gigantism typically is accompanied by evidence of acromegaly.

Growth hormone excess also is associated with a number of other disturbances, including abnormal glucose tolerance and diabetes mellitus, generalized muscle weakness, hypertension, arthritis, osteoporosis, and congestive heart failure. Prolactin is demonstrable in a number of growth hormone–producing adenomas and in some cases may be released in sufficient quantities to produce signs and symptoms of hyperprolactinemia.

## Adrenocorticotropic Hormone–Producing (Corticotroph Cell) Adenomas

Most corticotroph cell adenomas are small (microadenomas) at the time of diagnosis. These adenomas stain positively with periodic acid–Schiff (PAS) stains, as a result of

the accumulation of glycosylated ACTH protein. As in the case of other pituitary hormones, the secretory granules can be detected by immunohistochemical methods. By electron microscopy they appear as membrane-bound, electron-dense granules averaging 300 nm in diameter.

Corticotroph cell adenomas may be clinically silent or may cause *hypercortisolism,* manifested clinically as *Cushing syndrome,* because of the stimulatory effect of ACTH on the adrenal cortex. Cushing syndrome, discussed in more detail later with diseases of the adrenal gland, may be caused by a wide variety of conditions in addition to ACTH-producing pituitary neoplasms. When the hypercortisolism is caused by excessive production of ACTH by the pituitary, the process is designated *Cushing disease,* because it is the pattern of hypercortisolism originally described by Dr. Harvey Cushing. Large, clinically aggressive corticotroph cell adenomas may develop after surgical removal of the adrenal glands for treatment of Cushing syndrome. In most instances, this condition, known as *Nelson syndrome,* results from loss of the inhibitory effect of adrenal corticosteroids on a preexisting corticotroph microadenoma. Because the adrenals are absent in persons with Nelson syndrome, hypercortisolism does not develop. Instead, patients present with the mass effects of the pituitary tumor. In addition, because ACTH is synthesized as part of a larger prohormone substance that includes melanocyte-stimulating hormone (MSH), hyperpigmentation also may be a feature.

### Other Anterior Pituitary Neoplasms

- *Gonadotroph (luteinizing hormone [LH]–producing and follicle-stimulating hormone [FSH]–producing)* adenomas can be difficult to recognize, because they secrete hormones inefficiently and variably, and the secretory products usually do not cause a recognizable clinical syndrome. They are typically detected when the tumors have become large enough to cause neurologic signs and symptoms, such as impaired vision, headaches, diplopia, or pituitary apoplexy. The neoplastic cells usually demonstrate immunoreactivity for the common gonadotropin α-subunit and the specific β-FSH and β-LH subunits; FSH usually is the predominant secreted hormone.
- *Thyrotroph (thyroid-stimulating hormone [TSH]–producing) adenomas* account for about 1% of all pituitary adenomas and constitute a rare cause of hyperthyroidism.
- *Nonfunctioning pituitary adenomas* comprise both clinically silent counterparts of the functioning adenomas just described (for example, a *silent gonadotroph adenoma*) and true *hormone-negative* (null cell) adenomas; the latter are quite infrequent, and as noted, many have been reclassified using improved diagnostic techniques. Nonfunctioning adenomas constitute approximately 25% of all pituitary tumors. Not surprisingly, the typical presentation with nonfunctioning adenomas is one characterized by mass effects. These lesions also may compromise the residual anterior pituitary sufficiently to produce hypopituitarism.
- *Pituitary carcinomas are exceedingly rare.* In addition to local extension beyond the sella turcica, these tumors virtually always demonstrate distant metastases.

## SUMMARY

### Clinical Manifestations of Pituitary Adenomas

- *Prolactinomas*: amenorrhea, galactorrhea, loss of libido, and infertility
- *Growth hormone (somatotroph cell) adenomas*: gigantism (children), acromegaly (adults), and impaired glucose tolerance and diabetes mellitus
- *Corticotroph cell adenomas*: Cushing syndrome, hyperpigmentation
- All pituitary adenomas, particularly nonfunctioning adenomas, may be associated with mass effects and hypopituitarism.

## HYPOPITUITARISM

Hypofunction of the anterior pituitary may occur with loss or absence of 75% or more of the anterior pituitary parenchyma. This may be *congenital* (exceedingly rare) or may result from a wide range of *acquired* abnormalities that are intrinsic to the pituitary. Less frequently, disorders that interfere with the delivery of pituitary hormone–releasing factors from the hypothalamus, such as hypothalamic tumors, also may cause hypofunction of the anterior pituitary. *Hypopituitarism accompanied by evidence of posterior pituitary dysfunction in the form of diabetes insipidus* (see later) *is almost always of hypothalamic origin.* Most cases of anterior pituitary hypofunction are caused by

- Nonfunctioning pituitary adenomas (discussed earlier)
- Ischemic necrosis of the anterior pituitary, an important cause of pituitary insufficiency. The anterior pituitary has substantial reserve capacity; as a result, destruction of large amounts of the anterior pituitary (75% or greater) must occur before signs and symptoms of hypopituitarism develop. *Sheehan syndrome,* or postpartum necrosis of the anterior pituitary, is the most common form of clinically significant ischemic necrosis of the anterior pituitary. During pregnancy, the anterior pituitary enlarges considerably, largely because of an increase in the size and number of prolactin-secreting cells. This physiologic enlargement of the gland, however, is not accompanied by an increase in blood supply from the low-pressure portal venous system. The enlarged gland is thus vulnerable to ischemic injury, especially in women who experience significant hemorrhage and hypotension during the peripartal period. The posterior pituitary, because it receives its blood directly from arterial branches, is much less susceptible to ischemic injury and therefore usually is not affected. Clinically significant pituitary necrosis also may be encountered in other conditions, including disseminated intravascular coagulation, sickle cell anemia, elevated intracranial pressure, traumatic injury, and shock of any origin. The residual gland is shrunken and scarred.
- Ablation of the pituitary by surgery or irradiation
- Other, less common causes of anterior pituitary hypofunction, including inflammatory lesions such as

sarcoidosis or tuberculosis, trauma, and metastatic neoplasms involving the pituitary.

The clinical manifestations of anterior pituitary hypofunction depend on the specific hormones that are lacking. In children, growth failure (*pituitary dwarfism*) may occur as a result of growth hormone deficiency. Gonadotropin or gonadotropin-releasing hormone (GnRH) deficiency leads to amenorrhea and infertility in women and to decreased libido, impotence, and loss of pubic and axillary hair in men. TSH and ACTH deficiencies result in symptoms of hypothyroidism and hypoadrenalism, respectively, and are discussed later in the chapter. Prolactin deficiency results in failure of postpartum lactation. The anterior pituitary also is a rich source of MSH, synthesized from the same precursor molecule that produces ACTH; therefore, one of the manifestations of hypopituitarism is pallor from loss of stimulatory effects of MSH on melanocytes.

## POSTERIOR PITUITARY SYNDROMES

The posterior pituitary, or neurohypophysis, is composed of modified glial cells (termed *pituicytes*) and axonal processes extending from nerve cell bodies in the supraoptic and paraventricular nuclei of the hypothalamus. The hypothalamic neurons produce two peptides: antidiuretic hormone (ADH) and oxytocin. They are stored in axon terminals in the neurohypophysis and released into the circulation in response to appropriate stimuli. Oxytocin stimulates the contraction of smooth muscle in the pregnant uterus and of muscle surrounding the lactiferous ducts of the mammary glands. Impairment of oxytocin synthesis and release has not been associated with significant clinical abnormalities. The clinically important posterior pituitary syndromes involve ADH production. They include *diabetes insipidus* and *secretion of inappropriately high levels of ADH.*

ADH is a nonapeptide hormone synthesized predominantly in the supraoptic nucleus. In response to several different stimuli, including increased plasma oncotic pressure, left atrial distention, exercise, and certain emotional states, ADH is released from axon terminals in the neurohypophysis into the general circulation. The hormone acts on the collecting tubules of the kidney to promote the resorption of free water. ADH deficiency causes *diabetes insipidus,* a condition characterized by excessive urination (polyuria) caused by an inability of the kidney to properly resorb water from the urine. Diabetes insipidus can result from several causes, including head trauma, neoplasms, and inflammatory disorders of the hypothalamus and pituitary, and from surgical procedures involving the hypothalamus or pituitary. The condition sometimes arises spontaneously (*idiopathic*) in the absence of an underlying disorder. Diabetes insipidus from ADH deficiency is designated as *central,* to differentiate it from *nephrogenic* diabetes insipidus as a result of renal tubular unresponsiveness to circulating ADH. The clinical manifestations of both diseases are similar and include the excretion of large volumes of dilute urine with an inappropriately low specific gravity. Serum sodium and osmolality are increased as a result of excessive renal loss of free water, resulting in thirst and polydipsia. Patients who can drink water generally can compensate for urinary losses; patients who are obtunded, bedridden, or otherwise limited in their ability to obtain water may develop life-threatening dehydration.

In the *syndrome of inappropriate ADH (SIADH)* secretion, ADH excess is caused by several extracranial and intracranial disorders. This condition leads to resorption of excessive amounts of free water, with resultant hyponatremia. The most common causes of SIADH include the secretion of ectopic ADH by malignant neoplasms (particularly small cell carcinomas of the lung), non-neoplastic diseases of the lung, and local injury to the hypothalamus or neurohypophysis. The clinical manifestations of SIADH are dominated by hyponatremia, cerebral edema, and resultant neurologic dysfunction. Although total body water is increased, blood volume remains normal, and peripheral edema does not develop.

# THYROID

The thyroid gland consists of two bulky lateral lobes connected by a relatively thin isthmus, usually located below and anterior to the larynx. The thyroid gland develops embryologically from an evagination of the developing pharyngeal epithelium that descends from the foramen cecum at the base of the tongue to its normal position in the anterior neck. This pattern of descent explains the occasional presence of *ectopic thyroid tissue,* most commonly located at the base of the tongue (*lingual thyroid*) or at other sites abnormally high in the neck.

The thyroid is divided into lobules, each composed of about 20 to 40 evenly dispersed follicles. The follicles range from uniform to variable in size and are lined by cuboidal to low columnar epithelium, which is filled with thyroglobulin, the iodinated precursor protein of active thyroid hormone. In response to trophic factors from the hypothalamus, TSH (also called *thyrotropin*) is released by thyrotrophs in the anterior pituitary into the circulation. The binding of TSH to its receptor on the thyroid follicular epithelium results in activation and conformational change in the receptor, allowing it to associate with a stimulatory G protein (Fig. 19–5). Activation of the G protein eventually results in an increase in intracellular cAMP levels, which stimulates thyroid hormone synthesis and release mediated by cAMP-dependent protein kinases. Thyroid follicular epithelial cells convert thyroglobulin into *thyroxine* ($T_4$) and lesser amounts of *triiodothyronine* ($T_3$). $T_4$ and $T_3$ are released into the systemic circulation, where most of these

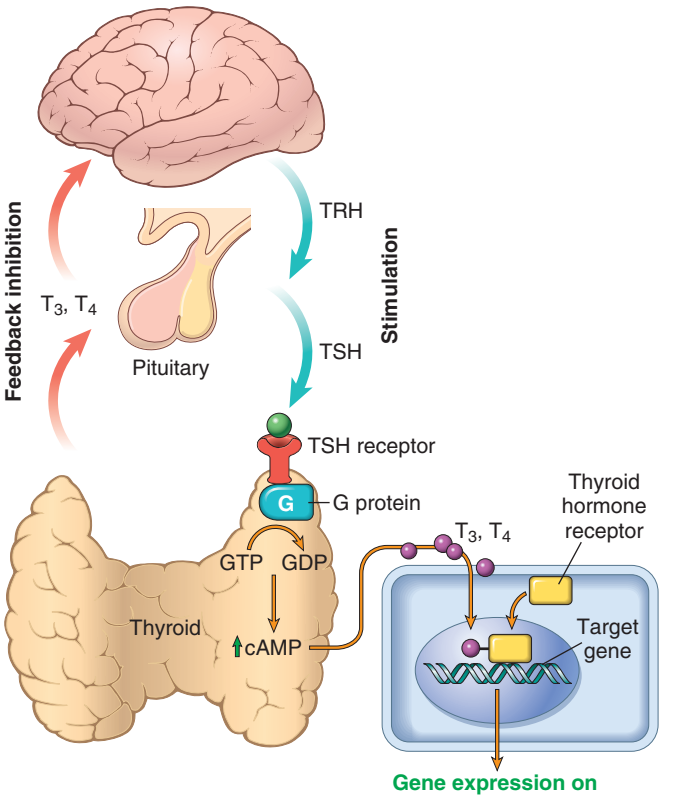


**Figure 19–5** Homeostasis in the hypothalamus-pituitary-thyroid axis and mechanism of action of thyroid hormones. Secretion of thyroid hormones ($T_3$ and $T_4$) is controlled by trophic factors secreted by both the hypothalamus and the anterior pituitary. Decreased levels of $T_3$ and $T_4$ stimulate the release of thyrotropin-releasing hormone (TRH) from the hypothalamus and thyroid-stimulating hormone (TSH) from the anterior pituitary, causing $T_3$ and $T_4$ levels to rise. Elevated $T_3$ and $T_4$ levels, in turn, suppress the secretion of both TRH and TSH. This relationship is termed a negative-feedback loop. TSH binds to the TSH receptor on the thyroid follicular epithelium, which causes activation of G proteins, release of cyclic AMP (cAMP), and cAMP-mediated synthesis and release of thyroid hormones (i.e., $T_3$ and $T_4$). In the periphery, $T_3$ and $T_4$ interact with the thyroid hormone receptor (TR) and form a complex that translocates to the nucleus and binds to so-called thyroid response elements (TREs) on target genes, thereby initiating transcription.

peptides are reversibly bound to circulating plasma proteins, such as $T_4$-binding globulin, for transport to peripheral tissues. The binding proteins serve to maintain the serum unbound (*free*) $T_3$ and $T_4$ concentrations within narrow limits while ensuring that the hormones are readily available to the tissues. In the periphery the majority of free $T_4$ is deiodinated to $T_3$; the latter binds to thyroid hormone nuclear receptors in target cells with 10-fold greater affinity than that observed for $T_4$ and has proportionately greater activity. *The interaction of thyroid hormone with its nuclear thyroid hormone receptor (TR) results in the formation of a hormone-receptor complex that binds to thyroid hormone response elements (TREs) in target genes, regulating their transcription.* Thyroid hormone has diverse cellular effects, including upregulation of carbohydrate and lipid catabolism and stimulation of protein synthesis in a wide range of cells. The net result of these processes is an increase in the basal metabolic rate.

Clinical recognition of diseases of the thyroid is important, because most are amenable to medical or surgical management. Such diseases include conditions associated with excessive release of thyroid hormones (hyperthyroidism), those associated with thyroid hormone deficiency (hypothyroidism), and mass lesions of the thyroid. Considered next are the clinical consequences of disturbed thyroid function, followed by an overview of the disorders that generate these problems.

## HYPERTHYROIDISM

Thyrotoxicosis is a hypermetabolic state due to elevated circulating levels of free $T_3$ and $T_4$. Because it is caused most commonly by hyperfunction of the thyroid gland, thyrotoxicosis often is referred to as hyperthyroidism. In certain conditions, however, the oversupply either is related to excessive release of pre-formed thyroid hormone (e.g., in thyroiditis) or comes from an extrathyroidal source, rather than a hyperfunctioning gland (Table 19–2). *Thus, strictly speaking, hyperthyroidism is only one (albeit the most common) category of thyrotoxicosis.* Despite this clear distinction, the following discussion adheres to the common practice of using the terms *thyrotoxicosis* and *hyperthyroidism* interchangeably.

The clinical manifestations of thyrotoxicosis are truly protean and include changes referable to the *hypermetabolic state* induced by excessive amounts of thyroid hormone as well as those related to *overactivity of the sympathetic nervous system*:

- *Constitutional symptoms*: The skin of thyrotoxic persons tends to be soft, warm, and flushed; *heat intolerance* and excessive sweating are common. Increased sympathetic activity and hypermetabolism result in *weight loss despite increased appetite.*
- *Gastrointestinal*: Stimulation of the gut results in hypermotility, malabsorption, and diarrhea.
- *Cardiac*: Palpitations and tachycardia are common; elderly patients may develop congestive heart failure

**Table 19–2** Causes of Thyrotoxicosis

| |
|---|
| **Associated with Hyperthyroidism** |
| Primary |
| Diffuse toxic hyperplasia (Graves disease) |
| Hyperfunctioning ("toxic") multinodular goiter |
| Hyperfunctioning ("toxic") adenoma |
| Iodine-induced hyperthyroidism |
| Secondary |
| TSH-secreting pituitary adenoma (rare)* |
| **Not Associated with Hyperthyroidism** |
| Granulomatous (de Quervain) thyroiditis (*painful*) |
| Subacute lymphocytic thyroiditis (*painless*) |
| Struma ovarii (ovarian teratoma with thyroid) |
| Factitious thyrotoxicosis (exogenous thyroxine intake) |

TSH, thyroid-stimulating hormone.
*Associated with increased TSH; all other causes of thyrotoxicosis associated with decreased TSH.

**Figure 19–6** Patient with hyperthyroidism. A wide-eyed, staring gaze, caused by overactivity of the sympathetic nervous system, is one of the classic features of this disorder. In Graves disease, one of the most important causes of hyperthyroidism, accumulation of loose connective tissue behind the orbits also adds to the protuberant appearance of the eyes.

as a consequence of aggravation of preexisting heart disease.

- *Neuromuscular*: Patients frequently experience nervousness, tremor, and irritability. Nearly 50% develop proximal muscle weakness (*thyroid myopathy*).
- *Ocular manifestations*: a wide, staring gaze and lid lag are present because of sympathetic overstimulation of the levator palpebrae superioris (Fig. 19–6). However, true *thyroid ophthalmopathy* associated with proptosis is a feature seen only in Graves disease (discussed later).
- *Thyroid storm* is used to designate the abrupt onset of severe hyperthyroidism. This condition occurs most commonly in patients with underlying Graves disease, probably resulting from an acute elevation in catecholamine levels, as might be encountered during stress. Thyroid storm constitutes a medical emergency: A significant number of untreated patients die of cardiac arrhythmias.
- *Apathetic hyperthyroidism* refers to thyrotoxicosis occurring in elderly persons, in whom the typical features of thyroid hormone excess seen in younger patients are blunted. In these patients the diagnosis is often made during laboratory workup for unexplained weight loss or worsening cardiovascular disease.

The diagnosis of hyperthyroidism is based on clinical features and laboratory data. *The measurement of serum TSH is the most useful single screening test for hyperthyroidism,* because TSH levels are decreased even at the earliest stages, when the disease may still be subclinical. In rare cases of pituitary- or hypothalamus-associated (secondary) hyperthyroidism, TSH levels are either normal or raised. A low TSH value usually is associated with increased levels of free $T_4$. In the occasional patient, hyperthyroidism results predominantly from increased circulating levels of $T_3$ ($T_3$ toxicosis). In such cases, free $T_4$ levels may be decreased, and direct measurement of serum $T_3$ may be useful. Once the diagnosis of thyrotoxicosis has been confirmed by a combination of TSH and free thyroid hormone assays, measurement of radioactive iodine uptake by the thyroid gland often is valuable in determining the etiology. For example, such scans may show diffusely increased (whole-gland) uptake in Graves disease, increased uptake in a solitary nodule in toxic adenoma, or decreased uptake in thyroiditis.

## HYPOTHYROIDISM

Hypothyroidism is caused by any structural or functional derangement that interferes with the production of adequate levels of thyroid hormone. As in the case of hyperthyroidism, this disorder is sometimes divided into primary and secondary categories, depending on whether the hypothyroidism arises from an intrinsic abnormality in the thyroid or from hypothalamic or pituitary disease (Table 19–3). Worldwide, the most common cause of hypothyroidism is dietary deficiency of iodine (see further on), while in most developed nations, autoimmune causes predominate. Genetic defects that perturb thyroid development itself (*thyroid dysgenesis*) or the synthesis of thyroid hormone (*dyshormonogenetic goiter*) are relatively rare.

The clinical manifestations of hypothyroidism include cretinism and myxedema.

- *Cretinism* refers to hypothyroidism developing in infancy or early childhood. This disorder formerly was fairly common in areas of the world where dietary iodine deficiency is endemic, including mountainous areas such as the Himalayas and the Andes (*endemic cretinism*). It is now much less frequent because of the widespread supplementation of foods with iodine. By contrast, enzyme defects that interfere with thyroid hormone synthesis are a cause of *sporadic cretinism.* Clinical features of cretinism include impaired development of the skeletal system and central nervous system, with severe mental retardation, short stature, coarse facial features, a protruding tongue, and umbilical hernia. The severity of the

**Table 19–3** Causes of Hypothyroidism

| |
|---|
| **Primary** |
| Rare developmental abnormalities (thyroid dysgenesis): mutations in *PAX8, FOXE1* |
| Congenital biosynthetic defect (dyshormonogenetic goiter)* |
| Postablative |
| Surgery, radioiodine therapy, or external irradiation |
| Autoimmune hypothyroidism |
| Hashimoto thyroiditis* |
| Iodine deficiency* |
| Drugs (lithium, iodides, *p*-aminosalicylic acid)* |
| **Secondary (Central)** |
| Pituitary failure |
| Hypothalamic failure (rare) |

*FOXE1*, forkhead box E1 gene; *PAX8*, paired box 8 gene.
*Associated with enlargement of thyroid ("goitrous hypothyroidism"). Hashimoto thyroiditis and postablative hypothyroidism account for a majority of cases of hypothyroidism in developed countries.

mental impairment in cretinism seems to be directly influenced by the timing of onset of the deficient state in utero. Normally, maternal hormones that are critical to fetal brain development, including $T_3$ and $T_4$, cross the placenta. If maternal thyroid deficiency is present before the development of the fetal thyroid gland, mental retardation is severe. By contrast, reduction in maternal thyroid hormones later in pregnancy, after the fetal thyroid has developed, allows normal brain development.

- Hypothyroidism developing in older children and adults results in a condition known as *myxedema.* Myxedema, or Gull disease, was first linked with thyroid dysfunction in 1873 by Sir William Gull in a paper addressing the development of a *cretinoid state* in adults. Manifestations of myxedema include generalized apathy and mental sluggishness that in the early stages of disease may mimic depression. Patients with myxedema are listless, cold intolerant, and often obese. Mucopolysaccharide-rich edematous fluid accumulates in skin, subcutaneous tissue, and a number of visceral sites, with resultant broadening and coarsening of facial features, enlargement of the tongue, and deepening of the voice. Bowel motility is decreased, resulting in constipation. Pericardial effusions are common; in later stages, the heart is enlarged, and heart failure may supervene.

Laboratory evaluation has a vital role in the diagnosis of suspected hypothyroidism. As in the case of hyperthyroidism, *measurement of serum TSH is the most sensitive screening test for this disorder.* The serum TSH is increased in primary hypothyroidism because of a loss of feedback inhibition of thyrotropin-releasing hormone (TRH) and TSH production by the hypothalamus and pituitary, respectively. The TSH concentration is not increased in persons with hypothyroidism caused by primary hypothalamic or pituitary disease. Serum $T_4$ is decreased in patients with hypothyroidism of any origin.

## THYROIDITIS

Thyroiditis, or inflammation of the thyroid gland, encompasses a diverse group of disorders characterized by some form of thyroid inflammation. These diseases include conditions that result in acute illness with severe thyroid pain (e.g., infectious thyroiditis, granulomatous [de Quervain] thyroiditis) and disorders in which relatively little inflammation occurs and the illness is manifested primarily by thyroid dysfunction (subacute lymphocytic ["painless"] thyroiditis and fibrous [Reidel] thyroiditis). This section focuses on the more common and clinically significant types of thyroiditis: (1) Hashimoto thyroiditis (or chronic lymphocytic thyroiditis); (2) granulomatous (de Quervain) thyroiditis; and (3) subacute lymphocytic thyroiditis.

### Chronic Lymphocytic (Hashimoto) Thyroiditis

*Hashimoto thyroiditis is the most common cause of hypothyroidism in areas of the world where iodine levels are sufficient.* It is characterized by gradual thyroid failure secondary to autoimmune destruction of the thyroid gland. It is most prevalent between the ages of 45 and 65 years and is more common in women than in men, with female predominance in a ratio of 10:1 to 20:1. Although it is primarily a disease of older women, it can occur in children and is a major cause of nonendemic goiter in children.

#### PATHOGENESIS

Hashimoto thyroiditis is caused by a breakdown in **self-tolerance** (Chapter 4) to thyroid autoantigens. Thus, circulating autoantibodies against thyroid antigens are present in the vast majority of patients, who demonstrate progressive depletion of thyroid epithelial cells (thyrocytes) and their replacement by mononuclear cell infiltration and fibrosis. The inciting events leading to breakdown in self-tolerance have not been fully elucidated, but multiple immunologic mechanisms that may contribute to thyrocyte damage have been identified (Fig. 19–7), including

- **CD8+ cytotoxic T cell–mediated cell death:** CD8+ cytotoxic T cells may cause thyrocyte destruction.
- **Cytokine-mediated cell death:** Excessive T cell activation leads to the production of inflammatory cytokines such as interferon-γ in the thyroid gland, with resultant recruitment and activation of macrophages and damage to follicles.
- Binding of **antithyroid antibodies** (antithyroglobulin, and antithyroid peroxidase antibodies), followed by antibody-dependent cell–mediated cytotoxicity (Chapter 4).

A significant genetic component to the disease pathogenesis is supported by the concordance of disease in as many as 40% of monozygotic twins, as well as the presence of circulating antithyroid antibodies in approximately 50% of asymptomatic siblings of affected patients. Increased susceptibility to Hashimoto thyroiditis is associated with polymorphisms in multiple immune regulation–associated genes, the most significant of which is the linkage to **cytotoxic T lymphocyte–associated antigen-4** gene (*CTLA4*), which codes for a negative regulator of T cell function (Chapter 4).

#### MORPHOLOGY

The thyroid usually is diffusely and symmetrically enlarged, although more localized enlargement may be seen in some cases. The cut surface is pale and gray-tan in appearance, and the tissue is firm and somewhat friable. Microscopic examination reveals widespread infiltration of the parenchyma by a **mononuclear inflammatory infiltrate** containing small lymphocytes, plasma cells, and well-developed **germinal centers** (Fig. 19–8). The thyroid follicles are atrophic and are lined in many areas by epithelial cells distinguished by the presence of abundant eosinophilic, granular cytoplasm, termed **Hürthle,** or **oxyphil, cells.** This is a metaplastic response of the normally low cuboidal follicular epithelium to ongoing injury; on ultrastructural examination, the Hürthle cells are characterized by numerous prominent

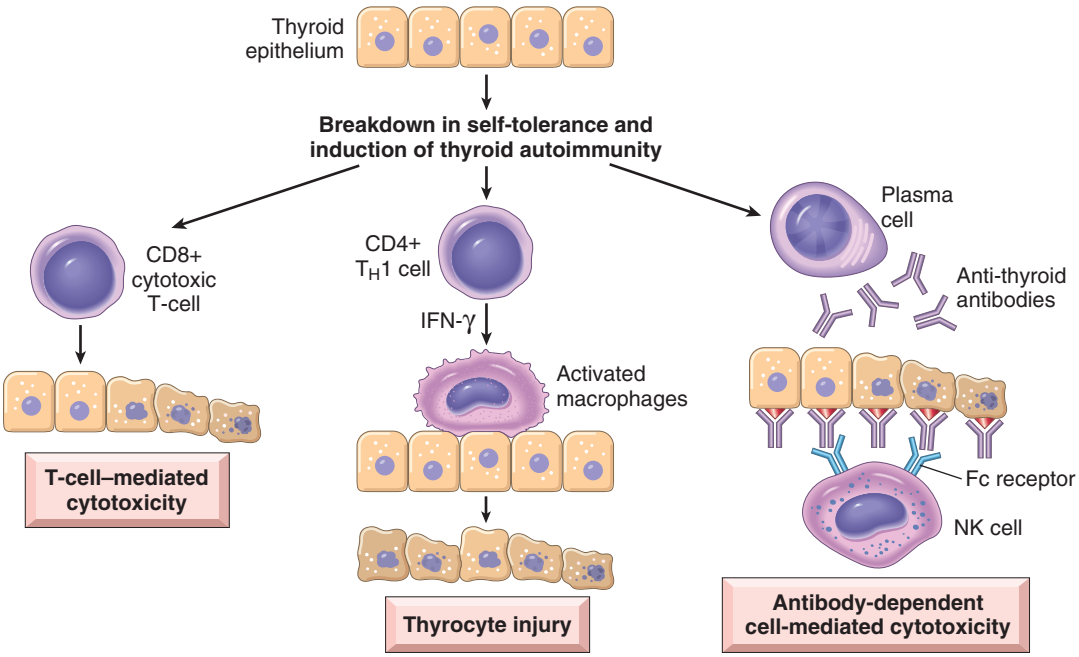


**Figure 19–7** Pathogenesis of Hashimoto thyroiditis. Breakdown of immune tolerance to thyroid autoantigens results in progressive autoimmune destruction of thyrocytes by infiltrating cytotoxic T cells, locally released cytokines, or antibody-dependent cytotoxicity.

mitochondria. Interstitial connective tissue is increased and may be abundant. Less commonly, the thyroid is small and atrophic as a result of more extensive fibrosis **(fibrosing variant).** Unlike in Reidel thyroiditis, the fibrosis does not extend beyond the capsule of the gland.

### Clinical Features

Hashimoto thyroiditis comes to clinical attention as *painless enlargement of the thyroid, usually associated with some degree of hypothyroidism,* in a middle-aged woman. The enlargement of the gland usually is symmetric and diffuse, but in some cases it may be sufficiently localized to raise suspicion for neoplasm. In the usual clinical course, hypothyroidism develops gradually. In some cases, however, it *may be preceded by transient thyrotoxicosis* caused by disruption of thyroid follicles, with secondary release of thyroid hormones (*hashitoxicosis*). During this phase, free $T_4$ and $T_3$ concentrations are elevated, TSH is diminished, and radioactive iodine uptake is decreased. As hypothyroidism supervenes, $T_4$ and $T_3$ levels progressively fall, accompanied by a compensatory increase in TSH. Patients with Hashimoto thyroiditis often have *other autoimmune diseases* and are at *increased risk for the development of B cell non-Hodgkin lymphomas* (Chapter 11), which typically arise within the thyroid gland. The relationship between Hashimoto disease and thyroid epithelial cancers remains controversial, with some morphologic and molecular studies suggesting a predisposition to papillary carcinomas.

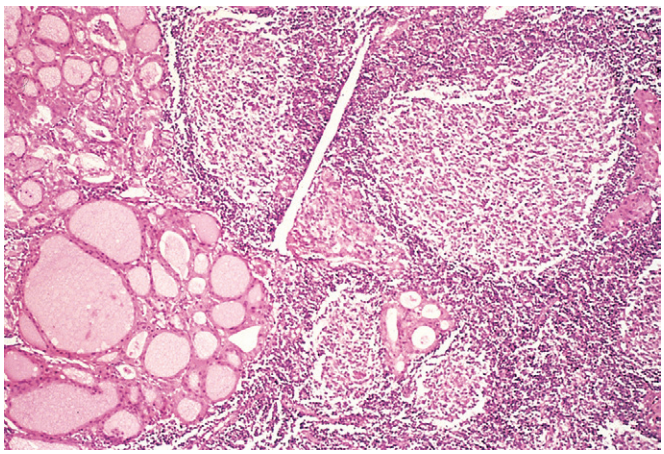

**Figure 19–8** Hashimoto thyroiditis. The thyroid parenchyma contains a dense lymphocytic infiltrate with germinal centers. Residual thyroid follicles lined by deeply eosinophilic Hürthle cells also are seen.

## Subacute Granulomatous (de Quervain) Thyroiditis

Subacute granulomatous thyroiditis, also known as de Quervain thyroiditis, is much less common than Hashimoto disease. De Quervain thyroiditis is most common between the ages of 30 and 50 and, like other forms of thyroiditis, occurs more frequently in women than in men. Subacute thyroiditis is believed to be caused by a viral infection or an inflammatory process triggered by viral infections. A majority of patients have a history of an upper respiratory infection just before the onset of thyroiditis. By contrast with autoimmune thyroid disease, the immune response is not self-perpetuating, so the process is limited.

### MORPHOLOGY

The gland is firm, with an intact capsule, and may be unilaterally or bilaterally enlarged. Histologic examination reveals disruption of thyroid follicles, with extravasation of colloid leading to a polymorphonuclear infiltrate, which is replaced over time by lymphocytes, plasma cells, and macrophages. The extravasated colloid provokes an exuberant granulomatous reaction with giant cells, some containing fragments of colloid. Healing occurs by resolution of inflammation and fibrosis.

Clinical Features

The onset of this form of thyroiditis often is acute, characterized by *pain* in the neck (particularly with swallowing), fever, malaise, and variable enlargement of the thyroid. Transient hyperthyroidism may occur, as in other cases of thyroiditis, as a result of disruption of thyroid follicles and release of excessive thyroid hormone. The leukocyte count and erythrocyte sedimentation rates are increased. With progression of disease and gland destruction, a transient hypothyroid phase may ensue. The condition typically is self-limited, with most patients returning to a euthyroid state within 6 to 8 weeks.

## Subacute Lymphocytic Thyroiditis

Subacute lymphocytic thyroiditis also is known as *silent* or *painless* thyroiditis; in a subset of patients the onset of disease follows pregnancy (*postpartum thyroiditis*). This disease is most likely to be autoimmune in etiology, because circulating antithyroid antibodies are found in a majority of patients. It mostly affects middle-aged women, who present with a *painless* neck mass or features of thyroid hormone excess. The initial phase of thyrotoxicosis (which is likely to be secondary to thyroid tissue damage) is followed by return to a euthyroid state within a few months. In a minority of affected persons the condition eventually progresses to hypothyroidism. Except for possible mild symmetric enlargement, the thyroid appears normal on gross inspection. The histologic features consist of lymphocytic infiltration and hyperplastic germinal centers within the thyroid parenchyma.

## Other Forms of Thyroiditis

*Riedel thyroiditis,* a rare disorder of unknown etiology, is characterized by extensive fibrosis involving the thyroid and contiguous neck structures. Clinical evaluation demonstrates a hard and fixed thyroid mass, simulating a thyroid neoplasm. It may be associated with idiopathic fibrosis in other sites in the body, such as the retroperitoneum. The presence of circulating antithyroid antibodies in most patients suggests an autoimmune etiology.

### SUMMARY

#### Thyroiditis

- Chronic lymphocytic (Hashimoto) thyroiditis is the most common cause of hypothyroidism in regions where dietary iodine levels are sufficient.
- Hashimoto thyroiditis is an autoimmune disease characterized by progressive destruction of thyroid parenchyma, Hürthle cell change, and mononuclear (lymphoplasmacytic) infiltrates, with or without extensive fibrosis.
- Multiple autoimmune mechanisms account for Hashimoto disease, including cytotoxicity mediated by CD8+ T cells, cytokines (IFN-γ), and antithyroid antibodies.
- Subacute granulomatous (de Quervain) thyroiditis is a self-limited disease, probably secondary to a viral infection, and is characterized by pain and the presence of a granulomatous inflammation in the thyroid.
- Subacute lymphocytic thyroiditis is a self-limited disease that often occurs after a pregnancy (postpartum thyroiditis), typically is painless, and is characterized by lymphocytic inflammation in the thyroid.

# GRAVES DISEASE

In 1835 Robert Graves reported on his observations of a disease characterized by "violent and long continued palpitations in females" associated with enlargement of the thyroid gland. *Graves disease is the most common cause of endogenous hyperthyroidism.* It is characterized by a triad of manifestations:

- *Thyrotoxicosis,* caused by a diffusely enlarged, hyperfunctional thyroid, is present in all cases.
- An infiltrative *ophthalmopathy* with resultant exophthalmos is noted in as many as 40% of patients.
- A localized, infiltrative *dermopathy* (sometimes designated *pretibial myxedema*) is seen in a minority of cases.

Graves disease has a peak incidence between the ages of 20 and 40, with *women being affected up to seven times more commonly than men.* This very common disorder is estimated to affect 1.5% to 2.0% of women in the United States. Genetic factors are important in the causation of Graves disease; the incidence is increased in relatives of affected patients, and the concordance rate in monozygotic twins is as high as 60%. As with other autoimmune disorders, a genetic susceptibility to Graves disease is associated with the presence of certain human leukocyte antigen (HLA) haplotypes, specifically HLA-DR3, and polymorphisms in genes encoding the inhibitory T cell receptor CTLA-4 and the tyrosine phosphatase PTPN22.

### PATHOGENESIS

**Graves disease is characterized by a breakdown in self-tolerance to thyroid autoantigens, of which the most important is the TSH receptor.** The result is the production of multiple autoantibodies, including:

- **Thyroid-stimulating immunoglobulin:** An IgG antibody that binds to the TSH receptor and mimics the action of TSH, stimulating adenyl cyclase, with resultant increased release of thyroid hormones. Almost all persons with Graves disease have detectable amounts of this autoantibody, which is relatively specific for Graves disease.
- **Thyroid growth-stimulating immunoglobulins:** Also directed against the TSH receptor, these antibodies

have been implicated in the proliferation of thyroid follicular epithelium.

- **TSH-binding inhibitor immunoglobulins:** These anti-TSH receptor antibodies prevent TSH from binding to its receptor on thyroid epithelial cells and in so doing may actually **inhibit** thyroid cell function. The coexistence of stimulating *and* inhibiting immunoglobulins in the serum of the same patient is not unusual—a finding that may explain why some patients with Graves disease spontaneously develop episodes of hypothyroidism.

A T cell–mediated autoimmune phenomenon also is involved in the development of the **infiltrative ophthalmopathy** characteristic of Graves disease. In Graves ophthalmopathy, the volume of the retroorbital connective tissues and extraocular muscles is increased as a result of several causes, including (1) marked infiltration of the retroorbital space by mononuclear cells, predominantly T cells; (2) inflammatory edema and swelling of extraocular muscles; (3) accumulation of extracellular matrix components, specifically hydrophilic glycosaminoglycans such as hyaluronic acid and chondroitin sulfate; and (4) increased numbers of adipocytes (fatty infiltration). These changes displace the eyeball forward, potentially interfering with the function of the extraocular muscles.

*Autoimmune disorders of the thyroid thus span a continuum on which Graves disease, characterized by hyperfunction of the thyroid, lies at one extreme and Hashimoto disease, manifesting as hypothyroidism, occupies the other end.* Sometimes hyperthyroidism may supervene on preexisting Hashimoto thyroiditis (*hashitoxicosis*), while at other times persons with Graves disease may spontaneously develop thyroid hypofunction; occasionally, Hashimoto thyroiditis and Graves disease may coexist within an affected kindred. Not surprisingly, there is also an element of histologic overlap between the autoimmune thyroid disorders (most characteristically, prominent intrathyroidal lymphoid cell infiltrates with germinal center formation). In both disorders, the frequency of other autoimmune diseases, such as systemic lupus erythematosus, pernicious anemia, type 1 diabetes, and Addison disease, is increased.

## MORPHOLOGY

In the typical case of Graves disease, the thyroid gland is enlarged (usually symmetrically) due to **diffuse hypertrophy and hyperplasia** of thyroid follicular epithelial cells. The gland is usually smooth and soft, and its capsule is intact. On microscopic examination, the follicular epithelial cells in untreated cases are tall, columnar, and more crowded than usual. This crowding often results in the formation of small papillae, which project into the follicular lumen (Fig. 19–9). Such papillae lack fibrovascular cores, in contrast with those of papillary carcinoma. The colloid within the follicular lumen is pale, with scalloped margins. Lymphoid infiltrates, consisting predominantly of T cells, with fewer B cells and mature plasma cells, are present throughout the interstitium; germinal centers are common.

Changes in extrathyroidal tissues include generalized lymphoid hyperplasia. In persons with ophthalmopathy, the tissues of the orbit are edematous because of the presence of hydrophilic glycosaminoglycans. In addition, there is infiltration by lymphocytes, mostly T cells. Orbital muscles initially are edematous but may undergo fibrosis late in the course of the disease. The dermopathy, if present, is characterized by thickening of the dermis, as a result of deposition of glycosaminoglycans and lymphocyte infiltration.

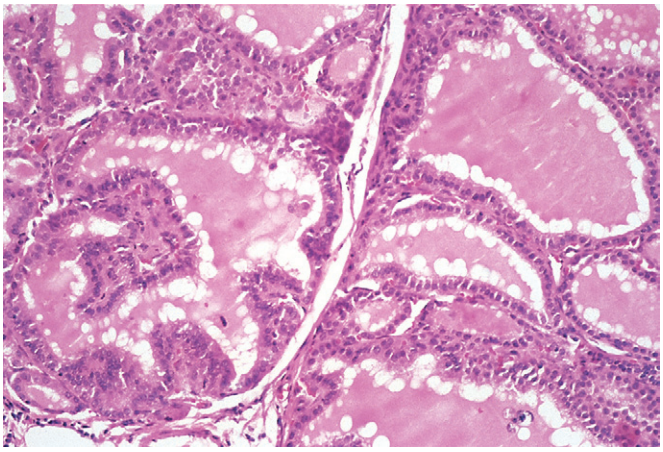

**Figure 19–9** Graves disease. The thyroid is diffusely hyperplastic. The follicles are lined by tall columnar epithelial cells that project into the lumina. These cells actively resorb the colloid in the centers of the follicles, resulting in the "scalloped" appearance of the edges of the colloid.

### Clinical Features

The clinical manifestations of Graves disease include those common to all forms of thyrotoxicosis (discussed earlier), as well as those associated uniquely with Graves disease: *diffuse hyperplasia of the thyroid, ophthalmopathy,* and *dermopathy*. The degree of thyrotoxicosis varies from case to case, and the related changes may sometimes be less conspicuous than other manifestations of the disease. Increased flow of blood through the hyperactive gland often produces an audible bruit. Sympathetic overactivity produces a characteristic wide, staring gaze and lid lag. The ophthalmopathy of Graves disease results in abnormal protrusion of the eyeball (exophthalmos). The extraocular muscles often are weak. The exophthalmos may persist or progress despite successful treatment of the thyrotoxicosis, sometimes resulting in corneal injury. The infiltrative dermopathy, or pretibial myxedema, most commonly involves the skin overlying the shins, where it manifests as scaly thickening and induration of the skin. The skin lesions may be slightly pigmented papules or nodules and often have an orange peel texture. Laboratory findings in Graves disease include elevated serum free $T_4$ and $T_3$ and depressed serum TSH. Because of ongoing stimulation of the thyroid follicles by TSIs, radioactive iodine uptake is increased, and radioiodine scans show a *diffuse uptake* of iodine.

## SUMMARY

### Graves Disease

- Graves disease, the most common cause of endogenous hyperthyroidism, is characterized by the triad of thyrotoxicosis, ophthalmopathy, and dermopathy.

- Graves disease is an autoimmune disorder caused by autoantibodies to the TSH receptor that mimic TSH action and activate TSH receptors on thyroid epithelial cells.
- The thyroid in Graves disease is characterized by diffuse hypertrophy and hyperplasia of follicles and lymphoid infiltrates; glycosaminoglycan deposition and lymphoid infiltrates are responsible for the ophthalmopathy and dermopathy.
- Laboratory features include elevations in serum free $T_3$ and $T_4$ and decreased serum TSH.

## DIFFUSE AND MULTINODULAR GOITER

Enlargement of the thyroid, or *goiter,* is the most common manifestation of thyroid disease. *Diffuse and multinodular goiters reflect impaired synthesis of thyroid hormone,* most often caused by dietary iodine deficiency. Impairment of thyroid hormone synthesis leads to a compensatory rise in the serum TSH, which in turn causes hypertrophy and hyperplasia of thyroid follicular cells and, ultimately, gross enlargement of the thyroid gland. The compensatory increase in functional mass of the gland is enough to overcome the hormone deficiency, ensuring a *euthyroid* metabolic state in the vast majority of affected persons. If the underlying disorder is sufficiently severe (e.g., a congenital biosynthetic defect), the compensatory responses may be inadequate to overcome the impairment in hormone synthesis, resulting in *goitrous hypothyroidism.* The degree of thyroid enlargement is proportional to the level and duration of thyroid hormone deficiency.

Goiters can be endemic or sporadic.

- *Endemic goiter* occurs in geographic areas where the soil, water, and food supply contain little iodine. The designation *endemic* is used when goiters are present in more than 10% of the population in a given region. Such conditions are particularly common in mountainous areas of the world, including the Himalayas and the Andes. With increasing availability of dietary iodine supplementation, the frequency and severity of endemic goiter have declined significantly.
- *Sporadic goiter* occurs less commonly than endemic goiter. The condition is more common in females than in males, with a peak incidence in puberty or young adulthood, when there is an increased physiologic demand for $T_4$. Sporadic goiter may be caused by several conditions, including the ingestion of substances that interfere with thyroid hormone synthesis at some level, such as excessive calcium and vegetables belonging to the Brassicaceae (also called Cruciferae) family (e.g., cabbage, cauliflower, Brussels sprouts, turnips). In other instances, goiter may result from hereditary enzymatic defects that interfere with thyroid hormone synthesis *(dyshormonogenetic goiter).* In most cases, however, the cause of sporadic goiter is not apparent.

### MORPHOLOGY

In most cases, TSH-induced hypertrophy and hyperplasia of thyroid follicular cells result initially in diffuse, symmetric enlargement of the gland **(diffuse goiter).** The follicles are lined by crowded columnar cells, which may pile up and form projections similar to those seen in Graves disease. If dietary iodine subsequently increases, or if the demands for thyroid hormone decrease, the stimulated follicular epithelium involutes to form an enlarged, colloid-rich gland **(colloid goiter).** The cut surface of the thyroid in such cases usually is brown, somewhat glassy-appearing, and translucent. On microscopic examination, the follicular epithelium may be hyperplastic in the early stages of disease or flattened and cuboidal during periods of involution. Colloid is abundant during the latter periods. With time, recurrent episodes of hyperplasia and involution combine to produce a more irregular enlargement of the thyroid, termed **multinodular goiter.** Virtually all long-standing diffuse goiters convert into multinodular goiters. Multinodular goiters typically are hormonally silent, although a minority (approximately 10% over 10 years) can manifest with thyrotoxicosis secondary to the development of **autonomous** nodules that produce thyroid hormone independent of TSH stimulation. This condition, known as toxic multinodular goiter or **Plummer syndrome,** is not accompanied by the infiltrative ophthalmopathy and dermopathy of Graves disease–associated thyrotoxicosis.

Multinodular goiters are multilobulate, asymmetrically enlarged glands, which may attain massive size. On cut surface, irregular nodules containing variable amounts of brown, gelatinous colloid are evident (Fig. 19–10, *A*). Older lesions often show areas of fibrosis, hemorrhage, calcification, and cystic change. The microscopic appearance includes colloid-rich follicles lined by flattened, inactive epithelium and areas of follicular epithelial hypertrophy and hyperplasia, accompanied by the regressive changes just noted (Fig. 19–10, *B*).

### Clinical Features

The dominant clinical features of goiter are those caused by the *mass effects* of the enlarged gland. In addition to the obvious cosmetic problem of a large neck mass, goiters also may cause airway obstruction, dysphagia, and compression of large vessels in the neck and upper thorax (so-called *superior vena cava syndrome*). As stated, a hyperfunctioning (*toxic*) nodule may develop within a long-standing goiter, resulting in *hyperthyroidism.* The incidence of malignancy in long-standing multinodular goiters is low (less than 5%) but not zero, and concern for malignancy arises with goiters that demonstrate sudden changes in size or associated symptoms (e.g., hoarseness).

## NEOPLASMS OF THE THYROID

The thyroid gland gives rise to a variety of neoplasms, ranging from circumscribed, benign adenomas to highly aggressive, anaplastic carcinomas. From a clinical standpoint, the possibility of a tumor is of major concern in patients who present with *thyroid nodules.* Fortunately, the overwhelming majority of solitary nodules of the thyroid

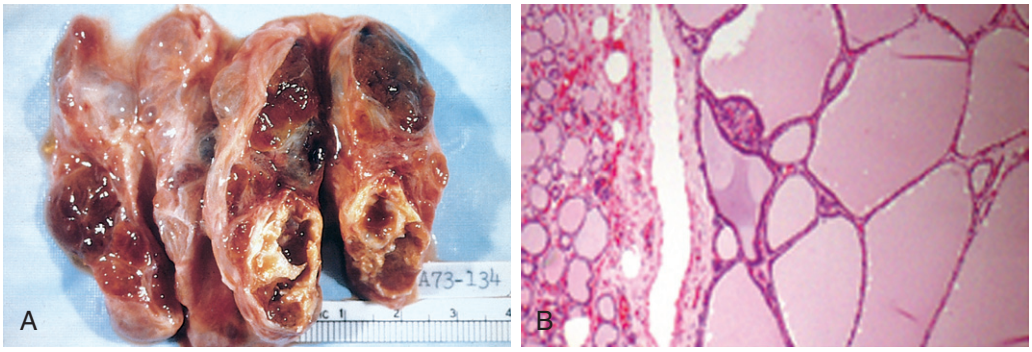


**Figure 19–10** Multinodular goiter. **A,** Gross morphologic appearance. The coarsely nodular gland contains areas of fibrosis and cystic change. **B,** Photomicrograph of specimen from a hyperplastic nodule, with compressed residual thyroid parenchyma on the periphery. The hyperplastic follicles contain abundant pink "colloid" within their lumina. Note the absence of a prominent capsule, a feature distinguishing such lesions from neoplasms of the thyroid.

*(B, Courtesy of Dr. William Westra, Department of Pathology, Johns Hopkins University, Baltimore, Maryland.)*

prove to be either follicular adenomas or localized, non-neoplastic conditions (e.g., a dominant nodule in multinodular goiter, simple cysts, or foci of thyroiditis). Carcinomas of the thyroid, by contrast, are uncommon, accounting for much less than 1% of solitary thyroid nodules. Several clinical criteria provide a clue to the nature of a given thyroid nodule:

- *Solitary nodules,* in general, are more likely to be neoplastic than are multiple nodules.
- *Nodules in younger patients* are more likely to be neoplastic than are those in older patients.
- *Nodules in males* are more likely to be neoplastic than are those in females.
- A history of *radiation* treatment to the head and neck region is associated with an increased incidence of thyroid malignancy.
- Nodules that take up radioactive iodine in imaging studies (*hot nodules*) are more likely to be benign than malignant, reflecting well-differentiated cells.

Such statistics and general trends, however, are of little significance in the evaluation of a given patient, in whom the timely recognition of a malignancy, however uncommon, can be lifesaving. Ultimately, it is the morphologic evaluation of a given thyroid nodule by fine needle aspiration, combined with histologic study of surgically resected thyroid parenchyma, that provides the most definitive information about its nature. This section presents an overview of the major thyroid neoplasms, including adenomas and carcinomas of various types.

## Adenomas

Adenomas of the thyroid are benign neoplasms derived from follicular epithelium. As in the case of all thyroid neoplasms, follicular adenomas usually are solitary. On clinical and morphologic grounds, they may be difficult to distinguish from a dominant nodule in multinodular goiter, for example, or from the less common follicular carcinomas. Although the vast majority of adenomas are nonfunctional, a small proportion produce thyroid hormones (*toxic adenomas*), causing clinically apparent thyrotoxicosis. In general, follicular adenomas are *not* forerunners to carcinomas; nevertheless, shared genetic alterations support the possibility that at least a subset of follicular carcinomas arise in preexisting adenomas (see further on).

### PATHOGENESIS

The TSH receptor signaling pathway plays an important role in the pathogenesis of toxic adenomas. Activating (gain-of-function) somatic mutations in one of two components of this signaling system—most often the gene encoding the TSH receptor itself (TSHR) and, less commonly, the α-subunit of $G_s$ (GNAS)—allow follicular cells to secrete thyroid hormone independent of TSH stimulation (thyroid autonomy). The result of this overabundance is symptomatic hyperthyroidism, with a "hot" thyroid nodule seen on imaging studies. Overall, somatic mutations in the TSH receptor signaling pathway seem to be present in slightly over half of toxic adenomas. Not surprisingly, such mutations also are observed in a subset of autonomous nodules that give rise to toxic multinodular goiters, as described earlier. A minority of nonfunctioning follicular adenomas (less than 20%) exhibit mutations of RAS or phosphatidylinositol-3-kinase (PIK3CA), or bear a *PAX8/PPARG* fusion gene, all of which are genetic alterations shared with follicular carcinomas. These are discussed in further detail under "Carcinomas" (see further on).

### MORPHOLOGY

The typical thyroid adenoma is a **solitary,** spherical lesion that compresses the adjacent non-neoplastic thyroid. The neoplastic cells are demarcated from the adjacent parenchyma by a **well-defined, intact capsule** (Fig. 19–11, *A*). **These features are important in making the distinction from multinodular goiters,** which contain multiple nodules on their cut surface (even though the patient may present clinically with a solitary dominant nodule), do not demonstrate compression of the adjacent thyroid parenchyma, and lack a well-formed capsule. On microscopic examination, the constituent cells are arranged in uniform follicles that contain colloid (Fig. 19–11, *B*). Papillary growth

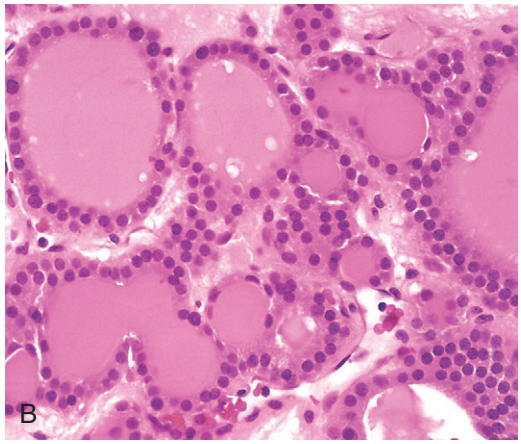


**Figure 19–11** Follicular adenoma of the thyroid. **A,** A solitary, well-circumscribed nodule is visible in this gross specimen. **B,** The photomicrograph shows well-differentiated follicles resembling those of normal thyroid parenchyma.

patterns, if present, should raise suspicion for an encapsulated papillary carcinoma (discussed later). Occasionally, the neoplastic cells acquire brightly eosinophilic granular cytoplasm (oxyphil or Hürthle cell change) (Fig. 19–12); the clinical presentation and behavior of a **Hürthle cell adenoma** are no different from those of a conventional adenoma. Similar to endocrine tumors at other anatomic sites, even benign follicular adenomas may, on occasion, exhibit focal nuclear pleomorphism, atypia, and prominent nucleoli **(endocrine atypia);** by themselves, these features do not constitute evidence of malignancy. The hallmark of all follicular adenomas is the presence of an intact well-formed capsule encircling the tumor. **Careful evaluation of the integrity of the capsule is therefore critical in distinguishing follicular adenomas from follicular carcinomas,** which demonstrate capsular and/or vascular invasion (see later).

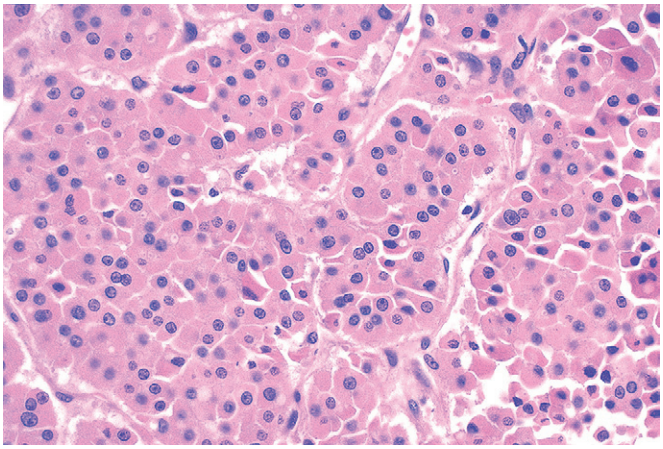

**Figure 19–12** Hürthle cell adenoma. On this high-power view, the tumor is composed of cells with abundant eosinophilic cytoplasm and small regular nuclei.
*(Courtesy of Dr. Mary Sunday, Brigham and Women's Hospital, Boston, Massachusetts.)*

### Clinical Features

Most adenomas of the thyroid manifest as painless nodules, often discovered during a routine physical examination. Larger masses may produce local symptoms such as difficulty in swallowing. As previously stated, persons with toxic adenomas can present with features of thyrotoxicosis. After injection of radioactive iodine, most adenomas take up iodine less avidly than normal thyroid parenchyma. On radionuclide scanning, therefore, adenomas appear as *cold* nodules relative to the adjacent normal thyroid gland. Toxic adenomas, however, will appear as *warm* or *hot* nodules in the scan. As many as 10% of *cold* nodules eventually prove to be malignant. By contrast, malignancy is rare in *hot* nodules. Essential techniques used in the preoperative evaluation of suspected adenomas are ultrasonography and fine needle aspiration biopsy. Because of the need for evaluating capsular integrity, *the definitive diagnosis of thyroid adenoma can be made only after careful histologic examination of the resected specimen.* Suspected adenomas of the thyroid are therefore removed surgically to exclude malignancy. Thyroid adenomas carry an excellent prognosis and do not recur or metastasize.

## Carcinomas

Carcinomas of the thyroid are relatively uncommon in the United States, accounting for about 1.5% of all cancers. A female predominance has been noted among patients who develop thyroid carcinoma in the early and middle adult years. By contrast, cases manifesting in childhood and late adult life are distributed equally between males and females. Most thyroid carcinomas (except medullary carcinomas) are derived from the thyroid follicular epithelium, and of these, the vast majority are well-differentiated lesions. The major subtypes of thyroid carcinoma and their relative frequencies are

- Papillary carcinoma (accounting for more than 85% of cases)
- Follicular carcinoma (5% to 15% of cases)
- Anaplastic (undifferentiated) carcinoma (less than 5% of cases)
- Medullary carcinoma (5% of cases)

Because of the unique clinical and biologic features associated with each variant of thyroid carcinoma, these subtypes are described separately. Presented next is an overview of the molecular pathogenesis of all thyroid cancers.

## PATHOGENESIS

Both genetic and environmental factors are implicated in the pathogenesis of thyroid cancers.

**Genetic Factors.** Distinct molecular events are involved in the pathogenesis of the four major variants of thyroid cancer. As stated, medullary carcinomas do not arise from the follicular epithelium. Genetic alterations in the three follicular cell–derived malignancies are clustered along two oncogenic pathways—the mitogen-activated protein (MAP) kinase pathway and the phosphatidylinositol-3-kinase (PI-3K)/AKT pathway (Fig. 19–13). In normal cells, these pathways are transiently activated by binding of soluble growth factor ligands to the extracellular domain of receptor tyrosine kinases, which results in autophosphorylation of the cytoplasmic domain of the receptor, permitting intracellular signal transduction. In thyroid carcinomas, as with many solid cancers (Chapter 5), gain-of-function mutations along components of these pathways lead to constitutive activation even in the absence of ligand, thus promoting carcinogenesis.

- **Papillary thyroid carcinomas: Activation of the MAP kinase pathway is a feature of most papillary carcinomas** and can occur by one of two major mechanisms. The first mechanism involves rearrangements of *RET* or *NTRK1* (neurotrophic tyrosine kinase receptor 1), both of which encode transmembrane receptor tyrosine kinases, and the second mechanism involves activating point mutations in *BRAF*, whose product is an intermediate signaling component in the MAP kinase pathway (Fig. 19–13). The *RET* gene is not normally expressed in thyroid follicular cells. In papillary cancers, chromosomal rearrangements place the tyrosine kinase domain of *RET* under the transcriptional control of genes that are constitutively expressed in the thyroid epithelium. The novel fusion proteins that are so formed are known as RET/PTC (papillary thyroid carcinoma) and are present in approximately 20% to 40% of papillary thyroid cancers. The frequency of *RET/PTC* rearrangements is significantly higher in papillary cancers arising in the backdrop of radiation exposure. Similarly, rearrangements of *NTRK1* are present in 5% to 10% of papillary thyroid cancers, and the resultant fusion proteins are constitutively expressed in thyroid cells, leading to activation of MAP kinase pathways. One third to one half of papillary thyroid carcinomas harbor a gain-of-function mutation in the *BRAF* gene, which most commonly is a valine-to-glutamate change on codon 600 ($BRAF^{V600E}$). Since chromosomal rearrangements of the *RET* or *NTRK1* genes and mutations of *BRAF* have redundant effects on the thyroid epithelium (both mechanisms result in activation of the MAP kinase signaling pathway), papillary thyroid carcinomas demonstrate either one or the other molecular abnormality, but not both. *RET/PTC* rearrangements and *BRAF* point mutations are not observed in follicular adenomas or carcinomas.
- **Follicular thyroid carcinomas:** Approximately one third to one half of follicular thyroid carcinomas harbor **mutations in the PI-3K/AKT signaling pathway,** resulting in constitutive activation of this oncogenic pathway. This subset of tumors includes those with gain-of-function point mutations of *RAS* and *PIK3CA,* those with amplification of *PIK3CA,* and those with loss-of-function mutations of *PTEN,* a tumor suppressor gene and negative regulator of this pathway. The progressive increase in the prevalence of *RAS* and *PIK3CA* mutations from benign follicular adenomas to follicular carcinomas to anaplastic carcinomas (see next) suggests a shared histogenesis and molecular evolution among these follicular cell–derived tumors. A unique (2;3)(q13;p25) translocation has been described in one third to one half of follicular carcinomas. This translocation creates a fusion gene composed of portions of *PAX8*, a paired homeobox gene that is important in thyroid development, and the peroxisome proliferator–activated receptor gene (*PPARG*), whose gene product is a nuclear hormone receptor implicated in terminal differentiation of cells. Less than 10% of follicular adenomas harbor ***PAX8/PPARG* fusion genes,** and thus far these have not been documented in other thyroid neoplasms.
- **Anaplastic carcinomas:** These highly aggressive and lethal tumors can arise de novo or, more commonly, by **dedifferentiation** of a well-differentiated papillary or follicular carcinoma. Molecular alterations present in anaplastic carcinomas include those also seen in well-differentiated carcinomas (e.g., *RAS* or *PIK3CA* mutations), albeit at a significantly higher rate, suggesting that the presence of these mutations might predispose existing thyroid neoplasms to transform. Other genetic *hits,* such as inactivation of *TP53*, are essentially restricted to anaplastic carcinomas and may also relate to their aggressive behavior.
- **Medullary thyroid carcinomas:** In contrast with the subtypes described earlier, these neoplasms arise from the

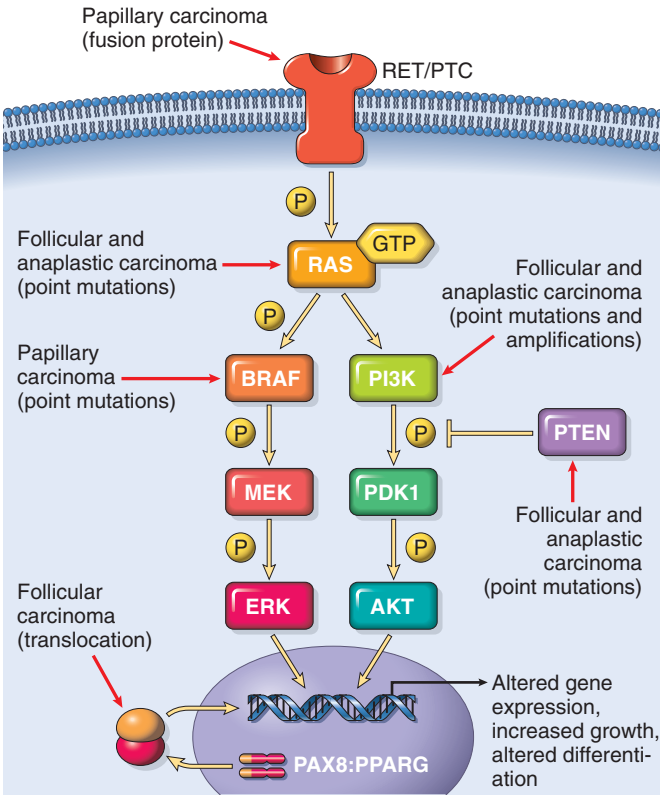


**Figure 19–13** Genetic alterations in follicular cell–derived malignancies of the thyroid gland.

parafollicular C cells, rather than the follicular epithelium. Familial medullary thyroid carcinomas occur in multiple endocrine neoplasia type 2 (MEN-2) (see later) and are associated with germline ***RET* proto-oncogene mutations** that lead to constitutive activation of the receptor. *RET* mutations are also seen in approximately one half of nonfamilial (sporadic) medullary thyroid cancers. Chromosomal rearrangements involving *RET,* such as the *RET/PTC* translocations reported in papillary cancers, are not seen in medullary carcinomas.

**Environmental Factors.** The major risk factor predisposing to thyroid cancer is exposure to **ionizing radiation,** particularly during the first 2 decades of life. In keeping with this finding, there was a marked increase in the incidence of papillary carcinomas among children exposed to ionizing radiation after the Chernobyl nuclear disaster in 1986. **Deficiency of dietary iodine** (and by extension, an association with goiter) is linked with a higher frequency of follicular carcinomas.

### *Papillary Carcinoma*

As mentioned earlier, papillary carcinomas represent the most common form of thyroid cancer. These tumors may occur at any age, and they account for the vast majority of thyroid carcinomas associated with previous exposure to ionizing radiation.

#### MORPHOLOGY

Papillary carcinomas may manifest as solitary or multifocal lesions within the thyroid. In some cases, they may be well circumscribed and even encapsulated; in other instances, they infiltrate the adjacent parenchyma with ill-defined margins. The lesions may contain areas of fibrosis and calcification and often are cystic. On cut surface, they may appear granular and sometimes contain grossly discernible papillary foci (Fig. 19–14, *A*). The definitive diagnosis of papillary carcinoma can be made only after microscopic examination. In current practice, **the diagnosis of papillary carcinoma is based on nuclear features** even in the absence of a papillary architecture. The nuclei of papillary carcinoma cells contain very finely dispersed chromatin, which imparts an **optically clear** appearance, giving rise to the designation **ground glass** or "Orphan Annie eye" nuclei (Fig. 19–14, *C* and *D*). In addition, invaginations of the cytoplasm may give the appearance of intranuclear inclusions (hence the designation **pseudoinclusions**) in cross-sections. A **papillary architecture** is common (Fig. 19–14, *B*); unlike hyperplastic papillary lesions seen in Graves disease, the neoplastic papillae have dense fibrovascular cores. Concentrically calcified structures termed **psammoma bodies** often are present within the papillae. Foci of lymphatic permeation by tumor cells are often present, but invasion of blood vessels is relatively uncommon, particularly in smaller lesions. Metastases to adjacent cervical lymph nodes are estimated to occur in about half of

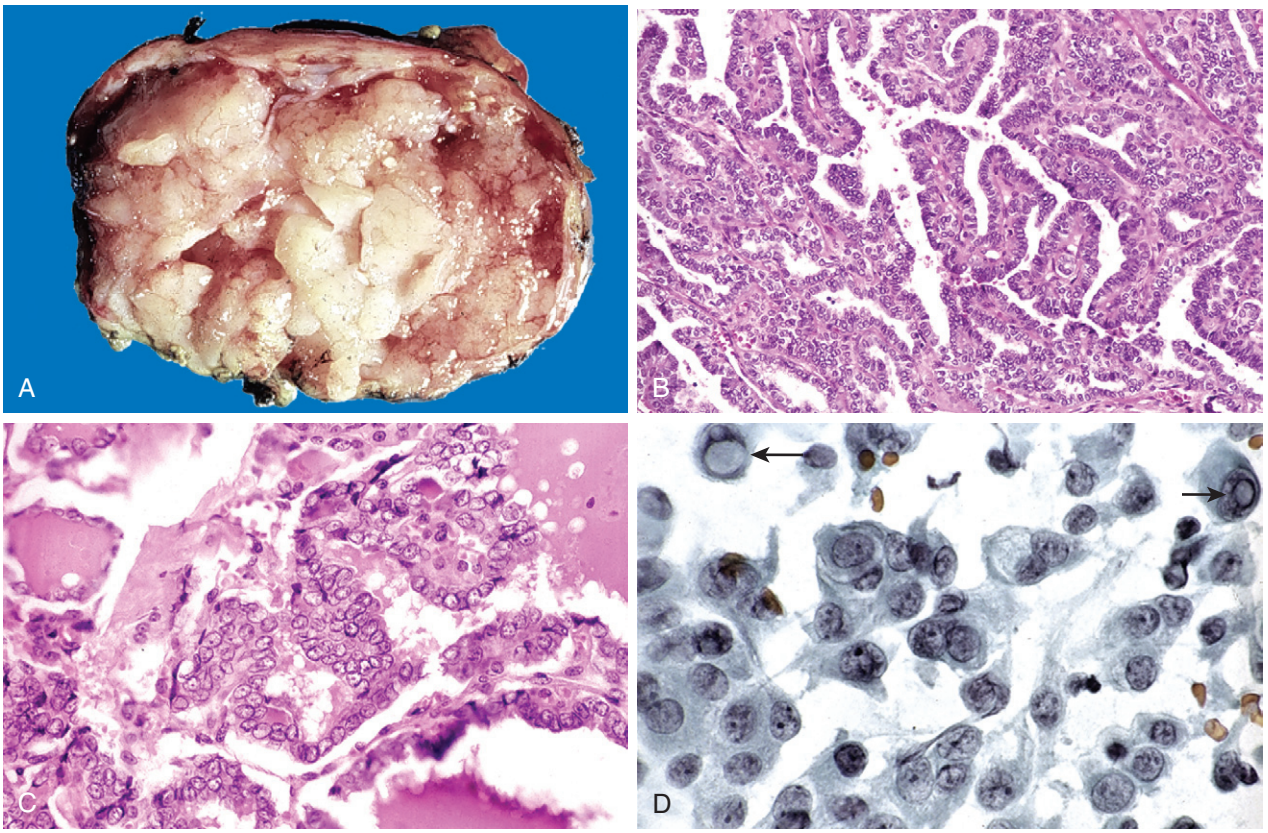


**Figure 19–14** Papillary carcinoma of the thyroid. **A–C,** A papillary carcinoma with grossly discernible papillary structures. In this particular example, well-formed papillae (**B**) are lined by cells with characteristic empty-appearing nuclei, sometimes termed "Orphan Annie eye" nuclei (**C**). **D,** Cells obtained by fine-needle aspiration of a papillary carcinoma. Characteristic intranuclear inclusions are visible in some of the aspirated cells (*arrows*).
*(Courtesy of Dr. S. Gokasalan, Department of Pathology, University of Texas Southwestern Medical School, Dallas, Texas.)*

cases. There are over a dozen variants of papillary thyroid carcinoma, but the most common is one composed predominantly or exclusively of follicles (**follicular variant** of papillary thyroid carcinoma). The follicular variant more frequently is encapsulated and is associated with a lower incidence of lymph node metastases and extrathyroidal extension than that typical for conventional papillary carcinomas.

Clinical Features

Papillary carcinomas are nonfunctional tumors, so they manifest most often as a painless mass in the neck, either within the thyroid or as metastasis in a cervical lymph node. A preoperative diagnosis usually can be established by fine-needle aspiration on the basis of the characteristic nuclear features described earlier. Papillary carcinomas are indolent lesions, with 10-year survival rates in excess of 95%. Of interest, the presence of isolated cervical nodal metastases does not seem to have a significant influence on the generally good prognosis of these lesions. In a minority of patients, hematogenous metastases are present at the time of diagnosis, most commonly to the lung. The long-term survival of patients with papillary thyroid cancer is dependent on several factors, including age (in general, the prognosis is less favorable among patients older than 40 years), the presence of extrathyroidal extension, and presence of distant metastases (stage).

### *Follicular Carcinoma*

Follicular carcinomas account for 5% to 15% of primary thyroid cancers. They are more common in women (occurring in a ratio of 3:1) and manifest at an older age than that typical for papillary carcinomas, with a peak incidence between the ages of 40 and 60 years. Follicular carcinoma is more frequent in areas with dietary iodine deficiency (accounting for 25% to 40% of thyroid cancers), while its incidence has either decreased or remained stable in iodine-sufficient areas of the world.

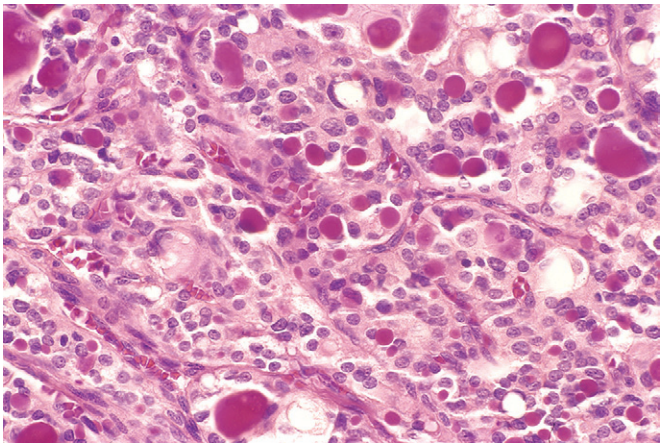

**Figure 19–15** Follicular carcinoma of the thyroid. A few of the glandular lumina contain recognizable colloid.

#### MORPHOLOGY

On microscopic examination, most follicular carcinomas are composed of fairly uniform cells forming small follicles, reminiscent of normal thyroid (Fig. 19–15); in other cases, follicular differentiation may be less apparent. As with follicular adenomas, Hürthle cell variants of follicular carcinomas may be seen. Follicular carcinomas may be **widely invasive,** infiltrating the thyroid parenchyma and extrathyroidal soft tissues, or **minimally invasive.** The latter type are sharply demarcated lesions that may be impossible to distinguish from follicular adenomas on gross examination. **This distinction requires extensive histologic sampling of the tumor capsule–thyroid interface, to exclude capsular and/or vascular invasion** (Fig. 19–16). As mentioned earlier, follicular lesions in which the nuclear features are typical of papillary carcinomas should be regarded as follicular variants of papillary cancers.

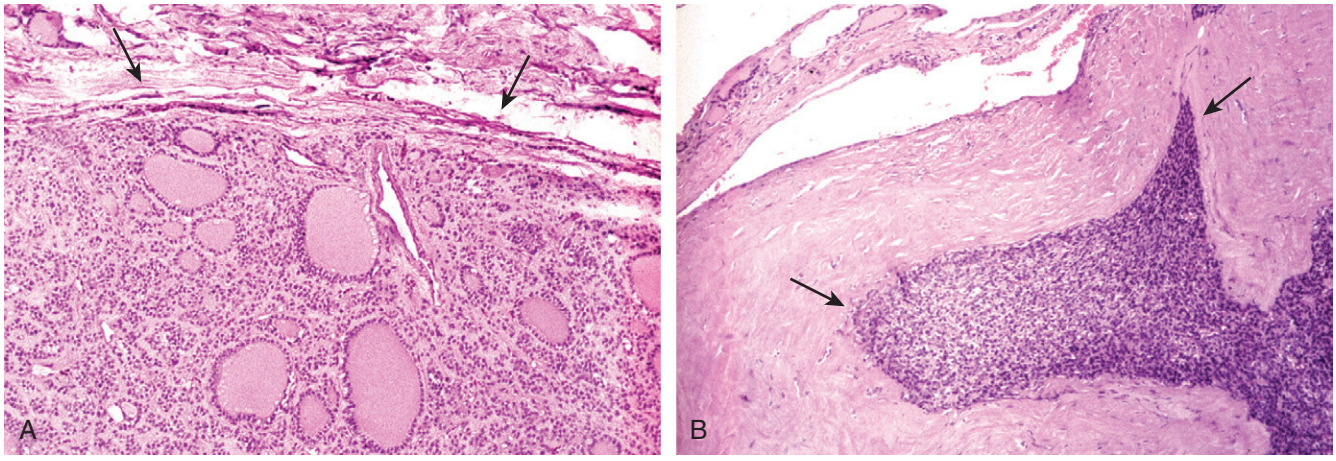


**Figure 19–16** Capsular invasion in follicular carcinoma. Evaluating the integrity of the capsule is critical in distinguishing follicular adenomas from follicular carcinomas. **A,** In adenomas, a fibrous capsule, usually thin but occasionally more prominent, surrounds the neoplastic follicles and no capsular invasion is seen (*arrows*); compressed normal thyroid parenchyma usually is present external to the capsule (*top*). **B,** By contrast, follicular carcinomas demonstrate capsular invasion (*arrows*) that may be minimal, as in this case, or widespread, with extension into local structures of the neck.

Clinical Features

Follicular carcinomas manifest most frequently as solitary *cold thyroid nodules*. In rare cases, they may be hyperfunctional. These neoplasms tend to metastasize through the bloodstream (*hematogenous dissemination*) to the lungs, bone, and liver. In contrast with papillary carcinomas, regional nodal metastases are uncommon. As many as half of patients with widely invasive carcinomas succumb to their disease within 10 years, while less than 10% of patients with minimally invasive follicular carcinomas die within the same time span. Follicular carcinomas are treated with surgical excision. Well-differentiated metastases may take up radioactive iodine, which can be used to identify and also ablate such lesions. Because better-differentiated lesions may be stimulated by TSH, patients usually are placed on a thyroid hormone regimen after surgery to suppress endogenous TSH.

### *Anaplastic Carcinoma*

Anaplastic carcinomas are undifferentiated tumors of the thyroid follicular epithelium, accounting for less than 5% of thyroid tumors. They are aggressive, with a mortality rate approaching 100%. Patients with anaplastic carcinoma are older than those with other types of thyroid cancer, with a mean age of 65 years. Approximately a quarter of patients with anaplastic thyroid carcinomas have a past history of a well-differentiated thyroid carcinoma, and another quarter harbor a concurrent well-differentiated tumor in the resected specimen.

#### MORPHOLOGY

Anaplastic carcinomas manifest as bulky masses that typically grow rapidly beyond the thyroid capsule into adjacent neck structures. On microscopic examination, these neoplasms are composed of highly anaplastic cells, which may take on any of several histologic patterns, including those populated by

- Large, pleomorphic giant cells
- Spindle cells with a sarcomatous appearance
- Mixed spindle and giant cell lesions

Foci of papillary or follicular differentiation may be present in some tumors, suggesting origin from a better-differentiated carcinoma.

Clinical Features

Anaplastic carcinomas grow with wild abandon despite therapy. Metastases to distant sites are common, but in most cases death occurs in less than 1 year as a result of aggressive local growth and compromise of vital structures in the neck.

### *Medullary Carcinoma*

Medullary carcinomas of the thyroid are neuroendocrine neoplasms derived from the parafollicular cells, or C cells, of the thyroid. Like normal C cells, medullary carcinomas secrete calcitonin, the measurement of which plays an important role in the diagnosis and postoperative follow-up evaluation of patients. In some cases, the tumor cells elaborate other polypeptide hormones such as somatostatin, serotonin, and vasoactive intestinal peptide (VIP). Medullary carcinomas arise *sporadically* in about 70% of cases. The remaining 30% are *familial* cases occurring in the setting of MEN syndrome 2A or 2B, or familial medullary thyroid carcinoma without an associated MEN syndrome, as discussed later. Of note, both familial and sporadic medullary forms demonstrate activating *RET* mutations. Sporadic medullary carcinomas, as well as familial cases without an associated MEN syndrome, occur in adults, with a peak incidence in the fifth and sixth decades. Cases associated with MEN-2A or MEN-2B, by contrast, have been reported in younger patients, including children.

#### MORPHOLOGY

Medullary carcinomas may arise as a solitary nodule or may manifest as multiple lesions involving both lobes of the thyroid. **Multicentricity** is particularly common in familial cases. Larger lesions often contain areas of necrosis and hemorrhage and may extend through the capsule of the thyroid. On microscopic examination, medullary carcinomas are composed of polygonal to spindle-shaped cells, which may form nests, trabeculae, and even follicles. **Amyloid deposits,** derived from altered calcitonin molecules, are present in the adjacent stroma in many cases (Fig. 19–17) and are a distinctive feature. Calcitonin is readily demonstrable both within the cytoplasm of the tumor cells and in the stromal amyloid by immunohistochemical methods. Electron microscopy reveals variable numbers of intracytoplasmic membrane-bound, electron-dense granules (Fig. 19–18). One of the peculiar features of familial medullary carcinomas is the presence of **multicentric C cell hyperplasia** in the surrounding thyroid parenchyma, a feature usually absent in sporadic lesions. Foci of C cell hyperplasia are believed to represent the precursor lesions from which medullary carcinomas arise.

Clinical Features

In the sporadic cases, medullary carcinoma manifests most often as a mass in the neck, sometimes associated with compression effects such as dysphagia or hoarseness. In

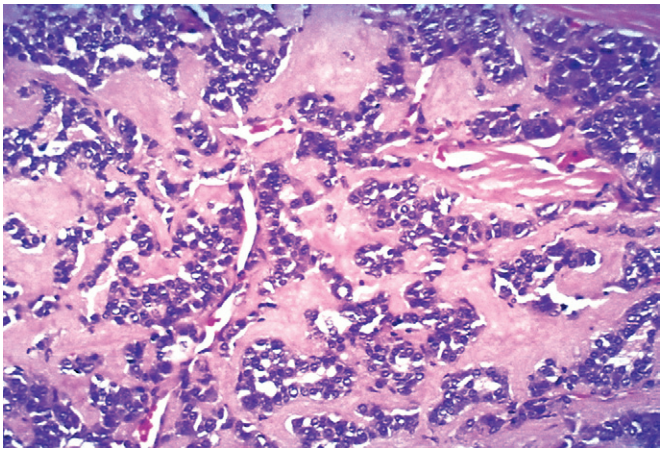

**Figure 19–17** Medullary carcinoma of the thyroid. These tumors typically contain amyloid, visible here as homogeneous extracellular material, derived from calcitonin molecules secreted by the neoplastic cells.

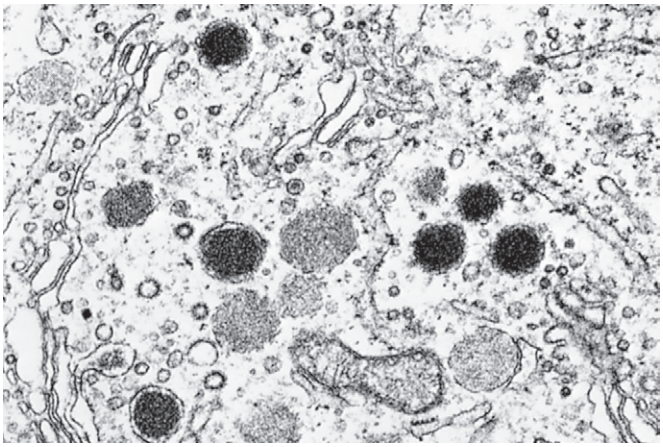

**Figure 19–18** Electron micrograph of medullary thyroid carcinoma. These cells contain membrane-bound secretory granules, which are the sites of storage of calcitonin and other peptides. (Original magnification ×30,000.)

some instances, the initial manifestations are caused by the secretion of a peptide hormone (e.g., diarrhea caused by the secretion of VIP). Screening of the patient's relatives for elevated calcitonin levels or *RET* mutations permits early detection of tumors in familial cases. As discussed at the end of this chapter, all members of MEN-2 kindreds carrying *RET* mutations are offered prophylactic thyroidectomies to preempt the development of medullary carcinomas; often, the only histologic finding in the resected thyroid of these asymptomatic carriers is the presence of C cell hyperplasia or small (less than 1 cm) *micromedullary* carcinomas. Recent studies have shown that specific *RET* mutations correlate with an aggressive behavior in medullary carcinomas.

## SUMMARY

### Thyroid Neoplasms

- Most thyroid neoplasms manifest as *solitary thyroid nodules*, but only 1% of all thyroid nodules are neoplastic.
- *Follicular adenomas* are the most common benign neoplasms, while papillary carcinoma is the most common malignancy.
- Multiple genetic pathways are involved in *thyroid carcinogenesis*. Some of the genetic abnormalities that are fairly unique to thyroid cancers include *PAX8/PPARG* fusion (in follicular carcinoma), chromosomal rearrangements involving the *RET* oncogene (in papillary cancers), and mutations of *RET* (in medullary carcinomas).
- *Follicular adenomas and carcinomas* both are composed of well-differentiated follicular epithelial cells; the latter are distinguished by evidence of capsular and/or vascular invasion.
- *Papillary carcinomas* are recognized based on nuclear features (ground glass nuclei, pseudoinclusions) even in the absence of papillae. These neoplasms typically metastasize by way of lymphatics, but the prognosis is excellent.
- *Anaplastic carcinomas* are thought to arise by dedifferentiation of more differentiated neoplasms. They are highly aggressive, uniformly lethal cancers.
- *Medullary cancers* are nonepithelial neoplasms arising from the parafollicular C cells and can occur in either sporadic (70%) or familial (30%) settings. Multicentricity and C cell hyperplasia are features of familial cases. Amyloid deposits are a characteristic histologic finding.

# PARATHYROID GLANDS

The parathyroid glands are derived from the developing pharyngeal pouches that also give rise to the thymus. They normally lie in close proximity to the upper and lower poles of each thyroid lobe but may be found anywhere along the pathway of descent of the pharyngeal pouches, including the carotid sheath and the thymus and elsewhere in the anterior mediastinum. Most of the gland is composed of *chief cells.* On hematoxylin-eosin (H&E) staining, the chief cells range from light to dark pink, depending on their glycogen content. They contain secretory granules of *parathyroid hormone* (PTH). *Oxyphil cells* are found throughout the normal parathyroid either singly or in small clusters. They are slightly larger than the chief cells, have acidophilic cytoplasm, and are tightly packed with mitochondria. *The activity of the parathyroid glands is controlled by the level of free (ionized) calcium in the bloodstream, rather than by trophic hormones secreted by the hypothalamus and pituitary.* Normally, decreased levels of free calcium stimulate the synthesis and secretion of PTH, with the following effects:

- Increase in renal tubular reabsorption of calcium
- Increase in urinary phosphate excretion, thereby lowering serum phosphate levels (since phosphate binds to ionized calcium)
- Increase in the conversion of vitamin D to its active dihydroxy form in the kidneys, which in turn augments gastrointestinal calcium absorption
- Enhancement of osteoclastic activity (i.e., bone resorption, thus releasing ionized calcium), mediated indirectly by promoting the differentiation of osteoclast progenitor cells into mature osteoclasts

The net result of these activities is an increase in the level of free calcium, which inhibits further PTH secretion. Abnormalities of the parathyroids include both hyperfunction and hypofunction. *Tumors of the parathyroid glands, unlike thyroid tumors, usually come to attention because of excessive secretion of PTH, rather than mass effects.*

## HYPERPARATHYROIDISM

Hyperparathyroidism occurs in two major forms, *primary* and *secondary,* and, less commonly, as *tertiary* hyperparathyroidism. The first condition represents an autonomous, spontaneous overproduction of PTH, while the latter two conditions typically occur as secondary phenomena in patients with chronic renal insufficiency.

## Primary Hyperparathyroidism

Primary hyperparathyroidism is a common endocrine disorder, and an important cause of *hypercalcemia.* There has been a dramatic increase in the detection of cases in the latter half of the last century, mainly as a result of the routine inclusion of serum calcium assays in testing for a variety of clinical conditions that bring a patient to the hospital. The frequency of occurrence of the various parathyroid lesions underlying the hyperfunction is as follows:

- Adenoma—85% to 95%
- Primary hyperplasia (diffuse or nodular)—5% to 10%
- Parathyroid carcinoma—1%

In more than 95% of cases, primary hyperparathyroidism is caused by a sporadic parathyroid adenoma or sporadic hyperplasia. The genetic defects identified in *familial primary hyperparathyroidism* include multiple endocrine neoplasia syndromes, specifically MEN-1 and MEN-2A (see further on). *Familial hypocalciuric hypercalcemia* is a rare cause of hyperparathyroidism, caused by inactivating mutations in the calcium-sensing receptor gene on parathyroid cells, leading to constitutive PTH secretion.

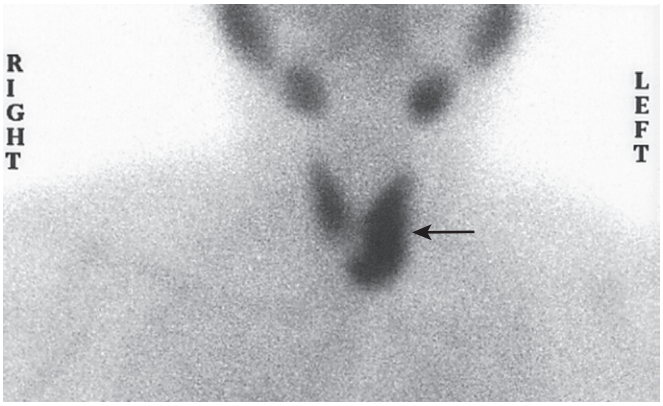


**Figure 19–19** Technetium-99 radionuclide scan demonstrates an area of increased uptake corresponding to the left inferior parathyroid gland (*arrow*). This proved to be a parathyroid adenoma. Preoperative scintigraphy is useful in localizing and distinguishing adenomas from parathyroid hyperplasia, in which more than one gland will demonstrate increased uptake.

### PATHOGENESIS

Although the details of genetic alterations in sporadic parathyroid tumors are beyond the scope of this discussion, abnormalities in two specific genes are commonly associated with these tumors:

- **Cyclin D1 gene inversions:** Cyclin D1 is a positive regulator of the cell cycle. A **chromosomal inversion** on chromosome 11 results in relocation of the *cyclin D1* gene (normally on 11q), so that it is now positioned adjacent to the 5′-flanking region of the *PTH* gene (on 11p), leading to abnormal expression of cyclin D1 protein and increased proliferation. Between 10% and 20% of adenomas have this clonal genetic defect. In addition, cyclin D1 is overexpressed in approximately 40% of parathyroid adenomas, suggesting that mechanisms other than *cyclin D1* gene inversion can lead to its overexpression.
- **MEN1 mutations:** Approximately 20% to 30% of parathyroid tumors not associated with the MEN-1 syndrome have mutations in both copies of the *MEN1* gene (see later). The spectrum of *MEN1* mutations in the sporadic tumors is virtually identical to that in familial parathyroid adenomas.

### MORPHOLOGY

The morphologic changes seen in primary hyperparathyroidism include those in the parathyroid glands as well as those in other organs affected by elevated levels of calcium. In 75% to 80% of cases, one of the parathyroids harbors a solitary **adenoma,** which, like the normal parathyroids, may lie in close proximity to the thyroid gland or in an ectopic site (e.g., the mediastinum). The typical parathyroid adenoma is a well-circumscribed, soft, tan nodule, invested by a delicate capsule. **By definition, parathyroid adenomas are almost invariably confined to single glands** (Fig. 19–19), and the remaining glands are normal in size or somewhat shrunken, as a result of feedback inhibition by elevated serum calcium. Most parathyroid adenomas weigh between 0.5 and 5 g. On microscopic examination, parathyroid adenomas are composed predominantly of chief cells (Fig. 19–20). In most cases, at least a few nests of larger oxyphil cells also are present. A rim of compressed, non-neoplastic parathyroid tissue, generally separated by a fibrous capsule, often is visible at the edge of the adenoma. This finding constitutes a helpful internal control, since the chief cells of the adenoma are larger and show greater nuclear size variability than that typical for the normal chief cells. Cells with bizarre and pleomorphic nuclei are often seen within adenomas (so-called **endocrine atypia**) and must not be taken as a sign of malignancy. Mitotic figures are rare. In contrast with the normal parathyroid parenchyma, adipose tissue is inconspicuous within adenomas.

**Parathyroid hyperplasia is typically a multiglandular process.** In some cases, however, enlargement may be grossly apparent in only one or two glands, complicating the distinction between hyperplasia and adenoma. The combined weight of all glands rarely exceeds 1.0 g and often is less. Microscopically, the most common pattern seen is that of chief cell hyperplasia, which may involve the glands in a diffuse or multinodular pattern. Less commonly, the constituent cells contain abundant clear cytoplasm as a consequence of accumulation of glycogen—a condition designated "water-clear cell hyperplasia." As in the case of adenomas, stromal fat is inconspicuous within foci of hyperplasia.

**Parathyroid carcinomas** may be circumscribed lesions that are difficult to distinguish from adenomas, or they may be clearly invasive neoplasms. These tumors enlarge one parathyroid gland and consist of gray-white, irregular masses that sometimes exceed 10 g in weight. The cells usually are uniform and resemble normal parathyroid cells. They are arrayed in nodular or trabecular patterns with a dense, fibrous capsule enclosing the mass. There is general agreement that a **diagnosis of carcinoma based on cytologic detail is unreliable, and invasion of surrounding tissues and metastasis are the only definitive**

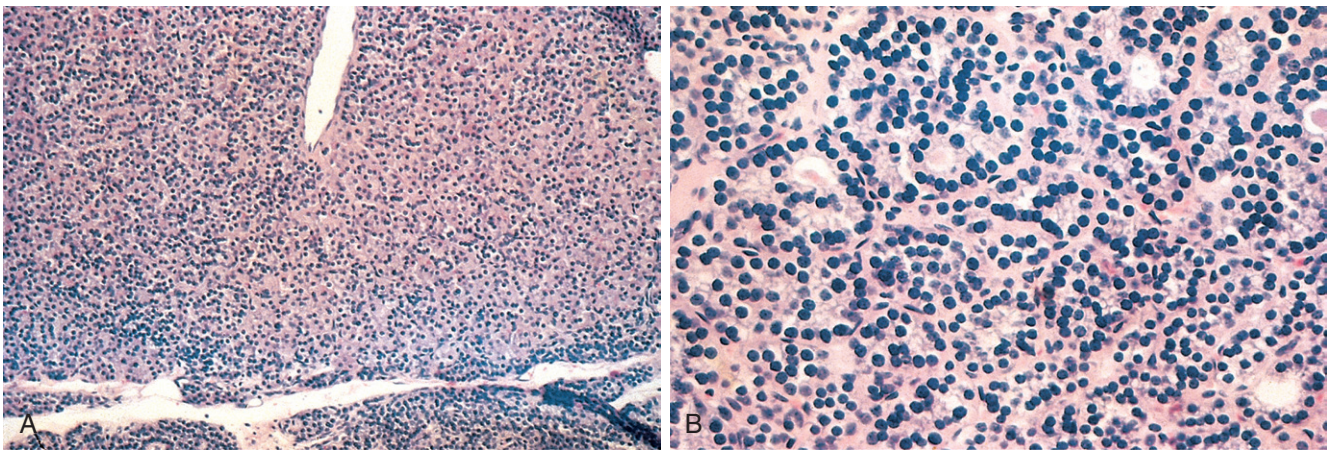


**Figure 19–20** Chief cell parathyroid adenoma. **A,** On this low-power view, a solitary adenoma is clearly delineated from the residual gland below. **B,** High-power detail shows slight variation in nuclear size and tendency to follicular formation but no anaplasia.

**criteria.** Local recurrence occurs in one third of cases, and more distant dissemination occurs in another third.

**Morphologic changes in other organs** deserving special mention are found in the skeleton and kidneys. **Skeletal changes** include increased osteoclastic activity, which results in erosion of bone matrix and mobilization of calcium salts, particularly in the metaphyses of long tubular bones. Bone resorption is accompanied by increased osteoblastic activity and the formation of new bone trabeculae. In more severe cases the cortex is grossly thinned and the marrow contains increased amounts of fibrous tissue accompanied by foci of hemorrhage and cysts **(osteitis fibrosa cystica)** (Chapter 20). Aggregates of osteoclasts, reactive giant cells, and hemorrhagic debris occasionally form masses that may be mistaken for neoplasms (**brown tumors** of hyperparathyroidism). PTH-induced hypercalcemia favors the formation of urinary tract stones (nephrolithiasis) as well as calcification of the renal interstitium and tubules (nephrocalcinosis). Metastatic calcification secondary to hypercalcemia also may be seen in other sites, including the stomach, lungs, myocardium, and blood vessels.

**Table 19–4** Causes of Hypercalcemia

| Raised PTH | Decreased PTH |
|---|---|
| Hyperparathyroidism | Hypercalcemia of malignancy |
| Primary (adenoma > hyperplasia)* | Osteolytic metastases |
| Secondary† | PTH-rP–mediated |
| Tertiary† | Vitamin D toxicity |
| Familial hypocalciuric hypercalcemia | Immobilization |
| | Drugs (thiazide diuretics) |
| | Granulomatous diseases (sarcoidosis) |

PTH, parathyroid hormone; PTH-rP, PTH-related protein.
*Primary hyperparathyroidism is the most common cause of hypercalcemia overall. Malignancy is the most common cause of *symptomatic* hypercalcemia. Primary hyperparathyroidism and malignancy together account for nearly 90% of cases of hypercalcemia.
†Secondary and tertiary hyperparathyroidism are most commonly associated with progressive renal failure.

## Clinical Features

Primary hyperparathyroidism usually is a disease of adults and is much more common in women than in men (gender ratio of nearly 4:1). *The most common manifestation of primary hyperparathyroidism is an increase in serum ionized calcium.* In fact, primary hyperparathyroidism is the most common cause of *clinically silent hypercalcemia.* Of note, other conditions also may produce hypercalcemia (Table 19–4). The most common cause of clinically apparent hypercalcemia in adults is paraneoplastic syndromes associated with *malignancy* and bone metastases (Chapter 5). The prognosis for patients with malignancy-associated hypercalcemia is poor, because it often occurs in those with advanced cancers. In persons with hypercalcemia caused by parathyroid hyperfunction, serum PTH is inappropriately elevated, whereas serum PTH is low to undetectable in those with hypercalcemia caused by nonparathyroid diseases, including malignancy. Other laboratory alterations referable to PTH excess include hypophosphatemia and increased urinary excretion of both calcium and phosphate.

Primary hyperparathyroidism traditionally has been associated with a constellation of symptoms that included "painful bones, renal stones, abdominal groans, and psychic moans." Pain, secondary to fractures of bones weakened by osteoporosis or osteitis fibrosa cystica and resulting from renal stones, with obstructive uropathy, was at one time a prominent manifestation of primary hyperparathyroidism. Because serum calcium is now routinely assessed in the workup of most patients who need blood tests for unrelated conditions, clinically silent hyperparathyroidism is detected early. Hence, many of the classic clinical manifestations, particularly those referable to bone and renal disease, are seen much less frequently. Additional signs and symptoms that may be encountered in some cases include

- *Gastrointestinal disturbances,* including constipation, nausea, peptic ulcers, pancreatitis, and gallstones
- *Central nervous system alterations,* including depression, lethargy, and seizures
- *Neuromuscular abnormalities,* including weakness and hypotonia
- *Polyuria* and secondary polydipsia

Although some of these alterations, for example, polyuria and muscle weakness, are clearly related to hypercalcemia,

the pathogenesis of many of the other manifestations of the disorder remains poorly understood.

### Secondary Hyperparathyroidism

Secondary hyperparathyroidism is caused by any condition associated with a chronic depression in the serum calcium level, because low serum calcium leads to compensatory overactivity of the parathyroids. *Renal failure is by far the most common cause of secondary hyperparathyroidism.* The mechanisms by which chronic renal failure induces secondary hyperparathyroidism are complex and not fully understood. Chronic renal insufficiency is associated with decreased phosphate excretion, which in turn results in hyperphosphatemia. The elevated serum phosphate levels directly depress serum calcium levels and thereby stimulate parathyroid gland activity. In addition, loss of renal substances reduces the availability of $\alpha_1$-hydroxylase enzyme necessary for the synthesis of the active form of vitamin D, which in turn reduces intestinal absorption of calcium (Chapter 7).

#### MORPHOLOGY

**The parathyroid glands in secondary hyperparathyroidism are hyperplastic.** As in the case of primary hyperplasia, the degree of glandular enlargement is not necessarily symmetric. On microscopic examination, the hyperplastic glands contain an increased number of chief cells, or cells with more abundant, clear cytoplasm **(water-clear cells),** in a diffuse or multinodular distribution. Fat cells are decreased in number. **Bone changes** similar to those seen in primary hyperparathyroidism also may be present. **Metastatic calcification** may be seen in many tissues.

#### Clinical Features

The clinical manifestations of secondary hyperparathyroidism usually are dominated by those related to chronic renal failure. Bone abnormalities (*renal osteodystrophy*) and other changes associated with PTH excess are, in general, less severe than those seen in primary hyperparathyroidism. Serum calcium remains near normal because the compensatory increase in PTH levels sustains serum calcium. The metastatic calcification of blood vessels (secondary to hyperphosphatemia) occasionally may result in significant ischemic damage to skin and other organs—a process sometimes referred to as *calciphylaxis.* In a minority of patients, parathyroid activity may become autonomous and excessive, with resultant hypercalcemia—a process sometimes termed *tertiary hyperparathyroidism.* Parathyroidectomy may be necessary to control the hyperparathyroidism in such patients.

#### SUMMARY

##### Hyperparathyroidism

- Primary hyperparathyroidism is the most common cause of asymptomatic hypercalcemia.
- In a majority of cases, primary hyperparathyroidism is caused by a sporadic parathyroid adenoma and, less commonly, by parathyroid hyperplasia.
- Parathyroid adenomas are solitary, while hyperplasia typically is a multiglandular process.
- Skeletal manifestations of hyperparathyroidism include bone resorption, *osteitis fibrosa cystica,* and *brown tumors.* Renal changes include nephrolithiasis (stones) and nephrocalcinosis.
- The clinical manifestations of hyperparathyroidism can be summarized as "painful bones, renal stones, abdominal groans, and psychic moans."
- Secondary hyperparathyroidism most often is caused by renal failure, and the parathyroid glands are hyperplastic.
- Malignancies are the most important cause of symptomatic hypercalcemia, which results from osteolytic metastases or release of PTH-related protein from nonparathyroid tumors.

## HYPOPARATHYROIDISM

Hypoparathyroidism is far less common than hyperparathyroidism. The major causes of hypoparathyroidism include the following:

- *Surgically induced hypoparathyroidism*: The most common cause is inadvertent removal of parathyroids during thyroidectomy or other surgical neck dissections.
- *Congenital absence*: This occurs in conjunction with thymic aplasia (Di George syndrome) and cardiac defects, secondary to deletions on chromosome 22q11.2 (Chapter 6)
- *Autoimmune hypoparathyroidism*: This is a hereditary polyglandular deficiency syndrome arising from autoantibodies to multiple endocrine organs (parathyroid, thyroid, adrenals, and pancreas). Chronic fungal infections involving the skin and mucous membranes (mucocutaneous candidiasis) are sometimes encountered in affected persons. This condition is caused by mutations in the *autoimmune regulator* gene (*AIRE*) and is discussed more extensively later on, in the context of autoimmune adrenalitis. As one consequence of the failure of self-tolerance, some of these patients make autoantibodies against their own IL-17, accounting for the increased susceptibility to *Candida* infections (in which the $T_H17$ response plays an important protective role).

The major clinical manifestations of hypoparathyroidism are secondary to hypocalcemia and include *increased neuromuscular irritability* (*tingling, muscle spasms, facial grimacing,* and *sustained carpopedal spasm or tetany*), cardiac arrhythmias, and, on occasion, *increased intracranial pressures* and *seizures.* Morphologic changes generally are inconspicuous but may include cataracts, calcification of the cerebral basal ganglia, and dental abnormalities.

# ENDOCRINE PANCREAS

The endocrine pancreas consists of about 1 million microscopic clusters of cells, the islets of Langerhans, which contain four major cell types—beta, alpha, delta, and PP (pancreatic polypeptide) cells. The cells can be differentiated morphologically by their staining properties, by the ultrastructural characteristics of their granules, and by their hormone content. *The beta cell produces insulin,* which is the most potent anabolic hormone known, with multiple synthetic and growth-promoting effects; *the alpha cell secretes glucagon,* inducing hyperglycemia by its glycogenolytic activity in the liver; *delta cells contain somatostatin,* which suppresses both insulin and glucagon release; and *PP cells contain a unique pancreatic polypeptide,* VIP, that exerts several gastrointestinal effects, such as stimulation of secretion of gastric and intestinal enzymes and inhibition of intestinal motility. The most important disease of the endocrine pancreas is diabetes mellitus, caused by deficient production or action of insulin.

# DIABETES MELLITUS

Diabetes mellitus is not a single disease entity but rather a *group of metabolic disorders sharing the common underlying feature of hyperglycemia.* Hyperglycemia in diabetes results from defects in insulin secretion, insulin action, or, most commonly, both. The chronic hyperglycemia and attendant metabolic deregulation of diabetes mellitus may be associated with secondary damage in multiple organ systems, especially the kidneys, eyes, nerves, and blood vessels. According to the American Diabetes Association, diabetes affects over 20 million children and adults, or 7% of the population, in the United States, nearly a third of whom are currently unaware that they have hyperglycemia. Approximately 1.5 million new cases of diabetes are diagnosed each year in the United States, and diabetes is the leading cause of end-stage renal disease, adult-onset blindness, and nontraumatic lower extremity amputations. A staggering 54 million adults in this country have *prediabetes*, which is defined as elevated blood sugar that does not reach the criterion accepted for an outright diagnosis of diabetes (discussed next); persons with prediabetes have an elevated risk for development of frank diabetes.

## Diagnosis

Blood glucose levels normally are maintained in a very narrow range, usually 70 to 120 mg/dL. The diagnosis of diabetes is established by elevation of blood glucose by any one of three criteria:

1. A random blood glucose concentration of 200 mg/dL or higher, with classical signs and symptoms (discussed next)
2. A fasting glucose concentration of 126 mg/dL or higher on more than one occasion
3. An abnormal oral glucose tolerance test (OGTT), in which the glucose concentration is 200 mg/dL or higher 2 hours after a standard carbohydrate load (75 g of glucose).

Derangements in carbohydrate metabolism proceed along a continuum. Persons with serum fasting glucose values less than 110 mg/dL, or less than 140 mg/dL for an OGTT, are considered to be euglycemic. However, those with serum fasting glucose greater than 110 but less than 126 mg/dL, or OGTT values of greater than 140 but less than 200 mg/dL, are considered to have *impaired glucose tolerance,* also known as *prediabetes.* Persons with impaired glucose tolerance have a significant risk for progression to overt diabetes over time, with as many as 5% to 10% advancing to full-fledged diabetes mellitus per year. In addition, those with impaired glucose tolerance are at *risk for cardiovascular disease,* as a consequence of abnormal carbohydrate metabolism and the coexistence of other risk factors (Chapter 9).

## Classification

Although all forms of diabetes mellitus share hyperglycemia as a common feature, the underlying causes of hyperglycemia vary widely. *The vast majority of cases of diabetes fall into one of two broad classes*:

- *Type 1 diabetes (T1D)* is characterized by an absolute deficiency of insulin secretion caused by pancreatic beta cell destruction, usually resulting from an autoimmune attack. Type 1 diabetes accounts for approximately 10% of all cases.
- *Type 2 diabetes (T2D)* is caused by a combination of peripheral resistance to insulin action and an inadequate compensatory response of insulin secretion by the pancreatic beta cells (*relative insulin deficiency*). Approximately 80% to 90% of patients have type 2 diabetes.

A variety of monogenic and secondary causes make up the remaining cases of diabetes (Table 19–5). An important point is that although the major types of diabetes arise by different pathogenic mechanisms, *the long-term complications in kidneys, eyes, nerves, and blood vessels are the same and are the principal causes of morbidity and death.*

## Normal Insulin Physiology and Glucose Homeostasis

Before discussing the pathogenesis of the two major types of diabetes, we briefly review normal insulin physiology and glucose metabolism. *Normal glucose homeostasis is tightly regulated by three interrelated processes*: (1) glucose production in the liver, (2) glucose uptake and utilization by peripheral tissues, chiefly skeletal muscle, and (3) actions of insulin and counterregulatory hormones (e.g., glucagon).

*The principal metabolic function of insulin is to increase the rate of glucose transport into certain cells in the body* (Fig. 19–21). These are the *striated* muscle cells (including myocardial cells) and, to a lesser extent, *adipocytes,* representing collectively about two thirds of total body weight. Glucose uptake in other peripheral tissues, most notably the brain, is insulin-independent. In muscle cells, glucose is then

**Table 19–5** Classification of Diabetes Mellitus

| |
|---|
| **1. Type 1 Diabetes** |
| Beta cell destruction, usually leading to absolute insulin deficiency |
| **2. Type 2 Diabetes** |
| Combination of insulin resistance and beta cell dysfunction |
| **3. Genetic Defects of Beta Cell Function** |
| Maturity-onset diabetes of the young (MODY), caused by mutations in:<br>Hepatocyte nuclear factor 4α gene (*HNF4A*)—MODY1<br>Glucokinase gene (*GCK*)—MODY2<br>Hepatocyte nuclear factor 1α gene (*HNF1A*)—MODY3<br>Pancreatic and duodenal homeobox 1 gene (*PDX1*)—MODY4<br>Hepatocyte nuclear factor 1β gene (*HNF1B*)—MODY5<br>Neurogenic differentiation factor 1 gene (*NEUROD1*)—MODY6 |
| Maternally inherited diabetes and deafness (MIDD) due to mitochondrial DNA mutations (3243A→G) |
| Defects in proinsulin conversion |
| Insulin gene mutations |
| **4. Genetic Defects in Insulin Action** |
| Insulin receptor mutations |
| **5. Exocrine Pancreatic Defects** |
| Chronic pancreatitis |
| Pancreatectomy |
| Neoplasia |
| Cystic fibrosis |
| Hemochromatosis |
| Fibrocalculous pancreatopathy |
| **6. Endocrinopathies** |
| Growth hormone excess (acromegaly) |
| Cushing syndrome |
| Hyperthyroidism |
| Pheochromocytoma |
| Glucagonoma |
| **7. Infections** |
| Cytomegalovirus infection |
| Coxsackievirus B infection |
| Congenital rubella |
| **8. Drugs** |
| Glucocorticoids |
| Thyroid hormone |
| β-Adrenergic agonists |
| **9. Genetic Syndromes Associated with Diabetes** |
| Down syndrome |
| Klinefelter syndrome |
| Turner syndrome |
| **10. Gestational Diabetes Mellitus** |
| Diabetes associated with pregnancy |

Modified from the American Diabetes Association: Position statement from the American Diabetes Association on the diagnosis and classification of diabetes mellitus. Diabetes Care 31(Suppl 1):S55–S60, 2008.

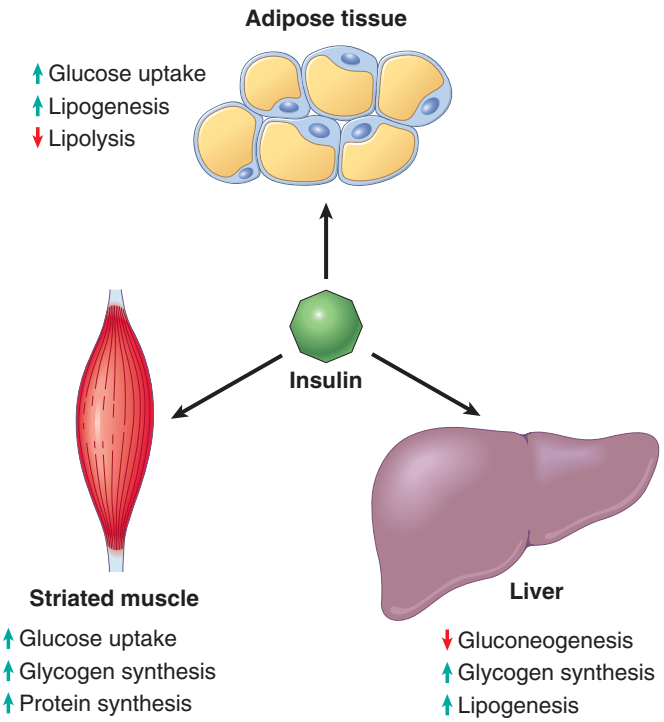


**Figure 19–21** Metabolic actions of insulin in striated muscle, adipose tissue, and liver.

either stored as glycogen or oxidized to generate adenosine triphosphate (ATP). In adipose tissue, glucose is stored primarily as lipid. Besides promoting lipid synthesis (lipogenesis), insulin also inhibits lipid degradation (lipolysis) in adipocytes. Similarly, insulin promotes amino acid uptake and protein synthesis while inhibiting protein degradation. *Thus, the metabolic effects of insulin can be summarized as anabolic, with increased synthesis and reduced degradation of glycogen, lipid, and protein.* In addition to these metabolic effects, insulin has several *mitogenic* functions, including initiation of DNA synthesis in certain cells and stimulation of their growth and differentiation.

*Insulin reduces the production of glucose from the liver.* Insulin and glucagon have opposing regulatory effects on glucose homeostasis. During *fasting* states, low insulin and high glucagon levels facilitate hepatic gluconeogenesis and glycogenolysis (glycogen breakdown) while decreasing glycogen synthesis, thereby preventing hypoglycemia. Thus, *fasting* plasma glucose levels are determined primarily by hepatic glucose output. After a meal, insulin levels rise and glucagon levels fall in response to the large glucose load. *The most important stimulus that triggers insulin release is glucose itself, which initiates insulin synthesis in the pancreatic beta cells.* In peripheral tissues (skeletal muscle and adipose tissue), secreted insulin binds to the *insulin receptor,* triggering a number of intracellular responses that promote glucose uptake and postprandial glucose utilization, thereby maintaining glucose homeostasis. Abnormalities at various points along this complex signaling cascade, from synthesis and release of insulin by beta cells to insulin receptor interactions in peripheral tissues, can result in the diabetic phenotype.

## PATHOGENESIS

### Type 1 Diabetes Mellitus

**Type 1 diabetes is an autoimmune disease in which islet destruction is caused primarily by immune effector cells reacting against endogenous beta cell antigens.** Type 1 diabetes most commonly develops in childhood, becomes manifest at puberty, and progresses with age. Most patients with type 1 diabetes depend on exogenous insulin for survival; without insulin they develop serious metabolic complications such as ketoacidosis and coma.

Although the clinical onset of type 1 diabetes is abrupt, this disease in fact results from a chronic autoimmune attack on beta cells that usually starts many years before the disease becomes evident (Fig. 19–22). The classic manifestations of the disease (hyperglycemia and ketosis) occur late in its course, after more than 90% of the beta cells have been destroyed. **The fundamental immune abnormality in type 1 diabetes is a failure of self-tolerance in T cells.** This failure of tolerance may be a result of some combination of defective clonal deletion of self-reactive T cells in the thymus, as well as defects in the functions of regulatory T cells or resistance of effector T cells to suppression by regulatory cells. Thus, autoreactive T cells not only survive but are poised to respond to self-antigens. Not surprisingly, **autoantibodies** against a variety of beta cell antigens, including insulin and the beta cell enzyme glutamic acid decarboxylase, are detected in the blood of 70% to 80% of patients. In the rare cases in which the pancreatic lesions have been examined early in the disease process, the islets show necrosis of beta cells and lymphocytic infiltration (so-called insulitis).

As with most autoimmune diseases, the pathogenesis of type 1 diabetes involves the interplay of genetic susceptibility and environmental factors. Genome-wide association studies (Chapter 6) have identified over 20 susceptibility loci for type 1 diabetes. Of these, **the principal susceptibility locus for type 1 diabetes resides in the chromosomal region that encodes the class II MHC molecules on *6p21 (HLA-D)*.** Between 90% and 95% of white patients with type 1 diabetes have *HLA-DR3*, or *DR4*, or both, in contrast with about 40% of normal subjects, and 40% to 50% of patients are *DR3/DR4* heterozygotes, in contrast with 5% of normal subjects. Of note, despite the high relative risk in persons with particular class II alleles, most people who inherit these alleles do not develop diabetes. Several *non-HLA genes* also confer susceptibility to type 1 diabetes, including polymorphisms within the gene encoding insulin itself, as well as *CTLA4* and *PTPN22*. CTLA-4 is an inhibitory receptor of T cells and PTPN-22 is a protein tyrosine phosphatase; both are thought to inhibit T cell responses, so polymorphisms that interfere with their functional activity are expected to set the stage for excessive T cell activation. Polymorphisms in the insulin gene may reduce expression of this protein in the thymus, thus reducing the elimination of T cells reactive with this self protein (Chapter 4). Additional evidence suggests that **environmental factors,** especially infections, may be involved in type 1 diabetes. It has been proposed that certain viruses (mumps, rubella, and coxsackie B viruses, in particular) may be an initiating trigger, perhaps because some viral antigens are antigenically similar to beta cell antigens **(molecular mimicry),** leading to bystander damage to the islets, but this idea is not conclusively established.

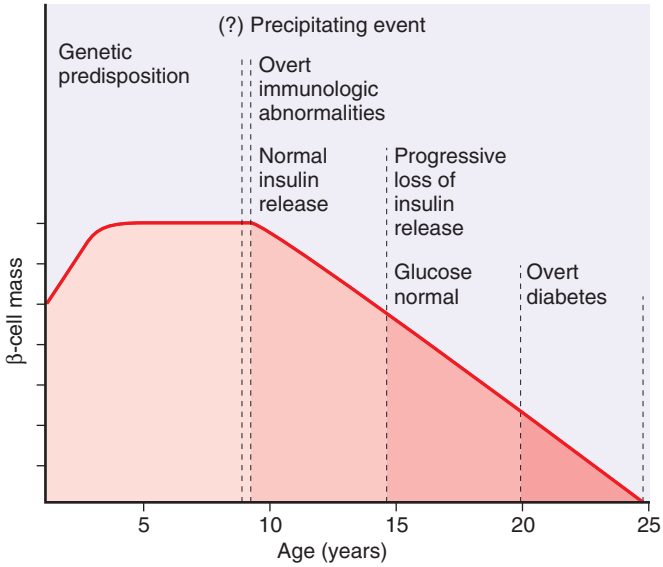


**Figure 19–22** Stages in the development of type 1 diabetes mellitus. The stages are listed *from left to right*, and hypothetical beta cell mass is plotted against age.

*(From Eisenbarth GE: Type 1 diabetes—a chronic autoimmune disease. N Engl J Med 314:1360, 1986.)*

### Type 2 Diabetes Mellitus

Type 2 diabetes is a prototypical complex multifactorial disease. Environmental factors, such as a sedentary life style and dietary habits, unequivocally play a role, as described in the subsequent discussion of the association with obesity. Genetic factors are also involved in the pathogenesis, as evidenced by the disease concordance rate of 35% to 60% in monozygotic twins compared with nearly half that in dizygotic twins. Such concordance is even greater than in type 1 diabetes, suggesting perhaps an even larger genetic component in type 2 diabetes. **Additional evidence for a genetic basis has emerged from recent large-scale genome-wide association studies, which have identified more than a dozen susceptibility loci called "diabetogenic" genes.** Unlike type 1 diabetes, however, the disease is not linked to genes involved in immune tolerance and regulation (e.g., *HLA, CTLA4*), and evidence of an autoimmune basis is lacking. The two metabolic defects that characterize type 2 diabetes are (1) a decreased ability of peripheral tissues to respond to insulin (insulin resistance) and (2) beta cell dysfunction that is manifested as inadequate insulin secretion in the face of insulin resistance and hyperglycemia (Fig. 19–23). Insulin resistance predates the development of hyperglycemia and usually is accompanied by compensatory beta cell hyperfunction and hyperinsulinemia in the early stages of the evolution of diabetes.

## Insulin Resistance

*Insulin resistance* is defined as the failure of target tissues to respond normally to insulin. It leads to decreased uptake of glucose in muscle, reduced glycolysis and fatty acid oxidation in the liver, and an inability to suppress hepatic gluconeogenesis. A variety of functional defects have been

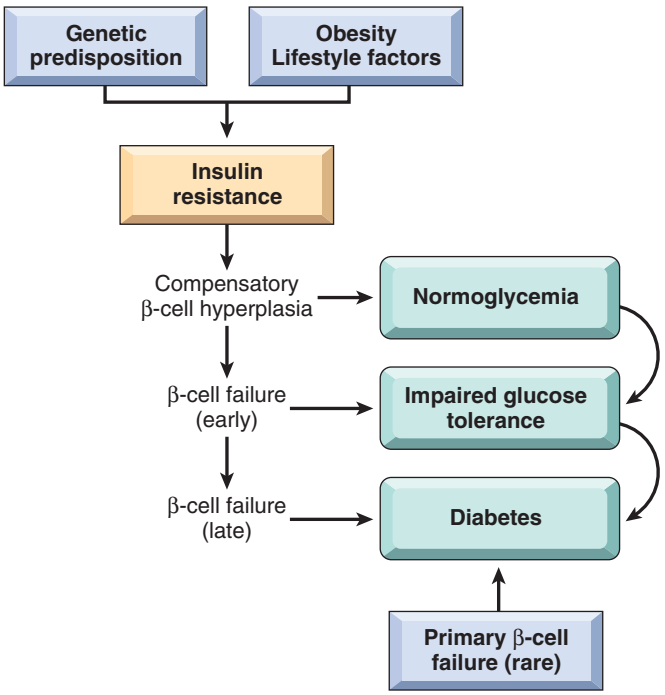


**Figure 19–23** Pathogenesis of type 2 diabetes mellitus. Genetic predisposition and environmental influences converge to cause insulin resistance. Compensatory beta cell hyperplasia can maintain normoglycemia, but eventually beta cell secretory dysfunction sets in, leading to impaired glucose tolerance and, ultimately, frank diabetes. Rare instances of primary beta cell failure can lead directly to type 2 diabetes without an intervening state of insulin resistance.

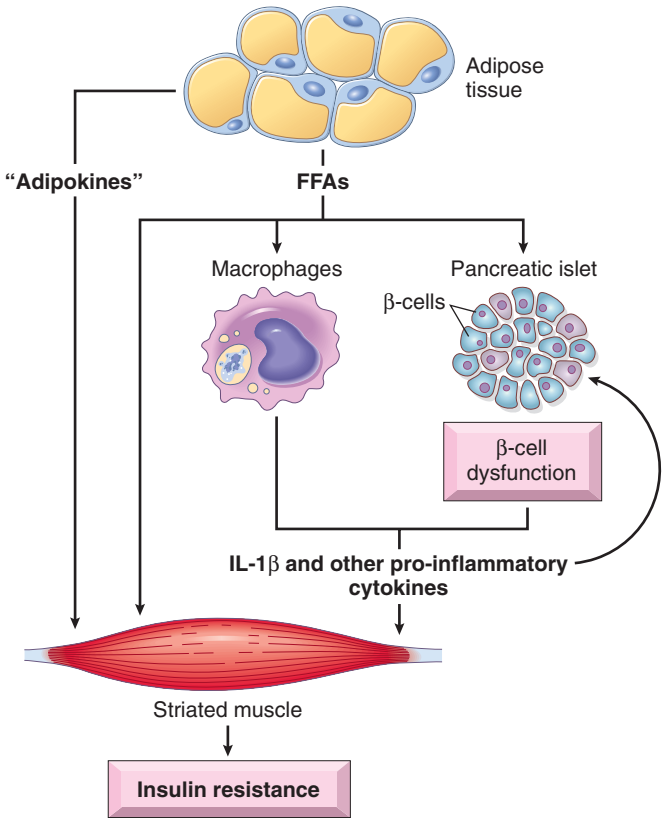


**Figure 19–24** Mechanisms of beta cell dysfunction and insulin resistance in type 2 diabetes. Free fatty acids directly cause beta cell dysfunction and induce insulin resistance in target tissues (such as striated muscle, *shown here*), and also induce the secretion of pro-inflammatory cytokines that cause more beta cell dysfunction and insulin resistance.

reported in the insulin signaling pathway in states of insulin resistance (for example, reduced phosphorylation-dependent activation of the insulin receptor and its downstream components), which attenuate signal transduction. *Few factors play as important a role in the development of insulin resistance as obesity.*

### *Obesity and Insulin Resistance*

The association of obesity with type 2 diabetes has been recognized for decades, with visceral obesity being common in a majority of affected patients. Insulin resistance is present even with simple obesity unaccompanied by hyperglycemia, indicating a fundamental abnormality of insulin signaling in states of fatty excess. In fact, the term *metabolic syndrome* has been applied to a constellation of findings dominated by visceral obesity, which is accompanied by insulin resistance, glucose intolerance, and cardiovascular risk factors such as hypertension and abnormal lipid profiles (Chapter 7). In the absence of weight loss and lifestyle modifications, persons with metabolic syndrome are at significant risk for the development of frank type 2 diabetes, underscoring the importance of obesity to the pathogenesis of this disease. The risk of diabetes increases as the body mass index (a measure of body fat content) increases, suggesting a dose-response relationship between body fat and insulin resistance. Although many details of the so-called *adipo-insulin axis* remain to be elucidated, recognition of some of the putative pathways leading to insulin resistance has increased substantially (Fig. 19–24):

- *Role of excess free fatty acids* (FFAs): Cross-sectional studies have demonstrated an inverse correlation between fasting plasma FFAs and insulin sensitivity. The level of intracellular triglycerides often is markedly increased in muscle and liver tissues in obese persons, presumably because excess circulating FFAs are deposited in these organs. Intracellular triglycerides and products of fatty acid metabolism are potent inhibitors of insulin signaling and result in an acquired insulin resistance state. These *lipotoxic* effects of FFAs are mediated through a decrease in activity of key insulin-signaling proteins.
- *Role of inflammation*: Over the past several years, inflammation has emerged as a major player in the pathogenesis of type 2 diabetes. It is now known that a permissive inflammatory milieu (mediated *not* by an autoimmune process as in type 1 diabetes but rather by pro-inflammatory cytokines that are secreted in response to excess nutrients such as FFAs) results in both peripheral insulin resistance and beta cell dysfunction (see later). Excess FFAs within macrophages and beta cells can engage the *inflammasome*, a multiprotein cytoplasmic complex that leads to secretion of the cytokine interleukin IL-1β (Chapter 2). IL-1β, in turn, mediates the

secretion of additional pro-inflammatory cytokines from macrophages, islets, and other cells that are released into the circulation and act on the major sites of insulin action to promote insulin resistance. Thus, excess FFAs can impede insulin signaling directly within peripheral tissues, as well as indirectly through the release of pro-inflammatory cytokines. Not surprisingly, there are now several ongoing trials of cytokine antagonists (particularly of IL-1β) in patients with type 2 diabetes.

- *Role of adipokines*: Adipose tissue is not merely a passive storage depot for fat; it can operate as a functional endocrine organ, releasing so-called *adipokines* in response to extracellular stimuli or changes in metabolic status. Thus, adipocytes also release IL-1β and other pro-inflammatory cytokines into the circulation in response to excess FFAs, which promote peripheral insulin resistance. By contrast, *adiponectin* is an adipokine with insulin sensitizing activity, which probably acts by dampening the inflammatory response.
- *Peroxisome proliferator-activated receptor-γ* (PPARγ): PPARγ is a nuclear receptor and transcription factor expressed in adipose tissue and plays a seminal role in adipocyte differentiation. A class of antidiabetic medications known as thiazolidinediones acts as agonist ligands for PPARγ and improves insulin sensitivity. Activation of PPARγ promotes secretion of antihyperglycemic adipokines such as adiponectin, and shifts the deposition of FFAs toward adipose tissue and away from liver and skeletal muscle.

## Beta Cell Dysfunction

Beta cell dysfunction in type 2 diabetes reflects the inability of these cells to adapt themselves to the long-term demands of peripheral insulin resistance and increased insulin secretion. In states of insulin resistance, insulin secretion initially is higher for each level of glucose than in controls. This hyperinsulinemic state is a compensation for peripheral resistance and often can maintain normal plasma glucose for years. Eventually, however, beta cell compensation becomes inadequate, and there is progression to hyperglycemia, which is accompanied by an absolute loss in beta cell mass. The molecular mechanisms underlying beta cell dysfunction in type 2 diabetes are multifactorial and in many instances overlap with those implicated in insulin resistance. Thus, excess nutrients such as FFAs and glucose can promote the secretion of pro-inflammatory cytokines from beta cells, which leads to recruitment of mononuclear cells (macrophages and T cells) into the islets, resulting in more local cytokine production. The consequences of this abnormal inflammatory microenvironment are beta cell dysfunction and, ultimately, beta cell death. Amyloid replacement of islets is a characteristic finding in persons with *long-standing* type 2 diabetes and is present in more than 90% of diabetic islets examined (see later). The islet amyloid polypeptide (IAPP), also known as amylin, is secreted by the beta cells in conjunction with insulin, and its abnormal aggregation results in amyloid. IAPP also engages the inflammasome and promotes IL-1β secretion, thus sustaining the inflammatory onslaught on surviving beta cells even late in the disease.

## Monogenic Forms of Diabetes

Type 1 and type 2 diabetes are genetically complex, and despite the associations with multiple susceptibility loci, no single-gene defect (mutation) can account for predisposition to these entities. By contrast, monogenic forms of diabetes (Table 19–5) are uncommon examples of the *diabetic phenotype occurring as a result of loss-of-function mutations within a single gene.* Monogenic causes of diabetes include either a primary defect in beta cell function or a defect in insulin receptor signaling. The largest subgroup of patients in this category traditionally was designated as having *maturity-onset diabetes of the young (MODY)* because of its superficial resemblance to type 2 diabetes and its occurrence in younger patients; MODY can be the result of inactivating mutations in one of six genes. Other uncommon causes include *maternally inherited diabetes and bilateral deafness,* secondary to mitochondrial DNA mutations, and mutations within the *insulin* gene itself, which most commonly manifests with diabetes in the neonatal period. Finally, rare instances of *insulin receptor* mutations that affect receptor synthesis, insulin binding, or downstream signal transduction can cause severe insulin resistance, accompanied by hyperinsulinemia and diabetes.

## Complications of Diabetes

Diabetes can be a devastating disease because the abnormal glucose metabolism and other metabolic derangements have serious pathologic effects on virtually all the systems of the body. The most significant complications of diabetes are vascular abnormalities, renal damage, and lesions affecting the peripheral nerves and eyes (Fig. 19–25). The pathologic findings in these tissues and their clinical consequences are described below. There is extreme variability among patients in the time of onset of these complications, their severity, and the particular organ or organs involved. In persons with tight control of their diabetes, the onset may be delayed.

*The pathogenesis of the long-term complications of diabetes is multifactorial, although persistent hyperglycemia (glucotoxicity) seems to be a key mediator.* At least three distinct metabolic pathways seem to be involved in the pathogenesis of long-term complications; it is likely that all of them play a role in a tissue-specific manner.

1. *Formation of advanced glycation end products* (AGEs). AGEs are formed as a result of nonenzymatic reactions between intracellular glucose-derived precursors (glyoxal, methylglyoxal, and 3-deoxyglucosone) with the amino groups of both intracellular and extracellular proteins. The natural rate of AGE formation is greatly accelerated in the presence of hyperglycemia. AGEs bind to a specific receptor (RAGE), which is expressed on inflammatory cells (macrophages and T cells) and in endothelium and vascular smooth muscle. The detrimental effects of the AGE-RAGE signaling axis within the vascular compartment include
   - Release of pro-inflammatory *cytokines and growth factors* from intimal macrophages
   - Generation of *reactive oxygen species* in endothelial cells

- Increased *procoagulant activity* on endothelial cells and macrophages
- Enhanced *proliferation of vascular smooth muscle cells and synthesis of extracellular matrix*

  In addition to receptor-mediated effects, *AGEs can directly cross-link extracellular matrix proteins,* which decreases protein removal while enhancing protein deposition. AGEs cross-linked proteins can *trap* other plasma or interstitial proteins; for example, low-density lipoprotein (LDL) gets trapped within AGE-modified large vessel walls, accelerating atherosclerosis (Chapter 9), while albumin can get trapped within capillaries, accounting in part for the basement membrane thickening that is characteristic of diabetic microangiopathy (see later).

2. *Activation of protein kinase C.* Activation of intracellular protein kinase C (PKC) by calcium ions and the second messenger diacylglycerol (DAG) is an important signal transduction pathway in many cellular systems. Intracellular hyperglycemia can stimulate the de novo synthesis of DAG from glycolytic intermediates and hence cause activation of PKC. The downstream effects of PKC activation are numerous and include production of *pro-angiogenic molecules* such as vascular endothelial growth factor (VEGF), implicated in the neovascularization seen in diabetic retinopathy, and profibrogenic molecules such as transforming growth factor-β, leading to increased deposition of extracellular matrix and basement membrane material.
3. *Disturbances in polyol pathways.* In some tissues that do not require insulin for glucose transport (e.g., nerves, lens, kidneys, blood vessels), hyperglycemia leads to an increase in intracellular glucose that is then metabolized by the enzyme *aldose reductase* to sorbitol, a polyol, and eventually to fructose, in a reaction that uses NADPH (the reduced form of nicotinamide dinucleotide phosphate) as a cofactor. NADPH is also required by the enzyme glutathione reductase in a reaction that regenerates reduced glutathione (GSH). As described in Chapter 1, GSH is one of the important antioxidant mechanisms in the cell, and any reduction in GSH increases cellular susceptibility to *oxidative stress.* In neurons, persistent hyperglycemia appears to be the major underlying cause of diabetic neuropathy (*glucose neurotoxicity*).

## MORPHOLOGY

### Diabetes and Its Late Complications

Pathologic findings in the diabetic pancreas are variable and not necessarily dramatic. The important morphologic changes are related to the many late systemic complications of diabetes. In most patients, morphologic changes are likely to be found in arteries **(macrovascular disease),** basement membranes of small vessels **(microangiopathy),** kidneys **(diabetic nephropathy),** retina **(retinopathy),** nerves **(neuropathy),** and other tissues. These changes are seen in both type 1 and type 2 diabetes (Fig. 19–25).

**Pancreas.** Lesions in the pancreas are inconstant and rarely of diagnostic value. One or more of the following alterations may be present:

- **Reduction in the number and size of islets.** This change most often is seen in type 1 diabetes, particularly with rapidly advancing disease. Most of the islets are small, inconspicuous, and not easily detected.
- **Leukocytic infiltration of the islets,** which are principally composed of mononuclear cells (lymphocytes and macrophages) (Fig. 19–26, *A*). Of note, both type 1 and type 2 diabetes may demonstrate islet inflammation early in the disease, although it is typically more severe in T1D. In both types inflammation is often absent by the time the disease is clinically evident.
- **Amyloid replacement of islets in long-standing type 2 diabetes,** appearing as deposition of pink, amorphous material beginning in and around capillaries and between cells. At advanced stages the islets may be virtually obliterated (Fig. 19–26, *B*); fibrosis also may be observed. While inflammation is observed early in the natural history of type 2 diabetes, amyloid deposition occurs in long-standing cases.
- **An increase in the number and size of islets, especially characteristic of nondiabetic newborns of diabetic mothers.** Presumably, fetal islets undergo hyperplasia in response to the maternal hyperglycemia.

**Diabetic Macrovascular Disease.** Diabetes exacts a heavy toll on the vascular system. The hallmark of diabetic macrovascular disease is accelerated atherosclerosis affecting the aorta and large and medium-sized arteries. Except for its greater severity and earlier age at onset, atherosclerosis in diabetics is indistinguishable from that in nondiabetics (Chapter 9). Myocardial infarction, caused by atherosclerosis of the coronary arteries, is the most common cause of death in diabetics. Significantly, it is almost as common in diabetic women as in diabetic men. By contrast, myocardial infarction is uncommon in nondiabetic women of reproductive age. Gangrene of the lower extremities, as a result of advanced vascular disease, is about 100 times more common in persons with diabetes than in the general population. The larger renal arteries also are subject to severe atherosclerosis, but the most damaging effect of diabetes on the kidneys is exerted at the level of the glomeruli and the microcirculation, as discussed later on.

**Hyaline arteriolosclerosis,** the vascular lesion associated with hypertension (Chapters 9 and 13), is both more prevalent and more severe in diabetics than in nondiabetics, but it is not specific for diabetes and may be seen in elderly persons who do not suffer from either diabetes or hypertension. It takes the form of an amorphous, hyaline thickening of the wall of the arterioles, which causes narrowing of the lumen (Fig. 19–27). Not surprisingly, in diabetic patients, its severity is related not only to the duration of the disease but also to the presence or absence of hypertension.

**Diabetic Microangiopathy.** One of the most consistent morphologic features of diabetes is **diffuse thickening of basement membranes.** The thickening is most evident in the capillaries of the skin, skeletal muscle, retina, renal glomeruli, and renal medulla. However, it also may be seen in such nonvascular structures as renal tubules, the Bowman

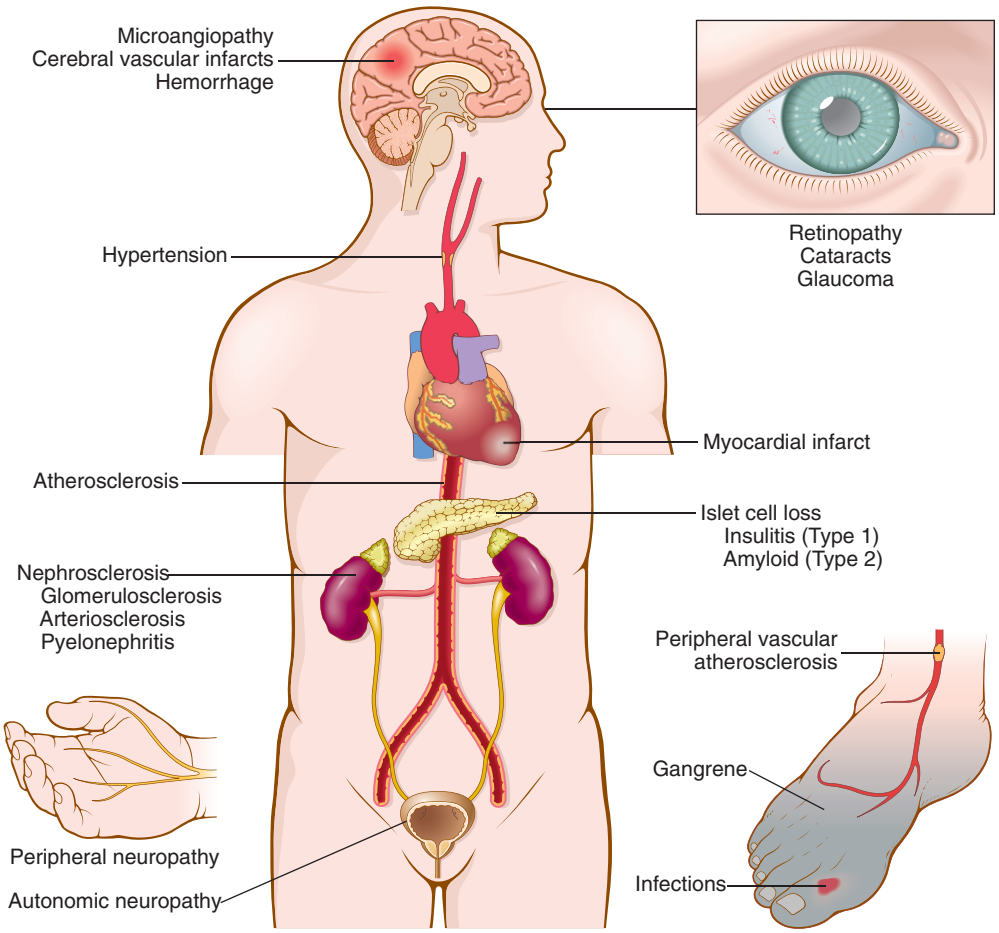


**Figure 19–25** Long-term complications of diabetes.

capsule, peripheral nerves, and placenta. By both light and electron microscopy, the basal lamina separating parenchymal or endothelial cells from the surrounding tissue is markedly thickened by concentric layers of hyaline material composed predominantly of type IV collagen (Fig. 19–28).

Of note, **despite the increase in the thickness of basement membranes, diabetic capillaries are more leaky than normal to plasma proteins. The microangiopathy underlies the development of diabetic nephropathy, retinopathy, and some forms of**

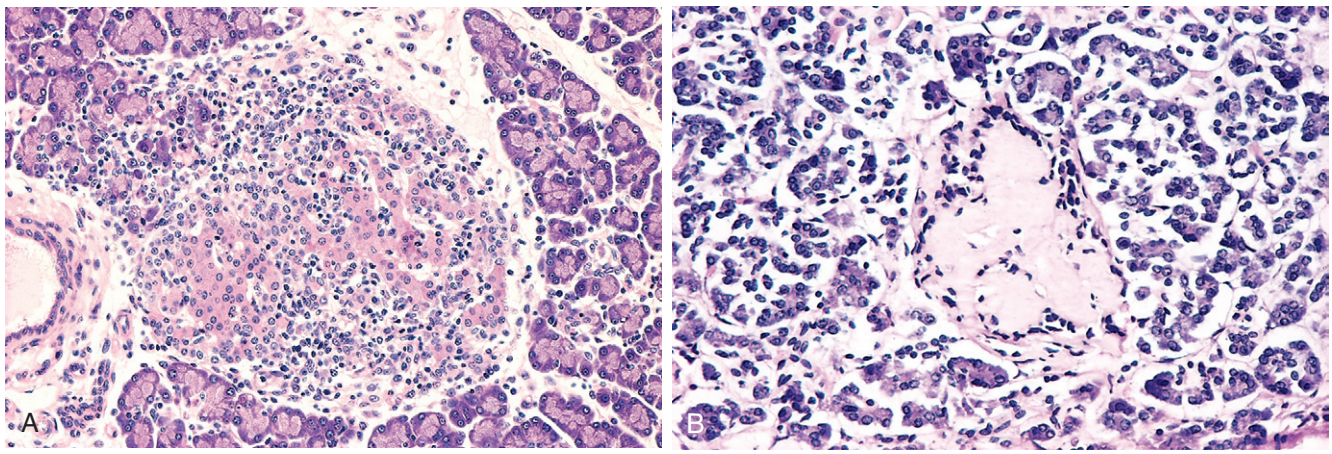


**Figure 19–26 A,** Autoimmune insulitis in a rat (BB) model of autoimmune diabetes. This disorder also is seen in type 1 human diabetes. **B,** Amyloidosis of a pancreatic islet in type 2 diabetes. Amyloidosis typically is observed late in the natural history of this form of diabetes, with islet inflammation noted at earlier observations.

*(A, Courtesy of Dr. Arthur Like, University of Massachusetts, Worcester, Massachusetts.)*

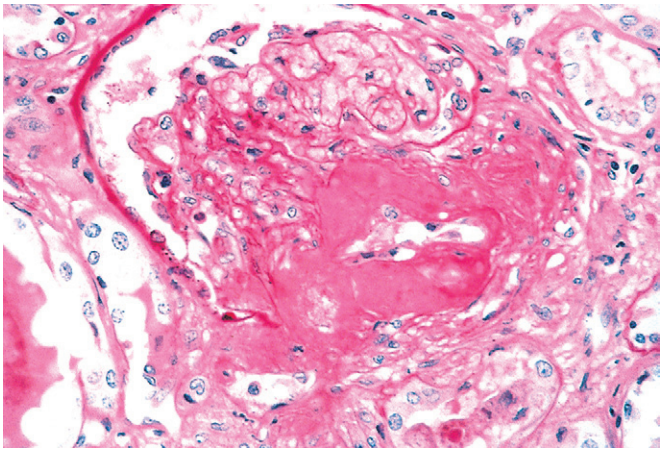

**Figure 19–27** Severe renal hyaline arteriolosclerosis in a periodic acid–Schiff stained specimen. Note the markedly thickened, tortuous afferent arteriole. The amorphous nature of the thickened vascular wall is evident.
*(Courtesy of Dr. M.A. Venkatachalam, Department of Pathology, University of Texas Health Science Center, San Antonio, Texas.)*

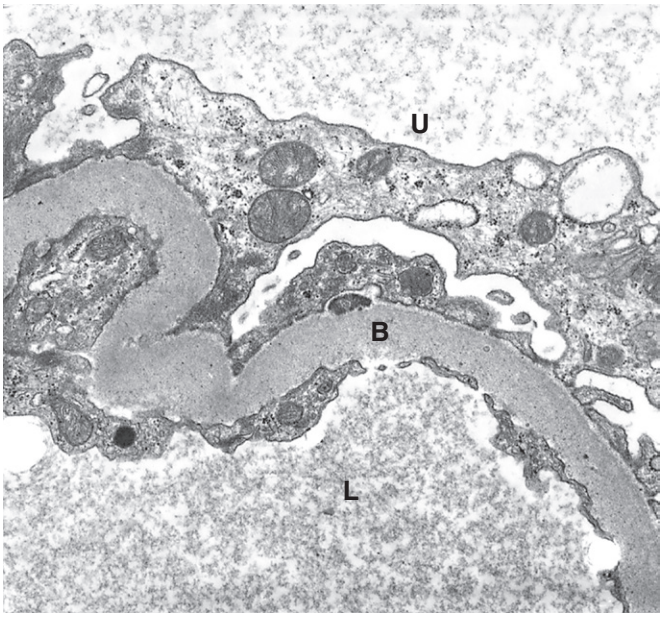


**Figure 19–29** Renal glomerulus showing markedly thickened glomerular basement membrane (B) in a diabetic. L, glomerular capillary lumen; U, urinary space.
*(Courtesy of Dr. Michael Kashgarian, Department of Pathology, Yale University School of Medicine, New Haven, Connecticut.)*

**neuropathy.** An indistinguishable microangiopathy can be found in aged nondiabetic patients, but rarely to the extent seen in persons with long-standing diabetes.

**Diabetic Nephropathy.** The kidneys are prime targets of diabetes (see also Chapter 13). Renal failure is second only to myocardial infarction as a cause of death from this disease. Three lesions are encountered: (1) glomerular lesions; (2) renal vascular lesions, principally arteriolosclerosis; and (3) pyelonephritis, including necrotizing papillitis.

The most important glomerular lesions are capillary basement membrane thickening, diffuse mesangial sclerosis, and nodular glomerulosclerosis. The glomerular capillary basement membranes are thickened along their entire length. This change can be detected by electron microscopy within a few years of the onset of diabetes, sometimes without any associated change in renal function (Fig. 19–29).

**Diffuse mesangial sclerosis** consists of a diffuse increase in mesangial matrix along with mesangial cell proliferation and is always associated with basement membrane thickening. It is found in most individuals with disease of more than 10 years' duration. When glomerulosclerosis becomes marked, patients manifest the nephrotic syndrome, characterized by proteinuria, hypoalbuminemia, and edema (Chapter 13).

**Nodular glomerulosclerosis** describes a glomerular lesion made distinctive by ball-like deposits of a laminated matrix situated in the periphery of the glomerulus (Fig. 19–30). These nodules are PAS-positive and usually contain trapped mesangial cells. This distinctive change has been called the **Kimmelstiel-Wilson lesion,** after the two pathologists who first described it. Nodular glomerulosclerosis is encountered in approximately 15% to 30% of persons with long-term diabetes and is a major contributor to

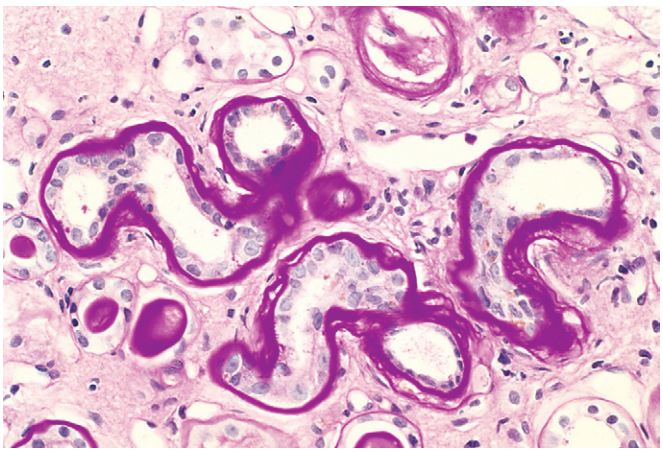

**Figure 19–28** Renal cortex showing thickening of tubular basement membranes in a specimen from a diabetic patient. Periodic acid–Schiff stain.

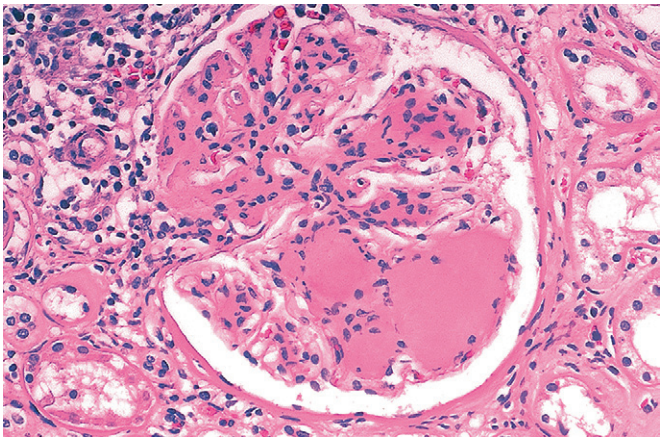

**Figure 19–30** Nodular glomerulosclerosis in a renal specimen from a patient with long-standing diabetes.
*(Courtesy of Dr. Lisa Yerian, Department of Pathology, University of Chicago, Chicago, Illinois.)*

morbidity and mortality. Diffuse mesangial sclerosis also may be seen in association with old age and hypertension; by contrast, the nodular form of glomerulosclerosis, once certain unusual forms of nephropathies have been excluded (Chapter 13), is essentially pathognomonic of diabetes. Both the diffuse and the nodular forms of glomerulosclerosis induce sufficient ischemia to cause scarring of the kidneys, manifested by a finely granular-appearing cortical surface (Fig. 19–31).

**Renal atherosclerosis and arteriolosclerosis constitute part of the macrovascular disease seen in diabetics.** The kidney is one of the most frequently and severely affected organs; however, the changes in the arteries and arterioles are similar to those found throughout the body. **Hyaline arteriolosclerosis affects not only the afferent but also the efferent arterioles.** Such efferent arteriolosclerosis is rarely if ever encountered in persons who do not have diabetes.

**Pyelonephritis is an acute or chronic inflammation of the kidneys that usually begins in the interstitial tissue and then spreads to involve the tubules.** Both the acute and chronic forms of this disease occur in nondiabetics as well as in diabetics but are more common in persons with diabetes than in the general population; once affected, diabetics tend to have more severe involvement. One special pattern of acute pyelonephritis, **necrotizing papillitis** (or papillary necrosis), is much more prevalent in diabetics than in nondiabetics.

**Ocular Complications of Diabetes.** Visual impairment, sometimes even total blindness, is one of the more feared consequences of long-standing diabetes. **The ocular involvement may take the form of retinopathy, cataract formation, or glaucoma.** Retinopathy, the most common pattern, consists of a constellation of changes that together are considered by many ophthalmologists to be virtually diagnostic of the disease. **The lesion in the retina takes two forms: nonproliferative (background) retinopathy and proliferative retinopathy.**

**Nonproliferative retinopathy** includes intraretinal or preretinal hemorrhages, retinal exudates, microaneurysms, venous dilations, edema, and, most importantly, thickening of the retinal capillaries (microangiopathy). The retinal exudates can be either "soft" (microinfarcts) or "hard" (deposits of plasma proteins and lipids) (Fig. 19–32). The microaneurysms are discrete saccular dilations of retinal choroidal capillaries that appear through the ophthalmoscope as small red dots. Dilations tend to occur at focal points of weakening, resulting from loss of pericytes. Retinal edema presumably results from excessive capillary permeability. Underlying all of these changes is the microangiopathy, which is thought to lead to loss of capillary pericytes and hence to focal weakening of capillary structure.

**The so-called proliferative retinopathy is a process of neovascularization and fibrosis.** This lesion leads to serious consequences, including blindness, especially if it involves the macula. Vitreous hemorrhages can result from rupture of newly formed capillaries; the subsequent organization of the hemorrhage can pull the retina off its substratum (retinal detachment).

**Diabetic Neuropathy.** The central and peripheral nervous systems are not spared by diabetes. The most frequent pattern of involvement is that of a peripheral, symmetric neuropathy of the lower extremities affecting both motor and sensory function, particularly the latter. Other forms include autonomic neuropathy, which produces disturbances in bowel and bladder function and sometimes sexual

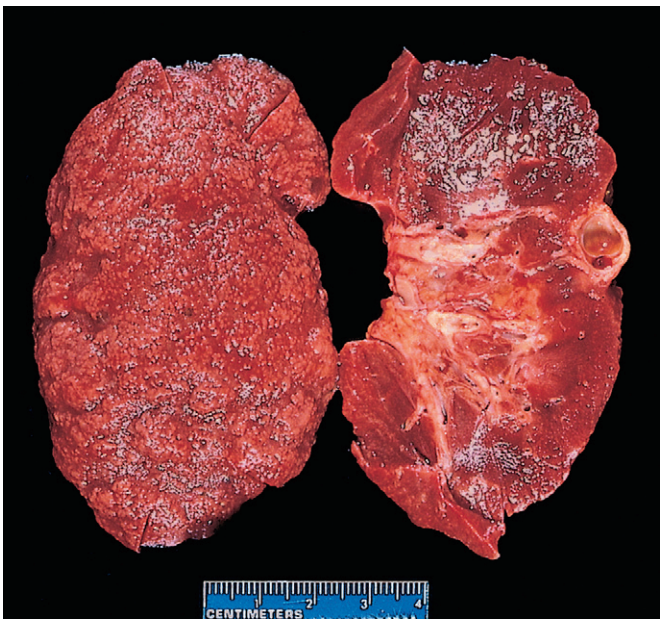


**Figure 19–31** Nephrosclerosis in a patient with long-standing diabetes. The kidney has been bisected to demonstrate both diffuse granular transformation of the surface (*left*) and marked thinning of the cortical tissue (*right*). Additional features include some irregular depressions, the result of pyelonephritis, and an incidental cortical cyst (*far right*).

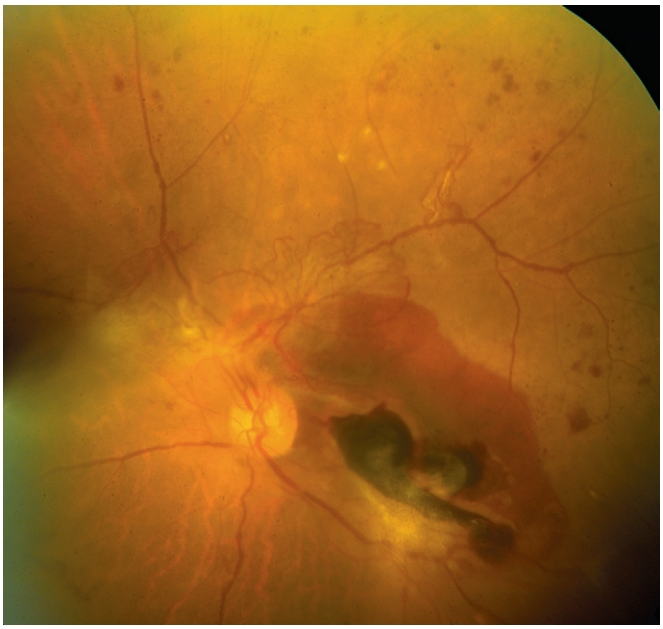

**Figure 19–32** Characteristic morphologic changes of diabetic retinopathy. Features include advanced proliferative retinopathy with retinal hemorrhages, exudates, neovascularization, and tractional retinal detachment (*lower right corner*).
*(Courtesy of Dr. Rajendra Apte, Washington University School of Medicine, St. Louis, Missouri.)*

impotence, and diabetic mononeuropathy, which may manifest as sudden footdrop or wristdrop or isolated cranial nerve palsies. The neurologic changes may be the result of microangiopathy and increased permeability of the capillaries that supply the nerves, as well as direct axonal damage.

### Clinical Features

It is difficult to discuss with brevity the diverse clinical presentations of diabetes mellitus. Only a few characteristic patterns are presented here. In the initial 1 or 2 years after manifestation of overt *type 1 diabetes* (referred to as the "honeymoon period"), exogenous insulin requirements may be minimal to none because of residual ongoing endogenous insulin secretion, but thereafter the beta cell reserve is exhausted and insulin requirements increase dramatically. Although beta cell destruction is a gradual process, the transition from impaired glucose tolerance to overt diabetes may be abrupt, heralded by an event associated with increased insulin requirements such as infection. The onset is marked by polyuria, polydipsia, polyphagia, and in severe cases, ketoacidosis, all resulting from metabolic derangements (Fig. 19–33).

Since insulin is a major anabolic hormone in the body, *deficiency of insulin results in a catabolic state that affects not only glucose metabolism but also fat and protein metabolism.* The assimilation of glucose into muscle and adipose tissue is sharply diminished or abolished. Not only does storage of glycogen in liver and muscle cease, but also reserves are depleted by glycogenolysis. The resultant hyperglycemia exceeds the renal threshold for reabsorption, and glycosuria ensues. The glycosuria induces an osmotic diuresis and, consequently, *polyuria,* causing a profound loss of water and electrolytes. The obligatory renal water loss combined with the hyperosmolarity resulting from the increased levels of glucose in the blood tends to deplete intracellular water, triggering the osmoreceptors of the thirst centers of the brain. This sequence of events generates intense thirst (*polydipsia*). With a deficiency of insulin, the scales swing from insulin-promoted anabolism to catabolism of proteins and fats. Proteolysis follows, and the gluconeogenic amino acids are removed by the liver and used as building blocks for glucose. The catabolism of proteins and fats tends to induce a negative energy balance, which in turn leads to increasing appetite (*polyphagia*), thus completing the classic triad of diabetes: *polyuria, polydipsia,* and *polyphagia.* Despite the increased appetite, catabolic effects prevail, resulting in weight loss and muscle weakness. The combination of polyphagia and weight loss is paradoxical and should always point to the diagnostic possibility of diabetes.

In patients with type 1 diabetes, deviations from normal dietary intake, unusual physical activity, infection, or any other forms of stress may rapidly influence the treacherously fragile metabolic balance, predisposing the affected person to *diabetic ketoacidosis.* The plasma glucose usually is in the range of 500 to 700 mg/dL as a result of absolute insulin deficiency and unopposed effects of counterregulatory hormones (epinephrine, glucagon). The marked hyperglycemia causes an osmotic diuresis and dehydration characteristic of the ketoacidotic state. The second major effect is activation of the ketogenic machinery. Insulin deficiency leads to activation of lipoprotein lipase, with resultant excessive breakdown of adipose stores, giving rise to increased FFAs, which are oxidized by the liver to produce *ketones.* Ketogenesis is an adaptive phenomenon in times of starvation, generating ketones as a source of energy for consumption by vital organs (e.g., brain). The rate at which ketones are formed may exceed the rate at which they can be used by peripheral tissues, leading to *ketonemia* and *ketonuria.* If the urinary excretion of ketones is compromised by dehydration, the accumulating ketones decrease blood pH, resulting in metabolic ketoacidosis.

*Type 2 diabetes mellitus* also may manifest with polyuria and polydipsia, but unlike in type 1 diabetes, patients often are older than 40 years and frequently are obese. Unfortunately, with the increase in obesity and sedentary life style in Western society, type 2 diabetes is now seen in children and adolescents with increasing frequency. In some cases, medical attention is sought because of unexplained weakness or weight loss. *Most frequently, however, the diagnosis is made after routine blood or urine testing in asymptomatic persons.*

In the decompensated state, patients with type 2 diabetes may develop *hyperosmolar nonketotic coma.* This syndrome is engendered by severe dehydration resulting from sustained osmotic diuresis and urinary fluid loss due to chronic hyperglycemia. Typically, the affected person is an elderly diabetic who is disabled by a stroke or an infection and is unable to maintain adequate water intake. The absence of ketoacidosis and its symptoms (nausea, vomiting, respiratory difficulties) delays recognition of the seriousness of the situation until the onset of severe dehydration and coma. Table 19–6 summarizes some of the pertinent clinical, genetic, and histopathologic features that distinguish between type 1 and type 2 diabetes.

As previously discussed, it is the long-term effects of diabetes, more than the acute metabolic complications, which are responsible for the overwhelming preponderance of morbidity and mortality attributable to this disease. In most instances, these complications appear approximately 15 to 20 years after the onset of hyperglycemia.

- In both forms of long-standing diabetes, cardiovascular events such as myocardial infarction, renal vascular insufficiency, and stroke (cerebrovascular accident) are the most common contributors to mortality. The impact of cardiovascular disease can be gauged by its involvement in as many as 80% of deaths among persons with type 2 diabetes; in fact, diabetics have a 3 to 7.5 times greater incidence of death from cardiovascular causes than nondiabetic populations. The hallmark of cardiovascular disease is accelerated atherosclerosis of the large and medium-sized arteries (i.e., macrovascular disease). The importance of obesity in the pathogenesis of insulin resistance has already been discussed, but it also is an independent risk factor for development of atherosclerosis.
- Diabetic nephropathy is a leading cause of end-stage renal disease in the United States. The earliest manifestation of diabetic nephropathy is the appearance of small amounts of albumin in the urine (greater than 30 but less than 300 mg/day—i.e., microalbuminuria). Without specific interventions, approximately 80% of patients with type 1 diabetes and 20% to 40% of those with type

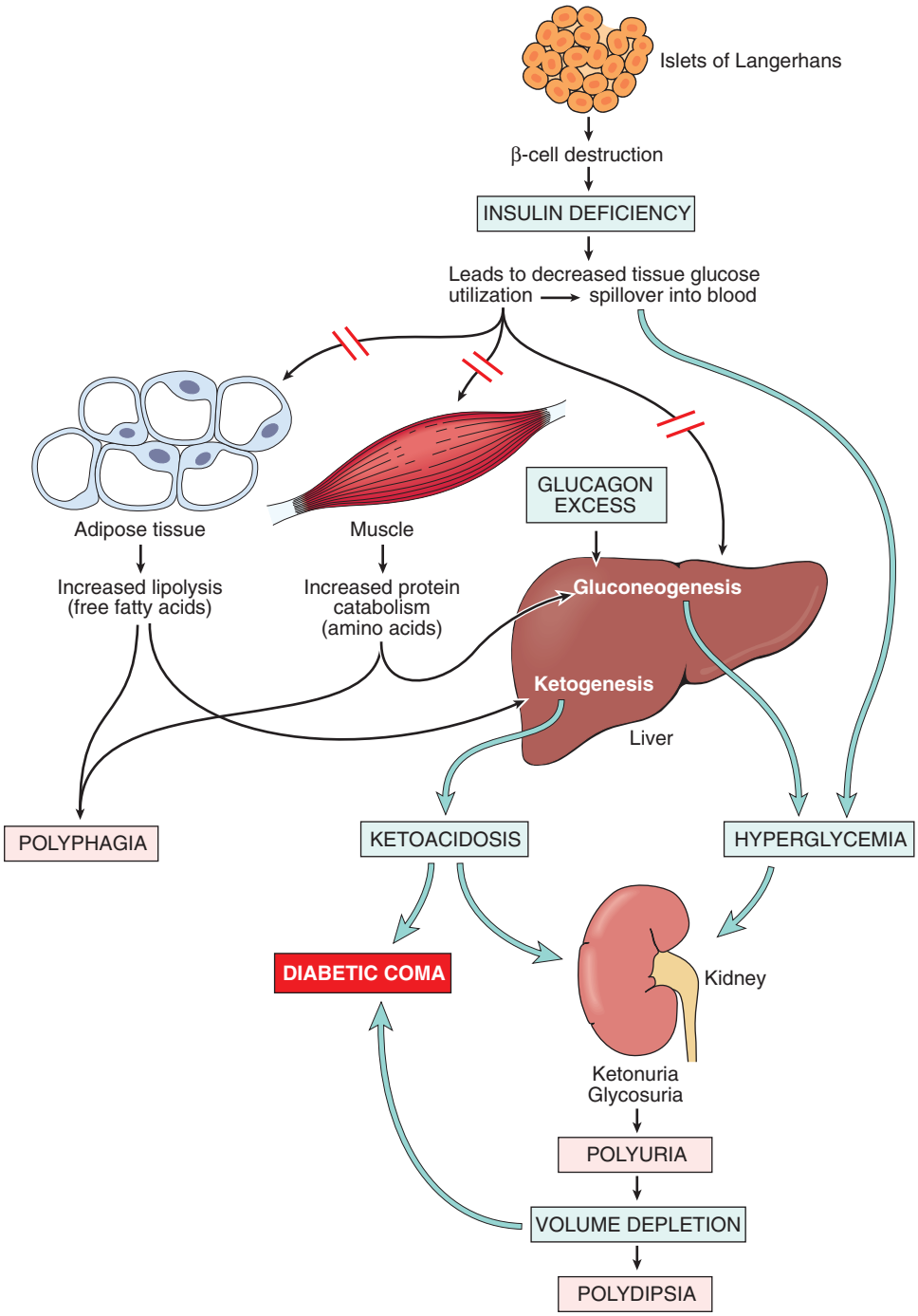


**Figure 19–33** Sequence of metabolic derangements leading to diabetic coma in type 1 diabetes mellitus. An absolute insulin deficiency leads to a catabolic state, eventuating in ketoacidosis and severe volume depletion. These derangements bring about sufficient central nervous system compromise to cause coma and, eventually, death if left untreated.

2 diabetes will develop overt nephropathy with macroalbuminuria (excretion of more than 300 mg/day) over the succeeding 10 to 15 years, usually accompanied by the appearance of hypertension. The progression from overt nephropathy to end-stage renal disease can be highly variable and is evidenced by a progressive drop in glomerular filtration rate. By 20 years after diagnosis, more than 75% of persons with type 1 diabetes and about 20% of those with type 2 diabetes with overt nephropathy will develop end-stage renal disease, necessitating dialysis or renal transplantation.

- Visual impairment, sometimes even total blindness, is one of the more feared consequences of long-standing diabetes. This disease currently is the fourth leading cause of acquired blindness in the United States. Approximately 60% to 80% of patients develop some form of diabetic retinopathy approximately 15 to 20 years after diagnosis. In addition to retinopathy, diabetic patients

**Table 19–6** Type 1 Versus Type 2 Diabetes Mellitus

| Type 1 Diabetes Mellitus | Type 2 Diabetes Mellitus |
|---|---|
| **Clinical** | |
| Onset usually in childhood and adolescence | Onset usually in adulthood; increasing incidence in childhood and adolescence |
| Normal weight or weight loss preceding diagnosis | Vast majority of patients are obese (80%) |
| Progressive decrease in insulin levels | Increased blood insulin (early); normal or moderate decrease in insulin (late) |
| Circulating islet autoantibodies | No islet autoantibodies |
| Diabetic ketoacidosis in absence of insulin therapy | Nonketotic hyperosmolar coma |
| **Genetics** | |
| Major linkage to MHC class I and II genes; also linked to polymorphisms in *CTLA4* and *PTPN22* | No HLA linkage; linkage to candidate diabetogenic and obesity-related genes |
| **Pathogenesis** | |
| Dysfunction in regulatory T cells (Tregs) leading to breakdown in self-tolerance to islet autoantigens | Insulin resistance in peripheral tissues, failure of compensation by beta cells<br>Multiple obesity-associated factors (circulating nonesterified fatty acids, inflammatory mediators, adipocytokines) linked to pathogenesis of insulin resistance |
| **Pathology** | |
| Autoimmune "insulitis" | *Early*: inflammation; *late*: amyloid deposition in islets |
| Beta cell depletion, islet atrophy | Mild beta cell depletion |

HLA, human leukocyte antigen; MHC, major histocompatibility complex.

also have an increased propensity for glaucoma and cataract formation, both of which contribute to visual impairment in diabetes.

- Diabetic neuropathy can elicit a variety of clinical syndromes, afflicting the central nervous system, peripheral sensorimotor nerves, and autonomic nervous system. The most frequent pattern of involvement is a distal symmetric polyneuropathy of the lower extremities that affects both motor and sensory function, particularly the latter (Chapter 21). Over time, the upper extremities may be involved as well, thus approximating a "glove and stocking" pattern of polyneuropathy. Other forms include autonomic neuropathy, which produces disturbances in bowel and bladder function and sometimes sexual impotence, and diabetic mononeuropathy, which may manifest as sudden footdrop, wristdrop, or isolated cranial nerve palsies.
- Diabetic patients are plagued by an enhanced susceptibility to infections of the skin, as well as to tuberculosis, pneumonia, and pyelonephritis. Such infections cause about 5% of diabetes-related deaths. In a person with diabetic neuropathy, a trivial infection in a toe may be the first event in a long succession of complications (gangrene, bacteremia, pneumonia) that may ultimately lead to death.

Several large-scale prospective studies have convincingly demonstrated that the long-term complications, and the associated morbidity and mortality, from diabetes are attenuated by strict glycemic control. For patients with type 1 diabetes, insulin replacement therapy is the mainstay of treatment, while non-pharmacologic approaches such as dietary restrictions and exercise (which improves insulin sensitivity) are often the "first line of defense" for type 2 diabetes. Most patients with type 2 diabetes will eventually require therapeutic intervention to reduce hyperglycemia, which can be achieved by administration of a number of agents that lower glucose levels through several distinct mechanisms of action. Glycemic control is assessed clinically by measuring the percentage of glycosylated hemoglobin, also known as HbA1C, which is formed by non-enzymatic addition of glucose moieties to hemoglobin in red cells. Unlike blood glucose levels, HbA1C is a measure of glycemic control over long periods of time (2 to 3 months) and is relatively unaffected by day-to-day variations. An HbA1C below 7% is taken as evidence of tight glycemic control, but patients with HbA1C levels in this range also have an increased risk of potentially life-threatening episodes of therapy-related hypoglycemia, and "optimal" control of glucose levels in diabetic patients remains an unsettled area of clinical investigation.

## SUMMARY

### Diabetes Mellitus: Pathogenesis and Long-Term Complications

- Type 1 diabetes is an autoimmune disease characterized by progressive destruction of islet beta cells, leading to absolute insulin deficiency. Both autoreactive T cells and autoantibodies are involved.
- Type 2 diabetes is caused by insulin resistance and beta cell dysfunction, resulting in relative insulin deficiency. Autoimmunity is not involved.
- Obesity has an important relationship with insulin resistance (and hence type 2 diabetes), probably mediated by cytokines released from adipose tissues (adipocytokines). Other players in the *adipo-insulin axis* include FFAs (which may cause *lipotoxicity*) and the PPARγ receptor, which modulates adipocytokine levels.
- Monogenic forms of diabetes are uncommon and are caused by single-gene defects that result in primary beta cell dysfunction (e.g., *glucokinase* mutation) or lead to

abnormalities of insulin–insulin receptor signaling (e.g., insulin receptor gene mutations).

- The long-term complications of diabetes are similar in both types and affect mainly blood vessels, and the kidneys, nerves and eyes. The development of these complications is attributed to three underlying mechanisms: formation of AGEs, activation of PKC, and disturbances in polyol pathways leading to oxidative stress.

## PANCREATIC NEUROENDOCRINE TUMORS

*Pancreatic neuroendocrine tumors (PanNETs),* also known as *islet cell tumors,* are rare in comparison with tumors of the exocrine pancreas, accounting for only 2% of all pancreatic neoplasms. PanNETs are most common in adults and may be single or multifocal; when they are malignant, the liver is the most common site of organ metastases. These tumors have a propensity to elaborate pancreatic hormones, but some are nonfunctional. The latter typically are larger lesions at diagnosis, since they come to clinical attention later in their natural history than functional PanNETs, which often present with symptoms related to excessive hormone production. All PanNETs, with the exception of insulinomas (see later), are regarded as having malignant potential, and in fact, 65% to 80% of PanNETs manifest with overtly malignant features of biologic aggressiveness, such as invasion into local tissues or distant metastases. The *proliferative rate of PanNETs* (measured using either mitotic counts or nuclear labeling with the proliferation marker Ki-67) is one of the best correlates of outcome. Genomic sequencing of sporadic PanNETs has identified recurrent somatic alterations in three major genes or pathways:

- *MEN1*, which causes familial MEN syndrome, type 1 (see later), is also mutated in many sporadic neuroendocrine tumors
- Loss-of-function mutations in tumor suppressor genes such as *PTEN* and *TSC2,* which are negative regulators of the oncogenic mammalian TOR (mTOR) signaling pathway
- Inactivating mutations in two genes, *ATRX* and *DAXX,* which have multiple cellular functions. Of note, nearly half of PanNETs have a somatic mutation in either *ATRX* or *DAXX,* but not both, suggesting that the encoded proteins function in a critical but redundant pathway.

### Insulinomas

Beta cell tumors (insulinomas) are the most common type of PanNET and may be responsible for the elaboration of sufficient insulin to induce clinically significant hypoglycemia. The characteristic clinical picture is dominated by attacks of hypoglycemia, which occur when plasma blood glucose levels fall below 50 mg/dL. The attacks consist principally of such central nervous system manifestations as confusion, stupor, and loss of consciousness. They are precipitated by fasting or exercise and are promptly relieved by feeding or parenteral administration of glucose. Most insulinomas are cured by surgical resection.

#### MORPHOLOGY

Insulinomas exhibit favorable biologic behavior, possibly because the vast majority are identified while they are small (less than 2 cm in diameter) and localized to the pancreas. Most are solitary lesions, although multifocal tumors or tumors ectopic to the pancreas may be encountered. Malignancy in insulinomas, constituting less than 10% of cases, is diagnosed on the basis of local invasion or metastases. On histologic examination, these benign tumors look remarkably like giant islets, with preservation of the regular cords of monotonous cells and their orientation to the vasculature. Not even malignant lesions present much evidence of anaplasia, and they may be deceptively encapsulated. **Deposition of amyloid** in the extracellular tissue is a characteristic feature of many insulinomas (Fig. 19–34, *A*). Under the electron microscope, neoplastic beta cells, like their normal counterparts, display distinctive round granules (Fig. 19–34, *B*).

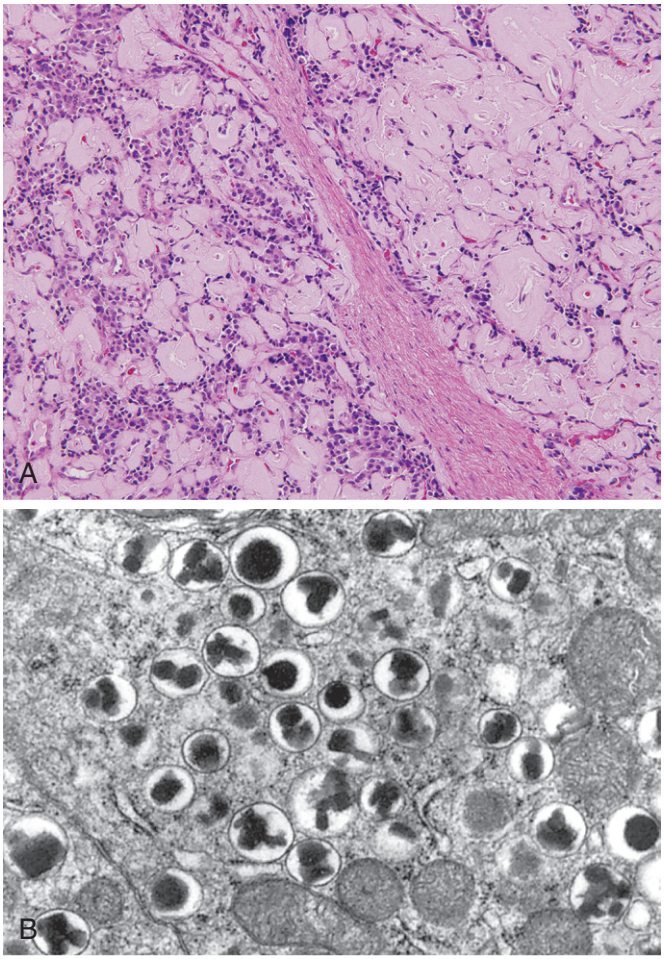


**Figure 19–34** Pancreatic neuroendocrine tumor (PanNET), also called islet cell tumor. **A,** The neoplastic cells are monotonous in appearance and demonstrate minimal pleomorphism or mitotic activity. There is abundant amyloid deposition, characteristic of an insulinoma. On clinical evaluation, the patient had episodic hypoglycemia. **B,** Electron micrograph of a normal beta cell shows the characteristic membrane-bound granules, each containing a dense, often rectangular core and distinct halo. Insulinomas contain comparable granules.

### Gastrinomas

Marked hypersecretion of gastrin usually has its origin in gastrin-producing tumors (*gastrinomas*), which are just as likely to arise in the duodenum and peripancreatic soft tissues as in the pancreas (the so-called gastrinoma triangle). Zollinger and Ellison first called attention to the *association of pancreatic islet cell lesions with hypersecretion of gastric acid and severe peptic ulceration,* which are present in 90% to 95% of patients with gastrinomas—the clinical hallmark of Zollinger-Ellison syndrome. In this condition, hypergastrinemia from a pancreatic or duodenal tumor stimulates extreme gastric acid secretion, which in turn causes *peptic ulceration.* The duodenal and gastric ulcers often are *multiple*; although they are identical to those found in the general population, they often are *unresponsive* to usual therapy. In addition, ulcers may occur in *unusual locations* such as the jejunum; when intractable jejunal ulcers are found, Zollinger-Ellison syndrome should be considered. More than half of the affected patients have diarrhea; in 30%, it is the presenting manifestation.

#### MORPHOLOGY

Gastrinomas may arise in the pancreas, the peripancreatic region, or the wall of the duodenum. **Over half of gastrin-producing tumors are locally invasive or have already metastasized at the time of diagnosis.** In approximately 25% of patients, gastrinomas arise in conjunction with other endocrine tumors, thus conforming to the MEN-1 syndrome (see further on); MEN-1–associated gastrinomas frequently are multifocal, while sporadic gastrinomas usually are single. As with insulin-secreting tumors of the pancreas, gastrin-producing tumors are histologically bland and rarely exhibit marked anaplasia.

## ADRENAL CORTEX

The *adrenal glands* are paired endocrine organs consisting of two regions, the cortex and medulla, which differ in their development, structure, and function. The *cortex* consists of three layers of distinct cell types. Beneath the capsule of the adrenal is the narrow layer of zona glomerulosa. An equally narrow zona reticularis abuts the medulla. Intervening is the broad zona fasciculata, which makes up about 75% of the total cortex. The adrenal cortex synthesizes three different types of steroids:

- *Glucocorticoids* (principally cortisol), which are synthesized primarily in the zona fasciculata, with a small contribution from the zona reticularis
- *Mineralocorticoids,* the most important being aldosterone, which are generated in the zona glomerulosa
- *Sex steroids* (estrogens and androgens), which are produced largely in the zona reticularis

The *adrenal medulla* is composed of chromaffin cells, which synthesize and secrete *catecholamines,* mainly epinephrine. This section deals first with disorders of the adrenal cortex and then of the medulla. Diseases of the adrenal cortex can be conveniently divided into those associated with cortical hyperfunction and those characterized by cortical hypofunction.

## ADRENOCORTICAL HYPERFUNCTION (HYPERADRENALISM)

There are three distinctive hyperadrenal clinical syndromes, each caused by abnormal production of one or more of the hormones produced by the three layers of the cortex: (1) *Cushing syndrome,* characterized by an excess of cortisol; (2) *hyperaldosteronism*; and (3) *adrenogenital* or *virilizing syndromes,* caused by an excess of androgens. The clinical features of some of these syndromes overlap somewhat because of the overlapping functions of some of the adrenal steroids.

### Hypercortisolism and Cushing Syndrome

Hypercortisolism, typically manifested as *Cushing syndrome,* is caused by any condition that produces an elevation in glucocorticoid levels. In clinical practice, the vast majority of cases of Cushing syndrome are the result of administration of exogenous glucocorticoids (iatrogenic). The remaining cases are endogenous, and the three most common etiologic disorders are (Fig. 19–35):

- Primary hypothalamic-pituitary diseases associated with hypersecretion of ACTH
- The secretion of ectopic ACTH by non-pituitary neoplasms
- Primary adrenocortical neoplasms (adenoma or carcinoma) and rarely, primary cortical hyperplasia

Primary hypothalamic-pituitary disease associated with hypersecretion of ACTH, also known as *Cushing disease,* accounts for approximately 70% of cases of spontaneous, endogenous Cushing syndrome. The prevalence of this disorder is about four times higher among women than among men, and it occurs most frequently during young adulthood (the 20s and 30s). In the vast majority of cases, the *pituitary gland contains an ACTH-producing microadenoma* that does not produce mass effects in the brain; some corticotroph tumors qualify as macroadenomas (larger than 10 mm across). In the remaining patients, the anterior pituitary contains areas of *corticotroph cell hyperplasia* without a discrete adenoma. Corticotroph cell hyperplasia may be primary or, much less commonly, secondary to excessive ACTH release by a hypothalamic corticotropin-releasing hormone (CRH)–producing tumor. The adrenal glands in patients with Cushing disease are characterized by a variable degree of bilateral nodular cortical hyperplasia (discussed later), secondary to the elevated levels of ACTH ("ACTH-dependent" Cushing syndrome). The cortical hyperplasia is in turn responsible for the hypercortisolism.

*Secretion of ectopic ACTH* by nonpituitary tumors accounts for about 10% of cases of Cushing syndrome. In

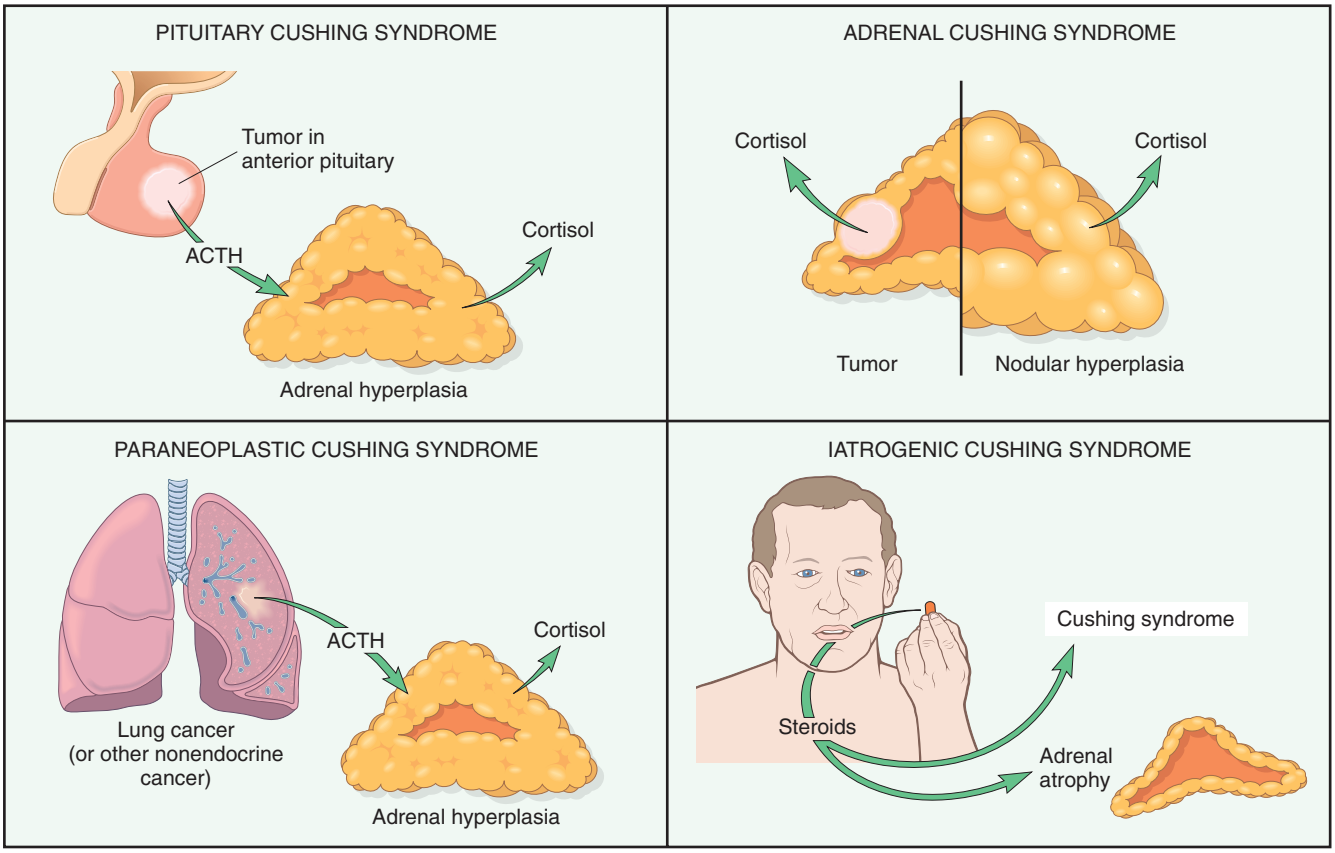


**Figure 19–35** Schematic representation of the various forms of Cushing syndrome: The three endogenous forms, as well as the more common exogenous (iatrogenic) form. ACTH, adrenocorticotropic hormone.

many instances the responsible tumor is a *small cell carcinoma of the lung*, although other neoplasms, including carcinoids, medullary carcinomas of the thyroid, and PanNETs, have been associated with the syndrome. In addition to tumors that elaborate ectopic ACTH, an occasional neuroendocrine neoplasm produces ectopic CRH, which in turn causes ACTH secretion and hypercortisolism. As in the pituitary variant, the adrenal glands undergo bilateral cortical hyperplasia secondary to elevated ACTH, but the rapid downhill course of patients with these cancers often cuts short the adrenal enlargement.

*Primary adrenal neoplasms,* such as adrenal adenoma and carcinoma, and rarely, *primary cortical hyperplasia,* are responsible for about 15% to 20% of cases of endogenous Cushing syndrome. This form of Cushing syndrome is also designated *ACTH-independent Cushing syndrome,* or adrenal Cushing syndrome, because the adrenals function autonomously. The biochemical hallmark of adrenal Cushing syndrome is elevated levels of cortisol with low serum levels of ACTH. In most cases, adrenal Cushing syndrome is caused by a unilateral adrenocortical neoplasm, which may be either benign (adenoma) or malignant (carcinoma). The overwhelming majority of hyperplastic adrenals are ACTH-dependent, and primary cortical hyperplasia of the adrenal cortices is a rare cause of Cushing syndrome. There are two variants of this entity; the first presents as macronodules of varying sizes (3 cm or greater in diameter) and the second as micronodules (1 to 3 mm).

## MORPHOLOGY

The main lesions of Cushing syndrome are found in the pituitary and adrenal glands. The **pituitary** in Cushing syndrome shows changes that vary with different causes. The most common alteration, resulting from high levels of endogenous or exogenous glucocorticoids, is termed **Crooke hyaline change.** In this condition, the normal granular, basophilic cytoplasm of the ACTH-producing cells in the anterior pituitary is replaced by homogeneous, lightly basophilic material. This alteration is the result of the accumulation of intermediate keratin filaments in the cytoplasm.

Morphologic changes in the adrenal glands also depend on the cause of the hypercortisolism and include: (1) cortical atrophy, (2) diffuse hyperplasia, (3) macronodular or micronodular hyperplasia, or (4) an adenoma or a carcinoma.

In patients in whom the syndrome results from exogenous glucocorticoids, suppression of endogenous ACTH results in bilateral **cortical atrophy,** due to a lack of stimulation of the zona fasciculata and zona reticularis by ACTH. The zona glomerulosa is of normal thickness in such cases, because this portion of the cortex functions independently of ACTH. In cases of endogenous hypercortisolism, by contrast, the adrenals either are hyperplastic or contain a cortical neoplasm. **Diffuse hyperplasia** is found in patients with ACTH-dependent Cushing syndrome (Fig. 19–36). Both glands are enlarged, either subtly or markedly, each weighing up to

**Figure 19–36** Diffuse hyperplasia of the adrenal (*bottom*) contrasted with normal adrenal gland (*top*). In cross-section, the adrenal cortex is yellow and thickened, and a subtle nodularity is evident. The abnormal gland was from a patient with ACTH-dependent Cushing syndrome, in whom both adrenals were diffusely hyperplastic. ACTH, adrenocorticotropic hormone.

30 g. The adrenal cortex is diffusely thickened and variably nodular, although the latter is not as pronounced as in cases of ACTH-independent nodular hyperplasia. The yellow color of diffusely hyperplastic glands derives from presence of **lipid-rich** cells, which appear vacuolated under the microscope. In primary cortical hyperplasia, the cortex is replaced almost entirely by **macro- or micronodules,** with the latter composed of 1- to 3-mm darkly pigmented nodules. The pigment is believed to be lipofuscin, a wear-and-tear pigment (Chapter 1).

**Functional adenomas or carcinomas** of the adrenal cortex as the source of cortisol are not morphologically distinct from nonfunctioning adrenal neoplasms (described later). Both the benign and the malignant lesions are more common in women in their 30s to 50s. Adrenocortical **adenomas** are yellow tumors surrounded by thin or well-developed capsules, and most weigh less than 30 g (Fig. 19–37, *A*). On microscopic examination, they are composed of cells similar to those encountered in the normal zona fasciculata (Fig. 19–37, *B*). The **carcinomas** associated with Cushing syndrome, by contrast, tend to be larger than the adenomas. These tumors are nonencapsulated masses frequently exceeding 200 to 300 g in weight, having all of the anaplastic characteristics of cancer, as detailed later on. With functioning tumors, both benign and malignant, the adjacent adrenal cortex and that of the contralateral adrenal gland are atrophic, as a result of suppression of endogenous ACTH by high cortisol levels.

### Clinical Features

The signs and symptoms of Cushing syndrome represent an exaggeration of the known actions of glucocorticoids. Cushing syndrome usually develops gradually and, like many other endocrine abnormalities, may be quite subtle in its early stages. A major exception to this insidious onset is with Cushing syndrome associated with small cell carcinomas of the lung, when the rapid course of the underlying disease precludes development of many of the characteristic features. Early manifestations of Cushing syndrome include *hypertension* and *weight gain.* With time, the more characteristic centripetal distribution of adipose tissue becomes apparent, with resultant truncal obesity, "moon facies," and accumulation of fat in the posterior neck and

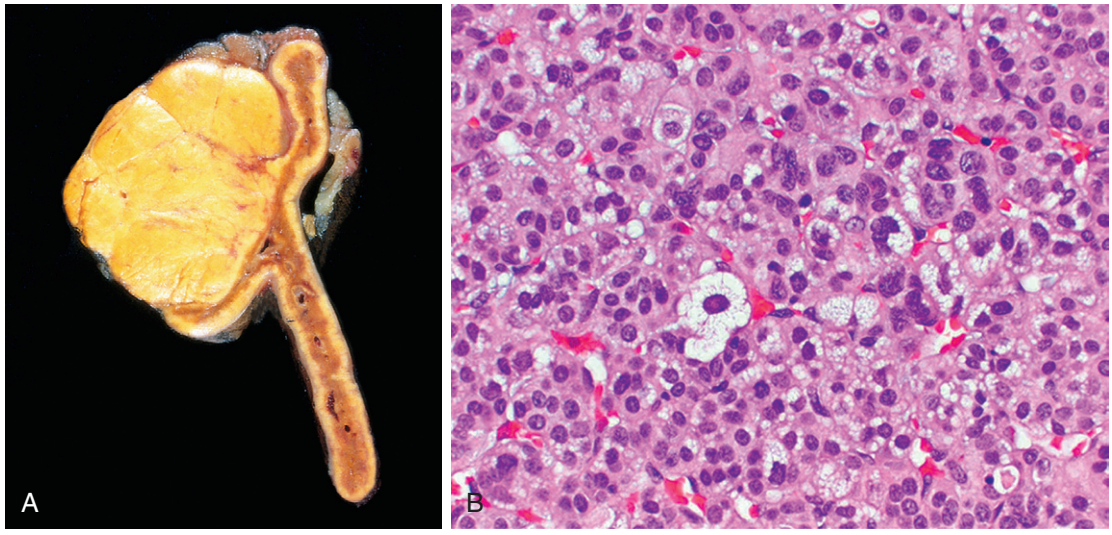


**Figure 19–37** Adrenocortical adenoma. **A,** The adenoma is distinguished from nodular hyperplasia by its solitary, circumscribed nature. The functional status of an adrenocortical adenoma cannot be predicted from its gross or microscopic appearance. **B,** Histologic features of an adrenal cortical adenoma. The neoplastic cells are vacuolated because of the presence of intracytoplasmic lipid. There is mild nuclear pleomorphism. Mitotic activity and necrosis are not seen.

**Figure 19–38** A patient with Cushing syndrome. Characteristic features include central obesity, "moon facies," and abdominal striae.
*(Reproduced with permission from Lloyd RV, et al: Atlas of Nontumor Pathology: Endocrine Diseases. Washington, DC, American Registry of Pathology, 2002.)*

back ("buffalo hump") (Fig. 19–38). Hypercortisolism causes selective atrophy of fast-twitch (type II) myofibers, with resultant decreased muscle mass and proximal limb weakness. Glucocorticoids induce gluconeogenesis and inhibit the uptake of glucose by cells, with resultant *hyperglycemia, glucosuria,* and *polydipsia,* mimicking diabetes mellitus. The catabolic effects on proteins cause loss of collagen and resorption of bone. Thus, the skin is thin, fragile, and easily bruised; *cutaneous striae* are particularly common in the abdominal area. Bone resorption results in the development of *osteoporosis,* with consequent increased susceptibility to fractures. Because glucocorticoids suppress the immune response, patients with Cushing syndrome also are at increased risk for a variety of infections. Additional manifestations include *hirsutism* and *menstrual abnormalities,* as well as a number of *mental disturbances,* including mood swings, depression, and frank psychosis. Extraadrenal Cushing syndrome caused by pituitary or ectopic ACTH secretion usually is associated with increased skin pigmentation secondary to melanocyte-stimulating activity in the ACTH precursor molecule.

## SUMMARY

### Hypercortisolism (Cushing Syndrome)

- The most common cause of hypercortisolism is exogenous administration of steroids.
- Endogenous hypercortisolism most often is secondary to an ACTH-producing pituitary microadenoma (*Cushing disease*), followed by primary adrenal neoplasms (*ACTH-independent* hypercortisolism) and paraneoplastic ACTH production by tumors (e.g., small cell lung cancer).
- The morphologic features in the adrenal include bilateral cortical atrophy (in exogenous steroid-induced disease), bilateral diffuse or nodular hyperplasia (most common finding in endogenous Cushing syndrome), or an adrenocortical neoplasm.

## Hyperaldosteronism

*Hyperaldosteronism* is the generic term for a group of closely related conditions characterized by chronic excess aldosterone secretion. Hyperaldosteronism may be primary, or it may be secondary to an extraadrenal cause. In *secondary hyperaldosteronism,* aldosterone release occurs in response to activation of the renin-angiotensin system. This condition is characterized by *increased levels of plasma renin* and is encountered in association with

- Decreased renal perfusion (arteriolar nephrosclerosis, renal artery stenosis)
- Arterial hypovolemia and edema (congestive heart failure, cirrhosis, nephrotic syndrome)
- Pregnancy (caused by estrogen-induced increases in plasma renin substrate)

*Primary hyperaldosteronism,* by contrast, indicates a primary, autonomous overproduction of aldosterone, with resultant suppression of the renin-angiotensin system and *decreased plasma renin activity.* The potential causes of primary hyperaldosteronism are:

- *Bilateral idiopathic hyperaldosteronism,* characterized by bilateral nodular hyperplasia of the adrenal glands. This mechanism is the most common underlying cause of primary hyperaldosteronism, accounting for about 60% of cases. The pathogenesis is unclear.
- *Adrenocortical neoplasm,* either an aldosterone-producing adenoma (the most common cause) or, rarely, an adrenocortical carcinoma. In approximately 35% of cases, primary hyperaldosteronism is caused by a solitary aldosterone-secreting adenoma, a condition referred to as *Conn syndrome.*
- Rarely, familial hyperaldosteronism may result from a genetic defect that leads to overactivity of the *aldosterone synthase* gene, *CYP11B2.*

## MORPHOLOGY

**Aldosterone-producing adenomas** are almost always solitary, small (less than 2 cm in diameter), well-circumscribed lesions. They are bright yellow on cut section and, surprisingly, are composed of lipid-laden cortical cells more closely resembling fasciculata cells than glomerulosa cells (the normal source of aldosterone). In general, the cells tend to be uniform in size and shape; occasionally there is some nuclear and cellular pleomorphism. A characteristic feature of aldosterone-producing adenomas is the presence of eosinophilic, laminated cytoplasmic inclusions, known as **spironolactone bodies.** These typically are found after treatment with the antihypertensive agent spironolactone, which is the

drug of choice in primary hyperaldosteronism. In contrast with cortical adenomas associated with Cushing syndrome, those associated with hyperaldosteronism do not usually suppress ACTH secretion. Therefore, the adjacent adrenal cortex and that of the contralateral gland are not atrophic. **Bilateral idiopathic hyperplasia** is marked by diffuse or focal hyperplasia of cells resembling those of the normal zona glomerulosa.

Clinical Features

*The clinical hallmark of hyperaldosteronism is hypertension*. With an estimated prevalence rate of 5% to 10% among unselected hypertensive patients, primary hyperaldosteronism may be the most common cause of secondary hypertension (i.e., hypertension secondary to an identifiable cause). The long-term effects of hyperaldosteronism-induced hypertension are cardiovascular compromise (e.g., left ventricular hypertrophy and reduced diastolic volumes) and an increase in the prevalence of adverse events such as stroke and myocardial infarction. *Hypokalemia* results from renal potassium wasting and, when present, can cause a variety of neuromuscular manifestations, including weakness, paresthesias, visual disturbances, and occasionally frank tetany. In primary hyperaldosteronism, the therapy varies according to cause. Adenomas are amenable to surgical excision. By contrast, surgical intervention is not very beneficial in patients with primary hyperaldosteronism due to bilateral hyperplasia, which often occurs in children and young adults. These patients are best managed medically with an *aldosterone antagonist* such as spironolactone. The treatment of secondary hyperaldosteronism rests on correcting the underlying cause of the renin-angiotensin system hyperstimulation.

## Adrenogenital Syndromes

Excess of androgens may be caused by a number of diseases, including primary gonadal disorders and several primary adrenal disorders. The adrenal cortex secretes two compounds—dehydroepiandrosterone and androstenedione—which require conversion to testosterone in peripheral tissues for their androgenic effects. Unlike gonadal androgens, adrenal androgen formation is regulated by ACTH; thus, excessive secretion can present as an isolated syndrome or in combination with features of Cushing disease. The adrenal causes of androgen excess include *adrenocortical neoplasms* and an uncommon group of disorders collectively designated *congenital adrenal hyperplasia* (CAH). Adrenocortical neoplasms associated with symptoms of androgen excess (*virilization*) are more likely to be carcinomas than adenomas. They are morphologically identical to other functional or nonfunctional cortical neoplasms.

CAH represents a group of autosomal recessive disorders, each characterized by a hereditary defect in an enzyme involved in adrenal steroid biosynthesis, particularly cortisol. In these conditions, decreased cortisol production results in a compensatory increase in ACTH secretion due to absence of feedback inhibition. The resultant adrenal hyperplasia causes increased production of cortisol precursor steroids, which are then channeled into synthesis of androgens with virilizing activity. Certain enzyme defects also may impair aldosterone secretion, adding salt loss to the virilizing syndrome. *The most common enzymatic defect in CAH is 21-hydroxylase deficiency,* which accounts for more than 90% of cases. 21-Hydroxylase deficiency may range in degree from a total lack to a mild loss, depending on the nature of the underlying mutation involving the *CYP21A2* gene, which encodes this enzyme.

### MORPHOLOGY

In all cases of CAH, the adrenals are **hyperplastic bilaterally,** sometimes expanding to 10 to 15 times their normal weights. The adrenal cortex is thickened and nodular, and on cut section, the widened cortex appears brown as a result of depletion of all lipid. The proliferating cells mostly are compact, eosinophilic, lipid-depleted cells, intermixed with lipid-laden clear cells. In addition to cortical abnormalities, **adrenomedullary dysplasia** also has recently been reported in patients with the salt-losing 21-hydroxylase deficiency. This is characterized by incomplete migration of the chromaffin cells to the center of the gland, with pronounced intermingling of nests of chromaffin and cortical cells in the periphery. Hyperplasia of corticotroph (ACTH-producing) cells is present in the anterior pituitary in most patients.

Clinical Features

The clinical manifestations of CAH are determined by the specific enzyme deficiency and include abnormalities related to androgen metabolism, sodium homeostasis, and (in severe cases) glucocorticoid deficiency. Depending on the nature and severity of the enzymatic defect, the onset of clinical symptoms may occur in the perinatal period, later childhood, or (less commonly) adulthood.

In 21-hydroxylase deficiency, *excessive androgenic activity* causes signs of masculinization in females, ranging from clitoral hypertrophy and pseudohermaphroditism in infants to oligomenorrhea, hirsutism, and acne in postpubertal girls. In males, androgen excess is associated with enlargement of the external genitalia and other evidence of precocious puberty in prepubertal patients and with oligospermia in older patients. In some forms of CAH (e.g., 11β-hydroxylase deficiency), the accumulated intermediary steroids have mineralocorticoid activity, with resultant *sodium retention* and *hypertension*. In other cases, however, including about one third of persons with 21-hydroxylase deficiency, the enzymatic defect is severe enough to produce mineralocorticoid deficiency, with resultant *salt (sodium) wasting*. Cortisol deficiency places persons with CAH at risk for *acute adrenal insufficiency* (discussed later).

CAH should be suspected in any neonate with ambiguous genitalia; severe enzyme deficiency in infancy can be a life-threatening condition, with vomiting, dehydration, and salt wasting. In the milder variants, women may present with delayed menarche, oligomenorrhea, or hirsutism. In all such cases, an androgen-producing ovarian neoplasm must be excluded. Treatment of CAH is with exogenous glucocorticoids, which, in addition to providing adequate levels of glucocorticoids, also suppress ACTH levels, thereby decreasing the excessive synthesis of the

steroid hormones responsible for many of the clinical abnormalities.

## SUMMARY

### Adrenogenital Syndromes

- The adrenal cortex can secrete excess androgens in either of two settings: adrenocortical neoplasms (usually *virilizing* carcinomas) or congenital adrenal hyperplasia (CAH).
- CAH consists of a group of autosomal recessive disorders characterized by defects in steroid biosynthesis, usually cortisol; the most common subtype is caused by deficiency of the enzyme 21-hydroxylase.
- Reduction in cortisol production causes a compensatory increase in ACTH secretion, which in turn stimulates androgen production. Androgens have virilizing effects, including masculinization in females (ambiguous genitalia, oligomenorrhea, hirsutism), precocious puberty in males, and in some instances, salt (sodium) wasting and hypotension.
- Bilateral hyperplasia of the adrenal cortex is characteristic.

# ADRENAL INSUFFICIENCY

Adrenocortical insufficiency, or hypofunction, may be caused by either primary adrenal disease (primary hypoadrenalism) or decreased stimulation of the adrenals resulting from a deficiency of ACTH (secondary hypoadrenalism). The patterns of adrenocortical insufficiency can be divided into three general categories: (1) primary *acute* adrenocortical insufficiency (adrenal crisis); (2) primary *chronic* adrenocortical insufficiency (*Addison disease*); and (3) secondary adrenocortical insufficiency.

## Acute Adrenocortical Insufficiency

Acute adrenocortical insufficiency occurs most commonly in the clinical settings listed in Table 19–7. Persons with chronic adrenocortical insufficiency may develop an acute crisis after any stress that taxes their limited physiologic reserves. In patients maintained on exogenous corticosteroids, rapid withdrawal of steroids or failure to increase steroid doses in response to an acute stress may precipitate a similar adrenal crisis, because of the inability of the atrophic adrenals to produce glucocorticoid hormones. *Massive adrenal hemorrhage* may destroy enough of the adrenal cortex to cause acute adrenocortical insufficiency. This condition may occur in patients maintained on anticoagulant therapy, in postoperative patients who develop disseminated intravascular coagulation, during pregnancy, and in patients suffering from overwhelming sepsis; in this last setting it is known as the Waterhouse-Friderichsen syndrome (Fig. 19–39). This catastrophic syndrome is classically associated with *Neisseria meningitidis* septicemia but can also be caused by other organisms, including *Pseudomonas* spp., pneumococci, and *Haemophilus influenzae*. The pathogenesis of the Waterhouse-Friderichsen syndrome remains unclear but probably involves endotoxin-induced vascular injury with associated disseminated intravascular coagulation (Chapter 3).

**Table 19–7** Causes of Adrenal Insufficiency

| |
|---|
| **Acute** |
| Waterhouse-Friderichsen syndrome |
| Sudden withdrawal of long-term corticosteroid therapy |
| Stress in patients with underlying chronic adrenal insufficiency |
| **Chronic** |
| Autoimmune adrenalitis (60–70% of cases in developed countries)—includes APS1 and APS2 |
| Tuberculosis |
| Acquired immunodeficiency syndrome |
| Metastatic disease |
| Systemic amyloidosis |
| Fungal infections |
| Hemochromatosis |
| Sarcoidosis |

APS1, APS2, autoimmune polyendocrine syndrome types 1 and 2.

## Chronic Adrenocortical Insufficiency: Addison Disease

Addison disease, or chronic adrenocortical insufficiency, is an uncommon disorder resulting from progressive destruction of the adrenal cortex. More than 90% of all cases are attributable to one of four disorders: *autoimmune adrenalitis, tuberculosis,* the *acquired immune deficiency syndrome* (AIDS), or *metastatic cancer* (Table 19–7).

- *Autoimmune adrenalitis* accounts for 60% to 70% of cases and is by far the most common cause of primary adrenal insufficiency in developed countries. As the name implies, there is autoimmune destruction of steroid-producing cells, and autoantibodies to several key

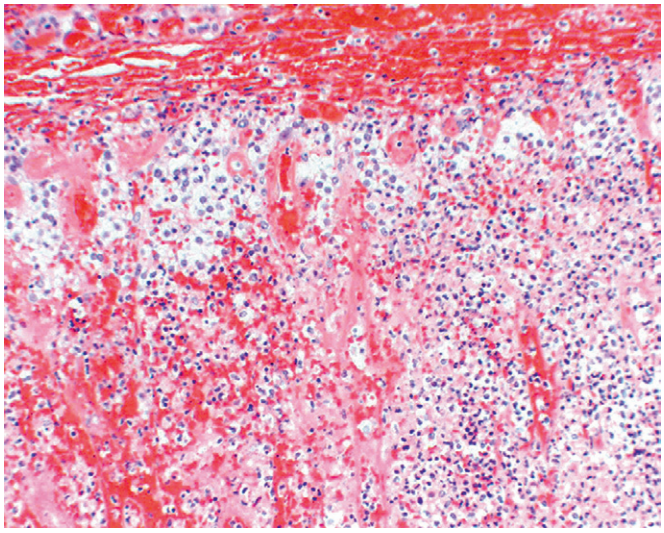

**Figure 19–39** Waterhouse-Friderichsen syndrome. Bilateral adrenal hemorrhage in an infant with overwhelming sepsis, resulting in acute adrenal insufficiency. At autopsy, the adrenals were grossly hemorrhagic and shrunken; in this photomicrograph, little residual cortical architecture is discernible.

steroidogenic enzymes have been detected in affected patients. Autoimmune adrenalitis occurs in one of two *a*utoimmune *p*olyendocrine *s*yndromes: APS1, which is caused by mutations in the *autoimmune regulator (AIRE)* gene on chromosome 21 and is characterized by chronic mucocutaneous candidiasis and abnormalities of skin, dental enamel, and nails (ectodermal dystrophy) occurring in association with a combination of organ-specific autoimmune disorders (autoimmune adrenalitis, autoimmune hypoparathyroidism, idiopathic hypogonadism, pernicious anemia) that result in destruction of target organs. The AIRE protein is involved in the expression of tissue antigens in the thymus and the elimination of T cells specific for these antigens (Chapter 4). The second setting is that of APS2, which manifests in early adulthood and manifests as a combination of adrenal insufficiency and autoimmune thyroiditis or type 1 diabetes. Unlike in APS1, in APS2 mucocutaneous candidiasis, ectodermal dysplasia, and autoimmune hypoparathyroidism do not occur.

- *Infections,* particularly tuberculosis and those produced by fungi, also may cause primary chronic adrenocortical insufficiency. Tuberculous adrenalitis, which once accounted for as many as 90% of cases of Addison disease, has become less common with the advent of antituberculosis therapy. With the resurgence of tuberculosis in many urban centers, however, this cause of adrenal deficiency must be borne in mind. When present, tuberculous adrenalitis usually is associated with active infection in other sites, particularly the lungs and genitourinary tract. Among fungi, disseminated infections caused by *Histoplasma capsulatum* and *Coccidioides immitis* also may result in chronic adrenocortical insufficiency. Patients with AIDS are at risk for the development of adrenal insufficiency from several infectious (cytomegalovirus, *Mycobacterium avium-intracellulare*) and noninfectious (Kaposi sarcoma) complications of their disease.
- *Metastatic neoplasms* involving the adrenals are another potential cause of adrenal insufficiency. The adrenals are a fairly common site for metastases in patients with disseminated carcinomas. Although adrenal function is preserved in most such instances, the metastatic growths sometimes destroy sufficient adrenal cortex to produce a degree of adrenal insufficiency. Carcinomas of the lung and breast are the source of a majority of metastases in the adrenals, although many other neoplasms, including gastrointestinal carcinomas, malignant melanomas, and hematopoietic neoplasms, also may metastasize to the organ.

## Secondary Adrenocortical Insufficiency

Any disorder of the hypothalamus and pituitary, such as metastatic cancer, infection, infarction, or irradiation, that reduces the output of ACTH leads to a syndrome of hypoadrenalism having many similarities to Addison disease. *With secondary disease, the hyperpigmentation of primary Addison disease is lacking because melanotropic hormone levels are low* (discussed later). ACTH deficiency may occur alone, but in some instances, it is only one part of panhypopituitarism, associated with multiple tropic hormone deficiencies. In patients with primary disease, serum ACTH levels may be normal, but the destruction of the adrenal cortex does not permit a response to exogenously administered ACTH in the form of increased plasma levels of cortisol. By contrast, secondary adrenocortical insufficiency is characterized by low serum ACTH and a prompt rise in plasma cortisol levels in response to ACTH administration.

### MORPHOLOGY

The appearance of the adrenal glands varies with the cause of the adrenocortical insufficiency. In **secondary hypoadrenalism** the adrenals are reduced to small, flattened structures that usually retain their yellow color because of a small amount of residual lipid. A uniform, thin rim of atrophic yellow cortex surrounds a central, intact medulla. Histologic evaluation reveals atrophy of cortical cells with loss of cytoplasmic lipid, particularly in the zona fasciculata and zona reticularis. **Primary autoimmune adrenalitis** is characterized by irregularly shrunken glands, which may be exceedingly difficult to identify within the suprarenal adipose tissue. On histologic examination, the cortex contains only scattered residual cortical cells in a collapsed network of connective tissue. A variable lymphoid infiltrate is present in the cortex and may extend into the subjacent medulla (Fig. 19–40). The medulla is otherwise preserved. In **tuberculosis or fungal diseases,** the adrenal architecture may be effaced by a granulomatous inflammatory reaction identical to that encountered in other sites of infection. When hypoadrenalism is caused by **metastatic carcinoma,** the adrenals are enlarged, and their normal architecture is obscured by the infiltrating neoplasm.

### Clinical Features

In general, clinical manifestations of adrenocortical insufficiency do not appear until at least 90% of the adrenal cortex has been compromised. The initial manifestations often include progressive weakness and easy fatigability, which may be dismissed as nonspecific complaints. *Gastrointestinal disturbances* are common and include anorexia, nausea, vomiting, weight loss, and diarrhea. In patients with primary adrenal disease, increased levels of ACTH precursor hormone stimulate melanocytes, with resultant *hyperpigmentation* of the skin and mucosal surfaces. The

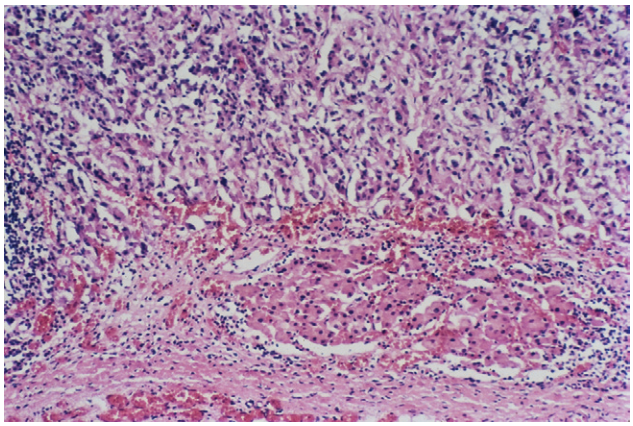

**Figure 19–40** Autoimmune adrenalitis. In addition to loss of all but a subcapsular rim of cortical cells, there is an extensive mononuclear cell infiltrate.

face, axillae, nipples, areolae, and perineum are particularly common sites of hyperpigmentation. By contrast, hyperpigmentation is not seen in patients with secondary adrenocortical insufficiency. Decreased mineralocorticoid (aldosterone) activity in patients with primary adrenal insufficiency results in potassium retention and sodium loss, with consequent *hyperkalemia, hyponatremia, volume depletion,* and *hypotension*, whereas secondary hypoadrenalism is characterized by deficient cortisol and androgen output but normal or near-normal aldosterone synthesis. Hypoglycemia occasionally may occur as a result of glucocorticoid deficiency and impaired gluconeogenesis. Stresses such as infections, trauma, or surgical procedures in affected patients may precipitate an acute adrenal crisis, manifested by intractable vomiting, abdominal pain, hypotension, coma, and vascular collapse. Death follows rapidly unless corticosteroids are replaced immediately.

### SUMMARY

#### Adrenocortical Insufficiency (Hypoadrenalism)

- Primary adrenocortical insufficiency can be acute (Waterhouse-Friderichsen syndrome) or chronic (Addison disease).
- Chronic adrenal insufficiency in the Western world most often is secondary to autoimmune adrenalitis, which occurs in the context of one of two autoimmune polyendocrine syndromes: APS1 (caused by mutations in the *AIRE* gene) or APS2.
- Tuberculosis and infections due to opportunistic pathogens associated with the human immunodeficiency virus and tumors metastatic to the adrenals are the other important causes of chronic hypoadrenalism.
- Patients typically present with fatigue, weakness, and gastrointestinal disturbances. Primary adrenocortical insufficiency also is characterized by high ACTH levels with associated skin pigmentation.

## ADRENOCORTICAL NEOPLASMS

It should be evident from the discussion of adrenocortical hyperfunction that functional adrenal neoplasms may be responsible for any of the various forms of hyperadrenalism. While functional adenomas are most commonly associated with hyperaldosteronism and with Cushing syndrome, a virilizing neoplasm is more likely to be a carcinoma. Not all adrenocortical neoplasms, however, elaborate steroid hormones. Determination of whether a cortical neoplasm is functional or not is based on clinical evaluation and measurement of the hormone or its metabolites in the laboratory.

### MORPHOLOGY

**Adrenocortical adenomas** were described earlier in the discussions of Cushing syndrome and hyperaldosteronism. Most cortical adenomas do not cause hyperfunction and usually are encountered as incidental findings at the time of autopsy or during abdominal imaging for an unrelated cause. In fact, the half-facetious appellation of **"adrenal incidentaloma"** has crept into the medical lexicon to describe these incidentally discovered tumors. On cut surface, adenomas usually are yellow to yellow-brown, owing to the presence of lipid within the neoplastic cells (Fig. 19–37). As a general rule they are small, averaging 1 to 2 cm in diameter. On microscopic examination, adenomas are composed of cells similar to those populating the normal adrenal cortex. The nuclei tend to be small, although some degree of pleomorphism may be encountered even in benign lesions **(endocrine atypia).** The cytoplasm of the neoplastic cells ranges from eosinophilic to vacuolated, depending on their lipid content; mitotic activity generally is inconspicuous.

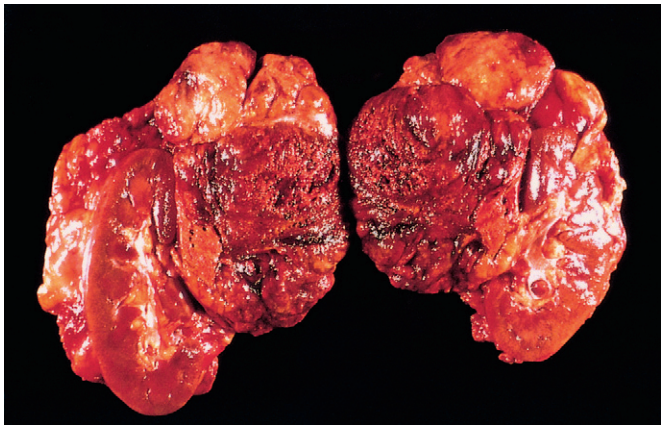

**Figure 19–41** Adrenal carcinoma. The tumor dwarfs the kidney and compresses the upper pole. It is largely hemorrhagic and necrotic.

**Adrenocortical carcinomas** are rare neoplasms that may occur at any age, including in childhood. Two rare inherited causes of adrenal cortical carcinomas are Li-Fraumeni syndrome (Chapter 5) and Beckwith-Wiedemann syndrome (Chapter 6). In most cases, adrenocortical carcinomas are large, invasive lesions that efface the native adrenal gland. On cut surface, adrenocortical carcinomas typically are variegated, poorly demarcated lesions containing areas of necrosis, hemorrhage, and cystic change (Fig. 19–41). Microscopic examination typically shows these tumors to be composed of well-differentiated cells resembling those seen in cortical adenomas or bizarre, pleomorphic cells, which may be difficult to distinguish from those of an undifferentiated carcinoma metastatic to the adrenal (Fig. 19–42). Adrenal

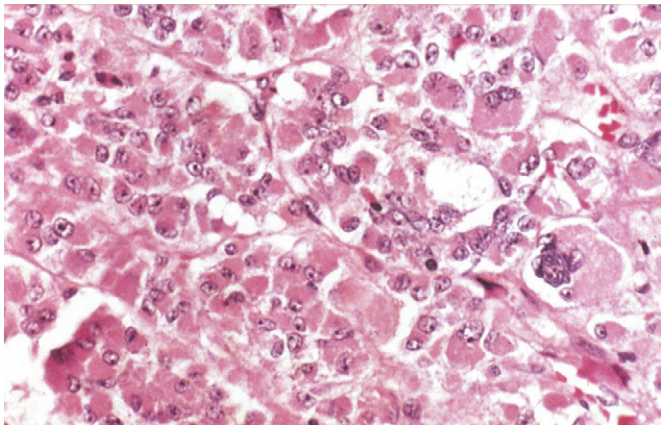

**Figure 19–42** Adrenal carcinoma with marked anaplasia.

cancers have a strong tendency to invade the adrenal vein, vena cava, and lymphatics. Metastases to regional and periaortic nodes are common, as is distant hematogenous spread to the lungs and other viscera. Bone metastases are unusual. The median patient survival is about 2 years. Of note, carcinomas metastatic to the adrenal cortex are significantly more frequent than a primary adrenocortical carcinoma.

# ADRENAL MEDULLA

The adrenal medulla is embryologically, functionally, and structurally distinct from the adrenal cortex. It is populated by cells derived from the neural crest (*chromaffin cells*) and their supporting (sustentacular) cells. The chromaffin cells, so named because of their brown-black color after exposure to potassium dichromate, synthesize and secrete catecholamines in response to signals from preganglionic nerve fibers in the sympathetic nervous system. Similar collections of cells are distributed throughout the body in the extraadrenal paraganglion system. The most important diseases of the adrenal medulla are neoplasms, which include both neuronal neoplasms (including neuroblastomas and more mature ganglion cell tumors) and neoplasms composed of chromaffin cells (pheochromocytomas).

## TUMORS OF THE ADRENAL MEDULLA

### Pheochromocytoma

Pheochromocytomas are neoplasms composed of chromaffin cells, which, like their non-neoplastic counterparts, synthesize and release catecholamines and, in some cases, other peptide hormones. These tumors are of special importance because although uncommon, they (like aldosterone-secreting adenomas) give rise to a surgically correctable form of hypertension.

Pheochromocytomas usually subscribe to a convenient "rule of 10s":

- *10% of pheochromocytomas are extraadrenal,* occurring in sites such as the organ of Zuckerkandl and the carotid body, where they usually are called *paragangliomas,* rather than pheochromocytomas.
- *10% of adrenal pheochromocytomas are bilateral*; this proportion may rise to 50% in cases that are associated with familial syndromes.
- *10% of adrenal pheochromocytomas are malignant,* although the associated hypertension represents a serious and potentially lethal complication of even *benign* tumors. Frank malignancy is somewhat more common in tumors arising in extraadrenal sites.
- One "traditional" 10% rule that has since been modified pertains to familial cases. It is now recognized that *as many as 25% of persons with pheochromocytomas and paragangliomas harbor a germ line mutation* in one of at least six known genes, including *RET*, which causes type 2 MEN syndromes (described later); *NF1*, which causes type 1 neurofibromatosis (Chapter 21); *VHL*, which causes von Hippel-Lindau disease (Chapters 13 and 22); and three genes encoding subunits within the succinate dehydrogenase complex (*SDHB, SDHC,* and *SDHD*), which is involved in mitochondrial oxidative phosphorylation.

#### MORPHOLOGY

Pheochromocytomas range in size from small, circumscribed lesions confined to the adrenal to large, hemorrhagic masses weighing several kilograms. On cut surface, smaller pheochromocytomas are yellow-tan, well-defined lesions that compress the adjacent adrenal (Fig. 19–43). Larger lesions tend to be hemorrhagic, necrotic, and cystic and typically efface the adrenal gland. Incubation of the fresh tissue with potassium dichromate solutions turns the tumor dark brown, as noted previously.

On microscopic examination, pheochromocytomas are composed of polygonal to spindle-shaped chromaffin cells and their supporting cells, compartmentalized into small nests, or **Zellballen,** by a rich vascular network (Fig. 19–44). The cytoplasm of the neoplastic cells often has a finely granular appearance, highlighted by a variety of silver stains, because of the presence of granules containing catecholamines. Electron microscopy reveals variable numbers of membrane-bound, electron-dense granules, representing catecholamines and sometimes other peptides. The nuclei of the neoplastic cells are often quite pleomorphic. Both

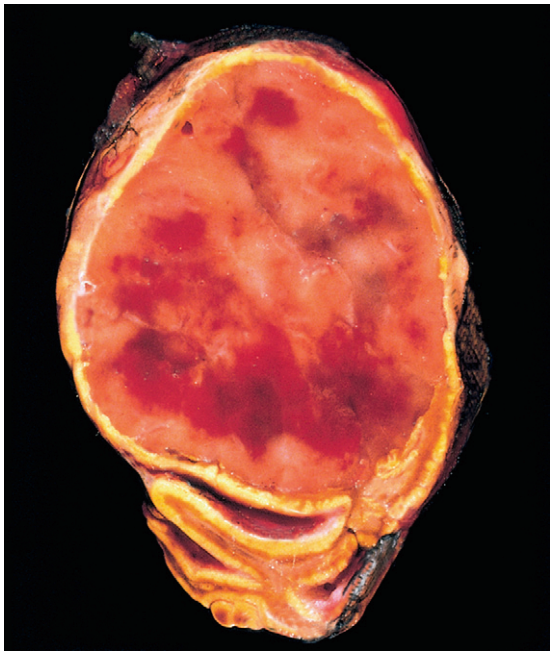

**Figure 19–43** Pheochromocytoma. The tumor is enclosed within an attenuated cortex and demonstrates areas of hemorrhage. The comma-shaped residual adrenal is seen *below*.

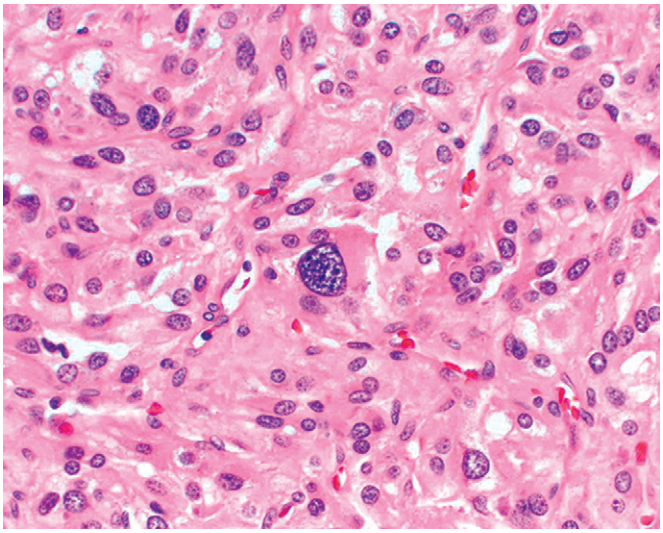

**Figure 19–44** Photomicrograph of pheochromocytoma, demonstrating characteristic nests of cells (*Zellballen*) with abundant cytoplasm. Granules containing catecholamine are not visible in this preparation. It is not uncommon to find bizarre cells even in pheochromocytomas that are biologically benign, and this criterion by itself should not be used to diagnose malignancy.

capsular and vascular invasion may be encountered in benign lesions, and the mere presence of mitotic figures does not imply malignancy. **Therefore, the definitive diagnosis of malignancy in pheochromocytomas is based exclusively on the presence of metastases.** These may involve regional lymph nodes as well as more distant sites, including liver, lung, and bone.

### Clinical Features

The predominant clinical manifestation of pheochromocytoma is *hypertension.* The characteristic presentation with a hypertensive episode is one of abrupt, precipitous elevation in blood pressure, associated with tachycardia, palpitations, headache, sweating, tremor, and a sense of apprehension. Such episodes also may be associated with pain in the abdomen or chest, nausea, and vomiting. In clinical practice, *isolated, paroxysmal episodes of hypertension occur in fewer than half of patients* with pheochromocytoma. In about two thirds of patients the hypertension occurs in the form of a chronic, sustained elevation in blood pressure, although an element of labile hypertension often is present as well. Whether sustained or episodic, the hypertension is associated with an increased risk of myocardial ischemia, heart failure, renal injury, and stroke (cerebrovascular accident). Sudden cardiac death may occur, probably secondary to catecholamine-induced myocardial irritability and ventricular arrhythmias. In some cases, pheochromocytomas secrete other hormones such as ACTH and somatostatin and may therefore be associated with clinical features related to the effects of these and other peptide hormones. The laboratory diagnosis of pheochromocytoma is based on demonstration of increased urinary excretion of free catecholamines and their metabolites, such as vanillylmandelic acid and metanephrines. Isolated benign pheochromocytomas are treated with surgical excision. With multifocal lesions, long-term medical treatment for hypertension may be required.

## Neuroblastoma and Other Neuronal Neoplasms

Neuroblastoma is the most common extracranial solid tumor of childhood. These neoplasms occur most commonly during the first 5 years of life and may arise during infancy. Neuroblastomas may occur anywhere in the sympathetic nervous system and occasionally within the brain, but they are most common in the abdomen; a majority of these tumors arise in either the adrenal medulla or the retroperitoneal sympathetic ganglia. Most neuroblastomas are sporadic, although familial cases also have been described. These tumors are discussed in Chapter 6, along with other pediatric neoplasms.

# MULTIPLE ENDOCRINE NEOPLASIA SYNDROMES

The MEN syndromes are a group of inherited diseases resulting in proliferative lesions (hyperplasias, adenomas, and carcinomas) of multiple endocrine organs. Like other inherited cancer disorders (Chapter 5), endocrine tumors arising in the context of MEN syndromes have certain distinctive features that are not shared with their sporadic counterparts:

- These tumors occur at a *younger age* than that typical for sporadic cancers.
- They arise in *multiple endocrine organs,* either *synchronously* or *metachronously.*
- Even in one organ, the tumors often are *multifocal.*
- The tumors usually are preceded by an *asymptomatic stage of endocrine hyperplasia* involving the cell of origin of the tumor (for example, patients with MEN-2 almost universally demonstrate C cell hyperplasia in the thyroid parenchyma adjacent to medullary thyroid carcinomas).
- These tumors are usually *more aggressive* and *recur* in a higher proportion of cases than similar endocrine tumors that occur sporadically.

Unraveling the genetic basis of the MEN syndromes with clinical application of this knowledge in therapeutic decision making has been one of the success stories of translational research. The salient features of the MEN syndromes are discussed next.

## Multiple Endocrine Neoplasia Type 1

MEN type 1 is inherited in an autosomal dominant pattern. The gene (*MEN1*) is located at 11q13 and is a tumor suppressor gene; thus, inactivation of both alleles of the gene is believed to be the basis for tumorigenesis. Organs most commonly involved are the parathyroid, the pancreas, and the pituitary—the "3 Ps."

- *Parathyroid*: *Primary hyperparathyroidism* is the most common manifestation of MEN-1 (80% to 95% of patients) and is the initial manifestation of the disorder in most patients, appearing in almost all patients by age 40 to 50. Parathyroid abnormalities include both hyperplasia and adenomas.
- *Pancreas*: Endocrine tumors of the pancreas are the leading cause of death in MEN-1. These tumors usually are aggressive and manifest with metastatic disease. It is not uncommon to find multiple "microadenomas" scattered throughout the pancreas in conjunction with one or two dominant lesions. Pancreatic endocrine tumors often are functional (i.e., secrete hormones). Zollinger-Ellison syndrome, associated with gastrinomas, and hypoglycemia, related to insulinomas, are common endocrine manifestations. Of note, the gastrinomas arising in MEN-1 syndrome are far more likely to be located within the duodenum than in the pancreas.
- *Pituitary*: The most frequent pituitary tumor in patients with MEN-1 is a prolactin-secreting macroadenoma. In some cases, acromegaly develops in association with somatotropin-secreting tumors.

## Multiple Endocrine Neoplasia Type 2

MEN type 2 actually comprises two distinct groups of disorders that are unified by the occurrence of activating (i.e., gain-of-function) mutations of the *RET* proto-oncogene at chromosomal locus 10q11.2. A strong *genotype-phenotype correlation* has been recognized for the MEN-2 syndromes, and differences in mutation patterns account for the variable features in the two subtypes. MEN-2 is inherited in an autosomal dominant pattern.

### *Multiple Endocrine Neoplasia Type 2A*

Organs commonly involved in MEN type 2A include

- *Thyroid*: Medullary carcinoma of the thyroid develops in virtually all untreated cases, and the tumors usually occur in the first 2 decades of life. The tumors commonly are multifocal, and foci of C cell hyperplasia can be found in the adjacent thyroid. *Familial medullary thyroid cancer* is a variant of MEN-2A characterized by medullary thyroid cancers, but not the other characteristic manifestations listed here. In comparison with MEN-2, familial medullary carcinoma typically occurs at an older age and follows a more indolent course.
- *Adrenal medulla*: Adrenal pheochromocytomas develop in 50% of the patients; fortunately, no more than 10% of these tumors are malignant.
- *Parathyroid*: Approximately 10% to 20% of patients develop parathyroid gland hyperplasia with manifestations of primary hyperparathyroidism.

### *Multiple Endocrine Neoplasia Type 2B*

Patients with MEN-2B harbor a distinct germline *RET* mutation involving a single–amino acid change. Organs commonly involved include the thyroid and the adrenal medulla. The spectrum of thyroid and adrenal medullary disease is similar to that in MEN-2A, with the following differences:

- *Primary hyperparathyroidism does not develop* in patients with MEN-2B.
- *Extraendocrine manifestations* are characteristic in patients with MEN-2B. These include ganglioneuromas of mucosal sites (gastrointestinal tract, lips, tongue) and a *marfanoid habitus,* in which overly long bones of the axial skeleton give an appearance resembling that in Marfan syndrome (Chapter 6).

Before the advent of genetic testing, relatives of patients with the MEN-2 syndrome were screened with annual biochemical tests, which often lacked sensitivity. Now, routine genetic testing identifies *RET* mutation carriers earlier and more reliably in MEN-2 kindreds; *all persons carrying germline RET mutations are advised to have prophylactic thyroidectomy to prevent the inevitable development of medullary carcinomas.*

## BIBLIOGRAPHY


Akirav EM, Ruddle NH, Herold KC: The role of AIRE in human autoimmune disease. Nat Rev Endocrinol 7:25, 2011. *[A comprehensive review on the function of AIRE gene, mutations of which are responsible for autoimmune adrenalitis and other manifestations of APS1.]*

Almeida MQ, Stratakis CA: Solid tumors associated with multiple endocrine neoplasias. Cancer Genet Cytogenet 203:30, 2010. *[An expert review on the spectrum of tumors observed in various MEN subtypes.]*

Bahn RS: Graves ophthalmopathy. N Engl J Med 362:726, 2010. *[A well-rounded article on the pathogenic mechanisms and management of ocular manifestations in Graves disease.]*

Bluestone JA, Herold K, Eisenbarth G: Genetics, pathogenesis and clinical interventions in type 1 diabetes. Nature 464:1293, 2010. *[An authoritative review on multiple facets of type 1 diabetes.]*

Cibas ES: Fine-needle aspiration in the work-up of thyroid nodules. Otolaryngol Clin North Am 43:257, 2010. *[A review on the most commonly used technique for diagnosing thyroid nodules from an expert on the histopathology and cytology of this disease.]*

Donath MY, Shoelson SE: Type 2 diabetes as an inflammatory disease. Nat Rev Immunol 2011. *[An authoritative review on inflammatory mechanisms leading to beta cell dysfunction and insulin resistance in type 2 diabetes.]*

Ekeblad S: Islet cell tumors. Adv Exp Med Biol 654:771, 2010. *[A comprehensive review on pancreatic neuroendocrine tumors, including genetics, histopathology, and clinical features.]*

Klibanski A: Clinical practice: prolactinomas. N Engl J Med 362:1219, 2010. *[An up-to-date review on the most common subtype of pituitary adenomas.]*

Leavy O: IAPP stokes the pancreatic fire. Nat Rev Immunol 10:748, 2010. *[A review highlighting the pathogenic role played by islet amyloid in aggravating beta cell dysfunction in type 2 diabetes.]*

Mazzone T, Chait A, Plutzky J: Cardiovascular disease risk in type 2 diabetes mellitus: insights from mechanistic studies. Lancet 371:1800, 2008. *[A well-rounded summary of the pathogenic mechanisms influencing cardiovascular risk, one of the most important contributors to mortality in type 2 diabetes.]*

McCarthy MI: Genomics, type 2 diabetes and obesity. N Engl J Med 363:2339, 2010. *[A summary of the major "diabetogenic" loci implicated in type 2 diabetes.]*

Michels AW, Eisenbarth GS: Immunologic endocrine disorders. J Allergy Clin Immunol 125:S226, 2010. *[A broad-spectrum and well-written review on immune-mediated endocrine diseases, including several that are discussed in this chapter.]*

Nieman LK: Approach to the patient with an adrenal incidentaloma. J Clin Endocrinol Metab 95:4106, 2010. *[A comprehensive review on incidental adrenal lesions that are being increasingly identified owing to greater use of sensitive imaging techniques.]*

Pivonello R, DeMartino MC, DeLeo M: Cushing syndrome. Endocrinol Metab Clin North Am 37:135, 2008. *[A succinct clinical review on causes and manifestations of Cushing syndrome.]*

Samuel VT, Petersen KF, Shulman GI: Lipid-induced insulin resistance: unraveling the mechanism. Lancet 75:2267, 2010. *[A scholarly review on the "adipo-insulin axis," which is one of the most profound influences on type 2 diabetes.]*

Silverberg SJ, Bilzekian JP: The diagnosis and management of asymptomatic primary hyperparathyroidism. Nat Clin Pract Endocrinol Metab 2:494, 2006. *[An older but still outstanding review on primary hyperparathyroidism.]*

Tomer Y, Huber A: The etiology of autoimmune thyroid disease: a story of genes and environment. J Autoimmun 32:231, 2009. *[An outstanding review on genetic and environmental contributions to the pathogenesis of autoimmune thyroid disorders, including Graves disease and Hashimoto thyroiditis.]*

Xing M: Genetic alterations in the phosphatidylinositol-3 kinase/Akt pathway in thyroid cancer. Thyroid 20:697, 2010. *[A comprehensive review on one of the most commonly afflicted pathways in follicular neoplasms of the thyroid.]*

This page intentionally left blank

See Targeted Therapy available online at studentconsult.com

CHAPTER 20

# Bones, Joints, and Soft Tissue Tumors

CHAPTER CONTENTS


**BONES 765**
Congenital Disorders of Bone and Cartilage 767
Osteogenesis Imperfecta 767
Achondroplasia and Thanatophoric Dwarfism 767
Osteopetrosis 767
Acquired Diseases of Bone 768
Osteoporosis 768
Paget Disease (Osteitis Deformans) 770
Rickets and Osteomalacia 771
Hyperparathyroidism 771
Fractures 772
Osteonecrosis (Avascular Necrosis) 773
Osteomyelitis 773
Pyogenic Osteomyelitis 773
Tuberculous Osteomyelitis 774
Bone Tumors 774
Bone-Forming Tumors 775
Cartilage-Forming Tumors 777
Fibrous and Fibroosseous Tumors 779
Miscellaneous Bone Tumors 780
**JOINTS 782**
Arthritis 782
Osteoarthritis 782
Rheumatoid Arthritis 784
Juvenile Rheumatoid Arthritis 786
Seronegative Spondyloarthropathies 786
Gout 786
Pseudogout 789
Infectious Arthritis 789
Joint Tumors and Tumor-Like Lesions 790
Ganglion and Synovial Cysts 790
Tenosynovial Giant Cell Tumor 790
**SOFT TISSUE 791**
Tumors of Adipose Tissue 792
Lipoma 792
Liposarcoma 792
Fibrous Tumors and Tumor-Like Lesions 792
Reactive Proliferations 793
Fibromatoses 793
Fibrosarcoma 793
Fibrohistiocytic Tumors 794
Benign Fibrous Histiocytoma (Dermatofibroma) 794
Pleomorphic Fibroblastic Sarcoma/ Pleomorphic Undifferentiated Sarcoma 794
Skeletal Muscle Tumors 794
Rhabdomyosarcoma 794
Smooth Muscle Tumors 795
Leiomyoma 795
Leiomyosarcoma 795
Synovial Sarcoma 795


The musculoskeletal system and the integrated neural connections enable locomotion by the human body. Aside from providing the fulcrums and levers against which muscles contract to allow movement, the skeleton is critical for mineral (particularly calcium) homeostasis and also protects viscera and supplies an environment conducive to both hematopoietic and mesenchymal stem cell development. The term diseases of the bones and joints embraces a large number of conditions ranging from localized, benign tumors of bone and soft tissue such as the osteochondroma and lipoma, respectively, to generalized disorders such as osteoporosis and osteogenesis imperfecta. In this chapter we will first consider some of the more common conditions affecting the bones and joints, then discuss tumors arising in the various soft tissues of the body. Diseases of the muscles and peripheral nerves are discussed in Chapter 21.

## BONES

The skeletal system is composed of 206 bones that vary in size and shape and are interconnected by a variety of joints that allow for a wide range of movement and promote structural stability. Bones are composed of a unique type of mineralized connective tissue that undergoes mineralization with a distinctive admixture of organic matrix (35%) and inorganic elements (65%). The inorganic mineral component consists mainly of calcium hydroxyapatite [$Ca_{10}(PO_4)_6(OH)_2$]. This mineral gives bone strength and hardness and serves as the storehouse for 99% of the body's calcium, 85% of the body's phosphorus, and 65% of the body's sodium and magnesium. The organic component

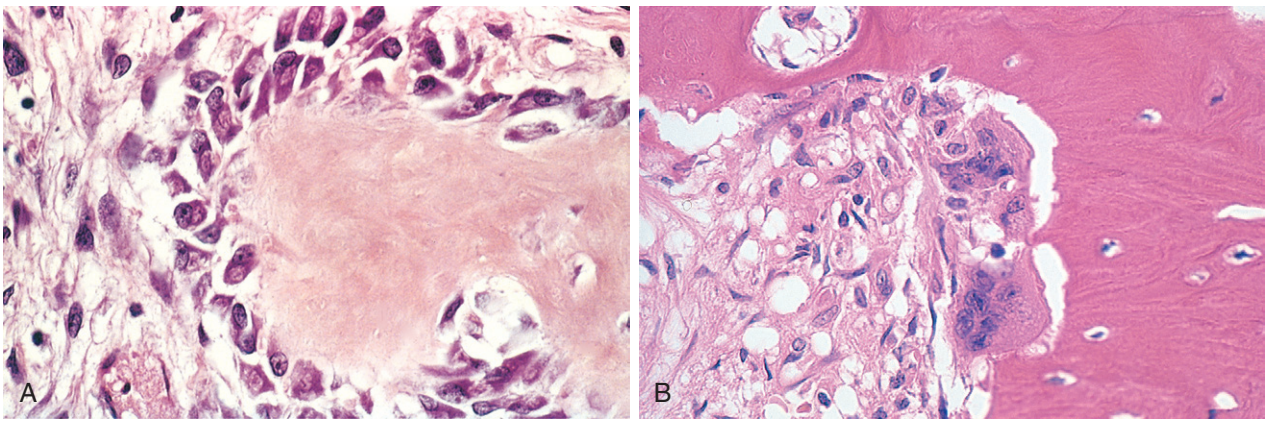


**Figure 20–1** Cells of bone. **A,** Active osteoblasts synthesizing bone matrix proteins. The surrounding spindle cells are osteoprogenitor cells. **B,** Two osteoclasts resorbing bone. The smaller blue nuclei surrounded by a halo of clearing in the dense pink lamellar bone are osteocytes in their individual lacunae.

includes the cells of bone and the proteinaceous osteoid. The bone-forming cells include osteoblasts and osteocytes, while cells of the bone-digesting lineage include osteoclast precursor cells and mature functional osteoclasts (Fig. 20–1).

To the uninitiated, bone appears to be an inert, stable tissue, but in fact it is very dynamic and subject to constant breakdown and renewal, a process referred to as *remodeling*. The net effects of remodeling may be bone maintenance, bone loss, or bone deposition, with the balance being determined by the relative activities of osteoblasts, which deposit bone, and osteoclasts, which resorb bone (Fig. 20–1, *A* and *B*). As might be imagined, osteoblast and osteoclast activity is highly regulated and tightly integrated under normal circumstances, both by local crosstalk between these two cell types and by circulating factors that impact their activity, such as vitamin D and parathyroid hormone.

Among the local factors that regulate bone remodeling, the most important are RANK (receptor activator for nuclear factor-κB), RANK ligand (RANKL), and osteoprotegerin (OPG) (Fig 20–2). RANK, a member of the tumor necrosis factor (TNF) receptor family, is expressed on the cell membranes of preosteoclasts and mature osteoclasts. Its ligand, RANKL, is expressed by osteoblasts and marrow stromal cells. RANK stimulation by RANKL leads to activation of the transcription factor NF-κB, which drives the expression of genes that stimulate osteoclast formation, fusion, differentiation, function, and survival. RANKL production is upregulated by factors that stimulate osteoclastic activity. The actions of RANKL can be blocked by another member of the TNF receptor family, OPG, which is a "decoy" receptor produced by a number of tissues including bone, hematopoietic marrow, and immune cells. OPG competitively binds to RANKL, preventing RANK from interacting with RANKL. OPG production is regulated by signals similar to those that stimulate RANKL. Therefore, these molecules enable osteoblasts and stromal cells to control osteoclast development and activity and provide a mechanism for a wide variety of biologic mediators (hormones, cytokines, growth factors) to influence the homeostasis of bone tissue and bone mass.

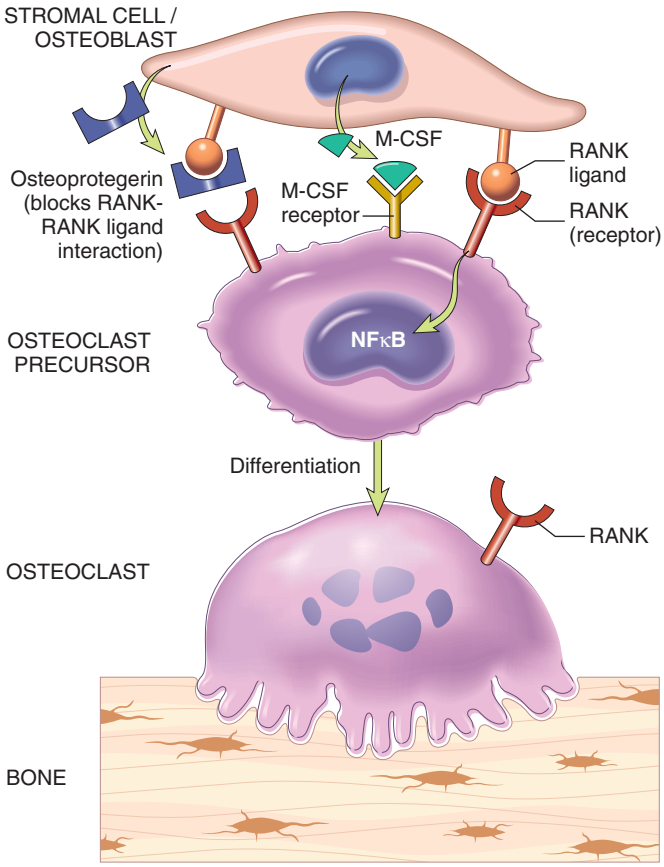


**Figure 20–2** Paracrine mechanisms regulating osteoclast formation and function. Osteoclasts are derived from the same stem cells that produce macrophages. RANK (*r*eceptor *a*ctivator for *n*uclear factor-κB) receptors on osteoclast precursors bind RANK ligand (RANKL) expressed by osteoblasts and marrow stromal cells. Along with macrophage colony-stimulating factor (M-CSF), the RANK-RANKL interaction drives the differentiation of functional osteoclasts. Stromal cells also secrete osteoprotegerin (OPG), which acts as a decoy receptor for RANKL, preventing it from binding the RANK receptor on osteoclast precursors. Consequently, OPG prevents bone resorption by inhibiting osteoclast differentiation.

Primary and secondary diseases of bone are varied and numerous and are classified in this chapter according to their perceived biologic defect or pathologic process.

# CONGENITAL DISORDERS OF BONE AND CARTILAGE

Congenital disorders of the skeleton are various and, depending on the resulting defect, become manifest at different ages. The most severe produce developmental abnormalities that are evident from the earliest stages of skeletogenesis.

- Developmental anomalies resulting from localized problems in the migration of mesenchymal cells and the formation of condensations are called *dysostoses* and may affect individual or a group of bones and can result from mutations in specific homeobox genes. The more common lesions include *aplasia* (e.g., congenital absence of a digit or rib), the formation of extra bones (e.g., supernumerary digits or ribs), and abnormal fusion of bones (e.g., premature closure of the cranial sutures or congenital fusion of the ribs). Such malformations may occur as isolated, sporadic lesions or as components of a more complex syndrome.
- Mutations that interfere with bone or cartilage formation, growth, and/or maintenance of normal matrix components have more diffuse effects; such disorders are called *dysplasias*—more specifically, *osteodysplasias* and *chondrodysplasias*. *Dysplasia* in this context refers to abnormal growth and does not imply precancerous lesions, as it does in other tissues (Chapter 5). They number well over 350, and only select examples are discussed here.
- Other genetic metabolic disorders not usually thought of as primary skeletal diseases (e.g., mucopolysaccharidoses such as Hurler syndrome) also affect the bone matrix; such conditions are discussed briefly with other genetic disorders in Chapter 6.

## Osteogenesis Imperfecta

*Osteogenesis imperfecta (OI), also known as "brittle bone disease," is actually a group of genetic disorders caused by defective synthesis of type I collagen.* Because type I collagen is a major component of extracellular matrix in other parts of the body, there are also numerous extraskeletal manifestations (affecting skin, joints, teeth, and eyes, for example). The mutations underlying OI characteristically involve the coding sequences for $\alpha_1$ or $\alpha_2$ chains of type I collagen. Because collagen synthesis and extracellular export require formation of a complete and intact triple helix, any primary defect in a collagen chain tends to disrupt the entire structure and results in its premature degradation (an example of a *dominant negative mutation*) (Chapter 6). As a consequence, most defects manifest as autosomal dominant disorders and may be associated with severe malformations. There is, however, a broad spectrum of severity, and mutations that result in qualitatively normal collagen but at only reduced levels generally have milder manifestations.

*The fundamental abnormality in all forms of OI is too little bone,* resulting in extreme skeletal fragility. Four major subtypes are recognized. The type II variant is uniformly fatal in utero or immediately postpartum as a consequence of multiple fractures that occur before birth. By contrast, patients with type I OI have a normal lifespan, with only a modestly increased proclivity for fractures during childhood (decreasing in frequency after puberty). The classic finding of *blue sclerae* in type I OI is attributable to decreased scleral collagen content; this deficit causes a relative transparency that allows the underlying choroid to be seen. *Hearing loss* can be related to conduction defects in the middle and inner ear bones, and *small misshapen teeth* are a result of dentin deficiency.

## Achondroplasia and Thanatophoric Dwarfism

*Achondroplasia is the most common form of dwarfism.* It is caused by activating point mutations in fibroblast growth factor receptor 3 (FGFR3), a receptor with tyrosine kinase activity that transmits intracellular signals. Signals transmitted by FGFR3 *inhibit* the proliferation and function of growth plate chondrocytes; consequently, the growth of normal epiphyseal plates is suppressed, and the length of long bones is severely stunted. The disorder can be inherited in autosomal dominant fashion, but many cases arise from new spontaneous mutations.

Achondroplasia affects all bones that develop by enchondral ossification. The most conspicuous changes include short stature, disproportionate shortening of the proximal extremities, bowing of the legs, and frontal bossing with midface hypoplasia. The cartilage of the growth plates is disorganized and hypoplastic.

*Thanatophoric dwarfism* is a lethal variant of dwarfism, affecting 1 in every 20,000 live births (*thanatophoric* means "death-loving"). This disease is caused by missense or point mutations most commonly located in the extracellular domains of FGFR3. Affected heterozygotes exhibit extreme shortening of the limbs, frontal bossing of the skull, and an extremely small thorax, which is the cause of fatal respiratory failure in the perinatal period.

## Osteopetrosis

*Osteopetrosis is a group of rare genetic disorders characterized by defective osteoclast-mediated bone resorption. Osteopetrosis* (literally, "bone-that-is-like-stone disorder") is an appropriate name, since the bones are dense, solid, and stone-like. Paradoxically, because turnover is decreased, the persisting bone tissue becomes weak over time and predisposed to fractures like a piece of chalk. Several variants are known, the two most common being an autosomal dominant adult form with mild clinical manifestations, and autosomal recessive infantile, with a severe/lethal phenotype.

The defects that cause osteopetrosis are categorized into those that disturb osteoclast function and those that interfere with osteoclast formation and differentiation. The

precise nature of the osteoclast dysfunction is unknown in many cases. Nevertheless, in some cases the abnormalities have been identified. These include carbonic anhydrase II deficiency, proton pump deficiency and chloride channel defect, all of which interfere with the ability of osteoclasts to resorb bone. A mouse model of osteopetrosis is caused by mutations in the monocyte-colony stimulating factor (M-CSF), which is required for osteoclast differentiation. No comparable defect has been identified in humans.

Besides fractures, patients with osteopetrosis frequently have cranial nerve palsies (due to compression of nerves within shrunken cranial foramina), recurrent infections because of reduced marrow size and activity, and hepatosplenomegaly caused by extramedullary hematopoiesis resulting from reduced marrow space. Morphologically, the primary spongiosa, which normally is removed during growth, persists, filling the medullary cavity, and bone is deposited in increased amounts woven into the architecture. Because osteoclasts are derived from marrow monocyte precursors, hematopoietic stem cell transplantation holds the promise of repopulating recipients with progenitor cells capable of differentiating into fully functional osteoclasts. Indeed, many of the skeletal abnormalities appear to be reversible once normal precursor cells are provided.

### SUMMARY

#### Congenital Disorders of Bone and Cartilage

- Abnormalities in a single or group of bones are called *dysostoses* and can result in the absence of bones, supernumerary bones, or inappropriately fused bones; some of these result from mutations in homeobox genes affecting localized migration and condensation of primitive mesenchymal cells.
- Abnormalities in bone or cartilage organogenesis are called *dysplasias*; these can be caused by mutations that affect signal transduction pathways or components of the extracellular matrix:
  - Achondroplasia and thanatophoric dwarfism occur as a consequence of constitutive FGFR3 activation, resulting in defective cartilage synthesis at growth plates.
  - Osteogenesis imperfecta (brittle bone disease) is a group of disorders caused by mutations in the genes for type I collagen that interfere with its normal production, with resultant bone fragility and susceptibility to fractures.
  - Osteopetrosis is caused by mutations that interfere with osteoclast function and is associated with dense but architecturally unsound bone owing to defective bone resorption.

## ACQUIRED DISEASES OF BONE

Many nutritional, endocrine, and systemic disorders affect the development of the skeletal system. Nutritional deficiencies causing bone disease include deficiencies of vitamin C (involved in collagen cross-linking; deficiency causes *scurvy*) and vitamin D (involved in calcium uptake; deficiency causes *rickets* and *osteomalacia*). Both of these are discussed in greater detail with other nutritional diseases in Chapter 7. Primary and secondary forms of hyperparathyroidism (discussed in Chapter 19) also cause significant skeletal changes, which are briefly reviewed in this section. Many of these disorders are characterized by inadequate osteoid, also called *osteopenia;* the most important clinically significant osteopenia is *osteoporosis*.

### Osteoporosis

*Osteoporosis is an acquired condition characterized by reduced bone mass,* leading to bone fragility and susceptibility to fractures. The bone loss may be confined to certain bones or regions, as in *disuse osteoporosis of a limb,* or be generalized, involving the entire skeleton. Generalized osteoporosis may be primary or occur secondary to a large variety of insults, including metabolic diseases, vitamin deficiencies, and drug exposures (Table 20–1).

Primary forms of osteoporosis are most common and may be associated with aging (senile osteoporosis) or the postmenopausal state in women. The drop in estrogen following menopause tends to exacerbate the loss of bone that occurs with aging, placing older women at high risk of osteoporosis relative to men. The risk of osteoporosis with aging is related to the peak bone mass earlier in life, which is influenced by genetic, nutritional, and environmental factors. Bone mass peaks during young adulthood; the greater the peak bone mass, the greater the delay in onset of osteoporosis. In both men and women, beginning in the third or fourth decade of life, bone resorption begins to outpace bone formation. The bone loss, averaging 0.5% per year, is a seemingly inevitable consequence of aging and is most prominent in areas containing abundant trabecular bone—namely the spine and femoral neck. The amount of bone loss with each cycle of remodeling is accelerated after menopause; hence, the vulnerability of women to osteoporosis and its complications. Regardless of the underlying cause, the progressive loss of bone mass is clinically significant because of the resultant increase in the risk of fractures. Roughly 1.5 million Americans each year experience an osteoporosis-related fracture, with those of greatest clinical significance involving the vertebrae and the hips. All told, the annual health care costs associated with osteoporosis-related fractures in the United States exceeds $18 billion.

### MORPHOLOGY

The hallmark of osteoporosis is a loss of bone. The cortices are thinned, with dilated haversian canals, and the trabeculae are reduced in thickness and lose their interconnections. Osteoclastic activity is present but is not dramatically increased, and the mineral content of the bone tissue is normal. Once enough bone is lost, susceptibility to fractures increases (Fig. 20–3). In postmenopausal osteoporosis, trabecular bone loss often is severe, resulting in compression

**Table 20–1** Categories of Generalized Osteoporosis

| |
|---|
| **Primary** |
| Postmenopausal |
| Senile |
| **Secondary** |
| Endocrine Disorders |
| Hyperparathyroidism |
| Hypo or hyperthyroidism |
| Hypogonadism |
| Pituitary tumors |
| Diabetes, type 1 |
| Addison disease |
| Neoplasia |
| Multiple myeloma |
| Carcinomatosis |
| Gastrointestinal Disorders |
| Malnutrition |
| Malabsorption |
| Hepatic insufficiency |
| Vitamin C, D deficiencies |
| Idiopathic disease |
| Drugs |
| Anticoagulants |
| Chemotherapy |
| Corticosteroids |
| Anticonvulsants |
| Alcohol |
| Miscellaneous |
| Osteogenesis imperfecta |
| Immobilization |
| Pulmonary disease |
| Homocystinuria |
| Anemia |

fractures and collapse of vertebral bodies. In senile osteoporosis, cortical bone loss is prominent, predisposing to fractures in other weight-bearing bones, such as the femoral neck.

## PATHOGENESIS

Osteoporosis occurs when the dynamic balance between bone formation by osteoblasts and bone resorption by osteoclasts (Fig. 20–2) tilts in favor of resorption. Several factors may tip the scales (Fig. 20–4):

- **Age-related changes.** With increasing age, the replicative and matrix production activities of osteoblasts progressively diminish. The various growth factors deposited in the extracellular matrix also diminish with time. Unfortunately, while new bone synthesis wanes with advancing age, osteoclasts retain their youthful vigor.

**Figure 20–3** Osteoporotic vertebral body (*right*) shortened by compression fractures, compared with a normal vertebral body. The osteoporotic vertebra exhibits a characteristic loss of horizontal trabeculae and thickened vertical trabeculae.

- **Hormonal influences.** The decline in estrogen levels associated with menopause correlates with an acceleration of cortical bone and trabecular (cancellous) bone loss. Over 30 to 40 years, this can result in the loss of up to 35% of cortical bone and 50% of trabecular bone! It is therefore not surprising that roughly half of postmenopausal women will suffer an osteoporotic fracture (compared with 2% to 3% of men of comparable age). It appears that the postmenopausal drop in estrogen leads to increased cytokine production (especially IL-1, IL-6, and TNF), presumably from cells in the bone. These stimulate RANK–RANK ligand activity and suppress OPG production (Fig. 20–2). There is some compensatory osteoblastic activity, but it is inadequate to keep pace with osteoclastic bone resorption. While estrogen replacement can ameliorate some of the bone loss, such therapy is increasingly associated with cardiovascular risks (Chapter 10).

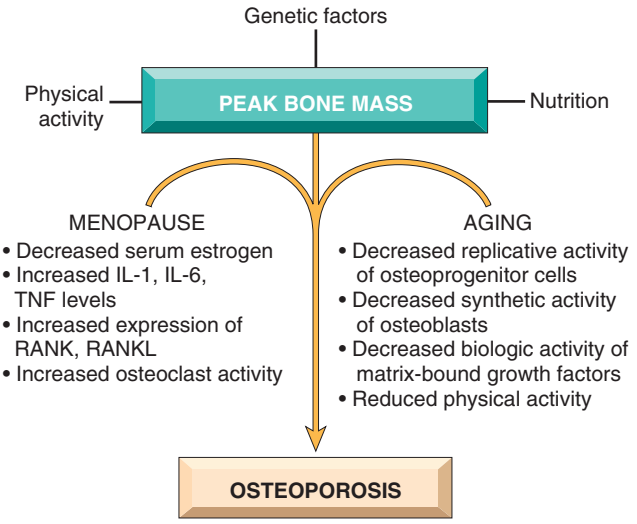


**Figure 20–4** Pathophysiology of postmenopausal and senile osteoporosis (see text).

- **Physical activity.** Because mechanical forces stimulate bone remodeling, reduced physical activity increases bone loss. This effect is obvious in an immobilized limb and also occurs throughout the skeleton in astronauts working in a gravity-free environment. Decreased physical activity in older persons also contributes to senile osteoporosis. Because the magnitude of skeletal loading influences bone density more than does the number of load cycles, the type of physical activity is important. Thus, resistance exercises such as weight training increase bone mass more effectively than endurance activities such as jogging.
- **Genetic factors.** Vitamin D receptor polymorphisms appear to influence the peak bone mass early in life. Additional genetic variables can influence either calcium uptake or PTH synthesis and responses.
- **Calcium nutritional state.** A majority of adolescent girls (but not boys) have insufficient dietary calcium. Unfortunately, this calcium deficiency occurs during a period of rapid bone growth. As a result, girls typically do not achieve the peak bone mass that could be otherwise expected and are accordingly more likely to develop clinically significant osteoporosis at an earlier age than their male counterparts.
- **Secondary causes of osteoporosis.** These include prolonged glucocorticoid therapy, which increases bone resorption and reduces bone synthesis. Cigarette smoking and excess alcohol also can result in reduced bone mass.

### Clinical Course

The clinical outcome with osteoporosis depends on which bones are involved. Thoracic and lumbar vertebral fractures are extremely common, leading to loss of height and various deformities, including kyphoscoliosis, which can compromise respiratory function. Pulmonary embolism and pneumonia are common complications of fractures of the femoral neck, pelvis, or spine and result in as many as 50,000 deaths annually.

Osteoporosis is difficult to diagnose because it is asymptomatic until skeletal fragility is announced with a fracture. Moreover, it cannot be reliably detected in plain radiographs until 30% to 40% of bone mass has already disappeared; serum levels of calcium, phosphorus, and alkaline phosphatase are notoriously insensitive. Current state-of-the-art methods for bone loss estimation consist of specialized radiographic techniques to assess bone mineral density, such as dual-energy absorptiometry and quantitative computed tomography.

Osteoporosis prevention and treatment begin with adequate dietary calcium intake, vitamin D supplementation, and a regular exercise regimen—starting before the age of 30—to maximize the peak bone mass. Calcium and vitamin D supplements later in life can also modestly reduce bone loss. Pharmacologic treatments include use of antiresorptive and osteoanabolic agents. The antiresorptive agents, such as bisphosphonates, calcitonin, estrogen, and denosumab, decrease bone resorption by osteoclasts. The main anabolic agent is parathyroid hormone or an analogue, given in amounts that stimulate osteoblastic activity.

## Paget Disease (Osteitis Deformans)

This unique skeletal disease is characterized by repetitive episodes of frenzied, regional osteoclastic activity and bone resorption (*osteolytic stage*), followed by exuberant bone formation (*mixed osteoclastic-osteoblastic stage*), and finally by an apparent exhaustion of cellular activity (*osteosclerotic stage*). The net effect of this process is a *gain in bone mass*; however, the newly formed bone is disordered and weak, so bones may become enlarged and misshapen.

Paget disease usually presents in mid- to late adulthood. Marked variation in prevalence has been reported in different populations: The disorder is rare in Scandinavia, China, Japan, and Africa and relatively common in much of Europe, Australia, New Zealand, and the United States, affecting up to 2.5% of the adult populations. Of interest, it appears that the incidence of Paget disease is decreasing.

### MORPHOLOGY

Paget disease may manifest as a solitary lesion (monostotic) or may occur at multiple sites (polyostotic) usually asynchronously. In the initial **lytic phase,** osteoclasts (and their associated Howship lacunae) are numerous, abnormally large, and have increased numbers of nuclei. Osteoclasts persist in the **mixed phase,** but the bone surfaces become lined by prominent osteoblasts. The marrow is replaced by loose connective tissue containing osteoprogenitor cells, as well as numerous blood vessels needed to meet the increased metabolic demands of the tissue. The newly formed bone may be woven or lamellar, but eventually all of it is remodeled into abnormal lamellar bone with a pathognomonic **mosaic pattern** (likened to a jigsaw puzzle) due to prominent haphazardly arranged cement lines (Fig. 20–5). As the osteoblastic activity ceases, the periosseous fibrovascular tissue recedes and is replaced by normal marrow. Although thickened, the resulting cortex is softer than normal and prone to deformation and fracture under stress.

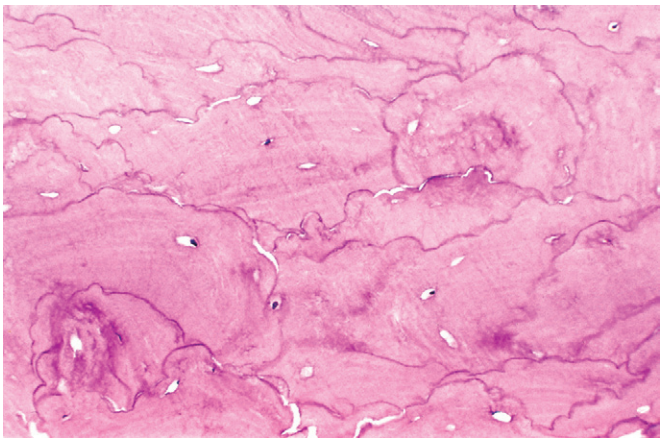

**Figure 20–5** Paget disease, showing a mosaic pattern of lamellar bone.

### PATHOGENESIS

When he first described the disease, Sir James Paget attributed the skeletal changes to an inflammatory process, and assigned the moniker **osteitis deformans.** After many years and multiple alternative theories, Paget's original idea may prove to be correct. It has long been postulated that a **paramyxovirus** infection (a slow virus) underlies Paget disease. Paramyxovirus antigens and particles resembling paramyxovirus can be demonstrated in osteoclasts. The causal connection is that paramyxoviruses can induce IL-1 and IL-6 secretion from infected cells, and these cytokines—as well as macrophage colony-stimulating factor (M-CSF)—are produced in large amounts in pagetic bone. As noted earlier, these potently activate osteoclasts. Nevertheless, as intriguing as these observations are, no infectious virus has been isolated from affected tissue. About 10% of affected patients have germline mutations in the gene *SQSTM1*, which encodes a protein that appears to increase osteoclastogenesis; these mutations are associated with earlier onset disease, a greater number of affected bones, and an increased incidence of fractures.

#### Clinical Course

The clinical findings depend on the extent and site of the disease. Paget disease is *monostotic* (tibia, ilium, femur, skull, vertebrae, and humerus) in about 15% of cases and *polyostotic* in the remainder; the axial skeleton or the proximal femur is involved in as many as 80% of cases. Involvement of the ribs, fibulae, and small bones of the hands and feet is unusual. Although Paget disease can produce a plethora of skeletal, neuromuscular, and cardiovascular complications, most cases are clinically mild, and the bone changes are discovered only incidentally in radiographs. Elevations in serum alkaline phosphatase and increased urinary excretion of hydroxyproline reflect exuberant bone turnover.

In some patients, the early hypervascular bone lesions cause warmth of the overlying skin and subcutaneous tissue. With extensive polyostotic disease, hypervascularity can result in high-output congestive heart failure. In the proliferative phase of the disease involving the skull, common symptoms attributable to nerve impingement include headache and visual and auditory disturbances. Vertebral lesions cause back pain and may be associated with disabling fractures and nerve root compression. Affected long bones in the legs often are deformed, as a consequence of the inability of pagetoid bone to remodel appropriately in response to the stress of weight bearing. Brittle long bones in particular are subject to *chalkstick fractures.*

The development of sarcoma is a dreaded but fortunately rare complication of Paget disease, occurring in only an estimated 1% of patients. The sarcomas usually are osteogenic, although other histologic variants can occur. The distribution of osteosarcoma generally parallels that of the Paget disease lesions, with the exception of vertebral bodies, which rarely harbor malignancy. The prognosis for patients who develop secondary sarcomas is exceedingly poor, but otherwise Paget disease usually follows a relatively benign course. Most patients have mild symptoms that are readily controlled with bisphosphonates, drugs that interfere with bone resorption.

## Rickets and Osteomalacia

Both rickets and osteomalacia are manifestations of vitamin D deficiency or its abnormal metabolism (and are detailed in Chapter 7). The fundamental defect is an impairment of mineralization and a resultant accumulation of unmineralized matrix. This contrasts with osteoporosis, in which the mineral content of the bone is normal and the total bone mass is decreased. *Rickets* refers to the disorder in children, in which it interferes with the deposition of bone in the growth plates. *Osteomalacia* is the adult counterpart, in which bone formed during remodeling is undermineralized, resulting in predisposition to fractures.

## Hyperparathyroidism

As discussed in Chapter 19, parathyroid hormone (PTH) plays a central role in calcium homeostasis through the following effects:

- Osteoclast activation, increasing bone resorption and calcium mobilization. PTH mediates the effect indirectly by increased RANKL expression on osteoblasts.
- Increased resorption of calcium by the renal tubules
- Increased urinary excretion of phosphates
- Increased synthesis of active vitamin D, $1,25(OH)_2$-D, by the kidneys, which in turn enhances calcium absorption from the gut and mobilizes bone calcium by inducing RANKL on osteoblasts

The net result of the actions of PTH is an elevation in serum calcium, which, under normal circumstances, inhibits further PTH production. However, excessive or inappropriate levels of PTH can result from autonomous parathyroid secretion (*primary hyperparathyroidism*) or can occur in the setting of underlying renal disease (*secondary hyperparathyroidism*) (see also Chapter 19).

In either setting, *hyperparathyroidism leads to significant skeletal changes related to unabated osteoclast activity.* The entire skeleton is affected, although some sites can be more severely affected than others. PTH is directly responsible for the bone changes seen in primary hyperparathyroidism, but additional influences contribute to the development of bone disease in secondary hyperparathyroidism. In chronic renal insufficiency there is inadequate $1,25\text{-}(OH)_2$-D synthesis, which ultimately affects gastrointestinal calcium absorption. The hyperphosphatemia of renal failure also suppresses renal $\alpha_1$-hydroxylase, further impairing vitamin D synthesis; additional influences include metabolic acidosis and aluminum deposition in bone. As bone mass decreases, affected patients are increasingly susceptible to fractures, bone deformation, and joint problems. Fortunately, a reduction in PTH levels to normal can completely reverse the bone changes.

## MORPHOLOGY

The hallmark of PTH excess is **increased osteoclastic activity, with bone resorption.** Cortical and trabecular bone are diminished and replaced by loose connective tissue. Bone resorption is especially pronounced in the subperiosteal regions and produces characteristic radiographic changes, best seen along the radial aspect of the middle phalanges of the second and third fingers. Microscopically, there are **increased numbers of osteoclasts boring into the centers of bony trabeculae (dissecting osteitis) and expanding haversian canals (cortical cutting cones)** (Fig. 20–6, *A*). The marrow space contains increased amounts of loose fibrovascular tissue. Hemosiderin deposits are present, reflecting episodes of hemorrhage resulting from microfractures of the weakened bone. In some instances, collections of osteoclasts, reactive giant cells, and hemorrhagic debris form a distinct mass termed a **brown tumor of hyperparathyroidism** (Fig. 20–6, *B*). Cystic change is common in such lesions (hence the name **osteitis fibrosa cystica**), which can be confused with primary bone neoplasms.

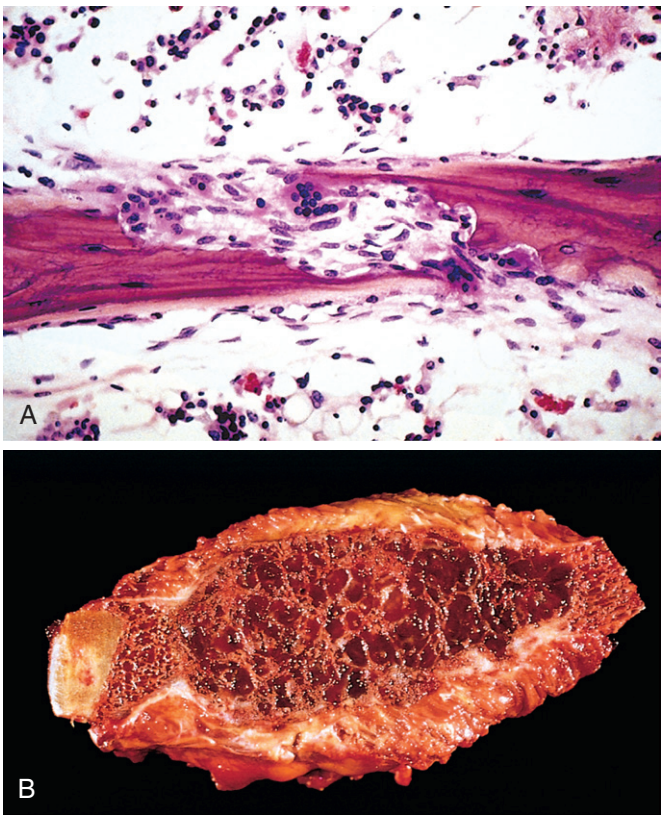


**Figure 20–6** Bone manifestations of hyperparathyroidism. **A,** Osteoclasts gnawing into and disrupting lamellar bone. **B,** Resected rib, with expansile cystic mass (so-called brown tumor).

## SUMMARY

### Acquired Diseases of Bone Development and Mass

- Nutritional deficiencies can affect bone integrity by altering the quality of the organic matrix (e.g., vitamin C is involved in collagen cross-linking) or by influencing bone mineralization (e.g., vitamin D is involved in calcium uptake).
- Osteoporosis results from decreased bone mass and is clinically significant because it predisposes bone to fracture. Although osteoporosis is multifactorial, the two most common forms are *senile osteoporosis* due to aging-related losses of osteoblast function, and *postmenopausal osteoporosis* due to increased osteoclastic activity caused by the relative absence of estrogen.
- Paget disease may result from a paramyxovirus infection in genetically susceptible persons and is caused by aberrant and excessive osteoclast activity, followed by exuberant—but structurally unsound—osteoblast deposition of bone.
- Primary or secondary (due to renal failure) overproduction of PTH (*hyperparathyroidism*) results in increased osteoclast activity and bone resorption, leading to fractures and deformities.

## FRACTURES

Fractures rank among the most common pathologic conditions of bone. They are classified as follows:

- *Complete* or *incomplete*
- *Closed,* in which the overlying tissue is intact, or *compound,* in which the fracture extends into the overlying skin
- *Comminuted,* in which the bone is splintered
- *Displaced,* in which the fractured bone is not aligned

If the break occurs at the site of previous disease (e.g., a bone cyst, a malignant tumor, or a brown tumor associated with elevated PTH), it is termed a *pathologic fracture.* A *stress fracture* develops slowly over time as a collection of microfractures associated with increased physical activity, especially with new repetitive mechanical loads on bone (as sustained in military bootcamp activities).

In all cases, the repair of a fracture is a highly regulated process that involves overlapping stages:

- The trauma of the bone fracture ruptures associated blood vessels; the resulting blood clot creates a fibrin mesh scaffold to recruit inflammatory cells, fibroblasts, and endothelium. Degranulated platelets and marauding inflammatory cells subsequently release a host of cytokines (e.g., platelet-derived growth factor, fibroblast growth factor) that activate bone progenitor cells, and within a week, the involved tissue is primed for new matrix synthesis. This *soft tissue callus* can hold the ends of the fractured bone in apposition but is noncalcified and cannot support weight bearing.
- Bone progenitors in the periosteum and medullary cavity deposit new foci of woven bone, and activated

mesenchymal cells at the fracture site differentiate into cartilage-synthesizing chondroblasts. In uncomplicated fractures, this early repair process peaks within 2 to 3 weeks. The newly formed cartilage acts as a nidus for *endochondral ossification,* recapitulating the process of bone formation in epiphyseal growth plates. This connects the cortices and trabeculae in the juxtaposed bones. With ossification, the fractured ends are bridged by a *bony callus.*

- Although excess fibrous tissue, cartilage, and bone are produced in the early callus, subsequent weight bearing leads to remodeling of the callus from nonstressed sites; at the same time there is fortification of regions that support greater loads. This process restores the original size, shape, and integrity of the bone.

The healing of a fracture can be disrupted by many factors:

- Displaced and comminuted fractures frequently result in some deformity; devitalized fragments of splintered bone require resorption, which delays healing, enlarges the callus, and requires inordinately long periods of remodeling and may never completely normalize.
- Inadequate immobilization permits constant movement at the fracture site, so that the normal constituents of callus do not form. In such instances, the healing site is composed mainly of fibrous tissue and cartilage, perpetuating the instability and resulting in delayed union and nonunion. Too much motion along the fracture gap (as in nonunion) causes the central portion of the callus to undergo cystic degeneration; the luminal surface can actually become lined by synovial-type cells, creating a false joint, or *pseudoarthrosis.* In the setting of a nonunion or pseudoarthrosis, normal healing can be achieved only if the interposed soft tissues are removed and the fracture site is stabilized.
- *Infection* (a risk in comminuted and open fractures) is a serious obstacle to fracture healing. The infection must be eradicated before successful bone reunion and remodeling can occur.
- Bone repair obviously will be impaired in the setting of inadequate levels of calcium or phosphorus, vitamin deficiencies, systemic infection, diabetes, or vascular insufficiency.

With uncomplicated fractures in children and young adults, practically perfect reconstitution is the norm. When fractures occur in older age groups or in abnormal bones (e.g., osteoporotic bone), repair frequently is less than optimal without orthopedic intervention.

## OSTEONECROSIS (AVASCULAR NECROSIS)

Ischemic necrosis with resultant bone infarction occurs relatively frequently. Mechanisms contributing to bone ischemia include

- Vascular compression or disruption (e.g., after a fracture)
- Steroid administration
- Thromboembolic disease (e.g., nitrogen bubbles in caisson disease—see Chapter 3)
- Primary vessel disease (e.g., vasculitis)
- Sickle cell crisis (Chapter 11)

Most cases of bone necrosis are due to fracture or occur after corticosteroid use, but in many instances the etiology is unknown.

### MORPHOLOGY

The pathologic features of bone necrosis are the same regardless of cause. Dead bone with empty lacunae is interspersed with areas of fat necrosis and insoluble calcium soaps. The cortex usually is not affected, because of collateral blood supply; in subchondral infarcts, the overlying articular cartilage also remains viable because the synovial fluid can provide nutritive support. With time, osteoclasts can resorb some of the necrotic bony trabeculae; any dead bone fragments that remain act as scaffolding for new bone formation, a process called **creeping substitution.**

### Clinical Course

Symptoms depend on the size and location of injury. *Subchondral infarcts* initially present with pain during physical activity that becomes more persistent with time. *Medullary infarcts* usually are silent unless large in size (as may occur with Gaucher disease, caisson disease, or sickle cell disease). Medullary infarcts usually are stable, but subchondral infarcts often collapse and may lead to severe osteoarthritis. Roughly 50,000 joint replacements are performed each year in the United States to treat the consequences of osteonecrosis.

## OSTEOMYELITIS

*Osteomyelitis* is defined as inflammation of bone and marrow, but in common use it is virtually synonymous with infection. Osteomyelitis can be secondary to systemic infection but more frequently occurs as a primary isolated focus of disease; it can be an acute process or a chronic, debilitating illness. Although any microorganism can cause osteomyelitis, the most common etiologic agents are pyogenic bacteria and *Mycobacterium tuberculosis.*

### Pyogenic Osteomyelitis

Most cases of acute osteomyelitis are caused by bacteria. The offending organisms reach the bone by one of three routes: (1) hematogenous dissemination (most common); (2) extension from an infection in adjacent joint or soft tissue; or (3) traumatic implantation after compound fractures or orthopedic procedures. Overall, *Staphylococcus aureus* is the most frequent causative organism; its propensity to infect bone may be related to the expression of surface proteins that allow adhesion to bone matrix. *Escherichia coli* and group B streptococci are important causes of acute osteomyelitis in neonates, and *Salmonella* is an especially common pathogen in persons with sickle cell

disease. Mixed bacterial infections, including anaerobes, typically are responsible for osteomyelitis secondary to bone trauma. In as many as 50% of cases, no organisms can be isolated.

### MORPHOLOGY

The morphologic changes in osteomyelitis depend on the chronicity and location of the infection. Causal bacteria proliferate, inducing an acute inflammatory reaction, with consequent cell death. Entrapped bone rapidly becomes necrotic; this non-viable bone is called a **sequestrum.** Bacteria and inflammation can percolate throughout the haversian systems to reach the periosteum. In children, the periosteum is loosely attached to the cortex; therefore, sizable **subperiosteal** abscesses can form and extend for long distances along the bone surface. Lifting of the periosteum further impairs the blood supply to the affected region, and both suppurative and ischemic injury can cause segmental bone necrosis. Rupture of the periosteum can lead to abscess formation in the surrounding soft tissue that may lead to a **draining sinus.** Sometimes the sequestrum crumbles, releasing fragments that pass through the sinus tract.

In infants (and uncommonly in adults), epiphyseal infection can spread into the adjoining joint to produce suppurative arthritis, sometimes with extensive destruction of the articular cartilage and permanent disability. An analogous process can involve vertebrae, with an infection destroying intervertebral discs and spreading into adjacent vertebrae.

After the first week of infection, chronic inflammatory cells become more numerous. Leukocyte cytokine release stimulates osteoclastic bone resorption, fibrous tissue ingrowth, and bone formation in the periphery. Reactive woven or lamellar bone can be deposited; when it forms a shell of living tissue around a sequestrum, it is called an **involucrum** (Fig. 20–7). Viable organisms can persist in the sequestrum for years after the original infection.

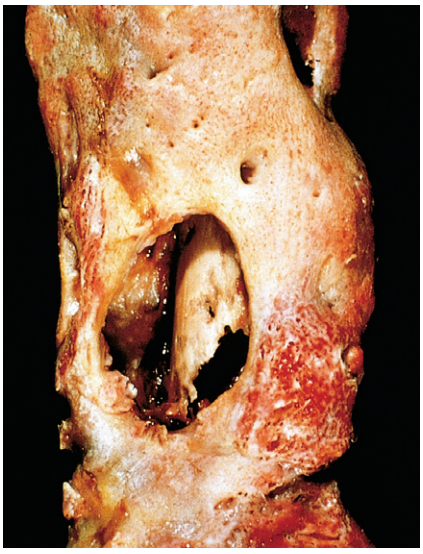

**Figure 20–7** Resected femur from a patient with chronic osteomyelitis. Necrotic bone (the sequestrum) visible in the center of a draining sinus tract is surrounded by a rim of new bone (the involucrum).

Clinical Features

Osteomyelitis classically manifests as an acute systemic illness, with malaise, fever, leukocytosis, and throbbing pain over the affected region. Symptoms also can be subtle, with only unexplained fever, particularly in infants, or only localized pain in the adult. The diagnosis is suggested by characteristic radiologic findings: a destructive lytic focus surrounded by edema and a sclerotic rim. In many untreated cases, blood cultures are positive, but biopsy and bone cultures are usually required to identify the pathogen. A combination of antibiotics and surgical drainage usually is curative, but up to a quarter of cases do not resolve and persist as chronic infections. Chronicity may develop with delay in diagnosis, extensive bone necrosis, abbreviated antibiotic therapy, inadequate surgical debridement, and/or weakened host defenses. Besides occasional acute flare-ups, chronic osteomyelitis also may be complicated by pathologic fracture, secondary amyloidosis, endocarditis, sepsis, development of squamous cell carcinoma if the infection creates a sinus tract, and rarely osteosarcoma.

### Tuberculous Osteomyelitis

Mycobacterial infection of bone has long been a problem in developing countries; with the resurgence of tuberculosis (due to immigration patterns and increasing numbers of immunocompromised persons) it is becoming an important disease in other countries as well.

Bone infection complicates an estimated 1% to 3% of cases of pulmonary tuberculosis. The organisms usually reach the bone through the bloodstream, although direct spread from a contiguous focus of infection (e.g., from mediastinal nodes to the vertebrae) also can occur. With hematogenous spread, *long bones and vertebrae are favored sites.* The lesions often are solitary but can be multifocal, particularly in patients with an underlying immunodeficiency. Because the tubercle bacillus is microaerophilic, the synovium, with its higher oxygen pressures, is a common site of initial infection. The infection then spreads to the adjacent epiphysis, where it elicits typical granulomatous inflammation with caseous necrosis and extensive bone destruction. *Tuberculosis of the vertebral bodies is a clinically serious form of osteomyelitis.* Infection at this site causes vertebral deformity, collapse, and posterior displacement (Pott disease), leading to neurologic deficits. Spinal deformities due to Pott disease afflicted several men of letters (including Alexander Pope and William Henley) and likely served as the inspiration for Victor Hugo's *Hunchback of Notre Dame.* Extension of the infection to the adjacent soft tissues with the development of psoas muscle abscesses is fairly common.

## BONE TUMORS

Primary bone tumors are considerably less common than bone metastases from other primary sites; metastatic disease is discussed at the end of this section.

*Primary bone tumors exhibit great morphologic diversity and clinical behaviors – from benign to aggressively malignant.* Most are classified according to the normal cell counterpart and line of differentiation; Table 20–2 lists the salient features

**Table 20–2** Tumors of Bone

| Tumor Type | Common Locations | Age (yr) | Morphology |
|---|---|---|---|
| **Bone-Forming** | | | |
| Benign | | | |
| Osteoma | Facial bones, skull | 40–50 | Exophytic growths attached to bone surface; histologically similar to normal bone |
| Osteoid osteoma | Metaphysis of femur and tibia | 10–20 | Cortical tumors, characterized by pain; histologic pattern consisting of interlacing trabeculae of woven bone |
| Osteoblastoma | Vertebral column | 10–20 | Arise in vertebral transverse and spinous processes; histologically similar to osteoid osteoma |
| Malignant | | | |
| Primary osteosarcoma | Metaphysis of distal femur, proximal tibia, and humerus | 10–20 | Grow outward, lifting periosteum, and inward to the medullary cavity; microscopy shows malignant cells forming osteoid; cartilage also may be present |
| Secondary osteosarcoma | Femur, humerus, pelvis | >40 | Complications of polyostotic Paget disease; histologically similar to primary osteosarcoma |
| **Cartilaginous** | | | |
| Benign | | | |
| Osteochondroma | Metaphysis of long tubular bones | 10–30 | Bony excrescences with a cartilaginous cap; may be solitary or multiple and hereditary |
| Enchondroma | Small bones of hands and feet | 30–50 | Well-circumscribed single tumors resembling normal cartilage; arise within medullary cavity of bone; uncommonly multiple and hereditary |
| Malignant | | | |
| Chondrosarcoma | Bones of shoulder, pelvis, proximal femur, and ribs | 40–60 | Arise within medullary cavity and erode cortex; microscopy shows well-differentiated cartilage-like or anaplastic features |
| **Miscellaneous** | | | |
| Giant cell tumor (usually benign) | Epiphysis of long bone | 20–40 | Lytic lesions that erode cortex; microscopy shows osteoclast-like giant cells and round to spindle-shaped mononuclear cells; most are benign |
| Ewing sarcoma | Diaphysis and metaphysis | 10–20 | Arise in medullary cavity; microscopy shows sheets of small round cells that contain glycogen; aggressive neoplasm |

of the most common primary bone neoplasms, excluding multiple myeloma and other hematopoietic tumors. Overall, matrix-producing and fibrous tumors are the most common, and among the benign tumors, osteochondroma and fibrous cortical defect occur most frequently. Osteosarcoma is the most common primary bone cancer, followed by chondrosarcoma and Ewing sarcoma. Benign tumors greatly outnumber their malignant counterparts, particularly before the age of 40 years; bone tumors in elderly persons are much more likely to be malignant.

Most bone tumors develop during the first several decades of life and have a propensity to originate in the long bones of the extremities. Nevertheless, specific tumor types target certain age groups and anatomic sites; these associations are often helpful in arriving at the correct diagnosis. For instance, most osteosarcomas occur during adolescence, with half arising around the knee, either in the distal femur or proximal tibia. By contrast, chondrosarcomas tend to develop during mid- to late adulthood and involve the trunk, limb girdles, and proximal long bones.

Most bone tumors arise without any previous known cause. Nevertheless, genetic syndromes (e.g., Li-Fraumeni and retinoblastoma syndromes) (Chapter 5) are associated with osteosarcomas, as are (rarely) bone infarcts, chronic osteomyelitis, Paget disease, irradiation, and use of metal orthopedic devices.

In terms of clinical presentation, benign lesions frequently are asymptomatic and are detected as incidental findings. Others produce pain or a slowly growing mass. Occasionally, a pathologic fracture is the first manifestation. Radiologic imaging is critical in the evaluation of bone tumors; however, biopsy and histologic study and, in some cases, molecular tests are necessary for diagnosis.

## Bone-Forming Tumors

The tumor cells in the following neoplasms all produce bone that usually is woven and variably mineralized.

### *Osteoma*

*Osteomas* are benign lesions most commonly encountered in the head and neck, including the paranasal sinuses, but which can occur elsewhere as well. They typically present in middle age as solitary, slowly growing, hard, exophytic

masses on a bone surface. Multiple lesions are a feature of Gardner syndrome, a hereditary condition discussed later. On histologic examination, osteomas recapitulate cortical-type bone and are composed of a mixture of woven and lamellar bone. Although they may cause local mechanical problems (e.g., obstruction of a sinus cavity) and cosmetic deformities, they are not locally aggressive and do not undergo malignant transformation.

### *Osteoid Osteoma and Osteoblastoma*

*Osteoid osteomas* and *osteoblastomas* are benign neoplasms with very similar histologic features. Both lesions typically appear during the teenage years and 20s, with a male predilection (2:1 for osteoid osteomas). They are distinguished from each other primarily by their size and clinical presentation. *Osteoid osteomas* arise most often beneath the periosteum or within the cortex in the proximal femur and tibia or posterior spinal elements and are by definition less than 2 cm in diameter, whereas osteoblastomas are larger. Localized pain, most severe at night, is an almost universal complaint with osteoid osteomas, and usually is relieved by aspirin. *Osteoblastomas* arise most often in the vertebral column; they also cause pain, although it often is more difficult to localize and is not responsive to aspirin. Local excision is the treatment of choice; incompletely resected lesions can recur. Malignant transformation is rare *unless* the lesion is treated with irradiation.

#### MORPHOLOGY

On gross inspection, both lesions are round-to-oval masses of hemorrhagic, gritty-appearing tan tissue. A rim of sclerotic bone is present at the edge of both types of tumors; however, it is much more conspicuous in osteoid osteomas. On microscopic examination, both neoplasms are composed of interlacing trabeculae of woven bone surrounded by osteoblasts (Fig. 20–8). The intervening stroma is loose, vascular connective tissue containing variable numbers of giant cells.

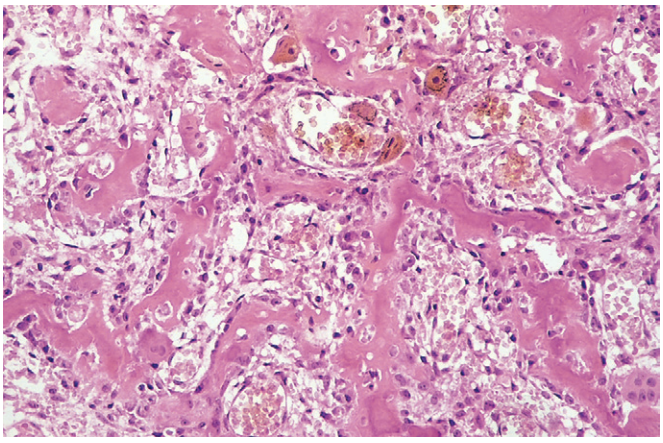

**Figure 20–8** Osteoid osteoma showing randomly oriented trabeculae of woven bone rimmed by prominent osteoblasts. The intertrabecular spaces are filled by vascular loose connective tissue.

### *Osteosarcoma*

*Osteosarcoma is a bone-producing malignant mesenchymal tumor.* After myeloma and lymphoma, osteosarcoma is the most common primary malignant tumor of bone, accounting for approximately 20% of primary bone cancers; a little over 2000 cases are diagnosed annually in the United States. Osteosarcomas occur in all age groups, but about 75% of patients are younger than 20 years of age, with a second peak occurring in elderly persons, usually in association with other conditions, including Paget disease, bone infarcts, and previous irradiation. Men are more commonly affected than women (1.6:1). Although any bone can be involved, most tumors arise in the metaphyseal region of the long bones of the extremities, with almost 60% occurring about the knee, 15% around the hip, 10% at the shoulder, and 8% in the jaw. Several subtypes of osteosarcoma are distinguished on the basis of the site of involvement within the bone (e.g., medullary versus cortical), degree of differentiation, number of involved sites, presence of underlying disease, and histologic features; the most common type of osteosarcoma is primary, solitary, intramedullary, and poorly differentiated, producing a predominantly bony matrix.

#### MORPHOLOGY

On gross evaluation, osteosarcomas are gritty-appearing, gray-white tumors, often exhibiting hemorrhage and cystic degeneration. Tumors frequently destroy the surrounding cortices, producing soft tissue masses (Fig. 20–9, *A*). They spread extensively in the medullary canal, infiltrating and replacing the marrow but only infrequently penetrating the epiphyseal plate or entering the joint space. Tumor cells vary in size and shape and frequently have large hyperchromatic

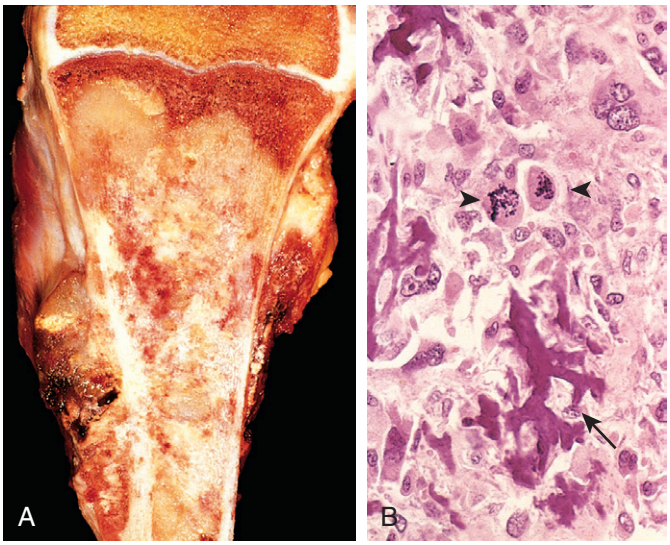


**Figure 20–9** Osteosarcoma. **A,** Mass involving the upper end of the tibia. The tan-white tumor fills most of the medullary cavity of the metaphysis and proximal diaphysis. It has infiltrated through the cortex, lifted the periosteum, and formed soft tissue masses on both sides of the bone. **B,** Histologic appearance, with coarse, lacelike pattern of neoplastic bone (*arrow*) produced by anaplastic tumor cells. Note the wildly aberrant mitotic figures (*arrowheads*).

nuclei; bizarre tumor giant cells are common, as are mitotic figures. **The production of mineralized or unmineralized bone (osteoid) by malignant cells is essential for diagnosis of osteosarcoma** (Fig. 20–9, *B*). The neoplastic bone typically is coarse and lacelike but also can be deposited in broad sheets. Cartilage and fibroblastic differentiation can also be present in varying amounts. When malignant cartilage is abundant, the tumor is called a **chondroblastic osteosarcoma.** Vascular invasion is common, as is spontaneous tumor necrosis.

## PATHOGENESIS

Several mutations are closely associated with the development of osteosarcoma. In particular, *RB* gene mutations occur in 60% to 70% of sporadic tumors, and persons with hereditary retinoblastomas (due to germline mutations in the *RB* gene) have a thousand-fold greater risk for development of osteosarcoma. Like many other cancers, spontaneous osteosarcomas also frequently exhibit mutations in *TP53* and in genes that regulate the cell cycle, including cyclins, cyclin-dependent kinases, and kinase inhibitors. Many osteosarcomas develop at sites of greatest bone growth, perhaps because rapidly dividing cells provide a fertile soil for mutations.

### Clinical Features

Osteosarcomas typically manifest as painful enlarging masses, although a pathologic fracture can be the first sign. Radiographic imaging usually shows a large, destructive, mixed lytic and blastic mass with indistinct infiltrating margins. The tumor frequently breaks through the cortex and lifts the periosteum, resulting in reactive periosteal bone formation. A triangular shadow on the x-ray film between the cortex and raised periosteum (*Codman triangle*) is characteristic of osteosarcomas. Osteosarcomas typically spread hematogenously; at the time of diagnosis, approximately 10% to 20% of patients have demonstrable pulmonary metastases, and a larger number have microscopic metastases.

Despite aggressive behavior, standard treatment with chemotherapy and limb salvage therapy currently yields long-term survivals of 60% to 70%.

Secondary osteosarcomas occur in older adults most commonly in the setting of Paget disease or previous radiation exposure. Like primary osteosarcomas, secondary osteosarcomas are highly aggressive tumors, but they do not respond well to therapy and are usually fatal.

## Cartilage-Forming Tumors

Cartilage-forming tumors produce hyaline or myxoid cartilage; fibrocartilage and elastic cartilage are rare components. Like the bone-forming tumors, cartilaginous tumors constitute a spectrum from benign, self-limited growths to highly aggressive malignancies; again, benign cartilage tumors are much more common than malignant ones. Only the more common types are discussed here.

### *Osteochondroma*

Osteochondromas are relatively common benign, cartilage-capped tumors attached by a bony stalk to the underlying skeleton. Solitary osteochondromas typically are first diagnosed in late adolescence and early adulthood (male-to-female ratio of 3:1); multiple osteochondromas become apparent during childhood, occurring as *multiple hereditary osteochondromas,* an autosomal dominant disorder. Inactivation of both copies of the *EXT1* or *EXT2* genes through mutation and loss of heterozygosity in chondrocytes of the growth plate is implicated in both sporadic and hereditary osteochondromas. These tumor suppressor genes encode glycosyltransferases essential for polymerization of heparin sulfate, an important component of cartilage. This finding and other molecular genetic studies support the concept that osteochondromas are true neoplasms and not developmental malformations.

Osteochondromas develop only in bones of endochondral origin arising at the metaphysis near the growth plate of long tubular bones, especially about the knee; they tend to stop growing once the normal growth of the skeleton is completed (Fig. 20–10). Occasionally they develop from bones of the pelvis, scapula, and ribs and in these sites frequently are sessile. Rarely, osteochondromas arise in the short tubular bones of hands and feet.

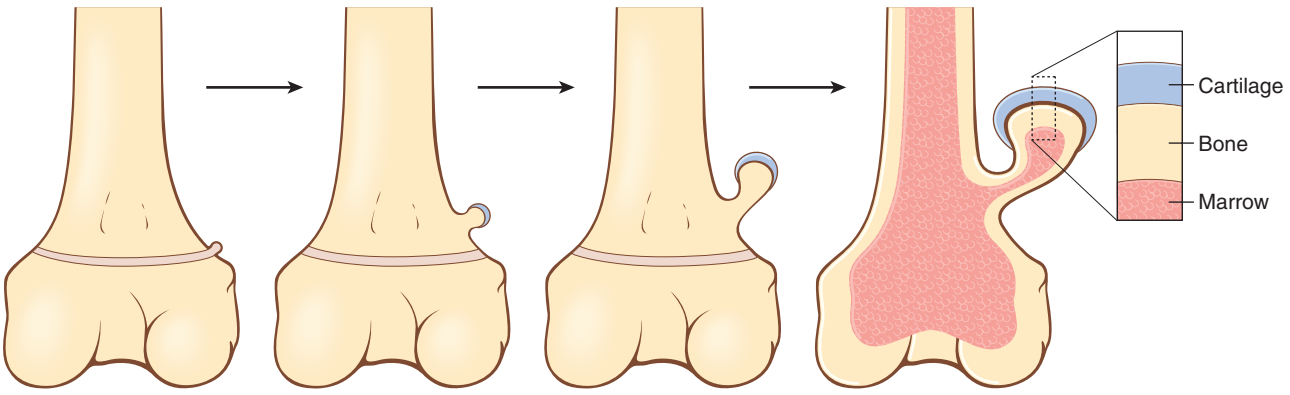


**Figure 20–10** The development of an osteochondroma, beginning with an outgrowth from the epiphyseal cartilage.

### MORPHOLOGY

Osteochondromas range from 1 to 20 cm in size and have a cartilaginous cap that is usually less than 2 cm in thickness. The hyaline cartilage resembles a disorganized growth plate undergoing endochondral ossification. Newly formed bone forms the inner portion of the head and stalk, with the stalk cortex and central region merging with the cortex and medullary cavity, respectively, of the host bone.

Clinical Features

Osteochondromas are slow-growing masses that can be painful if they impinge on a nerve or if the stalk is fractured. In many cases, they are incidental findings. In multiple hereditary osteochondromas, deformity of the underlying bone suggests an associated disturbance in epiphyseal growth. Solitary osteochondromas rarely progress to chondrosarcoma or other sarcomas, but malignant transformation occurs more frequently in those with multiple hereditary osteochondromas.

### *Chondroma*

Chondromas are benign neoplasms of hyaline cartilage. When they arise within the medulla, they are termed *enchondromas*; when on the bone surface, they are called *juxtacortical chondromas.* Enchondromas usually are diagnosed in persons between the ages of 20 and 50 years; they typically are solitary and located in the metaphyseal region of tubular bones, the favored sites being the short tubular bones of the hands and feet. *Ollier disease* is characterized by *multiple chondromas* preferentially involving one side of the body, and *Maffucci syndrome* is characterized by *multiple chondromas associated with soft tissue spindle cell hemangiomas.*

### PATHOGENESIS

Enchondromas occurring in Ollier disease and Maffucci syndrome frequently contain point mutations in either isocitrate dehydrogenase 1 (IDH1) or IDH2 that create a new enzyme activity. The same IDH mutations occur as somatic mutations in acute myeloid leukemias and gliomas, but in Ollier and Maffucci disease the mutations are also found at low frequency in normal tissues, suggesting the mutations occurred early during embryonic development, an example of genetic mosaicism.

### MORPHOLOGY

Enchondromas are gray-blue, translucent nodules usually smaller than 5 cm in greatest dimension. On microscopic examination, they are well circumscribed and composed of hyaline cartilage containing cytologically benign chondrocytes. At the periphery, there is endochondral ossification, while the center frequently calcifies and dies. In the hereditary multiple chondromatoses, the islands of cartilage exhibit greater cellularity and atypia, making them more difficult to distinguish from chondrosarcoma.

Clinical Features

Most enchondromas are detected as incidental findings; occasionally they are painful or cause pathologic fractures. On x-ray imaging, the unmineralized nodules of cartilage produce well-circumscribed oval lucencies surrounded by thin rims of radiodense bone (*O-ring sign*). Calcified matrix manifests as irregular opacities. The growth potential of chondromas is limited, and most remain stable, although they can recur if incompletely excised. Solitary chondromas rarely undergo malignant transformation, but those associated with enchondromatoses are at increased risk for such change. Maffucci syndrome is associated with an increased risk for development of other types of malignancies, including ovarian carcinomas and brain gliomas.

### *Chondrosarcoma*

Chondrosarcoma is a malignant connective tissue tumor (sarcoma) whose cells manufacture and secrete neoplastic cartilage matrix. It is subclassified according to site (e.g., *intramedullary* versus *juxtacortical*) and histologic variants (discussed next). Chondrosarcomas occur roughly half as frequently as osteosarcomas; most patients are age 40 or older, with men affected twice as frequently as women.

### MORPHOLOGY

**Conventional chondrosarcoma, the most common variant,** arises within the medullary cavity of the bone to form an expansile glistening mass that often erodes the cortex (Fig. 20–11, *A*). It is composed of malignant hyaline and myxoid cartilage. **Myxoid chondrosarcomas** are viscous and gelatinous in consistency, and the matrix oozes from the cut surface. The adjacent cortex is thickened or eroded, and the tumor grows with broad pushing fronts into marrow spaces and the surrounding soft tissue. Tumor grade is determined by cellularity, degree of cytologic atypia, and mitotic activity (Fig. 20–11, *B*). Low-grade tumors may be difficult to distinguish from enchondroma. Higher-grade lesions contain pleomorphic chondrocytes with frequent mitotic figures.

Approximately 10% of patients with conventional low-grade chondrosarcomas have a second high-grade poorly differentiated component **(dedifferentiated chondrosarcomas)** that includes foci of fibro- or osteosarcomas. Other histologic variants include **clear cell** and **mesenchymal chondrosarcomas.**

Clinical Features

Chondrosarcomas commonly arise in the pelvis, shoulder, and ribs; in contrast with enchondromas, chondrosarcomas rarely involve the distal extremities. They typically manifest as painful, progressively enlarging masses. A slowly growing low-grade tumor causes reactive thickening of the cortex, whereas a more aggressive high-grade neoplasm destroys the cortex and forms a soft tissue mass; consequently, the more radiolucent the tumor the greater the likelihood that it is high grade. There is also a direct correlation between grade and biologic behavior of the tumor. Fortunately, most conventional chondrosarcomas are indolent and low-grade, with a 5-year survival rate of 80% to 90% (versus 43% for grade 3 tumors); grade 1 tumors rarely

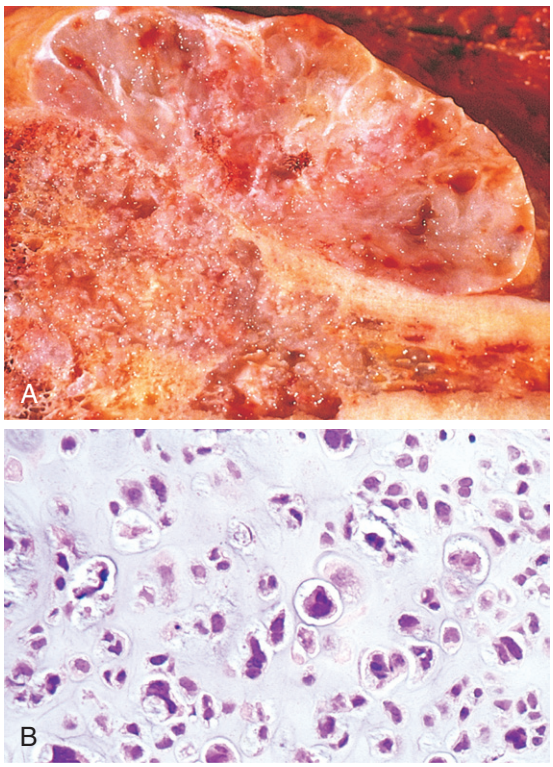


**Figure 20–11** Chondrosarcoma. **A,** Islands of hyaline and myxoid cartilage expand the medullary cavity and grow through the cortex to form a sessile paracortical mass. **B,** Anaplastic chondrocytes within a chondroid matrix.

metastasize, whereas 70% of the grade 3 tumors disseminate. Size is another prognostic feature, with tumors larger than 10 cm being significantly more aggressive than smaller tumors. Chondrosarcomas metastasize hematogenously, preferentially to the lungs and skeleton. Conventional chondrosarcomas are treated with wide surgical excision; chemotherapy is added for the mesenchymal and dedifferentiated variants because of their aggressive clinical course.

## Fibrous and Fibroosseous Tumors

Fibrous tumors of the skeleton are extremely common and exhibit a wide diversity of morphologic variants.

### *Fibrous Cortical Defect and Nonossifying Fibroma*

*Fibrous cortical defects* are probably developmental abnormalities rather than true neoplasms. The vast majority are smaller than 0.5 cm in diameter and arise eccentrically in the metaphysis of the distal femur or proximal tibia; almost 50% are bilateral or multiple. Larger lesions (5 to 6 cm) develop into *nonossifying fibromas.*

#### MORPHOLOGY

Fibrous cortical defects and nonossifying fibromas both manifest as sharply demarcated radiolucencies surrounded by a thin zone of sclerosis. On gross inspection, they are gray to yellow-brown; microscopic examination shows cellular lesions composed of cytologically benign fibroblasts and activated macrophages, including multinucleate forms. The fibroblasts classically exhibit a storiform (pinwheel) pattern (Fig. 20–12). Hemorrhage and hemosiderin deposits are a common finding.

#### Clinical Features

Fibrous cortical defects are asymptomatic and typically are detected only as incidental radiographic lesions. The usual clinical course is characterized by spontaneous differentiation into normal cortical bone within a few years, so as a rule, biopsy is not required. The few that enlarge into nonossifying fibromas can manifest with pathologic fracture; in such cases, biopsy is necessary to rule out other tumors.

### *Fibrous Dysplasia*

Fibrous dysplasia is a benign tumor in which all components of normal bone are present, but they fail to differentiate into mature structures. Fibrous dysplasia manifests with one of three clinical patterns: (1) involvement of a single bone (monostotic); (2) involvement of multiple bones (polyostotic); and (3) polyostotic disease, associated with café au lait skin pigmentations and endocrine abnormalities, especially precocious puberty (*McCune-Albright syndrome*). Mutations of the *GNAS* gene, resulting in a constitutively active $G_s$ protein (Chapter 2), are responsible for all forms of fibrous dysplasia. The mutation occurs during embryogenesis (somatic mutations) resulting in mosaicism in the fetus and adult. The extent of manifestation (mono-ostotic, polyostotic, or McCune-Albright syndrome) depends on (1) the stage of embryogenesis when the mutation is acquired and (2) the fate of the cell harboring the initial mutation.

*Monostotic fibrous dysplasia* accounts for 70% of cases. The tumor usually arises during the second and third decades of life; there is no gender predilection. In descending order of frequency, ribs, femur, tibia, jawbones, calvariae, and humerus are most commonly affected. Lesions often are asymptomatic and frequently are discovered incidentally. However, fibrous dysplasia can cause marked enlargement

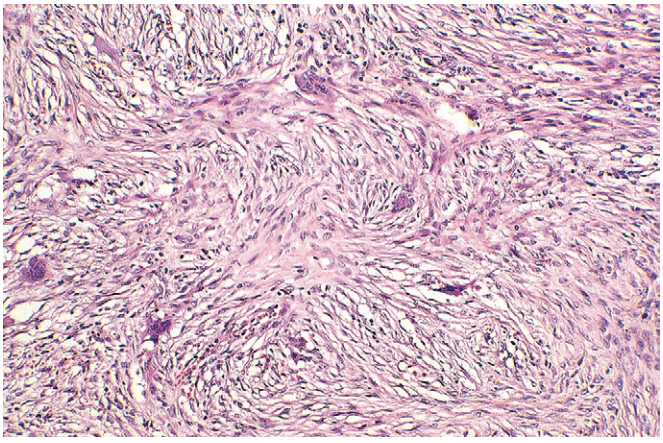

**Figure 20–12** Fibrous cortical defect or nonossifying fibroma. Characteristic storiform pattern of spindle cells interspersed with scattered osteoclast-type giant cells.

and distortion of bone, so that if the face or skull is involved, disfigurement can occur, or it can cause pain and pathologic fracture.

*Polyostotic fibrous dysplasia without endocrine dysfunction* accounts for a majority of the remaining cases. It manifests at a slightly earlier age than that for the monostotic type. In descending order of frequency, femur, skull, tibia, and humerus are most commonly involved. Craniofacial involvement is present in 50% of patients with moderate skeletal involvement and in 100% of patients with extensive skeletal disease. Polyostotic disease tends to involve the shoulder and pelvic girdles, resulting in severe deformities and spontaneous fractures.

*McCune-Albright syndrome* accounts for 3% of all cases. The associated endocrinopathies include sexual precocity (girls more often than boys), hyperthyroidism, growth hormone–secreting pituitary adenomas, and primary adrenal hyperplasia. The severity of manifestations depends on the number and cell types that harbor the G protein mutation. The bone lesions may be unilateral, and the skin pigmentation usually is limited to the same side of the body. The cutaneous macules classically are large, dark to light brown (*café au lait*), and irregular in configuration.

### MORPHOLOGY

On gross inspection, fibrous dysplasia is characterized by well-circumscribed, intramedullary lesions of varying sizes; large masses expand and distort the bone. Lesional tissue is tan-white and gritty-appearing; on microscopic examination, it exhibits curved trabeculae of woven bone (mimicking Chinese characters), without osteoblastic rimming, surrounded by a moderately cellular fibroblastic proliferation (Fig. 20–13).

#### Clinical Course

The natural history depends on the extent of skeletal involvement; patients with monostotic disease usually have minimal symptoms. On x-ray imaging, lesions exhibit a characteristic ground glass appearance with well-defined margins. Symptomatic lesions are readily cured by conservative surgery. Polyostotic involvement frequently is associated with progressive disease and more severe skeletal complications (e.g., fractures, long bone deformities, craniofacial distortion). Rarely, polyostotic disease can transform into osteosarcoma, *especially after radiotherapy*.

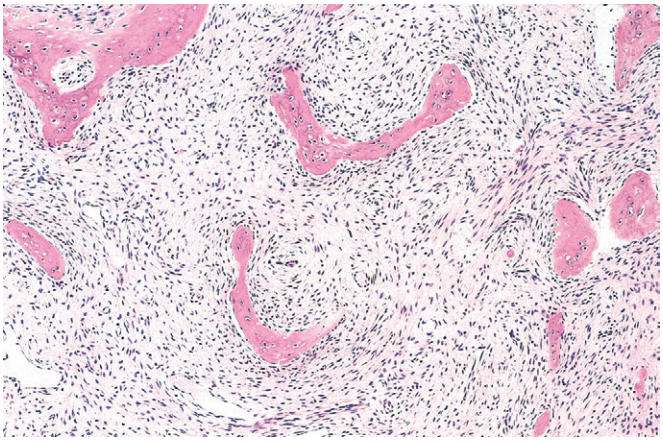

**Figure 20–13** Fibrous dysplasia. Curved trabeculae of woven bone arising in a fibrous tissue. Note the absence of osteoblasts rimming the bones.

## Miscellaneous Bone Tumors

### *Ewing Sarcoma and Primitive Neuroectodermal Tumor*

Ewing sarcoma and primitive neuroectodermal tumors (PNETs) are primary malignant small round cell tumors of bone and soft tissue. They share certain molecular features (described below) and are best viewed as variants of the same tumor, differing only in degree of neuroectodermal differentiation and clinical features. PNETs demonstrate clear neural differentiation, whereas Ewing sarcomas are undifferentiated.

Ewing sarcoma accounts for 6% to 10% of primary malignant bone tumors. After osteosarcoma, it is the second most common pediatric bone sarcoma. Most patients are 10 to 15 years of age, and 80% are younger than 20 years. Boys are affected slightly more frequently than girls, and there is a striking racial predilection for whites; blacks and Asians are rarely afflicted. The common chromosomal abnormality is a translocation that causes fusion of the *EWS* gene on 22q12 with a member of the *ETS* family of transcription factors. The most common fusion partners are the *FL1* gene on 11q24 and the *ERG* gene on 21q22. The resulting chimeric protein functions as a transcription factor, but precisely how it contributes to oncogenesis remains uncertain; effects on differentiation, proliferation, and survival have all been proposed. At a practical level, these translocations are of diagnostic importance, as approximately 95% of tumors have t(11;22)(q24;q12) or t(21;22)(q22;q12).

### MORPHOLOGY

Ewing sarcoma/PNET arises in the medullary cavity and invades the cortex and periosteum to produce a soft tan-white tumor mass, frequently with hemorrhage and necrosis. It is composed of sheets of uniform small, round cells that are slightly larger than lymphocytes; typically, there are few mitotic figures and little intervening stroma (Fig. 20–14). The cells have scant glycogen-rich cytoplasm. The presence of **Homer-Wright rosettes** (tumor cells circled about a central fibrillary space) indicates neural differentiation.

#### Clinical Features

Ewing sarcoma/PNET typically manifests as a painful enlarging mass in the diaphyses of long tubular bones (especially the femur) and the pelvic flat bones. Some patients have systemic signs and symptoms suggestive of infection. Imaging studies show a destructive lytic tumor with infiltrative margins and extension into surrounding soft tissues. There is a characteristic periosteal reaction with deposition of bone in an onion-skin pattern.

Treatment includes chemotherapy and surgical excision with or without irradiation. The 5-year survival rate is currently 75% for patients presenting with localized tumors.

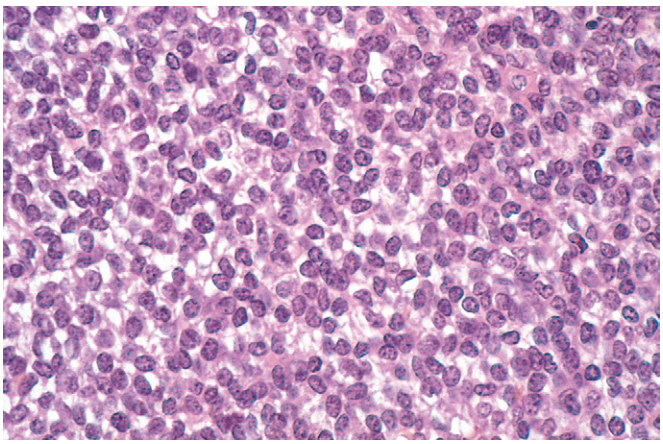

**Figure 20–14** Ewing sarcoma. Sheets of small round cells with scant, clear cytoplasm.

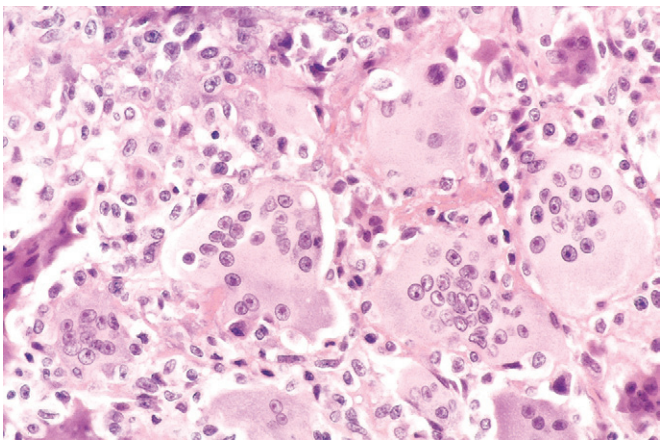

**Figure 20–15** Benign giant cell tumor showing abundant multinucleate giant cells and a background of mononuclear cells.

### *Giant Cell Tumor of Bone*

Giant cell tumors (GCTs) contain prominent by multinucleate osteoclast-type giant cells—hence the synonym *osteoclastoma.* GCT is a relatively common benign but locally aggressive bone tumor, usually arising in persons in their 20s to 40s. Despite the name, molecular analyses have shown that it is the mononuclear cells in the tumor that are neoplastic. These cells may be related to osteoblast precursor cells, as they express RANK ligand, which may stimulate the development of surrounding non-neoplastic osteoclast-like cells.

#### MORPHOLOGY

GCTs are large and red-brown, and often show cystic degeneration. They are composed of uniform oval mononuclear cells and scattered osteoclast-type giant cells containing 100 or more nuclei (Fig. 20–15). Mitotic figures are typically frequent. Necrosis, hemorrhage, and reactive bone formation also are commonly present.

#### Clinical Course

Although almost any bone may be involved, a majority of GCTs arise in the epiphysis and involve the metaphysis of long bones around the knee (distal femur and proximal tibia), frequently causing pain. Occasionally, GCTs manifest with pathologic fractures. Most are solitary tumors. Radiographically, GCTs are large, purely lytic, and eccentric; the overlying cortex frequently is destroyed, producing a bulging soft tissue mass with a thin shell of reactive bone. Although GCTs are considered benign, roughly half recur after simple curettage, and as many as 2% spread to the lungs as localized lesions that are cured by local excision.

### *Metastatic Disease*

*Metastatic tumors are the most common malignant tumors involving bone.* Pathways of spread include (1) direct extension, (2) lymphatic or hematogenous dissemination, and (3) intraspinal seeding. Any cancer can spread to bone, but certain tumors exhibit a distinct skeletal predilection. In adults more than 75% of skeletal metastases originate from cancers of the prostate, breast, kidney, and lung. In children, neuroblastoma, Wilms tumor, osteosarcoma, Ewing sarcoma, and rhabdomyosarcoma are the common sources of bony metastases.

Most metastases involve the axial skeleton (vertebral column, pelvis, ribs, skull, sternum), proximal femur, and humerus, in descending order. The red marrow in these areas, with its rich capillary network, slow blood flow, and nutrient environment rich in growth factors, facilitates tumor cell implantation and growth.

The radiologic appearance of metastases can be purely lytic, purely blastic, or both. In lytic lesions (e.g., with kidney and lung tumors and melanoma), the metastatic cells secrete substances such as prostaglandins, interleukins, and PTH-related protein (PTHrP) that stimulate osteoclastic bone resorption; the tumor cells themselves do not directly resorb bone. Similarly, metastatic tumors that elicit an osteoblastic response (e.g., prostate adenocarcinoma) do so by stimulating osteoblastic bone formation. Most metastases induce a mixed lytic and blastic reaction.

#### SUMMARY

##### Bone Tumors

- Most bone tumors are categorized according to their normal tissue counterpart; chondroid and bony matrices are roughly equally represented. Benign lesions far outnumber malignant tumors. Metastatic tumors are the most common form of skeletal malignancy.
- Major tumor types can be subdivided as follows:
  - Benign neoplasms
    - Fibrous cortical defect/nonossifying fibroma—spindle cells arranged in storiform pattern
    - Fibrous dysplasia—curvilinear trabeculae of woven bone surrounded by benign fibroblasts
    - Osteoid osteoma—islands of woven bone, typically involving the proximal femur or tibia
    - Osteochondroma—cartilage-capped outgrowths at epiphyseal growth plates

- Enchondroma—nodules of hyaline cartilage
- Giant cell tumor—composed of a mixture of neoplastic mononuclear cells and reactive osteoclast-like giant cells, typically occupying long bone epiphyses
- Malignant neoplasms
  - Osteosarcoma—malignant mesenchymal tumor forming bone; 20% of primary bone tumors
  - Chondrosarcoma—malignant mesenchymal tumor forming cartilage
  - Ewing sarcoma—aggressive small round cell tumor of adolescents with EWS gene rearrangements.

# JOINTS

The joints are subject to a wide variety of disorders, including degeneration, infections, immune-mediated injury, metabolic derangements, and neoplasms. Discussed in this section are the most common forms of arthritis—namely, osteoarthritis or degenerative joint disease, select autoimmune arthritides, gout, and infectious arthritis—along with the two most common benign joint tumors.

## ARTHRITIS

### Osteoarthritis

*Osteoarthritis,* or *degenerative joint disease,* is the most common joint disorder. It is a frequent, if not inevitable, part of aging and is an important cause of physical disability in persons older than 65 years of age. *The fundamental feature of osteoarthritis is degeneration of the articular cartilage;* structural changes in the underlying bone are likely secondary. Although the term *osteoarthritis* implies an inflammatory disease, osteoarthritis is primarily a degenerative disorder of articular cartilage in which the chondrocytes respond to biomechanical and biologic stresses in a way that results in breakdown of the matrix.

In most cases, osteoarthritis appears insidiously with age and without apparent initiating cause (*primary osteoarthritis*). In such cases the disease usually is *oligoarticular* (i.e., affecting only a few joints), with the joints of the hands, knees, hips, and spine most commonly affected. In the unusual circumstance (less than 5% of cases) when osteoarthritis strikes in youth, there is typically some predisposing condition, such as previous trauma, developmental deformity, or underlying systemic disease such as ochronosis, hemochromatosis, or marked obesity. In these settings the disease is called *secondary osteoarthritis* and often involves one or several predisposed joints. Gender has some influence; knees and hands are more commonly affected in women, whereas hips are more commonly affected in men. It is estimated that the economic toll of osteoarthritis in the United States is more than $33 billion annually.

#### MORPHOLOGY

The early changes in osteoarthritis include alterations in the composition and structure of the matrix. The chondrocytes have limited capacity to proliferate, and some divide to form small clones of cells that secrete newly synthesized matrix. Subsequently, vertical and horizontal **fibrillation and cracking of the matrix** occur as the superficial layers of the cartilage are degraded (Fig. 20–16, *A*). Gross examination at this stage reveals a soft granular-appearing articular cartilage surface, a condition known as **chondromalacia.** Eventually, full-thickness portions of the cartilage are lost, and the subchondral bone plate is exposed and is smoothened and burnished by friction, giving it the appearance of polished ivory **(bone eburnation)** (Fig. 20–16, *B*). The underlying cancellous bone becomes rebuttressed by osteoblastic activity. Small fractures can dislodge pieces of cartilage and subchondral bone into the joint, forming loose bodies

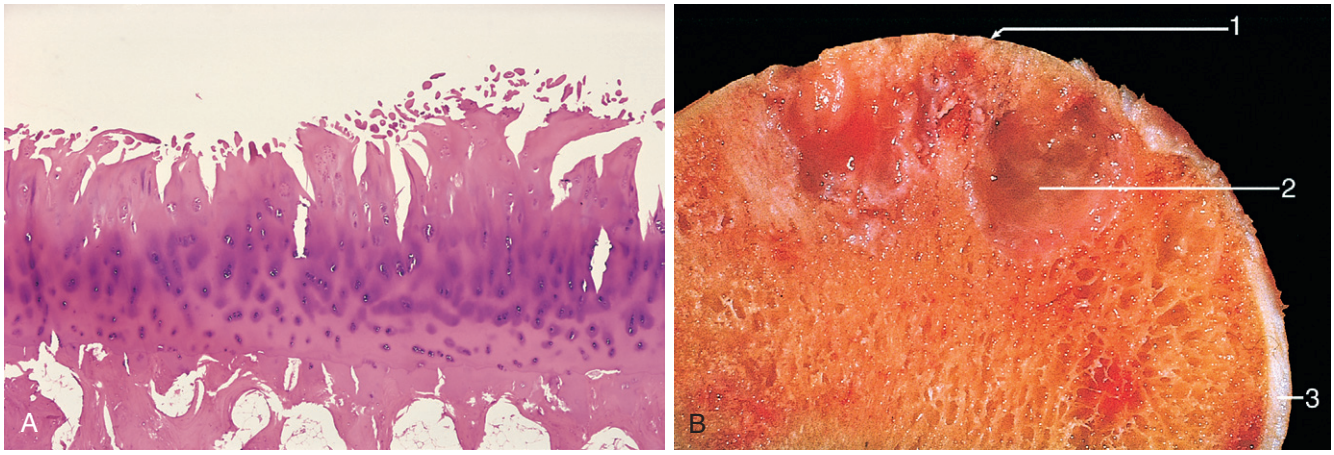


**Figure 20–16** Osteoarthritis. **A,** Histologic demonstration of the characteristic fibrillation of the articular cartilage. **B,** Severe osteoarthritis, with eburnated articular surface exposing subchondral bone (*1*), subchondral cyst (*2*), and residual articular cartilage (*3*).

**(joint mice).** The fracture gaps allow synovial fluid to be forced into the subchondral regions to form fibrous walled cysts. Mushroom-shaped **osteophytes** (bony outgrowths) develop at the margins of the articular surface. In severe disease, a fibrous synovial **pannus** covers the peripheral portions of the articular surface.

## PATHOGENESIS

**Articular cartilage bears the brunt of the degenerative changes in osteoarthritis.** Normal articular cartilage performs two functions: (1) Along with the synovial fluid, it provides virtually friction-free movement within the joint; and (2) in weight-bearing joints, it spreads the load across the joint surface in a manner that allows the underlying bones to absorb shock and weight. These functions require the cartilage to be elastic (i.e., to regain normal architecture after compression) and to have high tensile strength. These attributes are provided by proteoglycans and type II collagen, respectively, both produced by chondrocytes. As with adult bone, articular cartilage constantly undergoes matrix degradation and replacement. Normal chondrocyte function is critical to maintain cartilage synthesis and degradation; any imbalance can lead to osteoarthritis.

Chondrocyte function is affected by a variety of influences. Although osteoarthritis is not exclusively a wear-and-tear phenomenon, mechanical stresses and aging nevertheless figure prominently. **Genetic factors,** including polymorphisms and mutations in genes encoding components of the matrix and signaling molecules, contribute to osteoarthritis susceptibility. The risk of osteoarthritis also is increased with increasing bone density, as well as sustained high estrogen levels.

Regardless of the inciting stimulus, there is an imbalance in the expression, activity, and signaling of cytokines and growth factors that results in degradation and loss of matrix.

Early osteoarthritis is marked by degenerating cartilage containing more water and less proteoglycan (the proteoglycan component conveys turgor and elasticity). The type II collagen network also is diminished, presumably as a result of decreased local synthesis and increased breakdown; chondrocyte apoptosis is increased. Overall, cartilage tensile strength and resilience are compromised. In response to these degenerative changes, chondrocytes proliferate and attempt to "repair" the damage by synthesizing new collagen and proteoglycans. Although these reparative changes initially are able to keep pace, matrix changes and chondrocyte loss eventually predominate.

### Clinical Course

Osteoarthritis is an insidious disease, predominantly affecting patients beginning in their 50s and 60s. Characteristic symptoms and signs include deep, aching pain exacerbated by use, morning stiffness, crepitus (grating or popping sensation in the joint), and limitation in range of movement. Osteophyte impingement on spinal foramina can cause nerve root compression with radicular pain, muscle spasms, muscle atrophy, and neurologic deficits. Hips, knees, lower lumbar and cervical vertebrae, proximal and distal interphalangeal joints of the fingers, first carpometacarpal joints, and first tarsometatarsal joints of the feet are commonly involved. *Heberden nodes* in the fingers, representing prominent osteophytes at the distal interphalangeal joints, are characteristic in women. Aside from complete inactivity, there is no predicted way to prevent or halt the progression of primary osteoarthritis; it can stabilize for years but generally is slowly progressive. With time, significant joint deformity can occur, but unlike in rheumatoid arthritis (discussed next), fusion does not take place. Treatment usually is based on symptoms, with joint replacement in severe cases. A comparison of the important morphologic features of these two disorders is presented in Figure 20–17.

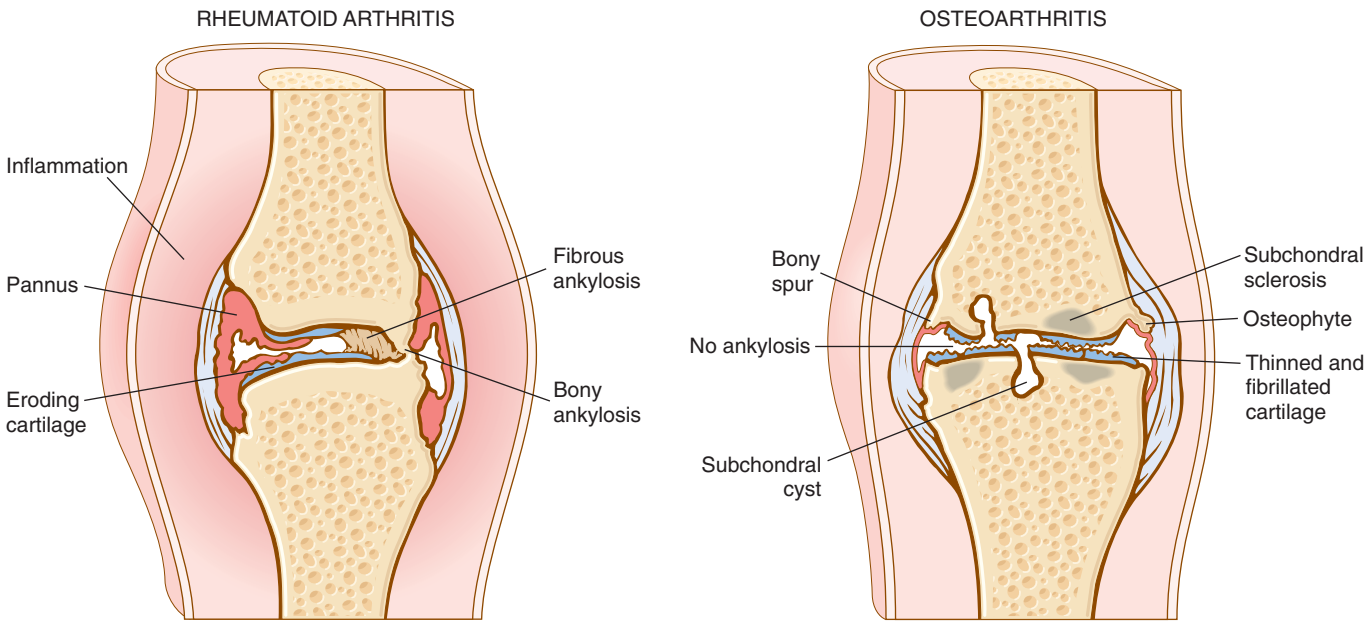


**Figure 20–17** Comparison of the morphologic features of rheumatoid arthritis (RA) and osteoarthritis.

## Rheumatoid Arthritis

*Rheumatoid arthritis (RA)* is a systemic, chronic inflammatory autoimmune disease affecting many tissues but principally attacking the joints. It causes a nonsuppurative proliferative synovitis that frequently progresses to destroy articular cartilage and underlying bone with resulting disabling arthritis. When extraarticular involvement develops—for example, of the skin, heart, blood vessels, muscles, and lungs—RA may resemble lupus or scleroderma.

RA is a relatively common condition, with a prevalence of approximately 1%; it is three to five times more common in women than in men. The peak incidence is in the second to fourth decades of life, but no age is immune.

### PATHOGENESIS

RA is an autoimmune disease involving complex, and still poorly understood, interactions of genetic risk factors, environment, and the immune system. The pathologic changes are caused mainly by **cytokine-mediated inflammation, with CD4+ T cells being the principal source of the cytokines** (Fig. 20–18). Many patients also produce **antibodies against cyclic citrullinated peptides (CCPs),** which may contribute to the joint lesions. CCPs are derived from proteins in which arginine residues are converted to citrulline residues posttranslationally. In RA, antibodies to citrullinated fibrinogen, type II collagen, α-enolase, and vimentin are the most important and may form immune complexes that deposit in the joints. These antibodies are a diagnostic marker for the disease and may be involved in tissue injury.

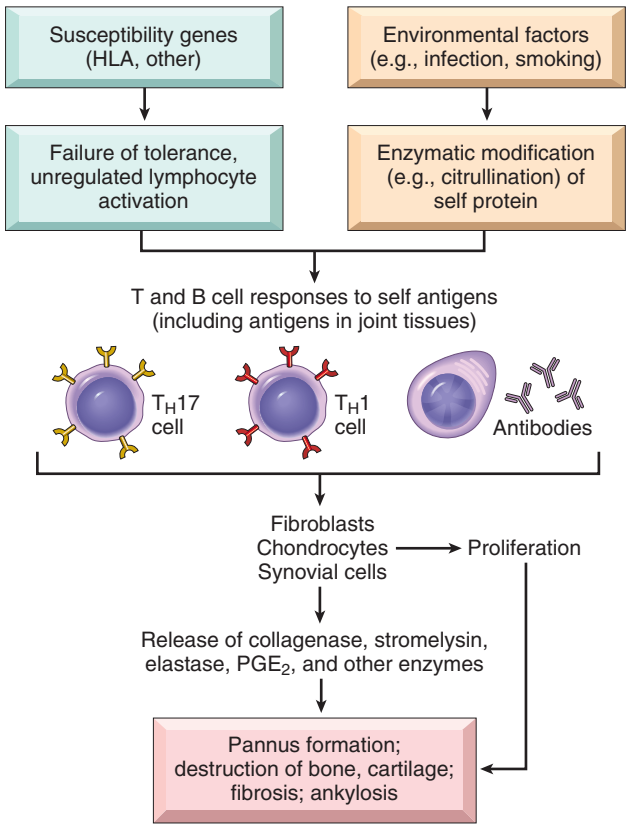


**Figure 20–18** Major processes involved in pathogenesis of rheumatoid arthritis.

Like other autoimmune diseases, RA is a disorder in which genetic and environmental factors contribute to the breakdown of tolerance to self-antigens.

- **Genetic factors:** It is estimated that 50% of the risk of developing RA is related to genetic factors. Susceptibility to rheumatoid arthritis is linked to the HLA-DRB1 locus. Recent linkage and genome-wide association studies have revealed a large number of non-HLA genes in which polymorphisms are associated with RA. There is a strong association with a polymorphism in the *PTPN22* gene, which encodes a tyrosine phosphatase that is postulated to inhibit T cell activation.
- **Environmental factors:** Many candidate infectious agents whose antigens may activate T or B cells have been considered, but none has been conclusively implicated. As mentioned above, in at least 70% of patients the blood contains anti-CCP antibody, which may be produced during inflammation. Inflammatory and environmental insults such as smoking and infections may induce the citrullination of some self proteins, creating new epitopes that trigger autoimmune reactions.

It is proposed that the disease is initiated in a genetically predisposed person by activation of CD4+ helper T cells responding to some arthritogenic agent, possibly microbial, or to a self-antigen such as CCP (Fig. 20–18). CD4+ $T_H1$ and $T_H17$ cells, activated B lymphocytes, plasma cells, and macrophages, as well as other inflammatory cells, are found in the inflamed synovium, and in severe cases, well-formed lymphoid follicles with germinal centers may be present. Numerous cytokines, including IL-1, IL-8, TNF, IL-6, IL-17, and interferon-γ, have been detected in the synovial fluid. Cytokines produced by the activated T cells recruit leukocytes such as macrophages, whose products cause tissue injury, and also activate resident synovial cells to produce proteolytic enzymes, such as collagenase, that mediate destruction of the cartilage, ligaments, and tendons of the joints. Increased osteoclast activity in the joints contributes to the bone destruction in rheumatoid arthritis; this may be caused by the production of the TNF family cytokine RANK ligand by activated T cells. Despite the plethora of cytokines produced in the joint in RA, TNF appears to play a pivotal role. This is demonstrated by the remarkable effectiveness of TNF antagonists in patients with the disease, even those who are resistant to other therapies.

It is suspected from a variety of experimental and clinical observations that antibodies also play a role in the disease. The contribution of anti-CCP was previously mentioned. About 80% of patients have serum immunoglobulin M (IgM) (and, less frequently, IgA) autoantibodies that bind to the Fc portions of their own (self) IgG. These autoantibodies are called **rheumatoid factor.** They may form immune complexes with self-IgG that deposit in joints and other tissues, leading to inflammation and tissue damage. However, the role of rheumatoid factor in the pathogenesis of the joint or extraarticular lesions has not been established. Of interest, there seem to be two variants of RA, one characterized by presence of anti-CCP and rheumatoid factor and another in which these autoantibodies are lacking.

## MORPHOLOGY

A broad spectrum of morphologic alterations are seen in RA; the most severe occur in the joints. RA typically manifests as **symmetric arthritis, principally affecting the small joints** of the hands and feet, ankles, knees, wrists, elbows, and shoulders. Most often, the proximal interphalangeal and metacarpophalangeal joints are affected, but distal interphalangeal joints are spared. Axial involvement, when it occurs, is limited to the upper cervical spine; similarly, hip joint involvement is extremely uncommon. On histologic examination, the affected joints show **chronic papillary synovitis,** characterized by (1) synovial cell hyperplasia and proliferation; (2) dense perivascular inflammatory cell infiltrates (frequently forming lymphoid follicles) in the synovium composed of CD4+ T cells, plasma cells, and macrophages; (3) increased vascularity due to angiogenesis; (4) neutrophils and aggregates of organizing fibrin on the synovial surface and in the joint space; and (5) increased osteoclast activity in the underlying bone, leading to synovial penetration and periarticular bone erosion. The classic appearance is that of a **pannus,** formed by proliferating synovial lining cells admixed with inflammatory cells, granulation tissue, and fibrous connective tissue; the overgrowth of this tissue is so exuberant that the usually thin, smooth synovial membrane is transformed into lush, edematous, frondlike (villous) projections (Fig. 20–19, *A–C*). With full-blown inflammatory joint involvement, periarticular soft tissue edema usually develops, classically manifested first by fusiform swelling of the proximal interphalangeal joints. With progression of the disease, the articular cartilage subjacent to the pannus is eroded and, in time, virtually destroyed. The subarticular bone also may be attacked and eroded. Eventually the pannus fills the joint space, and subsequent **fibrosis and ossification** may cause permanent **ankylosis.** The radiographic hallmarks are joint effusions and juxtaarticular osteopenia with erosions and narrowing of the joint space and loss of articular cartilage. Destruction of tendons, ligaments, and joint capsules produces the characteristic deformities, including radial deviation of the wrist, ulnar deviation of the fingers, and flexion-hyperextension abnormalities of the fingers (swan-neck deformity, boutonnière deformity).

**Rheumatoid subcutaneous nodules** develop in about one fourth of patients, occurring along the extensor surface of the forearm or other areas subjected to mechanical pressure; rarely, they can form in the lungs, spleen, heart, aorta, and other viscera. Rheumatoid nodules are firm, nontender, oval or rounded masses as large as 2 cm in diameter. They are characterized microscopically by a central focus of fibrinoid necrosis surrounded by a palisade of macrophages, which in turn is rimmed by granulation tissue and lymphocytes (Fig. 20–20).

Patients with severe erosive disease, rheumatoid nodules, and high titers of **rheumatoid factor** are at risk of developing vasculitic syndromes; acute necrotizing vasculitis may involve small or large arteries. Serosal involvement may manifest as fibrinous pleuritis or pericarditis or both. Lung parenchyma may be damaged by progressive interstitial fibrosis. Ocular changes such as uveitis and keratoconjunctivitis (similar to those seen in Sjögren syndrome; see Chapter 4) may be prominent in some cases.

### Clinical Features

Although RA is basically a symmetric polyarticular arthritis, there also may be constitutional symptoms such as weakness, malaise, and low-grade fever. Many of the systemic manifestations result from the same mediators that cause joint inflammation (e.g., IL-1, TNF). The arthritis first appears insidiously, with aching and stiffness of the joints, particularly in the morning. As the disease advances, the joints become enlarged, motion is limited, and in time complete ankylosis may appear. Vasculitic involvement of the extremities may give rise to Raynaud phenomenon and

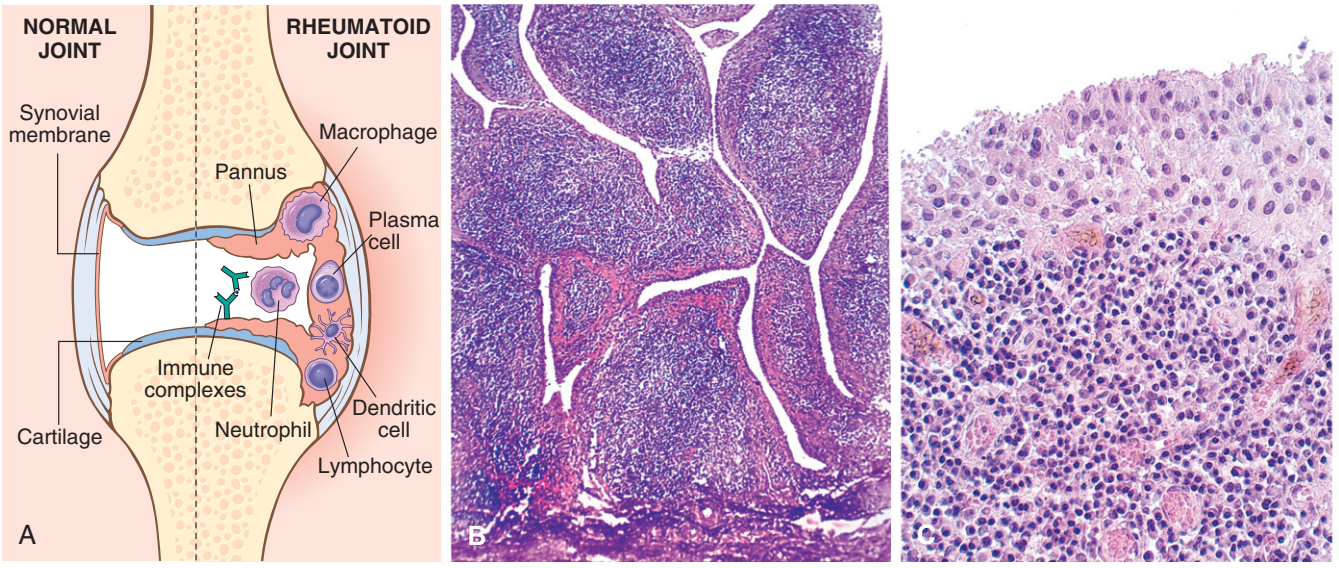


**Figure 20–19** Rheumatoid arthritis. **A,** A joint lesion. **B,** Synovium demonstrating papillary hyperplasia caused by dense inflammatory infiltrate. **C,** Hypertrophied synoviocytes with numerous underlying lymphocytes and plasma cells.

*(A, Modified with permission from Feldmann M: Development of anti-TNF therapy for rheumatoid arthritis. Nat Rev Immunol 2:364, 2002.)*

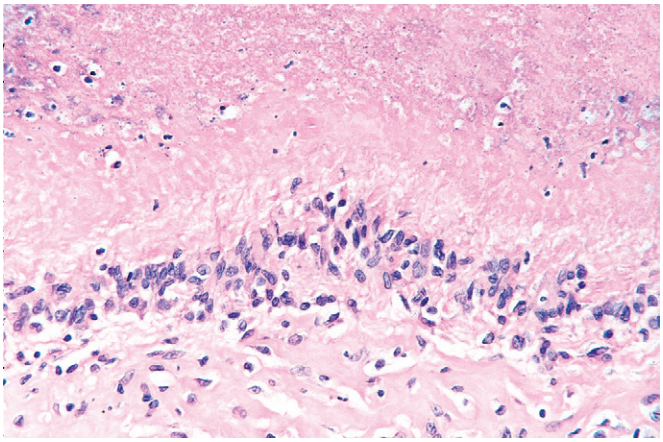

**Figure 20–20** Rheumatoid nodule. Serpiginous area of necrobiotic collagen surrounded by palisading histiocytes.

chronic leg ulcers. Such multisystem involvement must be distinguished from lupus, scleroderma, polymyositis, dermatomyositis, and Lyme disease, as well as other forms of arthritis. Helpful in making the correct diagnosis are (1) characteristic radiographic findings; (2) sterile, turbid synovial fluid with decreased viscosity, poor mucin clot formation, and inclusion-bearing neutrophils; and (3) anti-CCP and rheumatoid factor (80% of patients).

The clinical course of RA is highly variable. In a minority of patients, the disease may stabilize or even regress; in most patients, however, it pursues a chronic, remitting-relapsing course. Historically, the natural history of the disease has been one of progressive joint destruction leading to disability after 10 to 15 years. The outcome has been dramatically improved by recent advances in therapy, including aggressive treatment of early RA and the introduction of highly effective biologic agents that antagonize TNF. RA is an important cause of reactive amyloidosis (Chapter 4), which develops in 5% to 10% of these patients, particularly those with long-standing severe disease.

## Juvenile Rheumatoid Arthritis

*Juvenile rheumatoid arthritis* (JRA) is not a single disease but a group of multifactorial disorders with environmental and genetic components. These disorders are of unknown etiology and are classified according to their presentation into oligoarthritis, polyarthritis, and systemic (Still's disease) variants. Large joints often are affected, and symptoms and signs such as joint swelling, warmth, pain, and loss of function begin before the age of 16 years and persist for more than 6 weeks. Extraarticular inflammatory manifestations such as uveitis also may be present. Common risk factors include genetic susceptibility (such as particular HLA and PTPN22 gene variants) and perhaps infection. As in adult RA, the pathogenesis is likely to involve activation of $T_H1$ and $T_H17$ cells, which in turn activate B cells, macrophages, and fibroblasts to produce antibodies and a variety of cytokines including TNF, IL-1, and IL-6, which eventually result in damage to articular structures.

## Seronegative Spondyloarthropathies

Clinical, morphologic, and genetic features distinguish these disorders from rheumatoid arthritis and other arthritides. The spondyloarthropathies are characterized by the following:

- Pathologic changes that begin in the ligamentous attachments to bone rather than in the synovium
- Involvement of the sacroiliac joints, with or without arthritis in other peripheral joints
- Absence of rheumatoid factor (hence the designation *seronegative*)
- Association with HLA-B27

This group of disorders includes several clinical entities, of which ankylosing spondylitis is the prototype. Others include Reiter syndrome, psoriatic arthritis, spondylitis associated with inflammatory bowel diseases, and reactive arthropathies after infections (e.g., with *Yersinia, Shigella, Salmonella, Helicobacter,* or *Campylobacter*). Sacroiliitis is a common manifestation in all of these disorders; they are distinguished from one another by the particular peripheral joints involved, as well as on the basis of associated extraskeletal manifestations (for example, urethritis, conjunctivitis, and uveitis are characteristic of Reiter syndrome). Although triggering infections and immune mechanisms are thought to underlie most of the seronegative spondyloarthropathies, their pathogenesis remains obscure.

## Gout

Gout affects about 1% of the population, and shows a predeliction for males. It is caused by excessive amounts of *uric acid, an end product of purine metabolism, within tissues and body fluids.* Monosodium urate crystals precipitate from supersaturated body fluids and induce an acute inflammatory reaction. Gout is marked by recurrent episodes of acute arthritis, sometimes accompanied by the formation of large crystalline aggregates called *tophi,* and eventual permanent joint deformity. Although an elevated level of uric acid is an essential component of gout, not all such persons develop gout, and genetic and environmental factors also contribute to its pathogenesis. Gout traditionally is divided into primary and secondary forms, accounting for about 90% and 10% of cases, respectively (Table 20–3). *Primary gout* designates cases in which the basic cause is unknown or (less commonly) in which the disorder is due to an inborn metabolic defect that causes hyperuricemia. In *secondary gout,* the cause of the hyperuricemia is known, but gout is not necessarily the main or even dominant clinical disorder.

### MORPHOLOGY

The major morphologic manifestations of gout are acute arthritis, chronic tophaceous arthritis, tophi in various sites, and gouty nephropathy.

**Acute arthritis** is characterized by a dense neutrophilic infiltrate permeating the synovium and synovial fluid. Long, slender, needle-shaped **monosodium urate crystals**

**Table 20–3** Classification of Gout

| Clinical Category | Metabolic Defect |
|---|---|
| **Primary Gout (90% of cases)** | |
| Enzyme defects—unknown (85% to 90% of cases) | Overproduction of uric acid<br>Normal excretion (majority)<br>Increased excretion (minority)<br>Underexcretion of uric acid with normal production |
| Known enzyme defects—e.g., partial HGPRT deficiency (rare) | Overproduction of uric acid |
| **Secondary Gout (10% of cases)** | |
| Associated with increased nucleic acid turnover—e.g., leukemias | Overproduction of uric acid with increased urinary excretion |
| Chronic renal disease | Reduced excretion of uric acid with normal production |
| Inborn errors of metabolism | Overproduction of uric acid with increased urinary excretion, e.g., complete HGPRT deficiency (Lesch-Nyhan syndrome) |

HGPRT, hypoxanthine guanine phosphoribosyl transferase.

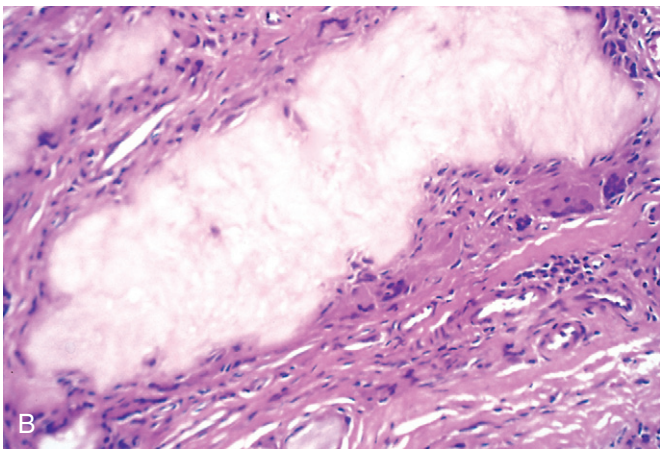


**Figure 20–21** Gout. **A,** Amputated great toe with white tophi involving the joint and soft tissues. **B,** Photomicrograph of a gouty tophus. An aggregate of dissolved urate crystals is surrounded by reactive fibroblasts, mononuclear inflammatory cells, and giant cells.

frequently are found in the cytoplasm of the neutrophils as well as in small clusters in the synovium. The synovium is edematous and congested and contains scattered mononuclear inflammatory cells. When the episode of crystallization abates and the crystals resolubilize, the attack remits.

**Chronic tophaceous arthritis** evolves from repetitive precipitation of urate crystals during acute attacks. The urates can heavily encrust the articular surfaces and form visible deposits in the synovium (Fig. 20–21, *A*). The synovium becomes hyperplastic, fibrotic, and thickened by inflammatory cells, forming a pannus that destroys the underlying cartilage, leading to juxtaarticular bone erosions. In severe cases, fibrous or bony ankylosis ensues, resulting in loss of joint function.

**Tophi are pathognomonic for gout.** They are formed by large aggregations of urate crystals surrounded by an intense inflammatory reaction of lymphocytes, macrophages, and foreign-body giant cells, attempting to engulf the masses of crystals (Fig. 20–21, *B*). Tophi can appear in the articular cartilage of joints and in the periarticular ligaments, tendons, and soft tissues, including the ear lobes, nasal cartilages, and skin of the fingertips. Superficial tophi can lead to large ulcerations of the overlying skin.

**Gouty nephropathy** refers to renal complications associated with urate deposition, variously forming medullary tophi, intratubular precipitations, or free uric acid crystals and renal calculi. Secondary complications such as pyelonephritis can occur, especially when there is urinary obstruction.

## PATHOGENESIS

Elevated uric acid levels can result from overproduction or reduced excretion of uric acid, or both (Table 20–3). Most cases of gout are characterized by a primary overproduction of uric acid. Less commonly, uric acid is produced at normal rates, and hyperuricemia occurs because of decreased renal excretion of urate. For an understanding of these influences, a brief review of normal uric acid synthesis and excretion is warranted.

- **Uric acid synthesis.** Uric acid is the end product of purine catabolism; consequently increased urate synthesis typically reflects some abnormality in purine nucleotide production. The synthesis of purine nucleotides involves two different but interlinked pathways: the de novo and salvage pathways.
- The **de novo pathway** is involved in the synthesis of purine nucleotides from nonpurine precursors.
- The **salvage pathway** is involved in the synthesis of purine nucleotides from free purine bases, derived from dietary intake and by catabolizing nucleic acids and purine nucleotides.
- **Uric acid excretion.** Circulating uric acid is freely filtered by the glomerulus and virtually completely resorbed in the proximal tubules of the kidney. A small fraction of the resorbed uric acid is subsequently secreted by the distal nephron and excreted in the urine.

Although the cause of excessive uric acid biosynthesis in **primary gout** is unknown in most cases, rare patients have identifiable enzymatic defects. For example, complete lack of

HGPRT, an enzyme essential in the salvage pathway, gives rise to the **Lesch-Nyhan syndrome.** In **secondary gout,** hyperuricemia can be caused by increased urate production (e.g., rapid cell lysis during chemotherapy for lymphoma or leukemia) or decreased excretion (chronic renal insufficiency), or both. Reduced renal excretion may also be caused by drugs such as thiazide diuretics, presumably because of effects on uric acid tubular transport.

Whatever the cause, increased levels of uric acid in the blood and other body fluids (e.g., synovium) lead to the precipitation of monosodium urate crystals. This, in turn, triggers a chain of events that culminate in joint injury (Fig. 20–22). Urate crystals are thought to directly activate the complement system, leading to production of chemotactic and pro-inflammatory mediators. The crystals are phagocytosed by macrophages and recognized by the intracellular sensor called the inflammasome (Chapter 2), which is activated and stimulates the production of the cytokine IL-1. IL-1 is a mediator of inflammation, and causes local accumulation of neutrophils and macrophages in the joints and synovial membranes. These cells become activated, leading to the release of a host of additional mediators including chemokines, other cytokines, toxic free radicals, and leukotrienes—particularly leukotriene $B_4$. The activated neutrophils also liberate destructive lysosomal enzymes. The cytokines can also directly activate synovial cells and cartilage cells to release proteases (e.g., collagenase) that exacerbate tissue injury. The resulting acute arthritis typically remits in days to weeks, even if untreated. Repeated bouts, however, can lead to the permanent damage seen in chronic tophaceous arthritis.

### Clinical Features

Gout is more common in men than in women; it does not usually cause symptoms before the age of 30. Risk factors for the disease include obesity, excess alcohol intake, consumption of purine-r ich foods, diabetes, the metabolic syndrome, and renal failure. Polymorphisms in genes involved in the transport and homeostasis of urate such as *URAT1* and *GLUT9* also are associated with hyperuricemia and gout.

Four stages are classically recognized: (1) asymptomatic hyperuricemia, (2) acute gouty arthritis, (3) "intercritical" gout, and (4) chronic tophaceous gout. *Asymptomatic hyperuricemia* appears around puberty in males and after menopause in women. After a long interval of years, *acute arthritis* appears in the form of sudden onset, excruciating joint pain associated with localized erythema, and warmth; constitutional symptoms are uncommon, except possibly mild fever. The vast majority of first attacks are monoarticular; 50% occur in the first metatarsophalangeal joint

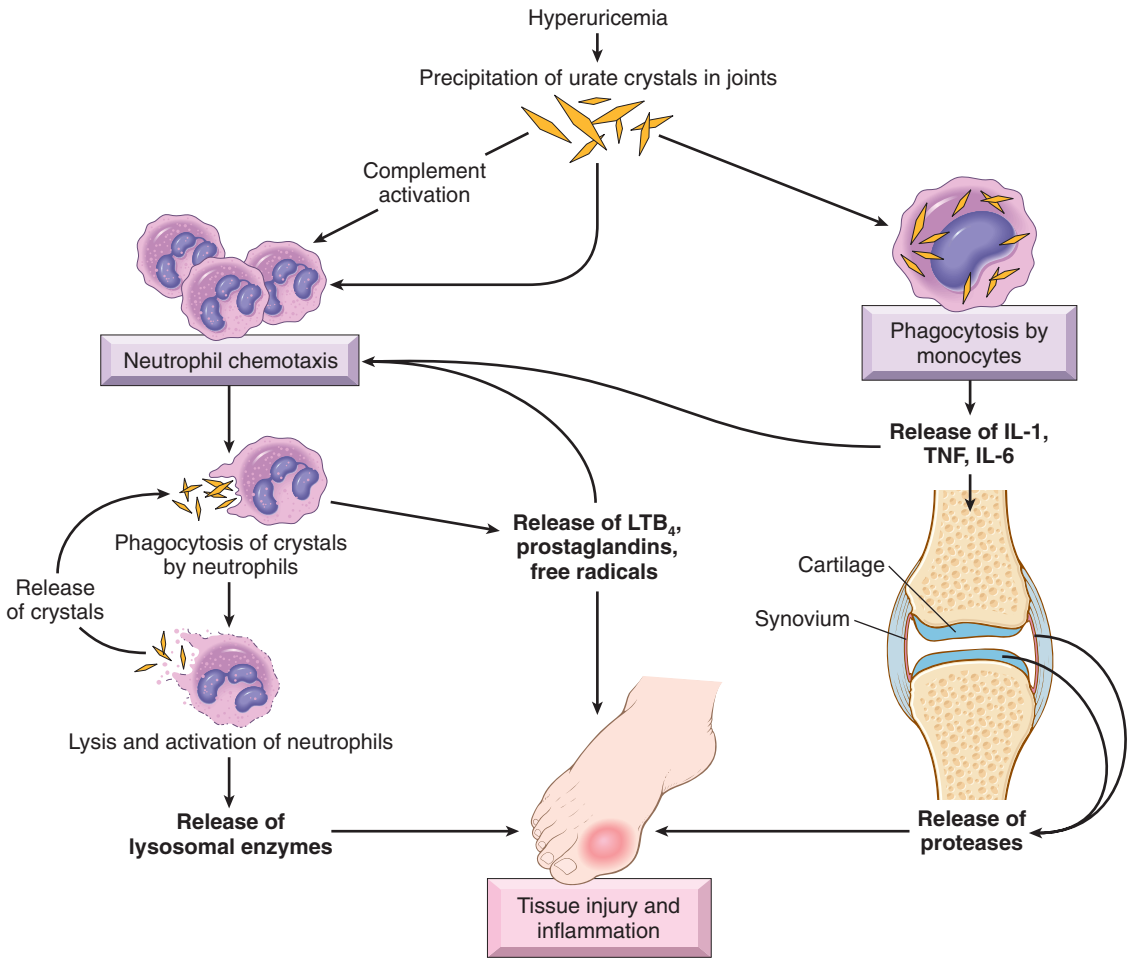


**Figure 20–22** Pathogenesis of acute gouty arthritis. IL, interleukin; $LTB_4$, leukotriene $B_4$; TNF, tumor necrosis factor.

(great toe), and 90% in the instep, ankle, heel, or wrist. Untreated, acute gouty arthritis may last for hours to weeks, but it gradually completely resolves, and the patient enters an *asymptomatic intercritical period.* Although some fortunate persons never have another attack, most experience a second episode within months to a few years. In the absence of appropriate therapy, the attacks recur at shorter intervals and frequently become polyarticular. Eventually, after a decade or so, symptoms fail to resolve completely after each attack, and the disease progresses to *chronic tophaceous gout.* At this stage, radiographs show characteristic juxtaarticular bone erosion caused by the crystal deposits and loss of the joint space. Progression leads to severe crippling disease.

Renal manifestations of gout can appear as renal colic associated with the passage of gravel and stones, and can evolve into chronic gouty nephropathy. About 20% of persons with chronic gout die of renal failure.

Numerous drugs are available to abort or prevent acute attacks of arthritis and mobilize tophaceous deposits. Their use is important, because many aspects of gout are related to the duration and severity of hyperuricemia. Generally, gout does not materially shorten the life span, but it can certainly impair quality of life.

## Pseudogout

*Pseudogout* also is known as *chondrocalcinosis* or, more formally, calcium pyrophosphate crystal deposition disease. The crystal deposits first appear in structures composed of cartilage such as menisci, intervertebral discs, and articular surfaces. When the deposits enlarge enough, they may rupture, inducing an inflammatory reaction. Pseudogout typically first occurs in persons 50 years of age or older, becoming more common with increasing age, and eventually reaching a prevalence of 30% to 60% in those age 85 or older. There is no gender or race predilection.

Although pathways leading to crystal formation are not understood, they are likely to involve the overproduction or decreased breakdown of pyrophosphate, resulting in its accumulation and eventual crystallization with calcium in the matrix surrounding chondrocytes. Mutations in a transmembrane pyrophosphate transporter are associated with a rare familial form of the disease, in which crystals develop relatively early in life and there is severe osteoarthritis.

Much of the subsequent joint pathology in pseudogout involves the recruitment and activation of inflammatory cells and is similar to that in gout (see earlier). Duration of clinical signs can be from several days to weeks, and joint involvement may be monoarticular or polyarticular; the knees, followed by the wrists, elbows, shoulders, and ankles, are most commonly affected. Ultimately, approximately 50% of patients experience significant joint damage. Therapy is supportive; no known treatment prevents or retards crystal formation.

## Infectious Arthritis

Microorganisms of any type can lodge in joints during hematogenous dissemination. Articular structures can also become infected by direct inoculation or by contiguous spread from osteomyelitis or a soft tissue abscess. Infectious arthritis is serious because it can cause rapid joint destruction and permanent deformities.

### *Suppurative Arthritis*

Bacteria can seed joints during episodes of bacteremia; joint infection with such microorganisms almost uniformly results in a suppurative arthritis. Although virtually any bacteria can be causal, *Haemophilus influenzae* predominates in children younger than 2 years of age, *S. aureus* is the main causative agent in older children and adults, and the gonococcus is prevalent in older adolescents and young adults. Patients with sickle cell disease are prone to *Salmonella* infection at any age. Both genders are affected equally, except for gonococcal arthritis, which occurs mainly in sexually active women. In this group, those with deficiency of certain complement proteins (C5, C6, and C7) are particularly susceptible to disseminated gonococcal infections and hence arthritis.

The classic presentation is one of sudden onset of pain, redness, and swelling of the affected joint(s), with restricted range of motion. Fever, leukocytosis, and elevated erythrocyte sedimentation rate are common. In gonococcal infections, the course tends to be more subacute. In 90% of cases of nongonococcal suppurative arthritis, the infection involves only a single joint—usually the knee—followed in order by hip, shoulder, elbow, wrist, and sternoclavicular joints. Joint aspiration typically yields a purulent fluid in which the causal agent can be identified.

### *Lyme Arthritis*

Lyme disease is caused by infection with the spirochete *Borrelia burgdorferi,* transmitted by deer ticks of the *Ixodes ricinus* complex; it is named for the Connecticut town where the disease was first recognized in the 1970s. With more than 20,000 cases reported annually, it is the leading arthropod-borne disease in the United States. As with another major spirochetal disease, syphilis, Lyme disease involves multiple organ systems and in its classic form progresses through three successive stages. In *stage 1, Borrelia* spirochetes multiply at the site of the tick bite and cause an expanding area of redness, often with an indurated or pale center. This skin lesion, called *erythema chronicum migrans,* may be accompanied by fever and lymphadenopathy but usually disappears in a few weeks' time. In *stage 2,* the *early disseminated stage,* spirochetes spread hematogenously and cause secondary annular skin lesions, lymphadenopathy, migratory joint and muscle pain, cardiac arrhythmias, and meningitis, often with cranial nerve involvement. Diagnostically useful antibodies (usually both IgM and IgG) against *Borrelia* antigens appear in the serum at this stage of the disease. Some spirochetes, however, escape host antibody and T cell responses by sequestering themselves in the central nervous system or within endothelial cells. In *stage 3,* the *late disseminated stage,* which occurs 2 or 3 years after the initial bite, Lyme *Borrelia* organisms cause a chronic arthritis, sometimes with severe damage to large joints, and an encephalitis that ranges in severity from mild to debilitating.

*Lyme arthritis* develops in roughly 60% to 80% of untreated patients and is the dominant feature of late

disease. The arthritis may be caused by immune responses against *Borrelia* antigens that cross-react with proteins in the joints, but the exact mechanisms are not yet understood. The disease tends to be migratory, with remissions and relapses. It involves mainly large joints, especially the knees, shoulders, elbows, and ankles, in descending order of frequency. Histologic examination reveals a chronic papillary synovitis with synoviocyte hyperplasia, fibrin deposition, mononuclear cell infiltrates, and onion-skin thickening of arterial walls; in severe cases, the morphology closely resembles that of rheumatoid arthritis. In only 25% of cases do silver stains reveal a sprinkling of organisms, and formal diagnosis of Lyme arthritis may depend on the clinical picture, including history, and/or appropriate serologic studies. Chronic arthritis with pannus formation and permanent deformities develops in roughly 1 in 10 patients.

### SUMMARY

#### Arthritis

- *Osteoarthritis (degenerative joint disease)* is by far the most common joint disease; it is primarily a degenerative disorder of articular cartilage in which matrix breakdown exceeds synthesis. Inflammation is secondary. The vast majority of cases occur without apparent precipitating cause except increasing age. Local production of proinflammatory cytokines and other mediators (IL-1, TNF, nitric oxide) may contribute to the progression of the joint degeneration.
- *Rheumatoid arthritis (RA)* is a chronic autoimmune inflammatory disease that affects mainly the joints, especially small joints, but can affect multiple tissues. RA is caused by an autoimmune response against self-antigen(s) such as citrullinated proteins, which leads to T cell reactions in the joint with production of cytokines that activate phagocytes that damage tissues and stimulate proliferation of synovial cells (synovitis). The cytokine TNF plays a central role, and antagonists against TNF are of great clinical benefit. Antibodies may also contribute to the disease.
- *Gout and pseudogout.* Increased circulating levels of uric acid (*gout*) or calcium pyrophosphate (*pseudogout*) can lead to crystal deposition in the joint space. Resulting inflammatory cell recruitment and activation lead to cartilage degradation, fibrosis, and arthritis.
- Either direct infection of a joint space (*suppurative arthritis*) or cross-reactive immune responses to systemic infections (e.g., in some cases of *Lyme arthritis*) can lead to joint inflammation and injury.

## JOINT TUMORS AND TUMOR-LIKE LESIONS

Primary neoplasms of joints are uncommon and usually benign; in general, they reflect the cells and tissue types (synovial membrane, vessels, fibrous tissue, and cartilage) native to the joints. Benign tumors are much more frequent than their malignant counterparts. The rare malignant neoplasms of these structures are discussed below with the soft tissue tumors. In comparison, reactive *tumor-like lesions such as ganglions and synovial cysts* are much more common than neoplasms; these typically result from trauma or degenerative processes. Here we discuss the more common or clinically significant tumor-like lesions and neoplasms of joints and associated soft tissues.

### Ganglion and Synovial Cysts

A *ganglion* is a small cyst (less than 1.5 cm in diameter) located near a joint capsule or tendon sheath; the wrist is an especially common site. Lesions manifest as firm to fluctuant pea-sized nodules that are translucent to light. Microscopically, they consist of fluid-filled spaces that lack a true cell lining, apparently because they stem from cystic degeneration of connective tissue. Coalescence of adjacent cysts can produce multilocular lesions. The cyst contents resemble synovial fluid, although often there is no communication with the joint space. Ganglions typically are completely asymptomatic. Classically, these can be treated by "Bible therapy": Whacking the affected area with a large tome usually is sufficient to rupture the cyst, but reaccumulation may recur. Despite their name, they have no relationship to ganglia of the nervous system.

Herniation of synovium through a joint capsule or massive enlargement of a bursa can produce a *synovial cyst.* A good example is the *Baker cyst* that occurs in the popliteal fossa.

### Tenosynovial Giant Cell Tumor

*Tenosynovial giant cell tumor* (TGCT) is a catchall term for several closely related benign neoplasms of synovium. Although these lesions previously were considered reactive proliferations (hence the earlier designation *synovitis*), they are consistently associated with an acquired (1;2) translocation that fuses the promoter of the collagen 6A3 gene to the coding sequence of the growth factor M-CSF. Classic examples are diffuse tenosynovial giant cell tumor, previously known as *pigmented villonodular synovitis* (PVNS), involving joint synovium, and localized tenosynovial giant cell tumor, also known as *giant cell tumor of tendon sheath*. Both types typically arise in people in their 20s to 40s, without gender predilection.

### MORPHOLOGY

Grossly, TGCTs are red-brown to orange-yellow. In the diffuse variant the joint synovium becomes a contorted mass of red-brown folds, finger-like projections, and nodules (Fig. 20–23, *A*). By contrast, the localized type is well circumscribed and contained. Tumor cells in both lesions resemble synoviocytes, and numerous hemosiderin-laden macrophages, osteoclast-like giant cells and hyalinized stromal collagen also are present (Fig. 20–23, *B*). The tumor cells spread along the surface and infiltrate the subsynovial compartment. In localized TGCT, the cells grow in a solid nodular aggregate. Other typical findings include hemosiderin deposits, foamy macrophages, multinucleate giant cells, and zones of scarring.

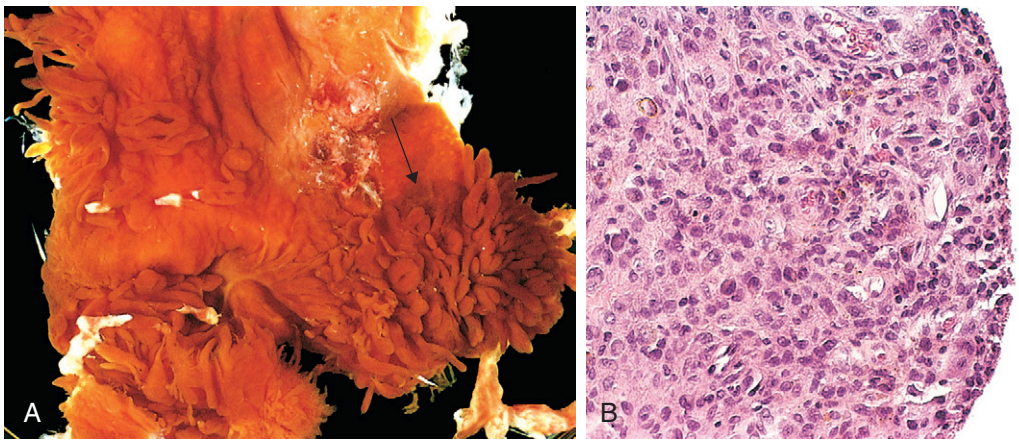


**Figure 20–23** Tenosynovial giant cell tumor, diffuse type. **A,** Excised synovium with fronds and nodules typical of the diffuse variant (*arrow*). **B,** Sheets of proliferating cells in tenosynovial giant cell tumor bulging the synovial lining.

### Clinical Features

Diffuse TGCT usually mimics a monoarticular arthritis; it affects the knee in 80% of cases, followed by the hip and ankle. Patients typically complain of pain, locking, and recurrent swelling. Tumor progression limits the range of movement of the joint. Aggressive lesions erode into adjacent bones and soft tissues, causing confusion with other tumors. In contrast, localized TGCT presents as a solitary, slowly growing, painless mass frequently involving wrist and finger tendon sheaths; it is the most common soft tissue tumor of the hand. Cortical erosion of adjacent bone occurs in approximately 15% of cases. Both lesions are amenable to surgical resection, but also prone to local recurrence. Recognition of the association of TGCT and M-CSF gene rearrangement and overexpression has inspired trials of antagonists of M-CSF or its cognate receptor (M-CSFR, a tyrosine kinase); some excellent responses have been reported.

## SOFT TISSUE

By convention, the term *soft tissue* describes any nonepithelial tissue other than bone, cartilage, central nervous system, hematopoietic, and lymphoid tissues. The focus of this section is on soft tissue tumors, which are classified according to the tissue type they recapitulate, including fat, fibrous tissue, and neurovascular tissue (Table 20–4). In some soft tissue neoplasms, however, no corresponding normal counterpart is known. Although soft tissue tumors are classified based on recognizable lines of differentiation, current evidence indicates that these tumors arise from pluripotent mesenchymal stem cells and are not the result of malignant transformation of mature mesenchymal cells. With the exception of skeletal muscle neoplasms (see further on), benign soft tissue tumors outnumber their malignant counterparts by at least a hundred-fold. In the United States, approximately 12,000 soft tissue sarcomas are diagnosed annually, representing less than 1% of all invasive malignancies. However, they cause 2% of all cancer deaths, reflecting their lethal nature.

Most soft tissue tumors arise without antecedent causes; rarely, radiation exposure, burn injury, or toxin exposure is implicated. Kaposi sarcoma (Chapter 9) is associated with the human herpesvirus 8, but viruses probably are not important in the pathogenesis of most sarcomas in humans. A small minority of soft tissue tumors are associated with genetic syndromes, most notably neurofibromatosis type 1 (neurofibroma, malignant schwannoma), Gardner syndrome (fibromatosis), Li-Fraumeni syndrome (soft tissue sarcoma), and Osler-Weber-Rendu syndrome (telangiectasia). Specific chromosomal abnormalities and genetic derangements in these syndromes provide important clues to the genesis of the neoplasms. Like their mesenchymal brethren, the hematopoietic neoplasms, many soft tissue tumors are associated with highly characteristic chromosomal rearrangements, most commonly translocations that provide insight into pathogenesis and are diagnostically useful. Indeed, some tumors, such as synovial sarcoma, are virtually defined by their associated translocations.

Soft tissue tumors can arise in any location, but approximately 40% of sarcomas occur in the lower extremities, especially the thigh. While the overall incidence of sarcomas increases with age, 15% arise in children. Certain sarcomas tend to appear in certain age groups—for example, rhabdomyosarcoma in childhood, synovial sarcoma in young adulthood, and liposarcoma and pleomorphic fibroblastic or undifferentiated sarcomas in later adult life. Soft tissue sarcomas usually are treated with wide surgical excision (frequently limb-sparing), with irradiation and systemic therapy reserved for large high-grade tumors.

Several features of soft tissue sarcomas influence prognosis:

- *Diagnostic classification.* This is based not only on histology, but also on immunohistochemistry, electron microscopy, cytogenetics, and molecular genetics, which are indispensable in assigning the correct diagnosis in some cases.

**Table 20–4** Soft Tissue Tumors

| |
|---|
| **Tumors of Adipose Tissue** |
| Lipomas |
| Liposarcoma |
| **Tumors and Tumor-Like Lesions of Fibrous Tissue** |
| Nodular fasciitis |
| Fibromatoses<br>Superficial fibromatoses<br>Deep fibromatoses |
| Fibrosarcoma |
| **Fibrohistiocytic Tumors** |
| Fibrous histiocytoma |
| Dermatofibrosarcoma protuberans |
| Pleomorphic fibroblastic sarcoma/pleomorphic undifferentiated sarcoma (malignant fibrous histiocytoma) |
| **Tumors of Skeletal Muscle** |
| Rhabdomyoma |
| Rhabdomyosarcoma |
| **Tumors of Smooth Muscle** |
| Leiomyoma |
| Smooth muscle tumors of uncertain malignant potential |
| Leiomyosarcoma |
| **Vascular Tumors** |
| Hemangioma |
| Lymphangioma |
| Hemangioendothelioma |
| Angiosarcoma |
| **Peripheral Nerve Tumors** |
| Neurofibroma |
| Schwannoma |
| Granular cell tumor |
| Malignant peripheral nerve sheath tumors |
| **Tumors of Uncertain Histogenesis** |
| Synovial sarcoma |
| Alveolar soft part sarcoma |
| Epithelioid sarcoma |

- *Grading.* Grading, usually on a scale of I to III, is based on the degree of differentiation, the average number of mitoses per high-power field, cellularity, pleomorphism, and an estimate of the extent of necrosis (presumably a reflection of rate of growth). Mitotic counts and necrosis are the most important predictors.
- *Staging.* With tumors larger than 20 cm, metastases develop in 80% of cases; by contrast, for tumors 5 cm or smaller, metastases occur in only 30% of cases.
- *Location.* In general, tumors arising in superficial locations (e.g., skin) have a better prognosis than deep-seated lesions; overall, the 10-year survival rate for sarcomas is approximately 40%.

Presented next is an overview of the individual tumors and tumor-like lesions; only the more common forms are covered here. Others are covered elsewhere in the book.

# TUMORS OF ADIPOSE TISSUE

## Lipoma

*Lipomas* are benign tumors of fat and are the most common soft tissue tumors in adults. Most lipomas are solitary lesions; multiple lipomas usually suggest the presence of rare hereditary syndromes. Lipomas can be subclassified on the basis of their histologic features and/or characteristic chromosomal rearrangements. Most lipomas are mobile, slowly enlarging, painless masses (although angiolipomas can manifest with local pain); complete excision usually is curative.

*Conventional lipomas* (the most common subtype) are soft, yellow, well-encapsulated masses of mature adipocytes; they can vary considerably in size. On histologic examination, they consist of mature white fat cells with no pleomorphism.

## Liposarcoma

*Liposarcomas* are malignant neoplasms with adipocyte differentiation. They occur most commonly in the fifth and sixth decades of life. Most liposarcomas arise in the deep soft tissues or in the retroperitoneum. The prognosis of liposarcomas is greatly influenced by the histologic subtype; well-differentiated tumors grow slowly and are associated with a more favorable outlook than the aggressive myxoid/round cell and pleomorphic variants, which tend to recur after excision and metastasize to lungs. Amplification of a region of 12q is common in well-differentiated liposarcomas; this region contains the *MDM2* gene, whose product binds and degrades the p53 protein. A t(12;16) chromosomal translocation is associated with myxoid/round cell liposarcomas; this rearrangement creates a fusion gene encoding an abnormal transcription factor that may interfere with adipocyte differentiation.

### MORPHOLOGY

Liposarcomas usually manifest as relatively well-circumscribed lesions. Several different histologic subtypes are recognized, including the low-grade variant, **well-differentiated liposarcoma,** and the **myxoid/round cell liposarcoma,** characterized by abundant, mucoid extracellular matrix. Some well-differentiated lesions can be difficult to distinguish from lipomas, whereas very poorly differentiated tumors can resemble various other high-grade malignancies. In most cases, cells indicative of fatty differentiation known as **lipoblasts are present;** they have cytoplasmic lipid vacuoles that scallop the nucleus (Fig. 20–24), and appearance recapitulating that of fetal fat cells.

# FIBROUS TUMORS AND TUMOR-LIKE LESIONS

Fibrous tissue proliferations are a heterogeneous group of lesions. At one end of the spectrum, *nodular fasciitis* is not a true tumor but rather a reactive, self-limited proliferation.

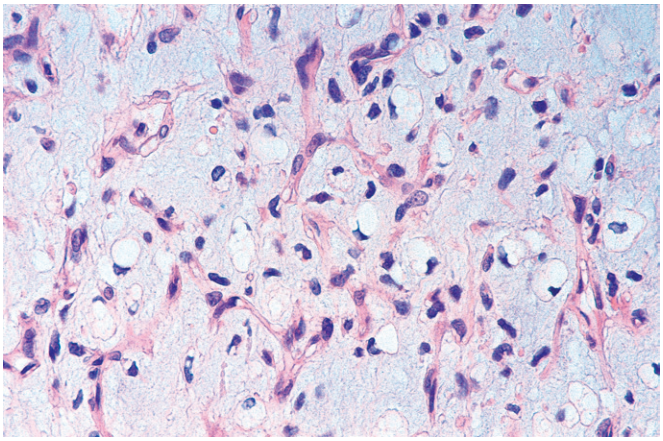

**Figure 20–24** Myxoid liposarcoma. Adult-appearing fat cells and more primitive cells, with lipid vacuoles (*lipoblasts*), are scattered in abundant myxoid matrix and a rich, arborizing capillary network.

At the other end, *fibrosarcomas* are highly malignant neoplasms that tend to recur locally and can metastasize. *Fibromatoses* fall somewhere in the middle; these are benign lesions that infiltrate locally and often can defy attempts at surgical excision. Distinguishing among the various lesions requires considerable skill and diagnostic experience.

## Reactive Proliferations

### *Nodular Fasciitis*

Nodular fasciitis is a self-limited fibroblastic proliferation (Fig. 20–25) that typically occurs in adults on the volar aspect of the forearm, the chest, or the back. Patients characteristically present with a several-week history of a solitary, rapidly growing, and occasionally painful mass. Preceding trauma is noted in 10% to 15% of cases. Nodular fasciitis rarely recurs after excision.

### *Myositis Ossificans*

Myositis ossificans is distinguished from other fibroblastic proliferations by the presence of *metaplastic bone.* It usually develops in the proximal muscles of the extremities in athletic adolescents and young adults after trauma. The affected area initially is swollen and painful, and subsequently evolves into a painless, hard, well-demarcated mass. It is critical to distinguish this lesion from extraskeletal osteosarcoma. Simple excision usually is curative.

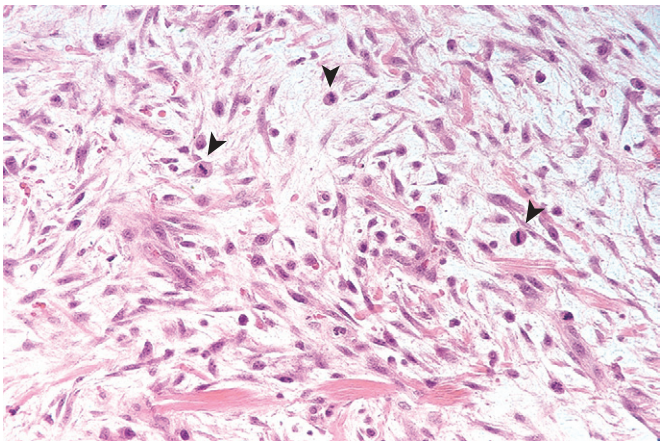

**Figure 20–25** Nodular fasciitis. A highly cellular lesion composed of plump, randomly oriented spindle cells surrounded by myxoid stroma. Note the prominent mitotic activity (*arrowheads*).

## Fibromatoses

The fibromatoses are a group of fibroblastic proliferations distinguished by their tendency to grow in an infiltrative fashion and, in many cases, to recur after surgical removal. Although some lesions are *locally aggressive, they do not metastasize.* The fibromatoses are divided into two major clinicopathologic groups: superficial and deep.

- The *superficial fibromatoses* arise in the superficial fascia and include such entities as palmar fibromatosis (*Dupuytren contracture*) and penile fibromatosis (*Peyronie disease*). Superficial lesions are genetically distinct from their deep-seated cousins and are generally more innocuous (they can be associated with trisomy 3 and 8); they also come to clinical attention earlier, because they cause deformity of the involved structure.
- The *deep fibromatoses* include the so-called *desmoid tumors* that arise in the abdominal wall and muscles of the trunk and extremities, and within the abdomen (mesentery and pelvic walls). They can be isolated lesions, or multiple, as a component of *Gardner syndrome,* an autosomal dominant disorder including colonic adenomatous polyps and osteomas. Mutations in the *APC* or β-catenin genes are present in a majority of these tumors. Deep fibromatoses tend to grow in a locally aggressive manner and often recur after excision.

### MORPHOLOGY

Fibromatoses are gray-white, firm to rubbery, poorly demarcated, infiltrative masses 1 to 15 cm in greatest dimension. On histologic examination, they are composed of plump spindle cells arranged in broad sweeping fascicles that penetrate the adjacent tissue; mitoses are few in number. Immunohistochemical and ultrastructural studies show that the tumor cells are fibroblasts and **myofibroblasts.** Some lesions may be quite cellular, particularly early in their evolution, whereas others contain abundant dense collagen.

In addition to being disfiguring or disabling, fibromatoses occasionally are painful. Although curable by adequate excision, they often recur when incompletely removed due to their infiltrative nature. For those tumors that cannot be resected, therapeutic options include watchful waiting, radiation therapy, and chemotherapy.

## Fibrosarcoma

Fibrosarcomas are malignant neoplasms composed of fibroblasts. Most occur in adults, typically in the deep tissues of the thigh, knee, and retroperitoneal area. They tend to grow slowly, and have usually been present for several years at the time of diagnosis. As with other

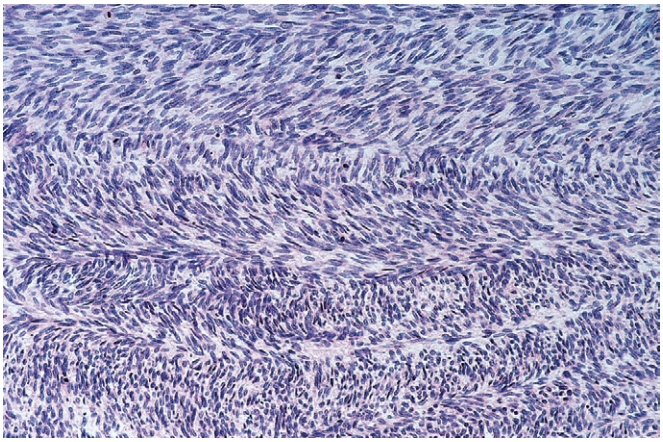

**Figure 20–26** Fibrosarcoma. Malignant spindle cells here are arranged in a *herringbone pattern*.

sarcomas, fibrosarcomas often recur locally after excision (in more than 50% of cases) and can metastasize hematogenously (in greater than 25% of cases), usually to the lungs.

### MORPHOLOGY

Fibrosarcomas are soft unencapsulated, infiltrative masses that frequently contain areas of hemorrhage and necrosis. Better-differentiated lesions can appear deceptively circumscribed. Histologic examination discloses all degrees of differentiation, from tumors that closely resemble fibromatoses, to densely packed lesions with spindle cells growing in a herringbone fashion (Fig. 20–26), while others have a myxoid stroma (myxofibrosarcoma), and some are highly cellular neoplasms exhibiting architectural disarray, pleomorphism, frequent mitoses, and necrosis.

## FIBROHISTIOCYTIC TUMORS

Fibrohistiocytic tumors are composed of a mixture of fibroblasts and phagocytic, lipid-laden cells resembling activated tissue macrophages (also called *histiocytes* by morphologists). The neoplastic cells in many cases are fibroblasts and myofibroblasts. Consequently, the term *fibrohistiocytic* is descriptive and does not connote a specific line of differentiation. These tumors span a broad range of histologic patterns and biologic behavior, from self-limited benign lesions to aggressive high-grade sarcomas.

### Benign Fibrous Histiocytoma (Dermatofibroma)

Dermatofibromas are relatively common benign lesions in adults manifesting as circumscribed, small (less than 1 cm) mobile nodules in the dermis or subcutaneous tissue. On histologic evaluation, these typically consist of bland, interlacing spindle cells admixed with foamy, lipid-rich histiocyte-like cells. The borders of the lesions tend to be infiltrative, but extensive local invasion does not occur. They are cured by simple excision. The pathogenesis of these lesions is uncertain.

### Pleomorphic Fibroblastic Sarcoma/Pleomorphic Undifferentiated Sarcoma

Tumors of this type originally fell under the diagnostic rubric "malignant fibrous histiocytoma," but with use of objective immunohistochemical markers it became evident that this was a wastebasket diagnostic category that included a number of poorly differentiated sarcomas, such as leiomyosarcomas and liposarcomas. The common histologic features that define this group of poorly differentiated sarcomas are cytologic pleomorphism, the presence of bizarre multinucleate cells, and storiform architecture. Currently, tumors with this histologic appearance that exhibit fibroblastic differentiation are designated undifferentiated pleomorphic spindle cell sarcoma or pleomorphic fibroblastic sarcoma (Fig. 20–27). They usually are large (5 cm to 20 cm), gray-white unencapsulated masses that often appear deceptively circumscribed. They usually arise in the musculature of the proximal extremities or in the retroperitoneum. Most of these tumors are extremely aggressive, recur unless widely excised, and have a metastatic rate of 30% to 50%.

## SKELETAL MUSCLE TUMORS

Tumors of skeletal muscle differentiation are almost all malignant. Rhabdomyoma, a benign type of skeletal muscle tumor, is rare and is most often found in the heart (Chapter 10).

### Rhabdomyosarcoma

Rhabdomyosarcoma is the most common soft tissue sarcoma of childhood and adolescence, usually appearing before age 20. Of interest, it occurs most commonly in the head and neck or genitourinary tract, usually at sites where there is little, if any, normal skeletal muscle.

This tumor occurs in three different histologic types, as described below. *Chromosomal translocations* are found in most cases of the alveolar variant; the more common t(2;13) translocation fuses the *PAX3* gene on chromosome 2 with the *FKHR* gene on chromosome 13. *PAX3* functions

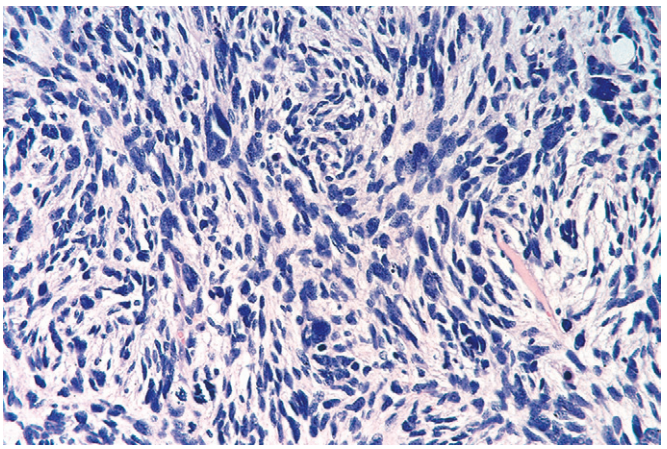

**Figure 20–27** Pleomorphic fibroblastic sarcoma. There are fascicles of plump spindle cells in a *swirling (storiform) pattern*.

upstream of genes that control skeletal muscle differentiation, and tumor development probably involves dysregulation of muscle differentiation by the chimeric PAX3-FKHR protein.

### MORPHOLOGY

Rhabdomyosarcoma is histologically subclassified into the **embryonal, alveolar,** and **pleomorphic** variants. The gross appearance of these tumors is variable. Some, particularly the embryonal variant when arising near the mucosal surfaces of the bladder or vagina, can manifest as soft, gelatinous, grapelike masses, designated **sarcoma botryoides.** In other cases they are poorly defined, infiltrating tan-white masses. The **rhabdomyoblast** is the diagnostic cell in all types; it has granular eosinophilic cytoplasm rich in thick and thin filaments. The rhabdomyoblasts may be round or elongated; the latter are known as **tadpole or strap cells** (Fig. 20–28) and may contain cross-striations visible by light microscopy. The diagnosis of rhabdomyosarcoma is based on the demonstration of skeletal muscle differentiation, either in the form of sarcomeres under the electron microscope or by immunohistochemical demonstration of skeletal muscle–specific transcription factors such as myogenin and MYOD-1, and the muscle-associated intermediate filament desmin.

Rhabdomyosarcomas are aggressive neoplasms treated with a combination of surgery, chemotherapy, and radiation. Location, histologic appearance, and tumor genetics all impact the likelihood of cure, with progressively worsening rates for embryonal, pleomorphic, and alveolar variants, in that order. The malignancy is curable in almost two thirds of children; the prognosis is much less favorable in adults with the pleomorphic type.

## SMOOTH MUSCLE TUMORS

### Leiomyoma

Benign smooth muscle tumors, or *leiomyomas,* are common, well-circumscribed neoplasms that can arise from smooth muscle cells anywhere in the body but are encountered most commonly in the uterus (Chapter 18) and the skin.

### Leiomyosarcoma

Leiomyosarcomas account for 10% to 20% of soft tissue sarcomas. They occur in adults, more commonly females. Skin and deep soft tissues of the extremities and retroperitoneum (inferior vena cava) are common sites. These neoplasms manifest as firm, painless masses; retroperitoneal tumors can be large and bulky and cause abdominal symptoms. Histologic examination shows spindle cells with cigar-shaped nuclei arranged in interwoven fascicles. Treatment depends on the size, location, and grade of the tumor. Superficial or cutaneous leiomyosarcomas usually are small and carry a good prognosis, whereas retroperitoneal tumors are large and difficult to excise and cause death by both local extension and metastatic spread.

## SYNOVIAL SARCOMA

Synovial sarcoma was originally believed to recapitulate synovium; however, the phenotype of the neoplastic cells bears no resemblance to a synoviocyte, and despite the name, less than 10% of tumors are intra-articular. Synovial sarcomas account for approximately 10% of all soft tissue sarcomas, typically occurring in persons in their 20s to 40s. They usually develop in deep soft tissues around the large joints of the extremities, with 60% to 70% occurring around the knee; many have been present for several years at the time of presentation. Most synovial sarcomas show a characteristic (X;18) translocation that produces a fusion gene encoding a chimeric transcription factor.

### MORPHOLOGY

On histologic examination, synovial sarcomas may be biphasic or monophasic. Classic **biphasic** synovial sarcoma exhibits differentiation of tumor cells into both epithelial-type cells and spindle cells. The epithelial cells are cuboidal to columnar and form glands or grow in solid cords or aggregates. The spindle cells are arranged in densely cellular fascicles that surround the epithelial cells (Fig. 20–29). Many synovial

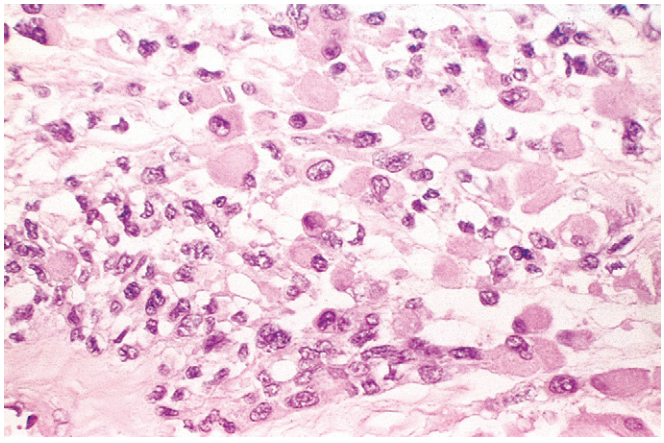

**Figure 20–28** Rhabdomyosarcoma. The rhabdomyoblasts are large and round and have abundant eosinophilic cytoplasm; no cross-striations are evident here.

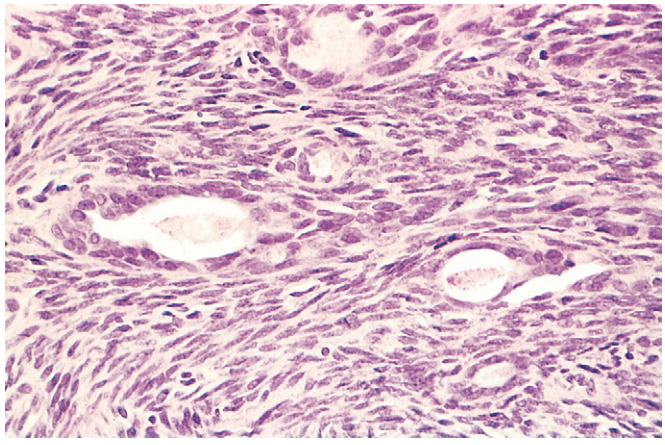

**Figure 20–29** Synovial sarcoma exhibiting a classic biphasic spindle cell and glandlike histologic appearance.

sarcomas are **monophasic**—that is, composed of spindle cells only. Lesions composed solely of spindle cells are easily mistaken for fibrosarcomas or malignant peripheral nerve sheath tumors. Immunohistochemistry is helpful, because the tumor cells are positive for keratin and epithelial membrane antigen, differentiating them from most other sarcomas.

Synovial sarcomas are treated aggressively with limb-sparing surgery and chemotherapy. Common metastatic sites are lung, bone, and regional lymph nodes. Reported 5-year survival rates range from 25% to 62%, and only 10% to 30% of the patients live longer than 10 years.

## BIBLIOGRAPHY


Bovée JV: EXTra hit for mouse osteochondroma. Proc Natl Acad Sci U S A 107:1813, 2010. *[Good explanation of the current understanding of the molecular and cellular genesis of osteochondroma and osteochondromatosis.]*

Bovée JV, Hogendoorn PC, Wunder JS, Alman BA: Cartilage tumours and bone development: molecular pathology and possible therapeutic targets. Nat Rev Cancer 10:481, 2010. *[A good review of the known genetic abnormalities in these tumors.]*

Cao L, Yu Y, Bilke S, et al: Genome-wide identification of PAX-3FKHR binding sites in rhabdomyosarcoma reveals candidate target genes important for development and cancer. Cancer Res 70:6497, 2010. *[Scholarly discussion of the PAX3-FKHR genetic translocation and its implications regarding target genes in alveolar rhabdomyosarcomas.]*

Flanagan AM, Delaney D, O'Donnell P: Benefits of molecular pathology in the diagnosis of musculoskeletal disease: part II of a two-part review: bone tumors and metabolic disorders. Skeletal Radiol 39:213, 2010. *[A good overview of molecular aberrations in bone tumors and select metabolic conditions.]*

Goldring M, Goldring S: Osteoarthritis. J Cell Physiol 213:626, 2007. *[Excellent review of biologic and biomechanical factors underlying the disorder.]*

Goldring M, Goldring S: Articular cartilage and subchondral bone in the pathogenesis of osteoarthritis. Ann N Y Acad Sci 1111:230, 2010. *[A succinct and thoughtful presentation of the review of the role of articular structures in the development of osteoarthritis.]*

Gorlick R, Khanna C: Osteosarcoma. J Bone Miner Res 25:6831, 2010. *[Current overview of the underlying genetic and pathologic basis for osteosarcoma.]*

Iliopoulou BP, Huber BT: Infectious arthritis and immune dysregulation: lessons learned from Lyme disease. Curr Opin Rheumatol 22:451, 2010. *[Current overview of the immune mechanisms underlying Lyme arthritis.]*

Jain S, Xu R, Prieto VG, Lee P: Molecular classification of soft tissue sarcomas and clinical implications. Int J Clin Exp Pathol 23:416, 2010. *[Succinct summary of the molecular alterations in a variety of soft tissue sarcomas and their clinical utility.]*

Kumar R, Thompson JR: The regulation of parathyroid hormone secretion and synthesis. J Am Soc Nephrol 22:216, 2011. *[Good review of mechanisms controlling parathyroid synthesis in health and renal disease.]*

Mazzaferro S, Pasquali M, Pirrò G, et al: The bone and the kidney. Arch Biochem Biophys 503:95, 2010. *[A well-written discussion about the interplay of kidney and bone in metabolic bone disease.]*

Pinto A, Dickman P, Parham D: Pathobiologic markers of the Ewing sarcoma family of tumors: state of the art and prediction of behaviour. Sarcoma 2011:856190, 2011. *[Excellent summary of the clinical findings in and molecular basis of Ewing sarcoma.]*

Prince F, Otten M, van Suijlekom-Smit LW: Diagnosis and management of juvenile idiopathic arthritis. BMJ 342:95, 2011. *[Concise discussion of the definition, etiology, and treatment of the disease.]*

Riminucci M, Robey PG, Saggio I, Bianco P: Skeletal progenitors and the GNAS gene: fibrous dysplasia of bone read through stem cells. J Mol Endocrinol 45:355, 2010. *[Excellent discussion of how a mutation can affect skeletal progenitor cells and cause the clinical expression of fibrous dysplasia.]*

Scott D, Wolfe FM, Huizinga T: Rheumatoid arthritis. Lancet 376:1094, 2011. *[Good review and update of pathogenesis and treatment of the disease.]*

Singer F: The etiology of Paget disease of bone: viral and genetic interactions. Cell Metab 13:1, 2011. *[Very good review about the viral and genetic pathways in Paget disease.]*

Sipos W, Pietschmann P, Rauner M, et al: Pathophysiology of osteoporosis. Wien Med Wochenschr 159:230, 2009. *[Good review and update of pathogenesis of osteoporosis.]*

Smith JL, Riedel RF: Emerging therapeutic targets for soft tissue sarcoma. Curr Oncol Rep April 27 Epub ahead of print, 2011. *[Interesting review of how elucidation of the genetics and cell pathways active in soft tissue sarcoma has provided new targets for molecular therapy.]*

Takahashi N, Maeda K, Ishihara A, et al: Regulatory mechanism of osteoclastogenesis by RANKL and Wnt signals. Front Biosci 16:21, 2011. *[Good review of the mechanisms of activating osteoclasts, and of the role of these pathways in disease.]*

Van Dijk FS, Pals G, Van Rijn RR, et al: Classification of osteogenesis imperfecta revisited. Eur J Med Genet 53:1, 2010. *[An overview of the current classification of osteogenesis based on clinical and molecular findings.]*

Vanitallie TB: Gout: epitome of painful arthritis. Metabolism 59(Suppl 1):S32, 2010. *[Excellent summary of the recent developments in the molecular and cellular biology underlying gout.]*

See Targeted Therapy available online at
studentconsult.com

CHAPTER 21

# Peripheral Nerves and Muscles

CHAPTER CONTENTS

**Disorders of Peripheral Nerves 797**
Patterns of Peripheral Nerve Injury 797
Disorders Associated with Peripheral Nerve Injury 798
**Disorders of Neuromuscular Junction 800**
Myasthenia Gravis 800
Lambert-Eaton Syndrome 801
Miscellaneous Neuromuscular Junction Disorders 801
**Disorders of Skeletal Muscle 801**
Patterns of Skeletal Muscle Injury 801
Inherited Disorders of Skeletal Muscle 802
Acquired Disorders of Skeletal Muscle 805
**Peripheral Nerve Sheath Tumors 806**
Schwannomas and Neurofibromatosis Type 2 806
Neurofibromas 807
Malignant Peripheral Nerve Sheath Tumors 808
Neurofibromatosis Type 1 808
Traumatic Neuroma 808

The major components of the neuromuscular system, the peripheral nerves and skeletal muscles, act as both effectors and sensors for the central nervous system, and in doing so allow thought and sensation to give rise to physical actions and cognitive responses. The principal component of the motor system is the *motor unit,* which is composed of one lower motor neuron and its associated peripheral axon, neuromuscular junctions, and innervated skeletal muscle fibers. Both the anatomic distribution of lesions and specific signs and symptoms are helpful in classifying neuromuscular diseases and in distinguishing them from diseases of the central nervous system. Accordingly, the discussion of neuromuscular disorders is organized along anatomic lines, highlighting the clinical features that are most useful in their diagnosis.

## DISORDERS OF PERIPHERAL NERVES

The two major functional elements of peripheral nerves are axonal processes and their myelin sheaths, which are made by Schwann cells. Axonal diameter and myelin thickness are correlated with each other and with conduction velocity; they can be used to distinguish among different types of axons, which mediate distinct sensory modalities and motor function. Light touch, for example, is transmitted by thickly myelinated large-diameter axons with fast conduction velocities, while temperature sensation is transmitted by slow, unmyelinated thin axons. In the case of myelinated axons, one Schwann cell makes and maintains exactly one myelin segment, or internode, along a single axon (Fig. 21–1, *A*). Adjacent internodes are separated by nodes of Ranvier. Peripheral nerves contain a mixture of different types of axons. These and the intervening endoneurial connective tissue are arranged into fascicles that are ensheathed by a layer of perineurial cells. The perineurial cells are similar to meningeal cells and help to maintain the blood-nerve barrier in the individual fascicles.

### Patterns of Peripheral Nerve Injury

Most peripheral neuropathies can be subclassified as either axonal or demyelinating, even though some diseases exhibit mixed features. *Axonal neuropathies* are caused by insults that directly injure the axon. The entire distal portion of an affected axon degenerates. Axonal degeneration is associated with secondary myelin loss (Fig. 21–1, *B*), a process sometimes referred to as *Wallerian* degeneration. Regeneration takes place through axonal regrowth and subsequent remyelination of the distal axon (Fig. 21–1, *C*). The morphologic hallmark of axonal neuropathies is a decrease in the density of axons, which in electrophysiologic studies correlates with a decrease in the strength of amplitude of nerve impulses.

*Demyelinating neuropathies* are characterized by damage to Schwann cells or myelin with relative axonal sparing, resulting in abnormally slow nerve conduction velocities. Demyelination typically occurs in individual myelin internodes randomly; this process is termed *segmental demyelination* (Fig. 21–1, *B*). Morphologically, demyelinating neuropathies show a relatively normal density of axons and features of segmental demyelination and repair. This is recognized by the presence of axons with abnormally thin myelin sheaths and short internodes (Fig. 21–1, *C*). These latter changes are best demonstrated on teased fiber preparations, which allow the examination of several adjacent myelin internodes along a segment of an individual axon (described later).

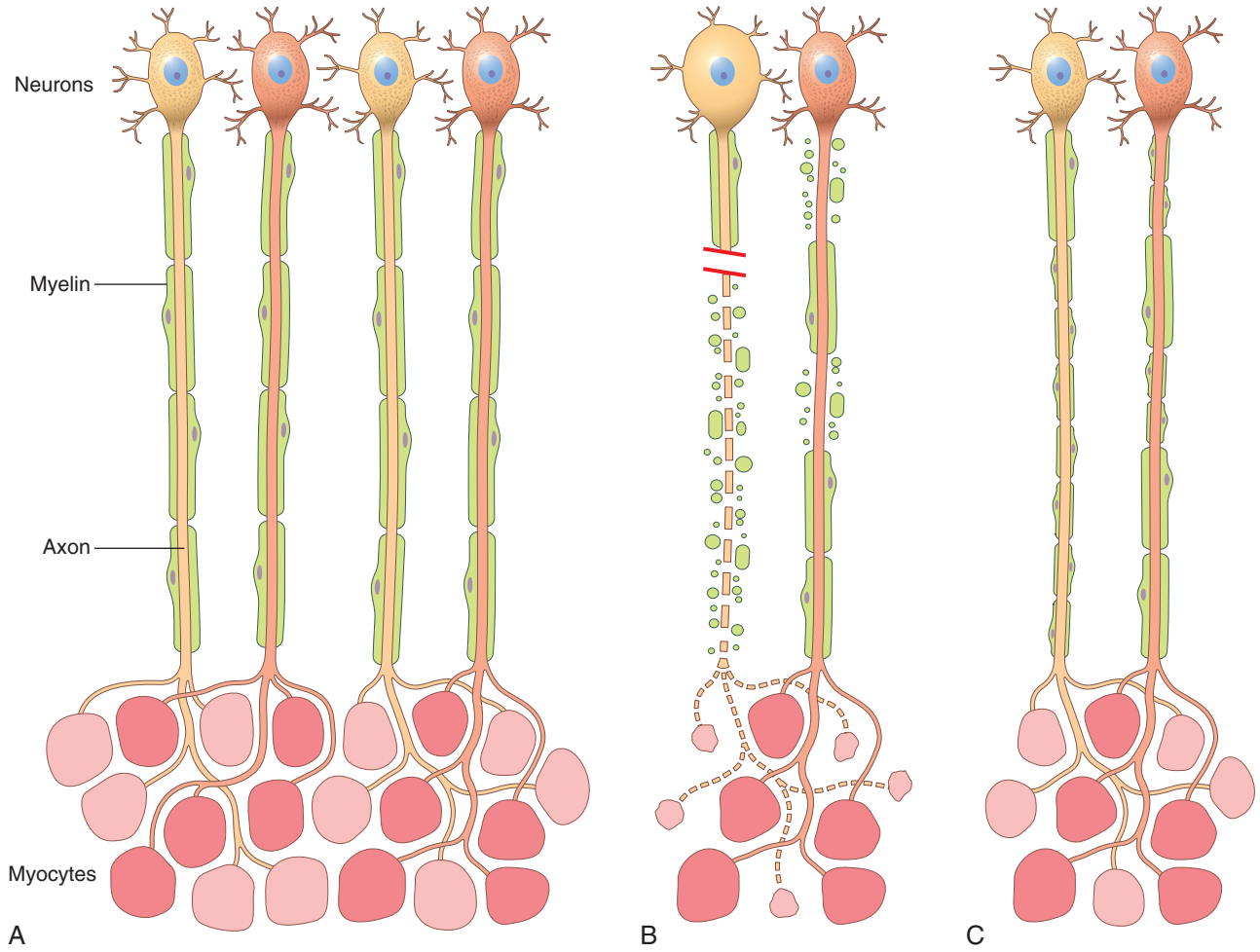


**Figure 21–1** Patterns of peripheral nerve damage. **A,** In normal motor units, type I and type II myofibers are arranged in a "checkerboard" distribution, and the internodes along the motor axons are uniform in thickness and length. **B,** Acute axonal injury (*left axon*) results in degeneration of the distal axon and its associated myelin sheath, with atrophy of denervated myofibers. By contrast, acute demyelinating disease (*right axon*) produces random segmental degeneration of individual myelin internodes, while sparing the axon. **C,** Regeneration of axons after injury (*left axon*) allows connections with myofibers to re-form. The regenerated axon is myelinated by proliferating Schwann cells, but the new internodes are shorter and the myelin sheaths are thinner than the original ones. Remission of demyelinating disease (*right axon*) allows remyelination to take place, but the new internodes also are shorter and have thinner myelin sheaths than flanking normal undamaged internodes.

Peripheral neuropathies fall into several anatomic patterns and may cause selective sensory or motor axon damage, or a mixture of both.

- *Polyneuropathies* usually affect peripheral nerves in a symmetric, length-dependent fashion. Axonal loss is typically diffuse and more pronounced in the distal segments of the longest nerves. Patients commonly present with loss of sensation and paresthesias that start in the toes and spread upward to the knees and then involve the hands in a "stocking-and-glove" distribution.
- *Polyneuritis multiplex,* in which the damage randomly affects portions of individual nerves, resulting (for example) in a right radial nerve palsy and wrist drop together with loss of sensation in the left foot
- A simple *mononeuropathy* involving only a single nerve most commonly is the result of traumatic injury or entrapment (e.g., carpal tunnel syndrome).

## Disorders Associated with Peripheral Nerve Injury

Many different diseases may be associated with peripheral neuropathy (Table 21–1). We discuss next in some detail selected entities that are prototypical for a specific type of polyneuropathy (e.g., Guillain-Barré syndrome) or are common (e.g., diabetic neuropathy).

### *Guillain-Barré Syndrome*

Guillain-Barré syndrome is one of the most common life-threatening diseases of the peripheral nervous system. It is a rapidly progressive acute demyelinating disorder affecting motor axons that results in ascending weakness that may lead to death from failure of respiratory muscles over a period of only several days. It appears to be triggered by an infection or a vaccine that breaks down self-tolerance,

**Table 21–1** Peripheral Neuropathies

| Etiologic Category | Causative Disorders/Agents |
|---|---|
| Nutritional and metabolic | Diabetes mellitus<br>Uremia<br>Vitamin deficiencies—thiamine, vitamin $B_6$, vitamin $B_{12}$ |
| Toxic | Drugs, including vinblastine, vincristine, paclitaxel, colchicine, and isoniazid<br>Other toxins—alcohol, lead, aluminum, arsenic, mercury, acrylamide |
| Vasculopathic | Vasculitis<br>Amyloidosis |
| Inflammatory | Autoimmune diseases: systemic lupus erythematosus, rheumatoid arthritis, sarcoidosis, Sjögren syndrome<br>Guillain-Barré syndrome<br>Chronic inflammatory demyelinating polyneuropathy (CIDP) |
| Infections | Herpes zoster—most often ganglionitis<br>Leprosy<br>HIV infection<br>Lyme disease—often facial nerve palsy |
| Inherited | Charcot-Marie-Tooth neuropathy, type 1: autosomal dominant (many cases with tandem duplications in *PMP22*)<br>Charcot-Marie-Tooth neuropathy, type 3: autosomal dominant or recessive (some with point mutations in *PMP22*)<br>Charcot-Marie-Tooth neuropathy, X-linked (connexin 32 gene mutations)<br>Hereditary neuropathy with liability to pressure palsy: autosomal dominant deletions of *PMP22* |
| Others | Paraneoplastic, some leukodystrophies |

thereby leading to an autoimmune response. Associated infectious agents include *Campylobacter jejuni*, Epstein-Barr virus, cytomegalovirus, and human immunodeficiency virus. The injury is most extensive in the nerve roots and proximal nerve segments and is associated with mononuclear cell infiltrates rich in macrophages. Both humoral and cellular immune responses are believed to play a role in the disease process. Treatments include plasmapheresis (to remove offending antibodies), intravenous immunoglobulin infusions (which suppress immune responses through unclear mechanisms) and supportive care, such as ventilatory support. Patients who survive the initial acute phase of the disease usually recover over time.

### *Chronic Inflammatory Demyelinating Polyneuropathy*

*Chronic inflammatory demyelinating polyneuropathy* (CIDP) typically manifests as a symmetric demyelinating disease. Both motor and sensory abnormalities are common, such as difficulty in walking, weakness, numbness, and pain or tingling sensations. Like Guillain-Barré syndrome, CIDP is immune-mediated and occurs at increased frequency in patients with other immune disorders, such as systemic lupus erythematosus and HIV infection. In contrast with Guillain-Barré syndrome, however, CIDP follows a chronic, relapsing-remitting or progressive course. The peripheral nerves show segments of demyelination and remyelination (Fig. 21-2, *A*). In long-standing cases, chronically regenerating Schwann cells may concentrically wrap around axons in multiple layers in an onion-skin pattern. Treatment includes plasmapheresis and administration of immunosuppressive agents. Some patients recover completely, but more often recurrent bouts of symptomatic disease lead to permanent loss of nerve function.

### *Diabetic Peripheral Neuropathy*

*Diabetes is the most common cause of peripheral neuropathy* (Chapter 19). Neuropathies usually arise in diabetics with long-standing disease. They include autonomic neuropathy, lumbosacral radiculopathies, and distal symmetric sensorimotor polyneuropathy; these may occur singly or together. *Autonomic neuropathy* is characterized by changes in bowel, bladder, cardiac, or sexual function. *Lumbosacral radiculopathy* usually manifests with asymmetric pain that can progress to lower extremity weakness and muscle atrophy. *Distal symmetric sensorimotor polyneuropathy* is the most common form of diabetic neuropathy. Sensory axons are more severely affected than motor axons, so the clinical presentation usually is dominated by paresthesias and numbness. This form of diabetic polyneuropathy results from the length-dependent degeneration of peripheral nerves and does not neatly fit into the axonal or demyelinating category but instead often exhibits features of both. The pathogenesis of diabetic neuropathy is complex; accumulation of advanced glycosylation end products, hyperglycemia, increased levels of reactive oxygen species, microvascular changes, changes in axonal metabolism, abnormal protein C levels, and neurotrophic factors all have been implicated. Strict glycemic control is the best form of therapy.

### *Toxic, Vasculitic, and Inherited Forms of Peripheral Neuropathy*

- *Drugs* and *environmental toxins* that interfere with axonal transport or cytoskeletal function often produce peripheral neuropathies. The longest axons are most susceptible, so the resulting clinical presentation is often most pronounced in the distal extremities.
- Peripheral nerves are often damaged in many different forms of *systemic vasculitis* (Fig. 21–2, *B*) (Chapter 9), including polyarteritis nodosa, Churg-Strauss syndrome, and Wegener granulomatosis. Overall, peripheral nerve damage is seen in about a third of all patients with vasculitis at the time of presentation. The most common clinical picture is that of *mononeuritis multiplex* with a painful asymmetric mixed sensory and motor peripheral neuropathy. Patchy involvement also is apparent at the microscopic level, as single nerves may show considerable interfascicular variation in the degree of axonal damage (Fig. 21–2, *C*).
- *Inherited diseases of peripheral nerves* are a heterogeneous but relatively common group of disorders, with a prevalence of 1 to 4 in 10,000. They can be demyelinating or axonal. Most such disorders manifest in adulthood and follow a slowly progressive course that may mimic that of acquired polyneuropathies. The most common cause is mutations in the *PMP22* gene, which encodes a protein that is a component of the myelin sheath.

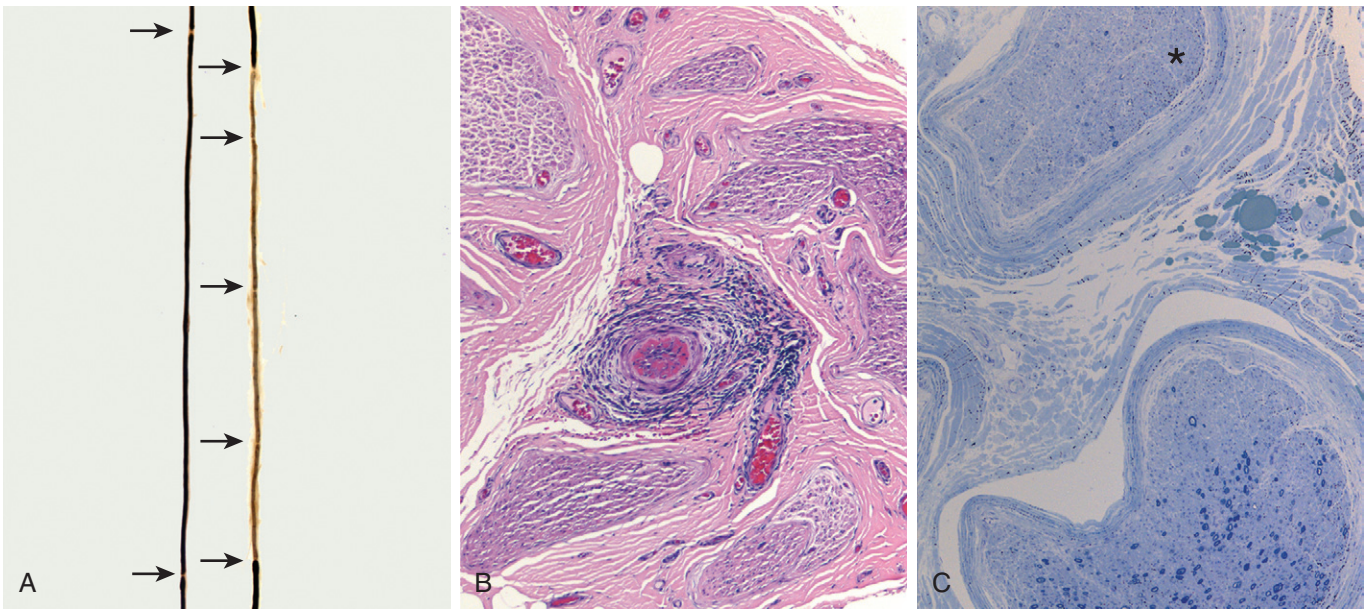


**Figure 21–2** Pathologic changes in peripheral neuropathies. **A,** Regeneration after segmental demyelination. Teased fiber preparations allow for examination of individual axons of peripheral nerves. A normal axon (*left*) has a myelin sheath of uniform thickness that is interrupted at the nodes of Ranvier (*arrows*). By contrast, the right axon contains a poorly myelinated segment with unevenly distributed nodes of Ranvier. The area of remyelination is segmental and therefore flanked by internodes with normal myelination. **B** and **C,** Vasculitic neuropathy. In **B,** the perineurial connective tissue contains a vasculocentric inflammatory infiltrate that has obliterated a small vessel. In **C,** a special stain that colors myelinated axons dark blue reveals that the nerve fascicle in the upper portion of this field (*asterisk*) has lost almost all of its large myelinated axons, in contrast with the other fascicle shown. Such interfascicular variation in axonal density often is seen in neuropathies resulting from vascular injury.

## SUMMARY

### Peripheral Neuropathies

- Peripheral neuropathies may result in weakness and/or sensory deficits and may be symmetric or consist of random involvement of individual nerves.
- Axonal and demyelinating peripheral neuropathies can be distinguished on the basis of clinical and pathologic features. Some disorders are associated with a mixed pattern of injury.
- Diabetes is the most common cause of peripheral neuropathy.
- Guillain-Barré syndrome and chronic idiopathic demyelinating polyneuropathy are immune-mediated demyelinating diseases that follow acute and chronic courses, respectively.
- Metabolic diseases, drugs, toxins, connective tissue diseases, vasculitides, and infections all can result in peripheral neuropathy.
- A number of mutations cause peripheral neuropathy. Many of these are late-onset diseases that may mimic acquired ones.

# DISORDERS OF NEUROMUSCULAR JUNCTION

The neuromuscular junction is a specialized interface between synaptic nerve endings and muscle fibers. Nerve impulses depolarize the presynaptic membrane, stimulating calcium influx and the release of acetylcholine into the synaptic cleft. Acetylcholine diffuses across the synaptic cleft to bind its receptor on the postsynaptic membrane, leading to depolarization of the myofiber and contraction through electromechanical coupling. Often disorders of the neuromuscular junction produce functional abnormalities in the absence of any significant alterations in morphology beyond ultrastructural changes. Considered in this section are some of the more common or pathogenically interesting disorders that disrupt the transmission of signals across the neuromuscular junction.

## Myasthenia Gravis

*Myasthenia gravis is caused by autoantibodies that block the function of postsynaptic acetylcholine receptors at motor end plates, which results in the degradation and depletion of the receptors.* The disease has an incidence of roughly 3 in 100,000 persons, can manifest at any age, and (like many autoimmune disorders) is more common in females. The disease can be transferred to animals with serum from affected patients, demonstrating the causal role of circulating anti-acetylcholine receptor antibodies. Some 60% of cases are associated with a peculiar reactive hyperplasia of intrathymic B cells (often referred to as thymic hyperplasia), and another 20% are associated with thymoma, a tumor of thymic epithelial cells (Chapter 11). These thymic lesions may perturb tolerance to self antigens, thereby setting the stage for the generation of autoreactive T and B cells.

Clinically, myasthenia gravis frequently manifests with *ptosis* (drooping eyelids) or *diplopia* (double vision) due to weakness in the extraocular muscles. This pattern of

weakness is distinctly different from that in most primary myopathic processes, in which there is relative sparing of facial and extraocular muscles. The severity of the weakness often fluctuates dramatically, sometimes over periods of only a few minutes. Characteristically, repetitive use or electrophysiologic stimulation of muscles makes the weakness more severe, whereas administration of cholinesterase inhibitors improves strength markedly; both of these features are diagnostically useful. Effective treatments include cholinesterase inhibitory drugs, immunosuppression, plasmapheresis, and (in patients with thymic lesions) thymectomy. These interventions have improved the 5-year survival rate to greater than 95%.

### Lambert-Eaton Syndrome

*Lambert-Eaton syndrome is caused by autoantibodies that inhibit the function of presynaptic calcium channels, which reduces the release of acetylcholine into the synaptic cleft.* In contrast with those suffering from myasthenia gravis, patients with Lambert-Eaton syndrome experience improvement in weakness with repetitive stimulation. This serves to build up sufficient intracellular calcium to facilitate acetylcholine release.

Like myasthenia gravis, however, the disorder can be transferred to animals through the serum of affected patients. It often arises as a paraneoplastic disorder, particularly in patients with small cell lung carcinoma. Cholinesterase inhibitors are not effective, and therapy is therefore directed toward reducing the titer of causative antibodies, through either plasmapheresis or immunosuppression. Owing to the strong link to lung cancer, the overall prognosis for patients with Lambert-Eaton syndrome is substantially worse than for those affected by myasthenia gravis.

### Miscellaneous Neuromuscular Junction Disorders

Several other neuromuscular junction disorders merit brief mention.

- *Congenital myasthenic syndromes* comprise a heterogeneous group of genetic diseases that result from mutations that disrupt the function of various neuromuscular junction proteins. Depending on the affected protein, the defects can occur at the level of acetylcholine release (presynaptic), the transport of acetylcholine across the synaptic cleft (synaptic), or the responsiveness of skeletal muscle (postsynaptic), and may produce symptoms suggestive of Lambert-Eaton syndrome or myasthenia gravis. Some forms respond to treatment with acetylcholinesterase inhibitors.
- *Infections* may be associated with defects in neural transmission and muscle contraction. *Clostridium tetani* and *Clostridium botulinum* (Chapter 8) both release extremely potent neurotoxins that interfere with neuromuscular transmission. Tetanus toxin (known as tetanospasmin) blocks the action of inhibitory neurons, leading to increased release of acetylcholine and sustained muscle contraction and spasm (tetanus). Botulinum toxin, by contrast, inhibits acetylcholine release, producing a flaccid paralysis. The purified toxin (Botox) is remarkably stable after injection, an attribute that has led to its widespread use as an antidote for wrinkles and a variety of other conditions associated with unwanted muscular activity (e.g., blepharospasm and strabismus).

#### SUMMARY

##### Neuromuscular Junction Disorders

- Disorders of neuromuscular junctions manifest with weakness that often affects facial and extraocular muscles and may show marked fluctuation in severity.
- Both myasthenia gravis and Lambert-Eaton syndrome, the most common forms, are immune-mediated, being caused by antibodies to postsynaptic acetylcholine receptors and presynaptic calcium channels, respectively.
- Myasthenia gravis often is associated with thymic hyperplasia or thymoma. Lambert-Eaton syndrome in a majority of cases is a paraneoplastic disorder; the strongest association is with small cell lung cancer.
- Genetic defects in neuromuscular junction proteins and bacterial toxins also can cause symptomatic disturbances in neuromuscular transmission.

## DISORDERS OF SKELETAL MUSCLE

### Patterns of Skeletal Muscle Injury

Skeletal muscle consists of different fiber types broadly classified as slow twitch "aerobic" type I and fast twitch "anaerobic" type II fibers. They are normally distributed in checkerboard pattern (Fig. 21–1, *A*). Function of both types of fibers depends on the unique protein complexes that make up the sarcomeres and the dystrophin-glycoprotein complex (Fig. 21–3), as well as enzymes that meet the special metabolic requirements of muscle.

*Primary muscle diseases or myopathies* have to be distinguished from *secondary neuropathic changes* caused by disorders that disrupt muscle innervation. Both are associated with altered muscle function and morphology, but each has distinctive features (Fig. 21–4). Myopathic conditions are often associated with segmental necrosis and regeneration of individual muscle fibers (Fig. 21–4, *B*). As discussed later on, specific types of myopathies have additional morphologic features, such as inflammatory infiltrates or intracellular inclusions. Disruption of muscle by endomysial fibrosis and fatty replacement is a feature of disease chronicity associated with myopathic or neuropathic conditions.

*Muscle fiber atrophy* is shared by both neuropathic and myopathic processes. However, certain disorders are associated with particular patterns of atrophy, as follows:

- *Neuropathic changes* are characterized by fiber type grouping and grouped atrophy. Changes in muscle innervation result in larger groups of fibers that share the same fiber type with the resultant replacement of the normal checkerboard distribution by groups of fibers that are type I or II (Fig. 21–4, *D*). The presence of fewer but larger motor units and the segregation of innervated fibers results in groups of atrophic fibers (Fig. 21–4, *C*). Remarkably, the fiber type of myofibers is not an

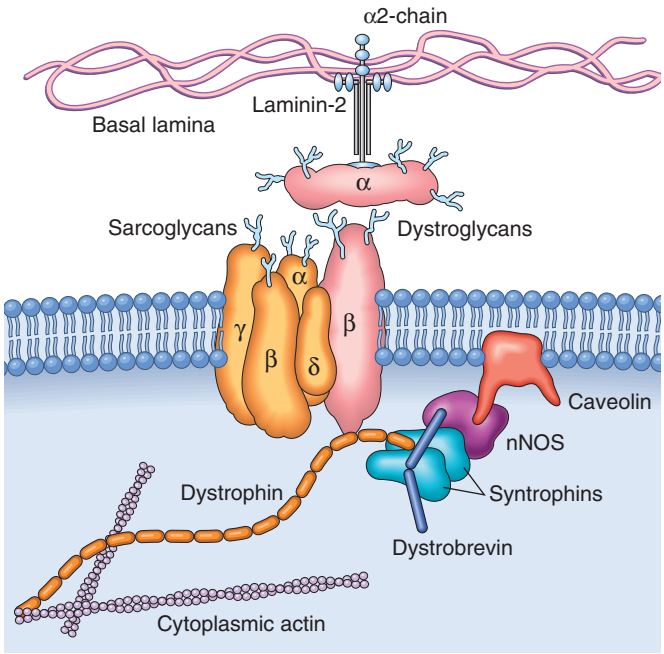


**Figure 21–3** The dystrophin-glycoprotein complex (DGC). This complex of glycoproteins serves to couple the cell membrane (the sarcolemma) to the extracellular matrix proteins such as laminin-2 and the intracellular cytoskeleton. One key set of connections is made by dystrophin, a scaffolding protein that tethers the myofibrillar cytoskeleton to the transmembrane dystroglycans and sarcoglycans, and also binds complexes containing dystrobrevin, syntrophin, neuronal nitric oxide synthetase (nNOS), and caveolin, which participate in intracellular signaling pathways. Mutations in dystrophin are associated with X-linked Duchenne and Becker muscular dystrophies; mutations in caveolin and the sarcoglycan proteins, with autosomal limb-girdle muscular dystrophies; and mutations in $\alpha_2$-laminin (merosin), with a form of congenital muscular dystrophy.

inherent feature, but is dictated by the innervating motor neuron. Thus, if injury and regeneration of peripheral nerves alters muscle innervation, it will change the distribution of type I and type II myofibers. Degeneration and regeneration of individual fibers and inflammatory infiltrates usually are absent in skeletal muscle disorders caused by abnormal innervation.

- *Prolonged disuse of muscles* due to any cause (e.g., prolonged bed rest in the sick, casting of a broken bone) can cause focal or generalized muscle atrophy, which tends to affect type II fibers more than type I fibers.
- *Glucocorticoid exposure,* whether exogenous or endogenous (e.g., in Cushing syndrome), also can cause muscle atrophy. Proximal muscles and type II myofibers are affected preferentially by these agents.

## Inherited Disorders of Skeletal Muscle

Genetic disorders affecting skeletal muscle include *muscular dystrophies, congenital muscular dystrophies, and congenital myopathies. Muscular dystrophies* are inherited diseases that result in progressive muscle injury in patients who usually appear normal at birth. *Congenital muscular dystrophies* are progressive, early-onset diseases. Some are also associated with central nervous system manifestations. *Congenital myopathies* are a heterogeneous group of inherited diseases that often have a perinatal or early childhood presentation and result in relatively static deficits.

The following discussion of the muscular dystrophies follows a long-standing classification that is based on inheritance patterns and clinical features. Of note, however, the classification of the muscular dystrophies is evolving based on new insights into the molecular pathogenesis of these disorders and genotype-phenotype relationships. For example, mutations in several different genes present as autosomal recessive limb-girdle muscular dystrophy, whereas different mutations in a single gene (such as dystrophin) can lead to two very different clinical phenotypes, the Duchenne and Becker types of muscular dystrophy.

### *Dystrophinopathies: Duchenne and Becker Muscular Dystrophy*

Dystrophinopathies are the most common form of muscular dystrophy. Duchenne muscular dystrophy (DMD) and Becker muscular dystrophy (BMD) are the two most important disease manifestations linked to mutations in the dystrophin gene. Duchenne muscular dystrophy has an incidence of about 1 per 3500 live male births and follows an inexorable fatal course. DMD becomes clinically evident by the age of 5 years; most patients are wheelchair-bound by the time they are teenagers and dead of their disease by early adulthood. The Becker type of muscular dystrophy is less common and much less severe.

#### MORPHOLOGY

The histologic alterations in skeletal muscles affected by DMD and BMD are similar, except that the changes are milder in BMD (Fig. 21–5). The hallmarks of these as well as other muscular dystrophies are ongoing myofiber necrosis and regeneration. Progressive replacement of muscle tissue by fibrosis and fat is the result of degeneration outpacing repair. As a result of ongoing repair muscles typically show marked variation in myofiber size and abnormal internally placed nuclei. Both DMD and BMD also affect cardiac muscles, which show variable degrees of myofiber hypertrophy and interstitial fibrosis.

#### PATHOGENESIS

Both DMD and BMD are caused by loss-of-function mutations in the **dystrophin** gene located on the short arm of the X chromosome (Xp21). Dystrophin is a very large protein (427 kD in molecular weight) found in skeletal and cardiac muscle, brain, and peripheral nerves; it is part of the dystrophin-glycoprotein complex (Fig. 21–3). This complex stabilizes the muscle cell during contraction and may be involved in cell signaling through interaction with other proteins. Dystrophin-glycoprotein complex defects are thought to make muscle cells vulnerable to transient membrane tears during contraction that lead to calcium influx, and may also disrupt intracellular signaling. The result is myofiber degeneration that with time outpaces the capacity for repair. The dystrophin-glycoprotein complex also is important for cardiac muscle function; this explains why cardiomyopathy eventually develops in many patients.

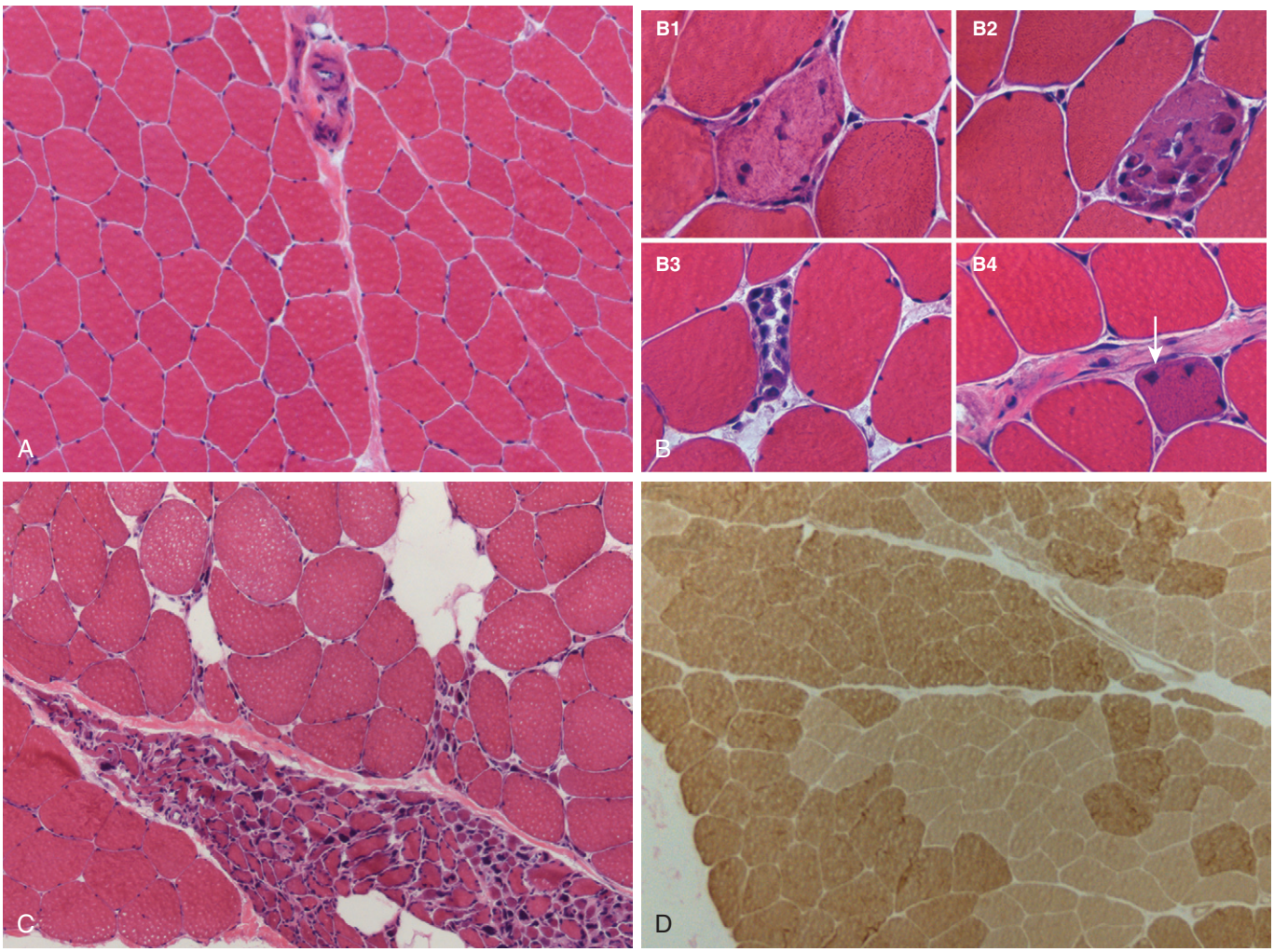


**Figure 21–4** Patterns of skeletal muscle injury. **A,** Normal skeletal muscle has relatively uniform polygonal myofibers with peripherally placed nuclei that are tightly packed together into fascicles separated by scant connective tissue. A perimysial interfascicular septum containing a blood vessel is present (*top center*). **B,** Myopathic conditions often are associated with segmental necrosis and regeneration of individual myofibers. Necrotic cells (*B1-B3*) are infiltrated by variable numbers of inflammatory cells. Regenerative myofibers (*B4*, *arrow*) are characterized by cytoplasmic basophilia and enlarged nucleoli (not visible at this power). **C** and **D,** Clusters of both atrophic myofibers **(C)** (grouped atrophy) and fiber-type grouping **(D),** patchy areas in which myofibers share the same fiber type, are features of neurogenic remodeling. The ATPase reaction shown in **D** is one method of distinguishing between fiber types, as type I fibers stain more lightly than type II fibers. Note loss of the "checkerboard" pattern (Fig 21–1, *A*).

The dystrophin gene spans roughly 2.4 megabases (about 1% of the X chromosome), making it one of the largest human genes. Its enormous size may explain in part its vulnerability to sporadic mutations that disrupt dystrophin production. The most common mutations are deletions, followed by frameshift and point mutations. Muscle biopsy specimens from patients with DMD show a complete absence of dystrophin, whereas patients with BMD have mutations that permit some dystrophin (albeit often a defective form) to be made; thus, **the severity of the disease correlates with the degree of the dystrophin deficiency.**

### Clinical Features

Often the first symptoms of DMD are clumsiness and an inability to keep up with peers due to muscle weakness. The weakness typically begins in the pelvic girdle and next involves the shoulder girdle. Enlargement of the calf muscles, termed *pseudohypertrophy,* is an important early physical finding. The increased muscle bulk initially stems from myofiber hypertrophy, but as myofibers progressively degenerate, an increasing part of the muscle is replaced by adipose tissue and endomysial fibrosis. Cardiac muscle damage and fibrosis can lead to heart failure and arrhythmias, which may prove fatal. Although no structural abnormalities in the central nervous system have been described, cognitive impairment is also sometimes seen and may be severe enough to manifest as mental retardation. Owing to ongoing muscle degeneration, high serum creatine kinase levels are present at birth and persist through the first decade of life but fall as muscle mass is lost during disease progression. Death results from respiratory insufficiency, pneumonia, and cardiac decompensation.

BMD becomes symptomatic later in childhood or adolescence and progresses at a slower and more variable rate. Many patients live well into adulthood and have a nearly normal life span. Cardiac involvement can be the dominant

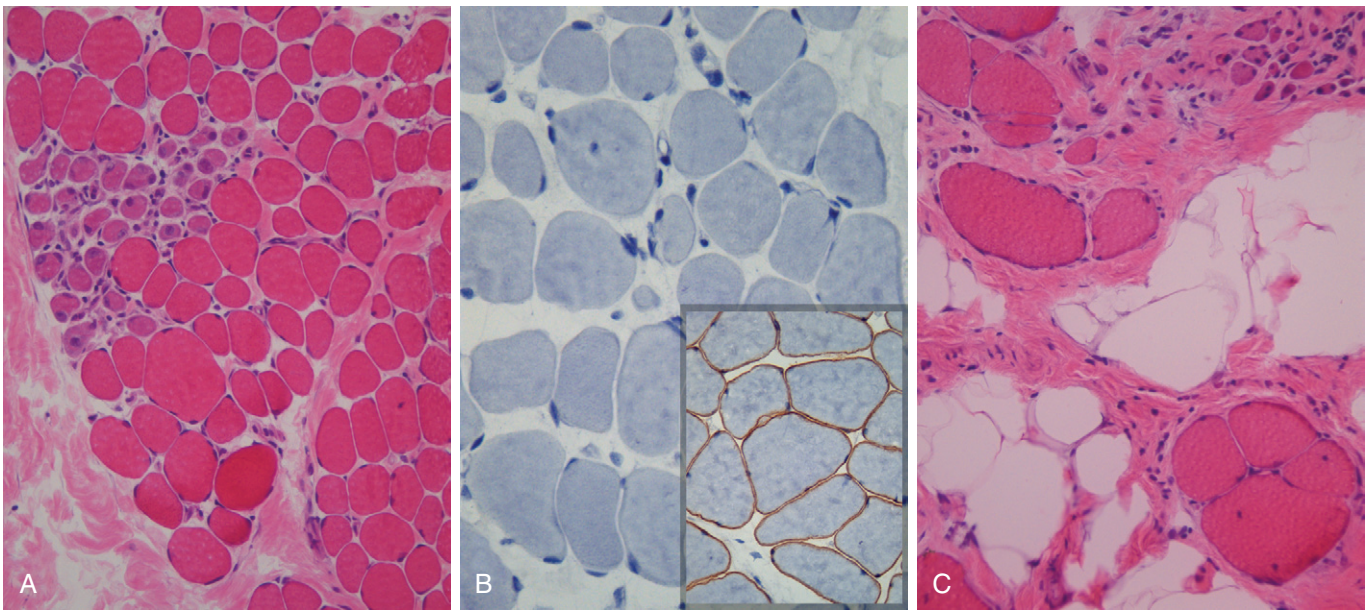


**Figure 21–5** Duchenne muscular dystrophy. Histologic images of muscle biopsy specimens from two brothers. **A** and **B,** Specimens from a 3-year-old boy. **C,** Specimen from his brother, 9 years of age. As seen in **A,** at a younger age fascicular muscle architecture is maintained, but myofibers show variation in size. Additionally, there is a cluster of basophilic regenerating myofibers *(left side)* and slight endomysial fibrosis, seen as focal pink-staining connective tissue between myofibers. In **B,** immunohistochemical staining shows a complete absence of membrane-associated dystrophin, seen as a brown stain in normal muscle (*inset*). In **C,** the biopsy from the older brother illustrates disease progression, which is marked by extensive variation in myofiber size, fatty replacement, and endomysial fibrosis.

clinical feature and may result in death in the absence of significant skeletal muscle weakness.

### *Other X-Linked and Autosomal Muscular Dystrophies*

Other forms of muscular dystrophy share some features with DMD and BMD but have distinct clinical, genetic, and pathologic features.

- *Myotonic dystrophy.* Myotonia, the sustained involuntary contraction of a group of muscles, is the cardinal neuromuscular symptom in myotonic dystrophy. Patients often complain of stiffness and difficulty releasing their grip, for instance, after a handshake. Myotonic dystrophy is inherited as an autosomal dominant trait. More than 95% of patients with myotonic dystrophy have mutations in the gene that encodes the dystrophia myotonica protein kinase (DMPK). In normal subjects, this gene contains fewer than 30 repeats of the sequence CTG, whereas in severely affected persons, several thousand repeats may be present. Myotonic dystrophy thus falls into the group of disorders associated with trinucleotide repeat expansions (Chapter 6). As is the case with other disorders with similar mutations, myotonic dystrophy exhibits the phenomenon of *anticipation,* characterized by worsening of the disease manifestations with each passing generation due to further trinucleotide repeat expansion. The CTG repeat expansion is located in the 3′ untranslated region of the DMPK mRNA, and the manner in which it produces disease is unclear. The disease often manifests in late childhood with gait abnormalities due to weakness of foot dorsiflexors, with subsequent progression to weakness of the intrinsic muscles of the hands and wrist extensors, atrophy of the facial muscles, and ptosis. Other tissues may also be affected, presenting as cardiac arrhythmias, cataracts, early frontal balding, endocrinopathies, and testicular atrophy.
- *Limb-girdle muscular dystrophies.* These autosomal muscular dystrophies preferentially affect the proximal musculature of the trunk and limbs. The genetic basis for these is heterogeneous. The growing list includes at least 6 dominant subtypes and 12 autosomal recessive subtypes. Some of the responsible mutations affect components of the dystrophin-glycoprotein complex other than dystrophin. Others affect proteins involved in vesicle transport and repair of cell membrane after injury (caveolin-3 and dysferlin), cytoskeletal proteins, or posttranslational modification of dystroglycan, a component of the dystrophin-glycoprotein complex.
- *Emery-Dreifuss muscular dystrophy* (EMD) is a rare but fascinating disorder caused by mutations affecting structural proteins found in the nucleus. An X-linked form results from mutations in the gene encoding the protein emerin, while an autosomal dominant form is caused by mutations in the gene encoding lamin A/C. It is hypothesized that defects in these proteins compromise the structural integrity of the nucleus in cells that are subjected to repetitive mechanical stress (e.g., cardiac and skeletal muscle). These proteins also may regulate chromatin structure. The clinical picture is characterized by progressive muscle weakness and wasting, contractures of the elbows and ankles, and cardiac disease. The cardiac involvement is severe, being associated with cardiomyopathy and arrhythmias that lead to sudden death in up to 40% of patients.
- *Fascioscapulohumeral dystrophy* is an autosomal dominant form of muscular dystrophy that is usually associated with deletions in chromosomal region 4q35. The pathophysiologic relationship between this chromosomal

defect and the disease phenotype is not known. Most patients become symptomatic by the age of 20 years, usually owing to weakness in the facial muscles and the shoulder. Patients also exhibit weakness in the lower trunk and the dorsiflexors of the foot. Most affected persons have a normal life expectancy.

### *Channelopathies, Metabolic Myopathies, and Mitochondrial Myopathies*

Other important inherited disorders of skeletal muscle are the result of defects in ion channels (channelopathies), metabolism, and mitochondrial function.

- *Ion channel myopathies* are a group of familial disorders characterized by myotonia, relapsing episodes of hypotonic paralysis associated with abnormal serum potassium levels, or both. As implied by their name, these diseases stem from inherited defects in genes encoding ion channels. *Hyperkalemic periodic paralysis* results from mutations in the gene encoding the skeletal muscle sodium channel protein SCN4A, which regulates sodium entry during contraction. *Malignant hyperthermia* is a rare syndrome characterized by a dramatic hypermetabolic state (tachycardia, tachypnea, muscle spasms, and finally hyperpyrexia). It is triggered when patients carrying mutations in the ryanodine receptor, a calcium release channel protein, are given halogenated anesthetic agents or succinylcholine during surgery. Some of these patients also show features of a congenital myopathy referred to as central core disease, so called because the center of the myofiber contains a collection of disorganized myofibrils.
- *Myopathies due to inborn errors of metabolism* include disorders of glycogen synthesis and degradation (Chapter 6), and abnormalities in lipid handling. The latter include disorders of the carnitine transport system or deficiencies of the mitochondrial dehydrogenase enzyme system, both of which can lead to significant accumulation of lipid in myocytes (lipid myopathies). These storage disorders can manifest as systemic disease or result in a muscle-specific phenotype. Some are associated with ongoing muscle damage and weakness. Others manifest with recurring episodes of massive exercise- or fasting-induced muscle damage, sometimes associated with acute renal failure and myoglobulinuria (rhabdomyolysis).
- *Mitochondrial myopathies* can stem from mutations in either the mitochondrial or nuclear genomes, the latter because some mitochondrial enzymes are encoded in nuclear DNA. The forms caused by mitochondrial mutations show maternal inheritance (Chapter 6). Mitochondrial myopathies usually manifest in early adulthood with proximal muscle weakness and sometimes with severe involvement of the ocular musculature (*external ophthalmoplegia*). There can also be neurologic signs and symptoms, lactic acidosis, and cardiomyopathy. Some mitochondrial diseases are associated with normal muscle morphology, whereas others show aggregates of abnormal mitochondria; the latter impart a blotchy red appearance in special stains—hence the term *ragged red fibers.* On ultrastructural examination, these correspond to abnormal aggregates of mitochondria with abnormal shape and size, some containing paracrystalline *parking lot inclusions*.

## Acquired Disorders of Skeletal Muscle

A diverse group of acquired disorders can manifest with muscle weakness, muscle cramping, or muscle pain. These include inflammatory myopathies, toxic muscle injuries, postinfectious rhabdomyolysis, and muscle infarction in the setting of diabetes. In most instances these are disorders of adults with acute or subacute onsets.

### *Inflammatory Myopathies*

Polymyositis, dermatomyositis, and inclusion body myositis are the most important primary inflammatory myopathies. Other immune disorders (e.g., SLE, sarcoidosis) also can involve skeletal muscle.

- *Polymyositis* is an autoimmune disorder associated with increased expression of MHC class I molecules on myofibers and predominantly endomysial inflammatory infiltrates containing CD8+ cytotoxic T cells. The autoimmune attack leads to myofiber necrosis and subsequent regeneration (Fig. 21–6, *A*). Patients with polymyositis are often successfully treated with corticosteroids or other immunosuppressive agents.
- *Dermatomyositis* is the most common inflammatory myopathy in children, in whom it appears as an isolated entity. In adults, it can manifest as a paraneoplastic disorder. In both contexts, it is believed to have an autoimmune basis. On microscopic examination, it is associated with perivascular mononuclear cell infiltrates, "dropout" of capillaries, the presence of so-called tubuloreticular inclusions in endothelial cells, and myofiber damage in a paraseptal or perifascicular pattern (Fig. 21–6, *B*). Type 1 interferon-induced gene products are strongly upregulated in affected muscles. Some patients have autoantibodies that are relatively specific for dermatomyositis; these include antibodies against Mi-2 (a nuclear helicase) and p155 and p140, proteins with uncertain functions.
- *Inclusion body myositis* is the most common inflammatory myopathy in patients older than 60 years of age. It is lumped in with other forms of myositis, but it has yet to be determined whether inflammation is cause or effect in this disorder. The morphologic hallmark of inclusion body myositis is the presence of rimmed vacuoles (Fig. 21–6, *C*) that contain aggregates of the same proteins that accumulate in the brains of patients with neurodegenerative diseases—hyperphosphorylated tau, amyloid derived from β-amyloid precursor protein and TDP-43 (Chapter 20)—leading some to speculate that this is a degenerative disorder of aging. Other features typical of chronic inflammatory myopathies, including myopathic changes, mononuclear cell infiltrates, endomysial fibrosis, and fatty replacement, also are evident. The disease follows a chronic, progressive course and generally does not respond well to immunosuppressive agents, another feature suggesting that inflammation is a secondary event.

### *Toxic Myopathies*

A number of insults can cause toxic muscle injury, including intrinsic factors (e.g., thyroxine) and extrinsic factors (e.g., acute alcohol intoxication, various drugs).

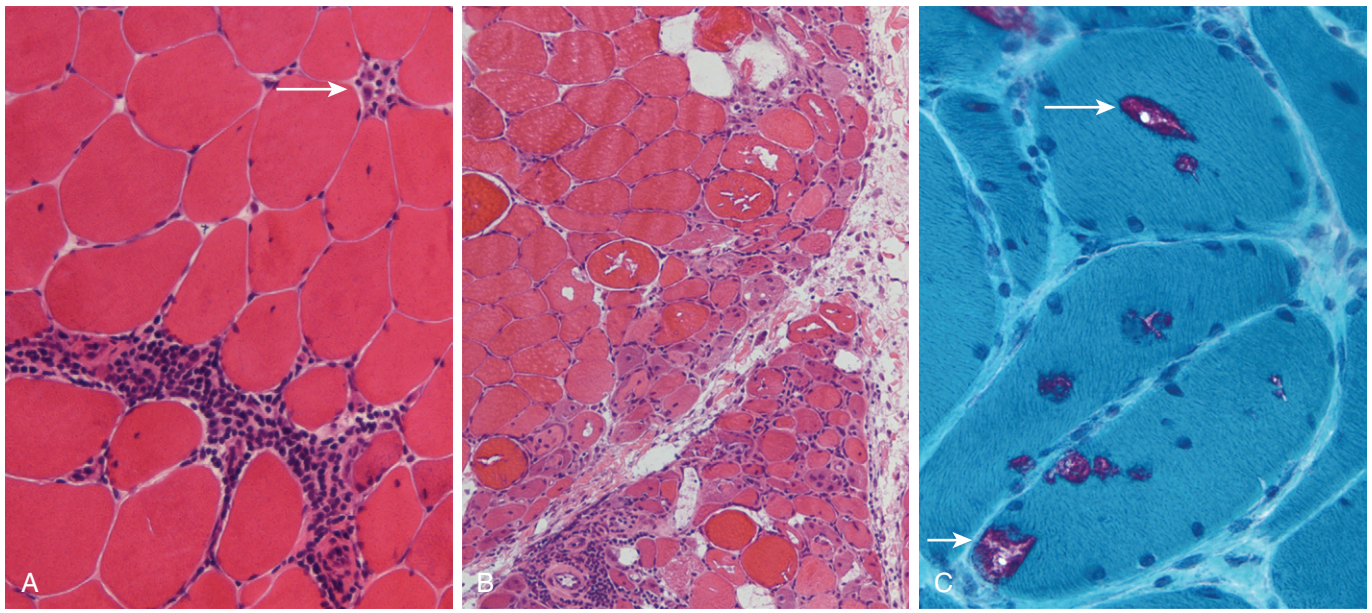


**Figure 21–6** Inflammatory myopathies. **A,** Polymyositis is characterized by endomysial inflammatory infiltrates and myofiber necrosis (*arrow*). **B,** Dermatomyositis often shows prominent perifascicular and paraseptal atrophy. **C,** Inclusion body myositis, showing myofibers containing rimmed vacuoles (*arrows*). Modified Gomori trichrome stain.

- *Thyrotoxic myopathy* may take the form of either acute or chronic proximal muscle weakness, and can be the first indication of thyrotoxicosis. Histologic findings include myofiber necrosis and regeneration.
- *Ethanol myopathy* occurs after an episode of binge drinking. The degree of rhabdomyolysis may be severe, sometimes leading to acute renal failure secondary to myoglobinuria. Patients usually complain of acute muscle pain, which may be generalized or confined to a single muscle group. Microscopically, there is myocyte swelling, necrosis, and regeneration.
- *Drug myopathy* can be produced by a variety of agents. Currently the most commonly implicated drugs are those belonging to the statin family. The affected muscles show evidence of myopathic injury, usually without an inflammatory component.

## SUMMARY

### Disorders of Skeletal Muscle

- Skeletal muscle function can be impaired secondarily because of problems with muscle innervation or by a primary myopathy that can be inherited or acquired.
- The genetic forms of myopathy fall into several fairly distinct clinical phenotypes, including muscular dystrophy, congenital myopathy, and congenital muscular dystrophy.
- Dystrophinopathies are X-linked disorders caused by mutations in the dystrophin gene and disruption of the dystrophin-glycoprotein complex. Depending on the type of mutation the disease may be severe, such as Duchenne muscular dystrophy, or mild (e.g., Becker dystrophy).
- Acquired myopathies have diverse causes, including inflammation and toxic exposures.

## PERIPHERAL NERVE SHEATH TUMORS

A number of different tumors arise from peripheral nerves. Such tumors may manifest as soft tissue masses or with pain or loss of function related to impingement on nerves or other surrounding structures. In most peripheral nerve tumors, the neoplastic cells show evidence of Schwann cell differentiation. These tumors usually occur in adults and include both benign and malignant variants. An important feature is their frequent association with the familial tumor syndromes neurofibromatosis type 1 (NF1) and neurofibromatosis type 2 (NF2). Tumors with skeletal muscle differentiation also occur; these are discussed in Chapter 20, along with other tumors of soft tissues.

### Schwannomas and Neurofibromatosis Type 2

Schwannomas are benign encapsulated tumors that may occur in soft tissues, internal organs, or spinal nerve roots. The most commonly affected cranial nerve is the vestibular portion of the eighth nerve. Tumors arising in a nerve root or the vestibular nerve may be associated with symptoms related to nerve root compression, which includes hearing loss in the case of vestibular schwannomas.

Most schwannomas are sporadic, but about 10% are associated with familial neurofibromatosis type 2. NF2 patients are at risk of developing multiple schwannomas, meningiomas, and ependymomas (the latter are described in Chapter 22). The presence of bilateral vestibular schwannomas is a hallmark of NF2. Affected patients carry a dominant loss of function mutation of the merlin gene on chromosome 22. Merlin is a cytoskeletal protein that functions as a tumor suppressor by facilitating E-cadherin–mediated contact inhibition (Chapter 5). Of note, merlin expression is also disrupted in sporadic schwannomas. Despite the name of the syndrome, neurofibromas are not a feature of NF2. Schwannomatosis is a familial condition

associated with multiple schwannomas in which vestibular schwannomas are absent. Some cases have recently been linked to loss-of-function mutations in a tumor suppressor gene on chromosome 22 that encodes a protein that regulates chromatin structure.

### MORPHOLOGY

On gross inspection, most schwannomas appear as circumscribed masses abutting an adjacent nerve. On microscopic examination, these tumors often show an admixture of dense and loose areas referred to as Antoni A and B, respectively (Fig. 21–7, *A* and *B*). They are comprised of a uniform proliferation of neoplastic Schwann cells. In the dense Antoni A areas, bland spindle cells with buckled nuclei are arranged into intersecting fascicles. These cells often align to produce nuclear palisading, resulting in alternating bands of nuclear and anuclear areas called Verocay bodies. Axons are largely excluded from the tumor. Thick-walled hyalinized vessels often are present. Hemorrhage or cystic change are also seen sometimes.

## Neurofibromas

Neurofibromas are benign peripheral nerve sheath tumors. Three important subtypes are recognized:

- *Localized cutaneous neurofibromas* arise as superficial nodular or polypoid tumors. These occur either as solitary sporadic lesions or as often multiple lesions in the context of neurofibromatosis type 1 (NF1).
- *Plexiform neurofibromas* grow diffusely within the confines of a nerve or nerve plexus. Surgical enucleation of such lesions is therefore difficult and is often associated with lasting neurologic deficits. Plexiform neurofibromas are virtually pathognomonic for NF1 (discussed later on). Unlike other benign nerve sheath tumors, these tumors are associated with a small but real risk of malignant transformation.
- *Diffuse neurofibromas* are infiltrative proliferations that can take the form of large, disfiguring subcutaneous masses. These also are often associated with NF1.

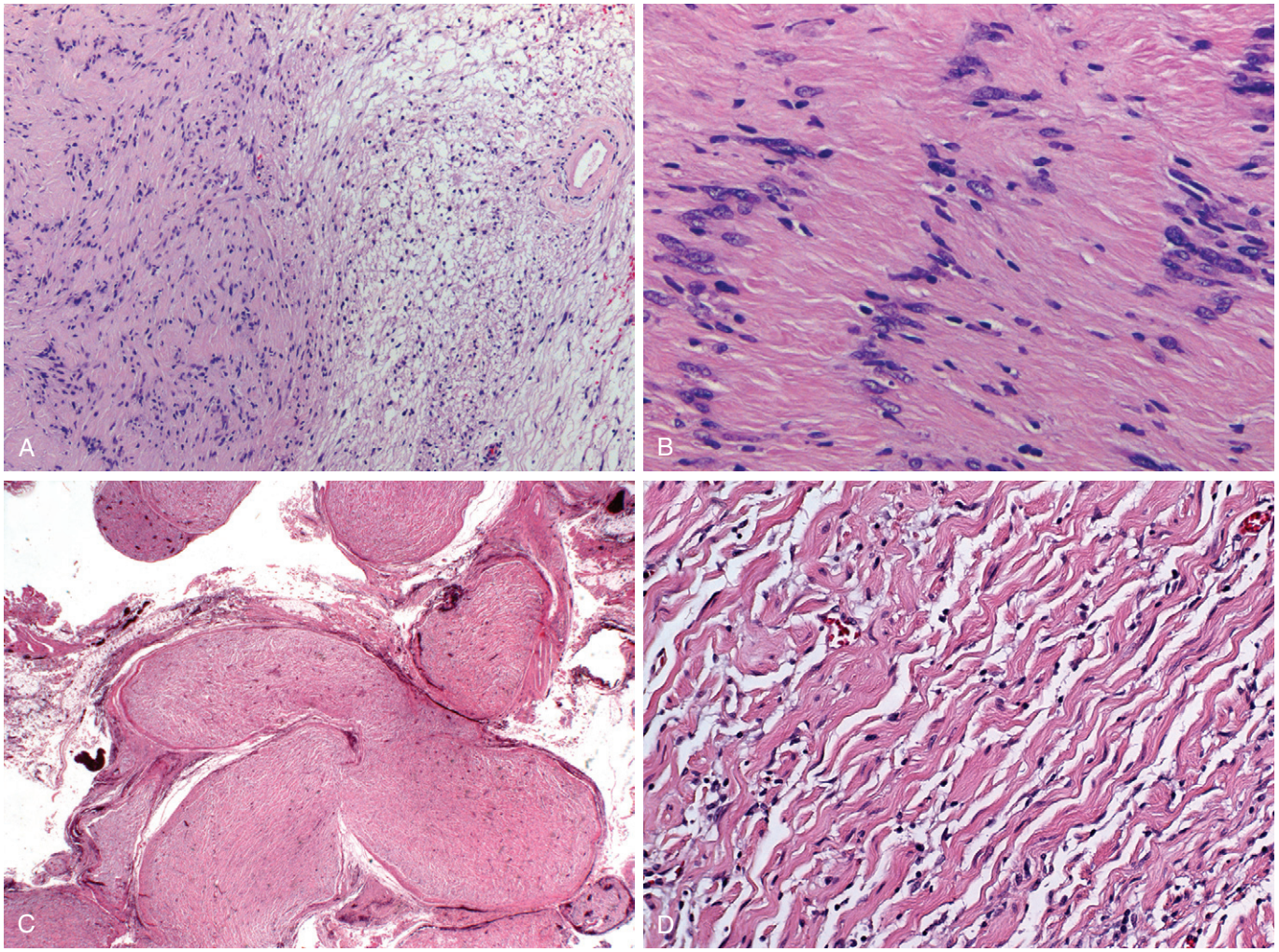


**Figure 21–7** Schwannoma and plexiform neurofibroma. **A** and **B,** Schwannoma. As seen in **A,** schwannomas often contain dense pink Antoni A areas (*left*) and loose, pale Antoni B areas (*right*), as well as hyalinized blood vessels (*right*). **B,** Antoni A area with the nuclei of tumor cells aligned in palisading rows. **C** and **D,** Plexiform neurofibroma. Multiple nerve fascicles are expanded by infiltrating tumor cells **(C),** which at higher power **(D)** are seen to consist of bland spindle cells admixed with wavy collagen bundles likened to carrot shavings.

### MORPHOLOGY

Unlike schwannomas, neurofibromas are not encapsulated. They may appear circumscribed, as in **localized cutaneous neurofibromas,** or exhibit a diffuse infiltrative growth pattern. Also in contrast with schwannomas, the neoplastic Schwann cells in neurofibroma are admixed with other cell types, including mast cells, fibroblast-like cells and perineurial-like cells. As a result, the cellular growth pattern of neurofibromas is more haphazard than that of schwannomas. The background stroma often contains loose wavy collagen bundles but also can be myxoid or contain dense collagen (Fig. 21–7, *D*). **Plexiform neurofibromas** involve multiple fascicles of individual affected nerves (Fig. 21–7, *C*). Residual axons are found embedded within the diffuse neoplastic Schwann cell proliferation, which expand the fascicles while leaving the perineurium intact. **Diffuse neurofibromas** show an extensive infiltrative pattern of growth within the dermis and subcutis of the skin.

## Malignant Peripheral Nerve Sheath Tumors

Malignant peripheral nerve sheath tumors are neoplasms seen in adults that typically show evidence of Schwann cell derivation and sometimes a clear origin from a peripheral nerve. They may arise from transformation of a neurofibroma, usually of the plexiform type. About one half of such tumors arise in patients with NF1, and 3% to 10% of all patients with NF1 develop a malignant peripheral nerve sheath tumor during their lifetime.

### MORPHOLOGY

Malignant peripheral nerve sheath tumors manifest as large, poorly defined soft tissue masses. On histologic examination, these tumors are highly cellular and exhibit features of overt malignancy, including anaplasia, necrosis, infiltrative growth pattern, pleomorphism, and high proliferative activity. The low-power view often shows alternating areas of high and low cellularity that result in an appearance described as "marble-like." Also frequently seen are perivascular areas of increased cellular density.

## Neurofibromatosis Type 1

NF1 is an autosomal dominant disorder caused by mutations in the tumor suppressor neurofibromin, encoded on the long arm of chromosome 17 (17q). Neurofibromin is a negative regulator of the potent oncoprotein Ras (Chapter 5). Disruption of neurofibromin function and Ras hyperactivity appear to be a cardinal feature of NF1-associated tumors. As would be anticipated for a tumor suppressor gene, the sole normal neurofibromin allele is mutated or silenced in tumors arising in the setting of NF1, which include neurofibromas of all three main types, malignant peripheral nerve sheath tumors, optic gliomas, and other glial tumors. In addition, patients with NF1 exhibit learning disabilities, seizures, skeletal abnormalities, vascular abnormalities with arterial stenoses, pigmented nodules of the iris (*Lisch nodules*), and pigmented skin lesions (axillary freckling and café au lait spots) in various degrees.

## Traumatic Neuroma

Traumatic neuroma is a non-neoplastic proliferation associated with previous injury of a peripheral nerve. Injuries that lead to the transection of axons activate a regenerative program (see Fig. 21–1) characterized by sprouting and elongation of processes from the proximal axonal stump. With severe injuries that disrupt the perineurial sheath, these new processes may "miss" their target, the distal end of the transected nerve. The misguided elongating axonal processes can induce a reactive proliferation of Schwann cells, leading to the formation of a painful localized nodule that consists of a haphazard mixture of axons, Schwann cells, and connective tissue.

### SUMMARY

#### Peripheral Nerve Sheath Tumors

- In most peripheral nerve sheath tumors, the neoplastic cells show evidence of Schwann cell differentiation.
- Peripheral nerve sheath tumors are important features of the familial tumor syndromes neurofibromatosis type 1 (NF1) and type 2 (NF2).
- Schwannomas and neurofibromas are benign nerve sheath tumors.
- Schwannomas are circumscribed, usually encapsulated tumors that abut the nerve of origin and are a feature of NF2.
- Neurofibromas may manifest as a sporadic subcutaneous nodule, as a large, poorly defined soft tissue lesion, or as a growth within a nerve. Neurofibromas are associated with NF1.
- About 50% of malignant peripheral nerve sheath tumors occur de novo in otherwise normal persons, while the remainder arise from the malignant transformation of a preexisting NF1-associated neurofibroma.

## BIBLIOGRAPHY


Amato AA, Barohn RJ: Evaluation and treatment of inflammatory myopathies. J Neurol Neurosurg Psychiatry 80:1060, 2009. *[Review of idiopathic inflammatory myopathies focused especially on clinical features and therapy.]*

Briemberg HR: Peripheral nerve complications of medical disease. Semin Neurol 29:124, 2009. *[Review of the ways medical diseases including diabetes, connective tissue diseases, cancer, and infections affect peripheral nerves.]*

Dalakas MC: Inflammatory muscle diseases: a critical review on pathogenesis and therapies. Curr Opin Pharmacol 10:346, 2010. *[Discussion of current concepts on the pathophysiology of idiopathic inflammatory myopathies.]*

Finsterer J, Stollberger C: Primary myopathies and the heart. Scand Cardiovasc J 42:9, 2008. *[Review of inherited myopathies with focus on associated cardiac involvement.]*

Gorson KC: Vasculitic neuropathies: an update. Neurologist 13:12, 2007. *[A good review of peripheral nerve disease with vasculitis.]*

Greenberg SA: Inflammatory myopathies: disease mechanisms. Curr Opin Neurol 22:516, 2009. *[Discussion of current concepts on the pathophysiology of idiopathic inflammatory myopathies.]*

Habib AA, Brannagan TH III: Therapeutic strategies for diabetic neuropathy. Curr Neurol Neurosci Rep 10:92, 2010. *[Review focused especially on clinical features and therapy of diabetic neuropathy.]*

Hewer E, Goebel HH: Myopathology of non-infectious inflammatory myopathies—the current status. Pathol Res Pract 204:609, 2008. *[Review focused on the pathologic features of inflammatory myopathies.]*

Klopstock T: Drug-induced myopathies. Curr Opin Neurol 21:590, 2008. *[Review focused especially on the effects of statins and nucleoside analogue reverse transcriptase inhibitors for HIV infection/AIDS.]*

Mahadeva B, Phillips LH, Juel VC: Autoimmune disorders of neuromuscular transmission. Semin Neurol 28:212, 2008. *[Review of myasthenia gravis and Lambert-Eaton syndrome.]*

McClatchey AI: Neurofibromatosis. Annu Rev Pathol 2:191, 2007. *[Review of features that distinguish neurofibromatosis type 1, neurofibromatosis type 2, and schwannomatosis, with a focus on the genetics.]*

Nelson SF, Crosbie RH, Miceli MC, et al: Emerging genetic therapies to treat Duchenne muscular dystrophy. Curr Opin Neurol 22:532, 2009. *[Good review of recent developments in the search for new therapies.]*

North K: What's new in congenital myopathies? Neuromuscul Disord 18:433, 2008. *[Review on new developments in congenital myopathies.]*

Obrosova IG: Diabetes and the peripheral nerve. Biochim Biophys Acta 1792:931, 2009. *[Detailed discussion of the pathophysiology of diabetic neuropathy.]*

Silberman J, Lonial S: Review of peripheral neuropathy in plasma cell disorders. Hematol Oncol 26:55, 2008. *[Review of the ways in which peripheral nerve diseases are related to plasma cell disorders and the chemotherapies used in their treatment.]*

van Adel BA, Tarnopolsky MA: Metabolic myopathies: update 2009. J Clin Neuromuscul Dis 10:97, 2009. *[Review of metabolic myopathies.]*

This page intentionally left blank

See Targeted Therapy available online at studentconsult.com

CHAPTER 22

# Central Nervous System

CHAPTER CONTENTS


**Patterns of Injury in the Nervous System 811**
**Edema, Herniation, and Hydrocephalus 812**
Cerebral Edema 812
Hydrocephalus 812
Herniation 813
**Cerebrovascular Diseases 814**
Hypoxia, Ischemia, and Infarction 814
Intracranial Hemorrhage 817
Other Vascular Diseases 819
**Central Nervous System Trauma 820**
Traumatic Parenchymal Injuries 820
Traumatic Vascular Injury 821
**Congenital Malformations and Perinatal Brain Injury 822**
Malformations 822
Perinatal Brain Injury 824
**Infections of the Nervous System 824**
Epidural and Subdural Infections 824
Meningitis 825
Parenchymal Infections 826
Prion Diseases 831
**Primary Diseases of Myelin 832**
Multiple Sclerosis 832
Other Acquired Demyelinating Diseases 834
Leukodystrophies 834
**Acquired Metabolic and Toxic Disturbances 835**
Nutritional Diseases 835
Metabolic Disorders 835
Toxic Disorders 835
**Neurodegenerative Diseases 836**
Alzheimer Disease 836
Frontotemporal Lobar Degeneration 838
Parkinson Disease 839
Huntington Disease 840
Spinocerebellar Ataxias 840
Amyotrophic Lateral Sclerosis 841
**Tumors 842**
Gliomas 842
Neuronal Tumors 844
Embryonal (Primitive) Neoplasms 844
Other Parenchymal Tumors 845
Meningiomas 846
Metastatic Tumors 846
Familial Tumor Syndromes 847


Degenerative, inflammatory, infectious, and neoplastic disorders of the central nervous system (CNS) are some of the most serious diseases of mankind. The pathology of these diseases has many features that reflect the unique properties of the CNS. In fact, the diagnosis and analysis of CNS disorders requires specialized expertise, a realization that has led to the creation of the field of neuropathology.

## PATTERNS OF INJURY IN THE NERVOUS SYSTEM

The cells of the nervous system respond to various forms of injury with distinct morphologic changes.

### MORPHOLOGY

**Features of Neuronal Injury.** In response to injury, a number of changes occur in neurons and their processes (axons and dendrites). Within 12 hours of an irreversible hypoxic-ischemic insult, acute neuronal injury becomes evident on routine hematoxylin and eosin (H&E) staining (Fig. 22–1, *A*). There is shrinkage of the cell body, pyknosis of the nucleus, disappearance of the nucleolus, and loss of Nissl substance, with intense eosinophilia of the cytoplasm ("red neurons"). Often, the nucleus assumes the angulated shape of the shrunken cell body. Injured axons undergo swelling and show disruption of axonal transport. The swellings **(spheroids)** can be recognized on H&E stains (Fig. 22–1, *B*) and can be highlighted by silver staining or immunohistochemistry. Axonal injury also leads to cell body enlargement and rounding, peripheral displacement of the nucleus, enlargement of the nucleolus, and peripheral dispersion of Nissl substance **(central chromatolysis)** (Fig. 22–1, *C*). In addition, acute injuries typically result in breakdown of the blood-brain barrier and variable degrees of cerebral edema (described later).

Many neurodegenerative diseases are associated with specific intracellular inclusions (e.g., Lewy bodies in Parkinson disease and tangles in Alzheimer disease), also described later. Pathogenic viruses can also form inclusions in neurons, just as they do in other cells of the body. In some neurodegenerative diseases, neuronal processes also become thickened and tortuous; these are termed **dystrophic neurites.** With age, neurons also accumulate complex lipids **(lipofuscin)** in their cytoplasm and lysosomes.

**Astrocytes in Injury and Repair.** Astrocytes are the principal cells responsible for repair and scar formation in the

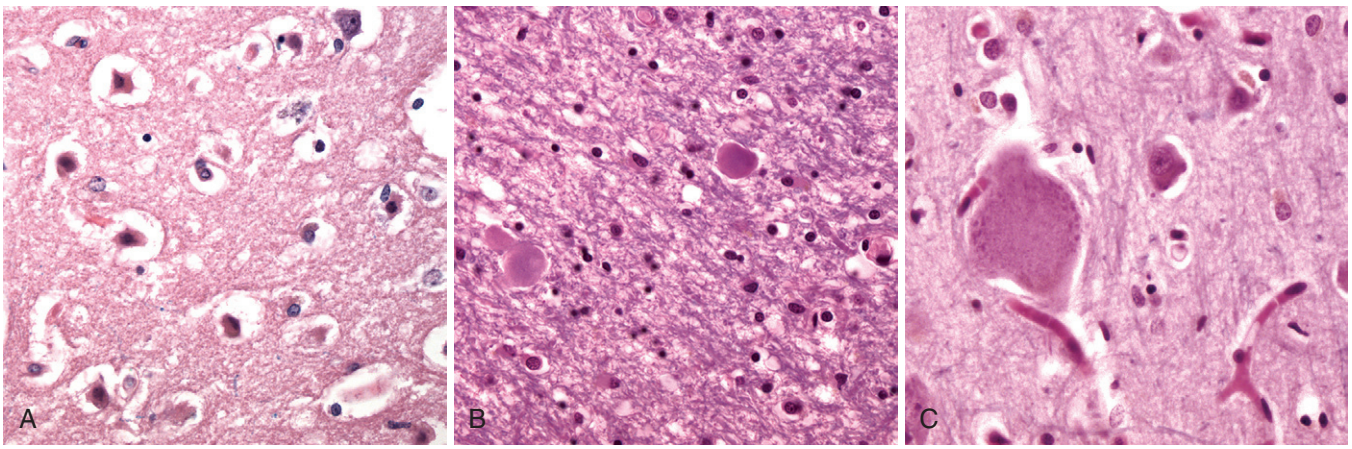


**Figure 22–1** Patterns of neuronal injury. **A,** Acute hypoxic-ischemic injury in cerebral cortex, where the individual cell bodies are shrunken, along with the nuclei. They also are prominently stained by eosin ("red neurons"). **B,** Axonal spheroids are visible as bulbous swellings at points of disruption, or altered axonal transport. **C,** With axonal injury there can be swelling of the cell body and peripheral dispersal of the Nissl substance, termed chromatolysis.

brain, a process termed **gliosis.** In response to injury, astrocytes undergo both hypertrophy and hyperplasia. The nucleus enlarges and becomes vesicular, and the nucleolus becomes prominent. The previously scant cytoplasm expands and takes on a bright pink hue, and the cell extends multiple stout, ramifying processes **(gemistocytic astrocyte).** Unlike elsewhere in the body, fibroblasts participate in healing after brain injury to a limited extent except in specific settings (penetrating brain trauma or around abscesses). In long-standing gliosis, the cytoplasm of reactive astrocytes shrinks in size and the cellular processes become more tightly interwoven **(fibrillary astrocytes). Rosenthal fibers** are thick, elongated, brightly eosinophilic protein aggregates found in astrocytic processes in chronic gliosis and in some low-grade gliomas.

**Changes in Other Cell Types. Oligodendrocytes,** which produce myelin, exhibit a limited spectrum of specific morphologic changes in response to various injuries. In progressive multifocal leukoencephalopathy, viral inclusions can be seen in oligodendrocytes, with a smudgy, homogeneous-appearing enlarged nucleus.

**Microglial cells** are bone-marrow–derived cells that function as the resident phagocytes of the CNS. When activated by tissue injury, infection, or trauma, they proliferate and become more prominent histologically. Microglial cells take on the appearance of activated macrophages in areas of demyelination, organizing infarct, or hemorrhage; in other settings such as neurosyphilis or other infections, they develop elongated nuclei **(rod cells).** Aggregates of elongated microglial cells at sites of tissue injury are termed **microglial nodules.** Similar collections can be found congregating around and phagocytosing injured neurons **(neuronophagia).**

**Ependymal cells** line the ventricular system and the central canal of the spinal cord. Certain pathogens, particularly cytomegalovirus (CMV), can produce extensive ependymal injury, with typical viral inclusions. **Choroid plexus** is in continuity with the ependyma, and its specialized epithelial covering is responsible for the secretion of cerebrospinal fluid (CSF).

## EDEMA, HERNIATION, AND HYDROCEPHALUS

The brain and spinal cord exist within the protective and rigid skull and spinal canal, with nerves and blood vessels passing through specific foramina. The advantage of housing the delicate CNS within such a protective environment is obvious, but this arrangement provides little room for brain parenchymal expansion in disease states. Disorders that may cause dangerous increases in brain volume within the fixed space of the skull include generalized cerebral edema, hydrocephalus, and mass lesions such as tumors.

### Cerebral Edema

Cerebral edema is the accumulation of excess fluid within the brain parenchyma. There are two types, which often occur together particularly after generalized injury.

- *Vasogenic edema* occurs when the integrity of the normal blood-brain barrier is disrupted, allowing fluid to shift from the vascular compartment into the extracellular spaces of the brain. Vasogenic edema can be either localized (e.g., increased vascular permeability due to inflammation or in tumors) or generalized.
- *Cytotoxic edema* is an increase in intracellular fluid secondary to neuronal and glial cell membrane injury, as might follow generalized hypoxic-ischemic insult or after exposure to some toxins.

The edematous brain is softer than normal and often appears to "over fill" the cranial vault. In generalized edema the gyri are flattened, the intervening sulci are narrowed, and the ventricular cavities are compressed (Fig. 22–2).

### Hydrocephalus

After being produced by the choroid plexus within the ventricles, CSF circulates through the ventricular system

**Figure 22–2** Cerebral edema. The surfaces of the gyri are flattened as a result of compression of the expanding brain by the dura mater and inner surface of the skull. Such changes are associated with a dangerous increase in intracranial pressure.

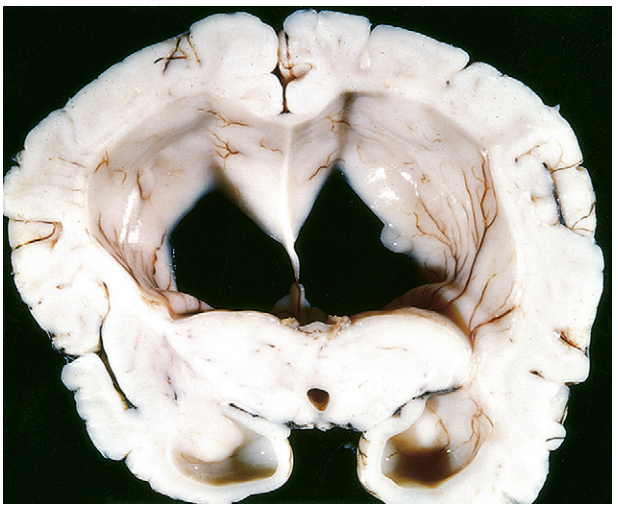

**Figure 22–3** Hydrocephalus. Dilated lateral ventricles seen in a coronal section through the midthalamus.

and flows through the foramina of Luschka and Magendie into the subarachnoid space, where it is absorbed by arachnoid granulations. The balance between rates of generation and resorption regulates CSF volume.

*Hydrocephalus* refers to the accumulation of excessive CSF within the ventricular system. This disorder most often is a consequence of impaired flow or resorption; overproduction of CSF, typically seen with tumors of the choroid plexus, only rarely causes hydrocephalus. If there is a localized obstacle to CSF flow within the ventricular system, then a portion of the ventricles enlarges while the remainder does not. This pattern is referred to as *noncommunicating hydrocephalus* and most commonly is caused by masses obstructing the foramen of Monro or compressing the cerebral aqueduct. In *communicating hydrocephalus,* the entire ventricular system is enlarged; it is usually caused by reduced CSF resorption.

If hydrocephalus develops in infancy before closure of the cranial sutures, the head enlarges. Once the sutures fuse, hydrocephalus causes ventricular expansion and increased intracranial pressure, but no change in head circumference (Fig. 22–3). In contrast with these states, in which increased CSF volume is the primary process, a compensatory increase in CSF volume can also follow the loss of brain parenchyma (*hydrocephalus ex vacuo*), as after infarcts or with degenerative diseases.

## Herniation

When the volume of tissue and fluid inside the skull increases beyond the limit permitted by compression of veins and displacement of CSF, intracranial pressure rises. The cranial vault is subdivided by rigid dural folds (falx and tentorium), and a focal expansion of the brain displaces it in relation to these partitions. If the expansion is sufficiently large, herniation occurs. Herniation often leads to "pinching" and vascular compromise of the compressed tissue, producing infarction, additional swelling, and further herniation. There are three main types of herniation (Fig. 22–4).

- *Subfalcine (cingulate)* herniation occurs when unilateral or asymmetric expansion of a cerebral hemisphere displaces the cingulate gyrus under the edge of falx. This may be associated with compression of the anterior cerebral artery.
- *Transtentorial (uncinate)* herniation occurs when the medial aspect of the temporal lobe is compressed against the free margin of the tentorium. As the temporal lobe is displaced, the third cranial nerve is compromised, resulting in pupillary dilation and impaired ocular

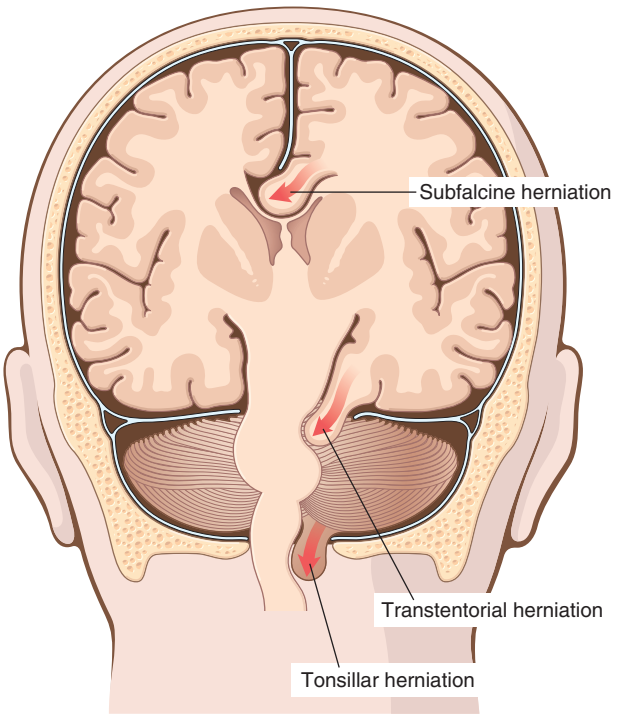


**Figure 22–4** Herniation syndromes. Displacement of brain parenchyma across fixed barriers can be subfalcine, transtentorial, or tonsillar (into the foramen magnum).

movements on the side of the lesion ("blown pupil"). The posterior cerebral artery may also be compressed, resulting in ischemic injury to tissue supplied by that vessel, including the primary visual cortex. If the amount of displaced temporal lobe is large enough, the pressure on the midbrain can compress the contralateral cerebral peduncle against the tentorium, resulting in hemiparesis ipsilateral to the side of the herniation (a so-called false localizing sign). The compression of the peduncle creates a deformation known as Kernohan's notch. Progression of transtentorial herniation is often accompanied by linear or flame-shaped hemorrhages in the midbrain and pons, termed *Duret hemorrhages* (Fig. 22–5). These lesions usually occur in the midline and paramedian regions and are believed to be the result of tearing of penetrating veins and arteries supplying the upper brain stem.

- *Tonsillar* herniation refers to displacement of the cerebellar tonsils through the foramen magnum. This type of herniation is life-threatening, because it causes brain stem compression and compromises vital respiratory and cardiac centers in the medulla.

## SUMMARY

### Edema, Herniation, and Hydrocephalus

- Cerebral edema is the accumulation of excess fluid within the brain parenchyma. Hydrocephalus is defined as an increase in CSF volume within all or part of the ventricular system.
- Increases in brain volume (as a result of increased CSF volume, edema, hemorrhage, or tumor) raise the pressure inside the fixed capacity of the skull.
- Increases in pressure can damage the brain either by decreasing perfusion or by displacing tissue across dural partitions inside the skull or through openings in the skull (herniations).

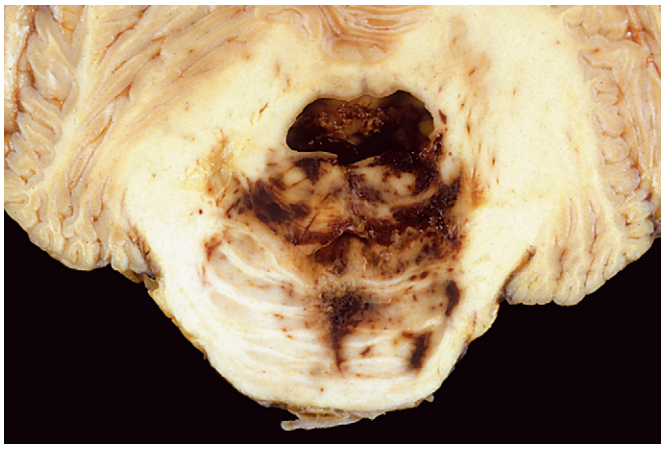

**Figure 22–5** Duret hemorrhage. As mass effect displaces the brain downward, there is disruption of the vessels that enter the pons along the midline, leading to hemorrhage.

# CEREBROVASCULAR DISEASES

Cerebrovascular diseases—the broad category of brain disorders caused by pathologic processes involving blood vessels—constitute a major cause of death in the developed world and are the most prevalent cause of neurologic morbidity. The three main pathogenic mechanisms are (1) thrombotic occlusion, (2) embolic occlusion, and (3) vascular rupture. *Stroke* is the clinical designation applied to all of these conditions when symptoms begin acutely. Thrombosis and embolism have similar consequences for the brain: loss of oxygen and metabolic substrates, resulting in infarction or ischemic injury of regions supplied by the affected vessel. Similar injury occurs globally when there is complete loss of perfusion, severe hypoxemia (e.g., hypovolemic shock), or profound hypoglycemia. Hemorrhage accompanies rupture of vessels and leads to direct tissue damage as well as secondary ischemic injury. Traumatic vascular injury is discussed separately in the context of trauma.

## Hypoxia, Ischemia, and Infarction

The brain is a highly oxygen-dependent tissue that requires a continual supply of glucose and oxygen from the blood. Although it constitutes no more than 2% of body weight, the brain receives 15% of the resting cardiac output and is responsible for 20% of total body oxygen consumption. Cerebral blood flow normally remains stable over a wide range of blood pressure and intracranial pressure because of autoregulation of vascular resistance. The brain may be deprived of oxygen by two general mechanisms:

- *Functional hypoxia,* caused by a low partial pressure of oxygen (e.g., high altitude), impaired oxygen-carrying capacity (e.g., severe anemia, carbon monoxide poisoning), or inhibition of oxygen use by tissue (e.g., cyanide poisoning)
- *Ischemia,* either *transient* or *permanent,* due to tissue hypoperfusion, which can be caused by hypotension, vascular obstruction, or both

### *Global Cerebral Ischemia*

Widespread ischemic-hypoxic injury can occur in the setting of severe systemic hypotension, usually when systolic pressures fall below 50 mm Hg, as in cardiac arrest, shock, and severe hypotension. The clinical outcome varies with the severity and duration of the insult. When the insult is mild, there may be only a transient postischemic confusional state, with eventual complete recovery. Neurons are more susceptible to hypoxic injury than are glial cells, and the most susceptible neurons are the pyramidal cells of the hippocampus and neocortex and Purkinje cells of the cerebellum. In some individuals, even mild or transient global ischemic insults may cause damage to these vulnerable areas. In severe global cerebral ischemia, widespread neuronal death occurs irrespective of regional vulnerability. Patients who survive often remain severely impaired neurologically and in a persistent vegetative state. Other patients meet the clinical criteria for so-called brain death, including evidence of diffuse cortical injury (isoelectric, or "flat," electroencephalogram) and brain

stem damage, including absence of reflexes and respiratory drive. When patients with this form of irreversible injury are maintained on mechanical ventilation, the brain gradually undergoes autolysis, resulting in the so-called "respirator brain."

## MORPHOLOGY

In the setting of global ischemia, the brain is swollen, with wide gyri and narrowed sulci. The cut surface shows poor demarcation between gray and white matter. The histopathologic changes that accompany irreversible ischemic injury (infarction) are grouped into three categories. **Early changes,** occurring 12 to 24 hours after the insult, include acute neuronal cell change (red neurons) (Fig. 22–1, *A*) characterized initially by microvacuolization, followed by cytoplasmic eosinophilia, and later nuclear pyknosis and karyorrhexis. Similar changes occur somewhat later in astrocytes and oligodendroglia. After this, the reaction to tissue damage begins with infiltration by neutrophils (Fig. 22–6, *A*). **Subacute changes,** occurring at 24 hours to 2 weeks, include necrosis of tissue, influx of macrophages, vascular proliferation, and reactive gliosis (Fig. 22–6, *B*). **Repair,** seen after 2 weeks, is characterized by removal of all necrotic tissue, loss of organized CNS structure, and gliosis (Fig. 22–6, *C*). The distribution of neuronal loss and gliosis in the neocortex typically is uneven with preservation of some layers and devastation of others—a pattern termed pseudolaminar necrosis.

**Border zone ("watershed") infarcts** are wedge-shaped areas of infarction that occur in regions of the brain and spinal cord that lie at the most distal portions of arterial territories. They are usually seen after hypotensive episodes. In the cerebral hemispheres, the border zone between the anterior and the middle cerebral artery distributions is at greatest risk. Damage to this region produces a band of necrosis over the cerebral convexity a few centimeters lateral to the interhemispheric fissure.

### *Focal Cerebral Ischemia*

Cerebral arterial occlusion leads first to focal ischemia and then to infarction in the distribution of the compromised vessel. The size, location, and shape of the infarct and the extent of tissue damage that results may be modified by collateral blood flow. Specifically, collateral flow through the circle of Willis or cortical-leptomeningeal anastomoses can limit damage in some regions. By contrast, there is little if any collateral flow to structures such as the thalamus, basal ganglia, and deep white matter, which are supplied by deep penetrating vessels.

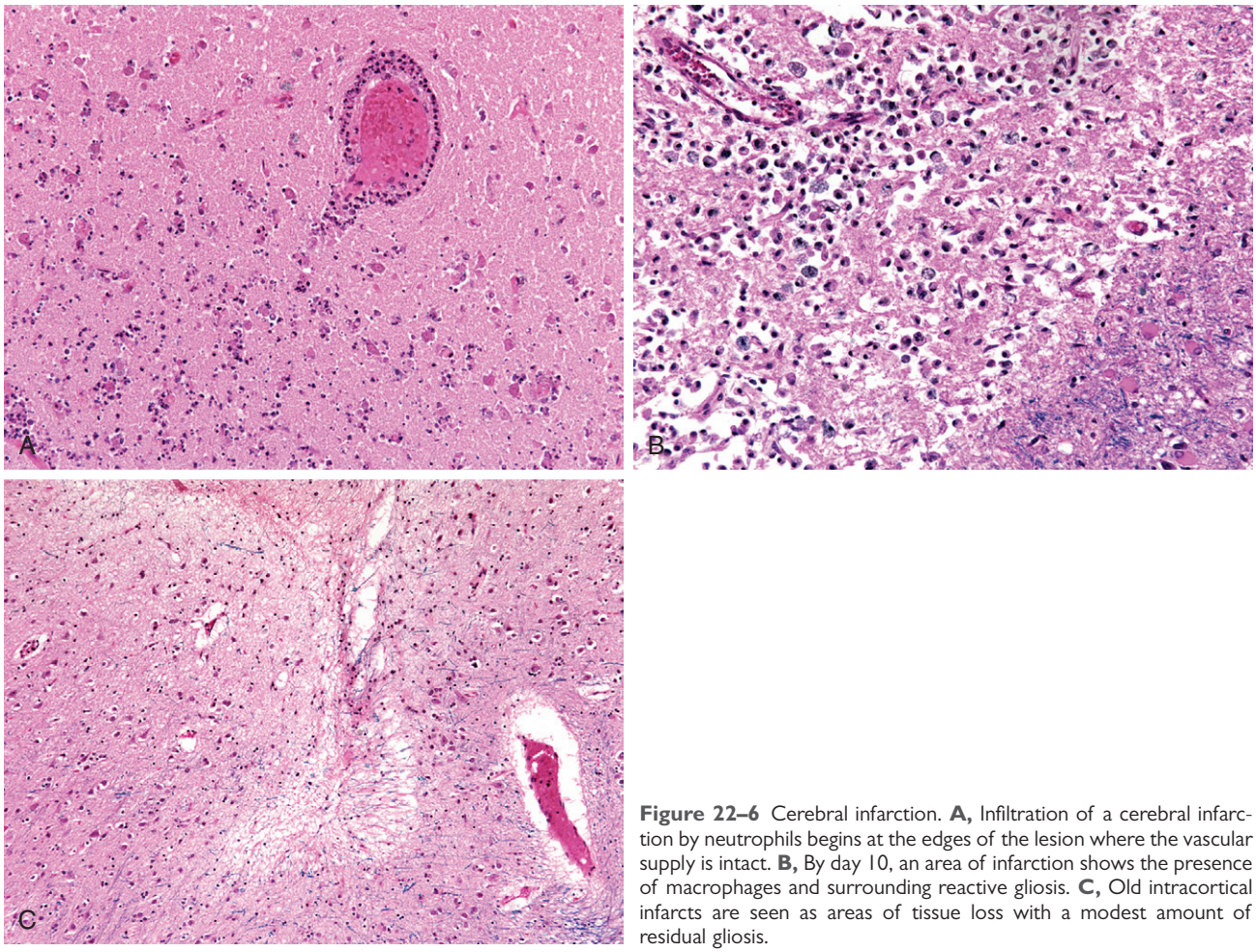


**Figure 22–6** Cerebral infarction. **A,** Infiltration of a cerebral infarction by neutrophils begins at the edges of the lesion where the vascular supply is intact. **B,** By day 10, an area of infarction shows the presence of macrophages and surrounding reactive gliosis. **C,** Old intracortical infarcts are seen as areas of tissue loss with a modest amount of residual gliosis.

*Embolic* infarctions are more common than infarctions due to *thrombosis.* Cardiac mural thrombi are a frequent source of emboli; myocardial dysfunction, valvular disease, and atrial fibrillation are important predisposing factors. Thromboemboli also arise in arteries, most often from atheromatous plaques within the carotid arteries or aortic arch. Other emboli of venous origin cross over to the arterial circulation through cardiac defects and lodge in the brain (paradoxical embolism; see Chapter 3); these include thromboemboli from deep leg veins and fat emboli, usually following bone trauma. The territory of the middle cerebral artery, a direct extension of the internal carotid artery, is most frequently affected by embolic infarction. Emboli tend to lodge where vessels branch or in areas of stenosis, usually caused by *atherosclerosis.*

Thrombotic occlusions causing cerebral infarctions usually are superimposed on atherosclerotic plaques; common sites are the carotid bifurcation, the origin of the middle cerebral artery, and at either end of the basilar artery. These occlusions may be accompanied by anterograde extension, as well as thrombus fragmentation and distal embolization.

Infarcts can be divided into two broad groups based on their macroscopic and corresponding radiologic appearance (Fig. 22–7). *Nonhemorrhagic infarcts* result from acute vascular occlusions and can be treated with thrombolytic therapies, especially if identified shortly after presentation. This approach is contraindicated in *hemorrhagic infarcts,* which result from reperfusion of ischemic tissue, either through collaterals or after dissolution of emboli, and often produce multiple, sometimes confluent petechial hemorrhages (Fig. 22–7, *A* and *B*).

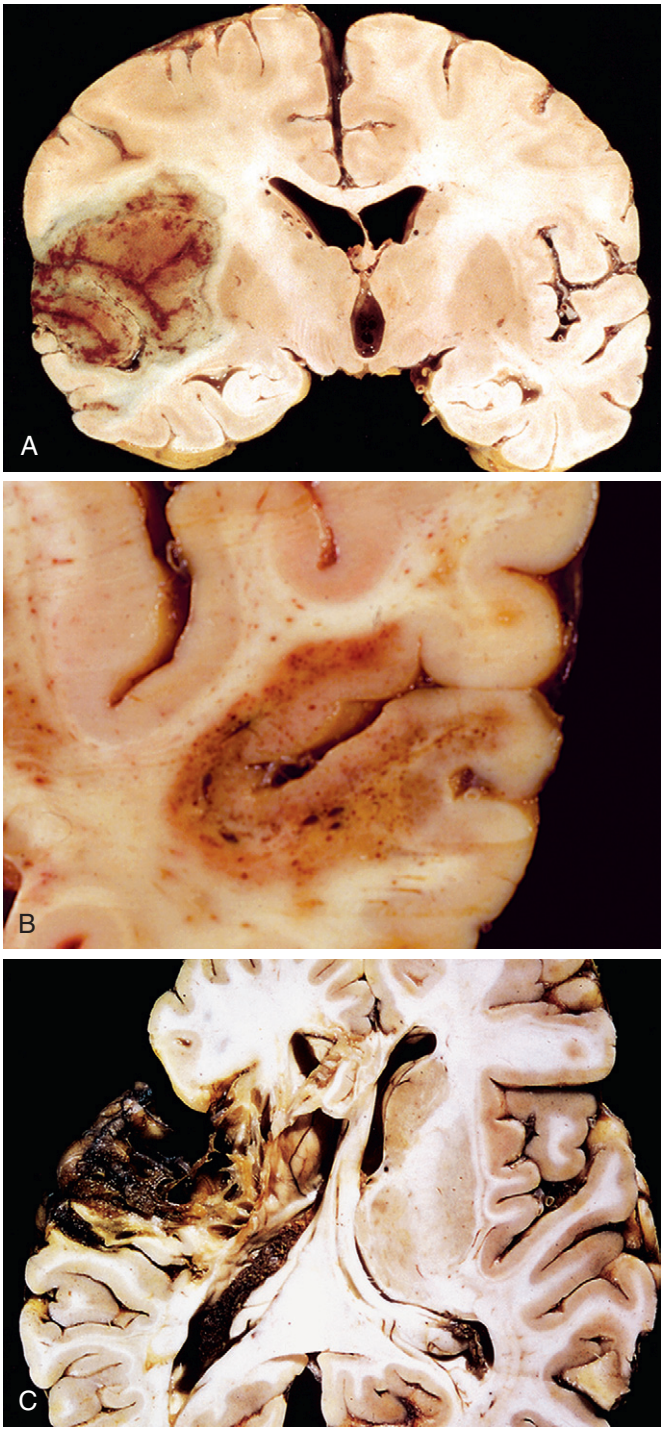


**Figure 22–7** Cerebral infarction. **A,** Section of the brain showing a large, discolored, focally hemorrhagic region in the left middle cerebral artery distribution (hemorrhagic, or red, infarction). **B,** An infarct with punctate hemorrhages, consistent with ischemia-reperfusion injury, is present in the temporal lobe. **C,** Old cystic infarct shows destruction of cortex and surrounding gliosis.

## MORPHOLOGY

The macroscopic appearance of a **nonhemorrhagic infarct** evolves over time. During the first 6 hours the tissue is unchanged in appearance, but by 48 hours, the tissue becomes pale, soft, and swollen. From days 2 to 10, the brain turns gelatinous and friable, and the boundary between normal and abnormal tissue becomes more distinct as edema resolves in the adjacent viable tissue. From day 10 to week 3, the tissue liquefies, eventually leaving a fluid-filled cavity lined by dark gray tissue, which gradually expands as dead tissue is resorbed (Fig. 22–7, *C*).

Microscopically, the tissue reaction follows a characteristic sequence. **After the first 12 hours,** ischemic neuronal change (red neurons) (Fig. 22–1, *A*) and cytotoxic and vasogenic edema predominate. Endothelial and glial cells, mainly astrocytes, swell, and myelinated fibers begin to disintegrate. **Up to 48 hours,** there is some neutrophilic emigration, which is followed by mononuclear phagocytic cells during the ensuing **2 to 3 weeks.** Macrophages containing myelin or red cell breakdown products may persist in the lesion for months to years. As the process of phagocytosis and liquefaction proceeds, astrocytes at the edges of the lesion progressively enlarge, divide, and develop a prominent network of cytoplasmic extensions.

**After several months,** the striking astrocytic nuclear and cytoplasmic enlargement regresses. In the wall of the cavity, astrocyte processes form a dense feltwork of glial fibers admixed with new capillaries and a few perivascular connective tissue fibers. In the cerebral cortex, the cavity is delimited from the meninges and subarachnoid space by a gliotic layer of tissue, derived from the molecular layer of the

cortex. The pia and arachnoid are not affected and do not contribute to the healing process.

The microscopic picture and evolution of **hemorrhagic infarction** parallel those of ischemic infarction, with the addition of blood extravasation and resorption. In persons with coagulopathies, hemorrhagic infarcts may be associated with extensive intracerebral hematomas.

## Intracranial Hemorrhage

Hemorrhages within the brain are associated with (1) hypertension and other diseases leading to vascular wall injury, (2) structural lesions such as arteriovenous and cavernous malformations, and (3) tumors. Subarachnoid hemorrhages most commonly are caused by ruptured aneurysms but also occur with other vascular malformations. Subdural or epidural hemorrhages usually are associated with trauma.

### *Primary Brain Parenchymal Hemorrhage*

Spontaneous (nontraumatic) intraparenchymal hemorrhages are most common in mid- to late adult life, with a peak incidence at about 60 years of age. Most are due to the rupture of a small intraparenchymal vessel. Hypertension is the leading underlying cause, and brain hemorrhage accounts for roughly 15% of deaths among persons with chronic hypertension. Intracerebral hemorrhage can be clinically devastating when it affects large portions of the brain or extends into the ventricular system; alternatively, it can affect small regions and be clinically silent. Hypertensive intraparenchymal hemorrhages typically occur in the basal ganglia, thalamus, pons, and cerebellum (Fig. 22–8), with the location and the size of the bleed determining its clinical manifestations. If the person survives the acute event, gradual resolution of the hematoma ensues, sometimes with considerable clinical improvement.

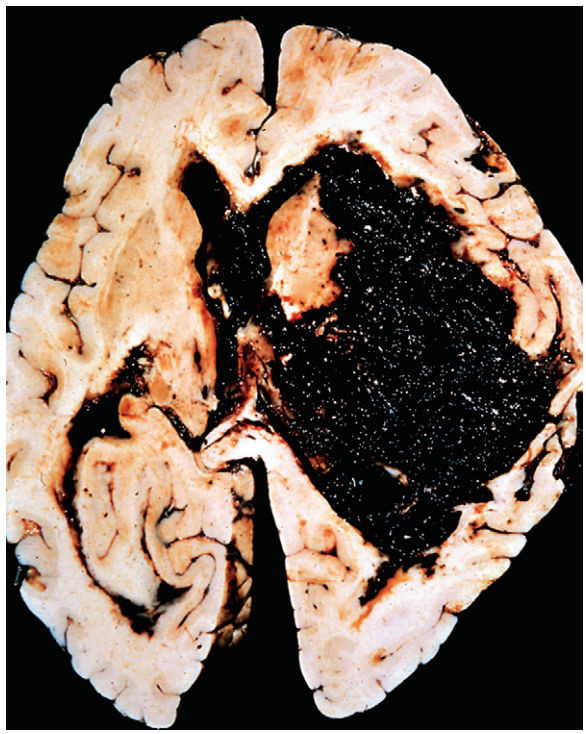

**Figure 22–8** Cerebral hemorrhage. Massive hypertensive hemorrhage rupturing into a lateral ventricle.

#### MORPHOLOGY

Acute hemorrhages are characterized by extravasated blood, which compresses the adjacent parenchyma. With time, hemorrhages are converted to a cavity with a brown, discolored rim. On microscopic examination, early lesions consist of clotted blood surrounded by brain tissue showing anoxic neuronal and glial changes as well as edema. Eventually the edema resolves, pigment- and lipid-laden macrophages appear, and proliferation of reactive astrocytes becomes visible at the periphery of the lesion. The cellular events then follow the same time course observed after cerebral infarction.

### *Cerebral Amyloid Angiopathy*

Cerebral amyloid angiopathy (CAA) is a disease in which amyloidogenic peptides, typically the same ones found in Alzheimer disease (discussed later), deposit in the walls of medium- and small-caliber meningeal and cortical vessels. The amyloid confers a rigid, pipelike appearance and stains with Congo red. Amyloid deposition weakens vessel walls and increases the risk of hemorrhages, which differ in distribution from those associated with hypertension. Specifically, CAA-associated hemorrhages often occur in the lobes of the cerebral cortex (*lobar hemorrhages*).

### *Subarachnoid Hemorrhage and Saccular Aneurysms*

The most frequent cause of clinically significant nontraumatic subarachnoid hemorrhage is rupture of a *saccular (berry) aneurysm.* Hemorrhage into the subarachnoid space also may result from vascular malformation, trauma (usually associated with other signs of the injury), rupture of an intracerebral hemorrhage into the ventricular system, hematologic disturbances, and tumors.

Rupture can occur at any time, but in about one third of cases it is associated with acute increases in intracranial pressure, such as with straining at stool or sexual orgasm. Blood under arterial pressure is forced into the subarachnoid space, and the patient is stricken with sudden, excruciating headache (classically described as "the worst headache I've ever had") and rapidly loses consciousness. Between 25% and 50% of affected persons die from the first bleed, and recurrent bleeds are common in survivors. Not surprisingly, the prognosis worsens with each bleeding episode.

About 90% of saccular aneurysms occur in the anterior circulation near major arterial branch points (Fig. 22–9); multiple aneurysms exist in 20% to 30% of cases. Although they are sometimes referred to as *congenital,* they are not present at birth but develop over time because of underlying defects in the vessel media. There is an increased risk of aneurysms in patients with autosomal dominant polycystic kidney disease (Chapter 13), as well as those with genetic disorders of extracellular matrix proteins. Overall, roughly 1.3% of aneurysms bleed per year, with the

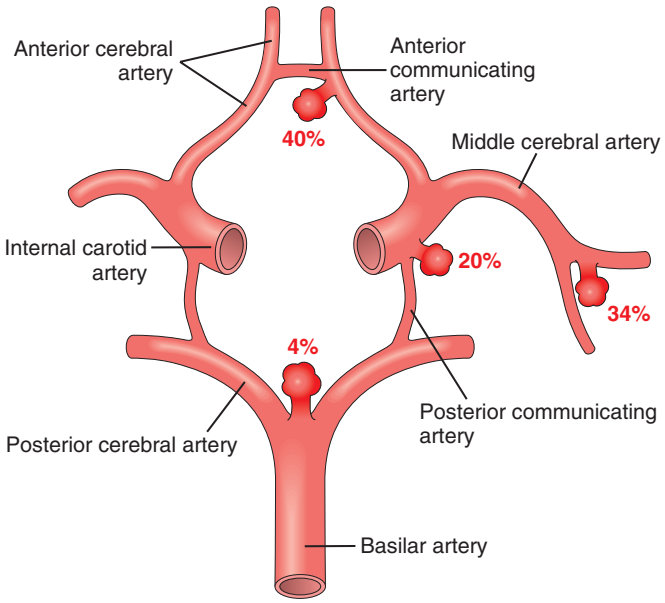


**Figure 22–9** Common sites of saccular aneurysms.

probability of rupture increasing nonlinearly with size. For example, aneurysms larger than 1 cm in diameter have a roughly 50% risk of bleeding per year. In the early period after a subarachnoid hemorrhage, there is an additional risk of ischemic injury from vasospasm of other vessels. Healing and the attendant meningeal fibrosis and scarring sometimes obstruct CSF flow or disrupt CSF resorption, leading to hydrocephalus.

## MORPHOLOGY

An unruptured saccular aneurysm is a thin-walled outpouching of an artery (Fig. 22–10). Beyond the neck of the aneurysm, the muscular wall and intimal elastic lamina are absent, such that the aneurysm sac is lined only by thickened hyalinized intima. The adventitia covering the sac is continuous with that of the parent artery. Rupture usually occurs at the apex of the sac, releasing blood into the subarachnoid space or the substance of the brain, or both.

In addition to saccular aneurysms, atherosclerotic, mycotic, traumatic, and dissecting aneurysms also occur intracranially. The last three types (like saccular aneurysms) most often are found in the anterior circulation, whereas atherosclerotic aneurysms frequently are fusiform and most commonly involve the basilar artery. Nonsaccular aneurysms usually manifest with cerebral infarction due to vascular occlusion instead of subarachnoid hemorrhage.

### *Vascular Malformations*

Vascular malformations of the brain are classified into four principal types based on the nature of the abnormal vessels: *arteriovenous malformations* (AVMs), *cavernous malformations, capillary telangiectasias,* and *venous angiomas.* AVMs, the most common of these, affect males twice as frequently as females and most commonly manifest between the ages of 10 and 30 years with seizures, an intracerebral hemorrhage, or a subarachnoid hemorrhage. Large AVMs occurring in the newborn period can lead to high-output congestive heart failure because of blood shunting from arteries to veins. The risk of bleeding makes AVM the most dangerous type of vascular malformation. Multiple AVMs can be seen in the setting of hereditary hemorrhagic telangiectasia, an autosomal dominant condition often associated with mutations affecting the TGFβ pathway.

## MORPHOLOGY

**AVMs** may involve subarachnoid vessels extending into brain parenchyma or occur exclusively within the brain. On gross inspection, they resemble a tangled network of wormlike

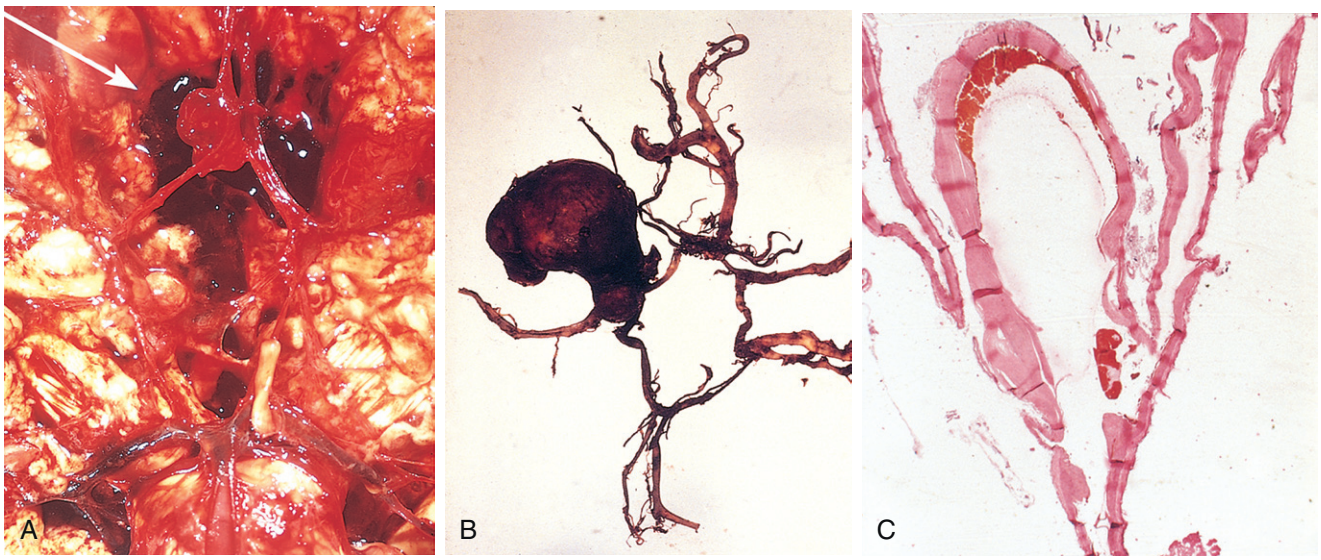


**Figure 22–10** Saccular aneurysms. **A,** View of the base of the brain, dissected to show the circle of Willis with an aneurysm of the anterior cerebral artery *(arrow)*. **B,** Circle of Willis dissected to show large aneurysm. **C,** Section through a saccular aneurysm showing the hyalinized fibrous vessel wall. Hematoxylin-eosin stain.

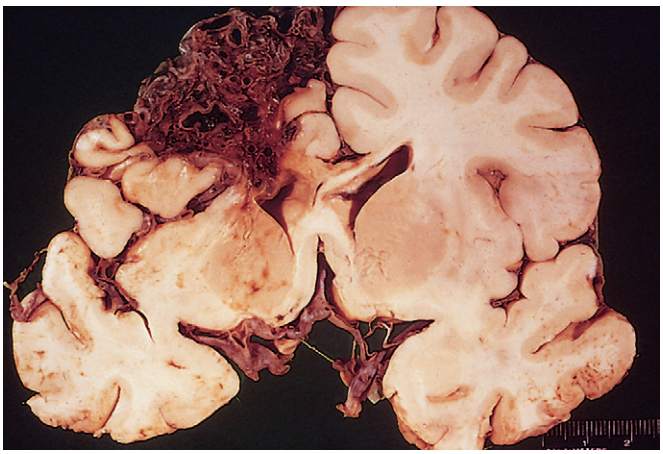

**Figure 22–11** Arteriovenous malformation.

vascular channels (Fig. 22–11). Microscopic examination shows enlarged blood vessels separated by gliotic tissue, often with evidence of previous hemorrhage. Some vessels can be recognized as arteries with duplicated and fragmented internal elastic lamina, while others show marked thickening or partial replacement of the media by hyalinized connective tissue.

**Cavernous malformations** consist of distended, loosely organized vascular channels with thin collagenized walls without intervening nervous tissue. They occur most often in the cerebellum, pons, and subcortical regions, and have a low blood flow without significant arteriovenous shunting. Foci of old hemorrhage, infarction, and calcification frequently surround the abnormal vessels.

**Capillary telangiectasias** are microscopic foci of dilated thin-walled vascular channels separated by relatively normal brain parenchyma that occur most frequently in the pons. **Venous angiomas** (varices) consist of aggregates of ectatic venous channels. These latter two types of vascular malformation are unlikely to bleed or to cause symptoms, and most are incidental findings.

## Other Vascular Diseases

### *Hypertensive Cerebrovascular Disease*

Hypertension causes *hyaline arteriolar sclerosis* of the deep penetrating arteries and arterioles that supply the basal ganglia, the hemispheric white matter, and the brain stem. Affected arteriolar walls are weakened and are more vulnerable to rupture. In some instances, minute aneurysms (*Charcot-Bouchard microaneurysms*) form in vessels less than 300 µm in diameter. In addition to massive intracerebral hemorrhage (discussed earlier), several other pathologic brain processes are related to hypertension.

- *Lacunes* or *lacunar infarcts* are small cavitary infarcts, just a few millimeters in size, found most commonly in the deep gray matter (basal ganglia and thalamus), the internal capsule, the deep white matter, and the pons. They are caused by occlusion of a single penetrating branch of a large cerebral artery. Depending on their location, lacunes can be silent clinically or cause significant neurologic impairment.
- *Rupture of the small-caliber penetrating vessels* may occur, leading to the development of small hemorrhages. In time, these hemorrhages resorb, leaving behind a slitlike cavity (*slit hemorrhage*) surrounded by brownish discoloration.
- *Acute hypertensive encephalopathy* most often is associated with sudden sustained rises in diastolic blood pressure to greater than 130 mm Hg. It is characterized by increased intracranial pressure and global cerebral dysfunction, manifesting as headaches, confusion, vomiting, convulsions, and sometimes coma. Rapid therapeutic intervention to reduce the intracranial pressure is essential. Postmortem examination may show brain edema, with or without transtentorial or tonsillar herniation. Petechiae and fibrinoid necrosis of arterioles in the gray and white matter may be seen microscopically.

### *Vasculitis*

A variety of inflammatory processes involving blood vessels may compromise blood flow and cause cerebral infarction. Infectious arteritis of small and large vessels was previously seen mainly in association with syphilis and tuberculosis, but is now more often caused by opportunistic infections (such as aspergillosis, herpes zoster, or CMV) arising in the setting of immunosuppression. Some systemic forms of vasculitis, such as polyarteritis nodosa, may involve cerebral vessels and cause single or multiple infarcts throughout the brain. *Primary angiitis of the CNS* is a form of vasculitis involving multiple small to medium-sized parenchymal and subarachnoid vessels that is characterized by chronic inflammation, multinucleate giant cells (with or without granuloma formation), and destruction of vessel walls. Affected persons present with a diffuse encephalopathy, often with cognitive dysfunction. Treatment consists of an appropriate regimen of immunosuppressive agents.

## SUMMARY

### Cerebrovascular Diseases

- *Stroke* is the clinical term for acute-onset neurologic deficits resulting from hemorrhagic or obstructive vascular lesions.
- Cerebral infarction follows loss of blood supply and can be widespread or focal, or affect regions with the least robust vascular supply ("watershed" infarcts).
- Focal cerebral infarcts are most commonly embolic; with subsequent dissolution of an embolism and reperfusion, a nonhemorrhagic infarct can become hemorrhagic.
- Primary intraparenchymal hemorrhages typically are due to either hypertension (most commonly in white matter, deep gray matter, or posterior fossa contents) or cerebral amyloid angiopathy.
- Spontaneous subarachnoid hemorrhage usually is caused by a structural vascular abnormality, such as an aneurysm or arteriovenous malformation.

# CENTRAL NERVOUS SYSTEM TRAUMA

Trauma to the brain and spinal cord is a significant cause of death and disability. The severity and site of injury affect the outcome: injury of several cubic centimeters of brain parenchyma may be clinically silent (if in the frontal lobe), severely disabling (spinal cord), or fatal (involving the brain stem).

A blow to the head may be *penetrating* or *blunt;* it may cause an *open* or a *closed* injury. The magnitude and distribution of resulting traumatic brain lesions depend on the shape of the object causing the trauma, the force of impact, and whether the head is in motion at the time of injury. Severe brain damage can occur in the absence of external signs of head injury, and conversely, severe lacerations and even skull fractures do not necessarily indicate damage to the underlying brain. When the brain is damaged, the injuries may involve the parenchyma, the vasculature, or both.

Recent evidence suggests that repetitive episodes of trauma (such as occurs in athletes participating in contact sports) can lead to later development of neurodegenerative processes. In addition to a long-recognized association of trauma with the risk of Alzheimer disease, a distinct form of trauma-associated degeneration has been described, *chronic traumatic encephalopathy,* which is characterized by a unique pattern of intraneuronal tau protein inclusions (described later).

## Traumatic Parenchymal Injuries

When an object impacts the head, brain injury may occur at the site of impact—a *coup injury*—or opposite the site of impact on the other side of the brain—a *contrecoup injury*. Both coup and contrecoup lesions are contusions, with comparable gross and microscopic appearances. A *contusion* is caused by rapid tissue displacement, disruption of vascular channels, and subsequent hemorrhage, tissue injury, and edema. Since they are closest to the skull, the crests of the gyri are the part of the brain that is most susceptible to traumatic injury. Contusions are common in regions of the brain overlying rough and irregular inner skull surfaces, such as the orbitofrontal regions and the temporal lobe tips. Penetration of the brain by a projectile such as a bullet or a skull fragment from a fracture causes a laceration, with tissue tearing, vascular disruption, and hemorrhage.

### MORPHOLOGY

On cross-section, contusions are wedge-shaped, with the widest aspect closest to the point of impact (Fig. 22–12, *A*). Within a few hours of injury, blood extravasates throughout the involved tissue, across the width of the cerebral cortex, and into the white matter and subarachnoid spaces. Although functional effects are seen earlier, morphologic evidence of injury in the neuronal cell body (nuclear pyknosis, cytoplasmic eosinophilia, cellular disintegration) takes about 24 hours to appear. The inflammatory response to the injured tissue follows its usual course, with neutrophils preceding the appearance of macrophages. In contrast with ischemic lesions, in which the superficial layer of cortex may be preserved, trauma affects the superficial layers most severely.

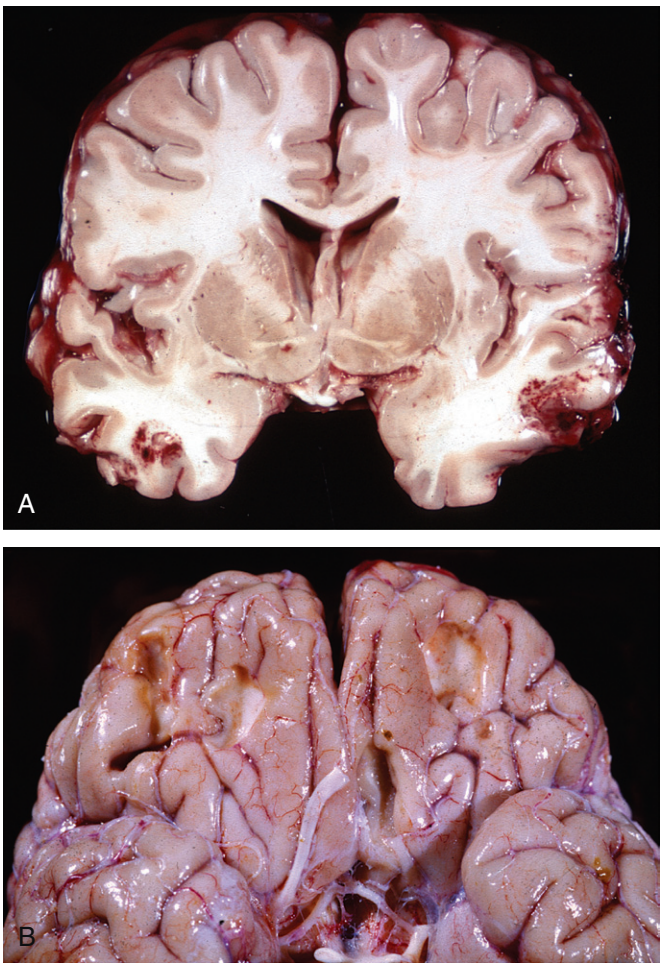


**Figure 22–12** Cerebral trauma. **A,** Acute contusions are present in both temporal lobes, with areas of hemorrhage and tissue disruption. **B,** Remote contusions, seen as discolored *yellow* areas, are present on the inferior frontal surface of this brain.

Old traumatic lesions have a characteristic macroscopic appearance: They are depressed, retracted, yellowish brown patches involving the crests of gyri (Fig. 22–12, *B*). More extensive hemorrhagic regions of brain trauma give rise to larger cavitary lesions, which can resemble remote infarcts. In sites of old contusions, gliosis and residual hemosiderin-laden macrophages predominate.

Although contusions are more easily seen, trauma can also cause more subtle but widespread injury to axons within the brain (called **diffuse axonal injury**), sometimes with devastating consequences. The movement of one region of brain relative to another is thought to disrupt axonal integrity and function. Angular acceleration, even in the absence of impact, may cause axonal injury as well as hemorrhage. As many as 50% of patients who develop coma shortly after trauma are believed to have white matter damage and diffuse axonal injury. Although these injuries may be widespread, the lesions usually are asymmetric and are most commonly found near the angles of the lateral ventricles and in the brain stem. They take the form of axonal swellings that appear within hours of the injury. These are best demonstrated with silver stains or by immunohistochemical stains for axonal proteins.

*Concussion* describes reversible altered consciousness from head injury in the absence of contusion. The characteristic transient neurologic dysfunction includes loss of consciousness, temporary respiratory arrest, and loss of reflexes. Although neurologic recovery is complete, amnesia for the event persists. The pathogenesis of the sudden disruption of nervous activity is unknown.

## Traumatic Vascular Injury

CNS trauma often directly disrupts vessel walls, leading to hemorrhage. Depending on the affected vessel, the hemorrhage may be *epidural, subdural, subarachnoid,* or *intraparenchymal* (Fig. 22–13, *A*), occurring alone or in combination. Subarachnoid and intraparenchymal hemorrhages most often occur at sites of contusions and lacerations.

### *Epidural Hematoma*

Dural vessels—especially the middle meningeal artery—are vulnerable to traumatic injury. In infants, traumatic displacement of the easily deformable skull may tear a vessel, even in the absence of a skull fracture. In children and adults, by contrast, tears involving dural vessels almost always stem from skull fractures. Once a vessel is torn, blood accumulating under arterial pressure can dissect the tightly applied dura away from the inner skull surface (Fig. 22–13, *B*), producing a hematoma that compresses the brain surface. *Clinically, patients can be lucid for several hours between the moment of trauma and the development of neurologic signs.* An epidural hematoma may expand rapidly and constitutes a neurosurgical emergency necessitating prompt drainage and repair to prevent death.

### *Subdural Hematoma*

Rapid movement of the brain during trauma can tear the bridging veins that extend from the cerebral hemispheres through the subarachnoid and subdural space to the dural sinuses. Their disruption produces bleeding into the subdural space. *In patients with brain atrophy, the bridging veins are stretched out, and the brain has additional space within which to move, accounting for the higher rate of subdural hematomas in elderly persons.* Infants also are susceptible to

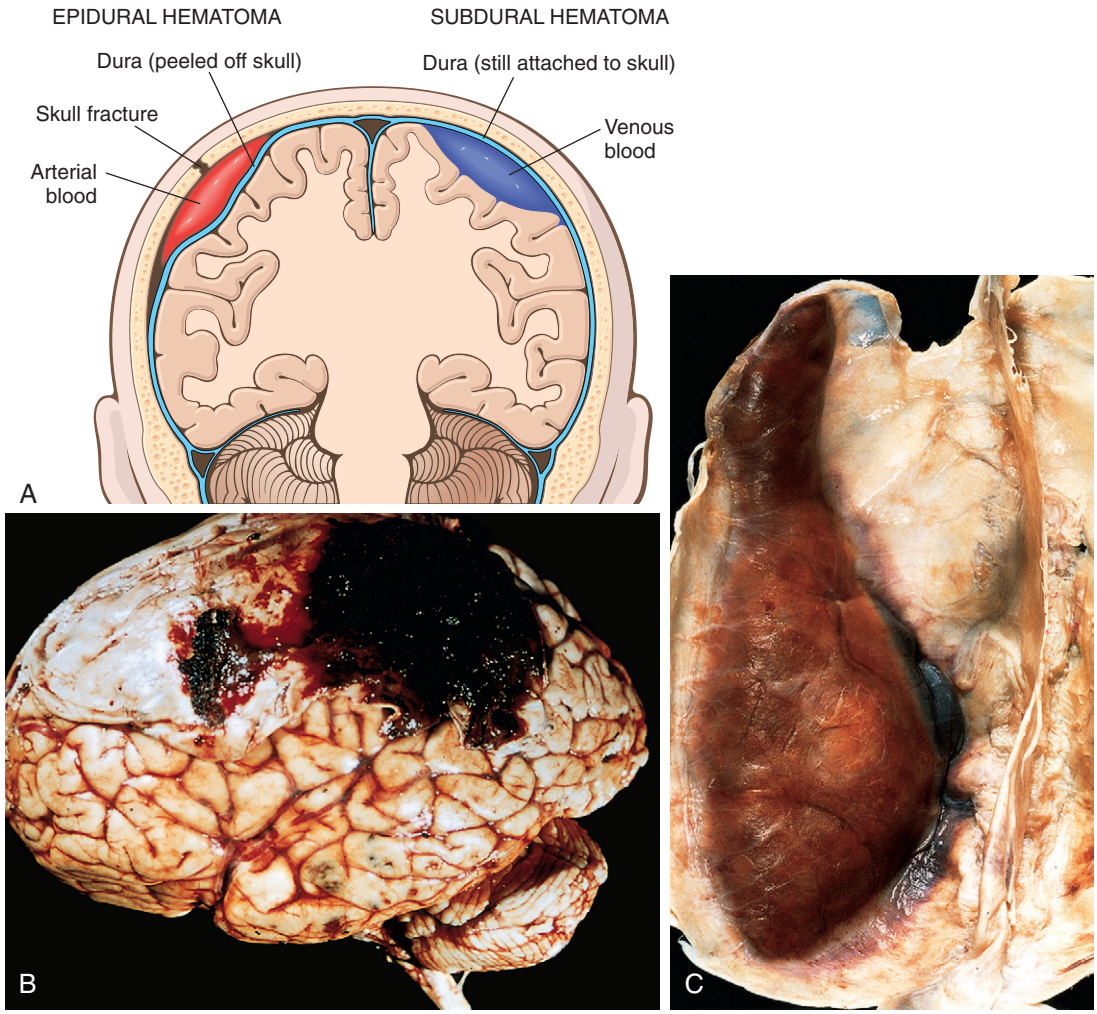


**Figure 22–13** Traumatic intracranial hemorrhages. **A,** Epidural hematoma (*left*) in which rupture of a meningeal artery, usually associated with a skull fracture, has led to accumulation of arterial blood between the dura and the skull. In a subdural hematoma (*right*), damage to bridging veins between the brain and the superior sagittal sinus has led to the accumulation of blood between the dura and the arachnoid. **B,** Epidural hematoma covering a portion of the dura. **C,** Large organizing subdural hematoma attached to the dura.
*(B, Courtesy of the late Dr. Raymond D. Adams, Massachusetts General Hospital, Boston, Massachusetts.)*

subdural hematomas because their bridging veins are thin-walled.

Subdural hematomas typically become manifest within the first 48 hours after injury. They are most common over the lateral aspects of the cerebral hemispheres and may be bilateral. Neurologic signs are attributable to the pressure exerted on the adjacent brain. Symptoms may be localizing but more often are nonlocalizing, taking the form of headache, confusion, and slowly progressive neurologic deterioration.

### MORPHOLOGY

An acute subdural hematoma appears as a collection of freshly clotted blood apposed to the contour of the brain surface, without extension into the depths of sulci (Fig. 22–13, *C*). The underlying brain is flattened, and the subarachnoid space is often clear. Typically, venous bleeding is self-limited; breakdown and organization of the hematoma take place over time. Subdural hematomas organize by lysis of the clot (about 1 week), growth of granulation tissue from the dural surface into the hematoma (2 weeks), and fibrosis (1 to 3 months). Organized hematomas are attached to the dura, but not to the underlying arachnoid. Fibrosing lesions may eventually retract, leaving only a thin layer of connective tissue ("subdural membranes"). Subdural hematomas commonly rebleed (resulting in **chronic subdural hematomas**), presumably from the thin-walled vessels of the granulation tissue, leading to microscopic findings consistent with hemorrhages of varying age. Symptomatic subdural hematomas are treated by surgical removal of the blood and associated reactive tissue.

### SUMMARY

#### Central Nervous System Trauma

- Physical injury to the brain can occur when the inside of the skull comes into forceful contact with the brain.
- In blunt trauma, if the head is mobile there may be brain injury both at the original point of contact (coup injury) and on the opposite side of the brain (contrecoup injury) owing to impacts with the skull.
- Rapid displacement of the head and brain can tear axons (diffuse axonal injury), often causing immediate severe, irreversible neurologic deficits.
- Traumatic tearing of blood vessels leads to epidural hematoma, subdural hematoma, or subarachnoid hemorrhage.

## CONGENITAL MALFORMATIONS AND PERINATAL BRAIN INJURY

The incidence of CNS malformations, giving rise to mental retardation, cerebral palsy, or neural tube defects, is estimated at 1% to 2%. Malformations of the brain are more common in the setting of multiple birth defects. Prenatal or perinatal insults may either interfere with normal CNS development or cause tissue damage. Since different parts of the brain develop at different times during gestation, the timing of an injury will be reflected in the pattern of malformation; earlier events typically lead to more severe phenotypes. Mutations affecting genes that regulate the differentiation, maturation, or intercellular communication of neurons or glial cells can cause CNS malformation or dysfunction. Additionally, various chemicals and infectious agents have teratogenic effects.

Not all developmental disorders are characterized by specific, recognizable gross or microscopic findings, yet such disorders may nevertheless be associated with profound neuronal dysfunction. Genetic underpinnings for various forms of *autism* have emerged recently; many of the implicated genes contribute to the development or maintenance of synaptic connections. Similarly, *Rett syndrome* is an X-linked dominant disorder associated with mutations in the gene encoding methyl-CpG–binding protein-2 (MeCP2), a regulator of epigenetic modifications of chromatin. Development in affected girls initially is normal, but neurologic deficits affecting cognition and movement appear by the age of 1 to 2 years, highlighting the importance of epigenetic processes in neuronal development and synaptic plasticity.

### Malformations

#### *Neural Tube Defects*

On of the earliest steps in brain development is the formation of the neural tube, which gives rise to the ventricular system, brain and spinal cord. Partial failure or reversal of neural tube closure may lead to one of several malformations, each characterized by abnormalities involving some combination of neural tissue, meninges, and overlying bone or soft tissues. Collectively, *neural tube defects* constitute the most frequent type of CNS malformation. The overall recurrence risk in subsequent pregnancies is 4% to 5%, suggesting a genetic component. Folate deficiency during the initial weeks of gestation also increases risk through uncertain mechanisms; of clinical importance, prenatal vitamins containing folate can reduce the risk of neural tube defects by up to 70%. The combination of imaging studies and maternal screening for elevated α-fetoprotein has increased the early detection of neural tube defects.

The most common defects involve the posterior end of the neural tube, from which the spinal cord forms. These can range from asymptomatic bony defects (*spina bifida occulta*) to severe malformation consisting of a flat, disorganized segment of spinal cord associated with an overlying meningeal outpouching. *Myelomeningocele* is an extension of CNS tissue through a defect in the vertebral column that occurs most commonly in the lumbosacral region (Fig. 22–14). Patients have motor and sensory deficits in the lower extremities and problems with bowel and bladder control. The clinical problems derive from the abnormal spinal cord segment and often are compounded by infections extending from the thin or ulcerated overlying skin.

At the other end of the developing CNS, *anencephaly* is a malformation of the anterior end of the neural tube that leads to the absence of the brain and the top of skull. An

**Figure 22–14** Myelomeningocele. Both meninges and spinal cord parenchyma are included in the cystlike structure visible just above the buttocks.

*encephalocele* is a diverticulum of malformed CNS tissue extending through a defect in the cranium. It most often involves the occipital region or the posterior fossa. When it occurs anteriorly, brain tissue can extend into the sinuses.

### *Forebrain Malformations*

In certain malformations, the volume of the brain is abnormally large (*megalencephaly*) or small (*microencephaly*). Microencephaly, by far the more common of the two, usually is associated with a small head as well (microcephaly). It has a wide range of associations, including chromosome abnormalities, fetal alcohol syndrome, and human immunodeficiency virus type 1 (HIV-1) infection acquired in utero. The unifying feature is decreased generation of neurons destined for the cerebral cortex. During the early stages of brain development, as progenitor cells proliferate in the subependymal zone, the balance between cells leaving the progenitor population to begin migration to the cortex and those remaining in the proliferating pool affects the overall number of neurons and glial cells generated. If too many cells leave the progenitor pool prematurely, there is inadequate generation of mature neurons, leading to a small brain.

Disruption of neuronal migration and differentiation during development can lead to abnormalities of gyration and the six-layered neocortical architecture, often taking the form of neurons ending up in the wrong anatomic location. Various mutations in genes that control migration result in these malformations, which include the following:

- *Lissencephaly* (*agyria*) or, with more patchy involvement, *pachygyria,* is characterized by absent gyration leading to a smooth-surfaced brain. The cortex is abnormally thickened and usually has only four layers. Many forms of lissencephaly are associated with defects in genes that control neuronal migration.
- *Polymicrogyria* is characterized by an increased number of irregularly formed gyri that result in a bumpy or cobblestone-like surface. These changes can be focal or widespread. The normal cortical architecture can be altered in various ways, and adjacent gyri often show fusion of the superficial molecular layer.
- *Holoprosencephaly* is characterized by a disruption of the normal midline patterning. Mild forms may just show absence of the olfactory bulbs and related structures (arrhinencephaly). In severe forms the brain is not divided into hemispheres or lobes, and this anomaly may be associated with facial midline defects such as cyclopia. Holoprosencephaly as well as polymicrogyria can be the result of acquired or genetically determined disruption of normal development. Several single-gene defects including mutations in sonic hedgehog have been linked to holoprosencephaly.
- Other examples are focally disordered cortex (confusingly called *dysplastic cortex*) and neurons stranded beneath the cortex, sometimes as nodules and other times as bands.

### *Posterior Fossa Anomalies*

The most common malformations in this region of the brain result in misplacement or absence of portions of the cerebellum. The *Arnold-Chiari malformation* (Chiari type II malformation) combines a small posterior fossa with a misshapen midline cerebellum and downward extension of the vermis through the foramen magnum; hydrocephalus and a lumbar myelomeningocele typically are also present. The far milder *Chiari type I malformation* has low-lying cerebellar tonsils that extend through the foramen magnum. Excess tissue in the foramen magnum results in partial obstruction of CSF flow and compression of the medulla, with symptoms of headache or cranial nerve deficits often manifesting only in adult life. Surgical intervention can alleviate the symptoms.

Syndromes characterized by "missing" cerebellar tissue include *Dandy-Walker malformation,* characterized by an enlarged posterior fossa, absence of the cerebellar vermis, and a large midline cyst, and *Joubert syndrome,* in which there is absence of the vermis and brain stem abnormalities resulting in eye movement problems and disrupted respiratory patterns. A range of recessive genetic lesions have been found to cause Joubert syndrome, with many involving alterations of the primary cilium.

### *Spinal Cord Abnormalities*

In addition to neural tube defects, structural alterations of the spinal cord can occur that are not associated with abnormalities of the bony spine or overlying skin. These include expansions of the ependyma-lined central canal of the cord (*hydromyelia*) or development of fluid-filled cleft-like cavities in the inner portion of the cord (*syringomyelia, syrinx*). These lesions are surrounded by dense reactive gliosis, often with Rosenthal fibers. A syrinx also may develop after trauma or with intramedullary spinal tumors.

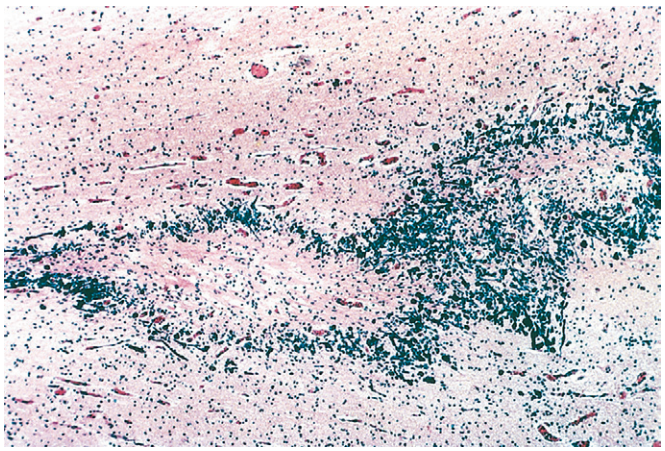

**Figure 22–15** Perinatal brain injury. This specimen from a patient with periventricular leukomalacia contains a central focus of white matter necrosis with a peripheral rim of mineralized axonal processes.

## Perinatal Brain Injury

A variety of exogenous factors can injure the developing brain. Injuries that occur early in gestation may destroy brain tissue without evoking reactive changes, sometimes making them difficult to distinguish from malformations. Brain injury occurring in the perinatal period is an important cause of childhood neurologic disability. *Cerebral palsy* is a term for nonprogressive neurologic motor deficits characterized by spasticity, dystonia, ataxia or athetosis, and paresis attributable to injury occurring during the prenatal and perinatal periods. Signs and symptoms may not be apparent at birth and only declare themselves later, well after the causal event.

*The two major types of injury that occur in the perinatal period are hemorrhages and infarcts.* These differ from the otherwise similar lesions in adults in terms of their locations and the tissue reactions they engender. In premature infants, there is an increased risk of *intraparenchymal hemorrhage* within the germinal matrix, most often adjacent to the anterior horn of the lateral ventricle. Hemorrhages may extend into the ventricular system and from there to the subarachnoid space, sometimes causing hydrocephalus. Infarcts may occur in the supratentorial periventricular white matter (*periventricular leukomalacia*), especially in premature babies. The residua of these infarcts are chalky yellow plaques consisting of discrete regions of white matter necrosis and mineralization (Fig. 22–15). When severe enough to involve the gray and white matter, large cystic lesions can develop throughout the hemispheres, a condition termed *multicystic encephalopathy.*

### SUMMARY

#### Congenital Malformations and Perinatal Brain Injury

- Malformations of the brain can occur because of genetic factors or external insults.
- The developmental timing and position of the injury determine its pattern and characteristics.
- Various malformations stem from failure of neural tube closure, improper formation of neural structures, and altered neuronal migration.
- Perinatal brain injury mostly takes one of two forms: (1) hemorrhage, often in the region of the germinal matrix with the risk of extension into the ventricular system; and (2) ischemic infarcts, leading to periventricular leukomalacia.

# INFECTIONS OF THE NERVOUS SYSTEM

The brain and its coverings, as with all other parts of the body, can be sites of infections. Some infectious agents have a relative or absolute predilection for the nervous system (e.g., rabies), while others can affect many other organs as well as the brain (e.g., *Staphylococcus aureus*). Damage to nervous tissue may be the consequence of direct injury of neurons or glial cells by the infectious agent or microbial toxins, or may be a consequence of the host innate or adaptive immune response.

Infectious agents may reach the nervous system through several routes of entry:

- *Hematogenous spread* by way of the arterial blood supply is the most common means of entry. There can also be retrograde venous spread, through the anastomoses between veins of the face and the venous sinuses of the skull.
- *Direct implantation* of microorganisms is almost invariably due to traumatic introduction of foreign material. In rare cases it can be iatrogenic, as when microbes are introduced with a lumbar puncture needle.
- *Local extension* can occur with infections of the skull or spine. Sources include air sinuses, most often the mastoid or frontal; infected teeth; cranial or spinal osteomyelitis; and congenital malformations, such as meningomyelocele.
- *Peripheral nerves* also may serve as paths of entry for a few pathogens—in particular, viruses such as the rabies and herpes zoster viruses.

## Epidural and Subdural Infections

The epidural and subdural spaces can be involved by bacterial or fungal infections, usually as a consequence of direct local spread. *Epidural abscesses* arise from an adjacent focus of infection, such as sinusitis or osteomyelitis. When abscesses occur in the spinal epidural space, they may cause spinal cord compression and constitute a neurosurgical emergency. Infections of the skull or air sinuses may also spread to the subdural space, producing *subdural empyema.* The underlying arachnoid and subarachnoid spaces usually are unaffected, but a large subdural empyema may produce a mass effect. In addition, thrombophlebitis may develop in the bridging veins that cross the subdural space, resulting in venous occlusion and infarction of the brain. Most patients are febrile, with headache and neck stiffness, and if untreated may develop focal

neurologic signs referable to the site of the infection, lethargy, and coma. With treatment, including surgical drainage, resolution of the empyema occurs from the dural side; if resolution is complete, a thickened dura may be the only residual finding. With prompt treatment, complete recovery is usual.

## Meningitis

*Meningitis* is an inflammatory process involving the leptomeninges within the subarachnoid space; if the infection spreads into the underlying brain it is termed *meningoencephalitis*. Meningitis usually is caused by an infection, but *chemical meningitis* also may occur in response to a nonbacterial irritant introduced into the subarachnoid space. Infectious meningitis can be broadly divided into *acute pyogenic* (usually bacterial), *aseptic* (usually viral), and *chronic* (usually tuberculous, spirochetal, or cryptococcal) subtypes. Examination of the CSF is often useful in distinguishing between various causes of meningitis.

### *Acute Pyogenic Meningitis (Bacterial Meningitis)*

Many bacteria can cause acute pyogenic meningitis, but the most likely organisms vary with patient age. In neonates, common organisms are *Escherichia coli* and the group B streptococci; in adolescents and in young adults, *Neisseria meningitidis* is the most common pathogen; and in older individuals, *Streptococcus pneumoniae* and *Listeria monocytogenes* are more common. In all age groups, patients typically show systemic signs of infection along with meningeal irritation and neurologic impairment, including headache, photophobia, irritability, clouding of consciousness, and neck stiffness. *Lumbar puncture reveals an increased pressure; examination of the CSF shows abundant neutrophils, elevated protein, and reduced glucose.* Bacteria may be seen on a smear or can be cultured, sometimes a few hours before the neutrophils appear. Untreated pyogenic meningitis is often fatal, but with prompt diagnosis and administration of appropriate antibiotics, many patients can be saved.

#### MORPHOLOGY

In acute meningitis, an exudate is evident within the leptomeninges over the surface of the brain (Fig. 22–16, *A*). The meningeal vessels are engorged and prominent. From the areas of greatest accumulation, tracts of pus can be followed along blood vessels on the brain surface. When the meningitis is fulminant, the inflammatory cells infiltrate the walls of the leptomeningeal veins and may spread into the substance of the brain (focal cerebritis), or the inflammation may extend to the ventricles, producing ventriculitis. On microscopic examination, neutrophils fill the entire subarachnoid space in severely affected areas or may be found predominantly around the leptomeningeal blood vessels in less severe cases. In untreated meningitis, Gram stain reveals varying numbers of the causative organism. Bacterial meningitis may be associated with abscesses in the brain (Fig. 22–16, *B*), discussed later. Phlebitis also may lead to venous occlusion and hemorrhagic infarction of the underlying brain. If it is treated early, there may be little or no morphologic residuum.

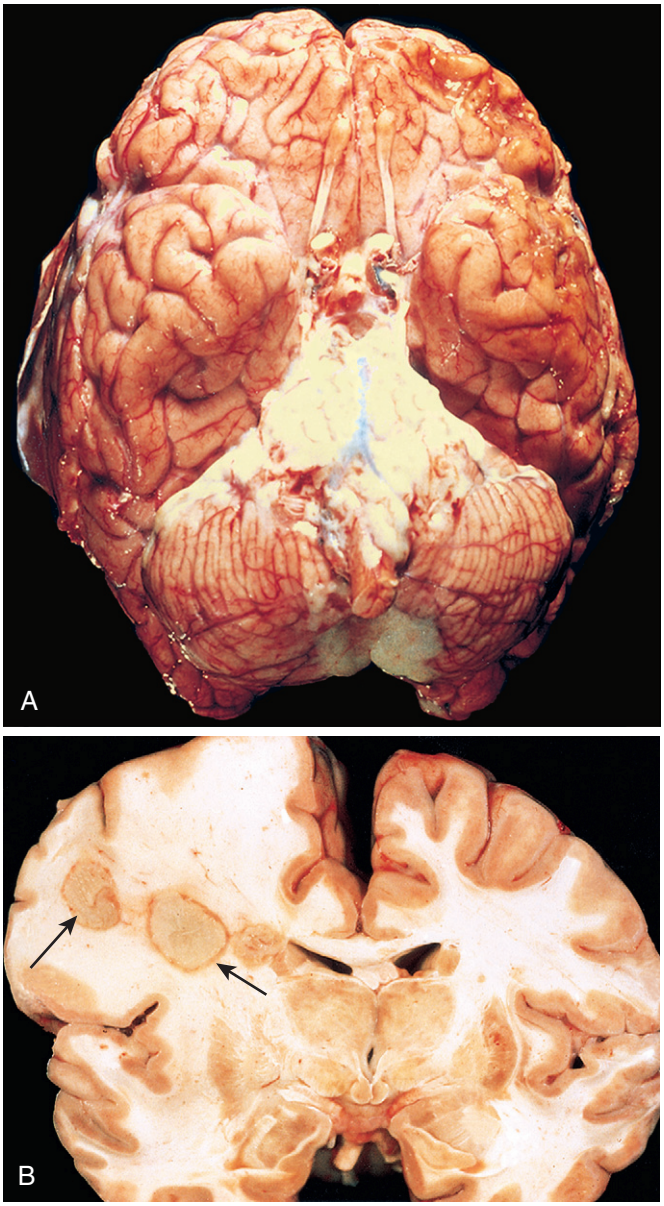


**Figure 22–16** Bacterial infections. **A,** Pyogenic meningitis. A thick layer of suppurative exudate covers the brain stem and cerebellum and thickens the leptomeninges. **B,** Cerebral abscesses in the frontal lobe white matter (*arrows*).

*(A, From Golden JA, Louis DN: Images in clinical medicine: acute bacterial meningitis. N Engl J Med 333:364, 1994. Copyright © 1994 Massachusetts Medical Society. All rights reserved.)*

### *Aseptic Meningitis (Viral Meningitis)*

*Aseptic meningitis* is a clinical term for an illness comprising meningeal irritation, fever, and alterations in consciousness of relatively acute onset. The clinical course is less fulminant than in pyogenic meningitis. In contrast to pyogenic meningitis, examination of the CSF often shows lymphocytosis, moderate protein elevation, and a normal glucose level. The disease typically is self-limiting. It is believed to be of viral origin in most cases, but it is often difficult to identify the responsible virus. There are no distinctive macroscopic characteristics except for brain swelling, seen in only some instances. On microscopic examination, there is either no recognizable abnormality or a mild to moderate leptomeningeal lymphocytic infiltrate.

### *Chronic Meningitis*

Several pathogens, including mycobacteria and some spirochetes, are associated with chronic meningitis; infections with these organisms also may involve the brain parenchyma.

#### Tuberculous Meningitis

Tuberculous meningitis usually manifests with generalized signs and symptoms of headache, malaise, mental confusion, and vomiting. There is only a moderate increase in CSF cellularity, with mononuclear cells or a mixture of polymorphonuclear and mononuclear cells; the protein level is elevated, often strikingly so, and the glucose content typically is moderately reduced or normal. Infection with *Mycobacterium tuberculosis* also may result in a well-circumscribed intraparenchymal mass (*tuberculoma*), which may be associated with meningitis. Chronic tuberculous meningitis is a cause of arachnoid fibrosis, which may produce hydrocephalus.

#### MORPHOLOGY

The subarachnoid space contains a gelatinous or fibrinous exudate, most often at the base of the brain, obliterating the cisterns and encasing cranial nerves. There may be discrete white granules scattered over the leptomeninges. Arteries running through the subarachnoid space may show **obliterative endarteritis** with inflammatory infiltrates and marked intimal thickening. On microscopic examination there are mixtures of lymphocytes, plasma cells, and macrophages. Florid cases show well-formed granulomas, often with caseous necrosis and giant cells, similar to the lesions of tuberculosis elsewhere.

#### Spirochetal Infections

Neurosyphilis, a tertiary stage of syphilis, occurs in about 10% of persons with untreated *Treponema pallidum* infection. Patients with HIV infection are at increased risk for neurosyphilis, which often is more aggressive and severe in this setting. The infection can produce chronic meningitis (*meningovascular neurosyphilis*), usually involving the base of the brain, often with an obliterative endarteritis rich in plasma cells and lymphocytes. There can also be parenchymal involvement by spirochetes (*paretic neurosyphilis*), leading to neuronal loss and marked proliferation of rod-shaped microglial cells. Clinically, this form of the disease causes an insidious progressive loss of mental and physical functions, mood alterations (including delusions of grandeur), and eventually severe dementia. *Tabes dorsalis* is another form of neurosyphilis, resulting from damage to the sensory nerves in the dorsal roots that produces impaired joint position sense and ataxia (locomotor ataxia); loss of pain sensation, leading to skin and joint damage (Charcot joints); other sensory disturbances, particularly characteristic "lightning pains"; and the absence of deep tendon reflexes.

Neuroborreliosis represents involvement of the nervous system by the spirochete *Borrelia burgdorferi,* the pathogen of Lyme disease. Neurologic signs and symptoms are highly variable and include aseptic meningitis, facial nerve palsies, mild encephalopathy, and polyneuropathies.

## Parenchymal Infections

The entire gamut of infectious pathogens (viruses to parasites) can potentially infect the brain, often in characteristic patterns. In general, viral infections are diffuse, bacterial infections (when not associated with meningitis) are localized, while other organisms produce mixed patterns. In immunosuppressed hosts, more widespread involvement with any agent is typical.

### *Brain Abscesses*

Brain abscesses are nearly always caused by bacterial infections. These can arise by direct implantation of organisms, local extension from adjacent foci (mastoiditis, paranasal sinusitis), or hematogenous spread (usually from a primary site in the heart, lungs, or distal bones, or after tooth extraction). Predisposing conditions include acute bacterial endocarditis, from which septic emboli are released that may produce multiple abscesses; cyanotic congenital heart disease, associated with a right-to-left shunt and loss of pulmonary filtration of organisms; and chronic pulmonary infections, as in bronchiectasis, which provide a source of microbes that spread hematogenously.

Abscesses are destructive lesions, and patients almost invariably present with progressive focal deficits as well as general signs related to increased intracranial pressure. The CSF white cell count and protein levels are usually high, while the glucose content tends to be normal. A systemic or local source of infection may be apparent or may have ceased to be symptomatic. The increased intracranial pressure and progressive herniation can be fatal, and abscess rupture can lead to ventriculitis, meningitis, and venous sinus thrombosis. Surgery and antibiotics reduce the otherwise high mortality rate, with earlier intervention leading to better outcomes.

#### MORPHOLOGY

Abscesses are discrete lesions with central liquefactive necrosis and a surrounding fibrous capsule (Fig. 22–16, *B*). On microscopic examination, the necrotic center is surrounded by edema and granulation tissue, often with exuberant vascularization. Outside the fibrous capsule is a zone of reactive gliosis.

### *Viral Encephalitis*

Viral encephalitis is a parenchymal infection of the brain that is almost invariably associated with meningeal inflammation (and therefore is better termed *meningoencephalitis*). While different viruses may show varying patterns of injury, the most characteristic histologic features are perivascular and parenchymal mononuclear cell infiltrates, microglial nodules, and neuronophagia (Fig. 22–17, *A* and *B*). Certain viruses also form characteristic inclusion bodies.

The nervous system is particularly susceptible to certain viruses such as rabies virus and poliovirus. Some viruses infect specific CNS cell types, while others preferentially involve particular brain regions (such as the medial temporal lobes, or the limbic system) that lie along the viral route of entry. Intrauterine viral infection may cause *congenital malformations,* as occurs with rubella. In addition to

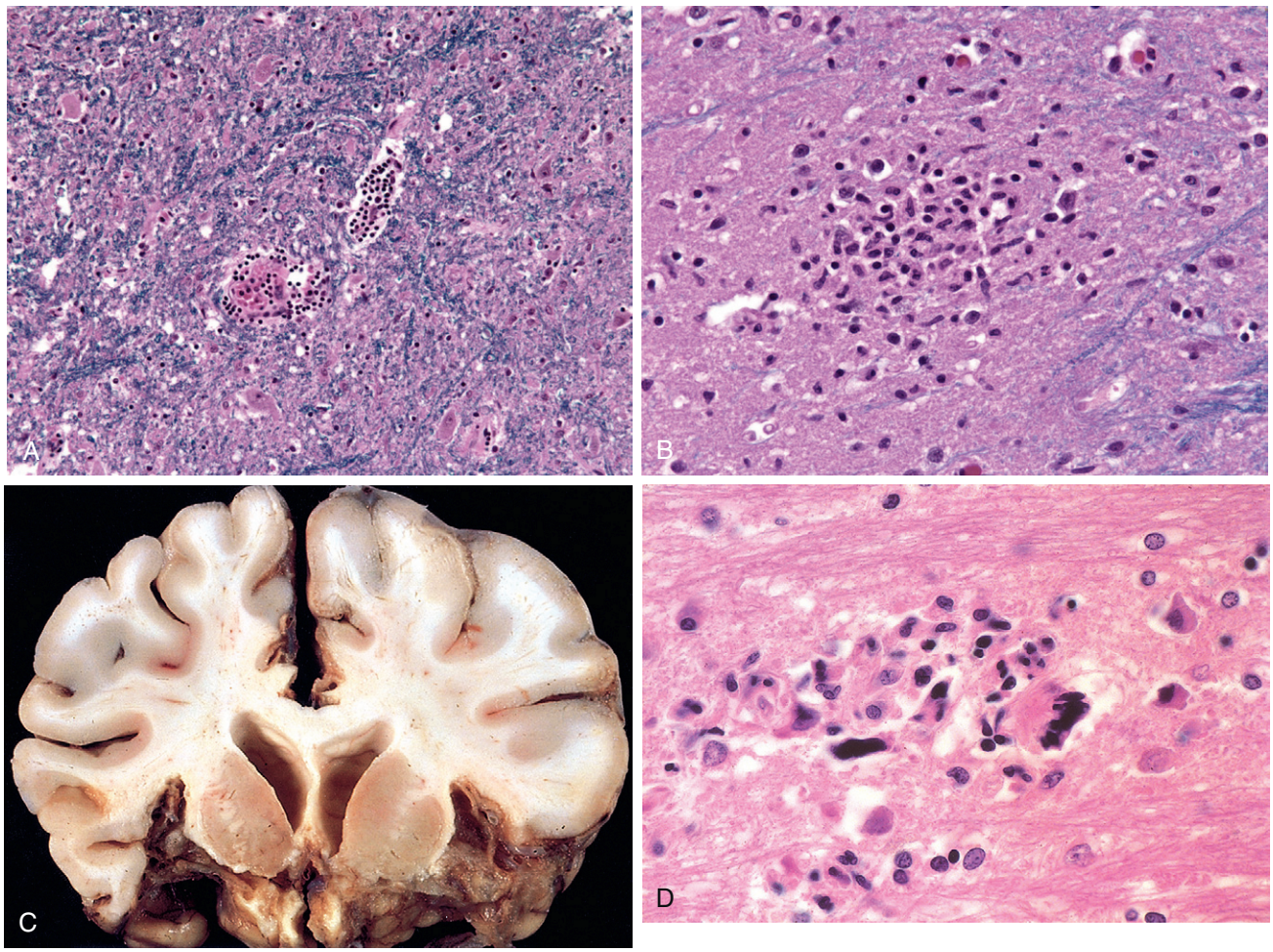


**Figure 22–17** Viral infections. **A** and **B,** Characteristic findings in many forms of viral meningitis include perivascular cuffing of lymphocytes **(A)** and microglial nodules **(B). C,** Herpes encephalitis showing extensive destruction of inferior frontal and anterior temporal lobes. **D,** Human immunodeficiency virus (HIV) encephalitis. Note the accumulation of microglia forming a microglial nodule and multinucleate giant cell.
*(C, Courtesy of Dr. T.W. Smith, University of Massachusetts Medical School, Worcester, Massachusetts.)*

direct infection of the nervous system, the CNS also can be injured by immune mechanisms after systemic viral infections.

### Arboviruses

Arboviruses (arthropod-borne viruses) are an important cause of epidemic encephalitis, especially in tropical regions of the world, and are capable of causing serious morbidity and high mortality. Among the more commonly encountered types are Eastern and Western equine encephalitis and West Nile virus infection. Patients develop generalized neurologic symptoms, such as seizures, confusion, delirium, and stupor or coma, as well as focal signs, such as reflex asymmetry and ocular palsies. The CSF usually is colorless but with a slightly elevated pressure and an early neutrophilic pleocytosis that rapidly converts to a lymphocytosis; the protein level is elevated, but the glucose is normal.

#### MORPHOLOGY

Arbovirus encephalitides produce a similar histopathologic picture. Characteristically, there is a perivascular lymphocytic meningoencephalitis (sometimes with neutrophils) (Fig. 22–17, *A*). Multifocal gray and white matter necrosis is seen, often associated with neuronophagia, the phagocytosis of neuronal debris, as well as localized collections of microglia termed microglial nodules (Fig. 22–17, *B*). In severe cases there may be a necrotizing vasculitis with associated focal hemorrhages.

### Herpesviruses

HSV-1 encephalitis may occur in any age group but is most common in children and young adults. It typically manifests with alterations in mood, memory, and behavior, reflecting involvement of the frontal and temporal lobes. Recurrent HSV-1 encephalitis is sometimes associated with inherited mutations that interfere with Toll-like receptor signaling (specifically that of TLR-3), which has an important role in antiviral defense.

#### MORPHOLOGY

Herpes encephalitis starts in, and most severely involves, the inferior and medial regions of the temporal lobes and the

orbital gyri of the frontal lobes (Fig. 22–17, *C*). The infection is necrotizing and often hemorrhagic in the most severely affected regions. Perivascular inflammatory infiltrates usually are present, and large eosinophilic intranuclear viral inclusions (Cowdry type A bodies) can be found in both neurons and glial cells.

HSV-2 also affects the nervous system, usually in the form of meningitis in adults. Disseminated severe encephalitis occurs in many neonates born by vaginal delivery to women with active primary HSV genital infections.

Varicella-zoster virus (VZV) causes chickenpox during primary infection, usually without any evidence of neurologic involvement. The virus establishes latent infection in neurons of dorsal root ganglia. Reactivation in adults manifests as a painful, vesicular skin eruption in the distribution of one or a few dermatomes (*shingles*). This usually is a self-limited process, but there may be a persistent pain syndrome in the affected region (*postherpetic neuralgia*). VZV also may cause a granulomatous arteritis that can lead to tissue infarcts. In immunosuppressed patients, acute herpes zoster encephalitis can occur. Inclusion bodies can be found in glial cells and neurons.

### Cytomegalovirus

CMV infects the nervous system in fetuses and immunosuppressed persons. All cells within the CNS (neurons, glial cells, ependyma, and endothelium) are susceptible to infection. Intrauterine infection causes periventricular necrosis, followed later by microcephaly with periventricular calcification. When adults are infected, CMV produces a subacute encephalitis, again often most severe in the periventricular region. Lesions can be hemorrhagic and contain typical viral inclusion–bearing cells.

### Poliovirus

Poliovirus is an enterovirus that most often causes a subclinical or mild gastroenteritis; in a small fraction of cases, it secondarily invades the nervous system and damages motor neurons in the spinal cord and brain stem (paralytic poliomyelitis). With loss of motor neurons, it produces a flaccid paralysis with muscle wasting and hyporeflexia in the corresponding region of the body. In the acute disease, death can occur from paralysis of respiratory muscles. Long after the infection has resolved, typically 25 to 35 years after the initial illness, a *postpolio syndrome* of progressive weakness associated with decreased muscle bulk and pain can appear. The cause of this syndrome is unclear. One hypothesis is that motor neurons that survive the initial insult sprout new nerve terminals to compensate for the death of their neighbors, and that over time the additional demands placed on these neurons leads to injury that diminishes function or causes cell death.

### Rabies Virus

Rabies is a severe encephalitic infection transmitted to humans from rabid animals, usually by a bite. Various mammals are natural reservoirs. Exposure to some bat species, even without evidence of a bite, is also a risk factor. Virus enters the CNS by ascending along the peripheral nerves from the wound site, so the incubation period depends on the distance between the wound and the brain, usually taking a few months. The disease manifests initially with nonspecific symptoms of malaise, headache, and fever. As the infection advances, the patient shows extraordinary CNS excitability; the slightest touch is painful, with violent motor responses progressing to convulsions. Contracture of the pharyngeal musculature may create an aversion to swallowing even water (hydrophobia). Periods of mania and stupor progress to coma and eventually death, typically from respiratory failure.

### Human Immunodeficiency Virus

In the first 15 years or so after recognition of AIDS, neuropathologic changes were demonstrated at postmortem examination in as many as 80% to 90% of cases, owing to direct effects of virus on the nervous system, opportunistic infections, and primary CNS lymphoma. Introduction of highly active antiretroviral therapy (HAART) has decreased the frequency of these secondary effects of HIV infection. However, cognitive dysfunction ranging from mild to full-blown dementia that is lumped under the umbrella term *HIV-associated neurocognitive disorder* (HAND) continues to be a source of morbidity. The cognitive symptoms are believed to stem from HIV infection of microglial cells in the brain. This leads to activation of innate immune responses, both in infected microglial cells and unaffected bystanders. The ensuing neuronal injury likely stems from a combination of cytokine-induced inflammation and toxic effects of HIV-derived proteins.

Aseptic meningitis occurs within 1 to 2 weeks of onset of primary infection by HIV in about 10% of patients; antibodies to HIV can be demonstrated, and the virus can be isolated from the CSF. The few neuropathologic studies of the early and acute phases of symptomatic or asymptomatic HIV invasion of the nervous system have shown mild lymphocytic meningitis, perivascular inflammation, and some myelin loss in the hemispheres. After the acute phase, an HIV encephalitis (HIVE) commonly can be found if affected persons come to autopsy.

#### MORPHOLOGY

HIV encephalitis is best characterized microscopically as a chronic inflammatory reaction with widely distributed infiltrates of **microglial nodules,** sometimes with associated foci of tissue necrosis and reactive gliosis (Fig. 22–17, *D*). The microglial nodules also are found in the vicinity of small blood vessels, which show abnormally prominent endothelial cells and perivascular foamy or pigment-laden macrophages. These changes occur especially in the subcortical white matter, diencephalon, and brain stem. An important component of the microglial nodule is the macrophage-derived **multinucleate giant cell.** In some cases, there is also a disorder of white matter characterized by multifocal or diffuse areas of myelin pallor with associated axonal swellings and gliosis. HIV is present in CD4+ mononuclear and multinucleate macrophages and microglia.

### Polyomavirus and Progressive Multifocal Leukoencephalopathy

Progressive multifocal leukoencephalopathy (PML) is caused by JC virus, a polyomavirus, which preferentially

infects oligodendrocytes, resulting in demyelination as these cells are injured and then die. Most people show serologic evidence of exposure to JC virus during childhood, and it is believed that PML results from virus reactivation, as the disease is restricted to immunosuppressed persons. Patients develop focal and relentlessly progressive neurologic symptoms and signs, and imaging studies show extensive, often multifocal, ring-enhancing lesions in the hemispheric or cerebellar white matter.

### MORPHOLOGY

The lesions are patchy, irregular, ill-defined areas of white matter destruction that enlarge as the disease progresses (Fig. 22–18). Each lesion is an area of demyelination, in the center of which are scattered lipid-laden macrophages and a reduced number of axons. At the edges of the lesion are greatly enlarged oligodendrocyte nuclei whose chromatin is replaced by glassy-appearing amphophilic viral inclusions. The virus also infects astrocytes, leading to bizarre giant forms with irregular, hyperchromatic, sometimes multiple nuclei that can be mistaken for tumor.

### *Fungal Encephalitis*

Fungal infections usually produce parenchymal granulomas or abscesses, often associated with meningitis. The most common fungal infections have distinctive patterns:

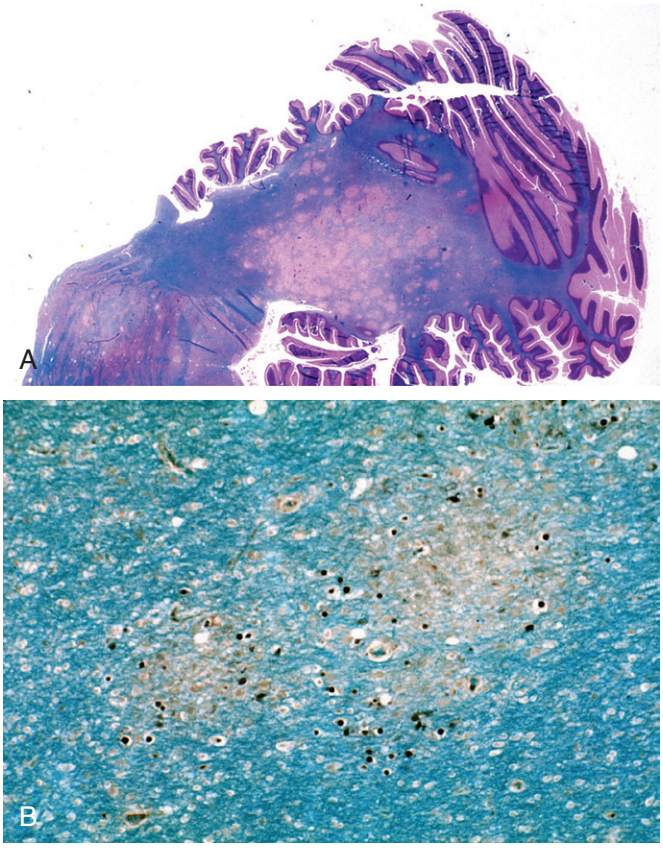


**Figure 22–18** Progressive multifocal leukoencephalopathy. **A,** Section stained for myelin showing irregular, poorly defined areas of demyelination, which become confluent in places. **B,** Enlarged oligodendrocyte nuclei stained for viral antigens surround an area of early myelin loss.

- *Candida albicans* usually produces multiple microabscesses, with or without granuloma formation.
- *Mucormycosis* is the term used to describe rhinocerebral infections caused by several fungi belonging to the order Mucorales. It typically presents as an infection of the nasal cavity or sinuses of a diabetic patient with ketoacidosis. It may spread to the brain through vascular invasion or by direct extension through the cribriform plate. The proclivity of Mucor to invade the brain directly sets it apart from other fungi, which tend to reach the brain by hematogenous dissemination from distant sites.
- *Aspergillus fumigatus* tends to cause a distinctive pattern of widespread septic hemorrhagic infarctions because of its marked predilection for blood vessel wall invasion and subsequent thrombosis.
- *Cryptococcus neoformans* can cause both meningitis and meningoencephalitis, often in the setting of immunosuppression. It can be fulminant and fatal in as little as 2 weeks or may exhibit indolent behavior, evolving over months or years. The CSF may have few cells but elevated protein, and the mucoid encapsulated yeasts can be visualized on India ink preparations. Extension into the brain follows vessels in the Virchow-Robin spaces. As organisms proliferate, these spaces expand, giving rise to a "soap bubble"–like appearance (Fig. 22–19). The diagnosis is usually established by a positive test for cryptococcal antigens in the CSF or the blood.

In endemic areas, *Histoplasma capsulatum, Coccidioides immitis,* and *Blastomyces dermatitidis* also can infect the CNS, especially in the setting of immunosuppression.

### *Other Meningoencephalitides*

While a wide range of other organisms can infect the nervous system and its covering, only three specific entities are considered here.

***Cerebral Toxoplasmosis.*** Cerebral infection with the protozoan *Toxoplasma gondii* can occur in immunosuppressed adults or in newborns who acquire the organism transplacentally from a mother with an active infection. In adults, the clinical symptoms are subacute, evolving during a 1- or 2-week period, and may be both focal and diffuse. Due to inflammation and breakdown of the blood-brain barrier at sites of infection, computed tomography and magnetic resonance imaging studies often show edema around lesions (so-called ring enhancing lesions). In newborns who are infected in utero, the infection classically produces the triad of chorioretinitis, hydrocephalus, and intracranial calcifications. Understandably, the CNS abnormalities are most severe when the infection occurs early in gestation during critical stages of brain development. Necrosis of periventricular lesions gives rise to secondary calcifications as well as inflammation and gliosis, which can lead to obstruction of the aqueduct of Sylvius and hydrocephalus.

### MORPHOLOGY

When the infection is acquired in immunosuppressed adults, the brain shows abscesses, frequently multiple, most often involving the cerebral cortex (near the gray-white junction) and deep gray nuclei. Acute lesions consist of central foci of

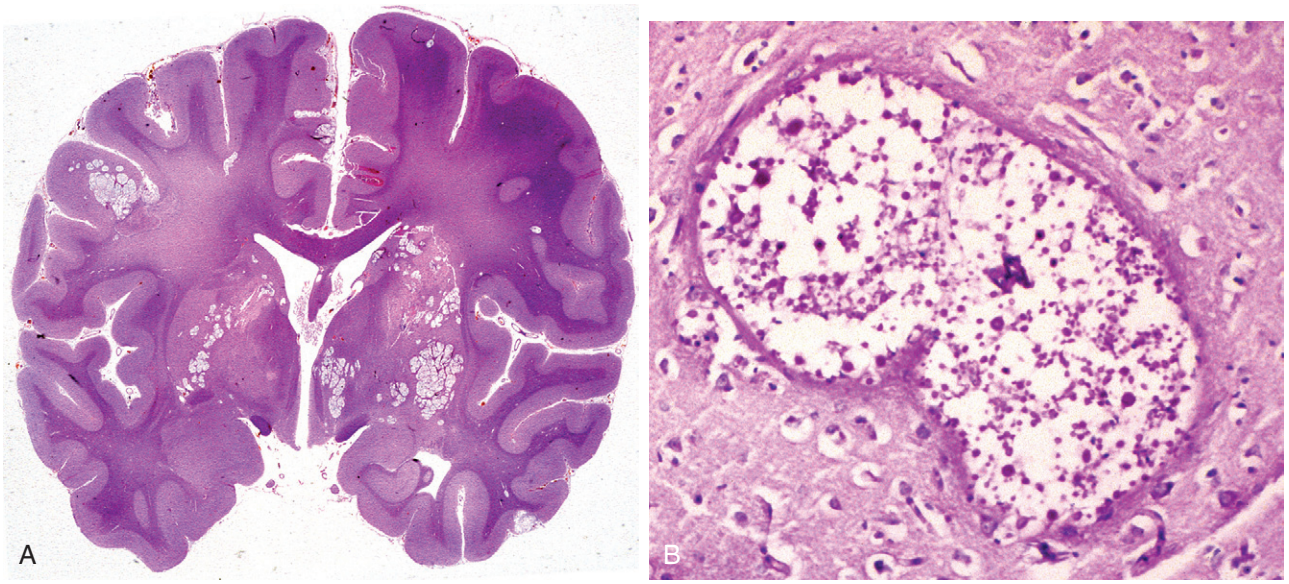


**Figure 22–19** Cryptococcal infection. **A,** Whole-brain section showing the numerous areas of tissue destruction associated with the spread of organisms in the perivascular spaces. **B,** At higher magnification, it is possible to see the cryptococci in the lesions.

necrosis with variable petechiae surrounded by acute and chronic inflammation, macrophage infiltration, and vascular proliferation. Both free tachyzoites and encysted bradyzoites may be found at the periphery of the necrotic foci (Fig. 22–20).

***Cysticercosis.*** Cysticercosis is the consequence of an end-stage infection by the tapeworm *Tenia solium.* If ingested larval organisms leave the lumen of the gastrointestinal tract, where they would otherwise develop into mature tapeworms, they encyst. Cysts can be found throughout the body but are common within the brain and subarachnoid space. Cysticercosis typically manifests as a mass lesion and can cause seizures. Symptoms can intensify when the encysted organism dies, as happens after therapy.

The organism is found within a cyst with a smooth lining. The body wall and hooklets from mouth parts are most commonly recognized. If the encysted organism has died, there can be an intense inflammatory infiltrate in the surrounding brain, often including eosinophils, which may be associated with marked gliosis.

***Amebiasis.*** *Amebic meningoencephalitis* manifests with different clinical syndromes, depending on the responsible pathogen. *Naegleria* spp., associated with swimming in nonflowing warm fresh water, cause a rapidly fatal

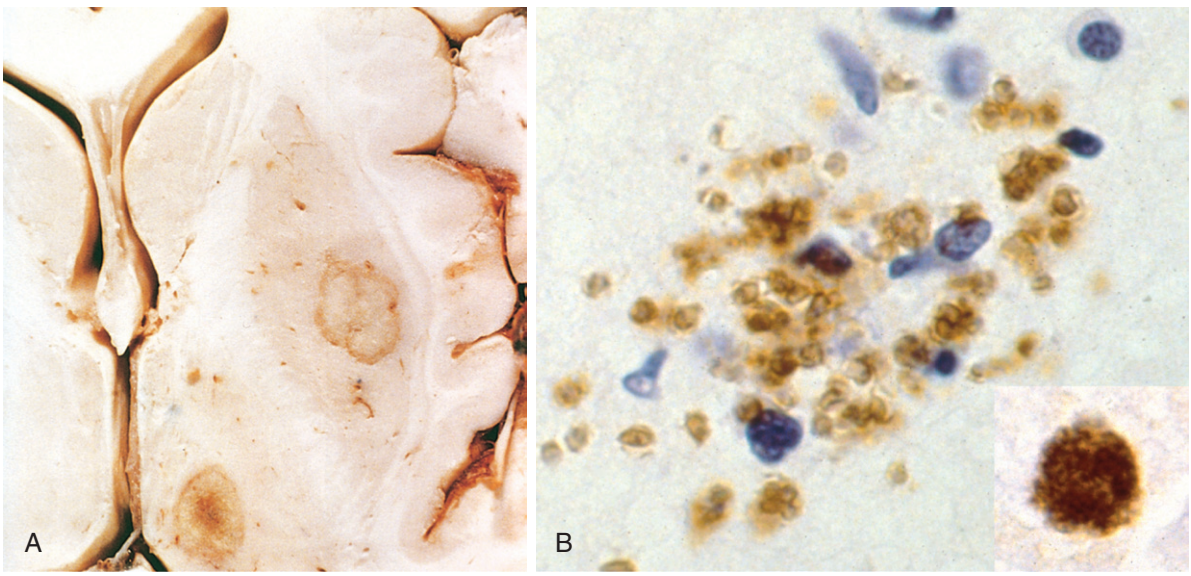


**Figure 22–20** *Toxoplasma* infection. **A,** Abscesses are present in the putamen and thalamus. **B,** Free tachyzoites are demonstrated by immunohistochemical staining. *Inset*, Bradyzoites are present as a pseudocyst, again highlighted by immunohistochemical staining.

necrotizing encephalitis. By contrast, *Acanthamoeba* causes a chronic granulomatous meningoencephalitis.

## Prion Diseases

Prion diseases are a group of rare but fascinating disorders that include sporadic, familial, iatrogenic, and variant forms of Creutzfeldt-Jakob disease (CJD), as well as animal diseases such as scrapie in sheep and bovine spongiform encephalopathy in cattle ("mad cow disease"). Unlike in other infectious diseases, the agent in prion diseases is an abnormal form of a cellular protein. This protein, termed prion protein (PrP), may undergo a conformational change from its normal shape ($PrP^c$) to an abnormal conformation called $PrP^{sc}$ (*sc* for scrapie). PrP normally is rich in α-helices, but $PrP^{sc}$ has a high content of β-sheets, a characteristic that makes it resistant to proteolysis (hence an alternative term for the pathogenic form, $PrP^{res}$—i.e., protease-resistant). More important, when $PrP^{sc}$ physically interacts with PrP molecules it induces them to also adopt the $PrP^{sc}$ conformation (Fig. 22–21), a property that accounts for the "infectious nature" of $PrP^{sc}$. Over time, this self-amplifying process leads to the accumulation of a high burden of pathogenic $PrP^{sc}$ molecules in the brain. $PrP^c$ also may change its conformation spontaneously (but at an extremely low rate), accounting for sporadic cases of prion disease (sCJD). Certain mutations in the gene encoding $PrP^c$ (*PRNP*) accelerate the rate of spontaneous conformational change; these variants are associated with early-onset familial forms of prion disease (fCJD). Accumulation of $PrP^{sc}$ in neural tissue seems to be the cause of cell injury, but the mechanisms underlying the cytopathic changes and eventual neuronal death are still unknown.

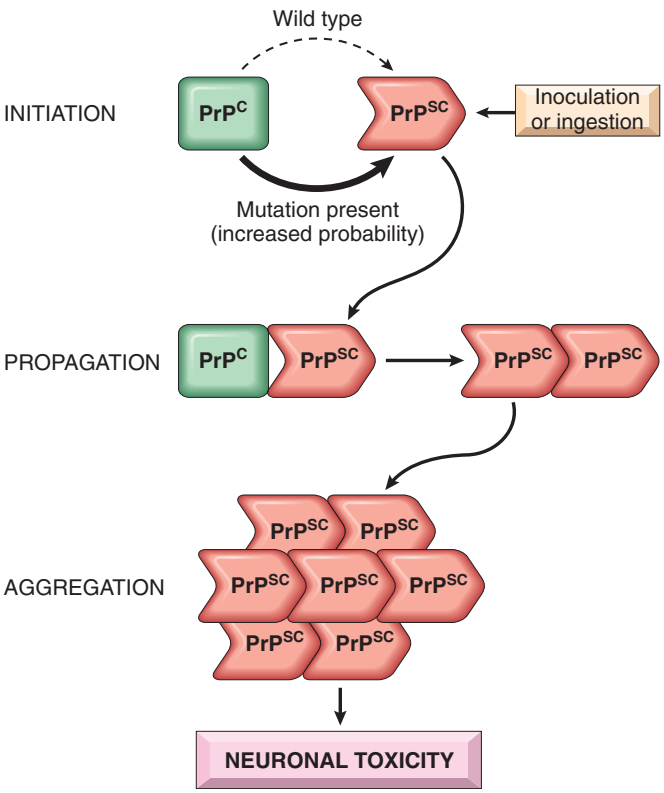


**Figure 22–21** Pathogenesis of prion disease. α-Helical $PrP^c$ may spontaneously shift to the β-sheet $PrP^{sc}$ conformation, an event that occurs at a much higher rate in familial disease associated with germ line PrP mutations. $PrP^{sc}$ may also be from exogenous sources, such as contaminated food, medical instrumentation, or medicines. Once present, $PrP^{sc}$ converts additional molecules of $PrP^c$ into $PrP^{sc}$ through physical interaction, eventually leading to the formation of pathogenic $PrP^{sc}$ aggregates.

### *Creutzfeldt-Jakob Disease*

CJD is a rapidly progressive dementing illness, with a typical duration from first onset of subtle changes in memory and behavior to death in only 7 months. It is sporadic in approximately 85% of cases and has a worldwide annual incidence of about 1 per million. While commonly affecting persons older than 70 years of age, familial forms caused by mutations in *PRNP* may present in younger people. In keeping with the infectious nature of $PrP^{sc}$, there are well-established cases of iatrogenic transmission by contaminated deep implantation electrodes and human growth hormone preparations.

#### MORPHOLOGY

The progression to death in CJD usually is so rapid that there is little, if any, macroscopic evidence of brain atrophy. On microscopic examination, the pathognomonic finding is a **spongiform transformation of the cerebral cortex and deep gray matter structures** (caudate, putamen); this multifocal process results in the uneven formation of small, apparently empty, microscopic vacuoles of varying sizes within the neuropil and sometimes in the perikaryon of neurons (Fig. 22–22, *A*). In advanced cases, there is severe neuronal loss, reactive gliosis, and sometimes expansion of the vacuolated areas into cystlike spaces ("status spongiosus"). No inflammatory infiltrate is present. Immunohistochemical staining demonstrates the presence of proteinase K–resistant $PrP^{sc}$ in tissue, while western blotting of tissue extracts after partial protease digestion allows detection of diagnostic $PrP^{sc}$.

### *Variant Creutzfeldt-Jakob Disease*

Starting in 1995, cases of a CJD-like illness appeared in the United Kingdom. The neuropathologic findings and molecular features of these new cases were similar to those of CJD, suggesting a close relationship between the two illnesses, yet this new disorder differed from typical CJD in several important respects: The disease affected young adults, behavioral disorders figured prominently in early disease stages, and the neurologic syndrome progressed more slowly than in other forms of CJD. Multiple lines of evidence indicate that this new disease, termed *variant Creutzfeldt-Jakob disease* (vCJD) is a consequence of exposure to the prion disease of cattle, called bovine spongiform encephalopathy. There has now also been documentation of transmission by blood transfusion. This variant form has a similar pathologic appearance to that in other types of CJD, with spongiform change and absence of inflammation. In vCJD, however, there are abundant cortical amyloid plaques, surrounded by the spongiform change (Fig. 22–22, *B*).

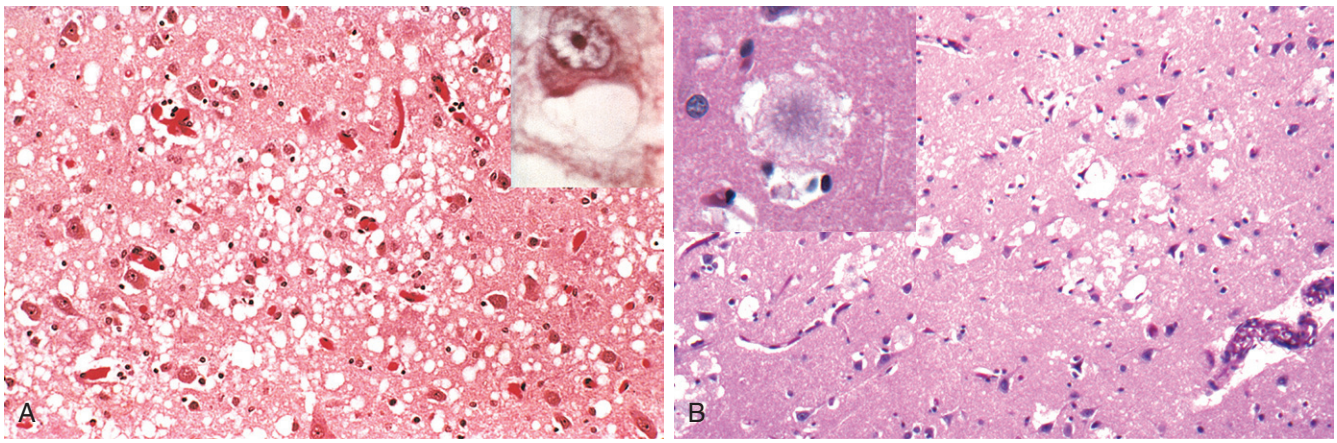


**Figure 22–22** Prion disease. **A,** Histologic features of Creutzfeldt-Jakob disease (CJD) include spongiform change in the cerebral cortex. *Inset*, High magnification of neuron with vacuoles. **B,** Variant CJD (vCJD) is characterized by amyloid plaques (see *inset*) that sit in the regions of greatest spongiform change.

## SUMMARY

### Infections of the Nervous System

- Pathogens from viruses through parasites can infect the brain; in addition, prion disease is a protein-induced transmissible disease unique to the nervous system.
- Different pathogens use distinct routes to reach the brain, and cause different patterns of disease.
- Bacterial infections may cause meningitis, cerebral abscesses, or a chronic meningoencephalitis.
- Viral infections can cause meningitis or meningoencephalitis.
- HIV can directly cause meningoencephalitis, or indirectly affect the brain by increasing the risk of opportunistic infections (toxoplasmosis, CMV) or CNS lymphoma.
- Prion diseases are transmitted by an altered form of a normal cellular protein. They can be sporadic, transmitted, or inherited.

# PRIMARY DISEASES OF MYELIN

Within the CNS, axons are tightly ensheathed by myelin, an electrical insulator that allows rapid propagation of neural impulses. Myelin consists of multiple layers of highly specialized, closely apposed plasma membranes that are assembled by oligodendrocytes. Although myelinated axons are present in all areas of the brain, they are the dominant component in the white matter; therefore, most diseases of myelin are primarily white matter disorders. The myelin in peripheral nerves is similar to the myelin in the CNS but has several important differences: (1) peripheral myelin is made by Schwann cells, not oligodendrocytes; (2) each Schwann cell in a peripheral nerve provides myelin for only one internode, while in the CNS, many internodes are created by processes coming from a single oligodendrocyte; and (3) the specialized proteins and lipids are also different. Therefore, most diseases of CNS myelin do not involve the peripheral nerves to any significant extent, and vice versa.

In general, diseases involving myelin are separated into two broad groups.

- *Demyelinating diseases* of the CNS are acquired conditions characterized by preferential damage to previously normal myelin. The most common diseases in this group result from immune-mediated injury, such as multiple sclerosis (MS) and related disorders. Other processes that can cause this type of disease include viral infection of oligodendrocytes, as in progressive multifocal leukoencephalopathy (see earlier), and injury caused by drugs and other toxic agents.
- By contrast, in *dysmyelinating diseases,* myelin is not formed properly or has abnormal turnover kinetics. As would be expected, dysmyelinating diseases are associated with mutations that disrupt the function of proteins that are required for the formation of normal myelin sheaths. The other general term for these diseases is *leukodystrophy.*

## Multiple Sclerosis

MS is an autoimmune demyelinating disorder characterized by *distinct episodes of neurologic deficits, separated in time, attributable to white matter lesions that are separated in space.* It is the most common of the demyelinating disorders, having a prevalence of approximately 1 per 1000 persons in most of the United States and Europe. The disease may become clinically apparent at any age, although onset in childhood or after age 50 is relatively rare. Women are affected twice as often as men. In most patients with MS, the illness shows relapsing and remitting episodes of neurologic impairment. The frequency of relapses tends to decrease during the course of the illness, but a steady neurologic deterioration is characteristic in a subset of patients.

## PATHOGENESIS

It is believed that MS, like other autoimmune diseases, is caused by a combination of environmental and genetic factors that result in a loss of tolerance to self proteins (in this case, myelin antigens). The nature of the initiating agent, often suggested to be an infectious agent, remains uncertain. Many lines of evidence indicate a significant contribution of genetic factors to the risk of developing MS. The disease risk is 15-fold higher when the disease is present in a first-degree relative, and the concordance rate for monozygotic twins is approximately 25%, with a much lower rate for dizygotic twins. A significant fraction of the genetic risk for MS is attributable to HLA-DR variants, the DR2 allele being the one that most significantly increases the risk for developing MS. Many other genetic polymorphisms have been linked to the disease by genome-wide association studies. Two that have received considerable recent interest are polymorphisms in the genes encoding receptors for the cytokines IL-2 and IL-7, which are known to control the activation and regulation of T cell–mediated immune responses.

In view of the prominence of chronic inflammatory cells within and around MS plaques as well as the genetic evidence, immune-mediated myelin destruction is thought to have a central role in MS. Evidence from human studies as well as from experimental allergic encephalomyelitis—an animal model of MS in which demyelination and inflammation occur after immunization with myelin, myelin proteins, or certain peptides from myelin proteins—has suggested that a range of immune cells contribute to lesion development in MS. A central role for CD4+ T cells has been suggested, with an increase in $T_H17$ and $T_H1$ CD4+ cells thought to be a critical component of the injury to myelin. There is also evidence for important contributions from CD8+ T cells and B cells. While MS is characterized by the presence of demyelination out of proportion to axonal loss, some injury to axons does occur. Toxic effects of lymphocytes, macrophages, and their secreted molecules have been implicated in initiating the process of axonal injury, sometimes even leading to neuronal death.

## MORPHOLOGY

MS is primarily a white matter disease with affected areas showing multiple, well-circumscribed, slightly depressed, glassy-appearing, gray-tan, irregularly shaped lesions termed **plaques** (Fig. 22–23, *A*). These commonly arise near the ventricles. They also are frequent in the optic nerves and chiasm, brain stem, ascending and descending fiber tracts, cerebellum, and spinal cord. The lesions have sharply defined borders at the microscopic level (Fig. 22–23, *B*). In an **active plaque** there is evidence of ongoing myelin breakdown with abundant macrophages containing myelin debris. Lymphocytes and macrophages are present, mostly as perivascular cuffs. Small active lesions often are centered on small veins. Axons are relatively preserved but may be reduced in number.

Active plaques fall into four classes, only one of which typically is seen in a particular affected patient. The recognized microscopic patterns are **type I,** which has macrophage infiltrates with sharp margins; **type II,** which is similar to type I but also shows complement deposition (suggesting an antibody-mediated component); **type III,** with less well-defined borders and oligodendrocyte apoptosis; and **type IV,** with nonapoptotic oligodendrocyte loss. When plaques become quiescent **(inactive plaques),** the inflammation mostly disappears, leaving behind little to no myelin. Instead, astrocytic proliferation and gliosis are prominent.

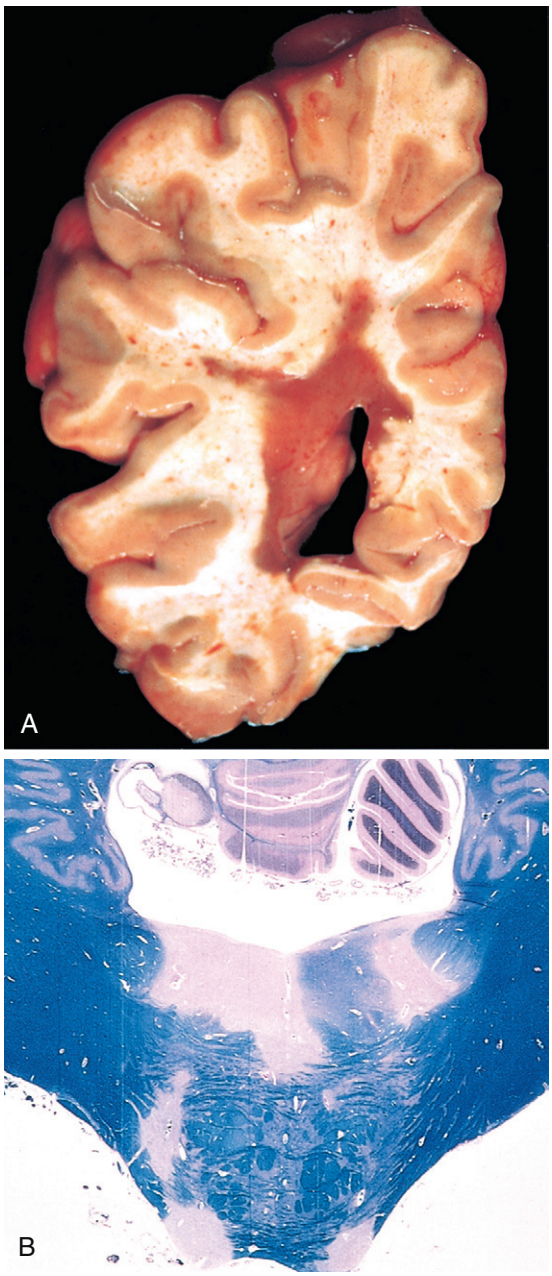


**Figure 22–23** Multiple sclerosis (MS). **A,** Section of fresh brain showing a plaque around occipital horn of the lateral ventricle. **B,** Unstained regions of demyelination (MS plaques) around the fourth ventricle. Luxol fast blue–periodic acid–Schiff stain for myelin.

### Clinical Features

The course of MS is variable, but commonly there are multiple *relapses* followed by episodes of *remission*; typically, recovery during remissions is not complete. As a consequence, over time there is usually a gradual, often stepwise, accumulation of neurologic deficits. Imaging studies

have demonstrated that there are often more lesions in the brains of patients with MS than might be expected from the clinical examination, and that lesions can come and go much more often than was previously suspected. Changes in cognitive function can be present, but are often much milder than the other deficits. In any individual patient, it is hard to predict when the next relapse will occur; most current treatments, which are intended to control the immune response, aim at decreasing the rate and severity of relapses rather than recovering lost function.

The CSF in patients with MS shows a mildly elevated protein level with an increased proportion of immunoglobulin; in one third of cases, there is moderate pleocytosis. When the immunoglobulin is examined further, *oligoclonal bands* usually are identified. These antibodies are directed against a variety of antigenic targets and can be used as markers of disease activity. Although B cells are clearly involved in the pathogenesis of MS, the contribution of these characteristic antibodies to the disease process is unknown.

## Other Acquired Demyelinating Diseases

Immune-mediated demyelination can occur after a number of systemic infectious illnesses, including relatively mild viral diseases. These are not thought to be related to direct spread of the infectious agents to the nervous system. Rather, it is believed that immune cells responding to pathogen-associated antigens are cross reactive against myelin antigens, resulting in myelin damage.

There are two general patterns of postinfectious autoimmune reactions to myelin; unlike in MS, they are associated with acute-onset monophasic illnesses. In *acute disseminated encephalomyelitis,* symptoms typically develop a week or two after an antecedent infection and are nonlocalizing (headache, lethargy, and coma), in contrast with the focal findings of MS. Symptoms progress rapidly, and the illness is fatal in as many as 20% of cases; in the remaining patients, there is complete recovery. *Acute necrotizing hemorrhagic encephalomyelitis* is a more devastating related disorder, which typically affects young adults and children.

*Neuromyelitis optica* (NMO) is an inflammatory demyelinating disease centered on the optic nerves and spinal cord. Previously thought to be a form of MS with stereotypic anatomic regions of susceptibility, this is now recognized to be an antibody-mediated autoimmune disorder. Antibodies to the water channel aquaporin-4 are both diagnostic and pathogenic.

*Central pontine myelinolysis* is a nonimmune process characterized by loss of myelin involving the center of the pons, most often after rapid correction of hyponatremia. The mechanism of oligodendroglial cell injury is uncertain, but it may be related to edema induced by sudden changes in osmotic pressure. It occurs in a variety of clinical settings including alcoholism and severe electrolyte or osmolar imbalance. Although the most characteristic lesion occurs in the pons, similar lesions can be found elsewhere in the brain. Because of the involvement of fibers in the pons carrying signals to motor neurons in the spinal cord, patients often present with rapidly evolving quadriplegia.

As discussed earlier, *progressive multifocal leukoencephalopathy* (PML) is a demyelinating disease that occurs after reactivation of JC virus in immunosuppressed patients.

## Leukodystrophies

*Leukodystrophies* exemplify inherited dysmyelinating diseases in which the clinical symptoms derive from abnormal myelin synthesis or turnover. Some of these disorders involve lysosomal enzymes, while others involve peroxisomal enzymes; a few are associated with mutations in myelin proteins. Most are of autosomal recessive inheritance, although X-linked diseases also occur (Table 22–1).

### MORPHOLOGY

Much of the pathologic change of leukodystrophy is found in the white matter, which is diffusely abnormal in color (gray and translucent) and volume (decreased). Early in their course, some diseases may show patchy involvement, while others have a predilection for occipital lobe involvement. In the end, though, nearly all of the white matter usually is affected. With the loss of white matter, the brain becomes atrophic, the ventricles enlarge, and secondary changes can be found in the gray matter. Myelin loss leads to infiltration of macrophages, which often become stuffed with lipid. Some of these diseases also show specific inclusions created by the accumulation of particular lipids.

### Clinical Features

Each of the various leukodystrophies has a characteristic clinical presentation, and most can be diagnosed by genetic or biochemical methods. Despite differences in underlying mechanisms, the leukodystrophies share many features because of the common myelin target. Affected children are normal at birth but begin to miss developmental milestones during infancy and childhood. Diffuse involvement of white matter leads to deterioration in motor skills, spasticity, hypotonia, or ataxia. In general, the earlier the age at onset, the more severe the deficiency and clinical course.

**Table 22–1** Selected Leukodystrophies

| Metabolic Disorder | Inheritance Mode | Abnormality |
|---|---|---|
| Metachromatic leukodystrophy | AR | Arylsulfatase A deficiency |
| Krabbe disease | AR | Galactocerebroside β-galactosidase deficiency |
| Adrenoleukodystrophy | AR, X | Peroxisomal defects; elevated very-long-chain fatty acids |
| Canavan disease | AR | Aspartoacylase deficiency |
| Pelizaeus-Merzbacher disease | X | Mutations in proteolipid protein |
| Vanishing white matter disease | AR | Translation initiation factor; link to myelin unclear |
| Alexander disease | AR | Mutations in glial fibrillary acidic protein |

AR, autosomal recessive; X, X-linked.

## SUMMARY

### Primary Diseases of Myelin

- Because of the critical role of myelin in nerve conduction, diseases of myelin can lead to widespread and severe neurologic deficits.
- Diseases of myelin can be grouped into *demyelinating diseases* (in which normal myelin is broken down for inappropriate reasons—often by inflammatory processes), and *dysmyelinating diseases* (metabolic disorders that include the leukodystrophies in which myelin structure or its turnover is abnormal).
- Multiple sclerosis, an autoimmune demyelinating disease, is the most common disorder of myelin, affecting young adults. It often pursues a relapsing-remitting course, with eventual progressive accumulation of neurologic deficits.
- Other, less common forms of immune-mediated demyelination often follow infections and are more acute illnesses.

# ACQUIRED METABOLIC AND TOXIC DISTURBANCES

Toxic and acquired metabolic diseases are relatively common causes of neurologic illnesses. Because of its high metabolic demands, the brain is particularly vulnerable to nutritional diseases and alterations in metabolic state. Surprisingly, even though metabolic alterations might be expected to affect the entire brain uniformly, there can be very distinct clinical presentations because of unique features or requirements of different anatomic regions. A few of the more common types of injury, particularly those with distinct patterns of damage, are discussed here.

## Nutritional Diseases

***Thiamine Deficiency.*** In addition to the systemic effects of thiamine deficiency (*beriberi*), there also may be abrupt onset of confusion, abnormalities in eye movement, and ataxia—a syndrome termed *Wernicke encephalopathy.* Treatment with thiamine can reverse these deficits. If the acute stages go untreated, they are followed by largely irreversible profound memory disturbances (Korsakoff syndrome). Because the two syndromes are closely linked, the term *Wernicke-Korsakoff syndrome* is often applied.

The syndrome is particularly common in the setting of chronic alcoholism but also may be encountered in patients with thiamine deficiency resulting from gastric disorders, including carcinoma and chronic gastritis, or from persistent vomiting.

## MORPHOLOGY

Wernicke encephalopathy is characterized by foci of hemorrhage and necrosis, particularly in the mammillary bodies but also adjacent to the ventricles, especially the third and fourth ventricles. Despite the presence of necrosis, there is relative preservation of many of the neurons in these structures. Early lesions show dilated capillaries with prominent endothelial cells and progress to hemorrhage. As the lesions resolve, a cystic space appears along with hemosiderin-laden macrophages. Lesions in the medial dorsal nucleus of the thalamus seem to best correlate with the memory disturbance in Korsakoff syndrome.

***Vitamin $B_{12}$ Deficiency.*** In addition to pernicious anemia, deficiency of vitamin $B_{12}$ may lead to neurologic deficits associated with changes in the spinal cord, collectively termed *subacute combined degeneration of the spinal cord*. As the name implies, both ascending and descending tracts of the spinal cord are affected. Symptoms develop over weeks. Early clinical signs often include slight ataxia and lower extremity numbness and tingling, which can progress to spastic weakness of the lower extremities; sometimes even complete paraplegia ensues. Prompt vitamin replacement therapy produces clinical improvement; however, if paraplegia has developed, recovery is poor.

## Metabolic Disorders

Several systemic derangements may produce CNS dysfunction; only those associated with glucose levels and liver dysfunction are considered here.

***Hypoglycemia.*** Since the brain requires glucose as a substrate for energy production, the cellular effects of diminished glucose generally resemble those of global hypoxia. Hippocampal neurons are particularly susceptible to hypoglycemic injury, while cerebellar Purkinje cells are relatively spared. As with anoxia, if the level and duration of hypoglycemia are sufficiently severe, there may be widespread injury to many areas of the brain.

***Hyperglycemia.*** Hyperglycemia is most common in the setting of inadequately controlled diabetes mellitus and can be associated with either ketoacidosis or hyperosmolar coma. Patients develop confusion, stupor, and eventually coma associated with intracellular dehydration caused by the hyperosmolar state. The hyperglycemia must be corrected gradually, because rapid correction can produce severe cerebral edema.

***Hepatic Encephalopathy.*** Decreased hepatic function may be associated with depressed levels of consciousness and sometimes coma. In the early stages, patients exhibit a characteristic "flapping" tremor (asterixis) when extending the arms with palms facing the observer. Elevated levels of ammonia, which the liver normally clears through the urea cycle, in combination with inflammation and hyponatremia, cause the changes in brain function. Because it is only one contributing factor, ammonia levels in symptomatic patients vary widely. Within the CNS, ammonia metabolism occurs only in astrocytes through the action of glutamine synthetase, and in the setting of hyperammonemia, astrocytes in the cortex and basal ganglia develop swollen, pale nuclei (called *Alzheimer type II cells*).

## Toxic Disorders

The list of toxins with effects on the brain is extremely long. Among the major categories of neurotoxic substances are

*metals,* including lead (often causing a diffuse encephalopathy), as well as arsenic and mercury; *industrial chemicals,* including organophosphates (in pesticides) and methanol (causing blindness from retinal damage); and *environmental pollutants* such as carbon monoxide (combining hypoxia with selective injury to the globus pallidus).

*Ethanol* has a variety of effects on the brain. While acute intoxication is reversible, excessive intake can result in profound metabolic disturbances, including brain swelling and death. Chronic alcohol exposure leads to cerebellar dysfunction in about 1% cases, with truncal ataxia, unsteady gait, and nystagmus, associated with atrophy in the anterior vermis of the cerebellum.

*Ionizing radiation,* commonly used to treat intracranial tumors, can cause rapidly evolving signs and symptoms including headaches, nausea, vomiting, and papilledema, even months to years after irradiation. Affected brain regions show large areas of coagulative necrosis, adjacent edema, and blood vessels with thickened walls containing intramural fibrin-like material.

## NEURODEGENERATIVE DISEASES

Degenerative diseases of the CNS are disorders characterized by the cellular degeneration of subsets of neurons that typically are related by function, rather than by physical location in the brain. Many of these disorders are associated with the accumulation of abnormal proteins, which serve as histologic hallmarks of specific disorders (Table 22–2). An important but unanswered question is why these abnormal proteins tend to accumulate in and preferentially affect particular kinds of neurons, since the involved proteins typically are widely expressed throughout the nervous system.

Subtle differences among subtypes of neurons are presumed to explain why particular neurons are affected in specific disorders. Understandably, the clinical manifestations of degenerative diseases are dictated by the pattern of neuronal dysfunction: those that affect the cerebral cortical neurons result in loss of memory, language, insight, and planning, all components of dementia; those that affect the neurons of the basal ganglia result in movement disorders; those that affect the cerebellum result in ataxia; and those that affect motor neurons result in weakness. Although many degenerative diseases have primary targets, other brain regions are often affected later in the course of the illness; thus, while Huntington disease often has movement disorders as an early symptom, later cortical involvement typically results in the development of cognitive changes as well. *Dementia* is defined as the development of memory impairment and other cognitive deficits severe enough to decrease the affected person's capacity to function at the previous level despite a normal level of consciousness. It arises during the course of many neurodegenerative diseases; it also can accompany numerous other diseases that injure the cerebral cortex (Table 22–3). Dementia is an increasing public health concern as the population ages.

**Table 22–2** Protein Inclusions in Degenerative Diseases

| Disease | Protein | Location |
|---|---|---|
| Alzheimer disease | Aβ<br>Tau | Extracellular<br>Neurons |
| Frontotemporal lobar degeneration | Tau | Neurons |
| Progressive supranuclear palsy | Tau | Neurons and glia |
| Corticobasal degeneration | Tau | Neurons and glia |
| Parkinson disease | α-Synuclein | Neurons |
| Multiple system atrophy | α-Synuclein | Glia and some neurons |
| Frontotemporal lobar degenerations | TDP-43 | Neurons |
| Amyotrophic lateral sclerosis | TDP-43<br>SOD-1 (familial disease) | Neurons<br>Neurons |
| Huntington disease | Huntingtin | Neurons |
| Spinocerebellar ataxias | Ataxins (various) | Neurons |

SOD-1, superoxide dismutase-1; TDP-43, TAR DNA-binding protein 43.

**Table 22–3** Some Causes of Dementia or Cognitive Impairment

| |
|---|
| **Primary Neurodegenerative Disorders** |
| Alzheimer disease |
| Frontotemporal lobar degeneration |
| Lewy body dementia |
| Huntington disease |
| Spinocerebellar ataxia (certain forms) |
| **Infections** |
| Prion disease |
| HIV associated neurocognitive disorder |
| Progressive multifocal leukoencephalopathy |
| Viral encephalitis |
| Neurosyphilis |
| Chronic meningitis |
| **Vascular and Traumatic Diseases** |
| Multifocal cerebral infarction |
| Severe hypertensive cerebrovascular disease |
| Cerebral autosomal dominant arteriopathy with subcortical infarction and leukoencephalopathy (CADASIL) |
| Chronic traumatic encephalopathy |
| **Metabolic and Nutritional Diseases** |
| Thiamine deficiency (Wernicke-Korsakoff syndrome) |
| Vitamin $B_{12}$ deficiency |
| Niacin deficiency (pellagra) |
| Endocrine diseases |
| **Miscellaneous** |
| Neuronal storage diseases |
| Toxic injury (from mercury, lead, manganese, bromides, others) |

### Alzheimer Disease

Alzheimer disease (AD) is the most common cause of dementia in the elderly population. The disease usually manifests with the insidious onset of impaired higher intellectual function and altered mood and behavior. Later, this progresses to disorientation, memory loss, and aphasia, findings indicative of severe cortical dysfunction, and over another 5 to 10 years, the patient becomes profoundly disabled, mute, and immobile. Death usually occurs from intercurrent pneumonia or other infections. Age is an

important risk factor for AD; the incidence is about 3% in persons 65 to 74 years old, 19% in those 75 to 84 years old, and 47% in those older than 84 years. Most cases of AD are sporadic, but at least 5% to 10% are familial. Sporadic cases rarely present before 50 years of age, but early onset is seen with some heritable forms.

## PATHOGENESIS

Study of the familial forms of AD supports a model in which a peptide called beta amyloid, or Aβ, accumulates in the brain over time, initiating a chain of events that result in AD. Aβ is created when the transmembrane protein amyloid precursor protein (APP) is sequentially cleaved by the enzymes β-amyloid converting enzyme (BACE) and γ-secretase (Fig. 22–24). APP also can be cleaved by α-secretase and γ-secretase, which liberates a different peptide that is nonpathogenic. Mutations in APP or in components of γ-secretase (presenilin-1 or presenilin-2) lead to familial AD by increasing the rate at which Aβ is generated. The *APP* gene is located on chromosome 21, and the risk of AD also is higher in those with an extra copy of the *APP* gene, such as patients with trisomy 21 (Down syndrome) and persons with small interstitial duplications of *APP*, presumably because this too leads to greater Aβ generation. The other major genetic risk factor is a variant of apolipoprotein E called ε4 (ApoE4). Each ApoE4 allele that is present increases the risk of AD by approximately 4 fold and also appears to lower the age of onset. How ApoE4 influences Aβ accumulation is unknown; it may increase Aβ aggregation or deposition, or decrease Aβ clearance.

While large deposits of Aβ are a feature of end-stage AD, small aggregates of Aβ may also be pathogenic, as they alter neurotransmission and are toxic to neurons and synaptic endings. Large deposits, in the form of plaques, also lead to neuronal death, elicit a local inflammatory response that can result in further cell injury, and may cause altered region-to-region communication through mechanical effects on axons and dendrites.

The presence of Aβ also leads to hyperphosphorylation of the neuronal microtubule binding protein tau. This increased

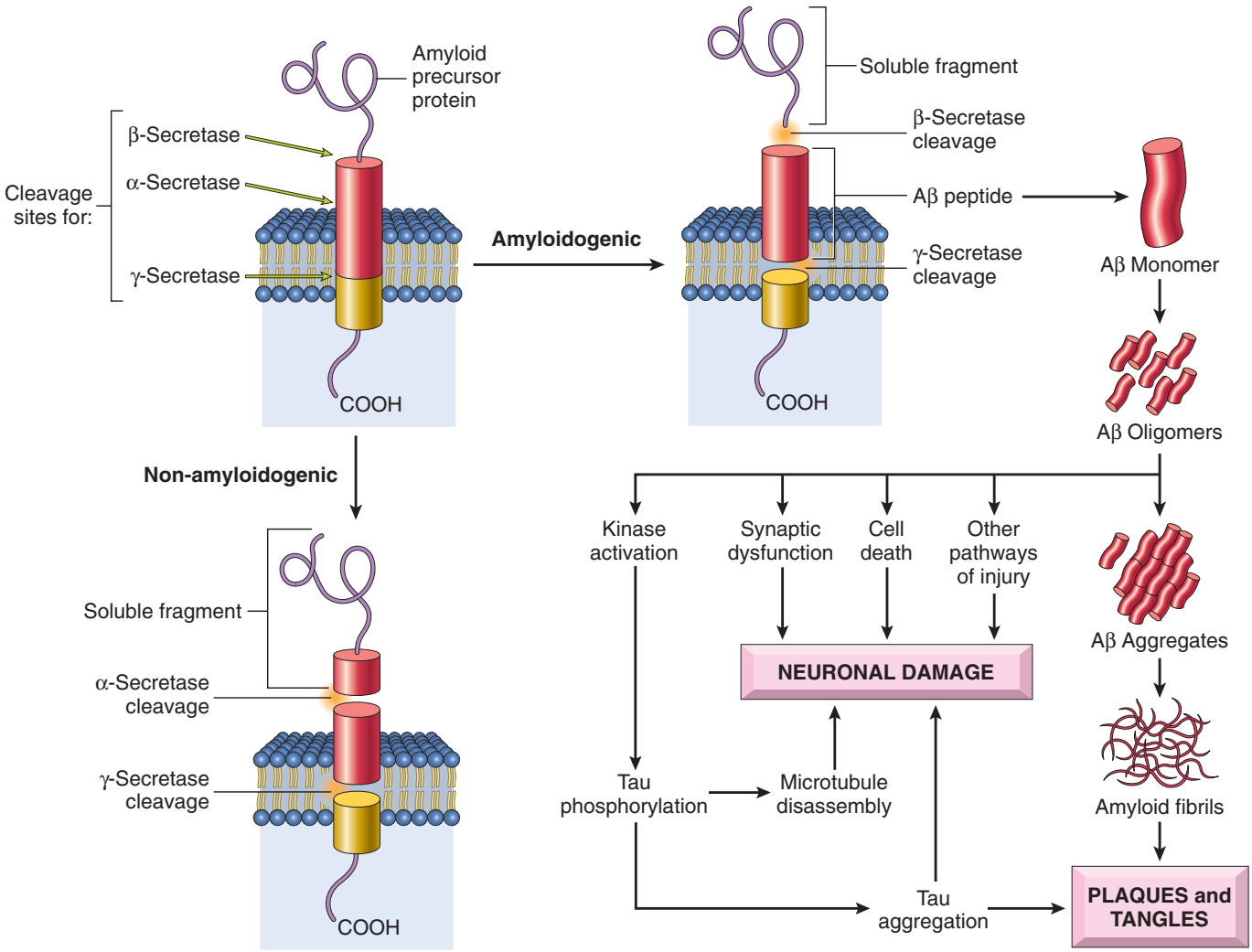


**Figure 22–24** Aβ peptide genesis and consequences in Alzheimer disease. Amyloid precursor protein cleavage by α-secretase and γ-secretase produces a harmless soluble peptide, whereas amyloid precursor protein cleavage by β-amyloid–converting enzyme (BACE) and γ-secretase releases Aβ peptides, which form pathogenic aggregates and contribute to the characteristic plaques and tangles of Alzheimer disease.

level of phosphorylation causes tau to redistribute from axons into dendrites and cell bodies, where it aggregates into tangles, which also contribute to neuronal dysfunction and cell death.

## MORPHOLOGY

Macroscopic examination of the brain shows a variable degree of cortical atrophy, resulting in a widening of the cerebral sulci that is most pronounced in the frontal, temporal, and parietal lobes. With significant atrophy, there is compensatory ventricular enlargement (hydrocephalus ex vacuo). At the microscopic level, AD is diagnosed by the presence of **plaques** (an extracellular lesion); and **neurofibrillary tangles** (an intracellular lesion) (Fig. 22–25). Because these may also be present to a lesser extent in the brains of elderly nondemented persons, the current criteria for a diagnosis of AD are based on a combination of clinical and pathologic features. There is a fairly constant progressive involvement of different parts of the brain: pathologic changes (specifically plaques, tangles, and the associated neuronal loss and glial reaction) are evident first in the entorhinal cortex, then in the hippocampal formation and isocortex, and finally in the neocortex. Silver staining or immunohistochemistry methods are extremely helpful in assessing the true lesional burden.

**Neuritic plaques** are focal, spherical collections of dilated, tortuous, silver-staining neuritic processes (dystrophic neurites), often around a central amyloid core (Fig. 22–25, *A*). Neuritic plaques range in size from 20 to 200 μm in diameter; microglial cells and reactive astrocytes are present at their periphery. Plaques can be found in the hippocampus and amygdala as well as in the neocortex, although there usually is relative sparing of primary motor and sensory cortices until late in the disease course. The amyloid core contains Aβ (Fig. 22–25, *B*). Aβ deposits also can be found that lack the surrounding neuritic reaction, termed **diffuse plaques;** these typically are found in the superficial cerebral cortex, the basal ganglia, and the cerebellar cortex and may represent an early stage of plaque development.

**Neurofibrillary tangles** are bundles of paired helical filaments visible as basophilic fibrillary structures in the cytoplasm of the neurons that displace or encircle the nucleus; tangles can persist after neurons die, becoming a form of extracellular pathology. They are commonly found in cortical neurons, especially in the entorhinal cortex, as well as in the pyramidal cells of the hippocampus, the amygdala, the basal forebrain, and the raphe nuclei. A major component of paired helical filaments is abnormally hyperphosphorylated **tau** (Fig. 22–25, *C*). Tangles are not specific to AD, being found in other degenerative diseases as well.

### Frontotemporal Lobar Degeneration

Another major category of disease that results in dementia is called *frontotemporal lobar degeneration* (FTLD). These disorders share clinical features (progressive deterioration of language and changes in personality) stemming from the degeneration and atrophy of temporal and frontal lobes; the clinical syndromes commonly are referred to as *frontotemporal dementias.* When the frontal lobe bears the greatest burden of disease, behavioral changes often dominate, whereas when the disease begins in the temporal lobe, language problems often are the presenting complaint. These symptoms precede memory disturbances, which can assist in their separation from AD on clinical grounds.

On gross inspection, there is atrophy of the brain that predominantly affects the frontal and temporal lobes. Different subgroups are characterized by neuronal inclusions involving the affected regions. In some cases the defining inclusions contain tau (FTLD-tau), but the configuration of the tau inclusions differs from the tau-containing tangles of AD. FTLD-tau sometimes is caused by mutations in the gene encoding tau. One well-recognized subtype of FTLD-tau is *Pick disease,* which is associated with smooth, round inclusions known as *Pick bodies.* The other major form of FTLD is characterized by aggregates containing the DNA/RNA-binding protein TDP-43 (FTLD-TDP43). This form of FTLD is associated with predominantly frontal lobe cognitive impairment. It is sometimes caused by mutations in the gene encoding TDP-43, which is also mutated in a subset of cases of amyotrophic lateral sclerosis (described later).

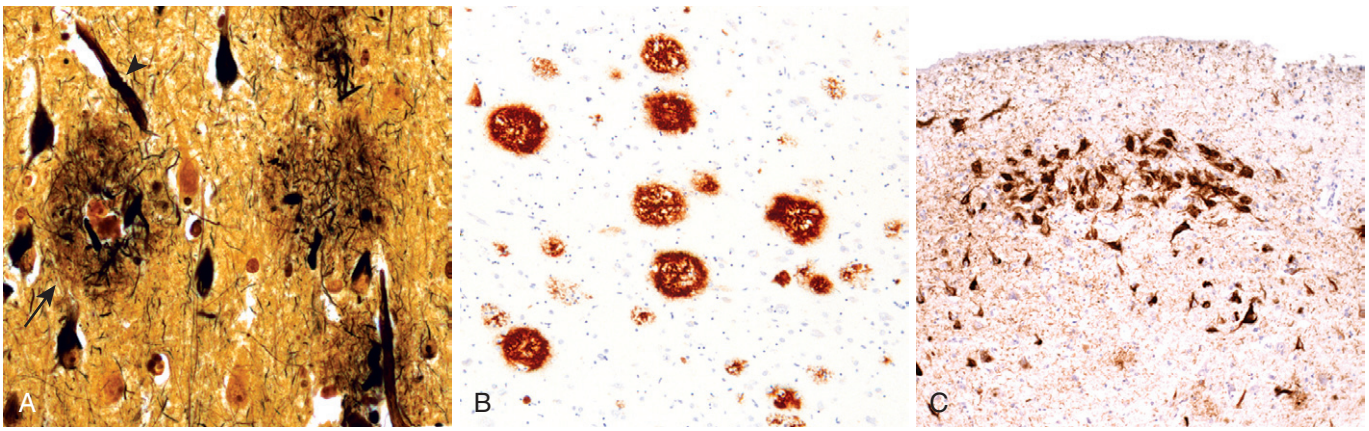


**Figure 22–25** Alzheimer disease. **A,** Plaques (*arrow*) contain a central core of amyloid and a surrounding region of dystrophic neurites (Bielschowsky stain). **B,** Immunohistochemical stain for Aβ. Peptide is present in the core of the plaques as well as in the surrounding region. **C,** Neurons containing tangles stained with an antibody specific for tau.

## Parkinson Disease

*Parkinsonism* is a clinical syndrome characterized by tremor, rigidity, bradykinesia and instability. These types of motor disturbances may be seen in a range of diseases that damage dopaminergic neurons, which project from the substantia nigra to the striatum. Parkinsonism can be induced by drugs such as dopamine antagonists or toxins that selectively injure dopaminergic neurons. Among the neurodegenerative diseases, most cases of parkinsonism are caused by *Parkinson disease* (PD), which is associated with characteristic neuronal inclusions containing α-synuclein. Other diseases in which parkinsonism may be present include *multiple system atrophy* (MSA), in which α-synuclein aggregates are found in oligodendrocytes; *progressive supranuclear palsy* (PSP) and *corticobasal degeneration* (CBD), which are both associated with tau-containing inclusions in neurons and glial cells; and *postencephalitic parkinsonism,* which was associated with the 1918 influenza pandemic.

### PATHOGENESIS

While PD in most cases is sporadic, both autosomal dominant and recessive forms of the disease also exist. Point mutations and duplications of the gene encoding α-synuclein, a protein involved in synaptic transmission, cause autosomal dominant PD. Even in sporadic PD, the diagnostic feature of the disease—the Lewy body—is an inclusion containing α-synuclein. The linkage between α-synuclein and disease pathogenesis is unclear, but other genetic forms of PD provide some clues. Two other causative genetic loci encode the proteins parkin, an E3 ubiquitin ligase, and UCHL-1, an enzyme involved in recycling of ubiquitin from proteins targeted to the proteasome, suggesting that defects in protein degradation may have a pathogenic role. Another tantalizing clue comes from the association of PD with mutations in a protein kinase called LRRK2; histopathologic examination of cases associated with LRRK2 mutations may show either Lewy bodies containing α-synuclein or tangles containing tau. Finally, some forms of familial PD are associated with mutations in the *PARK7* or *PINK1* genes, both of which appear to be important for normal mitochondrial function.

### MORPHOLOGY

A typical gross finding at autopsy is pallor of the substantia nigra (Fig. 22–26, *A* and *B*) and locus ceruleus. Microscopic features include loss of the pigmented, catecholaminergic neurons in these regions associated with gliosis. **Lewy bodies** (Fig. 22–26, *C*) may be found in those neurons that remain. These are single or multiple, intracytoplasmic, eosinophilic, round to elongated inclusions that often have a dense core surrounded by a pale halo. On ultrastructural examination, Lewy bodies consist of fine filaments, densely packed in the core but loose at the rim, composed of α-synuclein and other proteins, including neurofilaments and ubiquitin. The other major histologic finding is **Lewy neurites,** dystrophic neurites that also contain abnormally aggregated α-synuclein.

As implied by the occurrence of a broad array of neurologic deficits in PD, immunohistochemical staining for α-synuclein highlights more subtle Lewy bodies and Lewy neurites in many brain regions outside of the substantia nigra and in nondopaminergic neurons. These lesions appear first in the medulla and then in the pons, before involvement of the substantia nigra. As implied by the dementia, Lewy bodies and Lewy neurites eventually appear in the cerebral cortex and subcortical areas, including the cholinergic cells of the basal nucleus of Meynert and the amygdala.

### Clinical Features

PD commonly manifests as a movement disorder in the absence of a toxic exposure or other known underlying etiology. The disease usually progresses over 10 to 15 years, eventually producing severe motor slowing to the point of near immobility. Death usually is the result of intercurrent infection or trauma from frequent falls caused by postural instability.

Movement symptoms of PD initially respond to L-dihydroxyphenylalanine (L-DOPA), but this treatment does not slow disease progression. Over time, L-DOPA becomes less effective and begins to cause potentially problematic fluctuations in motor function.

While the movement disorder associated with loss of the nigrostriatal dopaminergic pathway is an important feature of PD, it is clear that the disease has more extensive clinical and pathologic manifestations. Lesions can be found lower

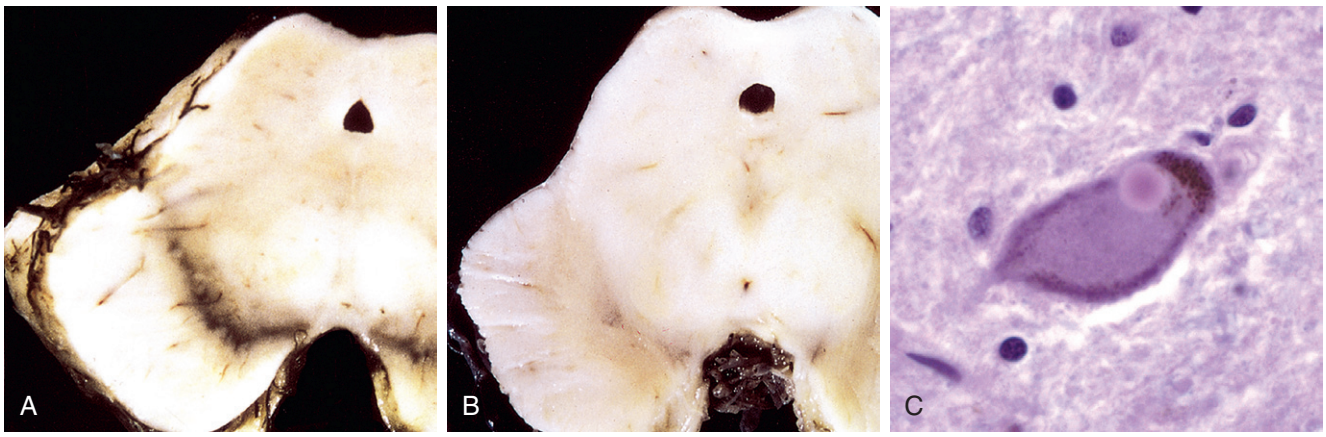


**Figure 22–26** Parkinson disease. **A,** Normal substantia nigra. **B,** Depigmented substantia nigra in idiopathic Parkinson disease. **C,** Lewy body in a neuron from the substantia nigra stains *pink*.

in the brain stem (in the dorsal motor nucleus of the vagus and in the reticular formation) in advance of nigral involvement, in line with clinical studies showing that autonomic dysfunction and behavioral disorders often are present in advance of the motor problems. Dementia, typically with a mildly fluctuating course and hallucinations, emerges in many persons with PD and is attributable to involvement of the cerebral cortex. When dementia arises within 1 year of the onset of motor symptoms, it is referred to *Lewy body dementia* (LBD).

## Huntington Disease

Huntington disease (HD) is an autosomal dominant movement disorder associated with degeneration of the striatum (caudate and putamen). The movement disorder is choreiform (dancelike), with increased and involuntary jerky movements of all parts of the body; writhing movements of the extremities are typical. *The disease is relentlessly progressive, resulting in death after an average course of about 15 years.* Early cognitive symptoms include forgetfulness and thought and affective disorders, and there may be progression to a severe dementia. As a part of these early behavioral changes, HD carries an increased risk of suicide.

### PATHOGENESIS

HD is caused by **CAG trinucleotide repeat expansions** in a gene located on 4p16.3 that encodes the protein huntingtin. Normal alleles contain 11 to 34 copies of the repeat; in disease-causing alleles the number of repeats is increased, sometimes into the hundreds. There is strong genotype-phenotype correlation, with larger numbers of repeats resulting in earlier-onset disease. Once the symptoms appear, however, the course of the illness is not affected by repeat length. Further expansions of the pathologic CAG repeats can occur during spermatogenesis, so paternal transmission may be associated with earlier onset in the next generation, a phenomenon referred to as **anticipation** (Chapter 6).

HD appears to be caused by a toxic gain-of-function mutation somehow related to the expanded polyglutamine tract in huntingtin. The mutant protein is subject to ubiquitination and proteolysis, yielding fragments that can form large intranuclear aggregates. As in other degenerative diseases, smaller aggregates of the abnormal protein fragments are suspected to be the critical toxic agent. These aggregates may sequester transcription factors, disrupt protein degradation pathways, perturb mitochondrial function, or alter brain-derived neurotrophic factor (BDNF) signaling. It is likely that some combination of these aberrations contributes to HD pathogenesis.

### MORPHOLOGY

On gross examination, the brain is small and shows striking atrophy of the caudate nucleus and, sometimes less dramatically, the putamen (Fig. 22–27). Pathologic changes develop over the course of the illness in a medial to lateral direction in the caudate and from dorsal to ventral in the putamen. The globus pallidus may be atrophied secondarily, and the lateral and third ventricles are dilated. Atrophy frequently is also seen in the frontal lobe, less often in the parietal lobe, and occasionally in the entire cortex.

Microscopic examination reveals severe loss of neurons from affected regions of the striatum. The medium-sized, spiny neurons that release the neurotransmitters γ-aminobutyric acid (GABA), enkephalin, dynorphin, and substance P are especially sensitive, disappearing early in the disease. Also seen is fibrillary gliosis, which is more extensive than in the usual reaction to neuronal loss. There is a strong correlation between the degree of degeneration in the striatum and the severity of motor symptoms; there is also an association between cortical neuronal loss and dementia. In remaining striatal neurons and in the cortex, there are intranuclear inclusions that contain aggregates of ubiquitinated huntingtin protein (Fig. 22–27, *inset*).

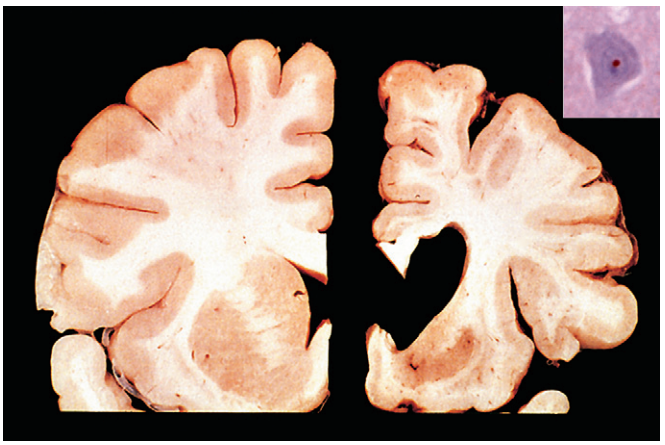

**Figure 22–27** Huntington disease. Normal hemisphere on the *left* compared with the hemisphere with Huntington disease on the *right* showing atrophy of the striatum and ventricular dilation. *Inset,* An intranuclear inclusion in a cortical neuron is strongly immunoreactive for ubiquitin. *(Courtesy of Dr. J.P. Vonsattel, Columbia University, New York, New York.)*

## Spinocerebellar Ataxias

Spinocerebellar ataxias (SCAs) are a clinically heterogeneous group of diseases that are frequently caused by trinucleotide repeat expansion mutations. They are distinguished from one another by differences in causative mutations, patterns of inheritance, age at onset, and signs and symptoms. This group of diseases affects, to a variable extent, the cerebellar cortex, spinal cord, other brain regions, and peripheral nerves. As a result, clinical findings may include a combination of cerebellar and sensory ataxia, spasticity, and sensorimotor peripheral neuropathy. Degeneration of neurons, often without distinctive histopathologic changes, occurs in the affected areas and is associated with mild gliosis. The additional clinical symptoms that accompany the ataxia can help distinguish between well-characterized subtypes. Although more than two dozen distinct genetic types of SCA have been identified, there remain many cases which do not fall into one of the already characterized forms.

As with Huntington disease, several forms of SCA (SCA types 1, 2, 3, 6, 7, and 17 and dentatorubropallidoluysian atrophy) are caused by CAG repeat expansions encoding polyglutamine tracts in various genes. In these forms of SCA, neuronal intranuclear inclusions are present containing the abnormal protein and there is an inverse correlation between the degree of repeat expansion and age of onset. Other SCAs are caused by trinucleotide repeat expansions in untranslated regions or by other types of mutations.

*Friedreich ataxia* is an autosomal recessive disorder that generally manifests in the first decade of life with gait ataxia, followed by hand clumsiness and dysarthria. Most patients develop pes cavus and kyphoscoliosis, and there is a high incidence of cardiac disease and diabetes. The disease usually is caused by a GAA trinucleotide repeat expansion in the gene encoding frataxin, a protein that regulates cellular iron levels, particularly in the mitochondria. The repeat expansion results in decreased protein levels through transcriptional silencing; rare cases in which point mutations produce a nonfunctional frataxin protein also have been described. Decreased frataxin leads to mitochondrial dysfunction as well as increased oxidative damage.

## Amyotrophic Lateral Sclerosis

*Amyotrophic lateral sclerosis* (ALS) results from the death of lower motor neurons in the spinal cord and brain stem, and of upper motor neurons (Betz cells) in the motor cortex. The loss of lower motor neurons results in denervation of muscles, muscular atrophy (the "amyotrophy" of the condition), weakness, and fasciculations, while the loss of upper motor neurons results in paresis, hyperreflexia, and spasticity, along with a Babinski sign. An additional consequence of upper motor neuron loss is degeneration of the corticospinal tracts in the lateral portion of the spinal cord ("lateral sclerosis"). Sensation usually is unaffected, but cognitive impairment does occur, sometimes as a frontotemporal dementia.

The disease affects men slightly more frequently than women and becomes clinically manifest in the fifth decade or later, usually beginning with subtle asymmetric distal extremity weakness. As the disease progresses to involve more of the motor system, muscle strength and bulk diminish and involuntary contractions of individual motor units, termed fasciculations, occur. The disease eventually involves the respiratory muscles, leading to recurrent bouts of pulmonary infection, which is the usual cause of death. The balance between upper and lower motor neuron involvement can vary, although most patients exhibit involvement of both. In some patients, degeneration of the lower brain stem cranial motor nuclei occurs early and progresses rapidly, a pattern of disease referred to as bulbar amyotrophic lateral sclerosis. With this disease pattern, abnormalities of swallowing and speaking dominate.

### PATHOGENESIS

While most cases are sporadic, 5% to 10% are familial, mostly with autosomal dominant inheritance. Familial disease begins earlier in life than sporadic disease, but once symptoms appear, the clinical course is similar in both forms. More than a dozen genes have been implicated, but the most frequent genetic cause (20% of cases) is mutations in the superoxide dismutase gene, *SOD-1*, on chromosome 21. These mutations are thought to generate abnormal misfolded forms of the SOD-1 protein, which may trigger the unfolded protein response and cause apoptotic death of neurons. The next two most common causative genes both encode DNA/RNA binding proteins, TDP-43 and FUS; how these mutations cause disease is unknown. As already mentioned, mutations in TDP-43 also can cause frontotemporal lobar degeneration (FTLD) or a disease with overlapping features of both ALS and FTLD.

### MORPHOLOGY

The most striking gross changes are found in anterior roots of the spinal cord, which are thin and gray (rather than white). In especially severe cases, the precentral gyrus (motor cortex) may be mildly atrophic. Microscopic examination demonstrates a reduction in the number of anterior horn cell neurons throughout the length of the spinal cord associated with reactive gliosis and loss of anterior root myelinated fibers. Similar findings are found with involvement of motor cranial nerve nuclei except those supplying the extraocular muscles, which are spared except in very longstanding survivors. Remaining lower motor neurons often harbor cytoplasmic inclusions that contain TDP-43, except in those cases in which the underlying cause is a mutation in SOD-1.

Death of upper motor neurons—a finding that may be hard to demonstrate microscopically—results in degeneration of the descending corticospinal tracts. This is usually easily seen in the spinal cord. With the loss of innervation from the death of anterior horn cells, skeletal muscles show neurogenic atrophy.

### SUMMARY

#### Neurodegenerative Diseases

- Neurodegenerative diseases cause symptoms that depend on the pattern of brain involvement. Cortical disease usually manifests as cognitive change, alterations in personality, and memory disturbances; basal ganglia disorders usually manifest as movement disorders.
- Many neurodegenerative diseases preferentially affect a primary set of brain regions, but other regions can be involved later in the disease course. This evolving process can change the phenotype of the disease over time—as with the appearance of cognitive impairments in people initially affected by the movement disorder of Parkinson disease.
- Many of the neurodegenerative diseases are associated with various protein aggregates, which serve as pathologic

hallmarks. It is unclear whether these striking inclusions and deposits are critical mediators of cellular degeneration. Familial forms of these diseases are associated with mutations in the genes encoding these proteins or controlling their metabolism.

# TUMORS

The annual incidence of CNS tumors ranges from 10 to 17 per 100,000 persons for intracranial tumors and 1 to 2 per 100,000 persons for intraspinal tumors; about half to three quarters are primary tumors, and the rest are metastatic. Tumors of the CNS make up a larger proportion of childhood cancers, accounting for as many of 20% of all pediatric tumors. Childhood CNS tumors differ from those in adults in both histologic subtype and location. In childhood, tumors are likely to arise in the posterior fossa; in adults, they are mostly supratentorial.

Tumors of the nervous system have unique characteristics that set them apart from neoplastic processes elsewhere in the body.

- These tumors do not have detectable premalignant or in situ stages comparable to those of carcinomas.
- Even low-grade lesions may infiltrate large regions of the brain, leading to serious clinical deficits, nonresectability, and poor prognosis.
- The anatomic site of the neoplasm can influence outcome independent of histologic classification due to local effects (e.g., a benign meningioma may cause cardiorespiratory arrest from compression of the medulla) or nonresectability (e.g., brain stem gliomas).
- Even the most highly malignant gliomas rarely spread outside of the CNS; in addition to local infiltration, the subarachnoid space allows for spread to distant sites along the neuroaxis.

## Gliomas

Gliomas are tumors of the brain parenchyma that are classified histologically on the basis of their resemblance to different types of glial cells. The major types of glial tumors are *astrocytomas, oligodendrogliomas,* and *ependymomas.* The most common types are highly infiltrative or "diffuse gliomas," including astrocytic, oligodendroglial, and mixed forms. In contrast, ependymomas tend to form solid masses.

### *Astrocytoma*

Several different categories of astrocytic tumors are recognized, the most common being diffuse and pilocytic astrocytomas. Different types of astrocytomas have characteristic histologic features, anatomic distributions, and clinical features.

#### Diffuse Astrocytoma

Diffuse astrocytomas account for about 80% of adult gliomas. They are most frequent in the fourth through the sixth decades of life. They usually are found in the cerebral hemispheres. The most common presenting signs and symptoms are seizures, headaches, and focal neurologic deficits related to the anatomic site of involvement. They show a spectrum of histologic differentiation that correlates well with clinical course and outcome. On the basis of histologic features, they are stratified into three groups: well-differentiated astrocytoma (grade II/IV), anaplastic astrocytoma (grade III/IV), and glioblastoma (grade IV/IV), with increasingly grim prognosis as the grade increases.

Well-differentiated astrocytomas can be static for several years, but at some point they progress; the mean survival is more than 5 years. Eventually, patients suffer rapid clinical deterioration that is correlated with the appearance of anaplastic features and more rapid tumor growth. Other patients present with glioblastoma from the start. Once the histologic features of glioblastoma appear, the prognosis is very poor; with treatment (resection, radiotherapy, and chemotherapy), the median survival is only 15 months.

Astrocytomas are associated with a variety of acquired mutations, which cluster in several important pathways. In glioblastoma, loss-of-function mutations in the p53 and Rb tumor suppressor pathways and gain-of-function mutations in the oncogenic PI3K pathways have central roles in tumorigenesis. Surprisingly, mutations that alter the enzymatic activity of two isoforms of the metabolic enzyme isocitrate dehydrogenase (IDH1 and IDH2) are common in lower-grade astrocytomas. As a result, immunostaining for the mutated form of IDH1 has become an important diagnostic tool in evaluating biopsy specimens for the presence of low-grade astrocytoma.

#### MORPHOLOGY

Well-differentiated astrocytomas are poorly defined, gray, infiltrative tumors that expand and distort the invaded brain without forming a discrete mass (Fig. 22–28, *A*). Infiltration beyond the grossly evident margins is always present. The cut surface of the tumor is either firm or soft and gelatinous; cystic degeneration may be seen. In glioblastoma, variation in the gross appearance of the tumor from region to region is characteristic (Fig. 22–28, *B*). Some areas are firm and white, others are soft and yellow (the result of tissue necrosis), and still others show regions of cystic degeneration and hemorrhage.

Well-differentiated astrocytomas are characterized by a mild to moderate increase in the number of glial cell nuclei, somewhat variable nuclear pleomorphism, and an intervening feltwork of fine, glial fibrillary acidic protein (GFAP)-positive astrocytic cell processes that give the background a fibrillary appearance. The transition between neoplastic and normal tissue is indistinct, and tumor cells can be seen infiltrating normal tissue many centimeters from the main lesion. Anaplastic astrocytomas show regions that are more densely cellular and have greater nuclear pleomorphism; mitotic figures are present. Glioblastoma has a histologic appearance similar to that of anaplastic astrocytoma, as well as either necrosis (often with pseudopalisading nuclei) or vascular proliferation (Fig. 22–28, *C*).

#### Pilocytic Astrocytoma

Pilocytic astrocytomas are relatively benign tumors, typically affecting children and young adults. Most commonly

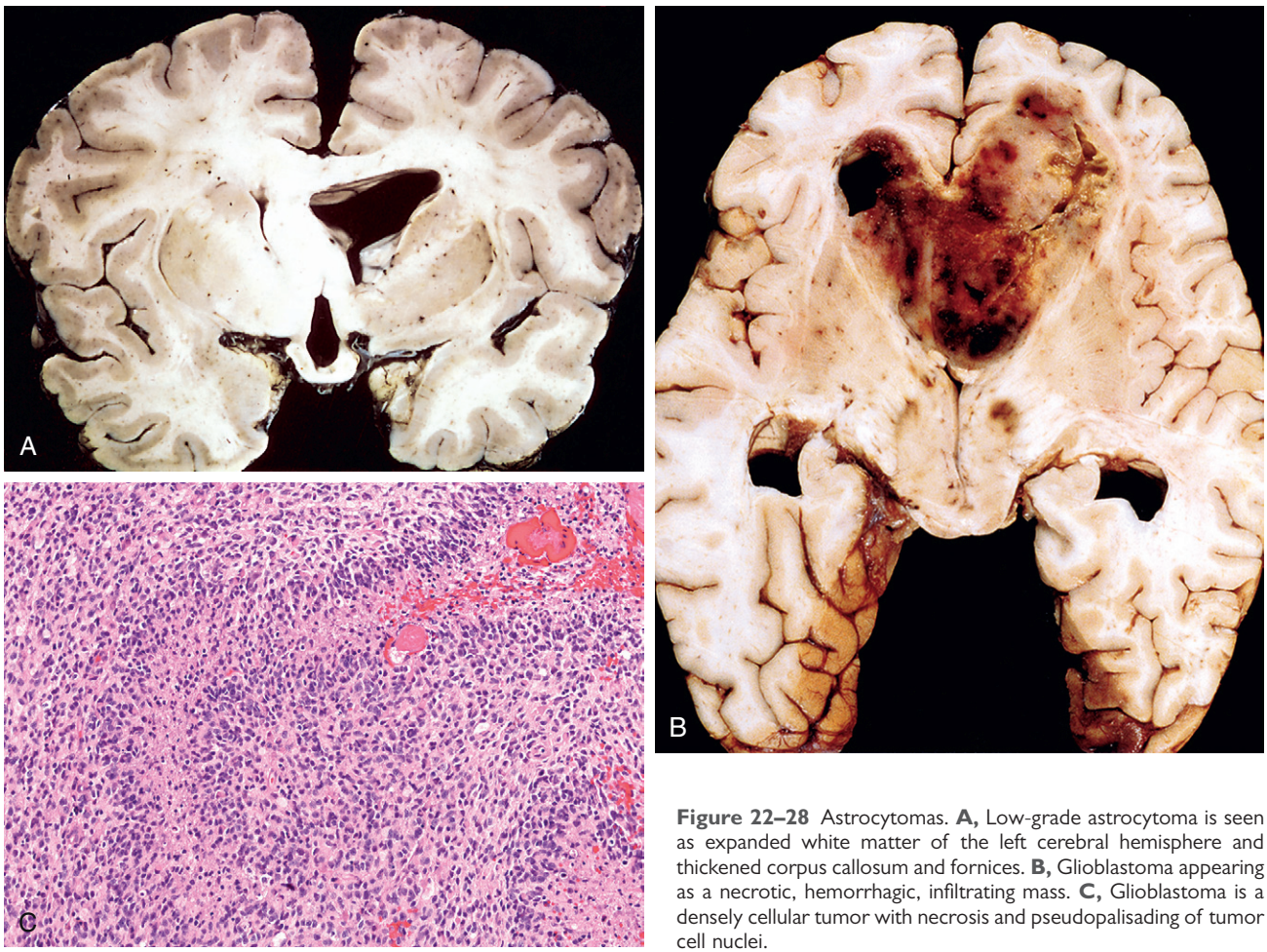


**Figure 22–28** Astrocytomas. **A,** Low-grade astrocytoma is seen as expanded white matter of the left cerebral hemisphere and thickened corpus callosum and fornices. **B,** Glioblastoma appearing as a necrotic, hemorrhagic, infiltrating mass. **C,** Glioblastoma is a densely cellular tumor with necrosis and pseudopalisading of tumor cell nuclei.

located in the cerebellum, they also may involve the third ventricle, the optic pathways, spinal cord, and occasionally the cerebral hemispheres. There is often a cyst associated with the tumor, and symptomatic recurrence from incompletely resected lesions is often associated with cyst enlargement, rather than growth of the solid component. Tumors that involve the hypothalamus are especially problematic because they cannot be resected completely.

A high proportion of pilocytic astrocytomas have activating mutations in the serine-threonine kinase BRAF—either a specific point mutation (V600E) that is also found in many other cancers (Chapter 5), or more commonly a partial tandem duplication event. Mutations in IDH1 and IDH2 (common in low-grade diffuse astrocytomas) are not found in pilocytic tumors. These genetic distinctions support the division of these astrocytomas into two diagnostic categories.

### MORPHOLOGY

A pilocytic astrocytoma often is cystic, with a mural nodule in the wall of the cyst; if solid, it is usually well circumscribed. The tumor is composed of bipolar cells with long, thin "hair-like" processes that are GFAP-positive. Rosenthal fibers, eosinophilic granular bodies, and microcysts are often present; necrosis and mitoses are rare.

### *Oligodendroglioma*

Oligodendrogliomas account for 5% to 15% of gliomas and most commonly are detected in the fourth and fifth decades of life. Patients may have had several years of antecedent neurologic complaints, often including seizures. The lesions are found mostly in the cerebral hemispheres, mainly in the frontal or temporal lobes.

Patients with oligodendrogliomas enjoy a better prognosis than that for patients with astrocytomas of similar grade. Treatment with surgery, chemotherapy, and radiotherapy yields an average survival of 10 to 20 years for well-differentiated (WHO grade II) or 5 to 10 years for anaplastic (WHO grade III) oligodendrogliomas. The most common genetic findings are deletions of chromosomes 1p and 19q, alterations that typically occur together. Tumors with deletions of 1p and 19q are usually highly responsive to chemotherapy and radiotherapy.

### MORPHOLOGY

Well-differentiated oligodendrogliomas (WHO grade II/IV) are infiltrative tumors that form gelatinous, gray masses and may show cysts, focal hemorrhage, and calcification. On microscopic examination, the tumor is composed of sheets of regular cells with spherical nuclei containing finely granular-appearing chromatin (similar to that in normal

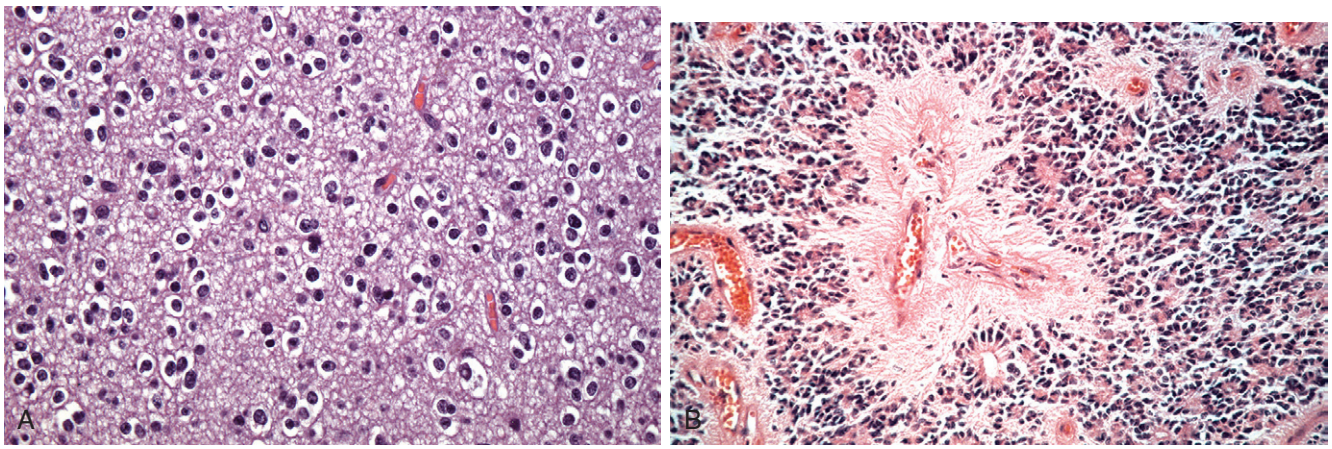


**Figure 22–29** Other gliomas. **A,** In oligodendroglioma tumor cells have round nuclei, often with a cytoplasmic halo. Blood vessels in the background are thin and can form an interlacing pattern. **B,** Microscopic appearance of ependymoma.

oligodendrocytes) surrounded by a clear halo of cytoplasm (Fig. 22–29, *A*). The tumor typically contains a delicate network of anastomosing capillaries. Calcification, present in as many as 90% of these tumors, ranges in extent from microscopic foci to massive depositions. Mitotic activity usually is difficult to detect. Anaplastic oligodendroglioma (WHO grade III/IV) is a more aggressive subtype with higher cell density, nuclear anaplasia and mitotic activity.

### *Ependymoma*

Ependymomas most often arise next to the ependyma-lined ventricular system, including the central canal of the spinal cord. In the first 2 decades of life, they typically occur near the fourth ventricle and constitute 5% to 10% of the primary brain tumors in this age group. In adults, the spinal cord is their most common location; tumors in this site are particularly frequent in the setting of neurofibromatosis type 2 (Chapter 21). The clinical outcome for completely resected supratentorial and spinal ependymomas is better than for those in the posterior fossa.

#### MORPHOLOGY

In the fourth ventricle, ependymomas typically are solid or papillary masses extending from the ventricular floor. The tumors are composed of cells with regular, round to oval nuclei and abundant granular chromatin. Between the nuclei is a variably dense fibrillary background. Tumor cells may form round or elongated structures **(rosettes, canals)** that resemble the embryologic ependymal canal, with long, delicate processes extending into a lumen (Fig. 23–29, *B*); more frequently present are **perivascular pseudorosettes** in which tumor cells are arranged around vessels with an intervening zone containing thin ependymal processes. Anaplastic ependymomas show increased cell density, high mitotic rates, necrosis, and less evident ependymal differentiation.

## Neuronal Tumors

*Central neurocytoma* is a low-grade neoplasm found within and adjacent to the ventricular system (most commonly the lateral or third ventricles), characterized by evenly spaced, round, uniform nuclei and often islands of neuropil.

*Gangliogliomas* are tumors with a mixture of glial elements, usually a low-grade astrocytoma, and mature-appearing neurons. Most of these tumors are slow-growing, but the glial component occasionally becomes frankly anaplastic, and the disease then progresses rapidly. These lesions often manifest with seizures.

*Dysembryoplastic neuroepithelial tumor* is a distinctive, low-grade childhood tumor that grows slowly and carries a relatively good prognosis after resection; it often manifests as a seizure disorder. It typically is located in the superficial temporal lobe and consists of small round neuronal cells arranged in columns and around central cores of processes. These typically form multiple discrete intracortical nodules that have a myxoid background. Also present are well-differentiated "floating" neurons within pools of mucopolysaccharide-rich myxoid fluid.

## Embryonal (Primitive) Neoplasms

Some tumors of neuroectodermal origin have a primitive "small round cell" appearance that is reminiscent of normal progenitor cells encountered in the developing CNS. Differentiation is often limited, but may progress along multiple lineages. The most common is the *medulloblastoma,* accounting for 20% of pediatric brain tumors.

### *Medulloblastoma*

Medulloblastoma occurs predominantly in children and exclusively in the cerebellum. Neuronal and glial markers are nearly always expressed, at least to a limited extent. It is highly malignant, and the prognosis for untreated patients is dismal; however, medulloblastoma is exquisitely radiosensitive. With total excision, chemotherapy, and irradiation, the 5-year survival rate may be as high as 75%. Tumors of similar histologic type and a poor degree of differentiation can be found elsewhere in the nervous system, where they are called *primitive neuroectodermal tumors* (PNETs).

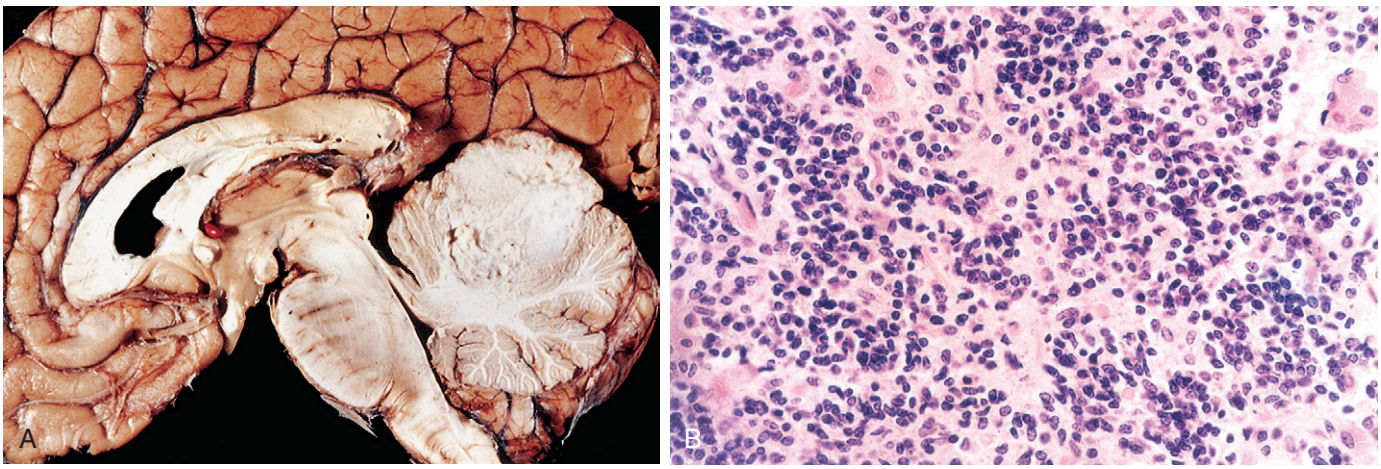

**Figure 22–30** Medulloblastoma. **A,** Sagittal section of brain showing medulloblastoma with destruction of the superior midline cerebellum. **B,** Microscopic appearance of medulloblastoma.

### MORPHOLOGY

In children, medulloblastomas are located in the midline of the cerebellum; lateral tumors occur more often in adults. The tumor often is well circumscribed, gray, and friable and may be seen extending to the surface of the cerebellar folia and involving the leptomeninges (Fig. 22–30, *A*). Medulloblastomas are extremely cellular, with sheets of anaplastic ("small blue") cells (Fig. 22–30, *B*). Individual tumor cells are small, with little cytoplasm and hyperchromatic nuclei; mitoses are abundant. Often, focal neuronal differentiation is seen in the form of the Homer Wright or neuroblastic rosette, which closely resembles the rosettes encountered in neuroblastomas; they are characterized by primitive tumor cells surrounding central neuropil (delicate pink material formed by neuronal processes).

Genetic analysis of medulloblastoma has revealed that morphologically similar tumors commonly exhibit distinct alterations, and that there is a relationship between the underlying mutations and outcome. In general, tumors with *MYC* amplifications are associated with poor outcomes, while those linked with mutations in genes of the WNT signaling pathway have a more favorable course. Many tumors also have mutations that activate the sonic hedgehog (shh) pathway, which has a critical role in tumorigenesis but an uncertain relationship to outcome. These genetic distinctions are beginning to be used to stratify patients into different risk groups and guide therapy. Ideally, it would be best to avoid CNS radiotherapy in young patients, and it is hoped that new therapies targeting mutated gene products will achieve this goal.

## Other Parenchymal Tumors

### *Primary Central Nervous System Lymphoma*

Primary CNS lymphoma, occurring mostly as diffuse large B cell lymphomas, accounts for 2% of extranodal lymphomas and 1% of intracranial tumors. It is the most common CNS neoplasm in immunosuppressed persons, in whom the tumors are nearly always positive for the oncogenic Epstein-Barr virus. In nonimmunosuppressed populations, the age spectrum is relatively wide, with the incidence increasing after 60 years of age. Regardless of the clinical context, primary brain lymphoma is an aggressive disease with relatively poor response to chemotherapy as compared with peripheral lymphomas.

Patients with primary brain lymphoma often are found to have multiple tumor nodules within the brain parenchyma, yet involvement outside of the CNS is an uncommon late complication. Lymphoma originating outside the CNS rarely spreads to the brain parenchyma; when it happens, tumor usually is also within the CSF or involvement of the meninges.

### MORPHOLOGY

Lesions often involve deep gray structures, as well as the white matter and the cortex. Periventricular spread is common. The tumors are relatively well defined as compared with glial neoplasms but are not as discrete as metastases. EBV-associated tumors often show extensive areas of necrosis. The tumors are nearly always aggressive large B-cell lymphomas, although other histologic types can be observed rarely (Chapter 11). Microscopically, malignant cells accumulate around blood vessels and infiltrate the surrounding brain parenchyma.

### *Germ Cell Tumors*

Primary brain *germ cell tumors* occur along the midline, most commonly in the pineal and the suprasellar regions. They account for 0.2% to 1% of brain tumors in people of European descent but as many as 10% of brain tumors in persons of Japanese ethnicity. They are a tumor of the young, with 90% occurring during the first 2 decades of life. Germ cell tumors in the pineal region show a strong male predominance. The most common primary CNS germ cell tumor is germinoma, a tumor that closely resembles testicular seminoma (Chapter 17). Secondary CNS involvement by metastatic gonadal germ cell tumors also occurs.

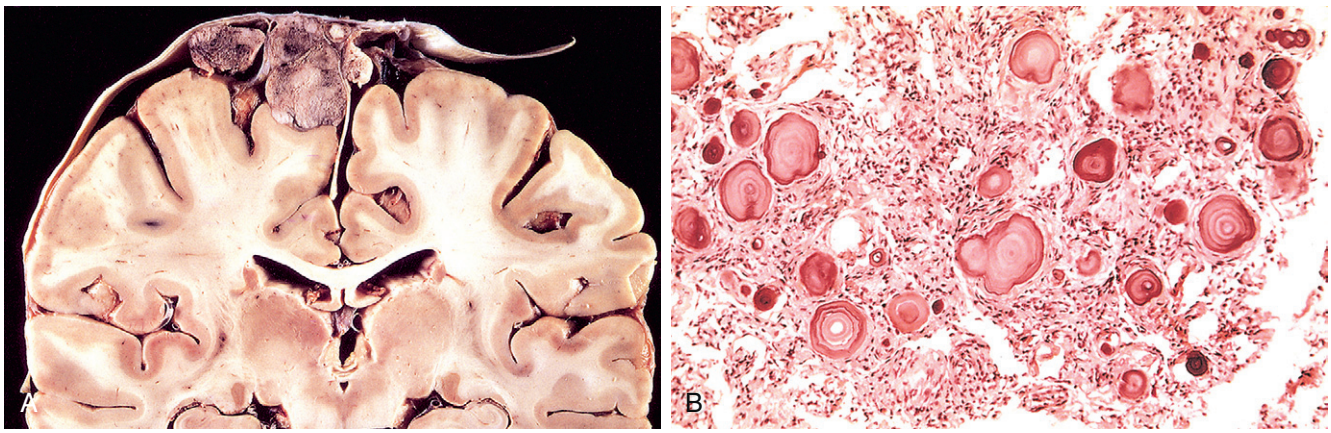

**Figure 22–31** Meningioma. **A,** Parasagittal multilobular meningioma attached to the dura with compression of underlying brain. **B,** Meningioma with a whorled pattern of cell growth and psammoma bodies.

## Meningiomas

*Meningiomas* are predominantly benign tumors that arise from arachnoid meningothelial cells. They usually occur in adults and are often attached to the dura. Meningiomas may be found along any of the external surfaces of the brain as well as within the ventricular system, where they arise from the stromal arachnoid cells of the choroid plexus. They usually come to attention because of vague nonlocalizing symptoms, or with focal findings referable to compression of adjacent brain. Although most meningiomas are easily separable from underlying brain, some tumors infiltrate the brain, a feature that is associated with an increased risk of recurrence. The overall prognosis is determined by the lesion size and location, surgical accessibility, and histologic grade.

When a person has multiple meningiomas, especially in association with eighth-nerve schwannomas or glial tumors, the diagnosis of neurofibromatosis type 2 (NF2) should be considered (Chapter 21). About half of meningiomas not associated with NF2 have acquired loss-of-function mutations in the *NF2* tumor suppressor gene on the long arm of chromosome 22 (22q). These mutations are found in all grades of meningioma, suggesting that they are involved with tumor initiation. Mutations in *NF2* are more common in tumors with certain growth patterns (fibroblastic, transitional, and psammomatous).

### MORPHOLOGY

**Meningiomas** (WHO grade I/IV) grow as well-defined dura-based masses that may compress the brain but do not invade it (Fig. 22–31, *A*). Extension into the overlying bone may be present. Among the varied histologic patterns are **syncytial,** named for whorled clusters of cells without visible cell membranes that sit in tight groups; **fibroblastic,** with elongated cells and abundant collagen deposition between them; **transitional,** which shares features of the syncytial and fibroblastic types; **psammomatous,** with numerous psammoma bodies (Fig. 22–31, *B*); and **secretory,** with gland-like PAS-positive eosinophilic secretions known as pseudopsammoma bodies.

**Atypical meningiomas** (WHO grade II/IV) are recognized by the presence of certain histologic features (prominent nucleoli, increased cellularity, pattern-less growth), and often have a higher mitotic rate. These tumors demonstrate more aggressive local growth and a higher rate of recurrence; they may require therapy in addition to surgery.

**Anaplastic (malignant) meningiomas** (WHO grade III/IV) are highly aggressive tumors that may resemble a high-grade sarcoma or carcinoma, although there usually is some histologic evidence of a meningothelial cell origin.

## Metastatic Tumors

Metastatic lesions, mostly carcinomas, account for approximately one fourth to one half of intracranial tumors. The most common primary sites are lung, breast, skin (melanoma), kidney, and gastrointestinal tract—together these account for about 80% of cases. Metastases form sharply demarcated masses, often at the gray-white junction, and elicit edema (Fig. 22–32). The boundary between tumor and brain parenchyma is sharp at the microscopic level as well, with surrounding reactive gliosis.

In addition to the direct and localized effects produced by metastases, *paraneoplastic syndromes* may involve the peripheral and central nervous systems, sometimes even preceding the clinical recognition of the malignant neoplasm. Many but not all patients with paraneoplastic syndromes have antibodies against tumor antigens. Some of the more common patterns include

- *Subacute cerebellar degeneration* resulting in ataxia, with destruction of Purkinje cells, gliosis, and a mild inflammatory infiltrate
- *Limbic encephalitis* causing a subacute dementia, with perivascular inflammatory cells, microglial nodules, some neuronal loss, and gliosis, all centered in the medial temporal lobe

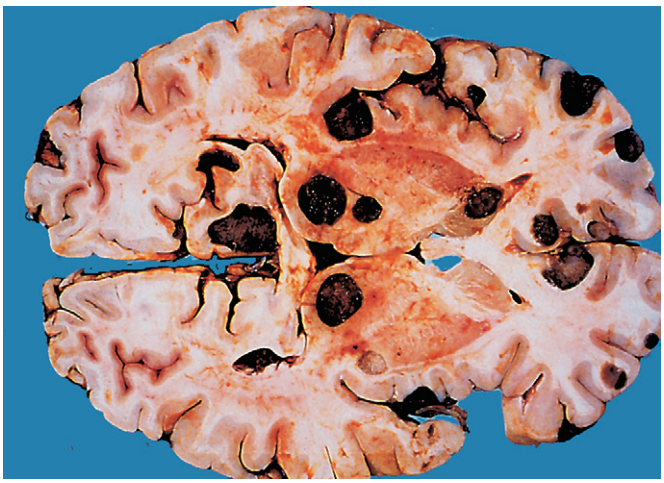

**Figure 22–32** Metastatic melanoma. Metastatic lesions are distinguished grossly from most primary central nervous system tumors by their multicentricity and well-demarcated margins. The dark color of the tumor nodules in this specimen is due to the presence of melanin.

- *Subacute sensory neuropathy* leading to altered pain sensation, with loss of sensory neurons from dorsal root ganglia, in association with inflammation
- *Syndrome of rapid-onset psychosis, catatonia, epilepsy, and coma* associated with ovarian teratoma and antibodies against the *N*-methyl-D-aspartate (NMDA) receptor

## Familial Tumor Syndromes

Several inherited syndromes caused by mutations in various tumor suppressor genes are associated with an increased risk of particular types of cancers. Those with particular involvement of the CNS are discussed here; familial syndromes associated with tumors of the peripheral nervous system are covered in Chapter 21.

### *Tuberous Sclerosis*

Tuberous sclerosis (TSC) is an autosomal dominant syndrome characterized by the development of hamartomas and benign neoplasms involving the brain and other tissues. CNS hamartomas variously consist of cortical tubers and subependymal hamartomas, including a larger tumefactive form known as subependymal giant cell astrocytoma. Because of their proximity to the foramen of Monro, they often present acutely with obstructive hydrocephalus, which requires surgical intervention and/or therapy with an mTOR inhibitor (see below). Seizures are associated with cortical tubers and can be difficult to control with antiepileptic drugs. Extracerebral lesions include renal angiomyolipomas, retinal glial hamartomas, pulmonary lymphangiomyomatosis, and cardiac rhabdomyomas. Cysts may be found at various sites, including the liver, kidneys, and pancreas. Cutaneous lesions include angiofibromas, leathery thickenings in localized patches (shagreen patches), hypopigmented areas (ash leaf patches), and subungual fibromas. TSC results from disruption of either *TSC1,* which encodes hamartin, or *TSC2,* which encodes tuberin. The two TSC proteins form a dimeric complex that negatively regulates mTOR, a kinase that "senses" the cell's nutrient status and regulates cellular metabolism. Loss of either protein leads to increased mTOR activity, which disrupts nutritional signaling and increases cell growth.

#### MORPHOLOGY

Cortical hamartomas are firmer than normal cortex and have been likened in appearance to potatoes—hence the appellation "tubers." They are composed of haphazardly arranged large neurons that lack the normal cortical laminar architecture. These cells may exhibit a mixture of glial and neuronal features, having large vesicular nuclei with nucleoli (like neurons) and abundant eosinophilic cytoplasm (like gemistocytic astrocytes). Similar abnormal cells are present in the subependymal nodules, in which large astrocyte-like cells cluster beneath the ventricular surface.

### *von Hippel–Lindau Disease*

In this autosomal dominant disorder, affected persons develop hemangioblastomas within the cerebellar hemispheres, retina, and, less commonly, the brain stem, spinal cord, and nerve roots. Patients also may have cysts involving the pancreas, liver, and kidneys and have an increased propensity to develop renal cell carcinoma. The disease frequency is 1 in 30,000 to 40,000. Therapy is directed at the symptomatic neoplasms, including surgical resection of cerebellar tumors and laser ablation of retinal tumors. The affected gene, the tumor suppressor *VHL,* encodes a protein that is part of a ubiquitin-ligase complex that targets the transcription factor hypoxia-inducible factor (HIF) for degradation. Tumors arising in patients with von Hippel–Lindau disease generally have lost all VHL protein function. As a result, these tumors express high levels of HIF, which drives the expression of VEGF, various growth factors, and sometimes erythropoietin, leading to a form of paraneoplastic polycythemia.

#### MORPHOLOGY

The cerebellar **capillary hemangioblastoma,** the principal neurologic manifestation of the disease, is a highly vascular neoplasm that occurs as a mural nodule associated with a large, fluid-filled cyst. On microscopic examination, the lesion consists of numerous capillary-sized or somewhat larger thin-walled vessels separated by intervening stromal cells with vacuolated, lightly PAS-positive, lipid-rich cytoplasm.

#### SUMMARY

##### Tumors of the Central Nervous System

- Tumors of the CNS may arise from the cells of the coverings (meningiomas), the brain (gliomas, neuronal tumors, choroid plexus tumors), or other CNS cell populations (primary CNS lymphoma, germ cell tumors), or they may originate elsewhere in the body (metastases).

- Even low-grade or benign tumors can have poor clinical outcomes, depending on where they occur in the brain.
- Distinct types of tumors affect specific brain regions (e.g., cerebellum for medulloblastoma, an intraventricular location for central neurocytoma) and specific age populations (medulloblastoma and pilocytic astrocytomas in pediatric age groups, and glioblastoma and lymphoma in older patients).
- Glial tumors are broadly classified into astrocytomas, oligodendrogliomas, and ependymomas. Increasing tumor malignancy is associated with more cytologic anaplasia, increased cell density, necrosis, and mitotic activity.
- Metastatic spread of brain tumors to other regions of the body is rare, but the brain is not comparably protected against spread of distant tumors. Carcinomas are the dominant type of systemic tumors that metastasize to the nervous system.

## BIBLIOGRAPHY

*In general, many areas of neuropathology and neurologic diseases are well covered in the following standard texts:*


Burger PC, Scheithauer BW (eds): Tumors of the Central Nervous System. AFIP Atlas of Tumor Pathology: Series 4. Washington, DC, American Registry of Pathology, 2007.

Louis DN, Frosch MP, Mena H, et al (eds): Non-Neoplastic Diseases of the Central Nervous System. AFIP Atlas of Nontumor Pathology: Series 1. Washington, DC, American Registry of Pathology, 2009.

Louis DN, Ohgaki H, Wiestler OD, Cavenee WK (eds): WHO Classification of Tumours of the Central Nervous System (IARC), 4th ed. Geneva, World Health Organization, 2007.

Love S, Louis DN, Ellison DW (eds): Greenfield's Neuropathology, 8th ed. Oxford, Oxford University Press, 2008.

Perry A, Brat DJ: Neuropathology patterns and introduction. In: Perry A, Brat DJ (eds): Practical Surgical Neuropathology, Elsevier/Churchill Livingstone, Philadelphia, 2010.

Ropper AH, Samuels MA (eds): Adams and Victor's Principles of Neurology, 9th ed. New York, McGraw-Hill Professional, 2009.


*For some topics covered in this chapter, there have been recent changes in classification, advances in understanding of pathogenesis, therapeutic interventions, and better understanding of clinicopathologic correlations. For these selected topics, additional reading recommendations are provided.*

### CENTRAL NERVOUS SYSTEM TRAUMA


McKee AC, Cantu RC, Nowinski CJ, et al: Chronic traumatic encephalopathy in athletes: progressive tauopathy after repetitive head injury. J Neuropathol Exp Neurol 68:709, 2009.


### CONGENITAL MALFORMATIONS AND PERINATAL BRAIN INJURY


Copp AJ, Greene ND: Genetics and development of neural tube defects. J Pathol 220:217, 2010.

Diaz AL, Gleeson JG: The molecular and genetic mechanisms of neocortex development. Clin Perinatol 36:503, 2009.

Kriegstein A, Alvarez-Buylla A: The glial nature of embryonic and adult neural stem cells. Annu Rev Neurosci 32:149, 2009.

Lee JE, Gleeson JG: Cilia in the nervous system: linking cilia function and neurodevelopmental disorders. Curr Opin Neurol 24:98, 2011.

Lim Y, Golden JA: Patterning the developing diencephalon. Brain Res Rev 53:17, 2007.

Na ES, Monteggia LM: The role of MeCP2 in CNS development and function. Horm Behav 59:364, 2011.

Ten Donkelaar HJ, Lammens M: Development of the human cerebellum and its disorders. Clin Perinatol 36:513, 2009.

Thompson BL, Levitt P: The clinical-basic interface in defining pathogenesis in disorders of neurodevelopmental origin. Neuron 67:702, 2010.

Walsh CA, Morrow EM, Rubenstein JL: Autism and brain development. Cell 135:396, 2008.


### INFECTIONS OF THE NERVOUS SYSTEM


Gambetti P, Cali I, Notari S, et al: Molecular biology and pathology of prion strains in sporadic human prion diseases. Acta Neuropathol 121:79, 2011.

Ironside JW: Variant Creutzfeldt-Jakob disease. Haemophilia 16(Suppl 5):175, 2010.

Johnson T, Nath A: Neurological complications of immune reconstitution in HIV-infected populations. Ann N Y Acad Sci 1184:106, 2010.

Martin-Blondel G, Delobel P, Blancher A, et al: Pathogenesis of the immune reconstitution inflammatory syndrome affecting the central nervous system in patients infected with HIV. Brain 134(Pt 4):928, 2011.

Parchi P, Strammiello R, Giese A, Kretzschmar H: Phenotypic variability of sporadic human prion disease and its molecular basis: past, present, and future. Acta Neuropathol 121:91, 2011.

Singer EJ, Valdes-Sueiras M, Commins D, Levine A: Neurologic presentations of AIDS. Neurol Clin 28:253, 2010.

Wright EJ: Neurological disease: the effects of HIV and antiretroviral therapy and the implications for early antiretroviral therapy initiation. Curr Opin HIV AIDS 4:447, 2009.


### PRIMARY DISEASES OF MYELIN


Comabella M, Khoury SJ: Immunopathogenesis of multiple sclerosis. Clin Immunol 10:399, 2011.

Hu W, Lucchinetti CF: The pathological spectrum of CNS inflammatory demyelinating diseases. Semin Immunopathol 31:439, 2009.

Jarius S, Wildemann B: AQP4 antibodies in neuromyelitis optica: diagnostic and pathogenetic relevance. Nat Rev Neurol 6:383, 2010.

Oksenberg JR, Baranzini SE, Sawcer S, Hauser SL: The genetics of multiple sclerosis: SNPs to pathways to pathogenesis. Nat Rev Genet 9:516, 2008.


### NEURODEGENERATIVE DISEASES


DeKosky ST, Carrillo MC, Phelps C, et al: Revision of the criteria for Alzheimer's disease: A symposium. Alzheimers Dement 7:e1, 2011.

Durr A: Autosomal dominant cerebellar ataxias: polyglutamine expansions and beyond. Lancet Neurol 9:885, 2010.

Pandolfo M: Friedreich ataxia. Arch Neurol 65:1296, 2008.

Kiernan MC, Vucic S, Cheah BC, et al: Amyotrophic lateral sclerosis. Lancet 377:942, 2011.

Ross CA, Tabrizi SJ: Huntington's disease: from molecular pathogenesis to clinical treatment. Lancet Neurol 10:83, 2011.

Selkoe DJ: Biochemistry and molecular biology of amyloid beta-protein and the mechanism of Alzheimer's disease. Handb Clin Neurol 89:245, 2008.

Storch A, Hofer A, Krüger R, et al: New developments in diagnosis and treatment of Parkinson's disease—from basic science to clinical applications. J Neurol 251(Suppl 6):VI33, 2004.

Thinakaran G, Koo EH: Amyloid precursor protein trafficking, processing, and function. J Biol Chem 283:29615, 2008.

Vidailhet M: Movement disorders in 2010: Parkinson disease-symptoms and treatments. Nat Rev Neurol 7:70, 2011.

## TUMORS

Cancer Genome Atlas Research Network: Comprehensive genomic characterization defines human glioblastoma genes and core pathways. Nature 455:1061, 2008.

Cho YJ, Tsherniak A, Tamayo P, et al: Integrative genomic analysis of medulloblastoma identifies a molecular subgroup that drives poor clinical outcome. J Clin Oncol 29:1424, 2011.

Dubuc AM, Northcott PA, Mack S, et al: The genetics of pediatric brain tumors. Curr Neurol Neurosci Rep 10:215, 2010.

Maher ER, Neumann HP, Richard S: von Hippel-Lindau disease: A clinical and scientific review. Eur J Hum Genet 19:617, 2011.

Mawrin C, Perry A: Pathological classification and molecular genetics of meningiomas. J Neurooncol 99:379, 2010.

Orlova KA, Crino PB: The tuberous sclerosis complex. Ann N Y Acad Sci 1184:87, 2010.

Riemenschneider MJ, Jeuken JW, Wesseling P, Reifenberger G: Molecular diagnostics of gliomas: state of the art. Acta Neuropathol 120:567, 2010.

This page intentionally left blank

See Targeted Therapy available online at studentconsult.com

CHAPTER 23

# Skin

CHAPTER CONTENTS

**Acute Inflammatory Dermatoses 852**
Urticaria 852
Acute Eczematous Dermatitis 852
Erythema Multiforme 853
**Chronic Inflammatory Dermatoses 854**
Psoriasis 854
Lichen Planus 855
Lichen Simplex Chronicus 856
**Infectious Dermatoses 856**
Bacterial Infections 856
Fungal Infections 857
Verrucae (Warts) 857
**Blistering (Bullous) Disorders 857**
Pemphigus (Vulgaris and Foliaceus) 858
Bullous Pemphigoid 859
Dermatitis Herpetiformis 861
**Benign and Premalignant Tumors 862**
Benign and Premalignant Epithelial Lesions 862
Malignant Epidermal Tumors 863
Melanocytic Proliferations 865

Skin diseases are common and diverse, ranging from irritating acne to life-threatening melanoma. Many are intrinsic to the skin, but some are manifestations of diseases involving many tissues, such as systemic lupus erythematosus or genetic syndromes such as neurofibromatosis. In this sense, the skin is a uniquely accessible "window" through which numerous disorders can be viewed and recognized.

Skin is not a mere protective mantle but rather a complex organ that actively participates in regulated cellular and molecular events that govern the body's interactions with the external environment. It is constantly bathed with microbial and nonmicrobial antigens. These are processed by intraepithelial Langerhans cells, which bear their antigenic cargo to regional lymph nodes and initiate immune responses. Squamous cells (keratinocytes) help maintain skin homeostasis by providing a physical barrier to environmental insults and by secreting a plethora of cytokines that influence both the squamous and dermal microenvironments. The dermis contains both CD4+ helper and CD8+ cytotoxic T lymphocytes, some of which home to the skin by virtue of specialized receptors such as cutaneous lymphocyte antigen. The epidermis contains intraepithelial lymphocytes, including γ/δ T cells, which constitute a component of the innate immune system. Local immune responses involving these immune cells and cytokines account for the microscopic patterns and clinical expressions of cutaneous inflammatory and infectious diseases.

This chapter focuses on a small subset of common and pathogenically illustrative skin diseases. In considering these diseases, it is important to appreciate that the practice of dermatopathology relies on close interactions with clinicians, particularly dermatologists. The clinical history and the gross appearance and distribution of lesions reported by clinicians are often as important as the microscopic findings in arriving at a diagnosis.

Diseases of the skin can be confusing for the student, in part because dermatologists and dermatopathologists use a large and unique lexicon to describe skin lesions. Because knowledge of this vocabulary forms the basis of clear understanding and communication, some of the terms and descriptors that are most commonly used are defined below.

### Terms for Macroscopic Lesions

**Excoriation:** Traumatic lesion breaking the epidermis and causing a red linear mark (i.e., a deep scratch); often self-inflicted.

**Lichenification:** Thickened and rough skin characterized by prominent skin markings; usually the result of repeated rubbing (see under "Lichen Simplex Chronicus").

**Macule:** Flat, circumscribed area, 5 mm or less in diameter, distinguished from surrounding skin by coloration. If greater than 5 mm, referred to as a **patch.**

**Papule:** Elevated dome- or flat-topped lesion 5 mm or less in diameter. If greater than 5 mm in diameter, referred to as a **nodule.**

**Plaque:** Elevated flat-topped lesion, usually greater than 5 mm in diameter.

**Pustule:** Discrete, pus-filled raised lesion.

**Scale:** Dry, horny, platelike excrescence; usually the result of imperfect cornification.

**Vesicle:** Fluid-filled raised area 5 mm or less in diameter. If greater than 5 mm in diameter, referred to as a

*The authors thank Drs. Ronald Rapini and Robert Jordan and the Department of Dermatology at the University of Texas Medical School at Houston for many of the clinical photographs in this chapter. The contributions of Dr. George Murphy to this chapter in previous editions are gratefully acknowledged.*

**bulla. Blister** is common term for both vesicles and bullae.

Microscopic Terms

**Acantholysis:** Loss of intercellular adhesion of keratinocytes.

**Acanthosis:** Diffuse epidermal hyperplasia.

**Dyskeratosis:** Abnormal keratinization occurring prematurely within individual cells or groups of cells below the stratum granulosum.

**Hyperkeratosis:** Hyperplasia of the stratum corneum, often associated with a qualitative abnormality of keratin.

**Lentiginous:** Linear melanocyte proliferation along the epidermal basal cell layer; can occur as a reactive change or as part of a melanocytic neoplasm.

**Papillomatosis:** Surface elevation caused by hyperplasia and enlargement of dermal papillae.

**Parakeratosis:** Keratinization characterized by retention of the nuclei in the stratum corneum. On squamous mucosal membranes, such as buccal mucosa, parakeratosis is normal.

**Spongiosis:** Intercellular edema of the epidermis.

# ACUTE INFLAMMATORY DERMATOSES

Thousands of inflammatory dermatoses exist, challenging the diagnostic acumen of even experienced clinicians. In general, acute lesions last from days to weeks and are characterized by inflammation (often marked by mononuclear cells rather than neutrophils and defined as acute due to the limited course of their natural history), edema, and sometimes epidermal, vascular, or subcutaneous injury. Some acute lesions may persist, resulting in transition to a chronic phase, while others are characteristically self-limited.

## Urticaria

Urticaria ("hives") is a common disorder mediated by *localized mast cell degranulation, which leads to dermal microvascular hyperpermeability.* The resulting erythematous, edematous, and pruritic plaques are termed *wheals.*

### PATHOGENESIS

In most cases, urticaria stems from an immediate (type I) hypersensitivity reaction (Chapter 4), in which antigens trigger mast cell degranulation by binding to immunoglobulin E (IgE) antibodies displayed on the mast cell surface. The responsible antigens include pollens, foods, drugs, and insect venom. IgE-independent urticaria may result from exposure to substances that directly incite mast cell degranulation, such as opiates and certain antibiotics. In the vast majority of cases, no clinical cause is discovered despite extensive searching. Hereditary angioedema is caused by an inherited deficiency of C1 esterase inhibitor, which results in uncontrolled activation of complement (Chapter 3). The ensuing urticaria affects the lips, throat, eyelids, genitals, and distal extremities. When the larynx is affected, the condition can be dangerous, since airway patency may be compromised.

### MORPHOLOGY

The histologic features of urticaria often are subtle. There is usually a sparse superficial perivenular infiltrate of mononuclear cells, rare neutrophils, and sometimes eosinophils. Superficial dermal edema creates more widely spaced collagen bundles. Degranulation of mast cells, which normally reside around superficial dermal venules, is difficult to appreciate with routine hematoxylin-eosin (H&E) stains but can be highlighted using a Giemsa stain.

Clinical Features

Urticaria typically affects persons between 20 and 40 years of age, but no age is immune. Individual lesions usually develop and fade within hours, but episodes can persist for days or even months. Persistent lesions sometimes are due to urticarial vasculitis, which is often associated with deposition of complement in dermal venules. Lesions range in size and nature from small, pruritic papules to large, edematous, erythematous plaques. Increased vascular permeability leads to localized dermal edema. Lesions can be confined to a particular part of the body or generalized. In a specific type of urticaria, termed *pressure urticaria,* lesions are found only in areas exposed to pressure (such as the feet or the buttocks). Although not life-threatening, urticaria can compromise quality of life by causing severe pruritus and social embarrassment. Most cases are treated with antihistamines. Systemic steroids are used in more severe refractory cases.

## Acute Eczematous Dermatitis

*Eczema* is a clinical term that embraces a number of conditions with varied underlying etiologies. New lesions take the form of *red papules, often with overlying vesicles, which ooze and become crusted.* With persistence, these lesions develop into raised, *scaling plaques.* The nature and degree of these changes vary among the clinical subtypes, which include the following:

- *Allergic contact dermatitis,* which stems from topical exposure to an allergen
- *Atopic dermatitis,* which has traditionally been attributed to allergen exposure, but is now thought to stem from defects in keratinocyte barrier function, many with a genetic basis
- *Drug-related eczematous dermatitis,* a hypersensitivity reaction to a drug
- *Photoeczematous dermatitis,* in which eczema appears as an abnormal reaction to UV or visible light
- *Primary irritant dermatitis,* which results from exposure to substances that chemically, physically, or mechanically damage the skin

In most cases, the skin lesions resolve completely when the offending stimulus is removed or exposure is limited,

stressing the importance of investigating the underlying cause. Only the most common form, *contact dermatitis,* is considered here.

Contact dermatitis is triggered by exposure to an environmental contact sensitizing agent, such as poison ivy, that chemically reacts with self-proteins. The self-proteins modified by the agent are processed by epidermal Langerhans cells, which migrate to draining lymph nodes and present the antigen to naive T cells. This sensitization event leads to acquisition of immunologic memory; on reexposure to the antigen, the activated memory CD4+ T lymphocytes migrate to the affected skin sites. There they release cytokines that recruit additional inflammatory cells and also mediate epidermal damage, as in any delayed-type hypersensitivity reaction (Chapter 4).

### MORPHOLOGY

In the case of contact dermatitis, the pattern of skin involvement is limited to sites of contact with the triggering agent (Fig. 23–1, *A*), whereas in other forms of eczema, lesions may be widely distributed. **Spongiosis,** or epidermal edema, characterizes all forms of acute eczematous dermatitis—hence the synonym **spongiotic dermatitis.** Edema fluid seeps into the epidermis, where it splays apart keratinocytes (Fig. 23–1, *B*). Intercellular bridges are stretched and become more prominent and are easier to visualize. This change is accompanied by a superficial perivascular lymphocytic infiltrate, edema of dermal papillae, and mast cell degranulation. Eosinophils may be present and are especially prominent in spongiotic eruptions provoked by drugs, but in general the histologic features are similar regardless of cause, emphasizing the need for careful clinical correlation.

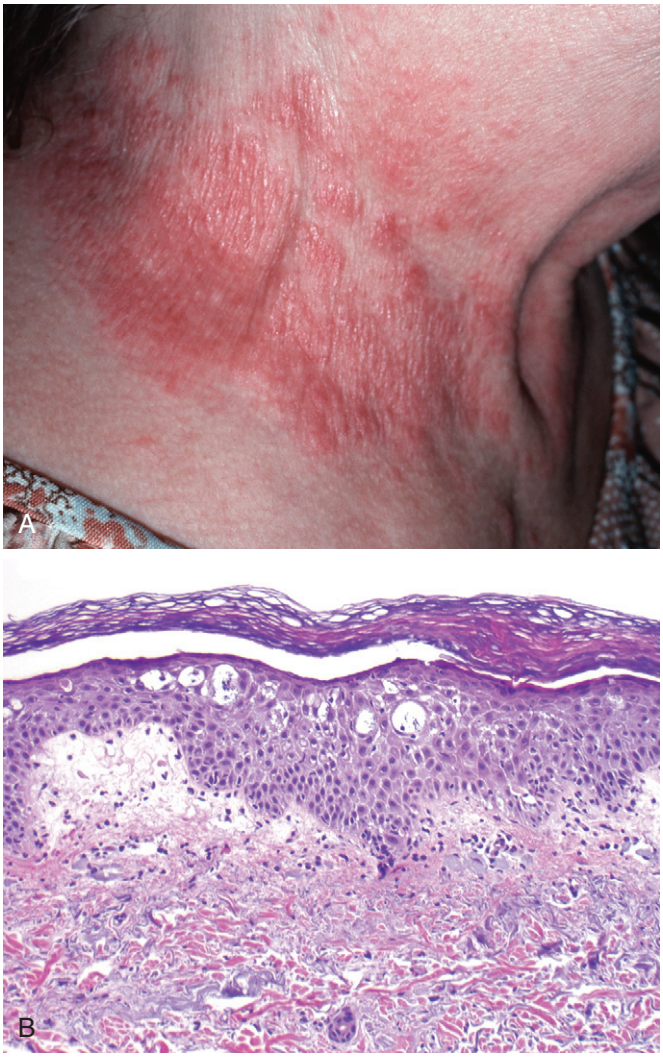


**Figure 23–1** Eczematous dermatitis. **A,** The patterned erythema and scale stems from a nickel-induced contact dermatitis produced by this woman's necklace. **B,** Microscopically, there is fluid accumulation (spongiosis) between epidermal cells that can progress to small vesicles if intercellular connections are stretched until broken.

#### Clinical Features

Lesions of acute eczematous dermatitis are pruritic (itchy), edematous, oozing plaques, often containing vesicles and bullae. With persistent antigen exposure, lesions may become progressively scaly (hyperkeratotic) as the epidermis thickens (acanthosis). Some changes are produced or exacerbated by scratching or rubbing of the lesion (see later under "Lichen Simplex Chronicus"). The clinical causes of eczema are sometimes divided into "inside jobs"—reaction to an internal circulating antigen (such as ingested food or drug)—and "outside jobs"—disease resulting from contact with an external antigen (such as poison ivy).

Susceptibility to atopic dermatitis is often inherited; the disorder is concordant in 80% of identical twins and 20% of fraternal twins. It usually appears in early childhood and in the majority of cases clears in adults. Children with atopic dermatitis often have asthma and allergic rhinitis, termed the atopic triad.

## Erythema Multiforme

Erythema multiforme is an uncommon, usually self-limited disorder that appears to be a *hypersensitivity response to certain infections and drugs.* Antecedent infections include herpes simplex and those caused by mycoplasmas and some fungi. The implicated drugs include sulfonamides, penicillin, salicylates, hydantoins, and antimalarials. Patients present with *a wide diversity of lesions (hence called "multiforme") including macules, papules, vesicles, and bullae, as well as characteristic targetoid lesions consisting of red macules or papules with pale vesicular or eroded centers* (Fig. 23–2). The epithelial damage is believed to result from the action of skin-homing cytotoxic T cells that attack the basal cells of the skin and the mucosae, which may display antigens that cross-react with the inciting drug or microbe.

### MORPHOLOGY

Well-developed lesions have a characteristic "targetoid" appearance (Fig. 23–2, *A*). Early lesions show a superficial perivascular, lymphocytic infiltrate associated with dermal edema and margination of lymphocytes along the dermoepidermal junction in intimate association with degenerating

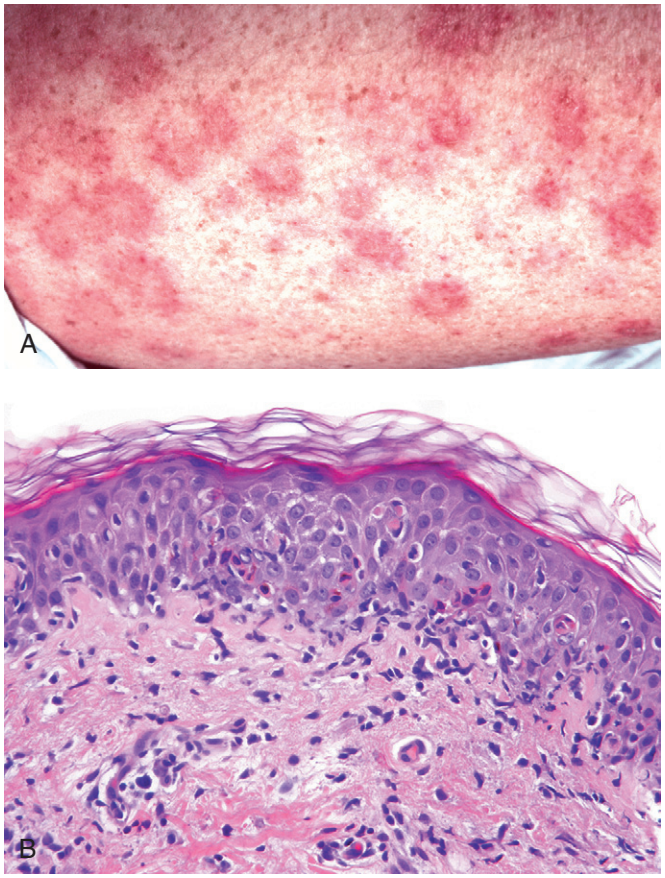


**Figure 23–2** Erythema multiforme. **A,** The target-like lesions consist of a pale central blister or zone of epidermal necrosis surrounded by macular erythema. **B,** Early lesions show a collection of lymphocytes along the dermoepidermal junction (interface dermatitis) associated with scattered keratinocytes with dark shrunken nuclei and eosinophilic cytoplasm that are undergoing apoptosis.

keratinocytes (Fig. 23–2, *B*). With time, discrete, confluent zones of basal epidermal necrosis appear, with concomitant blister formation. In the rarer and more severe form of this disease, **toxic epidermal necrolysis,** the necrosis extends through the full thickness of the epidermis.

### Clinical Features

Erythema multiforme exhibits a broad range of severity. The forms associated with infection (most often herpesvirus) are less severe. Erythema multiforme caused by medications can progress to more serious life-threatening eruptions, such as Stevens-Johnson syndrome or toxic epidermal necrolysis. These forms can be life-threatening because they can cause sloughing of large portions of the epidermis, resulting in fluid loss and infections akin to those seen in burn-injured patients. These severe forms most often occur as idiopathic reactions to drugs.

## CHRONIC INFLAMMATORY DERMATOSES

Chronic inflammatory dermatoses are persistent skin conditions that exhibit their most characteristic features over many months to years, although they may begin with an acute stage. The skin surface in some chronic inflammatory dermatoses is roughened as a result of excessive or abnormal scale formation and shedding (desquamation).

### Psoriasis

Psoriasis is a common chronic inflammatory dermatosis, affecting 1% to 2% of people residing in the United States. Recent epidemiologic studies have shown that psoriasis is associated with an increased risk of heart attack and strokes, a relationship that may be related to a chronic inflammatory state. Psoriasis is also associated in up to 10% of patients with arthritis, which in some cases may be severe.

#### PATHOGENESIS

Psoriasis is a multifactorial immunologic disease; both genetic (e.g., human leukocyte antigen [HLA] types) and environmental factors contribute to risk. It is not known if the inciting antigens are self or environmental. Sensitized populations of T cells home to the dermis, including CD4+ $T_H17$ and $T_H1$ cells and CD8+ T cells, and accumulate in the epidermis. These cells secrete cytokines and growth factors that induce keratinocyte hyperproliferation, resulting in the characteristic lesions. Psoriatic lesions can be induced in susceptible persons by local trauma **(Koebner phenomenon),** which may induce a local inflammatory response that promotes lesion development. GWAS studies have linked an increased risk of psoriasis to polymorphisms in HLA loci and genes affecting antigen presentation, TNF signaling, and skin barrier function.

#### MORPHOLOGY

The typical lesion is a **well-demarcated, pink to salmon–colored plaque covered by loosely adherent silver-white scale** (Fig. 23–3, *A*). There is marked epidermal thickening **(acanthosis),** with regular downward elongation of the rete ridges (Fig. 23–3, *B*). The pattern of this downward growth has been likened to "test tubes in a rack." Increased epidermal cell turnover and lack of maturation results in **loss of the stratum granulosum and extensive parakeratotic scale.** Also seen is thinning of the epidermal cell layer overlying the tips of dermal papillae (suprapapillary plates), and dilated and tortuous blood vessels within the papillae. These vessels bleed readily when the scale is removed, giving rise to multiple punctate bleeding points **(Auspitz sign).** Neutrophils form small aggregates within both the spongiotic superficial epidermis and the parakeratotic stratum corneum. Similar changes can be seen in superficial fungal infections, which need to be excluded with appropriate special stains.

### Clinical Features

Psoriasis most frequently affects the skin of the elbows, knees, scalp, lumbosacral areas, intergluteal cleft, and glans penis. Nail changes on the fingers and toes occur in 30% of cases. In most cases, psoriasis is limited in distribution, but

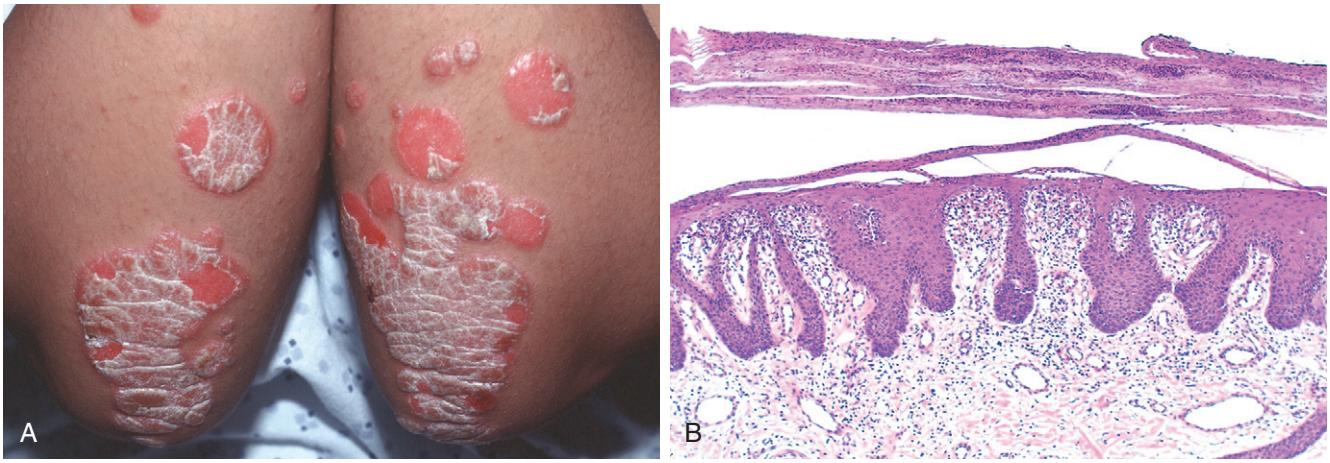

**Figure 23–3** Psoriasis. **A,** Chronic plaques of psoriasis show silvery-white scale on the surface of erythematous plaques. **B,** Microscopic examination reveals marked epidermal hyperplasia, uniform downward extension of rete ridges (psoriasiform hyperplasia), and prominent parakeratotic scale that is focally infiltrated by neutrophils.

it can be widespread and severe. The clinical subtypes are defined by pattern of involvement and severity. Treatment is aimed at preventing the release or actions of inflammatory mediators. Depending upon the disease severity, NSAIDS, immunosuppressive agents such as cyclosporin, and TNF antagonists are used. Newer agents that inhibit $T_H1$ and $T_H17$ immune responses are also being tested.

## Lichen Planus

"Pruritic, purple, polygonal, planar papules, and plaques" are the tongue-twisting *P*s that describe this disorder of skin and squamous mucosa. The lesions may result from a CD8+ T cell–mediated cytotoxic immune response against antigens in the basal cell layer and the dermoepidermal junction that are produced by unknown mechanisms, perhaps as a consequence of a viral infection or drug exposure.

### MORPHOLOGY

Cutaneous lesions of lichen planus consist of **pruritic, violaceous, flat-topped papules,** which may coalesce focally to form plaques (Fig. 23–4, *A*). These papules are often highlighted by white dots or lines called **Wickham striae.** Hyperpigmentation may result from melanin loss into the dermis from damaged keratinocytes. Microscopically, lichen planus is a prototypical **interface dermatitis,** so called because the lesions are concentrated at the interface of the squamous epithelium and papillary dermis. There is a dense, continuous infiltrate of lymphocytes along the dermoepidermal junction (Fig. 23–4, *B*). The lymphocytes are intimately associated with basal keratinocytes, which often atrophy or become necrotic. Perhaps as a response to damage, the basal cells take on the appearance of the more mature cells of the stratum spinosum (squamatization). This pattern of inflammation causes the dermoepidermal interface to assume an angulated, zigzag contour ("sawtoothing"). Anucleate, necrotic basal cells are seen in the inflamed papillary dermis and are referred to as colloid bodies or **Civatte bodies.**

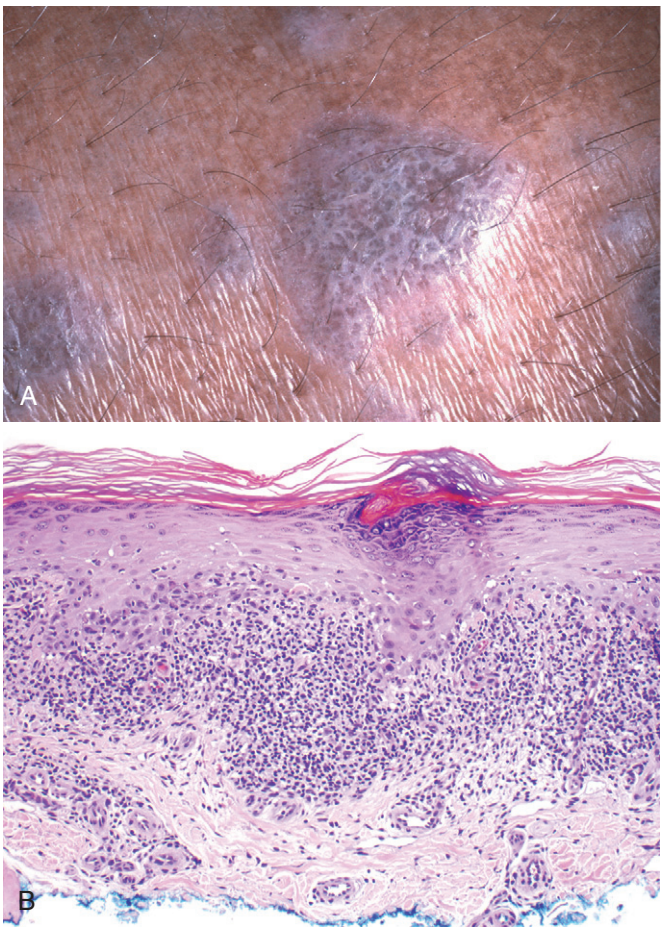

**Figure 23–4** Lichen planus. **A,** This flat-topped pink-purple polygonal papule has white lacelike markings referred to as Wickham striae. **B,** Microscopic features include a bandlike infiltrate of lymphocytes along the dermoepidermal junction, hyperkeratosis, hypergranulosis, and pointed rete ridges ("sawtoothing"), which results from chronic injury of the basal cell layer.

Although these changes bear some similarities to those in erythema multiforme (discussed earlier), lichen planus shows well-developed changes of chronicity, including epidermal hyperplasia, hypergranulosis, and hyperkeratosis.

Clinical Features

Lichen planus is an uncommon disorder that usually presents in middle-aged adults. The cutaneous lesions are multiple and are usually symmetrically distributed, particularly on the extremities, and often occur about the wrists and elbows and on the glans penis. In approximately 70% of cases the oral mucosa is also involved, where the lesions manifest as white papules with a reticulate or netlike appearance. The cutaneous lesions of lichen planus usually resolve spontaneously within 1 to 2 years, but the oral lesions may persist and be of sufficient severity to cause trouble with food intake.

## Lichen Simplex Chronicus

Lichen simplex chronicus manifests as roughening of the skin, which takes on an appearance reminiscent of lichen on a tree. It is a response to local repetitive trauma such as continual rubbing or scratching. Nodular forms exist that are referred to as *prurigo nodularis*. The pathogenesis of lichen simplex chronicus is not understood, but the trauma probably induces epithelial hyperplasia and eventual dermal scarring.

### MORPHOLOGY

Lichen simplex chronicus is characterized by **acanthosis**, **hyperkeratosis,** and **hypergranulosis.** Also seen are elongation of the rete ridges, fibrosis of the papillary dermis, and a dermal chronic inflammatory infiltrate (Fig. 23–5). Of interest, these lesions are similar in appearance to normal volar (palms and soles) skin, in which skin thickening serves as an adaptation to repetitive mechanical stress.

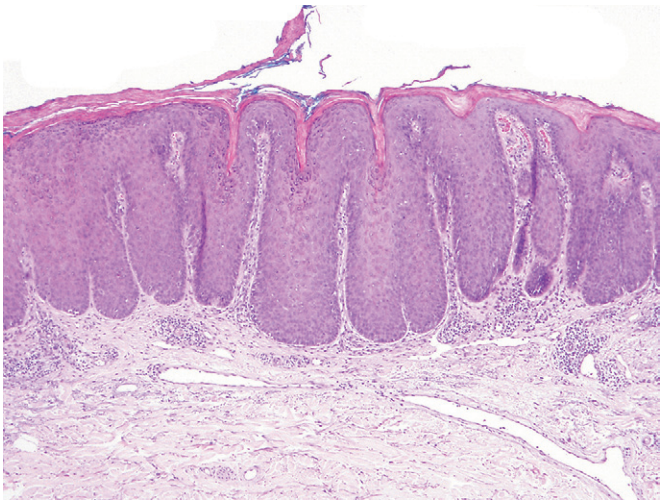

**Figure 23–5** Lichen simplex chronicus. Acanthosis with hyperkeratosis and hypergranulosis are distinctive. Superficial dermal fibrosis and vascular ectasia, both common features, also are present.

Clinical Features

The lesions often are raised, erythematous, and scaly and can be mistaken for keratinocytic neoplasms. Lichen simplex chronicus can be superimposed on and mask another (often pruritic) dermatosis. It is therefore important to rule out an underlying cause while recognizing that the lesion may be entirely trauma-related.

### SUMMARY

#### Inflammatory Dermatoses

- Many specific inflammatory dermatoses exist, which can be mediated by IgE antibodies (urticaria), antigen-specific T cells (eczema, erythema multiforme, and psoriasis), or trauma (lichen simplex chronicus).
- These disorders can be grouped based on patterns of inflammation (e.g., interface dermatitis in lichen planus and erythema multiforme).
- Clinical correlation is essential to diagnose specific skin diseases, since many have overlapping, non-specific histologic features.

# INFECTIOUS DERMATOSES

## Bacterial Infections

Numerous bacterial infections occur in skin. These range from superficial infections known as *impetigo,* to deeper dermal abscesses caused by anaerobes such as *Pseudomonas aeruginosa,* associated with puncture wounds. The pathogenesis is similar to that for microbial infections elsewhere (Chapter 8). Only impetigo is discussed here.

### MORPHOLOGY

Impetigo is characterized by an accumulation of neutrophils beneath the stratum corneum that often produces a subcorneal pustule. Nonspecific reactive epidermal alternation and superficial dermal inflammation accompany these findings. Bacterial cocci in the superficial epidermis can be demonstrated by Gram stain.

Clinical Features

*Impetigo,* one of the most common bacterial infections of the skin, is seen primarily in children. The causative organism is usually *Staphylococcus aureus* or, less commonly, *Streptococcus pyogenes,* and is typically acquired through direct contact with a source. Impetigo often begins as a single small macule, usually on the extremities or the face near the nose or the mouth (Fig. 23–6), which rapidly evolves into a larger lesion with a honey-colored crust of dried serum. Persons colonized by *S. aureus* or *S. pyogenes* (usually nasal or anal) are more likely to be affected. Microbiologic culture with assessment of sensitivity to various antibiotics can be useful clinically. A less common bullous form of childhood impetigo may mimic an autoimmune blistering disorder.

**Figure 23–6** Impetigo. This child's arm is involved by a superficial bacterial infection producing the characteristic erythematous scablike lesions crusted with dried serum.
*(Courtesy of Dr. Angela Wyatt, Bellaire, Texas.)*

## Fungal Infections

Fungal infections are varied and range from superficial infections with *Tinea* or *Candida* spp. to life-threatening infections of immunosuppressed persons with *Aspergillus* spp. Fungal infections can be superficial (stratum corneum, hair, and nails), deep (dermis or subcutis), or systemic, the last type arising through hematogenous spread, often in an immunocompromised patient.

### MORPHOLOGY

The histologic appearance varies depending on the organism, host response, and degree of superinfection. Superficial infections are often associated with a neutrophilic infiltrate in the epidermis. Some show a mild eczematous dermatitis with associated intraepidermal neutrophils, while other infections (e.g., *Candida*) can induce psoriasiform hyperplasia. Deep fungal infections produce greater tissue damage and often elicit a granulomatous response, probably induced by the more vigorous host immune response. *Aspergillus* can be angioinvasive. Periodic acid–Schiff (PAS) and Gomori methenamine silver stains can be helpful in identifying the fungal organisms.

#### Clinical Features

Superficial infections usually produce erythematous macules with superficial scale that can be pruritic, while deeper infections such as those seen with *Aspergillus* spp. in immunocompromised persons are erythematous and often nodular and sometimes show evidence of local hemorrhage. Superficial *Candida* infections often induce lesions that mimic psoriasis, so it is essential to exclude fungal infections when a new diagnosis of psoriasis is being considered.

## Verrucae (Warts)

Verrucae are common lesions of children and adolescents, although they may be encountered in any age group. They are caused by human papillomavirus (HPV). Transmission usually involves direct contact with an infected individual or autoinoculation. Verrucae generally are self-limited, most often regressing spontaneously within 6 months to 2 years.

### PATHOGENESIS

As mentioned earlier, verrucae are caused by HPV. Some members of the HPV family are associated with preneoplastic and invasive cancers of the anogenital region (Chapters 5 and 17). In contrast with HPV-associated carcinomas, most warts are caused by low-risk HPV subtypes that lack transforming potential. Like high-risk viruses, these low-risk viruses express viral E6 and E7 oncoproteins that lead to dysregulated epidermal cell growth and increased survival. Why low-risk viruses cause warts instead of cancer is unclear; subtle functional differences due to structural variation in E6 and E7 proteins that affect interactions with host proteins as well as differences in the abilities of different viral strains to evade the immune response have been proposed.The immune response normally limits the growth of these tumors, and immunodeficiency often is associated with increased numbers and larger sized verrucae.

### MORPHOLOGY

Different kinds of warts are identified on the basis of their gross appearance and location and generally are caused by distinct HPV subtypes. **Verruca vulgaris** (Fig. 23–7, *A*), the most common type of wart, can occur anywhere but is found most frequently on the hands, particularly on the dorsal surfaces and periungual areas, where it appears as a gray-white to tan, flat to convex, 0.1- to 1-cm papule with a rough, pebble-like surface. **Verruca plana,** or **flat wart,** is common on the face or dorsal surfaces of the hands. These warts are flat, smooth, tan macules. **Verruca plantaris** and **verruca palmaris** occur on the soles and palms, respectively. These rough, scaly lesions may reach 1 to 2 cm in diameter and then coalesce to form a surface that can be confused with ordinary calluses. **Condyloma acuminatum (venereal wart)** occurs on the penis, female genitalia, urethra, and perianal areas (Chapters 17 and 18). Histologic features common to verrucae include **epidermal hyperplasia,** which is often undulant in character (so-called verrucous or papillomatous epidermal hyperplasia) (Fig. 23–7, *B, top panel*), and cytoplasmic vacuolization **(koilocytosis),** which preferentially involves the more superficial epidermal layers, producing halos of pallor surrounding infected nuclei. Infected cells also may demonstrate prominent keratohyalin granules and jagged eosinophilic intracytoplasmic protein aggregates as a result of impaired maturation (Fig. 23–7, *B, bottom panel*).

# BLISTERING (BULLOUS) DISORDERS

Although vesicles and bullae (blisters) occur as a secondary phenomenon in several unrelated conditions (e.g., herpesvirus infection, spongiotic dermatitis), there is a group of

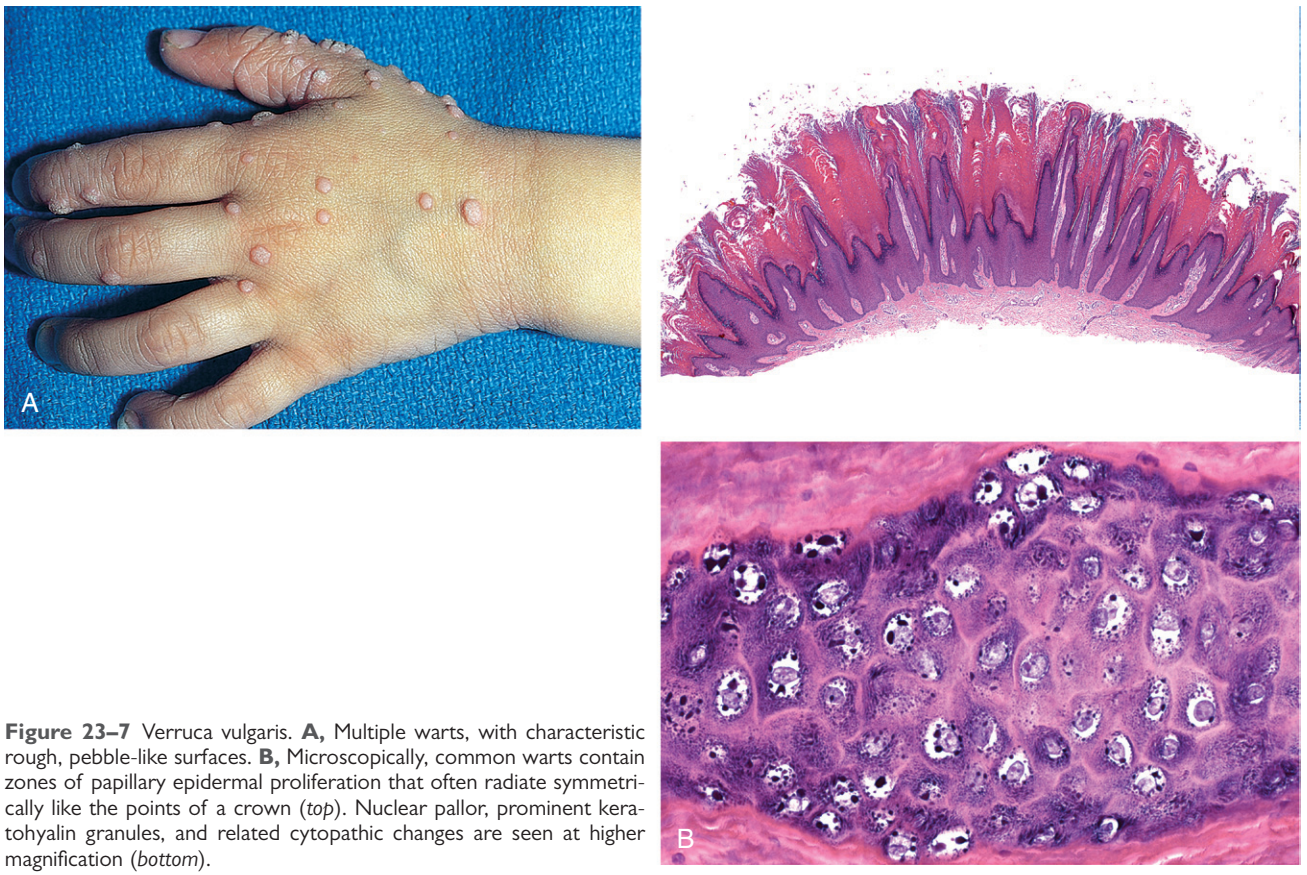


**Figure 23–7** Verruca vulgaris. **A,** Multiple warts, with characteristic rough, pebble-like surfaces. **B,** Microscopically, common warts contain zones of papillary epidermal proliferation that often radiate symmetrically like the points of a crown (*top*). Nuclear pallor, prominent keratohyalin granules, and related cytopathic changes are seen at higher magnification (*bottom*).

disorders in which blisters are the primary and most distinctive feature. Blistering in these diseases tends to occur at specific levels within the skin, a morphologic distinction that is critical for diagnosis (Fig. 23–8).

## Pemphigus (Vulgaris and Foliaceus)

Pemphigus is a rare autoimmune blistering disorder resulting from loss of normal intercellular attachments within the epidermis and the squamous mucosal epithelium. There are three major variants:

- Pemphigus vulgaris (the most common type)
- Pemphigus foliaceus
- Paraneoplastic pemphigus

The last entity is associated with internal malignancy and is not discussed here.

### PATHOGENESIS

Both pemphigus vulgaris and pemphigus foliaceus are autoimmune diseases in which the lesions are caused by antibody-mediated (type II) hypersensitivity reactions (Chapter 4). The

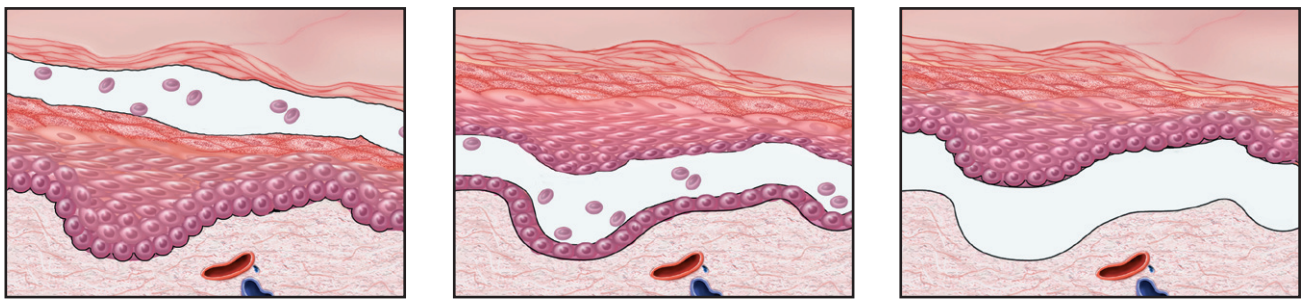


**Figure 23–8** Levels of blister formation. **A,** Subcorneal (as in pemphigus foliaceus). **B,** Suprabasal (as in pemphigus vulgaris). **C,** Subepidermal (as in bullous pemphigoid or dermatitis herpetiformis). The level of epidermal separation forms the basis of the differential diagnosis for blistering disorders.

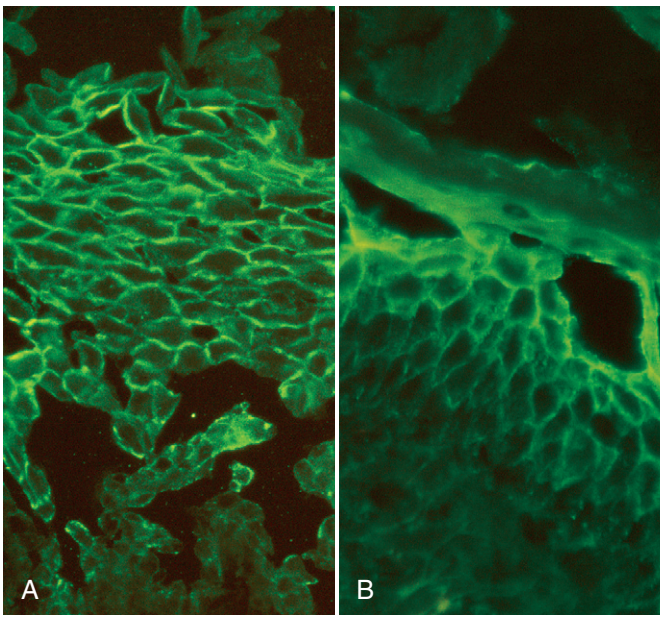


**Figure 23–9** Direct immunofluorescence findings in pemphigus. **A,** Pemphigus vulgaris. There is uniform deposition of immunoglobulin and complement (*green*) along the cell membranes of keratinocytes in a characteristic "fishnet" pattern. **B,** Pemphigus foliaceus. Immunoglobulin deposits are confined to superficial layers of the epidermis.

pathogenic antibodies are IgG autoantibodies that bind to intercellular desmosomal proteins (desmoglein types 1 and 3) of skin and mucous membranes. The antibodies disrupt the intercellular adhesive function of the desmosomes and may activate intercellular proteases as well. The distribution of these proteins within the epidermis determines the location of the lesions. By direct immunofluorescence study, lesional sites show a characteristic fishnet-like pattern of intercellular IgG deposits (Fig. 23–9). As in other autoimmune diseases, pemphigus shows linkage with particular HLA alleles.

## MORPHOLOGY

**Pemphigus vulgaris,** by far the most common type, involves both mucosa and skin, especially on the scalp, face, axillae, groin, trunk, and points of pressure. The lesions are superficial flaccid vesicles and bullae that rupture easily, leaving deep and often extensive erosions covered with a serum crust (Fig. 23–10, *A*). **Pemphigus foliaceus**, a rare, more benign form of pemphigus, results in bullae confined to skin, with only infrequent involvement of mucous membranes. The blisters in this disorder are superficial, such that more limited zones of erythema and crusting of ruptured blisters are seen (Fig. 23–11, *A*).

The common histologic denominator in all forms of pemphigus is **acantholysis,** lysis of the intercellular adhesive junctions between neighboring squamous epithelial cells that results in the rounding up of detached cells. In pemphigus vulgaris, acantholysis selectively involves the layer of cells immediately above the basal cell layer, giving rise to a **suprabasal acantholytic blister** (Fig. 23–10, *B*). In pemphigus foliaceus, acantholysis selectively involves the superficial epidermis at the level of the stratum granulosum (Fig. 23–11, *B*). Variable superficial dermal infiltrates comprised of lymphocytes, macrophages, and eosinophils accompany all forms of pemphigus.

### Clinical Features

Pemphigus vulgaris is a rare disorder that occurs most commonly in the elderly and more often in women than men. Lesions are painful, particularly when ruptured, and secondary infections are common. Most cases are associated with oropharyngeal involvement at some point in their course. Most patients require immunosuppressive therapy, sometimes for the remainder of their lives. Medications can cause pemphigus, and when they do, patients most often present with pemphigus foliaceus rather than pemphigus vulgaris. There is also an unusual endemic form of pemphigus foliaceus in South America (*fogo selvagem*) that is putatively associated with the bite of a black fly.

## Bullous Pemphigoid

Bullous pemphigoid is another distinctive acquired blistering disorder with an autoimmune basis.

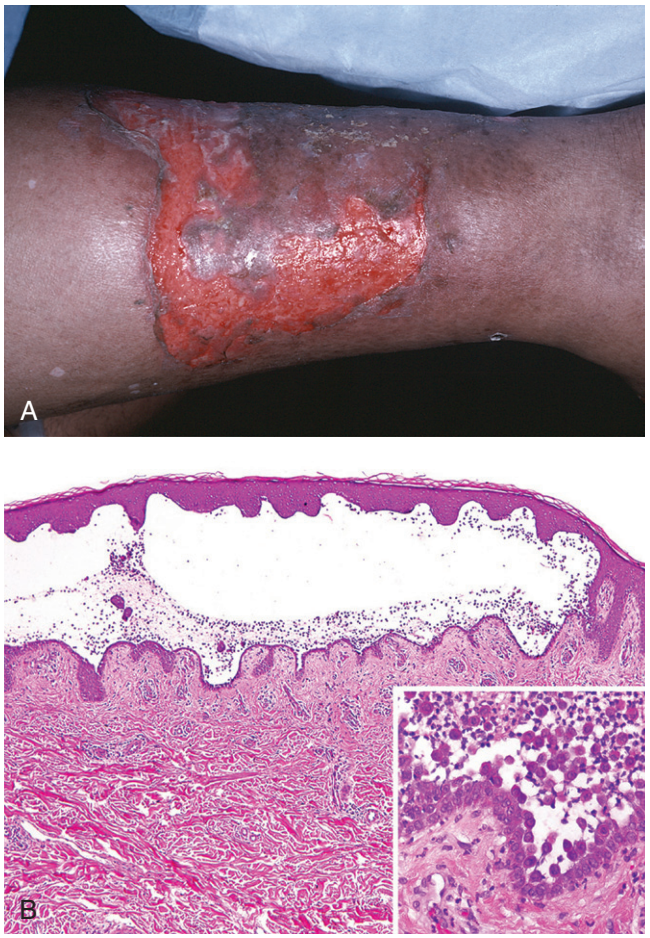


**Figure 23–10** Pemphigus vulgaris. **A,** This erosion on the leg represents a group of confluent, "unroofed" blisters. **B,** Suprabasal acantholysis results in an intraepidermal blister in which rounded, dissociated (acantholytic) keratinocytes are plentiful (*inset*).

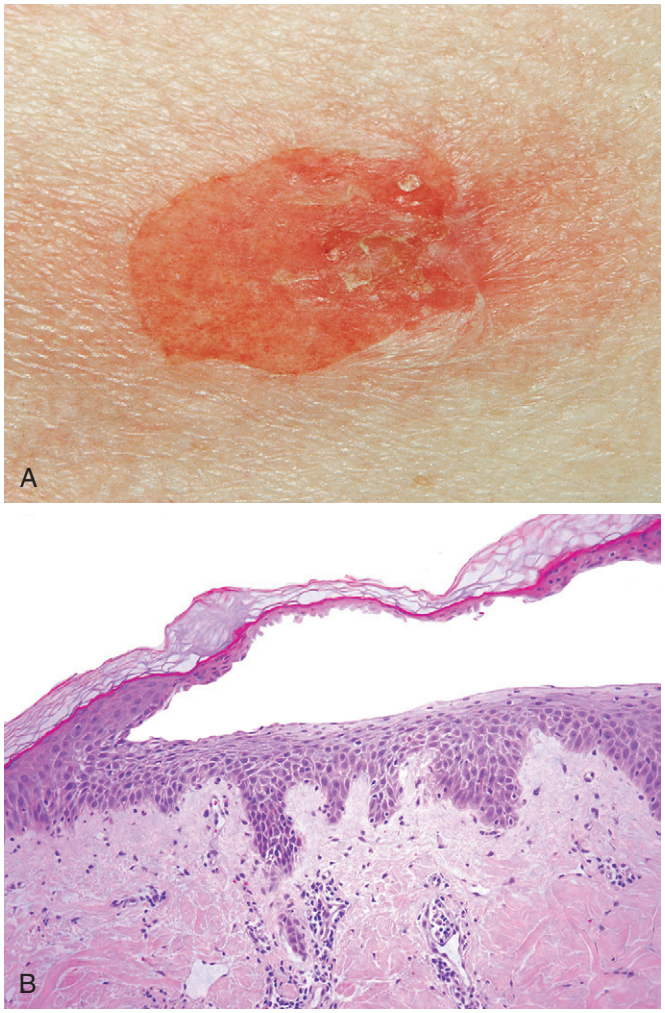

**Figure 23–11** Pemphigus foliaceus. **A,** Gross appearance of a typical blister, which is less severely eroded than those seen in pemphigus vulgaris. **B,** Microscopic appearance of a characteristic subcorneal blister.

## PATHOGENESIS

Blistering in bullous pemphigoid is triggered by the linear deposition of IgG antibodies and complement in the epidermal basement membrane (Fig. 23–12, *A*). Reactivity also occurs in the basement membrane attachment plaques (hemidesmosomes), where most of the bullous pemphigoid antigen (type XVII collagen) is located. This protein normally is involved in dermoepidermal adhesion. IgG autoantibodies to hemidesmosome components fix complement and cause tissue injury by recruiting neutrophils and eosinophils.

## MORPHOLOGY

Grossly, the lesions of bullous pemphigoid appear as tense bullae, filled with clear fluid, on normal or erythematous skin (Fig. 23–12, *B*). Bullous pemphigoid is characterized by **subepidermal nonacantholytic** blisters. Early lesions show a perivascular infiltrate of lymphocytes and variable numbers of eosinophils, occasional neutrophils, superficial dermal edema, and associated basal cell layer vacuolization. The vacuolated basal cell layer eventually gives rise to a fluid-filled

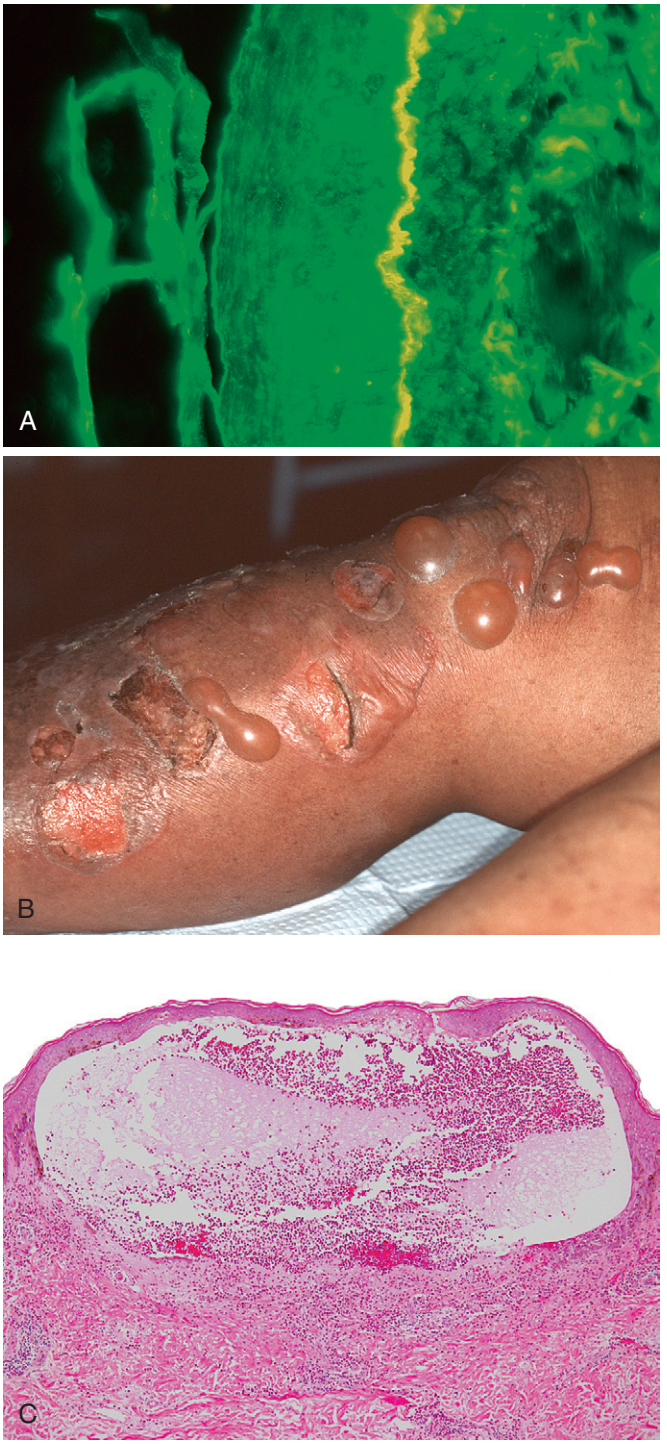

**Figure 23–12** Bullous pemphigoid. **A,** Deposition of IgG antibody detected by direct immunofluorescence as a linear band outlining the subepidermal basement membrane zone (epidermis is on the *left* side of the fluorescent band). **B,** Gross appearance of characteristic tense, fluid-filled blisters. **C,** A subepidermal vesicle with an inflammatory infiltrate rich in eosinophils.
*(C, Courtesy of Dr. Victor G. Prieto, Houston, Texas.)*

blister (Fig. 23–12, *C*). The blister roof consists of full-thickness epidermis with intact intercellular junctions, a key distinction from the blisters seen in pemphigus.

Clinical Features

The bullae do not rupture as readily as in pemphigus and, if uncomplicated by infection, heal without scarring. The disease tends to follow a remitting and relapsing course and responds to topical or systemic immunosuppressive agents. Gestational pemphigoid (also known as *herpes gestationis,* a misnomer) is a clinically distinct subtype that appears suddenly during the second or third trimester of pregnancy. It is also caused by autoantibodies against BPAG. It typically resolves after childbirth, but may recur with future pregnancies.

## Dermatitis Herpetiformis

Dermatitis herpetiformis is another type of autoimmune blistering disorder characterized by extremely *pruritic urticaria and grouped vesicles.* The disease affects predominantly males, often in the third and fourth decades of life. In up to 80% of cases, it occurs in association with celiac disease; conversely, only a small minority of patients with celiac disease develop dermatitis herpetiformis. Like celiac disease, dermatitis herpetiformis responds to a gluten-free diet.

### PATHOGENESIS

The strong association of dermatitis herpetiformis with celiac disease provides a clue to its pathogenesis. Genetically predisposed persons develop IgA antibodies to dietary gluten (derived from the wheat protein gliadin) as well as IgA autoantibodies that cross-react with endomysium and tissue transglutaminases, including epidermal transglutaminase expressed by keratinocytes. By direct immunofluorescence, the skin shows discontinuous, **granular deposits of IgA** selectively localized in the tips of dermal papillae (Fig. 23–13, *A*). The resultant injury and inflammation produce a subepidermal blister.

### MORPHOLOGY

The lesions of dermatitis herpetiformis are bilateral, symmetric, and grouped and preferentially involve the extensor surfaces, elbows, knees, upper back, and buttocks (Fig. 23–13, *B*). Initially, neutrophils accumulate selectively at the **tips of dermal papillae,** forming small microabscesses (Fig. 23–13, *C*). The basal cells overlying these microabscesses show vacuolization and focal dermoepidermal separation that ultimately coalesce to form a true **subepidermal blister.**

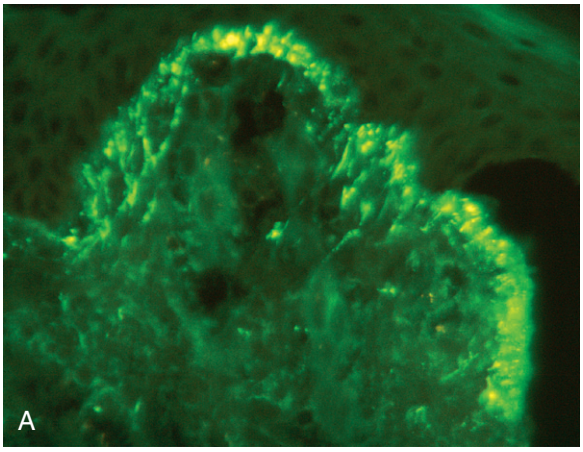

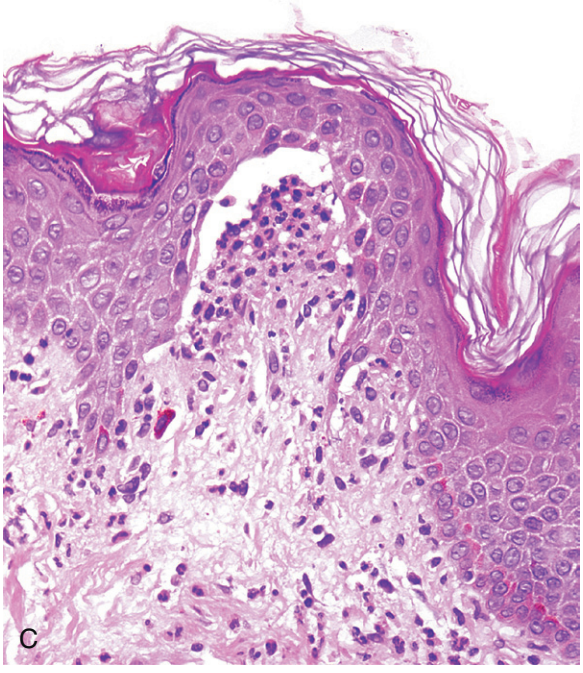


**Figure 23–13** Dermatitis herpetiformis. **A,** Selective deposition of IgA autoantibody at the tips of dermal papillae is characteristic. **B,** Lesions consist of intact and eroded (usually scratched) erythematous blisters, often grouped (seen here on elbows and arms). **C,** The blisters are associated with basal cell layer injury, initially caused by accumulation of neutrophils (microabscesses) at the tips of dermal papillae.
*(A, Courtesy of Dr. Victor G. Prieto, Houston, Texas.)*

## SUMMARY

### Blistering Disorders

- Blistering disorders are classified by the level of epidermal separation.
- These disorders are often caused by autoantibodies specific for epithelial or basement membrane proteins that lead to unmooring of keratinocytes (acantholysis).
- Pemphigus is associated with IgG autoantibodies to various intercellular desmogleins, resulting in bullae that are either subcorneal (pemphigus foliaceus) or suprabasalar (pemphigus vulgaris).
- Bullous pemphigoid is associated with IgG autoantibodies to basement membrane proteins and produces a subepidermal blister.
- Dermatitis herpetiformis is associated with IgA autoantibodies to fibrils that bind the epidermal basement membrane to the dermis, and is also characterized by subepidermal blisters.

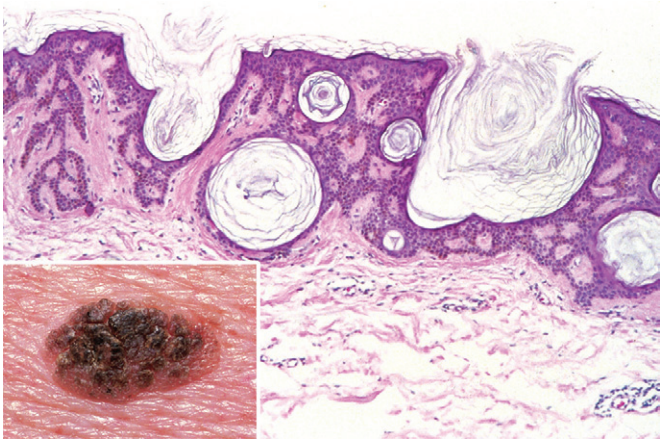

**Figure 23–14** Seborrheic keratosis. This roughened, brown, waxy lesion almost appears to be "stuck on" the skin (*inset*). Microscopic examination shows the lesion to consist of an orderly proliferation of uniform, basaloid keratinocytes that tend to form keratin microcysts (horn cysts).

# BENIGN AND PREMALIGNANT TUMORS

## Benign and Premalignant Epithelial Lesions

Benign epithelial neoplasms are common and probably arise from stem cells residing in the epidermis and hair follicles. These tumors grow to a limited size and generally do not undergo malignant transformation.

### *Seborrheic Keratosis*

These common pigmented epidermal tumors occur most frequently in middle-aged or older persons. They arise spontaneously and are particularly numerous on the trunk, although the extremities, head, and neck also may be sites of involvement.

A significant fraction of these tumors harbor activating mutations in *fibroblast growth factor (FGF) receptor 3*, which possesses a tyrosine kinase activity that stimulates Ras and the PI3K/AKT pathways. Except for cosmetic concerns, they are usually of little clinical importance. However, in rare patients hundreds of lesions may appear suddenly as a *paraneoplastic syndrome* (sign of Lesser-Trelat). Patients with this presentation may harbor internal malignancies, most commonly gastrointestinal tract carcinomas, which produce growth factors that stimulate epidermal proliferation.

#### MORPHOLOGY

Seborrheic keratoses are **round, exophytic, coin-like plaques** varying in diameter from millimeters to centimeters that have a **"stuck-on" appearance** (Fig. 23–14, *inset*). They are tan to dark brown and have a velvety- to granular-appearing surface. Occasionally, their dark color is suggestive of melanoma, leading to surgical removal.

Microscopically, seborrheic keratoses are composed of monotonous sheets of small cells that resemble the basal cells of the normal epidermis (Fig. 23–14). Variable melanin pigmentation is present within these basaloid cells, accounting for the brown coloration seen grossly. Hyperkeratosis occurs at the surface, and the presence of small keratin-filled cysts (horn cysts) and downgrowth of keratin into the main tumor mass (pseudo–horn cysts) are characteristic features.

### *Actinic Keratosis*

Overt malignancy of the epidermis (squamous cell carcinoma) may be preceded by a series of progressive dysplastic changes. Because such lesions usually are the result of chronic exposure to sunlight and are associated with hyperkeratosis, they are called actinic (sun-related) keratoses. Whether all actinic keratoses evolve to carcinoma with time is conjectural; many lesions regress or remain stable. Enough become malignant, however, to warrant local eradication. A high fraction of these lesions are associated with *TP53* mutations caused by UV light–induced DNA damage.

#### MORPHOLOGY

Actinic keratoses usually are less than 1 cm in diameter, tan-brown or red in color, and rough (sandpaper-like) to the touch (Fig. 23–15, *A*). Microscopically, lower portions of the epidermis show **cytologic atypia,** often associated with hyperplasia of basal cells (Fig. 23–15, *B*) or with atrophy and diffuse thinning of the epidermal surface. The dermis contains thickened, blue-gray elastic fibers (solar elastosis), the result of chronic sun damage. The stratum corneum is thickened with retained nuclei (parakeratosis). In some lesions full thickness epidermal atypia is seen; such lesions are considered forms of squamous cell carcinoma in situ (Fig. 23–15, *C*).

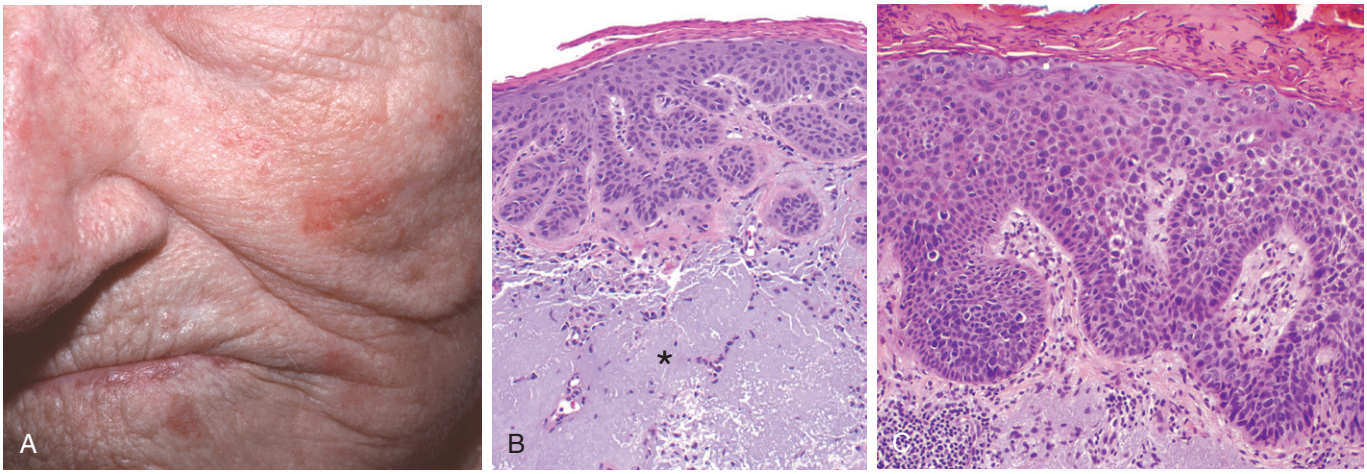


**Figure 23–15** Actinic keratosis. **A,** Most lesions are red and rough (sandpaper-like), owing to excessive scale, as seen in the lesions on the cheek, nose, and chin of this female patient. **B,** Basal cell layer atypia (dysplasia) with epithelial buds, and associated with marked hyperkeratosis, parakeratosis, and dermal solar elastosis (*asterisk*). **C,** More advanced lesions show full-thickness atypia, qualifying as squamous carcinoma in situ.

Clinical Features

Actinic keratoses are very common in fair-skinned people and increase in incidence with age and increasing sun exposure. As would be expected, there is a predilection for sun-exposed areas (face, arms, dorsum of the hands). The lesions can be treated with local cryotherapy (superficial freezing) or topical agents.

## SUMMARY

### Benign and Premalignant Epithelial Lesions

- *Seborrheic keratosis:* Round, flat plaques made up of proliferating monotonous epidermal basal cells, which sometimes contain melanin. Hyperkeratosis and keratin-filled cysts are characteristic.
- *Actinic keratosis:* Present on sun-exposed skin, these lesions show cytologic atypia in lower parts of epidermis and infrequently progress to carcinoma in situ.

## Malignant Epidermal Tumors

### *Squamous Cell Carcinoma*

Squamous cell carcinoma is *a common tumor arising on sun-exposed sites in older people.* These tumors have a higher incidence in men than in women. In addition to sunlight, predisposing factors include industrial carcinogens (tars and oils), chronic ulcers, old burn scars, ingestion of arsenicals, and ionizing radiation. As with squamous cell carcinomas at other sites, those in the skin may be preceded by in situ lesions.

## PATHOGENESIS

The most common exogenous cause of cutaneous squamous cell carcinoma is UV light exposure, which causes DNA damage (Chapter 5). *TP53* mutations caused by UV light–induced DNA damage are common, as are activating mutations in *HRAS* and loss-of-function mutations in Notch receptors, which transmit signals that regulate the orderly differentiation of normal squamous epithelia. In addition to inducing mutations, UV light (UVB in particular) may have a transient immunosuppressive effect on skin by impairing antigen presentation by Langerhans cells. This effect may contribute to tumorigenesis by weakening immunosurveillance. Patients who are immunosuppressed as a result of chemotherapy or organ transplantation, or who have **xeroderma pigmentosum,** are at increased risk. Tumors in immunosuppressed persons, particularly organ transplant recipients, are likely to be associated with HPV infection. *TP53* mutations caused by UV light–induced DNA damage are common, as are activating mutations in *HRAS*. As with squamous cell carcinomas at other sites, those in the skin may be preceded by in situ lesions.

## MORPHOLOGY

Squamous cell carcinomas in situ appear as sharply defined, red, scaling plaques; many arise from prior actinic keratoses. More advanced, invasive lesions are nodular, show variable scale, and may ulcerate (Fig. 23–16, *A*). Microscopically, squamous cell carcinoma in situ is characterized by highly atypical cells at **all levels** of the epidermis, with nuclear crowding and disorganization. Invasive tumors, defined by penetration of the basement membrane (Fig. 23–16, *B*), show variable degrees of differentiation, ranging from tumors with cells arranged in orderly lobules that exhibit extensive keratinization to neoplasms consisting of highly anaplastic cells with foci of necrosis and only abortive, single-cell keratinization (dyskeratosis).

Clinical Features

Invasive squamous cell carcinomas of the skin often are discovered while small and resectable. Less than 5% have metastasized to regional nodes at diagnosis. The likelihood of metastasis is related to the thickness of the lesion and degree of invasion into the subcutis. Tumors arising in the context of actinic keratoses may be locally aggressive but

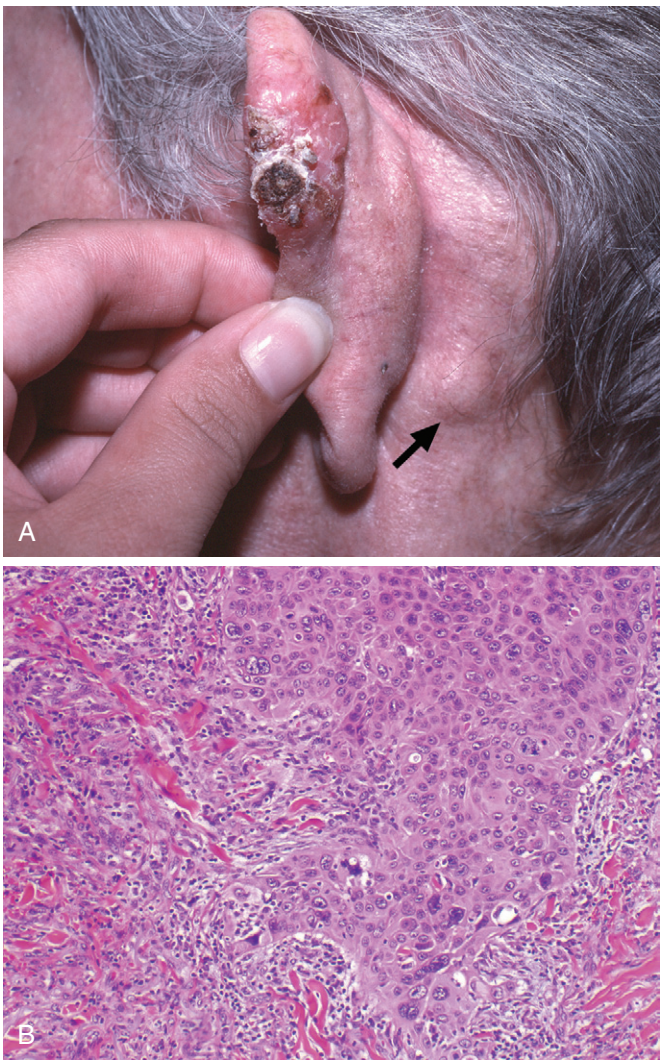


**Figure 23–16** Invasive squamous cell carcinoma. **A,** A nodular, hyperkeratotic lesion occurring on the ear, associated with metastasis to a prominent postauricular lymph node (*arrow*). **B,** The tumor invades the dermis infiltrating collagen as irregular projections of atypical squamous cells, which in this case exhibit acantholysis.

generally metastasize only after long periods of time, while those arising in burn scars, ulcers, and non–sun-exposed skin behave less predictably. Mucosal squamous cell carcinomas (oral, pulmonary, esophageal, etc.) generally are much more aggressive.

### *Basal Cell Carcinoma*

Basal cell carcinoma is a common *slow-growing cancer that rarely metastasizes*. It tends to occur at sites subject to chronic sun exposure and in lightly pigmented individuals.

## PATHOGENESIS

**Basal cell carcinoma is associated with dysregulation of the Hedgehog pathway.** Inherited defects in the *PTCH* gene, a tumor suppressor that regulates Hedgehog pathway signaling, cause familial basal cell carcinomas in Gorlin syndrome. The Hedgehog pathway is an important regulator of embryonic development, and subtle developmental anomalies are also often noted in affected persons. Some component of the hedgehog pathway is mutated in the great majority of sporadic basal cell carcinomas as well. Mutations in *TP53* are also common in both familial and sporadic tumors.

## MORPHOLOGY

Grossly, basal cell carcinomas manifest as **pearly papules, often with prominent, dilated subepidermal blood vessels (telangiectasia)** (Fig. 23–17, *A*). Some tumors contain melanin pigment and thus appear similar to melanocytic nevi or melanomas. Microscopically, the tumor cells resemble the normal epidermal basal cell layer from which they are derived. Because they may arise from either the epidermis or the follicular epithelium, they are not encountered on mucosal surfaces. Two common patterns are seen: **multifocal growths** originating from the epidermis (superficial pattern), or **nodular lesions** growing downward into the dermis as cords and islands of variably basophilic cells with hyperchromatic nuclei, embedded in a fibrotic or mucinous stromal matrix (Fig. 23–17, *B*). Peripheral tumor cell nuclei align in the outermost layer (a pattern termed palisading), which often separates from the stroma, creating a characteristic cleft (Fig. 23–17, *C*).

### Clinical Features

It is estimated that in excess of 1 million basal cell carcinomas are treated in the United States annually. By far the most important risk factor is sun exposure; basal cell carcinoma is more common in warm southern regions of the United States, and its incidence is 40-fold higher in sunny climates near the equator, such as Australia, than it is in Northern European locales. Individual tumors usually are cured by local excision, but approximately 40% of patients will develop another basal cell carcinoma within 5 years. Advanced lesions may ulcerate, and extensive local invasion of bone or facial sinuses may occur if the lesions are neglected for many years.

## SUMMARY

### Malignant Epidermal Tumors

- The incidence of both basal cell and squamous cell carcinoma is strongly correlated with increasing lifetime sun exposure.
- Cutaneous squamous cell carcinoma can progress from actinic keratoses but also arises from chemical exposure, at thermal burn sites, or in association with HPV infection in the setting of immunosuppression.
- Cutaneous squamous cell carcinoma has potential for metastasis but is much less aggressive than squamous cell carcinoma at mucosal sites.
- Basal cell carcinoma, the most common malignancy worldwide, is a locally aggressive tumor associated with mutations in the Hedgehog pathway. Metastasis is very rare.

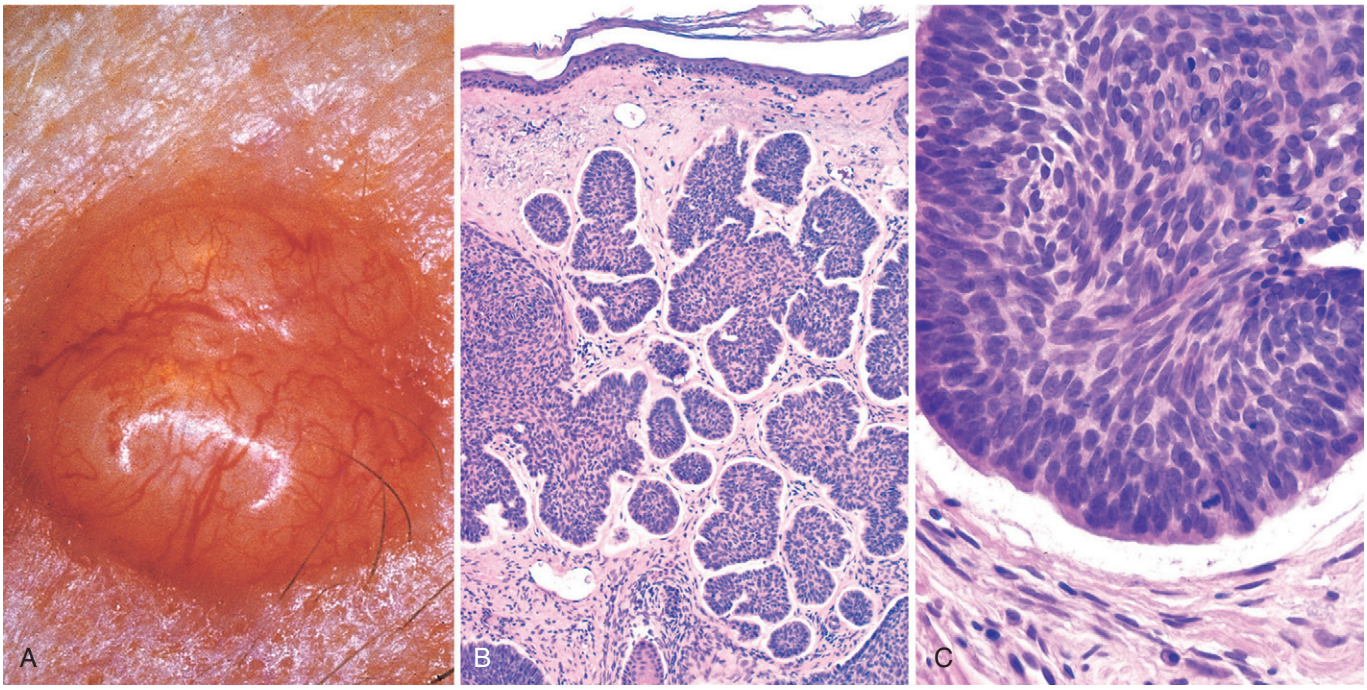


**Figure 23–17** Basal cell carcinoma. **A,** A prototypical pearly, smooth-surfaced papule with associated telangiectatic vessels. **B,** The tumor is composed of nests of basaloid cells infiltrating a fibrotic stroma. **C,** The tumor cells have scant cytoplasm and small hyperchromatic nuclei that palisade on the outside of the nest. The cleft between the tumor cells and the stroma is a highly characteristic artifact of sectioning.

## Melanocytic Proliferations

### *Melanocytic Nevi*

Strictly speaking, the term *nevus* denotes any congenital lesion of the skin. *Melanocytic* nevus, however, refers to any benign congenital or acquired neoplasm of melanocytes.

### PATHOGENESIS

Melanocytic nevi are benign neoplasms derived from melanocytes, highly dendritic, pigment-producing cells that are normally interspersed among basal keratinocytes. Progressive growth and migration of nevus cells from the dermoepidermal junction into the underlying dermis is accompanied by changes that are taken as evidence of cellular **senescence** (Fig. 23–18). Superficial nevus cells are larger and tend to produce melanin pigment and grow in nests; deeper nevus cells are smaller, produce little or no pigment, and grow in cords or single cells. The deepest nevus cells have fusiform contours and grow in fascicles. This sequence of morphologic changes is of diagnostic importance, since they are absent from melanomas. The majority of benign nevi have an activating mutation in *BRAF*, which encodes a serine/threonine kinase downstream from RAS in the extracellular regulated kinase (ERK) pathway, or less commonly in *NRAS* itself. Experimental evidence suggests that unbridled BRAF/RAS signaling initially induces melanocytic proliferation followed by senescence. How these opposing effects are coordinated is unclear, but it is believed that the "brake" on proliferation provided by induced senescence explains why very few nevi transform into malignant melanomas.

### MORPHOLOGY

Common melanocytic nevi are tan-to-brown, uniformly pigmented, small papules (5 mm or less across) with well-defined, rounded borders (Fig. 23–19, *A*). Early lesions are composed of round-to-oval cells that grow in "nests" along the dermoepidermal junction. Nuclei are uniform and round, and contain inconspicuous nucleoli with little or no mitotic activity. Such early-stage lesions are called **junctional nevi.** Eventually, most junctional nevi grow into the underlying dermis as nests or cords of cells **(compound nevi),** and in older lesions the epidermal nests may be lost entirely, creating an **intradermal nevi** (Fig. 23–19, *B*).

#### Clinical Features

There are numerous types of melanocytic nevi, with varied appearances. Although these lesions usually are of only cosmetic concern, they can become irritating or mimic melanoma, requiring their surgical removal. Compound and intradermal nevi often are more elevated than junctional nevi.

### *Dysplastic Nevus*

Dysplastic nevi may be *sporadic or familial*. The latter are important clinically because they are considered potential precursors of melanoma. As with conventional melanocytic nevi, activating *NRAS* or *BRAF* mutations are commonly found in dysplastic nevi and are believed to have a pathogenic role.

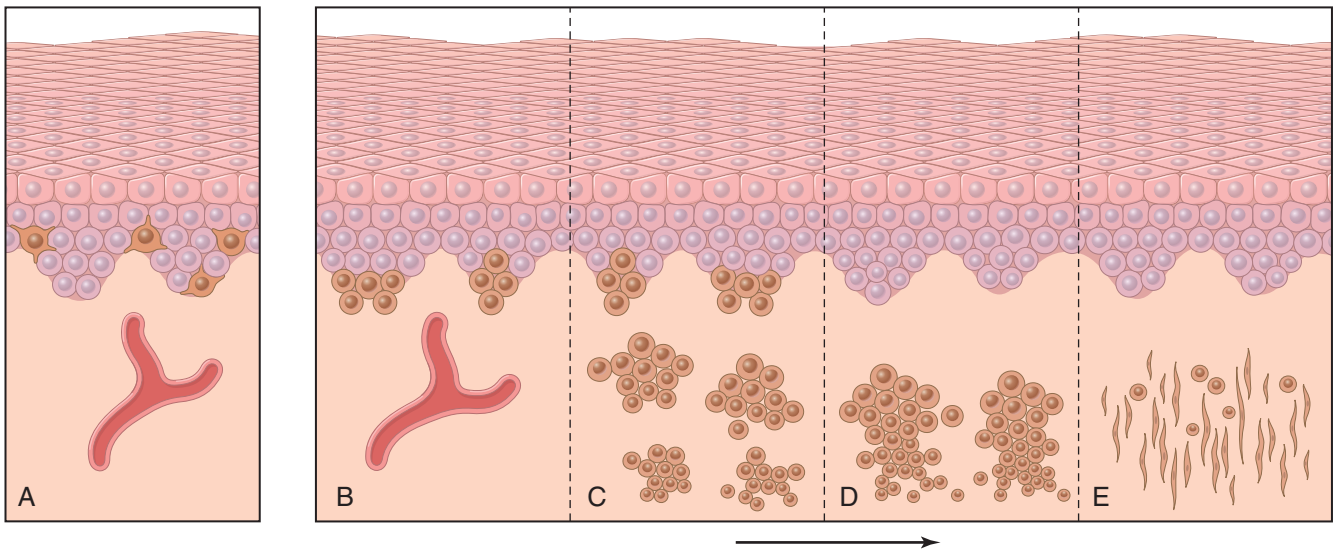


**Figure 23–18** Possible steps in development of melanocytic nevi. **A,** Normal skin shows only scattered melanocytes. **B,** Junctional nevus. **C,** Compound nevus. **D,** Intradermal nevus. **E,** Intradermal nevus with extensive cellular senescence.

## MORPHOLOGY

Dysplastic nevi are larger than most acquired nevi (often more than 5 mm across) and **may number in the hundreds** (Fig. 23–20, *A*). They are flat macules to slightly raised plaques, with a "pebbly" surface. They usually have variable pigmentation (variegation) and irregular borders (Fig. 23–20, *A, inset*).

Microscopically, dysplastic nevi are mostly compound nevi that exhibit both architectural and cytologic evidence of abnormal growth. Nevus cell nests within the epidermis may be enlarged and exhibit abnormal fusion or coalescence with adjacent nests (bridging). As part of this process, single nevus cells begin to replace the normal basal cell layer along the dermoepidermal junction, producing so-called lentiginous hyperplasia (Fig. 23–20, *B*). Cytologic atypia consisting of irregular, often angulated, nuclear contours and hyperchromasia is frequently observed (Fig. 23–20, *B* and *C*). Associated alterations also occur in the superficial dermis. These consist of a sparse lymphocytic infiltrate, release of melanin pigment that is phagocytosed by dermal macrophages (melanin incontinence), and linear fibrosis surrounding epidermal nests of melanocytes. These dermal changes are elements of the host response to these lesions.

### Clinical Features

Unlike ordinary nevi, *dysplastic nevi have a tendency to occur on body surfaces not exposed to the sun* as well as on sun-exposed sites. *Familial dysplastic nevus syndrome is strongly associated with melanoma*, as the lifetime risk for the development of melanoma in affected persons is close to 100%. In sporadic cases, only individuals with 10 or more dysplastic nevi appear to be at an increased risk for melanoma. Transformation of dysplastic nevus to melanoma has been documented, both clinically and histologically. However, such cases are the exception, as most melanomas arise de novo and not from a preexisting nevus. Thus, the likelihood that

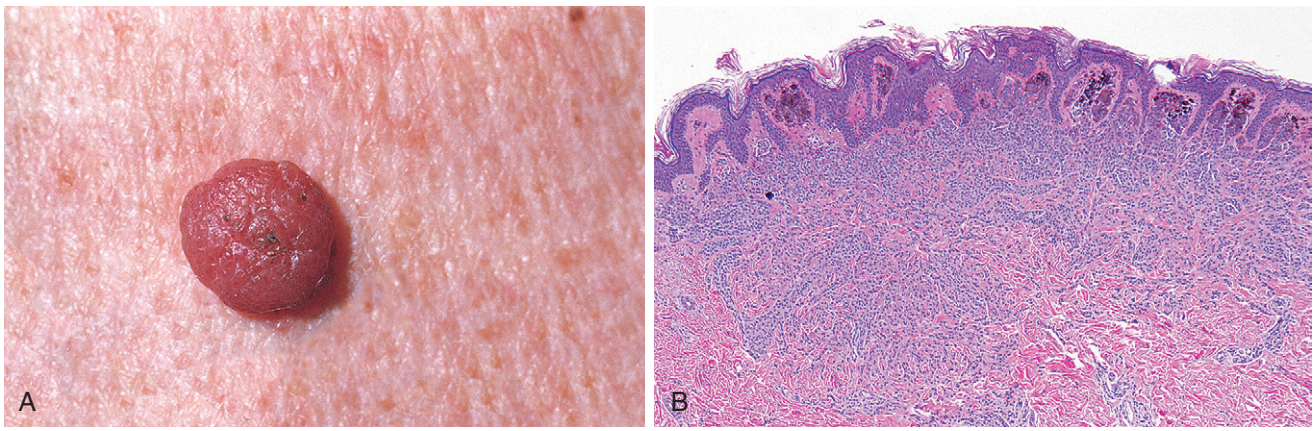


**Figure 23–19** Melanocytic nevus. **A,** Melanocytic nevi are relatively small, symmetric, and uniformly pigmented. **B,** This nevus shows rounded melanocytes that lose their pigmentation and become smaller and more separated as they extend into the dermis—all signs of cellular senescence that speak to the benign nature of the proliferation.

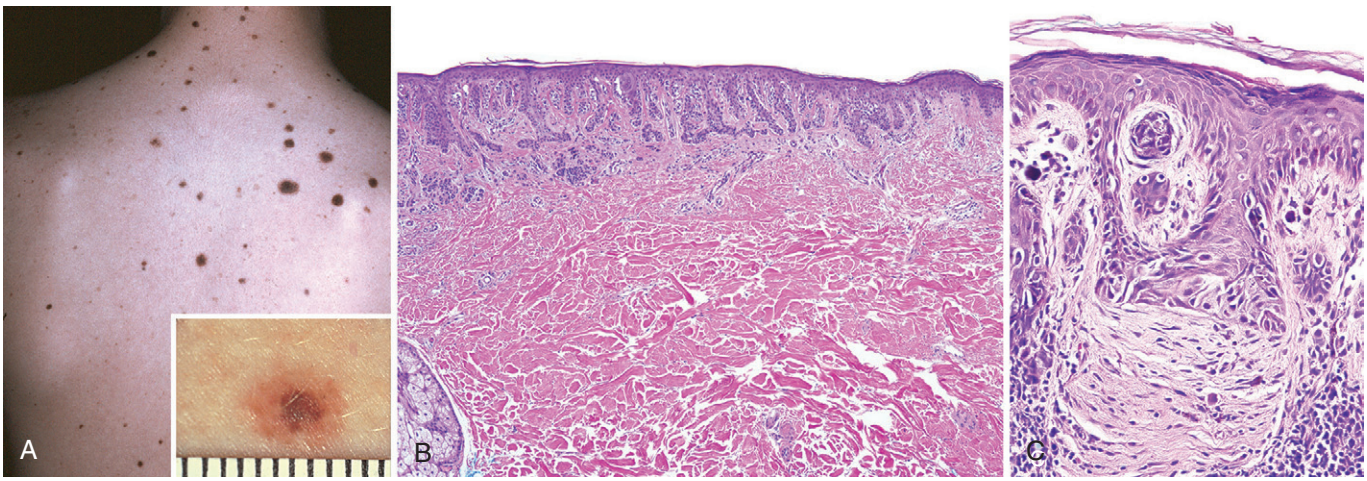


**Figure 23–20** Dysplastic nevus. **A,** Numerous irregular nevi on the back of a patient with the dysplastic nevus syndrome. The lesions usually are greater than 5mm in diameter and have irregular borders and variable pigmentation (*inset*). **B,** Compound dysplastic nevi feature a central dermal component with an asymmetric "shoulder" of exclusively junctional melanocytes (lentiginous hyperplasia). The former corresponds to the more pigmented and raised central zone (see **A,** *inset*), and the latter, to the less pigmented flat peripheral rim. **C,** Other important features are cytologic atypia (irregular, dark-staining nuclei) and characteristic parallel bands of fibrosis—part of the host response to these lesions.

any particular nevus, dysplastic or otherwise, will develop into melanoma is exceedingly low, and these lesions are best viewed as markers of melanoma risk.

### *Melanoma*

Melanoma is less common but much more deadly than basal or squamous cell carcinoma. Today, as a result of increased public awareness of the earliest signs of skin melanomas, most melanomas are cured surgically. Nonetheless, the incidence of these lesions has increased dramatically over the past several decades, at least in part as a result of increasing sun exposure and/or higher detection rates resulting from vigorous surveillance.

## PATHOGENESIS

As with other cutaneous malignancies, sunlight plays an important role in the development of melanoma. The incidence is highest in sun-exposed skin and in geographic locales such as Australia where sun exposure is high and much of the population is fair-skinned. Intense intermittent exposure at an early age is particularly harmful. Recent "deep sequencing" studies have confirmed that tumor genomes contain thousands of acquired mutations, most bearing a signature consistent with UV-induced DNA damage. Sunlight, however, is not the only predisposing factor; hereditary predisposition also plays a role, as already discussed under familial dysplastic nevus syndrome.

As with other cancers, it is believed that melanoma may arise in a stepwise fashion from precursor lesions (Fig. 23–21). **Key phases of tumor development are marked by radial and vertical growth. Radial growth** describes the initial tendency of a melanoma to grow horizontally within the epidermis (*in situ*), often for a prolonged period (Fig. 23–21, *D*). During this stage, melanoma cells do not have the capacity to metastasize, and do not induce angiogenesis. With time, a **vertical growth phase** supervenes, in which the tumor grows downward into the deeper dermal layers as an expansile mass lacking cellular maturation (Fig. 23–21, *E*). This event often is heralded by the development of a nodule in a previously flat lesion (Fig. 23-22, *A*) and correlates with the emergence of a clone of cells with metastatic potential.

Most melanomas occur sporadically, but a few are hereditary (with reported rates ranging from less than 5% to 10%). Molecular genetic analysis of familial and sporadic cases has provided important insights into the pathogenesis of melanoma. As with other tumors, malignant transformation of melanocytes is a multistep process that involves activating mutations in proto-oncogenes and loss-of-function mutations in tumor suppressor genes. Germline mutations in the *CDKN2A* gene (located on 9p21) are found in as many as 40% of the rare individuals who suffer from familial melanoma. This gene encodes the tumor suppressor p16, a cyclin-dependent kinase inhibitor that regulates the $G_1$-S transition of the cell cycle in a retinoblastoma protein–dependent fashion (Chapter 5). The *CDNK2A* gene also is silenced in some sporadic tumors by methylation. Somatic activating mutations in the proto-oncogenes *BRAF* or *NRAS* are observed in a high proportion of melanomas. These mutations, which promote cellular proliferation and survival by activating the extracellular signal–regulated protein kinase (ERK) pathway, generally are mutually exclusive, since *BRAF* functions downstream of *RAS*. Also frequently seen is loss of function of the tumor suppressor *PTEN,* an important negative regulator of PI3K-AKT pathway, which also promotes growth and survival. Some melanomas, particular those arising in acral and mucosal sites, have activating mutations in the c-KIT receptor tyrosine kinase. Agents that selectively inhibit mutant BRAF and c-KIT have produced dramatic responses in patients with metastatic tumors with BRAF and c-KIT mutations, respectively, an encouraging example of molecularly targeted therapy in an otherwise hopeless disease.

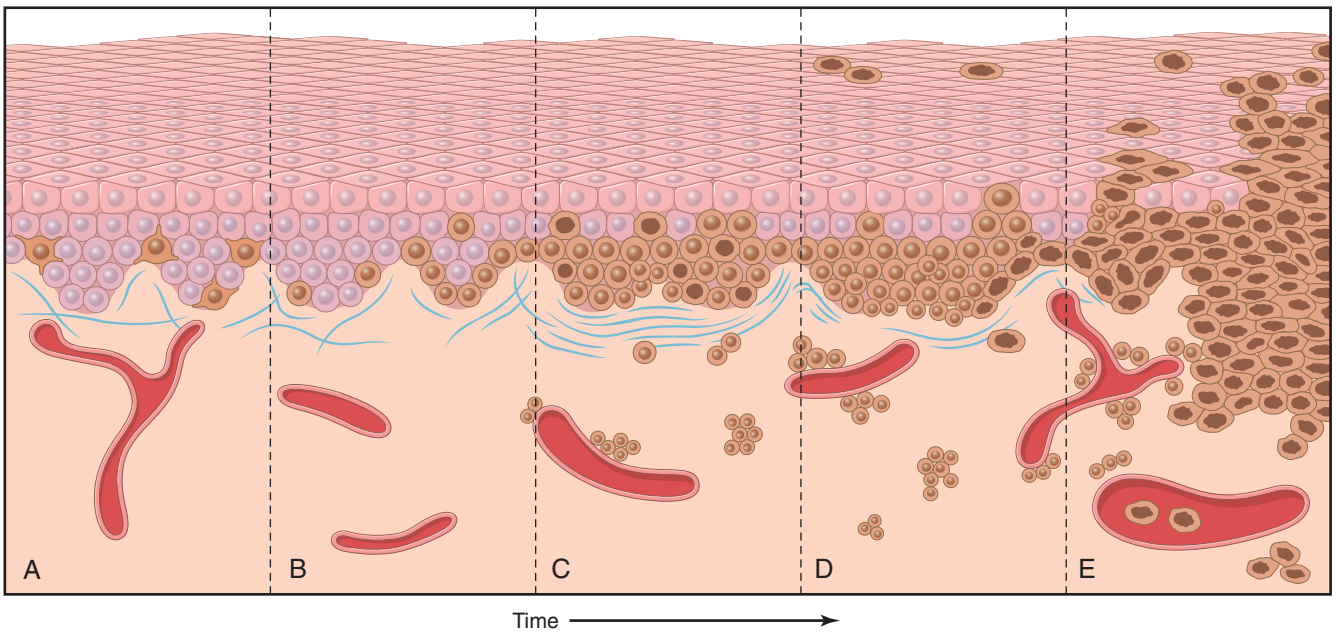


**Figure 23–21** Possible steps in development of melanoma. **A,** Normal skin shows only scattered melanocytes. **B,** Lentiginous melanocytic hyperplasia. **C,** Lentiginous compound nevus with abnormal architecture and cytologic features (dysplastic nevus). **D,** Early or radial growth phase melanoma (*large dark cells* in epidermis) arising in a nevus. **E,** Melanoma in vertical growth phase with metastatic potential. Note that no melanocytic nevus precursor is identified in most cases of melanoma. They are believed to arise de novo, perhaps all using the same pathway.

## MORPHOLOGY

Unlike benign nevi, melanomas exhibit **striking variations in pigmentation,** including shades of black, brown, red, dark blue, and gray (Fig. 23–22, *A*). The **borders are irregular** and often "notched."

Microscopically, malignant cells grow as poorly formed nests or as individual cells at all levels of the epidermis (pagetoid spread) and in expansile dermal nodules; these constitute the radial and vertical growth phases, respectively (Fig. 23–22, *B* and *C*). Of note, superficial spreading melanomas are often associated with a brisk lymphocytic infiltrate (Fig. 23–22, *B*), a feature that may reflect a host response to tumor-specific antigens. **The nature and extent of the vertical growth phase determine the biologic behavior of melanomas.** By recording and using these and other variables in aggregate, accurate prognostication is possible.

Individual melanoma cells usually are considerably larger than nevus cells. They have large nuclei with irregular contours, chromatin that is characteristically clumped at the periphery of the nuclear membrane, and prominent "cherry red" eosinophilic nucleoli (Fig. 23–22, *D*). Immunohistochemical stains can be helpful in identifying metastatic deposits (Fig. 23–22, *D, inset*).

### Clinical Features

Although most of these lesions arise in the skin, they also may involve the *oral* and *anogenital mucosal surfaces,* the *esophagus,* the *meninges,* and the *eye.* The following comments apply to cutaneous melanomas.

Melanoma of the skin usually is asymptomatic, although pruritus may be an early manifestation. *The most important clinical sign is a change in the color or size of a pigmented lesion.* The main clinical warning signs are

1. Rapid enlargement of a preexisting nevus
2. Itching or pain in a lesion
3. Development of a new pigmented lesion during adult life
4. Irregularity of the borders of a pigmented lesion
5. Variegation of color within a pigmented lesion

These principles are expressed in the so-called ABCs of melanoma: *a*symmetry, *b*order, *c*olor, *d*iameter, and *e*volution (change of an existing nevus). It is vitally important to recognize melanomas and intervene as rapidly as possible. The vast majority of superficial lesions are curable surgically, while metastatic melanoma has a very poor prognosis.

The probability of metastasis is predicted by measuring the depth of invasion in millimeters of the vertical growth phase nodule from the top of the granular cell layer of the overlying epidermis (Breslow thickness). Metastasis risk also is increased in tumors with a high mitotic rate and in those that fail to induce a local immune response. When metastases occur, they involve not only regional lymph nodes but also liver, lungs, brain, and virtually any other site that can be seeded hematogenously. Sentinel lymph node biopsy (of the first draining node[s] of a primary melanoma) at the time of surgery provides additional information on biologic aggressiveness.

In some cases, metastases may appear for the first time many years after complete surgical excision of the primary tumor, suggesting a long phase of dormancy, during which time the tumor may be held in check by the host immune response. Recognition of the likely role of the host immune response has led to therapeutic trials of immunomodulators. Some impressive responses in patients with advanced

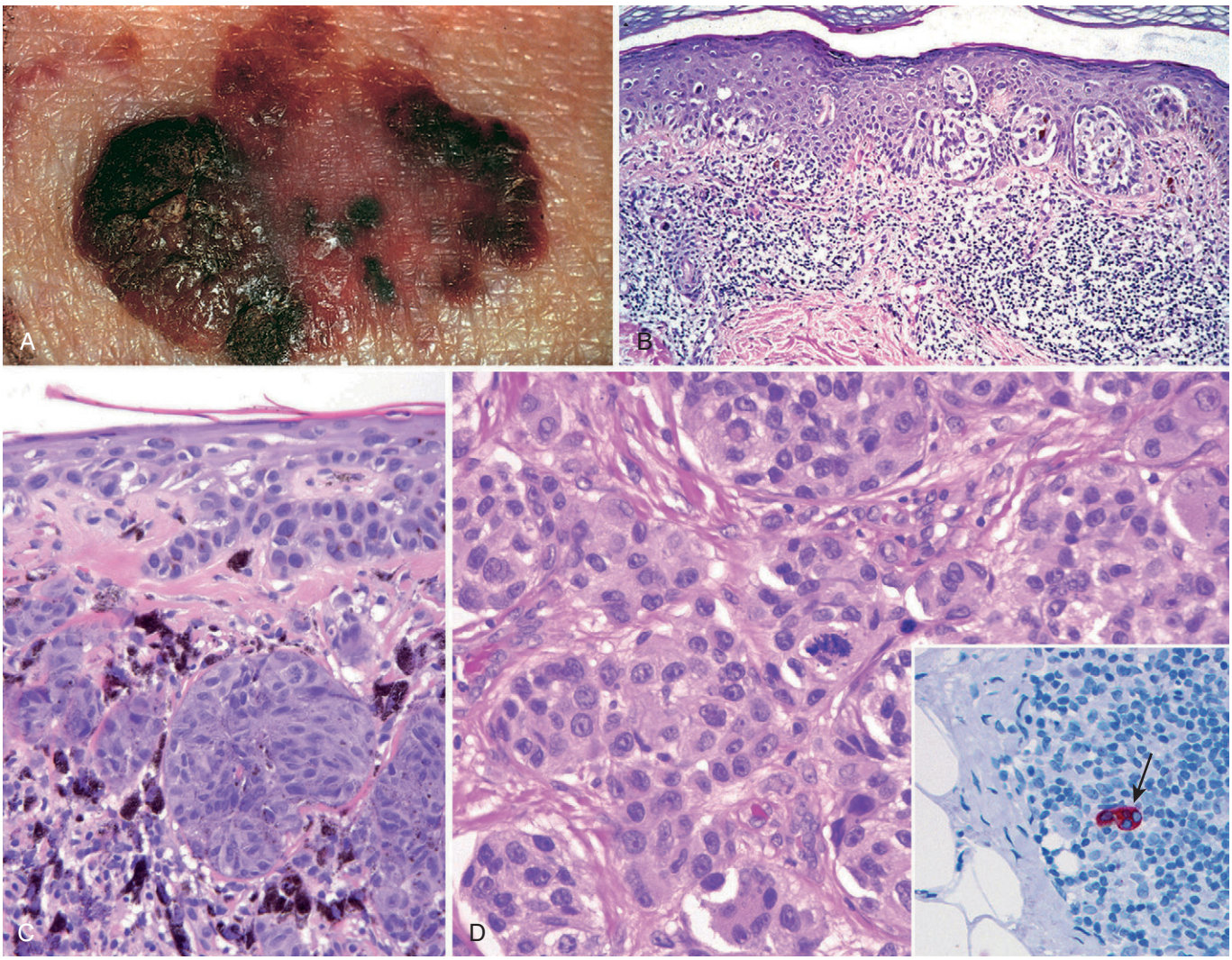


**Figure 23–22** Melanoma. **A,** On clinical evaluation, lesions tend to be larger than nevi, with irregular contours and pigmentation. Macular areas indicate early superficial (radial) growth, while elevated areas often indicate dermal invasion (vertical growth). **B,** Radial growth phase, with spread of nested and single-cell melanoma cells within the epidermis. **C,** Vertical growth phase, with nodular aggregates of infiltrating tumor cells within the dermis (epidermis is on the *right*). **D,** Melanoma cells have hyperchromatic nuclei of irregular size and shape with prominent nucleoli. Mitoses, including atypical forms such as seen in the center of this field, often are encountered. The *inset* shows a sentinel lymph node containing a tiny cluster of metastatic melanoma cells (*arrow*), detected by staining for the melanocytic marker HMB-45.

melanoma have been seen, especially to antibodies that block endogenous inhibitors of immune responses such as CTLA-4 and PD-1, and thus "release the brakes" on host antitumor immunity.

## SUMMARY

### Melanocytic Lesions, Benign and Malignant

- Most *melanocytic nevi* have activating mutations in *BRAF* or less often *NRAS*, but the vast majority never undergo malignant transformation.
- Most sporadic *dysplastic nevi* are best regarded as markers of melanoma risk rather than premalignant lesions. They are characterized by architectural and cytologic atypia.
- *Melanoma* is a highly aggressive malignancy; tumors only a few millimeters in thickness can give rise to deadly metastases.
- In most cases, melanoma progresses from an intraepithelial (in situ) to an invasive (dermal) form. Characteristics of the dermal tumor such as depth of invasion and mitotic activity correlate with survival.

## BIBLIOGRAPHY

Curtin JA, Fridlyand J, Kageshita T, et al: Distinct sets of genetic alterations in melanoma. N Engl J Med 353:2135, 2005. *[A modified classification of melanoma based on both clinical and genetic features. Such molecular classification schemes are critical for progress in targeted therapy.]*

Elder DE: Dysplastic nevi: an update. Histopathology 56:112, 2010. *[Balanced presentation of the histology and pathogenesis of dysplastic nevi and their relationship to melanoma.]*

Epstein EH: Basal cell carcinomas: attack of the hedgehog. Nat Rev Cancer 8:743, 2008. *[Epidemiology, clinical presentation, molecular pathogenesis, and novel treatment options are succinctly reviewed.]*

Ibrahim N, Haluska FG: Molecular pathogenesis of cutaneous melanocytic neoplasms. Annu Rev Pathol 4:551, 2009. *[The genetic pathways relevant to melanoma suggest future therapeutic interventions.]*

Kupper TS, Fuhlbrigge RC: Immune surveillance in the skin: mechanisms and clinical consequences. Nat Rev 4:211, 2004. *[Lymphocytic subtypes and targeting in relation to cutaneous inflammatory diseases providing insight into common pathogenic features.]*

Nestle FO, Kaplan DH, Barker J: Psoriasis. N Engl J Med 361:496, 2009. *[Pathogenesis, clinical features, and new targeted treatment options are discussed.]*

Khavari PA: Modelling cancer in human skin tissue. Nat Rev Cancer 6:270, 2006. *[Models of human epidermal carcinogenesis indicate that multiple mutations in specific pathways are required for malignant transformation.]*

Tsai KY, Tsao H: The genetics of skin cancer. Am J Med Genet 131C:82, 2004. *[The genetic bases for skin malignancies are presented along with their associations with predisposing human genetic syndromes that provide insight into their pathogenesis.]*

Ujiie H, Shibaki A, Nishie W, Shimizu H. What's new in bullous pemphigoid. J Dermatol 37:194, 2010. *[Recent review of bullous pemphigoid pathogenesis.]*

Yokoyama T, Amagai M. Immune dysregulation of pemphigus in humans and mice. J Dermatol 37:205, 2010. *[A review of immune disturbances that may underlie pemphigus.]*

# Index


A
AAT ($\alpha_1$-antitrypsin deficiency)
  clinical course of 632
  inherited metabolic diseases and 631–632
  morphology of 632b, 632f
  pathogenesis of 631b
Abdominal aortic aneurysm (AAA)
  clinical consequences of 346
  morphology of 346b, 346f
Abdominal hernia 574
Abetalipoproteinemia 580
ABL 180
ABO incompatibility 254
Acalculous cholecystitis, acute 641
Acetaminophen 284, 287
Achondroplasia 767–768
Acquired immunodeficiency syndrome (AIDS). *See also* Human immunodeficiency virus (HIV)
  epidemiology of 143–144
    mother-to-infant transmission of 144
    parenteral transmission of 144
    sexual transmission of 144
  etiology and pathogenesis of 144–149
  introduction to 143–153
  morphology of 152b
  summary for 149b–150b
Acquired metabolic and toxic disturbances
  metabolic disorders as 835
  nutritional diseases as 835
  toxic disorders as 835–836
Actinic keratosis
  clinical features of 857
  as epithelial lesions of the skin 862–863
  morphology of 862b, 863f
Acute lymphoblastic leukemia (ALL)
  clinical features of 431
  genetic features of 433
  immunophenotypic features of 433
  laboratory findings in 431–433
  lymphoid neoplasms and 430–433
  morphology of 431b–433b, 433f
  pathogenesis of 431b
  prognosis for 433
Acute myeloid leukemia (AML) 431, 431b–433b. *See also* Acute lymphoblastic leukemia (ALL)
  classification of 444–445, 445t
  immunophenotype of 433f, 445
  morphology of 433f, 444b, 445f
  as myeloid neoplasms 444–445
  pathogenesis of 444b
  prognosis for 445
  summary for 448–449
Acute respiratory distress syndrome (ARDS)
  acute lung injury and 461, 461t
  clinical features of 461
  morphology of 461b, 463f
  pathogenesis of 461b, 462f
  summary for 462b
Acute tubular injury (ATI)
  clinical course of 538
  diseases affecting tubules/interstitium and 537–538
  morphology of 538b
  pathogenesis of 537b–538b, 537f
  summary for 538b
Acute viral pericarditis 403b
Adaptive immunity 99–100
Adenocarcinoma, clear cell 685
Adenocarcinoma, ductal 653b–654b
Adenocarcinoma in situ (AIS)
  lung tumors and 506b–509b, 508f
Adenocarcinoma of the colon
  clinical features of 598–599, 599f, 600t
  colonic polyps and 596–599
  epidemiology of 597–599, 597f–598f
  morphology of 598b, 599f
  pathogenesis of 596t, 597b–598b
  summary for 600b
Adenoma
  of the colon
    morphology of 594b–595b, 595f
    summary for 600b
  of the thyroid
    clinical features of 730
    introduction to 729–730
    morphology of 729b–730b, 730f
    pathogenesis of 729b
Adenoma, growth hormone producing 719–720
Adenoma, Hürthle cell 729b–730b
Adenomyosis 689
  summary for 691
Adenosine triphosphate (ATP). *See* ATP
Adenosquamous carcinoma 653b–654b
Adhesion 30t, 35–36, 35f, 36t
Adhesion receptor 64
Adipose tissue 304–305
Adrenal cortex
  adrenal insufficiency and 757–759
  adrenocortical hyperfunction and 752–757
  adrenocortical neoplasms and 759
  endocrine system and 752–759
Adrenal insufficiency (hypoadrenalism)
  acute adrenocortical insufficiency and 757
  and the adrenal cortex 757–759
  chronic adrenocortical insufficiency and 757–758
  secondary adrenocortical insufficiency and 758–759
  summary for 759b
Adrenal medulla
  and endocrine system 760–761
  tumors of 760–761
Adrenocortical adenoma 754f, 759b–760b
Adrenocortical carcinoma 759b–760b, 759f


Page numbers followed by "f" indicate figures, "t," tables; "b," boxes.

Adrenocortical hyperfunction (hyperadrenalism)
and adrenal cortex 752–757
adrenogenital syndromes and 756–757
hyperaldosteronism and 755–756
hypercortisolism/Cushing syndrome and 752–755
Adrenocortical insufficiency, acute 757, 757f, 757t
Adrenocortical insufficiency, chronic 757–758, 757t
Adrenocortical insufficiency, secondary
and adrenal insufficiency 758–759
clinical features of 758–759
morphology of 758b, 758f
Adrenocortical neoplasm
and the adrenal cortex 759
morphology of 759b–760b
Adrenocorticotropic hormone producing adenoma 719–720
Adrenogenital syndrome
and adrenocortical hyperfunction 756–757
clinical features of 756–757
morphology of 756b
summary for 757b
Adverse drug reaction (ADR)
acetaminophen as 284
aspirin as 284
discussion of 282–284, 282f, 283t
exogenous estrogens as 282–283
oral contraceptives as 283–284
summary for 287b
Aganglionic megacolon, congenital 574b
Age, cancer and 171
Agenesis 646
Agranulocytosis 425–426
AIDS. *See* Acquired immunodeficiency syndrome
Air embolism 91–92
Air pollution
indoor air pollution as 273
outdoor air pollution as 272–273
Alcohol
effects of 280–282, 281f
summary for 282b
tobacco and 279
Alcoholism, chronic 280–282
malnutrition and 293
Allergy. *See* Hypersensitivity, immediate (Type 1)
Allograft, immune recognition of 135–136
Allograft arteriopathy 405, 405f
Alzheimer disease (AD)
morphology of 838b, 838f
neurodegenerative disease and 836–837
pathogenesis of 837b–838b, 837f
Amebiasis 830–831
Amniotic fluid embolism 91, 91f
Amyloid of aging 156
Amyloidosis. *See also* Misfolded protein
classification of 154–158, 155t
immune system and 153–158
morphology of 156b–158b, 157f
pathogeneses of 153b–154b, 153f–154f
restrictive cardiomyopathy and 401
Amyloidosis, familial 155–156
Amyloidosis, localized 156
Amyloidosis, secondary 154–155
Amyloidosis, senile cardiac 156
Amyloidosis, senile systemic 156
Amyotrophic lateral sclerosis (ALS)
morphology of 841b
neurodegenerative diseases and 841
pathogenesis of 841b
Anaplasia, neoplasm characteristics and 164–166
Anaplastic carcinoma of the thyroid
clinical features of 734
introduction to 734
morphology of 734b
pathogenesis of 731
summary for 735
Anaplastic meningiomas 846b
Anemia
of chronic disease
as anemia of diminished erythropoiesis 421
clinical features of 421
pathogenesis of 421b
summary for 424
of diminished erythropoiesis
anemia of chronic disease as 421
aplastic anemia as 424
iron deficiency anemia as 420–421
megaloblastic anemia as 422–423
myelophthisic anemia as 424
red cell disorders and 419–424
summary for 424b–425b
pathology of 409b
red cell disorders and 408–425
Anemia, aplastic
clinical course of 424
diminished erythropoiesis and 424
morphology of 424b
pathogenesis of 424b
summary for 425
Anemia, cold antibody immunohemolytic
immunohemolytic anemias as 418
Anemia, folate deficiency
clinical features of 423
as megaloblastic anemia 422–423
pathogenesis of 422b
Anemia, immunohemolytic
cold antibody immunohemolytic anemias and 418
as hemolytic anemia 417–418, 417t
summary for 419
warm antibody immunohemolytic anemias and 417–418
Anemia, pernicious 423, 423b. *See also* Vitamin $B_{12}$ deficiency anemia
Anemia, warm antibody immunohemolytic 417–418
Aneuploidy 175
Aneurysm 344–348, 344f
pathogenesis of 344b–345b, 345f
summary for 348b
Aneurysm, berry 330
Aneurysm, saccular 817–818, 818f
morphology of 818b, 818f
Angelman syndrome 243–245, 244f
Angina, unstable 376
Angina pectoris 376
Angiodysplasia 576
Angiogenesis
growth factors involved in 67
scar formation and 66–67, 67f
Angiogenesis, sustained
development of 191–192
summary for 192b
Angiosarcoma 361–362, 361f
morphology of 362b
Anitschkow cells 391b
Annular pancreas 646
Anorexia nervosa 295–296

Antibody-mediated disease
hypersensitivity reactions and 111, 114–115, 114t
mechanisms of 114–115, 115f
summary for 114b
Anti-endothelial cell antibody 350
Antigen-presenting cell (APC)
dendritic cells as 104
immune system and 104
other cells as 104
summary for 105
Anti-inflammatory drugs
prostaglandin production blockage by 46–47
Anti-neutrophil cytoplasmic antibody (ANCA) 349–350
Antiphospholipid antibody syndrome 87–88
Antitumor effector mechanism
cytotoxic T lymphocytes as 206
humoral mechanisms as 206–207
macrophages as 206
natural killer cells as 206
Aortic stenosis, calcific
clinical features of 390
degenerative valve disease and 389–390
morphology of 389f, 390b
Aortic valve sclerosis 390b
Aphthous ulcers (canker sores) 552, 552f
Apoptosis
causes of
in pathologic conditions 18
in physiologic situations 18
cell death and 18–22
evasion of cell death and 189f
summary for 190b
examples of 20–22
mechanisms of
activation and function of caspases as 19
clearance of apoptotic cells and 20
death receptor pathway of 19
introduction to 19–20, 20f
mitochondrial pathway of 19
morphology of 18b, 19f
summary of 22b
TP53 gene and 187b
Apoptotic cell, clearance of 20
Appendicitis, acute
the appendix and 600–601
clinical features of 601
morphology of 601b
pathogenesis of 600b–601b
Appendix
acute appendicitis and 600–601
summary for 601b
tumors of 601
Arachidonic acid (AA) metabolite 46–47, 46t, 47f, 50
Arbovirus 827
morphology of 827b, 827f
Arrhythmia
heart disease and 385–386
myocardial infarction complications and 384
sudden cardiac death and 386
summary for 386b
Arrhythmogenic right ventricular cardiomyopathy (ARVC)
dilated cardiomyopathy as 399–400, 399f
Arsenic 275–276
Arteriolosclerosis, hyaline 333b–334b
diabetes and 744, 746–747, 746f
Arterionephrosclerosis
as blood vessel disease of the kidney 539
clinical course of 539
morphology of 539b, 539f
pathogenesis of 539b
summary for 541
Arteriosclerosis 335
Arteriovenous (AV) fistula 330
Arteritis, Takayasu
clinical features of 351–352
morphology of 351b
vasculitis and 351–352, 351f
Arthritis
gout as 786–789
infectious arthritis as 789–790
juvenile rheumatoid arthritis as 786
osteoarthritis and 782–783
rheumatoid arthritis as 784–786
seronegative spondyloarthropathies as 786
summary for 790b
Arthritis, chronic tophaceous 786b–787b, 787f
Arthritis, infectious
the joints and 789–790
Lyme arthritis as 789–790
suppurative arthritis as 789
Arthritis, Lyme 789–790
Arthritis, suppurative 789
Asbestosis
clinical features of 477–478
morphology of 477b, 477f–478f
pathogenesis of 477b
as pneumoconiosis 477
summary for 478
Aschoff bodies 391b
Ascites
pathogenesis of 609b
and portal hypertension 609
Ascorbic acid. *See* Vitamin C
Aseptic meningitis 825
Aspergillus fumigatus 829
Aspiration pneumonia 488t, 492
Aspirin (acetylsalicylic acid) 284
Aspirin toxicity, chronic (salicylism) 284
Asthma
clinical features of 470
morphology of 469f–470f, 470b
as obstructive lung disease 468–470
pathogenesis of 468b, 469f
summary for 470b
types of 468–470
Asthma, atopic 468
Asthma, drug-induced 470
Asthma, non-atopic 468–470
Astrocytoma 842–843
morphology of 842b, 843f
Astrocytoma, diffuse 842
Asymptomatic hematuria 518
Atelectasis, compression 460
Atelectasis, contraction 460
Atelectasis of lung 460, 460f
Atherosclerosis. *See also* Atherosclerotic plaque
blood vessels and 335–343, 336f
clinical consequences of 342–343, 342f
epidemiology of
additional risk factors for 337–338, 338f
constitutional risk factors for 336
discussion of 335–338, 336t
modifiable major risk factors for 336–337, 337f
morphology of 340b–342b, 340f–341f
pathogenesis of 338b–340b, 339f
summary for 343b–344b

Atherosclerotic plaque
acute plaque change and 342–343, 342f–344f
atherosclerosis morphology and 340b–342b, 341f
Atherosclerotic stenosis 342
ATP, depletion of 12–13, 13f, 16
Atrial septal defect (ASD)
clinical features of 369t, 371
left-to-right shunts and 370–371
morphology of 371b
Atrophy 4–5, 4f
summary for 5b
Atypical adenomatous hyperplasia (AAH) 506b–509b
Autoimmune disease
immune system and 120–135, 121t
immunologic tolerance and 121–122
inflammatory myopathies and 135
mechanisms of autoimmunity and 122–125
mixed connective tissue disease and 135
polyarteritis nodosa/other vasculitides and 135
rheumatoid arthritis 131
Sjögren syndrome and 131–132
systemic lupus erythematosus and 125–131
systemic sclerosis and 132–134
Autoimmune regulator (AIRE) 121
Autoimmunity
genetic factors in 123, 123t–124t
infections and tissue injury and 123–125
mechanisms of 122–125, 123f
self antigens and 110
summary for 124b
Autophagy 22–23, 23f
evasion of cell death and 190
Autosomal dominant cancer syndrome 171–172, 172t
Autosomal dominant inheritance disorder 219–220
Autosomal dominant polycystic kidney disease
clinical course of 543–544
cystic diseases and 542–544
morphology of 543b, 543f
pathogenesis of 542b–543b
summary for 544
Autosomal recessive inheritance disorder 220
Autosomal recessive syndrome
of defective DNA repair 172
Autosplenectomy 412b–413b
Axonal neuropathy 797, 800

B

Bacillary angiomatosis 359, 359f
Bacteria 311–313, 311f–312f, 312t
normal microbiome and 313
Bacterial injury, mechanisms of
adherence to host cells as 320
bacterial toxins as 321, 321f
bacterial virulence as 320
virulence of intracellular bacteria as 320–321
Bacterial meningitis. *See* Pyogenic meningitis, acute
Bacterial pyelonephritis 438b–439b
Balanced translocation 174, 177
Barrett esophagus
clinical features of 562, 564
morphology of 561–562, 561b–562b, 561f
Barrett metaplasia 133–134
Basal cell carcinoma
clinical features of 864
malignant epidermal tumors and 864
morphology of 864b, 865f
pathogenesis of 864b
B cell
HIV infection progression and 149
systemic sclerosis and 127t, 133
B cell non-Hodgkin lymphoma 152
Becker muscular dystrophy (BMD)
clinical features of 803–804
dystrophinopathy and 802–804
morphology of 802b, 804f
pathology of 802b–803b, 802f
Benign prostatic hyperplasia (BPH)
clinical features of 664–665
diseases of the prostate and 664–665
morphology of 664b, 665f
summary for 665b
Beta cell dysfunction 743
Beta cell tumor. *See* Insulinoma
Bile acid 605–606. *See also* Bilirubin
Biliary atresia
clinical course of 642–643
extrahepatic bile ducts and 642–643
Biliary cirrhosis, secondary 642
Bilirubin
jaundice/cholestasis and 605–606, 605f
pathogenesis of 606b, 606t
Bioterrorism 315, 315t
Blastomycosis 499–500
Bleeding disorder
coagulation disorders as 454–455
disseminated intravascular coagulation as 450–452
hematopoietic system and 449–455
summary of 456b
thrombocytopenia as 452–454
Blistering (bullous) disorder
bullous pemphigoid as 859–861
dermatitis herpetiformis as 861
pemphigus as 858–859
the skin and 857–861, 858f
summary for 862b
Blood flow, abnormal 86
Blood flow into liver, impaired
hepatic artery inflow as 632
portal vein obstruction and thrombosis as 632–633
Blood flow through liver, impaired
circulatory disorders and 633
passive congestion and centrilobular necrosis as 633
Blood pressure regulation 330–331, 331f–332f
summary for 331b
Blood vessel
aneurysms/dissections and 344–348
arteriosclerosis and 335
atherosclerosis and 335–343
blood pressure regulation and 330–331
congenital anomalies and 330
disease of the kidney
arterionephrosclerosis as 539
introduction to 538–541
malignant hypertension as 539–540
summary for 541b
thrombotic microangiopathies as 540–541
disorders of hyperactivity of
myocardial vessel vasospasm as 355
Raynaud phenomenon as 355
disorders of hyperreactivity of 355
hypertensive vascular disease and 332–333
structure and function of 327–330, 328f
endothelial cells and 329–330
summary for 330b
vascular smooth muscle cells and 330

tumors and 357–362
vascular intervention pathology and 362–363
vascular wall response to injury and 334–335
vasculitis and 348–355
veins/lymphatics and 356–357
B lymphocyte 101f, 105, 124
activation of 108–109
Body mass index (BMI) 303
Bone disease, acquired
hyperparathyroidism as 771
osteoporosis as 768–770
Paget disease as 770–771
rickets and osteomalacia as 771
summary for 772b
Bone-forming tumor
osteoid osteoma and osteoblastoma as 776
osteoma as 775–776
osteosarcoma as 776–777
Bones
acquired diseases of 768–771
congenital disorders of cartilage and 767–768
fractures of 772–773
introduction to 765–781, 766f
osteomyelitis and 773–774
osteonecrosis and 773
tumors of 774–781
Bowel, vascular disorders of
hemorrhoids as 576
intestines and 574–576
ischemic bowel disease as 574–576
summary for 576b
Brain abscess 826
morphology of 825f, 826b
Brain injury, perinatal 822–824, 824f
summary for 824b
Breast
of the female
fibrocystic changes of 705–706
breast carcinoma and 706
nonproliferative changes and 705
proliferative changes and 705–706
summary for 707b
inflammatory processes and 707
morphology of 707b
introduction to 704–714, 704f
tumors of 707–713
lesions of the male 714
Breast carcinoma, noninvasive 710
Brenner tumor 698
Bronchiectasis
clinical features of 472
morphology of 471b, 471f
as obstructive lung disease 470–472
pathogenesis of 471b
Bronchiolitis, chronic 467b–468b
Bronchiolitis obliterans organizing pneumonia (BOOP). *See* Pneumonia, cryptogenic organizing
Bronchitis, chronic
clinical features of 467
morphology of 467b, 467f
as obstructive lung disease 467
pathogenesis of 467b
summary for 467b–468b
Bruton disease. *See* X-linked agammaglobulinemia (XLA)
Budd-Chiari syndrome. *See* Hepatic vein thrombosis
Buerger disease. *See* Thromboangiitis obliterans
Bulimia 295–296
Bullous emphysema 466
Bullous pemphigoid
blistering disorders and 859–862
clinical features of 861
morphology of 860b–861b, 860f
pathogenesis of 860b
Burkitt lymphoma
clinical features of 437
immunophenotypic features of 437
lymphoid neoplasms 436–437
morphology of 437b, 437f
pathogenesis of 436b–437b
summary for 443

C

Cachexia, cancer and 208–209
Cadmium 276
Calcification, dystrophic 13f, 25–26
Calcification, pathological
apoptosis and 9, 25–26
dystrophic calcification as 25–26
metastatic calcification as 26
morphology of 26b
summary for 26b
Calcium, influx of 13, 14f, 16
Calculous cholecystitis, acute 641, 643
Campylobacter enterocolitis
clinical features of 583
infectious enterocolitis and 582–583
morphology of 582b, 582f
pathogenesis of 582b
Cancer
of the bladder
clinical features of 670–671
morphology of 667f, 669b–670b, 669f–670f, 670t
neoplasms of the bladder and 669–671
pathogenesis of 669b
diet and 306
environmental radiation and 292–293
epidemiology of
acquired preneoplastic lesions and 172
age and 171
geographic/environmental variables for 170–171
heredity and 171–172
incidence of 170, 170f
summary for 173b
etiology of 198–204
hallmarks of 161–162
introduction to 161–162
laboratory diagnosis of
molecular diagnosis of 211
molecular profiling of 211–213
morphologic methods for 210–211
summary of 213b
tumor markers and 211
neoplasia and 169–172
obesity and 305
occupational radiation and 293
Cancer, familial 172–173
Cancer, genetic lesions in
cancer-associated mutations and 173–176
epigenetic modifications and 175–176
karyotypic changes and 173–175
microRNAs and 175
summary for 176b–177b
Candida albicans 829

Candidiasis
clinical features of 502–503
morphology of 502b, 503f
as opportunistic fungal infection 502–503
Canker sores. *See* Aphthous ulcers
Capillary hemangioma 358, 358f
Carbon monoxide (CO) 273
morphology of poisoning by 273b
Carcinogenesis
ionizing radiation and 290
molecular basis of cancer and 173
multistep process of
ability to invade or metastasize and 192–195
cancer progression and 198, 199f
development of sustained angiogenesis and 191–192
evasion of cell death and 189–190
evasion of immune system and 196
genomic instability as enabler and 196–197
insensitivity to growth inhibitory signals and 182–188
limitless replicative potential and 190–191
neoplasia and 177, 177f–178f
reprogramming energy metabolism and 195–196
self-sufficiency in growth signals and 178–182
tumor-promoting inflammation as enabler and 197–198
Carcinogenic agent
chemical carcinogens as 199–200
etiology of cancer and 198–204
radiation carcinogenesis and 200–201
viral and microbial oncogenesis and 201–204
Carcinoid heart disease
morphology of 395b, 396f
pathogenesis of 395b
valvular heart disease and 394f
Carcinoid tumor
of the lung 510–511
morphology of 510b, 511f
of the stomach and 571–573
clinical features of 571–572
morphology of 571b, 572f
Carcinoma
of the adrenal cortex 753b–754b, 754f
of the cervix
cervical neoplasms as 687–688
clinical course of 688
morphology of 688b, 688f
of the female breast
clinical course of 712–713
discussion of 708–713
epidemiology and risk factors of 708–713, 708t
pathogenesis of 709b–710b
summary for 713b–714b
of the gallbladder
clinical features of 643
introduction to 643
morphology of 643b, 643f
of the larynx
and laryngeal tumors 514, 514f
of the lung
clinical course of 510
etiology and pathogenesis of 505b–506b
lung tumors as 505–510, 505t
morphology of 506b–509b, 507f–509f, 509t, 710b–712b
summary for 510b
of the male breast 714
of the prostate
clinical features of 667–668
introduction to 665–668
morphology of 666b–667b, 666f–667f
pathogenesis of 666b
summary for 668b
of the thyroid
anaplastic carcinoma and 734
follicular carcinoma and 733–734
introduction to 730–735
medullary carcinoma and 734–735
papillary carcinoma and 732–733
pathogenesis of 731b–732b, 731f
summary for 735b
of the vulva 683
morphology of 683b
summary of 684
Carcinoma, chromophobe-type renal cell 548b
Carcinoma, embryonal (of testis) 660b–662b, 661f
Carcinoma, endometrial
clinical course of 692
HRT and 282–283
morphology of 692b, 693f
obesity and 305
oral contraceptives and 283
pathogenesis of 692b
proliferative lesions and 692
summary for 692b–693b
Carcinoma, endometrioid 692b, 693f
Carcinoma, follicular
carcinomas and 733–734
morphology of 733b, 733f
pathogenesis of 731
summary for 734–735
Carcinoma, invasive 711–712
Carcinoma, invasive ductal 711–712, 711f
Carcinoma, invasive lobular 711–712
Carcinoma, large cell
lung tumors and 506b–509b
Carcinoma, lymphoepithelioma-like 457b
Carcinoma, medullary 711–712, 712f
of the thyroid
clinical features of 734–735
introduction to 734–735
morphology of 734b, 734f–735f
pathogenesis of 731–732
summary for 735
Carcinoma, tubular 711–712
Cardiac angiosarcoma 405
Cardiac cirrhosis 368
Cardiac transplantation 405, 405f
rejection of 402f, 405
Cardiac tumor 404–405
Cardiac tumor, primary 404–405
Cardiac valve, mechanical 395
Cardiogenic shock 94
Cardiomyopathy
dilated cardiomyopathy as 397–400
heart disease and 396–403, 397f, 397t
hypertrophic cardiomyopathy as 400–401
myocarditis as 401–403
restrictive cardiomyopathy as 401
summary for 403b
Carpal ligaments of wrist 157–158
Carrier state, viral hepatitis and 620
Cartilage-forming tumor
bone tumors and 777–779
chondroma as 778
chondrosarcoma as 778–779
osteochondroma as 777–778
Caspases, activation and function of 19
Caspases, executioner 189

Cat-scratch disease 428
morphology of 428b
Cavernous hemangioma 358f, 359
CD4+ T cell
HIV life cycle and 147, 147t, 149
inflammatory reactions and 106f, 118–119, 120b
T lymphocyte effector function and 107–109
Celiac disease
clinical features of 579
and malabsorptive diarrhea 577–579
morphology of 578b–579b, 579f
pathogenesis of 578b, 578f
summary for 580
Celiac sprue. *See* Celiac disease
Cell cycle, normal 180–182, 181f, 185f
Cell cycle control protein 182
Cell death. *See also* Apoptosis
overview of 6
Cell death, evasion of 189–190, 189f
autophagy and 190
summary for 190b
Cell-derived mediator
arachidonic acid metabolites as 46–47, 46t, 47f
chemical mediators/regulators of inflammation and 46–49
cytokines as 48–49
lysosomal enzymes of leukocytes as 49
neuropeptides as 49
nitric oxide as 49
platelet-activating factor as 47–48
reactive oxygen species as 49
summary of 50b
vasoactive amines as 46–49
Cell injury
causes of 6–7
clinicopathologic correlation examples for
chemical injury as 17–18
ischemia-reperfusion injury as 17
ischemic and hypoxic injury as 17
mechanisms of
accumulation of oxygen-derived free radicals as 14–15
damage to DNA and proteins as 16
defects in membrane permeability as 16
depletion of ATP as 12–13
influx of calcium as 13
introduction to 11–16, 12f
mitochondrial damage and dysfunction as 13
summary for 16b
morphology of
introduction to 6f, 7t, 8–11, 8f
necrosis and 9
patterns of tissue necrosis and 9–11
reversible injury and 8
summary for 11b
morphology of cell and tissue injury and 2f, 8, 11
overview of 6
reversible injury and
morphology of 6f, 8b–9b, 9f
Cell proliferation
control of 59, 59f
Cellular adaptation to stress
atrophy as 4–5
hyperplasia as 4
hypertrophy as 3–4
metaplasia as 5
summary for 5b
Cellular aging 26–28, 27f
cell injury and 7
summary for 28b
Cellular event, leukocyte recruitment/activation as 34–39
Cellular protein, overexpressed 205
Cellular rejection, acute 137f, 138
Cellular response
to stress and noxious stimulus 1–3, 2f
Central nervous system (CNS)
acquired metabolic and toxic disturbances of 835–836
AIDS involvement and 152–153, 152b
cerebrovascular disease of 814–819
congenital malformations/perinatal brain injury and 822–824
edema, herniation, hydrocephalus and 812–814
HIV pathogenesis and 149
infections of 824–831
neurodegenerative diseases and 836–841
patterns of injury in 811
primary disease of myelin and 832–834
SLE morphology and 130
trauma and 820–822
tumors of 842–847
Central neurocytoma 844
Central pontine myelinolysis 834
Centriacinar emphysema 464, 464f, 465b
Centric pancreatitis, idiopathic duct 650b
Centrilobular hepatic necrosis 284
Centrilobular necrosis
circulatory disorders of liver and 633
morphology of 633b, 633f
Cerebral amyloid angiopathy (CAA) 817
Cerebral ischemia, focal 815–816, 816f, 819
morphology of 812f, 816b–817b
Cerebral toxoplasmosis 829–831
morphology of 829b–830b, 830f
Cerebrovascular disease
central nervous system and 814–819
hypoxia, ischemia, infarction and 814–816
intracranial hemorrhage and 817–818
other vascular diseases of 819
summary of 819b
Cervical intraepithelial neoplasia (CIN) 686, 686t, 687b
Cervical neoplasia
cervical pathology and 685–689, 685f
invasive carcinoma as 687–688
morphology of 687b, 687f–688f
pathogenesis of 685b–686b, 686f
summary of 688b–689b
Cervicitis
cervical pathology and 685
morphology of 685b
sexually transmitted diseases and
summary for 676b
Cervix
cervicitis and 685
neoplasia of 685–689
pathology of 685–689
Chagas myocarditis 402b, 402f
Chamber dilation 384
Chancroid (soft chancre)
morphology of 677b
sexually transmitted disease and 677
summary for 677b
Channelopathy 805
Chemical agent
cell injury and 7
toxicity of 271–272
Chemical carcinogen
direct-acting agents as 199
etiology of cancer and 199–200, 199t

Chemical carcinogen *(Continued)*
indirect-acting agents as 171t, 199–200
mechanisms of action of 200
summary for 200b
Chemical (toxic) injury 17–18
Chemical mediator, inflammation and 44–53, 45f, 45t
Chemokines 48–49
Chemotaxis 36–37, 37f
Chlamydia 311–313
Chloracne 276–277
Cholangiocarcinoma
clinical features of 644
extrahepatic biliary ducts and 643–644
morphology of 644b, 644f
Cholangitis 642
Cholecalciferol 298–299
Cholecystitis
acute acalculous cholecystitis and 641
chronic cholecystitis and 641–642
clinical features of 641–642
inflammation of gallbladder as 641–642
morphology of 641b
Cholecystitis, chronic 641–642
Choledocholithiasis 642
Cholelithiasis (gallstones)
clinical features of 641
gallbladder diseases and 639–641, 643
morphology of 640b, 640f
pathogenesis of 639b–640b
Cholera
clinical features of 582
infectious enterocolitis and 582
pathogenesis of 582b
Cholestasis. *See also* Jaundice
liver disease and 605–606
of sepsis 626–627, 626f
summary for 606b
Cholestasis, drug/toxin-induced 629
Cholestasis, neonatal 626
Cholestatic liver disease
cholestasis of sepsis as 626–627
drug/toxin-induced cholestasis as 628–629
introduction to 626–629
neonatal cholestasis as 626
primary biliary cirrhosis as 627
primary sclerosing cholangitis as 628–629
Cholesterol 23
Cholesterol metabolism, normal 222–223, 222f
Cholesteryl esters 23
Chondrocalcinosis. *See* Pseudogout
Chondroma
as cartilage-forming tumor 778
clinical features of 778
morphology of 778b
pathogenesis of 778b
Chondrosarcoma
as cartilage-forming tumor 778–779
clinical features of 778–779
morphology of 778b, 779f
summary for 782
Choriocarcinoma 660b–662b, 661f
Choristoma 163, 257
Chromosomal disorder 236–237, 249–250
Chronic inflammatory demyelinating polyneuropathy (CIDP) 799, 800f
Chronic lymphocytic leukemia (CLL)
clinical features of 434
immunophenotypic and genetic features of 434
as lymphoid neoplasms 433–434
morphology of 434b, 434f
pathogenesis of 433b–434b
summary for 443
Chronic myelogenous leukemia (CML)
clinical features of 447
morphology of 446b
as myeloproliferative disorder 446
pathogenesis of 446b, 446f
protein-coating gene mutations and 216
Churg-Strauss syndrome 354
Chylothorax 511–512
Circulatory disorder
hepatic outflow obstruction as 634
impaired blood flow into the liver as 632–633
impaired blood flow through the liver as 633
the liver and 632–634, 632f
summary for 634b
Cirrhosis
chronic alcoholism and 281
clinical features of 608
liver disease and 606–607
obesity and 305
pathogenesis of 607b–608b, 608f
summary for 608b
Cirrhosis, posthepatitic 611b–614b
Climate change, health effects of 270f
Clotting factor, activation of 80
Coagulation 51–52, 51f, 52t
Coagulation cascade 83–86, 83f–84f
summary for 86b
Coagulation disorders
bleeding disorder and 454–455
deficiencies of factor VIII-von Willebrand factor complex as 454–455
Coagulation factor
inhibitory effects on 80, 81f
summary for 86b
Coal dust 277
Coal worker's pneumoconiosis (CWP)
clinical features of 475
morphology of 475b
as pneumoconiosis 474t, 475f
summary for 478
Coarctation, adult 373b, 374f
Coarctation, aortic
clinical features of 373–374
morphology of 373b
obstructive lesions and 373–374
Coarctation, infantile 373b
Cobalamin. *See* Vitamin $B_{12}$ deficiency anemia
Cocaine 284–285, 286f
Coccidioidomycosis 499–500
Colitis, indeterminate 591
Colitis, microscopic 580
Colitis, pseudomembranous
clinical features of 585
infectious enterocolitis and 584–585
morphology of 584b, 584f
Colitis, ulcerative
clinical features of 591
inflammatory bowel disease and 590–592
morphology of 590b–591b, 591f
Colitis-associated neoplasia 591–592
Collagen 63
Collagen vascular disease, pulmonary involvement in 474
Collapse of lung. *See* Atelectasis

Colloid carcinoma 711–712, 712f
Colloid goiter 728b
Colonic polyp
adenocarcinoma and 596–599
adenomas as 593–594
familial syndromes and 595–596
hamartomatous polyps as 592–593
hyperplastic polyps as 593
inflammatory polyps as 592
intestines and 592–599
summary for 600b
Comedo ductal carcinoma in situ 710, 710f
Complement protein 142
Complex multigenic disorder 234
Condyloma 683, 683f
Congenital adrenal hyperplasia (CAH). *See* Adrenogenital syndrome
Congenital anomalies
blood vessels and 330
etiology of 247–248, 247t
pathogenesis of 248b–249b
pediatric diseases and 245–248, 245t, 246f
summary for 249b
Congenital disorder (of cartilage and bone)
achondroplasia and thanatophoric dwarfism as 767
introduction to 767–768
osteogenesis imperfecta as 767
osteopetrosis as 767–768
summary for 768b
Congenital heart disease
clinical features of 370
the heart and 368–374, 369t
left-to-right shunts and 370–372
obstructive lesions as 373–374
pathogenesis of 369b, 369t
right-to-left shunts and 372–373
summary for 374b
Congenital syphilis 673–674
Congestion 75
morphology of 75b–76b, 76f
Congestive heart failure (CHF) 365–368, 366f
Congestive hepatomegaly 368
Congestive splenomegaly 368
Conidia 313
Connective tissue
deposition of 66f, 68
growth factors involved in 68
remodeling of 68
Connective tissue disease, mixed 135
Contact inhibition 187–188
Contractile dysfunction 383
Coombs test. *See* Human anti-globulin test
Copy number abnormality
array-based genomic hybridization and 264
fluorescence in situ hybridization and 264
molecular diagnosis of 263–264
Copy number variation (CNV) 216–217
Coronary artery occlusion 377
Cor pulmonale
morphology of 387f, 388b
pulmonary hypertensive heart disease as 388, 388t
Corticotroph cell 720. *See also* Adrenocorticotropic hormone producing adenoma
Crescendo angina. *See* Angina, unstable
Crescentic glomerulonephritis, anti-glomerular basement membrane antibody–mediated 532
morphology of 522f, 532b, 532f
Crescentic glomerulonephritis, Pauci-immune
clinical course of 533
morphology of 533b
as rapidly progressive glomerulonephritis 532–533
Crescentic glomerulonephritis, immune complex–mediated 532
morphology of 532b
Cretinism 723–724
Creutzfeldt-Jakob disease (CJD) 831
morphology of 831b, 832f
Crohn disease
clinical features of 590
morphology of 589b–590b, 589f–590f
summary for 592
Cryoglobulinemia 440
Cryptorchidism 658–659, 659b
Cryptococcosis
clinical features of 504
morphology of 503f, 504b
as opportunistic fungal infection 503–504
Cryptococcus neoformans 829, 830f
Cryptogenic fibrosing alveolitis. *See* Idiopathic pulmonary fibrosis (IPF)
Cushing syndrome
adrenocortical hyperfunction 752–755, 753f
clinical features of 754–755, 755f
morphology of 753b–754b, 754f
summary for 755b
Cyclin. *See also* Cyclin-dependent kinase (CDK)
alterations in cell cycle control proteins and 182
normal cell cycle and 180–182
self-sufficiency in growth signals and 180–182, 181f
Cyclin-dependent kinase (CDK)
alterations in cell cycle control proteins and 182
normal cell cycle and 180–181, 181f
self-sufficiency in growth signals and 178–182, 181f
Cyst
morphology of 705b, 705f
nonproliferative changes and 705
Cyst, dentigerous 557
Cyst, follicle 695
Cyst, luteal 695
Cyst, odontogenic 557–558
summary for 558b
Cyst, periapical 557–558
Cyst, simple 542
Cystic disease
autosomal dominant polycystic kidney disease and 542–544
autosomal recessive polycystic kidney disease and 544
of the kidney 542–544
medullary disease with cysts as 544
simple cysts and 542
summary for 544b
Cysticercosis 830
Cystic fibrosis (CF)
clinical course of 226–227, 226t
gene encoding mutations and 223–227
and malabsorptive diarrhea 577, 580
morphology of 224b–226b, 225f
pathogenesis of 223b–224b, 225f
summary for 227b
Cystic hygroma 255–257
Cytogenetic disorder
chromosomal disorders as 236–237
introduction to 234–241
involving autosomes 237–239
introduction to 237–239, 238f
22q11.2 deletion syndrome as 237–239

Cytogenetic disorder *(Continued)*
summary for 239b
trisomy 21 (Down syndrome) as 237
involving sex chromosomes 239–241
discussion of 239–241
Klinefelter syndrome as 239–240
summary for 241b
Turner syndrome as 240–241
numeric abnormalities as 235
structural abnormalities as 235–236
Cytokines 48–50, 48f
immune system messengers and 106–107
Cytologic (Papanicolaou) smear 210, 210f, 213
Cytomegalovirus (CMV) infection 828
cytomegalovirus mononucleosis as 501
immunosuppressed persons and 501
morphology of 501b, 501f
pneumonia and 500–501
Cytomegalovirus mononucleosis 501
Cytopathic-cytoproliferative reaction 324
morphology of 311f, 324b
Cytotoxic T lymphocyte (CTL)
as antitumor effector mechanisms 206
mediated apoptosis and 22

D

Death receptor pathway 19, 22
Degenerative joint disease. *See* Osteoarthritis
Degenerative valve disease
calcific aortic stenosis and 389–390
myxomatous mitral valve and 390–391
valvular heart diseases and 389–391, 389f
Delayed-type hypersensitivity (DTH) 117–119, 120f
Deletion, chromosomal 174–175
Demyelinating neuropathy 797, 798f
Dendritic cell (DC), HIV infection and 149
Dermatitis, acute eczematous
acute inflammatory dermatoses and 852–853
clinical features of 853
morphology of 853b, 853f
Dermatitis herpetiformis
blistering disorders and 861–862
morphology of 861b, 861f
pathogenesis of 861b, 861f
Dermatofibroma. *See* Histiocytoma, benign fibrous
Dermatomyositis 805, 806f
Dermatosis, acute inflammatory
acute eczematous dermatitis as 852–853
erythema multiforme as 853–854
summary for 856b
urticaria as 852
Dermatosis, chronic inflammatory
lichen planus as 855–856
lichen simplex chronicus as 856
psoriasis as 854–855
the skin and 854–856
summary for 856b
Dermatosis, infectious
bacterial infections as 856
fungal infections as 857
verrucae as 857
Desquamative interstitial pneumonia (DIP) 481
Diabetes mellitus
beta cell dysfunction and 743
classifications of 739, 740t
clinical features of 748–750, 749f, 750t
complications of 743–750, 745f
morphology of 744b–748b, 745f–746f
summary for 750b–751b
diagnosis of 739
endocrine pancreas and 739–750
genetic heterogeneity and 218–219
insulin resistance and 741–743
monogenic forms of 740t, 743, 750–751
in mothers 248
normal insulin physiology/glucose homeostasis and 739–740
pathogenesis of 741b
summary for 750b–751b
Diabetic embryopathy 248
Diabetic macrovascular disease 744
Diabetic microangiopathy 744–746
Diabetic nephropathy 744, 746–747, 746f
Diabetic neuropathy 747–748
Diabetic peripheral neuropathy 799–800
Diarrhea, malabsorptive
abetalipoproteinemia and 580
celiac disease and 577–579
cystic fibrosis and 577
diarrheal disease and 576–580, 577t
environmental enteropathy and 579
graft-*versus*-host disease and 580
irritable bowel syndrome and 580
lactase deficiency and 579–580
microscopic colitis and 580
summary for 580b
Diet, systemic diseases and 306
Differentiation, neoplasm characteristic of 164–166
Differentiation antigen, cell-type specific 206
Diffuse alveolar hemorrhage syndrome
Goodpasture syndrome as 485
idiopathic pulmonary hemosiderosis as 485
pulmonary angiitis and granulomatosis as 485
as pulmonary disease 485
DiGeorge syndrome 237–239. *See also* Thymic hypoplasia
Dilated cardiomyopathy (DCM)
arrhythmogenic right ventricular cardiomyopathy as 399–400
cardiomyopathy as 397–400
clinical features of 398–399
morphology of 398b, 399f
pathogenesis of 397b–398b, 398f
Disaccharidase. *See* Lactase deficiency
Dissection, aortic
clinical consequences of 347–348, 348f
discussion of 346–348, 347f
morphology of 345f, 347b
pathogenesis of 347b
summary for 348b
Disseminated intravascular coagulation (DIC)
bleeding disorders and 450–452
clinical course of 452
morphology of 452b
pathogenesis of 450b–451b, 451f, 452t
summary for 456
thrombosis and 90
DNA
apoptosis and 16, 18
carcinogenesis and 290, 291f
cellular aging and 26
damage to 16, 20–21
DNA repair defect by homologous recombination 197
DNA virus, oncogenic
Epstein-Barr virus as 202–203
human papillomavirus as 202

microbial/viral oncogenesis and 202–203
summary for 203b
Down syndrome. *See* Trisomy 21 (Down syndrome)
Drug abuse
cocaine and 284–285
heroin and 285–286
marijuana and 286–287
nontherapeutic toxic agents and 284–287, 285t
other illicit drugs and 287
summary for 287b
Drug myopathy 806
Dubin-Johnson syndrome 606
Duchenne muscular dystrophy (DMD)
clinical features of 803–804
dystrophinopathy and 802–804
morphology of 802b, 804f
pathology of 802b–803b, 802f
Ductal carcinoma in situ (DCIS) 710, 713
Dyslipoproteinemia 338–339
Dysplasia 165–166, 166f
Dysplastic nevus
clinical features as 866–867
as melanocytic proliferations of the skin 865–867, 869
morphology of 866b, 867f
Dystrophinopathy
inherited disorder of skeletal muscle and 802–804, 806

E

Ectoparasite 314
Ectopia 558–559
Edema. *See also* Edema, cerebral; Fetal hydrops
clinical correlation of 78
increased hydrostatic pressure and 77, 77f
introduction to 75–78, 76t, 77f
lymphatic obstruction and 77
morphology of 78b
reduced plasma osmotic pressure and 77
sodium/water retention and 77–78
summary for 78b
Edema, cerebral 812, 813f
summary of 814b
Effector cell 104
Ehlers-Danlos syndrome (EDS) 221, 344b–345b
summary for 222
Eicosanoid. *See* Arachidonic acid (AA) metabolite
Elastin 64
Electrical injury 289
Embolism
discussion of 90–92
pulmonary thromboembolism as 90
summary for 92b
systemic thromboembolism as 91–92
Emery-Dreifuss muscular dystrophy (EMD) 804
Emphysema
clinical features of 466
conditions related to 466
morphology of 465b, 465f
obstructive lung disease and 463–466
pathogenesis of 464b–465b, 465f
summary for 466b
tobacco smoke and 278–279
types of 464–466, 464f
Emphysema, compensatory 466
Emphysema, distal acinar 464, 464f
Emphysema, irregular 464
Emphysema, mediastinal 466
Encephalitis, fungal 829
Encephalomyelitis, acute disseminated 834
Endobronchial, tuberculosis 497b
Endocarditis, infective
clinical features of 393–394
morphology of 393b, 394f
pathogenesis of 393b
thrombosis and 88b–89b
valvular heart diseases and 392–394
Endocarditis, subacute 393b
Endocrine amyloid 156
Endocrine pancreas
diabetes mellitus and 739–750
and endocrine system 739–752
pancreatic neuroendocrine tumors and 751–752
Endocrine system
adrenal cortex and 752–759
adrenal medulla and 760–761
endocrine pancreas and 739–752
introduction to 715
multiple neoplasia syndromes and 761–762
parathyroid glands and 735–738
pituitary and 716–721
thyroid and 721–735
Endometriosis
clinical features of 690
morphology of 690b, 690f
summary for 691
the uterus and 689–690, 690f
Endometritis 689
Endomyocardial fibrosis 401
Endothelial cell
activation and injury of 95–96
blood vessels and 329–330, 329f, 329t
coagulation and 81b
Endothelial injury 81f, 83f, 86
Endothelium
antithrombotic properties of 79–80
inhibitory effects and platelets and 79
inhibitory effects on coagulation factors and 80
hemostasis/thrombosis and 79–80, 81f
normal hemostasis and 79–80, 81f
prothrombotic properties of 80
activation of clotting factors and 80
activation of platelets and 80, 81f
antifibrinolytic effects and 80
summary for 81b
Endotracheal, tuberculosis 497b
Energy balance, obesity and 303–305, 304f
Energy metabolism, reprogramming of 195–196
Enteroaggregative *E. coli* (EAEC) 583
Enterohemorrhagic *E. coli* (EHEC) 583
Enteroinvasive *E. coli* (EIEC) 583
Enteropathogenic bacteria 316
Enteropathy, environmental 579
Enterotoxigenic *E. coli* (ETEC) 583
Environment
cancer and 170f, 171t
disease and 269
SLE and 126
Environmental disease
effects of alcohol and 280–282
effects of tobacco and 277–279
environmental pollution and 272–277
health effects of climate change and 269–271
injury by physical agents and 287–293
introduction to 269
summary for 273b
therapeutic drug injury/drugs of abuse and 282–287

Eosinophilic esophagitis 561f
Eosinophils 55
Ependymoma 844
  morphology of 844b, 844f
Epididymis 658–663
Epidural infection of nervous system 824–825
Epigenetic change 217
Epigenetics 175–176
Epithelial disorders, non-neoplastic
  of the vulva
    lichen sclerosus as 682
    lichen simplex chronicus as 682
    summary of 682b
Epithelial hyperplasia 705
  morphology of 705b–706b
Epithelial lesion, benign and premalignant
  actinic keratosis as 862–863
  seborrheic keratosis as 862
  summary for 863b
  as tumors of the skin 862–863
Epstein-Barr virus 202–203
  liver disease and 620
ER stress 20f, 21, 22f. *See also* Misfolded protein
Erythema multiforme
  acute inflammatory dermatoses and 853–854, 854f
  clinical features of 854
  morphology of 853b–854b, 854f
Erythroblastosis fetalis 256b, 256f, 257
Erythrocytosis. *See* Polycythemia
Erythroplakia 553–554
Escherichia coli 581t, 583
Esophageal adenocarcinoma
  clinical features of 562–563
  morphology of 562b, 562f
  pathogenesis of 562b
  tumors of the esophagus and 562–563
Esophageal varices
  morphology of 559b, 559f
  obstructive diseases and 559
  pathogenesis of 559b
Esophagitis
  Barrett esophagus as 561–562
  chemical and infectious damage and 560, 560f, 564
  eosinophilic esophagitis as 561
  lacerations and 559–560
  reflux esophagitis and 560–561
Esophagitis, eosinophilic 561
Esophagus
  esophageal tumors and 562–564
  esophagitis as 559–562
  obstructive and vascular diseases of 558–559
    ectopia as 558–559
    esophageal varices as 559
    functional obstruction as 558
    mechanical obstruction as 558
    summary for 564b
  summary for 564b
Esophagus, mechanical obstruction of 558, 564
Esophagus, functional obstruction of 558, 564
Esophageal tumor
  adenocarcinoma as 562–563
  squamous cell carcinoma as 563–564
Ethanol myopathy 806
Ewing sarcoma
  bone tumors and 780–781
  clinical features of 780
  morphology of 780b, 781f
  summary for 782
Expression profiling 211–212, 213f
Extracellular matrix (ECM)
  components of 63–64
  functions of 58f, 64–65
  growth factors involved in 68
  invasion of 192–194, 193f
  role in tissue repair 63–65, 65f
  summary for 64b
Extrahepatic bile duct, disorders of
  biliary atresia as 642–643
  choledocholithiasis and cholangitis as 642
  secondary biliary cirrhosis as 642
Extrinsic pathway, evasion of cell death and 189–190

F

Factor III. *See* Endothelial injury
Factor VIII-von Willebrand factor complex (vWF)
  coagulation disorders and 454–455, 454f
  hemophilia A-factor VIII deficiency and 455
  hemophilia B-factor IX deficiency and 455
  Von Willebrand disease and 455
Factor XII. *See* Hageman factor (factor XII)
Facultative intracellular bacteria 311
Fallopian tubes 695, 695f
  summary for 695b
Familial 215–216
Familial adenomatous polyposis (FAP)
  and familial syndromes 595–596, 596f, 600
Familial hypercholesterolemia 222–223
pathogenesis of 222b–223b
summary for 223b
Familial mental retardation protein. *See* FMRP
Familial syndromes
  colonic polyps and 595–596
  familial adenomatous polyps and 595–596
  hereditary nonpolyposis colorectal cancer and 596
Familial tumor syndrome
  tuberous sclerosis as 847
  von Hippel–Lindau disease as 847
Fascioscapulohumeral dystrophy 804–805
Fat embolism 91, 91f
Fat necrosis 707
  morphology of 707b
Fatty change (steatosis) 23–24, 26
Fatty liver disease, alcoholic/nonalcoholic
  alcoholic liver disease and 623–624
  drug/toxin-mediated injury with steatosis and 625
  liver diseases and 621
  morphology of 621b–622b, 621f–622f
  nonalcoholic liver disease and 625
Fatty streak 340, 340b–342b, 340f
Female genital system
  body of uterus and 689–694
  cervix and 685–689
  diseases of pregnancy and 700–704
  fallopian tubes and 695
  ovaries and 695–700
  vagina and 684–685
  vulva and 681–684
Fetal alcohol syndrome 248, 281
Fetal anemia 255–256
Fetal growth restriction 249–250
Fetal hydrops
  clinical course of 256–257
  immune hydrops as 254–255
  introduction to 254–257, 254t
  morphology of 256b

nonimmune hydrops as 255–257
summary for 257b
Fetal infection 249–250
Fetal red cells, Rh-positive 254–255
Fibrinoid necrosis 11, 11f
immune complex injury and 117b, 120f
Fibrinolysis 80
Fibroadenoma
morphology of 707b, 708f
as tumors of the breast 707
Fibroblasts, activation of 68
Fibroma, nonossifying 779. *See also* Fibrous cortical defect
Fibromatoses 793
morphology of 793b
Fibromuscular dysplasia 330
Fibrosarcoma 793–794
morphology of 794b, 794f
Fibrosing disease
collagen vascular disease as 474
cryptogenic organizing pneumonia as 473–474
drug- and radiation-induced pulmonary diseases as 478
idiopathic pulmonary fibrosis as 472–473
nonspecific interstitial pneumonia as 473
pneumoconioses as 474–478
summary for 474b
Fibrosis
clinical examples of 70–72
ionizing radiation and 290–291, 291f
morphology of 705b, 706f
nonproliferative changes and 705
parenchymal organs and 72
Fibrous cortical defect
clinical features of 779
fibrous tumors and 779
morphology of 779b, 779f
summary for 781
Fibrous dysplasia
clinical course of 780
fibrous tumors and 779–780
morphology of 780b, 780f
summary for 781
Fibrous proliferative lesion
of the oral cavity 552–554, 553f
Fine needle aspiration 210, 213
FISH (fluorescence in situ hybridization)
copy number abnormalities and 264, 264f
molecular diagnosis and 211
Flexner-Wintersteiner rosettes 261b, 261f
Flow cytometry 210–211, 213
Fluke (trematode) 314
Fluorescence in situ hybridization. *See* FISH
FMRP (familial mental retardation protein)
fragile X syndrome and 242f
Focal nodular hyperplasia (FNH) 635–636
Focal segmental glomerulosclerosis (FSGS)
clinical course of 526
morphology of 525b–526b, 526f
nephrotic syndrome and 525–526
pathogenesis of 525b
summary for 528
Folic acid. *See* Anemia, folate deficiency
Forebrain malformation 823
Fracture
of the bone 772–773
clinical course of 773
morphology of 773b
Fragile X syndrome
pathogenesis of 242–243, 242f–243f
single-gene disorders and 241, 242f
summary for 243b
Free radicals, oxygen-derived 14–15, 14f
Frontotemporal lobar degeneration (FTLD) 838
Fundic gland polyp 569
Fungal infection
clinical features of 857
infectious dermatoses and 857
morphology of 857b
Fungal infection, opportunistic
candidiasis as 502–503
cryptococcosis as 503–504
opportunistic molds as 504
opportunistic molds as 504
Fungi 313, 313f

G

Galactosemia 228
summary for 228
Gallbladder and extrahepatic biliary tract disorder
disorders of extrahepatic bile ducts 642–643
gallbladder diseases of 639–642
introduction to 639
summary for 643b
tumors of 643–644
Gallbladder disease
cholecystitis as 641–642
cholelithiasis as 639–641
Gallstones. *See* Cholelithiasis
GALT (galactose-1-phosphate uridyltransferase)
galactosemia and 228
Ganglion cyst 790
Ganglioglioma 844
Gangrenous necrosis 10
Gastric adenocarcinoma
clinical features of 571
epidemiology of 570
morphology of 570b, 571f
neoplastic disease of the stomach and 570–571, 573
pathogenesis of 570b
Gastric adenoma
as gastric polyps 569, 573
morphology of 569b
Gastric polyp
fundic gland polyps as 569
gastric adenoma as 569
inflammatory and hyperplastic polyps as 569, 572
Gastrinoma
morphology of 752b
and pancreatic neuroendocrine tumors 752
Gastritis, acute
inflammatory disease of the stomach and 564
morphology of 564b
pathogenesis of 564b, 565f
summary for 569b
Gastritis, acute erosive 284
Gastritis, autoimmune
chronic gastritis and 567, 567t, 569
clinical features of 562–563
morphology of 567b
pathogenesis of 567b
Gastritis, chronic
autoimmune gastritis as 567
*Helicobacter pylori* gastritis as 566–567
inflammatory disease of the stomach and 566–567
summary for 569b

Gastritis, *Helicobacter pylori*
chronic gastritis and 566–567, 569
clinical features of 586b
epidemiology of 566
morphology of 566b–567b, 566f
pathogenesis of 566b
Gastroesophageal reflux disease. *See* GERD
Gastrointestinal stromal tumor (GIST)
clinical features of 572
epidemiology of 572
morphology of 572b
neoplastic disease of the stomach and 572–573
pathogenesis of 572b
Gastrointestinal tract (GI tract)
microbe transmission/dissemination and 316
systemic sclerosis morphology and 133–134
Gaucher disease 231–232, 231f
Gene amplification 175, 175f
Genetic abnormalities
alterations in protein-coding genes as 237–239
mutations in protein-coding genes as 236–237
Genetic analysis, indications for 267–268
Genetic disease
complex multigenic disorders and 234
cytogenetic disorders and 234–241
genetic abnormalities contributing to human disease and 216–218
introduction to 215–244
Mendelian disorders and 218–234
single-gene disorders and 241–244
Genetic factor, cell injury and 7
Genital herpes simplex. *See also* Herpes simplex virus (HSV)
clinical features of 678
morphology of 678b
sexually transmitted disease and 678
summary for 678b–679b
Genital system, male
penis and 657–658
prostate and 663–668
scrotum, testis, and epididymis as 658–663
sexually transmitted diseases and 671–678
ureter, bladder, urethra as 663–668
Genome-wide association study (GWAS) 266–267
Genomic hybridization, array-based 264, 265f
Genomic imprinting
diseases caused by alterations of 243–244
summary for 245b
Genomic instability. *See also* Malignancy
Genomic instability, regulated 196–197
GERD (gastroesophageal reflux disease) 560–561, 564
Gestational choriocarcinoma 703
morphology of 703b, 703f
summary for 703
Gestational trophoblastic disease
diseases of pregnancy and 701–703
gestational choriocarcinoma as 703
hydatidiform mole as 701–702
invasive mole as 702–703
placental site trophoblastic tumor as 703
summary for 703b
Giant cell arteritis 350–351
clinical features of 351
morphology of 350b–351b, 350f
pathogenesis of 350b
Giant cell myocarditis 402b
Giant cell tumor of bone (GCT)
bone tumors and 781
clinical course of 781
morphology of 781b, 781f
summary for 782
Gilbert syndrome 606
Glioma
astrocytoma as 842–843
of brain parenchyma 842–844
ependymoma as 844
oligodendroglioma as 843
Global cerebral ischemia 814–815
morphology of 812f, 815b, 815f
Glomangiomas. *See* Glomus tumor (glomangiomas)
Glomerular disease
and the kidney 518–533, 519f–520f, 520t
mechanisms of injury and disease for 519–523
nephritic syndrome and 529–531
nephrotic syndrome and 523–528
rapidly progressive glomerulonephritis and 531–533
tubulointerstitial nephritis and 533–537
Glomerular injury
anti-glomerular basement membrane antibody–mediated glomerulonephritis as 521–522
glomerulonephritis caused by circulating immune complexes as 520
glomerulonephritis caused by in situ immune complexes as 520–521
mechanisms of 519–523, 521f
mediators of immune injury as 522–523, 522f
other mechanisms of glomerular injury as 522–523
summary for 523b
Glomerulonephritis
anti-glomerular basement membrane antibody–mediated 521–522, 521f–522f
caused by circulating immune complexes 522f
as glomerular injury 520, 522f
caused by in situ immune complexes 520–521
Glomerulonephritis, acute postinfectious
clinical course of 529
morphology of 529b, 530f
nephritic syndrome and 529
pathogenesis of 529b
summary for 531
Glomerulosclerosis, nodular 746–747, 746f–747f
Glomus tumor (glomangioma) 359
Glucose homeostasis 739–740. *See also* Insulin physiology, normal
Glucose-6-phosphate dehydrogenase deficiency (G6PD)
hemolytic anemias and 416–417
pathogenesis of 416b, 417f
summary for 419
Gluten-sensitive enteropathy. *See* Celiac disease
Glycogen 24
Glycogen storage disease
discussion of 232–233, 233t
hepatic type of 232–233, 234f
myopathic type of 233
summary for 233b
type II glycogenosis 233
Glycolipid 206
Glycoprotein 206
Glycoprotein, adhesive 64
Goiter, diffuse
morphology of 728b
the thyroid and 728
(*See also* Goiter, multinodular)
Goiter, multinodular
clinical features of 728
morphology of 728b, 729f

Gonadotroph adenoma 720
Gonorrhea
clinical features of 675
male genital system and 674–675
morphology of 675b, 675f
summary for 676b
Goodpasture syndrome 485
morphology of 485b, 486f
Gout
arthritis and 786–789, 787t
clinical features of 788–789
morphology of 786b–787b, 787f
pathogenesis of 787b–788b, 788f
summary for 790
Gouty nephropathy 786b–787b
Governor, tumor suppressor gene as 173
Grading, cancer tumors and 208–210
Graft rejection 136f, 137–138
Graft survival 138–139
Graft-*versus*-host disease (GVHD) 139
malabsorptive diarrhea and 580
Granulocytopenia 424
Granuloma inguinale
morphology of 677b
sexually transmitted disease and 677
summary of 677b
Granulomatosis 485
Granulomatous disease
hypersensitivity pneumonitis as 480–481
of the liver 635
sarcoidosis as 478–480
Granulomatous inflammation 56, 56t
morphology of 56b–57b, 56f, 324, 324b, 324f
Graves disease
clinical features of 727
morphology of 727b, 727f
pathogenesis of 726b–727b
summary for 727b–728b
the thyroid and 726–727
Growth factor
angiogenesis and 67
cell/tissue regeneration and 61–62, 62t
self-sufficiency in growth signals and 178
signaling mechanisms of receptors and 61–62, 62t
summary for 62b
Growth factor deprivation 20–22
Growth factor receptor
signaling mechanisms of 61–62, 62t, 178–179
summary for 62b
Growth inhibitory signal
introduction to 182–188
RB gene and 182–184, 184b–185b
summary for 184b
Growth signal, self-sufficiency in 178–182. *See also* Regeneration, cell and tissue
alterations in cell cycle control proteins 182
cyclin/cyclin-dependent kinases and 180–182
downstream signal-transducing proteins and 179–180
growth factor receptors/non-receptor tyrosine kinases and 178–179
growth factors and 178
nuclear transcription factors and 180
summary for 182b
Guardian, tumor suppressor gene as 173
Guillain-Barré syndrome 798–800
Gut hormone 305
Gynecomastia 713

H

*Haemophilus influenzae* 489
Hageman factor (factor XII) 51–52, 51f
Hairy cell leukemia 442–443
Hamartoma 163
infant/childhood tumors and 257
Haploinsufficiency 173
Happy puppet syndrome. *See* Angelman syndrome
Hashimoto thyroiditis. *See* Thyroiditis, chronic lymphocytic (Hashimoto)
HbSC disease 411
Heart
amyloidosis and 157, 157f
arrhythmias and 385–386
cardiac transplantation and 405
cardiac tumors and 404–405
cardiomyopathies and 396–403
congenital heart disease and 368–374
failure of 365–368
hypertensive heart disease and 386–388
ischemic heart disease and 374–385
overview of 365
pericardial disease and 403–404
valvular heart disuse and 388–396
Heart disease, valvular
carcinoid heart disease and 395
degenerative valve disease and 389–391
discussion of 388–396, 389f, 389t
infective endocarditis and 392–394
non-infected vegetations and 394–395
prosthetic cardiac valves and 395–396
rheumatic valvular disease and 389–391
summary for 396b
Heart failure
congestive heart failure as 365–368
left-sided heart failure as 367
right-sided heart failure as 368
summary for 368b
Heart failure, left-sided
clinical features of 367
discussion of 367
morphology of 367b
Heart failure, right-sided
clinical features of 368
discussion of 368
morphology of 368b
Heavy-chain disease 438
*Helicobacter pylori (H. pylori)* 204
summary for 204b
Helminth 313–314
Hemangioendothelioma 361
Hemangioma, juvenile 358
Hemangioma, vascular tumors and 358–359, 358f
Hemangiopericytoma 362
Hematoma, epidural 821–822, 821f
Hematopoiesis, extramedullary 256b
Hematopoietic stem cell (HSC) 139
Hematopoietic system
bleeding disorders and 449–455
red cell disorders and 408–425
white cell disorders and 425–449
Hemochromatosis
clinical features of 630
as inherited metabolic disease 629–630, 632
morphology of 630b, 630f
pathogenesis of 629b–630b
Hemochromatosis, secondary 416

Hemolytic anemia
glucose-6-phosphate dehydrogenase deficiency as 416–417
hereditary spherocytosis as 410–411
immunohemolytic anemias as 417–418
malaria as 418–419
mechanical trauma and 418
paroxysmal nocturnal hemoglobinuria as 417
red blood cell disorders and 408t, 409–419
sickle cell anemia as 411–413
summary for 419b
thalassemia as 413–416
Hemolytic anemia, chronic 411–412
Hemolytic disease, in newborn 254
Hemolytic uremic syndrome (HUS)
in the adult 541
in childhood 540–541
factor H and 51
summary for 456
thrombotic microangiopathies and 453–454
Hemophilia A-factor VIII deficiency 455
summary for 456
Hemophilia B-factor IX deficiency 455–456
Hemorrhage
anemia of blood loss as 409
introduction to 78–79, 79f
pulmonary diseases of vascular origin and 482–483
vitamin C and 301
Hemorrhage, germinal matrix 249
Hemorrhage, intraventricular matrix
premature infants and 249
preterm birth complications and 251
Hemorrhage, subarachnoid 817–819
Hemorrhoid
clinical features of 576
morphology of 576b
as vascular disorders of bowel 576
Hemosiderosis 24
Hemostasis, normal
coagulation cascade and 83–86
endothelium and 79–80
hemodynamic disorders and 79–86, 80f
platelets and 81–82
Hemothorax 511
Hepatic adenoma
liver tumors and 636, 636f
oral contraceptives and 284
Hepatic artery inflow 632
Hepatic encephalopathy 606–607, 835
Hepatic failure
clinical features of 604–605
liver disease and 604–605
Hepatic nodules. *See* Tumor
Hepatic vein outflow obstruction
hepatic vein thrombosis as 634
sinusoidal obstruction syndrome as 634
Hepatic vein thrombosis 634
morphology of 634b, 634f
Hepatitis, acute and chronic
liver disease and 611–621
morphology of 611b–614b, 612f–613f, 613t
Hepatitis, autoimmune 620–621
morphology of 621b
Hepatitis, chronic 619–620
Hepatitis, drug/toxin-mediated injury mimicking 621
Hepatitis, fulminant 619
Hepatitis, lobular 611b–614b, 613f
Hepatitis, viral
clinical features and outcomes for 614t, 619–620
hepatitis A virus and 614
hepatitis B virus and 614
hepatitis C virus and 617–618
hepatitis D virus and 618–619
hepatitis E virus and 619
summary for 620b
Hepatitis A virus (HAV) 614–620, 615f
Hepatitis B virus (HBV)
clinical course of 616, 616f
epidemiology and transmission of 615
liver disease and 614–616, 615f
morphology of 617b, 617f
structure and genome of 615–616
viral oncogenesis and 203
summary for 203b
Hepatitis C virus (HCV)
liver disease and 617–618, 617f
clinical course of 618, 618f
morphology of 613f, 618b
viral oncogenesis and 203
summary for 203b
Hepatitis D virus (HDV) 618–619
Hepatitis E virus (HEV) 619
Hepatocellular carcinoma (HCC)
clinical features of 639
epidemiology of 637–638
morphology of 638b–639b, 638f
pathogenesis of 638b
precursor lesions of
cellular dysplasia as 636–637, 637f
dysplastic nodules as 637, 637f
introduction to 636–637
summary for 639b
Hepatocyte ballooning 621
Hepatopulmonary syndrome 610
Hepatorenal syndrome 610
Hereditary hemorrhagic telangiectasia (Osler-Weber-Rendu disease) 358
Hereditary nonpolyposis colorectal cancer (HNPCC) syndrome 196–197, 596, 596t, 600
Hereditary spherocytosis
clinical features of 411
hemolytic anemias and 410–411
morphology of 410b, 411f
pathogenesis of 410b, 410f
summary for 419
Heredity
autosomal dominant cancer syndromes and 171–172
autosomal recessive syndromes and 172
familial cancers and 172
forms of cancer and 171–172, 172t
Herniation 813–814, 813f–814f
summary of 814b
Heroin 285–286
Herpes simplex virus (HSV) 552, 560f. *See also* Genital herpes simplex
liver disease and 620
Herpesvirus
morphology of 827b–828b, 827f
nervous system infections and 827–828
Heterogeneity, genetic 218–219
Heterotopia 257
High-grade squamous intraepithelial lesion (HSIL) 686, 686t
High-molecular-weight kininogen (HMWK) 52

Hippel-Lindau syndrome 257–258
infant hemangiomas and 257–258
Hirschsprung disease
as intestinal obstruction 573–574
morphology of 574b, 574f
pathogenesis of 574b
Histamine 46
Histiocytic neoplasm 449
Histiocytoma, benign fibrous 794
Histoplasmosis
clinical features of 499–500
epidemiology of 499–500
morphology of 499b, 500f
as pulmonary infection 499–500
HIV. *See* Human immunodeficiency virus (HIV)
HLA. *See* Human leukocyte antigen (HLA)
Hodgkin lymphoma
classification of 440–442
as lymphoid neoplasm 440–442
morphology of 440b–441b, 440f
pathogenesis of 441b–442b
staging and clinical features of 442, 442t
summary for 444
Hodgkin lymphoma, lymphocyte-predominance 441, 441f
Hodgkin lymphoma, nodular sclerosis 440, 440f–441f
Holoprosencephaly 247–248
Homologous recombination, DNA repair and 197
Homozygous 183
Host immune response 321–322
Human anti-globulin test (Coombs test) 256–257
Human immunodeficiency virus (HIV). *See also* Acquired immunodeficiency syndrome (AIDS)
B cells and other lymphocytes in 149
dendric cells and 149
etiology/pathogenesis of AIDS and 144–149
heroin and 286
life cycle of 145–146, 146f
mechanisms of T cell depletion in 147–148, 148f, 150
monocytes/macrophages in 148–149
morphology of 152b
natural history/clinical course for 150–153, 150f
acute phase of 150
chronic phase of 150
clinical features of 151–153, 151t
crises phase of 150–151
neoplasms and 151–152
opportunistic infections and 151
nervous system infections and 828, 832
morphology of 827f, 828b
pathogenesis of CNS involvement for 149
progression of infection and 146–147, 147f, 147t
pulmonary infections in 504
structure of 144–145, 145f
summary for 149b–150b
Human leukocyte antigen (HLA)
adoptive immunity and 102, 124t
genetic factors of SLE and 126
graft survival and 138
GVHD and 139
Human leukocyte antigen allele, polymorphisms and 234
Human papillomavirus (HPV) 202
Human papillomavirus (HPV) infection
morphology of 678b
sexually transmitted disease and 678
summary for 678b–679b
Humoral immunity 100, 108f
as antitumor effector mechanism 206–207
Humoral rejection, acute 137f, 138
Hunter syndrome. *See* Mucopolysaccharidosis (MPS)
Huntington disease (HD)
morphology of 840b, 840f
neurodegenerative diseases and 840
pathogenesis of 840b
Hurler syndrome. *See* Mucopolysaccharidosis (MPS)
Hyaline membrane disease. *See* Respiratory distress syndrome (RDS)
Hyaluronan 64
Hydatid cyst 314
Hydatidiform mole
as gestational trophoblastic disease 701–702, 702t
morphology of 702b, 702f
summary for 703b
Hydrocephalus 812–813, 813f
summary for 814b
Hydronephrosis
clinical course of 546–547
morphology of 546b, 546f
pathogenesis of 546b
and urinary outflow obstruction 545–547
Hydrops, nonimmune 255–257
Hydrops fetalis 254, 255f, 256b, 257
Hydrostatic pressure 77, 77f
Hyperadrenalism. *See* Adrenocortical hyperfunction
Hyperaldosteronism
and adrenocortical hyperfunction 755–756
clinical features of 756
morphology of 755b–756b
Hypercholesterolemia 336–337
Hypercholesterolemia, familial
gene encoding mutations and 222–223
pathogenesis of 222b–223b
summary for 223b
Hypercoagulability 87–88, 87t
Hypercortisolism. *See also* Cushing syndrome
and adrenocortical hyperfunction 752–755, 753f
summary for 755b
Hyperemia 75
morphology of 75b–76b, 76f
Hyperglycemia 835
Hyperhomocysteinemia 337–338
Hyper-IgM syndrome 141, 143
Hyperlipidemia 336–337
Hyperparathyroidism
acquired bone disease as 771
clinical features of 737–738, 737t
morphology of 736b–737b, 736f–737f, 772b, 772f
and parathyroid glands 735–738
pathogenesis of 736b
secondary hyperparathyroidism and 738
summary for 738b
Hyperparathyroidism, secondary
clinical features of 738
introduction to 738
morphology of 738b
summary for 738
Hyperpituitarism
and the pituitary gland 717–720
(*See also* Pituitary adenoma)
summary for 719b
Hyperplasia
as adaptive response 1–2
hypertrophy and 3
stress and 4
summary for 5b
vitamin A and 298

Hyperplasia, endometrial 691–692, 691f
summary for 692b–693b
Hyperplasia, nodular
of the prostate 664–665
Hyperplastic arteriolosclerosis 333b–334b, 334f, 539b–540b
Hyperplastic polyp
colonic polyps and 593, 600
morphology of 593b, 594f
gastric polyps and 569, 572
morphology of 569b
Hypersensitivity, immediate (Type 1)
clinical and pathological manifestations of 113–114
introduction to 111–114
sequence of events in 111–113, 111f, 113f
Hypersensitivity, Type II. *See* Antibody-mediated disease
Hypersensitivity, Type III. *See* Immune complex disease (Type III hypersensitivity)
Hypersensitivity, Type IV. *See* T cell-mediated hypersensitivity (Type IV)
Hypersensitivity myocarditis 401b–402b
Hypersensitivity pneumonitis
clinical features of 481
as granulomatous disease 480–481, 480t
morphology of 481b, 481f
Hypersensitivity reaction
antibody-mediated diseases as 114–115
causes of 109–110
immediate hypersensitivity as 111–114
immune complex diseases as 115–117
summary for 120b
T cell-mediated hypersensitivity as 117–120
types of 110–111, 110t
Hypertension
epidemiology of 332–333
morphology of 333b–334b, 334f
pathogenesis of 333b, 333t
summary of 334b
Hypertension, malignant
as blood vessel disease of the kidney 539–540
clinical course of 540
morphology of 540b, 540f
pathogenesis of 539b–540b
summary for 541
Hypertensive cerebrovascular disease 819
Hypertensive heart disease
cor pulmonale as 388
the heart and 386–388
summary for 388b
systemic hypertensive heart disease as 387
Hypertensive heart disease, Systemic (left-sided)
clinical features of 387
introduction to 387
morphology of 387b, 387f
Hypertensive vascular disease 332–333
epidemiology of hypertension and 332–333
Hyperthermia 289
Hyperthyroidism
and the thyroid 722–723, 722f–723f, 722t
Hypertrophic cardiomyopathy (HCM)
cardiomyopathy as 400–401
clinical features of 400–401
morphology of 400b, 400f
pathogenesis of 400b
Hypertrophy
cellular adaptations to stress and 2f–3f
summary for 5b
Hypoadrenalism. *See* Adrenal insufficiency
Hypoadrenalism, secondary 758b
Hypocalcemia 299–300
Hypogammaglobulinemia 433b–434b, 434
Hypoglycemia 835
Hypogonadism, Klinefelter syndrome and 239–240
Hypoparathyroidism 738
Hypoperfusion thrombosis 97b
Hypophosphatemia 299
Hypopituitarism 720–721
Hypothermia 289
Hypothyroidism
pathogenesis of 725f
and the thyroid 723–724, 723t
Hypoventilation syndrome, obesity and 305
Hypovolemic shock 94
Hypoxia 814–816
Hypoxic injury 17

I

Idiopathic pulmonary fibrosis (IPF)
clinical features of 473
as fibrosing disease 472–473
morphology of 472b–473b, 473f
pathogenesis of 472b, 473f
Idiopathic pulmonary hemosiderosis 485
Idiopathic pulmonary hypertension 134
IgA nephropathy
clinical course of 531
morphology of 530b, 531f
nephritic syndrome and 530–531
pathogenesis of 530b
summary of 531
IgG4-related disease (IgG4-RD) 135
IL-1. *See* Interleukin-1 (IL-1)
Immature teratoma 258
Immune complex-associated vasculitis 350
Immune complex disease (Type III hypersensitivity)
examples of 116t
introduction to 111, 115–117
local immune complex disease as 117
morphology of 117b
summary for 117b
systemic immune complex disease as 116–117
Immune deficiency
diseases of
acquired immunodeficiency syndrome as 143–153
introduction to 139–153
primary immune deficiency as 139–143
secondary immune deficiency as 143
hematopoietic stem cell transplant and 139
with thrombocytopenia and eczema 142
Immune evasion
by microbes 322–323, 322f, 322t, 323b
by tumors 207
Immune response, normal
cell-mediated immunity and 105–108
decline of responses in 109
humoral immunity and 106–107
microbial antigens and 105
overview of 105–109
response to microbes of 105
summary for 109b
Immune surveillance 204, 207
summary for 207b
Immune system
amyloidosis and 153–158
autoimmune diseases of 120–135

cells and tissues of 100–104
antigen-presenting cells and 104
effector cells and 104
lymphocytes and 100–104
lymphoid tissues and 104
summary for 104b–105b
evasion of 196
hypersensitivity reactions of 109–120
immune deficiency diseases of 139–153
innate/adaptive immunity in 99–100
rejection of transplants by 135–139
Immune thrombocytopenic purpura (ITP) 452–453
summary for 456
Immunity, adaptive 99–100
summary for 109
Immunity, innate
genetic deficiencies of 142–143
immune system and 99–100, 100f
summary for 109
Immunocyte dyscrasias with amyloidosis 155
Immunocytochemistry 213
Immunodeficiency
infections and 325
morphology of 311f, 325b, 326f
Immunodeficiency, common variable 141, 143
Immunologic memory 109
Immunologic reactions, cell injury and 7
Immunologic tolerance 121–122, 122f
Immunosuppression 207
Impetigo
bacterial infections and 856
clinical features of 856, 857f
morphology of 856b
Imprinting 217
Imprinting, genomic 218
Inactive hypophosphorylated state 199
Indirect recognition pathway 136
Indoor air pollution 273
Industrial exposure, toxic agents and environmental pollutants and 276–277, 277t
Infarction
cerebrovascular diseases and 814–816
factors influencing development of 93
introduction to 92–93
ischemic cell death as 75
morphology of 92b–93b, 93f
pulmonary diseases of vascular origin and 482–483
summary for 94b
systemic embolization and 90
Infarction, right ventricular 384
Infarction, subendocardial 379
Infection
immunodeficiencies and 325
inflammatory responses to 323–325
of the nervous system 824–831
neuromuscular junction disorders and 801
Infectious agent
categories of 309, 310t
cell injury and 7
identification techniques for 314, 314t
Infectious disease
bioterrorism and 315
emerging types of 314–315
how microorganism cause disease and 319–322
identification techniques for agents of 314
immune evasion by microbes and 322–323
inflammatory responses to 323–325
microbial pathogenesis and 309–314
transmission/dissemination of microbes and 315–318
Infectious enterocolitis
campylobacter enterocolitis as 582–583
cholera as 582
diarrheal disease and 580–586, 581t
Escherichia coli as 583
norovirus as 585
parasitic disease as 585–586
pseudomembranous colitis as 584–585
rotavirus as 585
salmonellosis as 583–584
shigellosis as 583
summary for 586b
typhoid fever as 584
Infectious vasculitis 355
Inferior vena cava syndrome 356
Inflammasome 32–33, 32f
pyrin and 156
Inflammation
antibody-mediated disease mechanisms and 112f, 115
chemical mediators and regulators of 44–53, 45f, 45t
anti-inflammatory mechanisms of 52–53
cell-derived mediators as 46–49
plasma protein-derived mediators as 50–52
immunity and 100
systemic effects of 46t, 48f, 57–58, 426t
summary for 58
Inflammation, acute
anti-inflammatory mechanisms and 52–53
defects in leukocyte function and 40–41, 41t
introduction to 31–42, 31f
leukocyte-induced tissue injury and 39–40, 41t
leukocyte recruitment/activation and 34–39
microbe, necrotic cell, foreign substance recognition and 32–33, 32f
morphologic patterns of 43
morphology of 43b–44b
morphology of 43
outcomes of 41–42, 42f
plasma protein-derived mediators and 50–52
summary for 52b
stimuli for 31
summary for 42b
vascular changes and 33–34
summary for 34b
Inflammation, chronic
acute inflammation and 42
cells and mediators of 53–56
lymphocytes as 55
macrophages as 54–55
other cells as 55–56
granulomatous inflammation and 56
introduction to 30t, 31f, 53–56, 53f
morphology of 56b–57b
overview of 29–30, 53–56
response to infection and 325
morphology of 325b
summary for 57b
Inflammation, fibrinous 43, 43f
Inflammation, mediators of
immediate hypersensitivity and 112, 113t, 114
Inflammation, serous 43, 43f
Inflammation, suppurative 43, 44f
morphology of 323–325, 323b–324b
Inflammation, tumor producing 197–198

Inflammation and tissue repair, overview of 29–30, 30f
summary for 31b
Inflammatory bowel disease (IBD)
colitis-associated neoplasia as 591–592
Crohn disease as 589–590
epidemiology of 587–588
indeterminate colitis as 591
intestinal disease and 587–592, 587f, 587t
pathogenesis of 588b–589b, 588f
summary for 592b
ulcerative colitis as 590–591
Inflammatory carcinoma 711–712
Inflammatory disease, immune-mediated 110
polymorphisms and 234
Inflammatory intestinal disease
inflammatory bowel disease and 587–592
sigmoid diverticulitis as 586–587
Inflammatory mediator 81f, 83f, 95
Inflammatory response
infection and 323–325, 323f
summary for 325b–326b
Influenza infection 491
Influenza virus type A/HINI infection 491
Inherited metabolic disease
$\alpha_1$-antitrypsin deficiency as 631–632
hemochromatosis as 629–630
summary for 632b
Wilson disease as 630–631
Injury
by nontherapeutic toxic agent
drug abuse as 284–287
by physical agent
electrical injury as 289
ionizing radiation as 289–293
mechanical trauma as 287
thermal injury as 288–289
by therapeutic drugs
adverse drug reactions and 282–284
Injury, immune-mediated
hypersensitivity reactions for 109–120
Injury, reversible 8
morphology of 6f, 8b–9b, 9f
Insulinoma
morphology of 751b, 751f
and pancreatic neuroendocrine tumors and 751
Insulin physiology, normal 739–740, 740f. *See also* Glucose homeostasis
Insulin resistance
diabetes mellitus and 741–743
obesity and 742–743, 742f
summary for 750
Interface hepatitis 611b–614b
Interleukin-1 (IL-1) 48, 48f
Interstitial cystitis (ureter) 668
Interstitial lung disease, chronic
fibrosing diseases and 472–478
granulomatous diseases as 478–481
pulmonary eosinophilia as 481
restrictive and infiltrative types of 460f, 472–481, 472t
smoking-related interstitial diseases and 481
Interstitial nephritis, drug-induced
clinical course of 536–537
morphology of 536b, 536f
pathogenesis of 536b
summary for 537
tubulointerstitial nephritis and 536–537
Interstitium. *See* Tubules and interstitium, disease affecting
Intestinal obstruction
abdominal hernia as 574
Hirschsprung disease as 573–574
summary for 574b
Intestinal tuberculosis 497b
Intestine
colonic polyps/neoplastic disease and 592–599
diarrheal disease and 576–586
inflammatory intestinal disease and 586–592
intestinal obstruction and 573–574
vascular disorders of bowel and 574–576
Intimal thickening, vascular injury and 334–335, 335f
Intracellular accumulation 23–24, 24f
Intracranial hemorrhage
cerebral amyloid angiopathy as 817
cerebrovascular disease and 817–818
primary brain parenchymal hemorrhage as 817
subarachnoid hemorrhage and saccular aneurysms as 817–818
vascular malformations as 818
Intraductal papillary mucinous neoplasm (IPMN) 652f
Intraductal papilloma
morphology of 708b
as tumors of the breast 708
Intrinsic pathway 189–190
Invasion-metastasis cascade
extracellular matrix invasion and 192–194
introduction to 192–195, 193f
summary for 195b
vascular dissemination/homing of tumor cells and 194–195
Ion channel myopathy 805
Ionizing radiation
DNA damage/carcinogenesis of 290
effect on organ systems of 292–293
fibrosis and 290–291
injury produced by 289–293
morphology of 291b–292b
summary for 293b
total body irradiation and 293
Iron deficiency anemia
as anemia of diminished erythropoiesis 420–421, 420f
clinical features of 421, 421f
morphology of 421f
pathogenesis of 421b
summary for 424
Irritable bowel syndrome (IBS) 580
Ischemia
cerebrovascular diseases and
focal cerebral ischemia as 815–816
global cerebral ischemia as 814–815
Ischemia-reperfusion injury 17
Ischemic bowel disease
clinical features of 575–576
morphology of 575b, 575f
pathogenesis of 575b
summary for 576
vascular disorders of 574–576
Ischemic coagulative necrosis 92b–93b
Ischemic heart disease (IHD)
angina pectoris and 376
cardiac stem cells and 385
chronic ischemic heart disease 384–385
epidemiology of 375
the heart and 374–385
myocardial infarction and 377–384
pathogenesis of 375b–376b, 376f
summary for 385b

Ischemic heart disease, chronic
cardiomyopathies and 384–385
clinical features of 385
morphology of 384b
Ischemic injury 17
Ischemic necrosis. *See* Infarction
Islet cell tumor. *See* Pancreatic neuroendocrine tumor (PanNET)
Isolated IgA deficiency 141
Isolated-organ tuberculosis 497b

J
Jaundice
bilirubin/bile acids and 605–606
galactosemia and 228
liver disease as 605–606
Joint
arthritis and 782–790
Ehlers-Danlos syndrome and 221
introduction to 782–791
SLE morphology and 130
tumors and tumor-like lesions of 790–791
Juvenile rheumatoid arthritis (JRA) 786
the joints and 785–786

K
Kaposi sarcoma (KS)
clinical features of 360–361
discussion of 360–361
HIV and 152
morphology of 360b, 361f
pathogenesis of 360b
Kaposi sarcoma herpesvirus (KSHV) 152
Karyotype
aneuploidy and 175
balanced translocations and 174
cytogenetic disorders and 234, 235f
deletions and 174–175
gene amplifications and 175
introduction to 173–175
Kawasaki disease
clinical features of 352
morphology of 352b
noninfectious vasculitis and 352
Keratoconjunctivitis sicca 131, 132b
Keratocyst, odontogenic 557–558
Keratomalacia 297–298
Kernicterus 256b, 256f, 257
Kidney
amyloidosis and 156–157
chronic kidney disease and 541–542
clinical manifestations of renal disease and 517–518
cystic diseases and 542–544
diseases affecting tubules and interstitium and 533–538
diseases involving blood vessels and 538–541
glomerular disease and 518–533
SLE and 128–130
systemic sclerosis morphology and 134
tumors and 547–549
urinary outflow obstruction and 545–547
Kidney disease, chronic
clinical course of 542
the kidney and 541–542
morphology of 541b–542b, 542f
Kidney injury, acute 518
Kinin system 51–52. *See also* Coagulation
*Klebsiella pneumoniae* 489–490
Klinefelter syndrome 239–241
Korsakoff psychosis 293
Kwashiorkor 294–295, 295f

L
Labile tissue 59, 61
Laceration, esophageal 559–560
Lactase deficiency 579–580
Lambert-Eaton syndrome 801
Laminin 64
Langerhans cell histiocytosis 449
Laryngeal tuberculosis 497b
Laryngeal tumor
carcinoma of the larynx and 514
nonmalignant lesions and 513–514
and upper respiratory tract lesions 513–514
Lead poisoning 274f–275f
morphology of 274b–275b
*Legionella pneumophila* 490
Leiomyoma
morphology of 693b, 694f
proliferative lesions of endometrium/myometrium and 693–694
summary for 694b
uterine lesions and 693–694, 795
Leiomyosarcoma
morphology of 694b
proliferative lesions of endometrium/myometrium and 694
smooth muscle tumors and 795
summary of 694b
Leptin, obesity and 304
Lesch-Nyhan syndrome 787b–788b
Lesion
of the endometrium
endometrial hyperplasia as 691–692
endometrial polyps as 693
leiomyoma as 693–694
leiomyosarcoma as 694
of the oral cavity
fibrous proliferative lesions and 552–553
leukoplakia and erythroplakia as 553
squamous cell carcinoma as 554
summary for 554
of the penis 657
of the testis 659
Lesion, acquired preneoplastic 173
Leukocyte
activation of
introduction to 37–39, 38f
killing/degradation of phagocytosed microbes and 38–39
neutrophil extracellular traps and 39
phagocytosis and 37–39
secretion of microbicidal substance and 39
summary of 40b
function of
defects in 40–41, 41t
lysosomal enzymes of 49
recruitment of
adhesion and 35–36
chemotaxis and 36–37
introduction to 34–39
margination and rolling as 35–37, 36t
summary for 37b
transmigration and 36
Leukocytoclastic vasculitis 353b, 353f
Leukocytosis 57–58

Leukocytosis, reactive
clinical features of 427
infectious mononucleosis and 426–427
morphology of 427b
pathogenesis of 426b–427b
white cell disorders and 426–427, 426t
Leukodystrophy
clinical features of 834
morphology of 834b
myelin diseases and 834, 834t
Leukoencephalopathy 319
Leukopenia
clinical features of 450b–451b
morphology of 426b
pathogenesis of 425b–426b
white cell disorders and 425–426
Leukoplakia 553–554, 553f
morphology of 554b
Leukotriene 46–47, 47f
Libman-Sacks endocarditis 394f, 395. *See also* Verrucous endocarditis
Lichen planus
chronic inflammatory dermatosis and 855–856
clinical features of 856
morphology of 855b–856b, 855f
Lichen sclerosus 682, 682f
summary of 682
Lichen simplex chronicus
chronic inflammatory dermatosis and 856
clinical features of 856
epithelial disorders and 682, 682f
morphology of 856b, 856f
summary of 682
Li-Fraumeni syndrome 187
Light chain (AL) amyloidosis 438b–439b
Linkage analysis 266–267
Linkage disequilibrium pattern 266–267
Lipofuscin 24, 25f
Lipoma 405, 792
Liposarcoma 792
morphology of 792b, 793f
Lipoxin 46–47
Liquefactive necrosis 10, 10f
Liver
acute and chronic hepatitis and 611–621
alcoholic and nonalcoholic fatty liver disease and 621–625
amyloidosis and 157, 157f
cholestatic liver diseases and 626–629
circulatory disorders of 632–634
clinical syndromes of 604–610, 604t
drug or toxin-induced disease of 610–611
inherited metabolic diseases of 629
introduction to 603
other inflammatory and infectious diseases of 635
SLE morphology and 130
tumors and hepatic nodules of 635–639
Liver disease, alcoholic
clinical features of 624
introduction to 623–624, 623f
pathogenesis of 623b–624b
summary for 624b
Liver disease, drug/toxin-induced 610–611, 611t, 612f
summary for 611b
Lobular carcinoma in situ (LCIS) 710, 711f, 713
Local invasion, neoplasm characteristics and 167–168
Loeffler endomyocarditis 401
Low-density lipoprotein (LDL) receptor gene
autosomal dominant disorders and 219–220
familial hypercholesterolemia and 222, 224f
Lumbar lordosis 300
Lung
acute injury of 460–461
atelectasis of 460
chronic interstitial lung disease and 472–481
discussion of 460f, 512–514
obstructive lung disease and 463–472
obstructive vs restrictive pulmonary diseases of 462–463
pleural lesions and 511–512
pulmonary disease of vascular origin and 482–485
pulmonary infections and 486–504
SLE morphology and 130
systemic sclerosis morphology and 134
tumors of 505–511
upper respiratory tract lesions and 512–514
Lung abscess
clinical features of 492
morphology of 492b
as pulmonary infection 492
Lung injury, acute
acute respiratory distress syndrome 461
discussion of 460–461
Lupus nephritis, diffuse
glomerular disease as 128–130
Lupus nephritis, mesangial proliferative 128–130
Lymphadenitis 497b
as acute nonspecific 428
morphology of 428b
as chronic nonspecific 428
morphology of 428b
Lymphadenitis, reactive
cat-scratch disease and 428
white cell disorders and 427–428
Lymphangiomas 359
Lymphangitis 356–357
Lymphatic obstruction 77
Lymphatic spread, malignant neoplasms and 168
Lymphedema 356–357
Lymph node, sentinel 168
Lymphoblastic lymphoma 430–433
Lymphocyte, self-reactive 21
Lymphocytes
activation defects in 142
chronic inflammatory cells and 55, 55f
immune system and 100–104
B lymphocytes as 103–104
major histocompatibility complex molecules as 102–103
natural killer cells as 104
T lymphocytes as 101–102
summary for 104
Lymphogranuloma venereum (LGV)
morphology of 676b
sexually transmitted disease and 676
summary for 677b
Lymphoid neoplasm
acute lymphoblastic leukemia/lymphoblastic lymphoma as 430–433
adult T cell leukemia/lymphoma 443
Burkitt lymphoma 436–437
chronic lymphocytic leukemia/small lymphocytic lymphoma as 433–434
diffuse large B cell lymphoma as 436
follicular lymphoma as 434–435
Hodgkin lymphoma as 440–442
mantle cell lymphoma as 435

miscellaneous lymphoid neoplasms as 442–443
multiple myeloma and related plasma cell tumors as 437–440
as neoplastic proliferations of white cells 429–448, 430f, 431t–432t
regulated genomic instability and 197
summary for 443b–444b
Lymphoid tissue 104
Lymphoma
as diffuse large B cell
clinical features of 436
immunophenotypic features of 436
as lymphoid neoplasms 436
morphology of 436b, 436f
pathogenesis of 436b
subtypes of 436
summary for 443
as extranodal marginal zone 442
neoplasm nomenclature and 163
of primary central nervous system 845
morphology of 845b
of the stomach 571, 573
Lymphoma, follicular
clinical features of 435
immunophenotypic features of 435
as lymphoid neoplasms 434–435
morphology of 434b–435b, 435f
pathogenesis of 434b
summary for 443
Lymphoma, mantle cell
clinical features of 435
immunophenotypic and genetic features of 435
as lymphoid neoplasms 435
morphology of 435b
summary for 443
Lymphoplasmacytic lymphoma 439–440
Lynch syndrome. *See* Hereditary nonpolyposis colorectal cancer (HNPCC) syndrome
Lyon hypothesis 239
Lymphangiomas 258
Lysosomal enzymes 49–50
Lysosomal storage disease
Gaucher disease as 231–232
gene encoding mutations and 228–232, 229f, 229t
mucopolysaccharidoses as 232
Niemann-Pick disease types A and B as 230–231
Niemann-Pick disease types C as 230–231
summary for 232b
Tay-Sachs disease as 229–230

M

Macroglossia 157–158
Macroorchidism 241
Macrophages
as antitumor effector mechanisms 206
chronic inflammatory cells and 54–55, 54f
HIV infection and 148–149
Major histocompatibility complex molecule (MHC) 102f, 123–125
allograft rejection and 135–136, 136f
Malakoplakia 668
Malaria
clinical features of 419
hemolytic anemia as 418–419
pathogenesis of 418b–419b
Malaria, fatal falciparum 419
Male breast, lesion of
carcinoma as 714
gynecomastia as 714
Malformation, congenital
of the central nervous system 822–824
forebrain malformations as 823
neural tube defects as 822–823
posterior fossa anomalies as 823
spinal cord abnormalities as 823
summary for 824b
Malformation syndrome 247
Malignancy
genomic instability as enabler of
hereditary nonpolyposis colon cancer syndrome and 196–197
introduction to 196–197
lymphoid neoplasms and 197
summary for 197b
xeroderma pigmentosum and 197
tumor-promoting inflammation as enabler of 197–198, 198f
Malignant, nomenclature for 162
Malignant transformation
carcinogenesis and 198
Mallory-Denk bodies 621, 622f
Malnutrition 293–294
chronic alcoholism and 282
Marasmus 294, 295f
Marfan syndrome
aneurysms/dissections and 344b–345b, 345f
gene encoding mutations and 220–221
morphology of 221b
summary for 221b–222b
Margination 35–37, 36t
Marijuana 286–287
Mast cell 55–56
Maternal imprinting 243–244, 244f
Maternal inheritance 243
Maternal PKU 227
Mechanical trauma
hemolytic anemias and 418
injury by physical agent and 287, 287f
morphology of 287b–288b
Medullary disease
clinical course of 544
as cystic disease 544
morphology of 544b
summary for 544
Medulloblastoma 844–845
morphology of 845b, 845f
Megaloblastic anemia
as anemia of diminished erythropoiesis 422–423
folate deficiency anemia as 422–423
morphology of 422b, 422f
pathogenesis of 422b
summary for 425
vitamin $B_{12}$ deficiency anemia as 423
Melanin 24
Melanocytic nevi
clinical features of 865
as melanocytic proliferations of the skin 865, 869
morphology of 865b, 866f
pathogenesis of 865, 865b, 866f
Melanocytic proliferations of the skin
dysplastic nevus as 865–867
melanocytic nevi as 865
melanoma as 867–869
summary for 869b
Melanoma
clinical features of 868–869
as melanocytic proliferations of the skin 867–869

Melanoma *(Continued)*
morphology of 868b, 868f–869f
pathogenesis of 867b, 868f–869f
Membrane attack complex (MAC)
plasma protein-derived mediators and 50–51
Membrane permeability, defects in 16, 16f
Membranoproliferative glomerulonephritis and dense deposit disease (MPGN)
clinical course of 528
morphology of 527b–528b, 528f
nephrotic syndromes and 527–528
pathogenesis of 527b
summary for 529
Membranous lupus nephritis
class V SLE glomerular disease as 128–130
Membranous nephropathy
clinical course of 527
morphology of 522f, 526b, 527f
nephrotic syndrome and 526–527
pathogenesis of 526b
summary for 529
Mendelian disorder
disease caused by mutations in genes encoding
enzyme proteins and 227–233
proteins that regulate cell growth and 233–234
receptor proteins or channels and 222–227
structural proteins and 220–221
single-gene defects and 218–234, 218t–219t
transmission patterns of 219–220
summary for 220b
Meningioma 846
morphology of 846b, 846f
Meningioma, atypical 846b
Meningitis
acute pyogenic meningitis as 825
aseptic meningitis as 825
chronic meningitis as 826
nervous system infections and 825–826
Meningitis, chronic
spirochetal infections as 826
tuberculous meningitis as 826
Mental retardation
fragile X syndrome and 241
phenylketonuria and 227
Mercury 275–276
Mesangial lupus nephritis, minimal
class I SLE glomerular disease as 128–130
Mesothelioma, malignant
morphology of 512b, 512f
as pleural lesion 512
Metabolic disorder
of the nervous system 835
Metabolic myopathy 805
Metal, as environmental pollutant
arsenic as 275–276
cadmium as 276
lead as 274
mercury as 275
summary for 276b
Metaplasia
cellular adaptation to stress and 5, 5f
summary for 5b
Metastasis
molecular genetics of 195
neoplasm characteristics and 168–169, 168f
Metastatic calcification 26
morphology of 26b
Metastatic disease
bone tumors and 781
Metastatic neoplasm
as cardiac tumors 404–405
other cardiac tumors and 405
primary neoplasms and 404–405
Metastatic tumor 846b, 847f
Methylation of promoter region 261–262
MHC molecule. *See* Major histocompatibility complex molecule (MHC)
Microangiopathic hemolytic anemia 418, 418f
Micro-angiopathic hemolytic anemia 450b–451b
Microangiopathy 744
Microbe
summary of 319b
transmission/dissemination of
within the body for 317–318, 317f
release from body of 318
routes of entry for 315–317
Microbe, cell-associated 105–108
Microbe, extracellular 108–109
Microbe, phagocytosed
killing and degradation of 14f, 38–39, 39f
Microbial antigen, capture and display of 101f, 105, 106f
Microbial infection, autoimmunity and 124
Microbial pathogenesis
categories of infectious agents and 309–314, 310t
general principles of 309–314
Microbial substance, secretion of 39
Microorganism
disease caused by 319–322, 322b
host immune response and 321–322
mechanism of bacterial injury and 320–321
mechanism of viral injury and 319–320
MicroRNA (miRNA) 175, 176f, 177
Microscopic infarct 379
Microscopic polyangiitis 352–353
clinical features of 353
morphology of 353b, 353f
Mikulicz syndrome 479b–480b
Miliary pulmonary disease 497b
Minamata disease 275
Minimal-change disease
clinical course of 524–525
morphology of 524b, 525f
nephrotic syndrome and 524–525
summary for 528
Misfolded protein 156b–158b, 158. *See also* Amyloidosis
Misfolded protein, accumulation of 18, 21, 21t
Missense mutation 216
Mitochondrial damage 13, 13f, 16
Mitochondrial gene 243
Mitochondrial myopathy 805
Mitochondrial (intrinsic) pathway of apoptosis 19, 20f–21f, 22
Mixed-cellularity Hodgkin lymphoma 441, 441f
Mixed tumor 163, 163f
Modifier gene 219
Mold, opportunistic
clinical features of 504
as fungal infections 504
morphology of 504b
Mole, invasive 702–703
summary for 703b
Molecular diagnosis
of cancer 211
ectoparasites and 314

of Mendelian and complex disorders
discussion of 263–268
genetic analysis and 267–268
linkage analysis/genome-wide association studies and 266–267
Molecular profiling of tumor
expression profiling as 211–212
summary for 213
whole genome sequencing as 212–213
Mönckeberg medial sclerosis 335
Monocyte
HIV infection and 148–149
Mononeuropathy 798
Mononucleosis, infectious 426–427, 427f
clinical features of 427
Mononuclear inflammation 324
morphology of 324b, 324f
*Moraxella catarrhalis* 489
Morphologic method, of cancer diagnosis
cytologic (Papanicolaou) smears as 210
fine needle aspiration as 210
flow cytometry as 210–211
immunocytochemistry as 210
Mosaicism 235
Mucinous cystic neoplasm 652, 652f
Mucinous tumor of the ovary 697–698
morphology of 698b, 698f
Mucoepidermoid carcinoma 557
morphology of 557b
Mucopolysaccharidosis (MPS) 232
Mucormycosis 829
Mucosa-associated lymphoid tissue (MALT)
gastrointestinal tract and 316
*H. pylori* and 204
Multicentric C cell hyperplasia 734–735
Multifactorial inheritance 248
Multiple endocrine neoplasia syndrome (MEN)
and endocrine system 761–762
and the endocrine system 761–762
multiple endocrine neoplasia type 1 as 761–762
multiple endocrine neoplasia type 2 as 762
Multiple endocrine neoplasia (MEN) type 1 761–762
Multiple endocrine neoplasia (MEN) type 2
multiple endocrine neoplasia syndromes and 762
multiple endocrine neoplasia type 2A and 762
multiple endocrine neoplasia type 2B and 762
Multiple endocrine neoplasia type 2A 762
Multiple endocrine neoplasia type 2B 762
Multiple myeloma
clinical features of 439–440
as lymphoid neoplasms 437–440
lymphoplasmacytic lymphoma as 438
monoclonal gammopathy of undetermined significance as 438
morphology of 438b–439b, 439f
pathogenesis of 438b
solitary plasmacytoma and 437
summary for 443
Multiple sclerosis (MS)
clinical features of 833–834
morphology of 833b, 833f
myelin diseases and 832–835
Mural thrombus 383f, 384
Muscle disease, primary 801
Muscle fiber atrophy 801–802
Muscular dystrophy, limb-girdle 804
Musculoskeletal system 134
Mutated genes, products of 205
Mutation 216
Mutator phenotype 173
Myasthenia gravis 800–801
Myasthenic syndromes, congenital 801
Mycoplasma 313
Mycosis fungoides 443
Myelin
leukodystrophies and 834, 834t
multiple sclerosis as 832–834
other acquired demyelinating diseases and 834
primary diseases of 832–834
summary for 835b
Myelodysplastic syndrome (MDS)
summary for 449
morphology of 445b
as myeloid neoplasms 445–446
pathogenesis of 445b
Myelofibrosis, primary
as chronic myeloproliferative disorder 448
clinical course of 448
morphology of 448b, 448f
pathogenesis of 448b
Myeloid leukemia, trisomy 21 and 237
Myeloid neoplasm
acute myeloid leukemia as 444–445
chronic myeloproliferative disorders and 446–448
myelodysplastic syndromes as 445–446
as neoplastic proliferations of white cells 444–448
summary for 448b–449b
Myeloma nephrosis 438b–439b
Myelophthisic anemia
as anemia of diminished erythropoiesis 424
summary for 425
Myeloproliferative disorders, chronic
chronic myelogenous leukemia as 446
as myeloid neoplasms 446–448
polycythemia vera as 447
primary myelofibrosis as 448
summary for 449
Myocardial infarction (MI)
clinical features of 382–383, 382f
consequences and complications of 383–384, 383f
infarct modification by reperfusion 381–383
ischemic heart disease as 377–384
morphology of 379b–381b, 380f–381f, 380t
pathogenesis of 376f, 377b–379b, 378f–379f
Myocardial rupture 383f, 384
Myocardial vessel vasospasm 355
Myocarditis
cardiomyopathy as 401–403
clinical features of 403
morphology of 402b, 402f
pathogenesis of 401b–402b
Myopathy, inflammatory
dermatomyositis as 805
inclusion body myositis as 805
polymyositis as 805
Myositis, inclusion body 805, 806f
Myositis ossificans 793
Myotonic dystrophy 804
Myxedema 743
Myxoid chondrosarcoma 778b
Myxomas
clinical features of 405
morphology of 404b
primary neoplasms and 404, 404f

Myxomatous mitral valve
clinical features of 390–391
degenerative valve disease as 390–391
morphology of 390b, 390f
pathogenesis of 390b

N

Nasopharyngeal carcinoma 513
Natural killer (NK) cell 105, 125–131
as antitumor effector mechanisms 206
Necrosis
clinicopathologic correlation examples for 16–18
morphology of 6f, 9b
morphology of cell and tissue injury and 9
patterns of 9–11
morphology of 10b–11b, 10f–11f
Necrotizing arteriolitis 333b–334b
Necrotizing enterocolitis (NEC)
discussion of 252, 252f
premature infants and 249
preterm birth complications and 251
Necrotizing glomerulonephritis, focal and segmental 353b–354b
Necrotizing granulomatous vasculitis 353b–354b, 353f
Necrotizing vasculitis 117b
Necrotizing vasculitis, acute 128
Necrotizing vasculitis, noninfectious 135
Neoplasia. *See also* Tumor, benign; Tumor, malignant
cancer and
etiology of 198–204
genetic lesions in 173–176
molecular basis of cancer and 173
process of carcinogenesis and 177
tumor immunity and 204–207
characteristics of 164–169, 169f
clinical aspects of 207–213
effects of tumor on host and 207–208
grading/staging of 207–208
laboratory diagnosis of 210–213
summary for 209b–210b
discussion of 161–162
epidemiology of 169–172
nomenclature for 162–163, 164t
Neoplasm
characteristics of
differentiation/anaplasia and 164–166
local invasion and 167–168
metastasis and 168–169
rate of growth and 166–167
summary for 169b
of the penis 657–658, 658f
summary of 658b
of the salivary glands 555–557, 556t
mucoepidermoid carcinoma as 557
pleomorphic adenoma as 556
Neoplasm, benign
differentiation and anaplasia of 164
local invasion and 167f–168f
metastasis and 168–169
nomenclature for 162
rate of growth of 166–167
summary for 169b, 169f
Neoplasm, embryonal 844–845
medulloblastoma as 844–845
neuroectodermal tumors and 844–845
Neoplasm, malignant
differentiation and anaplasia of 164–165, 165f
local invasion and 167–168, 167f–168f
metastasis and 168–169
nomenclature for 162–163
rate of growth of 166
summary for 169b, 169f
Neovascularization 251
Nephritic syndrome
acute postinfectious glomerulonephritis as 529
glomerular disease and 529–531
hereditary nephritis as 531
IgA nephropathy as 530–531
renal syndromes and 517–518
summary for 531b
Nephritis, hereditary
clinical course of 531
morphology of 531b
nephritic syndromes and 531
pathogenesis of 531b
summary for 531
Nephrolithiasis 518
Nephron loss 523
Nephrosclerosis 333b–334b
Nephrotic syndrome
amyloidosis and 158
focal segmental glomerulosclerosis as 525–526
and glomerular disease 523–528, 524t
membranoproliferative glomerulonephritis and dense deposit disease as 527–528
membranous nephropathy as 526–527
minimal-change disease as 524–525
renal diseases and 518
summary for 528b–529b
Nervous system
infections of 824–831
epidural and subdural infections of 824–825
meningitis as 825–826
parenchymal infections and 826–831
prion diseases and 831
summary for 832b
patterns of injury in
morphology of 811b–812b, 812f
Neural tube defect 822–823, 823f
Neuroblastic 258–259
Neuroblastoma
of the adrenal medulla 761
clinical course and prognosis for 259–260, 260t
discussion of 258–260
morphology of 259b, 259f
summary for 260b
Neuroborreliosis 826
Neurodegenerative disease
Alzheimer disease as 836–837
amyotrophic lateral sclerosis as 841
of the central nervous system 836–841, 836t
frontotemporal lobar degeneration as 838
Huntington disease as 840
Parkinson disease as 839–840
spinocerebellar ataxias as 840–841
summary of 841b–842b
Neurofibroma
morphology of 808b
of peripheral nerve sheath 807–808
Neurofibroma, diffuse 807, 808b
Neurofibroma, localized cutaneous 807
Neurofibromatosis type 1 808
Neurofibromatosis type 1, familial 179–180
Neurofibromatosis type 2 (NF2) 806–807
Neurohypophysis. *See* Posterior pituitary syndrome

Neuromuscular junction, disorders of
introduction to 800–801
Lambert-Eaton syndrome as 801
miscellaneous disorders of 801
myasthenia gravis as 800–801
summary for 801b
Neuromyelitis optica (NMO) 834
Neuropeptides 49
Neurosyphilis 826
Neutropenia 425–426
Neutrophil extracellular trap (NET) 39, 40f
Nevus flammeus 357
Newborn, hemolytic disease in 254
NextGen sequencing 265–266, 267f
NF2 187–188
Niemann-Pick disease types A and B 230–231, 230f
Niemann-Pick disease types C (NPC) 231
Night blindness 297
Nitric oxide (NO) 49–50
Nodular fasciitis 793
Nomenclature
benign tumors and 162
malignant tumors and 162–163
for neoplasia 162–163
Nonalcoholic fatty liver disease (NAFLD)
introduction to 625
pathogenesis of 625b
summary for 625b
Nonbacterial thrombotic endocarditis (NBTE) 394–395, 395f
Non-coding RNA (ncRNA) 217–218, 217f
Nongonococcal urethritis (NGU) 676
summary for 676b
Non-infected vegetation
Libman-Sacks endocarditis as 395
nonbacterial thrombotic endocarditis as 394–395
Noninfectious vasculitis
anti-endothelial cell antibodies as 350
anti-neutrophil cytoplasmic antibodies as 349–350
immune complex-associated vasculitis as 348–350
Nonspecific interstitial pneumonia (NSIP) 473
Nontuberculous mycobacterial disease
as chronic pneumonia 499
Norovirus 585
Noxious stimuli, cellular responses to 1–3, 2f
Nuclear transcription factor 180
Numeric abnormality, cytogenetic disorders and 235
Nutmeg liver 368
Nutritional disease
anorexia nervosa/bulimia as 295–296
diet and cancer as 306
diet and systemic diseases as 306
discussion of 293–306
malnutrition as 293–294
neurologic illnesses and 835
obesity as 302–305
protein-energy malnutrition as 294–295
summary for 302b
Nutritional imbalance, cell injury and 7

O

Obesity
adipose tissue and 304–305
clinical consequences of 305
gut hormones and 305
leptin and 304
nutritional diseases and 302–305
summary for 305b
Obligate intracellular bacteria 311
Obstructive lesion, aortic coarctation and 373–374
Obstructive lung disease
asthma as 468–470
bronchiectasis as 470–472
chronic bronchitis as 467
discussion of 463–472, 463t, 464f
emphysema as 463–466
Obstructive overinflation 466
Occupational asthma 470
Occupational cancer 171t
Oligodendroglioma 843
morphology of 843b–844b, 844f
Oligohydramnios sequence 246–247, 247f
Oncocytoma 547
Oncofetal antigens 206
Oncogene 173, 182
Oncogene, mutated 204–205
Oncogene addiction 180
Oncology 162
Onion-skin lesion 130
Opsonization 114–115, 115f, 117
Oral candidiasis (thrush) 552
Oral cavity
disease of salivary glands and 555–557
odontogenic cysts and tumors of 557–558
oral inflammatory lesions of 552
proliferative and neoplastic lesions of 552–554
summary for 554b
Oral contraceptive (OC) 283–284
Oral inflammatory lesion
aphthous ulcers as 552
herpes simplex virus infections as 552
oral candidiasis as 552
summary for 552b
Organic solvent 276
Organochlorine 276
Organ systems, ionizing radiation effects and 292–293, 292f, 292t
Osler-Weber-Rendu disease. *See* Hereditary hemorrhagic telangiectasia
Osteitis deformans. *See* Paget disease
Osteoarthritis
clinical course of 783, 783f
the joints and 782–790
morphology of 782b–783b, 782f
obesity and 305
pathogenesis of 783b
summary for 790
Osteoblastoma 776
morphology of 776b
Osteochondroma
as cartilage-forming tumors 777–778, 777f
clinical features of 778
morphology of 778b
summary for 781
Osteogenesis imperfecta (OI) 767–768
Osteoid osteoma
as bone-forming tumor 776
morphology of 776b, 776f
summary for 781
Osteoma 775–776
Osteomalacia
acquired bone disease and 771
morphology of 300b–301b
vitamin D and 298–300
Osteomyelitis
acquired diseases of bone and 773–774
pyogenic osteomyelitis as 773–774
tuberculous osteomyelitis as 774

Osteopetrosis 767–768
Osteoporosis
  acquired bone disease and 768–770, 769t, 772
  clinical course of 770
  exogenous estrogens and 282–283
  morphology of 768b–769b, 769f
  pathogenesis of 766f, 769b–770b, 769f
  vitamin D and 299–300
Osteosarcoma
  bone tumors as 776–777
  clinical features of 777
  morphology of 776b–777b, 776f
  pathogenesis of 777b
  summary for 782
Ostium primum ASD 371b
Ostium secundum ASD 371b
Outdoor air pollution 272–273
  morphology of 273b
Ovary
  follicle and luteal cysts and 695
  other tumors of 698–700, 699t
  polycystic ovarian disease and 695–696
  tumors of 696–698
Oxidative stress. *See* Free radicals, oxygen-derived
Oxygen deprivation 7
Ozone 272–273, 272t

P

Paget disease (osteitis deformans)
  acquired bone disease as 770–771
  clinical course of 771
  morphology of 770b, 770f
  pathogenesis of 771b
  summary for 772
Paget disease, extramammary 683–684, 684f
  summary of 684
Paget disease of the nipple 710
Panacinar emphysema 464, 464f, 465b
Pancarditis 391b
Pancreas
  congenital anomalies of
    agenesis and 646
    annular pancreas as 646
    congenital cysts as 646
    ectopic pancreas as 646
    pancreas divisum as 646
  overview of 645
  pancreatic neoplasms and 651–654
  pancreatitis and 646–651
Pancreas, congenital cysts of 646
Pancreas, ectopic 646
Pancreas, endocrine
  diabetes mellitus and 739–750
  pancreatic neuroendocrine tumors and 751–752
Pancreas divisum 646
Pancreatic abnormality 223–227
Pancreatic carcinoma
  clinical features of 654
  introduction to 652–654
  morphology of 653b–654b, 654f
  pathogenesis of 653b, 653f
Pancreatic neoplasm
  cystic neoplasms as 651–652
    intraductal papillary mucinous neoplasms as 652
    mucinous cystic neoplasms as 652
    serous cystadenomas as 651
  pancreatic carcinoma and 652–654
  summary for 654b
Pancreatic neuroendocrine tumor (PanNET)
  endocrine pancreas and 751–752
  gastrinomas and 752
  insulinomas and 751
Pancreatic pseudocyst
  acute pancreatitis and 649
  morphology of 649b, 649f
Pancreatitis
  acute pancreatitis and 646–649
  chronic pancreatitis and 649–651
  and the pancreas 646–651
  summary for 651b
Pancreatitis, acute
  clinical features of 648–649
  inflammatory disorders of 646–649, 646t
  morphology of 647b, 647f
  pancreatic pseudocysts as 648–649
  pathogenesis of 647b–648b, 648f
Pancreatitis, chronic
  clinical features of 651
  morphology of 650b, 650f
  the pancreas and 649–651
  pathogenesis of 650b
Pancreatitis, hemorrhagic 647b
Pancreatitis, lymphoplasmacytic sclerosing 650b
Pancytopenia 442–443
Papanicolaou smear. *See* Cytologic (Papanicolaou) smear
Papillary carcinoma of the thyroid
  clinical features of 733
  morphology of 732b–733b, 732f
  summary for 735
  the thyroid and 732–733
Papillary fibroelastoma 405
Papillary muscle dysfunction 383–384
Papilloma 162
Paraneoplastic syndromes 208–209, 209t
Parasitic disease 585–586
Parathyroid carcinoma 736b–737b
Parathyroid gland
  endocrine system and 735–738
  hyperparathyroidism and 735–738
  hypoparathyroidism and 738
Parathyroid hyperplasia 736b–737b
Parenchymal hemorrhage, primary brain 817, 817f, 819
  morphology of 817b
Parenchymal infection
  arboviruses and 827
  brain abscesses and 826
  cytomegalovirus and 828
  fungal encephalitis and 829
  herpesviruses and 827–828
  human immunodeficiency virus and 828
  of nervous system 826–831
  other meningoencephalitides as 829–831
  poliovirus and 828
  polyomavirus and progressive multifocal leukoencephalopathy as 828–829
  rabies virus and 828
  viral encephalitis and 826–829
Parenchymal injury, traumatic 820–821
  morphology of 820b, 820f
Parkinson disease (PD)
  clinical features of 839–840
  morphology of 839b, 839f
  parkinsonism and 839–840
  pathogenesis of 839b

Paroxysmal nocturnal hemoglobinuria (PHN)
hemolytic anemias and 417
pathogenesis of 417b
Parvovirus B19 255–256, 256f
Passive congestion
circulatory disorders of liver and 633
morphology of 633b, 633f
Passive smoke inhalation. *See* Tobacco smoke, environmental
Patent ductus arteriosus
clinical features of 372
left-to-right shunts and 369t, 370f, 371–372
Patent foramen ovale 370–371
Pathology, introduction to 1
Pediatric disease
congenital anomalies and 245–248, 246f
fetal hydrops and 254–257
introduction to 245–268, 245t
molecular diagnosis of Mendelian/complex disorders and 263–268
necrotizing enterocolitis and 252
perinatal infections and 249
prematurity/fetal growth restrictions and 249–250
respiratory distress syndrome and 250–251
sudden infant death syndrome and 252–254
tumors/tumor-like lesions and 257–262
Pemphigus (vulgaris and foliaceus)
blistering disorders and 858–859, 862
clinical features of 859
morphology of 859b, 859f–860f
pathogenesis of 858b–859b, 859f
Penis
inflammatory lesions of 657
malformations of 657
neoplasms of 657–658
Peptic ulceration, acute
clinical features of 565
inflammatory disease of the stomach and 565
morphology of 565b
pathogenesis of 565b
Peptic ulcer disease (PUD)
clinical features of 568–569
epidemiology of 568
inflammatory diseases of the stomach and 568–569
morphology of 568b, 568f
pathogenesis of 565f, 568b
Peptide display system 123–125
Pericardial disease
heart diseases and 403–404
pericardial effusions as 404
pericarditis as 403–404
Pericardial effusion 404
Pericarditis
clinical features of 403–404
morphology of 403b, 403f
pericardial disease as 384, 403–404
Pericarditis, acute bacterial 403b
Pericarditis, chronic 403b
Pericarditis, constrictive 403b
Perinatal infection 249
Peripheral nerve disorder
introduction to 797–799, 798f
nerve injury disorders and 798–799
patterns of injury and 797–798
summary for 800b
Peripheral nerve injury
disorders associated with 799t
chronic inflammatory demyelinating polyneuropathy as 799
diabetic peripheral neuropathy as 799
Guillain-Barre syndrome as 798–799
summary for 800b
toxic, vasculitic, inherited forms of 799–800
patterns of 797–798, 798f
Peripheral nerve sheath
malignant tumors of 808
neurofibromas as 807
neurofibromatosis type 1 as 808
Schwannomas and neurofibromatosis type 2 as 806–807
traumatic neuroma as 808
tumors of 806–808
Peripheral nerve sheath schwannoma 806–808
morphology of 807b, 807f
Peripheral nerve sheath tumor, malignant 808
morphology of 808b
Peripheral neuropathy
summary for 800b
toxic, vasculitic, inherited forms of 799, 800f
Peripheral T cell lymphoma 443
Peutz-Jeghers syndrome 592–593, 594f
Phagocyte oxidase 143
Phagocytosis 37–39, 39f, 112f, 114–115
Phenylketonuria (PKU) 227–228, 227f
summary for 228, 228b
Pheochromocytoma
adrenal medulla tumors and 760–761
clinical features of 761
morphology of 760b–761b, 760f–761f
Phlebothrombosis 356. *See also* Venous thrombosis
Phyllodes tumor 707
Physical agent
cell injury and 7
injury by
electrical injury and 289
ionizing radiation and 289–293
mechanical trauma as 287
thermal injury and 288–289
toxicity of 271–272
Pickwickian syndrome 305
Pigeon breast deformity 300
Pigment 24, 25f
Pilocytic astrocytoma 842–843
morphology of 843b
Pituitary adenoma
adrenocorticotropic hormone producing adenomas as 719–720
growth hormone producing adenomas as 719
morphology of 718b, 718f–719f
other anterior pituitary neoplasms as 720
pathogenesis of 718b
and pituitary gland 717–720, 717t
(*See also* Hyperpituitarism)
prolactinomas as 719
summary of 719, 720b
Pituitary adenoma, nonfunctioning 720
Pituitary carcinoma 720
Pituitary gland
as endocrine system 716–721, 716f–717f
hyperpituitarism/pituitary adenomas and 717–720
hypopituitarism and 720–721
posterior pituitary syndromes and 721
prolactinomas and 719
PKU. *See* Phenylketonuria (PKU)
Placental-fetal transmission 318
Placental inflammation/infection 701

Plasma protein-derived mediator
coagulation and Kinin system as 51–52
complement system as 50–51, 50f
summary for 52b
Plasminogen activator inhibitor (PAI) 80, 85f
Platelet
activation of 80, 82
adhesion and 82
aggregation of 82
discussion of 81–82
endothelial interaction with 81f, 82
normal hemostasis and 80f
normal hemostasis and 79
summary for 82b
Platelet-activating factor (PAF) 47–48
Platelet activation 82, 82b
Platelet adherence 79
Platelet adhesion 80f–81f, 82
Platelet aggregation 81f, 82, 82b
Platelet contraction 82
Pleiotropy 218–219
Pleomorphic undifferentiated sarcoma 794
Pleomorphic adenoma 163, 556–557, 557f
morphology of 556b–557b
Pleomorphic fibroblastic sarcoma 794, 794f
Pleomorphism 165, 165f
Pleural effusion 511
Pleural lesion
of the lungs 511–512
malignant mesothelioma as 512
pleural effusion and pleuritis as 511
pneumothorax, hemothorax, chylothorax as 511–512
Pleuritis 511
Plexiform neurofibroma 807, 808b
Plummer syndrome 728b
Pneumoconiosis
asbestosis as 477
coal worker's pneumoconiosis as 475
as fibrosing disease 474–478, 474t
mineral dust and 277
pathogenesis of 474b–475b
silicosis as 476
summary for 478b
*Pneumocystis* pneumonia
in the immunocompromised host 501–502
morphology of 502b, 502f
Pneumonia
caused by other pathogens
*Haemophilus influenzae* as 489
*Klebsiella pneumoniae* as 489–490
*Legionella pneumophila* as 490
*Moraxella catarrhalis* as 489
*Pseudomonas aeruginosa* as 490
*Staphylococcus aureus* as 489
community-acquired acute
morphology of 488b, 489f
pneumonias caused by other important pathogens and 488–490
as pulmonary infection 486–490
*streptococcus pneumoniae* infections as 487–488
community-acquired atypical
clinical features of 490–491
influenza infections as 491
influenza virus type A/HINI infection as 491
morphology of 490b, 491f
as pulmonary infections 490–491
summary for 491b
in the immunocompromised host
cytomegalovirus infections and 500–501
*pneumocystis* pneumonia and 501–502
as pulmonary infection 500–502
Pneumonia *(P. jiroveci)*
HIV infections and 151, 151t, 313
Pneumonia, chronic
nontuberculous mycobacterial disease as 499
as pulmonary infection 492–499
tuberculosis and 493–498
Pneumonia, cryptogenic organizing 473–474, 474f
Pneumonia, hospital-acquired 491–492
Pneumothorax 511
Podocyte injury 522f, 523, 528
Poliovirus 828
Pollution, environmental
air pollution as 272–273
industrial/agricultural exposures as 276–277
metals as 273–276
Polyarteritis nodosa (PAN)
autoimmune diseases and 135
clinical features of 352
morphology of 352b, 352f
vasculitis and 352
Polycystic kidney disease, autosomal recessive
clinical course of 544
cystic diseases and 544
morphology of 544b
summary for 544
Polycystic ovarian disease 695–696
Polycythemia 425, 425t
Polycythemia vera
as chronic myeloproliferative disorder 447
clinical course of 447–448
morphology of 447b
Polymerase chain reaction (PCR) analysis 264–266, 266f
Polymerase chain reaction (PCR) analysis
molecular diagnosis and 211
Polymorphism
complex multigenic disorders and 234
genetic abnormalities and 216–217
linkage analysis and 245–246
P-450 enzymes and 271–272
Polymyositis 805, 806f
Polyneuritis multiplex 798
Polyneuropathy 798
Polyomavirus 828–829
Polyp, endometrial 693
Polyp, hamartomatous
colonic polyps and 592–593, 593t, 600
juvenile polyps as 592
Peutz-Jeghers syndrome as 592–593
Polyp, inflammatory
colonic polyps as 592, 600
gastric polyps and 569, 572
morphology of 569b
Polyp, juvenile 592
morphology of 592b, 594f
Polyp, nomenclature for 162, 163f
Polypoid cystitis (ureter) 668
Portal hypertension
ascites and 609
liver disease and 608–609, 609f
Portal vein obstruction/thrombosis 632–634
Portopulmonary hypertension 610
Port wine stain 357
Posterior fossa anomaly 823
Posterior pituitary syndrome 721

Postmortem clot 88b–89b
Postnatal genetic analysis 268
Potter sequence. *See* Oligohydramnios sequence
Prader-Willi syndrome 243–245, 244f
Preeclampsia/eclampsia
  clinical features of 704
  diseases of pregnancy and 703–704
  morphology of 704b
  summary for 704b
Pregnancy, diseases of
  ectopic pregnancy as 701
  gestational trophoblastic disease as 701–703
  placental inflammations and infections as 701
  preeclampsia/eclampsia as 703–704
Pregnancy, ectopic
  diseases of pregnancy and 701
  morphology of 701b
  summary for 701b
Prematurity, infant 249–250
Primary amyloidosis
  immunocyte dyscrasias as 155
  lymphoplasmacytic lymphoma and 438
Primary biliary cirrhosis (PBC)
  cholestatic liver diseases and 627, 627t
  clinical course of 627
  morphology of 627b–628b, 627f–628f
  pathogenesis of 627b
Primary hypercoagulability 81f, 87
Primary immune deficiency
  common variable immunodeficiency as 141
  genetic deficiencies of innate immunity as 142–143
  hyper-IgM syndrome as 141
  introduction to 139–143, 140f
  isolated IgA deficiency as 141
  lymphocyte activation defects as 142
  severe combined immunodeficiency as 142
  summary for 142–143, 143b
  with thrombocytopenia and eczema 142
  thymic hypoplasia as 141
  X-linked agammaglobulinemia as 140–141
Primary sclerosing cholangitis (PSC)
  cholestatic liver diseases and 627t, 628–629
  clinical course of 629
  morphology of 628b, 629f
Primary syphilis 672, 673f
Primary tuberculosis 495–496, 496f
Primitive neuroectodermal tumor (PNET). *See* Ewing sarcoma
Prinzmetal angina 376
Prion 309–314
Prion disease
  Creutzfeldt-Jakob disease as 831
  nervous system infections and 831–832, 831f
  variant Creutzfeldt-Jakob disease as 831
Progressive massive fibrosis (PMF) 475, 475f. *See also* Coal worker's pneumoconiosis (CWP)
Progressive multifocal leukoencephalopathy (PML) 828–829
  morphology of 829b, 829f
Progressive pulmonary tuberculosis 497b
Prolactinoma 719–720
Prostaglandin
  anti-inflammatory drugs and 46–47
  arachidonic acid metabolites and 46–47
Prostate
  benign prostatic hyperplasia and 664–665
  carcinoma of 665–668
  male genital system and 663–668, 663f
  prostatitis and 663–664
Prostatitis
  clinical features of 664
  prostate disease and 663–664
  summary for 664b
Prosthetic cardiac valve 395–396
Protein
  damage to 16
  intracellular accumulation of 23
Protein, signal-transducing
  ABL and 180
  introduction to 179–180
  RAS protein and 179–180
Protein-coding gene
  alterations other than mutations
    epigenetic changes as 217
    genetic abnormalities and 216–218
    non-coding RNA alterations as 217–218
    sequence and copy number variations as 216–217
  mutations in 216
Protein-energy malnutrition (PEM)
  discussion of 294–295
  kwashiorkor as 294–295
  marasmus as 294
  morphology of 295b
  secondary protein-energy malnutrition and 295
Proteoglycan 64
Protozoa 313
PSA test 211
Pseudogout 789–790
*Pseudomonas aeruginosa* 490
Psoriasis
  chronic inflammatory dermatosis and 854–855
  clinical features of 854–855
  morphology of 854b, 855f
  pathogenesis of 854b
Pulmonary angiitis 485
Pulmonary anthracosis 475b
Pulmonary disease
  as drug- and radiation-induced 478
  of vascular origin
    diffuse alveolar hemorrhage syndromes as 485
    pulmonary embolism, hemorrhage, infarction as 482–483
    pulmonary hypertension as 484
Pulmonary disease, obstructive vs restrictive 462–463
Pulmonary embolism, hemorrhage, infarction
  clinical features of 483
  diseases of vascular origin and 482–483
  morphology of 482b, 483f
  summary for 483b
Pulmonary eosinophilia 481
Pulmonary hypertension
  clinical features of 484
  morphology of 484b, 485f
  pathogenesis of 484b
  of vascular origin 484
Pulmonary hypertension, secondary 134
Pulmonary hypertensive heart disease. *See* Cor Pulmonale
Pulmonary infection
  aspiration pneumonias as 492
  chronic pneumonias as 492–499
  community-acquired acute pneumonias as 486–490
  community-acquired atypical pneumonias as 490–491
  histoplasmosis, coccidioidomycosis, blastomycosis as 499–500
  hospital-acquired pneumonias as 491–492
  in human immunodeficiency virus infection 504
  lung abscess as 492
  the lungs and 486–504, 487f, 488t

Pulmonary infection *(Continued)*
opportunistic fungal infections as 502–504
pneumonia in the immunocompromised host as 500–502
Pulmonary thromboembolism 90, 90f
Purulent inflammation. *See* Inflammation, suppurative
Pyelonephritis 746–747
Pyelonephritis, acute
clinical course of 534f, 535
morphology of 534b–535b, 534f
pathogenesis of 533b–534b, 534f
summary for 537
tubulointerstitial nephritis and 533–535
Pyelonephritis, chronic
clinical course of 536
morphology of 535b, 536f
summary for 537
tubulointerstitial nephritis and 535–536
Pyelonephritis, chronic obstructive 535
Pyelonephritis, chronic reflux-associated 535
Pyogenic granuloma 358, 358f
Pyogenic liver abscess 635
Pyogenic meningitis, acute 825
morphology of 825b, 825f
Pyogenic osteomyelitis
acquired bone disease and 773–774
clinical features of 774
morphology of 774b, 774f
Pyrin 155–156

R

Rabies virus 828
Radiation. *See* Ionizing radiation
Radiation carcinogenesis 200–201
summary for 201b
Radon 273
Rapidly progressive glomerulonephritis (RPGN) 531–533. *See also* Crescentic glomerulonephritis
anti-glomerular basement membrane antibody–mediated crescentic glomerulonephritis as 532
and glomerular diseases 531–533
immune complex–mediated crescentic glomerulonephritis as 532
pathogenesis of 532b
pauci-immune crescentic glomerulonephritis as 532–533
summary for 533b
RAS protein 179–180, 179f
Rate of growth
cancer stem cells/lineages and 166–167
neoplasms and 166–167
Raynaud phenomenon 355
RB gene 182–184
summary for 184b–185b
RDS. *See* Respiratory distress syndrome (RDS)
Reactive oxygen species (ROS)
accumulation of 14–16, 14f–15f
cell-derived mediators and 49–50
ischemia-reperfusion injury and 17
production of 38
Reactive proliferation
myositis ossificans as 793f
nodular fasciitis as 793, 793f
Reactive systemic amyloidosis 155
Reactive tuberculosis. *See* Tuberculosis, secondary
Recurrent sinonasal polyp 226
Red cell disorder
anemia of blood loss 409
anemias of diminished erythropoiesis and 419–424
hematopoietic system and 408–425, 408t–409t
hemolytic anemias and 409–419
polycythemia and 425
summary for 409b
Red infarct 92b–93b, 93f, 94
Red thrombi 88b–89b
Reflux esophagitis
clinical features of 560–561
diseases of the esophagus and 560–561
the esophagus and 560–561
morphology of 560b, 561f
pathogenesis of 560b
Reflux nephropathy 535–536
Regeneration, cell and tissue
control of cell proliferation and 59, 59f
growth factors of 61–62
introduction to 59–65
proliferative capacities of tissue and 59–60
role of extracellular matrix in 63–65, 63f
role of regeneration in tissue repair and 65
stem cells and 60
summary of 61b
Rejection, acute 138
Rejection, antibody-mediated 137–138
Rejection, chronic 137f, 138
Rejection, hyperactive 137–138
Rejection, hyperacute 137–138, 137f
Renal atherosclerosis 746–747
Renal cell carcinoma
chromophobe renal carcinomas as 548
clear cell carcinomas as 547
clinical course of 548–549
morphology of 548b, 548f
papillary renal cell carcinomas as 547–548
summary for 549b
as tumors of the kidney 547–549
Renal cell carcinoma, papillary 548b
Renal disease 517–518
Renal stones
clinical course of 545
morphology of 545b
pathogenesis of 545b, 545t
urinary outflow obstruction and 545
Reperfusion 381–383, 382f
Replicative potential, limitless
cancer cells and 190–191, 191f
summary for 191b
Resorption atelectasis 460
Respiratory bronchiolitis 481
Respiratory distress syndrome (RDS)
of the newborn 250–251, 250f
clinical features of 251
morphology of 251b, 251f
pathogenesis of 250b–251b
summary 251b–252b
premature infants and 249
Respiratory tract
microbe transmission/dissemination through 316–319
Restrictive cardiomyopathy 401
morphology of 401b
Retinoblastoma (RB)
clinical features of 261
discussion of 260–261
morphology of 261b
Retinoblastoma (RB) gene 182–184
pathogenesis of 183f
Retinopathy, diabetic 744, 747, 747f
Retroperitoneal fibrosis (ureter) 668
Rhabdomyomas 404b

Rhabdomyosarcoma 794–795
morphology of 795b, 795f
Rheumatic fever, acute 391b
Rheumatic heart disease 110, 391b
Rheumatic valvular disease
clinical features of 391–392
morphology of 391b, 392f
pathogenesis of 391b
valvular heart disease as 391–392
Rheumatoid arthritis (RA)
autoimmune diseases 131
clinical features of 785–786
of the joints 784–786
morphology of 785b, 785f–786f
pathogenesis of 784b, 784f
summary for 790
Rheumatoid vasculitis 355
Rickets
acquired bone disease and 771
morphology of 300b–301b
vitamin D and 298–300, 300f
Rickettsia 311–313
Riedel thyroiditis 726
RNA virus, oncogenic 201, 201f
summary for 202b
Rolling 35–37, 36t
ROS. *See* Reactive oxygen species (ROS)
Rotavirus 585–586
Roundworms (nematode) 314, 314f

S

Sacrococcygeal teratoma 258, 258f
Saddle embolus 90, 90f
Salivary gland, disease of
neoplasms as 555–557
sialadenitis as 555
summary for 557b
xerostomia as 555
Salmonellosis
infectious enterocolitis and 583–584
pathogenesis of 584b
Sanger sequencing 265, 266f
Sarcoidosis
clinical features of 480
epidemiology of 478–479
etiology and pathogenesis of 479b
as granulomatous disease 478–480
morphology of 479b–480b, 479f
summary for 480b
Sarcoma 162
Sarcoma botryoides 685
Scar formation
angiogenesis and 66–67
connective tissue remodeling and 68
fibroblasts and connective tissue in 68
growth factors involved in 42f, 68
introduction to 65–68
remodeling of connective tissue and 68
steps in 65–66, 66f
summary for 69b
Scarring
chronic inflammation and 309–314
morphology of 325b, 325f
Scleroderma. *See* Systemic sclerosis (SS)
Scleroderma, limited 132
Sclerosing adenosis 706
morphology of 706b, 706f
Scrotum 658–663
Scurvy 301
Seborrheic keratosis
as epithelial lesions of the skin 862–863
morphology of 862b, 862f
Secondary immune deficiency 143
Secondary syphilis 672–673
Secondary tuberculosis
clinical features of 498
morphology of 497b, 497f–498f
as type of tuberculosis 496
Seminoma 163
Sensorimotor polyneuropathy, distal symmetric 799
Septic shock 94, 95f
Sequence 216–217
Sequencing, whole genome 212–213, 212f–213f
Serous carcinoma 692b, 693f
Serous cystadenoma 651, 651f
Serous tumor, ovarian epithelial 697
morphology of 697b, 697f
Severe combined immunodeficiency (SCID) 142–143
Sexually transmitted disease (STD)
chancroid as 677
genital herpes simplex as 678
gonorrhea and 674–675
granuloma inguinale as 677
human papillomavirus infection as 678
lymphogranuloma venereum as 676
male genital system and 671–678, 671t
microbe dissemination and 318
nongonococcal urethritis and cervicitis as 676
trichomoniasis as 677–678
Sézary syndrome 443
Sheehan postpartum pituitary necrosis 452b
Shigellosis
clinical features of 584b
infectious enterocolitis and 583
morphology of 583b
pathogenesis of 583b
Shock
clinical course for 97
introduction to 94–97, 94t
morphology of 97b
pathogenesis of 94–96
stages of 96–97
summary for 97b
Shock lung 97b
Shunt, left-to-right
atrial septal defect/patent foramen ovale and 370–371
congenital heart disease and 370–372, 370f
patent ductus arteriosus and 371–372
ventricular septal defects and 371
Shunt, portosystemic
hepatorenal syndrome and 610
liver disease and 609–610
portopulmonary hypertension/hepatopulmonary syndrome and 610
splenomegaly and 609
Shunt, right-to-left
congenital heart disease and 372–373, 372f
tetralogy of Fallot and 372–373
transposition of the great arteries and 373
Sialadenitis 555, 556f, 557
Sicca syndrome 131
Sickle cell anemia
clinical course of 413
hemolytic anemias and 411–413
incidence of 411–413
morphology of 411f, 412b–413b

Sickle cell anemia *(Continued)*
pathogenesis of 411b–412b, 412f
summary for 419
SIDS. *See* Sudden infant death syndrome (SIDS)
Sigmoid diverticulitis
clinical features of 586–587
inflammatory intestinal disease and 586–587
morphology of 586b, 586f, 591f
pathogenesis of 586b
summary for 587b
Silicosis
clinical features of 476
morphology of 476b, 476f
as pneumoconiosis 476
summary for 478
Single-gene disorder
with atypical patterns of inheritance 241–244
alterations of imprinted region disease as 243–244
mutations in mitochondrial genes disease as 243
triplet repeat mutations as 241
Single-gene disorder, transmission patterns of
autosomal dominant inheritance as 219–220
autosomal recessive inheritance as 220
summary for 220b
X-linked disorders as 220
Single-nucleotide polymorphism (SNP) 222–223
array-based genomic hybridization and 264
linkage analysis and 266
sequence and copy number variations and 216–217
Sinusoidal obstruction syndrome 634, 634f
Sinus venosus ASD 371b
Sjögren syndrome
discussion of 131–132
morphology of 132b, 132f
pathogenesis of 127t, 131b
summary for 132b
Skeletal muscle
acquired disorders of 805–806
inflammatory myopathies as 805
toxic myopathies as 805–806
inherited disorders of 802–805
channelopathies, metabolic and mitochondrial myopathies as 805
dystrophinopathies as 802–804
X-linked and autosomal muscular dystrophies as 804–805
patterns of injury for 801–802, 803f
summary for 806b
Skeletal muscle tumor, rhabdomyosarcoma as 794–795
Skin
benign and premalignant tumors of 862–869
blistering disorders of 857–861
chronic inflammatory dermatoses and 854–856
infectious dermatoses and 856–857
introduction and terminology for 851
microbe transmission/dissemination and 316, 318–319
SLE morphology and 130, 130f
systemic sclerosis morphology and 133, 134f
Skin wound
healing by first intention and 70–71, 70f
healing by second intention and 70f–71f, 71–72
summary for 72b
wound strength and 72
Small airway disease. *See* Chronic bronchiolitis
Small cell carcinoma (SCLC) 506b–509b, 509f
Small-for-gestational-age (SGA) infant 249–250
Small lymphocytic lymphoma (SLL) 433–434
summary for 443
Smog 272–273
Smokeless tobacco 277, 279
Smoking-related interstitial disease 481, 482f
and chronic interstitial lung disease 481
Sodium retention 77–78
Soft tissue
fibrohistiocytic tumors and 794
fibrous tumors and tumor-like lesions of 792
introduction to 791–796, 792t
skeletal muscle tumors and 794–795
smooth muscle tumors and 795
synovial sarcoma and 795
tumors of adipose tissue and 792
Spermatocytic seminoma 660b–662b
Spider telangiectasias 357–358
Spinal cord abnormality 823
Spinocerebellar ataxia (SCA) 840–841
Spirochetal infection
neuroborreliosis as 826
neurosyphilis as 826
Spleen 456–457
amyloidosis and 157
SLE morphology and 130
splenomegaly as 456
Splenomegaly
CML and 447
hairy cell leukemia and 442–443
portosystemic shunt and 609
spleen disorders and 456
Spondyloarthropathy, seronegative 786
Spontaneous maturation 258–259
Spontaneous regression 258–259
Squamous cell carcinoma
clinical features of 863–864
of the esophagus 563–564
clinical features of 563–564
morphology of 563b, 563f
pathogenesis of 563b
lung tumors and 506b–509b
malignant epidermal tumors and 863–864
morphology of 863b, 864f
nomenclature for 162–163, 165f
of the oral cavity 554
morphology of 554b, 555f
pathogenesis of 554b
pathogenesis of 863b
of the vagina 684
Staging, cancer tumor and 208–210
*Staphylococcus aureus* 489
Stasis thrombi. *See* Red thrombi
Steatohepatitis, nonalcoholic 305
Steatosis. *See* Fatty change
Steatosis, drug/toxin-mediated injury with 625
morphology of 626b
Steatosis, hepatocellular 621b–622b, 621f
Stem cell 60, 61b, 61f
cancer of 166–167
Stem cell, adult 60
Stem cell, cardiac 385
Stem cell, embryonic (ES cell) 60
Stenting, endovascular 362, 363f
Stomach
carcinoid tumor as 571–572
gastric adenocarcinoma as 570–571
gastric polyps as 569
gastrointestinal stromal tumor as 572
inflammatory diseases of 564–569
acute gastritis as 564
acute peptic ulceration as 565

chronic gastritis as 565
peptic ulcer disease as 568–569
lymphoma as 571
neoplastic disease of 569–572
carcinoid tumor as 571–572
gastric adenocarcinoma as 570–571
gastric polyps as 569
gastrointestinal stromal tumor as 572
lymphoma as 571
summary for 572b–573b
Streptococcus pneumoniae infection 487–488
Stress
cellular adaptations to 3–5
cellular response to 1–3, 2f
Structural abnormality, cytogenetic disorders and 235–236, 235f–236f
Sturge-Weber syndrome 257–258. *See also* Port wine stain
Subdural hematoma 821–822
morphology of 821f, 822b
Subdural infection of nervous system 824–825
Sudden cardiac death (SCD) 386, 386f
Sudden infant death syndrome (SIDS)
discussion of 252–254, 253t
morphology of 253b
pathogenesis of 253b
summary for 254b
Sulfur dioxide 273
Superior vena cava syndrome 356
Surface epithelial tumor (ovarian) 696–697
Syndrome of inappropriate ADH (SIADH) 721
Synovial cyst 790
Synovial sarcoma
morphology of 795b–796b, 795f
soft tissue disease and 795–796
Syphilis
congenital syphilis and 673–674
male genital system and 671–674
morphology of 672b
primary syphilis and 672, 673f
secondary syphilis and 672–673
serologic tests for 674
summary for 674b
tertiary syphilis and 673
Systemic disease
diet and 306
Systemic immune complex disease 116–117, 116f
Systemic inflammatory response syndrome (SIRS) 94–95
Systemic lupus erythematosus (SLE)
autoantibodies in 127
as autoimmune disease 125–131, 125t
clinical manifestations of 127t, 131
mechanisms of tissue injury in 127–131
morphology of 125t, 128b–130b, 129f
pathogenesis of 125b–127b, 126f
summary for 131b
Systemic miliary tuberculosis 497b
Systemic sclerosis (SS)
as autoimmune disease 132–134
clinical course for 134
morphology of 133b–134b
pathogenesis of 133b, 133f
summary for 134b–135b

T

Tapeworm (cestode) 314
Tay-Sachs disease 229–230, 230f
T cell
HIV and 146
systemic sclerosis and 133
T cell leukemia, adult 443
T cell lymphoma, adult 443
T cell-mediated hypersensitivity (Type IV)
CD4+ T cell inflammatory reactions and 118–119
delayed-type hypersensitivity and 119
introduction to 111, 117–120, 118t, 119f
summary for 120b
T cell-mediated cytotoxicity and 119–120
T cell mediated rejection 137
T cell receptor (TCR) 101, 101f
Tenosynovial giant cell tumor (TGCT)
clinical features of 791
joint tumors and 790
morphology of 790b, 791f
Teratoma, benign cystic 163, 698–700, 700f
Teratoma, immature malignant 700
Teratoma, specialized 700
Tertiary syphilis 673
Testicular atrophy 658–659
Testicular neoplasm 659–663, 660t
clinical features of 662–663
morphology of 660b–662b, 660f–662f
summary for 663b
Testicular torsion 659
Testis
cryptorchidism/testicular atrophy and 658–659
inflammatory lesions of 659
male genital system and 658–663
neoplasms of 659–663
vascular disturbances and 659
Tetany, hypocalcemic 298
Tetralogy of Fallot
clinical features of 372–373
morphology of 372b
right-to-left shunts and 369t, 372–373, 372f
Thalassemia
clinical course of 416
hemolytic anemias and 413–416
morphology of 415b–416b
pathogenesis of 413b–415b, 414f–415f, 414t
summary for 419
Thanatophoric dwarfism 767
Thermal burn
morphology of 288b–289b
thermal injury and 288
Thermal injury
hyperthermia as 289
hypothermia as 289
thermal burns as 288
Thiamine deficiency 835
Thoracic aortic aneurysm 346
Thrombocytopenia, heparin-induced 453
Thrombin
coagulation cascade and 81f, 83, 85f
platelet aggregation and 82
Thromboangiitis obliterans (Buerger disease) 354–355
clinical features of 354–355
morphology of 354b, 354f
Thrombocytopenia 78, 87, 424
disseminated intravascular coagulation and 452–454, 453t
heparin-induced thrombocytopenia and 453
immune thrombocytopenic purpura and 452–453
thrombotic microangiopathies as 453–454
Thrombocytopenic syndrome, heparin-induced 87

Thromboembolism
embolism and 75, 90
HRT and 283
oral contraceptives and 284
Thromboembolism, systemic
air embolism as 91–92
amniotic fluid embolism as 91
embolism and 91–92
fat embolism as 91
Thrombophlebitis 356
Thromboplastin. *See* Endothelial injury
Thrombosis
abnormal blood flow and 86
clotting and 75
endothelial injury and 86
fate of thrombus and 89
hypercoagulability and 87–88
introduction to 86–89, 86f
morphology of 88b–89b, 88f
summary for 90b
Thrombotic microangiopathy
pathogenesis of 453b–454b
summary for 541
as blood vessel disease of the kidney 540–541
clinical course of 541
morphology of 541b
pathogenesis of 540b–541b
summary of 541
thrombocytopenia and 453–454
Thrombotic thrombocytopenic purpura (TTP) 541
summary for 456
thrombotic microangiopathies and 453–454
Thromboxane 46
Thrombus
clinical correlations for 89
venous thrombosis and 89
fate of 89, 89f
Thrush. *See* Oral candidiasis
Thymic carcinoma 457b
Thymic hyperplasia 457
Thymic hypoplasia 141
Thymoma
clinical features of 457
morphology of 457b
thymus disorders and 457
Thymoma type I, malignant 457b
Thymus disorder
introduction to 456–457
thymic hyperplasia as 457
thymoma as 457
Thyroid
diffuse/multinodular goiter and 728
and endocrine system 721–735, 722f
Graves disease as 726–727
hyperthyroidism and 722–723
hypothyroidism and 723–724
neoplasms of 728–735
adenomas as 729–730
carcinomas of 730–735
introduction to 728–735
summary of 735b
thyroiditis as 724–726
Thyroiditis
chronic lymphocytic and
clinical features of 725
hypothyroidism and 724–725
morphology of 724b–725b, 725f
pathogenesis of 724b, 725f
chronic lymphocytic (Hashimoto) and
summary for 726
chronic lymphocytic thyroiditis and 724–725
other forms of thyroiditis and 726
subacute granulomatous thyroiditis and 725–726
subacute granulomatous thyroiditis (de Quervain) and
clinical features of 726
morphology of 726b
summary for 726
the thyroid and 725–726
subacute lymphocytic thyroiditis and 726
summary of 726b
and the thyroid 724–726
Thyrotoxic myopathy 806
Thyrotroph adenoma 720
Tinea 313
Tissue injury
morphology of 8–11
SLE mechanisms of 127–131
summary of 11b
Tissue injury, leukocyte-induced 39–40, 41t
Tissue necrosis. *See also* Necrosis
inflammatory response to infection by 324
morphology of 324b
morphology of 9b
patterns of 9–11
summary of 11
Tissue repair
clinical examples of 70–72
fibrosis in parenchymal organs and 72
healing skin wounds and 70–72
influencing factors of 69–70, 69f
overview of 29–30, 58–59, 58f
role of extracellular matrix in 63–65
summary for 64b
role of regeneration in 65, 65f
T lymphocyte
cell-mediated immunity and 105–108
effector functions of 107–108, 107f
immune system and 101–102, 101f
summary for 104
Tobacco smoke
carcinogens in 279, 279t
combined with alcohol 279, 279f
components of 278–279, 279t
discussion of 277–279, 278t
effects of 277–278, 278f–279f, 278t, 280
indirect-acting chemicals and
SLE and 126
summary for 280b
Tobacco smoke, environmental 279
Toll-like receptor (TLR) 32, 32f, 52
Total-body irradiation 293, 293t
Toxic agents, agricultural exposure to 276–277
Toxic disorder, nervous system and 835–836
Toxic metabolite 271, 271f–272f
Toxic myopathy 805–806
*TP53* gene
evasion of cell death and 190
as guardian of genome 185–187, 186f
summary for 187b
tumor suppressor gene as 173
Transforming growth factor-β pathway (TGF-β pathway)
discussion of 187
summary of 188b–189b
Transmigration 36
Transmural infarct 379

Transplant
effector mechanisms of graft rejection and 137–138
hematopoietic stem cell transplant and 139
immune recognition of allografts and 135–136
summary for 138b
improving graft survival and 138–139
morphology of 137b–138b, 137f
rejection of 135–139
Transposition of the great arteries
clinical features of 373
right-to-left shunts and 372f, 373
Trauma
central nervous system and 820–822
summary of 822b
parenchymal injuries and 820–821
vascular injury and 820–821
Traumatic hemolysis 418
Traumatic neuroma 798f, 808
Trichomoniasis 677–678
Trisomy 21 (Down syndrome) 237, 238f, 239
Trophoblastic tumor, placental site 703
summary for 703
Trophozoite 313
Tuberculosis
as chronic pneumonia 493–498
etiology of 493
morphology of 495b, 495f–496f
pathogenesis of 493b–495b, 494f
primary tuberculosis and 495–496
secondary tuberculosis and 496
summary for 499b
Tuberculous meningitis 826
morphology of 826b
Tuberculous osteomyelitis 774
Tuberous sclerosis (TSC) 847
morphology of 847b
Tubules and interstitium, disease affecting
acute tubular injury and 537–538
the kidney and 533–538
tubulointerstitial nephritis as 533–537
Tubulointerstitial nephritis (TIN)
acute pyelonephritis as 533–535
chronic pyelonephritis and reflux nephropathy as 535–536
diseases affecting tubules/interstitium and 533–537
drug-induced interstitial nephritis as 536–537
summary for 537b
Tumor
of adipose tissue
lipoma and 792
liposarcoma and 792
of the adrenal medulla
neuroblastoma and 761
pheochromocytoma as 760–761
of the appendix 601
of the bone
bone-forming tumors and 775–777
cartilage-forming tumors and 777–779
diseases of the bone and 774–781, 775t
fibrous/fibroosseous tumors and 779–780
miscellaneous bone tumors and 780–781
summary for 781b–782b
of the breast 707–713
carcinoma as 708–713
fibroadenoma as 707
intraductal papilloma as 708
phyllodes tumor as 707
of the central nervous system
embryonal neoplasms as 844–845
familial tumor syndromes as 847
introduction to 842–847
meningiomas as 846
metastatic tumors as 846–847
neuronal tumors as 844
other parenchymal tumors as 845
summary for 847b–848b
effects on host 207–208
of infancy/childhood
benign tumors and 257–258, 257f
clinical course and prognosis for 259–260
of the joint
ganglion and synovial cysts as 790
joint disease and 790–791
tenosynovial giant cell tumor as 790–791
of the kidney 547–549
oncocytoma as 547
renal cell carcinoma as 547–549
Wilms tumor as 549
of the liver
benign tumors as 635–639
hepatocellular carcinomas as 637–639
liver diseases and 635–639
precursor lesion of hepatocellular carcinoma as 636–637
summary for 639b
of the lung
carcinoid tumors as 510–511
carcinomas and 505–510
introduction to 505–511
neoplasia and 162
of the ovary
Brenner tumor and 698
clinical correlations of 700
endometrioid tumors and 698
introduction of 696–698, 696f
mucinous tumors and 697–698
serous tumors and 697
summary for 700b
surface epithelial tumors and 696–697
of the skin
benign and premalignant epithelial lesions as 862–863
malignant epidermal tumors as 863–864
melanocytic proliferations as 865–869
of the ureter 668
of the vulva 683–684
carcinoma and 683
condylomas and 683
extramammary Paget disease and 683–684
Tumor, benign
focal nodular hyperplasia as 635–636
hepatic adenoma as 636
of infancy and childhood 259–260
of the liver 635–636
Tumor, dysembryoplastic neuroepithelial 844
Tumor, endometrioid 698
Tumor, fibrohistiocytic
benign fibrous histiocytoma as 794
pleomorphic fibroblastic sarcoma/pleomorphic undifferentiated sarcoma 794
and soft tissue 794
Tumor, fibroosseous 779–780
Tumor, fibrous
of the bone
fibrous cortical defect and nonossifying fibroma as 779
fibrous dysplasia as 779–780

Tumor, fibrous *(Continued)*
fibromatoses and 793
fibrosarcoma as 793–794
reactive proliferations and 793
of the soft tissue 792–794
Tumor, germ cell 845
Tumor, Krukenberg 698b
Tumor, malignant
in infancy and childhood 258–262, 258t
neuroblastoma as 258–260
retinoblastoma as 260–261
Wilms tumor as 261–262
Tumor, malignant epidermal
basal cell carcinoma as 864
squamous cell carcinoma as 863–864
summary for 864b
Tumor, neuronal 844
Tumor, odontogenic 558
Tumor, parenchymal
germ cell tumors as 845
primary central nervous system lymphoma as 845
Tumor, smooth muscle
leiomyoma as 795
leiomyosarcoma as 795
Tumor, vascular
benign and tumor-like conditions of 357–359
intermediate-grade of 360–361
introduction to 357–362, 357t
malignant tumors as 361–362
summary for 362b
Tumor antigen
differentiation antigens and 206
glycolipids/glycoproteins and 206
introduction to 204–206, 205f
mutated oncogenes/tumor suppressor genes and 204–205
oncofetal antigens and 206
oncogenic viruses and 206
other mutated genes and 205
overexpressed cellular proteins and 205
Tumor cell, homing of 194–195
Tumor immunity
antigens and 204–206
introduction to 204–207
surveillance and evasion by 207
Tumor marker 211
Tumor necrosis factor (TNF) 48, 48f
Tumor suppressor gene
carcinogenesis and 173, 177, 184
inherited mutations and 171–172
Turner syndrome 240–241, 240f
nonimmune hydrops and 255–256
22q11.2 deletion syndrome 237–239
Type 1 diabetes (T1D)
clinical features of 748, 750t
diabetes mellitus and 739
pathogenesis of 741, 741f
summary for 750
Type 2 diabetes (T2D)
clinical features of 748, 750t
diabetes mellitus and 739
pathogenesis of 741, 742f
summary for 750
Type 1 hypersensitivity. *See* Hypersensitivity, immediate
Type II hypersensitivity. *See* Antibody-mediated disease
Type III hypersensitivity. *See* Immune complex disease
Type I interferon, SLE and 126
Typhoid fever 584
Tyrosine kinases, non-receptor 178–179

U

Ultraviolet (UV) radiation 126
Upper respiratory tract acute infection 512–513
Upper respiratory tract lesion
acute infections and 512–513
laryngeal tumors and 513–514
nasopharyngeal carcinoma and 513
Ureaplasma 313
Ureter 668–671
Ureteropelvic junction (UPJ) obstruction 668
Urinary bladder
neoplasms of 669–671
non-neoplastic conditions of 668–669
Urinary outflow obstruction
hydronephrosis and 545–547
renal stones and 545
Urinary tract infection 518
Urogenital tract 317, 319
Urolithiasis 545
Urticaria
acute inflammatory dermatoses and 852
clinical features of 852
morphology of 852b
pathogenesis of 852b
Uterus, body of
abnormal uterine bleeding and 690–691, 690t
adenomyosis and 689
endometriosis and 689–690
endometritis and 689
proliferative lesions of endometrium/myometrium and 691–694
summary for 691b

V

Vagina
female genital system and 684–685
malignant neoplasms of 684–685
clear cell adenocarcinoma as 685
sarcoma botryoides as 685
squamous cell carcinoma as 684
vaginitis and 684
Vaginitis 684
Variant Creutzfeldt-Jakob disease (vCJD) 831, 832f
Varicose vein
of the extremities 356
clinical features of 356
of other sites 356
Vascular change
acute inflammation and 31, 31f, 33–34
changes in vascular caliber and flow and 31f, 33–34
increased vascular permeability and 33–34, 33f
lymphatic vessel responses and 34
summary of 34b
Vascular dissemination
invasion-metastasis cascade and 194–195
Vascular ectasias 357–358
Vascular injury, traumatic
central nervous system and 821–822, 821f
epidural hematoma as 821
subdural hematoma as 821–822
Vascular intervention, pathology of
endovascular stenting and 362
vascular replacement and 363

Vascular malformation 818
morphology of 818b–819b, 819f
Vascular organization 328–329, 328f
Vascular replacement 363
Vascular smooth muscle cell 330
Vascular tumor, benign
bacillary angiomatosis as 359
glomus tumors as 359
hemangiomas as 358–359
lymphangiomas as 359
vascular ectasias as 357–358
Vascular tumor, intermediate-grade
hemangioendotheliomas as 361
Kaposi sarcoma as 360–361
Vascular tumor, malignant
angiosarcomas as 361–362
hemangiopericytomas as 362
Vascular wall, response to injury by
intimal thickening and 334–335, 335f
Vasculitis 819
discussion of 348–355, 349f
infectious type of 355
noninfectious type of 348–355
summary for 355b
Vasoactive amines 112
Vein, disease of
superior and inferior vena cava syndromes as 356
thrombophlebitis and phlebothrombosis as 356
varicose veins of the extremities as 356
Velocardiofacial syndrome 237–239
Venoocclusive disease. *See* Sinusoidal obstruction syndrome
Venous thrombosis (phlebothrombosis) 87t, 89
paroxysmal nocturnal hemoglobinuria and 417b
Ventricular aneurysm 383f, 384
Ventricular septal defect
clinical features of 371
left-to-right shunts and 369t, 371, 371f
morphology of 371b
Verrucae (warts)
infectious dermatoses and 857
morphology of 857b, 858f
pathogenesis of 857b
Verrucous endocarditis 88b–89b
Verrucous endocarditis, nonbacterial 130
Viral encephalitis 826–829, 827f
Viral hepatitis, acute 619
Viral injury, mechanism of 319–320, 319f
Viral meningitis. *See* Aseptic meningitis
Virchow's triad 86, 86f
Virus
autoimmunity and 124
infectious agents as 309–310, 310t, 311f
Virus, oncogenic 206
Vitamin A
deficiency states of 297–298
discussion of 296–298, 297f–298f
function of 296–298
toxicity of 298
Vitamin $B_{12}$ deficiency 835
Vitamin $B_{12}$ deficiency anemia
clinical features of 423
as megaloblastic anemia 423
pathogenesis of 423b
Vitamin C (ascorbic acid)
deficiency of 301
discussion of 301–302
function of 301–302
toxicity of 301–302
Vitamin D
deficiency states of 299–301, 301f
discussion of 298–301
functions of 299, 299f
metabolism of 298–299, 299f
toxicity of 301
Vitamin deficiency
nutritional disease and 296–302, 302t–303t
Vitamin A and 296–298
Vitamin C and 301–302
Vitamin D and 298–301
Von Gierke disease 232–233, 233t
von Hippel-Lindau disease 847
morphology of 847b
Von Willebrand disease 455
summary for 456
von Willebrand factor (vWF) 80, 81f
Vulva
non-neoplastic epithelial disorders of 682
tumors of 683–684
summary for 684b
vulvitis and 681–682
Vulvitis 681–682

W

WAGR syndrome 261–262
Waldenström macroglobulinemia 439–440
Warts. *See* Verrucae
Waterhouse-Friderichsen syndrome
disseminated intravascular coagulation and 452b
metabolic abnormalities and 96
Water retention 77–78
Wegner granulomatosis (WG) 353–354
clinical features of 354
diffuse alveolar hemorrhage syndromes and 485
morphology of 353b–354b, 353f
Wernicke-Korsakoff syndrome 281, 302t, 835
morphology of 835b
White cell disorder
hematopoietic system and 425–449
neoplastic proliferations of
histiocytic neoplasms and 449
neoplastic proliferations of 428–449
lymphoid neoplasms and 429–443
myeloid neoplasms as 444–448
as white cell disorders 428–449
non-neoplastic disorders of 425–428
leukopenia as 425–426
reactive leukocytosis as 426–427
reactive lymphadenitis as 427–428
White infarcts 92b–93b, 93f, 94
Wilms tumor
discussion of 261–262
morphology of 262b, 262f–263f
summary for 262b–263b
tumors of the kidney and 549
Wilson disease
clinical features of 631
as inherited metabolic disease 630–632
morphology of 631b
pathogenesis of 631b
Wood smoke 273
Wrist, carpal ligaments of 157–158

X
Xenobiotics 271, 271f–272f
summary for 273
Xeroderma pigmentosum 197
Xerophthalmia (dry eye) 297–298
Xerostomia 131, 132b, 555
X-linked agammaglobulinemia (XLA) 140, 143
X-linked disorder 220

Y
Yellow fever 620
Yolk sac tumor 660b–662b, 661f

Z
Zollinger-Ellison syndrome 568b