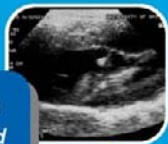
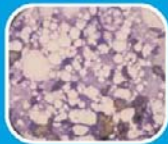
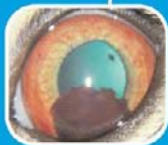Self-Assessment
Colour Review of

LEARN • REVISE • REINFORCE

Feline Medicine

Andrew Sparkes
Sarah Caney



*Clinical cases
Problem based
Full colour*

MANSON
PUBLISHING

www.Ebook777.com

Self-Assessment Colour Review of Feline Medicine



This page intentionally left blank

Self-Assessment Colour Review of

Feline Medicine

Andrew Sparkes

BVetMed PhD DipECVIM MRCVS
RCVS Specialist in Feline Medicine
Head of the Feline Unit
Animal Health Trust, Newmarket, UK

Sarah Caney

BVSc PhD DSAM(Feline) MRCVS
RCVS Specialist in Feline Medicine
The Feline Clinic, Downland Veterinary Group
Emsworth, UK

MANSON PUBLISHING/THE VETERINARY PRESS

Acknowledgements

Both authors would like to thank the following organizations and individuals for their help in providing some of the pictures used in this book:

The Feline Advisory Bureau, colleagues at the University of Bristol and the Animal Health Trust, Dr Kostas Papasouliotis, Prof Timothy Gruffydd-Jones, Prof Sheila Crispin, Dr Séverine Tasker, and Prof Stefano Romagnoli.

Copyright © 2005 Manson Publishing Ltd
ISBN 1-84076-047-8

All rights reserved. No part of this publication may be reproduced, stored in a retrieval system or transmitted in any form or by any means without the written permission of the copyright holder or in accordance with the provisions of the Copyright Act 1956 (as amended), or under the terms of any licence permitting limited copying issued by the Copyright Licensing Agency, 33-34 Alfred Place, London WC1E 7DP, UK.

Any person who does any unauthorized act in relation to this publication may be liable to criminal prosecution and civil claims for damages.

A CIP catalogue record for this book is available from the British Library.

For full details of all Manson Publishing Ltd titles please write to:
Manson Publishing Ltd, 73 Corringham Road, London NW11 7DL, UK.

Tel: +44(0)20 8905 5150
Fax: +44(0)20 8201 9233

Email: manson@mansonpublishing.com
Website: www.manson-publishing.co.uk

Commissioning editor: Jill Northcott
Project management: Paul Bennett
Page layout: Initial Typesetting Services
Colour reproduction: Tenon & Polert Colour Scanning Ltd, Hong Kong
Printed in China by New Era Printing Company Ltd

Preface

'The smallest feline is a masterpiece.' Leonardo da Vinci

It is often said that there is nothing so certain as change, and that is undoubtedly true in the field of veterinary science. The plethora of veterinary textbooks now devoted to feline medicine illustrates the importance that cats have assumed as domestic pets. The quantity and depth of knowledge of feline diseases is constantly developing, and there is no doubt that by the time you read this, some of the information in this book will already be out of date – for that we apologize! Nevertheless, we have attempted to draw together questions and answers on a very broad range of feline disorders that we hope will be stimulating, interesting, and informative.

We hope this book will be of value to students, practitioners, and those studying for postgraduate clinical qualifications. By its nature, it cannot be a comprehensive handbook of feline medicine, yet we have tried to give sufficient breadth of coverage to make it of real practical benefit. Questions are arranged randomly (with an index of topics to allow specific types of questions to be located), and each is followed by its answer. Each question is independent of any others, thus the book can be dipped into as desired. Individuals or groups of clinicians can work through the questions, and a problem-solving approach has been encouraged throughout. The questions contain illustrations of the patient, radiographs, cytology, and so on, which we hope will add to the value of the text as well as make it more interesting to read. We have endeavoured to maintain accuracy throughout this book, but recognize that in many cases there may not be a definitive correct answer, and this therefore represents our own approach to diagnosis and management of medical cases. For convenience, we have included both conventional (American) and SI units for laboratory data in the text, and reference ranges are given, where appropriate, to allow interpretation of the data.

Most of all, we hope this will be a book that you enjoy dipping into and find stimulating – for any aelurophile, feline medicine is a fascinating and exciting subject and we hope that the information in this book will encourage enquiring minds to want to know more!

Enjoy!

Andy Sparkes and Sarah Caney

'Again I must remind you that a dog's a dog – a cat's a cat.' TS Eliot

Dedication

Sarah and Andy would like to dedicate this book to their immediate families: Sarah's parents, Elizabeth and Stephen Caney; Andy's wife, Debbie, and children, Ben and Catherine, and Andy's parents, Doris and Douglas Sparkes. Without their love and support this book would never have been possible. We would also like to acknowledge our own very special feline friends (pictured clockwise from top left, page 1): Hobi, Tigger, Kita, Holly, Penny, and Cookie!

Author biographies

Andrew Sparkes BVetMed PhD DipECVIM-CA MRCVS

Andrew Sparkes graduated from the Royal Veterinary College (University of London) in 1983, and after a period of 4 years in general practice undertook an intern/residency position in feline medicine at the University of Bristol from 1987–1990. Following this, Andrew undertook a 3-year research programme, which led to the successful completion of a PhD. Andrew was then appointed as a lecturer in Feline Medicine at the University of Bristol, a position funded by the Feline Advisory Bureau (a UK-based charity dedicated to promoting the health and welfare of cats). In 1999 he was promoted to senior lecturer and in 2000 he moved to the Animal Health Trust, to take up a position as Head of the Feline Unit, with responsibilities for clinical referral work and clinical research. He has published widely in the field of feline medicine, is a diplomate of the European College of Veterinary Internal Medicine and an RCVS recognized specialist in feline medicine. He is a member of the executive committee of the European Society of Feline Medicine and is the founding and current co-editor of the Journal of Feline Medicine and Surgery, the official journal of both the ESFM and the AAFP. Andrew is also the current chairman of the Feline Advisory Bureau.

Sarah Caney BVSc PhD DSAM(Feline) MRCVS

Sarah graduated from the University of Bristol in 1993. She spent 1 year as a small animal intern at the Royal Veterinary College before returning to Bristol for a 3-year residency in feline medicine. She subsequently undertook a PhD studying feline immunodeficiency virus infection. Sarah has her RCVS Diploma in Small Animal Medicine (Feline), is an RCVS Specialist in Feline Medicine and was the Feline Advisory Bureau Lecturer in Feline Medicine at the University of Bristol from January 2001 to July 2004. In October 2004, Sarah moved to Downland Veterinary Group in Emsworth where she established a first opinion and referral feline clinic. Sarah is the secretary of the European Society of Feline Medicine and loves cooking, opera and her cat Hobi!

Abbreviations

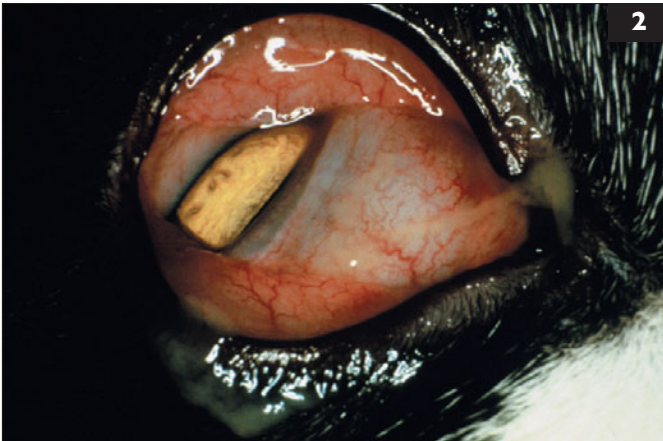AA	amyloid A	HCT	haematocrit
ACD	acid citrate dextrose	hpf	high power field
ACE	angiotensin converting enzyme	IFA	immunofluorescent antibody
ACTH	adrenocorticotrophic hormone	IGF	insulin-like growth factor
ADH	anti-diuretic hormone	IGR	insect growth regulator
ALP	alkaline phosphatase	IM	intramuscularly
ALT	alanine aminotransferase	IV	intravenously
AML	anterior mediastinal lymphoma	IVS	interventricular septum
ANA	antinuclear antibody	kg	kilogram
APTT	activated partial thromboplastin time	LDH	lactate dehydrogenase
ARF	acute renal failure	LMN	lower motor neurone
AST	aspartate aminotransferase	LUTD	lower urinary tract disease
ATP	adenosine triphosphate	LV	left ventricle
AZT	azathioprine	MCV	mean cell volume
BID	twice daily	MDI	metered dose inhaler
BIPS	barium-impregnated polyethylene spheres	MHC	major histocompatibility complex
BW	body weight	MRI	magnetic resonance imaging
cfu	colony-forming units	NAC	N-acetylcysteine
CK	creatinine kinase	PAS	periodic acid schiff
CNS	central nervous system	PCR	polymerase chain reaction
COP	cyclophosphamide, vincristine (Oncovin), prednisolone	PCV	packed cell volume
COX-2	cyclo-oxygenase-2	PEG	percutaneous endoscopic gastrostomy
CRF	chronic renal failure	PIVKA	proteins induced by vitamin K absence
CSF	cerebrospinal fluid	PKD	polycystic kidney disease
CT	computed tomography	PLN	protein-losing nephropathy
CVP	central venous pressure	PLR	pupillary light reflex
DDAVP	desmopressin	PPDH	peritoneopericardiodiaphragmatic hernia
DIC	disseminated intravascular coagulation	PT	prothrombin time
DJD	degenerative joint disease	RBC	red blood cell
DNA	deoxyribonucleic acid	RER	resting energy requirement
DSH	domestic shorthaired	RNA	ribonucleic acid
DV	dorsoventral	SAMe	s-adenosyl methionine
ECG	electrocardiogram	SBP	systolic blood pressure
EDTA	ethylenediamine tetra-acetic acid	SC	subcutaneously
EGC	eosinophilic granuloma complex	SG	specific gravity
ELISA	enzyme-linked immunosorbent assay	T3	tri-iodothyronine
EPI	exocrine pancreatic insufficiency	T4	thyroxine
FCV	feline calicivirus	TCC	transitional cell carcinoma
FeLV	feline leukaemia virus	TRH	thyrotrophin releasing hormone
fg	French gauge	TSH	thyroid stimulating hormone
FHV	feline herpesvirus	U	units
FIA	feline infectious anaemia	UCCR	urinary cortisol to creatinine ratio
FIP	feline infectious peritonitis	UDCA	ursodeoxycholic acid
FIV	feline immunodeficiency virus	UMN	upper motor neurone
FORL	feline odontoclastic resorptive lesion	UPC	urine protein:creatinine ratio
fTLI	feline trypsin-like immunoreactivity	USG	urine specific gravity
GHLO	gastric <i>Helicobacter</i> -like organism	VD	ventrodorsal
GnRH	gonadotrophin releasing hormone	VLDL	very low density lipoprotein
HAC	hyperadrenocorticism	WBC	white blood cell
hCG	human chorionic gonadotrophin	ZN	Ziehl-Nielsen (acid fast stain)

Broad classification of cases

Some cases appear under more than one category

Musculoskeletal	1, 14, 33, 34, 39, 132, 185, 192
Endocrinological	11, 17, 19, 21, 30, 49, 51, 60, 74, 89, 102, 114, 116, 143, 147, 168, 181, 193, 213, 225
Dermatological	3, 16, 48, 58, 65, 74, 79, 121, 131, 137, 169, 170, 171, 175, 184, 200, 221
Haematopoietic	4, 7, 9, 44, 57, 63, 86, 101, 106, 112, 148, 154, 163, 179, 190, 218, 222, 223
Upper respiratory	5, 27, 40, 54, 57, 78, 91, 111, 145, 157, 167, 195, 201, 214
Ocular	2, 6, 13, 24, 28, 30, 43, 219
Infectious	2, 6, 10, 13, 32, 40, 47, 52, 56, 58, 61, 62, 76, 78, 96, 97, 104, 109, 110, 115, 117, 122, 126, 131, 138, 149, 160, 169, 172, 175, 180, 195, 198, 202, 218
Gastrointestinal	8, 10, 18, 25, 31, 50, 62, 84, 90, 98, 103, 107, 117, 127, 128, 160, 180, 198, 203, 207, 217
Urological	4, 12, 23, 26, 29, 60, 67, 69, 72, 73, 80, 81, 92, 95, 100, 134, 141, 142, 149, 153, 159, 161, 162, 174, 176, 185, 187, 188, 190, 191, 196, 204, 209, 213
Cardiovascular	15, 20, 28, 30, 37, 57, 82, 83, 87, 108, 120, 129, 132, 152, 197, 216
Metabolic	12, 33, 34, 51, 60, 63, 70, 80, 94, 130, 190, 206, 225
Oral diseases	16, 38, 41, 42, 56, 156, 179
Neurological	24, 35, 46, 53, 59, 105, 125, 132, 135, 136, 139, 192, 208, 211, 220
Reproduction/developmental	22, 37, 55, 70, 72, 85, 93, 109, 133, 138, 144, 155, 212
Liver/pancreas	25, 31, 44, 61, 68, 94, 118, 130, 164, 177, 182, 206, 213, 215
Oncological	27, 29, 40, 49, 65, 71, 75, 79, 84, 95, 111, 123, 124, 151, 168, 171, 204, 205, 207, 221
Lower respiratory/pleural	32, 36, 47, 52, 66, 77, 88, 91, 115, 119, 123, 124, 146, 150, 158, 166, 173, 178, 183, 214
Nutritional	45, 64, 99, 165, 186, 189, 194, 199, 224
Therapeutics/toxicity	44, 75, 113, 142, 177, 178, 188, 191, 205, 210, 223

1 A 10-month-old neutered male cat (1) presents with a slow onset, 3–4-week history of fluctuating signs, characterized by reluctance to walk and a stiff, stilted gait. There is poorly localizable pain on palpation of the spine and limbs (muscles, bones, and joints) and on manipulation of joints. What are the major differential diagnoses for this cat and how should initial investigations be approached?



2 The diagnostic laboratory has isolated *Chlamydophila felis* from a conjunctival swab collected from an 18-month-old cat (2). The owner of the cat is a breeder and there are currently three adult cats, one of which is pregnant, and one 6-month-old kitten in the household.

- i. How should this infection be managed?
- ii. What management strategies can be followed in order to prevent future problems?

I, 2: Answers

1 The cat is exhibiting signs of musculoskeletal pain, but from the history and clinical signs this could be either muscle pain, joint pain, or skeletal pain.

- Common causes of generalized muscle pain include inflammatory myopathies (e.g. toxoplasmosis, immune-mediated myositis), metabolic myopathy (hypokalaemic polymyopathy), or degenerative myopathy (myositis ossificans).
- Causes of joint pain include infections (bacterial polyarthritis, mycoplasma polyarthritis, FCV-associated polyarthritis, endocarditis), immune-mediated polyarthritis (proliferative, erosive and idiopathic polyarthritis; systemic lupus erythematosus), haemarthrosis (as a result of a bleeding disorder), and degenerative joint disease.
- Causes of skeletal pain in this cat could include developmental abnormalities (e.g. osteogenesis imperfecta with secondary pathological fractures), nutritional causes (e.g. nutritional secondary hyperparathyroidism with osteopenia and possible pathological fractures, vitamin-D deficient rickets, hypervitaminosis A – classically associated with a liver-rich diet).

Consideration may also need to be given to the possibility of severe pain with, for example, a spinal disorder (e.g. discospondylitis).

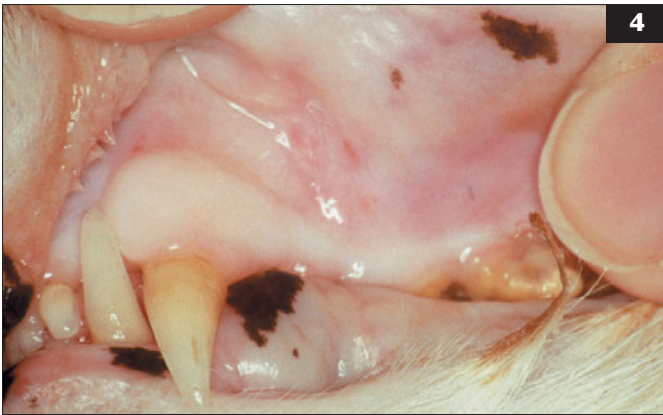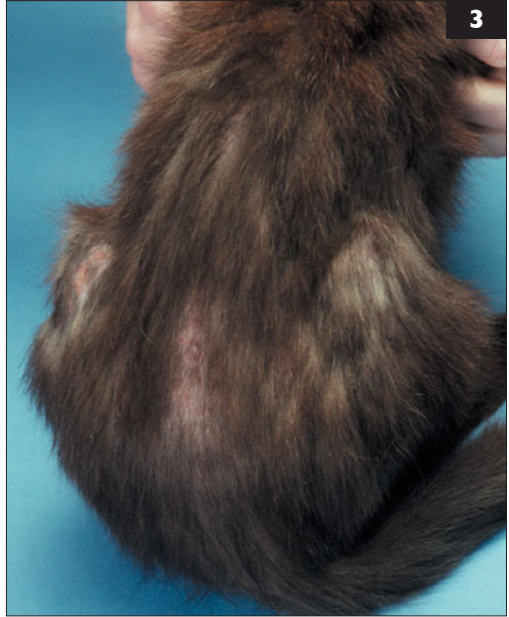
Priorities for further investigation and a minimum database for adequate assessment would include a neurological assessment, a dietary history, blood/urine analyses, and radiography. A blood panel should include assessment of muscle inflammation/damage (elevations in CK, AST, and possibly ALT), and electrolyte evaluation (especially potassium, calcium, and phosphate). Radiography is a high priority for evaluation of joints and bones, and, if joint disease is suspected on clinical or radiographic grounds, cytology of multiple joint taps is indicated.

Other investigations would depend on the findings from the initial investigations.

2 i. All of the cats in the house should be treated for at least 4 weeks, and for at least 2 weeks beyond the time at which the cats appear clinically normal. The treatment of choice for adult cats is oral doxycycline at 10 mg/kg once daily. Pregnant queens and kittens whose teeth are still developing (<9 months of age) can be safely treated orally with amoxicillin–clavulanate at 12.5 mg/kg twice daily although a longer period of treatment may be required and future recrudescence of infection is more commonly seen following treatment with this drug. Azithromycin is sometimes recommended as a treatment for *Chlamydophila* but clinical trials have not supported its use.

ii. Once all of the cats have been treated, strategies can be followed to prevent future outbreaks. Any new cats purchased should be screened for *Chlamydophila* (by serology or conjunctival swab) prior to entry to the household. Vaccination of all cats is also an option although, as with any vaccine, this does not completely eliminate the risk of infection occurring in the household.

3 A 4-year-old neutered female DSH cat (3) presented with severe pruritus, miliary dermatitis and peripheral lymphadenopathy. Fleas and flea dirt were evident on examination and an intradermal skin test showed a strong positive reaction to flea extract. Using knowledge of flea biology, how should this cat be treated?



- 4 i. What is the most obvious feature on examination of the mucous membranes of the oral cavity in this 11-year-old cat with established CRF (4)?
- ii. What is the likely cause of this problem and how should its management be approached?

3, 4: Answers

3 *Ctenocephalides felis* adults feed almost immediately they move onto their host. Copulation and egg-laying can take place within 24–48 hours of the first blood meal. The eggs are laid in the fur and fall off into the environment. Under appropriate conditions, eggs hatch in 1–6 days. Larvae feed on flea dirt shed by adults and this stage typically lasts 1–3 weeks. The pupa develops within a cocoon, and adults can emerge within a week, although this can be much delayed. The complete life cycle takes around 2–40 weeks (typically 3–5) depending on environmental conditions.

Treatment must be aimed at the affected cat, in-contact animals, and the environment. Short-acting glucocorticoids and/or antihistamines may be needed to control pruritus.

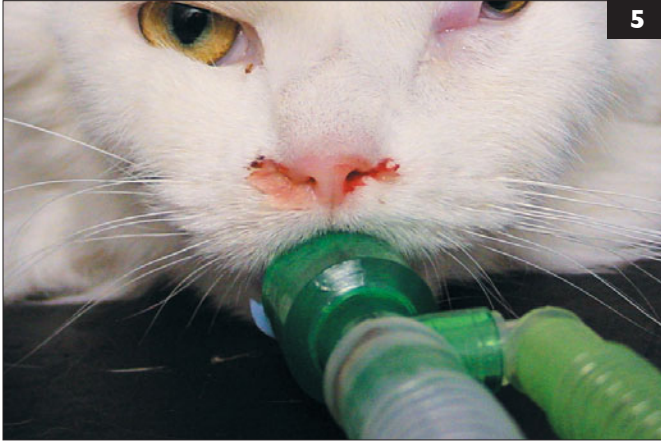Adulticides are essential and should be used on all in-contact animals. Efficacious topical ('spot-on') products include fipronil, imidacloprid, and selamectin. Fipronil is also available as a spray and is favoured by some for initial therapy of flea allergic dermatitis. Nitenpyram is an oral adulticide with a rapid knock-down time. Adulticides must be administered on a regular basis, to maintain effective control. Adulticides should be combined with IGRs which may be hormone analogues (e.g. pyriproxyfen) or chitin synthetase inhibitors (e.g. lufenuron), the former given topically, the latter systemically.

The environmental stages may make up to 95% of the total flea population and both mechanical cleaning (vacuuming, washing) and environmental chemical sprays/foggers (e.g. IGRs, such as pyriproxyfen and methoprene, usually combined with an adulticide) should be used to control infestation here.

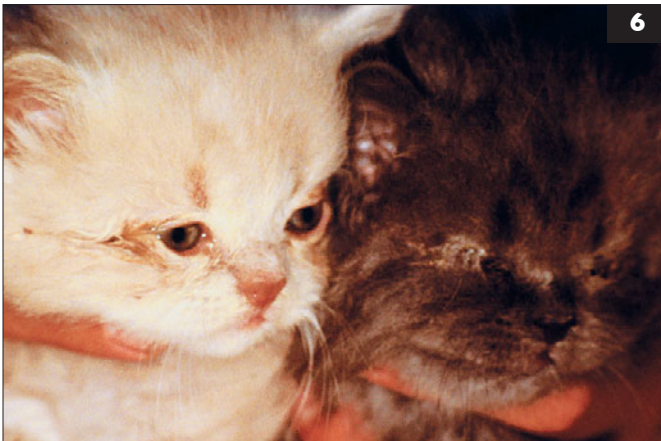4 i. The most obvious abnormality in this cat is the marked pallor of the mucous membranes indicating probable underlying anaemia. Although in this case the marked pallor is highly suggestive, routine haematology would be needed to confirm this, and a reticulocyte count should be performed to determine whether it is regenerative or not.

ii. Anaemia in CRF has a multifactorial aetiology. Reduced production of erythropoietin from the failing kidneys results in a relative or absolute lack of this hormone causing a non-regenerative anaemia. The production of uraemic toxins reduces the half-life of circulating RBCs, and chronic blood loss can also contribute to anaemia of CRF. Blood loss may be secondary to uraemic thrombopathy, but more commonly occurs due to gastrointestinal ulceration and chronic bleeding. Determination of iron and ferritin status may be required to identify iron deficiency.

If the anaemia is accompanied by iron deficiency, iron supplementation should be provided (50–100 mg/day ferrous sulphate) and H₂-blockers and/or sucralfate administered. Anabolic steroids have some role in stimulating erythrocyte production but their efficacy is relatively poor. Recombinant human erythropoietin (100 U/kg SC three times weekly) has been used to correct the erythropoietin deficiency and can be dramatically effective (as long as the cat is not iron-deficient). However, around 30% of cats develop antibodies negating its effect. Trials are currently being carried out with recombinant feline erythropoietin.



5 A 6-year-old neutered female DSH cat (5) presents with a chronic history (many months) of bilateral nasal discharge and persistent productive mucopurulent sneezing. Two years previously the cat had a severe acute upper respiratory tract infection assumed to be due to FHV. Investigations suggest chronic 'post-viral' rhinitis. What options should be considered for the management of this cat?



6 A client is a breeder of Persian cats. For some time now, several of her cats have suffered with intermittent signs of conjunctivitis (6).

- i. What are the major infectious causes of conjunctivitis in cats?
- ii. What is a possible diagnostic plan?

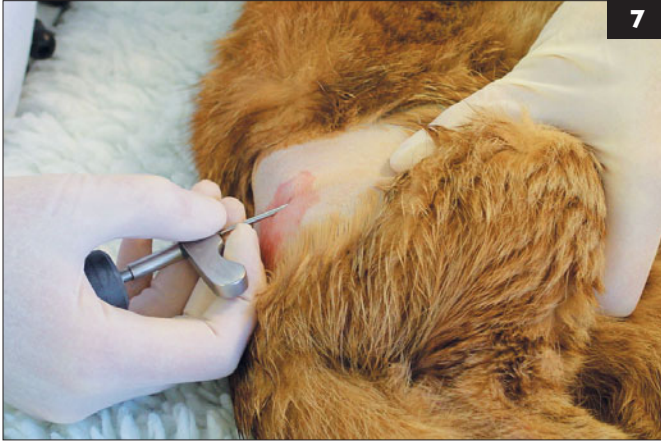5, 6: Answers

5 Therapy aims to improve nasal/sinus drainage, reduce mucus formation, and control infection/inflammation. For most cases, clinical signs can be improved but not resolved. Strategic, intermittent, or persistent therapy may be required:

- Flushing the nasal cavities under anaesthesia can be useful to clear inspissated secretions. Flushing can be retrograde (via catheters inserted through the nares) or antegrade (via a Foley catheter in the nasopharynx). Copious volumes of sterile saline are used, with the nose pointed down, a cuffed endotracheal tube in place, and the pharynx packed with swabs.
- Saline nebulization or steam inhalation (e.g. placing the cat in a hot, steamy bathroom) can reduce the viscosity of secretions and encourage productive sneezing. Also, one to two drops of sterile saline can be administered in each nostril, as required, up to several times daily.
- Strategic systemic antibiotics are required as opportunistic infections with the normal upper respiratory tract flora are common due to the altered micro-environment. Prolonged (6–8 weeks) therapy may be required initially, as some cases are associated with turbinate osteomyelitis. Mixed infections, including anaerobes, are typical.
- Topical glucocorticoids (inhaled or drops) appear to benefit some cats. Nasal biopsies often show a predominantly lymphoplasmacytic infiltrate and there is some rationale for topical steroids in these cases.
- Rhinotomy, turbinectomy, and fat transplantation into the frontal sinuses has been advocated. However, the benefit is highly questionable in most cats.

6 i. The major infectious causes of conjunctivitis are the cat ‘flu’ viruses FHV and FCV and the ocular pathogen *Chlamydomphila felis* (previously referred to as *Chlamydia psittaci* var *felis*).

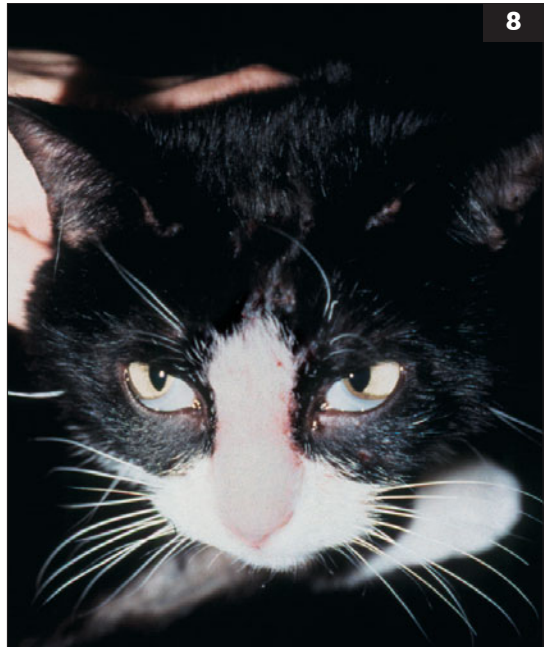ii. If any of the cats are currently showing signs of conjunctivitis, conjunctival swabs should be taken and submitted for diagnostic tests. These might include PCR testing and/or *Chlamydomphila* and ‘flu’ virus isolation. *Chlamydomphila* serology can also be extremely helpful in screening a cattery for evidence of recent infection and is worth considering in those catteries where the cats are free of signs at the time of examination. Fluorescent antibody titres to *Chlamydomphila* persist for several months and a high titre (>512) indicates recent or active infection. Low titres (<32) are generally not considered to be significant. If an intermediate titre (32–512) is seen in a cat with conjunctivitis, it may be worth repeating the serology in 2–4 weeks and looking for a rising titre in case the cat is in the early stages of infection. Intermediate titres in cats with no clinical signs indicate infection in the past year. Serology cannot be used as a diagnostic test in cats that have been vaccinated for *Chlamydomphila* as antibodies induced by vaccination will be detected by the test.



7 A bone marrow aspirate is being performed in this cat (7). What are the indications for performing this procedure?

8 A 4-year-old DSH (8) presented with chronic diarrhoea.

- i. How could small or large bowel diarrhoea be differentiated?
- ii. What relevant feature is shown by this cat?
- iii. What is the likely diagnosis and what treatment should be given?



7, 8: Answers

7 Bone marrow aspirates will aid diagnosis in the following situations:

- Non-regenerative anaemias, leucopenias, thrombocytopenias, and pancytopenias where systemic diseases such as CRF, infectious diseases (e.g. FeLV, FIV), and toxic insults have been ruled out as possible causes.
- Suspected leukaemias, e.g. lymphocytic, neutrophilic.
- Suspected hypereosinophilic syndrome.
- Pyrexia of unknown origin.
- Detection of FeLV latent infection via specialist culture of the bone marrow.
- Suspected primary erythrocytosis.

8 i. Reliably differentiating small and large bowel diarrhoea can be difficult at times, and some cases have disease involving both regions of the intestine. The table below acts as a guide to distinguish the two.

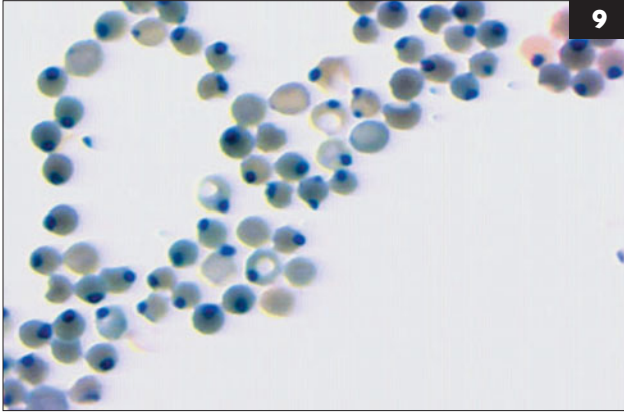
ii. In addition to the diarrhoea, this cat is showing bilateral protrusion of the nictitating membranes.

iii. There is a well recognized, although still poorly understood, syndrome of chronic small intestinal diarrhoea associated with persistent or intermittent nictitating membrane protrusion in cats. Epidemiological studies have strongly suggested there is an infectious cause for this syndrome, and further investigations have suggested a viral cause. A torovirus (related to coronaviruses) has been isolated from some of these cases but definitive cause and effect have not yet been established.

The diarrhoea in these cases is self-limiting, but it can take from a few weeks to many months for the signs finally to resolve (with waxing and waning of signs in some cats). There is rarely significant systemic disease or weight loss. Feeding of a bland diet is commonly recommended, but other therapeutic interventions have failed appreciably to alter the course of the disease or the severity of the diarrhoea in most affected cats. The use of antibiotics is contraindicated as this can exacerbate the diarrhoea through alteration of the intestinal microflora.

Signs of small and large bowel diarrhoea


Signs	Small bowel	Large bowel
Frequency of defecation	± Mildly increased	Increased
Urgency/tenesmus/dyschezia	Absent	Present
Faecal mucus	Absent	Present
Faecal consistency	Loose	Loose to formed
Faecal blood	± Melaena	± Haematochezia
Steatorrhoea	Sometimes	Absent
Faecal colour	Variable	Usually brown
Weight loss	Common	Rare



- 9 The blood smear stained with new methylene blue (9) is from an anaemic cat.
- What type of anaemia is present?
 - What are the potential causes of this anaemia?

10 The proprietor of a rescue centre reports that several cats in their care have suddenly developed very watery diarrhoea (10).

- What infectious causes of diarrhoea should be considered?
- What is your diagnostic plan?



9, 10: Answers

9 i. The blood smear shows many Heinz bodies within the RBCs. Heinz bodies (also known as erythrocyte refractile bodies or Schmauch bodies) are round or oval red cell inclusions which represent denatured haemoglobin, resulting from oxidative injury to the erythrocyte. They are best stained with supravital stains (e.g. new methylene blue or brilliant cresyl green) and are usually seen at the edge of the RBC, sometimes protruding from the surface of the cell. With Romanowsky staining, Heinz bodies appear as circular pale areas within the RBC. A small proportion (<5–10%) of RBCs with Heinz bodies is a normal finding in cats. Presence of small Heinz bodies is not usually associated with anaemia but reflects the vulnerability of feline haemoglobin to oxidative damage.

ii. Pathological numbers of Heinz bodies accumulate in situations that lead to permanent oxidation of the RBCs. Damaged RBCs are removed by the reticulo-endothelial system leading to a haemolytic anaemia. Potential causes include:

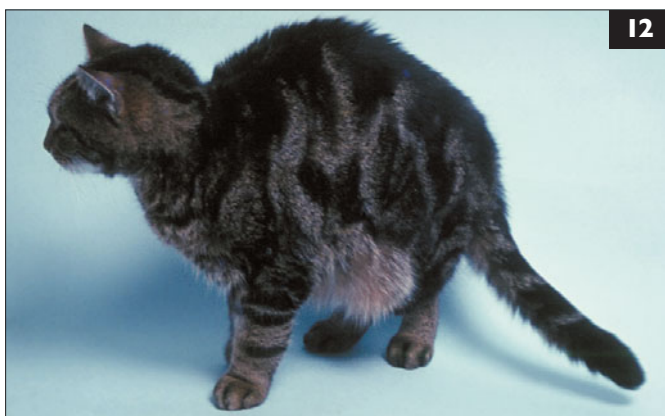- Intoxications, e.g. propylene glycol preservative, onions, methylene blue, zinc, acetaminophen (paracetamol).
- Diabetes mellitus (ketoacidosis).
- Hypophosphataemia.
- Rare causes of clinically significant Heinz body formation:
 - Lymphoma.
 - Hyperthyroidism.

10 i. Infectious causes of diarrhoea include:

- Viruses, e.g. feline panleucopenia virus, feline coronaviruses, torovirus ('third eyelid diarrhoea syndrome'), immunosuppression due to FeLV or FIV infections. Rotavirus, reovirus, and astrovirus have been reported as uncommon causes of diarrhoea.
- Bacteria, e.g. *Salmonella* spp., *Campylobacter* spp., *Clostridium* spp.
- Protozoa, e.g. *Giardia*, *Cystoisospora*, *Cryptosporidia* spp.
- Parasitic causes include ascarids (e.g. *Toxocara* spp.), hookworms (e.g. *Ancylostoma* spp.), whipworms (e.g. *Trichuris* spp.), tapeworms (e.g. *Dipylidium caninum*).
- Mycotic causes, e.g. *Histoplasma capsulatum*.
- Granulomatous disease caused by a variety of possible causes, e.g. FIP, mycobacteria, *Prototheca*, *Cryptococcus* infection.

ii. Further questioning and clinical examination are required to establish the severity of the disease, whether the cats are vaccinated and whether any other clinical signs are present (e.g. third eyelid protrusion). Faecal bacteriology and examination for parasites and protozoal organisms are indicated. Intermittent shedding occurs with some of these infections so pooling faecal samples from several cats increases the chance of identifying the causal agent. Faecal electron microscopy, faecal antigen testing, faecal PCR and serology for anti-viral antibodies may be helpful in identifying viral causes in unvaccinated cats. If panleucopenia is considered, haematology may reveal a leucopenia.

11 A diabetic cat is presented. It was well stabilized with insulin when in hospital. It has been at home for 2 weeks following stabilization and the owner now reports that the cat is again showing signs of uncontrolled diabetes (polydipsia, polyuria, and polyphagia). What is the best approach to this case?



12 A 6-year-old neutered male DSH presented with pitting oedema of the legs, ventral abdomen, and ventral thorax (12). Radiography revealed a mild thoracic and abdominal effusion. Some ascitic fluid was collected and analysis revealed a total protein of 1.5 g/l (0.15 g/dl).

- i. What are the possible differential diagnoses for this cat and what is the primary differential diagnosis?
- ii. How could this be confirmed and treated?

11, 12: Answers

11 Causes of insulin ineffectiveness seen shortly after discharge from the hospital most commonly relate to owner problems such as:

- Administration problems:
 - Not adhering to a strict routine, e.g. injections given at a different time each day.
 - Incorrect injection technique, including inaccurate dosage of insulin.
- Insulin-related factors:
 - Unrecognized underdosage resulting from use of insulin which is out of date, improperly stored, or improperly mixed before withdrawal from the bottle.
 - The more active cat in its home environment may have higher insulin requirements than when it was hospitalized.

Careful questioning of the owner and asking them to demonstrate how they inject their cat with insulin often reveals the cause of the problem. If not, the cat should be re-examined and assessed for evidence of concurrent disease and admitted for blood glucose evaluation (11) and stabilization.

12 i. The presence of both oedema and effusions could be due to congestive heart failure but is more likely to be due to hypoalbuminaemia. The presence of a pure transudate in the abdomen confirms the cause to be hypoalbuminaemia, and serum albumin is usually <15 g/l (<1.5 g/dl) for this to occur.

Major causes of hypoalbuminaemia are:

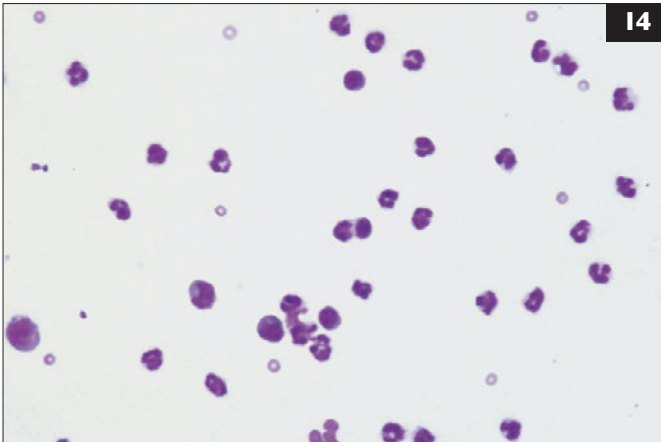
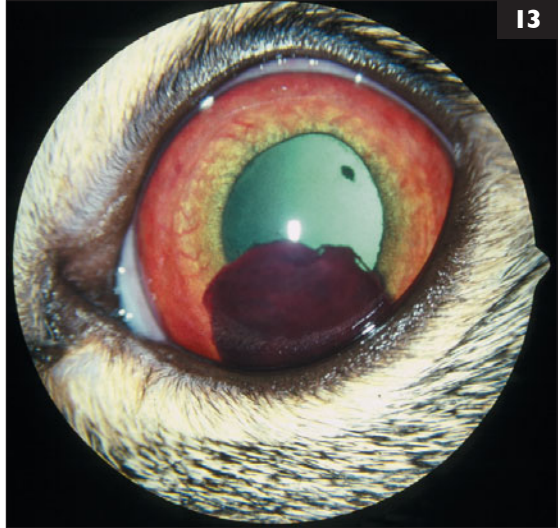
- Glomerulonephritis (most common cause and results in selective albumin loss).
- Renal amyloidosis would be a consideration in dogs, but usually causes renal failure rather than PLN in cats.
- Insufficient synthesis (malnutrition or liver failure, but these are rare causes).
- Gastrointestinal loss of albumin (protein-losing enteropathy – a rare cause of such severe hypoalbuminaemia, and usually causes panhypoproteinaemia).

ii. A PLN can be confirmed by evaluating urine protein loss with a UPC. In healthy cats the UPC is <0.5 , and in cats with PLN it is typically >3 and may be >10 . The UPC has to be interpreted with caution with lower urinary tract inflammation/bleeding. Renal biopsy could confirm immune-mediated glomerulonephritis.

Treatment involves searching for and removing the inciting cause where possible (underlying infection, neoplasia, drug therapy). Many cases are idiopathic and require symptomatic therapy which is controversial. Diuretic use should be avoided. Protein supplementation is contraindicated, and glucocorticoids are generally unhelpful. Protein restriction is not valuable unless the disease has progressed to renal failure. ACE inhibitors (ramipril, enalapril, benazepril) have proven efficacy in canine glomerulonephritis, reducing proteinuria and improving clinical response, and are likely to be beneficial in cats also. Non-steroidal anti-inflammatories (e.g. aspirin) may help by reducing inflammation and any tendency for clotting due to anti-thrombin III loss.

13 A 7-month-old DSH cat is presented with a 2-month history of waxing and waning inappetence, lethargy, and some weight loss. The owner has noticed that both of the eyes look abnormal (13).

- i. What abnormalities are visible?
- ii. What is the likely diagnosis?
- iii. What are the possible causes of this condition?



14 Microscopy of a direct smear from the joint of a 4-year-old cat is shown (14). Aspirates from multiple joints revealed a similar picture.

- i. What does this smear show?
- ii. What clinical signs would be expected and how should this case be managed?

13, 14: Answers

13 i. There is obvious hyphaema (blood in the anterior chamber) which has clotted, suggesting a high fibrin content. The remaining view of the aqueous chamber is slightly hazy due to aqueous flare. The iris blood vessels are very prominent suggestive of an intense vasculitis. A focal deposit is visible on the anterior lens capsule and is likely to be a persistent pupillary membrane. The pupil has slightly irregular margins.

ii. Anterior uveitis (inflammation of the iris and/or ciliary body) with hyphaema.

iii. Differential diagnoses include:

- Infectious causes, e.g. FIP, FeLV, FIV, *Toxoplasma gondii*, and systemic mycoses (e.g. histoplasmosis, blastomycosis, cryptococcosis). Recently, FHV and *Bartonella henselae* have been implicated as possible causes of uveitis.
- Idiopathic uveitis.
- Disseminated neoplasia, especially lymphoma.
- Autoimmune disease.
- Blunt and penetrating trauma to the eye.

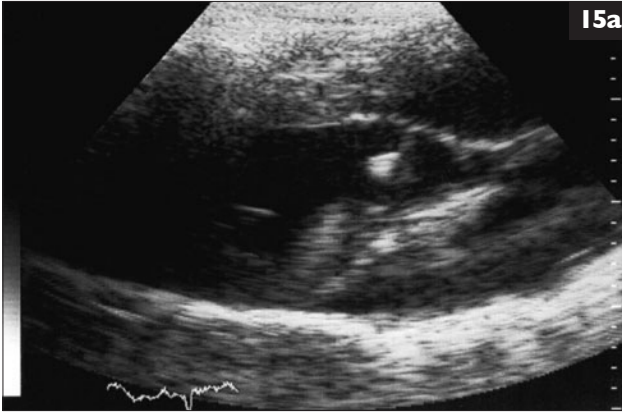
FIP was diagnosed in this case. The cat had very high serum globulin levels (69 g/l [6.9 g/dl]), predominantly comprising gamma globulins on serum protein electrophoresis. Haematology revealed a mild anaemia, and lymphopenia.

14 i. The picture shows a predominance of mature non-degenerate neutrophils in the smear, with some macrophages and some RBCs. Normal joint fluid has a low cellularity (less than three to five cells per high power field) and a predominance of mononuclear cells. This picture is typical of an inflammatory arthropathy and, as several joints are affected, this cat is suffering from polyarthritis.

ii. Typical clinical signs of polyarthritis are stiffness and reluctance to walk, shifting lameness, pain on joint manipulation, joint swelling, and heat. This may be accompanied by systemic signs such as pyrexia, lethargy, inappetence, and depression.

Inflammatory polyarthritis is either septic or non-septic. The former can be associated with *Mycoplasma* infections and endocarditis, but such cases are uncommon in cats. Joint fluid cultures, echocardiography, and blood and urine cultures can be helpful. FCV infection can produce a transient polyarthritis.

Most cases of feline polyarthritis are non-septic and immune-mediated. With these the priority is to seek a treatable underlying cause and/or to manage the joint inflammation. Proliferative and erosive forms are well described in addition to non-deforming polyarthritis. There may be an association with FeLV and FIV infections, and some cases may have a polysystemic disorder such as systemic lupus erythematosus, thus evaluating ANA titres and looking for evidence of other immune-mediated disease (anaemia, proteinuria) is important. Some cases of immune-mediated polyarthritis will be associated with underlying neoplasia, infections or inflammatory disease. Treatment of idiopathic cases is with immunosuppression, initially using glucocorticoids.

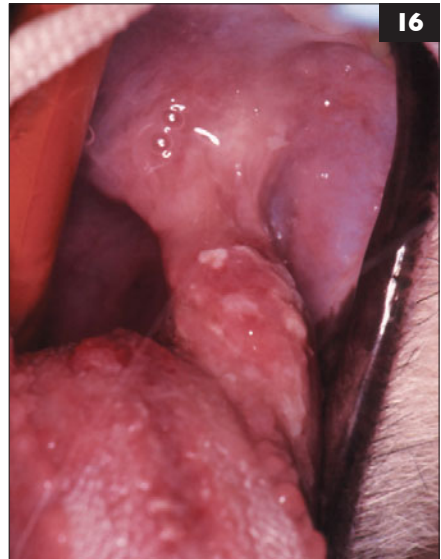

15 A 5-year-old Siamese cat is presented with a 2-week history of anorexia and depression. On examination the cat is pyrexia and a grade III systolic murmur, loudest at the left heart base, is audible on thoracic auscultation. Echocardiography is performed (15a) (the picture is a long axis view showing the left ventricular outflow tract).

- i. What is the diagnosis?
- ii. What further tests are indicated?

16 An 8-year-old neutered female DSH cat presents with a 3-week history of dysphagia. Oral examination reveals bilateral proliferative lesions at the fauces (glossopalatine folds) and on the caudodorsal tongue (16).

- i. What are the major differential diagnoses?
- ii. Histopathology of a representative biopsy reveals 'granulomatous inflammation with macrophages and giant cells around areas of collagenolysis with occasional mast cells and eosinophils'. What is the diagnosis and possible approach to management of this cat?

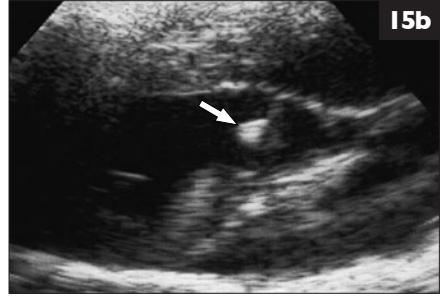

15, 16: Answers

15 i. A nodular hyperechoic vegetative lesion is visible on an aortic valve leaflet (15b, arrowed). The most likely diagnosis is bacterial endocarditis.

ii. Aerobic and anaerobic blood and urine cultures are indicated before starting antibiotic therapy (which should ideally be given IV to begin with) in the hope that it will be possible to isolate the causal agent and thus choose an appropriate antibiotic on the basis of culture and sensitivity results. *Bartonella* spp. have also been associated with endocarditis so

specialist blood culture and/or PCR testing for this organism may be indicated. Whilst awaiting results and in the face of negative bacterial cultures, empirical antibiotic treatment using a broad-spectrum agent such as amoxicillin–clavulanate is indicated, in addition to general supportive care. In those cats where no other underlying disease is present, the prognosis with appropriate treatment can be very good.



16 i. The major differential diagnoses for the proliferative lesions in this cat would be lymphoplasmacytic stomatitis, squamous cell carcinoma, and EGC.

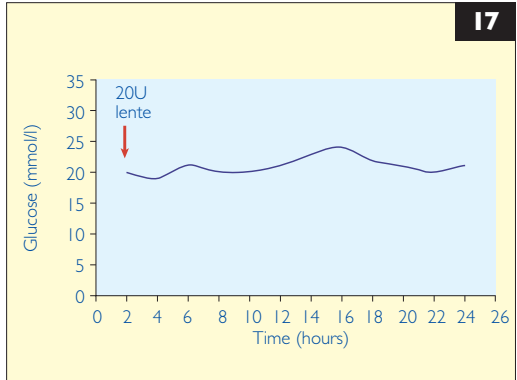
ii. The appearance of this lesion and the histological changes are typical of an eosinophilic granuloma (biopsy is always needed to confirm the diagnosis).

EGC is a collection of skin 'reaction patterns' in cats rather than an aetiological diagnosis. The presence of eosinophils does not necessarily imply an underlying allergic disease, especially as eosinophils are often relatively sparse. Nevertheless, allergic and parasitic infections are often cited as the major differential diagnoses for these lesions (atopy; flea bite, mosquito bite, and food hypersensitivities; *Cheyletiella* spp., *Otodectes* spp., and *Notoedres* spp., infections). Bacteria are observed within biopsies of some cases, but their presence is probably secondary to the disease rather than its cause. Genetic predispositions may occur for EGC lesions and the underlying cause in many cases remains uncertain (idiopathic).

Clinical management involves searching for and eliminating endo- and ectoparasites; searching for underlying hypersensitivity reactions (e.g. flea therapy, food trial). If an aetiology can be determined, treatment is based on eliminating or avoiding this. Symptomatic treatment is used where the aetiology is undetermined and where needed on clinical grounds. Oral prednisolone or methylprednisolone is the drug of choice. Cyclosporine or other immunosuppressive agents have been used in intractable cases. Although many cases respond well to megestrol acetate, the side effects with this drug preclude its use as a first-line therapy. Antibiotics may be indicated for secondary infections, but there is little evidence that bacteria can cause these lesions.

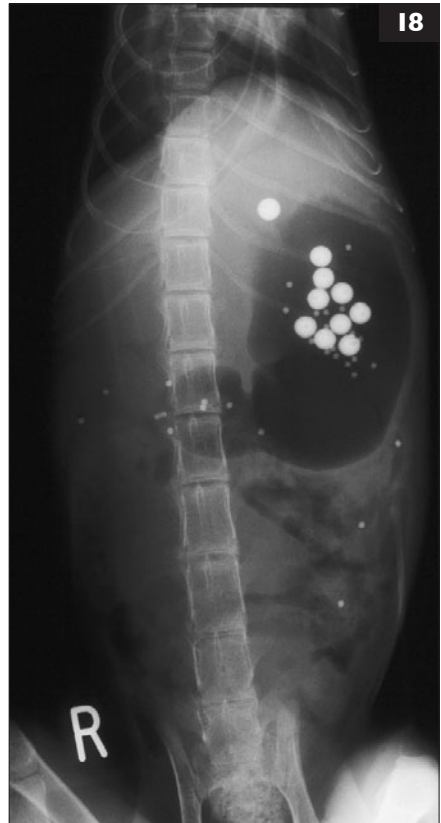17 The graph (17) shows the blood glucose results obtained from a 6 kg diabetic cat which is being treated in hospital with 20 U of lente insulin once daily. Normal blood glucose concentrations would be between 3.5–7.5 mmol/l (63–135 mg/dl).

- What is the assessment of this case?
- What differential diagnoses need to be considered?



18 A 2-year-old Siamese cat presented with persistent vomiting of partially digested food several hours after feeding. The VD abdominal radiograph (18) was taken 16 hours after the administration of BIPS.

- What abnormalities can be seen?
- What diagnosis does this suggest and what treatment options should be considered?



17, 18: Answers

17 i. The glucose curve suggests that the cat is insulin resistant. Insulin resistance is usually defined as being present in cats remaining hyperglycaemic and glycosuric in spite of receiving >1.5 U of insulin per kg bodyweight per dose, or in cats requiring >2.2 U/kg to maintain glycaemic control.

ii. Mild insulin resistance can be seen with a variety of physiological and pathological conditions including dioestrus, pregnancy, and severe obesity. Concurrent diseases of an inflammatory, infectious, hormonal, or neoplastic nature may all contribute to poor stabilization via secretion of diabetogenic hormones (glucagon, adrenaline, cortisol, growth hormone). Common concurrent diseases include urinary tract infections, ketoacidosis, hyperthyroidism, pancreatitis, and chronic renal failure. Affected cats generally demonstrate variable or continuously poor control of their diabetes. Acromegaly and HAC are important causes of more severe insulin resistance. Other endocrine tumours (islet cell glucagonoma, pheochromocytoma) are rare potential causes of marked insulin resistance. Improper storage and handling of insulin may also be a cause of apparent insulin resistance.

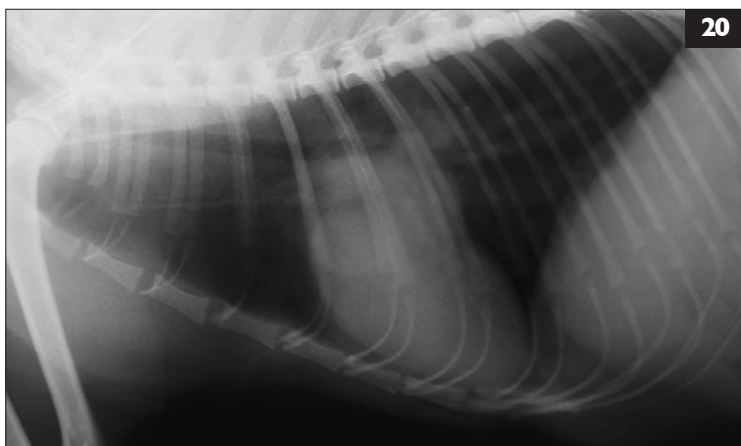
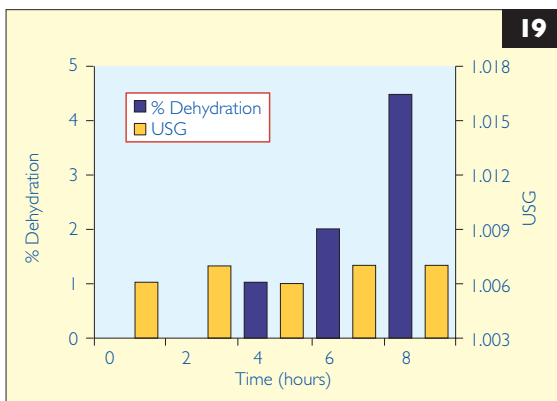
18 i. All the large (5 mm diameter) BIPS, and most of the small (1.5 mm diameter) BIPS are still in the stomach. This suggests there is delayed gastric emptying. Although gastric emptying times are very variable in normal cats, small BIPS will usually completely empty from the stomach within 14 hours (often much quicker) and large BIPS should at least start to empty by this time. In addition to the abnormal retention of BIPS, the stomach body and antrum are gas-filled and dilated. This can be seen with pyloric stenosis and other conditions interfering with gastric emptying, and can also be seen with aerophagia (e.g. secondary to dyspnoea). However, this cat was not dyspnoeic, and there is no abnormal air in the intestines.

ii. These changes are typical of 'pyloric stenosis'. This is a well recognized congenital problem in Siamese cats, although there is no apparent true 'stenosis', but rather a functional motility problem resulting in poor gastric emptying in affected cats.

No treatment is universally successful for these cases. Dietary manipulation may help: feeding a low fat diet and feeding liquid or semi-liquid foods may encourage more rapid gastric emptying. Prokinetic drugs such as metoclopramide (metoclopramine), cisapride, and erythromycin may help in some individuals. Pyloromyotomy has also been reported to be helpful in some of these cats. As there is usually no physical obstruction, this should probably be reserved for those cats where medical therapy fails. Pyloromyotomy allows more rapid gastric emptying, but as with the other treatments, the response varies considerably between individuals.

19 A water deprivation test followed by an ADH response test has been performed in a cat with clinical signs and initial assessment consistent with diabetes insipidus. The water deprivation test was stopped after 8 hours as the cat was noted to be clinically dehydrated. Results are shown graphically (19). Following ADH administration the USG increased to 1.020.

- What is the diagnosis?
- What are the treatment options?
- What is the prognosis?



20 This lateral thoracic radiograph (20) was taken from a 9-year-old DSH cat with a history of lethargy, episodes of breathlessness and some weight loss over the past month. On thoracic auscultation a grade III systolic heart murmur is heard over the left apex. Heart rate and rhythm are normal.

- What abnormalities are visible on the radiograph?
- What is the assessment of this case?
- What further tests are indicated?

19, 20: Answers

19 i. The absence of change in USG following water deprivation is consistent with diabetes insipidus. The response to ADH is diagnostic of central diabetes insipidus.

ii. The treatment options include:

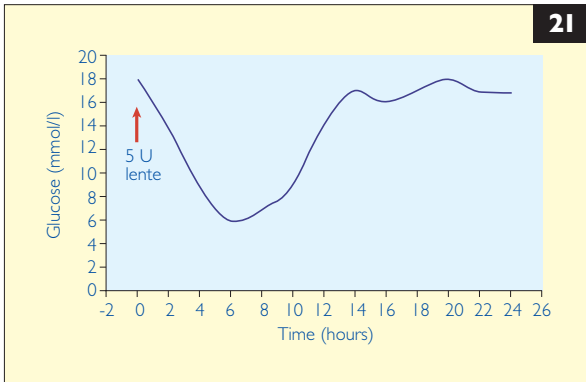
- As long as constant access to water is ensured so that the cat does not become dehydrated, and the owner is happy to live with a very polydipsic and polyuric cat, treatment is not mandatory. The owner should be informed of the risk of rapid, life-threatening dehydration which can occur if access to water is restricted or illness (e.g. vomiting or diarrhoea) occurs.
- Treatment with DDAVP, a synthetic analogue of ADH. DDAVP is available as oral, parenteral, and intranasal preparations licensed for human use. A starting dose of 1–5 µg per cat once to twice a day is recommended; in general higher doses are required when oral dosing is used (e.g. 50 µg per cat twice daily). The intranasal preparation can be administered by the conjunctival route and comprises 100 µg/ml (one drop corresponds to 1.5–4 µg). The dose is modified to produce remission of clinical signs. In some cases, severe polydipsia is not completely controlled by DDAVP alone and non-hormonal treatment may be added to the regime. Chlorpropamide (40 mg/day) potentiates the renal tubular effects of ADH and can help to stabilize cats with central or partial central diabetes insipidus. It should be used with some caution in view of the fact that in humans it is a potent hypoglycaemic. Thiazide diuretics can also be used in this situation and have a paradoxical effect to reduce polyuria.

iii. The prognosis depends on the cause of the disease but is good with congenital and idiopathic central diabetes insipidus, as long as the cat has free access to water. Central diabetes insipidus has been reported following CNS trauma and may improve/resolve with time. Where central diabetes insipidus is associated with neoplasia, the prognosis is dependent on the rate of progression of the tumour.

20 i. The radiograph shows generalized cardiomegaly with especially marked left atrial enlargement. There is no evidence of pulmonary oedema or a pleural effusion which can be associated with cardiac disease.

ii. The history, clinical, and radiographic findings are consistent with a cardiac problem. Marked left atrial dilation is most frequently associated with hypertrophic cardiomyopathy. However, this is not diagnostic for hypertrophic cardiomyopathy and can also be seen in cases of restrictive cardiomyopathy and other cardiac diseases.

iii. Electrocardiography may add some useful information regarding cardiac enlargement and abnormal conduction, but echocardiography is likely to be most useful to assess the nature and severity of cardiac disease. Serum T4 levels are also indicated since hyperthyroidism can be associated with cardiac disease (in particular left ventricular hypertrophy). SBP measurement is indicated where left ventricular hypertrophy is found to rule out systemic hypertension as a cause of this.



21 A 4 kg diabetic cat is being treated in hospital with 5 U of lente insulin once daily. The blood glucose results are illustrated graphically (21). Normal blood glucose concentrations are approximately 3.5–7.5 mmol/l (63–135 mg/dl).

- i. What is the assessment of this case?
- ii. How should this patient be managed?



22 A Siamese queen is presented in late-stage pregnancy (22).

- i. What are the first signs of parturition and describe the three stages of labour in cats.
- ii. What are the common causes of dystocia in cats?

21, 22: Answers

21 i. Insulin treatment is resulting in a fall in blood glucose levels but the duration of action is insufficient and blood glucose levels stay below the renal threshold (12–14 mmol/l [216–253 mg/dl]) for less than 10 hours of the day.

ii. This patient will benefit from a change to the insulin regime. One option would be to treat the cat with twice daily lente insulin. Another option would be to change to protamine zinc insulin which is a longer-lasting preparation. In many cats, once daily protamine zinc insulin is sufficient to control the diabetes. The glucose curve obtained in this cat suggests that twice daily therapy with lente insulin would provide excellent control. The goals of stabilization are:

- Resolution of clinical signs associated with diabetes (polyuria, polydipsia, polyphagia, and weight loss being the major ones).
- Production of a 'normal' blood glucose curve.

Achieving these goals should be associated with prevention/minimization of ketoacidosis, hypoglycaemia or the development of long-term complications of diabetes such as peripheral neuropathy. A blood glucose of <14 mmol/l (253 mg/dl) throughout the day usually achieves these aims. Tighter control of the glucose curve may not be of additional clinical benefit since the complications associated with long-term diabetes in man (vasculopathy, nephropathy, coronary arterial disease) are uncommon in cats.

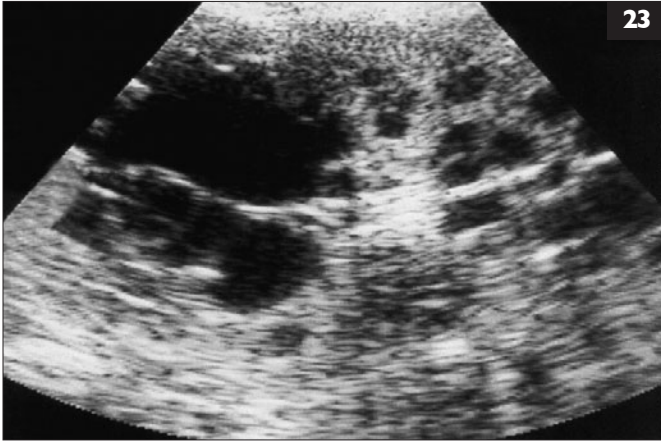
22 i. Many queens become inappetent or anorexic in the 24–48 hours prior to parturition, but a prepartum drop in rectal temperature does not occur. The average gestation length is 63–65 days but with a wide spread (between 58 and 70 days is not considered abnormal).

Stage I of labour involves dilation of the cervix, has a typical duration of 6–12 hours, and is accompanied by restlessness and nesting behaviour. Stages II (delivery of the foetus) and III (delivery of the placenta) are usually mixed in cats as multiple kittens are usually born. The onset of stage II is marked by abdominal contractions and straining and the first kitten is normally delivered within 2–6 hours. The interval between births is highly variable and it is not uncommon for a queen to have a long interval (occasionally up to 48 hours) between some births.

ii. Dystocia is relatively uncommon in cats, but pedigree breeds appear to be at a higher risk. Dystocia is divided into maternal and foetal causes:

- Maternal dystocia: primary uterine inertia appears to be the single most common cause of dystocia and may respond to medical therapy (3–5 U oxytocin IM every 30 minutes). Other maternal factors include a narrow birth canal, uterine prolapse, uterine torsion, and uterine rupture.
- Foetal dystocia: common foetal causes of dystocia are malpresentation, foetal oversize, and foetal death.

Surgery is indicated where there is an obstructive cause of the dystocia.



23 The ultrasound image (23) shows the right kidney of a cat with CRF.

- i. What is the diagnosis?
- ii. What causes this condition, what is the typical clinical presentation and which breeds are predisposed to the condition?

24 A 5-year-old neutered male Chinchilla is presented with a history of acute onset mydriasis and lack of direct and indirect pupillary light responses (24).

- i. How is normal pupil size regulated?
- ii. What are the differential diagnoses that should be considered?
- iii. What is a possible approach to investigating this case?



23, 24: Answers

23 i. The ultrasound image shows multiple anechoic areas of various sizes within the renal parenchyma, with a loss of normal renal architecture and no discernible corticomedullary demarcation. This appearance is typical of PKD. The size of the kidney cannot be determined from the still picture, but it was grossly enlarged (58 mm in length).

ii. PKD is inherited as an autosomal dominant condition. Multiple microscopic cysts are present from birth and enlarge with time. By the time clinical disease is apparent they vary in size from <1 mm to >1 cm in diameter. The size of the cysts eventually results in displacement of normal functional renal tissue, and causes CRF to develop. The cysts usually grow slowly, so most affected cats do not show signs of renal failure until middle age or later (typically 7–8 years of age). However, PKD does vary in severity and in some cases progression to renal failure will occur at a much younger age. The clinical signs seen are typical of CRF, but abdominal palpation usually reveals enlarged, irregular, and readily palpable kidneys.

The disease is inherited in pedigree Longhair cats. Studies in several countries have shown that in general 30–50% of Persian cats are affected. Other cat breeds that have been developed using Persian bloodlines, such as Burmillas and Exotic shorthairs, also have a significant proportion of affected cats, but in unrelated breeds it is a rare condition.

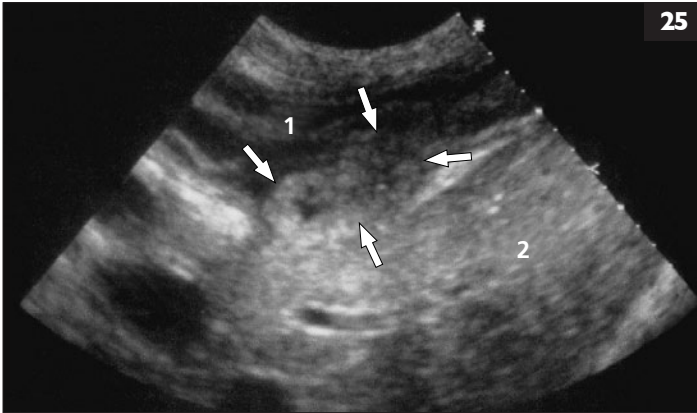
24 i. Pupil size is controlled by the oculomotor nerve (cranial nerve III). A normal PLR requires a functional retina, optic nerve ipsilateral to the side stimulated, and oculomotor nerve ipsilateral and contralateral to the side stimulated. In dark conditions, shining a light into one eye should result in constriction of the pupil stimulated (direct PLR) and of the pupil of the other eye (indirect PLR).

ii. Differential diagnoses of mydriasis include:

- Retinal disease, e.g. retinal degeneration, detachment, glaucoma.
- Optic nerve or optic tract disease, e.g. optic neuritis, neoplasia.
- Optic chiasm lesion, e.g. neoplasia.
- Midbrain lesion, e.g. compression due to tentorial herniation, neoplasia.
- Central blindness caused by hypoxia/anoxia during or following general anaesthesia.
- Lesion affecting function of the oculomotor nerve, e.g. feline dysautonomia, neoplasia, FeLV-associated ‘spastic pupil syndrome’.
- Mydriatic drugs, e.g. ketamine, anaesthetic agents, atropine.
- Iris disease affecting its ability to constrict, e.g. iris hypoplasia, iris atrophy.

iii. Assessment of vision and a complete ophthalmological and neurological examination will help to localize the lesion causing the mydriasis. Depending on these results, further investigations may include virus screening tests and CT or MRI of the brain.

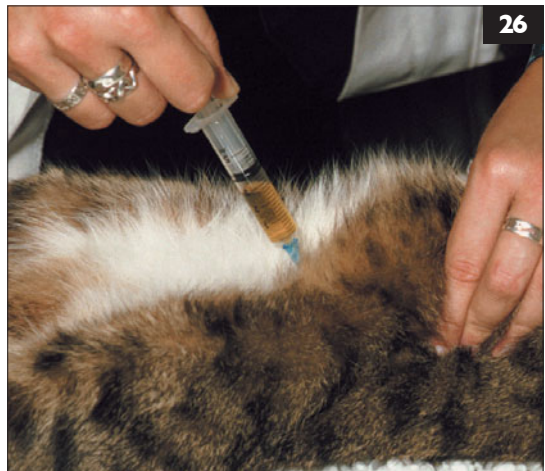
The diagnosis in this case was feline dysautonomia. The cat also had reduced tear and saliva production, bradycardia, urine retention, and constipation.



25 The sonogram (25; 1 duodenum, 2 liver) is from a 10-year-old neutered female DSH presented with a chronic (several months) history of inappetence, weight loss, vomiting, and intermittent diarrhoea. Thoracic and abdominal radiographs were unremarkable.

- i. Comment on the appearance of the pancreas (outlined by arrows). What is a possible interpretation of this?
- ii. What additional diagnostics may be indicated?

- 26 i. What technique is being performed here (26)?
- ii. How is this technique performed?
- iii. What are the indications for this procedure?
- iv. What are the disadvantages of this procedure?



25, 26: Answers

25 i. The sonogram demonstrates patchy hyperechogenicity of the pancreas, which has taken on a somewhat nodular appearance. This is a non-specific finding and could be associated with inflammatory or infiltrative (neoplastic) change. However, the lack of gross enlargement of the pancreas and the chronicity of the signs would suggest that neoplasia is less likely.

The sonogram is thus suggestive of pancreatitis, and the mottled increased echogenicity suggests this may be chronic rather than acute or oedematous. The significance of this is uncertain. Chronic pancreatitis is a common incidental finding in older cats, but chronic active pancreatitis can be a cause of morbidity in its own right (causing various but often vague clinical signs), or can be a component of other diseases such as inflammatory bowel disease and/or cholangiohepatitis.

ii. Currently used blood tests are notoriously unreliable for the diagnosis of active pancreatitis in cats; amylase and lipase have long been recognized to have little or no diagnostic value in the cat, and the assay of fTLI has been very controversial. While high fTLI levels may be supportive of active pancreatitis, many cats with pancreatitis have normal serum fTLI levels and mild to moderate elevations may be seen in some cats without appreciable pancreatic disease. The test therefore is neither sensitive nor specific and results need to be interpreted with caution. Assay of feline pancreatic lipase immunoreactivity may be of more clinical value.

In this case, an exploratory laparotomy was performed to evaluate the pancreas and rule out neoplasia. Biopsies confirmed chronic active pancreatitis, with concomitant lymphoplasmacytic inflammatory bowel disease and mild lymphocytic portal hepatitis. An fTLI assay was normal.

26 i. Cystocentesis is being performed with the cat in dorsal recumbency.

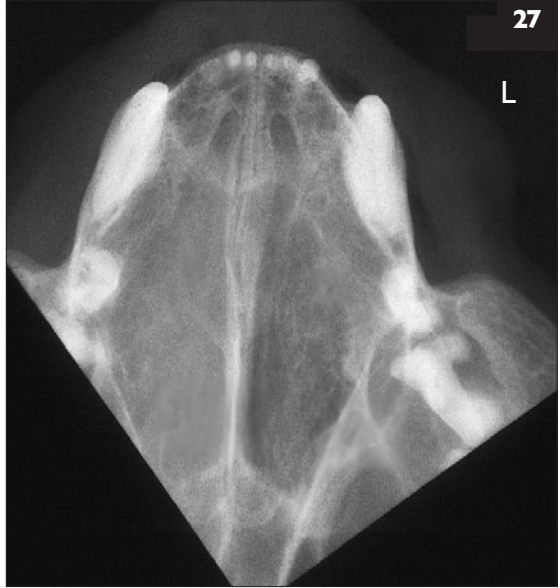ii. Cystocentesis can be performed in conscious, sedated, or anaesthetized cats in any position, as long as the bladder can be palpated. The bladder is gently stabilized and a 5–20 ml syringe with a 1–2 inch 23 gauge needle is introduced at an oblique angle, to reduce the risk of urine leakage, and directed into the bladder cranial to the junction between the bladder and urethra. Once the sample has been aspirated, pressure on the bladder is released and the needle is withdrawn.

iii. This is a simple technique for obtaining urine samples for urinalysis and, in particular, urine culture. Cystocentesis can be used to drain the bladder in cats with urethral obstruction and severe bladder enlargement.

iv. Cystocentesis complications are rare. Additional care is necessary with urethral obstruction, as there is a higher risk of urine leakage or bladder rupture – a greater volume of urine should be removed to relieve bladder pressure. Very rarely, cats have been reported to retch/vomit, pant, and temporarily collapse after cystocentesis, presumably as a result of vagal stimulation. Spontaneous recovery occurs within minutes.

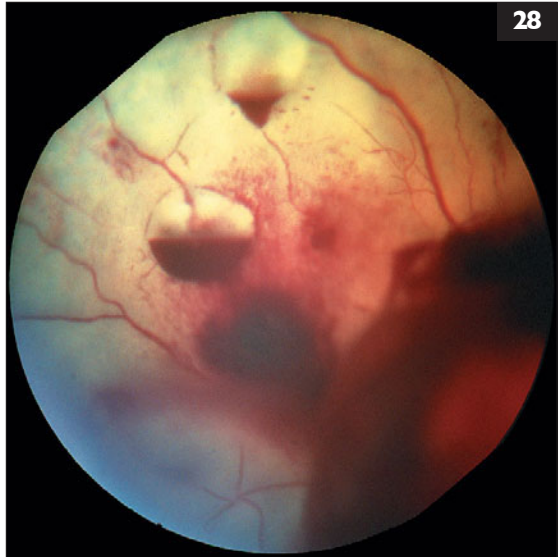
27 This intra-oral nasal radiograph (27) is from an 11-year-old neutered male DSH cat.

- i. What abnormalities can be seen radiographically?
- ii. What is the likely diagnosis and how would this be confirmed?
- iii. What clinical signs is the cat likely to be showing?



28 A 15-year-old neutered male DSH cat is presented with a history of sudden onset blindness. On further questioning the owner reveals that the cat has been somewhat lethargic and depressed for some time. Both eyes contain similar changes, a picture of the right fundus is shown (28).

- i. What abnormalities can be seen?
- ii. For what condition are these changes typical?
- iii. What ocular changes can generally be seen with this disease?



27, 28: Answers

27 i. The radiograph demonstrates a relatively normal appearance to the left nasal chamber with the turbinate structure still being visible. There appears to be a mild increase in soft-tissue density on the left side, particularly rostrally, and the external nares are not clearly visible suggesting some nasal discharge in and from this side. The right nasal cavity has a marked diffuse increase in soft tissue density along with loss of most of the normally visible turbinate structures. This is consistent with turbinate destruction and an expansive soft tissue mass which is most likely to be neoplastic. Granulomatous fungal rhinitis or destructive rhinitis with inspissated fluid/pus would also be possible but less likely.

ii. The likely diagnosis in this case is nasal neoplasia, primarily affecting the right nasal cavity, with possible extension to, or reaction in, the left nasal chamber. The diagnosis would be best confirmed by nasal biopsy (guided via rhinoscopy or blind) using suction-catheter or grab-forceps techniques. The two most common nasal tumours in cats are lymphoma and adenocarcinoma. Radiotherapy may be an option for both tumours (lymphoma generally responding very well) and chemotherapy would also be an option for lymphoma.

iii. The cat would be likely to be showing progressive signs of inspiratory dyspnoea, stertor, nasal discharge, and sneezing. Severe dyspnoea may cause inappetence and weight loss. Local expansion of a tumour mass may cause facial distortion, and this is important to assess during clinical examination along with any distortion to the hard palate and enlargement of regional lymph nodes.

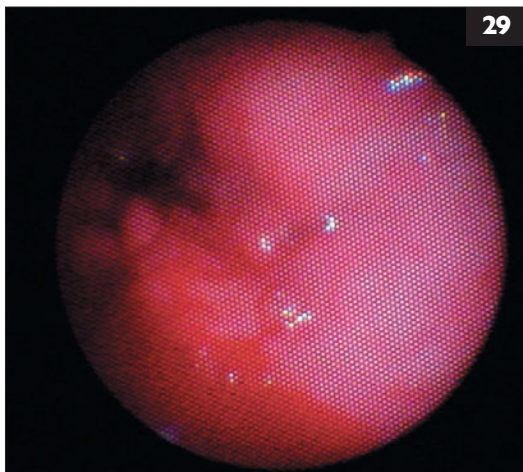
28 i. There are large areas of retinal detachment (from 2 o'clock to 7 o'clock) and extensive intraocular haemorrhage. Two blood-filled bullae are clearly visible (10 o'clock and 12 o'clock); blood in these has originated from ruptured aneurysms, probably involving retinal arterioles.

ii. Hypertensive chorioretinopathy.

iii. Systemic hypertension can be associated with many ocular abnormalities. Ocular haemorrhage can involve the anterior chamber in some cases (hyphaema) and haemorrhage into the vitreous can extend to involve the anterior chamber. Fundic examination may reveal subtle changes such as focal areas of effusion from choroidal vessels producing areas of subretinal oedema which may progress to bullous detachments, and, in severe cases, total retinal detachment. Retinal vessel abnormalities which may be visible include frank haemorrhage, apparent variation in the diameter of the vessels along their length, arteriovenous nipping, and aneurysms. Areas of retinal detachment may reattach and, when this occurs, retinal folds may be seen. Subtle papilloedema may be seen in some cases. Over a long period of time retinal degeneration, recognized as areas of hyperreflectivity, and optic atrophy may develop. Abnormalities are usually detected in both eyes although they may be more severe in one.

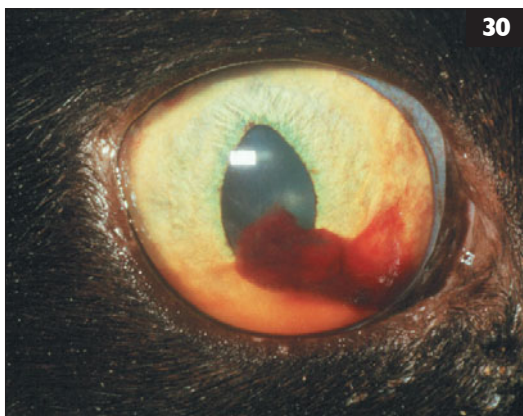29 A 13-year-old neutered female DSH cat presents with recurrent and progressive signs of dysuria and haematuria. Physical examination reveals an irregularly thickened bladder wall and cystoscopy of the bladder apex is shown (29).

- What changes are evident and what are the differential diagnoses?
- What is the most likely diagnosis in this case and how could treatment be attempted?



30 The laboratory results below were obtained from a 6-year-old neutered male domestic long-haired cat which was presented with a history of lethargy and inappetence. The owner also reported that one eye looked abnormal (30).

- What is the assessment of this case based on the results shown?
- What are the differential diagnoses and what further tests are appropriate?
- If a single disease is responsible for this cat's signs, what is it most likely to be and how might it be managed?



Parameter	Result	Reference range
Urea mmol/l (mg/dl)	7.2 (20.2)	6.0–10.5 (17.0–29.0)
Creatinine μ mol/l (mg/dl)	112 (1.3)	<175 (<2.0)
Phosphate mmol/l (mg/dl)	1.8 (5.6)	0.95–1.95 (2.9–6.0)
Sodium mmol/l (mEq/l)	151	145–160
Potassium mmol/l (mEq/l)	2.9	4.0–5.0
Calcium mmol/l (mg/dl)	2.1 (8.4)	2.0–2.7 (8.0–10.8)
Glucose mmol/l (mg/dl)	4.8 (86)	3.5–7.5 (60–135)
Urine specific gravity	>1.050	
Systolic blood pressure (SBP)	245 mmHg	

29, 30: Answers

29 i. Cystoscopy shows the presence of haemorrhage from the bladder wall and an irregular, poorly defined polypoid-like mass lesion. The major differential diagnoses would be:

- Neoplasia – most likely TCC.
- Polypoid cystitis.
- Severe cystitis secondary to urolithiasis.

ii. TCC would be the most likely diagnosis in this cat. Urolithiasis could be ruled out by diagnostic imaging, but a bladder biopsy (surgical or catheter biopsy) would be required to make a definitive diagnosis. Cytology of urine sediment or a fine needle aspirate may be diagnostic, but TCCs do not always exfoliate neoplastic cells, and even when neoplastic cells are present they can be difficult to distinguish from reactive cells. Thoracic radiographs and abdominal radiography and ultrasonography would be indicated to look for metastases, as by the time a diagnosis is made, metastases are common.

In cats, TCCs commonly affect the apex rather than the trigone of the bladder, so surgical excision is often feasible and is regarded as the treatment of choice where possible and appropriate. In dogs and humans, COX-2 inhibitors appear to help many cases of TCC, probably because these tumours over-express COX-2 and this enzyme may play a role in tumourigenesis. On this basis, COX-2 selective non-steroidal anti-inflammatory drugs may have a role in managing feline patients too. Piroxicam has produced anecdotal beneficial effects, but drugs such as meloxicam and carprofen may have greater COX-2 selectivity. Cats receiving these drugs should have renal function monitored and be monitored for gastrointestinal side effects.

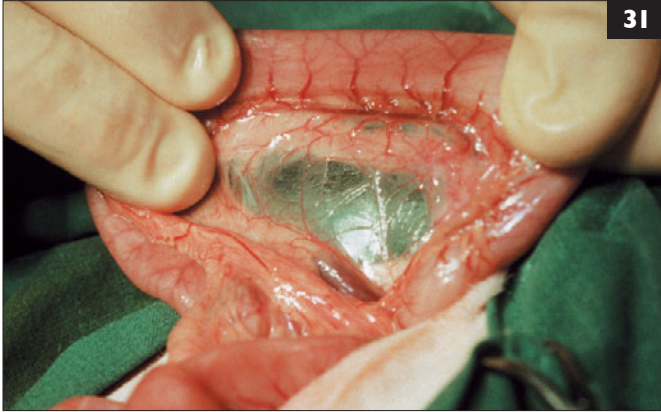
30 i. Hyphaema is evident in the picture and, given the SBP reading, this is most likely to be a result of systemic hypertension. The most striking laboratory finding is a marked hypokalaemia. Renal function is normal so this is not the cause of the hypokalaemia.

ii. Differential diagnoses for hypokalaemia in this cat include:

- Diuretic therapy, e.g. furosemide.
- Overzealous intravenous fluid therapy.
- Persistent prolonged poor appetite (usually only mild hypokalaemia with this).
- Hyperaldosteronism.

Further diagnostic tests to be considered include serum aldosterone assay and adrenal ultrasonography (in order to try to locate an adrenal tumour). Retinal examination may be helpful in order to identify further changes consistent with hypertension.

iii. Given the clinical and laboratory findings in this case, hyperaldosteronism is most likely. Medical management of these cases includes potassium supplementation (intravenously or orally) and use of spironolactone, an aldosterone antagonist. Surgical removal of the tumour, where possible, is also an option.



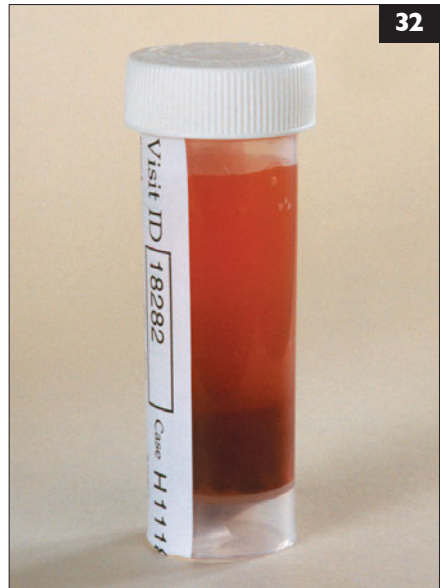
31

31 An exploratory laparotomy is performed in a 9-year-old neutered female DSH cat; the proximal duodenum is displayed (31).

- i. What abnormality can be seen?
- ii. What clinical signs would this cat be expected to show?
- iii. What other diagnostic tests would be valuable?
- iv. What would be the recommended treatment in this case?

32 A 3-year-old entire male DSH cat presents with lethargy, pyrexia and depression of 5 days' duration. Clinical examination reveals inspiratory dyspnoea and bilateral ventral dullness on thoracic percussion. Thoracocentesis yields a turbid foul-smelling fluid (32).

- i. What is the likely diagnosis in this cat? What are the typical biochemical and cytological findings with the fluid?
- ii. What causes this condition in cats and how does it differ from that found in dogs?



32

31, 32: Answers

31 i. The picture shows the proximal small intestine and the pancreas. The pancreas appears severely hypoplastic/aplastic. There is no obvious associated inflammation of the pancreas, peripancreatic fat, mesentery, or intestine.

ii. This cat would probably be suffering from EPI. This is an uncommon disorder in cats, and would result in chronic diarrhoea, often with steatorrhoea (malodorous, pale faeces) and weight loss, possibly in the face of an increased appetite. Faeces are often voluminous and examination may reveal undigested meat fibres and fat. The hair coat, particularly around the perineum, may become very greasy. If the pancreatic pathology also affected the endocrine portion (i.e. β -cells) this cat could also have diabetes mellitus.

iii. Histology of the pancreas would be valuable. In this case, histology revealed normal pancreatic islets, but only occasional foci of acinar cells along with several foci of lymphoid infiltrates, suggesting a possible immune-mediated aetiology of the EPI. Assay of serum fTLI is a sensitive and specific non-invasive marker of pancreatic function and is reliable for the detection of EPI (low serum levels being diagnostic). The majority of cases of feline EPI also have very low (sometime unmeasurable) serum B_{12} concentrations as 'intrinsic factor' secreted by the pancreas is required for its efficient absorption from the small intestine. Measurement of faecal trypsin activity is notoriously unreliable for the diagnosis of this condition.

iv. Treatment of feline EPI is similar to canine EPI with supplementation of pancreatic enzymes, ideally in the form of powder supplementation mixed in with food. The food should be given as small frequent meals. B_{12} supplementation may be required.

32 i. The clinical signs and foul-smelling nature of the effusion are typical of pyothorax. The fluid in cases of pyothorax is an exudate with a high protein and cell content. Cytology reveals abundant degenerate neutrophils and often both intracellular and extracellular bacteria are seen.

ii. The foul smell of the fluid is due to the presence of anaerobic bacteria. Feline pyothorax is usually a mixed infection, with anaerobic Gram-negative rods (*Bacteroides* spp., *Fusobacterium* spp.), anaerobic Gram-positive rods and cocci (*Clostridia* spp., *Peptostreptococcus* spp.), and *Pasteurella multocida* being common isolates. If there is a significant delay in a sample reaching the laboratory, cultures may be sterile if there are only strict anaerobes present.

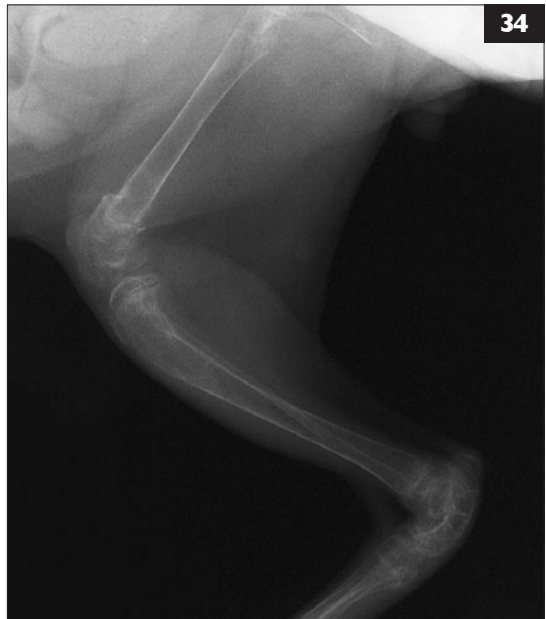Pyothorax is more common in the cat than the dog and can arise from a penetrating wound, haematogenous spread, a migrating foreign body, or local extension of infection (e.g. oesophageal rupture, bronchopneumonia). In dogs, it is more common to identify a specific underlying cause (e.g. foreign body), whereas in cats, many cases remain idiopathic. In dogs, the most common bacteria isolated are *Nocardia*, *Actinomyces*, and *Bacteroides* spp.



- 33 i. What feature is being shown by this 18-month-old neutered female Burmese cat (33)?
- ii. What is the most likely cause of this sign and its aetiopathogenesis in this cat?

34 Examine the radiograph (34).

- i. What abnormalities can be seen?
- ii. What is the most likely cause of these changes and what is the likely aetiopathogenesis?
- iii. What clinical signs would this cat be expected to show?
- iv. What laboratory abnormalities might be present?
- v. How should this case be managed?



33, 34: Answers

33 i. The most obvious feature is ventroflexion of the neck; the head is therefore not being held in a normal position. This is a non-specific sign of muscle weakness in cats and can occur as a result of numerous myopathies and junctionopathies.

ii. The single most common cause for neck ventroflexion is hypokalaemic polymyopathy, which can occur for a variety of different reasons. A recognized breed-related and probably inherited form of hypokalaemic polymyopathy has been described in Burmese cats in several countries. Affected cats usually display signs of polymyopathy by 2–6 months of age, and the disease varies in severity. Many cats display intermittent hypokalaemia/polymyopathy and therefore clinical signs may be episodic. The disease has some resemblance to periodic hypokalaemic polymyopathy in humans where there is a sudden shift of potassium from extracellular fluid to intracellular fluid resulting in hypokalaemia, altered muscle resting membrane potential, and, if severe enough, myonecrosis. In affected cats, serum potassium concentrations are typically <3 mmol/l (<3 mEq/l) and there is often very marked elevation in serum CK concentrations. The precise aetiopathogenesis of the condition in Burmese cats has not yet been elucidated but it is likely to represent either an intracellular shift of potassium, and/or inappropriate kaliuresis.

34 i. The radiograph is from an immature cat (growth plates not yet fused) and demonstrates severe osteopenia with thinning of the bone cortices and a pathological fracture of the distal femur.

ii. These findings are characteristic of nutritional secondary hyperparathyroidism which is seen occasionally in cats fed an all meat diet. In this condition the osteopenia results from excessive bone resorption. An all meat (or mainly all meat) diet is rich in phosphate but deficient in calcium. A meat diet provides a Ca:P ratio of around 1:20 as opposed to the 1:1 ratio recommended for cats. The hypocalcaemia causes hyperparathyroidism, resulting in calcium resorption from bone and increased urine phosphate excretion.

iii. Typical clinical signs are pain, lameness, stiffness, reluctance to move, and pain on handling. There may be mild pyrexia and pathological fractures are common. Vertebral fractures may cause neurological signs.

iv. Due to the hyperparathyroidism, serum calcium and phosphate levels may be normal, but calcium will tend to be low and phosphate will tend to be high. There will be a marked increase in parathyroid hormone concentrations and a high fractional clearance of phosphate in the urine with a low fractional clearance of calcium.

v. Affected cats usually respond rapidly to therapy. Cats should be confined for a few weeks to prevent fracture formation and the diet should be altered to a balanced one containing a recommended Ca:P ratio.

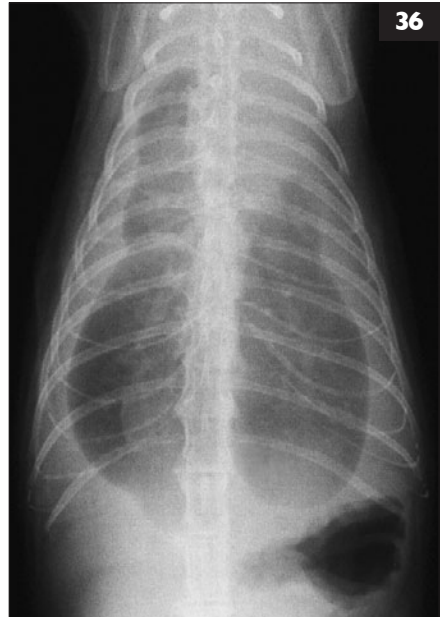35 A 7-year-old male neutered DSH presented because it has an abnormal gait (walking with the hocks touching the ground) and posture (35). There is no history of trauma and the owner believes that these abnormalities have developed over the last few weeks. On further questioning, the owner reveals that the cat has been losing weight for the last 2 months, during which time it has also been noticeably polydipsic and polyuric.



- i. Describe the cat's posture.
- ii. What are the differential diagnoses?
- iii. What is the most likely cause of the cat's clinical signs?

36 A 6-year-old male DSH cat presents with inspiratory dyspnoea and pyrexia.

- i. What features can be seen on the DV radiograph (36)?
- ii. Cytological examination of fluid collected reveals numerous degenerate neutrophils and abundant bacteria (Gram-positive and Gram-negative). How should this case be managed?
- iii. What is the value of glucose and pH measurements in monitoring response to therapy?



35, 36: Answers

35 i. The cat has a bilateral plantigrade stance.

ii. The posture and gait abnormalities are suggestive of bilateral LMN disease and likely causes include:

- Metabolic/endocrine causes of polyneuropathy such as diabetes mellitus, lipid granulomas impinging on nerves (hyperlipidaemic cats).
- Toxic polyneuropathy caused for example by exposure to organophosphates, heavy metals, or vincristine.
- Infectious and inflammatory causes of polyneuropathy, e.g. *Toxoplasma gondii*, idiopathic polyneuritis, FeLV- or FIV-associated polyneuropathy.
- Spinal cord disease (e.g. neoplasia, disc compression, inflammatory disease) causing LMN deficits.
- Neoplasia affecting peripheral nerves (unlikely to be bilaterally symmetrical), paraneoplastic causes of peripheral neuropathy.
- Idiopathic polyneuropathy (often associated with other nerve involvement).

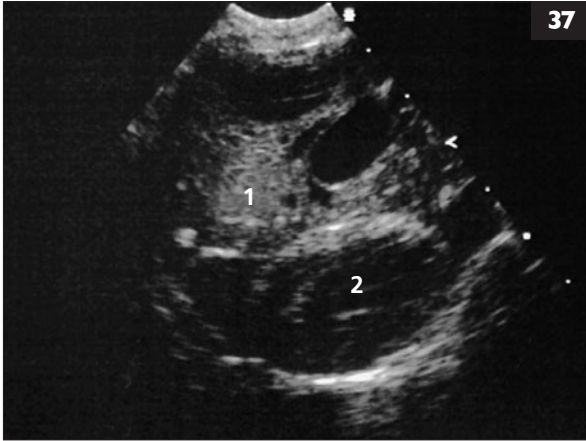
iii. In this case the most likely cause is diabetic neuropathy.

36 i. The DV radiograph demonstrates the presence of a bilateral pleural effusion, with retraction and rounding of the lung lobes. It is impossible to see the diaphragm, but the gas-filled fundus of the stomach appears to be in a normal position.

ii. The cytology is consistent with a diagnosis of pyothorax. Regular pleural drainage is necessary for successful therapy, and to relieve dyspnoea. Repeat needle thoracocentesis can be performed, but in most cases the treatment of choice is an indwelling thoracic drain(s). Frequency of drainage will depend in part on the rate of accumulation of fluid but will typically be two to three times daily, or more initially. Drainage should be continued until radiographic resolution occurs, the fluid is free of bacteria, and is of a small volume (2–4 ml/kg/day). If pleural fluid is very viscous or pocketing of fluid occurs, pleural lavage (with 10 ml/kg warmed sterile saline) can be performed twice daily. Radiography and/or ultrasonography can be helpful in monitoring response.

Systemic antibiotics should be administered for a minimum of 4–6 weeks. Culture and sensitivity testing is ideal, but empirical therapy is required, at least initially, and should be broad-spectrum, covering the mixed infection commonly seen, which generally includes anaerobes and facultative anaerobes. Antibiotic combinations are required for adequate cover and common combinations are metronidazole with ampicillin/amoxicillin, or clindamycin with enrofloxacin/marbofloxacin. Antibiotic therapy should be continued for at least 2 weeks beyond clinical resolution of disease. Studies have shown no benefit from local (intrapleural) instillation of antibiotics.

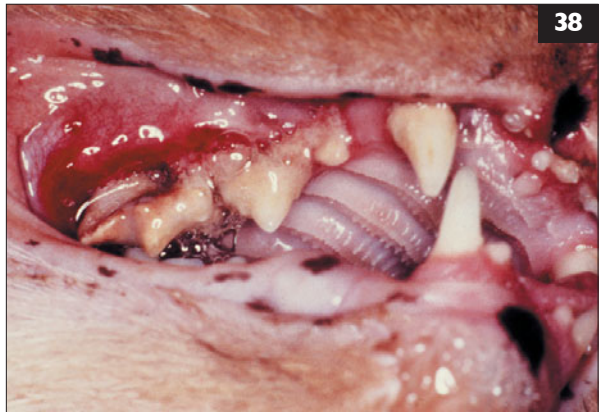
iii. In pyothorax, both the pH of the exudate and the glucose content are low. This can be used to monitor response as levels return to those found in blood as the condition resolves.



37 Thoracic radiographs from a 4-year-old domestic longhaired cat show gross cardiomegaly. Thoracic ultrasonography reveals liver (1) adjacent to the left ventricle (2) in the pericardial sac (37).

- i. What is this condition?
- ii. What is the cause of this condition?
- iii. What is its significance to the cat?
- iv. What advice should be given regarding treatment?

38 An 8-year-old neutered male DSH cat presented with anorexia, pain on opening the mouth, and severe foul-smelling purulent discharge around the gingiva. The cat was re-examined after 5 days of broad-spectrum bactericidal antibiotics.



- i. What is demonstrated in this picture (38)?
- ii. What is the diagnosis/differential diagnosis for this cat?
- iii. How should this case be investigated and treated?

37, 38: Answers

37 i. A PPDH with liver contained in the pericardial sac.

ii. PPDH arises as a relatively common congenital condition and breeds at particular risk include British Shorthair and domestic longhaired cats. In this condition there is a communication between the pericardial sac and the peritoneal cavities allowing herniation of abdominal contents.

iii. PPDHs are often clinically insignificant and in some cases only identified because screening thoracic radiographs have been performed. Most commonly, liver is present in the pericardial sac. Where present, clinical signs vary according to the nature and volume of the herniated contents and therefore can include muffled heart sounds on auscultation, and respiratory and gastrointestinal signs such as dyspnoea and vomiting.

iv. Corrective surgery can be performed in those cases where the PPDH is associated with clinical signs. In most cases this is associated with a good prognosis although the presence of adhesions can complicate surgery and worsen the prognosis. Where a PPDH has been identified as an incidental finding in an older animal, surgery may not be needed.

38 i. This cat demonstrates severe necrotizing periodontal disease affecting the 2nd and 3rd upper premolars, with marked erythema, gingival and periodontal destruction (revealing the tooth root), and erosion/bleeding. There is a moderate amount of dental calculus present. Saliva, and saliva staining, on the hair around the chin suggest the presence of ptyalism due to oral pain.

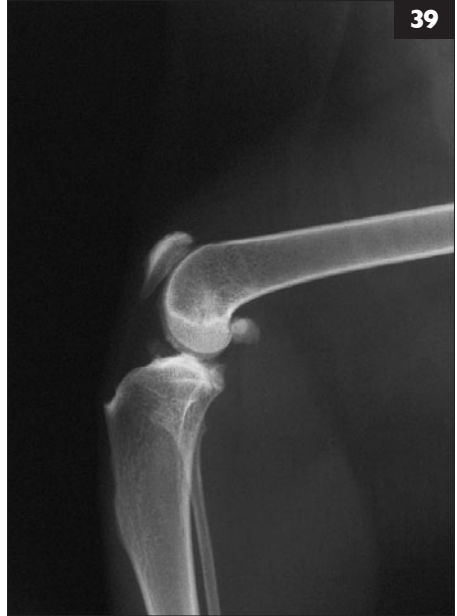ii. Acute necrotizing ulcerative gingivitis is an unusual disease in cats, and is similar to 'Vincent's infection' or 'trench mouth' in humans. In humans, the disease is caused by a mixed infection with anaerobes (especially *Fusobacterium* spp. and *Bacteroides* spp.) which accounts for the particularly unpleasant smell, due to production of volatile fatty acids by the anaerobic bacteria. It is typically associated with poor oral hygiene, malnutrition, and immunosuppression, including that due to human immunodeficiency virus infection.

Similar bacteria are responsible for the disease in cats, and there is often pre-existing periodontal disease (as in this cat). Immunosuppression with either FeLV or FIV infection is a recognized predisposing factor in cats.

iii. Testing for FeLV and FIV is important in the evaluation of cases of acute necrotizing ulcerative gingivitis. The disease can affect the gingivae, periodontal structures, tongue, and pharynx. Surgical debridement of affected tissue may be required along with dental extraction as necessary. Broad-spectrum antibiotics with good activity against anaerobes should be used such as metronidazole, penicillin, or clindamycin. Prognosis is good if there is not severe underlying disease.

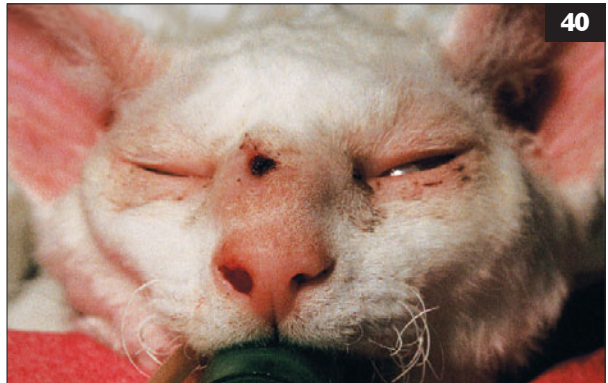
In this case the cat was infected with FIV, and developed other complications, despite control of the necrotizing periodontal disease with a combination of metronidazole and amoxicillin.

- 39 i. What feature(s) can be seen in this lateral view of the right stifle (39) from a 12-year-old neutered female DSH cat presented for investigation of dyspnoea?
- ii. What is the likely cause of these changes and how could this be confirmed? Comment on the significance of this finding.



40 A 5-year-old neutered female Cornish Rex cat presents with a 3-month history of sneezing and inspiratory dyspnoea. The appearance of the cat at the time of examination is shown (40).

- i. What abnormalities can be seen?
- ii. What are the major differential diagnoses?
- iii. If this is due to an infection, what is the most likely cause and how should this be diagnosed?



39, 40: Answers

39 i. The lateral stifle radiograph shows peri- and intra-articular new bone formation with no evidence of joint swelling or a joint effusion.

ii. The most likely diagnosis would be DJD but a joint tap and cytology would be needed to rule out an inflammatory arthropathy. With DJD there may be a small number of neutrophils present along with mononuclear cells in the joint fluid, but these are present in low numbers. In contrast, there is a very high number of neutrophils in inflammatory arthropathies ($>5,000/\mu\text{l}$) and these cells are the predominant type.

Relatively little attention has been paid to DJD in cats, although recent retrospective radiographic studies have suggested that it is actually a common phenomenon in older cats (radiographic evidence of DJD being present in at least 90% of cats over 12 years of age in one study). The DJD evident in this cat is likely to be unrelated to its dyspnoea, but DJD has been an under-recognized problem in cats.

Clinical signs of DJD in cats may potentially be much more subtle than in dogs. The lifestyle of cats may mean that they can mask signs more readily and a lack of overt lameness should not necessarily be taken as evidence of a lack of joint pain. Signs such as reduced agility, reduced activity, and altered attitude (aggression, reduced grooming, inappropriate urination) are common in older cats, and chronic joint pain could be a potential cause of these.

Trial therapy may be justified with, for example, non-steroidal anti-inflammatory agents, injectable or oral pentosan polysulphate, or oral glucosamine.

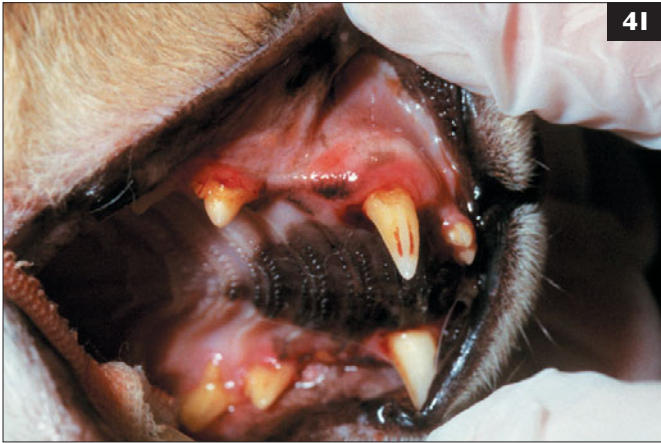40 i. A red mass can be seen protruding from the right nostril with swelling over the bridge of the nose, especially on the right, and a small crusted lesion.

ii. The two major differential diagnoses for these changes would be:

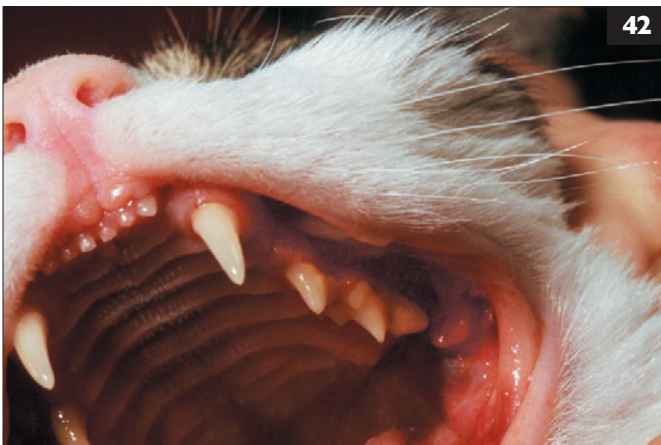- Neoplasia (e.g. lymphoma), or fungal infection (e.g. cryptococcosis).

iii. If this lesion is due to an infection, then nasal cryptococcosis would be most likely as *Cryptococcus neoformans* is the most common cause of fungal rhinitis in the cat. There are two varieties of *C. neoformans*: *C. neoformans* var *neoformans* and *C. neoformans* var *gattii*. The former has a worldwide distribution (more common in warmer environments) and is found in pigeon droppings and decaying vegetable matter, whereas the latter is present in tropical/subtropical environments and is strongly associated with various eucalyptus trees. Cats probably become infected by inhalation of spores, although cutaneous or ocular inoculation, or ingestion may also occur.

Diagnosis is based on finding the organism in cytological examination of exudates, impression smears, aspirates, or on histopathology. *C. neoformans* has a typical appearance with a thick capsule surrounding the organism. The organism can also be cultured from samples, although false positives can occur as a result of transient contamination. Serological testing (latex agglutination test) for serum antigen is useful, and is a relatively sensitive and specific indicator of infection. A decreasing titre during treatment is a good prognostic indicator.



41 What can be seen on the right upper canine tooth of this cat undergoing routine dental prophyllaxis (41)? What is known about the nature of these lesions and what treatment is recommended?



42 The picture (42) is of a 5-year-old neutered male DSH with lymphoplasmacytic gingivostomatitis. What treatment options should be considered for this cat based on knowledge of the aetiopathogenesis of this condition?

41, 42: Answers

41 The right upper canine tooth of this cat shows a classic ‘neck’ lesion at the gingival margin. ‘Neck’ lesions or FORLs are commonly recognized in cats, occurring in an estimated 20–60%. Most affected cats are over 4 years old, the prevalence increases with age, and apparently also with FIV infection. Lesions are most common on the buccal tooth surface.

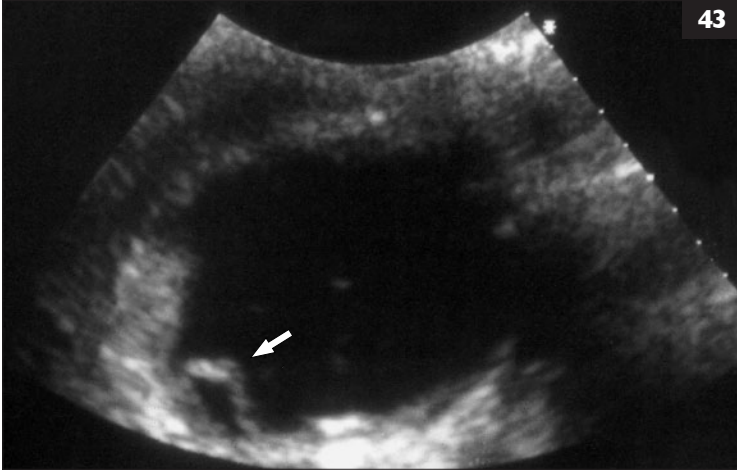
The underlying aetiology remains obscure, but there is an odontoclastic resorptive process which is typically seen at the cervical (cemento-enamel) junction. The presence of gingivitis has been suggested to be an initiating factor, promoting osteoclastic activity and the erosive process. The resorption is progressive, leading to pain and frequently resulting in fracture and loss of teeth. Some studies have suggested the disease begins in the tooth root rather than the subgingival cervical region, and is not associated with inflammation but possibly a dysregulation of the normal resorptive/repair process. Regardless of the precise aetiology, these lesions are quite distinct from dental caries. Radiographically, affected teeth show destruction of root and periodontal bony tissue, and there may be extensive resorption within the tooth but only a small visible surface lesion. Resorptive lesions are typically filled with granulation tissue.

Most advanced FORLs are probably best treated by tooth extraction. Attempts at restoration have generally been unsuccessful in the long term.

42 Lymphoplasmacytic gingivostomatitis is a common but poorly understood disease. There is often a superficial neutrophilic infiltrate, but the deeper tissues have a heavy lymphoplasmacytic infiltrate. Serum biochemistry commonly reveals a hyperproteinaemia and hyperglobulinaemia which is usually due to a polyclonal hypergammaglobulinaemia. Investigation of the antibody response has shown high titres to a number of normal oral bacteria (including common anaerobes found in the gingival sulcus). Numerous studies have also shown that the majority of affected cats have FCV infection and there is a clear epidemiological link between the two. A proportion of affected cats are also FIV-positive.

Affected cats appear to have an over-exuberant immune response to persistent antigenic challenge, most likely from the normal oral bacterial flora (particularly anaerobes) and/or persistent FCV infection. FIV infection may contribute to this.

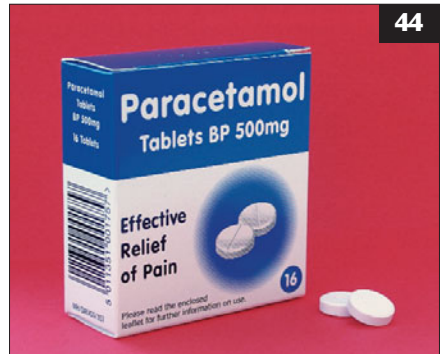Medical therapy is aimed at maintaining optimal oral hygiene (dental prophylaxis) to control bacterial numbers, but if this alone fails to control the signs then additional therapy with immunosuppressives to combat the inflammatory response is indicated (initially prednisolone, progressing to more potent drugs such as chlorambucil as necessary). Dental extraction (removing all the molars and premolars) has been reported to have a high efficacy rate in the management of this disease, presumably by reducing the anaerobic bacterial burden by removing the gingival sulcus. In many cats the disease can be controlled but not cured.



43 This image (43) was obtained by ultrasound examination of the left eye of a 12-year-old female neutered DSH cat.

- i. What is the arrow pointing to?
- ii. What is a working diagnosis given the information available at this stage?
- iii. What differential diagnoses need to be considered?
- iv. Which tests should be performed?

44. An owner brings a cat in with a history of lethargy. The owner administered half of one of the tablets shown (paracetamol or acetaminophen) (44) the previous day and that morning, but reports that the cat has deteriorated. What are the likely effects of the owner's action and what treatment should be administered?



43, 44: Answers

43 i. The arrow is pointing to a portion of bullous detachment of the retina. The detached retina appears thickened which is most likely to be because of intra-retinal oedema and/or haemorrhage. The optic nerve head is prominent, possibly due to papilloedema, and there is some peripapillary oedema adjacent to this. A small area of retinal detachment is also visible.

ii. Bullous retinal detachment with a variety of additional subtle retinal changes.

iii. Causes of retinal detachment include:

- Systemic hypertension (serous or haemorrhagic detachment).
- Inflammatory disease, e.g. infectious causes (FIP, FeLV, FIV, toxoplasmosis, cryptococcosis), immune-mediated panuveitis.
- Neoplasia.
- Subretinal haemorrhage following trauma, vasculitis or a coagulopathy.
- Hyperviscosity, e.g. due to polycythaemia.

iv. A thorough history and clinical examination should be performed in order to look for evidence of trauma (e.g. scuffed nails), systemic hypertension (e.g. ocular changes consistent with this, raised SBP), causes of systemic hypertension (e.g. thyroid nodule), and other evidence of systemic diseases listed above. Haematology, biochemistry, virus screening tests, coagulation profiles, and other investigations (e.g. radiography, ultrasonography to identify neoplasia) may be required to diagnose some of the other causes listed above.

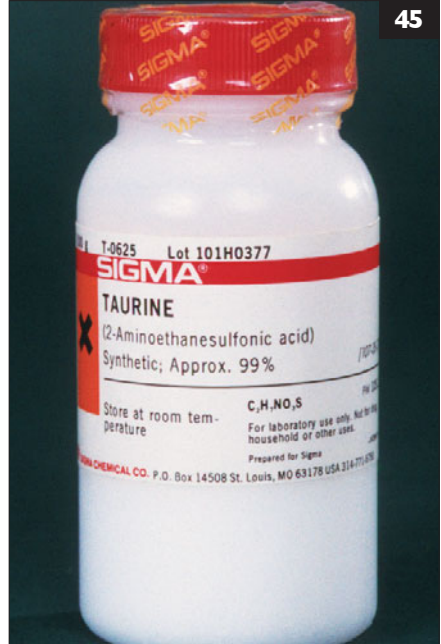44 Paracetamol (acetaminophen) is highly toxic to cats, with doses of 50–60 mg/kg producing toxic effects. Paracetamol is metabolized in the liver by conjugation to inactive glucuronide and sulphate metabolites. Oxidation via the cytochrome P-450 system also occurs, producing a highly toxic metabolite (NAPQI) that is inactivated by glucuronidation with glutathione. Due to the relative defectiveness of the feline glucuronidation pathway, cats are very susceptible to paracetamol intoxication. Accumulation of NAPQI causes hepatocyte injury and death, erythrocyte oxidative stress (haemolysis and Heinz body formation), and methaemoglobin production.

Clinical signs of intoxication include depression, weakness, dyspnoea, cyanosis, jaundice, vomiting, methaemoglobinaemia (chocolate-brown blood colour), haemoglobinuria, bilirubinuria, facial and paw oedema, liver necrosis, and death.

Treatment involves induction of emesis and/or gastric lavage for recent ingestion, followed by use of activated charcoal (1–3 g/kg). NAC can provide an alternative substrate for conjugation of metabolites and help replenish glutathione. 5% NAC is given at 140 mg/kg, then three to five treatments at half this dose every 4 hours. It can be given orally or slowly IV. Cimetidine (5–10 mg/kg orally or IV every 8 hours) may help by inhibiting cytochrome P-450 activity. Additional supportive therapy with oxygen, blood transfusions or ‘Oxyglobin’, and antioxidants (e.g. SAME) may be required.

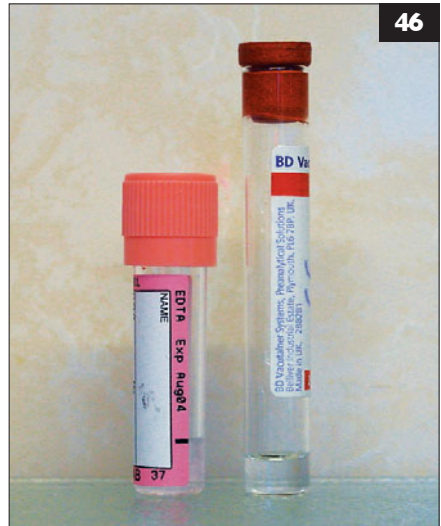45 Taurine (45) is an essential micro-nutrient in cats.

- i. What is taurine and what is its physiological role?
- ii. What are the common clinical signs associated with taurine deficiency?
- iii. How can taurine status be assessed?



46 The picture (46) shows CSF collected from a cat with neurological disease.

- i. What diagnostic tests should be performed on the CSF?
- ii. Are there any contraindications to collection of CSF?



45, 46: Answers

45 i. Taurine is classified as a β -amino sulphonic acid; it is not, strictly speaking, an amino acid and it does not form part of polypeptides or proteins. Taurine is produced from the metabolism of sulphur-containing amino acids such as methionine and cysteine, but the enzymes responsible for this have minimal activity in cats, so cats rely on exogenous sources of this nutrient. Many species use either taurine or glycine to conjugate bile acids prior to excretion in the bile, but cats only conjugate to taurine resulting in an obligatory loss of (and therefore requirement for) taurine.

Taurine is thus an essential nutrient for cats, and is known to have a number of physiological roles including acting as an antioxidant. Within the retina, taurine is believed to stabilize cell membranes, and in the heart, taurine is involved in regulation of calcium flux through ion channels. Taurine also affects reproduction and is thought to act as a neurotransmitter in the foetus.

ii. The classic syndromes of taurine deficiency occur after prolonged deprivation and include progressive central retinal degeneration and/or dilated cardiomyopathy. While the former is permanent, the latter may be reversible with taurine supplementation. Reproductive failure and foetal abnormalities may also occur in queens that are taurine deficient.

iii. Taurine status is best assessed using a whole blood assay, as plasma taurine can be affected by recent feeding or haemolysis.

46 i. The CSF should be collected into EDTA tubes for cytology and plain tubes for biochemical analysis. (0.5–1 ml for each of these). It is important to process the sample quickly since cellular degeneration will make interpretation difficult. It is therefore recommended that cytological analysis takes place within 30 minutes of sampling. CSF protein levels are more stable. If a bacterial infection is suspected then a Gram-stained smear may be helpful in detecting microorganisms. Culture is indicated where organisms have been seen on CSF cytology but false-negative results are common. If cryptococcosis is suspected then a drop of India ink may be mixed with CSF sediment allowing detection of encapsulated yeasts. CSF analysis may be performed by commercial veterinary laboratories, veterinary school cytologists, or pathologists and it may be possible to use local hospital laboratories on an individual basis.

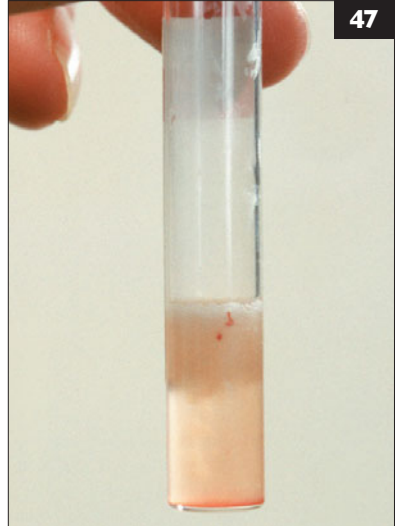
ii. CSF collection is not advised in the following cases:

- Known or suspected cases of increased intracranial pressure, e.g. cranial trauma. CSF collection in these cases may precipitate herniation of the brain through the foramen magnum.
- Fractures, dislocations, or bony lesions involving structures adjacent to the site of CSF collection.
- Known or suspected intracranial haemorrhage where sampling may precipitate further haemorrhage or herniation.

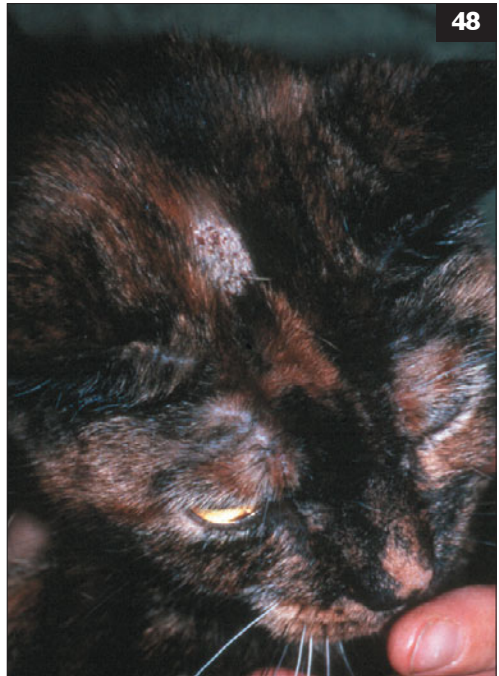
Normal CSF characteristics

Gross appearance	Clear and colourless
Nucleated cell count	<6 cells per mm ³ (<6 × 10 ⁶ /l)
Protein	<30 mg/dl (<300 mg/l)

47 Bronchoalveolar lavage fluid (47) has been retrieved from a 5-year-old Siamese cat with a history of chronic, persistent coughing and a marked bronchial pattern on radiography. Cytology revealed mainly neutrophilic inflammation and culture of the fluid yielded a scanty growth of *Mycoplasma felis*. What is known about the potential role of mycoplasmas in feline lower respiratory tract disease and how should this case be managed?



48 *Microsporium canis* was identified in fungal culture from hair pluckings taken from the periphery of the lesion visible in this cat (48), which came from a multi-cat household where several other cats were also showing characteristic skin lesions. What treatment regime should be used to control the dermatophyte infection in such a situation?



47, 48: Answers

47 The significance of *Mycoplasma* spp. in bronchoalveolar lavage fluid from cats is controversial and their role as feline pathogens not well characterized. From several studies it appears that *Mycoplasma* spp. are commonly found in the upper respiratory tract of cats (especially oropharynx, but also the nose and eyes) and they are probably a normal commensal organism at this site. However, they are less frequently isolated from the lower respiratory tract where their detection may be significant.

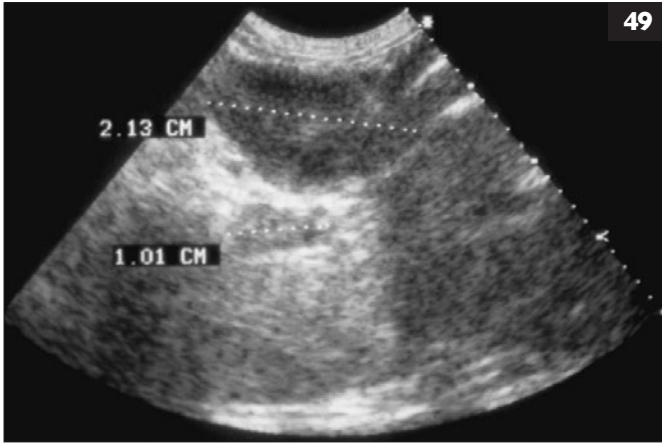
Although mycoplasmas have often been regarded as secondary ‘opportunistic invaders’ in feline respiratory disease there is recent evidence that they may also be primary pathogens and may be a potential cause of chronic bronchial disease and pneumonia. There are now many reports of *Mycoplasma* spp. being isolated in pure culture from some of these cases and/or cats showing clinical improvement to appropriate therapy. There is growing evidence in human medicine that *Mycoplasma* spp. may also have a role in provoking and/or exacerbating asthma.

Although the role of *Mycoplasma felis* in the respiratory disease of this cat would be unknown, its isolation is sufficient grounds for trial therapy. Drugs known to have good anti-mycoplasma activity include macrolides and azalides (e.g. erythromycin, clindamycin, azithromycin), tetracyclines (e.g. doxycycline), and fluoroquinolones.

48 The major infectious particles of dermatophytes are arthrospores, present around infected hairs. Transmission can occur through direct contact with an infected cat, or through contact with a contaminated environment (spores can survive for 1–2 years).

In catteries, treatment must be aimed at eliminating the organism from the environment and the cats, but this can be extremely difficult, time consuming, and expensive. Rather than segregating infected and uninfected cats, it is better to treat all the cats in the household/cattery. Ideally the cats should be treated with a combination of systemic and topical therapy. Systemic therapy with an efficacious anti-fungal agent (e.g. itraconazole) should be used in all cats where possible (avoiding use in pregnant and very young cats). Studies have clearly demonstrated the high efficacy of twice weekly shampooing with an anti-fungal shampoo (e.g. a combination of chlorhexidine and miconazole); this significantly reduces the shedding of viable arthrospores into the environment and may also enhance clinical recovery. If a shampoo cannot be used, lesional therapy with an anti-fungal cream may also be of value.

Environmental control should incorporate regular and thorough vacuum cleaning (ideally followed by burning of the vacuum bag), disinfection of surfaces where possible (e.g. with glutaraldehyde), and possibly steam-cleaning soft furnishings. After therapy of the cats for 2–4 weeks (when new healthy, uninfected hair growth should be visible), careful clipping of hairs around the lesions can also be performed to remove remaining arthrospore-infected hairs. Monitoring efficacy with Wood’s lamp examination and fungal culture is needed.

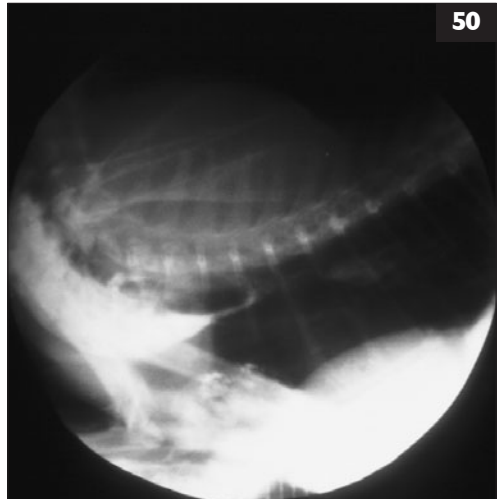


49 Adrenal ultrasonography was performed in a 7-year-old female neutered DSH cat. The adrenal glands, measured, are indicated in the picture (49).

- i. What is the assessment of the adrenal glands?
- ii. What differential diagnoses need to be considered?

50 A 6-month-old neutered male Balinese cat presents with recent onset persistent regurgitation after feeding.

- i. What are the differential diagnoses?
- ii. What can be seen on the contrast oesophagram taken after the cat was offered food mixed with barium (50)? Suggest a likely diagnosis.
- iii. What would be a suitable treatment regimen?



49, 50: Answers

49 i. The adrenal glands differ in size. One adrenal gland has normal dimensions (1.01 cm long); the other adrenal gland is enlarged.

ii. Differential diagnoses which need to be considered include:

- Neoplasia of the adrenal gland, e.g. adenoma, carcinoma, teratoma.
- Hyperplasia of the adrenal gland; unlikely since the disease is unilateral.
- Other causes of unilateral adrenomegaly, e.g. haematoma, abscess, cyst. The ultrasound appearance can be helpful in diagnosing these causes. Organizing haematomas and inspissated pus can have a similar echogenicity to soft tissue but cystic fluid is usually very hypoechoic.

HAC, hyperaldosteronism, hyperprogesteronism, and pheochromocytoma are conditions which can be caused by adrenal tumours.

50 i. There are many differential diagnoses for regurgitation, but they can broadly be divided into obstructive disorders (luminal, mural, and extramural), inflammatory disease, and motility disorders.

- Luminal causes include foreign bodies and oesophageal diverticulae, mural causes include neoplasia and strictures, while extramural obstructions include anterior thoracic masses and vascular ring anomalies (persistent right aortic arch).
- Oesophagitis can occur secondary to persistent vomiting, secondary to reflux of gastric juice, secondary to hiatal hernia, and following ingestion of caustic substances.
- Oesophageal motility disorders include primary megaesophagus, myasthenia gravis, dysautonomia, and polymyopathy.

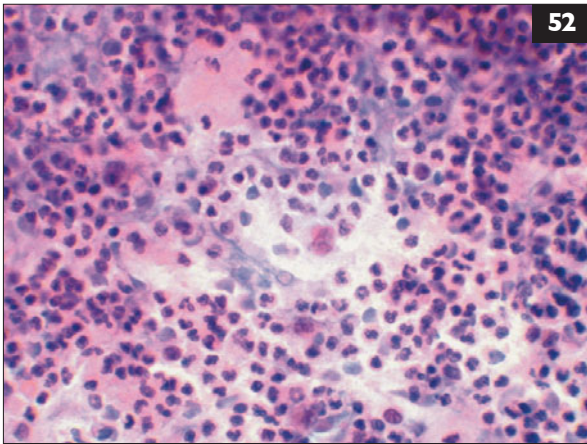
Of these potential causes, acute onset regurgitation in a young cat would be most commonly due to oesophagitis, oesophageal stricture, foreign body, anterior mediastinal lymphoma, primary megaesophagus, and persistent right aortic arch. The recent onset of signs would suggest the latter two are less likely.

ii. The spot fluoroscopy film demonstrates accumulation of a barium bolus in the cervical and proximal thoracic oesophagus, cranial to a tapered area of barium typical of a stricture. The narrowed area is too far cranial to be due to a persistent right aortic arch. This cat had been anaesthetized for castration 2 weeks previously, and this was a post-anaesthetic (reflux) stricture.

iii. Optimal treatment for this case would be repeat balloon dilation of the stricture (several dilations may be required initially at 2–3 day intervals but less frequently as the condition improves), combined with medical therapy. This comprises a mucosal protectant (e.g. sucralfate), an H₂-blocker (e.g. famotidine), anti-inflammatory doses of prednisolone, possibly colchicine (to inhibit fibrosis and stricture reformation), and a low-fat diet to encourage gastric emptying.

51 A 7-month-old male DSH cat (51) is presented for evaluation. The owner is concerned that the kitten is very small, seems generally lethargic, mentally dull and suffers from constipation. She also reports that she has not been able to litter train him.

- i. What obvious abnormalities can be seen from the picture?
- ii. What is the main differential diagnosis?
- iii. How can this suspicion be confirmed?
- iv. What treatment can be offered?
- v. What is the prognosis?



52 A 3-year-old neutered female DSH cat presents with a 10-day history of productive coughing and progressive, mainly expiratory, dyspnoea. Radiography reveals patchy bronchoalveolar infiltrates, mainly in the cranioventral lung fields. The picture (52) shows the cytological appearance of a bronchoalveolar lavage conducted under general anaesthesia.

- i. What can be seen on the cytology?
- ii. What does this suggest as the cause of the cat's disease and how should management be approached?

51, 52: Answers

51 i. The kitten is disproportionately stunted with very short legs and a short body. The head is quite large and broad.

ii. Congenital hypothyroidism is the most likely possibility given the history of mental retardation, disproportionate stunting, and constipation which are all common features of this condition.

iii. Routine laboratory profiles may reveal hypercholesterolaemia and mild anaemia although these are not consistent findings. Basal serum total T4 levels are low normal or below normal in affected cats. A TRH stimulation test is needed to confirm the diagnosis. Serum is collected for measurement of total T4 before, and 4 hours after, administration of 100 µg of TRH intravenously. Hypothyroid kittens have a low serum total T4 which does not increase on stimulation.

iv. Clinically hypothyroid cats can be treated with L-thyroxine at 10–20 µg/kg orally daily.

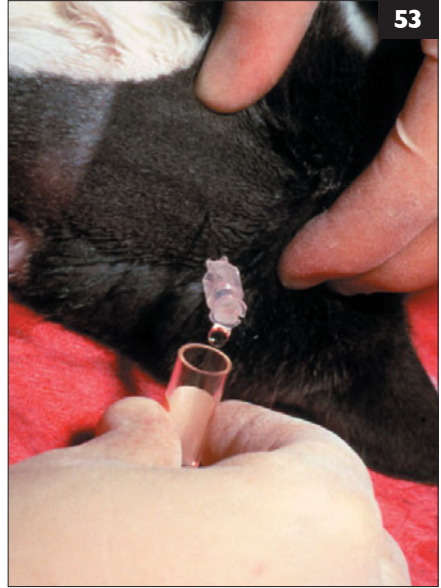
v. The prognosis depends on the severity of disease and when treatment is instituted. Even when treatment is prescribed at an early age, it is not always effective in resolving the clinical signs and some owners elect for euthanasia in cats where the quality of life is considered to be poor.

52 i. The cytology (if representative) demonstrates a highly cellular lavage fluid with a proteinaceous background. There are abundant neutrophils present; this indicates the presence of predominantly neutrophilic inflammation. Some of these neutrophils are degenerate suggesting an underlying infectious process. On higher magnification, both extra- and intracellular bacteria could be seen.

ii. This appearance would be typical of a bronchopneumonia lavage fluid. There is unequivocal evidence of bacterial infection with intracellular bacteria and degenerate neutrophils, and this is also consistent with the radiographic appearance. This could be a primary bacterial infection, or it could be secondary to another disease process (e.g. foreign body inhalation, aspiration pneumonia, primary viral infection, FIV infection); thus, in addition to treating the pneumonia, consideration of underlying causes is necessary.

Antibiotics should ideally be based on culture and sensitivity testing, but empirical ‘four quadrant’ bactericidal therapy is required at least initially (covering Gram-positives, Gram-negatives, aerobes, and anaerobes) as mixed infections are common. In addition, good hydration should be maintained (to reduce the viscosity of secretions), and oxygen therapy may be required in severe cases. Nebulization with sterile saline (using a nebulizer in a semi-closed cage) for approximately 10 minutes three to four times daily can also be beneficial in decreasing the viscosity of secretions, and, if tolerated, this can be combined with gentle coupage. Bronchodilators (terbutaline or theophylline systemically, salbutamol by inhalation) may help.

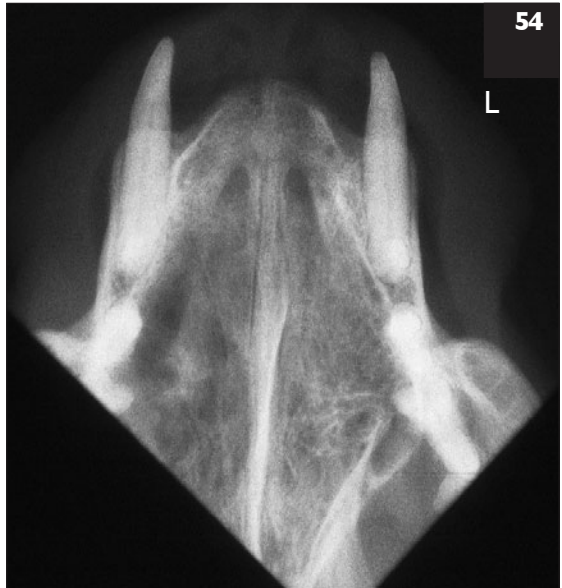- 53 i. What procedure is being performed in this cat (53) and what are the indications for this procedure?
 ii. How is this procedure performed?



53

54 A 6-year-old neutered male DSH presents with a 6-week history of unilateral nasal discharge (mucopurulent) and productive sneezing. An intra-oral nasal radiograph is taken (54).

- i. What can be seen on this radiograph?
 ii. What is the likely diagnosis/differential diagnosis and how should this case be managed?



54

L

53, 54 Answers

53 i. A cisternal puncture is being performed in order to obtain a sample of CSF (CSF tap). In most cats, 1–2 ml of CSF can be collected from this site. CSF analysis is useful where differential diagnoses include infectious causes (e.g. cryptococcus, FIP, toxoplasmosis), neoplasia (e.g. lymphoma), previous trauma and haemorrhage (look for xanthochromia), and inflammatory disease (e.g. sterile meningitis). Inflammatory, infectious, and neoplastic conditions often result in an increase in the number of cells and amount of protein present. Neoplastic cells may occasionally be seen in CSF.

ii. The anaesthetized cat is intubated to allow administration of oxygen and anaesthetic gases and placed in right lateral recumbency. The hair over the occipital and cervical region is clipped and this area is aseptically prepared. The neck is flexed so that the head is at a 90 degree angle to the neck, with the line of the nose and the occipital crest parallel to the table. Palpating the external occipital protuberance with the middle finger, the cranial border of the wings of the atlas with the thumb, the index finger is placed in the midline halfway between these first two points. A 22 gauge 1.5 inch spinal needle is introduced perpendicular to the skin at the point where the index finger was placed and directed slightly cranially. The stylet is removed once the needle is fully through the skin allowing the needle to be gently advanced. Once the needle enters the subarachnoid space there is a sudden loss of resistance after which CSF is seen flowing up the needle. Where frank blood is seen, the needle should be withdrawn and the procedure repeated using a midline approach, since the cervical venous sinuses which run on either side of the spinal cord are likely to have been penetrated. If bone is hit then the needle should be redirected more cranially or caudally until the subarachnoid space is entered. Between 1 and 2 ml of CSF should be collected allowing the fluid to drip into collection tubes. If the flow of CSF is very slow then gentle suction using a 1 ml syringe can be performed.

54 i. The radiograph demonstrates a normal appearance to the left nasal chamber with good definition of the turbinate bones. The right nasal chamber contains an area of lucency, primarily medial to the second maxillary premolar. There is some mild increase in soft tissue density medially and rostrally to the area of lucency consistent with some accumulation of nasal discharge.

ii. The appearance is highly suggestive of periapical loss of bone due to a tooth root abscess. Additional radiographs would be required to confirm this (as was the case in this cat); other differentials would include fungal infection and neoplasia.

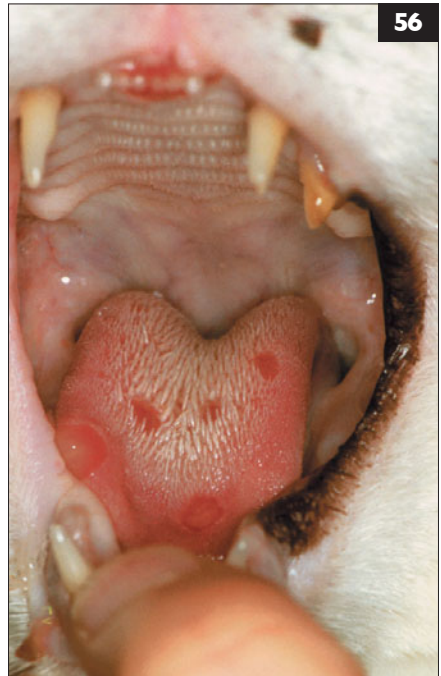
In any cat with chronic nasal discharge, particularly if it is unilateral, the possibility of underlying dental disease and tooth root abscess or oronasal fistula should be considered. Thorough examination of the teeth, probing of the gingival sulci, and radiographs are therefore an important part of the evaluation and disease should be treated as appropriate.

55 What are the implications for the immune status of a kitten (55) that is deprived of colostrum/milk for the first 24 hours of life? What practical measures can be taken to overcome this?



56 A 5-year-old DSH cat is presented which has been depressed, anorexic, and showing upper respiratory tract signs (sneezing, nasal discharge) for the last 2 days. On clinical examination, the cat is pyrexic and has several small lingual ulcers (56).

- i. What is the most likely diagnosis?
- ii. What are the most likely causal infectious agents?
- iii. What treatment is recommended?
- iv. How can this illness be explained in a fully vaccinated cat?



55, 56: Answers

55 Failure of passive transfer of maternal antibodies is a well recognized cause of morbidity and mortality in neonates. In cats, the vast majority of antibodies are transferred to the kitten post-partum via the colostrum, such that newborn kittens have undetectable serum IgG concentrations prior to suckling. The intestine of the neonate is uniquely permeable, and this allows the direct absorption of antibodies when kittens suck immediately after birth. However, this permeability only lasts 24 hours, following which no further antibodies will be absorbed; in addition to this, the concentration of antibodies in colostrum declines dramatically 24–48 hours after birth.

Thus kittens deprived of colostrum in the first 24 hours of life will have virtually no maternal-derived antibodies and be at significant risk of disease. However, studies have shown that subcutaneous administration of adult cat serum at a dose of approximately 150 ml/kg (approximately 15 ml for a newborn kitten) can achieve serum IgG concentrations in a kitten equivalent to that seen following normal suckling. This is a simple and practical way to overcome lack of passive transfer of antibodies, although it is important to ensure the serum is from a matched blood type (to avoid erythrolysis) and that it is free of infectious diseases.

56 i. The acute onset of clinical signs and pyrexia are suggestive of an infectious cause, therefore cat ‘flu’ is the most likely diagnosis.

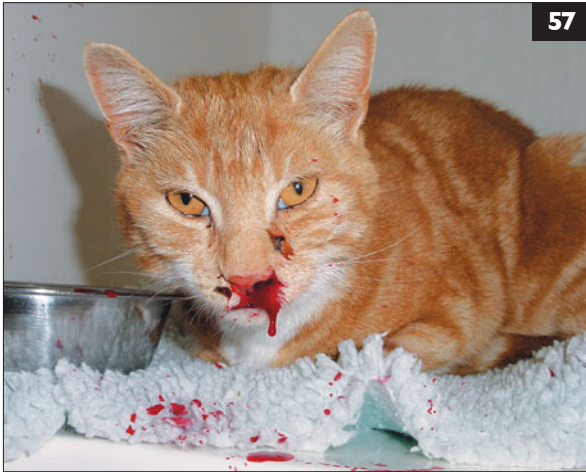ii. FHV and FCV are the most likely causal agents. FCV is more frequently associated with tongue ulcers although both viruses can cause all of the signs described in this case.

iii. Supportive care of the individual cat is a priority and may include:

- Antibiotic cover for secondary bacterial infections.
- General nursing care, intravenous fluid therapy, and nutritional support.
- Steam therapy and/or nebulization.
- Use of antiviral agents such as interferon has been shown to be helpful in experimental FHV infection and may be of benefit.
- If the cat is hospitalized, barrier nursing is required in order to reduce the risk of spreading infection to other hospitalized patients.

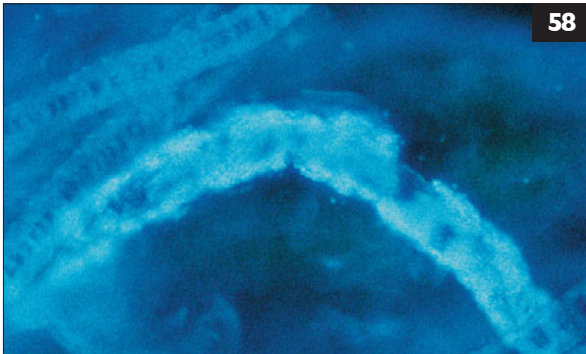
iv. No vaccine offers 100% protection and potential causes of ‘vaccine failure’ include:

- Overwhelming challenge.
- Immunosuppressed individual (due to other disease, e.g. FIV, FeLV, or chemotherapy treatment).
- The cat was incubating the disease when vaccinated.
- Many different isolates of FCV exist in the field and the vaccine virus strains used will not provide cross protection for all of these.
- Clinical signs may not be caused by FCV or FHV infection.
- The cat was already a carrier of FCV or FHV and shedding of virus was associated with recurrence of clinical signs of disease.



57 A 4-year-old DSH cat is presented with a 2-week history of progressively worsening sneezing and epistaxis (57). Initially the owner reports epistaxis from the left nostril only but now both nostrils are affected.

- i. What differential diagnoses should be considered?
- ii. What is a possible approach to managing this case?



58 The picture (58) shows fluorescent microscopy of hair pluckings from a cat, stained with calcofluor white.

- i. What does this picture demonstrate?
- ii. How else could this condition be identified and what are the advantages and disadvantages of the various techniques?

57, 58: Answers

57 i. Differential diagnoses for epistaxis include:

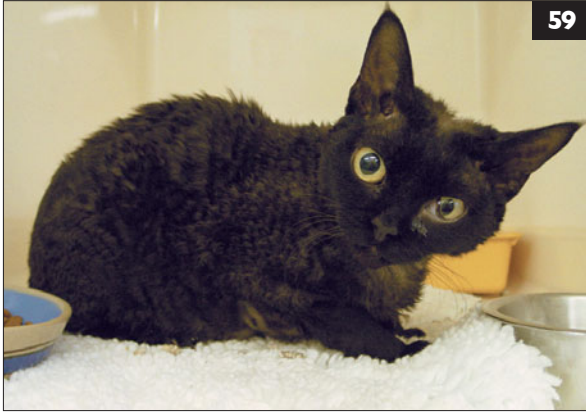- Bleeding disorder, e.g. thrombocytopenia, thrombocytopathy, vasculitis.
- Clotting disorder, e.g. rodenticide toxicity, liver disease, DIC.
- Trauma.
- Foreign body.
- Neoplasia.
- Hypertension.
- Fungal rhinitis, severe chronic rhinitis, or bacterial rhinitis.
- Hamartomatous nasal polyp.

ii. Haematology should be performed in order to assess the platelet count and look for evidence of anaemia. Serum biochemistry including pre- and post-prandial bile acids enables assessment of liver function. Clotting profiles (PT, APTT, fibrin degradation products, fibrinogen) and systemic blood pressure should be assessed. Nasal radiography, rhinoscopy, nasal flushes, and biopsies may help to identify some of the nasal causes of disease. Whilst awaiting results, the cat should be kept calm and supportive treatment including blood transfusion administered if needed.

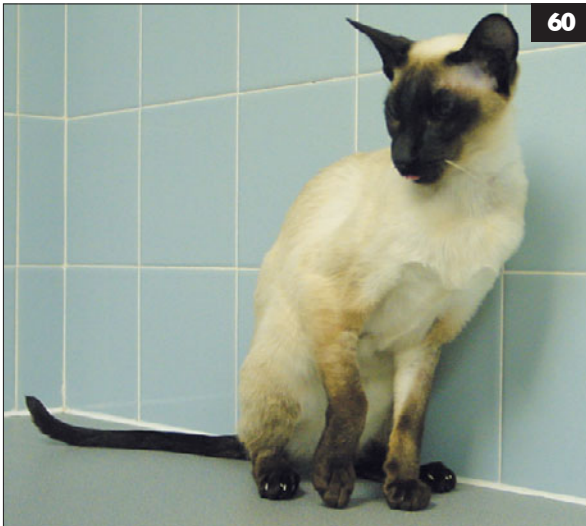58 i. Calcofluor white binds to polysaccharides in fungal cell walls causing them to fluoresce under appropriate lighting. This picture demonstrates a hair shaft surrounded by a mass of arthrospores and is diagnostic of an ectothrix dermatophyte infection, most likely *Microsporum canis*.

ii. The three tests most widely used for dermatophyte diagnosis are:

- Wood's lamp illumination: hairs infected with *M. canis* may produce a characteristic yellow-green fluorescence and thus examination of lesions or plucked hairs can be valuable. However, of the dermatophytes that infect cats and dogs, only *M. canis* fluoresces and only a reported 50–60% of *M. canis* infections result in fluorescence. It is valuable as a rapid screening test, but the lamp should be warmed for 5–10 minutes prior to use, and the examination should take place in a darkened room. Positive results should be confirmed by other tests.
- Direct microscopy: examination of hair/scale is simple and valuable. It is rapid and provides unequivocal evidence of dermatophytosis if infection is identified. Positive diagnoses are typically achieved in around 40–60% of infections. Fluorescence microscopy with calcofluor white increases the sensitivity.
- Fungal culture is generally regarded as the 'gold standard', and culture of representative material from a lesion, or by brushing the coat with a sterile brush is sensitive and allows speciation of the dermatophyte. Passive carriage of spores can lead to occasional 'false-positive' results, and prior treatment can lead to 'false-negative' results, emphasizing the value of using all three techniques.



59 What neurological abnormalities are present in this 4-year-old Devon Rex cat (59)? List the major differential diagnoses.



60 A 7-year-old male neutered Siamese cat (60) is reported by its owner to be drinking excessively.

- i. What water consumption is considered to be abnormally high?
- ii. What are the major differential diagnoses for polydipsia in cats?
- iii. What is a possible initial diagnostic plan?

59, 60: Answers

59 The cat has a left-sided head tilt and left-sided Horner's syndrome (third eyelid protrusion, miosis and ptosis affecting the left eye). The major differential diagnoses for these signs are otitis media/interna caused by inflammatory disease, neoplasia (e.g. lymphoma), trauma, or a polyp. Assuming that the disease is not multifocal, idiopathic vestibular disease is not a differential diagnosis since the cat has Horner's syndrome.

60 i. A water intake >60–100 ml/kg per day is generally considered to be abnormal. Water consumption in cats receiving a totally wet diet is normally less than in those receiving a dry diet although upper limits of normality are not well defined in cats.

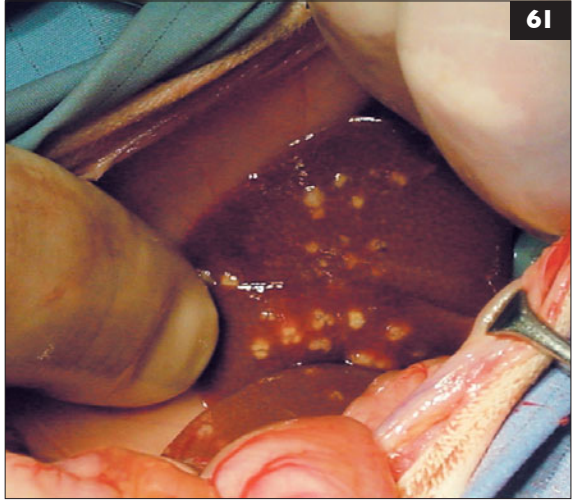
ii. Major differential diagnoses are endocrine and renal disorders:

- Endocrine causes:
 - Hyperthyroidism.
 - Diabetes mellitus.
 - Acromegaly (may be associated with secondary diabetes mellitus which causes the polyuria and polydipsia).
 - HAC (may be associated with secondary diabetes mellitus or may cause polyuria and polydipsia without this).
 - Central diabetes insipidus.
 - Hypoadrenocorticism.
- Renal causes:
 - ARF.
 - CRF.
 - Pyelonephritis.
 - Nephrogenic diabetes insipidus.
 - Primary renal glucosuria.
- Electrolyte disturbances:
 - Hypercalcaemia.
 - Hypokalaemia.
- Other causes include:
 - Hepatic disease.
 - Polycythaemia.
 - Iatrogenic causes (e.g. diuretic therapy, phenobarbitone, salt supplementation).
 - Psychogenic polydipsia has not been well documented in cats.

iii. The most important initial step would be quantification of water intake and confirmation of polydipsia. Clinical examination and thorough history taking may guide subsequent tests but urinalysis, routine haematology, and biochemistry are likely to be required.

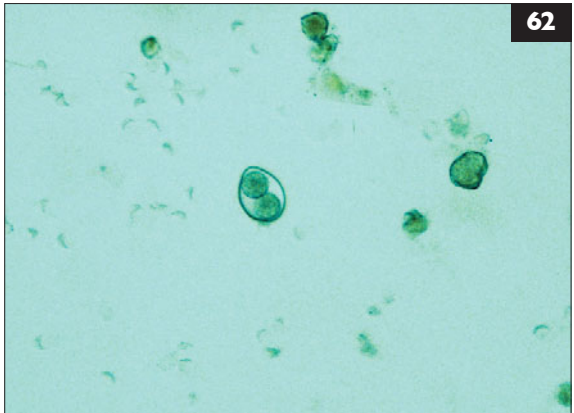
61 An exploratory laparotomy is performed on an 18-month-old Oriental cat which has been presented with a 1-month history of progressively worsening anorexia, abdominal discomfort, lethargy, and weight loss.

- i. What abnormalities are evident on examination of the liver (61)?
- ii. What are the differential diagnoses based on this picture?
- iii. What is a possible diagnostic plan?



62 A 2-year-old DSH cat presents with diarrhoea and mild haematochezia of 5 days' duration. Faecal culture reveals *Campylobacter jejuni*, and microscopy of faecal flotation reveals many of the objects shown in the picture (62).

- i. Identify the structure in the picture (it measures approximately 50 μm in length).
- ii. What is the significance of the findings and how should the cat be treated?



61, 62: Answers

61 i. Multiple cream coloured nodules are visible over the surface of the liver.

ii. Differential diagnoses include:

- Inflammatory and infectious causes e.g. FIP pyogranulomatous lesions, hepatic abscessation, granulomas associated with bacterial causes (e.g. mycobacterial infections).
- Neoplasia.
- Regenerative hepatic nodules.
- Others, e.g. areas of calcification, fibrin deposits on the surface of the liver.

iii. A liver biopsy incorporating one or more of these lesions is required in order to make a diagnosis. Biopsy tissue should be submitted for histopathology and bacteriology. Ideally, a portion of tissue should be frozen at -20°C (-4°F) in case future submission for specialist mycobacterial culture or PCR is required.

In this case, histopathology revealed FIP as the cause of the disease.


62 i. The picture shows a typical coccidian oocyst. The two species most commonly affecting cats are *Cystoisospora (Isospora) rivolta* and *Cystoisospora (Isospora) felis*. The latter of the two has larger oocysts (measuring 40–50 μm in length) and the former are slightly smaller (20–30 μm).

ii. The significance of both findings (*Cystoisospora felis* and *Campylobacter jejuni*) is uncertain. Both can be primary pathogens, but may also be found in healthy cats. Infection with coccidian parasites is extremely common in cats, especially in kittens from crowded environments. The life cycle is direct or indirect (via paratenic hosts), and replication occurs in the enterocytes of the distal small intestine. Sporulation of oocysts occurs within 24–48 hours, after which they are infectious. Severe infections in kittens are more likely to cause clinical signs and in this case, the age of the cat suggests that the infection may be coincidental. Where warranted, suggested treatments include sulphonamides (sulfonamides) and sulphonamide (sulfonamide)/trimethoprim combinations, amprolium, and furazolidone, although the response is variable.

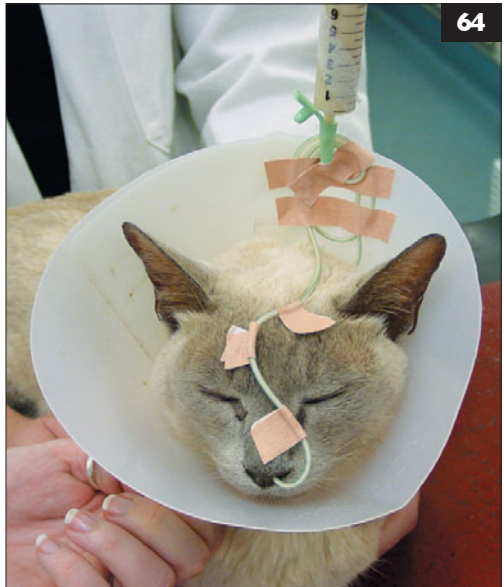Campylobacter jejuni can be a commensal, a secondary pathogen, or a primary pathogen in the gastrointestinal tract. As a primary pathogen it is commonly associated with acute haemorrhagic diarrhoea, and so could be responsible for the clinical signs in this case. Treatment is probably also justified based on the fact that the organism is a zoonosis. Unlike *Salmonella* infections, there is little evidence that treatment will induce or prolong a carrier state. Treatment should ideally be based on results of sensitivity testing, but empirical treatment is possible with erythromycin, clindamycin, enrofloxacin, or doxycycline.

63 This blood (63) was collected from a 6-week-old kitten that had been fasted for 7 hours before sampling.

- i. Describe the appearance of the blood sample.
- ii. What are the potential causes of the appearance?
- iii. What other investigations should be performed?



- 64 i. What technique is being performed here (64)?
- ii. How should it be performed?



63, 64: Answers

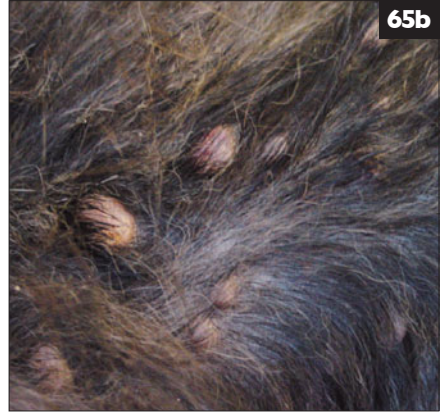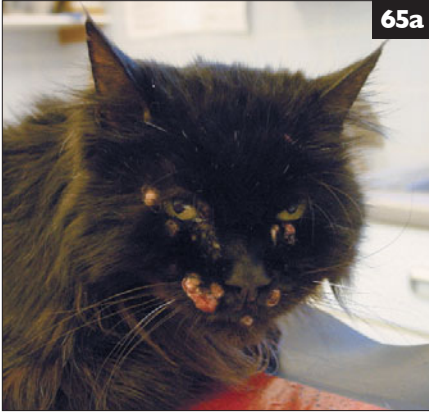63 i. The appearance is similar to strawberry milkshake or creamy tomato soup.
 ii. The appearance is suggestive of profound lipaemia (visible when the triglyceride content is $>3.5\text{--}4.5$ mmol/l [$300\text{--}400$ mg/dl]). Chylomicrons and VLDLs are large triglyceride-containing lipoproteins which give the milky/lactescent appearance.
 iii. Affected kittens are likely to have lipaemia retinalis (white retinal vessels, seen when the serum triglyceride is >11 mmol/l [1000 mg/dl]). Chylomicrons present will separate in serum left to stand for longer than 6 hours at 4°C (38°F), rising to the top of the serum forming a cream layer, whereas VLDLs remain suspended. This observation can be used to assess whether the lipaemia is due to hyperchylomicronaemia and/or excessive levels of VLDLs. Lipoprotein electrophoresis and other specialist assays can be performed to obtain a full lipid analysis of the sample.

Causes of hyperlipoproteinaemia in cats are:

- Physiological causes, e.g. post prandial, excessive dietary lipid intake.
- Secondary to other diseases, e.g. pancreatitis, diabetes mellitus, HAC, nephrotic syndrome, neoplasia, cholestatic liver disease, hypothyroidism.
- Primary abnormality of lipoprotein metabolism, e.g. familial hyperchylomicronaemia due to a deficiency of lipoprotein lipase.
- Hyperchylomicronaemia has been reported as a transient abnormality in anaemic kittens with either heavy flea burdens and/or FIA. Investigation of this kitten identified anaemia related to *Mycoplasma haemofelis* infection (FIA).

64 i. The cat is being fed a liquid diet via a naso-oesophageal (nasogastric) feeding tube.
 ii. Naso-oesophageal feeding tubes are easy to place in conscious cats and allow nutritional support of anorexic patients. Local anaesthetic drops (0.5% proxy-metacaine) are applied to the nostril before placing a 4–8 fg tube. The lubricated tube is passed through the nostril in a ventromedial direction until it reaches the 8th–10th rib space. When correctly placed, the tube should terminate in the distal oesophagus rather than the stomach to reduce the risk of gastric reflux. Before the tube is secured in place, an empty syringe should be attached to the tube and aspirated. After a small amount of air, a vacuum should be encountered if the tube is in the oesophagus. 5–10 ml of sterile water or saline can then be injected down the tube and the cat should not cough. Once it is established that the tube is in the oesophagus, it can be secured in place by supergluing tape attached to the tube to the bridge of the nose and top of the cat's head. Alternatively, the tube can be sutured in place although this requires sedation or anaesthesia. An Elizabethan collar is placed to stop the cat from pulling the tube out.

The cat should be fed one-third of its calculated energy requirements on the first day, two-thirds on the second day, and all of the requirements from the third day onwards. Proprietary liquid foods designed for cats should be used.



65 A 5-year-old female neutered domestic longhaired cat is presented for investigation of skin disease. The pictures show the cat's head (65a) and an area of the lateral trunk (65b).

- i. Describe the lesions that can be seen.
- ii. What are the differential diagnoses?
- iii. How should diagnosis of this case be approached?

66 The fluid in the bottle (66) has been drained from the pleural space of this 7-year-old neutered male domestic longhaired cat.

- i. What is this fluid?
- ii. What routine laboratory tests would confirm the diagnosis?
- iii. What potential underlying causes should be considered for this cat?
- iv. If additional investigations yielded no specific identifiable cause, what should the approach be to therapy?



65, 66: Answers

65 i. Multiple cutaneous nodules of varying size are visible on the cat's face and body. Some of the facial nodules appear erythematous and/or ulcerated.

ii. Differential diagnoses include:

- Neoplasia, e.g. mast cell tumour, epitheliotropic lymphoma, histiocytoma (rarely causes multiple nodules), multiple papillomas, amelanotic melanomas.
- Fungal infection, e.g. cryptococcosis, histoplasmosis, sporotrichosis.
- Bacterial infections, e.g. mycobacterial infections, tularaemia, feline leprosy.
- Other possibilities, e.g. follicular cysts, panniculitis.

iii. Investigation of nodular skin disease should include biopsy for histology (including special stains for fungal and bacterial organisms) and bacterial and fungal culture. Fine needle aspirate cytology may also be of some diagnostic value.

In this case, biopsy confirmed multiple mast cell tumours.

66 i. The milky appearance of this fluid suggests it is chyle, a chylomicron-rich fluid that has leaked from the thoracic duct. Chylous effusions have a milky-white appearance, although they can be blood-tinged causing a pink ('strawberry milkshake') appearance.

ii. Definitive diagnosis of chylothorax is achieved by demonstrating chylomicrons on agar lipoprotein electrophoresis. More practically, comparing chyle with serum reveals triglyceride levels are typically higher in chyle, and cholesterol levels equivalent to or lower in chyle compared with serum. Cytology usually reveals a predominance of mature lymphocytes, and there may be lipid-laden macrophages.

iii. Recognized causes of chylothorax include:

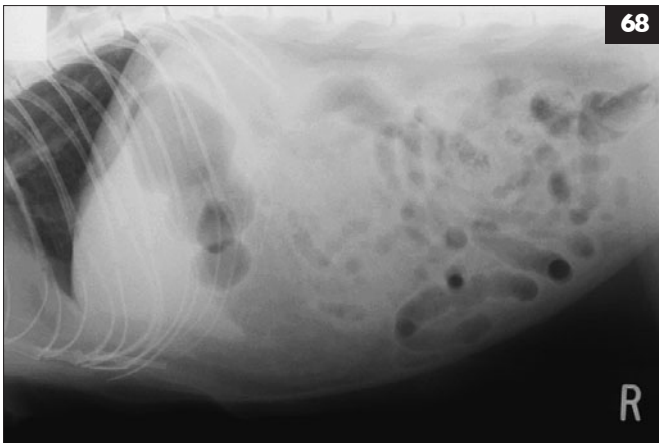
- Cardiomyopathy/congestive heart failure.
- Traumatic rupture of the thoracic duct.
- Anterior mediastinal neoplasia (lymphoma, thymoma).
- Heartworm disease.
- Lymphangiectasia.
- Idiopathic chylothorax: in many cases, an underlying cause is not found.

iv. Management of idiopathic cases involves initially conservative treatment with repeat thoracocentesis as necessary (possibly via an indwelling chest drain) and reducing the flow of chyle by feeding a low fat diet. Addition of medium chain triglycerides is not recommended; it is questionable whether they are absorbed directly into the circulation (rather than via lymphatics) and their use has been associated with hepatic lipidosis in cats. The benzopyrone derivative, rutin (250–500 mg/cat three times daily, orally), has been recommended, but evidence supporting its efficacy is lacking, and some cases will resolve spontaneously.

Where conservative management fails, surgical treatment is recommended with ligation of the thoracic duct. Fibrosing pleuritis can be a long-term complication.



67 A 5-year-old neutered female DSH cat (67) is presented. The owner complains that the cat urinates in the house and fails to use a litter tray. How should inappropriate urination be differentiated from LUTD?



68 The radiograph (68) is from a 6-year-old neutered male DSH with a 14-day history of progressive inappetence and intermittent vomiting and retching. On examination the abdomen had an indistinct 'doughy' feel on palpation, the cranial abdomen was uncomfortable and a cranial abdominal mass was suspected.

- i. What radiographic changes can be seen?
- ii. If acute pancreatitis is suspected how should the case be further investigated and managed?

67, 68: Answers

67 LUTD is often accompanied by dysuria, pollakiuria, and haematuria. The results of urinalysis typically reveal evidence of inflammation. If LUTD is accompanied by urination outside the litter tray the volume will often be variable, it may be grossly abnormal (e.g. contain blood) and it will typically be on random, horizontal surfaces.

Inappropriate urination may occur for a number of different reasons. It can be stress-related, related to litter tray problems (litter preference, litter hygiene), or related to territory marking. Inappropriate urination is not associated with pollakiuria or dysuria, and classically involves repeat urination at the same location(s).

Urine spraying is one form of inappropriate urination and is done far more frequently by males than females. It typically involves small volumes of urine sprayed onto vertical surfaces and is the most common form of territorial marking. House soiling is a form of inappropriate urination most often caused by anxiety or litter tray-related problems that can involve small or normal volumes of urine being passed on horizontal surfaces. It can be more difficult to differentiate from LUTD, although the same location(s) are used and results of urinalysis are normal.

Occasionally diseases other than LUTD may result in urination outside a litter tray (e.g. polyuria/polydipsia, arthritis); the urination will tend to occur in random places.

68 i. The radiograph shows poor serosal detail, especially in the cranial abdomen. This suggests serosal inflammation (peritonitis) and/or the presence of free fluid.

ii. Serum biochemistry, diagnostic imaging, and abdominal fluid analysis may assist the diagnosis of acute pancreatitis. Pancreatic lipase immunoreactivity may be a better test than fTLI for acute pancreatitis in cats, and in severe cases ionized hypocalcaemia may be present.

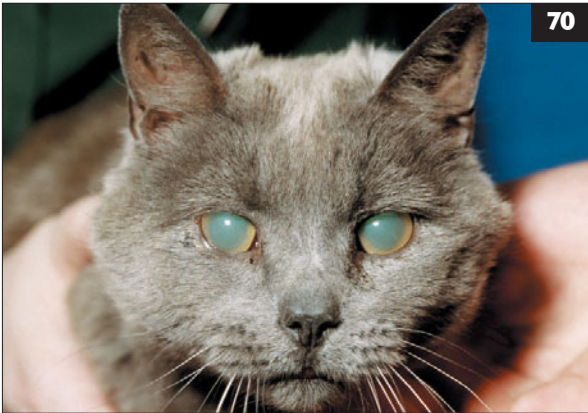In this case, abdominal ultrasonography confirmed the presence of an enlarged pancreas, which had a patchy hypoechoic architecture, consistent with acute inflammation. There was evidence of secondary biliary stasis. Definitive diagnosis would require biopsy, but the signs, clinical findings, and imaging were all consistent with acute pancreatitis. Ultrasonography also confirmed some ascites, and assay of lipase in this fluid revealed levels more than 10 times higher than serum concentrations.

Feline acute pancreatitis is increasingly recognized, but treatment remains controversial. Supportive therapy is with analgesics, intravenous fluids, and antiemetics (e.g. chlorpromazine, prochlorperazine, or ondansetron) as necessary. Broad-spectrum antibiotics are prudent as bacterial translocation from the intestine may exacerbate the disease. Unless contraindicated due to vomiting, feeding is recommended in cats with acute pancreatitis, and tube feeding is warranted if they are inappetent. There is little or no evidence that feeding exacerbates the disease, whereas starvation has many adverse effects. While there is little evidence that glucocorticoids cause or exacerbate pancreatitis, there is also little evidence that they are of benefit.



69 A 3-year-old neutered male DSH cat is presented having been involved in a road traffic accident. The cat is admitted to the hospital for monitoring and supportive care (intravenous fluids and naso-oesophageal tube feeding) (69). In spite of this therapy, the cat does not pass any urine for 36 hours.

- i. Is this finding of concern?
- ii. What are the possible reasons for this lack of urination?
- iii. What investigative procedures may be worth pursuing at this stage?



70 A 2-year-old neutered female DSH cat presents with slowly progressive, persistent clinical signs that were first noticed at around 4 months of age. In addition to the features visible in the picture (70), the cat has pectus excavatum, hindlimb lameness and ataxia, and reduced cervical movement (flexibility).

- i. What features are evident from the picture?
- ii. What is the most likely diagnosis and how could this be confirmed?
- iii. What, if any, treatment is available?

69, 70: Answers

69 i. Lack of urination is of concern, since it may be associated with post-renal ARF, hyperkalaemia, and metabolic acidosis.

ii. Rupture of the bladder and/or ureters or urethra, or obstruction to urinary outflow from the bladder are two concerning possibilities. Rupture is more likely given the history of trauma. Another possibility is that the cat is unwilling to urinate for other reasons such as stress or pain on posturing to urinate.

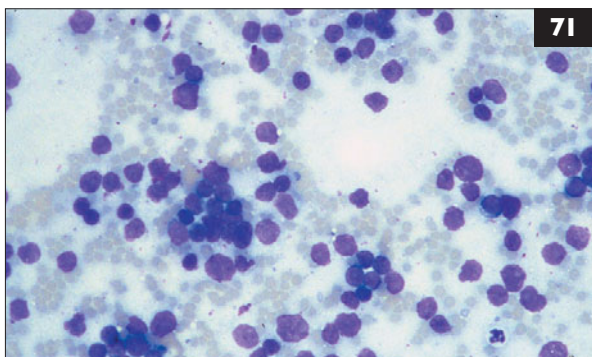
iii. Palpation of the bladder will identify bladder distension where present but the bladder may still be palpable in those cases where small bladder tears or urethral rupture are present. Plain radiography may be useful in confirming the presence of urine in the abdominal cavity. Contrast studies (e.g. retrograde urethrogram, intravenous excretory urography) may be necessary to identify and locate rupture of the urinary tract.

70 i. The picture of the cat shows two obvious abnormalities: there is clouding of both corneas (it is impossible to tell the cause from this picture, it could be oedema, lipid, or some other cause), and there is depression of the nasal bridge (difficult to see from this view). Although equivocal, the ears also appear somewhat small.

ii. All these signs are typical of the lysosomal storage disease, mucopolysaccharidosis. There are in fact many different forms of mucopolysaccharidosis, several of which have been documented in cats, including mucopolysaccharidosis I which can affect DSH cats. Mucopolysaccharidosis I is caused by a deficiency of the enzyme α -L-iduronidase. Typical signs are lameness and spinal abnormalities (due to skeletal malformation such as coxofemoral subluxation, bone dysplasia, and vertebral fusion), a broad face with depressed nasal bridge, small ears, corneal clouding, hepatosplenomegaly, and hindlimb proprioceptive deficits.

Diagnosis may be suspected from typical clinical signs. Affected cats also excrete excessive amounts of glycosaminoglycans in urine, and simple commercial tests are available to detect this, which strongly supports the diagnosis. On histological examination, various tissues (neurones, myocytes, hepatocytes, fibroblasts and chondrocytes) show accumulations of glycosaminoglycan within the cells. However, specific diagnosis relies on demonstration of low α -L-iduronidase activity, and this is usually achieved by assaying the enzyme on cultured fibroblasts (usually from a skin punch biopsy), or lymphocytes. Several laboratories will screen for a panel of inborn errors of metabolism from these cell cultures.

iii. Enzyme replacement therapy with weekly injections of recombinant α -L-iduronidase has been reported and was partially successful in reversing the effects of the disease in some tissues. Although not currently available this may offer hope for future treatment.



71 A 5-year-old neutered male Siamese cat presents with inspiratory dyspnoea and intermittent regurgitation. Radiography reveals a large anterior mediastinal mass. A fine needle aspirate (71) is taken from the mass.

- i. Describe what can be seen.
- ii. What is the diagnosis?
- iii. What are the typical clinical features of this disease?
- iv. How should management be approached in this case?
- v. What is the best predictor of long-term response to therapy?



72 A 7-year-old neutered male cat presents with a 4-month history of weight loss, reduced appetite, and polyuria/polydipsia.

- i. What breed of cat is this (72)?
- ii. If the signs are due to an inherited disease, what is this likely to be?
- iii. What other inherited diseases are recognized or postulated in this breed and what are their clinical manifestations?

71, 72: Answers

71 i. The cytological sample reveals an abundance of polymorphic lymphocytes showing distinct characteristics of neoplasia (variable nuclear size, coarse chromatin and prominent nucleoli).

ii. This picture is typical of AML.

iii. Cats affected with AML typically present with either dyspnoea (due to the size of the mass and/or the presence of an effusion), regurgitation (due to external pressure from the mass on the oesophagus), or a combination of the two. Typically cats with AML are <2 years of age, and historically approximately 70% of these tumours have been reported to be associated with FeLV viraemia, although recent studies suggest that this proportion may now be lower. Results of a number of studies and clinical observations suggest that young Siamese cats may be predisposed to this form of lymphoma, independent of FeLV infection. AML can occur alone, or it can be part of more widespread or multicentric lymphoma.

iv. This cat would need to be staged (examined for lymphoma elsewhere), have retrovirus status evaluated, and be checked for paraneoplastic syndromes (e.g. hypercalcaemia, although this is unusual with feline lymphoma). Good responses are reported to standard chemotherapy protocols (e.g. COP protocol).

v. Studies suggest the single most valuable predictor of long-term response to chemotherapy is the quality of the response in the first few (1–3) weeks.

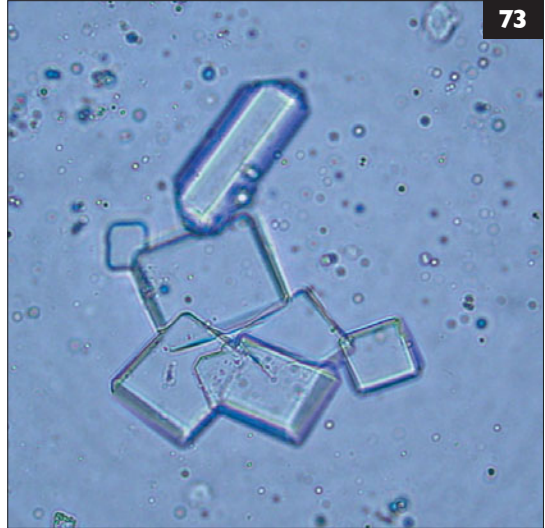
72 i. This is an Abyssinian cat.

ii. Several inherited diseases have been described in this breed, but the presentation and signs would be consistent with renal amyloidosis.

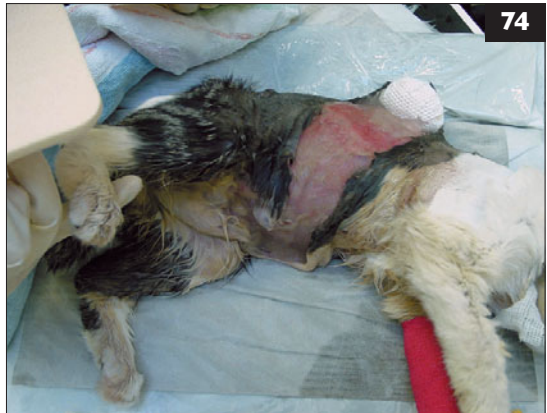iii. Inherited diseases in this breed include:

- Serum AA amyloidosis has been identified, but the mode of inheritance is not yet known. Age of onset and severity are variable; the amyloid is preferentially laid down in the kidneys resulting in progressive CRF.
- Progressive retinal atrophy occurs in two inherited forms in Abyssinian cats. One is an autosomal dominant trait manifested in kittens, the other an autosomal recessive manifested in young adults. Both cause progressive retinal atrophy and blindness.
- Congenital hypothyroidism due to dysmorphogenesis has been identified in a group of Abyssinian cats with a probable autosomal recessive inheritance. Typical signs (disproportionate dwarfism, constipation, and goitre) have been reported.
- Osmotic fragility of erythrocytes causing a chronic intermittent severe haemolytic anaemia has been identified in young adult Abyssinian and Somali cats. It has been proposed that this may be an inherited disorder of the erythrocyte membrane.
- Pyruvate kinase deficiency has been identified as an autosomal recessive disease and results in chronic intermittent haemolytic anaemia in affected individuals due to erythrocyte membrane instability.

- 73 i. What can be seen in the picture (73) of a urine sediment analysis?
- ii. What is the significance of this finding and how should it be interpreted?
- iii. What is the potential relationship with bacterial infections, and how common is this in cats?



74 A 7-year-old cat that has a skin wound on its lateral body wall is presented for evaluation. The owner reports that the cat was normal this morning and came in with the wound after a few hours outside. When attempting to suture this wound, the skin is found to be extremely fragile and tears easily producing an extensive wound over the cat's ventrum and lateral body wall (74).



- i. What differential diagnoses need to be considered for skin with this description?
- ii. What investigations are required to confirm the cause of the disease?
- iii. What is the most likely diagnosis?

73, 74: Answers

73 i. This urine sediment analysis shows the typical appearance of struvite (magnesium ammonium phosphate) crystals.

ii. The finding of struvite crystals in urine sediment analysis is not necessarily abnormal and in many cases may be an *in vitro* artefact (i.e. the crystals precipitate in the urine after it has been collected due to cooling of the urine). Even when seen in freshly collected, immediately examined urine, this can be a normal finding. It indicates relative supersaturation of the urine with crystalloids, but crystals themselves are not a pathological finding. Epidemiological studies have not found any relationship between the prevalence of crystalluria and cystitis. Although their presence may be regarded as a risk factor for urolith development, in most cats they are of no clinical significance. Cats on dry diets are more likely to have crystalluria than those on 'wet' diets.

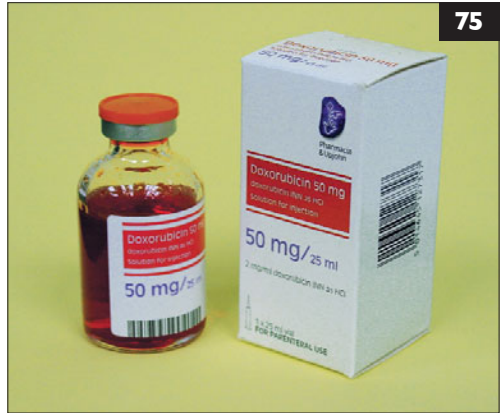iii. Bacterial cystitis with urease-producing organisms (staphylococci, *Proteus*) can predispose to struvite crystalluria and urolith formation by degradation of urea and release of ammonium (one of the struvite constituents) and by increasing the pH (thus decreasing the solubility of struvite crystals). Bacterial urinary tract infections are uncommon in cats, and generally only account for 2–3% of cases of lower urinary tract disease. Compromise to normal defences (catheter placement, perineal urethrostomy) will predispose to bacterial infections, as will a lower USG.

74 i. Major differential diagnoses are:

- Endocrinopathies, e.g. HAC (Cushing's disease), diabetes mellitus.
 - Concurrent therapy affecting skin fragility, e.g. corticosteroids, progestagens.
 - Paraneoplastic skin fragility.
 - Ehlers–Danlos syndrome (cutaneous asthenia). This is a group of inherited connective tissue disorders whereby affected cats suffer from loose, fragile skin which is hyperextensible and prone to tears. Since this is a congenital defect, it would be unlikely in this case since no previous history of skin wounds is reported.
- ii. A thorough history and physical examination should be helpful in eliminating some of the possibilities considered (e.g. concurrent drug therapy). Further investigations are likely to include laboratory profiles (e.g. haematology, serum biochemistry including blood glucose, fructosamine levels, urinalysis) and more specific tests as indicated (e.g. dexamethasone screening test for HAC). Survey radiographs of the chest and abdomen may be helpful in identifying adrenomegaly, metastatic spread of tumours, and abnormalities consistent with other problems (e.g. hepatomegaly is common with diabetes and HAC). Histopathology (and possibly electron microscopy) of a skin biopsy may be helpful particularly in diagnosing Ehlers–Danlos and neoplastic disease.
- iii. Spontaneous or iatrogenic HAC as causes of skin fragility are most likely given the lack of previous history of problems.

75 Doxorubicin (adriamycin) (75) is a drug that is being used with increasing frequency in feline medicine.

- i. What is this drug and what is its mechanism of action?
- ii. What are the clinical indications for its use, its practical application, and potential side effects?



76 A breeder client has a litter of 6-week-old kittens which are showing signs including depression, coughing, and dyspnoea (76). One kitten has required extensive nursing care and is deteriorating rapidly.

- i. What are the most likely infectious causes of these clinical signs?
- ii. What is a possible diagnostic plan?
- iii. How should the kittens be treated while awaiting laboratory results?

75, 76: Answers

75 i. Doxorubicin is a water-soluble anthracycline antibiotic. It is a cytotoxic drug used in the treatment of various neoplasms and acts principally by interfering with DNA and RNA synthesis by inhibiting topoisomerase II. It is a cell-cycle non-specific cytotoxic. Following administration it is cleared by hepatic metabolism and excreted in bile and urine. It does not penetrate into the CNS.

ii. Doxorubicin has a broad range of anti-neoplastic activity. It is usually used as part of a multidrug regime, and its reported uses in feline medicine include:

- Lymphoma. In cats doxorubicin is not useful as a sole induction agent, but there is some evidence that its incorporation in a multidrug regime may prolong remission and survival times.
- Sarcomas (e.g. fibrosarcomas, vaccine-associated sarcomas).
- Carcinomas (e.g. thyroid carcinoma, prostatic carcinoma, mammary carcinoma).

Doxorubicin is very irritant perivascularly and must be given by careful IV infusion over at least 10–15 minutes (usually in dextrose saline or lactated Ringer's). In addition to typical side effects (bone marrow suppression, anorexia, weight loss, and gastrointestinal disturbances) doxorubicin exerts additional side effects, in part due to generation of oxygen free radicals. These cause cardiotoxicity (thought to occur with cumulative doses >170–240 mg/m²) and at these doses some cats also exhibit nephrotoxicity. Current recommendations are for a dose of 20–30 mg/m² (or 1 mg/kg) IV every 3 weeks to a maximum cumulative dose of 180–240 mg/m². Close monitoring of haematology, cardiac and renal function is important.

76 i. The main possibilities are the 'flu' viruses, FHV and FCV, and the bacterium *Bordetella bronchiseptica*. Other possibilities would include *Mycoplasma* spp. infection and secondary infection with other bacteria (e.g. *Escherichia coli*, *Staphylococcus*, *Streptococcus*, and *Pasteurella* species). *Chlamydophila felis*, reovirus, systemic poxvirus, and severe parasitism (involving lung migration) would represent rare potential causes of these signs.

ii. Diagnostic tests that are helpful in this situation include oropharyngeal swabs for 'flu' virus isolation and/or PCR tests. *Bordetella bronchiseptica*, *Mycoplasma*, and other bacteria can be isolated from oropharyngeal swabs or bronchoalveolar lavage fluid culture, although special media may be required, so the laboratory should be informed of what infections are being considered when samples are submitted.

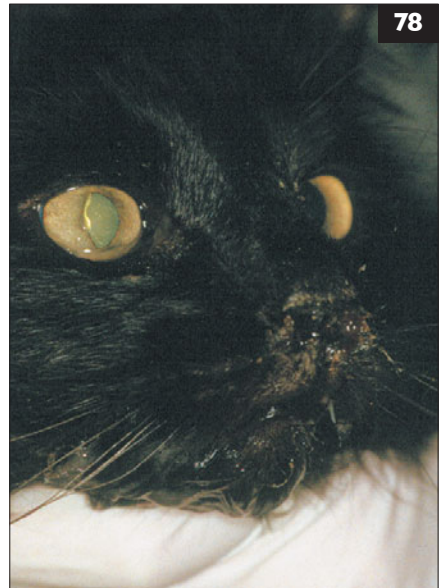
iii. The kittens should be treated supportively (fluids, warmth, general nursing, oxygen, nebulization, and nutritional support as required) whilst awaiting results. Antibiotic cover should be provided and, in this situation, a tetracycline (e.g. doxycycline) is an appropriate choice since this will have activity against *Bordetella bronchiseptica*, *Mycoplasma* spp., and also *Chlamydophila*.



77 A 7-year-old neutered male DSH cat (77) is presented having been imported to the UK from Australia 18 months previously. During this time the cat has had five episodes of acute-onset dyspnoea characterized by severe expiratory effort, but had no signs prior to coming to the UK. The cat has apparently responded to administration of glucocorticoids each time with resolution of the clinical signs within 24–48 hours. What are the major differential diagnoses for this cat? If its previous residence in Australia is relevant what is the likely cause of the clinical signs?

78 Infection with cat ‘flu’ viruses (78) may lead to development of a ‘carrier status’.

- i. What is meant by the term ‘carrier status’?
- ii. What is the clinical relevance of carrier status?
- iii. What percentage of cats develop carrier status?
- iv. How can carrier cats be identified?



77, 78: Answers

77 The expiratory effort present would suggest that the dyspnoea is due to a lower respiratory tract problem. The major differential diagnoses for acute-onset episodic lower respiratory tract dyspnoea would be:

- Recurrent ‘flash oedema’ – acute onset pulmonary oedema typically due to underlying restrictive or hypertrophic cardiomyopathy.
- Feline ‘asthma’ syndrome – the relatively good apparent response to therapy would be consistent with acute onset reversible bronchoconstriction, one of the classic features of ‘asthma’.
- Feline heartworm (*Dirofilaria immitis*) infection. Although not endemic in the UK, heartworm is present in Australia and if this part of the history is relevant, this would be the most likely cause.

Dirofilariasis is less common in cats than dogs (they are naturally more resistant), but can occur anywhere that the organism is endemic. Cats generally harbour less than six adult worms in the right ventricle or pulmonary artery. Persistent or episodic clinical signs include coughing, dyspnoea, vomiting, anorexia, and neurological signs. Acute intermittent respiratory signs may be seen as a result of the death of adult worms.

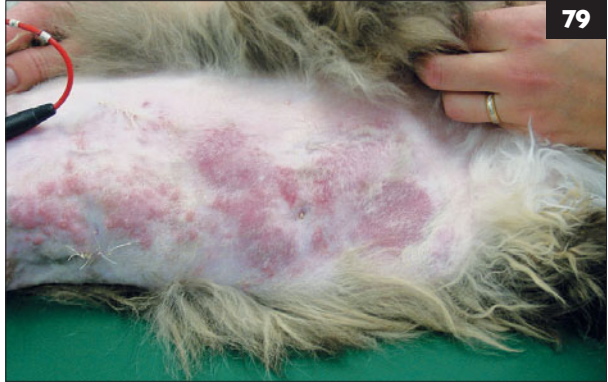78 i. A carrier cat is one which is not showing clinical signs of disease although it is infected with one or both of the ‘flu’ viruses (FHV and FCV). Development of carrier status is a potential sequela to infection.

ii. Carrier cats can be a source of infection to other cats and environmental contamination.

iii. Following FHV infection, it is thought that 80–100% of cats develop carrier status with up to 50% of these cats shedding virus from time to time. FCV carrier status declines with time with 100% shedding at 30 days post infection, 50% at 75 days, and a smaller proportion that remain long-term carriers. FCV carriers shed the virus continuously although the amounts of virus shed vary from cat to cat and from day to day.

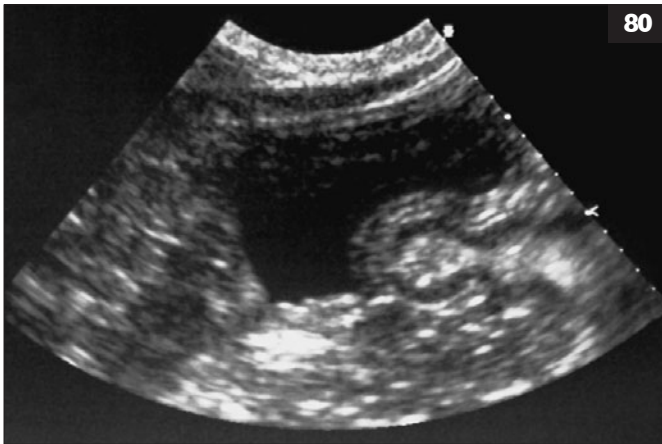
iv. FCV carrier cats can be identified by taking oropharyngeal swabs and performing virus isolation or, where available, PCR testing. FHV carrier cats are harder to identify since their carrier status is characterized by latent infection of the trigeminal ganglia, ocular and nasal tissues. Whilst in the latent state, there is no viral replication and virus cannot be isolated from oropharyngeal or conjunctival swabs. Viral shedding may be reactivated spontaneously or following stressful events (e.g. parturition, attending a cat show), other illness, or administration of corticosteroids. Typically viral shedding starts 1 week after the stressful event and lasts for 1–2 weeks. PCR testing for FHV may be a more sensitive test for identification of carriers: some studies have shown that this test identifies a higher proportion of infected cats than is achieved with virus isolation.

79 A 9-year-old neutered male domestic long-haired cat presents with progressive non-pruritic coalescing plaque-like cutaneous lesions over the ventral abdomen and thorax (79). There is some erythema and scaling present. The lesions are non-ulcerated and nodular in some areas. The owner reports that these lesions have been



slowly enlarging over the past 4 months. A fine needle aspirate from one nodule reveals mixed inflammatory cells with a high proportion of lymphocytes.

- i. What are the differential diagnoses?
- ii. What is the likely diagnosis?
- iii. What are the potential treatment options?



80 A 3-year-old male neutered DSH cat presents with a history of lack of urination since a road traffic accident 2 days ago. Ultrasonography is performed and a picture taken of the cranioventral abdomen (80).

- i. What can be seen?
- ii. What additional tests should be performed?
- iii. How should this case be managed?

79, 80: Answers

79 i. Major differential diagnoses for nodular/plaque-like lesions over the trunk would be:

- EGC (eosinophilic plaques).
- Multicentric sebaceous adenocarcinoma.
- Cutaneous lymphoma/epitheliotropic lymphoma.
- Cutaneous metastases of mammary neoplasia.
- Multiple mast cell tumours.
- Fibrosarcomas/fibromatoses.
- Atypical mycobacterial infections.
- Subcutaneous fungal infections.

ii. The long and progressive history, lack of ulceration and/or exudation, and the results of the fine needle aspirate are all consistent with a diagnosis of cutaneous epitheliotropic lymphoma (mycosis fungoides). This was confirmed by biopsy. In many reported cases the lesions may be pruritic, and there may be quite marked scaling. This is an uncommon tumour in cats, mostly being seen in individuals >10 years of age. These are T cell lymphomas, but non-epitheliotropic cutaneous lymphoma can be either B or T cell in origin. Most reported cases have been FeLV-negative.

iii. Isolated lesions can be removed surgically or treated with radiation therapy (although full staging is recommended). Traditional multi-agent chemotherapy can be used for non-epitheliotropic cutaneous lymphoma but little has been published on the treatment of mycosis fungoides in cats. Retinoids (e.g. isotretinoin at 3–4 mg/kg/day orally, or etretinate at 1.25 mg/kg/day orally) have been recommended, but efficacy is unknown.

80 i. There is free abdominal fluid in the abdomen (black) adjacent to abdominal organs (liver is visible on the left of the ultrasound image and bowel is visible on the right).

ii. Given the history, it is likely that the fluid in the abdomen is urine. Although large amounts of urea and creatinine are present in urine, urea present in fluid within the peritoneal cavity will rapidly equilibrate with that in the blood stream. Therefore, if the rupture is thought to have been present for greater than 24 hours, as in this case, creatinine should be assayed in blood and fluid. In bladder rupture cases, the fluid creatinine levels are typically double the serum levels. Similarly, fluid potassium levels are much greater than serum levels.

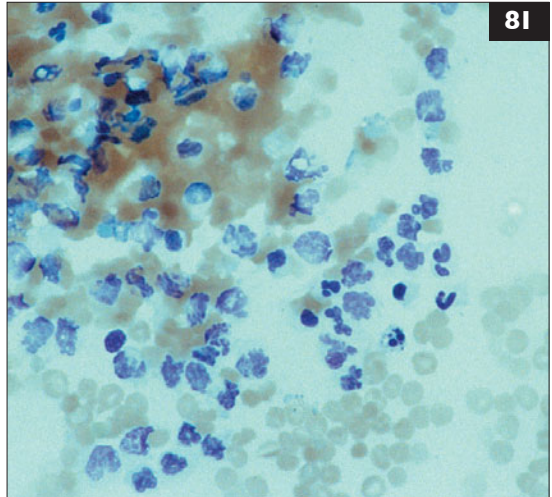
iii. The cat needs supportive care which may include:

- Drainage of urine from the abdomen and peritoneal dialysis.
- Intravenous fluid therapy with electrolyte and acid–base therapy as needed.
- Analgesia and general nursing, e.g. warmth, nutritional support.

Once stable, contrast radiographs of the bladder and urethra should be taken to locate the site of the rupture so that appropriate curative therapy can be performed.

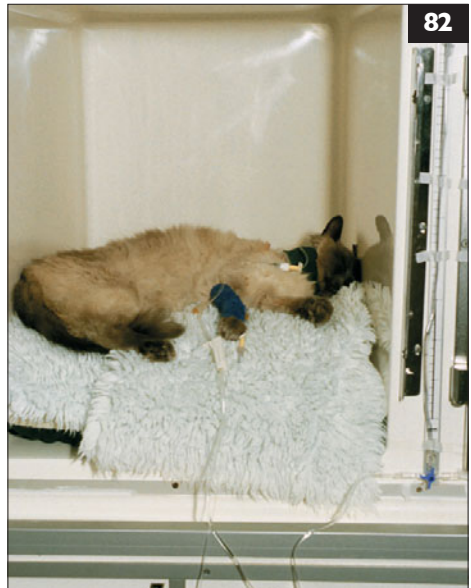81 The picture (81) shows microscopy of urine sediment from a cat.

- i. How would urine sediment microscopy be performed and what are considered normal/abnormal findings?
- ii. How should the findings in this cat be interpreted?



82 The cat (82) is having its CVP monitored.

- i. Why is it useful to monitor CVP?
- ii. What is the normal CVP?
- iii. How, practically, is CVP measured?



81, 82: Answers

81 i. Prior to microscopy the urine (5–10 ml) is sedimented by centrifugation at approximately 500g for 5–10 minutes. Most of the supernatant is removed leaving only 0.2–0.5 ml in which the sediment is resuspended, effectively concentrating the urine sediment by approximately 20-fold. A wet preparation of the sediment can be examined by pipetting two drops onto a clean microscope slide and placing a coverslip on top. The sediment is examined under $\times 400$ magnification, and normal urine will contain <10 erythrocytes/hpf and <5 leucocytes/hpf. There should be no bacteria and only occasional epithelial cells and hyaline or granular casts. If preferred, new methylene blue or a commercial urine sediment stain can be added (one drop of stain to one drop of sediment), which makes cytology easier (although it may make examination of crystals and casts more difficult). Air-dried smears can also be made.

ii. In this cat, there are clearly large numbers of erythrocytes and leucocytes (mainly neutrophils). This finding is consistent with a severe inflammatory process. Bacteria are not obvious, but examination under higher magnification would be needed to exclude this possibility. Major differential diagnoses would be sterile inflammation (idiopathic cystitis, urolithiasis, neoplasia) or infection (bacterial cystitis); the presence of degenerate neutrophils makes the latter more likely.

82 i. CVP gives a measure of right atrial pressure and evaluates cardiac function, blood volume and indirectly assesses vasomotor tone. A low CVP is seen with hypotension and hypovolaemia. Elevated CVP is associated with volume overload, cardiac failure, vasoconstriction, and pericardial effusion.

ii. Normal CVP is 0–10 cm water.

iii. An intravenous catheter, bag of intravenous fluids, extension set, water manometer, and three-way tap are required. The catheter is placed into the anterior vena cava via the jugular vein and an extension set joined to this is attached to the fluid line via the three-way tap. A water manometer is also attached to the three-way tap and the three-way tap is held or taped at the level of the right atrium (the top of the manubrium). The fluid bag giving set is attached to the third port of the three-way tap. The stopcock of the three-way tap is initially turned so that fluid flows from the fluid bag through the catheter to check the patency of this. The stopcock is then turned towards the patient so that fluid fills the water manometer. Finally, the stopcock is turned towards the fluid bag; the level of fluid in the water manometer will fall until the pressure in this column of fluid is equal to the patient's central venous pressure. The top of the fluid column should oscillate up and down with the cat's heart beat and breathing. Following trends of CVP is more useful than single measurements.

CVP can be crudely estimated by observing filling of the jugular vein when moving the head up or down. Animals with raised CVP will have veins distended above the level of the right atrium.

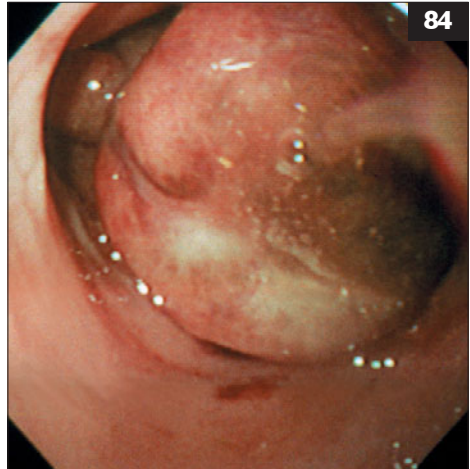


83 A Holter monitor is being used in this cat (83).

- i. What is the Holter recording?
- ii. What are the indications for performing a Holter test in cats?
- iii. What are the disadvantages of this test?

84 A 9-year-old neutered male DSH cat presents with diarrhoea characterized by progressive haematochezia and dyschezia of 2 months' duration.

- i. What differential diagnoses should be considered?
- ii. Colonoscopy is performed and the picture (84) is taken in the proximal descending colon. What can be seen and what are the differential diagnoses and treatment options?



83. 84: Answers

83 i. A Holter continuously records the ECG over a 24-hour period. Patients are able to move around whilst the recordings are measured. The unit can be taped to the body (although many Holters are too cumbersome to allow this in cats) or kept alongside the patient and attached to them by an 'umbilical cord' as shown in the picture.

ii. Analysis of Holter recordings allows assessment of heart rate, rhythm, and presence of normal and abnormal complexes. Holter assessment is indicated in cases where episodic arrhythmias are suspected and can be used to assess treatment efficacy. Holter analysis allows determination of frequency of arrhythmias and can help to identify whether arrhythmias are associated with clinical signs.

iii. The equipment required is expensive and specialist analysis of the results can be very time consuming. Body movement, day to day variation, and the rapid heart rate present in most feline patients can make assessment and diagnosis difficult.

84 i. Haematochezia, dyschezia, and passage of mucus-covered faeces of variable consistency are typical signs of large bowel (colonic) diarrhoea. In some cases the underlying disease may be affecting both the small and large intestine and this can sometimes be difficult to determine. The presence of weight loss, if the appetite remains good, would be suggestive of small bowel involvement.

Major differentials for haematochezia and dyschezia would be:

- Dietary indiscretion/abrasive colitis (less common in cats than dogs!).
- Dietary hypersensitivity.
- Idiopathic inflammatory bowel disease (some studies suggest there is colonic involvement in up to 40–50% of cases).
- Infection (*Salmonella*, *Campylobacter*, *Clostridia*, *Giardia*, *Cryptosporidia*, hookworms).
- Neoplasia.
- Idiopathic large bowel diarrhoea.
- Other inflammatory/granulomatous disease (e.g. FIP, mycobacteria).

ii. In this case, the colonoscopy shows a large irregular intraluminal mass in the proximal descending colon. This is likely to be neoplastic. The most common colonic neoplasia in cats are lymphoma or adenocarcinomas. Other tumour types (e.g. mast cell tumours and neuroendocrine carcinomas) are rare. The treatment depends on the tumour type and on the presence or absence of metastases. Colectomy would be indicated as a potentially curative or palliative procedure. Follow-up chemotherapy would be indicated for lymphoma (e.g. vincristine, cyclophosphamide, and prednisolone). Adenocarcinomas are more difficult to manage, and, if surgery yielded incomplete margins, the prognosis would be poor. There has been interest in the use of COX-2 inhibitors for the treatment of carcinomas, and such agents (e.g. piroxicam, meloxicam) although not licensed for this purpose, may also produce clinical improvement in some cases.



85 A 3-year-old neutered female DSH cat (85) is showing recurring signs of oestrus behaviour (vocalization, lordosis, rolling) after being neutered (ovariohysterectomized) 6 months previously.

- i. What are the likely and potential causes of this?
- ii. How should this case be investigated and managed?



- 86 i. What is the mode of inheritance of the major blood groups described in cats?
- ii. Are there any breed associations with blood types in cats?

85, 86: Answers

85 i. This cat is showing typical signs of ‘ovarian remnant syndrome’, a relatively common problem. The most common cause of this problem is remnants of ovarian tissue left behind at the time of surgery (ovariohysterectomy) or possibly ovarian tissue that is ‘seeded’ to the abdomen during the surgical procedure. Other explanations are possible but rare or undocumented. These include oestrogen production from the adrenal glands (possible adrenal tumour) and behavioural problems, although these are likely to cause persistent rather than episodic signs.

ii. Oestradiol assays are variable in both intact and ovariectomized cats and thus are unreliable in determining the presence of functional ovarian tissue. During oestrus behaviour, the cat can be injected with 50–100 U hCG IM to induce ovulation and formation of a corpus luteum. Serum progesterone can be measured after 5–7 days, and, if $>4\text{--}6\text{ nmol/l}$, this confirms the presence of functional ovarian tissue. This is not entirely reliable however, and should be combined with performing vaginal cytology during oestrus behaviour to see if cornified epithelial cells are present (not always present, but this is a reliable indicator if they are evident).

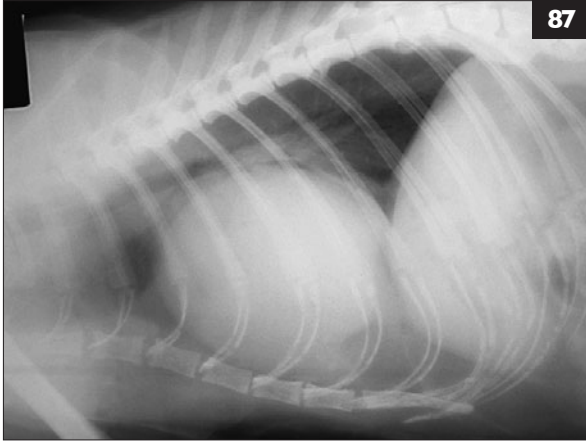
Definitive treatment involves repeat surgery to search carefully for the ovarian remnant. It has been recommended that this should be done during oestrus behaviour to make identification of the tissue easier.

86 i. The AB blood group system is the major blood group system in cats and includes type A, type B, and type AB. Feline blood type is determined by red cell surface antigens. Blood types are inherited with type A being dominant to type B, thus type B cats are homozygous for the B allele (B/B) whereas type A cats can be homozygous (A/A) or heterozygous (A/B). Blood type AB (rare) is inherited separately.

ii. Blood type A is the most prevalent overall but the frequency varies according to the breed of cat and geographical area it is from. Certain breeds (British Shorthair and Rex cats) have a high prevalence of type B in contrast to other breeds, such as Siamese, where all of the cats are type A. Type AB cats are generally rare; most studies show a $<5\%$ prevalence. The table summarizes current prevalence data for type B cats. Some of the data has been obtained from studies involving only small numbers of cats from each breed.

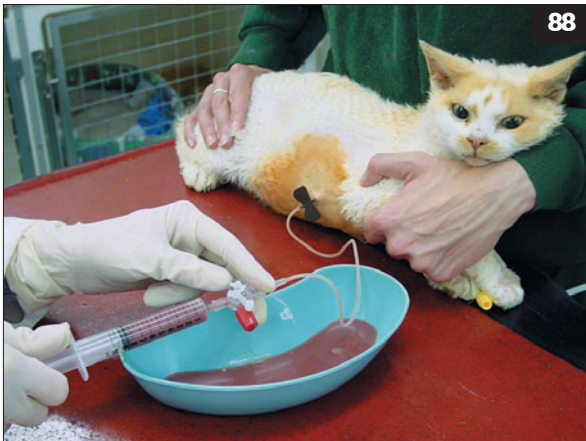Approximate prevalence (%) of type B cats according to breed and geographical location (na: data not available)

Breed	UK	USA	Italy	Australia	Japan
DSH and DLH	8	5	13	27	12
Siamese	0	0	0	na	na
Burmese	10	0	0	na	na
Abyssinian	0	25	20	na	na
Persian	12	25	24	na	na
Birman	29	25	18	na	na
Rex	0	50	43	na	na
British Shorthair	59	50	59	na	na



87 The lateral thoracic radiograph (87) was taken from a 4-year-old domestic longhaired cat.

- i. What major abnormalities are evident in the radiograph?
- ii. What are the differential diagnoses?
- iii. What further diagnostic test is most appropriate?



88 This cat (88) is having its chest drained.

- i. What are the indications for this procedure?
- ii. How is it performed?
- iii. What analysis should be performed on the fluid obtained?

87, 88: Answers

87 i. The cardiac silhouette is dramatically enlarged and globular in outline and the trachea is elevated.

ii. Differential diagnoses are:

- Pericardial effusion, or pericardial mass.
- Generalized cardiomegaly.
- Combination of the above.
- PPDH.

iii. Ultrasound examination is likely to be the most helpful test. In the absence of suitable facilities, a contrast study such as a non-selective angiogram may be helpful in eliminating or confirming some of the possibilities identified above.

88 i. Thoracocentesis is indicated (diagnostically and therapeutically) whenever fluid or air is present in the pleural space.

ii. Thoracocentesis can be performed in conscious, sedated, or anaesthetized cats; the choice of these depends on the cat's temperament and condition. Oxygen therapy by mask (if tolerated) should be initiated while preparing the patient.

The equipment needed includes:

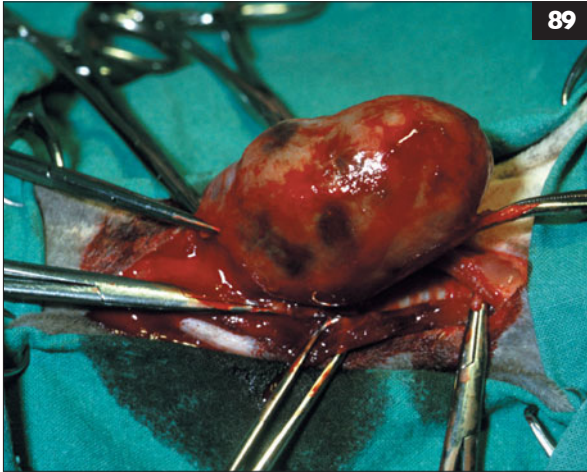
- 19 or 21 gauge butterfly needle, a three-way tap, and 10 or 20 ml syringes.
- Kidney dish.
- EDTA and plain tubes, and microscope slides.

The chest should be clipped and aseptically prepared on both sides from the 5th to the 10th rib. The site of thoracocentesis is at the level of the costochondral junction if an effusion is suspected (dorsal third of the chest for pneumothorax). The patient is positioned in sternal recumbency. The needle is introduced immediately in front of the 7th or 8th rib (the blood vessels and nerves run just behind the ribs) at an angle of approximately 30 degrees to the chest wall, angling cranially to minimize trauma to the lungs. Fluid can be aspirated and then, once samples have been collected, expelled into the kidney dish via the three-way tap. Although local anaesthesia can be used prior to centesis, this is rarely needed in the emergency situation. Bilateral drainage is usually required for optimal treatment.

Although an over-the-needle catheter allows removal of the needle, so preventing lung trauma, the catheter frequently kinks or occludes and is generally less successful for thoracocentesis.

iii. Samples should be submitted for

- Cytology (EDTA tube and smear).
- Biochemistry (plain tube: total protein, albumin, globulin, and possibly LDH, cholesterol, triglycerides, glucose, and pH).
- Bacterial culture if indicated (plain tube with air evacuated submitted with accompanying charcoal swab).

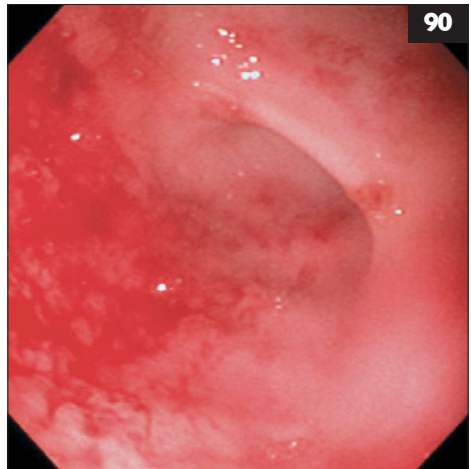


89 Thyroid histology results have just been received from a hyperthyroid patient on whom a surgical thyroidectomy has been performed (89). The cat has a thyroid carcinoma.

- i. How common is this condition?
- ii. What is the prognosis?

90 i. What can be seen on this gastroscopic picture (90) from a 3-year-old neutered male cat with a 6-month history of recurrent episodic severe vomiting?

- ii. What would the differential diagnoses be?
- iii. In general, what are the advantages and disadvantages of endoscopy for the investigation of gastrointestinal disease?



89, 90: Answers

89 i. Thyroid carcinomas are a very rare cause of hyperthyroidism, probably present in, at most, 2% of all hyperthyroid cats. The majority of thyroid carcinoma cases described have resulted in hyperthyroidism although non-functional carcinomas may also occur.

ii. The tumour is extremely likely to recur and surgical removal is rarely effective as a sole treatment. This cat is vulnerable to local tumour regrowth and metastasis, most commonly to the lungs. Further surgery is contraindicated as this is unlikely to be completely effective and the risk of damage to or removal of the parathyroid glands increases with successive surgeries. The treatment of choice for functional carcinomas is high dose radioactive iodine (around 30 mCi, 1.11 GBq) available at certain specialist centres. This is a highly effective and safe treatment and, as long as no other complicating factors or concurrent diseases are present, the cat's prognosis following therapy is good. Non-functional carcinomas are more difficult to treat.

90 i. The endoscopic picture shows the body (to the left), angulus, and antrum of the stomach. The mucosal surface has an irregular appearance with evidence of erosion (ulceration) and bleeding.

ii. Differential diagnoses would include neoplasia, foreign body, irritant gastritis, *Helicobacter*-induced gastritis, uraemic gastritis, idiopathic chronic gastritis/ulceration, inflammatory bowel disease, and parasitic gastritis (*Ollulanus tricuspis*).

In this cat, there was a mixed inflammatory infiltrate and recurrent acute gastritis due to dietary indiscretion was diagnosed.

iii. The major advantages of endoscopy are:

- The ability to view the lumen and mucosal lining in a non-invasive manner.
- The ability to retrieve foreign bodies, obtain fluid and brushings for cytology, and/or culture of organisms.
- The ability to obtain mucosal biopsy material.


Although endoscopy is an extremely valuable technique for investigating signs of chronic gastrointestinal disease (unrelated to systemic disease) it has some disadvantages:

- The equipment needed is relatively expensive (an insertion tube diameter of <8 mm is generally required for duodenoscopy in cats).
- Not all the intestinal tract is readily viewed endoscopically (the distal half of the small intestine is especially difficult).
- Biopsies obtained with the endoscope are relatively superficial in nature and small, making orientation and interpretation of sections potentially difficult. Significant pathology may therefore be missed if it is in a part of the gastrointestinal tract inaccessible endoscopically, if the significant pathology lies deep to the biopsies, or if the sections examined are distorted.

As endoscopic biopsies are small, it is recommended that a minimum of eight biopsies should be obtained and submitted from each site of the gastrointestinal tract examined.



91 A 3-year-old neutered female DSH presents with dyspnoea (91). Describe how the history, character, and nature of the dyspnoea should be used to help narrow down the potential differential diagnoses of the aetiology of the condition.



92 A 5-year-old neutered male cat presented with typical signs of urethral obstruction. The obstruction (urethral plug) was removed promptly and easily, and the bladder flushed with sterile saline. There was no radiographic or ultrasonographic evidence of uroliths or debris in the bladder or urethra, but the cat still showed signs of dysuria (92), passing small volumes of urine despite having a distended bladder. What is the most likely cause of this and how should the case be managed?

91, 92: Answers

91 Historical features may indicate an obvious cause of dyspnoea such as trauma or inhalation of a foreign body (rare in cats). With recurrent dyspnoea, history may reveal a seasonal or environmental trigger. The speed of onset of the dyspnoea can be misleading however, as the adaptability of cats may mean that even a chronic disease process results in few overt clinical signs until a 'critical threshold' is reached.

The clinical examination should be directed at localizing the source and assessing the severity of the dyspnoea. Severe dyspnoea may require emergency symptomatic treatment.

- Inspiratory dyspnoea implies either upper respiratory tract disease (obstruction) or decreased lung capacity (thoracic effusion, pneumothorax, large mass).
- Upper respiratory tract disease may be (but is not necessarily) accompanied by nasal discharge, sneezing, stertor (snorting/snoring), stridor (wheezing), facial deformity, and dysphagia. Dysphonia may be present with laryngeal disease.
- Expiratory dyspnoea is usually a sign of lower respiratory tract disease.
- Tachypnoea (polypnoea) and hyperpnoea (increased depth) do not localize the cause of the dyspnoea. However, obstructive disease (e.g. pleural effusion, large lung mass) tends to result in slow deep breathing whereas restrictive disease tends to result in shallow rapid breathing.
- Orthopnoea (dyspnoea in sternal recumbency with neck extended and abducted forelimbs) and open-mouth breathing are signs of severe dyspnoea.

92 Recurrent obstruction could occur as a result of new plug formation or due to urolithiasis, but the initial investigations suggest that this is unlikely and the cat is able to pass some urine. The process of catheterization to remove the plug and flush the bladder, if not done carefully, can result in urethral stricture formation and subsequent partial urethral obstruction, but this is likely to take 1–2 weeks to develop.

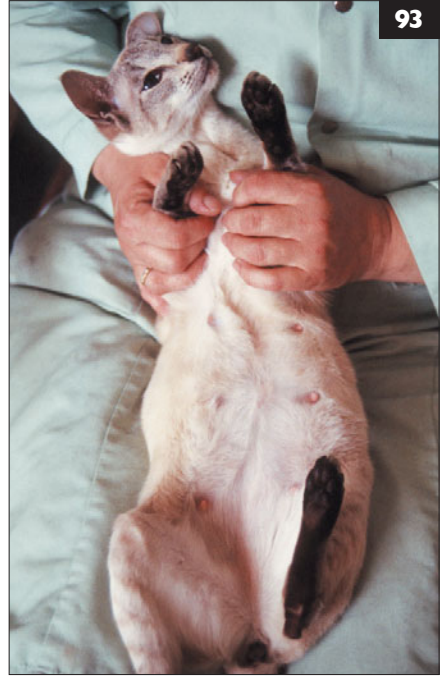The persistence of signs after removal of the plug suggests that the problem is likely to be due either to urethral swelling caused by local inflammation and/or a result of urethral spasm induced by local inflammation/irritation, and this is a common complication ('spastic urethra'). Other possibilities would include an 'UMN' bladder, and prolonged bladder distension leading to detrusor atony.

Treatment in this cat would be aimed at inducing urethral relaxation; the urethra contains both smooth and striated muscle and thus a combination of skeletal and smooth muscle relaxants provides optimum therapy.

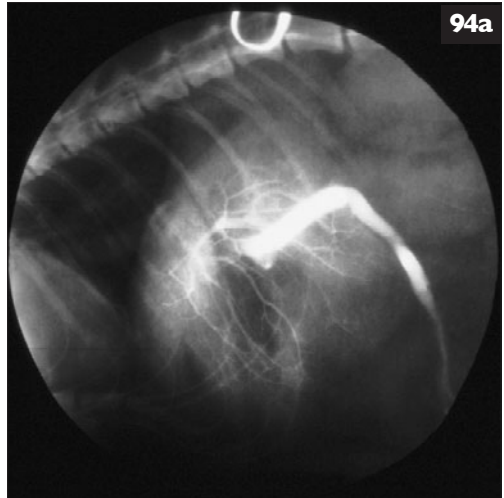
Skeletal muscle relaxation is typically achieved with diazepam (2–5 mg/cat orally two to three times daily) or dantrolene (2–10 mg/cat orally three times daily). The latter is preferred as diazepam can cause hepatic necrosis in cats.

Alpha-blockers are used to provide smooth muscle relaxation and most commonly phenoxybenzamine (2.5–7.5 mg/cat orally once to twice daily) or prazosin (0.5 mg/cat orally once to three times daily) are used.

93 Pregnancy (93) is not always desirable, even in pedigree breeding cats! What forms of pregnancy control/oestrus suppression should be recommended for a queen intended for future breeding and what are the advantages and disadvantages of these methods?



94 i. What procedure is illustrated (94a) and when is it indicated?
ii. What is the assessment in this case?



93, 94: Answers

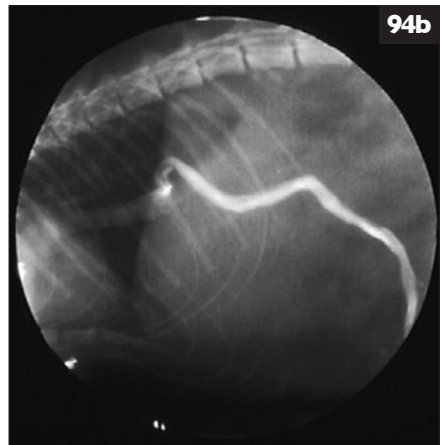
93 Potential solutions include:

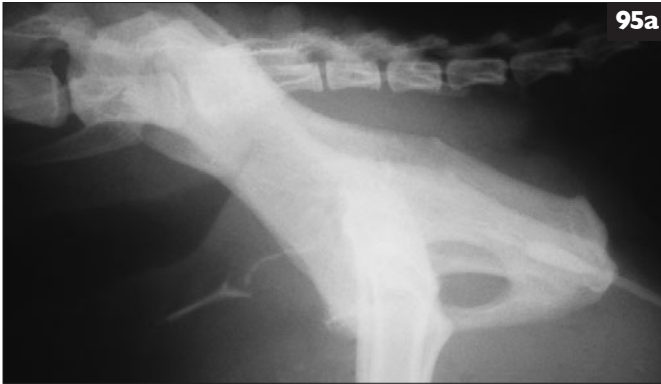- Allow the queen to cycle normally but prevent any possibility of mating by keeping her physically separated (not always practical, and undesirable for some queens).
- Use a vasectomized tom to mate the queen during oestrus and induce ovulation, or use manual stimulation of the vagina (e.g. glass rod or cotton-tipped swab) to induce ovulation. These give only short-term control of oestrus unless repeated.
- Use progestagens to suppress oestrus. Although these can be given in oestrus or dioestrus, high doses are required and it is safer to start using these during anoestrus. Injectable (proligestone, medroxyprogesterone acetate) or oral (megoestrol acetate) preparations have been used, but the latter is preferable as it can be stopped if any side effects occur. Megoestrol acetate is used at a dose of 2.5 mg orally once weekly when started in anoestrus. The use of progestagens increases the risk of cystic endometrial hyperplasia, mammary tumours, mammary hyperplasia, diabetes mellitus, adrenal suppression, and behavioural changes.
- Recently, oestrus control has been attempted with induction of antibodies against porcine zona pellucida antigens (unsuccessfully) designed to prevent fertilization of the ovum; with a long-acting injectable GnRH analogue (successfully) aimed at down-regulating GnRH receptors; and alternative progestagens (successfully) with potentially fewer side effects.

94 i. A portovenogram is being performed. This technique is indicated in cases where congenital or acquired portosystemic vascular anomalies are suspected on the basis of clinical findings, laboratory results (e.g. fasting hyperammonaemia and elevated pre- and/or post-prandial bile acid results), or hepatic ultrasonography.

ii. A normal portovenogram is shown. Contrast material is injected into a mesenteric vein where it flows to the liver via the hepatic portal vein. Once within the liver, the blood flow is often described as arborizing like the branches of a tree. A portovenogram from a cat with a congenital portosystemic vascular anomaly is shown (94b). In this case,

contrast in the hepatic portal vein bypasses the liver via a single anomalous vessel.





95 This contrast retrograde urethrogram (95a) was obtained from a 7-year-old male neutered cat that was showing signs of dysuria, haematuria, and constipation.

- i. What abnormalities are evident?
- ii. What are the differential diagnoses?
- iii. How can the cause of the disease be confirmed?

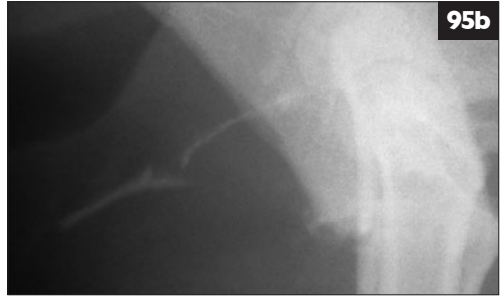
96 FeLV infection has been diagnosed in one of the cats pictured (96). The cat is one of a group of cats housed in a rescue centre.

- i. In a household where FeLV is endemic, what are the potential outcomes following exposure to FeLV?
- ii. What factors influence the outcomes in any individual cat?



95, 96: Answers

95 i. There is irregular filling of the urethra at the level of the prostate (95b). The colon is gas filled and there is dorsal deviation of gas within the distal colon consistent with a mass below this.



ii. Major differential diagnoses are

- Prostatic disease, e.g. neoplasia, prostatitis, abscessation.
- Urethral disease, e.g. neoplasia, urethritis.

iii. Ultrasonography of the prostate is likely to be helpful and may allow fine needle aspirate or core biopsies to be obtained. Prostatic washes and urethral suction catheter biopsies can also be performed and assessed cytologically.

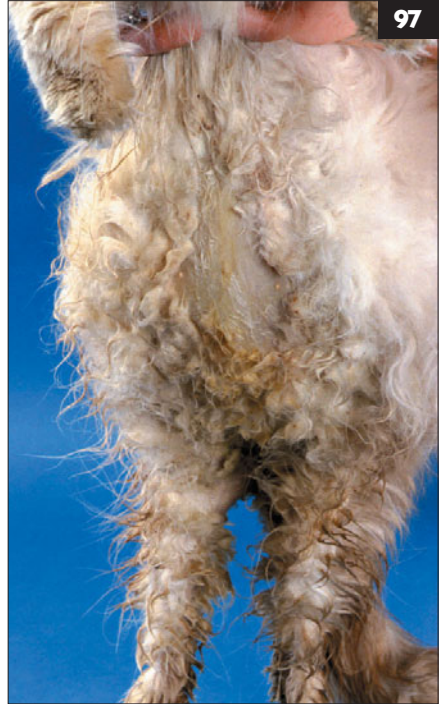96 i. There are five potential outcomes:

- Persistent viraemia likely to be associated with disease in the future.
- Latent infection of certain tissues, most commonly the bone marrow. Virus-neutralizing antibodies produced by the cat inhibit viral replication. The lack of viral replication means that virus and viral antigens are not detectable in blood samples. Most latently infected cats are thought eventually to eliminate the infection completely. In a small proportion of cats, latent infection may later result in haematopoietic disease or reversion to persistent viraemia.
- Focal or localized infection of certain tissues with viral replication at these sites (this appears to be a rare outcome following infection). For example focal infection of the mammary tissue has been reported to result in transmission of infection to kittens via the milk.
- Transient infection after which the cat is able to eliminate the infection. Elimination of the infection may take several weeks and is usually associated with production of high levels of virus-neutralizing antibodies. Many, if not all, transiently infected cats will go through a period of latent infection before they completely eliminate the virus.
- Insufficient exposure to establish infection. Transmission of FeLV is generally inefficient and may require prolonged periods of close contact to be successful.

ii. The outcome following infection is affected by many factors including the age of the cat (cats <6 months old are particularly vulnerable to developing persistent viraemia) and the dose and route of infection (infection via a bite is more efficient than oronasal infection). Cats with reduced immune status due to other illnesses or medications are vulnerable to persistent infection.

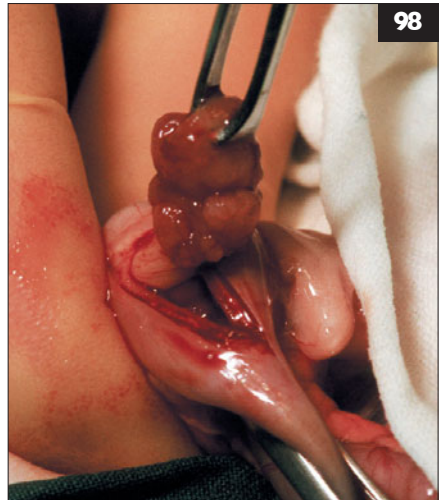
97 A 10-month-old Persian cat is brought in with a history of 1 month's vague lethargy, inappetence, and malaise. The owner also reports recent abdominal distension (97). Clinical examination suggests that the distension is due to ascites but does not reveal any more abnormalities.

- i. What laboratory tests should be performed initially?
- ii. What are the major differential diagnoses for ascites in a young cat?
- iii. What further tests may be helpful in this case?



98 A 5-year-old neutered female DSH cat presented with chronic, persistent vomiting. At exploratory surgery an intra-luminal pedunculated mass was found in the proximal duodenum (98).

- i. What are the differential diagnoses?
- ii. Suggest the likely diagnosis, treatment, and prognosis for the cat.



97, 98 Answers

97 i. The most important initial diagnostic test is abdominocentesis, with sampling and analysis of fluid obtained. Fluid cytology and biochemistry are essential to assess the nature of the ascitic fluid present. Bacterial culture should be performed if indicated on the gross and/or cytological appearance of the fluid. Haematology, biochemistry, and virus screening tests (FeLV, FIV especially) may also be helpful.

ii. Major differential diagnoses at this stage are:

- FIP.
- Lymphocytic cholangitis with abdominal effusion.
- Abdominal neoplasia with effusion.
- Right-sided heart failure.

iii. Further tests which may be helpful in this case include:

- Thoracic and abdominal radiography: if pleural and abdominal fluid is present then causes such as lymphocytic cholangitis can be ruled out.
- Abdominal ultrasonography: may identify hepatic disease or presence of abdominal masses.
- Echocardiography to rule out cardiac disease as a cause.
- Detailed ophthalmic examination: may identify ocular inflammatory disease consistent with infectious diseases such as FIP.
- Serum protein electrophoresis: increased levels of gamma globulins and other acute phase proteins are often identified in cats with FIP.

98 i. The major differential diagnoses for this mass would be:

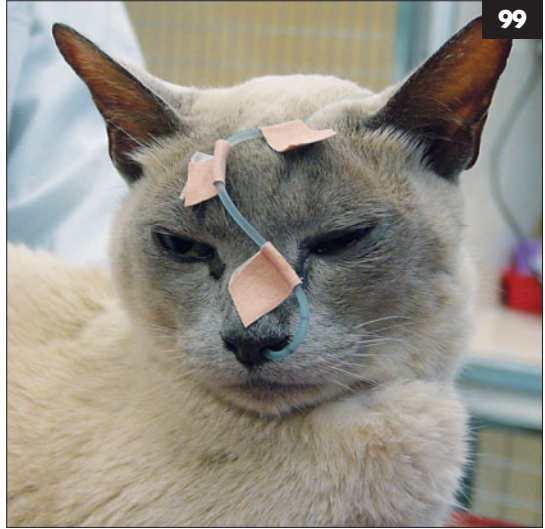- Neoplasia: lymphoma, adenocarcinoma, mast cell tumour.
- Focal inflammation/infection.
- Regional granulomatous duodenitis.
- Foreign body reaction.
- Gastric heterotopia/ectopia.
- Duodenal polyp: small intestinal polyps have been described in both the proximal and distal small intestine in cats.

ii. The pedunculated nature of the mass, and the multi-nodular appearance would be most suggestive of a benign polyp in this case. Histological examination of resected tissue revealed that it was composed of a mix of ectopic hypertrophied and distorted glandular pyloric mucosal tissue and adenomatous polypoid duodenal mucosa/submucosa. Similar adenomatous polyps have been well described in cats, albeit relatively uncommonly. These generally occur within 1 cm of the pylorus. The polyps cause clinical signs of partial obstruction typical of delayed gastric outflow or proximal intestinal obstruction.

These polyps are benign and respond extremely well to simple resection.

99 Placement of nasoesophageal feeding tubes (99) offers a simple and effective method of providing nutritional support to anorexic cats.

- i. Are there any contraindications to their use?
- ii. How can the ideal nasoesophageal tube be selected?
- iii. How long can a nasoesophageal tube be left in place?
- iv. Are there any useful tips for unblocking tubes when blockage occurs?



99

100 What are the advantages, disadvantages, and limitations of 'dipstick' evaluation of urine chemistry (100)?



100

99, 100: Answers

99 i. Naso-oesophageal tubes are contraindicated in some circumstances, e.g. cats with oesophageal or gastric disease, persistent vomiting, unconscious, or severely obtunded cats. In cats with nasal or pharyngeal disease, placement may be resented due to discomfort and alternative strategies (e.g. oesophagostomy tube) may be preferable. If long-term nutritional support is anticipated then other techniques such as oesophagostomy or gastrostomy tube feeding should be considered.

ii. The largest gauge tube that can be comfortably passed should be chosen. A variety of different tube types are available including polyurethane, silicone, and PVC. Polyurethane tubes are preferable as these have the largest internal diameter and cause the least local tissue reaction. Silicone tubes have a smaller internal diameter but are a good second choice as these also cause very little tissue reaction *in situ*.

iii. Naso-oesophageal tubes are suitable for short-term nutritional support (1–2 weeks).

iv. Proprietary liquid foods should be used where possible to prevent blockages from occurring. It is important to flush the tube with water before and after each feed to prevent blockage. If the tube does become blocked, flushing with warm water or a carbonated soft drink may help break the blockage down.

100 The major advantages of urine ‘dipstick’ evaluation are the speed, availability, and relative reliability for a number of urine chemistries. The disadvantage is that the sticks are generally designed for human use, so are not always appropriate for use in animals and some results have to be interpreted with caution. The strips are also labile so need to be stored and used correctly, and must not be used beyond their expiry date.

The strips are valuable for determination of:

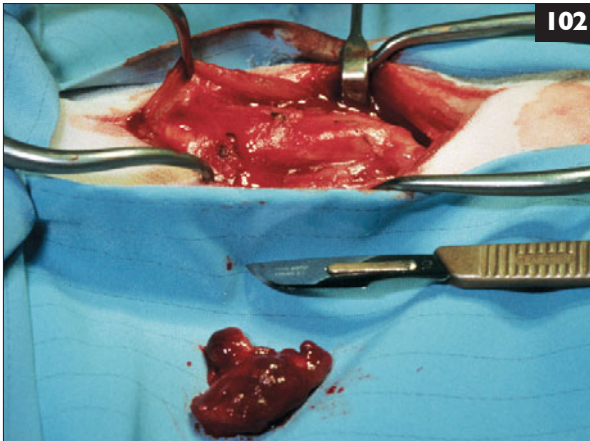
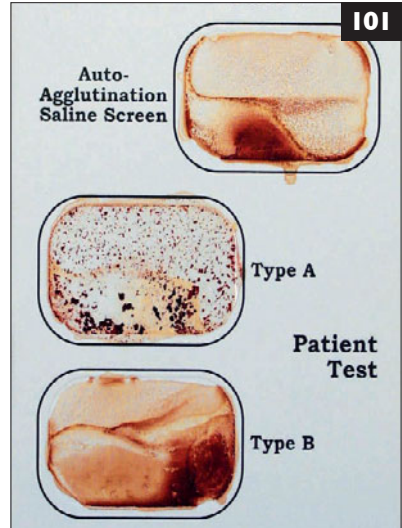
- pH: generally reliable. If accuracy is very important, a pH meter can be used.
- Protein: the strips provide semi-quantitative determination and are mainly sensitive to albumin. A UPC is required for quantitative assessment of proteinuria.
- Glucose: reliable, semi-quantitative assessment. False positives occur with contaminating oxidants (e.g. sodium hypochlorite), and false negatives with administration of ascorbic acid (vitamin C) supplements.
- Blood: the strips react with erythrocytes, haemoglobin, and myoglobin thus further analysis, including sediment examination, is required when there are positive results. Sodium hypochlorite or iodine contamination give false positives.
- Bilirubin: generally reliable. False-positive results have been reported with chlorpromazine and etodolac use, and false negatives with ascorbic acid use.
- Ketones: reliable semi-quantitative assessment of acetone and acetoacetate, but the strips do not detect β -hydroxybutyrate which is usually the major ketone in cats.

Dipstick analysis is unreliable for the following in cats:

- Specific gravity (this should be performed with a refractometer), nitrate, leucocytes.
- Additionally, urobilinogen measurement is not a useful test in small animals.

101 The picture (101) shows a Rapid H feline blood typing card. These cards are widely available and provide a quick, simple, and reliable method of blood typing in the practice situation. The test requires 0.25 ml of EDTA blood.

- i. What blood type is this cat?
- ii. What are the indications for blood typing?
- iii. How else can feline blood types be determined?



102 A bilateral thyroidectomy has just been performed (102) in a hyperthyroid patient.

- i. How soon after surgery will hypocalcaemia develop if the parathyroid glands have been damaged or removed?
- ii. What clinical signs are associated with hypocalcaemia?

101, 102: Answers

101 i. This cat is blood type A.

ii. Blood typing prior to transfusion helps to minimize the risk of transfusion reactions. Blood typing is also advisable pre-mating in breeding cats where the prevalence of type B cats is significant in order to prevent neonatal isoerythrolysis from developing. If pre-mating blood typing has not been possible then any kittens born to type B queens can be blood typed, using cord blood, at the time of birth. Any type A kittens identified should be separated from their mother and hand-reared for the first 24 hours whilst colostral antibodies are capable of crossing the bowel.

iii. Many commercial laboratories offer blood typing services which generally require 1 ml blood in EDTA or ACD anti-coagulants. Alternatively, cross-matching or back typing tests can be done using previously typed donor samples. Cross-matching detects presence of antibodies to blood group antigens and requires 1 ml EDTA blood collected from the patient and donor/s. The samples are centrifuged and plasma separated from the red cells which are washed two to three times by resuspending these in 2 ml saline, re-centrifuging and removing the supernatant. Finally the red cells are resuspended in sufficient saline to give a 2–4% solution of red cells. (For example 0.1 ml pelleted red cells resuspended in 2.4 ml gives a 4% solution.) Cross-matching can be done using small blood tubes or ELISA plate wells as follows:

- Incubate samples at 37°C [98°F] for 15 minutes before observing for gross and microscopic evidence of agglutination.
- Major cross-match: two drops patient plasma and one drop donor RBC solution.
- Minor cross-match: two drops donor plasma and one drop patient RBC solution.
- Donor control: two drops donor plasma and one drop donor RBC solution.
- Patient control: two drops patient plasma and one drop patient RBC solution.

'Back typing' can be done in a similar manner but using known type A and B plasma and cells. Plasma from all type B cats contains naturally occurring anti-A antibodies resulting in agglutination when mixed with type A red cells. Type A patients typically have no or only very low levels of naturally occurring anti-B antibodies and so show little or no agglutination with type B red cells; type AB cats show no agglutination with either type A or type B red cells.

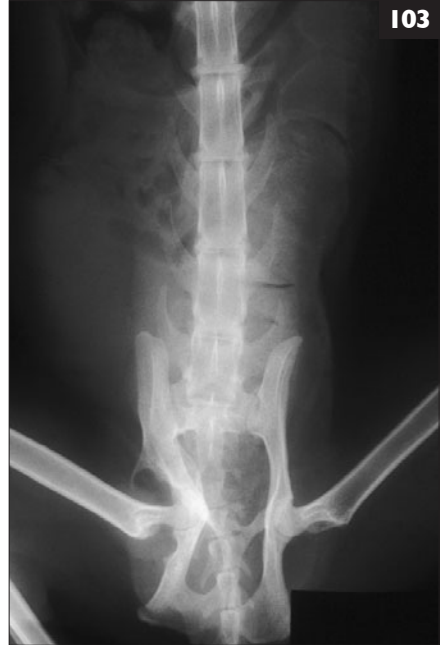Rapid emergency cross-matching can also be done using two drops of patient plasma and one drop of whole donor blood placed directly onto a microscope slide.

102 i. Hypocalcaemia is usually evident within 72 hours of surgery.

ii. Mild hypocalcaemia may not result in any clinical signs although it will be detectable on blood tests. Early clinical signs of hypocalcaemia include behavioural changes including restlessness and irritability, stiffness, weakness, hyperaesthesia to touch and sound, and muscle twitches. More profound signs include severe generalized muscle tremors, seizures, coma, and death.

103 The VD abdominal radiograph (103) is from a 6-year-old cat presented with a 12-month history of recurrent constipation.

- i. What is the diagnosis?
- ii. What alternatives should be considered for the long-term management of the problem?



104 FeLV viraemia has been confirmed in a healthy cat from a multi-cat household (104).

- i. What preventive medicine plan should be recommended for this cat?
- ii. What is the risk to the other cats it is housed with?

103, 104: Answers

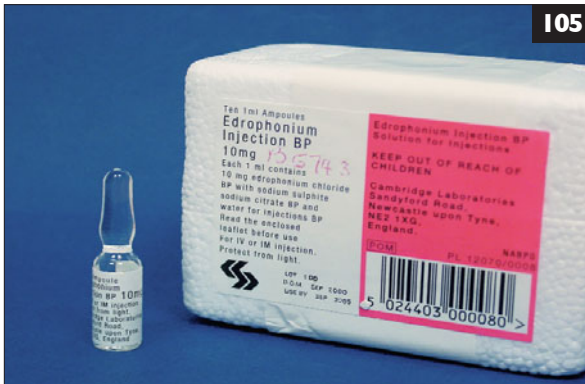
103 i. The radiograph shows severe constipation with a distended colon, and a significantly narrowed pelvic canal due to an acetabular fracture on the right hand side. The constipation is likely to be secondary to the narrowed pelvic canal and the degree of colonic distension suggests that this has potentially progressed to megacolon.

ii. There are three options for long-term management: medical control of the constipation using a combination of dietary and drug therapy, sub-total colectomy, or surgery to correct the pelvic canal stenosis. If megacolon has been present in excess of 6 months, correcting the stenosis is unlikely to resolve the constipation, although, depending on the severity of the pelvic canal narrowing, it may still be helpful.

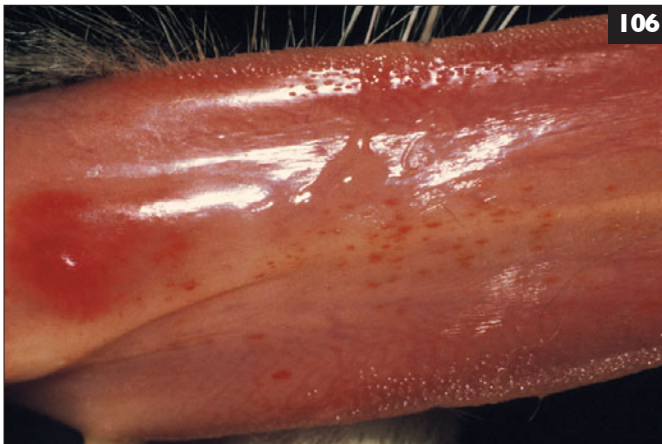Addition of fibre to the diet to promote bulk and water retention in the faeces may help, but with severe constipation this is often ineffective on its own, and indeed low residue diets may be more effective in cases of megacolon. Various laxative drugs are available which act in different ways. Emollient laxatives (e.g. dioctyl sodium sulphosuccinate, 50 mg/day) promote water penetration into faeces, stimulant laxatives (e.g. bisacodyl, 5 mg/day) stimulate colonic motility, and osmotic laxatives (e.g. lactulose, 0.5–1.0 ml/kg two to three times daily) promote water retention by osmotic effects. Of these drugs, lactulose is probably the most useful for long-term control and the dose can be adjusted according to effect. Sub-total colectomy is a very valuable procedure for cats with severe intractable constipation and produces excellent long-term results in most patients.

104 i. Vaccination for FHV, FCV, and feline panleucopenia is especially important since FeLV-infected cats may be more susceptible to infection and, if infected, are likely to develop more severe disease. Use of killed vaccines, where available, may be advisable since this minimizes the potential risk of an attenuated virus strain causing disease in an immunosuppressed patient. Additional boosters may be warranted before the cat goes to any ‘high risk’ situation such as a cattery or for elective procedures at a veterinary hospital. There is no benefit in vaccinating an FeLV-infected cat with FeLV vaccines. Flea treatment is recommended to minimize the risk of FIA transmission and the cat should be prevented from hunting or eating raw meat in order to reduce the risk of *Toxoplasma gondii* infection. The owner should be advised to keep the cat indoors as this will minimize contact with other disease-carrying cats in the area, reduce the risk of fight wounds or other traumatic injuries, and also limit the transmission of FeLV to other cats.

ii. The risk of infection of healthy adult cats living for several months or longer in the same household as an FeLV-infected cat is estimated at 10–30%. All of the in-contact cats should be tested to establish whether or not they are already infected and would benefit from the preventive health measures outlined above. Segregation of infected and uninfected cats is important to limit the spread of infection.



105 The picture shows a vial of ‘Tensilon’, or edrophonium chloride injection (105). What is this drug, how does it work and what is the major indication for its clinical use in feline medicine? What alternatives are there to the use of this product?



106 An 8-year-old DSH cat is presented with a 4-week history of gradually progressive lethargy, inappetence and weight loss. The cat is an indoor only cat and there is no history of toxin exposure. Abnormalities are seen on oral examination, especially when examining the under side of the tongue (106).

- i. What abnormalities can be seen?
- ii. What are the possible causes of this?
- iii. What is a possible initial diagnostic plan?

105, 106: Answers

105 Edrophonium chloride is a short-acting anticholinesterase. By inhibiting endogenous cholinesterase at neuromuscular junctions it potentiates neuromuscular transmission at the motor end plate. Overdose can result in a cholinergic crisis (miosis, muscle tremors, bronchoconstriction, salivation, urination, vomiting, defecation, and bradycardia).

Edrophonium is mainly used in the diagnosis of myasthenia gravis; the effects are seen within 1 minute of IV injection and last up to 10–15 minutes. The initial dose is 0.2 mg/cat IV, but incremental doses of 0.1 mg IV can be given every minute up to a total dose of 1 mg.

The response to edrophonium (increased muscle strength) may be marked, but both false-positive and false-negative results occasionally occur. Alternative or additional tests include electromyography to demonstrate a decremental response to repetitive nerve stimulation, muscle biopsy and immunohistopathology to demonstrate reduced numbers of acetylcholine receptors in cases of congenital myasthenia gravis (rare), and a positive serum acetylcholine receptor antibody titre in cases of acquired disease (normal values <0.3 nmol/l at the Comparative Neuromuscular Laboratory, University of California, with some affected cats having titres >8.0). The latter is considered the most reliable test for acquired myasthenia gravis.

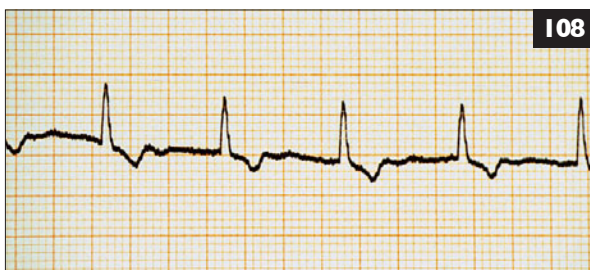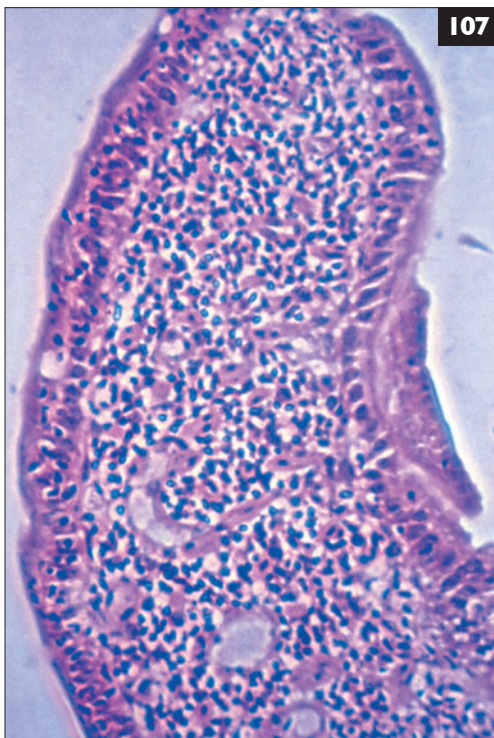
106 i. There is petechiation visible.

ii. This can be caused by:

- Thrombocytopenia.
- Abnormal platelet function (thrombocytopathy) caused by exposure to drugs (e.g. non-steroidal anti-inflammatory agent, anti-coagulant drugs), secondary to another disease (e.g. hepatic disease, uraemia), or due to a congenital defect.
- An unlikely possibility in this case would be a coagulopathy. Coagulopathies can be seen as rare inherited problems or following exposure to anti-coagulant rodenticide poisons.
- Vascular disease.
- DIC.

iii. A complete blood count and differential haematology are required initially to assess the platelet numbers. Platelet clumping is a common phenomenon with feline blood that accounts for falsely low machine platelet counts, therefore it is important to evaluate platelet numbers on a blood smear. If this assessment proves normal then further investigations are required and may include a buccal mucosal bleeding time (assesses platelet and vascular function), coagulation tests (PT, APTT), and fibrin degradation products.

107 The histological section (107) is of a small intestinal villus from a cat with chronic diarrhoea. The biopsy report suggested there were increased numbers of mononuclear cells (mainly lymphocytes and plasma cells) in the lamina propria and some increased numbers of intra-epithelial lymphocytes. What is a possible diagnosis in this cat and what further investigations are indicated?



108 A lead II ECG is shown (108). The paper speed is 25 mm/second and amplitude is set so that 1 cm is equivalent to 1 mV.

- i. What is the heart rate?
- ii. Is the heart rate regular?
- iii. Describe the complexes present.
- iv. What is your assessment of this ECG?

107, 108: Answers

107 The changes described are typical of 'lymphocytic-plasmacytic' inflammatory bowel disease. Such changes can be focal/regional (affecting only part of the gastrointestinal tract) or generalized (affecting stomach, small intestine, and colon).

Lymphocytic-plasmacytic inflammatory bowel disease is not a diagnosis but rather an inflammatory reaction pattern commonly seen in the gastrointestinal tract. It implies an active immune response, but the histological features cannot determine the causative antigen(s). Further investigations must be aimed at identifying potential antigens that could be causing the inflammation.

The first priority in such cases would be to exclude enteropathogens as an underlying cause. Faecal samples should be examined for the presence of nematode and cestode parasites. A minimum of three faecal samples should be evaluated for the presence of *Giardia* and *Cryptosporidia* organisms, and faecal cultures should be performed for recognized bacterial pathogens (e.g. *Salmonella*, *Campylobacter*).

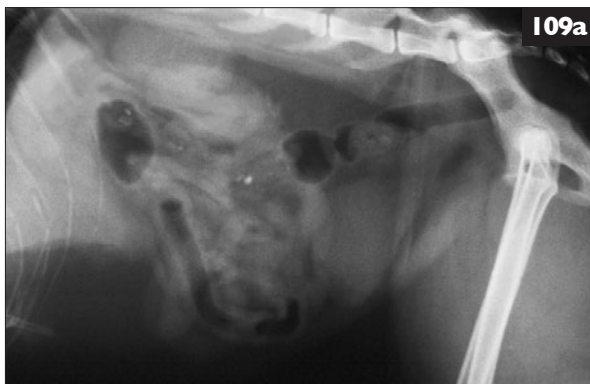
If enteropathogens are excluded as a cause of the inflammation, a dietary trial should be performed to exclude dietary hypersensitivity. Suitable diets would be composed of a single, ideally novel protein source, or composed of hydrolysed proteins. A response is usually seen within 3 weeks if there is an underlying dietary hypersensitivity. Only if these causes are excluded can a diagnosis of idiopathic inflammatory bowel disease be made.

108 i. The easiest way to assess heart rate on an ECG is to count the number of complexes present in 6 seconds and then multiply this number by 10 to obtain a heart rate in beats per minute. In this question, only a short trace is included which means that this technique cannot be used. Since the heart rhythm is regular, the heart rate can be calculated by measuring the distance between the QRS complexes. If the paper speed is 25 mm/second, there will be 1500 mm/minute, thus the heart rate is $1500 \div \text{distance between two complexes}$. Using the formula in this case, the heart rate is estimated to be 100 beats per minute.

ii. Yes, the heart rate is very regular.

iii. There are no visible P waves and the QRS complexes are wider than they should be (around 0.06 seconds; normal QRS duration is <0.04 seconds). It is also important to check the traces from other leads for presence of P waves.

iv. This is an example of atrial standstill with an escape rhythm. Failure of atrial activity (which can be confirmed on echocardiography) may be present because of hyperkalaemia (e.g. hypoadrenocorticism, diabetes mellitus ketoacidosis, lower urinary tract obstruction), toxicity (e.g. digoxin), or severe cardiac disease. Escape rhythms are characterized by their slow rate and wide QRS complexes and they occur when the normal pacemaker tissue fails to discharge for a prolonged period. Ventricular escape rhythms originating in the tissues closest to the atrioventricular node (junctional escape complexes) appear most like normal QRS complexes, as in this example.



109 A 5-year-old neutered female DSH cat presents with a persistent purulent vulval discharge. The cat is constantly licking the perineal area but is able to defecate and urinate normally and the urine and faeces are grossly normal.

- i. What changes can be seen on this lateral abdominal radiograph (109a) and what is the likely diagnosis?
- ii. How should this cat be treated, and how should an entire breeding queen with a similar problem be treated?

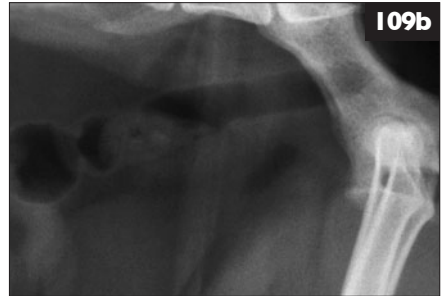110 Some clients have found a stray kitten which they wish to adopt (110). On examination, the kitten is very bright, in reasonable condition, and you estimate it is around 10 weeks old. Blood is collected for FeLV antigen and FIV antibody testing. The FIV antibody test is positive.

- i. How reliable is this test result as an indicator of persistent infection?
- ii. What should be the advice to the kitten's prospective new owners?



109, 110: Answers

109 i. A soft tissue density can be clearly seen between the neck of the bladder ventrally and the descending colon dorsally (109b). This is a typical finding in uterine 'stump' pyometra where a remnant of uterine tissue is left behind at ovariectomy and subsequently develops infection. This is an unusual condition, probably in part because cystic endometrial hyperplasia often precedes pyometra and in ovariectomized cats there is no progesterone secretion that could cause this.



Pyometra is also uncommon in entire cats, as they are induced and not spontaneous ovulators, again there is less progesterone drive for endometrial hyperplasia.

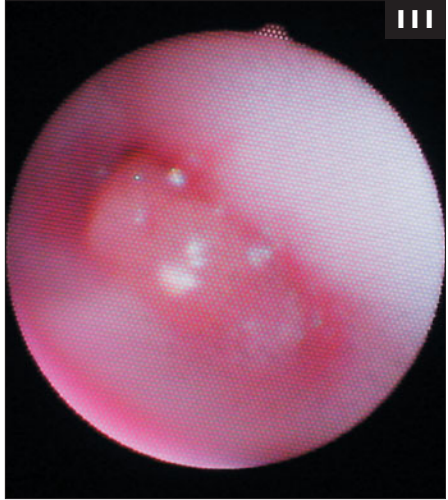
ii. In this cat, the treatment of choice would be surgical resection of the infected tissue (which was performed and was curative). In a breeding female with an open pyometra, natural prostaglandin $F_{2\alpha}$ (0.1–0.2 mg/kg SC every 12–24 hours) therapy for 3–5 days is highly successful when combined with appropriate broad-spectrum antibiotics. Temporary side effects that typically resolve within 30–60 minutes of injecting the prostaglandin $F_{2\alpha}$ include panting, salivation, vomiting, urination, and defecation.

Recurrence of pyometra after successful medical treatment is not uncommon, and so it is usually recommended that queens are bred from at their next oestrus.

110 i. A positive FIV antibody test result is found in the following situations:

- Persistently infected cat.
 - Kitten born to an FIV-infected queen. Maternally-derived anti-FIV antibodies are passively acquired via the colostrum and these antibodies will be detected when the kitten is blood tested. Although all of the kittens born to an FIV-infected queen may be antibody positive, not all of them will necessarily be infected with the virus. Maternally-derived antibodies may persist for up to 4 months and, in infected kittens, it may be a further 2 months before they seroconvert. It is therefore recommended that kittens born to FIV-infected queens are not antibody tested until they are at least 6 months old.
 - Kittens born to a queen that has been vaccinated for FIV will also passively acquire maternally-derived antibodies via the colostrum.
 - False-positive result: no test is 100% accurate.
- ii. Further options include repeating the antibody test when the kitten is older or considering an alternative diagnostic test such as PCR, where available.

111 A 5-year-old female domestic longhaired cat presents with progressive stertorous breathing over a 2-month period. There is occasional non-productive sneezing. Clinical examination shows poor movement of air through both nostrils, and the stertor resolves during open-mouth breathing. The picture (111) is of nasopharyngoscopy under general anaesthesia looking towards the choanal area.



- i. What abnormality can be seen?
- ii. What are the major differential diagnoses?
- iii. In cases such as this, what can be done to obtain tissue for histology either with or without an endoscope?

112 A haematology report is presented for this cat (112).



- i. What is the assessment of this leucogram?
- ii. What differential diagnoses need to be considered?
- iii. What is a possible diagnostic plan?

Haematology

Parameter ($10^9/l$)	Value	Reference range
WBC	10.4	5–19
Neutrophils	3.4	2.5–12.5
Lymphocytes	2.2	1.5– 6.0
Monocytes	0.5	0.1–0.7
Eosinophils	4.3	<1.5

III, 112: Answers

111 i. In a normal cat, nasopharyngoscopy allows visualization of the internal nares (choanae) as two small dark openings at the rostral nasopharynx. In this case the choanae are obliterated by a smooth, lobulated, pink/red mass in this region.

ii. Major differential diagnoses would be:

- Neoplasia (lymphoma, confirmed in this case, or adenocarcinoma).
- Fungal granuloma (cryptococcosis).
- Inflammatory polyp (probably extension/expansion of a nasal polyp as this is too far rostral to be a classic nasopharyngeal polyp).

iii. With a flexible endoscope, forceps can be advanced through the biopsy channel to allow guided biopsy of the mass. The forceps have to be passed prior to retroflexing the scope, as the acute angle would otherwise result in damage to the biopsy channel while passing the forceps. Alternatively, either forced nasal flushing or catheter biopsy can be attempted via the external nares.

To perform forced flushing, the nasopharynx is packed with swabs, and the nozzle of a 10–20 ml syringe filled with sterile saline is placed in one of the external nares, the other being occluded by digital pressure. The saline is flushed through under significant pressure, and the procedure repeated if necessary. If a mass is present, tissue is often dislodged. A flexible catheter with a side opening (e.g. feeding tube) can also be passed via the nose to the level of the choanae (measured radiographically) and a suction biopsy can be attempted.

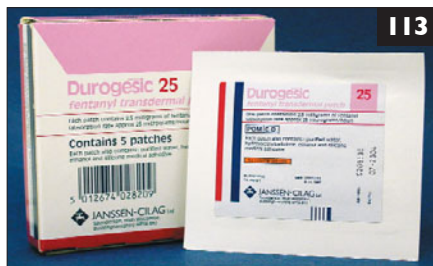112 i. The leucogram shows a moderate eosinophilia.

ii. Differential diagnoses include:

- Parasitic causes, e.g. intestinal nematodes and cestodes, heartworm, and external parasites including fleas and mites.
- Allergic causes, e.g. feline ‘asthma’, food allergy. Fleas and flea allergy are the single most common cause of a circulating eosinophilia in cats.
- EGC.
- Eosinophilic inflammatory bowel disease.
- Drug therapy, e.g. methimazole, carbimazole.
- Chronic tissue damage, e.g. pancreatitis, eosinophilic myositis.
- Mast cell tumour.
- Hypereosinophilic syndrome (often marked hypereosinophilia).
- Bone marrow disorders including eosinophilic and mixed cell leukaemias.

iii. Thorough clinical examination may be helpful in diagnosing one of the above causes. Trial anti-parasitic treatment is warranted in cases where there are no specific clinical signs to investigate. Where specific clinical signs (e.g. coughing, diarrhoea) are present, further investigations are targeted at these areas initially (e.g. bronchoscopy and bronchoalveolar lavage, endoscopy, and intestinal biopsy as appropriate). Persistent unexplained hypereosinophilia is one indication for bone marrow biopsy.

113 The picture (113) shows a fentanyl transdermal patch. What is this used for and what is known about the use of this product in cats?



114 An owner is concerned that her cat is polydipsic and has measured her cat's water intake as between 450 and 600 ml per day (118–158 ml/kg/day) (114). Examine the laboratory results.

- What are the main differential diagnoses you are considering in this case?
- What is your approach to confirming the diagnosis?



Haematology

Within normal limits

Biochemistry

	Value	Reference range
Urea mmol/l (mg/dl)	10.3 (28.8)	6.0–10.5 (17.0–29.0)
Creatinine μ mol/l (mg/dl)	126 (1.4)	<175 (<2.0)
Phosphate mmol/l (mg/dl)	1.2 (3.7)	0.95–1.95 (2.9–6.0)
Glucose mmol/l (mg/dl)	5.0 (90)	3.5–7.5 (60–135)
Total protein g/l (g/dl)	69 (6.9)	55–80 (5.5–8.0)
Albumin g/l (g/dl)	34 (3.4)	24–35 (2.4–3.5)
Globulin g/l (g/dl)	35 (3.5)	21–50 (2.1–5.0)
Alanine aminotransferase (IU/l)	43	15–45
Alkaline phosphatase (IU/l)	47	15–60
Calcium mmol/l (mg/dl)	2.3 (9.2)	2.0–2.5 (8.0–10.0)
Sodium mmol/l (mEq/l)	151	145–160
Potassium mmol/l (mEq/l)	4.4	4.0–5.0
Total T4 nmol/l (μ g/dl)	37 (2.8)	19–65 (1.5–5.0)

Urinalysis

SG	1.006
pH	6.7
Protein:creatinine ratio	0.21
Glucose/blood/ketones	negative
Sediment	scant struvite crystals

113, 114: Answers

113 Fentanyl is a synthetic μ -agonist opioid with potent analgesic activity. Transdermal fentanyl has been widely used to provide effective analgesia in many situations, and especially for postoperative pain. Dose-related side effects of respiratory, CNS, and cardiovascular depression, and possibly mild sedation can occur. Dysphoria or agitation is also seen occasionally.

Transdermal fentanyl is delivered at a constant rate, the dose being proportional to the surface area of the patch. A patch delivering 25 $\mu\text{g/hr}$ is used in cats. It takes approximately 4–8 hours for effective plasma concentrations to be achieved, and the patches should therefore be applied pre-emptively, or additional therapy should be provided for the initial period (e.g. methadone by injection). Fentanyl patches provide sustained release of the drug at therapeutic concentrations for approximately 4–5 days.

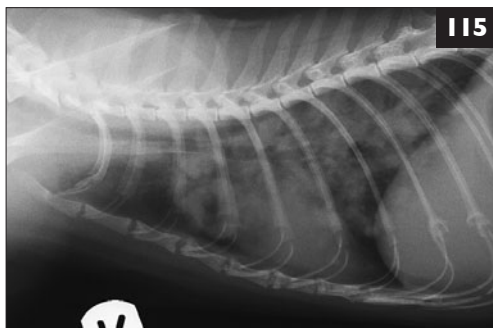Disadvantages of transdermal fentanyl include some variability in absorption between individuals, and if subjected to heat there will be a greater release/absorption of the drug (treated cats should not sleep on heated beds). Care must be exercised to ensure accidental human exposure is avoided (e.g. children chewing patches). A 25 $\mu\text{g/hr}$ patch is suitable for most cats, but if side effects occur, or for small cats, it is possible to remove the backing from only half the patch to slow the absorption (care should be taken to avoid damaging the patch). Prior to application, the hair should be clipped close to the skin and the skin cleaned with alcohol and dried. Hand-warming the patch prior to application and then holding it in place with a hand for 1–2 minutes ensures good adhesion to the skin (through heat activation of the adhesive). The patches are usually applied high on the flank and cranially to avoid cats licking them off, and lightly bandaged if necessary.

114 i. The haematology is reported to be normal with no evidence of dehydration or other abnormalities. The urine is hyposthenuric and serum biochemistry is normal. Therefore, the main differential diagnoses under consideration are:

- Central diabetes insipidus.
- Nephrogenic diabetes insipidus.
- Psychogenic polydipsia (extremely rare).

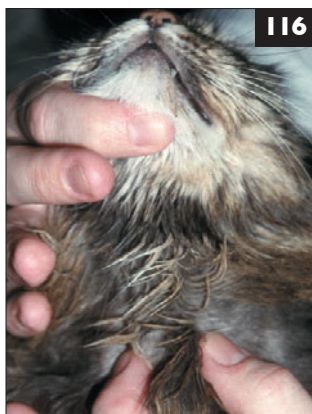ii. A modified water deprivation test is indicated in cats where all causes of polyuria/polydipsia other than diabetes insipidus and psychogenic polydipsia have been ruled out. In long-standing cases of polyuria/polydipsia, medullary washout may be present and can confuse interpretation of results. Gradual restriction of water intake for 3 days leading up to the start of the water deprivation test may help to minimize the effects of this. To determine whether central or nephrogenic diabetes insipidus are present, an ADH response test should be started at the end of the water deprivation test.

115 An 8-year-old neutered female DSH cat presents with 12 months' progressive submandibular lymphadenomegaly, and recent coughing. Lymph node aspirates reveal mixed inflammation (neutrophils, macrophages, lymphocytes). A routine blood panel and urinalysis are unremarkable other than persistent hypercalcaemia (3.9 mmol/l [15.6 mg/dl], reference range 2.0–2.5 [8–10 mg/dl]). Parathyroid hormone concentrations are subnormal, and retrovirus screening tests are negative.



- i. What abnormalities can be seen on the lateral thoracic radiograph (115) from this cat?
- ii. What differential diagnoses should be considered and how should this case be investigated?

116 An 11-year-old female neutered domestic longhaired cat that has a 3-month history of progressively worsening weight loss in spite of a voracious appetite is presented. The owner also reports that the cat is hyperactive and irritable. On clinical examination, the cat is bright and, although thin, is in reasonable condition. A nodule is palpated in the ventral neck (116) and the cat is tachycardic (>240 beats per minute). Serum biochemistry results are shown.



- i. What is the assessment of this case on the basis of what is known at this stage?
- ii. What is a possible diagnostic plan?

Biochemistry

Parameter	Result	Reference range
Urea mmol/l (mg/dl)	10.2 (28.6)	6.0–10.5 (17.0–29.0)
Creatinine μmol/l (mg/dl)	110 (1.2)	<175 (<2.0)
Phosphate mmol/l (mg/dl)	2.0 (6.2)	0.95–1.95 (2.9–6.0)
Glucose mmol/l (mg/dl)	6.3 (113)	3.5–7.5 (60–135)
Total protein g/l (g/dl)	75 (7.5)	55–80 (5.5–8.0)
Albumin g/l (g/dl)	35 (3.5)	24–35 (2.4–3.5)
Globulin g/l (g/dl)	40 (4.0)	21–50 (2.1–5.0)
Alanine aminotransferase (IU/l)	324	15–45
Alkaline phosphatase (IU/l)	216	15–60
Total T4 nmol/l (μg/dl)	56 (4.3)	19–65 (1.5–5.0)

115, 116: Answers

115 i. The lateral radiograph reveals a diffuse, patchy/nodular predominantly alveolar and interstitial infiltrate affecting most of the visible lung fields. The cardiac silhouette is partially obscured but does not look grossly abnormal.

ii. Major differential diagnoses for this radiographic appearance would be:

- Primary or metastatic neoplasia.
- Fungal pneumonia (*Cryptococcus*, *Blastomyces*, *Histoplasma*, *Coccidioides*).
- Tuberculous mycobacterial infection.

Other less likely causes would include parasitic pneumonia and severe asthma.

If the enlarged submandibular lymph nodes are part of the same disease process, then lymphoma would be the most likely neoplastic disease, but while paraneoplastic hypercalcaemia could occur with this, the cytology from the lymph node aspirate suggests inflammatory rather than neoplastic disease. Both fungal and mycobacterial disease can cause granulomatous lung disease, and hypercalcaemia can be seen secondary to this. Further investigations should include:

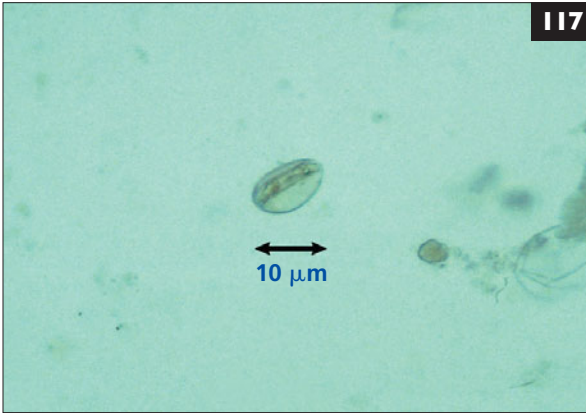- Lymph node biopsy for histology and staining for fungal (e.g. PAS) and mycobacterial (e.g. ZN) organisms (\pm culture or PCR analysis).
- Bronchoalveolar lavage for cytology, bacterial, and fungal cultures, and/or PCR testing for appropriate microorganisms (e.g. mycobacteria).
- Serological testing as appropriate (e.g. cryptococcal antigen titres).

If treatment has to be delayed pending results of investigations, the hypercalcaemia should be managed with IV fluids and, possibly, calcitonin or bisphosphonates.

This cat had mycobacterial infection confirmed, probably *Mycobacterium microtii*.

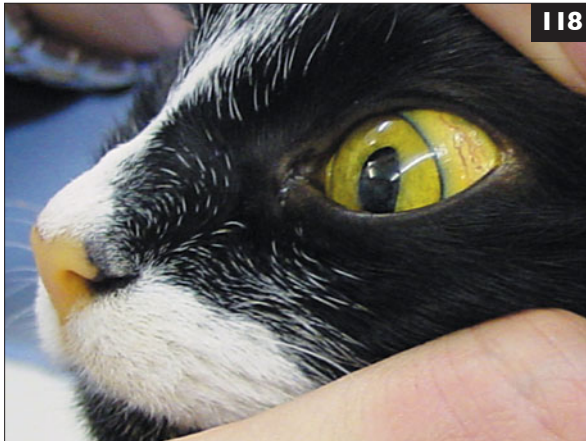116 i. The history and clinical findings are most suggestive of hyperthyroidism. Serum biochemistry shows elevation of liver enzymes and a mild hyperphosphataemia which are common in hyperthyroid cats, but the total T4 results are normal meaning that the nodule palpated may be a non-functional thyroid mass. Blood glucose results are normal ruling out diabetes mellitus as a potential cause of the cat's clinical signs. Other differential diagnoses that cannot be ruled out at this stage would be primary liver disease and gastrointestinal disease, although these would not explain the behaviour changes and tachycardia.

ii. The serum T4 is at the top of the reference range which is unusual in an elderly cat and suspicious of underlying hyperthyroidism. This result is consistent with early or mild hyperthyroidism when variation in serum T4 levels includes fluctuation in and out of the reference range. Another possibility would be that the T4 is being suppressed by the presence of other illnesses ('sick euthyroid'). Since the cat is currently bright and reasonably well, it may be simplest to repeat the serum T4 in 2–4 weeks' time. Further tests for other diseases (e.g. survey radiographs, abdominal ultrasonography) can also be considered at this stage.



117 The structure in the picture (117) is seen on microscopy following faecal flotation from a cat with diarrhoea.

- i. What is this structure and what is its significance?
- ii. What is the optimal method of making a diagnosis of this infection, and how should the cat be managed?



118 A 3-year-old DSH cat that has marked jaundice is presented to you (118).

- i. What are the three categories of causes of jaundice?
- ii. How can it be established which one of these is present in this cat?

117, 118: Answers

117 i. This is a *Giardia* cyst. *Giardia* preferentially infects the distal small intestine of cats, and infections can range from being completely asymptomatic to being a cause of profound debilitating diarrhoea. Diarrhoea may be acute, chronic, or intermittent, and is frequently characterized by steatorrhoea. *Giardia* infections will cause lymphoplasmacytic intestinal inflammation, and the organism can directly inhibit brush-border enzymes. Therapy is always warranted when *Giardia* is detected, and the organism is regarded as a likely zoonosis.

ii. *Giardia* cysts are best identified by the zinc sulphate centrifugation technique as routine faecal flotation methods will cause distortion of the cysts making them difficult to identify. Cysts may only be shed intermittently, and thus optimal diagnosis requires the examination of at least three faecal samples collected at 24–48 hour intervals. Other methods of diagnosis include examination of faecal smears (wet preparations) to look for the characteristic binucleate motile trophozoites (less sensitive than looking for cysts), and faecal ELISA tests to detect *Giardia* antigens. If the latter is used, care should be taken to use a test that has been validated for use in cats.

A variety of drugs have been used to treat *Giardia* in cats, but the two most commonly employed are metronidazole (20–25 mg/kg twice daily for 5–10 days) and fenbendazole (50 mg/kg daily for 5 days). Due to concerns over possible resistance to metronidazole, fenbendazole is now commonly recommended. Treatment should include all animals in a household as asymptomatic carriers could be present, and recent evidence suggests shampooing at the same time as systemic treatment may reduce the risk of recurrence by removing any cysts present in the haircoat.

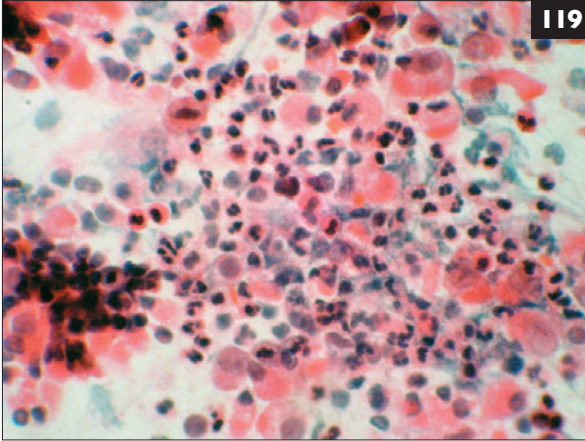
118 i. Jaundice can be classified as being:

- Prehepatic, hepatic, or post-hepatic (obstructive jaundice).

ii. A logical plan involves:

- Thorough history taking may identify exposure to toxins such as acetaminophen (paracetamol) which can cause oxidative damage to RBCs leading to a Heinz body haemolytic anaemia.
- Clinical examination should pay particular attention to palpation of the cranial abdomen for the presence of a mass causing obstruction to the bile duct and other evidence of systemic causes of jaundice such as ascites due to FIP.
- Haematology and serum biochemistry help to identify haemolytic anaemia (prehepatic jaundice), elevation of liver enzymes (hepatic disease).
- Imaging by radiography and ultrasonography may allow visualization of abnormal hepatic tissue or evidence of post-hepatic obstruction of the bile duct. Cats with FIP may have pleural effusion and/or ascites.

In most cases, further specific diagnostic tests will be required to confirm the exact cause of disease. Haematology to rule out haemolytic anaemia and ultrasonography to rule out biliary obstruction are valuable early tests.

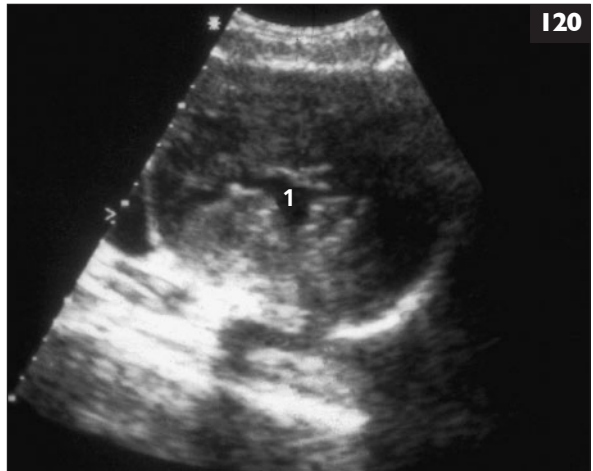


119 A 4-year-old neutered male Siamese cat presents with persistent paroxysmal coughing and intermittent episodes of dyspnoea of varying severity. A routine blood panel is unremarkable, but radiography reveals a moderate to marked generalized bronchial pattern. A bronchoalveolar lavage is performed which yields a turbid fluid with much mucus. The cytological appearance of the fluid is shown (119).

- i. What does this reveal and how should this finding be interpreted?
- ii. What differential diagnoses should be considered?

120 A short axis view of the heart in diastole from a 7-year-old DSH cat is shown (120). The left ventricular lumen is indicated (1).

- i. Comment on the appearance of the left ventricle.
- ii. What further tests are appropriate?



119, 120: Answers

119 i. The cytology in this case shows a predominance of eosinophils with some neutrophils, lymphocytes, and macrophages. This is difficult to interpret in cats as bronchoalveolar lavage cytology in healthy cats is very variable. In most healthy cats, alveolar macrophages predominate in bronchoalveolar lavage fluid, and account for around 70% of all the cells. However, eosinophils, neutrophils, and lymphocytes can all make a significant but variable contribution. Unlike most species, eosinophils form a large proportion of the cells present in bronchoalveolar lavage from healthy cats; they are typically the second most common cell and account for 20–30% of the total. However, even in healthy cats, eosinophils can predominate, and can make up as much as 80–85% of the total cells. The finding of a large proportion of eosinophils alone is thus not abnormal but has to be evaluated in the light of the total cell count and other findings (e.g. presence of mucus, radiographic findings) to assess its significance. In this case, the high cellularity and appearance of the fluid suggest this is genuinely eosinophilic inflammation.

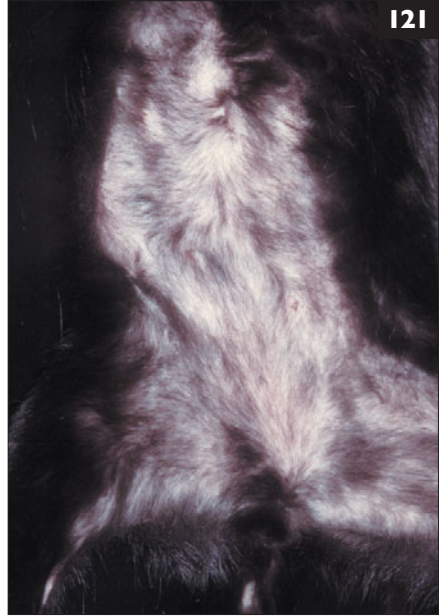ii. The true significance of eosinophilic airway inflammation in cats has yet to be established; however, when found it is believed that this is most likely to reflect underlying asthma or respiratory parasitism. The history of this cat would be consistent with asthma, but parasites could not be ruled out. These would include *Aelurostrongylus abstrusus*, *Dirofilaria immitis*, *Paragonimus* spp., *Capillaria aerophila*.

120 i. The left ventricular lumen appears subjectively reduced in size and the wall subjectively thickened.

ii. Measurements of the left ventricle free wall, internal diameter and interventricular septum should be taken and compared to the reference range. These measurements should be performed via right parasternal echocardiography of the left ventricle in short axis view. Ideally, M-mode (motion mode), which allows the user to place a cursor line through the left ventricle at the level of the chordae tendinae, is used to make these measurements. This produces a trace of the movement of the section of the heart transected by the cursor (y axis) against time (x axis). The trace is frozen and measurements are recorded. Diastole is measured at the onset of the QRS complex on a simultaneously recorded ECG trace; systole is taken as the point when the septal wall motion is at its nadir.

Parameter	Normal range (mm)
Left ventricle free wall systole	4–9
Left ventricle free wall diastole	2.5–5
Left ventricle internal diameter systole	6–10
Left ventricle internal diameter diastole	11–16
Interventricular septum systole	5–9
Interventricular septum diastole	2.5–5

121 A 3-year-old neutered female DSH presents with ventral alopecia (121) of 4 months' duration, which the owner reports is non-pruritic. What would be your major differential diagnoses and approach to investigation?



122 An entire male stray cat (122) is presented for a general health check prior to rehoming. The cat seems healthy other than some evidence that he has been a fighter in the past. A patient-side FeLV and FIV test gives a positive FIV antibody result.

- i. What is the significance of this result to the stray cat?
- ii. The client has three other cats. What is the risk of transmission of infection to these?



121, 122: Answers

121 The absence of owner-observed pruritus would not rule out a pruritic skin disease, and thus both pruritic and non-pruritic causes of ventral alopecia should be considered. These would include:

- Flea bite hypersensitivity.
- Atopy.
- Dermatophytosis.
- Food hypersensitivity.
- Paraneoplastic alopecia.
- Telogen effluvium.
- Self-induced alopecia due to behavioural causes ('stress-induced').
- Ectoparasites (*Cheyletiella*, *Otodectes*, *Demodex*, *Felicola*).

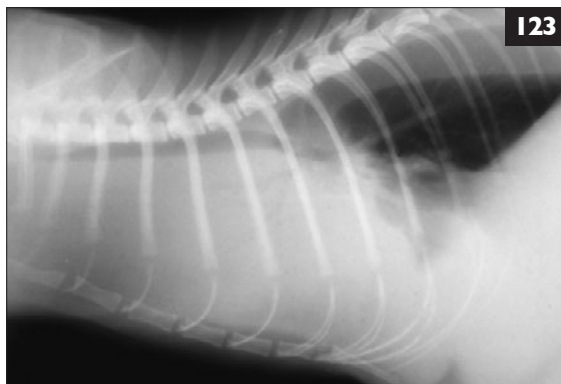
Pertinent facts relate to lifestyle and background, current and previous diet, systemic illness, progression of signs, previous signs, and signs on other animals and/or the owner.

A trichogram (microscopic examination of 20–30 plucked hairs) is important to determine if the alopecia is self-induced (evidenced by fractured hairs/damaged hair shaft and a normal telogen:anagen ratio). Flea hypersensitivity would be the most common cause of self-induced alopecia, and examination for fleas (examination of the coat, flea combing, and a 'wet paper test' on coat brushings) should be performed and appropriate treatment given if there is any evidence of infestation.

Additional diagnostic procedures would include a 'sticky tape test' and skin scraping to look for ectoparasites (*Cheyletiella*, *Otodectes*, *Demodex*); and Wood's lamp illumination, hair microscopy, and culture to look for dermatophytes. Intra-dermal skin testing (or blood testing) may be indicated if atopy is suspected and a food trial with a hypoallergenic (e.g. hydrolysed protein) or restricted (and ideally novel) protein diet would be indicated to rule out food hypersensitivity. A skin biopsy (for histology and culture) may be valuable, especially if the alopecia is not self-induced.

122 i. Anti-FIV antibodies are associated with persistent infection with this virus. False-positive test results can occur, although the prevalence of FIV infection is higher in free-roaming, entire male stray cats so this is likely to be a genuine result. Since this cat is clinically healthy, it may be advisable to submit blood for confirmatory testing at a commercial laboratory (PCR or western blot techniques can be used in addition to routine antibody tests).

ii. The prime mode of transmission is via a bite from an infected cat. Other modes of transmission that are less efficient at spreading infection include vertical transmission, sexual intercourse, mutual grooming, sharing food bowls, and possibly via blood-sucking arthropods such as fleas. The risk of transmission via benign social contact is considered to be very low so many owners elect to keep the household as it is if the cats do not fight.

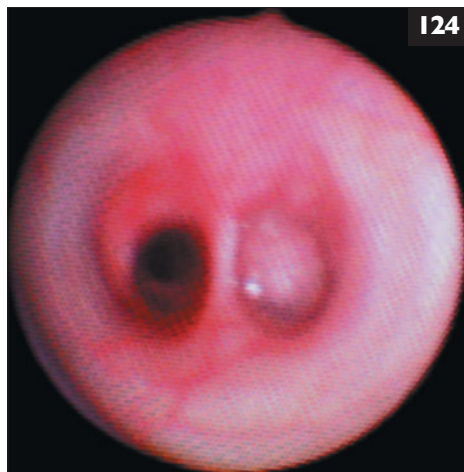


123 The lateral thoracic radiograph (123) is from a 9-year-old neutered female DSH cat that presented with progressive inspiratory dyspnoea over a 3-month period.

- i. What radiographic features can be seen and what are the major differential diagnoses?
- ii. What findings would be expected on clinical examination of this cat?
- iii. How readily could you distinguish between the two major differential diagnoses in this case? How would you do this?

124 A 10-year-old neutered male DSH cat presents with a 2-month progressive history of predominantly inspiratory dyspnoea, lethargy, inappetence, and weight loss. Radiographic examination reveals a large, well circumscribed homogenous soft tissue density occupying the left caudal lung lobe with obliteration of the bronchus supplying this lobe. Ultrasonography confirms the presence of homogenous consolidation of the left caudal lung lobe. Tracheoscopy is performed (124).

- i. What is evident on tracheoscopy?
- ii. What is the likely diagnosis/differential diagnosis?
- iii. What other changes are sometimes seen with this condition?



123, 124: Answers

123 i. The lateral radiograph shows a large soft-tissue density in the cranial thorax. This is causing marked dorsal displacement of the trachea, caudal displacement of the carina, and is obscuring the cranial lung fields. There is evidence of a pleural effusion and the cardiac silhouette is obscured.

The radiographic appearance is consistent with a large cranial mediastinal mass. The major differential diagnoses are anterior mediastinal lymphoma or thymoma (benign epithelial tumour). Other possibilities include extension/metastatic/ectopic thyroid adenocarcinoma, a mediastinal abscess, or a branchial cyst.

ii. Clinical examination would show reduced 'rib-spring' or compliance of the cranial thorax, an absence of lung sounds cranially, and dullness on percussion of the thorax cranially. There would also be caudal displacement of the normal cardiac sounds.

iii. Differentiating malignant lymphoma from thymoma is not always easy. Cytological examination of fine needle aspirates from the mass (or cytology of pleural fluid if present) can sometimes be diagnostic. Lymphomas often have large numbers of lymphoblasts and lymphocytes with evidence of malignancy, whereas thymomas may reveal atypical or neoplastic epithelial cells. However, atypical epithelial cells are not always present in aspirates from thymomas, and the predominant cell type is usually small lymphocytes. Some thymomas contain a very large proportion of lymphocytes (lymphocytic thymomas), and as some lymphomas are well differentiated lymphocytic forms, distinguishing these two tumours can be problematic. Even needle biopsies do not always give a definitive diagnosis and, where doubt exists, surgical biopsies may be required.

124 i. A pale pink mass is evident in the left main-stem bronchus and it appears to be completely obliterating the lumen.

ii. It is not clear from the picture whether this is a soft tissue mass (inflammation, neoplasia), a foreign body, or fluid (e.g. pus). However, given the radiographic and ultrasonographic findings, and the site of the lesion (caudal lung lobe), this is most likely to be a soft tissue mass caused by expansion of a tumour. The most common tumour at this site is bronchial/pulmonary adenocarcinoma. This diagnosis was confirmed (poorly differentiated carcinoma) by biopsy of the visible mass.

iii. Pulmonary and bronchial adenocarcinomas are aggressive tumours. Lameness has been reported in 5–25% of cases, most of these probably arising from musculoskeletal metastases. Digital metastases are well described often causing firm swelling of multiple digits (the so-called 'lung-digit syndrome'), but metastasis to muscle is also seen quite commonly. In a significant number of cases, lameness rather than respiratory signs is the presenting complaint, while other cases may present with vague clinical signs. Metastases can occur to the eyes, liver, kidneys, skin, and CNS and occasional cases of paraneoplastic neuropathy, paraneoplastic hypercalcaemia, and hypertrophic osteopathy secondary to the lung mass have been reported.



125 A client brings in a cat which has had several generalized seizures in the last hour. Clinical examination reveals a subdued cat but no further abnormalities are evident (125).

- i. What initial laboratory work is most important?
- ii. While the laboratory samples are being processed, the cat has another seizure in the hospital. What emergency treatment is most appropriate?

126 A 7-month-old Burmese cat is brought in with a 2-month history of poor growth, reduced appetite, and lethargy (126). The owner reports that the kitten does not play much and seems generally depressed. On previous occasions the kitten has been pyrexic when examined.



- i. One of the differential diagnoses under consideration is FIP. Which of the following laboratory tests, on its own, is likely to be least helpful in diagnosing this condition and why?

- Haematology.
- Serum biochemistry.
- Feline coronavirus antibody test ('FIP' titre).

- ii. What other investigations might be helpful in diagnosing this condition?

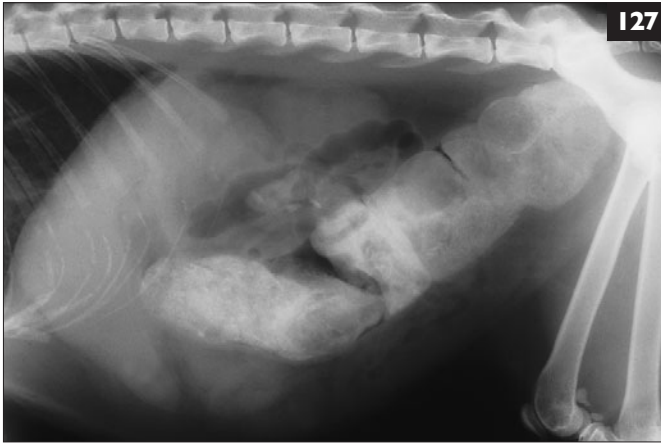
125, 126: Answers

125 i. Metabolic causes of seizures should be investigated before the cat has another seizure since specific treatment may be indicated. Causes include hypoglycaemia, hypocalcaemia, marked azotaemia, hepatic encephalopathy and, rarely, causes such as hyperviscosity syndrome (due to polycythaemia or marked hyperproteinaemia) and severe electrolyte disturbances such as hypernatraemia. Therefore an essential minimum database for a seizure patient includes blood glucose, urea, calcium, PCV, total protein, ammonia and, where possible, sodium, potassium, liver enzymes, and bile acids. Where available, arterial blood gas analysis may be indicated as hypoxia is another important cause of seizures. Inflammatory disease is a common cause of seizures in cats so samples should be submitted for infectious disease screening (FIV, FeLV, coronavirus serology, *Toxoplasma gondii* titres).

ii. Ideally the cause of the seizure is treated specifically, e.g. calcium in hypocalcaemic patients. If the cause of the seizure is not known then a bolus injection of 0.5–1.0 mg/kg diazepam is indicated. If intravenous access is not possible then the diazepam can be administered per rectum. Repeated doses of diazepam may be required if seizures continue; alternatively a diazepam infusion can be provided. Other therapeutic agents include phenobarbitone (phenobarbital) injection (1.0–2.5 mg/kg IV twice daily) although this has a slower onset of action (10–30 minutes). Pentobarbitone (pentobarbital) can be used IV to control seizures but has several disadvantages. Anaesthesia is induced, which increases monitoring requirements, and it is a less effective anticonvulsant than diazepam or phenobarbitone (phenobarbital).

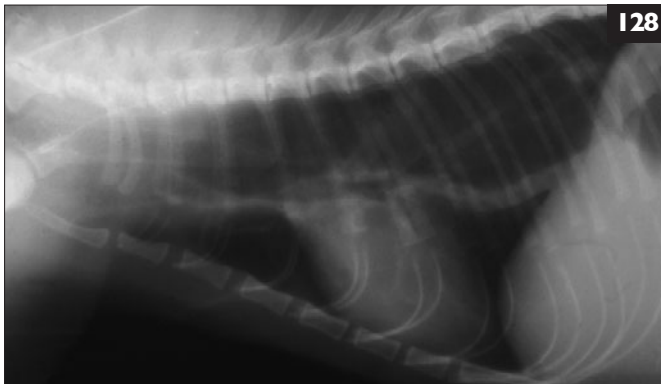
126 i. Coronavirus antibody testing is least helpful. A positive result confirms exposure to a coronavirus but is not specific for FIP. Coronavirus titres are common in pedigree cats and cats from multi-cat households, so it is likely that this cat will have a positive titre. Negative coronavirus antibody titres can be obtained from cats with confirmed FIP so a negative result does not rule out the possibility of this disease.

ii. A thorough clinical examination including complete neurological and ophthalmological examination is important in order to look for evidence of inflammatory disease which can be associated with dry (non-effusive) FIP. Imaging of the brain and/or spinal cord by MRI or CT and CSF sampling and analysis may be indicated in those cats with neurological disease. Survey radiography and ultrasonography of the chest and abdomen may identify free pleural and/or abdominal fluid which can be sampled for cytology and biochemistry. Ultrasonography may also identify lymphadenopathy or serosal lesions (FIP granulomas) which can be aspirated for cytology. Routine serum biochemistry and haematology may also give some clues of FIP (e.g. hyperglobulinaemia, hyperbilirubinaemia, mild non-regenerative anaemia, lymphopenia, mature neutrophilia). Unfortunately, no laboratory tests are specific for FIP and histology of affected organ tissue remains the only definitive way to confirm the suspicion of FIP.



127 A lateral abdominal radiograph (127) from a cat with recurrent dyschezia and constipation is shown.

- i. What does the radiograph reveal?
- ii. What are the differential diagnoses?
- iii. How should the case be investigated?



128 The lateral thoracic radiograph (128) is from a 15-month-old Siamese cat that, according to the owner, has been persistently 'throwing up'.

- i. How should vomiting be distinguished from regurgitation in such a case?
- ii. What abnormality(ies) can be seen on the radiograph?

127, 128: Answers

127 i. The radiograph demonstrates severe constipation/obstipation with a dilated and faeces-filled colon. The descending colon is clearly grossly distended with faeces.

ii. These findings are consistent with severe constipation and megacolon, but the cause of this is unclear. Major causes of severe constipation include idiopathic megacolon, pelvic canal stenosis, and pelvic nerve injury. Other potential causes or contributory factors to consider with chronic constipation include dysautonomia, neoplasia, hypothyroidism, pain when posturing to defecate, electrolyte disturbances (hypokalaemia, hypercalcaemia), rectal diverticulae, rectal strictures, rectal masses/foreign bodies, other painful anorectal disorders, inappropriate diet, environmental changes, and inappropriate or soiled litter trays (i.e. psychological factors). Excessive ingestion of hair, especially in longhaired cats, can be a significant factor.

iii. Routine evaluation of constipation should include radiography (two views) to assess the severity of the constipation and the integrity of the pelvic canal. A neurological assessment is important to rule out potential neuromuscular diseases, spinal cord disease, or dysautonomia. The dietary history and environment should be reviewed, and consideration should be given to assessment of thyroid status in young cats (congenital hypothyroidism commonly results in constipation).

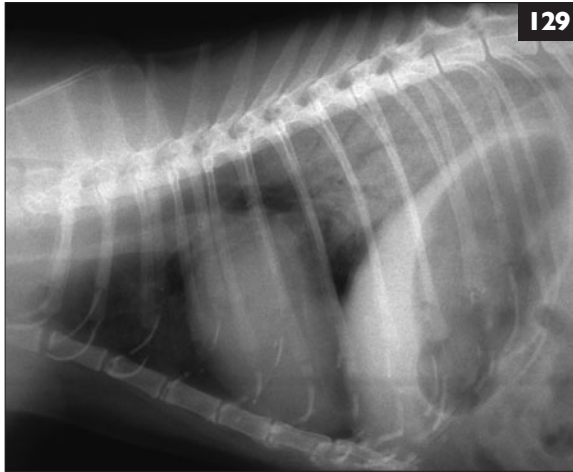
If necessary following resolution of the constipation, further imaging, radiography (\pm barium contrast), ultrasonography, and/or endoscopy can be used to rule out structural changes to the rectum and colon.

128 i. Distinguishing true vomiting from regurgitation can be difficult (see table below), especially if owners do not observe the cat during the process. In some circumstances fluoroscopy may be needed to make a diagnosis.

ii. The radiograph shows a widely dilated oesophagus throughout the thorax. This appearance is typical of severe megaesophagus.

Differentiation of regurgitation and vomiting

Signs	Regurgitation	Vomiting
Appetite	Usually good \pm eating regurgitated food	Variable, often reduced
Dysphagia/pain on swallowing	Variable	Uncommon
Signs of nausea	Absent	\pm Present
Observed activity	Passive	Active (retching) \pm abdominal contractions
Time after feeding	Usually within minutes (occasionally delayed)	Variable minutes–hours
Appearance of food	\pm Tubular, digested or undigested	Variable, digested or undigested
Presence of blood	\pm Fresh blood	\pm Fresh or digested blood
Presence of bile	No	Variable

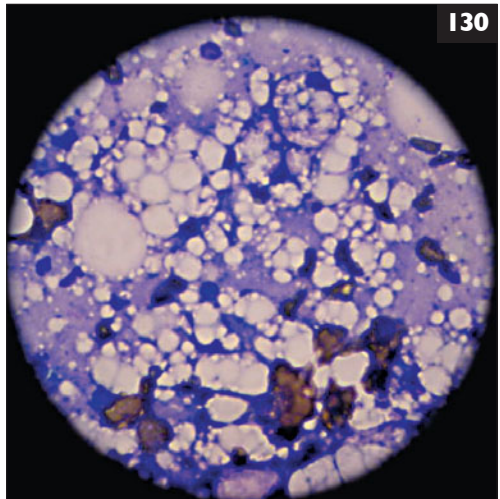


129 This right lateral thoracic radiograph (129) is of a 9-year-old male neutered DSH cat presented as an emergency with a history of acute onset dyspnoea and lethargy. When examined the cat was found to be very depressed and moist râles were audible throughout the lung fields. No sedation was required for radiography.

- i. What abnormalities are evident?
- ii. What action should be taken?

130 A 4-year-old Maine Coon cat presents with recent anorexia, marked weight loss, lethargy, and vomiting. There is severe jaundice and elevation of serum liver enzyme concentrations. Ultrasonography shows hepatomegaly with a diffuse increase in liver echogenicity. Cytology of a fine needle aspirate from the liver is shown (stained with 'Diff-Quick') (130).

- i. What is the likely diagnosis in this case?
- ii. What is known concerning the pathogenesis of this condition?
- iii. How should the cat be treated?



129, 130: Answers

129 i. The heart is tall with an increased cranial to caudal diameter. An intense alveolar lung pattern is visible in the caudodorsal and, to a lesser extent, cranioventral lung fields. Air bronchograms are evident in the caudodorsal thorax. This lung pattern is consistent with severe oedema, haemorrhage, or infiltration. Given the cardiac enlargement, cardiogenic pulmonary oedema is the most likely possibility.

ii. Cage rest and oxygen therapy (e.g. oxygen cage) are indicated in addition to more aggressive treatment. Diuretic therapy, for example, using intravenous furosemide at 2–4 mg/kg given up to every 6 hours can be used to reduce the oedema. If intravenous access is not possible then this agent can be given IM. Serum potassium levels should be monitored as furosemide can precipitate hypokalaemia.

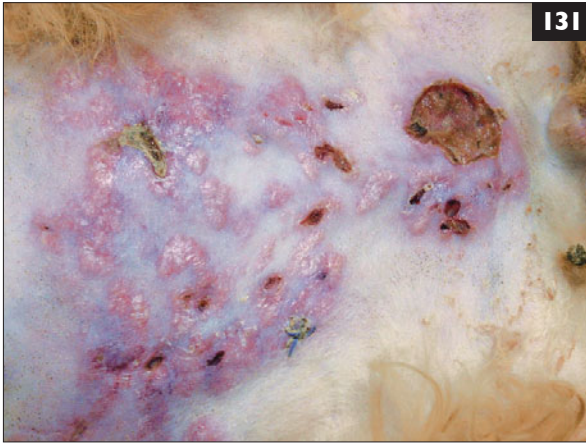
Glycerol trinitrate cream can be applied every 6–12 hours as an emergency vasodilator. A 0.6–1.2 cm (0.25–0.5 inches) line of cream should be applied to the skin of the pinna or onto a clipped area of skin then covered with tape to prevent iatrogenic human dosing. Oral therapy, with agents such as furosemide and spironolactone, should be instituted as soon as the cat is more stable and further cardiac assessment (e.g. echocardiography) performed in order to characterize the specific cause of the cardiac disease which will allow choice of further appropriate treatment.

130 i. A substantial proportion of the cells in the smear show vacuolation with large accumulations of non-staining material (likely to be lipid accumulation). This cytology is typical of hepatic lipidosis. Although care must be taken with interpretation of hepatic fine needle aspirate cytology as samples may not be representative, the degree of vacuolation observed and the consistent history, signs, and ultrasonography would all be strongly supportive of this diagnosis.

ii. Hepatic lipidosis can either be primary (often associated with recent anorexia and weight loss) or can be secondary to other diseases such as diabetes mellitus. Hepatic lipidosis also occurs with inflammatory bowel disease, pancreatitis, and cholangiohepatitis, although the pathogenesis in these conditions may be similar to idiopathic cases. Thorough investigation to identify concurrent diseases is important.

Idiopathic hepatic lipidosis is characterized by massive triglyceride accumulation within hepatocytes. This results from either increased production of triglyceride (e.g. due to lipolysis associated with anorexia) and/or a decreased ability of the liver to oxidize or excrete them in the form of VLDLs. Relative carnitine deficiency has been proposed to be involved, possibly causing reduced hepatic oxidation of fatty acids.

iii. Despite uncertainties over the precise pathogenesis, treatment is usually successful, but involves aggressive nutritional support (usually initially via an oesophagostomy or PEG tube) without protein restriction except if hepatic encephalopathy develops. Supplementation with carnitine and taurine (both at 250–500 mg/cat/day) has been recommended but objective data on efficacy is lacking. The prognosis depends on the severity, response to therapy, and any underlying/concurrent diseases.

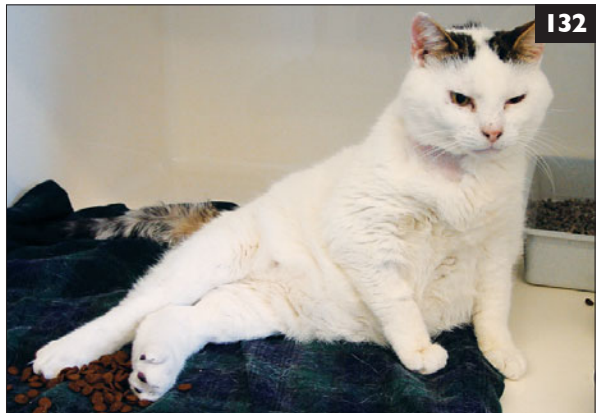

131 A 4-year-old neutered male domestic longhaired cat presents with a 2-month history of inguinal swelling and discharge. On clinical examination, subcutaneous swelling is palpable. The area is clipped (131).

- i. What abnormalities are evident in the picture?
- ii. What are the differential diagnoses?
- iii. What investigations are required to confirm the cause of the disease?
- iv. How should the patient be handled while awaiting results?
- v. What is the most probable diagnosis and how is this likely to have been caused?

132 A 10-year-old female neutered DSH cat is brought in with a history of being found in the owner's garden with sudden onset hindlimb paralysis (132).

- i. What are the main differential diagnoses that should be considered initially?
- ii. What is a possible diagnostic plan?



131, 132: Answers

131 i. Irregular swelling/nodules are visible over the ventral abdomen, inguinal area and prepuce. Some of these areas are ulcerated.

ii. Major differential diagnoses are:

- Opportunistic mycobacterial infection.
- Other (less likely) infectious causes, e.g. fungal (e.g. *Cryptococcus*, subcutaneous dermatophyte infection), viral (e.g. poxvirus), bacterial (e.g. *Rhodococcus equi*, *Actinomyces*). The severity of signs would make pox and dermatophytosis unlikely.
- Foreign body, causing a secondary panniculitis.
- Underlying disease causing immunosuppression, e.g. FeLV, FIV.
- Concurrent therapy affecting wound healing or ability to eliminate opportunistic infections, e.g. corticosteroids, progestagens, cytotoxic agents.
- Pansteatitis, e.g. related to pancreatitis, vitamin E deficiency.
- Neoplasia.

iii. A skin biopsy should be taken. Impression smears should be stained with Gram, ZN, PAS and examined for infectious organisms. Biopsy material should be submitted for histopathology (including specialist stains for bacteria and fungi) and bacterial culture. If possible, a portion of tissue should be frozen at -20°C (-4°F) in case future mycobacterial culture or PCR is required following histology results.

iv. Some of the differential diagnoses are potentially zoonotic although the risk is generally low. Gloves, protective clothing and eyeglasses should be worn when handling the cat and the minimum number of staff possible should be involved in its care. Immunosuppressed, pregnant, very young and very elderly people should avoid contact with the cat.

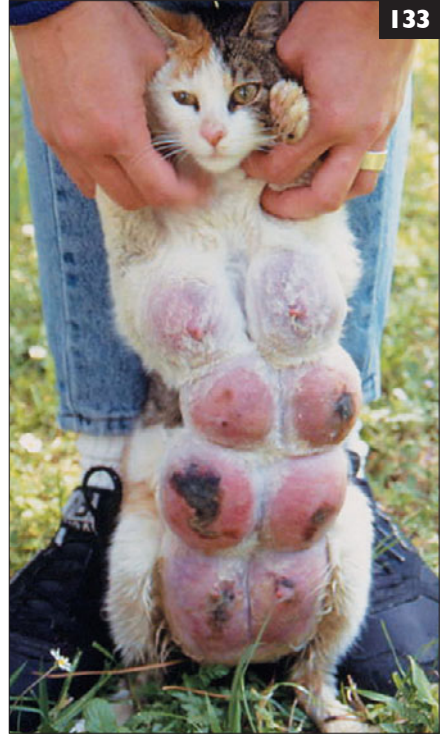v. Opportunistic mycobacterial infection. This is likely to have been acquired following opportunistic infection of a minor skin wound.

132 i. Spinal trauma and distal aortic thromboembolic disease are the two main differential diagnoses that should be considered initially.

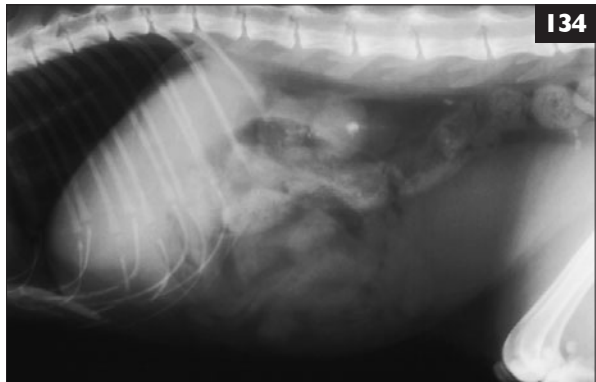
ii. Thorough clinical examination should pay particular attention to cardiac auscultation since cardiac disease is the most common cause of feline thromboembolic disease. Evaluation of hindlimb circulation may include palpation or use of a Doppler probe to detect presence of peripheral pulses, assessment of hindlimb warmth and colour of non-pigmented pads. Blood flow can be assessed by pin pricking a pad. Tissue necrosis in thromboembolic cases may result in dramatic elevation of creatinine phosphokinase and a reperfusion hyperkalaemia which can become life threatening. Radiography may aid diagnosis of spinal fracture/luxation as well as evidence of cardiac disease such as cardiomegaly. Further cardiac investigation, where indicated, should include echocardiography. In cats with thromboembolic disease caused by cardiac disease, left atrial dilatation, spontaneous contrast ('smoke' in the left atrium) and a thrombus may be visible in addition to other evidence of the primary cardiac disease.

133 A 3-year-old neutered female cat presents with firm non-painful roughly symmetrical swelling of the mammary glands (133). The cat is systemically well and showing no other signs.

- i. What is the likely cause of the swelling and how can the diagnosis be confirmed?
- ii. What is known about the cause(s) of this disease, and how can such cases be managed?



134 What is evident on this lateral abdominal radiograph (134) from a 15-year-old neutered female Burmese cat with weight loss and inappetence? Explain why an ACE inhibitor such as benazepril might be recommended for this individual.



133, 134: Answers

133 i. This is most likely to be a case of mammary hyperplasia (fibroadenomatous/fibroepithelial hyperplasia). It occurs in both male and female cats, but is more common in the latter. There is usually a very marked increase in the size of one or, more usually, multiple mammary glands. The swelling can get to such a size that it causes overlying cutaneous ulceration. The diagnosis is confirmed by biopsy and this differentiates it from other conditions such as neoplasia and mastitis.

ii. Most affected cats are young entire females, and it is assumed that the hyperplasia develops in response to excessive progesterone production (although serum concentrations are not necessarily abnormal). In other cats, there is a history of exogenous progestagen use (oral, or depo-injectable drugs) which has been clearly linked to mammary fibroepithelial hyperplasia in cats. In a small proportion of cases, the disease occurs in neutered females or male cats with no exogenous progestagens having been administered. It is not clear if these cats also have excessive endogenous progesterone from another source.

Spontaneous resolution of the condition typically (but not always) follows removal of the presumed source of progesterone (withdrawing drug therapy, neutering an entire female) but this can be very slow. If response is inadequate, or if there is not an obvious source of progestagens, administration of the progesterone receptor antagonist, aglepristone, has recently been reported to be highly successful. Doses used have been 10 mg/kg SC twice weekly or 20 mg/kg SC once weekly for 1–4 weeks, or 10 mg/kg SC daily for 4–5 days.

134 This radiograph demonstrates bilateral small kidneys (<2× the length of L2), both appearing to have irregular margins. There is probable nephrocalcinification or (more likely) a nephrolith in the left kidney. These findings suggest probable CRF.

In humans, both hypertension and proteinuria are well recognized risk factors for progression of CRF, and ACE inhibitor therapy is well established. Patients with moderate to severe proteinuria (a marker of glomerular damage) benefit most, and ACE inhibitors have demonstrated renoprotective effects over and above simple control of blood pressure. This is thought to be mediated through reduced intraglomerular pressure, caused by greater dilation of the efferent glomerular arteriole than the afferent arteriole. Other potential benefits include reduced oxidative stress, and reduced mesangial and glomerular hypertrophy. However, not all types of nephropathy necessarily benefit from ACE inhibitor therapy.

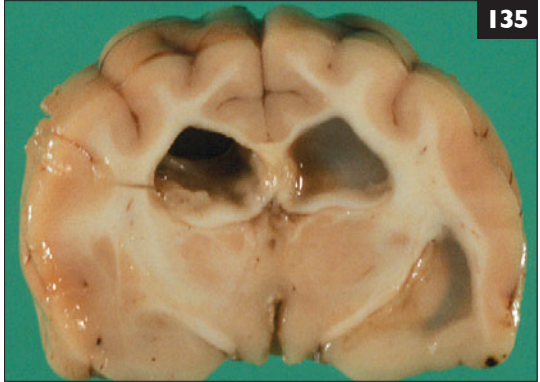
ACE inhibitor therapy in feline CRF is still controversial. Based on human studies there is good rationale for their use, but ACE inhibitors alone do not control systemic hypertension well in cats, and there is little knowledge of the role of proteinuria in progression of CRF. Nevertheless, initial studies of natural and experimental CRF do suggest potential benefit, although further studies are required.

135 A 9-year-old neutered female domestic longhaired cat is presented with a 3-week history of progressively worsening neurological signs which include restlessness, constant pacing, excessive vocalization, and mild ataxia. The cat is euthanased at the owner's request and a post-mortem examination is performed.

i. What abnormality is evident on cross-section of this brain (135)?

ii. What are the causes of this as an acquired abnormality?

iii. How can the diagnosis be made ante-mortem?



136 A Siamese cat is presented that has a 4-week history of circling to the right and a right-sided head tilt (136).

i. Assuming that the disease is not multifocal, what are the differential diagnoses?

ii. What is a possible diagnostic plan?



I 35, I 36: Answers

135 i. The lateral ventricles are markedly dilated which is diagnostic of internal hydrocephalus.

ii. Causes of obstructed CSF drainage include:

- Inflammatory disease, e.g. FIP, fungal (*Cryptococcus*), foreign body granuloma, or haematoma following trauma.
- Neoplastic causes, e.g. choroid plexus neoplasia, lymphoma.

iii. Specialist imaging techniques (MRI, CT) are required to make this diagnosis and will help to establish the severity of hydrocephalus as well as potential causes of the disease.

136 i. The cat has a right-sided head tilt which is most commonly caused by ipsilateral vestibular disease. Other commonly seen signs would include nystagmus with the slow phase towards the side of the lesion (the right side in this case), circling, ataxia, and rolling. Differential diagnoses can be separated into:

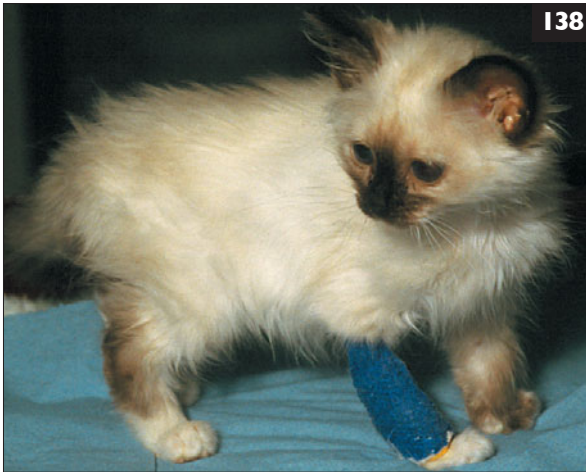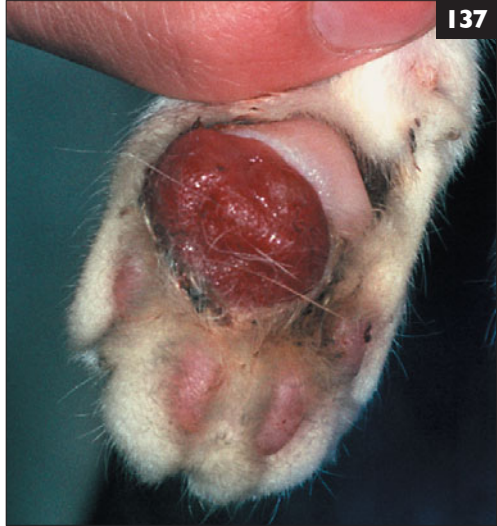- Central vestibular disease: lesion affecting the vestibular nuclei or cerebellum. Causes include inflammatory or neoplastic disease, thiamine deficiency, infectious causes (e.g. FIP, toxoplasmosis), lead toxicity, spread from otitis media/interna, trauma. Cerebellar lesions can result in paradoxical vestibular syndrome where the head tilt, circling, and nystagmus are in the opposite direction to that seen with classic vestibular syndrome.
- Peripheral vestibular disease: lesion affecting the vestibular nerve or inner ear. Causes include polyps, neoplasia involving temporal bone or vestibulocochlear nerve, otitis media/interna, idiopathic vestibular syndrome, aminoglycoside toxicity, trauma.

ii. The most important initial step is to determine whether the cat has central or peripheral vestibular signs. Clinical and neurological examination usually make this possible using the table below. Further investigations depending on the results of this assessment may include otoscopy, radiography of the skull (pharynx and bullae), examination of the nasopharynx, CSF collection and analysis, and MRI.

Distinguishing central and peripheral vestibular disease

Clinical sign	Central disease	Peripheral disease
Vestibular signs	+	+
Proprioceptive deficits	± (ipsilateral)	-
Weakness	± (ipsilateral)	-
Facial (VII) paralysis	±	±
Other neurological deficits	± other cranial nerve deficits (especially V, VI and VII), central depression	± Homer's syndrome

137 A cat presented with 'spongy' swollen metacarpal and metatarsal pads, some of which were ulcerated (137). What are these lesions characteristic of, and how should this be managed?



138 A breeder presents the two remaining kittens of a litter of 6-week-old Birman (138). He has recently lost three of the kittens to 'fading kitten syndrome'. This has happened to several litters previously with different queens. The kittens are dying at between 2 and 6 weeks of age. What differential diagnoses should be considered for this and what investigations should be undertaken?

137, 138: Answers

137 This cat has ulcerative pododermatitis. Differential diagnoses could include metastatic pulmonary carcinoma, vasculitis, EGC, contact dermatitis, and toxic epidermal necrolysis. However, the appearance and distribution of the lesions is typical of plasma cell pododermatitis. The diagnosis can be confirmed by biopsy of the pads.

Plasma cell pododermatitis is an uncommon disease in cats, but usually results in spongy swelling of multiple (metacarpal and metatarsal) pads. The swelling is characteristically soft and 'spongy' and there is often pain leading to lameness. The pain is significantly exacerbated by any ulceration that occurs.

Secondary infections occur after ulceration and it is important to keep the pads clean and treat infections promptly with appropriate antibiotics. Systemic signs seen in a minority of cats include pyrexia, lymphadenopathy, lethargy, and anaemia. Some recent studies have suggested a link between FIV infection and the development of plasma cell pododermatitis (which may account for the systemic signs in some), but the aetiology of the lesions has not been determined. The intense plasma cell infiltration has led to speculation that this is an autoimmune or immune-mediated condition, and affected cats frequently have a polyclonal gammopathy.

The lesions often regress spontaneously, and efficacy of therapy is uncertain. Immunosuppression is commonly recommended. Where ulceration occurs, surgical debulking and closure of the wound may be attempted.

138 It is estimated that approximately 50% of kitten mortalities are within the first week of life when environmental, nutritional, and congenital factors are the most likely causes. These include low birth weight, failure to suck, birth defects, maternal neglect, failure of milk let-down, neonatal isoerythrolysis, and hypothermia.

From 1 week of age onwards, environmental and congenital diseases can still be important, but infectious diseases become more important, and often an entire litter of kittens may be affected. Kittens that have failed to suck adequately in the first 24 hours of life are most susceptible due to poor maternally-derived immunity. Overwhelming septicaemia may occur (most commonly with streptococci or Gram-negative enteropathogens), and this may cause peracute death, which is sometimes only diagnosed at post-mortem. Bordetellosis can be a cause of pneumonia. As kittens get older (typically 4–7 weeks old) parasitic diseases (e.g. coccidiosis, flea infestation, and ascaridiasis), and viral infections (e.g. FCV, FHV, feline panleucopenia virus, feline coronavirus) can also be a common and significant cause of disease. Again, severe or overwhelming infections may cause acute death with little or no preceding signs. Toxin exposure should also be considered.

A repeated problem with different queens suggests an environmental or infectious cause of the problem. Most information is likely to be gained from a thorough review of husbandry policies, complete post-mortem examination of kittens that die, and appropriate clinical investigations of any sick kittens.


139 An 18-month-old neutered male Siamese cat (139) presents with a history of progressively worsening ataxia and dysmetria.

- i. What clinical abnormality is apparent?
- ii. What is the most likely cause of the cat's clinical signs?
- iii. How can a diagnosis be confirmed?
- iv. What treatment is recommended?



140 This cat (140) is suspected of having an infectious disease. An FeLV test is performed. What is meant by the following terms?

- i. Sensitivity.
- ii. Specificity.
- iii. Prevalence.
- iv. Positive predictive value.
- v. Negative predictive value.



139, 140: Answers

139 i. The cat has a very domed skull.

ii. This appearance is most consistent with a diagnosis of hydrocephalus. Congenital hydrocephalus has been reported as an autosomal recessive trait in Siamese cats and given the age and breed of this cat, this is a likely possibility. Other causes of hydrocephalus in kittens include exposure to toxins such as griseofulvin in gestation and feline panleucopenia virus in late gestation or early life. Idiopathic congenital hydrocephalus would be another possibility. Clinical signs vary and include forebrain signs such as behavioural changes (disorientation, inability to learn), gait abnormalities (dysmetria, ataxia), and seizures. Affected cats may have a domed skull with ventrolateral deviation of eye position and an open fontanelle.

iii. In some cases, ultrasonography can be performed via the open fontanelle confirming this diagnosis. Plain skull radiographs show a large domed calvarium with a ground glass appearance, thinning of the cortical bone, open suture lines, and persistence of the fontanelle. Specialist imaging techniques such as MRI and CT can also be used to confirm the diagnosis.

iv. Medical management is aimed at reducing CSF production and includes prednisolone (0.25–0.5 mg/kg once to twice a day) and furosemide (0.5–2.0 mg/kg once to twice a day). Oral carbonic anhydrase inhibitors such as methazolamide have also been used to reduce CSF production although these agents may be associated with side effects (e.g. sedation, bone marrow suppression, electrolyte disturbances; the latter are more severe in patients receiving glucocorticoids). Where appropriate, seizure control using anticonvulsants should be instituted. Methazolamide can affect the absorption and excretion of anticonvulsants and can cause osteomalacia when given with primidone or phenytoin. Surgical management of hydrocephalus is also an option via placement of a shunt from the ventricles to the abdominal cavity (ventriculoperitoneal shunt).

140 i. The sensitivity of a test is the probability that the test result is positive in an animal which has the disease (i.e. the proportion of diseased animals that test positive).

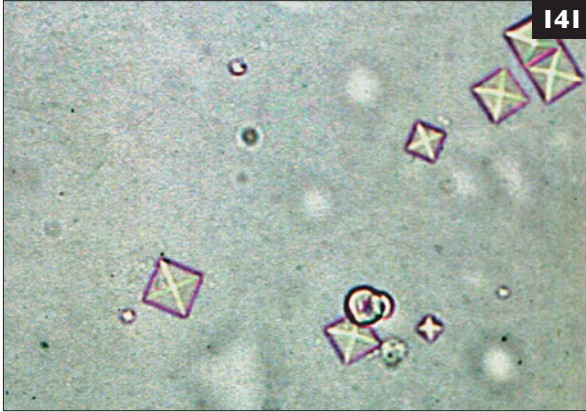
ii. The specificity is the probability that the result is negative in an animal which does not have the disease (i.e. the proportion of non-diseased animals which test negative).

iii. The prevalence of a disease is the total number of cases of that disease which are present in a defined population at a certain time.

iv. The positive predictive value of a test is the probability that an animal with a positive test result has the disease being tested for.

v. The negative predictive value of a test is the probability that an animal with a negative test result does not have the disease being tested for.

Predictive values of a test take into account both the sensitivity and specificity of the test, *and* the prevalence of disease.



141 The picture (141) shows urine sediment microscopy from a 3-year-old neutered male Persian with recurrent signs of lower urinary tract disease and an owner history of 'probable' polyuria/polydipsia. The cat is being fed a commercial dry cat food.

- i. What is present in the picture?
- ii. What potential significance should be placed on this finding and what further investigations should be carried out as a priority?



142 An 8-year-old neutered female DSH (142) presents with depression and a history of antifreeze (ethylene glycol) ingestion.

- i. What are the consequences of ethylene glycol intoxication?
- ii. What specific therapy should be considered for this cat?

141, 142: Answers

141 i. The picture demonstrates the presence of calcium oxalate crystals.

ii. Crystalluria alone is a non-specific finding, often unrelated to signs of lower urinary tract disease. However, its presence can indicate significant disease (e.g. urolithiasis) or serve as an indicator of other disease processes.

The feeding of dry food often leads to lower overall water consumption that may favour the production of crystalluria. However, while calcium oxalate crystals can be seen in the urine sediment of healthy cats, they are less commonly observed than struvite crystals and, additionally, this cat is displaying features of polyuria/polydipsia. There may, therefore, be other factors predisposing to their appearance. It would be helpful to know the pH of the urine of this cat, as acidic urine is known to favour calcium oxalate crystal formation. Additionally diets designed to minimize struvite crystal formation appear to predispose to calcium oxalate crystals, probably in part through lowering the pH and in part through magnesium restriction (magnesium is an inhibitor of oxalate crystal formation). It would be important to ascertain the calcium status of this cat. Hypercalcaemia and hypercalciuresis are recognized risk factors for calcium oxalate crystal formation, and hypercalcaemia could also explain the apparent polyuria/polydipsia.

Radiography of this cat to detect any uroliths would also be a high priority (calcium oxalate uroliths are radiodense and would be evident on plain radiography).

142 i. Ethylene glycol is an alcohol and a potent toxin, being one of the most common causes of ARF in cats.

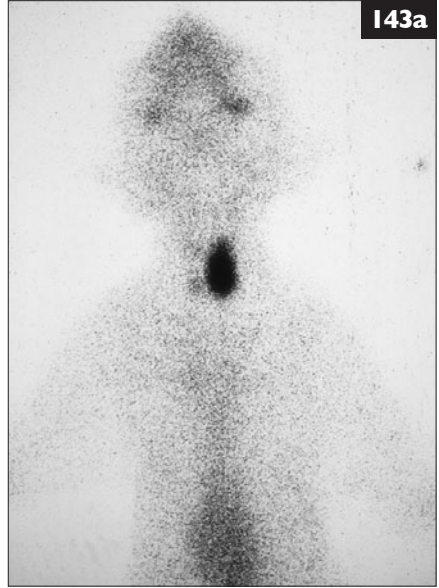
Ethylene glycol itself is relatively non-toxic (although it causes hyperosmolality). As a result of liver metabolism via alcohol- and aldehyde-dehydrogenase enzymes, toxic metabolites (glycoaldehyde and glycolic acid) are produced, which are directly toxic to renal tubular cells. Glycolic acid produces a profound acidosis and is also transformed to glyoxylate and oxalate, which may be deposited as calcium oxalate crystals in the kidney (causing further damage), urine, and other tissues. Ethylene glycol ingestion can also result in hypocalcaemia and acidosis which may need treatment.

Initial signs (1–12 hours following ingestion) are due to CNS toxic effects with depression, nausea, vomiting, nystagmus, ataxia, and seizures. These can be followed by cardiopulmonary signs before renotoxic effects which occur within 24–72 hours.

ii. Immediate treatment (within 1 hour of ingestion) involves inducing vomiting, gastric aspiration, and gastric lavage. If cats are presented within 3 hours of ingestion then ethanol therapy is recommended as this saturates the alcohol dehydrogenase enzyme system which is the rate-limiting step for ethylene glycol metabolism. Ethanol is given at 5 ml/kg of 20% solution by intravenous or intraperitoneal injection every 6 hours for five treatments then every 8 hours for a further four treatments.

143 Hyperthyroidism is suspected in a 9-year-old neutered female DSH cat. The total T4 was 61 nmol/l (reference range 19–65 nmol/l).

- i. How would technetium scintigraphy be performed in a cat?
- ii. What is the interpretation of the scan obtained (143a)?
- iii. What other tests may be helpful in diagnosing hyperthyroidism in this case?



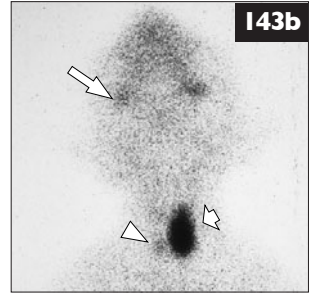
144 What major inherited diseases have been described in Devon Rex cats (144)?



143, 144: Answers

143 i. Radioactive technetium ^{99m}Tc , pertechnetate) is injected IV. Twenty minutes later, the cat is sedated and placed on a gamma camera which allows radionuclide thyroid imaging.

ii. Pertechnetate is concentrated in the salivary glands, thyroid tissue, gastric mucosa, and choroid plexus. The quantity and ratio of uptake of pertechnetate by thyroid compared to salivary tissue is equal in normal cats but increased in hyperthyroidism. In this case, unilateral hyperthyroidism can be diagnosed with a large uptake of technetium on the left side. The unaffected thyroid lobe appears atrophied and has reduced uptake of pertechnetate (143b; arrow, salivary gland; arrowhead, atrophied right thyroid; short arrow, left thyroid adenoma).



iii. Further tests for hyperthyroidism include:

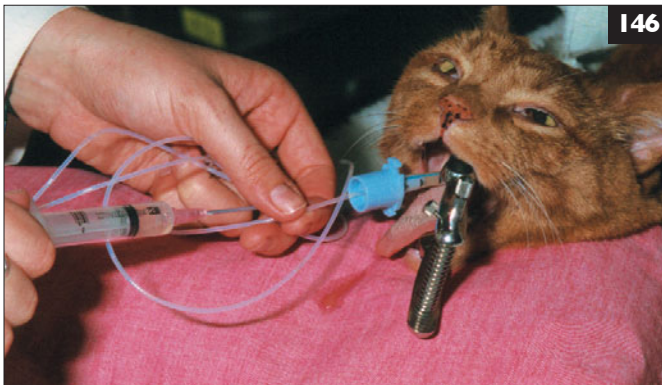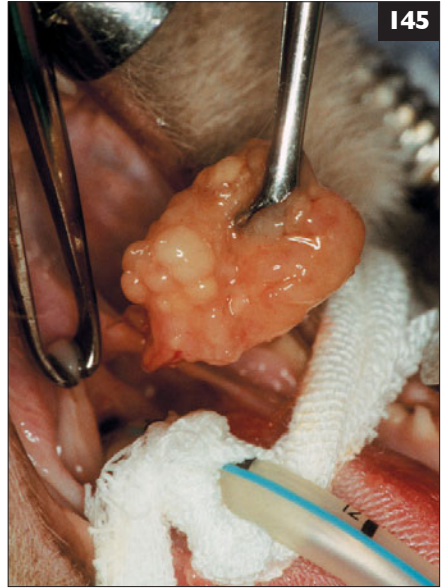
- T3 suppression test: blood is collected for basal total T4 and T3. The cat is dosed with exogenous T3 (20–30 μg per cat three times daily for seven doses). A second blood sample is collected for total T4 and T3 2–4 hours after the last pill is given. In normal cats, administration of T3 inhibits TSH secretion via negative feedback and therefore inhibits production and release of thyroid hormones. Total T4 levels fall by at least 30% and are <20 nmol/l (<1.6 $\mu\text{g}/\text{dl}$). In hyperthyroid cats, there is resistance to the negative feedback therefore there is little or no reduction in the T4 which remains >20 nmol/l (>1.6 $\mu\text{g}/\text{dl}$). Serum T3 levels are measured to confirm that exogenous dosing with T3 has been successful.
- The TRH stimulation test has been used in the past but recent studies suggest that this is an unreliable way of diagnosing hyperthyroidism.
- Free T4 (equilibrium dialysis technique). False positive results are seen in approximately 7% of cats so this test is not suitable for use as a routine screening test, although 98–99% of hyperthyroid cats have elevated free T4.

144 Devon Rex cats suffer from a number of inherited diseases:

- Spasticity associated with an inherited myopathy. Affected cats have severe paresis, ventroflexion of the neck, and are unable to jump normally. These cats often die at a young age as a result of suffocation resulting from aspiration of food.
- Vitamin K-dependent coagulopathy. Affected cats suffer from a coagulopathy caused by deficiency of vitamin K-dependent clotting factors (Factors II, VII, IX, and X) in the absence of either liver disease, gastrointestinal disease, fat malabsorption, or exposure to rodenticide poisons. Liver biopsies collected from affected cats show a defective gamma-glutamyl-carboxylase enzyme which has reduced affinity for vitamin K. Treatment with vitamin K normalizes the clotting times and can be used as a long-term treatment in these cats.
- The characteristic curly coat of the Rex cat is due to a mutant gene.

145 A 5-year-old neutered female Balinese cat presents with progressive inspiratory dyspnoea with stertorous breathing. Retraction of the soft palate reveals a mass in the nasopharynx (145).

- i. What is the likely diagnosis in this case?
- ii. What is the underlying cause and what further investigations are indicated?
- iii. How should this case be managed?



- 146 i. What procedure is being performed in this cat (146)?
- ii. What are the indications for this and how should it be performed?

145, 146: Answers

145 i. The clinical signs and appearance of the mass are typical of a nasopharyngeal polyp. These are usually pink and smooth, but can be irregular (as in this case).

ii. Nasopharyngeal polyps are relatively common and occur in cats of all ages. They are benign and slowly enlarge, eventually causing nasopharyngeal obstruction. They arise from the mucosal lining of either the tympanic bulla or the Eustachian tube and a 'stalk' can usually be seen on the polyp where it originated from (or passed through) the Eustachian tube, as can be seen in this case. Occasionally, polyps expand into the external auditory canal rather than the nasopharynx, or can be present at both sites. Investigations should include bulla radiographs as the presence or absence of middle ear disease may affect the treatment and/or likelihood of recurrence.

iii. The simplest treatment is to retract the soft palate rostrally and remove the polyp by gentle traction. Only rarely is it necessary to split the soft palate. Histology should be performed and typically reveals fibrous connective/granulation tissue often with a lymphoplasmacytic inflammatory infiltrate, and an epithelial surface. Although inflammatory in nature, the cause of these polyps is unknown, and studies have failed to show an association with respiratory virus infections.

As most polyps do not recur, traction alone can be used, but bulla osteotomy should be considered if there is evidence of middle ear disease and certainly for those cases where there is recurrence. There is some evidence that corticosteroids (1–2 mg/kg prednisolone for 4–6 weeks) after traction may reduce the likelihood of recurrence.

146 i. This cat is having either tracheal lavage or bronchoalveolar lavage performed; it is impossible to tell which from the picture.

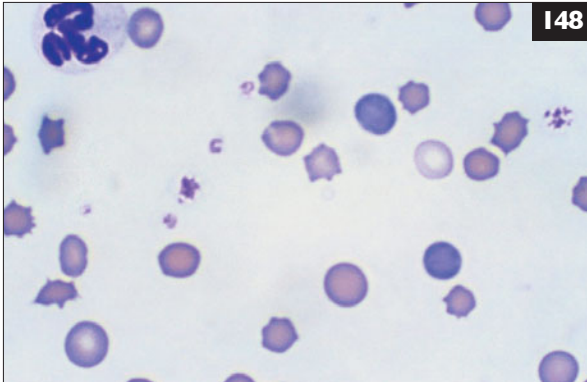
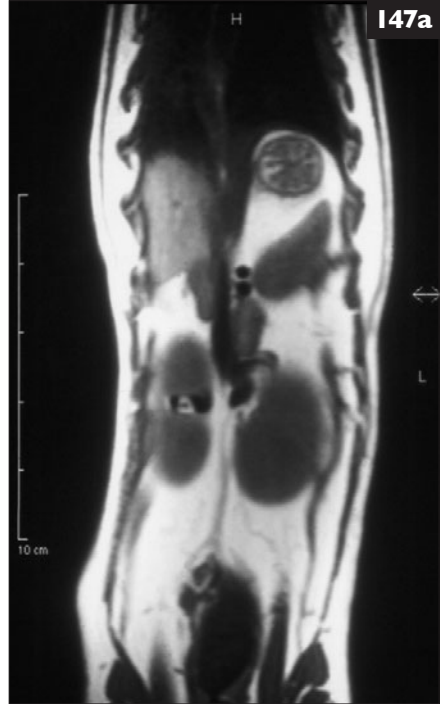
ii. These techniques are indicated for the investigation of tracheobronchial or parenchymal lung disease of undetermined aetiology.

Tracheobronchial washing is easily achieved through a sterile endotracheal tube (as shown) under light general anaesthesia. A sterile small diameter catheter (e.g. urinary catheter) is passed into the distal trachea (carina) where direct aspiration of mucus may be attempted. Following this, one or two aliquots of warm sterile saline (approximately 0.5 ml/kg, or 2–3 ml total) are instilled and immediately aspirated.

Bronchoalveolar lavage involves collection of samples from the lower respiratory tract, including alveoli. Bronchoalveolar lavage can be performed in lateral or sternal recumbency as appropriate. A long flexible catheter is passed through the sterile endotracheal tube until it lodges in a small bronchus in the affected area of the lung. Warmed sterile saline is infused at 2–3 ml/kg, or 10 ml total volume for a cat. The saline is aspirated and the procedure repeated once or twice if necessary. The gross appearance of the lavage fluid is noted and aliquots should be submitted for bacterial culture (PCR assay if appropriate) and cytological examination (in EDTA), along with direct smears. Both procedures can also be performed through a bronchoscope.

147 This is a T1-weighted abdominal MRI scan picture (147a) from a 7-year-old DSH cat in which HAC has been diagnosed. The cat also has insulin-resistant diabetes mellitus as a result of its HAC.

- i. What does this scan reveal about this case?
- ii. How should this patient be managed?

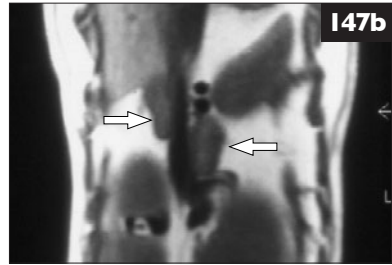


- 148 i.** What are the features of a regenerative anaemia that may be evident on examination of a Romanowsky-stained blood smear?
- ii. The blood smear (148) was made using blood collected from a severely anaemic cat. Is the anaemia regenerative?

147, 148: Answers

147 In T1-weighted MRI scans, fat appears bright, whereas water, air, and bone appear dark.

i. Bilateral adrenomegaly is evident in this cat with both adrenals being clearly visible in the fat cranial to the kidneys (147b), making a diagnosis of pituitary HAC likely. Further imaging in this case revealed a pituitary mass confirming the diagnosis.



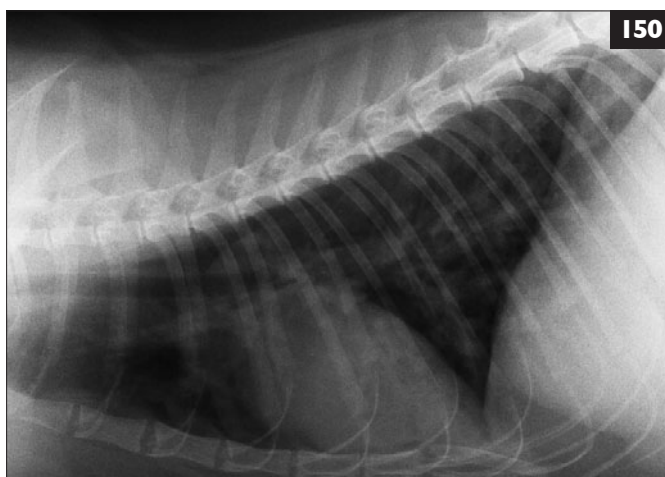
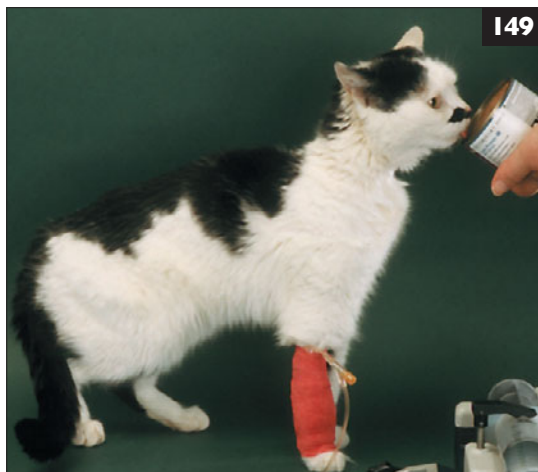ii. A variety of different agents, including mitotane, trilostane, ketoconazole, and metyrapone have been used with variable success reported and adverse effects in some cases. Bilateral adrenalectomy is the preferred treatment, if the patient is considered a good surgical candidate, in situations where appropriate facilities are available to perform the surgery and support the patient. Hypophysectomy and radiation therapy of the pituitary have also been performed successfully in a small number of cases. Insulin-resistant cats need high doses of insulin to stabilize their disease and are best treated using a twice daily regime of intermediate-acting preparations (e.g. lente insulin) which are often more effective at lowering blood glucose levels than longer-acting insulin preparations since they are potent and have a rapid onset of action. Very high doses of insulin should be avoided as some HAC cats have variable secretion of cortisol which can result in hypoglycaemic episodes. An improvement in the diabetes is often seen with successful management of the HAC.

148 i. Features of regenerative anaemia evident on a Romanowsky-stained blood smear are:

- Anisocytosis: variation in the size of the RBCs.
- Polychromasia: variation in the colour of the RBCs. Residual RNA present in immature RBCs stains blue. When these cells are stained with supravital stains such as new methylene blue, they can be identified as reticulocytes.
- Macrocytosis: larger RBCs. When present in significant numbers, the mean cell volume is raised.
- Increased numbers of immature RBCs including nucleated RBCs, RBCs with nuclear remnants (e.g. Howell-Jolly bodies).
- A very regenerative bone marrow response to anaemia may also result in an increase in other cell types such as the leucocytes and platelets due to non-specific stimulation of the bone marrow.

ii. Yes. There is evidence of anisocytosis and polychromasia on the blood smear.

149 Dietary management is one of the main aspects of management of CRF (149). Explain the most important aspects of dietary control, the rationale for their recommendation, and their likely benefit.



150 A 2¹/₂-year-old neutered male DSH cat presents with a 7-month history of recurrent bouts of coughing and wheezing/dyspnoea. There are five other unaffected cats in the household. The clinical signs are getting gradually worse. Routine blood tests are unremarkable, but thoracic radiographs show widespread changes throughout the lung fields (150).

- i. What changes are evident in the radiograph?
- ii. What are the major differential diagnoses for these changes and how should this case be investigated?

149, 150: Answers

149 The most important aspect of dietary management of CRF is maintaining fluid balance. Dehydration is common in CRF, and can contribute both to the clinical signs and, if severe, to progression of CRF through poor renal perfusion. Feeding of moist (canned) rather than dry foods is recommended, and adding water to the food, if tolerated, can be helpful. Other methods include intermittent intravenous or subcutaneous administration of fluids or giving fluids via an oesophagostomy or PEG tube.

Recently, phosphate restriction has emerged as an important goal of dietary management. There is good evidence that this is able to reverse and control renal secondary hyperparathyroidism, may minimize some of the histological changes seen with progressive renal failure, and recent studies suggest that phosphate restriction appreciably slows progression of renal failure and prolongs survival of affected cats.

The evidence for a beneficial effect of protein restriction is less compelling. It is recommended to help alleviate some of the uraemic manifestations and therefore clinical signs of the disease, but whether it has any effect on progression of disease is debatable. Any effect is likely to be very small, and some cats find low protein diets very unpalatable; a normal diet with a phosphate binder is a good alternative.

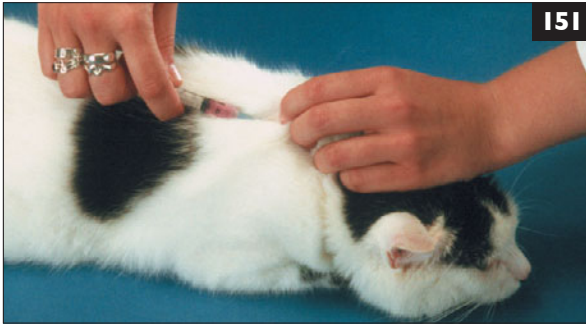Ensuring adequate potassium and water-soluble vitamins in the diet and avoiding urinary acidifying diets (which exacerbate kaliuresis and metabolic acidosis) are also important in CRF. There may be a role for omega-3 fatty acid supplementation (support of glomerular filtration rate and reduced renal inflammation) and soluble fibre supplementation (intestinal nitrogen trapping) but further studies are needed.

150 i. There is a severe, generalized, peribronchial infiltrate, and a mild interstitial infiltrate. There are areas of bronchiectasis suggesting chronic damage.

ii. This is a non-specific radiographic change, but the diffuse bronchial or broncho-interstitial pattern is typical of cats with chronic bronchial disease. Other common changes that can be seen with chronic bronchial disease include collapse of the right middle lung lobe (or more rarely other lung lobes such as the left cranial), hyperinflation of the lungs due to air trapping and, in severe cases, flattening of the diaphragm and a barrel-shaped chest again due to air trapping. Occasionally, a patchy alveolar pattern, patchy or diffuse interstitial patterns, and emphysema are reported and, if there is severe dyspnoea, there may be aerophagia and increased gas in the gastrointestinal tract. There is little correlation between the severity of the radiographic changes and the severity of the clinical signs.

Major differential diagnoses for these changes would be chronic bronchitis, feline asthma, or parasitism (e.g. *Aelurostrongylus abstrusus*, *Dirofilaria immitis*). Other differentials may include neoplasia and infectious bronchitis (viral, bacterial, mycoplasma).

Further investigations would be required to determine the aetiopathogenesis including bronchoscopy and bronchoalveolar lavage for cytology and culture, faecal examination for parasites, serology for *Dirofilaria*, and ideally lung function tests.

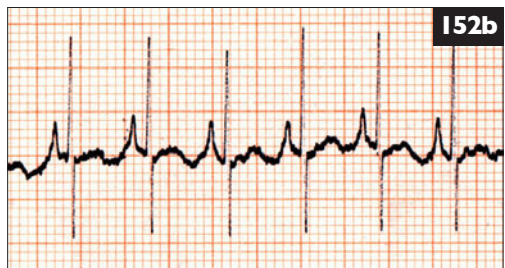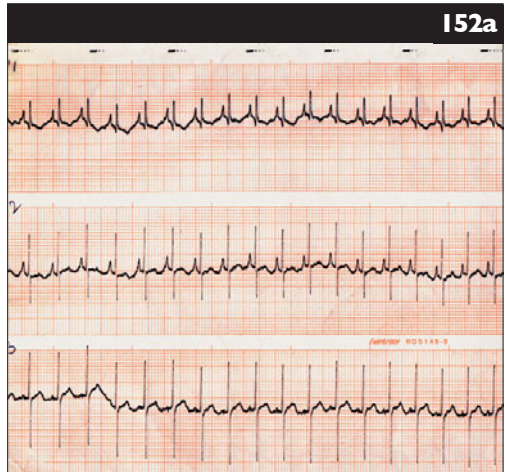


151 A cat that was vaccinated 2 months ago (151) is returned because the owner can feel a 2 cm diameter lump at the site of vaccination.

- i. What are the possible causes of this lump?
- ii. What is the most appropriate diagnostic plan?

152 This ECG recording (152a) was taken from a 10-year-old neutered female DSH cat. The ECG machine has been calibrated so that 1 cm = 1 mV on the y axis and 25 mm = 1 second on the x axis (seconds marked with a dash at the top of the trace). An enlarged section of the lead 2 trace is also shown (152b).

- i. What information can be gathered from an ECG?
- ii. Describe, step by step, the interpretation of this ECG.



151, 152 Answers

151 i. The lump could be inflammatory, for example, a granuloma caused by an inflammatory reaction to the vaccine constituents. The main alternative concern would be that this represents a vaccine site-associated sarcoma. Other causes, unrelated to vaccination, would include a cat bite abscess.

ii. One option would be to monitor the lump for a further month by which time most inflammatory reactions will have disappeared or reduced in size. However, at 2 months post-injection, because of the concern over potential vaccine site-associated sarcoma, an incisional or needle biopsy should ideally be performed (either of these would be far preferable to a fine needle aspirate, results of which would be more difficult to interpret). The lump should not be completely excised as this usually makes further radical surgery (such as that required for treatment of vaccine site-associated sarcoma) much more difficult and less successful.

152 i. An ECG uses positive and negative electrodes to record the electrical activity of the heart over a period of time and describes the heart rate and rhythm for the period recorded. Evaluating the characteristics of the complexes seen on an ECG trace is helpful in diagnosing arrhythmias and evidence of chamber enlargement.

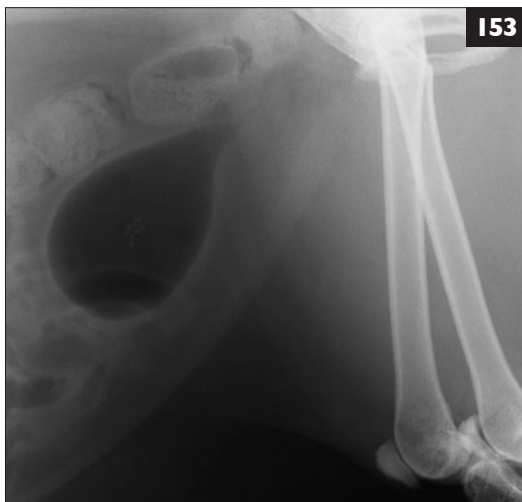ii. Six seconds of leads I, II, and III are shown. The trace is of adequate quality to interpret (see table below). The heart rate is approximately 170 beats per minute (17 complexes in 6 seconds), is regular and all complexes have PQRS morphology: there is a P wave for every QRS and a QRS for every P (no ectopic beats). Measurement of the complexes themselves reveals that the P waves are tall and wide, the R waves are tall and the S waves are deep. Tall P waves are indicative of right atrial enlargement ('P-pulmonale'), wide P waves indicate left atrial enlargement ('P-mitrale'), tall R waves are suggestive of left ventricular enlargement, deep S waves are indicative of right ventricular enlargement but can also be seen with right bundle branch block. These findings indicate that generalized cardiomegaly is likely to be present.

Interpretation of the feline ECG

Parameter	Normal range	This ECG
Heart rate	120–200	170
P wave amplitude (mV)	<0.2	0.45
P wave duration (s)	<0.04	0.06
PR interval (s)	0.05–0.09	0.08
R wave amplitude (mV)	<0.9	1.3
S–T segment	No depression/elevation	Normal
T wave (mV)	<0.3	0.1
QT interval (s)	0.12–0.18	0.18
Mean electrical axis	0° to +160°	Not determined

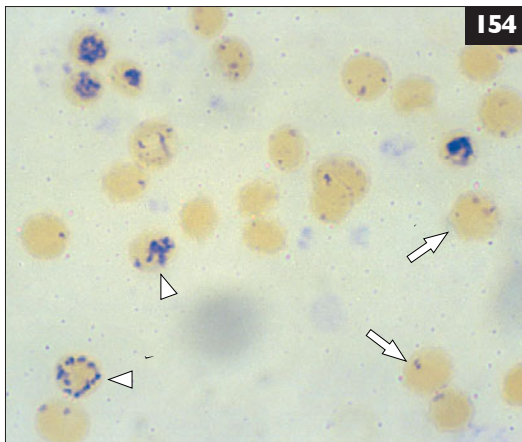
153 The lateral abdominal radiograph (153) is from a 12-year-old neutered male DSH cat, with recurrent signs of pollakiuria and haematuria. The cat has been treated with a commercial dry urine-acidifying diet for 9 months for signs of cystitis and the presence of 'struvite' urine crystals. The urine has a pH of 6.2, and sediment analysis reveals evidence of inflammation, many calcium oxalate crystals but no bacteria.

- i. What can be seen on the radiograph?
- ii. What is the likely diagnosis?
- iii. What treatment and management should be recommended?



154 Feline blood contains two types of reticulocytes (immature RBCs) which can be identified on new methylene blue staining (154).

- i. Identify the two types of reticulocytes present, indicated by the arrows and arrowheads.
- ii. Which type of reticulocytes should be counted when assessing whether an anaemia is regenerative or not?



153, 154: Answers

153 i. The radiograph shows the presence of multiple small radiodense objects within the urinary bladder, consistent with cystic calculi, and the bladder wall is thickened (consistent with inflammation secondary to the calculi).

ii. The presence of large numbers of oxalate crystals in the urine, and the radiodense nature of the calculi suggest they are probably calcium oxalate uroliths. Feeding a dry, acidifying, magnesium-restricted diet may have predisposed to their formation.

iii. Calcium oxalate uroliths cannot be dissolved medically and their physical size together with this being a male cat would preclude attempting urohydropropulsion. Surgical removal of the uroliths via cystotomy is therefore required, and their composition should be confirmed using X-ray diffraction.

Irrespective of the uroliths' composition, encouraging fluid intake ('wet' rather than dry food, and encouraging drinking with flavoured waters) will help to reduce the likelihood of recurrence. Acidifying diets should be avoided in the future with the aim of producing a more neutral urine pH (around 6.5–7.5) and this should be checked intermittently. If the urine remains too acid, addition of potassium citrate (50–75 mg orally twice daily) may help. Additionally, the cat should be monitored for hypercalcaemia, and this should be investigated and treated if found.

154 i. The arrows are pointing to punctate reticulocytes; the arrowheads are pointing to aggregate reticulocytes.

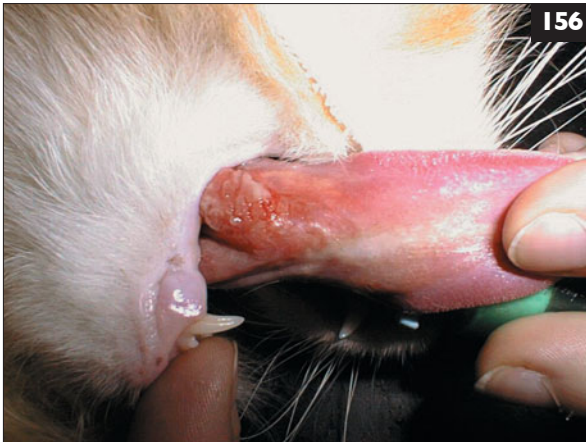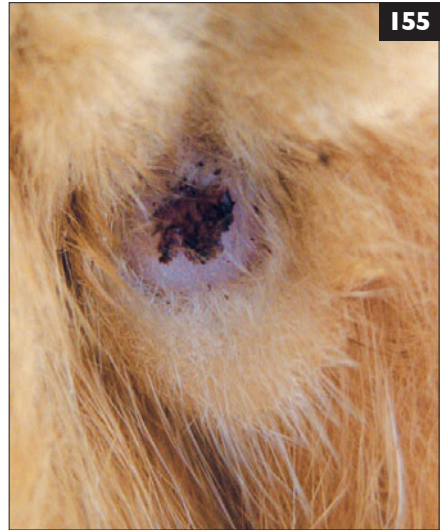ii. The aggregate form is the more immature form of reticulocyte which contains clumps of medium to large dark-staining precipitated ribosomes. Normal feline blood smears contain <0.5% aggregate reticulocytes as this form is retained in the marrow until most of the ribosomal RNA has been eliminated. The punctate form is the mature form of reticulocyte which remains in the circulation for several weeks before maturing to a normal RBC. Punctate reticulocytes contain smaller clumps of precipitated ribosomes. Since they last for so long in this form, normal feline blood can contain up to 10% punctate reticulocytes. In anaemic cats, only aggregate reticulocytes should be counted to assess the response to anaemia. The 'corrected' reticulocyte percentage accounts for the severity of the anaemia.

- Corrected reticulocyte count (%) = observed reticulocyte % × (observed PCV + 37)
- In normal cats, the corrected reticulocyte count is <0.4%. The magnitude of the reticulocyte count indicates how strongly regenerative the anaemia is (see table below).
- Alternatively, the absolute reticulocyte count (cells/μl) can be calculated by multiplying the red cell count (cells/μl) by the percentage of aggregate reticulocytes. Normal cats have <30,000 aggregate reticulocytes/μl; numbers >60,000 indicate that the anaemia is regenerative.

Corrected reticulocyte count (%)	
Slightly regenerative	0.5–2.0
Moderately regenerative	2.0–4.0
Very regenerative	>4.0

155 A 2-year-old entire male DSH cat is presented because the owner has noticed some discharge at the prepuce (155). On examination, the tip of the penis has a blue appearance. No other lesions are evident on thorough clinical examination.

- What differential diagnoses could account for these signs?
- What further tests could be helpful?



156 An 11-year-old neutered male DSH cat was presented with a 3 month history of progressive dysphagia and ptyalism. Oral examination under anaesthesia revealed the lesion pictured (156). What are the differential diagnoses? Suggest treatment options for these.

155, 156: Answers

155 i. Differential diagnoses for bruising/ischaemia to the penis include:

- Trauma to the penis, e.g. associated with mating.
- Ischaemia caused by thrombosis of the cavernous sinuses.
- Bruising associated with bleeding or clotting disorders.
- Balanoposthitis (inflammation of the penis and prepuce) caused by trauma, lacerations, foreign body, neoplasia, abscessation.

ii. Further investigations that may be of help include obtaining a reproductive history, haematology (platelet count), and clotting times (APTT, PT, fibrin degradation products).

156 Major differential diagnoses for a proliferative sublingual lesion would be:

- Oral squamous cell carcinoma.
- EGC lesion.
- Bacterial granuloma (e.g. *Dermatophilus* spp., actinomycotic mycetoma).
- Mycotic granuloma (e.g. *Cryptococcus neoformans*, or mycetomas caused by opportunistic fungal infections).
- Foreign body reaction.
- FIP granuloma.

Biopsy with or without culture would be required to differentiate these conditions. Bacterial and fungal granulomas often arise following a penetrating wound, but they are rare causes of oral mass lesions in cats. Treatment may include local excision/debulking of infected tissue. *Actinomyces* and *Dermatophilus* infections respond to penicillins, whereas sulphonamides (sulfonamides) are recommended for *Nocardia* mycetomas. Cryptococcosis more commonly affects the nasal cavity (via inhalation) although spread or penetration to the mouth can occur. Treatment is with debulking and systemic antifungal agents (itraconazole, fluconazole, amphotericin B). Rarely, FIP has been reported to cause oral granulomas; biopsies (possibly with immunohistochemistry) would be diagnostic and no treatment is successful.

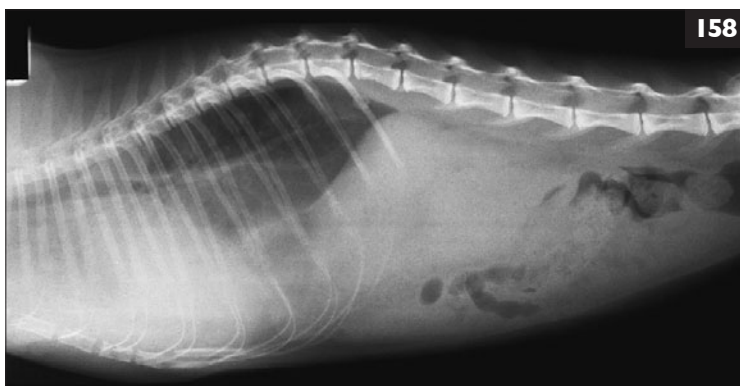
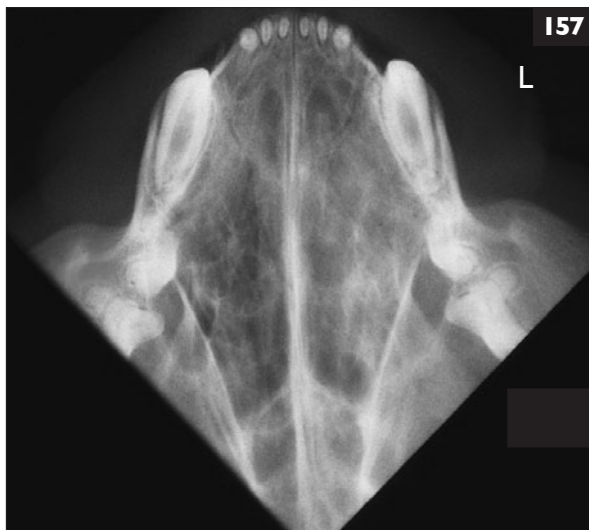
The major differential diagnoses for this cat would be EGC and squamous cell carcinoma (sublingual tissue, especially caudal to the frenulum is a predilection site for the latter). Squamous cell carcinoma is difficult to treat: surgery is usually not possible without loss of lingual function. Radiation and photodynamic therapy may be palliative, but the prognosis is very poor. Palliative treatment may also be tried with non-steroidal anti-inflammatory drugs (COX-2 inhibitors).

Biopsy in this cat revealed the lesion to be an eosinophilic granuloma. Treatment involved searching for an underlying allergen (unsuccessful in this case) and symptomatic therapy. The cat failed to show any response to antibiotic therapy but there was rapid regression with oral prednisolone.

157 The intra-oral nasal radiograph (157) is from a 9-year-old neutered male DSH cat with progressive signs of sneezing and mucopurulent nasal discharge. The discharge is bilateral but more marked on the left side.

i. From the radiograph, is it possible to determine whether this is a tumour or chronic rhinitis?

ii. Briefly, how would material be obtained from the nasal cavity to diagnose neoplasia?



158 A lateral thoracic and abdominal radiograph (158) is taken of a 1-year-old neutered male DSH cat with a 4–5 month history of lethargy, weight loss, and mild inspiratory dyspnoea. These signs are non-progressive.

i. What abnormalities are evident on the radiograph?

ii. What is the diagnosis?

iii. Are there any other diagnostic tests which can be performed for confirmation?

157, 158: Answers

157 i. From clinical and radiographic signs it is impossible to differentiate tumour from lateralized chronic rhinitis in this cat. There is an increase in the soft tissue density in the nasal cavity (much more marked on the left than the right), there is evidence of loss of turbinates on the left, and deviation of the septum to the right. Retrospective studies have shown that 'aggressive' radiological findings including an increase in soft tissue density, lysis of the turbinates and/or facial bones, and lysis or deviation of the nasal septum can be seen with both chronic rhinitis and neoplasia and do not help in their differentiation radiographically. However, entirely or predominantly unilateral aggressive signs are more likely to be due to neoplasia. In this case, subsequent investigations revealed chronic rhinitis and not a neoplasm.

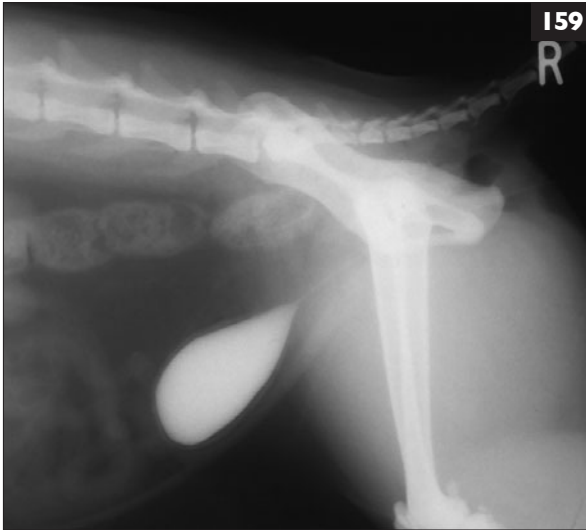
ii. Tissue can be obtained for cytology/histology by a number of means. Nasal flushings are least likely to yield representative material. Traumatic nasal flushings using a catheter with nicks cut along the length to 'rasp' the nasal mucosa while flushing through sterile saline have been recommended and, if there is a large mass, 'core' biopsies can sometimes be obtained using an open-ended rigid catheter that is inserted into the mass while gentle suction is applied via a syringe. However, generally the use of endoscopic grab biopsy forceps yields a good tissue harvest with minimal trauma and a good diagnostic yield. These can be inserted 'blind' via the nares to obtain grab biopsies (ensuring they are not inserted beyond the level of the medial canthus), or can be inserted alongside a small rigid endoscope for guided biopsy if required. Forced nasal flushings (with the pharynx packed, the nozzle of a 10–20 ml syringe filled with sterile saline is placed in one nares, the other is occluded and the saline flushed through under pressure) or retroflexed nasopharyngoscopy can be useful for obtaining tissue from caudal nasal masses.

158 i. The radiograph reveals an increase in soft tissue density in the ventral thorax possibly with some retraction of the caudal lung lobes consistent with the presence of pleural fluid. The trachea is elevated and the cardiac silhouette is obscured. The outline of the diaphragm is obscured and there is a suggestion of a loss of integrity of the diaphragm ventrally. There is poor abdominal contrast consistent with a thin cat but the abdomen also appears 'empty' consistent with loss of some of the viscera.

ii. Diaphragmatic rupture with abdominal contents present in the thoracic cavity.

iii. Ultrasound examination of the chest and abdomen is likely to be most helpful in confirming this suspicion and ruling out other possibilities such as neoplasia and cardiac disease. If ultrasound is not available, a barium contrast study may be helpful.

In this case, ultrasound examination confirmed diaphragmatic rupture as the cause of the radiographic abnormalities and surgical correction was performed. Careful postoperative monitoring is important (for at least 48 hours following surgery) as, with chronic lung lobe atelectasis, post-inflation oedema can be a severe complication.

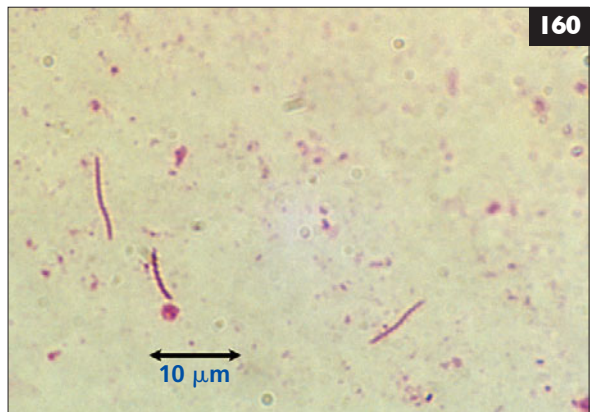


159 The lateral abdominal contrast cystogram (159) is taken from an 8-year-old neutered female DSH cat with recurrent signs of dysuria and pollakiuria.

- i. What is revealed on the radiograph?
- ii. What are the differential diagnoses and what further investigations should be performed?
- iii. Assuming this is a case of idiopathic cystitis what treatment options should be considered?

160 Microscopic examination of mucosal brushings from the stomach of a 4-year-old Abyssinian cat with persistent vomiting revealed the spiral bacteria shown (160).

- i. What are these most likely to be, and what is their significance?
- ii. How should treatment be attempted?



159, 160: Answers

159 i. The cystogram demonstrates a generalized increased bladder wall thickness.

ii. The thickening is uniform and smooth suggesting it is a result of inflammation rather than neoplasia. There are no filling defects indicative of cystic calculi, but a plain and double-contrast radiograph (and/or ultrasonography) would be necessary to exclude this completely. Additionally, a catheter or cystocentesis urine sample should be analysed and submitted for culture. If the findings suggested sterile cystitis, a diagnosis of idiopathic cystitis can be made by exclusion.

iii. Treatment of idiopathic cystitis is controversial. There may be multiple underlying aetiologies explaining some of the variability in observed responses. Encouraging the production of large volumes of more dilute urine, and more frequent urination appears to be consistently helpful. This is achieved by feeding moist (canned) rather than dry food, by adding additional fluid to the diet and by encouraging the cat to drink (e.g. provide running water or rain water). Preventing obesity, encouraging exercise, and providing adequate clean litter trays may also encourage more frequent urination. Unless there is very heavy crystalluria or a risk of urethral blockage (male cats), the use of diets specifically to prevent crystal formation is generally not indicated.

Few drugs have been demonstrated to have any efficacy in the long-term management of refractory cases of idiopathic cystitis. Amitriptyline (2.5–10 mg/cat orally daily) may help to reduce the frequency and severity of clinical signs in some cats. Glycosaminoglycan replacers such as pentosan polysulphate and N-acetyl glucosamine anecdotally help some cats.

160 i. This picture shows a typical GHLO. As with most GHLO recovered from cats it is relatively large (5–10 µm), suggesting it is most likely to be *Helicobacter heilmannii* or a *H. heilmannii*-like organism.

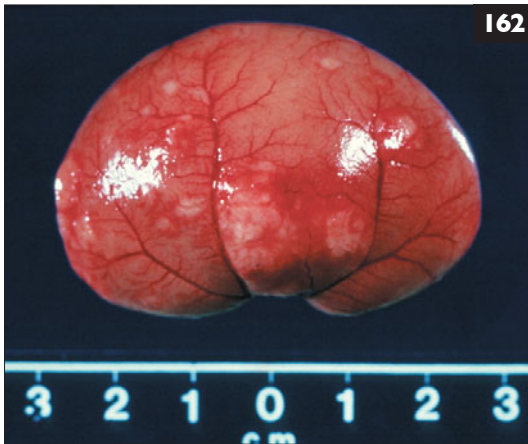Helicobacter spp. are Gram-negative spiral organisms found in the stomach, intestines, and liver of various species. Studies have shown widespread gastric colonization of cats with GHLO, irrespective of whether there is gastric disease.

In humans, *H. pylori* is a well recognized cause of gastritis and gastric ulceration, but the relationship of other *Helicobacter* species to disease is often less clear. Cats experimentally infected with *H. pylori* develop chronic gastritis with moderate to marked inflammation, but *H. pylori* is a small *Helicobacter* (measuring 1.5–3 µm) and infection with this species appears to be very rare in cats. *Helicobacter felis* is a large species (like *H. heilmannii*), and this can induce gastritis in cats following experimental infection, but again natural infection with this species appears to be rare. Currently, there is little or no evidence that infection with *H. heilmannii* or *H. heilmannii*-like organisms causes appreciable gastric pathology in cats and these are the species most commonly found.

ii. Although most infections are probably asymptomatic, the difficulty in identifying the *Helicobacter* species involved can make trial therapy justified where the organism is identified in association with significant gastric inflammation. Combination therapy with metronidazole (20 mg/kg/day), amoxicillin (20 mg/kg twice daily), and omeprazole (0.5–1.0 mg/kg twice daily) has been recommended.

161 A 3-year-old neutered male DSH cat developed pollakiuria and dysuria; the owner collected a urine sample (161). Within 2 days the cat developed repeated unproductive attempts to urinate. Physical examination revealed a distended bladder.

- i. What does the urine sample show?
- ii. What is the most common cause of the signs shown by the cat, and what differential diagnoses should be considered?
- iii. Describe how immediate relief of this cat's problem should be attempted.



162 The picture (162) shows a kidney removed from a cat at post mortem.

- i. Comment on the size of this kidney and how renal size is normally assessed ante mortem.
- ii. Is speculation on the diagnosis possible from the gross appearance in this case?
- iii. In general, what are the indications and precautions for renal biopsy?

161, 162: Answers

161 i. The urine sample shows macroscopic evidence of haematuria or haemoglobinuria (or even potentially myoglobinuria).

ii. Additional testing, and in particular urine sediment analysis would be needed to characterize the changes further, but haematuria and cystitis would be highly likely.

Major differential diagnoses for the initial clinical signs would be idiopathic (sterile) cystitis, urolithiasis, infectious cystitis, and lower urinary tract neoplasia. Of these, in a young adult cat, idiopathic sterile cystitis would be most common. The clinical signs that the cat subsequently developed are typical of urethral obstruction. Obstruction can occur for various reasons (uroliths, neoplasia) but it is most commonly due to a relatively soft urethral 'plug', composed of a proteinaceous matrix with various cellular debris and crystals trapped within it.

iii. If the cat is metabolically stable, relief of the urethral obstruction is the first treatment objective, but prior diagnostic imaging (radiography and/or ultrasonography) will help to establish if a urolith is present. Gentle digital massage of the penile and pelvic urethra followed by gentle bladder compression occasionally results in extrusion of the urethral plug. If this is unsuccessful, sedation or anaesthesia may be needed to allow catheterization with a soft, atraumatic, open-ended, lubricated catheter. Flushing of the urethral lumen with large volumes of sterile saline may allow softening, removal, or retropulsion of the plug. If this is unsuccessful, decompressive cystocentesis should be performed to prevent complications associated with ARF.

162 i. The kidney pictured is close to 60 mm in length and thus clearly enlarged. Renal size can be determined subjectively by abdominal palpation, but is better determined by radiography or ultrasonography.

On a VD radiograph, the normal renal size varies between 2.0 and 3.0 times the length of L2. Ultrasonographically, normal renal size in cats varies between 30 and 44 mm.

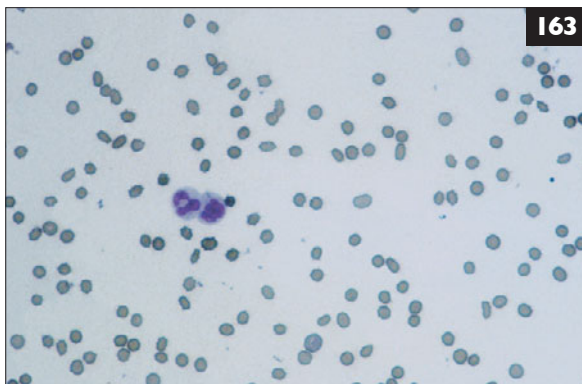
ii. The kidney pictured is grossly enlarged and multiple pale lesions varying in size from approximately 1–4 mm in diameter are visible on the serosal surface. The lesions are slightly raised giving an uneven surface to the kidney.

The lesions suggest a multifocal infiltrative or inflammatory disease. Major differential diagnoses would be lymphoma, FIP, and mycobacterial infection. In this case histology confirmed the diagnosis of FIP.

iii. A fine needle aspirate is usually sufficient to diagnose lymphoma; renal biopsy is indicated to confirm suspected FIP or other focal infiltrative/inflammatory diseases. Renal biopsy (for histology and culture) can also be valuable in investigation of significant proteinuria and in other cases of renal disease where the results could lead to significantly improved therapy (e.g. pyelonephritis). Renal biopsy should only be performed after careful patient evaluation and assessment of the risk:benefit ratio. A coagulation profile is essential prior to renal biopsy. Ultrasound-guided or surgical needle biopsy, ensuring that the needle stays within the renal cortex, is likely to be the safest method.

163 The haematology results are received from a 7-year-old DSH cat that is presented with a 3-week history of lethargy and poor appetite. The blood smear is illustrated (163).

- i. What is the assessment of this haemogram?
- ii. What differential diagnoses should be considered?

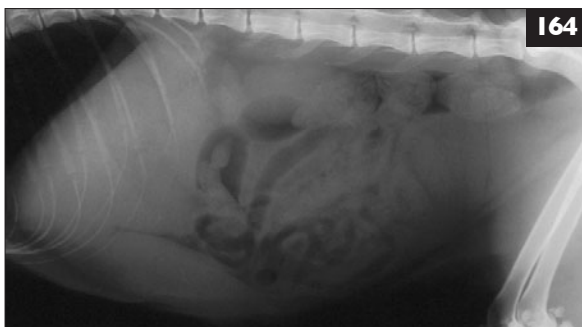


Parameter	Value	Reference range
Haemoglobin (g/dl)	11.8	8.0–15.0
HCT (%)	37.4	25.0–45.0
RBC ($10^{12}/l$)	7.8	5.5–10.0
MCV (fl)	47.6	40–55
Platelets ($10^9/l$)	97	200–700
WBC ($10^9/l$)	3.21	4.9–19.0
Neutrophils ($10^9/l$)	2.05	2.4–12.5
Lymphocytes ($10^9/l$)	1.00	1.4–6.0
Monocytes ($10^9/l$)	0.13	0.1–0.7
Eosinophils ($10^9/l$)	0.03	0.1–1.6

Smear comment: platelet clumps seen, platelets plentiful.

164 A 10-year-old neutered male DSH cat presents with jaundice, inappetence, and weight loss. A lateral abdominal radiograph is taken (164).

- i. What abnormalities can be seen?
- ii. What are the major differential diagnoses?
- iii. Briefly, how would liver tissue be obtained for further investigations and what are the advantages/disadvantages of the possible methods?



163, 164: Answers

163 i. A leucopenia comprising a neutropenia, lymphopenia, and eosinopenia is present. Although the machine platelet count is low, platelet clumping and adequate numbers of platelets were noted on the blood smear. Platelet clumping is a common phenomenon with feline blood that accounts for falsely low machine platelet counts.

ii. Differential diagnoses for leucopenia include:

- Toxic bone marrow suppression caused by, for example, exposure to drugs (e.g. chemotherapy agents such as cyclophosphamide, antibiotics including chloramphenicol, idiosyncratic drug reactions), heavy metals, or other chemicals.
- Viral infections, e.g. FeLV, FIV, feline panleucopenia virus infections.
- Increased removal, e.g. immune-mediated destruction, overwhelming sepsis.
- Endotoxaemia.
- Bone marrow disease resulting in reduced production of WBCs, e.g. myelodysplasia, myeloproliferative disease, lymphoproliferative disease, myelophthisis.
- Artefact causing leucopenia, e.g. clot in sample or WBC clumping.

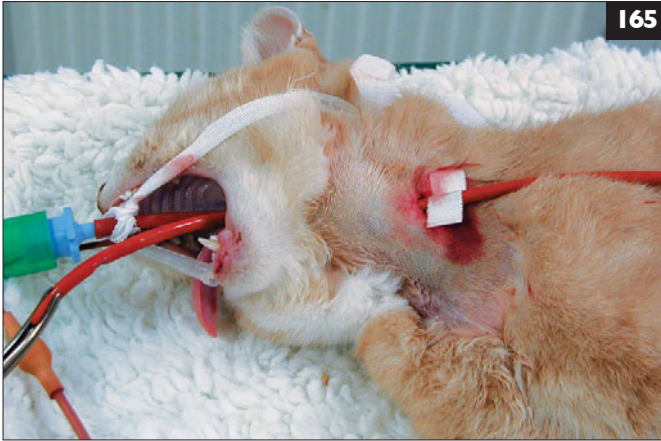
164 i. The most obvious abnormality on the radiograph is a marked increase in soft tissue density in the cranial abdomen consistent with hepatomegaly. There is good abdominal contrast and thus no evidence of ascites.

ii. Major differential diagnoses for jaundice and marked hepatomegaly would be:

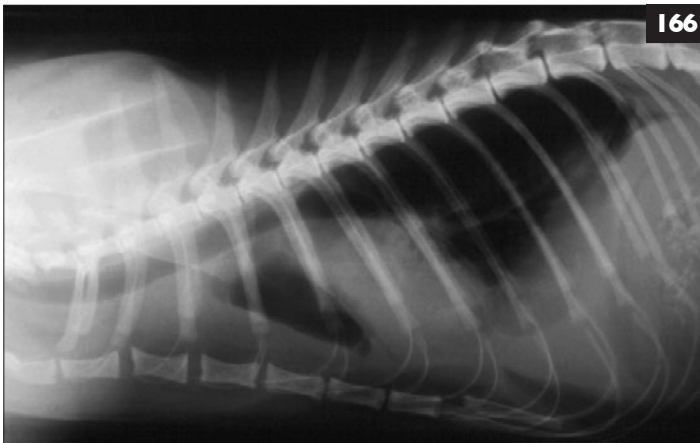
- Non-suppurative cholangiohepatitis (lymphocytic cholangitis).
- Hepatic lipidosis.
- Primary or secondary hepatic neoplasia.
- Hepatic amyloidosis.
- Suppurative cholangiohepatitis (less likely given hepatomegaly).

iii. Diagnostic samples of liver tissue are most commonly obtained by fine needle aspiration, needle biopsy, or surgical biopsy. Other available techniques include laparoscopy. Before obtaining tissue samples a clotting profile should always be run as liver disease is frequently associated with clotting abnormalities. Prolonged clotting times may respond to vitamin K supplementation.

- Fine needle aspirates are potentially the most misleading of the tissue samples obtainable. Although they may be diagnostic for diffuse, generalized disease such as lipidosis or lymphoma, they can also be misleading and may miss the presence of other significant disease (e.g. cholangiohepatitis associated with lipidosis).
- Needle biopsies (ideally performed with ultrasound guidance to obtain representative tissue) are more reliable than fine needle aspirates and are suitable for diagnosis of most hepatic pathologies. However, a substantial proportion of needle biopsy diagnoses are at variance with wedge biopsy or post-mortem diagnoses.
- Wedge biopsies collected at surgery are the most reliable method of obtaining diagnostic material and should be considered when equivocal, unexpected, or non-diagnostic samples are obtained by other means.



- 165 i. What type of tube is being placed for nutritional support in this cat (165)?
ii. Briefly, how would this tube be placed and what are its advantages and disadvantages?



166 The lateral thoracic radiograph (166) is from a 7-year-old neutered male Burmese cat with dyspnoea.

- i. What changes can be seen on this radiograph?
ii. What type of dyspnoea would be expected with this cat?
iii. What differential diagnoses should be considered and what is likely to be the single most useful diagnostic test?

165, 166: Answers

165 i. An oesophagostomy tube is being placed.

ii. Intubation requires a short general anaesthetic, with the cat in right lateral recumbency. The left cervical region is prepared for surgery. Curved Carmalt forceps are passed into the oesophagus via the mouth, turned outwards and opened to allow sharp and blunt dissection from the skin into the oesophageal lumen via a small skin incision. The distance from the incision to the ninth rib is measured and marked on the tube, so that the tube tip is placed in the distal oesophagus. The tip of the tube is grasped with the forceps and drawn into the mouth (as shown). The tube is then repositioned and pushed into the distal oesophagus past the ostomy site to the pre-marked position, and then secured to the skin using a Chinese finger-trap suture.

Oesophagostomy tubes are suitable for long-term (several weeks) nutritional support and have proved to be remarkably valuable with very few complications. The larger tube diameter (typically a 10 or 12fg) allows administration of a liquidized regular diet (although some need blending with water and sieving to remove large particles). Rarely, infection at the ostomy site occurs, so careful and regular cleaning is important, and the area should be dressed and protected by a neck bandage. When the tube is removed, the ostomy site heals within 2 weeks and oesophageal strictures have not been reported. If vomiting occurs, correct placement of the tube should be checked (radiography) before feeding is continued.


166 i. The radiograph demonstrates the presence of a pleural effusion. The diaphragm appears to be intact, the liver is in a normal position, and the stomach can also be seen in a normal position and contains ingesta. The trachea appears elevated dorsally – this can be seen as a result of cardiomegaly or an anterior mediastinal mass, but can also occur simply as a result of pleural effusion. The cardiac silhouette and the anterior mediastinum are partly obscured due to the pleural effusion. Additional investigations (ultrasonography or repeat radiography post drainage) would be necessary to evaluate the heart and anterior mediastinum.

ii. A pleural effusion will produce inspiratory dyspnoea, often with tachypnoea.

iii. Major differential diagnoses for pleural effusion in the cat are:

- Congestive heart failure.
- FIP.
- Pyothorax.
- Neoplasia (lymphoma, thymoma, pulmonary carcinoma).
- Haemothorax (trauma, coagulopathy).
- Chylothorax.
- Ruptured diaphragm (no evidence in this case).
- Iatrogenic (fluid overloading).

Thoracocentesis with biochemical, cytological and possibly bacterial culture of the fluid is the single most useful test to narrow down further the differential diagnoses.

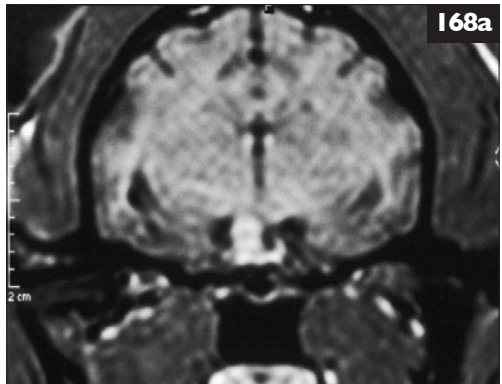


167 A 7-year-old neutered male Siamese cat (167) presents with unilateral mucopurulent nasal discharge that has been present for 3–4 months. The cat has been sneezing and the signs have been getting gradually worse. There is now some mild epistaxis accompanying the discharge.

- i. Which side is the nasal discharge and why?
- ii. What are the major differential diagnoses for this presentation?

168 An ACTH-stimulation test and a T1-weighted MRI brain scan (168a) were performed in a cat with severe insulin-resistant diabetes mellitus. The ACTH stimulation test protocol involved administering 0.125 mg synthetic ACTH IV and taking blood samples at the time points stated in the table.

- i. What is the assessment of these results?
- ii. What alternative tests can be done to diagnose HAC in cats?



Time post-ACTH (mins)	Cortisol nmol/l (ng/ml)	
	Result	Reference range
0	450 (163)	<250 (<90)
60	760 (275)	<650 (<235)
120	1027 (372)	<650 (<235)

167, 168: Answers

167 i. The discharge is from the right side. Examining the picture there is a marked difference in the hair colouration beneath the eyes on the two sides of the face, the right side being considerably paler than the left side. The coat colour in Siamese is known to be temperature-dependent. More melanin is produced at lower temperatures accounting for the darker markings of the extremities. Conversely, less melanin is deposited at higher temperatures and the reduced pigmentation over the right nasal area is consistent with chronic inflammation in the right side of the nose causing a slight rise in temperature locally.

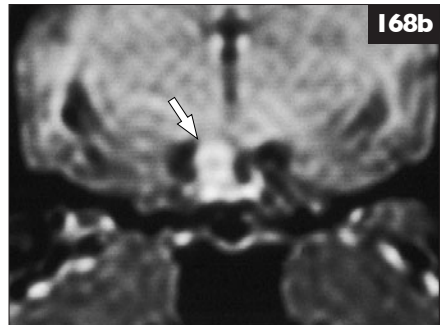ii. Major differential diagnoses for a unilateral nasal discharge would be: inflammation (nasal polyps, rare); infection: fungal (e.g. aspergillosis, cryptococcosis); bacterial rhinitis (often bilateral); post-viral rhinitis (often bilateral); foreign body rhinitis, e.g. blade of grass; neoplasia, e.g. lymphoma, adenocarcinoma; chronic dental disease, e.g. tooth root abscess; trauma, e.g. oronasal fistula.

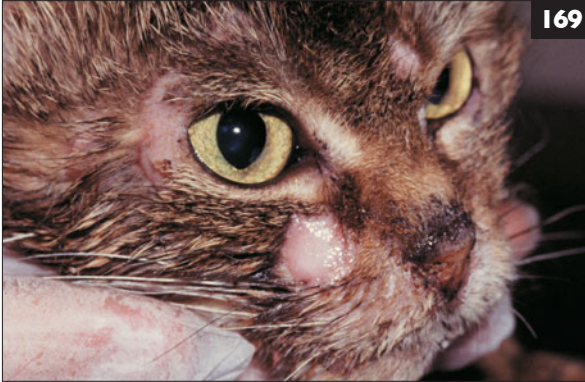The fact that the discharge is unilateral, progressive, and that there is now some associated bleeding suggests possible invasion/erosion of tissues and would be typical of neoplasia or a fungal infection. However, on further examination this cat was found to have a tooth root abscess causing the nasal discharge.

168 i. The ACTH results are consistent with HAC (Cushing's disease). The MRI scan (on a T1 scan the CSF appears dark) shows that the pituitary is asymmetrically enlarged (**168b**, arrowed) consistent with the presence of a pituitary macroadenoma.

ii. Alternative tests include:

- Dexamethasone screening tests are preferred by some clinicians: blood samples are assayed for cortisol levels before, and 4 and 8 hours after administration of 0.1 mg/kg dexamethasone IV. Normal basal cortisol values are <250 nmol/l (<90 ng/ml), and <30 nmol/l (<11 ng/ml) after dexamethasone.
- Imaging by ultrasonography which may reveal uni- or bilateral adrenomegaly. Adrenal calcification can be seen as an incidental radiographic finding in up to 30% of normal cats and is not indicative of adrenal neoplasia in cats.
- Measurement of endogenous ACTH has recently been used in confirmed cases of HAC in order to distinguish between pituitary and adrenal forms. Low levels of ACTH are found in adrenal HAC; high or high-normal levels are found in pituitary HAC cases.
- UCCR: this is only useful in ruling out HAC where normal results are obtained (normal UCCR is <30). Stress and non-adrenal diseases may falsely elevate the UCCR.



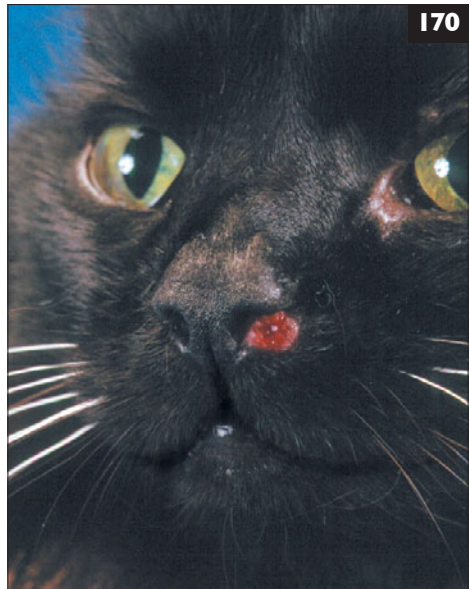


169 A 2-year-old neutered female DSH cat from the UK is brought in with nodular/crusted lesions on the face (169) and right forelimb, 2 weeks after the owners noticed that the cat had been bitten on the leg. An impression smear reveals eosinophilic intracytoplasmic inclusion bodies.

- i. What are the differential diagnoses and likely diagnosis?
- ii. How would a definitive diagnosis be achieved?
- iii. How should this cat be treated?

170 An owner brings in a 9-year-old neutered female domestic longhaired cat for evaluation. A small lesion is evident on the left nares (170).

- i. What are the differential diagnoses?
- ii. What is the most appropriate diagnostic plan?



169, 170: Answers

169 i. Major differential diagnoses for crusting/ulcerative nodular cutaneous lesions are:

- Infectious:
 - Cutaneous fungal infection.
 - Feline leprosy.
 - Poxvirus.
 - Parapoxvirus.
- Inflammatory, e.g. EGC.
- Neoplasia, e.g. mast cell tumour, fibrosarcoma.

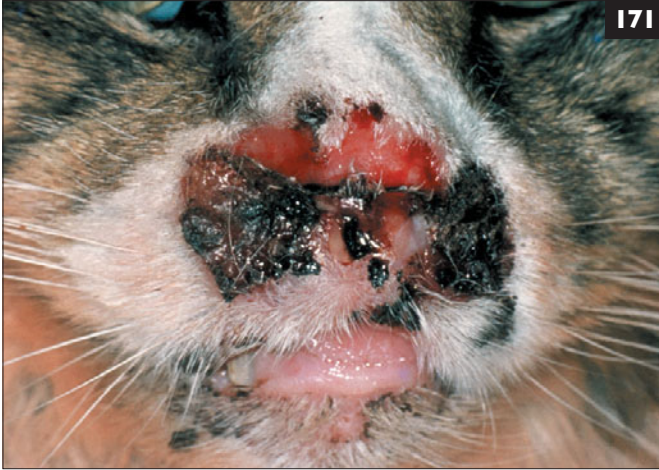Given the presenting history and clinical and laboratory findings, poxvirus (cowpox) infection is most likely. This is most commonly diagnosed in the autumn in cats that enjoy hunting. Infection is usually transmitted via a bite from an infected small mammal and causes an initial scab at the site of the bite (most commonly face and forelimbs). Secondary skin lesions develop over the whole body 10–20 days later.

ii. Scabs or biopsy material can be submitted for virus isolation or electron microscopy (electron microscopy is particularly useful in identifying feline parapoxvirus which is difficult to culture). Serology confirms exposure to this agent: high titres are strongly supportive of the diagnosis. Histology (including immunostaining) of skin biopsies can be used to identify virus localized in characteristic lesions.

iii. In most cases, no specific treatment is required and the cat recovers. In cases where secondary bacterial infection is present, broad-spectrum antibiotics and topical antibacterial washes (e.g. chlorhexidine) can be used. Immunosuppression can lead to viral dissemination and systemic disease which may be fatal to the cat. Glucocorticoids, progestagens, and immunosuppressive agents are therefore contraindicated. Feline poxvirus (cowpox) can be spread to people (usually via pre-existing skin wounds) although this is uncommon. Infection of healthy humans can cause skin lesions and mild systemic signs. In babies, ill, elderly, or immunosuppressed people, systemic signs can be particularly severe and may rarely be fatal. Careful hygiene, ideally including wearing of disposable gloves when handling the cat, should be sufficient to prevent the spread of infection to healthy humans. Occasional cat-to-cat transmission can occur although this is rare.

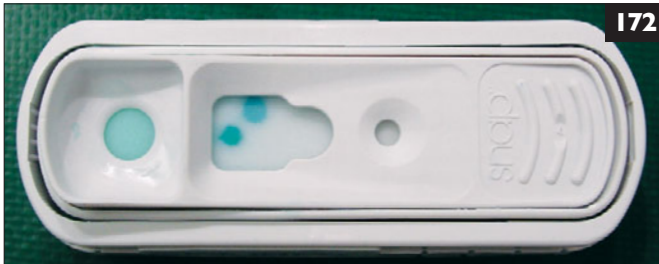170 i. Differential diagnoses for a nasal proliferative lesion include:

- Neoplasia, e.g. basal cell tumour, squamous cell carcinoma.
 - Inflammatory lesions, e.g. EGC.
 - Infectious causes, e.g. fungal granuloma.
- ii. A biopsy is indicated. Tissue collected should be submitted for histology and possibly fungal and bacterial culture. Where feasible, a portion of biopsy material should be stored at -20°C (-4°F) in case mycobacterial culture is indicated following histological studies. In this case, basal cell tumour was diagnosed.



171 The picture shows a 12-year-old neutered male DSH cat with a crusting ulcerated nasal lesion (171). Biopsy revealed squamous cell carcinoma.

- i. What is the natural course of this disease?
- ii. What treatment options should be considered and what is the prognosis?



172 This is a patient-side FeLV test kit (172).

- i. What is the kit detecting in the cat's serum?
- ii. How reliable is a positive test result?

171, 172: Answers

171 i. Squamous cell carcinoma is a common malignant tumour of keratinocytes. Exposure to sunlight is considered an important risk factor for the development of these tumours and there is a precancerous stage of ‘actinic dermatitis’ characterized by hyperplasia, abnormal keratinocytes, erythema, and scaling. The lesions are far more common on non-pigmented skin.

Actinic dermatitis progresses to squamous cell carcinoma *in situ*; i.e. squamous cell carcinoma where the tumour remains localized to the epidermal layers and hair follicle (otherwise referred to as non-invasive squamous cell carcinoma). This may progress to invasive squamous cell carcinoma where the tumour breaks through the epidermal basement membrane and invades the underlying dermis. Once this occurs, there is the potential for metastatic spread to occur, although the tumours tend to be locally invasive but slow to spread. Occasional cases of paraneoplastic hypercalcaemia have been associated with squamous cell carcinoma in cats.

ii. Treatment modalities include surgery and cryosurgery, radiotherapy, and photodynamic therapy. External beam radiotherapy can be successful, and for superficial lesions ⁹⁰strontium plesiotherapy (a form of superficial radiotherapy) is highly successful and causes little disfigurement. Similarly, photodynamic therapy carries a good success rate for superficial tumours (several treatments are usually needed for these therapies). Chemotherapy is not a successful option.

The prognosis varies markedly with tumour stage; for squamous cell carcinoma *in situ* and for small superficial tumours (<2 mm diameter), the prognosis is excellent.

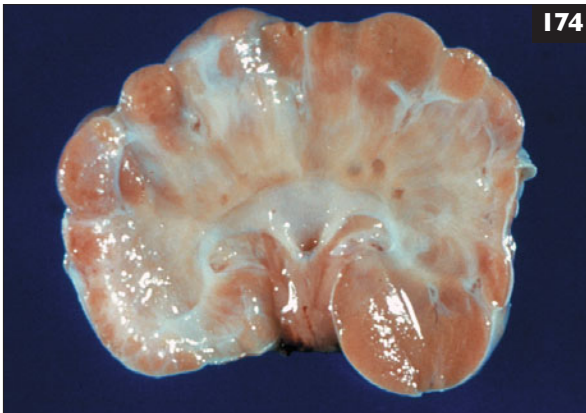
172 i. FeLV patient-side test kits detect FeLV antigen (core p27 antigen) present in serum samples.

ii. No diagnostic test kit is 100% perfect. Patient-side test kits vary in their sensitivity and specificity although many have values between 98% and 100% for both of these. Since FeLV has a very low prevalence in the healthy cat population of most countries (<2%), there is a real risk that a positive test result received from a healthy cat is a false-positive result. For example:

- If a test kit used has a specificity of 98% there will be two false-positive results for every 100 cats tested.
- Prevalence of true infection is 2% giving two genuinely positive results per 100 healthy cats tested.
- Therefore, if 100 healthy cats are tested, two will be genuine positive and two will be false-positive results, i.e. there is a 50% chance of a false-positive test result.
- Therefore, if a healthy cat is tested and found to be positive, euthanasia should not be undertaken. The result should be confirmed by virus isolation, PCR, or IFA at a commercial laboratory. Since the prevalence of infection is much higher in sick cats, false-positive results are less of an issue in this situation.



173 A 4-year-old neutered female DSH presents with severe, recent-onset dyspnoea (173). On clinical presentation the cat is in considerable distress, persistently breathing with an open mouth and demonstrating orthopnoea. What emergency procedures and/or treatments should be considered to stabilize such a patient?



174 i. Comment on the appearance of this kidney (length = 32 mm) (174) removed at post mortem from a cat with renal failure.
 ii. What common serum biochemical abnormalities are associated with this disease, and what are the underlying pathophysiological mechanisms of these changes?

173, 174: Answers

173 Minimizing stress is essential and restraint for diagnostic imaging, even for ultrasonography, may not be practical in some cases, necessitating symptomatic and supportive therapy.

Oxygen therapy is usually the first priority as virtually all dyspnoeic cats will benefit from this. If a pleural effusion or pneumothorax is suspected and diagnostic imaging contraindicated, trial thoracocentesis is justified and can rapidly stabilize a patient.

Historical and/or clinical features may help narrow down the likely cause of the dyspnoea, and attempts should be made to distinguish upper respiratory, pleural space, lower respiratory, and non-respiratory disorders (e.g. anaemia) as causes of the dyspnoea.

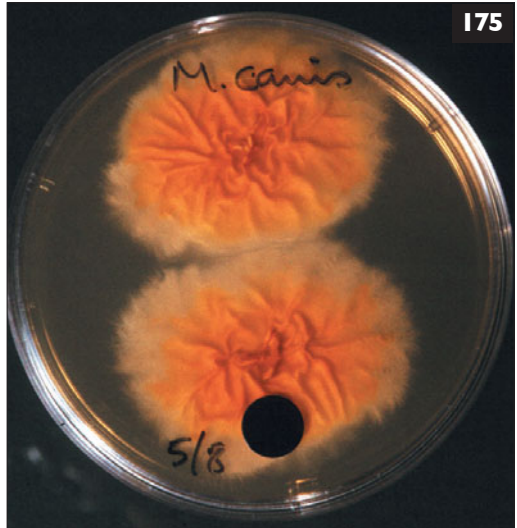Although drugs should not be used indiscriminately, severe dyspnoea may be life threatening and emergency 'trial therapy' may be appropriate. If the dyspnoea is thought to be due to pulmonary oedema, diuresis with furosemide is recommended and can be given by intravenous injection (typically 2–4 mg/kg). Contraindications would be extreme dehydration or the presence of hypokalaemia. Additionally, if congestive heart failure is considered likely, glyceryl trinitrate (nitroglycerine) ointment (0.25–0.5 cm) can be applied to the inner surface of the pinna. Blood pressure should be monitored as glyceryl trinitrate is a potent vasodilator.

If bronchoconstriction is suspected (e.g. asthmatic attack) β_2 -agonists can be given, e.g. terbutaline at 10 $\mu\text{g}/\text{kg}$ IV or salbutamol/albuterol by inhalation. Soluble glucocorticoids, e.g. prednisolone sodium succinate at 50–100 mg/cat IV, may also be useful.

174 i. This kidney shows typical changes of end-stage chronic interstitial nephritis with extensive scarring and fibrosis causing marked distortion with little normal cortex and medulla remaining. The size is at the bottom end of the normal range for cats.

ii. CRF is characterized by azotaemia – elevation of serum urea and/or creatinine, which are products of protein catabolism. Urea is synthesized by the liver from ammonia, and creatinine is derived from spontaneous breakdown of phosphocreatine in myocytes. Both are excreted by glomerular filtration and a reducing glomerular filtration rate (nephron loss) results in their accumulation. Hyperphosphataemia is also commonly encountered for the same reason, although compensatory hyperparathyroidism may increase renal excretion of phosphate and maintain normophosphataemia until later in the disease. A metabolic acidosis is common: the kidneys excrete acid derived from metabolism of proteins and other compounds, partly in the form of ammonium ions produced by the tubules. In CRF, increased ammoniogenesis within remaining tubules may fail to compensate for the loss of nephrons and thus acidosis develops. Hypokalaemia is seen in some cats and appears to result from inappropriate kaliuresis. Hyperproteinaemia may be seen as a result of uncompensated polyuria resulting from reduced concentrating ability of the kidneys.

175 The picture shows the typical appearance of *Microsporum canis* colonies grown on a Sabouraud's dextrose agar plate when viewed from beneath (175). This plate was inoculated with hairs from a cat showing alopecic/crusting lesions around the face and one forelimb. What systemic drugs should be considered for use in this cat and what are their advantages/disadvantages?



176 Urinalysis (176) forms an important part of the investigation of cats with CRF. What specific aspects of urinalysis are of major importance and why?



175, 176: Answers

175 Traditionally griseofulvin (10–200 mg/kg/day orally) has been the treatment of choice for feline dermatophytosis. However, it is fungistatic not fungicidal, it is a recognized teratogen, and therapeutic concentrations will be maintained for <72 hours in the stratum corneum after administration is stopped, resulting in the requirement for long courses of treatment (many weeks). Drug-induced myelosuppression and neutropenia have been recognized in some treated cats.

Itraconazole (10 mg/kg/day orally) has been widely used for the treatment of dermatophytosis in cats. It is a triazole antifungal drug with a greater inherent activity against dermatophytes than griseofulvin. Although it is still regarded as fungistatic, it concentrates in the stratum corneum and therapeutic concentrations may be maintained for 2–4 weeks after cessation of therapy.

Terbinafine is an allylamine antifungal, regarded as fungicidal and having high efficacy against dermatophytes. It has not been used as extensively in cats, but studies suggest good efficacy with a dose of 30–40 mg/kg/day orally. As with itraconazole, the drug concentrates well in the stratum corneum and therapeutic concentrations persist for 2–4 weeks beyond cessation of therapy, allowing for shorter duration of treatment.

Recent interest has surrounded the use of lufenuron in dermatophytosis, but, despite some promising initial reports, controlled trials have failed to show any clinically valuable efficacy with this agent.

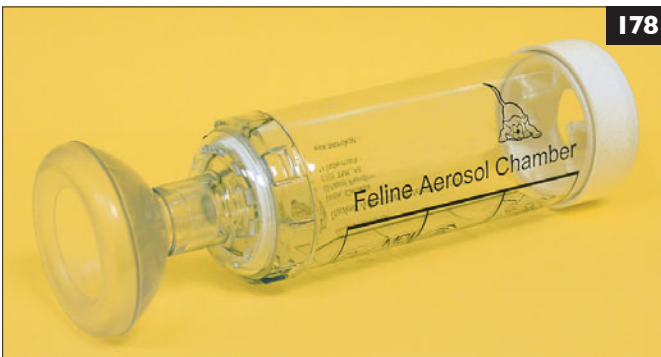176 Evaluation of USG (which must be performed with a refractometer as urine ‘dipsticks’ are inaccurate) is the most important analysis. To interpret serum urea and creatinine concentrations it is essential to have a concomitant urine sample. Generally, the presence of azotaemia with a USG <1.035 implies intrinsic renal failure. Exceptions to this would be the administration of any drugs that might interfere with urine concentrating ability (e.g. diuretics, glucocorticoids) and the presence of other diseases that may affect urine concentrating ability (e.g. hyper- and hypoadrenocorticism, hypercalcaemia, hyperthyroidism). If these factors are eliminated, the USG can confirm the presence of renal failure. However, a USG >1.035 does not necessarily rule out renal failure as, unlike dogs, occasionally cats do manage to concentrate urine quite well in the presence of renal failure.

Microscopic examination of urine sediment (\pm culture) is also important, as this may provide evidence of the underlying aetiology of the renal disease or the presence of complicating factors/disease. Inflammatory sediments may be present with infections, and bacteria may be seen (e.g. pyelonephritis). There may also be tubular casts of various types (fatty, waxy, hyaline) giving evidence of underlying renal disease/pathology. Although crystalluria can be a normal finding, some types of crystals may also be indicative of potential underlying disease (e.g. calcium oxalate with nephroliths, ureteroliths, or ethylene glycol toxicity).

Quantitative assessment of proteinuria (UPC) is valuable to assess glomerular disease, but little is known about its value in CRF *per se* in cats.



177 UDCA and SAMe (177) are two drugs commonly used in the treatment of hepatic disease, particularly inflammatory liver disease. What are these drugs and what are their purported benefits? Are any precautions necessary with their use?



- 178 i. What is illustrated in this picture (178)?
ii. What are the indications for its use and what drugs are commonly administered with this?

177, 178: Answers

177 UDCA (ursodeoxycholic acid) is a synthetic bile acid, and is unusual in that it is hydrophilic, whereas most bile acids are lipophilic (having a role in fat emulsification). UDCA has a number of potential benefits documented in humans and other species, principally through altering the bile acid pool. In cholestatic diseases, bile acids accumulate in the liver and can cause cell membrane damage and cell necrosis. By competitively replacing endogenous bile acids, the lipophobic UDCA reduces damage to cell membranes, has a choleric action and a potential immunomodulating role. In cats, UDCA (15 mg/kg/day) has been demonstrated to be safe, although there may be some increase in serum bile acid concentrations following its administration. Although commonly used in liver disease, to date no controlled studies have assessed its efficacy. Due to its choleric action, its use is contraindicated if there is biliary obstruction.

SAMe (S-adenosyl methionine) is derived from methionine and ATP, and approximately 50% of the daily methionine intake is normally used for this purpose. SAMe plays a major role in many cellular biochemical processes and is involved in the production of glutathione, a major cellular antioxidant. In liver disease, levels of both SAMe and glutathione are commonly depleted. Depletion of both can be reversed by SAMe supplementation, which may result in amelioration of various toxic and inflammatory liver diseases. A dose of 15–20 mg/kg/day is commonly recommended.

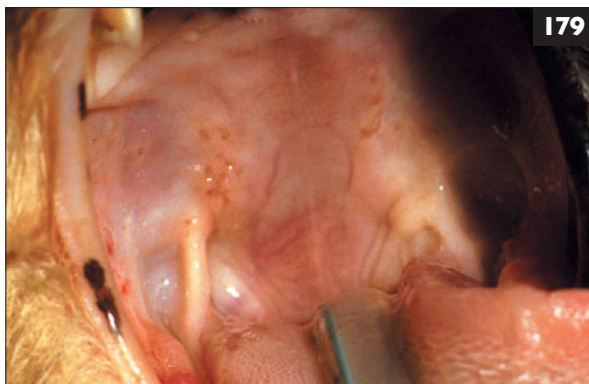
178 i. The picture illustrates a ‘spacer’ device for administration of medications via a MDI.
ii. A MDI delivers an aerosol containing a specified dose of medication and is widely used for treatment of chronic bronchitis and asthma. MDIs are typically designed for use in adult humans where actuation of the MDI (aerosolization of a dose) can be timed to coincide with a deep intake of breath. This, however, is impractical in animals (and neonatal/paediatric humans). The alternative is to use a spacer with a breathing mask that incorporates a one-way valve. The MDI is actuated, delivering the aerosol into the spacer, and the cat can then inhale the medication by placement of the nose and mouth in the close-fitting face mask and allowing normal respiration for 15–30 seconds. The device pictured (‘Aerokat’) has been specifically designed for feline use.

The two most common drugs administered via this route are β_2 -adrenergics and glucocorticoids. The β_2 -adrenergics are bronchodilators. The two commonly used agents are salbutamol/albuterol (onset of action 5–10 minutes, maximum duration 2–4 hours) which can be used as required; and salmeterol (slower onset, but duration of action of around 12 hours) which may be preferable for long-term use.

Fluticasone propionate given twice daily is a commonly recommended glucocorticoid, having high potency but virtually no systemic absorption and therefore no systemic side effects. Cheaper glucocorticoids (e.g. beclomethasone dipropionate) can also be used, but at high doses they may have systemic effects. High-strength MDIs of these products (generally 200–250 μg /actuation) have been used in cats.

179 The oral cavity of a cat (179) and the accompanying blood results are presented.

- i. What is the assessment of this haemogram?
- ii. What diagnostic test is appropriate next?

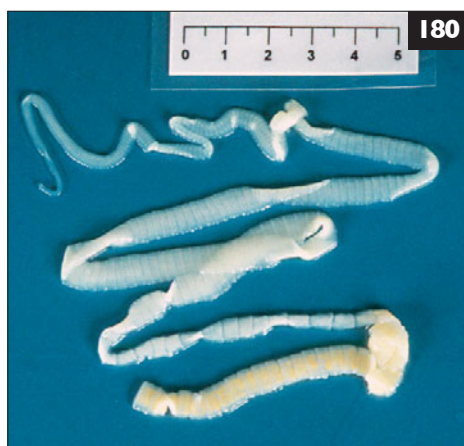

Parameter	Value	Reference range
Haemoglobin (g/dl)	4.4	8–15
HCT (%)	14	25–45
RBC ($10^{12}/l$)	3.3	5.5–10.0
MCV (fl)	42.2	40–55
Platelets ($10^9/l$)	7	200–700
WBC ($10^9/l$)	3.80	5–19
Neutrophils ($10^9/l$)	2.28	2.5–12.5
Lymphocytes ($10^9/l$)	1.14	1.5–6.0
Monocytes ($10^9/l$)	0.15	0.1–0.7
Eosinophils ($10^9/l$)	0.23	<1.5

Smear: Platelets sparse, thrombocytopenia.

180 This cestode (180) was recovered from the small intestine of an adult cat in the UK.

- i. What is the most likely species and what is its intermediate host?
- ii. What other common cestodes affect cats and what are their intermediate hosts?
- iii. What treatment(s) should be recommended for cestode infections?



179, 180: Answers

179 i. The cat has a marked pancytopenia – reduced levels of all cells produced by the bone marrow (RBCs, WBCs, and platelets) and there is evidence of petechial haemorrhage in the mouth. Causes of pancytopenia include:

- Toxic insults to the bone marrow caused by exposure to drugs such as griseofulvin and chloramphenicol, or heavy metals such as thallium.
- Bone marrow disorders such as myeloproliferative and lymphoproliferative disorders, myelophthisis, myelofibrosis, immune-mediated destruction, idiopathic marrow hypoplasia.
- Infectious causes, e.g. FeLV, FIV, FIP, histoplasmosis (*Histoplasma capsulatum*), tularaemia (*Francisella tularensis*).

ii. A bone marrow aspirate is indicated and consideration given to blood transfusion.

180 i. This cestode is most likely to be *Taenia taeniaformis*; the characteristic appearance and location in the cat would strongly suggest this. It has a worldwide distribution, with cats being the definitive host. As with all *Taenia* species, there is a mammalian intermediate host which in this case is a rodent (mouse, rat) or occasionally rabbit. Infected cats are asymptomatic, but motile proglottids may be seen in the faeces or on the perineal fur.

ii. *Dipylidium caninum* is the most common cestode infection of cats, but the adults are narrower and shorter than *Taenia* species. Flea larvae ingest the *Dipylidium* eggs, and cats are infected when they ingest adult fleas during grooming.

Other geographically widespread cestodes of cats include *Mescestoides lineatus*; the first intermediate host of this parasite is unknown, but presumed to be an arthropod, with numerous animals (amphibians, reptiles, birds, mammals) acting as the second intermediate host.

Other cestodes with more limited geographical distribution include:

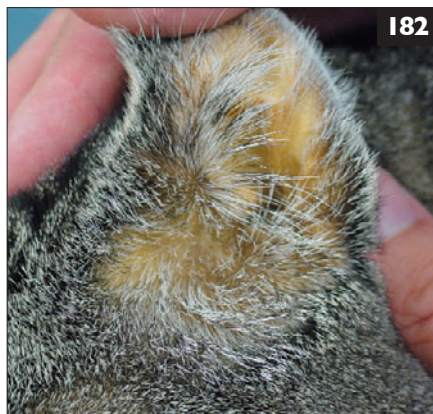- *Diphyllobothrium latum* (mainly northern and eastern Europe and Japan, intermediate host is fish).
- *Spirometra erinaceieuropaei* (mainly in Europe, South America, Asia, and Australia; intermediate hosts are amphibians, reptiles, and rodents).
- *Spirometra mansonoides* (mainly in America; intermediate hosts are amphibians, reptiles, and rodents).
- *Diplopylidium acanthotetra*, *D. nolleri*, and *Joyeuxiella pasqualei* (mainly southern Europe and Middle East; intermediate hosts are lizards).
- *Joyeuxiella fuhrmanni* and *J. echinorhyncoides* (mainly Africa; intermediate hosts are lizards).

iii. Praziquantel is the most useful drug for cestodes in general. Some species (*Diphyllobothrium*, *Spirometra*, *Diplopylidium*, *Joyeuxiella*) require a higher dose (30–35 mg/kg) than the standard one (5–10 mg/kg).



181 Laboratory results are shown (below) for a 10-year-old DSH (181) that has been presented with a history of chronic weight loss in spite of a good appetite.

- i. What is the interpretation of these results?
- ii. What further tests would be helpful?



182 A 6-year-old neutered male DSH cat presents with lethargy, inappetence, and intermittent vomiting.

- i. What is the most obvious abnormality illustrated (182)?
- ii. What are the two most common forms of inflammatory liver disease in cats, and how should these be treated?

Serum biochemistry

Parameter	Result	Reference range
Urea mmol/l (mg/dl)	8.9 (24.9)	6.0–10.5 (17.0–29.0)
Creatinine μ mol/l (mg/dl)	112 (1.6)	<175 (<2.0)
Phosphate mmol/l (mg/dl)	1.6 (5.0)	0.95–1.95 (2.9–6.0)
Glucose mmol/l (mg/dl)	15.6 (281)	3.5–7.5 (60–135)
Total protein g/l (g/dl)	77 (7.7)	55–80 (5.5–8.0)
Albumin g/l (g/dl)	34 (3.4)	24–35 (2.4–3.5)
Globulin g/l (g/dl)	43 (4.3)	21–50 (2.1–5.0)
Alanine aminotransferase (IU/l)	178	15–45
Alkaline phosphatase (IU/l)	124	15–60

181, 182: Answers

181 i. Renal function appears normal on the basis of these results; however, the liver enzymes (ALT, ALP) are elevated and there is a hyperglycaemia. Causes of raised liver enzymes would include a primary hepatopathy or these changes could be secondary to another disease such as hyperthyroidism or diabetes mellitus. The raised blood glucose result is consistent with either stress or diabetes mellitus.

ii. Repeating the blood glucose test may be helpful in assessing if the elevation is due to stress or diabetes mellitus. Another option would be to send the cat home and ask the owner to try to collect a urine sample in a few days' time when the cat will presumably be less stressed. Another useful test would be serum fructosamine levels. An elevation in serum fructosamine indicates that there has been significant hyperglycaemia during the previous 2–3 weeks and therefore helps to discriminate between stress-induced hyperglycaemia and diabetes mellitus.

Serum total thyroxine levels should be measured to rule out hyperthyroidism before investigations of liver function which might include pre- and post-prandial bile acid measurement, radiography, ultrasonography, and liver biopsy.

182 i. This cat is showing marked icterus (jaundice). The mucous membranes and sclera are the easiest sites to detect icterus.

ii. The common inflammatory hepatopathies in cats can be broadly divided into suppurative and non-suppurative cholangiohepatitis.

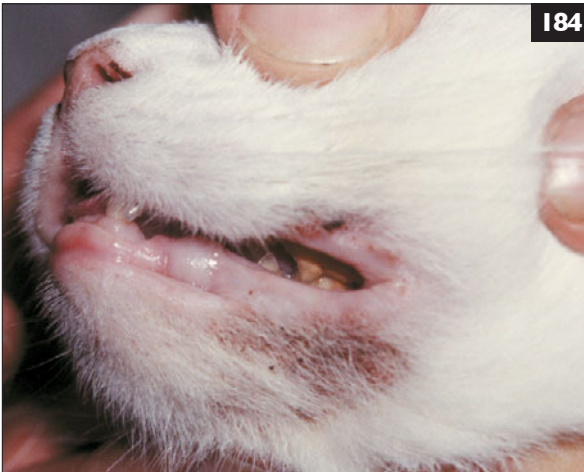
Suppurative cholangiohepatitis is characterized by a neutrophilic portal/periportal infiltrate, often containing degenerate neutrophils within dilated bile ducts. This usually results from a bacterial infection ascending from the duodenum. *Escherichia coli* is the most common organism isolated, but others include *Staphylococcus*, *Streptococcus*, *Clostridia*, and *Bacteroides* spp. Antibiotics should ideally be based on culture and sensitivity results. Antibiotics that are concentrated/excreted in bile include penicillins, cephalosporins, and fluoroquinolones. Metronidazole can be valuable if anaerobes are suspected/cultured.

Non-suppurative cholangiohepatitis probably encompasses a number of disease syndromes. A mixed inflammatory infiltrate is seen in some, whereas there is a predominance of lymphocytes and plasma cells in the portal/periportal areas of others ('lymphocytic cholangitis' or 'lymphocytic portal hepatitis'). The inflammation can be accompanied by marked bridging fibrosis. An immune-mediated pathogenesis is often suspected in cases with marked lymphoplasmacytic infiltration, and these are frequently treated initially with immunosuppressive doses of glucocorticoids. Other immunosuppressives (e.g. chlorambucil or methotrexate) are used if the response is poor. Cases characterized by a mixed inflammatory infiltrate are commonly treated with anti-inflammatory doses of glucocorticoids initially. Additional therapy may include antifibrotic agents (e.g. colchicine), UDCA, SAME and, dietary manipulation.



183 The fluid (183) has been aspirated from the pleural space of a cat presented for dyspnoea. The fluid has a total protein content of 32 g/l (3.2 g/dl) and an albumin content of 19 g/l (1.9 g/dl). There are $3.8 \times 10^9/l$ nucleated cells, and numerous erythrocytes (PCV 2.2%).

- i. What are the three classical categories of pleural/ascitic fluid and how should this fluid be characterized?
- ii. How does this type of characterization help in narrowing down differential diagnoses of pleural or ascitic effusions?



184 A 6-year-old neutered male DSH cat presents with crusting lesions around the mouth (184), ears, ventral abdomen, and nail beds. Histopathology reveals subcorneal pustules with acantholytic keratinocytes.

- i. What is this disease?
- ii. What is its cause and how should it be treated?
- iii. What is the prognosis for the cat?

183, 184: Answers

183 i. Fluids are typically classified as transudates, modified transudates, and exudates. Approximate values for these are:

- Transudates: these are usually clear fluids with a low total protein (<10 g/l [1 g/dl]) and nucleated cell count (<1.0 × 10⁹/l) in which mesothelial cells are usually dominant.
- Modified transudates: these have variable appearance (clear or cloudy, and usually yellow or pink) and have moderate amounts of protein (10–50 g/l [1–5 g/dl]) and nucleated cells (1–5 × 10⁹/l). The predominant cell type varies according to the aetiology. The fluid in the question falls into this category.
- Exudates: these have a high total protein (>35 g/l [3.5 g/dl]) and nucleated cell count (usually >5 × 10⁹/l). They can be clear, cloudy, or opaque and vary in colour from yellow to brown.

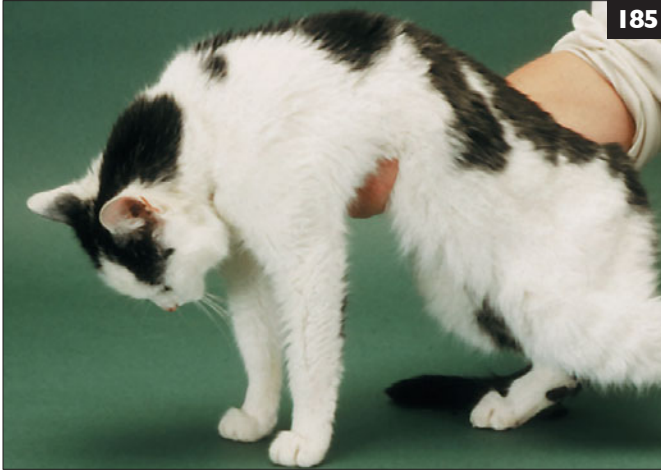
ii. Although such a classification scheme is arbitrary, it can be helpful in narrowing down differential diagnoses. A pure transudate suggests passive loss of fluid from vessels into the pleural/peritoneal space through lack of oncotic pressure (hypoalbuminaemia). The higher cell and protein content of modified transudates suggest loss of fluid at least in part by raised intracapillary pressure (e.g. congestive heart failure or vascular occlusion secondary to neoplasia or ruptured diaphragm). The high cell and protein content of exudates suggests loss of integrity of blood vessels such as may occur with vasculitis (e.g. FIP) or secondary to infection (e.g. pyothorax, bacterial peritonitis).

184 i. The clinical signs and histopathology in this cat are typical of pemphigus foliaceus.

ii. Pemphigus foliaceus is an autoimmune skin disease with deposition of autoantibodies in the epidermis targeted against intercellular adhesion molecules (cadherin desmosomal glycoproteins) causing loss of cellular adhesion.

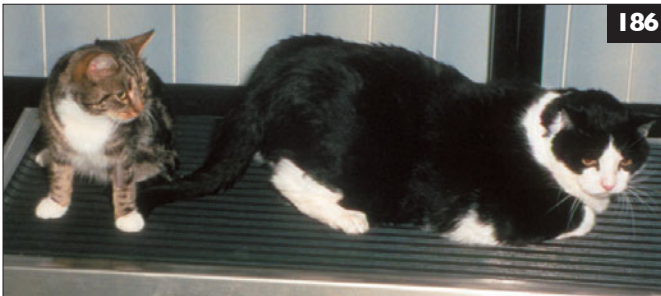
Pemphigus foliaceus lesions most commonly affect the nose and ears, but lesions may be more generalized and affect the nail beds and foot pads. The primary lesions are vesicles, bullae, or pustules. However, these are relatively superficial in the epidermis and are very fragile, so are rarely seen. Erosions and ulcers with crusting and exudation are therefore the common signs. Cytology of exudate may be helpful diagnostically as it may reveal the rounded acantholytic keratinocytes typical of the disease, and immunofluorescence can be used to demonstrate the deposition of antibodies in the lesions.

iii. The prognosis for pemphigus foliaceus is good with most cases responding well to immunosuppressive therapy, although prolonged and sometimes life-long therapy may be required. Glucocorticoids are the treatment of choice (e.g. 2–4 mg/kg/day oral prednisolone, followed by a reducing dose when in remission). If glucocorticoid-sparing therapy is needed, chlorambucil often produces good results.



185 This 10-year-old neutered female DSH cat (185) has a history of polydipsia/polyuria, weight loss, and intermittent vomiting.

- i. What is the most obvious feature this cat is displaying?
- ii. What differential diagnoses should be considered?
- iii. What are the priorities for further investigation?



186 An owner brings in a 6-year-old neutered male DSH cat (186, right) for a routine booster vaccination and check-up. The cat weighs 11 kg and is noticeably obese. How can obesity be assessed in a clinical situation?

185, 186: Answers

185 i. This cat is showing ventroflexion of the neck, a classic sign of neuromuscular weakness.

ii. This is not a specific clinical sign and can be caused by numerous myopathies, neuropathies, or 'junctionopathies'.

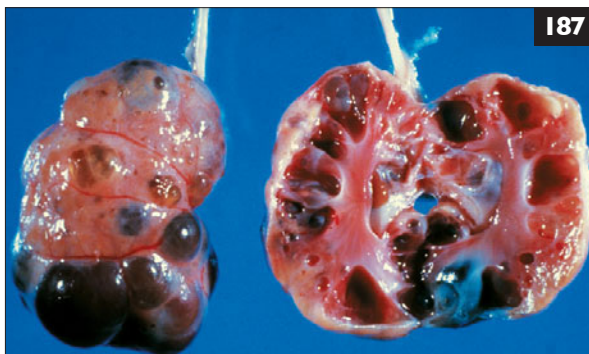- Neuropathies: chronic organophosphate poisoning, thiamine deficiency, chronic relapsing polyradiculoneuropathy, toxoplasmosis, paraneoplastic disease, botulism.
- Polymyopathies: inflammatory/infectious (toxoplasmosis, immune-mediated, possibly retrovirus-associated), metabolic (hypokalaemia, hypernatraemia), paraneoplastic, hyperthyroid-associated, HAC.
- Junctionopathies: myasthenia gravis (congenital, acquired, paraneoplastic), organophosphate intoxication.

Hypokalaemia is probably the single most common cause of this type of presentation. In this cat, the accompanying clinical signs (polydipsia, polyuria, weight loss, and intermittent vomiting) would be strongly suggestive of hypokalaemia secondary to CRF. However, hyperthyroidism would also be an important differential, as would paraneoplastic disease (e.g. with hypercalcaemia causing polyuria and polydipsia).

iii. Priorities for further investigation would be a thorough history, physical and neurological examination. A neurological examination should aim to detect any specific deficits, and distinguish muscle weakness from neurological disease (e.g. by careful assessment of proprioceptive responses). Initial screening blood tests should include serum biochemistry (including CK, urea, creatinine, calcium, phosphate, sodium, potassium, thyroxine) and urinalysis.

186 Several methods are available for the assessment of obesity:

- Relative bodyweight can be calculated by dividing the cat's actual weight by its estimated optimum weight. Obese animals weigh >120% of their optimum weight although it has been suggested that health concerns do not exist until the cat has a relative bodyweight >140%. Most domestic cats have optimal body weights between 3.2 and 4.5 kg, and cats weighing >6.5 kg are likely to be obese unless they have a very large body frame.
- Body condition scoring is a subjective scoring system. Systems with five categories (1–5) are used to give the cat a score which describes its condition, 3.0 being normal condition. Intervention is advised in cats with a body condition score >4.0.
- Morphometric techniques have been described as a way of assessing obesity. Specific measurements are taken and used with the cat's bodyweight in kg to provide an estimate of percentage body fat using complex mathematical equations. Individual measurements (e.g. the pelvic circumference which is the abdominal circumference in front of the hindlimbs) can be used to monitor progress of obese cats on a weight reduction regime, although reproducibility of these measurements can be difficult to guarantee.



- 187 i. What is demonstrated in these kidneys (187) removed from a cat with CRF at post mortem?
- ii. What is the current optimal way to detect the disease ante mortem, and at what age can this be done?
- iii. How is the disease inherited and how could it be controlled?



- 188 A 6-year-old neutered male Birman is presented with acute onset of depression, lethargy, weakness, and vomiting. The owner has observed the cat chewing on leaves of a plant (188).
- i. What is this plant and the likely result following ingestion of it?
- ii. What general supportive treatment should be provided for this toxicity and how should the likely major complications be addressed?

187, 188: Answers

187 i. These kidneys demonstrate the classic changes of PKD, an inherited disease in pedigree Longhair and related breeds.

ii. Currently the responsible gene has not been identified, and routine diagnosis is based on renal ultrasonography. With appropriate expertise and equipment (high-definition ultrasound machine with a minimum 7.5 MHz transducer), ultrasonography can be very reliable. With an experienced ultrasonographer, its accuracy has been reported to be around 98% in cats aged 10 months or older. Screening younger cats is possible, but if found to be negative they should be re-screened at 10 months due to the greater sensitivity and reliability (presence of larger cysts) at this age.

iii. The disease is inherited as an autosomal dominant gene. Breeding studies suggest the homozygote state is lethal (PKD homozygotes die *in utero*), and that affected cats are all heterozygotes, thus:

- Every cat with the abnormal gene will have PKD (there are no unaffected carriers).
- Only one parent needs to be affected with PKD in order to pass the condition on.
- Every breeding cat with PKD will pass the disease on to a proportion of its kittens.

Cats should not be bred from until scanned as above and, to eliminate the disease, affected cats should not be bred. Approved registration schemes are available in some countries (e.g. the Feline Advisory Bureau PKD scheme in the UK).

188 i. The plant is a Tiger Lily and both the leaves and flowers are known to be toxic to cats causing severe ARF, although the precise toxin is unknown. Although highly toxic, recovery is possible in many cases with adequate supportive care.

ii. Aggressive treatment of ARF involves intravenous fluid administration, with mild volume overload to promote urine production and diuresis. If oliguria persists (<1–2 ml/kg/hr) then furosemide (2–6 mg/kg IV) and/or mannitol (0.25–0.5 g/kg IV) can be administered to promote urine production. Other supportive care such as H₂-antagonists, antiemetics, and nutritional support may be required.

The major metabolic consequences of ARF are hyperkalaemia and acidosis which can be profound. Mild changes may respond to intravenous fluid therapy but severe changes need prompt therapy. Severe hyperkalaemia (>8 mmol/l [>8 mEq/l]) requires 0.5–1.0 ml/kg 10% calcium gluconate slowly IV to provide cardioprotection. Sodium bicarbonate (typically 1–2 mmol [mEq] per kg) given slowly IV will help address both acidosis and hyperkalaemia. Additionally 1 g/kg 20% glucose can be given IV with or without approximately 0.2 U/kg soluble insulin to cause cellular uptake of potassium. Careful monitoring of response (potassium, glucose, and acid–base status) is required. Severe acidosis (pH <7.15) requires bicarbonate therapy using 1–2 mmol or mEq per kg slowly IV or calculated from: $0.3 \times \text{bodyweight (kg)} \times (\text{desired bicarbonate} - \text{measured bicarbonate})$. Half of the calculated dose is given IV over 20–30 minutes and the remainder added to the intravenous fluids. The dose required varies between cases though, and should be adjusted according to response.



- 189 i. What are the main health concerns in obese cats (189)?
- ii. How should obese cats be managed?



- 190 A breeder is worried about one of her 2-day-old kittens, which is depressed and passing bloody urine. She has brought in the blood-stained bed (190). The breeder is concerned that the kitten may have neonatal isoerythrolysis.
- i. What is neonatal isoerythrolysis?
 - ii. How can this be prevented?

189, 190: Answers

189 i. In man, obesity is associated with increased mortality related to cardiovascular disease, diabetes mellitus, and cancer. Obese cats are at an increased risk of a range of problems including:

- Metabolic problems, e.g. insulin resistance, hyperlipidaemia, glucose intolerance, hepatic lipidosis.
- Endocrine diseases, e.g. diabetes mellitus.
- Physical problems caused by the obesity, e.g. reduced mobility, joint pain, dyspnoea, dystocia, exercise intolerance, heat intolerance.
- Other suggested diseases linked to obesity include feline lower urinary tract disease and hypertension.

ii. The first important step will be in persuading the owner that their cat is obese and that this is increasing its risk of health problems. A weight reduction strategy that involves achievable targets for slow, sustained weight loss is recommended. Options for this include dietary management (altering the amount and types of food that the cat is offered and how it is fed) as well as increasing the amount of exercise that the cat is receiving. Restricting the amount of the cat's normal diet that is fed is one option, although this may result in deficiency of some nutrients since commercial cat foods are formulated to provide maintenance requirements of all nutrients when fed at a normal energy requirement. Feeding specific 'weight loss' diets eliminates this problem. A target bodyweight is calculated (initially this should not involve >15% weight loss) and the cat is fed 60% of its maintenance requirements. In severely obese cats a second target weight may need to be calculated once the first target is reached. Re-weighing at fortnightly intervals is important to monitor the patient.

190 i. Blood type B cats have high levels of naturally occurring antibodies directed at the blood type A antigen. Prior exposure to type A blood is not required to trigger antibody production. Neonatal isoerythrolysis occurs when a queen with blood type B is mated to a tom with blood type A. The kittens born will be mostly or entirely blood type A since the gene for type A is dominant. Type B queens pass high levels of anti-A antibodies to the kittens via the colostrum in the first 24 hours, and this causes severe haemolysis, haemoglobinaemia, and haemoglobinuria. Neonatal isoerythrolysis can also occur when type AB kittens are born to a type B queen. It is not a problem in type A queens giving birth to type B kittens as type A cats do not generally produce naturally occurring antibodies to other blood type antigens.

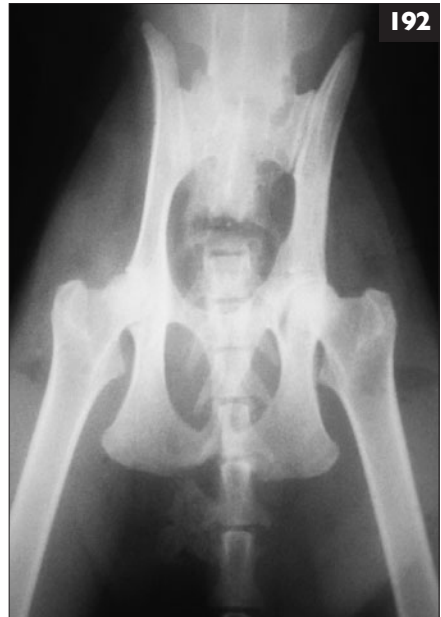ii. Breeds of cats with a high prevalence of blood type B (e.g. British Shorthairs, Birman, Rex, Persians) are at particular risk of neonatal isoerythrolysis, and blood typing prior to mating is recommended so that type B queens can be mated only to type B toms. If this is not possible then the kittens' cord blood can be typed at the time of birth. Type A kittens born to type B queens should be foster-reared for the first 24 hours while colostrum antibodies can be absorbed across their bowel.



191 Potassium supplementation (191) is commonly recommended in cats with CRF. What is the relationship between potassium and CRF in the cat, and what is the rationale for potassium supplementation?

192 An 18-month-old neutered male DSH cat is presented soon after being hit by a car. Clinical examination reveals paralysis of the tail. The cat is admitted for observation and given intravenous fluids and analgesia. Over the following 12 hours, although relatively bright, the cat fails to make any attempts to urinate and the bladder is palpably distended. A VD pelvic radiograph is taken (192).

- i. What abnormality is evident on this radiograph?
- ii. How should this case be managed?
- iii. What is the long-term prognosis in this case?



191, 192: Answers

191 Potassium depletion has been recognized as a complicating feature of feline CRF for many years. Some cats develop excessive urinary loss of potassium as part of their nephropathy, but the precise mechanism(s) involved is uncertain. CRF has been identified as the single most common cause of significant hypokalaemia in cats. Additionally, studies have shown that feeding an acidifying, potassium-depleted diet to healthy cats can induce renal disease and histological changes of chronic interstitial nephritis.

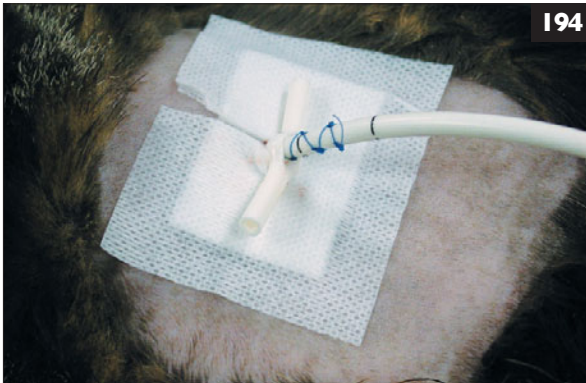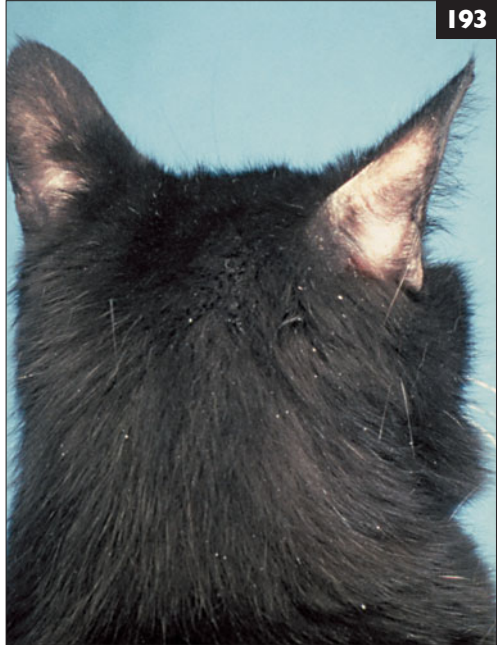
Moderate to severe hypokalaemia (serum potassium <3 mmol/l [<3 mEq/l]) is relatively common in feline CRF, and at this level will often result in a polymyopathy characterized by generalized weakness, neck ventroflexion, and elevated serum CK concentrations. However, the hypokalaemia appears also to contribute to the progression of renal failure through a variety of mechanisms including renal vasoconstriction, reducing the renal responsiveness to vasopressin, and causing increased renal ammoniogenesis, thus potentially contributing to further renal structural damage.

Severe hypokalaemia should initially be managed by administration of potassium-supplemented intravenous fluids, whereas less severe cases can be managed by oral supplementation alone (potassium gluconate dosed to effect, but typically 1–3 mmol/cat [1–3 mEq/cat] twice daily). In many cats there is an apparent improvement in renal function (reduction in azotaemia) following potassium supplementation. Studies suggest that in normokalaemic cats with CRF there is no overt benefit from potassium supplementation.

- 192 i. There is a displaced sacral fracture consistent with a ‘tail pull’ injury.
- ii. The cat’s failure to urinate following its injury is most likely to be a result of trauma to or around the spinal nerves innervating the bladder. The cat is showing no awareness of bladder distension and is therefore suffering from urinary retention. If left untreated, overflow urinary incontinence will result and chronic distension of the bladder is in danger of causing detrusor atony which can leave the bladder muscle permanently non-functional. Short-term management includes emptying the bladder to prevent development of long-term consequences. Bladder expression is preferable to catheterization (which carries a risk of iatrogenic infection) and in most cases of tail pull injuries the bladder is relatively easy to express. In those cases where this does cause difficulties, drugs which help to relax the bladder sphincter and urethral smooth muscle (e.g. phenoxybenzamine 2.5–7.5 mg/cat one to two times daily, with diazepam 2–5 mg/cat two to three times daily, or dantrolene 2–10 mg/cat three times daily with prazosin 0.5 mg/cat one to three times daily) may be helpful in addition to analgesics.
- iii. It is difficult to predict the outcome in individual cases at the time of diagnosis. In those cats where no improvement is seen within a month of the injury, the prognosis for complete recovery is significantly diminished. However, some owners are comfortable to take on bladder expression and can manage their cat at home.

193 This picture (193) was taken of a 14-year-old neutered female DSH cat that had recently received radioactive iodine therapy for treatment of hyperthyroidism.

- i. What abnormalities are evident in the picture?
- ii. What has caused these?
- iii. How can the cause of the problem be confirmed?



194 A cat requiring nutritional support has a gastrostomy tube (194).

- i. What is the importance of nutritional support in sick cats?
- ii. What adverse effects does malnutrition have?
- iii. What guidelines should be employed in deciding whether nutritional support is needed?

193, 194: Answers

193 i. The cat has lost the fur over the pinnae and has evidence of seborrhoea sicca.

ii. Iatrogenic hypothyroidism is the most likely possibility.

iii. A basal total T4 can be measured but a TRH stimulation test is needed to confirm the hypothyroidism. Serum T4 is measured before and 4 hours after administration of 100 µg TRH IV. In normal and sick euthyroid cats administration of TRH causes an increase in T4 levels of between 50–100%. Clinically hypothyroid cats can be treated with L-thyroxine at 10–20 µg/kg daily. The dose is adjusted according to the clinical response which is generally good in acquired cases of hypothyroidism.

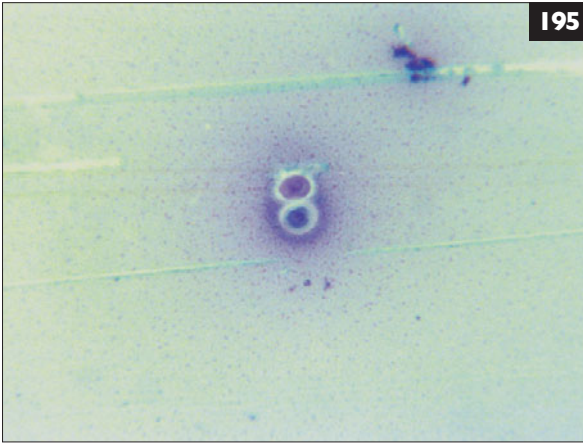
194 i. In normal individuals, food deprivation (starvation) produces an adaptive down-regulation of the basal metabolic rate, which results in a decreased caloric requirement. However, in disease the metabolic effects of illness increase production of ‘catabolic’ hormones (such as glucagon, catecholamines, and cortisol), resulting in abrogation of the normal adaptive responses, and an increase in energy requirements proportional to the severity of the disease process. The increased need for calories and protein in a diseased anorexic/inappetent individual causes protein energy malnutrition. However, even healthy cats have less ability to adapt to a reduced dietary intake, and thus an increased susceptibility to protein energy malnutrition, as they are unable to down-regulate the activity of their liver transaminases in response to reduced protein intake. If their protein requirement is not met by dietary intake, endogenous protein sources will be utilized.

ii. The adverse effects of protein energy malnutrition can be profound and are well documented, varying according to the severity and duration of the protein energy malnutrition. They include:

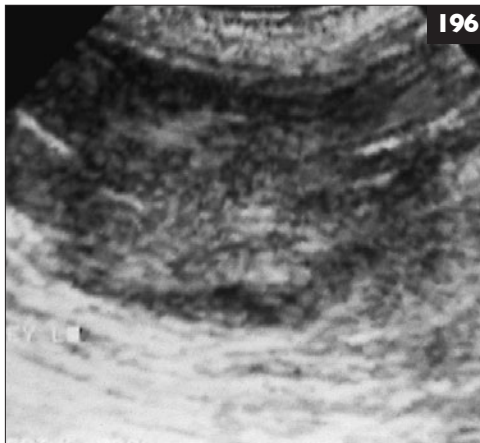
- Lymphopenia, specifically T-cells, with impaired immune responses.
- Impaired humoral immune response.
- Impaired neutrophil function.
- Reduced serum complement levels.
- Hypoproteinaemia.
- Anaemia.
- Delayed wound and fracture healing.
- Muscle weakness.
- An increased incidence of sepsis.
- Increased mortality.

iii. Nutritional support should be considered for any cat with

- A recent (7–14 days) significant loss in bodyweight ($\geq 10\%$).
- Anorexia or marked inappetence of ≥ 3 days duration.
- The presence of cachexia or inadequate body fat/muscle mass.
- Patients with direct protein/energy loss (e.g. exudative peritonitis/pleuritis).



- 195** This impression smear (195) is from the nasal exudate of a 6-year-old Siamese cat with chronic sneezing and nasal discharge.
- What does this indicate as the likely cause of the nasal discharge?
 - How should this cat be treated?



- 196** The ultrasound image (196) is of the left kidney of a 5-year-old neutered female Havana cat with irregular and small kidneys on abdominal palpation.
- What abnormalities can be seen?
 - What potential historical features and abnormalities on clinical examination would there be?

195, 196: Answers

195 i. The picture shows the typical appearance of *Cryptococcus neoformans*. The large non-staining capsule around the yeast gives a ‘halo-like’ appearance.

ii. Optimal treatment should be based on culture so that the variety of *C. neoformans* is determined, and if possible *in vitro* antifungal sensitivity performed. Experience has suggested that *C. neoformans* var. *gattii* infections may be more susceptible to itraconazole than fluconazole.

Surgical removal of infected tissue will aid in the recovery and thus curettage and/or forced nasal flushing may be a very valuable first step in the treatment.

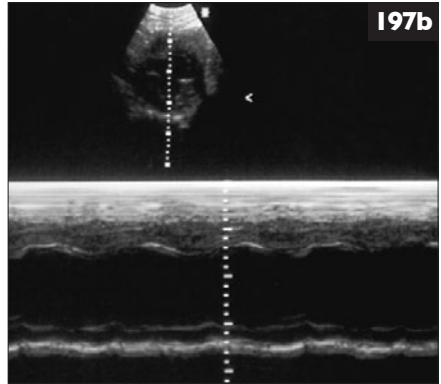
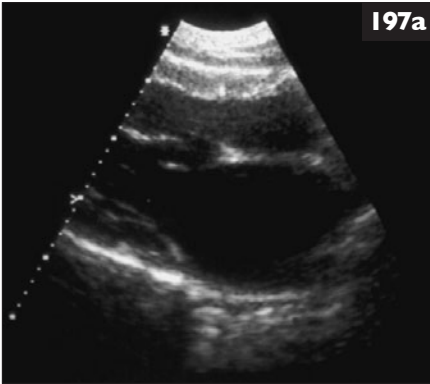
Treatment of choice for cats with severe or widespread cryptococcosis is a combination of amphotericin B and flucytosine. However, amphotericin B is nephrotoxic and has to be administered with fluid loading to minimize this potential.

For cats with mild to moderate disease, the recommendations are to treat with itraconazole (50–100 mg/cat daily with food) or fluconazole (25–100 mg/cat twice daily). Therapy is typically required for 2–6 months and should be continued until complete clinical and microbiological resolution is achieved. A four- to five-fold decline in serum antigen titre supports successful therapy, although continuing therapy until titres are zero is advised. Fluconazole can be used instead of itraconazole, but it is considerably more expensive, and some isolates of *C. neoformans* var. *gattii* appear to be relatively resistant. Fluconazole is water soluble and has very good tissue penetration, including the CNS.

196 i. The ultrasound image shows virtually no recognizable renal architecture at all. The renal outline can be seen and appears somewhat irregular, but there is a lack of internal structure suggesting severe alteration to normal renal anatomy. The medulla appears relatively echogenic suggesting possible fibrosis (possible ‘end-stage’ changes). It is impossible to assess renal size as there is no scale, although the kidney was in fact small.

ii. Assuming that these changes are bilateral, this cat is likely to be in renal failure. The most common clinical signs associated with renal failure in the cat are vague and non-specific: dehydration, lethargy, inappetence, and weight loss. Polyuria and polydipsia are not as frequently reported in cats with CRF as in dogs (where it is a common and early sign). This may be because cats retain a greater urine concentrating ability than dogs in the face of CRF, but also because polyuria and polydipsia may be more difficult to recognize as a result of the lifestyle of cats. Vomiting also occurs less commonly in cats with renal failure than dogs but is seen in up to one-third of cases.

Other possible historical and clinical findings in CRF, depending on the stage and severity, include pale mucosae (due to anaemia), depression and weakness (malnutrition, cachexia, hypokalaemia), oral ulceration and halitosis, poor coat, diarrhoea, and sudden onset blindness or hypertensive retinopathy due to systemic hypertension. Other features may also be present depending on the underlying cause of the renal failure.

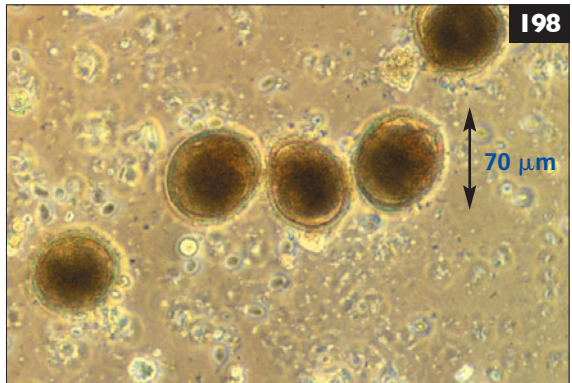


197 Right parasternal long axis and left ventricular M mode echocardiograms (197a and b) have been obtained from a 3-year-old neutered male cat. The table shows measurements obtained from the M mode echo (reference range in brackets).

	Diastole	Systole
IVS thickness (cm)	0.5 (0.25–0.5)	0.7 (0.5–0.9)
LV free wall thickness (cm)	0.4 (0.25–0.5)	0.5 (0.4–0.9)
LV internal diameter (cm)	1.7 (1.1–1.6)	1.5 (0.6–1.0)
Fractional shortening (%)	12 (29–55)	

- i. What is the diagnosis?
- ii. What questions should the owner be asked relevant to this condition?
- iii. Are there any other tests that should be done?
- iv. What treatment is indicated?

- 198 i. Identify these ova (198) found on faecal flotation from a cat. What are their characteristic features?
- ii. What is the life cycle of the organism involved?
 - iii. What is the potential clinical significance of the organism?
 - iv. What treatment should be recommended?



197, 198: Answers

197 i. Dilated cardiomyopathy – this is characterized by an increase in the left ventricular diameter in systole and diastole, thinning of the left ventricular free wall in systole, reduced fractional shortening, and an increase in the end point to septal separation (E-septal separation).

ii. The owner should be questioned as to the cat's diet since taurine deficiency is a known nutritional cause of dilated cardiomyopathy.

iii. Fundic examination should be performed in order to look for evidence of central retinal degenerative changes which can also be seen in taurine-deficient cats. Whole blood taurine levels should be measured.

iv. In cats known or suspected to be deficient, supplementation with taurine at 250–500 mg/cat/day is indicated. Other agents which may be of benefit include:

- Positive inotropes to improve contractility, e.g. digoxin, pimobendan.
- Reduction of preload using diuretics such as furosemide and spironolactone.
- Improved forward flow by use of vasodilators such as the ACE inhibitors.
- Management of dysrhythmias where needed, e.g. propranolol.
- Aspirin at up to 20 mg/kg two to three times a week may be of benefit in reducing platelet aggregation and hence the risk of thromboembolic disease.

198 i. These are *Toxocara cati* ova. Characteristic features include their size (approximately 70 µm), they are almost round, and they have a thick, pitted wall. *Toxascaris leonina* ova are a similar size but more oval, and have a smooth wall.

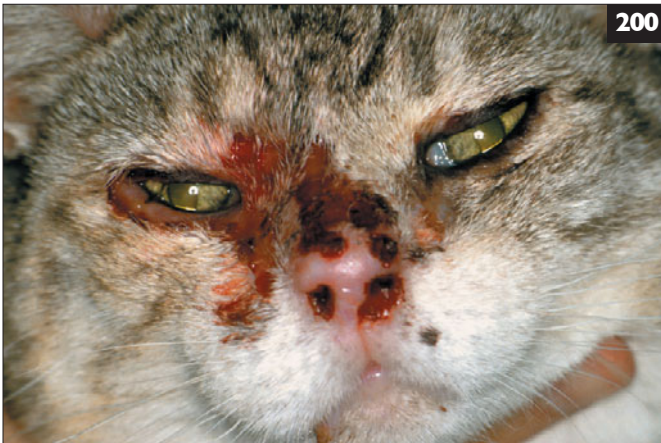ii. *Toxocara cati* is a common nematode parasite. Adult worms (8–15 cm long) are found in the small intestine. The life cycle is either direct or indirect. Developing larvae moult twice within the ova. Infective third stage larvae are released following ingestion of the ova, penetrate through the gastrointestinal tract and undergo a liver–lung migration path, returning to the gastrointestinal tract via the trachea (being coughed up and swallowed). Larvae then complete development into adults in the intestine. Larvae are also present in tissues of paratenic hosts (mice, chickens, earthworms, cockroaches) that have eaten ova. This is a common source of infection for cats (via ingestion), following which the larvae usually develop to adults within the gastrointestinal tract without further migration. A third route of infection is via the milk in suckling kittens. Larvae released from ingested ova migrate to many tissues where they remain dormant, but can subsequently be recovered from the mammary tissue and milk of suckling queens. There is no transplacental migration.

iii. Patent infections occur in kittens as young as 6 weeks of age, but clinical signs are uncommon. Heavy infections can cause unthriftiness, weight loss and vomiting/diarrhoea in kittens. *Toxocara cati* is a rare zoonosis (visceral/ocular larva migrans), most human disease being caused by *T. canis*.

iv. Treatments include fenbendazole, milbemycin, pyrantel, febantel, and selamectin.



199 Anorexia and inappetence (199) can be caused by a wide variety of disorders in cats. What is understood by the term ‘food aversion’ and what measures should be taken to prevent or overcome this phenomenon?



200 A 4-year-old neutered female DSH cat is presented with a 5-month history of lethargy, poor appetite, facial crusting, and ulceration (200). In the initial few weeks of illness, the owner also reported additional signs of sneezing and nasal and ocular discharges.

- i. What differential diagnoses should be considered in cats with ulcerative skin disease?
- ii. What is the most likely cause in this case, and how can this suspicion be confirmed?

199, 200: Answers

199 Food aversion is increasingly recognized as a potentially significant cause of anorexia in cats. Food aversion can happen when cats are offered food at the same time as they are vomiting or feeling nauseous or in pain. Cats that refuse food offered at this time may continue to refuse to eat the same food even when the feeling of nausea or pain has subsided, due to the continued association between the two.

Avoiding food aversion is important where possible, and this means considering adequate antiemetic therapy, in particular, and attempting to identify and treat nausea and vomiting as rapidly and effectively as possible.

If food aversion occurs or is suspected, tube feeding may be needed for a period of time, and initially food should not be offered at all. For less severe cases, appetite stimulation can be employed. Consideration should be given to the cat's environment (noise, temperature, ability to hide), adequate analgesia, the use of pheromone sprays (e.g. 'Felifriend') for cats in unfamiliar surroundings, and petting/stroking to encourage the cat to eat. Offering a variety of foods and textures (small amounts frequently), warming food, and offering high fat/protein content foods with a strong odour may all help.

Pharmacological appetite stimulation may be a valuable alternative to tube feeding although potential side effects of the drugs should be considered:

- Cyproheptadine: 2 mg/cat orally twice daily.
- Diazepam: 0.05–0.2 mg/kg IV two to three times daily.
- Oxazepam: 0.25–0.5 mg/kg orally twice daily.
- Megoestrol acetate: 1 mg/kg orally twice daily.

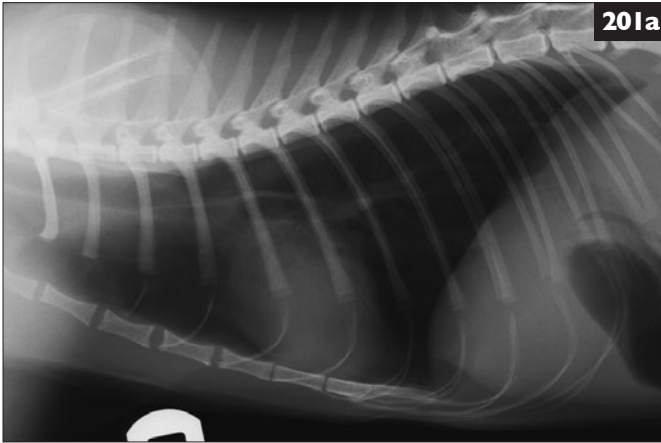
Intravenous diazepam and oral cyproheptadine are the most commonly used agents.

200 i. Important causes of ulceration of the skin include:

- Infection, e.g. bacterial, mycotic, viral (FHV).
- Autoimmune skin disease.
- Cutaneous neoplasia.
- Self-trauma.
- Inflammatory disease.

ii. In this case, the preceding history of upper respiratory tract signs is most suggestive of FHV infection. FHV infection can be diagnosed by submitting skin biopsy material for virus isolation, histology (including immunostaining where available), electron microscopy, and PCR. Oropharyngeal swabs can also be submitted for FHV isolation and PCR. Fungal and bacterial culture should be performed on biopsy samples in order to rule out other infectious causes. In unvaccinated cats, FHV serology may support diagnosis of recent infection.

FHV infection was confirmed in this case. The cat was treated supportively in addition to oral and topical recombinant human interferon but unfortunately a poor response was seen, eventually necessitating euthanasia on humane grounds.



201 A 3-year-old neutered female DSH cat presents with a history of being missing for 36 hours, 3 weeks previously. On return it had left hindlimb pain and lameness. The cat responded to conservative management and was assumed to have been hit by a car. Around a week later the cat developed a cough and progressive inspiratory dyspnoea, which is marked on presentation. There is no dyspnoea.

- i. What does the radiograph (taken under general anaesthesia) (201a) suggest is the cause of the dyspnoea?
- ii. What other signs might the cat show and what, if any, additional diagnostic tests should be undertaken?
- iii. What treatment is recommended?

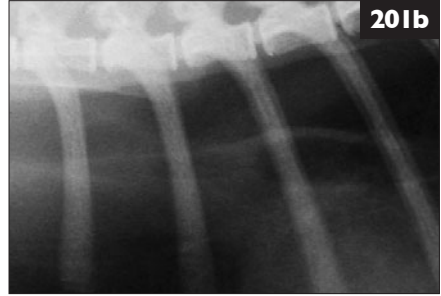
202 A 6-month-old kitten, has recently died of confirmed FIP. The client still owns two litter mates (202) and another 8-year-old cat.

- i. What is the best advice regarding the care of the remaining cats?
- ii. How soon is it safe for the owner to consider getting a new kitten?



201, 202: Answers

201 i. The radiograph shows a flaccid, air-filled oesophagus, which is presumably a result of anaesthesia. The intrathoracic trachea appears dilated cranially but narrows to a small diameter between ribs 3 and 5. The normal diameter is seen again just cranial to the carina (**201b**). These changes could reflect tracheal stenosis or stricture, or an inflammatory or neoplastic lesion, but given the recent clinical history this would be highly suggestive of tracheal avulsion. Tracheal necrosis can also be iatrogenic from prolonged use of an over-inflated cuff around an endotracheal tube.



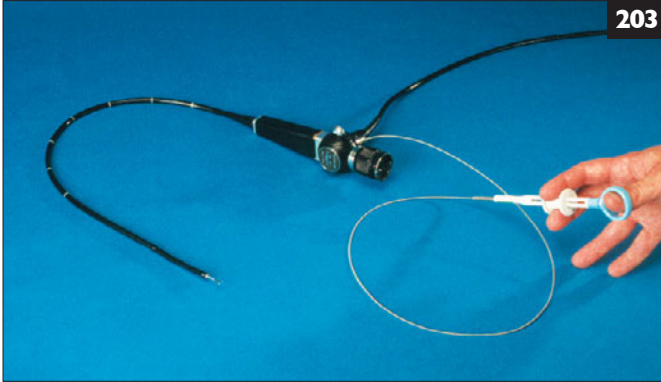
ii. Tracheal avulsion is an unusual condition that typically follows blunt trauma to the chest. Commonly, but not invariably, the avulsion will result in significant pneumomediastinum with subsequent pneumothorax and/or subcutaneous emphysema which may take several days/weeks to resolve.

Tracheoscopy is helpful in confirming the diagnosis and in this case revealed the tracheal tear, and a narrow tubular pseudomembrane that had formed.

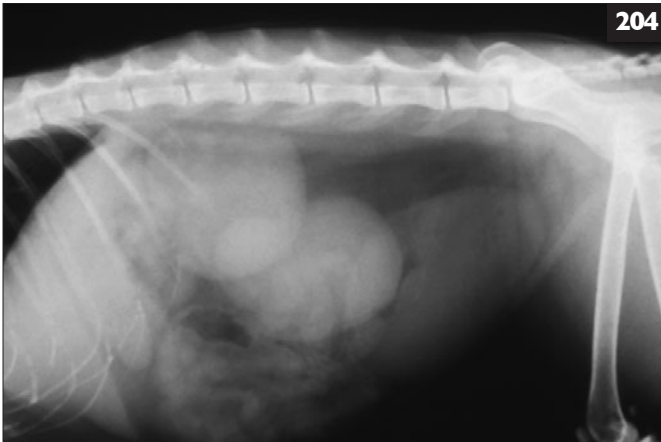iii. Treatment is surgical with resection and anastomosis of tracheal rings as necessary. The prognosis is good and this cat made a complete recovery.

202 i. FIP most commonly only affects one cat in the household but there is a possibility that other cats may develop disease. The litter mates are most vulnerable. Young cats have immature immune systems which make them vulnerable to FIP and it is also thought that genetic factors influence susceptibility. No specific treatment is indicated and no diagnostic tests will be able to identify whether the kittens are likely to develop FIP in the near future. The cats should be treated as normal and stress should be minimized by avoiding any changes (e.g. new cats, going to cat shows, elective veterinary procedures). If possible signs of disease develop, the cats should be returned for examination and investigation as appropriate. The incubation time for this disease is variable and there are reports of incubation times as long as 1 year or more, although in most cases it is considerably shorter than this (2–4 months).

ii. FIP is a fairly labile virus, although in the optimum conditions of temperature and humidity it can survive for as long as 7 weeks in the environment. Infected cats may shed coronavirus for several months or longer. The virus is destroyed by bleach (sodium hypochlorite) mixed with water at a ratio of 1:32. The owners should avoid getting a new cat for at least 6 months. If the remaining cats are well at this point, then it will probably be safe to introduce a new kitten. Measures which reduce the stress of rehoming in the new kitten, such as delaying this until after it is fully vaccinated, are worth considering.



203 Endoscopy (203) is commonly used in the investigation of gastrointestinal diseases in cats. How should a patient be prepared for gastroduodenoscopy and for colonoscopy?



204 Examine the radiograph (204) from a 7-year-old neutered male DSH cat.

- i. What changes can be seen?
- ii. What are the possible differential diagnoses and which of these is most likely?
- iii. How should this diagnosis be investigated further?

203, 204: Answers

203 For gastroduodenoscopy, the stomach must be empty of food and fluid to allow good visualization of the mucosal and anatomical structures. In most cats this can be achieved by withholding food for 12–18 hours prior to endoscopy and by withholding water/fluids for 3–4 hours. However, if there is evidence of partial obstruction or functional disturbance causing delayed gastric emptying, these times may have to be prolonged. If a barium meal has been administered, a minimum of 24 hours should be allowed before endoscopy, as barium will coat and adhere to the mucosa. Similarly, mucosal protectants such as sucralfate should be discontinued for at least 24 hours. General anaesthesia is required, but where possible atropine and opioids should be avoided, as they increase pyloric tone making duodenoscopy more difficult. Gastroduodenoscopy is routinely performed with the cat in left lateral recumbency; it is important to have the patient intubated and to use a mouth gag.

For colonoscopy, the colon needs to be adequately clean and free of faecal material. Food should preferably be withheld for 36–48 hours. Bowel cleansing solutions (e.g. 'Klean-Prep', 'GoLyteLy') should be used to ensure the colon is free of solid material. These are typically given at a dose of 25–30 ml/kg, and administered via a nasogastric tube. Two doses, 1–2 hours apart, are given the night before the procedure and, if necessary, a further dose is given on the morning of the procedure. An enema (e.g. 50–75 ml warm water) should also be given prior to the procedure.

204 i. The radiograph demonstrates marked bilateral renomegaly along with a moderately full bladder which may suggest concurrent polyuria.

ii. Possible causes of marked renomegaly would be perinephric pseudocysts, renal lymphoma, and hydronephrosis (although bilateral disease would cause ARF before the kidneys enlarged to this extent). The kidneys have a smooth outline suggesting polycystic kidney disease is unlikely. FIP, amyloidosis, glomerulonephritis, and ARF (various causes) can cause renomegaly, but none are likely to give such marked changes. The smooth outline and marked changes suggest renal lymphoma is most likely.

iii. Priorities for initial investigation would be:

- Evaluation of renal function and complications potentially arising from renal failure (haematology, serum chemistry, urinalysis with urine culture).
- Confirming lymphoma as the cause, most readily achieved by fine needle aspiration cytology from the renal cortex.
- Staging the lymphoma by determining the FeLV and FIV status of the cat and looking for presence of lymphoma elsewhere (physical examination, further radiography, ultrasonography, haematology ± bone marrow aspiration cytology).

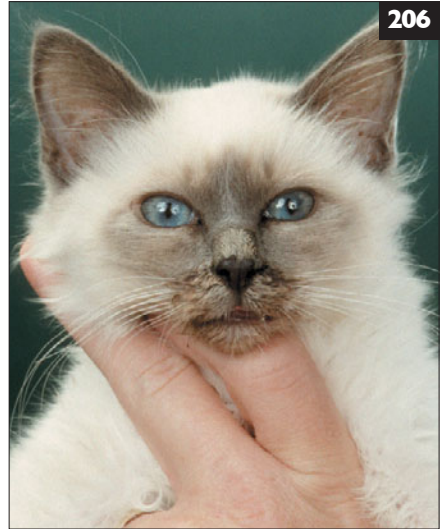Lymphoma was confirmed in this cat, which was retrovirus negative. Successful chemotherapy resulted in improvement in renal function and normalization of renal size. The cat remained in remission for 5 months.

205 A cat is receiving combination chemotherapy for treatment of lymphoma.

- i. How should the patient be cared for within the hospital: what are the implications from a health and safety point of view?
- ii. The cat's owner is concerned about her safety in handling the cat and its cytotoxic pills. Are her concerns well founded?

206 A 6-month-old Birman cat (206) presents with poor growth, intermittent ataxia, disorientation, and lethargy. Examine the laboratory results.

- i. What is your assessment of these results?
- ii. How would you approach treatment of this cat?



Serum biochemistry

Parameter	Result	Reference range
Urea mmol/l (mg/dl)	6.4 (17.9)	6.0–10.5 (17.0–29.0)
Creatinine μ mol/l (mg/dl)	98 (1.1)	<175 (<2.0)
Phosphate mmol/l (mg/dl)	2.2 (6.8)	0.95–1.95 (2.9–6.0)
Glucose mmol/l (mg/dl)	4.4 (79)	3.5–7.5 (60–135)
Total protein g/l (g/dl)	66 (6.6)	55–80 (5.5–8.0)
Albumin g/l (g/dl)	26 (2.6)	24–35 (2.4–3.5)
Globulin g/l (g/dl)	40 (4.0)	21–50 (2.1–5.0)
Alanine aminotransferase (IU/l)	117	15–45
Alkaline phosphatase (IU/l)	95	15–60
Fasting bile acids (μ mol/l)	32	<15
Postprandial bile acids (μ mol/l)	178	<30

205, 206: Answers

205 i. Local health and safety regulations vary but, in general, measures should be taken to avoid any contact with cytotoxic drugs. Tablets should never be split or crushed. Animals and contaminated items should be handled with the minimum of contact. Workers should wear gloves, plastic disposable aprons, and safety glasses when handling drugs and body fluids. Where possible disposable bedding, food bowls, and litter trays should be used. In the case of

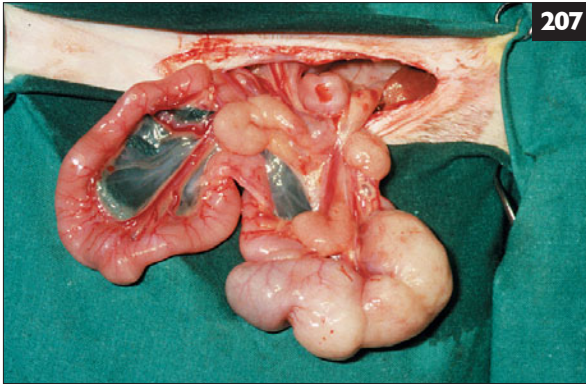


contamination or spills, it is possible to inactivate some chemotherapeutic agents; for example, doxorubicin is inactivated by sodium hypochlorite. All soiled litter, urine, and faeces should be double bagged and incinerated. If possible, an area of the ward can be dedicated to care of chemotherapy patients (205).

ii. Contact with cytotoxic agents carries a risk of gene mutation, hepatotoxicity, and reproductive problems. The main risks are associated with handling the drugs prior to administration, equipment used for administration of the drugs, and excreta from treated patients. Contact with cytotoxic agents can occur directly across the skin, or via inhalation or ingestion. Gloves should be worn when handling cytotoxic tablets and litter or body fluids (urine, faeces, vomit). Most cytotoxic agents are excreted in the urine and/or faeces for up to 4 days following treatment. Owners should be advised as to the duration and route of excretion of the agents that their cat is receiving.

206 i. The dramatically elevated postprandial bile acids are suggestive of a hepatopathy. Given the clinical signs and background, the most likely diagnosis is of a congenital portosystemic shunt. The low-normal urea is consistent with this diagnosis. The serum phosphate is mildly elevated; this is normal in a growing young cat.

ii. Initial medical management should be aimed at controlling the hepatic encephalopathy that accounts for the cat's clinical signs. In cats with congenital portosystemic shunts, an anomalous vessel takes blood from the hepatic portal vein into the systemic circulation without delivering this to the liver first. Feeding a low protein diet limits the amount of protein breakdown products which contribute towards hepatic encephalopathy. Oral dosing of antibiotics (e.g. metronidazole, ampicillin) reduces ammonia absorption by reducing the numbers of urease-producing bacteria in the intestine. Oral lactulose produces an acidic environment which helps to bind ammonia in the bowel, and reduces gastrointestinal transit time. When stable, portovenography and shunt ligation can be attempted.



207 An exploratory laparotomy is performed in a 10-year-old neutered male DSH cat with a history of progressively worsening vomiting over 4–6 months, severe weight loss, and polyphagia. The distal small intestine, mesentery, and areas of the ileocaecocolic junction are displayed (207).

- i. What abnormalities can be seen?
- ii. What is the most likely cause for these changes?
- iii. How should this condition be treated?



208 A 3-year-old neutered male DSH cat has been investigated for a 10-month history of generalized seizures which are reported to be occurring approximately every 4 weeks (208). The cat is clinically normal between seizures and all of the clinical, neurological, and laboratory tests performed are normal. Based on a provisional diagnosis of idiopathic epilepsy:

- i. When should anti-seizure medication be instigated in this cat?
- ii. What are the treatment options and how should this cat be managed?

207, 208: Answers

207 i. The picture shows a large irregular mass at the ileocaecocolic junction, there is significant enlargement of mesenteric lymph nodes, and there is also at least one, and possibly more, smaller masses in the distal small intestine.

ii. This has a typical appearance of neoplasia. Lymphoma and adenocarcinoma are the two most common intestinal tumours of the cat and the long history, multiple lesions, and proliferative nature of the lesions would be strongly suggestive of lymphoma. Histology or fine needle aspiration cytology would be needed to confirm the diagnosis.

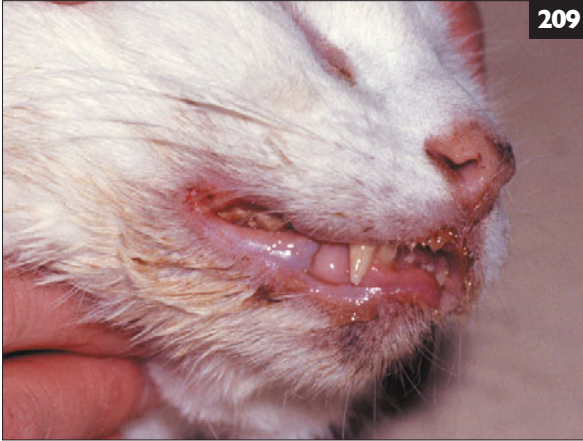iii. Prior to treatment, staging of the disease, retrovirus testing, and screening for secondary or concomitant disease would be prudent as this could affect treatment and prognosis. Surgical debulking of the tumour burden by removal of the gut-associated masses could be attempted and would be valuable for the immediate relief of any gastrointestinal obstruction. Following healing of the surgical wounds, chemotherapy would be required. Various treatment protocols have been used in cats with lymphoma. The most widely used protocol would involve administration of cyclophosphamide, vincristine ('Oncovin'), and prednisolone (the so-called COP protocol) and this has been used successfully to manage intestinal lymphoma. More recently, a protocol using just chlorambucil and prednisolone has been reported to give very good results in well differentiated lymphocytic intestinal lymphoma in cats.

208 i. Anti-seizure medication is generally recommended in cats when:

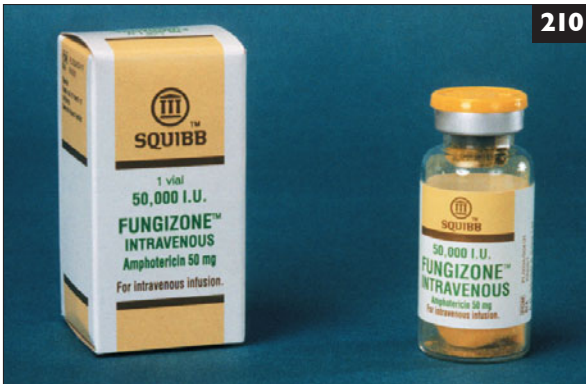- Seizures are occurring more frequently than every 6–8 weeks.
- The seizure frequency is increasing.
- Individual seizures last more than 5 minutes.
- Clusters of seizures or status epilepticus occur.

The seizure frequency in this case warrants treatment. Repeated seizures damage the brain and increase the likelihood of future seizures.

ii. Long-term maintenance management is usually safely and effectively achieved using phenobarbitone (phenobarbital) at 2–3 mg/kg every 12 hours. Sedation may be seen in the first few days of therapy and other potential side effects include polyuria/polydipsia, polyphagia, and weight gain. Serum levels should be checked 7–14 days after starting therapy or modifying the dose, and levels of 20–40 µg/ml are generally required for effective control. Alternative anti-seizure medication includes diazepam (0.2–2 mg/kg two to three times a day) used alone or in combination with phenobarbitone (phenobarbital), although idiosyncratic hepatic necrosis has been reported with this drug. In refractory cases, potassium bromide at 30–40 mg/kg once a day can be used alone or in combination with phenobarbitone (phenobarbital). The 11–22 day half-life of this agent means that it takes a long time for steady blood levels to be reached (8–15 weeks). Bronchitis has been reported as a side-effect in some cats. Phenytoin is generally not recommended in cats as accumulation and hepatotoxicity can occur.



209 A 5-year-old neutered female DSH cat presents with recent onset of depression, lethargy, anorexia, adipsia, vomiting, and ptyalism (209). There is a distinct 'uraemic' smell to the breath and there is oral ulceration present. ARF is suspected. How can ARF be differentiated from CRF?



210 The picture shows a preparation of the drug amphotericin B (210).

- i. What are the indications for use of this drug?
- ii. What important side effects are there with this agent?
- iii. How is it used in clinical practice?

209, 210: Answers

209 Differentiating ARF from CRF is important as the former is potentially reversible. Distinction between the two is not always easy, and is complicated by the fact that ARF may occur superimposed on existing CRF in some cases.

Typically with ARF the onset of signs is very rapid (hours to days) and the progression of azotaemia is also rapid if this is monitored, at least in the early stages. In CRF the onset of clinical signs is usually insidious, with stable or slowly progressing azotaemia. However, in some cases of CRF, the overt clinical signs may appear to be fairly rapid in onset as a result of decompensation of a stable state of renal failure. On careful questioning there are often other preceding signs of uraemia in cases of CRF, such as gradual weight loss, polyuria and polydipsia, and poor appetite, whereas in uncomplicated ARF the recent history will be unremarkable. Osteodystrophy is sometimes evident with CRF but is not a feature of ARF. Kidney size is of little help in the differentiation: it can be normal or increased in ARF, and is normal, increased, or decreased with CRF.

Haematology and serum biochemistry may help to distinguish the two: hyperkalaemia is common in ARF, whereas potassium is usually normal or low in CRF. Anaemia may be present with CRF but is usually absent with ARF.

210 i. Amphotericin B is a polyene macrolide antifungal agent that binds to ergosterol (and other sterols) in fungal cell membranes altering cell membrane permeability and causing cellular damage. Amphotericin has activity against many fungi, including *Cryptococcus* (probably its most common use), *Coccidioides*, *Histoplasma*, and *Blastomyces*. The *in vivo* activity against *Aspergillus* is poor.


ii. The major side effect is nephrotoxicity, with induction of ARF due to renal tubular toxicity and vasoconstriction. Hypomagnesaemia and hypokalaemia are also commonly seen and close monitoring of patients is required. The high potential for toxicity suggests other safer drugs should be tried first.

iii. Amphotericin is traditionally administered by intravenous infusion. Various doses have been used; typically around 0.25 mg/kg is given three times weekly to a maximum cumulative dose of 9–12 mg/kg, or until toxicity occurs. Combined therapy with flucytosine (250 mg/cat/day orally in divided doses) is usually used for cryptococcosis. The calculated dose of amphotericin is usually diluted in 30 ml 5% dextrose and infused over 15 minutes, but further dilution and prolonged infusion may reduce nephrotoxicity. An alternative regime is to administer 0.5–0.8 mg/kg in a warmed bag of 350–400 ml glucose–saline (2.5% glucose, 0.45% saline) which is infused SC. This is repeated two to three times weekly (maximum dose of 1.6 mg/kg weekly). Typically 6–12 weeks' therapy is required for cryptococcosis but side effects may be lower.

Lipid emulsions of amphotericin have less nephrotoxicity and are given at approximately 1 mg/kg IV (diluted in 5% dextrose) three times weekly.

211 A 7-month-old Persian cat is presented (211). The owner reports that for some time now the cat has been behaving strangely with episodes of mania/aggression and a wobbly gait, interspersed with times when the cat is very lethargic. The cat is very small compared to its litter mates. On further questioning the owner reports excessive salivation (ptyalism) and pupil dilation as being commonly present.

- i. What are the differential diagnoses for this combination of clinical signs?
- ii. What laboratory tests should be performed next?



212 A 4-year-old female Chinchilla presents (212). She has had two previous litters of kittens, but now, despite showing signs of oestrus and being mated with different proven toms, she has failed to produce any kittens during the past 12 months. What are the major differential diagnoses for this problem and which further investigations should be performed?



211, 212: Answers

211 i. Differential diagnoses for poor growth, neurological signs, ptialism, and pupil dilatation need to be considered. Possibilities which would potentially produce all of these clinical signs include:

- A congenital portosystemic vascular anomaly.
- Exposure to toxins including lead.
- Congenital lysosomal storage disease.
- Infectious neurological disease including *Toxoplasma gondii*, FIP, FeLV, and FIV.

Given the age of cat and combination of clinical signs, a congenital portosystemic vascular anomaly is the most likely of these possibilities.

ii. Initial diagnostic tests should be performed to evaluate the possibility of a portosystemic shunt. Routine haematology, biochemistry, and urinalysis evaluation may give some clues of this (microcytosis, low urea, mildly raised liver enzymes, hyperammonaemia, and urate crystalluria may be present) but a dynamic bile acid test is the most useful test. Further tests to evaluate some of the other differential diagnoses (e.g. *Toxoplasma* IgG and IgM serology) may be necessary.

212 For a queen that is accepting a proven, fertile tom and being mated, there are three possible causes of infertility: failure to ovulate, failure to implant, and pregnancy loss following implantation.

- Ovulation failure can occur because cats are induced ovulators. Some queens will apparently spontaneously ovulate but up to four or more matings are required for optimal LH secretion and ovulatory stimulation. Ovulation can be determined by measuring serum progesterone 1–2 weeks after mating. It should exceed 6 nmol/l if ovulation has occurred. Failure to ovulate is usually treated by ensuring multiple matings, although 25 µg GnRH can be given IM at the time of mating.
- Cystic endometrial hyperplasia (± bacterial endometritis) is the most common cause of failure to conceive/implant in a queen that has previously been bred from. Definitive diagnosis is made by biopsy, but if other causes are ruled out, antibiotic therapy may allow conception at the next mating. Anatomical defects can be a cause in nulliparous queens.
- Early pregnancy loss can be caused by cystic endometrial hyperplasia, metritis, systemic infections (viral, bacterial, mycoplasmal, parasitic and, possibly, chlamydophilosis), foetal defects, inadequate progesterone production to maintain pregnancy (serum concentrations <6 nmol/l).

Investigation is aimed at demonstrating ovulation (serum progesterone assay), and evaluating the uterus for abnormalities by ultrasonography. Following mating regular repeat ultrasound investigations are needed to determine if foetal implantation occurs and, if so, to determine at what stage foetal death and resorption is occurring. Hysterotomy may be required to obtain tissues to determine the cause of foetal death.

213 A 16-year-old neutered male DSH cat (213) is presented with a 6-month history of severe weight loss. On clinical examination, the cat is noted to be extremely thin, weighing only 2.7 kg, and has bilateral thyroid nodules palpable in the neck. Examine the laboratory results which were obtained using blood collected after an 8-hour fast.

- What is the assessment of these results?
- What are the treatment options for this cat?
- Which of these options should be recommended to the owner and why?



Serum biochemistry

Parameter	Result	Reference range
Urea mmol/l (mg/dl)	16.7 (46.8)	6.0–10.5 (17.0–29.0)
Creatinine μ mol/l (mg/dl)	161 (1.8)	<175 (<2.0)
Phosphate mmol/l (mg/dl)	2.1 (6.5)	0.95–1.95 (2.9–6.0)
Total protein g/l (g/dl)	67 (6.7)	55–80 (5.5–8.0)
Albumin g/l (g/dl)	28 (2.8)	24–35 (2.4–3.5)
Globulin g/l (g/dl)	39 (3.9)	21–50 (2.1–5.0)
Alanine aminotransferase (IU/l)	189	15–45
Alkaline phosphatase (IU/l)	156	15–60
Total T4 nmol/l (μ g/dl)	129 (10.0)	19–65 (1.5–5.0)

Urinalysis

Specific gravity	1.023
Dip stick	normal
Sediment examination	normal

214 A 6-year-old DSH cat is presented in acute respiratory distress, mouth breathing (214).

- How can the cat be stabilized with oxygen therapy prior to further assessment?
- How would thoracic radiographs of a severely dyspnoeic cat be taken?



213, 214: Answers

213 i. Several abnormalities are present. The cat is hyperthyroid and other laboratory changes (increased liver enzymes, hyperphosphataemia) are likely to be secondary to this disease. The cat is also azotaemic. Creatinine levels are normal but this may be because of reduced muscle mass since the cat is very thin. The reduced USG suggests intrinsic renal disease rather than a prerenal problem, although polydipsia associated with hyperthyroidism could also account for this value.

ii. The treatment options available for this patient include surgical thyroidectomy, medical management (e.g. carbimazole or methimazole), and radioactive iodine.

iii. There is a concern that this cat has renal failure which is being masked to an extent by its poor muscle mass and concurrent thyroid disease. Hyperthyroidism increases the glomerular filtration rate which can 'mask' pre-existing renal disease and it is a worry that treatment of the hyperthyroidism could result in precipitation of overt renal failure. The safest treatment option is, therefore, one of the medical agents, since these are reversible. The cat should be started on a low dose of carbimazole or methimazole and monitored closely (clinically and biochemically). Should any worsening of the azotaemia be seen, treatment can be reduced or stopped. If the cat remains stable, treatments such as thyroidectomy can be considered.

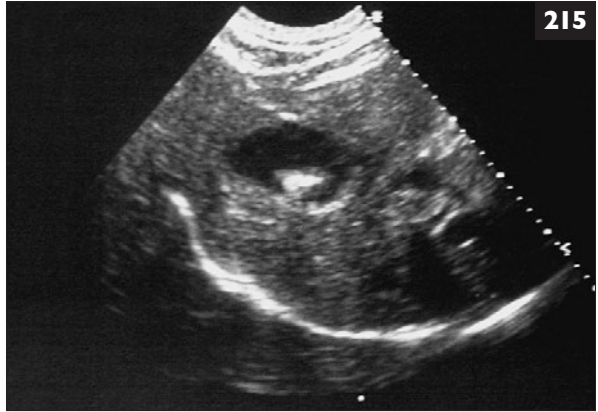
214 i. The cat can be placed in an oxygen-enriched environment using one of several techniques which include:

- Oxygen cage: created by covering a cat basket or cage front with Perspex or a plastic bag through which oxygen is piped at high flow rates. Alternatively, oxygen can be piped into a paediatric incubator into which the cat is placed.
- 'Flow by': an anaesthetic circuit is held close to the cat's nostrils so that oxygen can 'flow by' creating a locally oxygen-enriched environment.
- Face mask: the head is held in a face mask attached to an anaesthetic circuit.
- Buster (Elizabethan) collar oxygen tent: cling film is placed loosely over the front of a buster collar leaving space at the top to avoid re-breathing and condensation. Oxygen is piped in via a catheter under the collar.
- Nasal prongs: special plastic tubing with two short ends designed for inserting into the nostrils is attached to an oxygen supply.
- Nasal catheter: placement of a catheter, attached to an oxygen line, into the nasopharynx via a nostril.

In general, oxygen cage techniques are best tolerated with the minimum of stress. Low flow rates (0.5–1.0 l/minute) should be used for the other techniques.

ii. For radiography, sternal positioning with minimal restraint is likely to be best tolerated by the patient and this can be used to take conventional dorsoventral radiographs. If horizontal beam radiography is possible, a lateral thoracic radiograph can be taken with the cat sitting in sternal recumbency. It is useful to have a non-radiodense cat carrier in which to place the unrestrained cat for radiographic studies.


215 A 3-year-old DSH cat presents with a 10-day history of inappetence, lethargy, and yellowing of the mucous membranes. There is marked jaundice on examination and pyrexia (39.8°C or 104°F). Blood samples show a neutrophilic leucocytosis with a left shift and elevated liver enzymes, bilirubin, and bile acids. Hepatic ultrasonography is performed: the view shown (215) is a section through the liver with the gall bladder in the centre.



- i. What is the most striking abnormality visible?
- ii. What are the major differential diagnoses for this cat?
- iii. How should this cat be further investigated and treated?

216 A patient with longstanding CRF has come in for a routine check-up. SBP measured using the Doppler technique is 182 mmHg (216).

- i. Comment on this result.
- ii. What should be done next?



215, 216: Answers

215 i. Hepatic architecture is difficult to assess from the picture, but a mass is evident within the lumen of the gall bladder which appears to be causing some 'shadow' effect. The gall bladder does not appear excessively dilated.

ii. The mass could be a cholelith (most likely), inspissated bile, an inflammatory mass, or a neoplastic lesion.

The history and clinical findings in this cat suggest a hepatic cause for the jaundice and the blood findings and pyrexia suggest an infectious cause. Important differential diagnoses include:

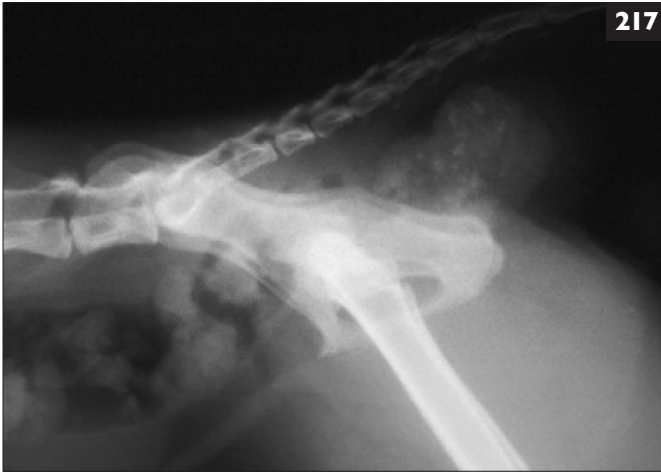- Suppurative cholangiohepatitis.
- FIP.
- *Platynosomum concinnum*.
- *Toxoplasma gondii*.
- *Cytauxzoon felis*.
- Systemic fungal infections.

Suppurative cholangiohepatitis (usually caused by an ascending bacterial infection from the small intestine) is the most common infectious cause of liver disease in cats, and there is a recognized association between this and cholelithiasis.

iii. Further investigations should include hepatic biopsy (e.g. ultrasound-guided needle biopsy, after assessment of clotting times) for histology and culture, and aspiration of bile for culture. *Escherichia coli* is the most common organism causing suppurative cholangiohepatitis, but infection can occur with a wide variety of organisms including anaerobes. Empirical therapy should be with broad-spectrum antibiotics that achieve high concentrations in bile (e.g. clavulanate/amoxicillin, cephalosporins, fluoroquinolone, ± metronidazole) pending culture results. Progression should be monitored with ultrasonography, and the cholelith removed if there is evidence that it is causing obstruction.

216 i. Reported reference ranges for SBP in conscious cats generally consider readings above 170–180 mmHg to be abnormally high. Stress or genuine hypertension could account for this result.

ii. The first step would be to repeat the blood pressure readings causing as little stress as possible. This should be done with the cat in a quiet room allowing it at least 10 minutes to acclimatize to the environment before the blood pressure is measured. A detailed ophthalmic examination should also be performed to look for ocular manifestations of hypertension such as haemorrhage, retinal oedema, and detachment. Although CRF can be a cause of hypertension, other causes, such as hyperthyroidism, should also be considered. If the SBP readings remain persistently above 170–180 mmHg then treatment with anti-hypertensive agents is warranted. Doppler SBP should be kept below 170 mmHg in cats with CRF.

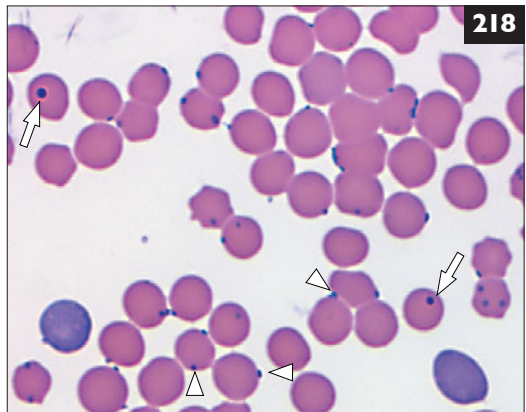


217 A 4-year-old neutered male Siamese is presented with a 6-month history of recurrent constipation and persistent perineal licking. On clinical examination the anal ring appeared swollen and there was a swelling to the left of the anus. Examine the lateral radiograph (217).

- i. What abnormality can be seen?
- ii. What is the diagnosis and treatment for this cat?

218 This Wright-Giemsa stained blood smear (218) was obtained from a 6-year-old neutered female DSH cat with a 10-day history of lethargy and inappetence.

- i. Identify the structures indicated by the arrows and arrow-heads.
- ii. What additional information is evident on the blood smear?
- iii. What is the likely diagnosis and how should it be confirmed?
- iv. What treatment is recommended?



217, 218: Answers

217 i. The radiograph shows the presence of faecal boluses in the descending colon and in the rectum. The rectum is occupying an abnormally caudal position, which is also displacing the anus caudally. It would appear that a faecal bolus within the rectum is responsible for the swelling around the anal region.

ii. These findings are consistent with a diagnosis of perineal hernia, and rectal palpation under general anaesthesia confirmed the diagnosis in this case.

Although common in dogs, perineal hernias are relatively rare in cats. The normal pelvic diaphragm is composed of the anal sphincter, which is apposed to the coccygeus and levator ani muscles laterally and dorsally, and the internal obturator muscle ventrally. In this case, the anal sphincter had become completely separated from the other muscles allowing the rectal deviation and perineal hernia.

Initial treatment is surgical correction of the defect to restore the normal anatomy. Persistent straining due to constipation, or in some cases lower urinary tract disease, appears to be a predisposing factor for perineal hernia formation, thus long-term control involves the use of laxatives such as lactulose and/or fibre added to the diet (e.g. sterkulia; ispaghula husk) to promote regular passage of soft faeces.

218 i. The arrows are pointing to red blood cells containing densely staining nuclear remnants (Howell-Jolly bodies) indicating that these are immature red cells. The arrowheads are pointing to small densely staining structures on the surface of red cells which are most likely to represent feline haemoplasmas (*Mycoplasma haemofelis* or *Candidatus Mycoplasma haemominutum*, formerly known as *Haemobartonella felis*, *H. felis*). Alternative possibilities would include artefacts such as stain precipitate.

ii. There is evidence of regeneration as anisocytosis and polychromasia are present.

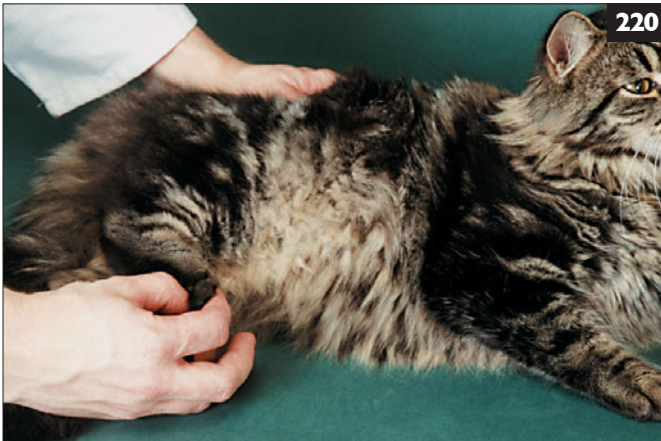iii. FIA due to feline haemoplasma infection. This can be confirmed by PCR testing of an EDTA blood sample which is a much more sensitive and reliable method of diagnosis than examination of blood smears. It also enables characterization of which haemoplasma infection is involved. *Mycoplasma haemofelis* (formerly *H. felis* large form) is most often associated with causing an immune-mediated haemolytic anaemia whereas *Candidatus Mycoplasma haemominutum* (formerly *H. felis* small form) can be identified in clinically normal, non-anaemic cats. It has been suggested that *Candidatus Mycoplasma haemominutum* can be an opportunistic cause of immune-mediated haemolytic anaemia in immunosuppressed individuals such as those with FIV infection.

iv. Feline haemoplasma infections respond to treatment with antibiotics, doxycycline or enrofloxacin at 10 mg/kg/day for 21 days. Although most cats respond rapidly to this treatment, it is usually not possible to eliminate infection completely and relapses can be seen. Additional supportive care including intravenous fluid therapy, blood transfusion, or haemoglobin-based oxygen carriers may be helpful in some cases. Use of glucocorticoids (at anti-inflammatory or immunosuppressive doses) in these cases is controversial, but may be of help in severely affected individuals.



219 A 3-year-old neutered male DSH cat presented with bilateral uveitis (219). The cat was negative on screening retrovirus and coronavirus antibody tests. Toxoplasmosis is suspected.

- i. If this is toxoplasmosis, how would the cat have acquired infection?
- ii. How would a diagnosis of this disease be attempted?
- iii. Assuming it is toxoplasmosis, how should the cat be treated?



220 The flexor (withdrawal) reflex is being tested on a cat with suspected spinal cord disease (220). Explain how the assessment of the response to this test would be used to help localize a neurological lesion.

219, 220: Answers

219 i. Cats are the definitive host for *Toxoplasma gondii*. Although oocysts shed in cat faeces can be infective for other cats, this is an unusual method of transmission. Most cats acquire infection through ingestion of an infected intermediate host (e.g. prey species, raw meat) where *T. gondii* is present in tissue cysts (bradyzoites). Some individuals will acquire infection *in utero* via transplacental migration of the parasite.

ii. A presumptive diagnosis of toxoplasmosis is usually based on serological testing of blood samples. Most feline infections are asymptomatic, and long-standing infections are established with the organism present in tissue cysts. High IgG antibody titres develop in most infected cats, but the magnitude of the titre cannot distinguish symptomatic from asymptomatic cats. A four-fold or greater rise in antibody titre over a 2–4 week period is indicative of recent infection, but in most cats, by the time clinical signs develop, IgG antibody titres are already very high. Assay of IgM antibodies is of greater diagnostic value. A high IgM antibody titre is indicative of recent and/or active *T. gondii* infection and, combined with appropriate clinical signs, this is a good basis for trial therapy. However, tissue biopsy and the demonstration of active infection histopathologically is the only way of confirming clinical disease.

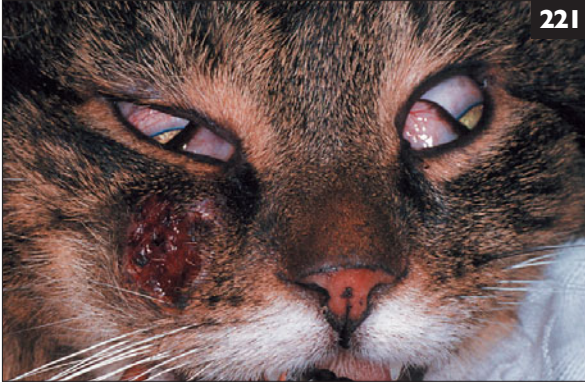iii. The treatment of choice for toxoplasmosis is clindamycin (12.5 mg/kg twice daily) given for a minimum of 4 weeks and for 2 weeks beyond clinical cure. Topical glucocorticoids would also be necessary to manage the ocular inflammation.

220 Localization of a spinal lesion is helped by evaluating withdrawal reflexes in the forelimbs and hindlimbs, along with other reflexes such as the patellar, perineal (anal), and panniculus. These reflexes are characterized as normal, increased (hyperreflexic), or decreased (hyporeflexic). Hyporeflexia indicates a LMN lesion (i.e. spinal cord disease in the segment of cord supplying the nerves involved in the reflex), whereas hyperreflexia indicates an UMN lesion (an exaggerated reflex due to loss of inhibitory neurones proximal to the reflex arc being tested) (see table below).

Other findings may also be valuable in neurolocalization, such as the presence of a crossed-extensor reflex, postural reactions, degree of muscle tone (increased with UMN lesions), and muscle wastage (more rapid and severe with LMN lesions).

Assessment of reflex responses

Site of lesion	Cranial nerves	Forelimbs	Hindlimbs	Tail/bladder
C1–C5	Normal	UMN	UMN	UMN
C6–T2	Normal	LMN	UMN	UMN
T3–L2	Normal	Normal	UMN	UMN
L2–S3	Normal	Normal	LMN	UMN

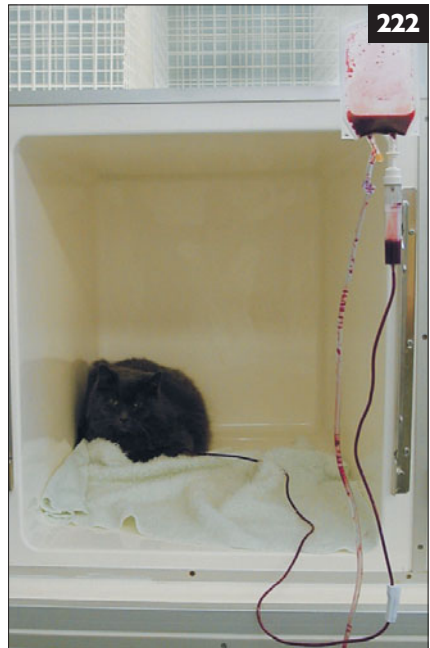

221 A 12-year-old neutered female DSH cat was brought in with an ulcerated facial nodule, which had been present for at least 6–8 weeks (221). A fine needle aspirate revealed mixed inflammatory cells and mast cells.

- i. What is the diagnosis?
- ii. What is the behaviour of this disease and how should this cat be treated?

222 i. What are the characteristics of the 'ideal' blood donor?

ii. How should blood be collected and a transfusion administered (222) to an anaemic cat?



221, 222: Answers

221 i. The clinical signs and cytology are typical of mastocytic cutaneous mast cell tumour.
 ii. Although multiple mast cell tumours can occur in cats, most are reported to be solitary and the head is the most commonly affected site. Mast cell tumours occur in both a histiocytic and mastocytic form, the latter being more common.

The uncommon histiocytic form of tumour usually requires a biopsy for diagnosis as the cells are less characteristic of typical mast cells. Siamese cats may be predisposed and, in contrast to a mean age of 10 years for the mastocytic form, the histiocytic form occurs in younger cats with a mean age of about 2½ years. Spontaneous regression has been reported with these after a variable time period (months to years).

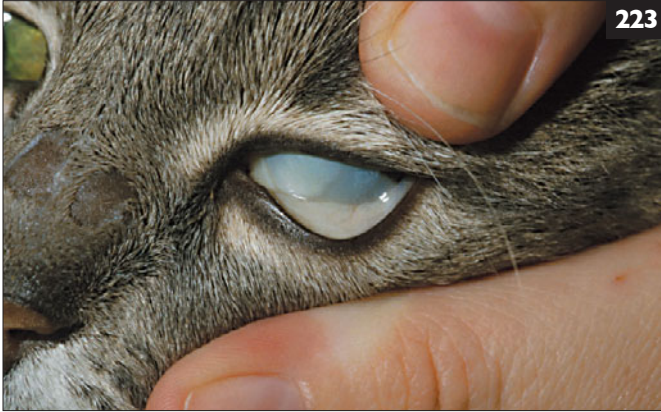Most cutaneous mast cell tumours in cats are mastocytic and well differentiated, and behave in a benign manner (in contrast to what is often the case with visceral mast cell tumours). Nevertheless, some cases will have both cutaneous and visceral involvement and thus further investigations (in particular abdominal radiography and ultrasonography looking for intestinal or splenic involvement) and routine haematology should be performed.

Most cutaneous mastocytic mast cell tumours behave in a benign manner. Surgical excision is the treatment of choice. Histiocytic forms may either be removed or monitored, as most will regress spontaneously.

222 i. The 'ideal' donor weighs at least 4.5 kg, is clinically healthy, has a PCV of at least 30%, and has been blood typed. The cat should be screened and negative for key blood-borne infections including FeLV and FIV (ELISA), FIA (haemoplasma PCR), *Bartonella* (PCR) and, where relevant, *Ehrlichia*.

ii. Blood is collected from a conscious or sedated donor. 7–14 ml blood per kg donor bodyweight can be collected directly into syringes or into a blood bag preflushed and then mixed with anticoagulant (1:9 ratio of acid citrate dextrose: blood). Following blood collection, the donor should receive 2–3 times the volume collected as replacement fluids (e.g. normal saline) IV to avoid hypovolaemia.

The blood type of the recipient should be known so that appropriate blood can be given. Blood should be administered IV through a filter as soon after collection as possible at a rate not exceeding 5 ml/minute. Feline erythrocytes crenate rapidly after collection making transfusion of stored cells more vulnerable to rapid removal. Where cross-matching and typing has not been performed, a test dose of 0.5–1.0 ml of blood should be administered and the patient observed for 20 minutes for evidence of transfusion reaction (tachycardia, facial pruritus, vomiting, tachypnoea) before continuing. If a transfusion reaction is suspected, the transfusion should be stopped and administration of antihistamines (diphenhydramine 2 mg/kg IV) and general shock therapy considered. Where needed, oxygen therapy and maintenance of a patent airway may also be required.

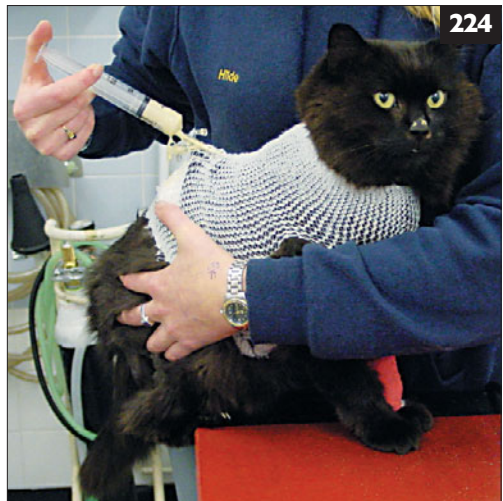

223 A 5-year-old neutered male DSH cat is presented with a 24-hour history of severe lethargy progressing to collapse. Mucous membranes are noticeably pale on physical examination (223) and haematology reveals a severe anaemia. The cat is a known hunter from a rural background and on further questioning the owner reports that rat poison is used on the local farm.

- i. How could a suspicion of anti-coagulant rodenticide poisoning be confirmed in this case?
- ii. How should this patient be managed?

224 An anorexic 3.2 kg patient is admitted (224) for assisted nutritional support (tube feeding).

- i. How can the energy requirements of this cat be calculated?
- ii. If a veterinary liquid diet has 0.9 calories/ml, what volume does the cat require per day to meet its energy requirements?
- iii. What is the maximum meal size and how should the cat be fed?



223, 224: Answers

223 i. Anticoagulant rodenticides are inhibitors of the enzyme responsible for recycling vitamin K in the liver. Toxicity causes inhibition of production of the vitamin K dependent coagulation factors II, VII, IX, and X, resulting in spontaneous haemorrhage. In this case diagnosis is suspected from the history and can be confirmed by identifying:

- Prolonged coagulation times: factor VII has the shortest half-life of the factors affected so PT is prolonged before APTT.
- Positive PIVKA test.
- Haematology may reveal a non-regenerative anaemia in acute cases; within a few days a strong regenerative response should be seen.
- Normal fibrinogen and fibrin degradation products rule out DIC.

ii. The type of rodenticide should be confirmed where possible. Half-lives of anticoagulant rodenticides vary from 14 hours (first generation products such as warfarin) to 6 days (second generation products such as brodifacoum), and residual anticoagulant effects may still be present for up to 3 weeks with some products. Treatment includes 2.5–5 mg/kg vitamin K₁ (phytonadione) given by oral or subcutaneous routes for 14 (first generation) to 21 (second generation) days. PT can be monitored to assess response to vitamin K₁ and should be checked 2–5 days after stopping treatment. Additional supportive care may include:

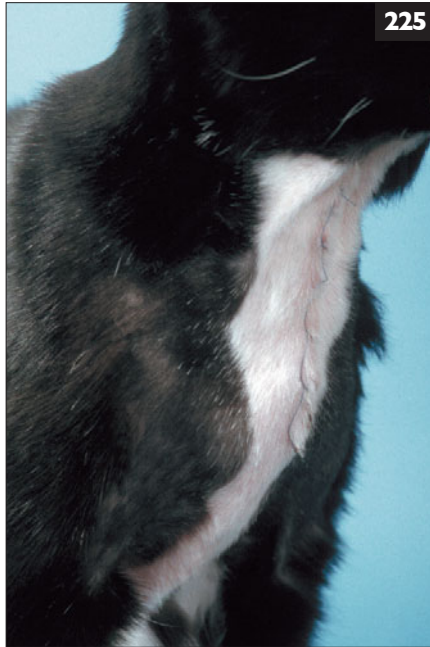
- 9 ml/kg fresh plasma (may be easiest given as a whole blood transfusion).
- Intravenous crystalloid fluids (e.g. normal saline) if the patient is hypovolaemic.
- Whole blood or packed red cells if severely anaemic.
- Haemoglobin-based oxygen carrier (e.g. Oxyglobin® at 5–10 ml/kg IV).
- Specific treatment according to the site of haemorrhage.
- Colloid products such as hetastarch and dextrans should be avoided as anticoagulation effects have been reported.

224 i. The cat's RER should be calculated first. RER is the resting energy requirement for a normal, non-fasted cat at rest in thermoneutral conditions. It is calculated as:

- Cats >2 kg bodyweight: $RER = [30 \times BW(\text{kg})] + 70$.
- Cats <2 kg bodyweight: $RER = 70(BW \text{ kg})^{0.75}$.
- In sick cats, the RER is usually multiplied by an illness factor (typically 1.2) to calculate the illness energy requirements.

ii. This cat's RER is 167 calories per day. Using a standard illness factor of 1.2, this cat requires 200 calories per day. This will be supplied by 222 ml of food ($200 \div 0.9$).

iii. The maximum meal size is 45 ml/kg (stomach capacity of the cat). Initially the cat should be fed four to six equal sized meals a day, although the meal frequency can subsequently be reduced in those patients requiring long-term support (weeks or longer). The cat is fed one third of the RER (74 ml) on day 1, two thirds of the RER (148 ml) on day 2, and all of the RER from day 3 onwards. On the first 2 days, water is also supplied via the tube to ensure that the cat's requirements for this are met.



225 This cat (225) had a bilateral thyroidectomy performed 24 hours previously. Now, the cat is inappetent and the total serum calcium level is 1.7 mmol/l (6.8 mg/dl). How significant is this result, and how should the cat be managed?

225: Answer

225 The main concern in finding a calcium of 1.7 mmol/l (6.8 mg/dl) at this time after surgery, is that the levels may fall further, potentially resulting in life-threatening clinical signs. A total calcium of 1.7 mmol/l (6.8 mg/dl) may be associated with mild clinical signs (restlessness, irritability, hyperaesthesia) although it is quite possible that the cat will appear clinically normal. Calcium is present in three forms in the blood: ionized calcium (50–60% of the calcium; the only form available for immediate action on cells), protein-bound (35–40%), and complexed (to, for example, phosphate and bicarbonate ions). Total calcium levels should be interpreted in relation to serum albumin levels and electrolyte and acid-base status. Unlike dogs, the relationship between total serum calcium and albumin levels is not close enough to provide a mathematical formula which can be used to compensate for hypo- or hyperalbuminaemia.

Close monitoring of blood calcium levels or prophylactic treatment is recommended according to the guidelines in the table (below).

Calcitriol (vitamin D₃) is rapidly effective (24–96 hours) and most cats can be maintained on this alone within 5 days with no need for additional calcium supplementation. Subsequently, the dose of calcitriol should be titrated to the lowest effective dose, aiming for blood calcium levels in the low-normal range. The cat should be gradually weaned off therapy by reducing the daily dose or dosage frequency. Several months of supplementation may be required but most cats can be weaned off all treatment within 3 months of surgery.

Interpretation of blood calcium levels post thyroidectomy

Calcium mmol/l (mg/dl)	Interpretation	Action required
1.8–2.0 (7.2–8.0)	Mild, usually no signs	Monitor calcium once to twice daily, no treatment required at this stage
1.5–1.8 (6.0–7.2)	Moderate, may need treatment	If no clinical signs, can either monitor closely or treat prophylactically: Calcium: 10% calcium gluconate: 5–15 ml/kg/day in intravenous fluids or diluted with an equal volume of 0.9% saline and given SC; 25–50 mg/kg elemental calcium orally twice daily Vitamin D3: active calcitriol, 0.03–0.06 µg/kg/day
<1.5 (<6.0)	Severe, requires treatment	Cats showing severe clinical signs (seizures, coma) require immediate treatment: Calcium gluconate: 10% IV at 0.5–1.5 ml/kg diluted in 25–50 ml of 0.9% saline given slowly (over 20–30 minutes) to effect, monitoring for bradycardia. Cats showing milder clinical signs can be treated with subcutaneous therapy. In both situations, subsequent oral calcium and vitamin D therapy are required (as above)

Index

Note: references are to case numbers

- Abyssinian cat 72, 86
acetaminophen (paracetamol) 44, 118
acidosis 174, 188
acromegaly 17
actinic dermatitis 171
adenocarcinoma
 bronchial/pulmonary 124
 colon 84
adrenal glands
 bilateral enlargement 147, 168
 unilateral enlargement 49
adrenocorticotrophic hormone (ACTH) 168
adriamycin (doxorubicin) 75
Aelurostrongylus abstrusus 150
aglepristone 133
albuterol 173, 178
allergic disorders 112
 see also hypersensitivity
alopecia, ventral 121
alpha-blockers 92
amitriptyline 159
amoxicillin 36, 38, 160
amoxicillin-clavulanate 2, 215
amphotericin B 156, 195, 210
ampicillin/amoxicillin 36
amyloidosis 12, 72
anaemia
 in CRF 4
 haemolytic 9
 regenerative 148, 218
 rodenticide toxicity 223
analgesia 113
angiotensin-converting enzyme (ACE) inhibitors 12, 134, 197
anisocytosis 148, 218
anorexia 61, 199, 209
 see also appetite loss
anterior mediastinal lymphoma (AML) 71, 123
antibodies, maternal transfer 55, 110
anticholinesterase 105
anticonvulsants 139
anti-diuretic hormone (ADH), response test 19, 114
antimetetics 68
antifreeze ingestion 142
antifungal agents
 systemic 48, 156, 175, 195, 210
 topical 48
antihistamines 222
antioxidants 44
appetite
 loss 25, 30, 61, 68, 163, 199, 209
 see also anorexia
 stimulation 199
arthritis 1, 14
ascites 68, 80, 97, 183
aspirin 197
asthma 77, 119, 173, 178
ataxia 139
atrial standstill 108
azalides 47
azithromycin 2, 47
azotaemia 174, 176, 213
Bacteroides spp. 182
balanoposthitis 155
barium-impregnated polyethylene spheres (BIPS) 18
Bartonella spp. 13, 15
basal cell tumour, nasal 170
beclothemason propionate 178
benazepril 12, 197
β₂-adrenoceptor agonists 52, 173, 178
Birman cat 86
bisacodyl 103
bladder
 distension 161
 drainage 26, 161
 expression 192
 rupture 69, 80
 tumour 29
 wall thickening 159
bleeding disorders 57
blindness, sudden onset 28
blood, collection for transfusion 222
blood donor, 'ideal' 222
blood glucose 17, 21, 181
blood pressure measurement 216
blood smear
 haemolytic anaemia 9
 haemoplasma infection 218
 leucopenia 163
 new methylene blue-stained 9, 154
 regenerative anaemia 148
 reticulocytes 154
 Romanowsky-staining 9, 148
 Wright-Giemsa stained 218
blood transfusion 101, 222
blood types 86, 190, 222
blood typing 101
body condition scoring 186
bodyweight
 reduction 189
 relative 186
bone marrow biopsy, indications 7, 112, 179
bone marrow disorders 112, 163, 179
Bordetella bronchiseptica 76
breeds
 blood type prevalence 86, 190
 inherited disorders 23, 33, 72, 144, 187
British Shorthair 37, 86
bronchial disease, chronic 150, 178
 see also asthma
bronchoalveolar lavage
 cytology 47, 52, 119
 procedure 146
bronchoconstriction 173
bronchodilators 52, 173, 178
bronchopneumonia 52
bullae osteotomy 145
Burmese cat 33, 86, 126
calcitriol (vitamin D3) 225
calcium:phosphate ratio 34
calcium, blood levels 34, 102, 225
calcium gluconate 225
calcium oxalate crystals/uroliths 141, 153
calcofluor white 58
Campylobacter jejuni 62
Candidatus Mycoplasma haemominutum 218
carbimazole 213
carbonic anhydrase inhibitors, oral 139
cardiac disease 15, 108, 120
 causing thromboembolic disease 132
cardiac silhouette
 enlarged 87
 obscured 158, 166
cardiomegaly 20, 37, 129
 ECG 152
cardiomyopathy
 dilated 197
 hypertrophic 20
carnitine deficiency, relative 130
carprofen 29
central venous pressure (CVP) measurement 82
cephalosporins 182, 215
cerebrospinal fluid (CSF)
 analysis 46
 collection procedure 53
 contraindications to collection 46
 drainage obstruction 135
 reducing production 19
cestodes 180
charcoal, activated 44
chemotherapy 71, 84
 doxorubicin 75
 health and safety 205
 lymphoma 207
chest drainage 36, 66, 88
Chlamydomphila felis 2, 6, 76

Index

- chlorambucil 137, 182, 184, 207
 chlorhexidine 48, 169
 chlorpromazine 68
 chlorpropamide 19
 cholangiohepatitis 182, 215
 cholangitis, lymphocytic 164
 chorioretinopathy, hypertensive 28
 chronic renal failure (CRF)
 ACE inhibitor therapy 134
 anaemia 4
 biochemical abnormalities 174, 191
 clinical signs 196
 dietary control 149
 differentiating from ARF 209
 hypertension 216
 kidney changes 174
 PKD 23
 urinalysis 176
 chylomicrons 63
 chylothorax 66
 cimetidine 44
 ciprofloxacin 47
 cisapride 18
 cisternal puncture 53
 clavulanate/amoxicillin 2, 215
 clindamycin 36, 38, 47, 219
Clostridia 182
 coagulation disorders 57, 106, 144
 coat colour 167
 coccidian parasites 62
 colchicine 50
 collapse 223
 colloid products 223
 colon, tumours 84
 colonoscopy 203
 colostrum 55, 110
 congenital disorders 18, 37, 51, 72, 94, 139, 206, 211
 conjunctivitis 2, 6
 constipation 51, 95, 103, 127, 217
 evaluation 127
 management 103
 severe 103, 127
 cornea, clouding 70
 Cornish Rex cat 40
 coronavirus antibody testing 126
 corticosteroids 145
 see also named agents
 cryptococcosis
 nasal 40, 195
 oral 156
Cryptococcus neoformans 40, 195
 crystalluria 73, 141, 176
Ctenocephalides felis 3
 Cushing's syndrome
 (hyperadrenocorticism) 17, 74, 147, 168
 cutaneous lesions, *see* skin lesions
 cyclo-oxygenase-2 (COX-2)
 inhibitors 29, 84, 156
 cyclophosphamide 84, 207
 cyclosporine 16
 cyproheptadine 199
 cystitis 81
 bacterial 73
 idiopathic 159, 161
 cystocentesis 26, 161
Cystoisospora (Isospora) spp. 62
 cytochrome p450 system 44
 dantrolene 92, 192
 degenerative joint disease (DJD) 39
 dehydration, CRF 149
 dermatitis
 actinic 171
 flea allergic 3
 dermatophyte infection 121
 diagnosis 58
 environmental control 48
 treatment 48, 175
 desmopressin (DDAVP) 19
 Devon Rex cat 59, 144
 dexamethasone screening test 168
 diabetes insipidus 19, 114
 diabetes mellitus
 control of blood glucose 21
 diagnosis 181
 insulin ineffectiveness 11
 insulin resistance 17, 168
 neuropathy 35
 diaphragm
 hernia 37
 rupture 158
 diarrhoea 62, 117
 chronic 107
 chronic small bowel 8
 differentiating small and large bowel disorders 8
 haematochezia and dyschezia 84
 infectious causes 10
 diazepam 92, 125, 192, 199, 208
 diet
 calcium:phosphate ratio 34
 CRF 149
 dry foods 73, 141, 153
 hypersensitivity 107, 121
 meat only 34
 for weight loss 189
 digoxin 197
 dioctyl sodium succinate 103
 diphenhydramine 222
Dipylidium caninum 180
 dirofilariasis 77, 150
 diuretics 19, 129, 173, 197
 Doppler SBP measurement 216
 doxorubicin (adriamycin) 75
 doxycycline 2, 47, 76, 218
 duodenum, mass 98
 dysautonomia, feline 24
 dyschezia 84, 127
 dysmetria 139
 dysphonia 91
 dyspnoea 36, 39, 52
 emergency procedures 173
 expiratory 77, 91
 history and examination 91
 inspiratory 40, 71, 91, 124, 145, 158, 166, 201
 recurrent 150
 severe 173, 214
 dystocia 22
 dysuria 29, 95, 159, 161
 echocardiography 15, 20, 120
 M mode 197
 edrophonium chloride injection 105
 Ehlers–Danlos syndrome 74
 electrocardiography (ECG) 20
 24 hour (Holter) 83
 escape rhythms 108
 heart rate assessment 108, 152
 interpretation 152
 enalapril 12, 197
 encephalopathy, hepatic 206
 endocarditis, bacterial 15
 endometrial hyperplasia, cystic 109, 212
 endoscopy, gastrointestinal 90, 203
 energy requirements, resting (RER) 224
 enrofloxacin 36, 47, 218
 enteropathogens 10, 62, 107
 eosinophilia, differential diagnoses 112
 eosinophilic airway inflammation 119
 eosinophilic granuloma complex (EGC) 16, 156
 epistaxis 57, 167
 erythrocyte refractile bodies, *see* Heinz bodies
 erythrocytes, *see* red blood cells
 erythromycin 18, 47
 erythropoietin 4
Escherichia coli 182, 215
 ethanol therapy 142
 ethylene glycol ingestion 142
 etretinate 79
 'fading kitten syndrome' 138
 faecal analysis 10, 107, 117, 198
 famotidine 50
 febantel 198
 feline calicivirus (FCV) infection 6, 14, 42, 56, 76
 carrier cat 78

- feline herpes virus (FHV)
infection 6, 13, 56, 76, 200
carrier cat 78
- feline immunodeficiency virus (FIV) 13, 14, 38, 41
oral disease 41, 42
positive test 110, 122
transmission 122
- feline infectious anaemia (FIA) 104, 218
- feline infectious peritonitis (FIP) 13, 97, 118, 162, 202
diagnosis 126
pyogranulomatous lesions 61
transmission risks 202
- feline leukaemia virus (FeLV) 13, 14, 38, 71
outcomes of exposure 96, 104
outcomes of infection 96
patient-side test kit 172
preventative plan 104
test 140
- feline odontoclastic resorptive lesion (FORL) 41
- feline trypsin-like immunoreactivity (FTLI) 25, 31, 68
- femur, distal pathological fracture 34
- fenbendazole 117, 198
- fentanyl, transdermal 113
- ferrous sulphate 4
- fipronil 3
- flea infestation
hypersensitivity 3, 121
treatment 3
- fleas, life cycle 3
- flexor (withdrawal) reflexes 220
- fluconazole 156, 195
- flucytosine 195, 210
- fluoroquinolones 47, 182, 215
- fluticasone propionate 178
- food aversion 199
- foods, *see* diet; nutritional support
- fracture, acetabulum 103
- fractures
pathological of femur 34
sacrum 192
- fructosamine, serum 181
- fungal culture 58
- furosemide 129, 139, 173, 197
- gait abnormalities 35
- gall bladder mass 215
- gastric emptying 18
- gastric *Helicobacter*-like organism (GHLO) 160
- gastritis 90, 160
- gastrointestinal tract
endoscopy 90, 203
inflammatory disease 107
tumours 84, 207
- Giardia* infection 117
- gingivitis 41
necrotizing ulcerative 38
- gingivostomatitis,
lymphoplasmacytic 42
- glomerular filtration rate 174, 213
- glomerulonephritis 12
- glucocorticoids 5, 68, 169, 173, 178, 182, 184, 218
- glucosamine 39, 159
- glutaraldehyde 48
- glutathione 177
- glyceryl trinitrate 129, 173
- glycosaminoglycans 70
replacers 159
- gold salts 137
- gonadotrophin releasing hormone (GnRH) analogues 93
- granuloma
eosinophilic 16, 156
oral 156
- griseofulvin 175
- growth, restriction/stunting 51, 126, 206, 211
- H₂-blockers 4, 50
- haematochezia 62, 84
- haematuria 29, 95, 161
- haemoplasma infection 218
- head tilt
left-sided 59
right-sided 136
- health and safety, cytotoxic agents 205
- heart failure, congestive 173
- heart rate, assessment from ECG 108, 152
- heart rhythm 108
- heartworm, feline 77, 150
- Heinz bodies 9
- Helicobacter* spp. 160
- hepatomegaly 164
- hernia
diaphragmatic 37
perineal 217
- Holter monitoring 83
- Horner's syndrome 59
- Howell-Jolly bodies 218
- human chorionic gonadotrophin (hCG) 85
- hydrocephalus
congenital 139
internal 135
- hyperactivity 116
- hyperadrenocorticism (HAC) 17, 74, 147, 168
- hyperaldosteronism 30
- hypercalcaemia 141
- hyperchylomicronaemia 63
- hyperglycaemia 181
- hyperkalaemia 188
- hyperlipoproteinaemia 63
- hyperparathyroidism, secondary
nutritional 34
- hyperphosphataemia 174
- hyperpnoea 91
- hyperproteinaemia 174, 176, 213
- hypersensitivity
dietary 107, 121
fleas 3, 121
- hypertension 28, 43
in CRF 216
ocular abnormalities 28, 30, 43
- hyperthyroidism 20, 89, 116, 181, 185, 213
diagnosis 143
masking of renal disease 213
radioactive iodine therapy 193
- hyphaema 13, 28, 30
- hypoalbuminaemia 12
- hypocalcaemia 34, 102, 225
- hypokalaemia 30, 33, 174, 185, 191
- hypothyroidism 72, 193
congenital 51
- ileocaecocolic junction, mass 207
- imidacloprid 3
- immune-mediated disorders 14, 184
- immunity, maternal transfer 55, 110, 138
- immunoglobulin G (IgG) 55, 219
- immunoglobulin M (IgM) 219
- immunosuppressive therapy 137, 182, 184
- impression smear 169, 195
- infertility, queen 212
- inflammatory bowel disease,
lymphocytic-plasmacytic 107
- inhalation, steam 5
- inhaler, metered dose 178
- inherited disorders 23, 33, 72, 144, 187
- insect growth regulators 3
- insulin resistance 17, 147
- insulin therapy 21, 147
ineffectiveness 11
- interferon, recombinant human 200
- intrinsic factor 31
- iodine, radioactive 89
- iron deficiency 4
- isoelectrolysis, neonatal 101, 190
- isotretinoin 79
- itraconazole 48, 156, 175, 195

Index

- jaundice 118, 164, 182, 215
- joints
degenerative disease 39
inflammation 14
pain 1, 39
- joint smear 14
- 'junctionopathies' 185
- keratinocytes, acantholytic 184
- ketoconazole 147
- kidneys
amyloidosis 12
biopsy 162
CRF 174
lymphoma 204
polycystic disease 23, 187
size 134, 162, 174, 196, 204
- kittens
causes of mortalities 138
infectious disease 76, 138
maternal antibodies 55, 110, 138
neonatal isoerythrolysis 190
- labour 22
- lactulose 103, 206, 217
- laparotomy 61, 207
- laxative agents 103, 217
- left ventricle
enlargement 152
hypertrophy 20
wall thickening 120
- leucopenia 163
- lily toxicity 188
- lipaemia 63
- lipidosis, hepatic 130
- liver
biopsy 164, 215
congenital conditions 206
enlargement 164
lipidosis 130
nodular lesions 61
paracetamol (acetaminophen) toxicity 44
- liver disease, drugs 177
- Longhair cats 23, 187
- lower motor neurone (LMN) disease 35
- lufenuron 3, 175
- lungs
cardiogenic oedema 129
infiltrative disease 115
tumour 124
- lymphoadenomegaly, submandibular 115
- lymphoma 115
anterior mediastinal (AML) 71, 123
cutaneous epitheliotropic 79
intestinal 84, 207
renal 204
treatment 75, 205
- lysosomal storage disease 70
- macrolides 47
- magnesium ammonium phosphate (struvite) 73
- magnetic resonance imaging (MRI) 147, 168
- malnutrition 194
- mammary glands, hyperplasia 133
- marbofloxacin 36
- mast cell tumours 65, 221
- meat-only diets 34
- mediastinum, mass 71, 123
- megacolon 103, 127
- megaesophagus 128
- megestrol acetate 16, 93, 199
- melanin 167
- meloxicam 29, 84
- mental retardation 51
- Mescestoides lineatus* 180
- metered dose inhaler (MDI) 178
- methazolamide 139
- methimazole 213
- methoprene 3
- methotrexate 182
- methylprednisolone 16
- metoclopramide 18
- metronidazole 36, 38, 107, 117, 160, 182, 215
- metryrapone 147
- miconazole 48
- Microporum canis* 48, 58, 175
- milbemycin 198
- mitotane 147
- mucopolysaccharidosis 70
- mucous membranes, pallor 4
- muscle relaxants 92, 192
- musculoskeletal pain 1, 39
- myasthenia gravis, diagnosis 105
- mycobacterial infections 115, 131
- Mycoplasma* spp. 47, 76
- Mycoplasma haemofelis* 104, 218
- mycosis fungoides 79
- mydriasis 24
- N-acetylcysteine (NAC) 44
- nasal bridge, depression 70
- nasal cavity
biopsy 157, 170
bleeding 57
cryptococcosis 40, 195
flushing 5, 111, 157
neoplasia 157
- nasal discharge 5, 56, 157, 195
unilateral 54, 167
- nasal lesions
crusting/ulcerated 171
proliferative 170
- naso-oesophageal feeding 64, 99
- nasopharyngoscopy 111
- nasopharynx
biopsy 111
mass 111, 145
- nebulization, saline 5, 52
- neck ventroflexion 33, 185
- nephrolith 134
- nephropathy, protein-losing 12
- neuromuscular disorders 185
- neuropathies 35
- newborn, *see* kittens
- nictitating membrane, protrusion 8
- nitenpyram 3
- nitroglycerine 173
- non-steroidal anti-inflammatory drugs 12, 29, 84, 156
- nutritional disorders 34, 194
- nutritional support 130
energy requirements 224
importance in sick cat 194
indications for 194
naso-oesophageal tube 64, 99
oesophagostomy 165
- nystagmus 136
- obesity
assessment 186
risks and management 189
- ocular disorders
infectious 2, 6, 13, 219
neurological 24
systemic hypertension 28, 30, 43
- oedema
pulmonary 129, 173
subcutaneous pitting 12
- oesophagostomy tube 165
- oesophagus, stricture 50
- oestrus, control 93
- oestrus behaviour, following
neutering 85
- omega-3 fatty acids 149
- omeprazole 160
- ondansetron 68
- opioids 113
- oral disease 16, 38, 41, 42, 56, 156, 179
- oral hygiene 42
- orthopnoea 91
- osteopenia 34
- ovarian remnant syndrome 85
- ovulation, induction 93
- ovulation failure 212
- oxazepam 199
- oxygen therapy 214
- pads, spongy swelling 137
- pallor 4
- pancreas, hypoplasia/aplasia 31
- pancreatitis 25
feline acute 68

- pancytopenia 179
 paracetamol (acetaminophen) 44, 118
 paralysis, hindlimb 132
 paraneoplastic disease 74, 115
 parasites 112
 intestinal 180
 nematode 198
 protozoa 10, 62
 respiratory 77, 119, 150
 see also flea infestation
 parathyroid glands,
 damage/removal 102
 parathyroid hormone 34
 paws, pododermatitis 137
 pelvic canal, narrowing 103
 pemphigus foliaceus 184
 penicillins 38, 182
 penis, bruising/ischaemia 155
 pentobarbitone (pentobarbital) 125
 pentosan polysulphate 39, 159
 perineal hernia 217
 periodontal disease, necrotizing 38
 pericardioperitoneal
 diaphragmatic hernia (PPDH) 37
 Persian cat 23, 86, 97, 187
 petechiation 106
 phenobarbitone (phenobarbital) 125, 208
 phenoxylbenzamine 92, 192
 phenytoin 139, 208
 pheromone sprays 199
 phosphate restriction 149
 photodynamic therapy 171
 pimobendan 197
 piroxicam 29, 84
 pituitary gland, mass 147, 168
 platelet clumping 106, 163
 pleural effusion 36, 166
 pleural fluids, categories 183
 pneumonia 52
 pododermatitis, ulcerative 137
 poisoning, *see* toxicities
 pollakiuria 159, 161
 polyarthritis, inflammatory 1, 14
 polychromasia 148, 218
 polycystic kidney disease (PKD) 23, 187
 polydipsia 72, 114, 141, 196
 differential diagnoses 60
 polymyopathies 33, 185
 polyneuropathy 35
 polyp
 duodenal 98
 nasopharyngeal 145
 polyuria 72, 114, 141, 196
 portosystemic vascular anomaly 94, 206, 211
 portovenogram 94
 potassium bromide 208
 potassium citrate 153
 potassium supplementation 191
 poxvirus (cowpox) infection 169
 praziquantel 180, 198
 prazosin 92, 192
 prednisolone 16, 50, 84, 85, 107, 137, 139, 145, 184, 207
 prednisolone sodium succinate 173
 pregnancy
 control 93
 early loss 212
 labour 22
 prepuce, discharge 155
 primidone 139
 prochlorperazine 68
 progestagens 93, 133, 169
 progesterone, endogenous 85, 133
 progesterone receptor antagonists 133
 prostaglandin F_{2α} 109
 prostatic disease 95
 protein energy malnutrition 194
 protein restriction 12, 149, 206
 proteinuria 176
 protozoan infections 10, 62, 117
 proxymetacaine 64
 pseudocysts, perinephric 204
 psyalism 156, 211
 pulmonary oedema 129, 173
 pulmonary tumour 124
 pupil dilation 211
 pupil size 24
 'pyloric stenosis' 18
 pyloromyotomy 18
 pyometra, 'uterine' stump 109
 pyothorax 32, 36
 pyrantel 198
 pyrexia 56
 pyriproxyfen 3
 pyruvate kinase deficiency 72
 radioactive iodine therapy 193
 radiotherapy 171
 ramipril 12
 Rapid H blood typing card 101
 red blood cells
 fragility 72
 Heinz bodies 9
 Howell–Jolly bodies 218
 immature 154
 reflexes 220
 regurgitation
 differential diagnoses 50
 distinguishing from vomiting 128
 intermittent 71
 renal failure
 acute (ARF) 188, 210
 differentiating acute and chronic 209
 see also chronic renal failure (CRF)
 renomegaly 162, 187, 204
 resting energy requirement (RER) 224
 reticulocytes 154
 retina
 central degeneration 197
 detachment 28, 43
 progressive atrophy 72
 retinoids 79
 Rex cats 40, 59, 86, 144
 rhinitis
 chronic 5, 157
 fungal 27, 40
 post-viral 5
 treatment 5
 rhinotomy 5
 road traffic accidents 69, 80, 192, 201
 rodenticide toxicity 223
 rutin 66
 sacrum, fracture 192
 S-adenosyl methionine (SAMe) 177, 182
 salbutamol 52, 173, 178
 sarcoma, vaccine site 151
 seborrhoea sicca 193
 seizures 125
 medical management 208
 selamectin 3, 198
 Siamese cats 18, 86, 136, 139, 167
 'sick euthyroid' 116
 skeletal pain 1, 39
 skin fragility 74
 skin lesions
 multiple nodular 65
 nodular/plaque-like 79
 nodular/ulcerative 169, 221
 pemphigus foliaceus 184
 squamous cell carcinoma 171
 ulcerative 200
 skull, domed 139
 sneezing 40, 56, 57, 91, 157, 195
 sodium hypochlorite 202
 'spacer' device 178
 spasticity 144
 spinal injuries 132, 192
 spinal lesion 220
 spironolactone 30, 129, 197
 squamous cell carcinoma 156, 171

Index

- Staphylococcus* 182
 starvation 194
 steatorrhoea 31
 stifle joint, degenerative disease 39
Streptococcus 182
 struvite crystals 73
 sublingual lesion, proliferative 156
 sucralfate 4, 50
 sulphonamides 156
- tachycardia 116
 tachypnoea 91
Taenia taeniaformis 180
 'tail pull' injury 192
 taurine 45, 130
 deficiency 45, 197
 functions 45
 supplementation 130
 technetium 99m 143
 teeth
 extraction 41, 42
 'neck' lesions 41
 root abscess 54, 167
 Tensilon 105
 terbinafine 175
 terbutaline 52
 tetracyclines 47, 76
 theophylline 52
 thiazide diuretics 19
 thoracocentesis 36, 66, 166
 fluid analysis 32, 88
 procedure 88
 thrombocytopenia 106
 thromboembolic disease, distal 132
 thymoma 123
 thyroidectomy, hypocalcaemia after 102, 225
 thyroid mass 116
 carcinoma 89
 nodule 213
 thyrotropin releasing hormone (TRH) stimulation test 51, 143, 193
 L-thyroxine 51, 193
 thyroxine (T4) levels 20, 51, 116, 143, 181
 tongue
 petechiation 106
 proliferative lesions 16, 156
 ulceration 56
 torovirus 8
Toxocara cati 198
 toxicities
 ethylene glycol 142
 lily 188
 paracetamol (acetaminophen) 44
 rodenticides 223
Toxoplasma gondii 13, 104, 219
 tracheal avulsion 201
 tracheal lavage 146
 tracheoscopy 124, 201
 transfusion reaction 222
 transitional cell carcinoma (TCC) 29
 traumatic injury 69, 80, 192, 201
 trichogram 121
 tri-iodothyronine (T3)
 suppression test 143
 trilostane 147
 turbinectomy 5
- ulceration
 skin 171, 200
 tongue 56
 urethra, obstruction 26, 92, 161
 urethrogram, retrograde 95
 urinary cortisol to creatinine ratio (UCCR) 168
 urinary protein:creatinine ratio (UPC) 12
 urinary retention 192
 urinary tract disease
 lower 67, 73, 95, 141
 see also parts of urinary tract
 urination
 encouraging frequent 159
 inappropriate 67
 lack of 69, 192
 urine
 culture 26
 dipstick evaluation 100
 pH 141, 153
 urine sediment analysis 73, 81, 141, 176
 urine specific gravity (USG) 19, 176, 213
 uroliths 141, 153, 176
 ursodeoxycholic acid (UDCA) 177, 182
 uveitis 13, 219
- vaccination
 Chlamydia 2
 FeLV-infected cat 104
 site-associated sarcoma 151
 very low density lipoproteins (VLDLs) 63
 vestibular disease 136
 vincristine 84, 207
 viral infections 10
 vitamin B₁₂ 31
 vitamin D₃ (calcitriol) 225
 vitamin K₁ (phytonadione) 223
 vitamin K-dependent
 coagulopathy 44
- vomiting 25, 128
 distinguishing from regurgitation 128
 intermittent 68, 182
 persistent 18, 90, 98, 160
 progressive 207
 recurrent severe 90
 vulval discharge 109
- warfarin toxicity 223
 water deprivation test 19, 114
 water intake 60, 114
 see also polydipsia
 weight loss 13, 25, 31, 61, 72, 116, 130, 134, 181, 185, 213
 in obesity 189
 withdrawal reflexes 220
 Wood's lamp 48, 58
- zinc sulphate centrifugation 117
 zona pellucida antigens, porcine 93
 zoonoses 117, 131, 169, 198