

The AHA Clinical Series

SERIES EDITOR ELLIOTT ANTMAN

Adult Congenital Heart Disease

To Jane Somerville, who taught so many of us about congenital heart disease;
for inspiring me to follow a different path.

The AHA Clinical Series

SERIES EDITOR ELLIOTT ANTMAN

Adult Congenital Heart Disease

EDITED BY

Carole A. Warnes, MD

Mayo Clinic
Rochester, MN
USA

 **WILEY-BLACKWELL**

A John Wiley & Sons, Ltd., Publication

This edition first published 2009, © 2009 American Heart Association
American Heart Association National Center, 7272 Greenville Avenue, Dallas, TX 75231, USA
For further information on the American Heart Association:
www.americanheart.org

Blackwell Publishing was acquired by John Wiley & Sons in February 2007. Blackwell's publishing program has been merged with Wiley's global Scientific, Technical and Medical business to form Wiley-Blackwell.

Registered office: John Wiley & Sons Ltd, The Atrium, Southern Gate, Chichester, West Sussex, PO19 8SQ, UK
Editorial offices: 9600 Garsington Road, Oxford, OX4 2DQ, UK
The Atrium, Southern Gate, Chichester, West Sussex, PO19 8SQ, UK
111 River Street, Hoboken, NJ 07030-5774, USA

For details of our global editorial offices, for customer services and for information about how to apply for permission to reuse the copyright material in this book please see our website at www.wiley.com/wiley-blackwell

The right of the author to be identified as the author of this work has been asserted in accordance with the Copyright, Designs and Patents Act 1988.

All rights reserved. No part of this publication may be reproduced, stored in a retrieval system, or transmitted, in any form or by any means, electronic, mechanical, photocopying, recording or otherwise, except as permitted by the UK Copyright, Designs and Patents Act 1988, without the prior permission of the publisher.

Wiley also publishes its books in a variety of electronic formats. Some content that appears in print may not be available in electronic books.

Designations used by companies to distinguish their products are often claimed as trademarks. All brand names and product names used in this book are trade names, service marks, trademarks or registered trademarks of their respective owners. The publisher is not associated with any product or vendor mentioned in this book. This publication is designed to provide accurate and authoritative information in regard to the subject matter covered. It is sold on the understanding that the publisher is not engaged in rendering professional services. If professional advice or other expert assistance is required, the services of a competent professional should be sought.

The contents of this work are intended to further general scientific research, understanding, and discussion only and are not intended and should not be relied upon as recommending or promoting a specific method, diagnosis, or treatment by physicians for any particular patient. The publisher and the author make no representations or warranties with respect to the accuracy or completeness of the contents of this work and specifically disclaim all warranties, including without limitation any implied warranties of fitness for a particular purpose. In view of ongoing research, equipment modifications, changes in governmental regulations, and the constant flow of information relating to the use of medicines, equipment, and devices, the reader is urged to review and evaluate the information provided in the package insert or instructions for each medicine, equipment, or device for, among other things, any changes in the instructions or indication of usage and for added warnings and precautions. Readers should consult with a specialist where appropriate. The fact that an organization or Website is referred to in this work as a citation and/or a potential source of further information does not mean that the author or the publisher endorses the information the organization or Website may provide or recommendations it may make. Further, readers should be aware that Internet Websites listed in this work may have changed or disappeared between when this work was written and when it is read. No warranty may be created or extended by any promotional statements for this work. Neither the publisher nor the author shall be liable for any damages arising herefrom.

Library of Congress Cataloging-in-Publication Data

Adult congenital heart disease / edited by Carole Warnes.

p. ; cm. – (The AHA clinical series)

Includes bibliographical references.

ISBN 978-1-4051-7820-4

1. Congenital heart disease. I. Warnes, Carole A. II. American Heart Association. III. Series.

[DNLM: 1. Heart Defects, Congenital—Case Reports. 2. Adult. WG 220 A2445 2008]

RC687.A452 2008

616.1'2043—dc22

A catalogue record for this book is available from the British Library.

Set in 9/12 pt Palatino by Aptara® Inc., New Delhi, India

Printed and bound in Singapore

1 2009

Contents

Contributors, vii

Preface, xi

Foreword, xiii

- 1 Secundum atrial septal defect, 1
Sabrina D. Phillips
- 2 Atrioventricular septal defects, 9
Frank Cetta
- 3 Pulmonary stenosis/right ventricular outflow tract obstruction, 25
Elyse Foster and Katy Lease
- 4 Ventricular septal defect, 41
Naser M. Ammash
- 5 Pulmonary arterial hypertension in Eisenmenger Syndrome, 57
Kevin Owusu-Ansah, Zeksen Lim, and Gruschen R. Veldtman
- 6 Congenitally corrected transposition of the great arteries, 76
Sara A. Thorne
- 7 Left ventricular outflow tract obstruction, 87
Craig S. Broberg
- 8 Coarctation of the aorta and aortic disease, 102
Michelle Z. Gurvitz
- 9 Transposition of the great arteries after a Mustard atrial switch procedure, 126
Folkert Meijboom and Gary Webb

- 10 Tetralogy of Fallot, 139
Judith Therrien
- 11 Single ventricle physiology, 157
Michael A. Gatzoulis and Lorna Swan
- 12 Ebstein's anomaly, 174
Heidi M. Connolly
- 13 Imaging in adult congenital heart disease, 190
Candice K. Silversides and Samuel C. Siu
- 14 The chest x-ray in congenital heart disease, 208
Joseph K. Perloff
- 15 Arrhythmias in congenital heart disease, 221
Barbara J. Deal
- 16 Pregnancy and contraception, 237
Rachel M. Wald and Jack M. Colman
- Index, 260
- Author Disclosure Table, 272

Contributors

Editor

Carole Warnes, MD

Mayo Clinic
Rochester, MN
USA

Contributors

Naser M. Ammash, MD

Division of Cardiovascular Diseases and Internal Medicine
Mayo Clinic and Mayo Foundation
Rochester, MN
USA

Craig S. Broberg, MD, FACC

Director, Adult Congenital Heart Disease Program
Assistant Professor
Division of Cardiovascular Medicine
Oregon Health and Science University
Portland, OR
USA

Frank Cetta, MD

Divisions of Pediatric Cardiology and Cardiovascular Diseases
Departments of Pediatrics and Medicine
Mayo Clinic College of Medicine
Rochester, MN
USA

Jack M. Colman, MD

Toronto Congenital Cardiac Centre for Adults
Peter Munk Cardiac Centre
University Health Network and Mount Sinai Hospital
University of Toronto
Toronto
Canada

Heidi M. Connolly, MD

Mayo Clinic
Rochester, MN
USA

Barbara J. Deal, MD

Feinberg School of Medicine
Northwestern University
Department of Cardiology
Children's Memorial Hospital
Chicago, IL
USA

Elyse Foster, MD

Director, Echocardiography Laboratory
Professor of Clinical Medicine
Araxe Vilensky Endowed Chair in Medicine
Department of Medicine; Cardiology
University of California
San Francisco, CA
USA

Michael A. Gatzoulis, MD, PhD, FACC, FESC

Adult Congenital Heart Centre and Centre for Pulmonary Hypertension
Royal Brompton Hospital, and National Heart and Lung Institute
Imperial College, London, UK

Michelle Z. Gurvitz, MD

Departments of Pediatrics and Medicine
Seattle Children's Hospital and University of Washington Medical Center
University of Washington School of Medicine
Seattle, WA
USA

Katy Lease, MD

University of California
Department of Medicine
Division of Cardiology
San Francisco, CA
USA

Zeksen Lim, MBChB, MRCP

The Congenital Cardiac Unit
Southampton University Hospital
Southampton General Hospital
Southampton
UK

Folkert Meijboom, MD, PhD

Department of Cardiology and Pediatrics
University Medical Centre Utrecht
Utrecht, The Netherlands

Kevin Owusu-Ansah, MBChB, BSc (Hons)

The Congenital Cardiac Unit
Southampton University Hospital
Southampton General Hospital
Southampton
UK

Joseph K. Perloff, MD

Streisand/American Heart Association
Emeritus
USA

Sabrina D. Phillips, MD, FACC

Division of Cardiovascular Diseases and Internal Medicine
Mayo Clinic
Rochester, MN
USA

Candice K. Silversides, MS, MD, FRCPC

Assistant Professor
University of Toronto Staff Cardiologist and Echocardiographer
Toronto Congenital Cardiac Center for Adults
Toronto General Hospital/University Health Network
Toronto
Canada

Samuel C. Siu, MD, SM, FRCPC, FACC, FASE

City-Wide Chief of Cardiology
London Teaching Hospitals Gunton Professor of Medicine
Divisional Chair of Cardiology Schulich School of Medicine and Dentistry, University of
Western Ontario
University Hospital, London Health Sciences Centre
Ontario
Canada

Lorna Swan, MB ChB, MRCP, MD

Royal Brompton Hospital
London
UK

Judith Therrien, MD

Department of Medicine
MAUDE Unit, McGill University
Montreal, Quebec
Canada

Sara A. Thorne, MBBS, MD, FRCP

University of Birmingham
Birmingham
UK

Gruschen R. Veldtman, MBChB, MRCP

The Congenital Cardiac Unit
Southampton University Hospital
Southampton General Hospital
Southampton
UK

Rachel M. Wald, MD

Toronto Congenital Cardiac Center for Adults
Peter Munk Cardiac Centre
University Health Network and Mount Sinai Hospital
University of Toronto
Toronto
Canada

Gary Webb

Philadelphia Adult Congenital Heart Center
University of Pennsylvania
Philadelphia, PA
USA

Preface

The last fifty years have witnessed dramatic changes in the world of congenital heart disease; innovative cardiac surgeries, noninvasive imaging, and intensive care have all resulted in the successful survival of the majority of babies born with congenital heart disease. Now, there are approximately one million adults in North America with congenital heart disease, some of whom have had prior surgery and others who were surprised to learn as adults that they were born with heart disease. Although there are now more adults than children with congenital heart disease, the medical community has been ill-prepared to deal with their complex problems. The American College of Cardiology/American Heart Association have recently recognized the importance of this patient population by publishing guidelines to help medical practitioners manage some of their problems. The aim of this book is to offer further practical advice to physicians about common congenital anomalies and associated complications seen frequently in practice.

I believe our best learning experiences result from our clinical cases, and so each chapter of this book begins with a common clinical scenario related to each anomaly. This is followed by a description of the anatomy, features of the clinical diagnosis, a discussion of the imaging modalities, and appropriate treatment strategies. Each chapter then concludes with a discussion about the treatment used for each case and the outcome that resulted. Separate chapters on arrhythmias and imaging are also included.

The authors are an international group of experts in their field, and their contributions are very much appreciated. I hope the readers will benefit from the wealth of clinical experience included herein.

Carole Warnes, MD

Foreword

The strategic driving force behind the American Heart Association's mission of reducing disability and death from cardiovascular diseases and stroke is to change practice by providing information and solutions to health care professionals. The pillars of this strategy are Knowledge Discovery, Knowledge Processing, and Knowledge Transfer. The books in the AHA Clinical Series, of which *Adult Congenital Heart Disease* is included, focus on high-interest, cutting-edge topics in cardiovascular medicine. This book series is a critical tool that supports the AHA mission of promoting healthy behavior and improved care of patients. Cardiology is a rapidly changing field and practitioners need data to guide their clinical decision-making. The AHA Clinical Series serves this need by providing the latest information on the physiology, diagnosis, and management of a broad spectrum of conditions encountered in daily practice.

Rose Marie Robertson, MD, FAHA
Chief Science Officer, American Heart Association

Elliott Antman, MD, FAHA
Director, Samuel A. Levine Cardiac Unit,
Brigham and Women's Hospital

Secundum atrial septal defect

Sabrina D. Phillips

A 20-year-old woman presented for evaluation of palpitations and one episode of near syncope after exertion. Her past medical history was remarkable only for a diagnosis of exercise-induced asthma. She was involved in competitive sports at her University, participating on the track team. She denied any chest discomfort, dyspnea at rest, or perceived exercise limitation. She had never had lower extremity edema, orthopnea, or paroxysmal nocturnal dyspnea. There was no history of cardiac or pulmonary disease in her family. Physical exam revealed a normal jugular venous pressure. The carotid upstroke was normal. The lungs were clear to auscultation and percussion bilaterally. The cardiac exam was notable for a 1+ right ventricular impulse with a normal left ventricular impulse. The first heart sound (S1) was normal, but the second heart sound (S2) was persistently split, with no variation with respiration. The pulmonary component of S2 was mildly accentuated. A systolic crescendo-decrescendo murmur, grade I/VI, was heard at the upper left sternal margin. No diastolic murmur or added heart sounds were heard. There was no evidence of cyanosis, clubbing, or edema of the extremities.

Evaluation included a chest x-ray (Fig. 1.1) that demonstrated increased pulmonary vascular markings, enlarged central pulmonary arteries, and cardiac enlargement involving the right heart chambers. An electrocardiogram revealed normal sinus rhythm with right axis deviation and right bundle branch block. The P-R interval was normal. Two-dimensional (2-D) echocardiogram was notable for moderate-severe right heart enlargement, mild tricuspid valve regurgitation, and a secundum atrial septal defect (ASD) measuring 22 mm. The estimated pulmonary artery systolic pressure was 40 mm Hg. The pulmonary valve was normal. A Holter monitor revealed no atrial or ventricular arrhythmias.

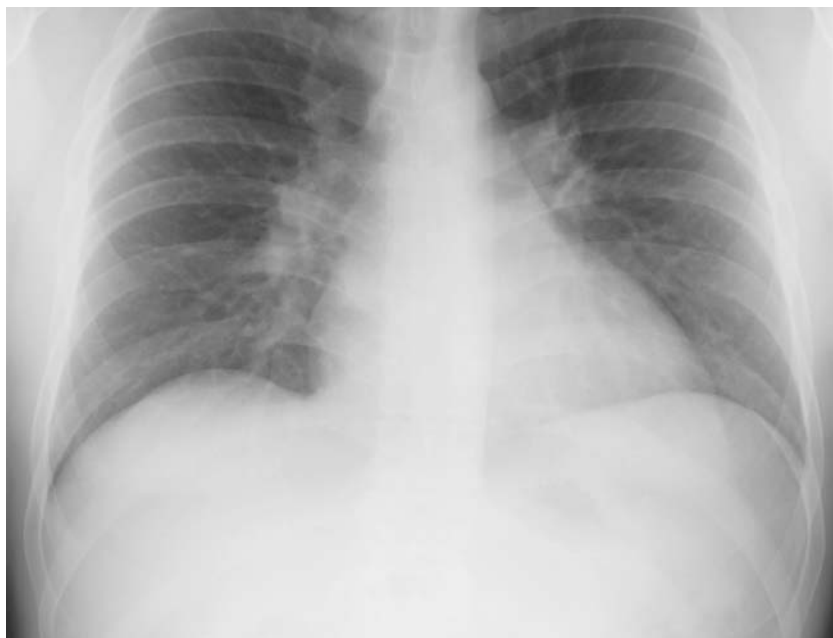

Fig. 1.1 Chest x-ray demonstrating enlarged cardiac silhouette, enlarged central pulmonary arteries, and increased pulmonary vascularity.

Embryology and anatomy

Atrial septation is a complex embryological event that occurs in the first 60 days after conception. Throughout the septation process, a channel for blood flow must be maintained between the left and right atria so that placental blood (oxygenated) that is entering the right atrium can be shunted to the left atrium and into the systemic circulation. As endocardial cushion tissue closes the ostium primum, the ostium secundum forms via fenestrations in the anterosuperior position of the septum primum. The septum secundum then develops and eventually provides partial closure of the ostium secundum. At the completion of atrial septation, the limbus of the fossa ovalis is the septum secundum and the septum primum is the valve of the fossa ovalis. Secundum ASDs occur when there is inadequate septum primum. The underlying cause of this malformation is usually multifactorial, although there are a few recognized genetic defects that result in secundum ASD, such as Holt-Oram syndrome.

Pathophysiology

A secundum ASD allows blood to cross the atrial septum. The amount of shunt is determined by the end-diastolic pressures of the ventricles, the size of the

defect, and the status of the atrioventricular valves. Usually, the right ventricular end-diastolic pressure is lower than the left ventricular end-diastolic pressure, creating a left-to-right shunt. Right-to-left shunting can occur when there is significant tricuspid valve disease or when the right ventricular end-diastolic pressure is elevated by pulmonary valve disease, abnormal compliance of the right ventricle, or pulmonary hypertension.

A left-to-right shunt at the atrial level results in volume overload of the right atrium and right ventricle. Volume overload leads to dilatation of these chambers, which can eventually result in right ventricular systolic dysfunction. Tricuspid valve regurgitation can also progress as a result of right ventricular enlargement and subsequent annular dilatation. Pulmonary artery systolic pressure is proportional to the pulmonary vascular resistance multiplied by the pulmonary arterial flow ($PAP \approx PVR \times Q_p$). Therefore, mildly elevated pulmonary artery pressures are not unexpected, even when the pulmonary vascular resistance is normal, since the pulmonary arterial blood flow is increased secondary to the left-to-right shunt. However, increased blood flow through the pulmonary arteries increases shear stress on the arterial wall and can lead to changes in the pulmonary vasculature that result in increased pulmonary vascular resistance and pulmonary hypertension. In the setting of severe pulmonary hypertension, a right-to-left shunt at the atrial level results in systemic desaturation that is unresponsive to supplemental oxygen. This right-to-left shunt in the setting of pulmonary vascular disease is called Eisenmenger Complex and occurs in approximately 5% of secundum ASDs, most commonly in women. Left atrial enlargement will occur, but left ventricular enlargement is unusual given the compliance characteristics of the left ventricular myocardium.

Natural history

The presentation of secundum ASD depends on the size of the shunt and the associated cardiac status. Defects associated with very large shunts may present in infancy with failure to thrive, but it is not uncommon for large defects to be diagnosed for the first time in adulthood. Left ventricular compliance tends to diminish with age, often in association with the onset of hypertension or coronary artery disease. The stiffer left ventricle then increases the left-to-right shunt through the ASD, causing progressive right ventricular and right atrial enlargement. Often patients present for the first time in their 40s and 50s with atrial fibrillation. Other symptoms include exercise intolerance, frequent upper respiratory tract infection, and palpitations.

Diagnosis

The physical exam may demonstrate a pronounced right ventricular impulse, but the left ventricular impulse is usually normal. The second heart sound

(S2) may be widely split, with no variation with respiration. The pulmonary component of the second heart sound (P2) is variably accentuated, depending on the pulmonary artery pressures. A systolic murmur from increased flow through the pulmonary valve is heard at the upper left sternal margin. If the left-to-right shunt is significant ($Q_p:Q_s > 2.5:1$), a diastolic murmur representing increased flow across the tricuspid valve can be heard.

The chest x-ray findings of secundum ASD include cardiomegaly related to right-sided cardiac enlargement, central pulmonary artery enlargement, and prominent pulmonary vascularity secondary to pulmonary overcirculation.

The electrocardiogram will usually demonstrate a right bundle branch block with right axis deviation. Crochetage (Fig. 1.2), a notch seen in the QRS in lead II and III, has also been reported in secundum ASD [1].

Transthoracic echocardiography is invaluable in the diagnosis of secundum ASD. Even if the defect itself cannot be visualized, the hemodynamic consequence of the shunt can be assessed by an evaluation of the right heart size and function. Identification of the defect by surface echocardiogram is influenced by

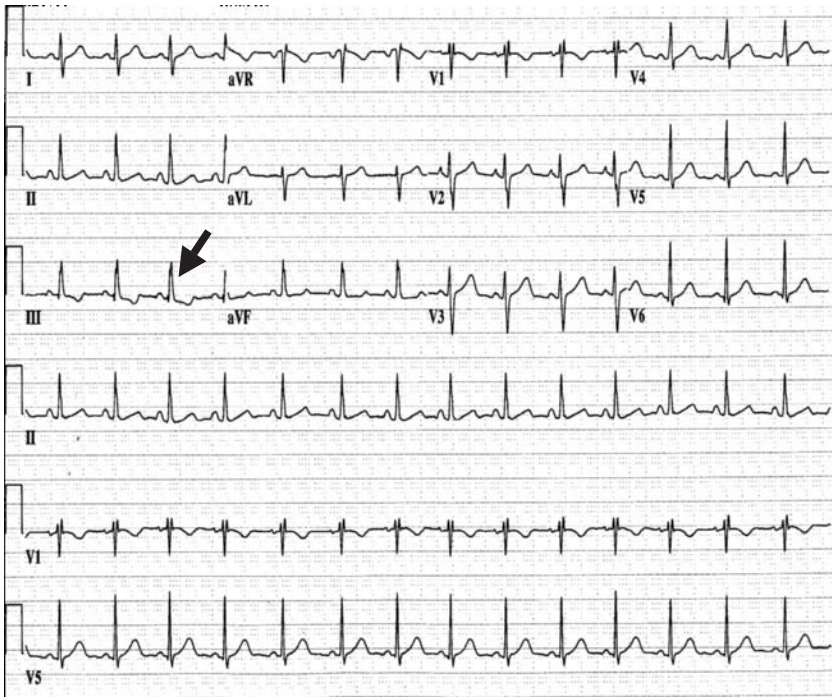


Fig. 1.2 Crochetage. Note the notch at the peak of the QRS complex in leads II, III, and aVF.

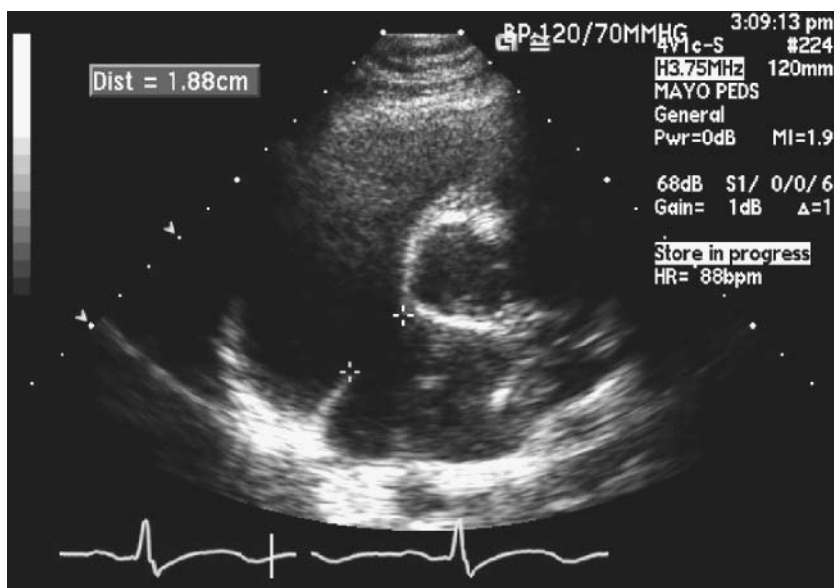


Fig. 1.3 Transthoracic echocardiogram, parasternal short axis view. The atrial septal defect measures 1.88 cm.

the size of the defect. The subcostal window provides a good look at the atrial septum and should be used. The parasternal short axis view at the base of the heart may also demonstrate the defect (Fig. 1.3). The apical four-chamber view can be misleading; when the atrial septum is parallel to the echocardiographic signal, drop out may occur. Tilting the apical view off-axis will align the atrial septum at an angle and allow for better 2-D and color interrogation. The degree of tricuspid valve regurgitation should be assessed, as this may influence the mode of repair. The pulmonary artery pressures should be estimated via the modified Bernoulli equation ($\Delta P = 4v^2$), with the systolic pressure calculated from the tricuspid valve regurgitation velocity (assuming there is no pulmonary stenosis) and the diastolic pressure estimated from the pulmonary regurgitation end-diastolic velocity. There is very little usefulness in calculating the ratio of pulmonary blood flow to systemic blood flow ($Q_p:Q_s$) by echocardiography, as the measurements are often inaccurate.

Transesophageal echocardiography allows improved visualization of the atrial septum and therefore enhanced diagnostic accuracy. Transesophageal echocardiography should be employed if the diagnosis is in question or if there is a concern about the adequacy of the residual atrial septal tissue when device closure is being considered. Transesophageal echocardiography also allows improved visualization of the pulmonary venous return and can be used to

rule out anomalous pulmonary venous connection, which is an important differential diagnosis if a patient is found to have right ventricular enlargement and no ASD.

Cardiac catheterization provides accurate pressure measurements. Flow measurements can be obtained through various methods. These measurements can then be used to calculate pulmonary vascular resistance and quantitate the shunt volume. However, in the modern era, cardiac catheterization is unnecessary unless coronary angiography is being performed or the patient has important pulmonary hypertension. Cardiac catheterization should be employed when there is a question regarding pulmonary artery pressure and vascular resistance before committing to defect closure. Currently, the main role for cardiac catheterization in the patient with isolated secundum ASD is therapeutic.

A secundum ASD that is associated with right ventricular volume loading should be considered for closure. The demonstration of a Qp:Qs greater than 1.5:1 is not required. Magnetic resonance imaging (MRI) can detect ASDs and can provide right ventricular volume measurements, as well as an evaluation of the pulmonary venous return [2,3]. Shunt calculations can also be determined [4]. MRI is not a first-line test in the evaluation of secundum ASD because of cost, time, and availability constraints, but it should be considered as an excellent alternative in patients who cannot undergo transesophageal imaging.

Treatment

Hemodynamically significant ASDs (those that have resulted in right heart enlargement) should be closed to prevent the complications of right heart failure, atrial dysrhythmia, and pulmonary hypertension. Closure of important secundum ASDs before the age of 25 years results in an excellent long-term prognosis. Closure after the age of 40 years reduces the complications related to right heart failure, but the increased risk of atrial dysrhythmia remains [5].

Closure of a secundum ASD can be accomplished surgically or percutaneously. Surgical closure has been performed successfully since 1953 [6]. The surgical approach is via midline sternotomy or right thoracotomy. Minimally invasive technique through a right thoracotomy is currently being used in some centers. At the time of surgery, the ASD can be suture closed or patched, depending on the size. Patch closure may involve autologous material, bovine pericardium, or artificial material. The mortality for surgical closure of ASD is reported as 0.3% in the STS database [7] for procedures performed between 1998 and 2002. Complications include incomplete closure, obliteration of the inferior caval orifice, heart block, and atrial arrhythmias.

Percutaneous closure can now be accomplished. There are several devices available for use. Percutaneous closure can be considered for defects up to 38 mm in stretched diameter, but closure becomes more difficult for defects greater than 30 mm. Adequate septal tissue rims must be present to anchor the

device, but patients with deficient retro-aortic rims have undergone successful percutaneous closure. The success rate of percutaneous closure is greater than 90%, with a complication rate of about 7%. Reduction in right ventricular size is seen in the majority of patients. Complications include atrial fibrillation, cardiac perforation, device migration, and access site complications [8]. Infection and thrombosis of the device have been reported after successful closure.

The mechanism of closure should be determined based on anatomic characteristics and patient preference. Patients with other cardiac anomalies that need treatment, including anomalous pulmonary venous return, should undergo surgical repair. Patients with more than moderate tricuspid valve regurgitation may need to be considered for combined surgical ASD closure and tricuspid valve repair. Patients with a history of atrial fibrillation may benefit from a surgical MAZE procedure, although catheter-based arrhythmia management can be considered in conjunction with device closure. Any catheter-based arrhythmia procedure must be performed prior to device closure, as access to the left atrium will be difficult after device implantation.

Patient follow-up

The patient elected to proceed with percutaneous closure of the defect. The closure was successful without residual shunt. On a follow-up visit, 1 year after the procedure, the patient was asymptomatic and had improved her 200-meter race times dramatically. Echocardiogram was notable for normal right ventricular size and function, mild tricuspid valve regurgitation, and an estimated pulmonary artery systolic pressure of 28 mm Hg.

References

1. Heller J, Hagege AA, Besse B, et al. "Crochetage" (notch) on R wave in inferior limb leads: a new independent electrocardiographic sign of atrial septal defect. *J Am Coll Cardiol* 1996;27:877–82.
2. Chin SP, Kiam OT, Rapae A, et al. Use of non-invasive phase contrast magnetic resonance imaging for estimation of atrial septal defect size and morphology: a comparison with transesophageal echo. *Cardiovasc Intervent Radiol* 2006;29:230–4.
3. Greil GF, Powell AJ, Gildein HP, Geva T. Gadolinium-enhanced three dimensional magnetic resonance angiography of pulmonary and systemic venous anomalies. *J Am Coll Cardiol* 2002;39:335–41.
4. Beerbaum P, Korperich H, Barth P, et al. Noninvasive quantification of left-to-right shunt in pediatric patients: phase-contrast cine magnetic resonance imaging compared with invasive oximetry. *Circulation* 2001;103:2476–82.
5. Murphy JG, Gersh BJ, McGoon MD, et al. Long term outcome after surgical repair of isolated atrial septal defect. Follow-up at 27 to 32 years. *N Engl J Med* 1990;323(24):1645–50.

6. Lewis FJ, Roufle M. Closure of atrial septal defects with aid of hypothermia: experimental accomplishments and the report of one successful case. *Surgery* 1953;33:52–9.
7. *STS Congenital Heart Surgery Data Summary*. Available at: <http://www.sts.org>.
8. Butera G, Carminati M, Chessa M, et al. Percutaneous versus surgical closure of secundum atrial septal defect: comparison of early results and complications. *Am Heart J* 2006;151:228–34.

Atrioventricular septal defects

Frank Cetta

Case #1

A 17-year-old girl born with partial atrioventricular septal defect (AVSD) had closure of the primum atrial septal defect (ASD) and repair of a cleft in the anterior leaflet of the mitral valve when she was 18 months of age. She did well and her growth and development were normal. She participated in high school sports and had no limitations. It was noted several years prior to the current presentation that she had developed a systolic ejection murmur. Echocardiography demonstrated the images shown in Fig. 2.1. That echocardiogram also demonstrated trivial mitral valve regurgitation and mild aortic valve regurgitation.

The echocardiograph in Fig. 2.1 demonstrates tissue in the left ventricular outflow tract (LVOT) that represents accessory connections from the anterior leaflet of the mitral valve to the septum.

Case #2

A 58-year-old woman originally presented at age 45 years with progressive dyspnea on exertion. She was an aerobics instructor at the time and noticed that her workout routine had become progressively more difficult over the previous 3–4 years. She denied any chest pains, palpitations, or other symptoms. She had never had cardiac rhythm issues. Her work-up 13 years before included a chest x-ray that demonstrated cardiomegaly. This prompted an echocardiogram that showed a large primum ASD and moderate mitral valve regurgitation. At that time, she underwent repair of a primum ASD and closure of a cleft in the anterior leaflet of the mitral valve. It was

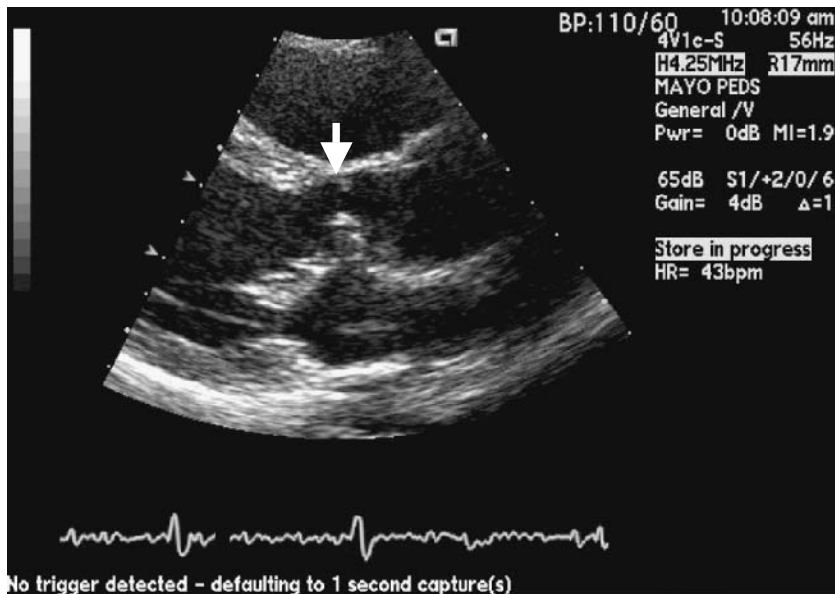


Fig. 2.1 Parasternal long axis projection demonstrating a subaortic membrane (arrow) that developed in a teenager, 15 years after repair of partial AVSD.

noted immediately postoperatively that there was mild narrowing of the LVOT. A soft systolic ejection murmur was present, and Doppler echocardiography demonstrated a mean gradient of 12 mm Hg across the LVOT. She had mild residual mitral valve regurgitation.

Now, at age 58 years, she has not seen a cardiologist for 5 years. Her primary care physician noted a loud systolic ejection murmur during a routine physical exam. This prompted re-evaluation in an adult congenital heart disease clinic. She has two systolic murmurs. The first is a harsh 3/6 ejection murmur best at the mid left sternal border radiating toward the right upper sternal border. There is no ejection click. The second heart sound is physiologically split. The second murmur is a 2/6 harsh holosystolic murmur best at the apex radiating to the left axilla. She has retired from her job as an aerobics instructor since her previous cardiology evaluation. She currently lives a more sedentary lifestyle and does not note any significant limitations. She denies symptoms of palpitations or chest pain.

Echocardiographic examination at this time demonstrates severe LVOT obstruction with a mean gradient of 60 mm Hg. There is mild aortic valve regurgitation and moderate mitral valve regurgitation. The anterior leaflet of the mitral valve is markedly thickened and, during systole portions of the anterior leaflet, appears to obstruct the left ventricular outflow tract (Fig. 2.2).

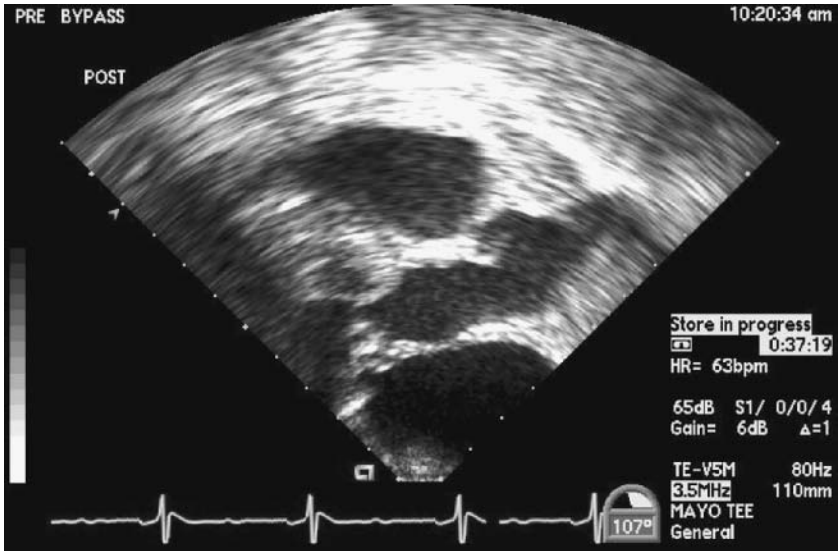


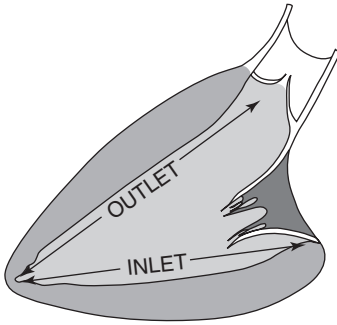
Fig. 2.2 Intraoperative transesophageal echocardiogram performed prior to cardiopulmonary bypass from a 58-year-old woman with a history of repair of partial AVSD and now with LVOT obstruction due to a combination of septal hypertrophy and redundant accessory mitral attachments.

Case discussion

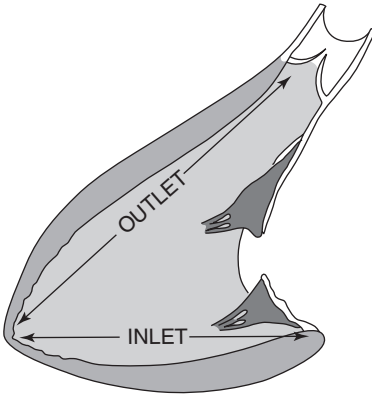
Progressive LVOT obstruction occurs in up to 15% of patients after repair of partial AVSD. It occurs more frequently in patients with the “partial” form of AVSD than in patients with the “complete” form. Several factors contribute to this anatomic substrate. The LVOT in AVSD is more elongated than in normal hearts, displaying the so-called “gooseneck deformity.” In these hearts, the distance from the aortic valve to the cardiac apex is longer than the distance from the mitral valve to the apex (in normal hearts, these distances are roughly equal; Fig. 2.3). In addition, subaortic membranes and ridges may develop de novo in this area. Accessory mitral valve tissue can also contribute to subaortic obstruction. The papillary muscle positions may be rotated anteriorly in AVSD, contributing to outflow obstruction. For these reasons, after “reparative” surgery, these patients require meticulous and lifelong surveillance for development/progression of LVOT obstruction as well as development of aortic valve regurgitation and progression of mitral valve regurgitation.

NOMENCLATURE (synonyms):

- Atrioventricular Septal Defects (AVSD)
- Atrioventricular Canal Defects (AV Canal)
- Endocardial Cushion Defects



NORMAL



ATRIOVENTRICULAR SEPTAL DEFECT

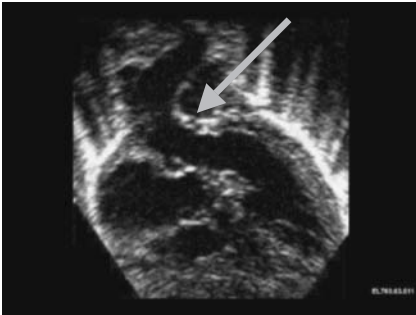
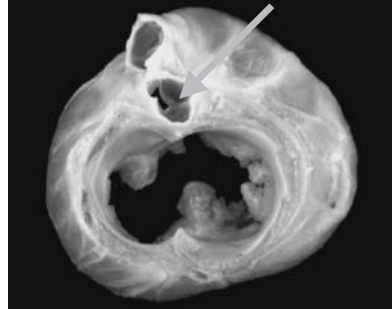

Fig. 2.3 (Diagrams) In the normal heart, the distance from the apex to the aortic annulus and the distance from the apex to the mitral annulus are roughly equal. In contrast, in patients with AVSD, the distance from the apex to the aortic annulus is greater than the distance from the apex to the mitral annulus. (With permission from Robert Anderson, MD) This occurs because the aortic valve is “sprung” anteriorly. (Right) Pathologic specimen demonstrating the anteriorly displaced aortic valve (arrow) in complete AVSD. (Bottom) Two-dimensional echocardiograph from a subcostal frontal projection demonstrating the elongated LVOT “gooseneck.”

FORMS OF AVSD:

- **Complete:**
 - Common AV valve + large primum ASD + large inlet ventricular septal defect (VSD)
- **Partial:**
 - **Primum ASD + cleft anterior leaflet of the mitral valve**

This group of lesions will be referred to in this chapter as “atrioventricular septal defects” (AVSDs). AVSDs are anomalies that have a defect of the atrioventricular septum and a variety of abnormalities of the atrioventricular valves. AVSDs are divided into “partial” and “complete” forms. In “partial” AVSD, a primum ASD is always present and there are two distinct mitral and tricuspid valve annuli. The mitral valve is always cleft. In “complete” AVSD, a primum ASD is contiguous with an inlet ventricular septal defect (VSD) and a common atrioventricular valve has a single annulus. Several other subclassifications have been used to describe AVSDs. “Transitional” AVSD is a subtype of partial AVSD. This term is used when a partial AVSD also has a small inlet VSD that is partially occluded by dense chordal attachments to the ventricular septum. “Intermediate” AVSD is a subtype of complete AVSD that has distinct right and left atrioventricular valve orifices despite having only one common annulus. These separate orifices are referred to as “right” and “left” atrioventricular valve orifices rather than “tricuspid” and “mitral.” This description is also used after repair of complete AVSD. Rather than relying on the terminology of these subtypes, the clinician, echocardiographer, and surgeon should communicate by simply describing the anatomy and shunting observed (Fig. 2.4) [1]. Two-dimensional echocardiography is the primary imaging technique for diagnosis of AVSD [2–4]. It is particularly useful for delineating the morphology of the atrioventricular valves.

Partial AVSD**Pathology**

In partial AVSD, the mitral and tricuspid annuli are separate. The most frequent form of partial AVSD consists of a primum ASD and a cleft anterior mitral valve leaflet. Most primum ASDs are large and located anteroinferior to the fossa ovalis. The defect is bordered by a crescentic rim of atrial septal tissue posterosuperiorly and by mitral–tricuspid valvular continuity anteroinferiorly.

The mitral and tricuspid valves achieve the same septal insertion level because the mitral annulus is displaced toward the apex. The defect imparts a “scooped-out” appearance to the inlet ventricular septum, and the distance from the mitral annulus to the left ventricular apex is less than the distance from the aortic annulus to the apex (Fig. 2.3).

The cleft in the anterior mitral leaflet is usually directed toward the mid-portion of the ventricular septum, along the anteroinferior rim of the septal

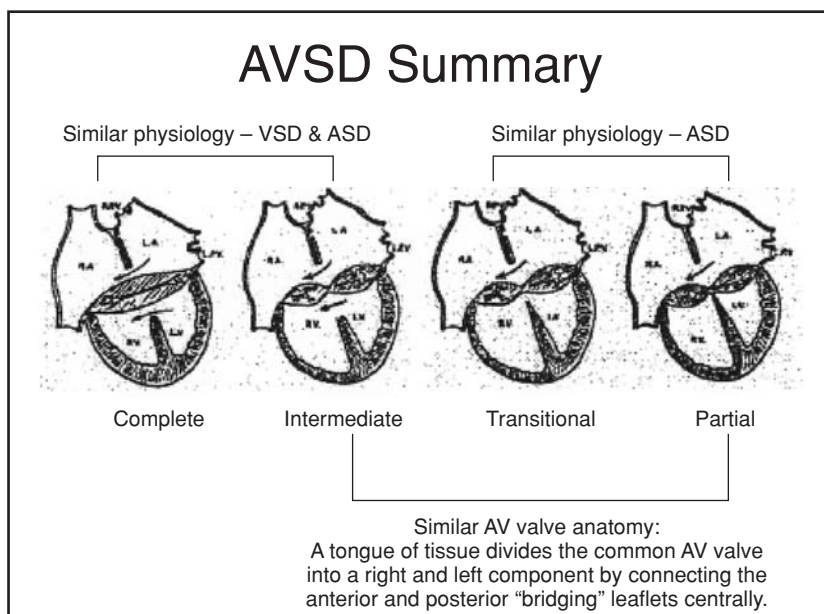


Fig. 2.4 Diagram depicting the physiologic and anatomic similarities and differences of the different forms of AVSD.

defect (Fig. 2.5). In contrast, isolated mitral clefts (not otherwise associated with AVSD) are directed toward the aortic valve annulus [5]. The mitral orifice is triangular, rather than elliptical as in a normal heart, and resembles a mirror-image tricuspid orifice. The cleft mitral valve usually is regurgitant and, with time, becomes thickened and exhibits secondary hemodynamic alterations in morphology that resemble mitral valve prolapse.

Clinical presentation

The child with partial AVSD is usually asymptomatic. Frequently, the lesion is detected at a young age because of a murmur. In the current era, the primum ASD is closed and the cleft in the mitral valve is addressed usually by 2 years of age. Surgical intervention in a very young child may be suboptimal if the cleft cannot be adequately closed without creating hemodynamically important mitral stenosis. If the patient with partial AVSD escapes diagnosis in childhood, then presentation in adulthood occurs due to symptoms of exercise intolerance, dyspnea on exertion, or palpitations from a new atrial arrhythmia. The patients may exhibit the typical physical exam findings of an ASD (systolic ejection murmur at the left upper sternal border, a widely split and fixed second heart sound, and a diastolic rumble along the lower left sternal border from increased flow

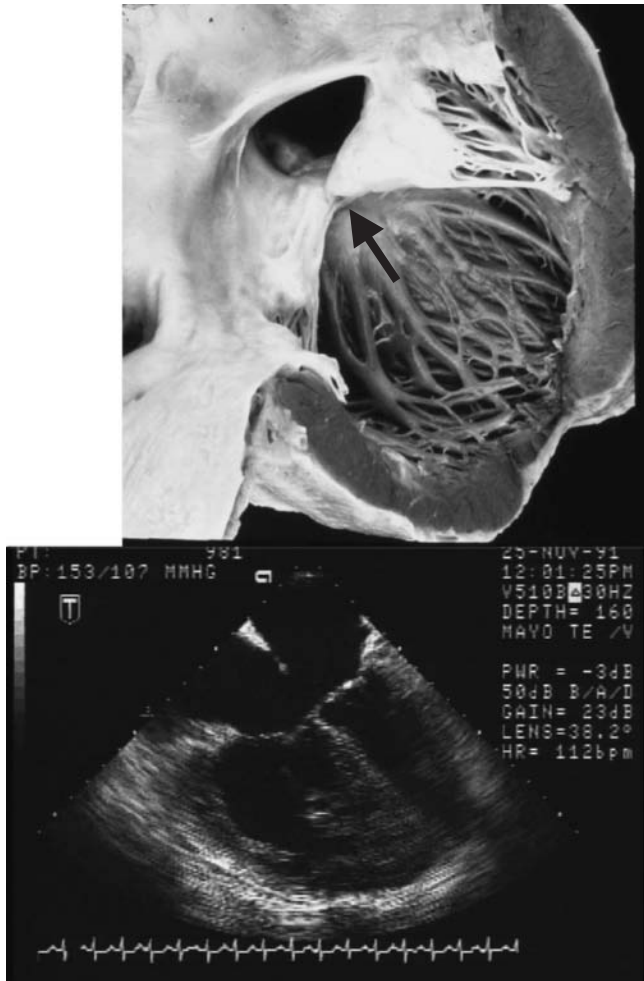

Fig. 2.5 (Top) Pathologic specimen demonstrating a cleft (arrow) in the anterior mitral leaflet. (Bottom) Intraoperative transesophageal echocardiogram demonstrating a large primum ASD in partial AVSD.

across the tricuspid valve). The diagnosis may also be serendipitous when a chest x-ray demonstrates cardiomegaly, an electrocardiogram demonstrates left axis deviation, or an echocardiogram is performed. A murmur of mitral regurgitation (due to the cleft anterior leaflet) may also prompt echocardiographic evaluation. Rarely, mitral stenosis will develop in an adult with unrepaired partial AVSD. These patients usually have a single left ventricular papillary muscle.

Once detected, repair of partial AVSD is typically recommended due to volume overload of the right-sided chambers caused by the left-to-right shunt at atrial level. In addition, closure of the mitral cleft is indicated to hopefully halt progression of mitral regurgitation. Echocardiography performed in an imaging laboratory experienced with children and adults with congenital heart is preferred. Electrocardiography will demonstrate left axis deviation in at least two-thirds of patients. Chest radiographs may demonstrate cardiomegaly with increased pulmonary vascularity. The role of cardiac catheterization is limited to adult patients if concern exists that pulmonary vascular resistance is elevated. Typically, one would prefer pulmonary arteriolar resistance to be less than 6 units (m^2) to consider safe repair. If baseline resistance is elevated above this value but reactivity with provocative testing in the catheterization laboratory is demonstrated, then cautious postoperative care including use of nitric oxide may be indicated. In patients age 40 years and older, noninvasive assessment for coronary artery disease is typically performed prior to surgery for the congenital cardiac defect. Coronary angiography may also be performed if these patients are having hemodynamic catheterization performed. Primum ASDs are not amenable to closure with transcatheter devices.

Echocardiographic evaluation of partial AVSD

Echocardiographic evaluation of a patient with partial AVSD needs to include assessment of right atrial and right ventricular sizes. Volume overload will produce right atrial and right ventricular dilation early in childhood. Right ventricular volume estimation should be made from multiple imaging planes due to the inherent flaws in this assessment. The finding of ventricular septal flattening is useful for assessment of right ventricular volume overload; however, its utility in prediction of right ventricular pressure in this clinical setting has been questioned [6].

The internal cardiac crux is the most consistent echocardiographic imaging landmark, typically imaged in the apical four-chamber imaging plane. The primum ASD is seen as an absence of the lower atrial septum. The size of the primum ASD is made reliably from this imaging position (Fig. 2.5). Accurate visualization of the cardiac crux also permits assessment of the atrioventricular valves. Several two-dimensional echocardiographic features are shared by all forms of AVSD: deficiency of a portion of the inlet ventricular septum, inferior displacement of the atrioventricular valves, and attachment of a portion of the left atrioventricular (mitral) valve to the septum. The atrioventricular valves are displaced toward the ventricles, with the septal portions inserting at the same level onto the crest of the ventricular septum. Therefore, in these defects, the two separate atrioventricular valve orifices are equidistant from the cardiac apex (Fig. 2.6).

Spectral and color flow Doppler hemodynamic assessment are useful to determine the severity of atrioventricular valve stenosis or regurgitation, and to

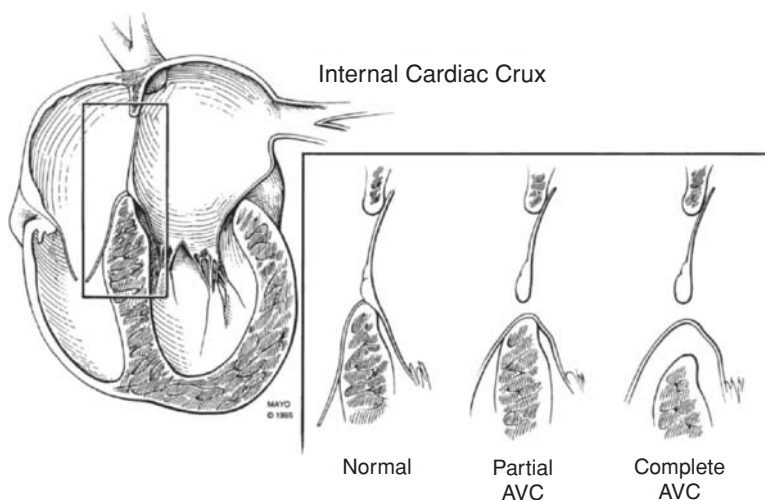


Fig. 2.6 Diagram depicting the normal inferior displacement of the septal leaflet of the tricuspid valve relative to the insertion point of the anterior mitral leaflet as compared with the relationship of the atrioventricular valves in AVSDs.

quantitate right ventricular systolic pressure. Doppler echocardiography is not reliable for evaluating mitral stenosis in the setting of a primum ASD because a large interatrial communication will decompress pressure from the left atrium.

Other mitral valve abnormalities are typical with both the partial and complete forms of AVSD [1]. The most common abnormality, a cleft, is best visualized from the parasternal and subcostal short axis imaging planes. Rarely, a parachute or a double-orifice mitral valve also occurs.

Associated anomalies

The most common associated anomalies with partial AVSD are a secundum ASD and persistence of a left superior vena cava connecting to the coronary sinus. Less frequently, tetralogy of Fallot, double-outlet right ventricle, pulmonary valve atresia, and anomalous pulmonary venous connections are associated with complete AVSD but are less frequent with partial defects. In contrast, atrioventricular valve abnormalities and left ventricular hypoplasia are more frequent in two orifice atrioventricular connections. Coarctation of the aorta occurs with equal frequency in partial and complete AVSD [7–9].

Surgical treatment of partial AVSD

The objectives of surgical repair include closure of the interatrial communication and restoration and preservation of mitral valve competence (Fig. 2.7).

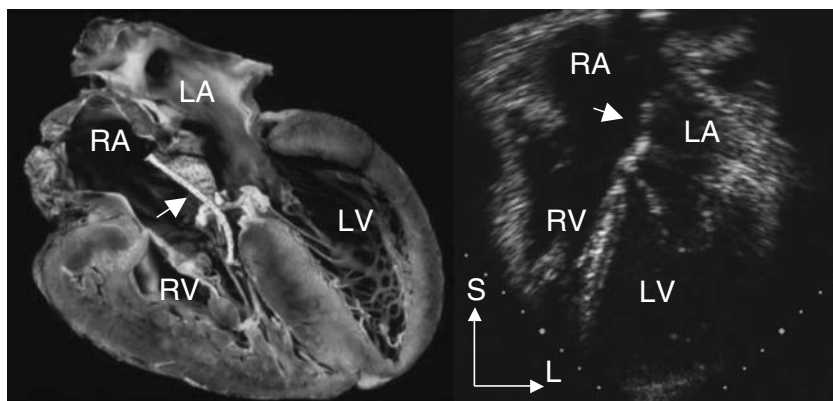


Fig. 2.7 (Left) Pathology specimen of a heart with patch (arrow) closure of a primum ASD. In addition, the anterior leaflet of the mitral valve is thickened in the region of the cleft repair. (Right) Corresponding apical four-chamber echocardiograph.

These objectives can be accomplished by careful approximation of the edges of the valve cleft [10]. This repair results in a two-leaflet valve. In an alternative technique, the left atrioventricular valve is considered a trileaflet valve, considering the cleft as a commissure. With this approach, the cleft remains unsutured and various annuloplastic sutures are placed to enable coaptation [11–13]. Long-term survival after surgical repair in childhood has been excellent, and cumulative 20-year survival of 95% has been reported. In 1995, the Mayo Clinic group reported a 6% early mortality for patients with partial AVSD who had surgical repair after 40 years of age [14]. Long-term issues in this group were uncommon, but continued surveillance is warranted for late arrhythmia. Postoperative echocardiographic surveillance is indicated at least every few years after surgery. Reoperation awaits at least 25% of patients due to progressive mitral valve regurgitation or development of left ventricular out-flow tract obstruction [15].

Complete atrioventricular septal defect

Pathology

The complete form of AVSD is characterized by a large septal defect with interatrial and interventricular components and a common atrioventricular valve that spans the entire septal defect [16]. The septal defect extends to the level of the membranous ventricular septum, which is usually deficient or absent.

The common atrioventricular valve has five leaflets (a posterior bridging leaflet drapes over the inlet ventricular septum, two lateral leaflets, a right-sided anterior leaflet, and the so-called anterior bridging leaflet). The extent to which

the anterior bridging leaflet actually straddles into the right ventricle varies considerably and has formed the basis for a classification system of complete AVSD into Rastelli types A, B, and C [17]. In the modern era, its clinical and surgical significance has become less important. The common atrioventricular valve may be divided into distinct right and left orifices by a tongue of tissue that connects the two bridging leaflets, representing the “intermediate” form of AVSD.

Clinical presentation of complete AVSD

The child with complete AVSD typically presents with a loud systolic ejection murmur or failure to thrive. This defect may have been detected during prenatal ultrasound screening due to the markedly abnormal apical four-chamber image. A child born with Down syndrome should have echocardiographic screening in the newborn period. Children with Down syndrome have a 40% incidence of congenital heart disease, and approximately 40% of these children will have an AVSD. Chest radiographs typically demonstrate cardiomegaly and increased pulmonary vascularity consistent with the large left-to-right shunt. Electrocardiographs typically demonstrate a superior frontal plane axis (extreme left-axis deviation) and voltage criteria for ventricular hypertrophy.

Children with complete AVSD usually have surgical repair at 3–6 months of age, depending on issues with growth and development. Children with Down syndrome may have persistent pulmonary hypertension despite early repair. Similarly, patients with complete AVSD who are not repaired in the first 9 months of life are likely to have persistent pulmonary hypertension.

Patients with complete AVSD followed in an adult congenital heart disease clinic typically had repair of the lesion in early childhood and require continued meticulous surveillance for development of hemodynamically important left AV valve regurgitation or stenosis. Some of the patients may require reoperation in adulthood. The left AV valve is frequently replaced, but the surgery should be performed by a congenital cardiac surgeon with expertise in the care of children and adults with congenital heart disease. The patient stands a better chance of having successful re-repair and preservation of the native left AV valve with an experienced congenital heart disease surgeon.

Currently, another group of patients with complete AVSD followed in adult congenital heart clinics are those who did not benefit from repair in childhood. Although born with a large left-to-right shunt, they developed irreversible pulmonary vascular obstructive disease and have Eisenmenger physiology as adults. Patients with pulmonary hypertension can be treated with pulmonary vasoactive agents, such as sildenafil, bosentan, or flolan, and subjective improvement in symptoms may occur. These patients also suffer from progressive left and right AV valve regurgitation as well as progressive biventricular systolic dysfunction. Survival for this subgroup of patients beyond the fifth decade has been reported but is rare. These patients require management

of secondary erythrocytosis, urate nephropathy, hemoptysis, thromboembolic events, and usually succumb from arrhythmia. Consideration of these patients for heart–lung transplantation is controversial.

Echocardiographic assessment of complete AVSD

Two-dimensional echocardiography is the primary diagnostic tool for evaluation of complete AVSDs [18,19]. As described earlier, assessment of the internal cardiac crux from the apical and subcostal four-chamber projections provides excellent detail of the size and locations of defects in both the atrial and ventricular septa. Additional secundum ASDs, a fairly common associated finding, can be detected from the subcostal four-chamber coronal view and with clockwise rotation of the transducer from the subcostal sagittal imaging plane. The VSD is located posteriorly in the inlet septum. Both right-sided and left-sided components of the common atrioventricular valve are displaced toward the ventricles and are associated with variable deficiency of the inflow ventricular septum. Spectral and color Doppler serve as adjuncts to assess the sites of shunting, severity of atrioventricular valve regurgitation, and connections of the pulmonary veins. Anomalous pulmonary venous connections are rarely associated with complete AVSDs and can be assessed with two-dimensional and two-dimensional Doppler echocardiography from multiple imaging planes.

Other atrioventricular valve abnormalities

Double-orifice left atrioventricular valve occurs rarely in AVSDs. This abnormality occurs usually when two distinct right and left atrioventricular valve orifices are present. The combined effective valve area of a double-orifice valve is always less than the valve area of a single-orifice valve. This predisposes the valve to postoperative stenosis. Standard subcostal and parasternal short axis views usually demonstrate the double-orifice valve characteristics.

Another rare association with complete AVSD is a single left ventricular papillary muscle. Similar to the double-orifice valve, a single papillary muscle will reduce the effective valve area. In patients with a single left ventricular papillary muscle, valve repair may be compromised due to relative leaflet hypoplasia. Echocardiographic imaging techniques for this abnormality are similar to those for double-orifice left atrioventricular valves.

The term “unbalanced AVSD” has been applied when one ventricle and its corresponding atrioventricular valve are hypoplastic while the other ventricle receives the larger portion of the common atrioventricular valve. In this circumstance, the most common arrangement is a dominant right ventricle with a hypoplastic left ventricle. The left-sided component of the common atrioventricular valve may be stenotic after two-ventricle repair has been performed. Depending on the size of the diminutive ventricle, some of these patients may be best managed with a surgical strategy designed for patients with functional single-ventricle physiology. This would ultimately result in a Fontan operation [1].

Surgical repair of complete AVSD

The objectives of surgical repair include closure of interatrial and interventricular communications, construction of two separate and competent atrioventricular valves from available leaflet tissue, and repair of associated defects. Techniques for the surgical repair of complete AVSD have been standardized and are based on the use of a single patch or double patch (separate atrial and ventricular patches) to close the ASD and VSD and then reconstruction of the left atrioventricular valve as a bileaflet valve. Puga and McGoon have described these techniques in detail [20].

In contrast, other groups [12,21] consider the cleft of the left atrioventricular valve a true commissure and envision this valve as a trileaflet valve. On the basis of these concepts, Carpentier [11] prefers the two-patch technique. The left atrioventricular valve remains a trileaflet structure. In most centers, the two-patch technique has become the method of choice.

Clinical evaluation after repair of AVSD

Over the last four decades, surgical repair of AVSD has been one of the success stories in congenital heart disease. However, as with most congenital cardiac lesions, these patients require lifelong cardiology surveillance at centers that specialize in the care of adults with congenital heart disease. Patients who are doing well after repair of AVSD are typically seen every 2–3 years and have electrocardiographic and echocardiographic testing performed. Exercise treadmill testing is useful to periodically obtain objective evidence of patient fitness. Many of these patients are able to participate fully in sports activities. Pregnancy results for women with AVSD have been good [22,23], although a recent review indicated that atrial arrhythmia may complicate as many as 10% of pregnancies in women with AVSD [24]. It is generally recommended that women with unrepaired AVSD undergo repair prior to contemplating pregnancy, but in women with partial AVSD, pregnancy is usually well tolerated. Pregnancy is contraindicated in women with unrepaired AVSD who have Eisenmenger physiology.

Rarely, these patients will have hemodynamically significant residual shunts after surgery. These shunts are typically not amenable to closure with commercially available closure devices due to the proximity of the atrioventricular valves. If a patient with history of AVSD repair requires repeat surgery for atrioventricular valve surgery or relief of LVOT obstruction, this is best managed by a surgeon skilled in the care of children and adults with congenital heart disease.

Patient follow-up

Both of these cases illustrate a common consequence of repair of AVSD. In the first case, the patient was a small child at the time of the initial repair, and it is not surprising that residual LVOT obstruction developed once she was fully grown. The second case is illustrative of the fact that, even in an adult, progressive LVOT obstruction may

occur after “successful” repair of partial AVSD. The surgical approach to both patients differed due to the etiology of the obstruction.

Case #1

This patient underwent repeat cardiac surgery for excision of the accessory mitral valve tissue. The mitral valve remained intact and competent. There was no change in the severity of mitral regurgitation as compared with her preoperative echocardiogram. Two years after that surgery, her echocardiogram demonstrated no residual LVOT obstruction, no aortic valve regurgitation, and only mild mitral valve regurgitation. She remained active and is currently a college student participating in intramural athletics.

Case #2

The cardiologist and congenital cardiac surgeon who cared for the patient believed that the abnormal morphology of the mitral valve was contributing to the LVOT obstruction, and it was anticipated that she would require mitral valve replacement with a mechanical prosthesis. However, at the time of surgery, an extended septal myectomy/myotomy was performed; in addition, fibrous tissue was peeled from the ventricular surface of the mitral valve (Fig. 2.8). The native mitral valve was preserved, and the patient left the operating room with no residual LVOT obstruction and only mild mitral regurgitation.

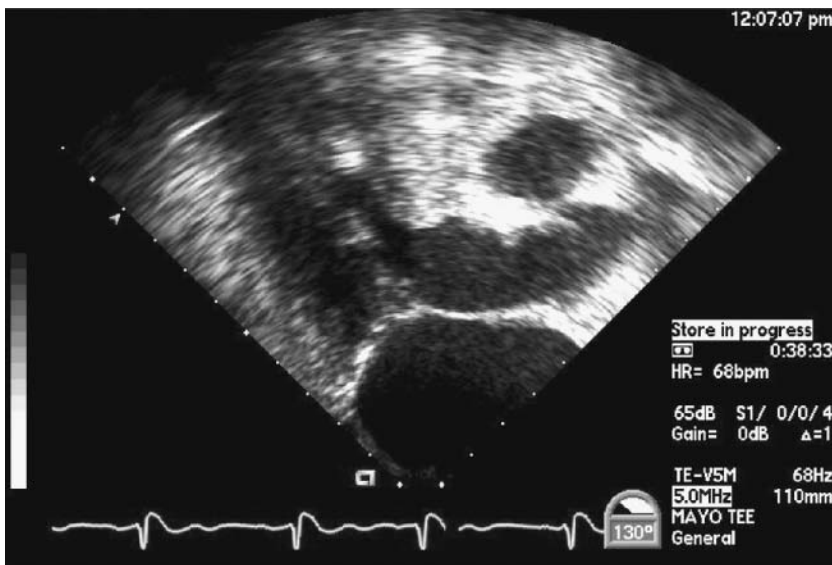


Fig. 2.8 A similar image to Fig. 2.2 from the same patient after septal myectomy/myotomy and peeling of fibrous tissue from the undersurface of the anterior mitral leaflet. This image demonstrates no residual obstruction. The patient’s mitral valve was preserved and she has only mild residual regurgitation.

References

1. Cetta F, Minich LL, Edwards WD, Dearani JA, Puga FJ. Atrioventricular septal defects. In: Allen HD, Shaddy RE, Driscoll DJ, Feltes TF, eds. *Heart Disease in Infants, Children, and Adolescents*. Philadelphia: Lippincott Williams and Wilkins, 2007:646–67.
2. Seward JB, Tajik AJ, Hagler DJ. Two-dimensional echocardiographic features of atrioventricular canal defect. In: Lundström N-R, ed. *Pediatric Echocardiography: Cross Sectional, M-Mode and Doppler*. New York: Elsevier/North Holland, 1980:197–206.
3. Silverman NH, Ho SY, Anderson RH, et al. Atrioventricular septal defect with intact atrial and ventricular septal structures. *Int J Cardiol* 1984;5:567–72.
4. Snider RA, Serwer GA, Ritter SB, eds. Defects in cardiac septation. In: *Echocardiography in Pediatric Heart Disease*, 2nd edition. St. Louis: Mosby-Year Book, 1997:277–89.
5. di Segni E, Edwards JE. Cleft anterior leaflet of the mitral valve with intact septa: a study of 20 cases. *Am J Cardiol* 1983;51:919–26.
6. Nielsen JC, Kamenir SA, Ko HSH, Lai WW, Parness IA. Ventricular septal flattening at end systole falsely predicts right ventricular hypertension in patients with ostium primum atrial septal defects. *J Am Soc Echocardiogr* 2002;15:247–52.
7. Goel AK, Ganesan L, Edelstein M. Atrioventricular septal defect with cor triatriatum: case report and review of the literature. *Pediatr Cardiol* 1998;19:243–5.
8. LaCorte MA, Cooper RS, Kauffman SL, et al. Atrioventricular canal ventricular septal defect with cleft mitral valve: angiographic and echocardiographic features. *Pediatr Cardiol* 1982;2:289–95.
9. Silverman NH, Ho SY, Anderson RH, et al. Atrioventricular septal defect with intact atrial and ventricular septal structures. *Int J Cardiol* 1984;5:567–72.
10. Thiene G, Wenink ACG, Frescura C, et al. Surgical anatomy and pathology of the conduction tissues in atrioventricular defects. *J Thorac Cardiovasc Surg* 1981;82: 928–37.
11. Carpentier A. Surgical anatomy and management of the mitral component of atrioventricular canal defects. In: Anderson RH, Shinebourne EA, eds. *Paediatric Cardiology*. Edinburgh: Churchill Livingstone, 1978:477–90.
12. Piccoli GP, Wilkinson JL, Macartney FJ, et al. Morphology and classification of complete atrioventricular defects. *Br Heart J* 1979;42:633–9.
13. Aubert S, Henaine R, Raïsky O, et al. Atypical forms of isolated partial atrioventricular septal defect increase the risk of initial valve replacement and reoperation. *Eur J Cardiothorac Surg* 2005;28:223–8.
14. Bergin ML, Warnes CA, Tajik AJ, Danielson GK. Partial atrioventricular canal defect: Long-term follow-up after initial repair in patients >40 years old. *J Am Coll Cardiol* 1995;25:1189–94.
15. McGrath LB, Gonzalez-Lavin L. Actuarial survival, freedom from reoperation, and other events after repair of atrioventricular septal defects. *J Thorac Cardiovasc Surg* 1987;94:582.
16. Titus JL, Rastelli GC. Anatomic features of persistent common atrioventricular canal. In: Feldt RH, McGoon DC, Ongley PA, et al., eds. *Atrioventricular Canal Defects*. Philadelphia: WB Saunders, 1976:13–35.
17. Rastelli GC, Kirklin JW, Titus JL. Anatomic observations on complete form of persistent common atrioventricular canal with special reference to atrioventricular valves. *Mayo Clin Proc* 1966;41:296–308.

18. Minich LL, Snider AR, Bove EL, et al. Echocardiographic evaluation of atrioventricular orifice anatomy in children with atrioventricular septal defect. *J Am Coll Cardiol* 1992;19:149–53.
19. Seward JB, Tajik AJ, Edwards WD, Hagler DJ, eds. Congenital heart disease. In: *Two-Dimensional Echocardiographic Atlas* (Vol. 1). New York: Springer-Verlag, 1987:284–9.
20. Puga FJ, McGoon DC. Surgical treatment of atrioventricular canal. *Mod Technics Surg* 1980;26:1–13.
21. Studer M, Blackstone EH, Kirklin JW, et al. Determinants of early and late results of repair of atrioventricular septal (canal) defects. *J Thorac Cardiovasc Surg* 1982;84:523–42.
22. Drenthen W, Pieper PG, van der Tuuk K, et al. Cardiac complications relating to pregnancy and recurrence of disease in the offspring of women with atrioventricular septal defects. *Eur Heart J* 2005;26:2581–7.
23. Zuber M, Gautschi N, Oechslin E, Widmer V, Kiowski W, Jenni R. Outcome of pregnancy in women with congenital shunt lesions. *Heart* 1999;81:271–5.
24. Drenthen W, Pieper PG, Roos-Hesselink JW, et al. Outcome of pregnancy in women with congenital heart disease. *J Am Coll Cardiol* 2007;49:2303–11.

Pulmonary stenosis/right ventricular outflow tract obstruction

Elyse Foster and Katy Lease

A 67-year-old man with a history of congenital valvular pulmonary stenosis had a history of surgical pulmonary valvotomy at age 14. He was referred for evaluation of a heart murmur, and also had a history of hypertension, hyperlipidemia, and diabetes mellitus type II. At the initial evaluation, he was feeling well, with no cardiac symptoms, but did not exercise regularly. He was able to climb two flights of stairs but did report tiring easily on longer distances. The physical exam revealed an absent P2 component of the second sound and a mid-peaking systolic murmur in the left parasternal region with no diastolic murmur but was otherwise normal. Electrocardiogram revealed right ventricular hypertrophy with incomplete right bundle branch block. Echocardiogram showed right ventricular hypertrophy (Fig. 3.1) with preserved right ventricular systolic function. The pulmonary valve appeared thickened and there was a peak gradient of 61 mm Hg across the valve in parasternal views. Subcostal views revealed a peak gradient of 89 mm Hg. There was an associated late-peaking dynamic gradient in the right ventricular outflow tract reaching 25 mm Hg (Fig. 3.2). The main pulmonary artery appeared to be significantly dilated.

Introduction

Pulmonary stenosis (PS) is almost always a congenitally acquired obstruction to right ventricular outflow. The site of right ventricular outflow obstruction can be valvular, subvalvular, or supra-valvular. Of the three types, valvular PS is by far the most common and accounts for approximately 10% of congenital heart defects [1]. The lesion may be associated with other congenital defects, but isolated PS will be the primary focus of this chapter. Among congenital

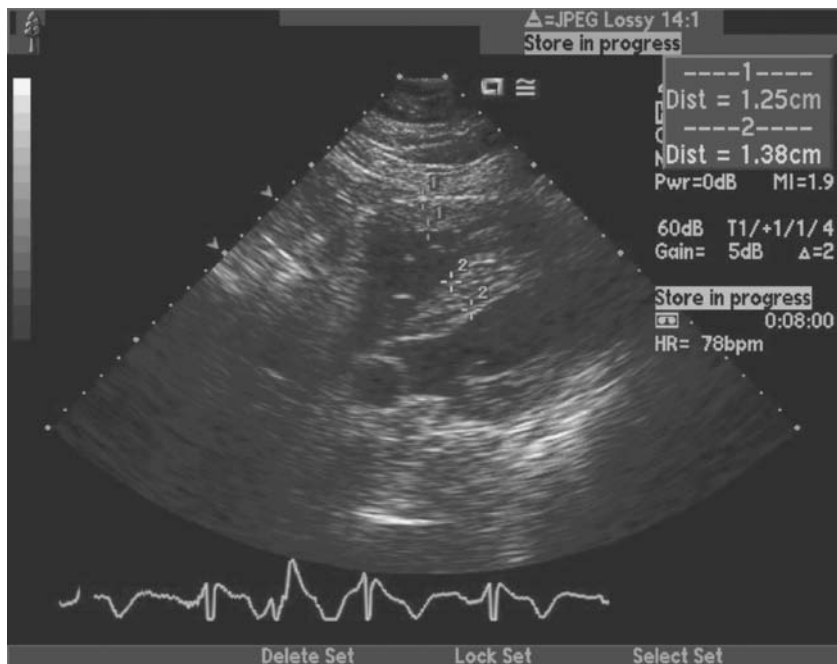


Fig. 3.1 Echocardiography reveals significant right ventricular hypertrophy in the subcostal view. (Courtesy of Dr. George Cohen.)

heart defects, PS is a disorder with a comparatively mild clinical course and an excellent prognosis. For this reason, it is a congenital heart condition that may present relatively late and may be first diagnosed in adulthood. Many patients will never require treatment, and those who do will often be successfully treated with percutaneous approaches.

Valvular pulmonary stenosis

Pathology

The pulmonary valve in valvular PS is usually trileaflet; however, fusion of the commissures leads to a narrowed central orifice. The valve leaflets remain thin and during systole display a doming appearance as they restrict right ventricular outflow of blood. Varying degrees of fibrous thickening of the leaflets may be seen; however, calcification is rare. Less commonly, the pulmonary valve leaflets are not fused but instead are myxomatous, dysplastic, and immobile, thereby restricting right ventricular outflow [1,2]. A bicuspid pulmonary valve is a very rare congenital etiology for PS. Finally, PS may be acquired in few

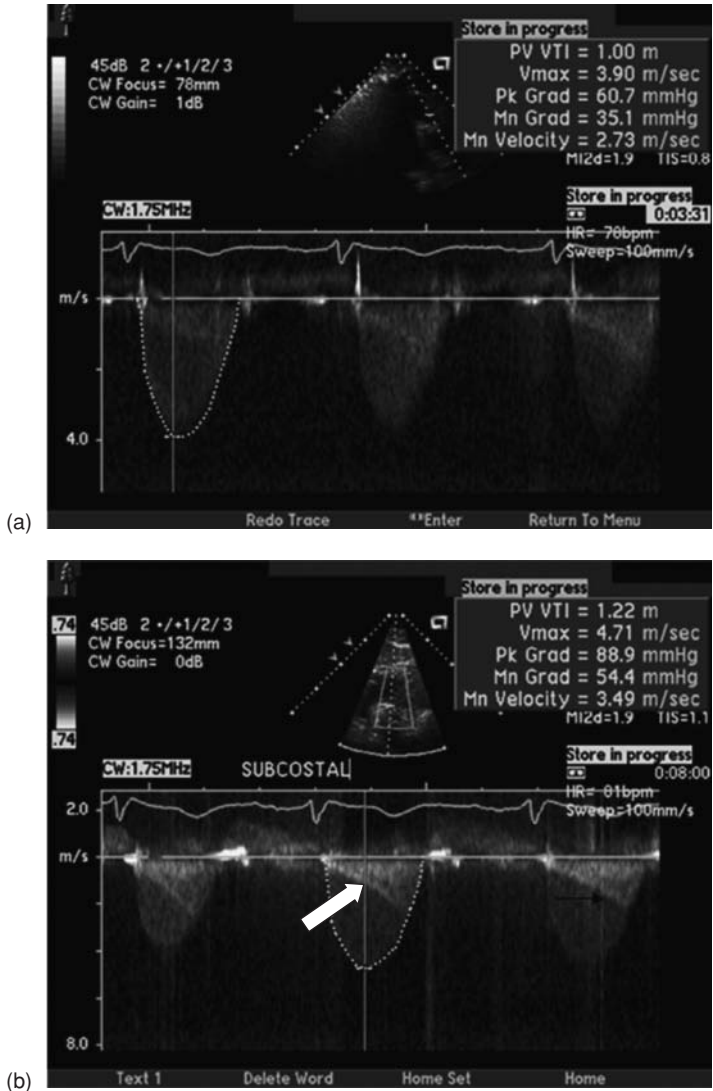


Fig. 3.2 (a) Continuous wave Doppler in the parasternal short axis view reveals a peak gradient across pulmonary valve of 61 mm Hg. (b) Imaging in subcostal plane reveal significantly higher Doppler gradient, measuring 89 mm Hg. Note superimposed late peaking gradient which measures 25 mm Hg (arrow), representing dynamic outflow obstruction due to infundibular hypertrophy. (Courtesy of Dr. George Cohen.)

cases of the uncommon condition, carcinoid syndrome, usually with associated involvement of the tricuspid valve.

Congenital PS may be seen in association with one of several inherited conditions. Noonan syndrome is a genetic condition with cardiac involvement in about half of cases. The most common cardiac malformation is PS, frequently of the dysplastic valve type. Williams syndrome and congenital rubella syndrome are other rare conditions usually associated with supra-avalvular PS.

Pathophysiology

The hemodynamic consequences of PS vary depending on the severity of the fixed stenosis. Transvalvular gradients can reach suprasystemic levels with a severe increase in right ventricular afterload. There is compensatory right ventricular hypertrophy. Secondary subvalvular stenosis due to infundibular hypertrophy may occur and result in a dynamic component of right ventricular outflow obstruction. Pulmonary arterial pressure remains normal or low in PS, due to decreased pulmonary blood flow in the face of obstruction. Anatomically, however, post-stenotic dilatation of the main and left pulmonary arteries is common in the doming form of valvular PS. This is likely due to a high-velocity jet of blood flow through a narrowed orifice, anatomically aimed more toward the left pulmonary artery. Interestingly, PS with a dysplastic pulmonary valve usually does not demonstrate this post-stenotic dilatation of the pulmonary artery.

Clinical features

Patients with PS are often asymptomatic, even when stenosis is severe. Thus, it is a congenital lesion that is relatively frequently detected in adults. In infancy, the condition is usually detected when a characteristic murmur is heard on physical examination. Similarly, in adulthood, the diagnosis may be made after an incidental detection of a murmur or increased transvalvular gradient on echocardiography. When PS is critical, patients most commonly present with dyspnea, or, less commonly, arrhythmia, chest pain, or syncope may be the presenting symptom. Chest pain may be due to right ventricular ischemia in the setting of hypertrophied myocardium. Other symptoms are generally felt to be due to the inability to augment right ventricular output.

The physical examination in PS is notable for a crescendo–decrescendo ejection murmur heard best in the second intercostal space. As in aortic stenosis, the shape of the murmur changes with severity of the valvular lesion. As severity increases, the murmur peaks later in systole and extends in length such that, in the most severe cases, the murmur extends beyond the aortic component of the second heart sound. Another characteristic finding on auscultation is a high-pitched ejection click heard after the first heart sound (S1). With milder stenosis, the click occurs later following S1, whereas in severe PS, the click occurs earlier and may merge with S1. Unlike other right-sided heart sounds, the ejection

click in PS decreases in intensity with inspiration. This respiratory decrease in intensity as well as the location of the click helps distinguish it from an aortic valve ejection click. Additionally, as severity of PS increases, the splitting of the second heart sound gets wider, and, in some severe cases, the P2 component may decrease in intensity and even become inaudible [3]. The jugular venous pulsation usually shows a prominent “a” wave that reflects increased atrial pressure as the right atrium contracts to fill the noncompliant right ventricle.

In addition to the physical exam, diagnostic studies can help determine severity of PS. The electrocardiogram may be normal but often displays evidence of right ventricular hypertrophy, right axis deviation, and right atrial enlargement. The height of the R wave in V1 has been shown to correlate with severity of PS [1,2].

Echocardiography can characterize the location, morphology, and severity of obstruction. The basal parasternal short-axis plane is typically the best two-dimensional echocardiographic view to image the pulmonic valve and right ventricular outflow tract (Fig. 3.3). If imaging is inadequate in this plane, the sub-costal short axis is an additional view that is often useful. Doppler echocardiography allows for measurement of the PS gradient using the modified Bernoulli equation. Continuous wave Doppler is useful to obtain the peak instantaneous

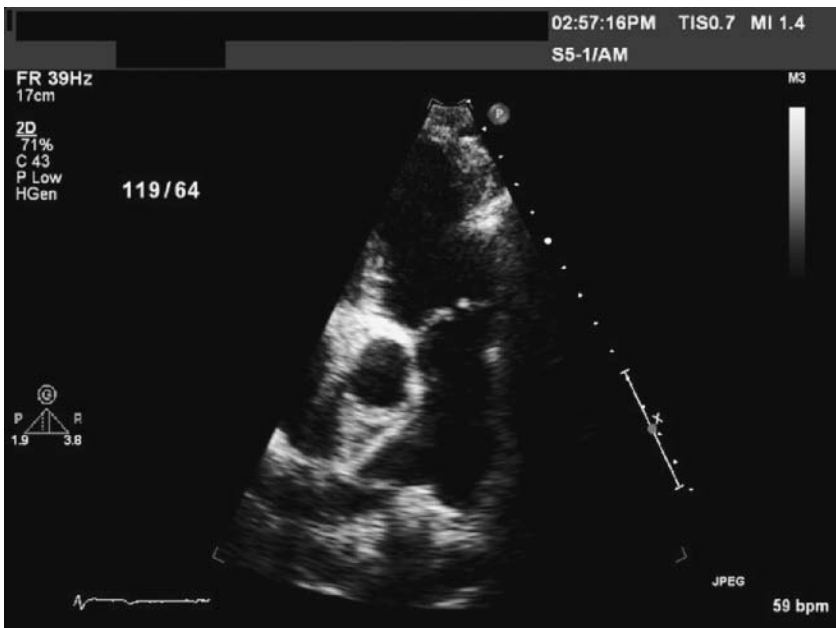

Fig. 3.3 Thickened pulmonary valve leaflets seen by echocardiography in parasternal short-axis view of right ventricular outflow tract.

gradient. Color and pulsed wave Doppler are helpful to locate the site of obstruction and thereby distinguish valvular PS from subvalvular or supra-valvular PS. Morphologic features such as doming of the pulmonary valve may be seen in most common types of valvular PS. In addition, post-stenotic dilatation of the pulmonary artery can often be appreciated [4]. Myxomatous, fused valve leaflets are seen in the less common dysplastic form of PS, and, in this disorder, the main pulmonary artery is not dilated. A challenge for the echocardiographer is to measure the severity of subvalvular dynamic obstruction that often accompanies valvular PS, due to secondary infundibular hypertrophy, which is characterized by a late-peaking jet similar to that of dynamic left ventricular outflow tract obstruction. Subcostal views often provide more accurate measurement due to optimal alignment of the Doppler with the high-velocity jet of flow across the pulmonary valve.

Cardiac magnetic resonance (CMR) imaging is an adjunctive imaging modality that may be useful in certain cases of PS. CMR provides detailed imaging of the right ventricle and outflow tract, offering an additional method to identify the site of obstruction. This can be especially useful when valvular PS is accompanied by, or to be distinguished from, subvalvular obstruction, such as in the case of hypertrophied muscle bands or supra-valvular obstruction, such as branch pulmonary artery stenosis. Additionally, CMR provides a method to quantify right ventricular size and function, which are notoriously more difficult to assess by conventional two-dimensional echocardiography [5].

Cardiac catheterization is an alternative, albeit invasive, method to assess severity of PS. However, due to the accuracy of Doppler echocardiography, diagnostic catheterization is reserved for the unusual cases where severity remains uncertain. Catheterization should be performed in combination with an interventional procedure to relieve the stenosis: percutaneous valvuloplasty. Pressure tracings at the time of catheterization may reveal right ventricular systolic pressure that approaches or exceeds left ventricular pressure as well as an enhanced "a" wave on the right atrial recording in severe PS. Angiography is performed in a straight lateral or anteroposterior view, demonstrating a stenotic valve orifice and often a hypertrophied right ventricular outflow tract [6].

Therapeutic approach

Prior to the 1980s, surgical valvotomy was the preferred therapy for patients with PS. The surgical approach may include simple valve commissurotomy or a more complex reconstruction of the right ventricular outflow tract with or without graft material. A pulmonary valve replacement may be required for a dysplastic pulmonary valve.

In 1982, percutaneous balloon valvuloplasty was described for PS in children [7] and in adults [8]. Because of excellent results, this has become the preferred method of treatment in both age groups. The technique most commonly described involves usage of the Inoue balloon, a short and flexible balloon used

to minimize trauma to the right ventricular outflow tract, with short inflation times to minimize hemodynamic compromise [9–12]. Double balloon [13–16] and even triple balloon [17] techniques have been described when annulus size is large, as in adults. In general, the balloon size used is slightly larger than the pulmonary annulus diameter.

Prognosis

Multiple studies have shown that the prognosis of PS is excellent. The largest body of evidence regarding outcomes in PS is the Second Natural History Study of Congenital Heart Defects. This study followed clinical outcomes in 592 patients with valvular PS who were originally enrolled in the First Natural History Study of Congenital Heart Defects from 1958 to 1969. The data on all patients with PS suggest that overall 25-year survival is similar to that of the general population. In the study, most patients with peak gradients greater than 80 mm Hg received surgical therapy, most patients with peak gradients less than 25 mm Hg received no intervention, and those with gradients between 25 mm Hg and 80 mm Hg received either surgical or no therapy. Results of the study suggest that, if the peak gradient is less than 25 mm Hg, the likelihood of needing an operative repair is essentially nil, whereas patients with gradients of 25–49 mm Hg have a 20% chance of needing repair eventually. Patients with peak gradients of greater than 50 mm Hg will usually need repair at some point. Regardless of severity of disease and whether the patients were treated medically or surgically, patients were usually asymptomatic at follow-up [18]. When exercise tolerance on a Bruce protocol was examined at follow-up, patients with PS performed at a near normal level, with mean exercise duration of 94% predicted [19]. Patient quality of life was assessed and was deemed comparable to that of the general population [20]. The rate of bacterial endocarditis in both medically and surgically treated patients was exceedingly low [21]. On continuous electrocardiographic monitoring, there was an increased incidence of both ventricular and supraventricular ectopy compared with normals; however, no increased incidence in ventricular tachycardia was detected [22].

Additional follow-up studies of patients who received surgical valvotomy as children agree that outcomes are excellent with very low mortality. After 10 years of follow-up, re-intervention rates are low, from 3% to 4% [6,23]. Longer follow-up studies, however, suggest that there is a higher re-intervention rate after 20–30 years, ranging from 15–53%, with the most common indication being pulmonary valve regurgitation [24,25]. Thus, in adult patients who have had prior surgical pulmonary valvotomy, any atrial or ventricular arrhythmia, exercise intolerance, or cardiomegaly on chest x-ray should prompt the search for pulmonary regurgitation. Pulmonary valve replacement should be undertaken before there is any significant reduction in right ventricular systolic function.

During the 1980s, percutaneous valvuloplasty became more readily employed as a therapy for PS, and prognosis has been shown to be equally

Table 3.1 Follow-up studies after balloon pulmonary valvuloplasty involving primarily adults with at least eight subjects.

Author	No. patients	Age range (mean)	Δ Gradient in mm Hg (pre \rightarrow post)	Gradient at follow-up in mm Hg	Length of follow-up (mean)
Al Kasab et al. [26]	21	15–37 (24)	93 \rightarrow 26	23	12–26 months (17 months)
Sievert et al. [27]	24	17–72 (39)	92 \rightarrow 43	33	3 months to 3 years
Herrmann et al. [28]	8	23–66 (40)	62 \rightarrow 20	20	(24 months)
Kaul et al. [29]	40	18–56 (27)	107 \rightarrow 37	31	(24 months)
Chen et al. [9]	53	13–55 (26)	91 \rightarrow 38	19	0.2–9.8 years (6.9 years)
Sadr-Ameli et al. [30]	127	16–54 (30)	108 \rightarrow 22	20	6–8 years
Teupe et al. [31]	24 (<i>n</i> = 14 at follow-up)	19–65 (41)	82 \rightarrow 37	25	4.5–9.0 years (6.5 years)
Lip et al. [32]	22	16–46 (28)	53 \rightarrow 15	N/A	(20 months)
Fawzy et al. [33]	90 (<i>n</i> = 85 at follow-up)	15–54 (23)	105 \rightarrow 34	26	2–17 years (10 years)

promising as for those patients treated with surgery. Immediate results following percutaneous valvuloplasty show extremely effective lowering of transpulmonary gradients [9,26–34] (Table 3.1). When symptomatic patients undergo the procedure, there is almost uniform relief of symptoms and improvement in New York Heart Association functional class [30,31]. The complication rate of pulmonary valvuloplasty is extremely low, with most series reporting no significant complications. Rare complications encountered may include transient ventricular arrhythmias or premature contractions that are self-limited [33]. One complicating factor following the procedure is the not infrequent residual dynamic gradient across the right ventricular infundibulum that can occur immediately after relief of fixed valvular obstruction, the so-called “suicide right ventricle.” This is likely due to hypertrophied and hypercontractile infundibular muscle tissue. At times, this gradient may reach systemic

levels and rarely may cause hemodynamic consequences, such as hypotension or syncope. Acutely, beta-blockers such as propranolol are sometimes given to decrease or prevent high gradients. Follow-up studies reveal a decrease in this residual gradient over months, associated with regression of hypertrophy in the infundibular region [9,26–29,31,33]. It is rare (0–9%) that patients require a second intervention. Mild pulmonary regurgitation is not infrequently seen following valvuloplasty but is of little hemodynamic significance [9,29,31,34]. Rates of at least moderate pulmonary regurgitation immediately or at follow-up are 2–7% [30,33], significantly lower than that reported following surgical valvotomy.

Pregnancy

The prognosis in PS remains excellent in studies of women with the condition who become pregnant. Even when gradients suggest that the stenosis is severe, if patients are asymptomatic or only mildly symptomatic prior to pregnancy, the hemodynamic challenges during gestation are well tolerated with few cardiac complications [35,36]. There is some research suggesting that hypertensive disorders are increased in patients with PS. One possible explanation for this may be endothelial dysfunction in patients with congenital heart disease [37]. When pregnancy is rarely complicated by severe, symptomatic PS refractory to medical therapy, balloon valvuloplasty has been successfully performed [23,38].

Guidelines

The most recently published *American College of Cardiology/American Heart Association Guidelines for the Management of Patients with Valvular Heart Disease* provides a recommended approach to therapy for adults with PS. They do not recommend (Class III) routine diagnostic cardiac catheterization. A catheterization is recommended (Class I) only if the echocardiogram reveals significant PS with a peak gradient by Doppler of greater than 36 mm Hg *and* if pulmonary valvuloplasty is planned if indicated. Balloon valvuloplasty is recommended (Class I) in patients with a gradient across the pulmonary valve of greater than 30 mm Hg (peak-to-peak gradient by catheterization) and symptoms, such as dyspnea, chest pain, or syncope. For asymptomatic patients, valvuloplasty is recommended if the gradient is greater than 40 mm Hg. Furthermore, valvuloplasty can be considered (Class IIb) for asymptomatic patients with gradients from 30 mm Hg to 39 mm Hg [39]. Though not specifically addressed in the guidelines, it is generally accepted that surgical therapy with pulmonary valve replacement is reserved for cases involving dysplastic pulmonary valves, associated cardiac lesions which also require surgery, or the presence of hypertrophied muscle bands in the right ventricle which require resection. Of note, based on data from the Second Natural History Study of Congenital Heart Defects [21] and the most recent American Heart Association guidelines [40], patients with isolated PS without implanted graft or prosthetic material do not

require infective endocarditis prophylaxis prior to dental or other nonsterile procedures.

Subvalvular pulmonary stenosis

Subvalvular pulmonic stenosis is often seen in association with a ventricular septal defect and rarely may occur in isolation. The site of stenosis may be either in the infundibular portion of the right ventricular outflow tract, due to a fibromuscular obstruction, or in the right ventricular cavity, due to anomalous muscle bands and resulting in a double-chambered right ventricle [1]. In the case of double-chambered right ventricle, the site of the obstructing muscle bands may vary greatly in location and in severity of obstruction [41]. They result in a division of the right ventricle into high- and low-pressure chambers and therefore may be difficult to diagnose accurately. The severity of subvalvular PS tends to increase with time, and therefore may be first discovered during adulthood when symptoms manifest [42]. The pathophysiology is that of a dynamic obstruction to right ventricular outflow, rather than a fixed obstruction as in valvular PS. Consequences, however, are similar with increase in right ventricular pressure leading to right ventricular hypertrophy. When the VSD remains open, the direction of shunting depends on its location. When the VSD connects to the proximal high-pressure chamber, the shunt may be right-to-left, resulting in systemic desaturation either at rest or only during exercise. If the connection is at the level of the distal low-pressure chamber, the shunting is left-to-right.

Clinical manifestations are similar to those in valvular PS, resulting from right ventricular outflow obstruction. Patients may complain of dyspnea, chest pain, or, rarely, syncope. Because these symptoms may be a result of more common acquired heart disease, such as coronary artery disease, a high index of suspicion is required for the diagnosis. Physical exam reveals a systolic outflow murmur in the pulmonary area, which may be more harsh than that of valvular PS due to the dynamic obstruction. The absence of a pulmonary ejection click is helpful in distinguishing from a valvular stenosis [1]. If right ventricular hypertrophy has occurred, evidence of this may be seen on physical exam and electrocardiography. Diagnosis can usually be suspected by echocardiography, revealing a dynamic gradient in the right ventricular outflow tract. Two-dimensional echocardiography, often in subcostal images, usually reveals the site of morphologic obstruction as infundibular or due to anomalous hypertrophied muscle bands, as in double-chambered right ventricle. Imaging of the pulmonary valve is important, to exclude associated valvular PS, as is imaging of the ventricular septum with color Doppler to assess for associated ventricular septal defect. If ultrasound imaging is inadequate, magnetic resonance imaging may be helpful to identify anatomy [43,44]. Catheterization can be definitive in the diagnosis of double-chambered right ventricle, by delineating high-pressure

inflow and low-pressure outflow chambers. Right ventricular angiography may also provide good imaging of the narrowed outflow tract or trabeculated right ventricular chamber [41], although cardiac catheterization is seldom necessary to make the diagnosis in the current era.

Treatment of subvalvular PS is usually surgical via resection of a portion of the infundibulum or the hypertrophied anomalous muscle bands. Percutaneous methods such as balloon dilatation [45,46] and even alcohol ablation [47] have been reported, but are not well established as in valvular PS. Limited follow-up data is available; however, surgical outcomes are good for both fibromuscular infundibular [48] stenosis and for double-chambered right ventricle [49,50]. It is rare that reoperation is necessary; however, long-term care by a cardiologist is recommended to screen for sequelae of the condition.

Supravalvular pulmonary stenosis

Congenital isolated supravalvular PS, or stenosis of the pulmonary arteries, is very rarely seen in adult patients. Children diagnosed with the condition often have it in association with Williams syndrome or Alagille syndrome, and it is also seen in the presence of other congenital heart lesions, such as tetralogy of Fallot. Nevertheless, it is possible to diagnose peripheral pulmonary artery stenosis in the adult, and it may be misdiagnosed or confused for thromboembolic disease. Symptoms include dyspnea and fatigue, and diagnostic evaluation reveals lung perfusion defects and elevated right ventricular systolic pressure on catheterization. Balloon dilatation and stenting have been reported with good success [51,52].

Case

This patient was referred for catheterization and pulmonary valvuloplasty based on his markedly elevated gradients and the presence of right ventricular hypertrophy. A gradient of 80 mm Hg across the pulmonary valve was measured. Angiography revealed a doming pulmonary valve with a narrowed orifice and infundibular hypertrophy. The main pulmonary artery was massively dilated, measuring 6 cm (Fig. 3.4). Valvuloplasty was performed successfully by using a double-balloon technique. Post-procedure, the peak-to-peak transvalvular gradient was 14 mm Hg with a late-peaking dynamic gradient of 10 mm Hg (Fig. 3.5). The procedure was performed without complications, and the patient continues to do well, without hemodynamically significant pulmonary insufficiency, 1 year later. Given the exceedingly low rate of pulmonary artery rupture or dissection in the absence of pulmonary hypertension, surgical intervention for the post-stenotic dilatation alone is considered unnecessary.

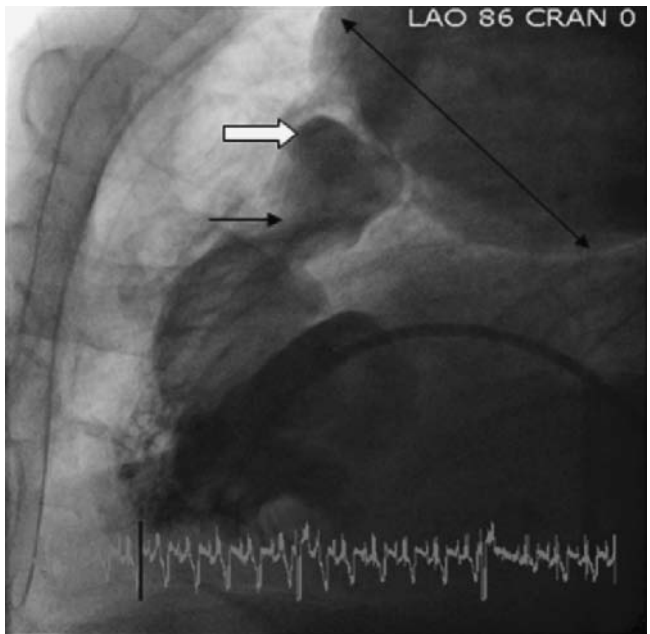
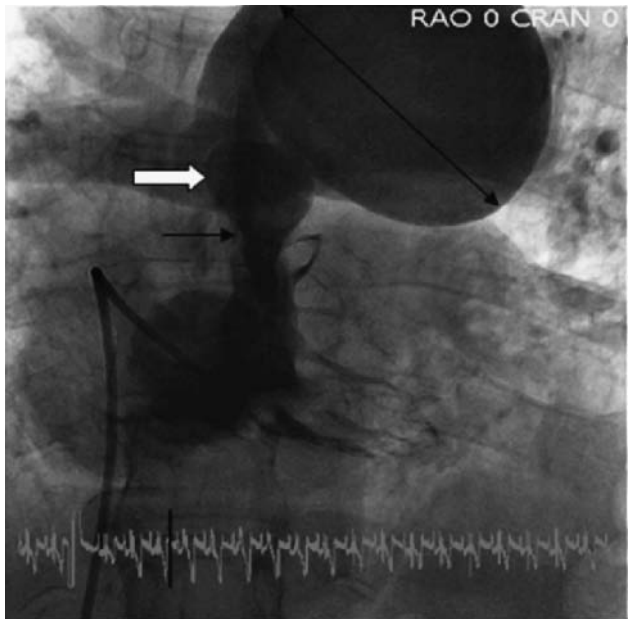


Fig. 3.4 Angiography in multiple views demonstrating narrowed infundibulum (single black arrow), domed pulmonary valve (white arrow), and severe post-stenotic dilatation of the pulmonary artery (double black arrow). (Courtesy of Dr. Thomas Ports.)

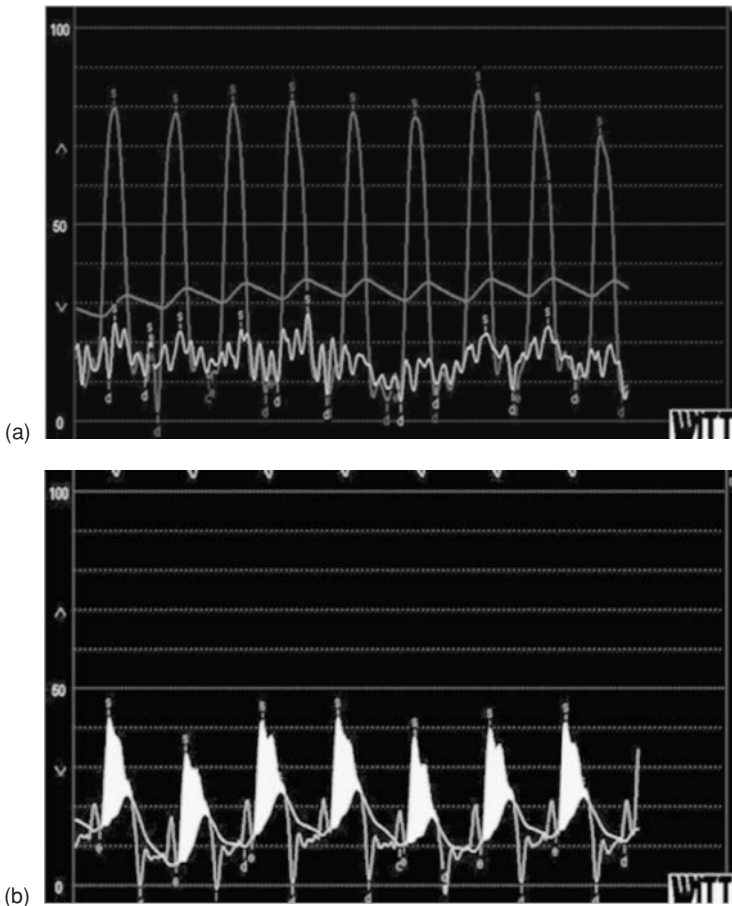


Fig. 3.5 (a) Pre- and (b) post-valvuloplasty hemodynamics reveal significant decrease in transvalvular pulmonary gradient. (Courtesy of Dr. Thomas Ports.)

Summary

Pulmonary stenosis is a congenital heart lesion that may be detected in adult patients when they present with dyspnea, chest pain, or palpitations. In addition, due to excellent outcomes after surgical valvotomy or pulmonary balloon valvuloplasty, most children with PS will reach adulthood and require periodic assessment by a cardiologist for the development of recurrent stenosis or pulmonary insufficiency. Echocardiography and, more recently, magnetic resonance imaging are useful noninvasive methods for measuring the degree of outflow tract obstruction and right ventricular function. Balloon valvuloplasty

is now the preferred therapy for both children and adults for the doming type of valvular PS. Guidelines recommend the procedure for adults with symptoms and a transvalvular gradient of greater than 30 mm Hg or in asymptomatic patients with a gradient of greater than 40 mm Hg. Subvalvular PS is less common; however, it may be encountered in adult patients. Treatment is usually surgical with good results.

References

1. Blieden L, Berant M, Zeevi B. Pulmonic stenosis. In: Moller J, Hoffman J, eds. *Pediatric Cardiovascular Medicine*, 1st edition. Philadelphia: Churchill Livingstone, 2000: 552–66.
2. Perloff JK, ed. Congenital pulmonary stenosis. In: *The Clinical Recognition of Congenital Heart Disease*, 5th edition. Philadelphia: Saunders, 2003:163–86.
3. Abrams J. *Synopsis of Cardiac Physical Diagnosis*, 2nd edition. Boston: Butterworth-Heinemann, 2001:95–101.
4. Feigenbaum H, Armstrong W, Ryan T. *Feigenbaum's Echocardiography*, 6th edition. Philadelphia: Lippincott, Williams & Wilkins, 1994:356–7, 574–6.
5. Davlouros PA, Niwa K, Webb G, et al. The right ventricle in congenital heart disease. *Heart* 2006;92:i27–38 (suppl 1).
6. Baim D, Grossman W. *Grossman's Cardiac Catheterization, Angiography, and Intervention*, 6th edition. Philadelphia: Lippincott, Williams & Wilkins.
7. Kan JS, White RI, Mitchell SE, et al. Percutaneous balloon valvuloplasty: a new method for treating congenital pulmonary-valve stenosis. *N Engl J Med* 1982;307:540–2.
8. Pepine CJ, Gessner IH, Feldman RL. Percutaneous balloon valvuloplasty for pulmonic valve stenosis in the adult. *Am J Cardiol* 1982;50:1442–5.
9. Chen CR, Cheng TO, Huang T, et al. Percutaneous balloon valvuloplasty for pulmonic stenosis in adolescents and adults. *N Engl J Med* 1996;335:128–34.
10. Fernandes V, Kaluza GL, Zymek PT, et al. Successful balloon valvuloplasty in an adult patient with severe pulmonic stenosis and aneurysmal post-stenotic dilatation. *Catheter Cardiovasc Interv* 2002;55:376–80.
11. Bahl VK, Chandra S, Wasir HS. Pulmonary valvuloplasty using Inoue balloon catheter. *Int J Cardiol* 1994;45:141–3.
12. Lau KW, Hung JS, Wu JJ, et al. Pulmonary valvuloplasty in adults using the Inoue balloon catheter. *Catheter Cardiovasc Diagn* 1993;29:99–104.
13. Al Kasab S, Ribeiro P, Al Zaibag M. Use of a double balloon technique for percutaneous balloon valvotomy in adults. *Br Heart J* 1987;58:136–41.
14. Park JH, Yoon YS, Yeon KM, et al. Percutaneous balloon valvuloplasty with a double-balloon technique. *Radiology* 1987;164:715–8.
15. Mullins CE, Nihill MR, Vick GW 3rd, et al. Double balloon technique for dilation of valvular or vessel stenosis in congenital and acquired heart disease. *J Am Coll Cardiol* 1987;10:107–14.
16. Ali Khan MA, Yousef SA, Mullins CE. Percutaneous transluminal balloon pulmonary valvuloplasty for the relief of pulmonary valve stenosis with special reference to double-balloon technique. *Am Heart J* 1986;112:158–66.

17. Escalera RB 2nd, Chase TJ, Owada CY. Triple-balloon pulmonary valvuloplasty: an advantageous technique for percutaneous repair of pulmonary valve stenosis in the large pediatric and adult patients. *Catheter Cardiovasc Interv* 2005;66:446–51.
18. Hayes CJ, Gersony WM, Driscoll DJ, et al. Second natural history study of congenital heart defects: results of treatment of patients with pulmonic valvar stenosis. *Circulation* 1993;87:128–37 (suppl).
19. Driscoll DJ, Wolfe RR, Gersony WM, et al. Cardiorespiratory responses to exercise of patients with aortic stenosis, pulmonary stenosis, and ventricular septal defect. *Circulation* 1993;87:1102–13 (suppl).
20. Gersony WM, Hayes CJ, Driscoll DJ, et al. Second natural history study of congenital heart defects: quality of life of patients with aortic stenosis, pulmonary stenosis, or ventricular septal defect. *Circulation* 1993;87:152–65 (suppl).
21. Gersony WM, Hayes CJ, Driscoll DJ, et al. Bacterial endocarditis in patients with aortic stenosis, pulmonary stenosis, or ventricular septal defect. *Circulation* 1993;87:1121–6 (suppl).
22. Wolfe RR, Driscoll DJ, Gersony WM, et al. Arrhythmias in patients with valvar aortic stenosis, valvar pulmonary stenosis, and ventricular septal defect: results of 24-hour ECG monitoring. *Circulation* 1993;87:189–101 (suppl).
23. Personal communication, Dr. Thomas Ports; University of California, San Francisco.
24. Roos-Hesslink JW, Meijboom FJ, Spitaels SEC, et al. Long-term outcome after surgery for pulmonary stenosis (a longitudinal study of 22–33 years). *Eur Heart J* 2006;27:482–8.
25. Earing MG, Connolly HM, Dearani JA, et al. Long-term follow-up of patients after surgical treatment for isolated pulmonary valve stenosis. *Mayo Clin Proc* 2005;80:871–6.
26. Al Kasab S, Ribeiro P, Al Zaibag M, et al. Percutaneous double balloon pulmonary valvotomy in adults: one- to two-year follow-up. *Am J Cardiol* 1988;62:822–4.
27. Sievert H, Kober G, Bussman WD, et al. Long-term results of percutaneous pulmonary valvuloplasty in adults. *Eur Heart J* 1989;10:712–7.
28. Herrmann HC, Hill JA, Krol J, et al. Effectiveness of percutaneous balloon valvuloplasty in adults with pulmonic valve stenosis. *Am J Cardiol* 1991;68:1111–3.
29. Kaul UA, Singh B, Tyagi S, et al. Long-term results after balloon pulmonary valvuloplasty in adults. *Am Heart J* 1993;126:1152–5.
30. Sadr-Ameli MA, Sheikholeslami F, Firoozi I, et al. Late results of balloon pulmonary valvuloplasty in adults. *Am J Cardiol* 1998;82:398–400.
31. Teupe CH, Burger W, Schrader R, et al. Late (five to nine years) follow-up after balloon dilation of valvular pulmonary stenosis in adults. *Am J Cardiol* 1997;80:240–2.
32. Lip GY, Singh SP, de Giovanni J. Percutaneous balloon valvuloplasty for congenital pulmonary valve stenosis in adults. *Clin Cardiol* 1999;22:733–7.
33. Fawzy ME, Hassan W, Fadel BM, et al. Long-term results (up to 17 years) of pulmonary balloon valvuloplasty in adults and its effects on concomitant severe infundibular stenosis and tricuspid regurgitation. *Am Heart J*. 2007;153:433–8.
34. Sherman W, Hershman R, Alexopoulos D, et al. Pulmonic balloon valvuloplasty in adults. *Am Heart J* 1990;119:186–90.
35. Elkayam U, Bitar F. Valvular heart disease and pregnancy. Part I. Native valves. *J Am Coll Cardiol* 2005;46:223–30.
36. Hameed AB, Goodwin TM, Elkayam U. Effect of pulmonary stenosis on pregnancy outcomes: a case-control study. *Am Heart J* 2007;154:852–4.

37. Drenthen W, Pieper PG, Roos-Hesselink JW, et al. Non-cardiac complications during pregnancy in women with isolated congenital pulmonary valvar stenosis. *Heart* 2006;92:1838–43.
38. Loya YS, Desai DM, Sharma S. Mitral and pulmonary balloon valvotomy in pregnant patients. *Indian Heart J* 1993;45:57–9.
39. Bonow RB, Carabello BA, Chatterjee K, et al. ACC/AHA 2006 guidelines for the management of patients with valvular heart disease: a report of the American College of Cardiology/American Heart Association Task Force on Practice Guidelines (writing committee to revise the 1998 Guidelines for the Management of Patients With Valvular Heart Disease): developed in collaboration with the Society of Cardiovascular Anesthesiologists: endorsed by the Society for Cardiovascular Angiography and Interventions and the Society of Thoracic Surgeons. *Circulation* 2006;114:e84–231.
40. Wilson W, Taubert KA, Gewitz M, et al. Prevention of infective endocarditis: guidelines from the American Heart Association: a guideline from the American Heart Association Rheumatic Fever, Endocarditis, and Kawasaki Disease Committee, Council on Cardiovascular Disease in the Young, and the Council on Clinical Cardiology, Council on Cardiovascular Surgery and Anesthesia, and the Quality of Care and Outcomes Research Interdisciplinary Working Group. *Circulation* 2007;116:1736–54.
41. Rowland TW, Rosenthal A, Castaneda AR. Double-chamber right ventricle: experience with 17 cases. *Am Heart J* 1975;89:455–62.
42. McElhinney DB, Chatterjee KM, Reddy VM. Double-chambered right ventricle presenting in adulthood. *Ann Thorac Surg* 2000;70:124–7.
43. Ibrahim T, Dennig K, Schwaiger M, et al. Assessment of double chamber right ventricle by magnetic resonance imaging. *Circulation* 2002;105:2692–3.
44. Sato Y, Komatsu S, Matsuo S, et al. Isolated subvalvular pulmonary stenosis: depiction at whole heart magnetic resonance imaging. *Int J Cardiovasc Imaging* 2007;23:49–52.
45. Chandrashekhar YS, Anand IS, Purshottam LW. Balloon dilatation of double-chamber right ventricle. *Am Heart J* 1990;120:1234–6.
46. Chandrashekhar YS, Anand IS. Balloon dilatation of primary infundibular stenosis of the right ventricular outflow tract. *Am Heart J* 1992;124:1385–6.
47. Park SJ, Lee CW, Hong MK, et al. Transcatheter alcohol ablation of infundibular hypertrophy in patients with idiopathic infundibular pulmonic stenosis. *Am J Cardiol* 1997;80:1514–6.
48. Shyu KG, Tseng CD, Chiu IS, et al. Infundibular pulmonic stenosis with intact ventricular septum: a report of 15 surgically corrected patients. *Int J Cardiol* 1993;41:115–21.
49. Kveselis D, Rosenthal A, Ferguson P, et al. Long-term prognosis after repair of double-chamber right ventricle with ventricular septal defect. *Am J Cardiol* 1984;54:1292–5.
50. Hachiro Y, Takagi N, Koyanagi T, et al. Repair of double-chambered right ventricle: surgical results and long-term follow-up. *Ann Thorac Surg* 2001;72:1520–2.
51. Kreutzer J, Landzberg MJ, Preminger TJ, et al. Isolated peripheral pulmonary artery stenosis in the adult. *Circulation* 1996;93:1417–23.
52. Rothman A, Levy DJ, Sklansky MS, et al. Balloon angioplasty and stenting of multiple intralobar pulmonary arterial stenoses in adult patients. *Catheter Cardiovasc Interv* 2003;58:252–60.

Ventricular septal defect

Naser M. Ammash

A 24-year-old lady with known ventricular septal defect since childhood presented for evaluation of dyspnea on exertion, fatigue, and atypical chest pain. She denied any orthopnea, nocturnal dyspnea, or edema. Her examination revealed a blood pressure of 120/70 mm Hg, with a heart rate of 56 bpm. The jugular venous pressure and carotid pulse were normal. The lungs were clear on auscultation. The cardiac examination demonstrated no heave or thrill. Heart sounds were normal with no additional sounds. There was a grade 3/6 holosystolic murmur at the apex and left sternal border with no diastolic murmur. The remainder of her examination was normal with no edema, clubbing, or cyanosis noted in the lower extremities. Her electrocardiogram and chest x-ray, were unremarkable with no definitive signs of left ventricular enlargement.

This case illustrates a common adult presentation of isolated ventricular septal defect (VSD). VSDs vary in size, location, and can be complicated by heart failure, endocarditis, aortic regurgitation (AR), pulmonary hypertension, or right ventricular outflow obstruction due to pulmonary valve stenosis or double-chambered right ventricle (DCRV) [1]. Management of the case illustrated above requires basic knowledge of the different types of VSD and their potential complications. The investigative approach must assess the specific features pertinent to these defects and help in the care of patients with one of the most common congenital cardiac malformations.

Anatomy and pathophysiology

The ventricular septum is a nonplanar, three-dimensional partition that divides the heart into five components: membranous, infundibular (or subarterial), inlet,

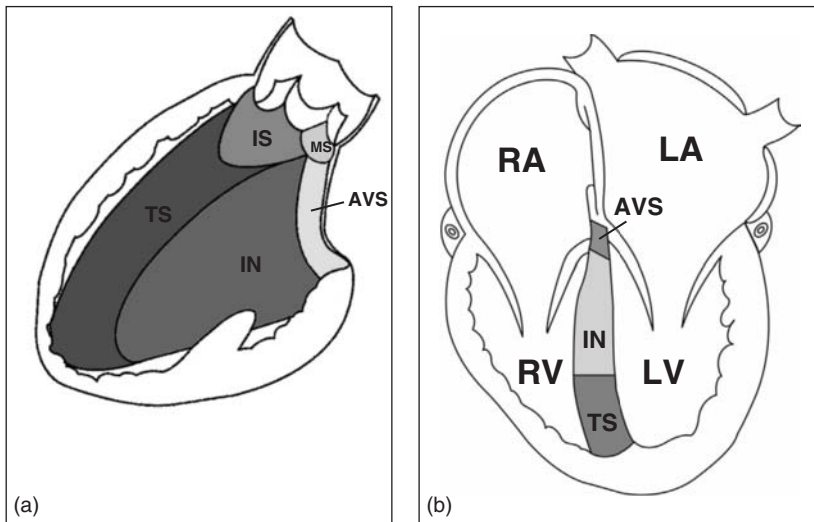


Fig. 4.1 Diagrammatic illustration of the different segments of the ventricular septum (a) left ventricular aspect, (b) apical aspect: membranous (MS), infundibular (IS), trabecular (TS), inlet (IN), atrioventricular (AVS). Ao, aorta; LA, left atrium; LV, left ventricle; PT, pulmonary trunk; RA, right atrium; RV, right ventricle.

muscular (or trabecular), and the atrioventricular septum (Fig. 4.1). Deficient growth or incomplete fusion of any of those components leads to VSDs that are accordingly classified into membranous (Fig. 4.2), infundibular (also called subarterial or supracristal; Figs. 4.2 & 4.3), inlet, muscular, and atrioventricular (also known as Gerbode) defects [2,3]. Membranous VSD, the most commonly seen defect (80%), is inferior to the aortic valve and borders the septal leaflet of the tricuspid valve (Fig. 4.2). It can extend into the muscular septum (perimembranous VSD) and can be associated with AR due to prolapse of the right or noncoronary cup into the defect. In adults, these defects are often associated with accessory septal tissue arising from the tricuspid valve that would account for partial or complete closure of the defect (up to 60%) and, at times, aneurysm of the membranous septum. Membranous VSDs can also be complicated by DCRV (3–10%) due to hypertrophy of anomalous muscle bundles in the direction of the jet created by VSD dividing the right ventricle into two chambers: proximal high-pressure and distal subpulmonic low-pressure right ventricular chambers (Fig. 4.4) [4].

Infundibular VSD (5–7% of VSDs in the U.S., 30% in southeast Asia) is a defect located beneath the pulmonary and aortic valve [2]. These defects do not close spontaneously but can get smaller because of the prolapsing right or left coronary cusp with associated increased risk of AR (Figs. 4.2 & 4.3). The risk of AR increases with age (87% of patients by age 20) and is 2.5 times that

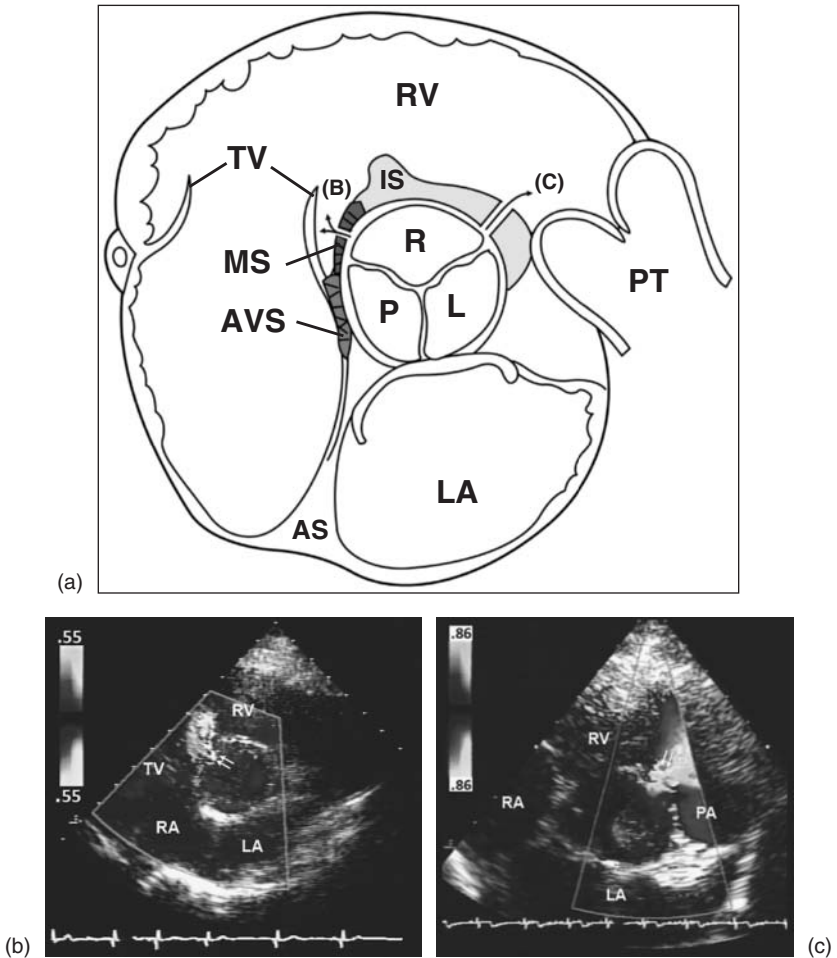


Fig. 4.2 (a) Standard parasternal short-axis echocardiographic view showing the membranous (MS), the infundibular (IS), and the atrioventricular septum (AVS) and the location of membranous (B) and supracrystal or subarterial defects (C). Ao, aorta; AS, advice septum; LA, left atrium; LV, left ventricle; RV, right ventricle. (b) Color flow Doppler demonstrating a membranous ventricular septal defect with a left-to-right shunt in proximity to the tricuspid valve (TV) (red flow from LV to RV). (c) Color flow Doppler demonstrating supracrystal or subarterial ventricular septal defect in the right ventricular outflow tract in proximity to the pulmonary valve (PV). Ao, aorta; LA, left atrium; PA, pulmonary artery; RA, right atrium; RV, right ventricle; P, posterior; R, right; L, left aortic cusps.

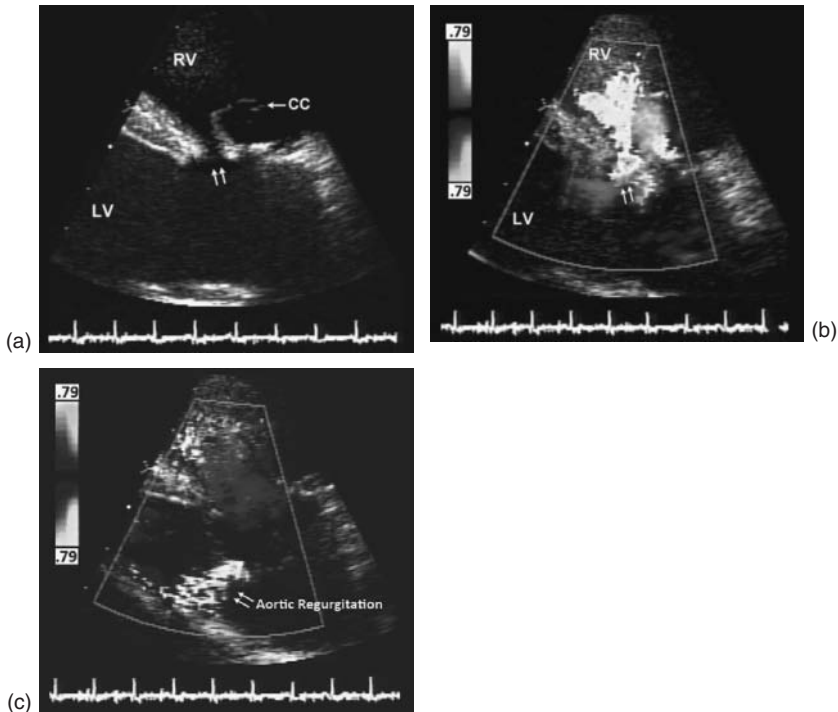


Fig. 4.3 Transthoracic echocardiogram showing a supracristal defect with and without color flow Doppler in systole and diastole. The aortic valve prolapse is seen in early systole (a), as blood is ejected from the left ventricle, the anatomically unsupported coronary cusp and aortic sinus are driven into the right ventricle (RV) by a Venturi effect. Color flow Doppler shows left to right shunt across the VSD (b). In diastole (c), the intra-aortic pressure forces the aortic valve leaflet to close, but the unsupported cusp (right or noncoronary) is pushed down into the left ventricular outflow tract away from the opposed coronary cusp, resulting in AR.

associated with membranous VSDs because of deficiency or hypoplasia of the conal septum in its superior border given its proximity to the semilunar valves [1,2,5,6]. Inlet VSDs are large defects that separate the mitral and tricuspid valve, lie beneath both atrioventricular valves, and extend to the chordal attachments of the tricuspid valve. Despite its proximity to the atrioventricular valves, this defect is not associated with mitral or tricuspid regurgitation unless in the setting of an atrioventricular septal defect [7]. When unrepaired, this defect in adult patients is commonly associated with pulmonary hypertension. Muscular VSDs (5–20% of VSDs) can be small or large defects, single or multiple, and located anywhere in the muscular septum. Finally, the atrioventricular defect is a rare defect in the atrioventricular septum leading to left ventricular to

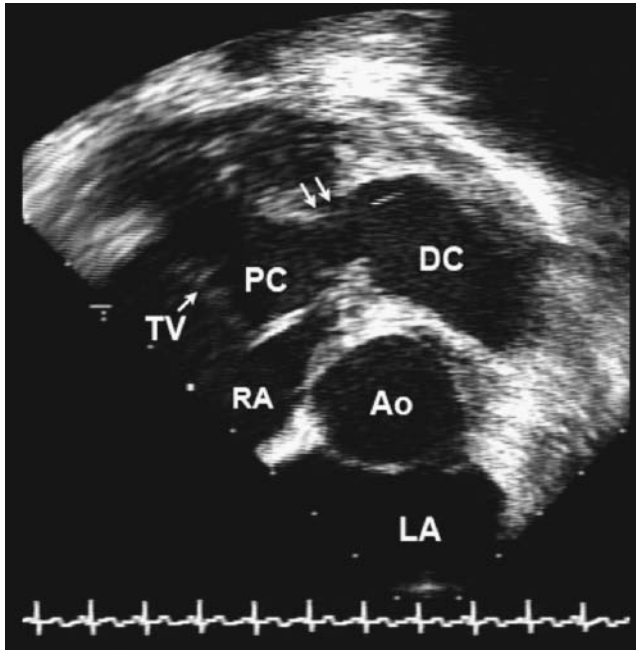


Fig. 4.4 Transesophageal echocardiographic view at the base of the heart showing hypertrophy of the right ventricular wall as noted in this example of a double chambered right ventricle (DCRV) with a proximal high-pressure (PC) and distal low-pressure (DC) chambers. Ao, aorta; LA, left atrium; RA, right atrium; TV, tricuspid valve.

right atrial shunt that has been reported following endocarditis and could be associated with tricuspid regurgitation and sinus node dysfunction [8,9].

The direction and severity of the left-to-right shunt created by the VSD depends on the functional size of the defect, systemic blood pressure, and the presence of AR, DCRV, and pulmonary hypertension. In adults, the shunt is predominantly systolic and left-to-right in the absence of severe pulmonary hypertension or right ventricular outflow obstruction. The resultant volume overload affects the pulmonary artery, left atrium, and ventricle. The right atrium can be enlarged in the presence of pressure (pulmonary hypertension, DCRV) or volume overload (Gerbode defect). The presence of AR, DCRV, and pulmonary hypertension also affects the severity of the shunt and ultimately the management of these patients. In presence of severe pulmonary vascular obstructive disease from long-standing, unrestricted left-to-right shunt, the right ventricular pressure is at or near systemic; as a result, there is minimal shunt across the VSD and, at times, reversal of the shunt with associated cyanosis. This right-to-left shunting known as Eisenmenger complex develops in 10–15% of patients with VSD, most commonly in the 2nd or 3rd decade of life [2,10]. In contrast, the

presence of significant pulmonary stenosis or DCRV limits pulmonary blood flow and prevents pulmonary hypertension at the cost of right ventricular outflow obstruction and hypertrophy. Finally, the presence of AR due to prolapse of a coronary cusp can result in reduction of functional size of the defect and the left-to-right shunt, but at the expense of aortic valve distortion, AR, and further volume overload of the left ventricle.

Practical approach to VSD in adults

Adults with isolated VSD commonly present as a small restrictive defect with small left-to-right shunt ("maladie de Roger") or possibly a larger defect that is partially closed by the fibromuscular proliferation or adherence of the septal leaflet of the tricuspid valve or hypertrophy of the ventricular septum. Depending on the size and type of VSD, and associated complications, patients can be asymptomatic, present with new onset dyspnea or fatigue, or present with heart failure, endocarditis, syncope, arrhythmias, or sudden death [1,2,11]. Syncope is often exertional and can be due to arrhythmias or significant right ventricular outflow obstruction caused by a large prolapsing aortic valve cusp, large aneurysm of membranous septum, or DCRV. Patients can also present with a changing murmur; a new murmur, such as the development of diastolic murmur due to AR; or heart failure because of progressive left ventricular volume overload and/or pulmonary hypertension. Patients with significant pulmonary hypertension or right ventricular outflow obstruction due to pulmonary stenosis or DCRV can present in adolescence with symptoms that could be wrongly attributed to childhood asthma, such as dyspnea, exercise intolerance, and cyanosis.

Most VSDs can be identified by auscultation, depending on their size and associated complications (Fig. 4.5). A palpable thrill in the third or fourth intercostal space is not uncommon in small VSDs or those defects associated with DCRV. The typical VSD murmur is harsh and holosystolic and is best heard in the left third and fourth intercostal spaces. However, a decrescendo systolic murmur that ends before the second heart sound is sometimes observed in small muscular defects due to complete obliteration of the defect in the later part of systole. A loud systolic ejection murmur at left sternal border is suggestive of severe right ventricular outflow obstruction and can obscure the holosystolic murmur of the VSD. The presence of left parasternal heave and thrill is suggestive of DCRV. On the other hand, a mid-systolic click followed by a late-systolic murmur is suspicious for an aneurysm of the membranous septum. Additional findings on examination that are of clinical importance include the presence of A wave on jugular venous examination caused by right ventricular hypertrophy and decreased compliance in presence of right ventricular outflow obstruction or severe pulmonary hypertension. The latter condition could also be associated with other exam findings including: (1) V wave and systolic

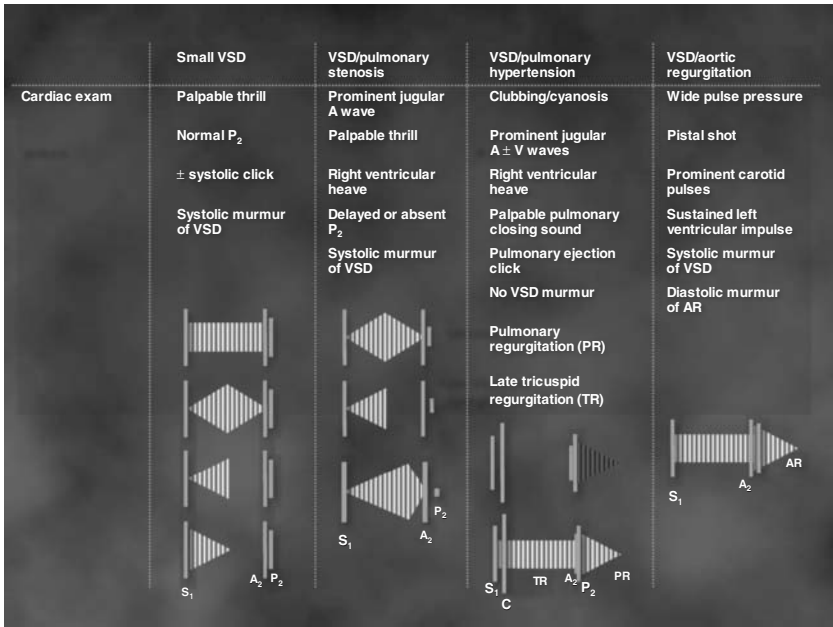


Fig. 4.5 Graphic illustration of the cardiac examination in small VSD, VSD with pulmonary stenosis, VSD with pulmonary hypertension, and VSD with aortic regurgitation. Please note the typical holosystolic murmur in small VSD that starts after the first heart sound (S₁) and that could be shortened when the VSD is muscular. In presence of pulmonary stenosis, the murmur could be systolic ejection type due to the more prominent pulmonary stenosis with delayed and reduced pulmonary closure sound (P₂). When the VSD is complicated by pulmonary hypertension (Eisenmenger Syndrome), there is no VSD murmur but a pulmonary ejection click (C), a loud palpable P₂ and pulmonary regurgitation diastolic murmur (PR). If such patient develops significant tricuspid regurgitation (TR), then a holosystolic murmur could be appreciated in the lower sternal border. Finally, in presence of aortic regurgitation, the VSD murmur is followed by the diastolic murmur of aortic regurgitation (AR). This diastolic murmur starts after the aortic closure sound (A₂).

murmur that increases with inspiration in association with a failing right ventricle and tricuspid regurgitation, (2) pulmonary ejection click due to dilated pulmonary artery, (3) palpable loud pulmonary closure sound, (4) absence of the typical holosystolic murmur of VSD due to systemic right ventricular pressure that abolishes the left-to-right shunt, and (5) diastolic blowing murmur of pulmonary regurgitation that may be heard in the left upper sternal border.

A normal 12-lead electrocardiogram is seen in up to 66% of patients [12]. Nonspecific intraventricular conduction delay and right bundle branch block are the most common abnormalities seen in patients with isolated VSD. The

presence of right axis deviation, right atrial enlargement, or right ventricular hypertrophy is suggestive of severe pulmonary hypertension or DCRV. On the other hand, the presence of electrocardiographic signs of left atrial, ventricular enlargement, and/or hypertrophy is not uncommon in the presence of volume overload of the left ventricle due to VSD shunt and/or associated AR.

The presence of a normal cardiac silhouette and pulmonary vascularity on chest x-ray is indicative of a small, uncomplicated VSD. On the other hand, cardiomegaly with left ventricular contour is directly related to the magnitude of the shunt and is often seen when ratio of pulmonary to systemic flow [Q_p/Q_s] > 2 . Less commonly, the left ventricular enlargement is due to the presence of significant AR. In contrast, cardiomegaly with right ventricular contour and possibly right atrial enlargement is suggestive of pulmonary hypertension or severe right ventricular outflow obstruction. In the presence of Eisenmenger complex, the chest x-ray also shows large proximal pulmonary arteries with pruning of outer pulmonary vessels, whereas in the presence of right ventricular outflow obstruction, the pulmonary vasculature is often reduced.

Echocardiogram

A thorough echocardiographic examination is the single most important non-invasive diagnostic test needed in the evaluation of VSD, associated congenital defects, and potential complications. It is most sensitive for VSD larger than 5 mm and those located in the membranous, inlet, or infundibular septum; it is least sensitive for those involving the apical septum. The ventricular septum and surrounding structures can be imaged in multiple planes by using color flow and spectral Doppler. The parasternal long axis views allow the distinct visualization of muscular, membranous, and infundibular defects. The latter two defects are seen below the aortic valve and are sometimes difficult to differentiate without parasternal short axis imaging that clearly and confidently demonstrates membranous defect in close proximity to the tricuspid valve, whereas infundibular defects are below the pulmonary valve (Fig. 4.2). The parasternal short axis view also allows visualization of an aneurysm of the membranous septum and assists in the evaluation of DCRV and/or AR. The apical views are best used to assess inlet, muscular and ventriculoatrial defects. It is often the best view to obtain a clear, distinct, noncontaminated tricuspid regurgitant velocity signal that allows an accurate estimation of the right ventricular and pulmonary artery systolic pressure [13]. If a clear signal cannot be obtained, then the pulmonary artery diastolic pressure or mean pulmonary artery pressure can be obtained by using end diastolic pulmonary regurgitant velocity and acceleration time, respectively [14,15]. Color flow and spectral Doppler analysis, when performed across the VSD, can determine the severity and the direction of the shunt. A proper continuous wave Doppler velocity signal of ≥ 4 m/s is suggestive of small restrictive VSD with small left-to-right shunt in the absence of significant systemic hypertension. On the other hand, smaller

values are observed in the presence of DCRV, pulmonary stenosis, or pulmonary hypertension. Under those conditions, the right ventricular pressure is elevated, and as a result, the pressure difference between the left and right ventricle is reduced with a resultant smaller Doppler-derived instantaneous gradient across the VSD. Finally, the echocardiographic examination can facilitate assessment of volume overload; for example, a normal left ventricular size is suggestive of a small left-to-right shunt, whereas enlargement of the left ventricle, atrium, and pulmonary artery is indicative of a large left-to-right shunt. Thus, a comprehensive echocardiographic examination allows the accurate identification of the morphologic features of the defect and its size and borders; provides an accurate hemodynamic assessment of the shunt severity and the secondary volume overload of the left atrium and ventricle; and assesses the presence and severity of DCRV, AR, pulmonary hypertension, or aneurysm of membranous septum [1,16–20]. In addition, serial echocardiographic imaging provides an accurate assessment of the progression of the lesion and associated complications. The latter has important prognostic implications, especially with regard to timing of intervention or surgical repair. Transesophageal echocardiography is reserved for the patient with poor precordial echocardiographic windows.

Additional diagnostic tests

Given the concerns about adaptability and the lack of reported symptoms in adult patients with congenital heart disease, it is not uncommon for a clinician to rely on exercise testing to document changes in exercise capacity over time, which may be useful in defining optimal timing of intervention. An unexplained decline in exercise tolerance might be an early sign of functional deterioration, even in the absence of reported cardiovascular symptoms.

Cardiac magnetic resonance has emerged as an accurate and reproducible technique for assessment of cardiac structure and function. This technique has advantages over echocardiography; images are not compromised by air, bone, or surgical scar, allowing unrestricted evaluation of cardiac chambers. Application of Simpson's rule for multiple tomographic slices acquired during ventricular systole and diastole permits direct and accurate measurement of left ventricular volume and function. In addition, phase contrast imaging provides an accurate method of evaluation of velocity, volume, and the pattern of blood flow that would allow accurate mapping and measurement of both systolic and diastolic pulmonary artery flow and calculation of shunt severity fraction [21]. However, until now, this technique has not gained wide recognition in the evaluation of VSD and has the disadvantage of radiation exposure.

Cardiac catheterization and left ventriculography performed using a large-volume contrast bolus given over a short time is an important adjunctive technique usually reserved for evaluation of VSDs whose hemodynamic significance is questionable. It is also very useful in the assessment of complicated VSDs, such as those that are multiple and especially those involving the apex,

ventriculoatrial septum, or VSD associated with DCRV, AR, or pulmonary hypertension. Cardiac catheterization can accurately assess the direction and severity of the shunt by angiography, indicator dilution curves, or calculation of the pulmonary to systemic flow ratio (Q_p/Q_s) using oximetry [7,11,16,22]. In the presence of DCRV or pulmonary stenosis, this technique can reliably measure the pressures in the different segments of the right ventricle and pulmonary arteries. Those findings have significant therapeutic implications. Similarly, cardiac catheterization is also the investigative method of choice in the assessment of VSD with pulmonary hypertension to accurately determine pulmonary artery pressure, pulmonary vascular resistance, and their reversibility in response to oxygen, vasodilators, or nitric oxide. This is very important in determining the suitability for surgical intervention. Finally, for those patients with suspected AR, additional aortography allows detection of aortic valve prolapse and helps grade the severity of AR [23].

Indication for intervention

Spontaneous closure has been reported to occur in 50–75% of membranous and muscular VSDs and occurs predominantly in childhood, but has been reported in 10% of adults between the ages of 17 and 45 years [2,24]. Defects that do not close spontaneously may predispose to arrhythmias, heart failure, AR, pulmonary hypertension, and endocarditis; therefore, periodic evaluation is recommended for optimal timing of intervention. The American Heart Association does not recommend antibiotic prophylaxis in the acyanotic uncomplicated VSD with no prior history of endocarditis [25]. Patients with small, uncomplicated, isolated VSD, especially those involving the muscular and membranous septum, do very well as long as they do not develop volume overload of the left heart chambers. In a study by Gabriel [26] of 222 patients (with a mean age at last follow-up of 30 ± 10 years), only one patient needed surgical repair. Thus, continued observation is recommended in small, isolated VSD until patients are symptomatic or have unexplained left ventricular dilatation or decline in functional aerobic capacity on stress testing ($<70\%$). Medium or large VSD, when seen in adults, are almost always associated with some degree of pulmonary hypertension. The exceptions are those defects that have become functionally smaller due to prolapse of the aortic valve with AR or those defects with associated pulmonary stenosis that produces right ventricular hypertension and limits the left-to-right shunt.

The indications for intervention in adult VSD are summarized in Table 4.1. The optimal timing of operation in patients who have VSD and AR is controversial. The usual guidelines for valve replacement in isolated AR do not apply to these patients, and surgical repair of VSD with AR should not be delayed until there is significant left ventricular enlargement or dysfunction [27]. Early intervention, with closure of the VSD and repair of the aortic valve, is feasible and indicated

Table 4.1 Indication for intervention in isolated VSD.

- 1 Attributable symptoms or signs
 - a Dyspnea on exertion, fatigue
 - b Decline in functional aerobic capacity on stress test
- 2 Significant left-to-right shunt
 - a Unexplained left ventricular enlargement
 - b $Q_p/Q_s \geq 1.7$ by cardiac catheterization
- 3 Unexplained deterioration of left ventricular function
- 4 Recurrent endocarditis
- 5 Aortic valve cusp prolapse with more than mild or progressive regurgitation
- 6 Pulmonary stenosis or DCRV with associated symptoms or peak gradient of ≥ 50 mm Hg
- 7 Pulmonary hypertension with:
 - a Pulmonary artery systolic pressure or vascular resistance less than 2/3 systemic
 - b Pulmonary artery arteriolar resistance less than 8 Wood units
 - c Reactive pulmonary vasculature with a net $Q_p/Q_s \geq 1.5/1$

depending on the defect type (subarterial or membranous), defect size, and degree of valve distortion, with better results achieved in younger patients [28–33]. In patients in whom aortic valve repair is not feasible because of extensive distortion, fenestration, or significant fibrosis or calcification, valve replacement should be considered [6]. The choice of valve prosthesis depends on the age of the patient and comorbidities.

Surgical closure of VSD decreases the risk of endocarditis by at least half, reduces pulmonary artery pressure, improves functional classification, and improves long-term survival [12,34–36]. Operative mortality of uncomplicated VSD is <2% [11]. This increases with multiple defects, moderate pulmonary hypertension (>50% of systemic), and in the presence of AR [12,36].

More recently, there has been an increased interest in trans-catheter device closure of VSD [37,38]. The latter has been successfully performed in children as well as adults and could be considered as a treatment option for isolated, uncomplicated muscular or membranous VSD in the presence of suitable anatomy. Recently, Butera reported his experience in 104 patients with membranous VSD. The defect was successfully closed in 100 patients (96%). The total occlusion rate in the latter group was 47% after the procedure, but increased to 99% after a median follow-up of 38.5 months [37]. Such promising nonsurgical techniques could also be used to repair ventriculoatrial shunts (Gerbode defect). However, the proximity of conduction system, the aortic and tricuspid valve to the borders of the defects, and the possible encroachment on the surrounding structures such as the aortic root and valve should be thoughtfully evaluated before such consideration. Butera reported complete heart block necessitating pacemaker implantation in 6% of his study cohort [37].

Prognosis

The prognosis of patients with isolated VSD is very favorable unless it is complicated by pulmonary hypertension. Asymptomatic patients with small VSD and normal left ventricular size and function have an excellent prognosis [26,39]. Gersony and colleagues [26,35] have demonstrated that more than 85% of patients treated medically or surgically were in good or excellent health while continuing to lead a productive life. Only 4.8% were in New York Heart Association functional class III or IV. In addition, natural history studies have demonstrated that the 25-year survival after surgical repair of VSD is 89% [12,40]. Although survival has been reported into the seventh decade, long-term survival is less favorable in presence of pulmonary hypertension [2,34,41]. In the setting of Eisenmenger syndrome, the reported 25-year survival rate is 41.7% compared with 95.9% for small VSD. Patients with Eisenmenger complex are at increased risk for endocarditis, hyperviscosity syndrome, stroke, renal dysfunction, gout, as well as heart failure and atrial and ventricular tachyarrhythmia [1].

For patients who had previous VSD repair, the potential late complications include the following:

- Conduction defects, most commonly right bundle branch block in association with left anterior hemiblock especially after ventriculotomy and patch closure of the defect. Late sinus node dysfunction, including complete heart block requiring pacemaker placement, is infrequent ($\leq 2\%$) [36,42–44].
- Tachyarrhythmia, especially with increased pulmonary artery pressure.
- Residual VSDs irrespective of surgical approach, but these are often hemodynamically insignificant with fewer than 10% of patients needing a second operation [7,12,36].
- Infective endocarditis, which occurs more in the presence of residual defect or AR.
- Residual ventricular dysfunction from long-standing volume overload that could be aggravated by acquired cardiovascular disease, such as hypertension and ischemic coronary disease.
- Residual AR (15–20%) necessitating reoperation in approximately 5% [45].
- Tricuspid regurgitation due to septal leaflet distortion during VSD repair.
- Residual pulmonary hypertension that compromises long-term outcome and might necessitate treatment with vasodilators, endothelin receptor antagonists, or prostacyclin analogs.

Conclusion

Isolated VSDs are variable in size and location and can be complicated by AR, DCRV, PHTN, or aneurysm of the membranous septum. All of these complications may influence their clinical presentation, cardiovascular examination,

as well as the hemodynamics significance of the VSD. As a result, a thorough clinical and echocardiographic assessment is very important in the evaluation of these patients to prevent the development of irreversible pulmonary vascular obstructive disease and to preserve the integrity of the aortic valve and left ventricular function. Medical as well as surgical expertise is essential for the optimal management of these patients. Adult patients with VSD, even those with Eisenmenger complex, when cared for appropriately, can lead productive lives.

Outcome of case

This young adult had a known VSD and now presents with dyspnea, fatigue, and atypical chest pain with no clinical signs of cyanosis, pulmonary hypertension, heart failure, or AR. Her electrocardiogram and chest x-ray showed no definitive signs of enlargement of the left ventricle, right heart chambers, or pulmonary arteries. A transthoracic echocardiogram demonstrated a membranous VSD (Fig. 4.2) underneath the aortic valve with left-to-right shunt by color flow Doppler. Most importantly, borderline left ventricular enlargement was noted with an end diastolic diameter of 54 mm (normal 39–53), moderate left atrial enlargement with a volume of 37cc/m² (normal <32), and a normal pulmonary artery diastolic pressure of 8 mm Hg. There were no complicating features, such as aortic valve prolapse, AR, or evidence of right ventricular outflow obstruction. The presence of left ventricular and atrial enlargement was indicative of volume overload of the left heart chambers without pulmonary hypertension. A cardiac catheterization was performed to exclude coronary artery disease as an alternative cause of left ventricular enlargement and to confirm the severity of the left-to-right shunt. It

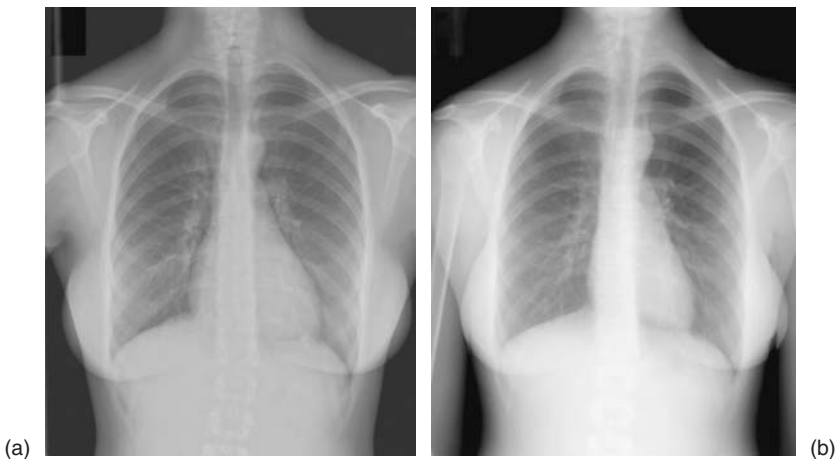


Fig. 4.6 Chest radiograph done before (a) and after (b) surgical repair of VSD defect, demonstrating a reduction in size of the cardiac silhouette.

demonstrated a moderately sized membranous VSD with left-to-right shunt, $Q_p/Q_s = 1.74$, as well as mild left ventricular enlargement with an end diastolic volume of 196 cc (112% of normal), a pulmonary pressure of 27/5 mm Hg, and normal coronary arteries. Given those findings, we recommended surgical repair based on the presence of symptoms and volume overload of the left heart chambers. The patient underwent suture closure of VSD via a median sternotomy. Her postoperative course was uneventful. On follow-up evaluation, she reported resolution of her fatigue and dyspnea and had no residual murmur or conduction defect on electrocardiogram. Her chest x-ray demonstrated improvement in her heart size with a reduction in cardiothoracic ratio from 54% to 44% (Fig. 4.6).

References

1. Ammash NM, Warnes CA. Ventricular septal defects in adults. *Ann Intern Med* 2001;135(9):812–24.
2. Perloff JK, ed. Ventricular septal defect. In: *The Clinical Recognition of Congenital Heart Disease* (4th edition). Philadelphia: W.B. Saunders, 1994:396–439.
3. Goor DA, Lillehei CW, Rees R, Edwards JE. Isolated ventricular septal defect. Development basis for various types and presentation of classification. *Chest* 1970;58(5):468–82.
4. Shepherd RL, Glancy DL, Jaffe RB, Perloff JK, Epstein SE. Acquired subvalvular right ventricular outflow obstruction in patients with ventricular septal defect. *Am J Med* 1972;53(4):446–55.
5. Momma K, Toyama K, Takao A, et al. Natural history of subarterial infundibular ventricular septal defect. *Am Heart J* 1984;108(5):1312–7.
6. Tatsuno K, Konno S, Ando M, Sakakibara S. Pathogenetic mechanisms of prolapsing aortic valve and aortic regurgitation associated with ventricular septal defect. Anatomical, angiographic, and surgical considerations. *Circulation* 1973;48(5):1028–37.
7. Prasad S. Ventricular septal defect. In: Gatzoulis MA, Webb GD, Daubeney PEF, eds. *Diagnosis and Management of Adult Congenital Heart Disease*. Philadelphia: Churchill Livingstone, 2003:171–8.
8. Battin M, Fong LV, Monro JL. Gerbode ventricular septal defect following endocarditis. *Eur J Cardiothorac Surg* 1991;5(11):613–4.
9. Michel C, Rabinovitch MA, Huynh T. Gerbode's defect associated with acute sinus node dysfunction as a complication of infective endocarditis. *Heart* 1996;76(4):379.
10. Neutze JM, Ishikawa T, Clarkson PM, et al. Assessment and follow-up of patients with ventricular septal defect and elevated pulmonary vascular resistance. *Am J Cardiol* 1989;63(5):327–31.
11. Warnes CA, Fuster V, Driscoll DJ, McGoon DC. Congenital heart disease in adolescents and adults. C. Ventricular septal defect. In: Giuliani ER, Fuster V, Gersh BJ, McGoon MD, McGoon DC, eds. *Cardiology: Fundamentals and Practice* (2nd edition). St. Louis: Mosby-Year Book, 1991:1639–52.
12. Kidd L, Driscoll DJ, Gersony WM, et al. Second natural history study of congenital heart defects. Results of treatment of patients with ventricular septal defects. *Circulation* 1993;87(2 Suppl):I38–51.

13. Currie PJ, Seward JB, Chan KL, et al. Continuous wave Doppler determination of right ventricular pressure: a simultaneous Doppler-catheterization study in 127 patients. *J Am Coll Cardiol* 1985;6(4):750–6.
14. Masuyama T, Kodama K, Kitabatake A, et al. Continuous-wave Doppler echocardiographic detection of pulmonary regurgitation and its application to noninvasive estimation of pulmonary artery pressure. *Circulation* 1986;74(3):484–92.
15. Chan KL, Currie PJ, Seward JB, et al. Comparison of three Doppler ultrasound methods in the prediction of pulmonary artery pressure. *J Am Coll Cardiol* 1987;9(3):549–54.
16. Nadas AS, Thilenius OG, Lafarge CG, Hauck AJ. Ventricular septal defect with aortic regurgitation: medical and pathologic aspects. *Circulation* 1964;29:862–73.
17. Pieroni DR, Nishimura RA, Bierman FZ, et al. Second natural history study of congenital heart defects. Ventricular septal defect: echocardiography. *Circulation* 1993;87(2 Suppl):I80–8.
18. Garg A, Shrivastava S, Radhakrishnan S, et al. Doppler assessment of interventricular pressure gradient across isolated ventricular septal defect. *Clin Cardiol* 1990;13(10):717–21.
19. Hagler DJ, Edwards WD, Seward JB, Tajik AJ. Standardized nomenclature of the ventricular septum and ventricular septal defects, with applications for two-dimensional echocardiography. *Mayo Clin Proc* 1985;60(11):741–52.
20. Schmidt KG, Cassidy SC, Silverman NH, Stanger P. Doubly committed subarterial ventricular septal defects: echocardiographic features and surgical implications. *J Am Coll Cardiol* 1988;12(6):1538–46.
21. Stauder NI, Miller S, Scheule AM, et al. MRI diagnosis of a previously undiagnosed large trabecular ventricular septal defect in an adult after multiple catheterizations and angiocardiograms. *Br J Radiol* 2001;74(879):280–2.
22. Soto B, Coghlan CH, Bargerson LM. Angiography in ventricular septal defects. In: Anderson RH SE, ed. *Paediatric Cardiology*. Edinburgh: Churchill Livingstone, 1987: 125–35.
23. Menahem S, Johns JA, del Torso S, et al. Evaluation of aortic valve prolapse in ventricular septal defect. *Br Heart J* 1986;56(3):242–9.
24. Neumayer U, Stone S, Somerville J. Small ventricular septal defects in adults. *Eur Heart J* 1998;19(10):1573–82.
25. Wilson W, Taubert KA, Gewitz M, et al. Prevention of infective endocarditis: guidelines from the American Heart Association: a guideline from the American Heart Association Rheumatic Fever, Endocarditis and Kawasaki Disease Committee, Council on Cardiovascular Disease in the Young, and the Council on Clinical Cardiology, Council on Cardiovascular Surgery and Anesthesia, and the Quality of Care and Outcomes Research Interdisciplinary Working Group. *J Am Dent Assoc* 2007;138(6):739–45, 747–60.
26. Gabriel HM, Heger M, Innerhofer P, et al. Long-term outcome of patients with ventricular septal defect considered not to require surgical closure during childhood. *J Am Coll Cardiol* 2002;39(6):1066–71.
27. Vahanian A, Baumgartner H, Bax J, et al. Guidelines on the management of valvular heart disease: The Task Force on the Management of Valvular Heart Disease of the European Society of Cardiology. *Eur Heart J* 2007;28(2):230–68.
28. Backer CL, Idriss FS, Zales VR, et al. Surgical management of the conal (supracristal) ventricular septal defect. *J Thorac Cardiovasc Surg* 1991;102(2):288–95, discussion 295–6.

29. Leung MP, Beerman LB, Siewers RD, et al. Long-term follow-up after aortic valvuloplasty and defect closure in ventricular septal defect with aortic regurgitation. *Am J Cardiol* 1987;60(10):890-4.
30. Lun K, Li H, Leung MP, et al. Analysis of indications for surgical closure of subarterial ventricular septal defect without associated aortic cusp prolapse and aortic regurgitation. *Am J Cardiol* 2001;87(11):1266-70.
31. Trusler GA, Moes CA, Kidd BS. Repair of ventricular septal defect with aortic insufficiency. *J Thorac Cardiovasc Surg* 1973;66(3):394-403.
32. Tweddell JS, Pelech AN, Frommelt PC. Ventricular septal defect and aortic valve regurgitation: pathophysiology and indications for surgery. *Semin Thorac Cardiovasc Surg Pediatr Card Surg Annu* 2006:147-52.
33. Kostolny M, Schreiber C, von Arnim V, et al. Timing of repair in ventricular septal defect with aortic insufficiency. *Thorac Cardiovasc Surg* 2006;54(8):512-15.
34. Ellis JH, Moodie DS, Sterba R, Gill CC. Ventricular septal defect in the adult: natural and unnatural history. *Am Heart J* 1987;114(1 Pt 1):115-20.
35. Gersony WM, Hayes CJ, Driscoll DJ, et al. Second natural history study of congenital heart defects. Quality of life of patients with aortic stenosis, pulmonary stenosis, or ventricular septal defect. *Circulation* 1993;87(2 Suppl):I52-65.
36. Otterstad JE, Erikssen J, Froysaker T, Simonsen S. Long term results after operative treatment of isolated ventricular septal defect in adolescents and adults. *Acta Med Scand Suppl* 1986;708:1-39.
37. Butera G, Carminati M, Chessa M, et al. Transcatheter closure of perimembranous ventricular septal defects: early and long-term results. *J Am Coll Cardiol* 2007;50(12):1189-95.
38. Hijazi ZM, Hakim F, Al-Fadley F, et al. Transcatheter closure of single muscular ventricular septal defects using the amplatzer muscular VSD occluder: initial results and technical considerations. *Catheter Cardiovasc Interv* 2000;49(2):167-72.
39. Magee AG, Fenn L, Vellekoop J, Godman MJ. Left ventricular function in adolescents and adults with restrictive ventricular septal defect and moderate left-to-right shunting. *Cardiol Young* 2000;10(2):126-9.
40. Weidman WH, Blount SG Jr, DuShane JW, et al. Clinical course in ventricular septal defect. *Circulation* 1977;56(1 Suppl):I56-69.
41. Wood P. The Eisenmenger syndrome or pulmonary hypertension with reversed central shunt. *Br Med J* 1959;II701-9.
42. Meijboom F, Szatmari A, Utens E, et al. Long-term follow-up after surgical closure of ventricular septal defect in infancy and childhood. *J Am Coll Cardiol* 1994;24(5):1358-64.
43. Tucker EM, Pyles LA, Bass JL, Moller JH. Permanent pacemaker for atrioventricular conduction block after operative repair of perimembranous ventricular septal defect. *J Am Coll Cardiol* 2007;50(12):1196-200.
44. Andersen HO, de Leval MR, Tsang VT, et al. Is complete heart block after surgical closure of ventricular septum defects still an issue? *Ann Thorac Surg* 2006;82(3):948-56.
45. Nygren A, Sunnegardh J, Berggren H. Preoperative evaluation and surgery in isolated ventricular septal defects: a 21 year perspective. *Heart* 2000;83(2):198-204.

Pulmonary arterial hypertension in Eisenmenger Syndrome

Kevin Owusu-Ansah, Zeksen Lim, and Gruschen R. Veldtman

A 45-year-old woman with Noonan syndrome, had cardiology screening at 8 years of age demonstrating severe pulmonary arterial hypertension, a large arterial duct, and arterial desaturation (80%). Diagnostic cardiac catheterization showed systemic pulmonary artery pressures (110/65, mean 80 mm Hg), a left-to-right shunt of 0.9:1, and pulmonary vascular resistance of 30 Wood Units, confirming Eisenmenger syndrome. She was advised against pregnancy and various contraceptive options were discussed.

At 36 years of age she was advised to have a venesection by her local physicians (Hb of 21.4 g/dL with a HCT of 65%). She declined because of needle phobia. Over the next 5 years, she did, however, have three venesections at times of presumed hyperviscosity symptoms. At age 40, she had moderate thrombocytopenia with a platelet count of 83,000 (saturation 75%). Her blood film is shown in Fig. 5.1.

During admission for surgical biopsy of a uterine mass, she became syncopal deteriorating into frank cardiorespiratory arrest from which she was fortunately successfully resuscitated.

At age 43, she had angina on effort. She then developed atrial flutter, congestive heart failure, and acute on chronic renal failure with frank proteinuria. Renal biopsy demonstrated mesangio-proliferative glomerulonephritis. Her proteinuria responded to ACE inhibition and steroid therapy. Her isthmus-dependent atrial flutter was successfully ablated. She was commenced on diuretics, ACE inhibition, low-dose beta-blockade, and anticoagulation. She was then referred to the adult congenital heart disease team for further management.

On physical examination, the following observations were made. There was upper body acne. Her toes were clubbed and had saturations of 75%. Right upper limb saturation was 94%. Jugular venous pressure was 9 cm above the angle of Louis, and there was

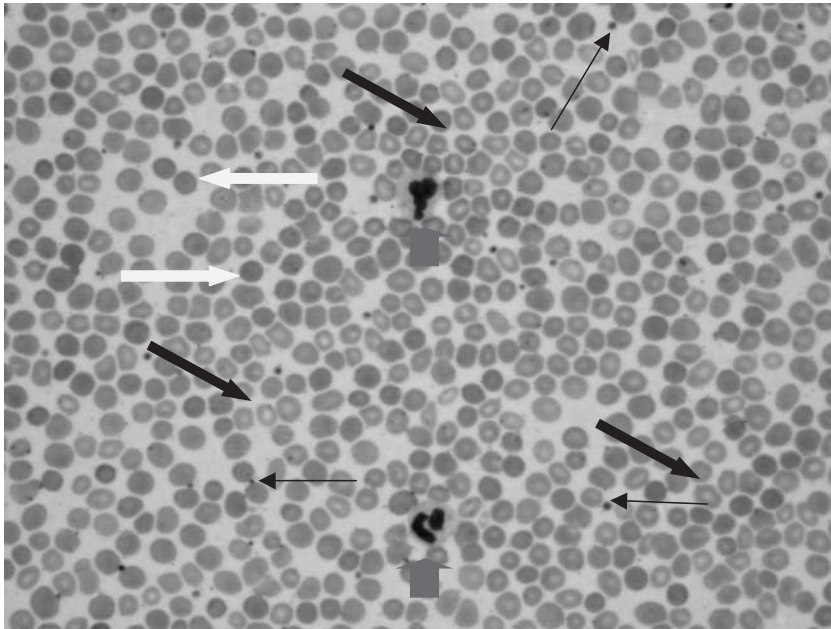


Fig. 5.1 Blood film of our patient demonstrating classical features of Eisenmenger syndrome. Polychromasia with increased reticulocytes (black arrows); spherocytes (white arrows); reduced platelet count (thin black arrows); and normal lymphocyte count (gray arrows).

peripheral edema. She had a right ventricular (RV) lift, loud P₂, and a Graham Steele murmur. She had a bilateral expiratory wheeze. Her 12-lead ECG is shown in Fig. 5.2.

Two-dimensional echocardiography and MRI showed severe biventricular systolic dysfunction, moderate left ventricular hypertrophy, severe RV hypertrophy and dilation, septal flattening (Fig. 5.3), and moderately severe tricuspid regurgitation. The estimated RV systolic pressure was 130–135 mm Hg. Her chest x-ray is shown in Fig. 5.4 and CT scan in Fig. 5.5.

Discussion

Introduction

Pulmonary arterial hypertension (PAH) is defined as resting mean pulmonary artery (PA) pressures >25 mm Hg or exercise-induced PA pressures >30 mm Hg. It is classified as idiopathic (IPAH), familial, or PAH secondary or associated with known risk factors [1]. In the past, PAH complicated approximately 10–20% of congenital heart disease (CHD) cases. This figure has declined in recent years as operative intervention is now extensively available. Current estimations are approximately around 4%.

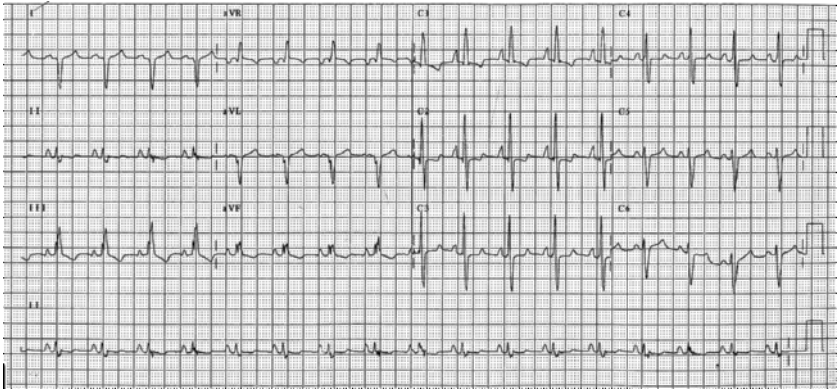


Fig. 5.2 12-Lead ECG of our patient with Eisenmenger syndrome. ECG shows p-pulmonale, right ventricular hypertrophy, strain, and right axis deviation.

Outcomes

Survival in Eisenmenger syndrome (ES) is distinctly better than in IPAH. A contemporary cohort suggests survival beyond 50 years is now common [2].

Patients with greater disease complexity, poor functional class, arrhythmia, Down syndrome, heart failure, longer QRS and QTC intervals, low serum albumin, and higher uric acid levels have worse outcomes. Modes of death

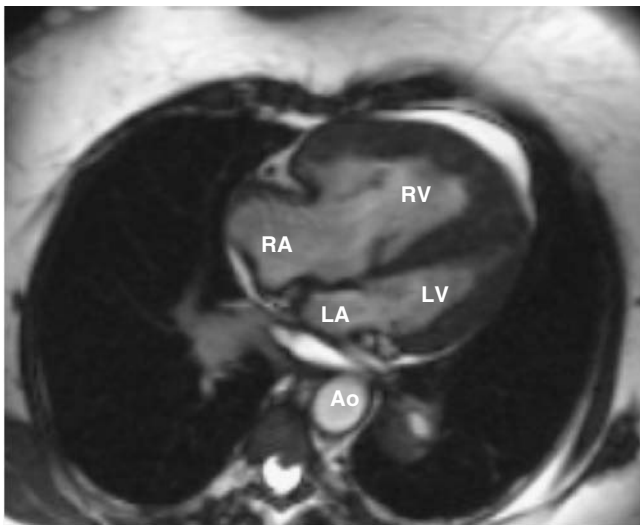


Fig. 5.3 MRI heart of our patient – four-chamber view. There is marked RVH and dilation with relative compression of LV cavity. Ao, aorta; LA, left atrium; LV, left ventricle; RA, right atrium; RV, right ventricle.

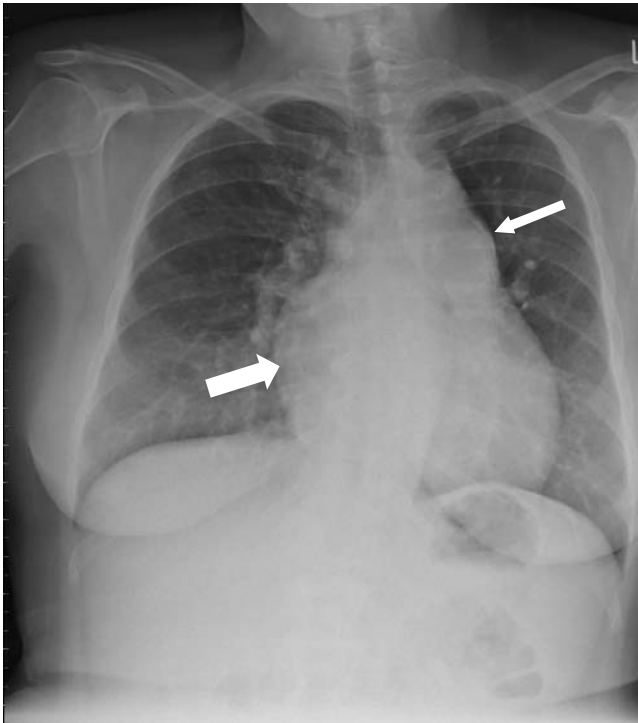


Fig. 5.4 Chest x-ray of our patient shows scoliosis, calcified and dilated pulmonary artery and patient ductus arteriosus (thin arrow), enlarged RA (big arrow), and increased cardiothoracic ratio.

are multifold. Noncardiac surgery (up to 38%) and pregnancy (40%) carry a particularly high mortality risk. Other mortality causes include sudden cardiac death (21–47%), congestive heart failure (23–42%), hemoptysis (3–29%), infective endocarditis (6%), and cerebrovascular accidents (6%) [3–5].

History

In 1987, Victor Eisenmenger described a 32-year-old man with a perimembranous ventricular septal defect (VSD) 2–2.5 cm in size who was cyanosed and in heart failure; he eventually died of hemoptysis. Only 50 years later was it revealed that such cases have systemic PA pressures and a right-to-left shunt. Paul Wood accordingly redefined the physiology of Eisenmenger complex as follows: “PAH at systemic level, due to high PVR (>800 dynes. s/cm⁶), with reversed or bidirectional shunting through a large VSD 1.5 to 3 cm in size” [5]. Wood noted that a large number of CHD lesions causing direct communication between the systemic and pulmonary circulations (>15 mm for VSD, 7 mm for aortopulmonary window, and >30 mm for atrial septal defect [ASD]) may cause this physiology (Table 5.1).

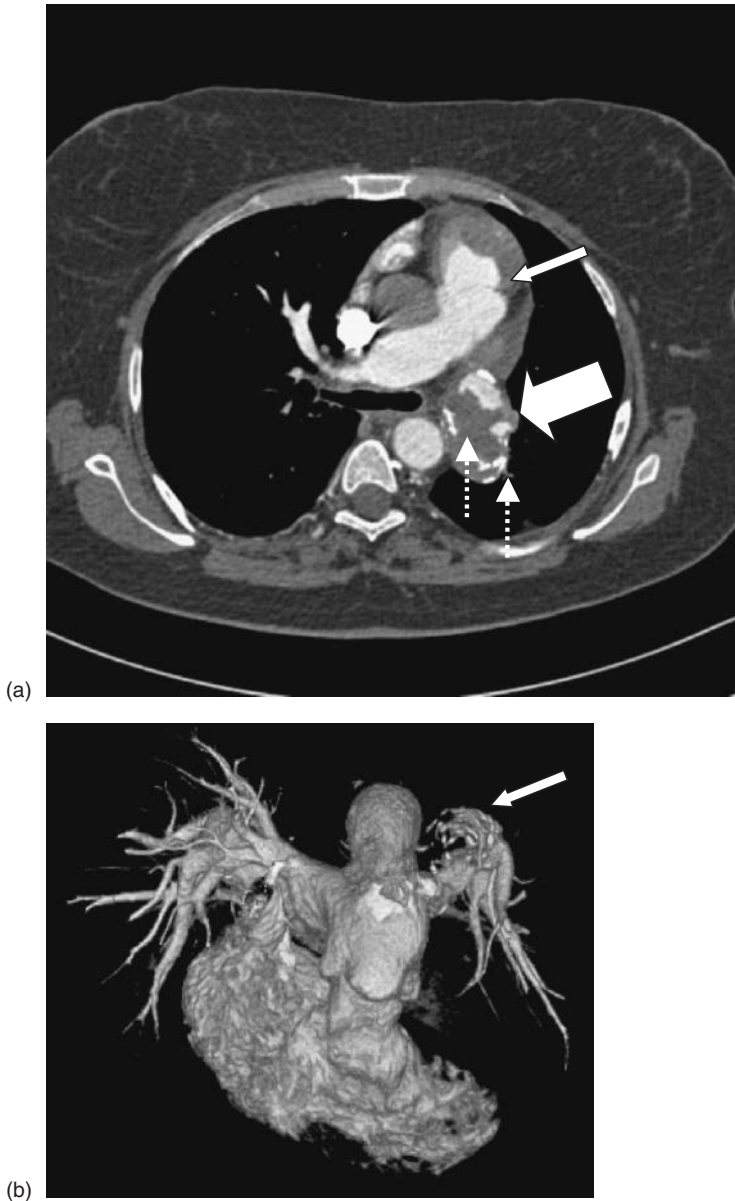


Fig. 5.5 CT angiogram of patient. (a) Markedly dilated central pulmonary arteries (thin arrow); extensive in situ thrombosis in proximal left pulmonary artery (LPA) (big arrow) with calcified older thrombus (dashed arrows). (b) Three-dimensional reconstruction: filling defect in proximal LPA and occluded upper lobe branch.

Table 5.1 Congenital lesions causing direct communication between the systemic and pulmonary circulations.

	Total No. of cases	No. with Eisenmenger reaction	Frequency of Eisenmenger reaction (%)
<i>Patent Ductus Arteriosus</i>	180	29	16
<i>Aortopulmonary Septal Defect</i>	10	6	60
<i>Persistent Truncus Arteriosus</i>	4	4	100
<i>Transposition of the Great Arteries with Ventricular Septal Defect</i>	12	7	58
<i>Congenitally Corrected Transposition of the Great Arteries with Ventricular Septal Defect</i>	3	3	100
<i>Single Ventricle</i>	6	6	100
<i>Ventricular Septal Defect</i>	136	21	16
<i>Common Atrioventricular Canal or Persistent Ostium Primum</i>	21	9	43
<i>Single Atrium</i>	—	—	—
<i>Atrial Septal Defect</i>	324	19	6
<i>Common Atrium Hemi-anomalous Pulmonary Venous Drainage</i>	3	0	0
<i>Total Anomalous Pulmonary Venous Drainage</i>	6	1	17
<i>Site Uncertain</i>	22	22	—

From: Wood's Croonian lectures.

The pathophysiology and genetics of PAH in ES

Multiple biologic pathways regulate PA pressure through vasoconstrictor and vasodilator interaction [6] (Fig. 5.6). These pathways are potentially subject to genetic mutation and resultant PAH. In CHD shunt lesions, there is high flow and/or pressure. The prominent shear stresses consistent with these lesions injure the pulmonary vascular endothelium. This injury triggers disorganized cellular proliferation and apoptosis, smooth muscle cell migration, fibrosis, inflammation, and disrupts normal endothelium function (i.e. activation of clotting pathways, release of growth factors, and altered release of vasoactive substances). Endogenous elastases and matrix metalloproteinases contribute to

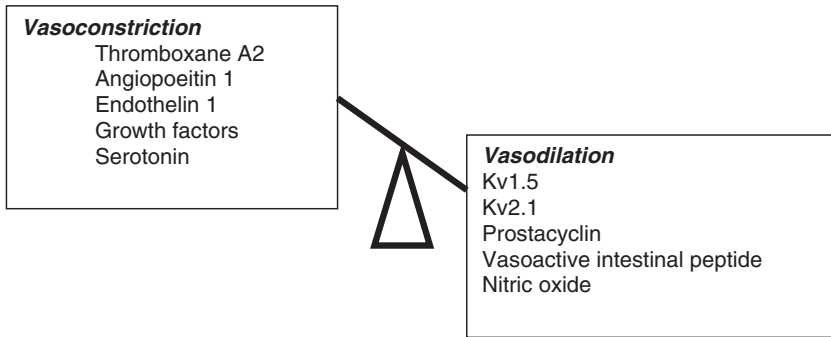


Fig. 5.6 Vasoconstrictor and vasodilatory homeostasis in the regulation of pulmonary artery pressures.

disruption of the extracellular matrix. Tenascin and fibronectin release magnify proliferative responses and promote smooth muscle cell migration.

Pathologically, early disease (potentially reversible) is marked by medial hypertrophy of small PAs and extension of muscularization into the intra-acinar pulmonary arterioles. Eventually there is loss of the PA bed through obliterative changes, loss of intra-acinar PAs, and development of the so-called plexiform lesions and necrotizing arteritis (considered irreversible). Pulmonary vascular resistance (PVR) rises due to this “fixed” reduction in the PA bed, compounded by a small dynamic component [7,8].

Sixty to eighty percent of familial PAH, and 6% of PAH secondary to CHD, is associated with germline mutations of bone morphogenetic protein receptor II, located on chromosome 2q33. Mutations in Alk 1, located on 12q13, have also been identified in IPAH and familial PAH [9].

In secondary PAH, such as ES, mechanisms other than those mediated by TGF- β mutations must be at work. Angiopoietin-1 [10], for example, a 70-kDa angiogenic factor essential for vascular lung development, is highly expressed in PAs affected by secondary PAH. It causes almost complete steady-state down-regulation of BMPRI1A, an essential cofactor for heterodimerization of the BMPRII receptor. Without this heterodimerization, downstream SMAD signaling may be compromised. The resultant effect may be signal transduction failure, as in the primary BMPRII mutations. Not surprisingly, angiopoietin-1 expression is closely correlated with measurements of PVR in patients with secondary PAH.

The evaluation of PAH in ES

ES is a multisystem disorder, and medical management must focus on the whole patient. The disease impacts physical, social, and emotional functioning, quality of life, and the ability to procreate. Good management necessitates multidisciplinary involvement (specialist nurse, surgeon, cardiologist, pulmonologist,

anesthesiologist, gynecologist and family planning expert, hematologist, orthopedic surgeon, psychologist, and physiotherapist).

General examination

Cyanosis, plethora, and conjunctival injection are characteristic features. Physical assessment includes evaluation of the integument for acne, which is common in ES. The joints and long bones are prone to hypertrophic osteoarthropathy, clubbing, and gout. The thoracic cage frequently has evidence of kyphoscoliosis, resulting in marked restrictive lung disease. In our experience, patients frequently have associated osteoporosis/osteopenia. A history of obstructive sleep apnea, which may exacerbate PAH, should be sought. The patient's general nutritional status also should be assessed.

Cardiac examination

Residua of the underlying clinical lesion may persist (e.g. wide splitting of the second sound in ASDs). Right ventricular lift and a retractile apex indicate RV hypertrophy. Tricuspid regurgitation may occur late and sometimes is loud and at higher frequency because of elevated RV pressures. Because of preserved right atrial compliance, V waves may not always be a reliable sign of severe tricuspid regurgitation. Venous pressures remain low for the same reason until late in the disease. The Graham-Steele murmur of high pressure pulmonary regurgitation and an RV third heart sound may be present.

Special investigations

Special investigations should be used to: confirm PAH and define the underlying anatomic lesion; establish disease severity; determine whether the cardiac lesion is operable; identify complications of ES; assess therapeutic responses; and prognosticate outcomes.

A 12-lead ECG usually demonstrates features of the underlying anatomic defect and additionally may indicate RA and RV hypertrophy with right axis deviation.

Two-dimensional echocardiography (\pm transesophageal echocardiography) together with bubble contrast study will often establish the underlying shunt lesion and any associated defects and will determine PA systolic and diastolic pressures. In the absence of tricuspid regurgitation, pulmonary acceleration and deceleration times [11], pre-ejection times, D-shaped ventricular septum, and steep early mitral inflow pattern are useful markers of PAH. Myocardial function, ventricular interaction, and left ventricular deformation can be assessed.

Cardiac catheterization is usually not necessary in the adult ES patient, perhaps with the following exceptions:

- The new patient with incomplete diagnostic information;
- Assessing operability where a significant left-to-right shunt is suspected;
- In complex lesions, e.g. single ventricle physiology, where common mixing makes the diagnosis of ES difficult.

Cardiac catheterization provides information on vasoreactivity (i.e. 20–30% decrease in PVR). Up to 29% of ES patients are responsive to inhaled nitric oxide, and these patients have a better midterm outcome [12]. Patients with a dominant right-to-left shunt are unlikely to be reactive. The Fick principle is commonly used to determine flow and resistances. Significant error is introduced when O₂ consumption is estimated and when the FiO₂ > 50%. In the latter situation, dissolved O₂ should be included in all hemodynamic calculations. PVR of greater than 6 Wood Units in the presence of vasodilators should be considered high risk if reparative surgery is undertaken.

CT and CTPA scan provide useful information regarding underlying lung pathology and the pulmonary vascular bed (thrombosis, neovascularization, PA size, hemorrhage, compression lesions) [13].

MRI complements functional and anatomic information obtained from the echocardiogram and additionally can elicit the resting right-to-left shunt and potentially detect enhanced PA flow in 100% oxygen.

Hemostatic defects

The patient in this case study had thrombocytopenia. She also had in situ PA thrombosis. ES patients have a hemostatic diathesis coexisting with a thrombotic tendency. The bleeding diathesis is characterized by prolonged INR, prothrombin, and activated partial thromboplastin times, thrombocytopenia, and thrombasthenia. Vitamin K-dependent clotting factors, including II, VII, IX, X, and factor V are reduced, as is von Willebrand factor antigen [14]. Tissue plasminogen activator is increased, promoting protein C-dependent anticoagulation. Thrombocytopenia is inversely correlated to the magnitude of right-to-left shunt and may be attributable to diminished megakaryocyte fragmentation in the lungs as the right-to-left shunt progresses [15]. Platelet release abnormalities correlate with erythrocytosis (PCV > 59%) and patient age (>45 years). Thrombocytopenia and platelet dysfunction improve quickly (within hours) following phlebotomy and also improve when better saturations are established with disease-targeting therapies. ES patients are therefore at increased risk of hemoptysis, gastrointestinal bleeding, and bleeding related to procedures such as dental intervention. In the presence of severe hemorrhage, consider replacement of coagulant factors, desmopressin when von Willebrand antigen is depressed, and platelet replacement.

The prothrombotic tendency may be in part attributable to the PA endothelial injury inherent to the disease [16] and activation of the clotting cascade. D-dimers increase with advancing patient age and lower saturations. These findings suggest increased cross-linked fibrinogen breakdown, i.e. following intravascular coagulation. This prothrombotic tendency, along with erythrocytosis and hyperviscosity-related sludging in the microcirculations, promotes thrombosis. The increased red cell mass causes hyperviscosity, leading to vascular stasis and poor perfusion. This could result in widespread intravascular

deposition of fibrin and platelet thrombi and consumption of platelet and coagulation factors, leading to disseminated intravascular coagulation. Dilated vessels with slow flow, as in the PAs in ES, are at high risk of thrombosis.

Intrapulmonary thromboses

This occurs at a high frequency of up to 30% [17]. Our patient had extensive left-sided thrombosis. Her risk factors were older age, female gender, severe dilation of proximal pulmonary arteries, history of atrial arrhythmia, and presence of ventricular dysfunction.

Female patients with lower oxygen saturations and an age >35 years are at highest risk. Recently Broberg and colleagues [18] demonstrated additional risk factors, including lower peak PA systolic velocities, greater PA size, and ventricular dysfunction.

Secondary erythrocytosis, iron deficiency, and stroke risk

Our patient had a total of three venesections. These were instituted because of presumed hyperviscosity symptoms. The isolated erythrocytosis seen in ES is secondary to tissue hypoxemia driving renal erythropoietin release. When serum erythropoietin levels normalize, appropriate red cell mass has been achieved, the so-called compensated state. With systemic arterial saturations <75%, homeostasis may not be achieved, resulting in hyperviscosity symptoms. When iron stores are low (previous phlebotomy, gastrointestinal or genitourinary bleeds), in the presence of a decompensated state, the risk of cerebrovascular accidents, either venous or arterial, is increased up to 14.7% [19]. Microcytosis and adversely altered rheology in the microcapillaries are believed to be responsible. The risk is highest in older patients or in the presence of arrhythmia and hypertension.

Routine venesection in asymptomatic patients who are iron-replete with high hematocrits is considered poor practice. Higher hematocrits are necessary for better oxygen transport and improved exercise capacity [25]. However, it is important to consider venesection when hyperviscosity symptoms are present (usually headache and poor concentration). The hematocrit in relation to iron status should dictate the approach to venesection (Table 5.2). Hyperviscosity symptoms are correlated with higher hematocrit but are not necessarily with associated iron deficiency. Venesection of one unit only with an equal volume of fluid replacement, and using air filters, needs to be undertaken slowly (over 1 hour) with adequate monitoring as sudden drops in systemic vascular resistance may occur. The ideal hemoglobin for a given degree of hypoxemia does not exist in the literature, but when symptoms are present, 500 cc venesectioned blood is usually sufficient.

Noncardiac surgery

Our patient had a syncopal episode while awaiting a surgical biopsy of her uterine mass. Potential reasons for this are dehydration, vasovagal syncope, and arrhythmia-related syncope.

Table 5.2 Management of Symptomatic Hyperviscosity

Hyperviscosity Symptoms	Hematocrit/Fe	Action
No	Any	No venesection (unless preoperatively)
Yes	>60/Fe replete Not dehydrated	Isovolumic venesection ~400 ml
Yes	<65/Fe deficient	Treat underlying cause of Fe deficiency. No venesection. Consider low dose Fe
Yes	>65/Fe deficient	Treat underlying cause of Fe deficiency. Avoid venesection. Cautious Fe +/- Hydroxyurea

Fe, iron.

Admission for noncardiac surgical procedures presents a potentially hazardous time for ES patients with an up to 30% mortality risk. A decrease in systemic vascular resistance (SVR) may promote right-to-left shunting, precipitating cardiovascular collapse and death. Where there is no ventricular or great arterial shunt (e.g. ASD), relative increases in PVR above SVR may precipitate RV ischemia and ventricular dysrhythmia as RV coronary supply is compromised. Sudden increases in SVR, on the other hand, may lead to depressed ventricular function as the fixed PVR remains high, adding to the ventricular systolic afterload. Patients with overt RV dysfunction and tricuspid regurgitation appear to be particularly at risk. Chronic hypoxia leads to reduction in ventricular diastolic compliance and overall myocardial reserve.

Preoperative starvation not appropriately managed may cause dehydration, potentially triggering venous and/or arterial thrombosis. Sedative premedication, popular because of its potential ability to reduce oxygen consumption, may reduce SVR.

Barbiturates tend to cause potent peripheral vasodilatation. In general, however, the rate and dose administered are more important than the actual drug used. The effect of right-to-left shunting on delaying the uptake of inhaled drugs is rarely problematic, although inhaled induction of anesthesia is prolonged. The bleeding diathesis of ES increases risk of hemorrhage, which may lead to a sudden decreased pre- and afterload that may precipitate cardiovascular collapse. Epidural and spinal anesthesia, though successfully applied in minor and short procedures, also has the potential hazard of dropping pre- and afterload. Perioperative arrhythmia may further destabilize hemodynamics.

In the postoperative phase, the patient is at risk of venous thrombosis and thromboembolism. Early after surgery, the relative postural hypotension that

occurs may drop SVR acutely. Good postoperative analgesia is essential in avoiding sympathetic overdrive, but care needs to be taken to avoid precipitous reduction in SVR.

The following measures may assist in reducing risk of noncardiac surgery in ES patients:

- 1 Careful preoperative evaluation (history, examination, ECG, x-ray, CT scan, full blood count, clotting profile, blood chemistry, echocardiography). The risk-benefit profile of the noncardiac surgery should be reviewed by the most experienced members of the team.
- 2 Preoperative venesection may be considered if the hematocrit is $>65\%$. This usually relieves the thrombocytopenia, and there may be a relative increase in cardiac output.
- 3 Air filters should be used on intravenous lines to avoid air embolism.
- 4 Intravenous fluids should be used when the patient is fasting. We normally would start intravenous fluids at midnight on the day prior to the proposed intervention.
- 5 Preoperative planning should permit the most capable surgeons and cardiac anesthesiologists to manage or contribute to the perioperative care of the patient.
- 6 The procedure should be as short and complication-free as possible and hemorrhage avoided. Changes in hemodynamics should be detected and treated early. This requires meticulous intraoperative monitoring with central venous and intra-arterial pressure monitoring and pre- and postductal saturations where appropriate. Direct PA pressure monitoring is not usually necessary as most patients with ES have an unrestrictive communication between the systemic and PA circuits necessitating equivalent systemic and PA pressures. Anesthetic agents that minimally alter the vascular tone are preferred. Our preferred strategy is a standard benzodiazepine/opiate cardiac anesthetic as it is the most neutral, with attention paid to preload using volume and manipulating SVR with phenylephrine.
- 7 Phenylephrine may be useful for treating systemic vasodilatation, although the combination alpha and beta agonist may also be considered.
- 8 Bleeding may respond to platelet transfusion, vitamin K-dependent clotting factors, and, when acquired von Willebrand syndrome is present, desmopressin.
- 9 Postoperatively deep venous thrombosis prophylaxis with elastic stockings, pneumatic venous compression devices, and heparin when the bleeding risk has been assessed.
- 10 General anesthesia is generally preferable to epidural and/or spinal anesthesia.
- 11 Local anesthesia is preferable whenever feasible.
- 12 Adequate pain management is crucial but not at the expense of dropping SVR.

13 When postoperative ventilation is necessary, the cardiopulmonary interaction needs to be critically evaluated. Paralysis and IPPV is generally preferable to avoid deep anesthesia and reflex movements in response to pain, and it also allows better control of carbon dioxide and hypoxia. Ventilator settings should preferably be kept around or just above the functional residual capacity.

Renal dysfunction

Our patient also had chronic renal failure with underlying mesangiocapillary glomerulonephritis. Though this likely reflects a non-ES cause for her renal disease, the histological characteristics of ES nephropathy are not well defined. Renal dysfunction is often present at the time of diagnosis of ES. Indeed, of all cyanotic patients, at least 30% have renal dysfunction, particularly in those with longer duration cyanosis and higher hematocrits [20]. They present with proteinuria and reduced glomerular filtration rates. Potential mechanisms include raised viscosity and microembolism. Hyperviscosity due to erythrocytosis may induce an angiogenic increase in the glomerulocapillary bed, causing glomerulomegaly. Megakaryocyte shunting into the arterial circulation bypassing normal fragmentation in the lungs has been documented in the glomerulus [21]. Glomerulopathy is probably the predominant lesion, although tubular dysfunction does coexist. This includes proximal and distal renal tubular acidosis [22]. In addition, there may be a failure of compensatory mechanisms to respond to reduced renal plasma flow by hyperfiltration, causing progression of nephropathy. ACE inhibitors are beneficial in reducing protein excretion but not other renal parameters [20]. Steroid therapy has variable success. Hyperuricemia reflects a decline in GFR as its excretion is reduced. Elevated uric acid levels are a risk for poor outcome in ES patients.

Coronary ischemia

Our patient had intermittent angina, particularly during exertion or tachycardia. RV ischemia in PAH is well recognized. Right coronary arterial flow is best autoregulated when there is both systolic and diastolic flow and when the PA pressures are low. In PAH, the RV functions at systemic pressures, making right coronary arterial flow predominantly diastolic. At high PA pressures, coronary flow autoregulation fails much earlier during systolic stress. The RV end-diastolic pressure rises, RV stroke volume decreases, and cardiac output falls, with a decrease in aortic pressure and therefore further reduction in coronary perfusion pressure. The patient therefore enters a spiral of decompensation, ending in cardiovascular collapse and ventricular dysrhythmia. These observations draw attention to the importance of maintaining good systemic blood pressures, preference given to selective pulmonary vasodilators, and aggressive management of events that raise myocardial oxygen demand acutely, e.g. arrhythmia.

More recently, left coronary arterial compression by either the main pulmonary trunk or the proximal right pulmonary artery as an additional mechanism of coronary insufficiency has been documented [23]. The enlarging RV displaces the left ventricle more apically and forces anticlockwise rotation of the heart relatively to the aorta. This combined with aneurysmal pulmonary arteries provides the anatomic substrate for left coronary ostial compression and associated ischemia. This has been successfully treated with coronary stenting while awaiting heart–lung transplantation. Our patient’s symptoms improved significantly once sildenafil was started.

Contraception

Because of the high risk of mortality (up to 50%) that pregnancy carries in ES and PAH associated with CHD, effective contraception is imperative [24]. The choice of contraception should take into account not only the presence of PAH, but also the presence of a right-to-left shunt (risk of paradoxical embolism), previous thrombotic events, including in situ pulmonary arterial thrombosis, presence of atrial fibrillation, previous endocarditis, ventricular dysfunction, and drug therapy that may interfere with the effectiveness of the contraceptive choice, and vice versa. By and large, estrogen (combined oral contraceptive pill)-containing contraceptives are contraindicated because of their prothrombotic risk, including both arterial and venous thrombosis, and barrier methods alone do not have a high enough success rate. Progesterone-only methods are recommended. These include the following:

- 1 Progesterone-only pill (Cerazette), which has a 12-hour window of safety if the pill has been omitted; Cerazette may affect the INR, and this has to be checked more frequently during initiation. Progestogens may cause fluid retention and therefore more careful monitoring of the patients is necessary if they already have congestive heart failure. Hepatic enzyme-inducing drugs (bosentan, antibiotics) reduce its efficacy and additional protection is required.
- 2 Depo-Provera injections, best given every 12 weeks, carry a high efficacy similar to sterilization. In the presence of Coumadin, however, there is a significant risk of hematoma formation. Many women become amenorrheic with Depo-Provera, and this carries an advantage when anticoagulated. As with all progesterone-based methods, caution should be exercised in the presence of congestive heart failure and when hepatic-inducing drugs are taken.
- 3 Implanon (subcutaneous implant) is highly effective, similar to sterilization. It can be inserted under local anesthesia and provides protection for a 3-year period; then it needs to be re-implanted. Hematoma formation is less of a problem. Around 20% of women become amenorrheic. This method is ideal for women with ES.
- 4 The Mirena implant can be implanted in nulliparous women and has high efficacy similar to contraception. Implantation, however, carries a very significant risk of vasovagal syncope in up to 5% of women, which may be fatal

in women with ES. It also carries a risk, albeit small, of infective endocarditis. Given these concerns, it is not the ideal first choice in women with ES, although in selected cases it may be necessary.

Sterilization causes some concerns in women with ES. It requires a surgical procedure, albeit possible through a mini-laparotomy, and carries a late failure rate especially in younger women. Ectopic pregnancy may occur in sterilized women, and this would be particularly problematic in a woman with ES, who is anticoagulated. Occasionally, however, this method is the only feasible option, and then it can be undertaken with relative safety using a combined low-dose epidural–spinal approach, and low-volume CO₂ (<200 cc). Careful patient monitoring in the presence of experienced and specialized staff used to dealing with such patients is necessary. More recently, hysteroscopic sterilization, using the Essure microinsert device, has been accomplished successfully and avoids the problems associated with surgical sterilization [25].

In summary, progesterone contraceptive methods are the method of choice for ES patients. The subcutaneous implant has many attractive features, making it the most ideal method. Other acceptable methods include a progesterone-only pill (Cerazette) and Depo-Provera.

Managing ES

General principles

Patients with ES should be assessed and followed up at a specialist adult CHD center with PAH expertise, or that has connections with such a center. The general and specific assessment of the ES patients has already been discussed above.

Patients should be advised on the following:

- 1 Exercise recommendation: avoidance of strenuous exercise.
- 2 Avoidance of dehydration.
- 3 Signs and symptoms of endocarditis and brain abscess so that the patients can help facilitate early detection and treatment.
- 4 Pregnancy and contraception need detailed discussion. Menstrual problems may need further evaluation.
- 5 Avoidance of cigarette smoking and recreational drugs.
- 6 Flying recommendations: air cabin pressures are maintained at a level equivalent to 2000 m. This is well tolerated by most patients with ES. General deep venous thrombosis prophylaxis precautions are also useful, including avoidance of dehydration, elastic leg stockings, and prolonged immobility.
- 7 The benefit of annual influenza vaccination and pneumovax.

Further considerations

Home oxygen

Early studies demonstrated a survival benefit in children with ES. This, however, has not been demonstrated in adults with advanced disease. In our experience,

some patients have, however, benefited symptomatically from having home supplemental oxygen, although its use is debated given the obligatory right-to-left shunt. Supplemental oxygen does raise arterial hemoglobin saturation in some adult ES patients, however, presumably through oxygen-mediated pulmonary vasodilatory effects [26].

Anticoagulation

Due to the coexistence of a bleeding tendency as well as a thrombotic tendency, anticoagulation is not routinely advised. In patients with in situ pulmonary thrombosis, the risk of anticoagulation needs careful evaluation against the risk of PA rupture and bleeding as well as bleeding from distal pulmonary infarcts.

Erythrocytosis

Maintaining a well-compensated, stable secondary erythrocytosis that is iron-replete is fundamental to ensuring good oxygen delivery and preventing stroke and hyperviscosity symptoms.

Heart–lung transplantation

Contrary to idiopathic PAH, the natural survival of patients with ES is often better than the survival benefit obtained with lung–heart transplantation (73% at 1 year, 51% at 5 years, and 28% at 10 years) [27]. This means that transplantation referral in clinical practice is a complex decision to make. Patients who are markedly symptomatic and who demonstrate risk factors for a poor life expectancy (poor functional class, congestive heart failure, poor saturations, onset of atrial and ventricular dysrhythmia, and patients beginning to demonstrate renal compromise) should be evaluated.

Disease-targeting therapies

Prostacyclin and its derivatives

Prostacyclin has well-established efficacy in IPAH with improved survival, functional class, and quality of life. In ES, its efficacy has been established in two small, open-label cohort studies [28,29]. It improved functional class in up to 80%, improvement in arterial saturation of 0–16%, decreased PVR by 50%, and improved 6-minute walk distance. The dosage of prostacyclin used in these trials was 14 ng/kg/min and 82 ng/kg/min. Prostacyclin is limited by its need for intravenous administration and side effect profile (jaw pain, headache, diarrhea and nausea, rash, extremity pain, impotence, weight loss, infection, thrombo-emboli, systemic hypotension, worsened ascites, coronary steal, rebound PAH upon cessation of infusion, and thrombocytopenia). These limitations have kindled important research into modifying delivery of prostacyclin and its analogues. These include subcutaneous Treprostinil, oral Beraprost, inhaled Iloprost and Treprostinil, and oral UT 15-C. Current reports on these agents in ES are limited, but small series demonstrate a beneficial effect.

Endothelin receptor blockade

Bosentan is a dual endothelin receptor antagonist that reduces PA resistance and the degree of fibrosis and inflammation in the lungs. It has established efficacy in ES. It results in improved functional class (57–100% improve by at least 1 class [30,31]. Arterial saturations improved by 5%, 0%, and 11%. PVR was reduced at 16 weeks by 9% versus a 5% worsening in the placebo group. Six-minute walk distance improved by 13% (43 minutes \pm 8 minutes) during the same time. One patient had significant side effects necessitating cessation of treatment, and two (5.5%) in the treatment arm needed to stop treatment because of elevation in liver enzymes. Long-term survival benefit still needs evaluation. Another endothelin receptor antagonist is Sitaxsentan, which is a selective endothelin A receptor inhibitor. There are currently no data of its use in ES.

Phosphodiesterase Inhibitors

Phosphodiesterase type 5 inhibitors have proven effective in the management of IPAH. The best known amongst this group is sildenafil. Others include Tadalafil (longer half-life) and Vardenafil. A small number of open-label studies looking at the acute hemodynamic effect and longer outcomes have demonstrated not only safety but also effectiveness in terms of modulating the ES hemodynamic profile. Saturations improved by 10% at 6 months, 7% at 19 months, and 5% at 3 months. PVR dropped by 50% at 6 months, 30% at 3 months, and 43% at 19 months [32–34]. SVR did not change except when a higher dose of sildenafil (276 mg/day) was used. This was associated with a significant increase in cardiac output (2.9–3.7 L/min/m²). There are currently no randomized, placebo-controlled trials confirming its efficacy. More recent data demonstrate that phosphodiesterase inhibition may stimulate inotropy in hypertrophied right ventricles [35].

Future therapeutic strategies

Future drugs are likely to tackle a number of the pathways outlined above that regulate intracellular signaling, smooth muscle cell migration, and membrane-bound receptor proteins, including Kv channels.

Case study

This patient was started on sildenafil 20 mg t.i.d., home oxygen therapy, and her heart failure therapy was intensified. This resulted in improved functional class and general sense of well-being.

References

1. Barst RJ, McGoon M, Torbicki A, et al. Diagnosis and differential assessment of pulmonary arterial hypertension. *J Am Coll Cardiol* 2004;43:40S–47S.

2. Diller GP, Dimopoulos K, Broberg CS, et al. Presentation, survival prospects, and predictors of death in Eisenmenger syndrome: a combined retrospective and case-control study. *Eur Heart J* 2006;27:1737–42.
3. Cantor WJ, Harrison DA, Moussadji JS, et al. Determinants of survival and length of survival in adults with Eisenmenger syndrome. *Am J Cardiol* 1999;84:677–81.
4. Daliento L, Rebellato L, Angelini A, et al. Fatal outcome in Eisenmenger syndrome. *Cardiovasc Pathol* 2002;11:221–8.
5. Wood P. The Eisenmenger syndrome or pulmonary hypertension with reversed central shunt. *Br Med J* 1958;2:755–62.
6. Humbert M, Morrell NW, Archer SL, et al. Cellular and molecular pathobiology of pulmonary arterial hypertension. *J Am Coll Cardiol* 2004;43:13S–24S.
7. Heath D, Edwards JE. The pathology of hypertensive pulmonary vascular disease; a description of six grades of structural changes in the pulmonary arteries with special reference to congenital cardiac septal defects. *Circulation* 1958;18:533–47.
8. Rabinovitch M, Haworth SG, Castaneda AR, Nadas AS, Reid LM. Lung biopsy in congenital heart disease: a morphometric approach to pulmonary vascular disease. *Circulation* 1978;58:1107–22.
9. Roberts KE, McElroy JJ, Wong WP, et al. BMPR2 mutations in pulmonary arterial hypertension with congenital heart disease. *Eur Respir J* 2004;24:371–4.
10. Du L, Sullivan CC, Chu D, et al. Signaling molecules in nonfamilial pulmonary hypertension. *N Engl J Med* 2003;348:500–9.
11. Mirrakhimov MM, Tenenbaum AM, Moldotashev IK, Niazova ZA, Zlatkovsky ML. New approaches to noninvasive assessment of pulmonary artery pressure. *Clin Cardiol* 1992;15:811–16.
12. Post MC, Janssens S, Van de Werf F, Budts W. Responsiveness to inhaled nitric oxide is a predictor for mid-term survival in adult patients with congenital heart defects and pulmonary arterial hypertension. *Eur Heart J* 2004;25:1651–6.
13. Sheehan R, Perloff JK, Fishbein MC, et al. Pulmonary neovascularity: a distinctive radiographic finding in Eisenmenger syndrome. *Circulation* 2005;112:2778–85.
14. Henriksson P, Varendh G, Lundstrom NR. Haemostatic defects in cyanotic congenital heart disease. *Br Heart J* 1979;41:23–7.
15. Lill MC, Perloff JK, Child JS. Pathogenesis of thrombocytopenia in cyanotic congenital heart disease. *Am J Cardiol* 2006;98:254–8.
16. Oechslin E, Kiowski W, Schindler R, et al. Systemic endothelial dysfunction in adults with cyanotic congenital heart disease. *Circulation* 2005;112:1106–12.
17. Perloff JK, Hart EM, Greaves SM, et al. Proximal pulmonary arterial and intrapulmonary radiologic features of Eisenmenger syndrome and primary pulmonary hypertension. *Am J Cardiol* 2003;92:182–7.
18. Broberg CS, Ujita M, Prasad S, et al. Pulmonary arterial thrombosis in Eisenmenger syndrome is associated with biventricular dysfunction and decreased pulmonary flow velocity. *J Am Coll Cardiol* 2007;50:634–42.
19. Ammash N, Warnes CA. Cerebrovascular events in adult patients with cyanotic congenital heart disease. *J Am Coll Cardiol* 1996;28:768–72.
20. Fujimoto Y, Matsushima M, Tsuzuki K, et al. Nephropathy of cyanotic congenital heart disease: clinical characteristics and effectiveness of an angiotensin-converting enzyme inhibitor. *Clin Nephrol* 2002;58:95–102.

21. Perloff JK, Latta H, Barsotti P. Pathogenesis of the glomerular abnormality in cyanotic congenital heart disease. *Am J Cardiol* 2000;86:198–204.
22. Vida VL, Mack R, Barnoya J, et al. The association of renal tubular acidosis and cyanotic congenital heart disease. *J Thorac Cardiovasc Surg* 2005;130:1466–7.
23. Guerin P, Warin-Fresse K, Crochet D. Kinking of the main stem of the left coronary artery in the setting of Eisenmenger syndrome: an unusual cause of angina pectoris. *Cardiol Young* 2007;1–3.
24. Thorne S, Nelson-Piercy C, MacGregor A, et al. Pregnancy and contraception in heart disease and pulmonary arterial hypertension. *J Fam Plann Reprod Health Care* 2006;32:75–81.
25. Famuyide AO, Hopkins MR, El-Nashar SA, et al. Hysteroscopic sterilization in women with severe cardiac disease: experience at a tertiary center. *Mayo Clin Proc* 2008;83:431–8.
26. Walker F, Mullen MJ, Woods SJ, Webb GD. Acute effects of 40% oxygen supplementation in adults with cyanotic congenital heart disease. *Heart (Br Cardiac Soc)* 2004;90:1073–4.
27. Stoica SC, McNeil KD, Perreas K, et al. Heart-lung transplantation for Eisenmenger syndrome: early and long-term results. *Ann Thorac Surg* 2001;72:1887–91.
28. Fernandes SM, Newburger JW, Lang P, et al. Usefulness of epoprostenol therapy in the severely ill adolescent/adult with Eisenmenger physiology. *Am J Cardiol* 2003;91:632–5.
29. Rosenzweig EB, Kerstein D, Barst RJ. Long-term prostacyclin for pulmonary hypertension with associated congenital heart defects. *Circulation* 1999;99:1858–65.
30. Christensen DD, McConnell ME, Book WM, Mahle WT. Initial experience with bosentan therapy in patients with the Eisenmenger syndrome. *Am J Cardiol* 2004;94:261–3.
31. Kotlyar E, Sy R, Keogh AM, et al. Bosentan for the treatment of pulmonary arterial hypertension associated with congenital cardiac disease. *Cardiol Young* 2006;16:268–74.
32. Chau EM, Fan KY, Chow WH. Effects of chronic sildenafil in patients with Eisenmenger syndrome versus idiopathic pulmonary arterial hypertension. *Int J Cardiol* 2007;120:301–5.
33. Garg N, Sharma MK, Sinha N. Role of oral sildenafil in severe pulmonary arterial hypertension: clinical efficacy and dose response relationship. *Int J Cardiol* 2007;120:306–13.
34. Mukhopadhyay S, Sharma M, Ramakrishnan S, et al. Phosphodiesterase-5 inhibitor in Eisenmenger syndrome: a preliminary observational study. *Circulation* 2006;114:1807–10.
35. Nagendran J, Archer SL, Soliman D, et al. Phosphodiesterase type 5 is highly expressed in the hypertrophied human right ventricle, and acute inhibition of phosphodiesterase type 5 improves contractility. *Circulation* 2007;116:238–48.

Congenitally corrected transposition of the great arteries

Sara A. Thorne

A 30-year-old business woman was referred for a second opinion after a single episode of atrial fibrillation. The initial diagnosis was congenitally corrected transposition of the great arteries (cTGA) with ventricular septal defect (VSD) and subpulmonary stenosis. She had undergone surgical repair with closure of the VSD and subpulmonary resection 20 years before. She was NYHA I. She was known to have at least moderate systemic tricuspid regurgitation (TR).

Physical examination revealed a right ventricular heave, single second heart sound, and a pan-systolic murmur at the left sternal edge. The electrocardiogram (ECG) is shown in (Fig. 6.1). The chest x-ray showed normal situs and heart size, scoliosis, and a straight left heart border. Her echocardiogram confirmed the diagnosis. There was severe central TR. The right ventricle (RV) was hypertrophied but not dilated, and function was preserved. She exercised for 8 minutes of the Bruce protocol.

Definition

Both the atrioventricular and ventriculoarterial connections are discordant in cTGA. Thus, systemic venous blood passes from the right atrium (RA) through a mitral valve (MV) into a morphologic left ventricle (LV), and then into the pulmonary artery (PA). Pulmonary venous blood passes from the left atrium (LA) through a tricuspid valve (TV) into a morphological RV and into the aorta (Fig. 6.2).

As a result, deoxygenated blood reaches the appropriate pulmonary circulation, and oxygenated blood reaches the systemic circulation, i.e., the circulation is physiologically "corrected." However, it is not anatomically correct, since the RV and TV support the systemic circulation.

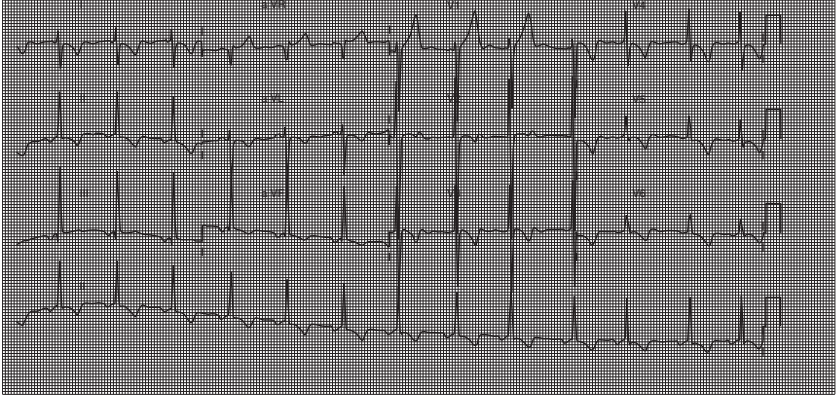


Fig. 6.1 The ECG shows sinus rhythm with right axis deviation, RV hypertrophy, and widespread T wave inversion.

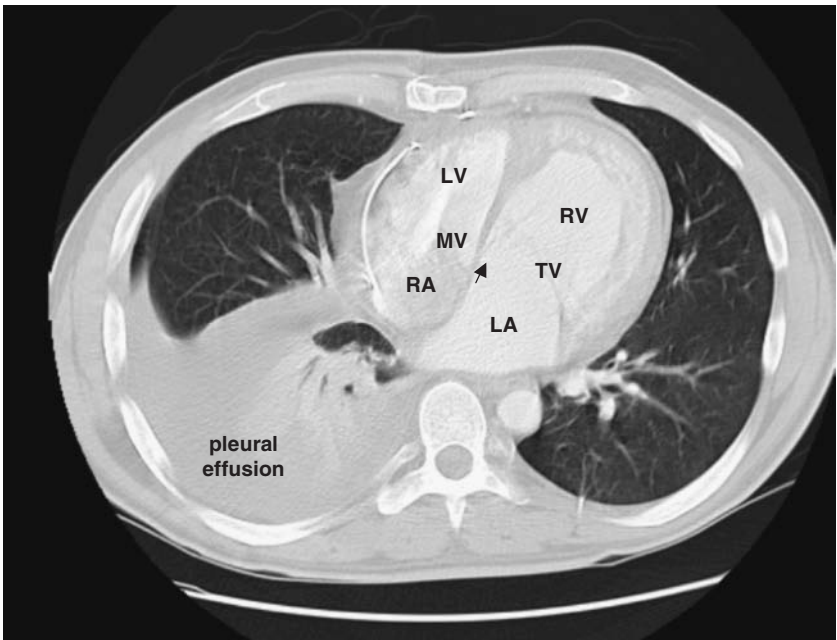


Fig. 6.2 Multislice CT scan of a 28-year-old man with cTGA. The systemic RV is dilated and hypertrophied, and the interventricular septum bows to the LV. There is apical displacement of the TV (arrow). The artefact across the MV is due to a pacing lead in the subpulmonary LV. He has a large right pleural effusion. LA, left atrium; LV, left ventricle; MV, mitral valve; RA, right atrium; RV, right ventricle; TV, tricuspid valve.

Terminology

- *Atrioventricular discordance*: The atria are connected to the wrong ventricles; the RA connects to the LV via an MV, and the LA connects to the RV via a TV.
- *Ventriculoarterial discordance*: The great vessels connect to the wrong ventricles (i.e., they are transposed), the aorta arises from the RV and the PA from the LV.
- *cTGA* is also known as *L-TGA*, from the abnormal left looping of the embryonic cardiac tube that underlies this defect. It results in the aorta lying anteriorly and to the left of the pulmonary trunk. By comparison, in simple TGA (*d-TGA*), there is right looping of the embryonic cardiac tube that usually results in the aorta lying anterior and to the right of the pulmonary trunk.

Incidence

cTGA is rare, accounting for <1% of all congenital heart disease. There are associated cardiac anomalies in 95% of cases. The diversity of these associated defects accounts for the broad clinical spectrum of cTGA and its presentation at any time from the neonatal period to the seventh decade of life.

Associated defects include:

- Ventricular septal defect (VSD)
- Pulmonary stenosis (PS) and atresia
- Ebstein-like anomaly of the TV
- Atrioventricular septal defect (AVSD)
- Coarctation of the aorta
- Abnormalities of situs, dextrocardia, mesocardia
- Congenital complete heart block

A VSD is present in 70% of cases and is usually perimembranous. If it is large and there is no protective PS, presentation will occur in early life, with heart failure.

PS occurs in 40% of cases. It may be valvar or subvalvar and due to a fibrous ring or an aneurysm of the interventricular septum.

The combination of a VSD and PS with cTGA is common, and if "well-balanced," patients may survive well into adult life without intervention, with minimal symptoms or cyanosis.

When there is an Ebstein-like anomaly of the TV, its orifice is displaced toward the apex of the systemic RV. In other respects, however, the abnormality of the TV is quite different than that of Ebstein's anomaly when it occurs in a normal heart and the valve is not amenable to repair. Some degree of abnormality of the TV is present in 90% of cases of cTGA. This, combined with its position in the systemic circulation and the inherent fragility of the TV, means that abnormal valves are likely to be regurgitant early in life, burdening the systemic RV with additional workload.

Where there is a coexistent VSD, the TV attachments may straddle the defect, making a biventricular repair difficult or impossible.

The atrioventricular (AV) node lies in an abnormal position and may be dual, with a long bundle of His that is susceptible to fibrosis. As a result, complete heart block may be present at birth or may occur at any time of life; it has a progressive incidence of around 2% per annum. The AV node is also susceptible to damage at the time of TV surgery.

Presentation

The timing and mode of the first presentation depends on TV and RV function and on the severity of associated lesions. Severe cases will present in neonatal life, but those without associated defects and with good TV and RV function may not present until late into adulthood, sometimes as a chance finding in the sixth decade.

Misdiagnosis is not uncommon for adults presenting for the first time, even after cardiac imaging. The most common presenting symptom is breathlessness, associated with systemic RV dysfunction, systemic TV regurgitation, or AV block [1].

This chapter will consider two variants of cTGA: (1) isolated, without other lesions, and (2) cTGA in association with VSD and PS.

Assessment and investigations

Examination findings depend on associated lesions. An RV heave is expected and there may be a pansystolic TR murmur. Cyanosis may be present if cTGA coexists with PS and a VSD. Signs of heart failure should be sought.

Following surgical repair with a conduit, there may be signs of conduit obstruction or regurgitation.

ECG

There are signs of RV hypertrophy. The right and left bundles are transposed along with the ventricles, so the activation pattern is abnormal, with septal activation occurring from left to right. As a result, the ECG may be misinterpreted as showing an inferior myocardial infarction with Q waves in leads II, III, and avF. There may be varying degrees of AV block.

Chest radiograph

If there is isolated dextrocardia, cTGA should always be suspected. There is usually a narrow pedicle, due to the abnormal relationship of the great vessels. The left heart border is unusually straight, as the aorta arises from the RV above a "shoulder" due to RV hypertrophy. Cardiomegaly is a late sign indicating cardiac failure.

Echocardiography

The characteristic two-dimensional echocardiographic appearances of cTGA may cause confusion to those without experience in congenital heart disease starting their examination in the parasternal long axis view. The subcostal and apical four-chamber views are most helpful in determining situs and AV–VA connections. The morphological TV is identified by its septal attachments and by its position more inferiorly toward the ventricular apex than the morphological mitral valve. Identification of the AV valves allows the ventricles to be identified: the morphological RV is served by a TV, and the LV by an MV. In addition, it may be possible to visualize the coarse trabeculations and moderator band of the morphological RV. The high parasternal short axis view shows the abnormally related great vessels. The aorta lies anteriorly and usually to the left of the PA. It may be possible to see the great vessels lying parallel to one another or to visualize them both on end.

MRI

MRI has a useful role in quantifying systemic RV volume and function and in describing the anatomy of other associated defects.

Cardiac catheterization

Cardiac catheterization is important to assess hemodynamics, ventricular function, AV valve regurgitation, and pulmonary vascular resistance.

Management

RV failure and TR

The failing systemic RV is the major problem for patients with cTGA and is often preceded by systemic TV regurgitation. Once symptomatic, the outlook is poor. TR and RV dysfunction often coexist; the two are closely related and appear to be the main determinants of long-term outcome.

Controversy exists over which is the primary abnormality; there are two main hypotheses that are not mutually exclusive.

First, the TV is morphologically abnormal in a large proportion of patients, so it may be that over time, progressive TR exerts an increasing volume load on the systemic RV, causing annular dilatation, worsening TR, and eventual failure of the RV.

The second hypothesis for the failure of the systemic RV is coronary perfusion mismatch [2]. The coronary supply to the systemic RV is different than that of a systemic LV, and may provide inadequate myocardial perfusion to meet the demands of a systemic ventricle. Even in those with normal resting myocardial perfusion, coronary reserve, assessed by adenosine-induced hyperemia, is decreased [3].

Whatever the pathogenesis, congestive cardiac failure is common in adults with cTGA. One-third of patients with isolated cTGA and two thirds with associated lesions and previous surgery are likely to develop heart failure by their forties [4]. Furthermore, once more-than-moderate TR is present, the mean time to developing cardiac failure is 5 years. In addition, TR was the major independent risk factor of death in a long-term study of 40 patients with cTGA. Unoperated 20-year survival with moderate or severe TR was 49% compared with 93% without TR, and postsurgical repair survival was 60% with TR compared with 100% with no TR [5].

If RV dysfunction is detected and significant TR is present, the TR should be assumed to be the underlying cause and consideration given to surgery to restore TV competence. However, although TV replacement can be performed with low operative mortality, there is little evidence that it alters the natural history, with continuing attrition that is largely due to progressive heart failure. Outcome is influenced by ventricular function at the time of surgery and supports the notion that patients should be referred early to centers with expertise in adult congenital heart disease for consideration of TV replacement. In one large single-center study, initial referral was late with the majority of patients being symptomatic with severe TR and a mean RV ejection fraction of 39% [6]. Although long-term survival may be improved if TV replacement is performed while RV function is "normal," i.e., RVEF >55%, no such studies have been reported.

The term "physiological repair" is used to describe any surgical approach that leaves the RV in the systemic circulation. An example is repair of cTGA with a VSD and PS with an LV to PA conduit and closure of the VSD so the RV ejects into the aorta. The problems of the systemic RV and TV have driven the development of "anatomical" surgical repairs that restore the LV and MV to the systemic circulation. Different operative approaches are discussed below.

Anatomical repair: operations to restore the LV and MV to the systemic circulation

The double-switch operation comprises both an atrial switch (Senning procedure) and an arterial switch operation. It is performed for cTGA with or without VSD in the absence of pulmonary stenosis or LV outflow tract obstruction (LVOTO).

For patients who have LVOTO, e.g., cTGA with VSD and PS, the double-switch approach would leave the patient with aortic or subaortic stenosis. Instead, a Senning procedure and a Rastelli procedure (closing the VSD so the LV connects to the aorta, ligating the main PA and placing an RV to PA conduit) are performed.

Both of these operative approaches restore the LV and MV to the systemic circulation. However, in order to be successful, a fundamental issue must be addressed, namely, whether the LV is able to support the systemic circulation.

For patients without LVOTO, the LV involutes rapidly after birth, since it only supports the pulmonary circulation. By as young as 6 weeks of age, such an LV would be unable to support the systemic circulation without first being “trained” by placing a PA band. The LV responds by becoming hypertrophied. It is likely to be suitable for a later double-switch operation and to support the systemic circulation if:

- It is able to generate pressures of 70% systemic without failing in the operating room, immediately after PA band placement.
- It maintains pressures of 70–80% of systemic pressure in the months prior to double switch.
- The posterior wall thickness reaches that of a normal systemic LV.
- There is no evidence of LV dysfunction.
- The LV pressure rises appropriately to dobutamine stress.

For patients who are born with LVOTO, the LV does not involute and so maintains its normal myocyte mass and function. Providing the LV pressure is >70% of systemic pressure, it is likely to support the systemic circulation after a Senning-Rastelli procedure.

These approaches to anatomical repair have a high early success rate, providing that patients are carefully selected [7]. Late complications include the need for conduit replacement after the Senning-Rastelli operation, atrial pathway obstruction after the Senning operation, neo-aortic regurgitation, and systemic LV failure in patients. Risk factors for LV failure include aortic regurgitation, pacemaker requirement, and a need for PA banding to train the LV prior to double switch [8].

Late LV failure in previously banded patients may reflect the fact that LV hypertrophy is a pathological process; the “trained,” hypertrophied LV may be a very different ventricle than the LV that always maintained a normal myocyte mass because of LVOTO. The response to pressure loading of an LV that has been “untrained” for many years is therefore unlikely to allow it to support systemic pressures in the long term. It is generally accepted that, after the age of ~14 years, attempting to train the LV is very unlikely to result in a successful double-switch operation [9]; therefore, conventional repairs are usually performed in adults.

A meta-analysis of reports on outcomes of anatomical repairs (restoring the LV to the systemic circulation) and traditional repairs (leaving the RV in the systemic circulation) suggests that the Rastelli-Senning procedure is associated with the best long-term outcomes [10].

Medical management issues

As with other forms of heart failure, a multidisciplinary team approach is helpful. Nurse specialists in adult congenital heart disease, heart failure, and

palliative care are all effective at improving quality of life, reducing hospital admissions, and optimizing drug therapy.

There is evidence of neurohormonal activation in cTGA and other patients with congenital heart disease with systemic ventricular dysfunction, systemic AV valve regurgitation, impaired exercise tolerance, and poor functional class [11,12]. However, there are scant data on the role of heart failure medication in cTGA, or in most forms of congenital heart disease. There are no large randomized studies; whether data from heart failure studies in patients with normally connected hearts can be extrapolated to those with cTGA is unclear. Studies of heart failure management in the general population naturally focus on those with a systemic LV and atherosclerotic risk factors and those who are older than the population with cTGA. The systemic RV, which responds so differently to pressure loading than the LV, is also likely to respond differently to heart failure interventions.

There are conflicting reports as to whether angiotensin converting enzyme inhibitors (ACEI) or angiotensin receptor blockers improve exercise capacity or RV function [13]. Furthermore, many studies combine patients with cTGA with those who underwent Mustard or Senning operations for simple TGA (VA discordance). The Mustard/Senning patients have abnormal restrictive atrial function and are likely to respond differently to ACEI therapy compared with those with cTGA. A small pilot study suggests that carvedilol may improve RV function in Senning and cTGA patients [14].

Little is known about the effects of cardiac resynchronization therapy for patients with cTGA and heart failure. However, there are concerns about failure of the subpulmonary LV after resynchronization pacing; prospective trials are needed before it can be considered a realistic therapy for patients with cTGA [15].

Transplantation is an option for patients with cTGA and a failed systemic ventricle. However, if there is abnormal situs, abnormal venous drainage, or scarring from previous operations, then the risk of transplant surgery is increased.

Pregnancy

The maternal risk of pregnancy depends on systemic ventricular function and the presence of any hemodynamically significant lesions. The risk is increased if the RV ejection fraction is <40%, especially if there is also moderate or severe TR, because the extra volume load of pregnancy may precipitate heart failure from which the ventricle may not recover. Stenotic lesions carry a high risk during pregnancy, so the patency of conduits and post-Senning pulmonary venous pathways should be demonstrated before pregnancy is considered.

Reliable contraception is important for all women with heart disease in whom an unplanned pregnancy may be dangerous. Estrogen-containing preparations can only be considered safe if there is no increased risk of thrombus formation.

As a result, the many women with significant TR and a dilated LA should use progestogen-only alternatives.

Follow-up

All patients with cTGA should have lifelong follow-up in a specialist adult congenital heart disease center. Most patients should be seen at least annually, with vigilance to detect heart block, TR, and ventricular dysfunction. For those who have undergone surgical repair, conduit function, venous pathways, and the neo-aorta should also be assessed. Electrocardiography and echocardiography should be performed as a minimum, and exercise testing and MRI should also be considered.

Case study

For this patient, TV replacement was recommended before she developed significant systemic ventricular dysfunction. The options of a tissue or mechanical valve were discussed. Her preference was a mechanical valve because she wished to avoid further surgery in the future. She accepted that this choice of valve would increase the risk of any future pregnancy because of the need for anticoagulation.

She underwent uneventful TV replacement with a 33-mm St. Jude prosthesis, but developed complete heart block postoperatively (Fig. 6.3). A permanent pacemaker was then implanted (Fig. 6.4). RV function remained good postoperatively.

She and her partner discussed the risks of pregnancy at a combined obstetric and cardiac pre-pregnancy counseling clinic. In view of the risks of anticoagulation and potential deterioration of ventricular function in pregnancy, they elected not to start a family. She had already been fitted with a Mirena[®] coil for contraception.

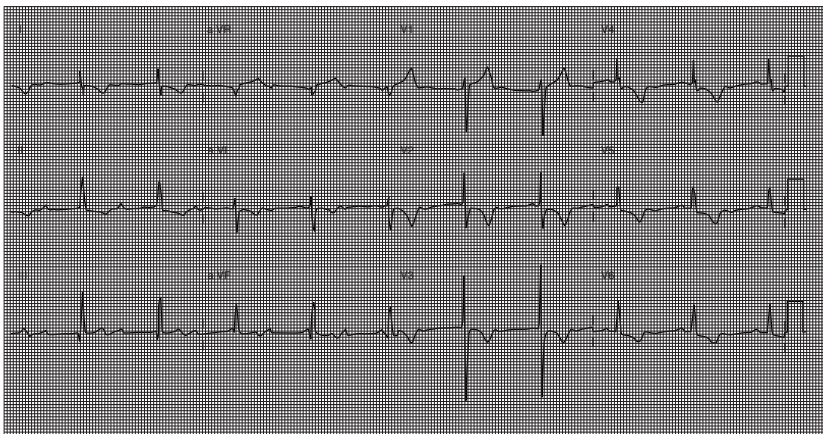


Fig. 6.3 The postoperative ECG shows complete heart block.

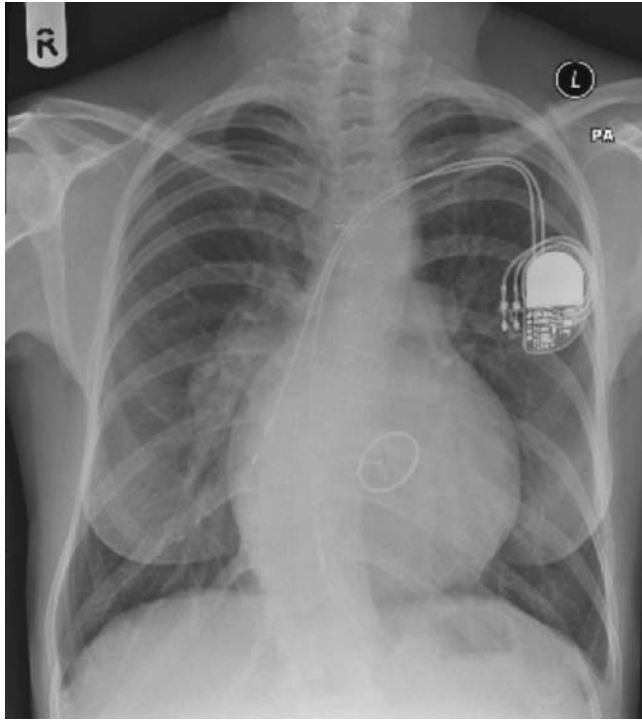


Fig. 6.4 Postoperative chest x-ray of a patient with cTGA, mesocardia, and a scoliosis. There is a dual-chamber permanent pacemaker. The ventricular lead is in the subpulmonary morphological LV. There is a 33-mm St. Jude TV.

At follow-up 7 years later, she continues to work and travel abroad. She has had no further atrial fibrillation, and her TV prosthesis functions normally. She now has NYHA II symptoms and echocardiography shows that her RV function has gradually deteriorated, now being moderately impaired.

References

1. Beauchesne L, Warnes CA, Connolly HM, et al. Outcome of the unoperated adult who presents with congenitally corrected transposition of the great arteries. *J Am Coll Cardiol* 2002;40:285–90.
2. Hornung TS, Bernard EJ, Jaeggi ET, et al. Myocardial perfusion defects and associated systemic ventricular dysfunction in congenitally corrected transposition of the great arteries. *Heart* 1998;80:322–6.
3. Hauser M, Bengel FM, Hager A, et al. Impaired myocardial blood flow and coronary flow reserve of the anatomical right systemic ventricle in patients with congenitally corrected transposition of the great arteries. *Heart* 2003;89:1231–5.

4. Graham TP, Bernard YD, Mellen BG, et al. Long-term outcome in congenitally corrected transposition of the great arteries: a multi-institutional study. *J Am Coll Cardiol* 2000;36:255–61.
5. Prieto LR, Hordof AJ, Secic M, et al. Progressive tricuspid valve disease in patients with congenitally corrected transposition of the great arteries. *Circulation* 1998;98:997–1005.
6. Van Son JA, Danielson GK, Huhta JC, et al. Late results of systemic atrioventricular-valve replacement in corrected transposition. *J Thorac Cardiovasc Surg* 1995;109:642–52.
7. Imamura M, Drummond-Webb JJ, Murphy DJ, et al. Results of the double switch operation in the current era. *Ann Thorac Surg* 2000;70:100–5.
8. Bautista-Hernandez V, Marx GR, Gauvreau K, et al. Determinants of left ventricular dysfunction after anatomic repair of congenitally corrected transposition of the great arteries. *Ann Thorac Surg* 2003;82:2059–66.
9. Quinn DW, McGuirk SP, Metha C, et al. The morphologic left ventricle that requires training by means of pulmonary artery banding before the double-switch procedure for congenitally corrected transposition of the great arteries is at risk of late dysfunction. *J Thorac Cardiovasc Surg* 2008;135(5):1137–44.
10. Alghamdi AA, McCrindle BW, van Ardeell GS. Physiologic versus anatomic repair of congenitally corrected transposition of the great arteries: a meta-analysis of individual patient data. *Ann Thorac Surg* 2006;81:1529–35.
11. Bolger AP, Sharma R, Li W, et al. Neurohormonal activation and the chronic heart failure syndrome in adults with congenital heart disease. *Circulation* 2002;106(1):92–9.
12. Koch AME, Zink S, Singer H. B-type natriuretic peptide in patients with systemic right ventricle. *Cardiology* 2008;110:1–7.
13. Dore A, Houde C, Khan KL, et al. Angiotensin receptor blockade and exercise capacity on adults with systemic right ventricles. *Circulation* 2005;112:2411–6.
14. Giardini A, Lovato L, Donti A, et al. A pilot study on the effects of carvedilol on right ventricular remodelling and exercise tolerance in patients with systemic right ventricle. *Int J Cardiol* 2007;114:241–6.
15. Kiesewetter C, Michael K, Morgan J, Veldtman GR. Left ventricular dysfunction after cardiac resynchronisation therapy in congenital heart disease patients with a failing systemic right ventricle. *Pacing Clin Electrophysiol* 2008;31:159–62.

Left ventricular outflow tract obstruction

Craig S. Broberg

A 24-year-old woman was born with coarctation of the aorta, bicuspid aortic valve, and muscular subaortic stenosis. At 4 months of age, she underwent coarctation repair with an end-to-end anastomosis. At 3 years of age, resection of a subaortic band and septal myectomy were performed. Residual stenosis was still present, so at age 5 she had an aortic root enlargement with an aortic valve replacement (19 mm St. Jude) as well as further myomectomy with patch enlargement of the left ventricular outflow tract (LVOT). A small perforation of the anterior mitral leaflet occurred at the time.

She continued to have regular follow-up with her pediatric cardiologist and remained asymptomatic. Echocardiography consistently showed a velocity of 4.1 m/s through her LVOT. She was advised to avoid strenuous activity, but no intervention was pursued given her lack of symptoms and multiple prior surgeries. The gradient remained stable over many years. She finished high school and went to college, although she gradually found it increasingly difficult to do physical activities.

She presented again after finishing college. Her blood pressure was 105/68, her pulse 86. She was thin and short for her age, but healthy in appearance. Her jugular venous pulse was mildly elevated. A 3/6 systolic murmur was best heard at the left of the upper sternum, radiating into the neck, as well as a holosystolic apical murmur. The apex beat was mildly displaced laterally. Her peripheral pulses were mildly diminished. Her electrocardiogram (ECG) showed sinus rhythm with left ventricular hypertrophy and occasional premature ventricular contractions. On a 24-hour ECG recording, she had a 5-beat run of ventricular tachycardia. Findings by echocardiography included moderate left ventricular hypertrophy but normal systolic function. There was moderate mitral regurgitation. The LVOT velocity was 4.8 m/s, with a mean gradient of 54 mm Hg. This was confirmed at catheterization; there was a 15 mm Hg subaortic gradient, and 35 mm Hg through the valve, in addition to a 10 mm Hg gradient across the coarctation.

Her left ventricular end-diastolic pressure was 24 mm Hg. She was seen at follow-up to discuss the appropriateness, timing, and type of further intervention.

General considerations

Obstruction of the LVOT is not benign. The normal complex interplay between LVOT, aortic valve, and root as a unique, integrated system has been masterfully described [1]. Because its constituent parts must work in harmony, disruption or alteration of one element can have consequences for the others. Although a wide spectrum of severity exists, many forms of LVOT obstruction can at times create serious dilemmas for the provider and patient because of the high prevalence of coexisting defects, the need for serial surgery, and the potential long-term strain on the left ventricle (LV), as the above case demonstrates. No patient with LVOT obstruction should go without routine clinical follow-up by an experienced provider. Even with close follow-up, clinical decisions can be difficult to make, with significant impact on the patient's life and outcome.

The topic of LVOT obstruction includes several congenital abnormalities that may be considered together because of their overlapping hemodynamic effects and because they often coexist. Obstruction can be valvular, subvalvular, or supravalvular, in descending order of prevalence. Although the major hemodynamic insult of each is similar, specific aspects of the various types of obstruction are worth considering and understanding separately. What follows is a review of "fixed" forms of LVOT obstruction. Dynamic outflow obstruction from eccentric septal thickening can complicate any form of LVOT obstruction, but its presence in the setting of hypertrophic cardiomyopathy merits its own discussion and is not included here.

Signs and symptoms of any type of LVOT lesion are not dissimilar to acquired aortic stenosis. Typical physical exam findings have recently been well-summarized [2] and depend on severity of obstruction. Auscultation may reveal a simple systolic ejection-type murmur or a severe ejection murmur with a thrill. The apex beat may be normal or displaced. Peripheral pulses may be diminished if the stenosis is severe. The ECG may be normal or show LV hypertrophy with strain. A bicuspid valve often produces a systolic ejection click, which occurs from the valve restricted in its opening (Fig. 7.1).

When significant obstruction is present, there is a theoretic risk of exertionally related syncope if cardiac output cannot increase to meet metabolic demand. Therefore, most providers will recommend avoidance of intense aerobic activity when moderate or severe stenosis is present. However, even intense aerobic exercise is unlikely to alter the natural progression of disease for a given patient [3].

Obstructive lesions during pregnancy are not as well tolerated as regurgitant lesions [4], and therefore the LVOT obstruction patients should have a careful assessment prior to an anticipated pregnancy, ideally with cardiopulmonary

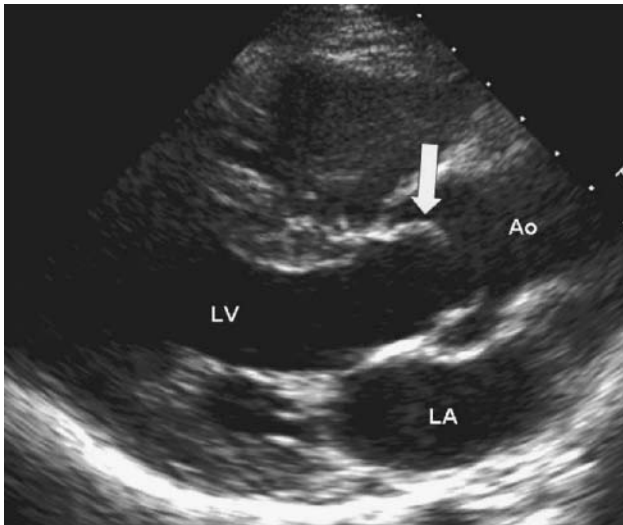


Fig. 7.1 Parasternal long-axis transthoracic echocardiogram of a patient with a normally functioning bicuspid aortic valve (BAV). During systole, the valve leaflet opening is limited by the leaflet size, forming a doming of the leaflet and creating an audible systolic ejection click. This finding is very typical of a BAV. LV, left ventricle; LA, left atrium; Ao, aorta.

exercise testing. Any pregnant patient with LVOT obstruction of any sort should be referred to a center with cardiology and obstetrical experience with such patients. Details regarding management through pregnancy and delivery are discussed elsewhere.

Valvular stenosis

Congenital valvular stenosis is almost always due to a bicuspid aortic valve (BAV). BAV is more common than all other congenital lesions combined. At times, the distinction between true bicuspid and “functionally bicuspid” is soft. Because the pathophysiology and prognosis for a BAV differs from a tricuspid valve, the distinction is important and an accurate diagnosis worthwhile. It is usually well recognized by echocardiography and can easily be shown by cardiac MRI or computed tomography when sought (Fig. 7.2).

Other causes of congenital aortic valve stenosis include unicuspid valves and quadricuspid valves. Unicuspid valves are far less common but more consistently cause stenosis at a younger age [5]; thus, they are clinically addressed in much the same way. These patients are also more predominantly male [5]. Quadricuspid valves are even rarer and sometimes accompany other congenital abnormalities, such as conotruncal abnormalities, ventricular septal defect, or other forms of LVOT obstruction. Usually the valve is regurgitant rather than stenotic [6].

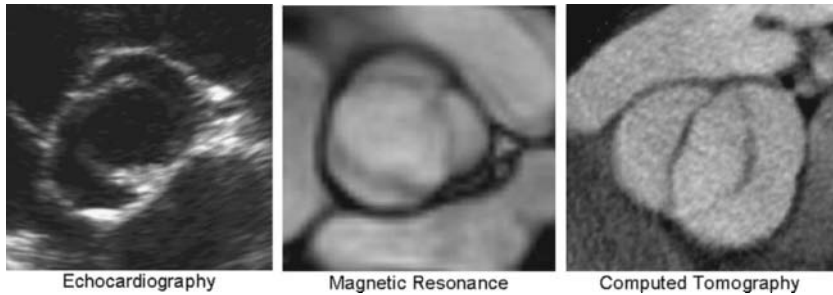


Fig. 7.2 BAVs as viewed using various imaging modalities. Echocardiography is the standard. MRI and CT offer some additional resolution of imaging the ascending and descending aorta when needed, but are otherwise not necessary if acoustic windows are adequate. As with echocardiography, MRI can also measure velocity and flow through a stenotic valve, but CT cannot. CT also requires contrast and radiation.

Despite being conceptually “simple,” the management of BAV is one of the most difficult and common clinical challenges in adult congenital heart disease. In fact, it has been claimed that, “BAV disease is responsible for more deaths and morbidity than all other congenital heart defects combined” [7]. Observations that support this claim are its common prevalence, its association with coarctation and aortopathy (discussed in more detail in Chapter 8), and the imperfect options available when valve replacement is necessary. Because of its association with other conditions, BAV can be viewed as part of a systemic disorder with specific molecular/subcellular abnormalities of the vascular wall [8,9]. With this in mind, providers who encounter patients with BAV should consider more than just the function of the valve and/or consider referral to a congenital heart specialist.

Prevalence

Approximately 1–2% of the population has a BAV, with varying estimates depending on the population studied. A large screening study of over 1000 neonates found BAV in 4.5%, one of the highest prevalence figures reported [10]. Obligatory screening of male recruits for the Italian police force found 0.8% with BAV, the majority of whom had some degree of valve dysfunction, usually regurgitation [11]. Many studies find prevalence figures between these extremes. One study found that 2.5% of otherwise healthy adults had BAV, in whom the majority already had valve dysfunction, an interesting finding considering these were all well-trained athletes [12], which ought to select out some of the more severe cases. Almost all prevalence studies show a predominance of male gender.

The function of a BAV can vary widely on the spectrum from severe stenosis, to normal function, to severe regurgitation. The valve may be severely stenotic

in childhood, or, at the other extreme, only mildly dysfunctional in a 70-year-old. The mechanical reasons for this wide variation are not fully known, although the degree of leaflet deformity at birth likely determines the clinical course to some extent. Although mild regurgitation is very common in population-screening studies, valvular stenosis is the more common complication that requires surgical intervention [2].

Pathophysiology

There are several possible mechanisms for progressive stenosis of a BAV. Bicuspid valves tested in pump preparations show abnormal shear and turbulence created by the valve, with leaflet deformation and creasing [13]. There is a relationship between form and function; congenital fusion of the right and non-coronary cusps is associated with more valve dysfunction than fusion of the right and left coronary cusps [14]. Consistent with this, leaflet orientation also changes the type of aortopathy seen, even when function of the valve is the same [15]. Pathophysiologic studies show evidence of inflammation, calcification, and fibrosis, similar to a stenotic valve with three cusps, and progression may even be related to hyperlipidemia [16]. Therefore, flow abnormalities coupled with an underlying vulnerability at the subcellular level both likely contribute to progressive valve dysfunction and aortopathy.

Intervention

BAV stenosis is predominantly a surgical disease, and the clinical management generally addresses only the timing of such surgery. Because symptoms may be subtle or not subjectively expressed, exercise testing is sometimes necessary to objectify patients symptoms, or lack thereof [17,18]. Yearly echocardiography in patients with more than trivial stenosis is generally recommended.

Options for intervention are surgery or balloon valvuloplasty. For a young patient in whom somatic growth is still expected, balloon valvuloplasty is often preferred and therefore more commonly used in pediatric centers. However, recurrent stenosis is likely. Once a patient reaches adulthood, there is usually little justification for balloon valvuloplasty when a more definitive surgical option is possible.

However, the surgical alternatives all have drawbacks. Options for valve replacement are a mechanical prosthetic valve, a bioprosthesis, or a pulmonary autograft with replacement of the pulmonary valve (Ross procedure). Mechanical valves require daily warfarin. Bioprosthetic valves have a finite durability, and a young patient will no doubt require further surgery. A Ross procedure does not prevent further aortic dilatation and has been criticized as a valid option in the BAV population. Some have used a modification to prevent this, with limited early success [19]. Still, the Ross procedure is certainly no guarantee against future aortic valve surgery. Another surgical option for children or young adults is a surgical valvotomy, though also usually palliative, as 40% will

require reoperation in 25 years [20]. Valve repair is possible for aortic regurgitation, although the need for additional surgery later is still likely [21].

BAV patients are younger, more likely to have concomitant aortic enlargement, more likely to consider pregnancy later, and far more likely to need successive surgery later in life than patients with tricuspid aortic stenosis. Because of this, no universal recommendation can be made regarding type of valve surgery. The diameter of the ascending aorta must be considered, and a combination valve-sparing root replacement or valved conduit in the ascending aorta (Bentall procedure) [22] is often desirable. Institutional surgical experience, comorbidity, patient lifestyle, and preference should all be considered in the decision-making process. The surgeon, cardiologist, and patient need to discuss the various options and hopefully reach an agreement about the best approach.

Long-term follow-up

Because of the above-mentioned complexities, no patient with prior surgery for BAV stenosis should be considered “cured,” and all should be seen regularly. Aortic regurgitation following valve-sparing replacement of the aortic root is common [21]. Bioprosthetic or autograft valves have a known failure rate. Patients should be educated about associated problems such as aortopathy (see Chapter 8) or endocarditis, and, when appropriate, women should have dedicated conversations about the appropriateness of future pregnancy. For all of these reasons, annual review including regular echocardiography is warranted for any patient with prior congenital aortic stenosis.

Endocarditis

BAV increases the risk of endocarditis. In a large series of endocarditis patients, 13% had BAV [23], an incidence far higher than what would be expected from the normal population. It affects 10–30% of patients with BAV over their lifetime [24], with a reported risk of 27/10,000 person-years [20]. Isolated bacteria are often streptococcal variants, including normal flora.

Previous publications nearly universally recommended antibiotic prophylaxis prior to dental work or other invasive procedures in contact with a nonsterile environment [24]. However, the recent 2007 AHA/ACC guidelines reverse this recommendation [25]. These new guidelines, written by a large multispecialty task force after consideration of all available data, concluded that current evidence does not justify antibiotic pretreatment for most patients. For dental work in particular, the point was made that bacteremia is common even with daily brushing and flossing, and not solely during dental intervention. The guidelines therefore emphasize the need for good routine oral hygiene and recommend antibiotics only in patients with recent prosthetic material insertion or in whom endocarditis would be particularly complicated, such as a patient with cyanosis. Therefore, most patients with BAV stenosis do not fall into this

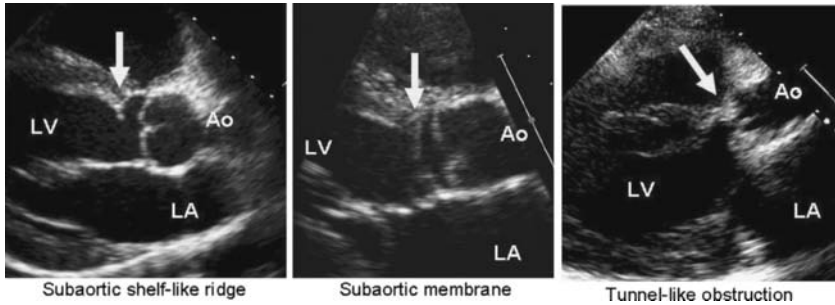


Fig. 7.3 Examples of types of SAS as viewed in the parasternal long-axis view by transthoracic echocardiography. LV, left ventricle; LA, left atrium; Ao, aorta.

category and no longer qualify for antibiotic prophylaxis under these new recommendations. This significant shift and its implications should be thoughtfully considered by each provider. For a full consideration of the guidelines and their rationale, the reader is encouraged to study the document in detail [25] and consult with patients on an individual basis.

Subvalvular aortic stenosis

Almost one-third of LVOT obstructions can be classified as subaortic stenosis (SAS). Predominantly this is excessive fibroelastic tissue spanning some part of the LVOT. It can be a discrete shelf-like ridge or, less commonly, circumferential narrowing forming a tunnel (Fig. 7.3). Degrees and types of defects vary considerably over a wide spectrum. Because such lesions can be thin and subtle, imaging may not demonstrate the full extent of the abnormality compared to intraoperative inspection [26]. As with many congenital defects, the literature often originates from surgical series at large tertiary institutions and therefore reflects a certain selection bias of more severe cases requiring intervention. Still, the reported experience with this type of defect highlights many important features relevant to the patient's management.

SAS is often associated with other congenital defects, and coexisting problems are almost the rule rather than the exception. Most commonly, a ventricular septal defect is found in up to one-third of patients [27]. Malalignment between the septum and the valve annulus or the distance between the aortic and mitral annuli can contribute to the obstruction [28]. Also common, BAV is present in nearly one-fourth of patients with SAS [29], although it is not more likely to become dysfunctional than a tricuspid valve in the same setting [2]. Other defects found together with SAS include coarctation, patent ductus arteriosus, left superior vena cava, hypoplastic aortic root, or mitral valve abnormalities. The mitral support system may contribute to the obstruction

from abnormal septal insertions near the LVOT [30]. Shone syndrome [31] is a collection of such stenoses serially, namely, coarctation, SAS, parachute mitral valve, or supra-aortic ring. Multiple stenoses, as demonstrated in the case above, add complexity and worsen prognosis [32]. An acquired form of SAS may develop after repair of other types of congenital defects, including atrioventricular septal defect (where the aorta is in an unwedged position and the outflow tract is elongated), and Rastelli-type repair of double-outlet right ventricle [33]. Like any form of increased afterload, hypertrophy of the subvalvular chamber may cause dynamic outflow obstruction in and of itself, creating a cycle of worsening obstruction and hence more hypertrophy.

Intervention

Like valvular stenosis, SAS is predominantly a surgical disease, and intervention is common. Sixty percent of patients with SAS assessed in infancy will have undergone surgery by the age of 17 [34]. The lesion should not be considered lightly, nor the risks of intervention, as early deaths are reported, often in the perioperative period [35]. Therefore, intervention is best performed by a surgeon familiar with the spectrum of SAS and its long-term complications.

A difficult clinical question is when to operate. Symptoms are not reliably indicative of the severity of obstruction [29]. A gradient of >50 mm Hg has a poor prognosis without intervention [36], and therefore, even in the absence of symptoms, resection should be offered when the peak instantaneous gradient is significantly elevated. Below this level, however, it is more difficult to say with certainty when an intervention is worthwhile, and most patients should be seen by cardiologists with expertise in this area to help guide these decisions.

Prospective randomized trials on the best management strategies and timing of intervention do not exist, but the general consensus from multiple surgical series tends to favor earlier rather than later intervention (i.e., >30 mm Hg mean gradient), particularly in children [34], female patients considering pregnancy, or athletes [2]. In otherwise asymptomatic adults, however, there seems to be little evidence that early intervention is favorable. A recent editorial summary suggested that adults with an echocardiographic gradient <50 mm Hg and no LV hypertrophy or symptoms should be watched, and that earlier operation as a way to maintain integrity of the aortic valve (see below) was not a justification for surgery [36]. Longer follow-up will determine the validity of these recommendations for adults.

Most operations are successful in the short term, ideally with no residual obstruction (Fig. 7.4). The outcome depends on the individual lesion and how aggressive the surgeon is in removing tissue. More resection increases the risk of atrioventricular conduction block, damage to the mitral valve leaflets or support apparatus, or creation of a septal defect. The surgeon may only remove the obstructing membrane, or, more commonly, do a more extensive

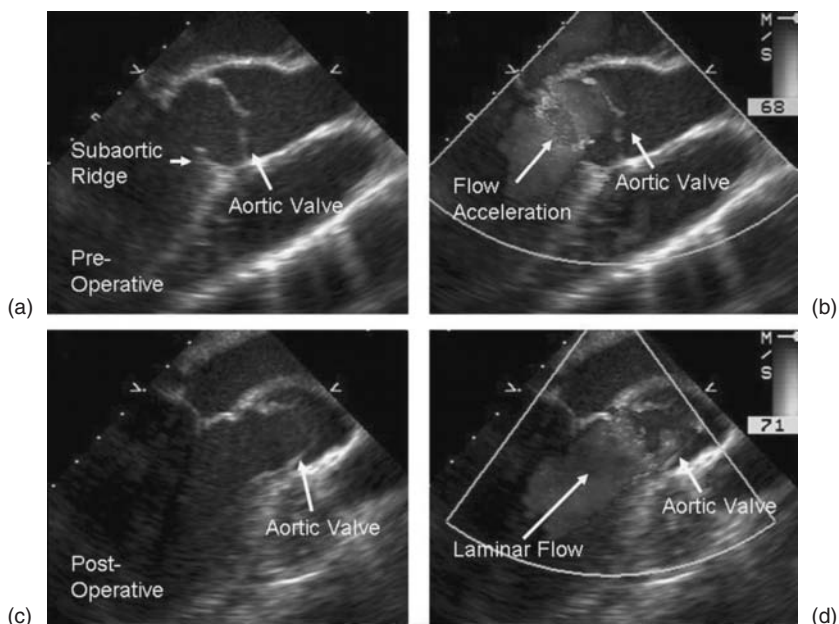


Fig. 7.4 Transesophageal echocardiography (110-degree rotation) both before (a, b) and after (c, d) surgical resection of a subaortic ridge, shown without (a, c) and with (b, d) two-dimensional color Doppler. Preoperatively, there is a discrete ridge (a), and subvalvular flow acceleration is easily appreciated in early systole (b); note that the valve leaflets are just starting to open. Postoperatively, the membrane has been removed (c), and laminar flow through the LVOT has been restored (shown at midsystole; d).

myectomy. For tunnel-like stenoses, an LVOT enlargement with placement of a diamond-shaped patch is typical, known as a Konno procedure [37], or its modification of leaving the aortic valve in place.

Long-term complications

Recurrence of obstruction is common, which, again, justifies careful long-term follow-up. Some degree of stenosis is often present even right after surgery [38], and 20–30% will have significant restenosis within 10 years [29]. Predictors of the need for repeat operation include the degree of stenosis preoperatively [34,39], a tunnel-like obstruction [29,40], and the degree of LVOT obstruction immediately after surgery [29,41]. These findings reinforce arguments for earlier intervention before the gradient becomes severe in childhood [29], although restenosis is less common when the patient is operated on as an adult [36].

Possible reasons for recurrence were explored in depth in an editorial published over a decade ago [26], and little has changed in the interim to clarify or

refute those arguments. The risk is higher in patients where the LVOT is inherently longer or narrower, where there is malalignment of the septum giving a steeper “aorto-septal” angle, and where the cellular response of the endothelium to altered flow mechanics and/or increased sheer leads to further fibroelastic growth or hypertrophy of existing muscle [26].

SAS is also associated with progressive aortic valve regurgitation, typically present in about one-fourth of cases followed over 10 years [40]. Regurgitation tends to be mild [42], although the need for aortic valve surgery late after subaortic resection occurs in nearly half of patients with a high gradient preoperatively [29]. The likely mechanism of aortic valve disease in the setting of SAS is believed to be turbulence striking the aortic leaflets and causing distortion, endothelial damage, leaflet redundancy, prolapse, and dysfunction [2]. Earlier intervention may mean less deterioration of the valve and hence preserved function [43], although not all studies reach similar conclusions [44].

Endocarditis

As with BAV stenosis, there is a known risk of infective endocarditis from SAS [2]. In contrast to previous recommendations [2,24], the current guidelines do not recommend routine antibiotic prophylaxis for SAS [25]. However, prophylaxis is still recommended in patients with “repaired congenital heart disease with residual defects at the site or adjacent to the site of a prosthetic patch or prosthetic device (which prevents endothelialization)” [25]. Some SAS patients with prior patch repair may potentially fall into this category. Therefore, the new guidelines should not be interpreted as a *carte-blanc* recommendation to give up the practice entirely. Again, all patients should be encouraged to practice good oral hygiene, and providers should educate their patients about the rationales for the new guidelines.

Supravalvular stenosis

Supravalvular aortic stenosis is the least common form of LVOT obstruction. It typically occurs at or near the sinotubular junction. Like valvular and subvalvular aortic stenosis, there may be a preponderance of male gender in reported literature [45].

Most often, supravalvular narrowing is encountered in patients with Williams-Beuren syndrome, which accounts for approximately 60% of cases. This rare syndrome, first defined in 1961, is an autosomal dominant defect characterized by vascular stenoses (aortic, pulmonary arterial, coarctation, and/or renal arterial stenoses), together with typical ocular-facial and psychosocial/cognitive characteristics, described in detail elsewhere [46,47]. Supra-aortic stenosis, present in the majority [46], together with the other endovascular

malformations no doubt reflects an arteriopathy. In both Williams syndrome and sporadic supravalvular obstruction cases, evidence of elastin gene mutations have been described [48]. Coexisting congenital lesions are the rule rather than the exception [49]. In addition to the above, BAV is common, as are coronary anomalies of both origin and form. Hence, whenever supravalvular stenosis is identified, the clinician should feel obligated to investigate both the pulmonary and systemic vascular trees further for other associated abnormalities, including the coronary arteries [50], rather than assume that the defect exists in isolation. In fact, due also to the relative hypertension in the coronaries, which arise proximal to the obstruction, patients should be screened for coronary artery disease and cautioned heavily about the need to modify atherosclerosis risk factors.

Supravalvular stenosis is likely to progress over time [51]. Surgical resection is typically indicated when significant stenosis is found, as determined by presence of symptoms, significant LV hypertrophy, or a worsening gradient over time. Unlike subvalvular stenosis, supravalvular stenosis, once resected, has a much lower incidence of late restenosis [52]. Long-term follow-up is warranted for management of hypertension and detection of other vascular stenoses which may become manifest over time.

Case conclusion

Considering the severity of the patient's subtle symptoms, the LVOT gradient, the relatively small St. Jude valve, and the raised LV end-diastolic pressure, and after much discussion with the patient, family, and extended care team at a center for congenital heart disease, a decision was made to proceed with redo aortic valve replacement with subaortic resection. Surgery was planned for the summer before the patient began an internship in her chosen profession.

Surgery was complicated by significant scarring. In resecting the previous St. Jude valve, the surgeons observed that there was disruption of the anterior mitral leaflet from the prior patch myectomy, with Dacron extending onto the anterior leaflet. The annular ring was no longer intact. The surgeons therefore needed to recreate this junction and repair the mitral valve. In the aortic position, even after extensive debridement of scar tissue, the annulus would only hold a 19-mm St. Jude valve, which would be no improvement over her prior situation. For this reason, the surgeons elected to replace it with a pulmonary autograft (Ross procedure). The surgery was extensive and long, but the patient was returned to the intensive care unit in stable condition.

Her recovery was extremely difficult. The patient had significant LV dysfunction requiring multiple inotropes and pressors. Her care was complicated by pulmonary edema necessitating prolonged intubation, acute renal failure treated with hemodialysis, atrial flutter, and complete heart block, eventually necessitating a permanent pacemaker. After 3 weeks, her condition had stabilized and she was discharged home

with family support. Her echocardiogram at discharge showed moderately reduced LV systolic function, but no significant outflow tract gradient.

Over the ensuing weeks, she made little progress and had several repeat admissions. Transplantation was considered but could not be offered acutely. Ten weeks after surgery, she was still not coping well and family members drove her back to the hospital; she passed out in the car. On the evening after admission, she had a cardiac arrest. She was stabilized initially, but over the ensuing days, her condition deteriorated further, despite aggressive inotropes and vasopressors. Her blood pressure fell and she could not be resuscitated. Autopsy showed intact surgical repair but severe LV hypertrophy with diffuse subacute myocardial necrosis probably from the time of her most recent cardiopulmonary bypass.

The patient's eventual demise reflected a combination of complex prior surgeries, LV hypertrophy with tenuous LV function preoperatively, the difficult dilemma intraoperatively regarding her aortic valve size, and prolonged cardiopulmonary bypass, culminating in severe ventricular dysfunction that could not be stabilized. Though tragic, her case is not extraordinary and is a reminder of the underlying complexities of this and many other types of congenital heart disease.

References

1. Yacoub MH, Kilner PJ, Birks EJ, Misfeld M. The aortic outflow and root: a tale of dynamism and crosstalk. *Ann Thorac Surg* 1999;68:S37–43.
2. Aboulhossn J, Child JS. Left ventricular outflow obstruction: subaortic stenosis, bicuspid aortic valve, supraaortic stenosis, and coarctation of the aorta. *Circulation* 2006;114:2412–22.
3. Spataro A, Pelliccia A, Rizzo M, et al. The natural course of bicuspid aortic valve in athletes. *Int J Sports Med* 2008;29:81–5.
4. Siu SC, Sermer M, Colman JM, et al. Prospective multicenter study of pregnancy outcomes in women with heart disease. *Circulation* 2001;104:515–21.
5. Collins MJ, Butany J, Berger MA, et al. Implications of a congenitally abnormal valve: a study of 1025 consecutively excised aortic valves. *J Clin Pathol* 2008;61:530–6.
6. Tutarel O. The quadricuspid aortic valve: a comprehensive review. *J Heart Valve Dis* 2004;13:534–7.
7. Verma S, Szmítko PE, Fedak PW, et al. Can statin therapy alter the natural history of bicuspid aortic valves? *Am J Physiol Heart Circ Physiol* 2005;288:H2547–9.
8. Fedak PW, de Sa MP, Verma S, et al. Vascular matrix remodeling in patients with bicuspid aortic valve malformations: implications for aortic dilatation. *J Thorac Cardiovasc Surg* 2003;126:797–806.
9. Warnes CA. Bicuspid aortic valve and coarctation: two villains part of a diffuse problem. *Heart* 2003;89:965–6.
10. Tutar E, Ekici F, Atalay S, Nacar N. The prevalence of bicuspid aortic valve in newborns by echocardiographic screening. *Am Heart J* 2005;150:513–15.
11. Nistri S, Basso C, Marzari C, et al. Frequency of bicuspid aortic valve in young male conscripts by echocardiogram. *Am J Cardiol* 2005;96:718–21.

12. Stefani L, Galanti G, Toncelli L, et al. Bicuspid aortic valve in competitive athletes. *Br J Sports Med* 2008;42:31–5.
13. Robicsek F, Thubrikar MJ, Cook JW, Fowler B. The congenitally bicuspid aortic valve: how does it function? Why does it fail? *Ann Thorac Surg* 2004;77:177–85.
14. Fernandes SM, Khairy P, Sanders SP, Colan SD. Bicuspid aortic valve morphology and interventions in the young. *J Am Coll Cardiol* 2007;49:2211–14.
15. Schaefer BM, Lewin MB, Stout KK, et al. Usefulness of bicuspid aortic valve phenotype to predict elastic properties of the ascending aorta. *Am J Cardiol* 2007;99:686–90.
16. Chan KL, Ghani M, Woodend K, Burwash IG. Case-controlled study to assess risk factors for aortic stenosis in congenitally bicuspid aortic valve. *Am J Cardiol* 2001;88:690–3.
17. Chambers J. Exercise testing to guide surgery in aortic stenosis. *Heart* 1999;82:7–8.
18. Das P, Rimington H, Chambers J. Exercise testing to stratify risk in aortic stenosis. *Eur Heart J* 2005;26:1309–13.
19. Slater M, Shen I, Welke K, et al. Modification to the Ross procedure to prevent autograft dilatation. *Semin Thorac Cardiovasc Surg Pediatr Card Surg Annu* 2005:181–4.
20. Keane JF, Driscoll DJ, Gersony WM, et al. Second natural history study of congenital heart defects. Results of treatment of patients with aortic valvar stenosis. *Circulation* 1993;87:116–27.
21. Alsoufi B, Borger MA, Armstrong S, et al. Results of valve preservation and repair for bicuspid aortic valve insufficiency. *J Heart Valve Dis* 2005;14:752–8, discussion 758–9.
22. Bentall H, De Bono A. A technique for complete replacement of the ascending aorta. *Thorax* 1968;23:338–9.
23. Choudhury R, Grover A, Varma J, et al. Active infective endocarditis observed in an Indian hospital 1981–1991. *Am J Cardiol* 1992;70:1453–8.
24. Brickner ME. Valvar aortic stenosis. In: Gatzoulis MA, Webb GD, Daubeney PE, eds. *Diagnosis and Management of Adult Congenital Heart Disease* (1st edition). London: Churchill Livingstone, 2003:213–21.
25. Wilson W, Taubert KA, Gewitz M, et al. Prevention of infective endocarditis: guidelines from the American Heart Association: a guideline from the American Heart Association Rheumatic Fever, Endocarditis, and Kawasaki Disease Committee, Council on Cardiovascular Disease in the Young, and the Council on Clinical Cardiology, Council on Cardiovascular Surgery and Anesthesia, and the Quality of Care and Outcomes Research Interdisciplinary Working Group. *Circulation* 2007;116:1736–54.
26. Freedom RM. The long and the short of it: some thoughts about the fixed forms of left ventricular outflow tract obstruction. *J Am Coll Cardiol* 1997;30:1843–6.
27. Kitchiner D, Jackson M, Malaiya N, et al. Morphology of left ventricular outflow tract structures in patients with subaortic stenosis and a ventricular septal defect. *Br Heart J* 1994;72:251–60.
28. Rosenquist GC, Clark EB, McAllister HA, et al. Increased mitral-aortic separation in discrete subaortic stenosis. *Circulation* 1979;60:70–4.
29. Brauner R, Laks H, Drinkwater DC Jr, et al. Benefits of early surgical repair in fixed subaortic stenosis. *J Am Coll Cardiol* 1997;30:1835–42.
30. Marasini M, Zannini L, Ussia GP, et al. Discrete subaortic stenosis: incidence, morphology and surgical impact of associated subaortic anomalies. *Ann Thorac Surg* 2003;75:1763–8.

31. Shone JD, Sellers RD, Anderson RC, et al. The developmental complex of "parachute mitral valve," supraaortic ring of left atrium, subaortic stenosis, and coarctation of aorta. *Am J Cardiol* 1963;11:714–25.
32. Bolling SF, Iannettoni MD, Dick M 2nd, et al. Shone's anomaly: operative results and late outcome. *Ann Thorac Surg* 1990;49:887–93.
33. Kalfa D, Ghez O, Kreitmann B, Metras D. Secondary subaortic stenosis in heart defects without any initial subaortic obstruction: a multifactorial postoperative event. *Eur J Cardiothorac Surg* 2007;32:582–7.
34. Karamlou T, Gurofsky R, Bojcevski A, et al. Prevalence and associated risk factors for intervention in 313 children with subaortic stenosis. *Ann Thorac Surg* 2007;84:900–6, discussion 906.
35. Erentug V, Bozbuga N, Kirali K, et al. Surgical treatment of subaortic obstruction in adolescent and adults: long-term follow-up. *J Card Surg* 2005;20:16–21.
36. Gersony WM. Natural history of discrete subvalvar aortic stenosis: management implications. *J Am Coll Cardiol* 2001;38:843–5.
37. Konno S, Imai Y, Iida Y, et al. A new method for prosthetic valve replacement in congenital aortic stenosis associated with hypoplasia of the aortic valve ring. *J Thorac Cardiovasc Surg* 1975;70:909–17.
38. Jones M, Barnhart GR, Morrow AG. Late results after operations for left ventricular outflow tract obstruction. *Am J Cardiol* 1982;50:569–79.
39. Parry AJ, Kovalchin JP, Suda K, et al. Resection of subaortic stenosis; can a more aggressive approach be justified? *Eur J Cardiothorac Surg* 1999;15:631–8.
40. van Son JA, Schaff HV, Danielson GK, et al. Surgical treatment of discrete and tunnel subaortic stenosis. Late survival and risk of reoperation. *Circulation* 1993;88:II159–69.
41. Serraf A, Zoghby J, Lacour-Gayet F, et al. Surgical treatment of subaortic stenosis: a seventeen-year experience. *J Thorac Cardiovasc Surg* 1999;117:669–78.
42. Oliver JM, Gonzalez A, Gallego P, et al. Discrete subaortic stenosis in adults: increased prevalence and slow rate of progression of the obstruction and aortic regurgitation. *J Am Coll Cardiol* 2001;38:835–42.
43. Coleman DM, Smallhorn JF, McCrindle BW, et al. Postoperative follow-up of fibromuscular subaortic stenosis. *J Am Coll Cardiol* 1994;24:1558–64.
44. de Vries AG, Hess J, Witsenburg M, et al. Management of fixed subaortic stenosis: a retrospective study of 57 cases. *J Am Coll Cardiol* 1992;19:1013–17.
45. Harikrishnan S, Manohar SR, Nair KK, et al. Supravalvar aortic stenosis: clinical and hemodynamic profile, and surgical outcome. *Indian Heart J* 2003;55:49–54.
46. Morris CA, Leonard CO, Dilts C, Demsey SA. Adults with Williams syndrome. *Am J Med Genet Suppl* 1990;6:102–7.
47. Morris CA, Demsey SA, Leonard CO, et al. Natural history of Williams syndrome: physical characteristics. *J Pediatr* 1988;113:318–26.
48. Ewart AK, Jin W, Atkinson D, et al. Supravalvular aortic stenosis associated with a deletion disrupting the elastin gene. *J Clin Invest* 1994;93:1071–7.
49. Wang CC, Hwu WL, Wu ET, et al. Outcome of pulmonary and aortic stenosis in Williams-Beuren syndrome in an Asian cohort. *Acta Paediatr* 2007;96:906–9.

50. van Pelt NC, Wilson NJ, Lear G. Severe coronary artery disease in the absence of supralvalvular stenosis in a patient with Williams syndrome. *Pediatr Cardiol* 2005;26:665–7.
51. Wren C, Oslizlok P, Bull C. Natural history of supralvalvular aortic stenosis and pulmonary artery stenosis. *J Am Coll Cardiol* 1990;15:1625–30.
52. Flaker G, Teske D, Kilman J, et al. Supralvalvular aortic stenosis. A 20-year clinical perspective and experience with patch aortoplasty. *Am J Cardiol* 1983;51:256–60.

Coarctation of the aorta and aortic disease

Michelle Z. Gurvitz

A 23-year-old female presented to an adult congenital heart clinic after 8 years with no follow-up. Her chief complaint was mild fatigue with exertion. She had a history of coarctation of the aorta and ventricular septal defect that were repaired in infancy. She had an initial patch repair of the aorta and required a second aortic surgery at age 10 due to recurrent coarctation. The second surgery was also performed with a patch aortoplasty.

On exam, she had a decreased left upper extremity pulse and right femoral pulse. She also had a right upper to lower extremity systolic blood pressure gradient of 32 mm Hg. Her echocardiogram had limited views of the arch, but showed a residual Doppler peak gradient of 41 mm Hg, blunted flow in the descending aorta with diastolic run-off, and mildly decreased left ventricular systolic function with an ejection fraction of 45–50%. MRI revealed a residual coarctation and aneurysm in the area of the patch repairs (Fig. 8.1).

Introduction

Congenital heart defects affect the heart and great vessels arising from it: the pulmonary artery and the aorta. This chapter focuses on abnormalities of the aorta. The topics discussed include coarctation of the aorta and conditions related to connective tissue abnormalities of the aorta. The diagnosis, presentation, treatment, and follow-up of these conditions are reviewed, concentrating on the conditions presenting in adulthood and the long-term sequelae of repaired or treated aortic conditions.

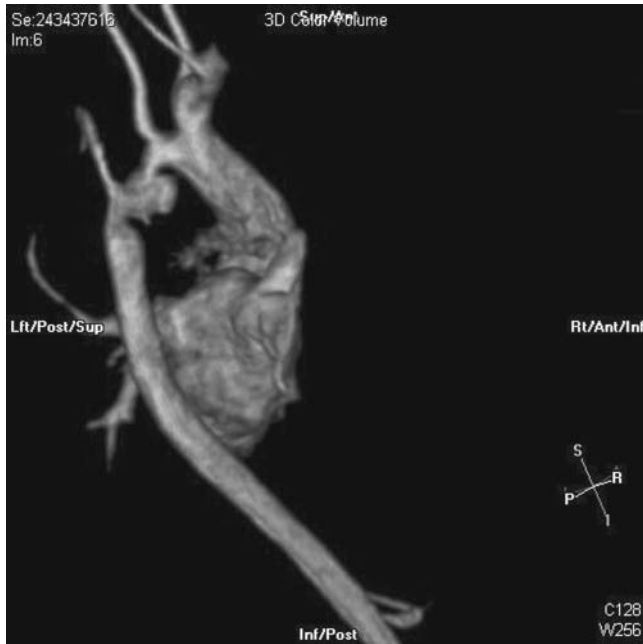


Fig. 8.1 MRI image of residual coarctation and aneurysm after patch aortoplasty.

Aortic embryology and development

The aorta is a complex structure in both its embryologic origin and tissue composition. Embryologically, the aorta is pieced together from parts of the truncus arteriosus, aortic sac, 3rd and 4th brachial arches, and the dorsal aorta. It is initially a paired structure, but multiple parts regress to give a single aortic arch. Segments of the truncus arteriosus and aortic sac form the ascending aorta, the 3rd arch forms part of the carotid and subclavian arteries, and the 4th arch helps complete the transverse aorta. The descending aorta is then formed from the embryologic dorsal aorta. The ductus arteriosus arises from the 6th arch, just beyond the left subclavian artery [1].

Irregularities in any of these segments can lead to aortic malformations or variations in the normal left-sided aortic arch. Examples of this include the aberrant right subclavian artery arising from the descending aorta and a right-sided aortic arch from abnormal regression of left-sided structures during development. The mirror-image right-sided aortic arch is rarely associated with coarctation, but is commonly found with other congenital heart anomalies, such as tetralogy of Fallot [2].

In histologic specimens, the aorta is a three-layered structure consisting of an intima, media, and adventitia. The intima is the innermost layer and is covered

by an endothelial lining. The media is the muscular layer and includes smooth muscle cells, fibrillin, elastin, and collagen, along with an extracellular matrix. The adventitia is the outer lining of the aorta [3].

Coarctation of the aorta

Definition and prevalence

Coarctation of the aorta is a narrowing in the aorta that causes a restriction of blood flow to the more distal vessels and organs and hypertension proximally. The severity of narrowing is variable, and it occurs most frequently in the proximal thoracic aorta just beyond the origin of the left subclavian artery in the area of the original ductus arteriosus. Less frequently, the narrowing occurs in the abdominal aorta, or there can be a diffusely hypoplastic transverse aortic arch.

Coarctation is a relatively common congenital heart condition comprising 6–8% of patients with congenital heart disease [4–6]. It occurs at least 1.5–2 times more often in males than females. Although the majority of cases are not inherited, recent articles have identified possible genetic associations with left-sided obstructive lesions that include coarctation of the aorta [7,8]. Coarctation is also associated with other genetic conditions, such as Turner syndrome (TS) [9,10].

The presentation of coarctation can be in isolation or in association with other congenital heart anomalies. Most often, the associated lesion is a bicuspid aortic valve (BAV), reported in 20–40% of patients [4,11]. Other associations include ventricular septal defect, patent ductus arteriosus (PDA), aortic stenosis, and mitral valve abnormalities [12]. In some cases of long-standing coarctation, a compensatory collateral circulation develops from the internal thoracic and intercostal arteries, bypassing the coarctation to provide circulation to the lower extremities.

Although the exact etiology of coarctation is unclear, there are two predominant theories. The first holds that coarctation is a flow-related phenomenon in which embryologic limitation of aortic blood flow causes abnormal arch development [12,13]. This theory is consistent with the common findings of BAV and ventricular septal defect. The second theory regards coarctation as the result of abnormal aortic tissue. Part of this tissue is that which extends from the ductus arteriosus into the aortic arch, causing varying degrees of constriction when the ductus closes. In pathologic specimens, the area of narrowing shows thickening and disruption of the aortic media and intimal hyperplasia. Recent studies also show abnormal tissue in the areas of the pre- and post-coarctation aorta, including collagen disarray, loss of smooth muscle, and increased aortic stiffness [14–16]. The recent evidence is more consistent with an underlying tissue abnormality; however, the hemodynamic effect of decreased flow may also play a role.

Presentation and diagnosis

Although aortic coarctation is a congenital malformation of the aorta, many patients are not diagnosed until childhood or adulthood. The presentation at diagnosis depends on the age of the patient. The most severe forms of coarctation of the aorta present in the neonatal period as the systemic blood flow is dependent on flow through the PDA, which bypasses the narrowed area. The diagnosis may be difficult if the PDA is open; however, some infants manifest differential cyanosis with increased cyanosis of the lower extremities. These infants will often present in severe distress with heart failure or cardiogenic shock when the PDA closes. Fortunately, they can be managed with intravenous prostaglandin to maintain patency of the ductus arteriosus, preserving systemic blood flow until surgery can be performed.

Less severe types of coarctation present later in childhood or adulthood. Although most patients will be asymptomatic, a small number will complain of cool feet or of leg fatigue or claudication with exercise. More commonly, the coarctation is diagnosed due to refractory hypertension or due to a murmur from the coarctation itself or an associated lesion.

A complete cardiovascular examination may strongly suggest the diagnosis of coarctation. In normal circumstances, the lower extremity blood pressure is higher than that of the upper extremities. The typical coarctation patient manifests a lower blood pressure in the leg than in the right upper extremity. In the unusual cases of large collaterals or an aberrant right subclavian artery, the blood pressure differential may be decreased, making the diagnosis more difficult. The brachial, radial, and femoral pulses should be checked for amplitude and timing. Like the lower extremity blood pressure in patients with coarctation, the femoral pulses are typically diminished in volume and delayed in timing compared with the right upper extremity pulses. The left arm pulse and blood pressure can be variable depending on the location of the left subclavian artery relative to the coarctation site.

The cardiac exam reveals an increased left ventricular impulse that may also be displaced due to the development of left ventricular hypertrophy. The usual murmur of coarctation is systolic and may extend briefly into diastole; it is most prominent in the left paravertebral region near the left scapula. If significant collateral circulation has developed around the coarctation site, continuous murmurs may be heard throughout the back. If the patient has an associated lesion, additional murmurs may be heard. The most common are the systolic and diastolic murmurs of aortic stenosis or regurgitation due to a BAV. The BAV may also have an audible systolic click.

Testing and imaging

If coarctation of the aorta is suspected, various tests can make a definitive diagnosis. Sophisticated cross-sectional imaging studies provide excellent anatomic information, but they are not always readily available. Other, more accessible

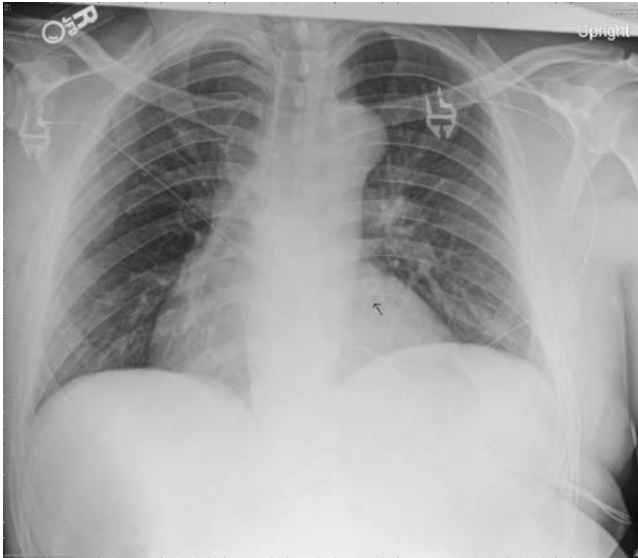


Fig. 8.2 Chest x-ray from an adult with an unrepaired coarctation. Note the dilated aortic shadow reflecting the dilated aorta above and below the coarctation. The black arrow indicates rib notching.

tests, such as a chest x-ray and electrocardiogram, are also useful. The chest x-ray in an older patient with coarctation may show mild cardiomegaly, mild dilation of the ascending aorta, prominence of the upper descending aorta, localized narrowing of the distal aortic arch, and mild dilation of the descending aorta. These dilations result in a classically described “figure 3” appearance of the descending aorta, although it is not commonly seen on many chest x-rays. The x-ray may also show “rib-notching,” which appears as erosions in the underside of the posterior mid-thoracic ribs and comes from enlargement of intercostal arteries due to the coarctation (Fig. 8.2).

The electrocardiogram in coarctation is relatively normal with the exception of chamber hypertrophy. Infants have pure right ventricular hypertrophy. Conversely, in older patients, the electrocardiogram shows left ventricular hypertrophy.

The most easily accessible and often definitive imaging test beyond a chest x-ray is two-dimensional (2D) and Doppler echocardiography. The echocardiogram provides excellent anatomic and hemodynamic information. At the same time, it gives information on the presence of additional congenital heart abnormalities. The aortic arch is best imaged from the suprasternal notch or high parasternal long axis views, where the presence of narrowing in 2D images and high velocity flow with antegrade diastolic run-off on spectral Doppler can be

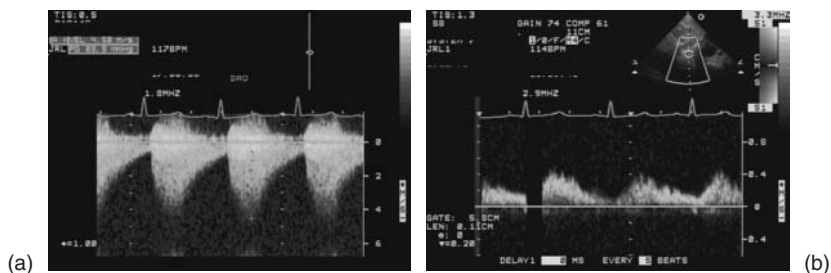


Fig. 8.3 Echo Doppler images suggesting coarctation. (a) Continuous wave Doppler showing increased peak velocity with antegrade diastolic run-off through the area of coarctation. (b) Blunted abdominal aortic flow.

seen (Fig. 8.3a). The peak and mean velocity detected with continuous wave Doppler through the coarctation site may help define the severity of the coarctation but may overestimate the gradient with long-segment stenosis or increased arterial stiffness. In the subcostal views, the abdominal aorta flow profile shows blunting of peak velocity and antegrade diastolic run-off (Fig. 8.3b).

In some patients, anatomic evaluation by echocardiography is limited due to poor imaging windows. Additional anatomic imaging with magnetic resonance imaging (MRI) or computed tomography (CT) scanning has proven useful in the diagnosis of coarctation and definition of aortic anatomy [17–19]. Both imaging modalities provide views of the aorta in multiple 2D planes as well as 3D reconstructions (Fig. 8.4). However, they remain expensive and many institutions do not have the experience or equipment for cardiac studies. Although MRI is often the test of choice, as it avoids radiation exposure and can provide some hemodynamic information, it is currently contraindicated in various patients, such as those with pacemakers or other metal devices. Like other x-ray imaging, the CT scan exposes patients to radiation but can be performed in patients with metal devices. Ultimately, the choice of imaging should be determined individually for each patient by providers with experience in congenital imaging.

Information regarding the significance of the coarctation, the true pressure gradient across the arch, or other invasive hemodynamics is obtained with cardiac catheterization. Because noninvasive imaging often suffices for accurate diagnosis, catheterization is otherwise reserved for therapeutic intervention, usually when the peak gradient exceeds 20 mm Hg.

Treatment

Once a diagnosis of coarctation is made, treatment options including both surgery and catheter-based interventions can be considered for relief of the narrowing. The coarctation requires repair at the time of diagnosis, as long-term

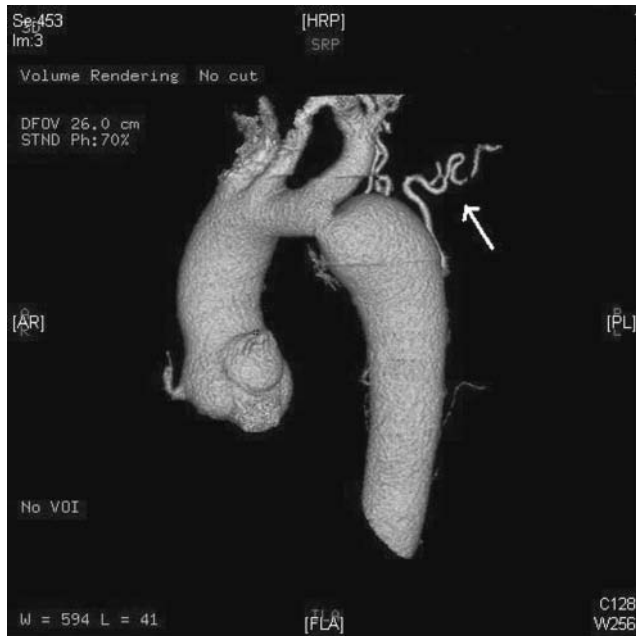


Fig. 8.4 CT scan of an adult with unrepaired coarctation. Note the dilated aorta above and below the narrowed segment. Arrow indicates collateral vessels.

outcome studies show worse morbidity and mortality in those who remain unrepaired or are repaired later in life [20–28]. In one study, patients with unrepaired coarctation had a high early mortality rate with a median age at death early in the fourth decade and 75% mortality by age 46 years [20]. Common causes of death in this group and by other autopsy studies were congestive heart failure and aortic rupture as well as endocarditis and intracranial hemorrhage [20–22]. Even in the more recent era, patients with repaired coarctation were found to have a limited life span, particularly if repaired after early childhood [23–28]. These patients have a high incidence of hypertension, and the leading causes of death include premature coronary artery disease (CAD), sudden death, and heart failure [23,26].

The indications for intervention in coarctation include a gradient that is greater than 20 mm Hg (by systolic blood pressure or by corrected gradient on echocardiogram or catheterization), evidence of hypertension, left ventricular dysfunction, or congestive heart failure. The development of collateral circulation is also an indication for repair, as the gradient may be underestimated in this situation. Currently, both surgical and catheter-based techniques are options for intervention, and, in many circumstances, the treatment of choice remains controversial.

Surgery

Coarctation of the aorta was one of the first surgically repaired congenital heart lesions. In the mid-1940s, Drs. Crooford and Nylin in Sweden and Dr. Gross in the United States successfully performed the first surgical repairs of aortic coarctation [29,30]. Since that time, surgical techniques have changed and improved, and the current surgical options include:

- 1 End-to-end (or extended end-to-end) anastomosis. The diseased segment is removed and the proximal and distal ends are sewn together.
- 2 Subclavian flap repair. The left subclavian artery is transected and the proximal portion is used to widen the narrowed aortic segment.
- 3 Bypass graft or interposition graft. A tube graft is used to bypass the narrowed segment.
- 4 Patch aortoplasty. A patch is sewn to the aorta to widen the narrowed segment.

The type of initial repair depends on the age and size of the patient, the anatomy of the aortic arch, and coarctation and presence of additional lesions. In neonates and infants, an end-to-end or extended repair is the most common surgery, with the subclavian flap repair reserved for longer segment lesions. In older children, adolescents, and adults, the end-to-end type of repair is usually performed; however, bypass or interposition grafts may be required for longer or more complex narrowings. Although the subclavian flap repair is a common option in neonates, there are some reports of decreased growth and neurologic pain syndromes in the left arm [31]. The patch aortoplasty is seldom used now, as it has been associated with aneurysm development and rupture over time and also with a relatively high risk of recurrent coarctation.

When performed by experienced congenital heart surgeons, surgical repair of coarctation carries a low mortality and morbidity. The complication rate may be increased in older patients and those with additional congenital heart lesions. Due to the proximity of the coarctation to other critical structures, complications can occur during the operation. These include injury to the recurrent laryngeal nerve or phrenic nerve, leading to vocal cord paralysis or diaphragmatic paralysis, respectively. One of the most serious, but uncommon, complications is that of spinal cord injury and paralysis. This is more likely in adults and children than neonates and probably results from spinal cord hypoperfusion and ischemia at the time of aortic cross-clamping in patients with inadequate collateral circulation [32–34]. Greater awareness of distal hypoperfusion, shorter cross-clamp periods, or partial cardiopulmonary bypass has further reduced the incidence of spinal injury.

The most common postoperative issue is paradoxical hypertension. The elevated blood pressure is likely secondary to increased catechol release and baro-receptor-mediated sympathetic activity as well as changes in the renin-aldosterone axis [35,36]. It often requires aggressive intravenous antihypertensive therapy in the initial postoperative period, but patients can usually be

converted to enteral therapy within a few days as the hypertensive response wanes. A more unusual complication is post-coarctectomy syndrome involving abdominal pain, distension, and vomiting. This may be related to hypertension and increased flow to the mesenteric vessels after repair, and can be prevented or managed with postoperative blood pressure control and no enteral intake for the immediate postoperative period.

Interventional catheterization

For almost 40 years, surgical intervention was the only option for treatment of patients with coarctation of the aorta. In the early 1980s, the first successful percutaneous balloon angioplasty was performed in a neonate [37]. More recently, catheter-based intervention with balloon angioplasty (with or without endovascular stent placement) has increased in prevalence and successful outcomes for native and recurrent coarctation (Fig. 8.5a,b).

Initially, balloon angioplasty enjoyed fairly good short-term success rates for native coarctation but had relatively high rates of recurrence and aneurysm formation when compared with surgical intervention. It also carried a risk of aortic dissection and rupture [38–41]. The clinical significance of small aneurysm formation is yet to be determined, as most have not required intervention in intermediate-term follow-up studies. Nonetheless, the persistent presence of abnormal aortic tissue, which would be removed in surgery, may play a role in increasing the risk of aneurysm formation or dissection.

The addition of expandable endovascular stents to angioplasty is thought to improve outcomes by providing a support structure to the expanded vessel, alleviating aortic overexpansion, and preventing elastic recoil of the aorta [38].

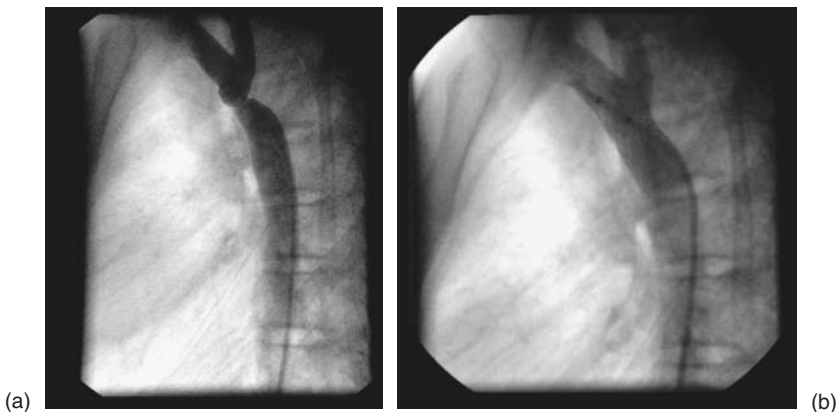


Fig. 8.5 Catheterization images of native coarctation pre-stent placement (a) and post-stent placement (b), showing relief of the coarctation.

In older children and adults, short-term studies show that balloon angioplasty with expandable stents for native and recurrent coarctation is a successful procedure with relief of coarctation in up to 98% of patients. This approach, however, carried a fairly high acute complication rate (14%). Although the majority of complications were minor and did not require intervention, the complications included aneurysm formation, aortic dissection, and death [42]. Other studies report similar results to surgery in relief of obstruction and hypertension, but the stent patients have a higher rate of recurrence and need for later intervention [43]. Certain patients, such as those with aortic atherosclerosis, vasculitis, connective tissue disease, or TS, require special consideration for catheter-based intervention due to their abnormal aortic tissue, as they may be at higher risk of complications. In sum, although the results of angioplasty and stent placement are intriguing and promising and the procedure avoids the need for surgical incision and prolonged recovery, the indication for the procedure in native coarctation remains controversial.

Recurrent coarctation

The recurrence of coarctation is relatively common, occurring in at least 5–10% of patients [23–28]. It is highest in neonatal repair, reported as up to 44% in this group. The recurrence is most likely related to scar formation and fibrosis in the area of repair. Newer techniques using resection with extended end-to-end anastomosis will likely have a lower recurrence rate.

When a recurrence is suspected, the evaluation and indications for intervention are similar to that for native coarctation. In postoperative patients, however, echocardiography may be more difficult to interpret and the additional sequelae of interventions, such as aneurysm formation, should be sought.

Depending on clinical and anatomic features, the recurrent coarctation may be treated with either surgical or catheter-based intervention. In some cases, such as aneurysm formation, recurrence near the origin of a carotid vessel, or additional lesions such as aortic valve stenosis, surgery may be preferred [44]. When patients have concomitant ascending aortic dilatation, aortic valve disease, or coronary disease, repair can be accomplished via a single median sternotomy by using an ascending–descending aortic bypass [45].

Most postoperative recurrent coarctation, however, is now treated with catheter-based intervention with balloon angioplasty with or without stenting. Catheter-based techniques for recurrent coarctation have an 80% success rate. The incidence of aneurysm, tear, or rupture in this circumstance is smaller than with native coarctation (~1.5%) [38]. The decreased complication rate is thought to be secondary to the prior surgical removal of abnormal tissue and the formation of scar in the aortic wall. Although the catheter-based approach is most common, there has been no large randomized, controlled trial between surgery and angioplasty/stent in this population.

Intervention summary

The decision for the type of intervention on native and recurrent coarctation is not straightforward and requires a discussion of the risk and benefits of different types of intervention for each patient. It is important to obtain opinions of those with experience in both types of interventional options, postprocedure complications, and long-term outcomes. Most neonates and infants less than 1 year of age will undergo surgical repair of native coarctation. For recurrent coarctation, there is general agreement that an attempt should be made with balloon angioplasty, with or without stent placement, if anatomically feasible. In older children and adults, both angioplasty with stent placement and surgical intervention are viable options. Ultimately, the decision will depend on the individual patient's anatomy, wishes, and balance of risks, as well as the experience of the surgeon and interventionalist available. If a catheter-based intervention is chosen, this type of procedure should only be performed in centers that have extensive experience in the procedure and have congenital cardiac surgical support.

Additional medical considerations

Hypertension

Patients with unrepaired coarctation of the aorta often present with hypertension. Hypertension can also persist after relief of the coarctation gradient, particularly if the repair occurred in later childhood or adulthood [23,25–27,46]. The increased incidence of hypertension in the absence of residual coarctation is likely due to underlying vascular abnormalities, including impaired peripheral vasoreactivity and increased aortic stiffness [46–48]. Another contributing factor may be the hyperdynamic state of the left ventricle, particularly if it is hypertrophied.

It is important to evaluate for hypertension at every clinical visit in patients with a history of coarctation. Aside from routine cuff pressure, some practitioners perform 24-hour blood pressure monitoring to diagnose an elevated mean blood pressure [49]. The presence of hypertension is thought to contribute significantly to the early mortality by increasing the risks of premature CAD and cerebrovascular accident, and thus requires prompt treatment.

Aside from resting hypertension, some patients will have an exaggerated blood pressure response to exercise. The meaning of this response and the need to treat it remains controversial. Correlation of peak exercise blood pressure with outcomes or with 24-hour ambulatory monitoring is variable [50–53]. Many specialized adult congenital heart disease practitioners treat exercise-induced hypertension with medication, commonly beta blockers. This is in an effort to reduce the shear stresses on the aorta, which has the inherent aortopathy and vulnerability to aneurysm, dissection, and rupture.

Coronary artery disease

Premature CAD is a common cause of death and morbidity among patients with coarctation [23,25–27]. The etiology of this finding has not been fully explained. It is likely at least partially related to hypertension. There may also be intrinsic arterial mechanisms involved. It is known that patients with impaired arterial vasoreactivity are at risk of CAD, and studies have shown some patients with coarctation to have this functional vascular abnormality [14,47,54]. Patients with repaired or unrepaired coarctation should have aggressive CAD risk factor screening and modification, including cholesterol levels, smoking cessation, and diabetes. Any anginal symptoms should prompt a complete evaluation for CAD impairment.

Cerebrovascular aneurysms

Another complication and cause of death in patients with coarctation is subarachnoid hemorrhage secondary to aneurysms. In the early 1900s, Dr. Maude Abbott noted this as a common cause of death in autopsy studies [22]. More recently, a series of patients with repaired coarctation were screened for brain aneurysms at the Mayo clinic [55]. Of 100 patients, 10 patients had aneurysms and 9 of them were asymptomatic. Most of the aneurysms were small, but the rate of occurrence was higher than that seen in the general population. The rate of rupture of small aneurysms is thought to be small, at least in the short term; however, the treatment for each individual patient is best left to the specialists in that field. At this time, there are no studies screening for aneurysms in children or in adults repaired at younger ages. The utility and benefits of routine screening for aneurysms in patients with coarctation are not clear at this time, but it remains a topic of interest for future care.

Aortic aneurysm and dissection

Aortic aneurysms and dissections can occur in the area of prior coarctation repair or in conjunction with a catheter-based procedure. There is also an association with ascending aortic aneurysm and dissection in patients with coarctation of the aorta. Mostly, this occurs in patients who also have a BAV, and it is unclear whether the risk among those with BAV and coarctation is greater than the risk with BAV alone. Ascending aortic aneurysm and dissection are also described in coarctation patients with worse or poorly controlled hypertension [24,56].

Routine follow-up

It is clear that coarctation of the aorta is a lifelong disorder that affects not just the narrowed aortic segment, and patients have persistent need for close follow-up after surgical or catheter-based intervention (Table 8.1). It is recommended that patients are followed by a center that specializes in adults with congenital heart

Table 8.1 Routine follow-up evaluation for patients with coarctation.

History	Annually to include symptoms of angina, exercise intolerance, heart failure, and claudication
Physical exam	Annually to include new murmur, upper and lower pulses, and blood pressures
Echocardiogram	Annually to include assessment of ascending aorta, aortic valve, LV size/wall thickness/function, aortic gradient, descending and abdominal aortic doppler
CT or MRI scanning	Variable frequency, more often with higher risk of aneurysm
Exercise testing	Variable frequency for hypertension
24-hour ambulatory BP monitor	Variable frequency for hypertension
Cardiac catheterization	Usually for intervention when required

CT, computed tomography; MRI, magnetic resonance imaging; BP, blood pressure; LV, left ventricle.

disease [57]. Most patients are followed at least yearly with a detailed history to exclude angina, heart failure, and claudication and a physical exam including upper and lower extremity pulses and blood pressures. Echocardiography is usually also performed on an annual basis to screen for recurrence, aneurysm, and left ventricular function and hypertrophy.

The performance of additional imaging studies, such as CT or MRI scanning, is dependent on the institution and the clinical situation, although serial CT scans expose the patient to considerable radiation. Patients with a repair or intervention should have at least one of these studies performed to screen for aneurysm formation. The frequency at which they are repeated varies, and there is no evidence-based standard. For patients at higher risk of aneurysms (e.g., patch aortoplasty, older age at repair, balloon angioplasty), this should be more frequent. In patients with endovascular stents, a CT scan may be required rather than an MRI due to stent artifact with MRI.

Blood pressure screening is important at every visit. As mentioned previously, consideration should be given to exercise testing or 24-hour ambulatory blood pressure monitoring as screening. Any evidence of hypertension should be treated accordingly to attain normal levels.

Many patients, particularly those of high school and college age will inquire about sports participation. Exercise and physical fitness are encouraged for these

patients, particularly because they are at higher risk for hypertension and early CAD. However, there may be some competitive sports limitations even for those with repaired coarctation, depending on any residual or associated lesions. The recommendations for competitive sports participation are reviewed in the 36th Bethesda Conference Guidelines from the American College of Cardiology [58].

When repaired patients require medical or surgical intervention, it is often for more than just a single condition, including any combination of hypertension, recurrent coarctation, coronary disease, aneurysms, or valve disease. An individualized and thorough approach is imperative. It is hoped that with regular follow-up, early intervention, and risk factor modification, survival and quality of life in this condition will continue to improve.

Aortopathy

Definition and pathology

Aortopathy is defined as any disease of the aorta. This section specifically considers inherited diseases of the aortic media (Table 8.2), BAV aortopathy, and the associated development of aortic aneurysms. Aneurysms are defined as an aortic size >1.5 times normal, and they predispose patients to the life-threatening consequences of aortic dissection and rupture. This section focuses on describing these inherited conditions and also provides a general approach to screening, monitoring, and intervention.

Most often, inherited aortic disease is related to abnormalities of the connective tissue of the aorta. There is degeneration and disruption of the balance of smooth muscle, collagen, elastin, and fibrillin in the aortic media. The histologic finding is termed “cystic medial necrosis” and is found in genetic conditions but is also seen as a part of the aorta with BAV, aging, and in association with hypertension [59].

Table 8.2 Inherited connective tissue syndromes with related aortic disease.

Marfan syndrome

Other fibrillinopathies

Ehlers-Danlos syndrome (types I, II, and IV)

TGFBR

Loeys-Dietz syndrome

Familial TAAD

Turner syndrome

TGFBR, transforming growth factor beta receptor mutation; TAAD, thoracic aortic aneurysm and dissection.

Connective tissue disorders

Marfan syndrome

Marfan syndrome (MFS) is a well-described autosomal dominant inherited connective tissue disorder. It results from a mutation in the fibrillin 1 gene with variable phenotypic expression and manifestations mainly in the cardiovascular, skeletal, and ocular systems. The diagnosis is made by clinical presentation using the revised Ghent nosology [60]. Genetic testing for the fibrillin mutation is also available.

The major cardiovascular manifestations of MFS include aortic root dilation (Fig. 8.6a) and mitral valve prolapse. The dilation most often occurs at the level of the aortic sinuses, and the aorta is prone to dissection or rupture. Patients with MFS are also at risk of dissection and aneurysm in the descending aorta, but this is much less common [61].

Other syndromes involve abnormalities in fibrillin and can have aortic root dilation without meeting clinical MFS criteria. These include MASS phenotype (Myopia, Aortic enlargement, nonspecific Skin/Skeletal findings), familial aortic aneurysm syndrome, and mitral valve prolapse syndrome [62].

Ehlers-Danlos syndrome

Ehlers-Danlos syndrome (EDS) has multiple types that manifest different clinical features. The type most associated with severe aortic manifestations is type IV EDS, or the malignant type. This is an autosomal dominant disorder with an abnormality of type III collagen. Patients with type IV EDS are at risk for large-vessel dissection, including the aorta, cerebral, and abdominal arteries. They typically do not have the skin and joint findings of the more common classic forms of EDS [63].

The classic forms of EDS, type I and II, have hyperextensibility and fragile skin and also have a small association with mitral valve prolapse and aortic root

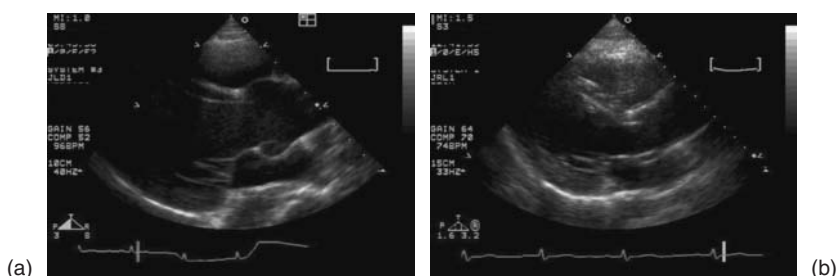


Fig. 8.6 Dilated aorta by echocardiography. (a) Dilated sinuses in a patient with Marfan syndrome. (b) Effacement of the sinotubular junction and dilation of the proximal ascending aorta in a patient with a BAV.

dilation. These patients have a lower risk of aneurysm and dissection than those with type IV. The most common type of EDS is type III, which has hypermobility but lacks aortic manifestations and does not require cardiology follow-up.

Transforming growth factor beta receptor mutations (Loeys-Dietz syndrome)

Transforming growth factor beta receptor (TGFBR) mutations have recently been implicated in conditions with aortic dilation and dissection. Mutations in TGFBR 1 and 2 are associated with a newly described condition called Loeys-Dietz syndrome (LDS). This syndrome has specific cardiac, skeletal, and neurologic manifestations, including hypertelorism, bifid uvula, and arterial tortuosity and aneurysms of the aorta. LDS appears to be a particularly aggressive type of aortic disease with a high rate of aneurysm formation and early mortality. In one retrospective study, 6 of 71 patients had dissection or rupture at aortic dimensions <4.5 cm and as young as 6 months of age [64,65].

Thoracic aortic aneurysm and dissection syndrome

Familial nonsyndromic thoracic aortic aneurysm and dissection syndrome is a genetic disorder with a pattern of autosomal dominant inheritance with decreased penetrance and variable phenotype. In this condition, there is familial clustering of aortic disease without the clinical features of other syndromes. One recent study showed a possible association with a TGFBR mutation [66].

Turner syndrome

TS is a genetic disorder (45,X) with a known association with hypertension, coarctation of the aorta, and BAV. Aortic root dilation occurs in up to 40% of TS patients, and there is a known increased risk of aortic dissection [9,10,67,68]. This risk is thought to exist beyond that of the other cardiovascular conditions associated with TS. The aorta has decreased compliance, and an intrinsic tissue abnormality has been implicated in dissection. Unlike some of the other conditions, however, this abnormality may be related to the lymphatic anomalies in TS [69].

Bicuspid aortic valve

BAV is a common condition affecting 1–2% of the general population. In addition to the abnormality of the valve, patients with a BAV are also at risk for aneurysms of the aortic root and ascending aorta [70]. Unlike MFS, where dilation is mostly at the level of the sinuses, patients with BAV have effacement of the sinotubular junction and dilation in the proximal ascending aorta (Fig. 8.6b). Patients with BAV have aortic dilation even in the presence of a hemodynamically normal valve. Super-imposed hemodynamic burdens, such as aortic stenosis or regurgitation, however, likely increase the degree of dilation or aneurysm formation [70,71].

Although not a typical connective tissue disorder, BAV is included in this section because recent pathology studies suggest an intrinsic tissue abnormality in the ascending aorta of patients with BAV. The medial irregularities identified include abnormalities in smooth muscle cells, elastic lamellae, inflammatory response, or expression of matrix metalloproteinases. The aortic tissue differs from the aorta of those with trileaflet valves and functionally has abnormal elastic properties with decreased vasoreactivity and decreased compliance [70-73].

Screening and monitoring

Aortic disease is difficult to diagnose as it is typically asymptomatic until a catastrophic event, such as dissection or rupture, occurs. When patients are diagnosed early, it is usually due to either a family history of an aortic event or a genetic condition or due to phenotypic characteristics of one of the related conditions. In conditions at risk of aortic disease, regular interval screening for aneurysm formation or growth is advocated. For all the conditions described previously, the screening recommendations are similar unless otherwise noted. For those with BAV, screening of first-degree relatives should also be performed since almost 20% will have either a BAV or some other cardiovascular anomaly [74].

Yearly imaging with a transthoracic echocardiogram is the recommended method of screening. Patients with a particularly aggressive form of disease, additional valvular lesions, or rapidly progressing aortic size (>0.5 cm/6 months), should be assessed at least every 6 months. Most patients should also have a baseline MRI or CT scan as part of the evaluation. This type of imaging is repeated at variable frequencies, depending on the individual. It is more frequent if the patient has changes noted on transthoracic echocardiogram, has symptoms, or has poor echocardiographic images. The impact of the radiation exposure from CT imaging requires consideration as these patients are usually relatively young and some may have scans as often as every 1–2 years [75]. Transesophageal echocardiography is another potential method for aortic evaluation; however, it is more invasive than CT or MRI and does not provide much additional information. It is usually reserved for evaluation of dissection in an emergent situation.

Treatment

Medical and surgical treatment options for aortic aneurysms in connective tissue disorders vary based on the underlying disease. Whereas recommendations are well described for certain conditions, like MFS, others remain less clear, like BAV. As most inherited conditions are relatively uncommon, many of the recommendations are extrapolated from literature on MFS and from aortic dissection in the general population.

Medical therapy

The mainstays of medical treatment for aortic dilation in MFS are beta blockers, aggressive treatment of hypertension, and lifestyle modification. The beta blocker medications are used in an attempt to delay progression of aortic dilation and decrease shear forces on the aorta. In recent years, the efficacy of beta blockers has come into question, and there is information showing angiotensin converting enzyme inhibitors to be potentially beneficial in delaying aortic root progression [76,77]. Even more recently, a murine model has shown substantial benefits from angiotensin receptor blockade, and trials with these medications are ongoing [78,79].

Additional noninvasive medical intervention includes family education and counseling about precautions for competitive sports and physical activity, such as limitations on contact or high-static activities [80,81]. It is also important to educate patients and families on the symptoms for which to seek medical attention, including severe chest or back pain as a sign of dissection. Pregnancy should be avoided if the aortic root exceeds 4 cm in diameter.

Other connective tissue disorders do not have additional evidence-based recommendations. Treatment of hypertension is important in any patients with aortic disease. There is, however, no universal recommendation for beta blockade in other connective tissue conditions beyond MFS. The angiotensin receptor blockers may be beneficial in LDS and are recommended by some practitioners for this condition. It is reasonable to extrapolate the activity limitations and symptom warnings for MFS to the other conditions. There are separate activity recommendations for patients with BAV and a dilated aorta [82].

Surgical therapy

Given the high risk of aortic dissection in MFS when the aorta reaches a certain size or is growing rapidly, prophylactic surgery may be recommended. The criteria are derived from retrospective studies of aortic dissection and MFS. When the aortic dimension reaches 6 cm, there is a 10% chance of dissection or rupture within the subsequent year, regardless of the etiology of the aortic dilation [83,84]. As such, prophylactic surgery is generally recommended at 5 cm or if rapid dilation is occurring (>0.5 cm/6 months) [61]. The European Society of Cardiology recommends surgery at 4.5 cm in MFS [85]. If there is moderate or more aortic regurgitation or a family history of dissection at a smaller aortic diameter, surgery is considered earlier.

There is scant literature in the other connective tissue conditions; however, given the data on aortic dissection in the general population, a criteria of 5 cm is often used as a level for consideration of prophylactic surgery. The recommendations for consideration for surgery in BAV with aortic dilation are discussed in the most recent American College of Cardiology/American Heart Association guidelines. The guidelines advocate surgery at 5 cm or at growth rates

greater than 0.5 cm/year with root replacement considered at smaller diameters if aortic valve surgery is being performed [86].

Some conditions may warrant surgery at a size smaller than 5 cm. Early reports show that LDS appears to be an aggressive form of aortic disease, and surgery is advocated at 4 cm for adults [64,65]. In TS, women are shorter than the general population, and dissection has been reported at dimensions <5 cm. In this case, using an indexed measurement of aortic size, such as $>2.5 \text{ cm/m}^2$, has been suggested [10].

When surgery is considered as prophylaxis, it is important to have a cardiothoracic surgeon with specific experience in operating on patients with connective tissue disorders. These surgeries can be more difficult due to the abnormal aortic tissue involved. Elective replacement of the aortic root can be performed with or without replacement of the aortic valve. If valve replacement is required, as in MFS with aortic regurgitation or BAV with aortic stenosis or regurgitation, a Bentall procedure is usually performed. This surgery incorporates replacement of the aortic root and ascending aorta from the valve to the innominate artery with reimplantation of the coronary arteries [87]. A prosthetic valve is employed within the graft, and patients require life-long anticoagulation. This procedure has 5-, 10-, and 20-year survival rates of 88%, 81%, and 75%, respectively [88]. More recently, valve-sparing procedures have been performed, where the aorta is replaced from the sinuses to the innominate artery with placement of a tube graft and reimplantation of the coronary arteries. The valve remains intact either implanted in the tube graft or left in situ below the graft [89–91]. The timing and type of surgery and risk involved is best discussed among the surgeon, cardiologist, and patient to make the best decision for that individual.

Case summary

The case at the beginning of this chapter described a 23-year-old woman with a recurrent coarctation and aneurysm at the site of her prior coarctation repair. She had a significant residual gradient by blood pressure and echocardiogram. The options for intervention for this woman were complicated by multiple factors, including the two prior patch repairs, the aneurysm, and the location of the head and neck vessels relative to the coarctation sites. The patient also had a history of some developmental delay and cerebral injury, possibly related to her prior operations. Given these considerations, an unusual hybrid approach was undertaken for her repair. She underwent a surgical intervention that first included relocation of her innominate and left common carotid arteries to a more proximal segment of the aorta. In the same procedure, she then had intraoperative placement of an endovascular covered stent for relief of the coarctation. The procedure was performed without the use of cardiopulmonary bypass and with maintenance of cerebral perfusion. She has had an excellent result so far with a <5 mm Hg gradient in the operating room, a 12 mm Hg mean gradient by echo with no diastolic run-off, and a

14 mm Hg systolic gradient by blood pressure. A 3-month follow-up CT scan revealed a patent stent, no residual coarctation, and no new aneurysm formation.

References

1. Sadler TW. *Langman's Medical Embryology* (6th edition). Baltimore: Williams and Wilkins, 1990.
2. Knight L, Edwards J. Right aortic arch: types and associated cardiac anomalies. *Circulation* 1974;50:1047–51.
3. Kumar V, Fausto N, Abbas A. *Robbins and Cotran Pathologic Basis of Disease* (7th edition). Philadelphia: Elsevier, 2005.
4. Aboulhosn J, Child JS. Left ventricular outflow obstruction, subaortic stenosis, bicuspid aortic valve, supravalvar aortic stenosis, and coarctation of the aorta. *Circulation* 2006;114:2412–22.
5. Keith JD. Coarctation of the aorta. In: Keith JD, Rowe RD, Vlad P, eds. *Heart Disease in Infancy and Childhood*. New York: Macmillan, 1978:736–57.
6. Fyler DC, Buckley LP, Hellenbrand WE, et al. Report of the New England regional infant cardiac program. *Pediatrics* 1980;65:432–6.
7. McBride KL, Pignatelli R, Lewin M, et al. Inheritance analysis of congenital left ventricular outflow tract obstruction malformations: segregation, multiplex relative risk, and heritability. *Am J Med Genet A* 2005;134(2):180–6.
8. Wessels MW, Berger RM, Frohn-Mulder IM, et al. Autosomal dominant inheritance of left ventricular outflow tract obstruction. *Am J Med Genet A* 2005;134(2):171–9.
9. Gotzsche CO, Krag-Olsen B, Nielsen J, et al. Prevalence of cardiovascular malformations and association with karyotypes in Turner's syndrome. *Arch Dis Child* 1994; 71(5):433–6.
10. Matura LA, Ho VB, Rosing DR, Bondy CA. Aortic dilatation and dissection in Turner syndrome. *Circulation* 2007;116:1663–70.
11. Nihoyannopoulos P, Karas S, Sapsford RN, et al. Accuracy of two-dimensional echocardiography in the diagnosis of aortic arch obstruction. *J Am Coll Cardiol* 1987; 10(5):1072–7.
12. Fyler D. Coarctation of the aorta. In: *Nadas' Pediatric Cardiology*. Philadelphia: Hanley and Belfus, 1992:535–55.
13. Rudolph AM, Heymann MA, Spitznas U. Hemodynamic considerations in the development of narrowing of the aorta. *Am J Cardiol* 1972;30:514.
14. Vogt M, Kuhn A, Baumgartner D, et al. Impaired elastic properties of the ascending aorta in newborns before and early after successful coarctation repair: proof of a systemic vascular disease of the prestenotic arteries? *Circulation* 2005;111(24):3269–73.
15. Niwa K, Perloff JK, Bhuta SM, et al. Structural abnormalities of great arterial walls in congenital heart disease: light and electron microscopic analyses. *Circulation* 2001; 103(3):393–400.
16. Isner JM, Donaldson RF, Fulton D, et al. Cystic medial necrosis in coarctation of the aorta: a potential factor contributing to adverse consequences observed after percutaneous balloon angioplasty of coarctation sites. *Circulation* 1987;75(4):689–95.
17. Nicol ED, Gatzoulis M, Padley SP, Rubens M. Assessment of adult congenital heart disease with multi-detector computed tomography: beyond coronary lumenography. *Clin Radiol* 2007;62(6):518–27.

18. Valente AM, Powell AJ. Clinical applications of cardiovascular magnetic resonance in congenital heart disease. *Cardiol Clin* 2007;25(1):97–110.
19. Teien DE, Wendel H, Bjornebrink J, Ekelund L. Evaluation of anatomical obstruction by Doppler echocardiography and magnetic resonance imaging in patients with coarctation of the aorta. *Br Heart J* 1993;69(4):352–5.
20. Campbell M. Natural history of coarctation of the aorta. *Br Heart J* 1970;32:633–40.
21. Reifenstein GH, Levine SA, Gross RE. Coarctation of the aorta: a review of 104 autopsied cases of the “adult type,” 2 years of age or older. *Am Heart J* 1947;33:146–68.
22. Abbot ME. Coarctation of the aorta of the adult type. II. A statistical study and historical retrospect of 200 recorded cases with autopsy, of stenosis or obliteration of the descending arch in subjects above the age of two years. *Am Heart J* 1928;3: 574.
23. Cohen M, Fuster V, Steele P, et al. Coarctation of the aorta: long-term follow-up and prediction of outcome after surgical correction. *Circulation* 1989;80:840–5.
24. Oliver JM, Gallego P, Gonzalez A, et al. Risk factors for aortic complications in adults with coarctation of the aorta. *J Am Coll Cardiol* 2004;44:1641–7.
25. Toro-Salazar OH, Steinberger J, Thomas W, Rocchini AP, Carpenter B, Moller JH. Long-term follow-up of patients after coarctation of the aorta repair. *Am J Cardiol* 2002;89(5):541–7.
26. Maron BJ, Humphries JO, Rowe RD, Mellits ED. Prognosis of surgically corrected coarctation of the aorta. A 20-year postoperative appraisal. *Circulation* 1973;47:119.
27. Vriend J, Mulder B. Late complications in patients after repair of aortic coarctation: implications for management. *Int J Cardiol* 2005;101:399–406.
28. Carr J, Amato J, Higgins R. Long-term results of surgical coarctectomy in the adolescent and young adult with 18-year follow-up. *Ann Thorac Surg* 2005;79:1950–6.
29. Crafoord C, Nylin G. Congenital coarctation of the aorta and its surgical treatment. *J Thorac Surg* 1945;14:347.
30. Gross RE. Coarctation of the aorta; surgical treatment of 100 cases. *Circulation* 1950;1:41–55.
31. Barreiro CJ, Ellison TA, Williams JA, et al. Subclavian flap aortoplasty: still a safe, reproducible, and effective treatment for infant coarctation. *Eur J Cardiothorac Surg* 2007;31(4):649–53.
32. Brewer LA III, Fosburg RG, Mulder GA, Verska JJ. Spinal cord complications following surgery for coarctation of the aorta: a study of 66 cases. *J Thorac Cardiovasc Surg* 1972;64:368–81.
33. Keen G. Spinal cord damage and operations for coarctation of the aorta: etiology, practice, and prospects. *Thorax* 1987;42:11–18.
34. Krieger KH, Sfiencer FC. Is paraplegia after repair of coarctation of the aorta due principally to distal hypotension during aortic cross clamping? *Surgery* 1985;97:2–7.
35. Rocchini AP, Rosenthal A, Barger AC, et al. Pathogenesis of paradoxical hypertension after coarctation resection. *Circulation* 1976;54(3):382–7.
36. Choy M, Rocchini AP, Beekman RH, et al. Paradoxical hypertension after repair of coarctation of the aorta in children: balloon angioplasty versus surgical repair. *Circulation* 1987;75(6):1186–91.
37. Singer MI, Rowen M, Dorsey TJ. Transluminal aortic balloon angioplasty for coarctation of the aorta in the newborn. *Am Heart J* 1982;103:131–2.

38. Inglessis I, Landzberg M. Interventional catheterization in adult congenital heart disease. *Circulation* 2007;115:1622–33.
39. Shaddy RE, Boucek MM, Sturtevant JE, et al. Comparison of angioplasty and surgery for unoperated coarctation of the aorta. *Circulation* 1993;87:793–9.
40. Fawzy ME, Awad M, Hassan W, et al. Long-term outcome (up to 15 years) of balloon angioplasty of discrete native coarctation of the aorta in adolescent and adults. *J Am Coll Cardiol* 2004;43:1062–7.
41. Cowley CG, Orsmond GS, Feola P, et al. Long-term, randomized comparison of balloon angioplasty and surgery for native coarctation of the aorta in childhood. *Circulation* 2005;111:3453–6.
42. Forbes TJ, Garekar S, Amin Z, et al. Congenital Cardiovascular Interventional Study Consortium (CCISC). Procedural results and acute complications in stenting native and recurrent coarctation of the aorta in patients over 4 years of age: a multi-institutional study. *Catheter Cardiovasc Interv* 2007;70(2):276–85.
43. Carr JA. The results of catheter-based therapy compared with surgical repair of adult aortic coarctation. *J Am Coll Cardiol* 2006;47:1101–7.
44. Attenhofer Jost CH, Schaff HV, Connolly HM, et al. Spectrum of reoperations after repair of aortic coarctation: importance of an individualized approach because of coexistent cardiovascular disease. *Mayo Clin Proc* 2002;77(7):646–53.
45. McKellar SH, Schaff HV, Dearani JA, et al. Intermediate-term results of ascending-descending posterior pericardial bypass of complex aortic coarctation. *J Thorac Cardiovasc Surg* 2007;133:1504–9.
46. Hager A, Kanz S, Kaemerrer H, et al. Coarctation Long-term Assessment (COALA): significance of arterial hypertension in a cohort of 404 patients up to 27 years after surgical repair of isolated coarctation of the aorta, even in the absence of restenosis and prosthetic material. *J Thorac Cardiovasc Surg* 2007;134:738–45.
47. Gardiner HM, Celermajer DS, Sorensen KE, et al. Arterial reactivity is significantly impaired in normotensive young adults after successful repair of aortic coarctation in childhood. *Circulation* 1994;89:1745.
48. Chen S, Donald A, Storry C, et al. Impact of aortic stenting on peripheral vascular function and daytime systolic blood pressure in adult coarctation. *Heart* 2008;94: 919–24.
49. de Divitiis M, Pilla C, Kattenhorn M, et al. Ambulatory blood pressure, left ventricular mass, and conduit artery function late after successful repair of coarctation of the aorta. *J Am Coll Cardiol* 2003;41:2259–65.
50. Simsolo R, Grunfeld B, Gimenez M, et al. Long-term systemic hypertension in children after successful repair of coarctation of the aorta. *Am Heart J* 1988;115:1268.
51. Kimball TR, Reynolds JM, Mays WA, et al. Persistent hyperdynamic cardiovascular state at rest and during exercise in children after successful repair of coarctation of the aorta. *J Am Coll Cardiol* 1994;24:194.
52. Instebo A, Norgard G, Helgheim V, et al. Exercise capacity in young adults with hypertension and systolic blood pressure difference between right arm and leg after repair of coarctation of the aorta. *Eur J Appl Physiol* 2004;93:116–23.
53. Vriend JW, van Montfrans GA, Romkes HH, et al. Relation between exercise induced hypertension and sustained hypertension in adult patients after successful repair of aortic coarctation. *J Hypertens* 2004;22:501–9.

54. Aggoun Y, Szezepanski I, Bonnet D. Noninvasive assessment of arterial stiffness and risk of atherosclerotic events in children. *Pediatr Res* 2005;58:173–8.
55. Connolly HM, Huston J 3rd, Brown RD Jr, et al. Intracranial aneurysms in patients with coarctation of the aorta: a prospective magnetic resonance angiographic study of 100 patients. *Mayo Clin Proc* 2003;78(12):1491–9.
56. von Kodolitsch Y, Aydin M, Koschyk D, et al. Predictors of aneurysmal formation after surgical correction of aortic coarctation. *J Am Coll Cardiol* 2002;39:617–24.
57. Landzberg MJ, Murphy DJ Jr, Davidson WR Jr, et al. Task Force 4: Organization of delivery systems for adults with congenital heart disease. *J Am Coll Cardiol* 2001;37:1187–93.
58. Graham TP Jr, Driscoll DJ, Gersony WM, et al. Task Force 2: Congenital heart disease. *J Am Coll Cardiol* 2005;45(8):1326–33.
59. Kingwell B, Boutouyrie P. Genetic influences on the arterial wall. *Clin Exp Pharmacol Physiol* 2007;34:652–7.
60. De Paepe A, Devereux RB, Dietz HC, et al. Revised diagnostic criteria for the Marfan syndrome. *Am J Med Genet* 1996;62(4):417–26.
61. Treasure T. Cardiovascular surgery for Marfan syndrome. *Heart* 2000;84:674–8.
62. Arbustini E, Grasso M, Ansaldi S, et al. Identification of sixty-two novel and twelve known FBN1 mutations in eighty-one unrelated probands with Marfan syndrome and other fibrillinopathies. *Hum Mutat* 2005;26(5):494.
63. Badauy CM, Gomes SS, Sant’Ana Filho M, Chies JA. Ehlers-Danlos syndrome (EDS) type IV: review of the literature. *Clin Oral Investig* 2007;11(3):183–7.
64. Loeys B, Schwarze U, Holm T, et al. Aneurysm syndromes caused by mutations in the TGF- β receptor. *N Engl J Med* 2006;355:788–98.
65. Williams J, Loeys B, Nwakanma L, et al. Early surgical experience with Loeys-Dietz: a new syndrome of aggressive thoracic aortic aneurysm disease. *Ann Thorac Surg* 2007;83:S757–63.
66. Pannu H, Tran-Fadulu V, Milewicz D. Genetic basis of thoracic aortic aneurysms and aortic dissections. *Am J Med Genet C Semin Med Genet* 2005;139C:10–16.
67. Elsheikh M, Dunger DB, Conway GS, Wass JA. Turner’s syndrome in adulthood. *Endocr Rev* 2002;23(1):120–40.
68. Weytjens C, Bove T, van der Niepen P. Aortic dissection and Turner’s syndrome. *J Cardiovasc Surg* 2000;41:2.
69. Loscalzo ML, Van PL, Ho VB, et al. Association between fetal lymphedema and congenital cardiovascular defects in Turner syndrome. *Pediatrics* 2005;115(3):732–5.
70. Braverman AC, Güven H, Beardslee MA, et al. The bicuspid aortic valve. *Curr Probl Cardiol* 2005;30(9):470–522.
71. Cecconi M, Nistri S, Quarti A, et al. Aortic dilatation in patients with bicuspid aortic valve. *J Cardiovasc Med (Hagerstown)* 2006;7(1):11–20.
72. LeMaire SA, Wang X, Wilks JA. Matrix metalloproteinases in ascending aortic aneurysms: bicuspid versus trileaflet aortic valves. *J Surg Res* 2005;123:40–8.
73. Grotenhuis H, Ottenkamp J, Westenberg J, et al. Reduced aortic elasticity and dilatation are associated with aortic regurgitation and left ventricular hypertrophy in non-stenotic bicuspid aortic valve patients. *J Am Coll Cardiol* 2007;49:1660–5.
74. Cripe L, Andelfinger G, Martin LJ, Shooner K, Benson DV. Bicuspid aortic valve is heritable. *J Am Coll Cardiol* 2004;44:138–43.

75. Brenner DJ, Hall EJ. Computed tomography: an increasing source of radiation exposure. *N Engl J Med* 2007;357(22):2277–84.
76. Yetman AT. Cardiovascular pharmacotherapy in patients with Marfan syndrome. *Am J Cardiovasc Drugs* 2007;7(2):117–26.
77. Selamet Tierney ES, Feingold B, Printz BF, et al. Beta-blocker therapy does not alter the rate of aortic root dilation in pediatric patients with Marfan syndrome. *J Pediatr* 2007;150(1):77–82.
78. Habashi JP, Judge DP, Holm TM, et al. Losartan, an AT1 antagonist, prevents aortic aneurysm in a mouse model of Marfan syndrome. *Science* 2006;312(5770):117–21.
79. Lacro RV, Dietz HC, Wruck LM, et al. Rationale and design of a randomized clinical trial of beta-blocker therapy (atenolol) versus angiotensin II receptor blocker therapy (losartan) in individuals with Marfan syndrome. *Am Heart J* 2007;154(4):624–31.
80. Maron BJ, Ackerman MJ, Nishimura RA, et al. Task Force 4: HCM and other cardiomyopathies, mitral valve prolapse, myocarditis, and Marfan syndrome. *J Am Coll Cardiol* 2005;45(8):1340–5.
81. Maron BJ, Chaitman BR, Ackerman MJ, et al. Recommendations for physical activity and recreational sports participation for young patients with genetic cardiovascular diseases. *Circulation* 2004;109(22):2807–16.
82. Bonow RO, Cheitlin MD, Crawford MH, Douglas PS. Task Force 3: valvular heart disease. *J Am Coll Cardiol* 2005;45(8):1334–40.
83. Juvonen T, Ergin MA, Galla JD, et al. Prospective study of the natural history of thoracic aortic aneurysms. *Ann Thorac Surg* 1997;63:1533–45.
84. Coady MA, Rizzo JA, Hammond GL, et al. What is the appropriate size criterion for resection of thoracic aortic aneurysms? *J Thorac Cardiovasc Surg* 1997;113:476–91.
85. Vahanian A, Baumgartner H, Bax J, et al. Guidelines on the management of valvular heart disease: The Task Force on the Management of Valvular Heart Disease of the European Society of Cardiology. *Eur Heart J* 2007;28(2):230–68.
86. Bonow RO, Carabello BA, Chatterjee K, et al. ACC/AHA 2006 guidelines for the management of patients with valvular heart disease. A report of the American College of Cardiology / American Heart Association Task Force on Practice Guidelines. *J Am Coll Cardiol* 2006;48:e1–148. [Published erratum in *J Am Coll Cardiol* 2007;49:1014.]
87. Bentall H, De Bono A. A technique for complete replacement of the ascending aorta. *Thorax* 1967;23:338–9.
88. Gott VL, Pyeritz RE, Magovern GJ Jr, et al. Surgical treatment of aneurysms of the ascending aorta in the Marfan syndrome. Results of composite-graft repair in 50 patients. *N Engl J Med* 1986;314(17):1070–4.
89. Underwood MJ, El Khoury G, Deronck D, et al. The aortic root: structure, function, and surgical reconstruction. *Heart* 2000;83:376–80.
90. Karck M, Kallenbach K, Hagl C, Rhein C, Leyh R, Haverich A. Aortic root surgery in Marfan syndrome: comparison of aortic valve-sparing reimplantation versus composite grafting. *J Thorac Cardiovasc Surg* 2004;127(2):391–8.
91. Kallenbach K, Karck M, Pak D, et al. Decade of aortic valve sparing reimplantation: are we pushing the limits too far? *Circulation* 2005;112(9 Suppl):I253–9.

Transposition of the great arteries after a Mustard atrial switch procedure

Folkert Meijboom and Gary Webb

A 28-year-old man was born with “simple” transposition of the great arteries, that is, with no significant associated anomalies (Fig. 9.1). He was cyanotic as a newborn and was palliated with a Rashkind balloon atrial septostomy (Fig. 9.2). By improving mixing of his venous and arterial circulations, his cyanosis improved, and he was 2 years old when he had a Mustard atrial switch procedure (Fig. 9.3). His childhood was uneventful. By age 14, he had developed a junctional rhythm. By age 21, moderate right ventricular (RV) systolic dysfunction was present. Mild systemic tricuspid regurgitation appeared. Inferior vena caval baffle stenosis was also identified and successfully treated by stent placement. As a young man, he enjoyed partying and drinking beer. His weight ballooned to 115 kg. By age 24, tricuspid regurgitation had become moderate. He took a job doing heavy physical work. He married and then became the father of a healthy daughter. Soon thereafter, he had his first episode of syncope while at a pub. A 24-hour Holter monitor showed junctional rhythm without ventricular tachycardia. Soon thereafter, an episode of documented ventricular fibrillation occurred, and he was resuscitated. An AICD was placed, and amiodarone was begun. His physical capacity had slipped. He could climb two flights of stairs, but not three. Systemic RV hypokinesia was now moderately severe. He had stopped drinking alcohol and was complying with his medical treatments. Transplantation is being considered.

This case presentation illustrates many of the problems that can occur in patients with transposition of the great arteries (TGA) after an atrial switch procedure in childhood. Some atrial switch patients do well and have no problems at all over many years. However, most of these patients do have problems, although they are seldom as extensive as in our patient. Congenital heart disease, in this case TGA, is a lifelong illness and not a disease that is cured by surgery.

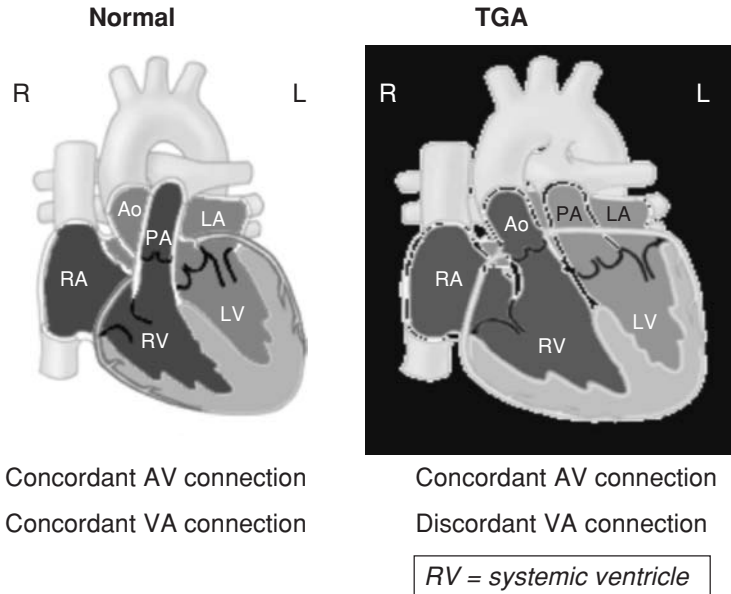


Fig. 9.1 Schematic drawing of a normal anatomy and circulation on the left side and a transposition of the great arteries with the resulting abnormal circulation on the right side. The anatomical description of a heart with a transposition of the great arteries is concordant AV (atrioventricular) connection and discordant VA (ventriculo-arterial) connection. RV = right ventricle. RA = right atrium. RV = right ventricle. LA = left atrium. LV = left ventricle. PA = pulmonary artery. Ao = aorta.

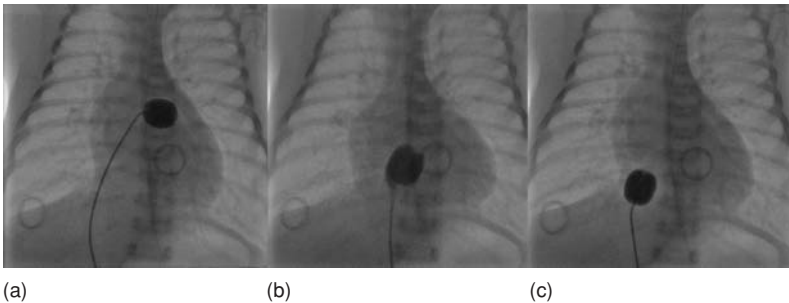


Fig. 9.2 A sequence of fluoroscopic images of the Rashkind balloon atrioseptostomy. (a) shows a catheter, coming from the inferior caval vein, going through the right atrium, having crossed the interatrial septum through a patent foramen ovale, with the balloon-locatrd at the tip of this catheter-inflated in the left atrium. In (b), the catheter is pulled out and the balloon is deformed when it is pressed against the interatrial septum and even more when it passes through the foramen ovale, tearing the fossa ovalis membrane (the actual goal of this procedure). (c) the inflated balloon is visible low in the right atrium; it has made a tear in the fossa ovalis membrane, which allows left-to-right shunting of oxygenated blood towards the systemic circulation.

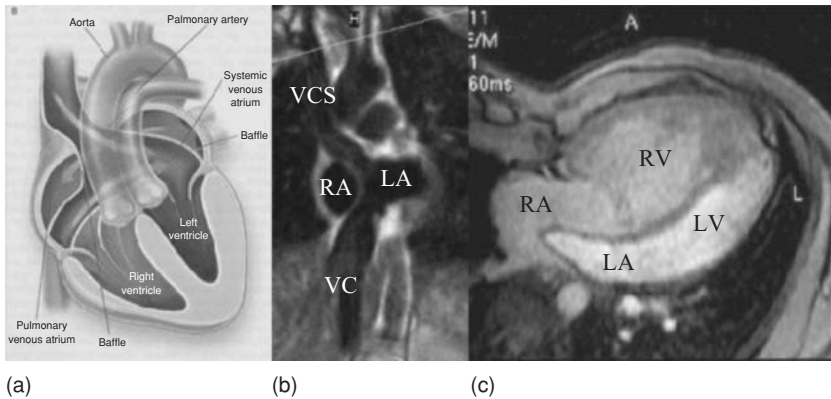


Fig. 9.3 In (a), a schematic drawing is shown of a TGA (transposition of the great arteries) after an atrial switch according to Mustard. Note that the superior baffle passes from right to left anterior from the pulmonary venous atrium and that the inferior baffle runs from right to left posteriorly in the right atrium, posterior from the connection between pulmonary venous atrium and right atrium. (b) shows a right lateral view of a Mustard situation, with both superior and inferior baffles connecting to the left-sided LA (left atrium). To the right of the junction of the baffles and the left atrium, a small part of the RA (right atrium) is visible. VCS = vena cava superior. VC = vena cava inferior. (c) is a CMR-image of the same patient. LV = left ventricle. LA = left atrium. RA = right atrium. RV = right ventricle. The left ventricle is squashed by the leftward bulging of the interventricular septum, a result from the high (systemic) pressures in the right ventricle (R = right). Posteriorly-left in this picture-the connection between the pulmonary venous atrium and the RA (= right atrium) is shown.

Background

TGA is one of the common cyanotic congenital cardiac malformations; approximately 5% of all the newborns with a congenital cardiac malformation have this lesion [1]. The cause is unknown. In general, it occurs spontaneously and is not familial. There is no known association with syndromes or chromosomal abnormalities. There is a 2:1 male preponderance. In two-thirds of patients, it is an isolated finding (i.e., without concomitant intracardiac defects) and so may be referred to as a "simple TGA." In one-third of cases, it occurs with other structural defects (most often a ventricular septal defect) and may be referred to as a "complex TGA." As a rule, these two groups of patients have different clinical presentations and natural histories. For patients with a "complex TGA," other types of surgical treatment can be offered, with uncommon names like the Rastelli operation, the Kawashima procedure, or REV [2,3]. These are beyond the scope of this chapter. The natural history of "simple TGA" (to be referred to as TGA) known from the era before cardiac surgery is very poor: only 10% survived the first year of life [4]. The possibility of making the correct

diagnosis and offering surgical treatment, introduced by the surgeons Mustard from Toronto and Senning from Zurich in the beginning of the 1960s, dramatically changed the prospects for children born with transposition [5,6]. These surgical techniques share the basic principle of the atrial switch: the TGA is left untouched and the systemic venous return is re-routed through surgically created tunnels (called baffles) to the left ventricle and then the pulmonary artery, leaving enough space behind the intra-atrial baffles for the pulmonary veins to drain into the right ventricle and then the aorta. The techniques differ in the choice of the material used for the baffle construction. In a Mustard, fabric is used (most often Dacron) and in a Senning, the baffles are made of tissue from the interatrial septum and atrial wall of the patients themselves.

Surgical mortality, morbidity, and long-term outcomes are similar for the two techniques [7]. The atrial switch is rarely performed anymore; since about 1985, it has been almost entirely replaced by the arterial switch operation, which is performed in the first 2 weeks of life. As a consequence, most adults born with transposition who are alive today will have had one of the atrial switch procedures, and most of today's children and adolescents with transposition will have had an arterial switch operation. The focus in this chapter is on adults with a TGA, therefore patients after a Mustard or a Senning atrial switch procedure. The most common problems in these adult TGA patients are:

- 1 Ventricular dysfunction;
- 2 Arrhythmia; and
- 3 Baffle-related problems.

These will be discussed below. Because of these problems, atrial switch patients should be regularly seen by a cardiologist with expertise in the care of patients with complex congenital heart defects.

Ventricular function

In patients who have had a Mustard or Senning operation, the main problem is that the right ventricle has to perform as the systemic ventricle. In contrast to the left ventricle, the right ventricle was not "designed" as a pressure pump. Its shape and orientation of muscle fibers in the ventricular wall are such that it performs best in the transport of large volumes of venous return against a low afterload, in the form of a low pulmonary vascular resistance. When the afterload of the right ventricle is not low, as in a patient with TGA, the right ventricle has to adapt to its high-pressure task. The adaptations begin to take place immediately after birth since, unlike the normal circulation, the afterload to the right ventricle does not decrease at all in this period. The physiologic reactions of the right ventricle to a decreasing afterload do not occur, so there is no thinning of the ventricular wall and no loss of the middle muscle layer, consisting of circularly oriented muscle fibers. The adaptations to a low pressure now occur in the left ventricle, from which the pulmonary artery arises. The left ventricle will become the flattened, low-pressure ventricle, curved around the round high-pressure right ventricle. These adaptations are very successful in

the short run in most patients. Until adolescence, RV function is usually judged as normal and tricuspid regurgitation is absent to mild.

Most atrial switch patients will do well in terms of ventricular function until at least age 20. However, from early adulthood on, many patients with TGA after an atrial switch will gradually develop signs of depressed RV function [8,9]. Then, as RV systolic dysfunction progresses, systemic tricuspid regurgitation will tend to become manifest. In atrial switch patients, there is a tendency to progressive RV dysfunction and tricuspid regurgitation over time, although the rate of these developments is unpredictable.

Left ventricular function is rarely a problem. Sometimes the high-pressure right ventricle causes posterior bulging of the interventricular septum to such a degree that left ventricular outflow tract (LVOT) obstruction develops. This narrowing can cause systolic anterior movement of the anterior mitral valve leaflet. The fixed narrowing, caused by the bulging of the interventricular septum, together with the dynamic obstruction of the systolic anterior movement can give rise to very high gradients across the LVOT. The development of subpulmonary LVOT obstruction is usually very slow, and the left ventricle adapts to it by becoming hypertrophied. Left ventricular function is rarely affected by this. Regular assessment of ventricular function is mandatory during follow-up of these patients.

Arrhythmia

The extensive atrial surgery and resultant atrial scarring often causes the loss of sinus rhythm and may form the substrate for atrial flutter variants [10]. Indeed, resting sinus bradycardia or junctional rhythm is very common in these patients, and perhaps 25% will eventually receive pacemakers because of unacceptable bradycardia. In follow-up of Mustard and Senning patients, sudden death is reported to occur relatively frequently. It is likely that these sudden deaths are caused by ventricular arrhythmias and, as in acquired heart disease, the occurrence of ventricular tachycardia or ventricular fibrillation is associated with poor function of the systemic ventricle [11]. Our patient illustrates this point.

A very fast heart rate as a result of a supraventricular tachycardia can also be life threatening, especially if the baffles are relatively narrow. In a structurally normal heart, a rise in atrial pressures in response to atrial fibrillation or flutter can facilitate adequate ventricular filling, despite the reduced filling time. In a patient with a Mustard or Senning circulation, with the noncompliant Mustard baffles and without the reservoir function of a normal atrium, fast supraventricular tachycardias may be poorly tolerated. Medical treatment of tachyarrhythmias may be made difficult by the commonly associated RV systolic dysfunction. As a result, all antiarrhythmic drugs with negative inotropic effects (virtually all except for digoxin and amiodarone) may be contraindicated. Digoxin is not a very potent drug. Amiodarone has obvious disadvantages because of the high frequency of side effects. However, because tachyarrhythmias are often poorly

tolerated, there is a low threshold to start amiodarone. Although very challenging for electrophysiologists and not always successful, transcatheter ablation of flutter circuits in Mustard patients should be considered as an alternative to amiodarone treatment.

Function of the atrial baffles

There is often confusion about the term "baffle." One of the reasons is that many schematic drawings are good enough to explain the physiology of the Mustard circulation, but are too schematic to understand the anatomical situation. The drawing presented of the case report is correct and understandable. The term "baffle" should be reserved for the tunnel-like connection between the caval veins and the left atrium and *not* for the connection of the pulmonary veins to the right atrium.

These baffles were surgically created in infancy or early childhood. After the operation, patients will continue to grow, but the baffles (consisting of Dacron in the Mustard operation or atrial septal tissue in the Senning situation) will have little or no growth. For most patients, these baffles will remain wide enough to function as transport tunnels, but in a subset of patients, these baffles will become relatively narrow or even obstructive. There are no agreed criteria for the size of baffles, providing a reason why there are no reliable data on the occurrence of baffle obstruction after a Mustard or Senning procedure. Even if a baffle is not narrowed, the fact that the normally compliant, contracting, and relaxing structure of the normal right atrium has been replaced by noncompliant baffles results in a different hemodynamic situation. The passive transport function is intact, but the other aspects of atrial function have been lost. A normal right atrium can quickly accommodate a large increase in venous return during exercise because of good active relaxation and a very compliant atrial wall. Because a baffle has very poor compliance, these rigid structures limit the increase in venous return to the heart. The capacity of these baffles may be good enough for cardiac output and venous return at rest, but fall short with exercise or with tachycardia. The capacity to increase preload is very limited, and thus the ability to increase cardiac output will be limited, even in young patients with normal or near-normal RV function. Compensatory mechanisms for this situation are a rapid increase in heart rate (if the sinus node is not too sick to allow this, and chronotropic incompetence is common) and peripheral vasoconstriction with exercise. This explains why patients after a Mustard or Senning operation often have warm hands at rest but very cold hands immediately after exercise.

Baffle obstruction

If the venous return of the upper or lower half of the body is obstructed and venous congestion is visible, a baffle stenosis should be suspected. However, the absence of venous congestion is not a reliable marker for absence of baffle stenosis. In the normal circulation, the azygos system, a venous system posterior

to the caval veins that runs in an inferior–superior direction parallel to the spine, is not very significant in terms of flow, but if the caval venous return to the heart is obstructed (either from superior or inferior baffle stenosis), the azygos system can act as a bypass system. If the superior baffle is obstructed, the venous return from the upper half of the body is redirected, through the azygos vein, to the inferior caval vein. The direction of the flow will be from the high-pressure (the potentially congested upper half of the body) to the low-pressure inferior caval vein, so from superior to inferior. If the inferior baffle is obstructed, the azygos vein will carry flow from the potentially congested lower part of the body in a cranial direction, toward the place where the azygos vein anastomoses with the superior caval vein. In these situations, the entire venous return may have to pass through one baffle. The potential increase in venous return during exercise will be limited even more than described above. This will limit exercise capacity. This, in itself, might be an indication for intervention. If atrial flutter or atrial fibrillation occurs, the ability to maintain cardiac output and blood pressure will be even more limited than when two baffles are patent (see above). We believe that patients with baffle obstruction are more at risk for hemodynamic derangement and at higher risk of sudden death when atrial tachyarrhythmias occur. This, in our opinion, is another reason why baffle stenosis should be diagnosed and treated.

Sometimes an obstruction to pulmonary venous drainage develops, most often at the site where the pulmonary venous atrium (the posterior part of the original left atrium into which the pulmonary veins drain) connects with the right atrium. Only if this obstruction is severe and gives rise to elevated pulmonary artery pressures should treatment be considered. Treatment in this situation is usually surgical, with a complete re-do of the atrial baffles. Retrograde catheterization with an attempt to balloon this narrowing is possible but seldom successful in clinical practice.

Baffle leaks

Baffle leaks can occur in perhaps one-quarter of the patients. The exact localization of the leak and pressure relations within the heart will dictate the direction of the shunt. In the absence of baffle stenosis, low filling pressures of the subpulmonary left ventricle, and slightly elevated filling pressures of the systemic right ventricle, it will be a left-to-right shunt: shunting of oxygenated blood from the pulmonary venous atrium or right atrium toward the baffles or left atrium, giving rise to volume overload of the subpulmonary left ventricle. The best clue to the existence of such a baffle leak is a larger-than-expected subpulmonary left ventricle on a routine echocardiogram. If the baffle is relatively small, which is very common in the Mustard situation, and the leak is proximal to this narrowing (e.g., the anastomosis of the inferior caval vein with the inferior baffle), the shunt will be right-to-left and hypoxemia may be present at rest or be precipitated by exercise.

Recommendation for follow-up in clinical practice

Routine follow-up, usually annual, is indicated for all patients with TGA after an atrial switch, even if they are asymptomatic. The investigations should be aimed at early detection of the expected problems, as described above, as well as the detection of unexpected problems. A check-up should always include a history, physical examination, a 12-lead electrocardiogram (ECG), and transthoracic echocardiogram (echo). If indicated, other examinations, such as a 24-hour ECG, magnetic resonance imaging (MRI), cardiopulmonary testing, lab tests, or cardiac catheterization, should be done. In the following text, some practical tips are offered to help achieve good clinical practice.

History

It is necessary to ask specifically about unprovoked tachycardia and syncope. One should determine, as precisely as possible, what a patient can physically accomplish, e.g., how many stairs he/she can climb; whether he/she is able to walk for 60 minutes at a normal pace or only at his/her own slower pace, etc. A change in exercise capacity over the years can be assessed this way.

Physical examination

If, at the handshake, the patient's hands are cold, the cardiac output at rest is probably depressed, or the patient just exercised, e.g., by walking to the outpatient clinic. Cyanosis and clubbing are usually absent, and pulse oximetry is normal or near normal. Mild desaturation (with oxygen saturation in the range of 94–96%) is common, due to the fact that the coronary sinus, with its deeply desaturated blood, drains into the right atrium, which is incorporated in the systemic circulation. A deeper desaturation suggests a right-to-left shunt, possibly from a baffle leak. The jugular venous pressure is usually normal. If it is substantially elevated, a superior baffle obstruction with an inadequate decompressing azygos bypass should be suspected. The RV impulse is virtually always palpable as a precordial heave. At the left 4th intercostal space, one should listen specifically for a high-pitched holosystolic murmur that could indicate tricuspid regurgitation. An ejection-type murmur can often be heard at the 2nd or 3rd left intercostal space, indicating some LVOT obstruction. Signs of venous congestion of the lower body half, a congested liver or edema of the legs, should always be sought, since this could suggest inferior limb baffle obstruction with insufficient decompression by the azygos bypass system or, alternatively, reflect heart failure.

ECG

Is there a P wave? If present, the width and amplitude should be noted. It happens often that the P wave, clearly visible at a young age, will gradually lose amplitude until it disappears. The resulting junctional escape rhythm has

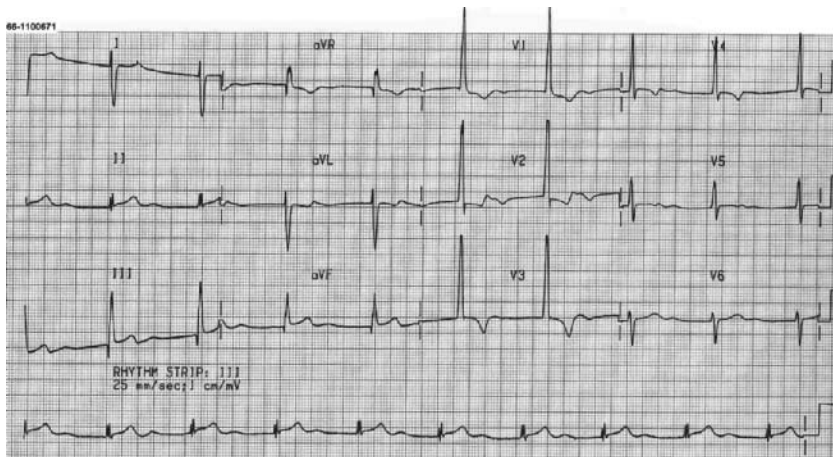


Fig. 9.4 Typical ECG of an adult patient with a TGA after a Mustard atrial switch. There is no visible P wave; there is a right axis deviation; and in the precordial leads, there is almost exclusively RV activity.

a narrow (or only slightly broadened) QRS complex. Significant or progressive prolongation of the QRS complex, usually as a complete RBBB, may indicate dilation of the right ventricle and/or worsening of RV function. There is usually right axis deviation and marked voltage evidence of RV hypertrophy. The left ventricle is electrically silent. If there is any evidence of left ventricular hypertrophy, this may indicate LVOT obstruction or pulmonary hypertension. Figure 9.4 shows a typical ECG for adult patients with a TGA after a Mustard or Senning atrial switch: junctional rhythm, right axis deviation, and RV hypertrophy in the precordial leads. If the resting heart rate is slow, as is common, 24-hour ECG monitoring should be considered to determine whether a pacemaker may be needed. An exercise test should often be done to assess both physical capacity and the degree of chronotropic incompetence. If severe chronotropic incompetence is discovered or if heart rates during the 24-hour ECG are very low (lower than 30 bpm at night, lower than 40 bpm during the day, or a mean heart rate of <50 bpm over the day), pacemaker implantation may be considered.

Echocardiography

Echocardiography can be used to assess RV size and function and to evaluate the atrial baffles and pulmonary venous drainage (Fig. 9.5). There are no reference values for RV size in Mustard patients, but measurement of RV dimensions is useful for serial follow-up of a patient. If the systemic right ventricle dilates in an adult patient, this should be seen as a sign of deterioration of ventricular function. Visual estimates of RV function (normal wall motion or a degree of

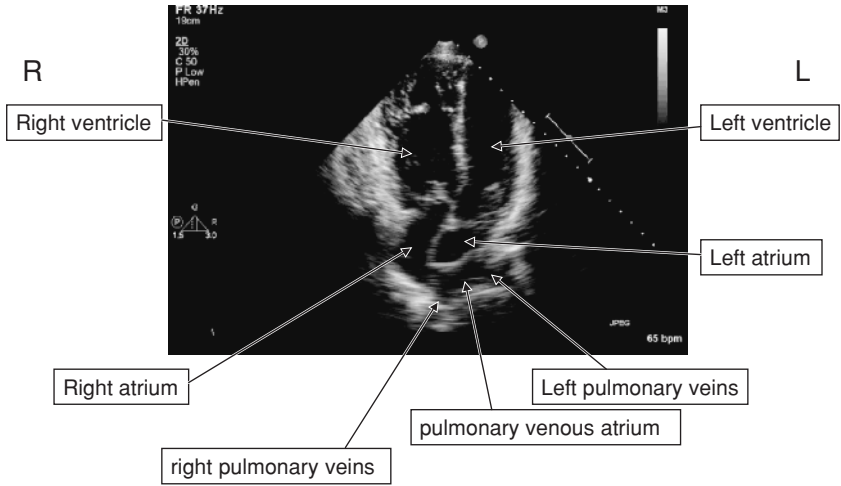


Fig. 9.5 An apical four-chamber view of a patient with a TGA after a Mustard procedure. R, right; L, left.

hypokineses) are most used in clinical practice, although their accuracy and reproducibility is limited. The use of echo contrast that passes the lungs may be very rewarding in the assessment of RV function in patients with a systemic right ventricle. One should consider doing contrast echo for RV function assessment in all patients in which the 2D image is less than perfect. Measurement of the size of the tricuspid annulus is also useful for serial follow-up of RV function, as is the color Doppler semiquantification of tricuspid regurgitation. Tricuspid annular plane systolic excursion (TAPSE) is always depressed in patients with systemic right ventricles when compared with right ventricles in structurally normal hearts. If, at longitudinal follow-up, the TAPSE deteriorates from previous values, this suggests worsening RV function.

Once an atrial switch patient is fully grown and the baffles are functioning normally, only periodic reassessment is necessary. For all new Mustard/Senning patients, or in patients in whom a baffle leakage or obstruction is suspected, a complete echo work-up is indicated. Direct echocardiographic visualization of the baffles is difficult but is often feasible if the sonographer has enough experience and understands the difficult anatomy. The anastomosis of the baffles with the caval veins and their connection to the left atrium can be seen if image quality is adequate. Not only should the baffles be imaged, but also the superior caval vein above the superior baffle and the inferior caval vein and hepatic veins below the inferior baffle. Color Doppler, set with very low Nyquist limits to detect low-flow velocities, and pulsed Doppler interrogation

at different levels will normally show very low-flow velocities, with only antegrade flow in diastole. If local acceleration of the flow is seen, stenosis should be suspected. Flow velocities in superior and inferior caval vein should be more or less comparable. If the flow velocity in one of the caval veins is much lower than in the other, a baffle stenosis can be suspected there. The higher flow velocity in the caval vein in the nonstenosed side can be explained by increased flow: the normal flow plus the amount that reaches the nonstenosed side through the azygos vein bypass. Sometimes the azygos vein can be visualized directly. In the case of an inferior baffle stenosis, the sniff test is very helpful: during short, powerful inspiration, the rapid fall in intrathoracic pressure leads to an almost complete collapse of the inferior caval vein. If there is no collapse, the lowering of the intrathoracic pressure is not transmitted to the inferior caval vein; there is a very high likelihood of a significant obstruction of the inferior baffle.

Contrast echo

The use of echo contrast that does *not* pass the lungs can be very helpful for the detection of baffle stenosis or leakage. If contrast, injected in an arm, enters the heart through the inferior baffle, there is a superior baffle obstruction and a functioning azygos bypass (and the other way around: if contrast injected in a leg appears in the superior baffle, an inferior baffle stenosis is present). If contrast injected in an arm appears in the right atrium and right ventricle within seconds, leakage of the superior baffle with right-to-left shunting is present. Leakage of the inferior baffle is diagnosed by injecting contrast in a vein below the diaphragm.

Exercise test

Both bicycle and treadmill tests can be done for the assessment of exercise capacity and heart rate response. Almost all patients after a Mustard or Senning have a decreased exercise capacity [12]. There are no reference values for Mustard patients, although many published data suggest that a “normal” exercise capacity after an atrial switch is only half that of normal individuals. The main value of exercise tests in clinical practice is the relative serial performance of individual patients. However, exercise testing not only reflects the patient’s cardiac condition but also the general physical condition. These factors should be taken into account in interpreting the serial data. Both maximal heart rate and maximal blood pressure during exercise tend to be less than expected in atrial switch patients.

Measurement of oxygen saturation during exercise can unmask baffle leakage with substantial right-to-left shunting that occurs only during exercise, when the systemic venous return is increased. Standard transcutaneous measurement of the oxygen saturation with the probe on the tip of a finger usually does not work, because most Mustard/Senning patients have marked peripheral vasoconstriction at exercise. With a probe affixed to an earlobe, oxygen saturation can be measured more accurately.

Magnetic resonance imaging (MRI)

MRI can provide the most reproducible measurements of ventricular volumes and function and is therefore the preferred method for longitudinal follow-up of these parameters in atrial switch patients [13]. MRI is also very valuable for the evaluation of the baffles. A good understanding of the difficult anatomy is necessary during the acquisition phase, which means that a cardiologist or a radiologist with special knowledge of congenital heart disease must be present during the image acquisition. A substantial proportion of patients after a Mustard procedure do have a pacemaker, which is a contraindication for MRI. CT angiography is an alternative for these patients when there is a specific question, but the high radiation dose that is unavoidable in doing a CT scan makes CT less attractive as an instrument for serial follow-up.

Cardiac catheterization

Because noninvasive imaging is now so excellent, a purely diagnostic cardiac catheterization is rarely required in the current era. Instead, the indication for the procedure will usually be a catheter intervention, such as stenting of a baffle stenosis or closing a baffle leak. Because of its invasive nature and the fact that it is rarely necessary, we think that these few catheterizations should only be done at centers with the most expertise and experience.

Case study

Throughout our patient's life, some findings and events prompted intervention, and others did not. The first event was the clinical presentation at neonatal age. The diagnosis of TGA always prompts treatment. If mixing of systemic and pulmonary venous blood is not adequate, a septostomy is done. Since Bill Rashkind's pioneering work, published in 1966, this can be done with a catheter and balloon technique. This is still the preferred treatment today. At the time that our patient was born, the atrial switch was the preferred technique. There were no events until the patient was 14 years old. At that time, he lost sinus rhythm. Although this is not an ideal situation (the loss of the atrial "kick" will reduce stroke volume and the maximal heart at exercise will be reduced) there was no indication for pacemaker insertion. At the age of 21, inferior baffle stenosis was diagnosed. Although the patient was asymptomatic, it was decided to treat this stenosis for the reasons mentioned earlier. By age 24, his ventricular function had deteriorated and the worsening systemic tricuspid regurgitation reflected this. In atrial switch patients, tricuspid regurgitation is almost always the result of RV dilatation and dysfunction. We started ACE-inhibitors even though there is little or no evidence that they are effective in a patient with a systemic right ventricle. At age 24, he had an out-of-hospital cardiac arrest, so an AICD was placed even though the role of these devices is not yet clear in these patients. Before age 30, our patient has developed heart failure symptoms due to progressive systemic RV dysfunction. He does not yet fulfill the criteria for cardiac transplantation, but, like many of these patients, he will probably become a candidate in the near future.

Conclusion

Patients with TGA after a Mustard or Senning atrial switch procedure have a high likelihood of developing problems in adult life. The most feared and least treatable is RV failure. The other problems (especially arrhythmias and baffle stenosis) should be anticipated and treated promptly. This chapter elaborates on the anatomy and physiologic principles in the Mustard and Senning situation (in many aspects very different from that of acquired heart disease) because understanding of these principles is necessary in order to provide these patients with high-quality medical care.

References

1. Hoffman JI, Kaplan S, Liberthson RR. Prevalence of congenital heart disease. *Am Heart J* 2004;147(3):425–39.
2. Kawashima Y, Fujita T, Miyamoto T, Manabe H. Intraventricular rerouting of blood for the correction of Taussig-Bing malformation. *J Thorac Cardiovasc Surg* 1971;62(5):825–9.
3. Vouhé PR, Tamisier D, Leca F, Ouaknine R, Vernant F, Neveux J-I. Transposition of the great arteries, ventricular septal defect and pulmonary outflow tract obstruction. Rastelli or Lecompte procedure? *J Thorac Cardiovasc Surg* 1992;103:428–36.
4. Liebman J, Cullum L, Belloc NB. Natural history of transposition of the great arteries. Anatomy and birth and death characteristics. *Circulation* 1969;40(2):237–62.
5. Mustard WT. Successful two-stage correction of transposition of the great vessels. *Surgery* 1964;55:469–72.
6. Senning A. Surgical correction of transposition of the great vessels. *Surgery* 1959;45:966–80.
7. Khairy P, Landzberg MJ, Lambert J, O'Donnell CP. Long-term outcome after the atrial switch for surgical correction of transposition of the great arteries: a meta-analysis comparing the Mustard and the Senning procedures. *Cardiol Young* 2004;14(3):284–92.
8. Piran S, Veldtman G, Siu S, et al. Heart failure and ventricular dysfunction in patients with single or systemic right ventricles. *Circulation* 2002;105:1189–94.
9. Roos-Hesselink JW, Meijboom FJ, Spitaels SE, et al. Decline in ventricular function and clinical condition after mustard repair for transposition of the great arteries (a prospective study of 22–29 years). *Eur Heart J* 2004;25(14):1264–70.
10. Warnes C. Transposition of the great arteries. *Circulation* 2006;114(24):2699–709.
11. Gelatt M, Hamilton RM, McCrindle BW, et al. Arrhythmia and mortality after the Mustard procedure: a 30 years single center experience. *J Am Coll Cardiol* 1997;29:194–201.
12. Hechter S, Veldtman G, Frederiksen PM, et al. Cardiopulmonary exercise performance in adult survivors of the Mustard procedure. *Cardiol Young* 2001;11(4):407–14.
13. Tulevski I, Groenink M, van der Wall EE, et al. Dobutamine-induced increase of right ventricular contractility without increased stroke volume in adolescent patients with transposition of the great arteries: evaluation with magnetic resonance imaging. *Int J Card Imaging* 2000;16(6):471–8.

Tetralogy of Fallot

Judith Therrien

A 20-year-old male was born with tetralogy of Fallot and underwent primary surgical repair at age 1, consisting of ventricular septal defect (VSD) patch closure with right ventricular outflow tract (RVOT) transannular patch. The postoperative course was uneventful, and annual pediatric cardiac follow-up revealed residual pulmonary regurgitation (PR) with a dilated right ventricle. The patient was otherwise asymptomatic, developing normally. At age 18, the patient was transferred to adult care. At his initial visit, the patient reported no symptoms other than occasional palpitations, not associated with dizziness or syncope. Physical examination was suggestive of a dilated right ventricle with significant PR, which was confirmed by echocardiography. Cardiac MRI revealed a severely enlarged right ventricle with a right ventricular end diastolic volume of 400 cc (235 cc/m²) and depressed systolic function. Holter monitor detected the presence of paroxysmal atrial fibrillation with rare premature ventricular complexes (PVCs).

Introduction

Tetralogy of Fallot (TOF) is the most common form of cyanotic congenital heart disease after 1 year of age, with an incidence approaching 10% of all forms of congenital heart disease. Most children who are now repaired experience increasing long-term survival and good quality of life [1–3]. Late complications, however, may occur as they reach adulthood, and careful follow-up of these patients is warranted.

Anatomy

The defect in TOF is due to anterocephalad deviation of the outlet septum, resulting in four features: (1) RVOT obstruction (RVOTO), which may be infundibular, valvar, or (usually) a combination of both, with or without supravalvar or branch pulmonary artery stenosis; (2) a nonrestrictive VSD; (3) an overriding aorta (<50%); and (4) consequent right ventricular hypertrophy (Fig. 10.1). The so-called pentalogy of Fallot includes an atrial septal defect. Accompanying features can include additional VSDs, anomalous coronary arteries, a right-sided aortic arch, aortic root dilatation, aortic regurgitation, and aortopulmonary collaterals.

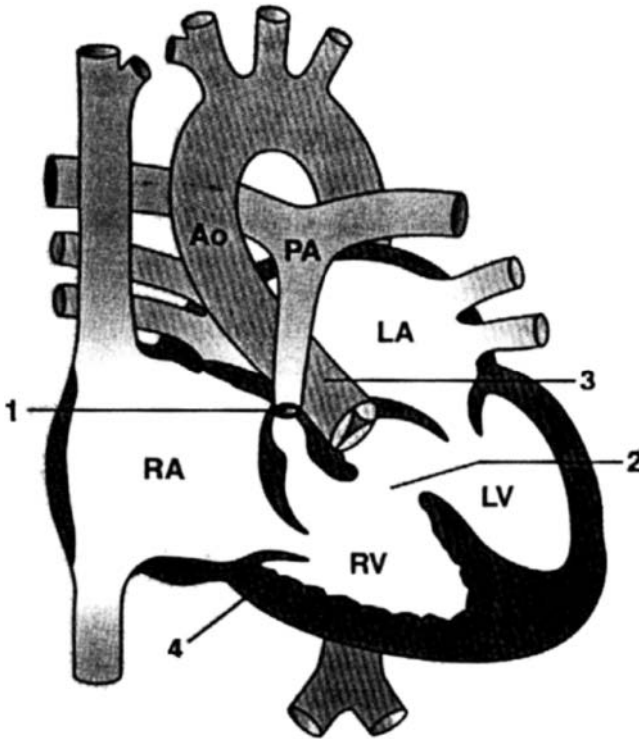


Fig. 10.1 Diagrammatic representation of tetralogy of Fallot. (1) Pulmonary stenosis. (2) Ventricular septal defect. (3) Overriding aorta. (4) Right ventricular hypertrophy. RA, right atrium; RV, right ventricle; LA, left atrium; LV, left ventricle; Ao, aorta; PA, pulmonary artery. (From Mullins CE, Mayer DC. *Congenital Heart Disease: A Diagrammatic Atlas*. New York: Wiley-Liss, 1988; with permission.)

Surgical repair

Most adults will have had surgery, either palliative or, more commonly, reparative, by the time they present to the cardiologist. Rarely, an adult patient will present without previous operations.

Reparative surgery involves closing the VSD and relieving the RVOT obstruction. The latter may involve pulmonary valvotomy, resection of infundibular muscle or RVOT, subannular patch (a patch across the RVOT that does not disrupt the integrity of the pulmonary valve annulus), or transannular patch (a patch across the pulmonary valve annulus that disrupts the integrity of the pulmonary valve annulus) (Fig. 10.2). Rarely, an extracardiac conduit may

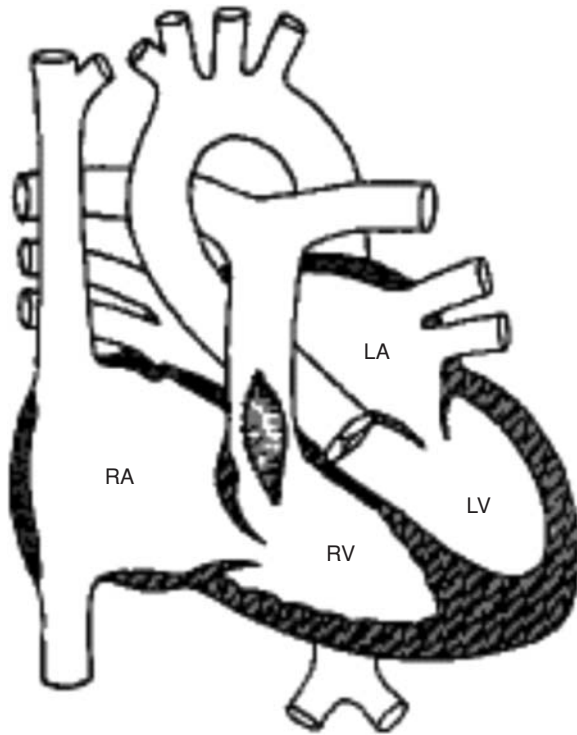


Fig. 10.2 Diagrammatic representation of the surgical repair of tetralogy of Fallot. (1) Patch closure of ventricular septal defect. (2) Right ventricular outflow and main pulmonary artery outflow patch (transannular patch). RA, right atrium; RV, right ventricle; LA, left atrium; LV, left ventricle; Ao, aorta; PA, pulmonary artery. (From Mullins CE, Mayer DC. *Congenital Heart Disease: A Diagrammatic Atlas*. New York: Wiley-Liss, 1988; with permission.)

be placed between the right ventricle and pulmonary artery in patients with pulmonary atresia, and for an anomalous coronary artery (an anomalous left coronary artery arising from the right coronary artery and crossing the RVOT, which occurs in approximately 4% of patients). A pulmonary valve implantation (homograft valve or porcine bioprosthesis) may also be performed at the time of initial repair in adolescents and adults undergoing late repair, as these patients usually do not tolerate PR well. Angioplasty/patch augmentation of central pulmonary arteries may be required in patients with hypoplastic main pulmonary trunk and/or stenoses of the central pulmonary arteries. Finally, a patent foramen ovale or secundum atrial septal defect, if present, needs closure.

Early on, data suggested that significant residual RVOT obstruction was a major determinant of poor outcome. Therefore, the surgeon's primary goal was to surgically alleviate any anatomic obstruction. Surgical approaches to the repair of tetralogy have evolved over the years [4–8]. Hence, early cohorts underwent repair through a right ventriculotomy [7], with “complete relief” of RVOT obstruction often necessitating the use of a large transannular patch, which usually creates free PR. Recent data, however, have shown detrimental long-term effects of a right large ventriculotomy and chronic PR on right ventricular (RV) function [9], with a propensity to clinical arrhythmia and sudden cardiac death (SCD) [1,10]. This has led to a modified approach of repairing the lesion with a combined transatrial/transpulmonary approach, involving closure of the VSD and relief of the RVOTO through the right atrium and the pulmonary artery [5,6]. A limited RV incision is often required for patch augmentation of the RVOT and/or the pulmonary valve annulus. Routine and generous transannular patching has thus been abandoned. Every effort is now made to maintain the integrity and competence of the pulmonary valve. It is of note that residual RVOT pressure gradients present in the immediate postoperative period, previously thought to carry a poor long-term prognosis, often regress within days. Furthermore, mild-to-moderate residual RVOTO in isolation is well tolerated long-term. Avoidance of free PR at the expense of some, albeit not severe, residual pulmonary stenosis is now a key therapeutic goal of reparative surgery.

The timing of repair has also changed. Contemporary patients often undergo primary repair at presentation or when they become symptomatic [4,5,8]. This approach may convey long-term benefits as it abolishes the cyanosis early in life and, by normalizing pulmonary blood flow, promotes pulmonary artery growth.

Older adult patients with repaired tetralogy, however, may have undergone one or more previous palliative procedures prior to undergoing definitive repair. Rarely, an adult patient may present having undergone only a palliative operation with the intention of augmenting pulmonary blood flow. Such procedures include the classic Blalock-Taussig shunt (subclavian artery to right pulmonary artery connection), Waterston shunt (ascending aorta to right

pulmonary artery), or the Potts shunt (descending aorta to left pulmonary artery). However, complications from these palliative shunts can be significant, including focal pulmonary artery stenosis; excessive pulmonary blood flow with pulmonary artery hypertension and eventually pulmonary vascular obstructive disease; and chronic left ventricular (LV) volume overload. Shunt procedures have now largely been abandoned in favor of earlier repairs.

Long-term complications after surgical repair

Pulmonary regurgitation

The overall survival of patients who have had operative repair is excellent, provided the VSD has been closed, the RVOT obstruction has been relieved satisfactorily, and severe PR, which may lead to RV dilatation and RV dysfunction, is absent. A 32- to 36-year survival of 86% and 85% has been reported [2,12]. Most adults with previous repair of TOF lead good quality lives [1–3]. Over 85% of patients after intracardiac repair are asymptomatic at follow-up. Symptoms do occur in about 10–15% of patients at 20 years following initial repair [11,12], and may take two main forms: (1) palpitations from atrial and ventricular tachycardias (VTs); and (2) diminished exercise tolerance, usually from progressive RV dilatation secondary to chronic PR.

Significant PR is almost always encountered when the transannular patch repair technique has been employed. PR is usually well tolerated if mild to moderate. Severe chronic PR, however, may lead to symptomatic RV dilatation and dysfunction [9]. The severity of PR and its deleterious long-term effects are augmented by coexisting proximal or distal pulmonary artery stenosis, or pulmonary artery hypertension. The severity of PR can be assessed by pulsed Doppler echocardiographic interrogation of antegrade versus retrograde pulmonary blood flow with a short diastolic flow (pressure half time <100 ms), indicative of significant PR [13] (Fig. 10.3). MRI phased velocity mapping can accurately measure PR regurgitant fraction and is used as the gold standard [14]. Severe PR can result in a large volume of PR and RV dilatation, but can also be associated with normal or only mildly increased RV size because of a so-called RV “restrictive physiology” [15] (see below).

RV dilatation

RV dilatation can also be secondary to severe residual RVOTO [9] or as a consequence of surgical scar (transventricular approach). Significant tricuspid regurgitation (TR) may occur as a consequence of RV dilatation, which begets more RV dilatation.

Restrictive right ventricle

Restrictive RV physiology after surgical repair is thought to be due to myocardial ischemia and necrosis from inadequate myocardial protection at the time

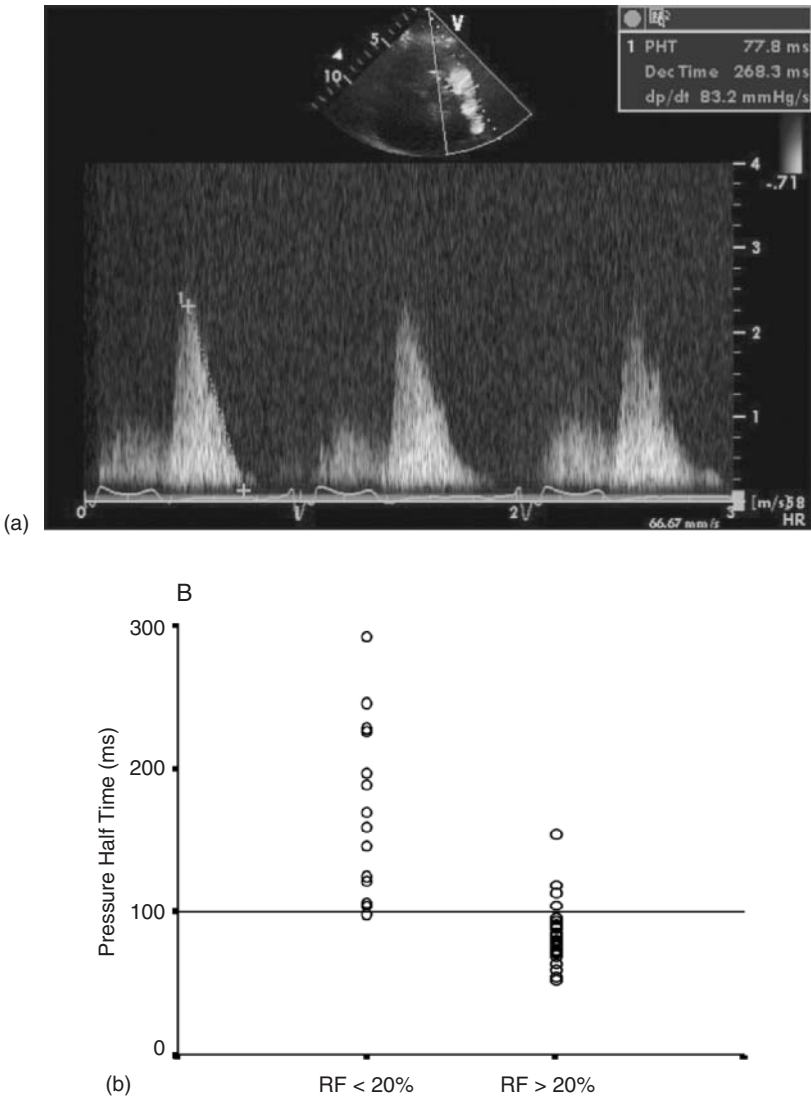


Fig. 10.3 (a) Pulsed echo Doppler signal of pulmonary regurgitant jet in diastole with pressure half-time of 77.8 ms. (b) Correlation between echo-obtained pressure half-time and regurgitation fraction on MRI. PHT, pressure half-time; RF, regurgitant fraction. (From Silversides, et al. *J Am Soc Echo* 2003;16:1057–62; with permission.)

of surgery [16]. Although restrictive RV physiology is associated with more precarious perioperative hemodynamics, long-term data would suggest that it may prevent progressive RV dilatation and increase exercise capacity in adults [15,17].

Residual RVOTO

Residual RVOTO can occur at the infundibular level, at the level of the pulmonary valve and main pulmonary trunk, and/or distally, beyond the bifurcation and occasionally into the branches of the left and right pulmonary arteries.

Aneurysmal dilatation of the RVOT

This is relatively common in patients with previous pericardial transannular patch repair and significant pulmonary regurgitation. Aneurysmal dilatation of the RVOT can be associated with regional RV hypokinesis and can be the arrhythmogenic focus of sustained VT. To date, no episodes of sudden rupture of these regions have been reported.

Residual VSD

Residual VSDs can be encountered from either partial patch dehiscence or failure of complete closure at the time of surgery, or alternatively, an undetected muscular VSD.

Aortic regurgitation with or without aortic root dilatation

Aortic regurgitation may be due to damage to the aortic valve during VSD closure or secondary to an intrinsic aortic root dilatation (more common in patients with pulmonary atresia and systemic to pulmonary artery collaterals). The pathological substrate for aortic root dilatation seems to be cystic medial necrosis [18].

LV dysfunction

Occasionally LV dysfunction can be seen from a variety of factors, including inadequate myocardial protection during previous repair(s), chronic LV volume overload due to long-standing palliative arterial shunts and/or residual VSD, injury to anomalous coronary artery (uncommon), or long-standing cyanosis before repair.

Alternatively, a markedly dilated right ventricle may cause significant abnormal displacement of the ventricular septum into the LV cavity, causing alterations in LV filling (ventricular/ventricular interaction) [15].

Supraventricular arrhythmia

Atrial flutter and atrial fibrillation are relatively common in the current cohort of adults with previous tetralogy repair. Atrial tachyarrhythmia occurs in about one-third of adult patients and contributes to late morbidity and even mortality

[19]. Atrial flutter and fibrillation are more common in patients who had long-lasting systemic-to-pulmonary artery shunts (therefore persisting volume overload) and those who required early reoperations for residual hemodynamic lesions (i.e., patients with a suboptimal result from initial reparative surgery). Older age at repair and moderate-to-severe TR are additional predictors of late sustained atrial flutter and/or fibrillation [1]. Often indicative of hemodynamic trouble (significant RV dilatation and dysfunction, significant TR), the substrate is most likely a surgical scar in the atria and the trigger, atrial dilatation.

Premature ventricular contractions

Nonsustained ventricular arrhythmia on Holter monitor is very common (up to 60%) following repair of tetralogy. The significance of PVCs, however, is not entirely clear [20], but ventricular ectopy of grade \geq II according to the modified Lown criteria (>30 uniform ventricular extrasystoles in any hour) appeared to be associated with increased risk of SCD.

Ventricular tachycardia

Sustained monomorphic VT is relatively uncommon [1]. Re-entry is the most common pathophysiologic mechanism, and multiple factors have been implicated for its pathogenesis [21]. Right ventricular dilatation [22], stretch and fibrosis [23] with slowed ventricular activation [10] probably serve as the trigger (PVC) for re-entry circuit arrhythmias, whereas the area around the VSD patch, RVOT area, and/or right ventriculotomy serve most commonly as the substrate for VT. Autonomic dysfunction with diminished heart rate variability and baroreflex sensitivity have been reported in these patients, but the extent of their contribution to VT mechanism remains to be determined [24].

The QRS duration from the standard surface electrocardiogram has been shown to correlate well with RV size in these patients [10,25]. A maximum QRS duration of 180 ms or more is a marker for sustained VT and SCD in adult patients with previous repair of tetralogy [10] (Fig. 10.4). QRS prolongation in these patients reflects: (1) initial damage to the bundle, during tetralogy repair [26] (right ventriculotomy, relief of muscular subpulmonary stenosis, and suture placement for VSD patch closure); and (2) late progressive QRS prolongation secondary to RV dilatation, which in turn is almost invariably the result of chronic PR. Change in QRS duration with time also predicts patients at risk [1].

Sudden cardiac death

The reported incidence of sudden death, presumably arrhythmic, in late follow-up series varies between 0.5% and 6% over 30 years, accounting approximately for one-third to one-half of late deaths [2,3,27]. Risk of sudden death increases incrementally after the first 20 years from repair of tetralogy (1.2% and 2.2% at 10 and 20 years, respectively, increased to 4% and 6% at 25 and 35 years) [1]. Prior

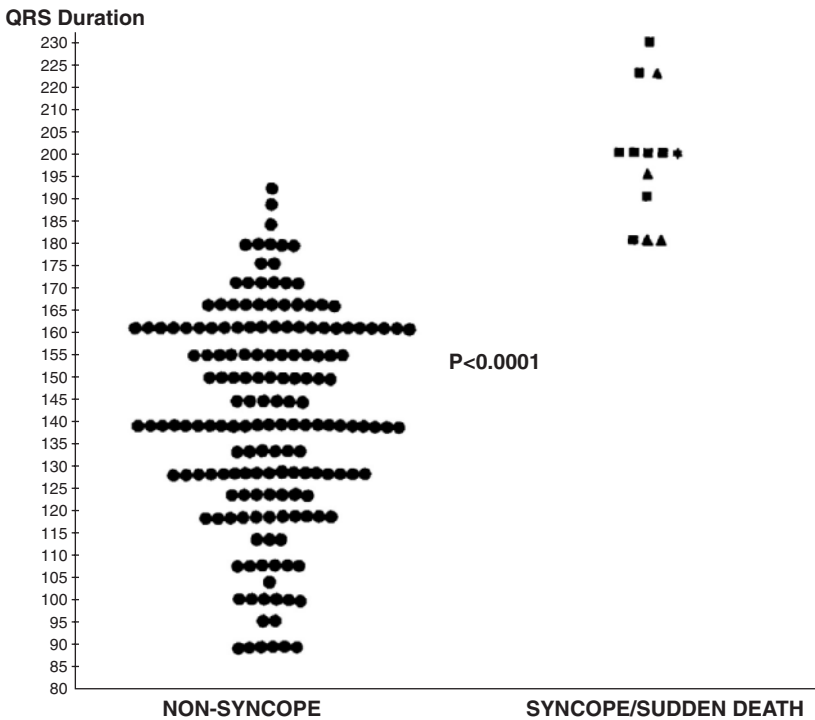


Fig. 10.4 Plot of maximum QRS duration in 182 patients with repaired TOF. Those with syncope due to sustained monomorphic VT (9 patients, squares), atrial flutter (1 patient, asterix), and SCD (4 patients, triangles) are plotted separately on the right column. (From Gatzoulis, et al. *Circulation* 1995;92:231–7; with permission.)

palliative shunts, older age at repair, and relative postoperative RV hypertension (to LV) have been previously shown to be risk factors for late sudden death [2]. Transannular patching, predisposing to free PR, and accelerated rate of QRS prolongation are additional predictors of sudden death [3]. The presence of LV dysfunction also increases the risk of SCD [28].

Psychiatric issues

Approximately 15% of patients with tetralogy have a deletion of chromosome 22q11 [29]. The incidence of 22q11 deletion is especially high in patients with right aortic arch, pulmonary atresia, and aorta-to-pulmonary collaterals. The clinical spectrum is summarized in the so-called “CATCH 22” syndrome (Cardiac defect, Abnormal facies, Thymic hypoplasia, Cleft palate, Hypocalcemia [neonatal], and 22q11 deletion). Patients with 22q11 deletion may have a propensity to late psychiatric disorder, most commonly depression. Hyperactivity and

attention deficit disorder problems have been seen in younger patients. Affected subjects, however, have a 50% risk of transmitting the deletion to their offspring, hence the need for family screening with the FISH (fluorescence in situ hybridization) test and genetic counseling.

Management of late problems after surgical repair

Significant PR

Relief of peripheral pulmonary artery stenosis whether surgically or by interventional catheterization may reduce the severity of PR [30]. Pulmonary valve implantation (with either a homograft or porcine bioprosthesis) may be necessary for severe PR. It carries a low operative risk [12,31] and leads to symptomatic improvement [32–34]. The optimal timing of pulmonary valve replacement (PVR), however, remains controversial.

Right ventricular dilatation

When RV dilatation is due to significant PR, timely PVR, before RV dilatation and irreversible RV dysfunction ensues, is of the essence [32]. The literature would suggest that RV remodeling post-PVR does not occur completely if PVR is performed at an RV end-diastolic (RVED) volumes ≥ 170 – 180 cc/m² [35,36]. There is, however, no proof that achieving timely RV remodeling incurs a survival benefit in these patients. Nonetheless, adverse clinical outcomes, such as death or VT, are more commonly associated with RVED volumes ≥ 170 – 180 cc/m² [37]. Concomitant tricuspid valve annuloplasty at the time of PVR may be warranted when at least moderate TR is present.

The restrictive right ventricle

Diuretics in the postoperative period should be used if restrictive RV physiology is the cause of persistent pleural effusion. Maintenance of sinus rhythm and atrioventricular synchrony in these patients is paramount, as a significant part of forward pulmonary blood flow, and cardiac output, depends on right atrial systole.

Residual RVOTO

Surgery may be necessary for residual significant RVOTO (RV systolic pressure $\geq 2/3$ systemic pressure) [38]. This may involve surgical resection of residual infundibular stenosis or placement of a RVOT or transannular patch. Balloon dilatation and stenting or surgery for branch pulmonary artery stenosis may also be needed. When a previously inserted pulmonary valved conduit (<22 mm) becomes stenotic, percutaneous PVR is an option and can be performed with similar mortality and favorable hemodynamic results [39] and less morbidity to the patient than surgical PVR, but should be reserved for ACHD centers with expertise in the procedure.

Aneurysmal dilatation of the RVOT

Although specific indicators have not been defined, progressive marked aneurysmal dilatation of the RVOT may warrant surgical resection [38].

Residual VSD

Surgical repair of a hemodynamically significant VSD should be considered when the $Q_p/Q_s \geq 2/1$ or $Q_p/Q_s = 1.5-2/1$ if concomitant LV dilatation or dysfunction exists [38] or if accompanied by a history of paradoxical emboli.

Dilatation of the aortic root

Aortic root replacement may be considered when the ascending aorta is ≥ 55 mm, if recent increasing aortic root diameters have been demonstrated, and/or in the presence of severe aortic regurgitation [38]. Aortic dissection or rupture, however, is extremely rare.

LV dysfunction

There are no data on the management strategy for LV dysfunction in these patients. Extrapolation from the data on ischemic and myopathic LV dysfunction would suggest that therapy with ACE inhibitors, digoxin, beta blockers and diuretics may be beneficial. Additional investigations to exclude coexisting coronary artery disease or persistent shunt may be indicated.

Supraventricular arrhythmia

Patients presenting with sustained atrial flutter and/or atrial fibrillation should undergo a thorough assessment of their hemodynamics and should have target residual hemodynamic lesions repaired (e.g., significant RV dilatation from PR with consequent TR needing PVR and tricuspid valve annuloplasty). Radiofrequency ablation, following mapping for atrial reentry, is now yielding better results for classical atrial flutter and/or incisional re-entrant tachycardia and should be performed either percutaneously (if there is no need for concomitant surgery) or intraoperatively at the time of surgical correction of underlying hemodynamic lesions [40]. For atrial fibrillation, a right atrial or bi-atrial maze procedure should also be considered and ideally be performed at the time of reoperation. Anti-arrhythmic medication and the new generation of atrial anti-tachycardia pacemakers can be used as adjunctive therapeutic tools.

Premature ventricular contractions

Currently, there is no justification for prophylactic anti-arrhythmic therapy to suppress asymptomatic ventricular arrhythmias documented on Holter in this relatively low-risk population.

Ventricular tachycardia

Abnormal right-sided hemodynamics, predominantly RV dilatation due to PR with or without pulmonary stenosis have been very common in patients presenting with sustained VT [1,11]. A detailed hemodynamic assessment is, therefore, of paramount importance. Furthermore, interventions to repair underlying residual lesions, usually right-sided, should be an essential part of risk modification and arrhythmia management in these patients. Transcatheter (if there is no need for surgery) or concomitant intraoperative ablative procedures of the VT pathway should be performed [33]. The role of AICD implantation in these patients is unclear but may be used as an adjunct therapy post-VT ablation since risk of VT recurrence postablation varies between 0% and 30% [11,39,41] or when VT ablation is not possible.

Sudden cardiac death

Patients with resuscitated SCD should undergo surgical repair of significant residual hemodynamic lesions with concomitant VT ablation. AICD implantation may be an adjuvant therapy for secondary prevention of sustained VT and SCD, even after repair of residual hemodynamic problems and VT ablation [11,39,41,42].

Prevention of late problems after surgical repair

Significant PR

Recent changes in the surgical technique [5,6] with a less aggressive approach toward complete relief of RVOTO and avoidance of a transannular patch will hopefully lessen the degree of PR.

RV dilatation

The newer transatrial approach [5] (rather than transventricular) at the time of reparative surgery will lessen the degree of RV damage at the time of surgery [43,44]. Changes in the surgical technique with a less aggressive approach toward complete relief of RVOTO with avoidance of transannular patches [5,6] and subsequent free PR will also hopefully lessen the degree of RV dilatation and dysfunction over time.

The restrictive right ventricle

Improved myocardial protection may reduce the degree of RV myocardial ischemia at the time of surgery and in turn the incidence of postoperative restrictive RV physiology.

Aneurysmal dilatation of RVOT

Minimizing the extent of RVOT incision and the size of the prosthetic patch used for RVOT reconstruction may lessen the incidence of RVOT aneurysmal dilatation.

LV dysfunction

Proceeding with surgical repair at an early age [4,5,8], avoiding prolonged cyanosis and the need for palliative shunts, and ensuring adequate myocardial protection at the time of surgery may significantly reduce the incidence of postoperative LV dysfunction. Modifying risk factors for premature coronary artery disease may also be indicated to protect against the later development of LV dysfunction.

Endocarditis

Patients with a previous history of endocarditis, prosthetic valves, residual shunt, persistent cyanosis, or within 6 months postoperation require protection against endocarditis [45].

Supraventricular arrhythmia

A surgical approach that would minimize atrial scars as well as avoid significant residual hemodynamic lesions causing right atrial dilatation may lead to a lower incidence of atrial flutter and fibrillation in these patients.

Sustained VT

A surgical approach that would minimize ventricular scarring as well as avoid significant residual hemodynamic lesions causing RV dilatation may lead to a lower incidence of VT [5,43,44]. The role of diagnostic electrophysiologic study in patients with asymptomatic dilated RVs is controversial but may be beneficial in “high-risk” patients (history of palpitation or syncope, older age at repair, transannular patch, QRS > 180 ms, modified Lown \geq II, etc.) as inducible VT or ventricular fibrillation seem to predict further development of such an arrhythmia [46].

Sudden cardiac death

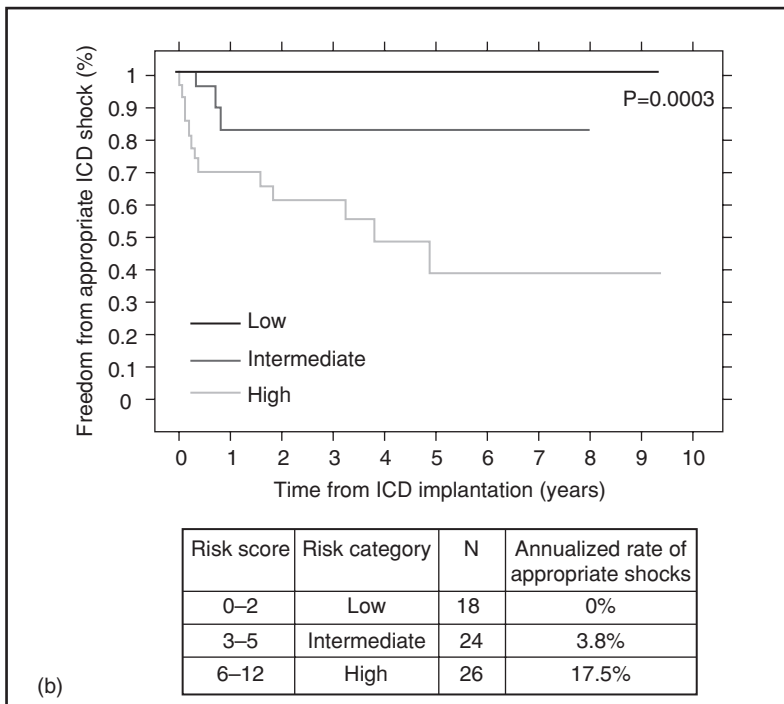
Primary prevention with AICD implantation in high-risk patients (prior palliative shunt, QRS > 180 ms, inducible VT, LV dysfunction,) for SCD may be beneficial [42] (Fig. 10.5) and is probably best reserved for patients with a high annual risk (\geq 3.5% per year) of SCD [47].

Case study

Our patient had a severely enlarged RV as well as paroxysmal atrial fibrillation in the setting of severe PR. Exercise testing also revealed limited functional aerobic capacity, although the patient believed himself to be asymptomatic. Because of these findings, he was sent for elective PVR as well as intraoperative right and left atrial MAZE procedure. The RV size improved after surgery but remained moderately enlarged.

Variable	Exp(β)	Points Attributed
Prior palliative shunt	3.2	2
Inducible sustained ventricular tachycardia	2.6	2
QRS duration ≥ 180 ms	1.4	1
Ventriculotomy incision	3.4	2
Nonsustained ventricular tachycardia	3.7	2
LVEDP ≥ 12 mm Hg	4.9	3
Total points	...	0–12

(a)



(b)

Fig. 10.5 (a) Risk score from appropriate implantable cardiac defibrillator shocks in primary prevention. (b) Kaplan-Meier survival curves for freedom from first appropriate implantable cardiac defibrillator shocks in primary prevention are plotted and compared according to risk score classification. ICD, implantable cardiac defibrillator. (From Khairy, et al. *Circulation* 2008;117:363–70; with permission.)

Synopsis

Long-term survival in adults with repaired TOF is excellent, and most patients lead unrestricted lives and are asymptomatic at follow-up. Residual RVOT problems such as significant PR and/or RVOTO, however, are common and may lead to gradual RV dilatation and dysfunction with consequent supraventricular or ventricular arrhythmias. Hemodynamic causes for such tachyarrhythmia (RV dilatation and dysfunction, significant PR) should be sought and corrected, and therapy directed at the arrhythmia (anti-arrhythmics, cryoablation, or AICD) should be carried out conjointly. Recent changes in surgical approaches to the initial repair of tetralogy will hopefully translate in the future into a lower incidence of late complications.

References

1. Gatzoulis MA, Balaji S, Webber SA, et al. Risk factors for arrhythmia and sudden death in repaired tetralogy of Fallot: a multi-centre study. *Lancet* 2000;356:975–81.
2. Murphy JG, Gersh BJ, Mair DD, et al. Long-term outcome in patients undergoing surgical repair of tetralogy of Fallot. *N Engl J Med* 1993;329:593–9.
3. Nollert G, Fischlein T, Bouterwek S, et al. Long-term survival in patients with repair of tetralogy of Fallot: 36-year follow-up of 490 survivors of the first year after surgical repair. *J Am Coll Cardiol* 1997;30:1374–83.
4. DiDonato RM, Jonas RA, Lang P, et al. Neonatal repair of tetralogy of Fallot with and without pulmonary atresia. *J Thorac Cardiovasc Surg* 1991;101:126–37.
5. Karl TR, Porniviliwan S, Mee RBB. Tetralogy of Fallot: favourable outcome of non-neonatal transatrial, transpulmonary repair. *Ann Thorac Surg* 1992;54:903–7.
6. Kawashima Y, Kitamura S, Nakano S, et al. Corrective surgery for tetralogy of Fallot without or with minimal right ventriculotomy and with repair of the pulmonary valve. *Circulation* 1981;64:147–53.
7. Lillehei CW, Cohen M, Warden HE, et al. Direct vision intracardiac surgical correction of the tetralogy of Fallot, pentalogy of Fallot, and pulmonary atresia defects; report of first ten cases. *Ann Surg* 1955;142:418–45.
8. Reddy VM, Liddicoat JR, McElhinney DB, et al. Routine repair of tetralogy of Fallot in neonates and infants less than three months of age. *Ann Thorac Surg* 1995;60: S592–6.
9. Redington AN, Oldershaw PJ, Shinebourne EA, Rigby ML. A new technique for the assessment of pulmonary regurgitation and its application to the assessment of right ventricular function before and after repair of tetralogy of Fallot. *Br Heart J* 1988;60: 57–65.
10. Gatzoulis MA, Till JA, Somerville J, Redington AN. Mechano-electrical interaction in tetralogy of Fallot. QRS prolongation relates to right ventricular size and predicts malignant ventricular arrhythmias and sudden death [see comments]. *Circulation* 1995;92:231–7.
11. Harrison DA, Harris L, Siu SC, et al. Sustained ventricular tachycardia in adult patients late after repair of tetralogy of Fallot. *J Am Coll Cardiol* 1997;30:1368–73.

12. Oechslin EN, Harrison DA, Harris L, et al. Reoperation in adults with repair of tetralogy of Fallot: Indications and outcomes. *J Thorac Cardiovasc Surg* 1999;118:245–51.
13. Silversides C, Veldtman G, Crossin J, et al. Pressure half time correlates with severity of pulmonary regurgitation in adults with repaired tetralogy of Fallot. *J Am Soc Echocardiogr* 2003;16:1057–62.
14. Rebergen SA, Chin JG, Ottenkamp J, van der Wall EE, de Roos A. Pulmonary regurgitation in the late postoperative follow-up of tetralogy of Fallot. Volumetric quantitation by nuclear magnetic resonance velocity mapping. *Circulation* 1993;88:2257–66.
15. Helbing WA, Niezen RA, LeCessie S, et al. Right ventricular diastolic function in children with pulmonary regurgitation after repair of tetralogy of Fallot: volumetric evaluation by magnetic resonance mapping. *J Am Coll Cardiol* 1996;28:1827–35.
16. Chatuverdi RR, Shore DF, Lincoln C, et al. Acute right ventricular restrictive physiology after repair of tetralogy of Fallot: association with myocardial injury and oxidative stress. *Circulation* 1999;100:1540–7.
17. Gatzoulis MA, Clark AL, Cullen S, et al. Right ventricular diastolic function 15 to 35 years after repair of tetralogy of Fallot: restrictive physiology predicts superior exercise performance. *Circulation* 1995;91:1775–81.
18. Niwa K, Perloff JK, Bhuta SM, et al. Structural abnormalities of the great arterial walls in congenital heart disease: light and electron microscopic analyses. *Circulation* 2001;103:393–400.
19. Roos-Hesselink J, Perlroth MG, McGhie J, et al. Atrial arrhythmias in adults after repair of tetralogy of Fallot. Correlations with clinical, exercise, and echocardiographic findings. *Circulation* 1995;91:2214–9.
20. Cullen S, Celermajer DS, Franklin RC, et al. Prognostic significance of ventricular arrhythmia after repair of tetralogy of Fallot: a 12-year prospective study. *J Am Coll Cardiol* 1994;23:1151–5.
21. Kugler JD, Pinsky WW, Cheatham JP, et al. Sustained ventricular tachycardia after repair of Fallot: new electrophysiological findings. *Am J Cardiol* 1983;51:1137–43.
22. Marie P-Y, Marcon F, Brunotte F, et al. Right ventricular overload and induced sustained ventricular tachycardia in operatively "repaired" tetralogy of Fallot. *Am J Cardiol* 1992;69:785–9.
23. Babu-Narayan SV, Kilner PJ, Li W, et al. Ventricular fibrosis suggested by cardiovascular magnetic resonance in adults with repaired tetralogy of Falot and its relationship to adverse markers of clinical outcome. *Circulation* 2006;113:405–13.
24. Davos CH, Davlourous PA, Wensel R, et al. Global impairment of cardiac autonomic nervous activity late after repair of tetralogy of Fallot. *Circulation* 2002;106:1-69–75.
25. Abd El Rahman HY, Abul-Khaliq H, Vogel M, et al. Relation between right ventricular enlargement, QRS duration, and right ventricular function in patients with tetralogy of Fallot and pulmonary regurgitation after surgical repair. *Heart* 2000;84:416–20.
26. Norgard G, Gatzoulis M, Moraes F, et al. The relationship between type of outflow tract repair and postoperative right ventricular diastolic physiology in tetralogy of Fallot: implications for long-term outcome. *Circulation* 1996;94:3276–81.
27. Silka MJ, Hardy BG, Menashe VD, Morris CD. A population-based prospective evaluation of risk of sudden cardiac death after operation for common congenital heart defects. *J Am Coll Cardiol* 1998;32:245–51.

28. Ghai A, Silversides C, Harris L, et al. Left ventricular dysfunction is a risk factor for sudden cardiac death in adults late after repair of tetralogy of Fallot. *J Am Coll Cardiol* 2002;40:1675–80.
29. Goldmuntz E, Clark BJ, Mitchell LE, et al. Frequency of 22q11 deletions in patients with conotruncal defects. *J Am Coll Cardiol* 1998;32:492–8.
30. Chaturvedi RR, Kilner P, White P, et al. Increased airway pressure and simulated branch pulmonary stenosis increase pulmonary regurgitation after repair of tetralogy of Fallot: real-time analysis using conductance catheter technique. *Circulation* 1997;95:643–9.
31. Yemets IM, Williams WG, Webb GD, et al. Pulmonary valve replacement late after repair of tetralogy of Fallot. *Ann Thorac Surg* 1997;64:526–30.
32. Therrien J, Siu S, Liu P, et al. Pulmonary valve replacement in adults late after repair of tetralogy of Fallot: are we operating too late? *J Am Coll Cardiol* 2000;36:1670–5.
33. Warner KG, Anderson JE, Fulton DR, et al. Restoration of the pulmonary valve reduces right ventricular volume overload after previous repair of tetralogy of Fallot. *Circulation* 1993;88:II-189–97.
34. Vliegen HW, van Straten A, de Roos A, et al. Magnetic resonance imaging to assess the hemodynamic effects of pulmonary valve replacement in adults late after repair of tetralogy of Fallot. *Circulation* 2002;106:1703–7.
35. Therrien J, Provost Y, Merchant N, et al. Optimal timing for pulmonary valve replacement in adults after tetralogy of Fallot repair. *Am J Cardiol* 2005;95:779–82.
36. Oosterhof T, van Straten A, Vliegen HW, et al. Preoperative thresholds for pulmonary valve replacement in patients with corrected tetralogy of Fallot using cardiovascular magnetic resonance. *Circulation* 2007;116:545–51.
37. Knauth AL, Gauvreau K, Powell AJ, et al. Ventricular size and function assessed by cardiac MRI predict major adverse clinical outcomes late after tetralogy of Fallot repair. *Heart* 2008;94:211–16.
38. Therrien J, Dore A, Gersony W, et al. Canadian Cardiovascular Society. CCS Consensus Conference 2001 update: recommendations for the management of adults with congenital heart disease. Part I. *Can J Cardiol* 2001;17:940–59.
39. Khambadkone S, Coats L, Taylor A, et al. Percutaneous pulmonary valve implantation in humans: results in 59 consecutive patients. *Circulation* 2005;112:1189–97.
40. Karamlout T, Sibler I, Lao R, et al. Outcomes after late reoperation in patients with repaired tetralogy of Fallot: the impact of arrhythmia and arrhythmia surgery. *Ann Thorac Surg* 2006;81:1786–93.
41. Therrien J, Siu S, Harris L, et al. Impact of pulmonary valve replacement on arrhythmia propensity late after repair of tetralogy of Fallot. *Circulation* 2001;103:2489–94.
42. Khairy P, Harris L, Landzberg MJ, et al. Implantable cardiac defibrillators in tetralogy of Fallot. *Circulation* 2008;117:363–70.
43. Dietl CA, Cazzaniga ME, Dubner SJ, et al. Life-threatening arrhythmias and RV dysfunction after surgical repair of tetralogy of Fallot: comparison between transventricular and transatrial approaches. *Circulation* 1994;90(part 2):II-7–12.
44. Kawashima Y, Matsuda H, Hirose H, et al. Ninety consecutive corrective operations for tetralogy of Fallot with or without minimal right ventriculotomy. *J Thorac Cardiovasc Surg* 1985;90:856–63.

45. Wilson W, Taubert DA, Gewitz M, et al. Prevention of infective endocarditis. AHA Guideline. *Circulation* 2007;116:1736–54.
46. Khairy P, Landzberg MJU, Gatzoulis MA, et al. Prognostic significance of electrophysiology testing post tetralogy of Fallot repair: a multicenter study. *Circulation* 2004;109:1994–2000.
47. Khairy P. Programmed ventricular stimulation for risk stratification in patients with tetralogy of Fallot: a Bayesian perspective. *Nat Clin Pract* 2007;6:292–3.

Single ventricle physiology

Michael A. Gatzoulis and Lorna Swan

This 22-year-old male presented shortly after birth with failure to thrive. Investigation revealed tricuspid atresia with transposed great arteries and an atrial septal defect. Symptoms did not improve with diuretics, and at the age of 1 year, a pulmonary artery band was placed. At the age of 7 years, a cardiac catheterization revealed a low pulmonary artery pressure (mean of 11 mm Hg), and a Kreutzer Fontan with direct right atrial appendage to pulmonary artery anastomosis was performed.

At the age of 20, the patient developed paroxysms of atrial tachycardia and was commenced on amiodarone in addition to enalapril and Coumadin.

At the age of 22, he presented acutely with New York Heart Association III symptoms. Examination revealed clubbing and resting saturations of 93%. The heart rate was 90 bpm and irregular. Resting blood pressure was 96/60. The jugular venous pressure was elevated 6 cm, and there was a trace of ankle edema. Auscultation of his chest was clear.

An electrocardiogram confirmed atrial fibrillation, and an urgent echocardiogram revealed a giant right atrium with a large right atrial clot. In addition, there was compression of the right-sided pulmonary veins and mild left ventricular impairment.

Bloodwork confirmed amiodarone-induced thyrotoxicosis. This required prolonged treatment with steroids, carbimazole, and lithium therapy before becoming quiescent.

Introduction

The term “single ventricle physiology” encompasses a heterogenous group of some of the most complex congenital heart disorders. Multiple anatomical definitions exist [1,2], but in adult practice, the term is usually used to describe a circulation where one of the ventricles is too small, or has a nonrepairable inlet

valve, to permit effective functioning of a sequential series circuit. This would include all those deemed in childhood to be unsuitable for biventricular repair.

This broad definition of so-called univentricular heart would therefore encompass those with hypoplastic left heart syndromes, atretic or hypoplastic atrioventricular (A-V) valves, unbalanced A-V septal defects, some heterotaxy syndromes, and double-inlet ventricles. This group may also include a complex double-outlet right ventricle with remote ventricular septal defect (VSD) given the inability to perform a biventricular repair.

Alternative descriptions would state that the entire A-V junction should be connected to one ventricular chamber. This would be a narrower definition, however, which would exclude this latter group and some hypoplastic left hearts.

Incidence

There are significant differences between the incidence and prevalence of single ventricle hearts in current adult versus pediatric practice. In the past, many of these disorders were fatal in childhood, and patients currently in the adult sector demonstrate pediatric surgical practice from 15 to 20 years ago. The prevalence of these conditions in adult congenital practice is dynamic. Older cohorts of patients with “old-style” procedures (such as a Kreutzer Fontan repair with direct right atrial to pulmonary artery anastomosis) are diminishing, and conversely, the numbers of new adults with palliated hypoplastic left heart syndromes are increasing [3]. Overall, the numbers of adults with complex univentricular circulations are increasing [4].

The truly natural history of these conditions is difficult to determine, but less than 30% of those with a single dominant left ventricle will survive beyond childhood without intervention [5]. The corresponding figure for a single right ventricle is even lower. The most common single ventricle circulations at birth are the hypoplastic left heart, tricuspid atresia, and the double-inlet left ventricle [6].

Etiology

As is the case for the majority of congenital heart lesions, there is a familial, non-Mendelian propensity toward recurrence of these complex lesions. This is in the context of a multifactorial etiology. For example, there is an increased risk of other congenital malformations in the siblings of children with hypoplastic left heart [7]. The degree of this familial recurrence varies with different lesions and is higher in certain subgroups, such as atrial isomerism [8,9]. There are occasional cases of complex single ventricular disorders that appear to have a Mendelian-like inheritance, for example, familial heterotaxy [9] and also isolated cases of tricuspid atresia associated with microdeletions (such as 22q11)

[10]. However, for the majority of cases, there are no identifiable chromosomal abnormalities or genetic mutation. Future research of known mouse models of congenital heart disease may help identify specific causative mutations in humans.

Key components of morphology

A systematic approach to describing these complex lesions is essential [11]. Description of the atrial arrangement, atrioventricular connections, ventricular morphology, and ventriculoarterial (V-A) connections are the core components. Anatomy of the systemic and pulmonary venous return and associated lesions are also required to effectively communicate a complete diagnosis (Table 11.1).

Table 11.1 Key clinical components of morphology

Atrial arrangement	Situs solitus, inversus, isomerism (left or right)
Atrio-ventricular connection	Double inlet ventricle - Two patent valves connecting to one ventricle (>50% of both valves committed to this ventricle) Common valve (e.g. unbalanced atrioventricular septal defect) One atretic valve (mitral or tricuspid atresia) One or two straddling valves
Ventricles	Dominant LV, dominant RV or rarely indeterminate (defined AV valve arrangement, position, trabecular pattern) Left heart hypoplastic syndrome
VA connection	Concordant, discordant, double-outlet
Pulmonary circulation	Stenotic, atretic or normal (unprotected)
Systemic venous return	Heterotaxy syndromes with variable venous return patterns
Pulmonary venous return	Anomalous pulmonary venous drainage
Conduction system	Sinus node variable in isomerism AV node and Hiss variations
Other lesions	Cardiac including aortic arch abnormalities and coarctation Noncardiac: variations in bronchial situs, abdominal abnormalities including asplenia, multiple spleens, biliary atresia

Ventricular morphology

A normal ventricle is described as having three components: an inlet, outlet, and trabecular component. The apical trabecular segment is the most characteristic. In a left ventricle, the trabeculations are fine; in a right ventricle, coarse. It is exceptional for there to be two noncomplimentary ventricles (i.e. not a pair of left and right). Rarely, a truly single indeterminate ventricle is present. Other diagnostic features of a ventricle are often lost in the setting of a single ventricle, for example, the normal septal attachments of the tricuspid valve, the apical positioning of the tricuspid valve, or the normal fibrous mitral–aortic continuity. Two other terms are used to describe ventricular relationships. The term “topology” is used to describe the stereotactic relationship between the ventricular masses (normal in a biventricular heart is right-hand topology), and “looping” refers to the bending of the embryological heart. In d-looping, the morphological right ventricle lies to the right of the left ventricle (normal); in l-looping, it lies to the left.

At presentation, the key components of morphology will influence the adequacy of the pulmonary and systemic circulations. In those with a hypoplastic left heart, a dramatic reduction in systemic cardiac output will occur following closure of the arterial duct. The presence or absence of an effective pulmonary circulation will also be evident early. Severe pulmonary stenosis or pulmonary atresia will present with profound cyanosis.

Initial presentation in childhood

Infants with a single ventricular circulation usually present early in life. Those with unprotected pulmonary vasculature may present with the hemodynamic effects of a large left-to-right shunt, namely, congestive heart failure and failure to thrive. Those with severely restricted pulmonary blood flow present with cyanosis following closure of the arterial duct. Neonates with critical left heart obstruction will also present early either with cardiovascular collapse or hypoperfusion of vital organs.

Occasionally, an infant may have a balanced circulation where there is a degree of pulmonary stenosis sufficient to prevent heart failure but not to the extent of producing profound cyanosis. In this circumstance, presentation may be later, especially when routine neonatal screening is not available [12].

Early palliative procedures

The majority of neonates will require initial palliative surgery. Again, the nature of this will depend on the underlying anatomy and physiology. Without surgical intervention, those with severe disease (e.g. hypoplastic left heart) will usually die in a matter of days. It has only been within the last decade that intervention on this extreme end of the single ventricle spectrum has become commonplace [13].

Pulmonary artery banding

When the pulmonary circulation is unprotected (i.e. there is no pulmonary stenosis), there will be a sizable left-to-right shunt. This will result in congestive failure, and later, if the child survives, pulmonary vascular disease. In this setting, the first procedure may be banding of the pulmonary artery to reduce, in a controlled manner, pulmonary blood flow. If the band is too loose, the pulmonary blood flow will still be excessive and, in the mid-term, place the infant at risk of developing pulmonary vascular disease and becoming unsuitable for further palliation. The pulmonary artery band needs to be placed carefully: not too distal to avoid origin stenosis of the branch pulmonary arteries, and not too proximal, particularly if the neonate may later require a Damus-Kaye Stansel procedure (anastomosis of the proximal main pulmonary artery with the ascending aorta to bypass systemic ventricular outflow obstruction).

Aortopulmonary shunts

In the presence of severe pulmonary stenosis (subvalvar, valvar, or supravalvar), pulmonary blood flow may be inadequate. A palliative aortopulmonary shunt will be required, which will allow for the neonate to grow and for the pulmonary vascular resistance to fall until a more definitive palliation can be offered. The initial aortopulmonary shunt was a classic Blalock-Taussig shunt with anastomosis of the disconnected subclavian artery to the side of the ipsilateral pulmonary artery (first described in 1945) [14]. Later came a generation of modifications with the Waterston shunt (ascending aorta to right pulmonary artery), Pott's anastomosis (descending aorta to left pulmonary artery), and finally, the modified Blalock-Taussig shunt using a small gortex shunt. Adults with single ventricle circulations will have been subject to many of these earlier surgical procedures before the pre-eminence of the modified Blalock-Taussig shunt.

Aortopulmonary shunts are also used in the setting of hypoplastic left heart surgery. In this setting, the native main pulmonary artery is used for the systemic circulation (Norwood procedure). An aortopulmonary shunt is therefore necessary to ensure pulmonary blood flow.

Other procedures may also be required in the early phase. This is particularly true if there are obstructive lesions present, for example, a restrictive ventricular septal defect (in the setting of discordant V-A connection) or aortic arch obstruction (coarctation). Atrial septectomy is often required in the setting of abnormal, stenotic, or atretic AV valves.

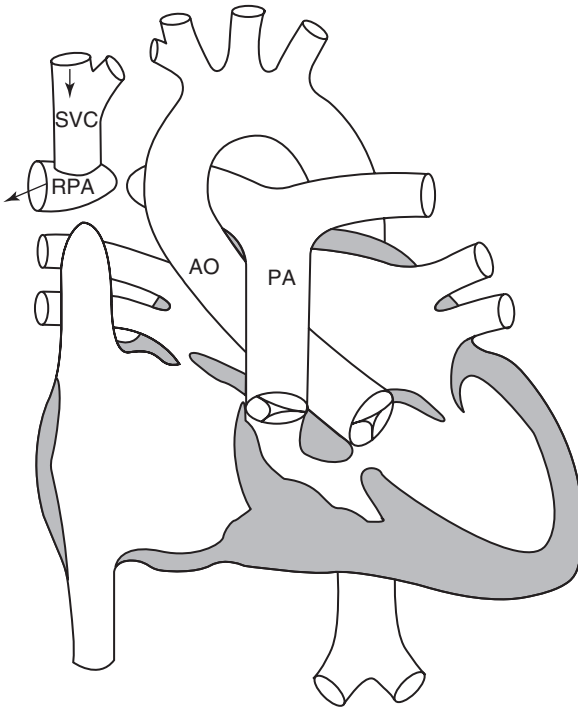
Cavopulmonary shunts

In 1957, Glenn described the first cavopulmonary shunt. This involved dividing the pulmonary arteries and anastomosing the end of the divided superior vena cava to the right pulmonary artery [15]. This first classic Glenn shunt was the first generation in the evolution of the cavopulmonary shunt. The total

caval pulmonary connection (TCPC) and the extra-cardiac Fontan is the latest (Fig. 11.1).

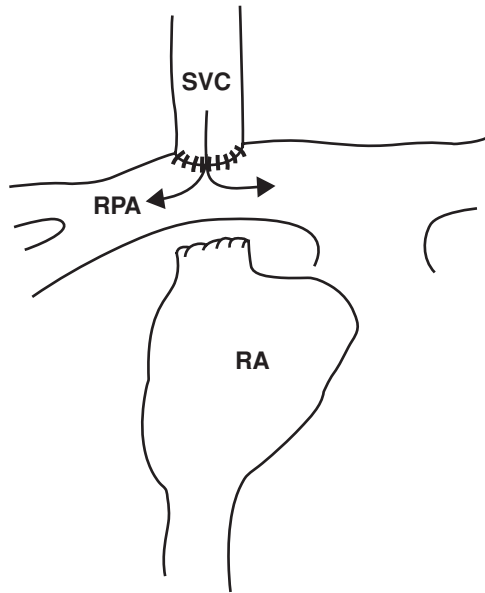
In 1971, Fontan described an operation where, following a classic Glenn, two homograft valves were placed: one in the inferior vena cava and a second between the right atrium and left pulmonary artery [16]. Since then there have been multiple modifications of this Fontan operation, all of which may be found in adult survivors. The TCPC was first described in 1987, and therefore, younger adults and teenagers will now be in the adult clinics with this most recent modification [17].

Historically, patients were believed to be suitable for a cavopulmonary anastomosis if they fulfilled "the 10 Commandments" of Fontan conversion. These included age between 4 and 15 years; normal systemic venous return; mean pulmonary artery pressure ≤ 15 mm Hg; good ventricular function; competent atrioventricular valves; and no evidence of pulmonary artery distortion [18].

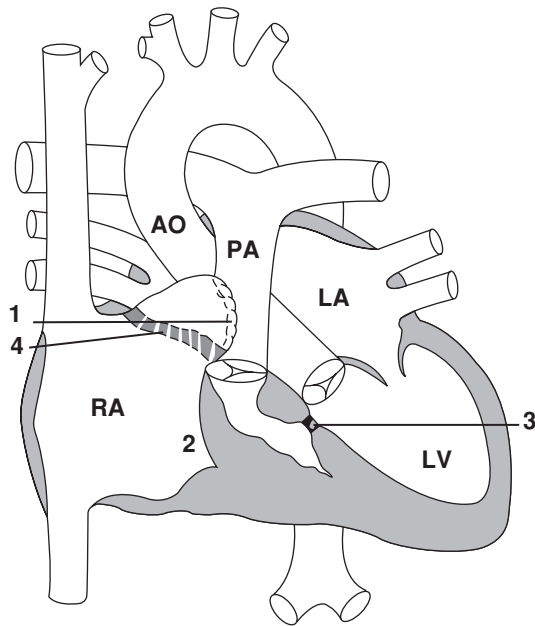


Classic Glenn

Fig. 11.1 Cavopulmonary connections. SVC, superior vena cava; RPA, right pulmonary artery; Ao, aorta; PA, pulmonary artery; RA, right atrium; LA, left atrium; LV, left ventricle; LPA, left pulmonary artery; RV, right ventricle; IVC, inferior vena cava; TCPC, total cavo-pulmonary connection.

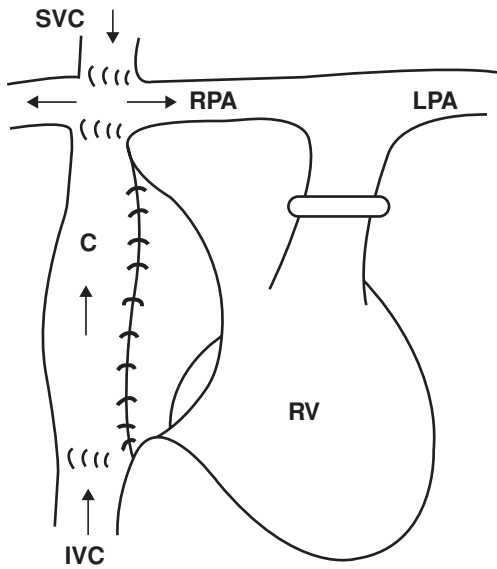


Bidirectional Glenn

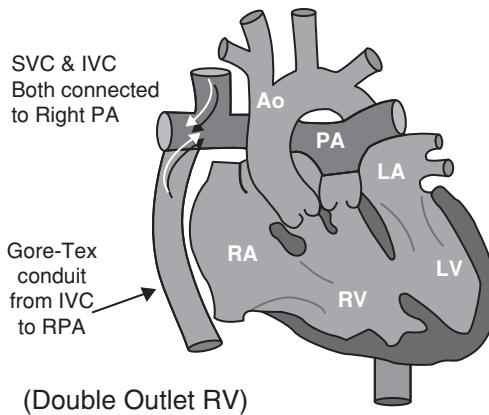


Kreutzer Fontan

Fig. 11.1 (Continued)



Lateral tunnel



Extracardiac Fontan (TCPC)

Fig. 11.1 (Continued)

Many adult patients may have had staged surgery in childhood. A Glenn anastomosis may initially support a child's circulation. However, with time, the relative contribution of the superior vena cava to total venous return diminishes and cyanosis increases, necessitating Fontan completion to restore oxygen saturations.

These palliative cavopulmonary shunts, including the Fontan procedure, transform the short to mid-term outlook of patients with single ventricles and rendered them pink. Although excellent mid-term outcomes have been reported (10-year survival in excess of 90%), there are legitimate concerns about the multiple complications, and long-term survival is still compromised. It is therefore important that these procedures are understood as being palliative rather than curative in nature.

Subtypes of single ventricle circulations

Hypoplastic left heart

Although the most common type of single ventricle physiology, there are few adult survivors of hypoplastic left heart syndrome at present. However, with advances in care, this will change, and many adult congenital heart disease units expect to see these patients in the next few years. Adult survivors will have been palliated with a Norwood procedure, hemi-Fontan (bidirectional Glenn), and then completion of the Fontan circuit. In the initial Norwood procedure, the pulmonary artery will have been over sewn and anastomosed to the proximal aorta. The aorta will thus have been augmented and a modified Blalock Taussig shunt been created to restore pulmonary circulation. In current practice, approximately 86% of infants with favorable anatomy will survive the first stage of the Norwood procedure [19].

Double-inlet ventricle

A double-inlet ventricle is present when more than 50% of both atria are connected to a single dominant ventricular chamber. This is usually through two separate A-V valves but may be via a common valve. The A-V valves may also be abnormal with hypoplasia, dysplasia, or atresia. Other common associations are V-A discordance (common), pulmonary stenosis (subvalvar or valvar), malalignment of the ventricular septum, restriction at the VSD level, and aortic coarctation.

In addition to the surgical procedures described above, this group of patients may require enlargement of a restrictive VSD, which may be causing subaortic obstruction. At the time of surgery, the anatomy of the conduction tissue needs to be carefully considered. When the left ventricle is dominant, the A-V node and His bundle are anterior and to the right. When there is extreme subaortic obstruction, a Damus-Kaye-Stansel operation can be utilized.

The presence of prior subaortic obstruction is a risk factor for subsequent Fontan repair due to excessive ventricular hypertrophy and diastolic dysfunction [20]. In childhood, a small subset of patients with an “ideal” double-inlet left ventricle may be suitable for biventricular repair. This is extremely rare in adulthood due to supervening additional lesions, such as pulmonary vascular disease.

Patients with double-inlet left ventricles (with l-looping) are at risk of complete heart block, and as with most complex lesions, there is an ongoing risk of sudden cardiac death presumably due to arrhythmia [21].

Atrioventricular valve atresia

Absence of an A-V valve is another subset of single-ventricle physiology. In this setting, the remaining valve connects to the dominant ventricular mass. The absent valve is usually completely missing with fibro-fatty material remaining at the site of the A-V junction. A-V valves can also be hypoplastic or imperforate; in this setting, there is still a biventricular A-V connection (anatomically but not functionally).

The most common form of A-V valve atresia is tricuspid atresia [22]. In this setting, there is a small rudimentary anterosuperior right ventricle. In 30% of cases, the right ventricle is the subaortic chamber (discordant V-A connection). Classic tricuspid atresia is associated with a concordant V-A connection. If present, a restrictive atrial septal defect will cause obstruction to systemic venous return as this provides the only access to the mitral valve and the ventricular mass.

Mitral atresia is less commonly seen in adult practice. This is usually associated with a dominant double-outlet right ventricle. In extreme cases, the mitral atresia is part of a hypoplastic left heart syndrome.

The surgical principles of palliating a patient with an absent A-V connection are as previously described, ensuring adequate pulmonary and systemic blood flow and preventing pulmonary vascular disease. In the ideal setting with a low pulmonary vascular resistance, the initial procedure may be a bidirectional Glenn.

In adult practice, the majority of adult patients with tricuspid atresia will have had a previous Fontan operation (usually the Kreutzer modification). Occasionally, adults with a balanced circulation may survive into adulthood without an operation.

Patients with previous palliation, such as a Blalock Taussig shunt or pulmonary artery banding, should be reassessed. Those with a low pulmonary vascular resistance (mean PA pressure of less than 15 mm Hg) may be suitable for a late Fontan. This is unusual, and the majority of patients will already have been considered for conversion and declined. A late Fontan in this setting,

Table 11.2 Associations with atrial isomerism

	Left atrial isomerism	Right atrial isomerism
Atrium	Finger-like appendage Smooth surface Absent sinus node	Triangular appendage Crista terminalis Pectinate muscle Duplicate sinus node
Venous connection	Absent IVC Azygous continuation Bilateral SVC Absent/small right SVC Abnormal coronary sinus AV septal defect (30%) Double-outlet RV (40%) Transposed great vessels (20%) Pulmonary stenosis (40%) Subaortic stenosis (9%)	Bilateral SVC Total anomalous pulmonary venous connection (usually supracardiac) Abnormal coronary sinus Large ASD Common AV valve (70%) Double-outlet RV with Transposed great vessels (80%) RV outflow obstruction (90%)
Abdomen	Polysplenia Biliary atresia Abdominal heterotaxy	Asplenia Abdominal heterotaxy

even when anatomy is ideal, is still associated with a significant perioperative mortality [23].

Heterotaxy syndromes

The term heterotaxy is used to describe disorders of arrangement of organs and vessels in both the thorax and the abdomen. Isomerism (“equal parts”) describes the duplication of a structure, be that the left atrium, right atrium, bronchial tree, or lung. The term “situs solitus” describes the normal atrial arrangement (right atrium on the right and left atrium on the left); “situs inversus” is a mirror-image arrangement. A subset of these patients will have complex anatomy with single-ventricle physiology. The associations with left and right atrial isomerism are described in Table 11.2.

Although the birth incidence on right atrial isomerism is higher, fewer of these patients survive to adulthood [24]. Even with improving surgical techniques, complex pulmonary venous obstruction and susceptibility to infection (due to inadequate splenic function) result in less than 30% reaching adulthood; the corresponding figure for left atrial isomerism is approximately 45% [25].

Table 11.3 Adults with single ventricle physiology

No previous surgery	“Balanced” circulation with pulmonary stenosis Pulmonary arterial hypertension
Palliative surgery	Pulmonary artery banding resulting in “balanced circulation” Inadequate banding leading to pulmonary vascular disease
Aortopulmonary shunts	Blalock-Taussig shunt(s) Waterston shunt Pott’s anastomosis
Venous shunts	Classic Glenn shunt Bidirectional Glenn Fontan (multiple modifications including Total Cavopulmonary Connection)
Other surgical procedures	VSD enlargement Atrial septectomy Coarctation repair Repair of atrioventricular valve Norwood procedure for hypoplastic left heart

Presentation in adulthood

Adults with a single-ventricle circulation will usually have had one or more surgical procedures in childhood. Occasionally, patients may have had no intervention and may either have a balanced circulation with a degree of pulmonary stenosis or have developed pulmonary hypertension (Table 11.3).

The majority of these patients will have objective evidence of impaired effort capacity [26], and those with cavopulmonary anastomoses will have evidence of a chronic low-cardiac output state. Despite this, many of these patients will be in relatively good health at least into their fourth decade. This group will therefore need counseling regarding career planning, pregnancy, and contraception.

The majority of patients with a univentricular circulation will have a degree of cyanosis. This includes many with a Fontan circulation or fenestrated TCPC. In the Fontan circulation, reduced saturations are due to residual fenestrations, patch leaks, or venous–venous collaterals. Progressive cyanosis is also present in the setting of a classic Glenn shunt due to arteriovenous malformations in the lung (AVM). These, in turn, are thought to develop because of the absence of intrinsic “hepatic factor” in the pulmonary circulation (hepatic venous return does not reach the right lung). These AVMs may regress on completion of a

circulation incorporating the hepatic venous return [27]. Unoperated patients or those with a palliative Blalock Taussig shunt may be profoundly cyanosed, especially on effort.

Secondary erythrocytosis (not polycythaemia) is common among patients with single-ventricle physiology and compensates for resting and exercise-induced cyanosis. Routine venesections have little place in this setting, whereas identification of iron deficiency followed by iron supplementation is to be encouraged [28].

Long-term outcome in adulthood

Single-ventricle physiology encompasses the most complex congenital cardiac lesions and, even following successful palliation, is associated with a reduced life expectancy [29]. Those with unoperated defects or palliated with an arterial or venous shunt will be exposed to the long-term implications of chronic cyanosis. With time, cyanosis increases either due to the development of pulmonary vascular disease or the inadequacy of shunts created in childhood. Chronic cyanosis results in multisystem pathology, including dramatic erythrocytosis (Table 11.4).

Chronic cyanosis, ventricular overload, and an innately abnormal ventricular geometry eventually lead to variable degrees of systolic and diastolic ventricular dysfunction. The presence of A-V valve regurgitation will exacerbate this. Furthermore, reduced pulmonary blood flow in the absence of a normal

Table 11.4 The multisystem consequences of chronic cyanosis

Erythrocytosis
Iron-deficiency (exaggerated if inappropriately venesected)
Thrombocytopenia with impaired platelet function
Coagulopathy
Thrombosis
Hyperviscosity (altered mentation, visual upset, parasthesia, fatigue)
Impaired immunity
Atypical infections (e.g. cerebral abscess, atypical tuberculosis)
Endocarditis
Hematuria, proteinuria,
Glomerulosclerosis
Chronic renal impairment
Hyperuricaemia, gout
Digital clubbing, hypertrophic osteoarthropathy
Cholelithiasis

subpulmonary ventricle further compromises an already impaired systemic cardiac output, leading to complications of right heart congestion.

Long-term implications of a Fontan circulation

The Fontan circulation is fundamentally flawed, and with time, all Fontan circulations will fail. Over the years, pulmonary vascular resistance increases as does the ventricular end-diastolic pressure. Both of these impair forward flow. In “old-style” Fontan circulations, the right atrial will become a very large and thickened structure. Local compression of the right-sided pulmonary veins is common. This large (at times in excess of 10 cm in diameter) right atrium is hemodynamically inefficient, arrhythmogenic, and thrombogenic (see Case study).

Any obstruction to flow in the Fontan circuit (2–3 mm Hg gradients) is poorly tolerated and should be treated aggressively. Such obstructions, often at the right atrial pulmonary artery anastomosis, are often amenable to transcatheter stenting [30]. The homograft valves placed in the original Fontan circuits were also prone to obstruction and therefore have been abandoned.

Chronic elevation of the systemic venous pressure also leads to disease. Fibrotic change in the liver, Fontan nodules, and cirrhosis ensue. Portal hypertension and esophageal varices are late manifestations [31]. Liver involvement may be a barrier to later cardiac transplantation.

Protein losing enteropathy (PLE) is also thought to be, at least in part, related to chronic elevations of venous pressure. PLE can herald the beginning of a viscous circle of fluid overload, poor nutrition, impaired immunity, and renal dysfunction. The diagnosis is suspected on clinical grounds (pleural effusion, ascites, peripheral edema, and gastrointestinal symptoms) and confirmed with a low serum albumin and elevated fecal alpha-1-antitrypsin. PLE is associated with a poor prognosis [32]. Multiple treatment options have been described (atrial pacing, the creation of an atrial fenestration, high protein medium chain triglyceride diet, steroids, chronic unfractionated heparin, octreotide, somatostatin, or even transplantation). None of them is always reliable.

Although many of these complications are reported with the older Fontan operations, it is likely that they will develop in patients with lateral tunnels or extracardiac Fontan circuits, albeit perhaps at an older age. The 15-year survival following traditional Fontan is only 60–75% [33].

Arrhythmias in Fontan patients

The majority of arrhythmias in the Fontan circulation are organized intra-atrial re-entrant tachycardia, generically labeled atrial flutter [34]. New-onset atrial arrhythmia may herald an underlying hemodynamic lesion (e.g. obstruction in the Fontan), and this needs to be actively investigated. Atrial flutter

should be treated as an emergency in this population. The Fontan patient relies on synchronized atrial contraction to maximize pulmonary blood flow and systemic cardiac output. Therefore, even relatively slow atrial flutter can be associated with hemodynamic instability. Leaving a patient in an atrial arrhythmia will also predispose to clot formation (as described in the clinical scenario at the beginning of the chapter). In the short-term, it is likely that electrical cardioversion will be required to restore sinus rhythm. Ideally, this should be performed with a transesophageal echocardiogram to exclude clot. An experienced cardiac anesthesiologist who is aware of the potential adverse effects of positive pressure ventilation will also be required.

High-level electrophysiological mapping and ablation should then be considered. Ablation in this setting is a highly specialized technique requiring advanced mapping and ablation catheter technologies and tertiary expertise. This is due to the grossly abnormal thickened right atrium and the multiple possible circuits present [35]. The onset of arrhythmia may also stimulate the discussion on Fontan conversion.

Sinus node disease is common in those with a Fontan circulation [36], whereas A-V nodal dysfunction may be seen in those with double-inlet ventricular connection or a previous VSD enlargement. Chronic atrial pacing may improve cardiac output and suppress atrial arrhythmias. Ventricular pacing is less common and usually requires an epicardial pacing system.

Fontan conversion

The term “Fontan conversion” is used to describe “upgrading” an old-style atriopulmonary Fontan to a total caval pulmonary anastomosis. The rationale behind this procedure is to establish a more hemodynamically efficient circulation, prevent or cure atrial arrhythmias, treat pulmonary vein compression, and thus improve cardiac output. Surgery includes “removing” much of the right atrium, performing a modified MAZE procedure, and prophylactically placing an epicardial pacing system. Selection criteria and timing of the Fontan conversion remains controversial. However, in expert hands and with an optimal candidate, the mid-term results are gratifying [37].

Case study

The patient remained significantly limited despite aggressive medical therapy and, after extensive discussion, underwent a Fontan conversion to a TCPC. Surgery included a biatrial MAZE and epicardial pacing. This was a complex and difficult procedure complicated by bleeding, renal dysfunction, and a prolonged stay in intensive care. After 12 months, the patient returned to work. He was in a paced atrial rhythm and was in NYHA II.

References

1. Anderson RH, Becker AE, Wilkinson JL. Proceedings: morphogenesis and nomenclature of univentricular hearts. *Br Heart J* 1975;37:781–2.
2. Khairy P, Poirier N, Mercier L. Univentricular hearts. *Circulation* 2007;115:800–12.
3. Mahle WT, Spray TL, Wernovsky G, et al. Survival after reconstructive surgery for hypoplastic left heart syndrome: a 15-year experience from a single institution. *Circulation* 2000;102:III136–41.
4. Wren C, O'Sullivan J. Survival with congenital heart disease and need for follow up in adult life. *Heart* 2001;85:438–43.
5. Moodie DS, Ritter DG, Tajik AJ, et al. Long-term follow-up in the unoperated univentricular heart. *Am J Cardiol* 1984;53:1124–8.
6. Marelli AJ, Mackie AS, Ionescu-Ittu R, et al. Congenital heart disease in the general population: changing prevalence and age distribution. *Circulation* 2007;115:163–72.
7. Whittemore R, Wells JA, Castellsague X. A second-generation study of 427 probands with congenital heart defects and their 837 children. *J Am Coll Cardiol* 1994;23:1459–67.
8. Gill HK, Splitt M, Sharland GK, Simpson JM. Patterns of recurrence of congenital heart disease: an analysis of 6,640 consecutive pregnancies evaluated by detailed fetal echocardiography. *J Am Coll Cardiol* 2003;42:923–9.
9. Alonso S, Pierpont ME, Radtke W, et al. Heterotaxia syndrome and autosomal dominant inheritance. *Am J Med Genet* 1995;56:12–15.
10. Marino B, Digilio MC, Novelli G, et al. Tricuspid atresia and 22q11 deletion. *Am J Med Genet* 1997;72:40–2.
11. Shinebourne EA, Macartney FJ, Anderson RH. Sequential chamber localization—logical approach to diagnosis in congenital heart disease. *Br Heart J* 1976;38:327–40.
12. Park SJ, Kwak CH, Hwang JY. Long-term survival in double inlet left ventricle combined with pulmonary stenosis and parachute mitral valve: a rare case. *Int Heart J* 2007;48:261–7.
13. Tibballs J, Kawahira Y, Carter BG, et al. Outcomes of surgical treatment of infants with hypoplastic left heart syndrome: an institutional experience 1983–2004. *J Paediatr Child Health* 2007;43:746–51.
14. Blalock A, Taussig HB. The surgical treatment of malformations of the heart in which there is pulmonary stenosis or pulmonary atresia. *J Am Med Assoc* 1945;128:189–92.
15. Glenn WWL. Circulatory bypass of the right side of the heart, IV: shunt between superior vena cava and distal right pulmonary artery: report of clinical application. *N Engl J Med* 1958;259:117–20.
16. Fontan F, Baudet E. Surgical repair of tricuspid atresia. *Thorax* 1971;26:240–8.
17. de Leval MR, Kilner P, Gewillig M, Bull C. Total cavopulmonary connection: a logical alternative to atriopulmonary connection for complex Fontan operations: experimental studies and early clinical experience. *J Thorac Cardiovasc Surg* 1988;96:682–95.
18. Choussat A, Fontan F, Besse B, et al. Selection criteria for Fontan's procedure. In: *Paediatric Cardiology*. New York: Churchill Livingstone, 1978:559–66.
19. Stasik CN, Goldberg CS, Bove EL, Devaney EJ, Ohye RG. Current outcomes and risk factors for the Norwood procedure. *J Thorac Cardiovasc Surg* 2006;131:412–17.
20. Jensen RA Jr, Williams RG, Laks H, et al. Usefulness of banding of the pulmonary trunk with single ventricle physiology at risk for subaortic obstruction. *Am J Cardiol* 1996;77:1089–93.

21. Polderman FN, Cohen J, Blom NA, et al. Sudden unexpected death in children with a previously diagnosed cardiovascular disorder. *Int J Cardiol* 2004;95:171–6.
22. Rao PS. Tricuspid atresia. *Curr Treat Options Cardiovasc Med* 2000;2:507–20.
23. Veldtman GR, Nishimoto A, Siu S, et al. The Fontan procedure in adults. *Heart* 2001;86:330–5.
24. Sadiq M, Stümper O, De Giovanni JV, et al. Management and outcome of infants and children with right atrial isomerism. *Heart* 1996;75:314–19.
25. Lim JS, McCrindle BW, Smallhorn JE, et al. Clinical features, management, and outcome of children with fetal and postnatal diagnoses of isomerism syndromes. *Circulation* 2005;112:2454–61.
26. Iserin L, Chua TP, Chambers J, Coats AJ, Somerville J. Dyspnoea and exercise intolerance during cardiopulmonary exercise testing in patients with univentricular heart. The effects of chronic hypoxaemia and Fontan procedure. *Eur Heart J* 1997;18:1350–6.
27. Lee J, Menkis AH, Rosenberg HC. Reversal of pulmonary arteriovenous malformation after diversion of anomalous hepatic drainage. *Ann Thorac Surg* 1998;65:848–9.
28. Spence MS, Balaratnam MS, Gatzoulis MA. Clinical update: cyanotic adult congenital heart disease. *Lancet* 2007;370:1530–2.
29. Oechslin EN, Harrison DA, Connelly MS, Webb GD, Siu SC. Mode of death in adults with congenital heart disease. *Am J Cardiol* 2000;86:1111–16.
30. Shahda S, Zahra M, Fiore A, Jureidini S. Stents in the successful management of protein-losing enteropathy after fontan. *J Invasive Cardiol* 2007;19:444–6.
31. Kiesewetter CH, Sheron N, Vettukattill JJ, et al. Hepatic changes in the failing Fontan circulation. *Heart* 2007;93:579–84.
32. Khairy P, Fernandes SM, Mayer JE Jr, et al. Long-term survival, modes of death, and predictors of mortality in patients with Fontan surgery. *Circulation* 2008;117:85–92.
33. Fontan F, Kirklin JW, Fernandez G, et al. Outcome after a "perfect" Fontan operation. *Circulation* 1990;81:1520–36.
34. Gelatt M, Hamilton RM, McCrindle BW, et al. Risk factors for atrial tachyarrhythmias after the Fontan operation. *J Am Coll Cardiol* 1994;24:1735–41.
35. Abrams DJ, Earley MJ, Sporton SC, et al. Comparison of noncontact and electroanatomic mapping to identify scar and arrhythmia late after the Fontan procedure. *Circulation* 2007;370:1530–2.
36. Cohen MI, Wernovsky G, Vetter VL, et al. Sinus node function after a systematically staged Fontan procedure. *Circulation* 1998;98:II352–8.
37. Mavroudis C, Backer CL, Deal BJ, Johnsrude C, Strasburger J. Total cavopulmonary conversion and maze procedure for patients with failure of the Fontan operation. *J Thorac Cardiovasc Surg* 2001;122:863–71.

Ebstein's anomaly

Heidi M. Connolly

A 33-year-old male presents with fatigue, a gradual decline in exercise capacity, and increasing palpitations. He was diagnosed with a heart murmur at age 14 years, but no medical or operative intervention was performed. He had no regular cardiovascular follow-up.

Mild digital clubbing and central cyanosis were noted on physical examination. The jugular venous pressure was 5 cm of water with A and V waves visible. There was a parasternal impulse. Two mid-systolic clicks and a grade 2/6 holosystolic murmur were noted at the left sternal border. The remainder of the physical examination was unremarkable.

Sinus bradycardia with right bundle branch block and first-degree atrioventricular block were noted on the electrocardiogram (Fig. 12.1). A narrow pedicle with features of cardiac enlargement and clear lung fields were noted on the chest radiograph (Fig. 12.2). Transthoracic echocardiography demonstrated marked right-sided cardiac chamber enlargement with reduced systolic function. A large redundant anterior tricuspid valve leaflet with variable tethering was noted. The septal and posterior leaflets were also tethered and apically displaced. There was severe tricuspid valve regurgitation (Fig. 12.3). A small atrial septal defect with bidirectional shunting was noted.

A cardiac magnetic resonance imaging (MRI) confirmed right-sided cardiac chamber enlargement with moderate reduction in right ventricular systolic function. The tricuspid valve was apically displaced with associated severe tricuspid valve regurgitation (Fig. 12.4).

The patient exercised 66% of predicted functional aerobic capacity on a treadmill exercise test. Oxygen desaturation (94% at rest to 84% at peak exercise) was noted during exercise. An episode of narrow complex tachycardia with a heart rate of 150 bpm

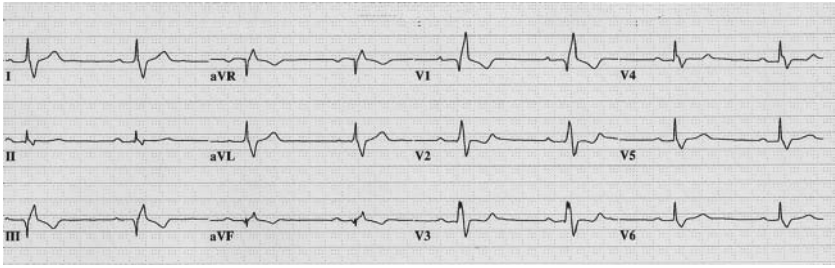


Fig. 12.1 Electrocardiogram from the patient presented. Note sinus bradycardia with first-degree atrioventricular block and right bundle branch block with secondary ST and T wave abnormalities.

was noted during monitored exercise. The patient noted palpitations but no lightheadedness.

Background

Ebstein's anomaly was initially described by Wilhelm Ebstein in 1866 in a report titled "Concerning a very rare case of insufficiency of the tricuspid valve caused by a congenital malformation." Ebstein's anomaly is an uncommon congenital heart disorder occurring in about 1 in 200,000 live births. It accounts for less than 1% of all cases of congenital heart disease.

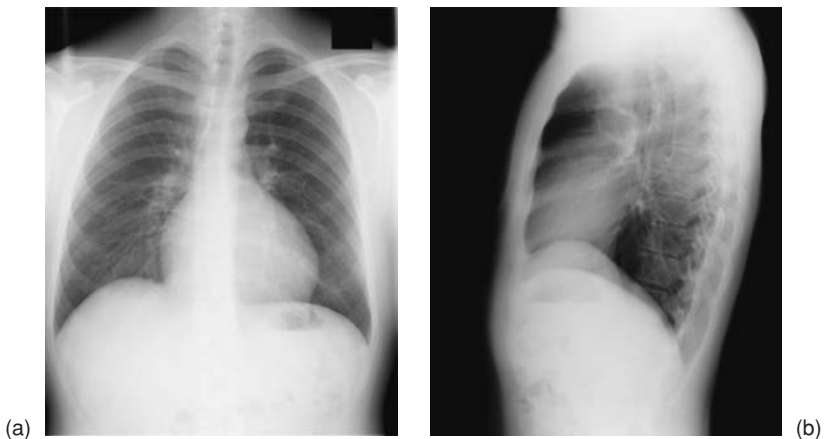


Fig. 12.2 Preoperative chest radiograph from the patient presented. Note enlargement of the cardiac silhouette and a narrow pedicle on the posteroanterior view (a). The lateral chest radiograph (b) demonstrates loss of retrosternal air space consistent with right heart enlargement.

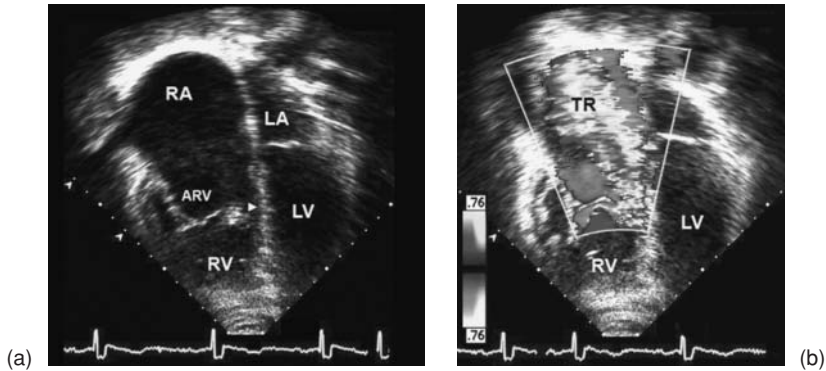


Fig. 12.3 Apical four-chamber, two-dimensional transthoracic echocardiographic image (a) demonstrates apical displacement of the septal tricuspid valve leaflet (arrowhead) compared with the anterior mitral valve leaflet, and tethering of the anterior tricuspid leaflet. There was associated (b) severe tricuspid valve regurgitation noted by color Doppler imaging. RA, right atrium; RV, right ventricle; ARV, atrialized right ventricle; LA, left atrium; LV left ventricle; TR, tricuspid regurgitation.

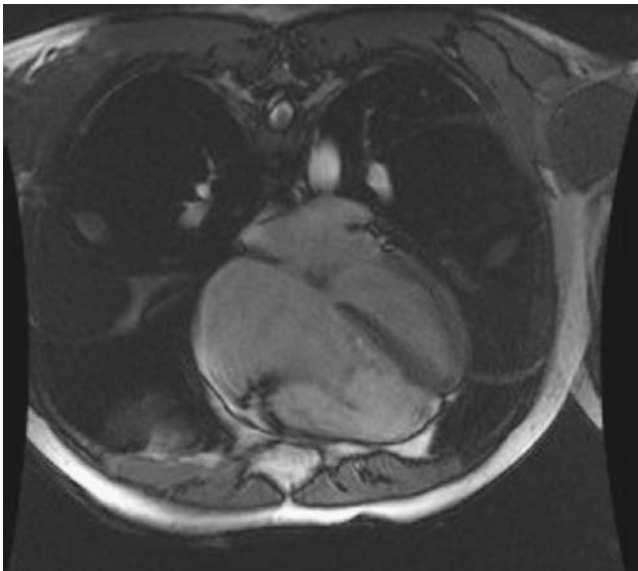


Fig. 12.4 Axial bright blood cardiac magnetic resonance image from the patient presented demonstrates characteristic apical displacement of the septal tricuspid valve leaflet, as well as marked right-sided cardiac chamber enlargement. The measured right ventricular end-diastolic volume was 435 mL. Moderate reduction of right ventricular systolic function was noted. The left ventricle is D-shaped due to volume overload of the right ventricle. The left ventricular function was preserved.

Pathology, genetics, and classification

Pathology

Ebstein's anomaly involves a wide spectrum of anatomic and functional abnormalities affecting primarily the morphologic tricuspid valve and right ventricle. The disorder is characterized by adherence of the septal and posterior tricuspid valve leaflets to the underlying myocardium due to failure of delamination during embryonic development. Failure of delamination causes downward or apical displacement of the functional annulus and dilatation of the atrialized portion of the right ventricle with varying degrees of wall thinning (Fig. 12.5) [1,2].

In normal human hearts, there is minimal apical displacement of the septal and posterior leaflets in relation to the anterior mitral valve leaflet. Non-Ebstein

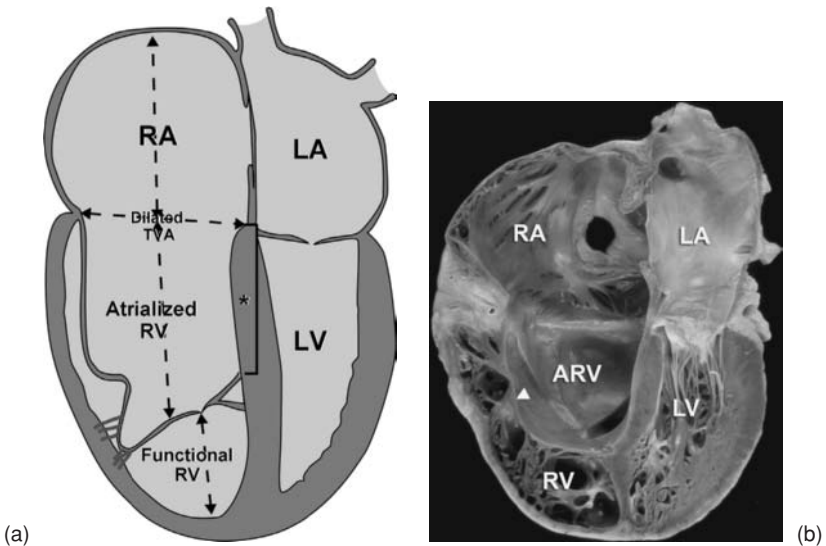


Fig. 12.5 (a) Schematic demonstrating features of Ebstein's anomaly in the apical four-chamber format with apical displacement of the septal tricuspid valve leaflet (asterisk) and tethering of the anterior tricuspid valve leaflet with resultant right heart abnormalities. Abbreviations: RA, right atrium; RV, right ventricle; LA, left atrium; LV, left ventricle; TVA, tricuspid valve annulus. (b) Pathology specimen of a heart with severe features of Ebstein's anomaly dissected in the apical four-chamber format. The posterior leaflet forms an intraventricular muscular shelf that delineates the atrialized portion of the right ventricle (ARV). The anterior leaflet is markedly tethered (arrowhead) and is attached to the free wall by numerous muscular stumps. The shape of the ventricular septum is distorted by the displaced septal leaflet. Marked dilatation involves the right atrium (RA), right ventricle (RV), and true tricuspid annulus. (Pathology image courtesy of Dr. W.D. Edwards, Department of Pathology, Mayo Clinic.)

patients with enlarged right-sided cardiac chambers will demonstrate less than 8 mm/m² body surface area displacement of the septal and posterior tricuspid valve leaflets. This is one of the methods used to differentiate Ebstein's anomaly from other causes of right heart enlargement by echocardiography.

The anterior tricuspid valve leaflet in Ebstein's anomaly is often redundant, with variable degrees of tethering and fenestrations. Occasionally, the anterior leaflet is so severely deformed that the only mobile leaflet tissue is displaced into the right ventricular outflow tract, where it may cause obstruction. The chordae tendineae related to the tricuspid valve are generally short and poorly formed [2,3].

The right ventricle is generally divided into two parts: the inlet portion, which is functionally integrated with the right atrium in Ebstein's anomaly, and the trabecular and outlet portions, which constitute the functional right ventricle. Marked dilatation of the true tricuspid valve annulus, which is not displaced, is often noted. The right coronary artery demarcates the level of the true annulus. There may be a large chamber separating this true annulus from the functional right ventricle, the so-called atrialized portion of the right ventricle [2,4].

The right ventricle is dilated in over 60% of patients with Ebstein's anomaly; this dilatation often involves not only the atrialized inlet portion of the right ventricle but also the functional right ventricular apex and outflow tract. Right ventricular dilatation may be so marked that the ventricular septum bulges leftward, compressing the left ventricular chamber [2]. In this situation, echocardiographic short-axis images demonstrate a circular right ventricle and a crescentic left ventricle. Left ventricular outflow tract obstruction can occur in extreme cases.

Genetics

Most cases of Ebstein's anomaly are sporadic, and familial cases are very rare. Heterogeneous factors are felt to be responsible for Ebstein's anomaly; genetic, reproductive, and environmental risk factors have been demonstrated in case-control studies. Ebstein's anomaly is more common in twins, in those with a family history of congenital heart disease, and in those with maternal exposure to benzodiazepines [5]. Maternal lithium therapy can also rarely lead to Ebstein's anomaly in the offspring [6].

Classification

Ebstein's anomaly can be classified as mild, moderate, or severe based on the extent of apical displacement of the valve leaflets with resultant tricuspid regurgitation and the degree of right-sided cardiac chamber dilation and dysfunction noted by echocardiography [7]. Alternate clinical and echocardiographic classifications have been reported [8]. A classification based on the anatomic findings at surgery emphasizes characteristics that surgeons find important. This classification proposed four grades of Ebstein's anomaly [4]:

- Type I: The anterior tricuspid leaflet is large and mobile but the posterior and septal leaflets are apically displaced, dysplastic, or absent. The atrialized ventricular chamber size varies from relatively small to large.
- Type II: The anterior, posterior, and often septal leaflets are present, but are relatively small and displaced toward the apex. The atrialized ventricular chamber is moderately large.
- Type III: The anterior leaflet has restricted motion with shortened, fused, and tethered chordae. Direct insertion of papillary muscles into the anterior leaflet is frequently present. The posterior and septal leaflets are displaced, dysplastic, and usually not reconstructible. The atrialized ventricular chamber is large.
- Type IV: The anterior leaflet is severely deformed and displaced into the right ventricular outflow tract. There may be few or no chordae, and direct insertions of the papillary muscles into the leading edge of the valve are common. The posterior leaflet is typically dysplastic or absent, and the septal leaflet is represented by a ridge of fibrous material descending apically from the membranous septum. Tricuspid valve tissue is displaced into the right ventricular outflow tract and may cause obstruction of blood flow (functional tricuspid stenosis). Nearly the entire right ventricular cavity is atrialized ventricle.

Clinical features

In the unoperated patient, the clinical presentation of Ebstein's anomaly depends on the extent of tricuspid valve leaflet distortion, the size of the right heart, right atrial pressure, degree of tricuspid valve regurgitation, the presence or absence of right-to-left shunt, and the presence and nature of associated arrhythmias. The age at presentation depends on the degree of anatomic and hemodynamic derangement.

Severely affected patients may die in utero or become symptomatic at an early age. Neonates with Ebstein's anomaly may present with cardiomegaly, congestive heart failure, and cyanosis. Neonates diagnosed with Ebstein's anomaly carry a poor prognosis; 20–40% will not survive 1 month and less than 50% will survive to age 5 years. The younger the age at presentation, the more severe the anatomic and hemodynamic derangement [9,10]. Predictors of poor outcome are NYHA functional Class III or IV symptoms, cardiothoracic ratio greater than 65%, or atrial fibrillation. Symptomatic children with Ebstein's anomaly may have progressive right heart enlargement, but most will reach adolescence and adulthood.

Electrophysiologic rather than hemodynamic symptoms are a common form of presentation in adolescent patients. Adult presentation includes symptoms of exercise intolerance with dyspnea, fatigue, and symptomatic arrhythmias or right heart failure. Varying degrees of cyanosis, particularly with exercise, may occur when an atrial septal defect or patent foramen ovale is present. Patients

are also at risk for paradoxical embolism causing transient ischemic attack, stroke, or cerebral abscess. Left-to-right shunts may also occur and contribute to right heart enlargement [8]. Exercise tolerance is dependent on age and oxygen saturation at rest and with exercise [11]. Patients with Ebstein's anomaly who reach late adolescence and adulthood often have an excellent outcome [8].

Rarely, patients with Ebstein's anomaly present with end-stage cardiovascular disease from severe tricuspid valve regurgitation and biventricular dysfunction. It may be precipitated by an arrhythmia such as atrial fibrillation or be related to neglected congenital heart disease. Late presentation is usually related to lack of adequate medical care, either on the part of the patient or physician. Failure to refer patients to Adult Congenital Centers continues to be a major cause of excess morbidity and mortality in all adult patients with congenital heart disease. Sudden cardiac death may occur and has been attributed to atrial fibrillation with accelerated conduction through an accessory pathway or from ventricular arrhythmias.

Patients presenting in adulthood with Ebstein's anomaly may be asymptomatic with no functional limitation, and generally demonstrate mild anatomic and functional variants. Survival to the ninth decade has been reported [12].

Associated cardiac lesions

Ebstein's anomaly is often associated with other congenital cardiac defects; these often have an important impact on clinical status. The most common association is a shunt at atrial level with either a patent foramen ovale or secundum atrial septal defect present in over 50% of patients, resulting in varying degrees of cyanosis [13].

Patients with Ebstein's anomaly are prone to tachy-palpitations related to their underlying cardiac disease, chamber enlargement, and the presence of one or more accessory conduction pathways. Accessory conduction pathways are present in about 25% of patients with Ebstein's anomaly and increase the risk of atrial tachyarrhythmias.

Less common associations include ventricular septal defect, right ventricular outflow tract obstruction, and abnormalities of the left heart, including mitral valve prolapse, bicuspid aortic valve, and abnormal left ventricular morphology and function, including left ventricular noncompaction [13].

Diagnosis

Physical examination

Mild forms of Ebstein's anomaly may demonstrate minimal findings on physical examination other than a loud first heart sound, one or more systolic clicks, and a short systolic murmur. The jugular venous pressure is often normal even in the presence of severe tricuspid regurgitation because of the large right atrium

absorbing all the regurgitant flow. With increasing severity of disease, peripheral cyanosis may be present due to the low cardiac output or right-to-left shunt at atrial level. The pulse volume may be low. A right ventricular lift is often present but subtle. The first sound is loud, and there may be one or more systolic clicks. The murmur of tricuspid regurgitation is holosystolic at the lower left sternal border and increases on inspiration. A musical character to the systolic murmur suggests leaflet fenestration. Pulsatile hepatomegaly is noted in some Ebstein patients with severe tricuspid regurgitation. End-stage disease with severe tricuspid valve regurgitation and ventricular dysfunction may manifest as right-sided heart failure with associated edema and ascites.

Electrocardiogram

The electrocardiogram is abnormal in most patients with Ebstein's anomaly. Careful review for an accessory pathway is recommended. A tall and broad P wave as a result of right atrial enlargement and complete or incomplete right bundle branch block are expected [14]. Atrial arrhythmias and occasionally first-degree atrioventricular block may be present. The QRS voltage over the right-sided chest leads may be low.

Chest radiography

The chest radiograph in Ebstein's anomaly varies according to severity of disease. The cardiac silhouette may be normal, mild, or moderately enlarged (Fig. 12.2) or may demonstrate marked globe-shaped enlargement with a narrow pedicle (Fig. 12.6). The pulmonary vascularity may be normal or decreased. The right atrial contour is often prominent, and the left heart border becomes straight or convex due to the dilated and displaced right ventricular outflow.

Echocardiography

Transthoracic echocardiography is the diagnostic test of choice in patients with known or suspected Ebstein's anomaly. Two-dimensional imaging documents the severity and degree of right-sided cardiac chamber enlargement, and is also used for assessment of ventricular function. The right atrium, atrialized portion of the right ventricle, and right ventricle are often markedly enlarged. The impact of Ebstein's anomaly on the left ventricle can also be readily assessed. Abnormal two-dimensional features of the tricuspid valve are also readily noted using the apical four-chamber window (Fig. 12.3).

Echocardiographic features of Ebstein's anomaly include apical displacement of the septal tricuspid valve leaflet ≥ 8 mm/m² body surface area compared with the anterior mitral valve leaflet insertion on the ventricular septum [3], the presence of a redundant elongated anterior tricuspid leaflet with variable tethering, and a diminutive posterior tricuspid valve leaflet. Color-flow, pulsed-wave, and continuous-wave Doppler is used to determine the severity of tricuspid valve regurgitation [15]. The location and severity of tricuspid regurgitation and

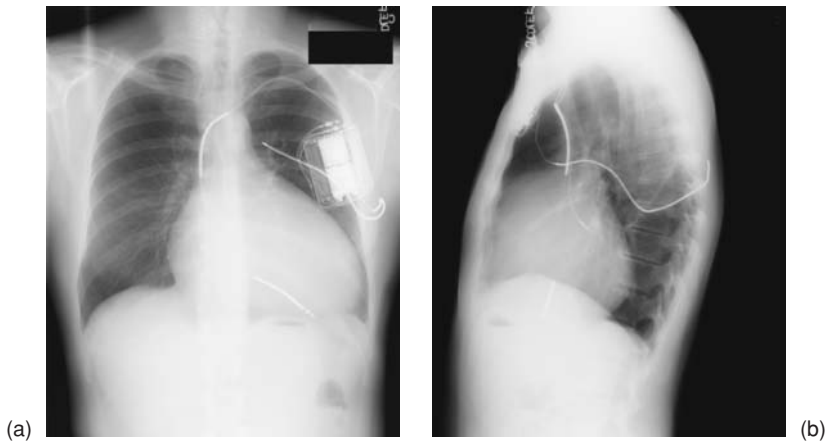


Fig. 12.6 Marked cardiac enlargement noted by (a) anteroposterior and (b) lateral chest radiography in a patient with advanced Ebstein's anomaly. Note the internal cardioverter defibrillator device and leads. The patient underwent assessment for syncope and was found to have inducible ventricular tachycardia. A device was placed. Despite ventricular tachycardia, the patient was not referred for congenital consultation or cardiac surgical intervention until he had severe symptoms of right heart failure, several years later.

potential for repair are assessed by echocardiography. In addition, the echocardiogram is used to identify associated lesions such as atrial septal defect or patent foramen ovale, ventricular septal defect, and right ventricular outflow tract obstruction.

Transesophageal echocardiography is rarely required to confirm the diagnosis of Ebstein's anomaly [16]. However, in select cases, the diagnostic work-up may require transesophageal echocardiogram to assess the presence of an atrial septal defect or to delineate intracardiac anatomy in patients with suboptimal transthoracic echocardiographic images. Intraoperative transesophageal echocardiography is used routinely to confirm anatomy prior to operation and assess surgical results following operative intervention [17].

Magnetic resonance imaging

Cardiac magnetic resonance imaging is increasingly used to assess right and left ventricular size and function in patients with congenital heart disease; however, limited information is available on the preoperative assessment by these modalities in Ebstein's anomaly (Fig. 12.4) [18,19].

Cardiac catheterization

Cardiac catheterization is rarely necessary for diagnostic purposes in patients with Ebstein's anomaly, other than for preoperative coronary angiography.

Right ventricular end diastolic pressure may be increased, but pulmonary artery pressures are usually normal in these patients. Right atrial pressure may be normal despite severe tricuspid regurgitation, due to marked right atrial enlargement.

Cardiac catheterization may be performed for percutaneous catheter closure of a secundum atrial septal defect in select patients with Ebstein's anomaly (see section on "Catheter ablation and intervention").

Differential diagnosis

The differential diagnosis of Ebstein's anomaly includes other causes of tricuspid valve regurgitation and right-sided cardiac chamber enlargement. The experienced echocardiographer can differentiate most cases of Ebstein's anomaly. Common misdiagnoses include tricuspid valve prolapse, tricuspid valve dysplasia, traumatic tricuspid valve injury, tricuspid valve endocarditis, carcinoid heart disease, and arrhythmogenic right ventricular cardiomyopathy [20].

Management

Medical

Patients with mild forms of Ebstein's anomaly may be followed medically for many years. Regular evaluation by a cardiologist with expertise in congenital heart disease is recommended. The patient's rhythm status should be carefully monitored because of the high incidence of supraventricular arrhythmias.

Endocarditis prophylaxis is recommended in cyanotic patients with Ebstein's anomaly and patients with a prosthetic valve, but is no longer necessary for the acyanotic unoperated patient [21].

Physical activity recommendations should follow the guidelines summarized in "Task Force 2 on Congenital Heart Disease" [22]. Athletes with mild forms of Ebstein's anomaly, nearly normal heart size, and no cyanosis or arrhythmias can participate in all sports. Athletes with Ebstein's anomaly and moderate tricuspid regurgitation can participate in low-intensity competitive sports if there is no evidence of important arrhythmia. Athletes with severe Ebstein's anomaly are precluded from competitive sports unless the anomaly has been optimally repaired, heart size is nearly normal, and the patient has no history of arrhythmias.

Patients with Ebstein's anomaly and symptoms of heart failure who have been evaluated by a congenital cardiologist and experienced congenital cardiac surgeon and are not candidates for reparative surgery are treated with standard heart failure therapy, including digitalis, digoxin, diuretics, and angiotensin-converting enzyme inhibitors. The efficacy of these medications in patients with Ebstein's anomaly who have right-sided heart failure is not proven.

Medical management of arrhythmias should be individualized, reviewed with an electrophysiologist, and combined with operative, catheter, or

device-based intervention. Anticoagulation with warfarin is recommended for patients with Ebstein's anomaly who have atrial fibrillation or a paradoxical embolus with an intracardiac shunt.

Pregnancy and reproduction

When patients with congenital heart disease are contemplating pregnancy, a pre-pregnancy consultation should be undertaken. Clinical evaluation by physicians with expertise in adult congenital heart disease and high-risk obstetrics is recommended. Pregnancy is generally well tolerated in acyanotic patients or repaired patients with Ebstein's anomaly who are asymptomatic or minimally symptomatic. An increased risk of pregnancy-related complications and fetal loss occurs with Ebstein's anomaly, especially among women who were cyanotic at the time of pregnancy [23]. Thus, Ebstein patients with severe tricuspid valve regurgitation, cyanosis, or symptomatic arrhythmias should be considered for intervention prior to pregnancy to reduce the risk of pregnancy-related complications.

A review of studies published between 1985 and 2007 found low rates of cardiovascular complications during pregnancies (>20 weeks gestation) among repaired and unrepaired women with Ebstein's anomaly. Cardiovascular complications included arrhythmias in 3.9%, heart failure in 3.1%, and no cardiovascular events (myocardial infarction, stroke, and cardiovascular mortality) in 128 pregnancies [24].

Pregnancy in Ebstein's anomaly is associated with an increased fetal risk of prematurity (22%), perinatal mortality (2.3%), and congenital heart disease, regardless of the presence or absence of maternal cyanosis. The reported rate of recurrence of congenital heart disease in offspring of patients with Ebstein's anomaly is approximately 4% [24]. Paternal Ebstein's anomaly also increases the risk of congenital heart disease in the offspring (observed rate of 1%) [23].

Catheter ablation and arrhythmia intervention

Radiofrequency catheter ablation success rates are lower in patients with Ebstein's anomaly than in those with a normal heart, and the risk of recurrence is increased. This is in part due to the multiple accessory pathways that are present in nearly 50% of patients with Ebstein's anomaly [25–28]. Thus, an electrophysiologist with experience in managing arrhythmias in patients with congenital heart disease should perform electrophysiologic testing and radiofrequency ablation of symptomatic accessory pathways in these patients. Supraventricular tachyarrhythmias associated with Ebstein's anomaly also can be ablated at the time of operative repair.

Unrepaired adult Ebstein patients may be faced with shunt-related cyanosis due to the combination of tricuspid regurgitation, right ventricular dysfunction,

and a patent foramen ovale or atrial septal defect. Patients with minimal tricuspid regurgitation that does not warrant surgical repair may benefit from closure of the atrial level shunt. This may reduce cyanosis and improve functional capacity sufficiently to outweigh the theoretic risk of right ventricular dysfunction.

Surgical indications and options

Operative intervention in patients with Ebstein's anomaly should be performed by surgeons experienced in congenital cardiac surgery. Indications for surgical intervention include: (1) class III or IV symptoms, or deteriorating exercise capacity; (2) cyanosis with or without paradoxical embolism; (3) progressive right ventricular dilatation or reduction of right ventricular systolic function; (4) development or progression of atrial and/or ventricular arrhythmias not amenable to or successfully treated with percutaneous procedures; and (5) ventricular pre-excitation not successfully treated in the electrophysiology laboratory [29].

Primary operation generally consists of closure of interatrial communication, arrhythmia procedures such as surgical division of accessory conduction pathways, cryoablation of atrioventricular nodal re-entrant tachycardias, or MAZE procedure. Selective plication or resection of portions of the atrialized right ventricle is also performed. The tricuspid valve is repaired when feasible, and tricuspid valve replacement is performed with a heterograft bioprosthesis or mechanical prosthesis when repair is not feasible or repair results are not satisfactory. A right reduction atrioplasty is often performed.

In high-risk surgical Ebstein's patients, including those with severe right ventricular dysfunction, preserved left ventricular function, and low left atrial pressure, a bidirectional cavopulmonary anastomosis is considered [30]. The single-ventricle Fontan pathway may be considered for profound right ventricular dysfunction, most often when operation is required during infancy. Heart transplantation is considered when severe biventricular dysfunction is present and there are important symptoms of heart failure.

Reoperation usually requires tricuspid valve replacement or re-replacement. Re-repair of the tricuspid valve is rarely successful. A concomitant MAZE procedure may be performed for intermittent or chronic atrial fibrillation and/or flutter. Indications for reoperation in patients with Ebstein's anomaly include: (1) symptoms, deteriorating exercise capacity, or functional class III or IV; (2) severe tricuspid regurgitation after repair with progressive right ventricular dilatation or reduction of right ventricular systolic function; (3) appearance/progression of atrial and/or ventricular arrhythmias related to recurrent severe tricuspid regurgitation; and (4) bioprosthetic tricuspid valve dysfunction with severe regurgitation, severe stenosis, or combined severe stenosis and regurgitation.

Postoperative findings

Operated patients with Ebstein's anomaly require life-long specialized surveillance for recurrent tricuspid valve dysfunction after repair, prosthetic valve dysfunction, arrhythmias, and ventricular dysfunction [31]. Postoperative exercise tolerance is generally significantly improved compared with preoperative exercise tolerance, especially in patients with an atrial septal defect. Age, gender, and heart size influence postoperative exercise tolerance [32]. Patients with repaired Ebstein's anomaly remain at risk for atrial and ventricular arrhythmias, and life-long follow-up is recommended.

Operative mortality for patients with Ebstein's anomaly is approximately 5–10% in experienced centers. Late survival is favorable, estimated to be 92% 10 years postoperatively. Placement of tricuspid valve prosthesis is associated with a high incidence of complete heart block at inexperienced centers.

Prognosis

The prognosis for patients with Ebstein's anomaly varies with the severity of the disease. In a review of 220 patients seen between 1958 and 1991, the actuarial survival for all liveborn patients was 67% at 1 year and 59% at 10 years [8].

The major causes of death were heart failure, perioperative, and sudden death. The main predictors of death were severity of disease based on echocardiographic grade, fetal presentation, and right ventricular outflow tract obstruction. The outcome was better in patients with less severe disease who presented in later childhood or adulthood.

Survival in patients with Ebstein's anomaly appears to be improving as advances in diagnostic and surgical techniques as well as postoperative care have led to improvements in surgical outcome. This was illustrated in a report of 158 patients who received a primary tricuspid bioprosthesis [31]. Ten-year survival was 93% with freedom from bioprosthesis replacement at 10 and 15 years of 98% and 81%, respectively; 92% were NYHA class I or II; and 94% were not receiving anticoagulation.

Conclusions

Ebstein's anomaly is a complex congenital malformation with a broad anatomic and clinical spectrum. Management must be carried out by physicians with knowledge about the differential anatomic and hemodynamic variables, as well as associated malformations and management options for individualized patient care. It is hoped that, with improved management strategies, survival of patients with Ebstein's anomaly of all ages will continue to improve.

Case study

Comprehensive review of the patient data by the congenital cardiologist, electrophysiologist, and cardiac surgeon was performed. Preoperative electrophysiology testing demonstrated no accessory pathway, but atrial flutter was easily induced. Cardiac catheterization was not felt to be necessary prior to planned operative intervention. Surgical intervention was recommended, including closure of the atrial septal defect, tricuspid valve repair, and MAZE procedure.

An intraoperative transesophageal echocardiogram was performed. The pre-bypass images confirmed the findings noted by transthoracic echocardiography. The operative procedure included tricuspid valve repair and atrial septal defect closure. In addition, a left-sided pulmonary vein isolation procedure and right-sided MAZE procedure with a radiofrequency device was performed. The left atrial appendage was ligated. Post-bypass transesophageal echocardiography demonstrated trivial tricuspid valve regurgitation and no stenosis following repair. The atrial septum was intact. The patient had an uneventful postoperative recovery. He was dismissed from hospital in normal sinus rhythm. Anticoagulation was recommended for 3 months after operation. At 6-month follow-up, the patient noted marked improvement in exercise capacity without desaturation or recurrence of atrial arrhythmias.

References

1. Dearani J, Danielson G. *Ebstein's Anomaly of the Tricuspid Valve* (3rd edition). Philadelphia: Mosby, 2003.
2. Edwards W. Embryology and pathologic features of Ebstein's anomaly. *Prog Pediatr Cardiol* 1993;2:5–15.
3. Shiina A, Seward J, Edwards W, et al. Two-dimensional echocardiographic spectrum of Ebstein's anomaly: detailed anatomic assessment. *J Am Coll Cardiol* 1984;3:356–70.
4. Dearani J, Danielson G. Congenital Heart Surgery Nomenclature and Database Project: Ebstein's anomaly and tricuspid valve disease. *Ann Thorac Surg* 2000;69: S106–17.
5. Correa-Villasenor A, Ferencz C, Neill C, et al. The Baltimore-Washington Infant Study Group. Ebstein's malformation of the tricuspid valve: genetics and environmental factors. *Teratology* 1994;50:137–47.
6. Cohen L, Friedman J, Jefferson J, et al. A reevaluation of risk of in utero exposure to lithium. *JAMA* 1994;271:146–50.
7. Attenhofer Jost C, Connolly H, Dearani J, et al. Ebstein's anomaly. *Circulation* 2007; 115:277–85.
8. Celermajer D, Bull C, Till J, et al. Ebstein's anomaly: presentation and outcome from fetus to adult. *J Am Coll Cardiol* 1994;23:170–6.
9. Celermajer D, Cullen S, Sullivan I, et al. Outcome in neonates with Ebstein's anomaly. *J Am Coll Cardiol* 1992;19:1041–6.
10. Yetman A, Freedom R, McCrindle B. Outcome in cyanotic neonates with Ebstein's anomaly. *Am J Cardiol* 1998;81:749–54.

11. MacLellan-Tobert S, Driscoll D, Mottram C, et al. Exercise tolerance in patients with Ebstein's anomaly. *J Am Coll Cardiol* 1997;29:1615-22.
12. Seward J, Tajik A, Feist D, Smith H. Ebstein's anomaly in an 85-year-old man. *Mayo Clin Proc* 1979;54:193-6.
13. Attenhofer Jost C, Connolly H, O'Leary P, et al. Left heart lesions in patients with Ebstein anomaly. *Mayo Clin Proc* 2005;80:361-8.
14. Giuliani E, Fuster V, Brandenburg R, Mair D. Ebstein's anomaly: the clinical features and natural history of Ebstein's anomaly of the tricuspid valve. *Mayo Clin Proc* 1979;54:163-73.
15. Zoghbi W, Enriquez-Sarano M, Foster E, et al. American Society of Echocardiography. Recommendations for evaluation of the severity of native valvular regurgitation with two-dimensional and Doppler echocardiography. *J Am Soc Echocardiogr* 2003;16:777-802.
16. Tworetzky W, McElhinney D, Brook M, et al. Echocardiographic diagnosis alone for the complete repair of major congenital heart defects. *J Am Coll Cardiol* 1999;33:228-33.
17. Randolph G, Hagler D, Connolly H, et al. Intraoperative transeophageal echocardiography during surgery for congenital heart defects. *J Thorac Cardiovasc Surg* 2002;124:1176-82.
18. Eustace S, Kruskal J, Hartnell G. Ebstein's anomaly presenting in adulthood: the role of cine magnetic resonance imaging in diagnosis. *Clin Radiol* 1994;49:690-2.
19. Hartnell G, Cohen M, Meier R, Finn J. Magnetic resonance angiography demonstration of congenital heart disease in adults. *Clin Radiol* 1996;51:851-7.
20. Ammash NM, Warnes CA, Connolly HM, et al. Mimics of Ebstein's anomaly. *Am Heart J* 1997;134:508-13.
21. Wilson W, Taubert K, Gewitz M, et al. Prevention of Infective Endocarditis. Guidelines From the American Heart Association. A Guideline From the American Heart Association Rheumatic Fever, Endocarditis, and Kawasaki Disease Committee, Council on Cardiovascular Disease in the Young, and the Council on Clinical Cardiology, Council on Cardiovascular Surgery and Anesthesia, and the Quality of Care and Outcomes Research Interdisciplinary Working Group. *Circulation* 2007;116:1736-54.
22. Graham T Jr, Driscoll D, Gersony W, et al. Task Force 2: Congenital heart disease. *J Am Coll Cardiol* 2005;45:1326-33.
23. Connolly H, Warnes C. Ebstein's anomaly: Outcome of pregnancy. *J Am Coll Cardiol* 2004;23:1194-8.
24. Drenthen W, Pieper P, Roos-Hesselink J, et al. Outcome of pregnancy in women with congenital heart disease: a literature review. *J Am Coll Cardiol* 2007;49:2303-11.
25. Chetaille P, Walsh E, Triedman J. Outcomes of radiofrequency catheter ablation of atrioventricular reciprocating tachycardia in patients with congenital heart disease. *Heart Rhythm* 2004;1:168-73.
26. Oh J, Holmes D Jr, Hayes D, et al. Cardiac arrhythmias in patients with surgical repair of Ebstein's anomaly. *J Am Coll Cardiol* 1985;6:1351-7.
27. Reich J, Auld D, Hulse E, et al. The Pediatric Radiofrequency Ablation Registry's experience with Ebstein's anomaly. *J Cardiovasc Electrophysiol* 1998;9:1370-7.
28. Smith W, Gallagher J, Kerr C, et al. The electrophysiologic basis and management of symptomatic recurrent tachycardia in patients with Ebstein's anomaly of the tricuspid valve. *Am J Cardiol* 1982;49:1223-34.

29. Bonow R, Carabello B, Chatterjee K, et al. ACC/AHA 2006 guidelines for the management of patients with valvular heart disease. A report of the American College of Cardiology/American Heart Association Task Force on Practice Guidelines (Writing committee to revise the 1998 guidelines for the management of patients with valvular heart disease) developed in collaboration with the Society of Cardiovascular Anesthetists endorsed by the Society for Cardiovascular Angiography and Interventions and the Society of Thoracic Surgeons. *J Am Coll Cardiol* 2006;48:e1-148.
30. Quinonez L, Dearani J, Puga F, et al. Results of the 1.5-ventricle repair for Ebstein anomaly and the failing right ventricle. *J Thorac Cardiovasc Surg* 2007;133:1303-10.
31. Kiziltan H, Theodoro D, Warnes C, et al. Late results of bioprosthetic tricuspid valve replacement in Ebstein's anomaly. *Ann Thorac Surg* 1998;66:1539-45.
32. Driscoll D, Mottram C, Danielson G. Spectrum of exercise intolerance in 45 patients with Ebstein's anomaly and observations on exercise tolerance in 11 patients after surgical repair. *J Am Coll Cardiol* 1988;11:831-6.

Imaging in adult congenital heart disease

Candice K. Silversides and Samuel C. Siu

A 35-year-old male with repaired tetralogy of Fallot presented with palpitations and syncope. He had initially undergone a Blalock-Taussig shunt at 2 months of age. This was followed by an intracardiac repair with a transannular patch across the right ventricular outflow at the age of 8 years. He had residual pulmonary regurgitation but clinically had been well until this presentation. On physical exam, he had a right ventricular heave and a murmur of pulmonary regurgitation, but no evidence of right-sided heart failure. His electrocardiogram showed sinus rhythm with a right bundle branch block (QRS duration 180 ms). He was admitted to the hospital for observation, and while on telemetry, 30 beats of symptomatic nonsustained ventricular tachycardia was documented. Which imaging test should be performed?

Because of the complex nature of congenital heart disease (CHD), cardiac imaging has an important role in the management of patients with these lesions. Every imaging modality has advantages and limitations, and physicians caring for patients with CHD need to have an understanding of these issues. The current clinical guidelines for the management of patients with CHD include recommendations on the use of various imaging modalities [1–4]. Furthermore, guidelines are available for the use of cardiac computed tomography (CT) [5], cardiac magnetic resonance (CMR) imaging (Table 13.1) [6], and radionuclide imaging (RNA) [7] as well as appropriate criteria [8,9] pertaining to CHD. Currently, no single imaging modality can obtain all of the information that is required for patient management, and frequently patients undergo imaging by a number of different complementary techniques. Imaging modalities and their strengths and limitations will be discussed along with an overview of imaging approaches for some of the straightforward congenital lesions.

Table 13.1 Indications for CMR in CHD [6]

Indication	Class
I. General indications	
Initial evaluation and follow-up of adult CHD	I
II. Specific indications	
Assessment of shunt size (Q_p/Q_s)	I
Anomalies of the visceratrial situs	
Isolated situs anomalies	II
Situs anomalies with complex CHD	I
Anomalies of the atria and venous return	
ASD	II
Anomalous pulmonary venous return especially in complex anomalies and cor triatriatum	I
Anomalous systemic venous return	I
Systemic or pulmonary venous obstruction following intra-atrial baffle repair or correction of anomalous pulmonary venous return	I
Anomalies of the atrioventricular valves	
Anatomic anomalies of the mitral and tricuspid valve	II
Functional valvular anomalies	II
Ebstein's anomaly	II
Atrioventricular septal defect	II
Anomalies of the ventricles	
Isolated VSDs	III
VSD associated with complex anomalies	I
Ventricular aneurysms and diverticula	II
Supracristal VSD	I
Evaluation of right and left ventricular volumes, mass, and function	I
Anomalies of the semilunar valves	
Isolated valvular pulmonary stenosis and valvular dysplasia	III
Supraventricular pulmonary stenosis	II
Pulmonary regurgitation	I
Isolated valvular aortic stenosis	III
Subaortic stenosis	III
Supravalvular aortic stenosis	I
Anomalies of the arteries	
Malpositions of the great arteries	II
Postoperative follow-up of shunts	I
Aortic (sinus of Valsalva) aneurysm	I
Aortic coarctation	I
Vascular rings	I
PDA	III

(continued)

Table 13.1 (Continued)

Indication	Class
Aortopulmonary windows	I
Coronary artery anomalies in infants	Inv
Anomalous origins of coronary arteries in adults and children	I
Pulmonary atresia	I
Central pulmonary stenosis	I
Peripheral pulmonary stenosis	Inv
Systemic to pulmonary collaterals	I

Abbreviations: Qp/Qs, pulmonary blood flow/systemic blood flow; VSD, ventricular septal defect; Inv, investigational.

Imaging modalities

Transthoracic echocardiography (TTE) has been one of the fundamental imaging modalities in the field of CHD because the equipment is portable and the test is easy to perform. Echocardiography can define cardiac anatomy and identify valvular pathology. Color Doppler imaging allows for visualization of small atrial and ventricular septal defects that may be difficult to visualize using other imaging techniques. Doppler has the advantage of allowing for noninvasive measurements of pressure gradients between chambers and assessing the diastolic properties of the heart. In many cases, echo can accurately quantitate left ventricular systolic function; however, assessment of right ventricular size and systolic function has been a major obstacle. Although echocardiographic measures, such as the tricuspid annular plane systolic excursion [10,11], velocity of tricuspid annular systolic motion [12], myocardial performance index [13–16], or isovolumic acceleration [17,18], may be helpful, CMR is the current standard of comparison for quantitation of right ventricular structure and function. New echocardiographic technologies continue to improve and allow for assessment of such parameters as regional ventricular function or strain imaging, torsion, synchrony, and perfusion. However, TTE can be limited in adult patients with poor acoustic windows due to large chest walls, chest wall deformities, or post-operative scar tissue. Improvements in three-dimensional echocardiography will likely translate into increased use of this imaging modality in clinical practice in CHD [19–21]. Like TTE, however, this imaging modality is limited by the acoustic windows of the patients, although the use of intravenous contrast may overcome this limitation. Transesophageal echocardiography (TEE) does not pose these same limitations; however, it is not a purely noninvasive procedure as it requires sedation in most instances, and there is a risk of esophageal trauma. The role of TEE has been described in detail elsewhere [22–24]. One

of the main roles of TEE in patients with CHD is in the operating room or the catheterization laboratory, where it can assist with guiding and monitoring interventions [25].

CMR imaging has become an increasingly important imaging modality in the field of CHD, specifically in patients with complex cardiac anatomy. In most cases, CMR allows for excellent visualization of cardiac anatomy, accurate calculation of ventricular volumes and ejection fraction, quantification of regurgitation and shunt flow, vessel-specific flow quantification, shunt characterization, and imaging of other structures in the thorax, such as the pulmonary vasculature tree. Excellent reviews on the role of CMR in CHD are available [26–28]. In the adult with complex cardiac repair, CMR allows for visualization of baffles, conduits, and cavopulmonary shunts [29–31]. Like echocardiography, newer technologies have improved, and the information that can be provided by CMR has expanded to include assessment of myocardial ischemia, viability, and tissue strain. Although rare, adverse reactions to the contrast agent gadolinium are reported and can be serious, specifically in patients with advanced renal disease [32]. CMR studies can be difficult for patients with claustrophobia, but in select cases, this can be treated with an anxiolytic prior to the procedure. Patient cooperation is required, and image acquisition time can be a limiting factor, but CMR acquisition time is expected to improve. In the near future, clinical images will be acquired in a single breath-hold or in a free-breathing state. In the CHD population, one of the main obstacles is the inability to perform studies in patients with pacemakers or defibrillators, although CMR-compatible pacing leads are being developed. Because there is no radiation exposure, CMR can be used in pregnancy when clinically indicated, although most centers prefer to avoid imaging during the first trimester [33].

Similar to CMR, technical advances have made multidetector CT an excellent tool for the assessment of cardiac and pulmonary structures in CHD [34–36]. CT also allows for assessment of the coronary artery anatomy [37]. Artifacts seen on CMR from biomedical devices such as stents, valves, and sternal wires can often be overcome with CT imaging (Fig. 13.1). Most importantly, CT can be used in patients with pacemakers and defibrillators. CT, however, does not have the ability to provide hemodynamic information to the same extent as CMR. Good image quality is dependent on a controlled heart rate, and patients may require pretreatment with beta blocker therapy; thus, beta blocker therapy cannot be contraindicated. The newer generation of multidetector CT scanners, with their ability to acquire images within a single cardiac cycle, may eliminate the need for beta blockers. Contrast allergy is another potential complication, although this is less of an issue with newer contrast agents. The main limitation of CT is the radiation exposure in this young population, an important consideration because some patients will require serial examinations. Although radiation doses are influenced by many factors, they are typically between 5 and 20 mSv for a contrast-enhanced scan [38–40].

Specific congenital cardiac lesions

Atrial septal defects

The secundum atrial septal defect (ASD) is the most common type of ASD. Other types of ASD include sinus venosus defects, primum ASD, and the unroofed coronary sinus. Shunts at the atrial level result in diastolic overload of the right ventricle and increased pulmonary blood flow. Echocardiography is the simplest method to image ASD and in most cases is sufficient (Fig. 13.2) [49,50], but CMR and CT can also be used, particularly if echocardiographic imaging windows are difficult or if quantitation of right ventricular volume is necessary in borderline cases [51,52]. Because sinus venosus defects can be difficult to identify on TTE, TEE is a better method of identifying these defects, especially in adults [53]. The shunt fraction can be calculated by using echocardiography, CMR, or RNA by calculating the pulmonary and systemic flow [54–57]. The hemodynamic effect of the shunt on the right ventricle can be determined by examining the right ventricular size [58]. There may be instances where quantification of right ventricular volumes and function using CMR or CT is important. The right ventricular systolic pressure can also be calculated by using the jet velocity of tricuspid regurgitation on echocardiography. Anomalous pulmonary venous

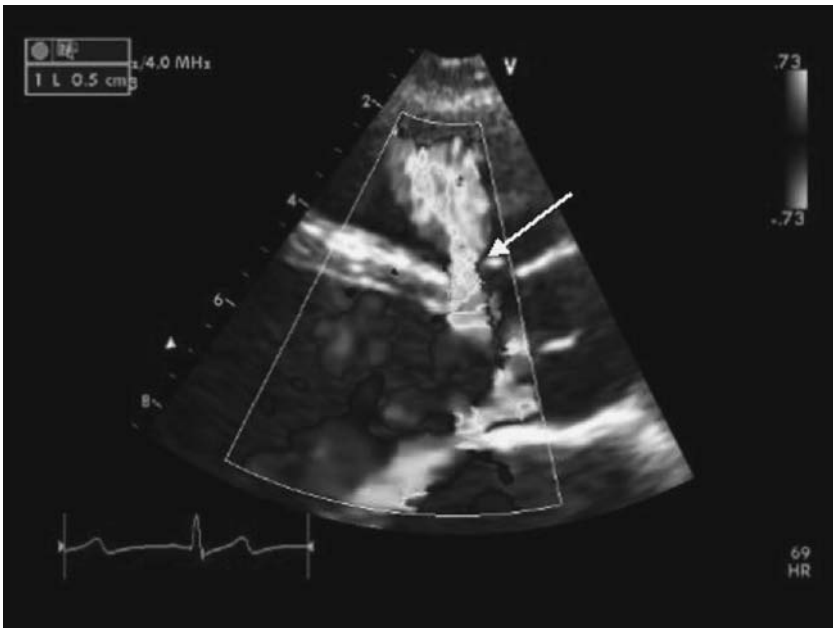


Fig. 13.2 Transthoracic echocardiogram parasternal view showing Doppler color flow across a restrictive perimembranous ventricular septal defects (arrow).

drainage can be imaged by using TEE, CMR, or CT. Although TEE imaging is useful in assisting with transcatheter closure of secundum ASDs, intracardiac echocardiography is being used as an alternative imaging modality at many centers [59].

Ventricular septal defect

Ventricular septal defects (VSDs) are classified by their location: membranous, muscular, inlet, and outlet portions of the septum. Small restrictive VSDs (high systolic gradient between the left and right ventricles) do not result in left ventricular volume overload and increased pulmonary blood flow, whereas a patient with a large nonrestrictive VSD (equalization of pressures between the left and right ventricles) is at risk for the development of Eisenmenger syndrome (irreversible pulmonary hypertension and right-to-left shunting). The most common type is the perimembranous VSD. Small defects or multiple defects are probably best seen on TTE with color Doppler (Fig. 13.3) [60,61] but can also be imaged using CMR [62]. In children, the VSD size is quantified by comparing it with the aortic root diameter. Continuous wave Doppler allows for transventricular peak instantaneous systolic gradient estimates [63,64]. However, with large nonrestrictive shunts, there may be no shunt flow or flow velocities. Shunt flow can be estimated by calculating the Qp:Qs [65] or by

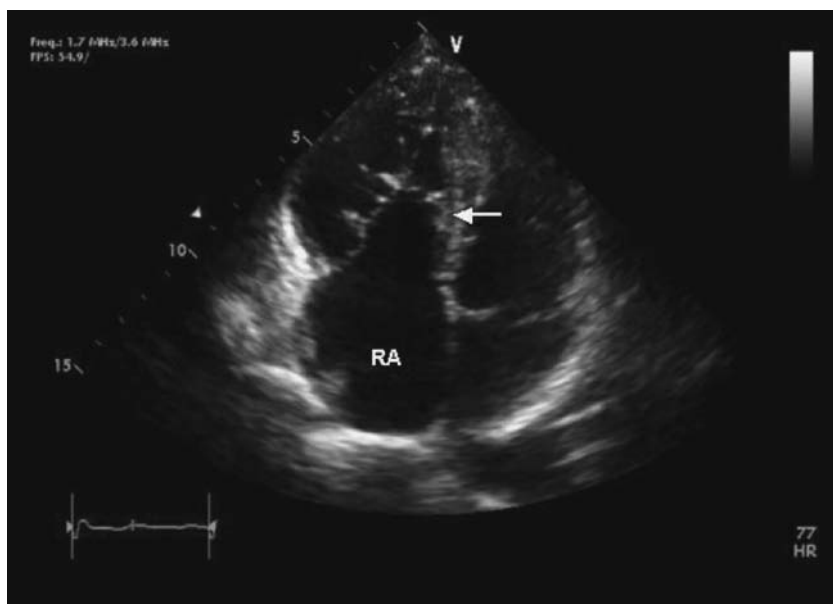


Fig. 13.3 Transthoracic echocardiogram apical four-chamber view of Ebstein anomaly demonstrating apical displacement of the septal leaflet of the tricuspid valve (arrow) and an enlarged right atria due to atrialization of the left ventricle. RA, right atrium.

using the proximal flow convergence on the left septal surface [66]. Both of these methods have limitations. The shunt fraction can also be calculated by using CMR or RNA. The pulmonary artery systolic pressures need to be routinely measured, and this is done most easily with echocardiography. Potential late complications, including aortic valve prolapse and subsequent regurgitation, right ventricular outflow tract obstruction secondary to infundibular hypertrophy, or partial closure of the VSD by the septal tricuspid valve leaflet with aneurysm formation, can usually be detected by TTE or TEE. TTE or TEE can be used to examine the size of the VSD and its relationship to other intracardiac structures prior to transcatheter device closure. TEE is usually reserved for circumstances when TTE is nondiagnostic.

Patent ductus arteriosus

A small restrictive patent ductus arteriosus (PDA) results in diastolic overload of the left ventricle. The characteristic continuous high-velocity shunt flow is usually seen on TTE but can also be imaged with CMR or CT [67–71]. The peak gradients between the aorta and pulmonary artery can be calculated, and, when necessary, the location, size, and maximal diameter of a PDA may be visualized with CMR or CT prior to interventions. TTE can be used to calculate the right ventricular systolic pressure. In a large, nonrestrictive PDA associated with Eisenmenger syndrome, flow may not be detected with TTE, and saline contrast injection may be required to identify the extracardiac shunting. Echocardiography, CMR, or CT can determine the effect of the shunt on the left ventricular size and function.

Right ventricular outflow tract obstruction

TTE is the simplest modality to assess uncomplicated valvular pulmonary stenosis and the hemodynamic effects on the right ventricle [72,73]. CMR and CT are useful to examine the main, branch, and peripheral pulmonary arteries. Echocardiography can be helpful for guidance at the time of transcatheter pulmonary valve implantation.

Tetralogy of Fallot

Tetralogy of Fallot (TOF) is one of the most common forms of cyanotic heart disease, and most patients with this lesion will undergo intracardiac repair. This includes VSD patch closure, infundibular resection, and, in some cases, transannular patching or pulmonary arterioplasties. Many patients are left with residual pulmonary regurgitation and, when the regurgitation is significant, right ventricular dilation and dysfunction can develop. Despite its prognostic importance, assessment of pulmonary regurgitation remains difficult. Qualitative assessment of pulmonary regurgitation can be done echocardiographically [74,75], but is more accurately quantitated by using CMR with either phase contrast methods or stroke volume differential (Fig. 13.4) [76]. Regurgitation in

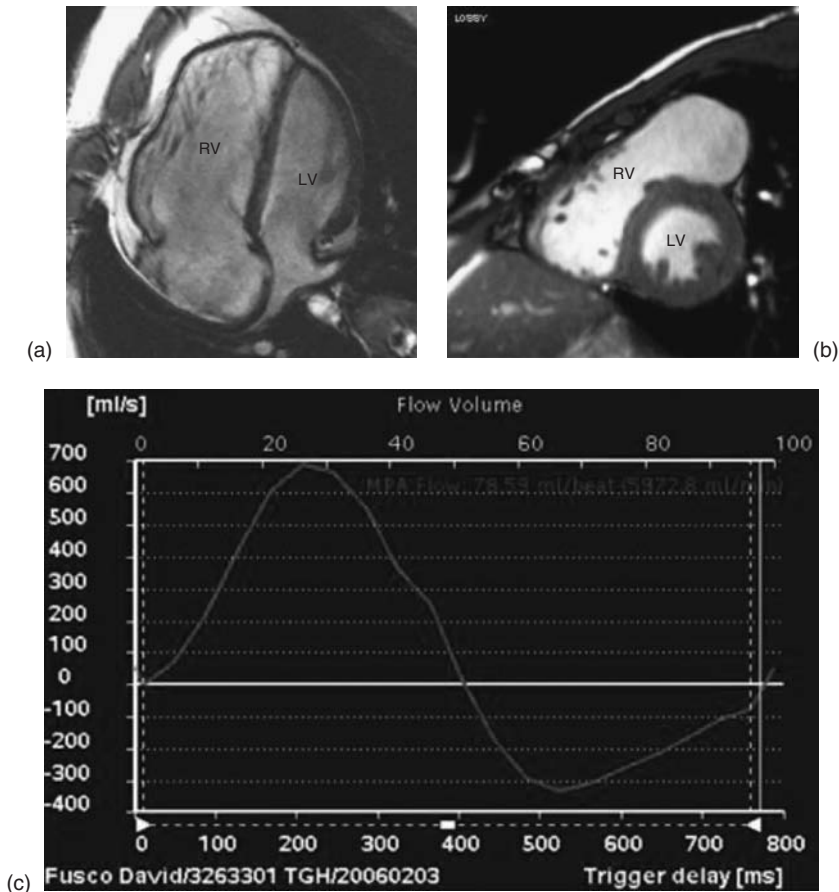


Fig. 13.4 Still images from cine cardiac magnetic resonance four-chamber (a) and short axis (b) views of a dilated right ventricle in a patient with repaired tetralogy of Fallot and significant pulmonary regurgitation. Velocity-encoded cine magnetic resonance imaging (c) of a flow-velocity-time curve demonstrating significant pulmonary regurgitation. RV, right ventricle; LV, left ventricle.

the branch pulmonary arteries needs to be assessed separately by CMR because there is often differential regurgitation [77]. More importantly, the effects of regurgitation on the right ventricle can be examined by using any quantitative method to assess right ventricular size and function (CMR, CT, 3D echocardiography, or RNA) [78–80]. Right ventricular outflow tract aneurysms have an adverse impact on the function of the right ventricle [81,82]. In addition, left ventricular function should also be examined because it has prognostic significance. Ventricular fibrosis detected by gadolinium enhancement on CMR may

have prognostic significance [83]. Because there is a well-described aortopathy associated with TOF, aortic root measurements should be followed serially.

Coarctation of the aorta

The majority of patients with coarctation will have undergone surgical repair including left subclavian flap repair, patch aortoplasty, end-to-end anastomosis, or jump grafts. Some patients, particularly adults with recoarctation, may have undergone angioplasty or stent insertion. Late complications are related to the type of repair and include aneurysms in patients who have undergone patch repairs and recoarctation in patients with end-to-end anastomosis. Echocardiography is suboptimal for visualization of the entire aorta, and therefore, other imaging techniques, such as contrast-enhanced CMR angiography or CT [84–90], have an important role in the imaging of coarctation (Fig. 13.5). Echo Doppler can be useful in assessing the pressure gradients and hemodynamic significance of the coarctation [91]. There are limitations with Doppler,

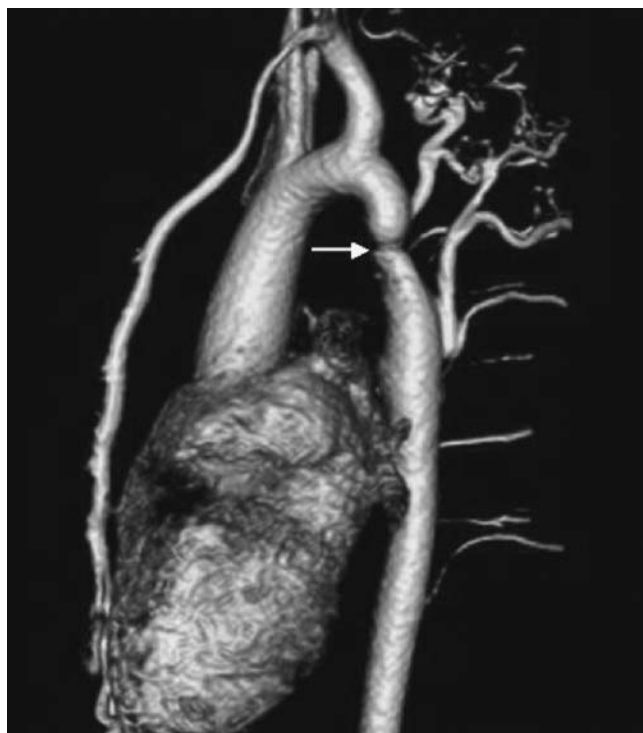


Fig. 13.5 Volume-rendered magnetic resonance reconstruction of coarctation of the aorta showing the typically narrowing distal to the left subclavian artery (arrow) and collateral vessels formation.

however, because, even with a nonguided transducer, it may be difficult to localize the peak velocity across the coarctation. Additionally, the severity of the coarctation may be underestimated because collateral flow may increase flow in the descending aorta thereby reducing the gradient, even when, anatomically, the coarctation is severe. Other errors occur when the velocity proximal to the coarctation is ignored, and the complete Bernoulli equation must be used. Other errors occur in the setting of long-segment stenosis when the Bernoulli equation becomes invalid. Alternatively, flow deceleration in the descending aorta can be measured by phase-velocity cine CMR [92]. Visualization of collateral vessels, suggestive of a significant coarctation, is done with CMR or CT. Potential complications can include left ventricular hypertrophy, wall motion abnormalities due to premature coronary disease and the associated aortic valve disease, and ascending aortic aneurysm, and can be identified by using a variety of imaging techniques. Aneurysms at the site of coarctation are best identified with CMR or CT [93].

Ebstein's anomaly

Echocardiography is usually used to assess the severity of Ebstein's anomaly, which is characterized by apical displacement of the septal leaflet, dysplasia of the septal and/or the posterior leaflet, tricuspid regurgitation, or, more rarely, tricuspid stenosis (Fig. 13.6) [94,95]. The size and function of the functional right ventricle and the atrialized portion of the right atrium are important determinants of outcome. CMR is a reasonable alternative imaging technique [96]. The elongation and mobility of the anterior leaflet and its suitability for repair are best assessed echocardiographically. Associated patent foramen ovale and ASD are common, and shunt reversal (right-to-left shunting) at the atrial level can occur with more advanced forms of Ebstein's anomaly.

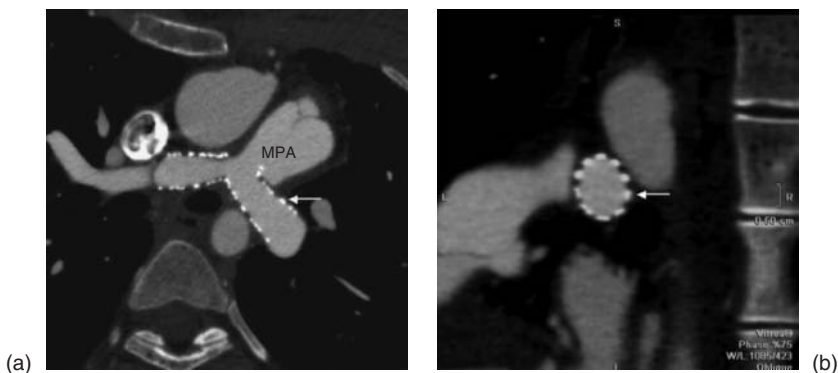


Fig. 13.6 Contrast-enhanced computed tomography double oblique projection of the branch pulmonary arteries demonstrating pulmonary artery stents (arrow) in long (a) and short axis (b).

Case outcome

Adverse hemodynamic lesions in patients with TOF can precipitate ventricular tachycardias. Therefore, this patient underwent a TTE and a CMR study to evaluate his cardiac anatomy. The TTE revealed a moderately dilated right ventricle with moderate right ventricular systolic dysfunction, severe pulmonary regurgitation, moderate tricuspid regurgitation, and normal right ventricular systolic pressures. The CMR showed a right ventricular end diastolic volume of 160 cc/m², a right ventricular ejection fraction of 30%, and a pulmonary regurgitation fraction of 40%. The left ventricular size and function were normal, and there was no branch pulmonary artery stenosis. The patient underwent pulmonary valve implantation and cryoablation at the time of surgery.

References

1. Therrien J, Dore A, Gersony W, et al. Canadian Cardiovascular Society Consensus Conference 2001 update: recommendations for the management of adults with congenital heart disease. Part I. *Can J Cardiol* 2001;17:940–59.
2. Therrien J, Gatzoulis M, Graham I, et al. Canadian Cardiovascular Society Consensus Conference 2001 update: recommendations for the Management of Adults with Congenital Heart Disease. Part II. *Can J Cardiol* 2001;17:1029–50.
3. Therrien J, Warnes C, Daliento L, et al. Canadian Cardiovascular Society Consensus Conference 2001 update: recommendations for the management of adults with congenital heart disease. Part III. *Can J Cardiol* 2001;17:1135–58.
4. Deanfield J, Thaulow E, Warnes C, et al. Management of grown up congenital heart disease. *Eur Heart J* 2003;24:1035–84.
5. Schroeder S, Achenbach S, Bengel F, et al. Cardiac computed tomography: indications, applications, limitations, and training requirements: report of a Writing Group deployed by the Working Group Nuclear Cardiology and Cardiac CT of the European Society of Cardiology and the European Council of Nuclear Cardiology. *Eur Heart J* 2008;29:531–56.
6. Pennell DJ, Sechtem UP, Higgins CB, et al. Clinical indications for cardiovascular magnetic resonance (CMR): Consensus Panel report. *Eur Heart J* 2004;25:1940–65.
7. Ritchie J, Bateman TM, Bonow RO, et al. Guidelines for clinical use of cardiac radionuclide imaging. A report of the American Heart Association/American College of Cardiology Task Force on Assessment of Diagnostic and Therapeutic Cardiovascular Procedures, Committee on Radionuclide Imaging, developed in collaboration with the American Society of Nuclear Cardiology. *Circulation* 1995;91:1278–303.
8. Douglas PS, Khandheria B, Stainback RF, et al. ACCF/AASE/ACEP/ASNC/SCAI/SCCT/SCMR 2007 appropriateness criteria for transthoracic and transesophageal echocardiography: a report of the American College of Cardiology Foundation Quality Strategic Directions Committee Appropriateness Criteria Working Group, American Society of Echocardiography, American College of Emergency Physicians, American Society of Nuclear Cardiology, Society for Cardiovascular Angiography and Interventions, Society of Cardiovascular Computed Tomography, and the Society for Cardiovascular Magnetic Resonance endorsed by the American College of Chest

- Physicians and the Society of Critical Care Medicine. *J Am Coll Cardiol* 2007;50:187–204.
9. Hendel RC, Patel MR, Kramer CM, et al. ACCF/ACR/SCCT/SCMR/ASNC/NASCI/SCAI/SIR 2006 appropriateness criteria for cardiac computed tomography and cardiac magnetic resonance imaging: a report of the American College of Cardiology Foundation Quality Strategic Directions Committee Appropriateness Criteria Working Group, American College of Radiology, Society of Cardiovascular Computed Tomography, Society for Cardiovascular Magnetic Resonance, American Society of Nuclear Cardiology, North American Society for Cardiac Imaging, Society for Cardiovascular Angiography and Interventions, and Society of Interventional Radiology. *J Am Coll Cardiol* 2006;48:1475–97.
 10. Kaul S, Tei C, Hopkins JM, Shah PM. Assessment of right ventricular function using two-dimensional echocardiography. *Am Heart J* 1984;107:526–31.
 11. Ghio S, Recusani F, Klersy C, et al. Prognostic usefulness of the tricuspid annular plane systolic excursion in patients with congestive heart failure secondary to idiopathic or ischemic dilated cardiomyopathy. *Am J Cardiol* 2000;85:837–42.
 12. Meluzin J, Spinarova L, Bakala J, et al. Pulsed Doppler tissue imaging of the velocity of tricuspid annular systolic motion; a new, rapid, and non-invasive method of evaluating right ventricular systolic function. *Eur Heart J* 2001;22:340–8.
 13. Eidem BW, O'Leary PW, Tei C, Seward JB. Usefulness of the myocardial performance index for assessing right ventricular function in congenital heart disease. *Am J Cardiol* 2000;86:654–8.
 14. Salehian O, Schwerzmann M, Merchant N, et al. Assessment of systemic right ventricular function in patients with transposition of the great arteries using the myocardial performance index: comparison with cardiac magnetic resonance imaging. *Circulation* 2004;110:3229–33.
 15. Schwerzmann M, Samman AM, Salehian O, et al. Comparison of echocardiographic and cardiac magnetic resonance imaging for assessing right ventricular function in adults with repaired tetralogy of fallot. *Am J Cardiol* 2007;99:1593–7.
 16. Eidem BW, Tei C, O'Leary PW, et al. Nongeometric quantitative assessment of right and left ventricular function: myocardial performance index in normal children and patients with Ebstein anomaly. *J Am Soc Echocardiogr* 1998;11:849–56.
 17. Vogel M, Schmidt MR, Kristiansen SB, et al. Validation of myocardial acceleration during isovolumic contraction as a novel noninvasive index of right ventricular contractility: comparison with ventricular pressure-volume relations in an animal model. *Circulation* 2002;105:1693–9.
 18. Frigiola A, Redington AN, Cullen S, Vogel M. Pulmonary regurgitation is an important determinant of right ventricular contractile dysfunction in patients with surgically repaired tetralogy of Fallot. *Circulation* 2004;110:III153–7.
 19. Niemann PS, Pinho L, Balbach T, et al. Anatomically oriented right ventricular volume measurements with dynamic three-dimensional echocardiography validated by 3-Tesla magnetic resonance imaging. *J Am Coll Cardiol* 2007;50:1668–76.
 20. Takahashi K, Guerra V, Roman KS, et al. Three-dimensional echocardiography improves the understanding of the mechanisms and site of left atrioventricular valve regurgitation in atrioventricular septal defect. *J Am Soc Echocardiogr* 2006;19:1502–10.

21. Kardon RE, Cao QL, Masani N, et al. New insights and observations in three-dimensional echocardiographic visualization of ventricular septal defects: experimental and clinical studies. *Circulation* 1998;98:1307–14.
22. Marelli AJ, Child JS, Perloff JK. Transesophageal echocardiography in congenital heart disease in the adult. *Cardiol Clin* 1993;11:505–20.
23. Miller-Hance WC, Silverman NH. Transesophageal echocardiography (TEE) in congenital heart disease with focus on the adult. *Cardiol Clin* 2000;18:861–92.
24. Masani ND. Transoesophageal echocardiography in adult congenital heart disease. *Heart* 2001;86(Suppl 2):II30–40.
25. Smallhorn JF. Intraoperative transesophageal echocardiography in congenital heart disease. *Echocardiography* 2002;19:709–23.
26. Geva T, Sahn D, Powell AJ. Magnetic resonance imaging of congenital heart disease in adults. *Progr Pediatr Cardiol* 2003;17:21–39.
27. Boxt LM. Magnetic resonance and computed tomographic evaluation of congenital heart disease. *J Magn Reson Imaging* 2004;19:827–47.
28. Wald RM, Powell AJ. Simple congenital heart lesions. *J Cardiovasc Magn Reson* 2006;8:619–31.
29. Fogel MA, Hubbard A, Weinberg PM. A simplified approach for assessment of intracardiac baffles and extracardiac conduits in congenital heart surgery with two- and three-dimensional magnetic resonance imaging. *Am Heart J* 2001;142:1028–36.
30. Brown DW, Gauvreau K, Powell AJ, et al. Cardiac magnetic resonance versus routine cardiac catheterization before bidirectional glenn anastomosis in infants with functional single ventricle: a prospective randomized trial. *Circulation* 2007;116:2718–25.
31. Canter CE, Gutierrez FR, Molina P, et al. Noninvasive diagnosis of right-sided extracardiac conduit obstruction by combined magnetic resonance imaging and continuous-wave Doppler echocardiography. *J Thorac Cardiovasc Surg* 1991;101:724–31.
32. Cowper SE, Robin HS, Steinberg SM, et al. Scleromyxoedema-like cutaneous diseases in renal-dialysis patients. *Lancet* 2000;356:1000–1.
33. Kanal E. Pregnancy and the safety of magnetic resonance imaging. *Magn Reson Imaging Clin N Am* 1994;2:309–17.
34. Cook SC, Raman SV. Unique application of multislice computed tomography in adults with congenital heart disease. *Int J Cardiol* 2007;119:101–6.
35. Goo HW, Park IS, Ko JK, et al. Computed tomography for the diagnosis of congenital heart disease in pediatric and adult patients. *Int J Cardiovasc Imaging* 2005;21:347–65, discussion 367.
36. Ou P, Celermajor DS, Calcagni G, et al. Three-dimensional CT scanning: a new diagnostic modality in congenital heart disease. *Heart* 2007;93:908–13.
37. Manghat NE, Morgan-Hughes GJ, Marshall AJ, Roobottom CA. Multidetector row computed tomography: imaging congenital coronary artery anomalies in adults. *Heart* 2005;91:1515–22.
38. Coles DR, Smail MA, Negus IS, et al. Comparison of radiation doses from multislice computed tomography coronary angiography and conventional diagnostic angiography. *J Am Coll Cardiol* 2006;47:1840–5.
39. Einstein AJ, Moser KW, Thompson RC, et al. Radiation dose to patients from cardiac diagnostic imaging. *Circulation* 2007;116:1290–305.

40. Einstein AJ, Henzlova MJ, Rajagopalan S. Estimating risk of cancer associated with radiation exposure from 64-slice computed tomography coronary angiography. *JAMA* 2007;298:317–23.
41. Baker EJ, Shubao C, Clarke SE, et al. Radionuclide measurement of right ventricular function in atrial septal defect, ventricular septal defect and complete transposition of the great arteries. *Am J Cardiol* 1986;57:1142–6.
42. Peter CA, Bowyer K, Jones RH. Radionuclide analysis of right and left ventricular response to exercise in patients with atrial and ventricular septal defects. *Am Heart J* 1983;105:428–35.
43. Reduto LA, Berger HJ, Johnstone DE, et al. Radionuclide assessment of right and left ventricular exercise reserve after total correction of tetralogy of Fallot. *Am J Cardiol* 1980;45:1013–8.
44. Baker EJ, Ellam SV, Lorber A, et al. Superiority of radionuclide over oximetric measurement of left to right shunts. *Br Heart J* 1985;53:535–40.
45. Hauser M, Bengel FM, Kuhn A, et al. Myocardial blood flow and flow reserve after coronary reimplantation in patients after arterial switch and ross operation. *Circulation* 2001;103:1875–80.
46. Millane T, Bernard EJ, Jaeggi E, et al. Role of ischemia and infarction in late right ventricular dysfunction after atrial repair of transposition of the great arteries. *J Am Coll Cardiol* 2000;35:1661–8.
47. Dedkov EI, Perloff JK, Tomanek RJ, et al. The coronary microcirculation in cyanotic congenital heart disease. *Circulation* 2006;114:196–200.
48. Hesse B, Tagil K, Cuocolo A, et al. EANM/ESC procedural guidelines for myocardial perfusion imaging in nuclear cardiology. *Eur J Nucl Med Mol Imaging* 2005;32:855–97.
49. Shub C, Dimopoulos IN, Seward JB, et al. Sensitivity of two-dimensional echocardiography in the direct visualization of atrial septal defect utilizing the subcostal approach: experience with 154 patients. *J Am Coll Cardiol* 1983;2:127–35.
50. Suzuki Y, Kambara H, Kadota K, et al. Detection of intracardiac shunt flow in atrial septal defect using a real-time two-dimensional color-coded Doppler flow imaging system and comparison with contrast two-dimensional echocardiography. *Am J Cardiol* 1985;56:347–50.
51. Diethelm L, Dery R, Lipton MJ, Higgins CB. Atrial-level shunts: sensitivity and specificity of MR in diagnosis. *Radiology* 1987;162:181–6.
52. Jacobstein MD, Fletcher BD, Goldstein S, Riemenschneider TA. Evaluation of atrioventricular septal defect by magnetic resonance imaging. *Am J Cardiol* 1985;55:1158–61.
53. Kronzon I, Tunick PA, Freedberg RS, et al. Transesophageal echocardiography is superior to transthoracic echocardiography in the diagnosis of sinus venosus atrial septal defect. *J Am Coll Cardiol* 1991;17:537–42.
54. Kitabatake A, Inoue M, Asao M, et al. Noninvasive evaluation of the ratio of pulmonary to systemic flow in atrial septal defect by duplex Doppler echocardiography. *Circulation* 1984;69:73–9.
55. Brenner LD, Caputo GR, Mostbeck G, et al. Quantification of left to right atrial shunts with velocity-encoded cine nuclear magnetic resonance imaging. *J Am Coll Cardiol* 1992;20:1246–50.
56. Dittmann H, Jacksch R, Voelker W, et al. Accuracy of Doppler echocardiography in quantification of left to right shunts in adult patients with atrial septal defect. *J Am Coll Cardiol* 1988;11:338–42.

57. Vargas Barron J, Sahn DJ, Valdes-Cruz LM, et al. Clinical utility of two-dimensional doppler echocardiographic techniques for estimating pulmonary to systemic blood flow ratios in children with left to right shunting atrial septal defect, ventricular septal defect or patent ductus arteriosus. *J Am Coll Cardiol* 1984;3:169–78.
58. Chen C, Kremer P, Schroeder E, et al. Usefulness of anatomic parameters derived from two-dimensional echocardiography for estimating magnitude of left to right shunt in patients with atrial septal defect. *Clin Cardiol* 1987;10:316–21.
59. Mullen MJ, Dias BF, Walker F, et al. Intracardiac echocardiography guided device closure of atrial septal defects. *J Am Coll Cardiol* 2003;41:285–92.
60. Ortiz E, Robinson PJ, Deanfield JE, et al. Localisation of ventricular septal defects by simultaneous display of superimposed colour Doppler and cross sectional echocardiographic images. *Br Heart J* 1985;54:53–60.
61. Ludomirsky A, Huhta JC, Vick GW 3rd, Murphy DJ Jr, Danford DA, Morrow WR. Color Doppler detection of multiple ventricular septal defects. *Circulation* 1986;74:1317–22.
62. Didier D, Higgins CB. Identification and localization of ventricular septal defect by gated magnetic resonance imaging. *Am J Cardiol* 1986;57:1363–8.
63. Murphy DJ Jr, Ludomirsky A, Huhta JC. Continuous-wave Doppler in children with ventricular septal defect: noninvasive estimation of interventricular pressure gradient. *Am J Cardiol* 1986;57:428–32.
64. Houston AB, Lim MK, Doig WB, et al. Doppler assessment of the interventricular pressure drop in patients with ventricular septal defects. *Br Heart J* 1988;60:50–6.
65. Kurokawa S, Takahashi M, Katoh Y, et al. Noninvasive evaluation of the ratio of pulmonary to systemic flow in ventricular septal defect by means of Doppler two-dimensional echocardiography. *Am Heart J* 1988;116:1033–44.
66. Moises VA, Maciel BC, Hornberger LK, et al. A new method for noninvasive estimation of ventricular septal defect shunt flow by Doppler color flow mapping: imaging of the laminar flow convergence region on the left septal surface. *J Am Coll Cardiol* 1991;18:824–32.
67. Smallhorn JF, Huhta JC, Anderson RH, Macartney FJ. Suprasternal cross-sectional echocardiography in assessment of patient ducts arteriosus. *Br Heart J* 1982;48:321–30.
68. Swensson RE, Valdes-Cruz LM, Sahn DJ, et al. Real-time Doppler color flow mapping for detection of patent ductus arteriosus. *J Am Coll Cardiol* 1986;8:1105–12.
69. Liao PK, Su WJ, Hung JS. Doppler echocardiographic flow characteristics of isolated patent ductus arteriosus: better delineation by Doppler color flow mapping. *J Am Coll Cardiol* 1988;12:1285–91.
70. Goitein O, Fuhrman CR, Lacomis JM. Incidental finding on MDCT of patent ductus arteriosus: use of CT and MRI to assess clinical importance. *AJR Am J Roentgenol* 2005;184:1924–31.
71. Morgan-Hughes GJ, Marshall AJ, Roobottom C. Morphologic assessment of patent ductus arteriosus in adults using retrospectively ECG-gated multidetector CT. *AJR Am J Roentgenol* 2003;181:749–54.
72. Lima CO, Sahn DJ, Valdes-Cruz LM, et al. Noninvasive prediction of transvalvular pressure gradient in patients with pulmonary stenosis by quantitative two-dimensional echocardiographic Doppler studies. *Circulation* 1983;67:866–71.
73. Mulhern KM, Skorton DJ. Echocardiographic evaluation of isolated pulmonary valve disease in adolescents and adults. *Echocardiography* 1993;10:533–43.

74. Silversides CK, Veldtman GR, Crossin J, et al. Pressure half-time predicts hemodynamically significant pulmonary regurgitation in adult patients with repaired tetralogy of fallot. *J Am Soc Echocardiogr* 2003;16:1057-62.
75. Li W, Davlouros PA, Kilner PJ, et al. Doppler-echocardiographic assessment of pulmonary regurgitation in adults with repaired tetralogy of Fallot: comparison with cardiovascular magnetic resonance imaging. *Am Heart J* 2004;147:165-72.
76. Rebergen SA, Chin JG, Ottenkamp J, et al. Pulmonary regurgitation in the late postoperative follow-up of tetralogy of Fallot. Volumetric quantitation by nuclear magnetic resonance velocity mapping. *Circulation* 1993;88:2257-66.
77. Kang IS, Redington AN, Benson LN, et al. Differential regurgitation in branch pulmonary arteries after repair of tetralogy of Fallot: a phase-contrast cine magnetic resonance study. *Circulation* 2003;107:2938-43.
78. Mentzer J, Weinberg PM, Fogel MA. Quantifying regional right ventricular function in tetralogy of Fallot. *J Cardiovasc Magn Reson* 2005;7:753-61.
79. Raman SV, Cook SC, McCarthy B, Ferketich AK. Usefulness of multidetector row computed tomography to quantify right ventricular size and function in adults with either tetralogy of Fallot or transposition of the great arteries. *Am J Cardiol* 2005;95:683-6.
80. Helbing WA, de Roos A. Clinical applications of cardiac magnetic resonance imaging after repair of tetralogy of Fallot. *Pediatr Cardiol* 2000;21:70-9.
81. Davlouros PA, Kilner PJ, Hornung TS, et al. Right ventricular function in adults with repaired tetralogy of Fallot assessed with cardiovascular magnetic resonance imaging: detrimental role of right ventricular outflow aneurysms or akinesia and adverse right-to-left ventricular interaction. *J Am Coll Cardiol* 2002;40:2044-52.
82. Uebing A, Gibson DG, Babu-Narayan SV, et al. Right ventricular mechanics and QRS duration in patients with repaired tetralogy of Fallot: implications of infundibular disease. *Circulation* 2007;116:1532-9.
83. Babu-Narayan SV, Kilner PJ, Li W, et al. Ventricular fibrosis suggested by cardiovascular magnetic resonance in adults with repaired tetralogy of fallot and its relationship to adverse markers of clinical outcome. *Circulation* 2006;113:405-13.
84. Therrien J, Thorne SA, Wright A, et al. Repaired coarctation: a "cost-effective" approach to identify complications in adults. *J Am Coll Cardiol* 2000;35:997-1002.
85. von Schulthess GK, Higashino SM, Higgins SS, Didier D, Fisher MR, Higgins CB. Coarctation of the aorta: MR imaging. *Radiology* 1986;158:469-74.
86. Simpson IA, Chung KJ, Glass RF, et al. Cine magnetic resonance imaging for evaluation of anatomy and flow relations in infants and children with coarctation of the aorta. *Circulation* 1988;78:142-8.
87. Rees S, Somerville J, Ward C, et al. Coarctation of the aorta: MR imaging in late postoperative assessment. *Radiology* 1989;173:499-502.
88. Hager A, Kaemmerer H, Leppert A, et al. Follow-up of adults with coarctation of the aorta: comparison of helical CT and MRI, and impact on assessing diameter changes. *Chest* 2004;126:1169-76.
89. Becker C, Soppa C, Fink U, et al. Spiral CT angiography and 3D reconstruction in patients with aortic coarctation. *Eur Radiol* 1997;7:1473-7.
90. Soulen RL, Kan J, Mitchell S, White RI Jr. Evaluation of balloon angioplasty of coarctation restenosis by magnetic resonance imaging. *Am J Cardiol* 1987;60:343-5.

91. Tan JL, Babu-Narayan SV, Henein MY, et al. Doppler echocardiographic profile and indexes in the evaluation of aortic coarctation in patients before and after stenting. *J Am Coll Cardiol* 2005;46:1045–53.
92. Nielsen JC, Powell AJ, Gauvreau K, et al. Magnetic resonance imaging predictors of coarctation severity. *Circulation* 2005;111:622–8.
93. Parks WJ, Ngo TD, Plauth WH Jr, et al. Incidence of aneurysm formation after Dacron patch aortoplasty repair for coarctation of the aorta: long-term results and assessment utilizing magnetic resonance angiography with three-dimensional surface rendering. *J Am Coll Cardiol* 1995;26:266–71.
94. Shiina A, Seward JB, Edwards WD, et al. Two-dimensional echocardiographic spectrum of Ebstein's anomaly: detailed anatomic assessment. *J Am Coll Cardiol* 1984;3:356–70.
95. Benson LN, Child JS, Schwaiger M, et al. Left ventricular geometry and function in adults with Ebstein's anomaly of the tricuspid valve. *Circulation* 1987;75:353–9.
96. Choi YH, Park JH, Choe YH, Yoo SJ. MR imaging of Ebstein's anomaly of the tricuspid valve. *Am J Roentgenol* 1994;163:539–43.

The chest x-ray in congenital heart disease

Joseph K. Perloff

In the 1950s, when I was a Fulbright Fellow at the National Heart Hospital in London, an engaging Irish radiologist, Peter Kerley, spent several hours a week with the Registrars, teaching us how to read chest x-rays. I still read x-rays as I learned from Dr. Kerley decades ago. And I still have my inscribed copy of Shanks and Kerley, the then authoritative *Text-Book of X-Ray Diagnosis*, the fourth edition of which appeared in 1973 [1].

If Peter Kerley were asked to “look at” an x-ray, he would reach for a book and virtually shout, “You don’t *look* at a book, you *read* it, always the same way, systematically from beginning to end. You don’t *look* at an x-ray, you *read* an x-ray, always the same way, systematically from beginning to end.” He underscored a central point: to minimize the risk of overlooking important details, x-rays should be read according to the same planned sequence, namely, technique (penetration, rotation, degree of inhalation), age and sex, right/left orientation, positions and malpositions (thoracic and abdominal *situs*), the bones, the extrapulmonary soft tissue densities, the intrapulmonary soft tissue densities (vascular and parenchymal), the great arteries and great veins, the atria, and lastly, the ventricles or ventricle (Table 14.1).

I’m also indebted to Larry Elliott and Gerold Schiebler, both of whom I knew, for their concise and incisive book, *X-Ray Diagnosis of Congenital Heart Disease* published in 1968. I still have my inscribed copy.

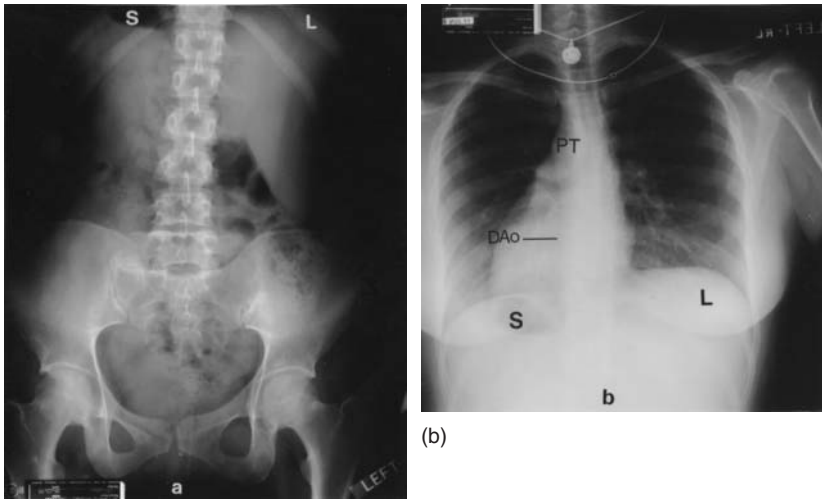
For Shanks and Kerley and for Elliott and Schiebler, interpretation of chest x-rays, especially, but not only, in congenital heart disease, was based on four views: posteroanterior, lateral, right oblique, and left oblique. “It should be stated that no cardiovascular examination is complete without the four

Table 14.1 Sequence for reading the chest x-ray

Quality and Technique
Right/left Orientation
Positions and Malpositions—Above and below the diaphragm, thoracic and abdominal <i>situs</i>
The Bones
Extrapulmonary Soft Tissue Densities
Intrapulmonary Soft Tissue Densities—Vascular and Parenchymal
The Great Arteries
The Great Veins
The Atria
The Ventricles or Ventricle

standard cardiac views” [2]. When only posteroanterior and lateral views became standard, there was concern that radiologic diagnosis would be compromised; a concern that I shared. But gradually and reluctantly, I was persuaded that these two views sufficed when properly interpreted. This chapter relies on that assumption.

The first necessity is to determine whether the x-ray is “readable” and whether the quality and technique are acceptable: penetration, rotation, and degree of inhalation. Age is then estimated, and if the x-ray is that of an adult, sex can be inferred by female breast tissue that should not to be mistaken for pectoral soft tissue in males. Correct right/left orientation avoids the embarrassment of overlooking *situs inversus* with mirror image dextrocardia (Fig. 14.1), which, when the x-ray is inadvertently reversed, is indistinguishable from *situs solitus* [2]. Positions and malpositions require interrogation above and below the diaphragm, even when only the chest x-ray is being read (Fig. 14.1). Kerley never tired of emphasizing that there is one diaphragm but two hemidiaphragms, and that the location of the cardiac apex coincides with the lower of the two hemidiaphragms, dispelling the notion that the liver elevates the ipsilateral half. The proof, he pointed out, is simple: in abdominal *situs solitus* with dextrocardia, the right hemidiaphragm is lower than the left because the apex is on the right. Conversely, in abdominal *situs inversus* with levocardia, the left hemidiaphragm is lower than the right because the apex is on the left (Fig. 14.2). When the liver is transverse, the hemidiaphragm is lower on the side of the cardiac apex (Fig. 14.3).



(a)

(b)

Fig. 14.1 X-rays from a 28-year-old female who presented with colicky left upper quadrant pain. (a) The abdominal film was secured in the emergency room. The stomach (S) on the right and the liver (L) on the left established the diagnosis of abdominal *situs inversus*, appropriate for biliary colic expressed in the left upper quadrant. (b) The chest x-ray disclosed thoracic *situs inversus* with dextrocardia, and confirmed mirror image *abdominal situs*. The pulmonary trunk (PT) was in its mirror image position, and the aorta (DAo) descended along the right side of the vertebral column.

In Down syndrome, both hemidiaphragms flatten when upper airway obstruction causes hyperinflation of the lungs.

A transverse liver is a hallmark of visceral isomerism (right or left) that can be established by determining whether the bronchi are symmetric right or symmetric left [2]. A morphologic right bronchus is short, wide, and relatively straight; a morphologic left bronchus is long, thin, and curved [2]. A morphologic right bronchus coincides with a trilobed right lung, and a morphologic left bronchus coincides with a bilobed left lung. Symmetric right bronchi are features of right isomerism (bilateral right-sidedness), and symmetric left bronchi are features of left isomerism (bilateral left-sidedness). The spleen is typically absent in right isomerism because the organ is normally unilateral on the left, so bilateral right-sidedness means that the left side is not represented. An important radiologic feature of left isomerism is inferior vena caval interruption with azygos continuation that can be mistaken in the x-ray for a right aortic arch and a right descending aorta (Fig. 14.3) [2]. The interrupted inferior cava continues into the thorax as a dilated azygos vein that runs in the posterior mediastinum along the right border of the vertebral column, and connects to a right superior vena cava (Fig. 14.3).

Secondary cardiac malpositions occur when the mediastinum shifts toward the smaller thoracic cavity as with congenital hypoplasia or agenesis of a lung,

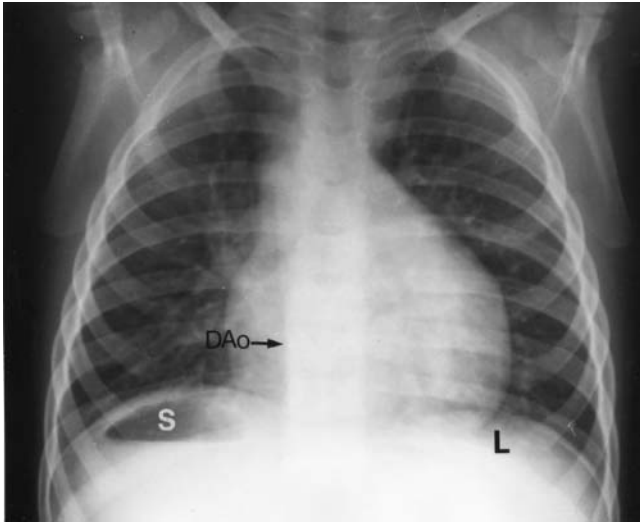


Fig. 14.2 X-ray from a 16-year-old male in *situs inversus* with *levocardia*. The stomach (S) is on the right and the liver (L) is on the left, but the cardiac apex is on the left. Accordingly, the left hemidiaphragm is lower than the right hemidiaphragm because the apex is on the left. The descending aorta (DAo) is concordant for *situs inversus*, but the position of the ascending aorta indicates a discordant d-bulboventricular loop.

the scimitar syndrome with a hypoplastic right lung, and, most dramatically, with congenital complete absence of the pericardium [2]. The ipsilateral hemidiaphragm is elevated and the ribs are close together.

The bones

An early step in analysis of the chest x-ray is determination of whether or not a surgical procedure has been performed. Unilateral absence of a rib or evidence of rib regeneration is usually incurred by a thoracotomy. Sternotomy wires readily reveal themselves in the lateral projection, but may not in the frontal view because of superimposition of the dorsal spine. Pectus excavatum and loss of thoracic kyphosis displace the heart toward the left. Kyphosis creates an ipsilateral density that can be striking and rotates the heart in the opposite direction. An absent or rudimentary 12th rib is a feature of Down syndrome, which in infants is accompanied by a double manubrial ossification center seen in the lateral projection. Seckel syndrome (microcephalic primordial dwarfism) is another phenotype in which there are 11 paired ribs [2]. Notching of the undersurfaces of the posterior ribs is a radiologic sign of coarctation of the aorta. The development of arterial collaterals depends on patency of the ipsilateral subclavian artery [2]. When coarctation obstructs the ostium of the left subclavian, ipsilateral collaterals fail to develop. Therefore, notching is unilateral on the right [2].

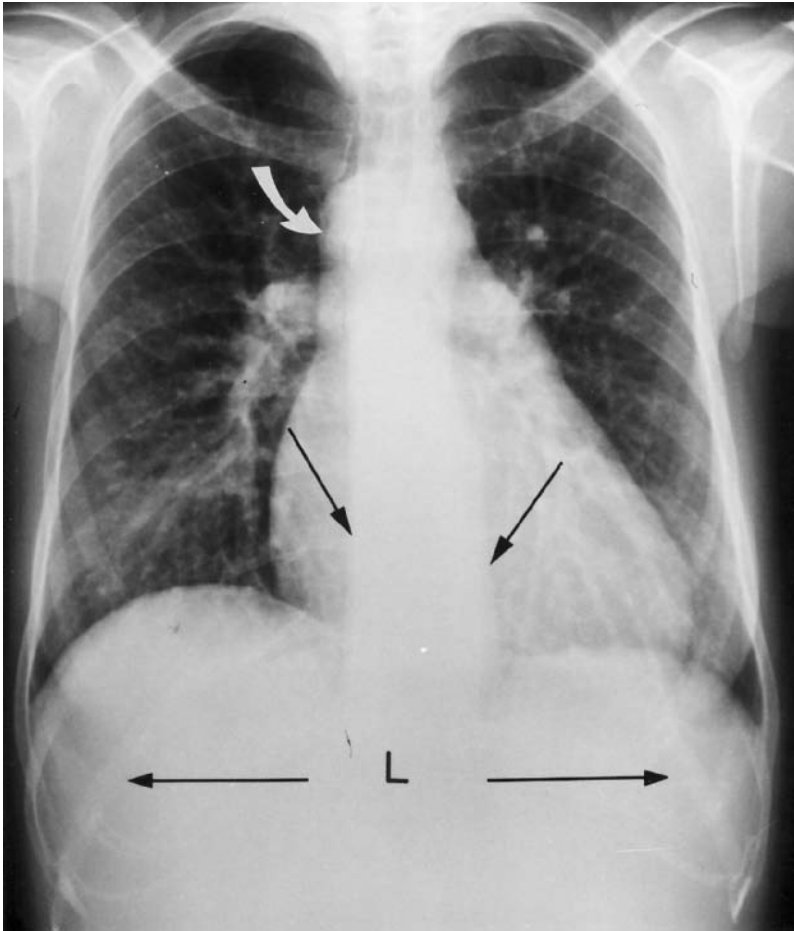


Fig. 14.3 X-ray from a 29-year-old female with a transverse liver (L), left isomerism, inferior vena caval interruption, and azygous continuation that ascends along the right side of the vertebral column (oblique black arrow), forming a knuckle (curved white arrow) as it courses anterior to join the right superior vena cava. A normal left aortic arch indents the trachea on its left, and descends along the left side of the vertebral column (second oblique black arrow).

Extrapulmonary soft tissue densities

In the posteroanterior view, large pectoral muscles in males can be distinguished from female breast tissue by ligaments to the axillae. Female breast tissue enhances lower lobe pulmonary arterial vascularity, which can be confirmed in the lateral projection by examining persistence of the vascular pattern behind the heart.

Intrapulmonary soft tissue abnormalities can be vascular or parenchymal, and vascular abnormalities can be pulmonary arterial, collateral arterial, or pulmonary venous. Increased pulmonary arterial vascularity of left-to-right shunts is distributed uniformly throughout all portions of the lung fields and extends to the periphery because of a greater degree of peripheral filling. When an intrapulmonary artery and its paired bronchus are seen end-on, the pulmonary artery is larger when pulmonary blood flow is increased.

The distribution of pulmonary blood flow in complete transposition of the great arteries favors the right lung because of the rightward direction of the pulmonary trunk [2]. The increase in blood flow to the right lung may result in a substantial decrease in perfusion to the left lung [2].

Bronchiectasis has its own significance. Primary ciliary dyskinesia, a loss of ciliary function during embryogenesis, is a link between situs inversus totalis, sinusitis, and bronchiectasis: the Kartagener triad [2]. Radiologically evident pectus excavatum often occurs with situs inversus and primary ciliary dyskinesia [8]. In restrictive perimembranous ventricular septal defects, the septal leaflet of the tricuspid is a common site of infective endocarditis because of the impact of the high-velocity jet. Radiologically characteristic septic pulmonary emboli originate from that site.

Pulmonary arteriovenous fistulae are distinctive intrapulmonary vascular densities that can be single or multiple, unilateral or bilateral, and typically involve the lower lobes or right middle lobe [2]. The fistulous densities may be hidden by the heart or diaphragm, so lateral views must be examined. Dilated channels from the hilus join the arteriovenous fistula, and dilated channels leave the fistula to join the hilus [2].

Decreased pulmonary arterial vascularity is a feature of Fallot's tetralogy and double-outlet right ventricle with pulmonary stenosis, malformations in which right ventricular blood is diverted into the biventricular or right ventricular aorta, reciprocally reducing pulmonary blood flow. The middle and outer thirds of the lung fields show a paucity of vascular markings because intrapulmonary arteries and veins are reduced in size [2]. In normal neonates, pulmonary vascularity is reduced until the arterioles involute and pulmonary vascular resistance falls.

Systemic arterial collaterals are features of Fallot's tetralogy with pulmonary atresia (Fig. 14.4), and are classified according to their origins as: (1) *bronchial arterial* because they originate from bronchi, as the name indicates, and anastomose to pulmonary arteries within the lungs; (2) *direct systemic arterial collaterals* that originate from the descending aorta, enter the hilum, and then assume the structure and distribution of intrapulmonary arteries; and (3) *indirect systemic arterial collaterals* that originate from internal mammary, innominate and subclavian arteries, and anastomose to proximal pulmonary arteries outside the lungs [2,4].

Pulmonary venous vascularity, including the thin dense horizontal linear streaks (Kerley lines), is most strikingly manifested by the stippled, reticular,

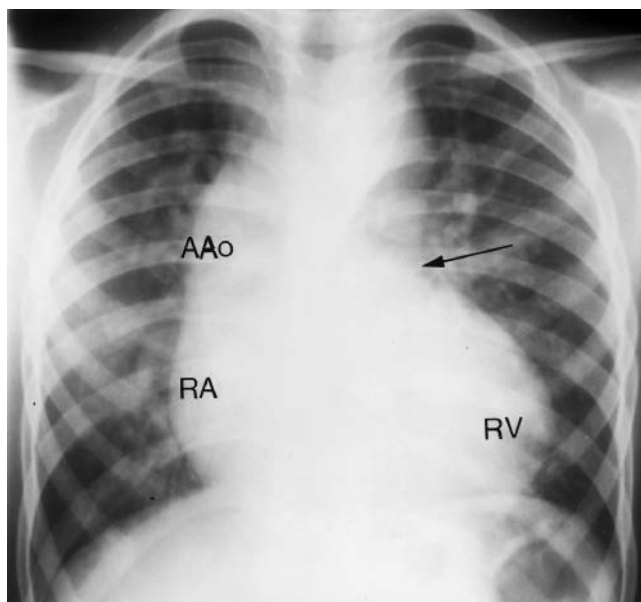


Fig. 14.4 X-ray from a three-year-old male with tetralogy of Fallot and pulmonary atresia. Pulmonary vascularity is bilaterally increased because of direct arterial collaterals that arose from the descending thoracic aorta and had hilar anastomoses. The main pulmonary artery is not border forming (arrow), but the ascending aorta (AAo) is conspicuously dilated. A convex right atrium (RA) occupies the right lower cardiac silhouette, and the apex is occupied by a convex right ventricle (RV).

ground glass appearance that occurs with the pulmonary venous obstruction of infradiaphragmatic total anomalous pulmonary venous connection [2]. Hallmarks of pulmonary venous vascularity (Fig. 14.5) are distribution to the upper lobes, obliteration of the hilar angle between the right upper lobe pulmonary vein and the right lower pulmonary artery, and peribronchial edema (cuffing).

Pulmonary neovascularity is the term recently applied to a distinctive radiographic finding in Eisenmenger syndrome [5]. Small nodular opacities in the chest x-ray correspond to tiny collaterals identified on CT scan and in microscopic sections at necropsy [5].

The great arteries are keys in the radiologic diagnosis of congenital heart disease. The aorta (ascending, transverse, and descending) and the pulmonary trunk are sequentially assessed for location and prominence. The normal heart in a posteroanterior chest x-ray is characterized by a triad of distinctive contours consisting of the ascending aorta on the right and the aortic knuckle and pulmonary trunk on the left. In complete transposition of the great arteries, the triad is lost. The vascular pedicle is narrow because the pulmonary trunk is posterior and medial to an anterior ascending aorta. The pedicle is narrowest

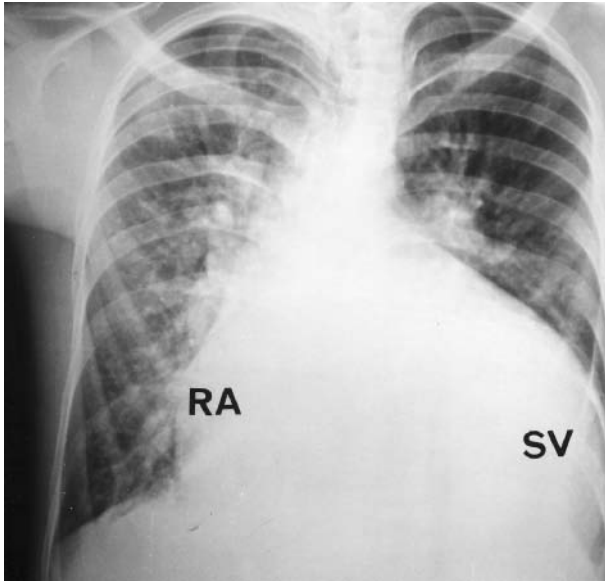


Fig. 14.5 X-ray from a seven-year-old male with a single morphologic left ventricle, a noninverted outlet chamber, and pulmonary vascular disease. The vascular pedicle is narrow because the outlet chamber is located at the right basal aspect of the heart in the noninverted position, and the posterior pulmonary trunk is not border forming. The right atrium (RA) is enlarged, and the single ventricle (SV) is strikingly dilated. There is marked pulmonary venous congestion (failure of the single ventricle) typically manifested by prominence of upper lobe vascularity and obliteration of the hilar angle between the right upper lobe pulmonary vein and the right lower pulmonary artery.

when the aorta courses vertically upward directly anterior to the posteromedial pulmonary trunk. The ascending aorta in complete transposition is not sufficiently rightward to be border-forming, except when it enlarges in the presence of leftward and posterior malalignment of the infundibular septum [2]. The distinctive appearance of the vascular pedicle is not obscured by a thymic shadow, which is seldom radiologically evident [2]. Absence of a thymic shadow is not due to aplasia or hypoplasia, because the shadow is sometimes radiologically present during the first 12 or 24 hours of life [2]. The vascular pedicle is distinctive in congenitally corrected transposition of the great arteries because the posterior pulmonary trunk is not border-forming, and the inverted ascending aorta does not ascend on the right but instead straightens the left upper cardiac border [2]. This configuration is the same in the x-ray of univentricular hearts of the left ventricular type when the outlet chamber is at the left basal aspect of the heart in the inverted position (see below).

Perhaps the most frequent cause of a dilated ascending aorta is a bicuspid aortic valve, whether functionally normal, stenotic, or incompetent [6]. Dilatation

is the consequence of inherent abnormalities of the media that set the stage for dilatation, dissection, and a further increase in size [6]. In Fallot's tetralogy with pulmonary atresia, a right aortic arch and a right descending aorta are relatively common, and the ascending aorta is prominent (Fig. 14.4). The ascending aorta is radiologically inconspicuous when a left-to-right shunt is intracardiac (atrial or ventricular level) because the shunt volume does not traverse the aorta. The converse is the case with patent ductus arteriosus or aortopulmonary window because the shunt volume traverses the ascending aorta, which is therefore prominent.

A normal transverse aorta deviates the trachea to the right, and the descending aorta forms a fine vertical line along the left edge of the vertebral column. A right aortic arch forms a prominent silhouette at the right thoracic inlet and deviates the trachea to the left, whereas the descending aorta forms a fine vertical line along the right edge of the vertebral column. These configurations radiologically resemble the thoracic portion of inferior vena caval interruption with azygous continuation to a right superior vena cava (Fig. 14.3) [2].

The normal pulmonary trunk is anterior to the ascending aorta and forms a convexity immediately below the knuckle of the transverse aorta. Prominence of the pulmonary trunk occurs with a left-to-right shunt, or above the mobile valve of typical congenital pulmonary valve stenosis, a distinction that can be made by examining the pulmonary vascular bed (discussed previously). Aneurysmal dilatation of the pulmonary trunk and its right branch are distinctive features of Fallot's tetralogy with congenital absence of the pulmonary valve [2]. Aneurysmal dilatation of the pulmonary trunk and either or both of its branches, often with mural calcification (Fig. 14.6), is a radiologic feature of Eisenmenger syndrome [7]. Intrapulmonary thrombus, often massive, is prone to embolize, causing pulmonary infarction and hemorrhagic pulmonary effusion (Fig. 14.6) [7]. Congenital absence of a pulmonary artery is associated with tetralogy of Fallot and almost always involves the left pulmonary artery [2]. The x-ray is diagnostically useful when the left hemithorax is small, the left hemidiaphragm is elevated, and the left lung is hypoplastic.

When the pulmonary trunk is not border-forming in the posteroanterior view, either of two conclusions can be drawn: that the main pulmonary artery is atretic or absent (pulmonary atresia or truncus arteriosus type 2), or that it is located posterior to the ascending aorta (complete transposition or congenitally corrected transposition of the great arteries) [2]. Occasionally, a dilated hypertensive posterior pulmonary trunk is border-forming in complete transposition.

Anomalies of the great veins include a wide range of abnormalities of vena caval connection that vary from minor to major, and that occur either in isolation or with coexisting congenital heart disease [2]. The normal right superior vena cava forms a linear shadow in the thoracic inlet just above the convexity of the ascending aorta. The superior vena cava can be right-sided, left-sided, or bilateral. The right superior vena cava can be atretic, absent, or connected to the left atrium. A left superior vena cava can join the coronary sinus or left atrium.

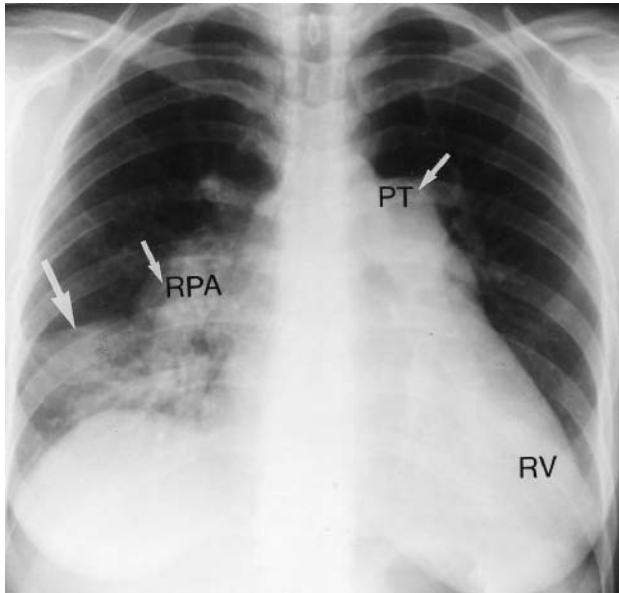


Fig. 14.6 X-ray from a 40-year-old woman with pulmonary hypertension and an atrial septal defect. Embolization of thrombus in the dilated calcified right pulmonary artery (RPA) caused a hemorrhagic right pleural effusion (large arrow). The pulmonary trunk (PT) is dilated, and an enlarged right ventricle (RV) occupies the apex.

A left superior vena cava forms a concave or crescentic radiologic shadow as it emerges from beneath the middle third of the left clavicle.

Specific sites of anomalous pulmonary venous connection are radiologically distinctive. The right superior vena cava is prominent at the right thoracic inlet when it receives the confluence of pulmonary veins via a right-sided anomalous venous channel or via the azygous vein. Most distinctive is the figure-eight or snowman silhouette that characterizes total anomalous pulmonary venous connection in which the left vertical vein originates from the confluence and ascends to join an innominate bridge to a prominent right superior vena cava [2]. The upper portions of the figure-eight are therefore formed by the vertical vein on the left and superior vena cava on the right, and the lower portions are formed by the dilated right atrium and right ventricle. The scimitar syndrome, so-called because the x-ray shadow resembles the shape of a Turkish sword, is characterized by connection of all of the right pulmonary veins to the inferior vena cava. The anomaly is usually accompanied by hypoplasia of both the ipsilateral lung and pulmonary artery with a shift of the heart into the right hemithorax (see Secondary positional abnormalities) [2].

The normal inferior vena cava forms a slightly concave or linear shadow located in the angle created by the posterior wall of the left ventricle and the left hemidiaphragm (lateral view). The shadow necessarily disappears when

the inferior vena cava is interrupted, and may disappear when the inferior vena cava connects to the left atrium because penetration of the diaphragm is not at the expected site [2]. Bilateral superior vena cavae are connected by an innominate bridge that can be widely patent, narrow, or atretic; the size of the left superior vena cava ranges from large to rudimentary [2].

The inferior vena cava can connect anomalously to the left atrium or can be interrupted (discussed previously). Very rarely, both the superior and the inferior vena cava join the left atrium; this is referred to as total anomalous systemic venous connection [2].

The atria

The left atrium, which is not “left” but rather posterior, resides between the paired left and right pulmonary veins. Radiologic abnormalities of the atria are represented by a generalized increase in size, by a decrease in size, or, less often, by a segmental (regional) abnormality in configuration. Generalized atrial enlargement is typically in response to the volume overload of a left-to-right shunt or atrioventricular valve regurgitation, or in response to the pressure overload of obstruction to atrioventricular flow. In Lutembacher syndrome, however, left atrial enlargement is limited because the obstructed chamber is decompressed through the atrial septal defect. However, the right atrium is considerably enlarged because resistance at the obstructed mitral valve augments the left-to-right shunt [2].

The left atrium is reduced in size in Fallot’s tetralogy because the chamber is underfilled (decreased pulmonary blood flow). A regional abnormality in atrial configuration characterizes congenital partial absence of the pericardium. Herniation of the left atrial appendage is represented in the x-ray by a convexity immediately below the pulmonary artery segment [2]. A larger herniation extends the convexity to the third left intercostal space (Fig. 14.7a). Similar, if not indistinguishable, is the radiologic appearance of a congenital intrapericardial aneurysm of the left atrial appendage [2]. A large congenital pericardial cyst resembles a dilated right atrium from which it must be distinguished (Fig. 14.7b). More typically, congenital pericardial cysts are represented by a smooth homogeneous radiodensity in the right cardiophrenic angle, touching the anterior chest wall and the anterior portion of the right hemidiaphragm [2].

A giant left atrium is usually reserved for mitral stenosis/regurgitation, accompanied by chronic active rheumatic fever. In congenital heart disease, large right atria are features of Ebstein’s anomaly of the tricuspid valve. When Ebstein’s anomaly is a component of pulmonary atresia with intact ventricular septum, the right atrium is immense [2].

In tricuspid atresia with normally related great arteries and a restrictive ventricular septal defect, the cardiac silhouette can be distinctive. The contour is characterized by a prominent right superior border caused by an enlarged right atrium and its appendage, and a flat receding inferior border caused by absence of the right ventricle [2].

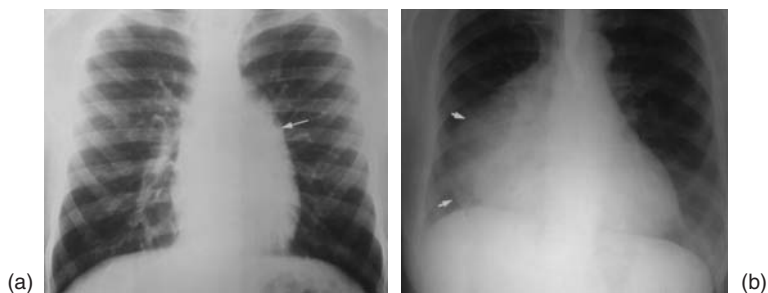

Fig. 14.7 Herniation of the left atrial appendage through congenital partial absence of the pericardium is represented in the x-ray by a convexity immediately below the pulmonary artery segment. (a) X-ray from a 19-year-old male with a larger herniation that extended the convexity to the third left intercostal space. (b) X-ray from a 32-year-old female with an unusually large pericardial cyst (arrows) that resembles a large right atrium.

The ventricles or ventricle are assessed last (Table 14.1) because, nearly a century and a half after Thomas Peacock's description, there is still no consensus regarding terminology for hearts with only one ventricle [2]. Single-ventricle or univentricular heart are terms applied when one ventricular chamber receives the entire flow from the right atrium and the left atrium, both of which, with the entire atrioventricular junction, are related to the univentricular or single-ventricle heart [2]. In 80–90% of cases, the ventricular chamber that receives the atrioventricular connections has left ventricular morphologic features, and incorporates at its base an outlet chamber that is an infundibular remnant devoid of a sinus or inlet component and is remote from the crux of the heart [2]. In 10–25% of cases, the ventricular chamber that receives the atrioventricular connections has right ventricular morphologic features and incorporates within its posterior, inferior, or lateral aspect a rudimentary trabecular pouch that represents a left ventricular remnant [2]. In less than 10% of cases, the single ventricle has intermediate morphologic features and incorporates neither an outlet chamber nor a trabecular pouch [2]. In univentricular hearts that are morphologically left ventricular, the outlet chamber is anteroposterior and lies either at the right basal aspect of the heart (noninverted position) (Fig. 14.5) or at the left basal aspect of the heart (inverted position), as would be the case in a two-chambered heart with congenitally corrected transposition of the great arteries [2]. Because the aorta arises discordantly from the outlet chamber, and the pulmonary trunk arises discordantly from the single morphologic left ventricle, the term transposition of the great arteries is appropriate [2]. In the uncommon, if not rare, Holmes heart, the great arteries arise concordantly [2]. When the univentricular heart is morphologically right ventricular, both great arteries necessarily arise from that chamber, an arrangement that is a form of double-outlet right ventricle. Similarly, both great arteries necessarily arise from a morphologically indeterminate single ventricle.

The location of the outlet chamber is an important radiologic feature of univentricular hearts. An inverted outlet chamber forms a localized convexity at the left upper cardiac border and gives rise to an aorta that is convex to the left or that arises vertically, as in congenitally corrected transposition of the great arteries [2]. A noninverted outlet chamber gives rise to an aorta that is convex to the right, as in complete transposition of the great arteries (Fig. 14.5) [2]. A posteromedial pulmonary trunk may lift a dilated right branch and create a waterfall appearance [2]. Absence of a thymic shadow is an important radiologic feature of complete transposition of the great arteries in biventricular hearts (discussed previously) but is not a feature of complete transposition in univentricular hearts. In univentricular hearts of right ventricular morphology, the vascular pedicle is narrow because the aorta is either anterior and the pulmonary trunk posterior to the aorta, or side by side [2].

“To read chest x-rays without knowledge of the pathologic anatomy or pathophysiology of congenital heart disease is akin to attempting to cross the English Channel after your first swimming lesson” [3]. Sophisticated high technology diagnostic methods provide contemporary clinicians with unprecedented information, but in so doing, risk de-emphasizing time-honored techniques, such as the chest x-ray, upon which previous generations were much more dependent and therefore much more adept in interpreting. Nevertheless, it remains gratifying, indeed amazing, to witness the amount of information that can be derived from a source seemingly so limited as relatively inexpensive posteroanterior and lateral chest x-rays systematically read according to a planned sequence.

References

1. Shanks SC, Kerley P. *A Text-Book of X-Ray Diagnosis* (4th edition). Philadelphia: WB Saunders, Philadelphia, 1973.
2. Elliott LP, Schiebler GL. *X-Ray Diagnosis of Congenital Heart Disease*. Springfield, IL: Charles C. Thomas Publisher, 1968.
3. Perloff JK. *The Clinical Recognition of Congenital Heart Disease* (5th edition). Philadelphia: WB Saunders, 2003.
4. Kennedy MP, Omran H, Leigh MW, et al. Congenital heart disease and other heterotaxic defects in a large cohort of patients with primary ciliary dyskinesia. *Circulation* 2007;115:2814–21.
5. Amplatz K, Moller JH, Castaneda-Zuniga W. *Radiology of Congenital Heart Disease*. New York: Thieme Medical Publishers, 1986.
6. Sheehan R, Perloff JK, Fishbein MC, Gjertson D, Aberle DR. Pulmonary neovascularity: a distinctive radiologic finding in Eisenmenger syndrome. *Circulation* 2005;112:2778–85.
7. Niwa K, Perloff JK, Bhuta S, et al. Structural abnormalities of great arterial walls in congenital heart disease. Light and electron microscopic analyses. *Circulation* 2001;103:393.
8. Perloff JK, Hart EM, Greaves SM, et al. Proximal pulmonary arterial and intrapulmonary radiologic features of Eisenmenger syndrome and primary pulmonary hypertension. *Am J Cardiol* 2003;92:182.

Arrhythmias in congenital heart disease

Barbara J. Deal

This 24-year-old man underwent surgical closure of a ventricular septal defect with resection of infundibular pulmonary stenosis and pulmonary valvotomy at age 14 months. At age 20 years, he began experiencing palpitations, and subsequently experienced two episodes of near-syncope while driving, associated with a racing heart beat. His exercise tolerance had decreased over the last few years. He was admitted to the hospital for evaluation, with frequent runs of rapid ventricular tachycardia on telemetry monitoring.

Cardiac examination was remarkable for a markedly hyperdynamic right ventricular impulse, with a thrill. Rhythm was regular with a widely split s2. A grade 4/6 systolic murmur was present, with a 1-2/6 diastolic murmur at the left upper sternal border. His liver was mildly enlarged.

Electrocardiogram showed normal sinus rhythm, with incomplete right bundle branch block, with a QRS duration of 110 ms.

Echocardiogram showed moderate right ventricular outflow tract obstruction and moderate pulmonary regurgitation, with a mildly dilated right ventricle.

Exercise testing revealed frequent premature ventricular contractions at the onset of exercise, progressing to sustained monomorphic ventricular tachycardia at 6 minutes (Fig. 15.1), with ventricular tachycardia rate accelerating to 260 bpm, associated with dizziness; the test was terminated. Peak oxygen consumption was 18 mL/kg/min. Ventricular tachycardia morphology was left bundle branch block, with an inferior axis.

Electrophysiology testing was performed, but neither atrial nor ventricular tachycardia was inducible with programmed stimulation.

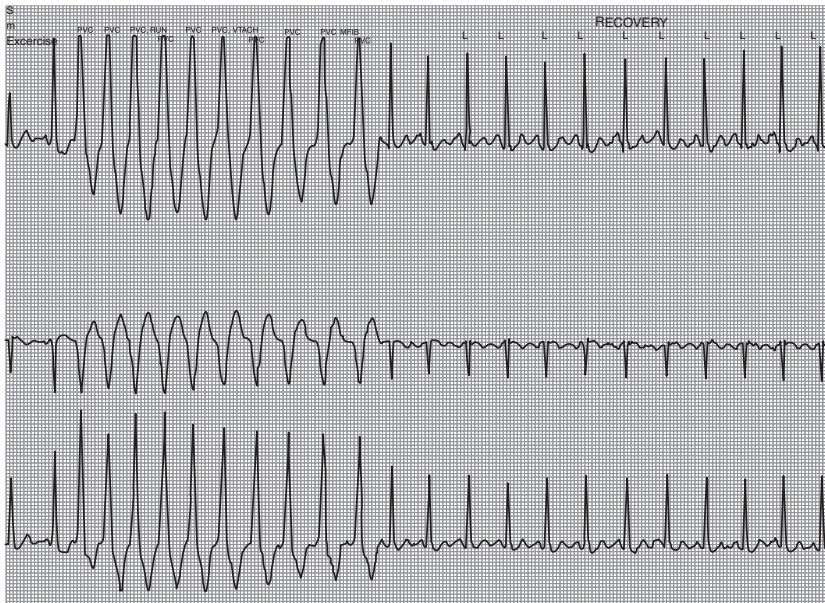


Fig. 15.1 Onset of ventricular tachycardia during exercise testing.

Introduction

The development of arrhythmias is the most common late sequela of congenital heart disease, occurring in 18–20% of adults with congenital heart disease. In addition, arrhythmias are the most common cause of sudden cardiac death in patients with known congenital heart disease, with an incidence more than twice that of heart failure [1]. Arrhythmias develop as part of the natural history of heart disease, occurring in both operated and unoperated patients with complex forms of heart disease.

A discussion of arrhythmias encompasses three distinct categories: the treatment and chronic management of existing arrhythmias; attempts to identify patients at risk for sudden cardiac death due to arrhythmias and interventions to reduce this risk; and efforts to reduce the incidence of developing arrhythmias.

Treatment of existing arrhythmias

The incidence of arrhythmias associated with congenital heart disease increases with advancing age from about 22% at 40 years of age to more than 40% by 55 years [2]. The incidence of arrhythmias associated with certain forms of congenital heart disease is summarized in Table 15.1. More than 40% of patients

Table 15.1 Incidence of late arrhythmias in congenital heart disease

Lesion	Incidence of arrhythmia
Atrial septal defect	5–40% SVT
Ebstein's anomaly	40–80% SVT
Single ventricle s/p atriopulmonary Fontan	30–60% SVT
Transposition of the great arteries s/p atrial switch repair	30–50% SVT
Congenitally corrected transposition of the great arteries	20–30% AV block
Tetralogy of Fallot	7% VT, 35% SVT
Tricuspid valve reoperation	35% SVT
Ventricular septal defect	<2% SVT, VT

with Ebstein's anomaly, atriopulmonary Fontan repairs, atrial switch repairs of transposition of the great arteries, and atrial septal defects repaired in adulthood will develop supraventricular tachycardia. In many lesions, the incidence of late arrhythmias parallels the need for reoperation for residual hemodynamic defects, giving rise to the concept of arrhythmias as "electro-mechanical problems" initially described in patients with repaired tetralogy of Fallot, but applicable to many other forms of heart disease as well. This underscores the need that, in any patient with congenital heart disease, the presence of an arrhythmia should prompt a detailed search for an underlying hemodynamic derangement, rather than a simple focus on the arrhythmia itself. Although ventricular tachycardia received extensive early attention as a common postoperative arrhythmia in patients with repaired tetralogy of Fallot, due to the increased risk of sudden death from this arrhythmia, the incidence of supraventricular tachycardia in most forms of congenital heart disease is at least four-fold greater than that of ventricular tachycardia, and is associated with significant morbidity such as heart failure and stroke.

Any discussion of the management of arrhythmias needs to begin with an understanding of the various mechanisms of tachycardia, particularly the various types of supraventricular tachycardia. Different forms of congenital heart disease are associated with distinct forms of arrhythmias, as summarized in Table 15.2. Supraventricular tachycardia utilizing an accessory connection, either manifest (associated with Wolff-Parkinson-White syndrome) or concealed, usually involves antegrade conduction over the atrioventricular node and return to the atrium using the accessory connection (known as orthodromic reciprocating tachycardia; Fig. 15.2). Less commonly, the tachycardia circuit may progress antegradely over the accessory connection and return

Table 15.2 Arrhythmias associated with specific forms of congenital heart disease

Arrhythmia	Congenital heart disease
Supraventricular tachycardia	
Accessory connection-mediated	<ul style="list-style-type: none"> Ebstein's anomaly Atrial septal defect Congenitally corrected transposition of the great arteries
Atrial reentry	<ul style="list-style-type: none"> Hypertrophic cardiomyopathy Atrial septal defect Single ventricle, with atriopulmonary Fontan repairs Mustard/Senning repairs of transposition of the great arteries Common atrioventricular septal defects Tetralogy of Fallot Total anomalous pulmonary venous connections
Atrioventricular nodal reentry	<ul style="list-style-type: none"> Mustard/Senning repairs of transposition of the great arteries Left ventricular outflow obstructive lesions
Atrial fibrillation	<ul style="list-style-type: none"> Mitral valve disorders Ebstein's anomaly of tricuspid valve Single ventricle, especially tricuspid atresia Atrial septal defects Tetralogy of Fallot Hypertrophic cardiomyopathy Eisenmenger's syndrome
Ventricular tachycardia	<ul style="list-style-type: none"> Tetralogy of Fallot Ventricular septal defects Aortic stenosis
Ventricular fibrillation	<ul style="list-style-type: none"> Aortic stenosis Hypertrophic cardiomyopathy Mustard/Senning repairs of transposition of the great arteries
Sinus bradycardia	<ul style="list-style-type: none"> Mustard/Senning repairs of transposition of the great arteries Single ventricle: atriopulmonary Fontan Atrial septal defects Common atrioventricular septal defects Anomalous pulmonary venous connection
Atrioventricular block	<ul style="list-style-type: none"> Congenitally corrected transposition of the great arteries Tetralogy of Fallot Atrial septal defects Common atrioventricular septal defects

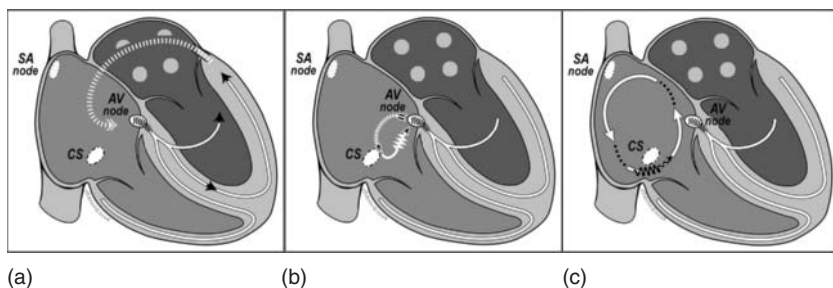


Fig. 15.2 Illustrations of mechanisms of supraventricular tachycardia. (a) Orthodromic reciprocating tachycardia. (b) Atrioventricular nodal re-entry tachycardia. (c) Macro-reentry atrial tachycardia. AV, atrioventricular; CS, coronary sinus; SA, sino atrial.

using the atrioventricular node (antidromic reciprocating tachycardia), or an atrial arrhythmia such as atrial fibrillation may be conducted rapidly over the accessory connection to the ventricles (pre-excited atrial tachycardia). As the accessory connection is a congenital abnormality with persistence of conducting tissue at the atrioventricular ring, lesions with abnormalities of the atrioventricular valve are more commonly associated with this form of supraventricular tachycardia (Ebstein's anomaly of the tricuspid valve, among others). In contrast, atrioventricular nodal re-entry tachycardia is associated with the development of functional differentiation of conduction over fast and slowly conducting atrioventricular nodal tissue or, less commonly, additional atrioventricular nodes associated with heterotaxy syndrome. In primary atrial arrhythmias, the tachycardia circuit is confined to atrial tissue, with conduction to the ventricles not critical to the maintenance of tachycardia; examples include atrial re-entry tachycardia, atrial flutter, and atrial fibrillation. The substrate for primary atrial arrhythmias may be congenital alterations of fiber array, creation of re-entrant circuits as a result of surgical incisions or patches, or the result of stretch and fibrosis as a result of abnormal hemodynamic stress. The acute treatment and natural history of the various mechanisms of supraventricular tachycardia differ substantially.

Ventricular tachycardia associated with congenital heart disease most commonly develops following surgical correction of lesions requiring ventriculotomies or ventricular patch placement, such as tetralogy of Fallot, ventricular septal defect, or truncus arteriosus. A re-entrant circuit may develop using areas of slow conduction between the incision or patch and an anatomic orifice; an example is the area between the ventricular septal patch and the right ventricular outflow tract in tetralogy of Fallot. Patchy areas of fibrosis may develop as a consequence of hypertrophy with resultant subendocardial ischemia in lesions with left ventricular outflow tract obstruction. Predisposing factors favoring the development of ventricular tachycardia include an older age at initial repair,

longer postoperative interval, right ventricular hypertension from residual outflow tract stenosis, right ventricular dilatation from pulmonary valve insufficiency, decreased ventricular ejection fraction, and prolongation of the QRS duration greater than 180 ms [3–6].

The presence of congenital heart disease alters the hemodynamic consequences of an arrhythmia and the risk to the patient, and thus the required acuity of treatment. Lesions associated with the highest risk to the patient from a sustained tachyarrhythmia include cyanotic heart disease, Ebstein's anomaly of the tricuspid valve with an atrial level shunt, single-ventricle physiology, atrial switch repairs of transposition of the great arteries, hypertrophic cardiomyopathy, and ventricular outflow obstructive lesions. The development of a sustained arrhythmia in these patients should be considered a potentially life-threatening emergency and treated urgently.

The basic principles of acute arrhythmia management in patients with congenital heart disease include early recognition of the presence of an arrhythmia, assessment of the hemodynamic stability of the patient, recognition of high-risk lesions as noted above, diagnosis of the mechanism of arrhythmia, and acute treatment of the arrhythmia, either with rate-control or termination of tachycardia. In patients with congenital heart disease, oftentimes recognition of the presence of an arrhythmia is difficult due to the vague nature of presenting complaints. Instead of symptoms of tachycardia or palpitations, patients may present with congestive heart failure, fatigue, malaise, abdominal pain, nausea, dizziness, or syncope. The presence of a ventricular rate greater than 100 bpm in older patients with repaired congenital heart disease should raise the suspicion of supraventricular tachycardia until proven otherwise; the presence of 2:1 or variable atrioventricular conduction may delay the recognition of an atrial arrhythmia. Similarly, the lack of heart rate variability may indicate the presence of atrial tachycardia, particularly in the setting of congestive heart failure. Tachycardia of duration greater than 48 hours, or uncertain duration, increases the risk of thrombus formation and the potential for embolization during cardioversion, and transesophageal echocardiogram to assess the presence of intracardiac thrombosis may be required. In certain high-risk patients, the hemodynamic consequences of ongoing tachycardia may outweigh the risk of potential embolization, and the difficult decision to proceed with cardioversion may be required. In other situations, the presence of intracardiac thrombus usually necessitates anticoagulation for at least 3 weeks with rate control prior to attempts to perform cardioversion.

Treatment of tachycardia begins with a decision to achieve rate control versus termination of tachycardia with presumed resumption of sinus rhythm; in some situations, this is a stepwise decision with acute rate control followed by cardioversion. Treatment options include medications, pacing, and direct-current cardioversion. Rate control with calcium-channel blocking medications or esmolol is usually a transient measure to improve hemodynamics while

preparing for definitive therapy. Two potential dangers lie in delaying cardioversion for hours or days, allowing congestive failure to worsen, or the use of multiple medication combinations which may prolong the QT interval and contribute to the development of life-threatening ventricular arrhythmias. Pharmacologic cardioversion may be achieved with adenosine, ibutilide, amiodarone, procainamide, or lidocaine, depending on the mechanism of tachycardia [7,8]. Atrial overdrive pacing using either transvenous or transesophageal access is highly effective in atrial re-entrant tachycardia, and offers the advantage of anti-bradycardia pacing immediately following cardioversion. Direct-current cardioversion is the treatment of choice for hemodynamically unstable arrhythmias, or arrhythmias not responding to initial pharmacological treatment. An anterior-posterior pad configuration for atrial tachycardia direct-current cardioversion is often more effective in patients with very large atria, such as single-ventricle physiology; attention to reversal of pad placement is necessary in patients with dextrocardia.

Following conversion to sinus rhythm, and optimization of decongestant therapy as needed, a thorough investigation of hemodynamics is important to assess the predisposing anatomic-mechanical factors favoring arrhythmia development. The natural history of tachycardia in patients with congenital heart disease indicates that arrhythmia recurrence is high and associated with significant morbidity. At a minimum, patients with atrial arrhythmias will require some form of chronic anticoagulation to minimize the risk of atrial thrombosis; medication with either atrioventricular nodal blocking medication (beta-blocking or calcium-channel blocking agents, digoxin) and/or chronic anti-arrhythmic medication will depend on the hemodynamic consequences of the arrhythmia, frequency of episodes, and access to care. Sotalol and dofetilide appear to have reasonable success rates for atrial tachycardia [9]; amiodarone has reasonable success in limiting recurrences at the expense of significant morbidity during chronic usage with a high incidence of thyroid, liver, and pulmonary side effects [10]. For this reason, chronic usage of amiodarone should be limited, and the lowest effective dose possible administered, along with regular monitoring of potential side effects.

Patients with reasonable hemodynamic status and atrial arrhythmias may be candidates for catheter ablation of the arrhythmia substrate, with acute success rates in the 50–85% range [11]. For atrial arrhythmias, catheter ablation is particularly effective in patients with atrial repairs of transposition of the great arteries and less complex lesions such as repaired atrial or ventricular septal defects [12,13]. Excellent reviews of the role of catheter ablation in repaired congenital heart disease have been published by several authors [11,14].

In the presence of significant hemodynamic abnormalities, or in patients with markedly enlarged and hypertrophied atrial, such as atriopulmonary Fontan patients, multiple atrial arrhythmia circuits are usually present; the early recurrence rate for tachycardia following catheter ablation is more than 60% [15].

Additionally, in these patients, extensive ablation may contribute to the development of atrial fibrillation or allow progression of underlying hemodynamic deterioration, which is often subtle. In Fontan patients, assessment of functional capacity using exercise testing, metabolic assessment including liver function, and serum albumin for detection of early protein-losing enteropathy are important supplements to echocardiogram and cardiac catheterization to guide timing of intervention options. Anti-bradycardia pacing may significantly reduce the number of tachycardia recurrences, particularly among patients with atrial repairs of transposition of the great arteries, and allows the use of anti-arrhythmic medications that might otherwise exacerbate bradycardia [16]. In patient populations at increased risk of sudden death, such as patients with repaired transposition of the great arteries, an assessment of the need for a defibrillator should be considered prior to implantation of a pacemaker.

Surgical intervention to improve hemodynamics in combination with arrhythmia surgery and pacemaker implantation has been shown to be highly successful and effective in selected patients with atrial tachycardia or atrial fibrillation [17]. In patients with prior atriopulmonary or lateral tunnel type Fontan repairs, our center and others have reported surgical results for conversion to an extracardiac total cavopulmonary connection with arrhythmia surgery and pacemaker implantation in over 175 patients [18–21]. Operative mortality at our center is less than 1%, although at least 7% of patients will subsequently be candidates for heart transplantation [18]. For patients with right atrial macro-reentrant circuits, a right atrial maze or modified maze for anatomic variations has been shown to reduce arrhythmia recurrence to approximately 10% during mid-term follow-up of more than 4 years [18,22]. The presence of atrial fibrillation requires performance of the additional left atrial maze surgery; using this approach, we have had no recurrence of atrial fibrillation, but approximately 15–20% recurrence of organized atrial tachycardia. The atrial tachycardia recurrences tend to be limited and usually responsive to either anti-tachycardia pacing or first-line anti-arrhythmic medications. Arrhythmia surgery requires careful patient selection and preoperative arrhythmia assessment. Patients with multi-organ system disease, poor cardiac function (not due to tachycardia, anti-arrhythmic medications, or correctable hemodynamic lesions), or protein-losing enteropathy are not considered good candidates for arrhythmia surgical intervention, and may be considered for cardiac transplantation.

Management of patients following acute treatment of sustained ventricular tachycardia or a cardiac arrest requires aggressive therapy. Patients with significant obstructive or regurgitant lesions should be considered for surgical intervention; patients with decreased cardiac ejection fractions are candidates for defibrillator implantation with resynchronization therapy, sometimes as a bridge to cardiac transplantation. Catheter ablation for ventricular tachycardia associated with good hemodynamic results has success rates of approximately 60–75% [23]; due to the risk of recurrent ventricular tachycardia, a defibrillator

may also be needed. Arrhythmia ablation during surgery for hemodynamic repair may be undertaken in patients whose arrhythmia circuit has been adequately mapped preoperatively. However, success rates for surgical ablation of ventricular tachycardia are approximately 50–60% [24,25]; as with transvenous catheter ablation for this substrate, implantation of a defibrillator is usually strongly considered. Empiric surgical ablation without adequate knowledge of the tachycardia circuit is not advised, as pro-arrhythmia may result in life-threatening consequences.

Risk of sudden death due to arrhythmias

Sudden death following repair of congenital heart disease has an event rate approaching 1/1000 patient years of follow-up, and the risk is incremental with increasing postoperative interval [26–28]. Approximately 65–75% of late deaths among patients with congenital heart disease are due to cardiac disease [28,29], and approximately 22–26% of cardiac deaths are sudden in origin [26,28,29]. Among patients with sudden death, arrhythmias account for 52–84% of deaths [26,28,29], followed by heart failure, pulmonary hypertensive crises, aortic dissection, and myocardial infarction. Lesions associated with the highest risk of arrhythmic sudden death are aortic stenosis, coarctation of the aorta, transposition of the great arteries, and tetralogy of Fallot, with these four lesions accounting for 90% of the sudden deaths in an early series [26]. Other lesions with significant risk of sudden death include Ebstein's anomaly, single-ventricle, atrioventricular septal defects, and ventricular septal defects. Both tachycardia and bradycardia were the cause of arrhythmic deaths; documented ventricular arrhythmias account for approximately half of lethal arrhythmias, with bradycardia noted in up to 20% [1,26].

Approximately 60% of patients with congenital heart disease dying suddenly have undergone prior corrective surgery [1]. Hypertrophic cardiomyopathy is the exceptional lesion with significant risk of arrhythmic sudden death without prior surgical intervention. Risk factors for sudden death in this lesion include certain genotypes, excessive thickness of the ventricular septum, severity of outflow tract obstruction, family history of sudden death, presence of ventricular tachycardia on ambulatory monitoring, fall in systolic blood pressure during exercise, and clinical history of syncope [30–32]; in the adult population, suggestions for defibrillator implantation based on ventricular septal thickness have been published [32]. In patients with operated lesions, interplay between residual hemodynamic defects, a systemic right ventricle, and atrial or ventricular arrhythmias combine to define the risk of sudden death. Hemodynamic lesions contributing to increased risk for sudden death include significant pulmonary regurgitation, ventricular outflow obstruction, conduit obstruction or conduit impingement on coronary arteries, and ventricular dysfunction. Clearly, early repair and timely interventions to reduce the impact of hemodynamic

abnormalities may be the single most important strategy to reduce the risk of sudden death, but as posed by Therrien and colleagues, the difficulty arises by “operating too late” [33]. The long-standing hemodynamic abnormalities contribute to both ventricular dysfunction, and creation of electrical scar due to stretch, fibrosis, and hypertension; both are substrates for potentially lethal arrhythmia development.

Markers for risk of sudden death include ventricular dysfunction, elevated brain natriuretic peptide (greater than 491 pg/mL), cardiomegaly (cardiothoracic ratio greater than 60%), progressive QRS widening, QRS duration greater than 180 ms, and QT dispersion greater than 60 ms, as well as a clinical history of sustained arrhythmia, syncope, or resuscitated cardiac arrest [3,34–37]. There have been extensive efforts to ascertain risk based on electrocardiogram and 24-hour ambulatory monitoring results. Cardiac autonomic dysfunction as evidenced by abnormalities of heart rate variability, and turbulence on ambulatory monitoring was a significant risk factor for sudden death in one small series [36]. In the early series by Garson, 57% of patients dying suddenly had evidence of arrhythmia on monitoring in the preceding year [6]; this paper was one of the earliest to relate the presence of arrhythmia as a marker for poor hemodynamic status at catheterization. Similarly, the presence of ventricular ectopy, and an increase in the amount of ventricular ectopy on Holter, may indicate changes in hemodynamic status that warrant attention, as opposed to anti-arrhythmic treatment directed at reducing the number of premature ventricular contractions.

The role of electrophysiologic testing in ascertaining risk of sudden death continues to evolve [38]. Electrophysiologic testing is most useful in patients presenting with a sustained arrhythmia or symptoms such as syncope, where the induction of the clinical or presumed arrhythmia can guide treatment. These data are extrapolated to the performance of ventricular stimulation testing in patients without clinical symptoms, and interpretation of the significance of induced arrhythmias in this setting needs to take into account the criteria for a significant arrhythmia (sustained versus nonsustained), hemodynamic status, and risk associated with the congenital lesion. Studies showing predictive value of electrophysiologic testing are skewed by the performance of testing in patients with significant symptoms, arrhythmias, and/or distinctly abnormal hemodynamic status, and cannot necessarily be extended to asymptomatic patients without arrhythmias and with excellent hemodynamic function. Nonetheless, the induction of sustained monomorphic or polymorphic ventricular tachycardia in this population correlates with a poor outcome [38]. Nonetheless, certain highest risk populations, such as patients with atrial repairs of transposition of the great arteries and tetralogy of Fallot/double outlet right ventricle/pulmonary atresia, are deserving of multicenter studies to determine the benefit of invasive screening. Patients with a clinical history of sustained ventricular arrhythmias or cardiac arrest are usually candidates for defibrillator

implantation, even after an acutely successful ablation procedure or surgical intervention. An increasingly common scenario is the performance of ventricular stimulation protocols to determine risk in patients without sustained ventricular arrhythmias or cardiac arrest, prior to undergoing reoperation for hemodynamic abnormalities. Improvement in hemodynamics usually decreases the risk of postoperative ventricular arrhythmias, in contrast to atrial arrhythmias (which persist or increase postoperatively). One approach is to restudy such patients postoperatively before making the decision for defibrillator implantation. High-risk patients undergoing pacemaker implantation or revision for traditional indications might optimally be treated by ventricular stimulation protocols, with defibrillator implantation for patients with inducible sustained ventricular arrhythmias. Continual improvement in implantable defibrillator technology, reliability, cost, and size will result in more widespread use of this device in patients with congenital heart disease.

The presence of complete or advanced atrioventricular block as a risk factor for sudden death has been clearly identified and reduced by widespread pacemaker use, but there remain a small number of patients at risk due to the late development of heart block; in most patients, perioperative conduction disturbances were present, but these historical data are often not available to the physician [39]. Patients with Down syndrome may be at increased risk for the late development of heart block [40]. In addition, the gene defect NKX 2.5 is associated with congenital heart lesions, conduction disturbances, cardiomyopathy, and sudden death [41]; increased screening for this defect, particularly among patients with atrial septal defects or first- and second-degree atrioventricular block, may provide risk stratification data, although enough data to clearly guide defibrillator implantation in these patients do not yet exist.

Prevention of arrhythmias

From the preceding discussion, it can be appreciated that arrhythmias develop in a significant number of patients with congenital heart disease, and that the treatment of existing arrhythmias is challenging and complex. Patients with anatomic lesions at high risk for developing arrhythmias have been clearly identified, and predisposing factors have been described. For atrial arrhythmias, congenital lesions at highest risk of developing arrhythmias are summarized in Table 15.2. For the development of atrial tachycardia, in addition to anatomic atrial defects, several factors have been shown to contribute to the milieu favoring arrhythmias. The placement of atrial incisions in patients with single ventricles has been shown in the dog model to contribute to atrial tachycardia [42]. The development of sinus node dysfunction has been associated with the development of atrial tachycardia in Fontan patients [43]; anti-bradycardia pacing may reduce the incidence of symptomatic arrhythmias [16]. In patients with tetralogy of Fallot, prolongation of the QRS duration greater

Table 15.3 Prophylactic management of arrhythmias

Substrate	Intervention
Accessory connection	Preoperative electrophysiology assessment; ablation of accessory connection pre- or intraoperatively
Atrial re-entry tachycardia	Minimize, alter, or avoid atrial incisions Preoperative assessment of inducible atrial tachycardia, particularly patients undergoing reoperation Operative ablation of re-entrant circuits Avoidance of atrial bradycardia; early anti-bradycardia pacing
Atrioventricular nodal re-entry	In absence of clinical arrhythmia, prophylactic therapy not usually advised
Atrial fibrillation	Surgical intervention prior to advanced atrioventricular valve regurgitation Operative left atrial maze procedure in older at-risk patients undergoing surgery (atrial septal defects, mitral regurgitation) Avoidance of prolonged catheter ablation procedures in patients with multiple atrial re-entrant circuits?
Ventricular tachycardia	Limit ventriculotomies as possible Earlier surgical intervention for chronic pulmonary regurgitation in tetralogy of Fallot Electrophysiology studies to assess inducibility of sustained ventricular tachycardia in at-risk populations; consider ablation, surgery, or defibrillator? Biventricular or multisite pacing to improve function in selected patients
Ventricular fibrillation	Defibrillator implantation in patients with low ejection fractions Defibrillator implantation for certain genetic lesions (NKX 2.5, channelopathies)? Biventricular or multisite pacing to improve function
Sinus bradycardia	Assessment of chronotropic incompetence in addition to profound bradycardia; epicardial lead implantation at time of surgery in at-risk populations Earlier pacing for chronotropic incompetence: not current guidelines for bradycardia pacing
Atrioventricular block	Monitor patients at risk for late development of atrioventricular block with periodic 24-hour rhythm monitors (perioperative block, bifascicular or trifascicular block; congenitally corrected transposition of the great arteries) Epicardial lead implantation at time of surgery in selected high-risk patients

than 160 ms was shown to be associated with atrial tachycardia development in one large study of patients undergoing reoperation [44]; the role of P wave duration prolongation in predicting arrhythmias has been reported [45]. Accessory connections are often associated with lesions with atrioventricular valve abnormalities; preoperative electrophysiology study to ascertain the presence of accessory connections and ablation when possible should be contemplated.

With this knowledge, the next phase of arrhythmia management should focus on efforts to minimize the risk of developing expected arrhythmias, rather than management of existing arrhythmias. Many alterations in surgical practice have been instituted in the past based in part on the future risk of developing arrhythmias, such as earlier corrective operation for tetralogy of Fallot, avoidance of suture placement in the region of sinus or atrioventricular nodal tissue, and changing from atrial to arterial switch repairs for transposition of the great arteries. Presently, due to an abundance of data regarding the incidence and morbidity of late postoperative arrhythmias, it is reasonable to enter an era of prophylactic arrhythmia surgery to interrupt known substrates for atrial arrhythmia circuits. Table 15.3 summarizes our center's approach to the expectant management of arrhythmias in congenital heart disease. This strategy encompasses preoperative evaluation with intervention as indicated: intraoperative arrhythmia surgery, optimization of chronotropic response with early pacing, ventricular resynchronization to optimize ventricular function, and judicious use of implantable defibrillators. It should be recognized that current recommendations for pacemaker implantation are based on prevention of sudden death or syncope; these suggestions are intended to optimize chronotropic competence and improve functional status while minimizing the development of arrhythmias.

Case study

In this patient with residual right ventricular outflow obstruction, surgery for resection of residual obstruction was planned. Because of his documented exercise-induced tachycardia, intraoperative electrophysiology testing with isoproterenol was performed and induced ventricular tachycardia at 180 bpm with a left bundle branch block, inferior axis. Epicardial and endocardial mapping was performed, showing the earliest activation of tachycardia arising from the right ventricular septal surface, above the ventricular septal defect patch. Endocardial resection of fibro-elastosis from the infundibular septum was performed, with resection of obstructive right ventricular muscle bundles, and patch augmentation of the right ventricular outflow tract.

Postoperatively, he had no ventricular arrhythmias. Electrophysiology testing, including adrenaline challenges, was negative. Exercise testing 8 weeks postoperatively showed one premature ventricular contraction at peak exercise and one ventricular couplet in recovery. Peak oxygen consumption was 36 mL/kg/min, with endurance time of 13 minutes. During 2 years of follow-up, he has no recurrent symptoms, and no

significant ventricular ectopy on continuous ambulatory electrocardiographic monitoring.

References

1. Polderman FN, Cohen J, Blom NA, et al. Sudden unexpected death in children with a previously diagnosed cardiovascular disorder. *Int J Cardiol* 2004;95:171–6.
2. van der Velde ET, Vriend JW, Mannens MM, et al. CONCOR, an initiative towards a national registry and DNA-bank of patients with congenital heart disease in the Netherlands: rationale, design, and first results. *Eur J Epidemiol* 2005;20:549–57.
3. Gatzoulis MA, Till JA, Somerville J, Redington AN. Mechano-electrical interaction in tetralogy of Fallot. QRS prolongation relates to right ventricular size and predicts malignant ventricular arrhythmias and sudden death. *Circulation* 1995;92:231–7.
4. Gatzoulis MA, Balaji S, Webber SA, et al. Risk factors for arrhythmia and sudden cardiac death late after repair of tetralogy of Fallot: a multicentre study. *Lancet* 2000;356:975–81.
5. Chandar JS, Wolff GS, Garson A Jr, et al. Ventricular arrhythmias in postoperative tetralogy of Fallot. *Am J Cardiol* 1990;65:655–61.
6. Garson A Jr, Randall DC, Gillette PC, et al. Prevention of sudden death after repair of tetralogy of Fallot: treatment of ventricular arrhythmias. *J Am Coll Cardiol* 1985;6:221–7.
7. Trappe HJ, Brandts B, Weismueller P. Arrhythmias in the intensive care patient. *Curr Opin Crit Care* 2003;9:345–55.
8. Deal BJ. Management of arrhythmias in patients with repaired congenital heart disease. In: Griffiths M, ed. *Management of Cardiovascular Conditions of Adults in Acute Care*. London: Blackwell Publishing, 2008.
9. Naccarelli GV, Wolbrette DL, Khan M, et al. Old and new antiarrhythmic drugs for converting and maintaining sinus rhythm in atrial fibrillation: comparative efficacy and results of trials. *Am J Cardiol* 2003;91:15D–26D.
10. Thorne SA, Barnes I, Cullinan P, Somerville J. Amiodarone-associated thyroid dysfunction: risk factors in adults with congenital heart disease. *Circulation* 1999;100:149–54.
11. Walsh EP. Interventional electrophysiology in patients with congenital heart disease. *Circulation* 2007;115:3224–34.
12. Collins KK, Love BA, Walsh EP, et al. Location of acutely successful radiofrequency catheter ablation of intraatrial reentrant tachycardia in patients with congenital heart disease. *Am J Cardiol* 2000;86:969–74.
13. Kannankeril PJ, Anderson ME, Rottman JN, et al. Frequency of late recurrence of intra-atrial reentry tachycardia after radiofrequency catheter ablation in patients with congenital heart disease. *Am J Cardiol* 2003;92:879–81.
14. Triedman JK, Alexander ME, Berul CI, et al. Electroanatomic mapping of entrained and exit zones in patients with repaired congenital heart disease and intra-atrial reentrant tachycardia. *Circulation* 2001;103:2060–5.
15. Triedman JK, Bergau DM, Saul JP, et al. Efficacy of radiofrequency ablation for control of intraatrial reentrant tachycardia in patients with congenital heart disease. *J Am Coll Cardiol* 1997;30:1032–8.

16. Silka MJ, Manwill JR, Kron J, McAnulty JH. Bradycardia-mediated tachyarrhythmias in congenital heart disease and responses to chronic pacing at physiologic rates. *Am J Cardiol* 1990;65:488–93.
17. Deal BJ, Mavroudis C, Backer CL. Beyond Fontan conversion: Surgical therapy of arrhythmias including patients with associated complex congenital heart disease. *Ann Thorac Surg* 2003;76:542–53, discussion 553–4.
18. Mavroudis C, Deal BJ, Backer CL, et al. J. Maxwell Chamberlain Memorial Paper for congenital heart surgery. 111 Fontan conversions with arrhythmia surgery: surgical lessons and outcomes. *Ann Thorac Surg* 2007;84:1457–65.
19. Morales DL, Dibardino DJ, Braud BE, et al. Salvaging the failing Fontan: lateral tunnel versus extracardiac conduit. *Ann Thorac Surg* 2005;80:1445–51.
20. Weinstein S, Chan D. Extracardiac Fontan conversion, cryoablation, and pacemaker placement for patients with a failed Fontan. *Semin Thorac Cardiovasc Surg* 2005;17:170–8.
21. Sheikh AM, Tang AT, Roman K, et al. The failing Fontan circulation: successful conversion of atriopulmonary connections. *J Thorac Cardiovasc Surg* 2004;128:60–6.
22. Deal BJ, Mavroudis C, Backer CL, et al. Comparison of anatomic isthmus block with the modified right atrial maze procedure for late atrial tachycardia in Fontan patients. *Circulation* 2002;106:575–9.
23. Morwood JG, Triedman JK, Berul CI, et al. Radiofrequency catheter ablation of ventricular tachycardia in children and young adults with congenital heart disease. *Heart Rhythm* 2004;1:301–8.
24. Harrison DA, Harris L, Siu SC, et al. Sustained ventricular tachycardia in adult patients late after repair of tetralogy of Fallot. *J Am Coll Cardiol* 1997;30:1368–73.
25. Deal BJ, Mavroudis C, Backer CL. Beyond Fontan conversion: Surgical therapy of arrhythmias including patients with associated complex congenital heart disease. *Ann Thorac Surg* 2003;76:542–53.
26. Silka MJ, Hardy BG, Menashe VD, Morris CD. A population-based prospective evaluation of risk of sudden cardiac death after operation for common congenital heart defects. *J Am Coll Cardiol* 1998;32:245–51.
27. Basso C, Frescura C, Corrado D, et al. Congenital heart disease and sudden death in the young. *Hum Pathol* 1995;26:1065–72.
28. Oechslin EN, Harrison DA, Connelly MS, et al. Mode of death in adults with congenital heart disease. *Am J Cardiol* 2000;86:1111–6.
29. Nieminen HP, Jokinen EV, Sairanen HI. Causes of late deaths after pediatric cardiac surgery: a population-based study. *J Am Coll Cardiol* 2007;50:1263–71.
30. Autore C, Quarta G, Spirito P. Risk stratification and prevention of sudden death in hypertrophic cardiomyopathy. *Curr Treat Options Cardiovasc Med* 2007;9:431–5.
31. Elliott PM, Gimeno JR, Tomé MT, et al. Left ventricular outflow tract obstruction and sudden death risk in patients with hypertrophic cardiomyopathy. *Eur Heart J* 2006;27:1933–41.
32. Spirito P, Bellone P, Harris KM, et al. Magnitude of left ventricular hypertrophy and risk of sudden death in hypertrophic cardiomyopathy. *N Engl J Med* 2000;342:1778–85.
33. Therrien J, Siu SC, Harris L, et al. Impact of pulmonary valve replacement on arrhythmia propensity late after repair of tetralogy of Fallot. *Circulation* 2001;103:2489–94.

34. Gatzoulis MA, Till JA, Redington AN. Depolarization-repolarization inhomogeneity after repair of tetralogy of Fallot. The substrate for malignant ventricular tachycardia? *Circulation* 1997;95:401–4.
35. Tateno S, Niwa K, Nakazawa M, et al. Risk factors for arrhythmia and late death in patients with right ventricle to pulmonary artery conduit repair—Japanese multicenter study. *Int J Cardiol* 2006;106:373–81.
36. Lammers A, Kaemmerer H, Hollweck R, et al. Impaired cardiac autonomic nervous activity predicts sudden cardiac death in patients with operated and unoperated congenital cardiac disease. *J Thorac Cardiovasc Surg* 2006;132:647–55.
37. Sun ZH, Happonen JM, Bennhagen R, et al. Increased QT dispersion and loss of sinus rhythm as risk factors for late sudden death after Mustard or Senning procedures for transposition of the great arteries. *Am J Cardiol* 2004;94:138–41.
38. Khairy P, Landzberg MJ, Gatzoulis MA, et al. Value of programmed ventricular stimulation after tetralogy of fallot repair: a multicenter study. *Circulation* 2004;109:1994–2000.
39. Krongrad E. Prognosis for patients with congenital heart disease and postoperative intraventricular conduction defects. *Circulation* 1978;57:867–70.
40. Banks MA, Jenson J, Kugler JD. Late development of atrioventricular block after congenital heart surgery in Down syndrome. *Am J Cardiol* 2001;88:A7, 86–9.
41. Benson DW. Genetics of atrioventricular conduction disease in humans. *Anat Rec A Discov Mol Cell Evol Biol* 2004;280:934–9.
42. Rodefeld MD, Bromberg BI, Schuessler RB, et al. Atrial flutter after lateral tunnel construction in the modified Fontan operation: a canine model. *J Thorac Cardiovasc Surg* 1996;111:514–26.
43. Fishberger SB, Wernovsky G, Gentles TL, et al. Factors that influence the development of atrial flutter after the Fontan operation. *J Thorac Cardiovasc Surg* 1997;113:80–6.
44. Karamlou T, Silber I, Lao R, et al. Outcomes after late reoperation in patients with repaired tetralogy of Fallot: the impact of arrhythmia and arrhythmia surgery. *Ann Thorac Surg* 2006;81:1786–93.
45. Koh M, Yagihara T, Uemura H, et al. Optimal timing of the Fontan conversion: change in the P-wave characteristics precedes the onset of atrial tachyarrhythmias in patients with atriopulmonary connection. *J Thorac Cardiovasc Surg* 2007;133:1295–302.

Pregnancy and contraception

Rachel M. Wald and Jack M. Colman

A 36-year-old woman presents for cardiac evaluation prior to conception. She was diagnosed with a mildly stenotic bicuspid aortic valve in early childhood, after a murmur was heard. She had an uncomplicated pregnancy 2 years ago, at which time her aortic valve was mildly–moderately stenotic (by continuous wave Doppler interrogation, maximum instantaneous gradient 30 mm Hg and estimated valve area 1.1 cm² with mild aortic regurgitation).

Although she continues to be asymptomatic with good functional capacity, the degree of aortic valve stenosis has progressed on echocardiographic assessment and is now severe (maximum instantaneous gradient 82 mm Hg, mean gradient 45 mm Hg, estimated valve area 0.7 cm²) with unchanged mild aortic regurgitation. The dimensions of the aortic root and ascending aorta are normal. Her electrocardiogram, which was previously normal, now shows evidence of increasing left ventricular voltages and repolarization abnormalities.

How should she be counseled regarding a future pregnancy?

Introduction

With some important exceptions, most women with congenital heart disease can be expected to do well during pregnancy with little need for medical intervention. For the woman with structural heart disease contemplating pregnancy, a preconceptual cardiac evaluation is of great value. At this visit, baseline testing can be arranged, pregnancy-related risk stratification can be established, and interventions can be planned prior to pregnancy when necessary. Medications should be reviewed and, depending on teratogenic potential, should be discontinued, altered, or, if safe, confirmed. Discussion regarding the impact of

pregnancy on and long-term outcome of specific forms of congenital heart disease should ideally take place before pregnancy; cardiac-related morbidity and mortality will certainly have impact on a woman's ability to care for her child.

In some cases, as will be described below, pregnancy imposes significant risk to the mother with congenital heart disease and/or her developing fetus; effective and consistent contraception should be used in these situations (see Table 16.1). It should be highlighted that, in a woman deemed to be "high risk," termination of pregnancy may itself carry considerable risk to the mother; pregnancy in these situations is best avoided altogether. Cardiologists should ensure that age- and circumstance-appropriate counseling regarding contraception and family planning occurs during routine follow-up of all females of child-bearing age, beginning during pediatric care.

In general, the physiologic adaptations to the pregnant state can be anticipated. The peak effect of these changes is generally seen late in the second trimester or early in the third trimester. Specifically, a decrease in total peripheral vascular resistance to 40–70% of pre-pregnancy levels, augmentation in blood volume by 30–50% compared with baseline, an increase in mean heart rate by 10–20 bpm, and ultimately a 30–50% increase in cardiac output can be expected to occur [1–3]. Physiologic anemia results from an increase in plasma volume which exceeds the increase in red blood cell mass [4,5]. The net effect of pregnancy can be summarized as decreased afterload mediated by a decline in peripheral vascular resistance and increased preload resulting from factors such as increased blood volume [6].

A management plan can be specifically determined for the individual patient when knowledge of the physiologic changes relating to normal pregnancy is coupled with an understanding of the pathophysiology of the underlying congenital heart defect. This article provides a framework for the practitioner aiming to care for women with congenital heart disease before, during, and after pregnancy.

Global risk assessment

Maternal risk

Comprehensive evaluation of the woman with congenital heart disease contemplating pregnancy should include a thorough history, a detailed physical examination including upper and lower extremity blood pressures, measurement of oxygen saturation at rest (and with exertion when appropriate), and assessment of dysmorphism that may suggest the presence of a syndrome or genetic anomaly. Evaluation also includes a 12-lead electrocardiogram and a detailed transthoracic echocardiogram applying the segmental approach to cardiac anatomy for evaluation of structural and functional cardiac abnormalities.

A maternal risk score may be derived that predicts the likelihood of developing an adverse cardiac event during pregnancy, as described by Siu and

Table 16.1 Risk of maternal morbidity or mortality related to pregnancy in women with congenital heart disease (modified from Thome et al. [52]).

Class 1: No risk	Class 2: Small risk	Class 2-3: Risk varies depending on the individual	Class 3: Significant risk	Class 4: Extremely high risk: pregnancy contraindicated
Uncomplicated, small or mild pulmonary stenosis, VSD, PDA	Unoperated ASD	Mild LV impairment	Mechanical valve	Pulmonary arterial hypertension of any cause
Successfully repaired simple lesions such as ASD, VSD, PDA, repaired anomalous pulmonary venous drainage	Repaired TOF	Native or tissue valvular heart disease not considered class 4	Systemic RV (complete TGA post atrial switch, congenitally corrected TGA)	Severe systemic ventricular dysfunction (LVEF <30% or NYHA functional class III-IV)
Isolated premature atrial or ventricular extrasystoles	Most arrhythmias	Marfan syndrome without aortopathy	Post-Fontan procedure Cyanotic heart disease or other complex lesions	Severe left heart obstruction Marfan syndrome with aortic dilation >40 mm
				Peripartum cardiomyopathy with any residual LV impairment

Abbreviations: ASD, atrial septal defect; LV, left ventricle; NYHA, New York Heart Association Functional Class; PDA, patent ductus arteriosus; RV, right ventricle; TGA, transposition of the great arteries; VSD, ventricular septal defect.

Table 16.2 Risk factors for maternal cardiac adverse events during pregnancy (adapted from Siu et al. [7] and Silversides et al. [8]).

Adverse maternal cardiac event	Risk factors
<ul style="list-style-type: none"> • Pulmonary edema • Arrhythmia • Stroke • Death 	<p>General:*</p> <ul style="list-style-type: none"> • Poor functional class (NYHA III or IV) or cyanosis • Systemic ventricular ejection fraction <40% • Left heart obstruction (mitral valve area <2 cm², aortic valve area <1.5 cm², peak left ventricular outflow gradient >30 mm Hg) • Cardiac event (arrhythmia, stroke, pulmonary edema) prior to pregnancy <p>Lesion-specific:</p> <ul style="list-style-type: none"> • As discussed in the text

*The general risk factors can be used to create a maternal risk index for adverse cardiac events related to pregnancy: 0 risk factors, <5% risk; 1 risk factor, ~27% risk; ≥2 risk factors, 75% risk.

colleagues in a multicenter prospective study [7]. In that study, independent predictors for pregnancy-related cardiac complications were identified, specifically poor functional class [New York Heart Association (NYHA) Functional Class > II] or cyanosis, systemic ventricular systolic dysfunction, left heart obstruction, and history of a previous adverse cardiac event (see Table 16.2). The overall risk of developing a cardiac-related complication during pregnancy was found to be low (5%) if no predictors were present, intermediate (27%) if one predictor was present, and high (75%) if more than one predictor was present. Because certain high-risk populations were under-represented in this study (e.g. Marfan syndrome, Eisenmenger syndrome, Fontan circulation, mechanical valves), the authors cautioned that the recommended global risk stratification should be used in conjunction with lesion-specific estimates and the highest risk estimate should be used to guide management if there is a discrepancy between the global assessment and the lesion-specific risk estimate [8].

In a subsequent single-center retrospective study by Khairy and colleagues, the global predictors of risk as listed above were again validated, and subpulmonary ventricular dysfunction and severe pulmonary regurgitation were identified as additional predictors of adverse cardiac outcomes [9]. In a meta-analysis of the outcome of 2491 pregnancies published in peer-reviewed journals, important pregnancy-related complications were seen in 11% of pregnancies in women with congenital heart disease. The most frequently encountered cardiac problems were clinically significant heart failure and arrhythmia (predominantly supraventricular) at a prevalence of 4.9% and 4.5%, respectively.

The use of various cardiovascular drugs during pregnancy has been recently and comprehensively reviewed [10,11]. With the exception of heparin, almost all cardiovascular medications can be expected to cross the placental barrier. Whenever possible, medications with the lowest risk profile should be used for the management of cardiac disease during pregnancy.

Fetal–neonatal risk

It is not surprising that women with congenital heart disease and compromised cardiovascular status may be at increased risk of adverse fetal and/or neonatal events, which may be related at least in part to insufficient uteroplacental perfusion. In a prospective controlled study of pregnant women with heart disease reported by Siu and coworkers, adverse fetal–neonatal events (prematurity, low birth weight, respiratory distress syndrome, intraventricular hemorrhage, fetal demise, and neonatal death) were associated with identified cardiovascular risk factors, namely, poor maternal functional class, cyanosis, and left heart obstruction (see Table 16.3). Risk of neonatal complications was further increased in women with heart disease who had established obstetric risk factors or multiple gestation, who smoked, or who received anti-coagulant therapy [12]. In a

Table 16.3 Risk factors for neonatal cardiac adverse events during pregnancy (adapted from Siu et al. [12] and Silversides et al. [8]).

Adverse neonatal events	Risk factors
<ul style="list-style-type: none"> • Premature birth • Small-for-gestational-age birth weight • Respiratory distress syndrome • Intraventricular hemorrhage • Fetal or neonatal death 	<p>Cardiac</p> <ul style="list-style-type: none"> • Maternal poor functional class (NYHA III or IV) or cyanosis • Maternal left heart obstruction (mitral valve area <2 cm², aortic valve area <1.5 cm², peak left ventricular outflow gradient >30 mm Hg) <p>General</p> <ul style="list-style-type: none"> • Maternal age <20 or >35 years • Anticoagulant therapy • Smoking during pregnancy • Multiple gestation pregnancy <p>Obstetric</p> <ul style="list-style-type: none"> • Premature delivery/premature membrane rupture • Incompetent cervix • Cesarean section • Intrauterine growth retardation • Bleeding >12 weeks gestation • Febrile illness • Uterine/placental abnormalities

large meta-analysis of outcome of 2491 pregnancies published in peer-reviewed journals, it was again noted that women with congenital heart disease were at increased risk of having children born prematurely or small for gestational age. Premature delivery occurred in 16% of pregnancies and was substantially higher in those with cyanotic and/or complex congenital heart disease. The overall mortality in offspring in this cohort was 4% and was related to the increased risk of prematurity and the overall recurrence risk of congenital heart disease [13].

The presence in the mother of a genetic or syndromic anomaly with autosomal dominance inheritance (such as 22q11 deletion or Holt Oram syndrome) can confer up to a 50% risk of recurrence in the offspring. In the absence of an identifiable anomaly with Mendelian inheritance in the mother, the risk of recurrence of congenital heart disease in the fetus is approximately 6%, compared with the background population risk of about 0.8% [14,15]. The type of congenital heart disease seen in offspring can differ from the lesion seen in the mother [16]. Recurrence risk of congenital heart disease in offspring varies by lesion and, in some reports, is as low as 0.6% in association with maternal transposition of the great arteries (TGA) [13] and as high as 18% in the presence of maternal left ventricular outflow tract obstruction [17].

The performance of transabdominal fetal echocardiography is accepted clinical practice for women with structural congenital heart disease and is best performed between 18 and 22 weeks gestation [18]. Fetal echocardiography not only allows for early counseling and decision-making for the expectant parents but, in some forms of congenital heart disease, the outcome of a fetus with an antenatal diagnosis of congenital heart disease is improved relative to an infant with the same cardiac lesion diagnosed postnatally [19,20]. Although most major structural and functional cardiac disease can be reliably excluded with fetal echocardiography [21,22], some forms of heart disease cannot be definitively diagnosed. The limitations of fetal echocardiography may be explained by features inherent in the fetal circulation (i.e. normal presence of an atrial level shunt and patent ductus arteriosus [PDA]), cardiac morphogenesis (i.e. frequent occurrence of muscular ventricular septal defects (VSD) during cardiac development), and the resolution of current ultrasound technology (i.e. difficulties with visualization of some lesions such as minor valvular abnormalities or anomalies of pulmonary or systemic venous return).

High-risk lesions which may preclude pregnancy

Before the ensuing discussion regarding the general management of pregnancy in a woman with congenital heart disease can occur, it is important to recognize that a select number of maternal cardiac conditions are associated with high maternal morbidity and mortality, and in such circumstances, pregnancy should be discouraged indefinitely or until reparative surgery can be performed. These

conditions include severe pulmonary hypertension, severe left heart obstructive lesions including aortic stenosis (with or without symptoms), Marfan syndrome with an aortic root diameter >40–44 mm, or systemic ventricular dysfunction (NYHA functional class III–IV or ejection fraction <40% or peripartum cardiomyopathy with residual ventricular dysfunction) [7,9,10,23–25]. In the discussion to follow, we will elaborate on the pregnancy-related risk ascribed to the aforementioned diagnoses as they relate to women with congenital heart disease.

Pregnancy and the woman with congenital heart disease: a lesion-specific approach

An approach to the management of the pregnant woman with heart disease can be developed when the expected physiologic changes of pregnancy are interpreted in the context of a specific congenital heart lesion. For instance, pregnancy is generally better tolerated in women with volume overload lesions as compared with pressure overload lesions, and close surveillance during pregnancy is warranted for the latter, if pregnancy is recommended at all. It should be noted that patients with congenital heart disease often defy simple classification, as a myriad of lesions in various stages of palliation may exist in the individual patient. Nevertheless, for the purpose of this review, a scheme is proposed so that the cardiologist caring for these patients can develop an approach to the clinical care of these women; it is not uncommon to find that heart disease within an individual straddles more than one of the categories discussed below.

Volume overload lesions

Conditions associated with volume overload, including left-to-right shunts and insufficient valves, are generally considered low risk for pregnancy-related complications as the effect of volume loading is attenuated by the reduced afterload mediated by lowered peripheral resistance.

Left-to-right shunts

Women with an unrepaired intracardiac shunt, such as an atrial septal defect (ASD), VSD or PDA, can be expected to do well during pregnancy in the absence of significant pulmonary hypertension. In women with larger shunts, potential pregnancy-related cardiac complications include deterioration in functional class, arrhythmias, pulmonary hypertension, and/or paradoxical embolization (particularly in the presence of an atrial level shunt) [23,26,27]. In a recent meta-analysis, arrhythmia was reported in 1/123 pregnancies with ASD (0.8%) and in no pregnancies with VSD; there were no reports of heart failure with either ASD or VSD [13].

An atrioventricular septal defect (AVSD), also called endocardial cushion defect or atrioventricular canal defect, is a more complex form of septal defect

that may be less well-tolerated in pregnancy as compared with simple defects. A review of balanced AVSDs in 48 pregnancies revealed that cardiovascular complications were not uncommon and included postpartum persistence of NYHA functional class deterioration, arrhythmia, and worsening of pre-existing left atrioventricular valvular regurgitation in 23%, 19%, and 17%, respectively [28].

Regurgitant valves

Significant pulmonary regurgitation (PR), although rare as an isolated lesion, is commonly seen after tetralogy of Fallot (TOF) repair, particularly when a transannular patch was used during the repair. Sequelae of severe PR may include right ventricular (RV) dilation and biventricular dysfunction. From a retrospective review of 82 successful pregnancies in women with TOF (including 20 pregnancies in women with unrepaired lesions), cardiovascular events occurred in 6 women (14%) and included supraventricular arrhythmia, heart failure, pulmonary hypertension, and pulmonary embolus. Cardiovascular complications were associated with the following hemodynamically significant lesions in 5 of 6 women: severe PR with RV dilation, RV hypertension (secondary to pulmonary vascular disease in 1 and hypoplastic pulmonary arteries in 1), and peripartum left ventricular dysfunction [29]. Another study of 50 pregnancies in women with repaired TOF found cardiac complications in 12% of pregnancies, consisting of heart failure, arrhythmia, or both, with symptomatic heart failure related to severity of PR [30].

Important congenital tricuspid valve regurgitation is commonly associated with structural disease, most often secondary to Ebstein's anomaly. Apical displacement of the tricuspid valve results in atrialization of the RV with compromise in functional RV size. A diminutive functional RV may not be able to accommodate the increased stroke volume of pregnancy resulting in worsening tricuspid regurgitation, raised right atrial pressure, and right-to-left shunting across the atrial septum. In a study of 42 pregnancies in women with Ebstein's anomaly, adverse pregnancy outcome was associated with arrhythmia (which may relate to the effect of pregnancy on an existing accessory pathway) and/or maternal cyanosis (arrhythmia and cyanosis during pregnancy are discussed separately later in this chapter) [31]. Another study of 111 pregnancies in women with Ebstein's anomaly did not find any serious maternal complications but did note increased risk of prematurity and fetal loss in offspring of this cohort; birth weight was significantly lower in cyanotic women as compared with those who were acyanotic [32].

Both mitral and aortic regurgitation during pregnancy are generally well tolerated, even if severe, due to reduced afterload mediated by a fall in peripheral vascular resistance. Medical therapy is generally sufficient if symptoms develop during pregnancy [10,33]. Due to the high incidence of fetal loss related to antenatal cardiac surgery, valve repair or replacement should be reserved for those with severe symptoms that are uncontrolled by medical therapy [34].

Pressure overload lesions: left heart

The normal adaptive responses to pregnancy may result in worsening of maternal left heart disease. In the presence of aortic stenosis, pressure gradients can worsen (if LV function is preserved) due to pregnancy-related increased stroke volume and decreased systemic vascular resistance. The pressure gradient across a stenotic mitral valve can increase secondary to augmented stroke volume. In addition, and importantly, elevations in heart rate reduce diastolic filling time. The consequent increase in left atrial pressure may result in the development of symptomatic heart failure and/or atrial arrhythmias. Also, a predisposition to aortic dissection has been noted during pregnancy, particularly in the presence of an underlying connective tissue disease, and may be explained in part by impaired collagen deposition in the media of large arteries in the presence of estrogen with resultant weakening of the vascular wall [10,35].

Aortic and mitral stenosis

Aortic stenosis in a pregnant woman is most commonly caused by congenital aortic valve disease. Whereas earlier studies reported significant morbidity and mortality in pregnant women with aortic stenosis [36,37], more recent studies have not reported pregnancy-related deaths despite a significant number of women with severe aortic stenosis [38–41], except one maternal death reported by Hameed and colleagues [40] that occurred 10 days postpartum in conjunction with aortic valve replacement in a woman with severe aortic stenosis and coarctation. Recent studies report heart failure requiring treatment in 7% (2/29) [39] and 17% (2/12) [38] of pregnancies with severe aortic stenosis; however, cardiovascular manifestations are less common than obstetric and fetal complications. Successful antenatal percutaneous balloon valvuloplasty to relieve symptomatic aortic stenosis has been reported [42–45]. Surgical repair during pregnancy carries significant risk to the fetus [46].

Mitral stenosis in pregnancy is most commonly related to previous rheumatic fever and, like aortic stenosis, should be managed medically if at all possible. In the presence of symptoms or more than moderate obstruction, intervention to relieve aortic or mitral stenosis should be undertaken prior to conception [10].

Coarctation of the aorta

The majority of patients with coarctation of the aorta have had an intervention prior to pregnancy; in these women, pregnancy is fairly well-tolerated, although there is an increased risk of pre-eclampsia and systemic hypertension [13,47,48]. The risk of developing hypertension appears to be mediated by the degree of arch narrowing [47,48]. Treatment of upper body hypertension may result in hypotension distal to the coarctation site, resulting in the potential for compromised uteroplacental perfusion. In women with previous surgical repair, a pre-conceptual evaluation of the arch, preferably by magnetic resonance imaging,

should be considered to exclude post-operative sequelae, such as aneurysm, pseudoaneurysm, or recoarctation [49]. In contrast to early literature [50], maternal deaths are rare in contemporary series [13,47,49]. Pregnancy-associated dissection after coarctation repair has been reported [47,51]. Medical therapy with beta-blockade may theoretically be protective due to decreased hemodynamic stress on the aortic wall; however, this has not been formally studied in pregnancy. The maternal and fetal outcomes in women with unrepaired coarctation are reported, surprisingly, to be similar to women after surgical repair [47].

Aortopathies

Dilation of the ascending aorta may be seen in presence of a connective tissue disease, such as Marfan syndrome, or in conjunction with a bicuspid aortic valve. The increased risk of aortic dissection during pregnancy is likely a result of the combined effects of pregnancy-related increases in cardiac output and alterations in aortic wall structure related to altered hormonal milieu. The risk of aortic dissection or rupture appears to increase as gestation advances and persists for some months post-partum.

In a prospective study of 21 women and 45 pregnancies, it was determined that women with an aortic root diameter <40 mm tolerate pregnancy well; increased risk of dissection or rapid aortic root dilation was seen in 3 women with previous aortic root surgery or aortic root diameter >40 mm prior to pregnancy. Of note, beta-blockade therapy was withheld during pregnancy in the majority of women in this study [25]. A more recent prospective study of 33 pregnancies in 23 women with Marfan syndrome reported favorable outcomes with aortic root diameter <45 mm and no previous history of dissection. There was a small but statistically significant increase in aortic root diameter during pregnancy in women with an initial diameter >40 mm as compared with those <40 mm [24]. Surgical repair should be offered to women prior to conception if the aortic root diameter is >40–45 mm [10,52], though this is unlikely to fully normalize the risk of dissection thereafter [53]. Despite the absence of trials specifically evaluating beta-blocker therapy in pregnancy, the potential benefit likely outweighs the relatively small risk of use of this medication during pregnancy.

Less is known about risk factors for dissection in pregnant women with a bicuspid aortic valve, although this complication has been reported in the pregnant population [35]. The histological features of aortopathy related to a bicuspid aortic valve are similar to what has been described in Marfan syndrome [54]. Some have suggested that management guidelines as described for Marfan syndrome should be applied to those with aortopathy related to a bicuspid aortic valve [10,35], though there are few published data to support the conclusion that the risk is equal.

With assisted reproductive technology, women with Turner syndrome can now become pregnant. Women with Turner syndrome are at particular risk for

dissection relatively early in life [55], even in the absence of recognized aortic root pathology or hypertension [56]. Pregnancy appears to significantly increase the risk of cardiovascular mortality in these women [57]. Recent literature has suggested that aortic measurements be indexed to body surface area due to the inherent short stature in this population [58]. At a minimum, occult aortic pathology should be excluded by aortic imaging prior to attempting such a pregnancy.

Pressure overload lesions: right heart

Obstruction confined to the pulmonary valve is generally well-tolerated during pregnancy even when severe, with no adverse maternal or fetal-neonatal effects reported. Conversely, pulmonary vascular obstructive disease resulting in significant pulmonary hypertension confers substantial risk of mortality during and after pregnancy. The early post-partum period is one of particular risk for women with pulmonary hypertension; this may be explained by the sudden increase in venous return related to the auto-transfusion of uteroplacental blood during delivery as well as aortocaval decompression after delivery. This volume increase may precipitate RV failure with ensuing death. Additional hemodynamic compromise may arise from elevations in pulmonary vascular resistance that have been observed early postpartum [59]. In patients with unrepaired TOF or pulmonary atresia with aorto-pulmonary collaterals, the predominant determinant of pregnancy outcome is cyanosis (see “Cyanotic congenital heart disease” below).

Pulmonary stenosis

Unlike aortic stenosis, pulmonary stenosis is associated with few cardiovascular complications during pregnancy [40]. In a recent case-control study, 17 pregnant women with pulmonary stenosis were matched with controls. In 2 women, there was deterioration of NYHA functional class, but no other maternal complications were reported. Of note, there were no statistically significant differences in fetal-neonatal outcome between cases and controls or between patients with mild and severe pulmonary stenosis [60]. A larger retrospective study evaluating 81 pregnancies in 51 women confirmed that there were no significant maternal cardiac complications, but did find increased obstetric complications, such as hypertension in 12 (15%), thromboembolic events in 3 (4%), and premature delivery in 14 (17%) [61]. When the severity of the obstruction merits intervention, percutaneous pulmonary valvuloplasty should be considered prior to conception.

Pulmonary hypertension

Pregnancy poses prohibitive risk for a woman with pulmonary hypertension. Current consensus opinion is to advise against conception and to offer early termination in the event of a pregnancy [62]. In women with Eisenmenger

syndrome, mortality has remained approximately 30% in separate reports spanning more than two decades [63,64]. Due to the requisite presence of an intracardiac right-to-left shunt in Eisenmenger syndrome, there is a fine balance between systemic and pulmonary vascular resistances. These women are particularly sensitive to volume depletion and hypotension as these conditions will augment intracardiac right-to-left shunting resulting in worsening cyanosis, hypoxemia, and vasoconstriction. Experience with targeted pulmonary vasodilator therapy is limited to case reports which, although few in number, suggest that such agents may improve outcome [65–68].

Cyanotic congenital heart disease

In the absence of pulmonary hypertension, mortality associated with pregnancy is rare in women with cyanotic congenital heart disease, though the risk of adverse events is high, as reported by Presbitero and colleagues. In their study of 96 pregnancies in 44 women with cyanotic heart disease, cardiovascular complications occurred in 32%, consisting of heart failure, arrhythmia, thrombosis, and endocarditis. Live birth rate was low (43%) for the entire cohort, and when women were stratified by maternal oxygen saturation, the live birth rate was found to be only 12% in those with an oxygen saturation <85% [69]. In cyanotic women, increased risk of fetal complications, including miscarriage, premature birth, and low birth weight, has been observed by many investigators [13,69–72].

Abnormalities of the systemic ventricle: systemic right ventricle and functional single ventricle

TGA: systemic right ventricle

The original palliation for ventriculo-arterial discordance or complete TGA was the atrial switch procedure (Mustard or Senning operation). Contemporary surgical management has replaced the atrial switch procedure with the arterial switch operation (Jatene procedure). However, women managed with an arterial switch operation have only recently reached childbearing age, and little is known about pregnancy in this population. Virtually all published data regarding pregnancy in women with TGA are derived from women after Mustard or Senning palliations. After the atrial switch procedure, the morphologic RV supports the systemic circulation; consequently, tricuspid regurgitation, RV dilation, and RV dysfunction are commonly seen. Additional post-operative sequelae may include sinus node dysfunction, atrial tachyarrhythmia, and baffle leak/obstruction.

Two retrospective studies of pregnancy in women following Mustard or Senning procedures were recently published. In the first series, the most common cardiac complication was arrhythmia, seen in 11 pregnancies (22%), and was more common if there was a previous history of arrhythmia prior to pregnancy. Although heart failure was only seen in 2 women, deterioration of NYHA

functional class was noted in 17 pregnancies (35%). Important obstetric complications (including premature rupture of membranes, premature labor, premature delivery, and thromboembolic events) were frequently seen (65% of pregnancies); mortality in the fetus or neonate was relatively high (12%) [73]. In the second series, cardiac complications included heart failure in 6 women (15%), arrhythmias in 5 women (13%), and hemoptysis in 2 women (5%). Cardiac transplantation took place in 1 woman with severe RV failure, sudden death occurred in 1 woman with heart failure, and there was 1 late death 4 years after pregnancy [74].

The late effects of pregnancy on the systemic RV after the Mustard operation were examined using serial echocardiography during and after pregnancy. Important observations during pregnancy included the presence of progressive RV dilation, which occurred in 5/18 women (21%), and worsening RV function, which was noted in 4/21 (25%). During a mean follow-up of 33 months after delivery, the RV remained enlarged in all 5 women (100%), and the RV dysfunction persisted in 3 of 4 women (75%) [75]. These data suggest that pregnancy may have a detrimental effect on the systemic RV, though this hypothesis remains to be tested in studies that employ more reproducible methods of RV quantification, such as cardiac magnetic resonance imaging.

In congenitally corrected transposition (ccTGA), characterized by atrioventricular and ventriculo-arterial discordance (double discordance), the morphologic RV supports the systemic circulation. Tricuspid regurgitation and RV dilation and dysfunction are frequently seen. Common associations include VSD, pulmonary stenosis, and Ebstein-like anomaly of the systemic tricuspid valve. In a study of 60 pregnancies in 22 women, cardiac complications were reported in 2 women: congestive heart failure resulting in systemic atrioventricular valve replacement 2 months postpartum in 1 woman and congestive heart failure, endocarditis, and myocardial infarction related to a single coronary artery in a second woman who had undergone 12 pregnancies [76]. In a contemporaneous study of 45 pregnancies (36% with cyanosis) in 19 patients, cardiovascular complications were seen in 5/19 (26%) women and included congestive heart failure in 3, worsening cyanosis in 1, and cerebrovascular accident in 1 [77]. No maternal deaths were reported.

Fontan palliation: functional single ventricle

The Fontan circulation was initially created to channel right atrial blood directly to the pulmonary arteries in patients with tricuspid atresia. The indications have since expanded to encompass a variety of congenital heart lesions with single-ventricle physiology. The right atrium to pulmonary artery anastomosis has been replaced by caval to pulmonary artery connections via a lateral tunnel or extracardiac conduit. Although the Fontan palliative procedure successfully decreases volume overload on the systemic ventricle and reduces or eliminates cyanosis, there remains an inherent limitation in the heart's ability to augment

cardiac output. Long-term sequelae may include arrhythmia, ventricular dysfunction, protein-losing enteropathy, and thromboembolic events.

In the largest series of pregnant women with Fontan palliation published to date, 33 pregnancies in 14 mothers were reviewed. Preconception morbidity included atrial flutter in 1 woman and a combination of ventricular dysfunction, aortic regurgitation, and atrioventricular valve regurgitation in another. The single cardiac complication reported in this study was supraventricular tachycardia in 1 woman [78]. In a subsequent study of 4 pregnancies, maternal cardiac complications included atrial tachyarrhythmia in 2 women, ventricular dysfunction requiring medical therapy in 2 women, and raised systemic venous pressures resulting in peripheral edema/ascots in 2 women; all infants were born prematurely in this study [79]. The most recently published study reviewed 10 pregnancies in 6 women and found cardiovascular complications in 1 patient consisting of NYHA functional class deterioration and atrial fibrillation requiring cardioversion [80].

Pregnancy and the woman with congenital heart disease: additional considerations

Thrombosis and anticoagulation

The prothrombotic state of pregnancy relates, at least in part, to hypercoagulability and venous stasis. Adequate anticoagulation merits careful consideration in women at increased risk for thromboembolic events. Tissue valves (bioprosthetic, homograft, or autograft) may be preferable to mechanical valves as these do not usually require warfarin anticoagulation during pregnancy. There is no clear evidence to support accelerated bioprosthetic valve degeneration related to pregnancy [81–84]. However, bioprosthetic valves have an inherently limited life span, which commits the woman to an earlier valve replacement than is likely with a mechanical valve.

Mechanical valves require anticoagulation, and pregnancy-related thrombosis risk relates to the interplay of several factors, including valve type (more likely in older-generation valves), position (greater in the mitral position versus the aortic position), prenatal level of valve function, and type of anticoagulation used [85]. All anticoagulation strategies must balance maternal and fetal risks, specifically the risks of bleeding, thrombosis, and, in the case of warfarin, embryopathy. A systematic review of anticoagulation in pregnant women with prosthetic heart valves was published by Chan and colleagues. The pooled maternal mortality was 2.9%. The use of oral anticoagulation throughout pregnancy was associated with the lowest thrombosis risk (4%). If unfractionated heparin was limited to use between 6 and 12 weeks gestation, the risk of thrombosis was elevated (9%). If dose-adjusted unfractionated heparin was used throughout pregnancy, the risk of thrombosis was further increased (25%). The risk of warfarin embryopathy was about 6% with the main vulnerability

occurring between 6 and 12 weeks gestation [86]. Fetal embryopathy risk may be reduced if the effective maternal warfarin dose is ≤ 5 mg per day [87]. Warfarin should be discontinued 2 weeks prior to delivery due to risk of fetal intracranial hemorrhage. The use of low molecular weight heparin with careful serial monitoring of anti-Xa levels, limited to the 6–12 week gestation window or throughout pregnancy, is now recognized as an alternate anticoagulation strategy, although data are limited [10]. Optimal management of anticoagulation during pregnancy should include participation of a hematologist (preferably in conjunction with a thrombosis clinic), cardiologist, and obstetrician.

Arrhythmia

The pregnant state may increase arrhythmia propensity related to several factors, including altered hormonal milieu, enhanced sympathetic tone, and cardiac chamber dilation [88]. Women with a previous history of arrhythmia are at increased risk of recurrence during pregnancy [89]. Adverse fetal and neonatal outcomes have been related to recurrent arrhythmia during pregnancy [89]. In a recent meta-analysis, women at particular risk of arrhythmia were those with TGA postatrial repair (Mustard or Senning), those after Fontan palliation (particularly with atripulmonary anastomosis), and those with AVSD [13].

Management of labor and delivery

In our center, the mode of delivery in women with heart disease is generally vaginal unless there are obstetrical indications for cesarean delivery. Cardiac indications for cesarean section include risk of aortic dissection (i.e. Marfan with dilated aortic root) or significant bleeding risk (i.e. anticoagulation with warfarin maintained within 2 weeks of delivery). In order to optimally co-ordinate care for the complex cardiac patient in advance of labor and delivery, we have found that a “patient care conference” is invaluable; this forum brings together all involved members of the medical team (obstetricians, anesthetists, cardiologists, neonatologists, nurses, and others) so that a detailed management plan can be discussed and documented. Modification of labor is often employed by using early epidural to attenuate hemodynamic responses to labor pain, and assisted second stage to limit or avoid maternal expulsive efforts. In the presence of intracardiac shunts, bubble trap filters should be added to all intravenous lines. Invasive cardiac monitoring is generally determined on a case-by-case basis, and, aside from arterial pressure lines, rarely employed. Endocarditis prophylaxis is not recommended according to the American Heart Association Practice Guidelines published in May 2007 [90]. The hemodynamic changes related to pregnancy, labor, and delivery may not return to baseline for several weeks or months after delivery. In some patient populations, such as those with Eisenmenger syndrome, the risk of mortality is highest in the first few weeks after delivery, and so extended postpartum observation in these women is prudent.

Contraception

Discussions regarding family planning should begin when a young woman approaches childbearing age, during adolescence. Contraceptive methods should be individually tailored to the patient, keeping in mind, for each contraceptive method, personal preference, efficacy, and safety. Factors to be considered which relate directly to a woman's cardiac condition include the risk of thrombosis with estrogen-containing products, risk of endocarditis and vagal response with insertion of an intrauterine device, and maternal risk in the event of contraceptive failure. All barrier methods have a significant failure rate and are therefore not an optimal strategy for a population of women in whom pregnancy is best avoided.

Efficacy rates for oral contraceptive pills that combine estrogen and progesterone are extremely high, nearing 99.5% if optimally administered [91]. Newer modes of delivery for combined hormonal contraception include a vaginal ring containing ethinyl estradiol and etonogestrel (NuvaRing®), a contraceptive patch containing ethinyl estradiol and norelgestromin (OrthoEvra®), and an injectable preparation medroxyprogesterone acetate and estradiol cypionate (Lunelle®), all with similarly high efficacy rates [92]. However, women with congenital heart disease who are at particular risk of thromboembolic events (such as women with cyanosis and an obligatory right-to-left intracardiac shunt, pulmonary hypertension, Fontan circulation, sustained arrhythmias, mechanical heart valves, and/or significant ventricular dysfunction) should best avoid estrogen-containing contraceptive methods due to the increased risk of arterial and venous thrombosis (see Table 16.4). It should be noted that anticoagulation with warfarin does not completely protect against the thrombogenic effects of estrogen [52]. Risk of estrogen-related thromboembolism is further increased by traditional cardiovascular risk factors, such as smoking, hypertension, diabetes, and obesity [52].

The possible interaction between hormonal contraception and additional medications should be considered. Estrogen and progesterone can individually affect the metabolism of warfarin; heightened surveillance of anticoagulation efficacy is advised when hormonal contraception is initiated in these women [52]. Because of reports of combined oral contraceptive failure with concurrent antibiotic use (even when short-term), an additional method of contraception is recommended in such circumstances [93]. Bosentan, an endothelin antagonist used in the treatment of pulmonary hypertension, can decrease the efficacy of some hormonal preparations, and additional contraceptive precautions may be necessary in women with pulmonary hypertension [94].

Progestin-only contraceptive methods, which include oral, injectable, and implantable formulations, do not increase the risk of thromboembolism and are therefore commonly used when estrogen-containing products are deemed unsafe. The older generation progestin-only pills, or "mini-pills," have

Table 16.4 Combined hormonal contraception use in women with congenital heart disease (modified from Thome et al. [52]).

Class 1: Always useable	Class 2: Broadly useable	Class 3: Caution if used	Class 4: Use contraindicated
Minor valve disease (i.e. bicuspid aortic valve with normal function or mild pulmonary stenosis)	Tissue prosthetic valve lacking class 3 or 4 features	Thrombotic risk (even on warfarin): 1 Mechanical valve (bileaflet) 2 Previous thromboembolism 3 Atrial arrhythmia 4 Dilated left atrium >4 cm	Thrombotic risk (even on warfarin): 1 Mechanical valve (Starr Edwards, Bjork Shiley and any tricuspid valve prosthesis) 2 Pulmonary hypertension of any cause 3 Left ventricular dysfunction (ejection fraction <30%) 4 Fontan circulation 5 Previous coronary arteritis, e.g. Kawasaki disease
Repaired coarctation of the aorta with no aneurysm and no hypertension	Uncomplicated mild aortic or mitral valve disease	Risk of paradoxical embolism: 1 Potential reversal of left-to-right shunt (e.g. unoperated atrial septal defect)	Risk of paradoxical embolism: 1 Cyanotic heart disease 2 Pulmonary arteriovenous malformations
Simple lesions repaired in childhood with no residual sequelae	Most arrhythmias other than atrial fibrillation or flutter Uncomplicated Marfan syndrome Congenital heart disease lacking any class 3 or 4 features Small left-to-right shunt not reversible with physiologic maneuvers (e.g. small ventricular septal defect) Past cardiomyopathy with full recovery		

considerably lower efficacy as compared with combined oral contraceptive pills. A relatively new form of progestin-only pill containing desogestrel (Cerazette[®]) has significantly lower failure rates than older progestin-only pills, and the efficacy is similar to combined oral contraceptive preparations [52,95]. An intramuscular injection of medroxyprogesterone acetate (DepoProvera[®]) every 3 months is highly efficacious. Low-dose progestin implants, which are inserted in the subcutaneous tissue of the inner surface of the upper arm, containing etonogestrel (Implanon[®]) or levonorgestrel (Norplant[®]) provide reliable contraceptive protection for 3–5 years [92,93].

Intrauterine devices, although highly effective, may carry particular risk for some women with congenital heart disease. Bacteremia may occur, particularly at the time of insertion, which may result in bacterial endocarditis. Additionally, during instrumentation of the cervix, a vasovagal reaction can occur in up to 5% of women, and the drop in preload may have deleterious effects on women with Fontan circulation or pulmonary vascular obstructive disease [52]. A relatively new intrauterine device containing levonorgestrel (Mirena[®]) is reported to be more efficacious than sterilization [52]. Intrauterine devices generally must be replaced every 5 years.

Female sterilization may be achieved through ligation of the Fallopian tubes or intratubal stent implantation (Essure[®]). As an irreversible procedure, this method of contraception may be the desired approach in situations where the risk of pregnancy is exceedingly high. Intratubal device insertion can be successfully achieved hysteroscopically without anesthesia [96], making such an approach attractive in women in whom the risk of general anesthesia may be high (e.g. Eisenmenger syndrome) or laparoscopy poorly tolerated due to the need for abdominal insufflation with carbon dioxide (e.g. Fontan circulation) [52,92].

Case study recommendations

For the patient described in the vignette, the risk of pregnancy in the presence of severe aortic stenosis was thought to be prohibitively high for reasons outlined in the discussion above. Given the anticipated complexities of anticoagulation management in the setting of a mechanical aortic valve during pregnancy, this patient was referred for an elective Ross operation (pulmonary autograft in the aortic position with a pulmonary homograft in the pulmonary position) in order to allow a subsequent pregnancy to proceed at lower risk. In 2 reports, 24 completed pregnancies in women post-Ross operation were described and no significant cardiac complications were reported related to the pregnancy; one woman developed a dilated cardiomyopathy 6 months after delivery unrelated to semilunar valve dysfunction [81,82]. It should be kept in mind that a Ross procedure is by no means a definitive operation as future surgeries are inevitable due to the finite lifespan of a bioprosthesis in the pulmonary position [85]. The patient did conceive about 9 months after her Ross operation and had an uncomplicated pregnancy.

This case illustrates the importance of preconception planning to optimize pregnancy success in a woman with congenital heart disease.

References

1. Pirani BB, Campbell DM, MacGillivray I. Plasma volume in normal first pregnancy. *J Obstet Gynaecol Br Commonw* 1973;80:884–7.
2. Robson SC, Hunter S, Boys RJ, Dunlop W. Serial study of factors influencing changes in cardiac output during human pregnancy. *Am J Physiol* 1989;256:H1060–5.
3. Duvekot JJ, Cheriex EC, Pieters FA, et al. Early pregnancy changes in hemodynamics and volume homeostasis are consecutive adjustments triggered by a primary fall in systemic vascular tone. *Am J Obstet Gynecol* 1993;169:1382–92.
4. Taylor DJ, Lind T. Red cell mass during and after normal pregnancy. *Br J Obstet Gynaecol* 1979;86:364–70.
5. Abbas AE, Lester SJ, Connolly H. Pregnancy and the cardiovascular system. *Int J Cardiol* 2005;98:179–89.
6. Karamermer Y, Roos-Hesselink JW. Pregnancy and adult congenital heart disease. *Expert Rev Cardiovasc Ther* 2007;5:859–69.
7. Siu SC, Sermer M, Colman JM, et al. Prospective multicenter study of pregnancy outcomes in women with heart disease. *Circulation* 2001;104:515–21.
8. Silversides CK, Colman JM, Siu SC. Physiology and management of pregnancy in the young adult and child with congenital heart disease. In: Allen HD, Driscoll DJ, Shaddy RE, Feltes TF, eds. *Moss and Adams' Heart Disease in Infants, Children and Adolescents: Including the Fetus and Young Adult*, 7th edition. Philadelphia: Lippincott, Williams and Wilkins, 2007:1431–41.
9. Khairy P, Ouyang DW, Fernandes SM, et al. Pregnancy outcomes in women with congenital heart disease. *Circulation* 2006;113:517–24.
10. Bonow RO, Carabello BA, Kanu C, et al. ACC/AHA 2006 guidelines for the management of patients with valvular heart disease: a report of the American College of Cardiology/American Heart Association Task Force on Practice Guidelines (writing committee to revise the 1998 Guidelines for the Management of Patients With Valvular Heart Disease): developed in collaboration with the Society of Cardiovascular Anesthesiologists: endorsed by the Society for Cardiovascular Angiography and Interventions and the Society of Thoracic Surgeons. *Circulation* 2006;114:e84–231.
11. Khalil A, O'Brien P. Cardiac drugs in pregnancy. In: Steer P, Gatzoulis M, Baker P, eds. *Heart Disease and Pregnancy*. London: RCOG Press, 2006:79–95.
12. Siu SC, Colman JM, Sorensen S, et al. Adverse neonatal and cardiac outcomes are more common in pregnant women with cardiac disease. *Circulation* 2002;105:2179–84.
13. Drenthen W, Pieper PG, Roos-Hesselink JW, et al. Outcome of pregnancy in women with congenital heart disease: a literature review. *J Am Coll Cardiol* 2007;49:2303–11.
14. Nora JJ. From generational studies to a multilevel genetic-environmental interaction. *J Am Coll Cardiol* 1994;23:1468–71.
15. Uebing A, Steer PJ, Yentis SM, Gatzoulis MA. Pregnancy and congenital heart disease. *Br Med J* 2006;332:401–6.
16. Whittemore R, Wells JA, Castellsague X. A second-generation study of 427 probands with congenital heart defects and their 837 children. *J Am Coll Cardiol* 1994;23:1459–67.

17. Nora JJ, Nora AH. Maternal transmission of congenital heart diseases: new recurrence risk figures and the questions of cytoplasmic inheritance and vulnerability to teratogens. *Am J Cardiol* 1987;59:459–63.
18. Rychik J, Ayres N, Cuneo B, et al. American Society of Echocardiography guidelines and standards for performance of the fetal echocardiogram. *J Am Soc Echocardiogr* 2004;17:803–10.
19. Tworetzky W, McElhinney DB, Reddy VM, et al. Improved surgical outcome after fetal diagnosis of hypoplastic left heart syndrome. *Circulation* 2001;103:1269–73.
20. Franklin O, Burch M, Manning N, et al. Prenatal diagnosis of coarctation of the aorta improves survival and reduces morbidity. *Heart* 2002;87:67–9.
21. Oberhansli I, Extermann P, Jaggi E, Pfizenmaier M. Fetal echocardiography in pregnancies of women with congenital heart disease—clinical utility and limitations. *Thorac Cardiovasc Surg* 2000;48:323–7.
22. Yates RS. The influence of prenatal diagnosis on postnatal outcome in patients with structural congenital heart disease. *Prenat Diagn* 2004;24:1143–9.
23. Siu SC, Colman JM. Heart disease and pregnancy. *Heart* 2001;85:710–5.
24. Meijboom LJ, Vos FE, Timmermans J, et al. Pregnancy and aortic root growth in the Marfan syndrome: a prospective study. *Eur Heart J* 2005;26:914–20.
25. Rossiter JP, Repke JT, Morales AJ, et al. A prospective longitudinal evaluation of pregnancy in the Marfan syndrome. *Am J Obstet Gynecol* 1995;173:1599–606.
26. Actis Dato GM, Rinaudo P, Revelli A, et al. Atrial septal defect and pregnancy: a retrospective analysis of obstetrical outcome before and after surgical correction. *Minerva Cardioangiologica* 1998;46:63–8.
27. Zuber M, Gautschi N, Oechslin E, et al. Outcome of pregnancy in women with congenital shunt lesions. *Heart* 1999;81:271–5.
28. Drenthen W, Pieper PG, van der Tuuk K, et al. Cardiac complications relating to pregnancy and recurrence of disease in the offspring of women with atrioventricular septal defects. *Eur Heart J* 2005;26:2581–7.
29. Veldtman GR, Connolly HM, Grogan M, et al. Outcomes of pregnancy in women with tetralogy of Fallot. *J Am Coll Cardiol* 2004;44:174–80.
30. Meijer JM, Pieper PG, Drenthen W, et al. Pregnancy, fertility, and recurrence risk in corrected tetralogy of Fallot. *Heart* 2005;91:801–5.
31. Donnelly JE, Brown JM, Radford DJ. Pregnancy outcome and Ebstein's anomaly. *Br Heart J* 1991;66:368–71.
32. Connolly HM, Warnes CA. Ebstein's anomaly: outcome of pregnancy. *J Am Coll Cardiol* 1994;23:1194–8.
33. Elkayam U, Bitar F. Valvular heart disease and pregnancy part I: native valves. *J Am Coll Cardiol* 2005;46:223–30.
34. Weiss BM, von Segesser LK, Alon E, et al. Outcome of cardiovascular surgery and pregnancy: a systematic review of the period 1984–1996. *Am J Obstet Gynecol* 1998;179:1643–53.
35. Immer FF, Bansi AG, Immer-Bansi AS, et al. Aortic dissection in pregnancy: analysis of risk factors and outcome. *Ann Thorac Surg* 2003;76:309–14.
36. Arias F, Pineda J. Aortic stenosis and pregnancy. *J Reprod Med* 1978;20:229–32.
37. Easterling TR, Chadwick HS, Otto CM, Benedetti TJ. Aortic stenosis in pregnancy. *Obstet Gynecol* 1988;72:113–8.

38. Yap SC, Kouwenhoven GC, Takkenberg JJ, et al. Congenital aortic stenosis in adults: rate of progression and predictors of clinical outcome. *Int J Cardiol* 2007;122:224–31.
39. Silversides CK, Colman JM, Sermer M, et al. Early and intermediate-term outcomes of pregnancy with congenital aortic stenosis. *Am J Cardiol* 2003;91:1386–9.
40. Hameed A, Karaalp IS, Tummala PP, et al. The effect of valvular heart disease on maternal and fetal outcome of pregnancy. *J Am Coll Cardiol* 2001;37:893–9.
41. Lao TT, Sermer M, MaGee L, et al. Congenital aortic stenosis and pregnancy—a reappraisal. *Am J Obstet Gynecol* 1993;169:540–5.
42. Myerson SG, Mitchell AR, Ormerod OJ, Banning AP. What is the role of balloon dilatation for severe aortic stenosis during pregnancy? *J Heart Valve Dis* 2005;14:147–50.
43. Lao TT, Adelman AG, Sermer M, Colman JM. Balloon valvuloplasty for congenital aortic stenosis in pregnancy. *Br J Obstet Gynaecol* 1993;100:1141–2.
44. Bhargava B, Agarwal R, Yadav R, et al. Percutaneous balloon aortic valvuloplasty during pregnancy: use of the Inoue balloon and the physiologic antegrade approach. *Cathet Cardiovasc Diagn* 1998;45:422–5.
45. Banning AP, Pearson JF, Hall RJ. Role of balloon dilatation of the aortic valve in pregnant patients with severe aortic stenosis. *Br Heart J* 1993;70:544–5.
46. Arnoni RT, Arnoni AS, Bonini RC, et al. Risk factors associated with cardiac surgery during pregnancy. *Ann Thorac Surg* 2003;76:1605–8.
47. Beauchesne LM, Connolly HM, Ammash NM, Warnes CA. Coarctation of the aorta: outcome of pregnancy. *J Am Coll Cardiol* 2001;38:1728–33.
48. Friend JW, Drenthen W, Pieper PG, et al. Outcome of pregnancy in patients after repair of aortic coarctation. *Eur Heart J* 2005;26:2173–8.
49. Venning S, Freeman LJ, Stanley K. Two cases of pregnancy with coarctation of the aorta. *J R Soc Med* 2003;96:234–6.
50. Goodwin JF. Pregnancy and coarctation of the aorta. *Lancet* 1958;1:16–20.
51. Plunkett MD, Bond LM, Geiss DM. Staged repair of acute type I aortic dissection and coarctation in pregnancy. *Ann Thorac Surg* 2000;69:1945–7.
52. Thorne S, MacGregor A, Nelson-Piercy C. Risks of contraception and pregnancy in heart disease. *Heart* 2006;92:1520–5.
53. McDermott CD, Sermer M, Siu SC, et al. Aortic dissection complicating pregnancy following prophylactic aortic root replacement in a woman with Marfan syndrome. *Int J Cardiol* 2007;120:427–30.
54. Nistri S, Sorbo MD, Basso C, Thiene G. Bicuspid aortic valve: abnormal aortic elastic properties. *J Heart Valve Dis* 2002;11:369–73, discussion 373–4.
55. Gravholt CH, Landin-Wilhelmsen K, Stochholm K, et al. Clinical and epidemiological description of aortic dissection in Turner's syndrome. *Cardiol Young* 2006;16:430–6.
56. Lin AE, Lippe BM, Geffner ME, et al. Aortic dilation, dissection, and rupture in patients with Turner syndrome. *J Pediatr* 1986;109:820–6.
57. Increased maternal cardiovascular mortality associated with pregnancy in women with Turner syndrome. *Fertil Steril* 2006;86:S127–8.
58. Matura LA, Ho VB, Rosing DR, Bondy CA. Aortic dilatation and dissection in Turner syndrome. *Circulation* 2007;116:1663–70.
59. Slomka F, Salmeron S, Zetlaoui P, et al. Primary pulmonary hypertension and pregnancy: anesthetic management for delivery. *Anesthesiology* 1988;69:959–61.

60. Hameed AB, Goodwin TM, Elkayam U. Effect of pulmonary stenosis on pregnancy outcomes—a case-control study. *Am Heart J* 2007;154:852–4.
61. Drenthen W, Pieper PG, Roos-Hesselink JW, et al. Non-cardiac complications during pregnancy in women with isolated congenital pulmonary valvar stenosis. *Heart* 2006;92:1838–43.
62. Kiely DG, Elliot CA, Webster VJ, Stewart P. Pregnancy and pulmonary hypertension: new approaches to the management of a life-threatening condition. In: Steer P, Gatzoulis M, Baker P, eds. *Heart Disease and Pregnancy*. London: RCOG Press, 2006: 79–95.
63. Gleicher N, Midwall J, Hochberger D, Jaffin H. Eisenmenger’s syndrome and pregnancy. *Obstet Gynecol Surv* 1979;34:721–41.
64. Weiss BM, Zemp L, Seifert B, Hess OM. Outcome of pulmonary vascular disease in pregnancy: a systematic overview from 1978 through 1996. *J Am Coll Cardiol* 1998;31:1650–7.
65. Huang S, DeSantis ER. Treatment of pulmonary arterial hypertension in pregnancy. *Am J Health Syst Pharm* 2007;64:1922–6.
66. Elliot CA, Stewart P, Webster VJ, et al. The use of iloprost in early pregnancy in patients with pulmonary arterial hypertension. *Eur Respir J* 2005;26:168–73.
67. Monnery L, Nanson J, Charlton G. Primary pulmonary hypertension in pregnancy; a role for novel vasodilators. *Br J Anaesth* 2001;87:295–8.
68. Lynch TD, Laffey JG. Sildenafil for pulmonary hypertension in pregnancy? *Anesthesiology* 2006;104:382, author reply 383.
69. Presbitero P, Somerville J, Stone S, et al. Pregnancy in cyanotic congenital heart disease. Outcome of mother and fetus. *Circulation* 1994;89:2673–6.
70. Patton DE, Lee W, Cotton DB, et al. Cyanotic maternal heart disease in pregnancy. *Obstet Gynecol Surv* 1990;45:594–600.
71. Neumayer U, Somerville J. Outcome of pregnancies in patients with complex pulmonary atresia. *Heart* 1997;78:16–21.
72. Connolly HM, Warnes CA. Outcome of pregnancy in patients with complex pulmonic valve atresia. *Am J Cardiol* 1997;79:519–21.
73. Drenthen W, Pieper PG, Ploeg M, et al. Risk of complications during pregnancy after Senning or Mustard (atrial) repair of complete transposition of the great arteries. *Eur Heart J* 2005;26:2588–95.
74. Canobbio MM, Morris CD, Graham TP, Landzberg MJ. Pregnancy outcomes after atrial repair for transposition of the great arteries. *Am J Cardiol* 2006;98:668–72.
75. Guedes A, Mercier LA, Leduc L, et al. Impact of pregnancy on the systemic right ventricle after a Mustard operation for transposition of the great arteries. *J Am Coll Cardiol* 2004;44:433–7.
76. Connolly HM, Grogan M, Warnes CA. Pregnancy among women with congenitally corrected transposition of great arteries. *J Am Coll Cardiol* 1999;33:1692–5.
77. Therrien J, Barnes I, Somerville J. Outcome of pregnancy in patients with congenitally corrected transposition of the great arteries. *Am J Cardiol* 1999;84:820–4.
78. Canobbio MM, Mair DD, van der Velde M, Koos BJ. Pregnancy outcomes after the Fontan repair. *J Am Coll Cardiol* 1996;28:763–7.
79. Hoare JV, Radford D. Pregnancy after fontan repair of complex congenital heart disease. *Aust N Z J Obstet Gynaecol* 2001;41:464–8.

80. Drenthen W, Pieper PG, Roos-Hesselink JW, et al. Pregnancy and delivery in women after Fontan palliation. *Heart* 2006;92:1290–4.
81. Dore A, Somerville J. Pregnancy in patients with pulmonary autograft valve replacement. *Eur Heart J* 1997;18:1659–62.
82. Yap SC, Drenthen W, Pieper PG, et al. Outcome of pregnancy in women after pulmonary autograft valve replacement for congenital aortic valve disease. *J Heart Valve Dis* 2007;16:398–403.
83. North RA, Sadler L, Stewart AW, et al. Long-term survival and valve-related complications in young women with cardiac valve replacements. *Circulation* 1999;99:2669–76.
84. Salazar E, Espinola N, Roman L, Casanova JM. Effect of pregnancy on the duration of bovine pericardial bioprostheses. *Am Heart J* 1999;137:714–20.
85. Elkayam U, Bitar F. Valvular heart disease and pregnancy: part II: prosthetic valves. *J Am Coll Cardiol* 2005;46:403–10.
86. Chan WS, Anand S, Ginsberg JS. Anticoagulation of pregnant women with mechanical heart valves: a systematic review of the literature. *Arch Intern Med* 2000;160:191–6.
87. Vitale N, De Feo M, De Santo LS, et al. Dose-dependent fetal complications of warfarin in pregnant women with mechanical heart valves. *J Am Coll Cardiol* 1999;33:1637–41.
88. Mak S, Harris L. Arrhythmia in pregnancy. In: Wilansky S, Willerson JT, eds. *Heart Disease in Women*, First Edition. Philadelphia: Churchill Livingstone, 2002:497–514.
89. Silversides CK, Harris L, Haberer K, et al. Recurrence rates of arrhythmias during pregnancy in women with previous tachyarrhythmia and impact on fetal and neonatal outcomes. *Am J Cardiol* 2006;97:1206–12.
90. Wilson W, Taubert KA, Gewitz M, et al. Prevention of infective endocarditis: guidelines from the American Heart Association: a guideline from the American Heart Association Rheumatic Fever, Endocarditis, and Kawasaki Disease Committee, Council on Cardiovascular Disease in the Young, and the Council on Clinical Cardiology, Council on Cardiovascular Surgery and Anesthesia, and the Quality of Care and Outcomes Research Interdisciplinary Working Group. *Circulation* 2007;116:1736–54.
91. Fraser IS. Forty years of combined oral contraception: the evolution of a revolution. *Med J Aust* 2000;173:541–4.
92. Miner PD. Contraceptive choices for females with congenital heart disease. *Prog Pediatr Cardiol* 2004;19:15–24.
93. Canobbio MM, Perloff JK, Rapkin AJ. Gynecological health of females with congenital heart disease. *Int J Cardiol* 2005;98:379–87.
94. Bosentan: new preparation. Pulmonary hypertension: an option before epoprostenol infusion. *Prescrire Int* 2005;14:47–50.
95. Korver T, Klipping C, Heger-Mahn D, et al. Maintenance of ovulation inhibition with the 75-microg desogestrel-only contraceptive pill (Cerazette) after scheduled 12-h delays in tablet intake. *Contraception* 2005;71:8–13.
96. Lopes P, Gibon E, Linet T, Philippe HJ. Hysteroscopic tubal sterilization with Essure intratubal devices: A case-control prospective with inert local anesthesia or without anesthesia. *Eur J Obstet Gynecol Reprod Biol* 2008;138:199–203.

Index

Note: Italicized page numbers refer to figures and tables.

- accessory connection, 232*t*
- adult congenital heart disease
 - aortopathy, 115–20
 - atrioventricular septal defects, 9–23
 - coarctation of the aorta, 102–15
 - congenitally corrected transposition of the great arteries, 76–85
 - Ebstein's anomaly, 174–87
 - imaging in, 190–201
 - left ventricular outflow tract
 - obstruction, 87–98
 - pulmonary arterial hypertension, 57–73
 - pulmonary stenosis, 25–38
 - right ventricular outflow obstruction, 25–38
 - secundum atrial septic defect, 1–7
 - single-ventricle physiology, 157–71
 - tetralogy of Fallot, 139–53
 - transposition of great arteries, 126–38
 - ventricular septal defect, 41–53
- Alagille syndrome, 35
- aneurysmal dilatation of RVOT, 145, 149, 150
- aneurysms, 113
 - aortic, 113
 - case, 120–21
 - cerebrovascular, 113
 - definition of, 115
 - identification of, 200
 - thoracic aortic, 117
 - treatment of, 118–19
- angiography, 194
- angiopoietin-1, 63
- angiotensin receptor blockers, 83
- angiotensin-converting enzyme inhibitors (ACEI), 69, 83
- anterior bridging leaflets, 19
- anticoagulation, 72, 249–50
- aorta
 - development of, 103–4
 - embryology of, 103–4
- aorta, coarctation of, 102–15
 - aortic embryology/development, 103–4
 - associated lesions, 104
 - case, 102, 120–21
 - CT scanning, 107
 - definition of, 104
 - diagnosis, 105
 - echocardiogram, 106–7
 - electrocardiogram, 106
 - etiology, 104
 - imaging, 199–200
 - intervention summary, 112
 - interventional catheterization, 110–11
 - magnetic resonance imaging, 107

- medical considerations, 112–13
 - aortic aneurysms, 113
 - cerebrovascular aneurysms, 113
 - coronary artery disease, 113
 - hypertension, 112
- in pregnant women, 245–6
- presentation, 105
- prevalence, 104
- recurrence of, 111
- routine follow-up, 113–15
- surgery, 109–10
- testing, 105–7
- treatment of, 107–8
- aortic aneurysms, 113
- aortic regurgitation, 145
- aortic root, dilatation of, 149
- aortic stenosis, 245
- aortopathy, 115–20. *See also* coarctation of the aorta
 - connective tissue disorders, 115–18
 - bicuspid aortic valve, 117–18
 - Ehlers-Danlos syndrome, 115–16
 - Loeys-Dietz syndrome, 115–16
 - Marfan syndrome, 115–16
 - thoracic aortic aneurysm and dissection syndrome, 117
 - Turner syndrome, 117
 - definition of, 115
 - medical therapy, 119
 - pathology of, 115
 - and pregnancy, 246–7
 - screening and monitoring, 118
 - surgical therapy, 119–20
 - treatment of, 118–19
- aortopulmonary shunts, 161
- arrhythmias, 221–33
 - case study, 221
 - and catheter ablation, 184–5
 - in congenital heart disease, 221–33
 - case study, 221, 233–4
 - prevention of, 231–3
 - prophylactic management of, 232*t*
 - risk of sudden death, 229–31
 - treatment of, 222–9
 - in Fontan patients, 170–71
 - incidence of, 222–3
 - in pregnant women, 251
 - in transposition of great arteries, 130–31
- ascending aorta, 214–16
- atrial baffles, 130–32
 - functions of, 131
 - leaks, 132
 - obstructions, 131–2
- atrial fibrillation, 224*t*, 232*t*
- atrial isomerism, 166–7
- atrial reentry tachycardia, 224*t*, 232*t*
- atrial septal defect, 195–6, 223*t*, 243
- atrial septal defect (ASD), secundum, 1–7
 - anatomy of, 2–3
 - case, 1
 - closure of, 6–7
 - diagnosis, 4–6
 - cardiac catheterization, 5–6
 - magnetic resonance imaging, 5–6
 - transesophageal echocardiography, 4–5
 - embryology of, 2–3
 - natural history, 3–4
 - pathophysiology of, 3
 - patient follow-up, 7
 - treatment of, 6–7
- atrial septation, 2–3
- atrioventricular arrhythmias, 166–7
- atrioventricular block, 224*t*, 232*t*
- atrioventricular discordance, 78
- atrioventricular nodal reentry tachycardia, 224*t*, 225*f*, 232*t*
- atrioventricular septal defects (AVSD), 9–23
 - atrioventricular valve abnormalities, 21
 - case studies, 9–10, 22–3
 - clinical evaluation after repair, 22
 - clinical presentation, 19–20
 - complete, 19–21
 - double-orifice left atrioventricular valve, 21
 - echocardiographic evaluation of, 20–21
 - forms of, 12–14
 - intermediate, 14
 - left-to-right shunts, 243–4
 - partial, 14–19
 - pathology of, 19

- atrioventricular septal defects
 (AVSD) (*Contd.*)
 patient follow-up, 22–3
 in pregnant women, 243–4
 primum, 17–18
 progressive LVOT obstruction in, 10–11
 single left ventricular papillary muscle,
 21
 surgical repair of, 21
 transitional, 12–14
 unbalanced, 21
- azygos vein, 136
- baffles, 131–2. *See also* transposition of
 great arteries (TGA)
 functions of, 131
 leaks, 132
 obstructions, 131–2
- balloon pulmonary valvuloplasty, 32f
- barbiturates, 67
- Beraprost, 72
- Bernoulli equation, 4
- bicuspid aortic valve (BAV), 89–93. *See also*
 left ventricular outflow tract
 obstruction (LVOTO)
 and coarctation of the aorta, 104,
 117–18
 endocarditis, 92–3
 intervention, 91–2
 long-term follow-up, 92
 pathophysiology of, 91
 prevalence, 90–91
- bidirectional Glenn, 163f
- Blalock-Taussig shunt, 161
- bone morphogenetic protein receptor II, 63
- bones, 211
- bosentan, 70, 73, 252
- bronchial arterial collaterals, 213
- bronchiectasis, 213
- Bruce protocol, 31
- cardiac catheterization
 congenitally corrected transposition of
 the great arteries, 80
 Ebstein's anomaly, 182–3
 Eisenmenger syndrome, 64–5
 pulmonary stenosis, 30
 secundum atrial septic defect, 5–6
 transposition of great arteries, 137
 ventricular septal defect, 49
- cardiac magnetic resonance (CMR)
 imaging, 30, 49, 193
- cardiac silhouette, enlarged, 2f
- cardioversion, 227
- “CATCH 22” syndrome, 147
- catheter ablation, 184–5, 227
- cavopulmonary shunts, 161–5
- central pulmonary arteries, enlarged, 2f
- Cerazette, 70, 254
- cerebrovascular aneurysms, 113
- chest x-ray, 208–20
 atria, 218–20
 bones, 211
 in congenitally corrected transposition
 of the great arteries, 79
 in Ebstein's anomaly, 181
 extrapulmonary soft tissue densities,
 212–18
 sequence for reading, 209f
- coarctation of the aorta, 102–15
 aortic embryology/development, 103–4
 associated lesions, 104
 case, 102, 120–21
 CT scanning, 107
 definition of, 104
 diagnosis, 105
 echocardiogram, 106–7
 electrocardiogram, 106
 etiology, 104
 imaging, 199–200
 intervention summary, 112
 interventional catheterization, 110–11
 magnetic resonance imaging, 107
 medical considerations, 112–13
 aortic aneurysms, 113
 cerebrovascular aneurysms, 113
 coronary artery disease, 113
 hypertension, 112
 in pregnant women, 245–6
 presentation, 105
 prevalence, 104
 recurrence of, 111

- routine follow-up, 113–15
 - surgery, 109–10
 - testing, 105–7
 - treatment of, 107–8
- compensated state, 66
- complete atrioventricular septal defects, 19–22
 - clinical evaluation after repair, 22
 - clinical presentation of, 19–20
 - double-orifice left atrioventricular valve, 21
 - echocardiographic evaluation of, 20–21
 - pathology of, 19
 - single left ventricular papillary muscle, 21
 - surgical treatment of, 21
 - valve abnormalities in, 21
- computed tomography (CT), 107, 193
- conduction defects, 51
- congenital heart disease (CHD), 190–201
 - aortopathy, 115–20
 - arrhythmias in, 221–33
 - case study, 221, 233–4
 - prevention of, 231–3
 - prophylactic management of, 232*t*
 - risk of sudden death, 229–31
 - treatment of, 222–9
 - atrial septal defect, 195–6
 - atrioventricular septal defects, 9–23
 - case study, 190
 - chest x-ray in, 208–20
 - atria, 218–20
 - bones, 211
 - extrapulmonary soft tissue densities, 212–18
 - coarctation of the aorta, 102–15, 199–200
 - congenitally corrected transposition of the great arteries, 76–85
 - Ebstein's anomaly, 174–87, 200
 - imaging in, 190–201
 - imaging modalities, 192–4
 - cardiac magnetic resonance, 193
 - computed tomography, 193
 - positron emission tomography, 194
 - radionuclide angiography, 194
 - trans thoracic echocardiography, 192–3
 - indications for cardiac magnetic resonance imaging, 191–2*t*
 - left ventricular outflow tract obstruction, 87–98
 - patent ductus arteriosus, 197
 - and pregnancy, 237–55
 - case study, 237, 254–5
 - cyanotic, 248
 - fetal–neonatal risk, 241–2
 - Fontan palliation, 249–50
 - high-risk lesions, 242–3
 - left-to-right shunt, 243
 - maternal risk, 238–41
 - pressure overload lesions, 245–8
 - regurgitant valves, 244
 - systemic right ventricle, 248–9
 - volume overload lesions, 243–4
 - pulmonary arterial hypertension, 57–73
 - pulmonary stenosis, 25–38
 - right ventricular outflow obstruction, 25–38
 - right ventricular outflow tract obstruction, 197
 - secundum atrial septic defect, 1–7
 - single-ventricle physiology, 157–71
 - tetralogy of Fallot, 139–53, 197–9
 - transposition of great arteries, 126–38
 - ventricular septal defect, 41–53, 196–7
- congenital pulmonary stenosis, 28
- congenital rubella syndrome, 28
- congenitally corrected transposition of the great arteries (cTGA), 76–85
 - assessment and investigations, 79–80
 - chest radiograph, 79
 - echocardiography, 80
 - electrocardiogram, 79
- associated defects, 78
- associated with maternal conditions, 80
 - cardiac catheterization, 80
 - magnetic resonance imaging, 80
- atrioventricular discordance, 78
- case study, 76, 84–5
- definition of, 76
- follow-up, 84

- congenitally corrected transposition of the great arteries (cTGA) (*Contd.*)
 incidence, 78–9
 incidence of arrhythmia in, 223*t*
 medical management, 80–82
 issues, 81–2
 LV outflow tract obstruction, 81–2
 right ventricular failure, 80–81
 tricuspid regurgitation, 80–81
 medical management issues, 81–2
 multislice CT scan of, 77*f*
 and pregnancy, 83–4
 presentation, 79
 sinus rhythm, 77*f*
 ventriculoarterial discordance, 78
- connective tissue disorders, 115–18
 bicuspid aortic valve, 117–18
 Ehlers-Danlos syndrome, 115–16
 Loeys-Dietz syndrome, 115–16
 Marfan syndrome, 115–16
 thoracic aortic aneurysm and dissection syndrome, 117
 Turner syndrome, 117
- continuous wave Doppler, 27*f*, 29, 48, 107*f*, 196*f*, 237
- contraception, 70–71, 252–4
 contraceptive pills, 252
 contrast echo, 136
 coronary artery disease, 113
 coronary ischemia, 69–70
 Coumadin, 70
 crochetage, 5*f*
 cyanotic congenital heart disease, 248
 cystic medial necrosis, 115
- Depo-Provera injections, 70, 254
 desogestrel, 254
 diastolic pressure, calculation of, 4
 differential diagnosis, 182–3
 direct systemic arterial collaterals, 213
 double-inlet ventricle, 165–6
 double-orifice left atrioventricular valve, 21
 Down syndrome, 210, 211, 231
- Ebstein's anomaly, 174–87
 arrhythmia intervention, 184–5
 associated cardiac lesions, 180
 background, 175
 case study, 174–5, 187
 catheter ablation, 184–5
 classification, 178–9
 clinical features, 179–80
 diagnosis, 180–83
 cardiac catheterization, 182–3
 chest radiography, 181
 differential diagnosis, 182–3
 echocardiography, 181–2
 electrocardiogram, 181
 magnetic resonance imaging, 182
 physical examination, 180–81
 genetics, 178
 imaging, 200
 incidence of, 175
 incidence of arrhythmia in, 223*t*
 medical management, 183–4
 pathology of, 177–8
 postoperative findings, 186
 and pregnancy, 184
 prognosis, 186
 surgical indications, 185
 transthoracic echocardiography, 176*f*
- echocardiography
 atrioventricular septal defects, 20–21
 congenitally corrected transposition of the great arteries, 80
 Ebstein's anomaly, 181–2
 transposition of great arteries, 134–6
 valvular pulmonary stenosis, 29
 ventricular septal defect, 47–8
- Ehlers-Danlos syndrome, 115–16
 Eisenmenger syndrome, 57–73
 aneurysmal dilatation in, 216
 cardiac examination, 64
 case study, 57–8, 73
 congenital lesions, 62*t*
 contraception, 70–71
 coronary ischemia, 69–70
 definition of, 58

- disease-targeting therapies, 72–3
 endothelin receptor blockade, 73
 phosphodiesterase inhibitors, 73
 prostacyclin, 72
 evaluation of, 63–4
 general examination, 64
 genetics, 62–3
 hemostatic defects, 65–6
 history, 60
 intrapulmonary thromboses, 66
 iron deficiency, 66
 managing, 71–2
 anticoagulation, 72
 erythrocytosis, 72
 heart–lung transplantation, 72
 home oxygen, 71–2
 mortality risks, 59–60
 noncardiac surgery, 66–9
 pathophysiology of, 62–3
 pulmonary neovascularity in, 214
 renal dysfunction, 69
 secondary erythrocytosis, 66
 in secundum atrial septic defect, 3
 special investigations, 64–5
 stroke risk, 66
 in ventricular septal defect, 44, 51
 elastases, 62
 electrocardiogram, 79, 133–4, 181
 endocarditis, 151
 bicuspid aortic valve, 92–3
 subvalvular aortic stenosis, 96
 endothelin receptor blockade, 73
 erythrocytosis, 66, 72
 erythropoietin, 66
 Essure, 254
 estrogen, 70, 83, 245, 252
 etonogestrel, 254
 exercise test, 136
 extracardiac Fontan procedure, 164^f
 extrapulmonary soft tissue densities, 212–18
- fetal–neonatal risk, 241–2
 fibronectin, 63
 first heart sound (S1), 28
- First Natural History Study of Congenital Heart Defects, 31
 flow velocities, 136
 Fontan circulation, 169–70
 Fontan conversion, 171
 Fontan palliation, 249–50
- Gerbode defects, 42, 45, 51
 Ghent nosology, 115
 Glenn shunt, 161–2
 glomerulopathy, 69
- heart–lung transplantation, 72
 hematocrit, 66, 68–9
 Holt–Oram syndrome, 242
 home oxygen, 71
 hypertension, 112
 hypertrophic cardiomyopathy, 229
 hyperuricemia, 69
 hyperviscosity, 52, 57, 66, 67^t, 69, 72, 169^t
 hypoplastic left heart, 165
 hypoxia, 67, 69
- Iloprost, 72
 Implanon, 70, 254
 indirect systemic arterial collaterals, 213
 infective endocarditis, 52
 inferior vena cava, 217–18
 infundibular ventricular septal defect, 42–3
 inlet ventricular septal defect, 44
 Inoue balloon, 31
 intermediate atrioventricular septal defects, 12
 interventional catheterization, 110–11
 intrapulmonary thromboses, 66
 iron deficiency, 66
- Jatene procedure, 248
- Kaplan–Meier survival curves, 152^f
 Kartagener triad, 213
 Kawashima procedure, 128
 Kerley lines, 213–14

- Kreutzer Fontan procedure, 158, 163*f*
 kyphosis, 211
- leaflets, 19
- left atrial isomerism, 167*t*
- left atrium, 42*f*, 145*f*, 177*f*, 218
- left superior vena cava, 216–17
- left ventricle
 baffles, 129–32
 chest x-ray, 217
 congenitally corrected transposition of
 the great arteries, 76
 displacement of, 70
 double-inlet ventricle, 165
 electrocardiographic view, 43*f*
 enlargement of, 53
 illustration, 42*f*
 patent ductus arteriosus, 197
 secundum atrial septal defect, 4
 single-ventricle physiology, 158, 160
 tetralogy of Fallot, 140*f*, 141*f*
 transthoracic echocardiogram, 44*f*, 89*f*
- left ventricular dysfunction, 149, 151
- left ventricular outflow tract obstruction
 (LVOTO), 87–98
 anatomical repair, 81–2
 in atrioventricular septal defects, 10–11
 bicuspid aortic valve, 89–93
 case study, 87–8, 97–8
 congenital abnormalities, 88
 overview, 87
 and pregnancy, 88–9
 signs and symptoms, 88
 subvalvular aortic stenosis, 93–6
 supravalvular stenosis, 96–7
 valvular stenosis, 89–90
- left ventriculography, 49
- left-to-right shunt, 3, 45, 243–4
- levonorgestrel, 254
- Loeys-Dietz syndrome, 115–16
- Lunelle, 252
- LV dysfunction, 145
- macroreentry atrial tachycardia, 225*f*
- magnetic resonance imaging (MRI), 6, 80,
 107, 137, 182
- maladie de Roger, 46
- Marfan syndrome, 115–16
- maternal risk, 238–41
- matrix metalloproteinases, 62–3
- MAZE procedure, 7
- medroxyprogesterone acetate, 254
- megakaryocytes, 65, 69
- membranous ventricular septal defect,
 43*f*
- microcytosis, 66
- Mirena implant, 70–71, 84, 254
- mitral stenosis, 245
- murmurs, 10, 16, 25, 28, 41, 46–7, 105, 133,
 174
- muscular ventricular septal defect, 44
- Mustard atrial switch procedure,
 126–38
 arrhythmia, 130–31, 223*t*
 atrial baffles, 131
 baffle leaks, 132
 baffle obstruction, 131–2
 cardiac catheterization, 137
 case study, 126, 137
 contrast echo, 136
 echocardiography, 134–6
 electrocardiogram, 133–4
 exercise test, 136
 history, 133
 magnetic resonance imaging,
 137
 overview, 128
 physical examination, 133
 routine follow-up, 133
 schematic drawing, 128*f*
 ventricular function, 129–30
- NKX 2.5 gene defect, 231
- noncardiac surgery, 66–9
- Noonan syndrome, 28, 57
- Norplant, 254
- Norwood procedure, 161
- orthodromic reciprocating tachycardia,
 225*f*
- OrthoEvra, 252
- outlet chamber, 215, 219–20

- partial atrioventricular septal defects,
 14–19. *See also* atrioventricular
 septal defects (AVSD)
 associated anomalies, 18
 clinical presentation, 16
 echocardiographic evaluation of, 17–18
 pathology of, 14–16
 primum, 17
 surgical treatment of, 18–19
- patent ductus arteriosus, 62*t*, 197,
 216, 243
- pectus excavatum, 211
- percutaneous balloon valvuloplasty,
 30–31, 32
- percutaneous closure, 7
- phenylephrine, 68
- phosphodiesterase inhibitors, 73
- physical examination, 180–81
- polychromasia, 58*f*
- positron emission tomography (PET),
 194
- Pott's anastomosis, 161, 168*t*
- pregnancy, 237–55
 anticoagulation in, 249–50
 arrhythmia in, 251
 and congenital heart disease, 237–55
 case study, 237, 254–5
 cyanotic, 248
 fetal–neonatal risk, 241–2
 Fontan palliation, 249–50
 high-risk lesions, 242–3
 left-to-right shunt, 243
 maternal risk, 238–41
 regurgitant valves, 244
 systemic right ventricle, 248–9
 and congenitally corrected transposition
 of the great arteries, 83–4
 and Ebstein's anomaly, 184
 and LV outflow tract obstruction, 88–9
 management of labor and delivery, 251
 pressure overload lesions, left heart,
 245–7
 aortic stenosis, 245
 aortopathies, 246–7
 coarctation of the aorta, 245–6
 mitral stenosis, 245
 pressure overload lesions, right heart,
 247–8
 pulmonary hypertension, 247–8
 pulmonary stenosis, 247
 and pulmonary stenosis, 33
 thrombosis in, 250–51
 and transposition of great arteries,
 248–9
 volume overload lesions, 243–4
 premature ventricular contractions, 146,
 149
- pressure overload lesions
 left heart, 245–7
 aortic stenosis, 245
 aortopathies, 246–7
 coarctation of the aorta, 245–6
 mitral stenosis, 245
- right heart, 247–8
 pulmonary hypertension, 247–8
 pulmonary stenosis, 247
- primum atrioventricular septal
 defects, 17
- progesterone, 70, 252
- progestogens, 70
- prostacyclin, 63*f*, 72
- pulmonary arterial flow, 3
- pulmonary arterial hypertension (PAH),
 57–73
 cardiac examination, 64
 case, 57–8
 case study, 73
 congenital lesions, 62*f*
 contraception, 70–71
 coronary ischemia, 69–70
 definition of, 58
 disease-targeting therapies, 72–3
 endothelin receptor blockade, 73
 phosphodiesterase inhibitors, 73
 prostacyclin, 72
 evaluation of, 63–4
 general examination, 64
 genetics, 62–3
 hemostatic defects, 65–6
 history, 60
 intrapulmonary thromboses, 66
 iron deficiency, 66

- pulmonary arterial hypertension
(PAH) (*Contd.*)
managing, 71–2
 anticoagulation, 72
 erythrocytosis, 72
 heart–lung transplantation, 72
 home oxygen, 71–2
mortality risks, 59–60
noncardiac surgery, 66–9
outcomes, 59–60
pathophysiology of, 62–3
renal dysfunction, 69
secondary erythrocytosis, 66
special investigations, 64–5
stroke risk, 66
- pulmonary arterial pressure, 3–4
- pulmonary arteriovenous fistulae, 213
- pulmonary artery banding, 161
- pulmonary hypertension, 247–8
- pulmonary neovascularity, 214
- pulmonary regurgitation, 143, 148, 150, 244
- pulmonary stenosis, 25–38
angiography, 36f
case, 25, 35
congenital, 28
murmurs in, 28
overview, 25–6
pre- and post-valvuloplasty
 hemodynamics, 37f
in pregnant women, 247
subvalvular, 34–5
supravalvular stenosis, 35
valvular, 26–34
- pulmonary trunk, 216
- pulmonary vascular resistance, 3, 63
- pulmonary vascularity, increased, 2f
- pulmonary venous vascularity, 213–14
- QRS complex, 5f, 134
- radionuclide angiography (RNA), 194
- Rastelli procedure, 81–2, 128
- regurgitant valves, 244
- renal dysfunction, 51, 69, 170
- residual RVOTO, 145, 148
- residual ventricular septal defects, 145, 149
- restrictive right ventricle, 143–5, 148, 150
- right atrial isomerism, 167t
- right atrium, 2–3, 29, 45, 127f, 128f, 131–3, 135f, 140f, 215f
- right superior vena cava, 216–17
- right ventricle
 atrioventricular septal defects, 19
 dilated, 139, 145, 221
 double-chambered, 34–5
 echocardiogram, 44f
 enlarged, 217f
 hypertrophied, 33, 73, 76
 illustration, 42f
 imaging of, 30
 normal anatomy and circulation, 127f
 repair, 94
 restrictive, 143, 148
 secundum atrial septic defect, 3
 systemic, 248–9
 tetralogy of Fallot, 140f, 141f
 transthoracic echocardiogram, 44f
 unbalanced AVSD, 21
- right ventricular dilatation, 143, 148, 150
- right ventricular failure, 80–81
- right ventricular outflow tract obstruction (RVOTO), 141–2, 197
- right-to-left shunt, 3, 65, 67, 70, 133, 196, 200
- Seckel syndrome, 211
- second heart sound (S2), 4
- Second Natural History Study of Congenital Heart Defects, 31
- secundum atrial septic defect, 1–7
 anatomy of, 2–3
 case, 1
 closure of, 6–7
 diagnosis, 4–6
 cardiac catheterization, 5–6
 magnetic resonance imaging, 5–6
 transesophageal echocardiography, 4–5
 embryology of, 2–3
 natural history, 3–4
 pathophysiology of, 3

- patient follow-up, 7
 - treatment of, 6–7
- Senning procedure, 81–2, 248–9
- septation, 2–3
- Shone syndrome, 94
- sildenafil, 70, 73
- single left ventricular papillary muscle, 21
- single photon emission computed tomography (SPECT), 194
- single-ventricle physiology, 157–71
 - arrhythmias in Fontan patients, 170–71, 223*f*
 - case study, 157, 171
 - clinical components of morphology, 159
 - definition of, 157–8
 - early palliative procedures, 160–65
 - aortopulmonary shunts, 161
 - cavopulmonary shunts, 161–5
 - pulmonary artery banding, 161
 - etiology, 158–9
 - Fontan conversion, 171
 - incidence, 158
 - initial presentation in childhood, 160
 - long-term implications of Fontan circulation, 169–70
 - long-term outcome in adulthood, 169
 - in pregnant women, 249–50
 - presentation in adulthood, 167–9
 - subtypes, 165–7
 - atrioventricular valve atresia, 166–7
 - double-inlet ventricle, 165–6
 - heterotaxy syndromes, 166–7
 - hypoplastic left heart, 165
 - ventricular morphology, 160
 - single-ventricle heart, 219
 - sinus brachycardia, 224*t*, 232*f*
 - sinus solitus, 167
- Sitaxsentan, 73
- situs inversus, 167
- spherocytes, 58*f*
- sternotomy, 211
- subcutaneous implant, 70
- subvalvular aortic stenosis (SAS), 93–6. *See also* left ventricular outflow tract obstruction (LVOTO)
 - congenital defects in, 93–4
 - endocarditis, 96
 - intervention, 94–5
 - long-term complications, 95–6
 - overview, 93–4
- subvalvular pulmonary stenosis, 34–5
- sudden cardiac death, 146–7, 150, 151, 229–31
- suicide right ventricle, 32–3
- superior vena cava, 216–18
- supravalvar pulmonary stenosis, 35
- supravalvular stenosis, 96–7
- supraventricular arrhythmia, 145–6, 149, 151
- supraventricular tachycardia, 223–5
- surgical valvotomy, 31
- systemic arterial collaterals, 213
- systemic right ventricle, 248–9
- systemic vascular resistance (SVR), 67–8
- systolic pressure, calculation of, 4

- tachyarrhythmia, 52, 130, 145
- tachycardia, 223–7
- Tadalafil, 73
- tenascin, 63
- tetralogy of Fallot, 139–53
 - anatomy of, 140
 - aneurysmal dilatation of RVOT, 145, 149, 150
 - aortic regurgitation, 145
 - case study, 139, 151
 - dilatation of aortic root, 149
 - endocarditis, 151
 - imaging, 197–9
 - incidence, 139
 - incidence of arrhythmia in, 223*f*
 - Kaplan-Meier survival curves, 152*f*
 - left atrium in, 218
 - left ventricular dysfunction, 149, 151
 - long-term complications, 143–8
 - LV dysfunction, 145
 - management of late problems, 148–50
 - premature ventricular contractions, 146, 149
 - prevention of late problems, 150–51
 - psychiatric issues, 147–8
 - pulmonary arterial vascularity in, 213

- tetralogy of Fallot (*Contd.*)
- pulmonary regurgitation, 143, 148, 150
 - residual RVOTO, 145, 148
 - residual VSDs, 145, 149
 - restrictive right ventricle, 143–5, 148, 150
 - right ventricular dilatation, 143, 148, 150
 - risk score, 152^t
 - sudden cardiac death, 146–7, 150, 151
 - supraventricular arrhythmia, 145–6, 149, 151
 - surgical repair, 141–3
 - synopsis, 153
 - systemic arterial collaterals in, 213
 - ventricular tachycardia, 146, 150, 151
- thoracic aortic aneurysm and dissection syndrome, 117
- thrombocytopenia, 57, 65, 68, 169^t
- transabdominal fetal echocardiography, 242
- transesophageal echocardiography (TEE), 4–5, 64
- transforming growth factor beta receptor mutations (TGFB β R), 116–17
- transitional atrioventricular septal defects, 12
- transposition of great arteries (TGA), 126–38
- arrhythmia in, 130–31, 223^t
 - atrial baffles, 131
 - baffle leaks, 132
 - baffle obstruction, 131–2
 - cardiac catheterization, 137
 - case study, 126, 137
 - complex, 128
 - contrast echo, 136
 - echocardiography, 134–6
 - electrocardiogram, 133–4
 - exercise test, 136
 - history, 133
 - magnetic resonance imaging, 137
 - overview, 128
 - physical examination, 133
 - in pregnant women, 248–9
 - Rashkind balloon atrioseptostomy, 127^f
 - routine follow-up, 133
 - schematic drawing, 128^f
 - simple, 128
 - surgical techniques, 128–9
 - ventricular function, 129–30
- transthoracic echocardiography (TTE), 4, 192–3
- Treprostinil, 72
- tricuspid annular plane systolic excursion (TAPSE), 135
- tricuspid regurgitation, 52, 64, 76, 80–81, 126, 137, 143
- tricuspid valve reoperation, 223^t
- Turner syndrome, 104, 117, 246
- univentricular heart, 158, 219–20
- UT 15-C, 72
- vaginal ring, 252
- valvular pulmonary stenosis, 26–34
- clinical features, 28–30
 - guidelines, 33–4
 - pathology of, 26–8
 - pathophysiology of, 28
 - and pregnancy, 33–4
 - prognosis, 31–3
 - therapeutic approach, 30–31
- valvular stenosis, 34, 89–90
- Vardenafil, 73
- venesection, 57, 66, 67^t, 68
- ventricular fibrillation, 224^t, 232^t
- ventricular septal defect (VSD), 41–53
- in adults, 46–8
 - anatomy of, 41–5
 - cardiac examination in, 45–7
 - case, 41, 53–4
 - diagnostic tests, 49–50
 - echocardiogram, 48–9
 - imaging, 196–7
 - incidence of arrhythmia in, 223^t
 - indication for intervention, 50–52
 - infundibular, 42–3
 - inlet, 44

- ventricular septal defect (VSD) (*Contd.*)
 - left-to-right shunt in, 45
 - membranous, 42
 - muscular, 44
 - pathophysiology of, 41–6
 - potential late complications,
 - 51–2
 - in pregnant women, 243
 - prognosis, 51–2
 - spontaneous closure, 50
 - surgical closure, 51
- ventricular septum, segments,
 - 42*f*
- ventricular tachycardia, 146, 150, 151, 224*t*,
 - 225–6, 232*t*
- ventriculography, 49, 194
- volume overload lesions, 243–4
- Waterston shunt, 96, 142, 161, 168*t*
- Williams syndrome, 28, 35
- x-ray, chest, 208–20
 - atria, 218–20
 - bones, 211
 - in congenitally corrected transposition
 - of the great arteries, 79
 - in Ebstein's anomaly, 181
 - extrapulmonary soft tissue densities,
 - 212–18
 - sequence for reading, 209*t*

Author Disclosure Table									
Working group member	Employment	Research grant	Other research support	Speakers bureau/honoraria	Expert witness	Ownership interest	Consultant/advisory board	Other	Other
Ammash	Mayo Clinic	None	None	None	None	None	None	None	None
Broberg	Oregon Health and Science University	None	None	American College of Cardiology	None	None	None	None	None
Cetta	Mayo Clinic	None	None	None	None	None	None	None	None
Colman	University of Toronto	None	Modest	None	Modest	None	None	None	None
Connolly	Mayo Clinic	None	None	None	None	None	None	None	None
Deal	None	None	None	None	None	None	None	None	None
Foster	USCF	EBR Inc, Boston Scientific, Evalve Inc+	None	None	None	None	None	None	None
Gatzoulis	Royal Brompton Hospital	None	None	None	None	None	None	None	None

Gurvitz	None	None	None	None	None	None	None	None	None	None	None	None
Lease	University of California, San Francisco	None	None	None	None	None	None	None	None	None	None	None
Lim	Southampton Hospital											
Meijboom	UMC St. Radboud	None	None	None	None	None	None	None	None	None	None	None
Owusu-Anash	Southampton Hospital											
Perloff	Streisand/American Heart Association	None	None	None	None	None	None	None	None	None	None	None
Phillips	Mayo Clinic	None	None	None	None	None	None	None	None	None	None	None
Silversides	University Health Network, Toronto, Ontario	None	None	None	None	None	None	None	None	None	None	None
Siu	University of Western Ontario	None	None	None	None	None	None	None	None	None	None	None
Swan	Royal Brompton Hospital, London	None	None	None	None	None	None	None	None	None	None	None

(Continued)

Author Disclosure Table (Continued)

Working group member	Employment	Research grant	Other research support	Speakers bureau/honoraria	Expert witness	Ownership interest	Consultant/advisory board	Other
Therrien	Jewish General Hospital	None	None	None	None	None	None	None
Thorne	University Hospital, Birmingham	None	None	None	None	None	None	None
Veldtman	Southampton University Hospital Trust	None	None	None	None	None	None	None
Wald	Toronto General Hospital	None	None	None	None	None	None	None
Webb	University of Pennsylvania Health Systems	None	None	None	None	None	None	None

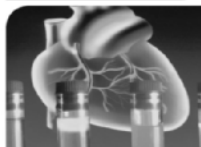*Modest

+Significant

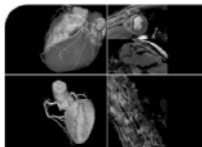
This table represents the relationships of writing group members that may be perceived as actual or reasonably perceived conflicts of interest as reported on the Disclosure Questionnaire which all writing group members are required to complete and submit. A relationship is considered to be "Significant" if (a) the person receives \$10,000 or more during any 12 month period, or 5% or more of the person's gross income; or (b) the person owns 5% or more of the voting stock or share of the entity, or owns \$10,000 or more of the fair market value of the entity. A relationship is considered to be "Modest" if it is less than "Significant" under the preceding definition.

The AHA Clinical Series

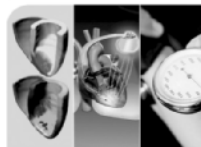

SERIES EDITOR • ELLIOTT ANTMAN



Biomarkers in Heart Disease
James A. de Lemos
9781405175715



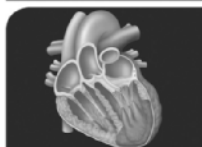
Novel Techniques for Imaging the Heart
Marcelo Di Carli & Raymond Kwong
9781405175333



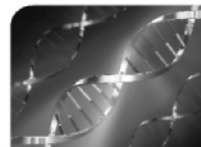

Pacing to Support the Failing Heart
Kenneth A. Ellenbogen
& Angelo Auricchio
9781405175340



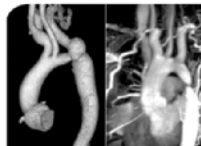

Metabolic Risk for Cardiovascular Disease
Robert H. Eckel
9781405181044



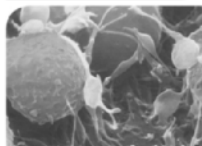
Cardiogenic Shock
Judith Hochman
& E. Magnus Ohman
9781405179263



Cardiovascular Genetics and Genomics
Dan Roden
9781405175401



Adult Congenital Heart Disease
Carole A. Warnes
9781405178204



Antiplatelet Therapy in Ischemic Heart Disease
Stephen Wiviott
9781405176262

American Heart Association 

Learn and Live

**AHA/ASA Premium
Professional Members
Save 20%**

To join and order visit
my.americanheart.org