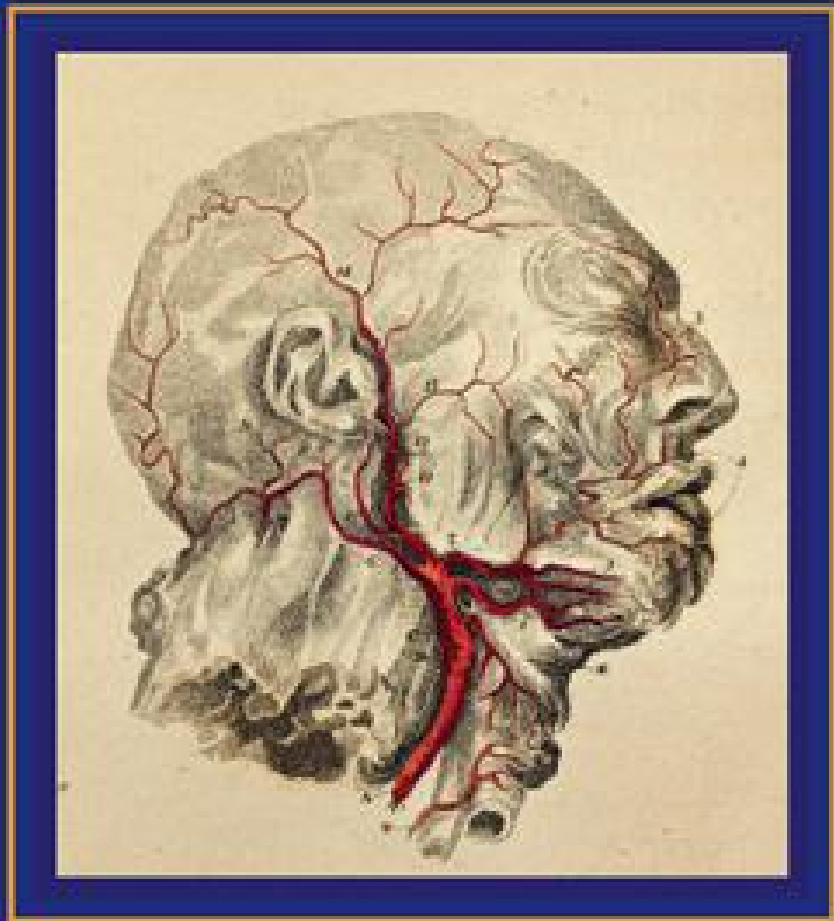


# FACIAL TOPOGRAPHY

*Clinical Anatomy of the Face*



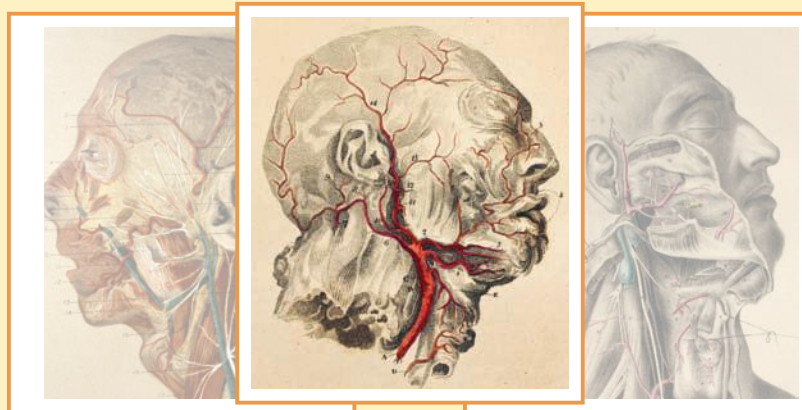Joel E. Pessa  
Rod J. Rohrich

ILLUSTRATOR  
Amanda Yarberry Behr

**FACIAL TOPOGRAPHY**  
*Clinical Anatomy of the Face*

This page intentionally left blank

# *Clinical Anatomy of the Face*



## **Joel E. Pessa, MD, FACS**

Associate Professor, Department of Plastic Surgery,  
University of Texas Southwestern Medical Center,  
Dallas, Texas

## **Rod J. Rohrich, MD, FACS**

Professor and Chairman; Crystal Charity Ball Distinguished Chair in Plastic Surgery;  
Betty and Warren Woodward Chair in Plastic and Reconstructive Surgery;  
Distinguished Teaching Professor, Department of Plastic Surgery,  
University of Texas Southwestern Medical Center, Dallas, Texas

### **ILLUSTRATOR**

Amanda Yarberry Behr, MA, CMI



**QUALITY MEDICAL PUBLISHING, INC.**

St. Louis, Missouri

2012

The artwork for this publication has been supported by an educational grant from Merz Aesthetics.

CRC Press  
Taylor & Francis Group  
6000 Broken Sound Parkway NW, Suite 300  
Boca Raton, FL 33487-2742

© 2012 by Taylor & Francis Group, LLC  
CRC Press is an imprint of Taylor & Francis Group, an Informa business

No claim to original U.S. Government works  
Version Date: 20140312

International Standard Book Number-13: 978-1-4822-4163-1 (eBook - PDF)

This book contains information obtained from authentic and highly regarded sources. While all reasonable efforts have been made to publish reliable data and information, neither the author[s] nor the publisher can accept any legal responsibility or liability for any errors or omissions that may be made. The publishers wish to make clear that any views or opinions expressed in this book by individual editors, authors or contributors are personal to them and do not necessarily reflect the views/opinions of the publishers. The information or guidance contained in this book is intended for use by medical, scientific or health-care professionals and is provided strictly as a supplement to the medical or other professional's own judgement, their knowledge of the patient's medical history, relevant manufacturer's instructions and the appropriate best practice guidelines. Because of the rapid advances in medical science, any information or advice on dosages, procedures or diagnoses should be independently verified. The reader is strongly urged to consult the relevant national drug formulary and the drug companies' printed instructions, and their websites, before administering any of the drugs recommended in this book. This book does not indicate whether a particular treatment is appropriate or suitable for a particular individual. Ultimately it is the sole responsibility of the medical professional to make his or her own professional judgements, so as to advise and treat patients appropriately. The authors and publishers have also attempted to trace the copyright holders of all material reproduced in this publication and apologize to copyright holders if permission to publish in this form has not been obtained. If any copyright material has not been acknowledged please write and let us know so we may rectify in any future reprint.

Except as permitted under U.S. Copyright Law, no part of this book may be reprinted, reproduced, transmitted, or utilized in any form by any electronic, mechanical, or other means, now known or hereafter invented, including photocopying, microfilming, and recording, or in any information storage or retrieval system, without written permission from the publishers.

For permission to photocopy or use material electronically from this work, please access [www.copyright.com](http://www.copyright.com) (<http://www.copyright.com/>) or contact the Copyright Clearance Center, Inc. (CCC), 222 Rosewood Drive, Danvers, MA 01923, 978-750-8400. CCC is a not-for-profit organization that provides licenses and registration for a variety of users. For organizations that have been granted a photocopy license by the CCC, a separate system of payment has been arranged.

**Trademark Notice:** Product or corporate names may be trademarks or registered trademarks, and are used only for identification and explanation without intent to infringe.

**Visit the Taylor & Francis Web site at**  
**<http://www.taylorandfrancis.com>**

**and the CRC Press Web site at**  
**<http://www.crcpress.com>**

*This book is dedicated to the donors and their families  
of the University of Texas Southwestern Willed Body Program—  
their priceless gift made this work possible*

This page intentionally left blank

# Preface

The surface of the face is a roadmap for the underlying anatomy. Anatomy is not arbitrary: structures show a remarkable consistency between individuals. It is the difference in the shapes of facial structures and their relationship to one another that determine the unique and distinct appearance of each individual. This is the premise of *Facial Topography: Clinical Anatomy of the Face*. The term *topography* in this context refers to more than a definition of anatomic structures; it encompasses and attempts to define *surface landmarks*—shapes, contours, creases, and lines—that help to predict the course and location of deeper structures. These shapes are first described as anatomic regions, strictly defined by superficial and deep boundaries. Within each region, anatomic subunits are likewise determined by true anatomic structures. Thus basic concepts and principles of facial anatomy can be developed that will enable us to systematically visualize and analyze the human face.

The potential clinical applications of such systematic analysis open exciting and challenging new avenues for exploration: the ability to predict the location of deeper structures based on surface landmarks is invaluable to both aesthetic and reconstructive surgeons. For example, knowledge of the facial fat compartments and how they atrophy not only helps us to understand their role in facial aging but also explains the disease processes of the face. As we refine techniques for facial rejuvenation and reconstruction, developing less-invasive procedures with smaller incisions and with greater reliance on the use of toxins, fillers, and fat for facial shaping, it is essential to fully understand the topography of each patient's face to determine the optimal anatomic location for surgical manipulation, volume enhancement, and facial contouring.

In writing this book, we had several goals in mind. The first was to demonstrate, in a clear and straightforward manner, how facial anatomy appears in real life. Fresh cadavers are priceless for achieving this end, and the images presented here will illuminate these anatomic units for all students of anatomy, whatever their level of expertise. Our conscious emphasis has been to show rather than tell; the dissections themselves speak volumes about the structures described succinctly in the text. The second goal was to demonstrate how the parts of the face are related to one another to help physicians create a three-dimensional model in their mind's eye. If we understand the anatomic subunits of a region and how they affect surface shape—the topography—we can then work backward using surface shapes as landmarks for the underlying anatomy.

By combining photographs of meticulous dissections of each region of the face with beautifully rendered parallel medical illustrations, we have endeavored to define the underlying structures of each area and to illuminate the clinical importance of the anatomic lessons that have been revealed.

Surface shapes are the common thread that runs throughout these pages as each region of the face is examined and analyzed. The book begins with a focus on the central forehead, a key area of facial expression. Next we turn our attention to the cheek, eyelids, nose, temporal fossa, and preauricular region. We conclude with a discussion of the lips and chin, two distinct anatomic regions that share the common denominator that less research has been directed at their basic soft tissue anatomy than for other facial regions. This last chapter serves as an example of how the tenets developed throughout the book can be applied in clinical practice to help us better understand the anatomy of any given region and how it influences potential outcomes.

The use of surface landmarks is an emerging science, made possible by synthesizing past and present research. The work presented here is based on findings in more than 1000 dissections and encompasses 20 years' worth of work. Many of these observations are presented for the first time, but each observation is backed by multiple dissections performed in a rigorously controlled manner. We anticipate that some of the observations will serve as the basis for future research: many of the concepts and principles discussed here can be applied to better define any given region.

Just as this book was written with several goals in mind, it is also intended for physicians in several fields and at various levels of expertise and training. For trainees, it provides valuable information for understanding key anatomic landmarks. For clinicians who deal with changing the shape and form of the face through surgical manipulation and/or the injection of toxins, fillers, or fat, the book presents critically important findings to ensure safe and effective treatment, suggesting techniques to achieve a successful result.

As with any emerging science, some of the conclusions reached in these pages may miss their mark. Future research is needed to redefine, reclassify, and advance our understanding of the information explored here. We hope that these basic concepts and principles set the stage for additional work in this area.

Mastering anatomy is a lifelong process, and we can say with complete certainty that we are finally ready to begin to learn this dynamic and fascinating science.

**Joel E. Pessa**  
**Rod J. Rohrich**

# Acknowledgments

We would like to thank all of the members of the University of Texas Southwestern Willed Body Program: Claudia Yellott, Brad Dillon, Liesl Brooke Shepard, Michael Cunningham, Ronnie Money, Yolanda King, Vanessa Lambright, and Justin Fisher. Their expertise and dedication helped facilitate this work; their enthusiasm made it a pleasure to be part of the team. The anatomy department graciously offered access to their dissection lab.

Kind thanks to William E. Maina for his help in reviewing the Rare Books Collection at the University of Texas Southwestern Library.

Our gratitude to the staff of Quality Medical Publishing: Karen Berger, Michelle Berger, Andrew Berger, Amy Debrecht, Amanda Behr, Suzanne Wakefield, Carol Hollett, Carolyn Reich, and Lane Wyrick for their hard work, patience, and guidance.

This page intentionally left blank

# Contents

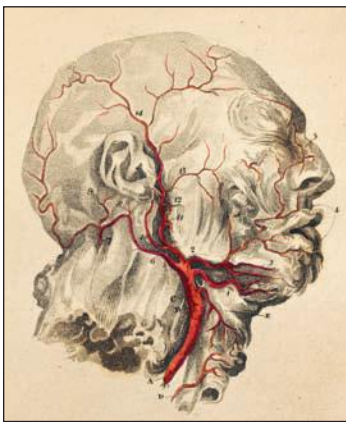
- 1** Terminology of Facial Topography 1
  - 2** The Central Forehead 13
  - 3** The Cheek 47
  - 4** The Eyelids 95
  - 5** The Nose 139
  - 6** The Temporal Fossa 177
  - 7** The Periauricular Region 219
  - 8** The Lips and Chin 251
- Index 293

This page intentionally left blank

## *Classic Cadaver Dissections Introducing Each Chapter*

---

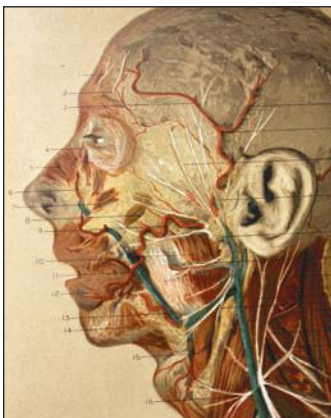
Each chapter is introduced using a classic dissection from one of the great atlases of human anatomy. In this way, we hope to show the continuity between the current subject, facial topography, and basic research preceding this work. Each dissection presented illustrates the association between surface form and underlying structure. Taken as a group, these dissections suggest many of the basic concepts and tenets of facial topography.



### **Chapter 1, Terminology of Facial Topography, and Chapter 8, The Lips and Chin**

Bell Charles, Bell John. Engraving of the Arteries. Philadelphia: Lea & Febiger, 1833. Reproduced with permission from the Rare Books Collection of the University of Texas Southwestern Medical Center.

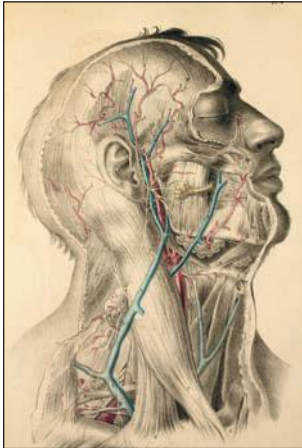
*Perhaps one of the greatest anatomists of all time, Sir Charles Bell is best remembered for his differentiation between the motor innervation of the fifth and seventh cranial nerves. However, Bell's dissections covered many other regions in addition to the face. His book, Engravings of the Arteries, described the vascular supply of the body in detail. This illustration is remarkable for its precision. It shows the ascending philtral arteries and the boundary vessels of the central lip. The boundary of the lateral lip compartment is defined, and the artery associated with the lip-chin crease is noted. On an even finer level, Bell showed the vessels to the corner of the lip and modiolus, thereby defining the origin of the lateral oblique chin crease and the boundary of the lateral lip compartment.*



### **Chapter 2, The Central Forehead**

McClellan G. Regional Anatomy in its Relation to Medicine and Surgery, vol 1. Philadelphia: JB Lippincott Co, 1892. Reproduced with permission from the Rare Books Collection of the University of Texas Southwestern Medical Center.

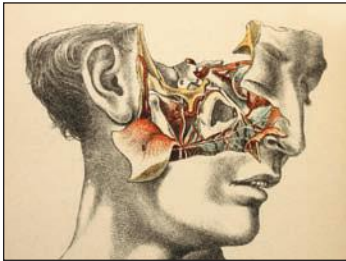
*McClellan was the grandson of the founder of Jefferson Medical College, Philadelphia, the nephew of Civil War General George McClellan, and the patron of anatomy at the College. McClellan set a precedent for studying surface anatomy and correlating it with underlying structure with his hand-colored photographs of predissection and postdissection images. The illustration presented here notes the intimate relationship between the nerves and vessels of the forehead, a basic principle of human anatomy.*



### Chapter 3, The Cheek

Maclise J. *Surgical Anatomy*. Philadelphia: Blanchard & Lea, 1859. Reproduced with permission from the Rare Books Collection of the University of Texas Southwestern Medical Center.

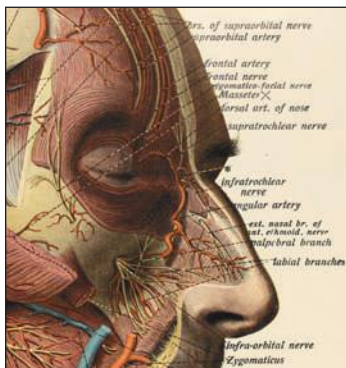
*Maclise's statements rank him among the earliest topographic anatomists: "The unbroken surface of the human figure is as a map to the surgeon, explanatory of the anatomy arranged beneath." The goal of his landmark book was, in his words, "to indicate the interior through the superficies." Maclise was trained as a classical artist, as well as a surgeon and anatomist; the plates of his book are each illustrative of his desire to show the relationship between surface form and underlying anatomy. This illustration details the proximity and superficial course of the frontal branch of the facial nerve to the lateral forehead artery as it approaches the frontalis muscle, a potential site of nerve injury.*



### Chapter 4, The Eyelids

Cloquet J. *Manuel D'Anatomie Descriptive du corps Humain*. Paris: Place de l'École de Médecine, 1825. Reproduced with permission from the Rare Books Collection of the University of Texas Southwestern Medical Center.

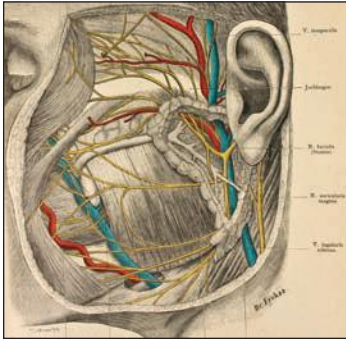
*Jules Cloquet was a celebrated Parisian surgeon as well as an accomplished lithographer. A prolific writer, Cloquet covered the entire breadth of human anatomy. Less well known is the fact that he was interested in cross-sectional anatomy. In this respect he predated all others, including Deaver, who studied the face, and Kanavel, who introduced the concept of spaces on the hand.*



### Chapter 5, The Nose

Sobotta J. *Atlas and Text-Book of Human Anatomy*. Philadelphia: WB Saunders, 1906. Reproduced with permission from the Rare Books Collection of the University of Texas Southwestern Medical Center.

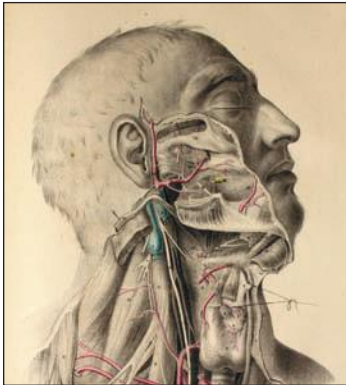
*Johannes Sobotta's textbook is one of the classic major treatises of human anatomy. After 15 editions, his work retains the freshness and clinical relevance of the original text. Sobotta's text is perhaps best appreciated for its superb illustration, rendered in a style that is still taught to this day. This illustration shows the lateral boundary of the nose as a separate anatomic region. The path of the infraorbital nerve is noted to cross the cheek-nose boundary, emphasizing the point that structures travel within and through anatomic subunits.*



### Chapter 6, The Temporal Fossa

von Bandeleben K, Haeckel H. Atlas der topographischen Anatomie. Jena, Germany: Verlag von Gustav Fischer, 1904. Reproduced with permission from the Rare Books Collection of the University of Texas Southwestern Medical Center.

*Fritz Frohse, better remembered for his work on the path of the radial nerve, here illustrates the pattern of nerve branching within the temporal region and their relationship to the frontal branch of the facial artery. A Berlin anatomist, Frohse and his brother worked on several texts, among them a well-known handbook of anatomy. This illustration is unique in that it is one of few that accurately portrays the extent of the preorbital part of the orbicularis oculi muscle. Frohse's detail is such that he included the minor branch of the transverse facial artery as it approaches the danger zone for nerve injury referred to as McGregor's patch.*



### Chapter 7, The Periauricular Region

Maclise J. Surgical Anatomy. Philadelphia: Blanchard & Lea, 1859. Reproduced with permission from the Rare Books Collection of the University of Texas Southwestern Medical Center.

*Joseph Maclise expertly defined the anatomy of the periauricular region, including its medial boundary, the superficial temporal artery. Maclise, as an engraver as well as a surgeon, helped to illustrate several other texts, including Quain's handbook on the vascular supply of the body.*

This page intentionally left blank

**FACIAL TOPOGRAPHY**  
*Clinical Anatomy of the Face*

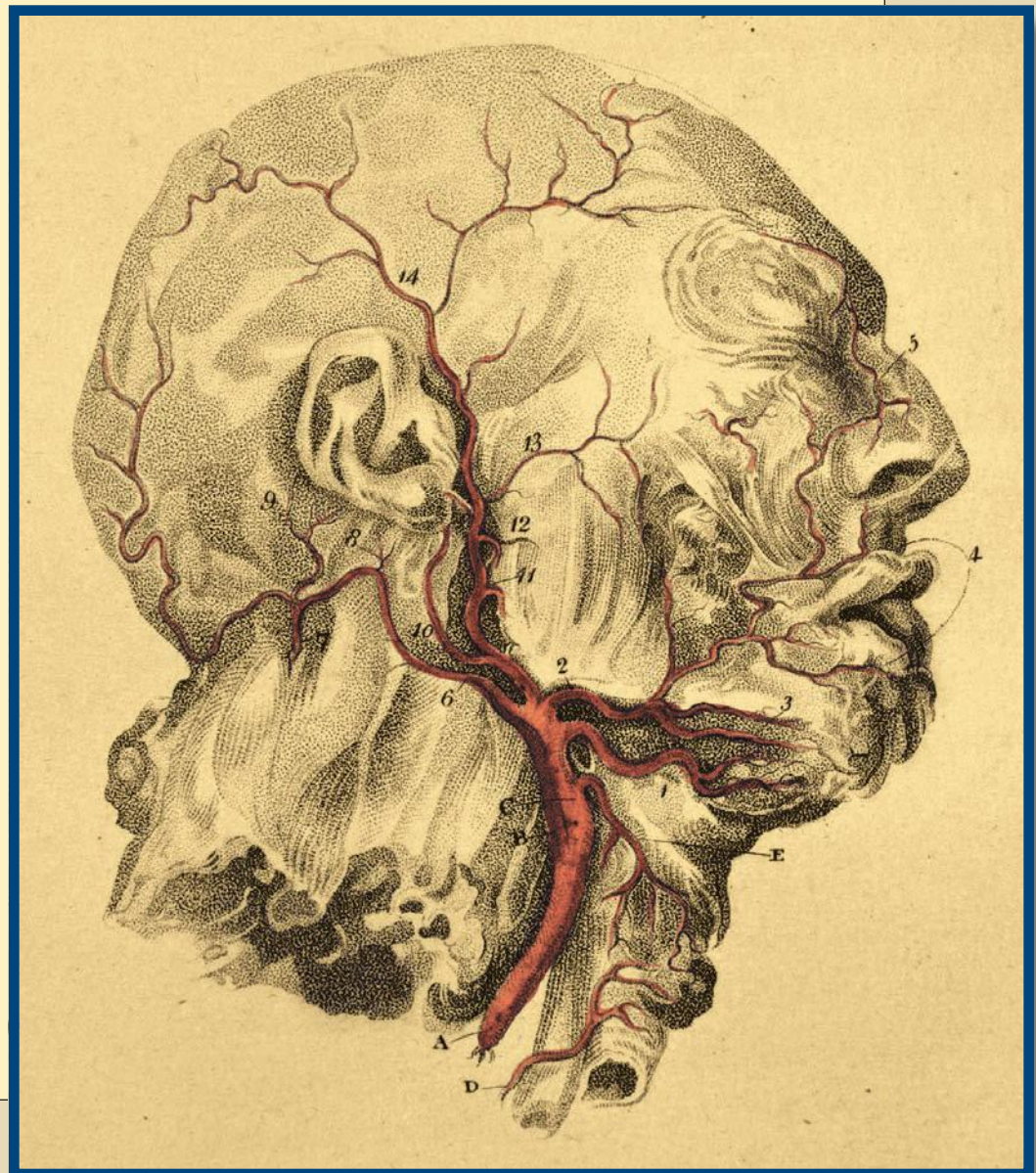
This page intentionally left blank

---

CHAPTER 1

---

# Terminology of Facial Topography



**T**he terminology of facial topography is unique: each word or phrase is considered in the context of how it relates to surface contour, shape, and form. This is slightly different from the thought process applied to standard anatomic terms.

For example, it is entirely correct to define the *angular artery* as a branch of the supratrochlear artery that anastomoses with the facial artery. In the field of reconstructive surgery, the angular artery might be described as a blood supply to the nasolabial flap. In cosmetic surgery, it may be added that the angular artery is near the nasomaxillary junction where the nasal bone will be fractured.

From the perspective of facial topography, the angular artery defines the superficial boundary between the nose and the cheek. The term is thought of in reference to how it affects, or is affected by, surface topography. The utility of this method is that information is not limited to one field or specialty; it can be applied to any endeavor that deals with the human face.

## TERMINOLOGY

**aesthetic subunits** Regions of the face defined by planes and reflected light. Aesthetic subunits are an aid to reconstructive surgery. (Compare *aesthetic subunits* with *anatomic subunits*.)

**A-frame deformity** Distinct peak of the upper eyelid between the transitional fat and the preaponeurotic fat pads that occurs in some individuals.

**alar cleft** Shallow groove in the ala of the nose that occurs between anatomic compartments. This cleft may develop a crease in some individuals. The thickness of subcutaneous fat and/or dermis is different on either side of this cleft.

**alar groove** Region of the lower nasal sidewall directly above the ala. Dermis and subcutaneous fat are thinner at the alar groove. The groove is a boundary zone between the ala and lateral nose and is a landmark for the course of the arterial arcade.

**alar rim** Aesthetic subunit of the lower third of the nose.

**anatomic compartments** Discrete regions of facial adipose tissue. Anatomic compartments may be superficial or deep. Superficial anatomic compartments are defined by blood supply; the nasolabial fold and malar mound are examples

of superficial anatomic compartments. Deep anatomic compartments are defined by fascia or fusion zones; buccal and temporal fat are examples of deep anatomic compartments.

**anatomic subunits** Areas of the face defined by the boundaries of a superficial and/or deep fat compartment. These consist of discrete compartments of adipose tissue, along with the muscles, nerves, and vessels that travel within and through them.

**angular artery** Vascular boundary of the lateral nasal sidewall. A reference point for the location of the levator labii superioris alaeque nasi muscle.

**anterior auricularis muscle** Inferiormost superficial muscle of the temporal fossa. Contraction of this muscle leads to vertical creases in front of the ear.

**anterior cheek projection** Forward projection of the cheek as measured at the medial cheek compartment. This measurement is affected by several factors: maxillary curvature, the thickness of deep medial cheek fat, and the thickness of medial cheek fat. It is usually assessed relative to the anterior cornea or orbital rim.

**apparent boundaries** Regions of the face where it appears that tissue is confluent between anatomic compartments. Examples occur at the nose-cheek junction and at the cheek-neck junction.

**arcus marginalis** Fusion zone of multiple fascias and periosteum along the inferior orbital rim. This occurs several millimeters above the lid-cheek crease.

**auriculotemporal nerve** Sensory nerve to the scalp that parallels the anterior superior auricular compartment.

**boundary zone** Area between two or more anatomic compartments. Nerves transit through boundary zones between compartments, both superficial and deep.

**buccal branch of facial nerve** Branch of the seventh nerve that travels through the buccal space. This branch innervates the upper lip and eyelid and provides ancillary innervation to the medial forehead muscles.

**buccal fat** Deep anatomic compartment situated posterior and lateral to the zygomaticus major muscle that exists as multiple lobes or lobules. The buccal fat helps to define the jowl. The inferior lobe of buccal fat is a topographic landmark for the parotid duct, the facial artery, and marginal mandibular nerve.

**buccal space** Deep space of the face defined by superficial and deep fascias. It is continuous from the temporal fossa to the lower cheek. Structures from the pterygopalatine fossa travel within this space, as does the buccal branch of the facial nerve.

**central chin crease** Crease between two superficial medial chin compartments. A fold forms on either side of this crease.

**central compartment of lower lip** Analogous structure in the lower lip to the central compartment of the upper lip. This is visible in some individuals, and likewise identifies the position of ascending arteries.

**central compartment of upper lip** Anatomic subunit of the upper lip, found between the two philtral columns. It is defined by ascending philtral arteries.

**central forehead artery** Vessel that defines the midline forehead wrinkle.

**central neck compartment** Superficial anatomic compartment directly caudal to the submental fat compartment. The boundaries of this compartment may tether the neck skin. Visible skin creases are the topographic landmarks for this compartment and its blood supply.

**cheek** Anatomic region with precise boundaries: the superior boundary is the lower eyelid, the lateral boundary the periauricular region, inferior boundary the neck, and the medial boundary is formed by the nose, lips, and chin. These boundary zones occur at both a superficial and a deep level.

**cheek-chin crease** Boundary between superficial anatomic compartments of the cheek and chin. Cheek tissue is thicker than chin tissue at this boundary.

**cheek-chin fold** Another name for the inferior part of the jowl.

**corrugator crease** Skin crease between the medial and lateral corrugator compartments. Because perforators from the supratrochlear artery define this crease, it is a topographic landmark for the position of the artery.

**corrugator supercilii muscle** Medial forehead muscle having two parts. The length of this muscle spans both the corrugator and supraorbital creases.

**crease** Surface landmark for underlying arterial vessels. A crease occurs between two superficial anatomic compartments of different thickness. Tonic muscular contraction accentuates the crease that occurs perpendicular to the direction of muscular contraction.

**danger zone** Area of increased risk of nerve injury, either sensory or motor. Danger zones can be predicated based on underlying anatomy. Three types of danger zones exist: transition zones between superficial compartments; fusion zones of fascias; and points where multiple compartments meet to form a tethering band.

**deep fat** Adipose tissue deep to superficial or deep fascia. Examples of deep fat include temporal fat below the deep fascia and deep medial cheek fat beneath the superficial fascia.

**deep lateral chin compartment** Fat compartment deep to the depressor anguli oris muscle. This is also referred to as *prejowl fat*.

**deep medial cheek fat** Deep anatomic compartment. This fat contributes to anterior cheek projection.

**depressor anguli oris muscle** Lower lip muscle that depresses or lowers the corner of the mouth. Tonic contraction of this muscle contributes to the cheek-lip crease.

**external nasal artery** Artery that determines the superficial lateral nasal compartment. The external nerve travels with this artery along a boundary zone.

**extraconal intraorbital fat** Precise definition of what is commonly referred to as *intraorbital fat*. The intraorbital fat pads, all identified by surface contour, are partially intraorbital and extraorbital.

**eyelid** Anatomic region of the face. The upper eyelid and lower eyelid have precise boundaries from the rest of the face and from one another.

**facial artery** Source vessel of the face, the position of which can be predicted based on surface landmarks such as creases and folds.

**facial muscles** Muscles of the face, either mimetic or involved with chewing. Facial muscles cross boundary zones between two or more anatomic compartments and do not define either compartments or subunits. The facial muscles are in the same plane or depth as the superficial fascia. Deep fat is found below any facial muscle where gliding is required. The presence of facial muscles is signified by the wrinkle or crease with which each is associated.

**facial nerve** Motor nerve to the mimetic facial muscles. The course of this nerve can be predicted based on topographic landmarks.

**fold** Contour change in surface topography of the face that is associated with different thicknesses of adjacent superficial compartments.

**forehead** Region of the face separate from the upper eyelid, temporal fossa, and nose. Deep and superficial boundaries exist between the forehead and other regions.

**forehead-lid crease** Crease defined by vascular arcade between the forehead and upper eyelid.

**frontal branch facial artery** Surface landmark beneath which the frontal branch of the facial nerve travels to the frontalis muscle.

**frontal branch of facial nerve** Technically the branch of the facial nerve that innervates the frontalis muscle. The frontal branches also innervate anterior, superior, and posterior auricularis muscles as well as the temporoparietalis muscle.

**frontalis muscle** One of the forehead muscles from which the frontal branch of the facial nerve takes its name. The frontalis muscle elevates the brow and forms the horizontal forehead wrinkles.

**fusion zones** Areas of fusion between superficial and deep fascia. Folds may form at fusion zones.

**great auricular nerve** Sensory nerve to the lateral cheek, ear, and ear sulcus. This nerve can be injured by improper transitioning techniques during surgery.

**inferior lobe buccal fat** Discrete lobe of fat within the buccal space that predicts the location of the parotid duct. A branch of the facial nerve and the facial artery travel at the inferior margin of this deep fat.

**inferior oblique muscle** Intraorbital muscle, the position of which can be predicted based on surface landmarks of the intraorbital lower eyelid fat.

**infraorbital nerve** Sensory nerve to cheek and upper lip. Its course and origin coincide with the convergence of the nasojugal and lid-cheek creases.

**intraorbital fat** Deep fat of the upper and lower eyelids beneath orbicularis oculi muscle.

**jowl** Region of the face defined by superficial superior and inferior compartments and buccal fat.

**jowl compartments** Superficial anatomic compartments directly lateral to the upper lip and chin.

**lateral neck fold** Oblique fold running from the ear downward. The greater auricular nerve travels along the lateral neck fold. This is an example of a fusion zone, where superficial fascia fuses to deep fascia. This is a danger zone for possible injury to the great auricular nerve.

**lateral orbital thickening** The orbicularis retaining ligament thickens at the orbital rim and zygomatic arch. This represents a deep boundary of the temporal fossa.

**lateral palpebral crease** Crease that travels from the upper eyelid horizontally across the temporal fossa. This is a landmark for its corresponding artery.

**lateral temporal cheek compartment** Lateralmost superficial compartment of the cheek. This compartment is the boundary between the cheek and peri-auricular region. The buccal branch of the facial nerve exits through the parotid gland beneath this compartment.

**levator palpebrae superioris muscle** Eyelid elevator muscle that may be inadvertently paralyzed by a botulinum toxin injection as a result of the imperfect seal between forehead and upper eyelid.

**lid-cheek junction** Boundary between lower eyelid and cheek. The lid-cheek crease is the topographic reference for this boundary.

**ligament** Fascial connection between bone or cartilage and muscle, or between cartilage and cartilage. Ligaments frequently occur at the origin of facial muscles; for example, the depressor anguli oris and zygomaticus major muscles.

**lip-chin crease** Anatomic term for the *labiomental crease*. The mental artery defines this crease. Adipose tissue of the mobile lower lip is thinner than that in the chin.

**loose areolar fat** Deep fat of the face, usually associated with the layer of fat in the temporal fossa below superficial fascia. It is here that the facial nerve travels on its way to the undersurface of the frontalis muscle.

**lower eyelid** Anatomic region with boundaries defined by vascularized membranes, the canthal tendons, and the lid margin. The lower eyelid is composed of several anatomic subunits.

**malar mound** The superior most superficial anatomic compartment of the cheek; it is prone to edema. This is a landmark for the more deeply situated lateral suborbicularis oculi fat.

**masticator space** Buccal space.

**medial cheek fat** Superficial anatomic compartment lateral to the nasolabial compartment. The thickness of this area contributes to the projection of the anterior cheek.

**medial corrugator compartment** Superficial adipose compartment defined by the supratrochlear artery and its branches. This compartment helps in locating both the artery and the corresponding muscle.

**medial upper eyelid fat pad** Intraorbital fat pad visible on examination that is the topographic landmark for an artery that ultimately communicates with the retinal artery.

**middle postauricular compartment** The superior border of this compartment coincides with the posterior auricularis tendon, beneath which lies a branch of the great auricular nerve and the postauricular artery.

**midline forehead crease** Midline forehead indentation, more accurately described as a wrinkle. This wrinkle helps to locate the midline artery arising from the supratrochlear artery.

**nasojugal crease** Accepted term for the crease between the lower eyelid, nose, and cheek (sometimes called the *nasojugal groove* or *tear trough*). This crease lies above the angular artery and vein. The nasojugal crease is an important landmark for the infraorbital artery and nerve.

**nasolabial compartment** Medialmost superficial cheek adipose compartment. Although an accepted term in current use, this compartment technically lies between the cheek and upper lip. The compartment in the upper lip between the nose and lip is the superior lip compartment.

**nasolabial crease** Cheek-lip crease.

**nasolabial fold** Cheek fold associated with the facial artery. This fold occurs as a result of increased thickness of cheek fat compared with the thinner fat of the mobile upper lip. It is a reference point for the course of the facial artery.

**negative vector** Describes the relationship between cornea and cheek, specifically when the anterior cheek lies posterior to the cornea on lateral view. A negative vector can occur from inadequate anterior cheek projection from any cause.

**orbicularis oculi muscle** Facial muscle that assists eyelid closure. This muscle spans different facial regions, including the eyelid, cheek, and forehead.

**orbicularis oculi retaining ligament (ORL)** Membranous ligament formed from orbicularis fascia that inserts at the arcus marginale of the orbital rim. This is the deep boundary of the upper and lower eyelid. This ligament stabilizes the orbicularis oculi muscle as it crosses the free edge of the orbital rim.

**orbicularis oris muscle** Most superficial muscle of the upper and lower lips.

**orbicularis oris retaining ligament** Analog to the ORL. This stabilizes the orbicularis oris muscle and is noted on submucosal dissection.

**orbital septum** Fascial structure that defines the boundaries of intraorbital fat, a deep anatomic compartment.

**parotid duct** Duct from parotid gland located above inferior lobe of the buccal fat.

**periauricular compartments** Regions of discrete adipose tissue around the ear. The subauricular compartment is the most important landmark for identifying the position of the great auricular nerve. The middle postauricular compartment is the landmark for the posterior branch of the great auricular nerve.

**piriform ligament** Deep boundary between the nose and cheek. This acts as a stabilizing ligament for the nasal cartilages.

**platysma retaining ligament** Posterior fascia of the platysma that fuses with periosteum along the mandibular border. This defines part of the deep inferior boundary of the cheek. As an analog to the ORL, this ligament stabilizes the platysma muscle as it crosses the free edge of the mandible.

**positive vector** Describes the relationship between the cornea and cheek when the soft tissue of the cheek is anterior on lateral view. This may indicate adequate thickness of deep medial cheek fat.

**preaponeurotic fat** Upper eyelid fat located lateral to the A-frame deformity.

**preauricular crease** Boundary between cheek and periauricular region defined by the superficial temporal artery. This is a topographic reference point for the artery and vein.

**prejowl fat** Deep fat compartment beneath the depressor anguli oris muscle. This is also referred to as the deep lateral chin compartment.

**prejowl sulcus** Hollow area medial to the inferior jowl compartment. The depth of this sulcus is affected by the volume of prejowl fat.

**procerus retaining ligament** Fascial condensation of fascia that fuses the posterior layer of procerus muscle to the frontal bone. This helps to prevent bowstringing during muscular contraction, much like the platysma retaining ligament. This defines in part the deep boundary between the forehead and the nose.

**pseudojowl** Example of an apparent boundary where cheek fat appears to be confluent with the neck.

**retaining ligaments** Fascial membranes that travel from periosteum to muscular fascia. There are numerous retaining ligaments of the face, and these are thought to stabilize muscles as they cross a free edge of the facial skeleton.

**retroorbicularis oculi fat (ROOF)** Deep fat compartment of the forehead. This facilitates gliding of the preorbital orbicularis oculi muscle.

**submental crease** Boundary between the chin and neck, formed by branches of the submental artery.

**suborbicularis oculi fat (SOOF)** Deep anatomic compartment that contributes to fullness along the orbital rim and medial zygoma.

**superficial fat** Facial adipose tissue that lies above the superficial fascia or above facial muscles.

**superior temporal fusion** Fusion zone of fascia to periosteum that defines the deep boundary between forehead and temporal fossa. This fusion zone restricts lateral motion of the forehead.

**supraorbital crease** Obliquely oriented crease that helps to identify the location of the supraorbital artery and nerve.

**supratarsal crease** Upper eyelid crease classically described as a fusion point of the levator palpebrae superioris muscle into skin. This may be a crease defined by a deep upper eyelid blood vessel. This is a true crease, because subcutaneous tissue is thicker above the crease than below and forms a fold.

**surgical transitioning** Surgical technique of maintaining proper depth when dissecting between adjacent superficial compartments of different thickness. This technique is critical to prevent inadvertent nerve injury.

**temporal fossa** Facial region defined by deep and superficial boundaries. Both muscle and superficial and deep anatomic compartments contribute to the shape and contour of this region.

**temporal nerve** Frontal branch of the facial nerve.

**Tenon's capsule** Intraorbital membrane, an extension of which appears as the boundary between middle and lateral lower eyelid intraorbital fat. This is readily visible on examination.

**transitional fat** Potential third deep anatomic compartment of the upper eyelid. Removal of this fat may contribute to the A-frame deformity.

**triangular compartment** Lateralmost and superiormost lower lip compartment.

**true boundary** Boundary that represents the anatomic distinction, either superficial or deep, between anatomic regions; for example, between the cheek and nose.

**wrinkle** Indentation in the skin that occurs between areas of uniform thickness. The central forehead wrinkle is a topographic landmark for the central forehead artery. Wrinkles first form above well-defined vessels, and with advancing age may pattern themselves to the superficial subdermal blood supply.

**zygomaticofrontal nerve** Sensory nerve that transits through the lateral SOOF. This nerve can be injured when manipulating or injecting the SOOF.

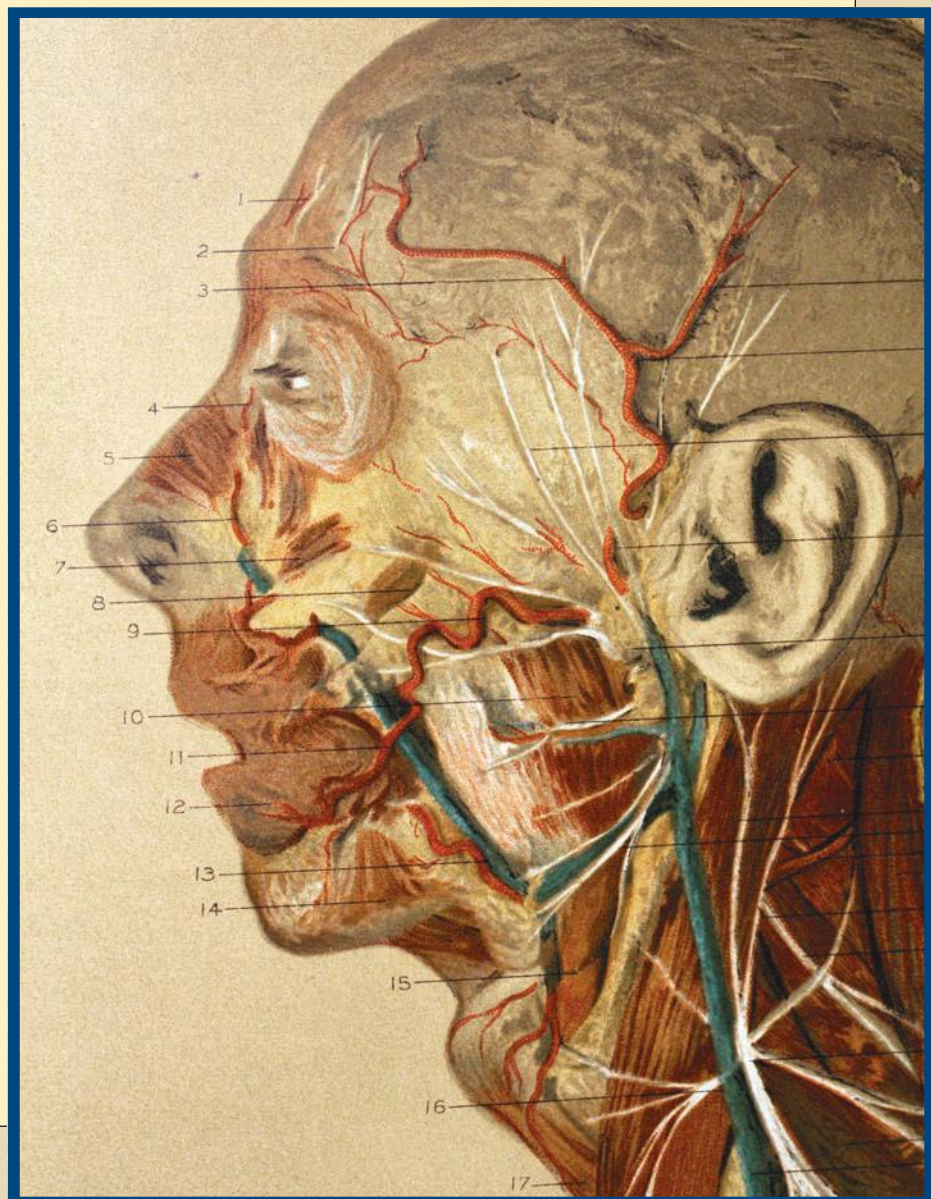
This page intentionally left blank

---

CHAPTER 2

---

# The Central Forehead

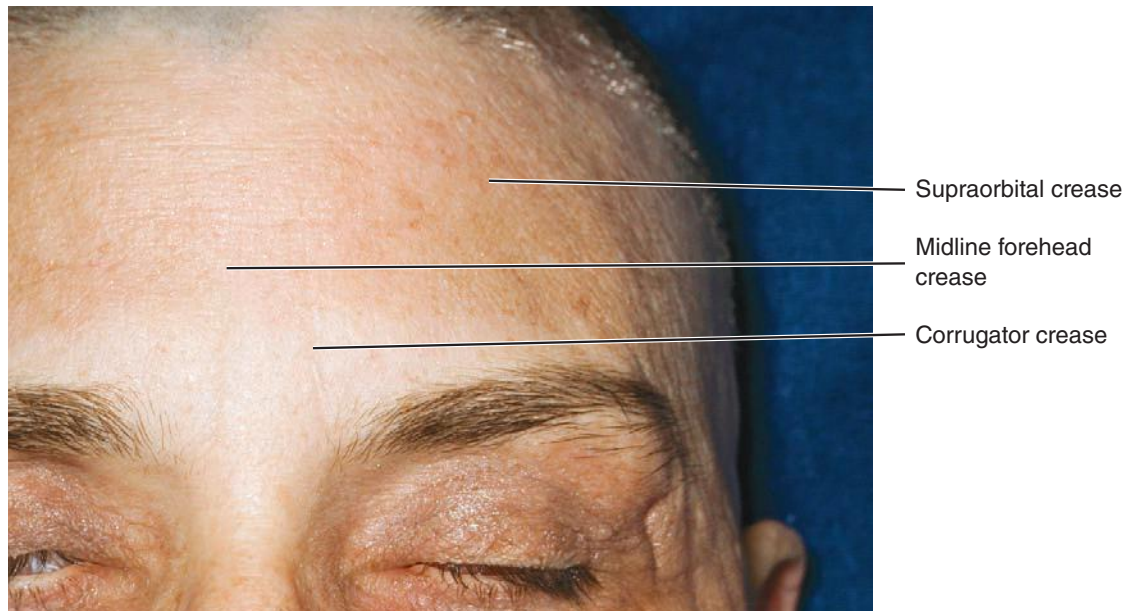


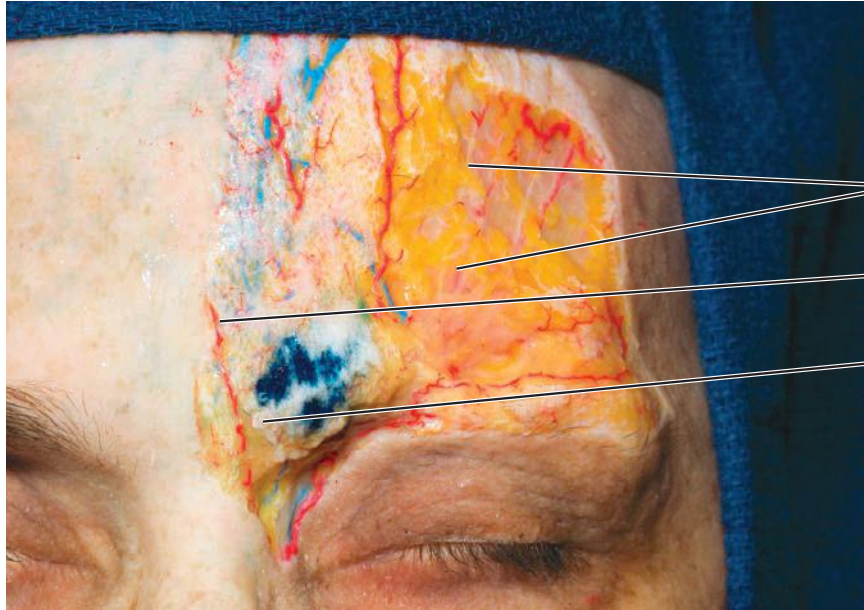
**T**he ability to predict the location of deeper structures based on surface landmarks is valuable. The advent of fillers for volume augmentation and the development of less-invasive techniques that rely on smaller incisions make this information especially relevant for the operating surgeon.

## SURFACE LANDMARKS

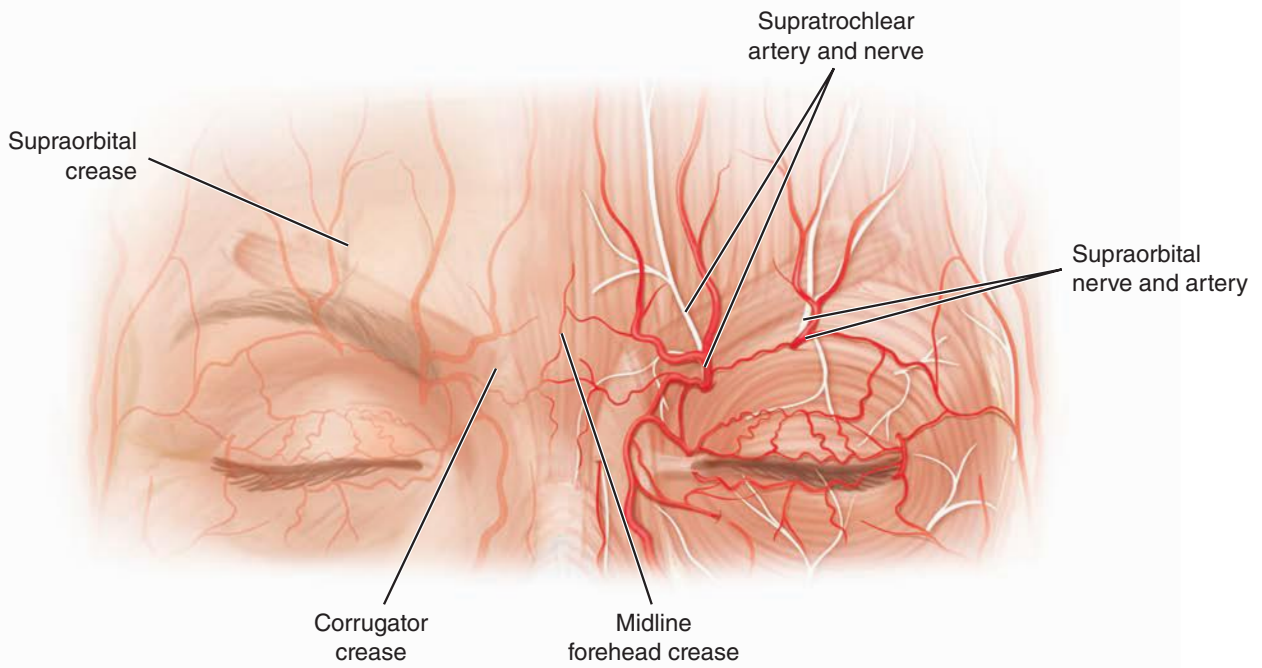
The central forehead is a good example of one anatomic area whose surface landmarks enable us to understand shape and form.

The central forehead is a key expressive part of the face. Over time, creases and wrinkles form in a predictable manner.





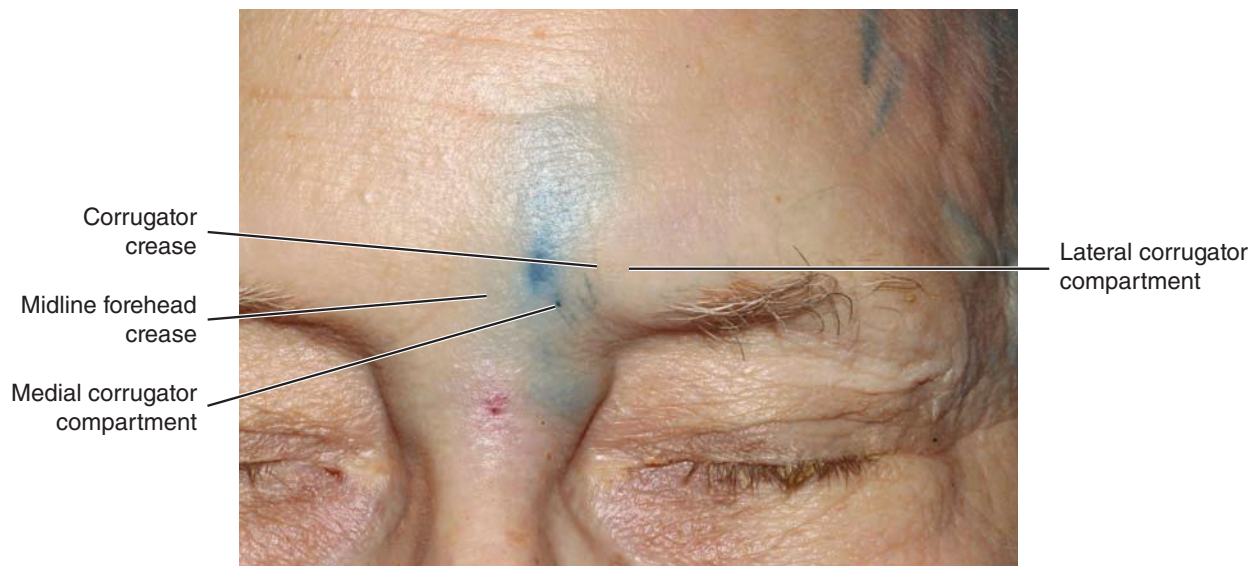
Location of supraorbital crease  
Location of midline forehead crease  
Location of corrugator crease



The corrugator crease, formed by contraction of the corrugator supercilii muscle, is a useful landmark that helps to identify not only the relative position of blood vessels, but also the positions of the nerves and muscles.

## UNDERLYING STRUCTURES

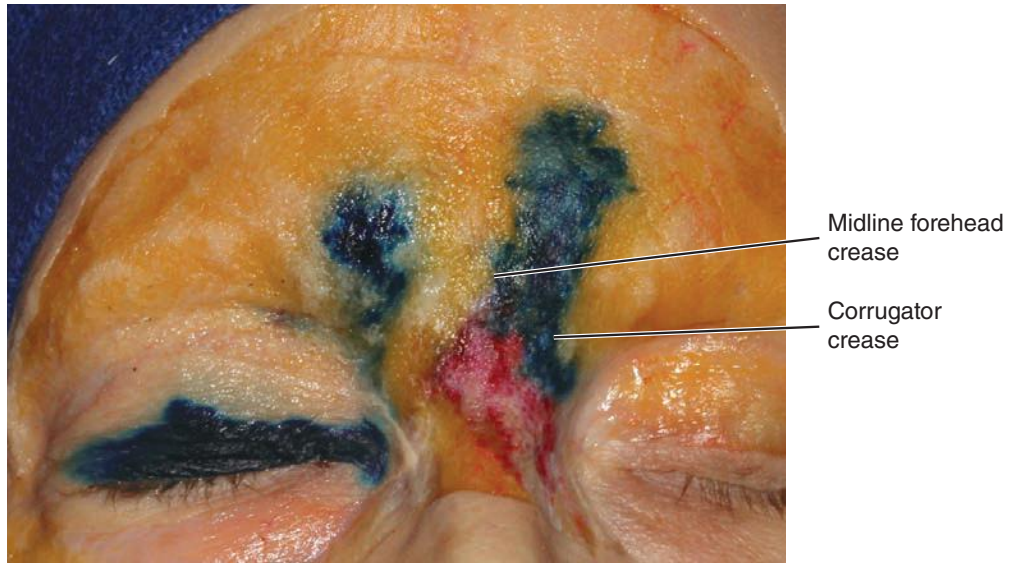The medial corrugator compartment is a discrete region of adipose tissue. Its boundaries are the corrugator crease and the midline forehead crease.



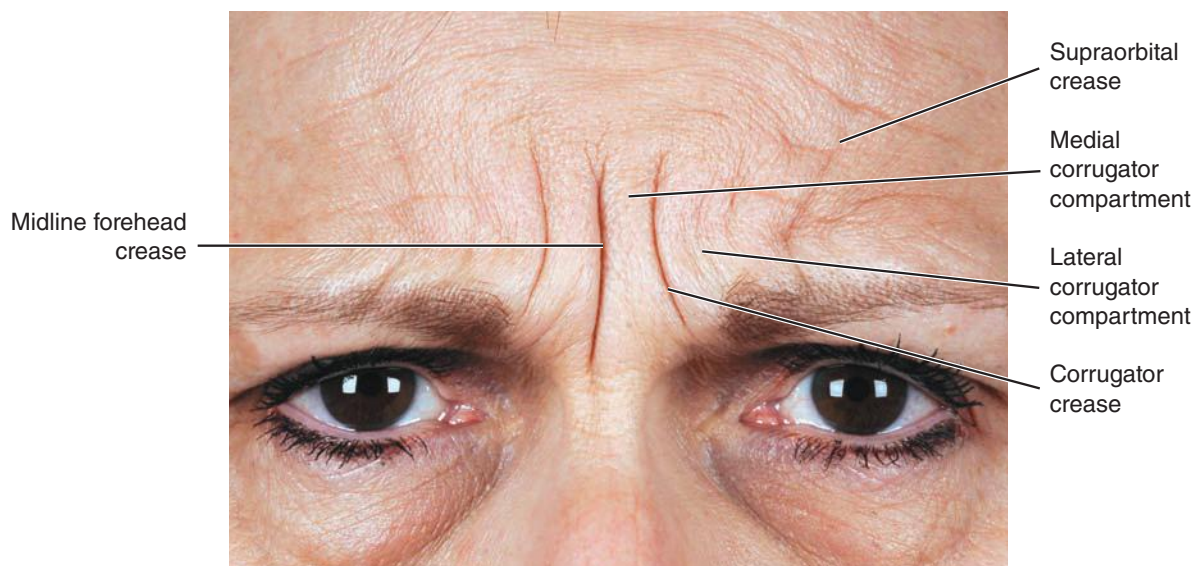Dye injected into this area, as seen above, does not diffuse past these creases, a finding that shows how facial adipose tissue exists in the face in regionalized zones.

The adipose tissue of the face exists as distinct regions and zones rather than as a confluent soft tissue mass.

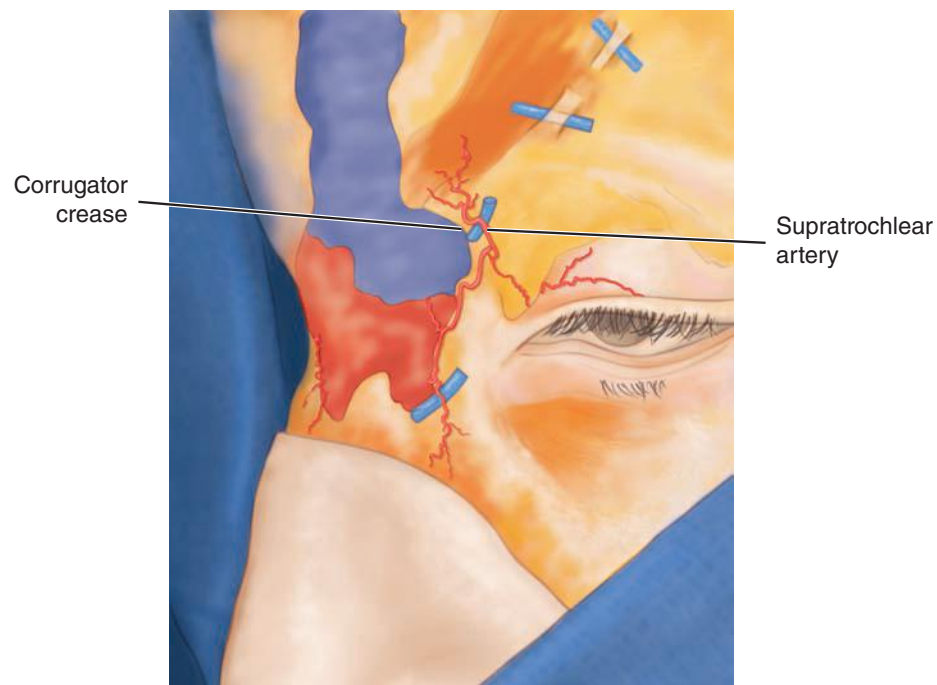
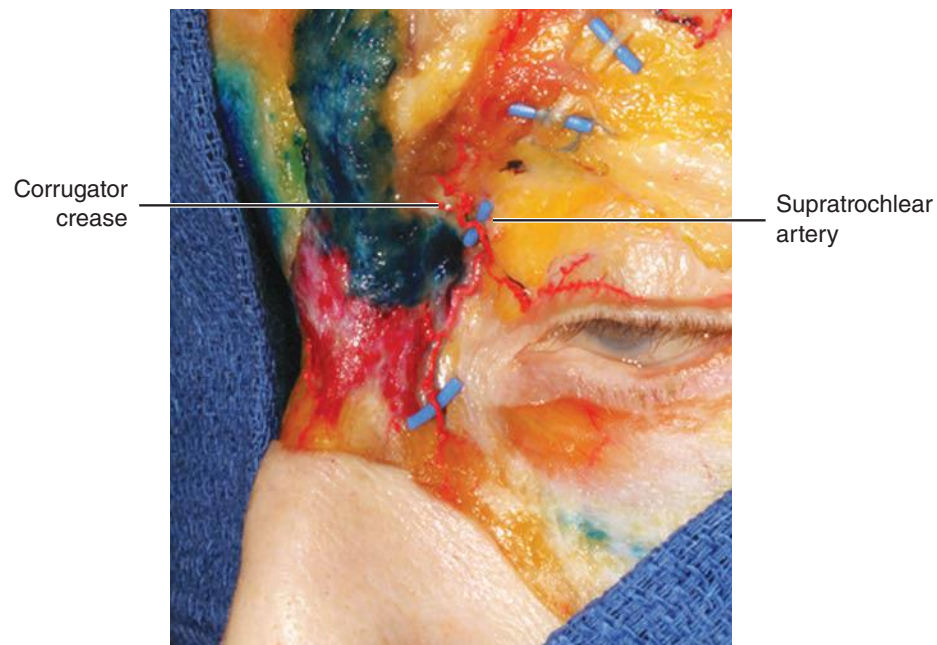
This is more apparent when the skin is removed from the face. The limit of dye diffusion identifies the boundaries that correspond very closely to the two creases described.



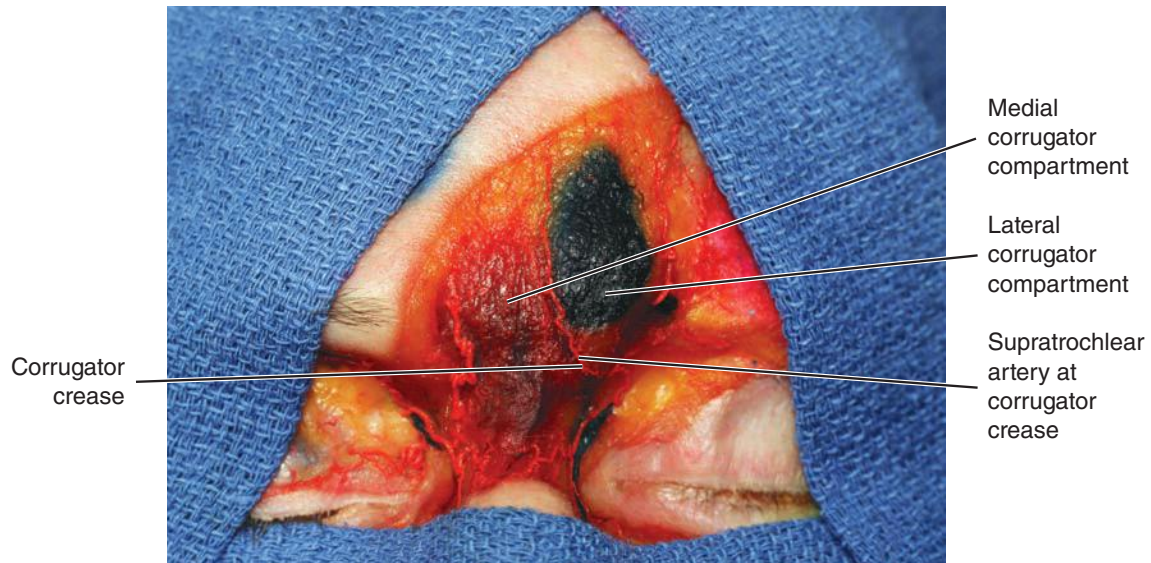
Contraction of the corrugator muscle during animation enhances the boundary zones on this region. Creases, as well as wrinkles, always occur roughly perpendicular to the direction of the controlling muscle.



On closer evaluation, it appears that the corrugator crease occurs along the course of the supratrochlear artery. If this is correct, it suggests that creases—the indentations that occur between folds—lie beneath a more deeply situated blood vessel. This would allow creases to be used as surface markers for the location of blood vessels.

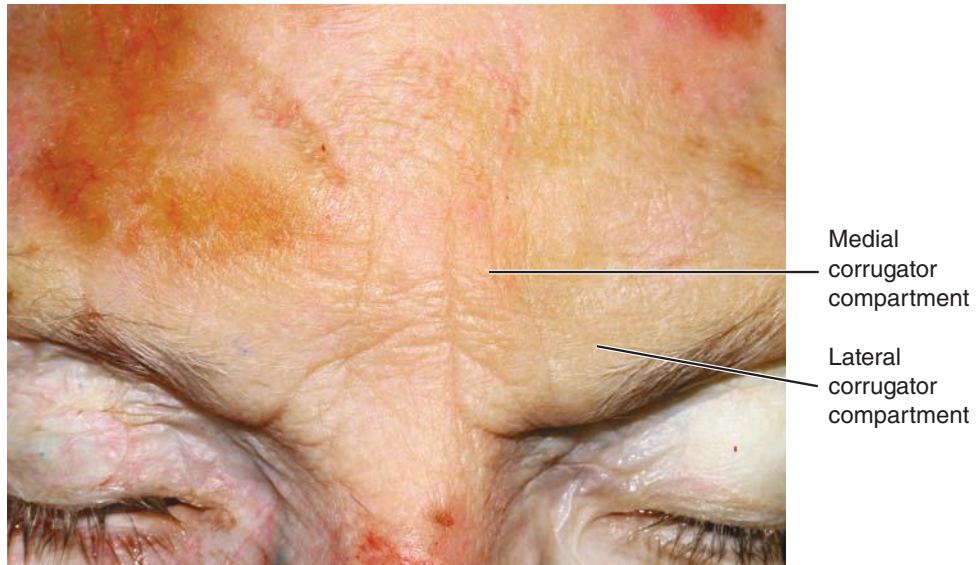

Injected latex defines the supratrochlear artery and shows its proximity to the corrugator crease.

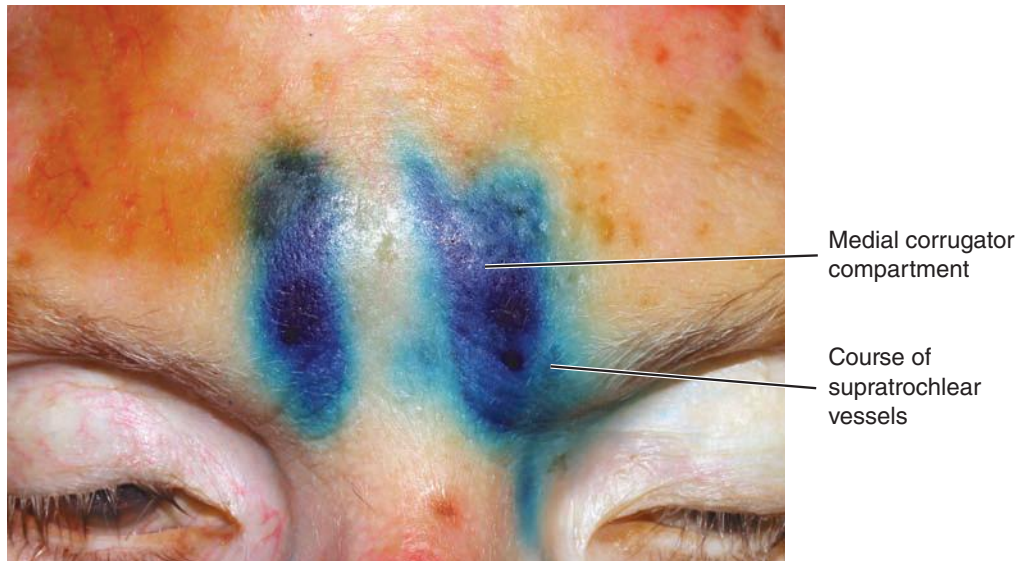

This information is valuable because if creases can serve as reliable landmarks to predict the location and direction of blood vessels, this is applicable to the design of surgical flaps. Such knowledge is also important because any filler injected directly into a crease at depth runs the risk of injuring the regional blood supply. This is one of the possible causes of the prolonged edema and skin damage described with the use of fillers—complications that could be avoided by analyzing the face in this manner.

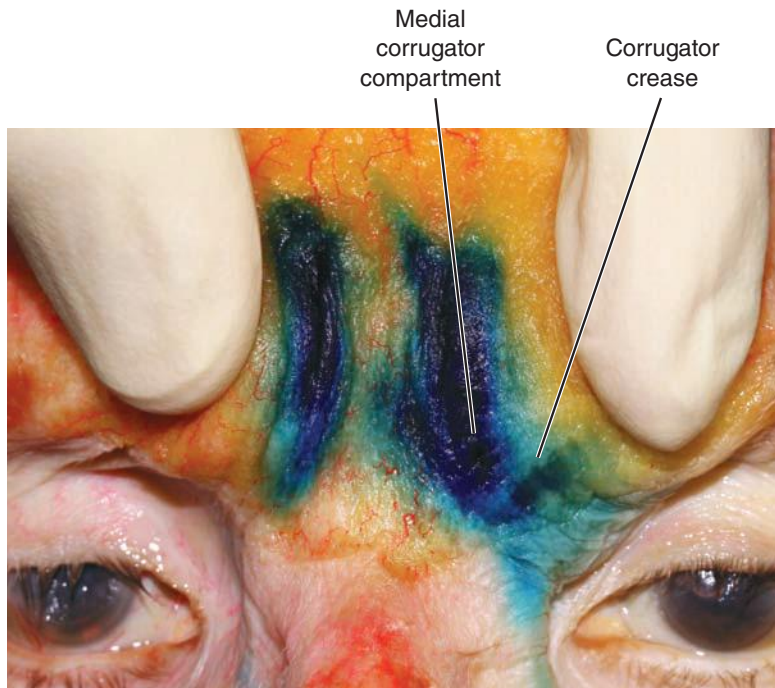
Another dissection illustrates this point.



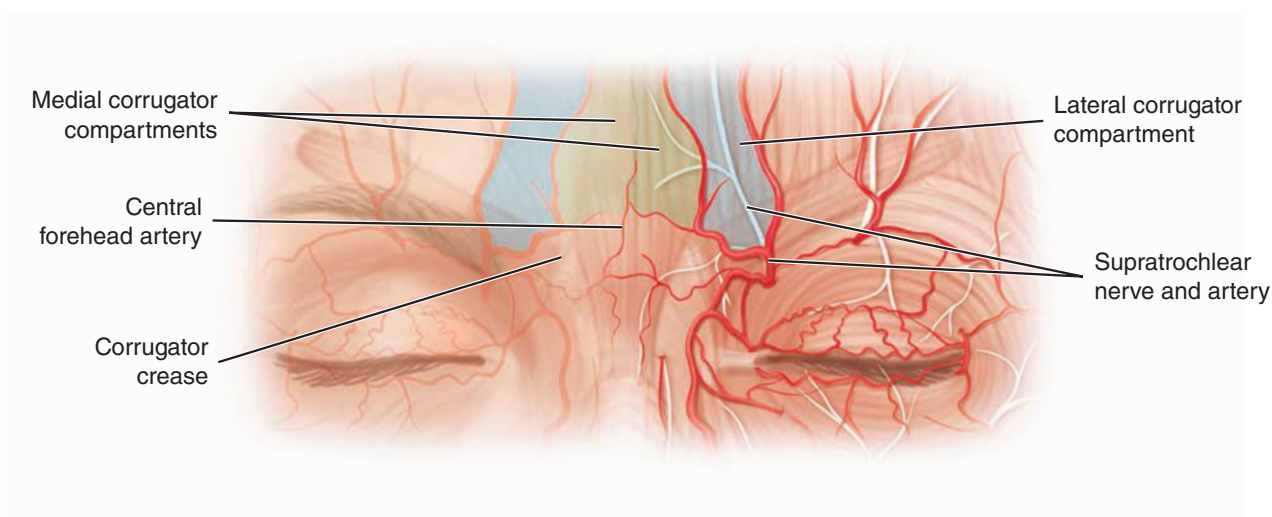
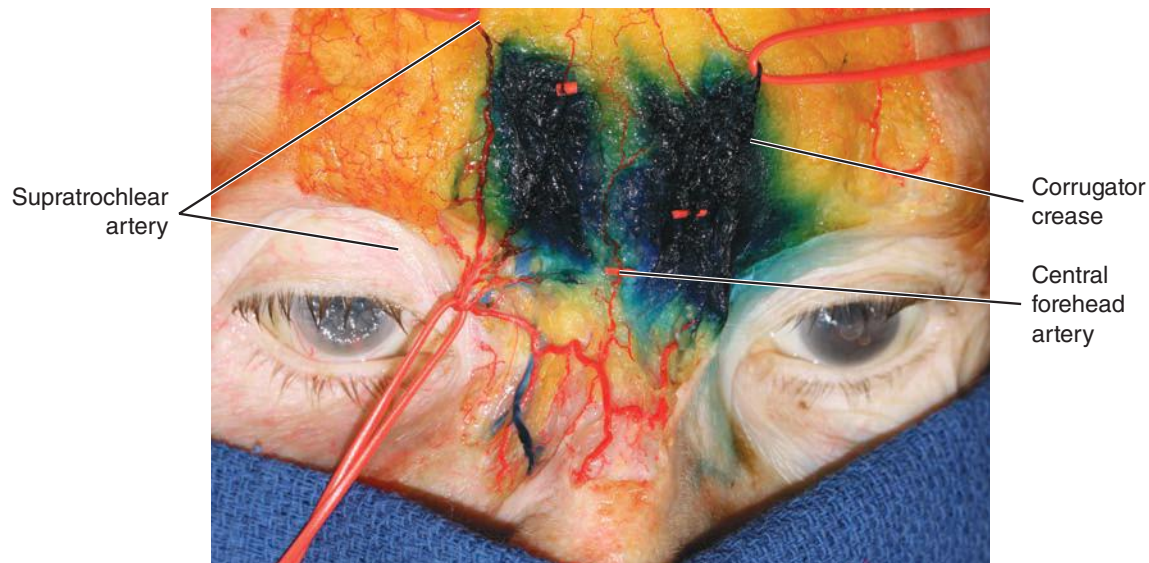The medial corrugator compartment lies between the central forehead and corrugator creases.



The dye technique shows how creases serve as the boundaries of this distinct compartment.



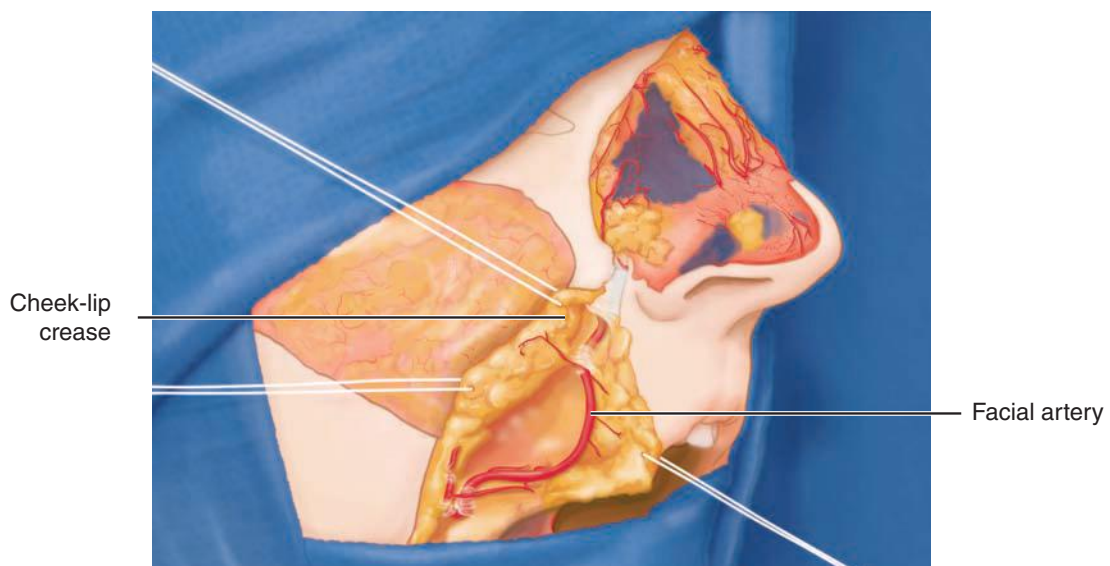
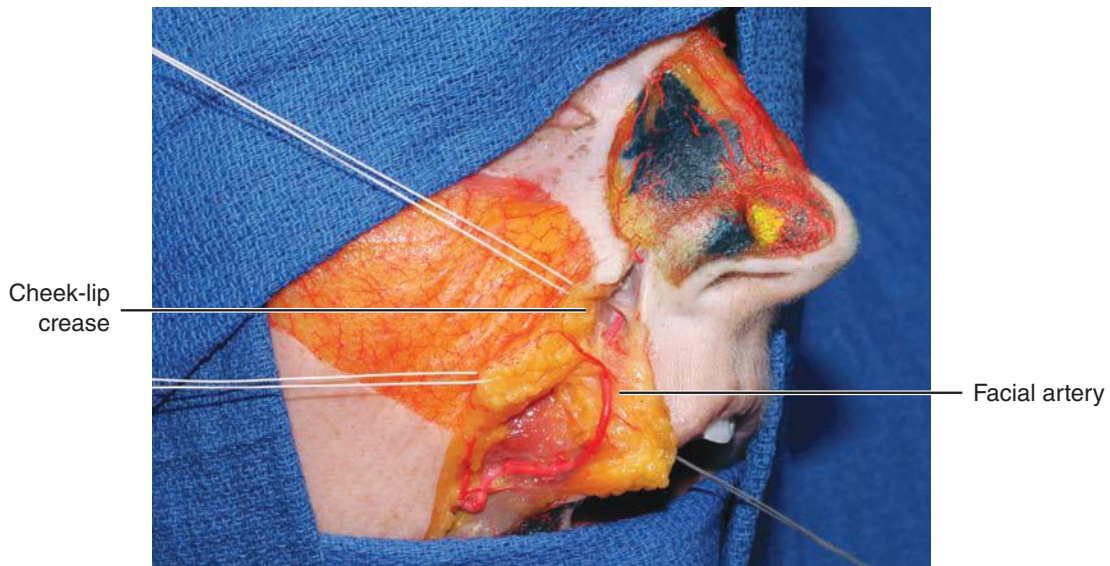
Additional dissection of latex-filled vessels shows how the supratrochlear artery parallels the course and direction of the corrugator crease.



The supratrochlear, central forehead, angular, and transverse nasal arteries are noted. The corrugator crease represents the boundary of a distinct region of fat, the medial corrugator compartment. It serves as a surface landmark for the position and course of the supratrochlear artery. This is the first example of how surface topography is defined by, and serves as a predictor of, underlying anatomy.

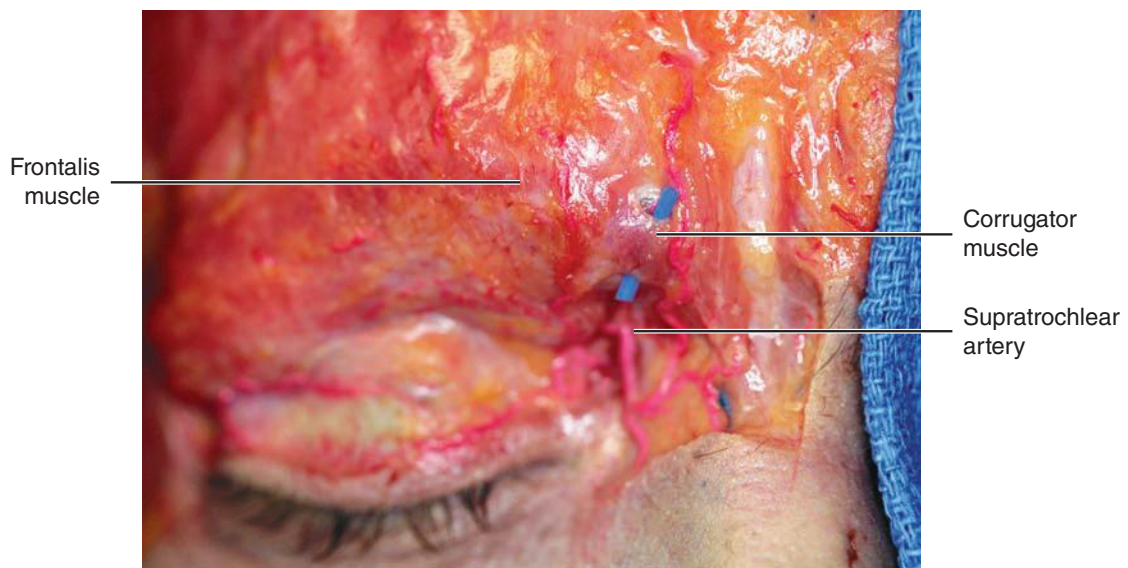
The topography of the face is defined by, and serves as an indicator of, the underlying anatomy. Blood vessels are associated with creases that help to identify the course and location of vessels in the clinical setting.

This applies to the entire face, as will be seen later. One familiar example is the cheek-lip crease, a surface landmark for the course of the facial artery.



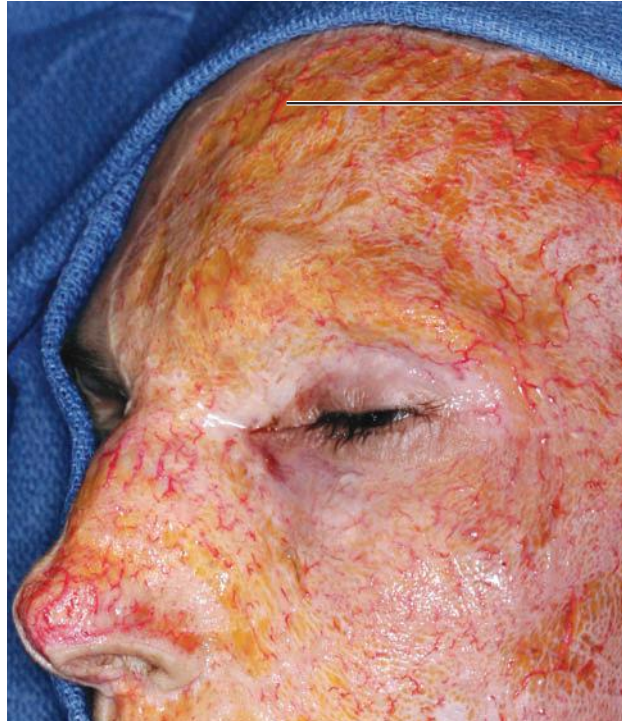Injections made deep in the soft tissue of the face directly beneath creases risk causing bleeding and direct injury to the blood supply. A key point is that these vessels are located deep, beneath subcutaneous tissue and even beneath muscles, making superficial injections safer. This is only true when the vessel is deep, as is true for the supratrochlear artery. Knowledge of which wrinkles and creases are associated with a deep artery and which are associated with superficial arteries is of critical importance clinically. The previous dissection illustrates this point.

The supratrochlear artery, the main blood supply to the forehead flap, travels beneath the corrugator and frontalis muscles.



*Creases* may be associated with deep vessels. *Wrinkles* are associated with superficial vessels and are more prone to inadvertent injury.

It does not become superficial until a more cephalad point, when it traverses the frontalis muscle to run directly beneath the skin.



Supratrochlear  
artery

The facial artery and superficial temporal arteries are also deep, beneath the orbicularis oris and anterior auricularis muscles respectively. However, the central forehead vessel is superficial, lying directly beneath the skin. It is this superficial position of the central forehead vessel that may contribute to reported complication risk of injections performed in the glabellar region.

## WRINKLES VERSUS CREASES

The terms *wrinkle* and *crease* are often used interchangeably, but a more exact anatomic definition allows the terms to be used more precisely. *In general, creases are associated with deep vessels.* This is true for the corrugator, nasolabial, cheek-chin, lip-chin, and preauricular creases. It appears that one of the conditions required for the formation of a facial crease is a deeply coursing arterial vessel.

---

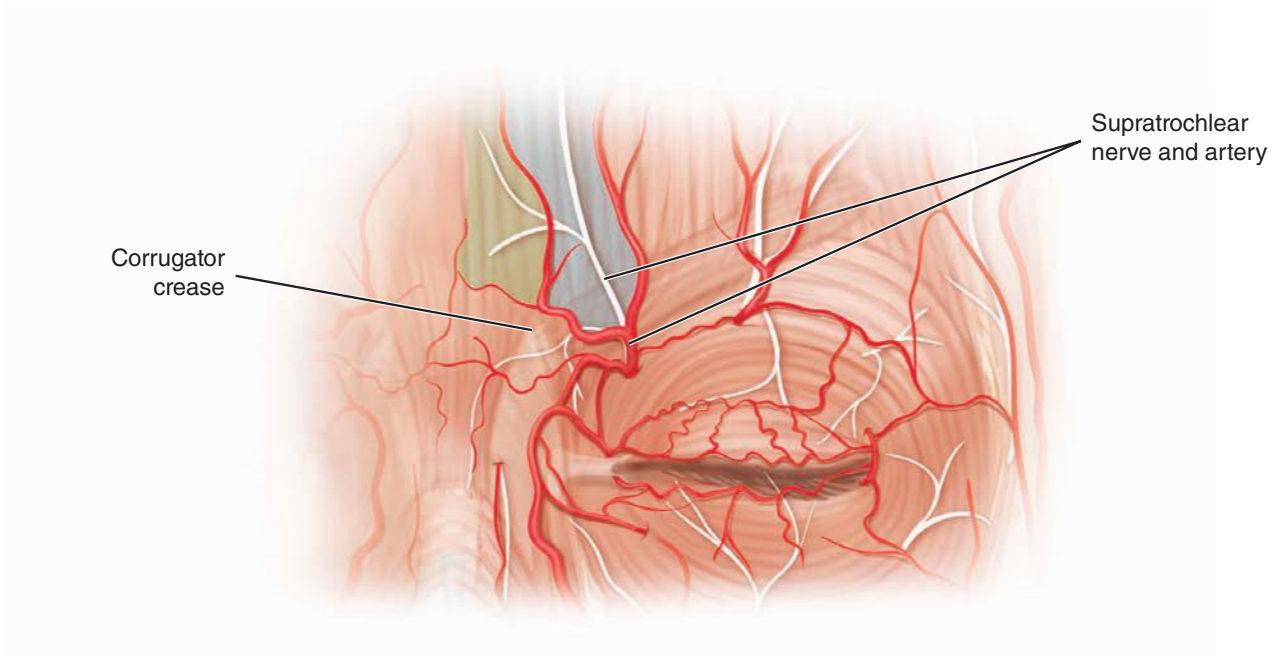
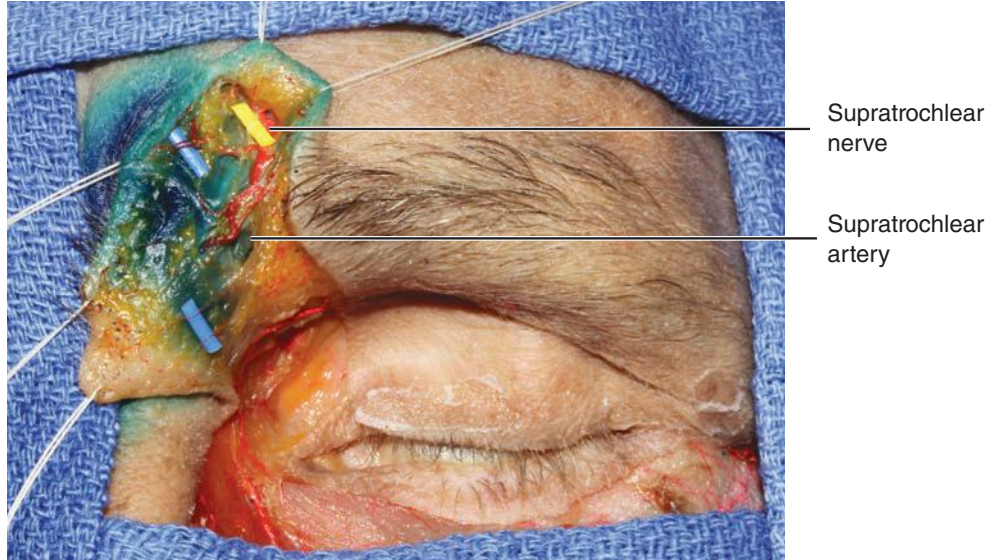
Creases serve as indicators of the position of deeply situated arterial vessels.

---

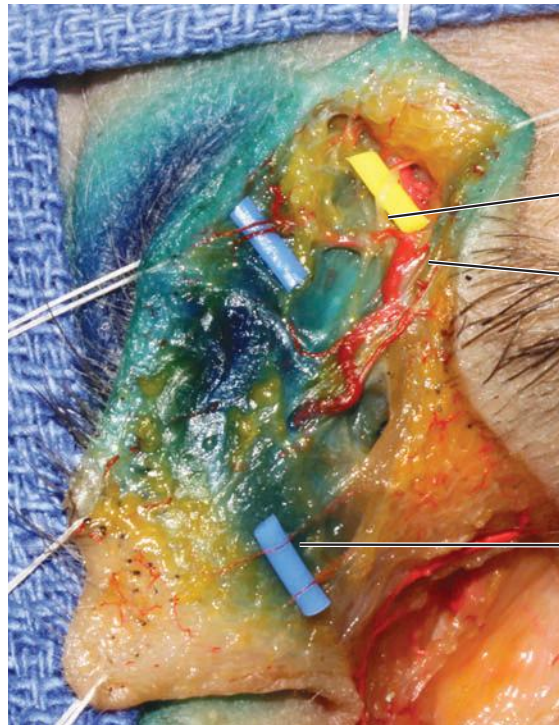
If this is true, injections of filler material performed directly beneath true creases should not be associated with a significant complication rate, as is seen in clinical practice. Wrinkles, on the other hand, may be predictors of the course of superficial vessels. By these criteria, the central forehead surface indentation would be termed a wrinkle, because it is associated with a superficial rather than a deep vessel.

The corrugator crease offers additional information about the anatomy.

Because the supratrochlear nerve runs with the artery, the crease indicates the relative position of both the artery and nerve.



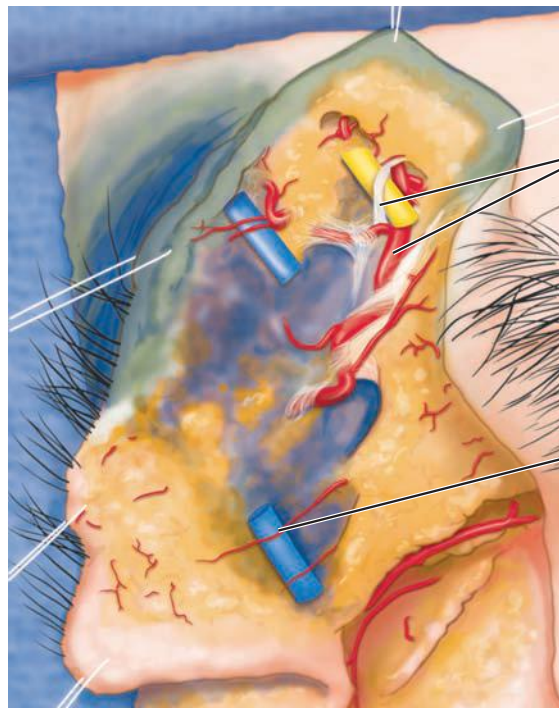
This is true for other creases in the central face.



Supratrochlear nerve

Supratrochlear artery

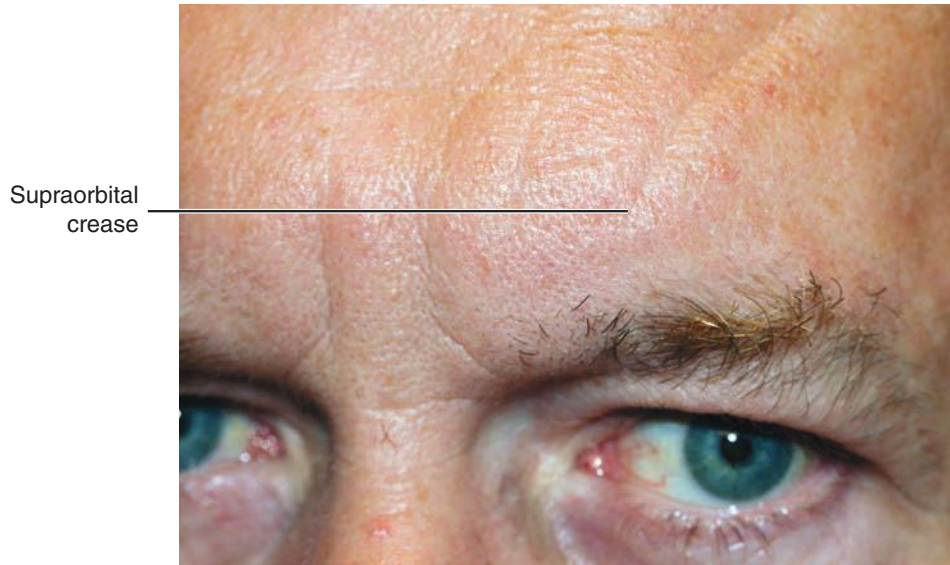Perforator vessels



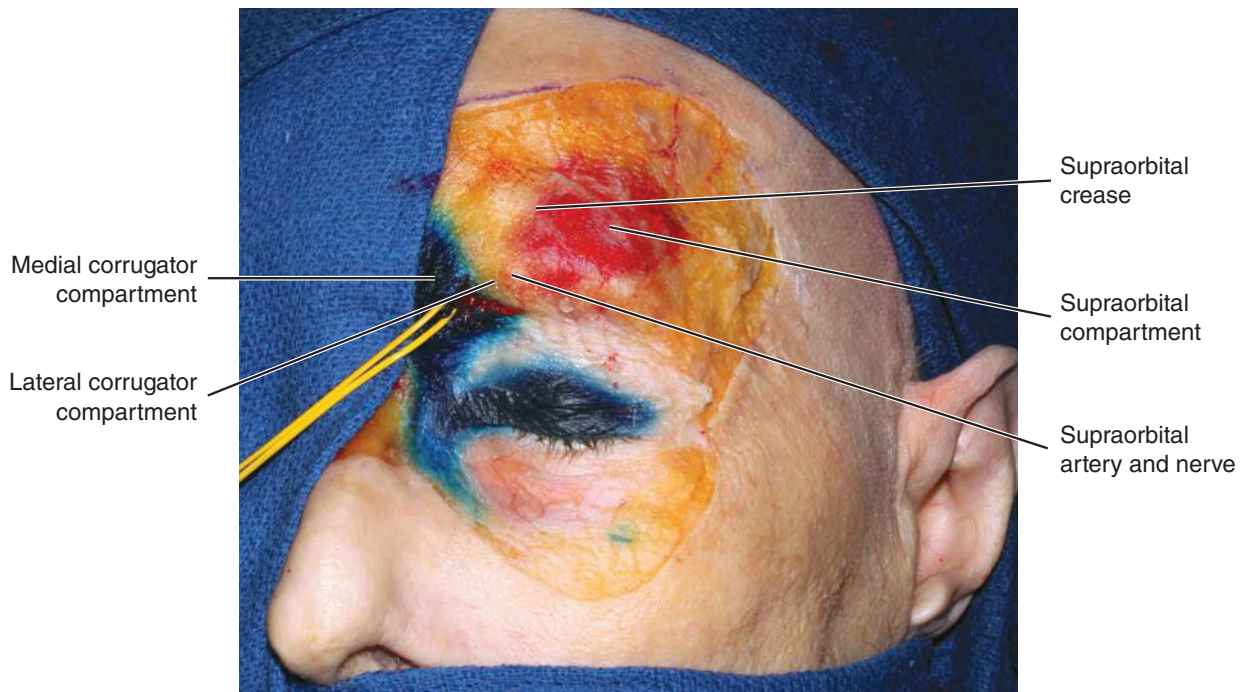Supratrochlear nerve and artery

Perforator vessels

This patient has a supraorbital crease, one less commonly seen.

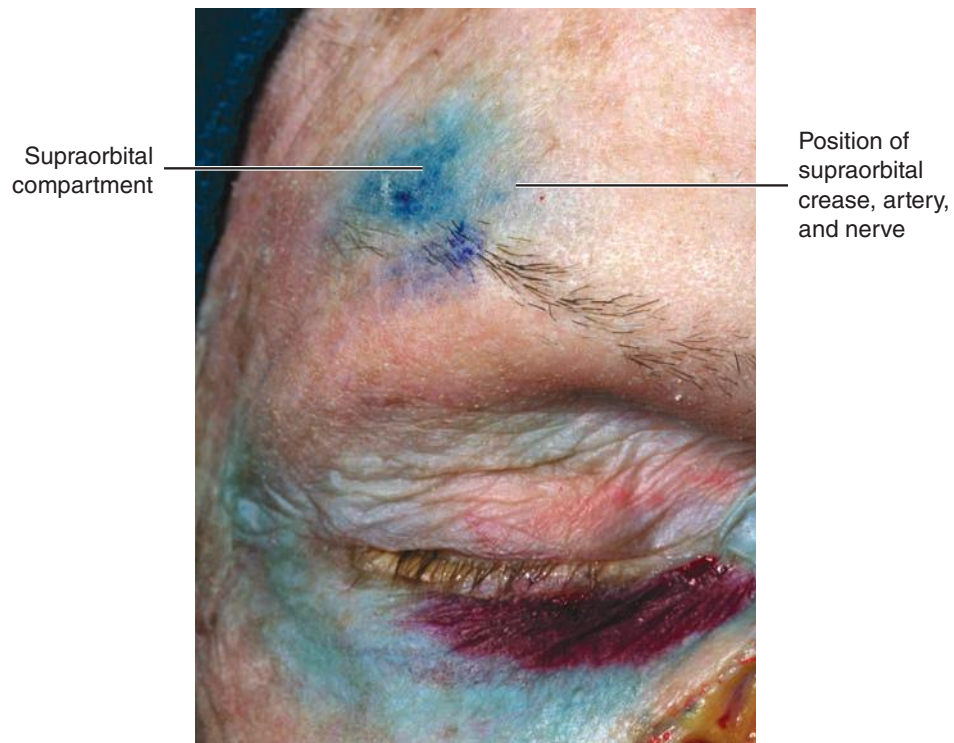


The supraorbital crease occurs above the supraorbital artery and nerve.

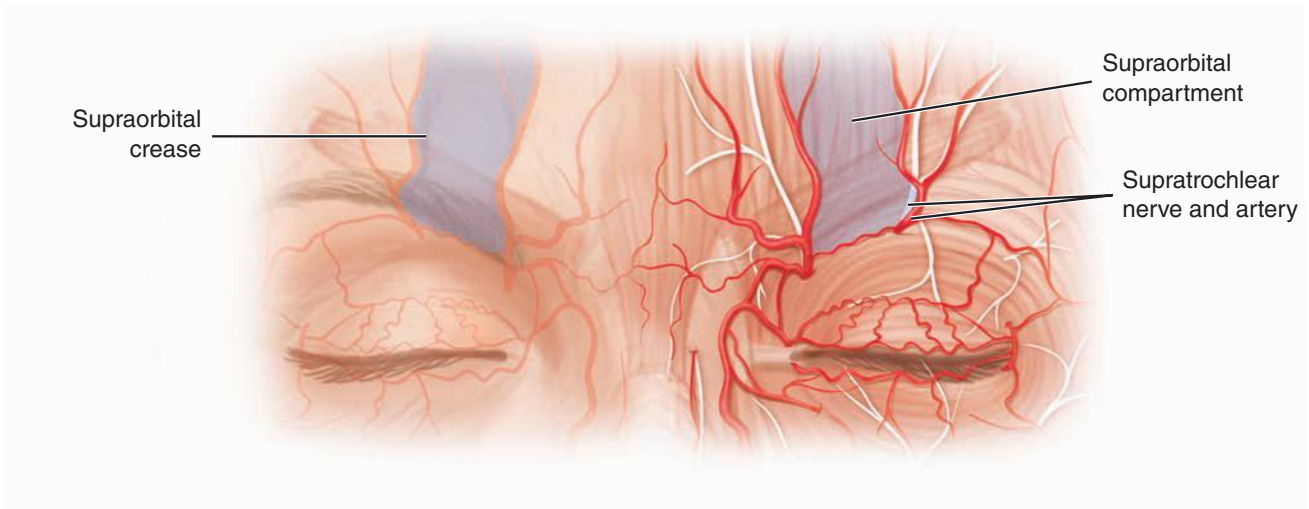
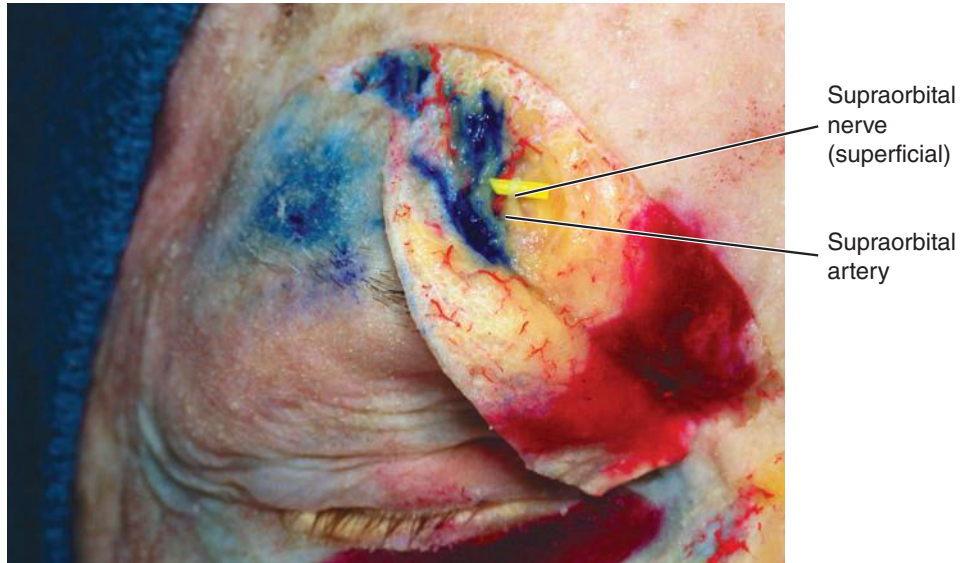

The supraorbital artery together with adjacent vessels describes a discrete region of adipose tissue. Another dissection further illustrates this point.

The supraorbital compartment is stained with water-soluble dye.

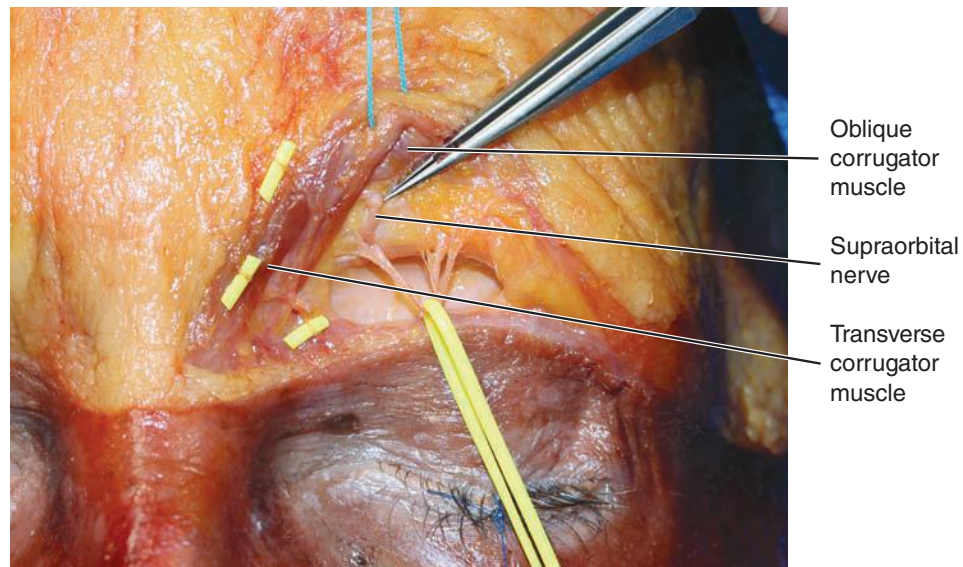


The supraorbital artery defines the medial boundary of the supraorbital compartment. The superficial branch of the supraorbital nerve runs alongside the vessel.

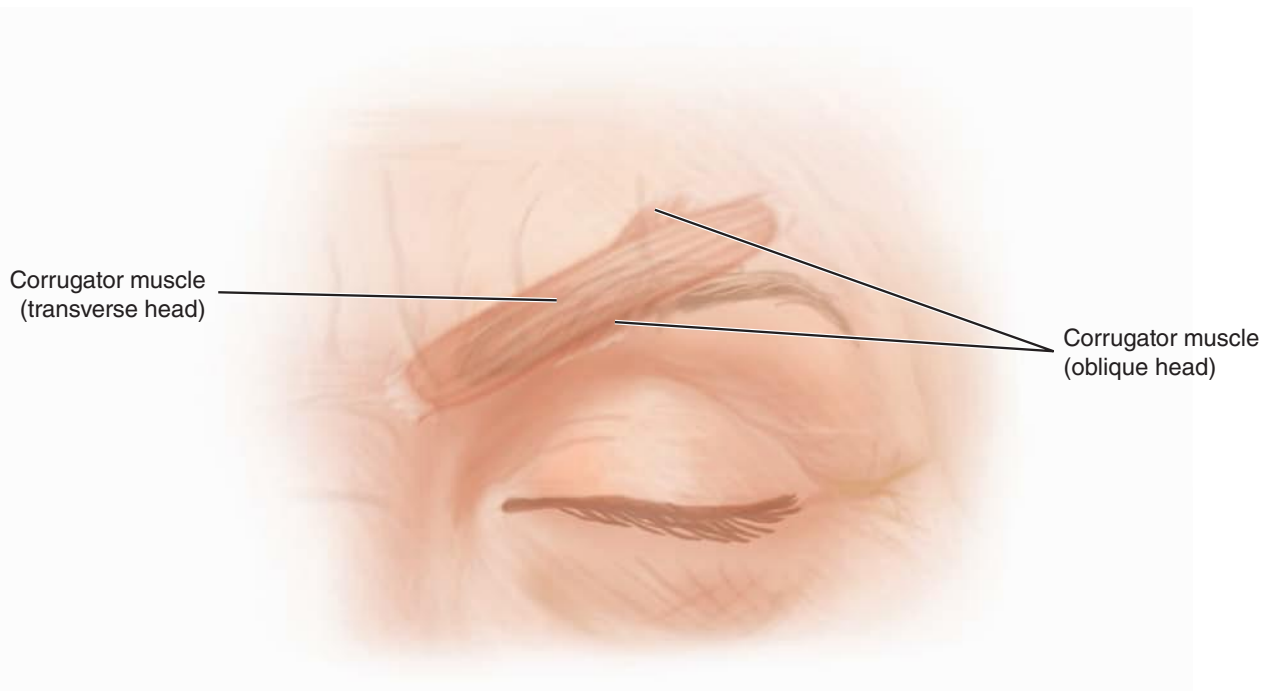
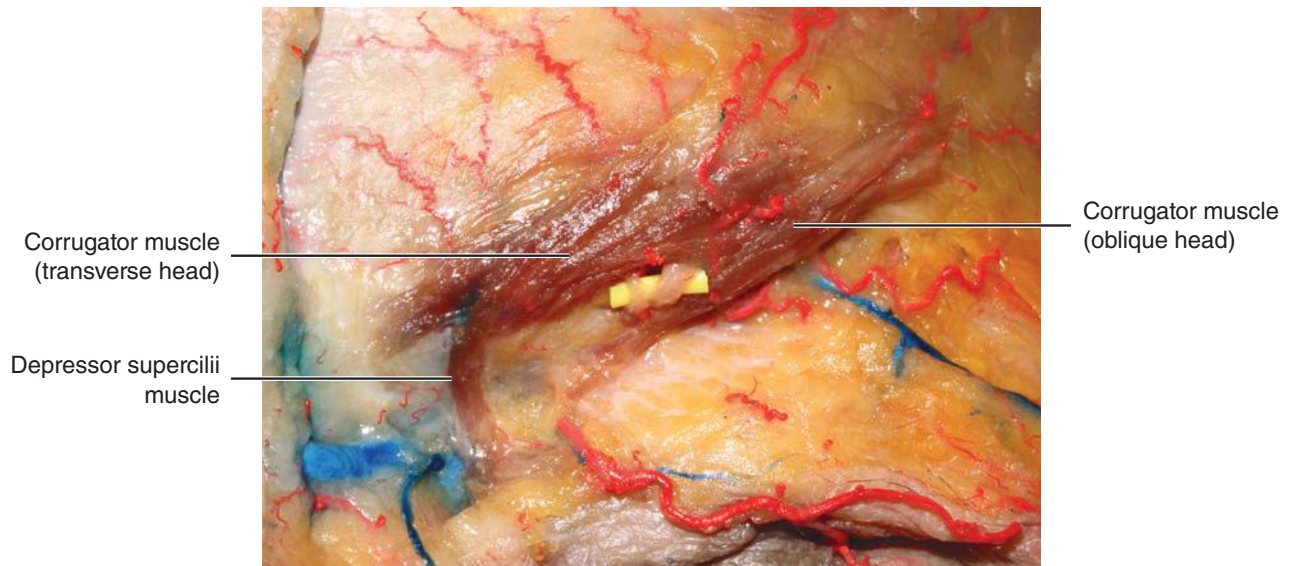


Any technique or procedure that has as its goal accessing the supraorbital nerve can rely on this crease as a landmark for locating the nerve. Together, the corrugator and supratrochlear creases help to define the position and general boundaries of muscular anatomy, in this case the anatomy of the corrugator muscle.

The corrugator muscle has two muscular bellies, a transverse and an oblique. The supraorbital nerve can divide at a point between the two.



A general principle is that creases and wrinkles occur over muscles, not at their origin or insertion. This may seem basic, but because the corrugator crease and the supraorbital crease occur as a result of contraction of the corrugator muscle, the muscle must extend past these two creases. The length of this muscle, in general, is longer than is usually anticipated.



Effective removal of the entire muscle then depends on extending the resection beyond these surface landmarks. The same can apply to the use of chemodenervation agents. The preceding dissection illustrates two additional points.

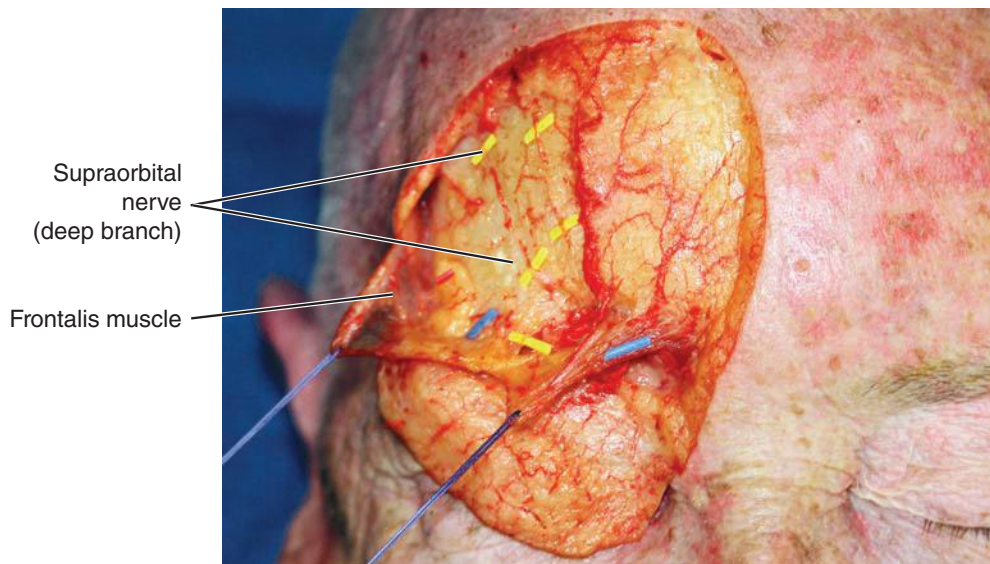
One can see the difference in the path and insertion of the oblique and transverse portions of the corrugator muscle. Chemodenervation to diminish creases and wrinkles is a common practice that requires knowledge of this anatomy. If only one part of the muscle is denervated the patient may have altered facial expression, relying only on the nondenervated portion.

The second point is similar and relates to the depressor supercilii muscle, the small vertically oriented muscle. It is not uncommon to miss this muscle when denervating the central forehead. This leads to a facial expression that may be unique to this scenario.

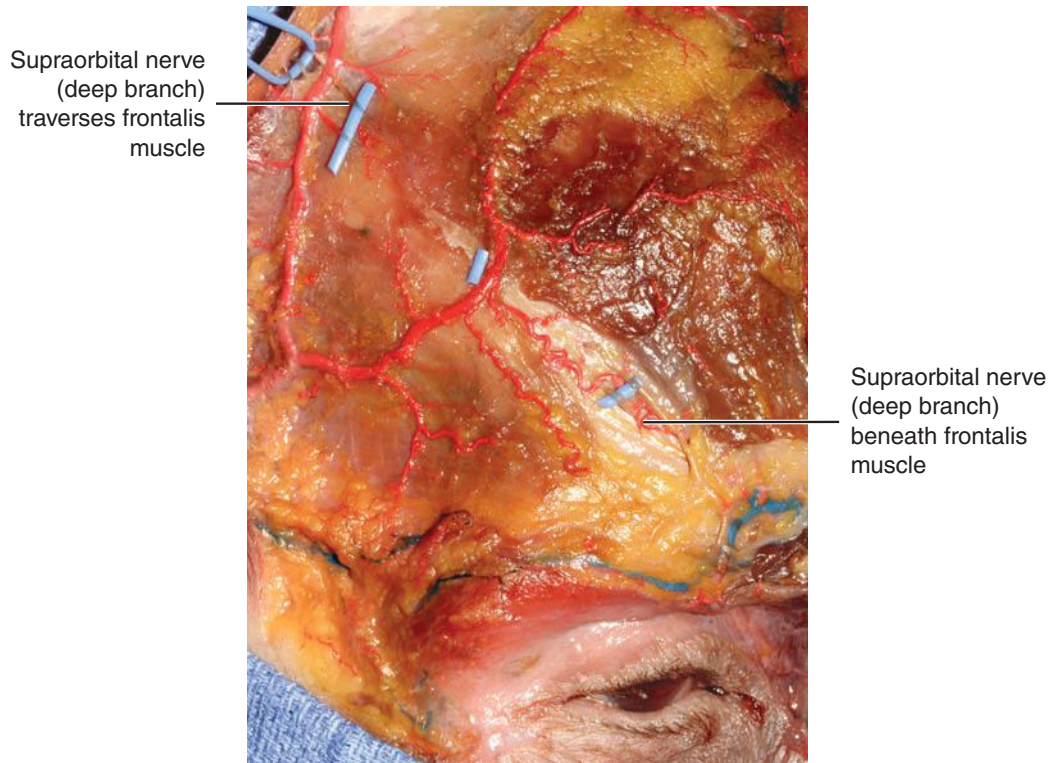
When an individual attempts to frown with both portions of the corrugator removed and with the depressor supercilii intact, he or she elevates only the medial edge of the frontalis muscle to compensate. This occurs because of an imbalance in the forces of muscular contraction. It is easily remedied by chemodenervation of the depressor supercilii muscle.

## BOUNDARY ZONES

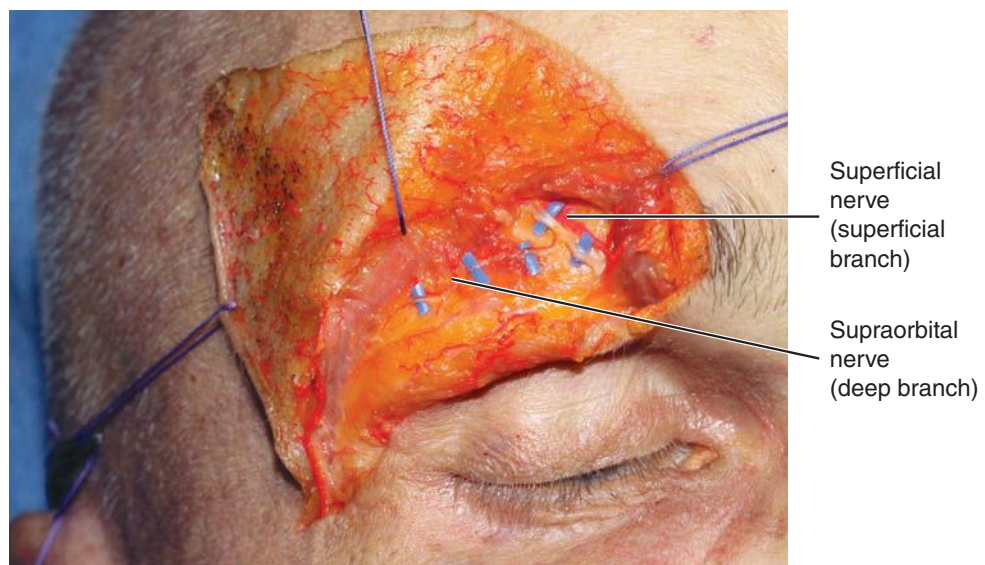
These dissections illustrate the point that the central forehead has distinct boundaries. It is separate from the nose and lateral forehead. The lateral edge of the supraorbital compartment is the boundary between the central forehead and temporal region. This boundary is clinically important, because it represents the path of the deep branch of the supraorbital nerve.



The deep branch of the supraorbital nerve runs below the frontalis muscle until it reaches the scalp.



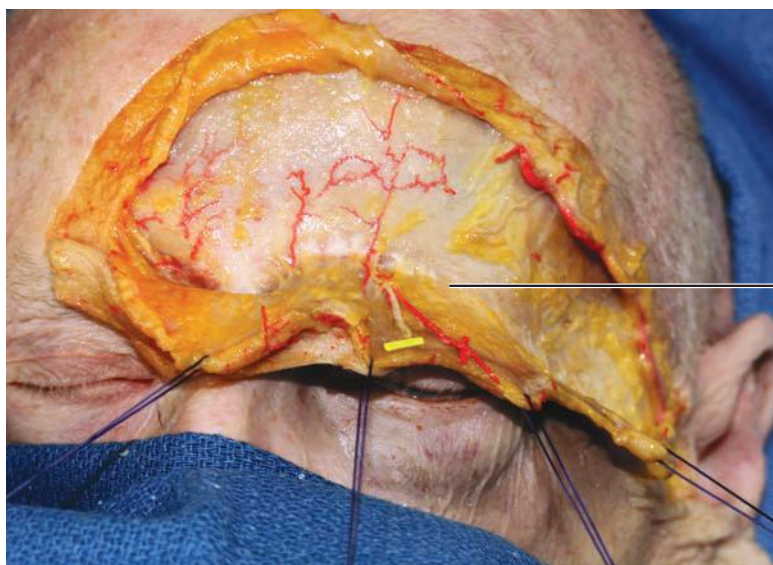
Anatomic work has shown that incisions placed over this boundary can damage the deep branch that supplies sensation to the scalp. A lateral branch of the supraorbital nerve to the lateral scalp and forehead parallels the course of the orbital rim.



Boundary zones are important clinically: many facial nerve injuries occur when dissection proceeds between boundary zones. Transition points between superficial fat compartments are one type of boundary zone. A second type occurs below fascia and muscle. Boundary zones also define the anatomic regions of the face.

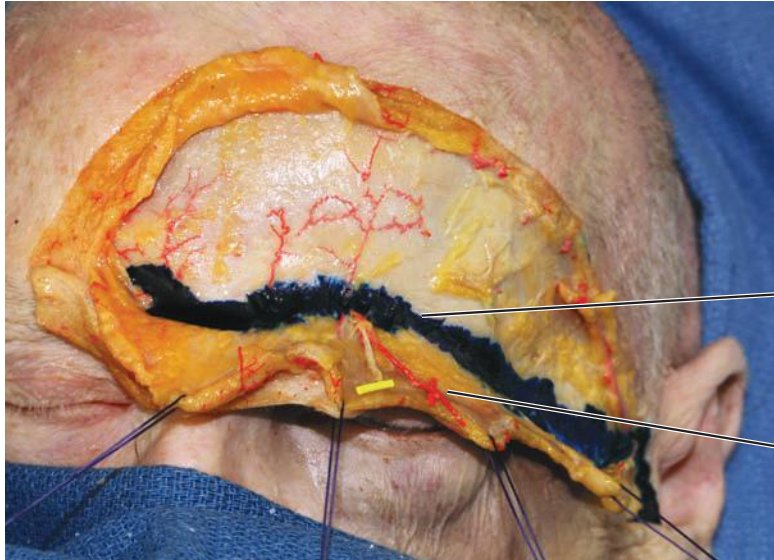
Boundary zones between anatomic regions can exist superficial and deep to fascia and muscle. Boundary zones are areas of increased risk of nerve damage during facial dissection.

For example, this dissection turns down the forehead flap at the subfascial level.



Fusion  
point of  
fascia to  
periosteum

Dye placed along this dissection limits its diffusion to the boundary between the central forehead and the nose and upper eyelid.



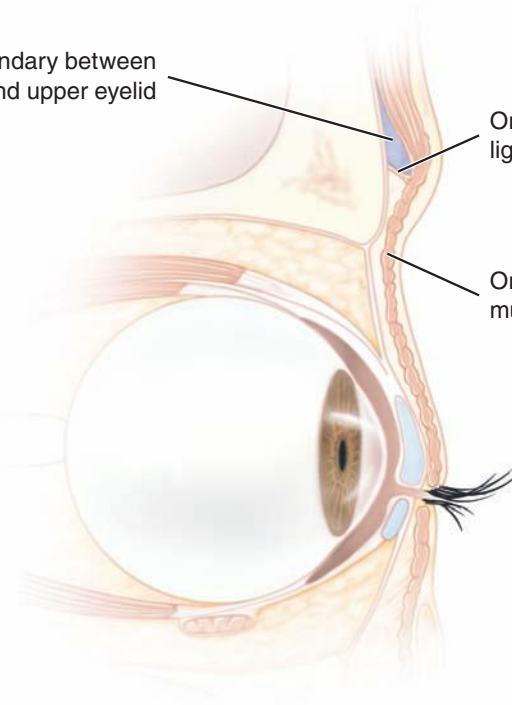
Deep boundary between forehead and upper eyelid

Frontalis and orbicularis oculi muscles reflected

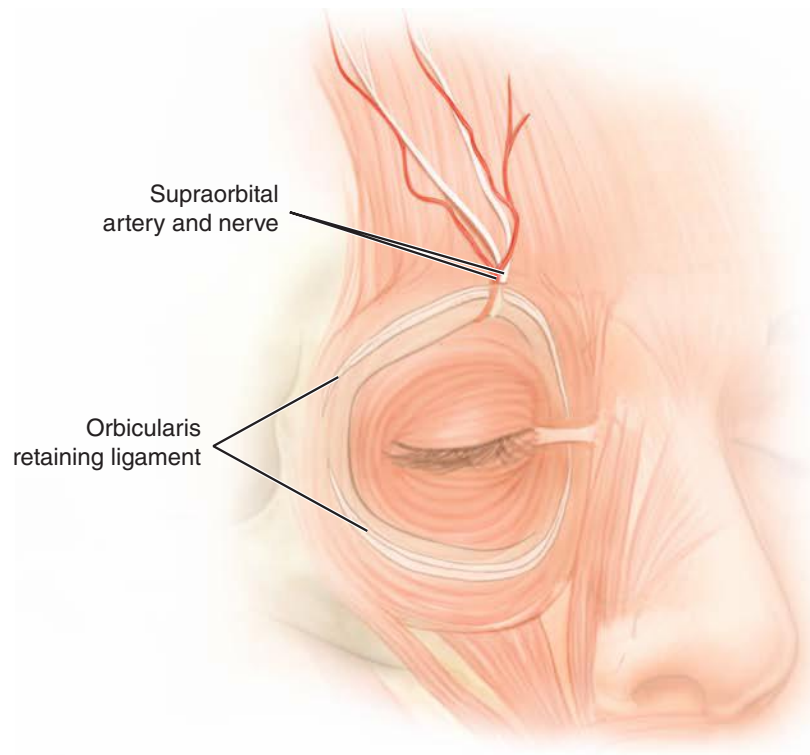
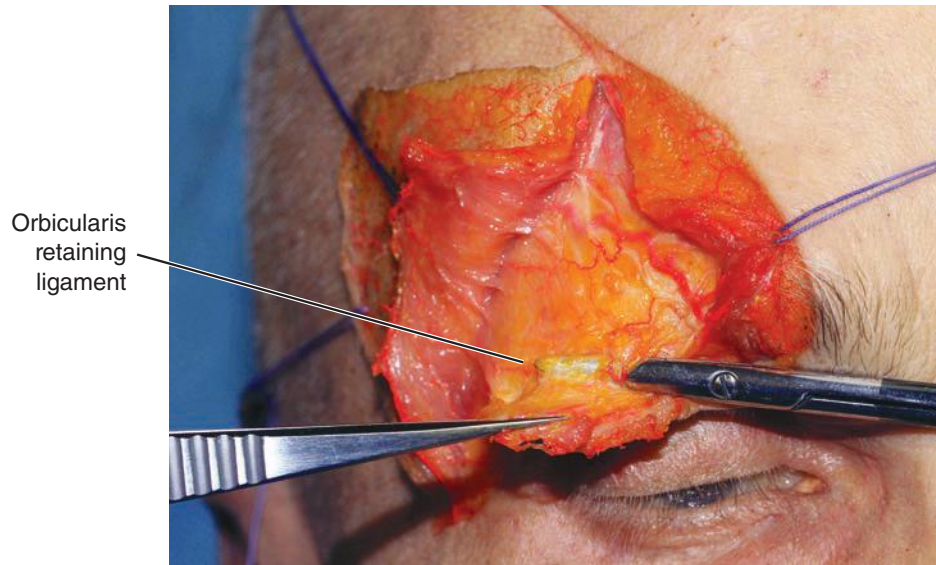
Deep boundary between forehead and upper eyelid

Orbicularis retaining ligament

Orbicularis oculi muscle

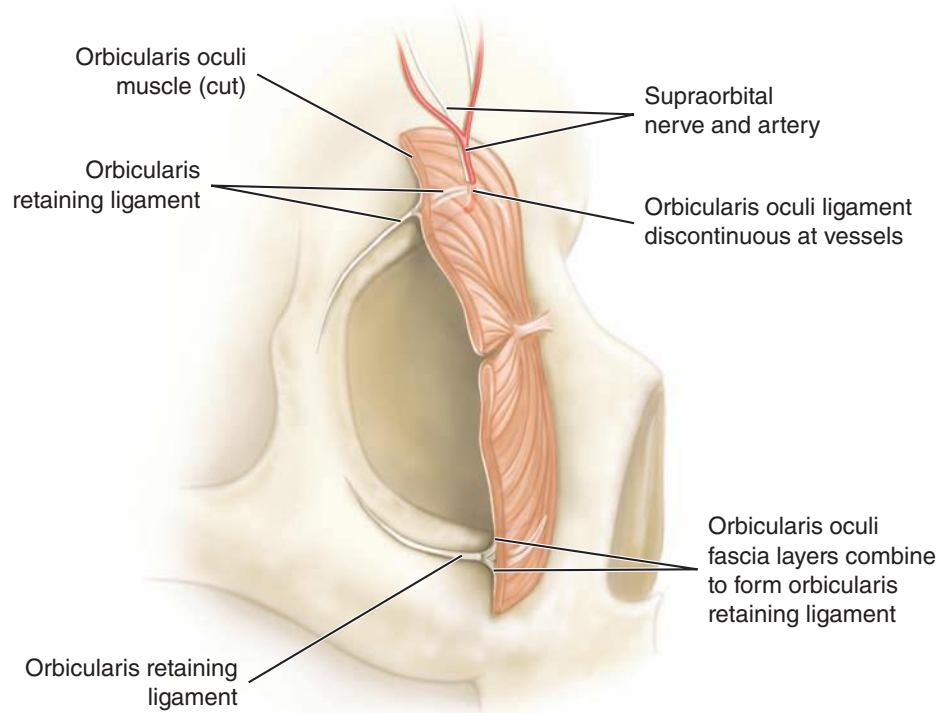


The orbicularis retaining ligament of the upper eyelid is the deep boundary between forehead and upper eyelid and is a fusion zone of orbicularis fascia to periosteum.

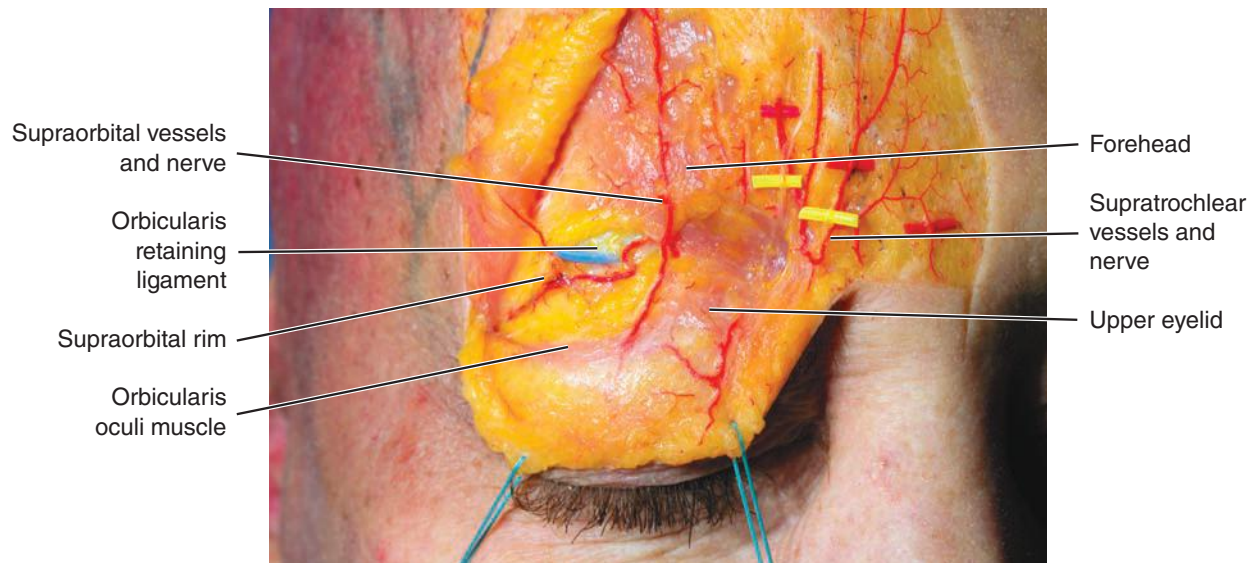


Extraorbital soft tissues exist superficial to the orbicularis retaining ligament. Once this ligament is transected, the intraorbital soft tissues are encountered.

The orbicularis retaining ligament is the membrane created when the fascia beneath the orbicularis oculi muscle inserts into the periosteum of the supra-orbital rim. It acts to tether the orbicularis oculi muscle and provides a point of stability. It also is a boundary between the forehead and the upper eyelid.



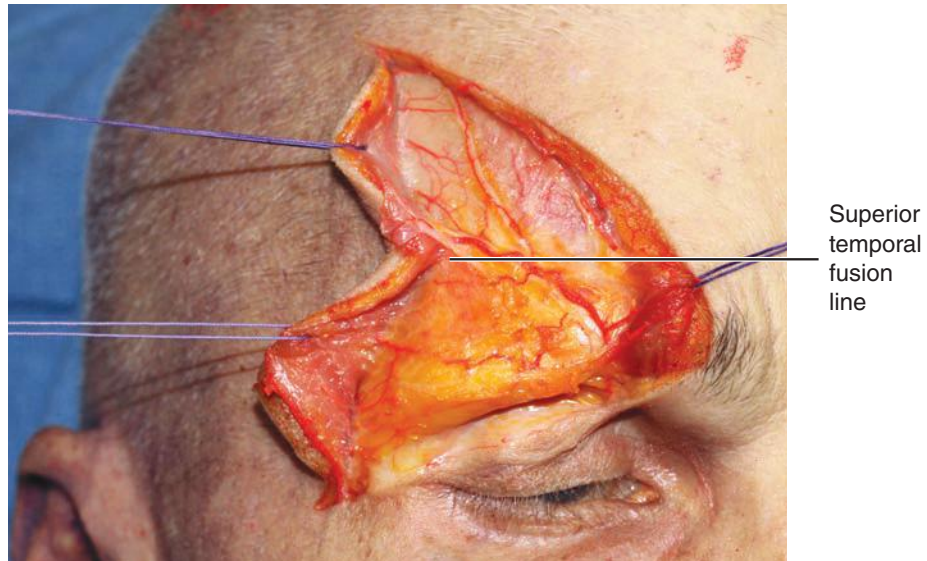
Any maneuver that transits through the orbicularis retaining ligament enters the soft tissues of the upper eyelid.



Deep boundaries represent points of fascial fusion into periosteum. Ligamentous structures are formed at these fusion zones.

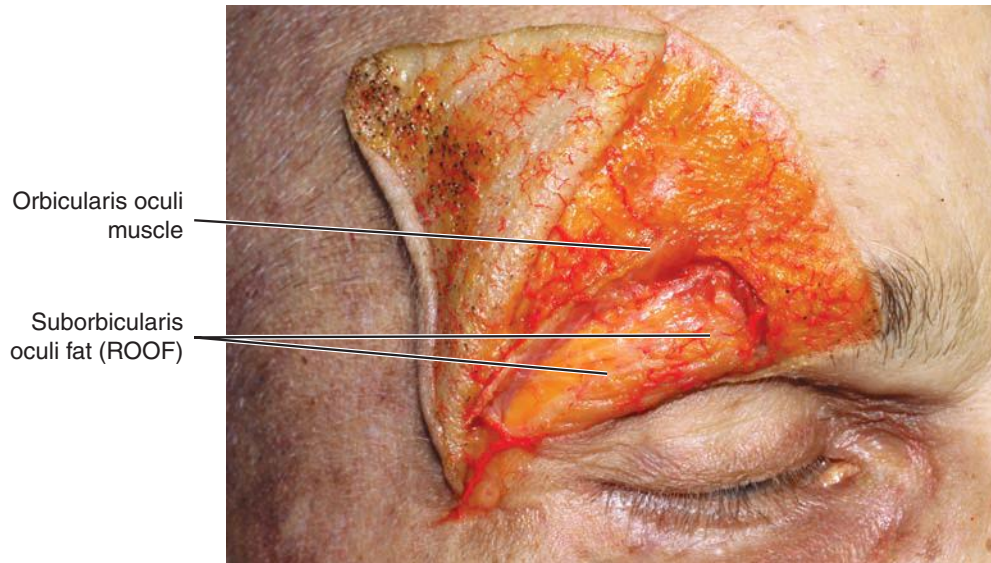
The orbicularis retaining ligament inserts 2 to 3 mm above the inferior edge of the supraorbital rim. This point is of extreme clinical importance. Any injection performed below this insertion point places material into the upper eyelid. This renders the levator muscle and fat liable to injury. This complication is avoidable if one palpates the supraorbital rim and always injects 2 to 3 mm above the inferior edge, above the insertion of the orbicularis retaining ligament.

The superior temporal fusion zone is the deep boundary between the central forehead and temporal region.

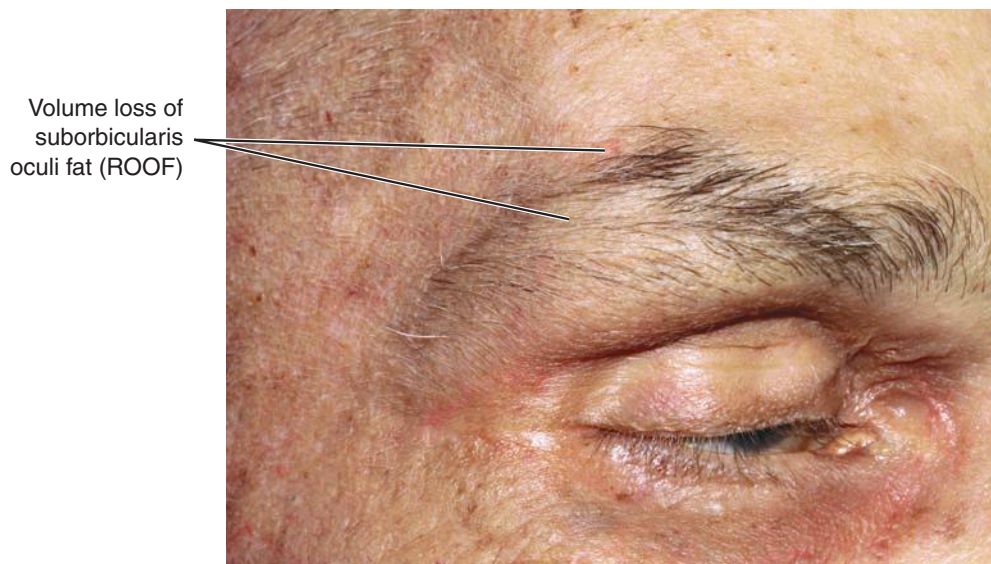


This fusion zone may be released to increase mobilization of the forehead during the forehead lift procedure.

Creases and wrinkles can predict the underlying anatomy. This is one type of topographic landmark. A second type is the analysis of shape and contour. Deep fat, that is, adipose tissue beneath muscle and fascia, contributes to facial shape. Retroorbicularis oculi fat (ROOF) exists along the orbital rim beneath muscle.



ROOF extends to the temporal fusion line. Hollowing of this area occurs with diminished volume of this fat.



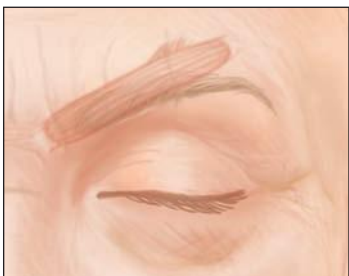Volume augmentation of this deep fat can restore shape. In addition, it may elevate the lateral brow by serving as support.

Deep fat determines facial shape to a significant degree. This is seen in the cheek and upper and lower eyelids, where shape is a particularly useful topographic landmark.

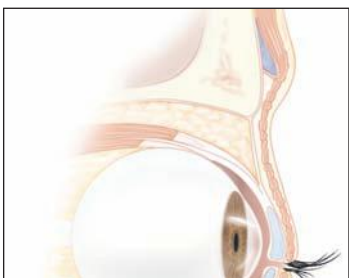### *Key Points*

- The adipose tissue of the face exists as distinct regions and zones rather than as a confluent soft tissue mass.
- The topography of the face is defined by, and serves as an indicator of, the underlying anatomy. Blood vessels are associated with creases that help to identify the course and location of vessels in the clinical setting.
- Creases serve as indicators of the position of deeply situated arterial vessels.
- Boundary zones between anatomic regions can exist superficial and deep to fascia and muscle. Boundary zones represent areas of increased risk of nerve damage during facial dissection.
- Deep boundaries represent points of fascial fusion into periosteum. Ligamentous structures are formed at these fusion zones.

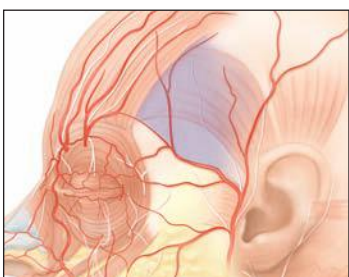
## CLINICAL CORRELATIONS



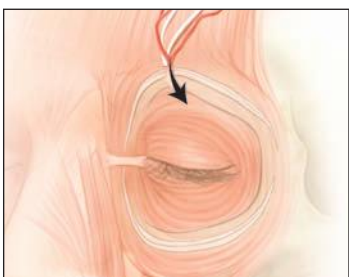
Chemodenervation of the corrugator muscle can be effectively performed by injecting medial and lateral to the corrugator crease, because muscles span the creases they create. This also limits bleeding complications.



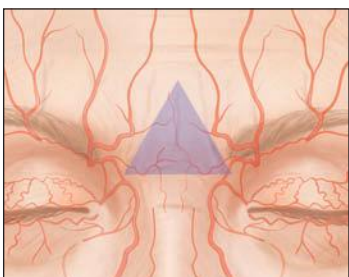
Recognizing the location of the deep boundary between the forehead and upper eyelid is important to avoid inadvertent injection into the levator palpebrae superioris muscle. This is the orbicularis retaining ligament that inserts several millimeters above the edge of the supraorbital rim. Injections should be performed above this inferior edge to avoid lid ptosis.



The lateral boundary of the central forehead describes a safe zone for placement of a scalp incision. The course of the deep branch of the supraorbital nerve is medial to this boundary.



The seal at the deep boundary between the forehead and upper eyelid is imperfect: injections placed directly at creases can travel along vessels and nerves that traverse anatomic compartments; for example, along the supraorbital artery and nerve. This dictates the technique used for muscle chemodenervation.



Creases are defined by deeply situated vessels. Wrinkles are more frequently associated with superficial vessels, for example, the central forehead crease. Superficial filler placement above a crease does not carry the same risk of skin necrosis as superficial placement around a wrinkle. This is especially true when the wrinkle is associated with an end perforator territory.

## Bibliography

The conceptual basis for this book can be extrapolated from these fifteen articles. The complexity of the facial musculature determines creases and lines that form perpendicular to the direction of muscular contraction. Nerves travel with veins that travel with arteries; veins and arteries are intimately related to the fascial network. Creases form where there are regional differences in adipose thickness, usually associated with perforator vessels ascending along a fascial membrane. Surface topography can suggest the location and position of more deeply placed structures.

Cook BE, Lucarelli MJ, Lemke BN. Depressor supercillii muscle: anatomy, histology, and cosmetic implications. *Ophthal Plast Reconstr Surg* 17:404-411, 2001.

*This article provides a good overview of the central forehead musculature, with emphasis on the depressor supercillii muscle.*

Hwang K, Jin S, Jun H, et al. Innervation of the procerus muscle. *J Craniofac Surg* 17:484-486, 2006.

*The authors described the contribution of the buccal branch to procerus innervation, highlighting the complexity of facial nerve patterns to the central forehead.*

Janis JE, Ghavami A, Lemmon JA, Leedy JE, Guyuron B. The anatomy of the corrugator supercillii muscle: part II. Supraorbital nerve branching patterns. *Plast Reconstr Surg* 121:233-240, 2008.

*An excellent review of corrugator innervation, this article described branching patterns of the supraorbital nerve relevant to clinical practice.*

Kazanjian VH. The repair of nasal defects with the median forehead flap. *Surg Gynecol Obstet* 83:32-49, 1946.

*Kazanjian's description of the midline forehead flap provides a basis for understanding blood supply to the central forehead.*

Kleintjes WG. Forehead anatomy: arterial variations and venous link of the midline forehead flap. *J Plast Reconstr Aesthet Surg* 60:593-606, 2007.

*The author presented the detailed architecture of the central forehead arterial venous system that serves as a guide to the adipose compartments of the central forehead.*

Kligman AM, Zheng P, Lavker RM. The anatomy and pathogenesis of wrinkles. *Br J Dermatol* 113:37-42, 1985.

*This classic article described the similarity between normal and wrinkled skin and provided indirect evidence that subdermal anatomy may contribute to the formation of wrinkles.*

Knize DM. An anatomically based study of the mechanism of eyebrow ptosis. *Plast Reconstr Surg* 97:1321-1333, 1996.

*Knize's description of the forehead gliding plane and fusion zones provides the basis for understanding deep boundaries between facial regions.*

Knize DM. Limited-incision forehead lift for eyebrow elevation to enhance upper blepharoplasty. *Plast Reconstr Surg* 97:1334-1342, 1996.

*A clinical paper describing the anatomic relationship between facial muscles and deeper fat compartments and suggesting the mechanical role of deep fat as an aid to the gliding mechanism.*

Knize DM. Muscles that act on glabellar skin: a closer look. *Plast Reconstr Surg* 105:350-361, 2000.  
*Knize provided a most detailed look at the anatomy of forehead creases and wrinkles and the muscular anatomy that contributes to these creases. This paper further illustrated the complexity of forehead innervation.*

Mitchell EL, Taylor GI, Houseman ND, et al. The angiosome concept applied to arteriovenous malformations of the head and neck. *Plast Reconstr Surg* 107:633-646, 2001.  
*The authors cited multiple examples of how arteriovenous malformations occur at the site of choke vessels between angiosomes. This article may support the idea that vascular malformations are confined to defined anatomic compartments; for example, the venous malformation of the supraorbital compartment.*

Saint-Cyr M, Wong C, Schaverien M, Mojallal A, Rohrich RJ. The perforasome theory: vascular anatomy and clinical implications. *J Plast Reconstr Surg* 124:1529-1544, 2009.  
*The initial description of the perforasome concept was presented.*

Taylor GI, Palmer JH. The vascular territories (angiosomes) of the body: experimental study and clinical applications. *Br J Plast Surg* 40:113-141, 1987.  
*Taylor and Palmer's paper is the classic article describing the arterial anatomy of the human body. The anatomic construct of source and perforator vessels, and their intimate relationship to fascia, provides the basis for defining adipose compartments and anatomic subunits, and understanding much of facial topography.*

Taylor GI, Caddy CM, Watterson PA, et al. The venous territories (venosomes) of the human body: experimental study and clinical implications. *Plast Reconstr Surg* 86:185-213, 1990.  
*This is the classic paper describing the venous anatomy of the human body. The concept that veins (and arteries) "hitchhike" with nerves provides the anatomic basis for understanding deep structure based on surface landmarks.*

Tsuji T, Yorifuhi T, Hayashi Y, et al. Light and scanning electron microscopic studies on wrinkles in aged persons' skin. *Br J Dermatol* 114:329-335, 1986.  
*This paper confirmed the finding that wrinkled and unwrinkled skin are similar on a microscopic level.*

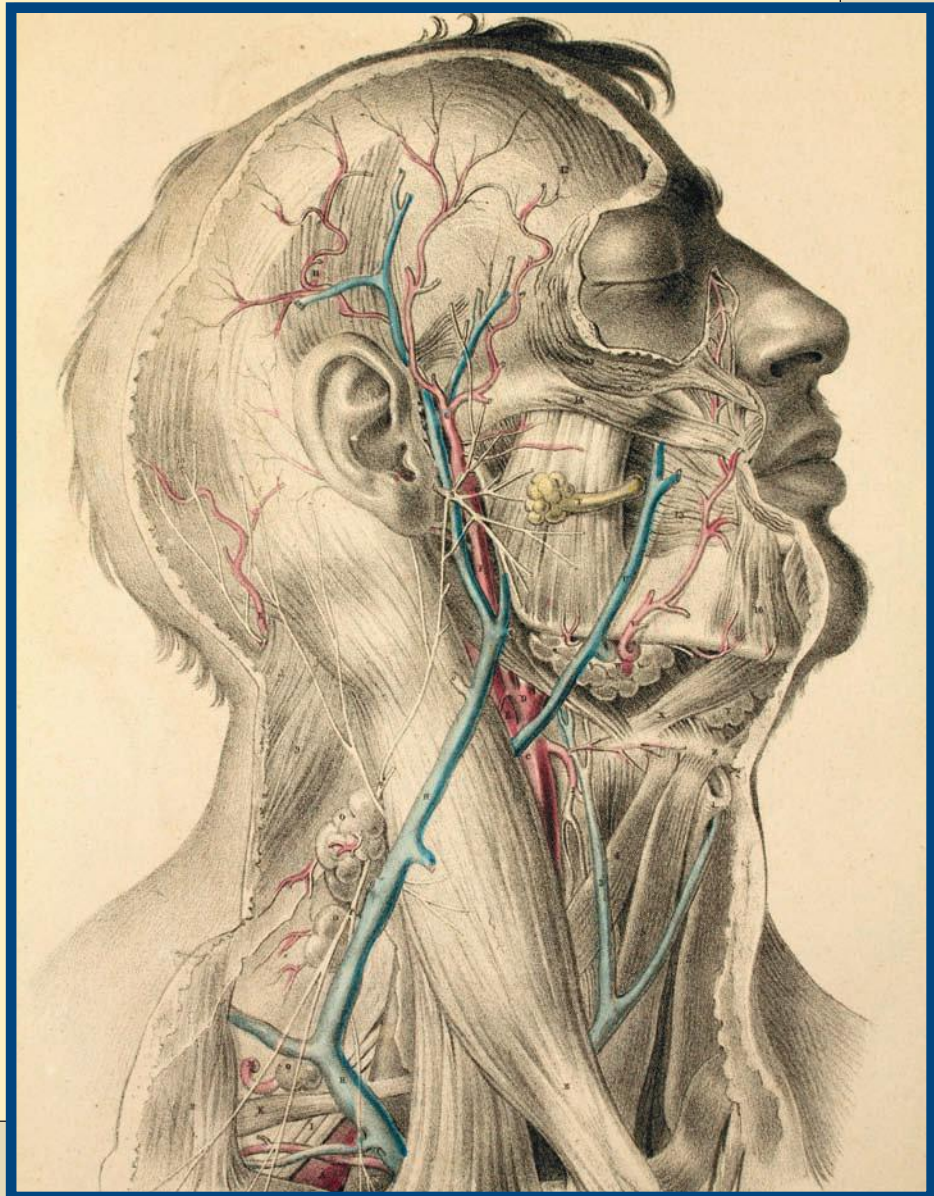
Yu D, Weng R, Wang H, et al. Anatomical study of forehead flap with its pedicle based on cutaneous branch of supratrochlear artery and its supplication in nasal reconstruction. *Ann Plast Surg* 65:183-187, 2010.  
*Reporting a recent study of the arterial anatomy of the central forehead, the authors provided an example of its clinical application.*

---

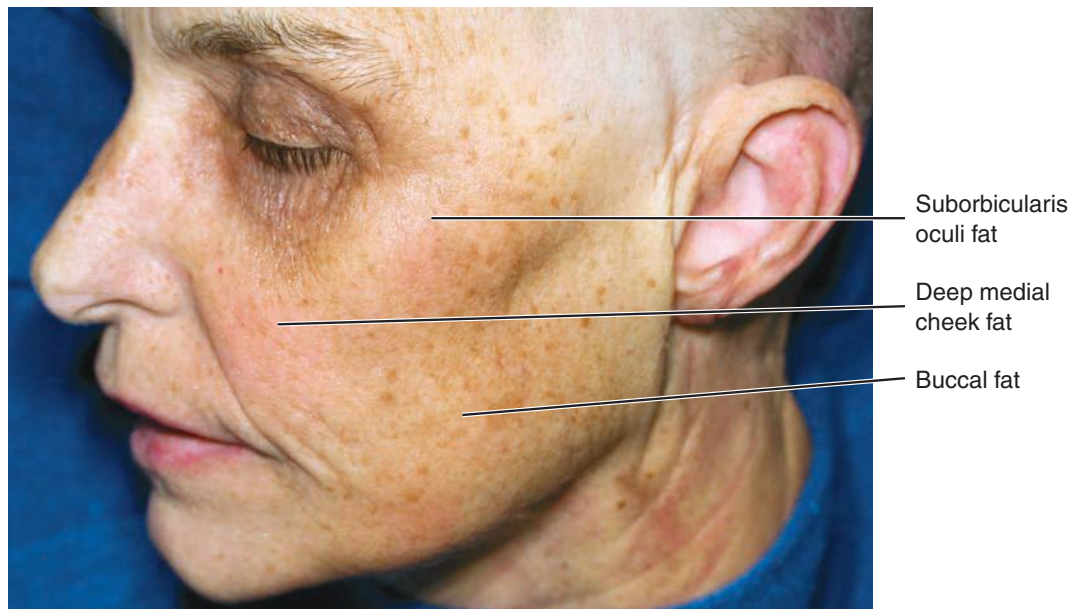
CHAPTER 3

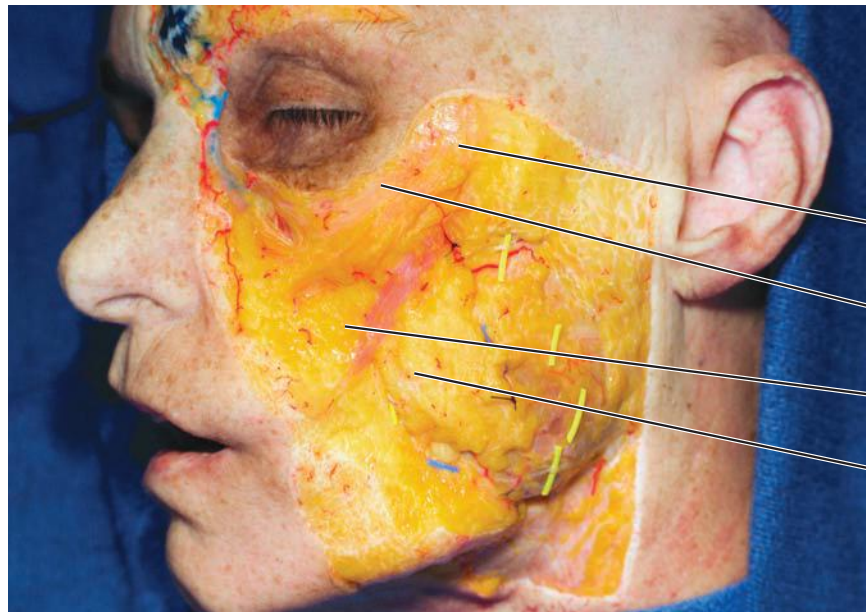---

# The Cheek

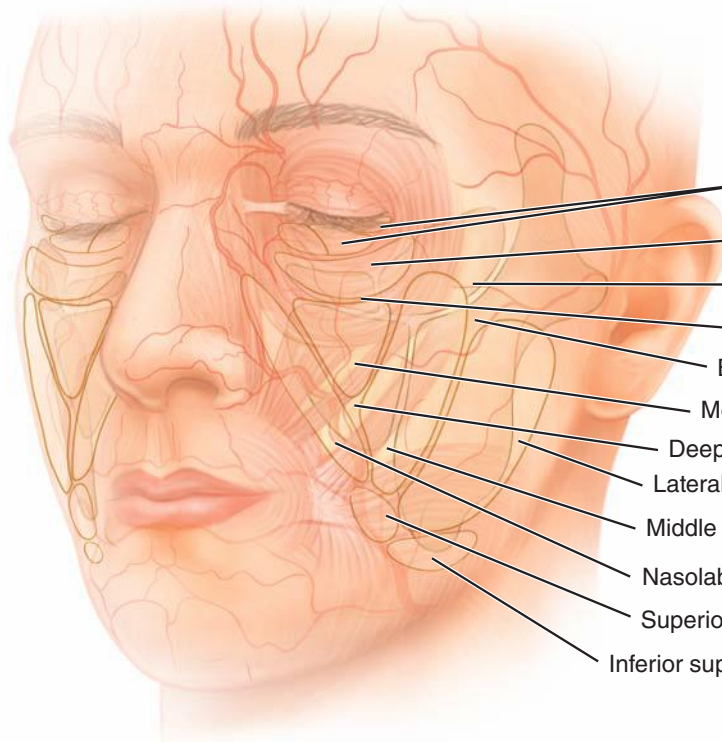


**E**xamination of the cheek yields a wealth of information to the observer. Just as deep fat of the central forehead provides volume to the brow, the contour of the upper cheek suggests the presence of deep fat here as well.





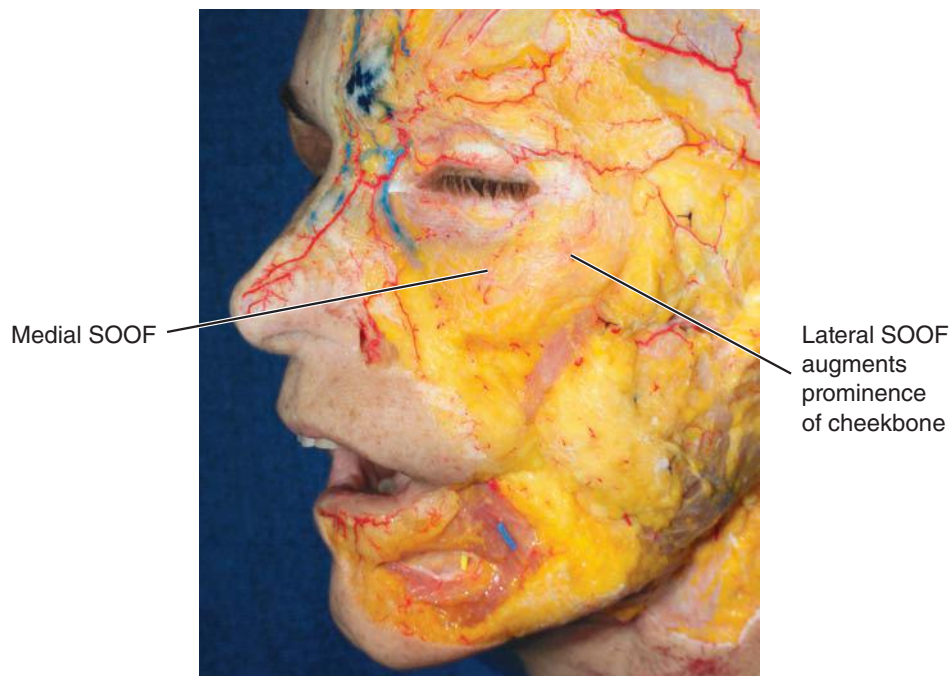
- Suborbicularis oculi fat
- Orbicularis oculi fat (preorbital)
- Deep medial cheek fat
- Buccal fat



- Intraorbital fat (lower eyelid)
- Infraorbital fat (malar mound)
- Lateral SOOF
- Medial SOOF
- Buccal fat
- Medial cheek fat
- Deep medial cheek fat
- Lateral cheek fat
- Middle cheek fat
- Nasolabial cheek fat
- Superior superficial jowl fat
- Inferior superficial jowl fat

This deep fat is the suborbicularis oculi fat (SOOF). Its presence manifests itself by the shape and contour of the upper cheek and cheekbone. If this fat occurs in adequate stores, it may appear that the individual has prominent cheekbones.

When there is a paucity of SOOF, the entire surface of the zygoma becomes apparent.

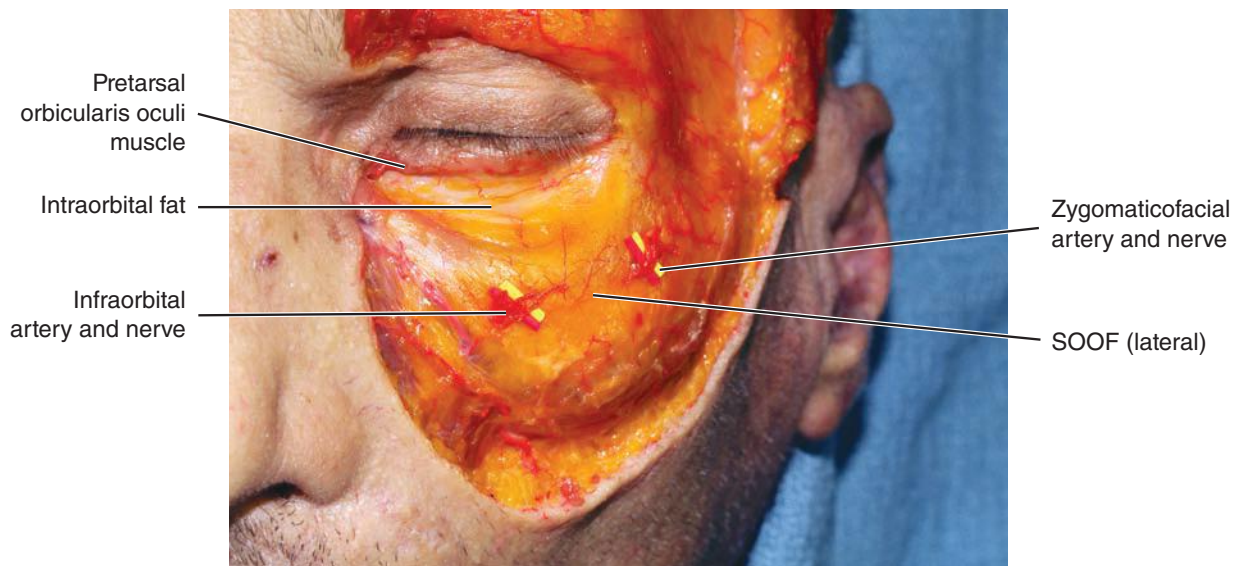


The volume of lateral suborbicularis oculi fat affects and can augment the prominence of the cheekbone.

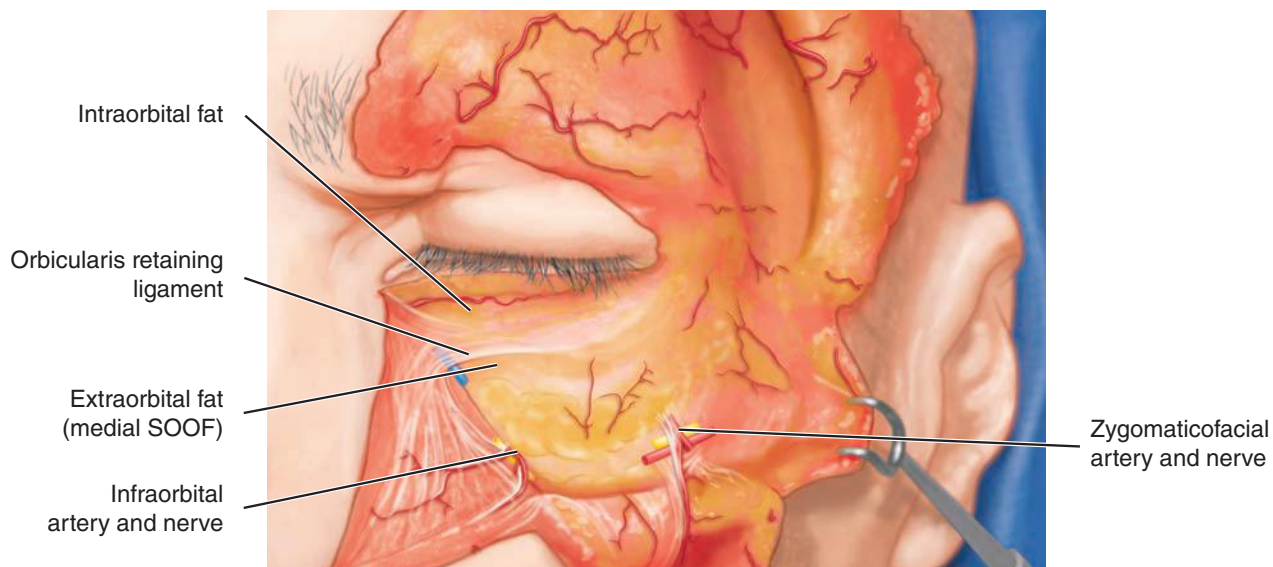
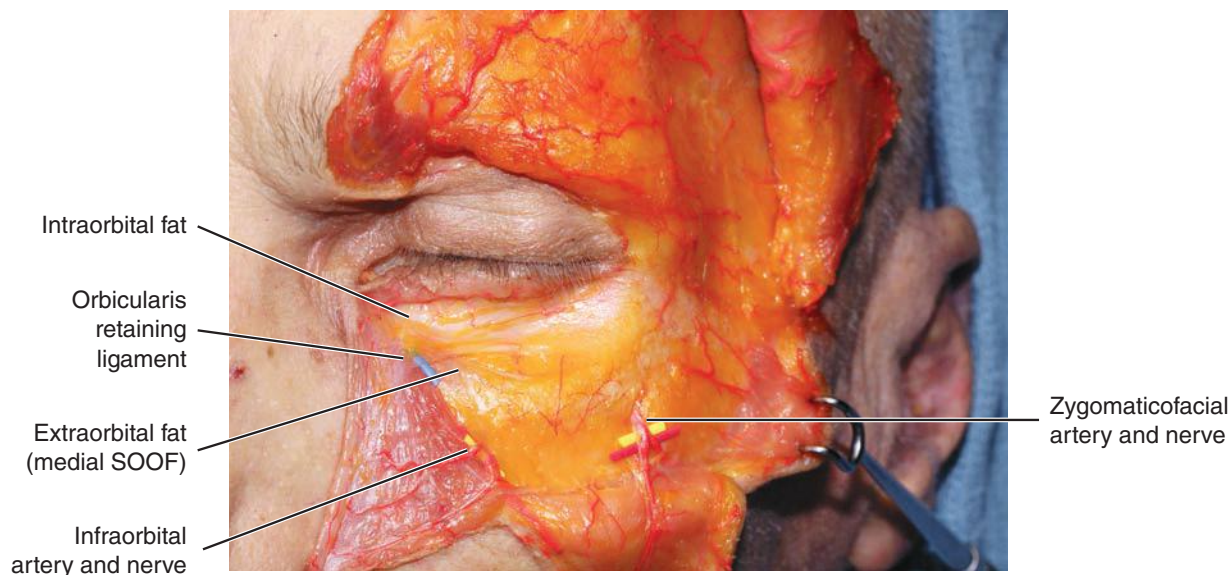
SOOF is the fat pad beneath the thin orbicularis oculi muscle, which itself always extends down the cheek farther than one might expect. It is a basic principle of anatomy that fat exists beneath facial muscles to facilitate glide.

Adipose tissue, as an areolar plane or as discrete compartments, lies both above and below facial muscles.

This principle applies to all facial muscles, from the neck platysma to the temporalis muscle. The cheek contains the orbital part of the orbicularis muscle, the part that drapes down almost to the base of the nose. There is deep fat beneath all parts of the orbicularis oculi muscle.



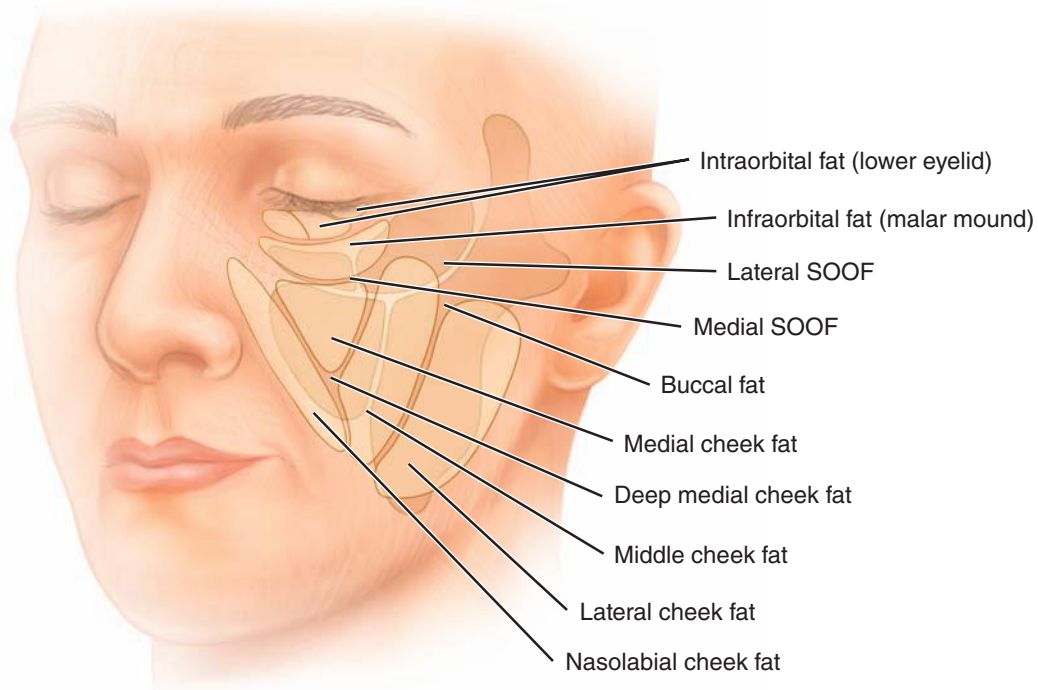
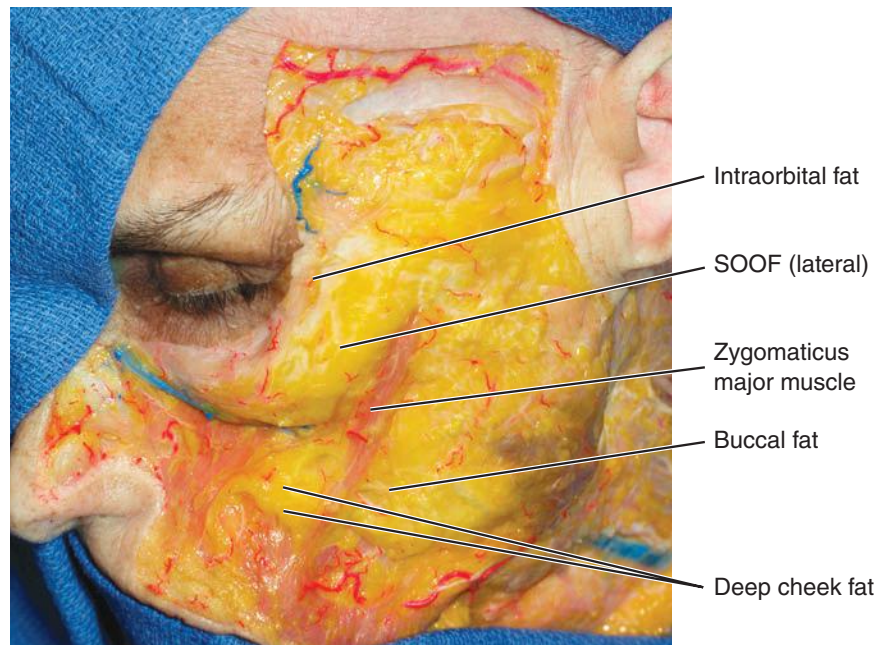
Nerves and vessels, such as the infraorbital and zygomaticofacial nerves, must transit through SOOF, making its position important clinically. With knowledge of this anatomy, the surgeon can accurately place nerve blocks and avoid bleeding complications during injections or surgery.



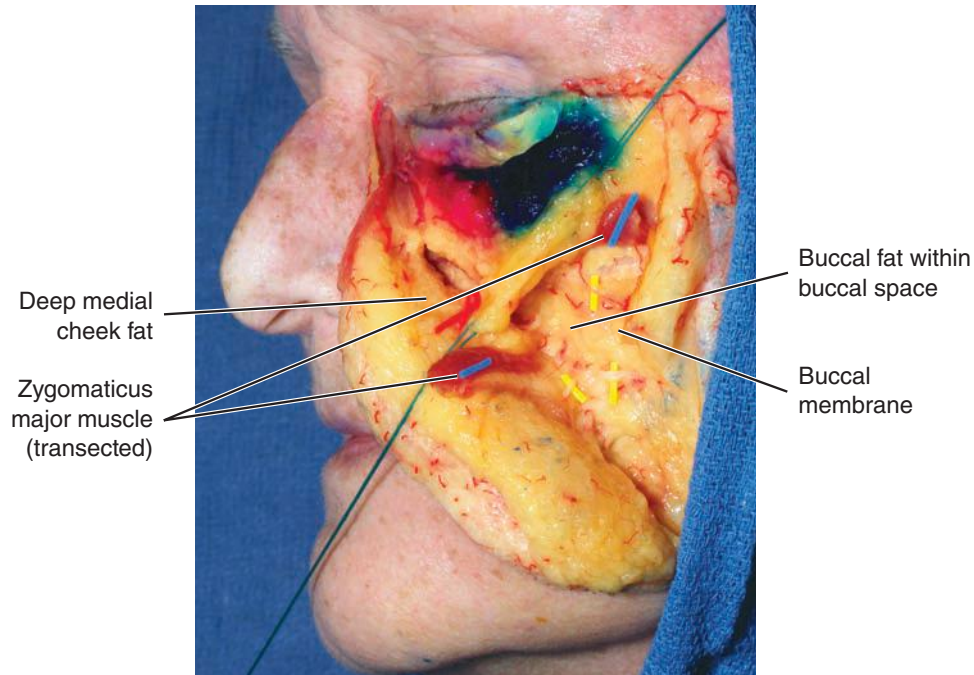
The boundary between the lower eyelid and cheek occurs at two levels. At the deep level, the orbicularis retaining ligament (ORL) separates the cheek from the lower eyelid, and from intraorbital fat. The superficial boundary is defined by the eyelid compartment and what is called the *malar mound* or *infraorbital fat*. The ORL inserts into the orbital rim just below its inferior border. This is important

clinically: injections administered at the rim always run the risk of entering the orbital fat. If one palpates the inferior orbital rim, similar to this maneuver in the forehead, the safe zone is 2 to 3 mm below this location. SOOF is extremely adherent to the periosteum here, so its mobility as a fat pad is limited.

The contour of the cheek is affected by several other deep fat pads. Deep medial cheek fat exists in the central cheek, extending from the lower eyelid to the cheek-lip crease.



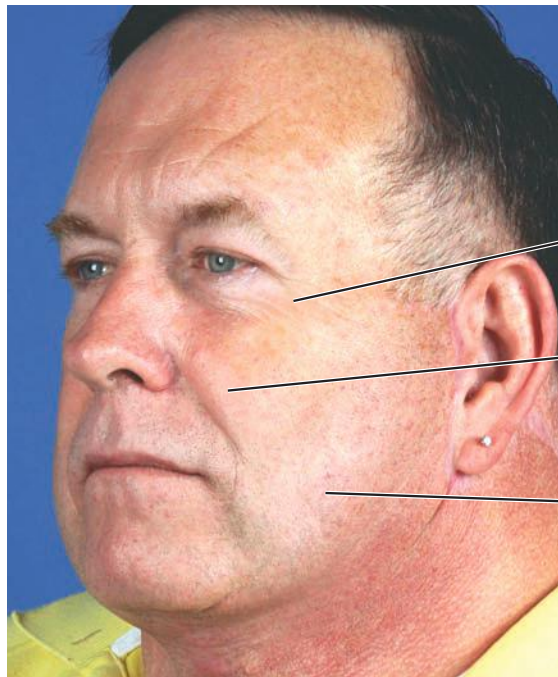
Buccal fat lies immediately adjacent to the deep medial cheek fat. When we examine the face and note a heavy jowl, a manifestation of buccal fat, the zygomaticus major muscle is just medial to this position. Buccal fat exists within its own capsule and is more extensive than classically described.



The contour of the cheek is significantly affected by the volume of deep adipose tissue—specifically, deep medial cheek fat and suborbicularis oculi fat.

## CONTOUR ANALYSIS

Contour analysis provides important information about the size and location of these deep fat pads. Facial atrophy underscores the importance of these fat regions in determining the shape and contour of the face: adequate stores of deep fat impart specific shapes and contours.

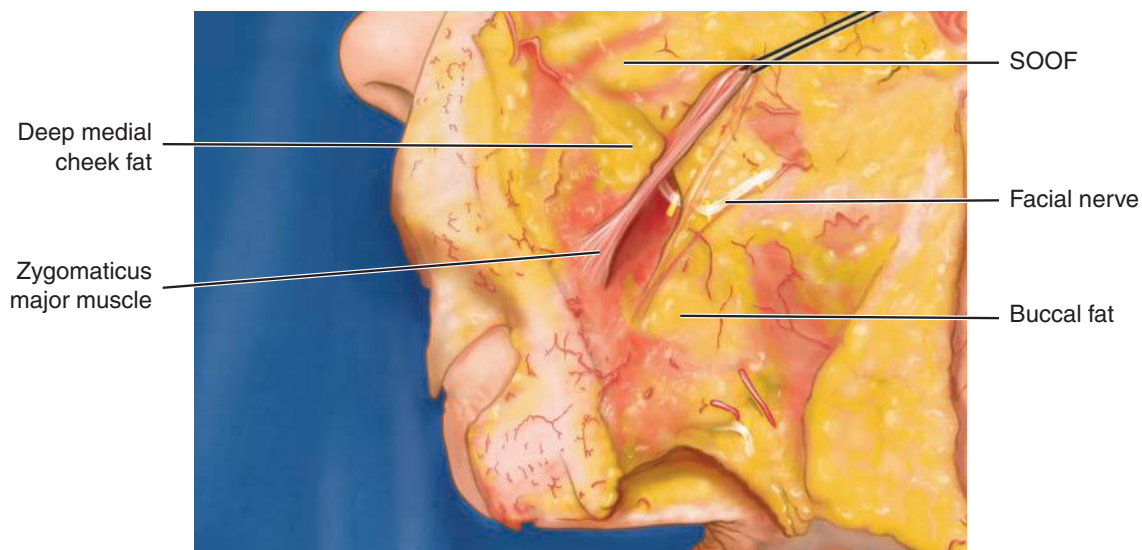
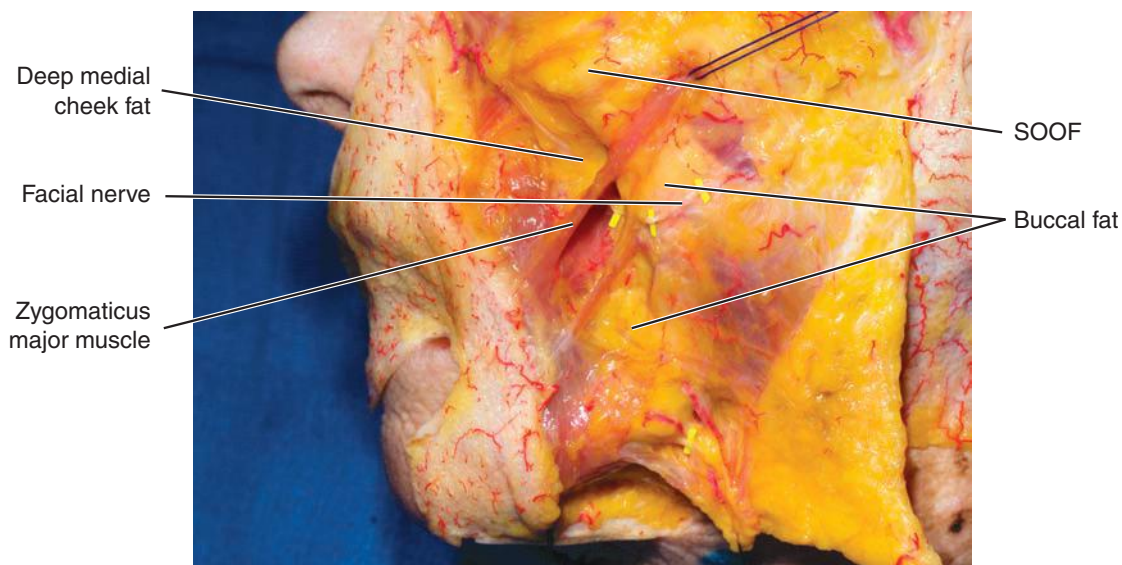


SOOF/smooth  
zygomatic arch

Deep medial  
cheek fat in  
augments cheek  
projection

Buccal fat  
affects  
prominence  
of jowl

The facial nerve lies immediately on top of most of these deep fat pads, with the exception of buccal fat. The nerve may actually penetrate buccal fat, as does the parotid duct. However, with proper knowledge of the anatomy of the buccal fat, it can be manipulated with safety.

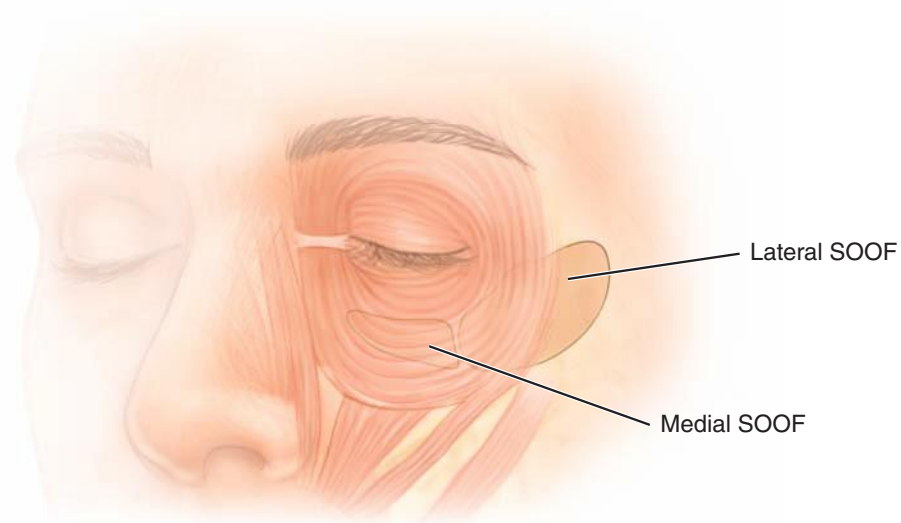
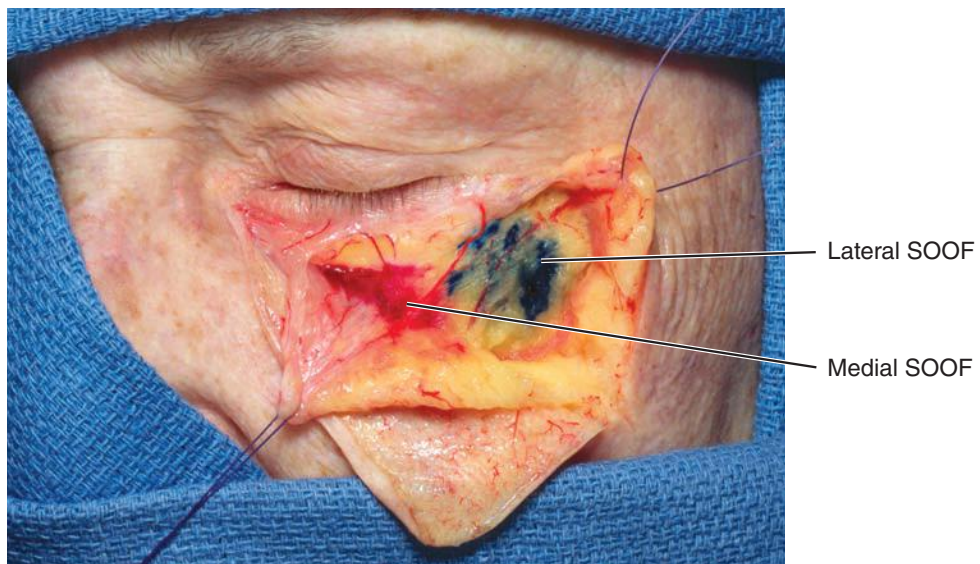


Identifying the contour boundary between the lower jowl and cheek provides information about the position of the zygomaticus major muscle. The boundary between the jowl and central cheek indicates the position of underlying facial musculature.

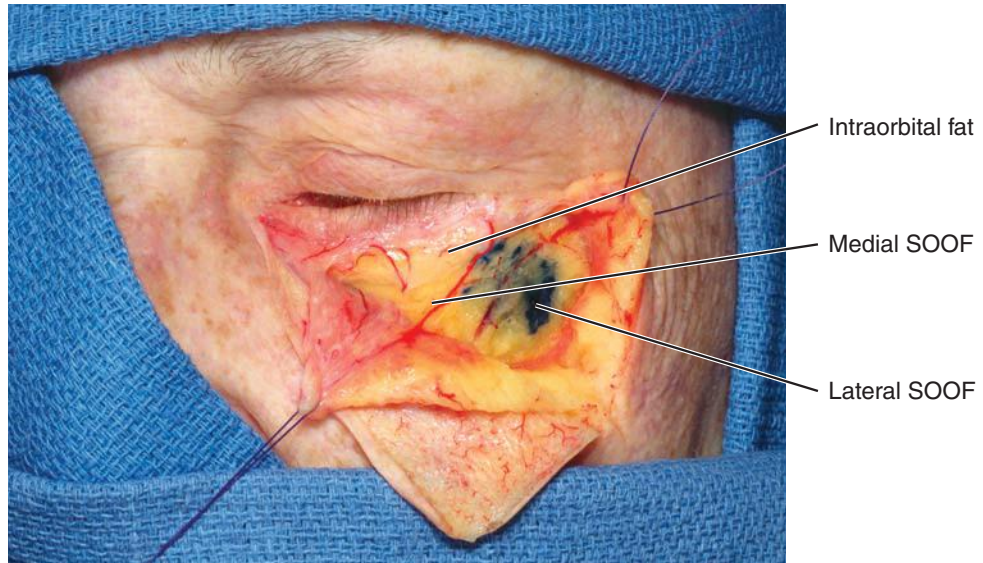
Each of the deep fat pads has separate parts, or lobes. Even these create their own effect on overlying shape and contour. The SOOF is a good example.

Deep fat pads impart a specific contour and shape to the overlying skin.

SOOF lies along the orbital rim and zygomatic arch. There are at least two parts to this fat pad, a medial and a lateral lobe. The medial lobe is the smaller of the two.



The lateral part of the SOOF extends past the lateral eyelid.



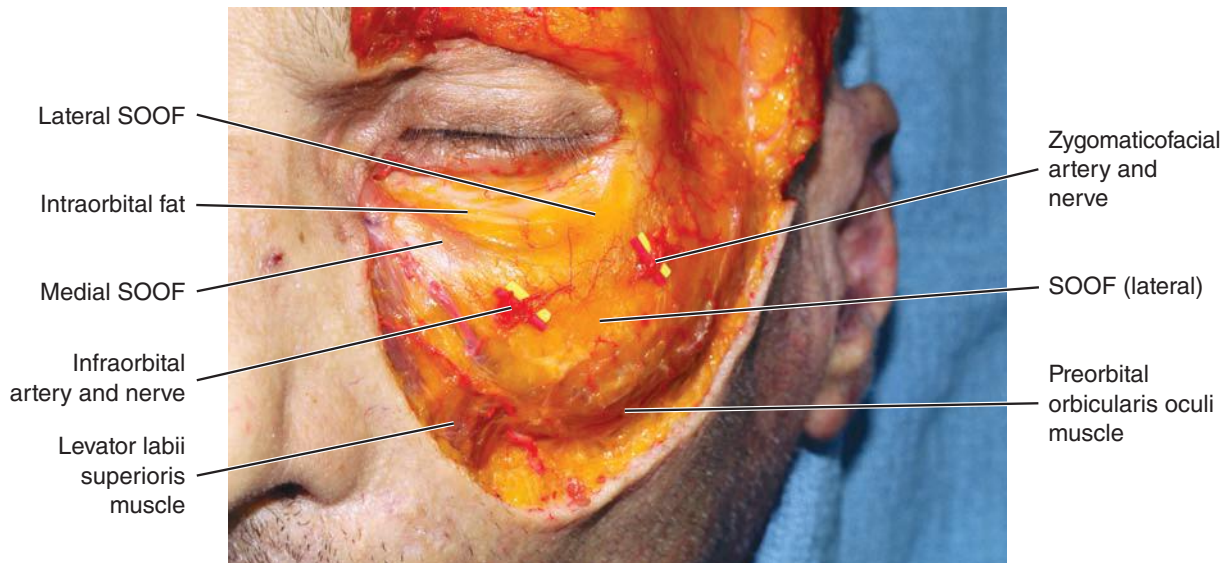The lateral SOOF does not completely cover the orbital rim; rather, it lies several millimeters below the rim, continuing down along the face of the maxilla. SOOF lies immediately above the orbital rim periosteum.

The prominence of the orbital rim and cheekbones is affected by the overlying soft tissue volume.

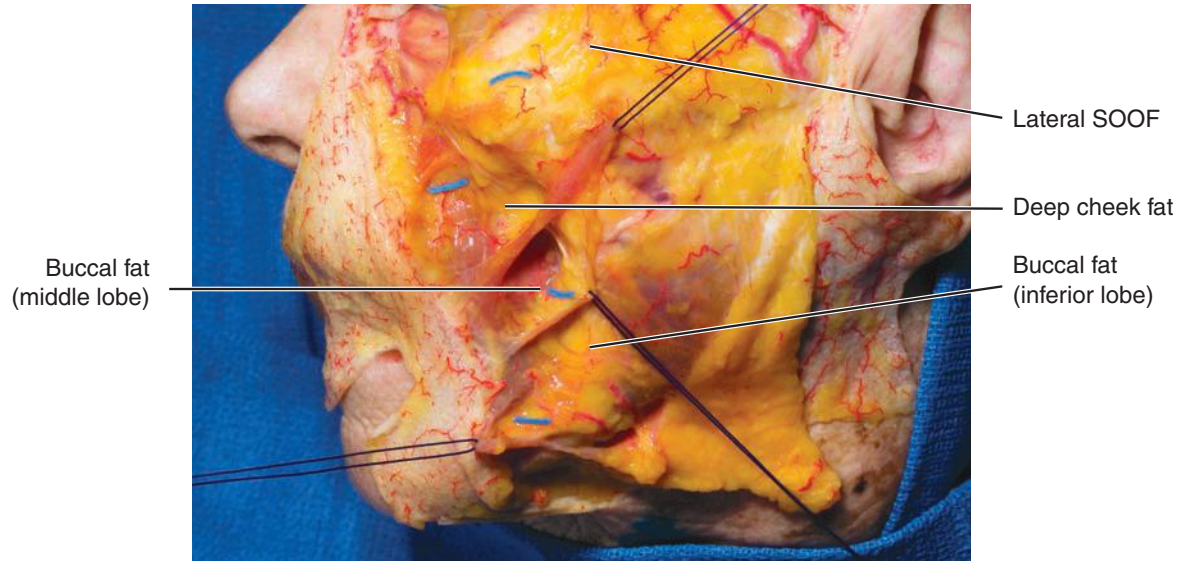
The infraorbital nerve travels through the medial SOOF or deep medial cheek fat; the zygomaticofacial nerve and artery travel through the lateral SOOF.

Knowledge of this anatomy is clinically important because injections or manipulation of the lateral SOOF can injure the frontal zygomatic bundle. This may result in bruising from bleeding complications, or in transient or permanent numbness of the lateral cheek.

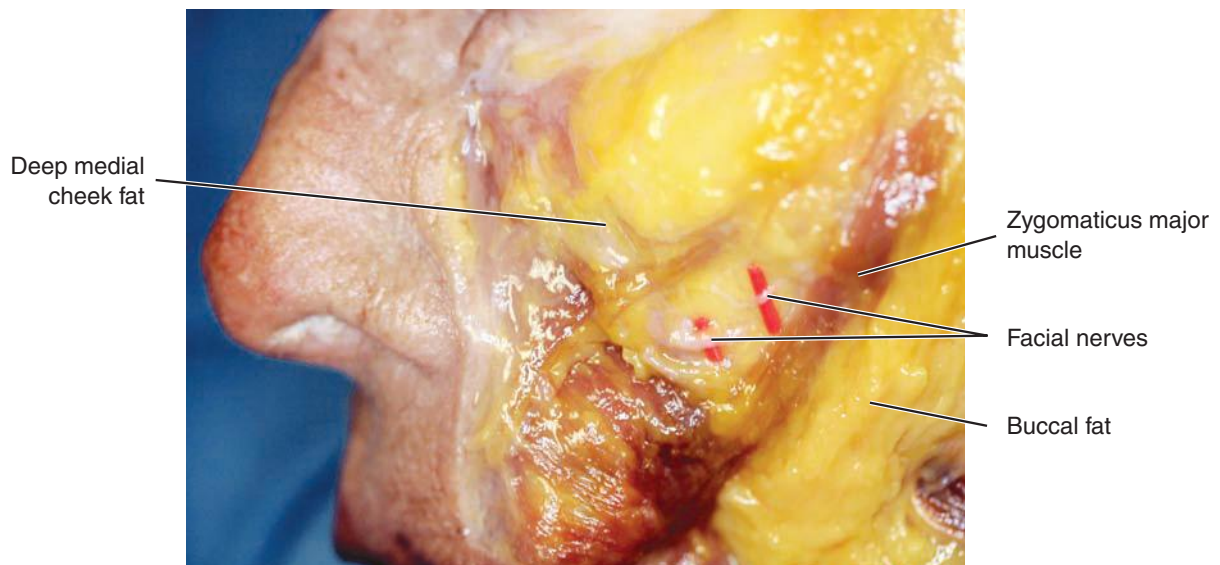
When the periosteum is elevated from the lateral zygoma, such as during a craniofacial procedure, the numbness will be permanent, because this nerve bundle has been transected.



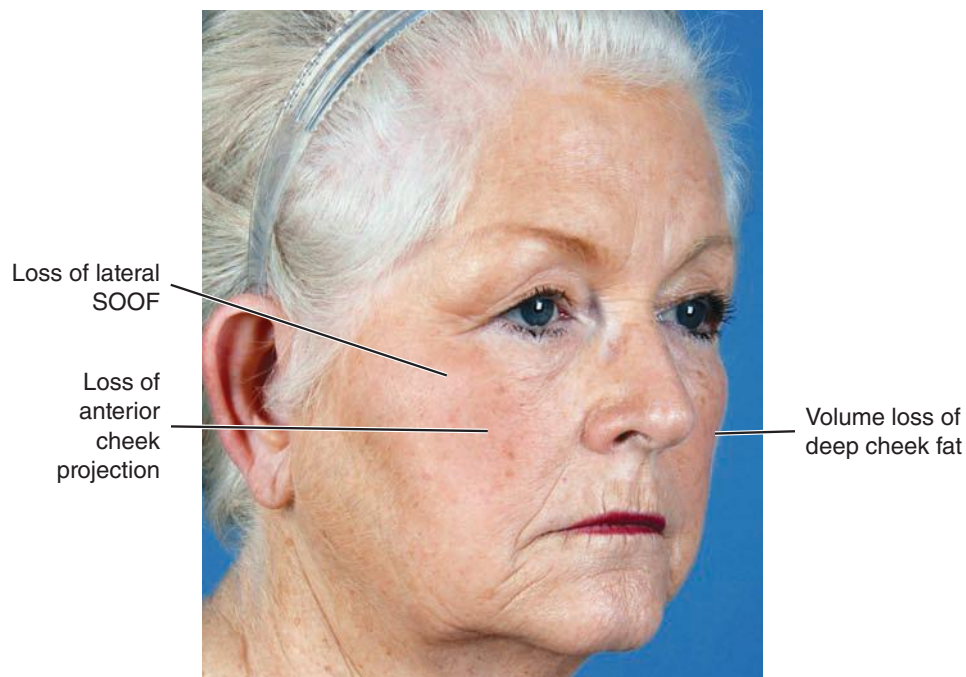
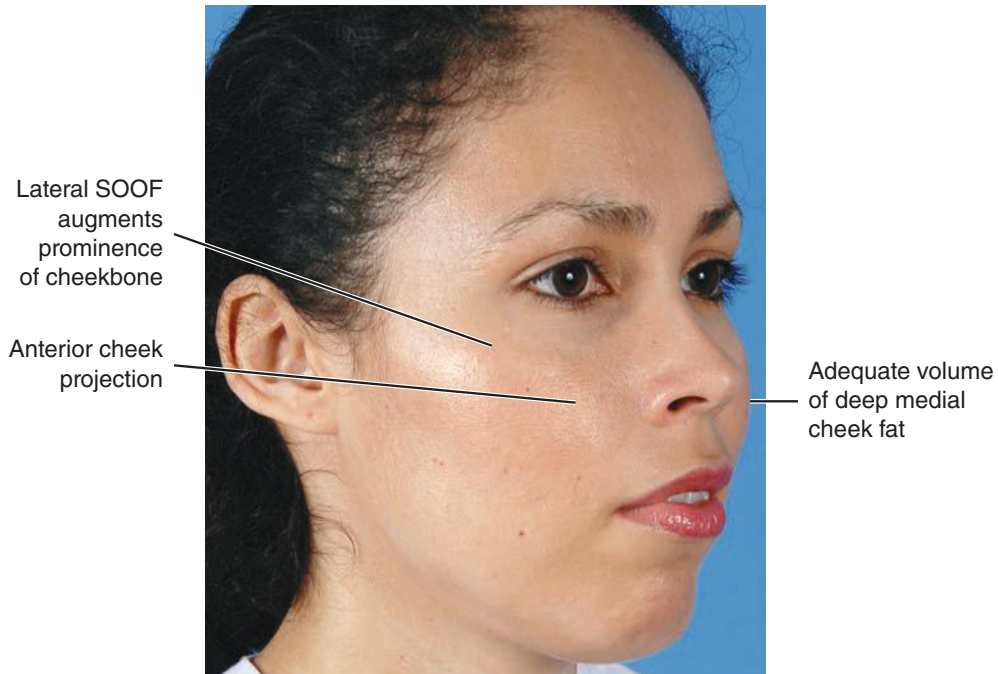
The adipose tissue of the cheek exists as superficial and deep layers that are further defined by vascularized membranes and fascial fusion layers, respectively.



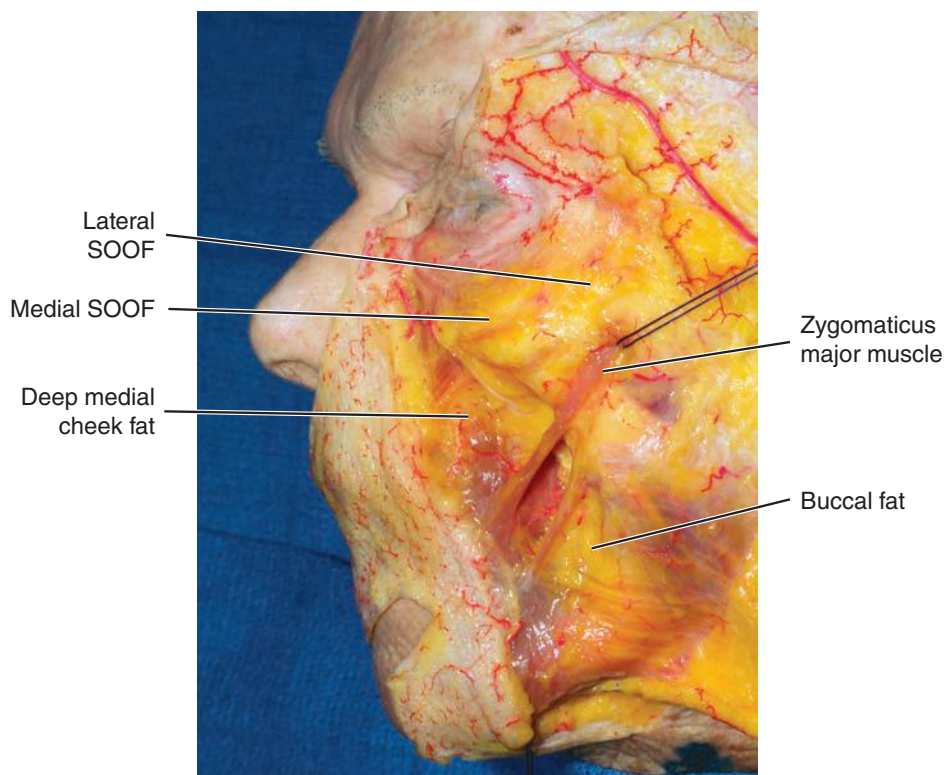
Deep cheek fat is located medial to the zygomaticus major muscle. The zygomaticus minor muscle, when present, lies above the deep medial cheek fat.



Deep medial cheek fat contributes to the anterior projection of the central cheek. An examination of an individual with adequate central cheek projection will indicate an adequate volume of deep medial cheek fat. Other factors in addition to adipose tissue, including bone support from the anterior maxilla, may contribute to this finding. Inadequate volume of deep medial cheek fat results in diminished anterior cheek projection.



Superficial fat also plays a role in central cheek projection, although it is the deep medial cheek fat that is perhaps more significant. Both deep cheek fat and SOOF together create the shape of the cheek. The cheek extends up to and over the zygomatic arch; deep medial cheek fat is located centrally. A full cheek is an indication of both deep medial cheek fat and adequate medial and lateral SOOF. One can analyze these regions according to their shape and then correlate shape with the underlying anatomy.



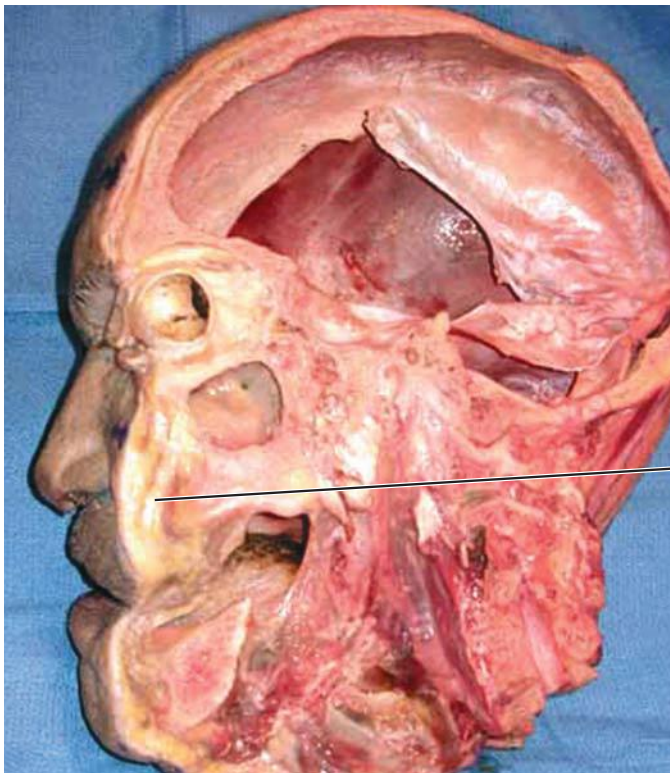
These observations suggest that fat can behave as structural support for the face.

Fat regions provide structural support for the overlying soft tissues.

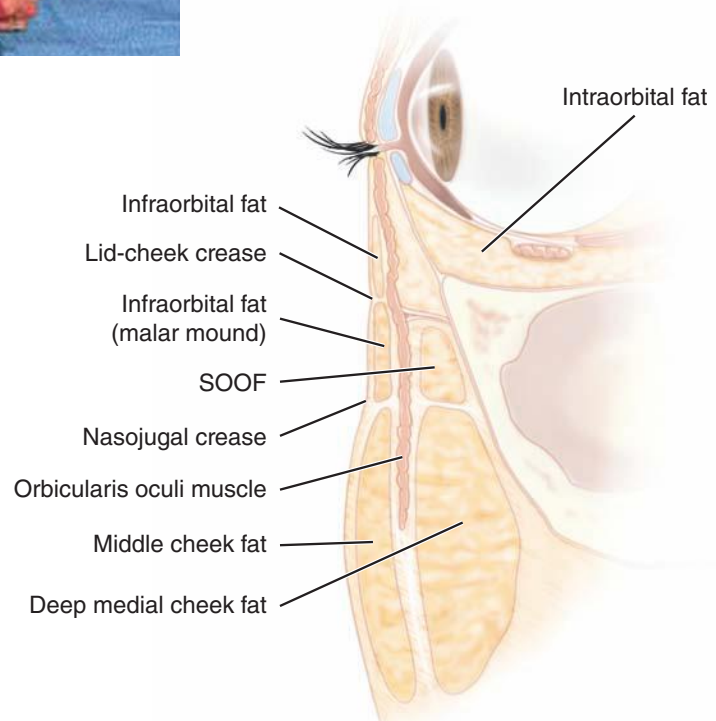
Fat is usually thought of as an amorphous mass, but these dissections show that fat exists as separate and distinct regions throughout the face. Clinical experience has shown that augmentation of SOOF can support the lower eyelid. Scleral show may be improved with an increased volume of SOOF.

Inadequate anterior projection of the central face may be caused by inadequate deep medial cheek fat. A negative vector is associated with scleral show. An inadequate volume of deep medial cheek fat is a contributing factor to the negative vector.

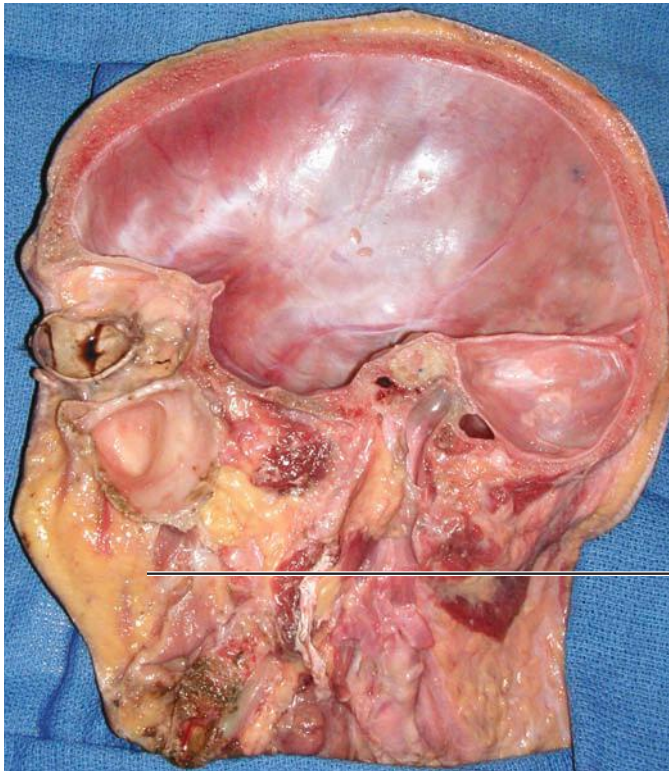
A sagittal section of the face illustrates the point that diminished reserves of deep adipose tissue contribute to an excess skin envelope.



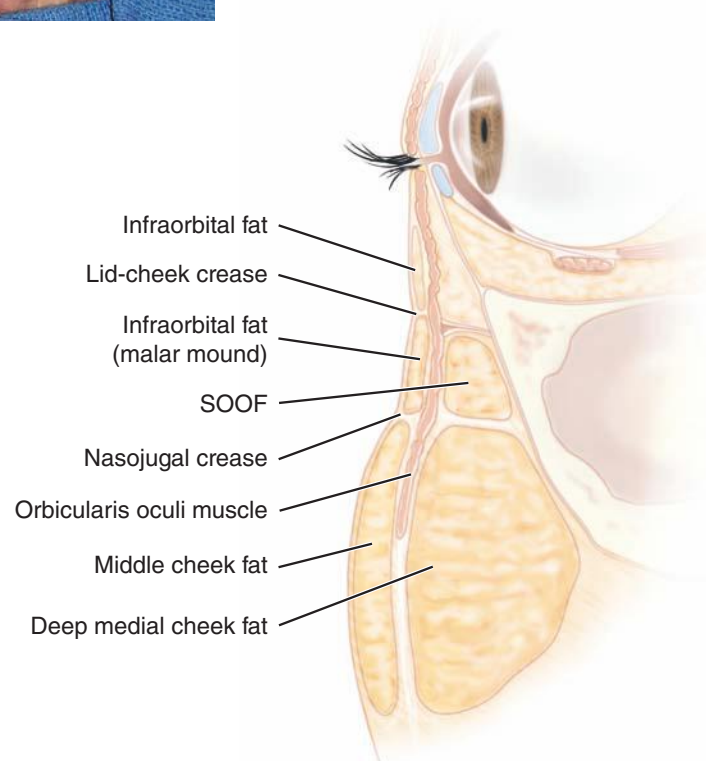
Deep cheek fat: minimal anterior cheek projection



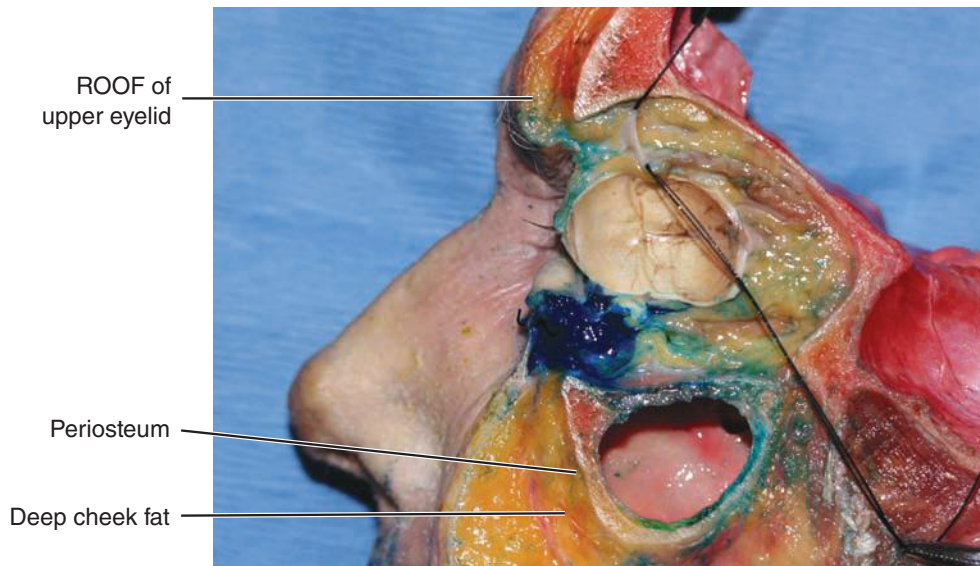
An increased volume of deep fat contributes to filling the skin envelope of the face. In terms of contour, this reveals itself as a smooth shape with fewer folds and creases. The clinical evidence for this is the tremendous utility and effectiveness of fillers and volume augmentation in restoring facial structure, when these techniques are used accurately.



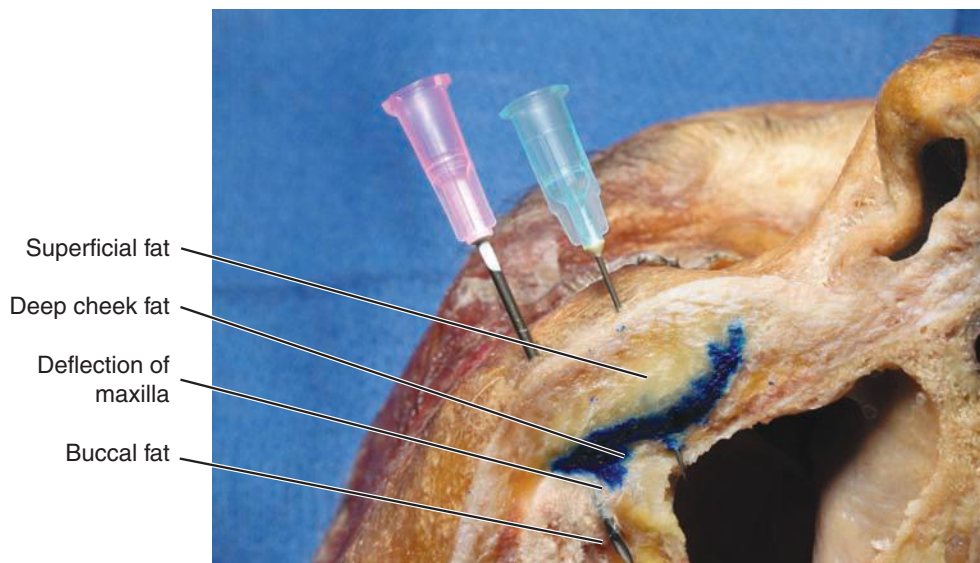
Deep cheek fat:  
adequate cheek  
projection



Deep medial cheek fat lies directly above the maxillary periosteum.

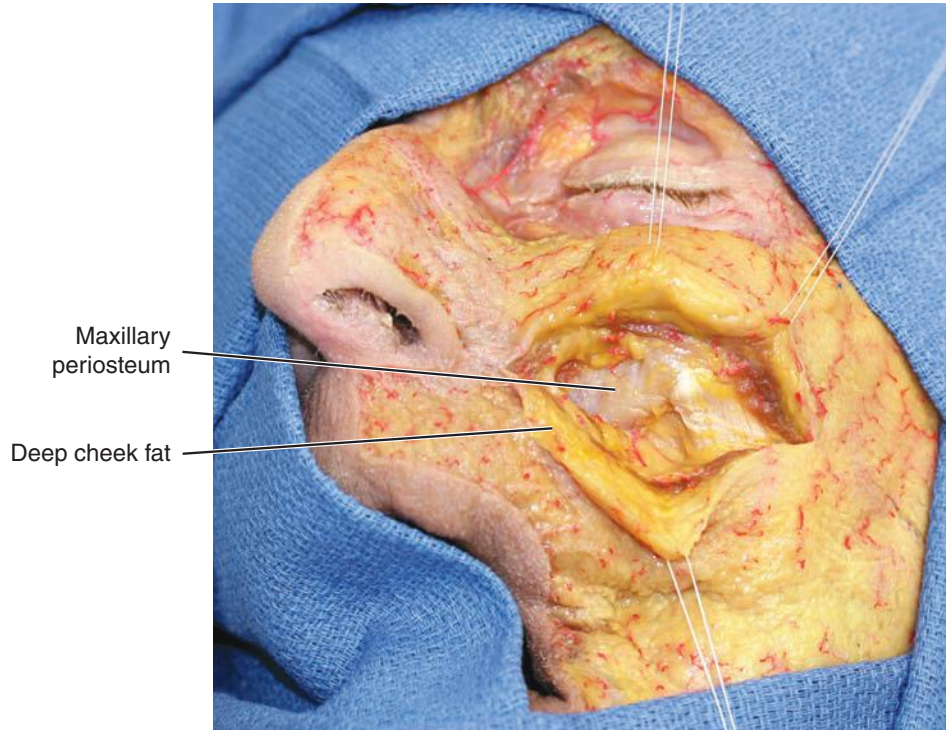


Clinical examination can easily define the position of deep medial cheek fat. Palpation is a useful technique, because deep medial cheek fat lies just medial to the deflection of the maxilla.



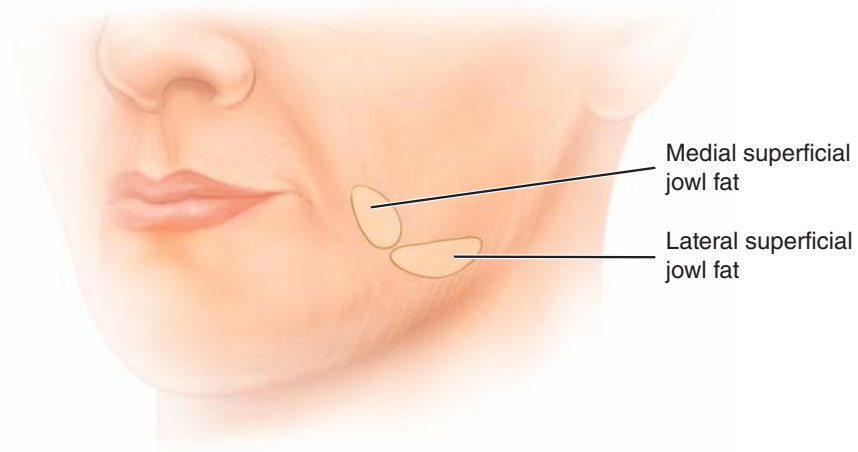
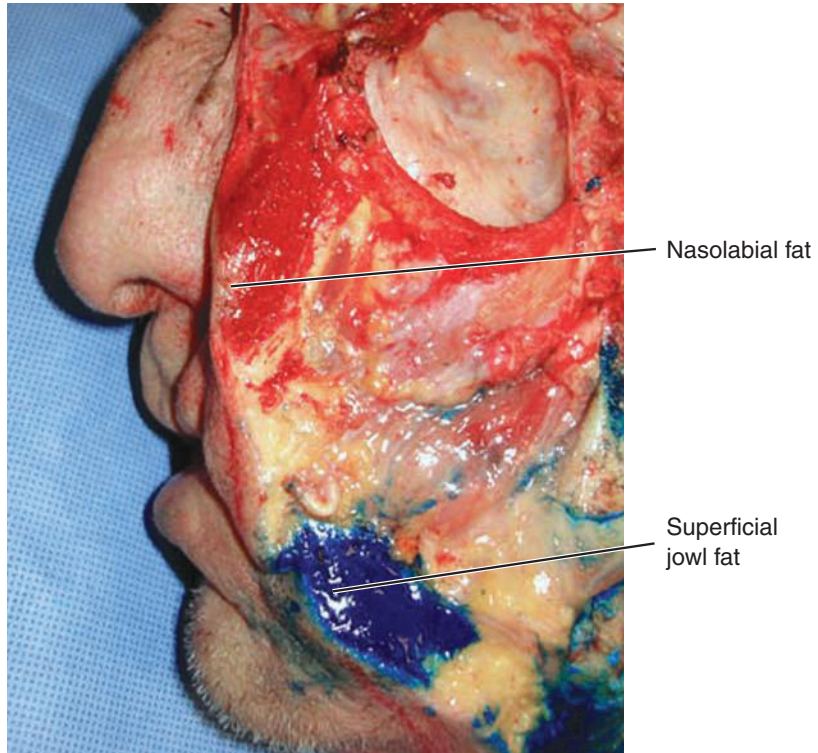
Injection medial to the deflection of the maxilla (*blue needle*) accesses the deep medial cheek fat. Injection lateral to the deflection (*pink needle*) augments buccal fat and increases jowl prominence.

This technique is useful in the clinical setting when volume augmentation of the deep medial cheek fat is required.

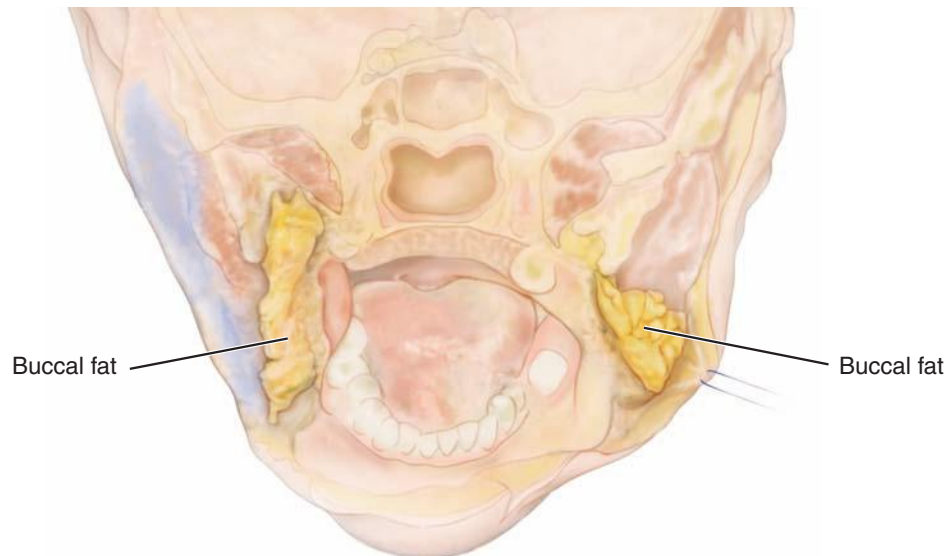
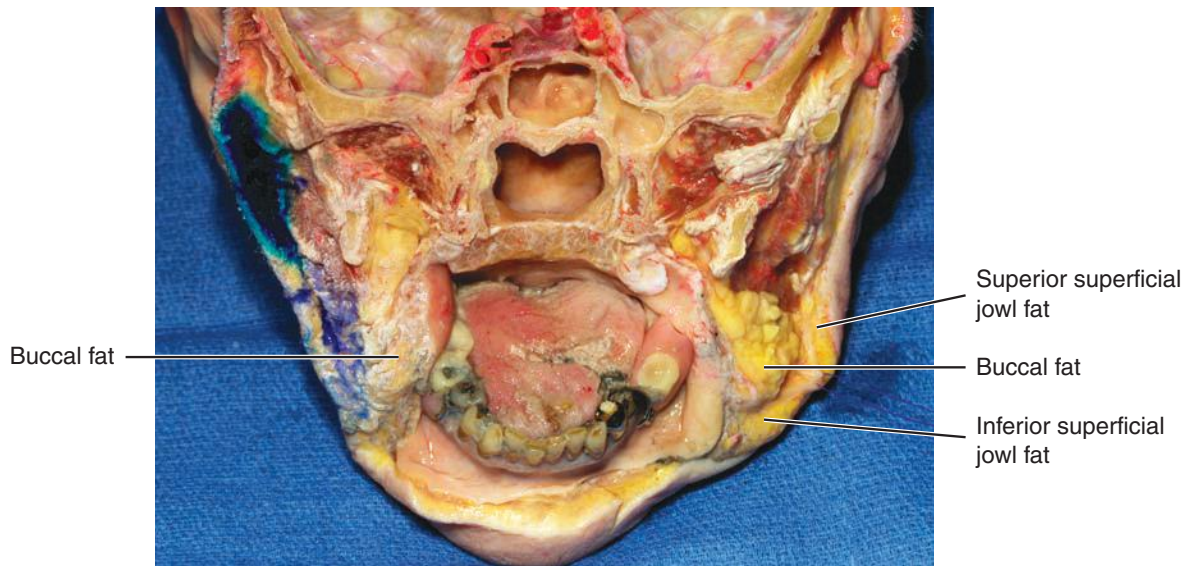


## JOWL CONTOUR

Superficial jowl fat is a thick adipose tissue layer that defines the boundary between the cheek and chin. Superficial fat is one factor that contributes to the prominence of jowls. Jowl fat occurs as two compartments, superior and inferior.

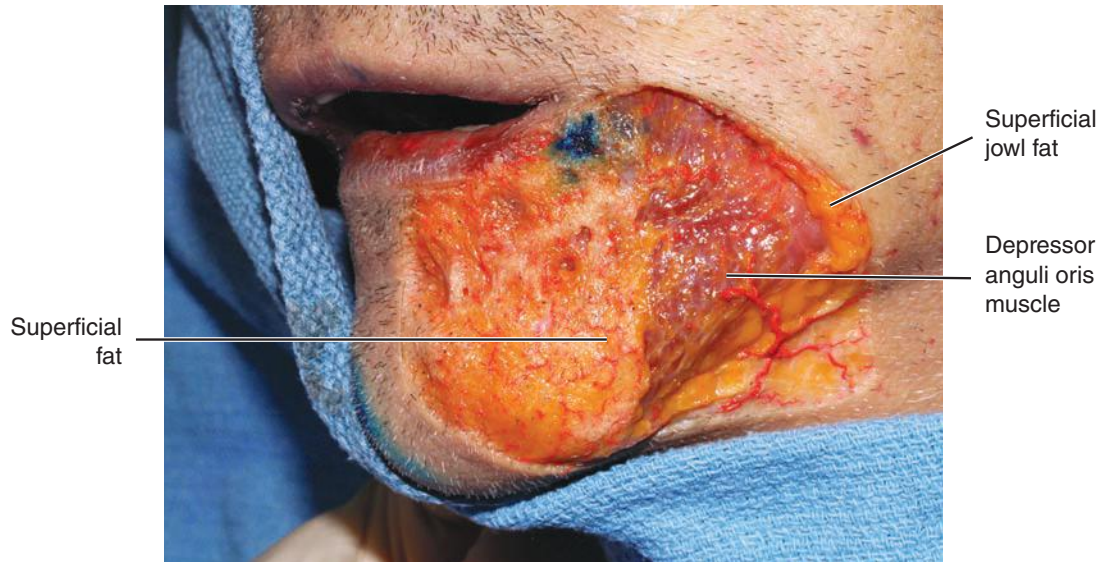
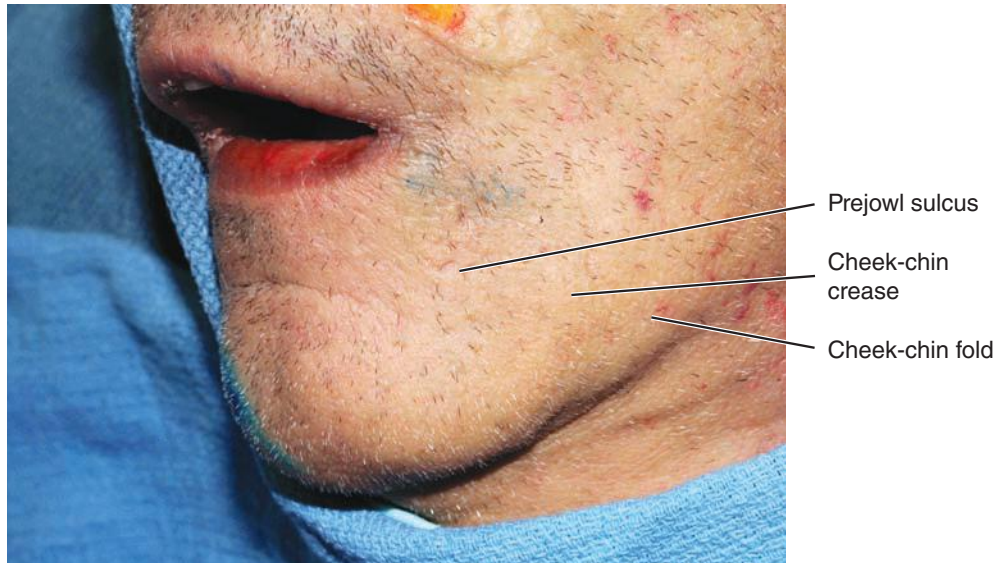

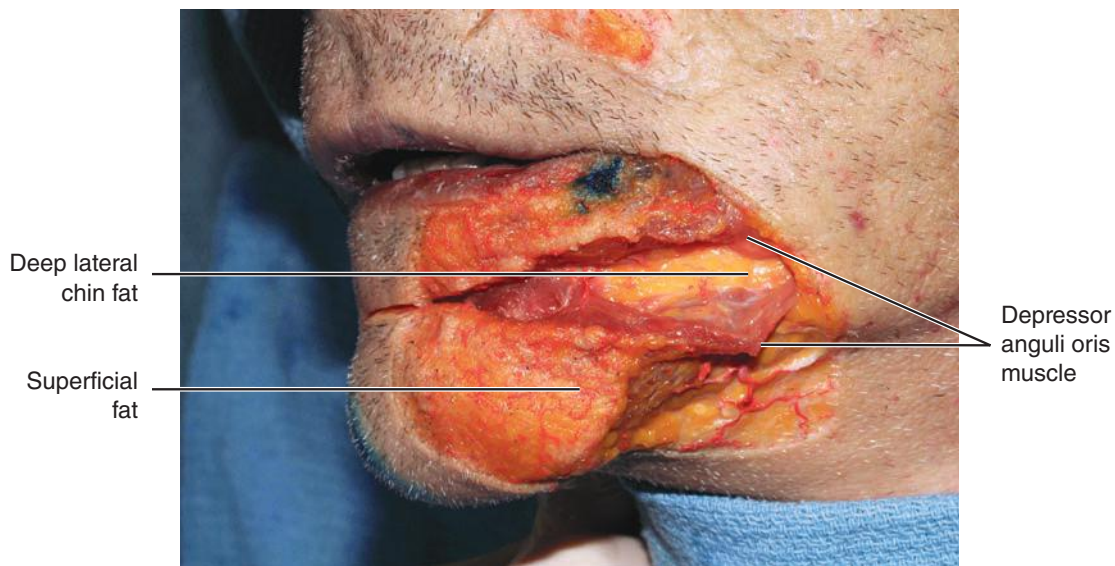
There are superior and inferior superficial jowl compartments.



The boundary between the cheek and chin occurs between superficial jowl fat and the lateral chin compartment. The topographic landmark for this junction is the cheek-chin crease and its associated fold.

The prejowl sulcus is located medial to the cheek-chin fold. It is augmented by placing filler material deep to the depressor anguli oris muscle, into the deep lateral chin adipose compartment. This lies beneath the lip depressor muscle.





The thickness of this fat pad affects the depth of the cheek-chin crease. This is as true as with the cheek-lip crease and its relationship to the deep medial cheek fat.

The size and depth of folds and creases are affected by the volume of more deeply located fat.

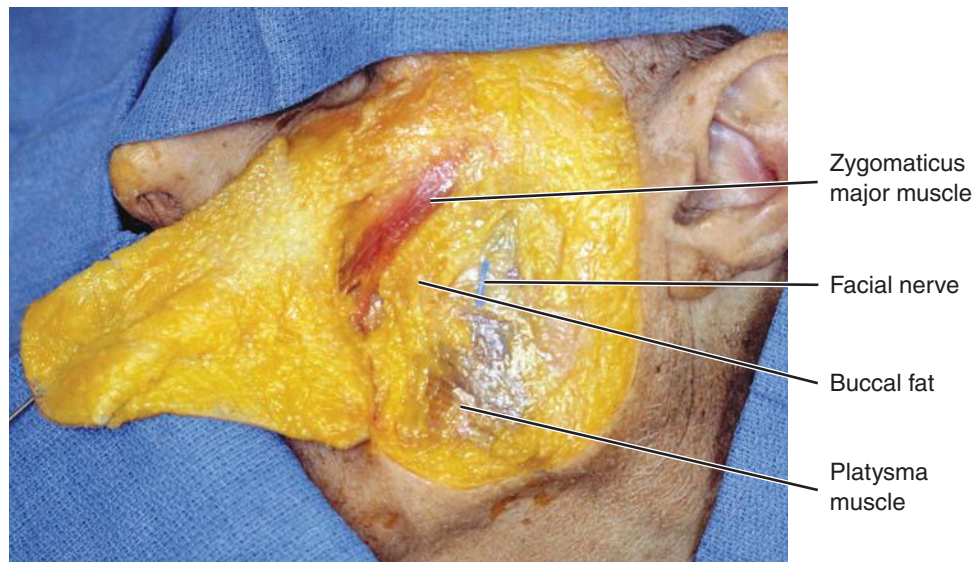
The analogy here is that deep medial cheek fat is related to the cheek-lip crease, and deep lateral chin fat is related to the cheek-chin crease. This has implications for access to these deep fat pads: access to the deep lateral chin fat is through the cheek-chin fold (jowl fold), and the deep medial cheek fat can be reached through the cheek-lip fold.

## ANATOMIC LANDMARKS

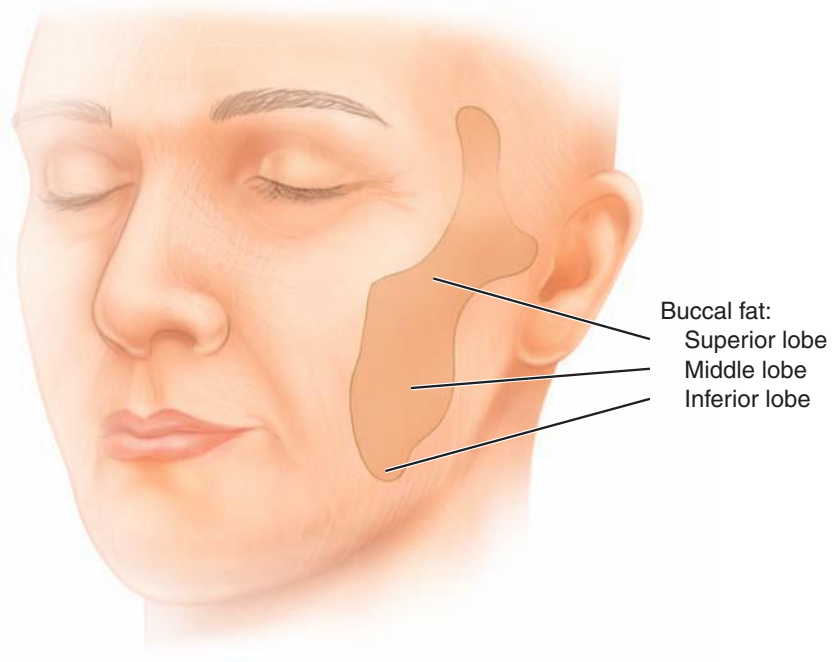
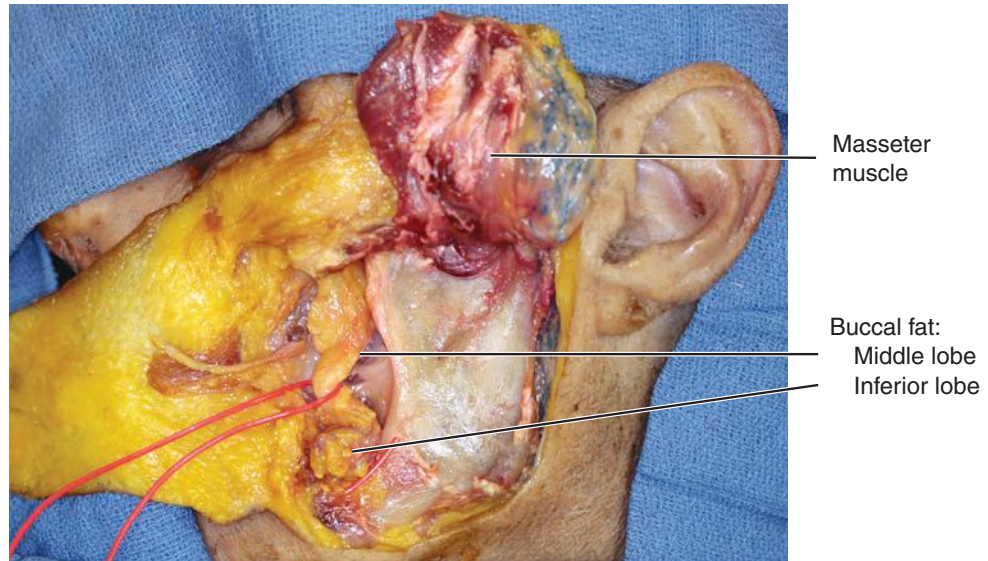
The anatomy suggests several important cheek landmarks. The mandibular ligament, if it exists, occurs at the origin of the depressor anguli oris muscle. In precise anatomic terms, this is a cheek muscle as well as a chin muscle, because it occurs lateral to the corner of the mouth and beneath the cheek-chin crease. This is analogous to the corrugator muscle crossing several anatomic compartments: a muscle must span the crease that it creates.

This simplifies locating the depressor anguli oris muscle for chemodenervation to elevate the corner of the mouth. The cheek-chin fold and mandibular ligament serve as topographic landmarks for access to the muscle.

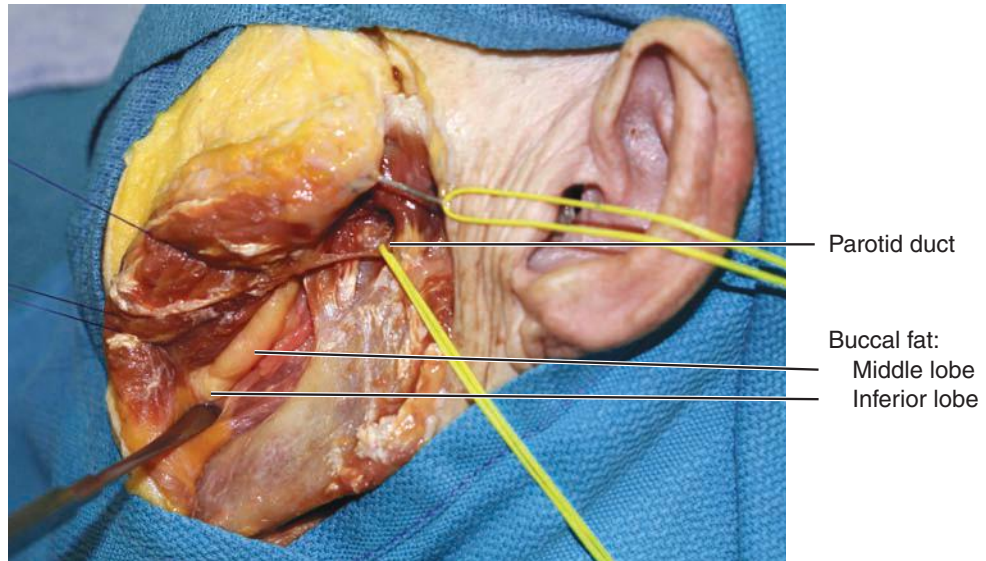
Buccal fat is another deep fat of the face. It may be an important contributing factor to the presence and size of jowls. Buccal fat occurs lateral to the zygomaticus major muscle, occasionally bifid, a possible cause of the cheek dimple. Buccal fat therefore indicates the position of underlying facial musculature.



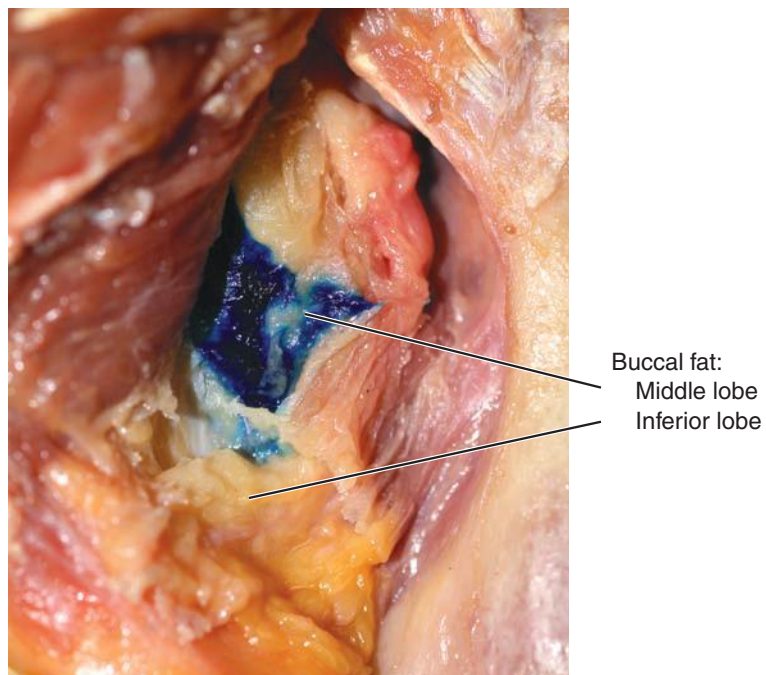
The territory of buccal fat is more widespread than is often appreciated. It extends from the edge of the upper mandible into the temporal region.



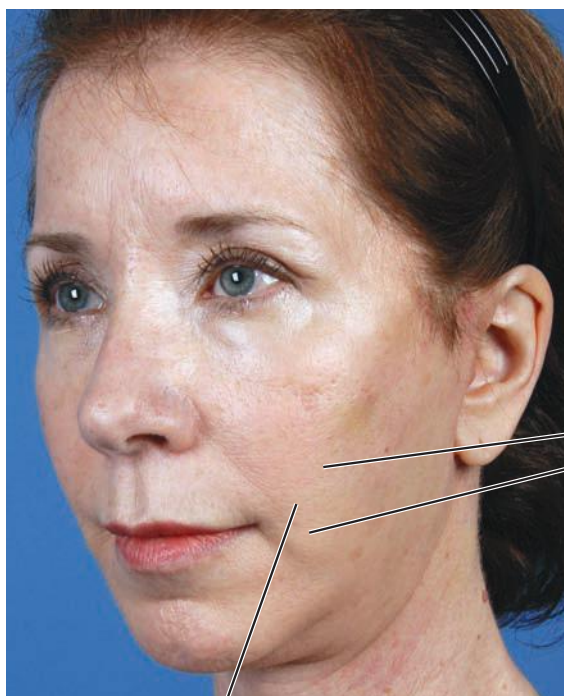Buccal fat can lie over the masseter muscle. It may prolapse over the edge of the mandible. Buccal fat exists as multiple lobes. These lobes are each contained within a separate capsule. The inferior lobe is particularly important in defining shape.



It is important to recognize that buccal fat has distinct lobes. The inferior lobe is a safe region to manipulate, because the parotid duct travels above this lobe, between the inferior and the middle lobe.

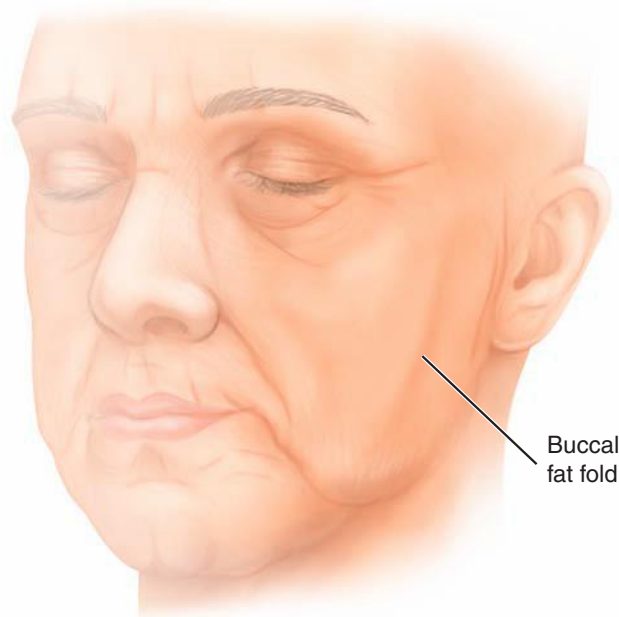


The inferior lobe imparts a characteristic appearance, one that is apparent when we recognize the distinction between the inferior and middle buccal fat lobes. Distinguishing the position of this fat pad tells the observer that the parotid duct must be located superior to this location. This is another way to identify the position of the parotid duct in addition to using its course toward the second molar.



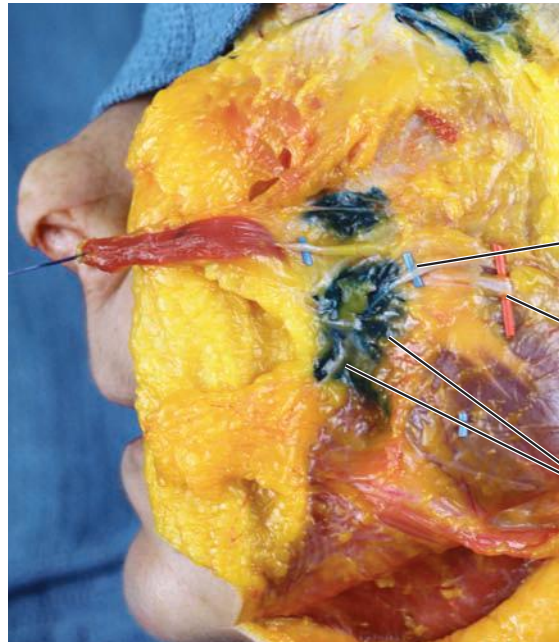Location of parotid duct

Buccal fat:  
Middle lobe  
Inferior lobe



Buccal  
fat fold

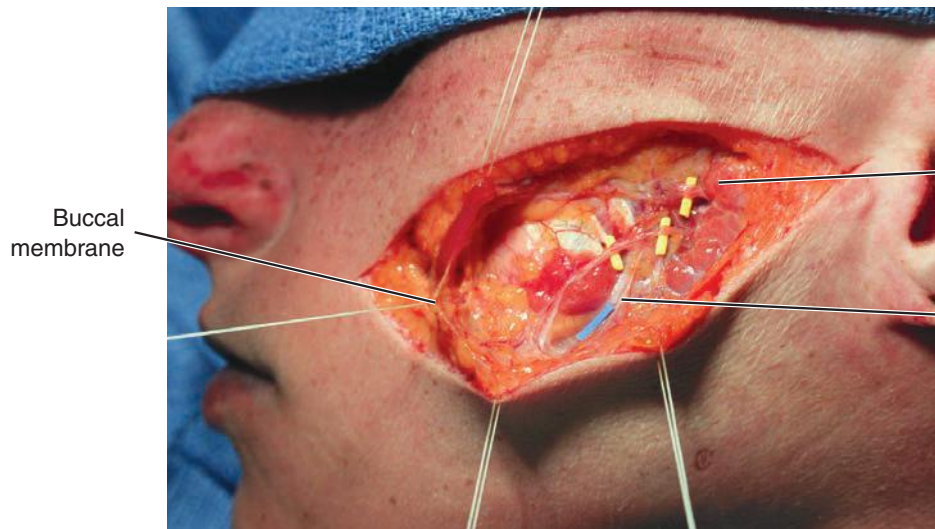
Buccal fat lies within its own space. The buccal space contains multiple structures, including motor nerves and the parotid duct, along with the lobes of buccal fat. It was first described as the masticator space. The size of this space varies between individuals and may increase with aging as a result of the forces exerted by chewing.



Facial nerve entering buccal space

Parotid duct

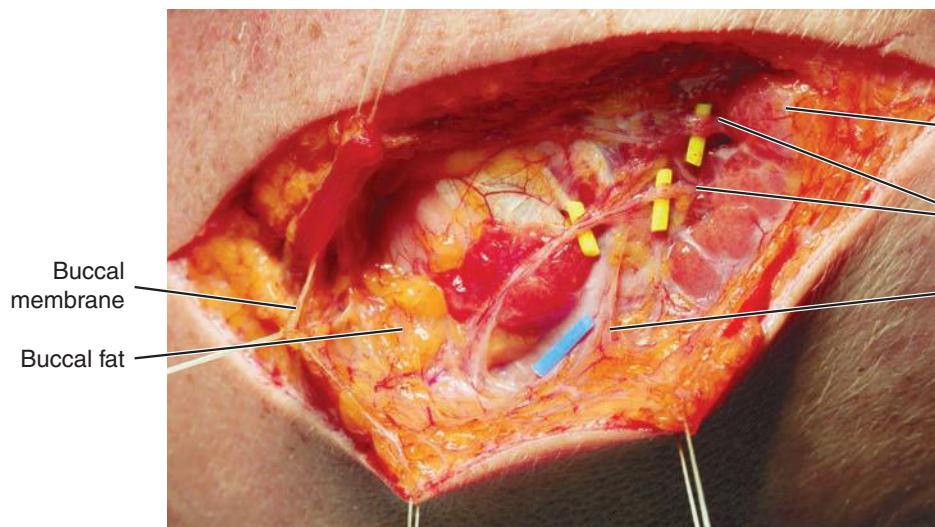
Buccal space



Buccal membrane

Parotid gland

Lateral edge of buccal space (jowl)



Buccal membrane

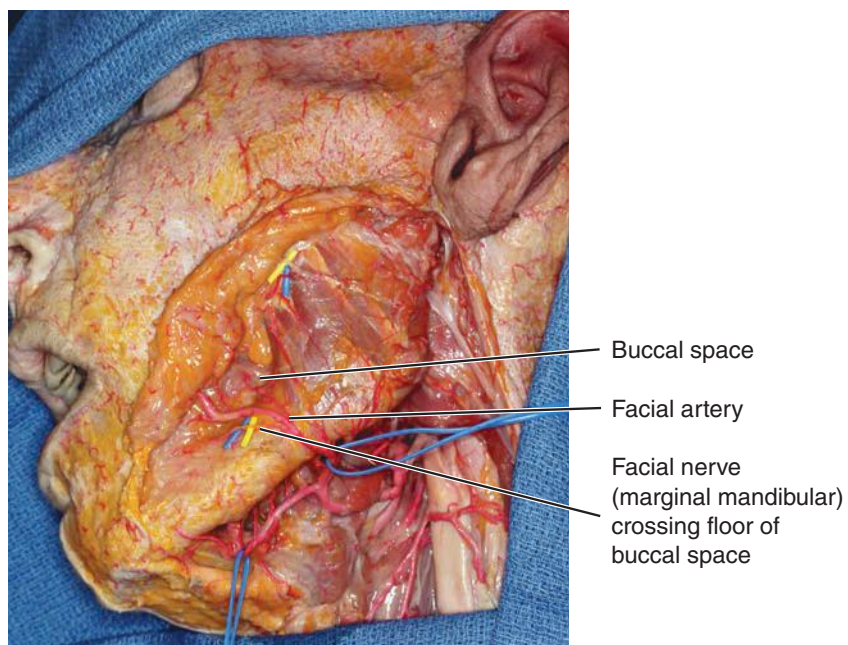
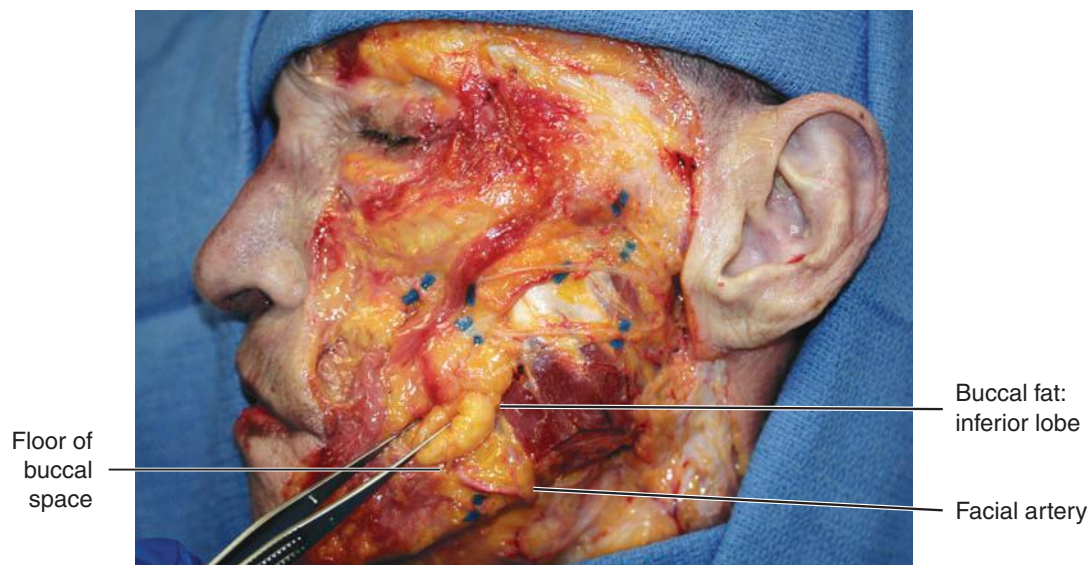
Buccal fat

Parotid gland

Facial nerve

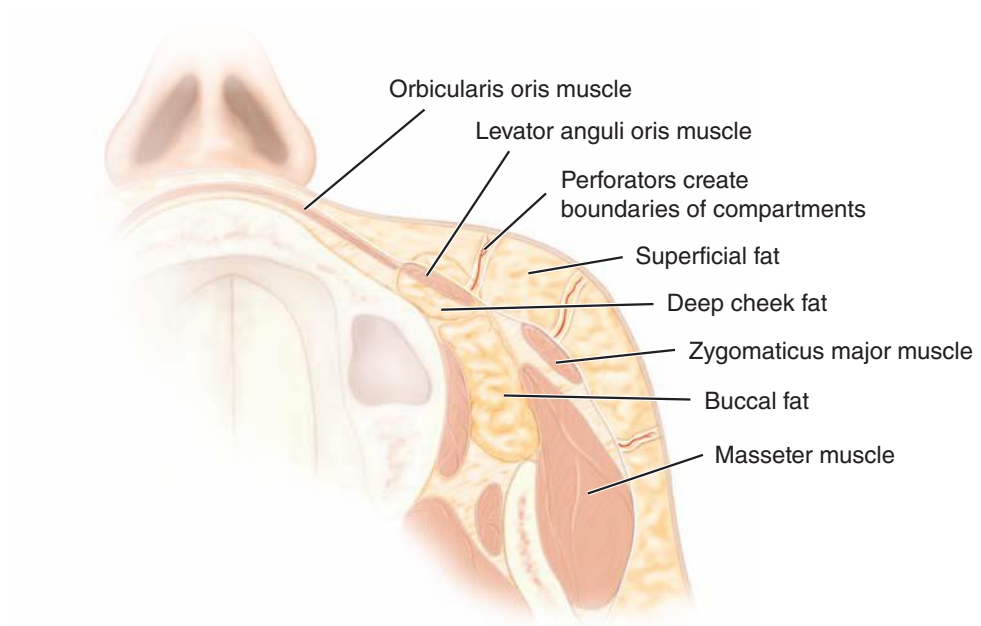
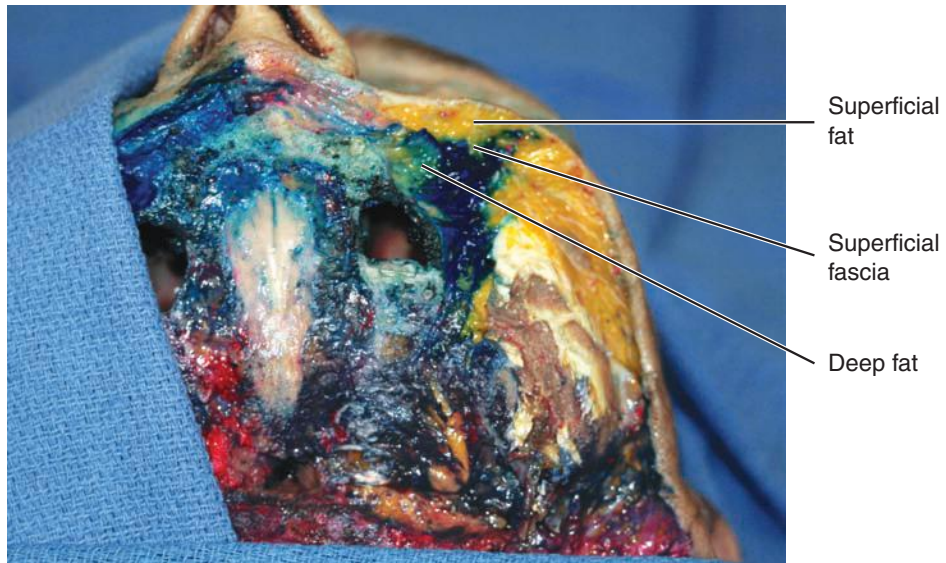
Buccal membrane

The inferior lobe is also important because it helps predict the location of the facial artery, which always crosses the mandible below the inferior lobe. The facial artery and the marginal mandibular nerve run along the floor of the inferior buccal space.

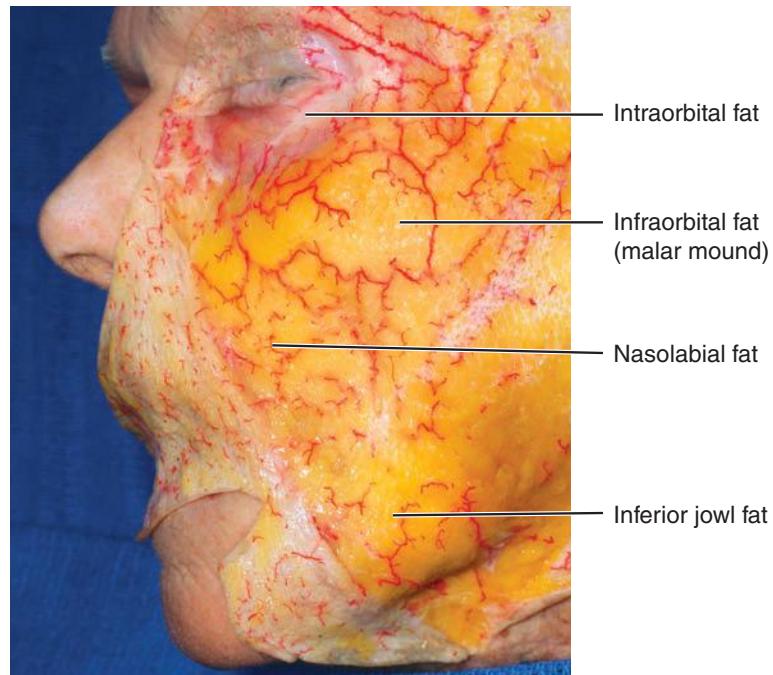
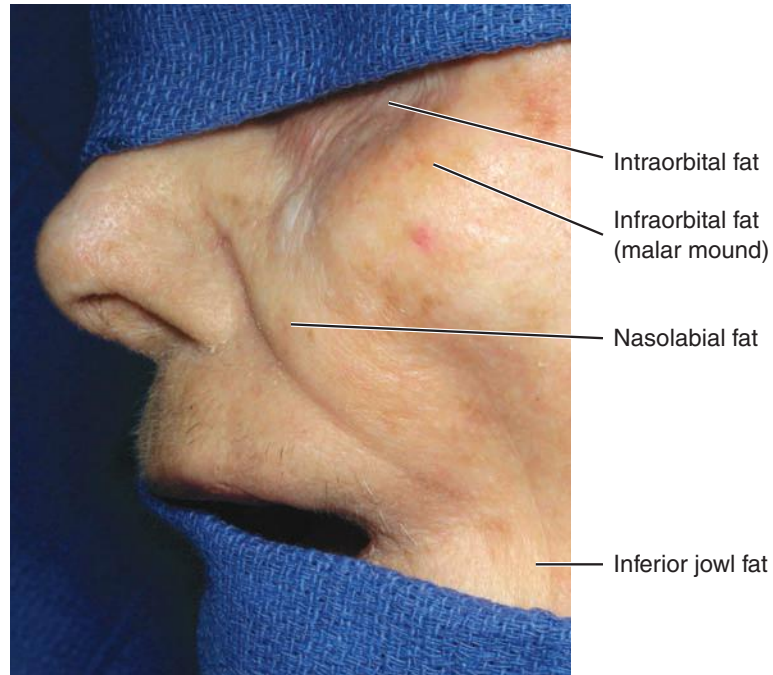


## SURFACE TOPOGRAPHY OF SUPERFICIAL FAT

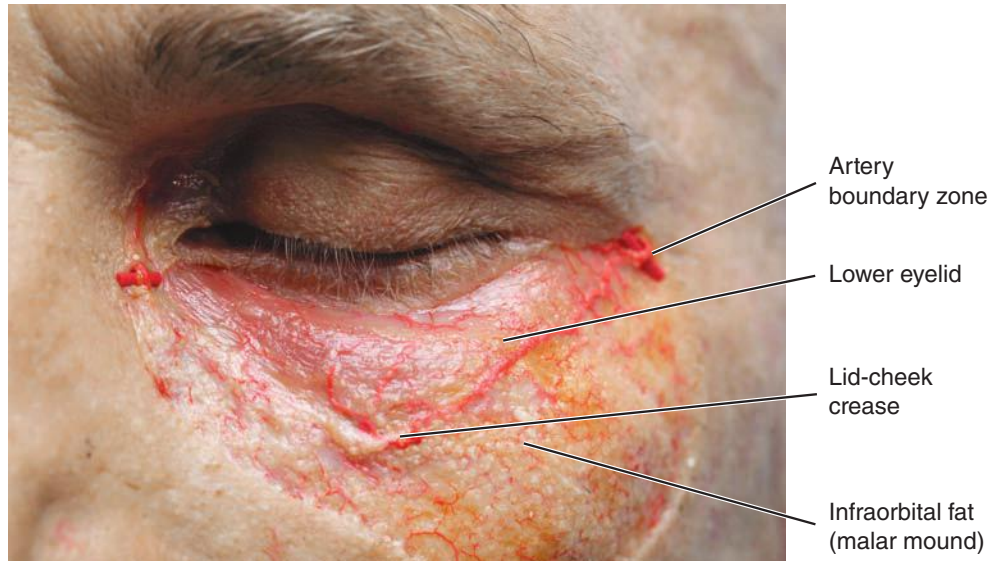
Superficial fat can also be located by inspection, and some superficial fat compartments of the cheek impart a highly specific contour. Superficial fat lies above the deep fat, above fascia, and above the facial muscles.



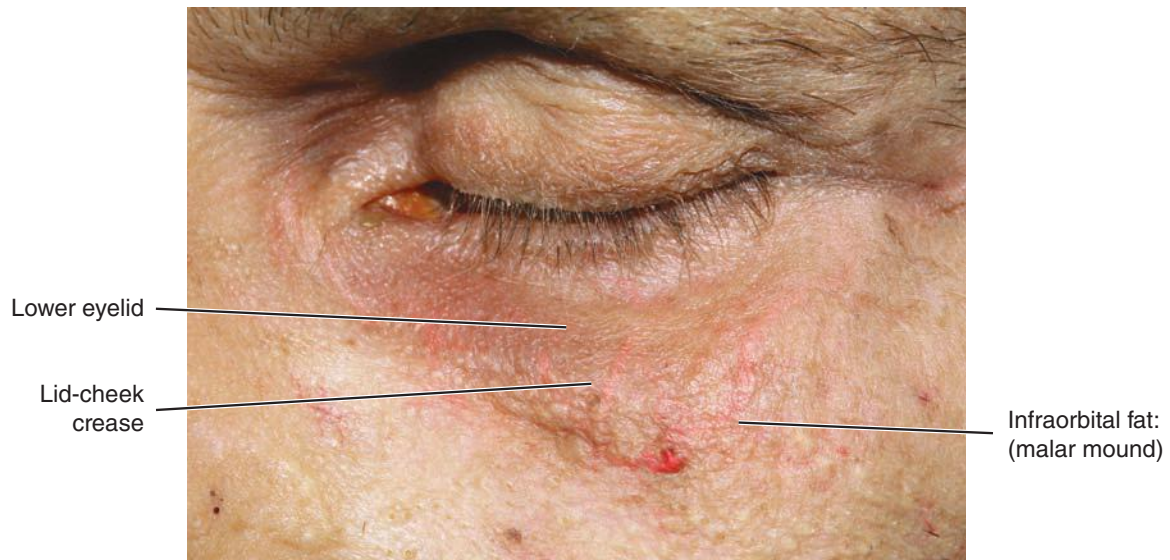Careful observation can define several of these superficial fat compartments. Identifying their position contributes important information about the deeper anatomy. Beneath the skin, these compartments are quite apparent.



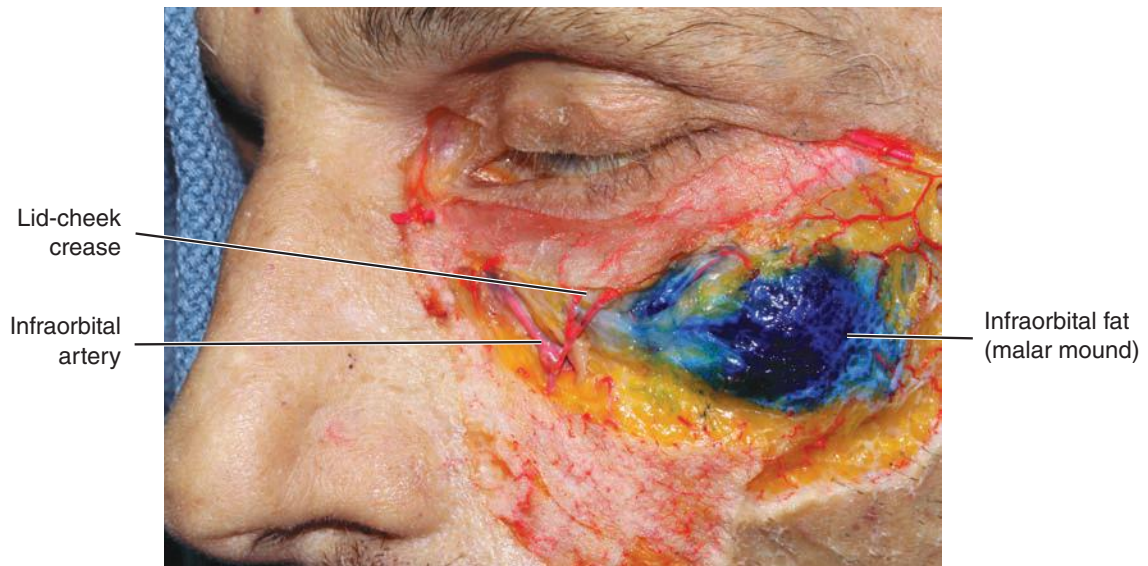
Infraorbital fat is often visible. Another commonly used name for this is the *malar mound*.



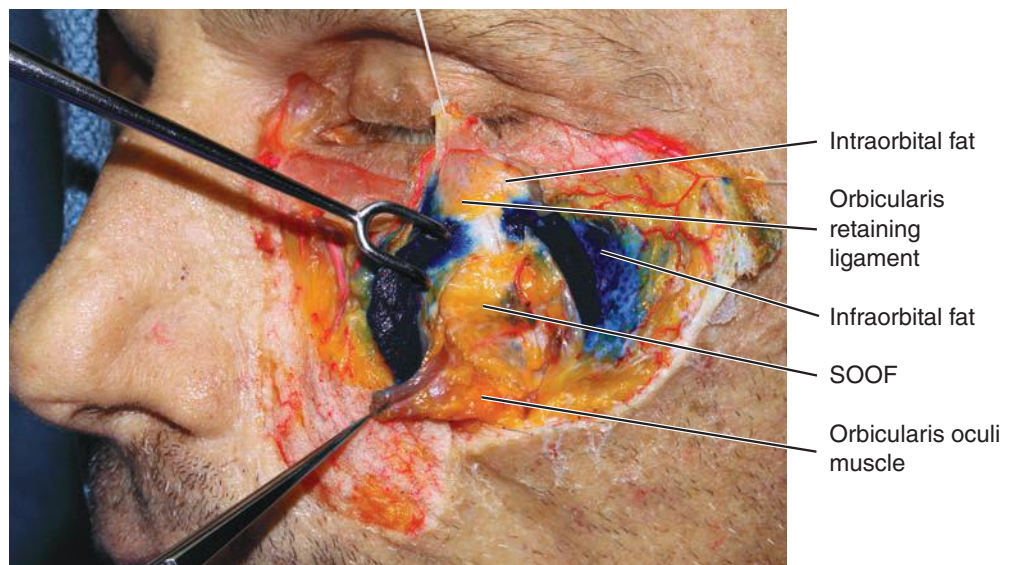
The boundary between the eyelid and cheek is the superior margin of the malar mound. This important landmark signifies the location and depth of the orbicularis oculi muscle. Above the orbit-cheek crease, the orbicularis oculi has little fat and is superficial. Below the orbit-cheek crease, the orbicularis oculi dives below the malar mound and extends down onto the cheek.



The malar mound stains with water-soluble dye.



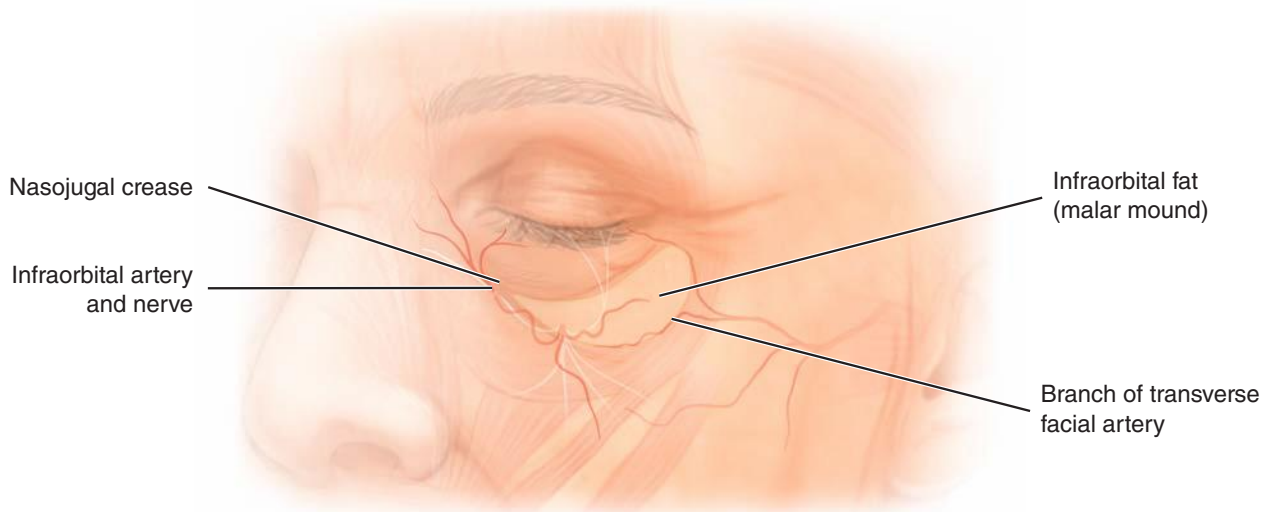
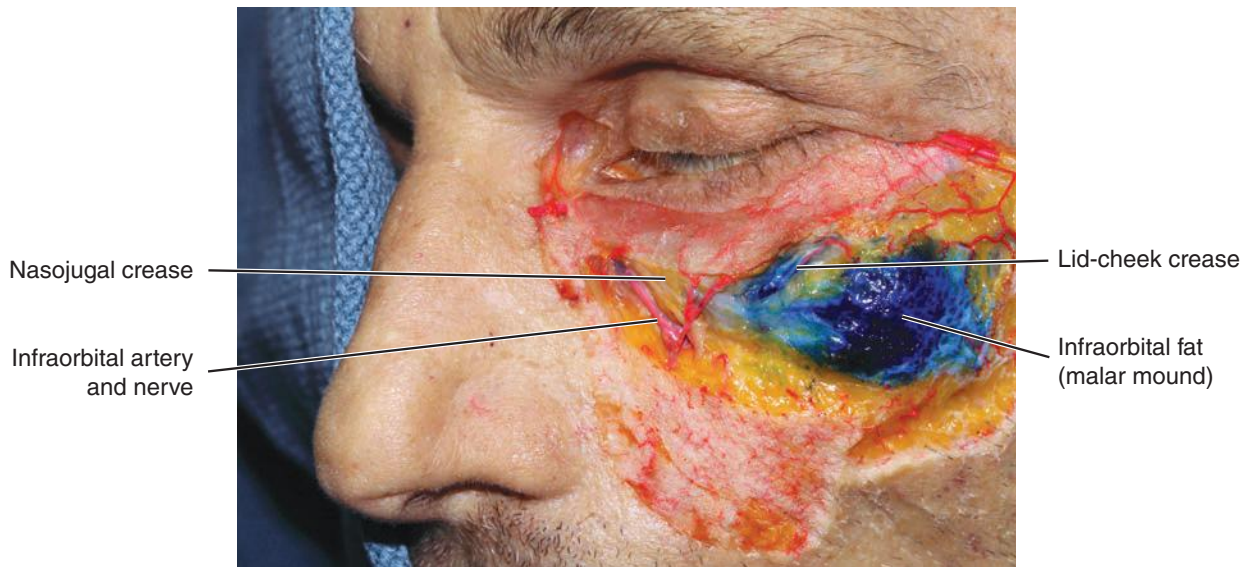The malar mound is a topographic landmark for the location of the lateral SOOF. It is also a critical marker for the position of the infraorbital neurovascular bundle.



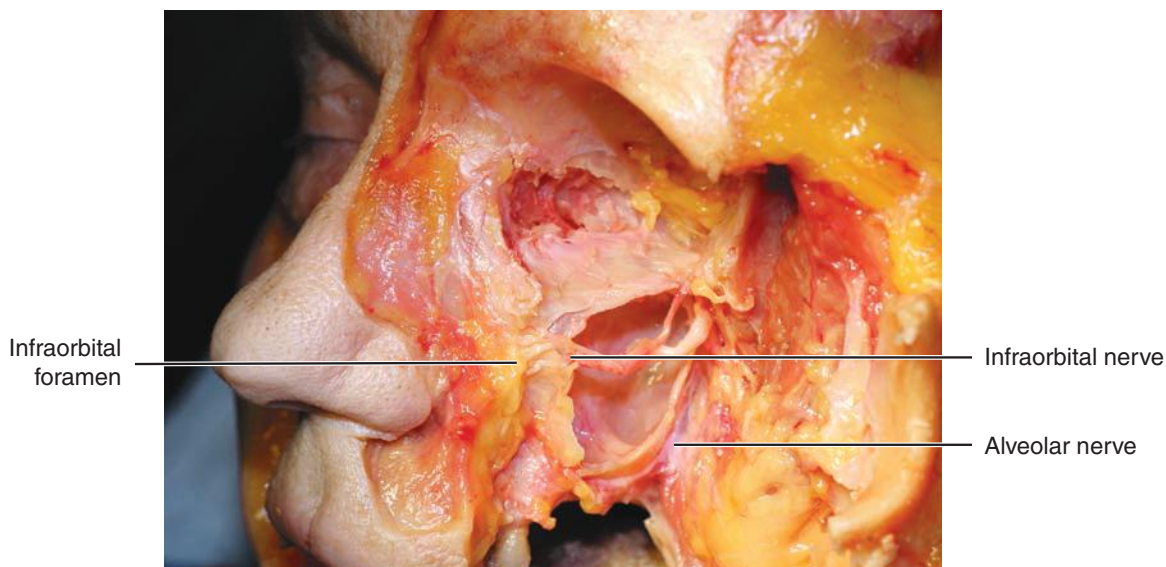
Volume augmentation should always be performed deep to the infraorbital (malar mound) fat. Injection into this compartment leads to prolonged edema.

The point at which the lid-cheek crease and nasojugal crease merge precisely identifies the infraorbital artery, because the infraorbital artery sends a branch along the nasojugal crease. It becomes superficial at the juncture of these two creases. The transverse facial artery sends branches along the inferior border of the malar mound.

Creases again indicate the presence and location of the underlying vasculature.

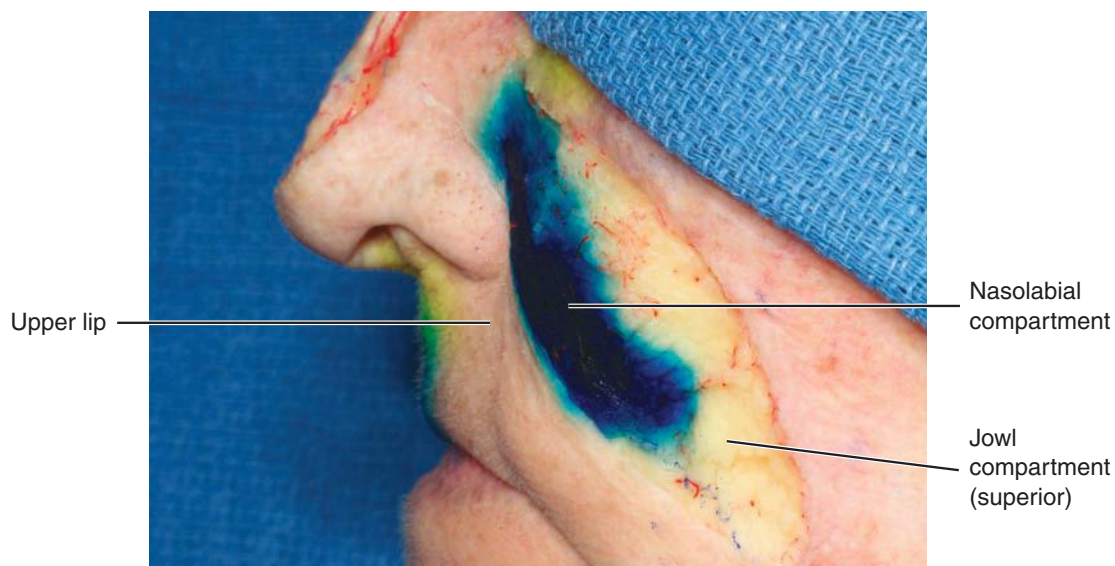


It is possible to minimize the potential for infraorbital nerve injury by recognizing these surface landmarks. Injection at the junction of the nasojugal crease and the lid-cheek crease risks injury to the infraorbital artery and nerve.



## ANATOMIC BOUNDARIES

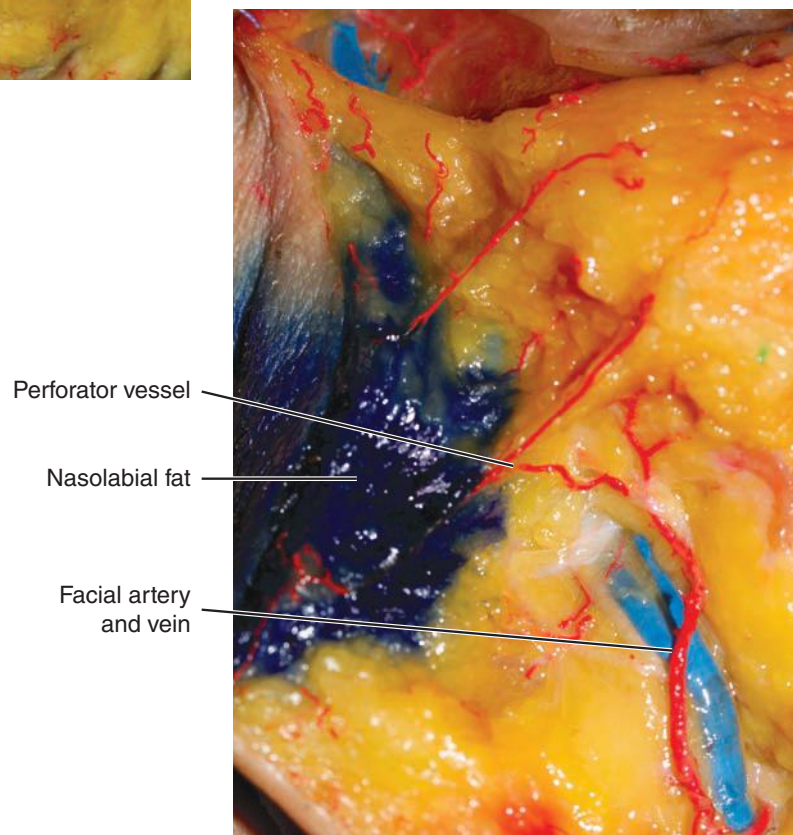
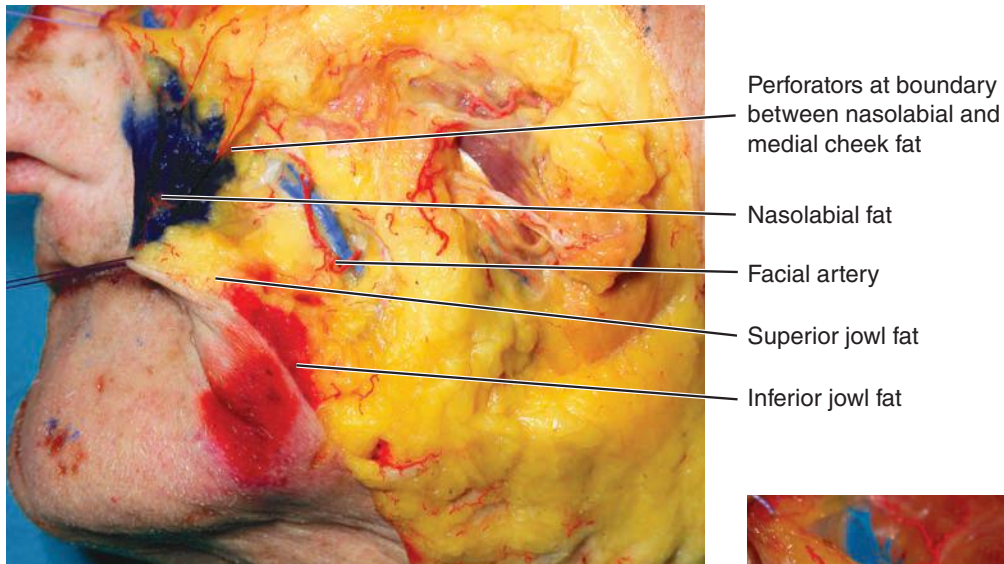
The nasolabial compartment is the medialmost of the superficial cheek compartments. Its medial border represents the boundary between cheek and upper lip.



Nasolabial adipose tissue lies adjacent to medial cheek fat and superior to the superficial jowl fat.

The nasolabial compartment is determined by fascia that encases perforators from the facial artery. The facial artery travels beneath this compartment.

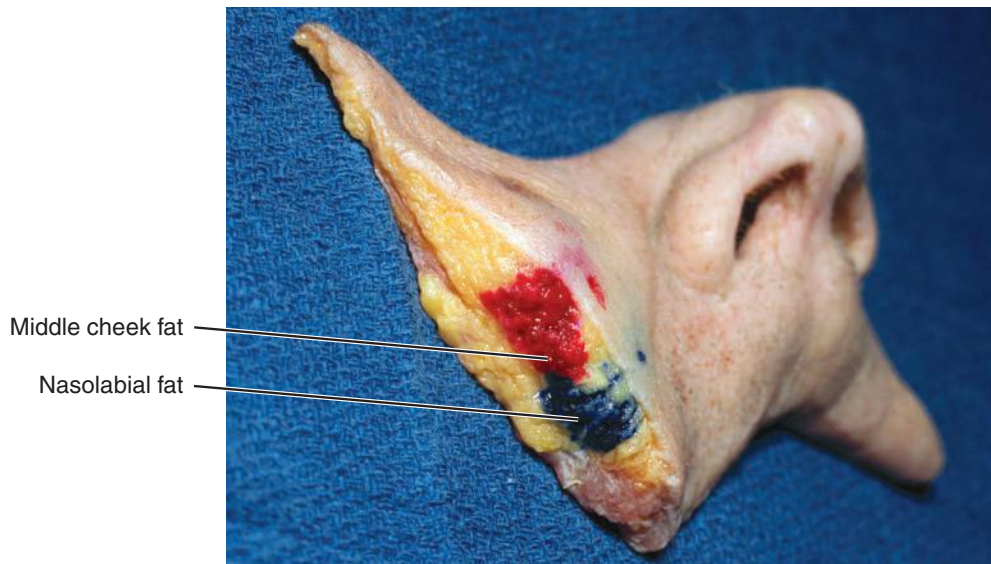
To perform injections or surgery in this area, one must take care to avoid inadvertent injury to the facial artery and its branches.



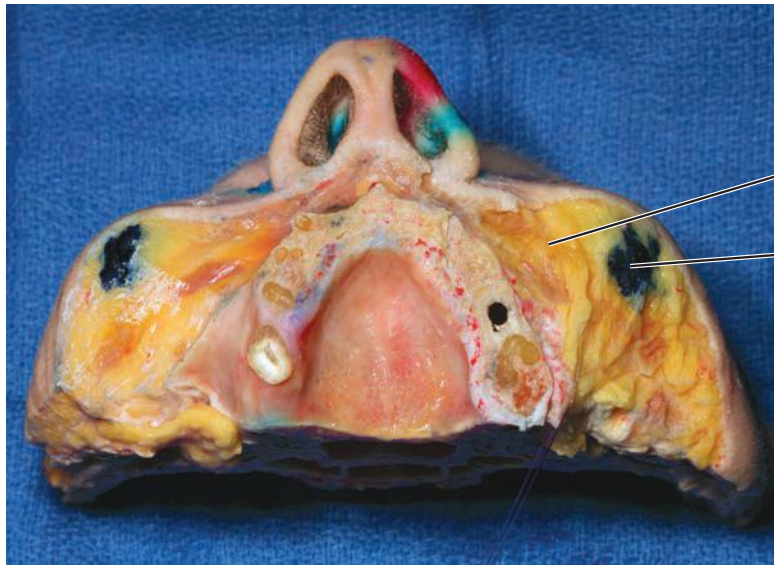## TRANSITION ZONES

It is valuable clinically to recognize that superficial fat compartments vary in thickness. Understanding this feature of the superficial fat layer may help to avoid possible nerve injury when elevating a cheek flap.

These compartments are not always oriented perpendicular to one another. The temporal compartment lies over the lateral cheek compartment. Another example is middle cheek fat, which overlaps the nasolabial fat.

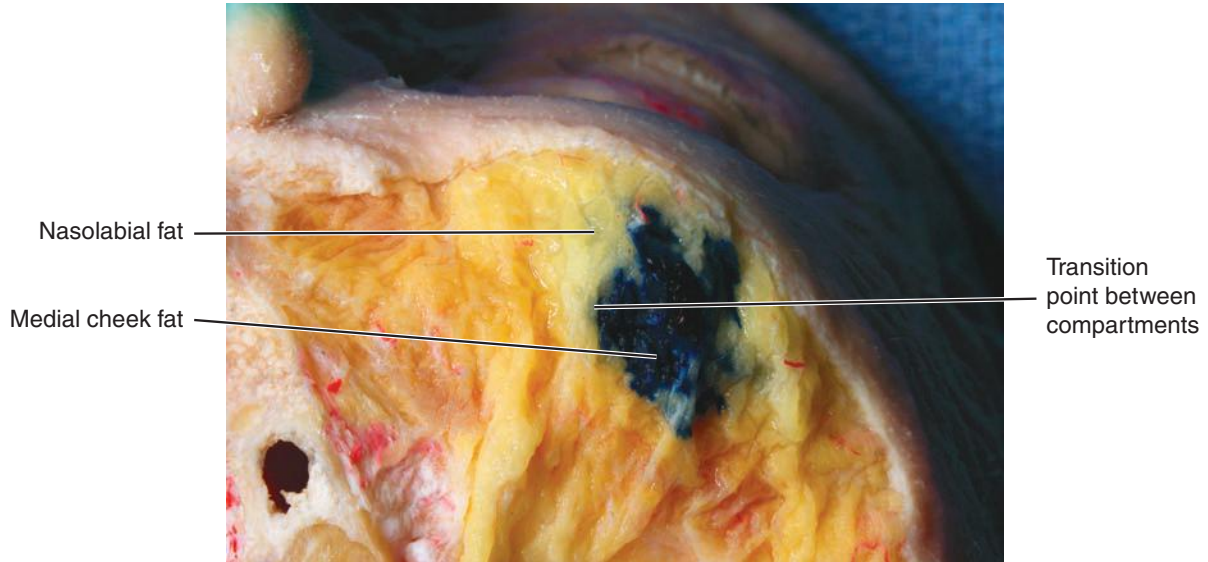


Transitioning between compartments surgically risks injury to the facial nerve if the surgeon is unaware of the different thicknesses of regional fat. For example, the medial cheek compartment is thinner than the nasolabial fat adjacent to it.



Nasolabial fat

Medial cheek fat



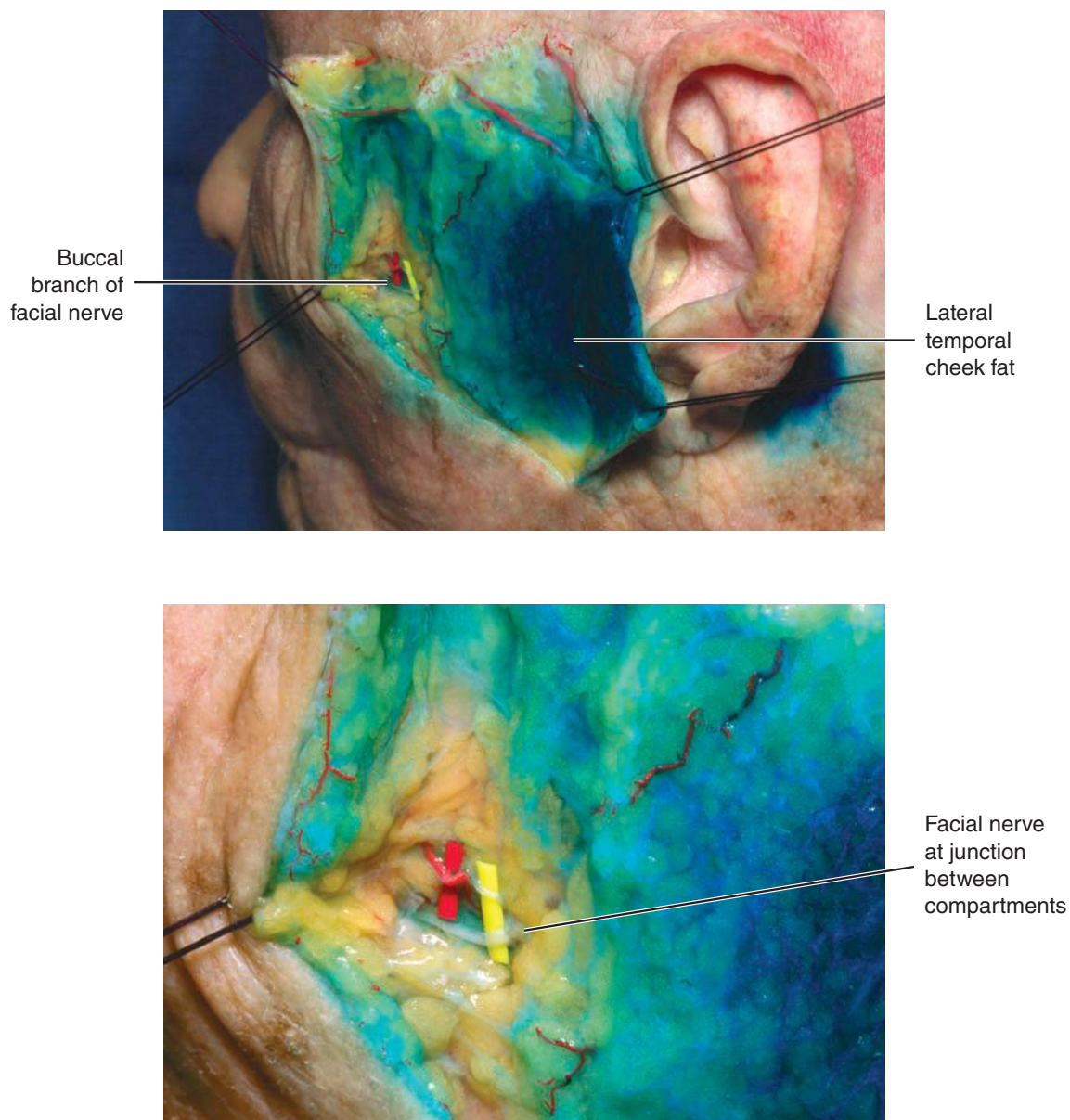
Nasolabial fat

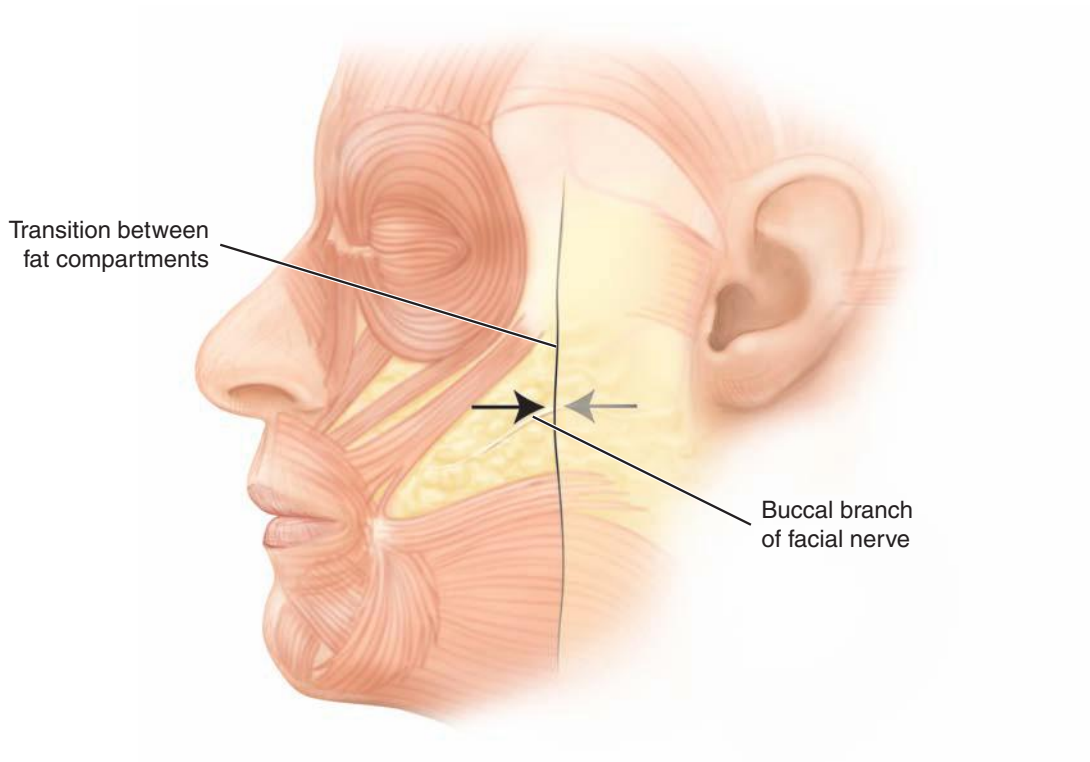
Medial cheek fat

Transition  
point between  
compartments

For the most part, zones or regions of potential injury to the facial nerve can be analyzed as the boundary between two or more superficial fat compartments.

Improper surgical dissection between adjacent fat compartments may account for the majority of direct facial nerve injuries. The buccal branch of the facial nerve may be encountered transitioning between the lateral temporal cheek compartment and the lateral cheek compartment.

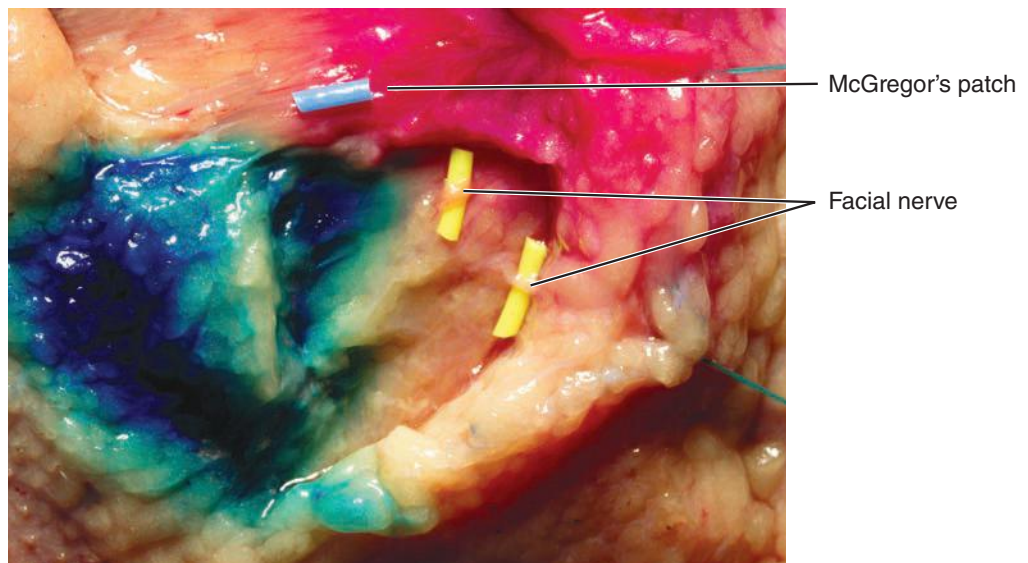
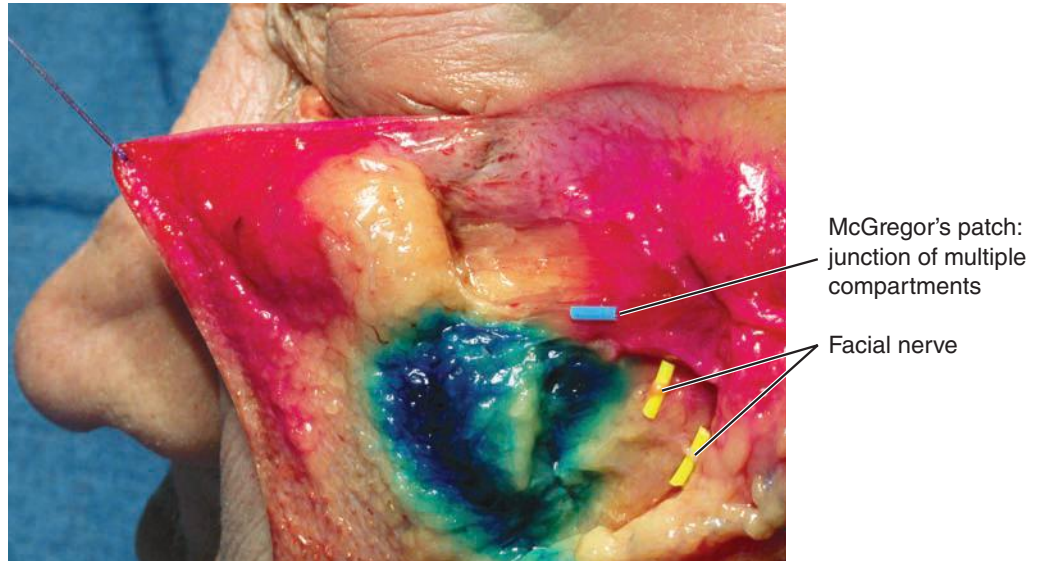




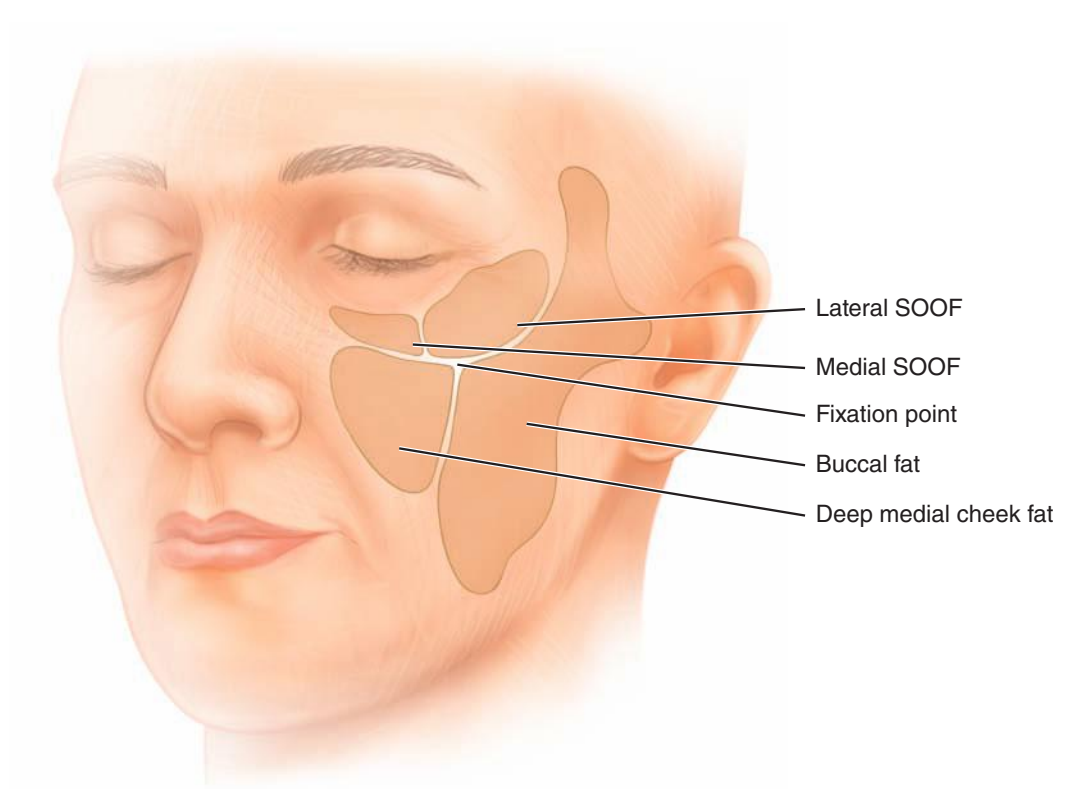
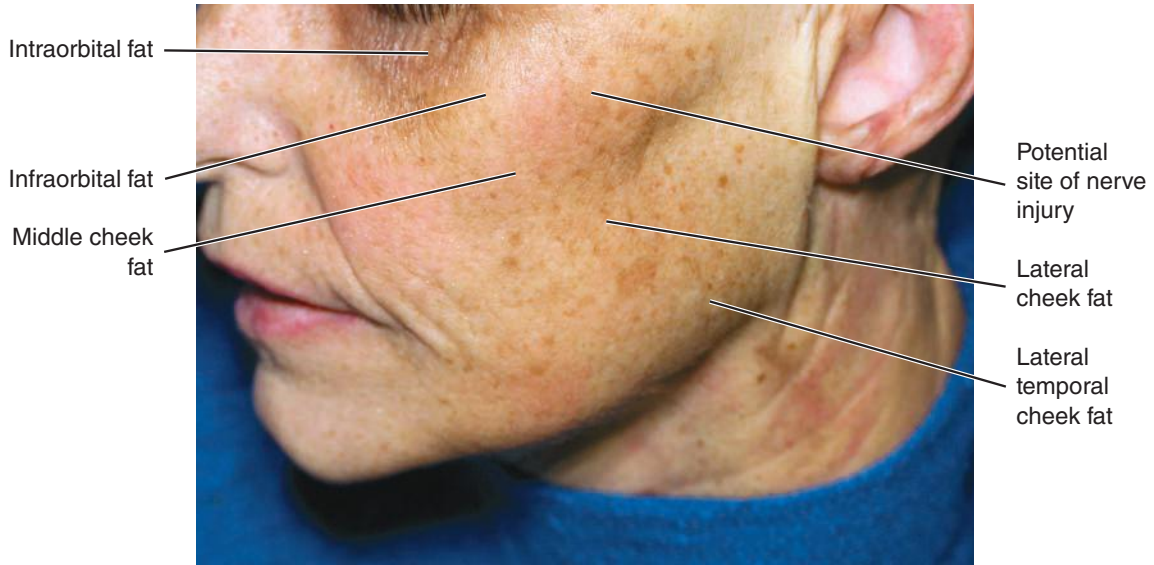Transition points between superficial compartments represent areas of potential injury to the facial nerve.

This area is directly beneath the edge of the malar mound, a point of convergence of several fat compartments.

At the junction of these compartments with the malar mound, the zygomaticus major muscle is adherent to skin. This area has been called *McGregor's patch* and represents a common location for buccal branch facial nerve injury.



Any point on the face where several compartments meet represents a region of greater fixation. These areas of dense fascial adherence may appear to be ligaments.

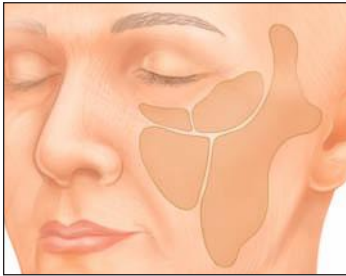


Surface topography can predict the location of many structures, including superficial and deep fat, nerves, and arteries. Some of the boundaries of the cheek have been described. The medial boundary of the cheek includes the upper lip and the nose. These structures likewise display surface contours that enable the observer to predict the structure of more deeply situated anatomy.

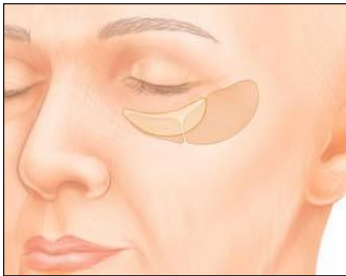
### *Key Points*

- The volume of lateral suborbicularis oculi fat affects and can augment the prominence of the cheekbone.
- Adipose tissue, as an areolar plane or as discrete compartments, lies both above and below facial muscles.
- The boundary between the jowl and central cheek is an indication of the position of underlying facial musculature.
- The contour of the cheek is significantly affected by the volume of deep adipose tissue—specifically, deep medial cheek fat and suborbicularis oculi fat.
- Deep fat pads impart a specific contour and shape to the overlying skin.
- Fat regions provide structural support for the overlying soft tissues.
- The boundary between the cheek and chin occurs between superficial jowl fat and the lateral chin compartment. The topographic landmark for this junction is the cheek-chin crease and its associated fold.
- The size and depth of folds and creases are affected by the volume of more deeply placed fat.
- The analogy here is that deep medial cheek fat is related to the cheek-lip crease, and deep lateral chin fat is related to the cheek-chin crease. This has implications for access to these deep fat pads: access to the deep lateral chin fat is through the cheek-chin fold (jowl fold), and the deep medial cheek fat can be reached through the cheek-lip fold.
- Volume augmentation should always be performed deep to the infraorbital (malar mound) fat. Injection into this compartment leads to prolonged edema.
- Transition points between superficial compartments represent areas of potential injury to the facial nerve.

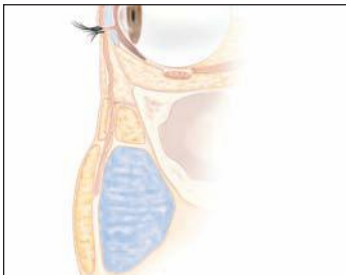
## CLINICAL CORRELATIONS



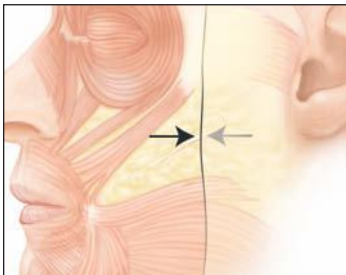Augmentation of the cheek can be performed in a site-specific manner to achieve a specific effect. For example, augmentation of the lateral SOOF creates fullness in the lateral third of the lower lid, and may diminish scleral show. Direct augmentation of deep medial cheek fat has a highly specific effect: it increases anterior cheek projection.



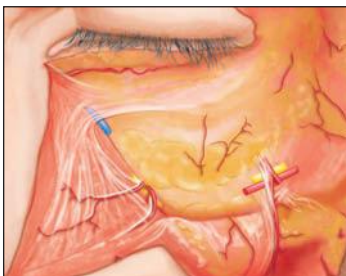The malar mound, a superficial anatomic compartment, is a topographic landmark to the position of lateral SOOF. To avoid inadvertent injection into the malar mound and prolonged edema, injections are placed directly above the periosteum. The needle bevel position is also important: bevel down directs filler deep, away from the more superficial malar mound.



Increasing the volume of deep anatomic compartments is one technique to address prominent superficial folds. For example, augmentation of deep medial cheek fat diminishes the cheek-lip fold.



Surgical transition between the lateral temporal cheek compartment and the lateral cheek compartment is important to avoid injury to the buccal branch of the facial nerve. If one dissects beneath the zygomaticus major muscle or into buccal fat, the nerve will likely be injured.



Because nerves travel within the medial and lateral SOOF, it is important to avoid performing multiple or crisscross passes with the needle at this plane, a technique that increases the risk for nerve injury.

## Bibliography

The following papers discuss some of the key elements of facial topography related to the cheek. These include discussions of true anatomic boundaries, deep fat compartments, fascial systems, and anatomic spaces. The concept of transition zones, as defined by regional differences in the thickness of superficial fat, is introduced in several of these papers.

Aiache AE, Ramirez OH. The suborbicularis oculi fat pads: an anatomic and clinical study. *Plast Reconstr Surg* 95:37-42, 1995.

*The deep fat pads of the lower eyelid are described, following earlier reports of similar fat in the upper eyelid.*

Barton FE Jr, Gyimesi IM. Anatomy of the nasolabial fold. *Plast Reconstr Surg* 100:1276-1280, 1997.

*The authors define the cheek lip junction and characterize it as a transition zone. The prime characteristic of a fold, a difference in the regional thickness of subcutaneous fat, is noted. The authors also use the term "true" in reference to this anatomic boundary, a term applicable to the study of facial topography.*

Gaughran GR. Fascia of the masticator space. *Anat Rec* 129:383-400, 1957.

*A description of the buccal fat and the masticator space defines boundaries of this area as superficial and deep leaflets of the masseteric fascia.*

Gosain AK, Yousif NJ, Madiedo G, et al. Surgical anatomy of the SMAS: a reinvestigation. *Plast Reconstr Surg* 92:1254-1263, 1993.

*The authors described the anatomic boundaries of the superficial fascia that defines superficial from deep cheek fat.*

Grodinsky M, Holyoke EA. The fasciae and fascial spaces of the head, neck and adjacent regions. *Am J Anat* 63:367-408, 1938.

*This is perhaps the most comprehensive investigation of the facial fascias; it provides an excellent bibliography on this complex topic. The authors described the surgical spaces of the face and neck, based on Juvara's initial description.*

Guyuron B, Michelow B. The nasolabial fold: a challenge, a solution. *Plast Reconstr Surg* 93:522-529, 1994.

*This paper offers a solution to diminish the transition zone between cheek and upper lip, based on strict topographic concepts.*

Haddock NT, Saadeh PB, Boutros S, et al. The tear trough and lid/cheek junction: anatomy and implications for surgical correction. *Plast Reconstr Surg* 123:1332-1340; discussion 1341-1342, 2009.

*This important paper describes the relationship of the orbit-cheek crease as a surface landmark for the position of the orbital rim. This paper defines the anatomic boundary between the eyelid and cheek and introduces the concept of superficial and deep anatomic boundaries between facial regions.*

Mendelsohn BC, Freeman ME, Woffles W, et al. Surgical anatomy of the lower face: the premas-seter space, the jowl, and the labiomandibular fold. *Aesthet Plast Surg* 32:185-195, 2008.

*Building on the line of work started by Juvara, these authors described a new space and suggested that buccal fat contributes to surface topography by increasing the prominence of the jowl.*

Mendelson BC, Muzaffar AR, Adams WP. Surgical anatomy of the midcheek and malar mounds. *Plast Reconstr Surg* 110:885-896, 2002.

*The glide plane of the upper cheek is defined in relationship to the overlying malar or medial cheek compartment.*

Nandy K. Surgical anatomy of the deep fascia of the neck. *Surg Clin North Am* 54:1297, 1301, 1974.

*The deep and superficial fascias of the face and neck are described, along with the anatomy of the parotid gland and its space. The concept of fusion zones and deep fat is introduced.*

Owsley JQ. Lifting the malar fat pad for correction of prominent nasolabial folds. *Plast Reconstr Surg* 91:463-474, 1993.

*Owsley coined the term "malar fat," correctly describing a thickened region of subcutaneous adipose tissue that is now referred to as the middle cheek compartment. Again, the common theme by multiple authors is the varying thickness of the superficial fat compartments.*

Seckel BR. *Facial Danger Zones: Avoiding Nerve Injury in Facial Plastic Surgery*. St Louis: Quality Medical Publishing, 1994.

*Seckel described in detail the most common potential sites for sensory and motor nerve injury on the face. This work was prescient: it was completed before we had any knowledge of boundary zones, transition zones, anatomic subunits, and the compartmentalization of fat. However, almost every danger zone can be linked to a transition point between compartments, or where nerves ascend to innervate the undersurface of a muscle. Much of our work on danger zones relies on Seckel's; analyzing his regions points to areas where transition zones can be identified in the anatomy lab.*

Stuzin JM, Baker TJ, Gordon HL. The relationship of the superficial and deep facial fascias: relevance to rhytidectomy and aging. *Plast Reconstr Surg* 89:441-449, 1992.

*The authors discussed the ligamentous attachments of the face and cheek and defined a fusion zone that imparts a specific shape to the overlying cheek skin.*

Yousif NJ, Mendelson BC. Anatomy of the midface. *Clin Plast Surg* 22:227-240, 1995.

*An excellent overview of the anatomy of the cheek.*

Yousuf S, Tubbs RS, Wartmann CT, et al. A review of the gross anatomy, functions, pathology, and clinical uses of the buccal fat pad. *Surg Radiol Anat* 32:427-436, 2010.

*The most up-to-date review of this deep facial adipose tissue, this article makes the point that buccal fat contributes to anterior inferior facial projection. This statement lends credibility to the concept that buccal fat is a contributing factor to the jowl.*

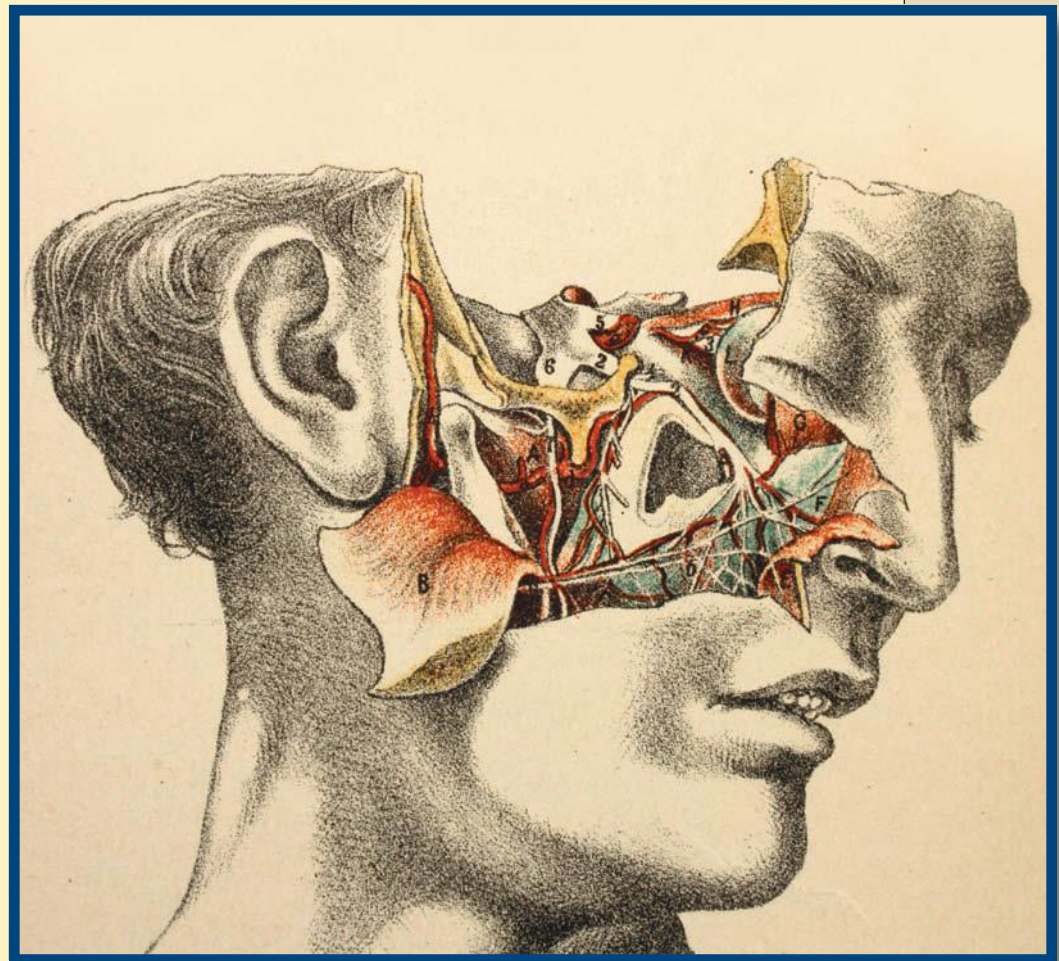
This page intentionally left blank

---

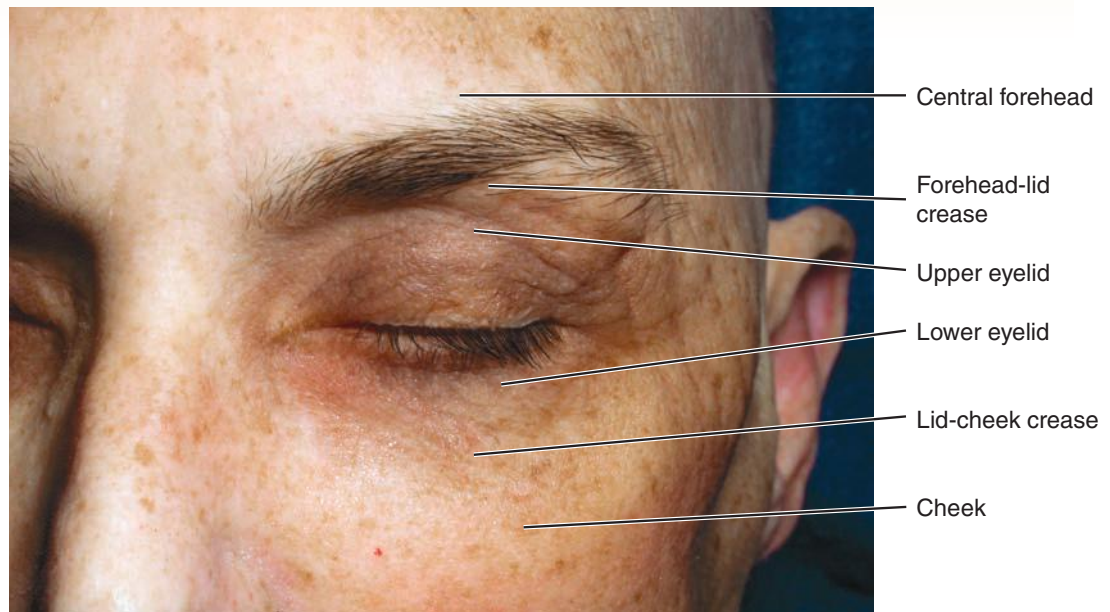CHAPTER 4

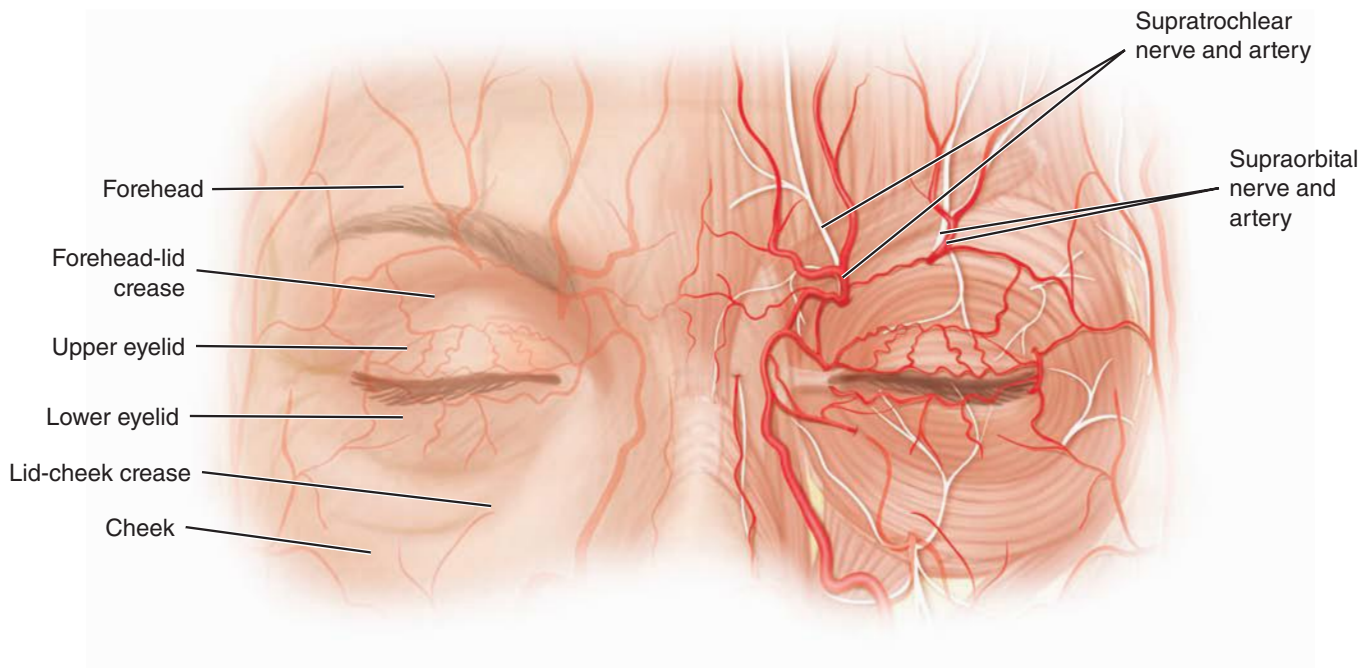
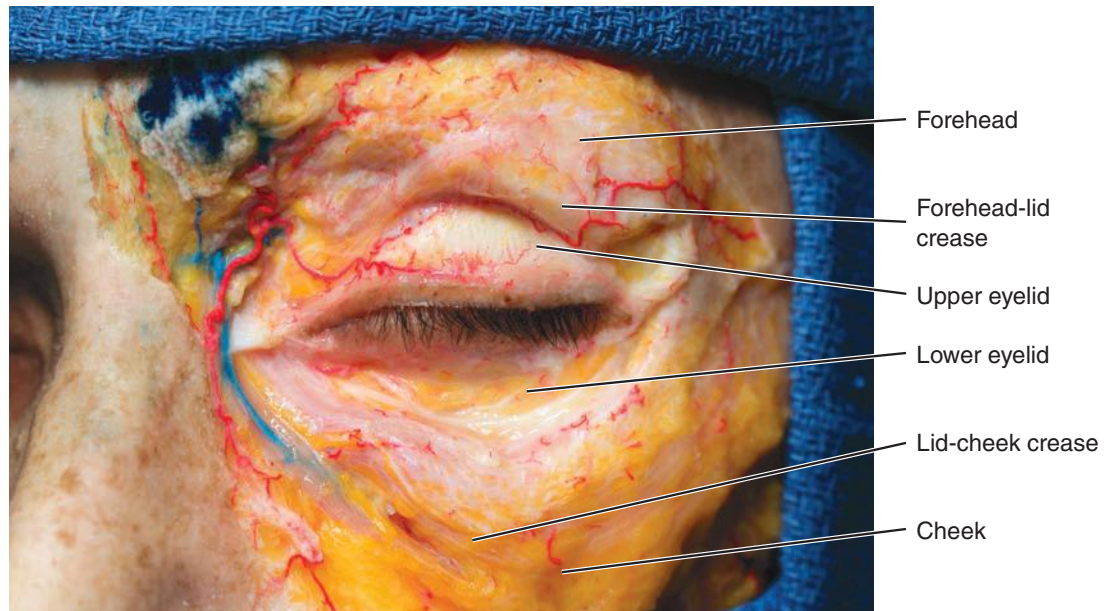---

# The Eyelids



**A** thorough understanding of the surface structures of the eye area and how they relate to the underlying anatomy enables surgeons to perform successful eyelid surgery while avoiding potential complications.

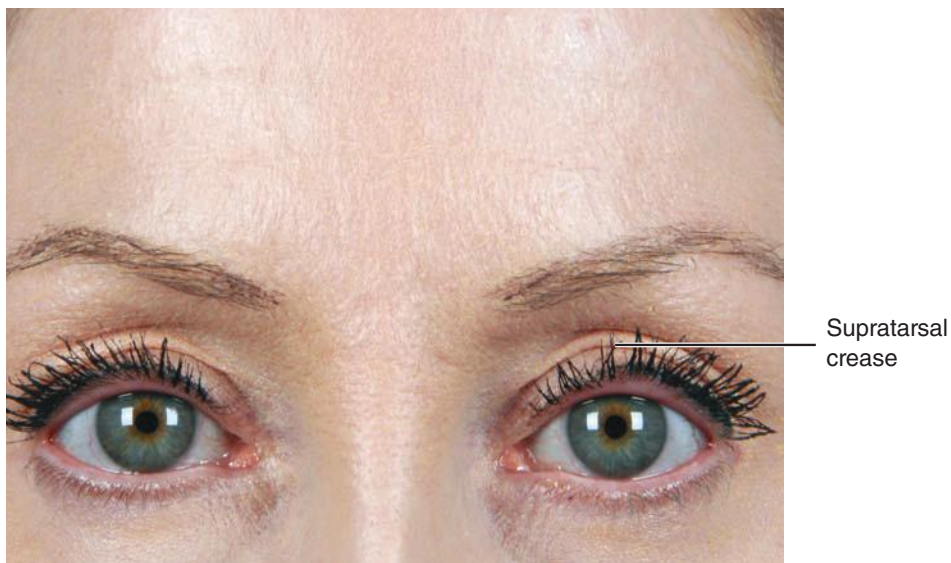



## EFFECTS OF TISSUE THICKNESS AND VASCULAR ARCADES

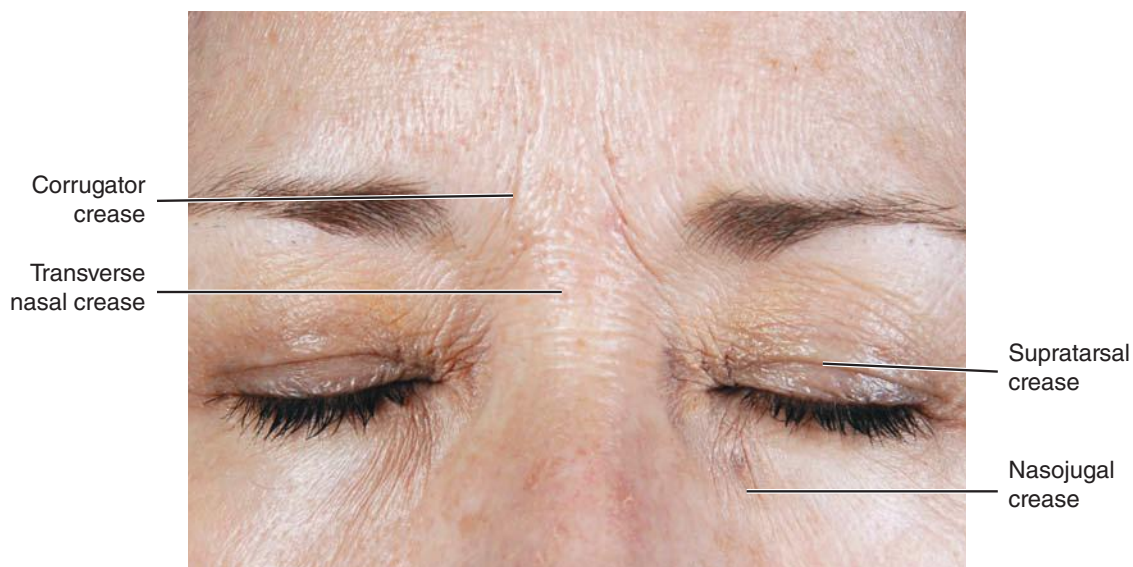Subcutaneous fat is always thinner over mobile areas such as the eyelids and perioral skin. The transition point between the thick adipose tissue of the forehead and the thinner adipose tissue of the upper eyelid creates a fold and a corresponding crease. Similarly, thin subcutaneous fat exists in the lower eyelid. At the junction between the lower eyelid and cheek, the thickness of adipose tissue increases, leading to a fold and its associated lid-cheek crease.

Applying basic concepts helps to approach any problem in a logical manner. The supratarsal crease is one example.



Creases may be related to the underlying blood supply.

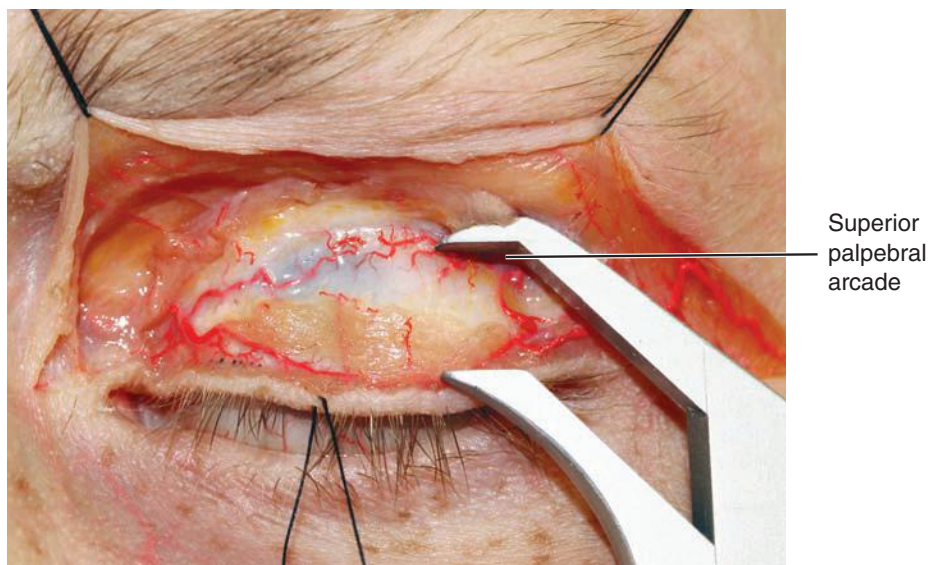
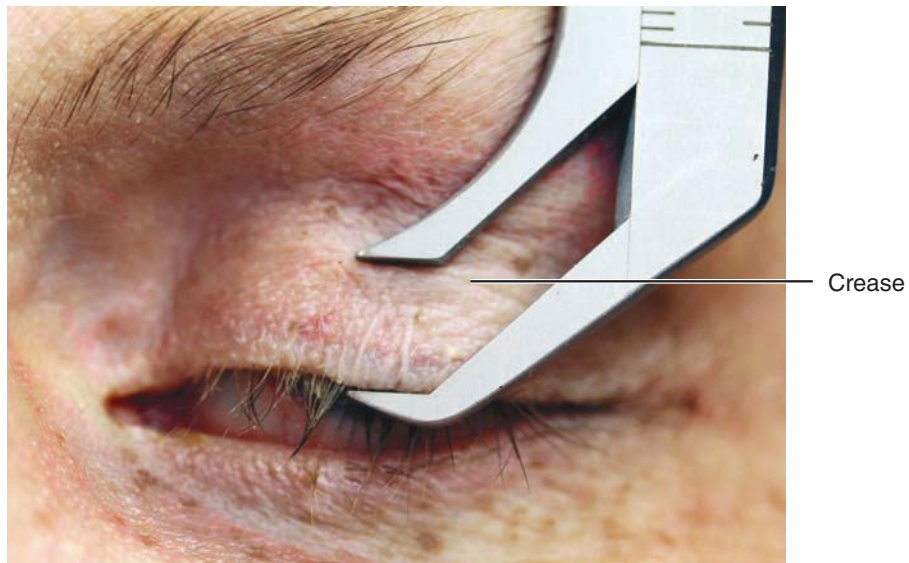
It is here that concepts can be applied to synthesize possible solutions. The supratarsal crease may be a manifestation of fascial extensions from the levator muscle. As a true crease, it may be related to the underlying blood supply and fascial membranes that stabilize the blood supply.



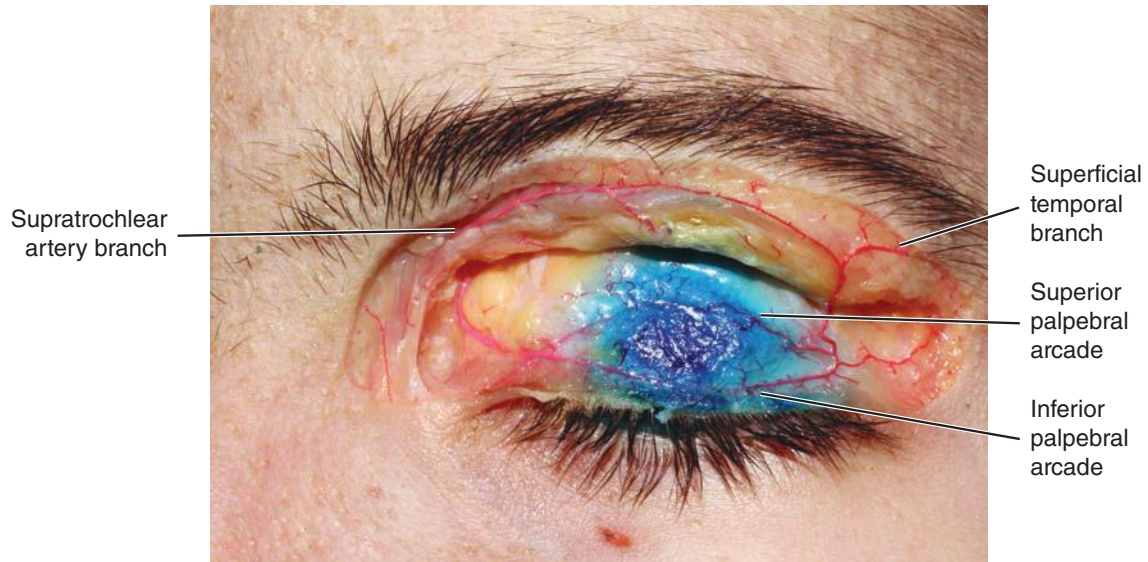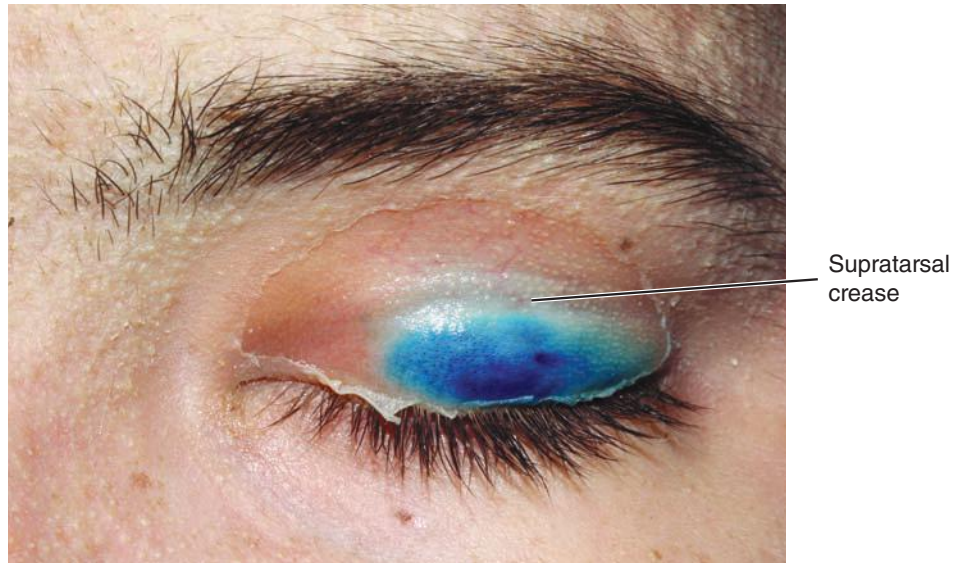The supratarsal crease occurs in a predictable location. Thicker skin folds over this crease.

Creases are associated with adjacent adipose compartments that have different thicknesses.

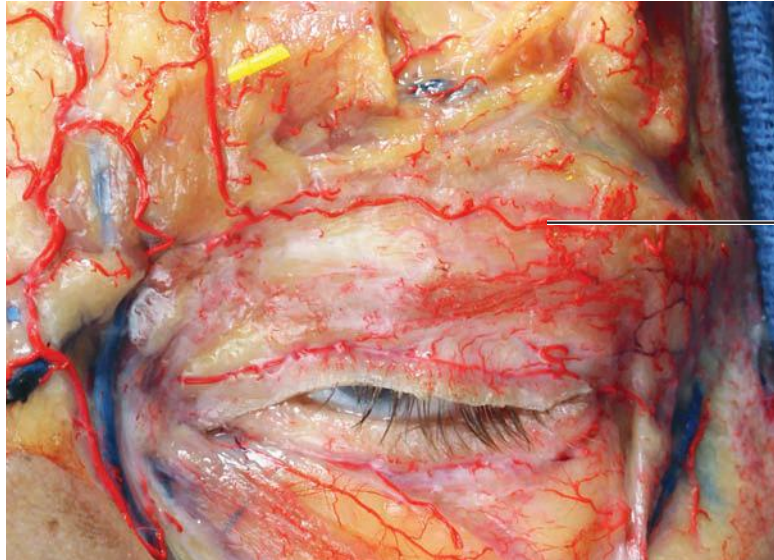Calipers are used to measure the height of the crease on the right eyelid of this dissection. The same height is transferred to the left eyelid of the same dissection. Submuscular dissection shows the presence of the superior palpebral arcade at this location.



This finding is reproducible. Routine staining defines a specific region between the inferior and superior arcades, and dissection shows that diffusion is limited to the extent of this compartment.

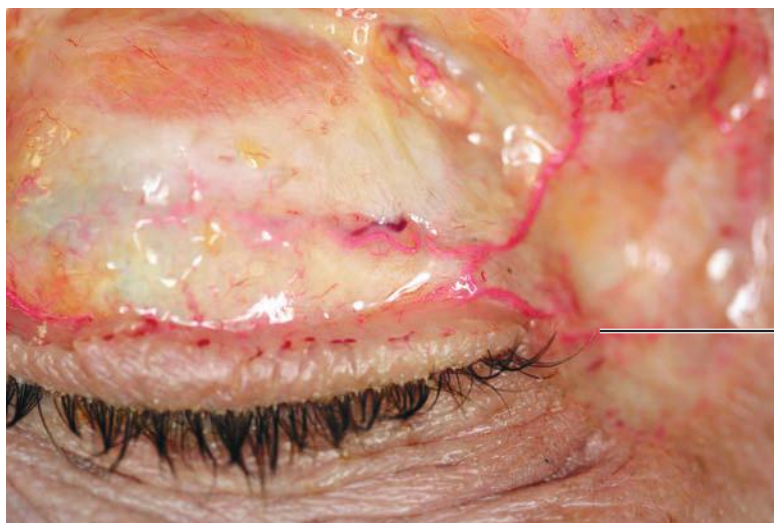


A more superiorly located arcade defines the upper eyelid and represents the superficial boundary between the forehead and upper eyelid.



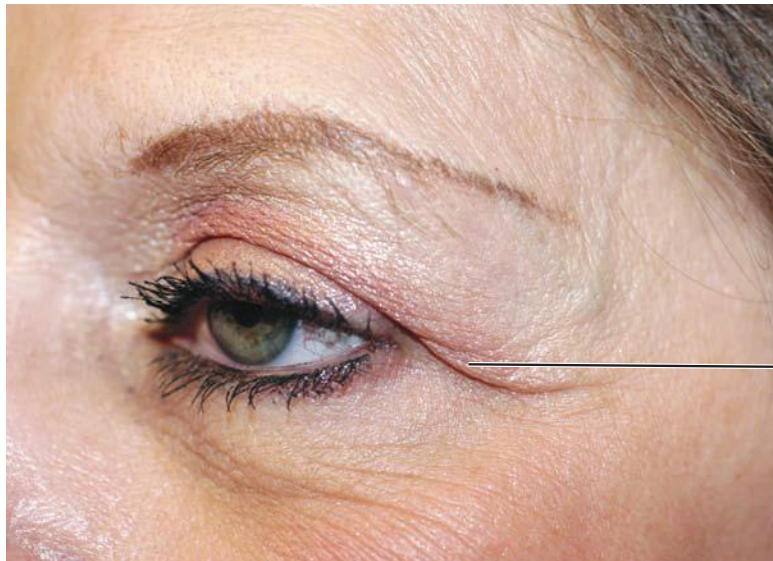Boundary between forehead and upper eyelid

Additional work may apply this concept to better understand the position of the lateral palpebral crease, a possible manifestation of the vascular supply.



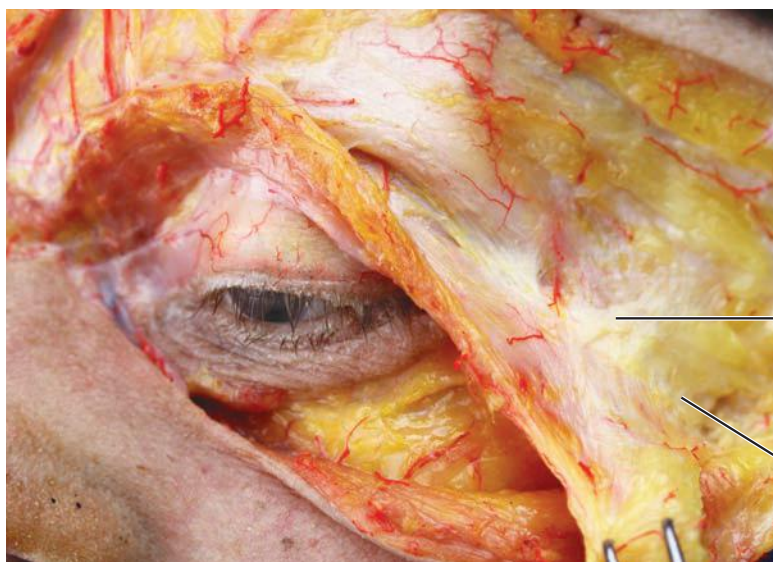Inferior palpebral artery

Fascial extensions from the lateral palpebral artery insert into skin. This defines an anatomic unit around the eyelid.



Location of artery at crease

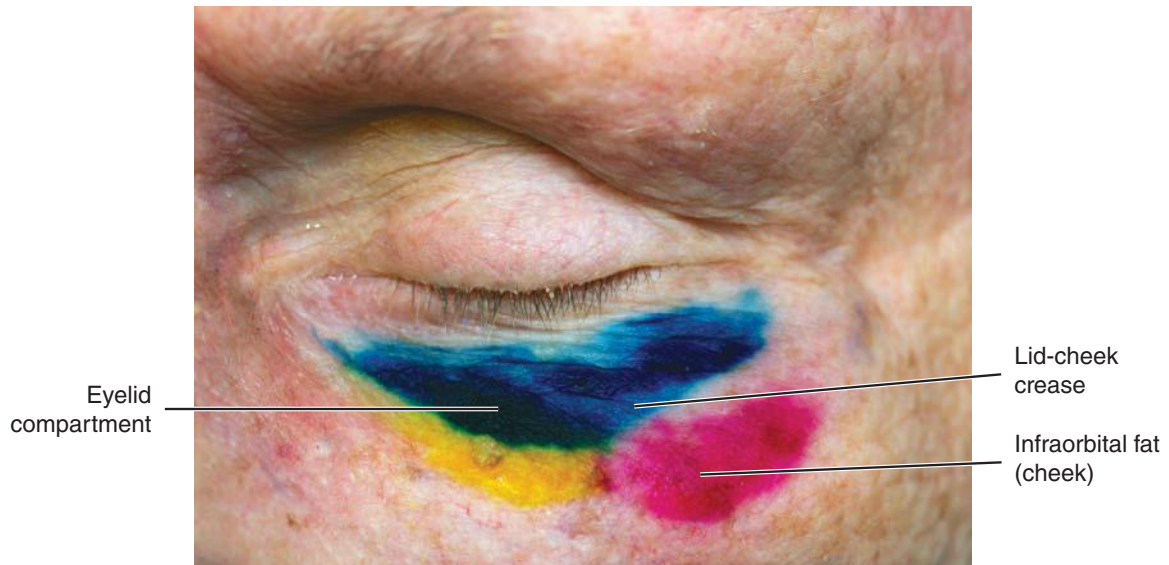The deep boundary between the upper eyelid and the temporal fossa may be related to the insertion of the orbicularis retaining ligament (ORL). This represents the deep boundary between the forehead and the upper eyelid. This distinction is important clinically to prevent inadvertent injection from the forehead into the upper eyelid or orbit. The ORL extends onto the zygomatic arch as the lateral orbital thickening.



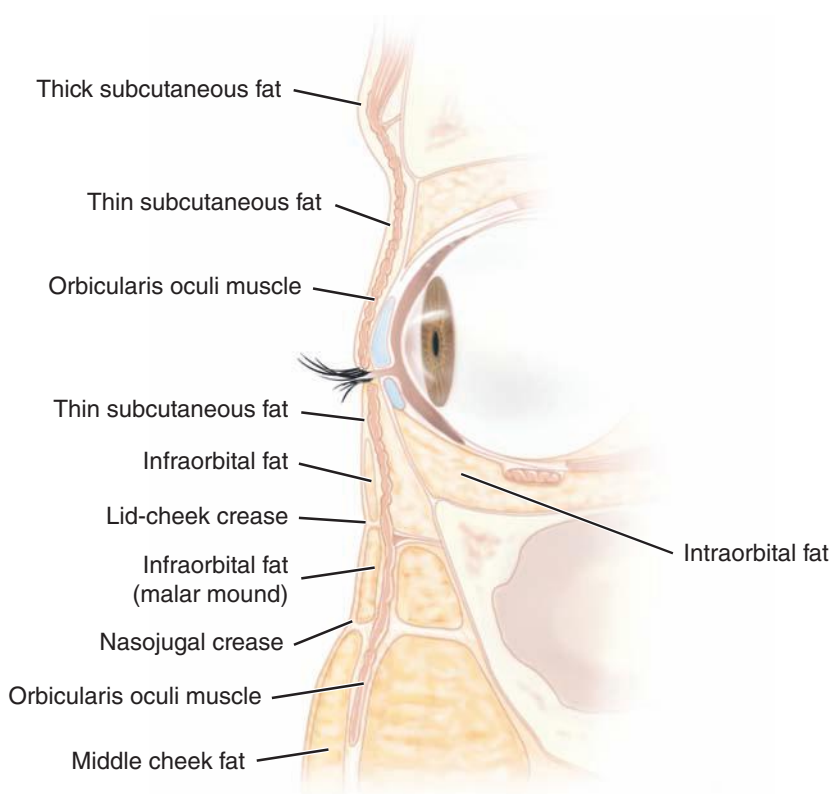
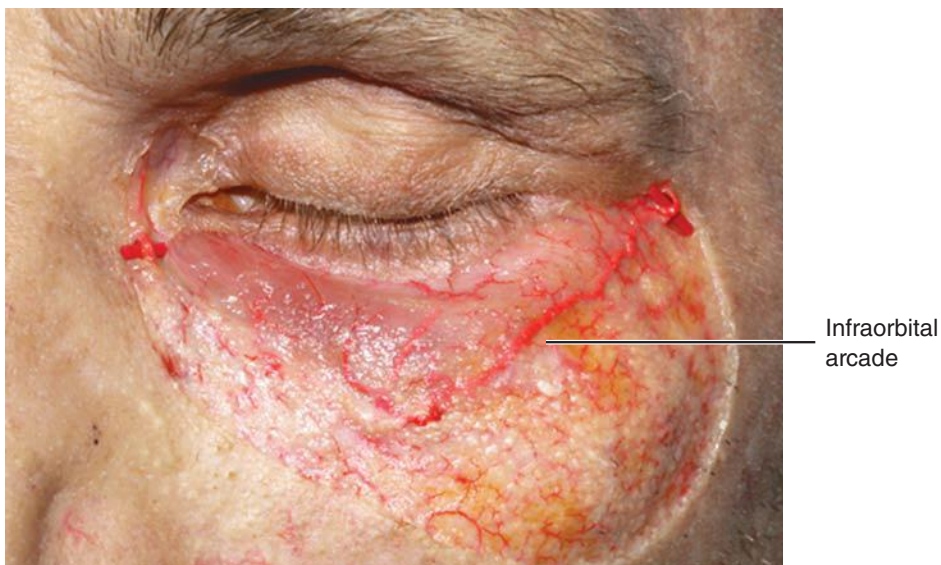Fusion of orbicularis retaining ligament with periosteum

Lateral orbital thickening

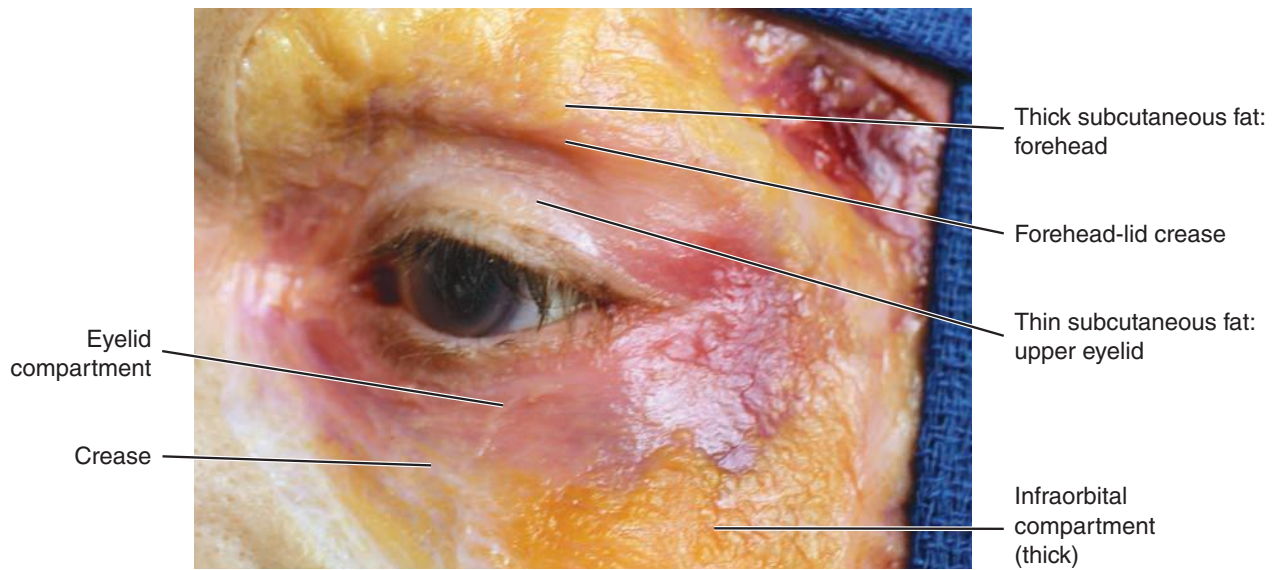
There is a distinct superficial boundary in the lower eyelid between the eyelid and cheek. The lid-cheek junction is also called the *lid-cheek crease*. It is the inferior orbital compartment.



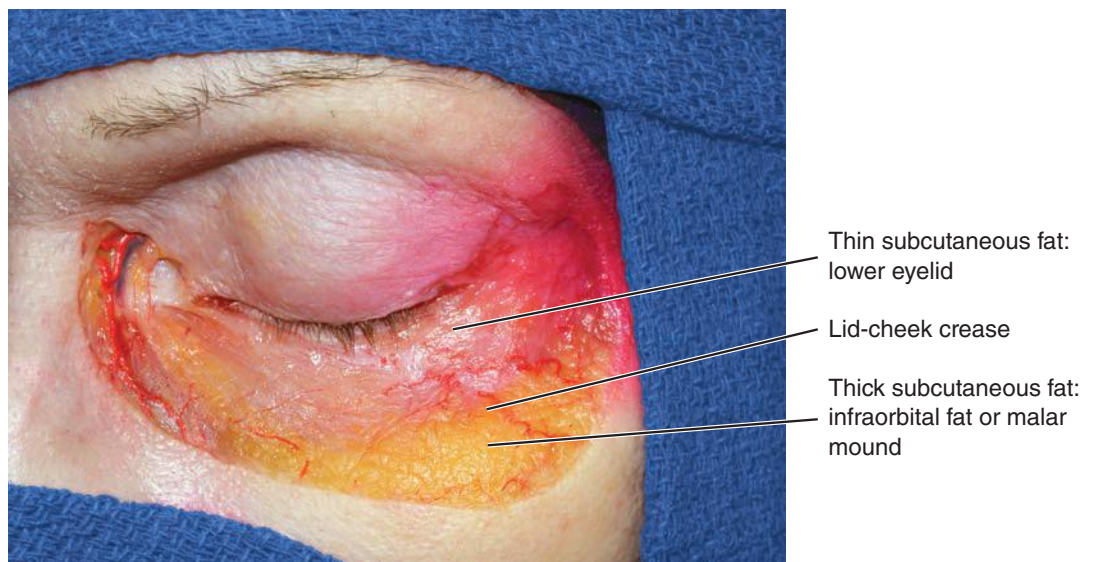
The infraorbital artery contributes to the blood supply along this crease, in addition to branches from the transverse facial artery. The position of the infraorbital artery relative to this crease is predictable.



Creases occur where there is a regional difference in the thickness of subcutaneous fat. The lid-cheek junction occurs where subcutaneous fat becomes thicker over the preorbital orbicularis oculi muscle.

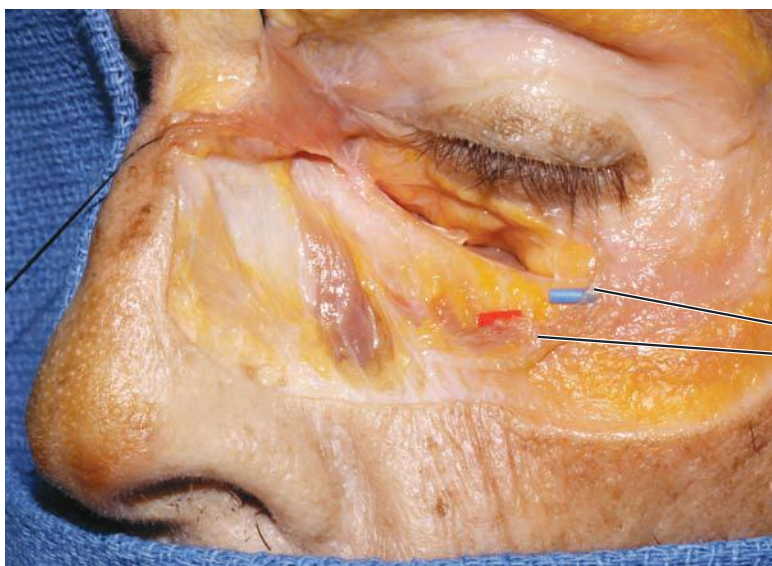

Another dissection with the skin removed illustrates this point. The lid-cheek junction is clearly seen.



This principle holds true for other creases, including the supratarsal crease, where the subcutaneous fat is thicker above the crease than below.

Other factors may help to define the location of the lid-cheek junction. There may be a superficial head of the orbicularis above, and a deep head below. This is similar to the two parts of the orbicularis oris muscle of the upper lip.

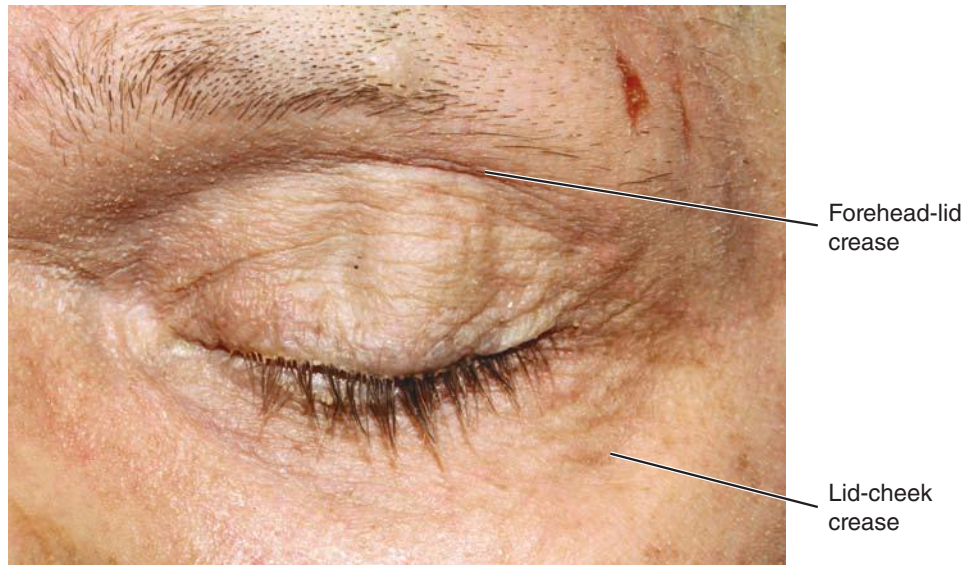


Orbicularis oculi  
muscle:  
Superficial  
Deep

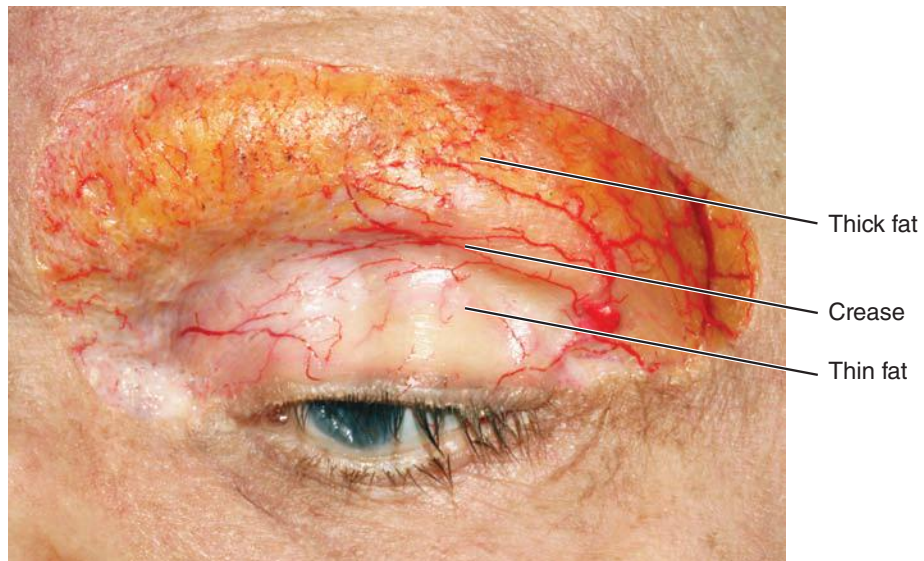
The lower eyelid shares many features with the upper eyelid. The ORL is the deep boundary of both and may form a lid-cheek and lid-forehead boundary. The upper eyelid may also have a crease and a lid-forehead junction.

In the clinical setting, complications may arise from failure to recognize the imperfect seal between the lid and cheek or the lid and forehead.

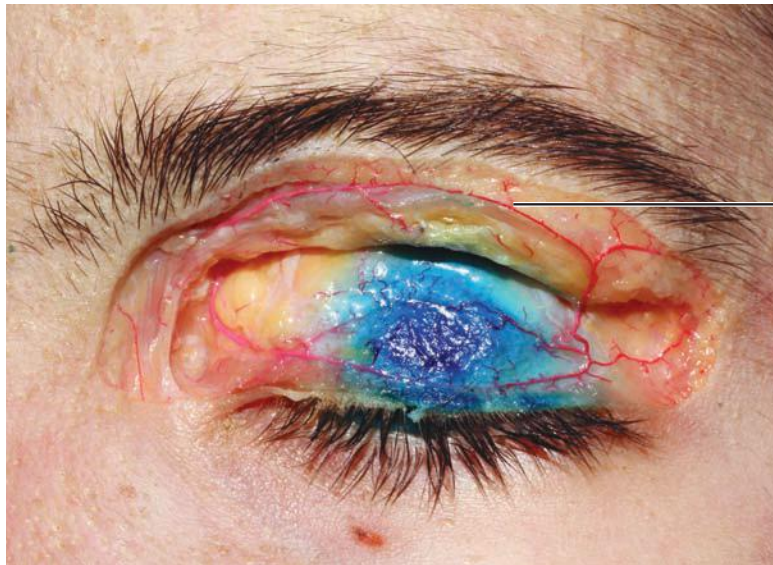A crease occurs above the upper lid at the superficial junction with the forehead.



An arcade is located at this boundary. The subcutaneous tissue is also thicker above this crease.



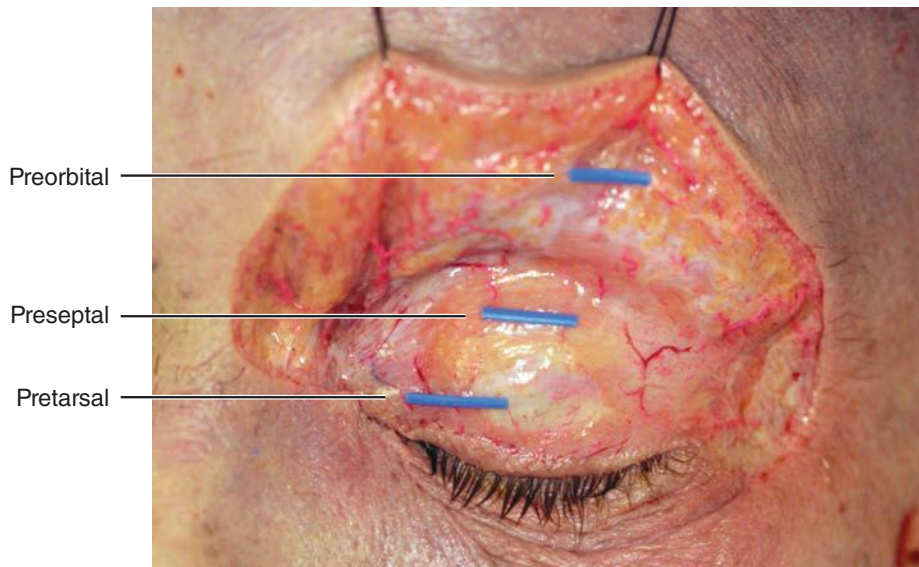
Another example of the regional difference in adipose tissue thickness at the junction of the forehead and upper eyelid is seen here.



Arcade at  
forehead-lid  
crease

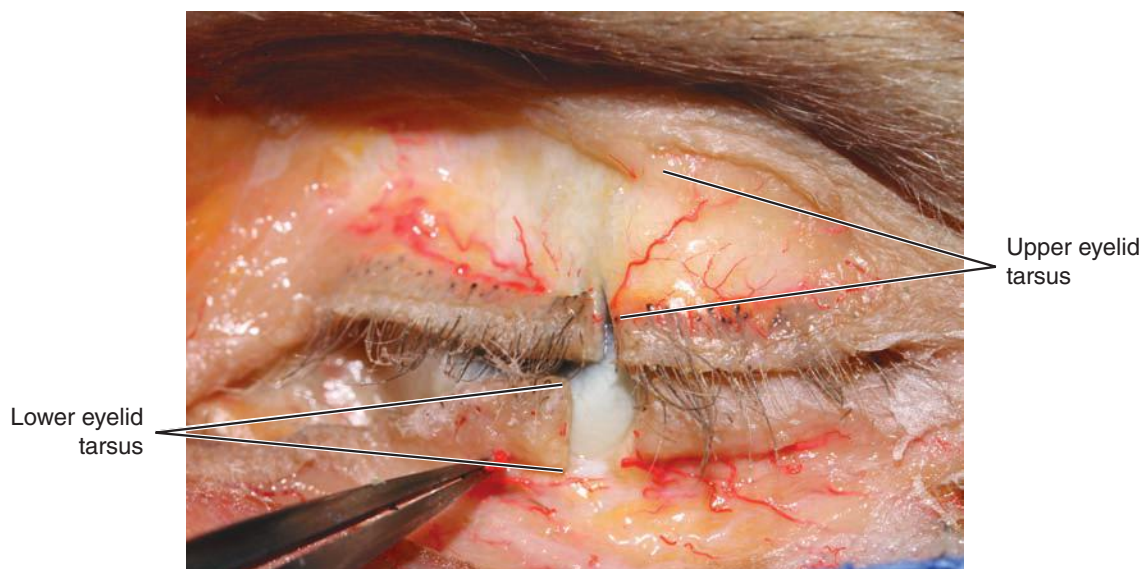
Creases are usually defined by a vascular arcade and regional differences in the thickness of fat. This definition can be used to distinguish creases from wrinkles where there is no difference in adipose tissue thickness.

The orbicularis oculi muscle of both the upper and lower eyelid has three parts: *preorbital*, *preseptal*, and *pretarsal*. It has not been stated that this nomenclature correlates with surface landmarks. However, known vessels—the superior palpebral arcade and the lateral branch of the supraorbital artery—do coincide with our definition of preorbital, preseptal, and pretarsal orbicularis oculi muscle.



In addition, the lid-cheek junction defines the point at which subcutaneous tissue changes dramatically in thickness. The preseptal-preorbital orbicularis oculi junction coincides with the lid-cheek crease. Therefore the overlying form suggests the thickness of superficial fat and the location and depth of orbicularis oculi muscle.

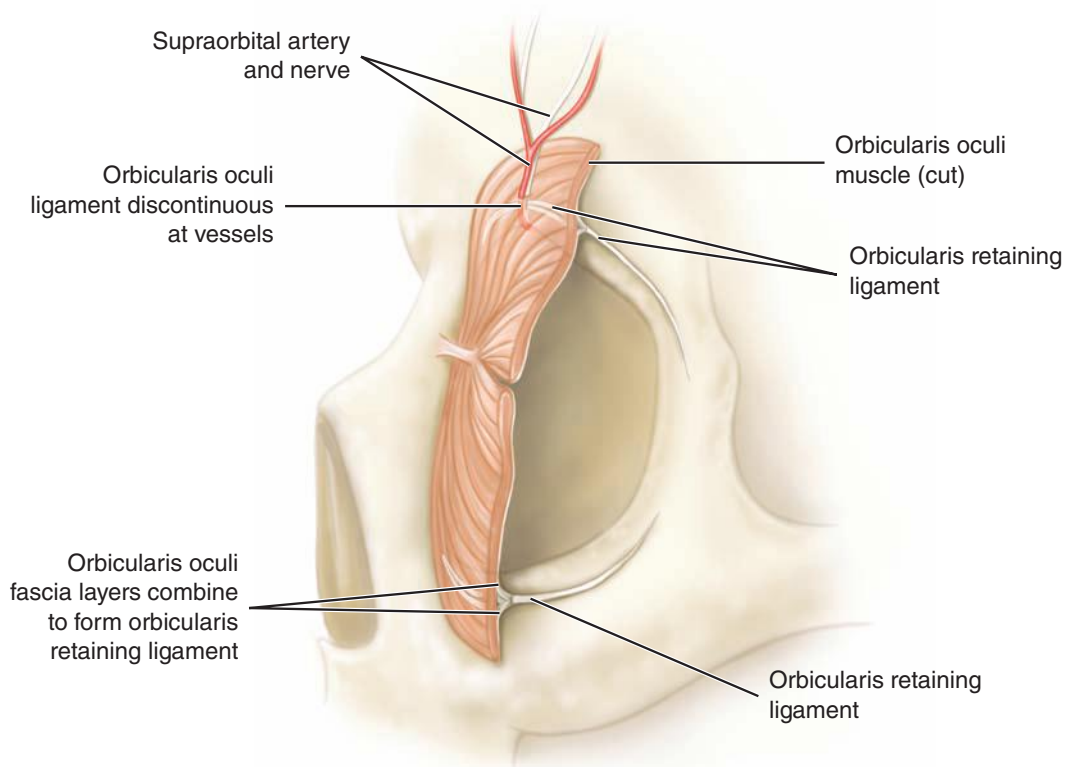
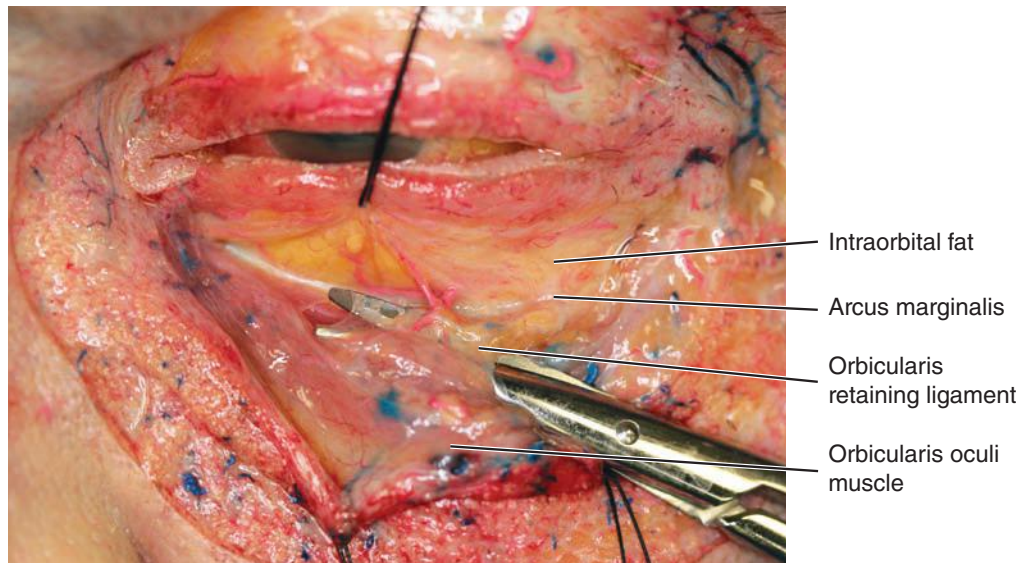
The eyelid is more mobile than the cheek or forehead. Adipose tissue may contribute to structural support. It is logical that the eyelid has a paucity of overlying fat, and that this crease is used to define the boundary between the eyelid and cheek, and the eyelid and forehead.



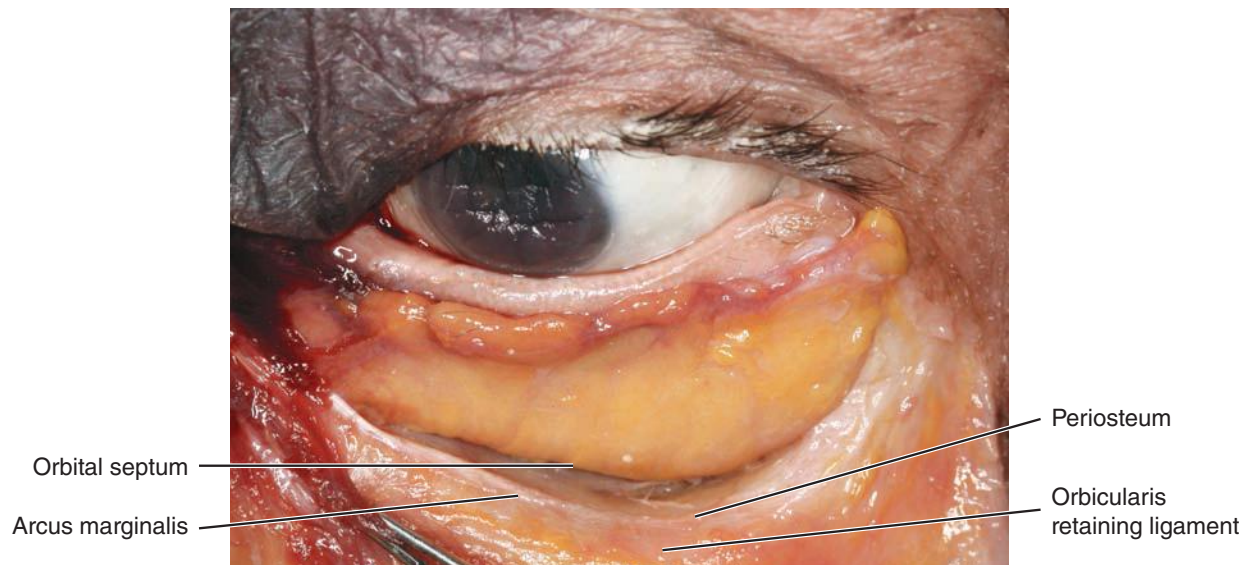
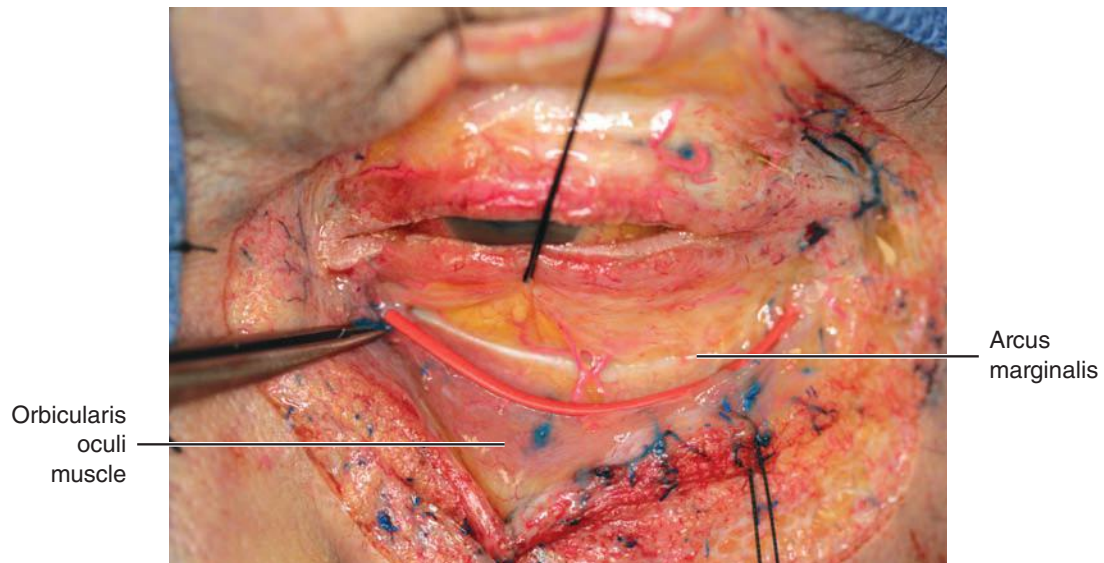
The tarsus contributes to the structural support of both lids. Its width is significantly greater in the upper eyelid.

## ORBICULARIS RETAINING LIGAMENT

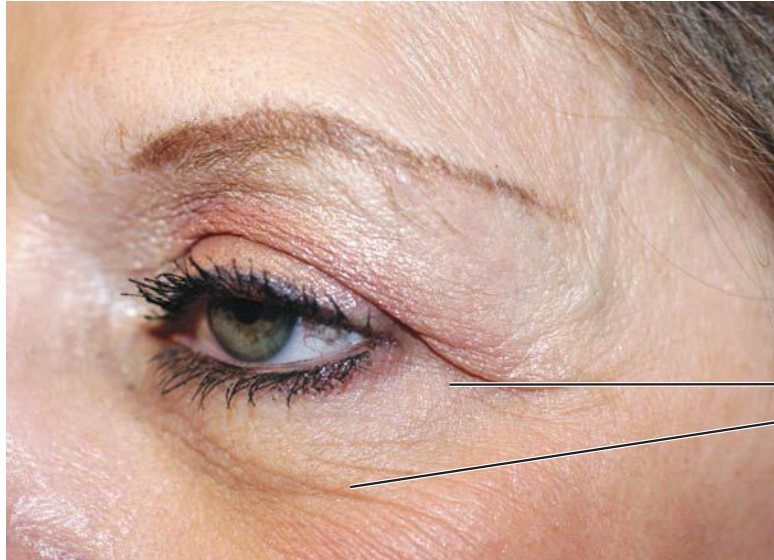The ORL inserts just inferior to the orbital rim. It is the boundary between extraorbital fat such as SOOF, and what is referred to as *intraorbital fat*.



The ORL of the lower eyelid fuses with periosteum to form a distinctive band, the *arcus marginalis*. This is simply a fusion zone of multiple fibrous tissues, including ligament and periosteum.



These observations help to predict the position and location of deep structures relative to the overlying lower eyelid soft tissues.



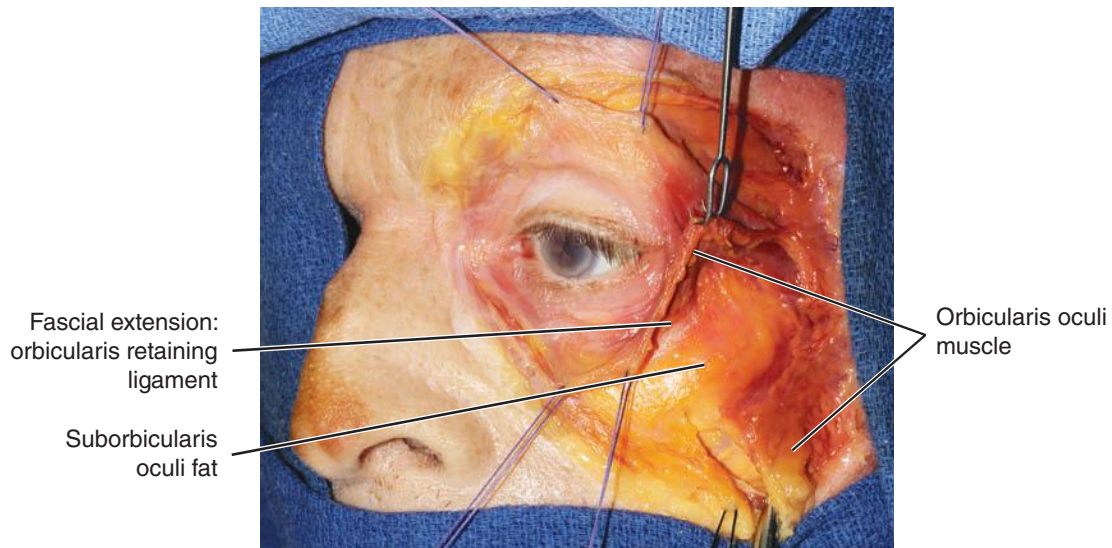
Orbicularis retaining  
ligament:  
Short laterally  
Long centrally

The ORL is formed by the fascia on the undersurface of the orbicularis oculi muscle. Its length is greatest near the center of the orbital rim. It is short medially and laterally near the canthi, where the orbicularis oculi muscle is almost fused to bone. The ORL can provide an additional point of insertion for this muscle to bone as it travels across the orbital rim. This is not a unique finding.

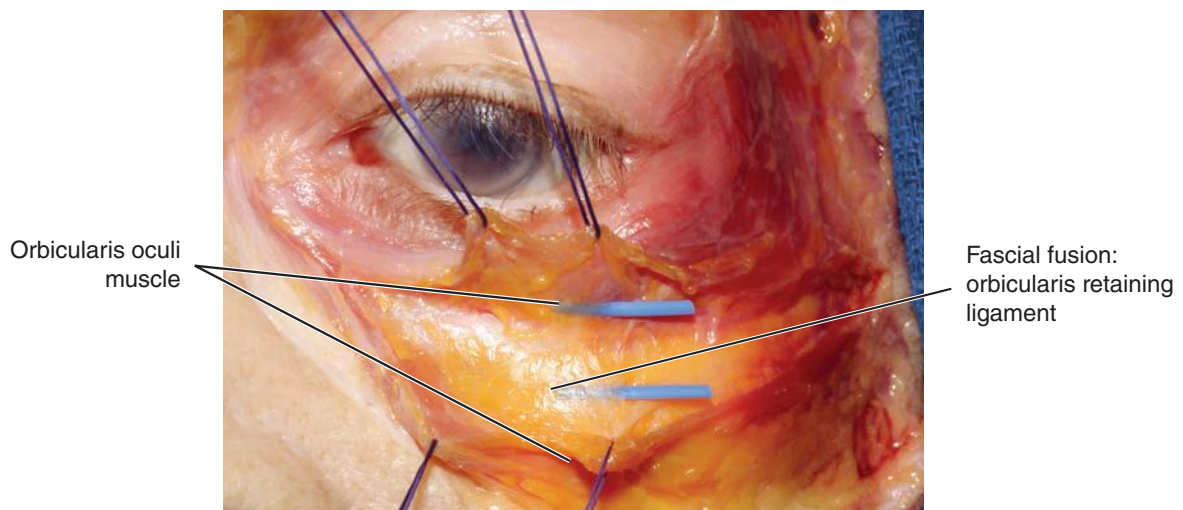
Muscles often form a fascial extension to bone as they cross a bony margin.

This facial extension to bone occurs with the platysma as it crosses the mandible. There is some evidence that the nasalis muscle does this at the piriform rim.

These attachments provide a mechanism for additional support and prevent the muscle from bowstringing when it contracts.

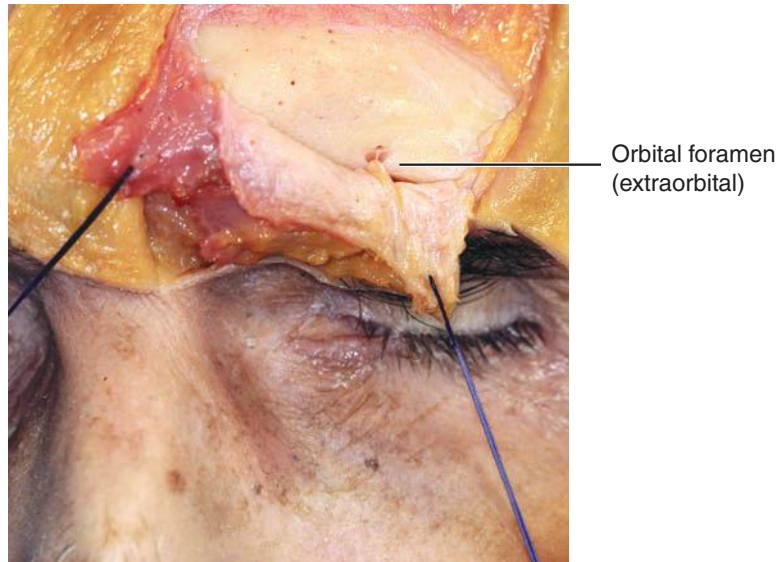


This concept is borne out in clinical practice. It is easier to change the position of the orbicularis oculi muscle when the ORL is released. This relates to vertical pull on the platysma as well. The ORL is the boundary between extraorbital and intraorbital. It is not a perfect boundary as far as being a seal.

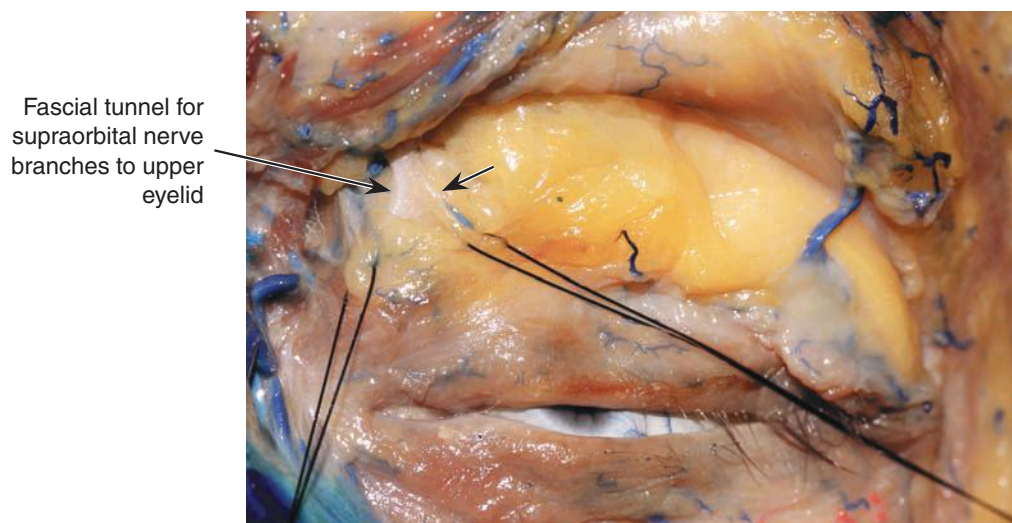


Nerves and arteries travel between compartments and across boundaries.

The supraorbital nerve travels through the ORL. It can be located by the surface landmark of the supraorbital crease.

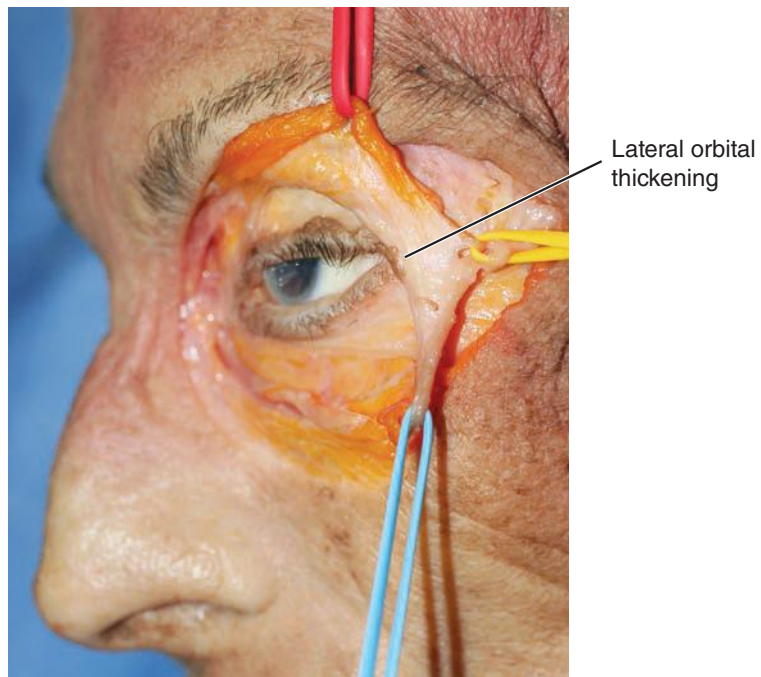


The supraorbital nerve traverses the ORL through a fascial tunnel. If an injection is placed *directly under the supraorbital crease*, fluid can migrate into the upper eyelid.

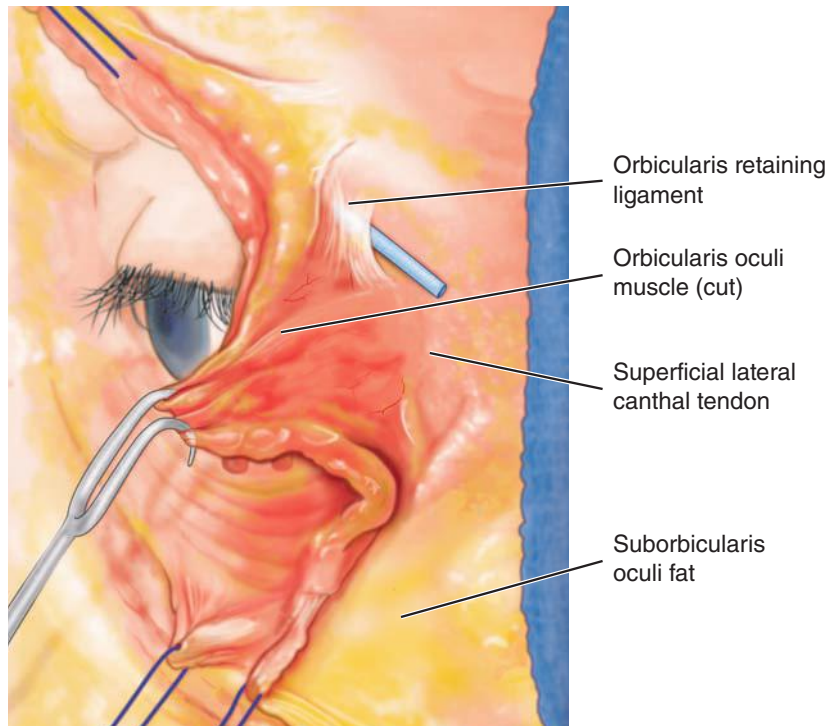
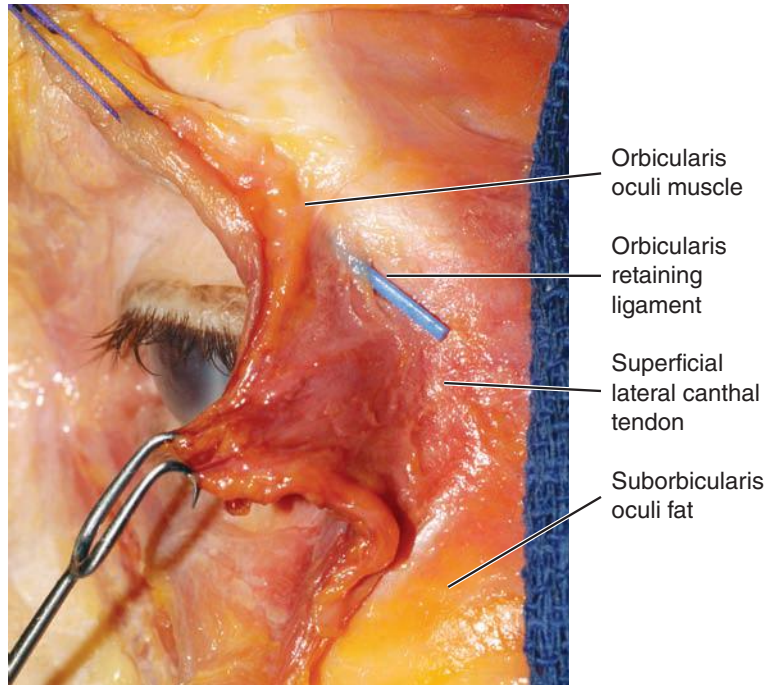


This is a suspected mechanism of chemodenervation of the levator palpebrae muscle when an extraorbital injection is performed. Creases may serve as landmarks of where to avoid a deep injection around the eyelid.

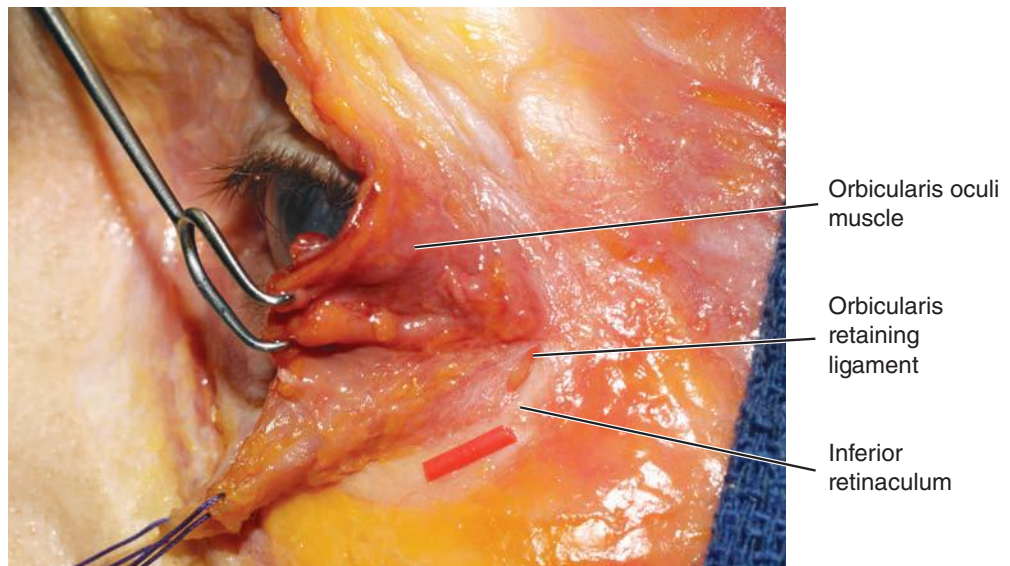
The lateral orbital thickening occurs near the lateral canthus.



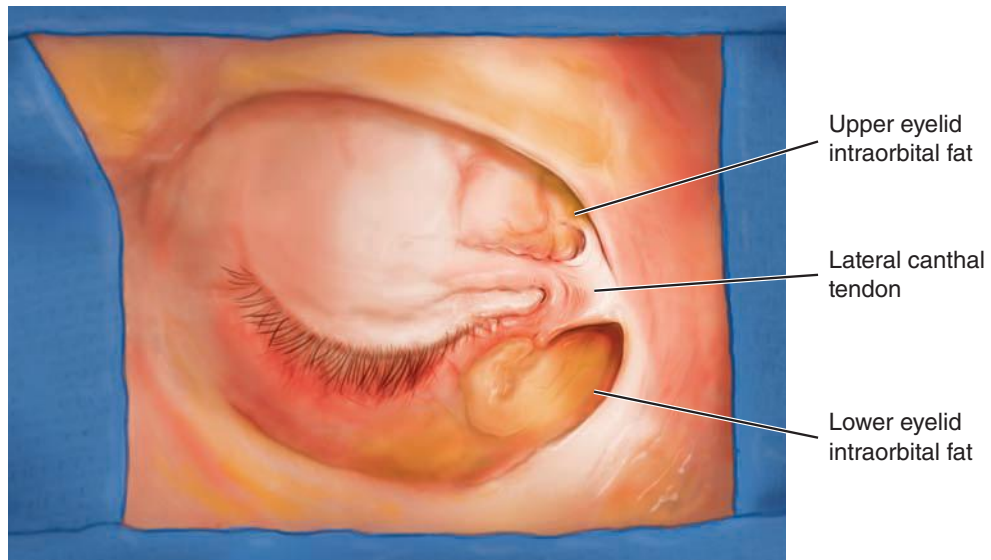
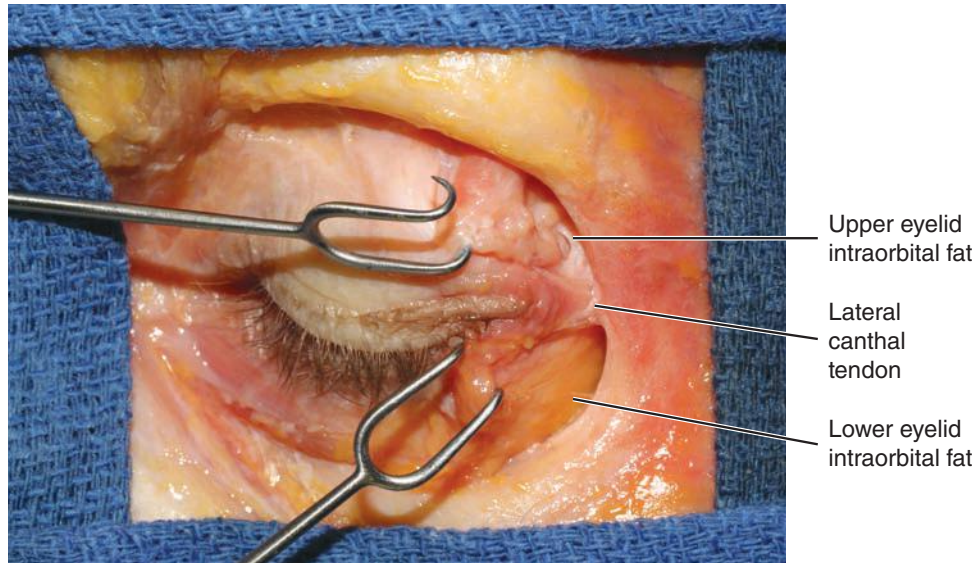
The lateral orbital thickening is palpable as it contributes to the superficial lateral canthal tendon.



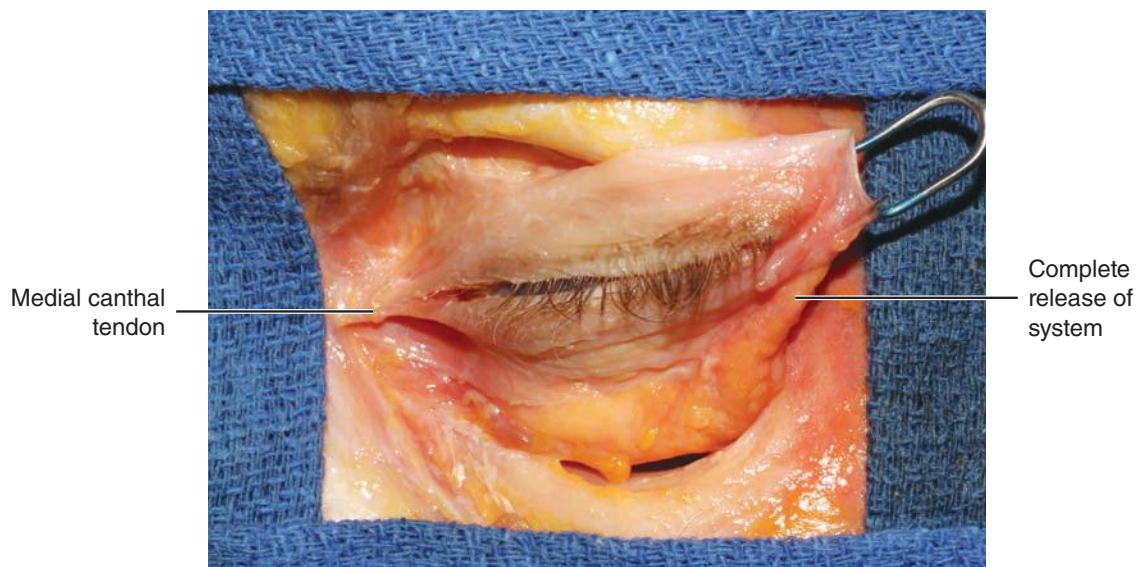
An inferior extension is densely adherent to bone.



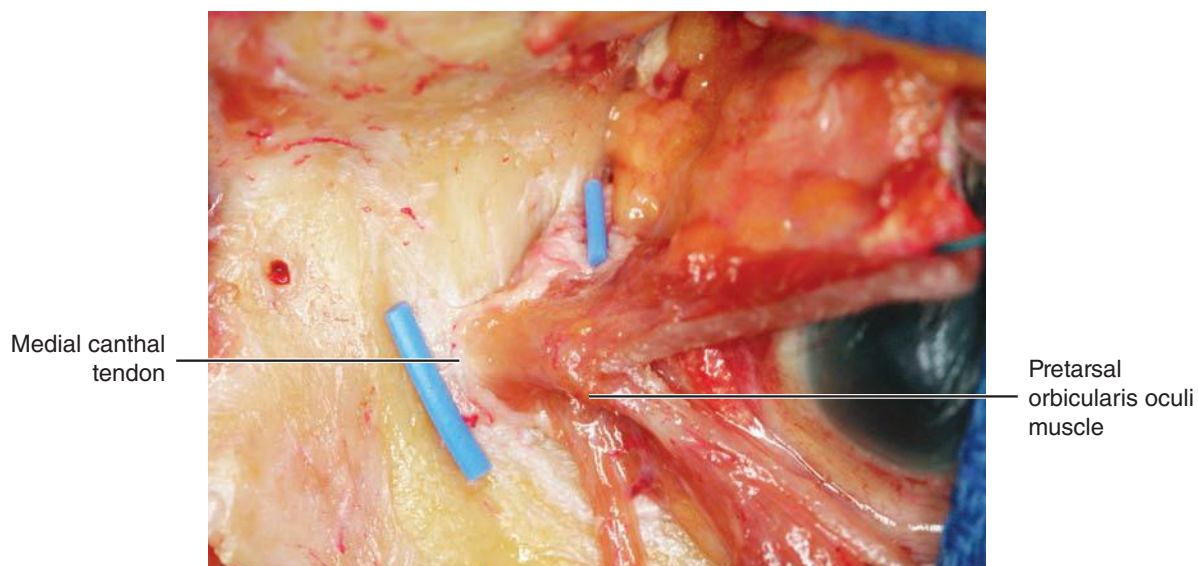
Once this membrane is released, the dissection enters the intraorbital space. The deep lateral canthal tendon is then visualized. The positions of the lateral canthal tendon and the medial canthal tendon indicate the difference in location of intraorbital fat of the upper and lower eyelids.



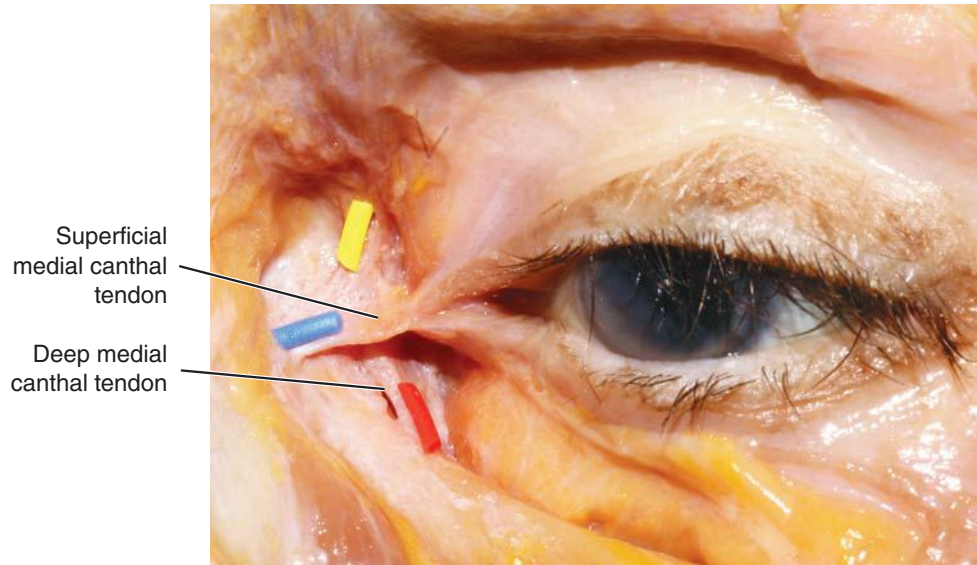
The lateral canthus is extremely stable because of this anatomy, relying on this static system for support. Only release of the system enables complete mobilization of the canthus.



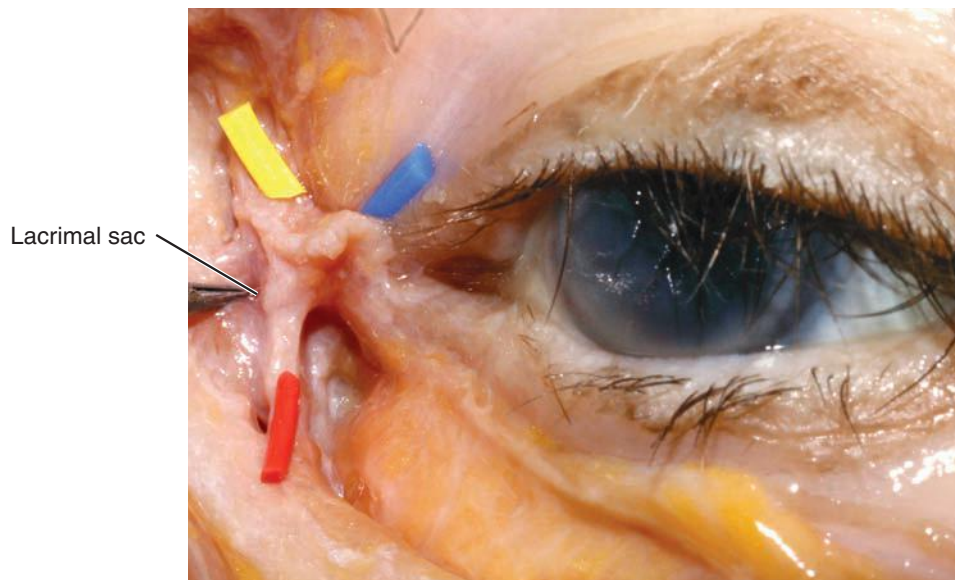
The medial canthal tendon is apparent on examination. It serves as a landmark for the position of the lacrimal sac. Pretarsal orbicularis oculi muscle contributes to the medial canthal tendon.



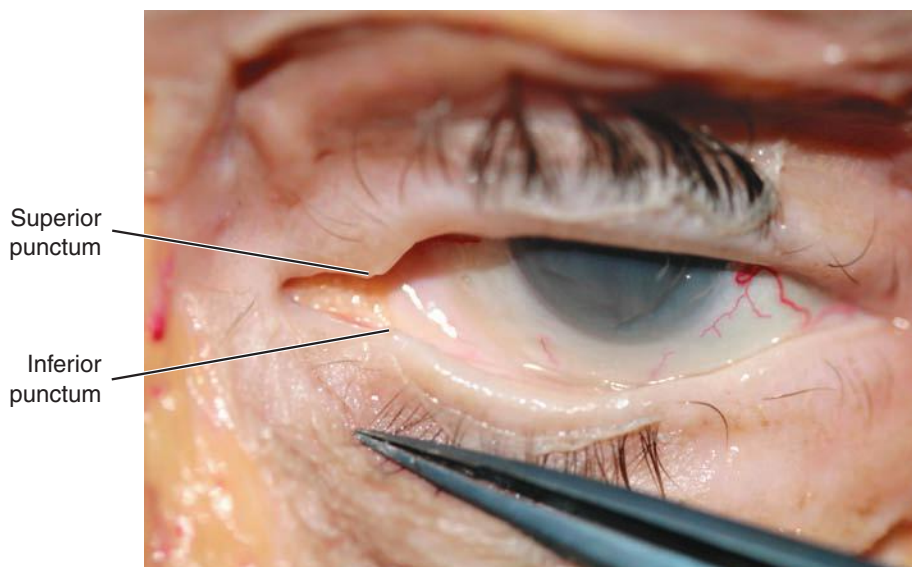
The medial canthal tendon also has superficial and deep parts.



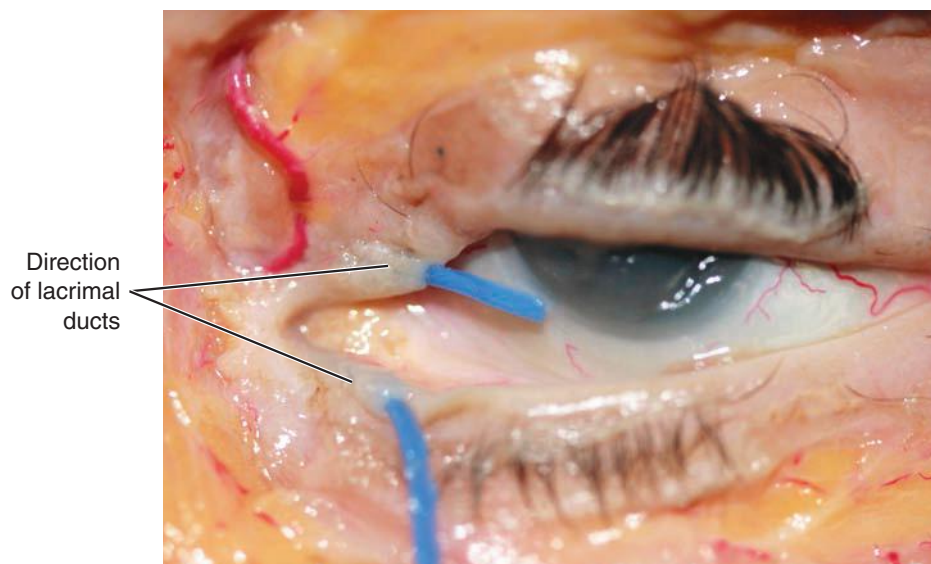
The lacrimal sac lies posterior to the medial canthal tendon.



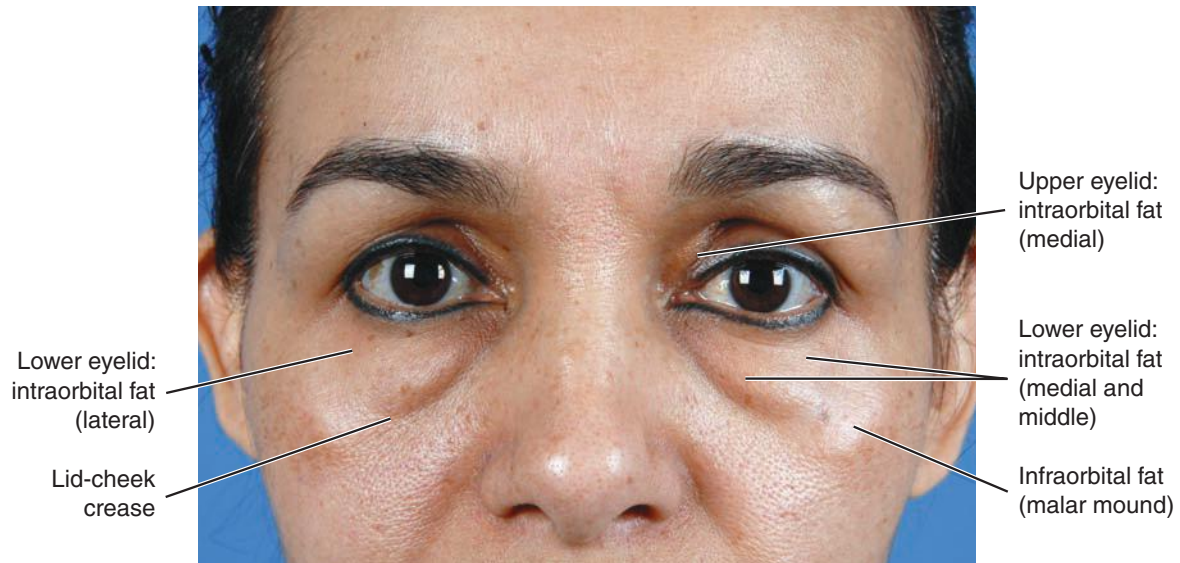The lids themselves indicate the position of the lacrimal ducts. The lacrimal ducts are anterior to the tendon, where they begin at the lacrimal puncta. They run horizontally along the lid margin.



The lacrimal ducts then run vertically behind the medial canthal tendon to enter the lacrimal sac.

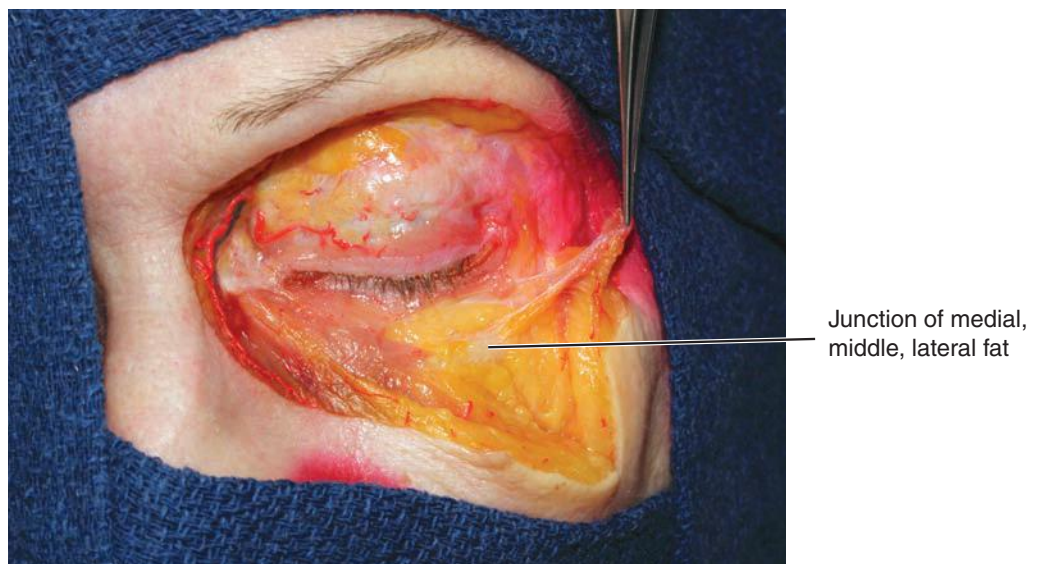


The medial and lateral canthal tendons indicate the position of upper and lower lid intraorbital fat. The intraorbital fat is evident on examination.

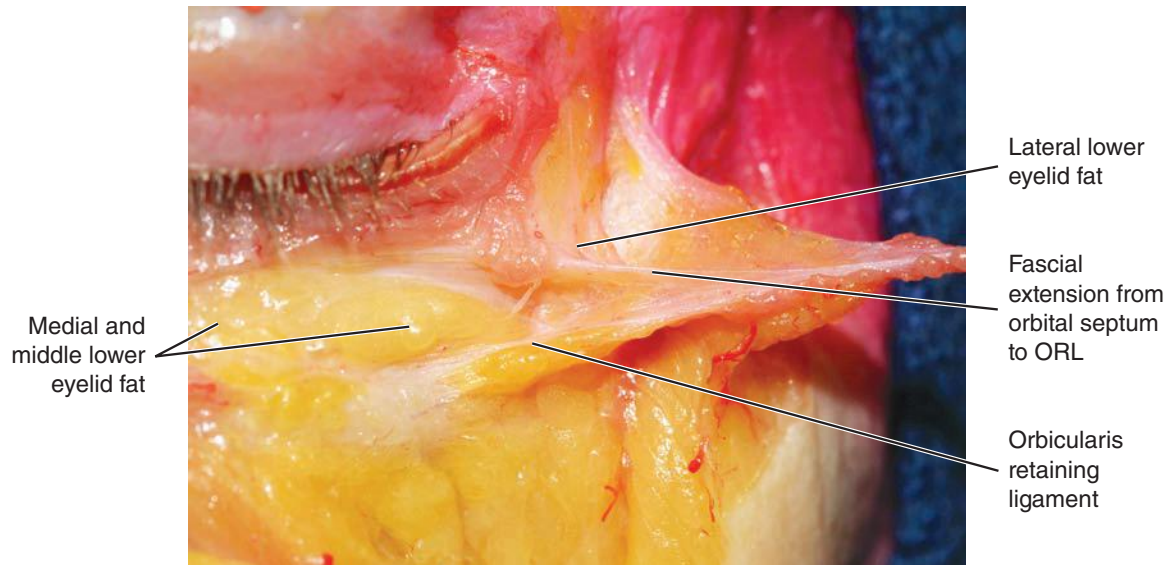


## FAT PADS OF THE LOWER EYELID

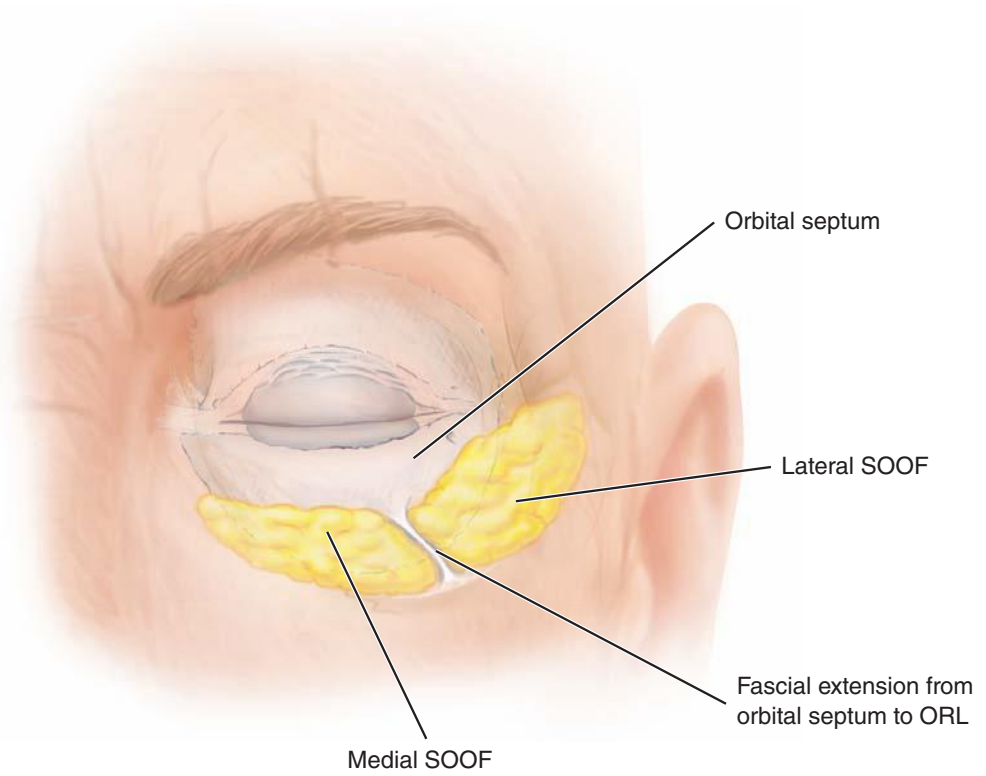
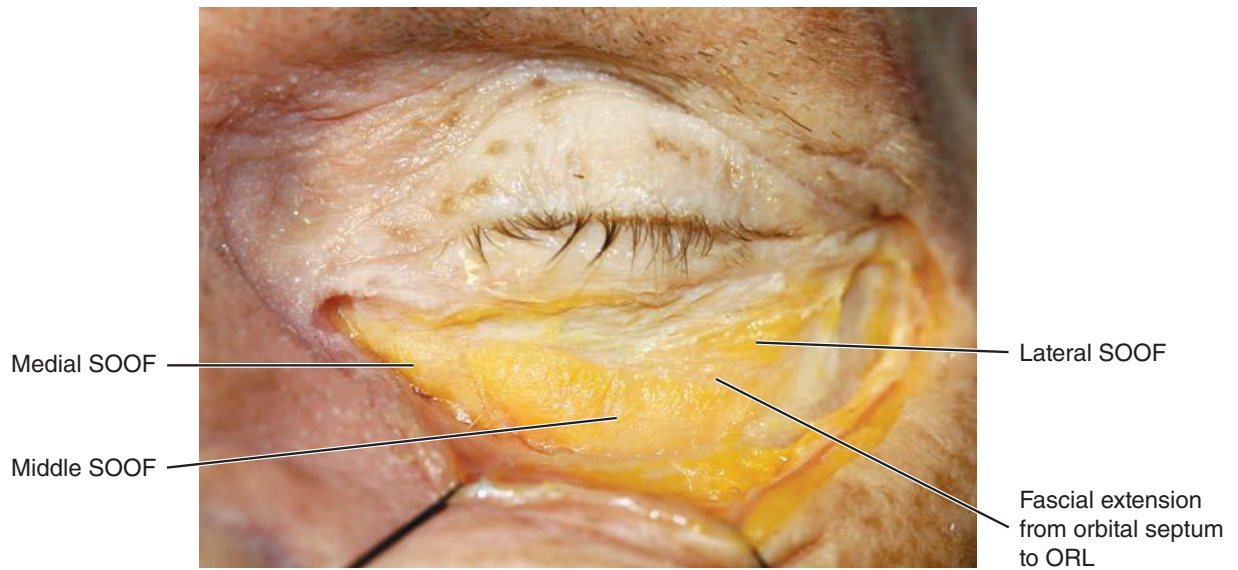
The lower lid has three fat pads: medial, middle, and lateral. The boundary between the middle and lateral fat pads is identified by a surface landmark, as seen in the previous image. This directly correlates with the underlying anatomy.



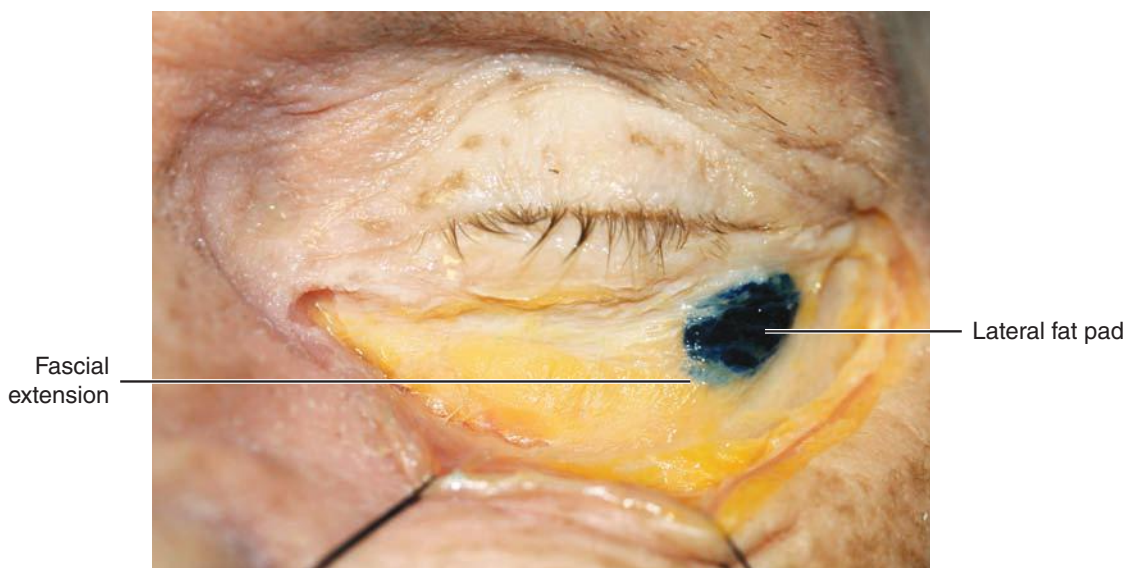
Fascia creates a vertical barrier between these the medial and lateral intraorbital fat that is noted as a lateral groove. This is thought to be an extension of Tenon's capsule, and may also relate to the orbital septum and ORL as well.



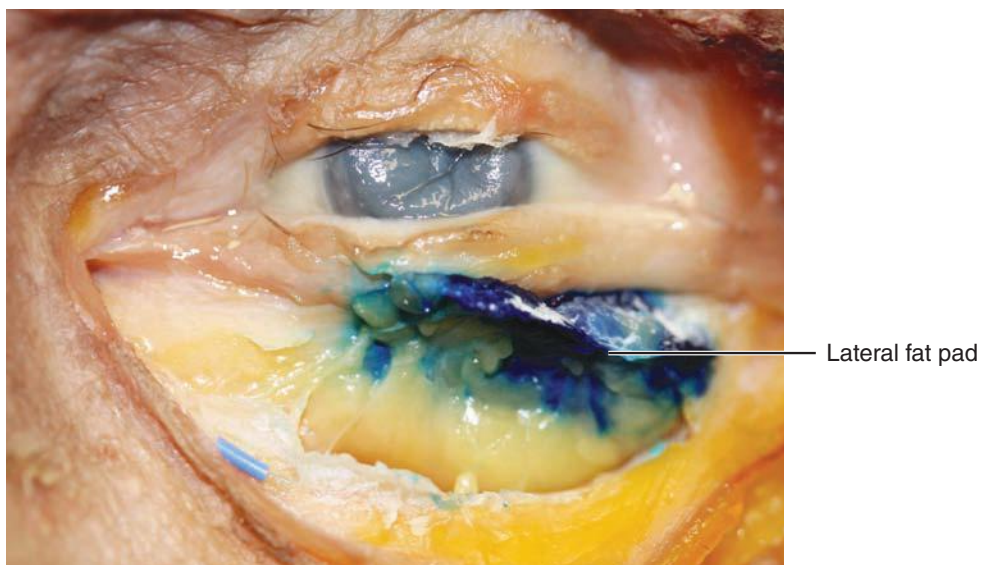
The lateral fat pad is distinct from the medial and middle fat pads.



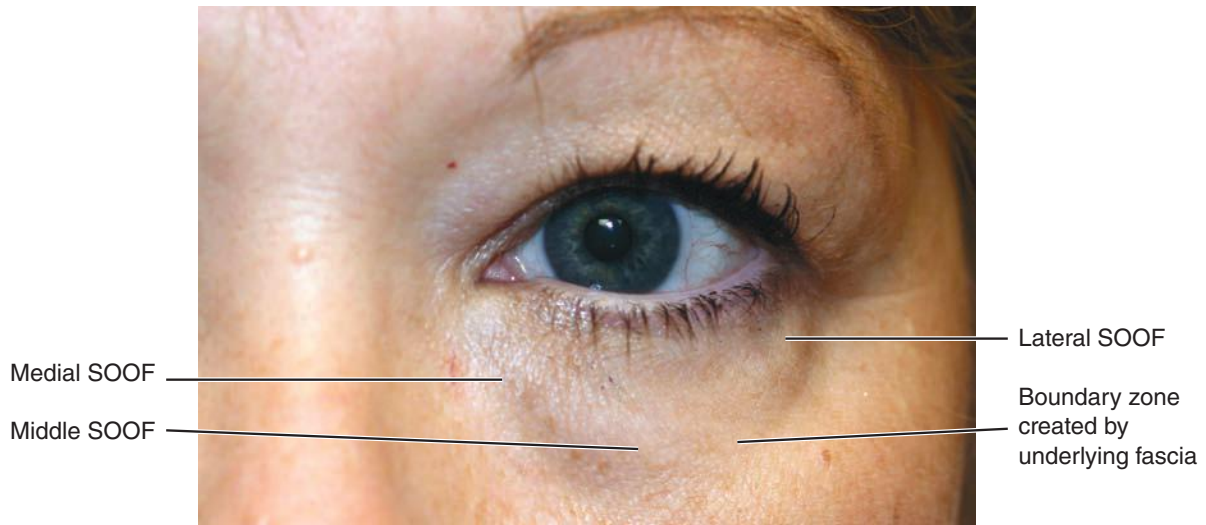
The lateral fat pad of the lower lid stains in a discrete fashion.



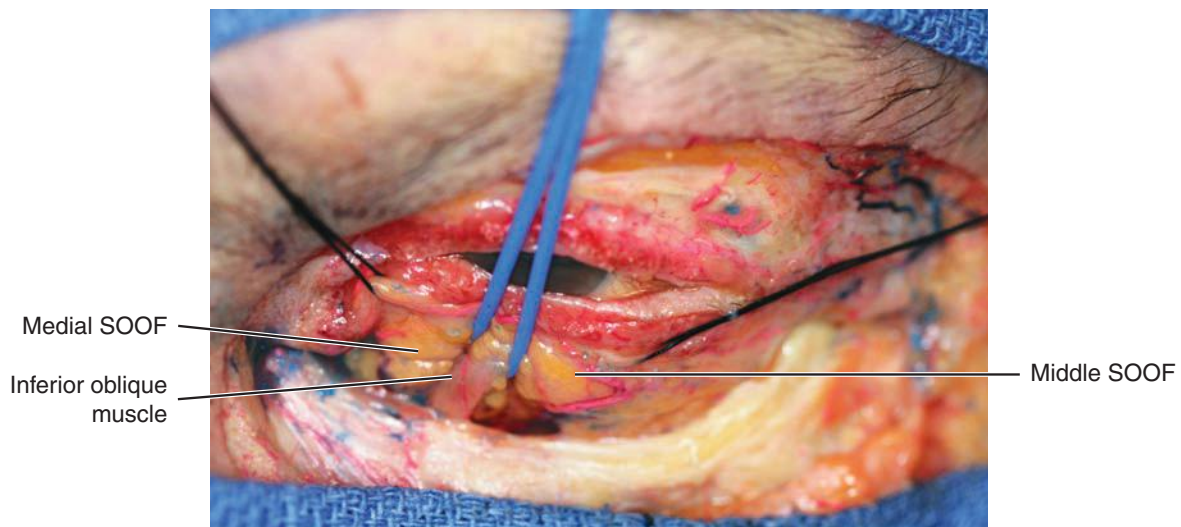
Two points should be mentioned regarding the lower lid intraorbital fat. In removing intraorbital fat during eyelid surgery, it is the lateral fat pad of the lower lid that is most frequently not addressed because of the difficulty in determining its location. However, this is avoidable.



Lateral fat (SOOF) sits slightly higher in the vertical plane than the middle fat, as is easily noted on examination. This is a result of the shape of the orbital rim, which curves superiorly at the junction of the middle and lateral third of the rim. The lateral fat pad also sits in a distinct groove inside the orbit.

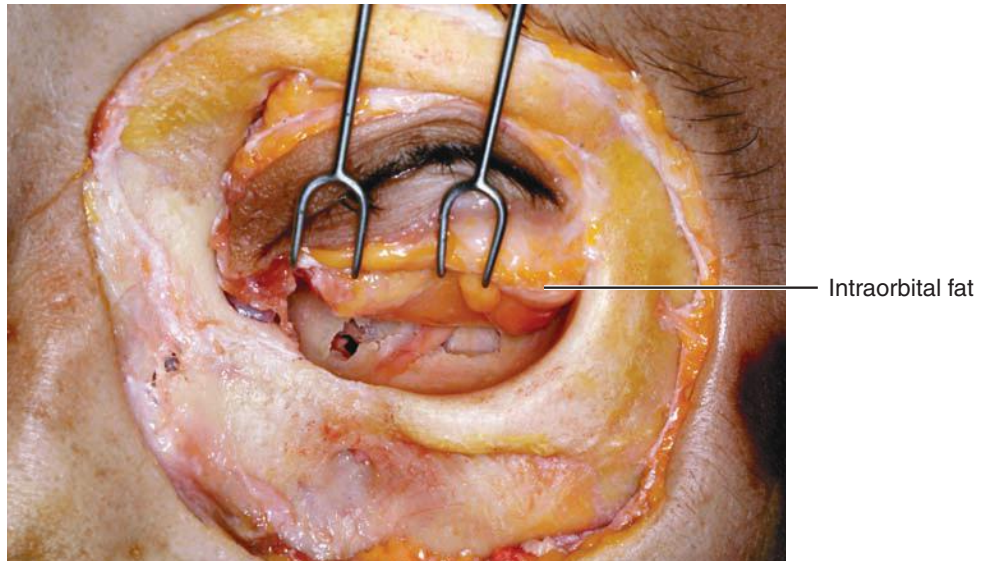


The second point is that the junction between the medial and middle lower lid fat represents the relative position of the inferior oblique muscle. This is a reliable landmark for determining the position of this muscle during surgery.

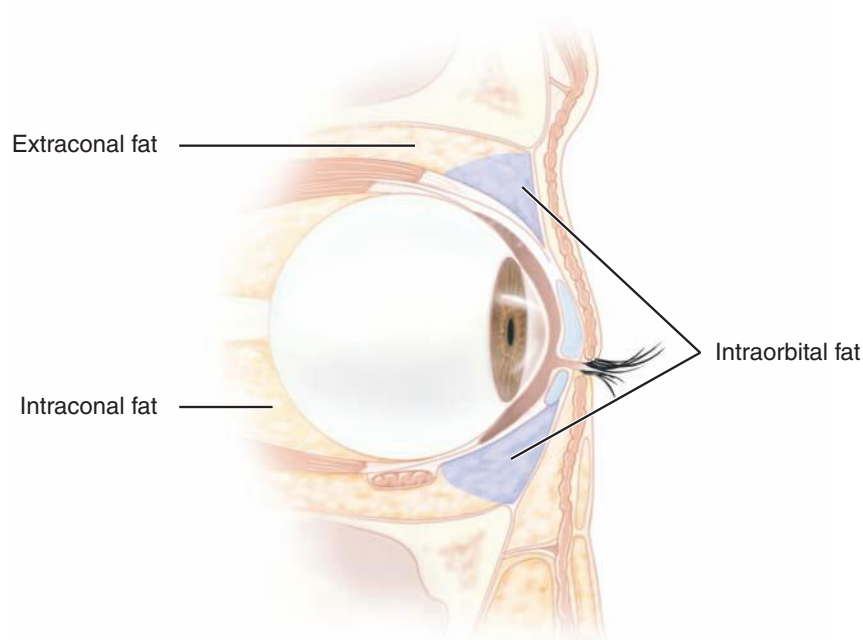


The junction between the medial and middle intraorbital fat is a topographic landmark for the inferior oblique muscle.

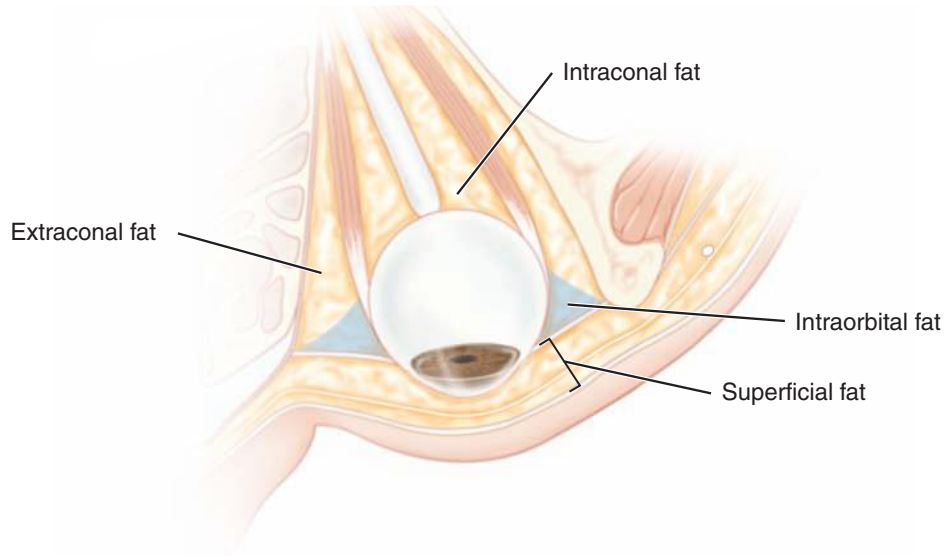
Intraorbital fat acts as a cushion and serves as a gliding tissue for the ocular globe. Its designation as intraorbital may not be entirely correct.



Anatomic dissection shows that this fat is distinct from other intraorbital fat, such as the intraconal and extraconal fat.



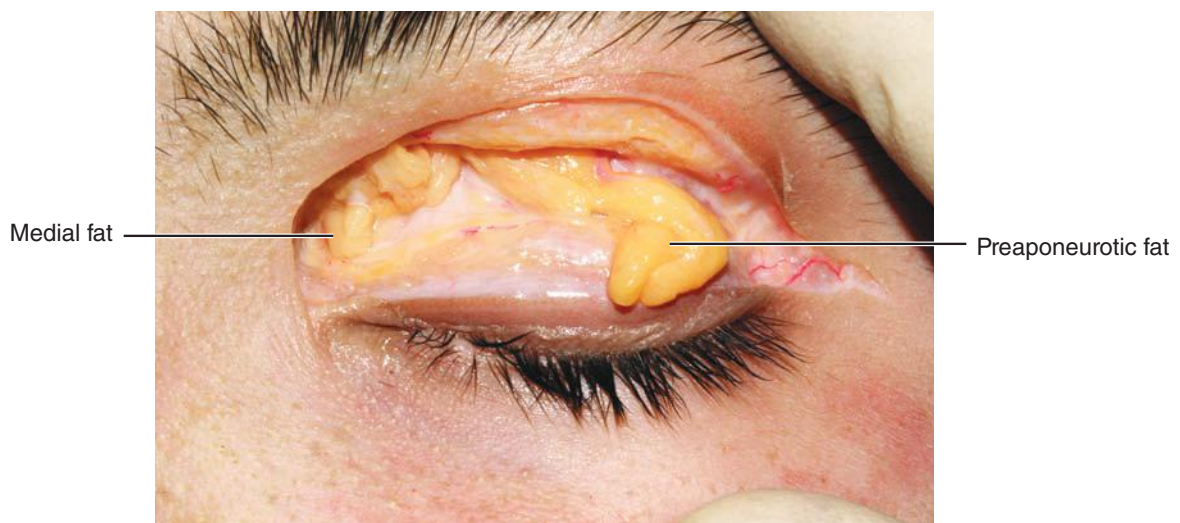
Dissection in the axial plane also suggests that this fat is different from the intraconal and extraconal fat.



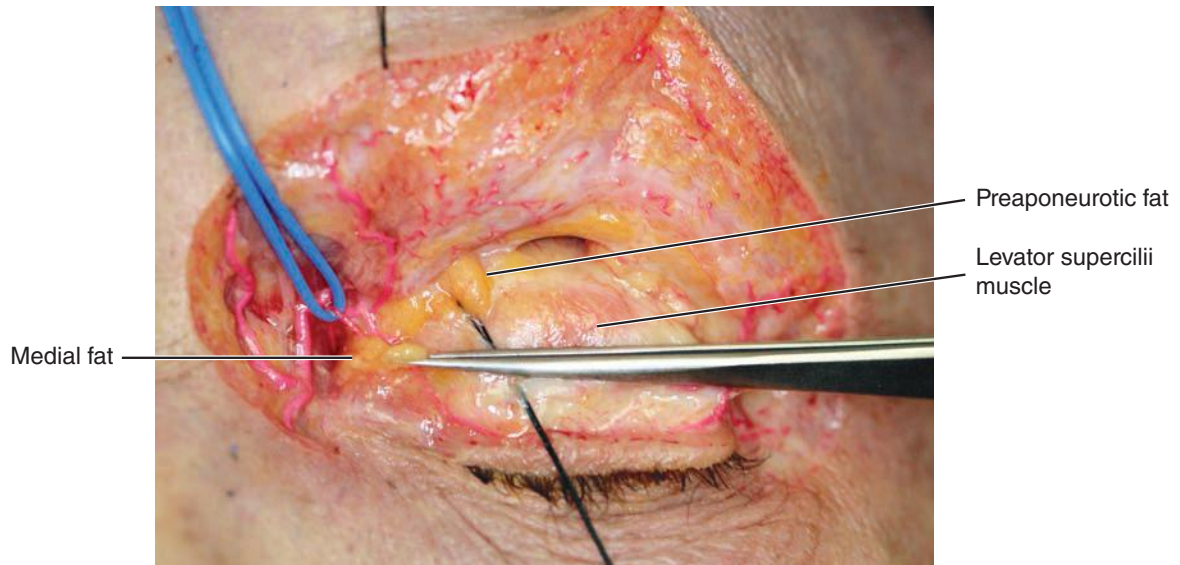
However, because nerves and vessels transition through anatomic boundaries such as fat, bleeding in the inferior lid fat pads can extend posteriorly into the orbit. This is the mechanism that explains the retrobulbar hematoma that may occur with manipulation of the lower lid fat alone.

## FAT PADS OF THE UPPER EYELID

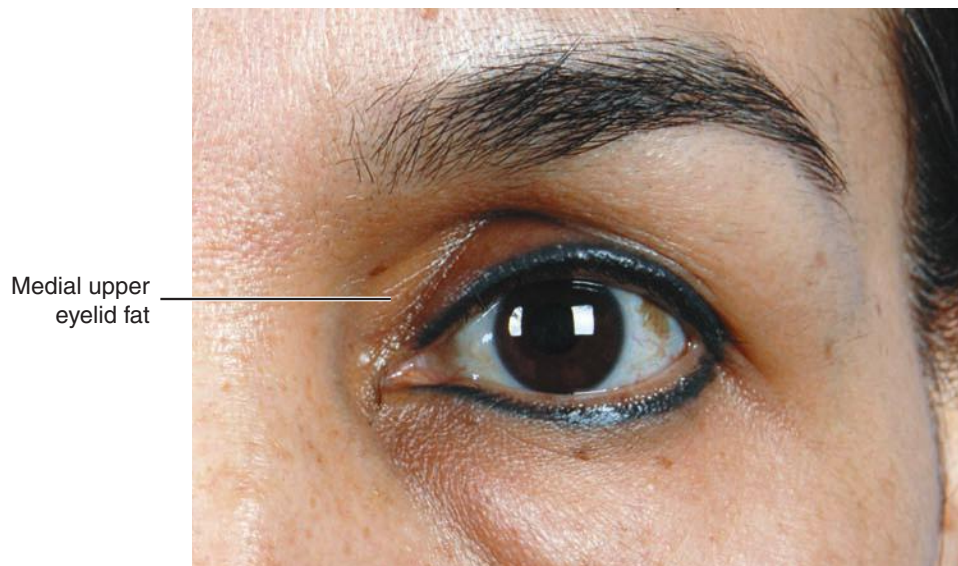
This also applies to upper eyelid intraorbital fat. There are two and perhaps three upper eyelid fat compartments. These are visible on examination. One fat pad sits in front of the levator palpebrae muscle tendon. It is designated as preaponeurotic or simply as supralevator fat.



The medial fat pad is distinguished by a more whitish color than the preaponeurotic fat. It is an important reference point and surface landmark in the clinical setting.



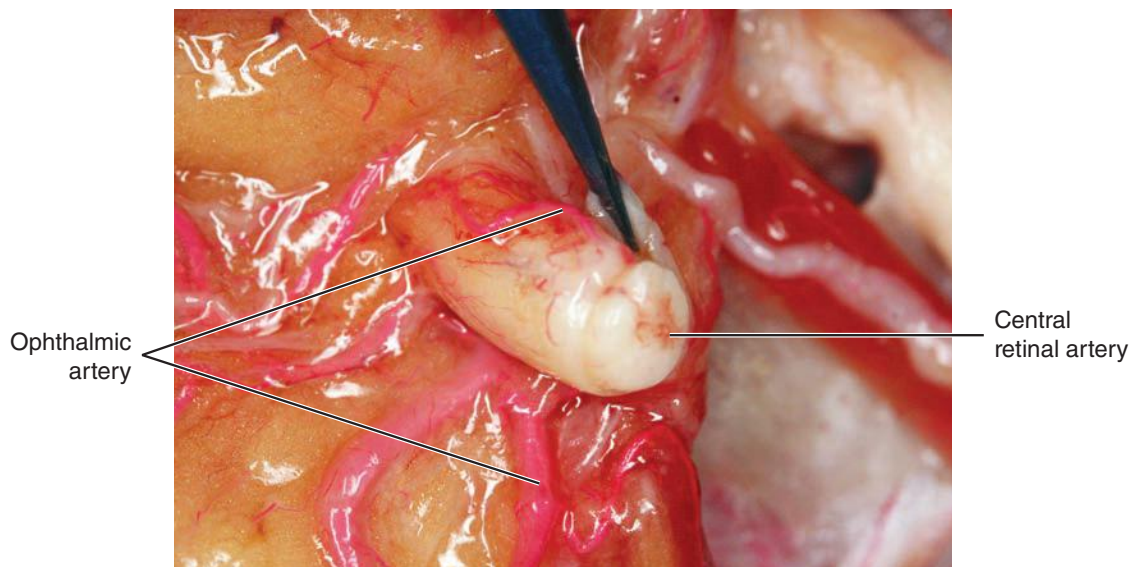
Medial fat creates a distinct outpocket in the superior medial upper eyelid.



Identifying this fat pad is important. An arterial branch from the ophthalmic artery always runs on top or alongside this fat pad.

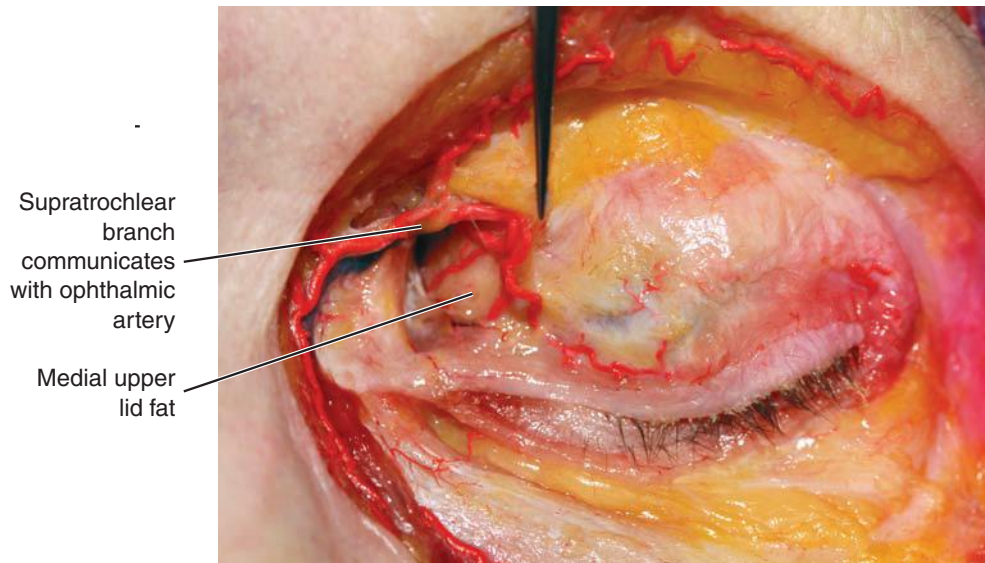
Fat pads may have highly distinct vascular supplies. This applies as much to upper eyelid medial fat as it does to the temporal fat pad.

If any material, even anesthetic, is injected in an injudicious manner around this location, retrograde flow may occur toward the posterior orbit. Intravascular injection can enter the central retinal artery because of its continuity with the ophthalmic artery.

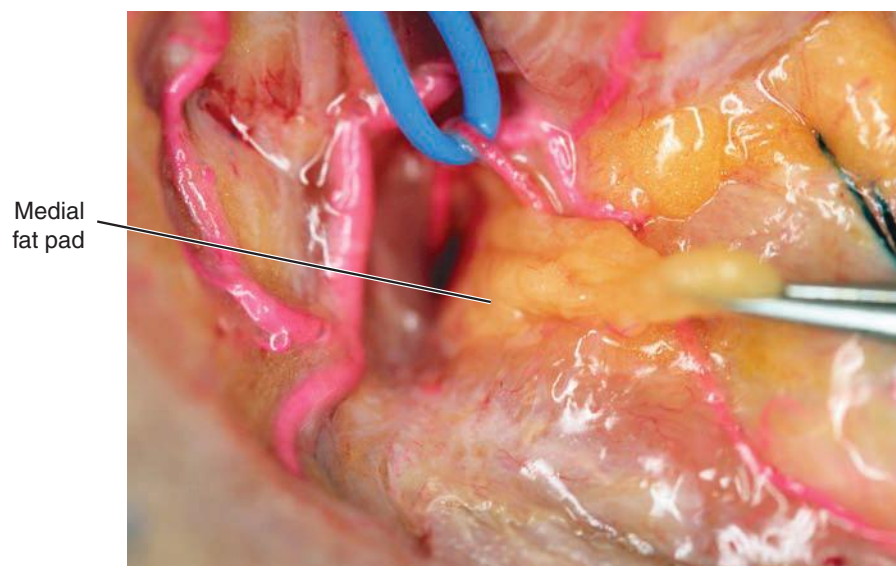


Knowledge of the communication between periorbital vessels and the intraorbital circulation, and how to locate these areas by surface landmarks, is of paramount importance in the clinical setting.

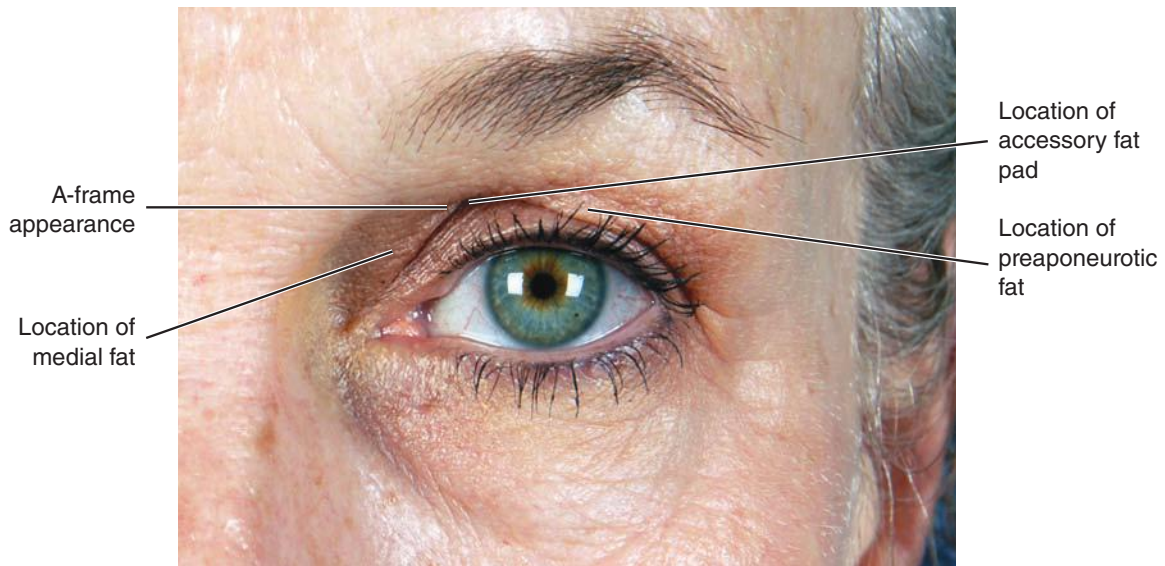
It is also noteworthy that the dorsal nasal artery and transverse nasal arteries, which may create creases that are recognized on the dorsal nasal skin, are in continuity with the ophthalmic artery and therefore the central retinal artery.



Awareness of this helps to limit complications from retrograde flow during injection. There may be a third upper eyelid fat pad, referred to as the *transitional fat pad*.



An A-frame deformity of the upper eyelid reliably predicts the location of this fat pad.



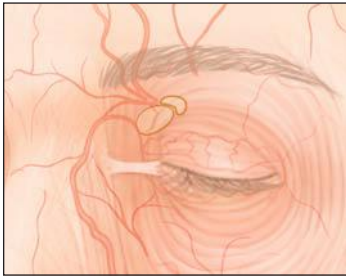
Removal of this fat can accentuate the A-frame appearance if it is noticeable preoperatively. An arterial branch is also located near this fat pad before it travels posteriorly into the orbit.

Using these surface landmarks to identify periorbital and intraorbital structures may contribute significantly to the ease and success of any procedure.

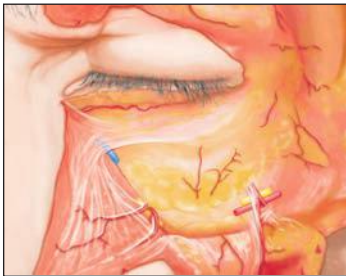## *Key Points*

- Creases may be related to the underlying blood supply.
- Creases are associated with adjacent adipose compartments that have different thicknesses.
- Creases occur where there is a regional difference in the thickness of subcutaneous fat. The lid-cheek junction occurs where subcutaneous fat becomes thicker over the preorbital orbicularis oculi muscle.
- The lower eyelid shares many features with the upper eyelid. The ORL is the deep boundary of both and may form a lid-cheek and lid-forehead boundary. The upper eyelid may also have a crease and a lid-forehead junction.
- In the clinical setting, complications may arise from failure to recognize the imperfect seal between the lid and cheek or the lid and forehead.
- Creases are usually defined by a vascular arcade and regional differences in the thickness of fat. This definition can be used to distinguish creases from wrinkles where there is no difference in adipose tissue thickness.
- Muscles often form a fascial extension to bone as they cross a bony margin.
- These attachments provide a mechanism for additional support and prevent the muscle from bowstringing when it contracts.
- Nerves and arteries travel between compartments and across boundaries.
- Fat pads may have highly distinct vascular supplies. This applies as much to upper eyelid medial fat as it does to the temporal fat pad.
- Knowledge of the communication between periorbital vessels and the intraorbital circulation, and how to locate these areas by surface landmarks, is of paramount importance in the clinical setting.

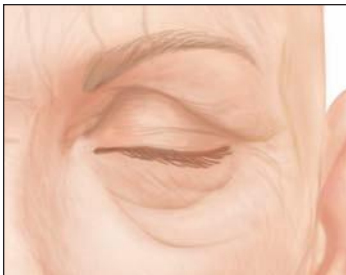
## CLINICAL CORRELATIONS



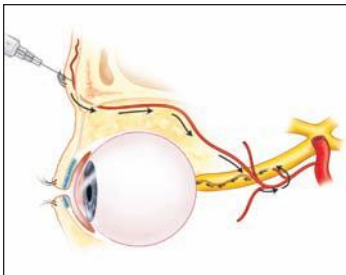
Medial upper eyelid fat is a reference point for an artery that communicates directly with the lacrimal, ophthalmic, and retinal arteries. Injections performed in the medial upper eyelid fat should be performed with due caution.



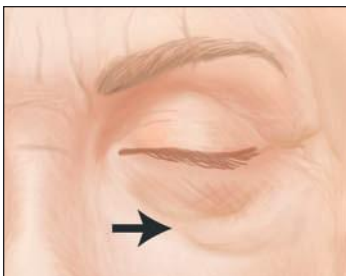The ORL stabilizes orbicularis oculi muscle to orbital rim. The effectiveness of canthal repositioning is improved by partial release of this structure.



Aggressive removal of upper eyelid fat not only predisposes to a hollow look, but can also lead to an A-frame deformity. Preservation of transitional fat decreases the risk of creating this deformity.



Periorbital injections are most safely performed with small volumes and low pressure. This decreases the risk of retrograde injection into the ophthalmic artery system.



The nasojugal crease helps to locate the infraorbital artery and therefore the infraorbital nerve. Using the junction of the nasojugal crease with the lid-cheek crease (orbit-cheek) improves accuracy when performing local nerve blocks.

## Bibliography

- Castañares S. The lateral fat compartment of the lower eyelid. *Aesthetic Plast Surg* 7:27-30, 1983.  
*The influence of the lateral fat pad on eyelid topography is illustrated, along with a clinical technique for treatment.*
- Furnas DW. Festoons, mounds, and bags of the eyelids and cheek. *Clin Plast Surg* 20:367-385, 1993.  
*This is the classic article that described the topography of creases and folds of the lower eyelid.*
- Gentry LR. Anatomy of the orbit. *Neuroimaging Clin N Am* 8:171-194, 1998.  
*The radiologic features of eyelid and periorbital anatomy were described.*
- Gioia VM, Linberg JV, McCormick SA. The anatomy of the lateral canthal tendon. *Arch Ophthalmol* 105:529-532, 1987.  
*An early study of the lateral canthal tendon described the tendon as a condensation of both levator aponeurosis and pretarsal orbicularis muscle. A fat compartment anterior to this tendon was noted, in agreement with Kestenbaum's earlier description.*
- Goldberg RA, Wu JC, Jesmanowicz A, et al. Eyelid anatomy revisited. *Arch Ophthalmol* 110:1598-1600, 1992.  
*This article documented the utility of noninvasive techniques for the study of cross-sectional anatomy and shape.*
- Hidalgo DA. An integrated approach to lower blepharoplasty. *Plast Reconstr Surg* 127:386-395, 2011.  
*The author described a modern approach to the treatment of the lower eyelid deformities, emphasizing anatomy and structural goals of this procedure.*
- Hirmand J, Codner MA, McCord CD, Hester RT Jr, Nahai F. Prominent eye: operative management in lower lid and midfacial rejuvenation and the morphologic classification system. *Plast Reconstr Surg* 110:620-628, 2002.  
*The authors described a classification for eye position relative to the orbital rim as a means of determining operative technique and potential risks for surgery.*
- Jelks GW, Giat PM, Jelks EB, et al. The inferior retinacular lateral canthoplasty: a new technique. *Plast Reconstr Surg* 100:1262-1270, 1997.  
*The authors presented a technique for the surgical correction of eyelid position that further defined the lateral canthal tendon complex.*
- Jeong S, Lemke BN, Dortzbach RK, et al. The Asian upper eyelid: an anatomical study with comparison with the Caucasian eyelid. *Arch Ophthalmol* 117:907-912, 1999.  
*One of the causes of the supratarsal crease was discussed in this study, as well as ethnic differences in preaponeurotic and subcutaneous adipose thickness. This article also described pretarsal adipose tissue, in keeping with the concept that fat exists above and below facial muscles to facilitate gliding.*
- Kakizaki H, Takahashi Y, Nakano T, et al. The posterior limb in the medial canthal tendon in Asians: does it exist? *Am J Ophthalmol* 150:741-743, 2010.  
*The complexity of medial canthal tendon anatomy was highlighted, along with the importance of the anterior segment that has been described as a topographic landmark for lacrimal structures.*

Kikkawa DO, Lemke BN, Dortzbach RK. Relations of the superficial musculoaponeurotic system to the orbit and characterization of the orbitomalar ligament. *Ophthal Plast Reconstr Surg* 12:77-88, 1996.

*This paper provided the first description of the ligament that determines the deep topographic boundary between lower eyelid and cheek and between the upper eyelid and forehead. This ligament is the classic example of a stabilizing architecture that occurs whenever muscle crosses a free border, such as the orbital rim.*

Knize DM. The superficial lateral canthal tendon: anatomic study and clinical application to lateral canthopexy. *Plast Reconstr Surg* 109:1149-1157, 2002.

*This excellent paper described tethering zones and planes, some of which serve as fixation points and boundary zones between anatomic regions.*

Koorneef L. Orbital septa: anatomy and function. *Ophthalmology* 86:876-880, 1979.

*One of the earliest descriptions of the orbital septa and their relationship to the intraorbital fat.*

McCord CD Jr, Codner MA, eds. *Eyelid & Periorbital Surgery*. St Louis: Quality Medical Publishing, 2008.

*The comprehensive textbook covering anatomy, morphology, and surgery of the periorbital region.*

Moss CJ, Mendelson BC, Taylor GI. Surgical anatomy of the ligamentous attachments in the temporal and periorbital regions. *Plast Reconstr Surg* 105:1475-1490, 2000.

*A study describing the fascial attachments of the periorbital region, as well as the use of fascial planes and ligaments as identifying landmarks for neurovascular anatomy.*

Muzaffar AR, Mendelson BC, Adams WP Jr. Surgical anatomy of the ligamentous attachments of the lower lid and lateral canthus. *Plast Reconstr Surg* 110:897-911, 2002.

*The authors expanded on an earlier article they had published and further characterized the fascial planes and attachments in the periorbital region.*

Tucker SM, Linberg JV. Vascular anatomy of the eyelids. *Ophthalmology* 101:1118-1121, 1994.

*This excellent detailed study of the vascular anatomy of the eyelids is important for understanding creases, wrinkles, and their relationship to neurovascular structures.*

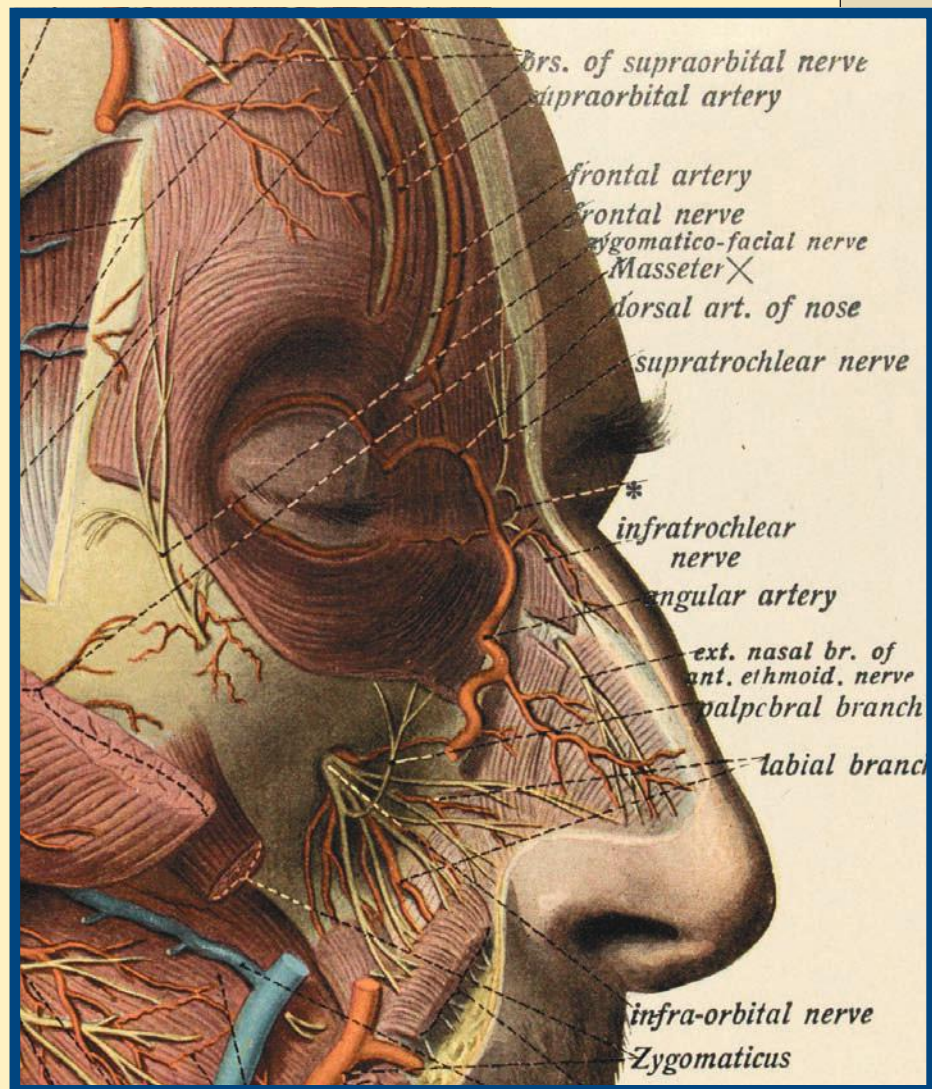


---

CHAPTER 5

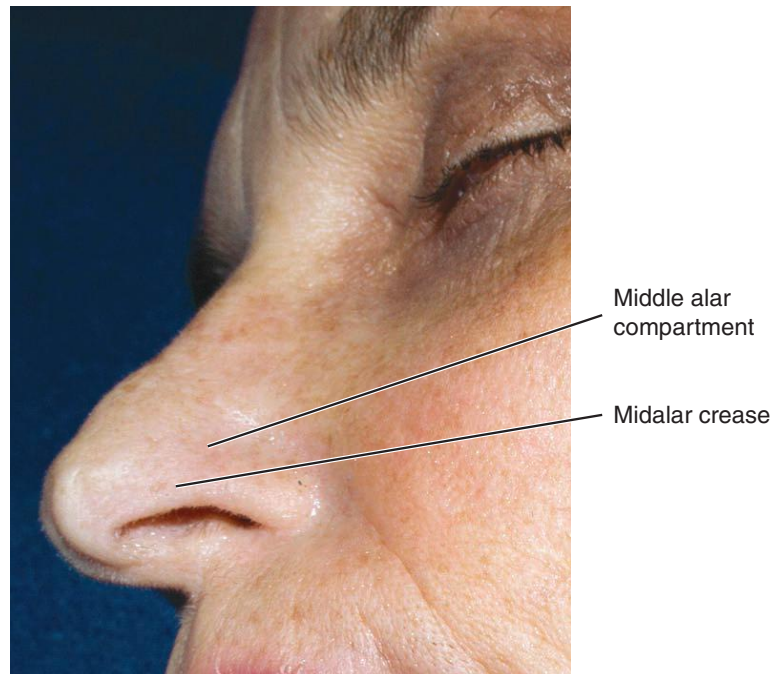
---

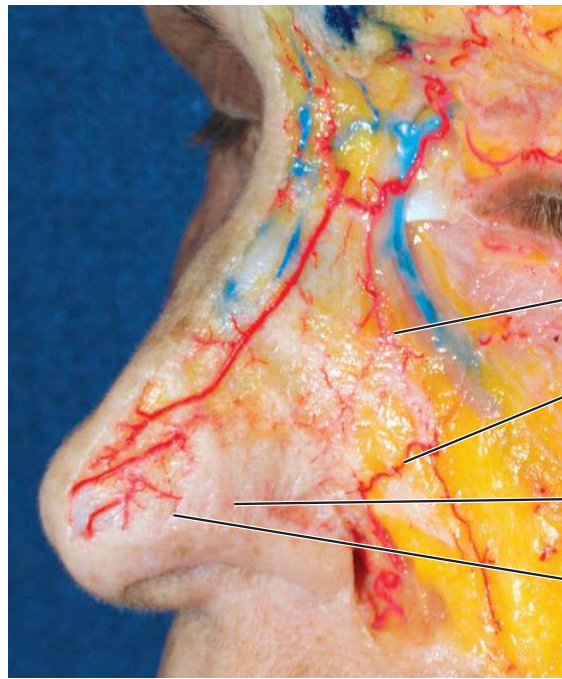
# The Nose



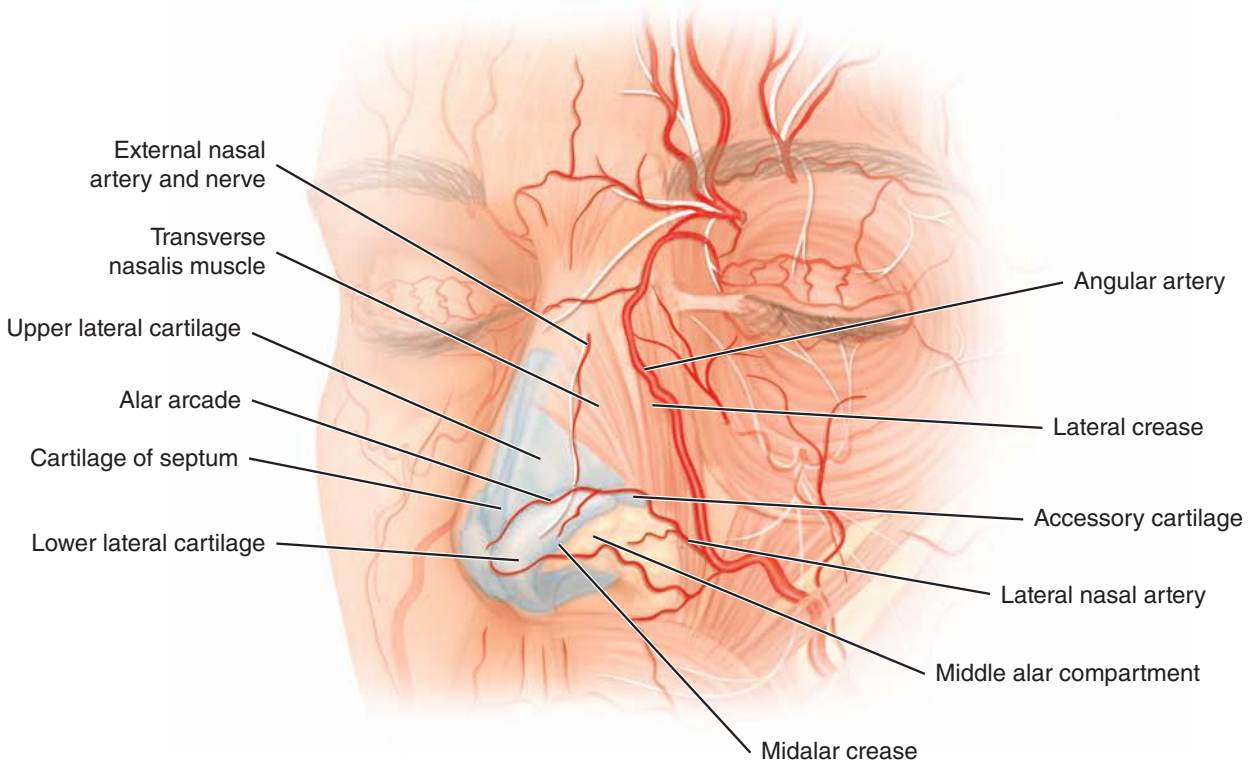
**H**ow shape and contour are defined by structure is perhaps best understood for the nose than for other regions of the face. A number of excellent texts offer a detailed review of nasal anatomy. To this knowledge base one can add a few points concerning topography.

Anatomic concepts that apply to the central forehead and cheek likewise apply to the nose.





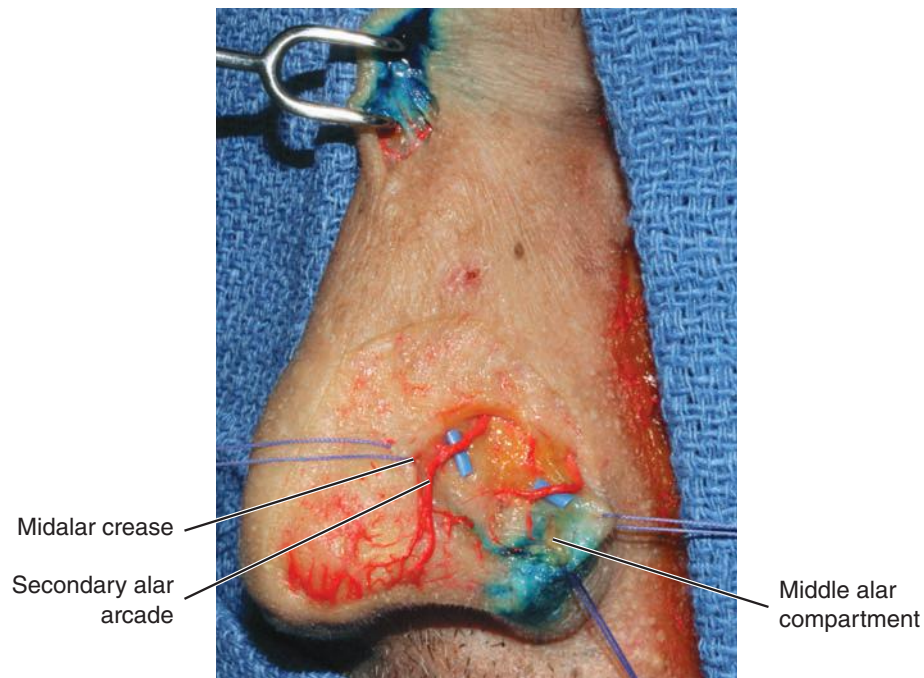
- Angular artery
- Lateral nasal artery
- Middle alar compartment
- Midalar crease



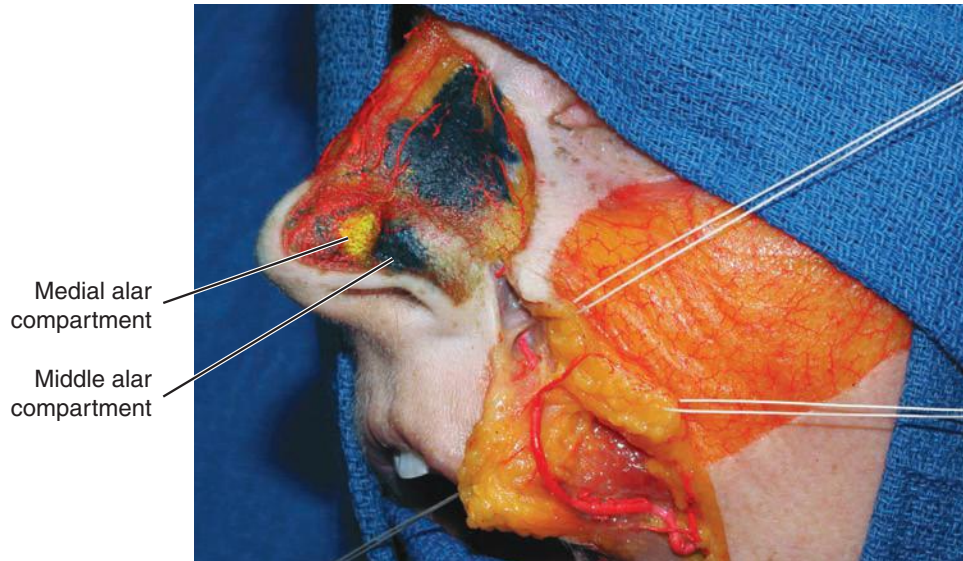- External nasal artery and nerve
- Transverse nasalis muscle
- Upper lateral cartilage
- Alar arcade
- Cartilage of septum
- Lower lateral cartilage
- Angular artery
- Lateral crease
- Accessory cartilage
- Lateral nasal artery
- Middle alar compartment
- Midalar crease

## ANATOMIC COMPARTMENTS AND AESTHETIC SUBUNITS

Nasal subcutaneous tissue exists as discrete compartments. The subcutaneous tissue along the rim of the nostril lies between the nasal arterial arcades. These originate from the lateral nasal artery, which in turn arises from the facial and angular arteries. These arcades supply the nostril skin through a system of delicate perforator vessels. It is the fascia that surrounds and encases these perforator vessels that forms the anatomic compartments of the nose. The cleft along the nostril rim in the middle ala represents a boundary between compartments.



The central cleft of the ala may form a wrinkle—an outward indication of the underlying blood supply.

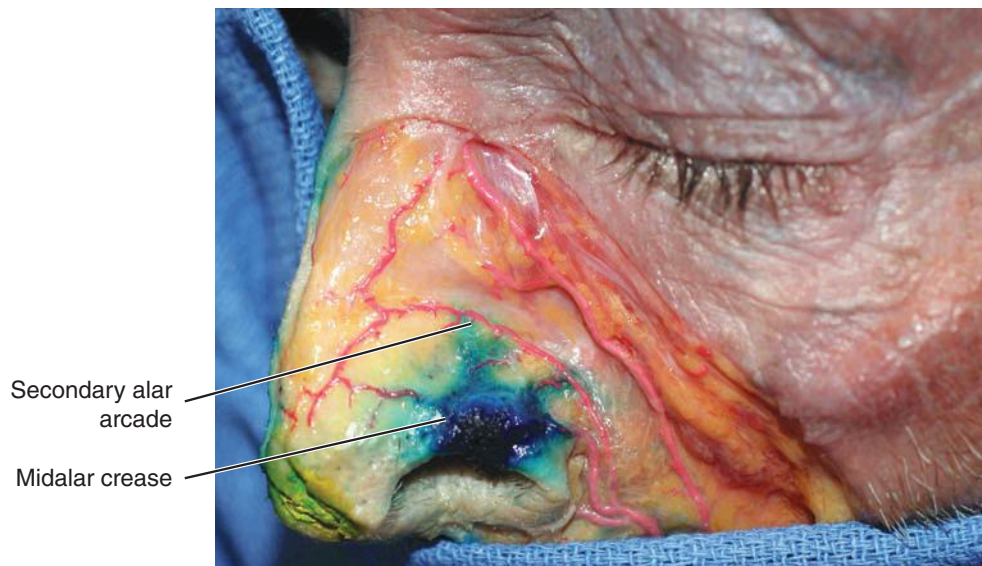


This suggests the concept that there are anatomic compartments of the nose.

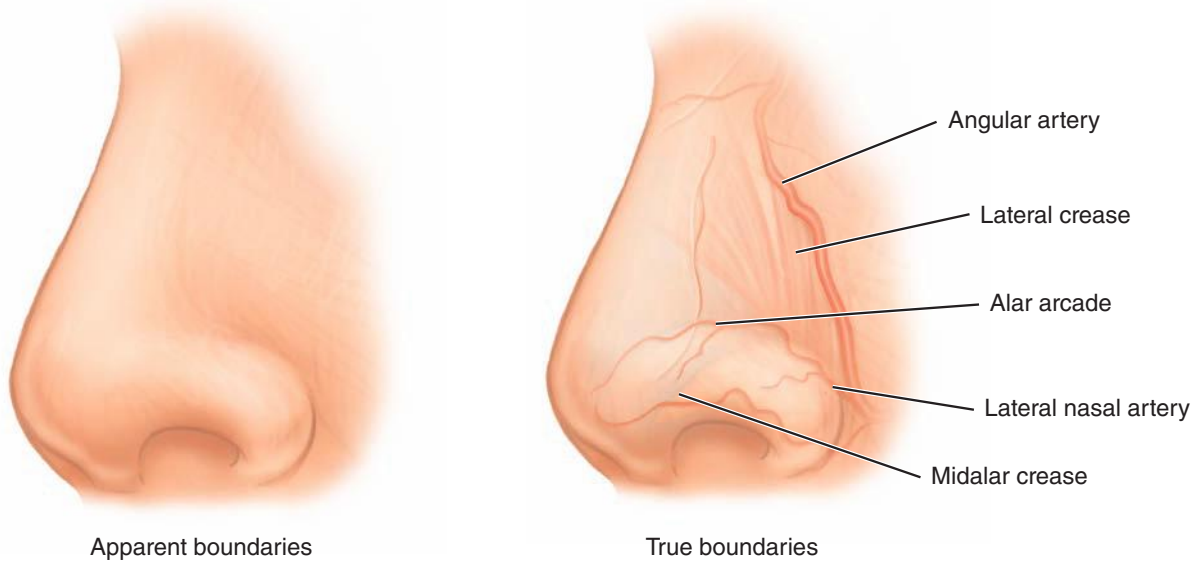
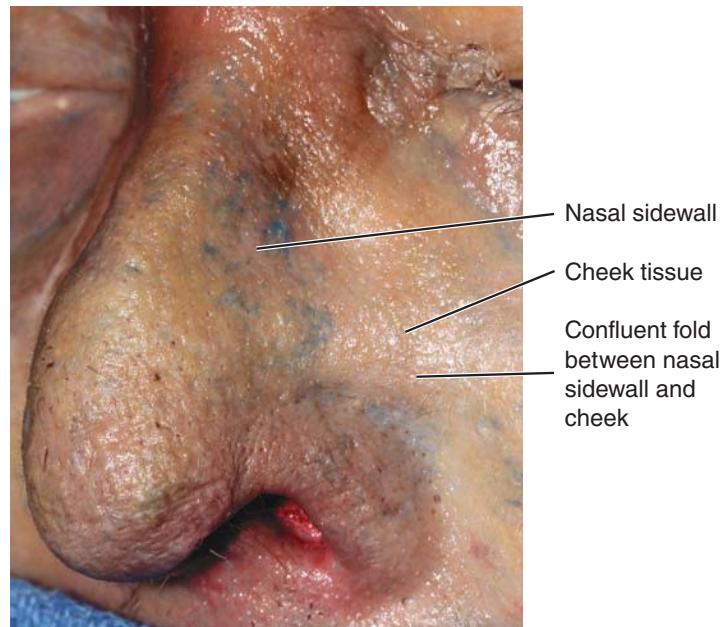
These compartments are determined by the underlying perforator blood supply.

*Anatomic compartments* are different from *aesthetic subunits*. Aesthetic subunits are based on light reflections, where surfaces form convex shapes and light planes. These aesthetic subunits, such as the alar rim, help us to visualize the region to be reconstructed. Anatomic compartments, on the other hand, help us to understand the regional blood supply.

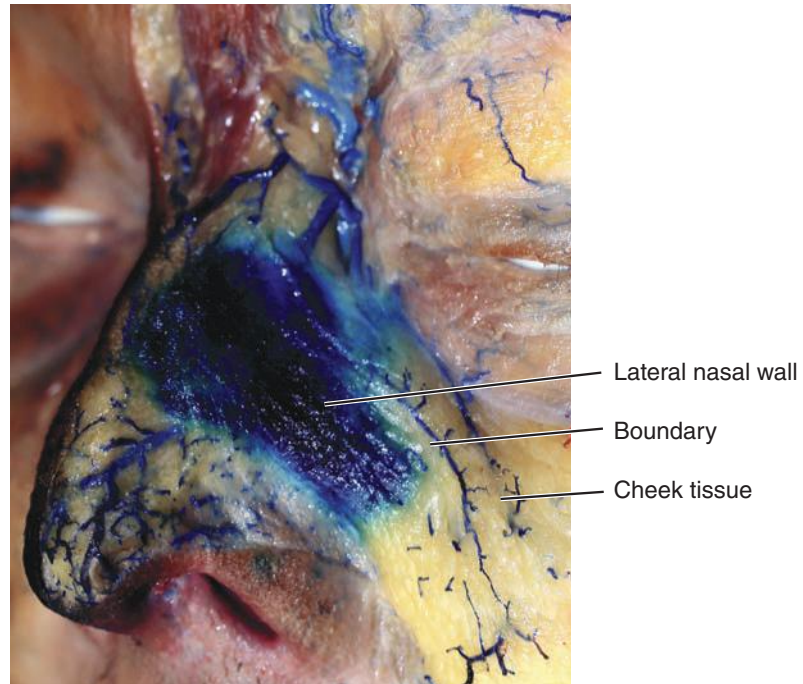
The boundaries of aesthetic subunits and anatomic compartments may overlap, as is seen in the alar rim. The alar rim consists of multiple small compartments. Transgressing the border of an anatomic compartment may at times be deleterious because it interrupts the regional blood supply.



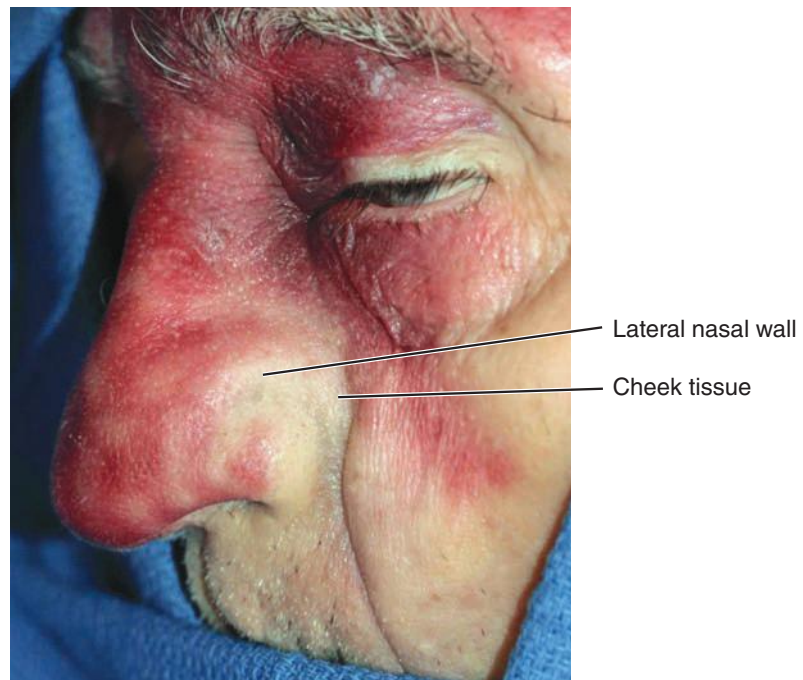
Examination of nasal shape underscores another point concerning topography. There may be apparent boundaries, some that appear confluent or that merge into one another. Observation of the interface between the nose and cheek illustrates this point. Soft tissue appears to exist as a fold that extends from the lateral nose onto the cheek.



However, dye stain indicates that there is a discrete border that extends vertically along the lateral nasal sidewall.



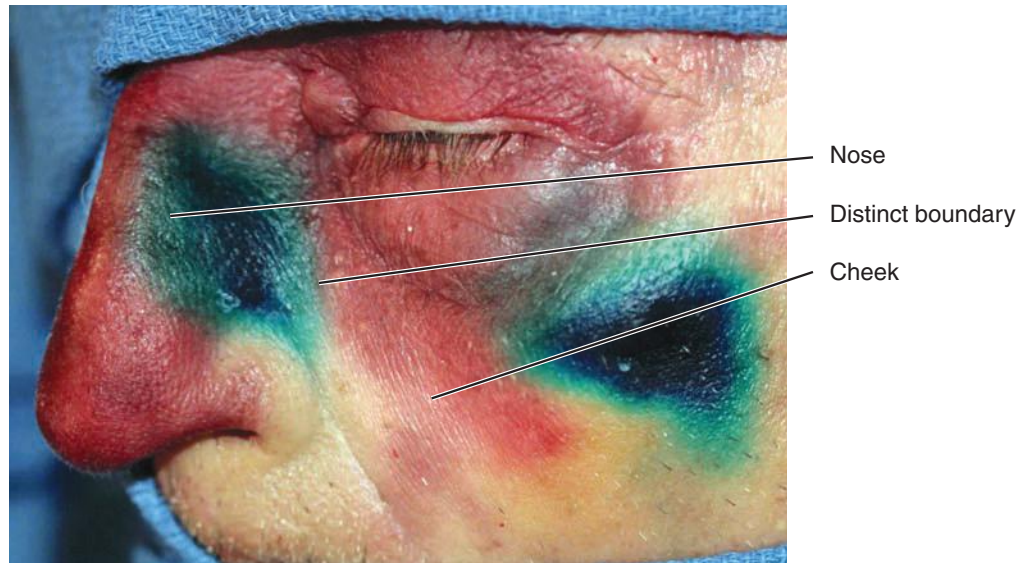
Multiple dissections confirm this finding.



## TRUE VERSUS APPARENT BOUNDARIES

It appears that soft tissue extends from the lateral nose to the cheek as a confluent mass.

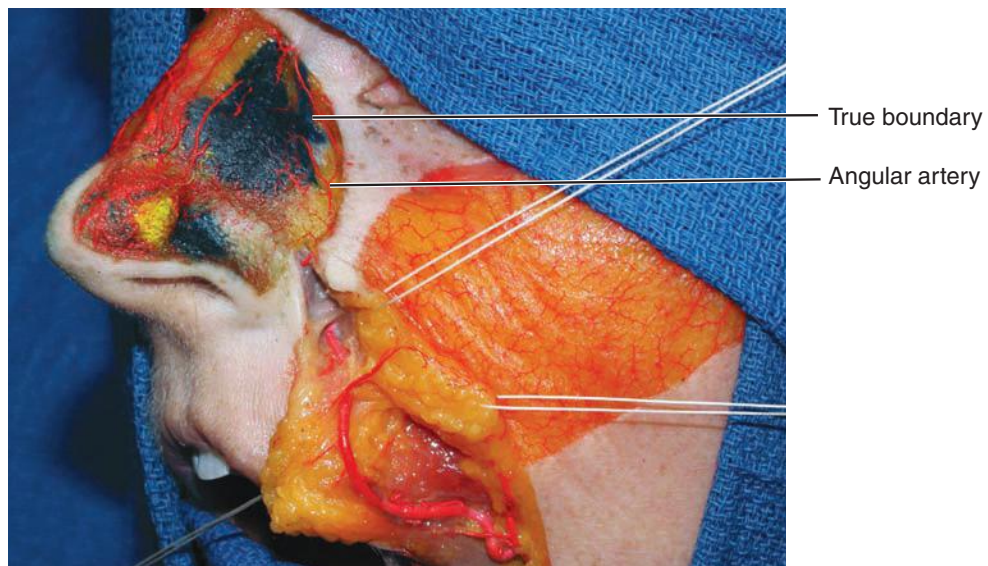
However, a *true anatomic boundary* exists along the lateral nose.



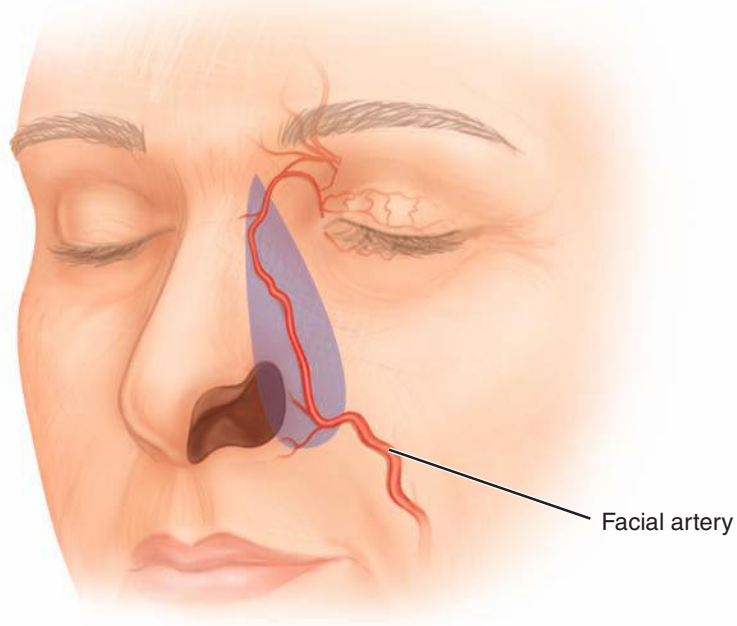
*Apparent boundaries* are boundaries that appear to extend between contiguous anatomic zones. This occurs on the lateral nose as well as along the border of the mandible at the medial jowl.

Apparent boundaries occur along the nose and mandible, suggesting that the soft tissue is confluent between anatomic structures. True boundaries are determined by regional blood supply.

True boundaries exist on both a macroscopic and microscopic or histologic level. It is important to be able to determine where true boundaries exist between anatomic structures. There is a true boundary between the nose and cheek. The angular artery determines this boundary. Often the true boundary between the lateral nose and cheek is visible.

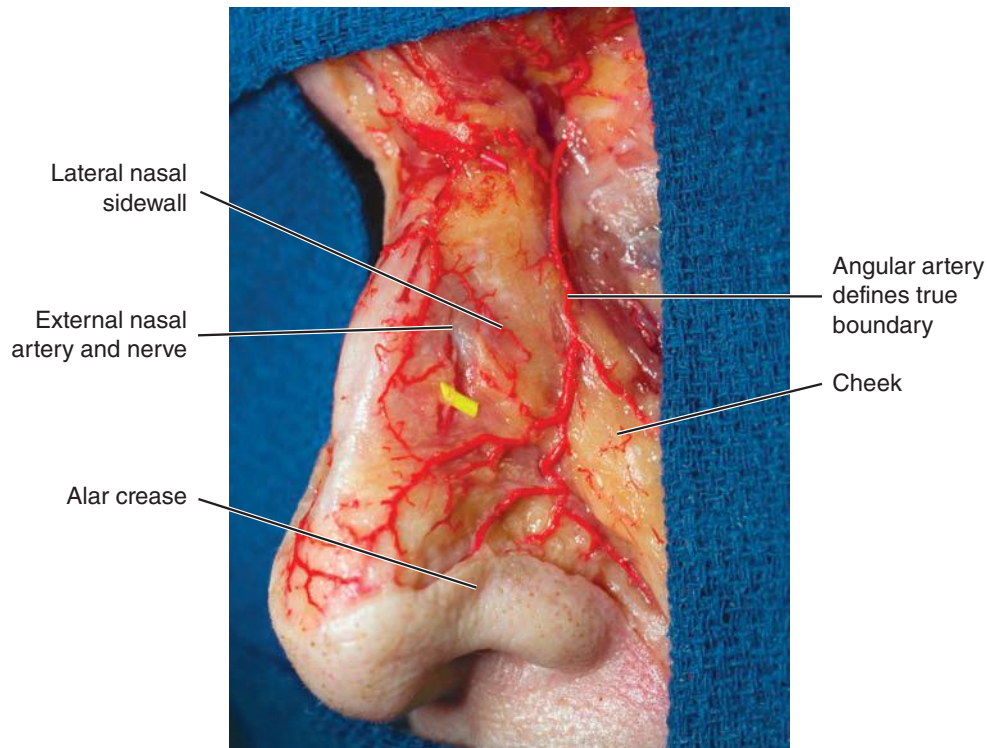


True boundaries, defined by blood supply, may correspond to sites where clefts occur. The Tessier 3 cleft occurs at the true boundary between the nose and cheek. This finding is true for many other facial clefts as well.



The transverse radix crease is a true boundary between the central forehead and nose. The transverse nasal artery, a branch of the supratrochlear artery, defines this crease. This is a useful topographic landmark for surgical planning or flap design. Including a crease within the border of a flap helps to include the underlying blood supply, a basic surgical principle.

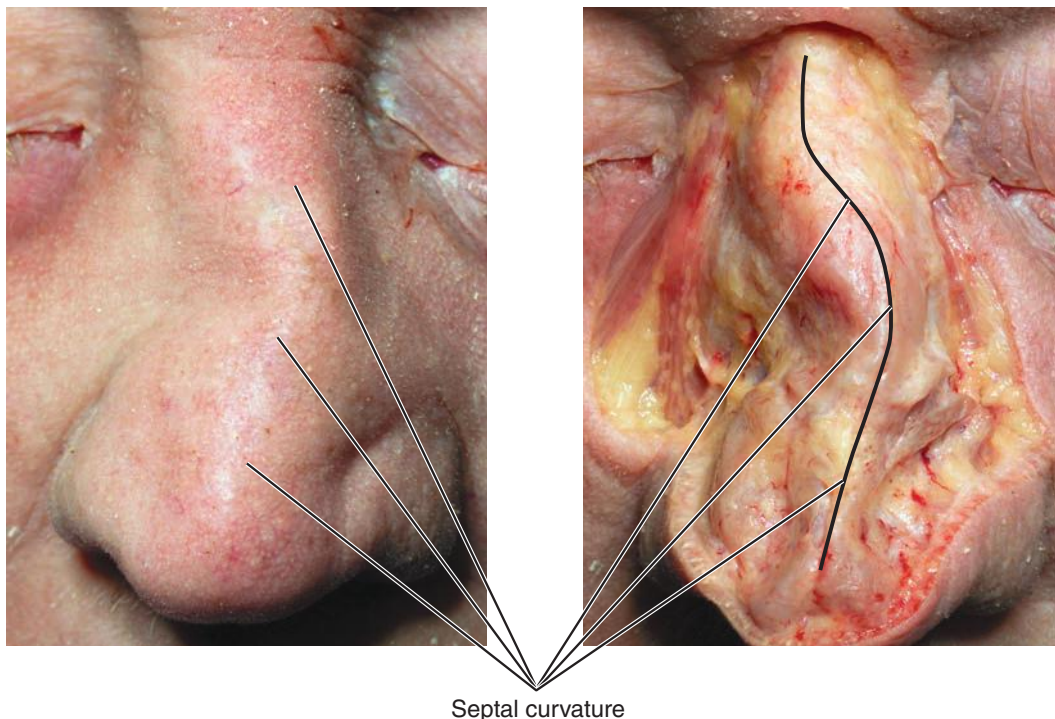
There is an anatomic compartment along the nasal dorsum, defined by the descending nasal artery. This serves as a guide to the location of the external nerve and is useful when injecting a local anesthetic to the nose.



Nerves, both sensory and motor, cross anatomic boundaries, as confirmed by dissection.

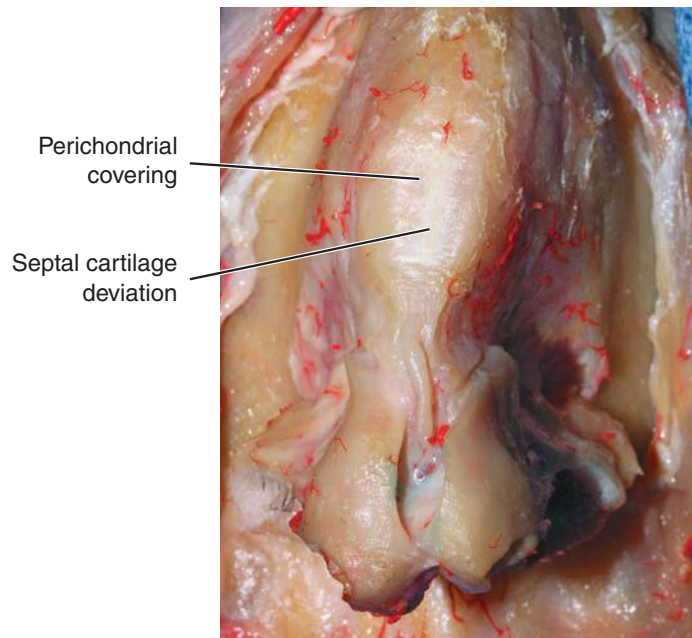
The infraorbital nerve crosses from the cheek and supplies the ala and some of the lateral nasal sidewall. This holds true for many anatomic regions. For example, the supraorbital nerve supplies some of the upper eyelid, yet it too crosses a boundary as it extends into the central forehead. This point is important clinically. Nerve blocks performed on the cheek affect the lateral nasal sidewall. Nerve blocks of the upper eyelid may affect the central forehead.

The underlying structure of the nose often manifests itself as surface shape. This is especially true when an individual has thin nasal skin. It is also of value to understand how underlying structure contributes to the shapes, angles, and measurements that are used to analyze the nose.

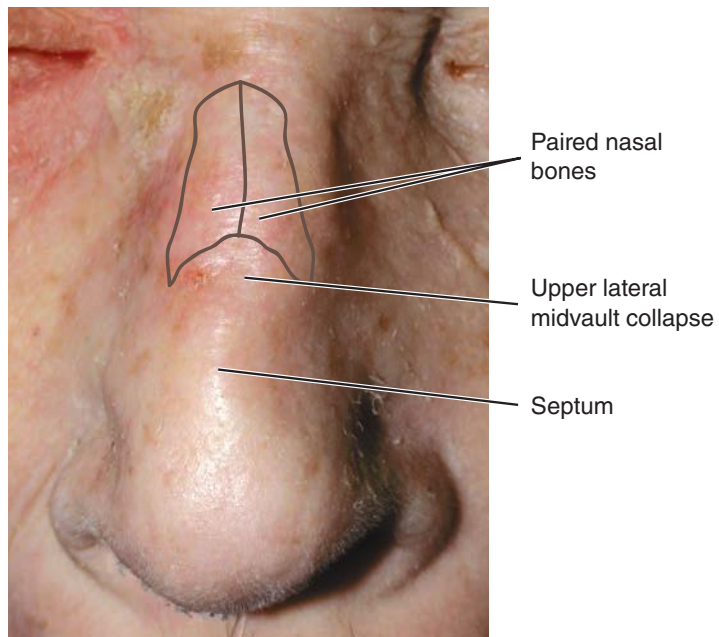


The curvature of the septum displays itself on frontal view. Ideally, the nose should be straight from the radix to the tip. Any curvature in the septum affects the position of the upper lateral cartilages and overlying soft tissue.

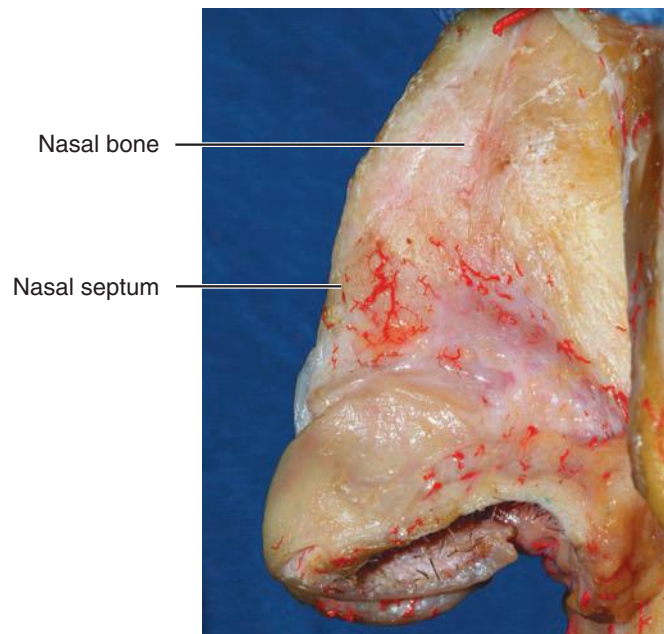
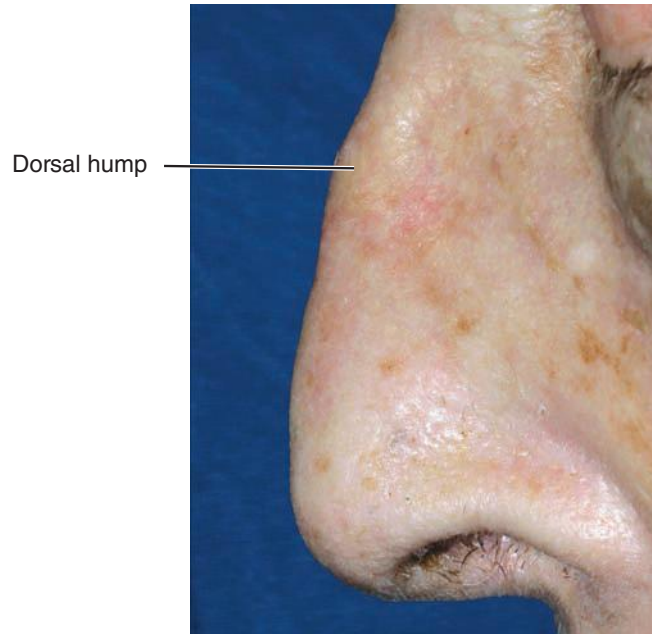
The septum is covered by perichondrium.



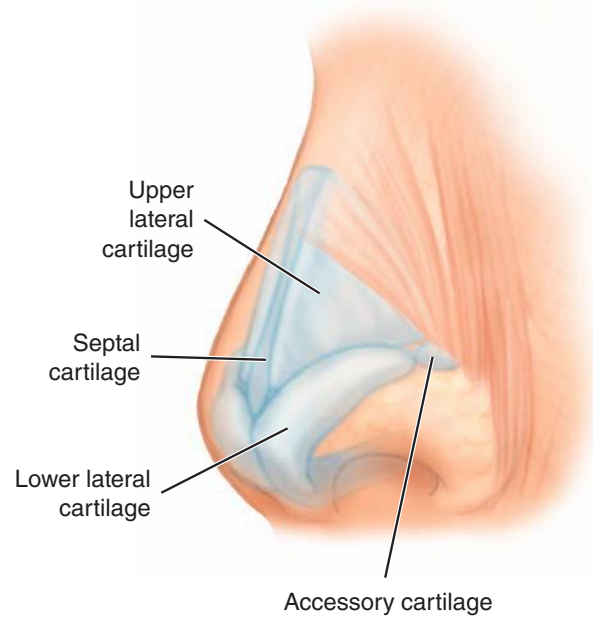
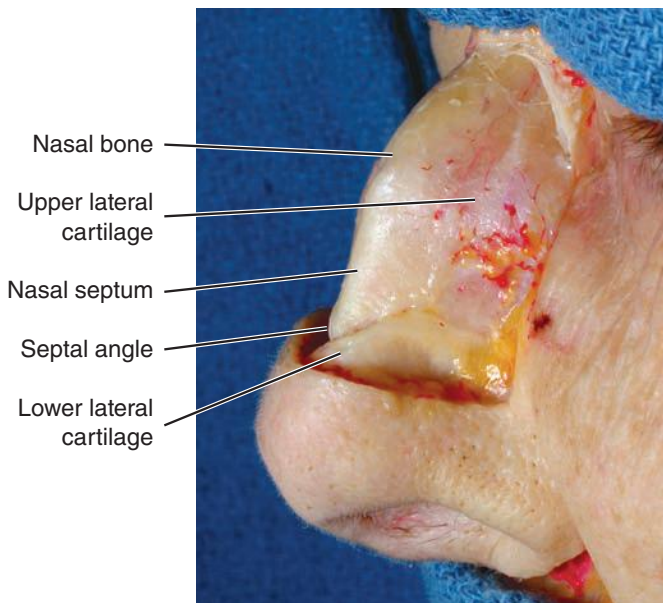
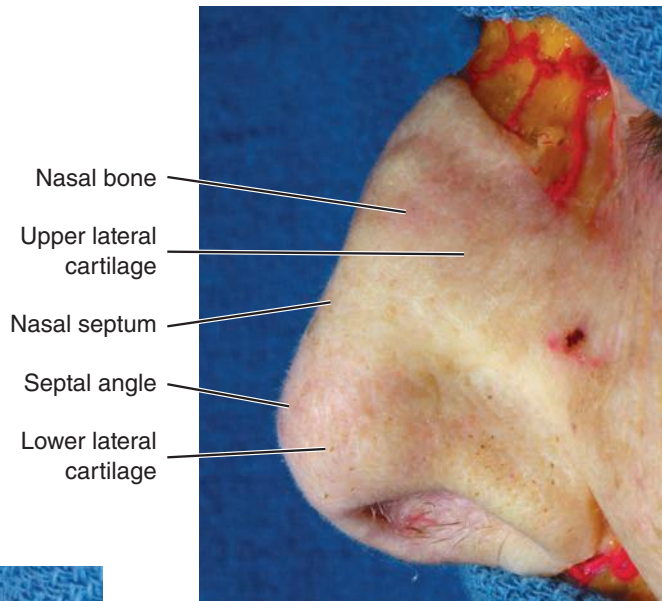
Along with the overlying subcutaneous tissue, this imparts a smooth contour to the nasal dorsum.



Both the nasal septum and nasal bone may contribute to the nasal hump. The lower lateral cartilages are seated above and superficial to the septum.



The septal angle is the anteriormost inferior part of the septum, the separating point between dorsal and caudal septum. It is visible when the upper lateral cartilages are reflected back and away from the septum. One can identify and see the septal angle by placing gentle digital pressure on the lower lateral cartilages.



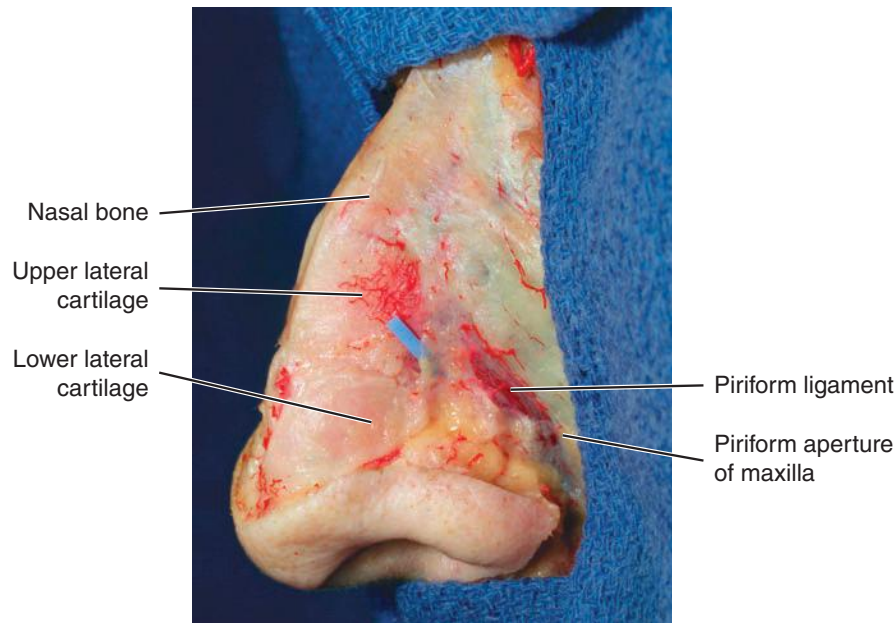
## STATIC AND DYNAMIC FORCES ON THE NOSE

The shape, position, and function of the nose are subject to both static and dynamic forces. For example, the height of the alar base is stable when the overlying soft tissue has been removed by dissection. Ligaments maintain the vertical position of the alar base in the absence of skin and muscular activity. This is not true for other facial structures. For example, although the canthus of the eyelid is stable because of ligaments, the corner of the mouth depends mostly on tonic muscular activity to maintain its position.

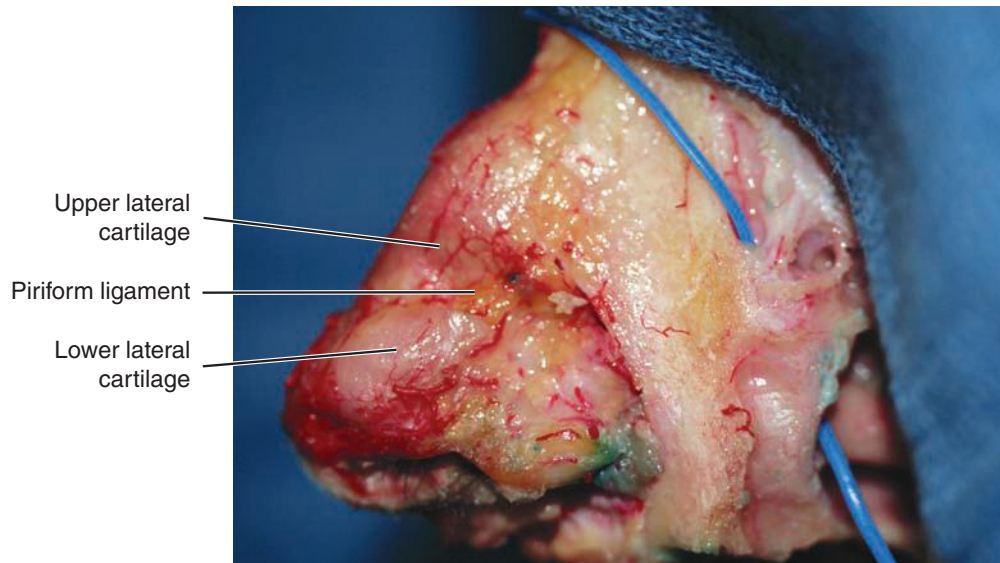
Ligaments are the fundamental structures that maintain anatomic components. On the face, they stabilize cartilage or muscle to bone.

Ligaments exist on the nose primarily as the piriform ligament and as a ligament between the lower lateral cartilages. The procerus ligament, which spans the nasal dorsum, stabilizes the procerus muscle to the radix. It also represents the deep boundary between the central forehead and the nose.

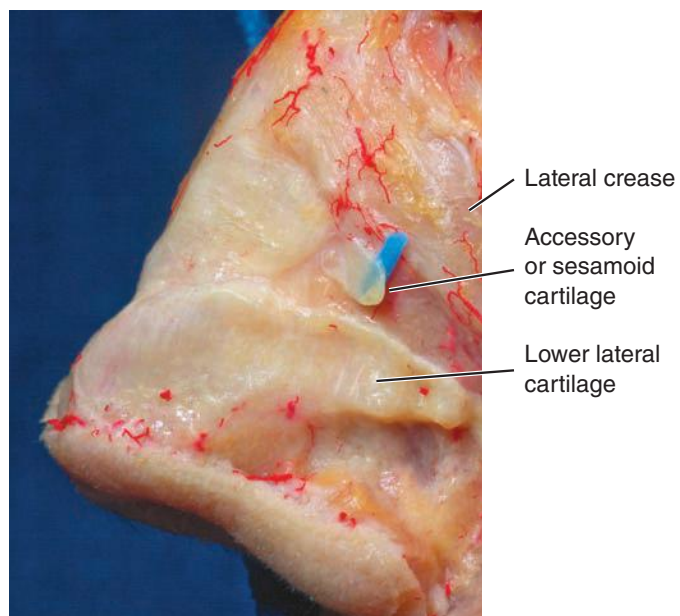
The piriform ligament helps to maintain the vertical position of the lower lateral cartilages and alar base.



The piriform ligament extends from the septum and upper lateral cartilages to the lower lateral cartilages. This helps to maintain the position of the nasal tip.

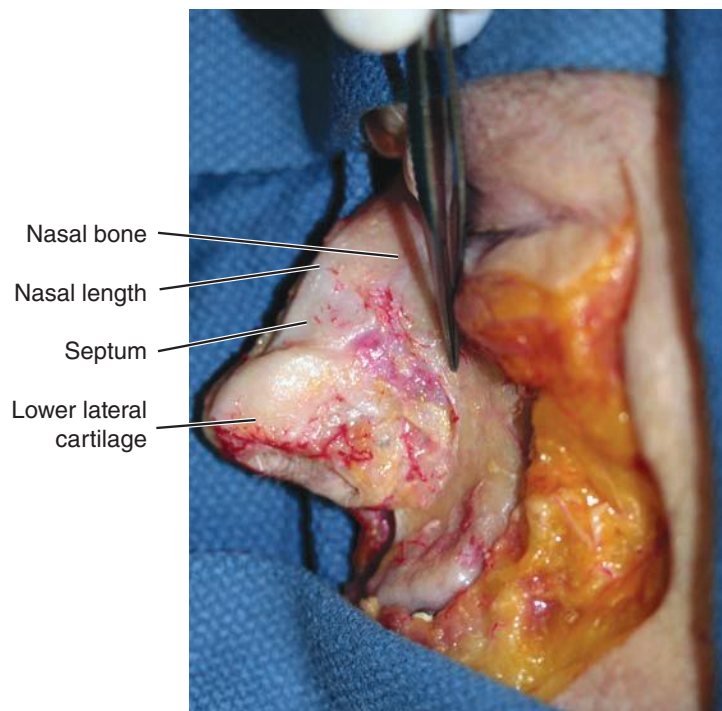


Accessory lower lateral cartilages are frequently noted. These add to the stability of the nasal tip and are in contact with the piriform ligament that attaches to the piriform rim of the maxilla.



Tip projection is a measurement commonly used in planning nasal surgery. It is measured from the alar base to the anteriormost part of the lower lateral cartilage. This anatomy shows how the septal height, lower lateral cartilage, and the relationship of the lower lateral cartilage to the septum are factors that contribute to nasal tip projection.

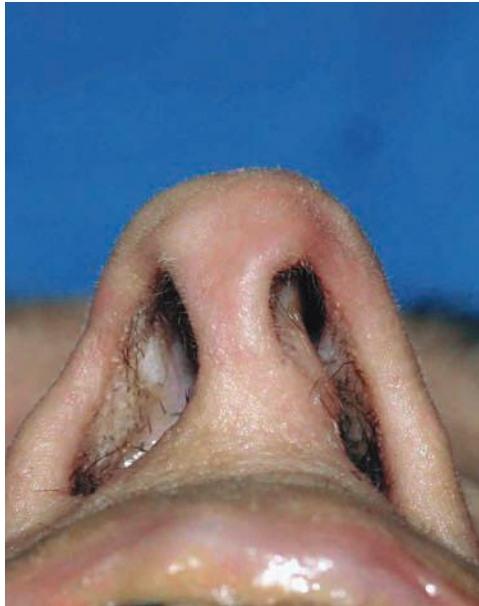Nasal length is measured from the radix, the posteriormost part of the nasal bone on lateral view, to the anterior inferior tip. Nasal bone, septum, and lower lateral cartilage all contribute to nasal length.



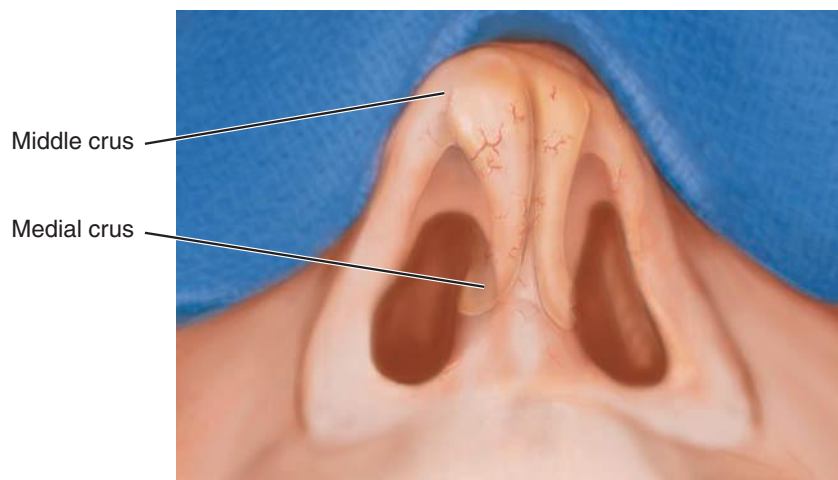
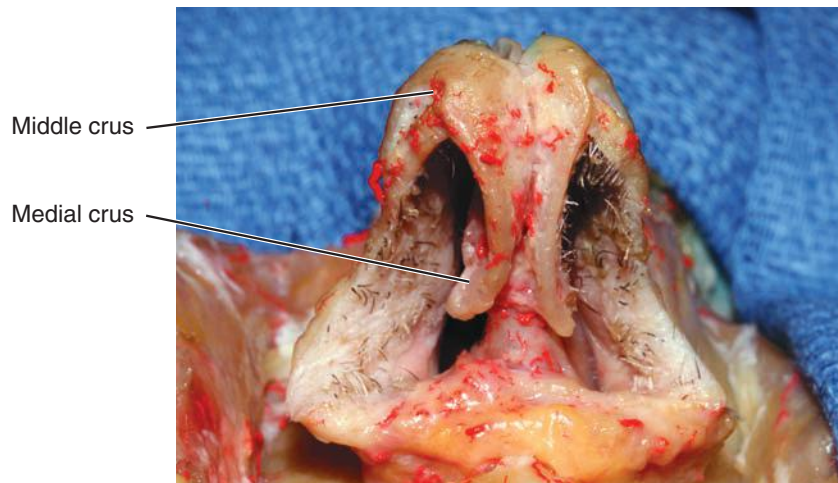
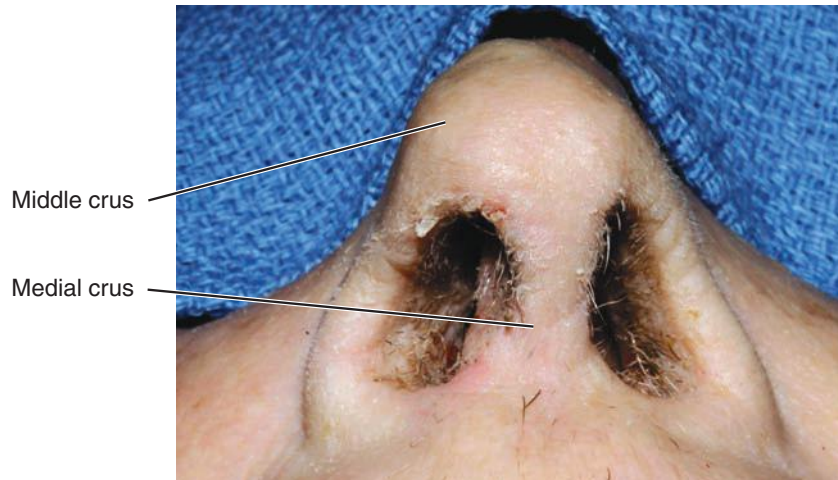A detailed review of all nasal measurements is beyond the scope of this book.

Any nasal measurement, angle, and shape can be measured and analyzed according to the contributing anatomic structures and their relationship to one another.

Examination of the nose from a basal view provides important information.

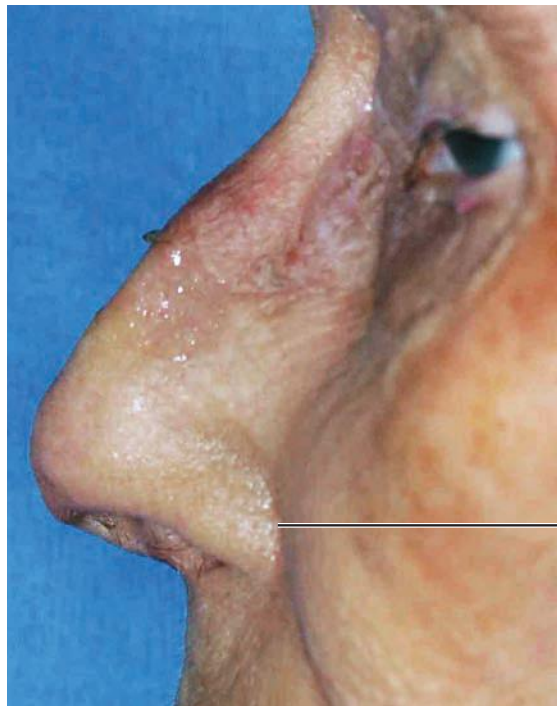

The shape of the nasal tip is determined largely by the shape of the lower lateral cartilages and their relationship to one another. In a thin-skinned nose, the underlying anatomy of the lower lateral cartilages is apparent.



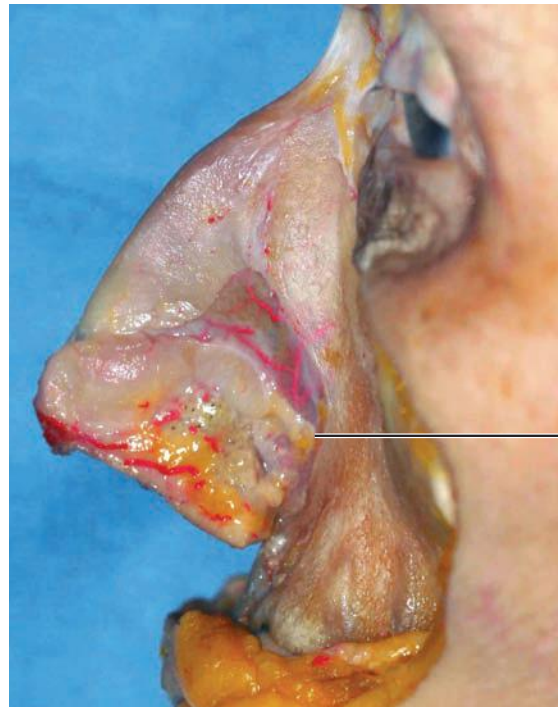Dissection of the nose and examination of the basal view emphasize the importance of skin as a structural support for the alar rim. Skin thickness varies widely over the face, from the thinnest skin of the eyelids to the thickest skin on the nasal ala. This thick skin of the ala helps maintain the patency of the external nasal valve. With dissection, the sides of the ala collapse, distorting nostril shape. This may also occur when the thick alar skin is removed by surgery.

This view also suggests that the anterior position of the alar base does not depend on skin or muscular tone. For example, the alar base projects anterior to the upper medial canthus before dissection.



Position of  
alar base

With all the skin and subalar fat removed, the alar base does not slump posteriorly.



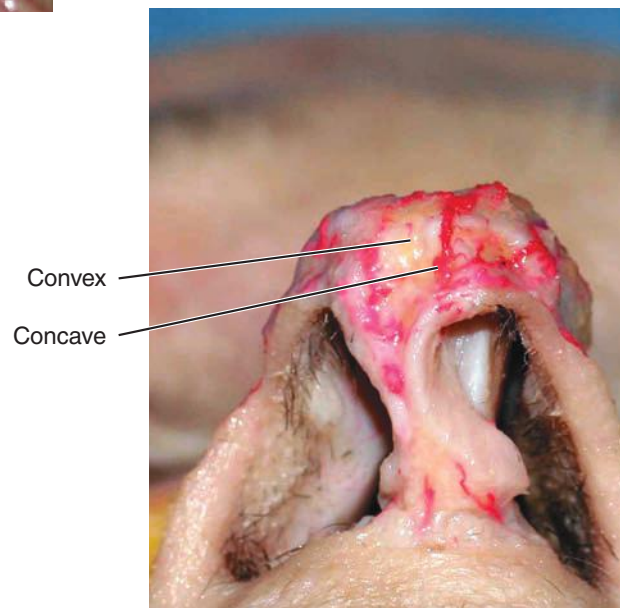
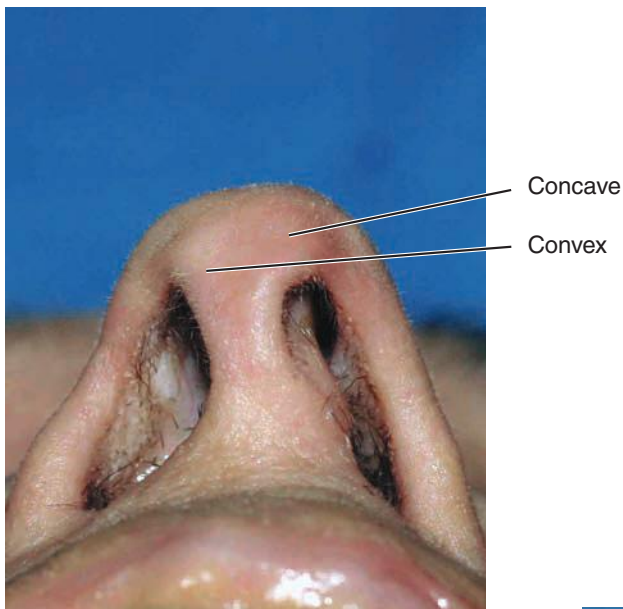
Position of  
alar base:  
static

This is in contradistinction to the cheek, where loss of fat as a structural support has profound effects on surface topography. This suggests the monumental importance of the dorsal septum in providing support for the position and shape of the alar base. It also suggests that the suspensory ligaments, such as the piriform ligament, play a crucial role in supporting the lower lateral cartilages.

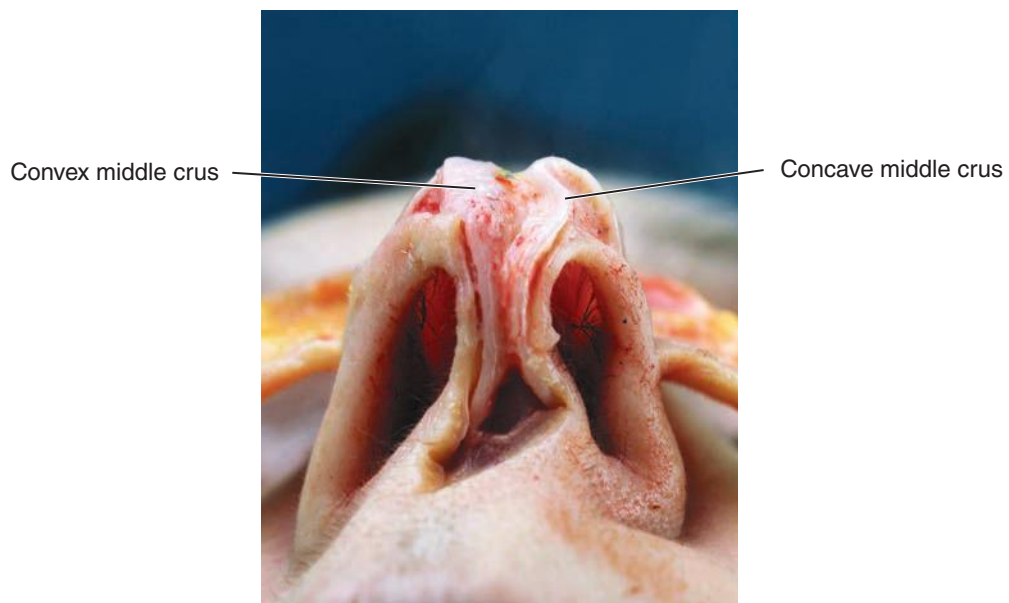
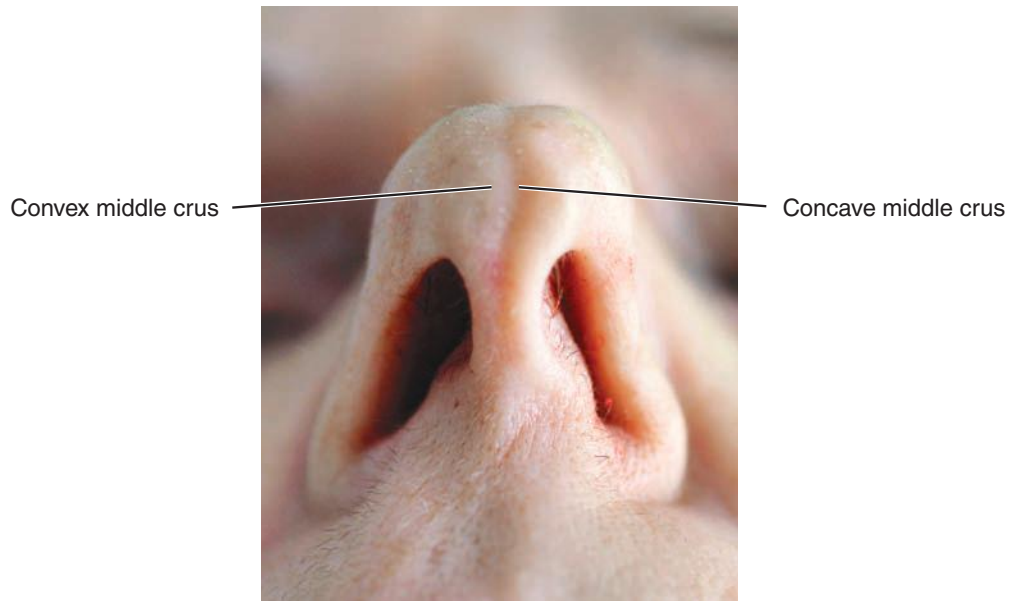
The dorsal septum is a critical support structure for the position and shape of the alar base.

Clinical observation lends support to this statement. A patient with inadequate dorsal septal height frequently displays a splayed alar base. The alar base splays laterally; it becomes more convex. This affects nostril shape. It also repositions itself posteriorly, more along the maxilla and canine fossa.

The relative position of the lower lateral cartilages to one another at the tip is noteworthy.

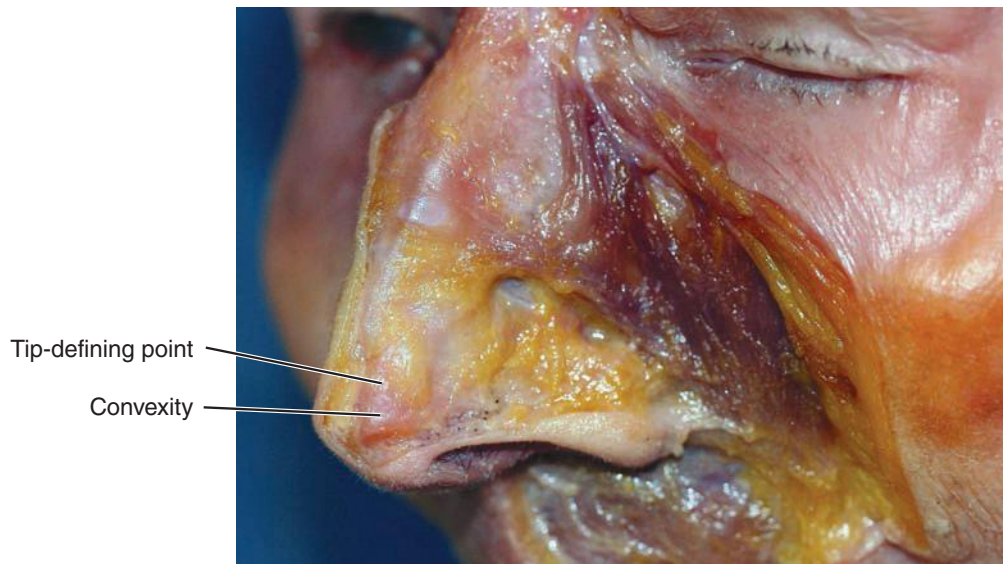


Careful observation shows that the middle crura of the lower lateral cartilages are not symmetrical; often one is convex and one concave. This orientation allows these cartilages to fit tightly against one another, the curve of one fitting into the groove of the other.

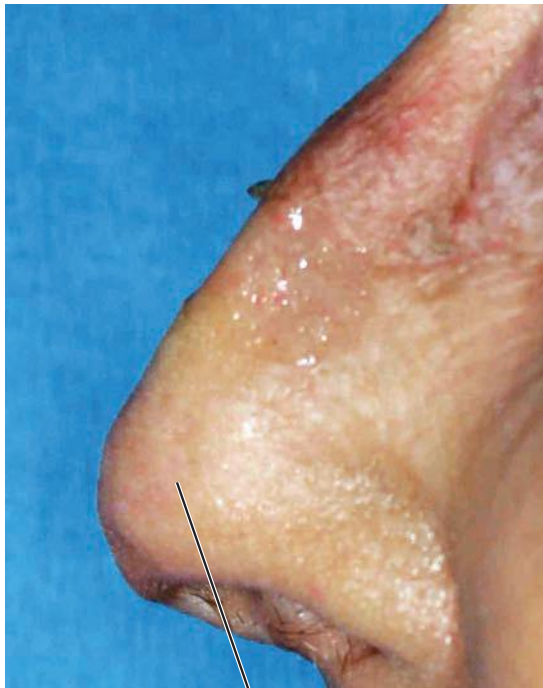

Together these impart a smooth contour to the topography of the nasal tip. However, it is important to recognize that not only the shape of parts, but also their relationship to one another, is what ultimately determines the shape of any facial structure.

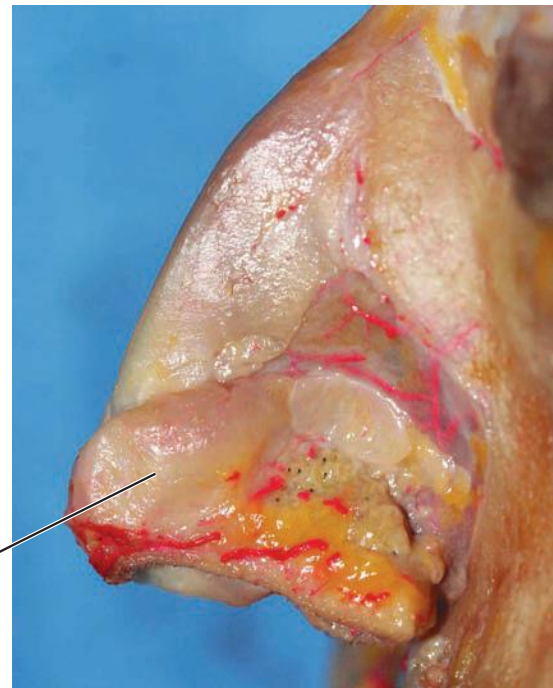
It is not that the individual shape is unimportant. For example, the tip-defining points, the highlights cast by light reflected off the middle crura, depend on the convexity of each lower lateral cartilage.



When we analyze the tip-defining points, they are defining the middle crura and their curvature. It follows that a lack of convexity of the middle crura is associated with poor tip-defining points.



Concave or flat



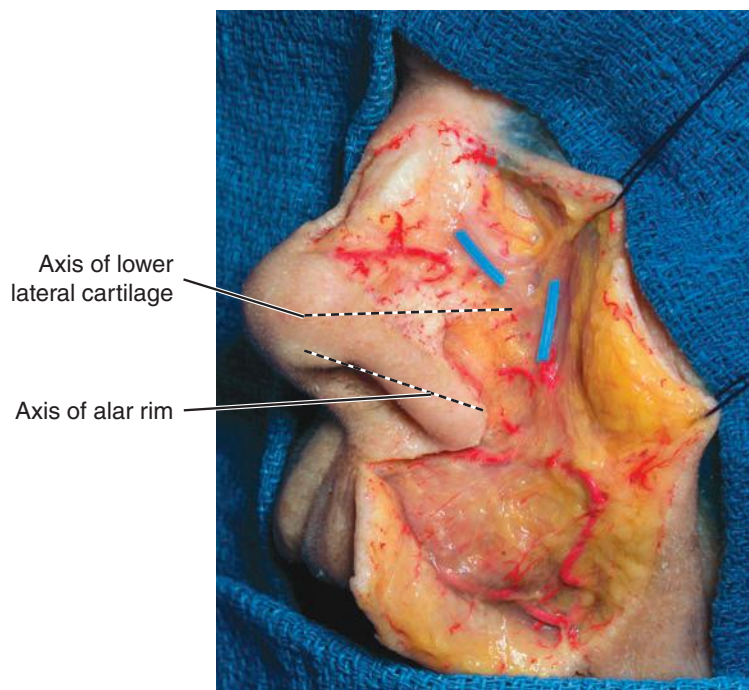
Lack of tip-defining point

This summarizes one of the basic anatomic concepts regarding facial topography.

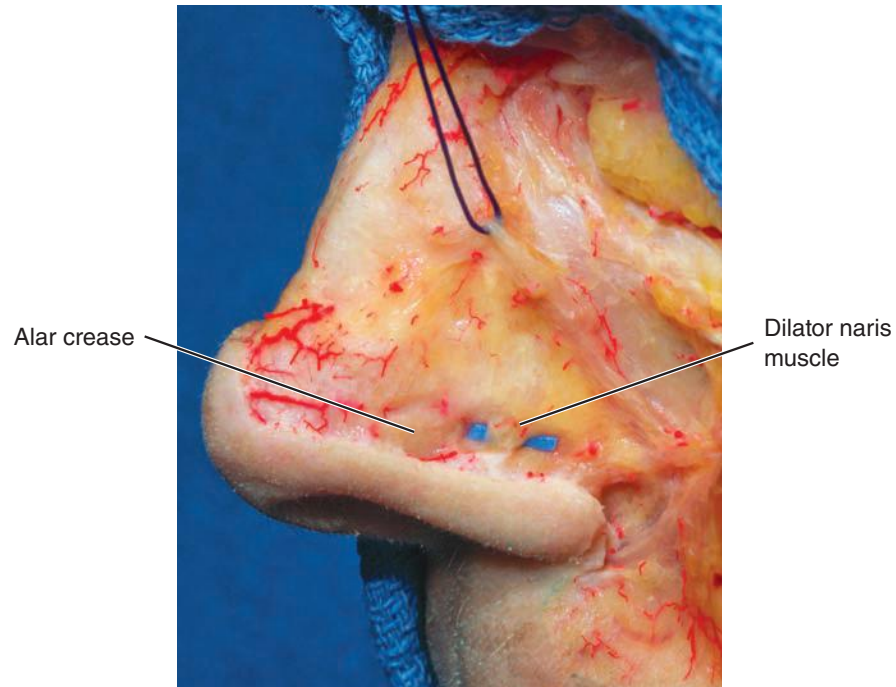
Both the shape of individual structures and their relationship to one another ultimately determine the topography of any facial region.

Nasal topography has a dynamic element, as does any facial region. Intrinsic and extrinsic musculature contributes to nasal function and shape. When the dilator naris muscle is injured, such as by a seventh nerve palsy, surgery, or disease, the nostril rim loses its normal convexity. Collapse of the rim during inspiration occurs here at the region defined as the external nasal valve.

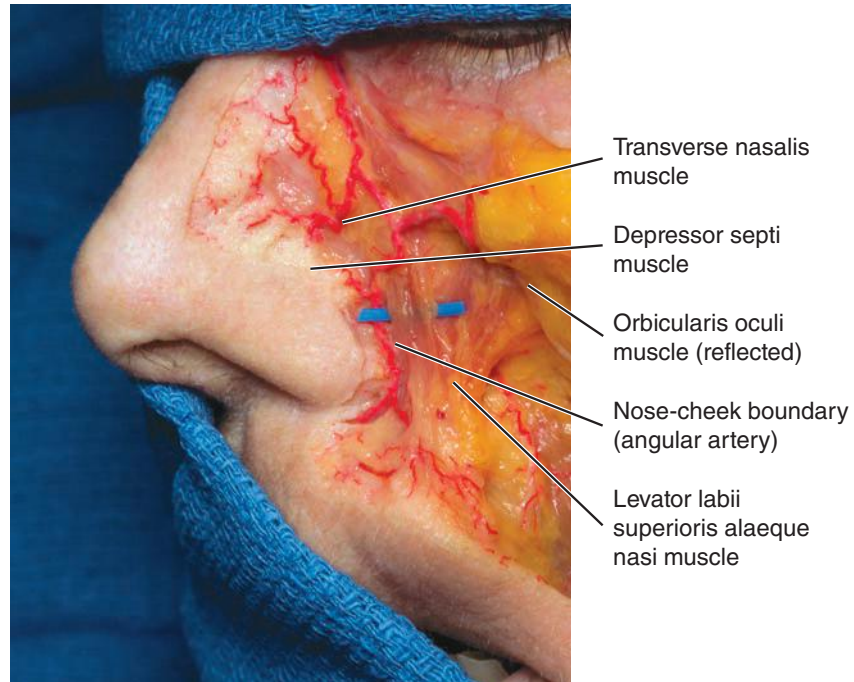
The lateral crus of the lower lateral cartilage does not travel parallel to the rim: its course diverges as it travels in a lateral and cephalad direction. Therefore patency of the external valve and the shape of the alar rim depend on functional as well as static elements.



A previous dissection showed how the dilator naris muscle lies posterior to the alar groove. When present, the groove can be used as a topographic landmark to estimate the position of this muscle.



Extrinsic muscles such as the levator labii superioris alaeque nasi contribute to nasal shape in a dynamic fashion. The name given to this muscle may be a misnomer, for the following reason. The levator alaeque nasi part of the muscle elevates the alar base when it contracts. This muscle has an origin near the medial canthus. It receives some of its blood supply from the angular artery.

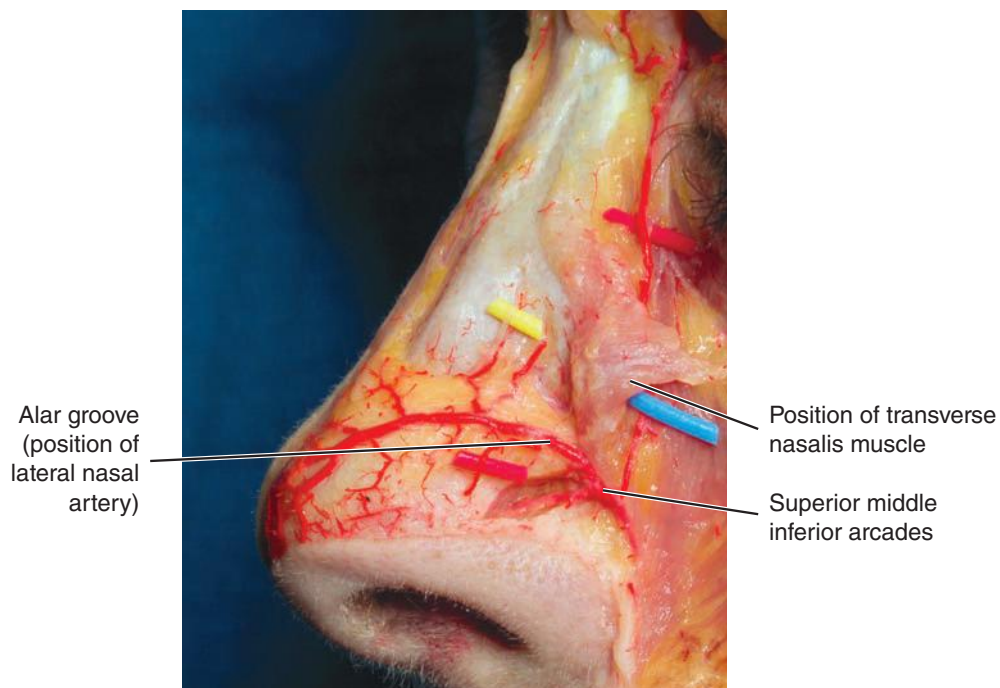


The angular artery defines the boundary between the nose and cheek. For this reason, one knows the levator alaeque nasi can be just lateral to the nose-cheek boundary. This is one way to reliably identify the position of this muscle; this is vital information when one attempts to denervate it to lower the alar base position.

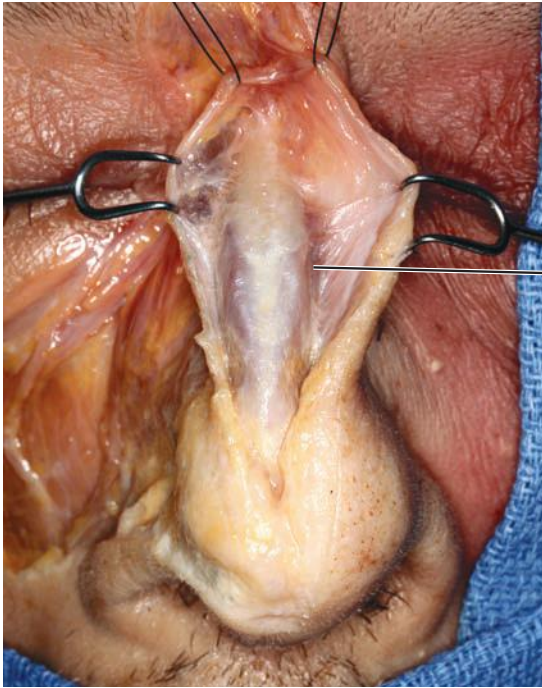
On the other hand, the levator labii superioris muscle receives its blood supply from the infraorbital artery, which is located at the junction between the orbit-cheek crease and the nasojugal crease. It is not surprising that this muscle would have a completely different origin, along the maxilla inferior to the orbital rim.

Because the blood supply defines anatomic compartments and boundaries, understanding the blood supply to nasal and facial muscles helps to predict their location.

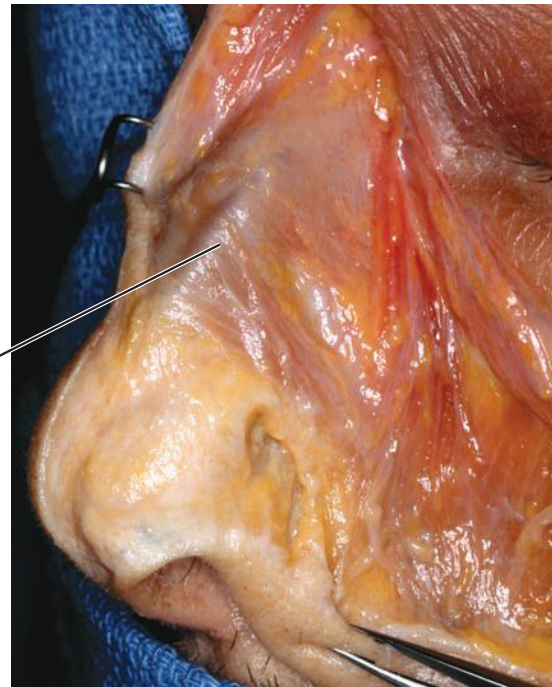
The transverse nasalis muscle receives some of its blood supply from the main nasal arcade artery. This travels above the alar groove, so we know that at least part of this muscle can be identified above the groove as a landmark.



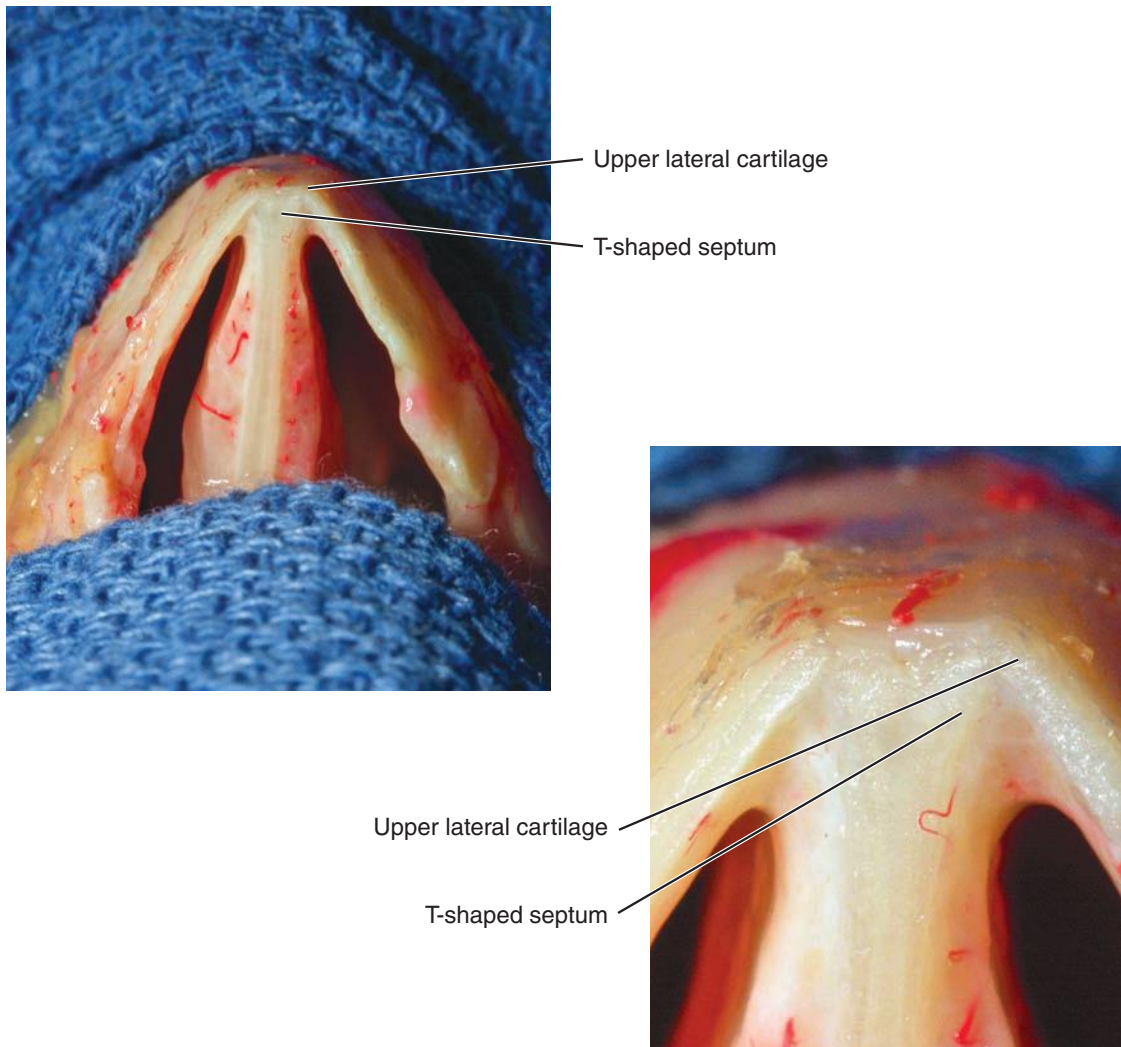
The other valve of the nose, the internal valve, is a dynamic structure as well. Careful dissection reveals how part of the nasalis muscle inserts into the upper lateral cartilages.



Nasalis muscle

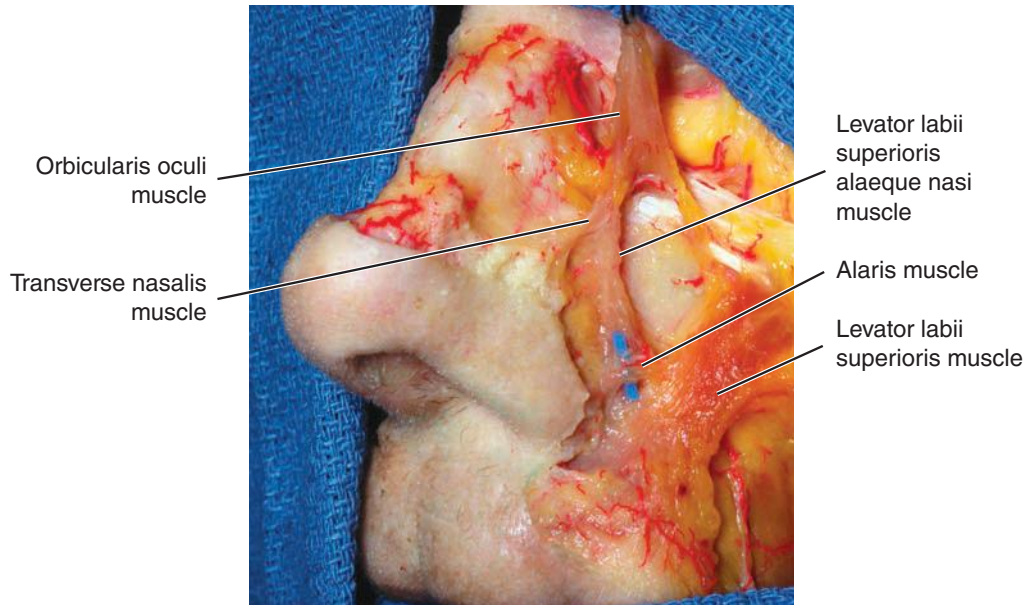
Upper lateral  
cartilage

Contraction of the nasalis muscle pulls the upper lateral cartilages away from the septum, increasing nasal airflow. As with the external valve, there are also static components to patency of this valve. The main factor is the T-shaped configuration of the junction of the septum with the upper lateral cartilages.

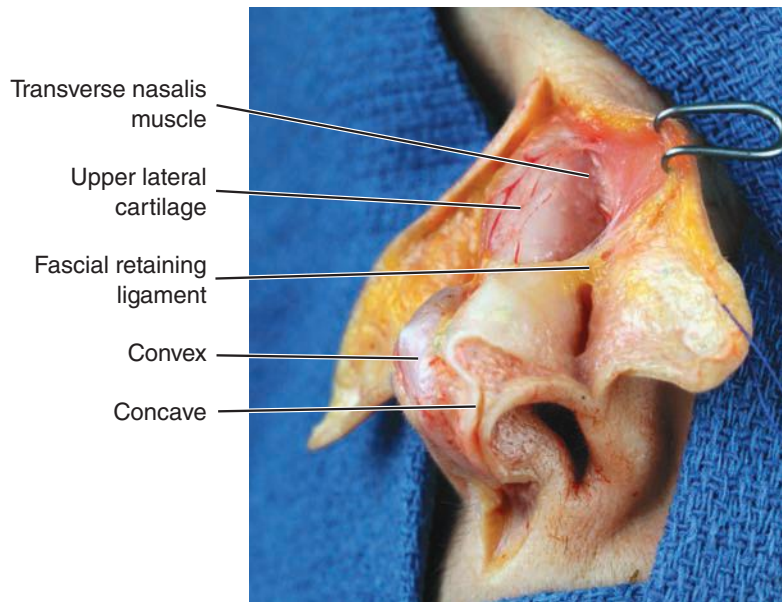


The septum is thicker where it meets the upper lateral cartilage because of this shape, which provides static support to the internal nasal valve.

Some extrinsic nasal muscles may be apparent. Although this is more precisely defined as an upper lip muscle, the small alaris muscle can be seen in some individuals as a transverse band when they smile.



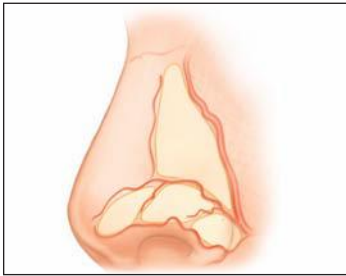Nasal shape is therefore partly defined by dynamic forces, these being tonic muscular contraction and contraction during animation. This principle applies equally to other regions of the face.



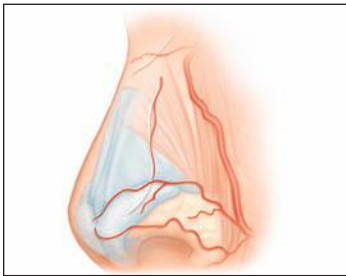
## *Key Points*

- Anatomic compartments of the nose are determined by the underlying perforator blood supply.
- Aesthetic subunits are based on light reflections; anatomic compartments are determined by the regional blood supply.
- Apparent boundaries occur along the nose and mandible, suggesting that the soft tissue is confluent between anatomic structures. True boundaries are determined by regional blood supply.
- Nerves, both sensory and motor, cross anatomic boundaries, as confirmed by dissection.
- Ligaments on the face stabilize cartilage or muscle to bone.
- Any nasal measurement can be analyzed according to the contributing anatomic structures and their relationship to one another.
- The dorsal septum is a critical support structure for the position and shape of the alar base.
- Both the shape of individual structures and their relationship to one another ultimately determine the topography of any facial region.
- Because the blood supply defines anatomic compartments and boundaries, understanding the blood supply to nasal and facial muscles helps to predict their location.

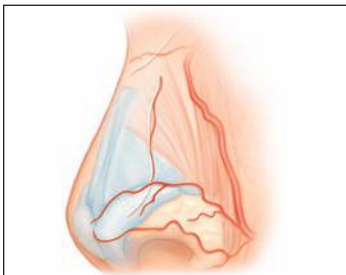
## CLINICAL CORRELATIONS



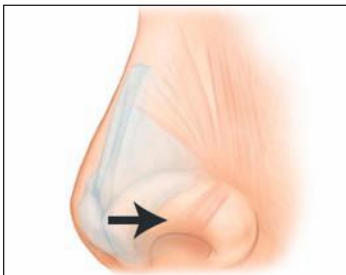The concept of anatomic subunits is useful to preserve blood supply during nasal reconstruction.



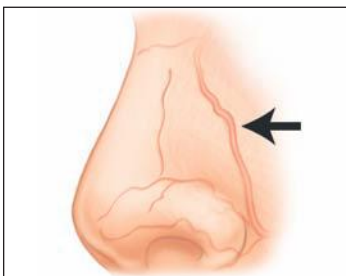
When applying an algorithm to analyze the nose preoperatively, any measurement can be analyzed according to the anatomic components involved.



A component reduction rhinoplasty, releasing all structures from one another, enables each structure to be modified for a contour-specific effect.



The alar crease or cleft is a landmark for the position of the dilator naris muscle. Removal of this muscle weakens the external nasal valve.



The nose-cheek junction is an anatomic boundary between compartments. Reconstructive efforts must recreate this true boundary.

## Bibliography

The nose is perhaps the best-analyzed region of the face from the perspective of topography and how anatomy defines shape. This short collection of reviews and papers illustrates the various ways in which function and anatomy contribute to nasal topography. The concepts of folds, creases, anatomic subunits, and superficial and deep boundaries also apply to nasal topography, as suggested by the following publications.

Ali-Salaam P, Kashgarian M, Davila J, et al. Anatomy of the alar groove. *Plast Reconstr Surg* 110:261-266; discussion 267-271, 2002.

*The authors discussed the anatomy of the alar groove, noting the difference in subcutaneous thickness between the lateral nasal sidewall and ala. This defines the groove as a crease: the superior tissue constitutes the fold.*

Burget GC, Menick FJ. The subunit principle in nasal reconstruction. *Plast Reconstr Surg* 76:239-247, 1985.

*The nose can be visualized according to shadows created by curved and angular surfaces. The authors applied this concept to reconstructive procedures, where the scar can be hidden along these borders. The concept of anatomic subunits is another way to understand and visualize nasal anatomy.*

Fischer H, Gubisch W. Nasal valves—importance and surgical procedures. *Facial Plast Surg* 22:266-280, 2006.

*The nasal valves constitute one type of system that regulates nasal airflow.*

Frileck SP. The nasal vestibule. *Ann Plast Surg* 17:141-150, 1986.

*This article presented several means to visualize and understand functional nasal anatomy.*

Gray LP. Deviated nasal septum. Incidence and etiology. *Ann Otol Rhinol Laryngol* 87(3 Pt 3 Suppl 50):3-20, 1978.

*The author presented the incidence and clinical presentation of septal deviation in detail.*

Gunter JP. Anatomical observations of the lower lateral cartilages. *Arch Otolaryngol* 89:599-601, 1969.

*A must-read, this paper in many ways represented the start of a trend away from the personal approach and toward a logical and structured method of approaching nasal surgery.*

Gunter JP, Rohrich RJ, Adams WP Jr, eds. *Dallas Rhinoplasty: Nasal Surgery by the Masters*, 2nd ed. St Louis: Quality Medical Publishing, 2006.

*A comprehensive textbook of nasal surgery that covers all aspects of anatomy, function, pre-operative analysis, and surgical technique.*

Hafezi F, Naghibzadeh B, Nouhi AH. Applied anatomy of the nasal lower lateral cartilage: a new finding. *Aesthetic Plast Surg* 34:244-248, 2010.

*Variations of the lower lateral cartilage and a system of subclassifying the anatomy are presented.*

Han SK, Lee DG, Kim JB, et al. An anatomic study of nasal tip supporting structures. *Ann Plast Surg* 52:134-139, 2004.

*This study defined the nasal tip supporting structures as ligamentous, fibromuscular, and loose connective tissue. A correlation between inadequate support between the medial crura and tip projection was noted.*

Hur MS, Hu KS, Youn KH, et al. New anatomical profile of the nasal musculature. *Clin Anat* 24:162-167, 2011.

*The anatomy of the nasalis and dilator naris muscles was defined and their effect on topography discussed.*

Lam SM, Williams EF. Anatomic considerations in aesthetic rhinoplasty. *Facial Plast Surg* 18:209-214, 2002.

*This short review of nasal anatomy highlighted a number of important concepts.*

Oneal RM, Beil RJ, Schlesinger J. Surgical anatomy of the nose. *Clin Plastic Surg* 23:195-222, 1996.

*One of the more extensive discussions of nasal anatomy and its effect on topography and function, this is an excellent in-depth review, providing an introduction into detailed nasal anatomy and including an extensive review of the literature.*

Natvig P, Sether LA, Gingrass R, et al. Anatomical details of the osseocartilaginous framework of the nose. *Plast Reconstr Surg* 48:528-532, 1971.

*A discussion of the lateral crura, this paper included a reference to the occasional concave-convex middle crura, predating the recurve concept of the nasal tip. The concept introduced was that it is the relationship of the parts as well as their individual architecture that determines overall topography.*

Peck GC, Michelson LN. Anatomy of aesthetic surgery of the nose. *Clin Plast Surg* 14:737-748, 1987.

*This review emphasized the interrelation between the various components of the nose and how they affect shape and form.*

Toriumi DM, Checcone MA. New concepts in nasal tip contouring. *Facial Plast Surg Clin North Am* 17:55-90, 2009.

*This article introduced the concept of shadowing, its effect on nasal topography, and its applications in the clinical setting.*

Zelnik J, Gingrass RP. Anatomy of the alar cartilage. *Plast Reconstr Surg* 64:650-653, 1979.

*This paper discussed nasal tip shape based on a classification of shapes of the lower lateral cartilage. Their study is a good example of how nasal anatomy has been studied in great detail.*

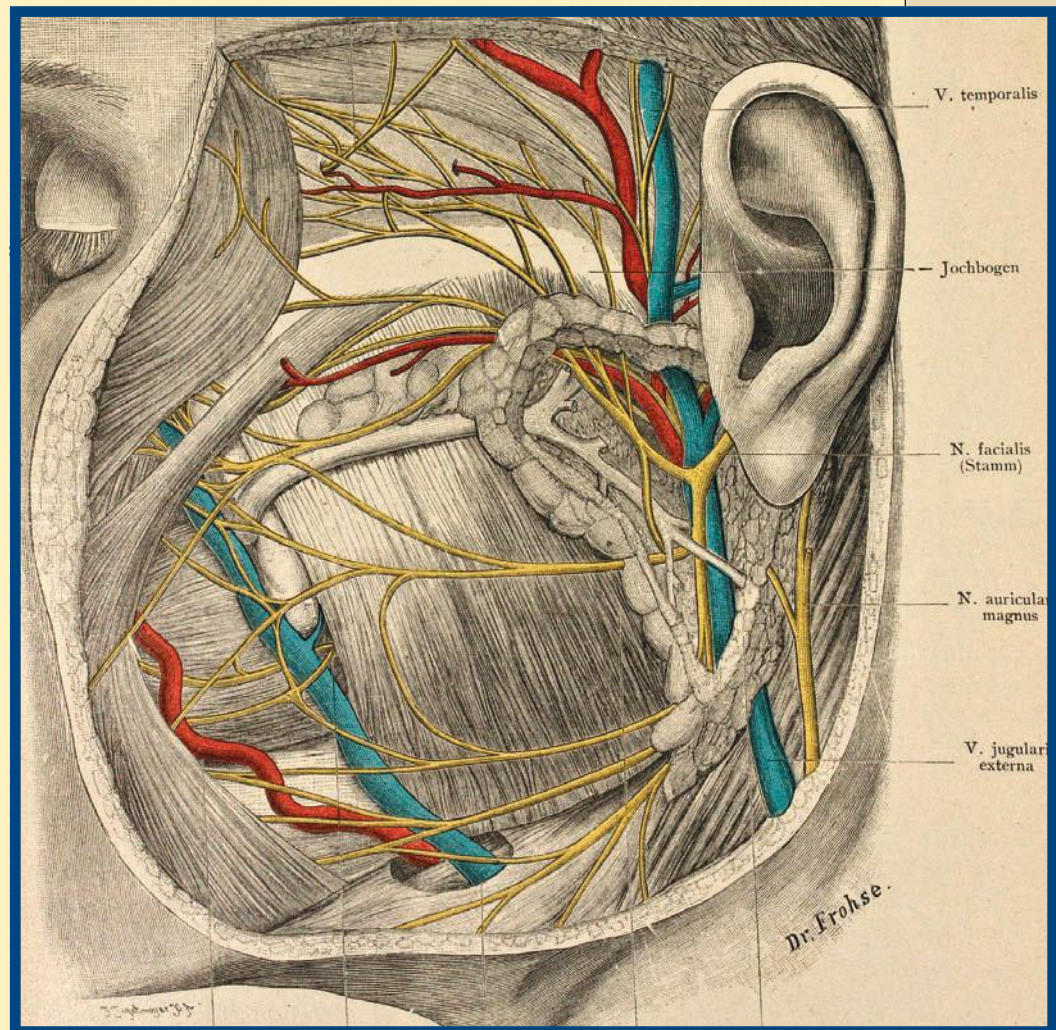
This page intentionally left blank

---

CHAPTER 6

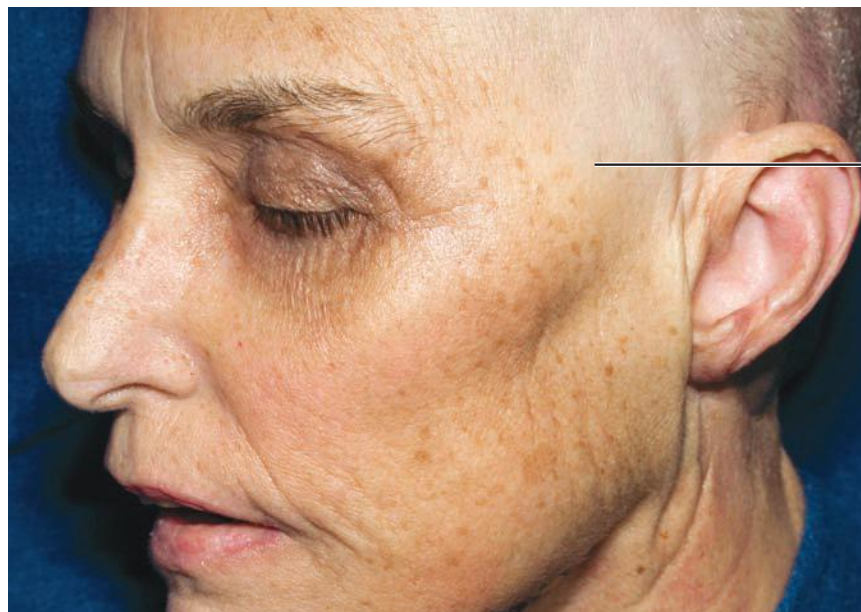---

# The Temporal Fossa

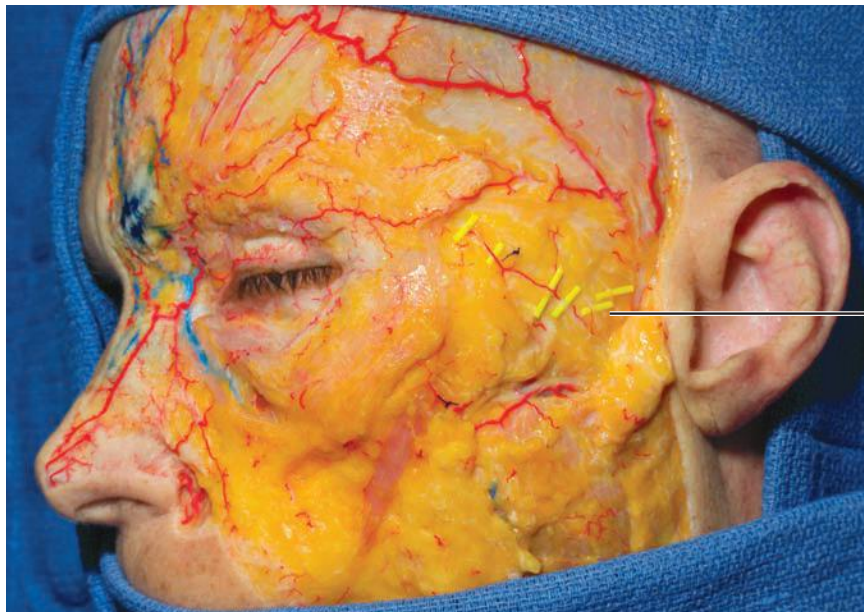

**A** number of fascial layers and fat pads or compartments help to define the temporal region. Knowledge of this area helps in the critical analysis of the temporal shape and contour. This information also facilitates safe dissection in a region prone to frontal nerve injury and temporal hollowing.

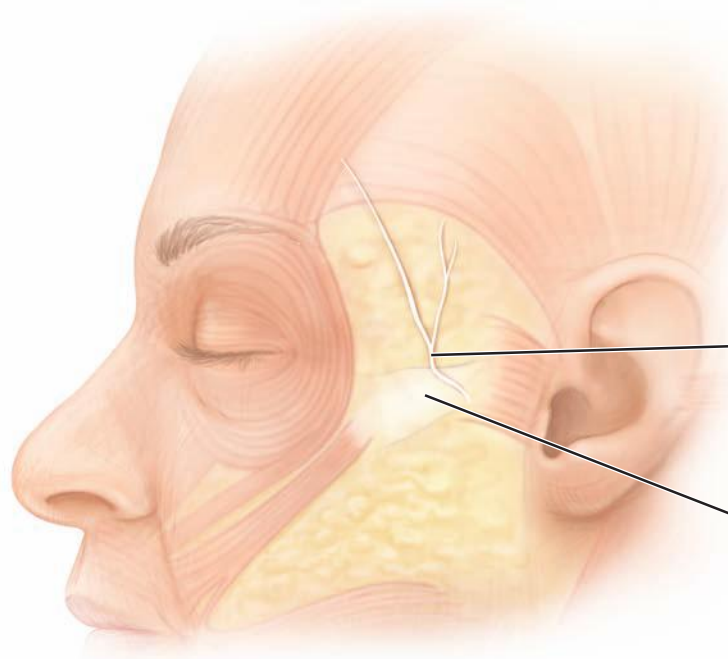
The temporal fossa has several distinct boundaries. Cross-sectional anatomy helps to define the deep boundary.



Temporal  
fossa



Facial nerve branches traveling through temporal fossa

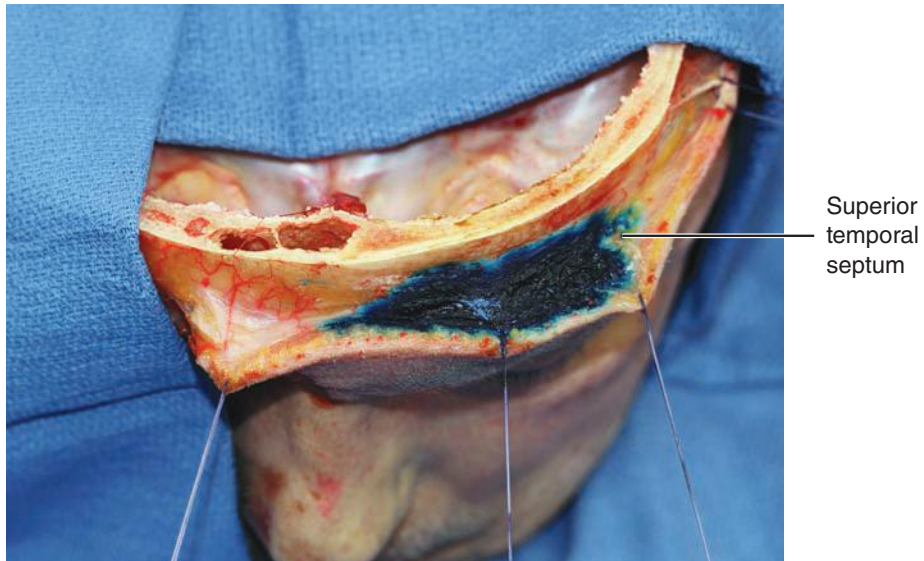


Frontal branch of facial nerve traveling through temporal fossa

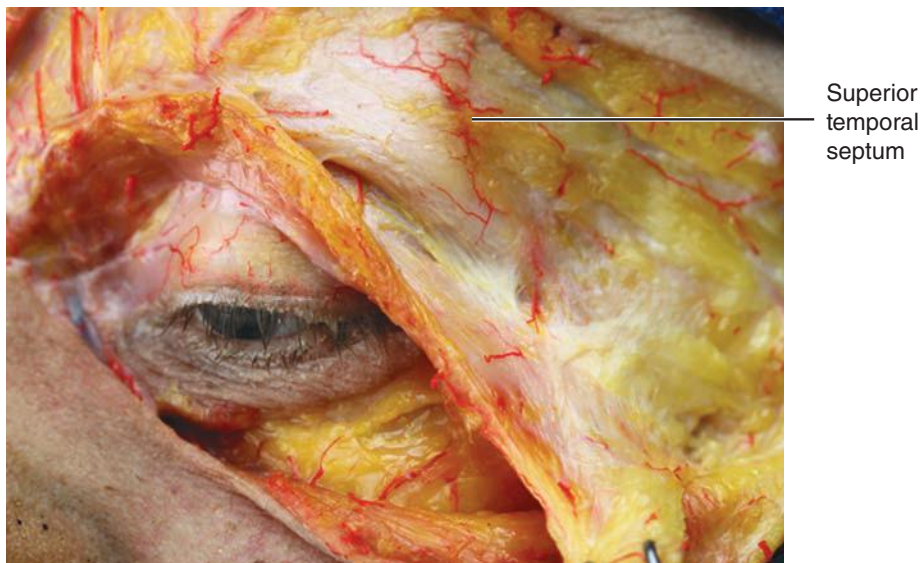Zygomatic arch

## BOUNDARIES

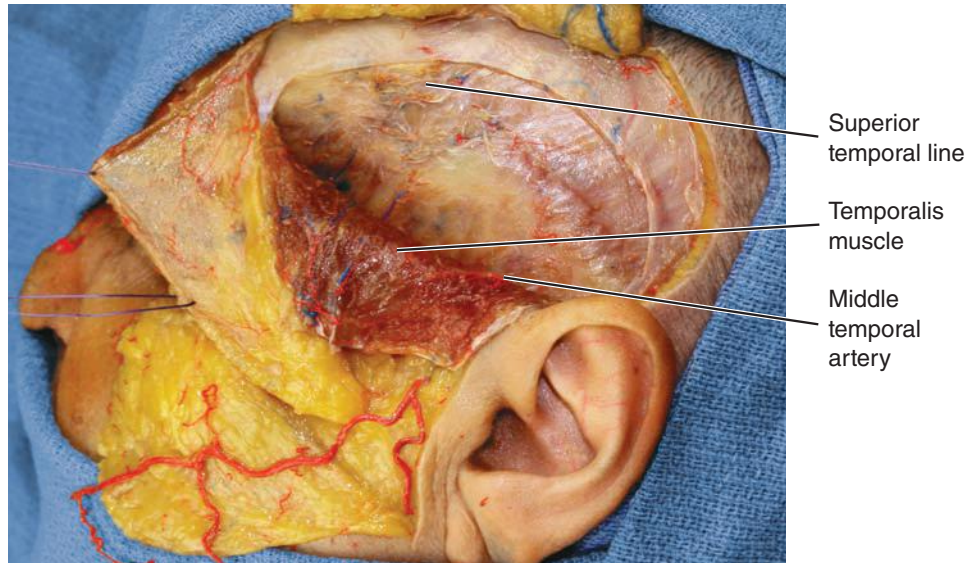
The superior temporal septum is the deep boundary between the central forehead and the temporal fossa.



The superior boundary is the temporal line.

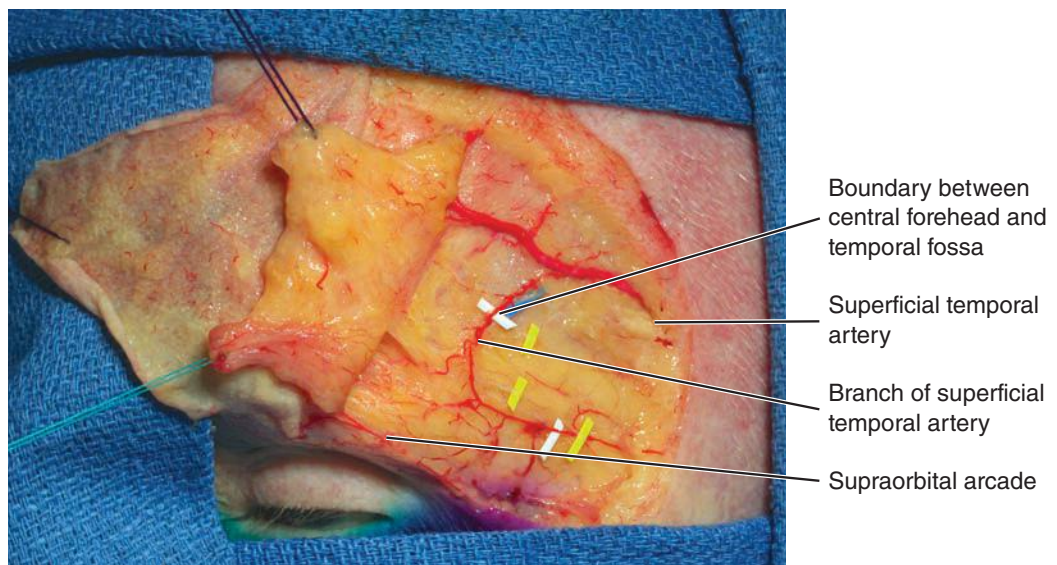


This is the origin of the temporalis muscle, which is innervated by the trigeminal nerve. The vascular supply is from a number of sources, including the middle and deep temporal arteries.

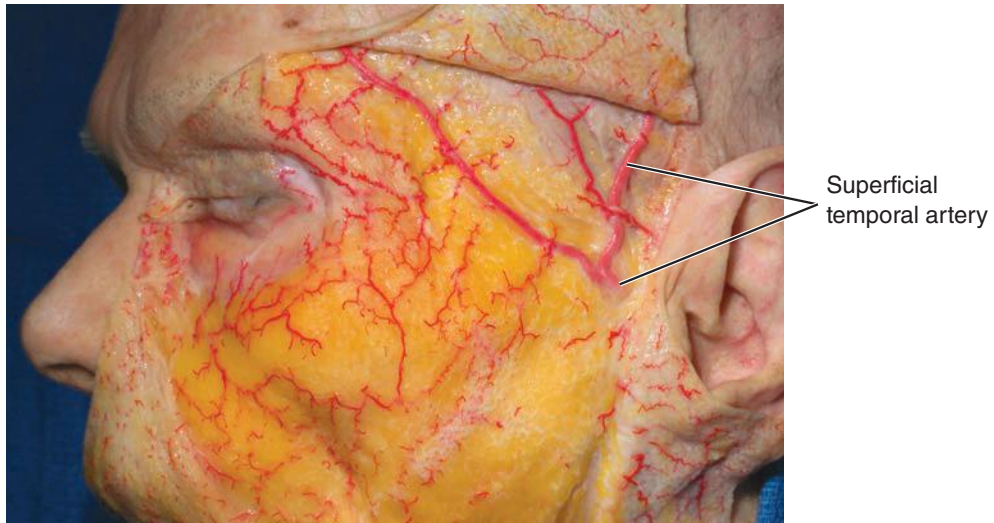


Superficial boundaries of the temporal region occur at the subcutaneous level. Here, fascial membranes associated with blood vessels create separate compartments. The arterial vessels are the roadmap for locating these compartments.

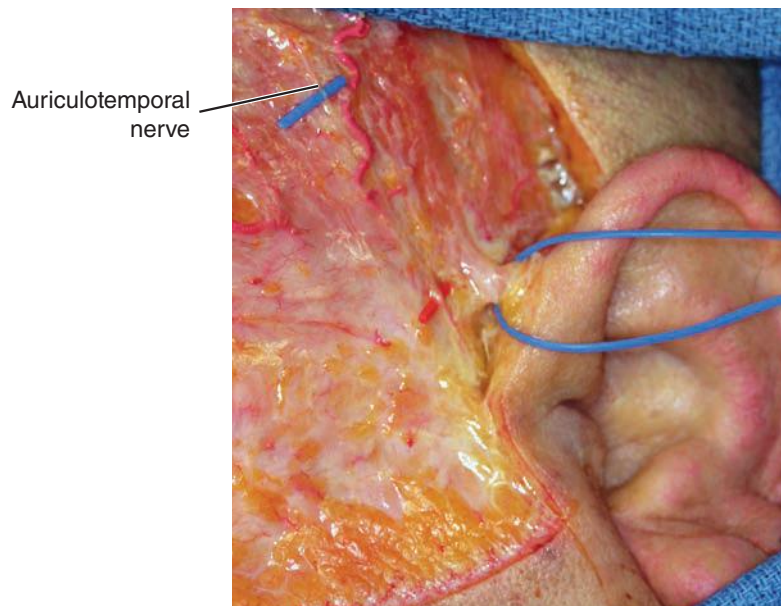
A branch of the supraorbital arcade, anastomosing with the superficial temporal artery, creates the boundary between the central forehead and the temporal region.



The superficial temporal artery marks the lateral boundary and corresponds to the preauricular crease.

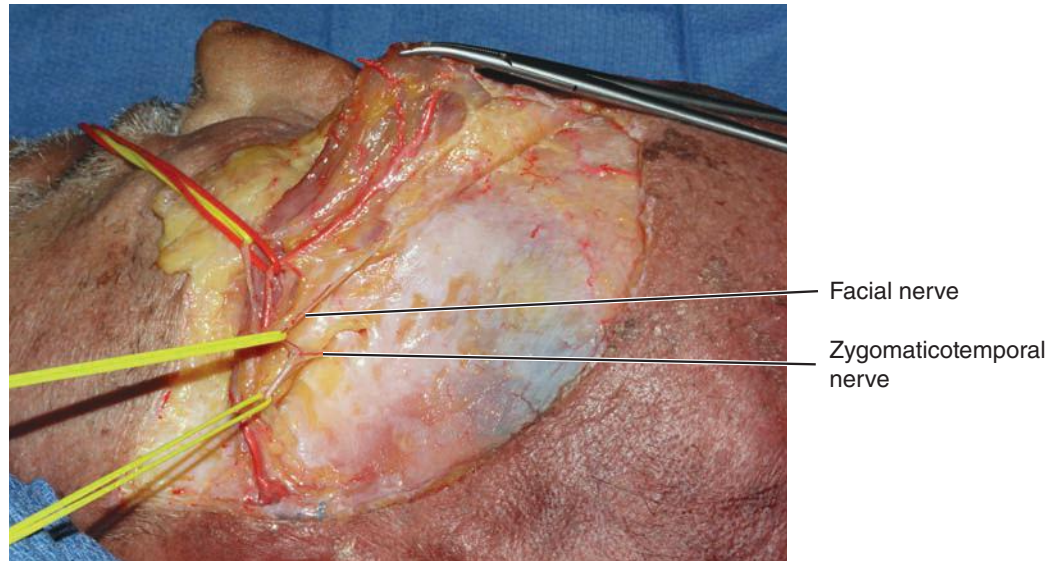


The course of three nerves is important clinically. The auriculotemporal nerve runs just medial to the auricle. It is easily differentiated from facial nerve branches because it travels in a more superficial plane above the muscles and fascia.



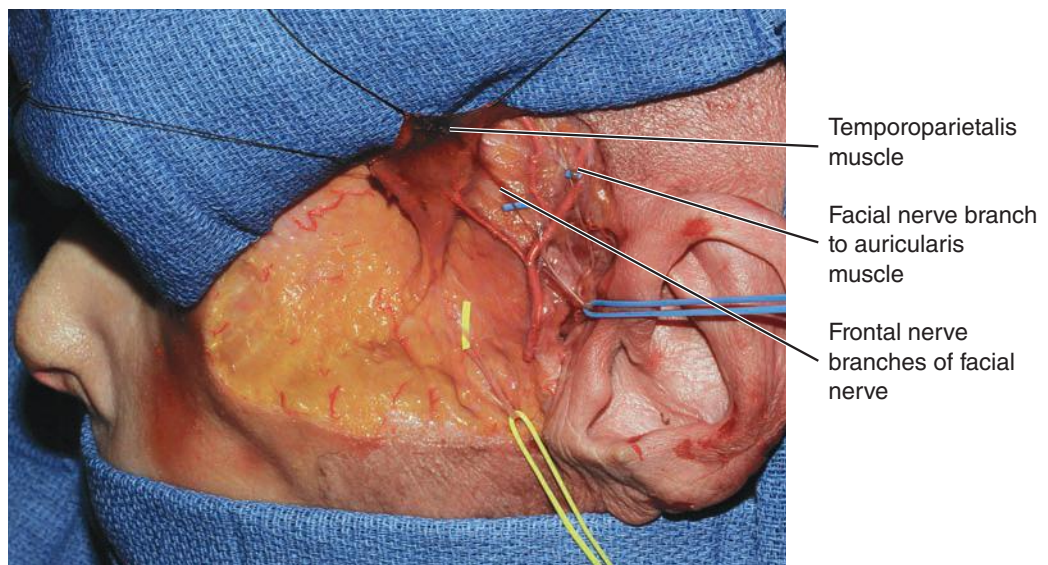
The superficial temporal artery travels with the auriculotemporal nerve and can serve as a topographic landmark for the position of the nerve.

The zygomaticotemporal nerve travels through the temporal fat pad. That it can send branches to travel with the facial nerve has been known for almost a century.



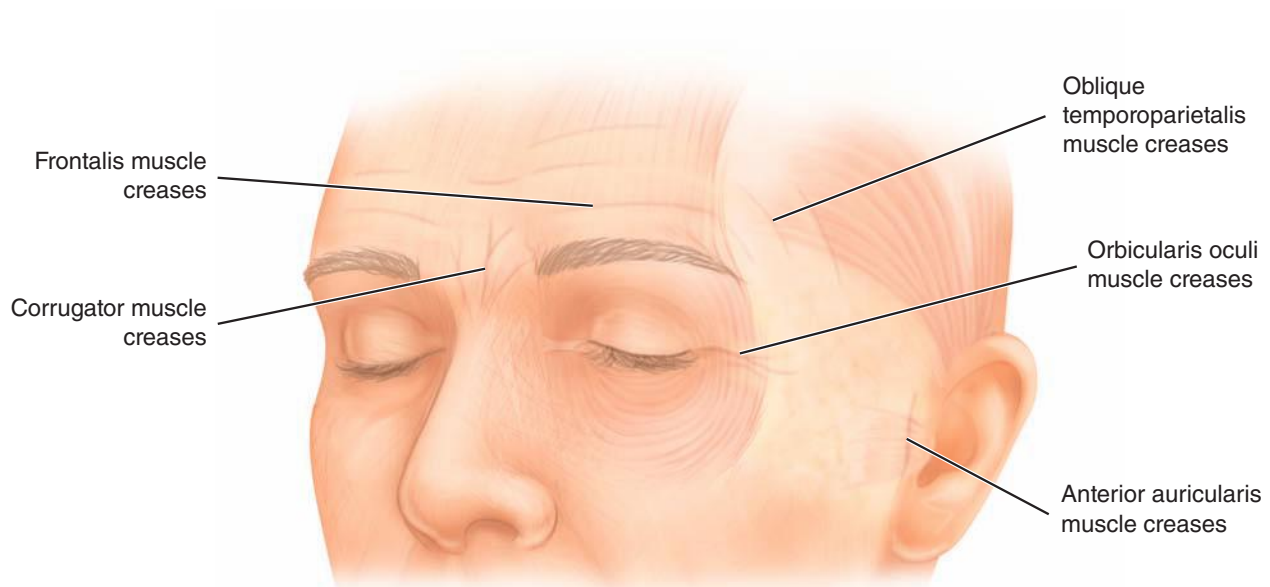
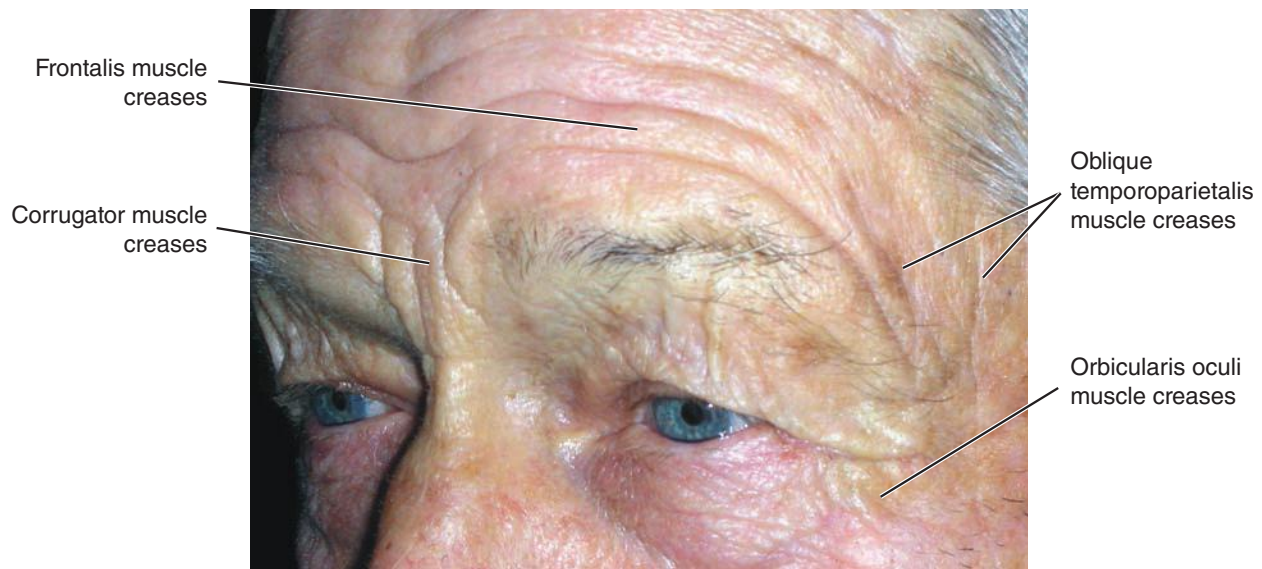The frontal branch of the facial nerve provides the main innervation to the forehead muscles and part of the innervation to the orbicularis oculi and corrugator supercilii muscles. Frontal branch injury results in near-complete paralysis of the frontalis muscle. Corrugator activity may be spared because of its additional innervation.

The term *temporal branch of the facial nerve* is used interchangeably with *frontal nerve branch*. There are multiple branches that run deep to the muscle they innervate.

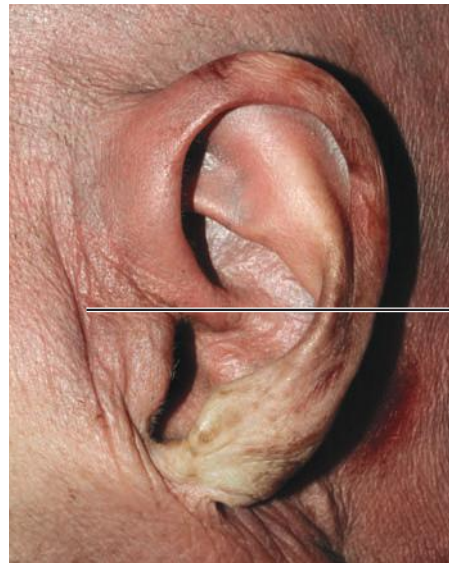


## WRINKLES AND CREASES

The location of forehead muscles can be predicted based on the direction of wrinkles or creases. Wrinkles and creases form perpendicular to the direction of muscle contraction. Frontalis creases are nearly horizontal. The presence of oblique and vertical creases suggests the presence of muscles with an orientation different from that of the frontalis muscle.

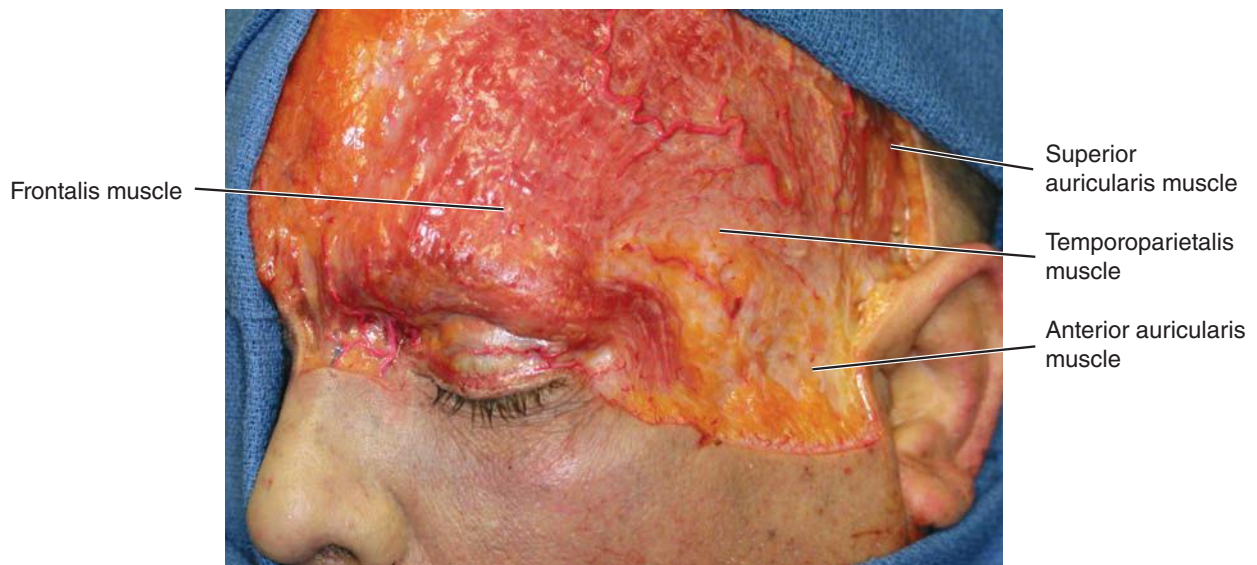

Vertical preauricular creases are associated with the anterior auricularis muscle that extends into the temporal fossa.



Anterior auricularis muscle crease

The anterior and superior auricularis and temporoparietalis muscles may be quite developed in certain individuals. In other individuals, these muscles may be almost vestigial. Instead, superficial fascia is noted.



Frontalis muscle

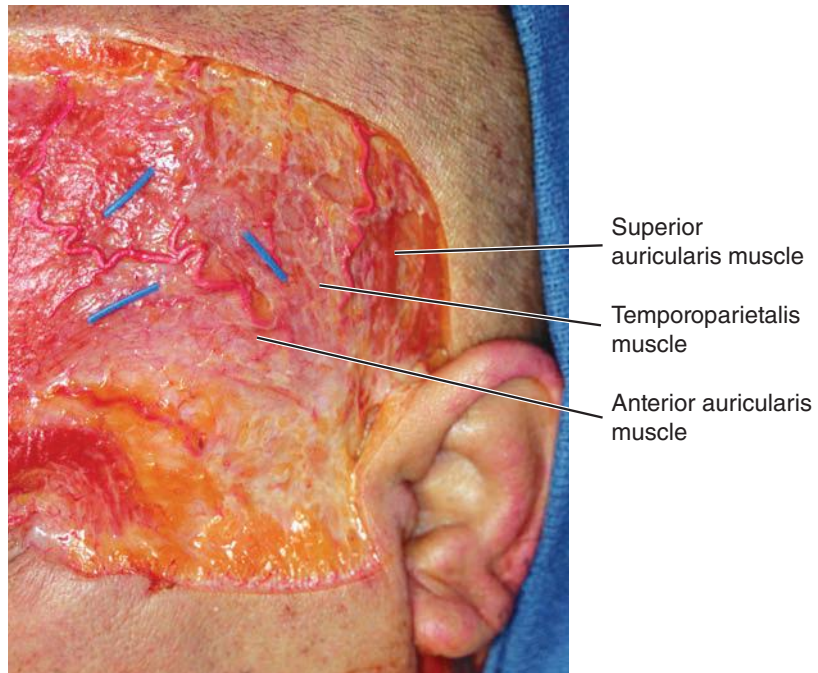
Superior auricularis muscle

Temporoparietalis muscle

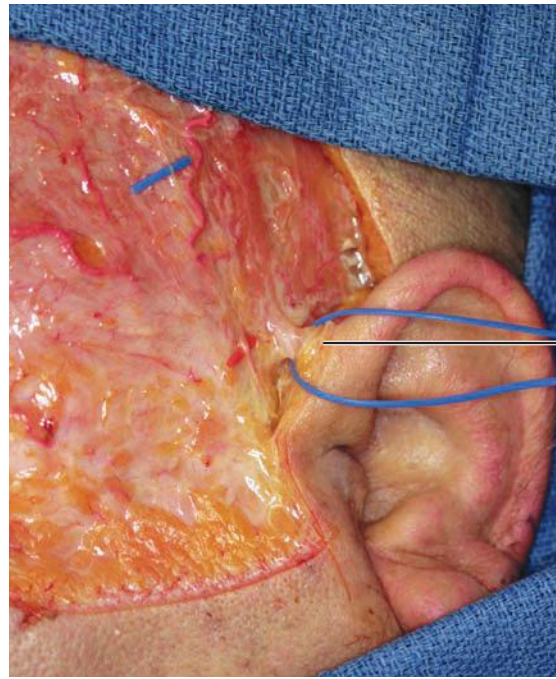
Anterior auricularis muscle

When present, each of these muscles has a slightly different orientation and therefore each creates a distinct crease or wrinkle.

The orientation of the forehead wrinkles helps to identify the presence and relative location of the forehead muscles.



The superior auricularis muscle has a well-developed tendon, similar to the posterior auricularis muscle.

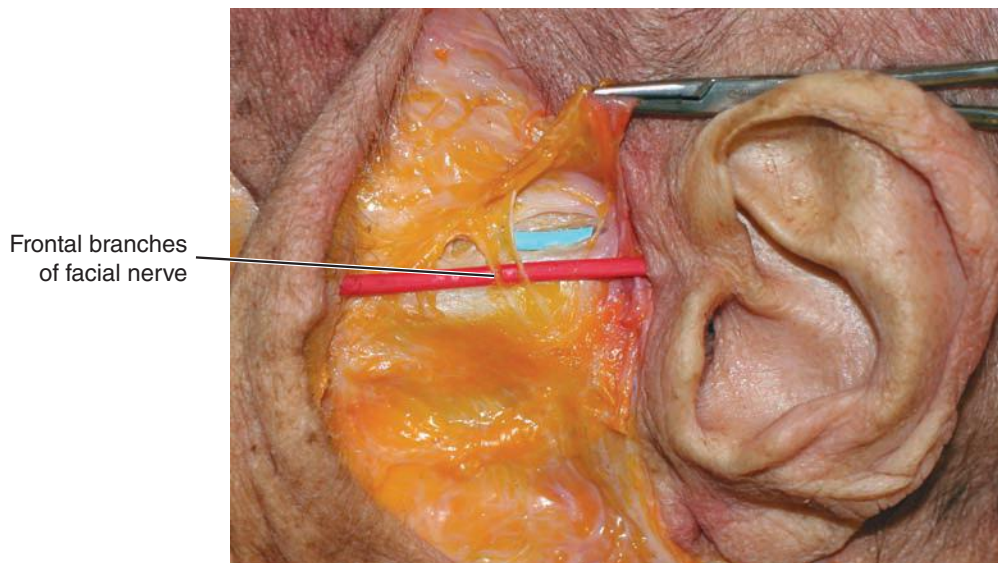


Tendon of superior auricularis muscle

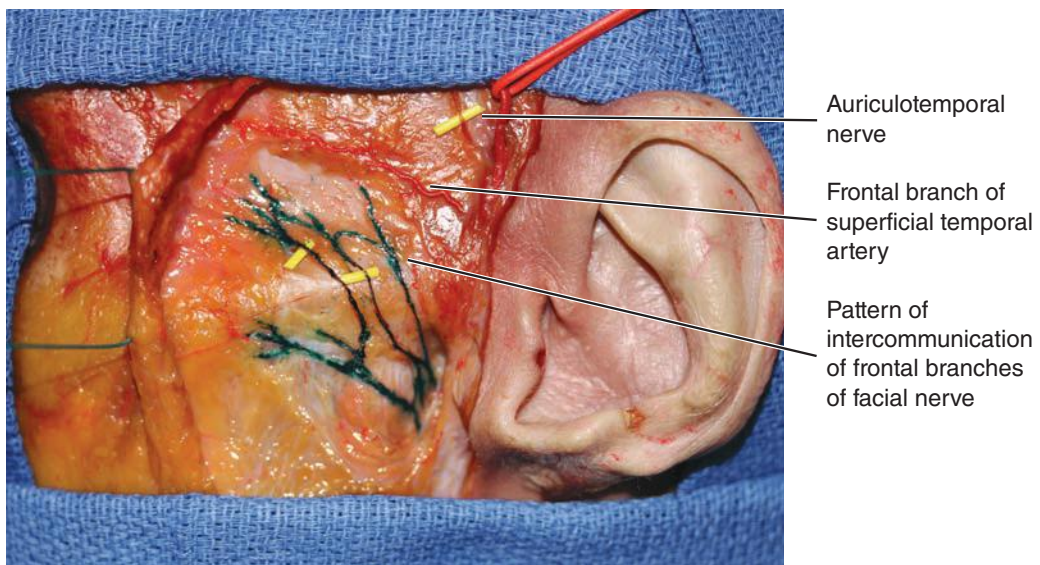
## PATH AND TRAJECTORY OF THE NERVES OF THE TEMPORAL REGION

All of these muscles, including the frontalis, are innervated by the frontal branch of the facial nerve, which enters these muscles on their undersurface. This defines the depth at which the frontal branch travels as it courses in the temporal fossa.

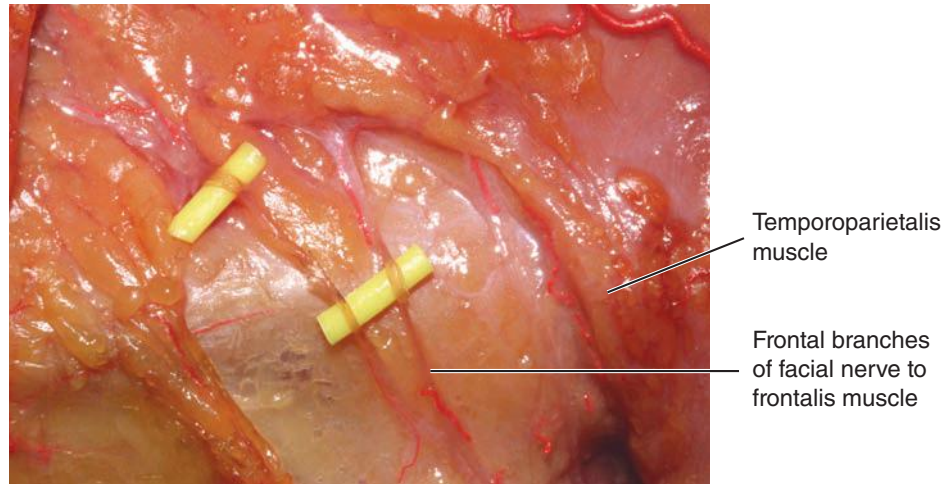
Because there are multiple forehead muscles, multiple branches of the frontal nerve exist. Usually two to four branches can be located.



Here, a braided pattern of communication between the multiple branches can be seen. Note the position of these branches to the frontal branch of the superficial temporal artery.

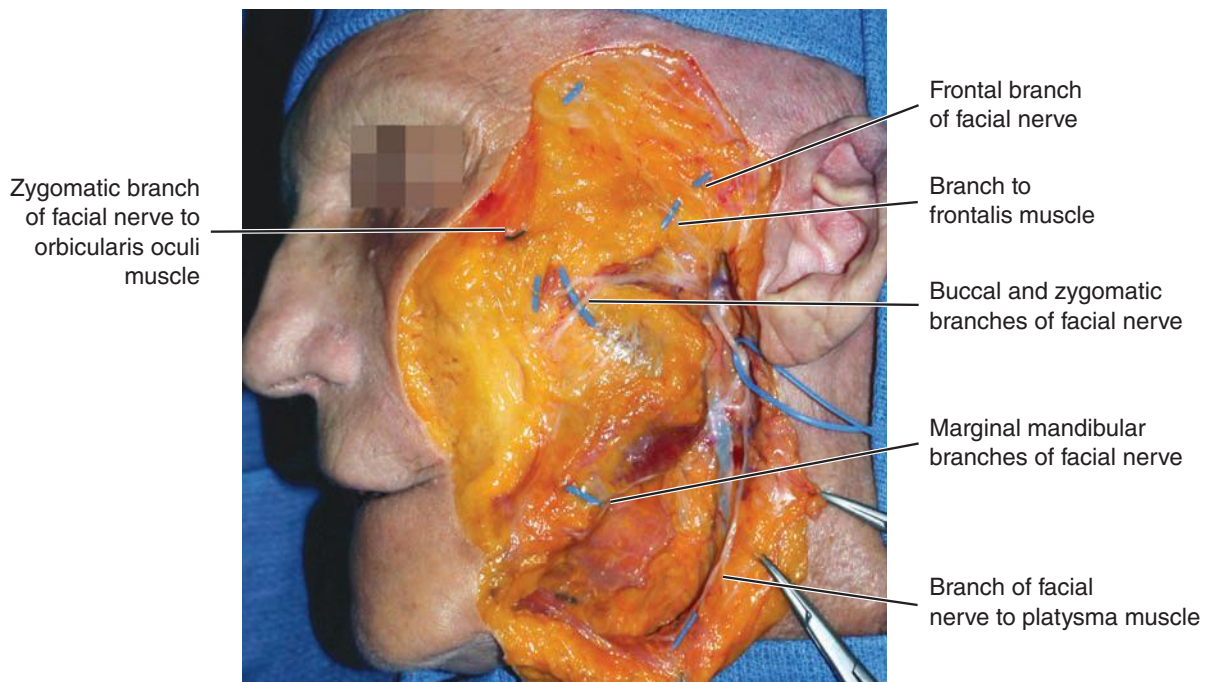


The frontal branch is mobile over the zygomatic arch.



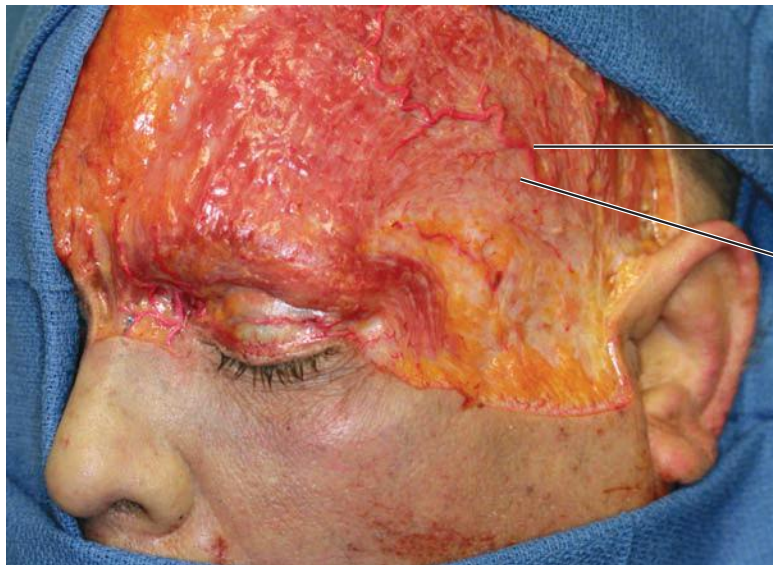The trajectory and path of each branch of the frontal nerve are determined by what muscle it innervates.

The most clinically significant forehead muscle is the frontalis. Knowledge of the path of its nerve is critical to avoid paresis or paralysis of this muscle.



Landmarks are useful to predict the course of this branch to the frontalis muscle. Estimates or measurements of where it crosses the zygomatic arch are variable.

The path of the frontal artery is a useful landmark for predicting the location and course of the frontal nerve.

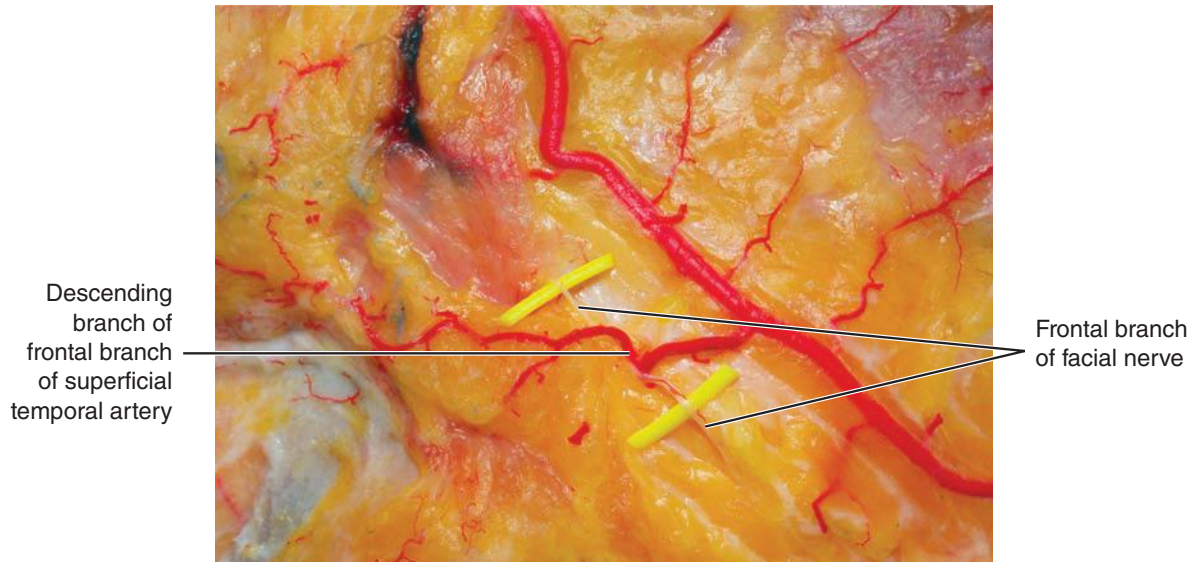
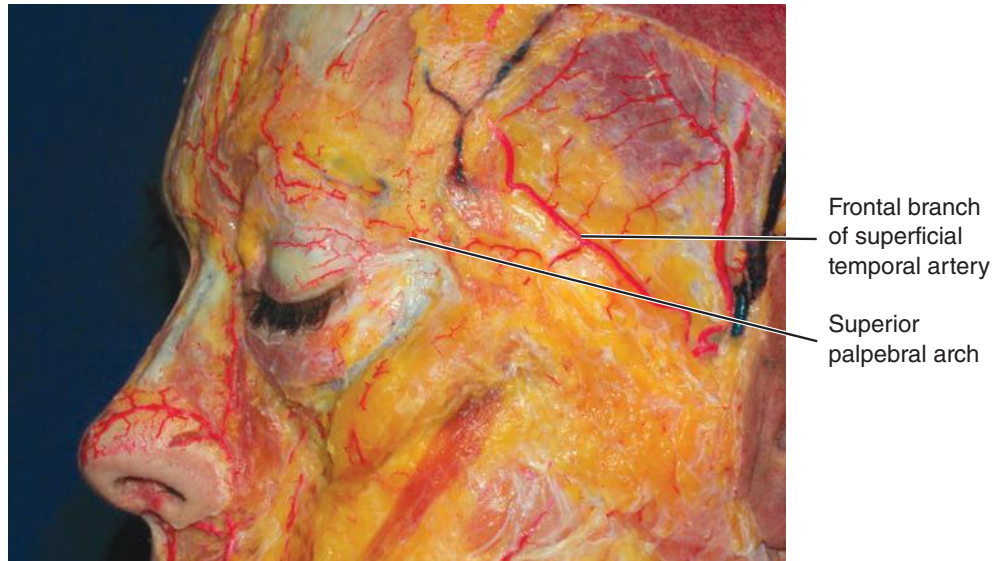


Course of  
frontal branch  
of superficial  
temporal artery

Nerve travels  
caudal to artery

All frontal nerve branches—the sole exception being the branch to the superior auricularis muscle—will travel in a line caudal to the path of the frontal branch of the superficial temporal artery.

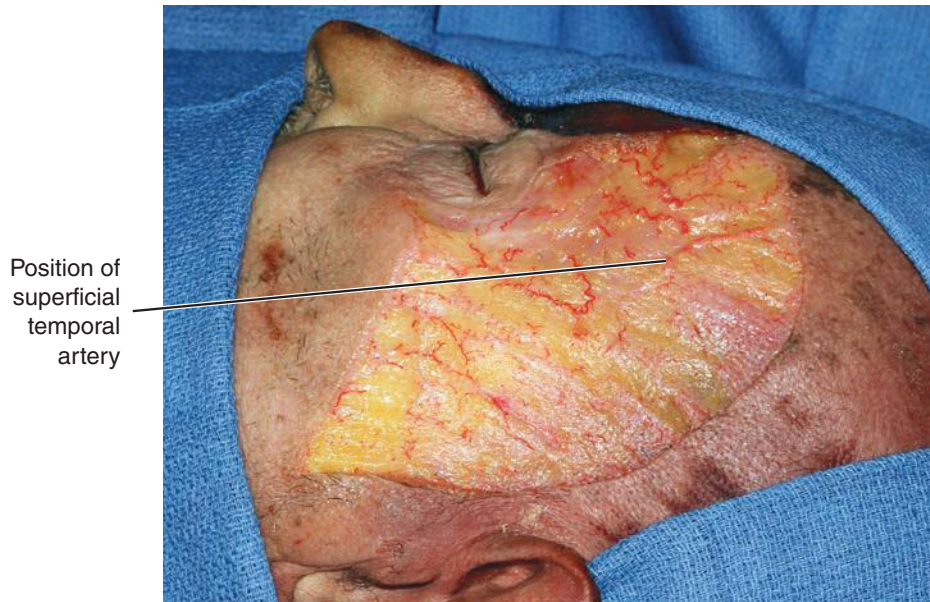The course of the frontal artery is superior (cephalad) to the course of the frontal nerve. This artery can usually be identified by observation or palpation. It may be apparent in some individuals. The frontal branch of the superficial temporal artery and superior palpebral arch are noted.



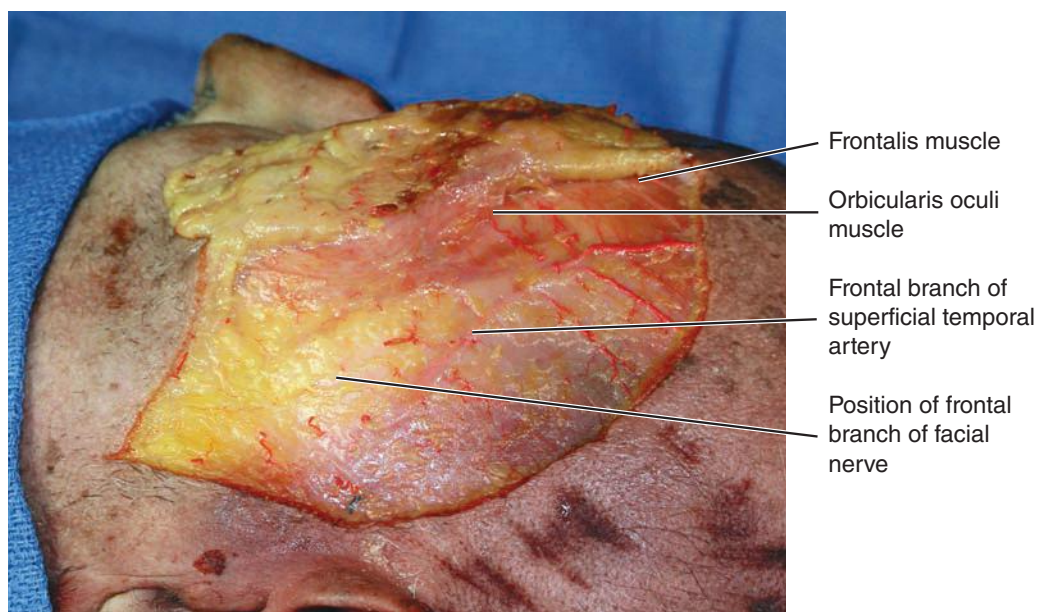
Note the position of the frontal branch of the facial nerve to the lateral palpebral artery. The nerve changes its plane from deep to superficial as it crosses this artery. It is here that many of the injuries to this nerve occur. The proximity of the nerve to the artery explains why cauterization of this vessel leads to frontalis muscle contraction.

Facial nerve branches change planes and become more superficial at the border of the muscle they animate.

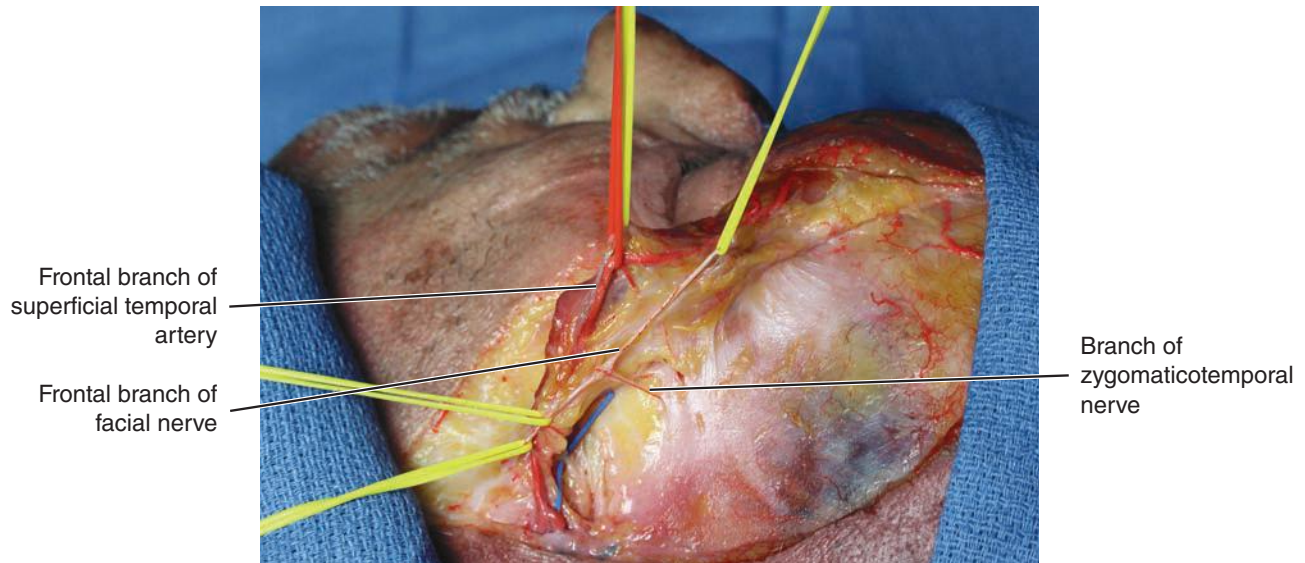
The following dissection illustrates the course and position of the frontal branch relative to the artery. The skin has been removed to reveal the subcutaneous tissues. The artery is immediately visible.



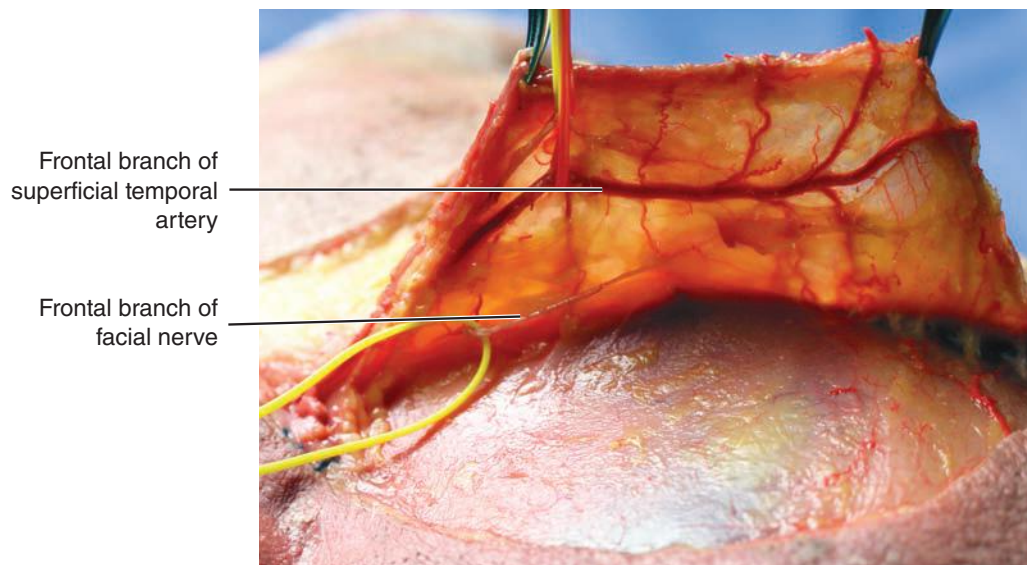
Dissection elevates the superficial fascia and the orbicularis and anterior auricularis muscles.



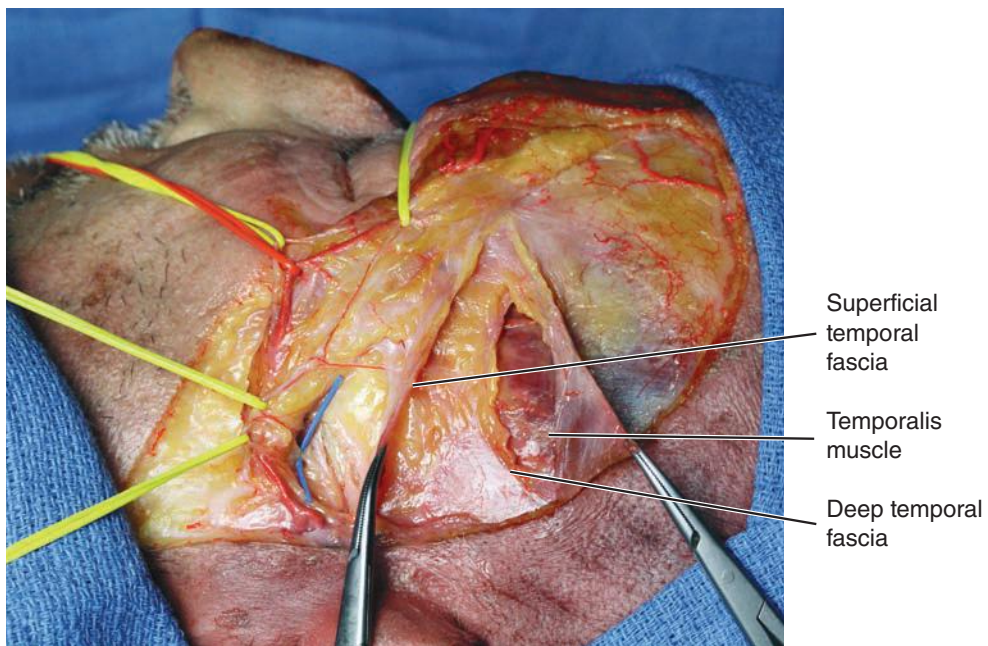
The artery and nerve are identified, along with a branch of the zygomaticotemporal nerve.



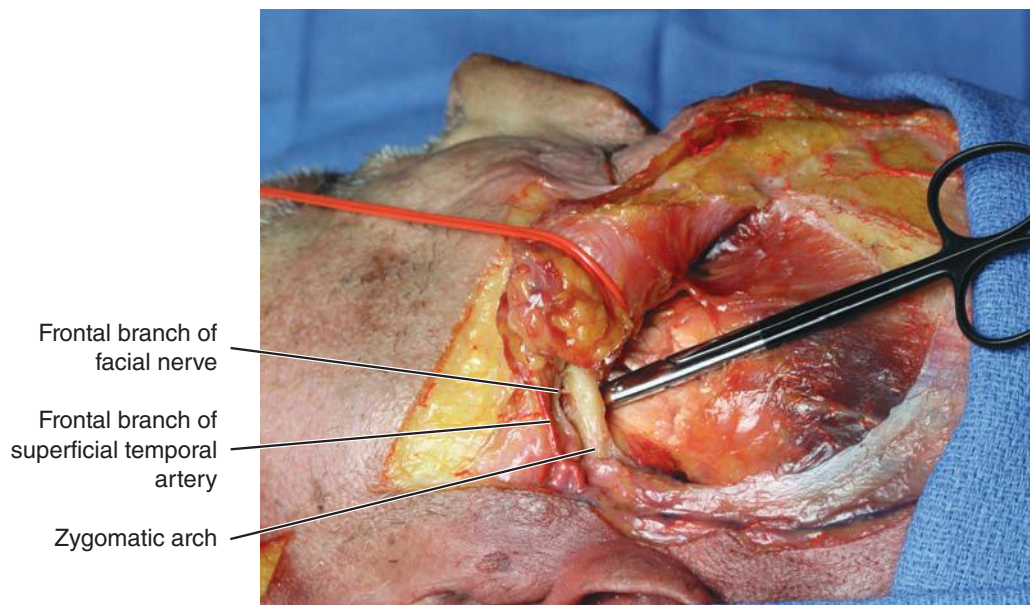
Transillumination shows the position of the frontal nerve caudal to the frontal artery. This is a reliable surface landmark for predicting the vertical location of frontal branch of the facial nerve.



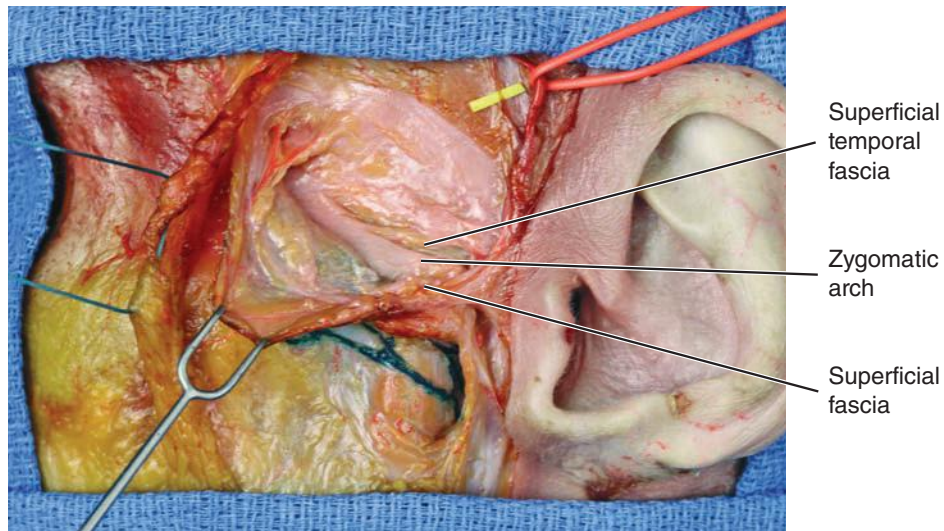
Continued dissection demonstrates one surgical technique for approaching the zygomatic arch. The plane of dissection is between the superficial and deep temporal fascia. The superficial fascia has been elevated and the deep temporal fascia incised.



Subperiosteal dissection reveals the zygomatic arch. The artery and nerve are noted.

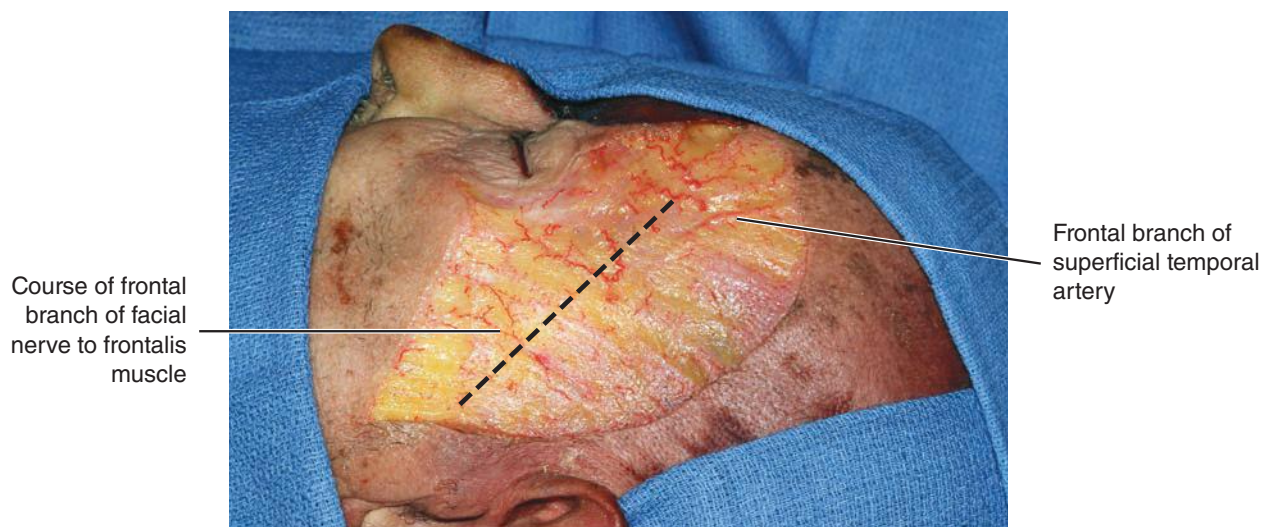


Dissection deep to the superficial temporal fascia is shown.

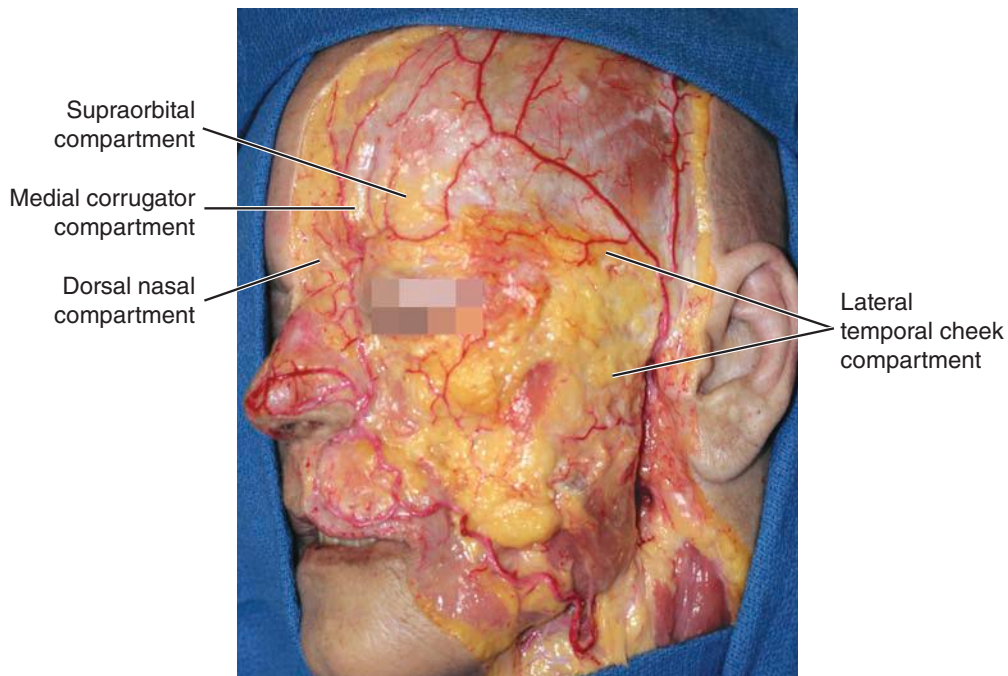


Subcutaneous dissection in this region, although possible, is difficult and risks nerve injury for two reasons. The first is that the subcutaneous tissue thickness is not uniform. Different adipose compartments have varying thicknesses, and the subcutaneous tissue may be extremely thin in elderly individuals. The second and main reason is that the anatomic compartments create dense fascial systems at the subcutaneous level.

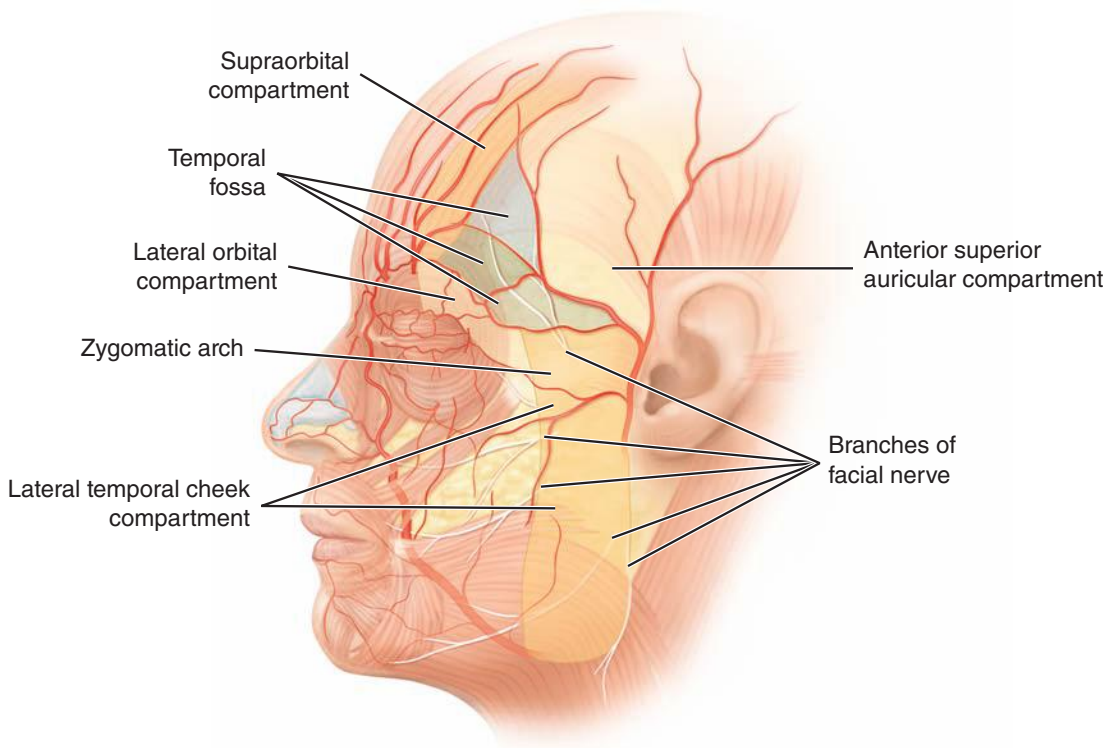
Transition zones between subcutaneous compartments are sites of potential facial nerve injury.



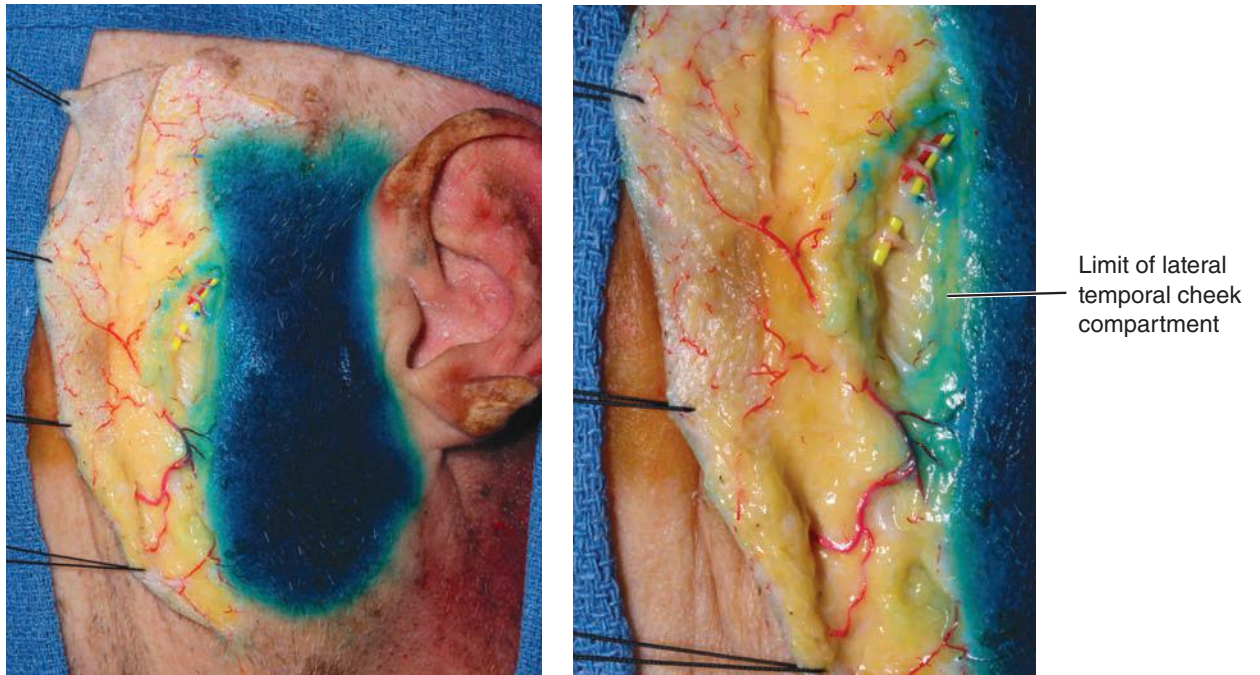
The compartments are defined by the regional blood supply. Their location correlates with the position of major source vessels.



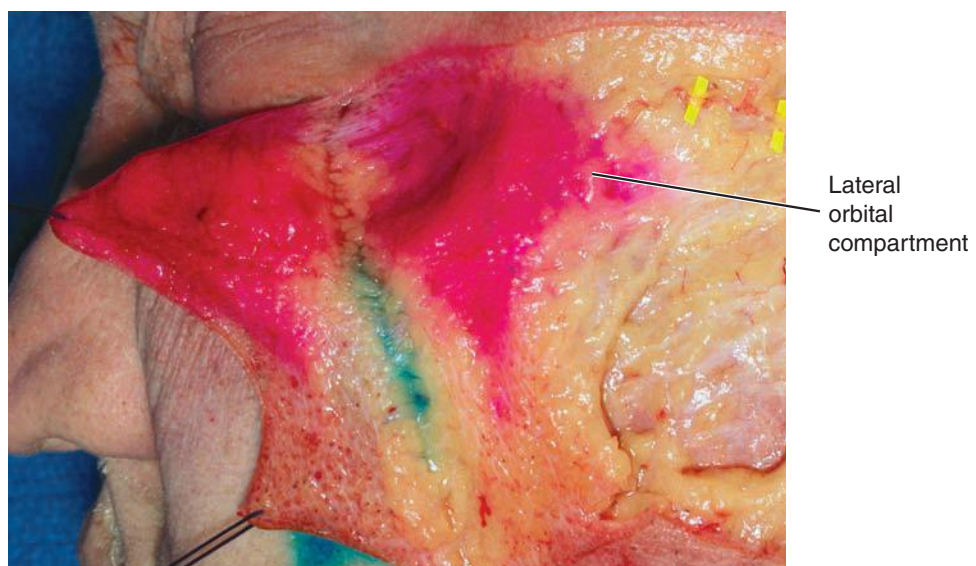The superficial boundaries of the temporal fossa are delineated below.



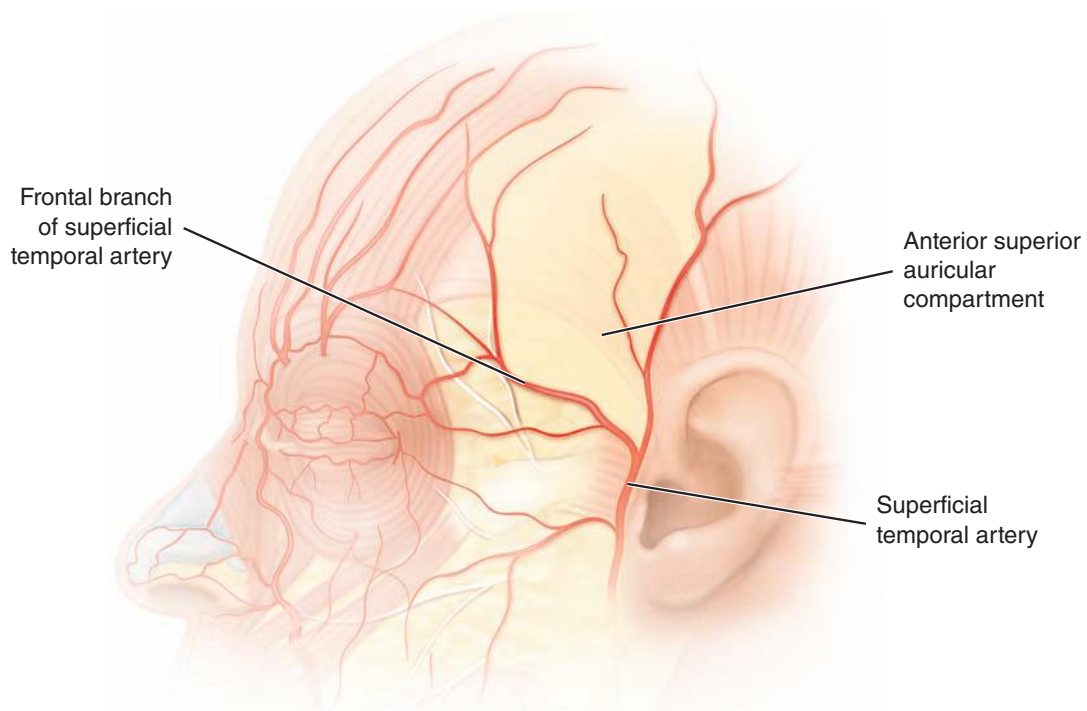
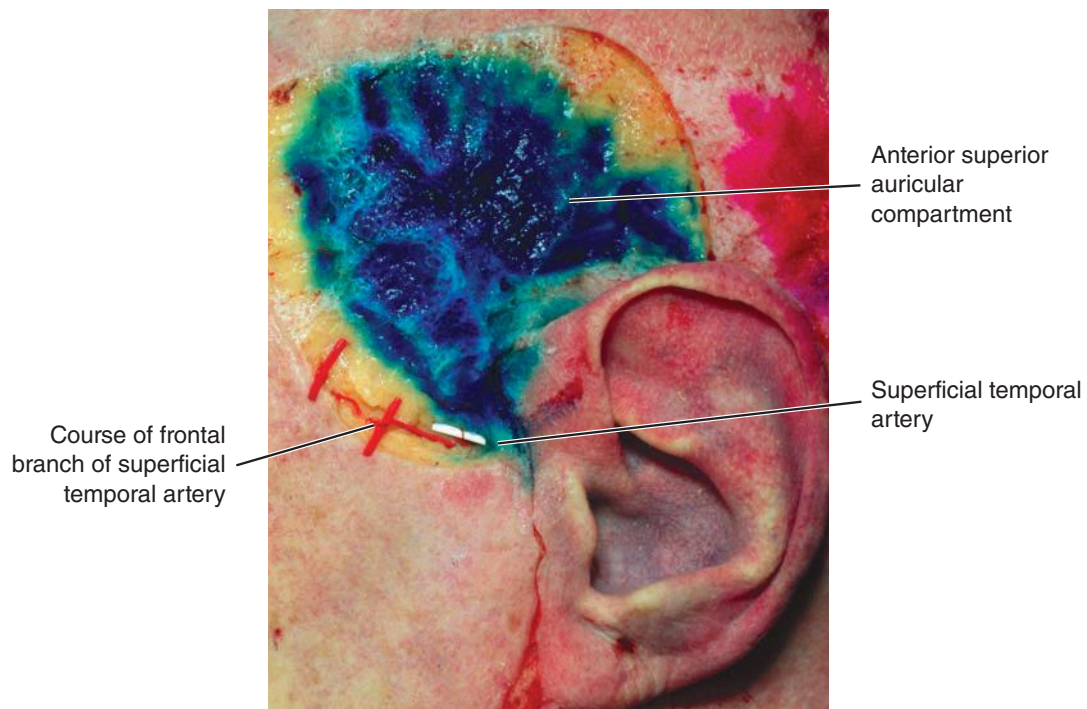
The limits of the lateral temporal cheek compartment are shown. This is a transition zone between the lateral cheek compartment and the lateral temporal cheek compartment, where the facial nerve may be injured.



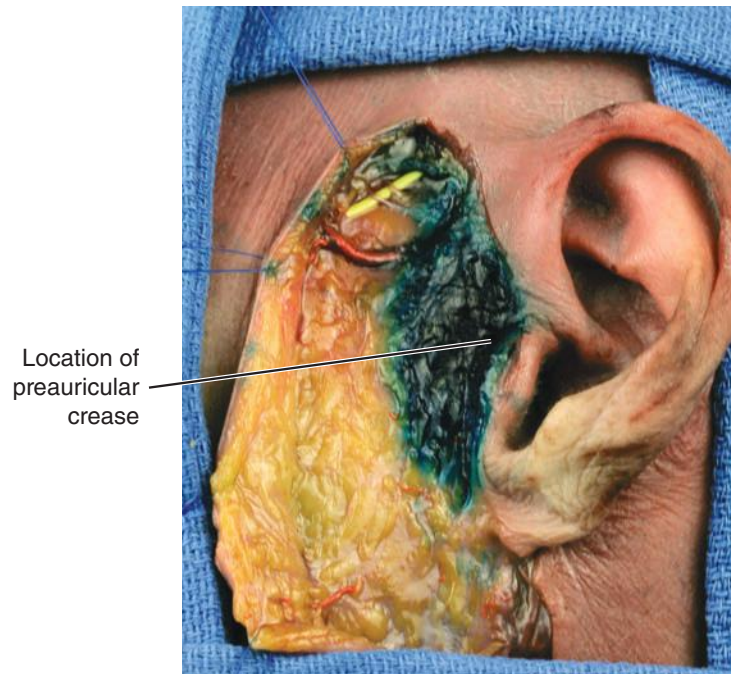
The lateral orbital subcutaneous compartment overlaps into the temporal fossa.



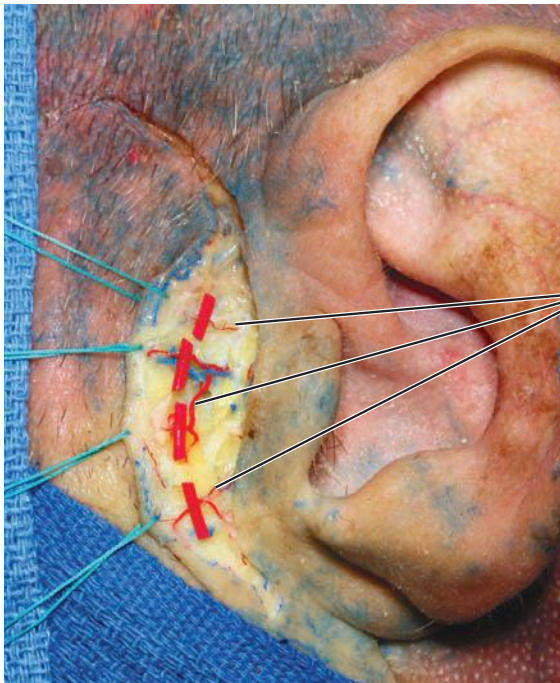
The location of the anterior superior auricular compartment coincides with the location of the superficial temporal and frontal branch arteries.



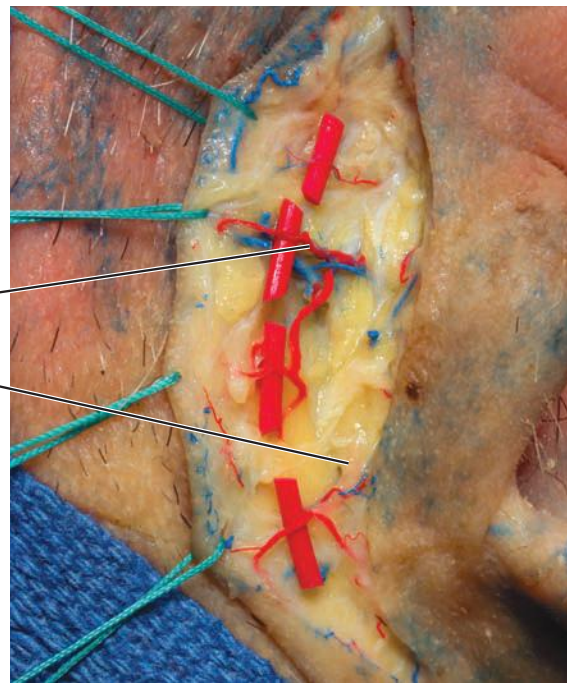
The preauricular crease is the anterior boundary of the preauricular compartment. This compartment extends into the temporal fossa.



Perforators from the superficial temporal artery define this compartment.

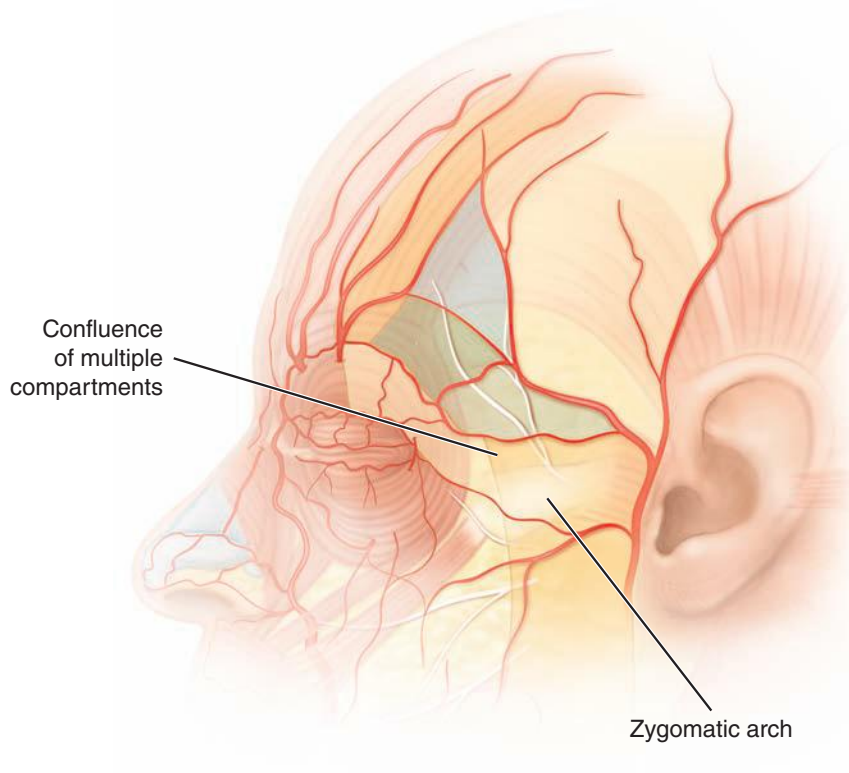
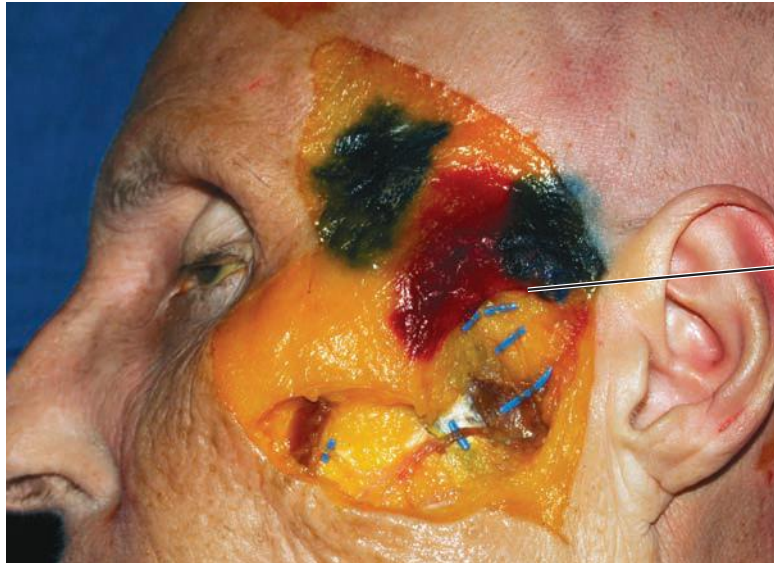

Perforators from superficial temporal artery define preauricular crease



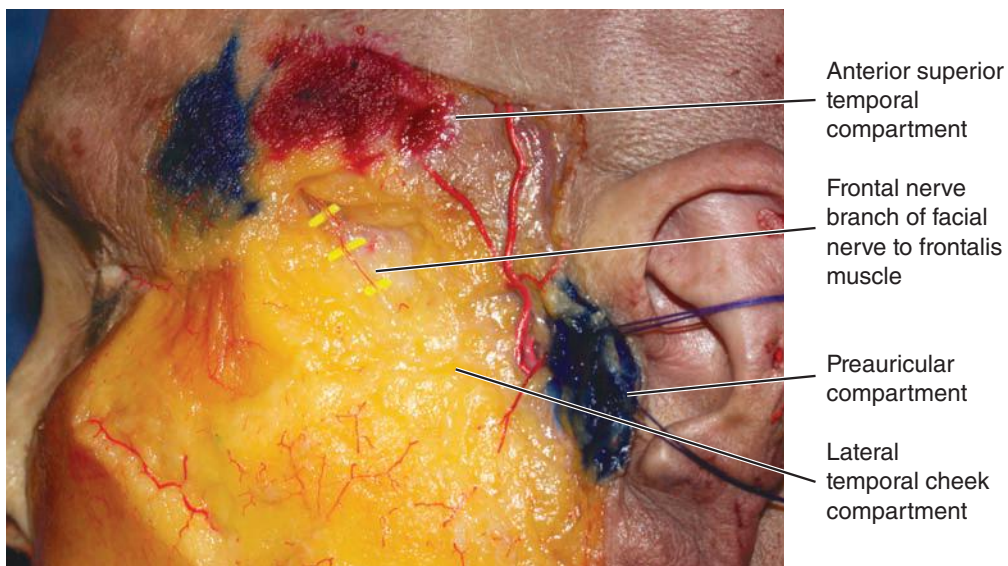
Perforator  
Superficial temporal artery

The point at which several compartments meet creates a dense fascial system; the skin is more tethered to the underlying fascia. Multiple compartments meet over the zygomatic arch, determined by the underlying blood supply.

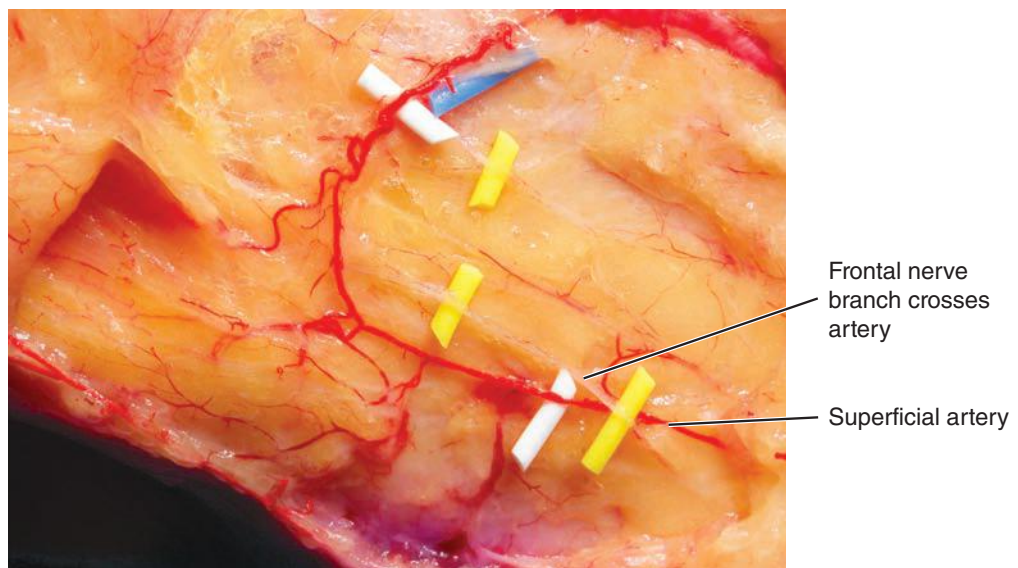
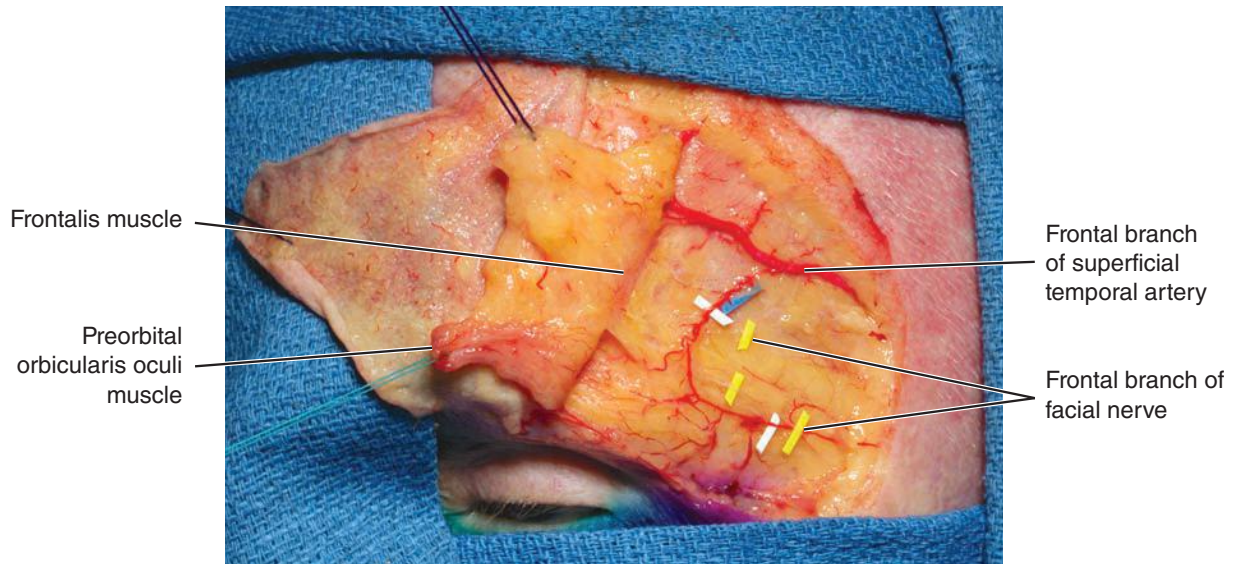


The frontal branch of the facial nerve travels over the zygomatic arch directly beneath the junction of the preauricular, anterior superior temporal, and lateral temporal compartments. This is a potential site of frontal nerve injury when subcutaneous dissection is performed.

The nerve is identified caudal to the frontal artery. This information enables the clinician to better understand the surgical planes through which the frontal nerve travels.



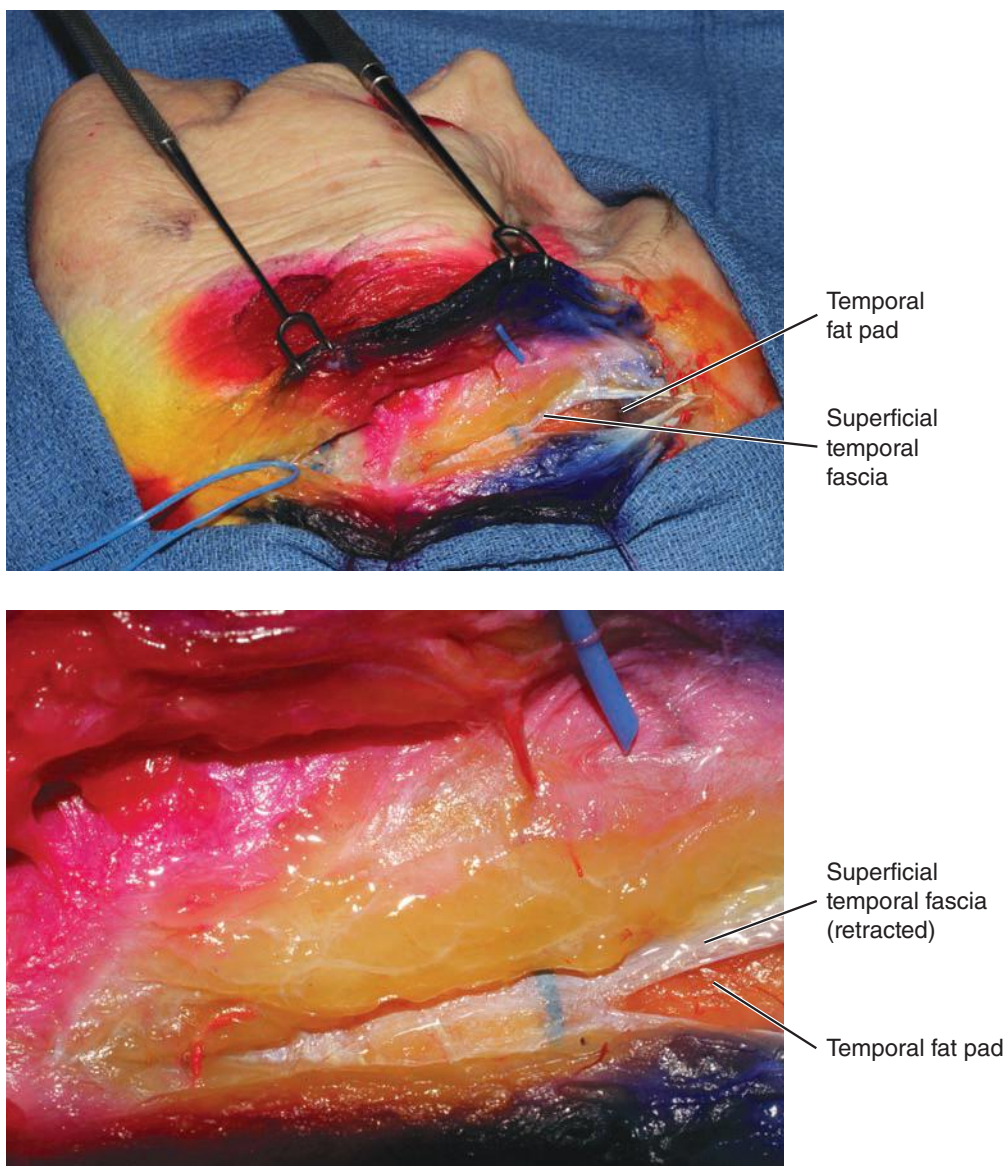
A most important concept is that motor nerves change planes from deep to superficial as they near their target muscle. Note how the frontal branch of the facial nerve crosses a superficial artery as it nears the frontalis muscle.



All motor nerves, including the frontal, buccal, and marginal mandibular branches, become most superficial at the border of the muscle they innervate. The lateral borders of these muscles are key landmarks for sites of potential motor nerve injury.

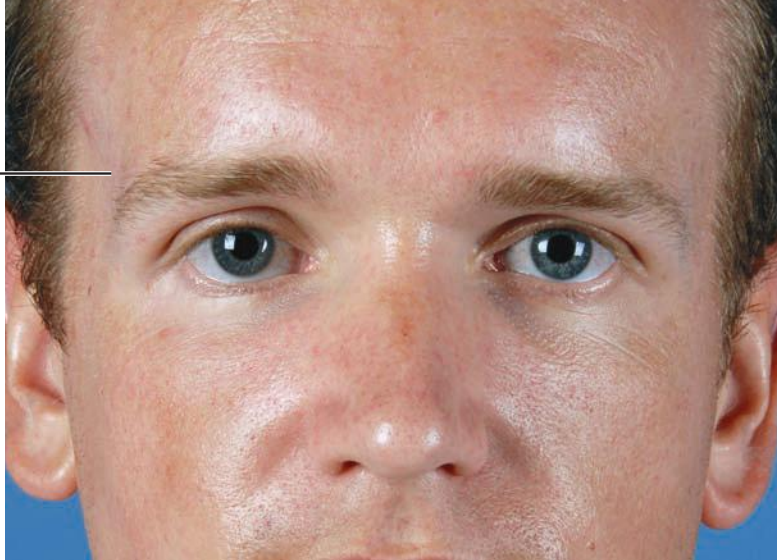## TEMPORAL HOLLOWING

Multiple fat pads and fat layers are found in the temporal region. Loss of fat, either due to aging or due to iatrogenic injury, can lead to temporal hollowing. Classically, *temporal hollowing* describes the characteristic appearance that occurs when there is loss of the superficial temporal fat pad. This pad can be highlighted by staining all the other adipose layers of the temporal fossa. The artery supplying this fat pad is at risk for injury with dissection in and above this fat pad.

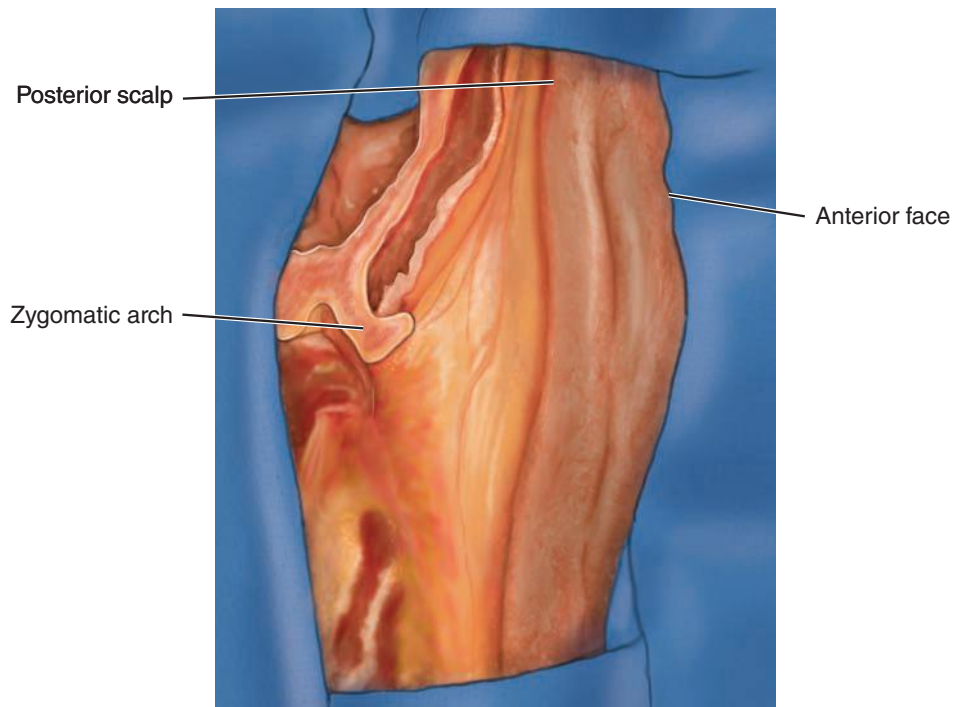
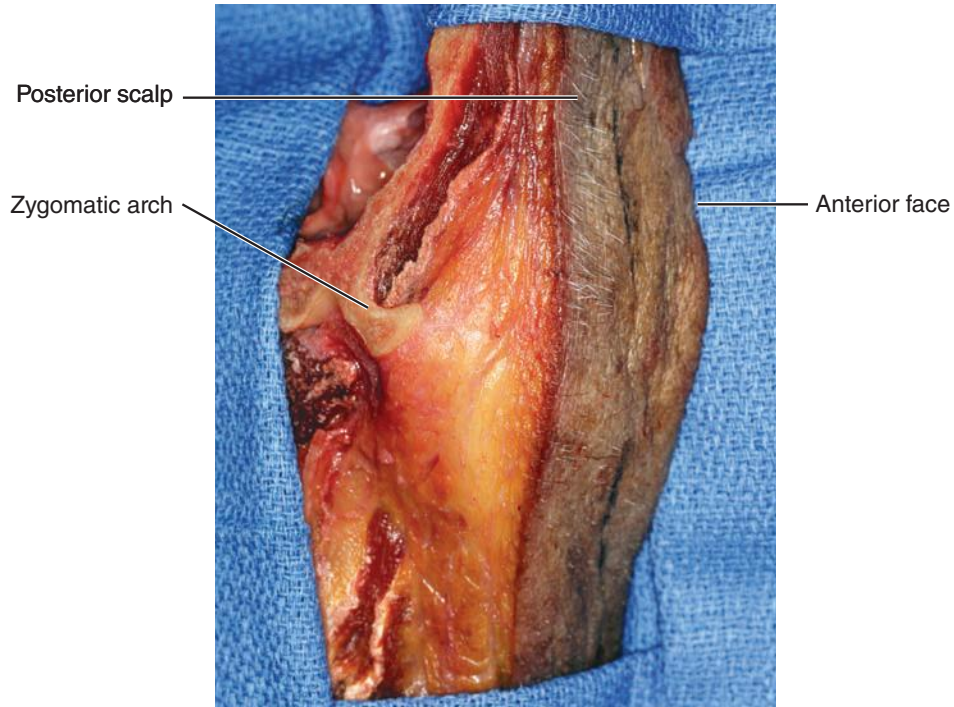


Temporal hollowing may also refer to other causes of volume loss of the temporal fossa.

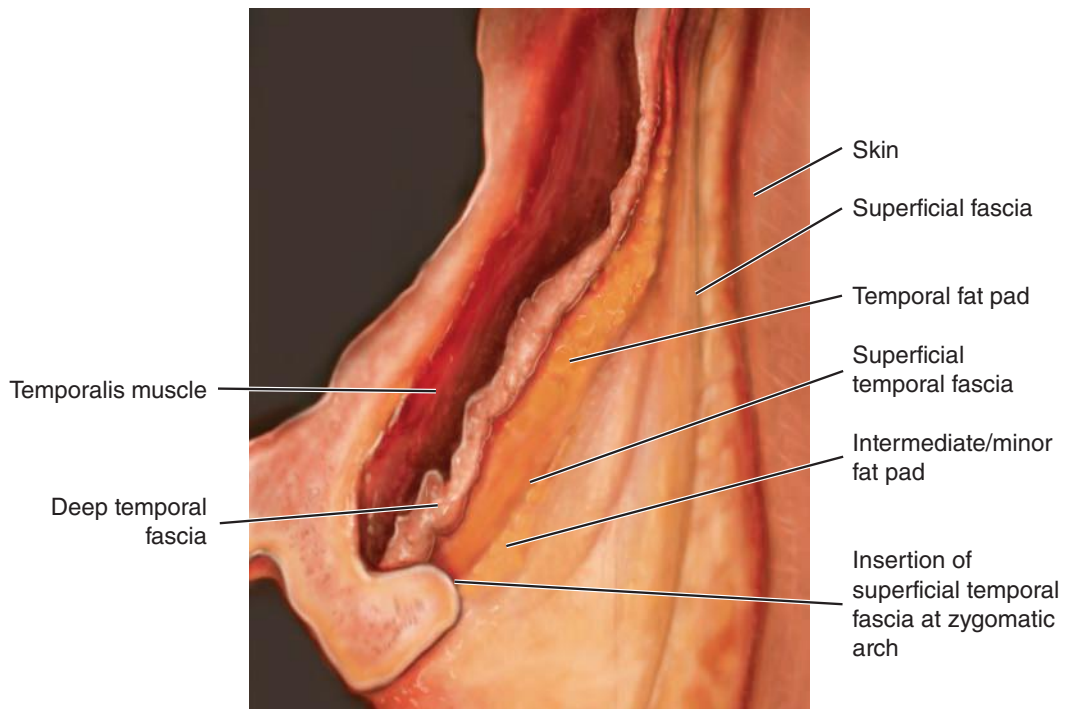
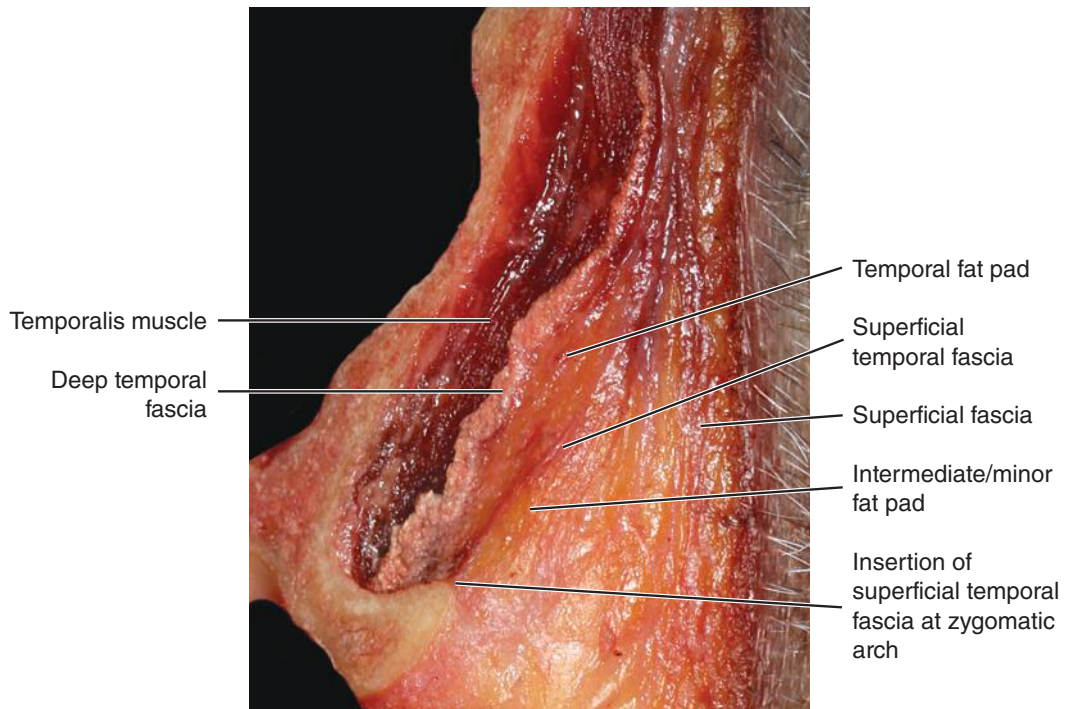
Temporal hollowing



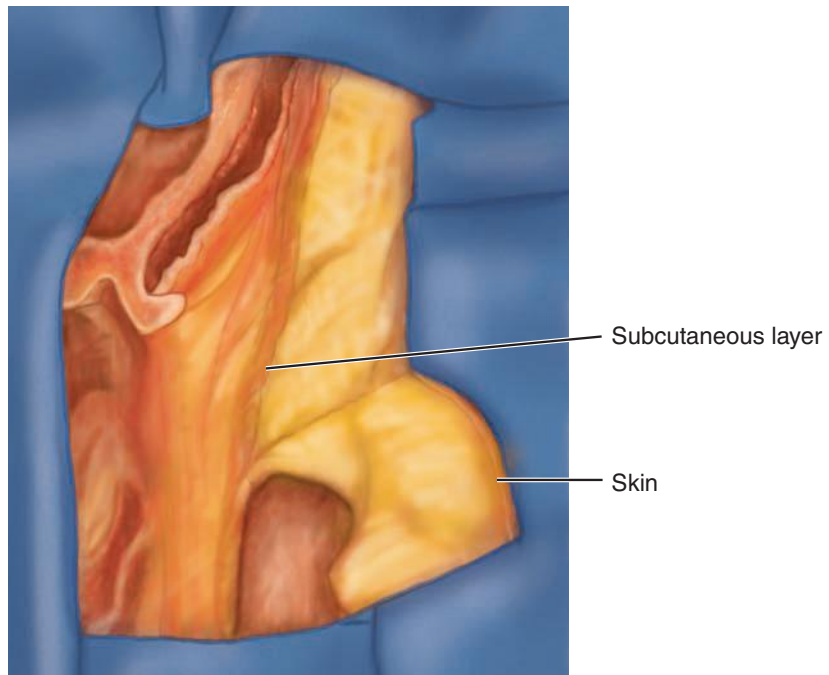
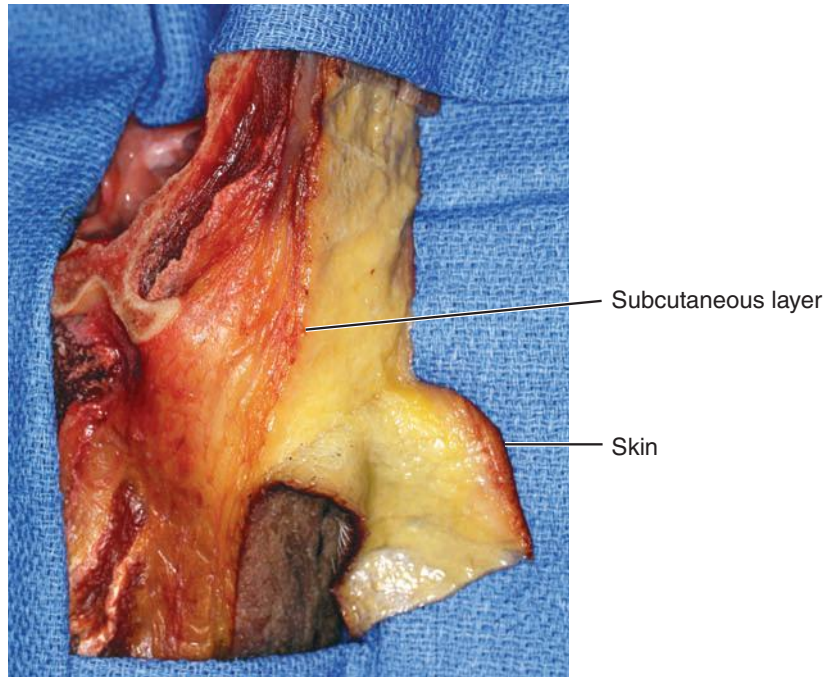
Dissection performed in the sagittal plane over the zygomatic arch helps to visualize the fat pads and layers in the temporal fossa. Careful observation before dissection identifies a number of adipose layers.



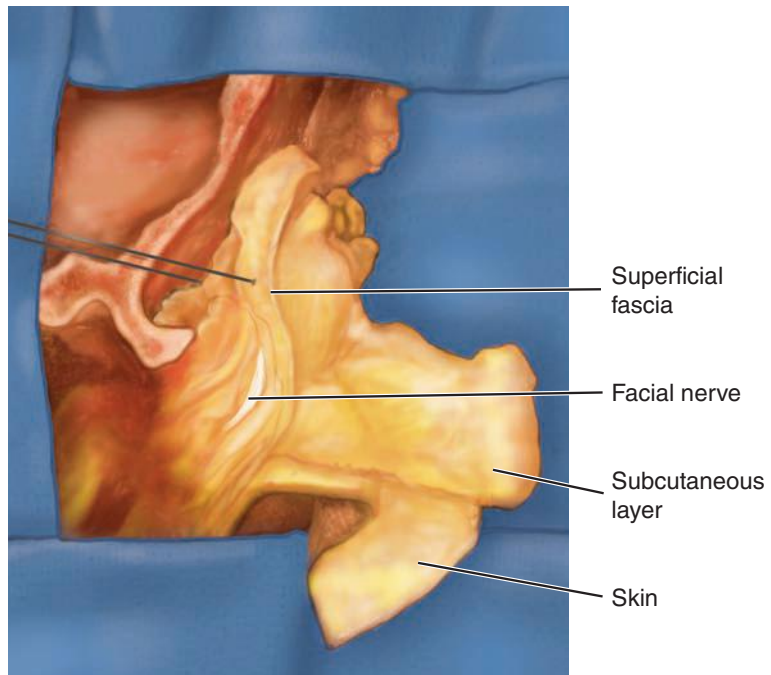
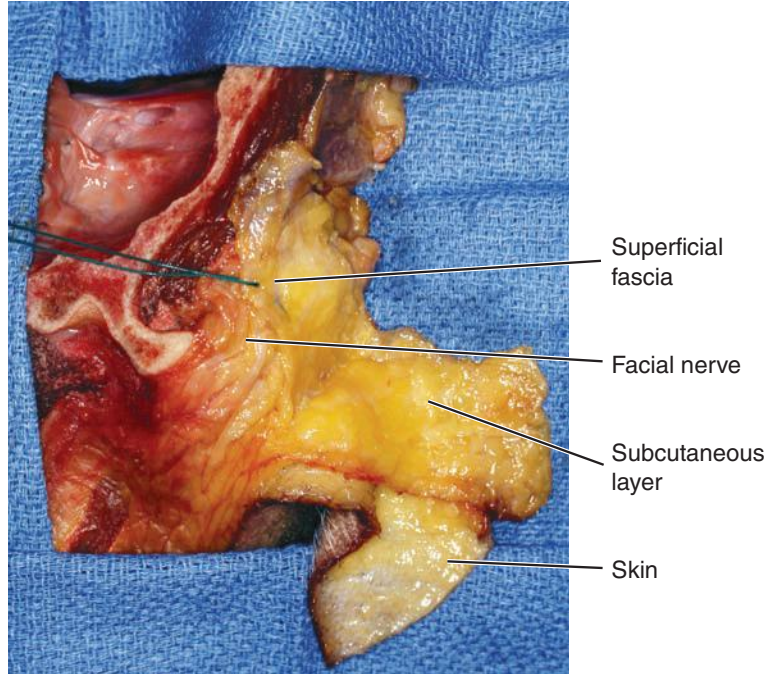
A magnified view helps to identify the layers.



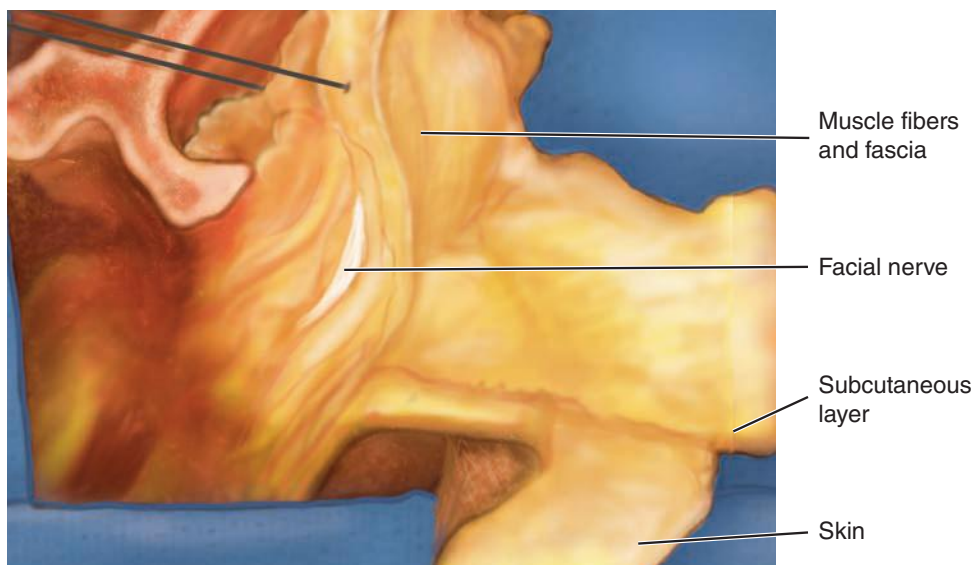
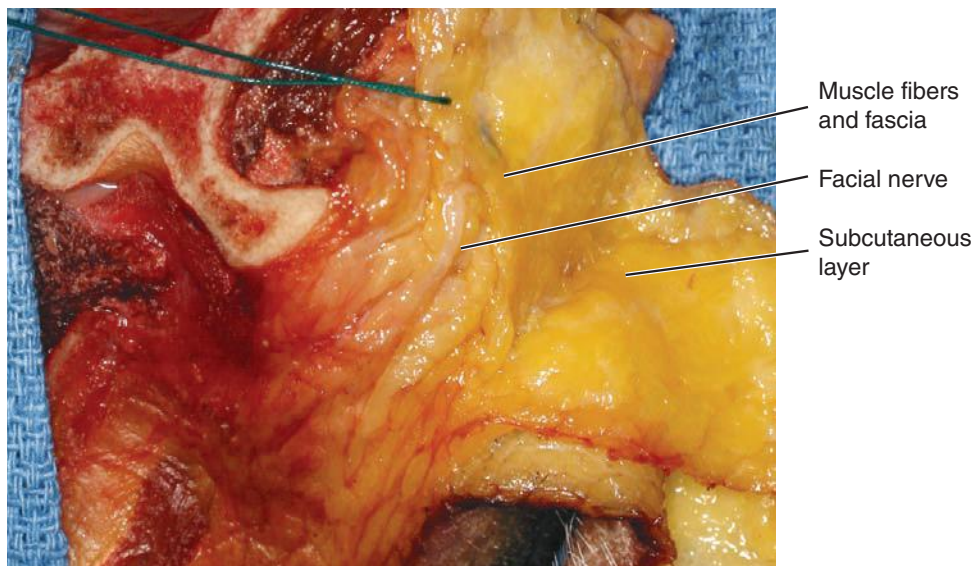Sequential dissection reveals the layers. The skin is turned down and the subcutaneous tissue is noted.



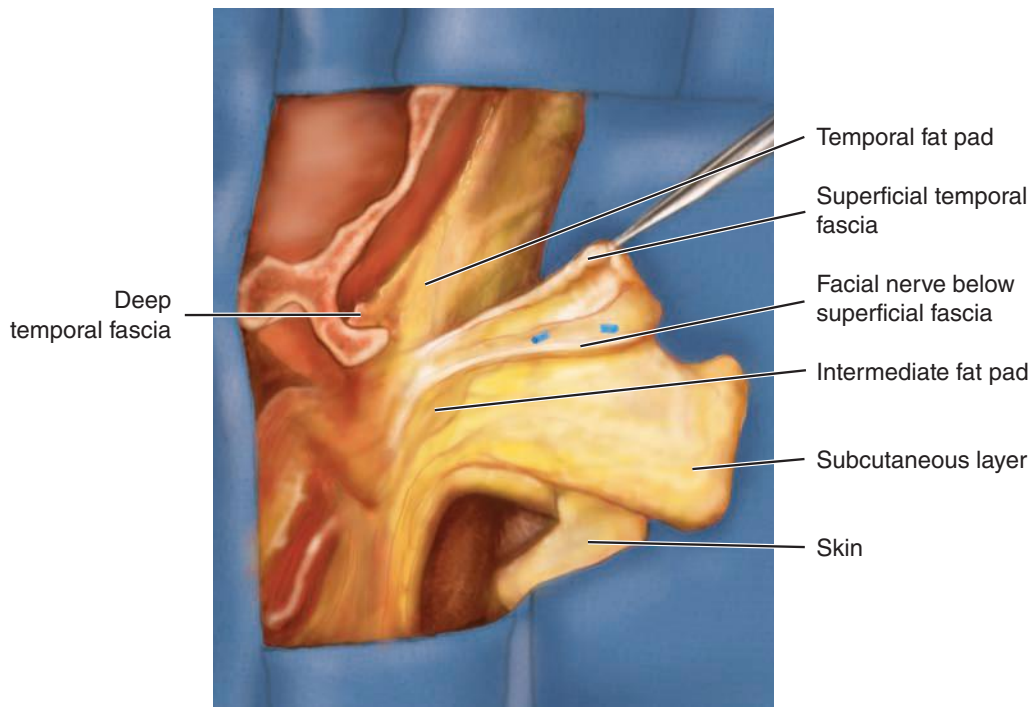
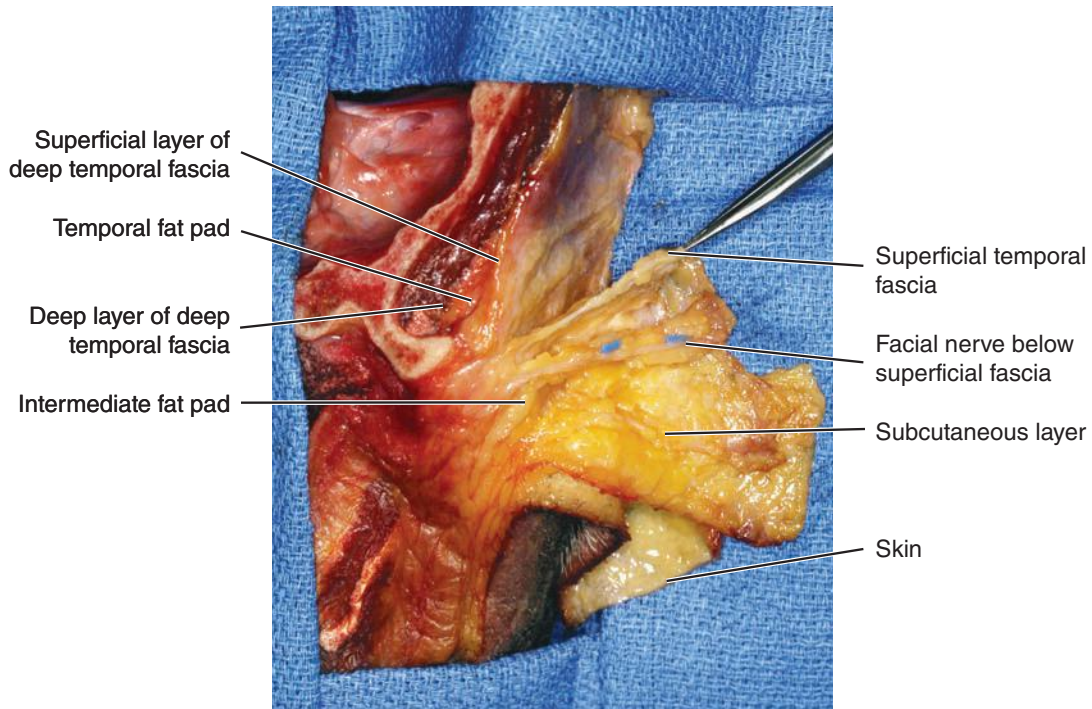
Dissection turns over the subcutaneous layer. Superficial fascia and muscle fibers are found directly beneath the subcutaneous fat.



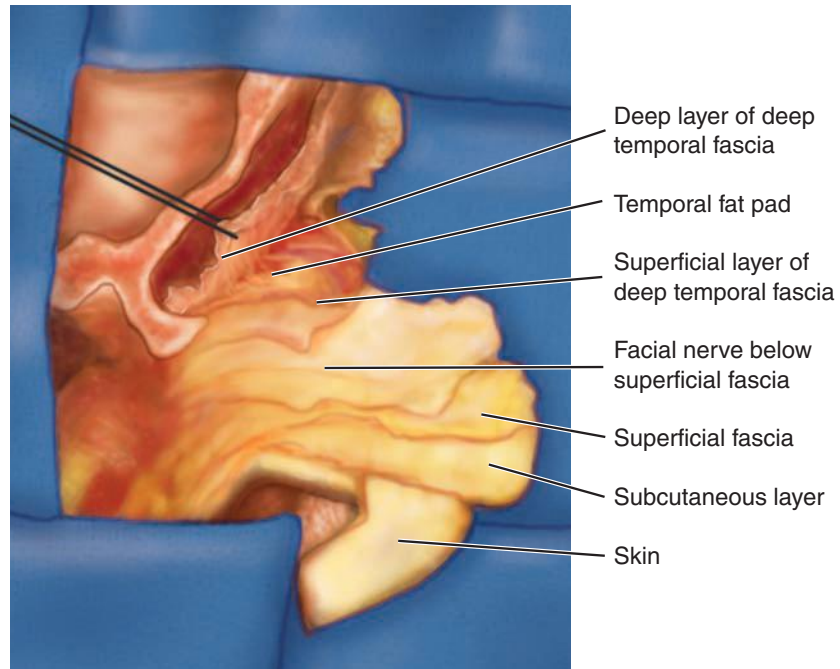
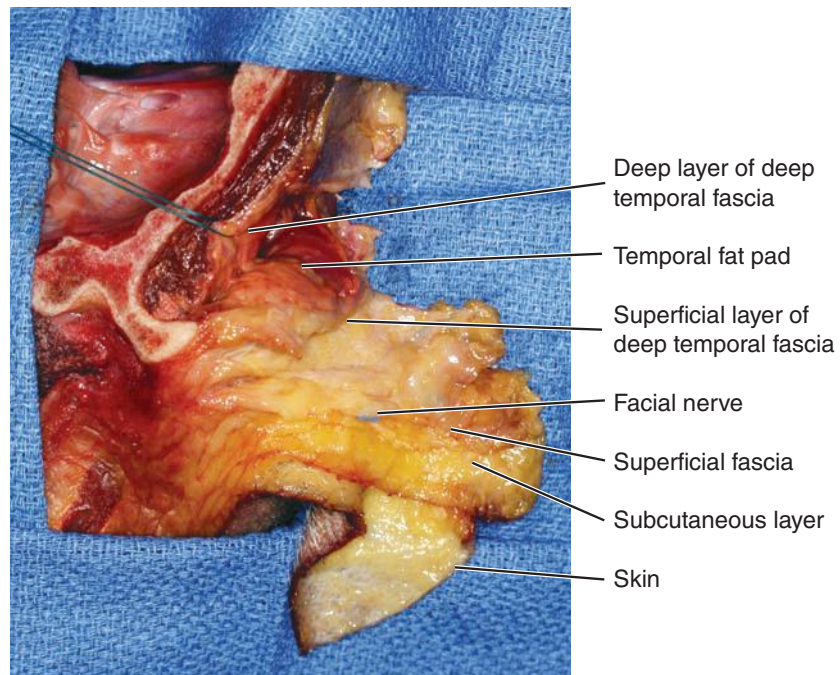
Muscle fibers can be seen, emphasizing the point that the term superficial temporal fascia includes the anterior auricularis muscle, temporoparietalis muscle, and superior auricularis muscle. The frontal branch of the facial nerve runs beneath this layer, along the undersurface of fascia, or, if present, the muscle it innervates.



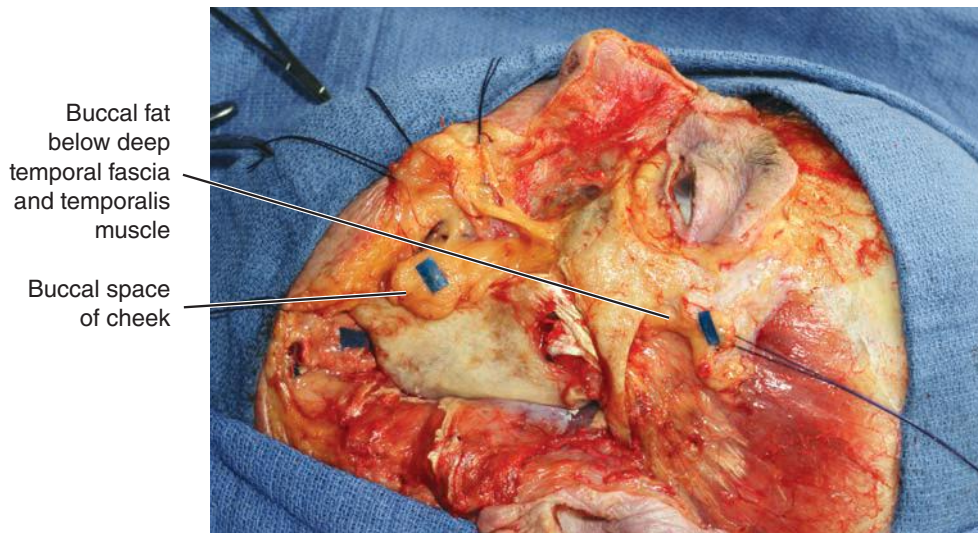
The layer of loose areolar tissue is elevated with the nerve. It is a thick layer in some individuals. A small suprafascial fat pad is identified in this dissection. The superficial temporal fascia inserts into the zygomatic arch.



The temporal fat pad lies directly above the deep temporal fascia.

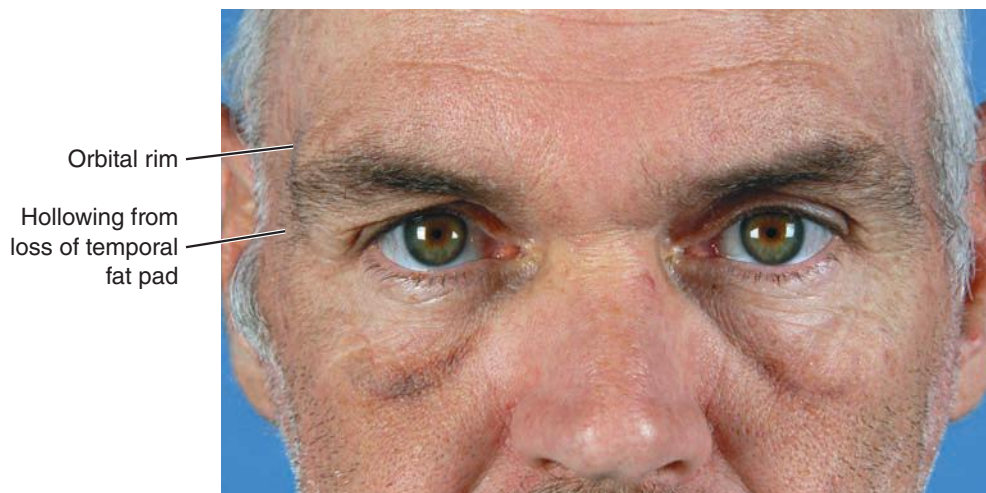


Buccal fat is the most deeply situated fat pad in the temporal fossa. It surrounds the medial part of the temporalis muscle. Like subcutaneous and submuscular fat, it facilitates muscular gliding. The buccal space, also called the *masticator space*, extends from the lower cheek into the temporal fossa. It contains the many neurovascular structures as well as the buccal fat.

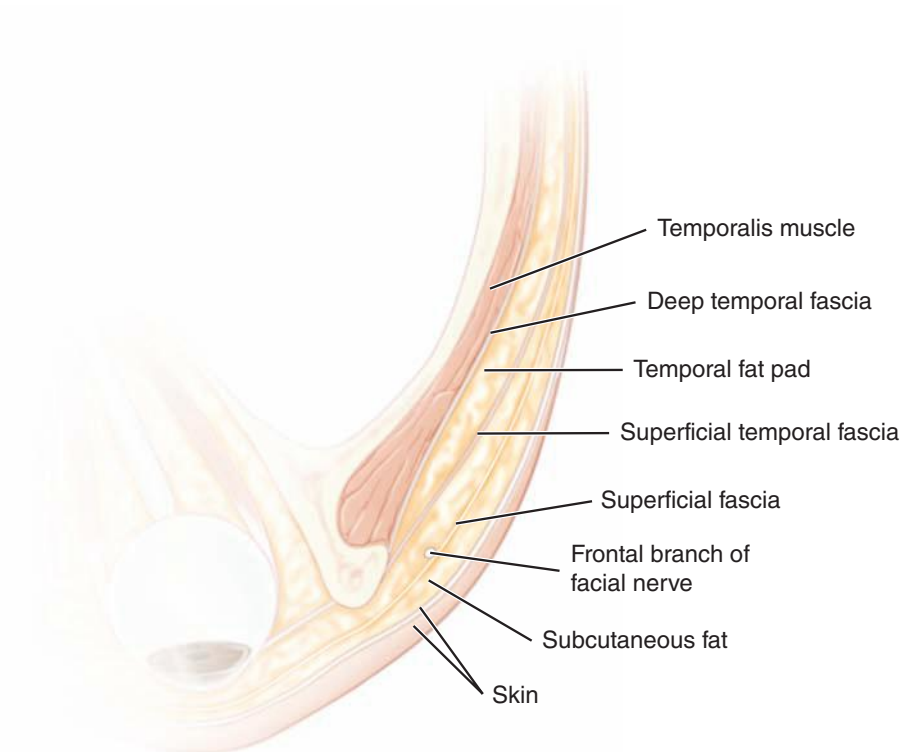
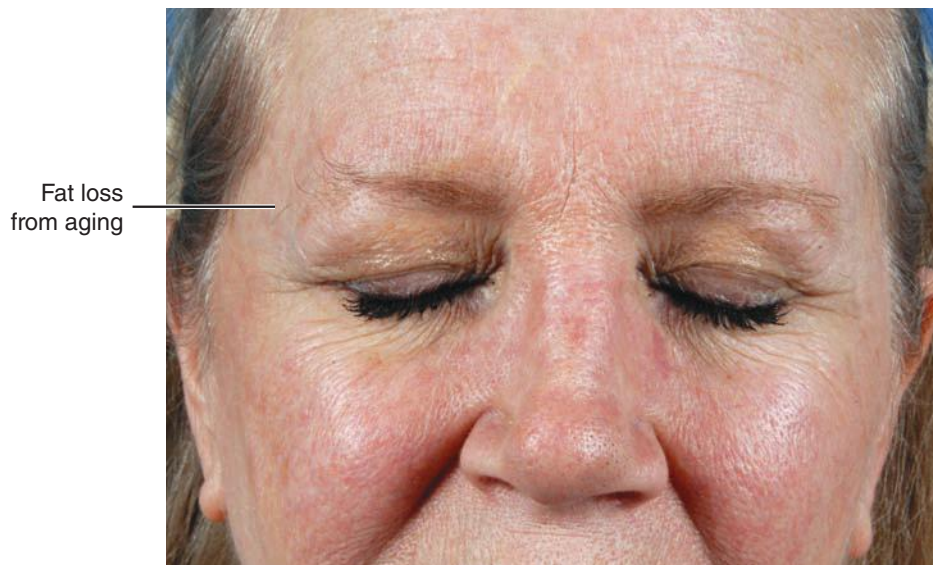

Fat loss from different layers and pads in the temporal fossa results in the various contour changes observed.

Fat loss from the temporal fat pad creates an appearance that is pathognomic for temporal fat pad atrophy. A visible orbital rim and anterior zygomatic arch defines this condition.



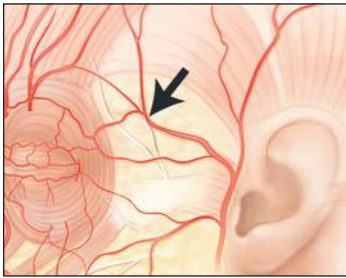
Aging also results in fat loss in the temporal region. However, it is suspected that the loose areolar plane loses volume with aging. This is the rationale for volume augmentation of the temporal fossa in the loose areolar plane.



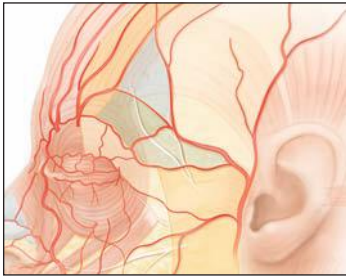
## *Key Points*

- The orientation of the forehead wrinkles helps to identify the presence and relative location of the forehead muscles.
- The frontal nerve branches innervate the forehead muscles, entering the muscle on the undersurface. This defines the depth at which this nerve travels through the temporal fossa.
- The trajectory and path of each branch of the frontal nerve are determined by what muscle it innervates.
- Transition zones between subcutaneous compartments are sites of potential facial nerve injury.
- The path of the frontal artery is a useful landmark for predicting the location and course of this nerve.
- Fat loss from different layers and pads in the temporal fossa results in the various contour changes observed.

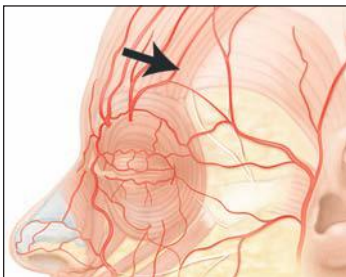## CLINICAL CORRELATIONS



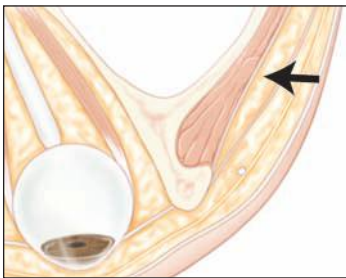
The frontal branch of the superficial temporal artery is a reliable landmark for the position of the frontal branch of the facial nerve. Dissection inferior to the artery decreases the risk of nerve injury.



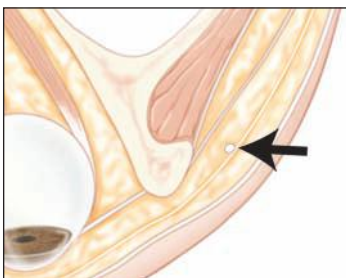It is important to understand the location of the superficial compartments of the temporal fossa: nerve injury is more common at the junction of multiple compartments.



The junction between the central forehead and temporal fossa is a useful landmark for the point at which the facial nerve enters the undersurface of the frontalis muscle.



Temporal hollowing is usually associated with loss of temporal fat. However, each structure within the temporal fossa may contribute to hollowing, each with its own characteristic appearance. Loss of the temporal fat pad increases the prominence of the lateral orbital rim and zygomatic arch.



Augmentation of the loose areolar plane is a valid technique for forehead augmentation in some individuals. Care must be taken when placing filler medially, because this is the plane through which the facial nerve travels.

## Bibliography

The following references discuss the anatomy of the temporal fossa as it pertains to contour, temporal hollowing, and possible injury to the frontal branch of the facial nerve. The key features of these articles include the importance of topographic landmarks for avoiding nerve injury through knowledge of layers and transition zones and the ability to analyze topographic changes based on the affected anatomic subunit.

Agarwal CA, Mendenhall SD III, Foreman KB, et al. The course of the frontal branch of the facial nerve in relation to fascial planes: an anatomic study. *Plast Reconstr Surg* 125:532-537, 2010.  
*The course of the frontal branch of the facial nerve in relation to fascial layers is defined by anatomical dissection.*

Baek RM, Heo CY, Lee SW. Temporal dissection technique that prevents temporal hollowing in coronal approach. *J Craniofac Surg* 20:748-751, 2009.  
*The authors suggested the utility of a dissection plane above the superficial leaflet of the temporal fascia and discussed the incidence of facial nerve injury associated with this particular approach.*

Coscarella E, Vishteh AG, Spetzler RF, et al. Subfascial and submuscular methods of temporal muscle dissection and their relationship to the frontal branch of the facial nerve. *J Neurosurg* 92:877-880, 2000.  
*The use of the superficial temporal artery as a topographic landmark for the frontal branch of the facial nerve was described.*

Davidge KM, van Furth WR, Agur A, et al. Naming the soft tissue layers of the temporoparietal region: unifying anatomic terminology across surgical disciplines. *Neurosurgery* 67(3 Suppl Operative):ons120-129; discussion ons129-130, 2010.  
*A precise, anatomically based definition of the layers of the temporal fossa is discussed. An excellent review article, this manuscript introduced the term "transition points" as potential sites of nerve injury.*

Ducic Y, Pontius AT, Smith JE. Lipotransfer as an adjunct in head and neck reconstruction. *Laryngoscope* 113:1600-1604, 2003.  
*Autologous fat grafting to the temporal fossa was described. The authors combine this technique with hydroxyapatite when indicated, adhering to the concept of addressing specific anatomic regions when treating temporal hollowing.*

Gosain AK. Surgical anatomy of the facial nerve. *Clin Plast Surg* 22:241-251, 1995.  
*The author discussed the anatomy of the facial nerve and its relationship to ligaments as potential sites of injury.*

Hwang SW, Abozed MM, Antoniou AJ, et al. Postoperative temporalis muscle atrophy and the use of electrocautery: a volumetric MRI comparison. *Skull Base* 20:321-326, 2010.  
*Postsurgical temporal hollowing from muscle atrophy has a distinct appearance when it occurs secondary to trigeminal nerve injury. This article suggested the possibility of analyzing temporal hollowing based on topographic features that may be distinct based on the tissue involved.*

Kim S, Matic DB. The anatomy of temporal hollowing: the superficial temporal fat pad. *J Craniofac Surg* 16:760-763, 2005.

*Injury to the zygomaticotemporal nerve and/or the middle and deep temporal arteries may result in temporal hollowing as a result of atrophy to the fat pad of the temporal fossa.*

Kleintjes WG. Forehead anatomy: arterial variations and venous link of the midline forehead flap. *J Plast Reconstr Aesthet Surg* 60:593-606, 2007.

*The author described the arterial and venous supply of the forehead and temporal fossa in detail. The artery over which the frontal branch of the facial nerve is noted to travel was named in this study as the "transverse branch of the frontal artery." This artery defines a specific anatomic subunit of the forehead through which the frontal branch varies in depth, resulting in a potential site of injury.*

Matic DB, Kim S. Temporal hollowing following coronal incision: a prospective, randomized, controlled study. *Plast Reconstr Surg* 121:379e-385e, 2008.

*Dissection of the temporal fossa above the superficial layer of the temporal fascia may result in a decreased incidence of frontal branch injuries.*

Seckel BR. *Facial Danger Zones: Avoiding Nerve Injury in Facial Plastic Surgery*. St Louis: Quality Medical Publishing, 1994.

Stuzin JM, Wagstrom L, Kawamoto HK, et al. Anatomy of the frontal branch of the facial nerve: the significance of the temporal fat pad. *Plast Reconstr Surg* 83:265-271, 1989.

*The path of the frontal branch of the facial nerve travels deep to the temporoparietal fascia.*

van der Meulen JJ, Nazir PR, Mathijssen IM, et al. Bitemporal depressions after cranioplasty for trigonocephaly: a long-term evaluation of (supra) orbital growth in 92 patients. *J Craniofac Surg* 19:72-79, 2008.

*An altered growth rate in the auriculotemporal region after cranioplasty may result in temporal hollowing.*

van der Meulen JJ, Willemsen J, van der Vlugt J, et al. On the origin of bitemporal hollowing. *J Craniofac Surg* 20:752-756, 2009.

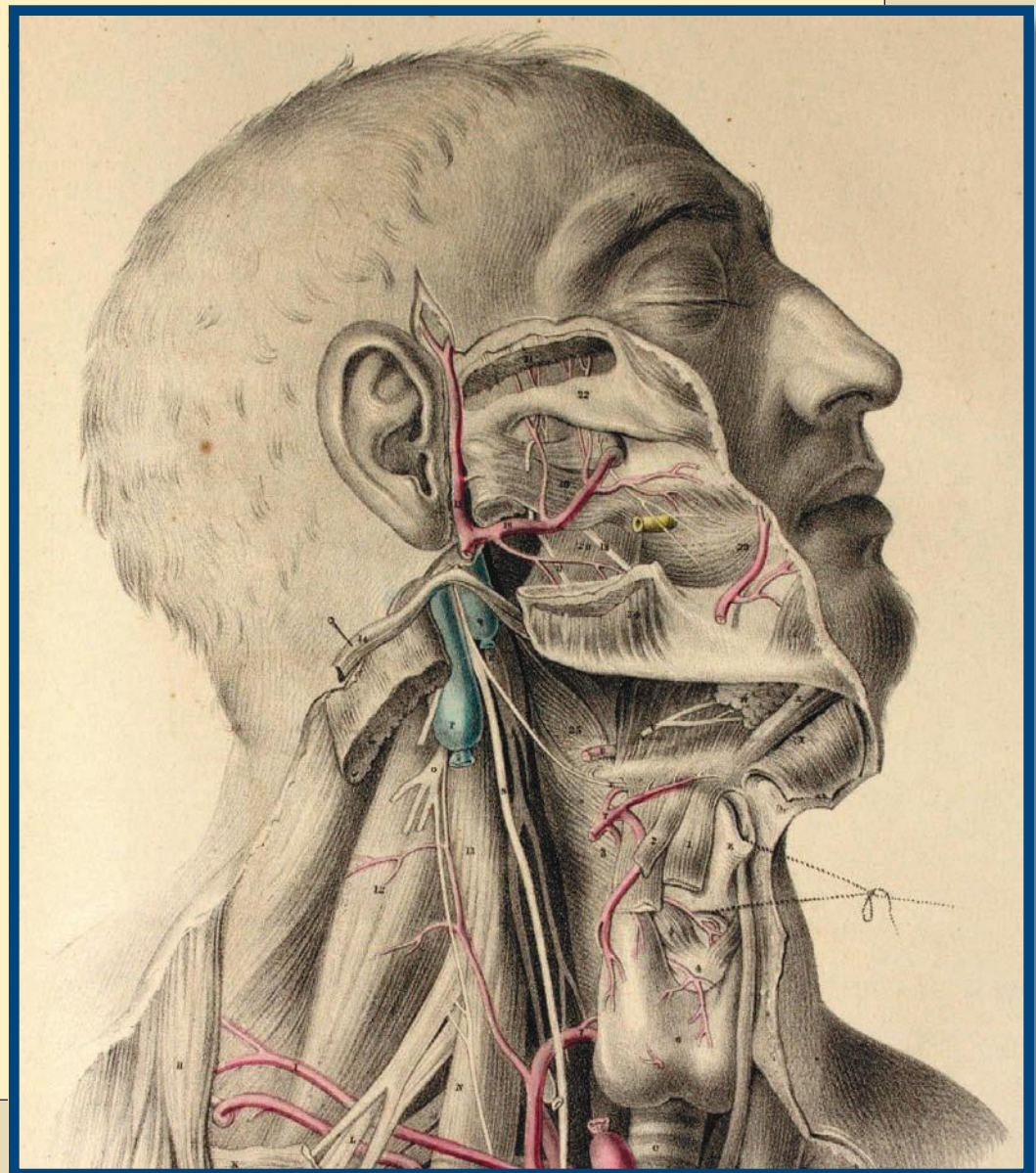
*The appearance of temporal hollowing secondary to growth alterations of bone after treatment of trigonocephaly may differ from that caused by muscle or fat pad atrophy.*

---

CHAPTER 7

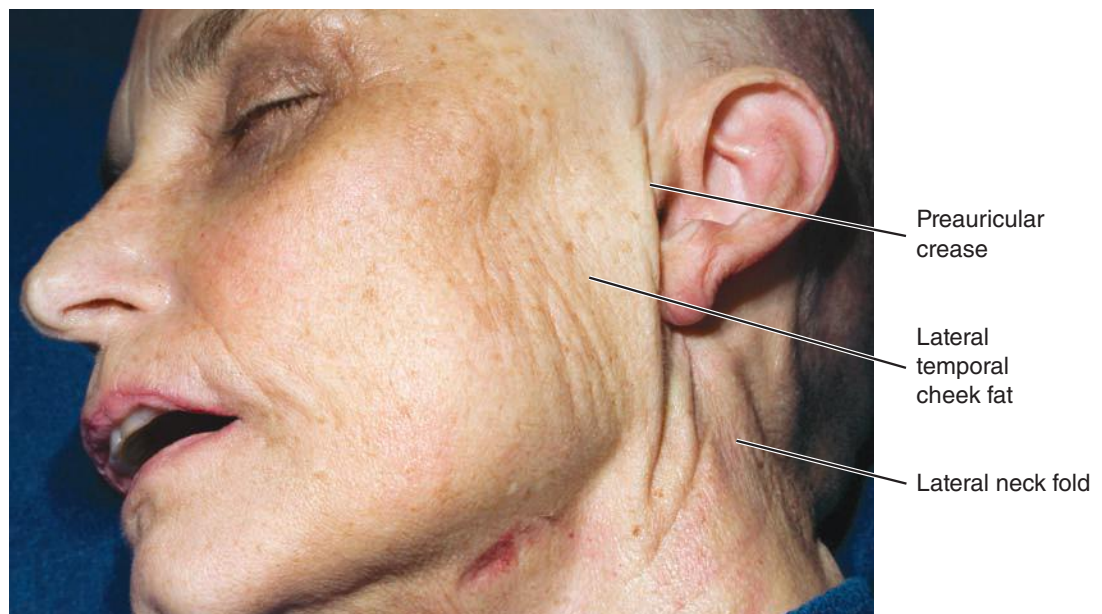---

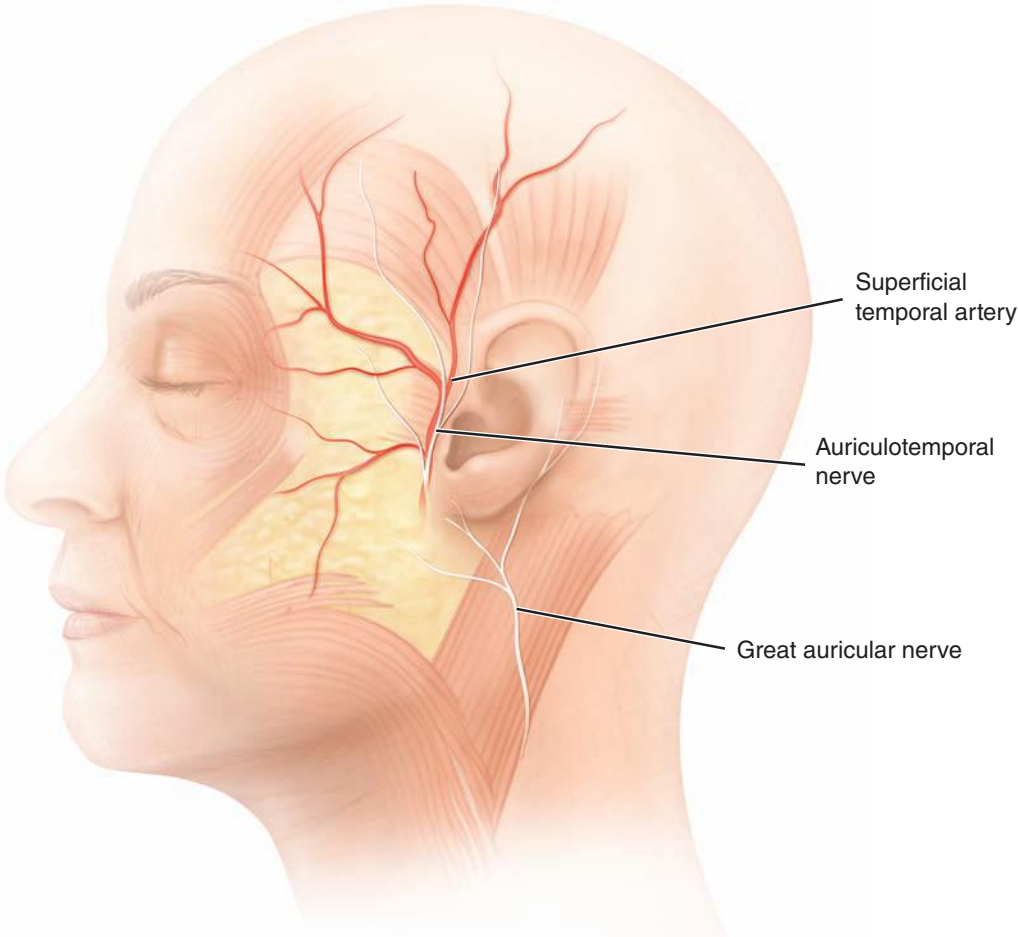
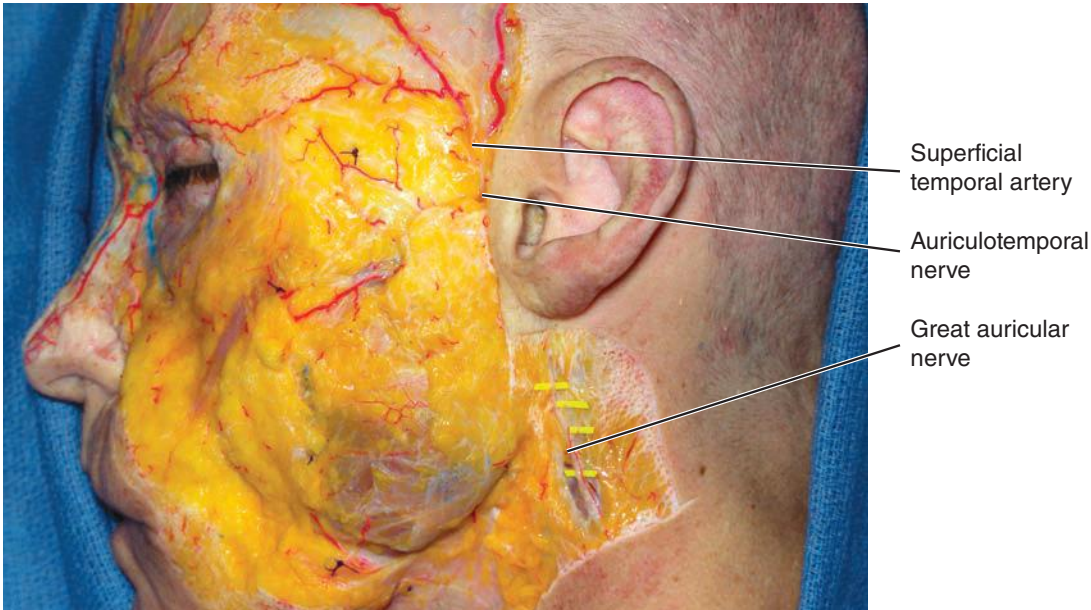
# The Periauricular Region



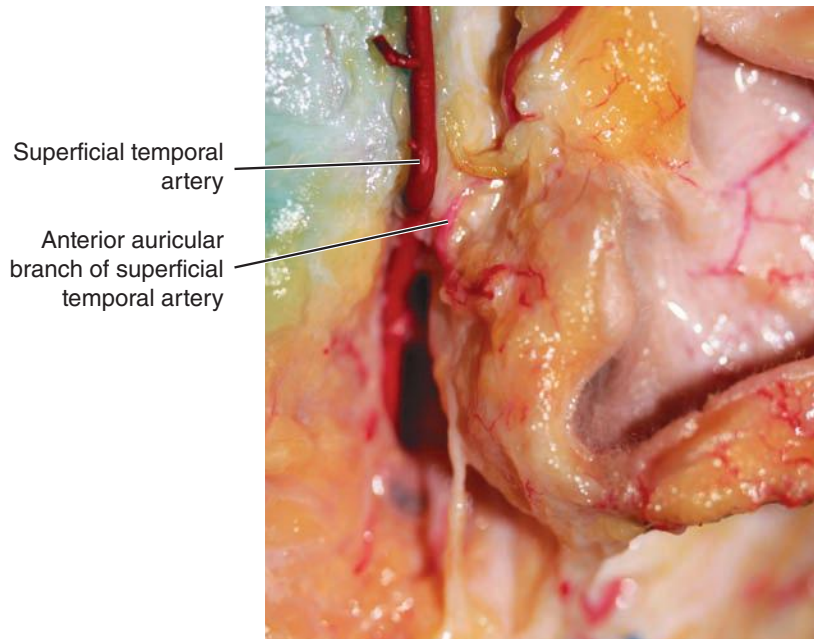
**C**areful analysis of topographic landmarks around the ear can help the surgeon to avoid neurovascular injuries and complications.

The main blood supply to the ear comes from two sources, both from the external carotid artery.

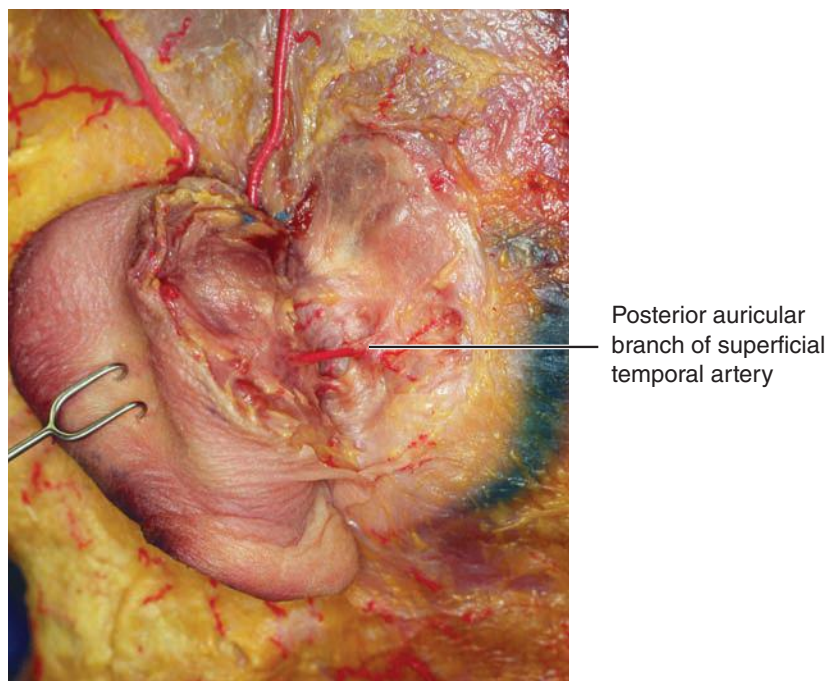




The superficial temporal artery is located in a shallow groove directly anterior to the ear.



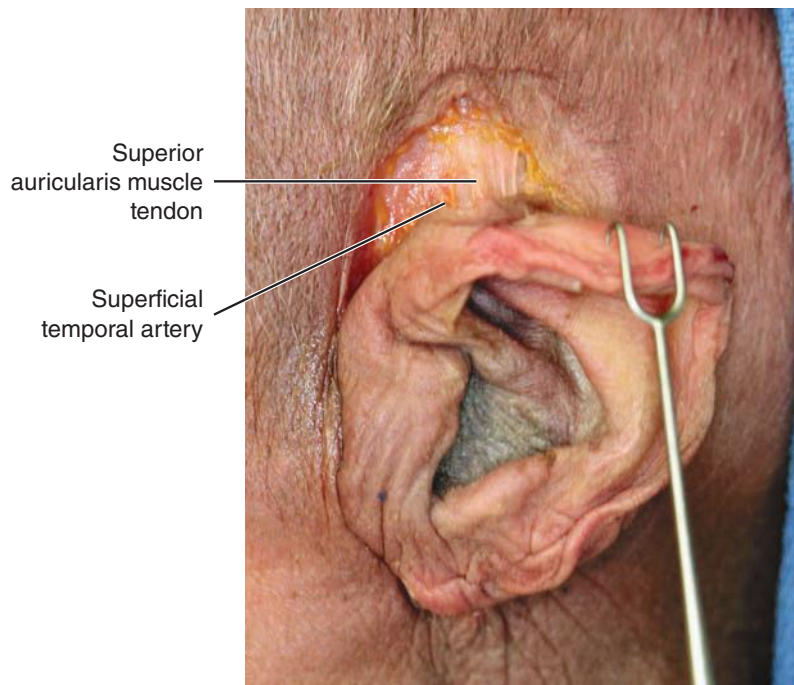
The superficial temporal artery supplies most of the anterior helix through the anterior auricular vessel. The posterior auricular artery is the major blood supply. It arises from the superficial temporal artery and travels behind the auricle.



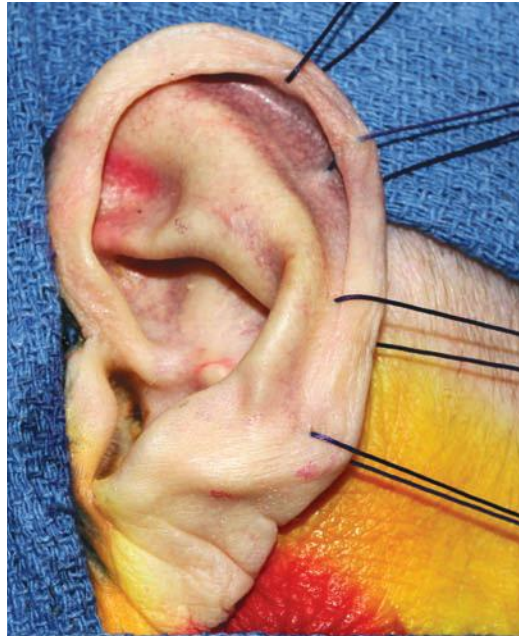## ANATOMIC LANDMARKS

Sometimes, such as during ear replantation, it is essential to identify the posterior auricular artery. There are landmarks that can reliably predict the location of the posterior auricular artery and the superficial temporal artery.

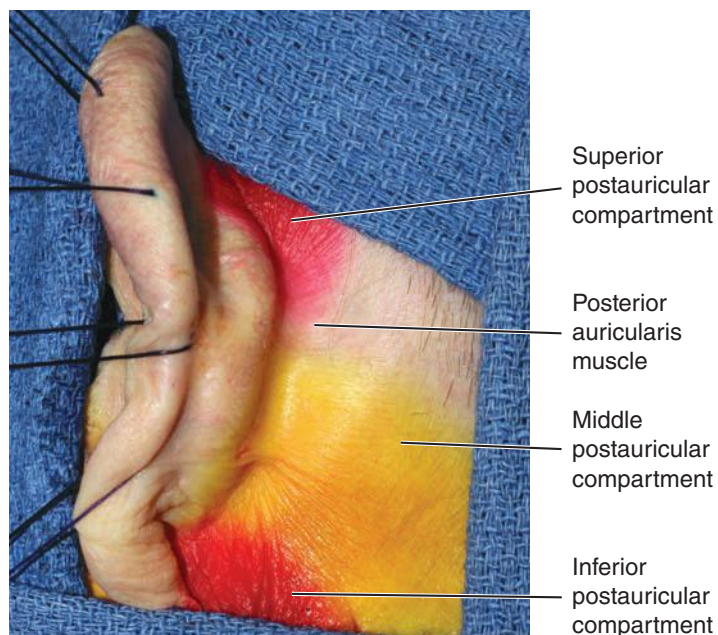
The upper pole of the ear has a tendon that is the origin of the superior auricularis muscle. This tendon coincides with the location of the superficial temporal artery. The same correlation applies to the tendons of other intrinsic ear muscles.



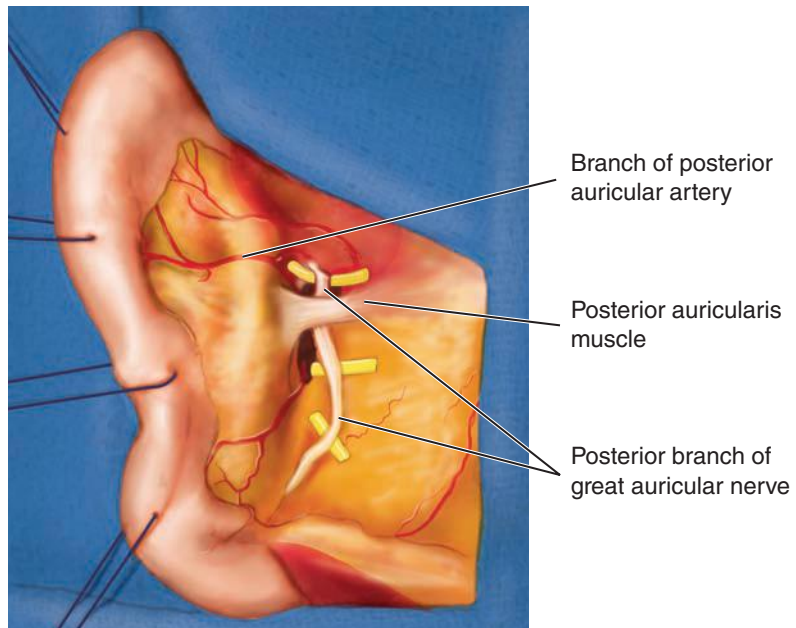
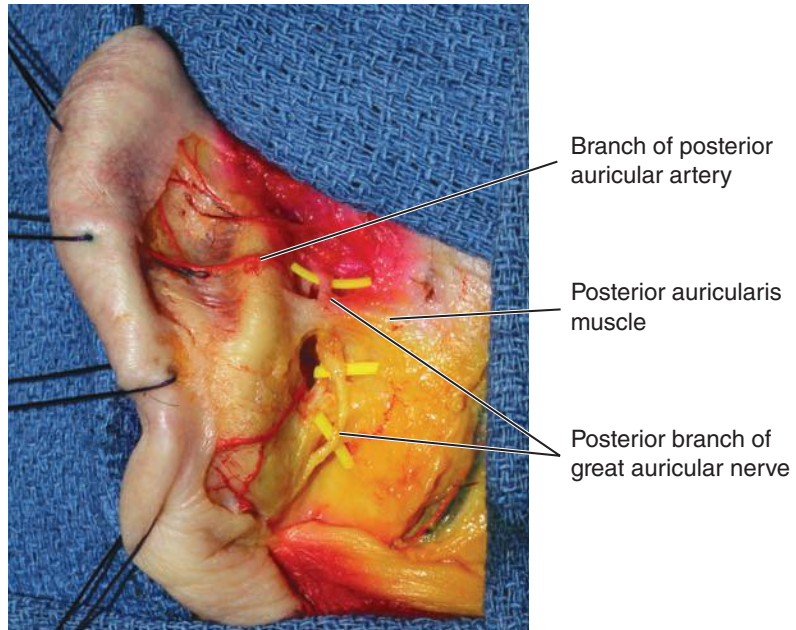
The posterior auricularis muscle is almost vestigial, but it is a useful topographic landmark for locating the posterior auricular artery. This dissection illustrates the anatomy.



The posterior auricularis muscle is located slightly above the midvertical point of the auricle. High-solubility dyes are used to identify the surrounding compartments. Routine latex injection is used. Vessels are noted through the thin postauricular skin.

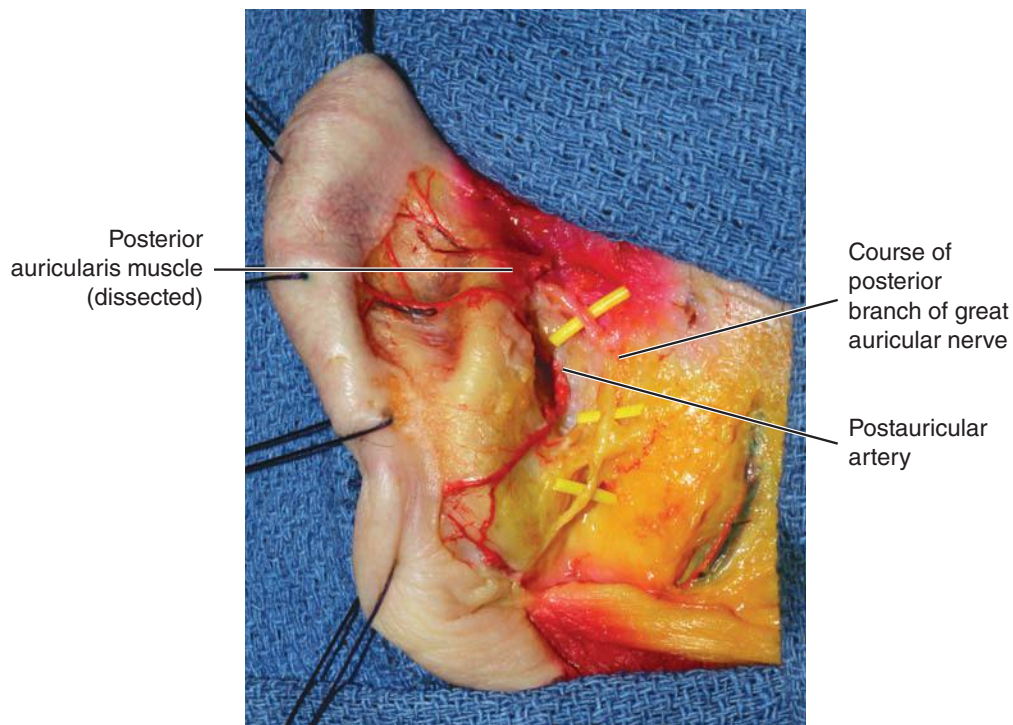


The skin is removed. Arcades arise from the main trunk of the postauricular artery. The muscle is superficial to the origin of these vessels.



Of particular importance is the finding of the close proximity of the great auricular nerve to the muscle. This nerve is easily damaged, especially if the muscle is routinely transected. A painful neuroma may result from this injury.

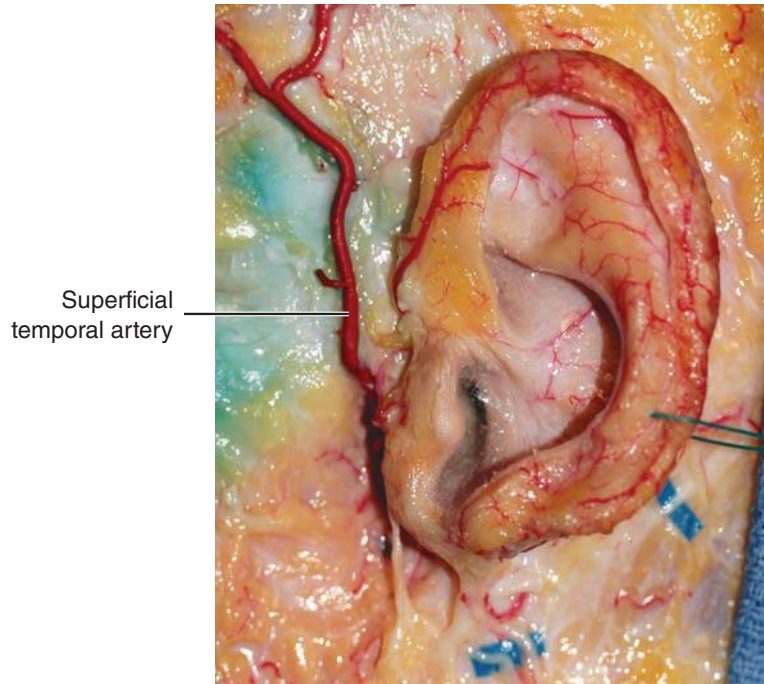
In this dissection, transection of the muscle reveals the position of the main trunk of the postauricular artery. The nerve is likewise posterior to this structure.



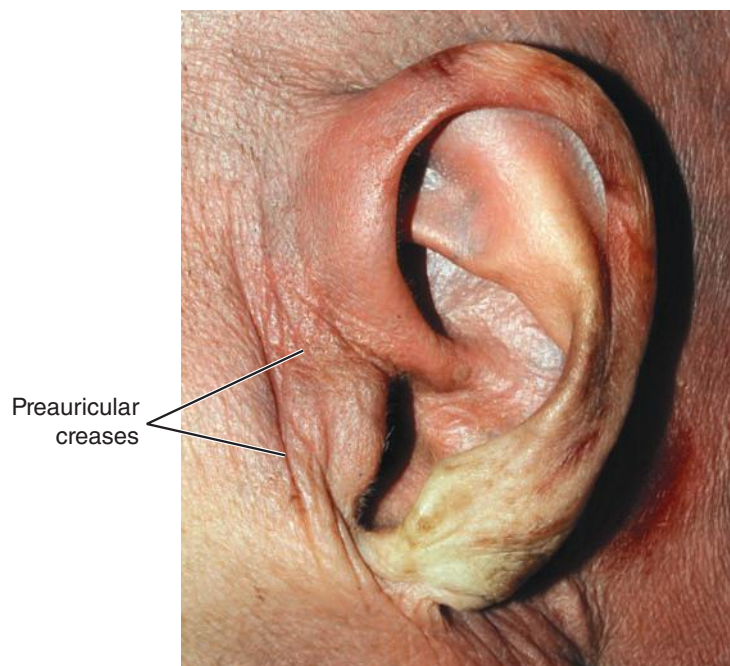
The posterior auricularis muscle is a reliable landmark for the position of the postauricular artery.

It also suggests the proximity of the posterior branch of the great auricular nerve. This structure is easily identified by placing traction on the muscle.

The anterior blood supply is as easily located. A most useful landmark to identify this vessel is the preauricular crease and its fold.

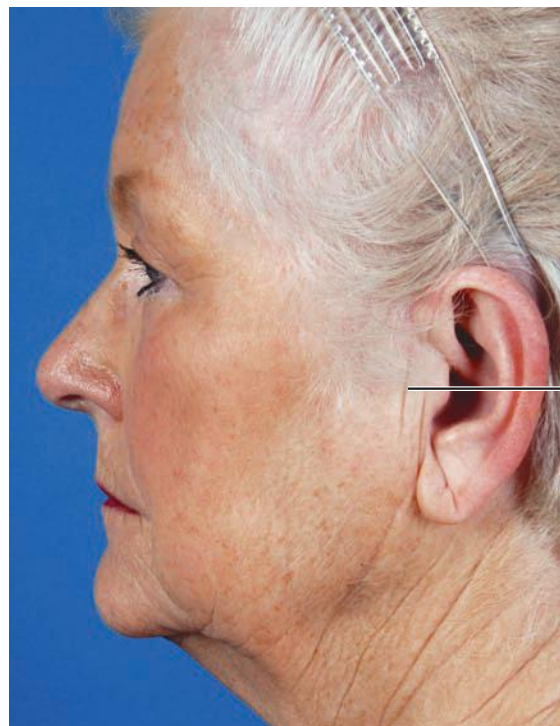

There are actually two preauricular creases. The more anterior crease is a deeper groove and most closely represents the location of the superficial temporal artery.



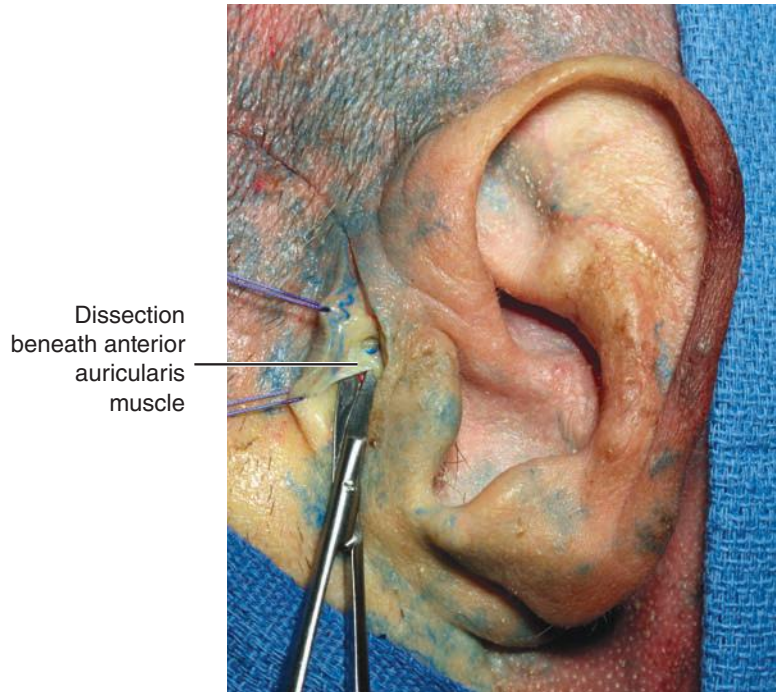
These creases are identified routinely. However, if an individual has not developed this crease, there is an easy method to re-create it: the clinician simply places pressure and displaces the preauricular tissues backward. A fold will form in front of any area where skin motion is restricted. Fascial membranes encase perforator vessels arising from the superficial temporal artery; this occurs at the preauricular crease.

Manipulation of skin and soft tissue can create folds and creases that signify underlying source vessels.

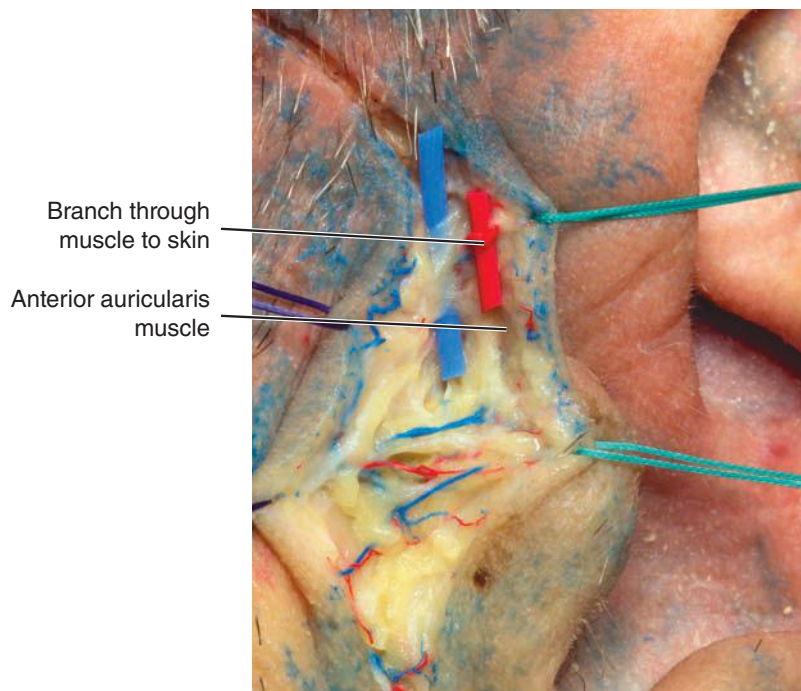


Position of  
superficial  
temporal artery

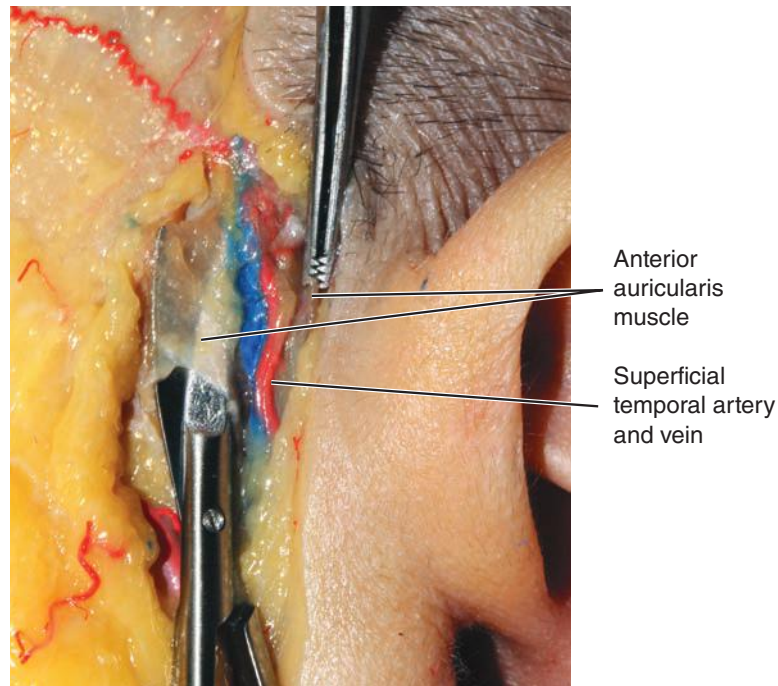
The superficial temporal artery lies deep in the preauricular sulcus or groove. Dissection through fascia or the anterior auricularis muscle is required to identify the main trunk.



Perforating vessels travel through this muscle on the way to the skin.



The anterior auricularis muscle is often well developed. It may be chemodenerated to diminish the preauricular crease and wrinkles, if present. It is important to understand the relationship between the vessels and this muscle when performing this procedure.



## SURGICAL TRANSITIONING

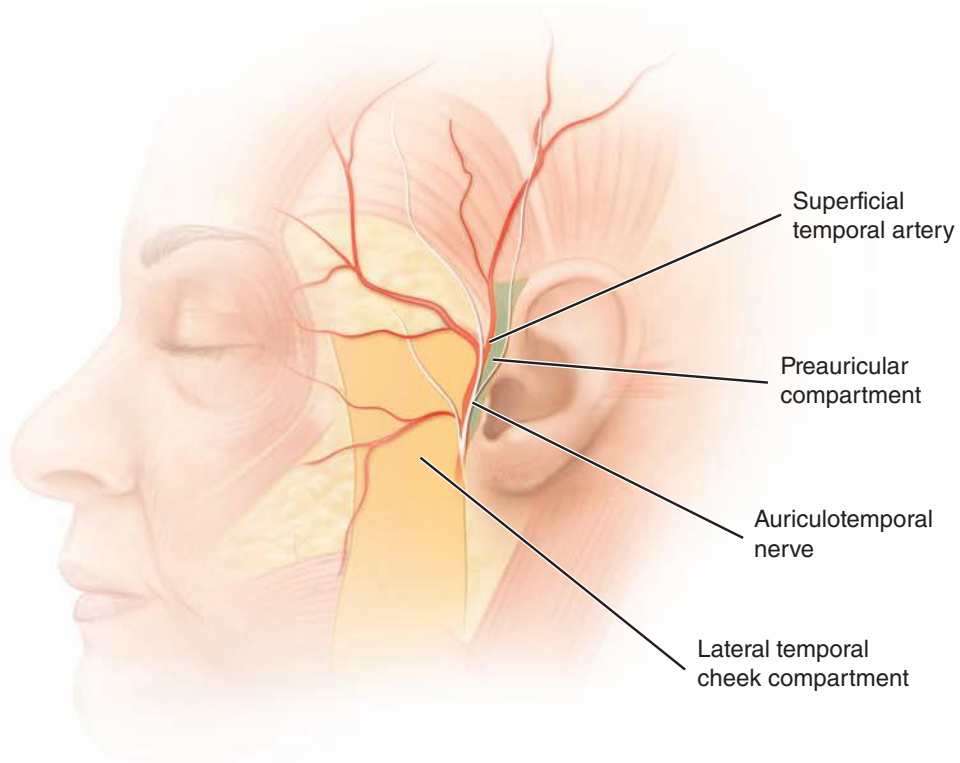
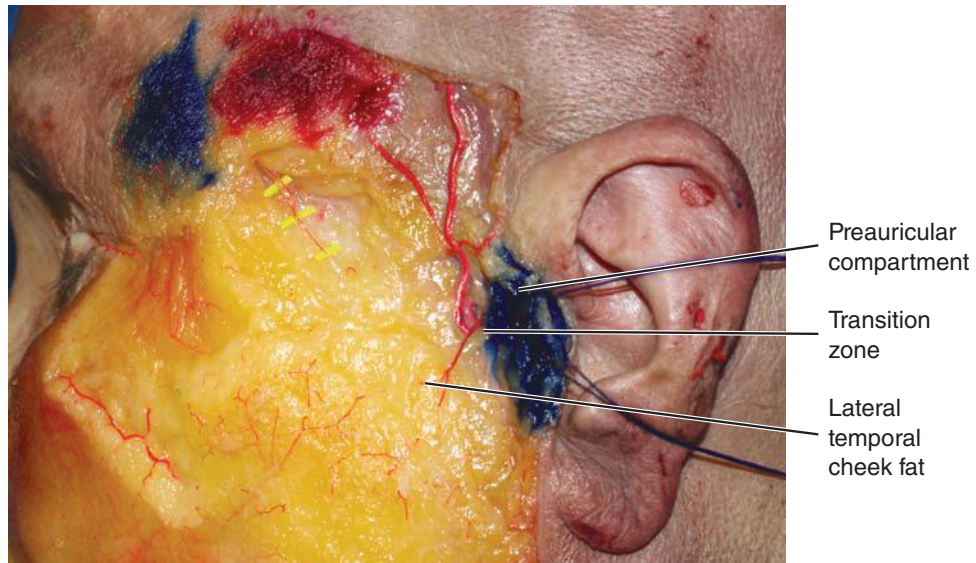
A major lesson gleaned for the clinician from the study of periauricular anatomy is that surgical transitioning between planes and different thicknesses of tissue is required to avoid nerve injury. Knowledge of the location of restricting bands—that is, compartment membranes—facilitates surgical technique. Transitioning is critical to avoid frontal nerve injury when elevating skin in the temporal fossa. The preauricular compartment abuts several others and forms a dense fascial restriction. Careful dissection is necessary to avoid injuring the nerve at this location.

To understand the concept of surgical transitioning, the clinician must understand that adipose tissue thickness is not equal across the face. If the surgeon dissects beneath a thick layer of adipose tissue and transitions at the same depth beneath a thinner compartment, nerves and vessels are at risk for transection.

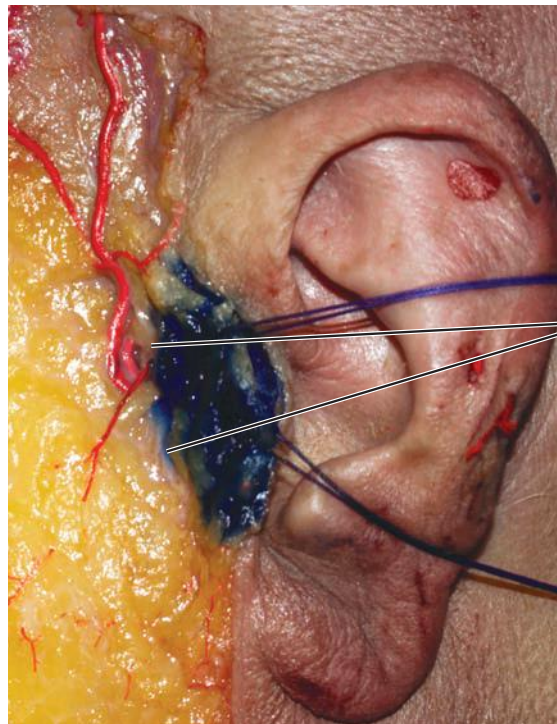
Transitioning requires identification of the proper plane between adjacent regions that vary in thickness.

A subcutaneous flap of uniform thickness is not anatomic, because the thickness of this layer varies in different compartments. However, understanding these principles helps the surgeon to develop the required technique.

The preauricular compartment is thicker than the adjacent lateral temporal cheek region.



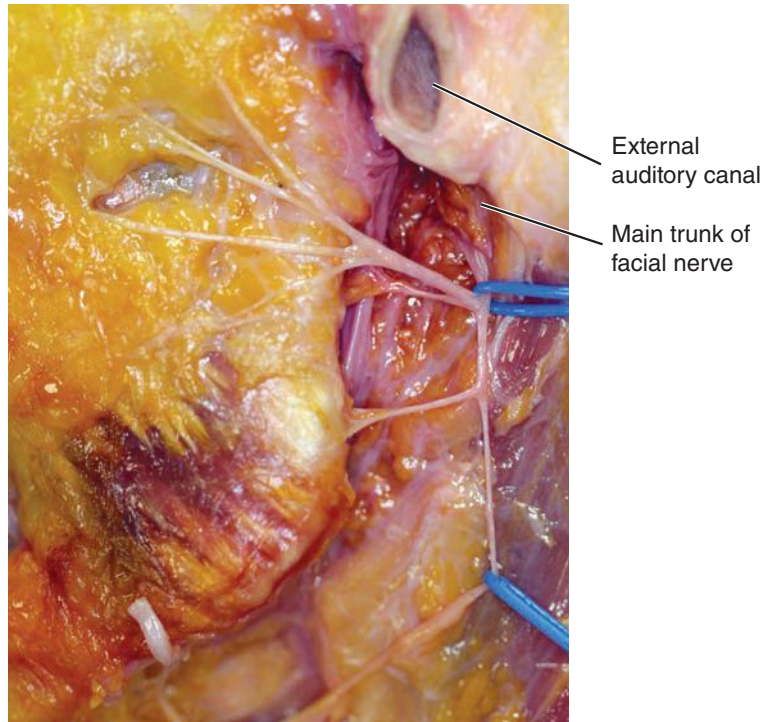
This is a danger zone, where the frontal branch of the facial nerve is at risk. Proper transitioning between adjacent compartments of different thicknesses avoids this complication.



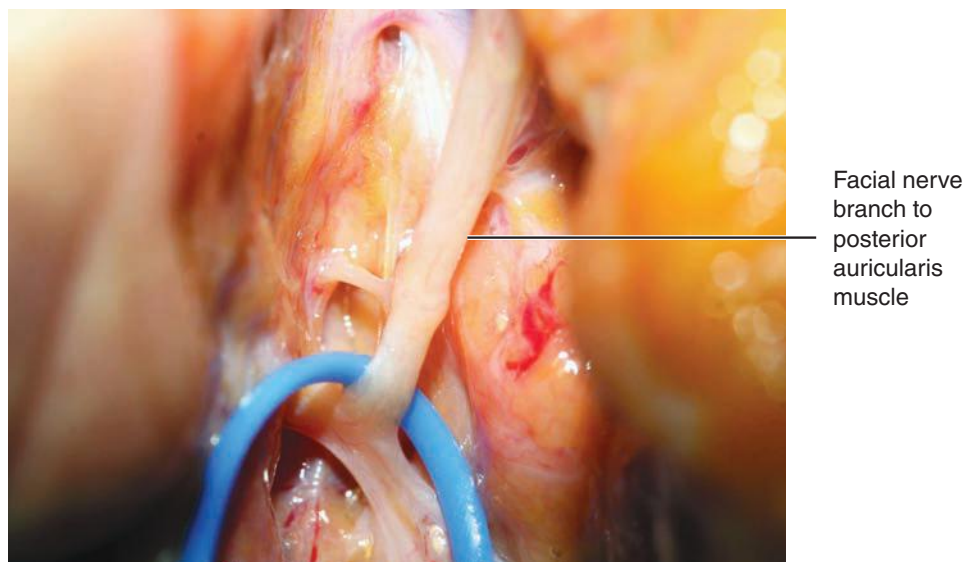
Sites of potential injury to facial nerve

Even if paresis or complete paralysis is avoided, annoying minor motor nerve complications may occur. The most common sign of a facial nerve injury, which is often not noted by the patient, is cross-innervation during the repair phase.

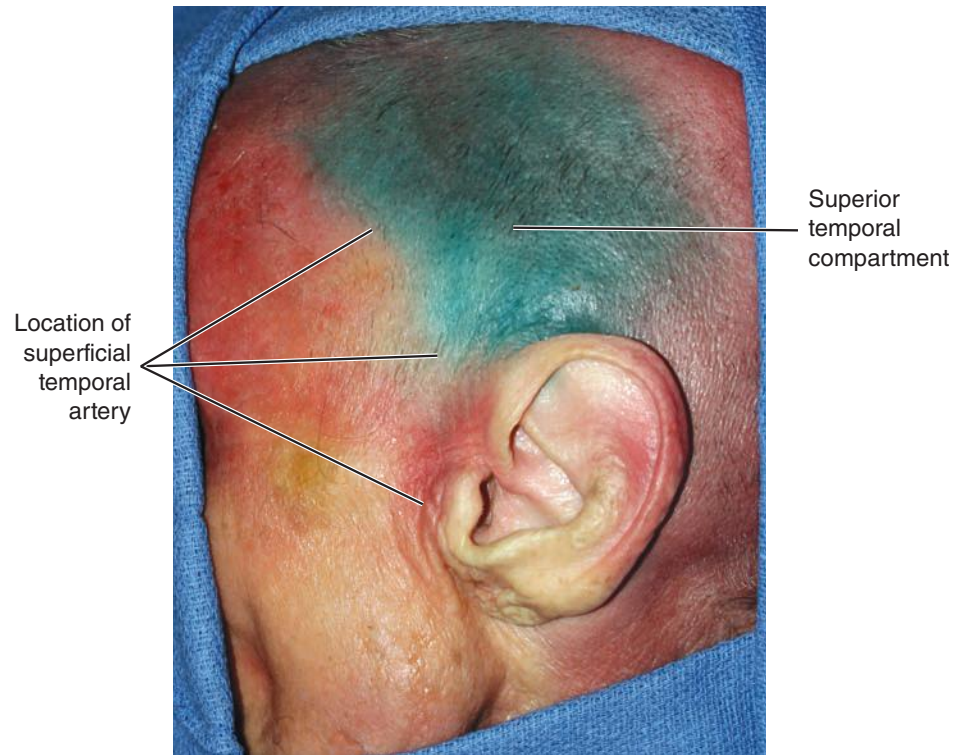
The jaw-wink reflex signifies an injury to the facial nerve and cross-regeneration between the buccal and zygomatic branches.



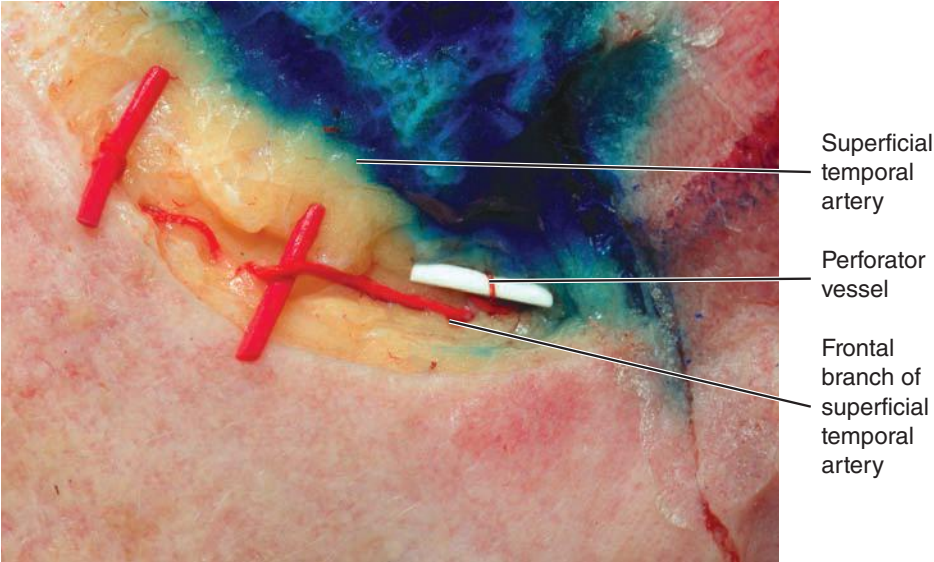
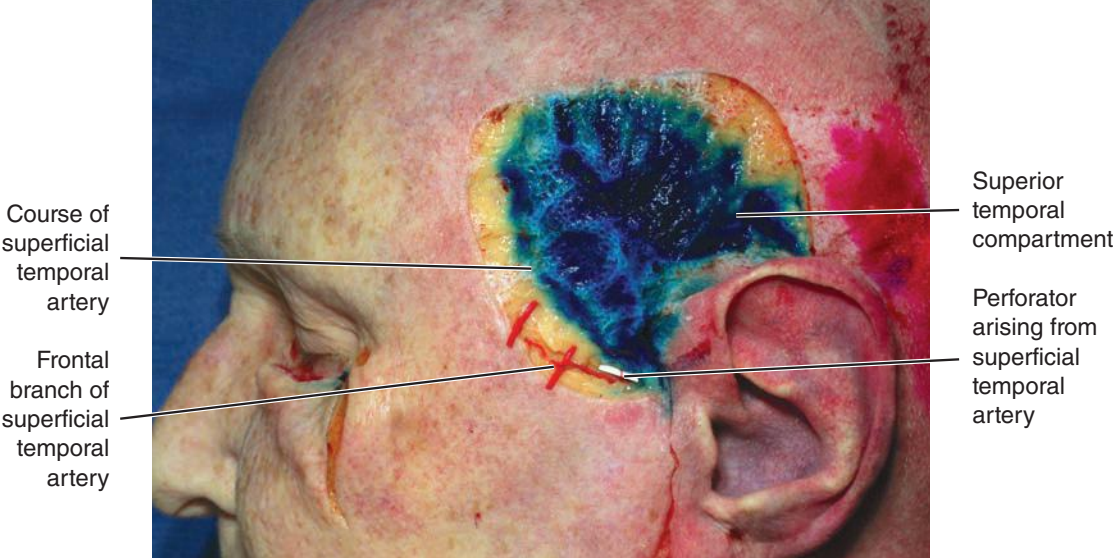A less frequently observed injury occurs to the sixth branch of the facial nerve; that is, to the branch to the posterior auricularis muscle.



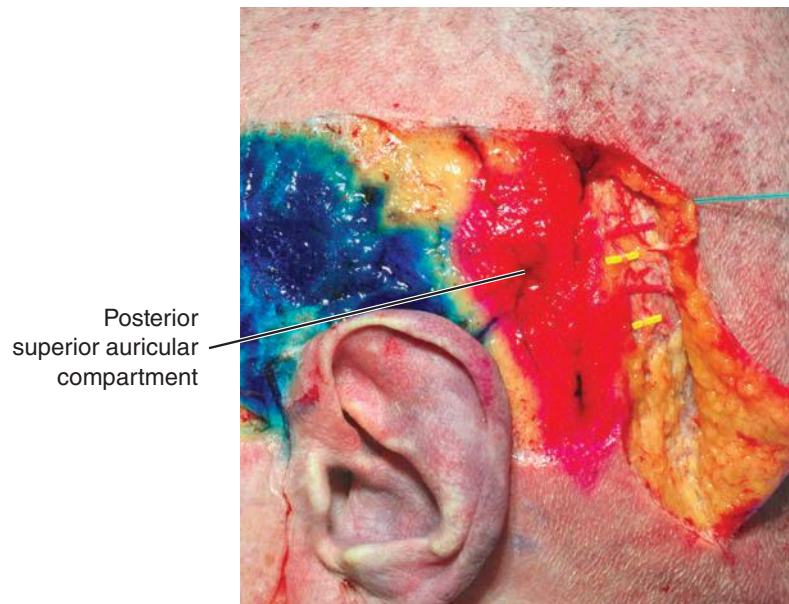
There are numerous periauricular compartments. The anterior superior compartment is related to the superficial temporal artery.



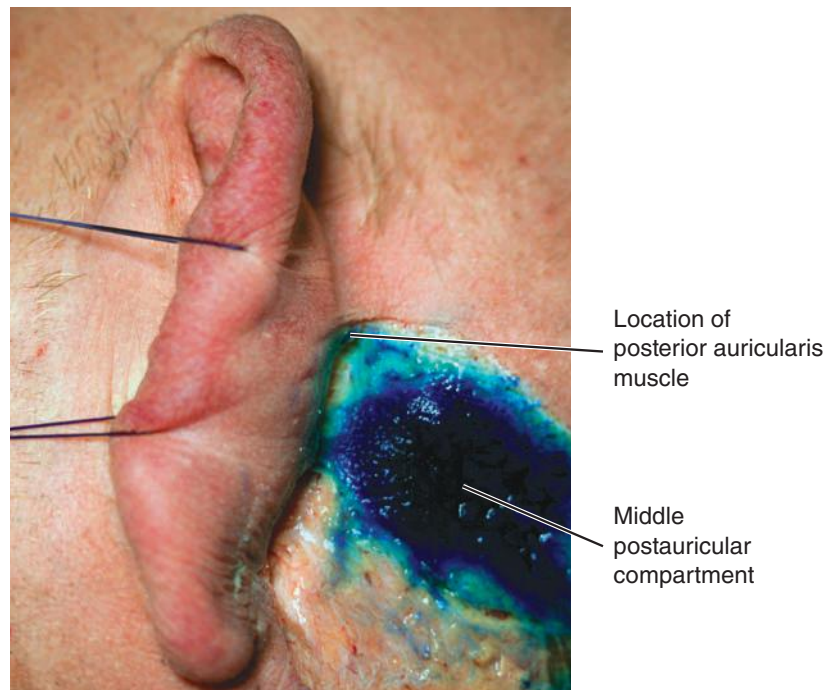
The frontal branch of the superficial temporal artery defines another compartment.



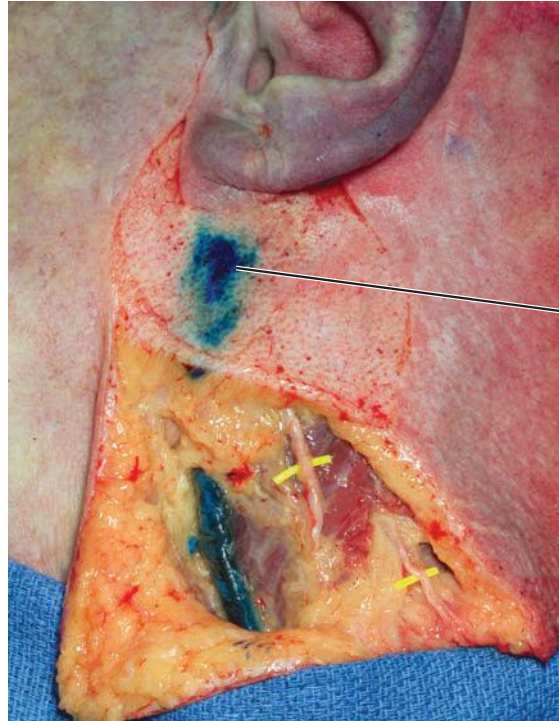
There is a posterior superior compartment.



A middle postauricular compartment lies directly inferior to the posterior auricularis muscle.

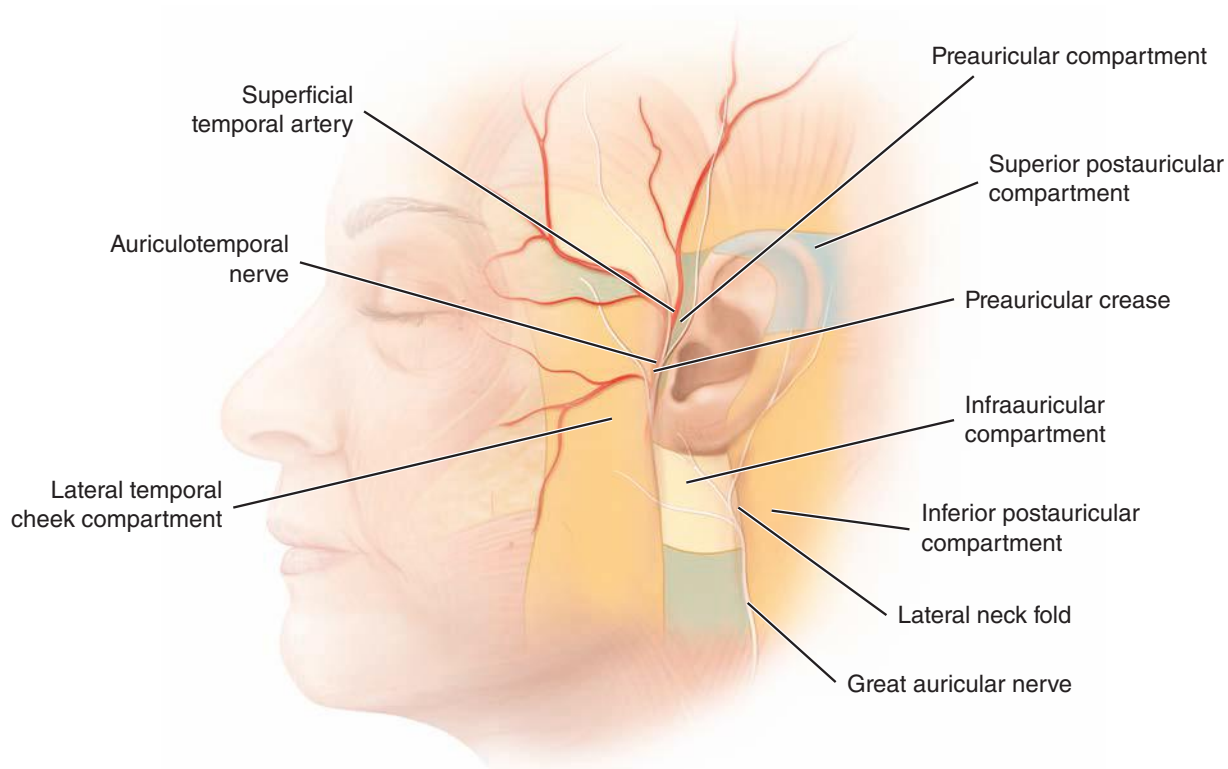
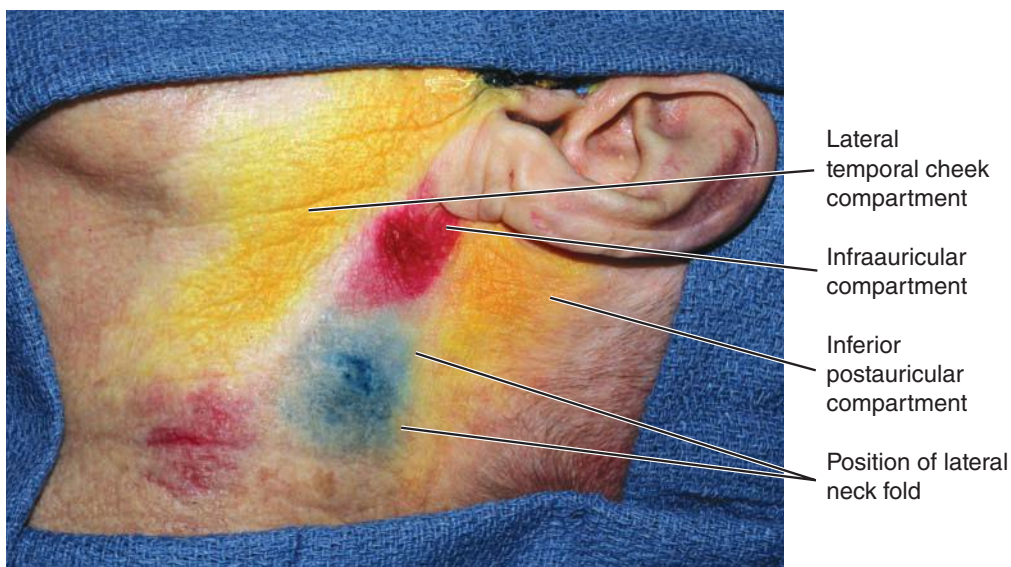

The infraauricular or subauricular compartment lies directly caudal to the lobule of the ear.



Infraauricular compartment

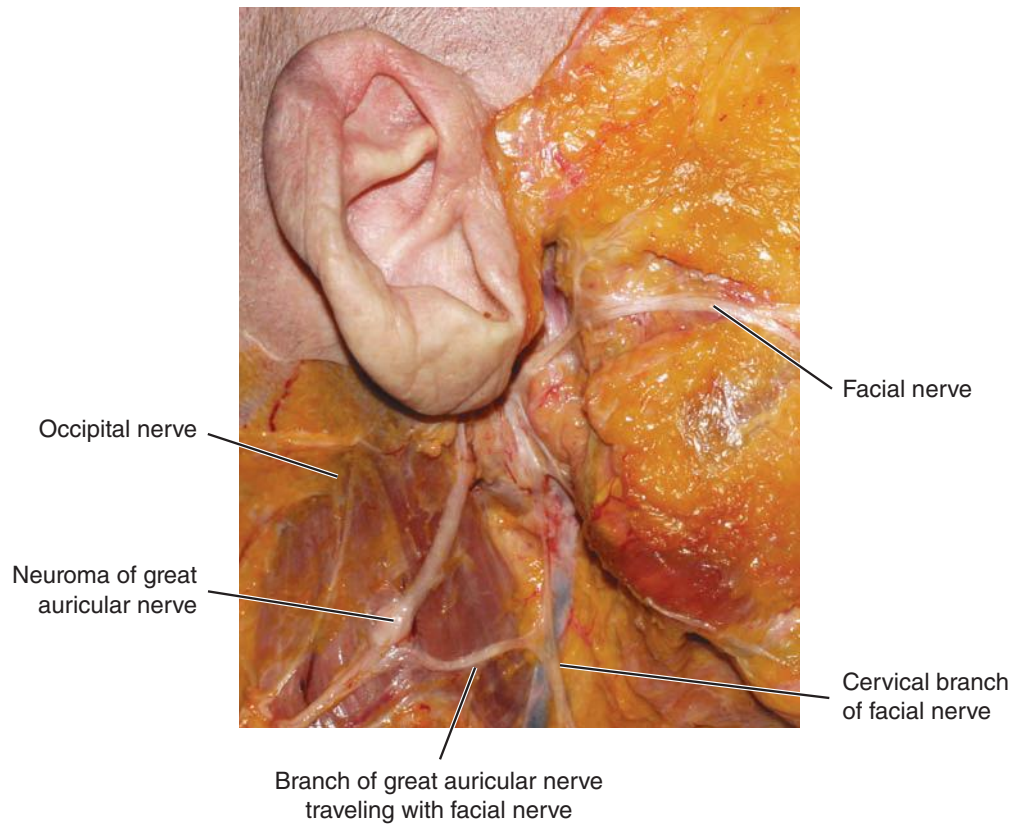
Water-based dyes with a high solubility index are used to identify these compartments and to show how they group together or “lock up.” The periauricular compartments beneath the ear illustrate a design that fits like the pieces of a puzzle.



This is the territory of the great auricular nerve, the most frequently injured nerve during facial surgery. Its injury is not unimportant. There is a reproducible surface landmark that helps to predict this nerve's position.

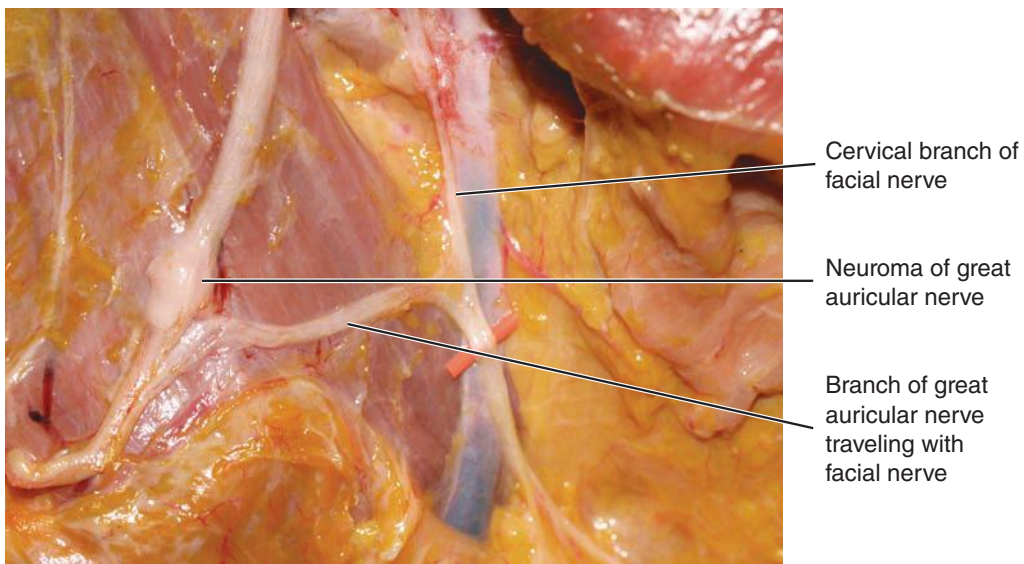
A frequent sequela of injury to the great auricular nerve is neuroma formation. Neuromas may be painful and require surgical removal.

This dissection revealed a great auricular neuroma from a previous operation.

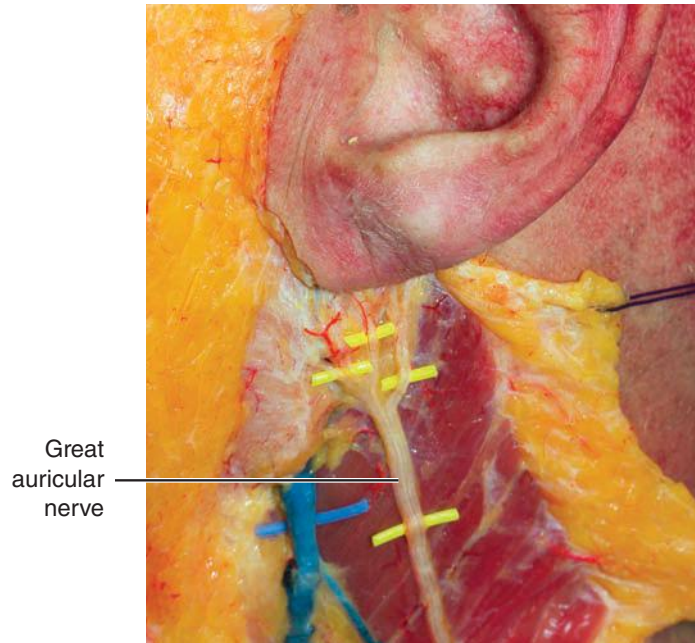


The nerve had been injured and healed in situ, although a neuroma formed. The dissection also shows how the great auricular nerve can send a branch that travels with the facial nerve. This is not uncommon.

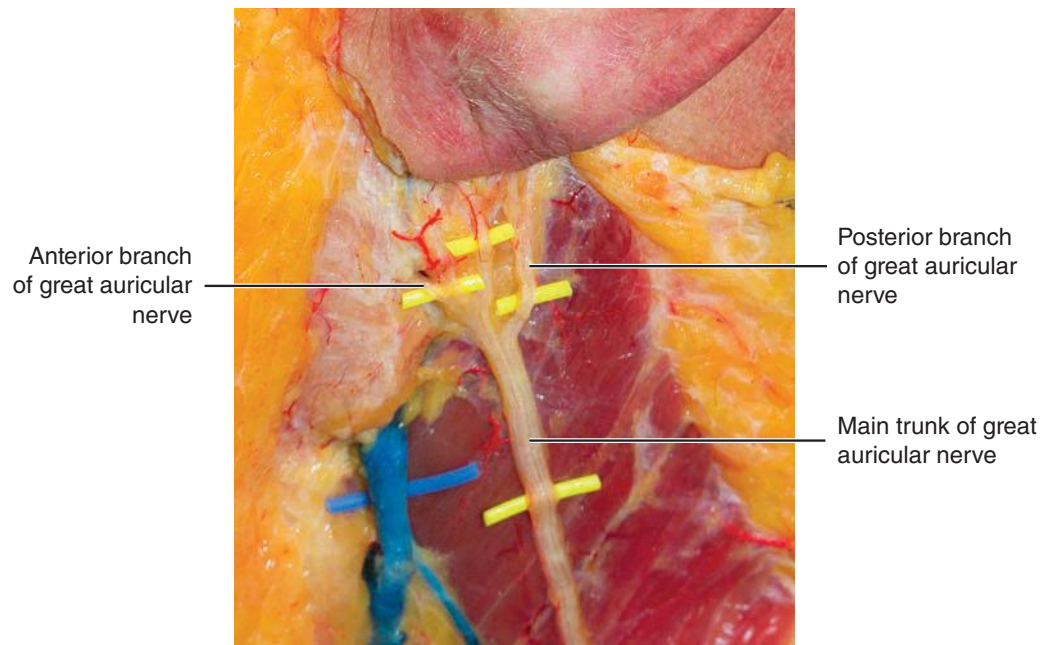
Previous dissections noted the zygomaticotemporal nerve running alongside the frontal branch of the facial nerve. It was these observations several hundred years ago that added confusion to understanding the motor function of the fifth and seventh cranial nerves.



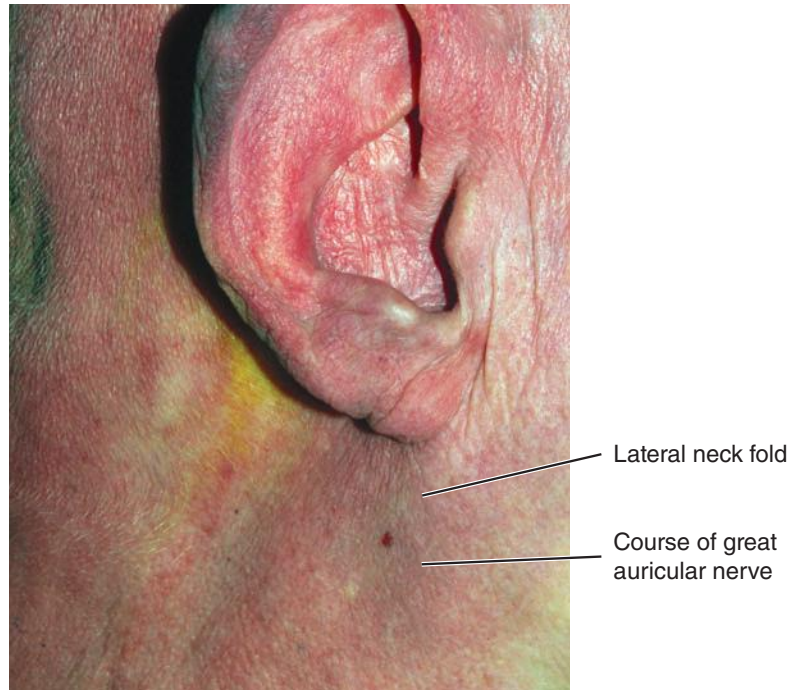
This dissection illustrates the main branches of the great auricular nerve.



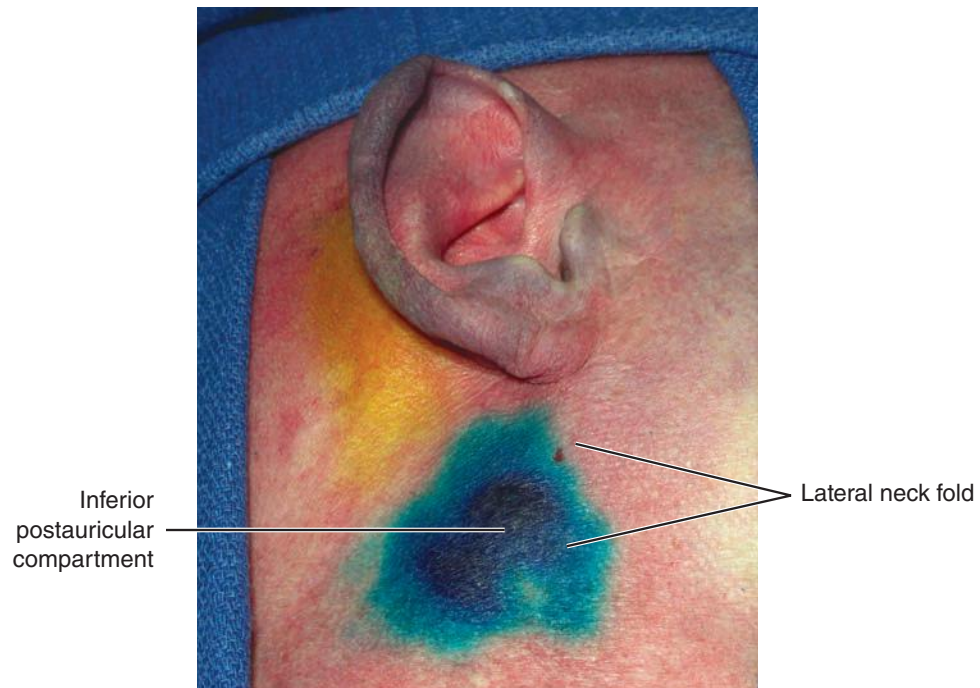
The main trunk dives beneath the parotid gland and beneath Lore's fascia before ascending toward the ear.



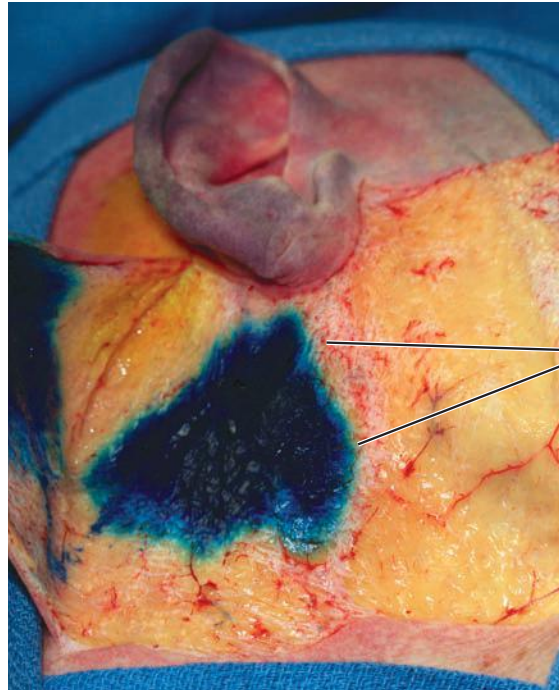
Topography predicts the location of the great auricular nerve. A lateral neck fold is noted on clinical examination. This is a consistent finding.



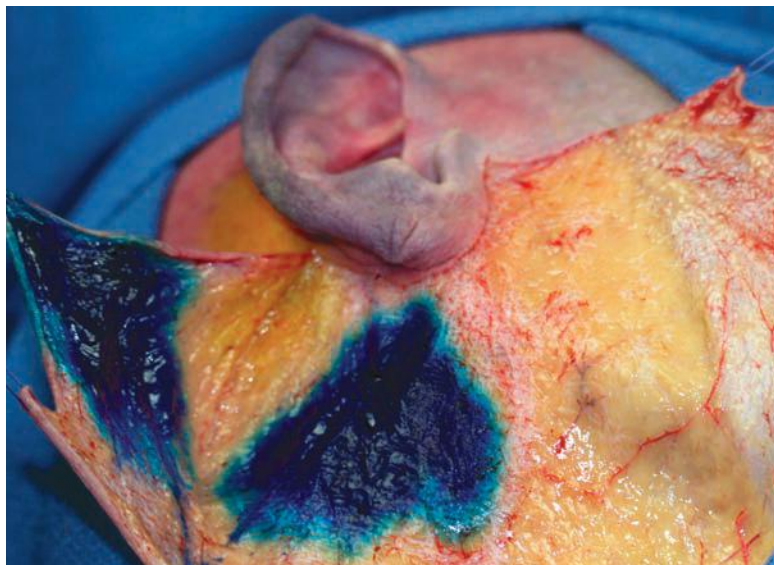Dye is used to identify a boundary along the lateral neck fold.



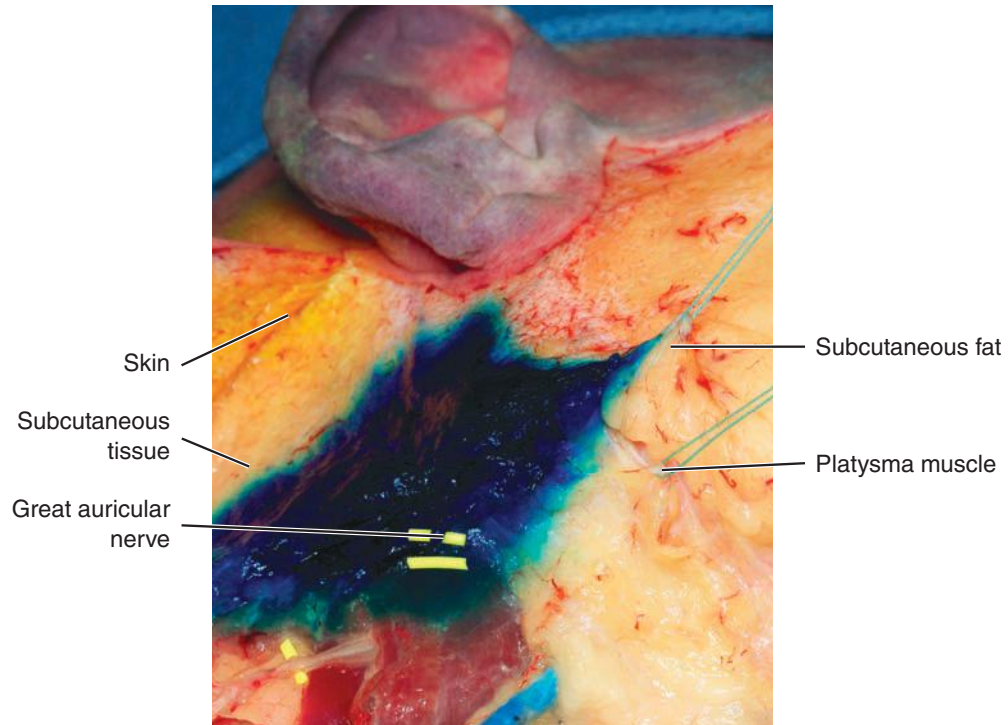
Dissection shows how dye cannot diffuse through this boundary zone. This finding is reproducible.



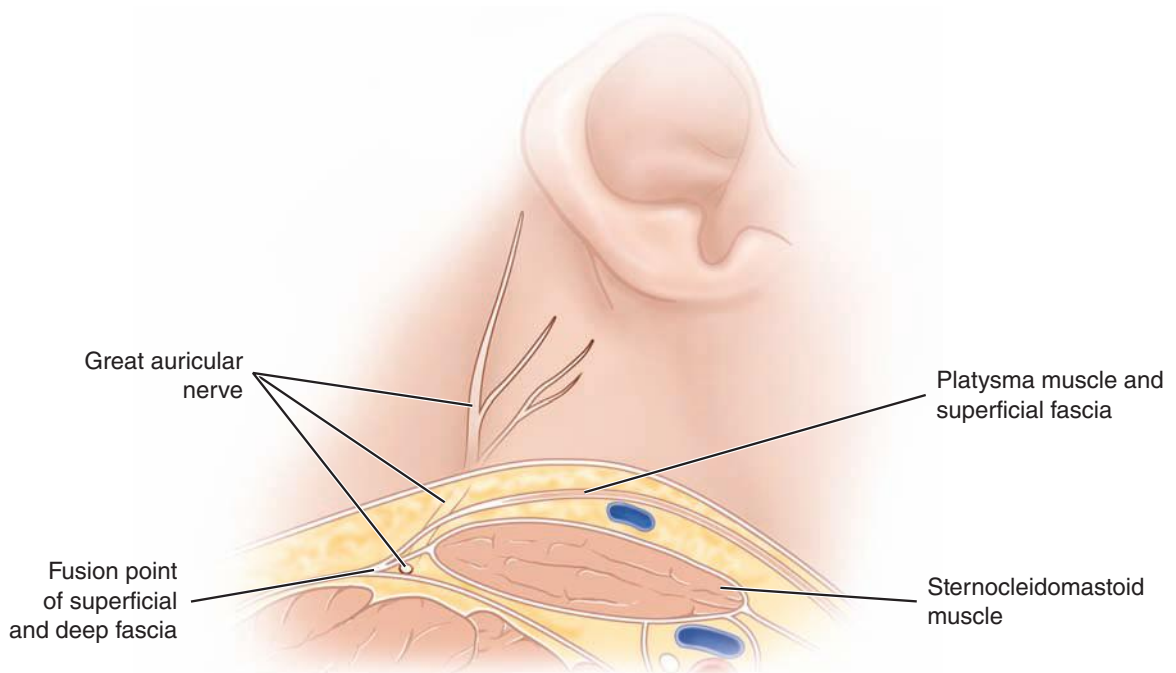
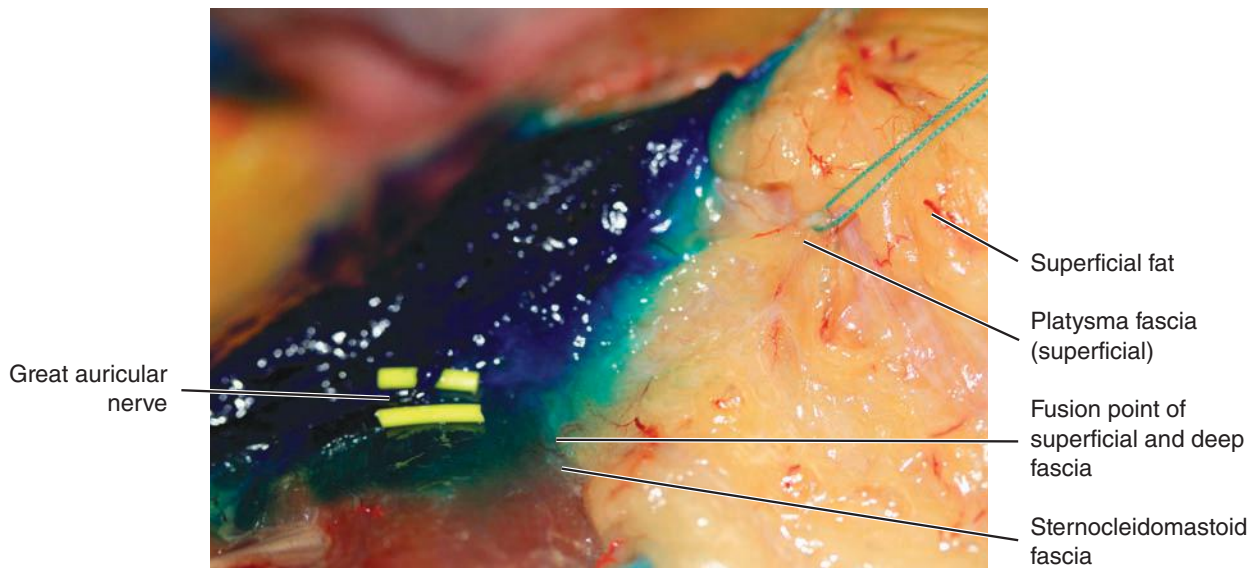
Lateral neck fold



Cross-sectional anatomy in the axial dimension reveals the underlying anatomy. The fascia medial to this boundary has two layers with intervening fat. There is platysma muscle and sternocleidomastoid fascia. The great auricular nerve lies beneath the deep fascia. Lateral to this boundary, the fascia has fused into one layer. This leads to tethering of the nerve and sets the scene for improper transitioning beneath the nerve.



In effect, there is a deep lateral subcutaneous layer and a thinner medial layer. If dissection is done beneath the thick lateral adipose layer at the same depth past this boundary, the dissection will proceed beneath the great auricular nerve. This is a classic example of a surgical transitioning problem. Maintaining the proper depth requires transitioning to a different thickness.

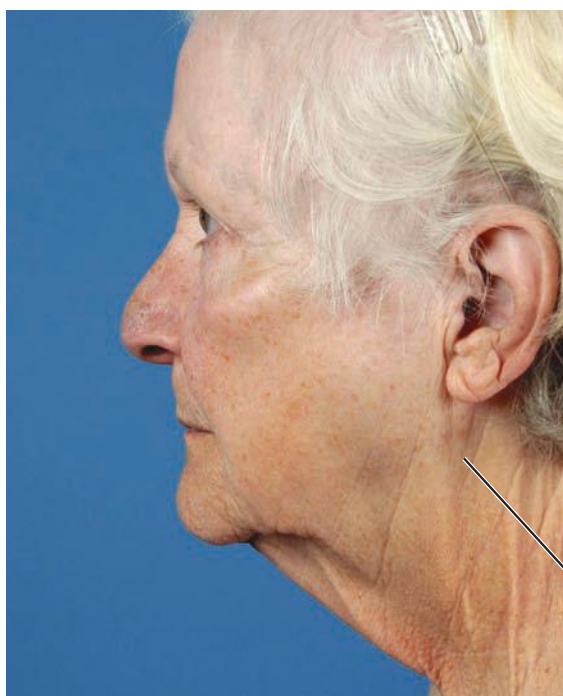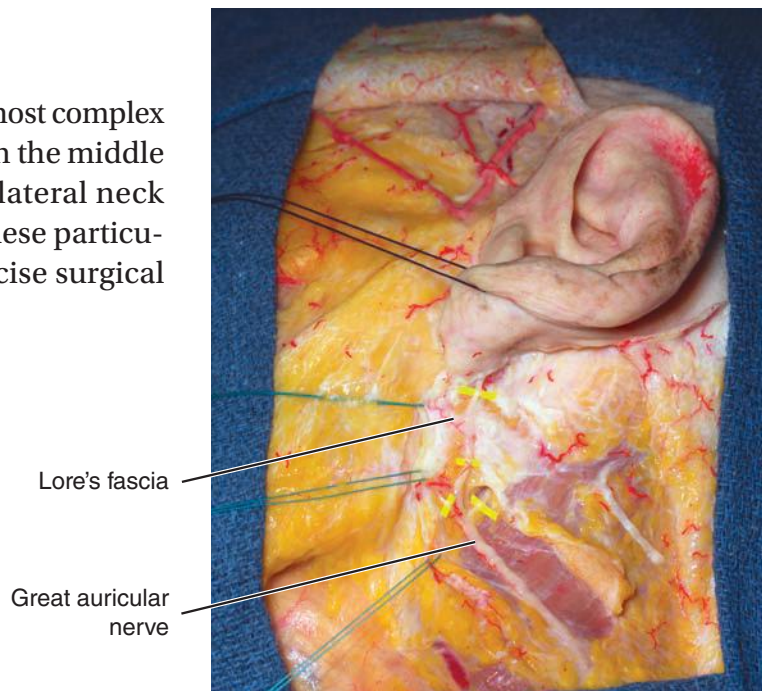


## FUSION ZONES

These observations illustrate how another cause of folds is based on fusion zones.

Skin folds can also form where layers of fascia fuse.

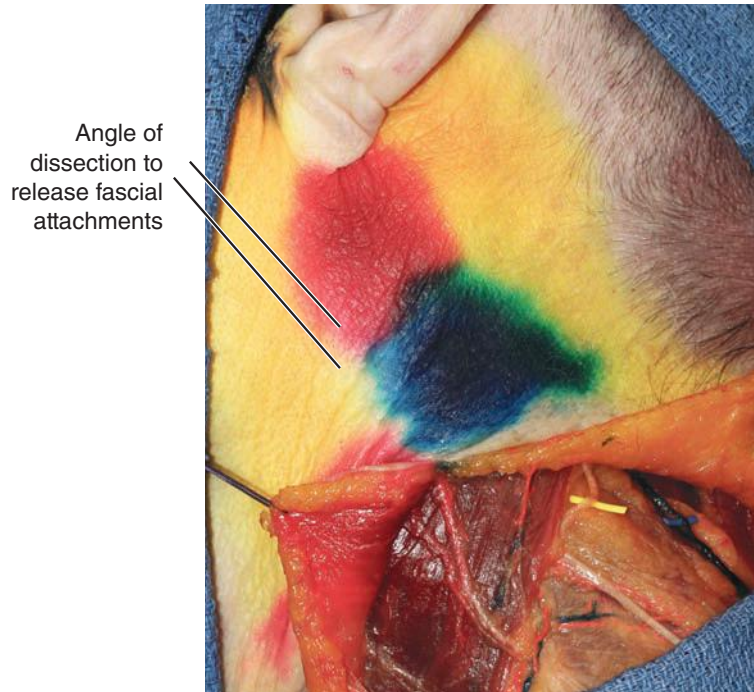
Fusion zones are some of the most complex facial anatomy. They occur on the middle cheek and in the neck. The lateral neck fold is one example of how these particular types of folds require precise surgical technique.



The incidence of nerve injury can be decreased by identifying the lateral neck fold before surgery. It is usually apparent, but clinical positioning of soft tissues can reveal its location as a point of tethering. These injuries can be avoided by understanding the location of the nerve relative to the lateral neck fold.

Course of  
great auricular  
nerve

Using a common surgical principle can also facilitate ease of dissection when surgery is performed parallel to transect the membrane between compartments.



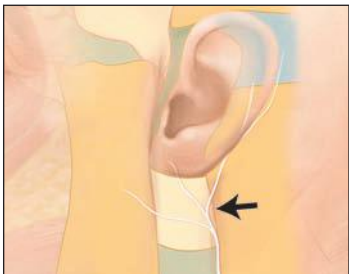
It is like trying to cut paper with scissors by cutting against its flat surface versus cutting against an edge. Dissecting parallel to the membranes that form between compartments is cutting against the edge.

The lateral neck fold can also serve as a guide for induction of local anesthesia, keeping in mind the depth the great auricular nerve travels as it ascends toward the lobule.

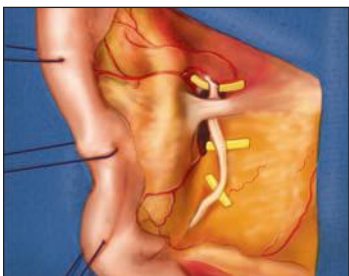
### *Key Points*

- The posterior auricularis muscle is a reliable landmark for the position of the postauricular artery.
- Manipulation of skin and soft tissue can create folds and creases that signify underlying source vessels.
- Transitioning requires identification of the proper plane between adjacent regions that vary in thickness.
- Skin folds can also form where layers of fascia fuse.

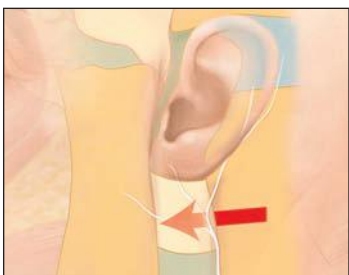
## CLINICAL CORRELATIONS



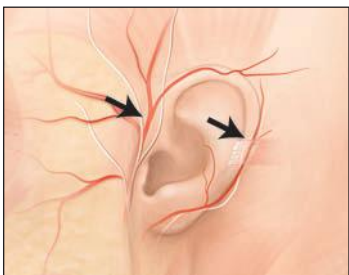
The lateral neck fold is the topographic landmark for the course of the great auricular nerve. This is the danger zone for potential injury to this sensory nerve.



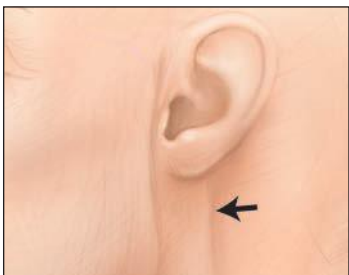By not routinely transecting the posterior auricularis tendon, the incidence of injury to the posterior branch of the great auricular nerve is significantly decreased.



Surgical transitioning is of extreme importance when dissecting from posterior to anterior at the lateral neck fold. Incorporating maneuvers into one's surgical technique to create a subcutaneous flap in accordance with the principle of surgical transitioning decreases the chance of great auricular nerve injury.



The anterior auricular crease is a reliable landmark for the superficial temporal artery and the anterior auricular branch; the tendon of the posterior auricularis muscle is a landmark for the posterior auricular artery. These landmarks are useful guides for identifying these arterial structures when required.



The lateral neck fold is an example of a fold associated with a fusion zone. Releasing this fusion zone is the surgical maneuver that softens this fold.

## Bibliography

The list of references for this chapter pertains to the great auricular nerve, its anatomy, and possible sequelae from injury. One of these references simplifies the description and improves understanding of the facial layers of the face and neck, since the risk of injury to this nerve is greatest at a fascial fusion zone. The variability of fixed measurements is noted, a finding that illustrates the value of defining surface topographic landmarks.

Becser N, Bovim G, Sjaastad O. Extracranial nerves in the posterior part of the head. Anatomic variations and their possible clinical significance. *Spine* 23:435-441, 1998.

*This article showed that there is significant variability in the course of the great auricular nerve if one uses surface measurements alone. The authors noted the proximity of the main occipital nerve (greater) branch to its artery, raising the possibility of identifying a boundary zone as a potential topographic landmark.*

Christensen NR, Jacobsen SD. Parotidectomy. Preserving the posterior branch of the great auricular nerve. *J Laryngol Otol* 111:556-559, 1997.

*A higher incidence of sensory morbidity was reported with routine transection of the posterior branch of the great auricular nerve.*

de Chalain T, Nahai F. Amputation neuroma of the great auricular nerve after rhytidectomy. *Ann Plast Surg* 35:297-299, 1995.

*A painful neuroma may present as a late complication of rhytidectomy and inadvertent injury of the great auricular nerve.*

de Ru JA, van Benthem PP, Hordijk GJ. Morbidity of parotid gland surgery: results 1 year post-operative. *Eur Arch Otorhinolaryngol* 263:582-585, 2006.

*Transection of the posterior branch of the great auricular nerve leads to greater sensory deficit.*

Diamond M, Wartmann CT, Tubbs RS, et al. Peripheral facial nerve communications and their clinical implications. *Clin Anat* 24:10-18, 2011.

*The authors described an anatomic variation of the great auricular nerve that may occur in as many as 10% of individuals.*

Hu J, Ye W, Zheng J, et al. The feasibility and significance of preservation of the lobular branch of the great auricular nerve in parotidectomy. *Int J Oral Maxillofac Surg* 39:684-689, 2010.

*The authors discussed the clinical significance of preservation of the lobular branch of the great auricular nerve.*

Lindner HH. The anatomy of the fasciae of the face and neck with particular reference to the spread and treatment of intraoral infections (Ludwig's) that have progressed in adjacent fascial spaces. *Ann Surg* 204:705-714, 1986.

*A general review of the facial fascias showing the proximity of superficial to deep fascia at the lateral and posterior neck boundary, a finding in agreement with the concept of fusion zones.*

McKinney P, Gottlieb J. The relationship of the great auricular nerve to the superficial musculoaponeurotic system. *Ann Plast Surg* 14:310-314, 1985.

*The course of the great auricular nerve travels deep to the superficial fascia of the head and neck.*

McKinney P, Katrana DJ. Prevention of injury to the great auricular nerve during rhytidectomy. *J Plast Reconstr Surg* 66:675-679, 1980.

*A description of the classic landmark for the location of the great auricular nerve relative to the bony ear canal.*

Moss CE, Johnston CJ, Whear NM. Amputation neuroma of the great auricular nerve after operations on the parotid gland. *Br J Oral Maxillofac Surg* 38:537-538, 2000.

*The authors noted a 6% incidence of painful neuroma after transection of the great auricular nerve, an important feature of the morbidity seen after inadvertent or routine sensory nerve transection.*

Peuker ET, Filler TJ. The nerve supply of the human auricle. *Clin Anat* 15:35-37, 2002.

*A frequently referenced article that defined the sensory innervation to specific regions of the ear.*

Tubbs RS, Salter EG, Wellons JC, et al. Landmarks for the identification of the cutaneous nerves of the occiput and nuchal regions. *Clin Anat* 20:235-238, 2007.

*The authors described distances relative to fixed bony landmarks for the sensory nerves of the neck.*

Zohar Y, Siegal A, Siegal G, et al. The great auricular nerve; does it penetrate the parotid gland? An anatomical and microscopical study. *J Craniomaxillofac Surg* 30:318-321, 2002.

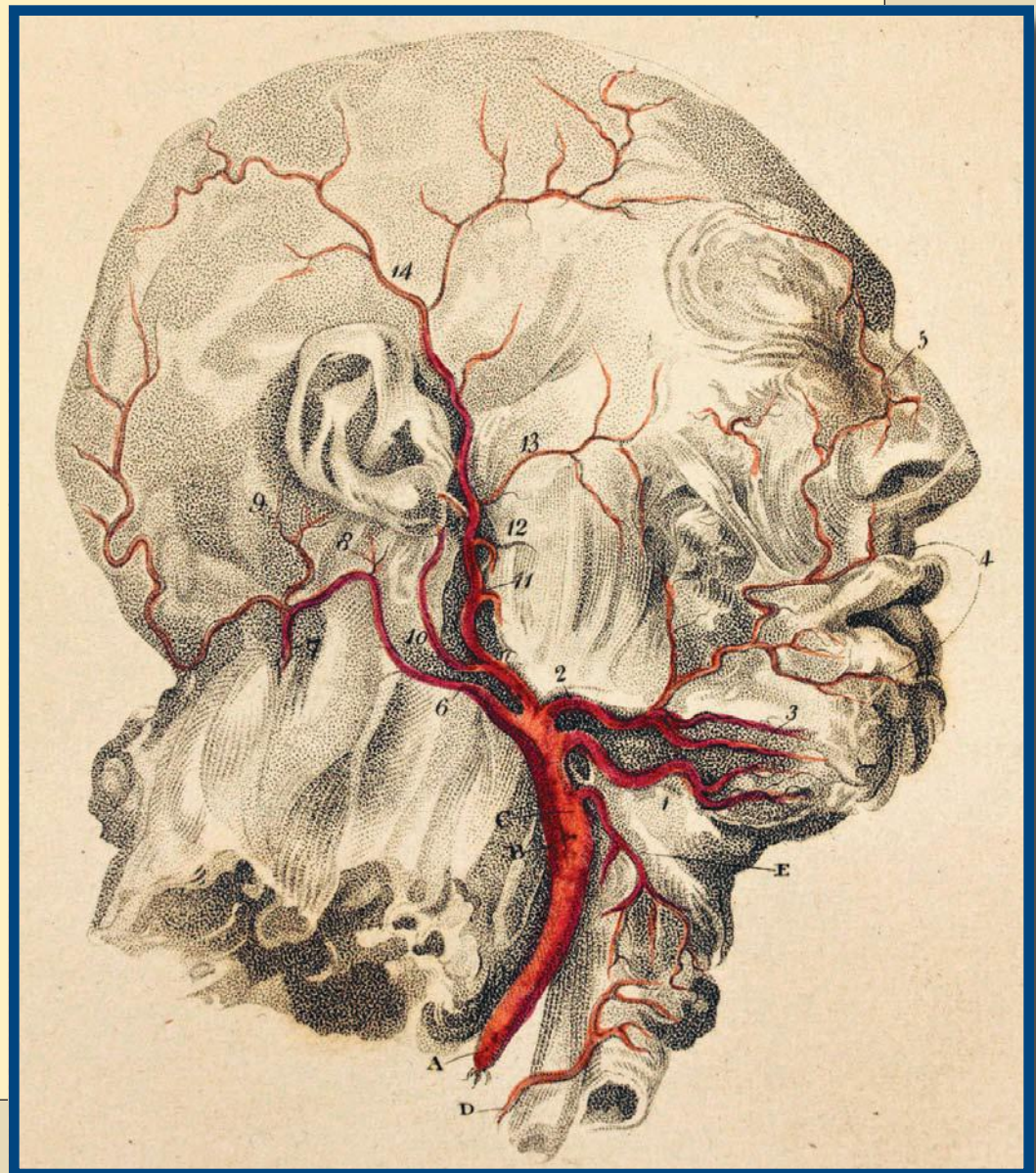
*The macroscopic and microscopic anatomy of the anterior branch of the great auricular nerve was described.*

---

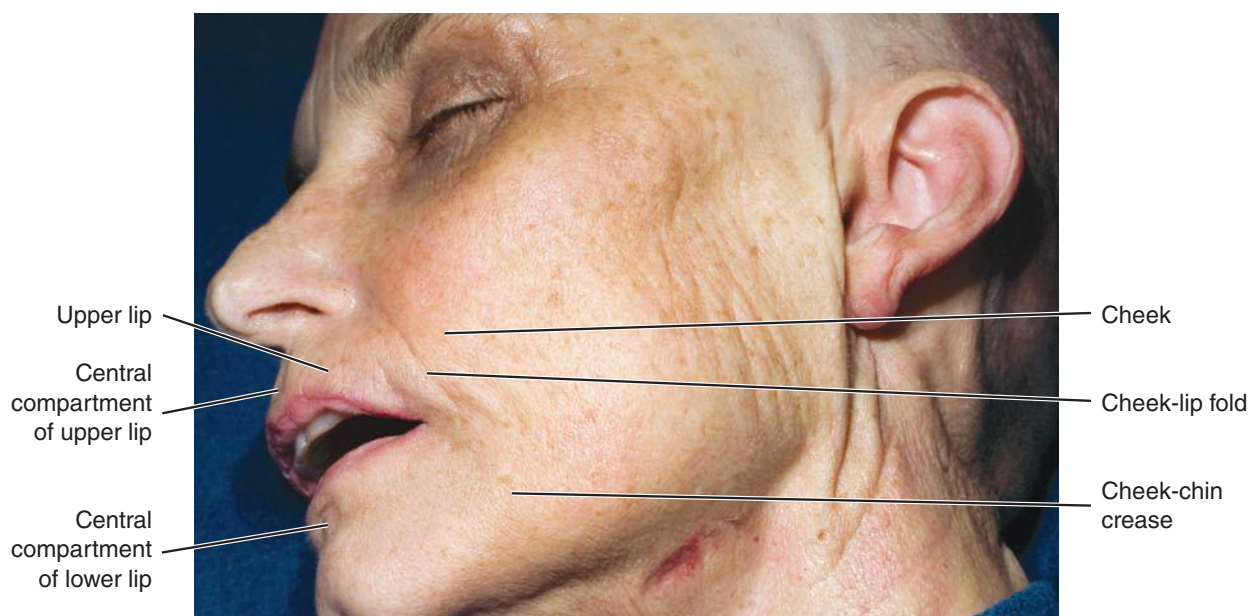
CHAPTER 8

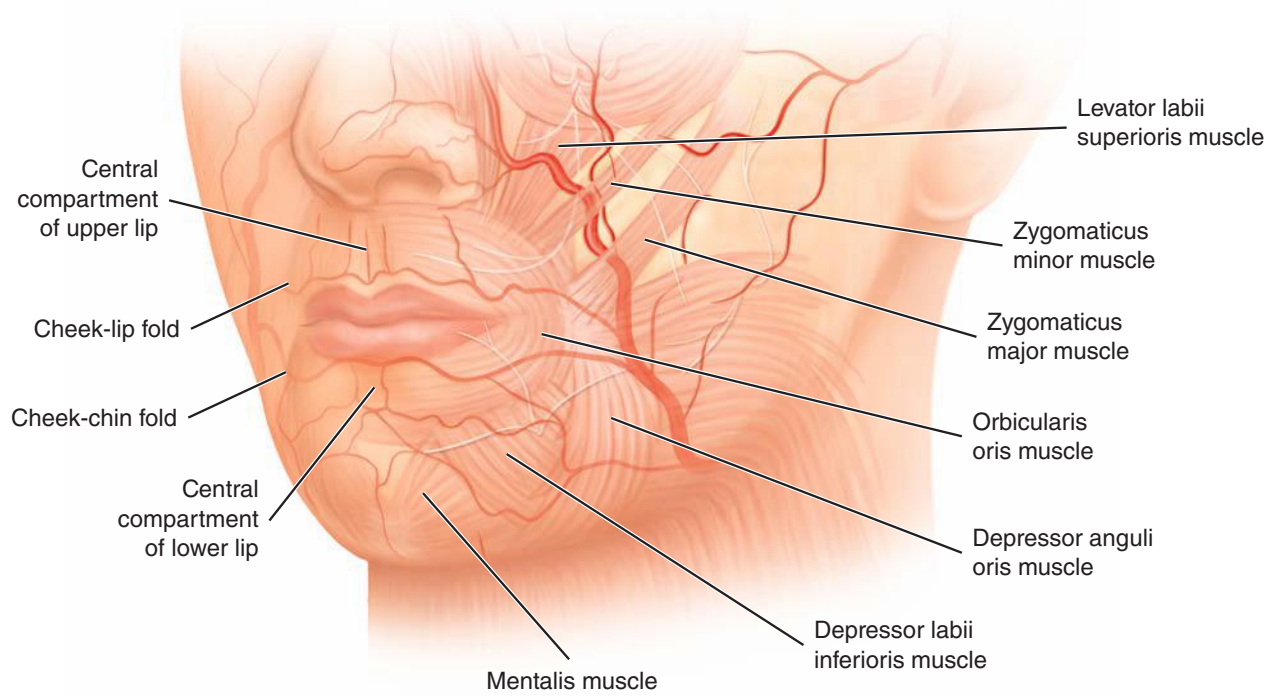
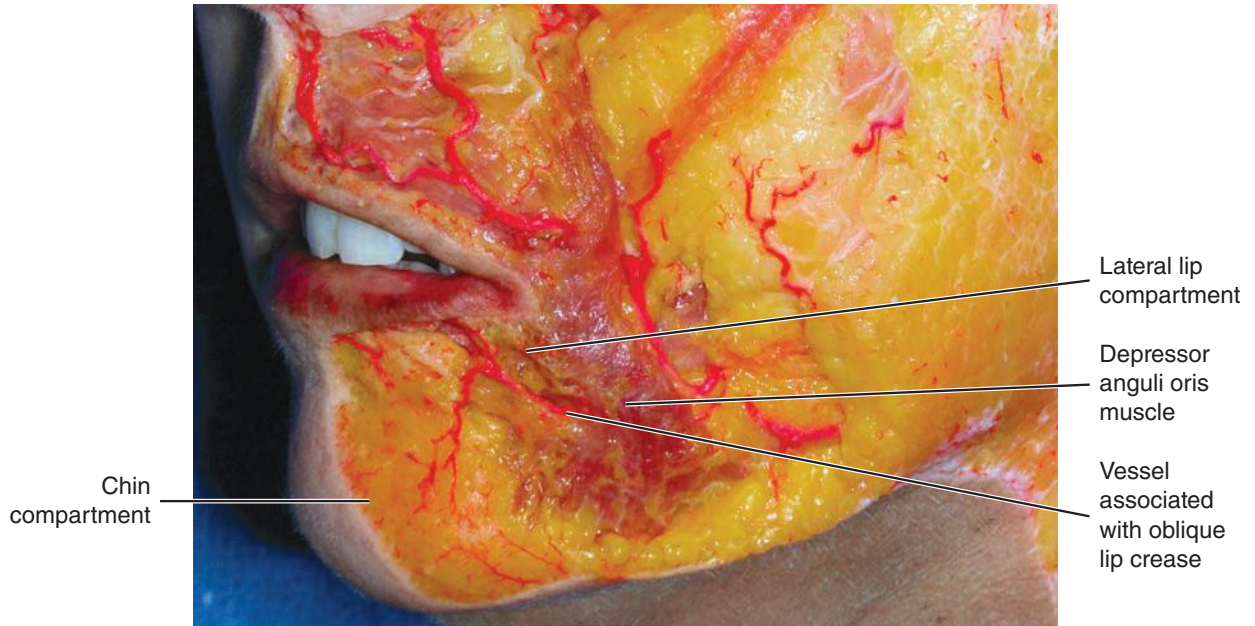
---

# The Lips and Chin

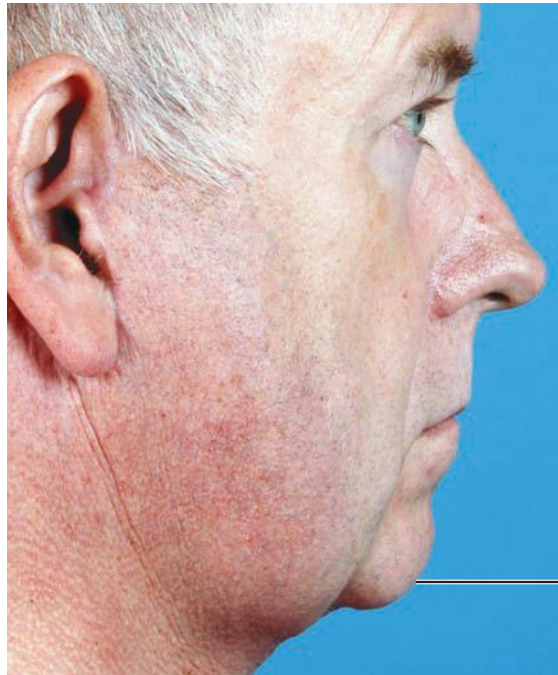


Of all the regions of the face, the lips are probably the least understood from the perspective of anatomic topography, although the muscular anatomy has been defined for centuries. Knowledge of this region is important for cleft surgery and facial reconstruction. For example, even a minor detail such as the insertion of the pars peripheralis of the orbicularis oris into the nasal base is critical to the success of cleft lip surgery.



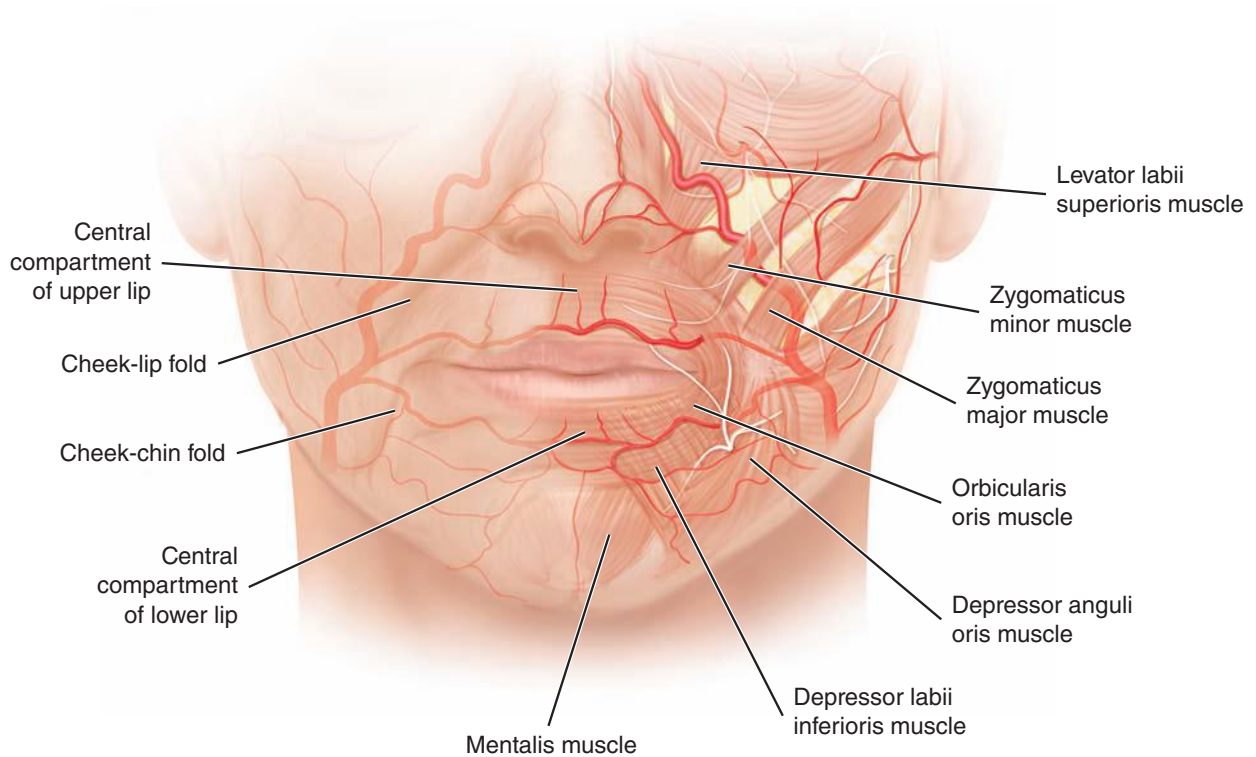
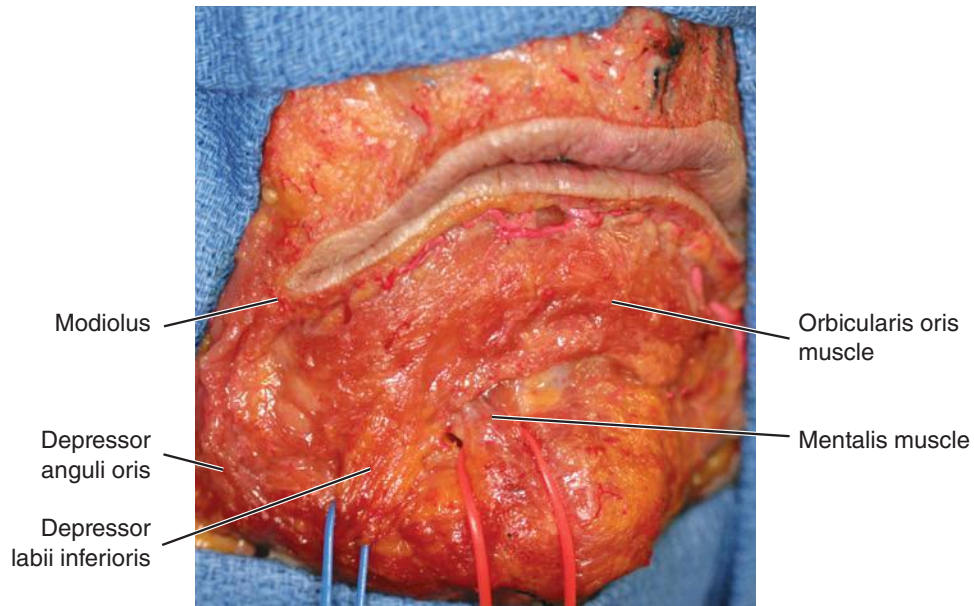


Other muscular anatomy has been precisely defined. For example, the effect of mentalis strain is easily recognized.



Mentalis  
activity  
muscle

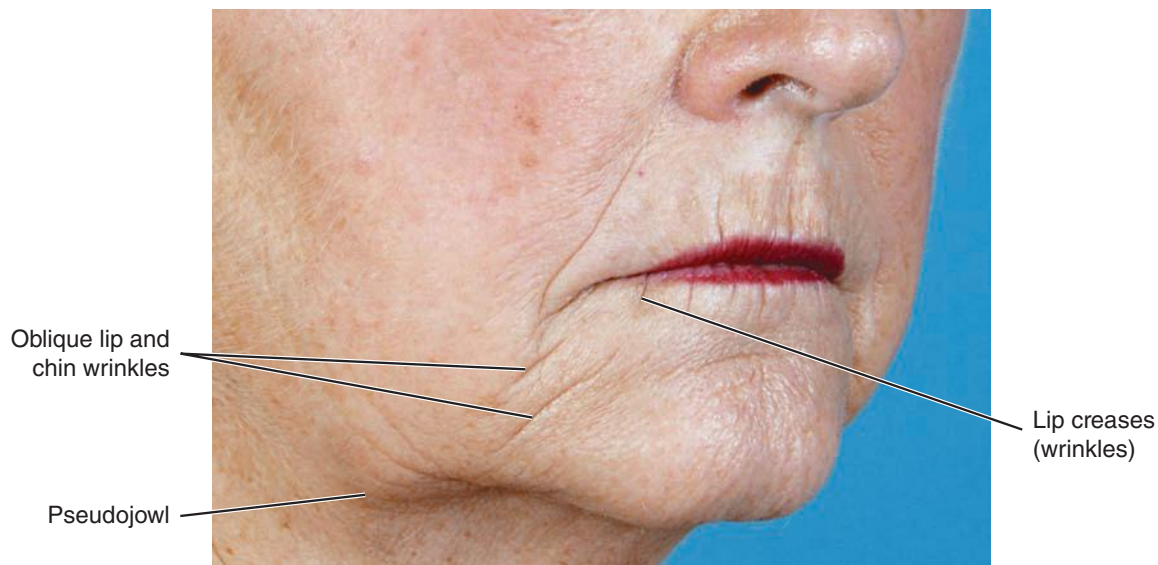The correlation between the mentalis and the depressor labii superioris muscle and the depressor anguli oris is well known. The platysma blends over the depressor, much like the relationship of the frontalis to the orbicularis oculi muscle. Thus the platysma muscle contributes to lower lip function.



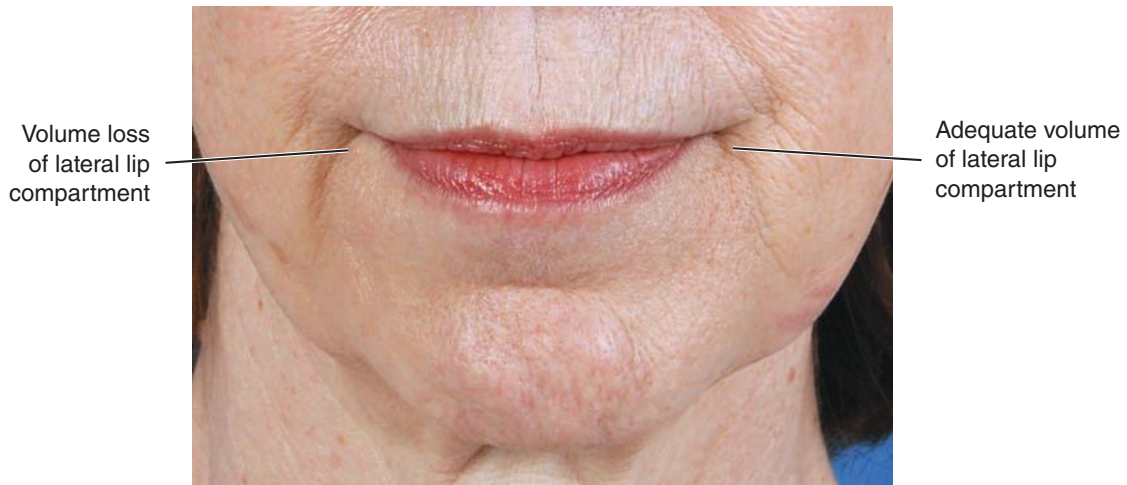The corner of the mouth was one of the earliest anatomic regions described in detail, almost a century ago. This information is the keystone for facial reanimation. The corner of the mouth, or *modiolus*, is a dynamic structure. Unlike the lateral canthus or the vertical position of the alar base, the corner of the mouth has little static support.

What is not as well understood is how tissues contribute to the shape and form of the lips, and less is understood about how surface structure can help to predict underlying anatomy. With the advent of techniques for changing the shape of the face, this knowledge becomes critically important.

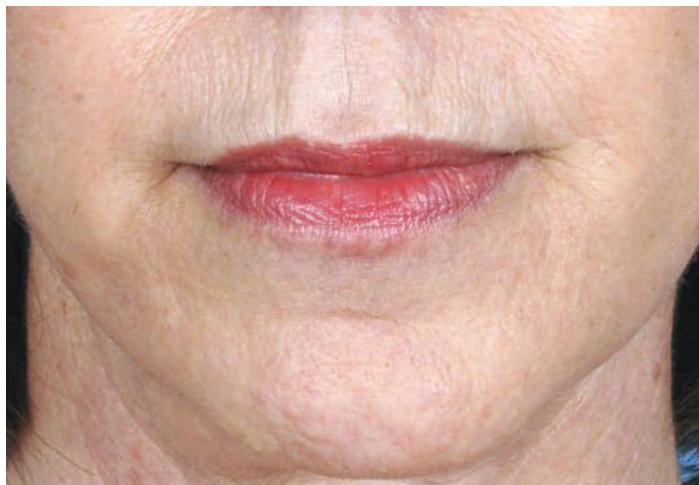Lips are usually considered in terms of their volume—whether there is sufficient or deficient volume.



Understanding the intricacies of lower lip and chin topography is paramount to the success of any filler procedure. Before surgery, this patient had a fairly apparent asymmetry of the corner of the mouth. Her face is shown in repose. This asymmetry is not muscular in nature; rather, as will be shown in dissections, it is secondary to a difference in distribution of adipose tissue.



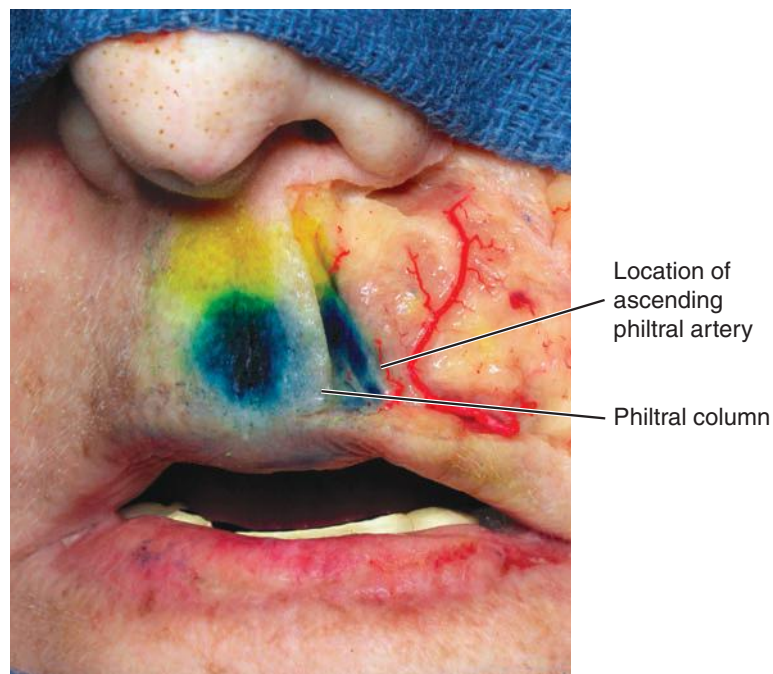
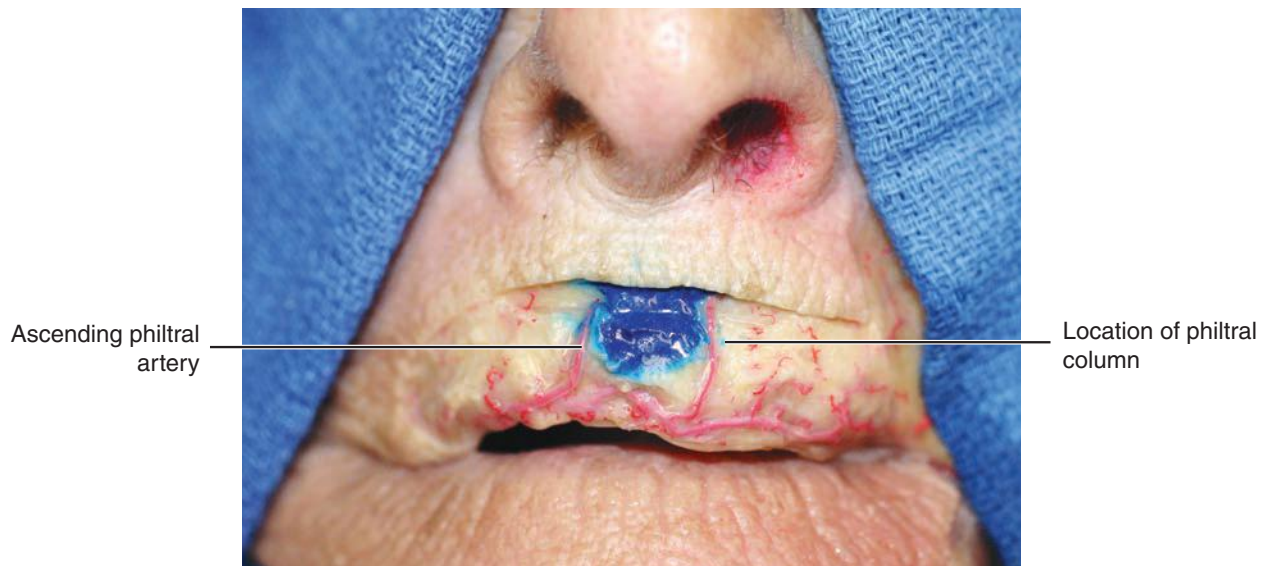
The results of her volume augmentation were based on understanding how the surface contour is determined by underlying structures.



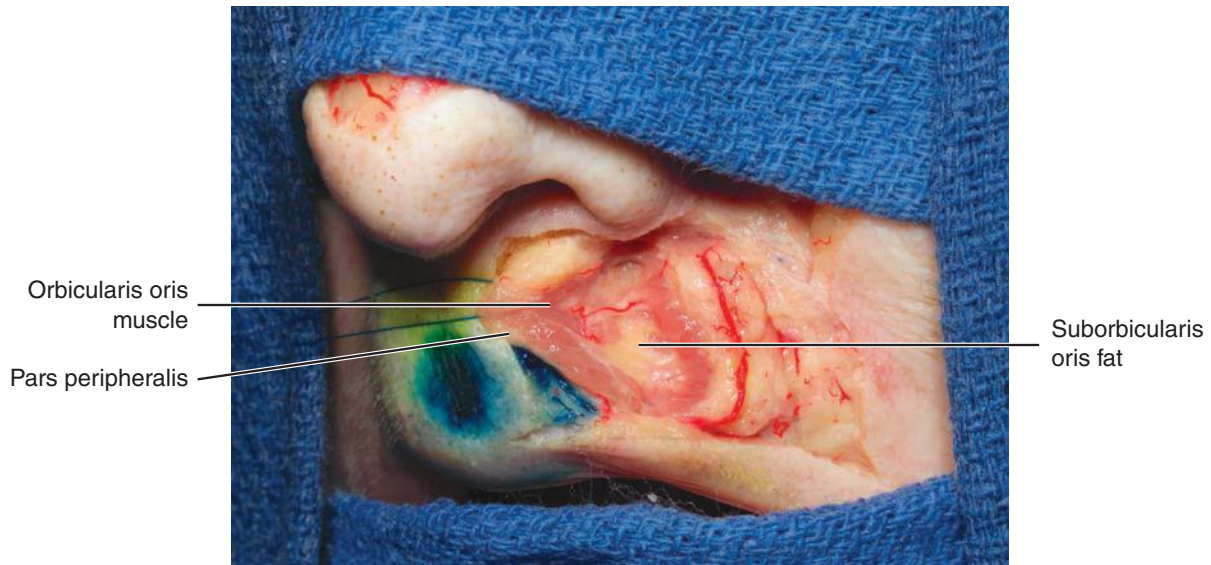
The knowledge of anatomic topography enabled an augmentation technique using 1 cc total volume to rebalance the corner of her mouth, augment the lips, restore the philtral columns, and efface the cheek-lip crease. Her lips are also less wide, a salutary effect of rebalancing volume. These results can be achieved by any clinician with knowledge of facial topography.

## APPLYING THE BASIC CONCEPTS OF ANATOMIC TOPOGRAPHY

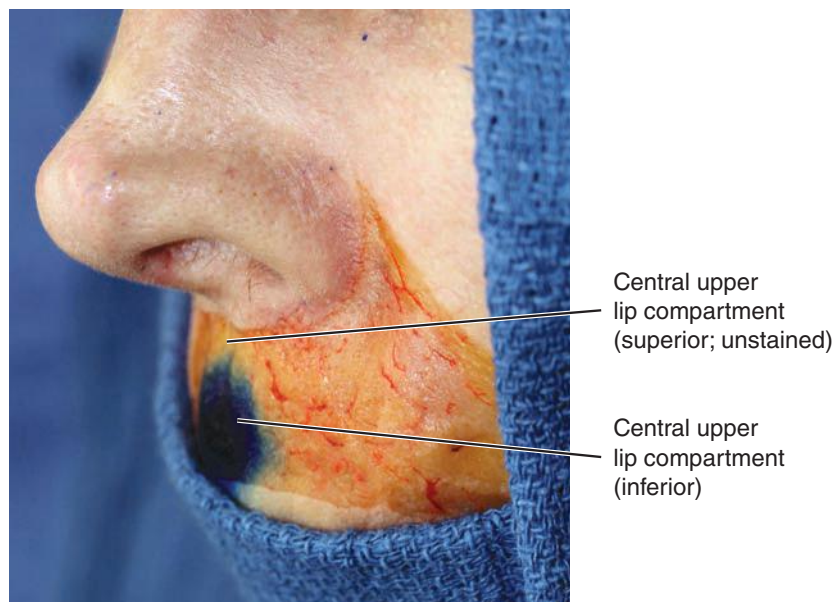
This chapter, as with preceding chapters, demonstrates how the basic concepts of anatomic topography can help to decipher any region of the face. At the beginning of this book, only two pieces of information about the lip region were available. The first was that the upper lip has a central adipose compartment based on vascular supply.



The second piece of information was the understanding of submuscular upper lip anatomy. The anatomy of the upper lip suborbicularis oris fat had been described.

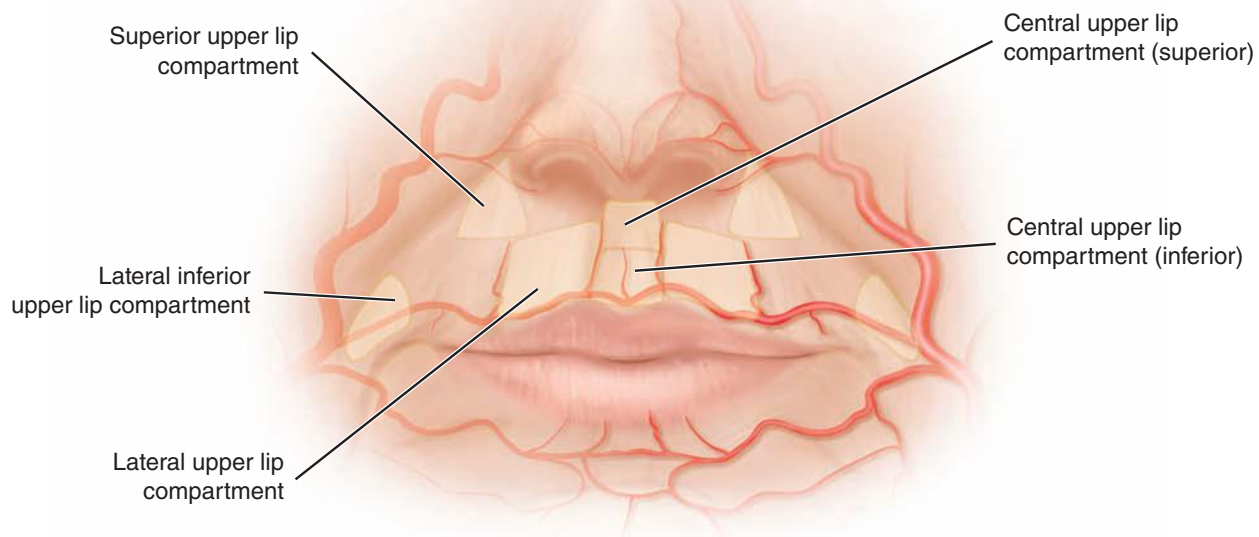
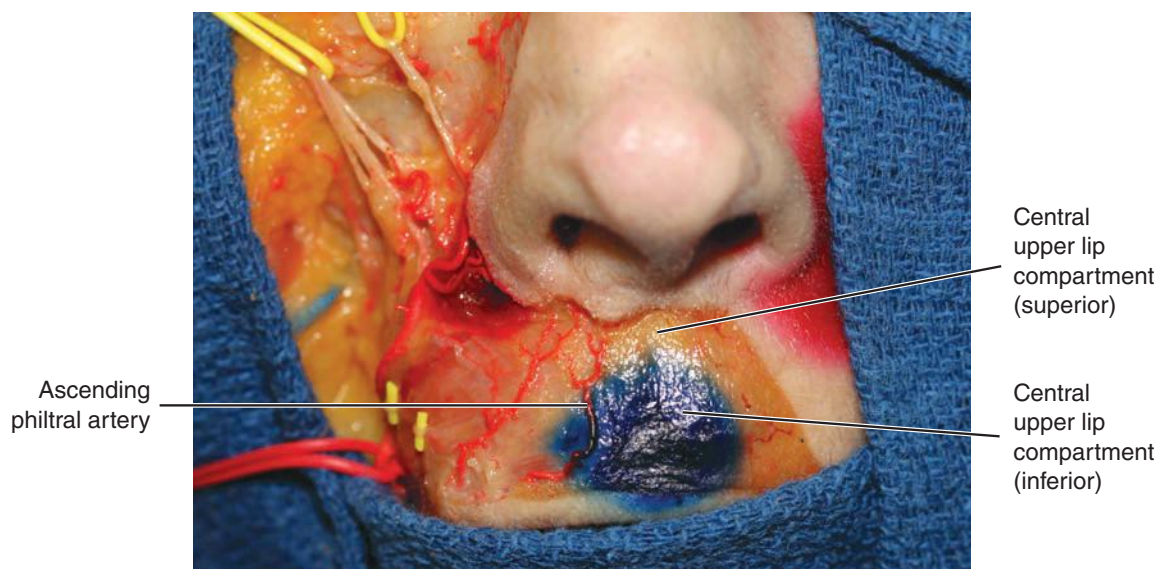


The question was whether applying the basic principles of topographic anatomy could help to decipher the anatomy of the lip and chin. The first step was to duplicate the previous upper lip dissection. The central upper lip compartment, between cupid's peaks, stains with dye.



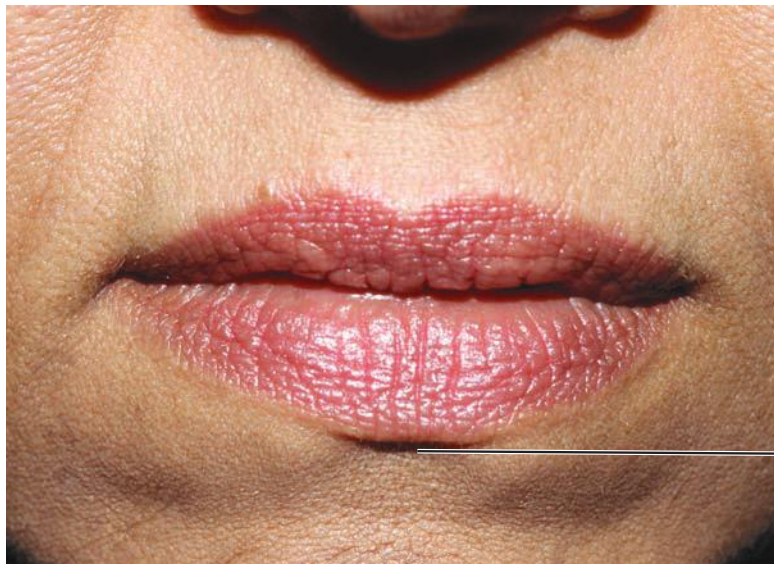Anatomic boundaries are defined in part by vascular anatomy.

Dissection confirmed the presence of ascending philtral vessels, one dissected at the boundary of the dye. The philtral columns are determined in part by the vascular anatomy and its associated membranes inserting into the skin. In addition, the central upper lip is further refined into superior and inferior compartments.



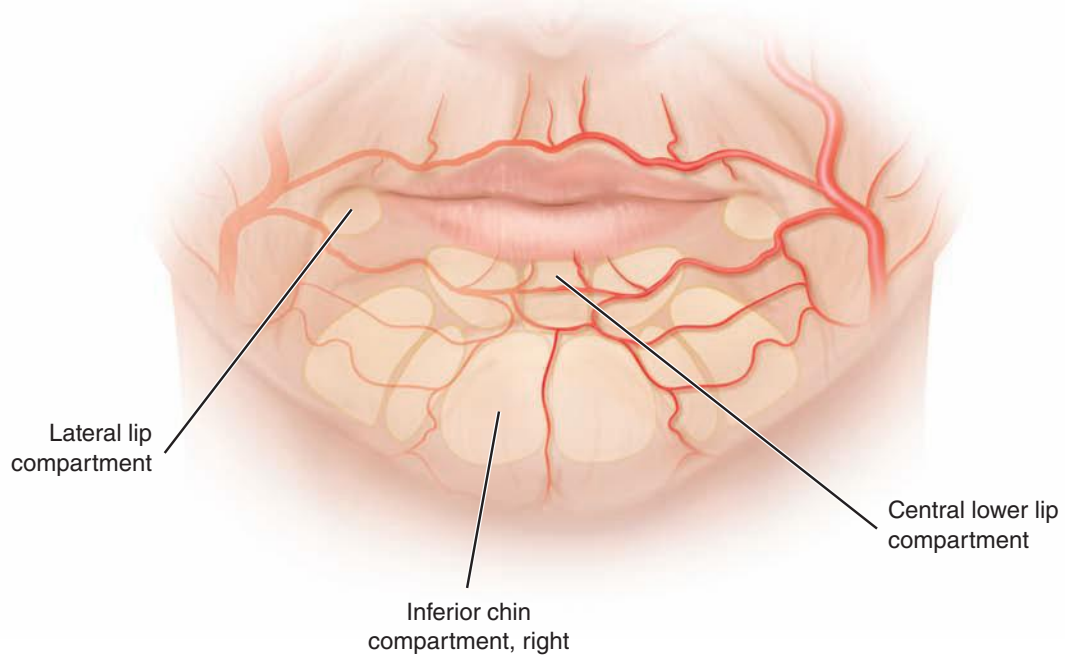
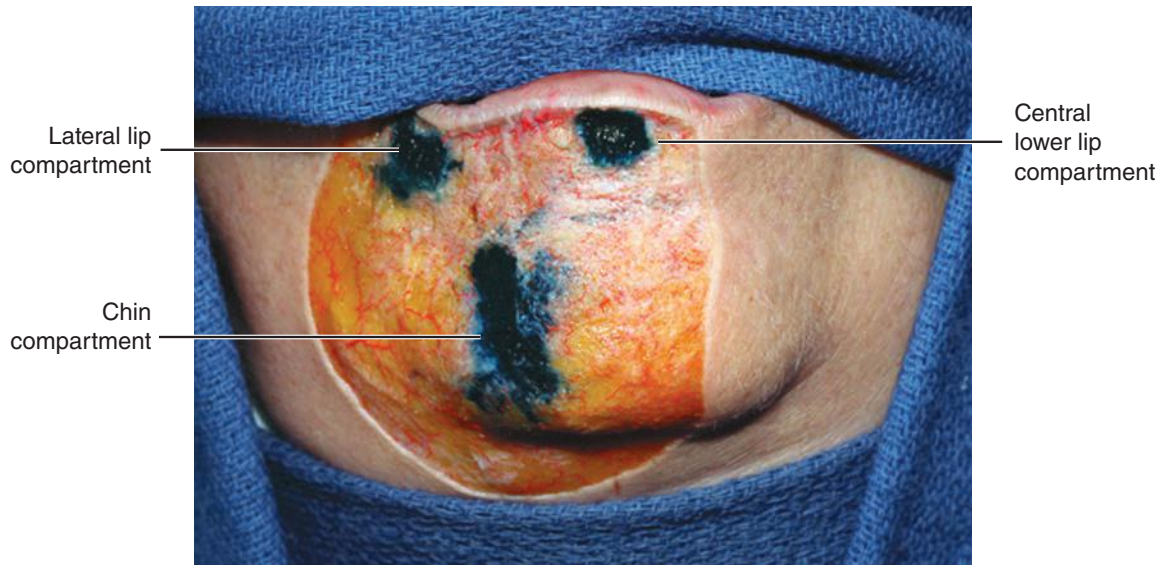
Most areas of the face duplicate the structural makeup of other regions.

If there is an upper lip central compartment, then possibly there is a lower lip central compartment. Adipose tissue is found in highly defined anatomic units or compartments. Clinical observation had suggested the possibility of there being a central lower lip compartment.



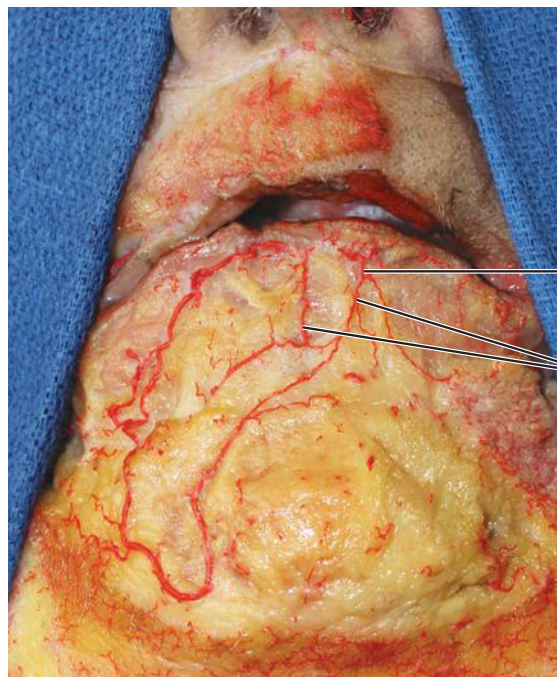
Indication of  
central lower lip  
compartment

The exact center of the lower lip is stained in this specimen. Other regions were stained based on preliminary data. The stain defines the lower lip central compartment.



Adipose units are based on underlying blood supply and its membranous fixation to skin.

Dissection of another specimen defined the characteristics of the lower lip vascular supply. There are two arteries on either side of the central lower lip compartment.

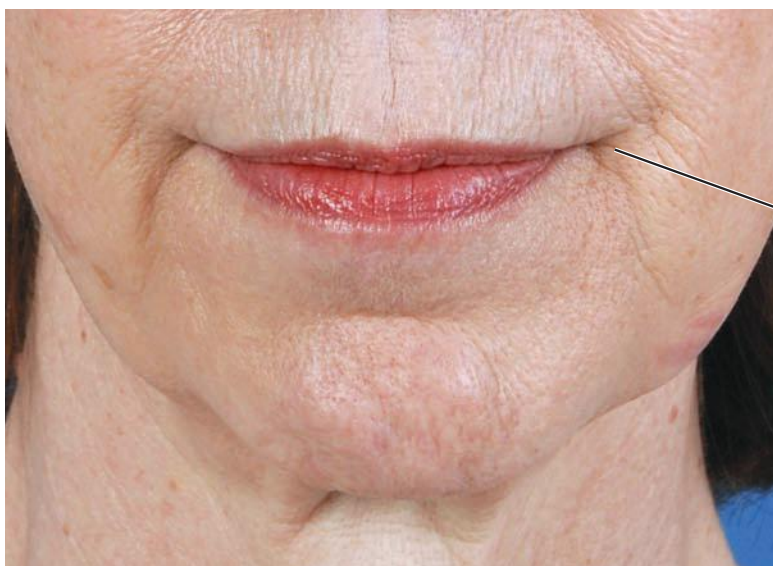

Boundary of  
central lower lip  
compartment

Branches of  
submental artery

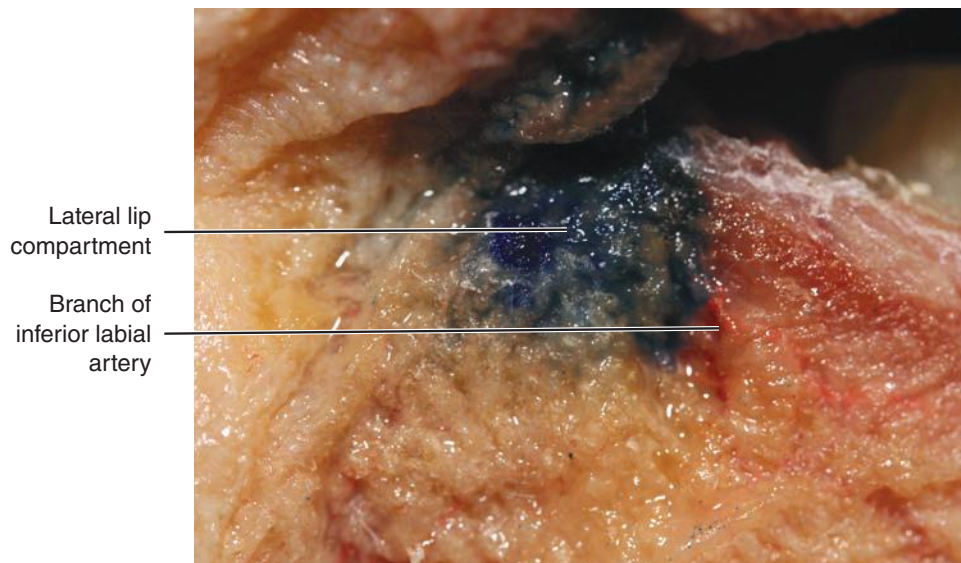
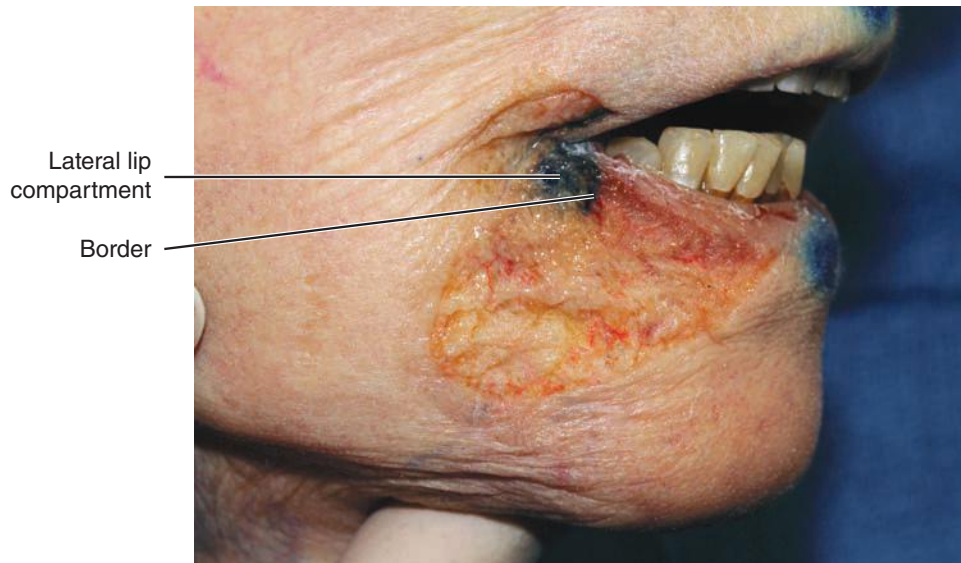This individual has a triangular region of soft tissue at the left commissure that is absent on the right. The shape suggests an anatomic unit.

Anatomic units are determined by the anatomy of the underlying blood supply.



Indication  
of lateral lip  
compartment

This region was carefully identified on a specimen, and dye injection was performed. The anatomic compartment seen on the left side of the patient's commissure is defined. A magnified view illustrates the relation of the adipose tissue to a boundary vessel.

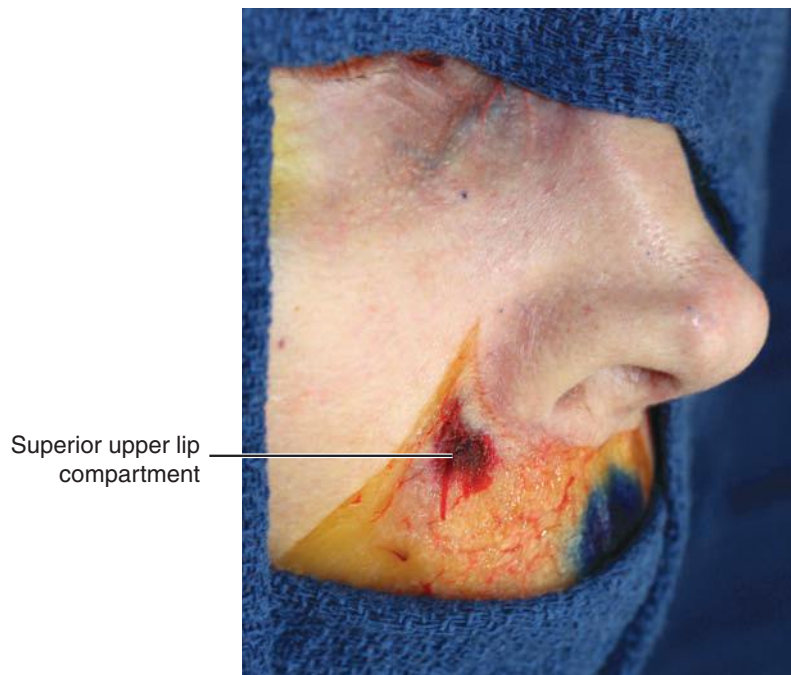

Thus the blood supply plays a significant role in determining the ultimate shape of the face, even on such a minor scale as the corner of the mouth. This anatomy helps to further define the boundary between the upper lip and face.

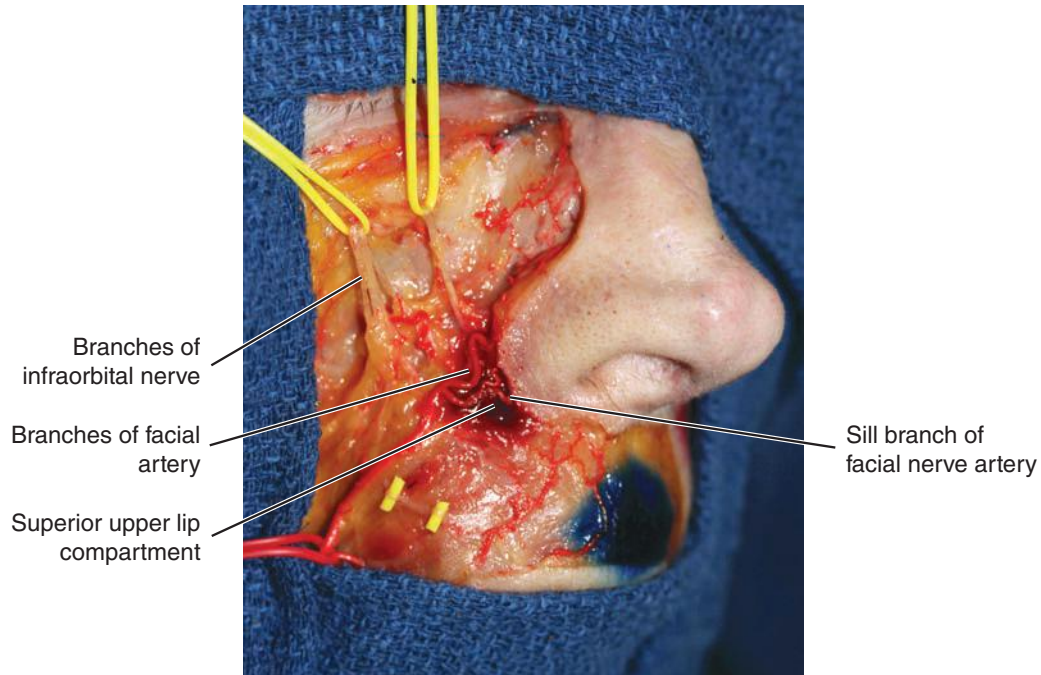
Understanding anatomic subunits and their vascular boundaries is essential information for lip reconstruction, just as aesthetic units have played a role in nasal reconstruction.

Previous dissections noted a set of boundary vessels at the top of the superior upper lip, between the upper lip and the nose, and the lip and cheek. Through these dissections we attempted to define this area as a compartment and to further confirm the blood supply. This region has been problematic; volume augmentation in this specific region has resulted in some instances of skin necrosis, as has been reported with central glabellar injections. Knowledge of the underlying anatomy would be helpful in understanding why this area is prone to complications.

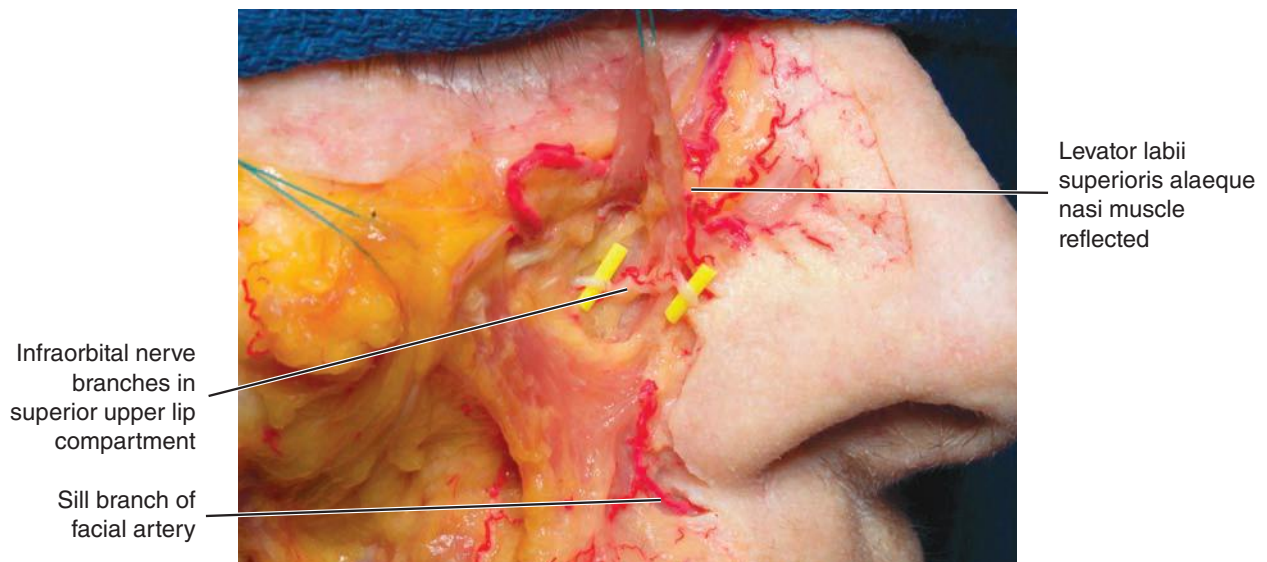
Dye stains a discrete compartment in this specimen. This is reproducible.



The superior labial vessel and the nasal sill artery create this anatomic unit. The infraorbital nerve branches are identified traveling to the alar base. Nerves travel through anatomic compartments.



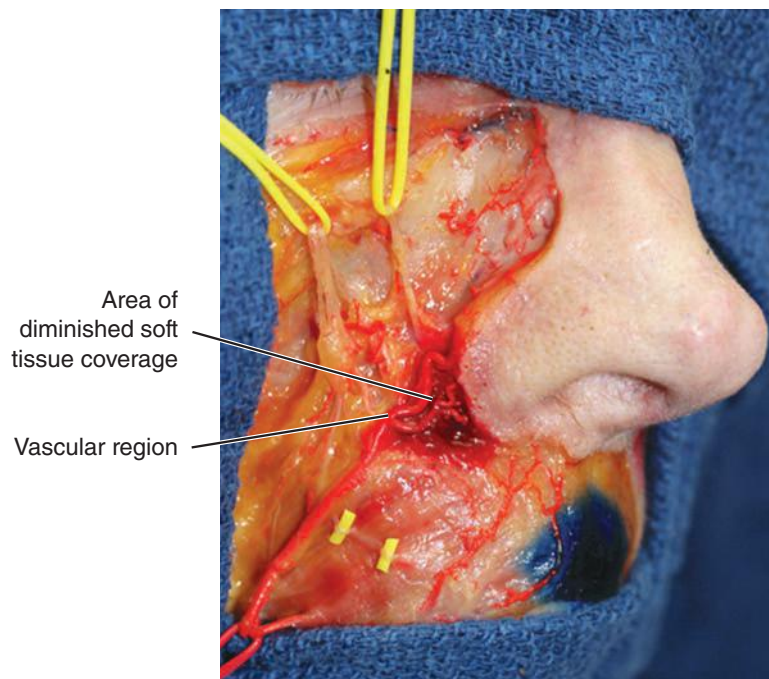
This is correlated with the work from previous dissections. The location of the nerve bundle makes this an attractive site for a nerve block. The high density of blood vessels explains why this area is prone to bruising.



Another observation gleaned by repeated dissection of the superior lip compartment is that there is a paucity of adipose tissue present. This is similar to the glabellar region, with its central wrinkle and central artery.

Areas with minimal soft tissue coverage over the blood supply are at risk for skin necrosis when even minor injections are performed.

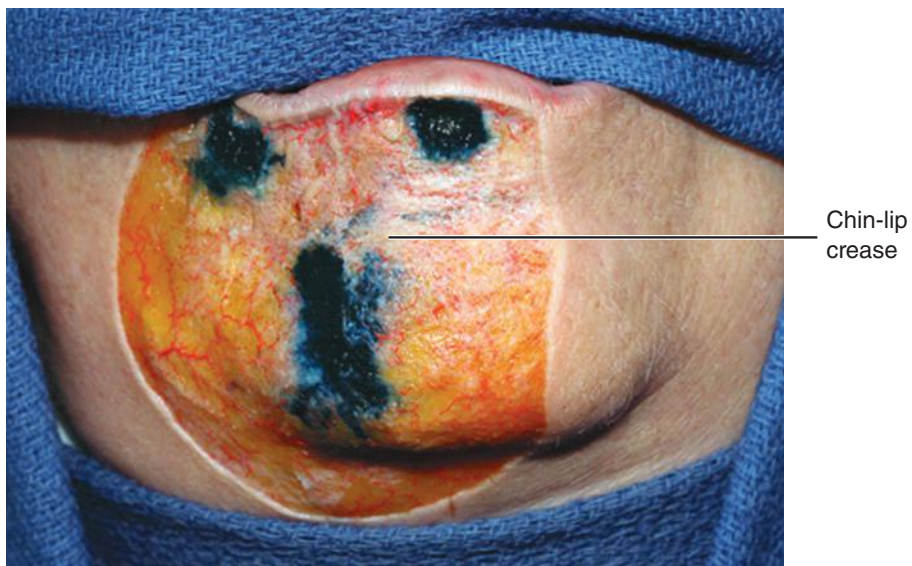
Injected volume applies pressure to the vessels and leads to diminished blood flow and tissue ischemia. This dictates the need to take extreme care when augmenting small anatomic units that have thin soft tissue coverage. Therefore it is helpful to know the location of these units.



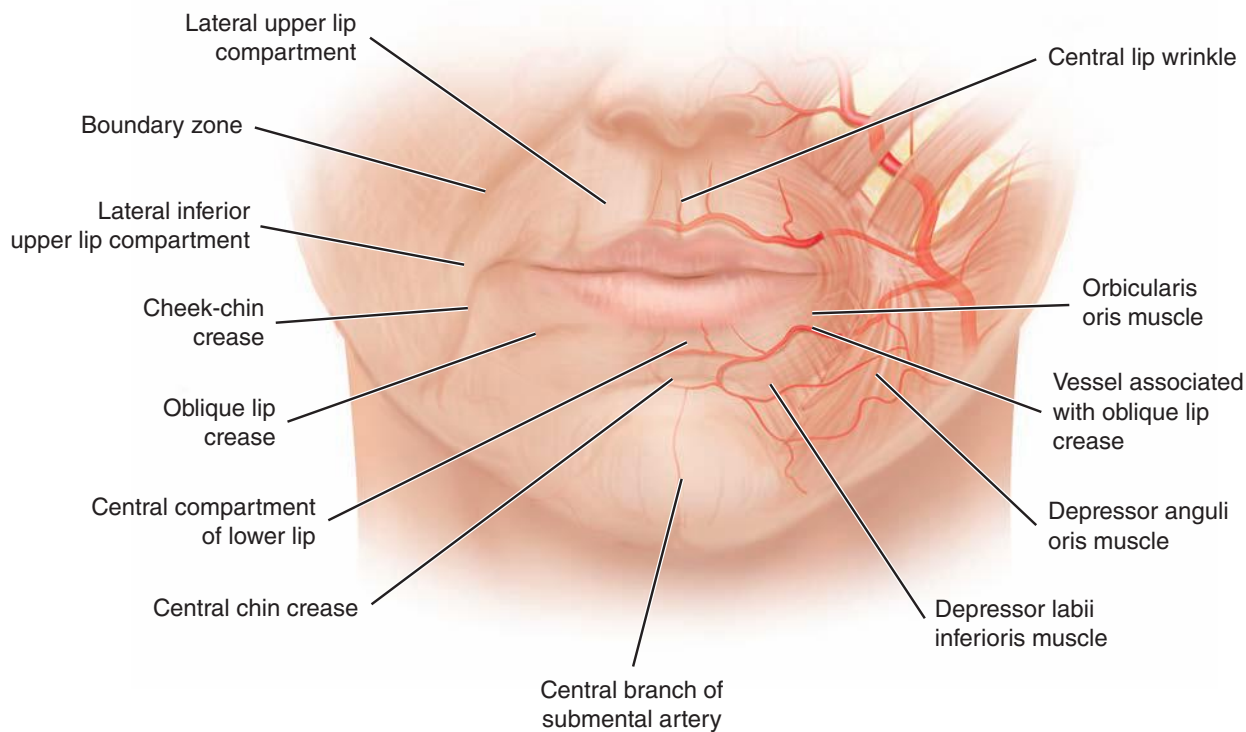
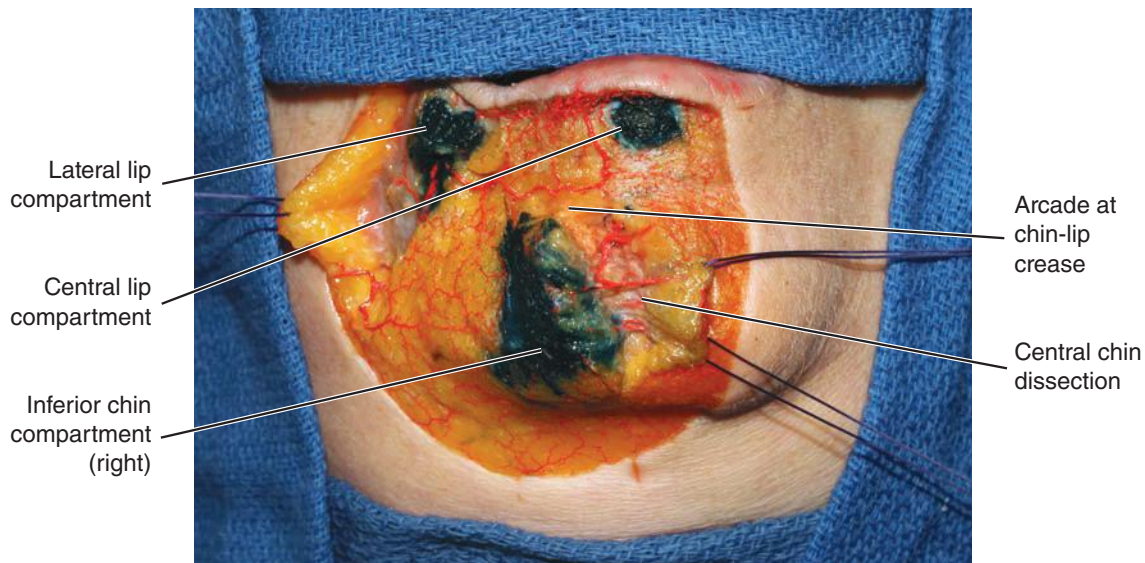
The precise anatomy of the boundary between the lip and chin has not previously been described. It is called the *labiomental crease*, but more precisely, it is a crease and a fold.

Folds occur between adjacent compartments of varying thicknesses.

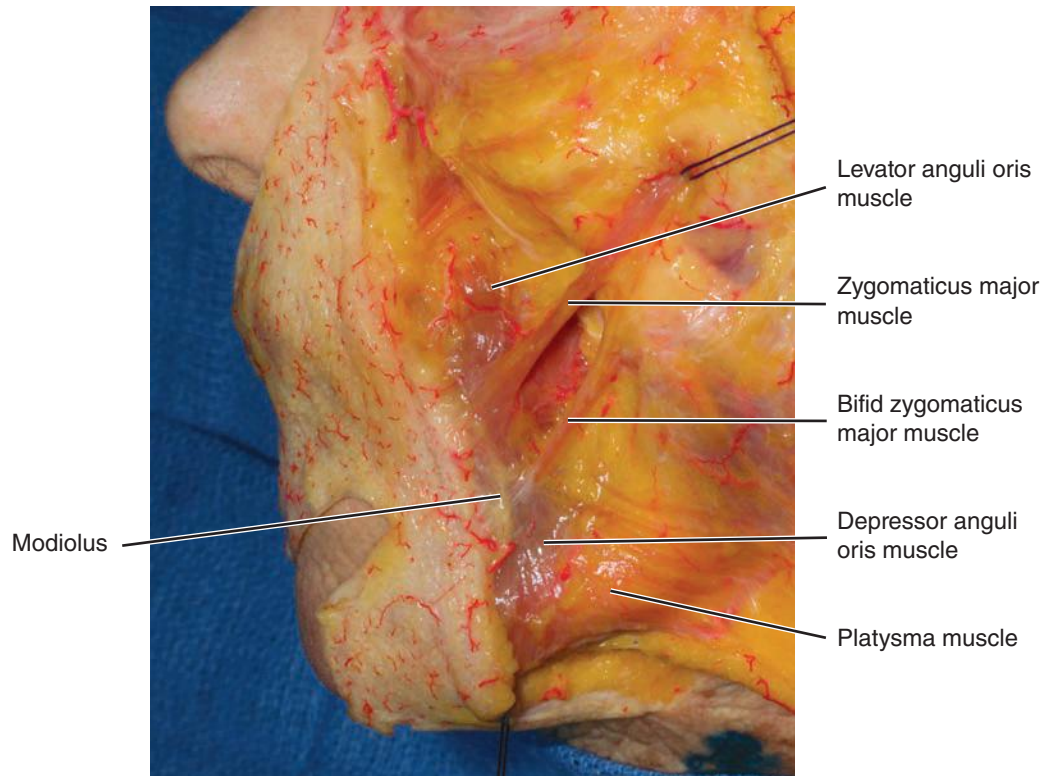
Dissection attempts to identify a compartment at the interface between the lip and chin.



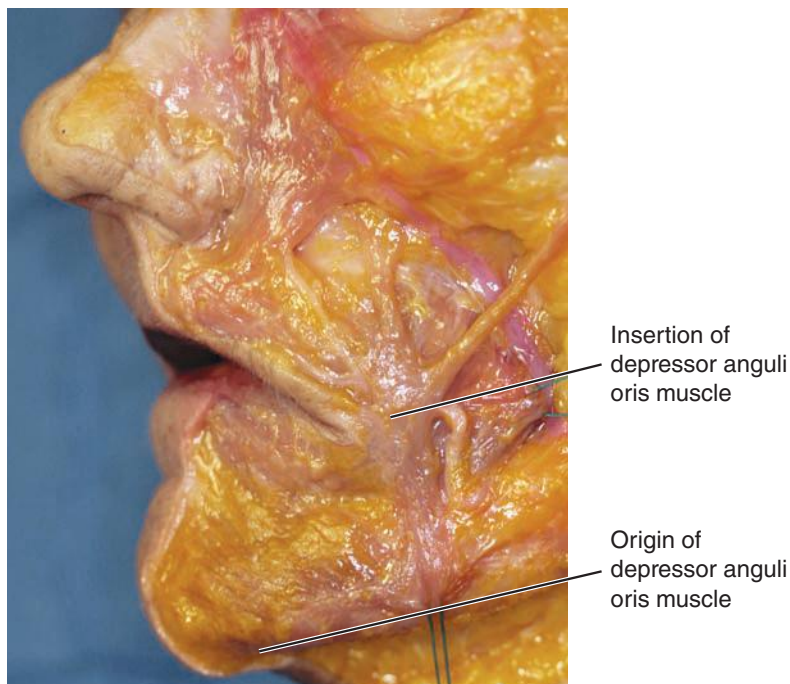
The superficial vessels are first defined, after which the deep vascular supply is identified.



This dissection defines the boundary between the lower lip and chin, as well as its blood supply. Additional dissection at the corner of the mouth in this specimen shows the position of the depressor anguli oris muscle relative to this lateral lower lip compartment.



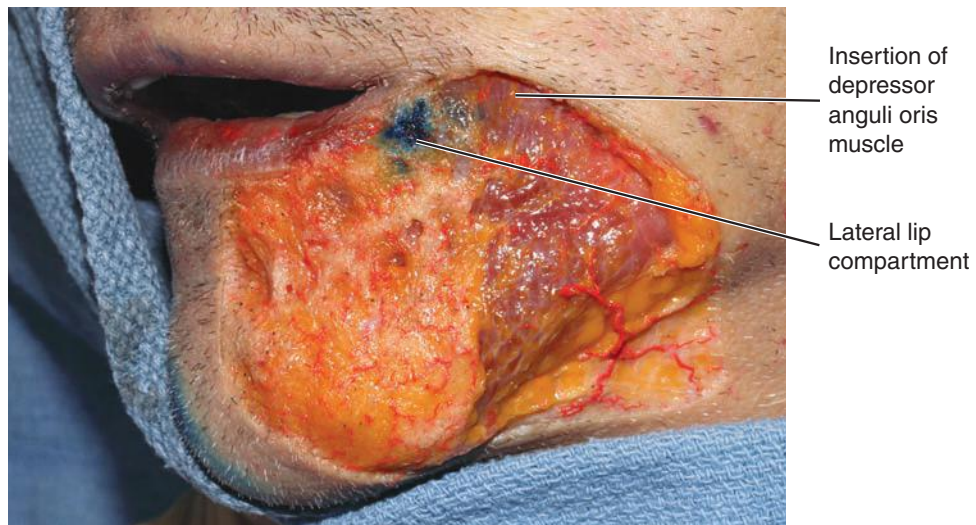
The depressor anguli oris muscle is the most important depressor of the oral commissure. It can be chemodenervated. A possible complication occurs if injection is performed into the depressor labii inferioris muscle: temporary lower lip incompetence occurs. This is avoidable knowing the position of the depressor anguli muscle. This muscle is sometimes drawn in anatomy texts as lying directly beneath the lower lip. It actually lies in a more lateral position.



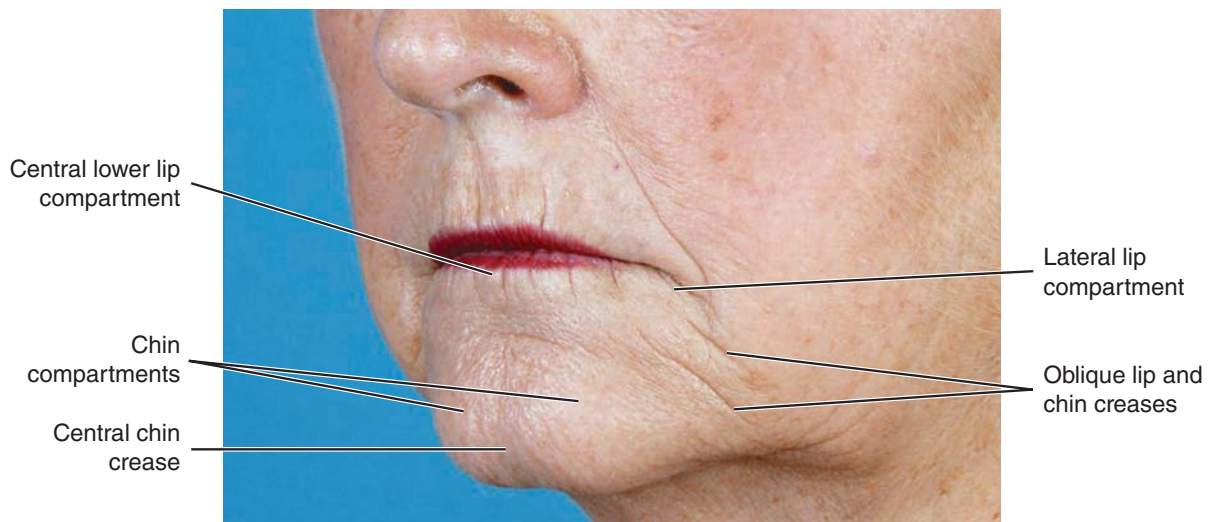The lateral lower lip compartment is a surface landmark for the position of the depressor anguli oris muscle. This muscle, as noted, has an origin at the mandibular ligament deep to chin soft tissue.

Ligaments may occur at the origin of certain facial muscles.

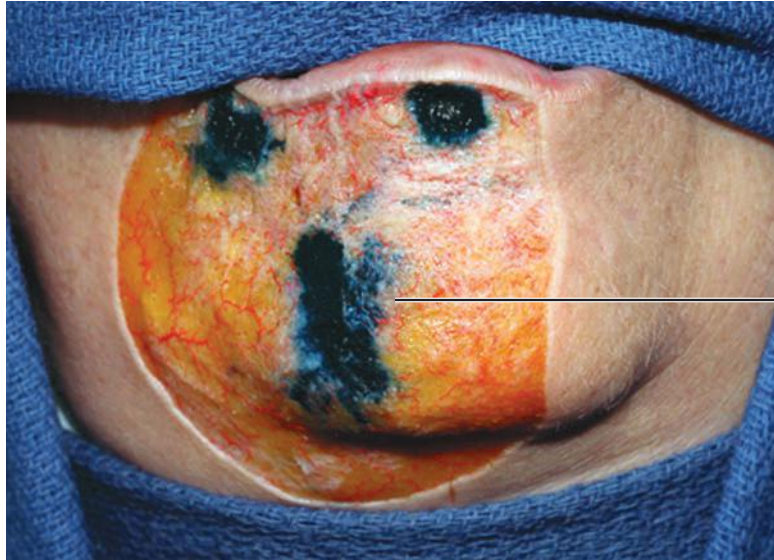
The depressor anguli oris muscle travels beneath the chin to insert beneath the superior jowl fat of the cheek. However, an injection lateral to this lower lip compartment does not approach the position of the depressor labii inferioris muscle, nor is this dependent on the depth of the injection, because these two muscles do not lie above one another lateral to this compartment. The depressor anguli oris muscle is safely approached 1 cm lateral and 1 cm inferior to the lateral lip compartment.



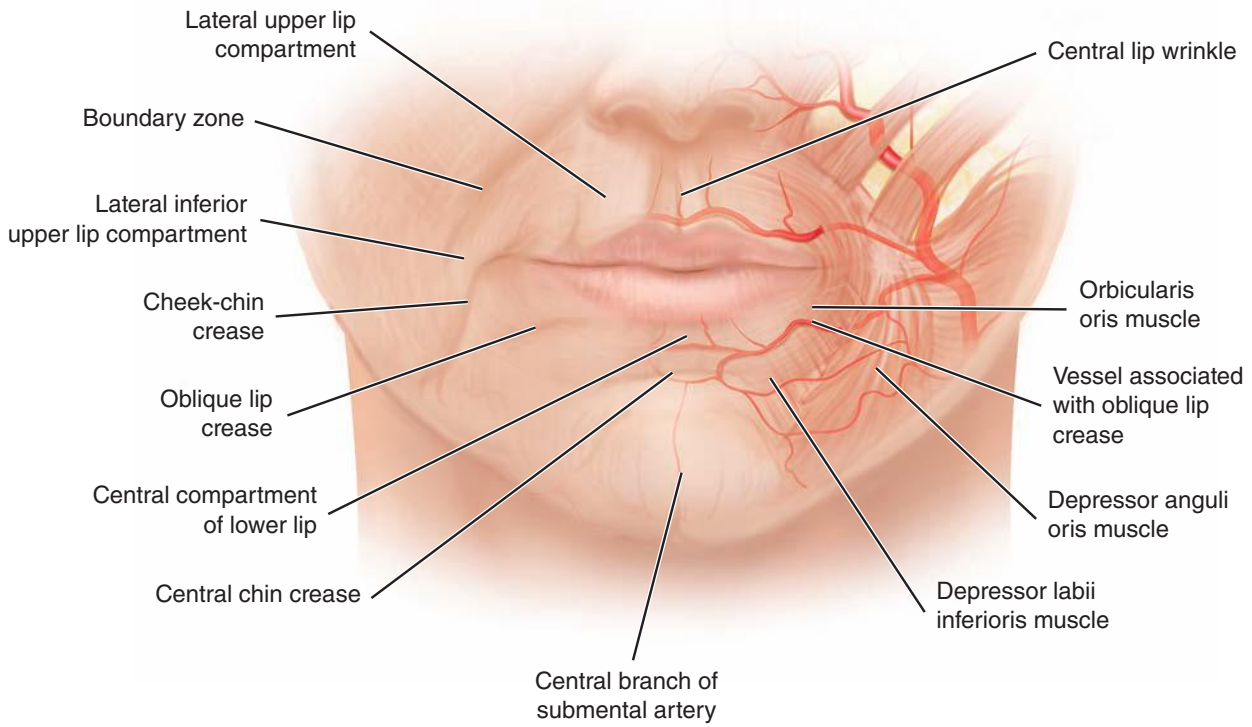
Observation suggests the chin pad has a central crease. Creases may be associated with a deeply placed blood vessel.



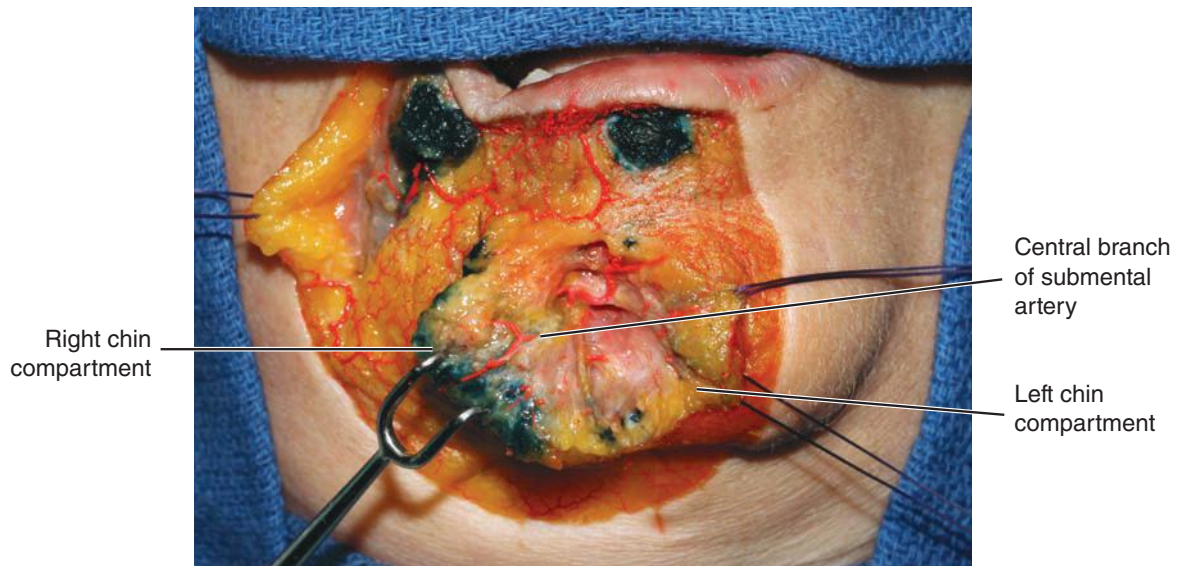
Dissection based on anatomic principles attempts to define the underlying blood supply.



Location of central chin crease

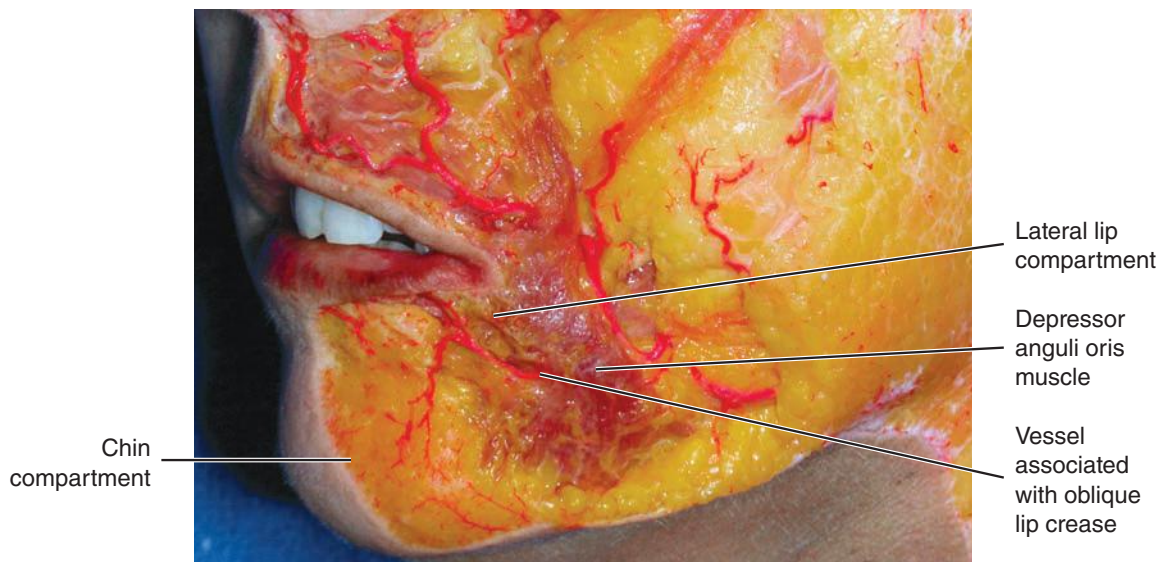


The central submental artery is identified in this dissection.



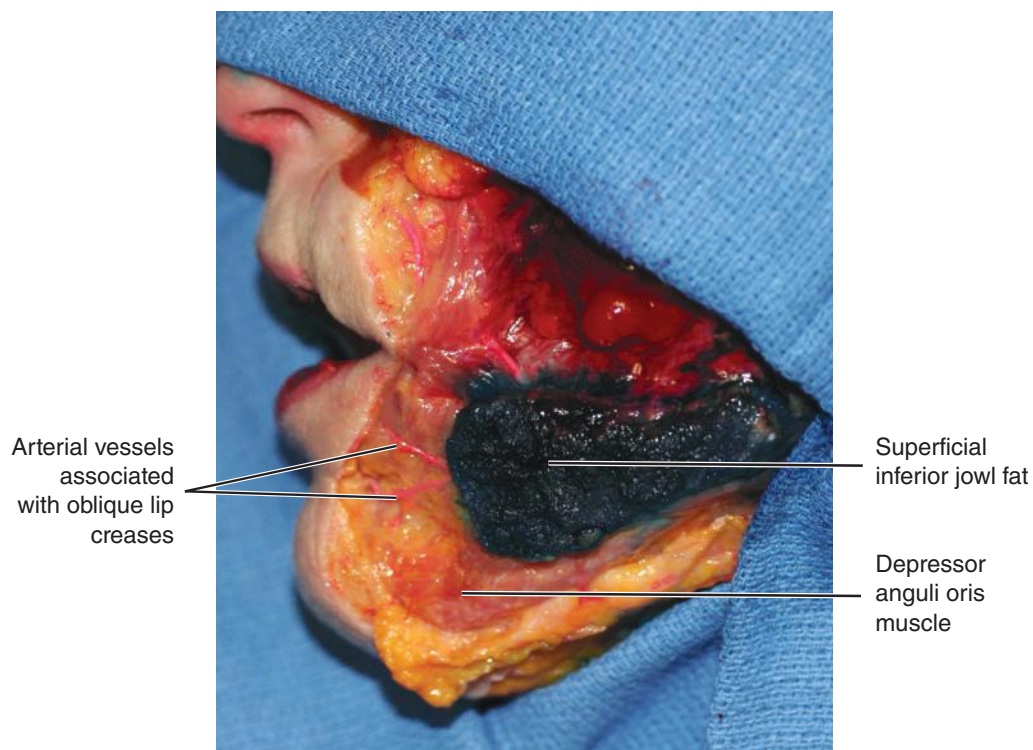
This adds new information to our understanding of the anatomy of the chin soft tissue.

In multiple dissections of the lower lip and chin, the anatomy of the vascular supply has been reproducible. There are often minor variations in the position of vessels, but the absence of vessels is most often related to technique of specimen preparation.

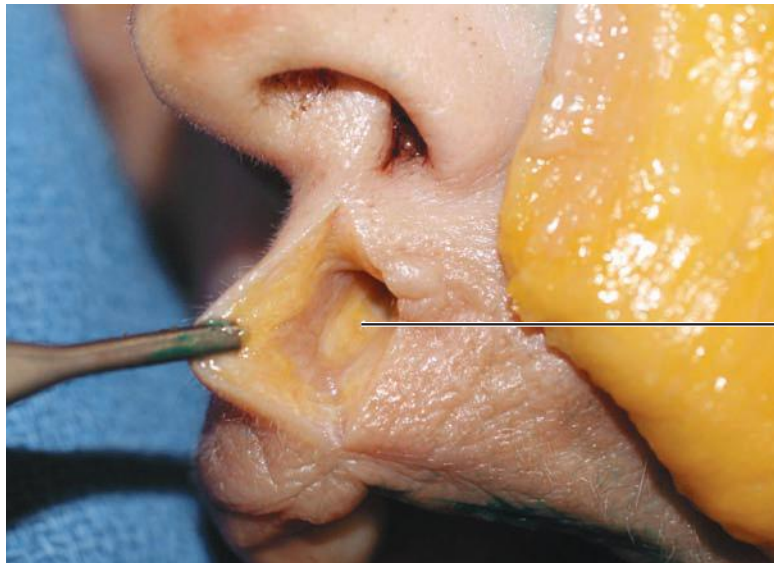


Applying the basic concepts of topographic anatomy enables us to analyze the lip more precisely. The position of blood vessels can be predicted for the two lower lip oblique creases.

These two vessels were described more than 200 years ago by Sir Charles Bell (see p. 251). Their significance is now better appreciated.

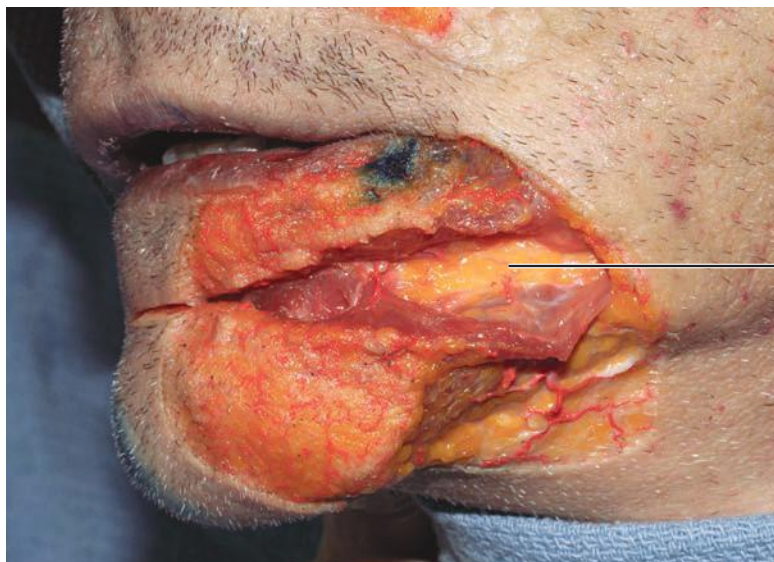


The upper lip suborbicularis oris fat pad was known at that time. Fat is located below facial muscles and facilitates the gliding mechanism.



Submuscular fat of upper lip

The depressor anguli oris muscle requires gliding ability. According to the basic anatomic concept, a fat pad should be present beneath this muscle. The fat pad is identified.



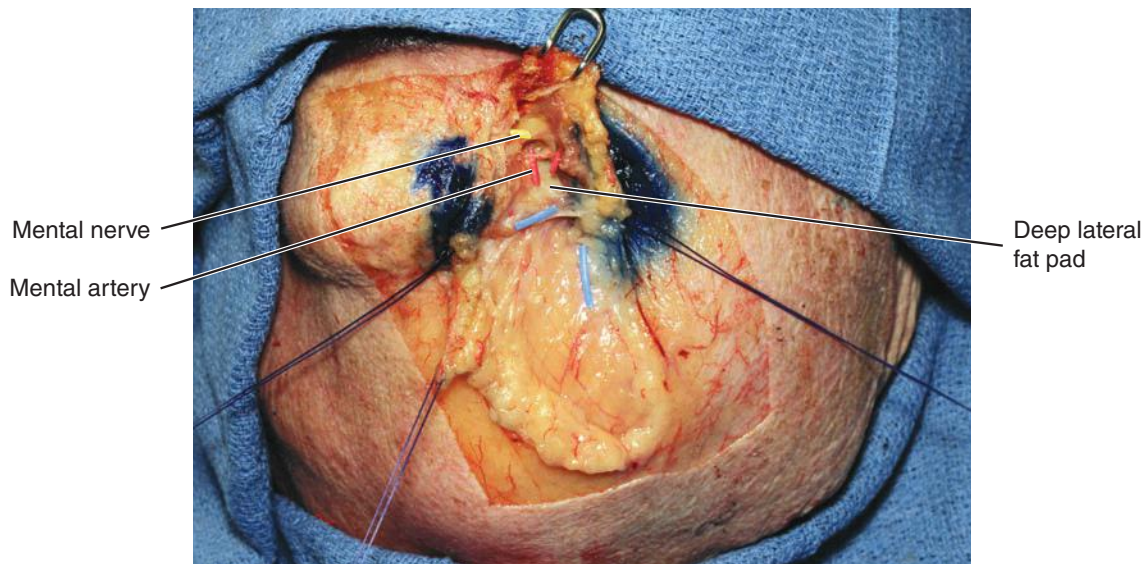
Submuscular fat of lower lip (deep lateral lip compartment)

The location of the muscle determines the position of its accompanying deep fat pad. The hollow in front of the lip-chin area is called the *prejowl sulcus*. Therefore this fat could be defined as prejowl fat or deep lateral lip fat.

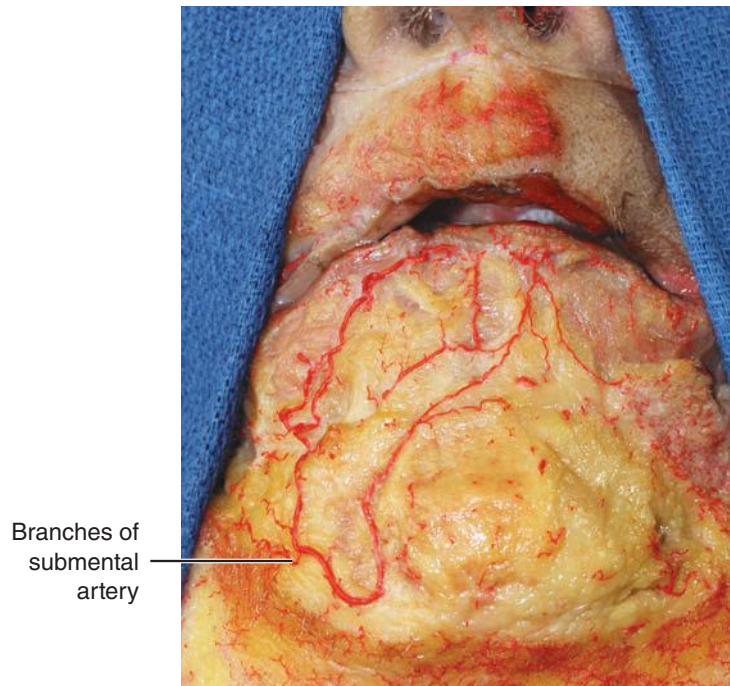
This information enables more precise volume augmentation of the jowl. Clinical experience suggests the role of volume augmentation of the area directly above the periosteum in the prejowl area. To be anatomically precise, this is augmenting the volume of prejowl deep fat.

This is similar in concept to how augmentation of deep medial cheek fat improves the overlying surface contour. The lip-chin crease and lip-cheek crease therefore share similar etiologic factors.

The mental artery supplies some of this fat pad, just as the infraorbital artery supplies some of the deep medial cheek fat. This predicts the approximate location of the mental artery and nerve, noted within the prejowl fat pad.



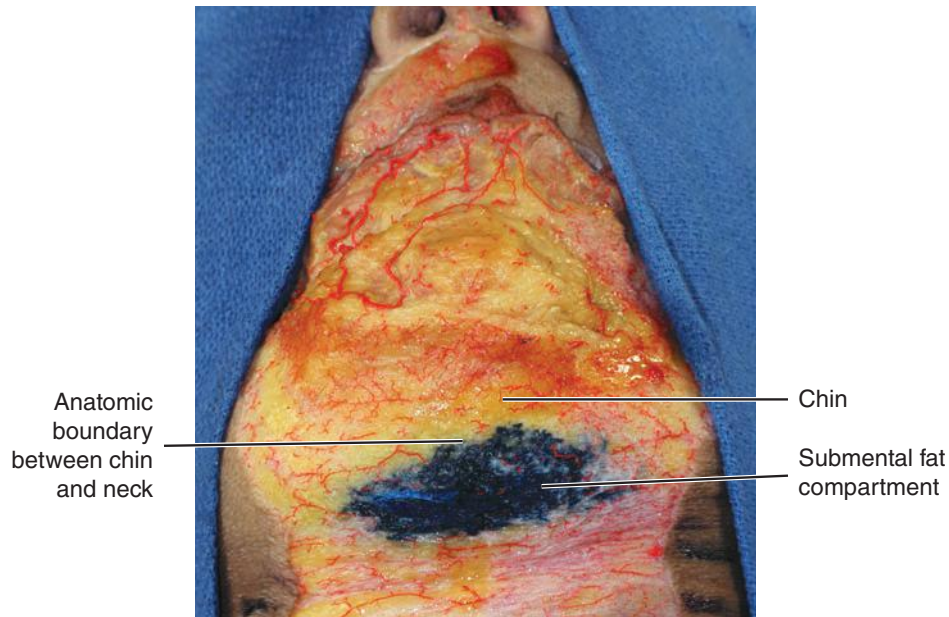The nerve is located just medial to the cheek-lip crease, within the deep lateral fat. This dissection illustrates another apparent boundary of the face, the pseudo-jowl. Tissue appears to be continuous from the cheek into the neck.



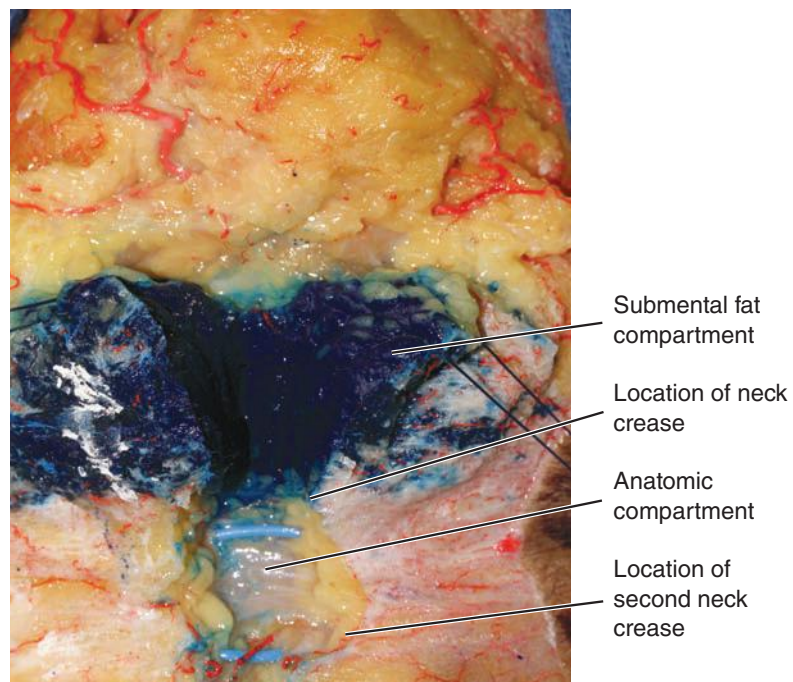
Apparent boundaries are related to aesthetic subunits. True boundaries are determined by the vascular supply.

The boundary between the chin and neck is further defined based on these concepts. The above dissection illustrates this boundary.

Perforator vessels are noted between adjacent compartments.

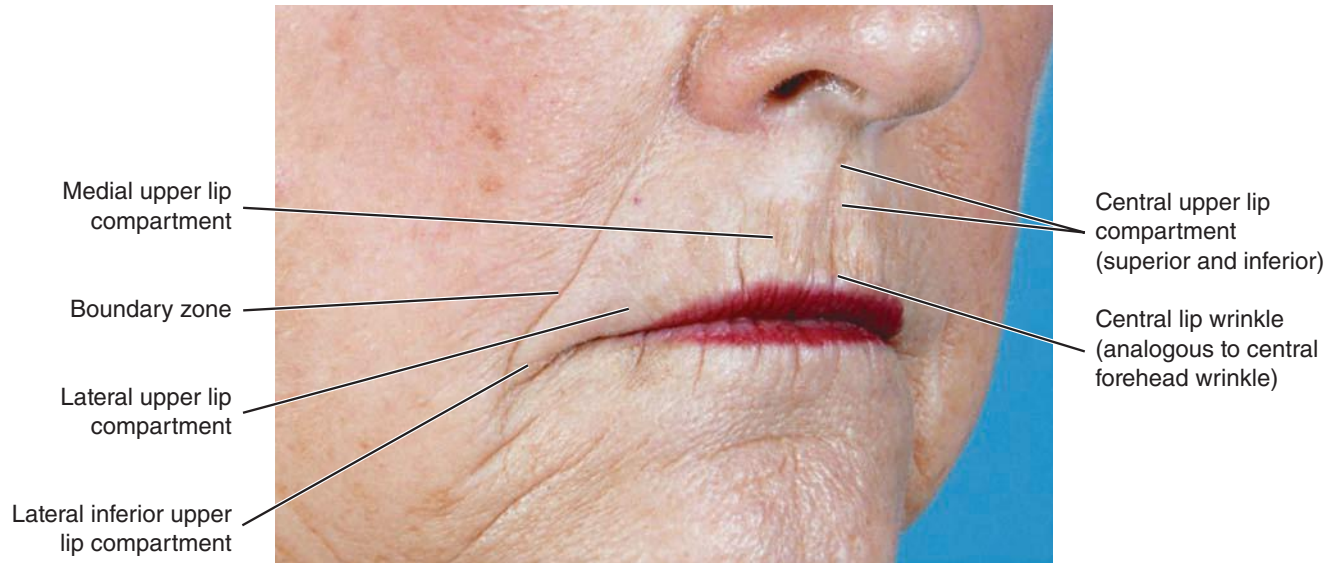

The submental arteries are identified. The neck is dissected vertically. There is a central compartment of superficial fat between the first and second neck creases.



This has not been previously identified as a tether zone, but clinically it is important to release this area for proper mobilization of neck skin during facial surgery. The defining vessels are shown.

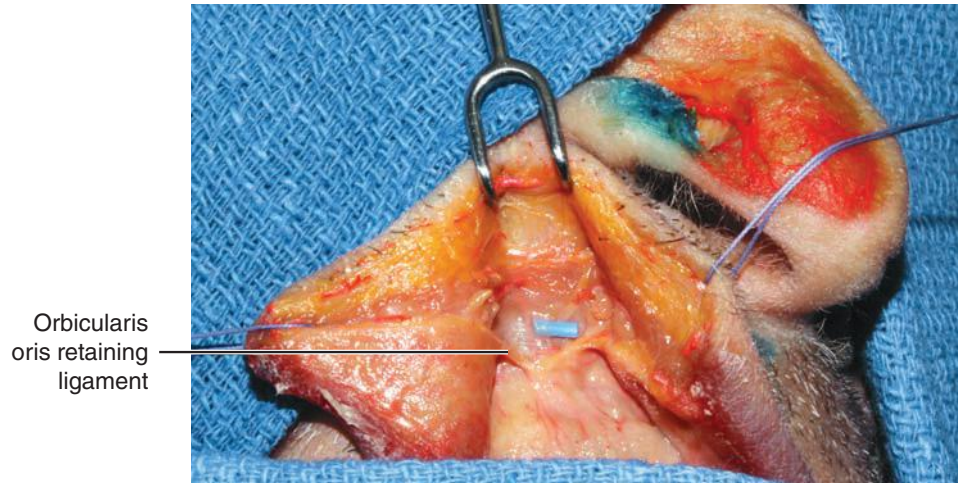
Other lip compartments exist, based on direct clinical observation. This information has direct clinical impact.



Other principles of facial topography can be applied to this region.

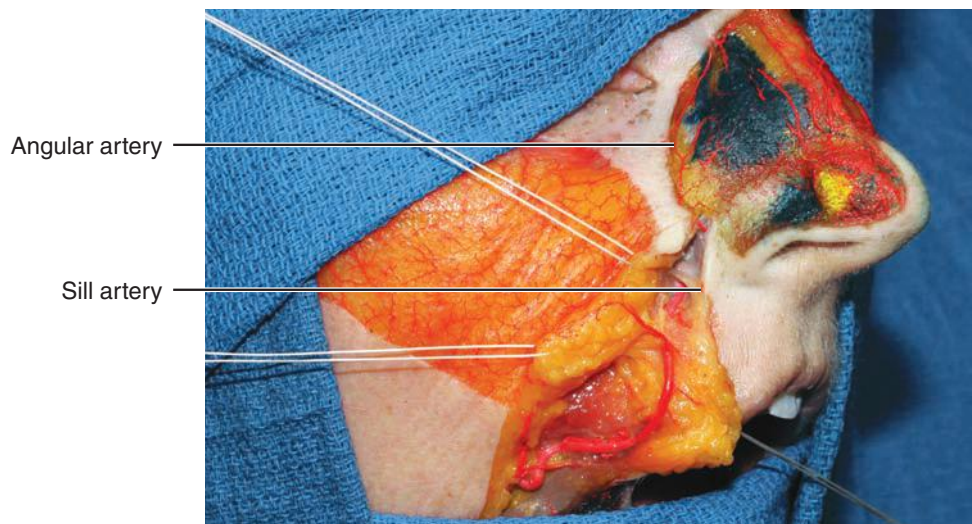
Muscles crossing skeletal boundaries frequently have a fascial extension to bone.

This occurs with the orbicularis oculi muscle as it crosses the orbital rim, with the platysma, and the procerus muscles. It probably occurs with the orbicularis oris as it crosses the lower maxilla and alveolus, with its retaining ligament.



Clefting of the upper lip occurs at the boundary of the philtral column and lip, directly at the site of the ascending philtral artery. This may be a principle of facial topography: some facial clefts may occur directly at boundary zones or at the junction of adipose compartments.

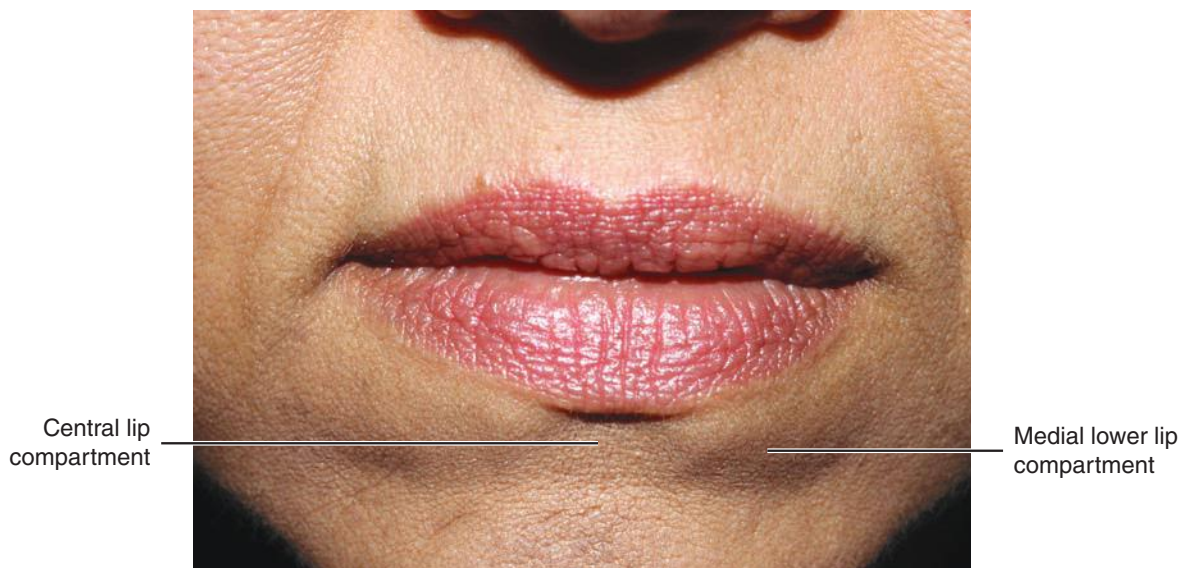The boundary between the upper lip and nasal base represents a vascular boundary, as does the junction of the nose and cheek.



Vascular boundaries—anatomic units—may be predisposed to clefts.

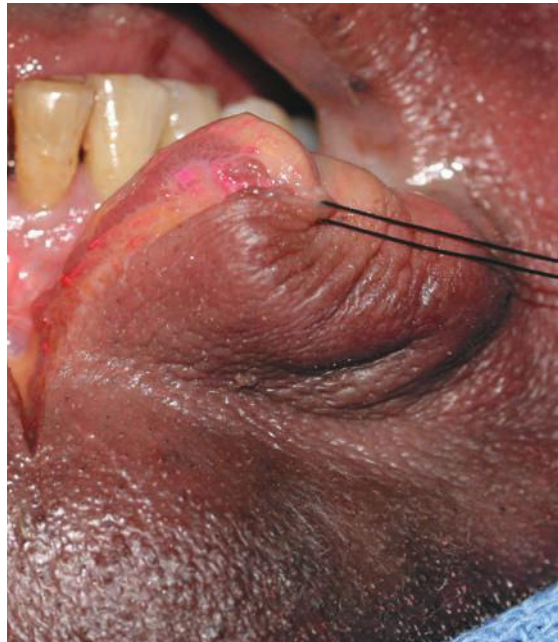This is the precise location of the Tessier 3 cleft, as previously mentioned. Tessier clefts are noted elsewhere; for example, at the corrugator and supraorbital compartment boundaries. This hypothesis will require additional research.

Other lower lip compartments exist, based on direct clinical observation. This information has significant clinical impact.



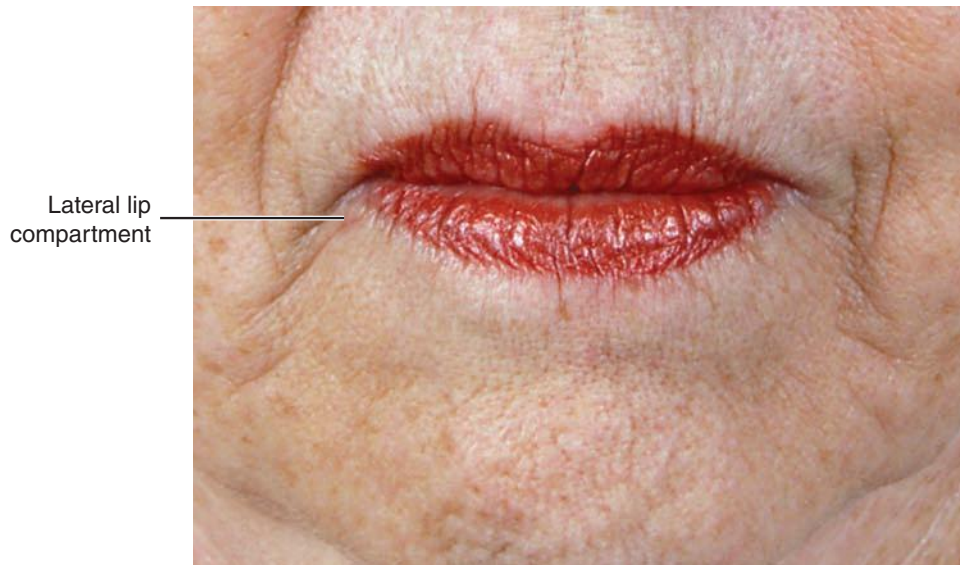The reason for this topography is the lack of fat in the central lower lip compartment. An alternative solution would be to augment this area. A topographic solution for surface smoothing would be to augment the central compartment when it is apparent.

Anatomy dictates surgical technique. One practice for lip augmentation was to inject filler along the white roll of the lip under pressure to fill the area of skin. This cannot work, at least not to fill adipose tissue, because boundaries exist all across the lower and upper lips. If injected filler or any material travels across the entire lower lip, the injection must have been performed in the muscular layer. The muscle edge is located at the vermilion-cutaneous junction.



The discontinuous nature of facial soft tissue dictates a site-specific technique of facial augmentation.

The triangular compartment at the lateral commissure that began these studies is again noted. Its presence is signified by the surface creases and shape.

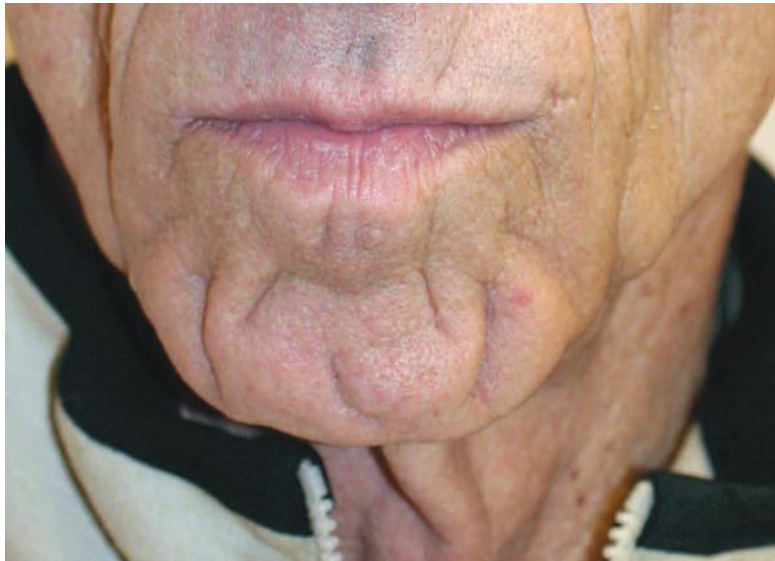


The position of the depressor anguli oris muscle can be predicted based on observation alone. The boundary between the lip and chin is understood, and the location of deep fat pads can be anticipated. The position of nerves can be predicted relative to surface landmarks. Clefting may occur in boundary zones between anatomic compartments.

## THE FUTURE

The basic concepts described here can define the topographic anatomy of any place on the face. Knowing these concepts enables the observer to “see” a face from a different perspective. It becomes possible to understand the underlying anatomy based on surface contour and shape. The topography becomes a roadmap for anatomy.

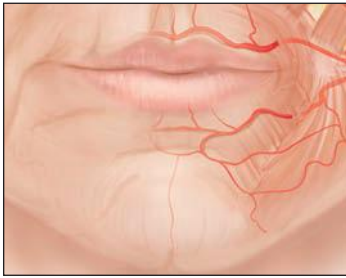Certainly, additional concepts will be defined in the future that will improve our understanding of how surface topography is determined by underlying structure. If we apply these basic principles of facial topography, lines of research will open up, limited only by work and imagination.



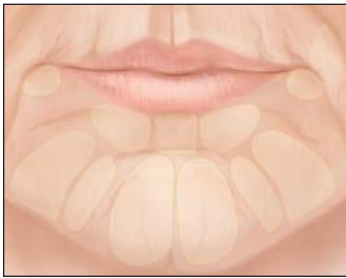## *Key Points*

- Adipose tissue is found in highly defined anatomic units or compartments.
- Anatomic boundaries are defined in part by vascular anatomy.
- Most areas of the face duplicate the structural makeup of other regions.
- Adipose units are based on the underlying blood supply and its membranous fixation to skin.
- Creases may be associated with a deeply placed blood vessel.
- Folds occur between adjacent compartments of varying thicknesses.
- Ligaments may occur at the origin of certain facial muscles.
- Fat is located below facial muscles and facilitates the gliding mechanism.
- Apparent boundaries are related to aesthetic subunits. True boundaries are determined by the vascular supply.
- Areas with minimal soft tissue coverage over the blood supply are at risk for skin necrosis with even minor injections.
- Vascular boundaries—*anatomic units*—may be sites predisposed to clefts.
- Muscles crossing skeletal boundaries frequently have a fascial extension to bone.

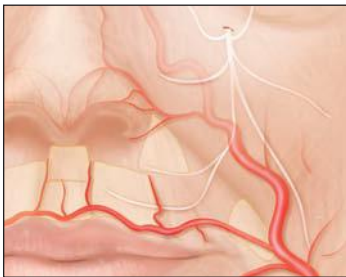## CLINICAL CORRELATIONS



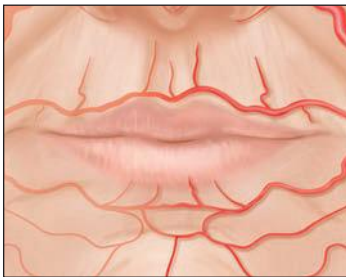
The lower lip as an anatomic subunit has thinner subcutaneous tissue than the chin. This is one cause of the lip-chin crease, and needs to be taken into account during lip and chin reconstruction. In general, more mobile regions or subunits have less subcutaneous fat.



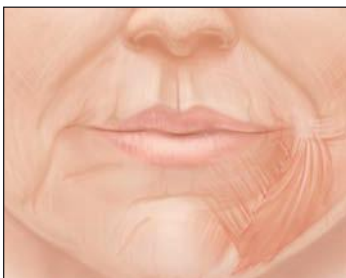The major wrinkles of the lower lip define superficial anatomic compartments. The junction between compartments is a boundary to injected fillers. Multiple injections are required to augment superficial fat on the cutaneous lip. This is not required if intramuscular injection is performed.



The superior upper lip compartment, while a possible site for intraorbital nerve branch blockade, is highly vascular. Injections in this compartment tend to cause bruising.



The Abbé flap, when it includes the ascending lower lip philtral arteries, has the potential to reconstruct the same anatomy present in the upper lip.



Muscles cross boundaries between anatomic compartments. This information is important clinically. For example, the depressor anguli oris muscle can be injected for chemodenervation in the chin medial to the cheek-chin crease, or in the cheek lateral to the cheek-lip crease.

## Bibliography

The lips and chin are perhaps the least studied anatomic regions of the face in terms of defining anatomic subunits, adipose compartments, boundary zones, and topographic landmarks. This group of references lends support to the concepts and ideas proposed in this chapter. What is more significant is that these concepts enable us to predict boundary zones between regions. The clinician or artist can visualize anatomic subunits of the chin and lips based on vascular boundaries. Future studies can be planned and meaningful results anticipated. A small fraction of the potential topographic landmarks have been defined. The articles in this list will enable the reader to glean clinical applications using fundamental concepts of facial anatomy.

Burget GC, Menick FJ. Aesthetic restoration of one-half the upper lip. *Plast Reconstr Surg* 78:585-593, 1986.

*This classic article applied the subunit principle of reconstruction to the upper lip. It has been pointed out that anatomic subunits differ from aesthetic subunits regarding how they are defined. However, folds and creases are regions where light reflection changes; therefore they represent borders of aesthetic subunits. Folds and creases also can help predict the location of the underlying blood supply. In this case, aesthetic subunits and anatomic subunits may correspond with one another, as with the medial two subunits between the philtral columns. This is an example of an advance in surgical precision representing an intuitive interpretation of anatomy that has later been substantiated by basic research.*

Culliford A IV, Zide B. Technical tips in reconstruction of the upper lip with the Abbé flap. *Plast Reconstr Surg* 122:240-243, 2008.

*The authors described technical modifications of the Abbé flap and showed how it may recreate either one or two philtral columns of the upper lip based on the width and its design. Closure of a lower chin incision in the labiomental crease preserves the normal architecture of the superficial boundary between these two anatomic regions. This is an excellent example of how technical advances in precision ultimately correlate with a more detailed understanding of the underlying anatomy.*

Gardetto A, Morigal B, Maurer H, et al. Anatomical basis for a new island pattern flap in the perioral region. *Surg Radiol Anat* 24:147-154, 2002.

*The authors defined a branch of the facial artery termed the “zygomatic branch” and used it as the perforator vessel for a new flap. Dye injection of the vessel is limited at the cheek lip crease—an anatomic boundary. It is possible that the artery represents the lateral boundary of the cheek lip crease, providing a possible link between the concepts of anatomic subunits and angiosomes and perforasomes.*

Hur MS, Hu KS, Cho JY, et al. Topography and location of the depressor anguli oris muscle with a reference to the mental foramen. *Surg Radiol Anat* 30:403-407, 2008.

*This is one of the few reports that has addressed the topography of the mental nerve. The data provided show that the mental foramen may occur at any point relative to the depressor anguli oris muscle. The foramen of the nerve was reliably found in the middle third of the muscle between the commissure and mandibular border. Adding this to the information provided in this chapter will enable the clinician to predict a “safe zone” for injection of this depressor muscle in the lower third of the chin anterior to the cheek-chin crease; injections in the upper third should be performed lateral to the cheek-chin crease, as published in the literature.*

Iwahira Y, Maruyama Y, Yoshitake M. A miniunit approach to lip reconstruction. *Plast Reconstr Surg* 93:1282-1285, 1994.

*Another example of an intuitive approach to advancing surgical technique, this article defined “miniunits” of the lips. The authors stated, “We have applied a miniunit principle that utilized existing or potential wrinkle lines as medial and lateral miniunit borders.” Thus the authors essentially defined anatomic subunits of the upper lip based on wrinkles and creases.*

Jacono AA. A new classification of lip zones to customize injectable filler augmentation. *Arch Facial Plast Surg* 10:25-29, 2008.

*The author intuitively defined the lips into structural zones, predating the concept of anatomic subunits. His discontinuous technique of injection is anatomically sound: the lip wrinkles may represent boundary zones that are impermeable to injected filler. The differentiation of the vermilion from subvermilion can be understood in light of the marginal arcade coursing across the lower lip, similar to the marginal and subtarsal arcades of the lower eyelid. The author stated that these areas can be injected “specifically”: site-specific injection is predicted based on anatomic subunits. The author also defined the lateral commissural zone—one that we defined with dye injection, predicted based on Bell’s classic work.*

Karapandzic M. Reconstruction of lip defects by local arterial flaps. *Br J Plast Surg* 27:93-97, 1974.

*Karapandzic’s classic article describing one of the earliest “crease” flaps, one relying on perforators found at a boundary zone between anatomic compartments. Karapandzic was actually performing an advancement perforator flap, identifying and preserving the facial artery branches ascending along their vascularized membrane as dissection progressed. This is one of the earliest uses of facial topography on which to base arterial flap design.*

Naranjian NS. An anatomical study of the facial artery. *Ann Plast Surg* 21:14-22, 1988.

*The author showed variations in terminal branching patterns of the facial artery. The location of the facial artery at the boundary between the anatomic regions of the cheek and lip was noted, with little variation. The author illustrated the ascending philtral arteries of both the upper and lower lip, predicting their corresponding anatomic subunits. The location of the mental foramen was accurately rendered: medial to the cheek-chin crease, a topographic landmark for its position as well as the deep lateral fat through which the nerve enters the chin.*

Pinar YA, Bilge O, Govsa F. Anatomic study of the blood supply of the perioral region. *Clin Anat* 18:330-339, 2005.

*This article set the stage for future studies defining anatomic subunits. Boundary zones can be anticipated based on the data provided; for example, the labiomenal artery beneath the labiomenal crease, another topographic landmark that defines the superficial boundary between two anatomic regions. An undescribed anatomic subunit of the upper lip can be visualized. The authors defined superficial and deep ascending branches of the philtral arteries, these being the deep anatomy predicted based on the location of the philtral columns.*

*Furthermore, they referred to the area between the philtral columns as “medial subunits,” terminology that if combined with knowledge of creases, vascularized membranes, and blood supply leads to the concept of anatomic subunits. The authors noted variations in the pattern of blood supply to the central lower lip. Variations have been noted in the width between the ascending philtral arteries of the lower lip; possibly this explains why there is such great individual variability in the prominence of lower lip philtral columns. Many other ideas and concepts were suggested by this study that remain to be tested.*

Wang TM, Shih C, Liu JC, et al. A clinical and anatomical study of the location of the mental foramen in adult Chinese mandibles. *Acta Anat* 126:29-33, 1986.

*This study provided confirmatory evidence to support the findings that the mental foramen is located in the middle third between the commissure and mandibular border and to predict safe zones in which to approach the depressor anguli oris muscle. The study also provided data to predict the location of the mental foramen for accurate nerve blocks.*

This page intentionally left blank

This page intentionally left blank

This page intentionally left blank

This page intentionally left blank